

**ASPECTS OF THE EPIDEMIOLOGY
OF HUMAN PAPILLOMAVIRUS**

R J HILLMAN

**Doctor of Medicine
University of Edinburgh
1994**



DECLARATION

This thesis has been composed entirely by the candidate.

The research was performed whilst working as part of a group. Mr Marc Botcherby and Ms Balvinda Ryait performed the laboratory analyses on the clinical samples. Professor David Taylor-Robinson oversaw the whole process.

The candidate had the original ideas, designed the studies, collected the clinical samples (other than those explicitly stated in the text), analysed the data, interpreted the results and wrote the thesis.

The thesis has not been submitted in candidature for any other degree, diploma or professional qualification.

UNIVERSITY OF EDINBURGH

ABSTRACT OF THESIS (Regulation 3.5.10)

Name of Candidate RICHARD JOHN HILLMAN

Address

Degree M.D. Date 9th MAY 1994

Title of Thesis ASPECTS OF THE EPIDEMIOLOGY OF HUMAN PAPILLOMAVIRUS

No. of words in the main text of Thesis 40,000

The objective of this thesis was to investigate various aspects of the epidemiology of human papillomavirus (HPV). Prospective studies were performed on a total of 334 patients attending two genitourinary medicine departments in London. The patients had either clinical indications for genital biopsy, urethral gonorrhoea, anogenital warts or a current partner with anogenital warts.

Biopsy, scrape, swab and blood samples were taken. In addition, a new method, the "Superglue (SG) technique" was devised. HPV types 6, 11, 16, 18, 31 and 33 were identified in the specimens by DNA extraction followed by the polymerase chain reaction, Southern blotting and hybridisation.

HPV DNA was detected in 31.8 to 96.6% of biopsies with histological evidence of wart virus infection, 83.3% of biopsies with neoplasia and 18.2% of those with other histological changes. HPV DNA was detected in 31.3 to 61.1% of urethral loop specimens, 18.0 to 24.8% of urethral swab specimens, 6.3 to 12.5% of urine specimens, 37.5% of vaginal washes and 21.4% of rectal swab specimens. Fifty percent of samples obtained with the SG technique containing human cells had detectable HPV DNA.

HPV types 6 and 11 tended to be found in biopsies from lesions clinically associated with HPV infection and in the urethras of men with warts seen near the urinary meatus. HPV types 16 and 18 tended to be found in specimens obtained by techniques other than the biopsy method and from clinically atypical lesions. Infections with multiple HPV types were common. Different sites from one patient sometimes had HPV types in common. Sexual partners did not consistently have HPV types in common and there was a poor correlation between the detection of HPV DNA and various lifestyle factors.

HPV DNA was found widely distributed in the anogenital areas of men and women with and without clinically apparent anogenital warts. Sexual activity may not be the only factor in the transmission of HPV infection. Sampling from a single site of the genitalia on one occasion may lead to significant underestimation of the rate of infection with HPV.

ACKNOWLEDGEMENTS

Many individuals have given me material, intellectual and moral support throughout the course of these studies.

Marc Botcherby helped develop the assay techniques over many months, to reach a reliable and consistent level of reproducibility. Balvinda Ryait performed many of the polymerase chain reactions, nucleic acid hybridization assays and repeated standardisation experiments which were crucial to the production of consistent results.

The meticulous surgical skills of Dr Nashat Hanna were instrumental in the collection of many of the samples of perianal warts. His enthusiasm concerning the pathogenesis of wart virus infection formed a significant contribution to the initial inspiration for this project.

Dr Marjorie Walker, Consultant Histopathologist at St Charles Hospital checked all, and reported most of the histopathological diagnoses. Her infectious enthusiasm for her specialty was a very welcome bonus.

Mrs Mary Phillips and Ms Fay Miller, Research Nurses, helped considerably in the collection of some of the data and urethral swabs in the study of men with urethral gonorrhoea.

I would like to thank the staff of The Jefferiss Wing, St Mary's Hospital, London and The Patrick Clements Clinic, Central Middlesex Hospital for their enthusiasm in referring patients to the various studies, sometimes providing an additional burden in an already pressurised environment. In particular, I would like to thank Dr JRW Harris whose overall leadership of the clinic created such a stimulating environment.

Professor Taylor-Robinson of the Medical Research Council was largely instrumental in creating the circumstances under which I could pursue my studies with the maximum of support and the minimum of hindrances. His constant guidance and helpful remarks provided timely inspiration when spirits were flagging. For this I am extremely grateful.

Dr McMillan acted as my adviser throughout and supported me through all the stages of this work.

Finally I would like to express my gratitude to the staff at the Department of Genitourinary Medicine at the Royal London Hospital, and in particular, Dr BT Goh for their patience whilst this thesis was completed.

CONTENTS

	<u>Page</u>
<u>INDEX OF FIGURES</u>	x
<u>INDEX OF TABLES</u>	xi
 <u>INTRODUCTION</u>	
1. <u>Historical Background</u>	
1.1 Introduction.....	2
1.2 The Greek and Roman periods.....	2
1.3 The nineteenth and twentieth centuries.....	3
1.3.1 The non-specific irritant theory.....	4
1.3.2 The unitary theory.....	5
1.4 The development of current concepts.....	6
2. <u>Virology</u>	
2.1 Viral structure.....	8
2.2 Species and site specificity.....	9
2.3 HPV types.....	10
2.4 The genetic structure of HPV	11
2.4.1 E (Early) region.....	12
2.4.2 L (Late) region.....	13
2.4.3 Nucleotide homology.....	14
2.5 Genitotropic HPVs.....	14
2.6 Multiple HPV infections.....	15
3. <u>Immunology</u>	
3.1 Introduction.....	16
3.2 Immunohistological considerations.....	16
3.2.1 Langerhans' cells.....	17
3.2.2 T lymphocytes.....	18
3.2.3 Natural killer cells (NK cells).....	18
3.2.4 Keratinocytes.....	18
3.3 The humoral immune response.....	20

4. Diagnostic Techniques

4.1	Introduction.....	22
4.2	Clinical examination.....	22
4.3	Subclinical infection.....	23
4.4	Colposcopy.....	24
4.5	Histopathology.....	25
4.6	Exfoliative cytology.....	27
4.7	Latent infection.....	28
4.8	The polymerase chain reaction.....	28
4.8.1	Technique of the PCR.....	28
4.8.2	Advantages of the PCR.....	30
4.8.3	Disadvantages of the PCR.....	31
4.9	Southern blotting with hybridisation.....	32
4.10	Other techniques.....	33

5. Epidemiology of anogenital HPV infection

5.1	Introduction.....	34
5.2	Anogenital warts (AGW).....	36
5.3	HPV DNA and AGW.....	40
5.4	Non-condylomatous clinically apparent HPV infection.....	42
5.5	Subclinical and latent infection.....	42
5.6	HPV and the upper genital tract.....	45
5.6.1	Bladder.....	45
5.6.2	Prostate.....	46
5.6.3	Semen.....	47
5.7	HPV in urine.....	47
5.8	HPV and the urethra.....	48
5.8.1	Condylomata acuminata.....	49
5.8.2	Urethroscopy.....	49
5.8.3	Urethral sampling techniques.....	50
5.8.4	Papanicolaou staining of urethral smears.....	50
5.8.5	HPV antigen detection in urethral specimens.....	51
5.8.6	HPV DNA in urethral specimens.....	51
5.8.7	Urethral carcinoma.....	52
5.9	HPV DNA in tissue with no histological evidence of HPV infection.....	53
5.10	HPV DNA in the normal adult penis.....	54
5.11	Natural history of anogenital HPV infection.....	56
5.12	Anogenital HPV infection and sexual behaviour.....	57
5.13	Possible vertical transmission of genitotropic HPV types.....	61

5.14	Genitotropic HPV types at non-urogenital sites	64
5.14.1	Laryngeal papillomatosis	64
5.14.2	Mouth	65
5.14.3	Oesophagus	65
5.14.4	Nasal cavities	66
5.14.5	Eye	66
5.14.6	Blood	66
5.14.7	Fomites	67
5.15	Anogenital neoplasia and HPV	67
5.16	The "high risk" male	69

METHODS

1.	<u>Introduction</u>	72
2.	<u>Recruitment of patients</u>	74
2.1	Genital dermatosis study	74
2.2	Resistant anogenital warts study	74
2.3	Urethral gonorrhoea study	74
2.4	Multifocal study	75
3.	<u>History and examination of patients</u>	75
4.	<u>Routine investigation and treatment of patients</u>	76
5.	<u>Sampling techniques</u>	
5.1	Biopsy specimens	79
5.2	Urethral specimens	83
5.3	Urine specimens	85
5.4	"Superglue" specimens	85
5.5	Other specimen types	89
6.	<u>Laboratory processing of specimens</u>	89
7.	<u>Processing of histological samples</u>	90

8.	<u>DNA extraction</u>	91
9.	<u>Detection of β-globin gene</u>	93
10.	<u>Analysis of DNA</u>	
10.1	Restriction enzyme digestion.....	93
10.2	Polymerase chain reaction.....	94
10.3	<u>Separation of DNA fragments by gel electrophoresis</u>	95
10.4	<u>Transfer of DNA on to nylon membranes by Southern blotting</u>	96
10.5	<u>Labelling of probes, hybridisation and autoradiography</u>	97
10.5.1	Random priming method.....	97
10.5.2	End-labelling method.....	99
10.6	<u>Re-hybridisation of DNA</u>	101

RESULTS

1.	<u>Genital dermatosis study</u>	
1.1	Clinical features of the patients.....	102
1.2	Detection of HPV in relation to specimen type and to histopathological findings.....	102
1.3	HPV in biopsy specimens.....	103
1.4	HPV in urethral swab specimens.....	106
1.5	HPV in urine specimens.....	107
1.6	Association between presence or absence of HPV and type of specimen.....	107
1.7	HPV in relation to possible risk factors and demographic details.....	107

2. Resistant anogenital warts study

2.1	Clinical features of the patients.....	118
2.2	HPV in biopsies from anogenital warts.....	119
2.3	HPV in urethral swab specimens.....	119
2.4	HPV in urethral loop specimens.....	120
2.5	HPV in urine specimens.....	121
2.6	Association between location of warts at time of biopsy and HPV detected in the urethra.....	121
2.7	Association between HPV types detected in warts and in the urethra.....	121
2.8	HPV in relation to possible risk factors and demographic details.....	122

3. Urethral gonorrhoea study

3.1	Clinical features of the patients.....	127
3.2	HPV in urethral swab specimens.....	127
3.3	HPV in urine specimens.....	128
3.4	HPV in relation to possible risk factors and demographic details.....	128

4. Multifocal study

4.1	Clinical features of the patients.....	132
4.2	HPV in biopsy specimens.....	135
4.3	HPV in non-biopsy specimens.....	135
4.4	HPV in "Superglue" specimens.....	135
4.5	HPV in relation to sample site and time of sampling.....	136
4.6	Types of HPV detected.....	137
4.7	HPV in pairs of partners.....	137

5. Comparison of findings from different study groups

5.1	Detection of HPV in different sample sites.....	145
5.2	Association between HPV detected and patient details.....	146

CONCLUSIONS

1. <u>Introduction</u>	153
2. <u>Methods used in the studies</u>	155
2.1 Biopsy.....	156
2.2 Cytology.....	157
2.3 Superglue method.....	158
2.4 Other sampling techniques.....	159
2.5 Laboratory methods.....	159
3. <u>Genital dermatosis study</u>	160
4. <u>Resistant anogenital warts study</u>	164
5. <u>Urethral gonorrhoea study</u>	166
6. <u>Multifocal study</u>	168
7. <u>Implications of the findings</u>	
7.1 Methods.....	171
7.2 Multifocal infection.....	173
7.3 Infection with multiple HPV types.....	174
7.4 Role of sexual activity in the acquisition of HPV.....	174
7.5 Role of HPV in neoplasia.....	176
7.6 Concluding remarks.....	176
<u>REFERENCES</u>	179

APPENDICES

Appendix 1

Questionnaire - genital dermatosis study

Appendix II

Questionnaire - resistant anogenital warts study

Appendix III

Questionnaire - urethral gonorrhoea study

Appendix IV

Questionnaires - multifocal study

Appendix V

1. Selective medium for the growth
of Neisseria gonorrhoeae
2. Collection of samples
 - 2.1 Phosphate buffered saline
 - 2.2 Formal saline

3. DNA extraction

- 3.1 Summers buffer
- 3.2 SDS (Sodium Dodecyl Sulphate)
- 3.3 Lysis mixture
- 3.4 TE-equilibrated phenol

4. β-globin primers

5. Polymerase chain reaction

- 5.1 General primers
- 5.2 Areas of the L1 genome Amplified during the PCR
- 5.3 PCR Reaction mixture
- 5.4 Near full length genomic probes
- 5.5 Oligonucleotide probes

6. Separation of DNA fragments by gel electrophoresis

- 6.1 Tris-Borate EDTA (TBE) buffer
- 6.2 SSC (Saline Sodium Citrate)
- 6.3 Prehybridisation mixture
- 6.4 Random priming mixture
- 6.5 End-labelling mixture

Appendix VI

Publications derived from the work in these studies

Published papers

1. Hillman RJ, Harris JRW, Walker MM. Value of performing biopsies in genitourinary clinics. Genitourin Med 1991;67:73.

2. Hillman RJ Botcherby M, Taylor-Robinson D. Genital human papillomavirus lesions of the male sexual partners: the diagnostic accuracy of peniscopy. Genitourin Med 1991;67:522-3.

3. Anonymous. Persistent anogenital warts. Lancet 1991;338:1114-5.
4. Hillman RJ, Waldron S, Walker MM, Harris JRW. Granuloma annulare of the penis. Genitourin Med 1992;68:47-9.
5. Hillman RJ, Walker MM, Harris JRW, Taylor-Robinson D. Penile dermatoses: a clinical and histopathological study. Genitourin Med 1992;68:166-9.
6. Hillman RJ, Botcherby M, Ryait BK, Taylor-Robinson D. Detection of human papillomavirus DNA in the urogenital tracts of men with anogenital warts. Sex Transm Dis 1993;20:21-7.
7. Hillman RJ, Ryait BK, Botcherby M, Taylor-Robinson D. Human papillomavirus DNA in the urogenital tracts of men with gonorrhoea, penile warts or genital dermatoses. Genitourin Med 1993;69:187-92.
8. Hillman RJ, Ryait BK, Botcherby M, Taylor-Robinson D. Human papillomavirus DNA in the urogenital tracts of men with genital dermatoses: evidence for multifocal infection. Int J STD AIDS 1993;4:147-54.
9. Hillman RJ, Ryait BK, Botcherby M, Taylor-Robinson D. Changes in HPV infection in patients with anogenital warts and in their partners. Genitourin Med 1993;69:450-6.

Published abstracts

1. Hillman RJ, Hanna N, Botcherby M, Ryait BK, Harris JRW, Taylor-Robinson D. Asymptomatic urethral carriage of HPV DNA in men with anogenital warts. Abstract 257, 10th International Papillomavirus Workshop, Seattle, USA, July 20-26, 1991.
2. Hillman RJ, Ryait BK, Botcherby M, Taylor-Robinson D. Abstract 4, Spring Meeting of the Medical Society for the Study of Venereal Diseases, Zurich, Switzerland, May 6-9, 1993.

INDEX OF FIGURES

	<u>Page</u>
<u>Figure 1</u> : Condylomata acuminata.....	37
<u>Figure 2</u> : New cases of selected genitourinary conditions, England 1981 to 1991.....	39
<u>Figure 3</u> : Pyramid model.....	44
<u>Figure 4</u> : Skin snip biopsy technique.....	81
<u>Figure 5</u> : Removal of perianal warts by the electrodesiccator.....	82
<u>Figure 6</u> : Loop and swab used in urethral sampling....	84
<u>Figure 7</u> : Superglue dispenser.....	86
<u>Figure 8</u> : Removal of Superglue slide.....	87
<u>Figure 9</u> : Superglue sample.....	88
<u>Figure 10</u> : Agarose gel - penile dermatosis study.....	104
<u>Figure 11</u> : Southern blot - penile dermatosis study....	105
<u>Figure 12</u> : Agarose gel - multifocal study.....	133
<u>Figure 13</u> : Southern blot - multifocal study.....	134

INDEX OF TABLES

	<u>Page</u>
<u>Table 1</u> : Histopathological diagnoses of biopsy specimens from 100 men with genital dermatoses.....	109
<u>Table 2</u> : HPV DNA types detected in relation to histopathological findings of biopsy specimens from men with genital dermatoses.....	110
<u>Table 3</u> : HPV in relation to type of specimen from men with genital dermatoses.....	111
<u>Table 4</u> : HPV in relation to histopathological findings of biopsy specimens from men with genital dermatoses.....	112
<u>Table 5</u> : HPV in relation to type of specimen from all men with genital dermatoses.....	113
<u>Table 6</u> : HPV in relation to type of specimen from men with genital dermatoses and no histological evidence of HPV infection.....	114
<u>Table 7</u> : Correlation between presence (+) or absence (-) of HPV DNA and type of specimen from men with genital dermatoses.....	115
<u>Table 8</u> : HPV in different specimens in relation to possible risk factors of men with genital dermatoses..	116
<u>Table 9</u> : HPV in different combinations of specimens in relation to possible risk factors of men with genital dermatoses.....	117

Table 10: HPV in relation to type of specimen
from men with anogenital warts.....123

Table 11: Location of warts in relation to
detection of urethral HPV DNA from men with
resistant anogenital warts.....124

Table 12: Location of warts in men with
resistant anogenital warts in relation to
urethral HPV type.....125

Table 13: HPV in different specimens in
relation to possible risk factors of men with
resistant anogenital warts.....126

Table 14: HPV in relation to type of specimen
from men with urethral gonorrhoea.....129

Table 15: Single and multiple types of HPV
found in urethra and urine of men with gonorrhoea.....130

Table 16: HPV in different specimens in
relation to possible risk factors of men with
urethral gonorrhoea.....131

Table 17: Clinical, histological and cytological
details of female patients in multifocal study.....139

Table 18: Clinical and histological details
of male patients in multifocal study.....140

Table 19: HPV DNA in biopsy and non-biopsy
specimens from women in multifocal study in relation
to types of specimens and times at which taken.....141

Table 20: HPV DNA in biopsy, non-biopsy and SG specimens from men in multifocal study in relation to types of specimens and times at which taken.....142

Table 21: HPV DNA findings SG specimens from women in multifocal study in relation to types of specimens and times at which taken.....143

Table 22: HPV type in relation to types of specimens in multifocal study.....144

Table 23: HPV in relation to specimens taken and study group.....147

Table 24: HPV in biopsy specimens in relation to study group.....148

Table 25: HPV in urethral swab specimens in relation to study group.....149

Table 26: HPV in urine specimens in relation to study group.....150

Table 27: HPV in different specimens in relation to possible risk factors of men with genital dermatoses or urethral gonorrhoea.....151

Introduction

1. HISTORICAL BACKGROUND

1.1 Introduction

Although satirical writers in classical times appreciated the role of sexual activity in the spread of anogenital warts (AGW), there was widespread confusion extending to the modern period between the clinical manifestations of AGW, non-genital warts and condylomata lata¹. It was not until the 1950s², and more particularly the 1970s³ that the sexual transmissibility of AGW became widely accepted. Interest in this field was initially limited, perhaps as the disease was not perceived to have any significance other than cosmetic inconvenience. In the 1980s⁴ there was increasing evidence linking HPV infection and cancer, and this was associated with a marked increase in interest in human papillomavirus (HPV). Methodological and, in particular, technical, advances occurring in the 1980s were essential to the further development of the understanding of HPV.

1.2 The Greek and Roman periods

Descriptions of abnormalities which were probably AGW occur in the writings of the ancient Greeks and Romans^{5,6}, when the term "condyloma", literally meaning "round swelling adjacent to the anus"⁷ was first coined. Celsus, in the 1st century A.D. described different physical types of warts, including those occurring in the anogenital area⁸ and in the 2nd century A.D., Soranus wrote a chapter entitled "On warty excrescences in the female genitalia"⁹. By the 6th century A.D., special clinics had been established for the treatment of anal condylomata¹. Satirical lay writers frequently connected perianal warts with anal sexual intercourse⁷, although there are no remaining records of what the Greek or Roman physicians thought of the aetiology of AGW. Although some dispute still remains⁶, it seems unlikely that syphilis existed in Europe during the Greek and Roman periods, and thus confusion with condylomata lata probably did not occur.

1.3 The nineteenth and twentieth Centuries

In the Dark and Middle Ages, documentation was generally less precise than in the classical period, but some of

the genital lesions described may have been AGW⁶, and there are sporadic records linking AGW with sexual activity¹. Even during the periods of the Renaissance and the Enlightenment, however, there was much confusion between syphilis, gonorrhoea and AGW¹.

1.3.1 The non-specific irritant theory

From the early nineteenth century onwards, AGW had been attributed to genital irritation caused by secretions "disordered through venery"³, an idea which persisted until the middle part of the 20th century¹⁰. According to this theory, any irritant to the genital area could lead to the production of warts, thus apparently explaining the frequently observed association between gonorrhoea and warts. Even as late as 1942, Kaplan¹, when introducing the treatment of genital warts with podophyllin (which is still currently in use), felt that an irritating discharge was the most likely cause of the lesions. Infectivity was, however, difficult to explain with this hypothesis.

With the discoveries of the gonococcus, Haemophilus ducreyi and Treponema pallidum, interest developed in the concept that a specific causative organism might be involved in the development of AGW. Various organisms, particularly spirochaetes¹ were put forward as possible aetiological agents, but eventually it became clear that these represented commensals rather than pathogens.

1.3.2 The unitary theory

The infectivity of common warts was not realised fully until the end of the 19th century¹. Soon afterwards it was noted that the inoculation of extracts of skin warts from one site on the body into the skin of other parts of the body sometimes led to the production of plane or common warts at the sites of inoculation¹¹. The concept therefore developed that skin warts were caused by an infectious agent, which filtration experiments established to be of viral size. Genital warts were thus regarded by some as a special kind of wart, modified in appearance and structure by arising from the genital epidermis¹, but caused by exactly the same virus as that causing skin warts. This "unitary theory" was held at the same time as the non-specific irritation theory.

Support for the unitary theory¹² was based on the histological similarities between skin warts and AGW, the frequent coexistence of skin warts and AGW, the similar treatment modalities for skin warts and AGW and the observation that the incubation periods for skin warts and AGW are similar.

The unitary theory also gained support from inoculation experiments. Unfiltered^{12,13,14} and filtered¹ inocula from AGW were shown to lead to the production of skin warts elsewhere. However, there has been only one unsuccessful and one successful documented experiment^{1,13} in which filtered extract from AGW led to the development of

genital lesions in the recipient. In addition, there has been one anecdotal report¹⁵ of a lesion developing on the finger of a surgeon who pricked himself whilst operating on a patient with condylomata acuminata. There have been no successful experiments in which skin wart extracts (filtered or unfiltered) have induced genital warts following inoculation¹. Observed incubation periods were in the range 2¹/₂ to 11 months. None of the inoculation experiments, however, was properly controlled and they are unlikely to be repeated in view of ethical considerations.

1.4 The development of current concepts

In the mid-twentieth century, virus particles were seen using electron microscopy in samples from common¹⁶ and anogenital^{17,18} warts. However, it was not until 1971³, that AGW were clearly demonstrated to behave in a different epidemiological fashion from common warts, and the unitary theory was therefore seriously questioned. Shortly after this¹⁹, technological advances allowed the differentiation of wart virus types on the basis of DNA homologies. It then became clear that AGW were separate from, but related to other aspects of HPV infection.

It has proven extremely difficult to cultivate papillomaviruses in cell cultures, as they require actively differentiating cells within which to complete their life cycle. Recently, however, HPVs have been successfully

grown in keratinocyte lines grafted onto nude mice ²⁰ and in a collagen raft culture system containing cells derived from a CIN lesion ²¹. Furthermore, typical condylo-matous changes have been induced in heterografted human foreskin tissue by HPV type 11²². Thus, HPV type 11 has now been unambiguously identified as an inducing agent of condylomata acuminata.

Parallel to these developments in our understanding of the virology and epidemiology of HPV has been an evolution in our appreciation of the complexities of the interactions between papillomaviruses and their hosts. It has become increasingly apparent that infection with HPV is probably a necessary but not a sufficient factor in the development of AGW and a variety of other clinical conditions.

2. VIROLOGY

2.1 Viral structure

Study of HPVs has been hampered by several factors, such as the impossibility of passaging HPV through a non-human host, the inability to culture the organism in artificial media, the difficulty of infecting human cell cultures with HPV and the low concentration of viral particles in AGW.

The HPVs have an icosahedral structure with 72 capsomeres and an overall diameter of approximately 55nm²². The viral capsid is made up of a 53-59 kilodalton polypeptide (constituting more than 80% of total viral protein) and a 70 kilodalton polypeptide. The genome of HPV is complexed with histones²⁴ and comprises a circular, double-stranded, super-helical DNA molecule of approximately 8,000 base pairs²⁵ with a molecular weight of 5.2×10^6 daltons.

Papillomaviruses were classified initially with polyomaviruses (such as simian vacuolating virus 40 [SV40] and the human BK and JC viruses) as papovaviruses²⁶ on the basis of structural similarities. Genetically, however, there are marked differences between papillomaviruses and polyomaviruses²⁷ and there are also different

antigenic properties²⁸. Only one DNA strand of papillomaviruses is transcribed, whereas half of each strand of polyomavirus DNA is transcribed. Polyomaviruses produce a lytic infection, whereas papillomaviruses typically produce proliferative lesions. It is now therefore generally accepted that papillomaviruses represent an entirely separate group from polyomaviruses.

2.2 Species and site specificity

Papillomaviruses are found in a wide variety of vertebrates such as rabbits, hamsters, sheep, goats, deer, cattle, dogs, monkeys, amphibians, reptiles and birds²⁹. They are highly species specific²⁵, as well as being specific to certain anatomical locations. Furthermore, disease states associated with papillomavirus infections seem to be a particular problem of domesticated animals and polygamous animals³⁰. Because of the stability of the virions to heat and desiccation, communication need not necessarily involve direct contact. For instance, farm animals can acquire cutaneous infections through abrasions resulting from rubbing against contaminated fences³⁰. Direct comparison of nucleotide sequences from animal and human papillomaviruses³¹ suggests that the papillomaviruses infecting different animals are distinct from those infecting man, but that they have an evolutionary relationship. HPVs have only been found in humans and infect squamous epithelia of keratinizing and non-

keratinizing surfaces. They have been found in the skin and mucosae of genital, anal, urethral, oral and respiratory regions.

2.3 HPV types

A unique HPV type is defined by the occurrence of less than 50% cross-hybridization with all other known HPV types in a liquid-phase DNA hybridization assay³². Different types are numbered according to the order of discovery. Subtypes, for example HPV types 6a-f, are defined as being the same virus type (as recognised by liquid-phase hybridisation assays), but displaying polymorphisms with respect to sites of cleavage by restriction endonucleases²³. On this basis, 68 different genotypes of HPV have so far been reported³³. Evidence suggests, however, that there are probably several more to be identified.

The above classification system may need to be revised. The correlation between DNA liquid reassociation kinetics and base sequence is a complex one. Furthermore, transmission electron microscopy of DNA:DNA heteroduplexes suggests that there is much more homology between various types than is indicated by reassociation kinetic studies³⁴. An example of the difficulties of the current classification system is illustrated by HPV types 6 and 11. These two HPV types show an overall nucleotide sequence homology of 82%, yet give a value of 25% hybridi-

sation in liquid reassociation kinetic reactions³⁵. A new classification based on less than 90% sequence homology in the open reading frames E6, E7 and L1 has recently been introduced in an attempt to adopt a more meaningful approach to the classification of HPV types³³.

Diversity of papillomavirus types does not appear to be due to a high mutation rate of the viral genome. The DNA sequences of given types of virus have appeared stable over a wide range of geographic locations and after decades of propagation in immortal cell lines³⁴.

2.4 The Genetic Structure of HPV

Recombinant DNA genomes have been constructed with the plasmid vector pBR³²² in Escherichia coli K-12²³ enabling the study of the structure and function of the genomes of various papillomaviruses. Most of the initial experiments on papillomaviruses were based on cellular transformation assays with bovine papillomavirus (BPV), but more recent work has given us considerable information concerning the functions of the various components of the human papillomavirus genomes.

The genome of papillomaviruses is very conserved and has been divided into "early" and "late" regions on the basis of the stage in the life cycle at which the different genes are expressed. Evidence suggests, however, that these terms are oversimplifications, but they have been retained for largely historical reasons.

2.4.1 E (Early) Region

The Early region contains 5 - 7 open reading frames (ORFs) encoding transformation, replication and regulation functions. These genes are expressed soon after infection, and prior to the initiation of DNA replication. E3 and E8 are not found consistently in all papillomaviruses, and probably do not represent coding sequences.

E1 is the longest and best conserved viral gene product amongst the papillomaviruses³⁶. It is the main viral replication protein.

E2 is a viral transcription regulator.

E1 and E2 control viral replication by forming a complex which binds DNA at the origin of replication³⁶. In contrast to BPV, E2 represses transcription of E6 and E7 proteins³⁷.

E4 is expressed late in the replicative cycle (despite its name), but is not incorporated into the virions. In HPV 1-induced lesions, E4 proteins are amongst the most abundant viral proteins found in the cytoplasm of stratified keratinocytes, and may play a role in virus maturation. E4 proteins act by binding and disrupting certain cytokeratins³³ allowing the release of formed viral particles³⁸.

E6 and 7 proteins are necessary and sufficient for immortalisation of human keratinocytes in vitro³⁹. Regulation of expression of E6 and E7 appears to be at the transcriptional level, by control of the initiation of their mRNAs, and yet both E6 and E7 proteins function as transcriptional transactivators³⁶. E6 proteins of HPV 16 and 18 complex the cellular p53 protein, which leads to accelerated degradation of p53⁴⁰⁻¹. HPV 16 E7 binds to retinoblastoma protein⁴² and the cell regulatory proteins kinase cdk2 and cyclin A⁴³. The levels of E6 and E7 proteins expressed in infected cells may thus be important in oncogenic conversion.

2.4.2 L (Late) Region

Late genes are expressed later in the viral life cycle and are usually involved in the maturation of viral particles. The late region contains 2 ORFs encoding the major and minor viral capsid proteins.

L1 This ORF contains sequences which are conserved in all papillomaviruses and codes for the major 55 kilodalton capsid protein.

L2 This ORF codes for a minor structural protein. It has been proposed that the L2 polypeptide represents type specific antigen, but this has yet to be verified with DNA sequencing work³³.

The URR (also known as the long control region) contains transcription regulatory sequences, plasmid maintenance sequences and the origin of replication⁴⁴. The non-coding region is an 800 base pair length of DNA containing promoter and enhancer elements⁴⁵.

2.4.3 Nucleotide Homology

All papillomaviruses share some nucleotide sequences. The most conserved areas are the carboxyl terminal half of E₁, the N and C terminal ends of E₂, and L₁. The least conserved areas of the genome are the regulatory region, E₄, E₅ and L₂.

2.5 Genitotropic HPVs

At least 27 different HPV types have been isolated from benign and malignant anogenital lesions³³. HPV 6, 11 and 42 are the types most frequently found in condylomata acuminata⁴⁶, with types 6 and 11 accounting for 80-90% of all clinically apparent lesions⁴⁷. Other types found in condylomata acuminata include HPV 44, 51, 53, 55 and 67³³. HPV types 16, 18 and 33 are most frequently found in cervical neoplasia⁴⁶. Other types found in intraepithelial neoplasia in the anogenital region are HPV 6, 11, 30, 31, 34, 35, 39, 40, 42, 43, 45, 51, 52, 56, 57, 59, 61, 62 and 64³³. HPV types 6, 11, 16, 18, 31, 33, 35, 39,

45, 51, 52, 54, 56 and 66 have been found in carcinomas of the anogenital region³³.

The DNA of a few HPV types has been found integrated with host cell DNA⁴⁸⁻⁹. Based on these integration properties and the frequency of detection in benign lesions or invasive carcinomas, HPV types have been classified⁵⁰ as "low-risk" (e.g. types 6 and 11) and "high-risk" (e.g. types 16 and 18).

2.6 Multiple HPV infections

Patients with evidence of HPV infection at one anogenital site frequently have infection at other anogenital⁵¹⁻³ and non-anogenital sites⁵⁴. Furthermore, there is evidence that infection with one viral type does not confer resistance to others²⁷. Individuals may therefore have infections with two or more HPV types, sometimes in the same lesion⁵⁵⁻⁶⁰. However, there is some evidence⁵⁸ that infection with one HPV type is rarely associated with concurrent active infection by a second viral type.

3. IMMUNOLOGY

3.1 Introduction

The human immune system responds to infection with HPV by mounting a humoral and cellular response. The result of that interaction may be any combination of clinically manifest disease, subclinical infection, or most commonly,⁶¹ the induction of latency. Furthermore, the stability of any latency may be disrupted by the induction of immunological dysfunction. In addition, the chronicity of HPV infection in immunocompetent hosts suggests that there may be a problem with papillomavirus antigen presentation to the immune system, or a failure of the immune system in recognising HPV-infected cells.

3.2 Immunohistological considerations

Infection with HPV is thought to be restricted to the epithelium, as virus particles appear incapable of penetrating the basement membrane. Mononuclear cell inflammatory infiltrates are the major morphological feature in regressing plane warts⁶² caused frequently by infection with HPV 4, but are not seen routinely in other types of regressing warts. Some of the components of these infiltrates are discussed below.

3.2.1 Langerhans' cells

The first line of defence against HPV infection is thought to be the Langerhans' cells, which are intra-epithelial dendritic antigen presenting cells (APCs). Langerhans' cells can be subdivided according to the markers present on their surfaces (for example T6, ATPase, MHC II and S-100)⁴⁴. Their functions are to process and present a variety of cutaneous antigens, and they are capable of activating primary T cell responses.

Most studies suggest that there is a significant decrease in the concentration of Langerhans' cells in cervical condylomata and CIN lesions⁶³⁻⁴. This reduction applies to all Langerhans' cell subpopulations examined⁶⁵ and is more significant in HPV 18-infected lesions compared with HPV 16-positive lesions⁶⁴.

It has been observed⁶⁶ that Langerhans' cells expressing HLA-DQ are diminished in warty tissue, compared to those expressing HLA-DR. As HLA-DQ is needed for the presentation of antigens to T-cells by macrophages, a reduction in the level of such Langerhans' cells was proposed as a means to explain persistent infection with HPV. However, it is currently unclear whether the reduced Langerhans' cell concentrations are the cause or the effect of persistent papillomavirus infections.

3.2.2 T lymphocytes

T4 (helper/inducer) cells and T8 (suppressor/cytotoxic) cells comprise the main immune response to tumours and virally infected cells. In one report, reversed T4/T8 ratios were found in the peripheral blood of patients with condylomata⁶⁷, and such a ratio has also been shown in the condyloma tissue itself⁶⁵.

Intra-epithelial T cells with γ δ receptors may also have a role in the recognition and elimination of HPV-infected keratinocytes.

3.2.3 Natural killer cells (NK cells)

NK cells are not normally present in the epidermis, but there is some evidence⁶⁶ to suggest the presence of markers consistent with their presence in condylomata acuminata. This would therefore support the suggestion that NK cells may be involved in the host response to HPV infection.

3.2.4 Keratinocytes

HPVs infect but do not kill keratinocytes. HPV replication depends on keratinocyte differentiation and it has therefore been postulated⁶⁸ that, as only complete viral particles are assembled in terminally differentiating keratinocytes, the majority of potential viral antigens

are only found relatively distant from, and less accessible to the immune system. The more accessible suprabasal layer only contains free HPV DNA, which is considerably less antigenic than complete viral particles.

Keratinocytes have been shown to be immunocompetent cells and to produce immune regulating cytokines that are likely to have a stimulatory effect on Langerhans' cells⁶⁸. HPV infection of the keratinocytes may alter this function and possibly cause a reduction of cytokine production that may, in turn, lead to decreased stimulation of Langerhans' cells and may explain why HPV infected tissues become depleted of Langerhans' cells. Thus the consequences of keratinocyte infection may possibly instigate the first step in a suppressive immune modulation.

T helper cells are not activated by HPV-infected keratinocytes, as these express no MHC Class 2 molecules⁶⁹. Furthermore, T helper cells do not recognise papillomavirus proteins presented by the local professional APCs, as epithelial cells are not killed by HPV infection and no papillomavirus particles or proteins are released, to be taken up by APCs. It can therefore be seen why HPV infection may fail to elicit an immune response. In this model, destructive therapy for HPV lesions facilitates the phagocytosis of disrupted HPV-infected cells by scavenging macrophages and papillomavirus proteins are thus presented to the immune system.

Cytotoxic effector T cells will recognise papillomavirus derived peptides on the surface of keratinocytes in

the context of MHC Class 1 molecules, but without any of the second signals for T cell activation from the keratinocytes, APCs or T helper cells. Effector T cells may therefore ignore the papillomavirus antigen-displaying keratinocytes, or be rendered tolerant⁷⁰.

In vitro studies have shown proliferation of peripheral blood T cells from normal individual in response to HPV 16 E6 and L1 proteins, thus demonstrating the antigenicity of these proteins⁷¹. It is currently unclear whether such proteins are also immunogenic, i.e. whether they are presented to the immune system.

3.3 The humoral immune response

Whilst cell-mediated immunity does seem to be important in the course of HPV infection, the role of humoral immunity is less clear. For example, patients with common variable immunodeficiency (a disease characterised by a failure of antibody production and only rarely a T cell deficit) are not especially prone to warts, unlike, for example patients with human immunodeficiency virus infection. Many of the early studies, however, were limited by poor antigen specificity, impure antigen sources, small quantities of antigen available and low assay sensitivities.

Several lines of evidence⁴⁴ suggest that the major capsid protein contains type specific epitopes on the virion surface and type common epitopes hidden within the

virion. Antisera raised against the L2 proteins also tend to react in a type-specific manner.

Circulating antibodies in genital HPV patients are principally to L1 and E4, E6/7 and E2 (in that order). Such antibodies are also detected in individuals without overt signs of disease (although presumably with sub-clinical infection)⁷²⁻³.

Unfortunately, no study to date has demonstrated a rising titre to any papillomavirus antigen following acute infection. Furthermore, serological positivity is often less than 50% in populations known to be infected with a specific HPV type.

4. DIAGNOSTIC TECHNIQUES

4.1 Introduction

Different techniques measure different aspects of the host-virus interaction with varying degrees of accuracy. There is currently no accepted "gold standard" for the detection of HPV. All methods have differing sensitivities and specificities and may be appropriate to use in differing circumstances. Varying estimates of the prevalence of HPV among healthy and diseased groups may be explained, at least in part, by differing abilities of different laboratories to detect and type HPV in given samples⁷⁴. Whatever the method used, it is important to bear in mind that a negative result from one sample is not necessarily indicative of the absence of HPV infection, in view of the focal nature of such infections. Furthermore, there may be fluctuations in the shedding of viral particles with time⁵⁰.

4.2 Clinical examination

Clinical examination with the unaided eye is the oldest diagnostic technique. Unfortunately, however, there is still no universally agreed terminology, with terms often not defined. In particular, the term "condylomata acuminata" is frequently used interchangeably with "anogenital warts". The classification system used in this thesis is

based on that of Oriel⁷⁵.

Classical condylomata acuminata are the most characteristic and most easily recognised clinical manifestation of infection of the anogenital region with HPV, although care has to be taken to avoid confusion with lesions such as condylomata lata. The naked-eye detection of condylomata acuminata formed the basis of epidemiological studies of anogenital HPV infection until the development of sophisticated laboratory-based techniques. Most condylomata acuminata are visible to the naked eye, although a hand lens or colposcope can significantly increase the number of lesions seen.

Sessile warts are macular or slightly elevated papular lesions which are most commonly seen on the shaft of the penis, but are also occasionally found elsewhere in the anogenital region. Verrucae vulgaris are hyperkeratotic warts which are normally found in the non-anogenital areas of the body, but which may also occur in the anogenital region⁷⁶⁻⁷.

4.3 Subclinical HPV infection

Subclinical HPV infection can be detected only by the use of special techniques, most commonly the application of 3-5% acetic acid followed by microscopic examination. Subclinical HPV infection can be found either alone or in association with other manifestations of HPV infection. For example, in one study of 51 men⁷⁸, 45 of them were found to have histological evidence of HPV infection in

biopsies obtained using a colposcope, but only 8 of these had epithelial changes which were visible to the unaided eye.

4.4 Colposcopy

"Colposcopy" was the term initially used to describe the examination of the female genital tract using a microscope, often following the application of acetic acid. Colposcopy has become an established technique for the investigation of the uterine cervix and gradually the term has been extended to include the microscopic examination of the whole female anogenital tract. The terms "peniscopy"^{52,79}, "androscope"⁸⁰⁻¹, "magnified penile surface scanning"⁸², "penoscopy"⁸³⁻⁴, as well as "colposcopy"^{78,85-9} have been used to describe examination of the male anogenital tract with the aid of a microscope.

The development of visible ("acetowhite") abnormalities following the application of acetic acid to an area of epithelium is due to hypercellularity, protein coagulation⁹⁰ and the predominance of nuclei in atypical cells⁹¹. The sensitivity and specificity of this technique depends on the operator and on the area studied. Well defined criteria have now been established for the interpretation of acetowhite changes of the cervix⁹². Abnormalities of epithelial surfaces of the external anogenital region which may turn acetowhite, therefore, include areas of inflammation such as folliculitis, psoriasis, eczema, candidiasis, chronic pruritus with

lichenification, molluscum contagiosum, microtrauma from recent intercourse, as well as HPV-related lesions^{57,80,82,90,93-4} and penile intraepithelial neoplasia^{57,95}. Lesions such as haemorrhoids, skin tags and naevi do not produce acetowhite changes⁸⁰. The specificity of this technique when applied to the male genitalia is generally low^{52,93,96-7}, especially for scrotal lesions⁹⁷. Although predominantly applied to the genitalia, acetic acid staining has also been used in the evaluation of other HPV-induced lesions, such as juvenile laryngeal papillomatosis⁹⁸. Even in experienced hands colposcopy, together with the application of acetic acid, may fail to detect infected areas, and it is incapable of differentiating between infection with different HPV types.

4.5 Histopathology

The processes involved in the development of histological changes associated with infection with HPV are poorly understood. Infection with HPV type 6 is histologically indistinguishable from infection with other HPV types⁴⁷. Furthermore, the detection of histological changes in infected tissue appears to be an insensitive index of infection, as histologically normal tissue has been found to contain HPV DNA⁹⁹.

Infection with papillomaviruses requires direct physical access to the basal cells, and it is speculated that establishment of infection may depend on activation of cell division during healing. The "transformation zone"

between columnar and squamous epithelium in the cervix (and also the nasal mucosa, larynx and at the border of healing wounds) is highly susceptible to the mucosotropic viral types³⁰. This concept is supported by the observation that condylomata acuminata tend to occur in areas submitted to trauma during sexual intercourse. It is postulated that trauma may induce multiple epithelial fissures on sites submitted to a high degree of friction, thereby facilitating virus introduction¹⁰⁰.

Free viral DNA precedes capsid formation and is found in the suprabasal layer of infected epithelia. Complete virus particles are found in the more superficial granular and corneal layers, eventually being shed into the environment with the keratinocytes¹⁰¹. Furthermore, it is believed that viral replication depends on keratinocyte differentiation.

Papillomaviruses induce warts, which are localised lesions with many different morphological and histological manifestations. Hyperplasia, a frequent finding of epithelia infected with papillomaviruses, may result from a combination of accelerated cell division of the basal cells and delayed maturation of the superficial keratinocytes, protracting their transit time to the surface. Some types of warts remain strictly benign, with the dividing cells confined as usual to the basal monolayer. Others can become dysplastic to varying degrees, and may exhibit nuclear atypia with continued viral replication and division of suprabasal cells, abnormal mitoses, and possible shifts in the chromosomal ploidy. In addition,

some papillomavirus lesions can progress to carcinoma in situ, and ultimately penetration of the basement membrane and frank carcinoma with metastases.

The expression of genes from regions of the viral genome which encode non-structural polypeptides probably result in an altered response of germinal epithelial cells to the factors that regulate their numbers and the frequency of their division²⁵. Furthermore, viral replication interferes with the terminal differentiation of the host cell¹⁰² and provokes cytopathic effects which seem to depend on the virus type. In the genitotropic HPVs, this effect is characterised by the perinuclear vacuolation of koilocytes. The presence of koilocytosis, reflecting a cytopathic effect of productive HPV infection, is regarded by many⁵⁷ as a pathognomonic light microscopic sign of biological activity of HPV. This marker correlates best with classical condylomata acuminata and is less consistently present in non-condylomatous manifestations of HPV infection^{99,103}.

4.6 Exfoliative cytology

Exfoliative cytology for the detection of HPV infection is used most commonly for uterine cervical lesions, but it has also been used in investigating the urethra, vagina, anus and external genitalia. The main advantage of this technique is that it is possible to sample from a larger area than is usually practicable by biopsy. It is based on the assumption that the koilocyte is pathogno-

nic of HPV infection. Exfoliative cytology does, however, have a low sensitivity⁴⁷, is unable to differentiate infection between different HPV types, and depends on the ability to reliably sample from the appropriate area.

4.7 Latent infection

Latent infection has been defined⁵⁰ as HPV infection which cannot be detected by the commonly used diagnostic procedures of clinical inspection, colposcopy, Papanicolaou smear and punch biopsy. Many microbiologists, however, use the term "latency" to indicate the presence of the virus, but with no evidence of any associated histological change. Latency may represent the most common clinical outcome of infection¹⁰⁴. The reservoir of viral DNA in infected but clinically normal epithelia is thought to be the basal cell layer, since these are the only cells in the epithelium that divide³⁰.

4.8 The Polymerase Chain Reaction (PCR)

The development of the PCR has been described as one of the most substantial technical advances in molecular genetics in the past decade¹⁰⁵.

4.8.1 Technique of the PCR

The primers used in the PCR are two single-stranded oligonucleotides which are synthesised to be complementary to known sequences of the target DNA. They define

the two ends of the stretch of DNA to be amplified. The two primers must not anneal to one another, and their sites of annealing to the target DNA must be sufficiently apart to allow the subsequent synthesis of new products. The most commonly used primers in HPV work are chosen in the L1 ORF of the HPV genome, and these were used in the studies presented in this thesis. These primers are consensus primers with which a large spectrum of HPV types can be amplified. However, problems may arise in the investigation of tumours with these primers, as this region may not be integrated into the host genome. Thus, E6 ORF or E7 ORF might be appropriate for the investigation of carcinomas, although the range of HPV types which can be detected by this system is more restricted compared to studies using consensus primers.

The PCR method is based on the repetitive cycling of three reactions. The first reaction is the denaturation of the target double-stranded DNA, where heat is used to break the hydrogen bonds which link the two complementary strands of DNA. Next, the extremely specific step of primer annealing occurs, when the two primers bind to flanking sides of the region of interest. Finally, DNA synthesis is initiated using heat stable Taq polymerase. In this step, each annealed primer is extended in the presence of excess deoxynucleotide triphosphates and a new single strand of DNA is synthesised from each annealed primer. Each new strand consists of the primer at its 5' end, trailed by nucleotides sequences which are complementary to those of the corresponding template. The

three reactions are then repeated, first by raising the temperature, so that all double-stranded DNA is converted to a single-stranded DNA, thus aborting any on-going polymerisation. In this manner, the newly synthesised products are then used as templates for new primer-extension reactions (i.e DNA synthesis), thus resulting in a geometric amplification of DNA products. It is the combination of this geometric amplification, together with the extremely high specificity of the annealing step which give PCR its high sensitivity in detecting target DNA. Typically 30-40 cycles are repeated. The "long products" produced during the first amplification step have 3' endings of variable lengths. However, when these fragments take part in the next round of amplification, "short fragments" are produced which exactly complement the initial region of interest. During subsequent amplification cycles, the short fragments increase geometrically, whereas the long fragments increase merely arithmetically. Thus, after, say, forty amplification cycles, the number of long fragments present in the reaction mixture is vanishingly small when compared to the number of short fragments.

4.8.2 Advantages of the PCR

The principal advantage of the PCR is its sensitivity. Theoretically, the amplification process of the PCR can increase the number of DNA strands exponentially to 2^n , where n is the number of cycles. It is thus possible to amplify specific sequences more than a million-fold in

only a few hours¹⁰⁵ and potentially detect one copy of a target sequence in a given sample¹⁰⁶⁻⁸. Although initially requiring highly skilled operators and specialised materials, increased automation and greater availability of primers has meant that the technique has become more widespread and costs per assay have diminished. Furthermore, as the product may be generated in large quantities, it is possible to use a range of detection systems as well as radio-labelling.

4.8.3 Disadvantages of the PCR

The main problem with the PCR is contamination. Unwanted, cross-reacting DNA may confound the reaction conditions as a result of contamination at any stage, from the initial taking of clinical samples to the final examination of the results. Contamination can be minimised by the careful collection of clinical material, the physical separation of reactions occurring before and after the PCR, the use of positive displacement or disposable pipettes and the repeated use of positive and negative controls throughout the experiments. In addition, the use of anti-contamination primers and the "wipe" test may be helpful¹⁰⁹⁻¹⁰. A further aspect of the PCR is that it gives no information on the host response to the presence of the virus. Careful standardisation, quantification of the amounts of HPV detected, and quality control of the PCR are all needed before this technique can safely be used in epidemiological studies concerned with the transmission and natural course of genital HPV infections.

A particular problem associated with the use of consensus primers is the preferential amplification of one particular HPV type, thus resulting in a significant underestimation of the incidence of multiple infections.

The absence of a "gold standard", and the lack of availability of established external quality controls indicate that caution should be adopted when interpreting results.

4.9 Southern blotting with hybridisation

In Southern blotting¹¹¹, electrophoretically separated denatured DNA on an agarose gel is transferred and fixed to a membrane. The DNA is then hybridised with a labelled HPV probe. The sensitivity of this process, is between 0.1 and 0.01 HPV genome copies per cell, depending on the amount of cellular DNA and specific activity of the probe³³. In combination with the PCR, it is theoretically possible to detect one viral genome per specimen.

Southern blot DNA hybridisation techniques are generally regarded as the most accurate means of detecting and typing HPV in biological samples¹¹², and come closest to the "gold standard" in HPV work⁷⁴. However, when the same samples are analysed even by experienced laboratories⁷⁴, there may be significant discrepancies both in terms of which specimens are regarded as being positive for HPV, and for which type. Unfortunately for routine diagnostic work this technique is too time consuming and labour intensive.

4.10 Other techniques

A variety of other techniques has been used to determine the presence of HPV in tissues. None of these has the combination of sensitivity and specificity offered by the PCR in combination with Southern blotting with hybridisation³³.

Electron microscopy allows the localisation of particles in tissue samples to be detected, but cannot differentiate between HPV type and can only reliably detect fully formed viral particles.

Antigen detection depends on the binding of specific, labelled antibodies to viral antigens. Initial problems with the specificity of antibodies have now been overcome by the use of genetic engineering techniques. The late structural proteins were the first HPV antigens to be detected, but it is now possible to detect early HPV antigens such as E4, E6, and E7 by a variety of techniques including immunofluorescence and radioimmunoprecipitation.

Problems with serological methods have arisen because of the lack of specificity of the early detection systems¹⁰¹. Furthermore, it is currently not clear to what extent (if any) local infections with HPV generate systemic antibody responses.

5. EPIDEMIOLOGY OF ANOGENITAL HPV INFECTION

5.1 Introduction

Information concerning the major epidemiological parameters, such as length of incubation period, efficiency of transmission, virus reservoirs outside the genital tract, and non-sexual transmission of HPVs is limited. In particular, there is a paucity of well-controlled partner studies, where both sexual partners have been examined, treated and properly followed up. Reasons for this restricted amount of information include the considerable morphological variation of clinically apparent lesions³, the large proportion of lesions undetectable to the naked eye⁸⁵ and the previous low level of interest in this infection. Further problems in our understanding of the epidemiology of HPV infections have arisen in light of recent observations from longitudinal studies that HPV infection presents a constantly changing clinical picture⁵⁰, with clinically apparent, subclinical and latent infection being found in the same patient over a period of months. Technical difficulties compound these problems, as we have no reliable in vivo or in vitro technique for assessing the infectivity of HPV¹¹³, and the

presence of infectious virions cannot be inferred as a result of finding viral DNA. Epidemiological and technical factors may thus explain some of the widely differing incidence and prevalence figures reported for infection of the anogenital area with HPV¹⁰⁴.

More information is available concerning the epidemiology of anogenital HPV infections in women than men. There are several reasons for this. Firstly, as part of screening programmes for cervical carcinoma, large numbers of cervical scrapes are taken from wide cross-sections of the population. The collecting spatula or the resulting slide stained by the Papanicolaou method can be relatively easily examined for the presence of HPV DNA. Secondly, the rapid expansion of colposcopy services has generated large numbers of biopsy specimens which are ideally suited for HPV studies. In comparison to women, men have lower rates of anogenital cancer and lack a standardised, readily applicable method for sampling the anogenital region. Furthermore, there is no male counterpart of the cervical screening and colposcopy services for women. For these reasons, much of the information concerning the epidemiology of anogenital HPV infections has been obtained from women. Differences in infectivity, persistence and susceptibility of the genital epithelium to HPV-induced transformation between men and women may explain differences in the epidemiology between men and women¹¹⁴⁻⁵.

The development of such concepts as the "high risk male", the sexual transmissibility of HPV, and evidence

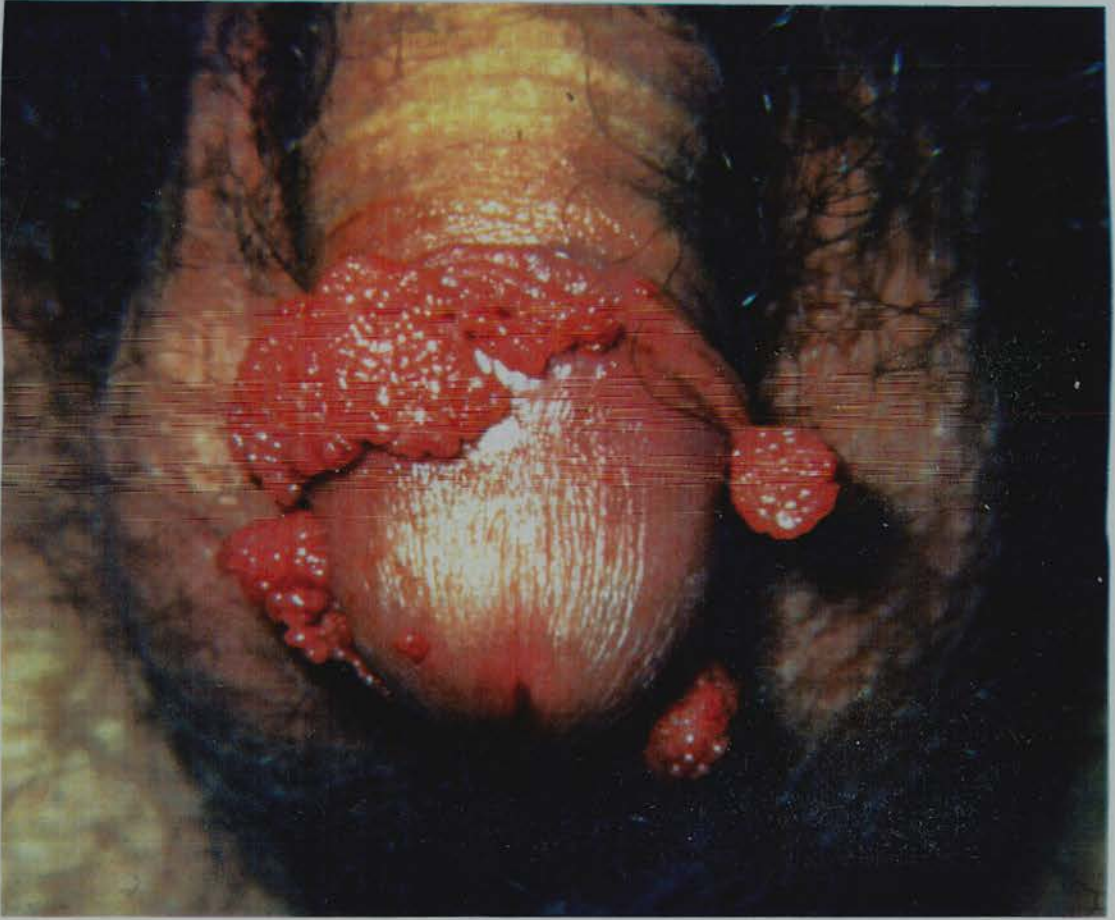suggesting a role for HPV in the development of penile dysplasia and cancer means that the epidemiology of HPV in the male anogenital tract warrants serious consideration. This review will therefore also particularly concentrate on the epidemiology of HPV infections in the male anogenital region.

5.2 Anogenital warts

The term condylomata acuminata and AGW are sometimes used synonymously, yet other warty lesions without the typical appearance of condylomata acuminata (Figure 1), such as verrucae vulgaris (flat keratotic plaques) and planar (papular) warts, may occur on the anogenital area⁷⁶⁻⁷ in a similar distribution⁷⁷. It is currently unknown whether the HPV types and epidemiology of verruca vulgaris and sessile warts of the anogenital area are identical. Some evidence¹¹⁶ suggests that clinical appearance is not a particularly helpful indicator of HPV type. Oriel¹¹⁷ has suggested that verruca vulgaris of the anogenital area may arise as a result of transfer of virus particles from the hands, although he presents no evidence in support of this contention.

There are currently no accepted methods for the description of type and estimation of size of AGW, making comparison between studies difficult. It is easy to overlook small warts on naked eye examination, and microscopy often reveals previously missed lesions.

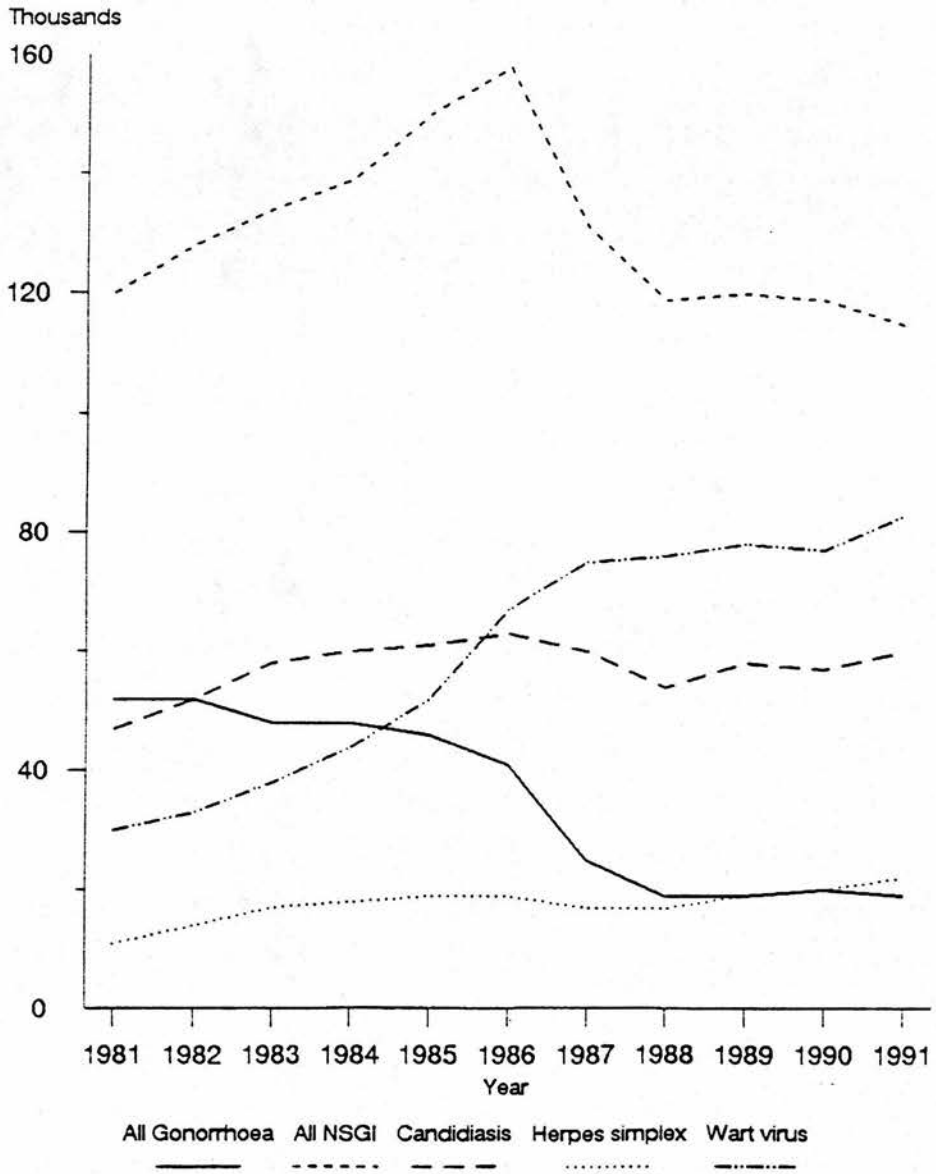
Figure 1



Condylomata acuminata

In the United Kingdom, condylomata acuminata are not a reportable communicable disease, although are reported to the Department of Health (DoH), and have been separately recorded as new or recurrent cases from 1988. These figures only represent cases presenting to genitourinary clinics, and therefore omit those managed by general practitioners and other medical specialities, and those which do not present clinically at all. Despite these problems, however, the DoH figures are generally regarded as the most reliable estimate available. In 1980, 17,930 men and 10,246 women attended GU medicine departments in England with genital warts. In 1990, the corresponding figures were 45,705 and 32,935, representing an overall increase of 358% over the ten year period¹¹⁸. The relationship of new cases of selected genitourinary conditions, including AGW, with time is illustrated in Figure 2¹¹⁹. It is unclear whether presenting behaviour has altered over this period, although anecdotal evidence from the clinic would suggest that patients, in the wake of STD education programmes have become increasingly aware of the potential importance of AGWs, and thus perhaps more likely to present¹²⁰. Furthermore, there is a suggestion¹²¹ that HPV infections of the genital tract are occurring at an earlier age. A similar increase in the numbers presenting with AGW has occurred in other Western countries^{32,104,122-6}. Unfortunately, however, few data exist as to the true incidence and prevalence rates of HPV infections in unselected populations⁵⁰.

Figure 2



New cases of selected genitourinary conditions,
England 1981 to 1991

It has been estimated in the United States that 0.1% of the general population¹²⁷, 0.5% to 1% of sexually active adults¹²⁷, 1% of women attending a student health clinic³⁴, 1.5% of obstetric patients¹²⁸ and 10% of STD clinic attenders³⁴ have AGW. In the United Kingdom the estimated prevalence of AGW in the general population is 0.05%¹²⁷. Of the 634,000 new cases attending genitourinary clinics in England in 1991, 83,000 (13%) had a new diagnosis of AGW¹¹⁹.

AGW typically occur at sites subjected to trauma during intercourse^{3,77,129-30}. In the male, the majority of lesions occur within the preputial sac⁷⁷, although the whole anogenital area may be affected⁷⁶. Early reports² that warts are more common in uncircumcised men have recently been challenged¹³¹. Men are often unaware of warty penile growths even if they are overt⁸⁸. The results of one study¹³² suggest that AGW are more common in whites than blacks, but it is unclear whether this is a true reflection of the epidemiology of AGW, or is related to different presenting behaviours.

5.3 HPV DNA and AGW

HPV DNA has been detected in 69⁵⁹ - 100%¹³³⁻⁴ of biopsies from AGW. The failure to detect HPV DNA in some AGW specimens may be explained in terms of technical problems or limitations, viral copy number below the detection limit of the assay system, and the possibility of infection with HPV types other than those tested for. In

addition, care should be taken to use a probe reflecting the part of the genome which likely to be integrated.

The commonest HPVs found in AGW are types 6 and 11, accounting for 34⁹⁴ - 100%^{77,135}, with HPV 6a the most common subtype¹³⁰. As HPV types 6 and 11 have an overall nucleotide sequence homology of 82%³⁵, even under high stringency conditions, cross-hybridisation may occur and so one must be cautious in assigning separate infection with these agents. HPV types 16, 18^{59,133}, 31^{134,136} and 33⁹⁵ are found occasionally in AGW, often in association with dysplasia⁷⁷. HPV 42 has been found in association with benign⁹⁵ and dysplastic⁵⁷ penile lesions. Infections with multiple HPV types occur^{77,133}. There is some evidence of geographical variation of HPV types found in AGW¹³⁰. HPV type may also depend on sexual orientation as HPV type 11 appears to be more common in the male homosexual population, possibly reflecting a greater predilection for anal mucosal infection⁵⁹.

There is conflicting evidence of possible associations between clinical appearance⁷⁷, anatomical location of the wart¹³⁰, light microscopic findings^{77,134}, response to treatment¹³⁷ and HPV type. HPV 6 may predominate in condylomata acuminata and papular lesions⁷⁷ whereas HPV 16 is more commonly found in papular lesions⁷⁷. HPV 6 seems to be relatively evenly distributed in AGW of the male⁷⁷, although some evidence¹³⁰ suggests that HPV 6a predominates in preputial sac lesions, including intra-meatal warts. HPV 11 may predominate in the coronal sulcus⁷⁷ and in more proximal lesions¹³⁰. Sessile warts

may be more likely to have dysplastic microscopic appearances⁷⁷.

5.4 Non-condylomatous clinically apparent HPV infection

Itch, burning and dyspareunia of the vulva have been reported in association with HPV infection¹³⁸⁻⁴⁰. In the male genitalia, HPV infection has been associated with balanoposthitis^{57,93,97,141}, although some reports⁵² suggest that non-condylomatous genital HPV lesions are rarely symptomatic. The epidemiology of these conditions is not known.

5.5 Subclinical and latent infection

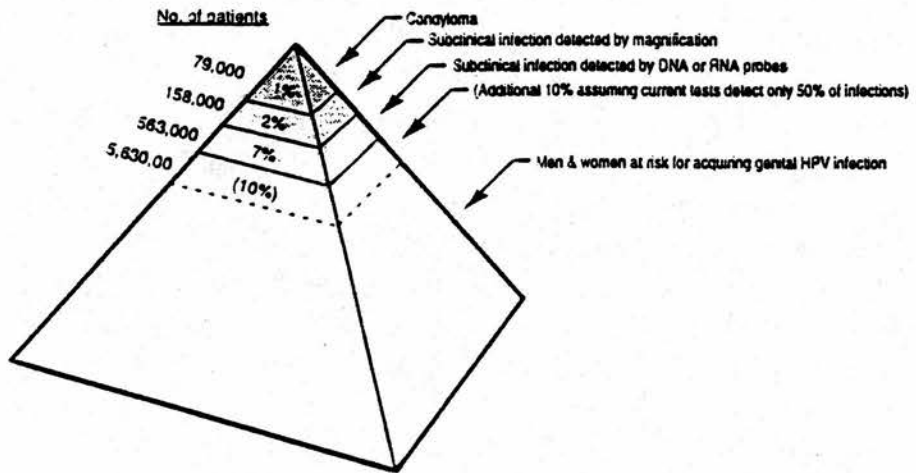
Many anogenital HPV infections are not visible to the naked eye^{76,95} and it has been estimated that genital warts may represent only 1%¹⁴² to 10%³⁴ of the total spectrum of genital HPV infections. The difference between these high rates of carriage of HPV and the relatively infrequent occurrence of clinical disease has been explained by the "pyramid"⁵⁰ or "tip of the iceberg"⁵⁷ concepts in which clinically overt disease is regarded merely as the tip. Below the tip is a much larger layer of individuals with clinically occult disease, but virological evidence of infection with HPV. At a lower level still of the pyramid is a large number of healthy individuals. Exchange between the layers of the pyramid occurs at an unknown rate in an unknown proportion of

individuals. Based on these data³⁴, the corresponding figures for England are given in Figure 3.

Using cytological criteria applied to Papanicolaou smears, the annual incidence of cervical HPV infection in the unselected Finnish population has been estimated to be 8%, with an estimated 79% of the female population having at least one genital HPV infection between the ages 20 and 79 year⁵⁰. In the United States, between 1 and 4% of women in routine cervical screening programmes have cytological evidence of HPV infection, rising to 16% of STD clinic attenders³². Using DNA hybridisation techniques, 2-11% of those with cytologically normal smears and 30-90% of women with abnormal smears in routine screening programmes have evidence of HPV infection³². Furthermore, there is some evidence of geographical variation of HPV types found in subclinical lesions⁵⁷.

The incidence of acetowhite changes in the population is unknown. Acetowhite changes were found in 36% of healthy male Swedish army volunteers, and HPV DNA was found in 7% of biopsies from these areas⁸³. Histological changes in biopsies of acetowhite areas are often inconclusive, and provide no information regarding HPV type¹⁰³. HPV DNA of the genitotropic types can only be detected in approximately 40%⁷⁶ - 60%⁵² of peniscopically visualised lesions.

Figure 3



Pyramid model

The distribution on the genitalia of acetowhite changes approximately mirrors that of AGW in the male^{52,91,94,97,103}, usually at sites of trauma during sexual intercourse⁵². The urethral meatus is also a common site for acetowhite changes¹⁴³. There is some evidence to suggest that scrotal lesions are more commonly subclinical⁵¹ and that lesions on sites other than the penis occur only in men who have penile lesions⁵³. The histological abnormalities of acetowhite areas appear to be the same regardless of the site⁵³. However, in view of the lack of specificity of acetowhite changes, some authors suggest that biopsy of acetowhite changes seen on the penis is mandatory⁹⁰ as dysplasia occurs in 5%⁵² - 33%⁹⁵ of biopsies taken from acetowhite genital areas in men^{53,85,94,97,99,103}, depending on the population studied. Partners of women with CIN have the highest incidence of PIN⁹⁵. It should be noted, however, that not all areas of penile dysplasia show acetowhite changes⁵². It has been noted^{76,85,94,136,143} that "high risk" HPV types (i.e. types 16, 18 and 31) are present in a larger proportion of subclinical male genital lesions than in clinically apparent AGW.

5.6 HPV and the upper genital tract

5.6.1 Bladder

Condylomata acuminata of the bladder have been occasionally reported¹⁴⁴⁻⁷, usually in association with external

genital lesions, and almost always in the context of general ill-health or immunosuppressive therapy. When bladder condylomata do occur, they frequently have an aggressive course and may be associated with malignant transformation¹⁴⁵.

5.6.2 Prostate

There have been several epidemiological studies suggesting that men who develop prostatic carcinoma may share risk factors such as early sexual debut, a history of sexually transmitted diseases and multiple sex partners, with women who are at increased risk of cervical carcinoma¹⁴⁸⁻⁹. Two groups have failed to find DNA from a variety of HPV types in samples of prostate¹⁵⁰⁻¹ but others^{115,152-4} have. HPV DNA has been found in approximately equal proportion of the samples, regardless of the histological diagnosis, and does not seem to depend on the whether the prostatic material is removed transurethraally or suprapubically¹⁵⁵. In addition, at least some of the HPV DNA may be integrated into prostatic cell genomes¹⁵⁵. Unfortunately, in none of the studies in which HPV DNA was detected in the prostate has there been comment on past history of genital warts in the patient or in their sexual partners, nor was urethral carriage assessed. It is possible that catheterisation prior to prostatectomy (regardless of the surgical technique used) may have introduced viral particles as far proximal as the prostatic urethra, leading to possible contamination

of the prostate with HPV. Furthermore, it is well established that pathological changes in the prostate are frequently very localised in nature, so that there is potential for large sampling errors. In addition, the prostatic luminal epithelium, which is the proposed site for HPV infection, is different from the cutaneous squamous epithelium characteristically infected with HPV.

5.6.3 Semen

HPV DNA has been detected in the cellular fractions of semen specimens provided by men with intrameatal warts, and it has been suggested that HPV DNA may be sloughed off from the urethral epithelium during ejaculation¹⁵⁶. However, another group¹⁵⁷ failed to find evidence of DNA from HPV types 6, 16 and 18 in a group of healthy volunteers, although they did detect DNA from HPV types 2 and 5 in three individuals particularly at risk of generalised HPV infection. Furthermore, a third group⁹⁴ could find no evidence of HPV types 6,11,16 or 18 in semen samples from a group of 19 male consorts of women with either condylomata acuminata or abnormal Papanicolaou smears.

5.7 HPV in urine

Cytological assessment^{53,158-60} of urine seems to lack sensitivity in the detection of HPV. Similarly, the dot blot method failed to detect HPV DNA in mid-stream urine specimens from men with visible penile warts and

from men who were the consorts of women with either abnormal Papanicolaou smears or condylomata acuminata⁹⁴. In addition, Southern blotting failed to detect HPV DNA in urine specimens from 3 men with HPV in their semen samples¹⁵⁷. However, HPV DNA has been detected by the PCR in urine specimens from men with meatal warts¹⁶⁰, from male consorts of women with cervical cancer¹⁶² and women¹⁶³. The PCR did, however, fail to detect HPV DNA in 14 presumed healthy males working in a laboratory¹⁶¹. The detection of HPV DNA in urine specimens obtained at the lower centrifugation speed of 1800g, suggests that the virus was cell-associated, rather than existing in a free state¹⁶¹. It has therefore been suggested¹⁶¹ that HPV in infected exfoliated urothelial cells might be present in the ejaculate of these men, thus acting as a possible route of transmission to sexual partners. However, the only data so far available showing possible sexual transmission by this route come from male partners of women in whom type 16 HPV DNA was detected in a cervical scrape. Type 16 HPV DNA was found¹⁶² in the urine specimens from 2 (22%) of 9 men.

5.8 HPV and the urethra

The lining of the distal portion of the male urethra undergoes a gradual transition from stratified columnar epithelium to stratified squamous epithelium¹⁶⁴. Thus, there is a transitional zone between the two epithelia which has been compared to the cervical squamo-columnar junction¹⁵¹. It has been postulated¹⁵¹ that, because of

the features of cellular turnover occurring there, the urethra is more likely to become productively infected with HPV at that site. The analogy with the cervix is further developed¹⁶⁵ by the observation that urethral carcinoma tends to occur in areas of columnar epithelium which have undergone squamous metaplasia as a result of local infections or other irritation.

5.8.1 **Condylomata acuminata**

Condylomata acuminata of the male genitalia involve the urethra in 0.5 to 5% of cases¹⁶⁶⁻⁷. However, one study from a British clinic for sexually transmitted diseases³ found that 23% of men with AGW had involvement of the urethral meatus. The majority of urethral warts occur in the distal 3cm of the urethra^{76,147}, and are thus visible on simple inspection of the meatus, preferably aided by an instrument such as an endocervical or a paediatric nasal speculum^{52,137}.

5.8.2 **Urethroscopy**

Urethroscopy allows the detection of urethral condylomata acuminata, but because of the risk of autoinoculation of viral particles from meatal to bladder ends of the urethra^{94,147}, and the low frequency of lesions at the bladder end of the urethra⁹⁴, it is not generally performed unless there are specific clinical indications⁷⁶. There is one report⁷⁶ of acetic acid being instilled within the lower urethra at cystoscopy. Many of these patients showed acetowhite changes, regardless of the HPV

status of the patient, and the procedure was abandoned by the authors. Acetowhite staining of the urethral meatus is also a common observation^{143,158}, but its significance is currently not understood.

5.8.3 Urethral sampling techniques

In view of the observation that the majority of urethral HPV infections occur in the distal urethra, and that this location is easily accessible, a number of techniques have been used to obtain specimens from this area. Brushes^{76,79,83} such as ureteral brushes¹³⁶ have the advantage that large numbers of cells are collected, but may have the disadvantage that this may traumatise the area and result in the production of a sterile urethritis (personal observation). The use of lignocaine jelly¹³⁶ reduces some of the immediate discomfort. Another approach is to use swabs^{52,100}. Although urethral swab specimens contain fewer cells, swabbing is a well established and validated method for the collection of urethral specimens for the investigation of other urethral infections, such as that caused by Chlamydia trachomatis.

5.8.4 Papanicolaou staining of urethral smears

Urethral samples examined cytologically by modified Papanicolaou staining techniques have been taken from male consorts of women with HPV infections^{52,79} and groups of men with a wide variety of risk factors for the acquisition of HPV¹⁶⁸. Specimens were obtained using

a cotton-tipped swab^{52,151,168} and brush⁷⁹. However, when compared directly to HPV DNA analysis of urethral samples⁷⁹, cytological assessment has been consistently shown to have lower sensitivity and specificity than DNA-based methods.

5.8.5 HPV antigen detection in urethral specimens

HPV antigen detection methods use labelled antibodies to papillomavirus capsid proteins and have the advantage of allowing determination of the exact anatomical location of the HPV infection. The main disadvantage is that these methods often only allow the detection of completed viral particles and so will miss latent infection. The use of antibodies specifically directed against early antigens may, however, avoid this problem.

Using such antigen detection systems, HPV antigen has been found in the urothelial cells of urethral smears⁷⁹ and the metaplastic epithelium adjacent to urethral warts¹⁶⁹. Antigen has been detected both in the nucleus¹⁶⁹ and the cytoplasm⁷⁷. In one study using this technique¹⁵¹, HPV antigen was present in 8 (47%) of 17 of those with a history of genital warts within the previous 2 years, 6 (33%) of 18 of those whose sex partner gave a history of venereal warts, and 11 (20%) of 56 of those with no personal or partner history of genital warts.

5.8.6 HPV DNA in urethral specimens

HPV DNA has been detected in urethral condylomata^{94,133}, most commonly types 6 and 11. HPV DNA has also been



detected in 18% of clinical normal urethral biopsies from men whose partners had abnormal cervical smears or who had external genital warts⁹⁴. In other studies, HPV DNA has been found in urethral smears from clinically normal urethras of a variety of groups of men^{76,151}, including men with AGW⁷⁶, and consorts of women with cervical dysplasia^{76,136}. Men with a history of AGW had the highest percentage of urethral smears containing HPV DNA (41%), followed by those whose sex partner had a history of venereal warts (33%), and those with no personal or sex partner history of genital warts (22%)¹⁵¹. Omar *et al*¹⁵¹ favour antigen detection as a method of screening for genital warts, on the grounds that it detects intact viral particles, rather than just DNA. However, this approach ignores the unclear relationship between the detection of viral capsid and infectivity. HPV types 6 and 11^{76,151} and 16 and 18¹³⁶ are most commonly found in urethral smears. Urethroscopy has been performed in men with HPV detected on urethral smears and no abnormalities found^{76,136}. Urethral biopsies taken from clinically normal areas were histologically normal in 5 of 6 cases⁷⁶. The one abnormal biopsy was described as "changes compatible with minimal HPV expression" and the authors concluded that urethral samples can detect latent, rather than active, HPV infection⁷⁶.

5.8.7 Urethral carcinoma

Urethral carcinoma is a rare tumour, usually of squamous epithelial origin with a poor prognosis and possibly

associated with a history of sexually transmitted diseases¹⁶⁵. The aetiology of this condition is unknown. HPV 6 DNA was detected by in situ hybridisation in the nuclei of tumour cells in one study¹⁶⁵. Southern blotting using probes to 27 other HPV types failed to find evidence of other types.

5.9 HPV DNA in tissue with no histological evidence of HPV infection

The results of some studies^{52,55,170-2} suggest that HPV is found only in histologically or cytologically abnormal tissue. However, several groups¹⁷³⁻⁶ have detected HPV DNA in apparently normal epithelium adjacent to condylomatous and dysplastic lesions. Furthermore, there is some evidence that such infections may be important in the recurrence of disease after treatment¹⁷⁷.

The proportion of women with HPV detected in their cervixes depends on the detection method employed and patient population. Cytological evidence of HPV infection of the cervix has been found in approximately 1% of women attending family planning clinics, with prevalence decreasing with age¹²⁵. However, cytological examination underestimates the incidence of HPV infection. For example, in St Mary's Hospital, London,¹⁷⁸ HPV DNA was found in 10.5% of women attending the STD clinic with histologically and colposcopically normal cervixes. HPV DNA has been detected in histologically and cytologically normal cervixes by a large number of groups^{99,179-87}. Using the PCR, up to 70% of normal cervixes have been shown to

contain HPV DNA¹⁸², but figures of 10-20%^{173,184,188} are more commonly reported. HPV 16 and 18 appear to be the commonest types detected in the normal cervix^{138,176}. Whilst the possibility of contamination has been raised⁵⁰ to explain some of the higher figures, it is now clear that HPV infection in cytologically normal cervixes is widespread.

Some studies indicate that when treatment by laser, cryotherapy or interferon results in a clinical cure, then there is associated clearance of HPV DNA^{50,190}. However, there is some evidence for persistence of HPV DNA in clinically and histologically normal areas which had been previously clinically infected¹⁹¹⁻².

HPV has also been found in morphologically normal vulval papillae¹³⁸, oral tissue¹⁹³ and normal colonic tissue¹⁹⁴. However, in a recent study¹⁹⁵ in which a variety of methods was used, including the PCR, very little evidence of HPV infection was found in a wide variety of premalignant lesions of the non-genital skin.

5.10 HPV DNA in the normal adult penis

It is difficult to gain access to a group of men who are truly representative of the general population, particularly as some sampling procedures for the detection of HPV are unpleasant.

HPV is not present in biopsies from coronal papillae^{55,172}, despite the fact that they may be clinically confused with condylomata acuminata¹⁹⁶. Similarly,

HPV has not been detected in biopsies of the penis with no histological evidence of HPV infection or carcinoma^{82,87,197}. However, HPV DNA from types 6,11,16 and 18 has been found in histologically normal penile biopsies from men with either condylomata acuminata elsewhere or who are sexual consorts of women with cervical cytological abnormalities^{57,94,99}.

Sampling procedures which are less invasive than biopsy have also been used. In one study, of 530 men attending a blood donor centre and a dermatology department in Germany¹⁹⁸, HPV DNA was found in 5.8% of cotton wool smears taken from the coronal sulcus and glans penis. None of the men had clinically apparent warts. Samples were analysed by filter in situ hybridisation. The authors postulate that the higher frequency of cervical swabs containing HPV DNA compared to penile swabs may be due to the greater number of cells that can usually be obtained from the cervix. A similar result was found by Schneider¹⁹⁹, and Eriksson *et al*⁸³ detected HPV DNA in 8% of urethral swabs from healthy Swedish army recruits. Using a similar method, Campion *et al*⁸⁵ investigated 25 sexual consorts of women with chlamydial cervicitis. There was no history of condylomata acuminata within the relationship and one man had a positive penile scrape for HPV. Three of 25 men had colposcopic and histological evidence of HPV infection.

Recently¹⁰⁰, 228 men attending a Stockholm STD clinic consecutively were analysed for the presence of HPV DNA. Samples were taken from the coronal sulcus and inner

foreskin by a cytology brush (Cytobrush™) and from the urethral meatus using a cotton-tipped swab. The specimens were then subjected to PCR using primers for HPV types 6 and 16, followed by analysis using agarose gel and dot blot hybridisation. Dot blot hybridisation results gave significantly higher positivity rates. The authors found that there was no difference between samples collected from the coronal sulcus and the urinary meatus. Eighty-one percent of men with condylomata acuminata had positive HPV 6 signals on dot blot analysis. Slightly lower percentages were recorded for men with a history of condylomata acuminata (62%), consorts of women with condylomata acuminata (67%) and men with no previous known exposure to AGW. The authors expressed concern that the dot blot method might have led to an over-estimate because crude cell extracts used in the PCR assay and denatured proteins could possibly have trapped the oligonucleotide probes used in the hybridisation step. They therefore conclude that the true carriage rate for their population lies between 43-76% for HPV type 6, and between 13-46% for type 16.

5.11 The natural history of anogenital HPV infection

Very few longitudinal studies have been conducted on the natural history of AGW. Only limited follow-up data are currently available on the progression rates of latent infection^{50,57}, and it not known whether permanent regression of latent HPV infections is possible.

The most detailed information comes from the cervical cytological studies from Finland by Syrjänen et al²⁰⁰⁻¹. During their five-year follow-up of untreated women, 40% spontaneously regressed cytologically, 45% persisted and 15% progressed to carcinoma in situ. Using life-table analysis, they found that neither grade of Papanicolaou smear nor HPV type were of predictive value for spontaneous regression, and the colposcopic pattern was only a poor predictor of regression or progression. The most notable observation of this study is that genital HPV infections run an extremely fluctuating course, varying from clinically apparent lesions to subclinical and latent infection. The majority of cases of subclinical cervical HPV lesions cleared spontaneously within 5 to 6 years^{50,202} and it has been postulated⁵⁷ that a focal inflammatory response might be associated with a more rapid resolution.

5.12 Anogenital HPV infection and sexual behaviour

Barrett et al² were the first to establish scientifically that condylomata acuminata were sexually transmissible. Later, Oriel³ traced 97 sexual contacts of 332 patients with AGW. Sixty two (64%) of these people subsequently developed AGW with incubation periods between 3 weeks and 8 months (although his follow-up period was only 9 months), with an average of 2.8 months. The data suggested that infectivity was inversely related to the duration of the AGW, an observation which has been correlated with the decreased number of viral particles present in older

lesions⁵⁹. Sexual activity has been established to be important in the development of anal warts in homosexual men²⁰³ but not heterosexual women²⁰⁴.

Subclinical and latent anogenital HPV infection has been found to correlate with sexual activity in the majority of studies^{34,127,203-9}, although not in all²¹⁰⁻⁵. Indeed, investigators in a study from Denmark and Greenland²¹³ and Latin America²¹⁴ found paradoxically that the earlier the age at first sexual intercourse and the greater the number of sexual partners, the lower the risk of HPV infection. HPV infection of the cervix has been found to be age dependent¹⁸⁹ or independent²¹⁶. Similarly, HPV infection of the penis has been found to be age dependent¹⁹⁸. Technical reasons^{215,217-8} may explain some of the discrepant results between the various studies.

The age distribution of individuals with AGW is similar to those with gonorrhoea³ and, depending on the methods used for diagnosis, the prevalence of HPV infections in STD clinic attenders varies from 12 to 41%²¹⁹. Patients with AGW frequently have other sexually transmissible infections^{2,3,15,118,220-225}. Furthermore, infection of the genital tract with other pathogens, in addition to HPV, may make the eradication of warts more difficult²²⁰. In particular, infection with the human immunodeficiency virus (HIV) may alter the clinical course of HPV infections of the cervix²²⁶⁻⁷, other genital areas²²⁸ and anus²²⁹⁻³⁰. Kaposi's sarcoma shows some of the epidemiological characteristics of a sexually transmissible

infection and occurs in the genitals even of those who are HIV negative²⁰⁹. HPV DNA²³² and papillomavirus antigens²³³ have been found in tissue from Kaposi lesions in both HIV infected and non-infected patients, leading to speculation that HPV may be involved in the aetiology of such lesions.

Evidence of anogenital infection with HPV has been found in the male sexual partners of women with AGW^{95,97}, cervical cytological abnormalities⁵² and biopsy-proven cervical dysplasia^{85,95,234}. Several studies fail to differentiate between women with cytological dysplasia and AGW^{79,87,235}. Techniques for assessing the men usually include colposcopy^{85,87,95,234}, histology of colposcopically abnormal areas^{85,87,95,234}, as well as DNA hybridisation of biopsy specimens^{85,87,95} and genital scrapes⁸⁵. Using these methods, 50%-66% of men whose consorts have abnormal cervical smears or AGW have evidence of anogenital HPV infection^{52-3,88,95,103,159}. Subclinical lesions in the male seem to be more common in those who have recently changed their sexual partner⁵². There is a suggestion that the consorts of women with dysplastic lesions of the cervix tend to have dysplastic penile lesions^{85,95}. The relative infectivity of condylomata, acetowhite areas and latent infection is not known. Studies are confounded by the multifocal and constantly changing clinical status of anogenital HPV infection⁵⁰, and the lack of adequate controls⁸⁵. Furthermore, in only a few studies²³⁶ have the female consorts of men with anogenital HPV infection been investigated.

Some evidence suggests that women treated for condylo-
mata acuminata develop recurrences unless the male
partner is also treated²³⁷. Likewise, reinfection from
the urethras of untreated sexual partners has been pro-
posed as a mechanism to explain why acetowhite areas may
be very resistant to treatment^{103,238}. However, con-
trolled trials have found that the simultaneous treatment
or otherwise of male sexual partners produced no differ-
ence in the response to treatment of women with condylo-
mata acuminata²³⁹ or cervical dysplasia²³⁴. Nevertheless,
a higher rate of regression of cervical dysplasia has
been observed when male partners use condoms²⁴⁰.

It is generally assumed^{188,241} that infection with HPV
develops following direct contact between fully formed
virions entering through small abrasions in the skin and
the lowest basal cells of the epithelium. Messenger RNA
from the early ORFs are found in the basal cells, whereas
late transcripts (which signify completed virion produc-
tion) appear only in the more differentiated epithelial
layers²⁴². Thus, in the absence of any method to directly
measure infectivity, it is thought that only the top
layers of the epithelium contain infectious viral parti-
cles²⁴³⁻⁴. Such particles are released along with the
desquamated cells which are shed from the skin or mucous
membranes¹⁸⁸.

HPV 6 and, to a lesser extent HPV 11, are the types
most readily transmitted by sexual intercourse⁵⁹. Trans-
missibility appears to be related to the number of virus
particles present, together with the duration and fre-

quency of exposure⁵⁹. It has been suggested²⁴⁵ that viral shedding may be greater in infections with HPV types 6 or 11, as the resulting lesions have relatively large numbers of virion-containing degenerative koilocytes. In contrast, lesions resulting from infection with HPV types 16 or 18 (mostly intra-epithelial neoplasia) are relatively poor in superficial koilocytes. Comparing the quantitative carriage rate of different individuals, it has been observed⁵⁹ that when both partners are infected, one always has a much higher carriage rate than the other. In addition, if only one partner was infected, the copy number was much lower.

5.13 Possible vertical transmission of genitotropic HPV types

Applying the PCR to samples obtained from tampons, Fairey *et al*²⁴⁶ were unable to detect HPV DNA in virgins, although they were successful with this technique in finding HPV DNA in tampon samples from sexually active women²⁴⁷. Sun-Kuie *et al*²³⁵, however, found colposcopic and histopathological evidence of genital HPV infection in 51% of the virginal women in their sample. Only one of the women in the latter study had typical condylomata acuminata and HPV DNA typing was not performed. It is therefore currently unclear whether virginal women have genital infection with HPV, and if so, to what extent vertical transmission plays a role.

HPV DNA has been detected in the amniotic fluid of clinically normal neonates born at Caesarian section²⁴⁸

and cord blood of neonates²⁴⁹, suggesting that transplacental infection prior to delivery may occur²⁴⁹. Furthermore, HPV DNA has been detected in the foreskins of up to 40% of newborns delivered to mothers carrying the similar viral types in their birth canal²⁵⁰⁻². DNA of the genitotropic HPV types has also been found in the conjunctivae of neonates born to mothers with AGW²⁵³ and in oral scrapings from preschool children¹²⁹.

AGW have been recorded in children at birth²⁵⁴ including those born by Caesarian section⁹⁸. Before 1980, only 19 cases of AGW, including intrameatal warts²⁵⁵, were reported in children⁹⁸, predominantly in girls²⁵⁶. Over the past decade, however, there has been a marked increase in the number of reported cases. It is not known whether this increase is due to greater awareness of AGW in children or a true increase in incidence, perhaps reflecting the increased incidence of AGW in the adult population. AGW in children usually contain HPV types 6 and 11, although the "high risk" types 16 and 18 have also been reported⁹⁸. The occasional finding of "non-genital" HPV types 1 and 2^{98,257} has led to the suggestion²⁵⁸ that transmission of HPV may occur from non-genital sites of the parents or child during toileting, bathing and other child care activities. Sexual abuse was initially regarded as the main cause of anogenital warts in children^{256,259-60}, but this may not always be established²⁵⁸.

Approximately 150-300 cases of juvenile laryngeal papillomatosis (JLP) are reported per year in the

USA²⁶¹, with a peak age at the time of diagnosis occurring between birth and 5 years of age²⁶². Subclinical lesions probably go unreported²⁶³. Half to two-thirds of children with JLP have mothers with visible condylomata acuminata²⁶⁴⁻⁶, and it has been estimated that the risk of acquiring JLP from a clinically infected mother ranges from 1 in 80 to 1 in 15,000 pregnancies^{261,267}. The lesions of JLP usually contain HPV types 6 and 11²⁶⁸. HPV DNA has been found in the nasogastric aspirates of approximately 30% of neonates²⁶³ and it has been suggested²⁶⁹ that infants may aspirate infected material during vaginal delivery. Caesarian section is usually protective²⁶¹ against JLP although JLP has been reported occasionally in children born by Caesarian section²⁷⁰. However, Caesarian section is probably not warranted in all cases of maternal AGW as the risk of JLP for the child is so small¹²⁷.

Further evidence of widespread infection of children with genitotropic HPV types comes from serological studies using expressed fusion proteins to detect the presence of specific antibodies to genitotropic HPV types^{56,129,271-2}. Antibody frequencies seem to be similar to those found in STD clinic attenders¹²⁹. In addition, in one study¹²⁹ there was evidence of passive transfer of antibodies against HPV from mother to neonate which disappeared within 6 months of birth.

5.14 Genitotropic HPV types at non-urogenital sites

5.14.1 Laryngeal papillomatosis

It is currently unclear whether JLP and adult laryngeal papillomata represent two separate entities, or are merely different manifestations of the same disease process. However, children with JLP may subsequently develop problems with laryngeal papillomata as adults²⁷³⁻⁴ and nearly one half of the cases of HPV-related laryngeal papillomata first present in adult life²⁶². HPV has been found in adult onset papillomata of the larynx²⁷⁵⁻⁷ and in verrucous carcinoma of the larynx^{55,278-80}. Furthermore, the vocal cord epithelium has a relatively high susceptibility to experimental HPV infection²⁸¹. There is strong evidence that patients with JLP retain latent HPV DNA in laryngeal epithelial cells for years. HPV DNA sequences are present in laryngeal biopsies of patients in remission¹⁹², and a case has been reported²⁸² of recurrence of laryngeal papillomata in a 37-year old man who previously manifested signs of JLP between 2 and 5 years of age. It has been postulated²⁸³ that recurrent laryngeal papillomatosis in adults may result from orogenital contact, although this was not confirmed in one recent study²⁸⁴.

JLP rarely involves the trachea and bronchi, suggesting that vertical transmission is an unlikely cause for the presence of HPV in the lung. In support of this, Carey *et al*²⁸⁵, investigating endobronchial squamous tumours, which have a strong morphological resemblance to virus-

associated tumours, found no evidence of HPV infection. However, HPV DNA has been found in squamous carcinoma of the lung^{274,286}.

5.14.2 Mouth

HPV DNA, mainly from types 6 and 16, has been found in oral scrapings of those without clinical oral abnormalities^{129,193}, oral leukoplakia¹⁹³, oral lichen planus¹⁹³, oral papillomata^{265,287} and squamous carcinoma of the buccal mucosa²⁷⁹ and tongue^{55,279,287-8}. Furthermore, HPV 6b and 16 have been found in oral scrapes from preschool children¹²⁹. Orogenital transmission of HPV is presumed to occur²⁸⁹, but the role of fomites, oral/hand contact and vertical transmission remain unclear.

5.14.3 Oesophagus

It has been proposed²⁹⁰ that clinically undetected oesophageal condylomata may occur when oral lesions are present, and that these two phenomena are related. HPV antigens have been found in oesophageal papillomata, focal hyperplasia and carcinoma²⁹¹⁻². HPV DNA from types 11²⁹³⁻⁴ and 16²⁹⁵ has been found in oesophageal carcinoma. Proposed methods of transmission include passage through an infected birth canal²⁷⁴, interpersonal spread in areas of poor hygiene²⁹⁶ and orogenital intercourse²⁹⁶⁻⁷.

5.14.4 Nasal cavities

HPV 16 has been found in the squamous carcinoma of the nasal cavities and paranasal sinuses, but not inflammatory lesions of these areas²⁹⁸. In this latter study, HPV status did not alter the clinical course of the lesions and the role of HPV in the pathogenesis in the sinus abnormalities is currently unclear.

5.14.5 Eye

HPV 16 DNA has been found in clinically normal eyes⁵⁴, conjunctival papillomata^{253,299}, dysplastic and malignant lesions of the ocular conjunctiva and cornea^{54,300} and dysplastic lesions of the eyelid³⁰¹. It is not clear how HPV reaches the eye, but sexually transmitted organisms, such as C. trachomatis, can be transmitted to the eye through hand-eye contact³⁰² and a loose association has been demonstrated between cervical carriage of HPV and the presence of HPV in the conjunctiva⁵⁴.

5.14.6 Blood

HPV DNA has been isolated from the peripheral blood mononucleocytes of women without clinically apparent HPV-related disease³⁰³, cord blood of neonates²⁴⁹ and patients with clinical disease³⁰³. HPV has also been found in serum samples³⁰³. These observations suggests that blood may have a role in recurrence following treatment and the development of multifocal HPV infections.

5.14.7 Fomites

The epidemiology of HPV is further complicated by the detection of HPV DNA on inanimate objects. HPV does not have a lipid membrane and so is relatively resistant to physical destruction. HPV DNA has been found in underwear¹¹³ of patients with clinically apparent lesions, although the frequency of finding it did not seem to correlate with the frequency of changing the underwear. HPV DNA has also been found on surgical instruments used for treating patients with clinical HPV-related disease³⁰³, although it does appear to be removed by conventional cleaning procedures³⁰⁵. Vapour produced during treatment of warts by laser³⁰⁶ and electrocautery³⁰⁷ also contains HPV DNA.

5.15 Anogenital neoplasia and HPV

There is considerable epidemiological evidence supporting the concept of a sexually transmissible factor in the genesis of cervical dysplasia^{50,212,214,208-12}. Furthermore, it has been proposed that specific HPV types (primarily HPV 16 or HPV 18) may play a major role in the aetiology of many, if not most, anal and genital tract cancers^{34,46,173,214,313-4}. The transcription of HPV DNA in tumours³¹⁵ and the presence of HPV DNA and RNA in cells derived from cervical cancers³¹⁵⁻⁶ argue against a passenger status of papillomavirus in tumours. Experimental studies^{46,317} have provided insight into how papillo-

maviruses alone, or in combination with other factors, may induce cellular proliferation, immortalisation, and transformation.

Although circumstantial evidence of a link between HPV and cervical carcinoma is strong, there are some inconsistencies in the evidence. Infection with HPV appears to be necessary for the development of certain malignant tumours, but not sufficient⁴⁶, as HPV is also found in a substantial proportion of disease-free women^{185,216}. Additional factors seem to be involved, for example: coinfection with other agents such as herpes simplex virus³¹⁸⁻²¹, Epstein Barr virus³⁰⁰ and HIV³²³⁻⁵, smoking³²⁶⁻⁹, naturally occurring and contraceptive steroid hormones^{310,329}, dietary factors such as vitamin A, beta carotene and vitamin C³³¹⁻² and local inflammatory responses such as mechanical trauma and radiation exposure³⁰. A synergistic interaction has been proposed^{206,333} in which infection with papillomaviruses leads to proliferation, with subsequent transformation in the malignant lesion depending on other carcinogenic insults.

Apart from the cervix, HPV DNA has been found in a variety of neoplasias such as those of the vulva³³⁴⁻⁷, vagina³³⁸⁻⁹, penis^{197,340-1} and anus^{230,342}.

Bowenoid papulosis is a cutaneous condition, usually occurring in the anogenital area, which has the appearance of erythematous macules, reddish or pigmented papules, or leukoplakia-like lesions⁷⁷. It appears to be clinically benign, but has the histological characteris-

tics of squamous cell carcinoma in situ. When occurring on the penis it therefore has the histopathological appearance of penile intraepithelial neoplasia (PIN) grade 3^{53,159}. The clinical counterparts of PIN 1 and PIN 2 are currently not characterised. Bowenoid papulosis has been found in association with HPV types 6, 11, 16, 18, 33, 34, 39, 40, 42 and 55³⁴³, although most commonly with type 16, which is found in up to 100% of cases^{77,344}.

Giant condyloma of Buschke-Löwenstein (also known as verrucous carcinoma) is a fungating, destructive, but non-invasive tumour which most commonly occurs on the prepuce of the penis. There have been occasional reports of it occurring on the vulva, anorectal area³⁴⁵ and oral cavity³⁴⁶. The aetiology of Buschke-Löwenstein tumours is unclear, but there have been several reports of the tumours arising in condylomata acuminata³⁴⁷⁻⁸ and the majority are associated with HPV types 6 and 11⁴⁷.

HPV DNA has also been found in neoplastic lesions of the mouth, larynx, oesophagus and bronchi⁵⁰. Indeed, current evidence suggests that HPVs may play an important part in the aetiology of the majority of benign and malignant tumours of the oral mucosa, as well as in head and neck tumours³³.

5.16 The "high risk" male

There are a number of studies suggesting that male sexual partners influence the likelihood that a woman will develop cervical dysplasia³⁴⁹, and this concept has led to the term the "high-risk male"³⁵⁰. Male consorts of

such women have earlier sexual débuts, more sexual partners^{126,351}, are more likely to travel away from home³⁵², have a higher incidence of smoking and are more likely to have penile cancer³⁵³⁻⁵. Furthermore, there is a four-fold increase in the risk of CIN in women whose husbands who have previously been married to a woman with CIN³⁰⁸ and neighbourhood clusters of CIN have been reported in association with cohabitation relationships between affected women and specific men³⁵⁶. There is thus a considerable amount of evidence of the influence of the male on the development of cervical dysplasia in sexual partners. The exact mechanism has yet to be finally established¹³⁹, but the high frequency of clinically inapparent infection with HPV 16 has been proposed as an important factor^{236,357}.

Methods

1. Introduction

The detection rate of HPV DNA may depend on the population studied³⁴. All studies in this thesis were conducted in departments of genitourinary medicine. Thus, in order to obtain a broad a view as possible of the epidemiology of HPV infections, several different groups of patients were studied. Furthermore, increasing evidence suggests that such infections may be multifocal, and so specimens from several sites from the same patient were taken.

It is difficult to determine the prevalence rate of HPV infection in the general population. In the **genital dermatosis study**, men with clinical indications for biopsy were chosen not in the belief that they represented the general male community, but that they would do so more closely than patients with "conventional" sexually transmitted diseases.

In the **resistant anogenital warts study**, a group of men with clinically apparent AGW was selected on the assumption that they would be likely to carry HPV in large quantities in their anogenital regions. Samples of wart tissue were taken for analysis and the results compared with those obtained from examining urethral and urine specimens. In this manner it was hoped to assess the distribution of HPV in the male urogenital tract.

Men with urethral gonorrhoea form a well characterised group³⁵⁸ whose lifestyles have put them at risk of acquiring sexually transmissible diseases. A group of men

with urethral gonorrhoea was therefore chosen for assessment in order to investigate the role of sexual activity in the epidemiology of HPV infections. The details of this study are given in the **urethral gonorrhoea study**.

In the **multifocal study**, a variety of samples were taken over several months from several sites of patients with and without AGW. In this manner it was hoped to characterise more fully the multifocal nature of HPV infection and its change with time.

Currently, the polymerase chain reaction (PCR) is the most sensitive technique for the detection of HPV DNA³³. Southern blotting¹¹¹ allows the confirmation of DNA sequences produced by the PCR and enables the type of HPV to be determined. In view of their combination of sensitivity and specificity, the PCR and Southern blotting techniques were chosen for the analysis of all specimens in this study.

In view of the extreme sensitivity of the PCR, careful measures were taken to avoid contamination of the specimens with extraneous DNA. Samples were taken under sterile conditions, using "no touch" techniques and wearing sterile disposable gloves. Disposable equipment was used at all stages apart from the biopsy sets and diathermy loops, which were hand-washed, placed in an ultrasonic cleaner (Olympus Keymed KS-2, Keymed U.K.) for 15 minutes followed by autoclaving at 134°C for 20 minutes (Little Sister 2, Eschmann Bros & Walsh Ltd, Lancing, W Sussex, England) before reuse.

2. Recruitment of Patients

Patients were recruited from the Jefferiss Wing, St Mary's Hospital, London and the Patrick Clements Clinic, Central Middlesex Hospital, London. All patients were offered full screening for the common urogenital pathogens.

2.1 Genital dermatosis study

A specific internal referral clinic, the penile dermatosis clinic was set up within the genitourinary medicine (GUM) department at St Mary's Hospital. The criteria for referral were men with persistent penile dermatoses which did not respond to treatment, or of which the diagnosis was in doubt and the clinician felt that biopsy would be helpful in establishing the diagnosis³⁵⁹. One hundred consecutive patients attending this clinic agreed to provide samples for this study.

2.2 Resistant anogenital warts study

Patients were referred to this clinic if they had any anogenital warts which had not responded to the first-line treatments of podophyllotoxin (used for penile warts only) and podophyllin with cryotherapy. Men with any intra-anal or meatal warts were also referred.

2.3 Urethral gonorrhoea study

Men presenting consecutively to the routine GUM clinics with an acute episode of urethral discharge or dysuria were asked to participate in the study. The men were only

included in the study if they consented and Neisseria gonorrhoeae was subsequently grown from a urethral specimen.

2.4 Multifocal study

Patients for this study were recruited from the main GUM clinic at St Mary's Hospital and invited to take part if either they or their sexual partner had a clinical diagnosis of AGW.

3. History and examination of patients

A full history was taken, and information recorded on specially designed sheets, which varied with each study (Appendices I-IV). Fewer demographic details were collected from the men in the resistant anogenital warts study compared to the patients participating in the other three studies.

All patients underwent a full genital examination, with proctoscopy if the man admitted to recent receptive anal intercourse, or had symptoms suggesting possible anal disease. All men with perianal warts underwent proctoscopy, regardless of their history. Patients taking part in the dermatosis study underwent a thorough examination of the whole skin surface and mucous membranes, followed by microscopic examination of the anogenital area with a Zeiss colposcope. Patients in the multifocal study had their anogenital areas examined using a Zeiss colposcope following the application of 3-5% acetic acid.

4. Routine investigation and management of patients

Urethral specimens were taken using a 10 μ l plastic loop (Nunc, Gibco, Paisley, Scotland), which was first smeared on to a glass slide for Gram staining, and then directly plated on to a medium selective for the growth of N. gonorrhoeae (Appendix V). The plates were then placed in an incubator at 37°C with an atmosphere containing 6% CO₂. Samples were subsequently collected and transported to the laboratory before further incubation for 48 hours under the same conditions. Colonies were identified initially by the oxidase reaction (N,N,N',N'-tetramethyl-p-phenylenediamine, obtained from Sigma, St Louis, Mo, USA). Oxidase positive cultures were Gram stained, and all those staining negative exposed to a immunofluorescent monoclonal antibody to N. gonorrhoeae (Syva Microtrak, Palo Alto, California, USA). Further verification was performed, if necessary, using standard carbohydrate utilisation tests.

In the clinic, a presumptive diagnosis of urethral gonorrhoea was made if intracellular Gram negative diplococci were seen on the smear. If this was the case, the patient was offered treatment with a single 500mg oral dose of ciprofloxacin, and referred to the Health Advisor for counselling.

The finding of equal to or more than 5 polymorphonuclear cells per high-power field on the Gram stain of the urethral smear, in the absence of intracellular Gram negative diplococci, led to a diagnosis of non-gonococcal

urethritis. A two glass urine test was undertaken in all cases, and the urine assessed for the presence of casts of mucopus from the urethra and urethral glands (known as "threads"). Non-gonococcal urethritis was treated with a single dose of doxycycline 200mg, followed by doxycycline 100mg daily for 6 days, unless there were any contra-indications. The commonest alternative regimes used in these cases were either erythromycin 250mg four times daily or co-trimoxazole 960mg four times daily, both for 2 weeks.

Occasionally, the microscopist was unable to definitely make a presumptive diagnosis of gonorrhoea. However, if Gram-negative diplococci were seen in large numbers, and there was a strong clinical suspicion of urethral gonorrhoea, then a diagnosis of "suspicious pairs" was made and appropriate treatment offered to the patient. Referral to a Health Advisor was not, however, made until a positive culture result was obtained.

For the women, an additional 10 μ l plastic loop specimen was taken from the cervical os and a cotton wool swab specimen taken from the anus. These specimens were then processed as for urethral loop specimens. Using the original 10 μ l plastic loop, further samples were taken from the posterior fornix of the vagina. These latter specimens were examined using wet film and Gram staining techniques to enable the detection of Trichomonas vaginalis, Candida albicans and bacterial vaginosis.

If the patients underwent proctoscopy, plain cotton swabs were inserted through the proctoscope and any

obvious pus collected. If no beads of pus were visible, then the rectal wall was generously swabbed. Swabs thus obtained were then smeared on to medium for the culture of N. gonorrhoeae.

If the patient admitted to receptive oro-genital intercourse, pharyngeal swabs were taken with a cotton-tipped swab and cultured for N. gonorrhoeae.

If there was evidence of balanitis, sub-preputial swabs were taken using a charcoal impregnated cotton wool swab and placed directly in bacteriological transport medium (Transwab, Medical Wire & Equipment Co Ltd, Potley, Corsham, Wilts, England), prior to transport to the laboratory. Once in the laboratory, the swabs were smeared on to separate plates of McConkey agar and blood agar, to be incubated at 37°C, the latter requiring the addition of 7% CO₂ to the atmosphere. A further plate was set up with Sabouraud's medium and incubated at 30°C. Colonies growing by 48 hours were identified using standard laboratory methods.

All patients were offered serological screening for syphilis. Treponema pallidum haemagglutination assay (TPHA) and the Venereal Disease Research Laboratory (VDRL) tests were used routinely, with the fluorescent treponemal antibody-absorbed test (FTA-ABS) included if indicated.

Counselling concerning testing for the human immunodeficiency virus (HIV) was offered to all patients and, if a request was made for it to be performed, written permission was obtained prior to the taking of blood.

5. Sampling techniques

5.1 Biopsy specimens

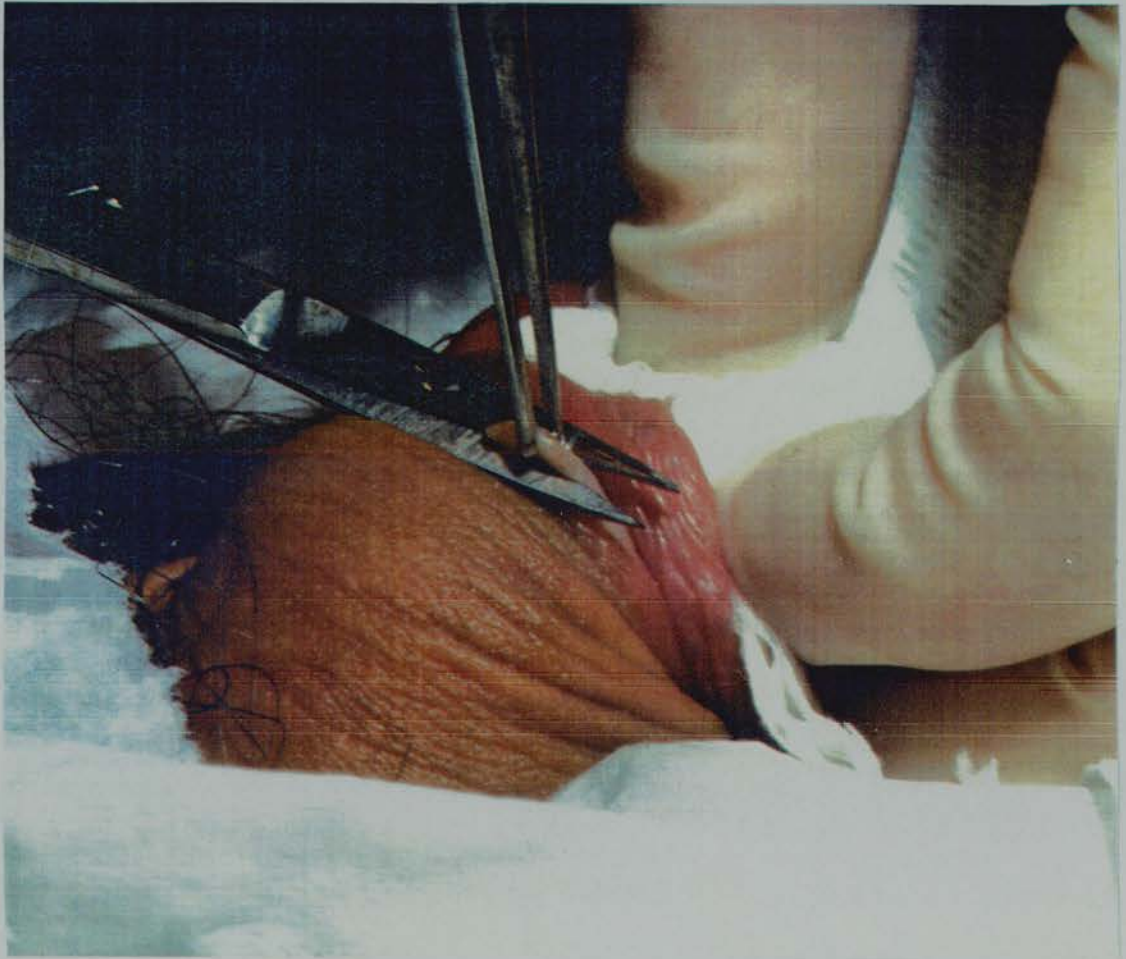
For the dermatosis study, men were asked to avoid applying any creams to their genital area for at least two weeks prior to their appointment, as it was felt that this might interfere with histopathological assessment. Biopsy was undertaken only after written permission had been obtained from the patient.

Under aseptic conditions, 1-2ml of 2% lignocaine with 1 in 200,000 adrenaline was injected using a disposable 26 gauge needle (B-D Microlance, Becton, Dickinson & Co, Dun Laoghaire, Co. Dublin, Eire) under a representative area of the lesion⁸². If the lesion was widespread, then foreskin or shaft skin was taken preferentially, as these areas were found to heal more quickly. A skin snip technique was used³⁵⁹ (Figure 4), based on that used by others^{80,85,158}. Samples were divided, one half being placed in formal saline for subsequent histopathological assessment, and the other in phosphate buffered saline (PBS) for DNA analysis. Silver nitrate was used to secure haemostasis of the biopsy site⁹⁷. As only small samples were taken, suturing was not necessary, and the wound healed by primary intention. Urethral swabs were taken by the accompanying nurse, and urine samples provided by the patients. Patients were instructed to perform regular wound toilet after the biopsy, and to avoid full sexual

intercourse for the following 2 weeks. Patients were told which symptoms would suggest wound infection, and arrangements made for any urgent medical attention required. On the small number of occasions when this was necessary, a short course of co-trimoxazole produced rapid resolution. All patients were reviewed at two weeks to assess wound healing, discuss the results of the biopsy, and arrange any necessary specific treatment.

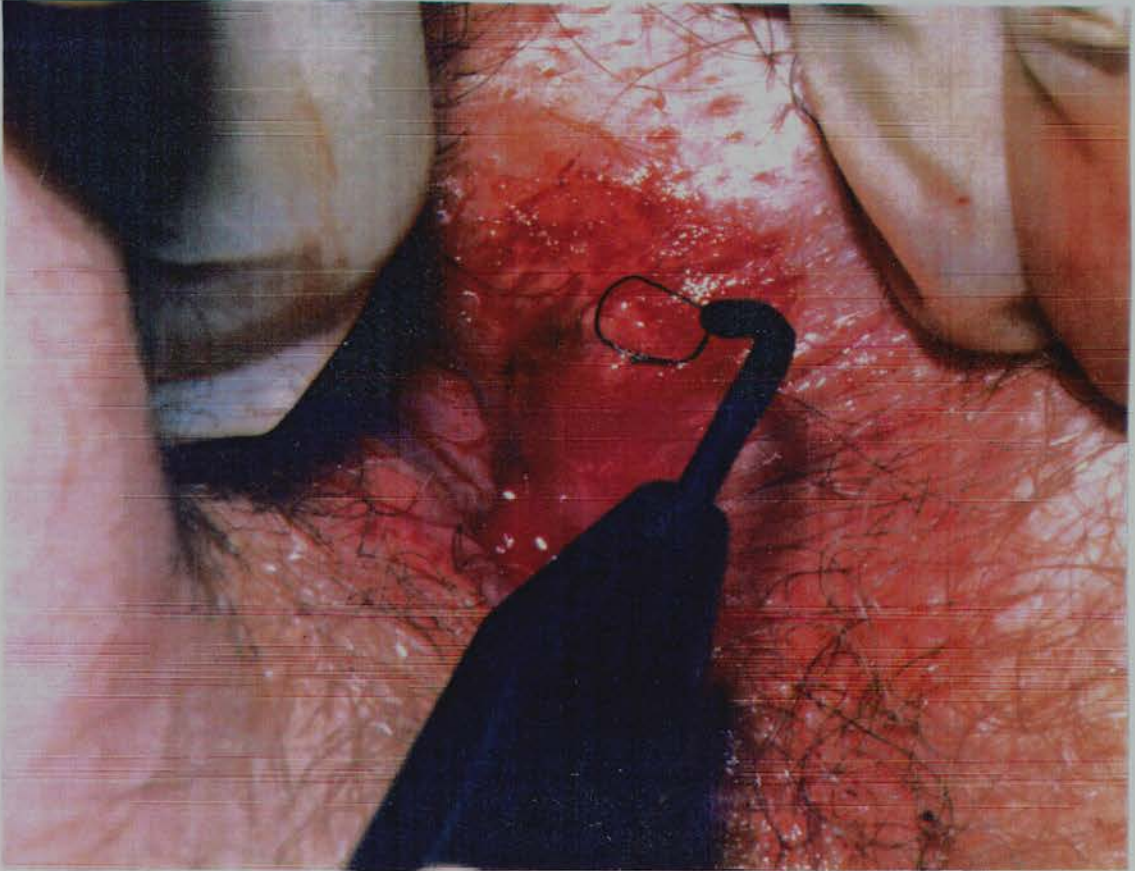
Prior to attending the clinic, all patients in the resistant AGW study were advised to apply Betadine antiseptic ointment (povidone-iodine 10% w/w, Napp Laboratories, Cambridge, England) to the clinically affected areas, as the clinician responsible for the care of the patients felt that this enhanced the clearance rate of the lesions. Local anaesthesia was first achieved by applying Emla cream (2.5% lignocaine with 2.5% prilocaine, Astra Pharmaceuticals, Kings Langley, England) to the area and waiting for 20 minutes. One percent lignocaine (without adrenaline) was then infiltrated beneath the warts with a 26 gauge disposable needle (B-D Micro-lance, Becton, Dickinson & Co, Dun Laoghaire, Co. Dublin, Eire). The warts were then removed by diathermy using a Surgitron STW-60 (Meditronix Ltd, Spain) machine with removable 5mm diameter loops (Figure 5). Specimens were placed immediately in PBS for subsequent DNA analysis, and further specimens placed in formal saline for histological assessment.

Figure 4



Skin snip biopsy technique

Figure 5

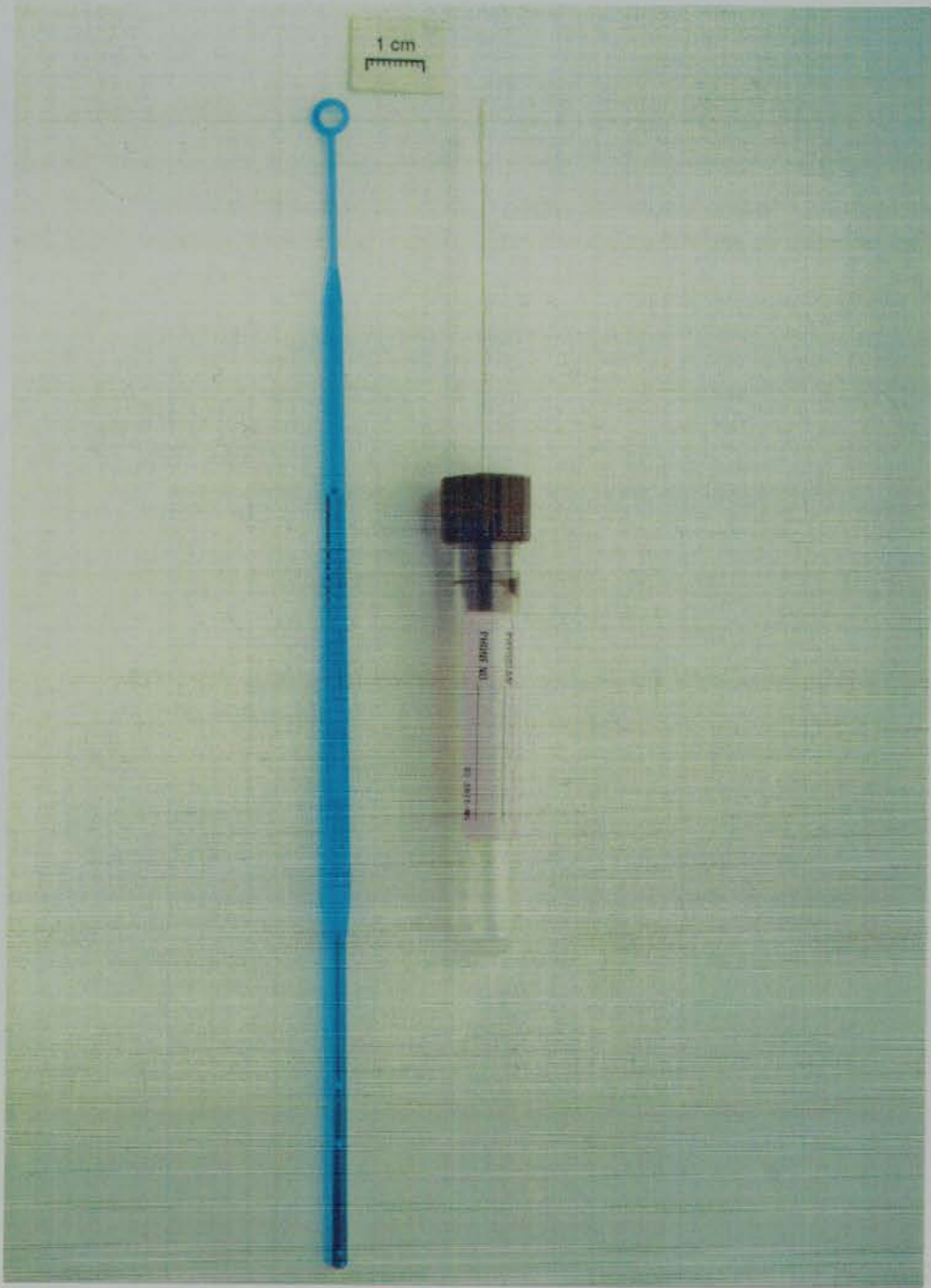


Removal of perianal warts by the electrodesiccator

5.2 Urethral specimens

In initial experiments in which urethral specimens were collected by the use of a brush^{79,85} it was found that, although this method provided adequate samples, it caused too much distress for the patient, and occasionally was associated with the subsequent development of a sterile urethritis. Furthermore, since the PCR was being used, only small samples of the urethral epithelium were necessary. The 10 μ l loop (Figure 6) normally used to investigate for the presence of urethritis in men was the first sampling method tried. However, as will be seen in the Results section, it was felt initially that this method failed to provide adequate samples, and a cotton wool swab (Figure 6) was used subsequently. The particular type of cotton wool swab chosen was "STD-Pen for Males" (Abbott Laboratories, Chicago, Illinois, USA), as these swabs had been used within the clinic for a considerable period of time for the detection of C. trachomatis, and had proved to be acceptable to patients. Although it is generally recommended that the swab be inserted 4cm into urethra, patients rarely tolerated insertion beyond 2cm. Samples were taken with gloved hands, carefully avoiding touching the glans penis, and immediately afterwards inserting the swab into a disposable, sterile container for subsequent processing. When biopsy specimens were taken at the same time, either a different member of staff or a fresh pair of gloves was used to take the urethral specimen.

Figure 6



Swab and loop used in urethral sampling

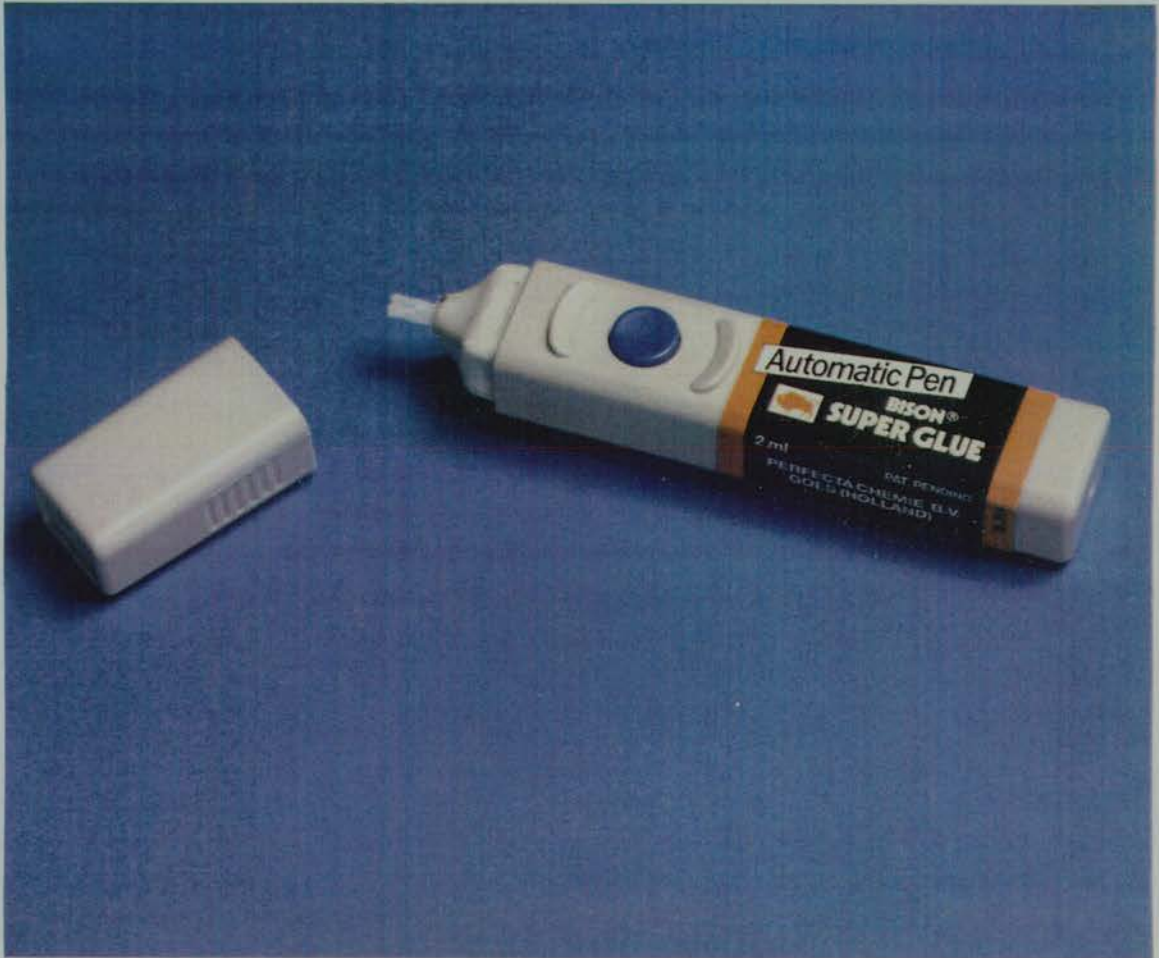
5.3 Urine specimens

Urine specimens are normally provided as part of the "two glass urine test" and their provision is well accepted by patients. For the studies documented in this thesis, the first 10ml of voided urine were collected directly into a sterile, disposable universal container.

5.4 "Superglue" (SG) specimens

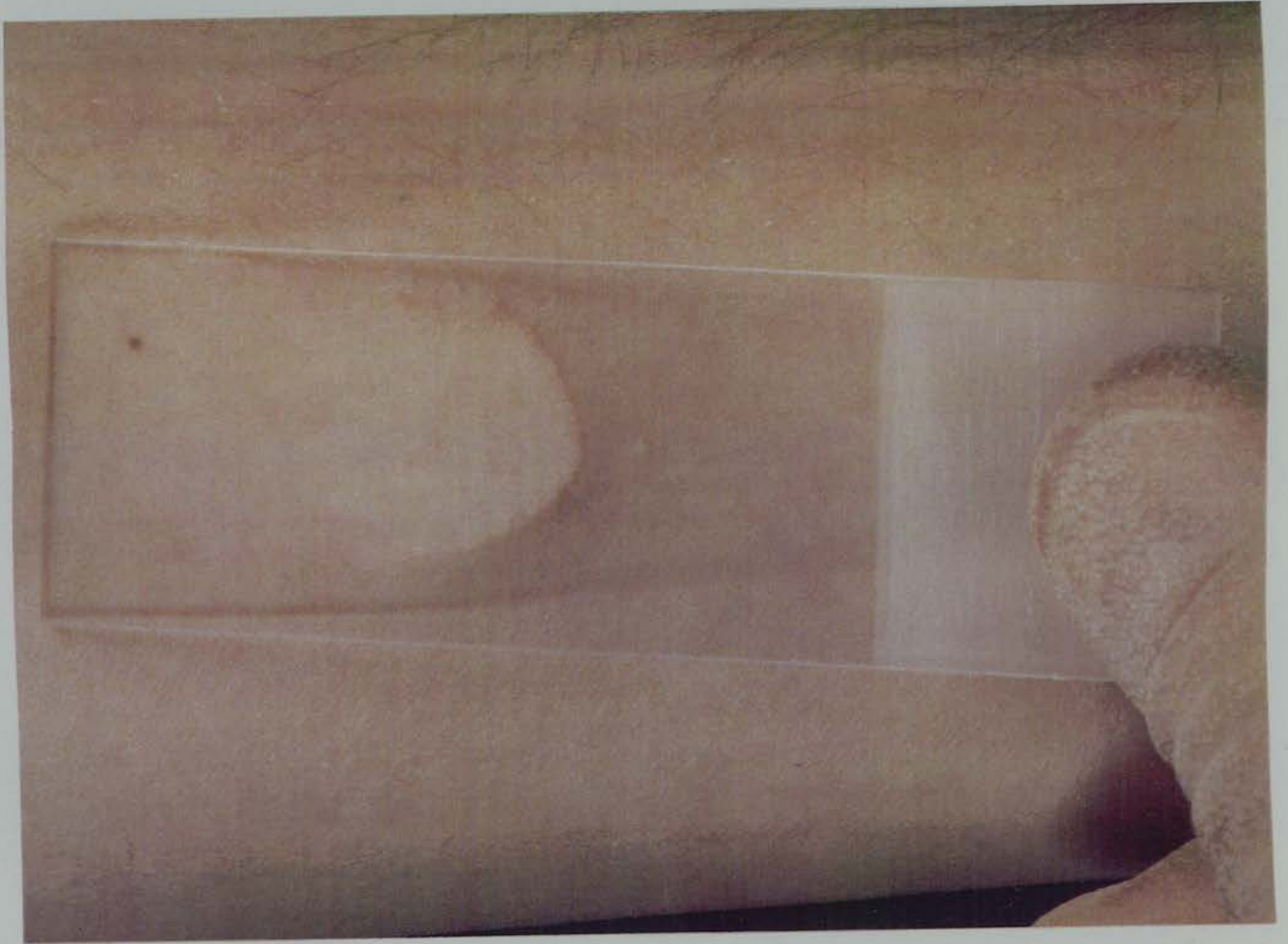
In the multifocal study, superficial layers of skin were sampled by using "Superglue" (SG) cyanoacrylate glue (BisonTM, Perfecta Chemie B.V., Goes, Holland) (Figure 7). One drop of SG was placed on a clean slide which was immediately applied to the skin. After one minute, the slide was gently removed (Figures 8 and 9), and placed in an individual slide box. This procedure was well tolerated by patients. If possible, SG samples were taken from areas of skin containing warts, or areas of skin with acetowhite changes.

Figure 7




Superglue dispenser

Figure 8



Removal of Superglue slide

Figure 9



Superglue sample

5.5 Other specimen types

Further specimens types were taken from patients in the multifocal study in the conventional manner as follows: Ayre's spatulas for cervical scrapes and cytological brushes ("Cytobrush", Rocket, London, UK) for endocervical specimens. Anal samples were obtained by inserting a Cytobrush 1cm into the anal canal and rotating it through 360°. Tongue depressors were drawn along the buccal surface of both sides of the mouth to obtain buccal scrapes. The tips of the sampling instruments used in the aforementioned procedures were broken off into individual disposable bottles containing 10ml of phosphate buffered saline (PBS). A vaginal sample was obtained by washing the vaginal walls and cervix with 10ml of one normal saline using a sterile syringe, aspirating the fluid and repeating the procedure. Blood was obtained using the "Vacutainer" (Becton Dickinson, Cowley, UK) system.

6. Laboratory processing of specimens

The laboratory processing of the specimens was performed in a Class 1 microbiological safety cabinet (Medical Air Technology Ltd., Manchester, UK) and the area where the PCR equipment was assembled was kept physically separate from that where amplification was performed and the PCR products were identified. Equipment was not moved between these areas. Positive displacement pipettes with disposable tips or single-use Pasteur pipettes were used for

distributing reagents for the PCR and for adding the DNA samples to the reaction mixtures. All reagents were autoclaved prior to use and mixed prior to distribution to the tubes, to minimise opening and manipulation. HPV-positive and HPV-negative controls were included in each experiment and not brought into the area where equipment was assembled. Laboratory staff were unaware of the clinical status of the patients.

7. Processing of histological specimens

Specimens sent to the histopathology department were processed routinely and stained with haematoxylin and eosin. Staining with the periodic acid Schiff method was additionally used for specimens in which a histopathological diagnosis of nonspecific dermatosis (NSD) was made. All specimens were reviewed by one histopathologist (Dr Marjorie Walker, Senior Lecturer in Histopathology, St Mary's Hospital Medical School, London). The histopathological criteria used for the diagnosis of viral warts⁹⁵ were the presence of koilocytes and at least one of the following: individual cell keratinization, giant cell formation or hyperkeratosis. Acanthosis was not regarded as being helpful in the diagnosis of wart virus infection. Standard histological criteria for the diagnosis of other dermatological conditions were used³⁶⁰.

8. DNA extraction

In order to break up the tissue, each biopsy specimen was placed in a sterile Eppendorf tube with 160 μ l of 2 x Summers' buffer, 164 μ l of lysis mixture (Appendix V) and three sterile glass beads and vortexed for 1min.

SG slides were abraded with a sterile disposable scalpel blade and the resulting material immersed in 160 μ l of 2 x Summers' buffer and 164 μ l of lysis mixture. The sodium dodecyl sulphate (SDS) in the lysis mixture dissolved the cyanoacrylate in the specimen, releasing the sample material from the specimen.

DNA was extracted from the biopsy and SG specimens by protease/SDS lysis, followed by phenol extraction and ethanol precipitation using a modification of standard procedures³⁶¹. To achieve this, the specimens as prepared above were incubated overnight at 37°C to enable the protease to inactivate proteins and the SDS to bring about cell lysis. After incubation, phenol/chloroform extraction was carried out to remove inactivated proteins and cellular debris, using 320 μ l of Tris EDTA equilibrated phenol (Appendix V). After centrifuging the samples at 14,000 rpm for 1 minute (Microcentaur, MSE, Fisons, Loughborough, UK), the upper, aqueous phase was transferred to sterile Eppendorf tubes and the phenol extraction step repeated. Next, 320 μ l of 1:24 iso-amyl alcohol in chloroform were added to the samples and, after centrifuging the samples at 14,000 rpm for 1 minute, the

upper, aqueous phase was transferred to sterile Eppendorf tubes. Twice the volume of ethanol ($640\mu\text{l}$) and one-tenth the volume ($32\mu\text{l}$) of 5M NaCl were then added to the samples. To enable efficient precipitation of the DNA to occur, the samples were then frozen at -70°C for 1 hour, after which they were centrifuged for 10 minutes at 14,000 rpm. The supernatant fluid from each sample was discarded, and $200\mu\text{l}$ of 70% ethanol was added to each pellet. These were then centrifuged at 14,000 rpm for 5 minutes to further precipitate the DNA. After discarding the supernatant, the pellets were dried in a vacuum desiccator for 30min, to remove all traces of ethanol. Once dried, the DNA pellets were resuspended in $40\mu\text{l}$ of double distilled water (ddH_2O) and stored at -70°C until DNA analysis could be performed.

Urethral swabs and loops, cervical and buccal scrapes and Cytobrush specimens were agitated in 10ml of PBS. Vaginal washes were tested directly. All these samples were subsequently denatured by heating to 95°C for 10min and then centrifuged at 14,000rpm for 2min to remove cellular debris and other extraneous material. The supernatant fluid was then used for the PCR. Urine specimens were centrifuged at 3000 rpm for 10 minutes, the supernatant fluid discarded and the deposit kept. This was then resuspended in $160\mu\text{l}$ 2 x Summers buffer. Blood samples were centrifuged at 2000rpm for 5 minutes and the serum decanted. This was used directly for the PCR.

9. Detection of β -globin gene

Only SG specimens containing human DNA were analysed for the presence of HPV DNA. In order to determine whether human DNA was detectable in the SG samples, part of the human β -globin gene was amplified. Amplification was carried out using 100 μ l of reaction mixture containing 50mM KCl, 10mM TRIS-HCl pH 8.3, 0.01% w/v gelatin, 200 μ M each of dATP, dCTP, dGTP and dTTP, 3.5mM MgCl₂, 2.5 units of Tag polymerase (GIBCO-BRL, Paisley, Scotland) and 0.2 μ M each of two β -globin primers³⁶² (Appendix V). The specimens were then subjected to 40 cycles of amplification. Each cycle included denaturation at 94°C for 30 sec, primer annealing at 55°C for 30 sec and chain elongation at 72°C for 60 sec. Positive controls were a fibroblast cell line derived from embryonic lung tissue (MRC-5) (Medical Research Council, Clinical Research Centre, Harrow, Middlesex, UK) and an epithelial cell line derived from cervical carcinoma tissue (HeLa-229). Double distilled water (ddH₂O) was used as a negative control.

10. Analysis of DNA

10.1 Restriction enzyme digestion

The presence of HPV DNA was confirmed by Southern blotting of Bam H1 restriction enzyme digested cellular DNA³⁶³. Twenty microlitres of each DNA-extracted sample

were made up to a total volume of 25 μ l with 10 units Bam H1 (GIBCO-BRL Life Technologies, Uxbridge, Middlesex, UK), sterile ddH₂O and 10 x restriction buffer (Northumbria Biologicals Limited, Cramlington, Northumbria, UK). This was incubated for 1 hour at 37°C and then 4 μ l of dye (bromophenol blue/xylene cyanol in 40% glycerol) were added. Dye was used to make the DNA visible and to increase its density, thus ensuring that the DNA remained in the wells. Near full length genomic probes to HPV 6,11,16, and 18 were used as positive controls, together with Caski cells (containing integrated full length HPV 16) and HeLa cells (fragments of integrated HPV 18). The human fibroblast cell line, MRC-5, was used as the negative control.

10.2 Polymerase chain reaction

Sequences within the L1 open reading frame were chosen for amplification, as they are known to be generally conserved, but have sufficient divergence to allow discrimination between HPV types 6,11,16,18,31 and 33. General primers GP5 and GP6 were used³⁶³ (Appendix V) which allow the amplification of specific areas of the L1 genome, depending upon the HPV type under investigation.

One hundred microlitres of the PCR reaction mixture¹⁰⁷ (Appendix V) were added to 50-100ng of DNA extracted from the sample under investigation. This was then overlaid with approximately 100 μ l of mineral oil to prevent evaporation, and subjected to 40 cycles of amplification using a thermal cycler (Hybaid, Teddington, Middlesex, UK).

Each cycle comprised denaturation at 94°C for 20 seconds, primer annealing at 40°C for 1 minute and chain elongation at 72°C for 20 seconds. Samples containing 100pg of near full length genomic probes of HPV types 6,11,16 and 18 (Appendix V) were used as positive controls. Negative controls were a human fibroblast cell line (MRC-5) and ddH₂O.

10.3. Separation of DNA fragments by gel electrophoresis

The separation of the DNA fragments was carried out by agarose gel electrophoresis, the percentage of agarose gel used depending on the size of the DNA fragments needing to be separated.

DNA fragments generated by Bam H1 digestion (i.e. the linearised whole genomes of the HPVs, approximately 7950 base pairs long) were separated. This was done on a 1% agarose gel with 1 x Tris-Borate EDTA (TBE) buffer (Appendix V) as the electrophoresis buffer, 10mA for approximately 16-20 hours, followed by ethidium bromide staining for 10 minutes to enable the fragments to be detected. Ethidium bromide was used because it binds irreversibly to DNA, and the product fluoresces bright orange in ultraviolet light.

DNA fragments generated by the PCR were separated using a 2% agarose gel made in TBE buffer, with 1µl ethidium bromide added, and run at 150V and 80mA for 45-60 minutes using 1 x TBE as the electrophoresis buffer. φX174 DNA (BRL, England) cut with the enzyme Hae III

(GIBCO-BRL Life Technologies, Uxbridge, Middlesex, UK) was used to produce molecular weight markers between 72 and 1352 base pairs long.

After separating the DNA fragments, the agarose gel was gently agitated for 30 minutes at room temperature in a solution containing 1.5M NaCl and 0.5M NaOH in order to denature the DNA, and then neutralised for 60 minutes in a solution containing 1.5M NaCl, 0.5M Tris pH 7.5 and 1mM EDTA.

10.4. Transfer of DNA on to nylon membranes by Southern blotting

Southern blotting was performed using a modification of standard protocols³⁶¹. DNA was transferred onto Gene Screen PlusTM nylon membrane (NEN Research Products, Dupont, Wilmington, DE, USA) by the capillary blot procedure, using 6 x SSC (0.9M NaCl with 0.09M sodium citrate) as the transfer buffer. The Southern blot was run overnight to allow adequate transfer from the gel to the membrane. After removing the membrane from the Southern blot, it was allowed to dry at room temperature to enable DNA to bind to the membrane (Gene Screen PlusTM membranes consist of positively charged nylon membranes which do not require baking to fix the DNA).

10.5 Labelling of the probes, hybridisation and autoradiography

In the resistant anogenital warts study, near full-length probes for detection of HPV types 6, 11, 16 and 18 were used for the analysis of the restriction enzyme and PCR products and so prehybridisation of the membranes used was carried out at 65°C for 2 hours, using prehybridisation mixture (Appendix V). In all other studies, oligonucleotide probes were available and so prehybridisation of the membranes was undertaken at 55°C for 2 hours.

10.5.1 Random priming method

This method was used to label near full-length genomic HPV probes of HPV types 6,11,16 and 18 (Appendix V), which have sequences complementary to the DNA fragments generated by restriction enzyme digestion and by the PCR. The procedure involves the generation of a labelled, complementary DNA strand to the original full length HPV genomic probe by the action of a DNA polymerase. This labelled strand then binds to complementary sequences on the DNA specimen being evaluated.

The Amersham Multiprime DNA labelling systemTM (Amersham International PLC, Aylesbury, Bucks, UK) was used. 100ng of genomic probe were used per membrane, made up to 12 μ l in ddH₂O, and denatured by heating at 97°C for 2 minutes. Random priming mix (Appendix V) was then added to the probe and incubated for a minimum of 1 hour.

Incorporated ^{32}P -dCTP-labelled probe was then separated from unincorporated ^{32}P -dCTP (β -emitter, half-life 14 days) by running the reaction mixture through a Sephadex G50 column (Pharmacia LKB Biotechnology, Sweden). Twenty fractions of the reaction mixture were collected. Two peaks of activity are usually found, the first representing the labelled probe, and the second, the unreacted ^{32}P -dCTP. Those fractions of the reaction mixture which emitted over 2,000 counts/second on the radiation detector (Mini monitor 5-10 E, Mini Instruments Ltd, Essex, UK) were pooled and subsequently used.

The probe was then denatured by adding $1/5$ th volume of 1M NaOH and left to react for 10 minutes, followed by neutralisation with the addition of $1/5$ th volume of 1M Tris pH 7.5 and $1/5$ th volume of 1M HCl. Finally, the probe was mixed with the hybridisation mixture, and allowed to react with the complimentary HPV DNA sequences of the specimens under investigation on the membranes for 16-24 hours at 65°C .

Once hybridisation was completed, the membranes were washed once with $2 \times \text{SSC}/0.1\% \text{ SDS}$ at 65°C for 1 hour and once with $0.1 \times \text{SSC}/0.1\% \text{ SDS}$ at 65°C . This first wash was of low stringency, thus removing non-specifically bound, labelled material. The second wash was of high stringency and removed all except probe bound to completely complementary DNA in the specimen, thus allowing differentiation between HPV types 6,11,16 and 18. The membranes were then subjected to auto-radiography for approximately 24 hours on Kodak X-OMAT S X-ray film

between intensifying screens at -70°C and the films developed using an automated developing machine (IGP Dürr Medicine 430, Germany).

10.5.2 End-labelling method

Full-length genomic probes were not available for HPV types 31 and 33, and the technique of end-labelling was used to label the oligonucleotide probe complementary to the products generated by PCR amplification.

Ten micromoles of the HPV 31 and 33 oligonucleotide probes ($1\mu\text{l}$ per membrane) were added to the end-labelling mixture (Appendix V) in a 1.5ml screw-capped Eppendorf tube. The reaction mixture was incubated at 37°C for 1 hour, and then the ^{32}P -dATP-labelled probe was separated from unincorporated ^{32}P -dATP by adding $40\mu\text{l}$ ddH₂O, $240\mu\text{l}$ 5M ammonium acetate and $750\mu\text{l}$ ice cold ethanol, and incubated at -70°C for 30 minutes. This solution was then centrifuged at 14,000 rpm for 10 minutes at 4°C and 1ml of ice cold 80% ethanol was added to the pellet, which contained the ^{32}P -dATP-labelled probe. After the second precipitation step, the pellet was redissolved in $200\mu\text{l}$ ddH₂O and added to the prehybridisation mixture (Appendix V), and the membranes were allowed to hybridise for approximately 24 hours at 55°C . On completion of the hybridisation, the membranes were washed twice with 2 x SSC/0.1% SDS at room temperature for 5 minutes (low stringency washes) and once with 2 x SSC/0.1% SDS at 55°C (high stringency wash) for 5 minutes. The membranes were then auto-radiographed for approximately 24 hours on

Kodak X-OMAT S X-ray film between intensifying screens at -70°C.

10.6 Re-hybridisation of DNA

As Gene Screen PlusTM membrane is not allowed to dry completely (otherwise irreversible binding of probe may result), the membranes were incubated at 45°C for 30 minutes in 0.4M NaOH to remove both the bound oligonucleotide and full length genomic HPV probes. They were then neutralised at 45°C for 30 minutes in a solution containing 0.1 x SSC, 0.1% SDS and 0.2 M Tris pH 7.5. Then it was possible to rehybridise the membranes with the other HPV probes used.

Results

1. GENITAL DERMATOSIS STUDY

1.1 Clinical features of the patients

One hundred men were recruited for this study. The age range of the men was 18.6 to 68.6 years (mean 35.9 years). Seventy-five were Caucasian, 10 Afro-Caribbean and 15 of other racial origins. Eighty-five of the men were heterosexual, 11 homosexual and 4 bisexual. The men admitted to a range of 1 to 1,000 (median 20) life-time sexual partners. No men had typical genital warts at the time of biopsy. Twenty men were circumcised, 69 were not and this information was not recorded in 11 cases. Nineteen men gave a history of anogenital warts, 76 did not, and this information was not recorded in 5 cases.

The lesions had been noticed by the men over a range of 1 to 180 months (mean 31 months). At the time of sampling, the predominant location of the dermatosis was on the glans penis in 44 of the men, coronal region in 12, frenulum in 2, foreskin in 14, shaft in 26 and scrotum in 2. The histological diagnoses of the biopsy specimens are shown in Table 1.

1.2 Detection of HPV in relation to specimen type and to histopathological findings

HPV DNA was detected in one or more biopsy, swab or urine specimens from 39 patients. Examples of this are shown in Figures 10 and 11. The histopathological findings in the

biopsy specimens in relation to the HPV types detected in the three types of specimen are shown in Table 2. The relation between HPV type detected, specimen type and histopathological findings is presented in Tables 4 and 5.

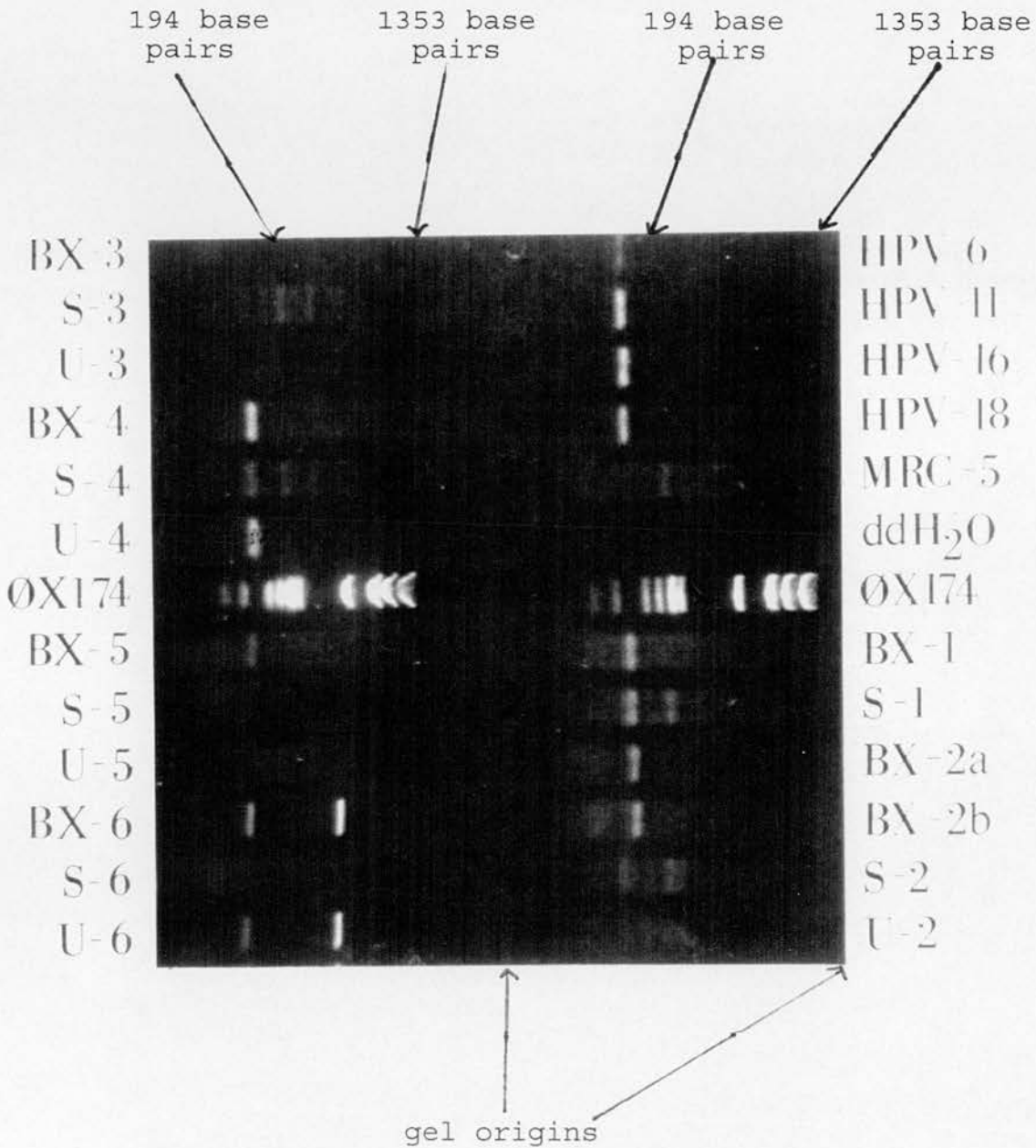
1.3 HPV in biopsy specimens

HPV DNA was detected in 29 of 100 biopsy specimens (Table 3). Seven (28%) of 25 biopsies from the glans, 3 (30%) of 10 from the corona, 1 (50%) of 2 from the frenulum, 9 (29%) of 31 from the foreskin, 8 (27%) of 30 from the shaft and 1 (33%) of 3 from the scrotum contained HPV DNA. Of the 20 circumcised men, 7 (35%) had HPV DNA in their biopsy specimens, that is 3 (33%) of 9 from the glans and corona and 4 (36%) of 11 from elsewhere on the genitalia. Of the 69 uncircumcised men, 18 (26%) had HPV DNA in their biopsy specimens, that is 5 (31%) of 13 from the glans, none of 6 from the corona, 1 (50%) 2 from the frenulum, 9 (29%) of 31 from the foreskin and 3 (18%) of 17 from elsewhere on the genitalia.

Of the 22 men who had histological evidence of typical HPV infection, 6 (27%) had a history of anogenital warts; of the 12 men who had histological evidence of neoplasia, 4 (33%) had a history of anogenital warts; of the 66 men who had no histological evidence of either typical HPV infection or neoplasia, 13 (20%) had a history of anogenital warts.

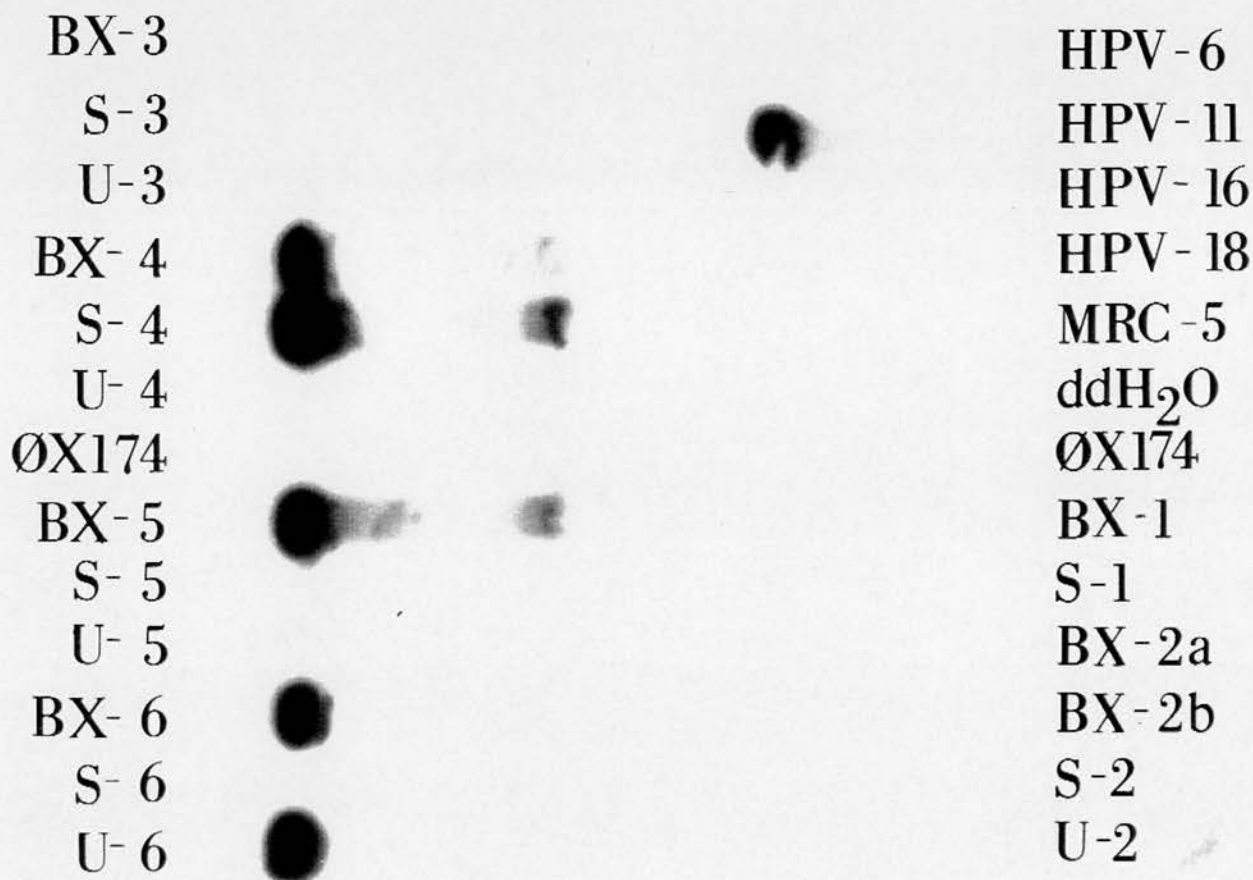
Figure 10

Agarose gel - penile dermatosis study



Ethidium bromide staining of PCR followed by agarose gel, with positive controls (HPV types 6,11,16 and 18), negative controls (MRC-5 fibroblasts and ddH₂O), molecular weight marker (ØX174) and specimens of DNA from biopsies (BX), swabs (S) and urine (U). Samples BX-2a and BX-2b are from two different sites on the scrotum of one patient. Positive results are seen with samples BX-4, S-4, U-4, BX-5, BX-6, U-6, BX-1, S-1, BX-2a and BX-2b.

Figure 11



Southern blot - penile dermatosis study

Hybridisation of PCR products with HPV type 11-specific probe on nylon membrane following Southern blot with positive control (HPV type 11), negative controls (HPV types 6, 16 and 18, MRC-5 fibroblasts and ddH₂O), molecular weight marker (ØX174) and specimens of DNA from biopsies (BX), swabs (S) and urine (U). Positive result are seen with HPV type 11 control, BX-4, S-4, BX-5, BX-6 and U-6.

HPV DNA was detected in 32% of biopsy specimens with histological evidence of typical warts, 83% of specimens with neoplasia and 18% of specimens in which histological evidence of either change was absent (Table 4). The detection of HPV DNA in urethral swab and urine specimens did not vary substantially between those men with and without histological evidence of HPV infection (Tables 5 and 6).

Wart specimens were associated most frequently with HPV DNA types 6 or 11, specimens showing neoplasia most frequently with type 16 and specimens having other histopathological changes with a variety of HPV types, most commonly HPV types 11 and/or 18 (Table 4). Of particular note, all three basal cell papillomata were associated with HPV type 6 (Table 2).

Infection with two or more HPV types was found in 7 (24%) of 29 biopsy specimens containing HPV DNA (Table 5).

1.4 HPV in urethral swab specimens

Urethral swab specimens were obtained from 85 men. Of these specimens, 21 (25%) contained HPV DNA (Table 3).

HPV DNA was more commonly detected in urethral specimens from men with histological evidence of neoplasia than from men with histological evidence of warts or other histological abnormalities (Table 4). HPV type 18 was the type most frequently detected in urethral swab specimens. Infection with more than one HPV type was found in approximately one-third of the swab specimens in

which HPV DNA could be detected (Table 3).

1.5 HPV in urine specimens

Urine specimens were obtained from 59 men. Of these specimens, only 6 (10%) contained HPV DNA (Table 3).

HPV DNA was not detected in urine specimens from men with histological evidence of warts, and only a small proportion of those with neoplasia or other histological abnormalities (Table 4). HPV type 18 was the type most frequently detected in urine specimens. Infection with more than one type occurred on one occasion (Table 5).

1.6 Association between presence or absence of HPV and type of specimen

A correlation between biopsy and swab and between biopsy and urine was less obvious than between swab and urine findings (Table 7). Ten (28%) of the 36 patients with HPV present in biopsy or urethral swab specimens had at least one HPV type in common.

1.7 HPV in relation to possible risk factors and demographic details

The proportion of biopsy, urethral swab and urine specimens containing HPV are given in relation to various possible risk factors and demographic details in Table 8 and Table 9. Although the numbers are too small for a valid statistical analysis, there is a suggestion that infection with HPV is more common in men admitting to at least 20 lifetime sexual partners than those with fewer

partners, and in those with a history of AGW compared to those without. An association between HPV infection and other factors is less clear.

Table 1 Histopathological diagnoses of biopsy specimens from 100 men with genital dermatoses

Category	Histopathological diagnosis	No. of patients
Wart	Typical wart virus infection	22
Neoplasia	Basal cell papilloma	3
	Dysplastic wart*	1
	PIN [§] 1	1
	PIN 2	5
	PIN 3	2
Other	Non specific dermatosis	24
	Lichen sclerosus	13
	Lichen planus	7
	Lichen nitidus	1
	Lichen simplex	1
	Psoriasis	7
	Fungal infection	2
	Miscellaneous [#]	11

*Histopathological change not amounting to PIN 1

[§]Penile intraepithelial neoplasia

[#]this group comprised: normal, not diagnostic, scarring, granuloma annulare, plasma cell balanitis, lentigo, venous haemangioma, sebaceous cyst wall, molluscum contagiosum, folliculitis and drug rash.

Table 2 HPV DNA types detected in relation to histopathological findings of biopsy specimens from men with genital dermatoses

Histo- pathological findings	HPV DNA types detected in indicated specimens		
	Biopsy	Urethral swab	Urine
Wart	6, 11	6, 11, 18	ns
Wart	6	-	-
Wart	18	-	-
Wart	6	-	-
Wart	6, 11	ns	ns
Wart	16	11, 18	ns
Wart	6, 11	-	-
Wart	-	18	-
Wart	-	33	-
<u>Neoplasia</u>			
Basal cell papilloma	6	6	ns
Basal cell papilloma	6	-	-
Basal cell papilloma	6	-	-
Dysplastic wart	16	-	-
PIN 1	6	-	-
PIN 2	-	18	18
PIN 2 + wart	16	ns	ns
PIN 2	16	18	ns
PIN 2	6	-	-
PIN 3	16	-	ns
PIN 3	16	16	ns
<u>Other</u>			
NSD	18	-	ns
NSD	18	18, 31	-
NSD	6, 11, 18	18, 33	ns
NSD	18	-	-
NSD	11, 18	11	ns
NSD	-	-	16
NSD	-	33	33
LS	11, 18	11, 18	ns
LS	18	6, 11	ns
LS	-	18, 31	ns
LS	11	11	11, 18
LS	-	18	-
LS	31	-	-
Lichen planus	31	ns	ns
Lichen planus	16	16	-
Psoriasis	-	18	18
Psoriasis	11, 18	11, 31	ns
Plasma cell balanitis	-	-	6
Venous haemangioma	-	6	-

- = no HPV DNA detected; ns = no specimen obtained; PIN = penile intraepithelial neoplasia; NSD = non-specific dermatosis; LS = lichen sclerosus

Table 3 HPV in relation to type of specimen from men with genital dermatoses

HPV type	No. of specimens of indicated type positive for HPV		
	Biopsy (n=100)	Urethral swab (n=85)	Urine (n=59)
Any HPV	29	21	6
6	10 (34)*	3 (14)	1 (17)
11	8 (27)	6 (29)	1 (17)
16	7 (24)	2 (9)	0 (0)
18	10 (34)	11 (52)	3 (50)
31	3 (10)	2 (9)	0 (0)
33	0 (0)	4 (19)	1 (17)
>1 type	7 (24)	8 (38)	1 (17)

*Figures in brackets are expressed as percentages of all that particular specimen type containing any HPV DNA

Table 4 HPV in relation to histopathological findings of biopsy specimens from men with genital dermatoses

HPV type	No. (%) of men with specified HPV type in given specimen according to histopathological diagnosis		
	Wart (n=22)	Neoplasia (n=12)	Other (n=66)
Any type in biopsy specimens	7 (32)	10 (83)	12 (18)
urethral swab specimens	4 (21 [*])	4 (36 [*])	13 (24 [*])
urine specimens	0	1 (14 [*])	5 (13 [*])
any specimen	9 (41)	11 (92)	19 (29)
Type 6 in any specimen	5 (23)	5 (42)	4 (6)
Type 11 in any specimen	4 (18)	0	6 (9)
Type 16 in any specimen	1 (5)	5 (42)	2 (3)
Type 18 in any specimen	4 (18)	2 (17)	12 (18)
Type 31 in any specimen	0	0	5 (8)
Type 33 in any specimen	1 (5)	0	2 (3)
>1 type in any specimen	4 (18)	1 (8)	8 (12)

* urethral swab and urine specimens were not obtained from all men. The figures in these instances refer to those men from whom urethral swab or urine specimens were taken.

Table 5 HPV in relation to type of specimen from all men with genital dermatoses

HPV type	No. of specimens positive for indicated type		
	Biopsy (n=100)	Urethral swab (n=85)	Urine (n=59)
Any HPV	29	21	6
6	11 (38)*	4 (19)	1 (17)
11	8 (27)	7 (33)	1 (17)
16	7 (24)	2 (9)	1 (17)
18	9 (31)	11 (52)	3 (50)
31	2 (7)	3 (14)	0 (0)
33	0 (0)	3 (14)	1 (17)
>1 type	7 (24)	8 (38)	1 (17)

*Figures in brackets are expressed as percentages of all that particular specimen type containing any HPV DNA

Table 6 HPV in relation to type of specimen from men with genital dermatoses and no histological evidence of HPV infection

HPV type	No. of specimens positive for indicated type	
	Urethral swab (n = 55)	Urine (n=39)
Any HPV	13	5
6	2 (15) *	1 (20)
11	5 (38)	1 (20)
16	1 (18)	1 (20)
18	6 (46)	2 (40)
31	2 (15)	0
33	3 (23)	1 (20)
>1 HPV type	5 (38)	1 (20)

*Figures in brackets are expressed as percentages of all that particular specimen type containing any HPV DNA

Table 7 Correlation between presence (+) or absence (-) of HPV DNA and type of specimen from men with genital dermatoses

	Biopsy		Biopsy		Swab							
	+	-	+	-	+	-	ns					
S	+	13	8	U	+	1	5	U	+	4	2	0
w				r				r				
a	-	13	51	i	-	12	41	i	-	6	46	1
b				n				n				
	ns	3	12	e	ns	16	25	e	ns	11	16	14

ns = no specimen obtained

Table 8 HPV in different specimens in relation to possible risk factors of men with genital dermatoses

Possible risk factors	Proportion* (percentage) of specimens of indicated specimen type positive for HPV		
	Biopsy	Urethral swab	Urine
<35 years old	17/57 (30)	13/49 (26)	5/32 (16)
≥35 years old	12/43 (28)	8/36 (22)	1/27 (4)
Heterosexual	28/85 (33)	16/72 (22)	4/48 (8)
Bi/homosexual	1/15 (7)	5/13 (38)	2/11 (18)
Caucasian	20/75 (27)	16/67 (24)	4/46 (9)
Non Caucasian	9/25 (36)	5/18 (28)	2/13 (15)
≥20 partners	16/45 (35)	14/44 (32)	5/30 (17)
<20 partners	9/39 (23)	5/37 (14)	1/28 (4)
C [¶] never used	10/29 (35)	6/28 (21)	1/17 (6)
C [¶] sometimes used	11/44 (25)	10/39 (26)	3/28 (11)
C [¶] always used	2/11 (18)	3/11 (27)	1/9 (11)
Smoker	14/39 (36)	9/37 (24)	2/20 (10)
Non-smoker	11/44 (25)	9/42 (21)	4/36 (11)
History [§]	9/19 (47)	6/17 (35)	1/8 (12)
No history [§]	19/76 (25)	14/64 (22)	5/49 (10)

*proportion for each possible risk factor: number of men with that specimen type containing HPV DNA, expressed as a proportion of all men with that risk factor and whose HPV status for that specimen type was known.

[¶]history of anogenital warts given by patient
[¶] condoms

Table 9 HPV in different combinations of specimens in relation to possible risk factors of men with genital dermatoses

Possible risk factors	Proportion* (percentage) of specimens of indicated specimen types positive for HPV	
	Biopsy, swab or urine	Urethral swab or urine
<35 years old	24/57 (42)	14/49 (29)
≥35 years old	15/43 (35)	9/37 (24)
Heterosexual	34/85 (40)	18/73 (25)
Bi/homosexual	5/15 (33)	5/13 (38)
Caucasian	28/75 (37)	20/75 (27)
Non Caucasian	11/25 (44)	9/25 (36)
≥20 partners	22/45 (49)	15/44 (44)
<20 partners	12/39 (31)	6/32 (19)
C [¶] never used	12/29 (41)	6/28 (21)
C [¶] sometimes used	16/44 (36)	11/40 (28)
C [¶] always used	4/11 (36)	4/11 (36)
Smoker	16/39 (41)	14/39 (36)
Non-smoker	17/44 (39)	11/44 (25)
History [§]	10/19 (53)	9/19 (47)
No history [§]	28/76 (37)	19/76 (25)

*proportion for each possible risk factor: number of men with that specimen type containing HPV DNA, expressed as a proportion of all men with that risk factor and whose HPV status for that specimen type was known.

[§]history of anogenital warts given by patient

2. RESISTANT ANOGENITAL WARTS STUDY

2.1 Clinical features of the patients

One hundred and sixteen men were recruited for this study. The age range of the men was 16.1 to 61.6 years (mean 28.6 years). Fifty-four (46.6%) of the 116 men were homosexual, 50 (43.1%) heterosexual, 7 (6.0%) bisexual and 5 (4.3%) were of unspecified sexual orientation. This distribution of sexual orientations was characteristic of the clinic from which the study group was chosen. A history of other previous sexually transmitted diseases was given by 51 (44.0%) of the men. Two (5.9%) of 34 men who had undergone testing for the human immunodeficiency virus within three years prior to sampling of their warts were found to carry antibody. Information concerning number of sexual partners, whether or not they smoked, ethnicity and condom usage was not obtained from these men.

The men had been aware of their warts for an average of 18.1 months (range 0.5 to 120 months) prior to undergoing biopsy. Histological assessment was performed on a random samples of 54 (46.6%) of the biopsy specimens, and all were found to have changes consistent with wart virus infection. None of the specimens showed evidence of dysplasia. The clinical appearance of the warts was described as classical condylomata acuminata in 94 (81.1%) of the men, planar in 10 (8.6%), hyperkeratotic

in 26 (22.4%), mixed type in 13 (11.2%) and pigmented in one.

At the time of sampling, warts were seen at the meatus in 7 (6.0%) of the men, the glans in 10 (8.6%), coronal region in 10 (8.6%), foreskin in 8 (6.8%), shaft in 26 (22.4%), scrotum in 4 (3.4%), inguinal region in 5 (4.3%), perineal area in 3 (2.6%), perianal area in 78 (67.2%) and intra-anal site in 14 (12.1%).

2.2 HPV in biopsies from anogenital warts

HPV DNA was detected in 112 (96.5%) of 116 wart specimens. Types 6 and 11 were the most common (84.8% and 82.1%, respectively) and types 31 and 33 the least common (0.9% and 2.7%, respectively) (Table 10). Infection with two or more types of HPV was found in 84 (72.4%) of the warts. The commonest multiple infection was with types 6 and 11, which occurred together in 58 (50.0%) of the men and in combination with other HPV types in a further 21 (18.1%) men. HPV type 6 was found in 83 (99%) of the 84 multiple infections and type 11 in 79 (94%) of such infections.

The distribution of HPV type found in the warts did not vary significantly with the site of the biopsy or age of the patient (data not shown).

2.3 HPV in urethral swab specimens

Twenty-two (19.0%) of the 116 urethral swabs contained HPV DNA. The detection rate did not vary with sexual orientation. Again, types 6 and 11 were the most common,

but type 16 was detected relatively more often than it was in the warts (Table 10). Fourteen (63.3%) of the 22 swabs contained a single HPV type. Multiple HPV types were found in 8 (36.3%) of the swabs in which any HPV DNA could be detected. HPV type 6 was found in 7 (87.5%) of the 8 swabs containing more than one type, and HPV type 11 in all 8. HPV type 16 was the most common single HPV type detectable, being found in 7 (50%) of the 14 swabs in which only one HPV type was found.

2.4 HPV in urethral loop specimens

HPV DNA was detected in 11 (61.1%) of the 18 urethral loop specimens. The detection rate did not vary with sexual orientation. Whether the loop or swab specimen was taken first had no appreciable effect on the rate of detection. The distribution of HPV types was similar to that seen with the swab specimens (Table 10). In 5 (27.8%) of 18 specimens there was evidence of a single HPV type, which was HPV type 16 in all cases. Of the 6 loop specimens in which multiple HPV types were detected, HPV type 6 was always present and HPV type 11 found in 5 (83.3%).

Of the 11 men who had HPV-positive loop samples, only 5 had urethral swab specimens that were also HPV-positive. In all cases where both loop and urethral swab specimens contained HPV, at least one HPV type was common to both specimens.

2.5 HPV in urine specimens

HPV DNA was detected in only 1 (6.7%) of 15 urine samples tested. This was found to comprise HPV types 16 and 18. The patient had only perianal warts and no history of warts elsewhere. Analysis of the wart specimen revealed HPV type 6 alone. No urethral loop sample was taken and HPV DNA was not detected in the urethral swab specimen.

2.6 Association between location of warts at time of biopsy and HPV detected in the urethra

The location of the visible warts in relation to the results of HPV DNA detection in urethral specimens is shown in Table 11. Six (85.7%) of the 7 men who had clinically apparent meatal warts had HPV DNA detected in their urethral swab specimens. Thereafter, it can be seen that the further away visible warts were from the meatus at the time of urethral sampling by swab or loop, the smaller the proportion of urethral samples containing HPV DNA. The association was not seen with loop samples, but the number examined was small.

2.7 Association between HPV types detected in warts and in the urethra

The relation between the location of warts and the HPV type in the urethra is shown in Table 12. HPV types 6 or 11 were found in diminishing frequency in the urethra as

the warts were located more distally from the urethral meatus. In contrast, there appeared to be no such association for HPV types 16, 18, 31 or 33.

Of the 22 swab samples in which HPV DNA was detected, 10 (45.4%) had at least one type in common with the corresponding warts. Furthermore, 6 (54.5%) of the 11 loop samples in which HPV DNA was detected had at least one HPV type in common with the corresponding warts.

2.8 HPV in relation to possible risk factors and demographic details

There was no clear association between age or sexual orientation and the detection of HPV DNA in any sample (Table 13).

Table 10 HPV in relation to type of specimen from men
with anogenital warts

HPV type	No. of specimens positive for indicated type		
	Biopsy (n = 116)	Urethral swabs (n=85)	Urethral loops (n=18)
Any HPV	112	22	11
6	95 (85) *	9 (41)	5 (46)
11	92 (82)	10 (46)	5 (46)
16	10 (9)	8 (36)	6 (55)
18	20 (18)	6 (27)	4 (36)
31	1 (1)	2 (9)	1 (9)
33	3 (3)	2 (9)	1 (9)
>1 HPV type	84 (72)	8 (36)	6 (54)

* Figures in brackets are expressed as percentages of all that particular specimen type containing any HPV DNA

Table 11 Location of warts in relation to detection of urethral HPV DNA from men with resistant anogenital warts

Location*	No. of patients (n = 116)	Swab with HPV DNA (%) (n = 116)	Loops with HPV DNA (%) (n = 18)	Total No. # (%)
Meatus	7	6 ^f /7 (85.7)	4/6 (66.7)	6 (85.7)
Glans	6	1/6 (16.7)	1/3 (33.3)	2 (33.3)
Corona	6	4/6 (66.7)	N.L.	4
Foreskin	4	0/4	N.L.	0
Shaft	19	1/19 (5.3)	2/3 (66.7)	3 (15.8)
Scrotum	2	0/2	1/1	1 (50)
Inguinal	2	0/2	N.L.	0
Perianal	67	10/67 (14.9)	3/5 (60)	13 (19.4)
Intra-anal	3	0/3	N.L.	0

*Location of clinically apparent warts seen nearest to the urinary meatus at the time of biopsy

n = total number of patients or of samples taken

= total number of patients in each category with swabs or loop specimens containing HPV DNA

^fNumerator signifies the number of samples with HPV DNA detected in that particular group

N.L. = No loop sample taken

Table 12 Location of warts in men with resistant anogenital warts in relation to urethral HPV type

Location*	No. swabs/loops containing HPV DNA	No. (%) swabs/loops containing indicated HPV types	
		6 or 11	16,18, 31 or 33
Meatus	6	6 (100)	5 (83)
Glans	2	2 (100)	1 (50)
Coronal	4	1 (25)	3 (75)
Shaft	3	1 (33)	2 (67)
Scrotum	1	0	1
Perianal	13	3 (23)	11 (85)

*Location of clinically apparent warts seen nearest to the urinary meatus at time of biopsy

Table 13 HPV in different specimens in relation to possible risk factors of men with resistant anogenital warts

Possible risk factors	Proportion* (percentage) of specimens of indicated specimen type positive for HPV									
	Any specimen		Warts		Urethral swab		Urethral loop		Urine	
<27 yrs	61/61	(100)	60/61	(98)	10/61	(16)	6/9	(67)	0/5	(0)
≥27 yrs	53/55	(96)	52/55	(94)	12/55	(22)	5/9	(56)	1/11	(9)
Hetero	48/50	(96)	47/50	(94)	12/50	(24)	8/14	(57)	0/9	(0)
Bi/homo	61/61	(100)	60/61	(98)	9/61	(15)	2/3	(67)	1/7	(14)

*proportion for each possible risk factor: number of men with that specimen type containing HPV DNA, expressed as a proportion of all men with that risk factor and whose HPV status for that specimen type was known.

3. URETHRAL GONORRHOEA STUDY

3.1 Clinical features of the patients

One hundred men were recruited for this study. The age range of the men was 17.0 to 55.6 years (mean 26.7 years). Fifty-two of the men were Afro-Caribbean, 34 Caucasian, eight African and four from other racial groups. Information on the ethnic origin of two men was not available. Seventy-six of the 100 men described themselves as heterosexual, 19 homosexual, and five bisexual. The mean number of lifetime sexual partners was 43, with a range of 3 to 200; in addition, one bisexual man claimed to have had 1000 lifetime sexual partners. A history of genital warts was given by six of the men. One of 85 of the men who gave blood specimens at the time of presentation had serological evidence of syphilis. Fifty-eight of the men were cigarette smokers. Of the 98 men who provided information on condom usage, 27 claimed always, 59 sometimes and 12 never to have used them.

3.2 HPV in urethral swab specimens

HPV was detected in 18 of 100 urethral swabs specimens. HPV types 11, 16 and 18 were the most common (Table 14). Infection with more than one HPV type was found in 8 (44%) of the 18 urethral swabs containing HPV DNA (Tables 14 and 15). DNA from HPV types 16,18 31 or 33 was found

in 15 (83%) of 18 urethral swab specimens in which any HPV DNA could be detected.

3.3 HPV in urine specimens

HPV was detected in 11 (12.5%) of 88 urine specimens. HPV types 11 and 16 were the most common (Table 14). Infection with more than one HPV type was found in 3 (27%) of the 11 urine specimens containing HPV DNA (Table 14 and 15). DNA from HPV types 16, 18, 31 or 33 was found in 8 (73%) of 11 urine specimens in which any HPV DNA could be detected.

3.4 HPV in relation to possible risk factors and demographic details

The proportions of urethral swab and urine specimens containing HPV are given in relation to various possible risk factors and demographic details in Table 16. Although the numbers are small, there is a suggestion that infection with HPV is more common in urethral swab specimens taken from men less than 27 years old compared to older men, heterosexuals compared to non-heterosexuals and non-Caucasians compared to Caucasians. An association between HPV infection and other factors is less clear, however the numbers were too small for a valid statistical analysis.

Table 14 HPV in relation to type of specimen from men
with urethral gonorrhoea

HPV type	No. of specimens positive for indicated type	
	Urethral swab (n = 100)	Urine (n=88)
Any HPV	18	11
6	5 (28)*	3 (27)
11	8 (44)	6 (54)
16	6 (33)	6 (54)
18	7 (39)	2 (18)
31	2 (11)	0
33	2 (11)	0
>1 HPV type	8 (44)	3 (27)

*Figures in brackets are expressed as percentages of all that particular specimen type containing any HPV DNA

Table 15 Single and multiple types of HPV found in urethra and urine of men with gonorrhoea

<u>HPV type</u>	<u>No. of specimens positive for indicated type</u>	
	<u>Swab</u> (n =18)	<u>Urine</u> (n=11)
6 alone	0	0
11 alone	3	3
16 alone	3	3
18 alone	4	2
31 alone	0	0
33 alone	0	0
6 and 11	3	0
6, 11 and 16	1	3
6 and 18	1	0
11, 16 and 18	1	0
16, 18, 31 and 33	1	0
31, 33	1	0

Table 16 HPV in different specimens in relation to possible risk factors of men with urethral gonorrhoea

Possible risk factors	Proportion* (percentage) of specimens of indicated specimen type positive for HPV		
	Urethral swab or urine	Urethral swab	Urine
<27 years old	13/55 (24)	10/55 (55)	5/50 (10)
≥27 years old	12/45 (27)	8/45 (18)	6/38 (16)
Heterosexual	22/76 (29)	16/76 (21)	10/69 (15)
Bi/homosexual	3/24 (13)	2/24 (8)	1/19 (5)
Caucasian	6/34 (18)	4/34 (12)	3/28 (11)
Non-Caucasian	19/64 (30)	14/64 (22)	5/58 (14)
≥20 partners	6/33 (18)	4/33 (12)	2/29 (7)
<20 partners	15/56 (27)	11/56 (20)	7/49 (14)
C [¶] never used	4/27 (15)	2/27 (7)	2/25 (8)
C [¶] sometimes used	20/59 (34)	15/59 (25)	8/53 (15)
C [¶] always used	1/12 (8)	1/12 (8)	1/7 (14)
Smoker	16/60 (27)	13/60 (22)	6/53 (11)
Non-smoker	9/36 (25)	5/36 (14)	5/31 (16)

*proportion for each possible risk factor: number of men with that specimen type containing HPV DNA, expressed as a proportion of all men with that risk factor and whose HPV status for that specimen type was known.

C[¶] condoms

4. MULTIFOCAL STUDY

4.1 Clinical features of patients

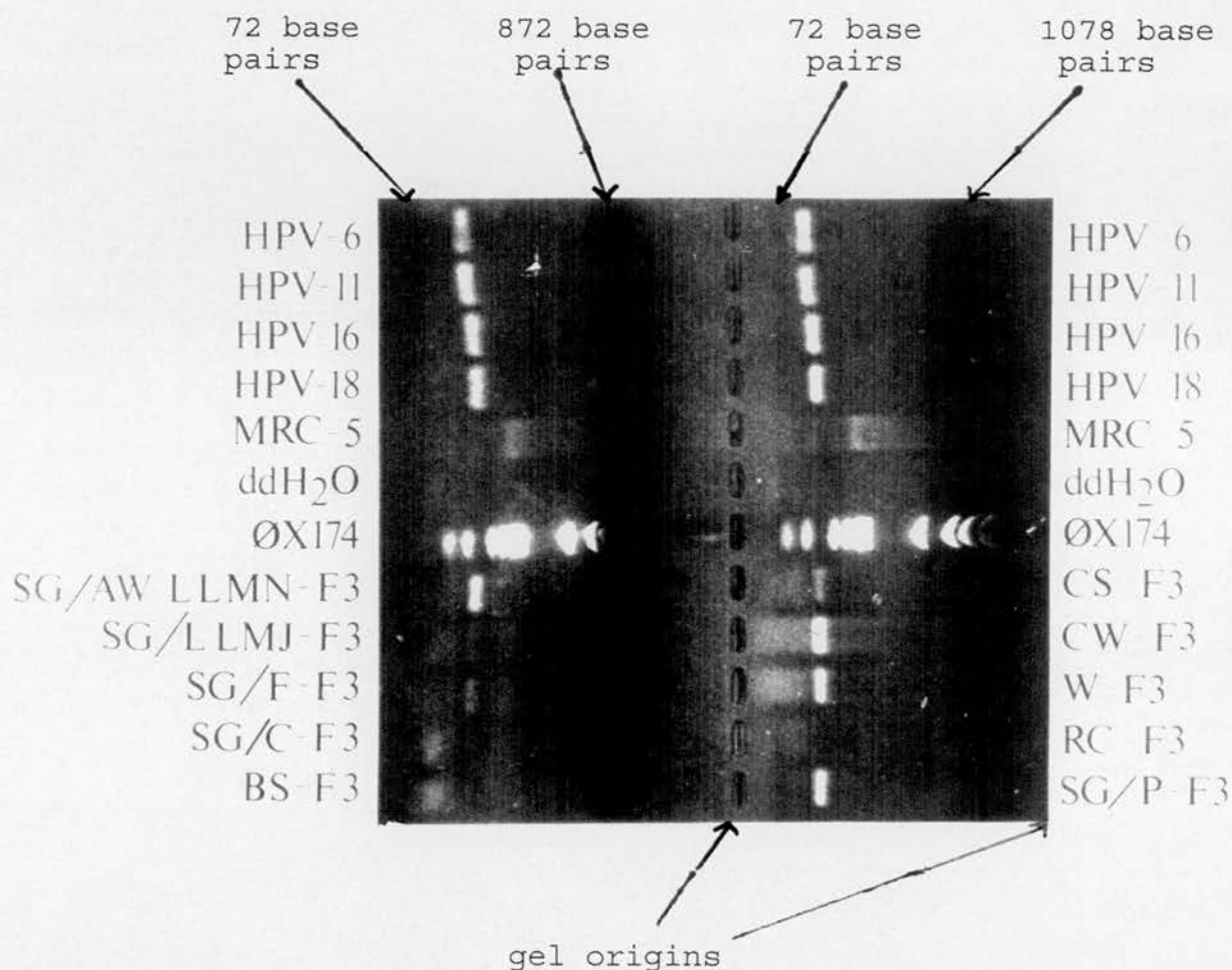
Nine women and 9 men took part in the study. All patients were heterosexual. The mean age of the women was 24.0 years (range 16.1 years to 36.2 years) and that of the men 28.4 years (range 22.9 years to 36.3 years). Clinical details of the patients are shown in Tables 17 and 18; there were 4 pairs of partners (F1-M3, F2-M8, F3-M2 and F7-M9), the partners of the other patients not being available for study. Patient F6 was referred by her general practitioner because of a suspicion of genital warts seen at the time of taking a cervical scrape. There was no evidence of anogenital warts at the time of assessment in the clinic, but a papillary lesion noted in the vagina was biopsied and found to be a skin tag. Apart from this, all other biopsies taken from clinically apparent warts were confirmed histologically as such. Biopsy of acetowhite changes on the labia of patient F8 showed changes of HPV infection.

To facilitate interpretation of results, specimens were divided into three groups. "Biopsy" specimens consisted of biopsies from clinically abnormal and acetowhite areas. "SG specimens" consisted of samples obtained using the SG technique. The term "non-biopsy" is used to describe all other types of specimens.

Examples of the results are shown in Figures 12 and 13.

Figure 12

Agarose gel - multifocal study




Ethidium bromide staining of PCR followed by agarose gel, with positive controls (HPV types 6,11,16 and 18), negative controls (MRC-5 and ddH₂O), molecular weight marker ϕ X174 (ϕ X174 DNA cut with Hae III enzyme) and specimens of DNA from patient F3. Abbreviations for the specimen descriptions:

SG = Superglue specimen BS = buccal smear
AW = specimen taken from acetowhite area CS = cervical scrape
LLMN = left labium minus CW = cervical wart
LLMJ = left labium majus W = external wart
F = fourchette RC = rectal cytobrush
C = clitoris P = perianal

Positive result seen for HPV controls, superglue specimens from the fourchette and perianal area, as well as an acetowhite area on the left labium minus. Cervical scrape, cervical wart and vulval wart specimens also contain HPV DNA.

Figure 13



Southern blot - multifocal study

Hybridisation of PCR products with HPV type 11-specific probe on nylon membrane following Southern blot. Abbreviations as for Figure 12, and:

G = glans
RLMJ = right labium majus
S = scrotum
SH = shaft

Positive result seen for HPV type 11 control, in addition to superglue specimen from the scrotum of patient M2 and the fourchette of patient F2.

4.2 HPV in biopsy specimens

Biopsies were taken from warts and acetowhite areas in women (Table 19) but only from warts in men. HPV DNA was detected in 5 (83%) of 6 biopsy specimens, with histological evidence of HPV infection, from women (Tables 17 and 19) and in 7 (78%) of 9 from men (Table 20). None of 4 biopsies of acetowhite areas in the women contained HPV DNA, nor did the biopsy of the skin tag (Table 19). Two (25%) of 8 cervical biopsies contained HPV DNA, of which one was histologically abnormal (Tables 17 and 19).

4.3 HPV in non-biopsy specimens

In women (Table 19), HPV DNA was detected in the following specimens: 4 (36%) of 11 cervical scrapes, 2 (25%) of 8 from the urethra, 3 (37%) of 8 from the vagina, 2 (33%) of 6 from the rectum and 0 of 5 buccal scrapes. Both cytologically abnormal cervixes (Table 17) contained HPV DNA.

In men (Table 20), HPV DNA was detected in the following specimens: 3 (37%) of 8 from the urethra, 1 (12%) of 8 from the rectum and 0 of 5 buccal scrapes.

None of the serum samples (taken from all 9 men and 6 of the 9 women) contained HPV DNA.

4.4 HPV in "Superglue" (SG) specimens

Forty SG samples were taken from women (Table 21) and 41 from men (Table 20). Thirty-seven (92%) of those from women and 18 (44%) of those from men contained the β -

globin gene. Of the samples containing the β -globin gene, 18 (49%) from women and 9 (50%) from men contained HPV DNA, detection rates which compare favourably with those of non-biopsy procedures.

Of SG samples from acetowhite areas, HPV DNA was detected in those from the labia of 4 of 5 women (Tables 17 and 21) and in those from the glans of 2 of 4 men (Tables 18 and 20).

Of the 6 men with shaft warts (Table 18), HPV DNA was detected in the shaft SG specimens of 4 of the 5 men whose shaft SG wart specimens contained the β -globin gene (Table 20). Similarly, HPV DNA was detected in the fourchette SG samples from all 3 women with fourchette warts who had this sample taken (Tables 17 and 21).

4.5 HPV in relation to sample site and time of sampling

Of the 12 possible sites in women (Tables 19 and 21) from which samples could have been taken on each occasion, 0-8 (mean 2.8) contained HPV DNA. Of the 8 possible sites in men (Table 20) from which samples could have been taken on each occasion, 1-5 (mean 1.25) contained HPV DNA.

Of the 8 patients from whom samples were taken on more than one occasion (Tables 19-21), 5 had HPV DNA detected in fewer sites and 2 in more sites than when first seen. In one patient, the number of sites in which HPV DNA was detected initially increased, but then decreased.

4.6 Types of HPV detected

Of the 56 samples in which HPV DNA was detected, 23 (41%) had evidence of infection with a single type, 27 (48%) with multiple types and 6 (11%) with undetermined types (Tables 18-21).

The distribution of HPV types in the various categories of specimens from women and men is shown in Table 22. HPV types 6 and 11 were found most frequently in the majority of specimen categories. However, the other types sought were found predominantly in the non-biopsy and SG specimen categories.

Samples taken from different sites of the same patient frequently contained the same HPV type. This is illustrated by samples from patients F4 and M4, the majority of which contained HPV type 6. However, in patients in whom multiple HPV types were detected, not all the types were found in each specimen.

4.7 HPV in pairs of partners

Partner pairs F1-M3, F2-M8 and F3-M2 had HPV types in common. Partner pair F7-M9 did not (Tables 19-21).

Abbreviations used on Tables 17 - 22

Pt = patient code

§ = partner in the study as indicated

ns = no specimen obtained

NAD = no histological or cytological abnormality detected

wart = histological changes of condylomatous wart virus infection

¥ = clinical status of partner as reported by study patient

CIN 1 = cervical intraepithelial neoplasia grade 1

WVI = histological changes of non condylomatous HPV infection

bdline = borderline mild dyskaryosis

koil = koilocytic atypia

Time = duration in months since first sample taken

neg = HPV types 6,11,16,18,31 and 33 not detected

* = biopsy from clinically apparent wart

+ = specimen contained HPV of types other than those tested for

β⁻ = β-globin gene not detected

- = no specimen of this type detected

Table 17 Clinical, histological and cytological details of female patients in multifocal study

<u>Pt</u>	<u>Sites of visible warts</u>	<u>Sites of acetowhite change</u>	<u>Status of partner</u>	<u>Histological or cytological changes in</u>		
				<u>Vulval biopsy</u>	<u>Cervical biopsy</u>	<u>Cervical scrape</u>
F1	none	cervix	warts (M3) §	ns	NAD	ns
F2	fourchette	cervix	warts (M8) §	ns	ns	NAD
F3	fourchette cervix	labia	warts (M2) §	wart	CIN 1 WVI	ns
F4	fourchette cervix	cervix labia	warts ¶	wart	NAD	bdline
F5	fourchette cervix	labia cervix	no warts ¶	ns	koil	bdline
F6	none	cervix	no warts ¶	skin tag	WVI	NAD
F7	none	labia	no warts (M9) §	ns	ns	NAD
F8	none	labia	warts ¶	WVI	ns	NAD
F9	fourchette labia	labia	no warts ¶	wart	ns	NAD

Table 18 Clinical and histological details of male patients in multifocal study

<u>Pt</u>	<u>Sites of visible warts</u>	<u>Sites of acetowhite change</u>	<u>Status of partner</u>	<u>Histological changes in skin biopsy</u>
M1	shaft	none	cervical dysplasia [¥]	ns
M2	shaft inguinal	glans	warts (F3) [§]	ns
M3	shaft	glans	no warts (F1) [§]	wart
M4	meatus glans	glans	no warts [¥]	wart
M5	shaft inguinal	none	no warts [¥]	wart
M6	corona	corona	warts [¥]	wart
M7	shaft glans	glans	warts [¥]	wart
M8	shaft	glans	warts (F2) [§]	wart
M9	glans	glans	no warts (F7) [§]	wart

Table 19 HPV DNA in biopsy and non-biopsy specimens from women in multifocal study in relation to types of specimens and times at which taken

<u>HPV DNA in sites and types of specimen indicated</u>								
<u>Pt</u>	<u>Time</u>	<u>Vulval biopsy</u>	<u>Cervical biopsy</u>	<u>Cervical scrape</u>	<u>Urethral loop</u>	<u>Vaginal wash</u>	<u>Rectal swab</u>	<u>Buccal scrape</u>
F1	0	neg	6	ns	neg	neg	neg	neg
	4	neg	neg	neg	neg	neg	ns	ns
	12	ns	ns	neg	ns	neg	ns	ns
F2	0	6,11,31*	ns	ns	ns	ns	ns	neg
	4	ns	neg	neg	ns	18,31	6,11	ns
F3	0	6,11*	ns	6,11,33	6,11,33	ns	ns	ns
	2	6,11*	6,11*	neg	ns	ns	ns	neg
F4	0	6*	neg*	6	6	+	6	neg
F5	0	neg*	neg*	6	neg	ns	ns	ns
F6	0	neg	ns	neg	neg	neg	neg	ns
F7	0	neg	ns	+	neg	16	ns	neg
F8	0	neg	neg	neg	ns	ns	neg	ns
F9	0	6,11*	neg	neg	neg	neg	neg	ns

Table 20 HPV DNA in biopsy, non-biopsy and SG specimens from men in multifocal study in relation to types of specimens and times at which taken

<u>HPV DNA in sites and types of specimen indicated</u>									
<u>Pt</u>	<u>Time</u>	<u>Biopsy</u>	<u>Urethra loop</u>	<u>Rectal swab</u>	<u>Buccal scrape</u>	<u>SG specimens from</u>			
						<u>Glans</u>	<u>Shaft</u>	<u>Scrotum</u>	<u>Anus</u>
M1	0	ns	ns	ns	ns	β ⁻	β ⁻	ns	neg
	7	ns	ns	ns	neg	β ⁻	18	neg	β ⁻
M2	0	ns	ns	neg	neg	β ⁻	β ⁻	6,11,18	β ⁻
	4	6,11	6	neg	ns	neg	ns	ns	ns
M3	0	neg	ns	ns	neg	neg	18	ns	ns
	4	ns	neg	neg	ns	neg	neg	β ⁻	ns
M4	0	6,11	6,11,16	6,11	ns	6,11	+	ns	β ⁻
	3	ns	ns	ns	ns	neg	β ⁻	β ⁻	β ⁻
M5	0	6	neg	neg	ns	18	6	ns	ns
M6	0	6	neg	neg	neg	6,31	β ⁻	ns	ns
M7	0	ns	ns	ns	ns	β ⁻	β ⁻	ns	ns
	1	6,33	6	neg	ns	ns	ns	ns	ns
	2	6,11	ns	ns	ns	ns	ns	ns	ns
	3	ns	ns	ns	ns	β ⁻	neg	β ⁻	β ⁻
M8	0	neg	neg	neg	ns	β ⁻	18	ns	neg
M9	0	6	neg	ns	neg	β ⁻	β ⁻	β ⁻	β ⁻

Table 21 HPV DNA findings SG specimens from women in multifocal study in relation to types of specimens and times at which taken

<u>HPV DNA in SG specimens from</u>						
<u>Pt</u>	<u>Time</u>	<u>Left labia</u>	<u>Right labia</u>	<u>Fourchette</u>	<u>Clitoris</u>	<u>Anus</u>
F1	0	neg	neg	ns	ns	neg
	4	+	18	ns	ns	+
	12	neg	neg	neg	ns	neg
F2	0	6, 11, 33	33	6, 11, 33	ns	18, 33
	4	6	neg	neg	β ⁻	ns
F3	0	6, 11, 18, 33	ns	ns	ns	6, 11
	2	neg	neg	+	neg	ns
F4	0	6, 11	6, 16, 18	ns	ns	6, 11, 18
F5	0	6	neg	6	ns	ns
F6	0	ns	β ⁻	neg	neg	ns
F7	0	neg	neg	neg	ns	neg
F8	0	ns	ns	ns	ns	ns
F9	0	6, 11	β ⁻	11	ns	ns

Table 22 HPV type in relation to types of specimens
in multifocal study

<u>Number of times (%) HPV of specified type in given sample type</u>							
<u>HPV type</u>	<u>Women</u>				<u>Men</u>		
	<u>Vulval biopsy</u>	<u>Cervical biopsy</u>	<u>Non- biopsy</u>	<u>SG</u>	<u>Wart</u>	<u>Non- biopsy</u>	<u>SG</u>
6	5 (50)	2 (67)	7 (41)	11 (34)	7 (64)	4 (57)	4 (31)
11	4 (40)	1 (33)	3 (17)	8 (24)	3 (27)	2 (29)	2 (15.5)
16	-	-	1 (6)	1 (3)	-	1 (14)	-
18	-	-	1 (6)	5 (15)	-	-	5 (38.5)
31	1 (10)	-	1 (6)	-	-	-	1 (7.5)
33	-	-	2 (12)	5 (15)	1 (9)	-	-
+	-	-	2 (12)	3 (9)	-	-	1 (7.5)
>1 type	4 (80)	1 (50)	4 (36)	9 (50)	4 (57)	2 (50)	3 (33)

5. COMPARISON OF FINDINGS FROM DIFFERENT STUDY GROUPS

The HPV findings from the biopsy, urethral swab and urine specimens of men with dermatoses not typically associated HPV infection, men with resistant anogenital warts and men with urethral gonorrhoea were compared (Tables 23-27).

5.1 Detection of HPV in different sample sites

There was little difference in the detection rate of HPV DNA in urethral swab and urine specimens between men with dermatoses not typically associated with HPV infection, men with resistant anogenital warts and men with urethral gonorrhoea (Table 23).

Concerning biopsy specimens, HPV 18 was the most common type detected in men with genital dermatoses and types 6 and 11 the most common in men with resistant anogenital warts (Table 24). Eighty-one percent of all biopsy specimens contained HPV types 6 or 11 and 16% contained types 16 or 18. In contrast, only 45% of urethral swab specimens contained HPV types 6 or 11, whereas 39% contained HPV types 16 or 18. Thus, in all three studies the "high-risk" HPV types were disproportionately more common in urethral swab and urine specimens than in those found in biopsy specimens (Tables 25 and 26).

5.2 Association between HPV detected and patient details

Demographic and possible risk factor details of the men in the genital dermatoses, resistant anogenital warts and urethral gonorrhoea studies were analysed. The mean age of the men in all 3 combined studies was 30 years.

Biopsy specimens were taken from men in the genital dermatoses and resistant anogenital warts studies. Combining the data from these two studies, HPV DNA was detected in 75 (56%) of 135 heterosexual men compared to 61 (80%) of 76 bisexual or homosexual men and 98 (76%) of 128 men less than 30 years old compared to 43 (49%) of 88 men aged 30 years or older.

Demographic data were available from the men with penile dermatoses or urethral gonorrhoea. The combined data from these two studies (Table 27) do not convincingly demonstrate evidence of sexual transmission, that is, there was no clear association between the detection of HPV DNA and age, number of lifetime sexual partners and claimed condom use.

Table 23 HPV in relation to specimens taken and study group

Specimen category	No. (%) with HPV detected in given study group		
	Other dermatoses* (n=66)	Resistant warts (n=116)	Gonorrhoea (n=100)
Urine or urethral swab specimen	12 (18)	23 (20)	25 (25)
Biopsy, urethral swab or urine specimen	19 (29)	113 (97)	25 ^f

*dermatoses not typically associated with HPV infection

^fbiopsies not taken from men with urethral gonorrhoea

Table 24 HPV in biopsy specimens in relation to study group

HPV type	No. (%) of biopsies from specified study group positive for indicated HPV type		
	Other dermatoses* (n=66)	Resistant warts (n=116)	Gonorrhoea (n=0)
Any HPV	12 (18)	112 (97)	-
6	1 (1.5)	95 (82)	-
11	5 (8)	92 (79)	-
16	1 (1.5)	10 (9)	-
18	8 (12)	20 (17)	-
31	2 (3)	1 (1)	-
33	0	3 (3)	-
>1 HPV type	4 (6)	84 (72)	-

*dermatoses not typically associated with HPV infection

Table 25 HPV in urethral swab specimens in relation to study group

HPV type	No. (%) of urethral swab specimens from specified study group positive for indicated HPV type		
	Other dermatoses* (n=55)	Resistant warts (n=116)	Gonorrhoea (n=100)
Any HPV	13 (24)	22 (19)	18 (18)
6	2 (4)	9 (8)	5 (5)
11	5 (9)	10 (9)	8 (8)
16	1 (2)	8 (7)	6 (6)
18	6 (11)	6 (5)	7 (7)
31	3 (5)	2 (2)	2 (2)
33	2 (4)	2 (2)	2 (2)
>1 HPV type	6 (11)	8 (7)	8 (8)

*dermatoses not typically associated with HPV infection

Table 26 HPV in urine specimens in relation to study group

HPV type	No. (%) of urine specimens from specified study group positive for indicated HPV type		
	Other dermatoses* (n=39)	Resistant warts (n=16)	Gonorr- hoea (n=88)
Any HPV	5 (13)	1 (6)	11 (13)
6	1 (3)	0	3 (3)
11	1 (3)	0	6 (7)
16	1 (3)	0	6 (7)
18	2 (5)	0	2 (2)
31	0	0	0
33	1 (3)	0	0
>1 HPV type	1 (3)	1 (6)	3 (3)

Table 27 HPV in different specimens in relation to possible risk factors of men with genital dermatoses or urethral gonorrhoea

Possible risk factors	Proportion* (percentage) of specimens of indicated specimen type positive for HPV		
	Urethral swab or urine	Urethral swab	Urine
§ <30 years old	47/197 (24)	42/197 (21)	11/100 (11)
§ ≥30 years old	24/105 (23)	19/104 (18)	7/63 (11)
§ Heterosexual	52/143 (36)	44/198 (22)	14/126 (11)
§ Bi/homosexual	19/98 (19)	16/98 (16)	4/37 (11)
Caucasian	26/109 (24)	20/101 (20)	7/74 (9)
Non-Caucasian	28/89 (31)	19/82 (23)	7/71 (10)
≥20 partners	21/77 (27)	18/77 (23)	7/59 (12)
<20 partners	21/88 (24)	18/93 (19)	8/77 (10)
C [¶] never used	10/56 (18)	8/56 (14)	3/42 (7)
C [¶] sometimes used	31/99 (31)	25/98 (26)	11/81 (14)
C [¶] always used	5/23 (22)	4/23 (17)	2/16 (13)
Smoker	30/99 (30)	22/97 (21)	8/73 (11)
Non-smoker	20/80 (25)	14/78 (18)	9/67 (13)

*proportion for each possible risk factor: number of men with that specimen type containing HPV DNA, expressed as a proportion of all men with that risk factor and whose HPV status for that specimen type was known.

¶ condoms

§ data also includes men with resistant anogenital warts

Conclusions

1. Introduction

The detection rate of HPV DNA may depend on the population studied and careful selection and definition of the study population characteristics are essential¹²¹. In prevalence studies it is important to assess rates of infection in as wide a range of the population as possible, yet the unpleasant nature of some of the sampling methods, coupled with associated ethical considerations limit the accessibility of much of the population. The four studies included in this thesis were designed in an attempt to obtain as wide a perspective of the epidemiology of anogenital HPV infection as possible.

Men with clinical indications for genital biopsy were chosen in the genital dermatosis study, not in the belief that they represented the general male community, but that they would do so more closely than patients with "conventional" STDs. Although recruited from a department of genitourinary medicine, the men were unusual for this source in that they were generally older, had fewer lifetime sexual partners, and did not have any clinically apparent STD at the time of biopsy. Men with genital dermatoses require biopsy procedures for full investigation, and tissue samples thus obtained have been studied extensively in other clinical settings³⁶⁰. It was therefore anticipated that men who did not have conventional STDs, yet in whom biopsy material was available, would provide a useful group in which to study HPV infection.

Biopsy specimens were obtained from a wide variety of sites from the male genitalia and many of these specimens had histopathological features which were not typically associated with HPV infection. Furthermore, it has been shown³⁵⁹ that the range of histopathological diagnoses seen in such a clinic is broadly similar to that seen in dermatology and urology departments. A large amount of information concerning possible risk factors for the acquisition of HPV infection was collected from this group of men and compared to the presence of HPV in biopsy, urethral swab and urine specimens. In this manner, it was intended to investigate the incidence of infection with HPV in relation to demographic factors and to compare the results of different sampling techniques.

Increasing evidence suggests that HPV infection of the female anogenital tract is multifocal³⁶⁴. Less is known of the distribution of HPVs in men. On the assumption that men with extensive AGW would be likely to have a large viral load, men attending a clinic for ablative treatment of anogenital warts were studied. Such a group had the additional advantage that tissue removed as part of treatment could be analysed for the presence of HPV, and the results compared to those obtained from samples from different sites of the same men.

The results of several studies^{118,221,223-5} have shown that 20%¹¹⁸ to 32%²²⁴ of men presenting to genitourinary clinics with genital warts have evidence of at least one other STD. In particular, the incidence of gonorrhoea in such men varies from 0%²²⁵ to 9.9%²²⁴. These studies

rely on the clinical identification of condylomata acuminata, and the question of how often men with gonorrhoea are infected with HPV has not been previously addressed. Men with gonorrhoea were therefore studied in an attempt to shed some light on the sexual transmissibility of HPV infections. In addition, it was postulated that the presence of a urethral discharge might increase the diagnostic yield for HPV in urethral swab specimens.

To further investigate the nature of multifocal anogenital HPV infection, to determine any change of infection with time, and to evaluate infectivity of HPV infection, a small group of patients and their partners was sampled extensively over a period of several months. Different sampling methods could be compared, and a novel technique (the "Superglue" (SG) method) investigated.

2. Methods used in the studies

Wide variations in reported prevalence rates of genital HPV infections may be related, at least in part, to the use of different methods of obtaining and preparing samples¹⁸⁴, as well as the use of different techniques for the detection of HPV. The most common method for screening for the presence of infection with HPV is by clinical examination. As already discussed, this detects only a minority of anogenital HPV infections. Colposcopy, with the aid of acetic acid staining, detects more cases, but, particularly when applied to areas other than the cervix, is neither sensitive^{83,143} nor specific^{90,93,97} for the detection of HPV infection.

2.1 Biopsy

Biopsy of the cervix⁹² and vulva³⁶⁵⁻⁶ are well-established in clinical practice and widely performed. Less is known about the cutaneous pathology of the penis^{141,164}. Although men may be reluctant to undergo penile biopsy⁵², in experienced hands the refusal rate is low⁵³ and the method safe³⁵⁹. In particular, men with persisting genital dermatoses are willing to undergo the procedure in order to establish the diagnosis³⁵⁹. Punch biopsies are commonly used for obtaining specimens from the vulva, and have also been used in men^{97,103}, but the skin snip technique³⁵⁹ was used in these studies as it was found to be technically easier and produced satisfactory samples with good subsequent healing.

Skin biopsy provides a sample which includes the lower epidermis, an area which is difficult to access by other sampling techniques, yet is the site of productive infection with HPV³⁰. The biopsy procedure also has the advantage of allowing the assessment, in a standardised fashion³⁶⁰, of histopathological changes which might be associated with the presence of HPV. However, the taking of biopsies only permits the detection of abnormalities in a small area and thus may lead to an underestimation of the infection rate. A negative result thus does not necessarily exclude infection. Furthermore, tissue sent for HPV studies is not exactly the same as that sent for

histopathological review, but rather an immediately adjacent sample, thus introducing a potentially significant sampling error⁵⁷.

2.2 Cytology

There are well defined criteria for the cytological assessment of cervical scrape specimens³⁶⁷. Attempts to extend these criteria for the detection of HPV in urethral swab specimens^{79,151,168} and urine specimens^{137,159-60} have been unsatisfactory. In addition, smears from keratinising squamous epithelia are usually scanty, contain only anucleate squames, and are difficult or impossible to assess cytologically⁵².

Epithelial cells, however, are easily removed from the urethra, a principle which is well established in diagnosing urethritis in the male. Urethral swabs designed for the detection of C. trachomatis and the 10 μ l "blue loop" routinely used for the investigation of urethritis in the male were initially chosen for the studies, as they have been found previously to be both acceptable to patients and effective in sampling the urethral epithelium for urogenital pathogens. Initial analysis of urethral specimens by Southern blotting showed that more DNA was present in the swab specimens than in those obtained by the loop method. It was on the basis of this finding that swab samples alone were taken from the rest of the men. However, when both loop and swab samples were taken from the same patient, 5 of the 6 patients whose swabs contained HPV DNA also had HPV DNA-positive loop specimens.

Furthermore, HPV DNA was detected in 5 loop samples but not in the corresponding swab. Use of the loop would, therefore, seem to be more sensitive for the detection of urethral HPV infection than that of the swab. It is possible that the use of brushes^{83,85,136} may have allowed the collection of specimens from the urethra with more HPV, but this procedure was found to be unacceptable to the patients and resulted in the production of a sterile urethritis (personal observations). Similarly, it was found that vigorously scraping the entire penile skin, including the foreskin and glans with a plastic spatula⁸⁵ or cytological brush¹⁰⁰ was also unacceptable. Furthermore, it has recently been established¹⁰⁰ that urethral swabs are as effective as abrading the preputial area in the detection of infection with HPV.

2.3 Superglue method

The SG technique has been used to assess changes in the stratum corneum³⁶⁸. In this study, the SG technique was chosen as it allowed the sampling of the skin surface with minimal trauma. Not only is this process more acceptable to patients than formal biopsy, but it also allows the monitoring of HPV-induced changes without inducing the brisk inflammatory response associated with biopsy. Inflammatory responses may alter the natural history of HPV infection³⁶⁹ and thus the SG technique was proposed as a means of assessing the natural history of HPV infection which would only marginally affect the process which it was designed to measure. Although the

number of cells harvested by this technique is small, the use of the PCR for the detection of the human β -globin gene allowed confirmation of the presence of human cells.

2.4 Other sampling techniques

HPV has been found in cervical scrapes²¹⁰, urethral specimens from women³⁷⁰, urine¹⁶¹⁻³, vaginal samples^{247,371}, rectal swabs³⁷², buccal scrapes¹²⁹ and serum samples³⁰³. All these specimens, as well as SG samples, were included in the multifocal study in order to investigate the widespread nature of anogenital HPV infections.

2.5 Laboratory methods

The PCR and Southern blotting were used to detect HPV DNA, as these methods are highly sensitive and specific³³, allowing the detection of very few viral particles. Consensus primers from the L1 area of the HPV genome were used to direct the amplification of DNA sequences common to many HPV types. The typing of the HPVs was then dependent upon the subsequent hybridisation with specific probes. The extreme sensitivity of the methods used meant that sample size could be small and genital trauma minimised. As great care was taken during the collection of clinical material, and both positive and negative controls were used at all stages of analysis of the specimens, the results are thought to reflect the true occurrence of HPV in the specimens, rather than contamination.

3. Genital dermatosis study

Biopsies from a wide variety of sites from the male genitalia were obtained, many of which had histopathological features which were not typically associated with HPV infection. Furthermore, it has been shown³⁵⁹ that the range of histopathological diagnoses seen in the penile dermatosis clinic is broadly similar to that seen in dermatology and urology departments.

A large amount of information concerning possible risk factors for the acquisition of HPV infection was collected from this group of men and compared to the presence of HPV in biopsy, urethral swab and urine specimens. The median number of sexual partners is given, as there was a small number of men claiming a very large number of sexual partners, and it was thus thought that the arithmetic mean would be unrepresentative. HPV DNA was more commonly found in all specimen types from men with larger numbers of lifetime sexual partners. Although less convincing, HPV DNA was also more commonly found in men less than 35 years old and in those who did not use condoms. These observations are consistent with sexual transmission. The detection of HPV DNA more commonly in smokers than in non-smokers is consistent with the finding of condylomata acuminata²⁰⁵ and occult anogenital HPV infection more commonly in smokers, although differing sexual practices between smokers and non-smokers may contribute to this phenomenon. Furthermore, the observa-

tion that HPV was more commonly detected in men with a history of anogenital warts than those without, is compatible with the concept of latent infection and is consistent with the findings of others¹⁵¹. The lower incidence of HPV DNA in biopsies from homosexual and bisexual men compared to heterosexual men contrasts with the converse in urethral swab and urine specimens. Sexual orientation has been shown by others⁵⁹ to influence the epidemiology of genitotropic HPV infection. On the basis of these observations it is therefore tempting to speculate that the differing sexual practices may influence the epidemiology of anogenital HPV infection.

The observation that HPV DNA was found in approximately similar proportions of biopsies from whatever site of the male genitalia, and regardless of whether the patient was circumcised, confirms the widespread distribution of HPV infection in men. Disruption of skin integrity may promote infection with HPV at sites of genital dermatoses. On the basis of this evidence, however, the possibility of a uniform distribution of HPV DNA throughout the intact male genital tract cannot be excluded. Such a distribution would contrast with the occurrence of condylomata acuminata at specific sites, frequently those traumatised during intercourse³, and suggests that factors other than the presence of HPV DNA may also be involved in the development of clinically apparent disease.

HPV DNA was found in only 32% of genital warts in this group of men, possibly reflecting the unusual sample of

warts. Only genital lesions which were clinically atypical were referred for biopsy, so that classical condylomata acuminata were not seen. It is thus possible that this sample of warts may have contained a large proportion of warts caused by non-genitotropic HPV types. However, the observation that HPV types 6 and 11 were the most common in biopsies with histological evidence of warty change is consistent with previous reports^{59,134}. Furthermore, the detection of HPV type 16 in the majority of biopsy specimens with histological evidence of dysplasia is in agreement with the findings of others^{77,95}.

Eighteen percent of biopsy specimens with no histological evidence of warts or dysplasia contained HPV DNA. This is contrary to the observations of other groups investigating the male urogenital tract, who have not been able to find HPV DNA in biopsy specimens that did not have histological evidence of warts or dysplasia^{52,55,172,197}. It is, however, in agreement with reports of others who have investigated the male genital tract⁹⁹. Furthermore, as we have seen, DNA from the genitotropic HPV types has been detected in the absence of histological abnormalities in the cervix¹⁸⁴, neonatal foreskin²⁵², the oropharynx¹⁹³ and conjunctiva⁵⁴. The predominance of HPV type 18 in biopsy specimens with no histological evidence of warts or neoplasia is difficult to explain. It would seem unlikely that this HPV type is involved in the pathogenesis of such a wide range of conditions. Perhaps the disrupted epithelial structure associated with the underlying

dermatological condition might facilitate the entry of the HPV into the basal layers of the epithelium and thus permit the replication of the HPV. Alternatively HPV type 18 might be a passive contaminant from other parts of the body, a recent sexual contact, or an inanimate object³⁰⁴.

The detection of HPV DNA in 25% of urethral swab specimens is in broad agreement with the findings of others^{151,373}. Contrary to what had been expected, HPV DNA was found less frequently in the urethral swab and urine specimens from men with histological evidence of HPV infection or dysplasia than in those from men with no such changes (Table 5). This suggests that the relationship between urethral HPV infection and clinically apparent warts might be a complex one, and the matter was further investigated in the study of men with resistant anogenital warts. The finding of HPV DNA in 10% of urine specimens, none of which was from men with histopathological changes of warts, suggests that the epidemiology of HPV in urine might also not be straightforward.

As large numbers of each specimen type were taken from the men in this study, the opportunity was taken to compare the detection of HPV in biopsy, urethral swab and urine specimen types (Table 6). The correlation between the presence or absence of HPV DNA and type of specimen was found to be generally poor. Furthermore, there was no discernible relationship between HPV types found in the different specimens from the same man (Table 2).

It was not surprising to have found HPV types 6 and 11

most commonly in biopsy specimens with histological changes of HPV infection (Table 2). It was surprising, however, to have found "high risk" types proportionally more often in urethral swab and urine specimens (Table 5). These observations suggest that the three different sampling methods may measure distinctly different aspects of the epidemiology of HPV infection in the urogenital tracts of men.

4. Men with resistant anogenital warts

This group of men was chosen on the assumption that they would be infected with large quantities of HPV. It was proposed, therefore, that study of these men might provide an insight into the distribution of HPV in those with extensive, clinically apparent HPV infection. In particular, it was hoped that further information would be gained about HPV infection of the urethra and its relation with clinical disease. Fewer demographic details were collected from this group of men compared to the studies of men with genital dermatoses and men with gonorrhoea.

The finding of HPV DNA in 96.6% of wart specimens in this study is consistent with the 69%⁵⁹ to 100%¹³⁴ found in other studies. The small proportion of warts without detectable HPV DNA presumably represents infection with HPV types not tested for, small quantities of viral DNA, or inadequate extraction of DNA from the samples.

Twenty-five men had HPV DNA detected in their urethras

and a further one man had HPV DNA in his urine. Thus, overall, there was evidence of genito-urinary tract infection with HPV in 26 (22.4%) of the men. This compares with one study³⁷⁴ in which HPV DNA was sought in the urethra using a cytological brush to remove cells and Southern blotting to determine the HPV type; 25 (33%) of 75 men with genital warts were HPV-positive in the urethra and 9 (36%) of these 25 men had HPV types 16, 18 or 31. Wikström et al¹⁰⁰, using the PCR in combination with the dot blot method, found that 46 (89%) of 52 men with anogenital warts had HPV DNA in their urethras. It is unclear whether this reflects a true difference in the epidemiology of HPV between the populations studied, or methodological differences.

The sample of men chosen in this study was unusual, containing a large proportion of homosexual men with perianal warts which had been present for some considerable time. As newer warts contain more viral particles than older ones³⁶⁹, it is possible that the urethral carriage rate would have been greater if a larger proportion of men with newly developed warts had been examined. Furthermore, urethral carriage was more common when warts were visible near the meatus, and the preponderance of men in this study with perianal warts may have led to a further underestimation of the typical carriage rate. It is noteworthy that the association of urethral HPV DNA carriage with proximity of clinically apparent warts to the meatus occurs with HPV types 6 and 11, but not with the other types considered (Table 12). The data from

this study suggest that types 16, 18, 31 and 33 may be true colonisers of the urethra, whereas types 6 and 11 may be occurring in the urethra as a result of contamination from adjacent warts.

A large number of warts were apparently infected with multiple HPV types. It is possible that this observation arose as a consequence of large amounts of HPV DNA in the wart specimens causing cross hybridisation. However, it is hoped that the rigorous experimental conditions used make this an unlikely explanation.

Fifteen percent of the HPV types detected in wart specimens were of the "high-risk" types, that is HPV 16, 18, 31 and 33. In comparison, 49% of the HPV types from urethral swab specimens and 54% of those from urethral loop specimens were "high-risk" (Table 10). These findings are thus in agreement, therefore, with those from men with genital dermatoses.

About half the men had one or more HPV types in the urethra that were in common with those in the warts, again suggesting that urethral HPV infection is not simply an extension of infection of the external genitalia.

5. Men with urethral gonorrhoea

In addition to allowing the assessment of urethral carriage of HPV in men whose lifestyles have put them at risk of acquiring a STD, it was postulated that the presence of a urethral discharge might increase the diagnostic yield for HPV in urethral swab specimens.

The detection of HPV DNA in the genito-urinary tracts of 25% of men with urethral gonorrhoea compares with the finding of HPV DNA in the genital tracts of 20% of men attending a STD clinic in the UK³⁷⁵ and the USA³⁷⁶ without evidence of condylomata acuminata but with HPV DNA detectable in genital swabs. One other group of workers¹⁰⁰ found HPV DNA in 191 (84%) of 228 men attending a Swedish STD clinic. The validity of this latter result has yet to be confirmed, the authors accepting that they may have overestimated the incidence.

There was a larger proportion of men in this study of Afro-Caribbean and African origins compared to those seen in the other studies. This is may be due, at least in part, to the fact that approximately half the men were recruited from the Central Middlesex Hospital, which serves a predominantly black community.

The lack of correlation between the presence of HPV DNA and the number of life-time sexual partners of the men seen in this study argues against sexual transmission, as does the reported condom usage, although the reliability of such reported behaviour is open to question. Furthermore, the finding that a greater proportion of heterosexual men than homosexual or bisexual men had HPV in their urethral swab and urine specimens is in contrast to the findings in men with genital dermatoses.

HPV DNA was detected in 12.5% of urine specimens from men with gonorrhoea and, overall, evidence of genito-urinary infection with HPV was found in 25 (25%) of the men. As only 88% of the men had urine specimens taken,

it is likely that the genito-urinary infection rate was even higher. Furthermore, as we have seen, it is possible that some of these men could have had HPV in their external genital skin, even though none of them had clinically apparent warts at the time of sampling.

Fifty-seven percent of the HPV types detected in urethral swab specimens and 47% of those in urine specimens were "high-risk" types (Table 14). These observations are, therefore, consistent with those from the studies of men with genital dermatoses and men with resistant anogenital warts.

6. Multifocal Study

This study is different from the other three studies, in that while only 18 patients took part, they were willing to undergo sampling from multiple sites, often on several occasions. It was thus hoped to obtain information concerning the behaviour of HPV infection in individuals rather than in populations.

The detection of HPV DNA in 11 (65%) of 17 biopsies with histological evidence of HPV infection is consistent with the findings of some⁵⁹, although lower than those of others¹³⁴. Because it was possible to detect HPV in a wide variety of other specimen types, it seems unlikely that low sensitivity of the method is the explanation. Infection with HPV types other than those tested for is perhaps more likely, particularly in view of the large number of specimens noted to have infection with untyped HPVs.

The detection of HPV DNA in 12-36% of non-biopsy specimens confirms the value of obtaining these specimens. Much work has been done on cervical scrapes, but, until recently, few other specimen types had been assessed for the presence of HPV DNA. In fact, the data in the current study suggest that cervical scrapes are no more likely to contain HPV DNA than other non-biopsy specimen types.

The proportion of SG samples containing the β -globin gene was much higher in women than in men. However, there was no difference between men and women in the proportion of β -globin-containing SG samples in which HPV DNA was found. It is possible that this observation may be related to the fact that the skin of the male external genitalia is more cornified than the female counterpart. The surface layers of cornified skin contain predominantly anucleate squames which, therefore, do not contain the β -globin gene. The ability to harvest infected cells by the SG method was confirmed by the observation that SG samples taken from areas with clinically apparent warts contained HPV DNA in the majority of cases.

The presence of HPV DNA in β -globin-containing SG samples from areas which did not develop acetowhite staining is consistent with the finding of HPV DNA in histologically normal skin¹⁷⁵. Furthermore, it suggests that staining with acetic acid may have limited value in evaluating the extent of infection with HPV and treatment strategies of anogenital HPV infections. It is possible that areas without acetowhite changes, but with detect-

able HPV DNA, may represent passive contamination of the skin with HPV from another site of the patient, or from a sexual partner, or they may represent infection of the epithelium with HPV which has not produced sufficient cellular changes to generate visible alterations following the application of acetic acid. The failure to detect HPV DNA in four biopsies and in three of nine SG samples from acetowhite areas is consistent with the knowledge⁵² that not all acetowhite areas develop as a result of infection with HPV. Furthermore, the finding of HPV DNA in only four of six β -globin-containing SG samples from men with acetowhite areas of the glans is in agreement with the suggestion⁹³ that acetowhite changes of the glans may develop as a result of subclinical balanitis not related to infection with HPV.

The persistence of HPV at various sample sites after treatment is in accord with the finding of others¹⁹¹ that treatment of clinical and histological abnormalities may not necessarily result in the eradication of infection. It is likely that persistent infection may explain, at least in part, the high recurrence rate of warts regardless of the treatment method¹⁷⁷. However, the occurrence of common HPV types in sexual partners, as noted previously⁵⁹, suggests that there may be an opportunity for reinfection to also play a role in the persistence of disease.

Eight percent of the HPV types detected in biopsy specimens, 43% of those in non-biopsy specimens and 37% of those in SG specimens were "high-risk" types (Table

22). Once again this illustrates that the epidemiology of different HPV types varies with specimen type.

For a given patient, specific HPV types were frequently found in common in the biopsy, non-biopsy and SG specimens. This observation was also true for those who had infections with multiple HPV types, which constituted a large proportion of all infections in this study (Table 22).

7. Implications of the findings

7.1 Methods

Consensus primers from the L1 component of the HPV genome were used in the studies as these allowed the simultaneous amplification of several HPV types. The use of primers in regions of the HPV genome which are retained after integration, such as the transforming genes E6 and E7³⁷⁷ would have possibly increased the number of specimens in which HPV had been detected. However, the nucleotide sequences of these genes are not sufficiently conserved between HPV types to allow the reliable use of consensus primers.

Southern blotting and PCR involve DNA extraction, and thus do not localise HPV DNA within the tissue sample. A positive HPV DNA signal might, therefore, arise from contaminant DNA from a recent sexual contact. The development of in situ PCR³⁷⁷⁻⁸ may be helpful in the future. By assessing the amount of virus present, the use of semi-quantitative PCR³¹⁴ may also shed some light on the

epidemiology of HPV infections.

The clinical and biological significance of the detection of small numbers of HPV genomes remains to be resolved. The number of HPV DNA copies within cancer cells may vary from large to small, eg. Caski cells contain approximately 400-500 copies of HPV 16/cell, whereas SiHa cells contain 1-2 copies of HPV 16 per cell³⁷⁷. It would, therefore, seem that a small number, perhaps even a single copy of HPV DNA, is capable of contributing to the neoplastic phenotype of a malignant cell if the viral genome is integrated in this way with the continued expression of E6 and E7³⁷⁷. However, the presence of infectious virions cannot be inferred as a result of finding viral DNA. Currently, we have no reliable in vivo or in vitro technique for assessing the infectivity of HPV¹¹⁴. Furthermore, it is currently very difficult to cultivate HPV in vitro, a situation which renders the screening of antiviral compounds problematical. Serology may be helpful in view of the multifocal and variable clinical nature of HPV infections, but, as indicated previously, much work needs to be done before this technique can provide clinically useful data.

The insensitivity of acetic acid staining of the external genitalia for the detection of HPV infection has been confirmed by the Multifocal study. The general introduction of this technique for men would have significant resource implications with no clearly established benefit^{234,239}. Furthermore, the use of this method may create unnecessary fear and anguish in potentially

healthy individuals⁵⁷ and enthusiastic calls for the widespread use of colposcopy for areas other than the cervix⁸⁰ should be resisted.

Urethral swab, urethral loop and urine specimens appear to measure distinctly different aspects of the epidemiology of HPV in the anogenital tract. Although only a small number of urethral loop specimens were collected, the evidence suggests that these produce a higher yield of HPV from men than do urethral swab specimens. The optimum circumstances for the collection of specimens remain to be defined. For example, it is currently unclear from where the HPVs in urine specimens originate and it is possible that larger volumes of urine¹⁶¹ or early morning urines may produce greater yields of HPV. In addition, different specimens from the same patient not infrequently contained different HPV types. Further studies are required to assess exactly what these specimens are measuring.

7.2 Multifocal infection

Multifocal infection of the anogenital area is recognised to occur in infection with N. gonorrhoeae, C. trachomatis³⁷⁹ and, most recently, HPV³⁷⁰. Furthermore, a woman with neoplasia in one area of her anogenital tract is predisposed to neoplasia elsewhere²³⁶, an observation which is consistent with the proposed role for HPV infection in the development of anogenital neoplasia. The data from all four studies suggest that, if just one sample had been taken, the occurrence of infection,

including multiple infection, with HPV would have been underestimated. To determine the true extent of anogenital HPV infections, multiple samples need to be taken, possibly over several months. In particular, the frequent use in studies of cervical scrape specimens to assess the epidemiology of HPV infections has been seen to be fundamentally flawed. The use of pooled specimens from different parts of the genitalia may increase the diagnostic yield of HPV infections³⁷⁵.

The "high-risk" HPV types were consistently more common in urethral specimens than in wart specimens. Furthermore, HPV types 16, 18, 31 and 33 appear to be true colonisers of the urethra, whereas the detection of HPV types 6 and 11 in the urethra may be a result of contamination from adjacent warts.

7.3 Infection with multiple HPV types

Multiple infections with different HPV types have been reported^{55,57,59,77,198}, although this has been disputed by others³⁸⁰. The use of full length genomic probes, high stringency hybridisation conditions and positive controls for all the HPV types, suggest that the results of the current studies are indicative of true multiple infections, rather than cross-hybridisation.

7.4 Role of sexual activity in the acquisition of HPV

The data in the current studies indicate that sexual activity may not be a major factor in the epidemiology of anogenital HPV infections. They are, however, consistent

with the proposal that sexual transmission of HPV results in the ubiquitous deposition and incorporation of the virus in the squamous epithelium of the whole genital tract³⁸¹. In this model, most HPV infections remain dormant and never come to clinical attention. Under the influence of, as yet, poorly defined host factors, the virus may propagate and cause clinical recognisable epithelial alterations of various types.

There is now a considerable body of information suggesting genital-genital and ano-genital transmission of HPV. Oro-genital transmission of HPV is presumed to occur²⁸⁹ and it has been postulated²⁸³ that recurrent laryngeal papillomatosis in adults may result from oro-genital contact. Direct evidence for oro-genital transmission of HPV is, however, lacking²⁸⁴. It is possible that safer sex practices, particularly the wider practise of oral sex may lead to a future epidemic of oral HPV-associated lesions. Cutaneous warts and AGW can occur simultaneously and it is therefore feasible that warts in the anogenital region might occasionally develop from other cutaneous warts¹²⁷. The roles of fomites, oral/hand contact and vertical transmission remain unclear.

The apparent lack of association between cervical infection with HPV types 6, 11, 16 or 18 and measures of sexual behaviour reported in some studies has been attributed²¹⁵ to misclassification of HPV status. Through a series of empirical simulations that assumed different levels of sensitivity and specificity for detection HPV infection, Franco²¹⁵ showed how even low levels of mis-

classification of HPV infection status could distort the true relationship between HPV and measures of sexual activity. It is difficult to assess whether these factors have significantly affected the results in this thesis.

7.5 Role of HPV in neoplasia

HPV type 16 is frequently found in dysplastic lesions such as PIN⁹⁵ and penile carcinoma¹⁹⁷, and a causal link has been postulated³⁴⁰. However, because HPV infection of the male urogenital tract by "high-risk" HPV types is widespread, any proposal to link infection by these types with neoplasia must take the common occurrence into account. Indeed, it provides a situation not dissimilar from that encountered in establishing a causal link between "high-risk" HPV types and cervical carcinoma³⁴ against a background of commonly occurring "high-risk" types. The ubiquitous occurrence of many types of HPV has been taken by some authors³⁸²⁻³ as evidence against their role in malignant transformation. However, the analogy between the equal ubiquity of tobacco smoking and its causal link with lung cancer suggests that a role for HPV is still possible. Additional host cell modifications, potentially mediated by endogenous as well as exogenous factors, are presumably required for malignant conversion to follow from infection with HPV³³.

7.6 Concluding remarks

Reproducible, standard methods are needed for the determination of the presence of HPV. The data from the cur-

rent studies suggest that sampling from a single site is unlikely to be reliable, no matter what assay technique is used. Careful selection of control groups is also important. Given the marked site and species specificity, it is possible that different HPV types may have different epidemiologies. Different types of HPV may be more infectious than others, as suggested by the observation that some types only seem to occur in immunosuppressed subjects.

Prevalence studies for HPV infection are based on an unknown mixture of new, persisting, recurrent and undetected infection. The interval between infection and detection of viral DNA and of development of clinical or colposcopic lesions is unclear. Furthermore, it is not known how long these lesions persist and how frequently they recur. The relative infectivity of the different stages of infection is likewise not known, although it is often assumed that latent infection is less infectious than condylomata acuminata, as intact viral particles are not produced in latent disease.

The exact mode of entry of HPV into host cells is not known. The molecular mechanisms for the induction of proliferation or latency need to be defined further¹⁸⁸, as do the means by which HPV apparently evades the immunological surveillance mechanisms of the host. An important aim of future work should be to try to develop measures that can distinguish the HPV infected individuals who are at risk of their lesions progressing to dysplastic lesions from those regressing without treat-

ment. So far it seems that infection with HPV type 16 is associated with a higher rate of progression than types 6, 11, 18. Currently, however, little is known of the progression rates of the more recently characterised types.

Research into the epidemiology of HPV infections opens up exciting new areas in molecular biology, immunology and oncogenesis which could have ramifications through a wide range of health care and human behaviour. However, such studies need to be carefully designed to take account of the many difficulties inherent in HPV-related research. Only by obtaining a clear understanding of the epidemiology of anogenital HPV infections can we hope to control this widespread and potentially dangerous condition.

References

REFERENCES

1. Oriel JD. Anogenital warts. University of London MD Thesis, 1970.
2. Barrett TJ, Sibar JD, McGinley JP. Genital warts - a venereal disease. JAMA 1954;154:333-4.
3. Oriel JD. Natural history of genital warts. Br J Vener Dis 1971;47:1-13.
4. Beutner RR. Human papillomavirus infection. Am J Acad Dermatol 1989;20:114-23.
5. Bäfverstedt B. Condyloma acuminata - past and present. Acta Derm Venereol 1967;47:376-81.
6. Hudson EH. Historical approach to the terminology of syphilis. Arch Dermatol 1961;84:545-62.
7. Oriel JD. Pathogenesis. In: Von Krogh G, Rylander E, eds. GPVI: genitoanal papillomavirus infection. Karlstad, Sweden: Conpharm AB, 1989:7-17.
8. Burns DA. "Warts and all" - the history and folklore of warts: a review. J Roy Soc Med 1992;85:37-40.
9. Champion MJ. Clinical manifestations and natural history of genital human papillomavirus infection. Obstet Gynecol Clin North Amer 1987;14:363-88.
10. Oriel JD. Condyloma acuminata as a sexually transmitted disease. Dermatol Clinics 1983;1:93-102.
11. Wile UJ, Kingery LB. The etiology of common warts. JAMA 1919;73:970-3.
12. Frey E. Zur Frage der ätiologischen Beziehungen der Warzen und spitzen Kondylome. Schweizerische Medizinische Wochenschrift 1924;5:215-9.
13. Waelsh L. Übertragungsversuche mit spitzen Kondylo-
men. Archiv für Dermatologie und Syphilis 1918;124:625-
6.zW
14. Goldschmidt H, Kligman AM. Experimental inoculation of humans with ectodermotropic viruses. J Invest Dermatol 1958;31:175-82.
15. Creadick AN. Condyloma acuminata. JAMA 1920;75:1057-60.

16. Strauss MJ, Shaw EW, Bunting H, Melnick JL. "Crystal-line" virus-like particles from skin papillomas characterized by intranuclear inclusion bodies. Proc Soc Exp Biol Med 1949;72:46-50.
17. Dunn AEG, Ogilvie MM. Intranuclear virus particles in human genital wart tissue observations on the ultrastructure of the epidermal layer. J Ultrastruct Res 1968;22:285-9.
18. Oriel JD, Almeida JD. Demonstration of virus particles in human genital warts. Br J Vener Dis 1970;46: 37-42.
19. Lutzner MA. Epidermodysplasia verruciformis: an autosomal recessive disease characterized by viral warts and skin cancer. A model for oncogenesis. Bull Cancer 1978;65:169-82.
20. Sterling J, Stanley M, Gatward G, Minson T. Production of human papillomavirus type 16 virions in a keratinocyte line. J Virol 1990;64:6305-7.
21. Meyers C, Frattini MG, Hudson JB, Laimins LA. Biosynthesis of human papillomavirus from a continuous cell line upon epithelial differentiation. Science 1992;257:971-3.
22. Kreider J, Howett M, Wolfe SA et al. Morphological transformation in vivo of human uterine cervix with papillomavirus from condylomata acuminata. Nature 1985;317:639-41.
23. Reichman RC, Strike DG. Pathogenesis and treatment of human genital papillomavirus infections: a review. Antiviral Res 1989;11:109-18.
24. Broker TR. Structure and genetic expression of papillomaviruses. Obstet Gynecol Clin N Am 1987;14:329-48.
25. Orth G, Favre M. Human papillomaviruses. Biochemical and biologic properties. Clin Dermatol 1985;3:27-42.
26. Pfister H. Biology and biochemistry of papillomaviruses. Rev Physiol Biochem Pharmacol 1984;99:111-81.
27. Smotkin D. Virology of human papillomavirus. Clin Obstet Gynecol 1989;32:117-26.
28. Jenson AB, Rosenthal JD, Olson et al. Immunologic relatedness of papillomaviruses from different species. J Natl Cancer Inst 1980;64:495-8.
29. Lancaster WD, Olson C. Animal papillomaviruses. Microbiol Rev 1982;56:191-207.

30. Broker TR, Botchan M. Papillomaviruses:retrospectives and prospectives. *Cancer Cells* 1986;4:17-36.
31. Danos O, Giry I, Thierry F et al. Papillomavirus genomes: sequences and consequences. *J Invest Dermatol* 1984;83:7s-11s.
32. Douglas JM, Werness BA. Genital human papillomaviruses. *Clin Lab Med* 1989;9:421-44.
33. De Villiers E-M. Laboratory techniques in the investigation of human papillomavirus infection. *Genitourin Med* 1992;68:50-4.
34. Koutsky LA, Galloway DA, Holmes KK. Epidemiology of genital human papillomavirus infection. *Epidemiol Rev* 1988;10:122-63.
35. Shah KV. Biology of human genital tract papillomaviruses. In: Holmes KK, Mård AA, Sparling PF, Weisner PJ, Cates W, Lemon SM, Stamm WE eds. Sexually transmitted diseases. 2nd ed. New York: McGraw-Hill 1990:425-31.
36. Thierry F. Proteins involved in the control of HPV transcription. *Papillomavirus Report* 1993;4:27-32.
37. Bernard BA, Bailly C, Lenoir MC, Darmon M, Thierry F, Yaniv M. The human papillomavirus type 18 (HPV 18) E2 gene product is a repressor of the HPV18 regulatory region in human keratinocytes. *J Virol* 1989;63:4317-24.
38. Doorbar J, Ely S, Sterling J, McLean C, Crawford L. Specific interaction between HPV-16 E1-E4 and cytokeratins results in collapse of the epithelial cell intermediate filament network. *Nature* 1991;352:824-7.
39. Münger K, Phelps WC, Bubb V, Howley PM, Schlegel R. The E6 and E7 genes of the human papillomavirus type 16 together are necessary and sufficient for transformation of primary human keratinocytes. *J Virol* 1989;63:4417-21.
40. Werness BA, Levine AJ, Howley PM. Association of human papillomavirus types 16 and 18 E6 proteins with p53. *Science* 1990;248:76-9.
41. Scheffner M, Münger K, Byrne JC, Howley PM. The state of the P53 and retinoblastoma genes in human cervical carcinoma cell lines. *Proc Natl Acad Sci USA* 1991;88:5523-7.
42. Defeo-Jones D, Vuocolo GA, Haskell KM et al. Papillomavirus E7 protein binding to the retinoblastoma protein is not required for viral induction of warts. *J Virol* 1993;67:716-25.

43. Tommasino M, Adamczewski JP, Carlotti F et al. HPV 16 E7 protein associates with the protein kinase p33^{CDK2} and cyclin A. *Oncogene* 1993;8:195-202.
44. Acs J, Reeves WC, Rawls WE. Persistence of human papillomaviruses. *Adv Exp Med Biol.* 1989;257:169-86.
45. Tindle R. Genital warts: molecular biology and immunology. *Immunol Cell Biol* 1990;68:71-4.
46. Zur Hausen H. The role of papillomaviruses in anogenital cancer. *Scand J Infect Dis Suppl* 1990;69:107-11.
47. Syrjänen KJ. Histopathology, cytology, immunohistochemistry and HPV typing techniques. In: Von Krogh G, Rylander E eds. GPVI: genitoanal papillomavirus infection. Karlstad, Sweden: Conpharm AB, 1989:33-67.
48. Dürst M, Gissmann L, Ikenberg H, zur Hausen H. A papillomavirus DNA from a cervical carcinoma and its prevalence in cancer biopsy samples from different geographic regions. *Pro Natl Acad Sci USA* 1983;80:3812-4.
49. Gissmann L, Boshart M, Dürst M, Ikenberg H, wagner D, zur Hausen H. Presence of human papillomavirus in genital tumors. *J Invest Dermatol* 1984;83:26s-28s.
50. Syrjänen KJ. Epidemiology of human papillomavirus (HPV) infections and their association with genital squamous cell cancer. *APMIS* 1989;97:957-70.
51. Rosemberg SK, Reid R. Sexually transmitted papillomaviral infections in the male: I. Anatomic distribution and clinical features. *Urology* 1987;29:488-92.
52. Hippeläinen M, Yliskoski M, Saarikoski S, Syjänen S, Syrjänen K. Genital human papillomavirus lesions of the male sexual partners: the diagnostic accuracy of peniscopy. *Genitourin Med* 1991;67:291-6.
53. Kennedy L, Buntine DW, O'Connor DT, Frazer IH. Human papillomavirus - a study of male sexual partners. *Med J Aust* 1988;149:309-11.
54. McDonnell JM, Wagner D, Ng ST, Bernstein G, Sun YY. Human papillomavirus type 16 DNA in ocular and cervical swabs of women with genital tract condylomata. *Am J Ophthalmol* 1991;112:61-6.
55. De Villiers E-M, Schneider A, Gross G, zur Hausen H. Analysis of benign and malignant urogenital tumors for human papillomavirus infection by labelling cellular DNA. *Med Microbiol Immunol* 1986;174:281-6.

56. Cason J, Kambo PK, Best JM, McCance DJ. Detection of antibodies to a linear epitope on the major coat protein (L1) of human papillomavirus type-16 (HPV-16) in sera from patients with cervical intraepithelial neoplasia and children. *Internat J Cancer* 1992;**50**:349-55.
57. Wikström A, Hedblad M-A, Johansson B, Kalantari M, Syrjänen S, Lindberg M, von Krogh G. The acetic acid test in evaluation of subclinical genital papillomavirus infection: a comparative study on penoscopy, histopathology, virology and scanning electron microscopy findings. *Genitourin Med* 1992;**68**:90-9.
58. Nuovo GJ, Darfler MM, Impraim CC, Bromley SE. Occurrence of multiple types of human papillomavirus in genital tract lesions. *Am J Path* 1991;**138**:53-8.
59. Wickenden C, Hanna N, Taylor-Robinson D et al. Sexual transmission of human papillomaviruses in heterosexual and male homosexual couples, studies by DNA hybridisation. *Genitourin Med* 1988;**64**:34-38.
60. Lauricella-Lefebvre M-A, Piette J, Lifrange E, Lambotte R, Gerard P, Rentier B. High rate of multiple genital HPV infections detected by DNA hybridization. *J Med Virol* 1992;**36**:265-70.
61. Schneider A. Latent and subclinical genital HPV infections. *Papillomavirus Report* 1990;**1**:2-5.
62. Rogozinski TT, Jablonska S, Jarzabek-Chorzelska M. Role of cell-mediated immunity in spontaneous regression of plane warts. *Int J Dermatol* 1988;**27**:322-6
63. Hughes RG, Norval M, Howie SE. Expression of major histocompatibility class II antigens by Langerhans' cells in cervical intraepithelial neoplasia. *J Clin Pathol* 1988;**41**:253-9.
64. Hawthorn RJ, Murdoch JB, MacLean AB, MacKie RM. Langerhans' cells and subtypes of human papillomavirus in cervical intraepithelial neoplasia. *Br Med J* 1988;**297**:643-6.
65. Tay SK, Jenkins D, Maddox P, Singer A. Lymphocyte phenotypes in cervical intraepithelial neoplasia and human papillomavirus infection. *Br J Obstet Gynaecol* 1987;**94**:16-21.
66. McMillan A, Bishop PE, Fletcher S. An immunohistological study of condylomata acuminata. *Histopathology* 1990;**17**:45-52.

67. Carson LF, Twiggs LB, Fukushima M, Ostrow RS, Faras AJ, Okagaki T. Human genital papilloma infections: an evaluation of immunologic competence in the genital neoplasia-papilloma syndrome. *Am J Obstet Gynecol* 1986;155:784-9.
68. Vardy DA, Baadsgaard O, Hansen ER, Lisby S, Vejlsgaard GL. The cellular immune response to human papillomavirus infection. *Internat J Dermatol* 1990;29:603-10.
69. Chen H-D, Zhao Y, Sun G, Yang C. Occurrence of Langerhans' cells and expression of class II antigens on keratinocytes in malignant and benign epithelial tumors of the skin: an immunohistopathologic study with monoclonal antibodies. *J Am Acad Dermatol* 1989;20:1007-14.
70. Bal V, McIndoe A, Denton G, Hudson D, Lombardi G, Lamb J, Lechler R. Antigen presentation by keratinocytes induces tolerance in human T cells. *Eur J Immunol* 1990;20:1893-7.
71. Strang G, Hickling JK, McIndoe GAJ et al. Human T cell responses to human papillomavirus type 16 L1 and E6 synthetic peptides: identification of T cell determinants, HLA-DR restriction and virus types specificity. *J Gen Virol* 1990;71:423-31.
72. Tindle RW, Frazer IH. Immunology of anogenital human papillomavirus (HPV) infection. *Aust NZ Obstet Gynecol* 1990;30:370-5.
73. Galloway DA. HPV serology: an update. *Papillomavirus Report* 1990;1(2):1-3.
74. Brandsma J, Burk RD, Lancaster WD, Pfister H, Schiffman MH. Interlaboratory variation in the identification of HPV DNA sequences by Southern blot sequences in clinical specimens. *Int J Cancer* 1989;43:260-2.
75. Oriel JD. Genitoanal papillomavirus infection - a diagnostic and therapeutic dilemma. *Semin Dermatol* 1990;9:141-7.
76. Rosemberg SK, Greenberg MD, Reid R. Sexually transmitted papillomaviral infection in men. *Obstet Gynecol Clin North Am* 1987;14:495-512.
77. Syrjänen SM, von Krogh G, Syrjänen KJ. Detection of human papillomavirus DNA in anogenital condylomata in men using in situ DNA hybridisation applied to paraffin sections. *Genitourin Med* 1987;63:32-9.
78. Sedlacek TV, Cunnane M, Carpinello V. Colposcopy in the diagnosis of penile condyloma. *Am J Obstet Gynecol* 1986;154:494-6.

79. Boon ME, Schneider A, Hogewoning CJA, van der Kwast TH, Bolhuis P, Kok LP. Penile studies and heterosexual partners: peniscopy, cytology, histology and immunocytochemistry. *Cancer* 1988;**61**:1652-9.
80. Pfenninger JL. Androscopy: a technique for examining men for condyloma. *J Fam Pract* 1989;**29**:286-8.
81. Epperson WJ. Preventing cervical cancer by treating genital warts in men: why male sex partners need androscopy. *Postgraduate Med* 1990;**88**:229-36.
82. Carpiello V, Sedlacek TV, Cunnane M, Schlecker B, Malloy T, Wein AJ. Magnified penile surface scanning in diagnosis of penile condyloma. *Urology* 1986;**28**:190-2.
83. Eriksson MBE, Claesson U, Kataoka A, Lindh E, Wikström K. Detection of HPV in urogenital specimens from Swedish army conscripts. Abstract FC/249, 7th World Congress of Cervical Pathology and Colposcopy, Rome, Italy, May 13-17, 1990.
84. Hillman RJ, Botcherby M, Taylor-Robinson D. Genital human papillomavirus lesions of the male sexual partners: the diagnostic accuracy of peniscopy. *Genitourin Med* 1991;**67**:522-3.
85. Champion MJ, McCance DJ, Mitchell HS, Jenkins D, Singer A, Oriel JD. Subclinical penile human papillomavirus infection and cervical dysplasia in consorts of women with cervical neoplasia. *Genitourin Med* 1988;**64**:90-9.
86. Comite SL, Castadot M-J. Colposcopic evaluation of men with genital warts. *J Am Acad Dermatol* 1988;**18**:1274-8.
87. Chow VTK, Tay SK, Tham KM, Lim-Tan SK, Bernard HU. Subclinical human papillomavirus infection of the male lower genital tract: colposcopy, histology and DNA analysis. *Int J STD AIDS* 1991;**2**:41-5.
88. Krebs H-B, Schneider V. Human papillomavirus-associated lesions of the penis: colposcopy, cytology and histology. *Obstet Gynecol* 1987;**70**:299-304.
89. Selvey L, Buntine DW, Kennedy L, Frazer IH. Male partners of women with genital human papillomavirus infection: an assessment of colposcopic abnormalities by histological examination and human papillomavirus hybridization. *Med J Australia* 1989;**150**:479-82.
90. Siegel JF, Mellinger BC. Human papillomavirus in the male patient. *Urol Clin North Am* 1992;**19**:83-91.
91. Rosemberg SK. Subclinical papilloma viral infection of male genitalia. *Urology* 1985;**26**:554-7.

92. Cartier R. Practical colposcopy. 2nd ed. Paris: Laboratoire Cartier, 1984.
93. Griffiths M, Penna LK, Tovey SJ. Aceto-white change of the glans penis associated with balanitis not human papillomavirus infection. *Int J STD AIDS* 1991;2:211-2.
94. Katelaris PM, Cossart YE, Rose BR, Thompson CH, Sorich E, Nightingale B, Dallas PB, Morris BJ. Human papillomavirus: the untreated male reservoir. *J Urol* 1988;140:300-5.
95. Barrasso R, De Brux J, Croissant O, Orth G. High prevalence of papillomavirus-associated penile intraepithelial neoplasia in sexual partners of women with cervical intraepithelial neoplasia. *N Eng J Med* 1987;317:916-23.
96. Tabrizi SN, Tan J, Quinn M, Borg AJ, Garland SM. Detection of genital human papillomavirus (HPV) DNA by PCR and other conventional hybridisation techniques in male partners of women with abnormal Papanicolaou smears. *Genitourin Med* 1992;68:370-3.
97. Schultz RE, Skelton HG. Value of acetic acid screening for flat genital condylomata in men. *J Urol* 1988;139:777-9.
98. Cohen BA, Honig P, Androphy E. Anogenital warts in children. *Arch Dermatol* 1990;126:1575-80.
99. Nuovo GJ, Hochman HA, Eliezri YD, Lastarria D, Comite SL, Silvers DN. Detection of human papillomavirus DNA in penile lesions histologically negative for condylomata: analysis by in situ hybridization and the polymerase chain reaction. *Am J Surg Path* 1990;14:829-36.
100. Wikström A, Lidbrink P, Johansson B, von Krogh G. Penile human papillomavirus carriage among men attending Swedish STD clinics. *Int J STD AIDS* 1991;2:105-9.
101. Vardy DA, Baadsgaard O, Hansen ER, Lisby S, Vejlsgaard GL. The cellular immune response to human papillomavirus infection. *Internat J Dermatol* 1990;29:603-10.
102. Croissant O, Breitburd F, Orth G. Specificity of cytopathic effect of cutaneous human papillomaviruses. *Clin Dermatol* 1985;3:43-55.
103. Schultz RE, Miller JW, MacDonald GR, Auman JR, Peterson NR, Ward BE, Crum CP. Clinical and molecular evaluation of acetowhite genital lesions in men. *J Urol* 1990;143:920-3.

104. Beutner KR, Becker TM, Stone KM. Epidemiology of human papillomavirus infections. *Dermatol Clin* 1991;9:211-9.
105. Eisenstein BI. The polymerase chain reaction: a new method of using molecular genetics for medical diagnosis. *N Engl J Med* 1990;322: 178-83.
106. Li H, Gyllesten UB, Cui X, Saiki RK, Erlich HA, Arnheim N. Amplification and analysis of DNA sequences in single human sperm and diploid cells. *Nature* 1988;335:414-7.
107. Van den Brule AJC, Claas HCJ, Du Maine M et al. Use of anti-contamination primers in the polymerase chain reaction for the detection of human papillomavirus genotypes in cervical scrapes and biopsies. *J Med Virol* 1989;29:20-7.
108. Saiki RK, Gelfand DH, Stoffel S et al. Primer-directed enzymatic amplification of DNA with a thermostable DNA polymerase. *Science* 1988;239:487-91.
109. Beyer-Finkler E, Pfister H, Girardi F. Anti-contamination primers to improve specificity of polymerase chain reaction in human papillomavirus screening. *Nature* 1990;335:1289-90.
110. Cone RW, Hobson AC, Huang M-LW, Fairfax MR. Polymerase chain reaction decontamination: the wipe test. *Lancet* 1990;336:686.
111. Southern EM. Detection of specific sequences among DNA fragments separated by gel electrophoresis. *J Mol Biol* 1975;98:503-17.
112. Schneider A. Methods of identification of human papillomaviruses. In: Syrjänen K, Gissmann L, Koss LG, eds. *Papillomavirus and human disease*. Berlin: Springer Verlag, 1987:19-39.
113. Bergeron C, Ferenczy A, Richart R. Underwear: contamination by papillomaviruses. *Am J Obstet Gynecol* 1990;162:25-9.
114. Beutner KR, Becker TM, Stone KM. Epidemiology of human papillomavirus infections. *Dermatol Clin* 1991;9:211-9.
115. McNicol PJ, Dodd JG. High prevalence of human papillomavirus in prostate tissues. *J Urol* 1991;145:850-3.
116. Padel AF, Venning VA, Evans MF, Quantril L, Fleming KA. Human papillomaviruses in anogenital warts in children: typing by in situ hybridisation. *Br Med J* 1990;300:1491-4.

117. Oriel JD. Genital warts. Sex Transm Dis 1981;8:326-9.
118. Carne CA, Dockerty G. Genital warts: need to screen for coinfection. Br Med J 1990;300:459.
119. Department of Health. New cases seen at NHS genito-urinary clinics in England. 1991 annual figures. Summary information from form KC60. London: Department of Health, 1993.
120. Byrne P, Woodman C, Meanwell C, Kelly K, Jordan J. Koilocytes and cervical human papillomavirus infection. Lancet 1986;i:205-6.
121. Galloway DA, McDougall JK. Human papillomaviruses and carcinomas. Adv Virus Res 1989;37:125-71.
122. Chuang T-Y, Perry HO, Kurland LT, Ilstrup DM. Condyloma acuminatum in Rochester, Minnesota 1950-1978. I. Epidemiology and clinical features. Arch Dermatol 1984;120:469-75.
123. Chuang T-Y, Perry HO, Kurland LT, Ilstrup DM. Condyloma acuminatum in Rochester, Minnesota 1950-1978. II. Anaplasia and unfavorable outcome. Arch Dermatol 1984;120:476-83.
124. Evans S, Dowling K. The changing prevalence of cervical human papilloma virus infection. Aust NZ Obstet Gynaecol 1990;30:375-7.
125. Becker TM, Stone KM, Alexander ER. Genital human papillomavirus infection. Obstet Gynecol Clin North Amer 1987;14:389-96.
126. Zunzunegui MV, King MC, Coria CF, Charlet J. Male influence of cervical cancer risk. Am J Epidemiol 1986;123:302-7.
127. Chuang TY. Condylomata acuminata (genital warts). An epidemiologic view. J Am Acad Dermatol 1987;16:376-84.
128. Cook TA, Cohn A, Brunschwig JP, Goepfert H, Butel JS, Rawls WE. Laryngeal papilloma: etiologic and therapeutic considerations. Ann Otol Rhinol Laryngol 1973;82:649-55.
129. Jenison SA, Yu XP, Valentine JM et al. Evidence of prevalent genital-type human papillomavirus infections in adults and children. J Infect Dis 1990;162:60-9.
130. Sakuma S, Minagawa H, Mori R, Kumazawa J, Sagiya K, Yanagi K. Human papillomavirus DNA in condylomata acuminata from Japanese males. Diagn Microbiol Infect Dis 1988;10:23-9.

131. Cook LS, Koutsky LA. Male circumcision and venereal warts. Abstract 92, 10th International Papillomavirus Workshop, Seattle, USA, July 20-26, 1991.
132. Becker TM. Genital warts - a sexually transmitted disease epidemic? *Colp Gynecol Laser Surg* 1984;1:193-9.
133. Del Mistro A, Braunstein JD, Halwer M, Koss LG. Identification of human papillomavirus types in male urethral condylomata acuminata by in situ hybridization. *Hum Pathol* 1987;18:936-40.
134. O'Brien WM, Jenson AB, Lancaster WD, Maxted WC, Human papillomavirus typing of penile condyloma. *J Urol* 1989;141:863-5.
135. Grussendorf-Conen EI. In situ hybridization with papillomavirus DNA in genital lesions. In: Peto R, zur Hausen H, eds. *Viral etiology of cervical cancer*. Banbury report 21. Cold Spring Harbor, New York: Cold Spring Harbor Laboratory 1986.
136. Zderic SA, Carpinello VL, Malloy TR, Rando RF. Urological applications of human papillomavirus typing using deoxyribonucleic acid probes for the diagnosis and treatment of genital condyloma. *J Urol* 1989;141:63-5.
137. Krebs H-B. Management of human papillomavirus-associated genital lesions in men. *Obstet Gynecol* 1989;73:312-6.
138. Growdon WA, Fu YS, Lebherz TB, Rapkin A, Mason GD, Parks G. Pruritic vulvar squamous papillomatosis: evidence for human papillomavirus and its etiology. *Obstet Gynecol* 1985;66:564-8.
139. Turner MLC, Marinoff SC. Association of human papillomavirus with vulvodynia and the vulvar vestibulitis syndrome. *J Reprod Med* 1988;28:533-7.
140. Deitch KV, Smith JE. Symptoms of chronic vaginal infection and microscopic condyloma in women. *J Obstet Gynecol Neonatal Nurs* 1990;19:133-8.
141. Arumainayagam JT, Sumathipala AHT, Smallman LA, Shahmanesh M. Flat condylomata of the penis presenting as patchy balanoposthitis. *Genitourin Med* 1990;66:251-3.
142. Von Krogh G. Genitoanal papillomavirus: diagnostic and therapeutic objectives in the light of current epidemiological observations. *Int J STD AIDS* 1991;2:391-404.
143. Schneider A, Kirchmayr R, De Villiers E-M, Gissmann L. Subclinical human papillomavirus infections in male sexual partners of female carriers. *J Urol* 1988;140:1431-4.

144. Batta AG, Engen DE, Reiman HM, Winkelmann RK. Intra-vesical condyloma acuminatum with progression to verrucous carcinoma. *Urology* 1990;**36**:457-64.
145. Murphy WD, Rovner AJ, Nazinitsky KJ. Condylomata acuminata of the bladder: a rare cause of intraluminal-filling defects. *Urol Radiol* 1990;**12**:34-6.
146. Pettersson S, Hansson G, Blohmé I. Condyloma acuminatum of the bladder. *J Urol* 1983;**115**:535-6.
147. Debenedictis TJ, Marmar JL, Praiss DE. Intraurethral condylomas acuminata: management and a review of the literature. *J Urol* 1977;**118**:767-9.
148. Steele R, Lees REM, Kraus AS, Rao C. Sexual factors in the epidemiology of cancer of the prostate. *J Chron Dis* 1971;**24**:29-37.
149. Schuman LM, Mandel J, Blackard C, Bauer H, Scarlett J, McHugh R. Epidemiologic study of prostatic cancer: preliminary report. *Cancer Treat Rep* 1977;**62**:181-6.
150. Masood S, Rhatigan RM, Powell S, Thompson J, Rodenroth N. Human papillomavirus in prostatic cancer: no evidence found by in situ DNA hybridization. *South Med J* 1991;**84**:235-6.
151. Omar R, Choudhury M, Fischer J, Ezpeleta C. A "Pap" test for men? : male urethral smears as screening tool for detecting subclinical human papillomavirus infection. *Urology* 1991;**37**:110-5.
152. McNicol PJ, Dodd JG. Detection of human papillomavirus DNA in prostate gland tissue by using the polymerase chain reaction amplification assay. *J Clin Microbiol* 1990;**28**:409-12.
153. Rady P, Scinicariello F, Saltzstein D, Orihuela E, Tyring S. Activated oncogenes in prostatic tumors containing HPV-16 DNA. Abstract 168, 10th International Papillomavirus Workshop, Seattle, USA, July 20-26, 1991.
154. Somers KD, Glickman SE, Wright GL. Detection of human papillomavirus DNA in carcinoma of the prostate and benign prostatic hyperplasia. Abstract 291, 10th International Papillomavirus Workshop, Seattle, USA, July 20-26, 1991.
155. McNicol PJ, Dodd JG. Detection of papillomavirus DNA in human prostatic tissue by Southern blot analysis. *Can J Microbiol* 1990;**36**:359-62.
156. Green J, Monteiro E, Gibson P. Detection of human papillomavirus DNA in semen from patients with intrameatal penile warts. *Genitourin Med* 1989;**65**:357-60.

157. Ostrow RS, Zachow KR, Niimura M, Okagaki T, Muller S, Bender M, Faras AJ. Detection of papillomavirus DNA in human semen. *Science* 1986;**231**:731-3.
158. Krebs H-B. Genital HPV infections in men. *Clin Obstet Gynec* 1989;**32**:180-90.
159. Levine RU, Crum CP, Herman E, Silvers D, Ferenczy A, Richart RM. Cervical papillomavirus infection and intraepithelial neoplasia: a study of male sexual partners. *Obstet Gynecol* 1984;**64**:16-20.
160. Nahhas WA, Marshall ML, Ponziani J, Jagielo JA. Evaluation of urinary cytology of male sexual partners of women with cervical intraepithelial neoplasia and human papilloma virus infection. *Gynecol Oncol* 1986;**24**:279-85.
161. Melchers WJG, Schiff R, Stoltz E, Lindeman J, Quint WGV. Human papillomavirus detection in urine samples from male patients by the polymerase chain reaction. *J Clin Microbiol* 1989;**27**:1711-4.
162. Nakazawa A, Inoue M, Fujita M, Tanizawa O, Hakura A. Detection of human papillomavirus type 16 in sexual partners of patients having cervical cancer by polymerase chain reaction. *Jpn J Cancer Res* 1991;**82**:1187-90.
163. Hansson BG, Bjerre B, Forslund O, Lindholm K, Nordenfelt E. Human papilloma virus infections in healthy control and colposcopy patients. Analysis of cervix and urine samples. Abstract 78, 10th International Papillomavirus Workshop, Seattle, USA, July 20-26, 1991.
164. Peterson RO. *Urologic Pathology*. Philadelphia: JB Lipincott, 1986.
165. Grussendorf-Conen E-I, Deutz J, De Villiers EM. Detection of human papillomavirus-6 in primary carcinoma of the urethra in men. *Cancer* 1987;**60**:1832-5.
166. Cetti NE. Condyloma acuminatum of the urethra: problems in eradication. *Brit J Surg* 1984;**71**:57.
167. Stein BS. Sexually transmitted disease: cutaneous lesions. *Semin Urol* 1991;**9**:2-8.
168. Giacomini G, Bianchi G, Moretti D. Detection of sexually transmitted diseases by urethral cytology, the ignored male counterpart of cervical cytology. *Acta Cytologica* 1989;**33**:11-5.
169. Dean P, Lancaster WD, Chun B, Jenson B. Human papillomavirus structural antigens in squamous papillomas of the male urethra. *J Urol* 1983;**129**:873-5.

170. Syrjänen K, Syrjänen S. Concept of the existence of human papillomavirus (HPV) DNA in histologically normal squamous epithelium of the genital tract should be re-evaluated. *Acta Obstet Gynec Scand* 1989;**67**:613-7.
171. Cornellisen MTE, van den Tweel JG, Struyk AHB et al. Localization of human papillomavirus type 16 DNA using the polymerase chain reaction in the cervix uteri of women with cervical intraepithelial neoplasia. *J Gen Virol* 1989;**70**:2555-62.
172. Ferenczy A, Richart RM, Wright TC. Pearly penile papules: absence of human papillomavirus DNA by the polymerase chain reaction. *Obstet Gynecol* 1991;**78**:118-22.
173. Fuchs PG, Girardi F, Pfister H. Human papillomavirus DNA in normal, metaplastic, preneoplastic and neoplastic epithelia of the cervix uteri. *Int J Cancer* 1988;**41**:41-5.
174. Colgan TJ, Percy ME, Suri M, Shier RM, Andrews DF, Lickrish GM. Human papillomavirus infection of morphologically normal cervical epithelium adjacent to squamous dysplasia and invasive carcinoma. *Human Pathol* 1989;**20**:316-9.
175. MacNab JCM, Walkinshaw SA, Cordiner JW, Clements JB. Human papillomavirus in clinically normal and histologically normal tissue of patients with genital cancer. *N Engl J Med* 1986;**315**:1052-8.
176. Walkinshaw SA, Cordiner JW, Clements JB, MacNab JCM. Prognosis of women with human papillomavirus DNA in normal tissue distal to invasive cervical and vulvar cancer. *Lancet* 1987;**i**:563.
177. Ferenczy A, Mitao M, Nagai N, Silverstein SJ, Crum CP. Latent papillomavirus and recurring genital warts. *N Engl J Med* 1985;**313**:784-8.
178. Wickenden C, Steele A, Malcolm ADM, Coleman DV. Screening for wart virus infection in normal and abnormal cervixes by DNA hybridisation of cervical scrapes. *Lancet* 1985;**i**:65-7.
179. Lorincz AT, Temple GF, Patterson JA, Jenson AB, Kurman RJ, Lancaster WD. Correlation of cellular atypia and human papillomavirus deoxyribonucleic acid sequences in exfoliated cells of the uterine cervix. *Obstet Gynecol* 1986;**68**:508-12.
180. Toon PG, Arrand JR, Wilson LP, Sharp DS. Human papillomavirus infection of the uterine cervix of women without cytological signs of neoplasia. *Br Med J* 1986;**293**:1261-46.

181. Tidy JA, Parry GCN, Ward P et al. High rate of human papillomavirus type 16 infection in cytologically normal cervixes. *Lancet* 1989;*i*:434.
182. Young LS, Bevan IS, Johnson MA et al. The polymerase chain reaction: a new epidemiological tool for investigating cervical human papillomavirus infection. *Br Med J* 1989;*298*:14-8.
183. Van den Brule AJC, Walboomers JMM, Maine MD, Kenemans P, Meijer CJLM. Difference in prevalence of human papillomavirus genotypes in cytomorphologically normal cervical smears is associated with a history of cervical intraepithelial neoplasia. *Int J Cancer* 1991;*48*:404-8.
184. Muñoz N, Bosch X, Kaldor JM. Does human papillomavirus cause cervical cancer? The state of the epidemiological evidence. *Br J Cancer* 1988;*57*:1-5.
185. Meanwell CA, Cox MF, Blackledge G, Maitland NJ. HPV 16 DNA in normal and malignant cervical epithelium: implications for the aetiology and behaviour of cervical neoplasia. *Lancet* 1987;*i*:703-7.
186. Johnson M, Blomfield PI, Bevan IS, Woodman CBJ, Young LS. Analysis of human papillomavirus type 16 E6/E7 transcription in cervical carcinomas and normal cervical epithelium using the polymerase chain reaction. *J Gen Virol* 1990;*71*:1473-9.
187. Schneider A, Kraus H, Schuhmann R, Gissmann L. Papillomavirus infection of the lower genital tract: detection of viral DNA in gynecologic swabs. *Int J Cancer* 1985;*35*:443-8.
188. Brown DR, Fife KH. Human papillomavirus infections of the genital tract. *Med Clin N Amer* 1990;*74*:1455-85.
189. Groff D, Mensch J. Asymptomatic HPV infections are preferentially associated with high risk types. Abstract 86, 10th International Papillomavirus workshop, Seattle, July 20-26, 1991.
190. Byrne MA, Taylor-Robinson D, Wickenden C, Malcolm ADB, Anderson MC, Coleman DV. Prevalence of human papillomavirus types in the cervixes of women before and after laser ablation. *Br J Obstet Gynaecol* 1988;*95*:201-2.
191. Reid R, Greenberg M, Jenson AB et al. Sexually transmitted papillomaviral infections. I. The anatomic distribution and pathologic grade of neoplastic lesions associated with different viral types. *Am J Obstet Gynecol* 1987;*156*:212-22.

192. Steinberg BM, Topp WC, Schneider PS, Abramson AL. Laryngeal papillomavirus infection during clinical remission. *N Engl J Med* 1983;**308**:1261-4.
193. Maitland NJ, Cox MF, Lynas C, Prime SS, Meanwell CA, Scully C. Detection of human papillomavirus DNA in biopsies of human oral tissue. *Br J Cancer* 1987;**56**:245-50.
194. Kirgan D, Manalo P, McGregor B. Immunohistochemical demonstration of human papilloma virus antigen in human colon neoplasms. *J Surg Res* 1990;**48**:397-402.
195. Kawashima M, Favre M, Obalek S, Jablonska S, Orth G. Premalignant lesions and cancers of the skin in the general population: evaluation of the role of human papillomaviruses. *J Invest Dermatol* 1990;**95**:537-42.
196. Neinstein LS, Goldenring J. Pink pearly papules: an epidemiologic study. *J Pediatr* 1984;**105**:594-5.
197. Varma VA, Sanchez-Lanier M, Unger ER et al. Association of human papillomavirus with penile carcinoma: a study using polymerase chain reaction and in situ hybridization. *Human Pathol* 1991;**22**:908-13.
198. Grußendorf-Conen E-I, Meinhof W, De Villiers E-M, Gissmann L. Occurrence of HPV genomes in penile smears of healthy men. *Arch Dermatol Res* 1987;**279**:S73-5.
199. Schneider A, Schuhmann R, de Villiers E-M, Knauf W, Gissmann L. Klinische Bedeutung von Papillomvirus (HPV-)Infektionen im unteren Genitaltrakt. *Geburtsh Frauenheilk* 1986;**46**:261-6.
200. Syrjänen KJ, Mäntyjärvi R, Saarikoski S et al. Factors associated with progression of cervical human papillomavirus (HPV) infections into carcinoma in situ during a long term prospective follow-up. *Br J Obstet Gynaecol* 1988;**95**:1096-1102.
201. Kataja V, Syrjänen K, Syrjänen S et al. Prospective follow-up of cervical HPV infections: life-table analysis of HPV typing data. *Eur J Epidemiol* 1989;**51**:1-7.
202. Syrjänen K, Syrjänen S. Epidemiology of human papilloma virus infections and genital neoplasia. *Scand J Infect Dis* 1990;**Suppl 69**:7-17.
203. Oriel JD. Anal warts and anal coitus. *Br J Vener Dis* 1971;**47**:373-6.
204. Law CL, Thompson CH, Rose BR, Cossart YE. Anal intercourse: a risk factor for anal papillomavirus infection in women? *Genitourin Med* 1991;**67**:464-8.

205. Daling JR, Sherman KJ, Weiss NS. Risk factors for condylomata acuminata in women. Sex Transm Dis 1986;13:16-8.
206. Einhorn N. Risk factors and etiology in gynecologic cancer. Curr Opin Oncol 1990;2:857-63.
207. Ley C, Bauer HM, Reingold A et al. Determinants of genital human papillomavirus infection in young women. J Nat Cancer Inst 1991;83:997-1003.
208. Rosenfeld WD, Vermund SH, Wentz SJ et al. High prevalence of human papillomavirus infection and association with abnormal Papanicolaou smears in sexually active adolescents. Am J Dis Child 1989;143:1443-7.
209. Moscicki A-B, Palefsky J, Gonzales J, Schoolnik GK. Human papillomavirus infection in sexually active adolescent females: prevalence and risk factors. Pediatr Res 1990;28:507-13.
210. Kiviat NB, Koutsky LA, Paavonen JA et al. Prevalence of genital papillomavirus infection among women attending a college student health clinic or a sexually transmitted disease clinic. J Infect Dis 1989;159:293-302.
211. Donnan SPB, Wong FWS, Ho SC, Lau EMC, Takashi K, Esteve J. Reproductive and sexual risk factors and human papilloma virus infection in cervical cancer among Hong Kong Chinese. Int J Epidemiol 1989;18:32-6.
212. Villa LL, Franco ELF. Epidemiologic correlates of cervical neoplasia and risk of human papillomavirus infection in asymptomatic women in Brazil. J Natl Cancer Inst 1989;81:332-40.
213. Kjaer SK, Engholm G, Teisen C et al. Risk factors for cervical papillomavirus and herpes simplex virus infections in Greenland and Denmark: a population-based study. Am J Epidemiol 1990;131:669-82.
214. Reeves WC, Brinton LA, Garcia M et al. Human papillomavirus infection and cervical cancer in Latin America. N Engl J Med 1989;320:1437-41.
215. Franco EL. The sexually transmitted disease model for cervical cancer: incoherent epidemiologic findings and the role of misclassification of human papillomavirus infection. Epidemiology 1991;2:98-106.
216. De Villiers EM, Wagner D, Schneider A et al. Human papillomavirus infections in women with and without abnormal cervical cytology. Lancet 1987;ii:703-?.

217. Franco EL. Viral etiology of cervical cancer: a critique of the evidence. *Rev Infect Dis* 1991;**13**:1195-206.
218. Singer A. Epidemiological features of lower genital tract neoplasia. In: Von Krogh G, Rylander E eds. *GPVI: genitoanal papillomavirus infection*. Karlstad, Sweden: Conpharm AB, 1989:33-67.
219. Horn JE, McQuillan GM, Shah KV et al. Genital human papillomavirus infections in patients attending an inner-city STD clinic. *Sex Transm Dis* 1991;**18**:183-7.
220. Fairris GM, Statham BN, Waugh MA. The investigation of patients with genital warts. *Br J Dermatol* 1984;**111**:736-8.
221. Harahap M. Asymptomatic gonorrhoea among patients with condylomata acuminata. *Br J Vener Dis* 1979;**55**:450.
221. Griffiths M, Overington LJ, Chard SC. Genital warts and the need for screening. *Genitourin Med* 1989;**65**:399.
223. Jayaweera DT, Ahmed IH, Bignell CJ, Rogstad KE. Genital warts and the need for screening. *Genitourin Med* 1990;**66**:305.
224. Kinghorn G. Genital warts: incidence of associated genital infections. *Br J Dermatol* 1978;**99**:405-9.
225. Crawshaw SC, Haran MV. Genital warts and the need for screening. *Genitourin Med* 1990;**66**:228-9.
226. Byrne MA, Taylor-Robinson D, Munday PE, Harris JRW. The common occurrence of human papillomavirus infection and intraepithelial neoplasia in women infected by HIV. *AIDS* 1989;**3**:379-82.
227. Palefsky JM. Human papillomavirus-associated anogenital neoplasia and other solid tumours in human immunodeficiency virus-infected individuals. *Curr Opin Oncol* 1991;**3**:881-5.
228. Drobacheff C, Mouglin C, Bastian P et al. Prevalence of oncogenic papillomavirus (HPV) detected by in situ hybridization in HIV-positive patients. Abstract MB2259, VIIth International Conference on AIDS, Florence, Italy, June 16-21, 1991.
229. Frazer IH, Medley G, Crapper RM, Brown TC, Mackay IR. Association between anorectal dysplasia, human papillomavirus and human immunodeficiency virus infection in homosexual men. *Lancet* 1986;**ii**:657-60.

230. Daling J, Weiss NS, Hislop TG et al. Sexual practices, sexually transmitted diseases, and the incidence of anal cancer. *N Engl J Med* 1987;317:973-7.
231. Lands RH, Ange D, Hartman DL. Radiation therapy for classic Kaposi's sarcoma presenting only on the penis. *J Urol* 1992;147:468-70.
232. Huang YQ, Li JJ, Rush MG et al. HPV-16-related DNA sequences in Kaposi's sarcoma. *Lancet* 1992;339:515-8.
233. Nickoloff BJ, Huang YQ, Li JJ, Friedman-Kien AE. Immunohistochemical detection of papillomavirus antigens in Kaposi's sarcoma. *Lancet* 1992;339:548-9.
234. Krebs H-B, Helmkamp BF. Does the treatment of genital condylomata in men decrease the treatment failure rate of cervical dysplasia in the female sexual partner? *Obstet Gynecol* 1990;76:660-3.
235. Sun-Kuie T, Tew-Hong H, Soo-Kim L-T. Is genital papillomavirus infection always transmitted? *Aust NZ J Obstet Gynaecol* 1990;30:240-2.
236. Campion MJ, Singer A, Clarkson PK, McCance DJ. Increased risk of cervical neoplasia in consorts of men with penile condylomata acuminata. *Lancet* 1985;i:943-6.
237. Baggish MS. Treating viral venereal infections with the CO₂ laser. *J Reprod Med* 1982;27:737-42.
238. Carpinello VL, Zderic SA, Malloy TR, Sedlacek T. Carbon dioxide laser therapy of subclinical condyloma found by magnified penile surface scanning. *Urology* 1987;29:608-10.
239. Krebs H-B, Helmkamp BF. Treatment failure of genital condylomata acuminata in women: role of the male sexual partner. *Am J Obstet Gynecol* 1991;165:337-9.
240. Richardson AC, Lyon JB. The effect of condom use on squamous cell cervical intraepithelial neoplasia. *Am J Obstet Gynecol* 1981;140:909-13.
241. Fletcher S, Norval M. On the nature of the deep cellular disturbances in human papillomavirus infection of the squamous cervical epithelium. *Lancet* 1983;ii:546-9.
242. Stoler MH, Wolinsky SM, Whitbeck A, Broker TR, Chow LT. Differentiation-linked human papillomavirus types 6 and 11 transcription in genital condylomata revealed by in situ hybridization with message-specific RNA probes. *Virology* 1989;172:331-40.

243. McCance DJ, Walker PG, Dyson JL et al. Presence of human papillomavirus DNA sequences in cervical intraepithelial neoplasia. *Br Med J* 1983;287:784-8.
244. Braun L, Farmer ER, Shah KV. Immunoperoxidase localization of papillomavirus antigen in cutaneous warts and bowenoid papulosis. *J Med Virol* 1983;12:187-93.
245. Ferenczy A, Winkler B. Cervical intraepithelial neoplasia and condyloma. In: Kurman R, ed. *Blaustein's pathology of the female genital tract*. 3rd ed. New York: Springer Verlag, 1987:1177-217.
246. Fairley CK, Chen S, Tabrizi SN, Leeton K, Quinn MA, Garland SM. The absence of genital human papillomavirus DNA in virginal women. *Int J STD AIDS* 1992;3:414-7.
247. Fairley CK, Chen S, Tabrizi SN et al. Tampons: a novel method for the assessment of genital HPV infection. *J Infect Dis* 1992;165:1103-5.
248. Sedlacek TV, Lindheim S, Eder C et al. Mechanism of human papillomavirus transmission at birth. *Am J Obstet Gynecol* 1989;161:55-9.
249. Tseng C-J, Lin C-Y, Wang R-L et al. Possible transplacental transmission of human papillomaviruses. *Am J Obstet Gynecol* 1992;166:35-40.
250. Fife KH, Rogers RE, Zwickl BW. Symptomatic nad asymptomatic cervical infection with human papillomavirus during pregnancy. *J Infect Dis* 1987;156:904-11.
251. Fife KH, Bubalo F, Boggs DL, Gaebler J. Vertical transmission of human papillomavirus; detection by DNA amplification. Eighth International Papillomavirus Workshop, Taos, USA, March 11-18, 1989.
252. Roman A, Fife K. Human papillomavirus DNA associated with foreskins of normal newborns. *J Infect Dis* 1986;153:855-61.
253. McDonnell PJ, McDonnell JM, Kessis T, Green WR, Shah KV. Detection of human papillomavirus type 6/11 DNA in conjunctival papillomas by in situ hybridization with radioactive probes. *Hum Pathol* 1987;18:1115-9.
254. Tang C, Shermata DW, Wood C. Congenital condylomata acuminata. *Am J Obstet Gynecol* 1978;131:912-3.
255. Redman JF, Meacham KR. Condyloma acuminata of the urethral meatus in children. *J Pediatr Surg* 1973;8:939-41.
256. De Jong AR, Weiss JC, Brent RL. Condylomata acuminata in children. *Am J Dis Child* 1982;136:704-6.

257. Fleming KA, Venning V, Evans M. DNA Typing of genital warts and diagnosis of sexual abuse of children. *Lancet* 1987;ii:454.
258. Oriel JD. Sexually transmitted diseases in children: human papillomavirus infection. *Genitourin Med* 1992;68:80-3.
259. American Academy of Dermatology Task Force on Pediatric Dermatology. Genital warts and sexual abuse in children. *J Am Acad Dermatol* 1984;11:529-30.
260. Stumpf PG. Increasing occurrence of condylomata in premenarchal children. *Obstet Gynecol* 1980;56:262-4.
261. Shah K, Kashima HK, Polk F, Shah F, Abbey H, Abramson A. Rarity of Cesarean delivery in cases of juvenile-onset respiratory papillomatosis. *Obstet Gynecol* 1986;68:795-9.
262. Cohen SR, Seltzer S, Geller KA, Thompson JW. Papilloma of the larynx and tracheobronchial tree: a retrospective study. *Ann Otol Rhinol Laryngol* 1980;89:497-503.
263. Ferenczy A. HPV-associated lesions in pregnancy and their clinical implications. *Clin Obstet Gynecol* 1989;32:191-9.
264. Quick CA, Watts SL, Krzyzek RA, Faras AJ. Relationship between condylomata and laryngeal papillomata. Clinical and molecular virological evidence. *Ann Otol Rhinol Laryngol* 1980;89:467-71.
265. Mounts P, Shah KV. Respiratory papillomatosis: etiologic relation to genital tract papillomaviruses. *Prog Med Virol* 1984;29:90-114.
266. Bennett RS, Powell KR. Human papillomaviruses: associations between laryngeal papillomas and genital warts. *Pediatr Infect Dis J* 1987;6:229-32.
267. Kashima H, Shah K. Recurrent respiratory papillomatosis. *Obstet Gynecol Clin North Am* 1987;14:581-8.
268. Terry RM, Lewis FA, Griffiths S, Wells M, Bird CC. Demonstration of human papillomavirus types 6 and 11 in juvenile laryngeal papillomatosis by in-situ DNA hybridization. *J Pathol* 1987;153:245-8.
269. Hallden C, Majmudar B. The relationship between juvenile laryngeal papillomatosis and maternal condylomata acuminata. *J Reprod Med* 1986;31:804-7.
270. Holinger PH, Shields JA, Maurizi DG. Laryngeal papilloma: review of etiology and therapy. *The Laryngoscope* 1989:1462.

271. Jochmus-Kudielka I, Schneider A, Braun R et al. Antibodies against the human papillomavirus type 16 early proteins in human sera: correlation of anti-E7 reactivity with cervical cancer. J Natl Cancer Inst 1989;81:1698-704.
272. Li CCH, Shah KV, Seth A, Gilden RV. Identification of the human papillomavirus type 6b L1 open reading frame protein in condylomas and corresponding antibodies in human sera. J Virol 1987;61:2684-90.
273. Helmrich G, Stubbs TM, Stoerker J. Fetal maternal laryngeal papillomatosis in pregnancy: a case report. Am J Obstet Gynec 1992;166:524-5.
274. Byrne JC, Tsao M-S, Frase RS, Howley PM. Human papillomavirus-11 DNA in a patient with chronic laryngo-tracheobronchial papillomatosis and metastatic squamous-cell carcinoma of the lung. N Engl J Med 1987;317:873-8.
275. Mounts P, Shah KV, Kashima H. Viral etiology of juvenile- and adult- onset squamous papilloma of the larynx. Proc Natl Acad Sci USA 1982;79:5425-9.
276. Mounts P, Kashima H. Association of human papillomavirus subtype and clinical course in respiratory papillomatosis. Laryngoscope 1984;94:28-33.
277. Gissmann L, Wolnik L, Ikenberg H, Koldovsky U, Schnürch HG, zur Hausen H. Human papillomavirus types 6 and 11 DNA sequences in genital and laryngeal papillomas and in some cervical cancers. Proc Natl Acad Sci USA 1983;80:560-3.
278. Abramson AL, Brandsma J, Steinberg B, Winkler B. Verrucous carcinoma of the larynx: possible human papillomavirus etiology. Arch Otolaryngol 1985;111:709-15.
279. Kiyabu MT, Shibata D, Arnheim N, Martin WJ, Fitzgibbons PL. Detection of human papillomavirus in formalin-fixed invasive squamous carcinomas using the polymerase chain reaction. Am J Surg Pathol 1989;13:221-4.
280. Brandsma JL, Steinberg BM, Abramson AL, Winkler B. Presence of human papillomavirus type 16 related sequences in verrucous carcinoma of the larynx. Cancer Res 1986;46:2185-8.
281. Kreider JW, Howett MK, Stoler MH, Zaino RJ, Welsh P. Susceptibility of various human tissues to transformation in vivo with human papillomavirus type 11. Int J Cancer 1987;39:459-65.
282. Bergstrom L. Laryngeal papillomatosis: recurrence after 33-year remission. Laryngoscope 1982;92:1160-3.

283. Anonymous. Recurrent respiratory papillomatosis. *Lancet* 1988;ii:1406.
284. Clarke J, Terry RM, Lacey CJ. A study to estimate the prevalence of upper respiratory tract papillomatosis in patients with genital warts. *Int J STD AIDS*. 1991;2:114-5.
285. Carey FA, Salter DM, Kerr KM, Lamb D. An investigation into the role of human papillomavirus in endobronchial papillary squamous tumours. *Respir Med* 1990;84:445-7.
286. Syrjänen KJ, Syrjänen SM. Human papillomavirus DNA in bronchial squamous cell carcinomas. *Lancet* 1987;i:168-9.
287. De Villiers E-M, Weidauer H, Otto H, zur Hausen H. Papillomavirus DNA in human tongue carcinomas. *Int J Cancer* 1985;36:575-8.
288. Brandsma JL, Abramson AL. Association of papillomavirus with cancers of the head and neck. *Arch Otolaryngol Head Neck Surg* 1989;115:621-5.
289. Syrjänen SM, Syrjänen KJ, Hipponen RP, Lamberg MA. In situ DNA hybridization of human papillomavirus (HPV) sequences in benign oral mucosal lesions. *Arch Dermatol Res* 1987;279:543-9.
290. Janson JA, Baillie J, Pollock M. Endoscopic removal of oesophageal condylomata acuminatum containing human papilloma virus. *Gastrointest Endosc* 1991;37:367-70.
291. Winkler B, Capo V, Reumann W et al. Human papillomavirus infection of the esophagus, a clinicopathologic study with demonstration of papillomavirus antigen by the immunoperoxidase technique. *Cancer* 1985;55:149-55.
292. Hille JJ, Margolius KA, Markowitz S, Isaacson C. Human papillomavirus infection related to esophageal carcinoma in black South Africans, a preliminary study. *S Afr Med J* 1986;69:417-20.
293. Chang F, Syrjänen S, Shen Q et al. Human papillomavirus (HPV) DNA in oesophageal precancer lesions and squamous cell carcinomas from China. *Int J Cancer* 1990;45:21-5.
294. Chang F, Shen Q, Zhou J et al. Detection of human papillomavirus DNA in cytologic specimens derived from esophageal precancer lesions and cancer. *Scand J Gastroenterol* 1990;25:383-8.

295. Kulski J, Demeter T, Sterrett GF, Shilkin KB. Human papilloma virus DNA in oesophageal carcinoma. *Lancet* 1986;ii:683-4.
296. Morris H, Price S. Langerhan's cells, papillomaviruses and esophageal carcinoma, a hypothesis. *S Afr Med J* 1986;69:413-6.
297. Goldsmith MF. Papillomavirus invades esophagus, incidence seems to be increasing. *JAMA* 1984;251:2185-7.
298. Furuta Y, Takasu T, Asai T et al. Detection of human papillomavirus DNA in carcinomas of the nasal cavities and paranasal sinuses by polymerase chain reaction. *Cancer* 1992;69:353-7.
299. Lass JH, Grove AS, Papale JJ, Albert DM, Jenson AB, Lancaster WD. Detection of human papillomavirus DNA sequences in conjunctival papilloma. *Am J Ophthalmol* 1983;96:670-4.
300. McDonnell JM, Mayr AJ, Martin WJ. DNA of human papillomavirus type 16 in dysplastic and malignant lesions of the conjunctiva and cornea. *N Engl J Med* 1989;320:1442-6.
301. Lauer SA, Malter JS, Meier JR. Human papillomavirus type 18 in conjunctival intraepithelial neoplasia. *Am J Ophthalmol* 1990;110:123-7.
302. Mannis JM. Chlamydial diseases. In: Kaufman HE, Barron BA, McDonald MB, Waltman SR, eds. *The cornea*. New York: Churchill Livingstone, 1988:201-16.
303. Pao CC, Lin S-S, Lin C-Y, Maa J-S, Lai C-H, Hsieh T-T. Identification of human papillomavirus DNA sequences in peripheral blood mononuclear cells. *Am J Clin Path* 1991;95:540-6.
304. McCance DJ, Champion MJ, Baram A, Singer A. Risk of transmission of human papillomavirus by vaginal specula. *Lancet* 1986;ii:816-7.
305. Ferenczy A, Bergeron C, Richart RM. Human papillomavirus DNA in fomites on objects used for the management of patients with genital human papillomavirus infections. *Obstet Gynecol* 1989;74:950-4.
306. Garden JM, O'Banion K, Shelnitz LS et al. Papillomavirus in the vapor of carbon dioxide laser-treated verrucae. *JAMA* 1988;259:1199-202.
307. Sawchuck WS, Weber PJ, Lowy DR, Dzubow LM. Infectious papillomavirus in the vapor of warts treated with carbon dioxide laser or electrocoagulation: detection and protection. *J Am Acad Dermatol* 1989;21:41-9.

308. Zhang Z-F, Parkin DM, Yu S-Z, Esteve J, Yang X-Z. Risk factors for cancer of the cervix in a rural Chinese population. *Int J Cancer* 1989;**43**:762-7.
309. Rotkin FD. A comparison review of key epidemiological studies in cervical cancer related to current searches for transmissible agents. *Cancer Res* 1973;**33**:1353-67.
310. Singer A, Jenkins D. Viruses and cervical cancer. Genital virus infections warrant surveillance rather than radical treatment. *Br Med J* 1991;**302**:251-2.
311. Kessler II. Human cervix cancer as a venereal disease. *Cancer Res* 1976;**36**:783-91.
312. Oriel D. Sex and cervical cancer. *Genitourin Med* 1988;**64**:81-9.
313. Wright TC, Richart RM. Role of human papillomavirus in the pathogenesis of genital tract warts and cancer. *Gynecol Oncol* 1990;**37**:151-64.
314. Cuzick J, Terry G, Ho L, Hollingworth T, Anderson M. Human papillomavirus type 16 DNA in cervical smears as predictor of high-grade cervical cancer. *Lancet* 1992;**339**:959-60.
315. Schwarz E, Freese UK, Gissmann L et al. Structure and transcription of human papillomavirus sequences in cervical carcinoma cells. *Nature* 1985;**314**:111-4.
316. Boshart M, Gissmann L, Ikenberg H, Kleinheinz A, Sheurlen W, zur Hausen H. *EMBO J* 1984;**3**:1151-7.
317. Zur Hausen H. Human papillomaviruses in the pathogenesis of anogenital cancer. *Virology* 1991;**184**:9-13.
318. Graham S, Rawls W, Swanson M, McCurtis J. Sex partners and herpes simplex virus type 2 in the epidemiology of cancer of the cervix. *Am J Epidemiol* 1982;**115**:729-35.
319. Iwasaka T, Yokoyama M, Hayash Y, Sugimori H. Combined herpes simplex virus type 2 and human papillomavirus type 16 or 18 deoxyribonucleic acid leads to oncogenic transformation. *Am J Obstet Gynecol* 1988;**159P**:1251-5.
320. Gius D, Laimins LA. Activation of human papillomavirus type 18 gene expression by herpes simplex virus type 1 viral transactivators and a phorbol ester. *J Virol* 1989;**63**:555-63.
321. Kjaer SK, de Villiers E-M, Haugaard BJ et al. Human papillomavirus, herpes simplex virus and cervical cancer incidence in Greenland and Denmark. A population-based study. *Int J Cancer* 1988;**41**:518-24.

322. Bevan IS, Blomfield PI, Johnson MA, Woodman CBJ, Young LS. Oncogenic viruses and cervical cancer. *Lancet* 1989;*i*:907-8.
323. Bradbeer C. Is infection with HIV a risk factor for cervical intraepithelial neoplasia? *Lancet* 1987;*ii*:1277-8.
324. Spurrett B, Jones DS, Stewart G. Cervical dysplasia and HIV infection. *Lancet* 1988;*i*:238.
325. Byrne M, Taylor-Robinson D, Harris JRW. Cervical dysplasia and HIV infection. *Lancet* 1988;*i*:239.
326. Herrero R, Brinton LA, Reeves C et al. Invasive cervical cancer and smoking in Latin America. *J Natl Cancer Inst* 1989;*3*:205-11.
327. Vessey MP. Epidemiology of cervical cancer: role of hormonal factors, cigarette smoking and occupation. *Banbury Rep* 1986;*21*:29-43.
328. Winkelstein W. Smoking and cervical cancer - current status: a review. *Am J Epidemiol* 1990;*131*:945-57.
329. Barton SE, Maddox PH, Jenkins D, Edwards R, Cuzick J, Singer A. Effects of cigarette smoking on cervical epithelial immunity: a mechanism for neoplastic change? *Lancet* 1988;*ii*:652-4.
330. Vessey MP, Lawless M, McPherson K, Yates D. Oral contraceptives and carcinoma in situ of the uterine cervix. *Lancet* 1983;*ii*:1358-9.
331. Wassertheil-Smoller S, Romney SL, Wylie-Rosett J et al. Dietary vitamin C and uterine cervical dysplasia. *Am J Epidemiol* 1981;*114*:714-24.
332. Verréault R, Chu J, Mandelson M, Shy K. A case-control study of diet and invasive cervical cancer. *Int J Cancer* 1989;*43*:1050-4.
333. Zur Hausen H. Human genital cancer: synergism between two virus infections or synergism between a virus infection and initiating events? *Lancet* 1982;*ii*:1370-2.
334. Gupta J, Pilotti S, Rilke F et al. Association of human papillomavirus type 16 with neoplastic lesions of the vulva and other genital sites by in situ hybridization. *Am J Pathol* 1987;*127*:206-15.
335. Kaufman RH, Bornstein J, Adam E et al. Human papillomavirus and herpes simplex virus in vulvar squamous cell carcinoma in situ. *Am J Obstet Gynecol* 1988;*158*:862-71.

336. Sutton GP, Stehman FB, Ehrlich CE et al. Human papillomavirus deoxyribonucleic acid in lesions of the female genital tract: evidence for type 6/11 in squamous carcinoma of the vulva. *Obstet Gynecol* 1987;**70**:564-8.
337. Zur Hausen H. Genital papillomavirus infections. *Prog Med Virol* 1985;**32**:15-21.
338. Okagaki T, Twiggs, LB, Zachow KR et al. Identification of human papillomavirus DNA in cervical and vaginal intraepithelial neoplasia with molecularly cloned virus-specific DNA probes. *Int J Gynaecol Pathol* 1983;**2**:153-9.
339. Sillman F, Stanek A, Sedlis A et al. The relationship between papillomavirus and lower genital intraepithelial neoplasia in immunosuppressed women. *Am J Obstet Gynecol* 1984;**150**:300-8.
340. McCance DJ, Kalache A, Ashdown K et al. Human papillomavirus types 16 and 18 in carcinomas of the penis from Brazil. *Int J Cancer* 1986;**37**:55-9.
341. Sigurgeirsson B, Lindelöf B, Eklund G. Condylomata acuminata and risk of cancer: an epidemiological study. *Br Med J* 1991;**303**:341-4.
342. Beckmann AM, Daling JR, Sherman KJ et al. Human papillomavirus infection and anal cancer. *Int J Cancer* 1989;**43**:1043-9.
343. Gross G. Bowenoid papulosis. In: Gross G, Jablonska S, Pfister H, Stegner H-E, eds. *Genital papillomavirus infections: modern diagnosis and treatment*. Berlin: Springer-Verlag, 1990:189-207.
344. Obalek S, Jablonska S, Beaudenon S, Walczak L, Orth G. Bowenoid papulosis of the male and female genitalia; risk of cervical neoplasia. *J Am Acad Dermatol* 1986;**14**:433-44.
345. Judge JR. Giant condyloma acuminatum involving vulva and rectum. *Arch Pathol* 1969;**88**:46-8.
346. Ackerman LV. Verrucous carcinoma of the oral cavity. *Surgery* 1948;**23**:670-8.
347. Lepow H, Leffler N. Giant condylomata acuminata (Buschke-Löwenstein tumor): report of two cases. *J Urol* 1960;**83**:853-8.
348. Bulkley G, Wendel R, Grayhack J. Buschke-Loewenstein tumor of the penis. *J Urol* 1967;**97**:731-7.
349. Turner MJ, White JO, Soutter WP. The male factor in cervical neoplasia. *Contemp Rev Obstet Gynaecol* 1988;**1**:36-42.

350. Singer A, Reid BL, Coppleson M. A hypothesis: the role of a high-risk male in the etiology of cervical carcinoma. A correlation of epidemiology and molecular biology. *Am J Obstet Gynecol* 1976;**126**:110-5.
351. Buckley JD, Harris RWC, Doll R, Vessey MP, Williams PT. Case-control study of the husbands of women with dysplasia and carcinoma of the cervix uteri. *Lancet* 1981;**ii**:1010-5.
352. Beral V. Cancer of the cervix: a sexually transmitted disease. *Lancet* 1974;**ii**:1037-41.
353. Martínez I. Relationship of squamous cell carcinoma of the cervix uteri to squamous cell carcinoma of the penis among Puerto Rican women married to men with penile carcinoma. *Cancer* 1969;**24**:777-80.
354. Graham S, Priore R, Graham M, Browne R, Burnett W, West D. Genital cancer in the wives of penile cancer patients. *Cancer* 1979;**44**:1870-4.
355. Cocks PS, Peel KR, Cartwright RA, Adib R. Carcinoma of penis and cervix. *Lancet* 1980;**ii**:855-6.
356. Blythe-Smith D, Jenkins RS. Cervical cancer in a housing project: report of a cluster of cases. *Am J Obstet Gynecol* 1969;**104**:603-5.
357. Barrasso R, Gross G. Male HPV-associated lesions: epidemiology and diagnostic criteria. In: Gross G, Jablonska S, Pfister H, Stegner H-E, eds. *Genital papillomavirus infections: modern diagnosis and treatment*. Berlin: Springer-Verlag, 1990:189-207.
358. Hook EW, Handsfield HH. Gonococcal infections in the adult. In: Holmes KK, Mård P-A, Sparling PF et al. *Sexually transmitted diseases*. 2nd ed. London: McGraw Hill, 1990:149-65.
359. Hillman RJ, Walker MM, Harris JRW, Taylor-Robinson D. Penile dermatoses: a clinical and histopathological study. *Genitourin Med* 1992;**68**:166-9.
360. Lever WF, Schaumberg-Lever G. *Histopathology of the skin*. 7th ed. Philadelphia: JB Lippincott Company, 1990.
361. Sambrook J, Fritsch EF, Maniatis T. *Molecular cloning: a laboratory manual*. 2nd ed. Cold Spring Harbor, New York: Cold Spring Harbor Laboratory Press, 1989.
362. Cann AJ, Zack JA, Go AS et al. Human immunodeficiency virus type 1 T-cell tropism is determined by events prior to provirus formation. *J Virol* 1990;**64**:4735-42.

363. Snijders P J F, van den Brule A J C, Schrijnemakers H F J, Snow G, Meijer C J L M, Walboomers J M M. The use of general primers in the polymerase chain reaction permits the detection of a broad spectrum of human papillomavirus genotypes. *J Gen Virol* 1990;71:173-81.
364. Coppleson M, Colposcopic features of papillomaviral infection and premalignancy in the female lower genital tract. *Obstet Gynecol N Amer* 1987;14:471-94.
365. Ridley C M. General dermatological conditions and dermatoses of the vulva. In Ridley C M ed. *The vulva*. Edinburgh: Churchill Livingstone, 1988:138-211.
366. Wilkinson E J. Pathology of vulva and vagina. Contemporary issues in surgical pathology. New York: Churchill Livingstone, 1987.
367. Koss L G. Diagnostic cytopathology. 3rd ed. Philadelphia: Lippincott, 1979.
368. Marks R, Dawber R P R. Skin surface biopsy: an improved technique for the examination of the horny layer. *Br J Derm* 1971;84:117-23.
369. Kirchner H. Immunobiology of human papillomavirus infection. *Prog Med Virol* 1986;33:1-41.
370. Rymark P, Forslund O, Hansson B G, Lindholm K. Genital HPV infection not a local but a regional infection: experience from a female teenage group. *Genitourin Med* 1993;69:18-22.
371. Morris B J, Flanagan J L, McKinnon K J, Nightingale B N. Papillomavirus screening of cervical lavages by polymerase chain reaction. *Lancet* 1988;ii:1368.
372. Law C L H, Qassim M, Thompson C H *et al*. Factors associated with clinical and sub-clinical anal human papillomavirus infection in homosexual men. *Genitourin Med* 1991;67:92-8.
373. Grussendorf-Conen E, De Villiers E-M, Gissmann L. Human papillomavirus genomes in penile smears of healthy men. *Lancet* 1986;ii:1092.
374. Rosemberg S K. Sexually transmitted papillomaviral infection in men: an update. *Dermatol Clin* 1991;9:317-31.
375. Mandal D, Haye K R, Ray T K, Goorney B P, Stanbridge C M, Corbitt G. Prevalence of occult human papillomavirus infection, determined by cytology and DNA hybridization, in heterosexual men attending a genitourinary medicine clinic. *Int J STD AIDS* 1991;2:351-5.

376. Douglas JM, Breese PL, Koleis J, Bartholow BN. Prevalence of clinical and subclinical genital HPV infection among unselected men attending a sexually transmitted disease (STD) clinic. Abstract 125, 10th International Papillomavirus Workshop, Seattle, USA, July 20-26, 1991.
377. Arends MJ. Identification of HPV: in situ hybridization or polymerase chain reaction? J Pathol 1991;164:191-3.
378. Greer CE, Peterson SL, Kiviat NB, Manos MM. PCR amplification from paraffin-embedded tissues. Effects of fixatives and fixation time. Am J Clin Pathol 1991;95:117-24.
379. Chernesky M, Sellors J, Mahony J, Jang D, Pickard L, Krepel J. Diagnosis of C. trachomatis infections in women by examining cervical and urethral swabs and urine with culture and enzyme immunoassay. In: Bowie W, Caldwell H, Jones R et al, eds. Chlamydial infections, proceedings of the seventh international symposium on human chlamydial infection. Cambridge: Cambridge University Press, 1990:433-6.
380. Beckmann AM, Sherman KJ, Myerson D, Daling JR, McDougall JK, Galloway DA. Comparative virologic studies of condylomata acuminata reveal a lack of dual infections with human papillomaviruses. J Infect Dis 1991;163:393-6.
381. Spitzer M, Krumholz BA, Seltzer VL. The multicentric nature of disease related to human papillomavirus infection of the female lower genital tract. Obstet Gynecol 1989;73:303-7.
382. Soutter WP. Viral infection, human papillomavirus DNA and cervical neoplasia. Br Med J 1988;296:789.
383. Skrabanek P. Cervical cancer in nuns and prostitutes: a plea for scientific continence. J Clin Epidemiol 1988;41:577-82.

Appendices

APPENDIX I

QUESTIONNAIRE - GENITAL DERMATOSIS STUDY

DATE .../.../....

CLINIC NO

D.O.B. / / 19....

REFERRED BY:

PRESUMPTIVE DIAGNOSIS:

COUNTRY OF ORIGIN

RACE

white
caribbean
african
indo/pakistani
chinese
other

het / homo/ bi

CONDOMS never/ sometimes/ always

CIGARETTE SMOKER yes/no

NO. OF LIFETIME SEX PARTNERS
(exact no. if poss.)

PREVIOUS STDS (number)

1
2-5
6-10
10-20
20-30
30-50
50-100
100-200
>200
unknown

G.C. N.S.U
syphilis T.V.
candida scabies
crabs molluscum
H.S.V. Other.....

GENITAL WARTS

PREVIOUS
CURRENT

SKIN WARTS
- VERRUCAS ?

PREVIOUS
CURRENT

VERRUCAS

CIRCUMCISED? YES / NO

LESION SITE: glans/foreskin/shaft/frenulum/other.....

BIOPSY SITE: glans/foreskin/shaft/frenulum/other.....

URETHRAL SWAB: Y / N

URINE SAMPLE: Y / N

BIOPSY SENT FOR: histopath/DNA/fungal culture/froz. section/other

FOLLOW UP:

REFERRAL:

APPENDIX III

QUESTIONNAIRE - URETHRAL GONORRHOEA STUDY

DATE .../.../....

CLINIC NO

D.O.B./..../ 19....

COUNTRY OF ORIGIN

RACE white
caribbean
african
indo/pakistani
chinese
other

het / homo/ bi

CONDOMS never/ sometimes/ always

CIGARETTE SMOKER yes/no

NO. OF LIFETIME SEX PARTNERS
(exact no. if poss.)

1
2-5
6-10
10-20
20-30
30-50
50-100
100-200
>200
unknown

PREVIOUS STDS (number)

G.C.
syphilis
candida
crabs
H.S.V.
WARTS

N.S.U
T.V.
scabies
molluscum
Other.....

PREVIOUS SKIN WARTS

- VERRUCAS ?

URETHRAL SWAB: Y / N

URINE SAMPLE: Y / N

APPENDIX IV

QUESTIONNAIRE - MULTIFOCAL STUDY - 1

NAME
ADDRESS
.....
.....
PHONE NO
Ethnic Origin :- Caucasian
 Afro-Caribbean
 Indo-Pakistani
 Arabic
 Other
PAST MEDICAL HISTORY
(esp. dermatol)
CURRENT MEDICATIONS (+ 1/12)
(inc. topical)
PREVIOUS STD: Thrush T.V.
 B.V. Chlamydia
 G.C. Syphilis
 P.I.D. H.S.V.
 Others
RECENT GENITAL TRAUMA
HISTORY OF INFECTION IN PAST / PRESENT PARTNERS ?
 (esp. warts)

DATE
STUDY NO
CLINIC NO
CONSORT'S NO
OCCUPATION
Date of Birth
No. Cigarettes -
 - ever?
FAMILY HISTORY
(esp. dermatol)
ALLERGIES

QUESTIONNAIRE - MULTIFOCAL STUDY

EXAMINATION - MALE 1

DATE

CLINIC NO.

FULL PHYSICAL EXAMINATION

GENITAL EXAMINATION

- inguinal nodes - tender ?
- contents of scrotal sac
- circumcised ?

INITIAL APPEARANCE

PHOTOGRAPHS ?

QUESTIONNAIRE - MULTIFOCAL STUDY

EXAMINATION - MALE 2

DATE

CLINIC NO

AFTER 3% ACETIC ACID

PHOTOGRAPHS ?

BIOPSIES - Formal Saline

- Liquid Nitrogen (in OCT)

- DNA

QUESTIONNAIRE - MULTIFOCAL STUDY

INVESTIGATIONS - MALE

DATE

CLINIC NO

BLOOD - FBC
- LFTs
- Syphilis Serology
- HIV
- Save

URINE - 20ml First voided (pref. EMU)
(into fixative)

URETHRAL SMEAR - Gram Stain
- G.C. Culture

DNA
Cytology

ANAL SWAB - G.C. culture
- H.S.V. culture

CYTOBRUSH - Cytology
- D.N.A.

BUCCAL SMEAR - Cytology
- D.N.A.

"SG" SPECIMEN - Meatus
- Glans
- Shaft - Left
- Right

- Corona
- Foreskin
- Perianal Region

OTHER INVESTIGATIONS ?

QUESTIONNAIRE - MULTIFOCAL STUDY

INVESTIGATIONS - FEMALE

DATE

CLINIC NO

BLOOD - FBC
- LFTs
- Syphilis Serology
- HIV
- Save

URINE - 20ml First voided (pref. EMU)
(into fixative)

URETHRAL SMEAR - Gram Stain
- G.C. Culture

DNA
Cytology

CERVICAL SCRAPE - Cytology
- DNA

CYTOBRUSH - EndoCx
(DNA)

CERVICAL SWABS - Gram Stain
- G.C. Culture

Chlamydia (Microtrak)
H.S.V. Culture

HIGH VAGINAL SWAB - For Candida

WET FILM MICROSCOPY - T.V. / B.V. / Candida

ANAL SWAB - G.C. culture
- H.S.V. culture

CYTOBRUSH - Cytology
- D.N.A.

"SG" SPECIMEN - Peri-urethral
- Labia Majora - Left
- Right
- Cervix

Posterior Introitus
Vagina - Left
-Right
Perianal Region

OTHER INVESTIGATIONS ? - VAGINAL WASHING (for DNA)

QUESTIONNAIRE - MULTIFOCAL STUDY

EXAMINATION - FEMALE 1

DATE

CLINIC NO

FULL PHYSICAL EXAMINATION

GENITAL EXAMINATION

- inguinal nodes - tender ?
- uterus - a/v or r/v ?
- adnexae - palpable ?

VULVA - MACROSCOPIC

PHOTOGRAPHS ?

VULVA - AFTER 5% ACETIC ACID

PHOTOGRAPHS ?

BIOPSIES - Formal Saline

- Liquid Nitrogen (in OCT)
- DNA

QUESTIONNAIRE - MULTIFOCAL STUDY

EXAMINATION - FEMALE 2

DATE

CLINIC NO

CERVIX - BEFORE AND AFTER APPLICATION OF 5% ACETIC ACID

PHOTOGRAPHS ? - Y / N

M = Mosaic

P = Punctation

W = Aceto - white

G = Grades 1 - 3

L = Leukoplakia

BIOPSIES - Formal Saline

- Liquid Nitrogen (in OCT)

- DNA

APPENDIX V

CONTENTS OF SOLUTIONS USED

1 Selective medium for the growth of N. gonorrhoeae

GC Medium base with 1 vial of Isovitalex and 1 vial of Antibiotic Cocktail

Isovitalex contains:

Vitamin B ₁₂	0.01g
L-glutamine	10.0g
Adenine	1.0g
Guanine hydrochloride	0.03g
p-Aminobenzoic acid	0.013g
L-cysteine	1.10g
Dextrose	100.0g
Diphosphopyridine nucleotide	0.25g
Coccarboxylase	0.1g
Ferric nitrate	0.02g
Thiamine hydrochloride	0.003g
Cysteine hydrochloride	25.0g

Antibiotic Cocktail contains:

Vancomycin (3,000µg/ml)	10ml
Colistin (20,000 units/ml)	50ml
Trimethoprim (2,500µg/ml)	20ml
Amphotericin B (750µg/ml)	20ml

2. Collection of samples

2.1 Phosphate buffered saline

pH 7.4
8g/l NaCl
0.2g/l KCl
1.15g/l Na_2HPO_4
0.2g/l KH_2PO_4

2.2 Formal saline

10% w/v formaldehyde solution (equivalent to 4% formalde-
hyde)
0.9% w/v NaCl

3. DNA extraction

3.1 Summers buffer

Stock solution = x 2

0.486g Tris
1.75g NaCl
0.84g Ethylenediaminetetraacetic acid (EDTA)
- tetrasodium salt
titrated to pH8.0 with concentrated HCl
made up to 100ml with ddH₂O

3.2 SDS (Sodium Dodecyl Sulphate)

10% stock solution = 100mg/ml

3.3 Lysis mixture

100μl sterile double distilled water (ddH₂O)
28μl 2.5% SDS (25mg/ml)
4μl of 0.8mg/ml t-RNA
32μl of 10mg/ml protease

The protease used was Pronase E, which is type XXV protease, from Streptomyces griseus (Sigma, St Louis, Mo, U.S.A.)

3.4 TE-equilibrated phenol

Tris EDTA (TE) buffer (pH 8.0) = 10mM
Tris(hydroxymethyl)-methylamine (Tris) (pH 8.0) in 1mM
disodium EDTA (pH 8.0)

Phenol crystals were dissolved at 65°C and 8-hydroxyquinoline added to give a yellow colour and to prevent oxidation. The phenol was then equilibrated in an equal volume of TE buffer and stored at 4°C.

4. β -globin primers

Kindly provided by the Medical Research Council AIDS
Directed Programme:

β -globin (14-33) ADP894.1/LA1-N:
5'ACA CAA CTG TGT TCA CTA GG 3'

β -globin (123-104) ADP894.2/LA2-C:
5'CAA CTT CAT CCA CGT TCA CC 3'

5.3 PCR Reaction mixture

<u>10x Buffer</u>	<u>Volume per 10 samples</u>	<u>Stock</u>
500mM KCl	250 μ l	2M
100mM Tris pH 8.3	100 μ l	1M
30mM MgCl ₂	30 μ l	1M
0.01% gelatin	10 μ l	10%
10 μ M General primer 5	100 μ l	100 μ M
10 μ M General Primer 6	100 μ l	100 μ M
2mM dNTP mix	100 μ l	20mM
ddH ₂ O	310 μ l	

Taq polymerase:

(Taq DNA polymerase, Thermus aquaticus, Gibco BRL, Uxbridge, Middlesex, U.K.)
0.5 μ l Taq polymerase of 5U/ μ l stock was made to 100 μ l with ddH₂O.

Each experiment comprised 100 μ l of the reaction mix as listed above, together with the Taq polymerase

5.4 Near full length genomic probes

Provided by kind permission of Dr H. zur Hausen, Heidelberg, Germany.

These probes contain double stranded DNA of the whole genomes of HPV types 11,16 and 18. The HPV 6 probe included 0.67 of the whole genome.

HPV 6 - 5300 base pairs
HPV 11 - 7945 base pairs
HPV 16 - 7945 base pairs
HPV 18 - 7945 base pairs

5.5 Oligonucleotide probes

Provided by the Medical Research Council, Clinical Research Centre, Harrow, Middlesex, U.K.

HPV 31 - 5'TCT GTT TGT GCT GCA ATT GCA 5'
HPV 33 - 5'CAC ACA AGT AAC TAG TGA CAG 3'

6. Separation of DNA fragments by gel electrophoresis

6.1 Tris-Borate EDTA (TBE) buffer

0.089M Tris
0.089M boric acid
0.002M disodium EDTA

6.2 SSC (Saline Sodium Citrate)

Stock solution (= "x 20") = 3M NaCl in 0.3M sodium citrate

6.3 Prehybridisation mixture

6 x SSC
20 x Denhardt's solution*
0.5% SDS (5mg/ml SDS)
1mM disodium EDTA
75 μ l salmon sperm DNA (50 μ g/ml) (Sigma, St Louis, Mo, U.S.A.)
sterile ddH₂O

*Denhardt's solution consists of:

0.4% bovine serum albumin (Promega, Southampton, U.K.)
0.4% Polyvinyl pyrrolidone (Sigma, St Louis, Mo, USA)
0.4% Ficoll 400 (Pharmacia, LKB Biotechnology, Uppsala, Sweden)

6.4 Random priming mixture

5 μ l Multiprime buffer solution RPN. 1601Y/Z (Amersham International PLC, Aylesbury, Bucks, U.K.)
5 μ l Primer solution RPN. 1601Y/Z (Amersham, U.K.)
4 μ l dATP
4 μ l dGTP
4 μ l dTTP
3 μ l ³²P labelled dCTP (30Ci/mmol)
2 μ l (2 units) Klenow fragment of DNA polymerase 1
ddH₂O (to make up to 50 μ l)

6.5 End-labelling mixture

2 μ l 10 x kinase buffer (Polynucleotide Buffer, Amersham, U.K.)
5 μ l ³²P labelled dATP (50Ci/mmol)
1 μ l (10 units) T4 polynucleotide kinase (Amersham, U.K.)
sterile ddH₂O to make up to 20 μ l volume

APPENDIX VI

The following publications have been derived from the work of this thesis. Permission for the inclusion of these publications in this thesis has been obtained from the co-authors and publishers.

Value of performing biopsies in genitourinary clinics

We read with interest the recent letter in your journal concerning the value of performing biopsies in genitourinary clinics.¹

Men with abnormalities of the skin of the penis frequently present to genitourinary physicians, who must therefore also be skilled in dermatology. This is particularly so in the light of the probable re-definition of our specialty as "dermato-venereology" in the unified post-1992 European Community.

In order to assess the specific dermatological problems encountered by a busy genitourinary medicine clinic, we set up an internal clinic for penile dermatoses. The criteria for referral were a penile dermatosis of uncertain diagnosis for which the clinician thought that a biopsy might prove helpful. The technique used was that of local anaesthesia followed by skin snip biopsy. All patients were thoroughly counselled before the procedure, which was generally regarded by the patient as not being as traumatic as initially envisaged.

Over a period of two months a total of 18 biopsies were performed with the following histopathological results: 5 nonspecific dermatitis, 3 viral warts, 3 lichen sclerosus et atrophicus, 2 lichen planus, 2 symptomatic subclinical papillomavirus infection, 1 granulomatous disease (currently undergoing investigation) and 1 trauma (probable dermatitis artefacta). Although only a small sample was taken, typically 0.5 mm in diameter, in only one case did the biopsy prove non-diagnostic.

It can be seen that in 11 out of 18 cases, a specific diagnosis was able to be made for which a management plan could be devised. We would draw particular attention to the diagnoses of lichen sclerosus et atrophicus (LSA). Not only are there multiple names for the same histopathological condition (LSA, balanitis xerotica obliterans and kraurosis vulvae), but the malignant potential of this common² condition remains undefined and a standard text¹ suggests six to twelve monthly follow-up for life.

Despite the longstanding combination of the specialties of dermatology and venereology on the continent, the literature on genital dermatology is scant. The three specialties of genitourinary medicine, dermatology and urology have overlapping interests in penile cutaneous disorders, but rarely have in-depth knowledge. Unlike the vulval cutaneous disorders,⁴ for example, there is no standard textbook in the English language on penile dermatoses. Furthermore, confusions still exist over relatively common disorders, as described above. It is thus important to develop and improve lines of communication between genitourinary physicians, dermatologists and histopathologists at regular audit meetings.

We would therefore wholeheartedly agree with the conclusion of Drs Arumainayagam and Sumathipala that penile biopsy is a very useful diagnostic procedure in the setting of a genitourinary clinic. The more widespread use of this simple and minimally invasive procedure would allow us to gain greater insight into the ill-understood incidence and nature of genital dermatoses.

R J HILLMAN

J R W HARRIS

Department of Genitourinary Medicine

M M WALKER

Department of Histopathology,

St Mary's Hospital, Praed St,

London W2 1NY, UK

- 1 Arumainayagam JT, Sumathipala AHT. Value of performing biopsies in genitourinary clinics. *Genitourin Med* 1990;66:407.
- 2 Chalmers RJG, Burton PA, Bennett R, Goring CC. Lichen sclerosus et atrophicus—a distinctive and common cause of phimosis in boys. *Br J Dermatol* 1982;107 (suppl):29–30.
- 3 Rowell NR. Lichen sclerosus. In: Rook A, Wilkinson DS, Ebling FJG, Champion RH, Burton JL eds. *Textbook of Dermatology*. Oxford: Blackwell Scientific Publication, 1986: 1368–74.
- 4 Wilkinson EJ ed. *Pathology of Vulva and Vagina*. New York: Churchill Livingstone, 1987.

Genital human papillomavirus lesions of the male sexual partners: the diagnostic accuracy of peniscopy

We were interested to read the article by Hippeläinen *et al*¹ concerning peniscopy and the carriage of human papillomavirus (HPV) DNA by male partners of women who had abnormal Papanicolaou smears. If we are to assume that HPV is transmitted predominantly by sexual contact,² it follows that men are involved in about half of the epidemic. This factor does not seem to be reflected in the current literature, which, despite the explosion of interest in the topic, still constitutes only a small minority of the publications. For example, only 20 (4.7%) of 424 papers presented at the recent papillomavirus workshop in Seattle directly concerned male carriage of HPV. This paucity of data is presumably, at least in part, due to the lack of a male counterpart of the Papanicolaou smear, which forms the basis of much current epidemiological work. The study of Hippeläinen *et al* is, therefore, a significant contribution to the field. However, we would like to raise several points.

The term "peniscopy" has been used previously,³ but other authors use terms such as "androscopey",⁴ "magnified penile surface scanning",⁵ and, probably the least appropriate term, "colposcopy".⁶ We suggest that the term "peniscopy" should be adopted, as its form is more consistent with the words used to describe other techniques which augment clinical visualisation, such as gastroscopy and bronchoscopy.

The whole area of HPV epidemiology is bedevilled by the absence of a universally agreed "gold standard". Clearly, from the data presented in this article, histology alone cannot be relied upon, as only 34 (35.4%) of 96 biopsies that showed histological criteria of HPV infection contained HPV DNA. As detection was not only by *in situ* hybridisation but also by the PCR, it seems likely that most of the lesions biopsied did not contain the so-called "genitotropic" HPVs tested for. This is surprising, as in most studies DNA of the genitotropic HPVs has been detected in approximately 90% of condylomata acuminata.⁷ Several explanations are possible for these observations. Penoscopically abnormal areas may be caused by HPV types which are dif-

ferent from those usually found in clinically apparent lesions. Alternatively, such lesions may be produced by mechanisms entirely different from infection with HPV. The fact that the authors, along with others,⁸ noted that penoscopic abnormalities occurred commonly at sites of likely epithelial trauma during intercourse, may be relevant. The finding that males with a long contact history had a lower incidence of abnormalities might be consistent with the observations that older genital HPV lesions contain fewer viral particles than fresher lesions⁹ and are less infectious.² It could be postulated that men who have had long term contact with women infected with HPV are, at the time of sampling, being exposed to a small viral load, and so are possibly less likely to have penile abnormalities attributable to HPV infection.

It is unfortunate that the men did not undergo full testing for other sexually transmitted diseases, for example, a urethral smear to detect non-gonococcal urethritis and syphilis and HIV serology. Furthermore, the finding that none of the men carried *Chlamydia trachomatis* in the urethra suggests that the population sampled was an unusual one. Several reports^{10,11} suggest that other infectious agents exist often in a large proportion of those with condylomata acuminata, and co-infection has been postulated to affect the natural history of HPV infections.¹²

The observation of a much greater correlation between histological criteria and the detection of HPV DNA in meatal and distal urethral biopsy specimens than elsewhere was interesting. This may be related to the fact that the epithelium in the meatus and urethra is perhaps more akin to some areas of the cervix, where more experience has been gained in interpreting histological changes. Most interesting of all was the observation that HPV DNA was not found in histologically normal skin. This is in agreement with our findings in a series of penile biopsies that did not show histological evidence of HPV infection (unpublished). HPV DNA was detected using the PCR in only 1 (3%) of 35 biopsies. This is in contrast to the findings in the female genital tract, where HPV may be detected in histologically normal tissue¹³ and suggests that the epidemiology of HPV in men may be fundamentally different.

Penoscopy undoubtedly has a role in attempting to understand the epidemiology of HPV infections. However, in view of the limitations of sensitivity and specificity highlighted by Hippeläinen *et al*, enthusiastic calls for its widespread introduction into routine clinical practice¹⁴ should be treated with caution. More disturbing are the recommendations of some authors¹ for extensive ablation of penoscopically abnormal areas. In view of the considerable anxiety already suffered by some of these patients, we prefer to wait for the results of further carefully controlled studies to determine the value of penoscopy before offering it routinely.

RJ HILLMAN
M BOTCHERBY
D TAYLOR-ROBINSON
*Division of Sexually Transmitted Diseases,
Clinical Research Centre,
Watford Rd, Harrow HA1 3UJ, UK*

- 1 Hippeläinen M, Yliskoski M, Saarikoski S, Syrjänen S, Syrjänen K. Genital human papillomavirus lesions of the male sexual partners: the diagnostic accuracy of penoscopy. *Genitourin Med* 1991;67:291-6.
- 2 Oriel JD. Natural history of genital warts. *Br J Venereal Dis* 1971;47:1-13.
- 3 Boon ME, Schneider A, Hogewoning CJA, van der Kwast TH, Bolhuis P, Kok LP. Penile studies and heterosexual partners: penoscopy, cytology, histology and immunocytochemistry. *Cancer* 1988;1:1652-9.
- 4 Epperson WJ. Preventing cervical cancer by treating genital warts in men: why male sex partners need androscopy. *Postgrad Med* 1990;88:229-36.
- 5 Carpiniello V, Schlecker B, Sedlacek TV, Malloy T, Cunnane M, Wein AJ. Magnified penile surface scanning in diagnosis of penile condyloma. *Urology* 1986;28:190-2.
- 6 Campion MJ, McCance DJ, Mitchell HS, Jenkins D, Singer A, Oriel JD. Subclinical penile human papillomavirus infection and dysplasia in consorts of women with cervical neoplasia. *Genitourin Med* 1988;64:90-9.
- 7 Gross G, Ikenberg H, Gissmann L, Hagedorn M. Papillomavirus infection of the anogenital region: correlation between histology, clinical picture, and virus type. Proposal of a new nomenclature. *J Invest Dermatol* 1985;85:147-52.
- 8 Krebs H-B, Schneider V. Human papillomavirus-associated lesions of the penis: colposcopy, cytology and histology. *Obstet Gynecol* 1987;70:299-304.
- 9 Vardy DA, Baadsgaard O, Hansen ER, Lisby S, Vejlsgaard GL. The cellular immune response to human papillomavirus infection. *Int J Dermatol* 1990;29:603-10.

- 10 Carne CA, Dockerty G. Genital warts: need to screen for coinfection. *BMJ* 1990;300:459.
- 11 Griffiths M, Overington LJ, Chard SC. Genital warts and the need for screening. *Genitourin Med* 1989;65:399.
- 12 Kinghorn GR. Genital warts: incidence of associated genital infections. *Br J Dermatol* 1978;99:405-9.
- 13 Ferenczy A, Mitao M, Nagai N, Silverstein SJ, Crum CP. Latent papillomavirus and recurring genital warts. *New Eng J Med* 1985;313:784-9.
- 14 Pfenninger JL. Androscopy: a technique for examining men for condyloma. *J Fam Pract* 1989;29:286-8.

Persistent anogenital warts

Anogenital warts are one manifestation of human papillomavirus (HPV) infection of the anogenital tract. Such HPV infections have an adjusted annual incidence of about 8% in an unselected Scandinavian female population,¹ and anogenital warts are the commonest viral sexually transmissible disease in England.² The patient's immune response probably determines whether infection will become manifested clinically and how well the resulting condylomas respond to treatment. HPV DNA replicates in the suprabasal cells of the epidermis, but the considerably more antigenic complete viral particles are produced only in differentiating keratinocytes, which are distant from cutaneous immunological defences. HPV infections may also be associated with local immunoparesis.^{3,4} Whatever treatment is used, efficacy probably depends on (a) removal of tissue containing viral particles and (b) disruption and release of previously sequestered viral antigens and their exposure to the immune system.

Scientific evaluation of treatment is difficult. For example, it may be hard to assess objectively the severity and response of clinically apparent lesions. Warts of different types and duration may not respond in the same way to different regimens, and the role of HPV typing in terms of clinical behaviour and therapeutic responsiveness has not been fully explored.⁵ Patient variables such as sexual practices, smoking, human immunodeficiency virus infection, oral contraceptive use, and nutritional status may likewise be important. Trials of therapy seldom control for all these factors, tending to concentrate instead on patients with newer lesions that are more responsive to most treatments than are persistent warts. Follow-up is often no more than 3 or 6 months, despite the known propensity of warts to relapse and to remit spontaneously.⁶ Reinfection during treatment may be difficult to exclude, and use of condoms during and after therapy may influence the results. Another complication is that fomites may help to maintain infection—in one trial⁷ the relapse rate was increased in patients whose underwear contained HPV DNA. It is unclear whether concurrent treatment of sexual partners enhances the success of treatment.

Fresher warts are associated with a more vigorous immune response⁸ and are generally more responsive to all the established treatments, so patients should be encouraged to present early. Nevertheless, a large minority of patients with anogenital warts do not respond adequately to first-line treatment with podophyllin, podophyllotoxin, or cryotherapy. The considerable distress and pressure on sexual relationships caused by the diagnosis are compounded by patients' increased awareness of the putative link between HPV infection and anogenital cancers. Repeated courses of podophyllin have progressively fewer benefits,⁸ and destructive methods such as cryotherapy, electrodesiccation, and laser fulguration, either separately or in various combinations, may be necessary. Choice of treatment largely depends on locally available skills and resources; cure rates vary from 27 to 91%.^{9,10}

Different types^{11,12} and doses of interferons given locally¹³ or systemically¹⁴ have been tried for various lengths of time. Most trials have been on patients with previously untreated warts, for which the chances of cure are better than with older, larger, or recalcitrant lesions.^{15,16} For persistent warts, interferon combined with a destructive method may improve the clearance rate.¹⁷ Although the frequency, dose, type, and indications for interferons in the treatment of anogenital warts remain to be fully established, use of a combination of methods should lead to at least temporary clearing of visible lesions in most cases; repeated treatments may be necessary occasionally.

We do not know whether HPV DNA is eradicated completely as a consequence of any of the wart treatments.¹⁸ Moreover, it will be some time before we know whether elimination of the clinical manifestations of genital HPV infection reduces infectivity for sexual partners or alters any risk of subsequent anogenital cancer. One view is that vigorous therapy should be used in the minority of individuals whose warts harbour so-called high-risk types (HPV 16, 18, 31, 33, 35, and 39); the more common "low-risk" types are HPV 6 and 11. However, several other factors influence the rate of progression of lesions,¹⁹ and HPV typing is not routinely available. Until these issues have been addressed, enthusiastic calls for widespread destruction of skin with evidence of subclinical HPV infection should be resisted.

Patients with anogenital warts are likely to have put themselves at risk of acquiring other sexually transmitted infections, including human immunodeficiency virus, so it is essential to offer counselling and screening for these disorders. Such screening not only allows treatment of previously undiagnosed conditions but also may aid management of the warts, since epidermal irritation caused by coincidental genital pathogens may encourage growth of the lesions.²⁰ Because wart treatment sometimes extends over several months, screening may have to be repeated as the patient's lifestyle changes. It is important to determine the patient's sexual history so that recent partners can be offered screening. In view of the concern about HPV and anogenital cancer, cervical cytology is recommended, in addition to biopsy of any atypical lesions.

The treatment of anogenital warts has fostered a rich heritage of folklore²¹ and the continuing controversy surrounding existing regimens, none of which is uniformly effective, safe, and cheap, shows how little we understand the pathogenesis and management of this infection. Ample scope here for properly controlled and blinded trials of new treatments.

1. Syrjänen KJ. Epidemiology of human papillomavirus (HPV) infections and their associations with genital squamous cell cancer. *APMIS* 1989; 97: 957-70.
2. Department of Health. New cases seen at NHS genito-urinary clinics in England years 1988/89 and 1989/90: summary information from form KC60. London: Department of Health, 1991.
3. McMillan A, Bishop PE, Fletcher S. An immunohistological study of condylomata acuminata. *Histopathology* 1990; 17: 45-52.
4. Vardy DA, Baadsgaard O, Hansen ER, Lisby S, Veisgaard GL. The cellular immune response to human papillomavirus infection. *Int J Dermatol* 1990; 29: 603-10.
5. Gal D, Friedman M, Mitrani-Rosenbaum S. Transmissibility and treatment failures of different types of human papillomavirus. *Obstet Gynecol* 1989; 73: 308-11.
6. Tying SK, Cauda R, Baron S, Whitely RJ. Condyloma acuminatum: epidemiological, clinical and therapeutic aspects. *Eur J Epidemiol* 1987; 3: 209-15.
7. Bergeron C, Ferenczy A, Richart R. Underwear: contamination by human papillomaviruses. *Am J Obstet Gynecol* 1990; 162: 25-29.
8. von Krogh G. Podophyllotoxin for condylomata acuminata eradication. Clinical and experimental comparative studies on podophyllum lignans, colchicine and 5-fluorouracil. *Acta Derm Venereol* 1981; 98 (suppl): 1-48.
9. Larsen J, Petersen CS. The patient with refractory genital warts in the STD-clinic. *Dan Med Bull* 1990; 37: 194-95.
10. Baggish MS. Improved laser techniques for the elimination of genital and extragenital warts. *Am J Obstet Gynecol* 1985; 153: 545-50.
11. Reichman RC, Oakes D, Bonnez W, et al. Treatment of condyloma acuminatum with three different interferons administered intravesically. *Ann Intern Med* 1988; 108: 675-79.
12. Zouboulis CC, Stadler R, Ikenberg H, Orfanos CE. Short-term systemic recombinant interferon- γ treatment is ineffective in recalcitrant condylomata acuminata. *J Am Acad Dermatol* 1991; 24: 302-03.
13. Eron LJ, Judson F, Tucker S, et al. Interferon therapy for condylomata acuminata. *N Engl J Med* 1986; 315: 1059-64.
14. Condylomata International Collaborative Study Group. Recurrent condylomata acuminata treated with recombinant interferon alfa-2a: a multicenter double-blind placebo-controlled clinical trial. *JAMA* 1991; 265: 684-87.
15. Gall SA, Hughes CE, Trofatter K. Interferon for the therapy of condyloma acuminatum. *Am J Obstet Gynecol* 1985; 153: 157-63.
16. Schonfeld A, Niike S, Schattner A, et al. Intramuscular human interferon- β injections in treatment of condylomata acuminata. *Lancet* 1984; i: 1038-42.
17. Petersen CS, Bjerring P, Larsen J, et al. Systemic interferon alpha-2b increases the cure rate in laser treated patients with multiple persistent genital warts: a placebo-controlled study. *Gemtoninn Med* 1991; 67: 99-102.
18. Ferenczy A, Mitao M, Nagai N, Silverstein SJ, Crum CP. Latent papillomavirus and recurring genital warts. *N Engl J Med* 1985; 313: 784-88.
19. Gissmann L. Linking HPV to cancer. *Clin Obstet Gynecol* 1989; 32: 141-47.
20. Kinghorn GR. Genital warts: incidence of associated genital infections. *Br J Dermatol* 1978; 99: 405-09.
21. Steele K. Wart charming practices among patients attending wart clinics. *Br J Gen Pract* 1990; 40: 517-18.

Granuloma annulare of the penis

R J Hillman, S Waldron, M M Walker, J R W Harris

Abstract

Granuloma annulare is an uncommon skin condition, most often found on the extremities of young females. A case of granuloma annulare occurring on the penis of a 61 year old man is reported and the current literature associating granuloma annulare and conditions likely to present to genitourinary clinics is reviewed.

Introduction

Granuloma annulare (GA), an uncommon dermatological disorder, usually occurs on the hands or feet of young women.¹ We report a case of penile granuloma annulare occurring on the penis and discuss the implications.

Case history

A 61 year old man presented to the genitourinary clinic with a one year history of a rash on his penis. He stated that the lesion was neither painful nor pruritic, that he had no other urogenital symptoms, and that he had never had a similar lesion before. He had a past medical history of adult onset asthma, for which he was currently taking beclomethasone and salbutamol inhalers, but there was

no significant past history of any dermatological conditions, and no family history of note. There was no known history of trauma to the genital area, although the patient spilt a large quantity of turpentine substitute on his groin around the time of the development of the lesion. He was not able to relate reliably whether this accident preceded or followed the development of his rash. The patient had been employed as a driver for a laundry business for 5 years, but had no other known history of exposure to potentially toxic chemicals.

The patient was exclusively heterosexual and had never been abroad. He had not indulged in any high risk activity likely to result in the acquisition of HIV. His last sexual intercourse was reported to be with a regular girlfriend, using a condom, several months prior to presentation.

On examination a serpiginous, raised, erythematous lesion 2 cm by 1 cm was noted on the shaft of the penis (fig 1). Genital examination was otherwise unremarkable; there was no lymphadenopathy and a full general examination failed to reveal any abnormalities. Urethral microscopy was unremarkable and culture of a swab from the urethra failed to reveal *Neisseria gonorrhoeae*. Syphilis serology, including the fluorescent

Department of
Genitourinary
Medicine, St Mary's
Hospital, London, UK
R J Hillman
S Waldron
J R W Harris

Department of
Histopathology, St
Mary's Hospital,
London, UK
M M Walker

Address for correspondence
to:
Dr R J Hillman, The Jefferiss
Wing, St Mary's Hospital,
Praed Street, London W2
1NY.

Accepted for publication
11 November 1991

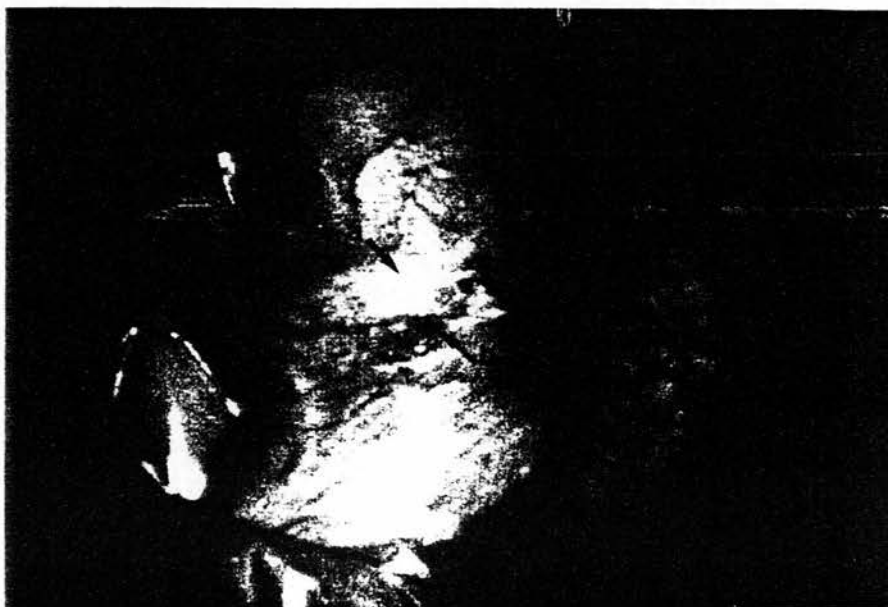
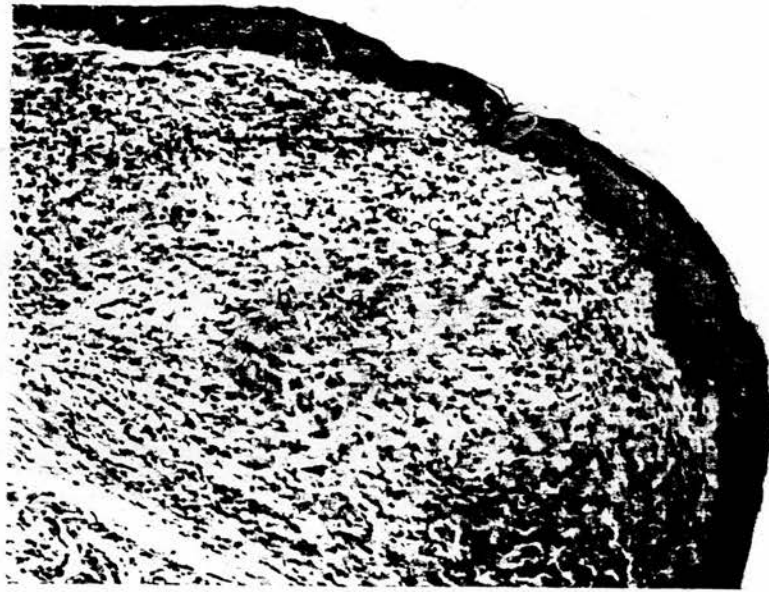
Figure 1 (a) Raised lesion of granuloma annulare on shaft of penis. (b) Healing biopsy site.

Figure 2 Biopsy of lesion, showing an epithelioid granuloma with central degeneration (a) and a surrounding lymphohistiocytic infiltrate (b) including sparse giant cells. (Haematoxylin and eosin; low power view $\times 50$).



treponemal antibody test, was negative. Swabs from the lesion site failed to reveal herpes simplex or *Haemophilus ducreyi* on specific culture, and routine bacteriological examination of a swab from the lesion showed normal skin flora only.

Full blood count was normal, as were fasting blood glucose and thyroid function tests. Antinuclear factor was detected in the patient's serum, but the DNA binding test was negative. Antibodies to mitochondria, smooth muscle, gastric parietal cells and thyroid cells were not present in the patient's serum. Following counselling, the patient declined to undergo testing for the human immunodeficiency virus (HIV).

In order to establish the diagnosis, a skin snip biopsy was performed following infiltration of the area with 2% lignocaine and 1 in 200,000 adrenalin for anaesthesia. The sample was then placed in 10% formal saline for routine histopathological examination. Sections showed foci of collagen degeneration, with a lymphohistiocytic infiltrate and sparse giant cell formation, as shown in fig 2. Acid fast bacilli were not seen using the Ziehl Nielsen technique and periodic acid Schiff staining for fungi was negative.

When reviewed six weeks after the biopsy, satisfactory healing of the biopsy wound had occurred, and the lesion was markedly reduced in size.

Discussion

Our patient presented with a lesion which was clinically typical of GA and had the characteristic histological findings and a consistent clinical history.

GA can occur in either localised or generalised forms, is commoner in females² than in males, and tends to predominate in younger age groups.^{1,3} The aetiology is unknown,²

however; local disease has been associated with trauma,⁴ contact with irritant materials,⁵ fungal infection,⁶ adenovirus,⁷ herpes zoster⁸ and diabetes mellitus.⁹ Generalised granuloma annulare has been associated with diabetes mellitus,² thyroid disease,¹⁰ chronic Lyme disease,¹¹ and the possession of HLA types A31, B35¹² and B8¹.

The lesions of GA occur most commonly on the surfaces of the dorsum of the hand and fingers,¹ and, to the best of our knowledge, there has only been one previous report of granuloma annulare of the penis.¹³

Lesions tend to disappear after 3 to 6 months. Trauma, such as the process of biopsy itself may precipitate disappearance, as happened in this case. Perforation of the lesions is the only potentially serious consequence of GA. The efficacies of treatments such as intralesional steroids, cryotherapy and radiotherapy are difficult to evaluate, in view of the tendency of lesions of GA to relapse spontaneously and remit.¹

GA currently has no established associations with other genitourinary conditions, although there has recently been a report linking it with scabies,¹⁴ and the condition has been confused with annular syphilid.¹⁵ Other potential clinical differential diagnoses of GA occurring in the genital tract include ringworm, annular lichen planus, sarcoidosis and necrobiosis lipoidica.¹ The histopathological differential diagnosis includes necrobiosis lipoidica, rheumatoid nodules and sarcoid. Clinico-pathological correlation is important in these cases.

One study² has suggested that only 16% of cases of GA can be related to a specific precipitant. It is unclear whether the incident with the turpentine substitute was a significant factor in the development of our patient's granuloma annulare, as he was uncertain of the exact temporal sequence.

Several papers report the occurrence of granuloma annulare in individuals infected with HIV^{7,10-18} and one article⁹ documents remission of generalised granuloma annulare in association with the initiation of zidovudine therapy.

Following counselling, our patient declined to undergo testing for HIV. He was not considered to be at particularly high risk, and had no stigmata to suggest advanced HIV disease.

In view of the developing epidemic of HIV, its possible association with GA and the potential confusion of GA with other genitourinary conditions, we believe that genitourinary physicians should consider GA in the differential diagnosis of any unusual dermatological condition and proceed to biopsy if there is any doubt.

- Cunliffe WJ. Necrobiotic disorders. In: Rook A, Wilkinson DS, Ebling FJG, Champion RH, Burton JL, eds. *Textbook of Dermatology*. 4th ed. Oxford: Blackwell Scientific Publications, 1986:1687-90.
- Dabski K, Winkelmann RK. Generalized granuloma annulare: laboratory findings in 100 patients. *J Am Acad Dermatol* 1989;20:39-47.
- Dahl MV, Goltz RW. Granuloma annulare. In: Fitzpatrick TB, Eisen AZ, Wolff K, Freedberg IM, Austen KF, eds. *Dermatology in General Medicine*. 2nd ed. New York: McGraw Hill, 1979:674-8.
- Fulghum DD. Octopus bite resulting in granuloma annulare. *South Med J* 1986;79:143-6.
- Stransky L. Contact granuloma annulare. *Contact Dermatitis* 1987;16:106.
- Ooi SP, Chen TT, Huang TH, Chang HS, Hsieh HY. Granuloma annulare-like skin lesion due to *Fusarium roseum*: therapy with ketoconazole (letter). *Arch Dermatol* 1987;123:167-8.
- Coldiron BM, Freeman RG, Beaudoin DL. Isolation of adenovirus from a granuloma annulare-like lesion in the acquired immunodeficiency syndrome-related complex. *Arch Dermatol* 1988;124:654-5.
- Friedman SJ, Fox BJ, Albert HL. Granuloma annulare arising in herpes zoster scars. Report of two cases and review of the literature. *J Am Acad Dermatol* 1986;14:764-70.
- Muhlemann MF, Williams DRR. Localised granuloma annulare is associated with insulin-dependent diabetes mellitus. *Br J Dermatol* 1984;111:325-9.
- Willemsen MJ, de Coninck AL, Jonckheer MH, Roseeuw DI. Autoimmune thyroiditis and generalised granuloma annulare: remission of the skin lesions after thyroxine therapy. *Dermatologica* 1987;175:239-43.
- Duray PH. Clinical pathologic correlations with Lyme disease. *Rev Infect Dis* 1989;11(Suppl 6):1487-93.
- Friedman-Birnbaum R, Gideoni O, Bergman R, Pollack S. A study of HLA antigen association in localised and generalised granuloma annulare. *Br J Dermatol* 1986;115:329-33.
- Kossard S, Collins AG, Wegman A, Hughes MR. Necrobiotic granuloma localised to the penis: a possible variant of subcutaneous granuloma annulare. *J Cutan Pathol* 1990;17:101-4.
- Vignale RA, Casella de Vilaboa E, Paciell J, Bruno J. [Disseminated annular granuloma in a patient with scabies]. *Med Cutan Ibero Lat Amer* 1990;18:252-6.
- Jain HC, Fischer BK. Annular syphilid mimicking granuloma annulare. *Int J Dermatol* 1988;27:340-1.
- Ghadially R, Sibbald RG, Walter JB, Haberman HF. Granuloma annulare in patients with human immunodeficiency virus infections. *J Am Acad Dermatol* 1989;20:232-5.
- Green TL, Hikado M, Greenspan D. Granuloma annulare of the buccal mucosa in association with AIDS. *Oral Surg Oral Med Oral Pathol* 1989;67:319-21.
- Jones SK, Harman RR. Atypical granuloma annulare in patients with the acquired immunodeficiency syndrome (letter). *J Am Acad Dermatol* 1989;20:299-300.
- Lecanutaphong V, Holzle E, Erckenbrecht J, Zuleger S, Plewig G. Remission of human immunodeficiency virus-associated generalised granuloma annulare under zidovudine therapy (letter). *J Am Acad Dermatol* 1988;19:1126-7.

Penile dermatoses: a clinical and histopathological study

R J Hillman, M M Walker, J R W Harris, D Taylor-Robinson

Abstract

Objective—To assess the spectrum of genital dermatological conditions affecting men and compare the clinical and histopathological diagnoses.

Design—Prospective study over a one year period.

Setting—A central London teaching hospital.

Patients—Seventy one patients with unresponsive penile dermatoses attending a specific internal referral clinic within the department of genitourinary medicine and 36 patients undergoing penile biopsy following attendance at other departments within the same hospital.

Methods—Full dermatological assessment of patients attending the specific clinic. Standard histopathological methods were used in the diagnosis of biopsy specimens.

Outcome measured—Clinico-pathological diagnosis of cutaneous penile abnormalities.

Results—Description of the range and relative frequency of penile dermatological conditions. The most common histopathological diagnosis was of non specific dermatitis. Twenty seven percent (16 of 61) of patients attending the specific clinic and 33% (12 of 36) of men attending other departments had conditions requiring long term follow up.

Conclusions—The ranges of penile dermatoses presenting to the different departments were broadly similar. Penile biopsy was shown to be a safe and clinically informative procedure. In the genitourinary clinic setting, clinical diagnosis prior to biopsy was found frequently to be inaccurate.

Introduction

Penile dermatoses encountered in genitourinary medicine (GUM) clinics frequently provide diagnostic difficulties. The diagnosis and treatment of such conditions is often empirical, based on the assumption that the rash is likely to be either fungal or eczematous. Not only is this approach unscientific, but it often fails to resolve, and in some cases, may exacerbate the problem. Patients with such dermatoses may persistently attend with relapsing rashes of uncertain aetiology, and potentially serious conditions can be overlooked. Presentation to other specialties such as general practice, urology, dermatology and general surgery also

occurs and such departments may lack the resources to diagnose accurately the wide range of sexually transmitted and other diseases affecting the penis.

The true nature and extent of penile dermatological conditions presenting to GUM clinics is unknown. In view of this, we investigated patients with persistent penile dermatoses by careful clinical evaluation, including biopsy. In addition, histopathological results from the specific referral clinic were compared with those of similar specimens submitted to the histopathology department over the same period from other departments.

Methods

A specific internal referral clinic, the Penile Dermatitis Clinic (PDC), was set up within the GUM department for men with persistent penile dermatoses which did not respond to treatment, or of which the diagnosis was in doubt and the clinician felt that biopsy would be helpful in establishing the diagnosis. All patients were screened for the commonly occurring sexually transmitted pathogens, and treatment was given where necessary. Patients were asked to avoid any specific local treatment to the area for a minimum of two weeks prior to assessment.

During the 45 minutes allocated for each patient, a full history, particularly including that of any personal or family dermatological conditions, was combined with a thorough examination of skin and mucous membranes, together with penoscopy. If a diagnosis could not be made at that point, or significant pathological changes could not be reasonably excluded on clinical grounds, the patient was counselled and offered a biopsy examination.

Under aseptic conditions the area to be biopsied, which included, where possible, the edge of the lesion and normal skin, was infiltrated with 1 to 2ml of 2% lignocaine with 1:200,000 adrenaline. Once anaesthesia had been achieved, the skin was gently pinched up using toothed forceps and an ellipse of approximately 1mm by 2mm was removed using scissors (fig). The biopsy specimen was then placed in 10% formal saline, processed routinely and stained by haematoxylin and eosin for histological examination. Haemostasis was achieved using silver nitrate sticks. In view of the small biopsy site, primary closure was not necessary, and the patient was given simple hygiene advice.

Samples from patients attending other specialties were received by the histopathology

Division of Sexually Transmitted Diseases, Clinical Research Centre, Watford Road, Harrow, Middlesex, HA1 3UJ
R J Hillman
D Taylor-Robinson
St Mary's Hospital, London, UK
Department of Histopathology
M M Walker
Department of Genitourinary Medicine
J R W Harris

Address correspondence to:
Dr R J Hillman, The Jefferies Wing, St Mary's Hospital, Praed Street, London W2 1NY, UK.

Accepted for publication
5 March 1992

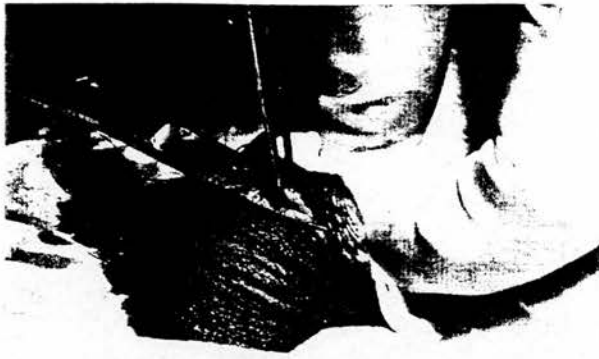

Figure Skin snip biopsy procedure

department in the course of routine clinical practice, without the patient being referred to the PDC. No patients were seen in more than one department.

Standard criteria were observed for the diagnosis of well recognised dermatological conditions, for example lichen sclerosus, lichen planus and dermatitis.¹ Previously established histopathological criteria for the diagnosis of wart virus infection and penile intraepithelial neoplasia (PIN) were applied.² All specimens in which a histological diagnosis of nonspecific dermatitis (NSD) was made were additionally stained by the periodic acid Schiff method.

The initial clinical diagnosis was made prior to biopsy and compared with the final diag-

Table 1 Clinical diagnoses in patients not undergoing penile biopsy (one patient in each category)

<i>Clinically apparent diagnosis</i>	
Fungal infection	1
Wart virus infection	1
Folliculitis	1
Herpes simplex virus infection	1
Atopic eczema	1
Pearly penile papules	1
Penile vein thrombosis	1
Vitiligo	1
Psychiatric illness	1
<i>Biopsy declined by patient</i>	
Wart virus infection	1
Atopic eczema	1

Table 2 Diagnoses in patients undergoing penile biopsy in the GUM department

Category	Diagnosis	No. of Patients n=60
Infection	Fungal infection	1
	Wart virus infection	14 (23%)
	Wart virus infection + dysplasia	1
Dermatosis	Non specific dermatitis	16 (26%)
	Lichen sclerosus	9 (15%)
	Lichen planus	4 (7%)
	Lichen simplex	1
	Psoriasis	2 (3%)
	Dermatitis artefacta	1
Neoplasia	PIN 2	2 (3%)
	PIN 3	2 (3%)
	Basal cell papilloma	1
Miscellaneous	Not diagnostic	2 (3%)
	Scarring	1
	Granulomatous disease ? cause	1
	Granuloma annulare	1
	Plasma cell balanitis	1

nosis which was based on the clinical features and histological findings. Thus, an essential part of the evaluation of the patient was discussion between the clinician and the histopathologist.

Results

Patients seen in the PDC

Seventy-one patients were seen in the PDC over a one year period. Seven (10%) of the patients were homosexual and one of them was known to be infected with the human immunodeficiency virus. The age range of all patients was 18.3 to 65.1 years (average 36.2 years). Sixty patients underwent biopsy, two declined to have biopsies and nine had clinical conditions for which biopsy was not considered necessary (table 1). The age range of those undergoing penile biopsy was 22.5 to 65.1 years (average 36.0 years). The age range of those not having a biopsy was 18.3 to 56.2 years (average 37.3 years).

A short course of antibiotics for secondary infection was required by three (5%) of the 60 patients undergoing biopsy, otherwise recovery was satisfactory, with minimal or no scarring, and return to full sexual activity usually within two weeks.

The diagnoses based on biopsy examination are shown in table 2.

Histological findings were consistent with the initial clinical diagnosis in 20 (33%) of the 60 patients undergoing biopsy. Lichen sclerosus (LSc) was diagnosed accurately prior to biopsy in seven (78%) of nine cases, wart virus infection in 7 (50%) of 14 cases, non specific dermatitis in five (31%) of 16 cases and lichen planus in one (25%) of four cases. Four (7%) of the biopsies undertaken in the PDC showed evidence of PIN, which had not been suspected prior to biopsy.

Patients seen in other departments

During the same period, the histopathology department received penile biopsy specimens from 36 patients attending other departments within the hospital, comprising 28 from the urologists and four each from the dermatologists and the general surgeons. The age range of these patients was 16.2 to 81.2 years (average 46.4 years).

Less clinical information was available on these patients. In view of this, clinical concordance was not assessed and the histological diagnoses (table 3) were used only to define the spectrum of penile dermatoses presenting to other departments. This was similar to that of lesions seen in the GUM clinic, with 8 (22%) patients with LSc, eight (22%) with non specific dermatitis (NSD), six (17%) with wart virus infection and one (3%) with PIN seen in other departments.

The histological diagnoses of these biopsies are shown in table 3.

Discussion

There is now considerable interest in vulval cutaneous disorders,^{3,4} but relatively little

Table 3 Diagnoses in patients undergoing penile biopsy in other departments

Department	Diagnosis	No. of Patients (n = 36)
Dermatology	Non specific dermatitis	1
	PIN 3	1
	Wart virus infection	1
	Haemangioma	1
General Surgery	Lichen sclerosus	2
	Wart virus infection	2
Urology	Non specific dermatitis	7
	Lichen sclerosus	6
	Normal (social circumcisions)	5
	Wart virus infection	3
	T ₁ carcinoma of prostate	1
	T ₂ carcinoma of bladder	1
	Cutaneous tuberculosis	1
	Epidermal cyst	1
	Squamous cell carcinoma	1
	Trauma	1
Plasma cell balanitis	1	

information is available about the cutaneous pathology of the penis.^{1,6}

Penile biopsy is a procedure which is performed rarely in GUM and other clinics, in contrast to many other specialties where the value of diagnostic biopsy is now well established. Whilst reluctance on behalf of the clinician and the patient may be easily understood, we have found the procedure to be technically straight forward, well tolerated and safe. Considerable clinically useful information was obtained, with few complications, and a cosmetically acceptable end result.

The variety of skin types found in different parts of the penis may account, at least in part, for the diversity of cutaneous abnormalities seen in this area. However, as with skin elsewhere, penile skin can react only in a limited number of ways to endogenous and exogenous influences, so providing a restricted number of clinical presentations. It may be difficult, therefore, to diagnose conditions such as plasma cell balanitis and PIN without a biopsy.

It is currently unknown to what extent treatment alters the histological features of penile skin, and it might prove difficult to obtain ethical approval for such a study. However, given that all forms of treatment were withheld for a minimum of two weeks prior to biopsy, we felt that such effects had been reasonably excluded.

We postulate that the relatively fragile glabrous skin of the glans penis may be particularly sensitive to external irritants, thus explaining why NSD was found frequently in our study, and its predominant location in the preputial sac. The clinical course had typically been a relapsing and remitting one, usually helped transiently by the application of 1% clotrimazole (Canesten) cream. The most frequent pre-biopsy diagnosis, therefore, was fungal balanitis. However, such cases of "candidal" or "fungal" balanitis were found to have histological changes of NSD, rather than the characteristic finding associated with fungal colonisation. The pathological changes of NSD can be produced by a wide variety of clinical conditions, including partially treated infections. Clearly inadequate hygiene in uncircumcised men could cause changes of NSD, but the patients seen were notably conscientious about their penile hygiene. Although it is

difficult to exclude completely a diagnosis of fungal infection, the majority of individuals had either a family or personal history of atopy, and it was considered that the most likely diagnosis was eczema. In these cases, clotrimazole cream may have been simply acting as an emollient or by some mechanism other than its antifungal activity.^{7,8}

The malignant potential of LSc is currently unclear. In one study,⁹ LSc was found in 48 (61%) of 78 women with vulval squamous carcinoma, either adjacent to the lesion or elsewhere on the body. There is less information on penile LSc, although three cases of penile squamous carcinoma have been reported in association with LSc;¹⁰ other reports are sporadic.^{11,12} The finding of LSc in biopsy specimens of genital cancer does not necessarily imply it is premalignant, particularly in view of its frequent occurrence in males circumcised for other reasons.¹³ However, in view of the current uncertainty about possible malignant development, long term monitoring would seem wise.¹⁴

Only 25% of cases of lichen planus (LP) were suspected prior to biopsy, and no men had any evidence of disease elsewhere. LP affects mucocutaneous membranes and exhibits characteristic histological features.¹ Vulval lichen planus can be solitary and erosive, which may be difficult to diagnose on both clinical and pathological grounds.¹⁵ Our experience would suggest that this is also true of penile LP.

Current views on the aetiology are that LP is a cell mediated immune disorder, in which the primary antigen has not yet been identified.^{16,17} Oral LP has a malignant potential, and it has been recommended that vulval LP be followed up long term.¹⁸ Less is known of penile LP. There have been two case reports of LP found in association with PIN and verrucous carcinoma of the penis,¹⁸ so it could be argued that penile LP should also be monitored indefinitely.

The four cases of PIN seen in this study were all referred on the grounds that they had atypical appearances which were similar to sessile warts. The concept of PIN has recently developed as an extension of the ideas behind the classification of cervical intraepithelial neoplasia (CIN) and vulval intraepithelial neoplasia. The histological features are well characterised,² although the clinical manifestations are less well reported. Like CIN, the malignant potential of PIN has still to be fully evaluated.

The range of histological diagnoses made in the other departments was broadly similar to that in the PDC. Men with penile dermatoses present to a variety of specialties, but each specialty may see only occasional cases. In view of the understandable concern of many patients that their penile dermatosis may have a sexually transmissible component, GUM physicians are ideally placed to exclude such diseases and provide any appropriate treatment and follow up. Our information indicates that, given the current lack of knowledge concerning the malignant potential of LSc, LP and

PIN, 27% (16 of 61) of patients attending the PDC and 33% of patients attending other departments may need long term review.

Information concerning the aetiology, natural history and treatment of penile dermatoses is sparse. Our data suggest that diagnoses based on clinical appearance alone are inadequate. The skin snip biopsy technique provides a simple, minimally invasive procedure which markedly improves the rate of diagnosis of such conditions. Pathological diagnoses were obtained in the majority of cases, thus allowing definitive treatment where indicated, and the chance to learn more in cases where our understanding is limited. It is often reassuring for the patient to know the diagnosis, even where current treatment options are limited.

- 1 Lever WF, Schaumburg-Lever G. *Histopathology of the Skin*. 7th ed. Philadelphia: JB Lippincott Company, 1990.
- 2 Barrasso R, De Brux J, Croissant O, Orth G. High prevalence of papillomavirus-associated penile intraepithelial neoplasia in sexual partners of women with cervical intraepithelial neoplasia. *N Engl J Med* 1987;317:916-23.
- 3 Ridley CM. General dermatological conditions and dermatoses of the vulva. In: Ridley CM ed. *The Vulva*. Edinburgh: Churchill Livingstone, 1988:138-211.
- 4 Wilkinson EJ ed. *Pathology of Vulva and Vagina. Contemporary Issues in Surgical Pathology*, Vol. 9. New York: Churchill Livingstone, 1987.
- 5 Peterson RO. Penis. In: Peterson RO, ed. *Urologic Pathology*. Philadelphia: JB Lippincott Company, 1986:699-704.
- 6 Arumainavagam JT, Sumathipala AHT. Value of performing biopsies in genitourinary clinics. *Gonorrhoea Med* 1990;66:407.
- 7 Holt RJ, Newman RL. Laboratory assessment of the antimycotic drug clotrimazole. *J Clin Pathol* 1972;25:1089-97.
- 8 Schaller K. In vitro antibacterial activity of different clotrimazole formulations. *Chemotherapy* 1982;28(Suppl.1):32-6.
- 9 Leibowitch M, Neill S, Pelisse M, Moval-Baracco MM. The epithelial changes associated with squamous cell carcinoma of the vulva: a review of the clinical, histological and viral findings in 78 women. *Br J Obstet Gynaecol* 1990;97:1135-9.
- 10 Dore B, Irani J, Aubert J. Carcinoma of the penis in lichen sclerosus et atrophicus. *Int Urol* 1990;18:153-5.
- 11 Bart RS, Kupf AW. Squamous-cell carcinoma arising in balanitis xerotica obliterans. *J Dermatol Surg Oncol* 1978;4:556-7.
- 12 Bingham JS. Carcinoma of the penis developing in lichen sclerosus et atrophicus. *Br J Venereal Dis* 1978;54:350-1.
- 13 Ledwig PA, Weigand DA. Late circumcision and lichen sclerosus et atrophicus of the penis. *J Am Acad Dermatol* 1989;20:211-4.
- 14 Iye FA, Wilkinson DS. Diseases of the umbilical, perianal and genital regions. In: Rook A, Wilkinson DS, Ebling FJG, Champion RH, Burton JL, eds. *Textbook of Dermatology*. 4th ed. Edinburgh: Blackwell Scientific Publications, 1986:2181-201.
- 15 Ridley CM. Chronic erosive vulval disease. *Clin Exp Dermatol* 1990;15:245-52.
- 16 Norris DA. Cytokine modulation of adhesion molecules in the regulation of immunologic cytotoxicity of epidermal targets. *J Invest Dermatol* 1990;65(6 Suppl):111S-120S.
- 17 Griffiths CE, Voorhees JJ, Nickoloff BJ. Characterisation of intracellular adhesion molecule-1 and HLA-DR expression in normal and inflamed skin: modulation by recombinant gamma interferon and tumour necrosis factor. *J Am Acad Dermatol* 1989;20:617-29.
- 18 Bain L, Geronemus R. The association of lichen planus of the penis with squamous cell carcinoma in situ and with verrucous squamous carcinoma. *J Dermatol Surg Oncol* 1989;15:413-7.

Detection of Human Papillomavirus DNA in the Urogenital Tracts of Men With Anogenital Warts

R. J. HILLMAN, MRCP, M. BOTCHERBY, MSc, B. K. RYAIT, MSc, N. HANNA, MB, AND D. TAYLOR-ROBINSON, FRCP

Increasing evidence suggests that human papillomavirus (HPV) infection of the female anogenital tract is multifocal. Less is known of the distribution of HPVs in men. To investigate this, a prospective study was conducted of 116 men consecutively attending a clinic for ablative treatment of anogenital warts. Wart tissue, urethral swabs, and urine were obtained from each patient. HPV DNA was extracted from the specimens and amplified using the polymerase chain reaction (PCR). HPV types 6, 11, 16, 18, 31, and 33 were identified using Southern blotting of the PCR product, followed by hybridization. HPV DNA was detected in 112 (96.6%) of 116 wart specimens and there was urethral infection with HPV in 26 (22.4%) of the men. Eleven (61.1%) of 18 urethral specimens taken with a loop and 22 (20.0%) of 116 urethral specimens taken using a cotton-tipped swab contained HPV DNA. One (6.3%) of 16 urine samples tested contained HPV DNA. HPV types 6 and 11 were found in the urethra most commonly when warts were seen near the urinary meatus, although HPV occurred in the urethras of men without clinically apparent meatal warts. The proportion of urethral samples with HPV DNA, including HPV types 16, 18, 31, and 33, was independent of the location of visible warts at the time of sampling.

THE WIDESPREAD AVAILABILITY of Papanicolaou staining of cervical scrapes and colposcopy services has resulted in a rapid growth in the understanding of the interaction between human papillomavirus (HPV) and the anogenital regions of women. Less is known of the corresponding relationship in men. Evidence suggests that the majority of anogenital HPV infections are sexually acquired,¹ so it would seem likely that men play a significant role in the epidemiology of the genitotropic HPVs.

Carriage of HPV in clinically normal cervixes is now well documented,² and the suggestion has been raised that such carriage may be important in resistance to treatment and recurrence after treatment.³ In view of the observation⁴ that urethral squamous papillomas tend to develop in areas of metaplastic squamous epithelium, it has been postulated⁴ that such areas of the male urethra

From the Division of Sexually Transmitted Diseases, Clinical Research Centre, Harrow, Middlesex, and The Jefferiss Wing, St. Mary's Hospital, London, United Kingdom

may be analogous to the transitional zone of the cervix, and may act as a reservoir for infection with HPV.⁶

The presence of HPV DNA in genital warts has been determined by a variety of methods.⁷ Currently, the polymerase chain reaction (PCR) is the most sensitive technique.³ Southern blotting⁹ allows the confirmation of DNA sequences produced by the PCR and enables the type of HPV to be determined. In view of their combination of sensitivity and specificity, the PCR and Southern blotting techniques were chosen for the analysis of all specimens in this study. The object of the study was to assess the distribution of HPV in the male anogenital tract. To achieve this, a group of men attending a genitourinary department with clinically apparent anogenital warts was selected on the assumption that they would be likely to carry HPV in large quantities in their anogenital regions. Samples of wart tissue were taken for analysis and the results compared with urethral specimens obtained by two different methods.

Methods

Patients and Collection of Specimens

Informed consent was obtained from 116 men attending consecutively a clinic for the surgical removal of anogenital warts. Referral to this clinic was based on the presence of warts that the clinician thought would be best treated by surgical ablation, either because of their anatomic location or their failure to respond to conventional treatment. All patients were offered screening for the common sexually transmitted infections, and these were treated before the patient entered the study.

Strict precautions against contamination of the specimens by HPVs were taken. Gloves were changed between patients, and all instruments were hand-washed, placed in an ultrasonic cleaner, and autoclaved before reuse. Specimens were collected using a "no touch" tech-

Reprint requests: Dr. R. J. Hillman, Ambrose King Centre, The Royal London Hospital Trust, London E1 1BB, United Kingdom.

Received for publication March 3, 1992, revised July 10, 1992, and accepted July 31, 1992.

nique and placed in sterile, disposable bottles before analysis in the laboratory.

Wart specimens were removed by a diathermy machine (Surgitron STW-60; Meditronix, Barcelona, Spain) and placed in phosphate-buffered saline (PBS). A random selection of biopsy specimens also was placed in formal saline and sent for routine histopathologic assessment.

Cotton-tipped swabs ("STD-Pen for Males"; Abbott Laboratories, Chicago, IL) were inserted 2 cm into the urethras of all 116 men; each swab was replaced in the container provided and sent to the laboratory for analysis. Using a 10- μ l plastic loop (Nunc; GIBCO, Paisley, Scotland), an additional specimen from the distal 2 cm of the urethra was taken from a randomly selected group of 18 of these men; the loop was used before the swab in 9 of the men. The loop was broken off in 10 ml of PBS and transported to the laboratory. Patients were asked to provide a 10-ml sample of first-pass urine after all urethral specimens had been taken.

Processing of Specimens

To avoid cross-contamination of DNA products, preparation of reagents, processing of patient material, and the PCR and Southern blotting took place in separate rooms. Positive displacement pipettes or single-use Pasteur pipettes were used for distributing reagents for the PCR and for adding the DNA samples to the reaction mixtures. Positive and negative controls were included in each experiment. Laboratory staff were unaware of the clinical status of the men.

Urine samples were centrifuged for 10 minutes at 3,000 rpm and the sediment suspended in 160 μ l of 2 \times Summers' buffer (40 mM TRIS-HCl, 0.3 M NaCl, and 20 mM EDTA-tetra sodium salt), pH 8.0. Three sterile glass beads were added to each wart sample and the tubes vortexed for 1 minute to break up the tissue. Wart specimens disrupted by this method and urethral swabs were then added directly to 160 μ l of 2 \times Summers' buffer. Twenty-eight microliters of 2.5% sodium dodecyl sulfate (SDS), 4 μ l of tRNA, and 100 μ l of sterile double distilled water (ddH₂O) were added to the samples, which were then incubated for 16 to 20 hours at 37 °C with pronase E (10 mg/ml). DNA was isolated by a modification of standard procedures,¹⁰ using two phenol extractions (TE-equilibrated phenol), followed by a chloroform-isooamyl alcohol (24:1) extraction and an ethanol precipitation step for 1 hour at -70 °C. The DNA pellet was collected by centrifugation for 10 minutes at 14,000 rpm, washed briefly with 70% ethanol, and dried under vacuum for 30 minutes. The resulting DNA pellet was resuspended in 40 μ l ddH₂O. From this, 20 μ l was used to determine the presence of DNA in the sample by restriction enzyme digestion with *Bam* HI. Bands were

then observed on an ethidium bromide-stained agarose gel.

Polymerase Chain Reaction

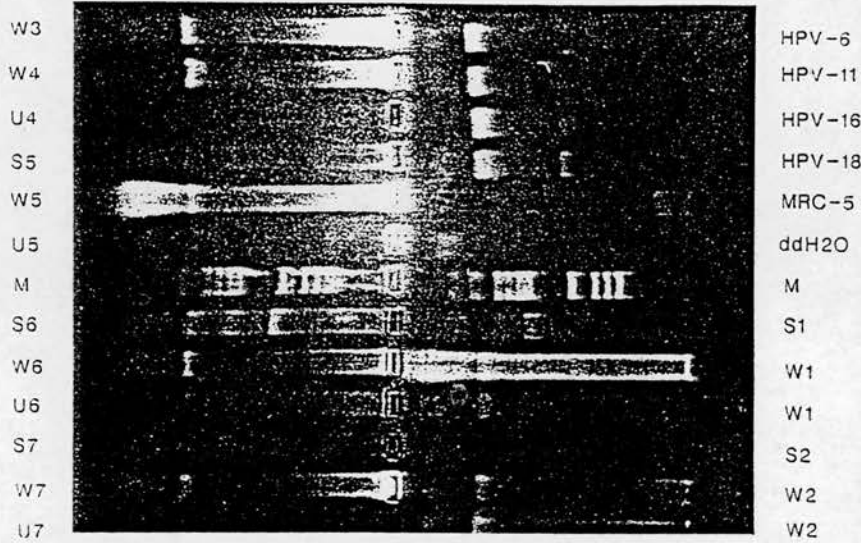
Target sequences on the L1 open-reading frame of HPV types 6, 11, 16, 18, 31, and 33 were amplified using general primers GP5 and GP6.¹¹ Amplification was carried out using a 100- μ l reaction mixture containing sample DNA, 50 mM KCl, 10 mM Tris-HCl pH 8.3, 3 mM MgCl₂, 0.01% w/v gelatin, 200 μ M each of dATP, dGTP, dTTP, and dCTP, 50 nmol each of GP5 and GP6 primers, and 2.5 units of *Taq* polymerase (GIBCO-BRL, Paisley, Scotland, United Kingdom). This mixture was overlaid with a few drops of mineral oil to prevent evaporation, and subjected to 40 cycles of amplification using a DNA thermal processor (Model HB-TR1, Hybaid, Teddington, United Kingdom). Each cycle included denaturation at 94 °C for 20 seconds, primer annealing at 40 °C for 60 seconds, and chain elongation at 72 °C for 20 seconds.^{12,13} Samples containing 100 pg of the full-length genome of HPV types 6, 11, 16, and 18 were used as positive controls. Negative controls were a fibroblast line (MRC-5) and ddH₂O (Figure 1). Titration experiments were performed for HPV types 6, 11, 16, and 18, and the detection limit of this system was found consistently to be 10⁻¹⁴ g or less of HPV DNA. This corresponded to approximately 10 molecules HPV DNA/100 μ l reaction mixture. Using standard methods,¹⁴ the sensitivity of detection of HPV types 31 and 33 was established to be 10⁻¹⁰ g of HPV DNA.

Southern Blot Analysis

The products of the PCR were analyzed by agarose gel electrophoresis with ethidium bromide staining. ϕ X174 DNA cut with *Hae* III restriction endonuclease was used to enable estimation of the sizes of the PCR products. Southern blotting was performed using a modification of standard protocols.¹⁰ The agarose gel was denatured for 30 minutes in 1.5 M NaCl/0.5 M NaOH, followed by neutralization for 60 minutes in 1.5 M NaCl/0.5 M Tris pH 7.5/1 mM EDTA. The DNA products were then transferred from the agarose gel to nylon membranes (GeneScreen Plus; DuPont, Wilmington, DE) by a capillary blot procedure using 6 \times SSC (0.9 M NaCl, 0.09 M sodium citrate) as the transfer buffer.

Hybridization for HPV types 6, 11, 16, and 18 was carried out at 65 °C using full-length genomic probes which had been labeled with ³²P-labeled dCTP by the random primer method. Hybridization for HPV types 31 and 33 was performed at 55 °C using oligonucleotide probes that had been end-labeled with ³²P-labeled dATP. Hybridization was undertaken in a solution containing 6 \times SSC, 20 \times Denhardt's solution (0.4% bovine serum

Fig. 1. Ethidium bromide staining of agarose gel with positive controls (human papillomavirus types 6, 11, 16, and 18), negative controls (MRC-5 and ddH2O), molecular weight marker (M) (pX174 DNA cut with Hae III), and specimens of DNA from swabs (S), warts (W), and urine (U).



albumin, 0.4% polyvinyl pyrrolidone, 0.4% Ficoll 400), 0.5% SDS, 1 mM EDTA-disodium salt, and 50 µg/ml salmon sperm DNA.

Where full-length probes were used, Southern blots were washed once for 60 minutes with 2× SSC/0.1% SDS at 65 °C and once for 60 minutes with 0.1× SSC/0.1% SDS at 65 °C to remove nonspecifically bound probe. In the case of oligonucleotide probes, the blots were washed twice for 5 minutes with 2× SSC/0.1% SDS at room temperature followed by one wash for 5 minutes with 2× SSC/0.1% SDS at 55 °C. Autoradiography was performed for 24 hours on Kodak (Rochester, NY) X-OMAT S film between intensifying screens at -70 °C. An example of this is shown in Figure 2.

Results

Clinical Features of the Patients

Fifty-four (46.6%) of the 116 men were homosexual, 50 (43.1%) heterosexual, 7 (6.0%) bisexual, and 5 (4.3%) were of unspecified sexual orientation. The age range of the men was 16.1 to 61.6 years (mean, 28.6 years). A history of other previous sexually transmitted diseases was given by 51 (44.0%) of the men. Two (5.9%) of 34 men who had undergone testing for the human immunodeficiency virus within 3 years before sampling of their warts were found to carry antibody.

The men had been aware of their warts for an average of 18.1 months (range, 0.5-120 months) before undergoing biopsy. Fifty-four (46.6%) of the biopsy specimens were assessed histologically, and all were found to have changes consistent with wart virus infection.¹⁴ None of the specimens showed evidence of dysplasia. The clinical

appearance of the warts was described as classical condylomata acuminata in 94 (81.1%) of the men, planar in 10 (8.6%), hyperkeratotic in 26 (22.4%), mixed type in 13 (11.2%), and pigmented in 1.

At the time of sampling, warts were seen at the meatus in 7 (6.0%) of the men, the glans in 10 (8.6%), coronal region in 10 (8.6%), foreskin in 8 (6.8%), shaft in 26 (22.4%), scrotum in 4 (3.4%), inguinal region in 5 (4.3%), perineal area in 3 (2.6%), perianal area in 78 (67.2%), and intraanal site in 14 (12.1%).




Fig. 2. Hybridization of polymerase chain reaction products with human papillomavirus (HPV) type 6-specific probe on nylon membrane after Southern blot. Abbreviations as for Figure 1. Positive result seen for HPV type 6 control, warts nos. 8, 9, 10, 12, 13, 15, and 16, and swab no. 14.

Types of HPV's in Anogenital Warts

HPV DNA was detected in 112 (96.5%) of 116 wart specimens. Types 6 and 11 were the most common (84.8% and 82.1%, respectively) and types 31 and 33 the least common (0.9% and 2.7%, respectively; Table 1). Infection with two or more types of HPV was found in 84 (72.4%) of the warts. The most common multiple infection was with types 6 and 11, which occurred together in 58 (50.0%) of the men and in combination with other HPV types in a further 21 (18.1%) men. HPV type 6 was found in 83 (99%) of the 84 multiple infections and type 11 in 79 (94%) of such infections.

The distribution of HPV type found in the warts did not vary significantly with the site of the biopsy or age of the patient (data not shown).

Types of HPV's in the Urethra

Swab specimens. Twenty-two (19.0%) of the 116 urethral swabs contained HPV DNA. Detection rate did not vary with sexual orientation. Again, types 6 and 11 were the most common, but type 16 was detected relatively more often than it was in the warts (Table 1). Fourteen (63.3%) of the 22 swabs contained a single HPV type. Multiple HPV types were found in eight (36.3%) of the swabs in which any HPV DNA could be detected. HPV type 6 was found in seven (87.5%) of the eight swabs containing more than one type, and HPV type 11 in all eight. HPV type 16 was the most common single HPV type detectable, being found in 7 (50%) of the 14 swabs in which only one HPV type was found.

Loop specimens. HPV DNA was detected in 11 (61.1%) of the 18 urethral loop specimens. Detection rate did not vary with sexual orientation. Whether the loop or swab specimen was taken first had no appreciable effect on the rate of detection. The distribution of HPV types was similar to that seen with the swab specimens (Table 1). In 5 (27.8%) of 18 specimens there was evidence of a single HPV type, which was HPV type 16

TABLE 1. Types of HPV DNA Found in Men With Anogenital Warts

HPV Type	No. of Specimens Positive for Indicated Type		
	Warts (n = 112)	Swabs (n = 22)	Loops (n = 11)
6	95 (84.8)*	9 (40.9)	5 (45.5)
11	92 (82.1)	10 (45.5%)	5 (45.5)
16	10 (8.9)	3 (36.3)	6 (54.5)
18	20 (17.8)	6 (27.3)	4 (36.3)
31	1 (0.9)	2 (9.1)	1 (9.1)
33	3 (2.7)	2 (9.1)	1 (9.1)

n = no. of specimens containing HPV DNA.

* Figures in brackets are percentages of samples containing HPV.

TABLE 2. Location of Warts in Relation to Detection of Urethral HPV DNA

Location*	No. of Patients (n = 116)	Swab With HPV DNA (%) (n = 116)	Loops With HPV DNA (%) (n = 18)	Total No.† (%)
Meatus	7	$\frac{6}{7}$ (85.7)	$\frac{4}{6}$ (66.7)	6 (85.7)
Glans	6	$\frac{1}{6}$ (16.7)	$\frac{1}{3}$ (33.3)	2 (33.3)
Corona	6	$\frac{4}{6}$ (66.7)	N.L.	4
Foreskin	4	$\frac{0}{4}$	N.L.	0
Shaft	19	$\frac{1}{19}$ (5.3)	$\frac{3}{3}$ (66.7)	3 (15.8)
Scrotum	2	$\frac{0}{2}$	$\frac{1}{1}$	1 (50)
Inguinal	2	$\frac{0}{2}$	N.L.	0
Perianal	67	$\frac{10}{67}$ (14.9)	$\frac{3}{5}$ (60)	13 (19.4)
Intra-anal	3	$\frac{0}{3}$	N.L.	0

n = Total number of patients or of samples taken; N.L. = no loop sample taken.

* Location of clinically apparent warts seen nearest to the urinary meatus at the time of biopsy.

† Total number of patients in each category with swabs or loop specimens containing HPV DNA.

‡ Numerator signifies the number of samples with HPV DNA detected in that particular group.

in all cases. Of the six loop specimens in which multiple HPV types were detected, HPV type 6 was always present and HPV type 11 found in five (83.3%).

Of the 11 men who had HPV-positive loop samples, only 5 had urethral swabs specimens that also were HPV-positive. In all cases where both loop and urethral swab specimens contained HPV, at least one HPV type was common to both specimens.

Urine specimens. HPV DNA was detected in only 1 (6.7%) of 15 urine samples tested. This was found to comprise HPV types 16 and 18. The patient had only perianal warts and no history of warts elsewhere. Analysis of the wart specimen revealed HPV type 6 alone. No urethral loop sample was taken and HPV DNA was not detected in the urethral swab specimen.

Association Between Location of Warts at Time of Biopsy and HPV Detected in the Urethra

The location of the visible warts in relation to the results of HPV DNA detection in urethral specimens is shown in Table 2. Six (85.7%) of the seven men who had clinically apparent meatal warts had HPV DNA detected in their urethral swab specimens. Thereafter, it can be seen that the further away visible warts were from the meatus at the time of urethral sampling by swab or loop, the smaller the proportion of urethral samples containing HPV DNA. The association was not seen with loop samples, but the number examined was small.

TABLE 3. Location of Warts in Relation to Urethral HPV Type

Location*	No. Swabs/Loops Containing HPV DNA	No. (%) Swabs/Loops Containing Indicated HPV Types	
		6 or 11	16, 18, 31, or 33
Meatus	6	6 (100)	5 (83)
Glans	2	2 (100)	1 (50)
Corona	4	1 (25)	3 (75)
Shaft	3	1 (33)	2 (67)
Scrotum	1	0	1
Penanal	13	3 (23)	11 (85)

* Location of clinically apparent warts seen nearest to the urinary meatus at time of biopsy.

Association Between HPV Types Detected in Warts and in the Urethra

The relation between the location of warts and the HPV type in the urethra is shown in Table 3. HPV types 6 or 11 were found in diminishing frequency in the urethra as the warts were located more distally from the urethral meatus. In contrast, there appeared to be no such association for HPV types 16, 18, 31, or 33.

Of the 22 swab samples in which HPV DNA was detected, 10 (45.4%) had at least 1 type in common with the corresponding warts. Furthermore, 6 (54.5%) of the 11 loop samples in which HPV DNA was detected had at least 1 HPV type in common with the corresponding warts.

Discussion

There have been several studies to determine the frequency and type of HPV DNA in anogenital warts in men. The finding of HPV DNA in 96.6% of wart specimens is consistent with the 69%¹⁵ to 100%¹⁶ found in previous studies. The small proportion of warts without detectable HPV DNA in our study presumably represents infection with HPV types not tested for, small quantities of viral DNA, or inadequate extraction of DNA from the samples.

The most common method for screening for the presence of infection with HPV is by clinical examination. It has been suggested that this should be supplemented by microscopic examination of the skin after the application of 3% to 5% acetic acid.¹⁷⁻¹⁹ In addition to the time and resources required to undertake such an examination, however, studies suggest that response to acetic acid staining is not specific for HPV infection.^{20,21} Most clinically apparent HPV-associated lesions of the urethra occur in the terminal 1 cm.²² Only one study⁵ has been concerned with the response of the urethra to acetic acid, and in this the procedure was found to be unhelpful. Urethroscopy is not only impractical in a clinic setting,

but also carries the theoretical risk of spreading HPV more proximally.

Another approach is to attempt to detect HPV directly in the anogenital area. The PCR is sufficiently sensitive so that sample size may be minimized to restrict genital trauma. The interpretation of the results of such extremely sensitive methods, however, must take into account contamination of the patients' genitalia from recent contact, as well as that potentially introduced during sample collection and processing. Epithelial cells are easily removed from the urethra, a principle that is well established in diagnosing urethritis in the male. Urethral swabs designed for the detection of *Chlamydia trachomatis* and the 10- μ l "blue loop" routinely used for the investigation of urethritis in the male were chosen for this study because they have been found previously to be both acceptable to patients and effective in sampling the urethral epithelium for urogenital pathogens. Initial analysis of urethral specimens by Southern blotting showed that more DNA was present in the swab specimens than in those obtained by the loop method. It was on the basis of this finding that swab samples alone were taken from the rest of the men. When both loop and swab samples were taken from the same patient, five of the six patients whose swabs contained HPV DNA also had HPV DNA in positive loop specimens. Furthermore, HPV DNA was detected in five loop samples but not in the corresponding swab. Use of the loop would therefore seem to be more sensitive for the detection of urethral HPV infection than that of the swab.

Attempts to detect HPV in urine by cytologic assessment,²³⁻²⁵ dot blot,²⁶ and Southern blotting²⁷ have been disappointing. Several groups^{12,28,29} have detected HPV DNA in urine using the PCR, so this too was included in our study; however, we did not find that testing urine was useful. It is possible that we may have detected more HPV if we had collected larger volumes of urine,¹² or had used early morning urine samples.

Twenty-five men had HPV DNA detected in their urethras and a further man had HPV DNA in his urine, although whether the latter was urethral in origin could not be assessed. Thus, overall there was evidence of genitourinary tract infection with HPV in 26 (22.4%) of the men. This compares with one study⁵ in which HPV DNA was sought in the urethra using a cytologic brush to remove cells and Southern blotting to determine the HPV type; 25 (33%) of 75 men with genital warts were HPV-positive in the urethra and 9 (36%) of these 25 men had HPV types 16, 18, or 31. Wikström et al.,³⁰ using the PCR in combination with the dot blot method, found that 46 (89%) of 52 men with genital warts had HPV DNA in their urethras. It is unclear whether this reflects a true difference in the epidemiology of HPV between the populations studied, or methodologic differences.

The sample of men chosen in our study was unusual, containing a large proportion of homosexual men with perianal warts that had been present for some considerable time. Because newer warts contain more viral particles than older ones,³¹ it is possible that the urethral carriage rate would have been greater if a larger proportion of men with newly developed warts had been examined. Furthermore, urethral carriage was more common when warts were visible near the meatus, and the preponderance of men in this study with perianal warts may have led to a further underestimation of the typical carriage rate. It is noteworthy that the association of urethral HPV DNA carriage with proximity of clinically apparent warts to the meatus occurs with HPV types 6 and 11, but not with the other types considered. We suggest that types 16, 18, 31, and 33 may be true colonizers of the urethra, whereas the finding of types 6 and 11 in the urethra may be occurring as a result of contamination from adjacent warts.

Multiple infections with different HPV types have been reported,^{15,32,33} although this has been disputed by others.³⁴ The use of full-length genomic probes, high-stringency hybridization conditions, and positive controls for all the HPV types provides us with the confidence that our results are indicative of true multiple infections, rather than cross-hybridization. In comparison to warts, urethral infections were less likely to occur with multiple HPV types, but more commonly with type 16. The latter finding is consistent with the predominance of HPV 16 in penoscopically abnormal areas.^{35,36} The high frequency of clinically inapparent infection with HPV 16 may be an important factor in the mechanism by which "high-risk males"^{36,37} increase the likelihood of their partners developing cervical cancer.

Only about half the men had one or more HPV types in the urethra that were in common with those in the warts. This mismatch is seen also, for example, in the HPV types found in neonatal foreskins and those in the maternal cervix.³⁸ The common occurrence in the genital tract of multiple infections with HPV and the failure to detect all HPV types may help to explain these situations.

Clearly, the PCR is not yet suitable for routine clinical practice, but it may be of value in helping to understand the epidemiology of HPV and thus to devise management strategies. Even if the PCR was more widely available, it is currently unclear whether the detection of HPV DNA in small quantities in the absence of clinical disease implies that the person is infectious to his sexual partners. Detectable HPV DNA probably implies that viral particles are being shed from the epithelium, however, and that the person is potentially infectious. Further studies are required to assess infectivity, and to determine how the presence of HPV varies with time, in other groups of men, and in response to treatment.

References

- Oriel JD. Natural history of genital warts. *Br J Vener Dis* 1971; 47:1-13.
- Wickenden C, Malcom ADB, Steele AS, Coleman D. Screening for wart virus infection in normal and abnormal cervixes by DNA hybridisation of cervical scrapes. *Lancet* 1985; 1:65-67.
- Ferenczy A, Mitao M, Nagai N, Silverstein SJ, Crum CP. Latent papillomavirus and recurring genital warts. *N Engl J Med* 1985; 313:784-788.
- Dean P, Lancaster WD, Chun B, Jensen B. Human papillomavirus structural antigens in squamous papillomas of the male urethra. *J Urol* 1983; 129:873-875.
- Rosemberg SK. Sexually transmitted papillomavirus infection in men: an update. *Dermatol Clin* 1991; 9:317-331.
- Omar R, Choudhury M, Fischer J, Ezpeleta C. A "Pap" test for men?: male urethral smears as screening tool for detecting subclinical human papillomavirus infection. *Urology* 1991; 37:110-115.
- Schneider A, Grubert T. Diagnosis of HPV infection by recombinant DNA technology. *Clin Obstet Gynecol* 1989; 32:127-140.
- De Villiers E-M. Laboratory techniques in the investigation of human papillomavirus infection. *Genitourin Med* 1992; 68:50-54.
- Southern EM. Detection of specific sequences among DNA fragments separated by gel electrophoresis. *J Mol Biol* 1975; 98:503-517.
- Sambrook J, Fritsch EF, Maniatis T. *Molecular Cloning: A Laboratory Manual*. 2nd ed. Cold Spring Harbor, NY: Cold Spring Harbor Laboratory Press, 1989.
- Snijders PJF, van den Brule AJC, Schrijnemakers HFJ, Snow G, Meijer CJLM, Walboomers JMM. The use of general primers in the polymerase chain reaction permits the detection of a broad spectrum of human papillomavirus genotypes. *J Gen Virol* 1990; 71:173-181.
- Melchers WJG, Schiff R, Stolz E, Lindeman J, Quint WGV. Human papillomavirus detection in urine samples from male patients by the polymerase chain reaction. *J Clin Microbiol* 1989; 27:1711-1714.
- Van den Brule AJC, Meijer CJLM, Bakels V, Kenemans P, Walboomers JMM. Rapid detection of human papillomavirus in cervical scrapes by combined general primer-mediated and type specific polymerase chain reaction. *J Clin Microbiol* 1990; 28:2739-2743.
- Lever WF, Schaumburg-Lever G. *Histopathology of the Skin*, 7th ed. Philadelphia: JB Lippincott, 1990.
- Wickenden C, Hanna N, Taylor-Robinson D, et al. Sexual transmission of human papillomaviruses in heterosexual and male homosexual couples, studies by DNA hybridisation. *Genitourin Med* 1988; 64:34-38.
- O'Brien WM, Jensen AB, Lancaster WD, Maxted WC. Human papillomavirus typing of penile condyloma. *J Urol* 1989; 141:863-865.
- Petersen CS, Albrechtsen J, Larsen J, et al. Subclinical human papilloma virus infection in condylomata acuminata patients attending a VD clinic. *Acta Derm Venereol* 1991; 71:252-255.
- Carpiniello V, Sedlacek TV, Cunnane M, Schlieker B, Malloy T, Wein AJ. Magnified penile surface scanning in diagnosis of penile condyloma. *Urology* 1986; 28:190-192.
- Law C, Merianos A, Thompson C, Rose B, Cossart Y, Grace J. Manifestations of anogenital HPV infection in the male partners of women with anogenital warts and/or abnormal cervical smears. *Int J STD AIDS* 1991; 2:188-194.
- Schultz RE, Miller JW, MacDonald GR, et al. Clinical and molecular evaluation of acetowhite genital lesions in men. *J Urol* 1990; 143:920-923.
- Griffiths M, Penna LK, Tovey SJ. Aceto-white change of the glans penis associated with balanitis not human papillomavirus infection. *Int J STD AIDS* 1991; 2:211-212.
- Oriel JD. HPV infections of the urethra. In: Gross G, Jablonska S, Pfister H, Stegner H-E, eds. *Genital Papillomavirus Infections: Modern Diagnosis and Treatment*. Berlin: Springer-Verlag, 1990:181-187.

23. Krebs H-B. Genital HPV infections in men. *Clin Obstet Gynecol* 1989; 32:180-190.
24. Levine RU, Crum CP, Herman E, Silvers D, Ferenczy A, Richart RM. Cervical papillomavirus infection and intraepithelial neoplasia: a study of male sexual partners. *Obstet Gynecol* 1984; 64:16-20.
25. Nahhas WA, Marshall ML, Ponziani J, Jagielo JA. Evaluation of urinary cytology of male sexual partners of women with cervical intraepithelial neoplasia and human papilloma virus infection. *Gynecol Oncol* 1986; 24:279-285.
26. Katelaris PM, Cossart YE, Rose BR, et al. Human papillomavirus: the untreated male reservoir. *J Urol* 1988; 140:300-305.
27. Ostrow RS, Zachow KR, Niimura M, et al. Detection of papillomavirus DNA in human semen. *Science* 1986; 231:731-733.
28. Nakazawa A, Fujita M, Ogawa H, Sasagawa T, Inoue M, Tanizawa O. Detection of human papillomavirus types 16 and 18 in exfoliated cervical cells of Japanese women and in urine samples from their male partners. (Abstract 166) Presented at the 10th International Papillomavirus Workshop, Seattle, Washington, July 20-26, 1991.
29. Hansson BG, Bjerre B, Forslund O, Lindholm K, Nordenfelt E. Human papilloma virus infections in healthy control and colposcopy patients: analysis of cervix and urine samples. (Abstract 78) Presented at the 10th International Papillomavirus Workshop, Seattle, Washington, July 20-26, 1991.
30. Wikstrom A, Lidbrink P, Johansson B, von Krogh G. Penile human papillomavirus carriage among men attending Swedish STD clinics. *Int J STD & AIDS* 1991; 2:105-109.
31. Kirchner H. Immunobiology of human papillomavirus infection. *Prog Med Virol* 1986; 33:1-41.
32. Syrjänen SM, von Krogh G, Syrjänen KJ. Detection of human papillomavirus DNA in anogenital condylomata in men using in situ DNA hybridisation applied to paraffin sections. *Genitourin Med* 1987; 63:32-39.
33. De Villiers E-M, Schneider A, Gross G, zur Hausen H. Analysis of benign and malignant urogenital tumors for human papillomavirus infection by labelling cellular DNA. *Med Microbiol Immunol* 1986; 174:281-286.
34. Beckmann AM, Sherman KJ, Myerson D, Daling JR, McDougall JK, Galloway DA. Comparative virologic studies of condylomata acuminata reveal a lack of dual infections with human papillomaviruses. *J Infect Dis* 1991; 163:393-396.
35. Campion MJ, McCance DJ, Mitchell HS, Jenkins D, Singer A, Oriel JD. Subclinical penile human papillomavirus infection and dysplasia in consorts of women with cervical neoplasia. *Genitourin Med* 1988; 64:90-99.
36. Barrasso R, Gross G. Male HPV-associated lesions: epidemiology and diagnostic criteria. In: Gross G, Jablonska S, Pfister H, Stegner H-E, eds. *Genital Papillomavirus Infections: Modern Diagnosis and Treatment*. Berlin: Springer-Verlag, 1990:23-33.
37. Campion MJ, Singer A, Clarkson PK, McCance DJ. Increased risk of cervical neoplasia in consorts of men with penile condylomata acuminata. *Lancet* 1985; 1:943-946.
38. Roman A, Fife K. Human papillomavirus DNA associated with foreskins of normal newborns. *J Infect Dis* 1986; 153:855-861.

Human papillomavirus DNA in the urogenital tracts of men with gonorrhoea, penile warts or genital dermatoses

R J Hillman, B K Ryaat, M Botcherby, D Taylor-Robinson

Abstract

Objective—To assess the presence of human papillomavirus (HPV) DNA in urethral and urine specimens from men with and without sexually transmitted diseases.

Design—Prospective study.

Setting—Two London departments of genitourinary medicine

Patients—100 men with urethral gonorrhoea, 31 men with penile warts and 37 men with genital dermatoses.

Methods—Urethral and urine specimens were taken, HPV DNA extracted and then amplified using the polymerase chain reaction. HPV types 6, 11, 16, 18, 31 and 33 were identified using Southern blotting followed by hybridisation.

Results—HPV DNA was detected in 18–31% of urethral swab specimens and in 0–14% of urine specimens. Men with penile warts had HPV detected in urethral swabs more often than did men in the other two clinical groups. "High risk" HPV types were found in 71–83% of swab specimens and in 73–80% of urine specimens containing HPV DNA.

Conclusions—HPV is present in the urogenital tracts of men with gonorrhoea, penile warts and with genital dermatoses. In men with urethral gonorrhoea, detection of HPV in urethral specimens is not related to the number of sexual partners, condom usage, racial origin or past history of genital warts. HPV DNA in the urethral swab and urine specimens may represent different aspects of the epidemiology of HPV in the male genital tract. The preponderance of HPV types 16 and 18 in all three groups of men may be relevant to the concept of the "high risk male".

(*Genitourin Med* 1993;69:187–192)

Introduction

Genital warts are the most common of the sexually transmitted viral diseases in the United Kingdom.¹ Evidence suggests² that the majority of condylomata acuminata are sexually acquired, but the epidemiology of subclinical and latent infections of the genital tract with HPV is less well understood.¹

DNA from the "genitotropic" HPV types has been isolated from clinically normal cervixes³ and it has been suggested⁴ that carriage

of HPV in adjacent histologically normal tissue may be an important factor in the recurrence of disease after treatment. The male counterpart of carriage of HPV in the absence of disease has not been fully defined, but HPV DNA has been detected in the genital tracts of 5.8% of men with no evidence of condylomata acuminata attending blood donor and dermatology clinics.⁷

Men with urethral gonorrhoea form a well characterised group,⁸ whose lifestyles have put them at risk of acquiring sexually transmitted diseases. In an attempt to improve the rational basis for the counselling of such men, we evaluated the frequency of carriage of HPV DNA in their urethras and urine. The results were then compared with those obtained from studying a group of men with penile warts and a group of men with no evidence of sexually transmitted diseases.

Methods

Patients and collection of specimens

One hundred male patients who attended consecutively one of two genitourinary medicine clinics during the period 1 July 1990 to 31 December 1990 were selected. Selection was on the basis of having symptoms or signs of urethritis, finding intracellular Gram-negative diplococci on the urethral smear, and no condylomata acuminata visible on clinical examination of the genitalia, including the meatus. A urethral sample taken with a 10 μ l plastic loop (GIBCO, Paisley, UK) was spread onto a glass slide for Gram staining and subsequently smeared onto a selective medium. Then, the plates were incubated at 37°C in an atmosphere of air and 6% CO₂ before transport to the laboratory for further incubation and identification using standard methods. Men were excluded if *Neisseria gonorrhoeae* was found not to have been cultured from the urethral swab.

After informed consent had been given, a detailed clinical history was obtained using a structured questionnaire. A second urethral sample was taken using a cotton-tipped swab ("STD-Pen for Males", Abbott Laboratories, Chicago, Illinois, USA) from all of the men. This and the first sample from the two glass urine test were kept for subsequent analysis in 88 of the cases.

Urethral swab and urine samples were also taken in the same manner from 32 men who attended the clinics with penile warts and from 37 men presenting with genital der-

Division of Sexually Transmitted Diseases, Clinical Research Centre, Watford Road, Harrow, Middlesex HA1 3UJ and The Jefferiss Wing, St Mary's Hospital, Praed St, London W2 1NY, UK
R J Hillman
B K Ryaat
M Botcherby
D Taylor-Robinson
Address for correspondence:
Dr R J Hillman, Ambrose King Centre, Royal London Hospital, Whitechapel, London E1 1BB, UK
Accepted for publication 6 January 1993

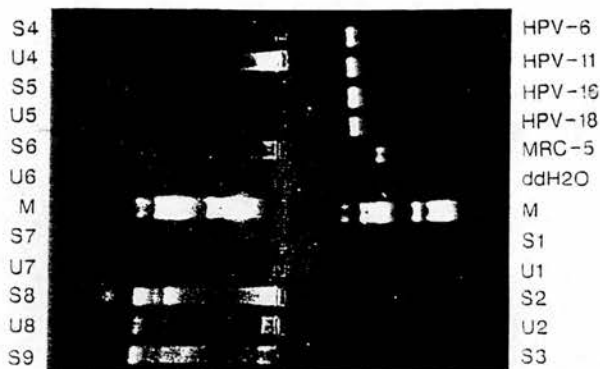

Figure 1 Ethidium bromide staining of agarose gel with positive controls (HPV types 6, 11, 16 and 18), negative controls (MRC-5 and ddH₂O), molecular weight marker (M) (ϕ X174 DNA cut with Hae III enzyme) and specimens of DNA from urine (U) and swabs (S).

matoses but with no evidence of sexually transmitted disease at the time of sampling. None of the men had meatal warts.

Processing of specimens

Attempts were made to avoid cross-contamination of DNA products by preparing of reagents, processing patient material, and undertaking the polymerase chain reaction (PCR) and Southern blotting in separate rooms. Positive displacement pipettes or single-use Pasteur pipettes were used to distribute reagents for the PCR and to add the DNA samples to the reaction mixtures. Positive and negative controls were included in each experiment.

DNA extraction

Urethral swabs were immersed in 320 μ l of lysis buffer containing 160 μ l of 2 \times Summers' buffer / pH 8.0 (40 mM TRIS-HCl, 0.3M NaCl and 20mM EDTA-tetra sodium salt), 100 μ l double distilled water (ddH₂O), 32 μ l pronase E (10 mg/ml), 28 μ l

of 2.5% sodium dodecyl sulphate (SDS) and 4 μ l of 0.8 mg/ml tRNA. Urine samples were centrifuged at 3000 rpm for 10 min and the pellet resuspended in 320 μ l of the same lysis buffer. Samples were incubated at 37°C overnight to allow lysis of the cells and disruption of proteins. DNA was isolated from the specimens by two TE-equilibrated phenol extraction followed by a 24:1 chloroform-isoamyl alcohol extraction and ethanol precipitation for 1 hour at -70°C. The DNA pellet was collected after centrifugation for 10 min at 14 000 rpm, washed briefly with 70% ethanol and dried under vacuum for 30 min. The resulting pellet was then resuspended in 40 μ l ddH₂O.

The PCR

The method was based on that of Saiki *et al.*,⁹ in which general primers GP5 and GP6¹⁰ were used to amplify DNA from the L1 open reading frame of HPV types 6, 11, 16, 18, 31 and 33.

Amplification of DNA was performed using 100 μ l of a reaction mixture containing 50mM KCl, 10 mM Tris-HCl pH 8.3, 0.01% w/v gelatin, 200 μ M each of dATP, dCTP, dGTP, and dTTP, 3.5 mM MgCl₂, 2.5 units of *Taq* polymerase (GIBCO, BRL Life Technologies, Uxbridge, Middlesex, UK) and 50nM each of GP5 and GP6. The mixture was overlaid with several drops of mineral oil to prevent evaporation and subjected to 40 cycles of amplification using a PCR processor (Hybaid, Teddington, UK). Each cycle included denaturation at 94°C for 20 seconds, primer annealing at 40°C for 60 seconds and chain elongation at 72°C for 20 seconds.^{11,12} Samples containing 100 pg of the full length genome of HPV types 6, 11, 16 and 18 were used as positive controls. Negative controls were a fibroblast line (MRC-5) and ddH₂O (fig 1). Serial dilutions of HPV DNA were tested and the detection limit was found consistently to be 10^{1.5}g or less of DNA. This corresponded to approximately 10 molecules of HPV DNA/100 μ l of reaction mixture.

Southern blotting

20 μ l of each of the products of the PCR were analysed by using agarose gel electrophoresis with ethidium bromide staining. ϕ X174 DNA cut with Hae III restriction endonuclease was used to enable estimation of the sizes of the PCR products. Southern blotting was performed using a modification of standard protocols.¹³ The agarose gel was denatured for 30 min in 1.5M NaCl/0.5M NaOH, followed by neutralisation for 60 min in 1.5M NaCl/0.5M Tris pH 7.5/1mM EDTA. The DNA products were then transferred from the agarose gel to nylon membranes (Gene-Screen Plus, DuPont, USA) by a capillary blot procedure using 6 \times SSC (0.9M NaCl, 0.09M sodium citrate) as the transfer buffer.

Hybridisation for the detection of HPV types 6, 11, 16, 18, 31 and 33 was performed at 55°C for 16 to 24 hours using oligonucleotide probes which had been end-labelled

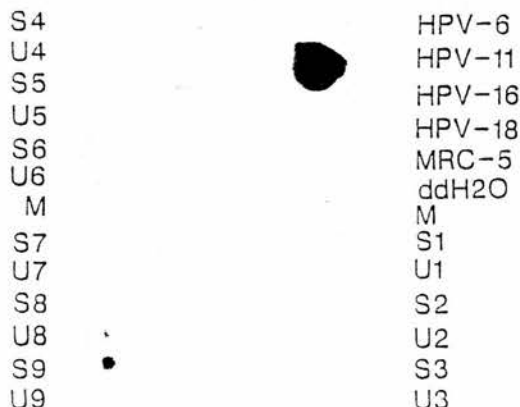


Figure 2 Hybridisation of PCR products with HPV type 11-specific probe on nylon membrane following Southern blot. Abbreviations as for fig 1. Positive result seen for HPV type 11 control, urine no. 8 and swab no. 9.

Table 1 Types of HPV DNA found in urethra and urine of men with urethral gonorrhoea

HPV type	No of specimens positive for indicated type		
	Swab (n = 18)	Urine (n = 11)	Swab or Urine (n = 25)
6	5 (28)*	3 (27)	7 (28)
11	8 (44)	6 (54)	13 (52)
16	6 (33)	6 (54)	10 (40)
18	7 (39)	2 (18)	8 (32)
31	2 (11)	0	2 (8)
33	2 (11)	0	2 (8)

*Figures in brackets are percentage of swab or urine specimens with HPV DNA present.

with ³²P-labelled dATP. Hybridisation was undertaken in a solution containing 6 × SSC, 20 × Denhardt's solution (0.4% bovine serum albumin, 0.4% polyvinyl pyrrolidone, 0.4% Ficoll 400), 0.5% SDS, 1mM EDTA-disodium salt and 50 µg/ml salmon sperm DNA (Sigma, Dorset, U.K.) To remove non-specifically bound probe, the Southern blots were washed in low stringency conditions of 2 × SSC/0.1% SDS for 5 min at room temperature, followed by one wash with 2 × SSC/0.1% SDS for 5 min at 55°C. Autoradiography was performed for 24 hours on Kodak X-OMAT S film between intensifying screens at -70°C. An example of this is shown in fig 2.

The oligonucleotide probes (prepared using a Milligen/Biosearch 7500 DNA Synthesizer) were:

HPV 6 5' ACA TGC GTC ATG TGG AAG AGT 3'

HPV 11 5' TAA ATC TGC TAC ATA CAC TAA 3'

HPV 16 5' TCT ACT TCA GAA ACT ACA TAT 3'

HPV 18 5' TGC TTC TAC ACA GTC TCC TGT 3'

HPV 31 5' CAC ACA AGT AAC TAG TGA CAG 3'

HPV 33 5' TCT GTT TGT GCT GCA ATT GCA 3'

Results

Demographic and clinical features of the patients

Seventy-six of the 100 men with urethral gonorrhoea described themselves as heterosexual, 19 homosexual, and five bisexual. Their age range was 17.0 to 55.6 years (mean 26.7 years). Fifty-two of the men were Caribbean, 34 Caucasian, eight African and four from

Table 2 Single and multiple types of HPV found in urethra and urine of men with gonorrhoea

HPV type	No of specimens positive for indicated type	
	Swab (n = 18)	Urine (n = 11)
6 alone	0	0
11 alone	3	3
16 alone	3	3
18 alone	4	2
31 alone	0	0
33 alone	0	0
6 and 11	3	0
6, 11 and 16	1	3
6 and 18	1	0
11, 16 and 18	1	0
16, 18, 31 and 33	1	0
31, 33	1	0

other racial groups. Information on the ethnic origin of two men was not available. The mean number of lifetime sexual partners was 43, with a range of 3 to 200; in addition, one bisexual man claimed to have had 1000 lifetime sexual partners. A history of genital warts was given by six of the men. One of 85 of the men who gave blood specimens at the time of presentation had serological evidence of syphilis. Fifty-eight of the men were cigarette smokers. Of the 98 men who provided information on condom usage, 27 claimed always, 59 sometimes and 12 never to have used them.

The demographic and clinical features of the men with penile warts or with no evidence of sexually transmitted diseases were not appreciably different from the men with gonorrhoea.

Types of HPV detected in swab and urine specimens from men with gonorrhoea

Eighteen of 100 urethral swabs and 11 (12.5%) of 88 urine specimens that were obtained contained HPV DNA. Overall, HPV DNA was detected in one or other specimen from 25 men; this comprised 15 (25.8%) of the 58 cigarette smokers and 10 (23.8%) of the 42 non-smokers. HPV types 11, 16 and 18 were the most common in both types of specimen (Table 1). The different combinations of types of HPV found in the specimens is shown in Table 2. DNA from HPV types 16, 18 31 or 33 (the so-called "high risk" types) was found in 15 (83%) of 18 swabs and in 8 (73%) of 11 urine specimens in which any HPV DNA could be detected.

HPV in relation to demographic and clinical details of men with gonorrhoea

The occurrence of HPV types in urethral or urine specimens was not associated significantly with racial origin, the number of lifetime sexual partners, a history of non-genital warts, condom usage, or whether cigarettes were smoked.

Twenty-one (28%) of the 75 men who were 30 years or less had detectable HPV, as compared to four (16%) of the 25 men who were older. Twenty-two (29%) of the 76 heterosexual men, three (16%) of the 19 homosexual men and none of the five bisexual men had HPV detectable. One (17%) of the six men with a history of genital warts had HPV present.

Table 3 Detection of HPV in urethral swab and urine specimens in relation to clinical group

Specimen type	Proportion (%) of specimens positive in patients with		
	Urethral gonorrhoea	Penile warts	Genital Dermatoses
Urethral swab	18/100 (18)	10/32 (31)	7/37 (19)
Urine	11/88 (13)	0/5	5/37 (14)
Urethral swab or urine	25/100 (25)	10/32 (31)	9/37 (24)
"High risk" HPV types			
Urethral swab specimen	15/18 (83)	8/10 (80)	5/7 (71)
Urine specimens	8/11 (73)	0/0	4/5 (80)

Detection of HPV in relation to clinical group

The results of testing urethral and urine specimens from men with gonorrhoea are compared with those from men with penile warts and with genital dermatoses in Table 3. The occurrence of HPV in the specimens from the men and the proportion of those with "high risk" types appear to be independent of clinical status.

Discussion

The results of several studies¹⁴⁻¹⁸ have shown that 20%¹⁶ to 32%¹⁴ of men presenting to genitourinary clinics with genital warts have evidence of at least one other sexually transmissible disease (STD). In particular, the incidence of gonorrhoea in such men varies from 0%¹⁷ to 9.9%.¹⁴ These studies rely on the clinical identification of condylomata acuminata, which probably represent only a minority of HPV infections of the anogenital area¹⁹ and they do not address the subject of this communication, namely the question of how often men with gonorrhoea are infected by HPV.

The use of DNA technology, in particular the PCR, has led to the detection of HPV in a large proportion of cervical scrapes from women with and without clinically apparent disease.² Understanding the epidemiology of HPV infection of the male genital tract has, however, been hampered by the lack of a satisfactory counterpart to the cervical scrape. Urethral cytology²⁰⁻²² and HPV antigen detection²³⁻²⁵ have been found insensitive for detecting HPV. Furthermore, there seems to be a poor correlation in men between cytological abnormalities and the presence of HPV DNA.²¹ Thus, the question of what constitutes an appropriate approach to sampling in men is pertinent.

Anogenital infection with HPV seems to be multifocal²⁶ and there is evidence of widespread subclinical infection which may be visualised by acetic acid staining.²⁶ However, this method is neither specific²⁷⁻²⁸ nor sensitive,²⁷ and its general introduction for the screening of men would have significant resource implications with no clearly established benefit.^{10,11}

In contrast, samples obtained by applying abrasive pads and brushes to the male genitalia^{19,32} have enabled specific detection of HPV. The majority of urethral condylomata acuminata develop in the distal 1 cm of the urethra³¹ and it has been postulated³² that this area of the urethra may be analogous to the transitional zone of the cervical epithelium and might act as a reservoir for infection with HPV.²² In view of these observations, the finding¹⁹ that urethral swabs are as effective as abrasive pads in detecting infection with HPV in male genitalia, and that the men had a urethral discharge, we undertook urethral sampling of our patients. Cotton wool-tipped swabs, designed originally for the detection of *C. trachomatis*, were used, as they have been found previously to be acceptable to patients and effective in sampling the urethral epitheli-

um for urogenital pathogens. As several groups^{11,34,35} have detected HPV DNA in urine, examination of urine also formed part of our study.

The PCR, when used under carefully controlled conditions, is currently the most sensitive technique for the detection of HPV,¹⁶ allowing detection of very few viral particles. Sample size, therefore, may be small and genital trauma minimised. As great care was taken during the collection of clinical material, and both positive and negative controls were used at all stages of analysis of the specimens, we are confident that the results reflect the true occurrence of HPV in the specimens, rather than contamination. Our detection of HPV DNA in the urogenital tracts of 24-31% of men attending the clinics compares with the finding of HPV DNA in the genital tracts of 31 (5.8%) of 530 men attending a blood donation centre and a dermatology department,⁷ and of 7 (8%) of 89 Swedish army recruits,²⁹ none of whom had clinical evidence of anogenital warts. Our findings are consistent with the 20% of men attending STD clinics in the UK²⁴ and the USA¹⁷ without evidence of condylomata acuminata but with HPV DNA detectable in genital swabs. One other group of workers¹⁹ found HPV DNA in 191 (84%) of 228 men attending a Swedish STD clinic. The validity of this result has yet to be confirmed, the authors accepting that they may have overestimated the incidence.

In an attempt to assess the significance of finding HPV in a proportion of the urethral swab specimens from men with gonorrhoea, we investigated two other groups of men from the same clinics. Men with penile warts were included in view of their clinically apparent infection with HPV and because of evidence¹⁸ suggesting that HPV may be found contaminating the urethra as a result of passive transfer from adjacent warts. We also included a group of men with no sexually transmitted disease at the time of sampling, that is, those with genital dermatoses. Of particular note is the observation that similar proportions of men with gonorrhoea and men with no sexually transmitted disease had HPV DNA detected in both their urethral swab and urine specimens. Furthermore, this observation suggests that urethral irritation per se in men with gonorrhoea is not a significant factor in the shedding of HPV from the urethra. The small number of urine specimens taken from men with penile warts makes interpretation of the results for this group of men difficult.

The detection of HPV DNA in the urine of 0-14% of the men in our study contrasts with that in the urine of 15 (88%) of 17 men with meatal warts and none of 14 healthy controls in one study,¹¹ and with that in the urine of two (22%) of 9 men whose partners had HPV infection.¹⁴ Condylomata acuminata occur rarely in the bladder³⁰ and there have been conflicting reports of HPV DNA in the prostate.^{10,11} As only a small proportion of men in each clinical group had HPV DNA

detectable in both the urine and urethral swab specimens, it may be that these different sampling techniques enable results in assessment of different aspects of infection of the urogenital tract with HPV.

The significance of detecting HPVs in the male urogenital tract is difficult to determine. It is possible that a few viral particles might remain on the genitalia from recent sexual contact, and even from underwear,⁴² without actually representing active infection. The natural history of subclinical HPV infection and, in particular the infectiousness for sexual partners, is also unknown. Indeed, it is currently unclear whether subclinical HPV infection is sexually acquired⁴³ as DNA of the genitotropic HPV types has been found in virgins,⁴⁴ the foreskin of neonates⁴⁵ and on fomites.⁴⁶ The lack of correlation between the presence of HPV DNA and the number of life-time sexual partners of the men seen in our study argues against sexual transmission, as does the reported condom usage, although the reliability of such reported behaviour is clearly open to question. Furthermore, the minor differences that we detected in the rates of HPV infection in men with and without sexually transmitted diseases suggest that sexual lifestyle may not be a major factor in determining infection with HPV. However, the greater incidence of HPV in men in younger age groups is consistent with sexual transmission. Other authors^{24,27} have also found ambiguous evidence of sexual transmission in clinically inapparent infections.

Our finding of a larger proportion of "high risk" HPV types than "low risk" types in asymptomatic infections normally found in condylomata acuminata, is consistent with the results of other studies.^{24,26,37} Furthermore, our observations were independent of both the sample type and patient group, and may be relevant to the concept of the "high risk male", whose sexual partner(s) are at increased risk of cervical dysplasia.^{46,47} In view of the evidence linking infection with HPV to anogenital neoplasia in both women and men,⁴⁸ further work needs to be done to fully evaluate the various methods for detecting HPV infection. In particular, the role of sexual activity in the acquisition and maintenance of genital HPV infection needs to be clarified. Only then will it be possible to understand the nature of this condition, and to develop rational management strategies.

The authors thank the staff of the Jefferiss Wing, St Mary's Hospital, London and the Patrick Clements Clinic, Central Middlesex Hospital, London for referring patients for this study. In particular, we appreciate the help of Dr JRW Harris and Dr S Murphy for allowing us to conduct the study in their clinics, and Mrs Mary Phillips and Ms Fay Miller who helped collect the specimens and clinical data.

- 1 Department of Health. *New cases seen at genito-urinary medicine clinics in England 1990/91. Summary information from Form KC60*. London: Department of Health, 1991.
- 2 Oriel JD. Natural history of genital warts. *Br J Venereal Dis* 1971;47:1-13.
- 3 Barrett TJ, Silbar JD, McGinley JP. Genital warts—a venereal disease. *JAMA* 1954;154:333-4.
- 4 Schneider A. Latent and subclinical genital HPV infections. *Papillomavirus Rep* 1990;1:2-5.
- 5 Wickenden C, Malcolm ADB, Steele, et al. Screening for

- wart virus infection in normal and abnormal cervixes by DNA hybridisation of cervical scrapes. *Lancet* 1985; i:65-7.
- 6 Ferenczy A, Mitao M, Nagai N, Silverstein SJ, Crum CP. Latent papillomavirus and recurring genital warts. *N Engl J Med* 1985;313:784-8.
- 7 Grussendorf-Conen E, De Villiers E-M, Gissmann L. Human papillomavirus genomes in penile smears of healthy men. *Lancet* 1986;ii:1092.
- 8 Hook EW, Handsfield HH. Gonococcal infections in the adult. In: Holmes KK, Mårdh P-A, Sparling PF et al eds. *Sexually Transmitted Diseases*. 2nd ed. London: McGraw Hill, 1990: 149-65.
- 9 Saiki RK, Gelfand DH, Stoffel S, et al. Primer-directed enzymatic amplification of DNA with a thermostable DNA polymerase. *Science* 1988;239:487-91.
- 10 Snijders PTF, van den Brule AJC, Schriinemakers HFJ, Snow G, Meier CJLM, Walboomers JMM. The use of general primers in the polymerase chain reaction permits the detection of a broad spectrum of human papillomavirus genotypes. *J Gen Virol* 1990;71:173-81.
- 11 Melchers WJG, Schiff R, Stoltz E, Lindeman J, Quint WGV. Human papillomavirus detection in urine from male patients by the polymerase chain reaction. *J Clin Microbiol* 1989;27:1711-4.
- 12 Van den Brule AJC, Meier CJLM, Bakels V, Kenemans P, Walboomers JMM. Rapid detection of human papillomavirus in cervical scrapes by combined general primer-mediated and type specific polymerase chain reaction. *J Clin Microbiol* 1990;28:2739-43.
- 13 Sambrook J, Fritsch EF, Maniatis T. *Molecular cloning: a laboratory manual*. 2nd ed. Cold Spring Harbour, New York: Cold Spring Harbor Laboratory Press, 1989.
- 14 Kinghorn GR. Genital warts: incidence of associated genital infections. *Br J Dermatol* 1978;99:405-9.
- 15 Harahap M. Asymptomatic gonorrhoea among patients with condylomata acuminata. *Br J Venereal Dis* 1979;55: 450.
- 16 Carne CA, Dockerty G. Genital warts: need to screen for coinfection. *BMJ* 1990;300:459.
- 17 Crawshaw SC, Haran MV. Genital warts and the need for screening. *Gemittourn Med* 1990;66:228-9.
- 18 Jayaweera DT, Ahmed IH, Bignell CJ, Rogstad KE. Genital warts and the need for screening. *Gemittourn Med* 1990;66:305.
- 19 Wikström A, Lidbrink P, Johansson B, von Krogh G. Penile human papillomavirus carriage among men attending Swedish STD clinics. *Int J STD & AIDS* 1991;2:105-9.
- 20 Boon ME, Schneider A, Hogewoning CJA, van der Kwast TH, Bolhuis P, Kok LP. Penile studies and heterosexual partners: penicopy, cytology, histology and immunocytochemistry. *Cancer* 1988;61:1652-9.
- 21 Giacomini G, Bianchi G, Moretti D. Detection of sexually transmitted diseases by urethral cytology, the ignored male counterpart of cervical cytology. *Acta Cytologica* 1989;33:11-5.
- 22 Omar R, Choudhury M, Fischer J, Ezpeleta C. A "Pap" test for men? male urethral smears as screening tool for detecting subclinical human papillomavirus infection. *Urology* 1991;37:110-5.
- 23 Dean P, Lancaster WD, Chun B, Jensen B. Human papillomavirus structural antigens in squamous papillomas of the male urethra. *J Urol* 1983;129:873-5.
- 24 Mandal D, Haye KB, Ray TK, Goorney BP, Stanbridge GM, Coxbier G. Prevalence of occult human papillomavirus infection, determined by cytology and DNA hybridization, in heterosexual men attending a genitourinary medicine clinic. *Internat J STD & AIDS* 1991; 2:351-5.
- 25 Wikström A, Hedblad M-A, Johansson B, Kalantari M, Syrjänen S, Lindberg M, von Krogh G. The acetic acid test in evaluation of subclinical genital papillomavirus infection: a comparative study on penicopy, histopathology, virology and scanning electron microscopy findings. *Gemittourn Med* 1992;68:90-9.
- 26 Barrasso R, De Brux J, Croissant O, Orth G. High prevalence of papillomavirus-associated penile intraepithelial neoplasia in sexual partners of women with cervical intraepithelial neoplasia. *N Engl J Med* 1987;317: 315-23.
- 27 Schultz RE, Skelton HG. Value of acetic acid screening for flat genital condylomata in men. *J Urol* 1988;139: 777-9.
- 28 Griffiths M, Penna LK, Tovey SJ. Aceto-white change of the glans penis associated with balanitis nor human papillomavirus infection. *Internat J STD & AIDS* 1991;2:211-2.
- 29 Eriksson MBE, Claesson U, Kataoka A, Lindh E, Wikström K. Detection of HPV in urogenital specimens from Swedish army conscripts. Supplement, 7th World Congress of Cervical Pathology and Colposcopy, Rome 13-17 May, 1990: Abstract FC/249.
- 30 Krebs H-B, Helmikamp BF. Treatment failure of genital condylomata acuminata in women: role of the male sexual partner. *Am J Obstet Gynecol* 1991;165:337-9.
- 31 Krebs H-B, Helmikamp BF. Does the treatment of genital condylomata in men decrease the treatment failure rate of cervical dysplasia in the female sexual partner? *Obstet Gynecol* 1990;76:660-3.
- 32 Rosemberg SK. Sexually transmitted papillomaviral infection in men: an update. *Dermatol Clin* 1991;9:317-31.
- 33 Oriel JD. HPV infections of the urethra. In: Gross G, Jablonska S, Pfister H, Stegner H-E eds. *Genital papillomavirus infections: modern diagnosis and treatment*. Berlin:

- Springer-Verlag, 1990: 181-7.
- 34 Nakazawa A, Fujita M, Ogawa H, Sasagawa T, Inoue M, Tanizawa O. Detection of human papillomavirus types 16 and 18 in exfoliated cervical cells of Japanese women and in urine samples from their male partners. Abstract 166, 10th International Papillomavirus Workshop, Seattle, 20-26 July, 1991.
 - 35 Hansson BC, Bjerre B, Forslund O, Lindholm K, Nordenfelt E. Human papilloma virus infections in health control and colposcopy patients. Analysis of cervix and urine samples. Abstract 78, 10th International Papillomavirus Workshop, Seattle, 20-26 July, 1991.
 - 36 De Villiers E-M. Laboratory techniques in the investigation of human papillomavirus infection. *Gentourin Med* 1992;68:50-4.
 - 37 Douglas JM, Breese PL, Kolcis J, Bartholow BN. Prevalence of clinical and subclinical genital HPV infection among unselected men attending a sexually transmitted disease (STD) clinic. Abstract 125, 10th International Papillomavirus Workshop, Seattle, 20-26 July, 1991.
 - 38 Hillman RJ, Botcherby M, Rvait BK, Hanna N, Taylor-Robinson D. Detection of human papillomavirus DNA in the urogenital tracts of men with anogenital warts. *Sex Transm Dis* 1993;20:21-7.
 - 39 Murphy WD, Rovner AJ, Nazinitsky KJ. Condylomata acuminata of the bladder: a rare cause of intraluminal-filling defects. *Urol Radiol* 1990;12:34-6.
 - 40 Masood S, Rhaugan RM, Powell S, Thompson J, Rodenroth N. Human papillomavirus in prostatic cancer: no evidence found by in situ DNA hybridization. *South Med J* 1991;84:235-6.
 - 41 McNicol PJ, Dodd JG. Detection of human papillomavirus DNA in prostate gland tissue by using the polymerase chain reaction amplification assay. *J Clin Microbiol* 1990;28:409-12.
 - 42 Bergeron C, Ferenczy A, Richart R. Underwear: contamination by human papillomaviruses. *Am J Obstet Gynecol* 1990;162:25-9.
 - 43 Sun-Kuie T, Tew-Hong H, Soo-Kim L-T. Is genital human papillomavirus infection always sexually transmitted? *Aust NZ J Obstet Gynaecol* 1990;30:240-2.
 - 44 Roman A, File K. Human papillomavirus DNA associated with foreskins of normal newborns. *J Infect Dis* 1986; 153:855-61.
 - 45 Ferenczy A, Bergeron C, Richart RM. Human papillomavirus DNA in fomites on objects used for the management of patients with genital human papillomavirus infections. *Obstet Gynecol* 1989;74:950-4.
 - 46 Barrasso R, Gross G. Male HPV-associated lesions: epidemiology and diagnostic criteria. In: Gross G, Jablonska S, Pfister H, Stegner H-E eds. *Genital Papillomavirus Infections: Modern Diagnosis and Treatment*. Berlin: Springer-Verlag, 1990:23-33.
 - 47 Campion MJ, Singer A, Clarkson PK. Increased risk of cervical intraepithelial neoplasia in consorts of men with penile condylomata acuminata. *Lancet* 1985;i:943-6.
 - 48 Zur Hausen H. The role of papillomaviruses in anogenital cancer. *Scand J Infect Dis Suppl* 1990;69:107-11.

ORIGINAL ARTICLE

Human papillomavirus DNA in the urogenital tracts of men with genital dermatoses: evidence for multifocal infection

R J Hillman MRCP¹, B K Ryaie MSc¹, M Botcherby MSc¹,
M M Walker MRCPATH² and D Taylor-Robinson FRCPATH¹

¹Division of Sexually Transmitted Diseases, Clinical Research Centre, Watford Road, Harrow, Middlesex HA1 3UJ, the Jefferiss Wing, St Mary's Hospital, London W2 1NY and ²the Department of Histopathology, St Mary's Hospital Medical School, Norfolk Place, London W2 1PG, UK

Summary: In an attempt to assess the multifocal nature of anogenital HPV infection in men, skin biopsies, urethral swabs and urine specimens were obtained from 100 men with genital dermatoses. The specimens were examined for the presence of human papillomavirus (HPV) types 6, 11, 16, 18, 31 and 33 using the polymerase chain reaction and Southern blotting techniques. HPV DNA was detected in one or more specimens from 39 patients, that is 29 of 100 biopsy specimens, 21 (25%) of 85 urethral swab specimens and 6 (10%) of 59 urine specimens. HPV DNA was more common in men with at least 20 lifetime sexual partners and in those who gave a history of anogenital warts. Twelve (18%) of 66 biopsy specimens with no histological evidence of warty change or neoplasia had detectable HPV DNA. HPV DNA was detected no more frequently in the urethral and urine specimens from men with histological evidence of warts or neoplasia than from men without such changes.

HPV types 6 and 11 were most common in biopsy specimens with histological changes of typical HPV infection. HPV type 16 was commonest in biopsy specimens with neoplasia and type 18 with other changes. Furthermore, 'high-risk' HPV types were found proportionately more often in urethral swab and urine specimens than in biopsy specimens. There was generally a poor correlation between the detection of HPV DNA at the different sites.

A greater understanding of the role of HPV in the production of genital abnormalities is required in order to develop a rational approach to the management of these patients.

Keywords: HPV, male urogenital tract, genital dermatoses

INTRODUCTION

There is increasing evidence linking human papillomavirus (HPV) infection of the female genital tract with neoplasia¹. The lack of a male counterpart to the cervical scrape, together with the lower incidence of penile carcinoma compared to cervical carcinoma², and the difficulty in interpreting the results of acetic acid staining of the male genitalia³ has led to less attention being paid to the interaction of the male genital tract with HPVs. The majority of the clinically apparent genital HPV infections are sexually acquired⁴, so we postulated that the frequency of genital HPV infection in men might be similar to that in women. To address this issue

we chose to examine men with and without HPV-associated disease who had clinical indications for genital biopsy.

Infection of the female genital tract with HPV is often multifocal⁵. To determine whether infection of the male genital tract with HPV is also multifocal, we examined samples taken from 3 different sites on the male genitalia. The polymerase chain reaction (PCR) in combination with Southern blotting were used to detect HPV DNA, as these methods are highly sensitive and specific⁶.

METHODS

Patients and collection of specimens

One hundred male patients consecutively undergoing genital biopsy at a genital dermatosis clinic were selected. Men were referred to this clinic from

Correspondence to: Dr R J Hillman, The Ambrose King Centre, The Royal London Hospital, Whitechapel, London E1 1BB, UK

the main genitourinary department if they had a persistent genital dermatosis which had not responded to treatment and the clinician felt that biopsy would help in confirming the diagnosis. In addition, patients were seen whose genital lesions were atypical in appearance and in whom a biopsy was considered necessary to establish the diagnosis⁷. Lesions of classical condylomata acuminata were not biopsied. All patients were screened for the commonly occurring sexually transmitted pathogens, and treated when necessary. After informed consent had been obtained, a detailed clinical history was taken using a structured questionnaire. The genitalia, including the meatus, were examined by naked eye and a biopsy taken from a representative area using the skin snip technique⁷. The sample was then cut into 2 pieces; one was placed in formal saline for subsequent histopathological analysis, and the other in phosphate-buffered saline (PBS) for HPV DNA analysis. Once haemostasis had been secured, a urethral sample was taken with a cotton-tipped swab ('STD-Pen for Males', Abbott Laboratories, Chicago, Illinois, USA) using a 'no touch' technique. The patient was then asked to provide 10 ml of first-pass urine. The results of one set of samples were recorded per patient.

Processing of specimens

Standard techniques were used for making histopathological diagnoses^{8,9}. All specimens in which a histopathological diagnosis of non-specific dermatitis was made were additionally stained by the periodic acid Schiff method.

To avoid cross-contamination of DNA products, preparation of reagents, the processing of patient material, and the PCR together with Southern blotting were performed at separate sites. Positive displacement pipettes or single-use Pasteur pipettes were used to distribute reagents for the PCR and to add the DNA samples to the reaction mixtures. Positive and negative controls were included in each experiment. Laboratory staff were unaware of the clinical status of the men.

DNA was extracted from the biopsy specimens and urethral swabs as described previously¹⁰. Urine samples were centrifuged for 10 min at 3000 rpm and the sediment suspended in 160 μ l of 2 \times Summers' buffer (40 mM TRIS-HCl, 0.3 M NaCl and 20 mM EDTA-tetra sodium salt) pH 8.0. Samples containing 100 pg of the full length genome of HPV types 6, 11, 16 and 18 were used as positive controls; types 31 and 33 were not available. Negative

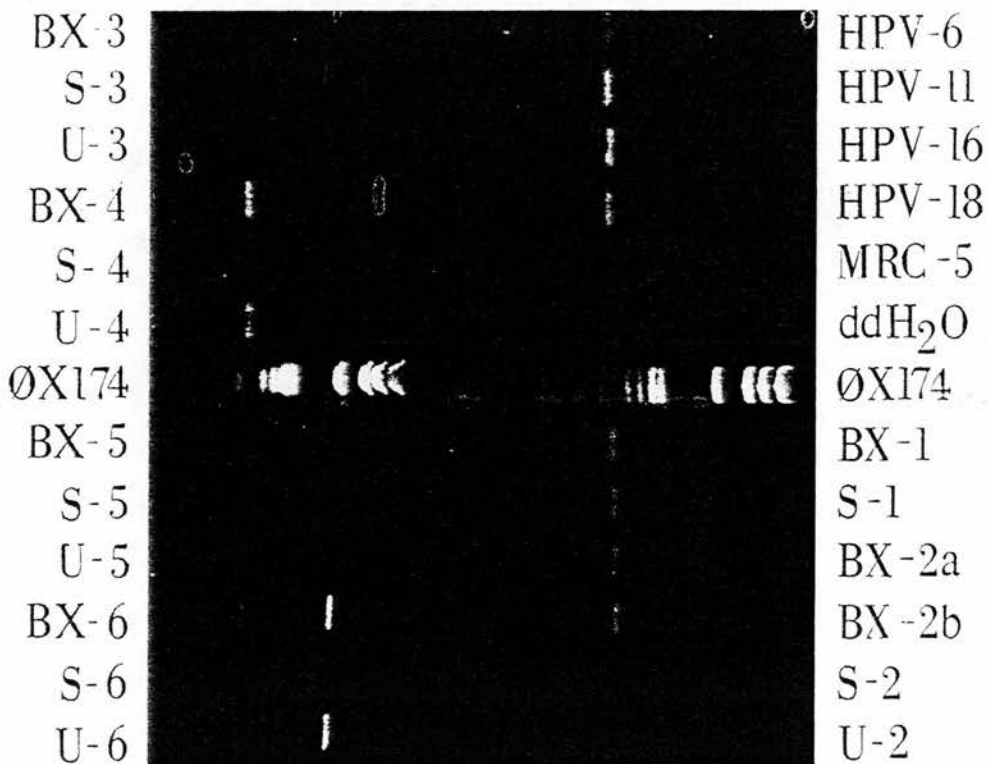


Figure 1. Ethidium bromide staining of agarose gel with positive controls (HPV types 6, 11, 16 and 18), negative controls (MRC-5 fibroblasts and ddH₂O), molecular weight marker (ØX174) and specimens of DNA from biopsies (BX), swabs (S) and urine (U). Samples BX-2a and BX-2b are from two different sites on the scrotum of one patient. Positive results are seen with samples BX-4, S-4, U-4, BX-5, BX-6, U-6, BX-1, S-1, BX-2a, and BX-2b

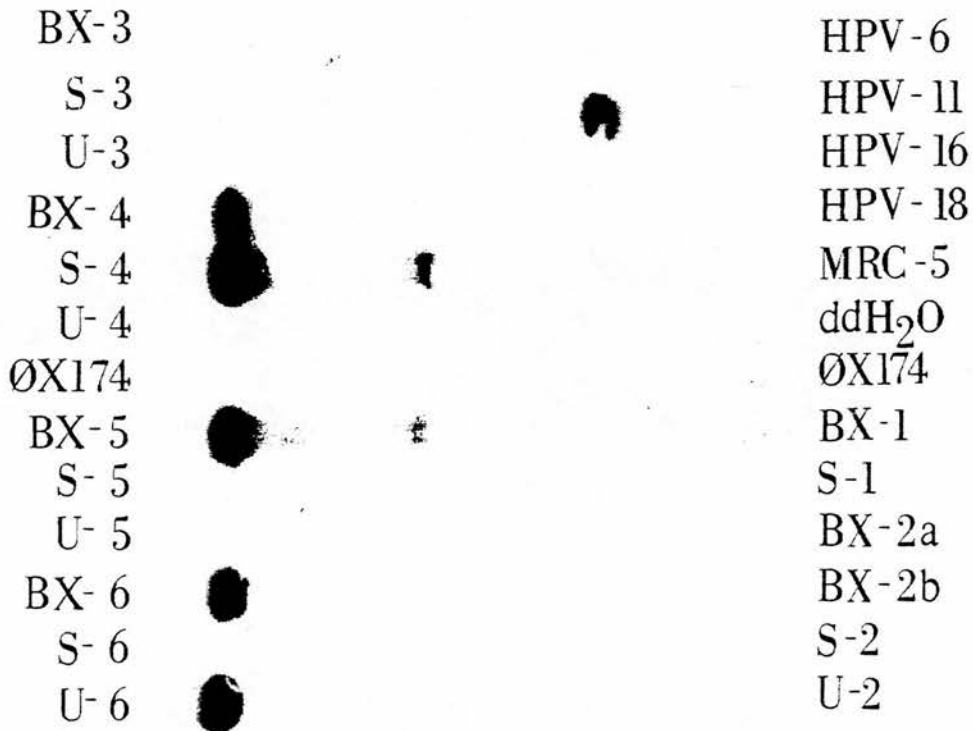


Figure 2. Hybridization of PCR products with HPV type 11-specific probe on nylon membrane following Southern blot. Abbreviations as for Figure 1. Positive results are seen with HPV type 11 control, BX-4, S-4, BX-5, BX-6 and U-6

controls comprised a fibroblast line (MRC-5) and ddH₂O (Figure 1).

The PCR method was based on that of Saiki *et al.*¹¹ and is described elsewhere¹⁰. The products were analysed by the Southern blot procedure, using agarose gel electrophoresis with ethidium bromide staining. Hybridization for the detection of HPV types 6, 11, 16, 18, 31 and 33 was performed at 55°C for 16 to 24 h using oligonucleotide probes* which had been end-labelled with ³²P-labelled dATP. Examples of this are shown in Figure 2.

RESULTS

Clinical features of the patients

The age range of the men was 18.6 to 68.6 yr (mean 35.9 yr). Seventy-five were Caucasian,

10 Afro-Caribbean and 15 of other racial origins. Eighty-five of the men were heterosexual, 11 homosexual and 4 bisexual. The men admitted to a range of one to 1000 (median 20) life-time sexual partners. No men had typical genital warts at the time of biopsy. Twenty men were circumcised, 69 were not and this information was not recorded in 11 cases. Nineteen men gave a history of anogenital warts, 76 did not, and this information was not recorded in 5 cases.

The lesions had been noticed by the men over a range of one to 180 months (mean 31 months). At the time of sampling, the predominant location of the dermatosis was on the glans penis in 44 of the men, coronal region in 12, frenulum in 2, foreskin in 14, shaft in 26 and scrotum in 2. The histological diagnoses of the biopsy specimens are shown in Table 1.

HPV in relation to possible risk factors and demographic details

The proportion of biopsy, urethral swab and urine specimens containing HPV are given in relation to various possible risk factors and demographic details in Table 2. Although the numbers are small, there is a suggestion that infection with HPV is more common in men admitting to at least 20 lifetime sexual partners than those with fewer partners, and

*Oligonucleotide probes (prepared using a Milligen/Biosearch 7500 DNA Synthesizer):

HPV 6	5' ACA TGC GTC ATG TGG AAG AGT 3'
HPV 11	5' TAA ATC TGC TAC ATA CAC TAA 3'
HPV 16	5' TCT ACT TCA GAA ACT ACA TAT 3'
HPV 18	5' TGC TTC TAC ACA GTC TCC TGT 3'
HPV 31	5' CAC ACA AGT AAC TAG TGA CAG 3'
HPV 33	5' TCT GTT TGT GCT GCA ATT GCA 3'

Table 1. Histopathological diagnoses of biopsy specimens from 100 patients

Category	Histopathological diagnosis	No. of patients
Wart	Typical wart virus infection	22
Neoplasia	Basal cell papilloma	3
	Dysplastic wart ^a	1
	PIN ^b 1	1
	PIN 2	5
	PIN 3	2
Other	Non specific dermatosis	24
	Lichen sclerosus	13
	Lichen planus	7
	Lichen nitidus	1
	Lichen simplex	1
	Psoriasis	7
	Fungal infection	2
	Miscellaneous ^c	11

^aHistopathological change not amounting to PIN 1

^bPenile intraepithelial neoplasia

^cThis group comprised: normal, not diagnostic, scarring, granuloma annulare, plasma cell balanitis, lentigo, venous haemangioma, sebaceous cyst wall, molluscum contagiosum, folliculitis and drug rash

in those with a history of anogenital warts compared to those without. An association between HPV infection and other factors is less clear.

Detection of HPV in relation to specimen type and to histopathological findings

HPV DNA was detected in one or more biopsy, swab or urine specimens from 39 patients. The histopathological findings in the biopsy specimens in relation to the HPV types detected in the 3 types of specimens are shown in Table 3. The relation between HPV type detected, specimen type and histopathological findings is presented in Tables 4 and 5.

HPV in biopsy specimens

HPV DNA was detected in 29 of 100 biopsy specimens (Table 4). Seven (28%) of 25 biopsies from the glans, 3 (30%) of 10 from the corona, one (50%) of 2 from the frenulum, 9 (29%) of 31 from the foreskin, 8 (27%) of 30 from the shaft and one (33%) of 3 from the scrotum contained HPV DNA. Of the 20 circumcised men, 7 (35%) had HPV DNA in their biopsy specimens, that is 3 (33%) of 9 from the glans and corona and 4 (36%) of 11 from elsewhere on the genitalia. Of the 69 uncircumcised men, 18 (26%) had HPV DNA in their biopsy specimens, that is 5 (31%) of 13 from the glans, none of 6 from the corona, one (50%) of 2 from the frenulum, 9 (29%) of 31 from the foreskin and 3 (18%) of 17 from elsewhere on the genitalia.

Of the 22 men who had histological evidence of typical HPV infection, 6 (27%) had a history of anogenital warts; of the 12 men who had histological evidence of neoplasia, 4 (33%) had a history of anogenital warts; of the 66 men who had no histological evidence of either typical HPV infection or neoplasia, 13 (20%) had a history of anogenital warts.

HPV DNA was detected in 32% of biopsy specimens with histological evidence of typical warts, 83% of specimens with neoplasia and 18% of specimens in which histological evidence of either change was absent (Table 5).

Wart specimens were associated most frequently with HPV DNA types 6 or 11, specimens showing neoplasia most frequently with type 16 and specimens having other histopathological changes with a variety of HPV types, most commonly HPV types 11 and/or 18 (Table 5). Of particular note, all 3 basal cell papillomata were associated with HPV type 6 (Table 3).

Infection with 2 or more HPV types was found in 7 (24%) of 29 biopsy specimens containing HPV DNA (Table 4).

Table 2. HPV in different specimens in relation to possible risk factors and some demographic details

Possible risk factors/ demographic details	Proportion ^a (percentage) of specimens of indicated specimen type positive for HPV			
	Any specimen	Biopsy	Urethral swab	Urine
≥20 partners	22/45 (49)	16/45 (35)	14/44 (32)	5/30 (17)
<20 partners	12/39 (31)	9/39 (23)	5/37 (14)	1/28 (4)
History ^b	10/19 (53)	9/19 (47)	6/17 (35)	1/8 (12)
No history ^b	28/76 (37)	19/76 (25)	14/64 (22)	5/49 (10)
Condoms not used	12/29 (41)	10/29 (34)	6/28 (21)	1/17 (6)
Condoms used	20/55 (36)	13/55 (24)	13/50 (26)	4/37 (11)
Smoker	16/39 (41)	14/39 (36)	9/37 (24)	2/20 (10)
Non-smoker	17/44 (39)	11/44 (25)	9/42 (21)	4/36 (11)
<35 years old	24/57 (42)	17/57 (30)	13/49 (26)	5/32 (16)
≥35 years old	15/43 (35)	12/43 (28)	8/36 (22)	1/27 (4)
Caucasian	28/75 (37)	20/75 (27)	16/67 (24)	4/46 (9)
Non Caucasian	11/25 (44)	9/25 (36)	5/18 (28)	2/13 (15)
Heterosexual	34/85 (40)	28/85 (33)	16/72 (22)	4/48 (8)
Homo/bisexual	5/15 (33)	1/15 (7)	5/13 (38)	2/11 (18)

^aProportion for each possible risk factor: number of men with that specimen type containing HPV DNA, expressed as a proportion of all men with that risk factor and whose HPV status for that specimen type was known.

^bHistory of anogenital warts given by patient

Table 3. HPV DNA types detected in relation to histopathological findings

Histopathological findings	HPV DNA types detected in indicated specimens		
	Biopsy	Urethral swab	Urine
Wart	6, 11	6, 11, 18	ns
Wart	6	—	—
Wart	18	—	—
Wart	6	—	—
Wart	6, 11	ns	ns
Wart	16	11, 18	ns
Wart	6, 11	—	—
Wart	—	18	—
Wart	—	33	—
<i>Neoplasia</i>			
Basal cell papilloma	6	6	ns
Basal cell papilloma	6	—	—
Basal cell papilloma	6	—	—
Dysplastic wart	16	—	—
PIN 1	6	—	—
PIN 2	—	18	18
PIN 2 + wart	16	ns	ns
PIN 2	16	18	ns
PIN 2	6	—	—
PIN 3	16	—	ns
PIN 3	16	16	ns
<i>Other</i>			
NSD	18	—	ns
NSD	18	18, 31	—
NSD	6, 11, 18	18, 33	ns
NSD	18	—	—
NSD	11, 18	11	ns
NSD	—	—	16
NSD	—	33	33
LS	11, 18	11, 18	ns
LS	18	6, 11	ns
LS	—	18, 31	ns
LS	11	11	11, 18
LS	—	18	—
LS	31	—	—
Lichen planus	31	ns	ns
Lichen planus	16	16	—
Psoriasis	—	18	18
Psoriasis	11, 18	11, 31	ns
Plasma cell balanitis	—	—	6
Venous haemangioma	—	6	—

—=No HPV DNA detected; ns=no specimen obtained; PIN=penile intraepithelial neoplasia; NSD=non-specific dermatosis; LS=lichen sclerosus

HPV in urethral swab specimens

Urethral swab specimens were obtained from 85 men. Of these specimens, 21 (25%) contained HPV DNA (Table 4).

HPV DNA was more commonly detected in urethral specimens from men with histological evidence of neoplasia than from men with histological evidence of warts or other histological abnormalities (Table 5). HPV type 18 was the type most frequently detected in urethral swab specimens. Infection with more than one HPV type was found in approximately one-third of the swab specimens in which HPV DNA could be detected (Table 4).

Table 4. HPV in relation to type of specimen

HPV type	No. of specimens of indicated type positive for HPV		
	Biopsy (n=100)	Urethral swab (n=85)	Urine (n=59)
Any HPV	29	21	6
6	10 (34)*	3 (14)	1 (17)
11	8 (27)	6 (29)	1 (17)
16	7 (24)	2 (9)	0 (0)
18	10 (34)	11 (52)	3 (50)
31	3 (10)	2 (9)	0 (0)
33	0 (0)	4 (19)	1 (17)
>1 type	7 (24)	8 (38)	1 (17)

*Figures in brackets are expressed as percentages of all that particular specimen type containing any HPV DNA

Table 5. HPV in relation to histopathological findings of biopsy specimens from men with genital dermatoses

HPV type	No. (%) of men with specified HPV type in indicated specimen, according to histopathological diagnosis		
	Wart (n=22)	Neoplasia (n=12)	Other (n=66)
Any type in biopsy specimens	7 (32)	10 (83)	12 (18)
urethral swab specimens	4 (21)*	4 (36)*	13 (24)*
urine specimens	0	1 (14)*	5 (13)*
any specimen	9 (41)	11 (92)	19 (29)
Type 6 in any specimen	5 (23)	4 (33)	4 (6)
Type 11 in any specimen	4 (18)	0	6 (9)
Type 16 in any specimen	1 (5)	6 (50)	2 (3)
Type 18 in any specimen	4 (18)	2 (17)	12 (18)
Type 31 in any specimen	0	0	4 (6)
Type 33 in any specimen	1 (5)	0	3 (4)
>1 type in any specimen	4 (18)	1 (8)	7 (11)

*Urethral swab and urine specimens were not obtained from all men. The figures in these instances refer to those men from whom urethral swab or urine specimens were taken

HPV in urine specimens

Urine specimens were obtained from 59 men. Of these specimens, only 6 (10%) contained HPV DNA (Table 4).

HPV DNA was detected in urine specimens from no men with histological evidence of warts, and only a small proportion of those with neoplasia or other histological abnormalities (Table 5). HPV type 18 was the type most frequently detected in urine specimens. Infection with more than one type occurred on one occasion (Table 4).

Correlation between presence or absence of HPV and type of specimen

A correlation between biopsy and swab and between biopsy and urine was less obvious than between swab and urine findings (Table 6). Ten (28%) of the 36 patients with HPV present in biopsy or urethral swab specimens had at least one HPV type in common.

Table 6. Correlation between presence (+) or absence (-) of HPV DNA and type of specimen

	Biopsy		Biopsy		Swab		
	+	-	+	-	+	-	ns
Swab			Urine		Urine		
+	13	8	+	1 5	+	4 2	0
-	13	51	-	12 41	-	6 46	1
ns	3	12	ns	16 25	ns	11 16	14

ns = no specimen obtained

DISCUSSION

The detection rate of HPV DNA may depend on the population studied¹. It is difficult to determine the prevalence rate of HPV infection in the general population. We chose men with clinical indications for genital biopsy not in the belief that they represented the general male community but that they would do so more closely than patients with 'conventional' sexually transmitted diseases. Furthermore, men with genital dermatoses require biopsy procedures for full investigation. Although recruited from a department of genitourinary medicine, the men were unusual for this source in that they were generally older, had fewer lifetime sexual partners, and did not have any clinically apparent sexually transmitted disease at the time of biopsy.

It has been suggested¹² that the wide variations in reported prevalence rates of genital HPV infections may be related, at least in part, to the use of different detection methods. The PCR allows the detection of very small quantities of DNA and Southern blotting with hybridization enables the specific detection of the products. The 'genitotropic' HPV types, that is, types 6, 11, 16, 18, 31 and 33 were investigated, as these seem to be some of the commonest papillomaviruses infecting the anogenital region¹³.

In order to investigate the multifocal nature of male genital HPV infections, we used three sample sites. Skin biopsy provides a sample which includes the lower epidermis, an area which is difficult to access by other sampling techniques, yet is the site of productive infection with HPV¹⁴. The biopsy procedure also has the advantage of allowing the simultaneous assessment of pathological changes which might be associated with the presence of HPV. However, it only permits the detection of abnormalities in a small area and thus may lead to an underestimation of the infection rate. Urethral sampling allows collection of material from a larger area, the distal urethra, which is proposed as the male counterpart of the squamo-columnar junction of the cervix¹⁵. We also tested urine samples since HPV has been detected in the urine of men^{16,17}. Acetic acid staining of the genitals was not used as it is neither sensitive¹⁸ nor specific^{3,19} when applied to men.

Condylomata acuminata appear to be sexually acquired in the majority of cases⁴. However, there

is less convincing evidence for the role of sexual behaviour in the development of other types of clinically apparent and inapparent disease associated with HPV infection of the female urogenital tract²⁰. Data from our study suggest that HPV DNA is more commonly found in those with larger numbers of lifetime sexual partners, an observation consistent with sexual transmission. The detection of HPV DNA more commonly in smokers than in non-smokers is consistent with the finding of condylomata acuminata more commonly in smokers²¹. Furthermore, the observation that HPV was more commonly detected in men with a history of anogenital warts than in those without is compatible with the concept of latent infection. The lower incidence of HPV DNA in biopsies from homosexual and bisexual men compared to heterosexual men contrasts with the converse in urethral swab and urine specimens. The reasons for this are obscure, but it is tempting to speculate that different sexual practices may be a contributory factor. Clearly, however, larger studies are needed to investigate this matter.

The observation that HPV DNA was found in approximately similar proportions of biopsies from whatever site of the male genitalia, and regardless of whether the patient was circumcized, confirms the widespread distribution of HPV infection in men. Disruption of skin integrity may promote infection with HPV at sites of genital dermatoses, but we cannot exclude the possibility of a uniform distribution of HPV DNA throughout the intact male genital tract. Such a distribution contrasts with the occurrence of condylomata acuminata at specific sites, frequently those traumatized during intercourse⁴, and suggests that other factors may be involved in the development of clinically apparent disease.

Our finding of HPV DNA in only 32% of genital warts may reflect the unusual sample of warts. Only genital lesions which were clinically atypical were referred for biopsy, so that classical condylomata acuminata were not seen. It is thus possible that our sample may have contained a large proportion of warts caused by non-genitotropic HPV types. However, the observation that HPV types 6 and 11 were the most common in biopsies with histological evidence of warty change is consistent with previous reports^{22,23}. Furthermore, the detection of HPV type 16 in the majority of biopsy specimens with histological evidence of dysplasia is in agreement with the findings of others^{9,24}.

Eighteen per cent of biopsy specimens with no histological evidence of warts or dysplasia contained HPV DNA. This is contrary to the observations of some other groups investigating the male urogenital tract, who have not been able to find HPV DNA in biopsy specimens with no histological evidence of warts or dysplasia²⁵⁻⁸. It is, however, in agreement with reports of others who have investigated the male genital tract²⁹. Furthermore, DNA from the genitotropic HPV types has been detected in the

absence of histological abnormalities in the cervix³⁰, neonatal foreskin³¹, the oropharynx³² and conjunctiva³³. The finding of HPV DNA in a substantial proportion of biopsies from men with a variety of dermatoses not typically associated with HPV infection is of interest. More work is required, however, to establish whether there is any causal association.

In the current study, HPV DNA was found in 25% of urethral swab specimens and 10% of urine specimens. These figures compare closely with those for a group of 116 men with anogenital warts; in these men, we detected HPV DNA in 20% of urethral swab and 6.3% of urine specimens¹⁰.

Contrary to our expectations, HPV DNA was found less frequently in the urethral swab and urine specimens from men with histological evidence of HPV infection or dysplasia than in those from men with no such changes (Table 5). In addition, the correlation between the presence or absence of HPV DNA and type of specimen was generally poor (Table 6). Furthermore, there was no discernible relationship between HPV types found in the different specimens from the same man (Table 3). These 3 observations lead us to suggest that the 3 different sampling methods measure distinctly different aspects of the epidemiology of HPV infection in the urogenital tracts of men.

We are not surprised to have found HPV types 6 and 11 most commonly in biopsy specimens with histological changes of HPV infection. We are surprised, however, to have found 'high-risk' types proportionally more often in urethral swab and urine specimens. HPV type 16 is frequently found in dysplastic lesions such as PIN⁹ and penile carcinoma²⁷, and a causal link has been postulated³⁴. However, due to the fact that HPV infection of the male urogenital tract by 'high-risk' HPV types is widespread, any proposal to link infection by these types with neoplasia must take the common occurrence into account. Indeed, it provides a situation not dissimilar from that encountered in establishing a causal link between 'high-risk' HPV types and cervical carcinoma¹ against a background of commonly occurring 'high-risk' types.

Finally, a clearer understanding of the epidemiology of urogenital HPV infections and any associated histological abnormalities is required before rational management strategies may be devised.

References

- 1 Koutsky LA, Galloway DA, Holmes KK. Epidemiology of genital human papillomavirus infection. *Epidemiol Rev* 1988; 10:122-63
- 2 Campion MJ, McCance DJ, Mitchell HS, Jenkins D, Singer A, Oriel JD. Subclinical penile human papillomavirus infection and cervical dysplasia in consorts of women with cervical neoplasia. *Genitourin Med* 1988;64:90-9
- 3 Griffiths M, Penna LK, Tovey SJ. Aceto-white change of the glans penis associated with balanitis not human papillomavirus infection. *Int J STD AIDS* 1991;2:211-2
- 4 Oriel JD. Natural history of genital warts. *Br J Vener Dis* 1971;47:1-13
- 5 Coppleson M. Colposcopic features of papillomaviral infection and premalignancy in the female lower genital tract. *Obstet Gynecol Clin North Am* 1987;14:471-94
- 6 De Villiers E-M. Laboratory techniques in the investigation of human papillomavirus infection. *Genitourin Med* 1992; 68:50-4
- 7 Hillman RJ, Walker MM, Harris JRW, Taylor-Robinson D. Penile dermatoses: a clinical and histopathological study. *Genitourin Med* 1992;68:166-9
- 8 Lever WF, Schaumberg-Lever G. *Histopathology of the skin*. 7th edn. Philadelphia: JB Lippincott Company, 1990
- 9 Barrasso R, De Brux J, Croissant O, Orth G. High prevalence of papillomavirus-associated penile intraepithelial neoplasia in sexual partners of women with cervical intraepithelial neoplasia. *N Engl J Med* 1987;317:916-23
- 10 Hillman RJ, Botcherby M, Ryait BK, Hanna N, Taylor-Robinson D. Detection of human papillomavirus DNA in the urogenital tracts of men with anogenital warts. *Sex Transm Dis* 1993;20:21-7
- 11 Saiki RK, Gelfand DH, Stoffel S, et al. Primer-directed enzymatic amplification of DNA with a thermostable DNA polymerase. *Science* 1988;239:487-91
- 12 Costa S, Syrjänen S, Vendra C, et al. Detection of human papillomavirus infections in the male sexual partners of women attending an STD clinic in Bologna. *Int J STD AIDS* 1992;3:338-46
- 13 Von Krogh G. Genitoanal papillomavirus infection: diagnostic and therapeutic objectives in the light of current epidemiological observations. *Int J STD AIDS* 1991;2:391-404
- 14 Broker TR, Botchan M. Papillomaviruses: retrospective and prospective. *Cancer Cells* 1986;2:17-36
- 15 Rosemberg SK. Sexually transmitted papillomaviral infection in men: an update. *Dermatol Clin* 1991;9:317-31
- 16 Melchers WJG, Schiff R, Stolz E, Lindeman J, Quint WGV. Human papillomavirus detection in urine samples from male patients by the polymerase chain reaction. *J Clin Microbiol* 1989;27:1711-4
- 17 Nakazawa A, Inoue M, Fujita M, Tanizawa O, Hakura A. Detection of human papillomavirus type 16 in sexual partners of patients having cervical cancer by polymerase chain reaction. *Jpn J Cancer Res* 1991;82:1187-90
- 18 Schneider A, Kirchmayr R, De Villiers E-M, Gissmann L. Subclinical human papillomavirus infections in male sexual partners of female carriers. *J Urol* 1988;140:1431-4
- 19 Siegel JF, Mellinger BC. Human papillomavirus in the male patient. *Urol Clin North Am* 1992;19:83-91
- 20 Franco EL. Viral etiology of cervical cancer: a critique of the evidence. *Rev Infect Dis* 1991;13:1195-206
- 21 Daling JR, Sherman KJ, Weiss NS. Risk factors for condyloma acuminatum in women. *Sex Transm Dis* 1986;13:16-8
- 22 Wickenden C, Hanna N, Taylor-Robinson D, et al. Sexual transmission of human papillomaviruses in heterosexual and male homosexual couples, studied by DNA hybridisation. *Genitourin Med* 1988;64:34-8
- 23 O'Brien WM, Jenson AB, Lancaster WD, Maxted WC. Human papillomavirus typing of penile condyloma. *J Urol* 1989;141:863-5
- 24 Syrjänen SM, von Krogh G, Syrjänen KJ. Detection of human papillomavirus DNA in anogenital condylomata in men using *in situ* DNA hybridisation applied to paraffin sections. *Genitourin Med* 1987;63:32-9
- 25 Ferenczy A, Richart RM, Wright TC. Pearly penile papules: absence of human papillomavirus DNA by the polymerase chain reaction. *Obstet Gynecol* 1991;78:118-22
- 26 Hippeläinen M, Yliskoski M, Saarikoski S, Syrjänen S, Syrjänen K. Genital human papillomavirus lesions of the male sexual partners: the diagnostic accuracy of peniscopy. *Genitourin Med* 1991;67:291-6

- 27 Varma VA, Sanchez-Lanier M, Unger ER, *et al.* Association of human papillomavirus with penile carcinoma: a study using polymerase chain reaction and in situ hybridization. *Human Pathol* 1991;22:908-13
- 28 De Villiers E-M, Schneider A, Gross G, zur Hausen H. Analysis of benign and malignant urogenital tumors for human papillomavirus infection by labelling cellular DNA. *Med Microbiol Immunol* 1986;174:281-6
- 29 Nuovo GJ, Hochman HA, Eliezri YD, Lastarria D, Comite SL, Silvers DN. Detection of human papillomavirus DNA in penile lesions histologically negative for condylomata: analysis by *in situ* hybridization and the polymerase chain reaction. *Am J Surg Pathol* 1990;14:829-36
- 30 Muñoz N, Bosch X, Kaldor JM. Does human papillomavirus cause cervical cancer? The state of the epidemiological evidence. *Br J Cancer* 1988;57:1-5
- 31 Roman A, Fife K. Human papillomavirus DNA associated with foreskins of normal newborns. *J Infect Dis* 1986;153:855-61
- 32 Maitland NJ, Cox MF, Lynas C, Prime SS, Meanwell CA, Scully C. Detection of human papillomavirus DNA in biopsies of human oral tissue. *Br J Cancer* 1987;56:245-50
- 33 McDonnell JM, Wagner D, Ng ST, Bernstein G, Sun YY. Human papillomavirus type 16 DNA in ocular and cervical swabs of women with genital tract condylomata. *Am J Ophthalmol* 1991;112:61-6
- 34 McCance DJ, Kalache A, Ashdown K, *et al.* Human papillomavirus types 16 and 18 in carcinomas of the penis from Brazil. *Int J Cancer* 1986;37:55-9

(Accepted 18 February 1993)

Changes in HPV infection in patients with anogenital warts and their partners

R J Hillman, B K Ryait, M Botcherby, D Taylor-Robinson

Abstract

Objectives—To investigate the relationship between clinical findings and the detection of human papillomavirus (HPV) DNA in a range of anatomical sites in patients with and without anogenital warts.

Subjects—Men and women with a clinical diagnosis of anogenital warts, or a current partner with anogenital warts.

Setting—A department of genitourinary medicine in central London.

Methods—The anogenital areas of the patients were thoroughly examined using a colposcope before and after application of acetic acid. Different types of specimens were taken from a variety of anatomical sites. Superficial skin sampling was performed by the application of slides covered with "Superglue" (SG) to clinically normal and abnormal areas of anogenital skin. The presence of human cells in the SG samples was confirmed by detection of the β -globin gene using the polymerase chain reaction (PCR). HPV DNA was extracted from the specimens and amplified by using consensus primers with the PCR. HPV types 6,11,16,18,31 and 33 were identified by Southern blotting followed by hybridisation.

Results—In women, HPV DNA was detected in 83% of wart biopsies, 29% of cervical biopsies, 36% of cervical scrapes, 25% of urethral loop specimens, 37% of vaginal washes and 33% of rectal swab specimens. In men, HPV DNA was detected in 67% of wart biopsies, 37% of urethral loop specimens and 12% of rectal swab specimens. Of the SG samples containing the β -globin gene, 49% from women and 50% from men contained HPV DNA. HPV DNA was not detected in buccal scrapes and serum samples from women or men. Of all specimens with detectable HPV DNA, there was evidence of a single HPV type in 41%, multiple types in 48% and undetermined types in 11%. Samples taken from different sites of a patient tended to have HPV types in common. Sexual partners, however, did not consistently have HPV types in common.

Conclusions—HPV DNA was distributed widely in the anogenital area, in warts, acetowhite areas and clinically normal skin. The SG technique was well tolerated by patients and produced results

consistent with other findings. Sampling from a single site of the genitalia on one occasion may significantly underestimate the infection rate with HPV. Multifocal infection of the anogenital area with HPV should be taken into consideration when interpreting epidemiological studies and management strategies.

(Genitourin Med 1993;69:450-456)

Introduction

Although there is considerable evidence that condylomata acuminata are usually sexually transmitted,^{1,2} the epidemiology of clinically inapparent infection with genitotropic human papillomavirus (HPV) types is less well understood.³ Studies of the uterine cervix have shown that HPV infection is common, may not be associated with cytological⁴ or histological⁵ abnormalities and has epidemiological characteristics which suggest that sexual transmission may not be the only mode of acquisition.⁶ Furthermore, the relationship between the detection of HPV and the development of histological and/or clinical changes is imperfectly understood, and the relationship may vary with time.⁷

In an attempt to characterise the multifocal nature of HPV infection and its possible change with time, we took a variety of samples over several months from patients with and without genital warts. The patients comprised those with anogenital warts and their partners who may or may not have had warts. Following extraction of DNA from the specimens, the polymerase chain reaction (PCR) was used, as this is currently the most sensitive technique for the detection of HPV.⁸ Southern blotting⁹ was then performed, as it allows the highly specific confirmation of DNA sequences produced by the PCR and enables the type of HPV to be determined.

Patients and methods

COLLECTION OF SPECIMENS

Patients were invited to take part in the study if either they or their sexual partner had clinically apparent anogenital warts. A standard history was taken and all patients were screened for the commonly occurring sexually transmitted diseases, and treated when appropriate. The genital and perigenital areas were then examined with the naked eye and any abnormalities documented diagrammatically.

Division of Sexually Transmitted Diseases, Clinical Research Centre, Watford Road, Harrow, Middlesex, HA1 3UJ and The Jefferiss Wing, St Mary's Hospital, Praed Street, London W2 1NY, UK
R J Hillman
B K Ryait
M Botcherby
D Taylor-Robinson

Address correspondence to: Dr R J Hillman, The Ambrose King Centre, The Royal London Hospital, Whitechapel, London E1 1BB

After application of 3–5% acetic acid to these areas, microscopic examination using a Zeiss colposcope was undertaken.

Informed consent was obtained from the patients and then samples were taken in the conventional manner as follows: 10 μ l plastic loops (Nunc, Gibco, Paisley, Scotland) for urethral specimens, Ayre's spatulas for cervical scrapes and cytological brushes ("Cytobrush", Rocket, London, UK) for endocervical specimens. Anal samples were obtained by inserting a Cytobrush 1 cm into the anal canal and rotating it through 360°. Tongue depressors were drawn along the buccal surface of both sides of the mouth to obtain buccal scrapes. The tips of the sampling instruments used in the aforementioned procedures were broken off into individual disposable bottles containing 10 ml of phosphate-buffered saline (PBS). A vaginal sample was obtained by washing the vaginal walls and cervix with 10 ml of normal saline using a sterile syringe, aspirating the fluid and repeating the procedure. Blood was obtained using the "Vacutainer" (Becton Dickinson, Cowley, UK) system. Superficial layers of the skin were sampled by using "Superglue" (SG) cyanoacrylate glue (Bison™, Perfecta Chemie B.V., Goes, Holland). One drop of SG was placed on a clean slide which was immediately applied to the skin. After one minute, the slide was gently removed and placed in an individual slide box. This procedure was well tolerated by patients. If possible, SG samples were taken from areas of skin containing warts, or areas of skin including acetowhite changes. Biopsies of the external genital area were taken by the skin snip technique¹⁰ following local anaesthesia. Biopsy specimens were taken from warts and acetowhite areas in women but only from warts in men. Cervical biopsy samples were obtained by cervical biopsy forceps without anaesthesia. Biopsy specimens were placed in PBS for DNA analysis and in formal saline for histopathological assessment.

Strict precautions against contamination of the specimens by HPVs were taken. All sampling instruments, except those used for taking biopsy specimens, were sterile and disposable. Biopsy specimens were taken with re-usable equipment which was hand-washed, placed in an ultrasonic cleaner (Olympus Keymed KS-2; Keymed, Southend on Sea, UK) for 15 min and autoclaved at 134°C for 20 min (Little Sister 2, Eschmann Bros & Walsh Ltd, Lancing, UK) before re-use. All specimens were collected using a "no touch" technique and placed in sterile, disposable bottles prior to analysis.

To facilitate interpretation of results, specimens were divided into three groups. "Biopsy" specimens consisted of specimens from clinically abnormal and acetowhite areas. SG specimens consisted of samples obtained using the SG technique. The term "non-biopsy" is used to describe all other types of specimens.

Clinically apparent warts were treated in the usual manner for the clinic, namely, the

application of liquid nitrogen and 15% podophyllin, both twice weekly until clinical disappearance. Warts that recurred were treated in a similar manner and any subsequent recurrence managed by excision under local anaesthesia.

Patients were counselled and kept fully informed of any abnormality. Male patients and male partners of patients were advised to use condoms for the whole study period.

PROCESSING OF SPECIMENS

In order to avoid cross-contamination of DNA products, preparation of reagents, processing of patient material, and the PCR and Southern blotting took place in separate rooms. Positive displacement pipettes or single-use Pasteur pipettes were used for distributing reagents for the PCR and for adding the DNA samples to the reaction mixtures. Positive and negative controls were included in each experiment, including the SG samples.

DNA EXTRACTION

Wart and biopsy specimens were placed in 320 μ l of lysis buffer containing 160 μ l of 2 \times Summers' buffer, pH 8.0 (40 mM TRIS-HCl, 0.3M NaCl and 20 mM EDTA-tetra sodium salt), 100 μ l of double distilled H₂O (ddH₂O), 32 μ l of pronase E (10mg/ml), 28 μ l of 2.5% sodium dodecyl sulphate (SDS) and 4 μ l of t-RNA (0.8mg/ml). Sterile glass beads were added to the biopsy specimens to facilitate the disruption of cells during vortexing.

SG slides were abraded with a sterile disposable scalpel blade and the resulting material immersed in 320 μ l of lysis buffer. SDS in the lysis buffer dissolved the cyanoacrylate in the specimen, releasing the sample material into the buffer.

Wart, biopsy and SG specimens were incubated in the buffer at 37°C overnight to help cells and disrupt proteins. DNA was isolated from the specimens using phenol extraction, followed by a chloroform-isoamyl alcohol (24:1) extraction and ethanol precipitation for 1 hr at -70°C. The DNA pellet was collected after centrifugation for 10 min at 10,000 g, washed briefly with 70% ethanol and dried under vacuum for 30 min. The resulting pellet was then resuspended in 40 μ l ddH₂O and stored at -70°C until further analysis.

Urethral loops, cervical and buccal scrapes and Cytobrush specimens were agitated in 10 ml of PBS, of which 1.5 ml was subsequently used for analysis. Vaginal washes were tested directly. These samples were subsequently denatured by heating to 95°C for 10 min and then centrifuged at 10,000 g for 2 min to remove cellular debris and other extraneous material. The supernatant fluid was then used for the PCR.

Blood samples were centrifuged at 2000 rpm for 5 min and the serum decanted. This was used directly for the PCR.

DETECTION OF β -GLOBIN GENE

In order to determine whether human DNA

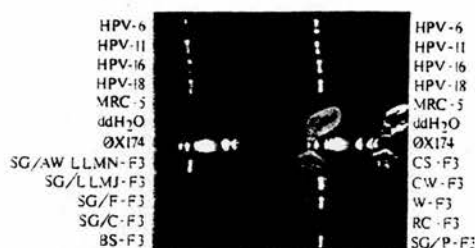


Figure 1 Ethidium bromide staining of agarose gel comprising positive controls (HPV types 6, 11, 16 and 18), negative controls (MRC-5 fibroblasts and ddH₂O), molecular weight marker ϕ X174 (ϕ X174 DNA cut with Hae III enzyme) and specimens of DNA from patient F3. Abbreviations for the specimen descriptions are as follows: SG = Superglue specimen; AW = specimen taken from acetowhite area; LLMN = left labium minus; LLMJ = left labium majus; F = fourchette; C = clitoris; BS = buccal smear; CS = cervical scrape; CW = cervical wart; W = external wart; RC = rectal cytobrush; P = perianal area. Positive results seen for HPV controls, SG specimens from the fourchette and perianal area, as well as an acetowhite area on the left labium minus. Cervical scrape, cervical wart and vulval wart specimens also contain HPV DNA.

was detectable in the SG samples, part of the human β -globin gene was amplified. Amplification was carried out using 100 μ l of reaction mixture containing 50 mM KCl, 10 mM TRIS-HCl pH 8.3, 0.01% w/v gelatin, 200 μ M each of dATP, dCTP, dGTP, and dTTP, 3.5 mM MgCl₂, 2.5 units of *Taq* polymerase (GIBCO-BRL, Paisley, Scotland) and 0.2 μ M each of two β -globin primers¹¹ (kindly provided by the Medical Research Council AIDS Directed Programme): β -globin (14-33) ADP894-1/LA1-N: 5'ACA CAA CTG TGT TCA CTA GG 3' and β -globin (123-104) ADP 894-2/LA2-C: 5'CAA CTT CAT CCA CGT TCA CC 3'. The specimens were then subjected to 40 cycles of amplification. Each cycle included denaturation at 94°C for 30 s, primer annealing at 55°C for 30 s and chain elongation at 72°C for 60 s. Positive controls were a fibroblast line derived from embryonic lung tissue (MRC-5) and an epithelial cell line derived from cervical carcinoma tissue (HeLa-229). ddH₂O was used as a negative control.




Figure 2 Hybridisation of PCR products with HPV type 11-specific probe on nylon membrane following Southern blot. Abbreviations as for fig 1 and as follows: G = glans; RLMJ = right labium majus; S = scrotum; SH = shaft. Positive results seen for HPV type 11 control, SG specimen from the scrotum of patient M2 and SG specimen from the fourchette of patient F2.

DETECTION OF HPV DNA

In the case of SG samples, only those containing detectable human β -globin DNA were tested for HPV DNA, whereas all specimens obtained by other methods were tested. The DNA extracted was amplified by 40 cycles of the PCR using general primers GP5 and GP6 which amplifies DNA from HPV types 6, 11, 16, 18, 31 and 33.¹² Amplification was carried out using 100 μ l of reaction mixture containing 50 mM KCl, 10 mM Tris HCl pH 8.3, 3 mM MgCl₂, 0.01% w/v gelatin, 200 μ moles each of dGTP, dATP, dTTP and dCTP, 10 μ moles each of GP5 and GP6¹² primers and 2.5 units of *Taq* polymerase (GIBCO-BRL, Paisley, Scotland). This mixture was overlaid with 100 μ l of mineral oil to prevent water loss and subjected to 40 cycles of amplification using a PCR processor (Hybaid, Teddington, UK). Each cycle included denaturation at 94°C for 20 s, annealing at 40°C for 60 s and chain elongation at 72°C for 20 s. Samples containing 100 pg of the full length genome of HPV types 6, 11, 16 and 18 were used as positive controls. Negative controls were a fibroblast line (MRC-5) and ddH₂O (fig 1). Detection of the products of the PCR was by agarose gel electrophoresis, confirmed by Southern blotting¹³ and hybridisation with radiolabelled oligonucleotide probes.¹⁴ Positive controls were full length genomic probes for HPV types 6, 11, 16 and 18. Negative controls were MRC-5, ddH₂O and "Superglue". Examples of this can be seen in figs 2 and 3.

Results

CHARACTERISTICS OF PATIENTS.

Nine women and nine men took part in the study. All patients were heterosexual. The mean age of the women was 24.0 years (range 16.1 to 36.2) and that of the men 28.4 years (range 22.9 to 36.3). Clinical details of the patients are shown in tables 1 and 2; there were four pairs of partners (F1-M3, F2-M8,

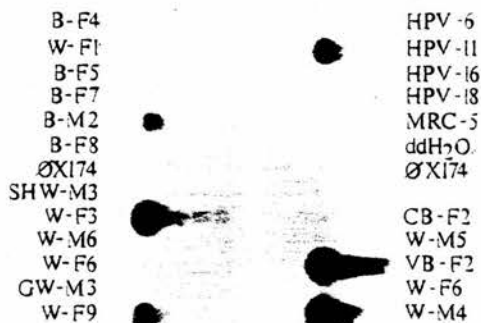


Figure 3 Hybridisation of PCR products with HPV type 11-specific probe on nylon membrane following Southern blot. Abbreviations as for fig 1 and as follows: B = biopsy, SHW = shaft wart; GW = glans wart; CB = cervical biopsy; VB = vulval biopsy. In women, biopsies were either from acetowhite areas or from clinically apparent warts. In men biopsies were always taken from clinically apparent warts. Positive results seen for HPV type 11 control, biopsies from patients M2 and F2, and warts from F9 and M4.

Table 1 Clinical, histological and cytological details of female patients

Pt	Sites of visible warts	Sites of acetowhite change	Status of partner	Cervical biopsy: histological changes
F1	none	cervix	warts (M3)§	NAD
F2	fourchette	cervix	warts (M8)§	ns
F3	fourchette, cervix	labia	warts (M2)§	CIN 1, WVI
F4	fourchette, cervix	cervix, labia	warts	NAD
F5	fourchette, cervix	labia, cervix	no warts	koil
F6	none	cervix	no warts	NCI
F7	none	labia	no warts (M9)§	ns
F8	none	labia	ns	ns
F9	fourchette, labia	labia	no warts	ns

Abbreviations used in tables:

Pt = patient code.

§ = partner in the study as indicated.

ns = no specimen obtained.

NAD = no histological or cytological abnormality detected.

wart = histological changes of condylomatous wart virus infection.

CIN 1 = cervical intraepithelial neoplasia grade 1.

NCI = histological changes of non-condylomatous HPV infection.

koil = koilocytic atypia.

Time = duration in months since first sample taken.

neg = HPV types 6, 11, 16, 18, 31 and 33 not detected.

* = biopsy from clinically apparent wart.

+ = specimen contained HPV of types other than those tested for; β = β -globin gene not detected.

- = HPV of indicated type not detected.

Table 2 Clinical and histological details of male patients

Pt	Sites of visible warts	Sites of acetowhite change	Status of partner
M1	shaft	none	cervical dysplasia
M2	shaft, inguinal	glans	warts (F3)§
M3	shaft	glans	no warts (F1)§
M4	meatus, glans	glans	no warts
M5	shaft, inguinal	none	no warts
M6	corona	corona	warts
M7	shaft, glans	glans	warts
M8	shaft	glans	warts (F2)§
M9	glans	glans	no warts (F7)§

F3-M2 and F7-M9), the partners of the other patients not being available for study. Patient F6 was referred by her general practitioner because of a suspicion of genital warts seen at the time of taking a cervical scrape. There was no evidence of anogenital warts at the time of assessment in the clinic, but a papillary lesion noted in the vagina was biopsied and found to be a skin tag. Four women (F1, F2, F5 and F7) and two men (M1 and M2) did not have skin biopsies. Apart from these, all other biopsies taken from clinically apparent warts were confirmed histologically as such. Biopsy of acetowhite changes on the labia of patient F8 showed changes of HPV infection.

OCCURRENCE OF HPV DNA IN BIOPSY, NON-BIOPSY AND SG SPECIMENS

Biopsy specimens

HPV DNA was detected in five (83%) of six biopsy specimens, with histological evidence of HPV infection, from women (tables 1 and 3) and in six (67%) of nine from men (table 4). None of four biopsies of acetowhite areas in the women contained HPV DNA, nor did the biopsy of the skin tag (table 3). Two (29%) of seven cervical biopsies contained HPV DNA, of which one was histologically abnormal (tables 1 and 3).

Non-biopsy specimens

In women (table 3), HPV DNA was detected in the following specimens: four (36%) of 11 cervical scrapes, two (25%) of eight from the urethra, three (37%) of eight from the vagina, two (33%) of six from the rectum and none of five buccal scrapes (patients F1, F2, F3, F4 and F7). Patients F4 and F5 had borderline cervical cytological changes. Both these cervical samples contained HPV DNA (table 3).

In men (table 4), HPV DNA was detected in the following specimens: three (37%) of 8 from the urethra, 1 (12%) of 8 from the rectum and none of five buccal scrapes (patients M1, M2, M3, M6 and M9).

Serum samples from all nine men and six of the nine women did not contain HPV DNA.

SG specimens

Forty SG samples were taken from women (table 5) and 41 from men (table 4). Thirty-seven (92%) of those from women and 18 (44%) of those from men contained the β -globin gene. Of the samples containing the β -globin gene, 18 (49%) from women and nine (50%) from men contained HPV DNA, detection rates which compare favourably with those of non-biopsy procedures.

Of SG samples from acetowhite areas, HPV DNA was detected in those from the labia of four of five women (tables 1 and 5) and in those from the glans of two of four men (tables 2 and 4).

Of the six men with shaft warts (table 2), HPV DNA was detected in the shaft SG specimens of four of the five men whose shaft

Table 3 HPV DNA in biopsy and non-biopsy specimens from women in relation to types of specimens and times at which taken

Pt	Time	HPV DNA in sites and types of specimen indicated					
		Vulval biopsy	Cervical biopsy	Cervical scrape	Urethral loop	Vaginal wash	Rectal stool
F1	0	neg	6	ns	neg	neg	neg
	4	neg	neg	neg	neg	neg	ns
	12	ns	ns	neg	ns	neg	ns
F2	0	6, 11, 31*	ns	ns	ns	ns	ns
	4	ns	neg	neg	ns	18, 31	6, 11
	0	6, 11*	ns	6, 11, 33	6, 11, 33	ns	ns
F3	2	6, 11*	6, 11*	neg	ns	ns	ns
	0	6*	neg*	6	6	+	6
	0	neg*	neg*	6	neg	ns	ns
F4	0	neg	ns	neg	neg	neg	neg
F7	0	neg	ns	+	neg	16	ns
F8	0	neg	neg	neg	ns	ns	neg
F9	0	6, 11*	neg	neg	neg	neg	neg

Table 4 HPV DNA in biopsy, non-biopsy and SG specimens from men in relation to types of specimens and times at which taken

Pt	Time	HPV DNA in sites and types of specimen indicated						
		Biopsy	Urethral loop	Rectal swab	SG specimens from			
					Glans	Shaft	Scrotum	Anus
M1	0	ns	ns	ns	β	β	ns	neg
	7	ns	ns	ns	β	18	neg	β
M2	0	ns	ns	neg	β	β	6, 11, 18	β
	4	6, 11	6	neg	neg	ns	ns	ns
M3	0	neg	ns	ns	neg	18	ns	ns
	4	ns	neg	neg	neg	neg	β	ns
M4	0	6, 11	6, 11, 16	6, 11	6, 11	-	ns	β
	3	ns	ns	ns	neg	β	β	β
M5	0	6	neg	neg	18	6	ns	ns
M6	0	6	neg	neg	6, 31	β	ns	ns
M7	0	ns	ns	ns	β	β	ns	ns
	1	6, 33	6	neg	ns	ns	ns	ns
	2	6, 11	ns	ns	ns	ns	ns	ns
	3	ns	ns	ns	β	neg	β	β
M8	0	neg	neg	neg	β	18	ns	neg
M9	0	6	neg	ns	β	β	β	β

SG wart specimens contained the β-globin gene (table 4). Similarly, HPV DNA was detected in the fourchette SG samples from all 3 women with fourchette warts who had this sample taken (tables 1 and 5).

HPV DNA AND TYPES IN RELATION TO SAMPLE SITE AND TIME OF SAMPLING

Site and time of sampling

Of the 12 possible sites in women (tables 3 and 5) from which samples could have been taken on each occasion, 0-8 (mean 2.8) contained HPV DNA. Of the eight possible sites in men (table 4) from which samples could have been taken on each occasion, 1-5 (mean 1.25) contained HPV DNA.

Of the 3 patients from whom samples were taken on more than one occasion (tables 3-5), five had HPV DNA detected in fewer sites and two in more sites than when first seen. In one patient, the number of sites in

which HPV DNA was detected initially increased, but then decreased.

Types of HPV detected

Of the 56 samples in which HPV DNA was detected, 23 (41%) had evidence of infection with a single type, 27 (48%) with multiple types and six (11%) with undetermined types (tables 2-5).

The distribution of HPV types in the various categories of specimens from women and men is shown in table 6. HPV types 6 and 11 were found most frequently in the majority of specimen categories. However, the other types sought were found predominantly in the non-biopsy and SG specimen categories.

Samples taken from different sites of the same patient frequently contained the same HPV type. This is illustrated by samples from patients F4 and M4, the majority of which contained HPV type 6. However, in patients

Table 5 HPV DNA findings in SG specimens from women in relation to types of specimens and times at which taken

Pt	Time	HPV DNA in SG specimens from				
		Left labia	Right labia	Fourchette	Clitoris	Anus
F1	0	neg	neg	ns	ns	neg
	4	-	18	ns	ns	-
	12	neg	neg	neg	ns	neg
F2	0	6, 11, 33	33	6, 11, 33	ns	18, 33
	4	6	neg	neg	β	ns
F3	0	6, 11, 18, 33	ns	ns	ns	6, 11
	2	neg	neg	+	neg	ns
F4	0	6, 11	6, 16, 18	ns	ns	6, 11, 18
F5	0	6	neg	6	ns	ns
F6	0	ns	β	neg	neg	ns
F7	0	neg	neg	neg	ns	neg
F8	0	ns	ns	ns	ns	ns
F9	0	6, 11	β	11	ns	ns

Table 6 HPV type in relation to types of specimens

HPV type	Number of times (%) HPV of specified type in given sample type						
	Women				Men		
	External wart	Cervical biopsy	Non-biopsy	SG	Wart	Non-biopsy	SG
6	5 (50)	2 (67)	7 (41)	11 (34)	7 (64)	4 (57)	4 (31)
11	4 (40)	1 (33)	3 (17)	3 (24)	3 (27)	2 (29)	2 (15.5)
16	-	-	1 (6)	1 (3)	-	1 (14)	-
18	-	-	1 (6)	5 (15)	-	-	5 (38.5)
31	1 (10)	-	1 (6)	-	-	-	1 (7.5)
33	-	-	2 (12)	5 (15)	1 (9)	-	-
+	-	-	2 (12)	3 (9)	-	-	1 (7.5)
Total	10 (100)	3 (100)	11 (100)	33 (100)	11 (100)	7 (100)	13 (100)

in whom multiple HPV types were detected, not all the types were found in each specimen.

HPV in pairs of partners

Partner pairs F1-M3, F2-M8 and F3-M2 had HPV types in common. Partner pair F7-M9 did not (tables 3-5).

Discussion

The PCR allows the detection of very small quantities of DNA,⁷ so that strenuous efforts must be taken to avoid contamination of specimens. The combination of strict clinical and laboratory protocols, repeated use of positive and negative controls throughout the experiments, together with the use of Southern blotting and hybridisation to confirm results give us confidence in their validity.

HPVs have been detected in biopsy specimens from genital warts,¹⁵ acetowhite areas¹⁶ and normal genital skin.¹⁷ They have also been found in cervical scrapes from women with warts,¹⁸ urethral samples,^{19,20} vaginal samples,^{21,22} rectal swabs,²³ buccal scrapes²⁴ and serum samples.²⁵ All these specimens, as well as SG samples, were included in our study in order to investigate the multifocal nature of anogenital HPV infections. The SG technique has been used to assess changes in the stratum corneum.²⁶ In our study, this technique was chosen as it allowed the sampling of the skin surface with minimal trauma. Not only is this process more acceptable to patients than formal biopsy, but it also allows the monitoring of HPV-induced changes without inducing the marked inflammatory response associated with biopsy. Such a response may alter the natural history of HPV infection²⁷ and thus assessment of the natural history should involve a sampling process which minimises this induced response. Although the number of cells harvested by the SG technique is small, the use of the PCR for the detection of the human β -globin gene allowed us to confirm that human cells were present and thus observe as closely as possible the natural history of HPV infection.

The detection of HPV DNA in 11 (65%) of 17 biopsies with histological evidence of HPV infection is consistent with the findings of some,¹⁵ although the proportion is smaller than that found by others.¹⁷ Infection with HPV types other than those sought by us is a possible explanation for this small proportion and is supported by the large numbers of specimens noted to contain untyped HPVs.

The detection of HPV DNA in 12-36% of non-biopsy specimens suggests that they are valuable to obtain. Cervical scrapes have been investigated frequently for the presence of HPV DNA but, until recently, few other specimen types had been assessed. In fact, our data suggest that other non-biopsy specimen types are just as likely to contain HPV DNA as cervical scrapes.

The proportion of SG samples containing the β -globin gene was much larger in women

than in men. However, the proportion of β -globin-containing SG samples containing HPV DNA did not differ between men and women. It is possible that this observation may be related to the fact that the skin of the male external genitalia is more cornified than the female counterpart. The surface layers of cornified skin predominantly contain anucleate squames which do not contain the β -globin gene. The ability to harvest infected cells by the SG method was confirmed by the observation that the majority of SG samples taken from areas with clinically apparent warts contained HPV DNA.

The presence of HPV DNA in β -globin containing SG samples from areas which did not develop acetowhite staining is consistent with the finding of HPV DNA in histologically normal skin.¹⁷ Furthermore, it suggests that staining with acetic acid may have limited value in evaluating the extent of infection with HPV and in assessing response to treatment. It is possible that areas without acetowhite changes but with detectable HPV DNA may represent passive contamination of the skin with HPV from another site of the patient, or from a sexual partner; or they may represent infection of the epithelium with HPV which has not produced sufficient cellular changes to generate visible changes following the application of acetic acid. The failure to detect HPV DNA in four biopsies and in three of nine SG samples from acetowhite areas is consistent with the knowledge²⁸ that not all acetowhite areas develop as a result of infection with HPV. Furthermore, the finding of HPV DNA in only four of six β -globin-containing SG samples from men with acetowhite areas of the glans is in agreement with the suggestion²⁹ that acetowhite changes of the glans may develop as a result of sub-clinical balanitis not related to infection with HPV.

The frequent occurrence of multiple HPV infections has been disputed,³⁰ but our data concerning the co-existence of multiple HPV types are consistent with those of others.³¹ For a given patient, specific HPV types were frequently found in common in biopsy, non-biopsy and SG specimens, as were multiple HPV types. The failure to show cross-hybridisation during the repeated experiments in which there were positive and negative controls indicates that the observations regarding multiple HPV types are not spurious.

The persistence of HPV at various sample sites after treatment supports the findings of others³² that treatment of clinical and histological abnormalities may not necessarily eradicate infection. It is likely that persistent infection explains, at least in part, the high recurrence rate of warts regardless of the method of treatment.³³ However, the occurrence of common HPV types in sexual partners noted in the current study and previously,¹⁵ suggests that there may be an opportunity for reinfection also to play a role in the persistence of disease.

Multifocal infection of the anogenital area

is recognised to occur in infection with *Neisseria gonorrhoeae*, *Chlamydia trachomatis*¹⁴ and, most recently, human papillomavirus.¹⁹ Furthermore, neoplasia of the female anogenital tract, a condition thought to be related to HPV infection,⁷ is frequently multifocal.¹⁵ Our data suggest that, if a sample had been taken from only one site, and at only one time, the occurrence of HPV infection, including infection with multiple HPV types, would have been underestimated. To determine the true extent of anogenital HPV infection, multiple samples need to be taken, possibly over several months. Studies in which single sites are sampled may lead to a serious underestimate of the rate of infection with HPV.

Samples from clinically uninfected areas contained a larger proportion of the "high risk" HPV types, namely types 16 and 18, than the "low risk" HPV types, 6 and 11, found predominantly in warts. This difference was particularly marked in the samples obtained by the SG technique. The preponderance of "high risk" HPV types in specimens other than those taken from clinically apparent warts has been noted previously, for example in specimens obtained from acetowhite areas,¹⁶ cervical scrapes¹⁸ and urethral swab specimens.^{19,27} Our understanding of the epidemiology of anogenital HPV infection, in particular the development of neoplasia, must take into account the detection of HPV in specimens from areas without clinically apparent disease. The problem has arisen because of the use of the highly sensitive PCR which is capable of detecting a few virus particles. Other factors, including quantity of virus present and host immunity,²⁷ may be at least as important as the mere presence of a few viral particles in the development of any clinical abnormalities. However, only by obtaining a clear understanding of the epidemiology of anogenital HPV infections will it be possible to develop rational approaches to their management.

- Oriel JD. Natural history of genital warts. *Br J Venereal Dis* 1971;47:1-13.
- Barrett TJ, Silbar JD, McGinley JP. Genital warts—a venereal disease. *JAMA* 1955;154:333-4.
- Koutsky L. Role of epidemiology in defining events that influence transmission and natural history of anogenital papillomavirus infections. *J Nat Cancer Inst* 1991;83:978-9.
- Toon PG, Arrand JR, Wilson LP, Sharp DS. Human papillomavirus infection of the uterine cervix of women without cytological signs of neoplasia. *BMJ* 1986;293:1261-4.
- Fuchs PG, Girardi F, Pfister H. Human papillomavirus DNA in normal, metaplastic, preneoplastic and neoplastic epithelia of the cervix uteri. *Int J Cancer* 1988;41:41-5.
- Muñoz N, Bosch X, Kaldor JM. Does human papillomavirus cause cervical cancer? The state of the epidemiological evidence. *Br J Cancer* 1988;57:1-5.
- Syrjänen KJ. Epidemiology of human papillomavirus (HPV) infections and their associations with genital squamous cell cancer. *APMIS* 1989;97:957-70.
- De Villiers E-M. Laboratory techniques in the investigation of human papillomavirus infection. *Gonorrhoea Med* 1992;68:50-4.
- Southern EM. Detection of specific sequences among DNA fragments separated by gel electrophoresis. *J Mol Biol* 1975;98:503-17.
- Hillman RJ, Walker MM, Harris RW, Taylor-Robinson D. Penile dermatoses: a clinical and histopathological study. *Gonorrhoea Med* 1992;68:166-9.
- Cann AJ, Zack JA, Go AS, et al. Human immunodeficiency virus type 1 T-cell tropism is determined by events prior to provirus formation. *J Virol* 1990;64:4735-42.
- Snijders PJF, van den Brul AJC, Schrijnemakers HFJ, Snow G, Meier CJLM, Walboomers JMM. The use of general primers in the polymerase chain reaction permits the detection of a broad spectrum of human papillomavirus genotypes. *J Gen Virol* 1990;71:173-81.
- Hillman RJ, Botcherby M, Ryait BK, Taylor-Robinson D. Detection of human papillomavirus DNA in the urogenital tracts of men with anogenital warts. *Sex Transm Dis* 1993;20:21-7.
- Hillman RJ, Ryait BK, Botcherby M, Taylor-Robinson D. Human papillomavirus DNA in the urogenital tracts of men with gonorrhoea, penile warts or genital dermatoses. *Gonorrhoea Med* 1993;69:187-92.
- Wickenden C, Hanna N, Taylor-Robinson D, et al. Sexual transmission of human papillomaviruses in heterosexual and male homosexual couples, studied by DNA hybridisation. *Gonorrhoea Med* 1988;64:34-8.
- Campion MJ, McCance DJ, Mitchell HS, Jenkins D, Singer A, Oriel JD. Subclinical penile human papillomavirus infection and dysplasia in consorts of women with cervical neoplasia. *Gonorrhoea Med* 1988;64:90-3.
- Katelians PM, Cossart YE, Rose BR, et al. Human papillomavirus: the untreated male reservoir. *J Urol* 1988;140:300-5.
- Kiviat NB, Koutsky LA, Paavonen JA, et al. Prevalence of genital human papillomavirus infection among women attending a college student health clinic or a sexually transmitted disease clinic. *J Infect Dis* 1989;159:293-302.
- Rymark P, Forslund O, Hansson BG, Lindholm K. Genital HPV infection not a local but a regional infection: experience from a female teenage group. *Gonorrhoea Med* 1993;69:18-22.
- Roseberg SK, Greenberg MD, Reid R. Sexually transmitted papillomaviral infection in men. *Obstet Gynecol Clin North Am* 1987;14:495-512.
- Morris BJ, Flanagan JL, McKinnon KJ, Nightingale BN. Papillomavirus screening of cervical lavages by polymerase chain reaction. *Lancet* 1988;ii:1368.
- Fairley CK, Chen S, Tabrizi SN, Quinn MA, McNeil JJ, Gardard SM. Tampons: a novel patient-administered method for the assessment of genital human papillomavirus infection. *J Infect Dis* 1992;165:1103-6.
- Law CLH, Qasim M, Thompson CH, et al. Factors associated with clinical and sub-clinical anal human papillomavirus infection in homosexual men. *Gonorrhoea Med* 1991;67:92-8.
- Jenson SA, Yu X-P, Valentine JM, et al. Evidence of prevalent genital-type human papillomavirus infections in adults and children. *J Infect Dis* 1990;162:60-9.
- Pao CC, Lin S-S, Lin C-Y, Maa J-S, Lai C-H, Hsieh T-T. Identification of human papillomavirus DNA sequences in peripheral blood mononuclear cells. *Am J Clin Pathol* 1991;95:540-6.
- Marks R, Dawber RPR. Skin surface biopsy: an improved technique for the examination of the horny layer. *Br J Dermatol* 1971;84:117-23.
- Kirchner H. Immunobiology of human papillomavirus infection. *Prog Med Virol* 1986;33:1-41.
- Hippeläinen M, Yliskoski M, Saarikoski S, Syrjänen S, Syrjänen K. Genital human papillomavirus lesions of the male sexual partners: the diagnostic accuracy of peniscopy. *Gonorrhoea Med* 1991;67:291-6.
- Griffiths M, Penna LK, Tovey SJ. Aceto-white change of the glans penis associated with balanitis not human papillomavirus infection. *Internat J STD & AIDS* 1991;2:212-3.
- Beckmann AM, Sherman KJ, Mverson D, Daling JR, McDougall JK, Galloway DA. Comparative virologic studies of condylomata acuminata reveal a lack of dual infections with human papillomaviruses. *J Infect Dis* 1991;163:393-6.
- Wikstrom A, Lidbrink P, Johansson B, von Krogh G. Penile human papillomavirus carriage among men attending Swedish STD clinics. *Internat J STD & AIDS* 1992;2:105-9.
- Steinberg BM, Topp WC, Schneider PS, Abramson AL. Laryngeal papillomavirus infection during clinical remission. *N Engl J Med* 1983;308:1261-4.
- Ferenczy A, Mitao M, Nagai N, Silverstein SJ, Crum CP. Latent papillomavirus and recurrent genital warts. *N Engl J Med* 1985;26:784-8.
- Chernesky M, Sellors J, Mahony J, Jang D, Pickard L, Krepel J. Diagnosis of *C. trachomatis* infections in women by examining cervical and urethral swabs and urine with culture and enzyme immunoassay. In: Bowie W, Caldwell H, Jones R, et al eds. *Chlamydial infections*. Proceedings of the Seventh International Symposium on Human Chlamydial Infection. Cambridge: Cambridge University Press, 1990:483-6.
- Campion MJ, Clarkson P, McCance DJ. Squamous neoplasia of the cervix in relation to other genital tract neoplasia. *Clin Obstet Gynecol* 1985;12:265-80.
- Barrasso R, De Bruix J, Croissant O, Orth G. High prevalence of papillomavirus-associated penile intraepithelial neoplasia in sexual partners of women with cervical intraepithelial neoplasia. *N Engl J Med* 1987;317:916-23.
- Roseberg SK. Sexually transmitted papillomaviral infection in men: an update. *Dermatol Clin* 1991;9:317-31.

ASYMPTOMATIC URETHRAL CARRIAGE OF HPV DNA IN MEN WITH ANO-GENITAL WARTS

Hillman RJ, *Hanna N, Botcherby, M, Ryait BK, *Harris JRW, Taylor-Robinson D. From the Division of Sexually Transmitted Diseases, MRC Clinical Research Centre, Watford Road, Harrow, England and the *Department of Genitourinary Medicine, St Mary's Hospital, London, England.

One hundred patients attending a Genitourinary clinic for ablative therapy for persistent anogenital warts provided a urethral specimen taken to 4cm with a cotton wool swab. At the same time, biopsy specimens were taken from the clinically apparent warts.

All samples were tested for HPV types 6,11,16 and 18 by Southern blotting, and for types 6,11,16,18, 31 and 33 by the PCR. PCR results were confirmed and the types assessed by DNA hybridisation.

Of 64 patients so far analysed on the basis of Southern blotting, 3 (5%) had HPV DNA in their urethral swabs, and 52 (82.5%) had HPV DNA in their wart biopsy specimens. Of the specimens from 90 patients analysed by the PCR, 37 (41%) urethral swabs and 87 (97%) biopsies contained HPV DNA.

The higher rate of detection of HPV DNA by the PCR is consistent with the greater sensitivity of this method compared to Southern blotting. Our results confirm the suggestion that HPV is carried asymptotically in the urethras of men with anogenital warts. This may have implications for the infectivity of warts, and recurrence following apparently full ablative treatment.

Multifocal anogenital HPV infection in patients with and without anogenital warts

RJ Hillman, BK Ryait, M Botcherby, D Taylor-Robinson

MRC Clinical Research Centre, Harrow, Middlesex

Objectives - To investigate the relationship between clinical findings and the detection of Human Papilloma Virus (HPV) DNA in a range of anatomical sites in 9 women and 9 men with and without anogenital warts.

Methods - Following examination of the anogenital areas, specimens were taken from a variety of anatomical sites. Superficial skin sampling was performed by the application of slides covered with "Superglue" (SG). The presence of human cells in the SG samples was confirmed by detection of the β -globin gene using the polymerase chain reaction (PCR). HPV DNA was extracted from the specimens, amplified by using consensus primers with the PCR and identified by Southern blotting, followed by hybridisation.

Results - In women, HPV DNA was detected in 83% of wart biopsies, 29% of cervical biopsies, 36% of cervical scrapes, 25% of urethral loop specimens, 37% of vaginal washes and 33% of rectal swab specimens. In men, HPV DNA was detected in 67% of wart biopsies, 37% of urethral loop specimens and 12% of rectal swab specimens. No HPV DNA was detected in buccal scrapes and serum samples from women or men. Of the SG samples containing the β -globin gene, 49% from women and 50% from men contained HPV DNA. Of all specimens with detectable HPV DNA, there was evidence of a single HPV type in 41%, multiple types in 48% and undetermined types in 11%. Samples taken from different sites from one patient tended to have HPV types in common.

Conclusions - HPV DNA was distributed widely in the anogenital area, in warts, acetowhite areas and clinically normal skin. The SG technique was well tolerated by patients and produced results consistent with other findings. Sampling from a single site of the genitalia may significantly underestimate the infection rate with HPV.