

/

AORTITIS WITH SPECIAL REFERENCE TO  
SYPHILITIC AORTITIS

---

On being demobilized from the Army I came into contact with a great many discharged soldiers both in Hospital and at the Medical Pensions Boards.

While working at the Ulster Volunteer Force Hospital for discharged soldiers, I found that a considerable number of the cases were cardiac ones.

I was greatly struck by the comparative frequency with which Aortic cases occurred. At the beginning most of these were men over 40 who gave a negative history as regards Rheumatic fever and also very often as regards Syphilis. The latter history could not always be credited as in the majority of cases a positive Wasserman was obtained. Last year I sent a paper on the subject to the "Lancet". At that time I had only a few cases on record but since then the number of cases has greatly increased and in this Thesis, I intend to go into the question from a clinical and pathological standpoint. In the latter, I have been somewhat handicapped owing to the difficulty of obtaining post mortem examinations. My specimens were typical macroscopically and microscopically but I was unable to find the Spirochaetes even after a prolonged search. My failure in this was probably due to my not being able to get the specimens soon

enough. In Warthim's work on the subject, he shows that the specimen must be examined within two or three hours after death. This is impossible in the North of Ireland where people have a very deeply rooted objection to post mortem examinations being held on their relatives.

I will first go into the questions of aetiology, age incidence, physical signs etc., and finish with the pathology of syphilitic aortitis.

In my series of 37 cases, I so often found it difficult to differentiate between anaortitis with an aneurism and one without that, I also intend to dwell briefly upon the question of aneurisms.

NAME	AGE	INFECTION	WASSERMAN	YEARS ILL	FIRST SYMPTOMS.
(1) Pens. J.K.	23	Denies Syphilis & Rheumatic Fever.	—	6 Months	Pains in Arms & legs, pain upper part of Chest.
(2) " J.P.	25	No Syphilitic History. Sub-acute endocarditis.	—	8 Months	Pain & tenderness Aortic area Dyspnoea.
(3) " J.B.	28	Syphilis 7 Years ago.	++	1 Year.	Tachycardia. Palpitation & Dyspnoea.
(4) " A.C.	30	Syphilis 7 years ago.	++	6 Weeks.	Dyspnoea. Substernal pain & palpitation.
(5) " T.M.	30	Denies Syphilis. Rheumatic Fever 5 Years ago.	—	3 Years.	Dyspnoea & fatigue.
(6) " J.B.	32	Denies Syphilis & Rheumatic Fever.	+ —	3 1/2 Years.	Dyspnoea.
(7) " W.J.B.	33	Rheumatic Fever Jan. 1916. Syphilis June 1917.	++	3 Years.	Dyspnoea & Substernal pain.

NAME	AGE	INFECTION	WASSERMAN	YEARS ILL	FIRST SYMPTOMS
(8) Pens T.P.	33	Denies Syphilis.	++	1 1/2 Years	pain over chest radiating to left nipple and general weakness.
(9) " J.R.	36	Denies Syphilis	++	1 Year	Dyspnoea &. General weakness. Pain lower praecardial region.
(10) " V.H.B	38	Denies Syphilis	++	3 Years	Pain &. Dyspnoea which he states started after dyspnoea.
(11) B.McC	39	Denies Syphilis	++	1 Year	Dull pain region of left nipple.
(12) " H.R.	40	Denies Syphilis. States was lucky.	++	3 Years	Pain between Shoulders.
(13) " J.T.	40	Syphilis 20 years ago.	++	4 1/2 Years.	Dyspnoea &. fatigue.
(14) " J.McG	40	Syphilis 12 years ago.	++	?	No Symptoms.

NAME	AGE	INFECTION	WASSERMAN	YEARS ILL	FIRST SYMPTOMS
(15) Pens J.B.	41	Denies Syphilis	++	2 1/2 Years	palpitation & Dyspnoea on exertion.
(16) " W.J.	41	Denies Syphilis	++	5 1/2 Years	pain in Back and across Lt. Chest.
(17) " E.G.	41	Syphilis 16 years ago.	++	1 1/2 Years	Sense of Sub-sternal Constriction. Dyspnoea.
(18) " J McD.	42	Syphilis 22 years ago.	++	2 1/2 Years	Giddiness, dyspnoea, on exertion and pain under upper part of Sternum.
(19) " D.H.T.	43	Syphilis 24 years ago.	++	1 1/2 years.	Dyspnoea and fatigue.
(20) " J.M.M.	45	Syphilis 20 years ago.	—	3 months.	pain Rt. side of Sternum and dyspnoea.
(21) " S.McC.	45	Denies Syphilis	—	3 months	Substernal pain & Dyspnoea.

NAME	AGE	INFECTION	WASSERMAN	YEARS ILL	FIRST SYMPTOMS.
(22) Pens. H. B.	45	Syphilis 26 Years ago.	—	2 Years	Dyspnoea at night. Vertigo Substernal pain.
(23) " J. I.	45	Denies Syphilis	++		No Symptoms.
(24) " H. B.	46	Syphilis 22 years ago.	++	3 Years	Substernal pain.
(25) " J. C.	46	Syphilis 23 years ago.	++	4 Years	Attacks like Malaria every few months.
(26) " R. B.	46	Gonorrhoea 24 years ago but denies Syphilis.	++	3 Years.	Dyspnoea.
(27) " J. N.	49	Syphilis 20 Years ago.	++	1 Year.	Dyspnoea. Gen-eral weakness & Substernal pain.
(28) " J. C.	52	Syphilis 28 Years ago.	++	6 Months.	Pain in left side below nipple.
(29) " J. G.	52	Denies Syphilis.	—	3 Years	Pain near Nipple & Gen-eral weakness.

NAME	AGE	INFECTION	WASSERMAN	YEARS ILL	FIRST SYMPTOMS
(30) Pens. S.R.	53	Denies Syphilis	+	6 Months	Pain Rt. Shoulder and Heart and down Rt. Arm.
(31) " R.McK.	53	Syphilis 29 Years ago.	+	2 Years	Pain near Lt. Nipple & Palpitation.
(32) " P.McN.	55	Syphilis 30 Years ago.	+	2 years.	Dyspnoea, cough. Pain in Back.
(33) " W.McC.	55	Syphilis 25 Years ago.	+	3 1/2 Years	Easily tired & Dyspnoea.
(34) " J.T.	55	Syphilis 30 Years ago.	+	3 Years	Dyspnoea & Substernal pain.
(35) " R.B.	58	Denies Syphilis	+	4 Years	Substernal pain.
(36) " W.A.	60	Syphilis 35 Years ago.	+	6 Years	Pain and discomfort upper sternal region
(37) " H.P.M.	60	Syphilis 27 Years ago.	-	1 Year	Dyspnoea & Soreness under Sternum.

## AETIOLOGY

Any infection may cause Aortitis, 'but some much more frequently than others'. The two most important infections, however, are Rheumatic fever and syphilis, the latter being probably much the most common causal factor. Among the cases described in the literature of the Subject are the following:-

Small pox, measles, Scarlet fever, pneumonia, Influenza, Typhoid, Malaria and Gonorrhoea.

Tubercular Aortitis has also been described by Mallory (36). Before coming to my own Series of cases I should like to give the following extracts from recent papers, bearing on the Aetiology of this condition.

McCrea (31) in a series of sixty cases of dilatation of the Aorta at the ~~John's~~ Hospital.

John's Hopkin's Hospital found that about one-third of the cases gave a history of Rheumatic fever, and of the cases under 40 years about one half had suffered from Rheumatic fever.

Syphilis - 17 cases. 3 Doubtful.

Rheumatic fever-13 cases. 6 doubtful.

Typhoid - 8 cases.

Uncertain - 8 cases.

Severe strain, Trauma, old age, alcohol and

muscular exertion were possible causes in some of these cases or at least helped.

According to Clifford Allbutt, however, strain and stress are not causes of Aortitis but are of Arterio-Sclerosis.

Jordan (19) describes a case of an Aneurism of the ascending Aorta in a small boy age 6 $\frac{1}{2}$  years who had had Otitis Media since infancy. He gave a history of headaches, vomiting and fever. His joints were swollen, but there were no physical signs of Aortitis or aneurism, the diagnosis being made on post mortem. Anders (5) found in 219 cases of Aortic incompetence that 133 cases or 60.7 % were clearly due to Syphilis. And even then the Syphilitic Aetiology is underestimated as many of the cases had not had a Wasserman done. He considers that in the absence of a history of Rheumatic fever, a case should be regarded as suspect of Syphilis even if the Wasserman is negative.

Mitchell Bruce (12) found in 100 cases of arterial damage that 92 were in men and 8 in women. In these 100 cases, syphilis caused 26% while 50% had influenza, typhoid, acute pneumonia or some other acute condition associated with it.

Klotz (21) showed that there were two forms of Rheumatic Arteritis, one of them being very similar to that of Syphilis except that it tended to recover spontaneously.

Josué and Solomons (20) described a case where lesions were found in the Aorta in a case of Rheumatic fever.

Benjamin and Havie (7) in a series of 33 cases of Aortic Insufficiency found that only 11% gave a positive Wasserman, while there was a history of Rheumatic fever in 57% of the cases.

Bock J. (9) found 385 cases of syphilitic Aortitis in 9690 autopsies at the Virchow Hospital, Berlin, between 1912 and 1917.

Brooks (10) in 50 cases of post mortems' on Syphilitics found that 66% died as a result of or with serious circulatory disease apparently of syphilitic origin. The pericardium was involved in 28 cases and the myocardium in 44 cases.

In my series of 37 cases syphilis was found to be the causal factor in 31 cases. Of these thirty-one 28 gave a positive Wasserman and in the remaining 3 a definite history of Syphilis was elicited - in one 20 years previously and the others 26 and 27 years. Of the remaining 6, one was found in a case of sub-acute endocarditis, while two others gave a definite

history of rheumatic fever. One had lived in the tropics for a long time and had a high blood pressure - 220 systolic. The remaining two cases gave no definite history of any previous illness.

AGE

The age incidence varies with the cause. As a general rule those due to syphilis are met with in people over 40 while those due to Rheumatic fever or other acute infections in those under 40. From the following sets of statistics, it is seen that the different forms of Aortitis may be met with at almost any age.

Thus McCrea (31) in his series of 60 cases of dilatation of the Aorta found the age incidence as follows:-

11-20	1 case	51-60	15 cases.
21-30	1 case	61-70	8 cases
31-40	16 cases	71-80	2 cases
41-50	16 cases		

Mitchell Bruce (12) found the average age in Syphilitic cases to be .49. In his 100 cases the average age in the 92 men was 58½ years, in the 8 women 63½.

Syphilis occurred in 26 of these cases.

Allbutt (2) states average age is between 30-50 years but may get it much younger in congenital Syphilis.

Bock (9) found in his 339 cases that 214 occurred between 40 and 60.

Lemann (25) in an Article giving statistics of age incidence of Thoracic aneurysm gives following table:-

AGE Yrs.	Lemann's Touro Series.	Lemann's Charity Autopsy series.	Bassett Hspl. Smyth.	Maximoff	Maximoff from Literature.	Bowesky from Literature.	Crisp.
1 -10	-	-	-	-	10	1	1
10 -20	-	-	-	-	9	2	5
20 -30	1	6	13	4	28	11	71
30 -40	15	17	28	4	71	43	198
40 -50	19	20	6 over	14	100	58	129
50 -60	8	9	-	14	56	46	65
60 -70	-	-	-	5	21	10	25
70 -80	-	-	-	-	5	4	8
over 80	-	1	-	-	4	-	3
unkeown	1	10					

In my Series of cases the age incidence was as follows:-

	<u>Syphilitic</u>	<u>Non Syphilitic</u>
20-29	1	2
30-39	6	2
40-49	15	1
50-59	7	1
60 over	2	-

In the Syphilitic cases there is considerable divergence in the time which elapses between the primary infection and the onset of symptoms or signs of Aortitis. In a great many cases there is probably a long period of latent infection of the Aorta during which no signs or symptoms are to be found.

The following are some extracts from literature showing the time between the primary sore and the onset of symptoms.

Bock (9) in his series of 50 cases found that 3 developed the lesion within 10 years . Average period being 23 years.

Elliott (14) quotes 2 cases in one of which rupture

of the Aorta was got 3 months after the primary lesion, and in the other there was a rapid development of an Aortitis within a few months of the lesion.

Mitchell Bruce (12) states that 25 years is the average after the primary infection.

Sullivan (49) showed two Post Mortem cases with definite signs of syphilitic Antites in young men who died suddenly, no definite history could be got as regards the time of infection.

Brooks (10) reports a case where the patient died from a perforation of the aorta before the secondary rash has fully appeared.

In my series of 31 Syphilitic Cases the following was found:-

<u>TIME</u>	<u>NUMBER of CASES</u>
Under 10 years	3
10-19	2
20-29	12
30-39	3
Denied infection but Wasserman Strongly Positive.	11
Total.	<u>31</u>

In these the duration of symptoms before admission to Hospital was:-

<u>TIME</u>	<u>Number of Cases</u>
3 months	2
6 "	2
1 Year	5
1-2 Years	7
2-3 "	8
3-4 "	3
4-5 "	1
6 Years	1

---

The remaining two gave no symptoms of Aortitis the condition being discovered during a routine examination at a Pension Board and confirmed in Hospital.

SYMPTOMS.

The early detection of any disease and more particularly disease of a vital organ such as the Aorta, is of the greatest importance. That this early recognition of Aortitis has been and still is extremely <sup>difficult</sup> accounts for the fact that Aortic lesions and even aneurisms have often advanced to a considerable degree before the patient's attention has been drawn to the fact that something is wrong. Even when he has complained of symptoms that might have warned the examiner of the possibility of an Aortitis, the absence of physical signs to account for the symptoms has obscured the diagnosis. Thus treatment is often delayed and the opportunity for trying to get rid of the cause and prevent further damage is lost.

The slow insidious spread of the diseased process in the majority of cases accounts for the long lapse of time between the primary infection and the onset of symptoms and the recognition of the physical signs. This slow gradual process, is the rule, but there are exceptional cases in which the process is much more rapid when death may occur within a comparatively short time of the initial lesion. Several such cases have already been quoted. In late primary and secondary syphilis one is constantly finding

examples of cases where there are evidences of Cardeo-vascular changes- changes which are very similar to those met with in any infection- such as tachycardia, irregularities of the pulse, dyspnoea on exertion, fatigue etc.,

Infection of the heart and Aorta takes place in this acute stage as has been proved by Post-Mortem evidences of syphilitic lesions.

Brooks (10) found in one case of his that died from an minute perforation of the Aorta, pronounced arteritis and periarteritis in the myocardium in addition to the acute Aortitis. In the majority of cases, however, the early acute infection appears to subside under treatment, but apparently unless such treatment is sufficiently thorough, the Spirochaetes may remain lurking in the Aorta to flare up again at some later date. In one of the cases in my series was a pensioner, aged 28, whom I saw at a Medical Board. All his symptoms were cardiac. He complained of dyspnoea, palpitation, occasional feeling of tightness in the upper chest.

He had tachycardia, pulse 130. His effort syndrome was poor. He had a well marked pseudo psoriasis skin condition all over his body. His Wasserman ++ with both Fleming and Harrison

technique. Examination showed little beyond the tachycardia. He received six injections of Novarsenobillon with considerable benefit. His skin condition cleared up completely and his symptoms, pulse etc., have improved very much. But unless anti specific treatment is carried out energetically over a sufficient period, this case, in the course of time will probably show some definite physical sign of the lesion of the aorta.

In a great many of the old standing cases where the onset has been slow- more especially in the type of person who has had to rough it and been taught to "work off" slight symptoms - it is often difficult to get a correct history as to what symptom was first in the field and when and how, this symptom first appeared. In my series of cases, a variety of symptoms were described by the patient as the first symptom. With most ~~XX~~ the history was one of dyspnoea, fatigue and a severe constriction or pain at upper part of sternum. In some cases there was pain in region of left nipple with an attack of palpitation; in others, pain between shoulders; while one case stated he had no complaint except attacks like malaria every two or three months. This man had not served in a malarial zone for about ten or

fifteen years.

While these are the symptoms most complained of, the general appearance of the patient was one of the chief characteristics. The majority of cases looked ill and had a peculiar sallow, septic appearance. It was this colour which often drew my attention to the possibility of a syphilitic basis and made me pay special attention to the aortic area. The symptoms met with are very varied though each case usually shows a combination of two or more of the following-: pain, dyspnoea, palpitation, fatigue, cough, hoarseness, vertigo, lassitude and depression.

I shall describe these symptoms more fully under their respective headings.

#### PAIN

There is no symptom in which there is such divergence in degree as in pain. It varies from the merest twinge- often a sense of constriction rather than pain- to the severe alarming condition associated

with the name of Angina pectoris. To understand this sensation one must consider briefly the various theories brought forward to account for its origin.

The older theories were that it arises from.

(I) Distensions of an enfeebled ventricle.

(II) Spasm of the heart muscle- analageous to the cramp of a voluntary muscle.

(III) Intermittent claudication.

(IV) Myocardial Ischaemia generally due to an affection of the coronary arteries.

(V) Neural stimulation.

The two theories advanced by Sir James Mackenzie and Sir Clifford Albutt (4) differ in that the former attributes the pain to a muscular spasm, the latter to the involvement of the outer coat of the aorta.

(Oxford Loose Leaf) Mackenzie (34) attributes pain in any muscle voluntary or involuntary, to contraction to an excessive degree or to continued work when the muscle is fatigued- the degree of contraction and the amount of work necessary to produce pain depending largely on the health of the muscle. He, therefore, maintains that anginal attacks are due to the exhaustion of a diseased heart muscle. He also claims that such attacks may be found in some cases

of aortic or coronary diseases whereas in other cases in which these areas are equally diseased pain is absent.

In connection with this theory of cardiac pain, Stevens (52) states - " Extensive lesions of the ventricular wall may be present without giving rise to either symptoms or signs because, as it has been expressed, a large part of the myocardium is silent. This term being used in precisely the same sense as when applied to certain areas of the brain".

Albutt (4) however, considers that the pain has its origin in the adventitial coat of the aorta due to the stretching of this coat when diseased and so producing the painful stimulus. He finds that a superficial intimal aortitis is unattended by pain so that in the acute infections it is not a prominent symptom whereas in syphilis it is usually quite definite. There is no direct relationship between the extent, the acuteness and the cause of the aortitis. It depends largely upon the extent of the involvement of the outer coats of the vessels, and is most frequently found when the first portion of the aorta and the aortic orifice are involved.

The supra sigmoid portion of the aorta is furnished with nerve end organs in its outer

investments. These end organs are sensitive to pressure and especially so to dragging tension. They have been found in the connective tissues of the pericardial, adventitial and other investments about the collar of the heart and along the larger blood vessels.

Now of these theories the last appears to be the most feasible from the point of view of an aortitis.

Although the myocardium and coronary arteries are involved in certain cases to a varying extent, the common feature in all cases is the involvement of the middle and outer coats of the aorta. The stretching of these sensitive nerve-endings in the outer coat produces painful stimuli which are conducted to the peripheral nerves most commonly to those in the region of the upper portion of the sternum, towards the left shoulder and also down the left arm to the hand and occasionally down the right arm, to the neck or sometimes to the back.

Pain varies in degree, seat of origin and distribution. In one extreme, it is severe and agonizing so that the patient feels as if he were in a vice. In other cases, pain may be very light and transient, almost escaping attention. In going

carefully into the history of such cases, one finds that the patient when climbing a hill may have to stop for a few seconds, belch some wind and then continue his journey as if in perfect health.

The usual site of origin is under the sternum, often at the junction of the Manubrium and body of the sternum. It may merely be a temporary sense of constriction or compression, the patient complaining of a tightness in the upper part of his chest without actual acute pain. In other cases the pain may be so severe that the patient has a dread of impending death.

This sub-sternal pain <sup>may</sup> radiate to the left shoulder or arm or into any other paths of distribution already described. In some instances one may find no actual substernal pain, the patient complaining rather of pain in one or both shoulders or in his back etc., -such pain being put down to rheumatism and so the correct diagnosis is often missed. In a few of my cases, the pain originated in the region of the left nipple and was usually accompanied by an attack of palpitation. This form of pain is attributed by some authorities to a myocardial lesion.

The frequency of the attacks and mode of onset

varies. Some cases appear to go for relatively long periods free from pain, while others have much more frequent attacks which are brought on by any slight exertion, excitement or even by some small error in diet. A characteristic feature is the presence of pain at night. Mix (40) states, "When a patient complains of anginal attacks coming on chiefly in the night, we ought not to assume that they are largely due to posture, but one ought rather to enquire whether they might not be due to syphilitic aortitis!"

Substernal pain which comes on without effort or a predisposing stimulus should always arouse the suspicion of an aortitis. In two of the cases that died while in the U.V.F. Hospital, this pain at night, accompanied by dyspnoea was very marked.

In certain chronic cases of aortitis without pain to any marked degree, attacks of more acute activity may be accompanied by a corresponding increase in the symptoms. Such symptoms may be cleared up by treatment. A dull ache may be present intermittently for days after an acute attack of pain. The crisis in Tabes are attributed by some to a syphilitic aortitis and myocarditis and are considered to be true anginal seizures.

Though syphilis is the most common cause of

aortitis and of this pain especially the substernal type radiating to the shoulders- other conditions may also cause it. Steele (50) describes two cases following rheumatic fever where such pain was a prominent feature. In two of my cases, there was a similar history but in neither was the pain so marked as in the average syphilitic case. This frequent occurrence of pain in the syphilitic form of aortitis should always make one suspect a luetic origin in all such cases. Dr Preble (44) states that in a man of thirty-five or under, pain near the cardiac or aortic area should make one suspect a specific aortitis.

The distinction between the milder varieties of pain and those of the more severe or definite major anginal attacks appears to be mainly one of degree. McCrea (31) however, makes a distinction in that, he states, that the pain of angina is aggravated by exertion, whereas that arising from a dilatation of the aorta in the milder forms is frequently relieved by moderate physical exercise. Moon (38) also contrasts the mode of origin of the two degrees of pain by stating that the minor attacks often comes on for the first time while the patient is resting and that the major attacks usually starts after

definite exertion.

We have seen, therefore, that pain is a frequent and important symptom in aortic cases and that it varies both in its extent and character.

What causes this great variation is not definitely known. Cases are found on Post Mortem where no symptoms were complained of during life but where extensive aortitis- or even a definite aneurism- was found at the autopsy. It may be due to the seat of the lesion- the supra sigmoid position of the aorta being the most important in this respect- or it may depend on the extent to which the adventitial coat is involved, Allbutt (3). Some attribute the difference in degree partly to the former condition and partly to the possibility of a difference in sensibility to pain in different people. A stimulus which may produce an acute pain in a sensitive person may produce practically no symptoms in a less highly strung person.

In my series there were several different kinds of pain complained of and of these I will give a few examples.

CASE 26.

Pens H.B. aged 46. Labourer.

Syphilis 1897. Admitted 12/6/20.

PAIN started 1916 in upper part of chest under sternum, was mild in character and did not radiate to arm.

At first it came on at intervals of from 1-2 months but has gradually become more severe and more frequent.

He is practically free from pain at night. Pain is becoming more boring in character and is accompanied by attacks of dyspnoea and vertigo. Wasserman ++.

Case (12)

Pensioner H.R. age 40. Merchant seaman.

Denies syphilis, admitted to Hospital 26/4/20.

This man was very deaf so that it was difficult to get a good history of his case.

Pain between shoulders in back; also in epigastric region after food: pain in legs. Symptoms started about 1906

On admission he complained of this pain between shoulders- of a dull aching character- of pain at lower portion of left chest , of a smothering sensation at root of neck, no radiation of pain to the arms. Wasserman ++ .

CASE 11

Pensioner B.McC. age 59. Admitted R.V.H. 16/1/20.

History of dull pain at left interspace near

sternum; 12 months duration.

Pain radiates up towards left side of neck, is intermittent in character and may last for an hour or more. It comes on during the night and in the day-time. Wasserman ++.

Case 10.

Pensioner J.B. age 38. Iron moulder. Wasserman ++.

Pain radiating from sternum down left arm; severe in character, preventing patient from sleeping; also of intense pain at back of left lung about angle of scapula (This man died). P.M. showed a dilated aorta with marked aortitis- an acute patch being ulcerated through into the trachea).

Case 13

Pensioner J.T. age 40. Admitted 15/1/20 Wasserman ++.

Condition started about 1915 with feeling of fatigue and shortness of breath. No actual pain but a sensation of tightness below upper end of sternum.

This would only last for a few minutes. In 1919, the attacks got worse and more frequent, but again were more in the nature of a sudden constriction at upper part of chest rather than of actual pain. The attacks were brought on by any exertion. When admitt-

ed to hospital he had definite pain as well as the feeling of contraction; pain radiated to back between shoulders- not to shoulders or down arms. The feeling of dread was very marked in this case, patient being afraid to do anything which might predispose an attack. Patient died and P.M. showed an definite aortitis with myocarditis. The aortitis had many acute patches in addition to the more chronic ones.

CASE 25

Pensioner J.C. age 46. Old soldier, admitted 17/5/20.  
Wasserman ++.

No pain no dyspnoea. Complained of attacks of fever which he called Malaria, about every two months.

CASE 30 11

Pensioner S.R. age 53. Labourer, Admitted 28/9/19.  
Wasserman ++.

Severe pain in right shoulder and right breast which radiated down right arm: fingers of right hand get numbed while attack is on.

CASE 42

Pensioner C. age 30. Seen at Pension's Board.  
Well marked physical signs of aortitis, but no

symptoms of this complained of till man was questioned about pain etc., when he stated that he had a gripping pain over left nipple of a few weeks duration.

CASE 31.

Pensioner R. McC.K. Age 53. Admitted 10/12/20.

Condition started 2 years ago with palpitation and pain near left nipple. Slight pain near left nipple now complained of, no soreness, sometimes a sharp catching pain making him stop for a few seconds when it goes away. Wasserman++.

CASE 2. XXXIV.

Pensioner J.P. Case of sub-acute endocarditis with an acute aortitis. Substernal pain and sense of soreness in upper part of sternum.

Dyspnoea next to pain is probably the most prominent and most important symptom. Like pain it varies to a great extent both in its severity and character. Its onset may be gradual, increasing in severity unless Anti-Syphilitic treatment is carried out. The usual history in such a case is that the patient complains of shortness of breath on exertion and inability to perform his daily work as well as formerly. Though this is a common mode of onset, another characteristic one is the sudden-acute attacks of dyspnoea occurring in a person who had previously no suspicion of any cardiac or respiratory trouble. These attacks may be more marked at night and are due partly to the Aortitis but more to the accompanying specific myocarditis. Mix (39) considers that such a sudden onset of dyspnoea associated with rapid action of the heart in a man about the forties with no obvious origin, should always arouse the suspicion of a syphilitic Aetiology.

Longhope.(27) describes two types of dyspnoea.

(1) That which arises on slight exertion and which is usually one of the first symptoms.

(2) A paroxysmal type coming on in attacks of 5-15 minutes duration and varying in number.

Sometimes there may be only two or three during

the course of the disease, or there may be four or five a day for a period of months. These paroxysms are most common in cases of insufficiency with failing circulation. They may come on with exertion but usually without any apparent cause and often waken the patient when asleep.

The dyspnoea does not seem to bear any definite relationship to the severity of the pain. In a typical-major Anginal attack the dyspnoea may not be marked for though there is a desire for breath, the patient seems to hold his breath, and the respiratory movements are short and shallow, with little quickening of the rate and not a true dyspnoea. When dyspnoea does occur it appears to be an expiratory one. The chest becoming emphysematous during the attack. In some cases the attacks may simulate a transient but severe Asthma.

Allbutt (4) describes the dyspnoea as a slight and retarded breathing independent of exertion while Tice (54) states that the condition is a expiratory one and describes it as the pulmonary type of Angina often referred to as air hunger.

This severe type of dyspnoea was always a bad prognostic sign in my series of cases. In the four cases that died, severe dyspnoea was one of the most

troublesome symptoms, preventing the patients from sleeping. In three of these cases there were definite signs of myocardial deficiency with generalized oedema. In the other case the dyspnoea was not so marked and was more intermittent in character.

The dyspnoea may be due to pressure from a dilated Aorta setting up a reflex stimulus; to early cardiac insufficiency; to the nutation at the root of the Aorta or to a combination of two or more of these conditions.

The paroxysmal attacks which are asthmatic in character, often end with the expectoration of mucus, sometimes blood stained. One of the cases that died from ulceration of an acute aortitic patch into the Bronchus, gave a history of acute attacks of dyspnoea with blood tinged sputum for some days before it finally terminated in a large haemoptysis which proved fatal.

Brown (11) considers that errors in diagnosis are often made in early cases of Aortitis on account of this respiratory trouble. Cases of specific Aortitis being mistaken for pulmonary T.B., Pneumonia, pleurisy etc., in these cases the presence of a temperature may be confusing as many cases of acute Aortitis are accompanied by a temperature. I had no

cases coming into this category though one patient while in hospital( having already <sup>been</sup> diagnosed as a specific Aortitis) developed a temperature with areas of congestion in both lungs and definite haemoptysis, which continued until his death, a few days later. A post mortem examination could not be obtained so the pathological condition of the lungs and aorta could not be ascertained.

The majority of cases in my series showed a much less severe type of dyspnoea. The usual history was that the patient was unable to carry on at his usual job; that it was too heavy for him; that if he exerted himself unduly he became " short of breath". In several this was the first symptom complained of and for some time the only symptom. As a rule, however, it was accompanied by a feeling of constriction at the root of the neck or by a mild degree of pain. This dyspnoea increases in severity as the disease progresses and may vary in character becoming more paroxysmal in type. The presence of a positive Wasserman with mild symptoms of dyspnoea or substernal pain should make one treat a case as a specific Aortitis even though the physical signs are negligible.

COUGH

Like the other symptoms, also varies in its type and degree. In some cases there may be short dry unproductive cough, often worse on lying down at night. In other cases a large amount of sputum may be brought up, and as already stated when speaking of dyspnoea, this sputum may be blood tinged. It is most commonly found in those cases in which definite aneurisms have formed but it is also got in cases in which there is merely a dilatation of the Aorta. The Aetiology of the cough is in some cases due to actual pressure in the bronchi; in others to reflex effect from pressure on the nerves especially the recurrent pharyngeal. In the latter case the cough is of a husky changing character and is usually associated with a hoarseness in speaking. In cases where the sputum is blood tinged the possibility of a leakage from an aneurism has to be remembered.

In my series of cases cough as a rule was not a prominent symptom but in two of the cases that died there was cough, worse at night and accompanied by profuse expectoration. In another case with a definite aneurism, the man's chief complaint was a short dry husky cough present day and night which prevented him from sleeping. In another case cough especially on lying down at night was very marked, the patient

being unable to get any sleep except when well propped up with pillows.

### FATIGUE

Is an early indefinite symptom and may with slight dyspnoea precede the other symptoms by some months especially in the chronic cases. It is more common in those cases which on examination are found to show evidence of Aortic regurgitation, and may be due to and accompanying myocarditis.

The patient's may be listless and feel a lack of inclination to exert themselves, more than an actual inability to carry out their daily routine. There is a peculiar lassitude and depression which is characteristic in many cases. They seem to fear the worst and they have not a hopeful outlook in life.

Abnormal sweating is sometimes found and, if the condition is accompanied by cough, spit, and slight fever as often happens, a diagnosis of incipient phthisis may be made, even though there are no

physical signs in the lungs to warrant it.

At the Medical Pension Boards, I have seen several pensioner's who had<sup>been</sup>/diagnosed as cases of Pulmonary Tuberculosis, and who had~~o~~ been treated ~~XXXXXX~~ at a Sanatorium for this condition but in whose sputum Tubercle Bacilli had never been found. On examination the symptoms and physical signs pointed to an Aortitis and a positive Wasserman help to confirm the diagnosis. Unfortunately it is impossible to follow up these cases to see what is the result of treatment.

#### TEMPERATURE

Another sign which is often a misleading is often the presence of fever. One is very apt to fight that syphilis alone may cause an increase in temperature, which may vary from a daily sweep of a degree or so to temperatures of 102-103° F. as the case may be.

McCrea (30) quotes a case with a temperature running from 90°-104° for 5-6 weeks, before a diagnosis of

syphilis was made though once Anti-Syphilitic treatment was started the temperature soon became normal. Stengel (51) describes febrile attacks in case of Arteriosclerosis and more particularly in cases of acute Aortitis.

In an Article on syphilitic fever, the type is described as septic or remittent. It may last for months and is often associated with chills or sweats. It may even resemble Malaria. One of the cases in my series gave a history very like that of attacks of Malaria every 6-8 weeks. No evidence of Malaria was found but there were definite signs of an Aortitis and aneurism, and a Wasserman reaction was positive. His general condition greatly improved under treatment and so far he has had no further febrile attacks. This was the only case in my series that showed a temperature that could be definitely associated <sup>with</sup> syphilis. One case that died developed a sudden temperature which continued for five days or so till he died. This temperature, however, appeared to be the result of a secondary acute infection of a broncho-pneumonia character. In long continued fevers for which a cause has not been found, the possibility of its being syphilitic should be borne in mind and a Wasserman test done.

VERTIGO

The importance of vertigo as a symptom depends largely on its cause. It is a common symptom in neurasthenics and is dyspepsia especially after stooping. Its origin may be central or peripheral - in the latter cases usually aural. A common cause of vertigo is syphilitic involvement of the cerebral Arteries and of the cerebellae arteries in the more severe cases.

Cabot (13) states " that cause ~~xxx~~ syphilis has probably also produced changes in the cerebral arteries whereby the amount of blood passing through them does not vary as it should, according to the demands of the moment. One can well conjecture that such vascular changes would produce Vertigo".

Mix (39) quotes recent work by Otologist on the subject of Vertigo. He states " It has been discovered that in Arterio Sclerosis very many attacks of vertigo are due not to Arterio Sclerosis of the cerebral arteries or to possible cerebral ischaemia but rather to an Arterio Sclerotic Aortitis. It seems that in Arterio-Sclerosis of the Arch of the Aorta perverted impulses through the Pneumogastric are responsible for the attacks of Vertigo".

In six of my series Vertigo was a prominent symptom being described by them as a giddiness; a dizziness or a lightness in the head. In one case

it was actually so severe as to cause the patient to fall to the ground. In all cases it was looked on by the patient as one of the most serious symptoms of his complaint and its presence invariably increased the dread which this type of case usually presents.

There are several other symptoms found in certain cases but usually to a less marked degree.

Palpitation sometimes causes considerable annoyance to the patient.

Flatulence, indigestion and other abdominal conditions may be complained of. General weakness; vague neurasthenic symptoms; Mental fatigue; headaches etc., may all be discovered, and may be simply part of the general syphilitic infection as each or all of them may be found in a secondary infection.

#### PHYSICAL SIGNS

Important as symptoms are and in the early cases they are often all that we have to base our diagnosis on. Physical signs must be carefully looked for so that we may find some evidences of a pathological change which could account for the symptoms complained of, and which, when all the facts and findings are put

together, enable us to make a definite diagnosis at as early a stage as possible and thus give therapeutic measures a reasonable chance of success.

Of the physical signs to be looked for some are more or less general to several forms of cardiac disease, while others especially if two or three of them are found together are characteristic of an Aortitis.

In dealing with these physical signs I shall first of all discuss those that can be seen on inspection before going on to those made out by palpitation, percussion, auscultation etc.,

One of the most striking features, in my opinion, of a syphilitic Aortitis, is the general appearance of the patient especially the peculiar colour of the skin generalised to a certain extent but most marked on the face. This colour was as a rule of a yellow sallow character, but in some the sallow tinge was not so marked and the colour was more of an earthy grey nature. This change in complexion was found in most of my syphilitic cases, and in several cases lead<sup>me</sup> to be on the lookout for an Aortitis.

Herbert(13) found that 70% of his cases showed this characteristic colour- pale grey with often a yellowish or brownish tint.

In some cases this change in the complexion may be accompanied by a falling out of the Patient's hair.

The whole aspect of the patients makes them look ill. Whether this condition is part of a generalised syphilis or whether it is confined to cases with involvement of the cardio-vascular system, is not important, in view of the recent work in the pathology of syphilis by Warthin. He found the spirochaetes in the Heart, Aorta etc., in a large percentage of syphilitic cases. Undoubtedly the response to treatment is usually shown first by a clearing of the complexion in addition to an abatement of the symptoms.

Another abnormality detected on inspection is a fullness in the neck and a dilatation of the veins in the neck, arms and about the shoulders. This is nearly always due to some obstruction of the superior Vena Cava, or some of its main branches. A common cause of the obstruction being pressure from an aneurism or a dilated Aorta. Though in certain cases the pressure may arise from a gumma or some syphilitic Mediastinal condition which is present in addition to the specific Aortitis. Back pressure from the right Auricle may in some cases cause, in others augment the dilatation of the veins.

pulsations either thoracic or in the vessels of the neck, are other important physical signs, to look for these the patient should be naked to the waist with a good light falling on the front of his chest and inspection carried out from different angles. It is often a good plan to get the eyes on a level with the chest wall with the patient lying flat on his back in bed. Pulsation to an abnormal degree may be seen in the following vessels.

Common Carotids Here it is due in some cases to the Aortic incompetence so frequently found in Aortitis, but in other cases it is due to a tortuosity of the Carotids caused by their point of origin being somewhat higher than normal and in consequence they are displaced.

Subclavians Also may show abnormal pulsations for similar causes to those in the carotids. In cases of the Aortitis especially with marked dilatation. The Subclavians may be pushed upwards, being visible above the clavicles. This apparent elongation of the Aorta is also responsible for another type of pulsation and one which is characteristic of an Aortitis namely pulsation in the Episternal notch. In marked cases the Aorta may be visible above the Sternum as a definite pulsating tumour. This was seen in one of

my series. (Case No.29)

On the Anterior aspect of the chest pulsations may be got in the first or second interspaces either on the right or the left side or in all of these spaces. The second right interspace is the most common sight of pulsation, then the second left, first right, first left in this order.

Normally pulsation may be got in the second left interspace but extensive pulsation at the upper end of the sternum usually means an Aortitis with or without an Aneurism. McCrea (31) considers that the pulsation in a dilatation of the Aorta is more diffuse than it is in a definite saccular aneurism. In many cases the pulsation is better seen than felt though in cases of Aneurism a pulsating tumour may be both seen and felt. If there is cardiac hypertrophy pulsation at the Manubrium Sterni is sometimes visible.

Palpation The physical signs detected on palpation are very similar to those seen on inspection.

Pulsations in the neck, sternal area etc., can be felt though in many cases they are better seen.

Tortuosity or abnormal position of the Subclavian or Carotids may be found. One of the most important findings, however, is the palpation of the Aorta in the Supra-Sternal notch. In this connection Bábes and Dumitrisci (6) describe a condition which they term the sign of the Aortic arch. "It consists in vigorous pulsation of the Aortic arch which can be felt synchronously with the heart beat at the upper border of Manubrium Sterni". The sign needs the three following conditions, either separately or combined.

- (1) Dilatation of the Aortic Arch.
- (2) Hypertrophy of the left ventricle.
- (3) Raising of the heart either by fluid in the pericardium or by intra-abdominal pressure, or by enlargement of the liver especially the left lobe.

It is, however, of less value, as a sign of Aortic dilatation than of Hypertrophy of the left ventricle and of pericarditis with effusion.

Normally the arch of the Aorta can not be felt

in the Suprasternal notch but is usually 2-2½ Cm. below it. It may be palpated in cases of high blood pressure, as well as in Aortitis. In acute Aortitis it is often tender to the touch.

In addition to pulsations in the first and second right or first and second left spaces, a shock, diastolic in time, or a thrill also usually diastolic can often be felt. If there is a definite dilatation of the Aorta this diastolic <sup>shock</sup> is usually well marked. A systolic thrill is, however, diagnostic not of a dilatation of the Aorta but of a stenosis of the Aorta valve.

The position of the Apex beat and the question of its mobility on change of position should also be gone into. In cases where in addition to the dilation there is an elongation of the Arch, one may find that the Apex beat moves on change of position to a much greater extent than normal. In cases where a pulsating tumour is visible palpation helps to differentiate between an aneurism with its expansile pulsation and the transmitted pulsation got in a mass lying over the Aorta. From an Aortitis standpoint the two most important signs in palpation are the Diastolic Shock and the Suprasternal pulsation.

Percussion also gives considerable assistance in arriving at a diagnosis; chiefly by estimating the extent of the Aortic dulness at the upper end of the Sternum.

Normally the Aorta in men should measure from 5-7 cm. and over 50 years about 8 cm. in women a little less. In Aortitis the general rule is to get an increase in this measurement, which increase in syphilitic cases rarely shows any diminution under treatment whereas in cases due to some acute infection such as rheumatism there is a tendency to recession as the disease subsides.

The increase in width naturally varies from a small degree to case where the Aortic dulness may measure as much as 14 cm. This dulness may be more marked on one side of the Sternum than on the other and usually extends upwards towards the Suprasternal notch. The commonest site is in the 2nd, right interspace, and here the dulness is much more diagnostic of Aortitis than say in the second Left interspace. Dulness on percussion over the Manubrium is also a useful help in diagnosis. McCrea (31) found that in 55 of his cases this dulness was present.

The size of the heart and the position of the

Apex beat have also to be determined. It is often difficult to do this with accuracy by percussion on account of the depression of the Apex beat in cases where the aorta is elongated as well as dilated. One case who died and on whom a post mortem was made, was found to have a small heart with a large dilated Aorta though the clinical findings gave the position of the Apex beat as the 6th, space almost in the nipple-line. An X-ray in this case was not taken as the man was very seriously ill when admitted to Hospital. The occurrence of a large hypertrophied heart is not so common in case of syphilitic regurgitation as in those cases due to some other infection. Sach (46). In the majority of my cases there was little or no increase in the size of the heart and practically no alteration in the position of the Apex beat. In some of the cases the heart appeared to be enlarged as the Apex beat was found in the 6th, interspace in or outside the nipple line. On X-ray this was found to be due to a dilated Aorta the heart being normal in size but pushed down by the Aorta condition.

Auscultation The changes found on Auscultation vary to a certain extent in individual cases but there are two fairly characteristic findings. Usually the first change met with is a peculiar quality of the 2nd, Aortic sound described by some as a clanging sound by others as a bruit de 'tabourka'. It varies to a certain extent in the same individual. Some days being much more marked than in others and though it usually retains the peculiar quality there may also be slight variations in this. When found/<sup>it</sup> should always make one suspect a specific Aortitis though it is not diagnostic of this condition being sometimes found in cases associated with High Blood pressure as in certain cases of Bright's disease, or in the other form of Aortitis due to some non-venereal infection.

This peculiar 2nd, sound may be accompanied by a diastolic bruit without losing its clanging quality. In the early cases the bruit is very difficult to detect and may only be audible when the patient holds his breath, or it may be brought out by exercise. It is often accompanied by a systolic bruit in fact this systolic bruit may precede the diastolic for a considerable time. As the disease advances and a definite pathological regurgitation takes place

at the Aortic orifice. Physical signs become much more definite and marked. On Auscultation one now finds a definite double Aortic bruit. The diastolic one especially being well marked and still as a rule having that clanging quality which has already been described with the 2nd, sound.

McCrea (30) describes this 2nd, sound as a musical bell like sound which is quite distinctive and which he has never heard in any other condition.

Tice (54) in discussing the character of the 2nd, sound in differentiating between Aortic Stenosis and Aortitis when a systolic bruit is present, states that if the 2nd, sound is present and is increased in intensity it means dilatation of the Aorta.

Allbutt (3) describes a chafing sound due to a dry basic per<sup>i</sup>carditis which is sometimes got along with an Aortitis. He states that such a pericarditis may arise from the outside invading the surface of the Aorta or <sup>from</sup> within from whence an Aortitis may spread to the investing pericardium. I had one case in my series which appeared to come into one or other of these types. A pensioner J.C. age 30. syphilis 7 years previously Wasserman ++. He was up at a Medical Board on account of an injury to his wrist. At first he gave no history of any

Cardéo-vascular trouble but on the routine examination a condition was found on Auscultation which appeared to be a combination of a double Aortic bruit with some chafing sound superadded. On questioning him for symptoms he stated that for the last 5 weeks he had had occasional mild attacks of substernal pain with slight dyspnoea and palpitation .

A well marked diastolic bruit usually means a definite and pathological insufficiency. It was formerly supposed that this insufficiency was a relative one, but recent investigations have proved it to be a true deficiency due to the involvement of the valves by the Spirochaetes. Syphilis always acts as a dilator.. According to Mix (40) there is no such thing as a syphilitic Aortic Stenosis. The presence of such an Aortic insufficiency <sup>in a patient</sup> ~~above 40~~ years with no previous history of heart trouble, and no history of Rheumatic fever, should always make one consider the possibility of a syphilitic Aortitis. Anders (5) considers that the most common Aetiological factor of Aortic incompetence is syphilis and that a combined mitral and Aortic lesions may be got. He found in 219 cases of Aortic incompetence that 133 or that 60.7% were clearly due to syphilis and of the remaining 86 cases a ~~good many~~ had not had a Wasserman



test done and thus the syphilitic aetiology is probably underestimated. He thinks that in the absence of a history of Rheumatism or some acute infection a case should be regarded as Suspect of syphilis even if the Wasserman test is negative, and that vigorous should be carried out.

Longhope (29) in an Article on the association of Aortic insufficiency with syphilitic aortitis gives some interesting tables. Thus in 930 post mortems at Pennsylvania Hospital 21 cases were found in which chronic Aortic endocarditis unassociated with lesions of any other valve were found in connection with a mesaortitis. Then in a series of 37 cases of Aortitis chronic Aorta endocarditis with insufficiency occurred in 13 or 35.1%. The following Table is given.

Table	Mesaortitis (L. pure Aortic Endocarditis.)	Endarteritis deformans. Pure Aortic endocarditis.	Rheumatic fever etc., combined with Aortic Endocarditis.
Aortic Insufficiency.	13	4	21
Chronic Aortic endocarditis with- out signs of Aortic insuff- iciency.	3	30	00
Total	21	34	21

Libman (26) also considers that syphilis very frequently involves the Aortic valves and that it is second to Rheumatism in the production of valve defects.

It usually attacks a health valve .

Mc Ilwaine (35) also draws attention to the frequency with which Aortic endocarditis and Aortitis are

associated. In contradiction to so many of those already quoted and to what I found in my own series, the report of Russell Wells (59) is a remarkable one. This report is based on the examination of ten thousand recruits and in the numerous heart cases examined he was unable to find any statistical evidence of Syphilis being a cause of valvular lesions. This is possibly due to the fact that men at an examination like that would probably deny a syphilitic infection and it would be impossible to have a Wasserman test done which would verify, or otherwise, their statement.

Longhope (27) again in an Article on syphilitic Aortitis states that in 22 cases of Aortic insufficiency 18 or 81.5% were associated with syphilitic aortitis while two cases of Aortic insufficiency with positive Wassermans were associated with a Mitral Stenosis. This possibility of a mixed infection has to be borne in mind. One of my series was a Pensioner W.J.B. age 33. who gave a history of Rheumatic in Jan. 1916. In June 1917 he contracted Syphilis and had very inadequate treatment. He was admitted to the U.V.F. Hospital on 1st, Jan. 1920. On admission he was found to have a well marked presystolic thrill and bruit in the ventral area with no definite

physical signs in the Aortic area. The symptoms of substernal/<sup>pain.</sup>stabbing in character and radiating across the left side of his chest and between his shoulders; his general appearance and the positive Wasserman point to a combined lesion. In cases with a double Aortic Bruit a Mitral murmur is often heard, due probably in the majority of cases to conduction, in others it may be a Flints murmur while in others it is a true mitral lesion.

Pulse In the chronic cases of Aortitis with no myocardial complications the pulse as a rule shows no deviation from the normal. From an Aortic standpoint the only changes got are those found when there is an aneurism present with a difference in the two pulses this is dealt with under aneurysms. Even when Aortic incompetence is present the pulse is not necessarily of the typical Water hammer type. In many cases it is not so "bounding".

In secondary syphilis the pulse may be intermittent, shows extrasystoles, or other disturbances

in rhythm. It is often increased in rate. In the older more chronic syphilis, with definite Aortic changes, the presence of an Arrhythmia is usually a serious sign, pointing to definite myocardial change and is often the preliminary sign to definite failure of compensation. A few cases in my series showed these changes (cases 13 and 27) both of whom died, had increased pulse rates with an irregular rhythm. Even in cases with well marked aneurysms only very slight changes in the two pulses were felt and these changes were chiefly in the volume of the pulse. There were no appreciable differences in the rate.

Blood Pressure Here again one finds, practically no characteristic change, As a rule, the Blood Pressure is not raised or if raised, is only to a very moderate degree. In cases complicated by Renal disease or generalized arterio Sclerotic changes an increase in the B.P. is usually found but without these complications any such increase is unusual.

The average Blood pressure in my series was between 130 and 140. The only cases with a really

high Blood Pressure were one with 220 systolic and 180 diastolic- a patient who gave no history of syphilis and whose Wasserman was negative, and another aged 55, with a history of Syphilis 30 years previously and a positive Wasserman, also had a B.P. of 220 systolic and 80 diastolic .

Wasserman reaction Of the newer methods of examination the Wasserman test has given us a very efficient means of arriving at a diagnosis of the Aetiology of many cases of Aortitis. Unfortunately, however, the presence of an negative Wasserman does not exclude syphilis. Other physical signs being present, without a definite history of Rheumatism or some acute infection. Anti Syphilitic treatment should be carried out even though a negative Wasserman is obtained. The routine examination and newer methods of treatment of Syphilis are not of sufficiently long duration to enable us to arrive at a correct estimate of the benefit of this test from a Therapeutic standpoint. In many cases in which vigorous Anti-Syphilitic treatment has been carried out over a long period one fails to get the blood negative, and several Authors have given us some Statistics of the results of the Wasserman reaction in a series of cases of cardio-vascular disease.

Thus Benjamin and Havie (7) examined 33 cases of Aortic insufficiency and found that only 11 percent gave a positive Wasserman, while 57 percent gave an undisputed history of Rheumatism.

Bock G. (9) in a paper on Syphilis of the Aorta and its relation to the Wasserman reaction found 385 cases (39.7%) of syphilis of the Aorta in 9690 autopsies made in the Victoria Hospital, Berlin, between 1912-1917. The Wasserman reaction was positive in only 66 or 47% of the cases of undoubted luetic aortitis in this series.

Herbert (18) found in 186 cases in which the Wasserman test was done that it was positive in 155 or 85%. 54 cases or 35% of the cases had Tabes.

Syphilis of the Aorta was the only sign of Tertiary Syphilis in the majority of cases. He considers that Aortic Syphilis constituted 70% of all cases of visceral syphilis. Twothirds of his cases were in men. In 35% of his cases there were no subjective disturbances and even in the few cases of Aortic incompetence and aneurism the patient did not complain.

In my series of 37 cases, 31 or 83.78% gave either a definite history of Syphilis or a positive Wasserman, 28 or 75.6% having a positive Wasserman.

In my series the test was of great value in determining the syphilitic factor as a good many of the patients denied having had syphilis till confronted with the positive result and even then some of them denied having had the disease. This was due to the fear that it might interfere with their getting pensions and the usual allowances associated with treatment.

All these tests were done by me while working at the Royal Victoria Hospital.

#### Aneurisms

It is often impossible to tell when an Aortitis with dilatation ends and a definite aneurism begins. The two are closely associated and it is because of this close association that I intend briefly to discuss the question of aneurism.

Shock and permanent dilatation in a normal Aorta is prevented by the property of extensibility, associated with that of elasticity possessed by the elastic element : as long as the Aortic wall remains normal, we do not expect to find dilatation or aneurismal formation.

In an aortitis and more especially in a syphilitic aortitis, we get partial destruction of the middle and outer coats of the Aorta, the

destruction often unvolving the elastic fibres to a marked degree. Such being the case, it is only natural that we should so often find dilatation, even though it may be slight in degree, and in many cases evidence of definite aneurismal formation.

A syphilitic Aortitis is the most frequent forerunner of aneurism.

Thus Anders (5) found in 626 cases of aneurism, 363 or 58.5 percent were definitely of leutic origin, while some of the cases had not been submitted to the Wasserman test.

Elliott (14) states that 30% of all syphilitic with clinical Aortitis are found to have developed aneurism and about an equal number sclerosis and retraction of the Aortic valve.

Osler (43) states that 80-85% of aneurisms are due to syphilis.

Syphilitic aneurisms are most commonly found in the ascending aorta and are rarest in the descending aorta. The symptoms are very similar to those of an ordinary syphilitic aortitis with in addition symptoms and physical signs, the result of pressure on neighbouring organs. These symptoms and signs of pressure vary in different cases as will be seen from the following cases quoted from recent liter-

ature.

Snyder (53) describes two unusual cases one which pressed on the superior Vena cava causing oedema of the upper part of the chest. The other case was diagnosed as a pneumonia on account of severe sudden pain the left chest, worse on deep inspiration and accompanied by dyspnoea and expectoration of blood-stained mucous, Temp. 102.3, P.M. showed a large aneurism involving the transverse portion of the arch, and perforation in to the adherent lung.

Wilson (60) describes two cases. One of these was diagnosed as duodenal ulcer; the other as mediastinal tumour. On P.M. they were both found to be aneurisms of the thoracic Aorta.

Hall (16) showed a case of thoracic aneurism with slight pain in region of swelling in front of chest.

Another case was described by Blumgarten (8) which showed an absence of the usual physical signs of aneurism, such as bruits etc., on account of a superadded pericardial effusion.

Robey (45) describes a distinct shaking or shock on each heart beat out of proportion to the heart impulse. P.M. showed a large aneurism of the descending aorta.

Jordan (19) describes an aortic septic aneurism

due to an embolism in a young boy of 6½ who had Otitis Media since infancy. There were no physical signs at all of aneurism during life.

Hamburger (17) describes a case with practically no symptoms or signs other than those of a myocardial breakdown.

These cases I have mentioned show unusual symptoms and signs. What one most commonly finds, however, are symptoms such as the following:-

Dyspnoea, due either to direct pressure in the oesophagus or to reflex spasms from pressure on the recurrent Laryngeal .

(2) Boring pain due to erosion of the sternum or vertebrae as the case may be.

(3) Tracheal tug which is also sometimes found in cases of Aortitis with dilatation and not definite aneurismal formation.

(4) Inequality of the pupils, due to pressure on the sympathetic.

(5) Irregularity of the pulses.

Williamson (61) attributes this irregularity of the pulses to the following factors-

(1) By aneurism extending over such a distance that it draws a large branch such as Innominate, into the aortic itself and in like manner becomes an

aneurism of the innominate as well.

(2) By pulling on the blood vessels the innominate being almost closed by the traction ( this is the most common way).

(3) By the Sac pressing on the innominate from without.

The inequality varies. There is usually very little difference in the time in the two pulses but one may be much more distinct than the other. In some cases the pulse on one side may be practically imperceptible. Thus Frothingham (15) describes a case where the left radial was entirely absent and the right radial was regular and of fair quality. Sailer (47) also describes a case where the patient was pulseless. Neither in radials, carotides, femorals, posterior tibials or dorsalis pedis arteries could he detect any pulsation what ever.

The position of the heart sometimes alters in cases of aneurisms of the arch. It may be pushed to one side or further down. According to Walsham (56) a common change is to find a transverse position of the heart in many cases of aortic aneurism.

Causes of death in aneurism are: Rupture.

Chronic interstitial pneumonia.

Exhaustion as a result of pain.

Chronic dilatation with broken-down heart, Oedema etc.,

Rupture is more usually got in a small acute aneurism than in larger ones. One case in my series showed a rupture into the bronchus, death being due to

Hæmoptysis.

Rupture, however, may take place into a variety of places and regions as is shown by the following cases quoted.

Oliver (42) describes a case of dissecting aneurism between middle and inner coats which finally ruptured into pericardium through a small opening in the adventitia.

McCrea (32) had a case when a small aneurism of transverse arch of the aorta ruptured and the blood passed behind the Oesophagus and dissected up the parietal pleura in the back wall of the thorax throwing the lung forward.

Smith's case (43) was an aneurism of the ascending and transverse arch of the aorta which had ruptured into the pulmonary artery. The left lung was fibrotic.

(23) Case of aneurism which had become visible in anterior chest wall, ruptured with profuse hæmorrhage. The opening was sutured and patient made a temporary improvement.

(66)

Other positions into which an aneurism may rupture are the superior vena cava, a rare event. Here the diagnosis is made by the sudden onset of symptoms such as Cyanosis oedema and distension of the veins of the upper part of the body with other evidences of obstruction to the circulation in the tributaries of the superior vena cava.

Norris (41) when lecturing to his students on syphilitis aortitis impressed on them" the desirability of bearing in mind the possibility of an aneurism especially in or beyond middle age, in any patient who complains of chest or back pain, dyspnoea, or cough which does not yield to treatment or for which a definite cause cannot be found".

In my series of cases there were several cases of definite aneurism some of which will be seen in the X-ray photos. In many cases it is very difficult to determine where exactly a case may be said to have developed a fusiform aneurism and not merely a dilatation due to an aortitis. It was on account of frequent finding of aneurism often as an end result of the aortitis that I have devoted a special paragraph to it.

### X-ray Examinations

However much one may suspect a lesion in the Aorta, a definite diagnosis of its extent, exact position and nature can often not be made until an X-ray photo of the heart and aorta is taken. By the methods of examination already described, we may find all the signs and symptoms of an aortitis but by them alone in the early stages we are unable to say whether an aneurism is forming or whether there is general dilatation of the aorta.

To appreciate pathological changes in the aorta, we must first consider the normal aortic shadows in the radiogram .

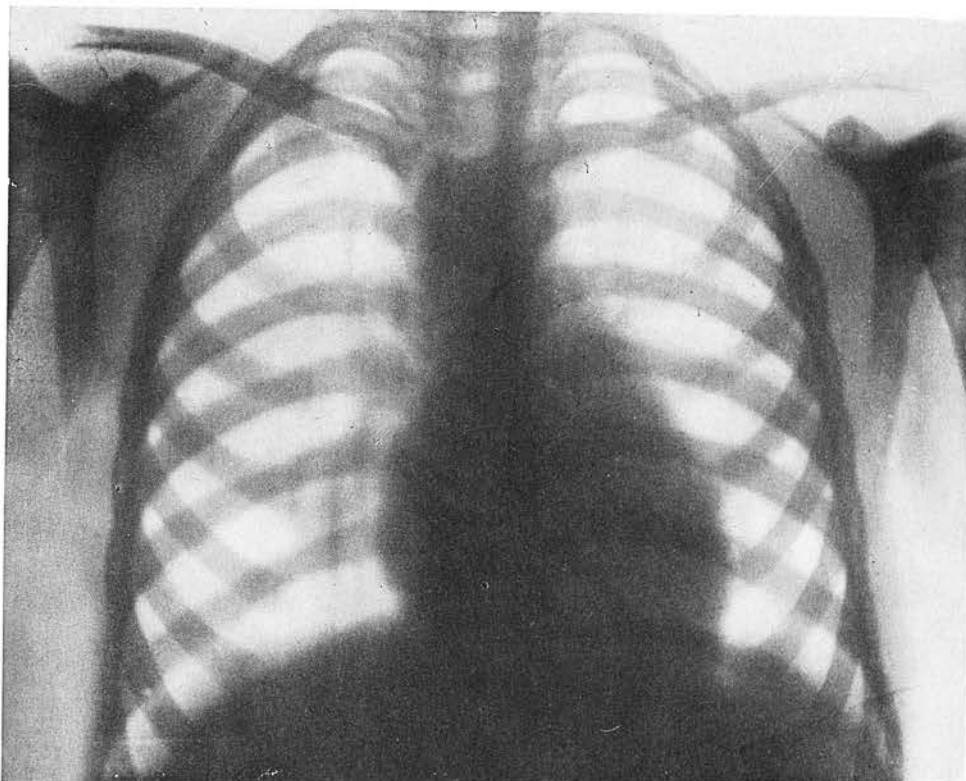
Elliott (14) states that it lies in the first portion behind the sternum and does not project beyond the right auricular curve. It curves backwards to the left at the arch where appears a more or less well-rounded knob distinct from the cardiac shadow. This is called the aortic knob and alterations in its form possess value in diagnosis. This knob varies. It may be so prominent as to be mistaken for an aneurism or it may hardly show at all. It varies according to

age becoming more prominent in adults and old people. The aorta cardiac shadows vary according to the type of chest. A long narrow-chested person usually has a similar type of long heart and narrow aorta. Slight variations in normal x-rays are numerous and often lead to mistakes in diagnosis. Many abnormal types are met with in aortitis varying from slight degrees of dilatation to a well-marked aneurism. Tice (54) describes 3 main types of syphilitic aortitis from the standpoint of the skiagraph. In the first there is no obliteration of the aorta knob due to ~~dilatation of the aorta~~ or, because of the filling of the space between the knob and the heart, the shadow becomes continuous. The second shows an increase of the aorta shadow to the right especially in case where there is no increase in the cardiac shadows. The aorta shadow extends further to the right than the right border of the heart. When this occurs it indicates a dilatation of the arch of the aorta. Thirdly there is a uniform dilation of the shadow: that is, there is a definite increase to the right and left of the aortic shadow. In addition to these three types described by Tice there are the numerous varieties of aneurisms which often cannot be definitely diagnosed without the aid of skiagram.

From a general standpoint we should look for alterations in the density of the shadow and a change in the contour.

This brief general description is given before becoming to my series of cases in a good many of which I was able to get X-ray photos of the heart and aorta- for these I am indebted to Dr Maitland Beath and Mr Crymble. With each case a short clinical history is given, in addition to the X-ray findings.

Copy of X-ray photo of normal chest in a boy age 12.  
(Dr. Melville's case)



PHYSIOLOGICALLY NORMAL CHEST.

Aortic knob not well marked owing to age of patient, Right auricle projects beyond the aortic shadow.

J.K. aged 23. Admitted R.V.H. 26/3/20.

No history of Rheumatic fever or Syphilis.

Bronchitis 2 years ago otherwise states no illnesses. 3 weeks before admission he began to be troubled with pains in back and legs. Later he found he was unable to continue at his work on account of fatigue and dyspnoea on exertion. His Doctor told him his heart was affected and advised Hospital treatment.

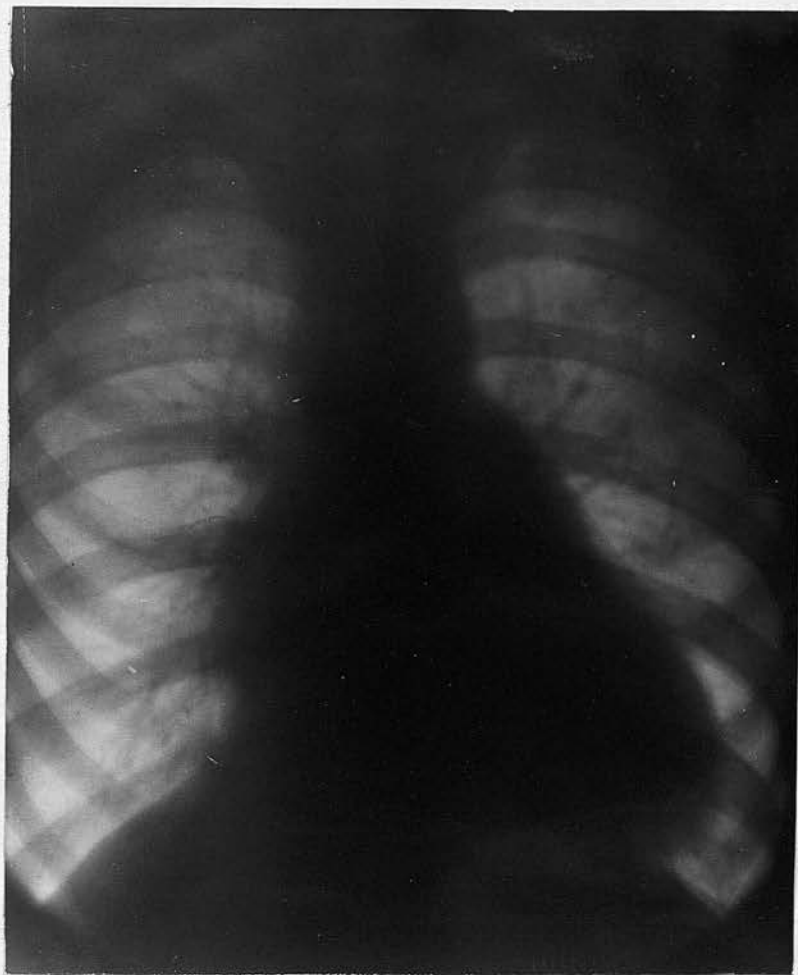Heart Apex beat 6th, space, 8" outside the nipple line. Aortic area shews a rough systolic and a softer diastolic bruit; mitral presystolic bruit.

Thrill in both aortic and mitral area.

Right border of heart was 2" to the right of sternum.

Marked enlargement.

Pulsation of vessels in neck. Pulse 110 of Corrigan type. Albumen in urine. Wasserman negative.



X-ray shews large heart. Aorta slightly dilated at first portion but otherwise normal.

J.P. age 25. Admitted to Hospital 20/7/20.

died 22/10/20. He joined Army in September 1916, and was in France for 2 years. While there he took Trench fever and was 6 months in Hospital. He was demobilized in March 1919 apparently fit. A few months before admission he began to complain of shortness of breath on exertion, of headaches, vertigo. He became easily tired and was unable to continue at his work.

On admission he looked ill with a pale drawn expression, his chief complaints were dyspnoea with occasional attacks of pain in precordial area. These were often worse at night preventing his sleeping. On examination his heart was found to be enlarged the apex beat being in 6th, interspace in nipple line. Impulse was heaving in character. Pulsation also present at upper part of Sternum 2nd, left space and in carotids and pulse one of Corrigan type.

There was a definite double aortic bruit with a suspicion of a systolic thrill, Mitral systolic also present but no evidence of Mitral XX. presystolic.

On 8th, August 1920, he developed a sharp pain in left side and also in Lt. ankle and knee. Spleen became enlarged and tender, there was definite clubbing of fingers and petechiac haemorrhage were quite distinct. The substernal pain became more marked and he required hypnotics at night in order to get any sleep.

Some days later a definite aneurism about the size of a hazel nut developed in left posterior tibial artery. His aortic dulness was found to be increased though no definite signs of an aortic aneurism. At intervals of 2-3 weeks he ran a temp. for a few days, temp. varied from 99-100°-101°.

He died on 22/10/20. a post mortem was not obtained.

Wasserman negative 27/7/20.

Lecky (24) Describes a somewhat similar case which resulted in a post tibial aneurism being formed.

No. 3. Pens. J.B. Age 28. Syphilis 7 years ago. Seen at Medical Board.

Symptoms. Dyspnoea on exertion; palpitation.

Physical signs. Tachycardia. Pulse 120. Second Aortic accentuated with clanging sound. No bruit. No diastolic shock. Slight pulsation in episternal notch, and slight increase in aortic dulness. Heart not enlarged. Marked pseudo psoriasis rash. Wasserman ++ X-ray not taken.

No 4. Pen. A.C. Age 30. Syphilis 7 years ago. Seen at Medical Board.

Symptoms. Complains of gripping pain in region of left nipple during last few weeks; of palpitation at night with some difficulty in breathing. Also states he has a wheezing noise in chest after exertion.

Physical signs. Large heart, apex beat 6th, space in nipple line. Increase in aortic dulness. Double aortic bruit with in addition a to and fro wheeze suggestive of a pericardial condition at base of heart.

Wasserman ++.  
X-ray not taken.

No 5. Pen. T.M. Age 30. Seen at Medical Board, no history of syphilis but Rheumatic fever 5 years ago. Complains of dyspnoea and fatigue. Heart slightly enlarged. Apex beat 6th, space in nipple line. Double Aortic bruit. No definite increase in aortic dulness. Wasserman negative. X-ray not taken.

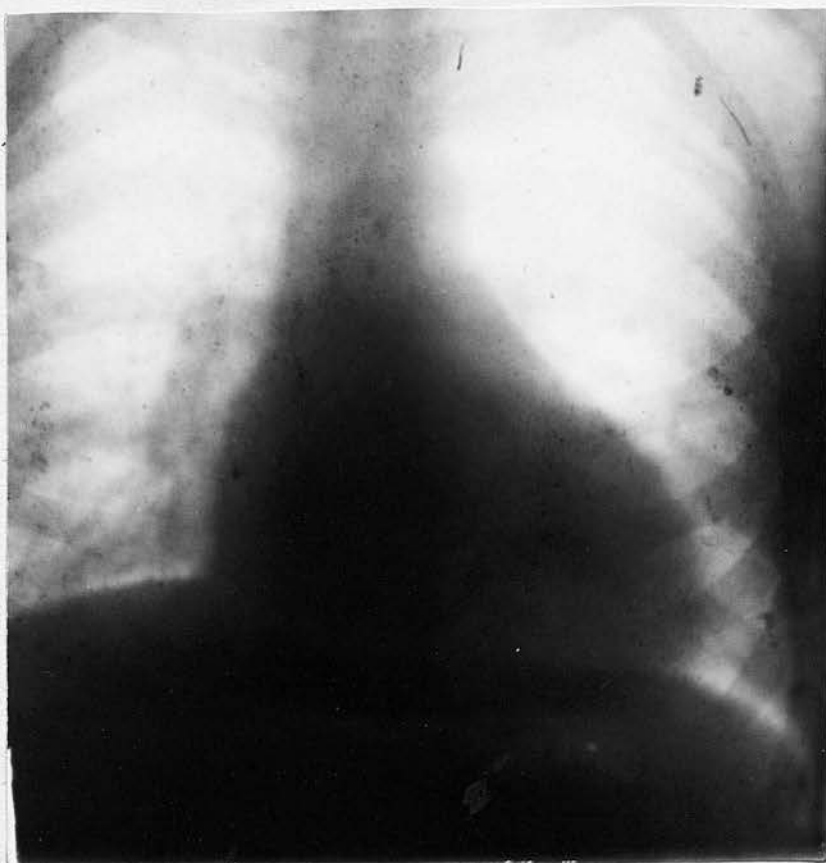
No. 6 Pen. J.B. Aged 32. Admitted April 1920.

No history of Rheumatic fever or syphilis.

Symptoms. Dyspnoea, general weakness, palpitation, slight vertigo, slight oedema of feet, occasional attacks of stabbing pain starting at lower end of sternum and radiating upwards.

Physical signs. Malar flush. Heart, apex beat heaving and diffuse 1" outside nipple line on 5th, space. Mitral systolic and well marked diastolic. Aortic systolic occasionally heard.

Wasserman ± B.P. 130.



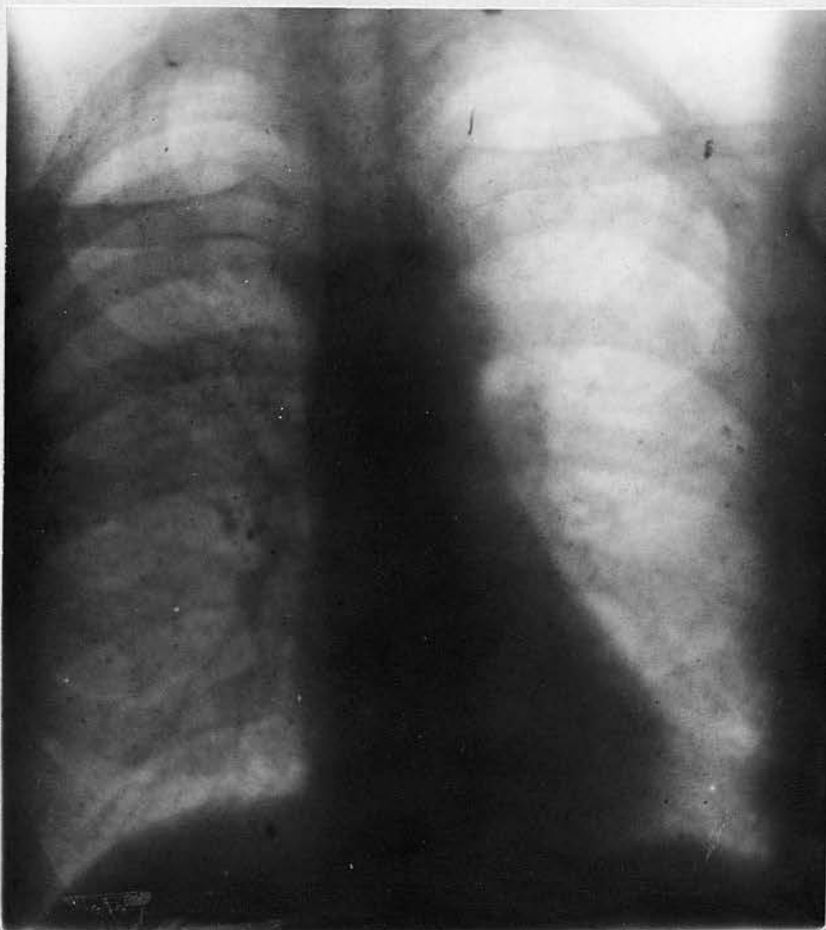X-ray. Shews slight increase in aortic shadow at first position of aorta.  
Heart increased in size.

No. 7. Pen. W.J.B. Age 53. Admitted Feby. 1920.

Rheumatic Fever 1916. Syphilis 1917.

Symptoms :- Dyspnoea, pain across upper portion of chest, of a sudden sharp stabbing character, occasional fainting turns.

Physical signs. Anxious expression with greyish complexion. Eyes sunken, diffuse pulsation all over chest and in vessels of neck. Rough presystolic mitral bruit, no increase in aortic dulness, no aortic bruits. Wasserman ++. Aortitis not definite but suspected on account of symptoms etc.,



X-ray shows normal but pear shaped heart and aorta.

No. 8. Pen. T.P. Age 33. Admitted 16/12/19. stated that he was quite healthy till June 1918 when he took influenza out of which he developed heart trouble (He was in my unit in France and was always below the average in fitness.)

Symptoms. On admission he complained of pains all over chest lasting from one to two hours and accompanied by weakness in the legs. He is greatly troubled with night sweats and has also a cough which becomes worse at night.

He denies syphilis. Wasserman ++. 18/12/19.

Physical signs. He looks anaemic and has a sallow complexion.

Heart. Apex beat 5th, space in nipple line; impulse heaving; pulse 80 regular.

Mitral systolic bruit well conducted towards axilla and associated with a reduplicated second sound.

Aortic systolic with a definite diastolic.

Slight pulsation in suprasternal notch.

In Jan. 1920, he developed a temperature; pain and dyspnoea got worse; evidence of Broncho-pneumonia patches in both lungs. Haemoptysis began about 17/1/20. and continued till death on 23/1/20.

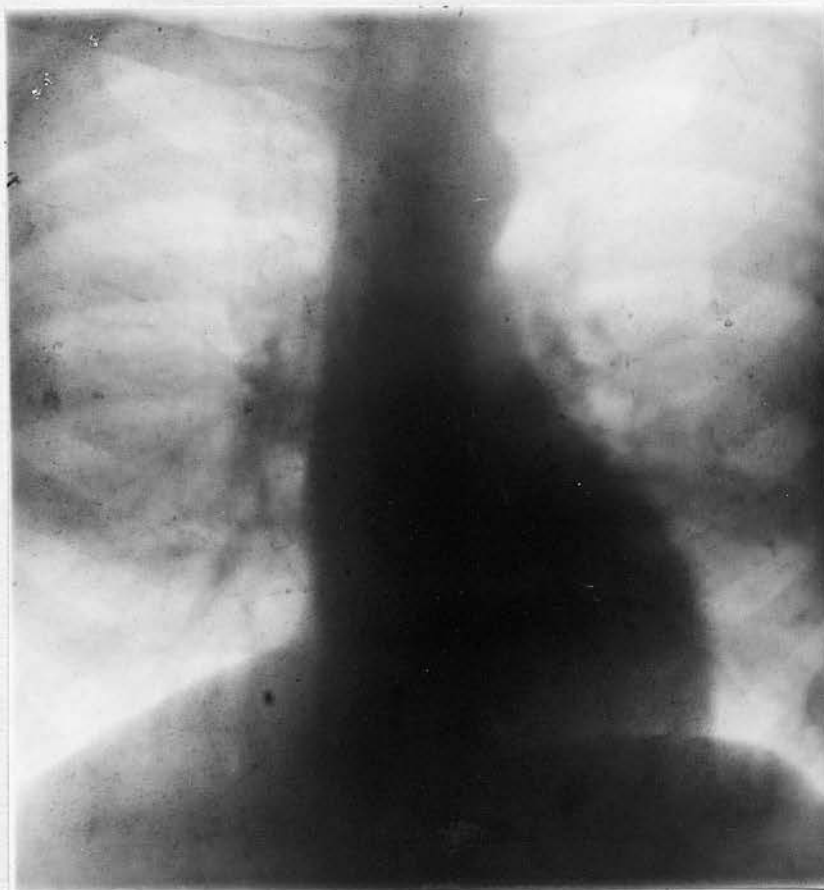Post mortem not obtained. X-ray not taken.

No.9. Pen. J.R. Aged 36. Labourer, Admitted to Hospital 10/12/20. Denies venereal disease in any form.

Symptoms. Dyspnoea, pain in right side of chest, vomiting, occasional palpitation with some pericardial pain.

Physical signs. Complexion yellowish grey in colour. Marked pulsation in supraclavicular regions especially at night. Aorta palpable in suprasternal notch. Definite diastolic shock. No apparent increase in aorta dulness. Hypersensitive area in region of left clavicle. Apex beat diffuse. Definite systolic and diastolic aortic bruits. Second aortic being somewhat clangy in character. Slight tracheal tug.

Wasserman ++. B.P.140.



X-ray shews no definite increase in aortic shadow.  
Aortic knob well marked.

No. 10. Pen. W.H.B. Aged 38. History; moderate drinker; denied syphilis; occupation iron moulder.

Influenza in France in October 1916. 4 months in bed. Since then has been troubled with his heart.

Discharged Jan. 1917, with V.D.H. Reenlisted in August 1918 and served till March 1919, when discharged with V.D.H. For 6 weeks before admission to Hospital, he got no sleep at night owing to dyspnoea and pain radiating from sternum and left side of chest down left arm. On admission, he looked very ill and very anaemic; eyes shining; could scarcely get a breath and complained of intense pain at back of left lung and down left arm.

Examination: Heart enlarged at base; dulness extending higher than normal upwards. Apex beat 6th rib in nipple line. Veins in front of left chest were markedly distended; vessels of neck pulsating; radial arteries thickened atheromatous; double Aortic bruit at base; diastolic being well marked.

Diastolic bruit in mitral area and systolic in pulmonary area.

Abdomen some dulness both flanks? fluid.

Wasserman +†

Teeth showed marked pyorrhoea. Discharged 1/10/19, feeling much better and anxious to resume work, but advised not to go back to his too strenuous job.

18  
Admitted to R.V.H. 1/12/19. with profuse Haemoptysis  
and died 2/12/19.

Post mortem showed normal heart with greatly dilated  
aorta with definite syphilitic aortitis and rupture into  
trachea.

No. 11. B. McC. Age 39. Labourer. Admitted 16/1/20.

Denies syphilis.

Symptoms. Complains of pulsation at upper end of sternum; and a dull intermittent pain in this region radiating up towards left side of neck; of general weakness; of dyspnoea on exertion.

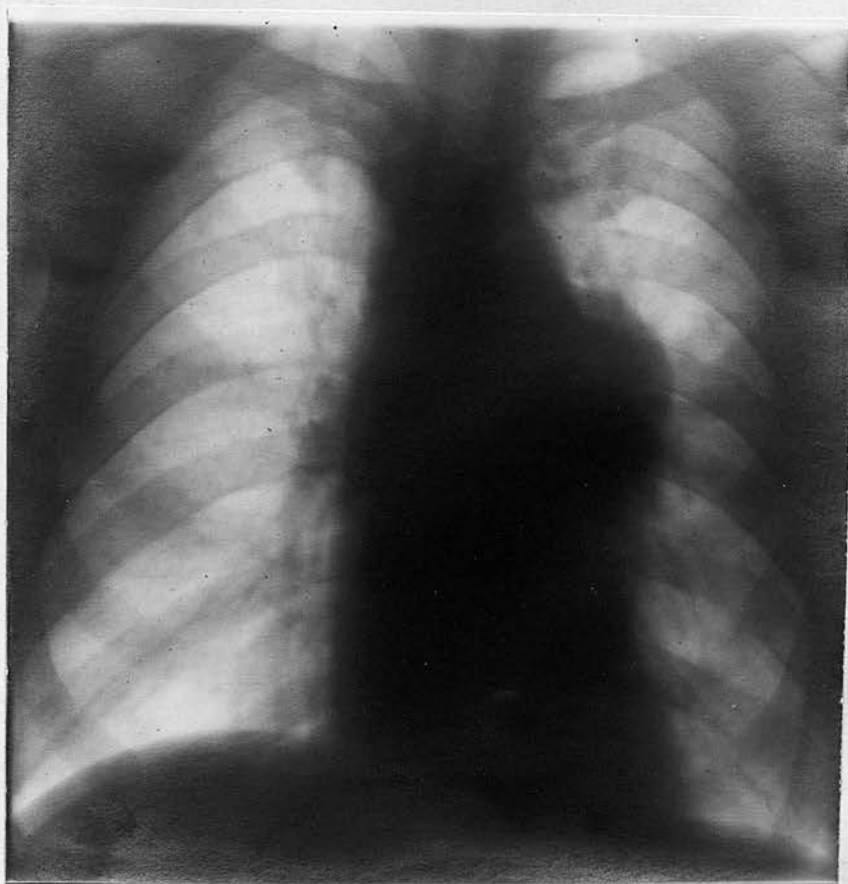
Physical signs. Sallow complexion; Heart not enlarged, definite pulsating swelling seen and felt in 2nd, left interspace. A faint thrill present. Diastolic shock well marked. Tracheal tug. Pupils equal.

Systolic and diastolic aortic bruits, latter is harsh and loud. Pulse left radial much smaller than right.

B.P. 110.80 right.

100.75 left.

Wasserman +.



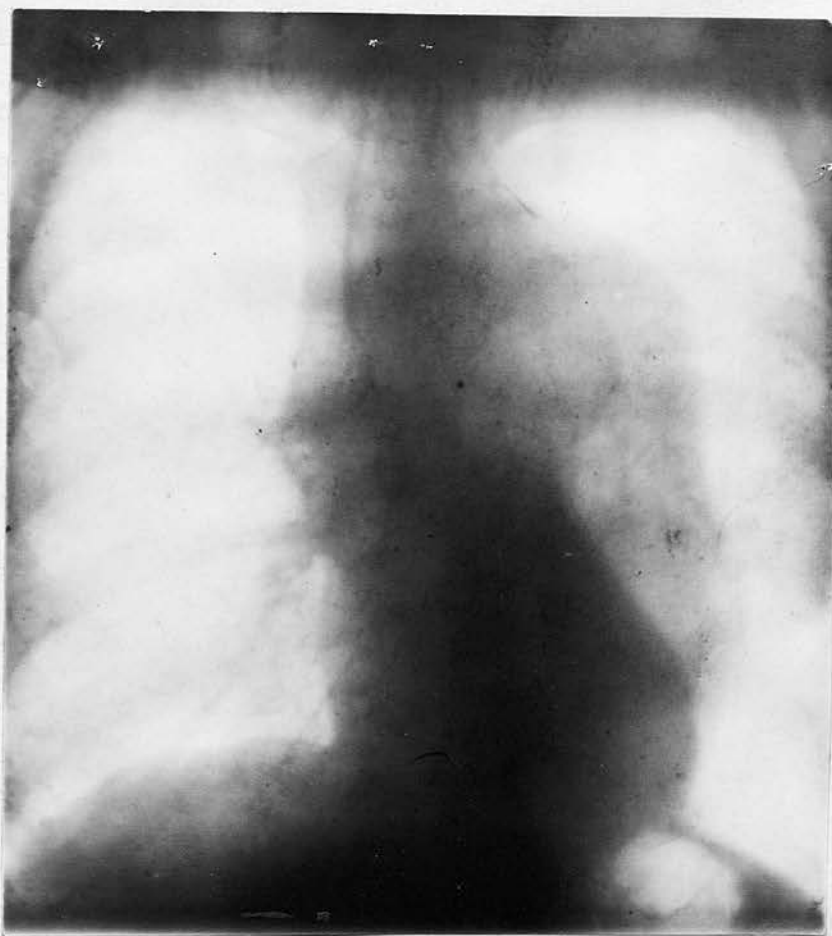
X-ray. Very elongated tubular type of heart swelling in aortic arch, to left side suggesting an aneurism of the arch and beginning of descending aorta.

No. 12. Pen. H.R. Age 40. Merchant Seaman. Admitted 26/4/20.

Denies syphilis. States he was lucky.

Symptoms. Complains of pain in back between shoulders, and at lower part of chest anteriorly. No radiation of pain to arms; of a smothering choking sensation at root of neck; of slight cough; of dizziness.

Physical signs:- Anaemic looking. Heart apex beat 5th, space in nipple line. Systolic mitral and, diastolic Aortic with second sound booming. Aortic dulness increased, 9.5 cm at level of 2nd rib. Suprasternal pulsation, Tracheal tug, pupils equal, pulses correspond. Wasserman++. B.P. 140.



X-ray shows a large aneurism of descending thoracic Aorta with dilatation of ascending Aorta. Heart shows no definite increase in size.

No. 13. J.T. Aged 40. Admitted 5/1/20.

He was discharged from Army in 1915, because of a G.S.Wd. right arm. Shortly after discharge he began to get easily tired and short of breath at times, though between attacks he felt quite fit. In the spring of 1919, these attacks got worse and became more frequent; no definite pain but a sense of constriction in upper part of chest which was made worse by exertion. On admission he looked ill and was collapsed.

Pulse rapid 108; temperature subnormal 97. He had a slightly cyanosed complexion but otherwise it was of a yellow, earthy character. He complained chiefly of the substernal pain and dyspnoea, both of which were worse at night and prevented his sleeping. No oedema on admission.

The feeling of dread was very marked.

Heart: Apex beat  $\frac{3}{4}$ " external to nipple line in 5th, space. Right border just outside of right edge of sternum. There was a well marked aortic diastolic bruit was also present. Pulsation generalised over praecardial area; slight episternal pulsation. No tracheal tug. Wasserman +.

He failed to respond to the usual treatment for his cardiac symptoms in conjunction with iodides and mercury. One dose of novarsenobillon was also given. His condition gradually became worse and he died three weeks after admission.

A post mortem was performed and a definite syphilitic aortitis with an enlarged heart was found. This will be described later.

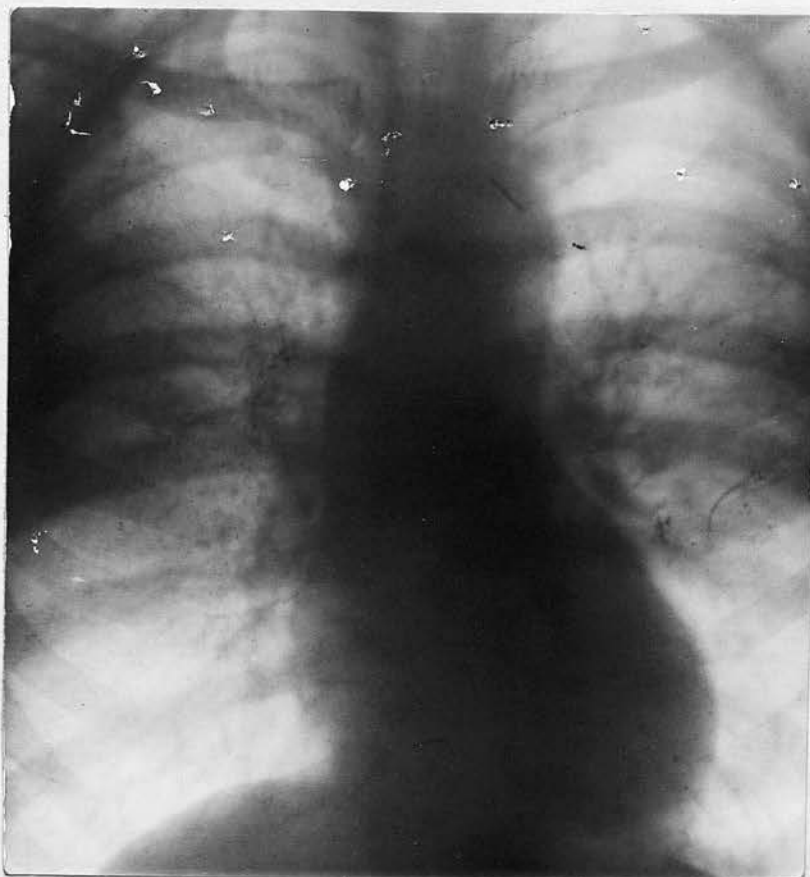An X-ray photo could not be taken because of the seriousness of his condition on and after admission.

No.15. Pen. J.B. Age 41. Admitted 8/3/21.

Denies syphilis.

Symptoms:- Palpitation and dyspnoea on exertion with twinges of pain at upper end of sternum and sense of tightness in upper part of chest on exertion.

Physical signs. Sallow complexion, marked pulsation in carotids, Supra clavicular and suprasternal notch. Aorta palpable, slight pulsation in second right space. Slight increase in aortic dulness. Well marked systolic and diastolic bruits. Doubtful diastolic shock. Wasserman $++$ . B.P. 145.



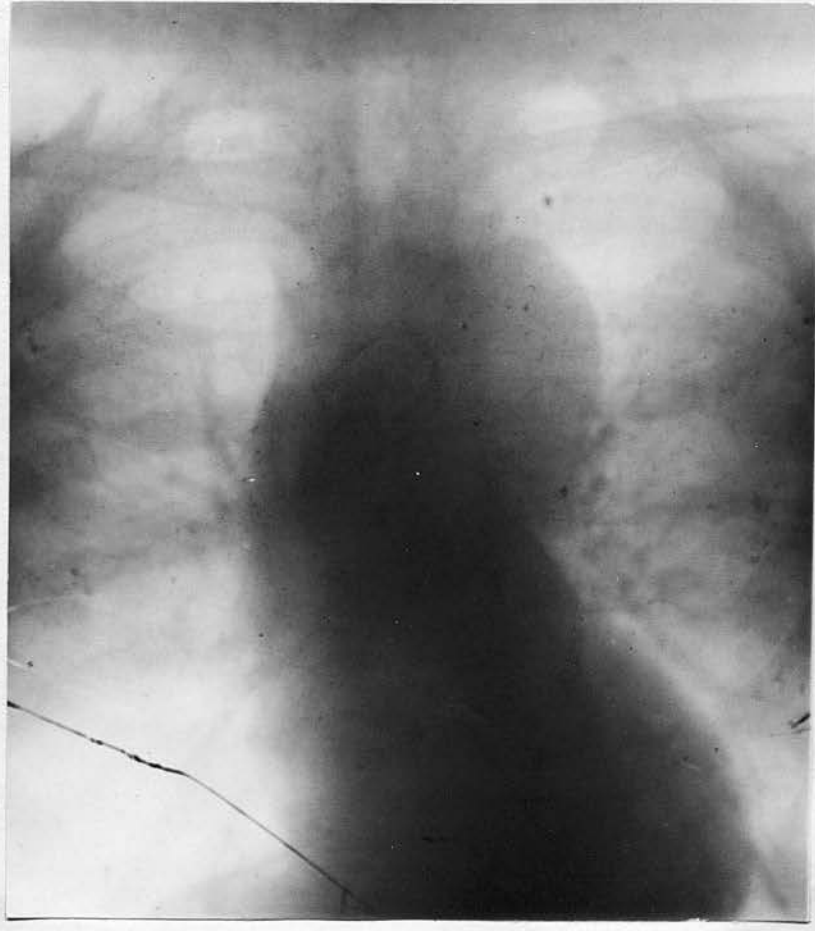
X-ray shows definite increase in Aortic shadow in ascending aorta. Aorta knob not well marked. No evidence of aneurism.

No. 16. Pen. W.J. Age 41. Admitted 15/3/20. Denies syphilis.

Symptoms:- Pain across chest and dyspnoea started 1916. On admission he complained of pain radiating towards left shoulder. It comes on after exertion or lying down at night. Dyspnoea is most marked at night. He states he is afraid of choking owing to a catch at upper part of sternum, slight vertigo, no cough, no dysphagia.

Physical signs. No anaemia, some fullness of veins in neck and upper part of chest. Pulse regular, not collapsing, right better felt than left.

Pulsation in supra sternal notch and slight in second right space. Aortic dulness increased, 9.5 cm. Heart enlarged. Double aortic bruit diastolic well marked, slight clanging characteristic, no definite shock, slight tracheal tug. Right pupil larger than left. B.P. 170.140. Wasserman ++.



X-ray shows dilatation of first part of Aorta with definite large aneurism of Transverse Aorta.

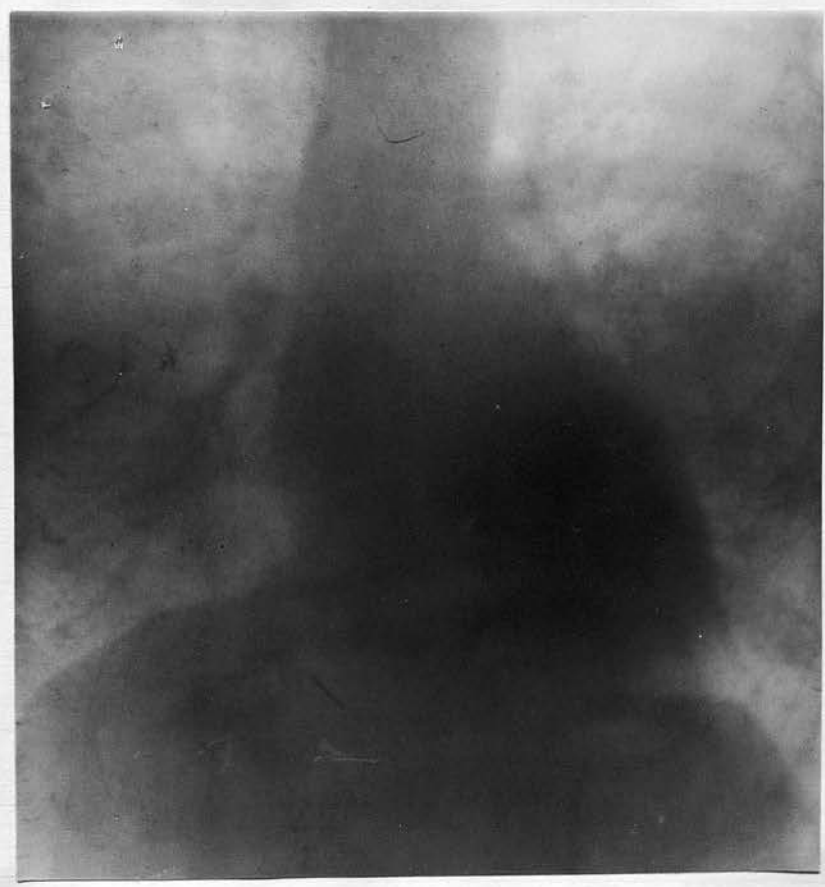
No. 17. Pen. E.G. Age 41. Admitted 15/1/21. States Syphilis in 1914.

Symptoms. Dyspnoea and "stuffed up" feeling in chest.

Pain, Substernal wrist in mornings immediately after rising. Palpitation at frequent intervals. Dyspnoea is worse at night and after exertion.

Physical signs. Pulsation in vessels of neck, in supra sternal notch and at second left interspace, with a diastolic shock on palpation. Slight pulsation 2nd right space, slight bulging 2nd left space. Heart is enlarged, apex beat 6th, space in nipple line.

Aortic dulness 8 cm. at level of 2nd space. Double aortic bruit. B.P. 160.40. Wassermann++.



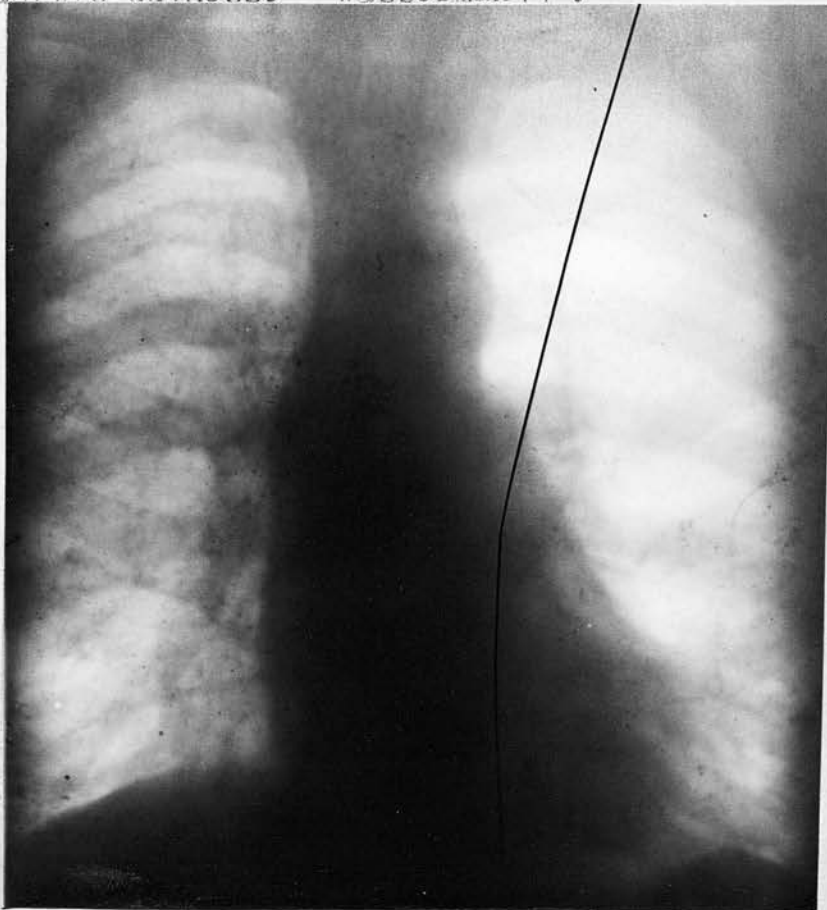
X-ray shows slight increase in aortic shadow at first part of aorta at its junction with heart. Aortic knob is lost. Heart slightly enlarged.

No. 18. Pen. J. McD. Age 42. Admitted 11/2/20.

Syphilis in 1899.

Symptoms:- Complains of giddiness, Dyspnoea and Substernal pain first noticed in 1917 and getting gradually worse. Also of pain and sense of soreness near left nipple, which is tender on pressure. Occasional shooting pains in upper part of chest after exertion.

Physical signs:- Heart sounds muffled. Soft blowing mitral systolic. Aortic diastolic shock. No increase in aortic dulness. Wasserman++.



X-ray shows signs of slight dilatation of first portion of ascending aorta.

No. 19. Pen. D.H.T. Age 43. Admitted 16/4/20.

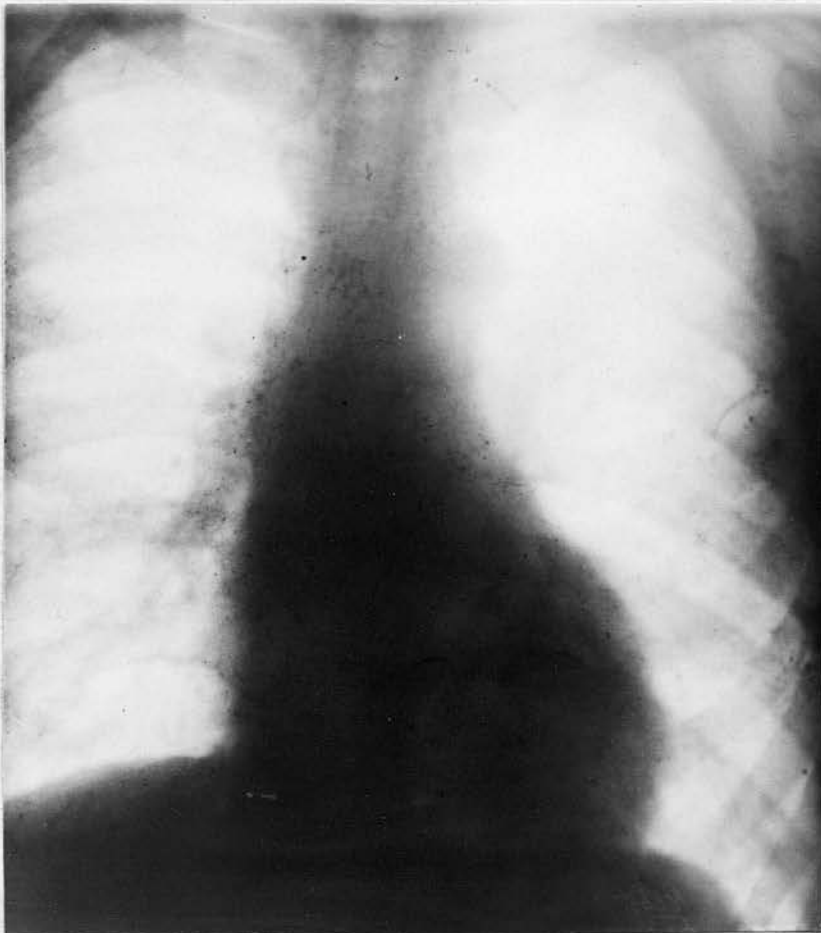
Syphilis 25 years.

Symptoms. In August 1918 suffered from Dyspnoea.

Cough and spit; became easily tired and had to fall out on Parade. Now complains of substernal pain worse at night or after exertion and radiating towards left shoulder, also of choking sensation at root of neck.

Numbness in hand, marked dyspnoea when pain is present, no vertigo.

Physical signs. Heart not enlarged; aortic dulness increased especially in left side 8.5cm. Double aortic bruit, diastolic clanging in character, diastolic shock, suprasternal pulsation also pulsation in neck. Faint Tracheal tug. Wasserman++. B.P. 140.

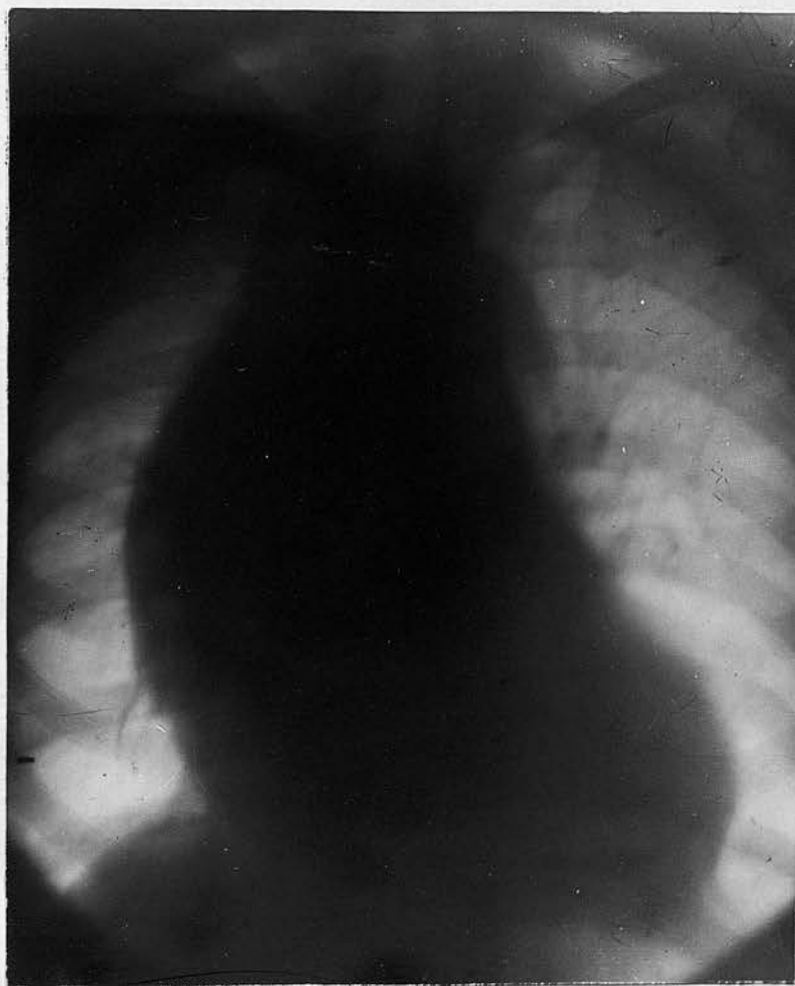


X-ray shows dilatation of ascending aorta most marked at first portion. Heart slightly enlarged.

No.20. J.M. Age 43. Seen at extern 3/5/20, States Syphilis 20 years ago.

Symptoms. 3 months ago began to be troubled with a pain in right side of chest to right of sternum about level of second and third ribs. This was associated with dyspnoea on exertion. Both pain and dyspnoea are present at night. Hoarseness and slight metallic cough.

Physical signs. Heart enlarged, definite pulsation in second right space, not so marked in suprasternal notch. Pulses unequal, pupils unequal. Double aortic bruit, diastolic is loud with clanging characteristic and is heard practically all over the upper part of chest. Tracheal tug not definite. B.P. 140. Wasserman Negative.



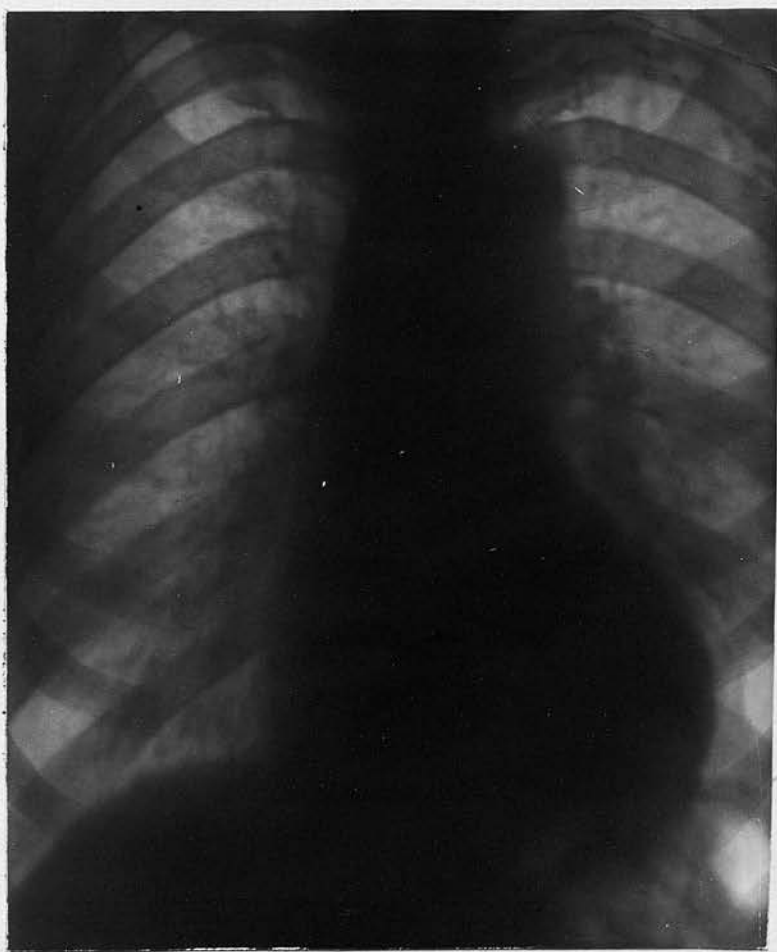X-ray. Heart greatly enlarged especially towards Right side. Aorta enlarged to both right and left of sternum and extending up to episternal notch. Aortitis with marked dilatation. ? Fusiform Aneurism.

No. 21. Pen.SMc.A. Age 45. Admitted 2/6/20. Colonial Medical Service. Numerous attacks of Malaria but denies syphilis.

Symptoms. Pain across chest radiating from upper end of sternum outwards towards left shoulder; dyspnoea on exertion.

Physical signs. Ears and face show marked cyanosis. Heart is enlarged, apex beat in 6th, space just external to nipple line. Well marked double aortic bruit, 2nd sound somewhat clanging in character. Pulsation in suprasternal notch, Aorta palpable. Increase in aorta dulness. 9 cm. by measurement at second left and second right spaces.

B.P. 220 systolic, 140 diastolic. Wasserman Negative.



X-ray shows definite well marked dilatation of ascending and transverse aorta. Aortic knob still visible. Heart shows marked enlargement.

No. 14. Pen. J.Mc.L. age 40. Seen at Medical Board, states Syphilis 12 years ago.  
 No symptoms pointing to cardiac condition.  
 Diastolic aortic bruit with diastolic shock.  
 2nd aortic sound has clanging characteristic, slight increase in aortic dulness.  
 Wasserman++ . X-ray not taken.

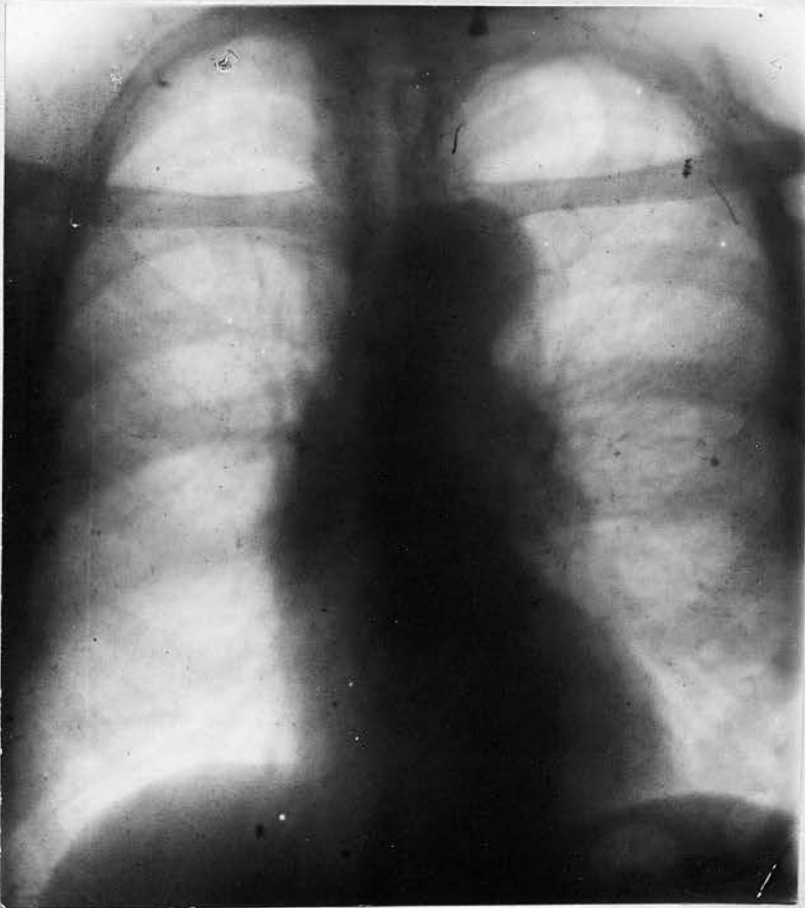No.22. Pen. H.B. Age 45. Seen at Medical Board. Syphilis in 1895.  
 Complains of dyspnoea,worse at night, dizziness, substernal pain radiating to left shoulder.  
 Heart not enlarged, pulsation in suprasternal notch.  
 Aortic systolic and diastolis. No definite diastolic shock.  
 Wasserman negative. X-ray not taken.

No 23. Pen. J. L. age 45. Denies Syphilis, seen at Medical Board.  
 No symptoms pointing to cardiac condition. Well marked aortic diastolic with definite diastolic shock. Slight pulsation 2nd left space. Slight increase in Aortic dulness.  
 Wasserman++. X-ray not taken.

No. 24. Pen. H.B. age 46. Admitted 12/6/20. Syphilis in 1897.

Symptoms. Cough, worse at night, husky in character, fainting attacks about once a week. Boring pains below sternum, dyspnoea on exertion, and at night, vertigo is often marked, causing him to fall. Sleep impaired on account of cough and dyspnoea.

Syphical signs. Pulsation in vessels in neck, and in suprasternal notch. Tracheal tug. and marked pulsation 2nd right space, diastolic shock, aortic dulness 8 cm. Double aortic bruit, diastolic well marked. Heart not enlarged. B.P. 190. Right pupil dilated. Right pulse better felt than left. Wasserman ++. X



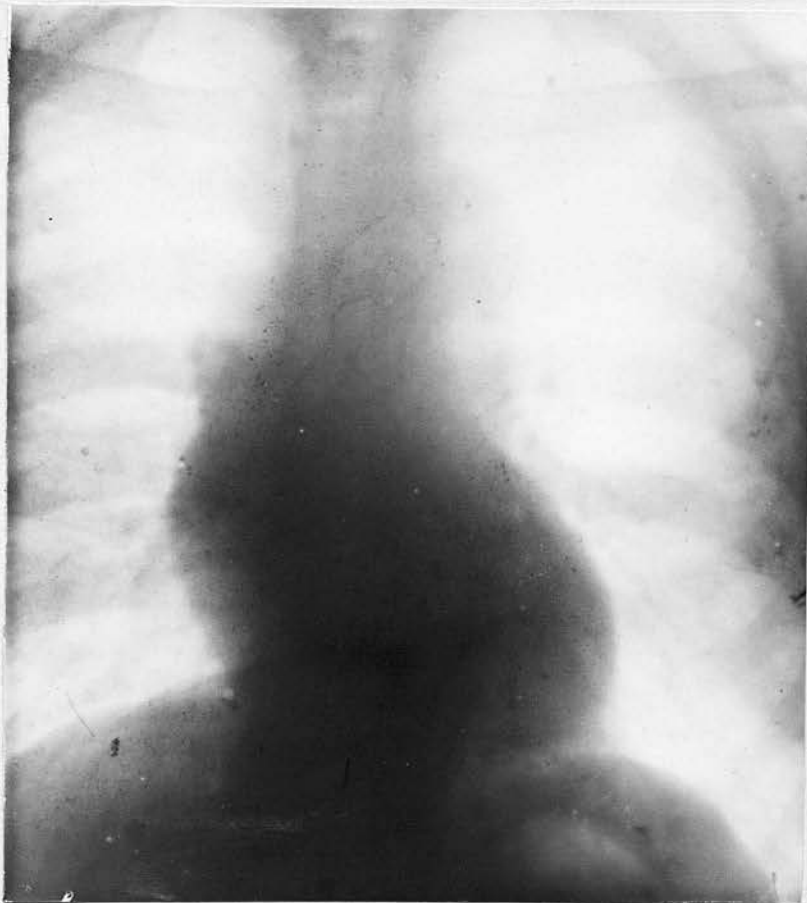X-ray shows increase in ascending and descending aortic shadows.

No. 25. Pen. L.C. Age 46. Admitted 17/5/20. Syphilis in 1897.

Symptoms. Attacks like Malaria every 2 months, but not exposed to infection for years. Attacks not typical, no other symptoms, no pain, no dyspnoea.

Physical signs. Slight increase in aortic dulness, no tracheal tug. Double aortic bruit. Pupils equal, pulses equal.

Wasserman++ . B.P. 150.



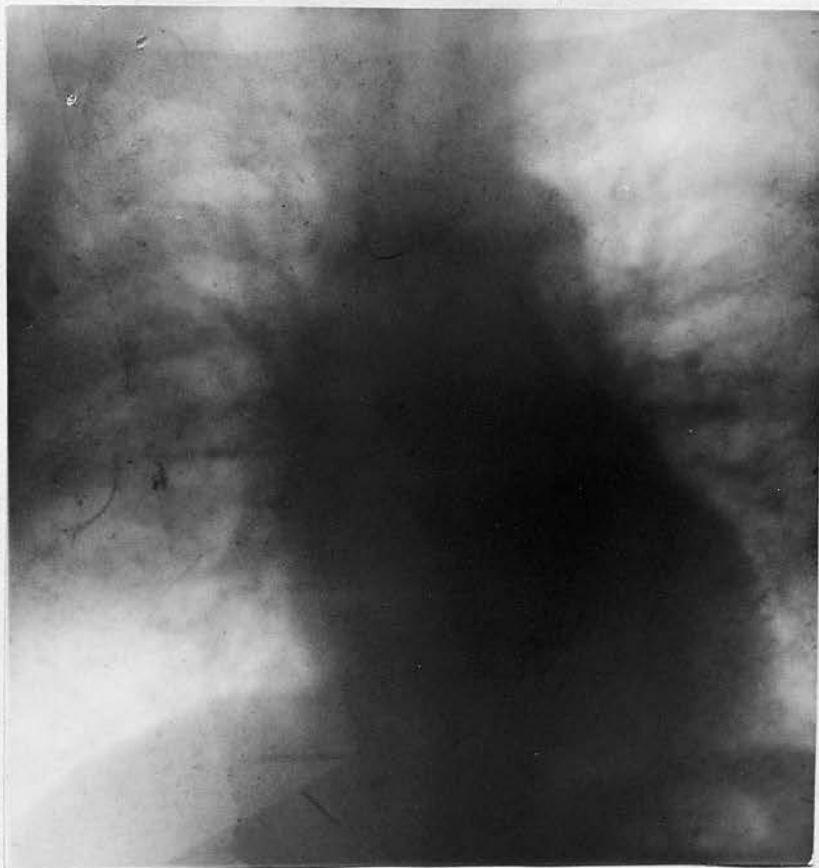X-ray shows aneurism of ascending portion of the Aortic Arch and increase in right auricular shadow. Heart is enlarged.

No. 26. Pen. R.B. age 46. Admitted 15/1/21. Denies syphilis but had gonorrhoea 24 years ago.

Symptoms. Started with dyspnoea in 1917. One year ago began to feel a gnawing intermittent pain in left axillary region. Now complains of this pain; of a smothering at night with sense of constriction in chest, no definite substernal pain but states pains down both shoulders and arms.

Physical signs. Increased dulness at level of 2nd right and 2nd left spaces, most marked at left. Hypersensitive area upper end of sternum. Diastolic shock, double aortic bruit, supra-sternal and supra-clavicular pulsation. Slight venous engorgement left side.

B.P. 160.50. Wasserman ++.



X-ray. Heart enlarged. Definite increase in width of aortic shadow. Aortic knob lost. No definite aneurism.  
Aortitis with marked dilatation.

No.27. Pen. J.N. Age 48. Admitted 25/9/19. House painter. States no previous illnesses except Syphilis 20 years ago. Demobilised Feby. 1919.

States that when coming home from France on leave towards the end 1918 he felt a severe pain over heart; felt weak and had some difficulty in breathing. It improved however, and he started work in March 1919, but had to give it up on account of a return of the pain and weakness. On admission his chief complaints were insomnia due to dyspnoea and a sense of soreness and constriction behind sternum. He had definite vertigo with occasional vomiting, no oedema of legs on admission.

Heart. Double mitral and double Aortic bruits.

Heart enlarged to left, Apex beat 6th space in nipple line. Aortic dulness increased 9 Cm. Marked pulsation in vessels in neck. Fulness of veins in neck and across chest. Some free fluid in abdomen. Liver slightly enlarged. Lungs show oedema of both bases. Cough was marked and sputum copious. Insomnia was chief complaint. Condition got gradually worse.

Heart did not respond to stimulants. He became very oedematous and died on the 5th, Novr., A post mortem was not obtained. He was too ill to be X-rayed.

Wasserman ++.

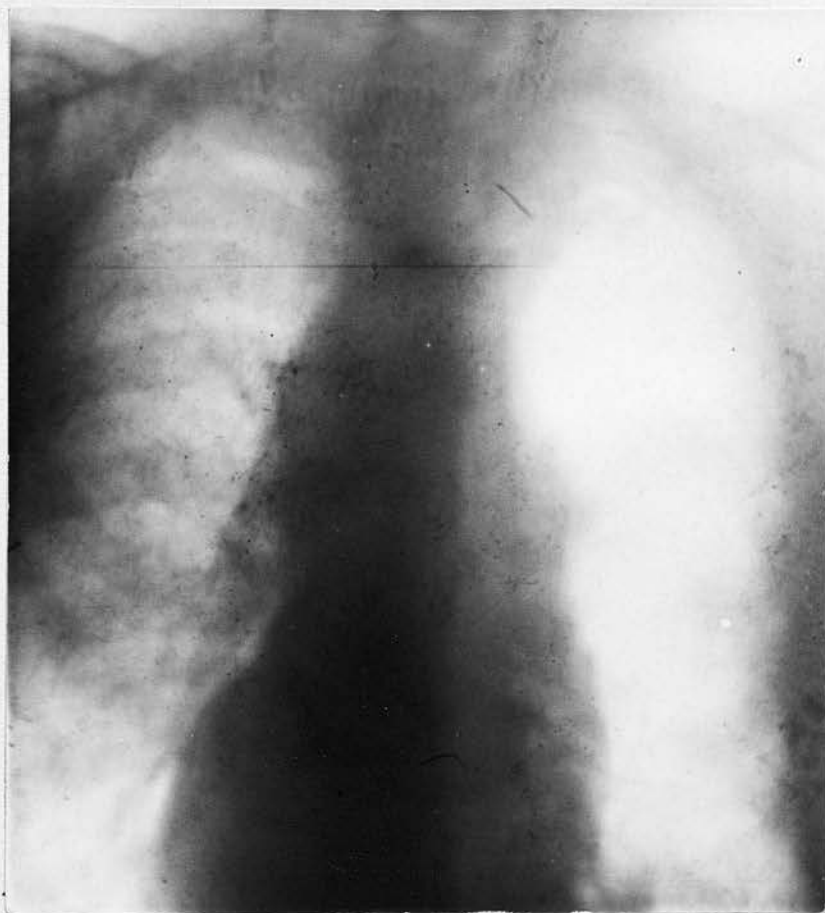
No. 28. Pen. J.C. Age 52. Admitted 8/12/19. Syphilis in 1991.

Symptoms. Pain in region of left nipple worse after exertion; dyspnoea; of a "Catch". (Sense of constriction) at root of neck. Occasional substernal pain.

Physical signs. Complexion sallow. No abnormal pulsation. Aortic dulness increased especially to right side .8 cm.

Aortic diastolic with a clanging second sound.  
Soft faint systolic.

Wasserman ++ . B.P. 140.

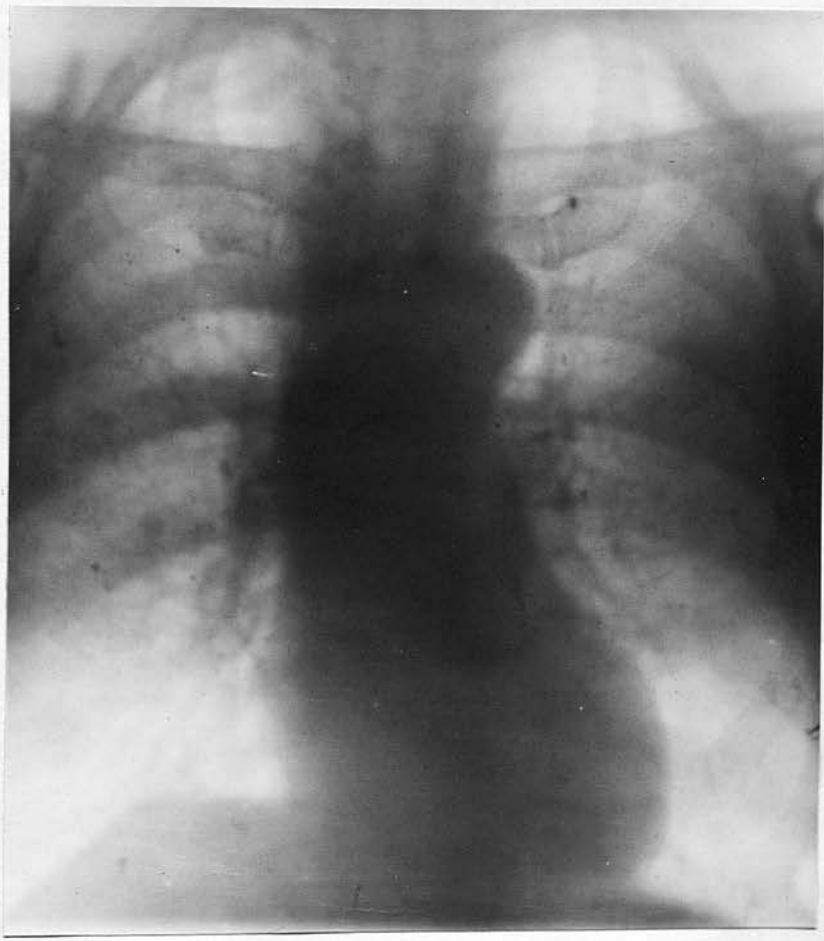


X-ray shows fusiform dilatation of ascending Aorta.  
Heart pushed somewhat to right side.

No. 29. Pen. J.G. Age 52. Admitted Novr. 1920. No History of Syphilis or Rheumatic fever.

Symptoms. Pain in left side at region of nipple, described by him as if a knife was pushed in and twisted round; general weakness, dyspnoea, on exertion, oedema, slight in evenings when he leaves off work, slight cough but no spit.

Physical signs. Heart not enlarged. Mitral systolic and diastolic bruits; Aortic systolic. Second sound distinct and accentuated. Marked pulsation in suprasternal notch. Subclavians palpable above the clavicles. Aorta palpable, dulness over manubrium Sterni. B.P. 150. Wasserman negative.



X-ray shows projection of Aortic shadow much more to left than normal. Some dilatation of ascending aorta. Shadow higher than normal. Heart normal in size.

No.30. Pen. S.R. Age 53. Admitted 28/9/19.

Moderate drinker, denies syphilis but states wife has had two miscarriages. Joined Army in 1914 but was discharged in 1915 on account of defective vision.

Symptoms. On 18/3/19 he took a severe pain in the right shoulder and breast, extending down to right

arm, almost to hand. This has increased in frequency and severity. On admission he complained of this pain, of marked dyspnoea, both were worse at night.

Fingers of right hand get a "dead" feeling when pain is present.

Cough Brassy in character but no spit.

Physical signs. Fulness of veins in neck and across the right side of chest. Pulsation in neck, Supra-

sternal notch and an expansile pulsation at 2nd right interspace. Aorta is palpable in suprasternal notch.

Increase in Aortic dulness, 10 cm. Pupils are equal.

Pulses are equal. Marked tracheal tug. Soft blowing systolic bruits at mitral and Aortic areas. Well marked diastolic shock and low pitched sound over pulsating area. Aneurism shows visible pulsation.

Wasserman ++ .

X-ray photo not taken.

No. 31.

Pen.R.Mc.K. Age 53. Admitted 10/12/20. Syphilis in 1891.

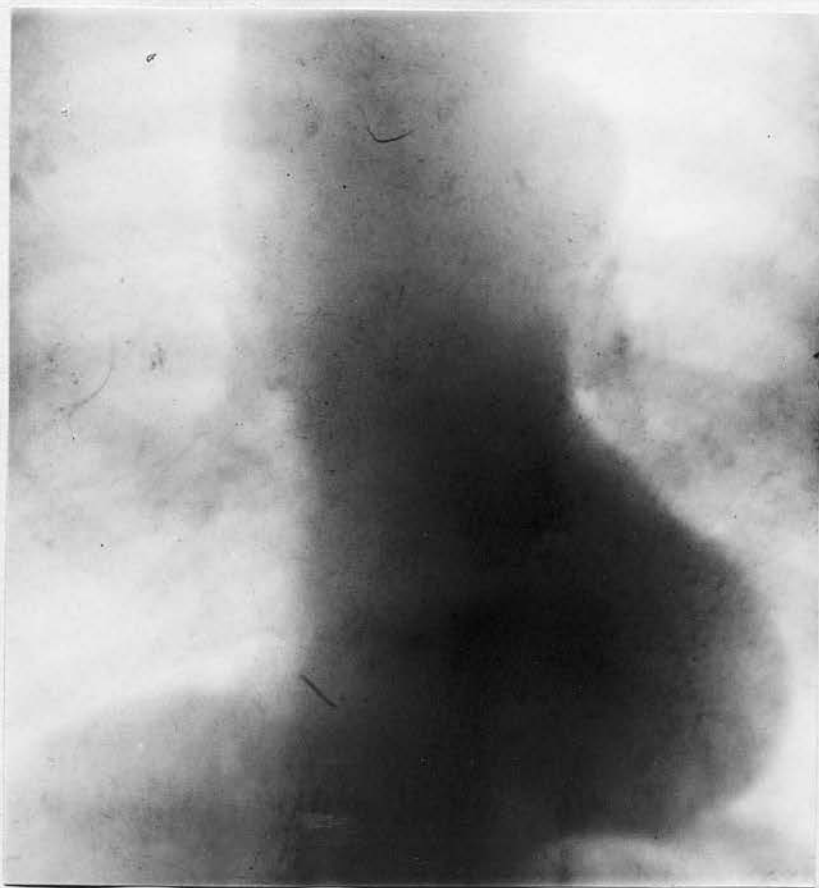Symptoms. Dizziness and faintness on walking. Dyspnoea, worse at night and after exertion. Pain and soreness in region of left nipple and at upper part of sternum. No radiation of pain but numbness in fingers. Sense of constriction in upper part of chest. Is easily tired. Hoarse clanging cough.

Physical signs. Complexion yellowish grey colour. Large pulsating swelling at 2nd, right space extending across sternum, Aortic dulness 11.5 cm. Suprasternal and Supraclavicular pulsation. Aorta palpable in Suprasternal notch. Pupils equal.

Heart enlarged, Apex beat 6th, space 1" outside nipple line. Loud 1st, Aortic sound and booming 2nd, sound with a faint bruit with each.

Pulses equal. B.P. 162.80.

Wasserman++.



X-ray shows definite aneurism involving the ascending and transverse portions of Aorta and extending to the to both sides of Sternum. Dilatation at 1st, part of Aorta. Heart not much enlarged.

No. 52. Pen. P.Mc.H. Aged 55. Admitted 11/5/20.  
He was an old soldier, rejoined Army in 1914.  
Home Service. Discharged Jan. 1919.

Two years ago he complained of Bronchitis-cough, spit;  
pains in back; shortness of breath. Legs began to  
swell, chiefly due to varicosity of veins.

On admission complained of pains in back and in  
muscles of left arm, of cough, shortness of breath, after  
coughing he felt a soreness in epigastrium.

Syphilis in Egypt about 30 years ago.

Wasserman++.

Heart.

Apex beat, feeble but not displaced. Doubtful aortic  
diastolic: 2nd sound clanging in character; no  
increase in Aortic dulness but Suprasternal pulsation  
present.

Pupils equal.

Tracheal tug absent.

Blood pressure; systolic 220; diastolic 80.

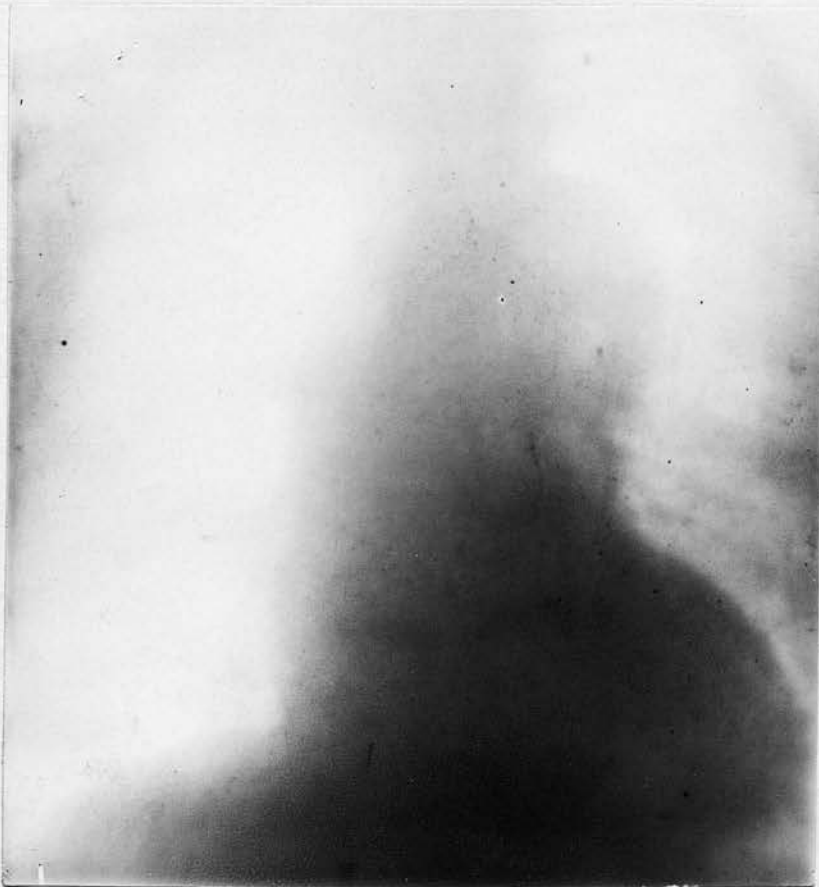X-ray shows normal Aorta.

Chest was screened. No photo available.

*General*  
No.33. W. Mc A. Age 55. Admitted 16/1/20. States had Syphilis in 1895.

Symptoms:- General fatigue and dyspnoea in 1916, but worked till 1918, when he complained of Vertigo, dyspnoea, sense of constriction upper part of chest, present either by day or at night, disappearing after a sensation of something like "wind", breaking.

Physical signs:- Sallow complexion, pulsation in vessels of neck. Systolic bruit heard in all areas. Aortic diastolic 2nd sound of clanging character. Some increase in Aortic dulness. Right pulse much better felt than left. B.P. 140.  
Wasserman ++.

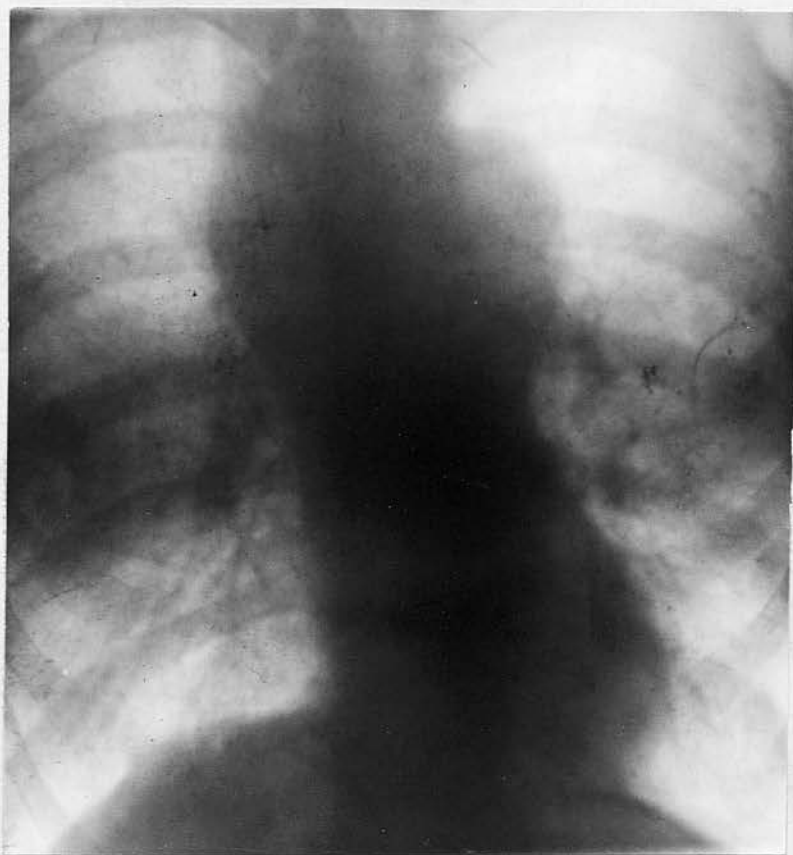

X-ray shows increased Aortic shadow in ascending and transverse position of Aorta. ? Aneurism or fusiform dilatation of Aortitis.

No. 54. Pen. J.T. Age 55. Admitted 27/9/20. States had Syphilis 30 years ago.

Symptoms. In 1917 became dyspnoic on exertion with pain at left side of sternum radiating down Sternum and to left shoulder and arm. Hoarseness and difficulty in swallowing.

Physical signs. Greyish Anaemic appearance. Veins prominent left side of neck. Thyroid and Cricoid bulged forward. Pupils equal, pulses regular, Tracheal tugging, pulsation well marked in carotids and supra-sternal notch. Slight pulsation in 2nd right and left spaces. Heart enlarged, Apex beat 6th, space outside nipple line. Aortic dulness 10.5 cm. 2nd Aortic sound markedly accentuated and of clanging character. B.P. 140.40. Wasserman ++.

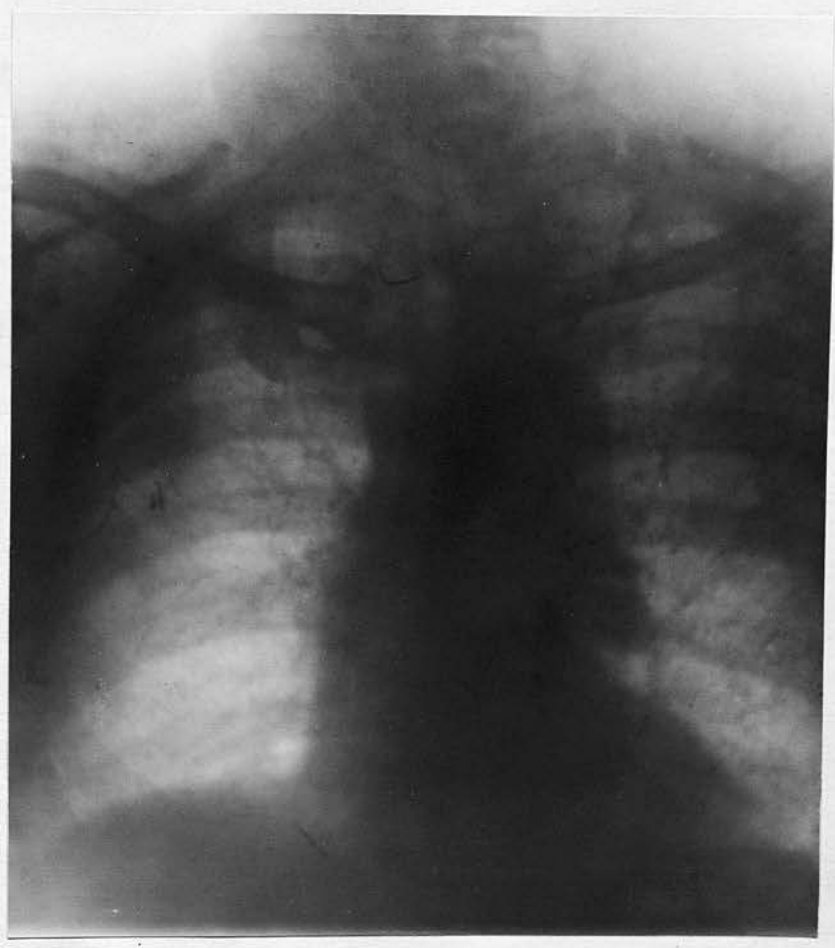


X-ray shows large aneurism of transverse and upper part of ascending Aorta. Heart not enlarged.

No. 35. Pen. R.B. Age 58. Admitted 6/9/20. Denies Syphilis.

Symptoms. Complains of pains in region of heart and of shortness of breath, pain most marked in upper sternal region.

Physical signs. Dyspnoic looking on admission. Complexion greyish, with a yellowish tinge. Pulsation in suprasternal notch, none in front of chest. Pulse irregular rate 90. Double Aortic bruit. 2nd sound clanging in character. B.P. 180.90. Wasserman +.

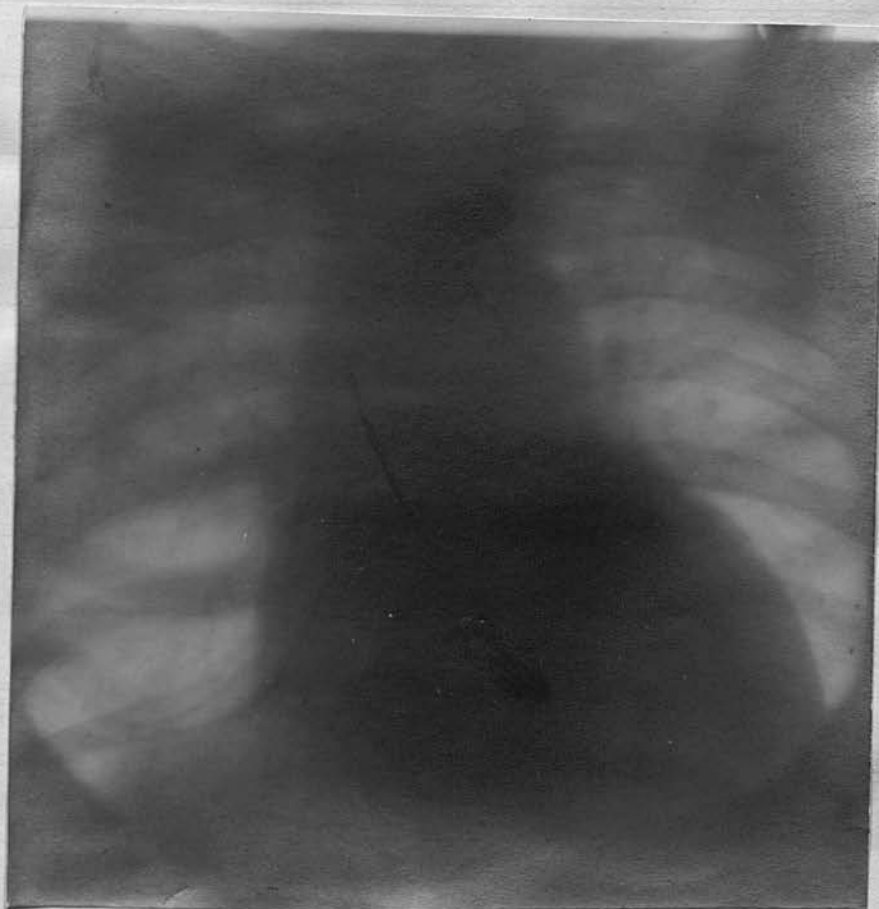


X-ray shows no evidence of aneurism but there is dilatation of first portion of Aorta. Knob not well marked.

No. 36. Pen. W.A. Age 60. Driller. Admitted 5/2/20.  
Syphilis 35 Years ago.

Symptoms. Pain and discomfort in region of heart,  
5 years duration; Dyspnoea and cough, much worse at  
night preventing him sleeping; general weakness.

Physical Signs. Sallow complexion. No oedema. Slight  
fulness of veins in neck and front of chest. Heart  
apex beat 5th, space  $\frac{1}{2}$ " outside nipple line. Increased  
Aortic dulness, diastolic shock, double Aortic bruit,  
diastolic harsh in character, right pupil slightly  
larger than left. Pulse right better felt than left.  
B.P. 155. Wasserman ++.



X-ray. Marked enlargement of heart, especially to left  
side. Shadow of descending Aorta seems uniformly dilated  
and extends well to right of middle line. Aorta shows  
general dilatation but no circumscribed aneurism.

Case 37. H.P.M. Age 60. Married. Boiler-maker.

Seen at Extern 24/9/20. Syphilis 27 years ago in Chili. No trouble till a few months ago.

Complaint. Cough with profuse expectoration worse at night. A feeling of a chill in the stomach associated with marked flatulence.

States has a soreness about middle of sternum. No pain on swallowing. Dyspnoea worse at night and after exertion. Onset was sudden. Lungs

Lungs. Shows some oedema at both bases.

Heart. Systolic and diastolic Aortic bruit, the latter having the clanging characteristic. Mitral systolic bruit, also present.

Pulse. Slight tachycardia 100, otherwise normal.

B.P.140. No tracheal tug, pupils equal.

He improved at first under mercury, iodides, and cardiac tonics. Two injections of Novarsenobillon.

Later, however, definite myocardial failure set in and persisted in spite of treatment till his death a few weeks later. Post mortem not obtained.

Wasserman negative even after provovative dose of Novarsenobillon.

X-ray not taken.

Prognosis

The prognosis in Aortitis depends on the situation of the lesion; on the occurrence of aneurisms, and what form they take and on the presence of complications. The unfavourable signs are the occurrence of aortic incompetence, and of myocardial changes. Case of syphilitic aortic incompetence as a rule died within 1-5 years after a diagnosis had been made.

Herbert (18) states that 48 of his cases died on an average of from 12 to 15 months after the disease was discovered. Three of my series who died had only complained of cardiac trouble for about one year and had been under medical care for a somewhat shorter period than this. Aortic incompetence cases from some acute infection such as Rheumatic fever, once the disease has subsided seemed to live for a considerably longer period than this. I know of two such cases one of whom was found to be suffering from Aortic incompetence 20 years ago. He had an active vigorous life till a few months before his death at the age of 75. The other case has also had Aortic disease for many years and is still alive and taking an active part both in his work and in sport. Cases like this do not occur in the syphilitic form

of Aortic incompetence.

Myocardial disease, especially when it shows evidence of failing compensation is a very serious prognostic sign . It is a common sequel to the incompetence. Recent work on the pathology of syphilis has shown that the myocardium is very frequently involved in this disease. When this causes a failure of compensation the outlook is bad. The usual signs one gets are changes in the pulse, oedema, severe dyspnoea etc.,

In aneurisms the prognosis depends on the situation; the liability to rupture and in many cases on the size. A small aneurism is much more liable to rupture than an old standing large aneurism, which has adhesions etc., to keep in its support.. The site of perforation has already been gone into under aneurism.

The prognosis materially depend largely on the amount of treatment given. If the actual disease has been checked and can be kept under control there is less chance of the dangerous signs and symptoms appearing.

Treatment. Is mainly on Anti- syphilitic lines, to try and limit the lesion and prevent further damage to the Aorta and the heart muscle.

The damage already done is permanent and one cannot hope for a dilated Aorta or a Sclerosed valve to resume its normal shape and size. Rest is an essential factor at first.

Mac Lachlan. (33) Considers that all cases showing evidence of aneurism should rest in bed for three months and limit their exercise for another nine months.

In any case even with no evidence of aneurism where there is evidence of myocardial defect rest is of the utmost importance. A few weeks in bed even without very active treatment will show definite improvement in the symptoms. If oedema and severe dyspnoea are present a bed rest is usually required as without it sleep is often impossible.

Medicinal treatment resolves itself into that required to combat certain symptoms that arise and the more definite antisyphilitic treatment. In the former the usual cardiac tonics, diaphoretics, Hypnotics etc., may be tried. Morphia may be indicated in severe cases of dyspnoea or pain.

Of the Antisyphilitic remedies we have three main stand-byes. Mercury, Iodides, and one or other of the arsenical compounds. Pot Iodide should be given in doses of 10-15 or more grains 3 times a day.

It helps to relieve the symptoms and to absorb any gummatous lesions that may be present, but according to McLaglan and others it has no action on the Spirochaetes.

On this account it should always be accompanied by mercury. This may be administered in several ways either by inunction, extra-muscular injection, or by the mouth.

The usual arsenical compound used in my series was Novarseniobillon. The patients were given two 3 gm. doses, then six 45 gm. doses, at intervals of 1 week. In practically every case there was a marked improvement after this course of injections. The first change noticed was in the complexion. The yellow or greyish/<sup>look</sup> was lost and the patients looked much better. The symptoms improved. The patients put on weight and in every way there was a change for the better.

Physical signs in the Aorta did not alter and in no case did the Wasserman reaction become negative, even after the patient had had two or three courses of injections. The patients could not be kept on indefinitely in the Hospital but on discharge they were all instructed to attend at one of the V.D. Clinics for further treatment.

Dr. Preble. (44) recommends that the arsenical compound should be given in smaller doses at an interval

of a few days. He usually starts with 1 mgr.

McLaghlan recommends 12 injections, six of 2 mgr.  
and 6 of 3 mgr.

In using the larger doses I never experienced any  
bad effects.

Pathology

A large amount of work has been done within recent years in the Pathology of Aortitis, more particularly of syphilitic Aortitis. This work has made a great advance in our knowledge of the condition and especially in bringing to light the early stage at which the Aorta and the other visceral organs are liable to invasion by the spirochaeta . It has also helped to differentiate between atheroma and Aortitis, a differentiation which Sir Clifford Allbutt was one of the first to make, and which other workers have confirmed . Among the most recent work on the subject that of Warthin has been of the greatest importance. He has shown that the Spirochaetes are present in the Aorta, the valves, heart muscle etc., and he has demonstrated them in cases, in which clinically, Syphilis or cardiac lesions had not been suspected during life.

The changes met with in the Aorta valves and Myocardium are both macroscopic and microscopic.

In the majority of cases a definite diagnosis can be made from the macroscopic examination alone, though in the early cases one has to depend on the microscopic examination to make the diagnosis certain.

In dealing with the subject I intend to quote

from some of the older and more recent literature;  
to describe briefly some cases of my own and then to  
describe in greater detail the various microscopic  
and macroscopic changes that may be met with.

Of the many writers on this subject none have  
done more to throw light on the actual condition and  
to stimulate others to investigate the subject than  
Sir Clifford Allbutt. In 1868<sup>(2)</sup> he first described  
a condition of the Cerebral arteries as a Syphilitic  
Arteritis, showing that it was a periarteritis starting  
in the outer coat and spreading inwards differentiating  
it from a true atheroma which is essentially an  
intimal condition. Since then he has published many  
papers on the subject and has embodied these in his  
excellent work on Diseases of the Arteries. He considers  
it difficult to estimate the starting point of Aortic  
syphilis clinically as the diagnosis cannot with  
certainty be made till the valves are affected. In his  
recent paper, however, he considers that the infection  
takes place in a very early stage and that the onset  
of signs and symptoms pointing specially to the heart  
and Aorta must be prevented by proper treatment.  
Until recently at any rate he also considered that the  
Aorta and heart muscle were rarely attacked simult-  
aneously.

Warthin's work, however, shows that this is not so and that the heart muscle shows syphilitic changes in most of the cases of syphilitic Aortitis.

Of the other types of Aortitis the most common one and the one most frequently described is that following Rheumatic fever.

Josa and Solomons.(20) describes a case of acute Rheumatic fever where inflamatory patches were found in the Aorta. These were different from those found in Syphilis.

Klotz. (21) describes two types of Rheumatic Arteritis, clinically and pathologically different. The first type is a simple inflammation surrounding the artery and accompanied by localized pain and throbbing along its course. The second is a type where the inflamatory process begins from within. It is an obliterating arteritis which is also accompanied by localized pain and it gives evidence of permanent obstruction of the vessel. These types differ in that the former shows the inflamatory ~~was~~<sup>change</sup> to be in the media and adventitia while the latter is a condition of primary endarteritis associated with thrombosis and embolism. The medial disease may be so severe that sacculation or aneurism may form. This happened in one of my series - a case of sub-acute endocarditis of uncertain

origin in which the Aorta was first involved and later the Post tibial artery showed a definite aneurism. In the first type the inflammatory Axudate is distributed about the vasa vasorum of the adventitia and follows the fine nutrient vessels lying in the outer portion of the Media, causing a destruction of the neighbouring muscle cells and elastic fibres.

This is very similar to what happens in syphilis except that in syphilis the condition is a progressive one whereas the Rheumatic type comes to an end spontaneously as the general infection subsides but it predisposes to recurrent attacks. Martin (37) in the clinical Journal describes a specific Aortitis in which there was a spread of the diseased condition to the valves.

O'Sullivan (49) In 1908 showed a specimen of a form of Aortitis associated with sudden death. The case was that of a young soldier who dropped dead on the March. On post mortem the appearance of the heart and Aorta was unusual and the following condition was described. "Immediately above the commencement of the Aorta along the line of the valves, there was an abrupt rise in the surface level which continued for about 1" upwards into the vessel and then as abruptly descended again, forming a sort of

Table land across the vessel one quarter of an inch or more higher than the rest of the surface. The left coronary artery was obstructed by the excrescence on the surface which he took to be the cause of death".

A similar case of a young man found dead in a lavatory. Sections of the Aorta were made. In these the intima showed an increase in its tissue but in the media the elastic tissue was cut, torn, and split by masses of cell infiltration which ran along the course of the vasa vasorum. Both of these cases were probably syphilitic but there was no direct evidence .

Watson (58) In the Lancet 1911 describes a case of acute vegetative endocarditis due to syphilis.

Longhope, Elliott, McCrea and other Americans have also written on this subject and will be quoted later.

(57) Of the more recent literature, however, that of Warthin (57) is about the most important . He was one of the first to discover the Spirochaeti in the Aorta, Heart muscle etc., and he shows that active

lesions and spirochaets are found in the tissues of clinically inactive or "cured" syphilis. In describing his technique he lays stress on the fact that the specimens must be fresh. The tissue should be got

2-3 hours after death if possible, fixed in formol 10%

for at least 24 hours but better for 3 days.

The formalin should be neutral in reaction. The tissue may be stained in bulk by the Levadite method but he has not found this satisfactory, preferring his own Silver Agar method.(63) His work is based on the result of 41 Autopsies at the University of Michigan. He divides these 41 cases in 3 classes as follows:-

- (1) Cases in which there was a known history of syphilis with treatment regarded as adequate and resulting in a cure.
- (2) Cases in which the syphilitic infection was recognised as still active, treatment being continued.
- (3) Cases in which a syphilitic history could not be obtained or was specifically denied by the patient; the clinical diagnosis not including syphilis and no Anti- syphilitic treatment given.

<u>Group</u>	<u>Number of cases.</u>	<u>Spirochaetes found in</u>
No.1.	11	Almost all.
2.	5.	5
3.	25.	10.

In this last group, many of the patients had been in total ignorance of any specific infection.

In all these cases the lesions of active Syphilis were practically of the same nature. Active syphilitic lesions were found in the heart in 36 cases, in the Aorta in 32, in the testes in 31, Liver in 4, adrenals 6, Spleen 6, pancreas 6, C.N.S. 5. This shews that at a post mortem the heart, Aorta and in the male the testes, should always be examined for evidence of active Syphilis.

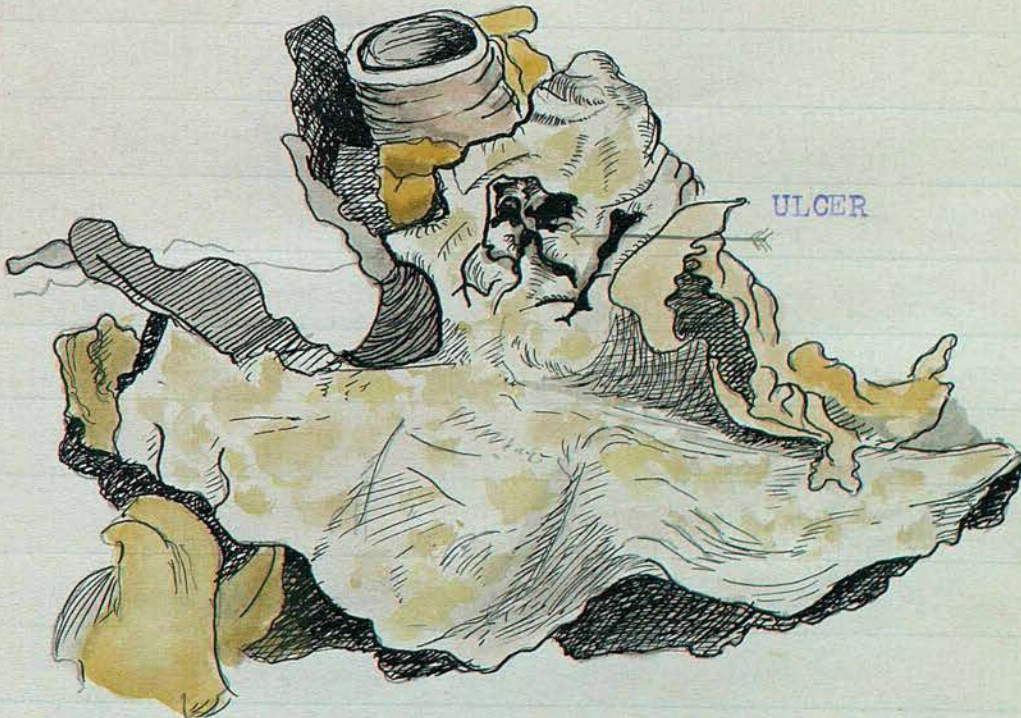In my series of cases there were 6 deaths 5 of them being syphilitic cases and the other the case of sub-acute endocarditis, out of these 6 I was able to get 2 post mortem examinations. A third post mortem was obtained in a case carried in dead to the Royal Victoria Hospital.

These with several old specimens in the Laboratory at the Royal Victoria Hospital were the material I cut sections from and in which I tried to put spirochaetes.

I intend to give a short description of the Post mortem findings and have three drawings to illustrate 2 of these cases. The microscopic changes will also be described more fully later but I first wish to demonstrate many of pathological characteristics by microscopic photographs which I took from my own sections.

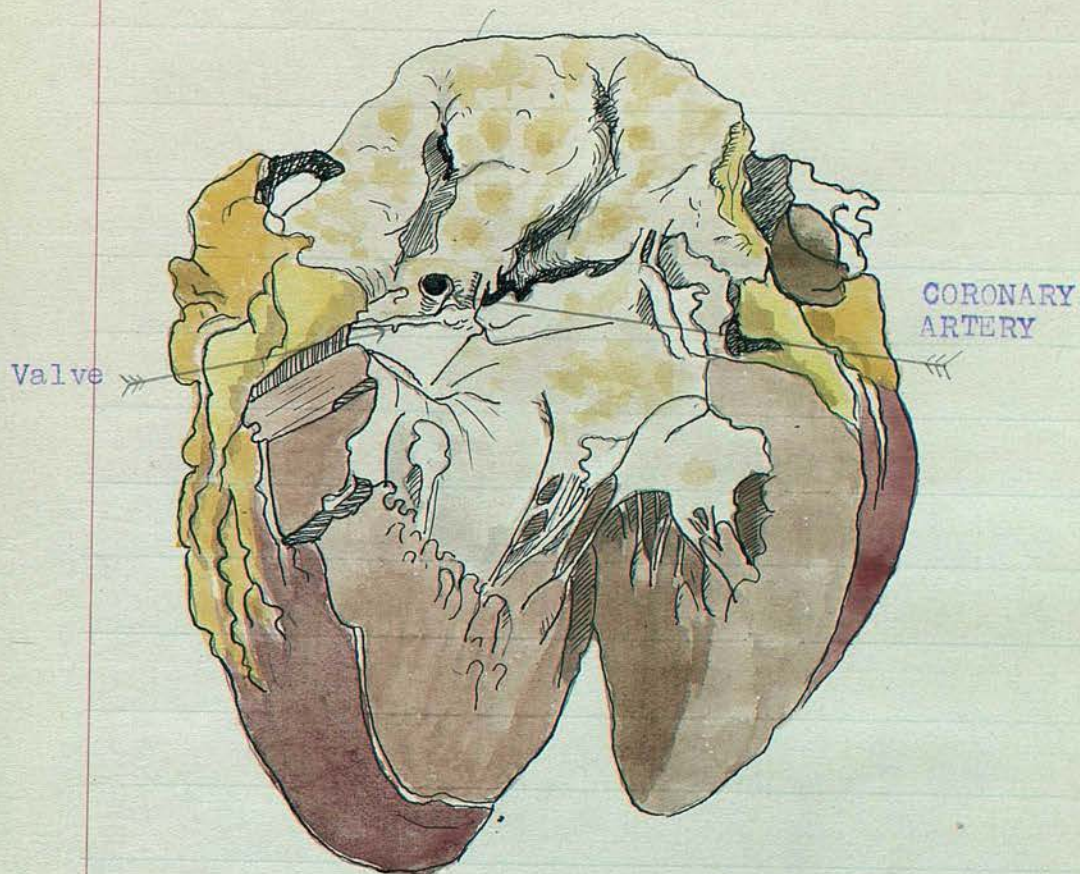
The first post mortem I was able to get on an aortitis case was that of a Pensioner W.H.B. aged 38. His history, symptoms etc., have already been described. This man died as the result of a profuse haemorrhage. The following condition was found at the autopsy. The heart was small with an apparently healthy muscle; the mitral valve was competent but the aortic valve shewed definite incompetence. This was partly due to a widening of the ring and partly to the chronic endocarditic condition of the valves. No vegetations were present but the valves were shrunken and distorted. The most typical finding was that of the aorta. Here there were well marked chronic syphilitic patches with considerable peri-aortic adhesions, the Bronchus being bound down to the transverse portion of the Aorta. Here a large ulcer had eaten its way through the aorta and Bronchus and perforated into the Bronchus thus accounting for the profuse haemorrhage. Both the ascending and descending portion of the Aorta shewed a uniform dilatation which was very marked in comparison with the small heart. The coronary arteries appeared healthy, their openings having no definite narrowing. The patches in the Aorta were for the most part chronic but in the region of the ulcer they appeared to be more active.

Case. Pen. W.H.B. Age 58. Who died from perforation  
of an Aortic patch into the Bronchus.



Shows marked irregular patches of Aortitis all over  
Aorta. ~~Ulcer~~ Bronchus is adherent to Aorta and the  
Ulcer is seen which perforated through the Bronchus.

Case. Pen.W.H.B. Age.38.



Shows heart and 1st, portion of Aorta. Valves are sclerosed. Marked Aortitic plaques. Mouth of coronary artery is seen, and appears healthy.

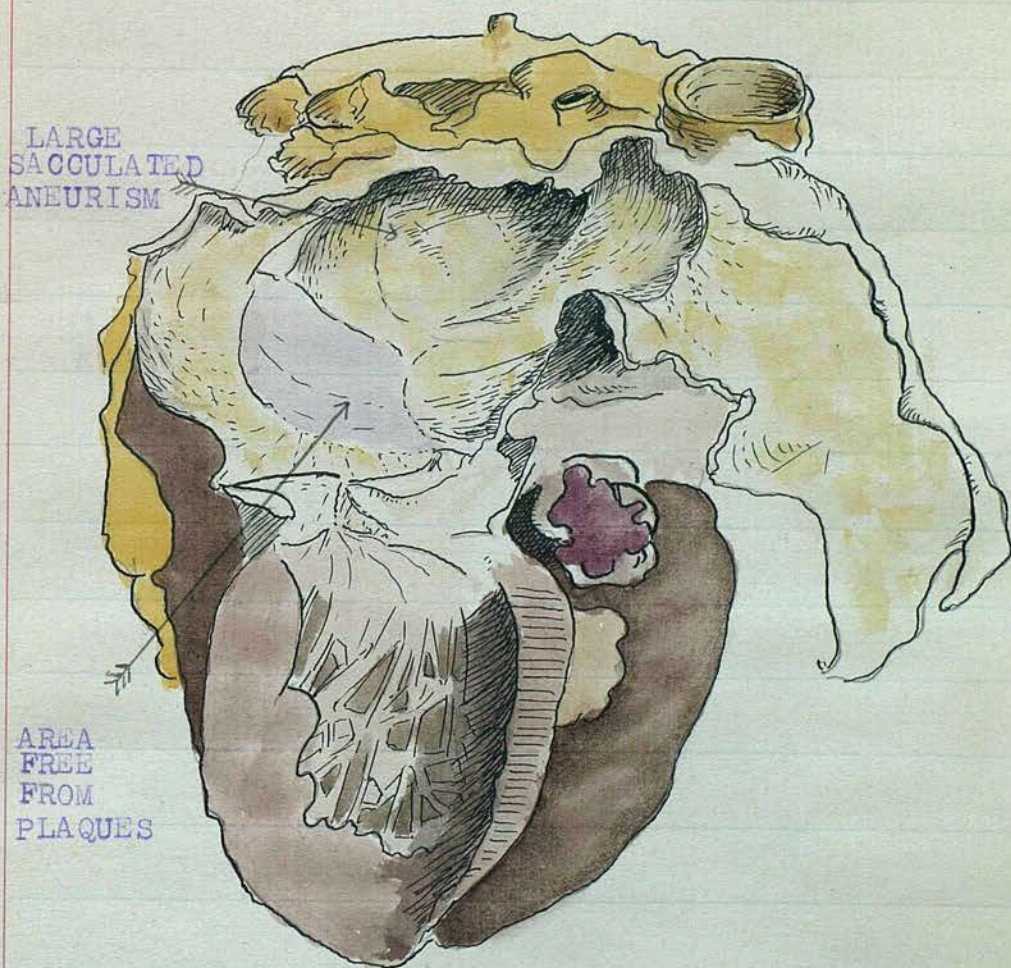
Heart muscle showed no definite macroscopic changes.

The second case was also that of a Pensioner J.T. aged 40, who died in the U.V.F. Hospital. His clinical history has already been given. This case was a complete contrast to the previous one in some respects. Here the heart was definitely enlarged and showed numerous white patches scattered over the inside, most marked in the left ventricle, involving also the papillary muscles. On section of the muscle, these white patches were found to extend in to the muscle substance for about one-third of its depth. The Aortic valves were incompetent and showed definite chronic syphilitic endocarditis. The ascending and transverse portions of the Aorta were dilated and shewed a considerable number of chronic syphilitic plaques but ~~XXXX~~ the most striking feature here was the presence of five or six large, fleshy, pink patches which were obviously active and of recent origin. This finding would fit in with the clinical history as he had had syphilis about 20 years before but had been in apparently good health till shortly before his death when an acute cardiac breakdown occurred. The coronary arteries showed a moderate degree of involvement their mouths being slightly secluded.

Another case where the post mortem findings differed somewhat was that of a man who dropped dead in the street, the body being brought into the Royal Victoria Hospital. Here in addition to the usual syphilitic changes, a large fusiform aneurism of the transverse aorta was found. The walls were thin and covered with numerous chronic yellow plaques. A peculiarity in this case was the presence of a smooth zone about one inch above the valves this zone was an inch in diameter and separated two definite syphilitic patches above and below it. This was similar to the case described by Klotz which has already quoted.

Drawing of heart and Aorta seen in next page.

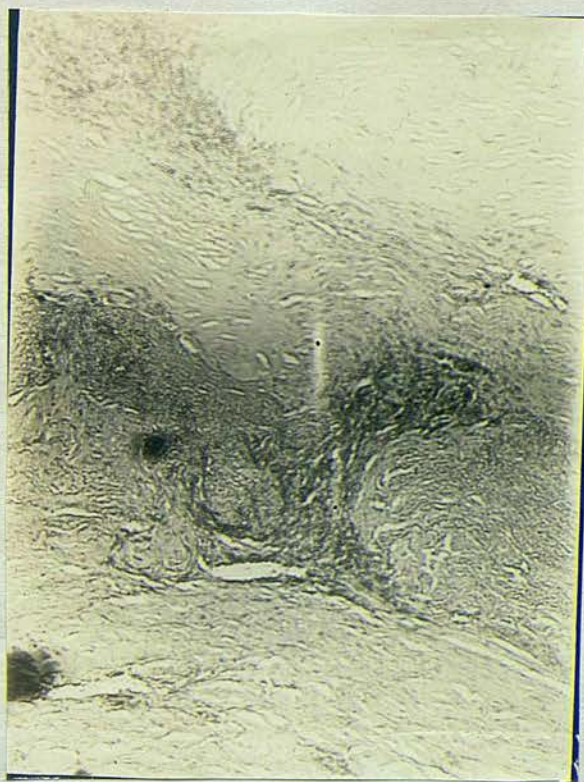Heart and Aorta from post mortem on a man carried in dead to the Royal Victoria Hospital.



Shows large Sacculated Aneurism with marked Aortitis. There is a smooth zone about the neck above the valves intervening between two areas with marked Aortitic changes.

A.


Section of Aorta stained by Haemotoxylin Eosin Method.



Shewing marked fibrosis of intima with a Mesoaortitis. Infiltration of lymphocytis and plasma cells round the vasa vasorum of media. Media is broken up by this infiltration.

B.

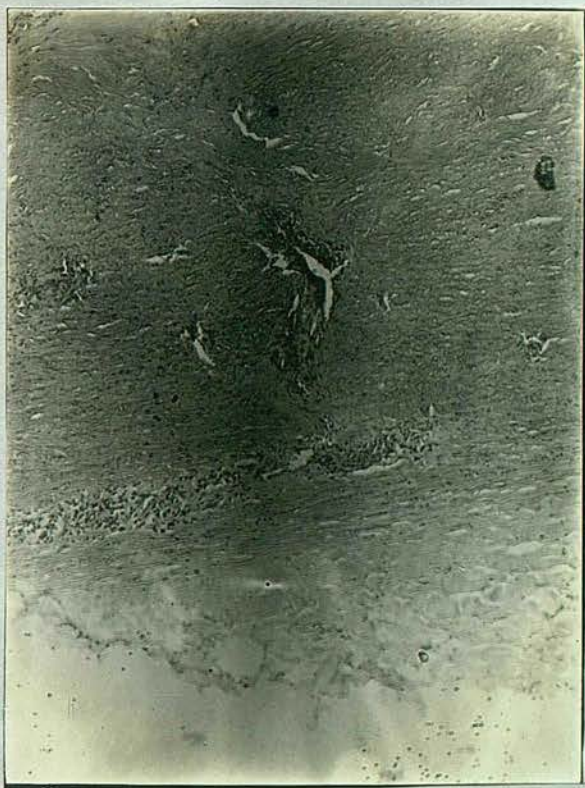Section of Aorta stained by Haemotoxylin Eosin method.



Shewing small vasa vasorum in media with well marked cellular infiltration extending into intima.

C.

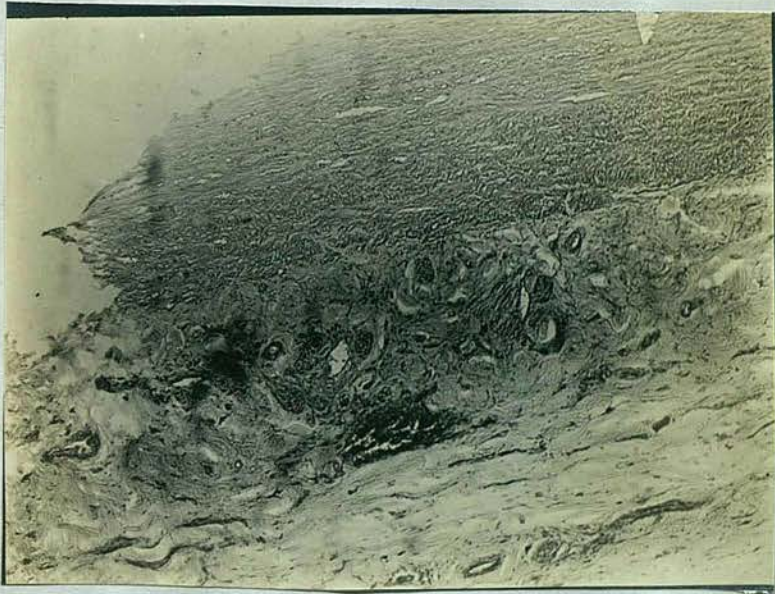Section of Aorta stained by Haemotoxylin Eosin Method.



Shewing vasa vasorum of media and adventitia with  
with periivascular cellular infiltration.

D.

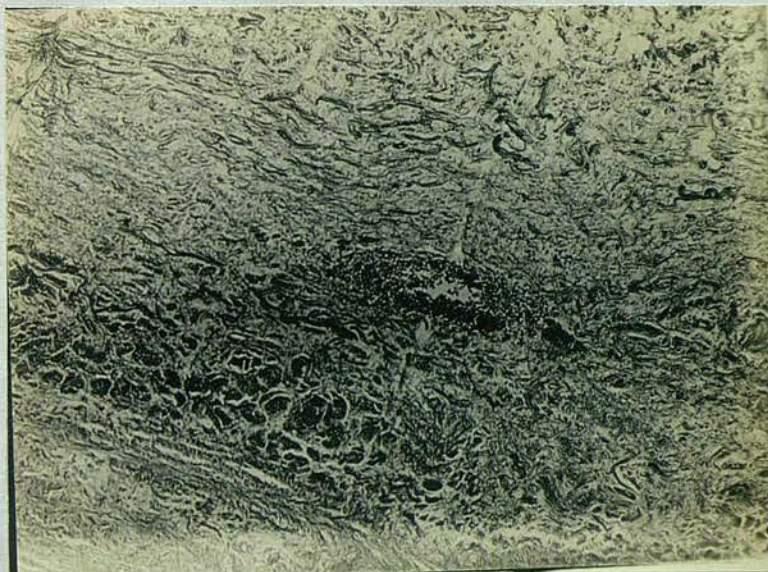
Section of Aorta stained by Warthin's Silver Agar method.



Showing gummatous focus in Media and adventitia. Vessels in adventitia show thickening of their walls. There is a cellular infiltration breaking up media.

E.

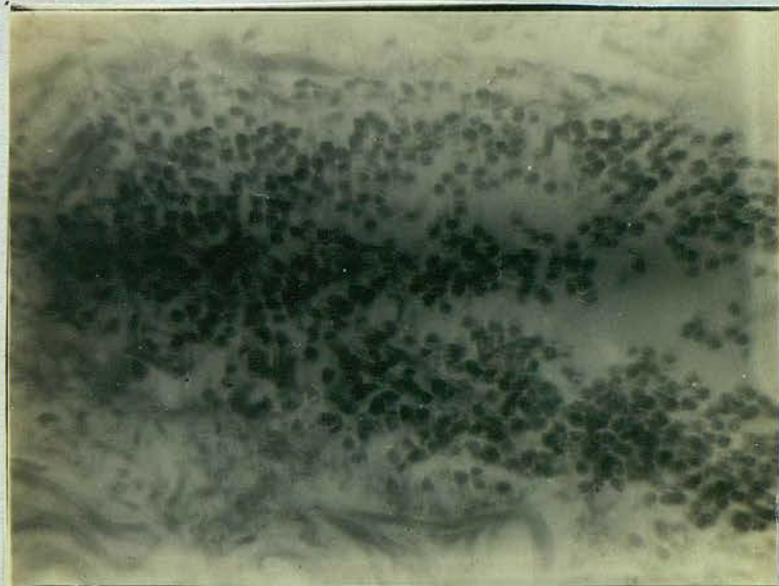
Section of Aorta stained by Warthin's Silver Agar  
Method.



Showing gummatous focus in Media with typical  
Meso aortitis.

F.

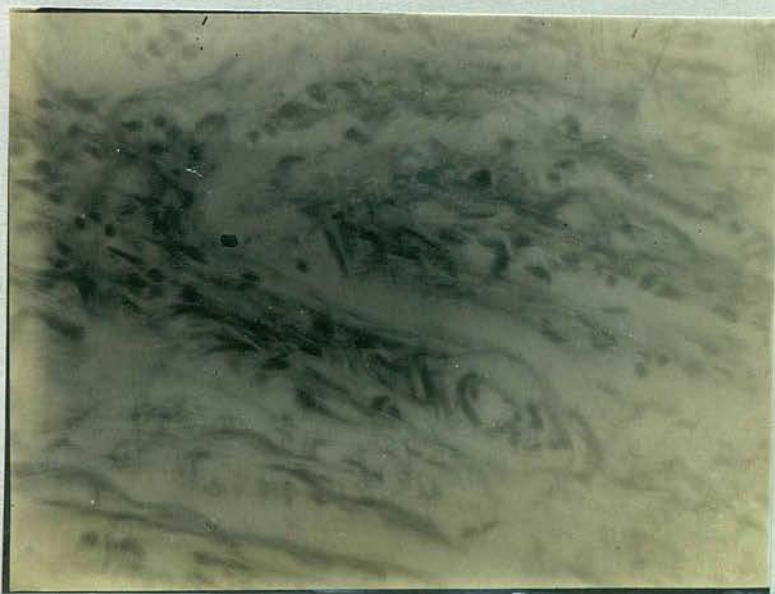Section of Aorta stained by Warthin's Silver Agar  
Method.



Higher power showing Gummatous focus seen in  
previous section.

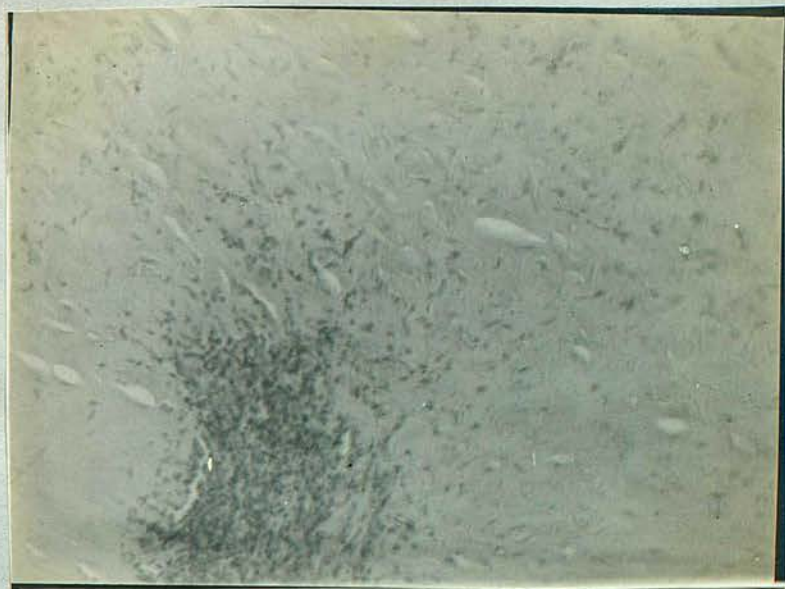
G.

Section of Aorta stained by Warthin's Silver Agar  
Method.



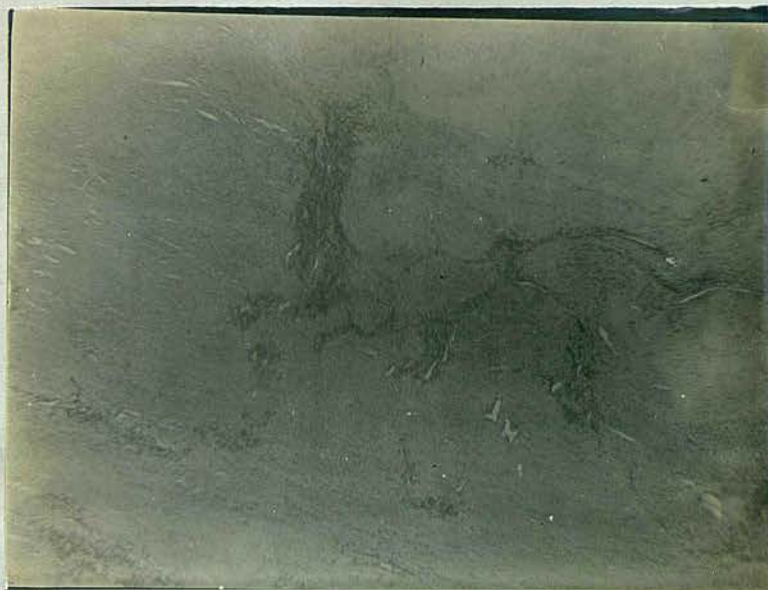Shewing small vasa vasorum with peri vascular  
infiltration of lymphocytis and plasma cells.

Section of Aorta stained by Haemotoxylin Eosin.



Shewing cellular infiltration round vasa vasorum in  
Media extending into intima.

Section of Aorta stained by Haemotoxylin Eosin Method.



Shewing Media broken up by peri vascular cellular infiltration.

The Arch of the Aorta has to bear the strain of the rush of blood from the left ventricle and as years go on, it often shows evidence of injury which is usually manifested by a varying degree of Atheroma. Stress and strain do not cause an aortitis but they have a bearing on the seat of origin of the infection and on its severity. Though syphilis is probably the most common cause of Aortitis and in my series decidedly so, any infection may produce the lesion. In these infection may be due to direct injury by the lesions on the inner coat, though generally the infection is spread by the vasa vasorum. Among the various causes of aortitis are found the following- Syphilis, Rheumatic fever, influenza, pneumonia, smallpox, Tubercle, Gonorrhoea, Diphtheria, Measles, Scarlet fever, Typhoid. Syphilis and Rheumatic fever are accountable for by far the largest percentage.

Rheumatic Aortitis has already been described briefly in quoting the work of Klotz (21) and I do not intend to go into details of this or any of the other more rare types. I shall, however, describe the syphilitic variety more fully.

Syphilitic Aortitis may be acute or chronic - more often the latter. The post mortem examinations one frequently finds patches of varying chronicity

in the same Aorta. In one of the cases in my series this was most striking. One found scars fibrous in character, almost like healed patches, intermingled with chronic thickened plaques having two or three raised, soft, red patches of apparently recent acute origin. These acute patches corresponded with the clinical facts for this patient had had no apparent cardiac trouble until a few weeks before death. Then he suddenly developed symptoms of myocardial failure and became acutely ill. The distribution of these patches varies and often determines whether the lesion will cause a general dilatation or a more localised aneurism.

The root of the Aorta and the arch are most commonly affected though the condition may be found anywhere. According to Elliott (14) and others the supra sigmoid portion of the Aorta is most commonly affected. The abdominal Aorta is sometimes involved especially at the point where the coeliac axis branches off. This distribution of the infection was supposed to be due to the spreading by the vasa vasorum but Klotz (22) considers that the lymphatics which follow the course of the vasa vasorum are the real means of spreading the disease. These lymphatics are found in greatest numbers in

the first part of the aorta hence the frequency with which the condition is found here. The peri vascular infiltration spreading from without inwards is also accounted for in this way.

The smallest and probably earliest patches recognisable consist of definite elevated patches of a pale grey and somewhat translucent appearance. The patch described by O'Sullivan comes into the category though perhaps somewhat larger than the average ones which are about 1-3 cm. in diameter. These patches in the intima are found on cutting the section to correspond to yellowish patches in the media and they occasionally sink beneath the level of the knife cut. As the disease advances, the patches become larger. They may remain isolated but in many cases form areas especially round the circumference of the vessels. If, as sometimes apparently happens, some of these patches heal we find in addition irregular shaped scars, all these changes being scattered between areas of apparently normal Aortic tissue, produce the scarred, puckered and often distorted aorta, which is typical of the advanced condition. Turnbull (55) describes this appearance thus:- "pearly in tint( a tint we may often see patchily in the gaping vessels of the circle of Willis)

rubbery in consistence, crenated in outline, pitted on the surface and passes into scar: calcification, if any, being scarce".

Though the disease usually shows itself about 2-4 cm. above the valve, the tendency is for it to spread. It does so upwards on the vessel wall and also downwards towards the valves. This spreading can as a rule be traced in the Aorta.

Norris (41) describes two cases one showing spread and involvement of the Aortic valves, the other, spread upwards and formation of an aneurism.

Klotz (22) however, describes a case where the valves were apparently affected independent of the Aorta, as a strip of healthy normal aorta intervened between the diseased valves and the diseased aorta.

As the disease spreads the aorta is found to consist of patches of diseased tissue with definite destruction in the media, the elastic tissue also being broken up, as will be seen later. This destruction causes a thinning of the coat in the weakest parts, the stretching of which may lead to a generalized dilatation of the aorta or to a definite aneurismal formation depending on the situation and distribution of the patches, even in cases of generalized dilatation one rarely sees a

uniform change on account of the thickened intimal patches which at places support the weakened media. The mouths of the branches of the aortic arch are frequently involved and we may find a narrowing of the innominate and left carotid arteries at their origin.

Calcification common in atheroma is rarely got in aortitis. The downward spreading of the disease towards the aortic ring often leads to involvement of the mouth of the coronary arteries, which may be partly or almost wholly occluded. The sinuses of Valsalva and the aortic ring becoming involved we find pouching of the former and distension of the latter. This leads to an incompetence of the aortic valves. This incompetence is augmented by the diseased process involving the valves themselves causing them to become thickened and crinkled but smaller than normal owing to their contraction. As will be seen later, this valvular change is due to a definite syphilitic infection, spirochaetes having been found in them by Warthin. The disease may spread below the flaps into the endocardium, greyish crescentic areas being formed in some instances.

Microscopic.

If one considers how Syphilis is spread and how it reaches the Aorta, it is easier to appreciate the changes found on microscopic examination. As already noted, the spread is a lymphatic one, involving the peri vascular tissue of the vasa vasorum. This spread starts in the adventitial coat of the Aorta going from thence to the Media and finally involving the intima, all three coats are therefore involved though to a varying extent. The vasa vasorum of the adventitia show a thickening of their walls and a proliferation of small round cells, plasma cells and epithelial cells, in the peri vascular tissue. Minute blood vessels extend into the media and these in turn are surrounded with cells. As the disease advances we find small areas of cellular infiltration in the media which may go on to necrosis. The elastic tissue is broken up and fragmented. The intima shows a proliferation of its cells and these are often collected into heaps causing a protrusion from the surface. This cellular infiltration of the Media often forms necrotic areas which in turn become surrounded by connective tissue. This in time may almost completely displace the Media, fragments of muscle and elastic tissue being visible through it.

The intima also becomes sclerosed with definite thickened areas. It rarely, however, goes on to calcification. Sometimes these cellular areas in the adventitia and Media may resemble small gummata.

All these changes are responsible for the dilatation of the Aorta and also for the formation of aneurisms. The walls losing their strength and elasticity become thin and attenuated and are unable to resist the force of the blood as it is pumped out of the heart.

The cellular and connective tissue increase may extend to within a short distance of the attachment of the valves. The fibrous ring also shows an increase in blood vessels and connective tissue, accumulations of small round cells and of plasma cells may infiltrate the valves, ultimately forming fairly cellular connective tissue and causing a thickening of the valves. Shrinking of this tissue, producing the distorted appearance of the valves that is seen on macroscopic examination.

My specimens showed most of the above changes but though I tried in two of my own series and in several old specimens from the Pathology Laboratory of the Royal Victoria Hospital, I was unable to find Spirochaetes in either the Aorta or heart muscle.

This I attribute to the fact that the Post mortems were not done immediately after death which Warthin says is essential. I used both Levaditi's Method and Warthin's new Agar Silver Method but with neither could I find Spirochaetes.

Warthin (57) in his work on the subject which has already been quoted, states that the number of spirochaetes in old latent cases of syphilis is small. He found them in small groups in the peri vascular infiltrations, especially outside the walls of small veins. He never found them in the intima, the usual habitat being the outer coat of the Media and more frequently the adventitia. Different forms of spirochaetes are described, such as irregular and a typical forms - beaded forms. Straight, thicker or thinner spirals, fragmented forms etc., He believes these to be involution forms.

The heart muscle shows changes to a varying extent in almost all cases of Syphilitic Aortitis.

Warthin has shown that this is due to an invasion of the muscle by the spirochaetes. The macroscopic appearance usually shows small whitish patches extending for a short distance into the Muscle substance, and seen sometimes near the Aortic crisis but most frequently near the tip of the left

ventricle. Small gummata are sometimes got and

ABT. (1) considers that these circumscribed gummata are the most common form of congenital Syphilis.

The other common type is the syphilitic myocarditis. In this type Warthin considers that the lightly staining patches of proliferating stroma represent localised colonies of the spirochaete.

Brooks (10) found that the muscle cells of the heart showed in the main a considerable degree of atrophy but with certain exceptions the atrophy appeared to be due to pressure and not to inherent disease of the muscle cells. The connective tissue is increased and is highly cellular in character. The disease lesions are often most marked in the papillary muscle. Small areas of infiltration and proliferation are found round the smallest branches of the coronary vessels especially the coronary veins. In these areas Warthin has found spirochaetes.

CONCLUSIONS.

- (1) That Aortitis is a very common form of visceral syphilitis.
- (2) That it is often found in cases with a negative Wasserman and no other clinical signs of syphilis.
- (3) That the average age is between 40 and 50.
- (4) That though usually found clinically in old standing cases of syphilis, it may be got at any stage- cases having been reported within a few months of the primary lesion.
- (5) That a sudden cardiac breakdown in a man over 40 without any definite exciting cause should make one suspect a syphilitic Aortitis.
- (6) That Aortic insufficiency is very frequently associated with a syphilitic Aortitis.
- (7) That an X-ray photo should be taken in all suspicious cases.
- (8) That a myocardial breakdown is of much more serious significance in syphilitic than in other forms of Aortitis.
- (9) That early and thorough treatment must be given in all cases of syphilis if this extremely serious form of vascular syphilis is to be eradicated.

- (1) Abt, Dr. Isaac A. - Congenital Syphilis.  
Medical Clinics of North America, Vol.1.No. 5.
- (2) Allbutt, Sir Clifford - StGeorge's Hospital reports, 1869.
- (3) Allbutt, Sir Clifford- Diseases of Arteries.
- (4) Allbutt, Sir Clifford- Cavendish Lecture on Diseases of ascending aorta. Lancet. July 18-1903.
- (5) Anders, J.M. - Certain Syphilitic affections of the heart and aorta. American Journal of the Medical Sciences. Dec. 1915. Vol.CL.No 5.
- (6) Babes, A and Dametresco,D.- Paris Medical April 17th, 1920. Epitome of current Medical Literature B.M.J. 31st, July.1920.
- (7) Benjamin and Havie- Medical Science Abstracts and Reviews. Vol. 11. No.2.
- (8) Blumgarten A.S.- Two cases illustrating the diagnosis of aortic syphilis. Medical Clinics of North America. Vol. 11. No. 4.
- (9) Bock, J. - Med. Science abstracts and Reviews. Vol. 111. No. 3.
- (10) Brooks, H.- The heart in Syphilis, American Journal of the Medical Sciences, Vol. 146.1913
- (11) Brown G.E.-Syphilitic Aortitis and its early recognition. Amer Journal, Med. Science 1919 157. (41.54)

- (12) Bruce, J. Mitchell- A clinical study of cardiovascular degeneration. Lancet 8th, July, 1911.
- (13) Cabot- vol.2. Physical diagnosis.
- (14) Elliott, Arthur R. - Syphilis of the aorta  
Med. Clinics of north America, Vol.1. P. 1305.
- (15) Frothingham, Charles- Aortic aneurism Med.  
Clinics of North America, Vol.11. No.5.
- (16) Hall- Cases of Thoracic Aneurism. Lancet  
April 16th, 1904.
- (17) Hamburger, Walter- Aneurism of the arch of the  
aorta and of the abdominal aorta. The role of  
syphilis in its aetiology. Med. Clinics of  
Chicago. Vol.1. P.183.
- (18) Herbert- Medical Science abstracts and Reviews  
Vol.1. No.1.
- (19) Jordan, A.C. - Lancet 1903 21st, Feby.  
Aneurisms of the ascending arch of the aorta.
- (20) Josue and Solomons-Lancet 21st, Nov.1903.
- (21) Klotz- Arterial Lesions associated with  
Rheumatic fever. Journal of Path.and Bacteriology  
1913-14.
- (22) Klotz- Syphilitic aorta.American Journal of  
Medical Sciences. Civ. 1918.
- (23) Lancet- 23rd, Sept. 1905.
- (24) Lecky- Embolic Aneurism of Posterior Tibial E.M.J. Dec.  
Oct.27th, 1906.

- (25) Lenmann- Aneurism of the Thoracic Aorta, its incidence, diagnosis and prognosis.  
A statistical study.  
American Journal of Med. Science 1916. clii.210.
- (26) Libman, E. - Some general considerations concerning affections of the valves of the Heart.  
Med. Clinics of North America. Vol. 1.P.573.
- (27) Longhope, W.T.- Syphilitic Aortitis, its diagnosis and treatment. Jan. 15th, 1913. Vol. XI.  
No. 1. Arch. Int. Med.
- (28) Longhope. W.T.- The association of Aortic Insufficiency with syphilitic aortitis. Journal of American Med. Association vol.54.No.2.
- (29) Matter and Odds.- Arch. des maldu coeur,  
July 1920.
- (30) McCrae, Thomas- Aortitis. Med. Clinics of North America. Vol.1.No.2.
- (31) McCrae, Thomas-Dilatation of the Aorta. The American Journal of Med. Sciences. Oct. 1910.
- (32) McCrae Thomas- Unusual rupture of an aneurism.  
Journal American Med. Association. Vol. LIV.No.2.
- (33) McLaghlan- The Medical treatment of Aortic aneurism. American Journal of the Med. Sciences Vol. 159. 1920.

- (34) McKenzie, Sir James- Oxford Loose Leaf.Vol.2.
- (35) McIlwaine. J.E.- Remarks on the Association of Aortic Endocarditis and Aortitis B.M.J. 27th, March, 1920.
- (36) Mallory-Principles of Pathological Histology.
- (37) Martin- Clinical Journal. June 20th, 1907.
- (38) Moon- Clinical Journal. March 1913.
- (39) Mix, Charles L.- Aneurism of the Aorta. Med. Clinics of Chicago. Vol.2. P.1017.
- (40) Mix, Charles L.- Aortic regurgitation, Aortitis and Aneurism in a syphilitic basis. Vol.1.No.5.
- (41) Norris, G.W.- Syphilitic Aortitis, Med. Clinics of North America, Vol.111. No.5.
- (42) Oliver, Thomas-Dissecting Aneurism of the Thoracic Aorta. Lancet April, 25th, 1908.
- (43) Osler- Practice of Medicine.
- (44) Preble- Syphilitic Aortitis. Factors governing prognosis. Med. Clinics of Chicago. Vol.1. P.319.
- (45) Robey, W.H.- Aneurism of the ascending Aorta. Med. Clinics of North America. Vol.1V. No.2.
- (46) Sach-Archives of diagnosis.
- (47) Sailer, Joseph- Aortic Aneurism. Med. Clinics of North America. Vol.1.P.249.

- (48) Smith, Fred J.-Case of Aneurism rupturing into the Pulmonary artery associated with fibrosis of one wing. Lancet 23rd, April, 1904.
- (49). O'Sullivan- Lancet 11th, April 1908.
- (50) Steele, Graham-Lancet 21st, Novr.1903. Pseudo Angina pectoris occurring in mitral stenosis.
- (51) Stengel, Alfred- Oct.20th, 1906.B.M.J.
- (52) Stevens, A.A.- Angina pectoris and allied condition. Med. Clinics of North America, Vol. 1.P.293.
- (53) Snyder- A discussion of 3 unusual cases of aneurism of the thoracicAorta etc., Med. Clinics of North America. Vol. 11. No.5.
- (54) Tice, Frederick- Syphilitic Aortitis. A differential diagnosis of the Aorta Valve. Med. Clinics of Chicago. Vol.1. P.147.
- (55) Turnbull- Quart.Journal Med. V111. 31. 1915.
- (56) Walsham,H. -Lancet. May 9th, 1903. A Note on the position of the heart, in some cases of Aortic Aneurism.
- (57) Warthin- American Journal of Medical Science, 1916. CL11 $\frac{1}{2}$ . 509.
- (58) ~~Watson~~<sup>Watson</sup>, A.S.- American Journal of Med.Sciences Oct. 1916. Vol. CL11. No.4.

Persistence of active lesions and spirochaetes

58. WATSON. Lancet Nov. 25<sup>th</sup> 1911. P 1463.

in the tissues of clinically inactive or cured syphilis.

- (59) Wells. Russell- Ten thousand recruits with doubtful heart lesions. B.M.J. 29th, May. 1920.
- (60) Wilson, A. Marcus- B.M.J. June 13th, 1908. Two cases of obscure Aortic Aneurism.
- (61) Williamson, Charles S. - Aortic Aneurism. The factors governing the inequality of the pulses. Med. Clinics of Chicago. Vol. 1. P. 353.
- (62) Med. Science. Abstracts and Reviews. Vol. 11. No.3.
- (63) Warthin and Starry- A more rapid and improved method of demonstrating spirochaetes in tissues. Report from American Journal of Syphilis. Vol.1V. No.1. Jan. 1920.
- Also second improved method for above.
- (64) Warthin- Demonstration of spirocheta pallida in wall of artery and aneurysmal Sac.
- Report from American Journal of Syphilis. Vol.1. No.4.
- (65) Warthin -and Starry- Improved methods for staining spirochaeta pallida in tissue, Reprint from the proceedings of the Society for Experimental Biology and Medicine. 1920. 28. P.P. 82-84.
- (66) Medical Science Abstracts and Reviews. Vol.11.No.3.