

T H E S I S

for the

DEGREE of DOCTOR of MEDICINE of EDINBURGH UNIVERSITY.

A Contribution to the PATHOLOGY and DIAGNOSIS of
TUBERCULOUS OTITIS MEDIA

by

GEORGE KERR GRIMMER, B.A. Canada, M.B. & C.M.,
F.R.C.S., Edin.



OBJECT OF INVESTIGATION.

The very considerable number of cases of suppurative otitis media, especially those with accompanying bone lesion, met with in the Ear and Throat Wards, and Out Patient Department of the Royal Infirmary, Edinburgh, which give rise to uncertainty as to whether tuberculosis is a factor in the causation or not, convinced me that such cases offer an important field for observation and research, both with the view to determining what clinical history and symptoms in a given case point with any certainty to its being of a tuberculous nature or not, and also what method or methods of pathological and bacteriological investigation of products from such ears can be held to establish a diagnosis beyond doubt, during life.

Recognising the great importance of arriving at an early and accurate diagnosis in such cases, as a guide to proper treatment, and the possible great advantages to be derived by the patient, of having that treatment from the earliest possible moment (especially in tuberculous cases) based on a definite and scientific knowledge of the pathological changes taking place in the diseased part, and in other tissues connected directly therewith, I determined to study all the available cases of the kind and to record the observations and experiments made, and the conclusions to be deduced therefrom, with the hope of adding something to our knowledge of tuberculosis of the middle ear.

The following appeared to me to be the chief points to be investigated and studied in the endeavour to elucidate this question:-

1. What light is thrown on the nature of the otitis by such symptoms as, the presence or absence of pain, bare bone felt through the external meatus, destruction of bone about the middle ear, facial paralysis, perforation of the inner wall of the mastoid process (Betzold's perforation), enlarged glands over the mastoid process, and in the neck, abscesses and sinuses in the same situations, and polypi in the external meatus?

2nd. What proportion of cases of suppurative otitis media, with bone lesion are tuberculous (a) in children, (b) in adults; and at what age is the tuberculous form most frequent?

3rd. Do the naked eye and microscopic appearances of pus, granulations, and of diseased mucous membrane (where such can be safely removed) from the middle ear, afford any reliable evidence, and also, what information is to be derived from a similar investigation of naso-pharyngeal adenoids, of an enlarged mastoid gland, and other enlarged glands near the diseased ear?

4th. From what source, and by what channel does the bacillus tuberculosis reach the tympanum, and what light is thrown on this point by microscopic examination of sections of the eustachian tubes, the tympanic membrane, (when it can be obtained, owing to the whole, or a portion of it having escaped destruction) and other neighbouring parts?

5th. What relation exists between tuberculous naso-pharyngeal adenoids and tuberculosis of the middle ear?

6th. Is tuberculosis of the middle ear, a primary, or a secondary infection, or may it be either one?

7th. Does the discovery of tuberculosis in other organs give any reliable indication as to the nature of the ear disease?

8th. How far may inoculation experiments on guinea pigs, with products of the diseased middle ear, assist in the diagnosis of tuberculosis?

Lastly. I have studied the best methods of preparing, mounting, and staining microscopic specimens

PRESENT STATE OF OUR KNOWLEDGE

PAST WORK.

-----o-----

In considering the literature of tuberculosis of the middle ear, an endeavour has been made to give an accurate account of the present state of our knowledge, fully yet briefly, accordingly, the original papers and the articles in the more important text books in English and two of the principal papers in German on this subject, have been reviewed, and the chief points taken down in chronological order.

That suppurative diseases of the middle ear occurred in certain phthisical persons was known to the older authors; e.g. Romber, Nelaton and Grisolle, while Virchow, Toynbee, Zaufal, von Troeltsche, and Schwarts made valuable anatomical and clinical observations of tubercular middle ear suppuration; but only since the discovery of the bacillus tuberculosis by Koch in 1882, has the pathology of this disease made any marked advance, and still the pathological changes on the mucous membrane of the middle ear are upon the whole little known.

Steinbrugge³ (H). recorded a case of a boy of five years, who had suffered from an affection of the left middle ear for two years: a sinus formed behind this ear, and an operation was done, but death occurred in a few days. The post mortem examination showed basilar meningitis following caries of the left temporal bone, cheesy degeneration of lymphatic glands in the neck, miliary tuberculosis of the lungs and other organs. The drum membrane was completely destroyed; the mucous membrane of the tympanum and mastoid cavity were thick and infiltrated with pus. A direct transmission⁵ of the disease to the brain membranes could not be discovered, but tubercular history could be traced in this case.

Eschle in 1883,⁶ would seem to have been the first to demonstrate the presence of tubercle bacillus in discharge from the ear; this was in a case of phthisis/

1. Politzer, Diseases of the Ear, ed. Dalby, 1894 p.406
2. Berliner klinische Wochenschrift 1882. (Koch)
3. Archives of Otology 1881. page 31. (Steinbrugge)
4. do. do. " 36. "
5. do. do. " 41. "
6. do. do, 1884 " 226 (Gottstein)

phthisis, with chronic otorrhoea. Eschle also found the bacillus in the discharge from the ear of a boy who had shortly before suffered from scarlet fever and diphtheria complicated by nephritis, without evidence of tuberculosis elsewhere. Hartmann subsequently saw this case, the tympanic membrane was then gone, but no bacilli were found.

As to the mode of entrance of the tubercle bacillus to the middle ear, Weigert's observations prove that this may follow tubercular disease of the nostrils: Gottstein considers failure to find the tubercle bacillus in discharge from the ear, of small diagnostic worth, because they may be in small number and easily escape detection; in support of this statement he quotes Konig and Marchand. He, however, believes it is probable that a piece of mucous membrane removed from the middle ear of a dead body and examined, would give positive results.

Moos (S.) in his study of the pathology of chronic purulent myringitis in tuberculous individuals found irregular hyperplasia in the malpighian layer, towards the cuticular layer, and in the cuticular layer the normal blood vessels were enlarged, and numerous new vessels, round cells, and connective tissue, while in the mucous membrane of the membrana tympani, there was hyperplasia caused by the inflammation. In the substantia propria he never found true vascular inflammation. In the handle of the malleus he found carious processes on the outer surface and increased thickening of the periostum on the inner side.

Macfie and Newman of Glasgow record a case of suppurative disease of the ear in a boy of 5 years, associated with tubercular nodules in the brain. No direct connection could be traced between the ear disease and that in the meninges. The discharge from the ear was copious and purulent, of 3 years duration, with enlarged glands, and a sinus below the ear and facial paralysis and evidences of tuberculosis in the extremities.

No effort seems to have been made to determine the exact nature of the disease in the ear in this case, by the microscope. Barr, who was present at the

1.	Archives of Otolaryngology, 1884, page 225.	(Gottstein 4)
2.	do. do. " 226.	" "
3.	do. do. " 228.	" "
4.	do. do. 1887 " 31.	(Moos S)
5.	do. do. 1887 " 32.	" "
6.	do. do. " " 33.	" "
7.	do. do. " " 35.	" "
8.	do. do. " " 36.	" "
8.	Macfie & Newman	Society
9.	Transactions of the Glasgow Pathological & Clinical Society, 1886-91	
10.	do. do. -Vol. III. page 71.	73 -91

the reading of this paper, stated that carious deposits are frequently found in the ear, and might lead to tuberculosis of the meninges or brain.

Eitelbery¹ (A.) states that suppurative inflammation of the tympanum in advanced cases of tuberculosis, is apt to lead to rapid and extensive perforation of the membrana tympani, unaccompanied by much pain. Three cases examined by the author, were typically tuberculous, and he could prove in one case², that the disease commenced from the eustachian tube, and he believes the other two did the same.

Milligan³ (W.) contends that tubercle may reach the middle ear by either the eustachian tube, the blood vessels and lymphatics, or through a previous perforation of the tympanic membrane. The eustachian tube being probably the most frequent channel of infection; the bacillus may be borne either through it mechanically, or by direct extension along its walls. This author thinks that tubercle in the middle ear, is probably most frequently secondary to the same disease in the larynx or lungs. He found tubercle bacilli in discharge from the middle ear in many cases, and in acute cases the bacilli were in considerable number. In chronic cases, miliary tubercles may be seen deposited in the mucous membrane of the middle ear. This disease may find its way to the internal ear⁴, to the mastoid, or to the intracranial substance. Nathan examined the pus from 40 cases of suppuration of the middle ear, and found the tubercle bacillus 12 times. Habermann, similarly examined pus from 21 cases, which, however, were each suffering from tuberculosis of an internal organ, and found the bacillus in only five cases.

Milligan, by means of inoculation experiments on guinea pigs, demonstrated the existence of tubercle in 80% of suspected cases in children. He experimented by inoculation on guinea pigs with scrapings of suspected granulations and bone, from the diseased area of the middle ear in ten cases, by Delepin's method;⁵ in eight of his ten cases he got positive results/

1.	Archives of Otology 1888.	Vol.18	page 236.	(Eitelbery A)
2.	do.	do.	" 238.	"
3.	British Medical Journal,	1895,	16th Nov page 1223	(Milligan W)
4.	do.	do.	do. " 1224	"
5.	do.	do.	do. " 1224	"

results. These eight cases were all in children under three years of age. Milligan from his own researches and those of others, draws up the following conclusions, viz:- Primary tuberculosis of the middle ear is a much more frequent condition than is usually supposed. The clinical picture presented by most of the cases, consists in the sudden and apparently painless onset of discharge from one or both ears; the early involvement of the glands around the auricle, and the frequent presence of facial paralysis. The amount of discharge is usually fairly profuse, at times sanious, and early becomes markedly foetid. Flabby granulation tissue, blocks the external auditory meatus, and this tissue is evidently connected with the rapid disintegration of bone.

Milligan lays stress on the early onset of facial paralysis as an important symptom. In his paper in the Manchester Medical Chronicle²; he gives the same opinions and results as noted in the previous articles, and also the following additional points of importance;- The clinical symptoms of tuberculous disease of the middle ear, differ from those in the non tuberculous cases, - still in practice, it is difficult to distinguish them, and the finding of the tubercle bacillus by inoculation or directly in sections or pus, is necessary to remove all doubt.

In Infants³, Milligan thinks the bacillus might be drawn into the tympanic cavity during nursing, owing to the change of air pressure in the nasopharynx, and also because the eustachian tube is relatively shorter, wider, and straighter than in the adult.

When once the tubercle bacillus reaches the cavum tympani, the disease may run an acute or chronic course. If acute, rapid caseous disintegration of the mucous membrane occurs; if chronic, miliary tubercles may be visible to the naked eye in the mucous membrane. These deposits early become caseous and/

1. British Medical Journal, 16th Nov 1895 page 1224 (Milligan's)
2. Manchester Medical Chronicle. IV. 1895-6 page 254. "
3. do. do. do. do. " 255. "

and ulcerate; fresh inoculations occur at deeper levels, and in the majority, extend to the underlying bone; in a few cases fibrous tissue may form, cutting off the advance of the disease, and so bringing about a cure. When the bone is attacked, a cario-necrosis is set up.

In addition to the symptoms already stated, which point to tuberculosis, Milligan says; a perforation covered by a creamy secretion in the centre of a pale oedematous uninfamed membrane, should always excite suspicion.

In suppurative middle ear disease of a simple inflammatory type? due to such organisms as streptococci and pneumococci, the clinical phenomena are usually of an acute type, and consist of acute pain in the ear and adjoining parts, a rise of temperature, severe tinnitus, and frequently vertigo. The tympanic membrane usually gives way, and there is an escape of pus, with the immediate relief of the patient? If these cases are properly treated, they subsequently, almost invariably do well.

In tuberculous cases, the course of events is as follows,- the inflammatory process is of an asthenic type, from the commencement; there is a gradual formation of a thin purulent fluid in the middle ear, unaccompanied by pain, rise of temperature, or any of the usual symptoms of sthenic inflammation; the membrana tympani gradually melts away, while the edges of the perforation thus produced, are found uninfamed and sodden in appearance,- a point of very great importance is the extensive destruction of the bone, which takes place at a comparatively early stage of the disease. In acute inflammatory cases, involvement of the bone is practically unknown, and in cases of this type, which have passed into the chronic state, involvement of the bone may be regarded as a late symptom. In tuberculous cases, matters are just reversed; large areas of carious bone being found at a very early stage, and frequently with hardly any evidence of what is going on. The whole interior of the petrous and/

1. Manchester Medical Chronicle, IV. 1895-6 page 256 (Milligan⁽¹⁾)
2. do. do. do. do. " 258
3. do. do. do. do. " 259

and the mastoid bones may be destroyed - a mere superficial shell remaining- while the interior is filled with masses of granulation tissue, containing caseous areas. The early appearance of facial paralysis in these cases, is an especially suspicious symptom, as it is so common in tuberculous cases, and so uncommon early in other cases of middle ear disease.

The prognosis, Author thinks, distinctly grave, and the younger the patient, the worse it is, and that the prognosis is much worse in hospital than private cases.

The treatment recommended, is to secure good drainage, and give a good diet, open air and tonics.

Milligan in 1899², at the International Otological Congress, gave the results of his then fuller experiences: he contends that a large portion of the cases of suppurative middle ear disease, with accompanying bone lesions, met with in practice, are of a tuberculous nature, and that the prognosis in such cases, is not very favourable. The characteristic features of tubercular middle ear disease, may be somewhat masked, on account of an accompanying pathogenic infection, and an accurate diagnosis may be impossible, if one relies upon finding the tubercle bacillus in the secretion from the middle ear. Author has failed to find this organism time after time, when inoculation experiment and the subsequent clinical history proved the tubercular nature of the lesion.

The following, are predisposing causes:- Hereditary tendency, unhealthy environments, unsuitable feeding, exposure to infection from tuberculous relatives, the presence of tuberculous naso-pharyngeal adenoids. In many of Milligan's cases, post nasal adenoids were present³, and in a small proportion, these were tuberculous. The eustachian catarrh, which accompanies adenoids, produces a soil favorable to the growth of tubercle bacilli, and when the middle ear is reached, the condition there is found favorable/

Milligan W
 1. Manchester Medicine Chronicle IV. 1895-6 page 260.
 2. Transactions 6th International Otological Congress 1899 p.35
 3. do. do. do. do. do. 1899 p.36

favourable for their growth, and the disease first appears as slightly elevated yellow points in the mucosa, - later breaking down and forming ulcers.

When the membrana tympani is attacked, multiple perforations may occur.

The complications to be feared in tuberculous disease of the middle ear are (1) Tubercular Meningitis (2) Tubercular enteritis, (3) general marasmus.

In discussing treatment² in these papers, the Author considers his cases from two points of view - 1st. Non operable cases, - 2nd Operable cases. In the first class he places infants, with marked debility and emaciation, with advanced facial paralysis and masses of enlarged glands, especially where these have been early symptoms, and where the discharge is foetid and abundant. In such cases, palliative measures alone can be used, and the prognosis is essentially bad. In the other class of case, where the general condition of the patient is good, the main essential is to provide free drainage by opening and cleaning the mastoid cells, preferable with a sharp spoon; all soft and carious bone being scraped away, and the cavity formed, allowing to granulate up. Frequently more than one scraping is necessary. In cases where the destruction of the middle ear has been so severe, that its future use as an organ of hearing, may be disregarded, the antrum, mastoid cells and tympanum should be thrown into one cavity; but short of this, the treatment should be conservative. All enlarged glands, however, should be removed.

In Milligan's paper in the Encyclopedia Medica³ on the same subject, he puts forward no new facts or opinions, excepting the following:- that in some cases, "in all probability the disease may be primary within the middle ear, infection being conveyed per tubam".

Haenel⁴ (W.) set himself to consider those cases of tuberculosis which, in addition to the middle ear, involve the inner ear. He found records of six previously/

(Milligan W)

1. Transactions 6th International Otological Congress 1899 p.37
2. " do. do. do. do. do. p.38
3. Encyclopedia Medica Vol.111 1900 page 151.
4. Archives of Otology (Knapp's) 1897, page 130 (Haenel W)

previously recorded cases. The points of perforation varied somewhat, from the carious base of the stapes to caries of the promontory and other points of the inner tympanic wall. A case of this kind recorded by Haenel, occurred in an infant 3 months old, whose mother died at its birth. There had been otorrhoea and facial paralysis of a month's duration. Bare bone was felt through the perforated membrane at its upper part, and in this position there were pale granulations. The post mortem examination showed tuberculosis in other organs.

Scheibe (A.) says experience teaches us, that that there is a severe and a mild form of Aural tuberculosis. In speaking of middle ear tuberculosis, this author says, "Cases of cure are rare; more so than in other organs, this is due not only to the unfavorable anatomical relations, but to the fact that most cases of middle ear tuberculosis occur in subjects with far advanced phthisis, where the body can no longer offer resistance to the tubercle bacillus. These cases which are the most frequent show a pronounced tendency to the destruction of tissues.

Between advanced cases, and those that get well, there are a number of intermediate forms in which the tuberculous process neither advances nor disappears, but comes to a standstill. The Author says these mild types have not previously been recognised, owing to the absence of very characteristic symptoms. He gives the details of the symptoms in six cases in support of his theory.- One symptom that appeared in each of these cases, abruptly lead him to a correct diagnosis, but it did not appear before three quarters of a year to six years of treatment; that symptom was the appearance of a membrane on the inner tympanic wall,- the following is the author's description of what he observed:- "On the occasions of the patient complaining of a freer discharge without known cause, we made a careful otoscopic examination and found the following condition,- Situated on the inner tympanic wall, usually on the promontory or near/

1. Archives of Otology 1898, page 129. (Scheibe)
2. do. do. " 130. "
3. do. do. " 132. "

near the tubal ostium, there was a greyish thick membrane, which could not be removed; occasionally bare bone could be felt through this membrane. The membrane was adherent for a long time and there: :by differs from the membrane on the drum membrane and bony wall of the auditory canal found in Otitis Externa Cuposa. The condition of the membrane remained stationary from two to six weeks, when small portions were dislodged by sprouting granulations, and in a few weeks more, the entire membrane disappear: :ed". During the presence of the membrane, tubercle bacilli were found in the discharge from the ear, and also in the membrane itself, while after the dis: :appearance of the membrane, repeated examination of the discharge proved negative, except on two occas: :ions. In these cases; the author states that the mucous membrane was granulating, and a large part of the tympanic cavity lived by epithetium with no destruction of tissue, while in phthisical cases, granulations are rare, and epidermis formation does not occur, and there is marked destruction of tissue.

The prognosis, Author considers, in mild cases, is not unfavorable. Author further expresses the opinion that when a case of chronic otorrhoea does not yield to regular antiseptic treatment during years, and cholesteatoma is not present, tuberculosis must be suspected. Author has never found Koch's bacillus in a case of Cholesteatoma. Histologically the membrane in question seems to be a secretion, consisting of a granular mass, containing no vessels, and is similar to fibrinoid, a fibrin like substance which stains badly, and named by Schmauss and Albrecht: :ht fibrinoid² because it does not stain by Weigert's method.

Lewis (R.Jr.) gives the following particulars regarding the case of a woman aged 24 years, in whose left external auditory meatus, offensive cheesy masses were found. She had suffered from a dis: :charge^{from} of this ear, for 20 years, without pain, which commenced after an attack of measles. Acute pain and left facial paralysis came on a month before/

1. Archives of Otology, 1898 page 133. (Schaebe A.)
2. do. do. " 134. "
3. do. do. 1898 Vol.27 page 411. (Lewis R. Jr)

before death; which took place during an operation for the relief of those symptoms. At this operation, the mastoid was found to contain offensive cheesy masses, a perforation in the roof of the tympanum, and above this and beneath the dura mater, an abscess, in which tubercle bacilli were found.

Winkler (E.) in his important papers published in 1898, entitled "Ueber Tuberculose des Mittelohres", gives his experience shortly, as follows;- Tuberculosis of the middle ear commences in the mucous membrane, and from this it leads to destruction of the surrounding bone. A small celled infiltration, with tubercle formation and giant cells takes place; the process spreads quickly in the Havercian Canals along their lining membrane. Before the drum membrane is affected, the mucous membrane of the tympanum is, and from there it spreads to the mastoid antrum. Occasionally the disease may commence in the mucous membrane of the antrum. Kürster believes this is the usual beginning, and that the tympanum is subsequently affected, but Habermann's researches shows that the tympanum is primarily affected. Haug has alone observed primary tuberculosis of the mastoid process, without any disease of the tympanum. As the disease advances, the footplate of the stapes is frequently left, while the limbs are always gone, the reason being that the foot-plate receives some of its nourishment from the vessels to the inner ear. At a later stage, the whole of the mucous membrane of the tympanum and antrum falls off, either by caseation of the tubercles or by granulations. These may fill the tympanum and mastoid antrum and burst through its cortical layer, and cause a fistula behind the ear. Generally, the drum membrane is destroyed at this stage. Embolism of the internal auditory artery is apt to occur, and according to its extent is the resulting necrosis of the labyrinth.

The favorite site of the commencement of this disease is the inner wall of the tympanum, especially the promontory. - This seat readily shows the dangerous/

^{Winkler E.}
1. A Wiener Medicinische Presse 1898, page 662.

dangerous nature of the disease, as it easily leads to involvement of the various parts of the labyrinth, or through the tegmen to the brain. The appearance of facial paralysis and paralysis of the superior petrosal nerve and exfoliation of the labyrinth, are important signs, and great danger may be caused by involvement of the bone, ^{around} the carotid artery and the artery itself may be involved, causing haemorrhage.

Spread of the disease to the meninges does not seem common, but in children it frequently leads to brain tuberculosis. After perforation of the drum, the infection soon becomes a mixed one, and the process a septic one, rather than the tuberculous. When the drum is perforated the tubercle bacilli may find their way in by this means, but when no perforation exists, they find their way into the tympanum, either by the eustachian tube or by the lymph or blood vessels.

Tuberculosis in the middle ear occurs most frequently when there is tuberculosis in other organs; but in relatively rare cases it occurs as a primary disease. It may remain a local affection or it may be an early symptom of a later tuberculosis of the lungs. According to Ostman the wasting in phthisis has an important bearing on this disease. On the outer wall of the eustachian tube there is a layer of fat tissue (Ostman) the object of which, is to keep the outer wall against the inner wall, - its object being to tone down certain impressions of sound, and prevent the passage of infectious material into the tympanum. In cases occurring in phthisical patients, on account of this fact, the disease is probably caused by a particle of sputum getting into the tympanum during forcible expiration or on swallowing.

As a cause we must consider also quiescent tuberculous conditions of the naso-pharynx which frequently extends into and up the eustachian tube. According to Straus the tubercle bacillus may occasionally be found in the nose and naso-pharynx of healthy persons.

In the early stages pain need not be present at all, and only occurs when the disease begins in the mastoid antrum. Inspection of the drum may give a negative/

Winkler's.
1. Wiener Medicinische Presse 1898, 1.663.

2.
3.
4.]

negative result in quite advanced cases. By percussion over the mastoid you relatively frequently find a difference of sound. If the cortex of the mastoid is broken through by the disease, then you find more or less pain by pressing on the point of the mastoid process. When the tuberculous process reaches the drum membrane, tubercles may be seen on it: the degenerative process quickly takes place, and two or more perforations may be seen; later the whole membrane is destroyed. These perforations occur without pain, not as in Staphylococcal and streptococcal inflammation, where there is great pain. In tuberculous cases the profuse creamy pus discharge is not infrequently tinged with blood, and the lymphatic gland upon the mastoid process is in the very early stages, infiltrated with tubercle (Wauscher and Haug).

In the later stages the disease has no distinctive symptoms to show, because it is then a mixed infection.

The diagnosis is difficult. - All cases of otorrhoea in tuberculous patients are not tuberculous: Microscopic inspection is necessary to prove the presence of a tuberculous process, and the examination can only be successfully carried out when one is in a position to remove the secretion by means of a swab directly from the tympanum, and even then, only rarely, as after the destruction of the drum membrane infections from other causes of inflammations must be counted with: however, after repeated microscopic examinations when the disease is well developed, a diagnosis can be made. In the early stages this is very difficult, especially in primary tuberculosis. The losing of hearing in one ear, while retaining bone conduction in a case with tuberculosis in other organs would be suspicious. Moldenhauer says only about 24% of consumptives, show a diminution of the normal hearing.

Sometimes the occurrence of facial paralysis with intact drum will strengthen the suspicion of tuberculosis of the middle ear. The presence of two or three/

Wunderl. 1.
1. A. Weiner Medicinische Presse, 1898 page 715.

three perforations in a swollen tympanic membrane, with discharge coming without pain, will make the diagnosis of tuberculosis very likely. In ordinary cases, there is only one perforation, and it takes place under great pain: facial paralysis is rare, while relatively frequent in tuberculous cases. Habermann says, the typical place for a tuberculous perforation in the tympanic membrane, is in its lower half. Buch says, above and behind.

Tuberculosis of the middle ear must be considered of serious prognosis, especially if complicated by phthisis.

Brieger,²(O.) paper entitled "Über Tuberculose des Mittelohres" read at the International Otological Congress in London in 1899, is one of the most important that has been added to the literature of this subject, as well as the most recent published in German. Following, is given as briefly as possible, the chief points of the paper, and the Author's views and conclusions.:- It is surprising, says the author, that clinical statistics give a smaller percentage of participation of the middle ear in tuberculosis, than does post mortem statistics. Secretion in the middle ear, with intact membrane, is relatively common in people dying of lingering diseases, and nearly constant in young children; from these cases, with care, it is easy to distinguish the rare cases in which a middle ear tuberculosis comes to a post mortem examination at the stage in which, while there is extensive tuberculous infiltration of the mucous membrane of the tympanum, yet the drum is not perforated, though even the stratum mucosum of the drum has been attacked by the tuberculous process. Even if one excludes all appearances, which are certainly known as non tuberculous, there still remains a considerably greater percentage of middle ear implications in tuberculosis, than clinical observations bring out. One can in general say, that in about one quarter of all post mortem cases of tuberculosis, changes are found in the organs of hearing.

In 141 cases of tuberculosis examined post mortem within two years by Author and his assistants, they/

Winkler E.

1. Wiener Medicinische Presse 1898, page 718.
 2. Transactions 6th International Otological Congress 1899 p.21
 3. do. do. do. do. do. p.22

they found, 37 times, chronic inflammatory processes in the middle ear spaces. In 18 of the 37, the tuberculous nature of this inflammatory process was ascertained for certain; and in the other cases, although not certain, still tuberculosis was not absolutely excluded.

The path by which the middle ear is infected, is the same as that by which nearly all other infections reach the middle ear (Habermann), namely the eustachian tube or its wall. Author considers actual tubercular ulceration of the pharynx, extremely rare, and has usually been absent in tuberculosis of the middle ear, this not being at all necessary for infection of the tube. In children, bear in mind, the possibility of infection from tuberculous adenoids (pharyngeal tonsil). The Author has frequently demonstrated latent adenoid tuberculosis with tuberculosis of the tympanic cavity. Such a relationship had been shown probable, by Schuetz, who ascribed the extraordinary frequency of tuberculosis of the middle ear in swine, being due to lymphatic pharyngeal catarrhs. When lupus of the nose is the cause, the author considers the infection of the ear is secondary, through the pharynx, which may show lupoid or tubercular processes. Besides, the infection by way of the tube or other means of infection, are extremely unimportant, e.g. (a) miliary tuberculosis, (b) infection by the external meatus.

A case has been observed² in which there was a deep tubercular ulcer of the external auditory meatus with erosion of the bone beneath it, and yet the tympanic membrane was intact.

Tuberculosis of the middle ear is characterized by the long latency of the process, and the occurrence of suppuration without pain; this painlessness persists even in very advanced cases, and even in cases in which the superior maxillary articulation is involved. Secondary infection with pyogenic organisms generally alters the course of the case.

A very important diagnostic sign³ is multiplicity of/

Breger, O.

1.	Transactions	6th International	Otological	Congress	Aug. '99	p.23
2.	"	"	"	"	"	p.24
3.	"	"	"	"	"	p.25

of perforations in the tympanic membrane in early cases, later through confluence of the perforations this point is lost.

In infiltration of the drum, which may be general or localised, injection of tuberculine will cause sloughing and a perforation of the membrane; the circumscribed infiltrations are not miliary tubercle, but granulation nodules. The Author mentions a case in which a circumscribed infiltration of the drum was removed, and on examination proved to be a tuberclose granulation; the sequel showed that the tympanic cavity had been involved previously.

In middle ear disease, mixed infection acts as it does elsewhere. ²The acute form of middle ear tuberculosis is probably due to tubercle plus mixed infection; these cases are characterised by very rapid granulation development after perforation, early involmment of bone and laberynthine symptoms.

One could imagine, says this author, that in a case of acute middle ear tuberculosis, that a latent tuberculosis was present, and that a mixed infection supervening caused acute symptoms to appear; this is not Brieger's opinion however, who found in his cases, no sign of such old involmment.

Chronic tuberculosis³ of the middle ear is very common in lupus cases, for infection of the middle ear in these cases, is very easy; but note that all the cases of middle ear disease, associated with lupus, are not all tuberculous. The author, in a case of lupus of the face, with middle ear disease, found the injection of tuberculine gave a positive reaction. The ossicles are infected through their periosteum, with tuberculosis, the stapes being early affected, and the fenestra rotunda perforated.

The frequency of perforation⁴ of the laberynthine foramina in tuberculosis is well known, and among author's post mortem reports, seven of these cases were described. The aditus wall and the facial canal are frequently affected, while involmment of the meninges of the brain is uncommon, because of fibrous tissue formation closing the lymph spaces. The tuberculous process may, however, reach the meninges by the eighth nerve, but this is very uncommon; it is more common for it to do so by erosion/

Brieger O.

1.	Transactions	6th International	Otological	Congress	1899	p.26
2.	"	"	"	"	"	p.27
3.	"	"	"	"	"	p.28
4.	"	"	"	"	"	p.29
5.	"	"	"	"	"	p.30

erosion of the carotid canal and the spread of the tuberculous process along the adventitia of the carotid artery and so infecting the pia mater.

In the mastoid process, primary tuberculosis is very rare, but it may be more common than is supposed. Brieger sites two cases in children, each under one year old; in each case a subperiosteal abscess was present, containing tubercular granulations, and removal of the tuberculous focus effected a cure: the tympanic cavity was healthy in both these cases.

Certain very rare cases of osteitis of the mastoid, have naked eye clinical appearances similar to tuberculosis, but are histologically not tubercle. The clinical diagnosis of these cases, Brieger considers difficult, because the tubercle bacillus is hard to demonstrate in them. In making the examination for the bacillus, he advises washing out the caseous masses from the tympanum by means of a canula, and then examining the sediment or the use of a centrifugal machine, and he warns the experimenter to be on his guard against the smegma bacillus, which resembles the tubercle bacillus and is common in Cholesteatomatous processes and in cerumen; he advises decolorization by means of absolute alcohol in addition to the usual method, as a means of detection. When granulations can be excised, these should be examined, - here again guard against error, as granulations with giant cells occur around foreign bodies, and even in ordinary suppuration; however, the tubercle bacillus is hard to demonstrate, so often we must be satisfied with demonstrating characteristic tuberculous structure, and especially characteristic tuberculous degenerative processes.

Some men (Haugaud Wautscher) lay stress upon swelling of the mastoid gland as a diagnostic point. Brieger recommends that it should be excised and examined if enlarged. If found tuberculous, it might throw some light on the disease of the bone beneath, but is no certain proof, and that mere enlargement of this gland, is no indication at all, as it may be caused by retrorhinal and pharyngeal catarrhs.

Siebmann/

Siebmann and Milligan have inoculated excised granulations on animals. The author's experience is that subcutaneous injections rarely give positive results; this is possibly owing to the bacillus being few in number. Intra peritoneal injections, on the other hand, owing to the frequency of mixed infections in tuberculous cases; cause generally a suppurative peritonitis, which prevents observations being obtainable regarding tubercle, owing to the animal dying before the evidence of tubercle has developed in it.

Broca and Barbon² recommend operation in middle ear tuberculosis, even when there is tuberculosis in other organs, and believe that the ear disease can be so cured; they also believe there is little or no danger of general tuberculosis following such an operation.

Bernstein³ (E.J.) expresses the opinion that the middle ear may become infected at any period in tuberculosis, but in a considerable number of cases, it is the primary seat of the disease. The discovery of the tubercle bacillus does not absolutely prove the existence or non-existence of the disease says this Author, yet he recommends that if any suspicion exists, search should be made for the bacillus: next he states that the membrana tympani may be first affected, small greyish yellow elevations forming, which on breaking down leave a "sieve like drum". Owing to the absorption of subcutaneous fat, the meatus is large and wide, and the skin lining it, is thin, hard, and dry. The left ear, Author thinks, is attacked by preference, and the disease, though usually unilateral, is frequently bilateral. Bernstein relates two cases of primary middle ear tuberculosis occurring in his practice.

Hartmann/

- 1. ^{Briegleb} Transactions 6th: International Otolological Congress 1899 page 32
- 2. ^{Broca - Barbon} Mastoid Abscesses and their Treatment Broca & Barbon *Travaux* Paris 1897 p. 184.
- 3. ^{Bernstein} Journal of Laryngology, Rhinology, ^{+ Otolology} Vol. 2 1896, page 302.

Hartmann states that von Tröltsche first pointed out that tuberculosis frequently occurs in the course of chronic otorrhoea. This author believes that in phthisical patients, the tympanic cavity may be infected directly by the transmission of sputum up the eustachian tube. The disease may also be primary in the middle ear, and may subsequently give rise to general tuberculosis. Tubercle bacilli were first detected in discharge from the ear, by Eschle in 1883.

Ear disease² associated with tubercular infection, says Hartmann, arises without definite symptoms, and mostly without inflammatory appearances; dulness of hearing and otorrhoea sets in with more or less extensive destruction of the tympanic membrane, the mucous membrane of the middle ear and its osseous walls.

Gruber³ states that tubercle is found primarily, both in the mucous membrane of the middle ear, and in the spongy tissue of the petrous portion of the temporal bone; but more frequently it is secondary to pulmonary or general tuberculosis. This author, says Voltolini, first demonstrates tubercle bacilli in ear discharge, and that in making the examination, the material should be taken from the deepest parts of the tympanum: Author says that in osseous sections of the eustachian tube, the most prominent signs of disease were at the ostium tympanicum and less so at the isthmus. Habermann thinks this may be due to the ciliated epithelium of the tube, which carry the bacilli up, and deposit them in the tympanum.

Gruber affirms that tubercle bacilli may be found in aural secretions, where no tuberculous affection exists in the ear; that the symptoms connected with tuberculous disease of the middle ear are similar to those of suppurative inflammation of that region with caries, and that a microscopic examination is necessary to establish a diagnosis. Where a negative result occurs, repeated examinations are necessary/

1. Diseases of the Ear. A.Hartman translated Wrskine 1887 p.180.
2. do. do. do. do. do. p.181
3. do. do. Gruber translated Law & Jewel 1890 p.488
4. Eschle do. do. do. do. do. p.489
5. Deutsche Med. Wochenschrift, 30th Nov. 1883
6. Diseases of the Ear, Author translated Law & Jewel 1890 p.488
- 7.

necessary.

Haemorrhage from the ear is frequent in tuberculous suppuration of the middle ear (Roosa).

MacNaughton, Jones, and Stewart, describe tuberculous otitis media as being first recognised by the discharge, which commences without pain, and that quickly following this is extensive destruction of surrounding bone; the petrous portion of the temporal bone being more particularly liable to become involved in this morbid process.

Politzer in 1865 mentions the clinical peculiarities of phthisical middle ear suppuration. Politzer's examination of a number of mastoid bones from phthisical patients, with suppurative otitis media, showed repeatedly, extensive destruction of the mucous membrane, lining the tympanum and mastoid; frequently this destruction was so complete as gave the appearance of a macerated bone. The tympanic membrane was frequently entirely gone, and the ossicles loosened. Author in one case found granulations containing giant cells and bacilli, in the lower circle of the cochlea and in the facial nerve tubercle nodules and bacilli. Politzer assents that suppurative middle ear inflammation develops in every stage of lung tuberculosis or with tuberculosis in other organs. In the majority of cases, its presence is known by the subjective disturbances of hearing, and a slight discharge; examination shows in recent cases, a pale membrana tympani covered with a creamy secretion softened, and perforated in the central portion or at the extreme periphery, and that these changes are attended with no reactionary symptoms, and rarely pain. In some cases, however complicated with extensive affection of the bone, there is severe pain, a profuse secretion, rapid destruction of the drum membrane, and mucous membrane of the tympanic cavity, with deep seated caries affecting the fallopian canal and facial nerve, the labyrinth, and even the cranial cavity; here also occurs caries, necrosis, and exfoliation of the ossicles and caries and necrosis in the mastoid progress, with the acute/

1. Diseases of the Ear. Roosa 1892.
2. ^{Politzer} " " " " McNaughton Jones & Stewart 1892, p.57.
3. Belenchtungsbilden des Trommelfels 1865, p.65.
4. Diseases of the Ear. Politzer edited Dalby 1894 p.407.
5. do. do. do. do. " 408.

acute formation of sequestra. Politzer has observed that this carious destruction may be combined with osteo-porosis and hyperostosis in the region of the carious spots.

This Author lays stress upon the point that all cases of purulent otitis in tuberculous persons must not be considered tuberculous, and that the appearances described as characteristic of tubercle, must be found in the ear, and an attempt made to find the characteristic bacillus, yet Author considers the presence or absence of the bacillus is not sufficient in itself to establish a positive diagnosis. In cases where severe pain occurs, this is due to the presence of streptococci (Moose). The prognosis is generally unfavourable; but where the disease is confined to the ear, with proper treatment, healing has often occurred; when phthisis is present, recovery is very rare. Politzer quotes three cases in which there was extensive carious destruction of the mastoid process without symptoms.

Field² considers as a rule that where, in spite of free drainage, there is chronic suppuration, its cause is generally tuberculosis, and that this statement applies to the ear, where the disease commences as an affection of the mucous membrane.

Hovel³ considers that tuberculosis of the middle ear is generally secondary, but may be primary: that the eustachian tube is the ordinary channel by which bacilli pass into the tympanum; but that the vessels to the pericostum or a perforation in the drum membrane, may be the channel. The eustachian tube may convey the infection mechanically, or by direct extension along its walls. Schwartz gave the first trustworthy account of the anatomical appearance when he described small grey miliary nodules in the inner wall of the tympanic cavity. Tuberculosis of the tympanum occurs in two forms, - the acute, and the chronic. In the first, diffuse cellular infiltration of the mucous membrane occurs, with proliferation of cell elements; giant cells are absent or few, and bacilli numerous: the result is necrosis and great loss of substance. In the second, or chronic/

1. Diseases of the Ear, Politzer edited Dalby 1894, p.501.
2. do. do. Field. " p.376
3. do. do. Hovel M. 1894, page 554.

chronic form, circumscribed masses of tubercle are first seen in the superficial layers of the mucous membrane; their centres caseate, giant cells develop and bacilli are few, superficial ulcers form, and deposits occur at deeper levels; granulations may spring up and result in fibrous tissue formation, and so isolate the disease and ultimately lead to recovery. In most cases the disease extends and involves the mastoid and labyrinth; sequestra may be formed and the brain may be invaded through the tegmen.

Hovel says the first symptom is a purulent discharge or a feeling of fulness, that acute pain is absent and that the absence of pain is characteristic. Before perforation of the tympanic membrane takes place, it becomes dull and yellowish grey with minute reddish-yellow patches on the surface, that here the membrane breaks down and perforations take place; the destructive change progresses rapidly, until the whole membrane is destroyed, and that this rapid destruction of the membrane is characteristic of tubercle. Author states that the perforations usually occur in the lower half of the membrane, the remainder being pale yellowish grey; that bacilli are not always found in the discharge; that the inner tympanum wall is sometimes ulcerated or dotted over with caseous masses. The prognosis, this author considers, very unfavourable, especially when of secondary origin. The treatment that author advised is that applicable to chronic suppuration, and tonics.

Shield finds that tuberculous otorrhoea is common and peculiarly intractable. A remarkable feature, says this author, in these cases, is their quick onset without much pain or constitutional disturbance, and the co-existence of most extensive destruction of the drum, and extensive deafness; the bacillus may be found in the discharge and general tuberculosis may result from middle ear tuberculosis.

Barr² expresses his opinions on this subject as follows;- "No doubt many cases of so called caries of the mastoid process, especially in children, who at the same time have enlarged lymphatic glands in the/

1. Diseases of the Ear, Shield M. 1895, page 138.
2. do. do. Barr 1896 " 56.

the neck, are really tubercular disease of the mastoid process, and the petrous portion of the temporal bone.

In chronic purulent middle ear disease there is reason to believe that many cases are really tuberculous, in which no bacilli can be found.

Dench states that tuberculosis of the ear is characterised by insidious onset; the first symptom recognised, being, a discharge from the ear, there having been previously no pain or noticeable impairment of hearing. On examination, the entire drum membrane may be wanting, and even the ossicles may have disappeared. Where only a portion of membrane has been destroyed, the perforation presents a somewhat characteristic appearance; it is usually circular, the edges thick and everted, and present, instead of the bright red colour commonly observed in simple perforations, a bluish white, glossy, or dematous appearance, comparable to that seen in the Arytaenoid cartilages in laryngeal phthisis. Another characteristic is two or more perforations in the same membrane: When the ossicles are involved, the surrounding bony structures are soon attacked, and the mastoid process may be broken down. In an early stage of the disease; this author recommends early removal of the diseased parts, as this may check the process and influence favourably the systemic condition, and even when an operation is done, we must not forget general medicinal and dietetic treatment.

Dr. McBride's article³ on tuberculous disease in the middle ear, (in the third edition of his Work,) is the most recent article that I have been able to consult. This author credits Volotini with being the first to demonstrate the occurrence of tubercle bacilli in phthisical otorrhoea, - while Hartmann deserves the credit of having shown that giant cells and bacilli actually occur in the lining membrane of the middle ear in certain cases of phthisis and, Von Troeltsch had years before⁴ described the typical form of/

1.	Diseases of the Ear, Dench (E.B.),	New York,	page 596	
2.	Do.	Do.	Do.	597
3.	Diseases of the Throat Nose & Ear	McBride D.	3rd Ed. 1900	p.546
4.	Do.	Do.	Do.	Do. p.547

of suppuration that runs its course without pain; while rapid destruction of the tympanic membrane takes place, owing, according to Schwartz, to the breaking down of small miliary nodules, which are visible, as grey cheesy deposits. The author recommends examining the discharge for bacilli in a suspected case. Dr. McBride regards the prognosis as unfavourable to hearing, and the tendency to bone invasion, he thinks, makes this disease dangerous to life. Author recommends treatment on general principles, and thinks the instillation of lactic acid worth a trial. He has never met with a case in its early stages, in which he felt justified in operating to remove the disease, but when caries and necrosis of bone have occurred, he advises a radical operation if the patient's general condition permits of it, and then if possible, to remove all diseased tissue from the mastoid antrum and tympanum.

S U M M A R Y .

Summarizing the foregoing, we may formulate the present state of our knowledge of tuberculosis of the middle ear as follows:-

von Troltsche first pointed out, that Tuberculosis frequently occurred, in the course of chronic otorrhoea, although the frequency with which chronic otorrhoea occurred, in persons suffering from Phthisis had been observed by several of the other older authors;- e.g. Romber, Grisolle, Nelaton and others.

Only since the discovery of the bacillus tuberculosis by Koch in 1882, has the pathology of this disease made any marked advance.

The first to demonstrate the tubercle bacillus in aural discharge, was Eschle in November 1883. McBride and Gruber give to Voltolini the credit of this discovery, but give no dates; while Habermann first demonstrated giant cells and tubercle bacilli in the mucous membrane of the middle ear in tuberculous otorrhoea.

The bacilli find their way into the tympanum in one of three ways: by the eustachian tube, mechanically, or by extension along its wall,; by the blood or lymphatic vessels; and through a previous perforation of the tympanic membrane. Milligan's statistics prove that this disease is frequent in children, and Brieger's, that there are more cases than clinical observations bring out. Brieger found 25% of post mortem cases, with tuberculosis, showed involvement of the ear, while Politzer, Sheibe, and Winkler maintain that the disease is most frequent in persons suffering from tuberculosis in other organs.

Among the chief predisposing causes which are mentioned by various authors, are Phthisis, Lupus of the nose, hereditary tendency &c., unhealthy environment; unsuitable feeding, tuberculous relatives; and in infants, tuberculous adenoids, while as a cause Winkler lays special stress upon the disappearance of fate from the lateral wall of the eustachian tube in wasting diseases, by making this tube ^{become} more patent. Childhood is looked upon as a predisposing cause/

cause, because then the eustachian tube is shorter, straighter, and more patent than in the adult.

It is admitted by all authorities that the disease may be primary or secondary, but most frequently the latter. There are differences of opinion as to the site at which the disease generally begins in the tympanum. Habermann, Winkler and Brieger, hold that it commences in the mucous membrane of the tympanum, especially near the promontory: Kurster in the antrum.

Tuberculosis of the ear may be acute, or chronic. In the acute variety (which Brieger says is really tuberculosis plus mixed infection) there is a diffuse cellular infiltration of the mucous membrane, with proliferated cell elements; giant cells are absent, while bacilli are numerous: the bone is soon involved, and great destruction of it takes place, frequently with the formation of sequestra, while rapid granulation formation is also a feature of the acute variety. In the chronic form, circumscribed masses of tubercle are first seen on the superficial portion of the mucous membrane of the tympanum; these caseate, giant cells develop, and bacilli are few; the process gradually spreads deeper by ulceration. The spread of the process may be stayed, however, by fibrous tissue formation cutting off its advance; but in most cases the bone becomes involved; the disease finding its way into the labyrinth or mastoid process. Spread of this disease to the brain membranes is not very common, except in children, owing to fibrous tissue formation closing the lymph spaces (Brieger).

Schwartz described small grey miliary tubercles on the inner wall of the tympanic cavity in Children the subject of tubercle, with purulent otitis, and visible as grey cheesy deposits.

Tuberculosis of the middle ear is characterised by the long latency of its process and the absence of pain (Brieger). Hartmann describes this disease as arising without definite symptoms. Politzer says "In the majority of cases its presence is known by the subjective disturbances of hearing, and a slight discharge". With reference to the affect on hearing during the early stages, authorities differ.
Hartmann/

"the subjective disturbances of hearing, and a slight "discharge". With reference to the affect on hearing, during the early stages, authorities differ. Hartmann says there is impairment, while Dench claims that no impairment is noticeable. Moldenhauer only found impairment of hearing in 2.4% of phthisical persons, while Brieger proved that 25% of persons dying of phthisis, show evidence of tuberculosis in the organs of hearing. Winkler considers the loss of hearing in one ear - bone conduction remaining good - would point to tuberculous involvement in a tuberculous patient.

Hovel says tubercles may be seen in the tympanic membrane before perforation, appearing as grey or minute reddish spots, and that when these break down, perforations appear, perhaps several in number; but the disease thus tends to rapid destruction of the membrane.

Multiple perforation in the drum membrane is a symptom recognised by all authorities as strongly pointing to a tuberculous origin.

Dench describes a tubercular perforation as follows:- It is circular, its edges thick and everted, of a bluish white colour, and oedematous; as opposed to a bright red colour seen in non-tuberculous inflammation. Milligan describes the edges of these perforations as pale and indolent looking.

Tuberculous ear discharge is described by Milligan as thin, profuse, purulent, and foetid: By Winkler as creamy, profuse, and at times blood stained in the early stages; After mixed infection occurs, its character changes. The granulations are described by Milligan as flabby; by others, pale and oedematous, frequently large, and filling the whole mastoid process which has been hollowed out by them. There is frequently destruction of the mucous membrane of the tympanum and antrum, leaving the underlying bone bare, which can be felt with a probe. (Politzer, Brieger).

Politzer says examination shows in recent cases a creamy secretion, a pale membrana tympani softened and perforated in the central portion or at the extreme/

extreme periphery. Hartmann considers the lower half of the drum, the typical place for these perforations to occur: While Bach thinks above and behind, the most typical situation.

Destruction of bone, often without external manifestation, is an important symptom, and this is often early and very extensive, consequently, facial paralysis is very liable to occur in this disease as an early symptom, owing to destruction of the wall of the falopian canal, while it is extremely rare in the early stages in non-tuberculous disease, owing to the bone not being involved in this type of case.

Owing to the hollowing out of the mastoid by tuberculous granulations, its cortical layer frequently gives way, causing an abscess to form behind the ear: By this bursting, a sinus is formed.

The importance of finding tubercle bacilli in aural discharge is viewed differently by Authors. Many of them take this as an absolute proof of the existence of tuberculous changes in the ear. Gruber and Bernstein do not admit this: all are, however, agreed at the importance of searching for them in suspicious cases, and advise that the discharge for examination, be taken direct from the tympanum.

That the bacilli may be difficult, or impossible, to find in an undoubted case, is also a point agreed on by authors. Brieger recommends taking a piece of granulation for microscopic examination if possible, and gives a warning not to be deceived by the smegma bacillus. Milligan advises inoculation experiments in guinea pigs as the best means of proving their presence. Brieger does not think well of this method, considering it unreliable, and says one may have to be satisfied with demonstrating characteristic tuberculous structure and degenerative processes in the tissues affected.

In making a diagnosis, all authorities agree that the following are the most important clinical indications:- a painless onset of discharge from the ear; two or more perforations; the presence of pale oedematous granulations; a creamy pus discharge; facial/

facial paralysis coming on at a very early stage, while bare bone may be felt through the meatus. During an operation, the bone being found soft and cheesy and much destroyed by granulations, is an important symptom.

Before rupture of the membrane, tubercles may be seen on the drum, or soon after rupture, on the tympanic wall.

Notwithstanding the many guiding symptoms, cases occur in which a diagnosis from clinical symptoms, is very difficult.

Authorities are also agreed that all cases of suppurative otitis in tuberculous persons are not always tuberculous. Percussion dullness over the mastoid is mentioned by Brieger as a symptom.

Field thinks that where in a case of suppurative middle ear disease in spite of free drainage, discharge continues, the disease may be looked upon as tuberculous; while Barr considers that caries of the mastoid along with otorrhoea and enlarged glands in the neck, especially in children, indicates tuberculous. In certain mild cases Scheibe describes a thick, greyish, very adherent membrane, situated in the inner tympanic wall as a positive indication of a tuberculous process.

The points in the non-tuberculous otorrhoea, which help to make a differential diagnosis are, that there is generally acute pain, associated with perforation of the tympanic membrane, that the inflammatory reaction is of a sthenic type; that there is much less destruction of bone in the early stages at all events, that perforations are not pale and multiple, but red and single; that the internal ear is not so liable to become involved, and that facial paralysis early, is very unfrequent.

Scheibe asserts that otorrhoea associated with cholesteatomata is never tuberculous.

The prognosis on the whole is unfavorable, owing to the tendency of the disease to involve bone and to spread to other organs, but especially so, if the case is already complicated by tuberculosis in other organs - e.g. lungs. If the disease involve the ear only, recovery may take place under suitable treatment/

treatment. As to retaining the hearing power in the affected ear, the prognosis is unfavorable.

Dench recommends in primary cases, early removal of the focus of the disease: McBride states he never met with a case in which he considered this treatment advisable; but when caries and necrosis of the bone have occurred, he advises a radical operation, if the patient's general condition permits.

Milligan divides cases for treatment into (1) Non-operable cases, such are infants with marked debility and emaciation, with advanced facial paralysis, masses of enlarged glands, and foetid blood stained discharge. (2) Operable cases: In these the general condition of the patient is good, and the main object should be to secure free drainage, by scraping away all diseased bone and even exposing the dura and walls of the lateral sinus, if necessary, in order to remove every trace of diseased tissue, and then an attempt should be made to secure granulation of the cavity formed, from the bottom. Enlarged glands in the neck should also be removed, while good nursing, fresh air, liberal diet and tonics are agreed by all authorities to form an essential part of the treatment.

Milligan further says, that when the ear has been destroyed as an organ of hearing, the antrum, tympanum and mastoid cells should be thrown into one cavity, and this view is that which is generally accepted by authorities.

Broca and Barbon think there is little danger of general tuberculosis following upon an operation for tuberculous middle ear disease, and they believe that such ear disease can be cured even when the patient has tuberculosis in other organs.

C A S E S .

of which

THE FOLLOWING ARE THE NOTES.-

Case 1. Tuberculous purulent otitis media, with left facial paralysis.

M.W. Age 5 months. Admitted to Children's Hospital, Edinburgh, 22nd December 1900.

History This infant was apparently in good health until 6 weeks ago, when her mother noticed that the left ear was discharging yellow pus. She also noticed at the same time, that the child had a cough, and that her face was twisted to the right side. Which of the three symptoms appeared first, the mother is unable to say, but it would seem that they all appeared about the same time. The child had not suffered from Measles or other Fever, and there had been no infectious disease in the district in which she resided, since her birth. The patient since turning ill has been feverish and cross most of the time, while her appetite and general health have gradually got worse.

A swelling was noticed behind the left ear shortly after the discharge commenced.

Previous History Patient had never had any previous illness excepting Bronchitis.

Family History. There is no history of tuberculosis, but one sister has had Bronchitis.

Present condition The child's general health is evidently impaired, as she is a thin, pale infant; for a few days there has been occasional vomiting.

The anterior fontanelle is wide and very slightly depressed; the head is held in the normal position, but there is complete left facial paralysis. The Orbicularis palpebrarum and corrugator supercilli and the occipito fontalis muscles are as much affected as the lower muscles of the face; the degree of paralysis being equal and total. From the left ear there was a copious discharge of pus, thick, creamy, and foetid, and a little blood has been noticed in it occasionally. The pus wells up on pressure over the mastoid, showing that there is a free communication between the tissues over the mastoid and the external auditory meatus. The posterior auricular glands, as well/

2.

well as those beneath the sterno mastoid muscle are slightly and uniformly enlarged, varying from the size of a pea to that of a bean: There is occasional cough, and slight diarrhoea.

24th December. There is slight holding back of head and commencing retraction, the vomiting has ceased. Slight tonic contraction of the right facial muscles is noticed.

27th December. The retraction of the head continues; the pupils are normal. There is a fullness over the mastoid region in which fluctuation can be felt. The discharge of thick yellow pus continues free. A view of the deeper portions of the meatus could not be obtained owing to the swelling of the meatal wall. The right drum membrane looks normal.

Operation 27/12/00. The usual incision was made behind the left ear, and an enlarged gland first came into view. (This gland was kept for future microscopic examination). On dividing the periosteum a large empty abscess cavity was found, the whole of the mastoid process being denuded of periosteum. The posterior wall of the meatus was also denuded of periosteum, resulting in a direct communication between the abscess cavity and the external auditory meatus through its posterior wall.

While scraping out this superficial abscess, bleeding was noticed from the nose and mouth, showing that there must have been a large perforation, or complete absence of the tympanic membrane allowing free passage of blood down the eustachian tube. No perforation was found in the bone over the mastoid antrum, but it was very thin and exceedingly soft (caseous) being easily scraped away with a sharp spoon. No pus was found in the mastoid antrum, which was found to be of large size and full of granulation. All the granulations and the soft caseous bone were scraped out, the ossicles coming away at the same time. The inner wall of the antrum and tympanum did not appear softened, feeling firm to the touch. No sequestrum was found, and the dura was not exposed. The bridge of bone between the antrum and tympanum was very soft and easily scraped away. When this and the other softened bone and granulations had been scraped away, a very large cavity remained: The cavity was stuffed with worsted in the usual way, as was/

3.

was the external auditory meatus.

The granulations were pale, red, and flabby and showed numerous grey caseating points, some of them and some of the softened bone were taken under strict antiseptic precautions, and placed in a sterile bottle for inoculation into a guinea-pig. Other granulations were placed in absolute alcohol for section cutting.

January 3rd The wound is healthy and clean, and the discharge is small in quantity. The retraction of the head is doubtful, and there is no other evidence of meningitis.

January 6th. The discharge is less, and granulations are beginning to appear. There are no further manifestations of meningitis.

January 9th. The child became very cold and cyanosed. There is no cry or twitching of the right side of the face reported by the Nurse. The pulse is small, rapid, very weak, and of a running character. Stimulants were given, but the swallowing power is impaired.

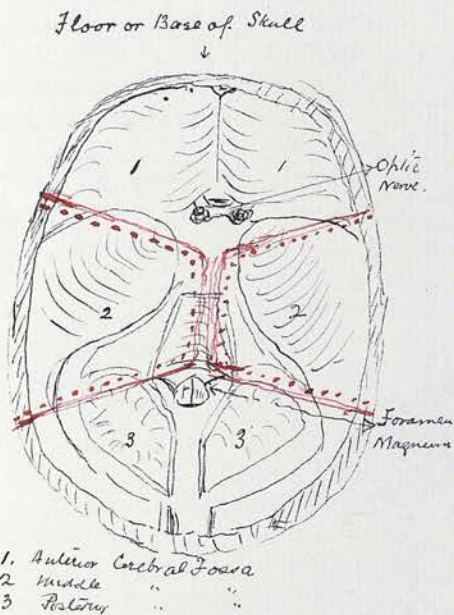
11 a.m. A large abscess behind the right mastoid region, evidently glandular, was incised, and packed.

January 10th The child died at 4.15 a.m. At 2 p.m. same day, I made a post mortem examination of the body at the Hospital Mortuary.

External Inspection The body is that of an ill nourished, emaciated female child, the skin is pale and post mortem lividity is well marked on its under surface. Post mortem rigidity is also well marked. The operation wound behind the left ear, shows only a feeble attempt at granulation; there is a undermined subcutaneous wound stuffed with worsted on the right side of the back of the neck. The opening of this wound is half the size of a threepenny-piece, but the cavity within is much larger, the skin being undermined at its edges. The occipital glands on the left side are enlarged, being about the size of beans. The abdomen is tumid and there is a small ulcer to the left of, and near the umbilicus, the size of a threepenny-piece, which shows no attempt to granulate. The eyes are blue and the hair is fair. The anterior fontanelle is wide and depressed.

Internal Inspection On removing the calvarium, there was an escape of about 2 ozs. of blood stained watery fluid/

fluid; the dura mater was firmly adherent to the skull. The surface of the brain looks pale, but otherwise appears normal. The brain was removed with ease, on dividing the nerves, no adhesions being found anywhere. The roof of the tegmen tympani in the middle fossa on the left side, is paler than that on the right. The pia mater at the base of the brain in the circle of Willis is greyish pink and looks thickened, but there are no visible tubercles along the vessels. (This portion of the pia mater was removed for section cutting)



The portion of bone between the dotted lines in the diagram was removed. It included a portion of the squamous, the whole of the mastoid, and petrous portions of the temporal bone on each side, together with the eustachian tube on the left side, and a portion of it on the right. Some adenoid tissue from the naso-pharynx was also removed.

The sections of the cerebral hemispheres showed the brain matter to be pale in colour, but otherwise it looked normal; the lateral ventricles were of normal size and contained no fluid.

The cerebellum on section looked normal.

On opening the abdomen, the stomach was found distended, and the great omentum, all the intestines, both large and small were matted together with masses of lymph, containing numerous nodules. At both sides of the abdomen in several places the intestines were adherent to the parietal peritoneum: The intestinal coils can be torn apart, showing the adhesion to be comparatively recent. The mesenteric glands are enlarged; the liver is large and pale, but shows no nodules on section, and is not adherent to the intestines or abdominal wall. The kidneys are pale and the spleen is enlarged and shows scattered nodules/

nodules.

On opening the thorax, some of the anterior mediastinal glands are found enlarged, the lungs distended and very pale, and through their whole substance shotty nodules could be felt; they are most numerous in the lower lobes on each side: The lungs were not adherent anywhere to the parietal pleura. The bronchial glands are not enlarged. The condition of the abdominal viscera is typical of tubercular peritonitis and that of the lungs, of miliary tubercular infiltration.

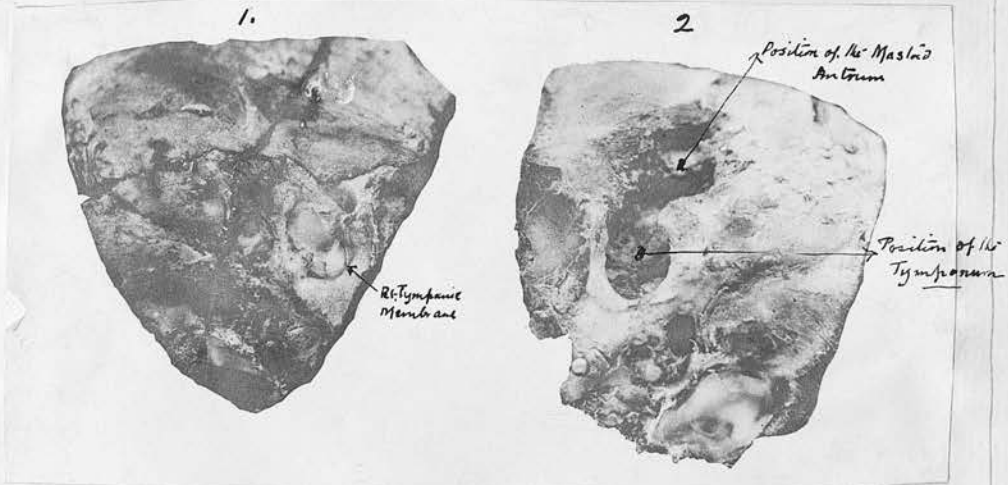
(A portion of the great omentum, mesenteric gland, a portion of the liver, the lungs and enlarged anterior mediastinal gland were taken for microscopic examination, as well as the other specimens previously mentioned.)

The naked eye examination of the left temporal bone shows the following:- On removing the dura mater from its inner surface, the tegmen tympani, although very thin, is still unperforated. On the outer surface of the bone, the cavity resulting from the operation is covered with a few weak pale granulations. After removing the soft parts it is seen that the disease has destroyed the bone of the walls surrounding the tympanum to some extent, but not sufficiently to have invaded the inner ear. About the antrum, the destruction has been extensive.

Perforation of the inner table has not taken place at any part. The bone surrounding the carotid artery has been attacked, but the artery has not been laid bare. The footplate of the stapes is still present; the bony walls of the left eustachian tube have also become involved. The out wall of the falopian canal is gone at the bend downward, and the facial nerve could not be found.

The right tympanic membrane was found unperforated and on its outer surface looked smooth and normal: On laying open the right mastoid antrum and tympanum by means of a saw, the mucosa was found much thickened and studded with small elevated grey points about the size of a pin's head. They were visible not only in the antrum and in the inner wall of the tympanum, but on the inner wall of the tympanic membrane, and in the eustachian tube. The underlying bone/

bone did not seem much, if at all, involved. The thickened mucosa almost occluded the cavities of the antrum and tympanum. The vestibule, cochlea and semi circular canals showed no visible involvement, the ossicles looked unaltered from ^{the} normal appearance. The conditions found, show that ^{the} mucous membrane of the right eustachian tube and tympanum had become implicated in the disease; ^{but} that the disease was in an early stage, the destructive changes being confined to the mucous membrane, so far as the naked eye investigation could determine.



1. Right Temporal bone with tympanic membrane of normal appearance to external examination.
 2. Left Temporal bone showing the destruction of bone about the middle ear.

The accompanying photograph shows these two bones, the right hand one being the left temporal bone, shows the destruction of bone that has occurred and that to the left shows its tympanic membrane still intact. Microscopic sections prepared from the right tympanic membrane, from the mucous membrane of the tympanum and antrum &c., are described under their proper heading.

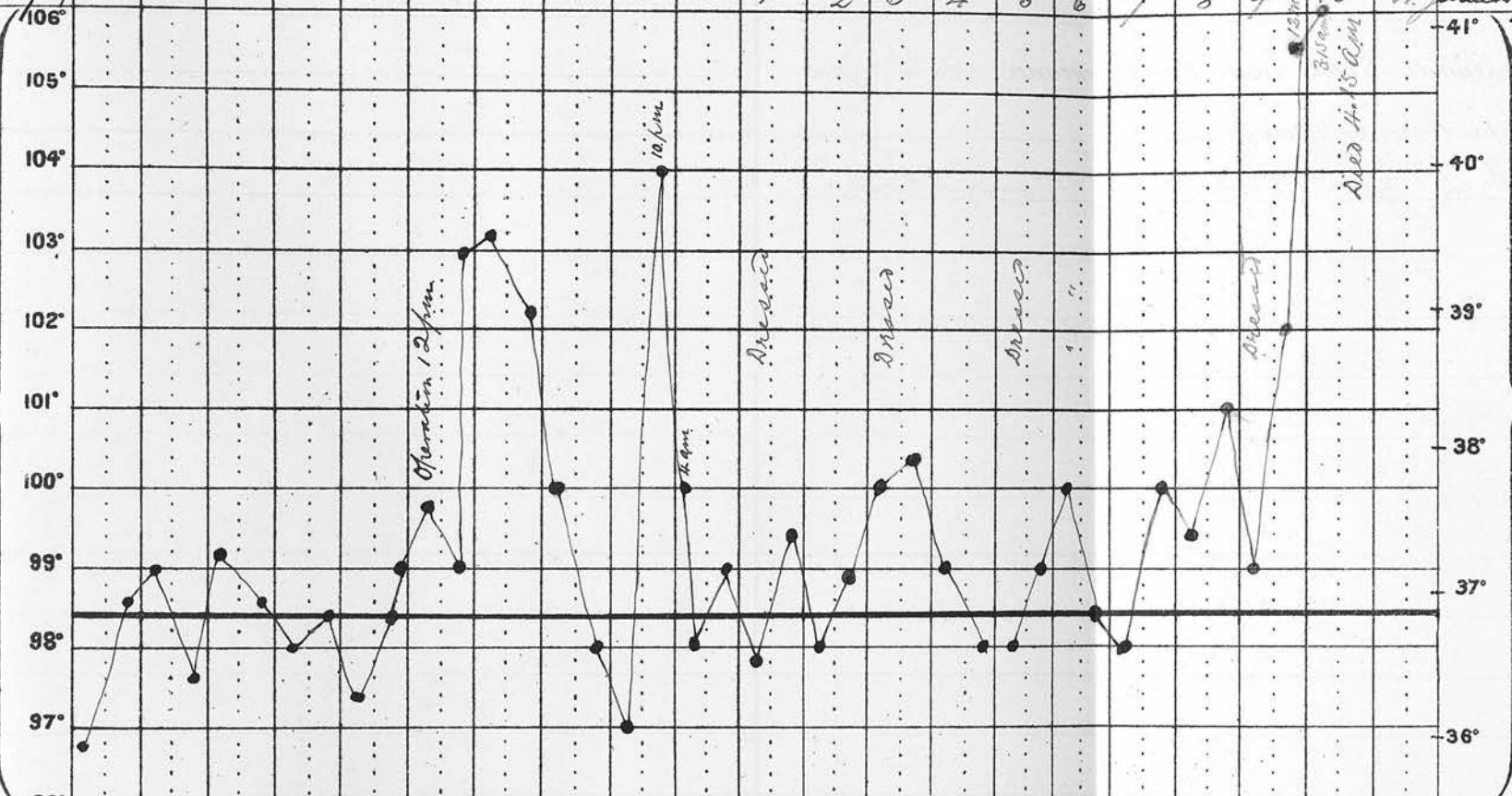
-----o-----
 Case/

Name *Marion Walker* Age *5 months* Disease *Left Middle Ear Suppuration* Result *died*

December 1900		22	23	24	25	26	27	28	29	30	31	1	2	3	4	5	6	7	8	9	10	11	December 1900	January 1901	
106°																								41°	
105°																									
104°																									
103°																									
102°																									
101°																									
100°																									
99°																									
98°																									
97°																									
96°																									
Pulse	m																								
Resp	m																								
Motions	ε	1	2.1	3.1	0.1	2.2	2.1	0.1	1.0	1.1	2.0	1.0	1.2	1.2	2.3	3.2	3.3	3.1	4.1	3.3					
Urine, ozs.					ε																				
Sp. Gr.																									
Reaction																									
Chlorides																									
Albumen																									
Day of Dis.							1	2	3	4	5	6	7	8	9	10	11	12	13	14	15				

TEMPERATURE FAHRENHEIT'S SCALE.

TEMPERATURE CENTIGRADE SCALE.



Case 2. Tuberculous purulent otitis media in both ears.

M.McI. Age 7½ years. Admitted to the Children's Hospital, Edinburgh, 14th September, 1900.

Family History Patient's father died of phthisis, with some brain complication. She has a brother 18 years of age and a sister of 4 years now suffering from consumption; other cases of phthisis have occurred in members of her father's family. On the mother's side there is no tuberculous history. There are six other children living, and four dead; one of consumption of the bowels (probably tubercular peritonitis) another died of meningitis.

Previous History The child was healthy at birth, although the labor was difficult: She was breast fed until 10 months old, and thrived well. Teething was late, the first tooth appeared at 12 months. Speaking also commenced late, the first attempt at this being at 2 years. She had pneumonia in her fourth year, and since then has never had good health.

Present Illness She has had a cough on and off ever since the attack of pneumonia. The discharge from her ears commenced about 12 months ago, previous to this her hearing was quite good, or rather the hearing got suddenly bad about three weeks before the discharge commenced. She also complained of some pain at that time, which was intermittent until about three days before the discharge appeared; when it became continuous and very distressing, entirely preventing sleep; the pain continued severe until the discharge appeared. The discharge was at first thin, but after a time it became thicker, yellower, and more offensive to smell; it has been continuous since its commencement, and the onset in both ears seemed to have been simultaneous.

Since the primary pain there has been little or none until three weeks ago, when the ears again became painful.

The child is emaciated, her skin is pale, soft and moist; her complexion is dark, eyelashes long, fingers somewhat chubbed. There is no cyanosis or jaundice, but she has had some cough and pain in the left side.

19th September. The ear discharge continues very offensive, although the ears are doused night and morning/

Name *Margaret McIntosh* Age *7 1/2 yr* Disease *Chrom. Inf. Otitis media* Result

October	13	14	15	16	17	18	19	20	21	22	23	24	25	26	27	28	29	30	31	1	2	October	
Nov.																							Nov.
106°																							41°
105°																							40°
104°																							39°
103°																							38°
102°																							37°
101°																							36°
100°																							
99°																							
98°																							
97°																							
96°																							
Pulse	m																						Pulse
Resp	&																						Resp
Motions	&																						Motions
Urine, ozs.																							Urine, ozs.
Sp. Gr.																							Sp. Gr.
Reaction																							Reaction
Chlorides																							Chlorides
Albumen																							Albumen
Day of Dis.																							Day of Dis.

TEMPERATURE CENTIGRADE SCALE.

Dressed.

Dressed.

Dressed.

Dressed.

Dressed.

"

Dressed.

Dressed.

Dressed.

Dressed.

0.0

1.0

0.0

1.1

0.0

1.0

1.0

0.0

1.0

1.0

1.0

0.0

1.1

0.0

1.1

1.0

0.0

2.1

1.0

0.0

1.0

0.37

0.37

0.37

0.37

0.37

0.37

0.37

0.37

0.37

0.37

0.37

0.37

0.37

0.37

0.37

0.37

0.37

0.37

0.37

0.37

0.37

Name *Margaret Mackintosh* Age *7 1/2 yrs* Disease *Chronic Sap. Otitis media* Result

Number	24	25	26	27	28	29	30	1	2	3	4	5	6	7	8	9	10	11	12	13	14	Member		
December																							December	
TEMPERATURE	106°																						41°	
	105°																						40°	
	104°																						39°	
	103°																						38°	
	102°	<i>dressed</i>	<i>dressed</i>		<i>dressed</i>	<i>operation night</i>					<i>dressed</i>			<i>dressed</i>		<i>dressed</i>			<i>dressed</i>				37°	
	101°																						36°	
	100°																							
	99°																							
	98°																							
	97°																							
	96°																							
Pulse	m																						Pulse	
	6																						6	
Resp	m																						Resp.	
	6																						6	
Motions	0.0	1.0	0.0	1.1	0.0	1.0	0.0	0.0	1.0	0.0	1.1	0.0	0.0	1.0	1.0	1.1	0.1	0.0	1.0	0.0	0.1		Motions	
Urine, ozs.																								Urine, ozs.
Sp. Gr.			<i>1.034</i>	<i>1.034</i>		<i>1.034</i>		<i>1.034</i>	<i>1.034</i>		<i>1.034</i>		<i>1.034</i>				<i>1.034</i>						Sp. Gr.	
Reaction																							Reaction	
Chlorides																							Chlorides	
Albumen																							Albumen	
Day of Dis.	64	65	66	67	68	69	70	71	72	73	74	75	76	77	78	79	80	81	82	83	84		Day of Dis.	

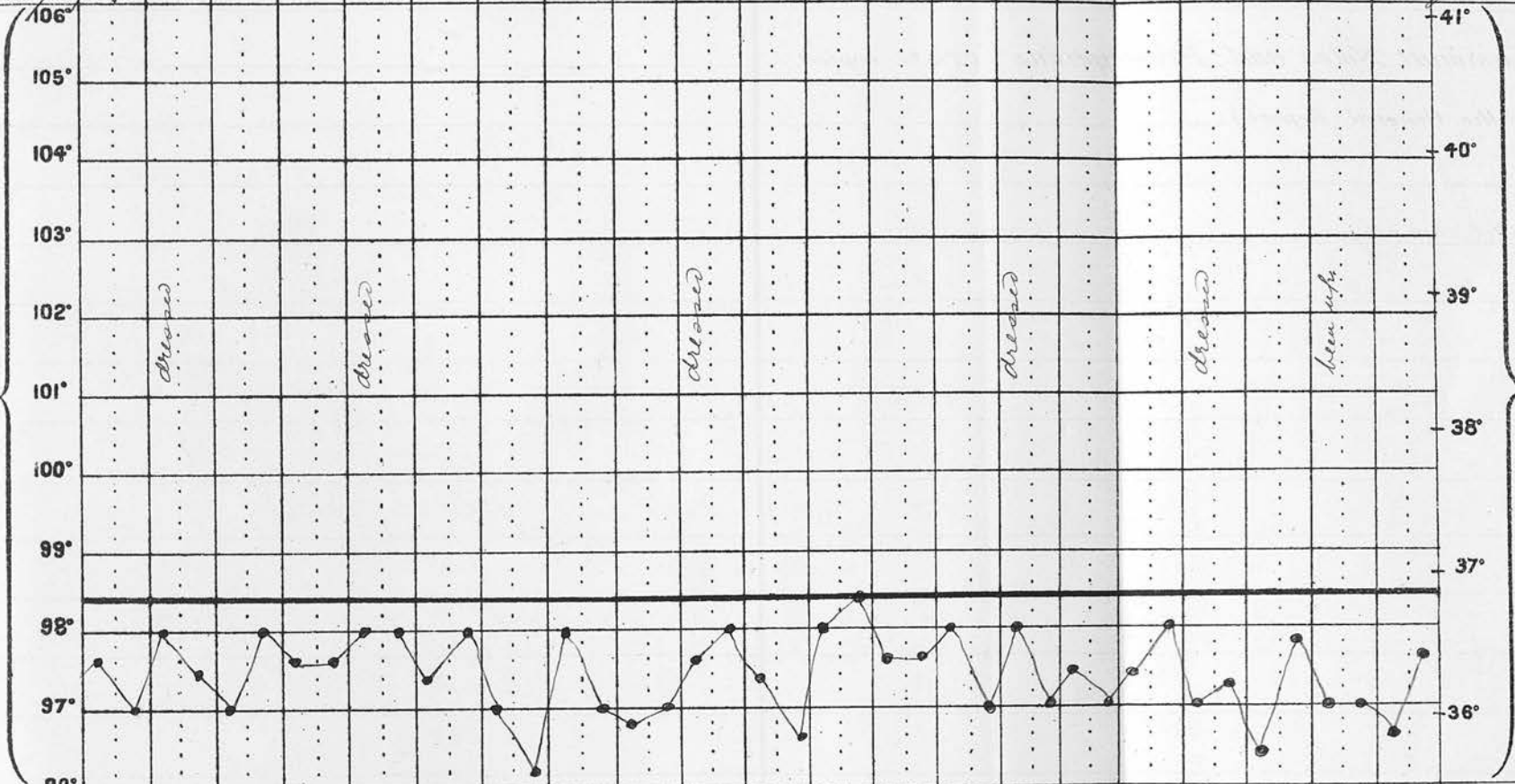
TEMPERATURE CENTIGRADE SCALE.

Name *Margaret McElwosh* Age *7 1/2 yrs* Disease *Chrom. Sup. Otitis media* Result

December 15 16 17 18 19 20 21 22 23 24 25 26 27 28 29 30 31 December 1900
 January 1901 1 2 3 4 January 1901

TEMPERATURE FAHRENHEIT'S SCALE.

TEMPERATURE CENTIGRADE SCALE.



Pulse																				Pulse		
Resp																				Resp.		
Motions	0.0	0.0	0.1	0.0	1.0	0.6	1.0	0.0	1.0	0.0	0.0	1.0	1.1	0.0	0.0	1.1	0.1	0.0	0.1	0.0	0.0	Motions
Urine, ozs.		0.37	Saliva	0.37	Saliva	0.37	Saliva	0.37	0.37	0.37	0.37	0.37	0.37	0.37	0.37	0.37	0.37	0.37	0.37	0.37	0.37	Urine, ozs.
Sp. Gr.		0.37	Saliva	0.37	Saliva	0.37	Saliva	0.37	0.37	0.37	0.37	0.37	0.37	0.37	0.37	0.37	0.37	0.37	0.37	0.37	0.37	Sp. Gr.
Reaction																				Reaction		
Chlorides																				Chlorides		
Albumen																				Albumen		
Day of Dis.	85	86	87	88	89	90	91	92	93	94	95	96	97	98	99	100	101	102	103	104	105	Day of Dis.

morning.

25th September. Right mastoid antrum was opened and scraped out, but the granulations were not kept for examination.

3rd October There is a foul-smelling, thick, yellow discharge from the left ear. There is no swelling or redness behind this ear. The tympanic membrane appears to be entirely gone, and bare bone can be felt through the meatus. There is no facial paralysis on the left side, but right facial paralysis followed the operation on the right side.

The operation on the left ear The usual incision was made behind the left ear and the mastoid exposed; no sinus or bare bone was found, but the bone covering the mastoid antrum was very thin, a mere shell. The granulations in the antrum could be seen shining through the bone, and looked of a bluish colour. The antrum was found filled with granulations, but very little pus. The bone surrounding the granulations was very soft and easily scraped away; the bridge of bone between the mastoid antrum and the tympanum and external auditory meatus was removed, and these cavities thrown into one, all softened bone being thoroughly scraped away.

During the operation, the Anaesthetist noticed twitching of the facial muscles on the left side. The granulations which were large and rather pale, without visible caseous points, and scrapings of bone were taken under strict sterile precautions for inoculation into a guinea-pig and microscopic examination.

A point noticed in this case was the large size of the mastoid antrum and the considerable distance it extended backwards without reaching the lateral sinus. Mr. Stiles, owing to whose courtesy I was able to observe and study this case, mentioned, having previously noticed this peculiarity in children.

After History. Granulation in both ear wounds was slow, and that in the right temporal bone remained in health, & required a second operation 29/11/00. The chart is sufficient to show the course of the case. The patient was still in hospital when I was compelled to leave Edinburgh at the end of June, at that time the left mastoid wound was an open cavity, & looked healthy. I have not been able to follow her history further.

Case 3. Tuberculous otitis media of the left ear with left facial paralysis.

A.H. Age 3 years. Admitted to the Royal Infirm: ary/

:ary, Ward 38., Edinburgh. 18.0ct 1900

History. When 3 months old, a discharge commenced from the left ear, apparently without pain. The labor had been normal, no forceps were used.

Shortly after the discharge commenced, the face was noticed to be twisted to the right side. The family doctor applied a blister behind the left ear without benefit. Once or twice glandular abscesses have formed and been opened behind this ear and also at the back of the neck, and she has been under chloroform twice, apparently for the removal of polypi. The right ear has occasionally discharged, but her hearing, so far as her friends have noticed, has been good.

Family History. Nothing to note.

Present condition. There is a foetid discharge from the left ear, of thick yellow pus. There is a sinus opening below this ear; the skin about it being undermined and of a strumous appearance. Bare bone is felt through the sinus and the left external auditory meatus is found completely blocked with a sequestrum bathed in pus and within half an inch from the surface.

Operation. 21/10/00. The usual mastoid incision was made, and a cavity found containing a sequestrum at the lower portion of the mastoid process. On removing the sequestrum with forceps, it was found to consist of one large piece about the size of a hazel nut and several smaller pieces. The sinus was found leading to the cavity containing the sequestrum; after the sequestrum was removed, numerous granulations were found surrounding it and lining the cavity. These were carefully scraped away, and the cavity stuffed with iodoform gauze. The sequestra were of a dark red colour as were the granulations sticking to them, but the granulations, lining the cavity in which they were lying, were of a paler red colour, and rather flabby. The sequestra were at some points hard and firm, at others soft and cheesy. (The sequestra were taken for microscopic examination and the granulations from the wall of the cavity were placed in a sterile bottle for inoculation experiment. An enlarged gland found over the mastoid, was also taken for examination.)

22/10/00. The wound was dressed to-day (the 2nd. day/

day after the operation) Patient seemed very well and appeared to suffer but little pain during the dressing. The dressing when removed was very foetid. The cavity was syringed out, and showed a surface covered with thin greyish looking tenacious discharge resembling a thin slough; thereafter dressed daily.


Dec.4th. The wound is still being dressed daily, and is showing practically no discharge and closing rapidly. The sinus below the lobe of the ear is, however, still open and granulating but feebly, with very scant discharge. A probe can be passed some distance in, but the exact distance cannot be estimated, owing to the struggles of the patient. For the last two nights she has had a high evening temperature, going up to 104; during the day, however, she has been afebrile.

Dec.5th. Last night her temperature remained normal; she had a good night and appears quite well to-day. Nothing definite has been found to account for the temperature of the two previous nights.

Dec.10th. Patient was anaesthetised and a probe passed into the sinus, it could be made to enter the meatus at the junction of its bony and cartilagenous portions; the sinus was scraped out and swabbed with pure carbolic acid and packed with cyanoid gauze. This sinus, ever since the case has come under treatment, has shown a weak, pale, imperfectly granulating surface, of unhealthy appearance.

Dec.26th. Both the wounds have been dressed every day since the last note was made, sulphate of copper being occasionally applied in addition to the ordinary dressing, but all attempts to obtain closure of the wounds has failed, there still being almost entire absence of granulations in the sinus, and the operation wound behind the ear is larger than a fortnight ago.

Jan.15th The facial paralysis remains unaltered, the wounds are still unhealed, but are showing signs of closing. Her general health is greatly improved since coming into hospital. There is now, practically no discharge from the meatus.



Case/

Name *Agnes Henderson*

Age *3*

Disease *Chronic Suppur. Otit. Media* Result

Date		18	19	20	21	22	23	24	25	26	27	28	29	30	31	1	2	3	4	5	6	7	
TEMPERATURE FAHRENHEIT'S SCALE.	106°																						
	105°																						
	104°																						
	103°																						
	102°																						
	101°																						
	100°																						
	99°																						
	98°																						
	97°																						
96°																							
Pulse	m																						
Resp.	m																						
Motions		1	1	0	1	1	1	0	2	1	1	1	2	2	1	0	3	2	1	2	1	1	
Urine, ozs.																							
Sp. Gr.																							
Reaction																							
Chlorides																							
Albumen																							
Day of Dis.																							

Operation

TEMPERATURE CENTIGRADE SCALE.

Pulse
Resp.
Motions
Urine, ozs.
Sp. Gr.
Reaction
Chlorides
Albumen
Day of Dis.

Name *Agnes Henderson*

Age *3*

Disease *Chrom. Supr. Otitis Media* Result

Date	29	30	1	2	3	4	5	6	7	8	9	10	11	12	13	14	15	16	17	18	19			
Nov. 1900																								
December 1900																								
TEMPERATURE FAHRENHEIT'S SCALE.																							TEMPERATURE CENTIGRADE SCALE.	
106°																							41°	
105°																							40°	
104°																							39°	
103°																							38°	
102°																							37°	
101°																							36°	
100°																								
99°																								
98°																								
97°																								
96°																								
95°																								
Pulse <i>m</i>																							Pulse <i>m</i>	
6																							6	
Resp <i>m</i>																							Resp <i>m</i>	
6																							6	
Motions	<i>1</i>	<i>1</i>	<i>0</i>	<i>2</i>	<i>1</i>	<i>0</i>	<i>2</i>	<i>1</i>	<i>1</i>	<i>1</i>	<i>2</i>												Motions	
Urine, ozs.																								Urine, ozs.
Sp. Gr.																								Sp. Gr.
Reaction																								Reaction
Chlorides																								Chlorides
Albumen																								Albumen
Day of Dis.																								Day of Dis.

After this part the temperature continues normal until discharge left hospital.

Case 5. Tuberculous otitis media of the right ear with hollowing out of the mastoid and a Betzold's Perforation.

D.P. Age 8 months. Admitted to a Private Home in Edinburgh, 22/5/00.

History The right ear has been running for four or five months; there have been two large abscesses in the neck on the right side, which have burst and left sinuses.

Present condition There is a foul-smelling discharge from the middle ear, of a thick, yellow, creamy pus, and there are several sinuses in the neck below the mastoid process and over the sterno mastoid muscle, evidently arising from suppurating glands in this region. Several large glands are also felt among the posterior border of the sterno mastoid on the right side; and the occipital glands are enlarged on the same side. When pressure is applied below the left ear, pus wells up freely from the external meatus, and also when pressure is applied over the mastoid behind the ear. On examining the external meatus with a speculum, after clearing away the pus, a perforation is seen on the anterior meatal wall at its lower part, and through this the pus appears on applying pressure as before mentioned. Nothing more could be made out by examination of the meatus. There are a number of flabby, oedematous, granulations about the orifices of the sinuses, and the skin is undermined in various directions, having a marked strumous appearance. There is also a perforation on the left side. This infant has not been taking its bottle well.

Operation 23/5/00. These sinuses were cut into one, and the pus, granulation tissue, and infiltrated gland tissues were cleared away with a sharp spoon. There is no swelling or redness over the mastoid process, but the usual incision for opening the mastoid antrum was made, and on removing a very thin plate of bone, the antrum was entered, and found to be full of granulations and pus. The whole of the mastoid process seemed hollowed out by the granulations, and there was a perforation on the inner wall (Betzold's perforation) near its tip. The dura mater was exposed at the upper part of the cavity, the pulsation of the brain being distinctly communicated to the/

the blood lying at this part.

All diseased bone and granulations were carefully scraped away, and the cavity stuffed with gauze, as was the wound in the neck.

The granulations were large, flabby, and rather pale in colour; several of these were taken under sterile precautions for inoculation into a guinea pig.

This being a private case, I was not able to see the patient again after the operation, consequently, I cannot give more of the clinical history, excepting that I was told that the infant made a satisfactory recovery. The same is true of Case 4.

-----o-----

Case 6. Chronic suppurative otitis media of the right ear, with right facial paralysis.

H.G. Aged 4 years. Admitted to Ward 38, Royal Infirmary, Edinburgh, 16/10/00.

History. The right ear began to discharge two years ago, shortly after the patient had suffered from measles and scarlet fever. The father, however, attributes the ear trouble to a fall. Since the discharge commenced, the ear has been syringed daily. Twelve months ago she had what her father calls a shock. She was apparently unconscious for an hour or two, and when she regained consciousness, it was noticed that her face was twisted to the left side. At this time there was considerable pain complained of in the region of the ear, the discharge from it was very free, and a swelling appeared at the angle of the jaw on the right side. This acute turn in symptoms caused her to be kept in bed for six weeks, from then until the present time, the discharge has been free and continuous and the facial paralysis has remained unaltered. She was running about up till the day of admission, being brought to Hospital not on account of any new development in her case, but to see if anything could be done for the ear and face.

Examination in the Waiting Room. It was noticed that she had well marked facial paralysis, and that the discharge from the right ear consisted of foetid yellow/

yellow pus. On probing, bare bone was felt, and she was sent up to Ward 38.

17/10/00 Since coming into the Ward, the temperature has ranged between 97 and 98.4. The pulse varies, last night it was 100, this morning 144. The respiration was 20 last night, 30 to-day. The patient is very fretful, takes nourishment with great difficulty and has been sick several times this morning, the vomit being a greenish mucous. She tends to be somewhat drowsy, but cries if moved; the right eye remains half open, and the right side of the face appears slightly swollen. She, however, still retains some power of depressing her right upper lid. There is no apparent swelling in the mastoid region on the right side, nor does there appear to be any special point tender, and no swelling or tenderness can be noticed in any of the glands in the neck. The physical signs in the heart and lungs are normal; the bowels were moved by an enema this morning, and nothing abnormal was noted.

Examination of the ear. The right ear is full of pus, which, up till this morning has been coming away freely, but less so during the last hour or two. The probe touches bare bone in the midst of the pus and close to the external meatus. The pus is very foetid; nothing beyond this can be seen, as the meatus is found blocked by the sequestrum.

Operation. 17/10/00. There is now pus coming quite freely from the right ear, and close within the meatus is felt a sequestrum, which is moveable with the probe. There is no redness or swelling behind the ear,

The child was placed under chloroform, and the usual incision was made behind the right ear, for exploring the mastoid antrum. The periosteum was removed from the mastoid process, and a thin layer of bone was removed from over the lower portion of the mastoid process. This portion of the process was found full of granulations, and the sequestrum was felt anteriorly. A portion of the posterior meatal wall was removed to expose the sequestrum more thoroughly, and an attempt made to extract it through the meatus, which failed. The cartilagenous portion of the meatus was then divided sufficiently to allow a free communication between the mastoid wound/

wound and the external meatus. The sequestrum was now successfully removed through the combined openings posteriorly. The cavity now left, was found lined with granulation tissue. This was very gently scraped, and stuffed with gauze. The ossicles were not seen.

In removing the sequestrum, it was broken into three pieces, the largest being of the size and shape of the terminal phalynx of the little finger. These were each of a firm bony consistence, but having a wormeaten appearance, and presenting a number of hard, sharp edges. No cheesy or caseous bone was found in any part of them. The granulations around them were large and red, and showed no caseous points. Some of the granulations were taken as usual in a sterile bottle for inoculation experiments, and the sequestrum was kept for further examination, and cover glass films were made from bits of the granulations.

After History 18/10/00. The patient remains in much the same condition as before the operation; there has been restlessness, alternating with drowsiness, and frequent sickness. The temperature varies from 97 to normal, the pulse 150. The facial paralysis remains the same. The wound was dressed under chloroform and looked very dry, there being no reaction. 18th evening. She was sick up till 3 o'clock, but has not been so since. Temperature 100 pulse 160; respiration 40.

19/10/00. She is restless at times, but at others, quite still; she is semi-conscious, and did not appear to recognise her own people this morning. She lies with her arms stretched out and her knees drawn up, and although not easily roused, she occasionally exhibits great restlessness. Nutrient enemata, with bromide have been retained with difficulty, and she has now developed diarrhoea, the motions being passed unconsciously. She bores her head into the pillow and keeps it retracted, but does not seem specially sensitive to movements of the head. Nothing can be detected in the lungs, but there is a slight cough; pulse 160; temperature 99; respiration 38. There has been no sweating. There is a tendency to collapse, but no cyanosis. There have been no muscular twitchings, but there has been occasional/

occasional grinding of the teeth. The tongue is fairly clean and there is no retraction of the abdomen. She takes a little milk and lime water by the mouth.

Second operation 4.30 p.m. 19/10/00. The symptoms pointing to brain complication, a trephine was applied to the skull about half an inch above the right external auditory meatus, but nothing was found. The dura mater was stitched up and the wound closed and patient put back to bed.
20/10/00. The patient never regained consciousness and died at 4 a.m.

A post mortem examination was made by the Infirmary Pathologist, who reported as follows:-

"External Appearance: well nourished and well developed child: general rigidity; slight lividity; recent trephine wound in right parietal bone.
"Internal Appearance. Thorax pericardium and pleura healthy. Heart, 3 ozs., apparently quite healthy
"Lungs - 5 ozs; somewhat congested, no pneumonia or tubercle.
"Abdomen. Peritoneum healthy: Mesenteric glands considerably enlarged, many soft and showing caseation. Liver; 1 lb. 3 ozs, Gall bladder, healthy. Liver of a uniform pale colour from anaemia and very extensive fatty changes. Spleen, 2 ozs. moderately firm, but in section shows a few scattered haemorrhages throughout pulp. Kidneys each 2½ ozs, were extremely fatty and anaemic. Intestines. Peyer's patches and solitary glands in lower ileum were congested, hypernemic and somewhat congested, but showed no ulceration. Head. There was a recent trephine opening in skull immediately above the right external auditory meatus; wound in dura closed by several sutures: There was a little oozing of blood into the subarachnoid tissue over the right temporo-sphenoidal lobe - probably result of operation. The convolutions over the vertex were somewhat flattened but there was no evidence of any meningitis vertical or basal.

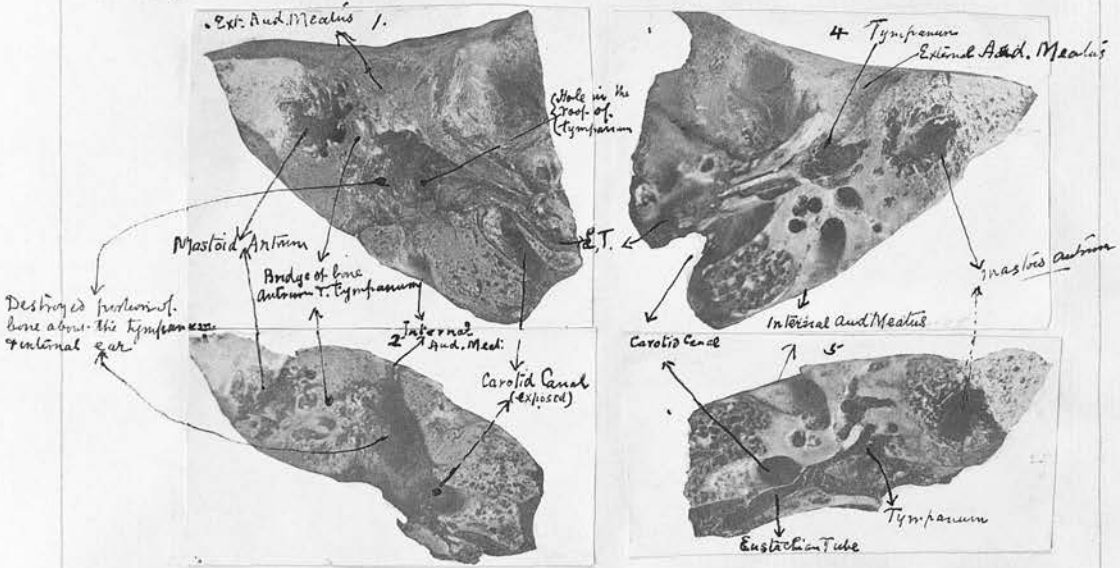
"Brain weighed 2 lbs 8 oz. There were some recent adhesions between the right lobe of the cerebellum and the right petrous bone.

"Cerebral sinuses were healthy. There was a little dark P.M. clot in right lateral sinus, not adherent/

"adherent and not septic.

On section the grey matter of the entire encephalon showed intense congestion, but there was no other lesion.

After removing the dura mater from over the roof of the tympanum on the right side, a perforation twice the size of a pin's head was found. The carotid artery on this side was found exposed in the cavity in which the sequestrum lay; the walls of the mastoid antrum were not involved in the destruction of bone, but practically the whole of the inner ear, including the cochlea, bony labyrinth and semicircular canals had been separated in the sequestrum and each of these parts are easily made out in the sequestrum. No miliary tubercles were visible on the mucosa of the eustachian tube. The accompanying photograph gives a good idea of the destructive changes that occurred.



The dissection of the left temporal bone shows no disease in any part. Descriptions of the microscopic appearance of sections from the sequestrum &c. are found under their proper heading.



Case/

1. & 2. are the two portions of the right temporal bone divided horizontally through the internal & external auditory meatus & show the area of bone destruction

3. The Sequestrum from 1. & 2.

4 & 5 are the two portions of the left temporal bone divided in the same plane as the right which were found healthy.

Case 7. Chronic suppurative otitis media of the left ear, with left facial paralysis.

A.R. (female) Aged 4 years. Admitted to Ward 38 Royal Infirmary, Edinburgh, 1/11/00.

History. Shortly after birth, which was normal, abscesses formed behind the left ear; these were lanced and soon after similar abscesses formed in front of the ear. About the same time as the abscesses formed, the left ear began to discharge and the discharge has continued ever since. The facial paralysis was noticed soon after the discharge commenced, but has gradually increased in degree: There is no tubercular family history.

Present condition There is complete left facial paralysis and there is a free, foul-smelling discharge of pus of a thick yellow consistence from the left ear, and a suppurating sinus over the lower portion of the mastoid process on the left side, with some pouting, pale, pinkish, flabby granulations around it, and about the size of an almond. Bare bone is felt within the sinus. On examining the patient under chloroform, a large sequestrum was felt quite near the surface, in the external auditory meatus, and was freely moveable.

Operation. 4/11/00. The sequestrum was readily removed through the meatus, by means of forceps, and found to be about the size of the thumb nail, but rather thicker, with the groove running along one side which appears to be one side of the eustachian canal ending in the tympanic cavity. The sequestrum was of hard consistence, uneven and rough on the surface and there are no caseous points. After the sequestrum had been removed, the wound behind the ear was enlarged by cutting upwards, the knife entering directly into the cavity from which the sequestrum had been removed. This cavity was found to be lined with granulations. When these had been removed it became evident that the whole of the posterior meatal wall, as well as the lower wall and a portion of the mastoid process, were gone; the cavity communicating freely with both the mastoid wound and the external auditory meatus. In the position of the anterior wall of the meatus, the parts felt soft, as if it had disappeared also. No cheesy or caseous bone was discovered and the granulations within the cavity/

cavity were somewhat different from those previously described around the sinus, as they were darker in colour and not nearly so flabby and oedematous. The diseased tissues were all carefully scraped away, and the cavities swabbed with pure carbolic acid, and stuffed with cyanoid gauze.

(Some granulations from the cavity were taken for inoculation experiment under the usual sterile precautions, and the sequestrum was kept for further examination)

After History. 7/11/00. The dressings had an offensive smell, and on being removed, some discharge was found of a most disagreeable odour; the cavity was syringed out with 1 in 4000 corrosive sublimate solution.

8/11/00. The wound was dressed again to-day, and was found much sweeter.

14/11/00. The wound has been dressed every second day since last note was made. On the 12th the right ear was noticed to be discharging, and before syringing had been done or any kind of treatment had been applied, I made several films from the pus taken from the deepest portion available.

26/11/00. Since the 14th., the wound has been swabbed daily with cyanoid gauze, both through the meatus and by the mastoid opening, and has been perfectly sweet all the time. There is a small enlarged gland just below the apex of the mastoid process over the sternal mastoid muscle. This has been noticed to be gradually increasing in size for the last few weeks; the sub occipital glands and a chain of glands behind the sterno mastoid also, are somewhat enlarged, being about the size of french beans, but are not tender. The mastoid wound is gradually closing.

15/12/00 The dressing has been done daily in the usual way, the mastoid wound is now very small, and there is practically no discharge from it or from the meatus; the gland previously mentioned, at the tip of the mastoid process, is still larger, and doubtful fluctuation is present, but very little acute inflammatory reaction is present. The facial paralysis remains unchanged. The patients general health has improved greatly.

22/12/00. The enlarged gland was distinctly fluctuating.

Name *Agnes Russell*

Age *4*

Disease *Clem. Sup. Otis media* Result

Moribus	1	2	3	4	5	6	7	8	9	10	11	12	13	14	15	16	17	18	19	20	21	<i>November 17</i>
TEMPERATURE FAHRENHEIT'S SCALE.																						TEMPERATURE CENTIGRADE SCALE.
Pulse <i>m</i>																						Pulse <i>m</i>
6																						6
Resp <i>m</i>																						Resp <i>m</i>
6																						6
Motions	<i>2</i>	<i>1</i>	<i>0</i>	<i>2</i>	<i>1</i>	<i>3</i>	<i>1</i>	<i>4</i>	<i>1</i>	<i>1</i>	<i>1</i>	<i>2</i>	<i>1</i>	<i>0</i>	<i>1</i>	<i>2</i>	<i>1</i>	<i>0</i>	<i>2</i>	<i>2</i>	<i>3</i>	Motions
-Urine, ozs.																						-Urine, ozs.
-Sp. Gr.																						-Sp. Gr.
-Reaction																						-Reaction
-Chlorides																						-Chlorides
-Albumen																						-Albumen
Day of Dis.	<i>1</i>	<i>2</i>	<i>3</i>	<i>4</i>	<i>5</i>	<i>6</i>	<i>7</i>	<i>8</i>	<i>9</i>	<i>10</i>	<i>11</i>	<i>12</i>	<i>13</i>	<i>14</i>	<i>15</i>	<i>16</i>	<i>17</i>	<i>18</i>	<i>19</i>	<i>20</i>	<i>21</i>	Day of Dis.

*Stomach
Control*

ing, consequently, the child was placed under chloroform and the gland dissected out, which was very readily done, owing to it having a complete capsule. The gland and capsule were taken for microscopic examination. The cavity, after removal of the gland, was scraped and swabbed with pure carbolic acid, and afterwards its sides were drawn together with horse hair stitches.

24/12/00. The gland wound healed by first intention and the mastoid wound is also completely healed, there being now no discharge from the meatus.

Syringing was never used in the treatment of this case, with the exception of the first dressing, since then, swabbing with cyanoid gauze kept in 1 in 20 carbolic, and wrung out as dry as possible, before use, had been used; this material has always been used as a dressing.

29/12/00. The patient is apparently quite well, there is no discharge from the middle ear, and on examination with a speculum, looks dry and free from discharge, and appears to be getting an epithelial covering. Both the wounds are soundly healed; the occipital glands and the others that were previously mentioned as being enlarged, are still so, but are gradually diminishing.

The patient was discharged to report in two months, or sooner, if any discharge re-appeared.

-----0-----

Case 8 Left chronic suppurative otitis media with left facial paralysis.

W.C. Aged 30 years. Admitted to Ward 37, Royal Infirmary, Edinburgh. 28/4/00.

History 13 years ago the left ear began to run, and it has discharged more or less ever since. Four years ago it became worse than usual, and continued bad for two years, when he came to the Infirmary for treatment. At this time he had a polypus removed; it returned, and was again removed about the beginning of this month. During the last two years, he has syringed and attended to his ear himself/

himself, intermittently; and for the last month, regularly. Two weeks after the removal of the second polypus, he had some granulations burned, and soon after this the pain became much worse. On the 27th of April, left facial paralysis was noticed, and the pain was very intense and localised to the mastoid region.

Operation. 29/4/00. The usual mastoid incision was made, and the mastoid antrum opened in the usual manner. The cortical layer of bone over the antrum was found much sclerosed. In the antrum were numerous granulations, but no pus; these were cleared out and some of them were taken with the usual sterile precautions for inoculation experiment. The posterior meatal wall was removed, thus throwing into one cavity the mastoid antrum and cells and the tympanum and the deeper portion of the meatus.

After History. This was uneventful; the facial paralysis disappeared in a few days, and the wound closed by granulations in about three weeks.

-----0-----

Case 9 Suppurative otitis media; probably tubercular.

A.T. Age 7 years. An out patient at the Eye, Ear and Throat Infirmary, Edinburgh.

History. 15/3/00. This patient has been suffering from phthisis for some months, for which he has been under treatment at the Lauriston Lane Chest Hospital. Through the night, four days ago, a discharge commenced from the right ear, without pain.

Family History His father died of pneumonia; his mother is delicate and suffers from disease in her lungs, probably also tuberculous, as she has been under treatment at Lauriston Lane Hospital for some time. There are other four children in the family all healthy. The patient has never had anything wrong with his ear before.

Present condition. There is a thin, yellow, purulent discharge from the right ear. This, on being wiped away, reveals a pale, sodden looking, tympanic membrane, with a small perforation at the posterior inferior/

inferior quadrant. The edges of the perforation are pale and swollen looking, but there is no evidence of acute inflammatory reaction. Pressure over the mastoid process, causes slight pain; the tonsils are slightly enlarged. Some of the pus was taken on a sterile swab from the deeper portion of the meatus, and prepared with sterile salt solution for inoculation into a guinea pig.

I have not been able to follow the history of this patient further.

Some pus from near the perforation was taken on a sterile swab and a solution for inoculation made with saline solution by the same method and with the same care used in preparing granulations in other cases.

-----o-----

Case 10. Chronic suppurative otitis, complicating pulmonary and laryngeal phthisis.

R.H. Aged 35 years. An out patient at the Ear and Throat Department of the Royal Infirmary, Edinburgh,

History There was no time to get this patient's history on his first visit, and as he never returned to the Hospital it has not been obtained.

Present condition 20/3/00. Before syringing, both ears show perforations fairly clean cut, the remaining tympanic membrane is white and on the inner wall a grey deposit is seen, through which at one part the pink mucosa appears.

After syringing. The membrane is seen to be somewhat thickened, and the deposit on the inner wall remained, even after drying. This description applies to both ears. Both perforations are now seen to be much bigger than they appeared before syringing. On the right side, the probe detects bare bone on the inner wall, and the same is true for the left side.

A scraping was taken from the right middle ear with a sharp spoon, with the usual sterile precautions for inoculation purposes.

-----o-----

Case/

Case 11. Right suppurative otitis media, with acute mastoiditis.

W. McK Age 39 years. Admitted to Ward 37, Royal Infirmary, Edinburgh. 20/3/00 (Brewery man)

History. Nine weeks ago the right ear commenced to discharge, without pain. The discharge was very profuse and of a pale yellow colour, it does not appear to have been bad smelling at the commencement, but soon became so. Eight days after the discharge appeared, pain commenced in the ear, becoming very soon almost constant and extremely severe, but was easier at intervals; Following a somewhat freer discharge, two weeks ago, a swelling appeared behind and above the right ear over the mastoid process and extending to the temporal region. There has been a throbbing sensation in the ear, almost from the first appearance of the discharge, and just before the swelling commenced, the discharge was somewhat less. There is a pinkish blue unhealthy swelling on the back of the right hand, which resulted from an injury, five weeks ago. There are similar swellings on the left elbow and on the right leg, all of which have a tuberculous appearance.

Of late years the patient has noticed that cuts or scratches have healed badly. He has been a heavy drinker for some years, but has enjoyed good health, excepting when fifteen years ago he had pneumonia.

Family History The patient's mother died of pneumonia, between the age of 50 and 60. One sister died of consumption at 33; Three brothers and another sister are dead, but not of consumption. Other cases of consumption have occurred in his mother's family. The patient is more like his mother than his father.

Present condition There is an acute inflammatory condition in the right mastoid region, extending well above the level of the auricle. This swelling is fluctuating at its centre, but hard and indurated around the periphery.

Examination of the external auditory meatus, with the speculum, shows the posterior and upper wall of the meatus to be bulging, rendering a view of/

of the deeper parts somewhat difficult, but a perforation and some granulations can be made out in the posterior portion of the tympanic membrane. Operation 22/3/00. The usual mastoid incision was made, opening at once into an abscess cavity, from which there was a copious flow of thick yellow pus; the walls of the abscess cavity were found lined with granulations; the bone was denuded with periosteum and looked unhealthy. The supra meatal spine was absent, consequently the gauge was applied at the level of the meatus, and on removing a very thin plate of bone, entered a cavity filled with pus and granulation tissue, which occupied nearly the whole of the mastoid. The overhanging edges of bone were removed, and the cavity cleaned with a sharp spoon. On applying a strong electric light, a granulation was seen on the upper anterior part, and a probe introduced, passed into the sinus. This was laid open and cleared out with a sharp spoon, finally, the edges and the projecting points were smoothed with a dental bur.

Some of the granulations were taken from the mastoid, with the usual sterile precautions and placed in a sterile tube. Other granulations were placed in a saturated solution of perchloride of mercury for section cutting.

-----o-----

Case 12. Chronic suppurative otitis media of the left ear, and mastoid sinus.

G.C. Age 11 years. Admitted to Ward 37, Royal Infirmary, Edinburgh. 3/3/00.

History After an acute attack of pain in the left ear, lasting three or four days, a discharge was noticed coming from it. This occurred some years ago, and the discharge has been constant almost ever since. There have been attacks of pain in the ear, followed by a more profuse discharge occasionally. About one month ago, a swelling formed behind the left ear and broke, discharging pus: Two weeks later, on the 4th March 1900, a large firm polypus was removed from the ear, by means of a snare. This polypus was/

was placed in a saturated solution of corrosive sub:
:limate for preparation for future microscopic exam:
:ination.

Present condition 10th March, 1900. There is a
foul-smelling discharge from the left external
auditory meatus. A probe passed in by the sinus
and another by the meatus cannot be made to touch one
another. Through the external auditory meatus, bare
bone can be felt on the floor of the meatus, on the
floor of the tympanum and on the posterior wall of
the tympanum.

Operation 10/3/00. The usual incision was made
behind the ear, and a radical operation was done.
Numerous granulations were found in the sinus and in
the mastoid antrum. Some granulations were taken
from each situation with sterile precautions, for
inoculation experiments.

-----O-----

Case 13. Left chronic purulent otitis media with
cholesteatomata of the mastoid antrum followed by
acute mastoiditis with Betzold's Perforation.

G.D. Aged 24 years. Admitted to the Eye, Ear
and Throat Infirmary, 12th March 1900.

History. There is no family history of tubercle.
The patient has suffered from a discharge of the left
ear since a child, when it followed an attack of
measles. It has been continuous, and more abundant
at some times than at others: Syringing with boracic
lotion has been carried out fairly regularly. For
the last six months, he has suffered a good deal of
pain at intervals. Three weeks ago a polypus was
removed from the ear; ten days ago a swelling
commenced to form behind this ear, associated with
pain which has been continuous and severe.

Present condition There is a good deal of swelling
and redness over the left mastoid region, and for
about three inches down the neck. No fluctuation
can be felt. There is a little discharge from the
ear, composed of thick, curdy very foul-smelling pus.
The meatus is very narrow, being only large enough to
admit the smallest size of ear speculum. All that
can/

can be seen is the stump of the polypus removed three weeks ago.

The patient is now suffering intense pain in the ear and has not slept for two days in consequence. Operation 14/3/00. Patient was placed under chloroform, and the usual incision for exploring the mastoid made. The outer wall of the mastoid was chiselled away just below the supra meatal spine, and the antrum was reached after removing about half an inch of very dense hard bone. In it was found cholesteatomatous masses, bathed in curdy pus. When these and some granulation tissue, which was also present at the lower portion of the mastoid process, occupying the cells in that situation, had been removed, pressure in the neck caused pus to flow into the cavity thus formed and examination of the cavity with a probe, revealed a perforation on the inner wall of the process near its tip. (Betzold's perforation).

The swelling in the neck was then incised and an abscess was found beneath the sterno mastoid. this was found to communicate freely with the mastoid wound. The mastoid cavity was thoroughly scraped and stuffed with gauze, and the abscess drained. The following specimens were taken for examination, - Pus on a sterile swab, from the mastoid antrum, granulations from the mastoid cells in a sterile bottle and granulations from the abscess cavity. After History 15/3/00. The patient has made a good recovery, the intense pain from which he had suffered previous to the operation being immediately relieved by it, but unfortunately he has complete left facial paralysis since the operation. The mastoid wound was allowed to heal by granulation from the bottom, this process being practically complete in four weeks. The wound in the neck also, was allowed to close gradually.

20/4/00 There is now a slight purulent discharge from the ear, and the facial paralysis persist, but it is much less marked.

10/7/00. Since the last note, the patient has been attending as an out patient. There is still some purulent discharge from the ear, but there has never been any return of pain since the operation. The facial paralysis is disappearing.

-/10/00. The facial paralysis has completely disappeared/

disappeared, otherwise the condition remains the same as in July.

-----o-----

Case 14 Right acute purulent otitis media followed by acute mastoiditis with Betzold's perforation.

A.M. Aged 21 years. Admitted to Ward 37, Royal Infirmary, Edinburgh, 27/11/00.

History This patient has always enjoyed good health, excepting when 12 years of age, he had an attack of Scarlet Fever: From this he suffered no ill after effects, and until 7 weeks ago, he never had any trouble of any kind with either ear, when his present illness commenced. At that time he says he was seized with Influenza, with severe sore throat, fever, and pains over the whole body. Four days after the initial seizure, both tonsils which had evidently been suppurating, are said to have both burst, a discharge of pus coming from each. The same night, he felt pain in his right ear, which continued for four days, when a discharge was noticed coming from this ear. Just previous to the discharge appearing the pain was intense in the ear, from which he got immediate relief on the first appearance of the pus. The discharge is large in quantity, and of a yellow colour, and of thick consistence, like which it has been from the first. On three occasions, about a week ago, some blood was noticed in the discharge during the syringing of the ear, but there has been none at any other time.

From the time the discharge commenced, until four days ago, there was little or no pain; at that time the pain returned, and the tissues behind the ear began to swell, the pain increasing in severity up to the present date. There is no family history of tubercle.

Present condition. Patient is pale, his tongue is coated, the left pupil is larger than the right, but this, patient states, is the result of previous disease in the eye; the optic disc shows nothing abnormal. The right ear stands out markedly from the side of the head; and there is a fluctuating swelling/

swelling behind it. The skin over the mastoid is red and the tissues are felt to be infiltrated over an area of the size of the palm of the hand. There is a very profuse discharge of thick yellow pus from the external auditory meatus. It is impossible to see the tympanic membrane, owing to the rapidity with which the pus returns after being cleared away with a swab. Pressure over the mastoid region, however, increases the rapidity with which the pus returns thus showing that the abscess cavity must communicate indirectly with the meatus through the tympanum, as there is no perforation visible in the wall of the meatus. No desquamation could be seen on any part of the body. An examination of the urine shows Specific Gravity to be 1025 with no sugar, but some albumen and a trace of blood.

Operation 28/11/00. The usual incision was made over the mastoid, down to the bone. This opened at once into an abscess cavity. After the pus had been evacuated and the haemorrhage stopped with forceps, the periosteum was removed from over the mastoid. No supra meatal spine being present, the external auditory meatus had to be used as the guide for opening the antrum; after removing a very thin layer of bone from over the antrum, granulations were met with, occupying the antrum and the mastoid cells. The granulations were of the oedematous, flabby type of large size, and numerous, presenting no caseating points: In colour they were red, but not pale red. They were scraped out, making a very large cavity in the bone; when this had been done, and the cavity was being explored with the probe, a perforation was discovered on the inner wall of the mastoid process, close to its tip. (Betzold's perforation)

No attempt was made to treat the tympanum directly, and after the granulations had been thoroughly scraped away, the cavity was stuffed with gauze. The bone around the granulations was soft, and showed evidence of rapid destruction, but was not caseous. There was slight twitching of the face, during one part of the operation, but no facial paralysis followed.

Several films were made from the pus which escaped from the abscess cavity, from pus in the antrum, and/

Name *Albert Maidment*

Age *21*

Disease *Sept. Otitis Media*

Result

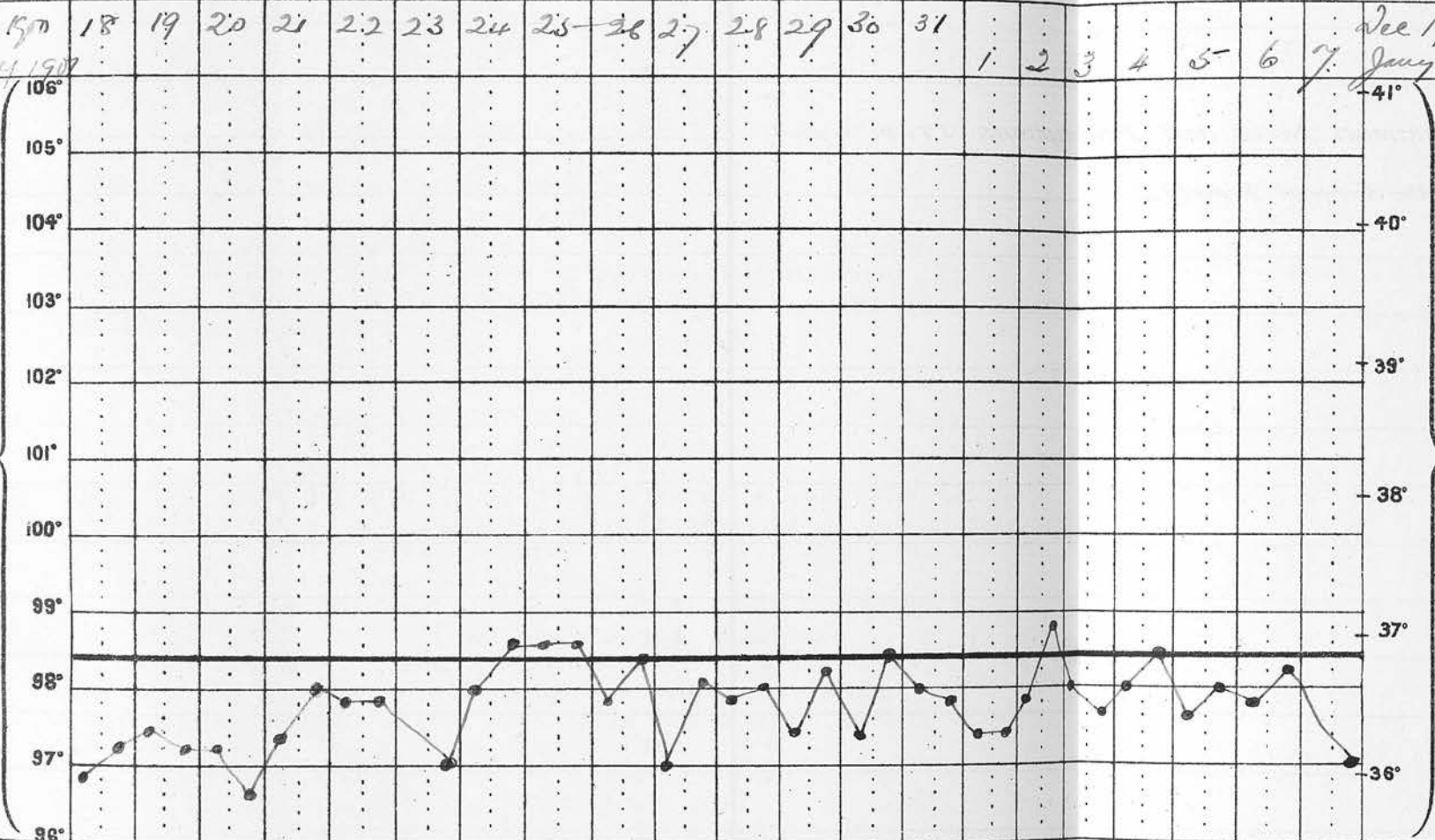
Apr Dec 1900	27	28	29	30	1	2	3	4	5	6	7	8	9	10	11	12	13	14	15	16	17	Apr Dec 1900	
TEMPERATURE FAHRENHEIT'S SCALE.																						TEMPERATURE CENTIGRADE SCALE.	
Pulse m																							Pulse m
Resp m																							Resp m
Motions		1	0	2	0		0	1	2	1	1	2	2	1	1	1	2	1	2	2	2	Motions	
Urine, ozs.																							Urine, ozs.
Sp. Gr.																							Sp. Gr.
Reaction	<i>Chol.</i>	<i>Edema</i>		<i>Eme.</i>																		Reaction	
Chlorides																							Chlorides
Albumen																							Albumen
Day of Dis.																							Day of Dis.

Name *Albert Maidmont* Age *21* Disease *Sup. Pth. medra.* Result

Dec. 15^m 18 19 20 21 22 23 24 25-26 27 28 29 30 31
 Jan. 1907 1 2 3 4 5 6 7 Dec 1900
 Jan. 1907

TEMPERATURE FAHRENHEIT'S SCALE.

TEMPERATURE CENTIGRADE SCALE.




Pulse																				Pulse		
Respiration																				Respiration		
Motions	1	1	2	2	2	2	0	1	2	2	2	1	1	2	1	1	1	1	2	1	2	Motions
Urine, ozs.																				Urine, ozs.		
Sp. Gr.																				Sp. Gr.		
Reaction																				Reaction		
Chlorides																				Chlorides		
Albumen																				Albumen		
Day of Dis.																				Day of Dis.		

and from an emulsion made from the granulations, in sterile normal salt solution. Some of the granulations were taken in the usual way for inoculation in guinea pigs, and a culture was made in blood serum. After treatment 29/11/00. Temperature is 101.4, and the wound on being dressed, is found healthy.

4/12/00 The wound was again dressed; the meatus was found practically dry.

20/12/00. The dressing has been done every third day since the last note was made. The meatus is now quite dry and there is no sign of pus in the mastoid wound; it being a dry granulating healthy surface.

26/1/01 The wound is now quite healed; the meatus is dry and the hearing good.



Case 15 Acute mastoiditis with Betzold's perforation following chronic suppurative otitis media.

Mr.C. Age 18 years. Admitted to a Private Home in Edinburgh, on the 10th November 1900.

History This patient has suffered from an intermittent discharge in the left ear, since childhood, which is stated to have been without any disagreeable odour. Six or eight weeks ago he was doing some mountain climbing in the Highlands and was conscious of catching a cold; this was followed by a more profuse discharge from the ear, and ten days later, a swelling commenced behind the left ear. The temperature is said at this time to have varied from 100 to 102. Syringing was done, and powdered boracic acid was blown into the meatus. There was slight improvement for a time, but a week ago the discharge entirely ceased, accompanied by considerable discomfort in the ear, and intermittent pain. These latter symptoms have increased up to the present time.

Present condition There is now no discharge from the ear, but there is a small perforation in the upper posterior quadrant of the membrana tympani with pouting edges, which are pale and oedematous, and of a coral colour. There is marked swelling and induration over the mastoid process on the left side, extending/

extending towards the neck, downwards and backwards; This swelling is indurated and brawny and there is redness of the skin over the mastoid. No fluctuation is felt and no pus can be made to escape from the perforation in the drum membrane, by pressure on the swelling. The left ear stands out from the head much more than the right, and the inflamed parts are very tender and painful.

Operation 11/11/00. The usual incision for opening the mastoid antrum was made; the periosteum over the mastoid process was removed, and the gauge applied over the antrum, and the intervening bone removed. The antrum was reached after removing about a quarter of an inch of bone; it was found filled with granulations; these were scraped out and a specimen was secured, with the usual sterile precautions, for inoculation experiment, and microscopic examination.

On passing a probe towards the tip of the process, it was found perforated on its inner side, and pressure on the neck below caused pus to well up into the wound. (Betzold's Perforation). A counter opening was made in the neck towards the tip, but no direct communication was obtained between the two openings. On gauging away the outer surface of the mastoid process, it was noticed to be softer than usual; the posterior wall of the meatus and the tympanic cavity were not interfered with. The granulations were of a dark red colour, and not flabby and there was no caseating foci.

I did not see this case again after the operation, but I was informed that the patient made a complete and uneventful recovery.

-----0-----

Case 16. Chronic suppurative otitis media of the right ear, with mastoiditis and cholesteatomatous masses.

C.S. Age 6 years. Admitted to Ward 37, Royal Infirmary, Edinburgh, 9/11/00.

History. There is no family history of tuberculosis. When the patient was a few months old he had an attack/

attack of acute inflammation in the right middle ear, accompanied by pain. The pain was evidently very severe for a few days, when the discharge from this ear was noticed, and since then till the present time it has been continuous. The existence of pain in the right ear, is inferred from the fact that the infant cried a great deal and slept badly, and was frequently noticed to put a hand up to the right side of the head. There is no history of measles or other acute disease: Attacks of pain have occurred in the ear from time to time, occasionally also, pain was complained of behind the ear. Deafness has not been marked, this is probably due to the fact that the left ear has never been affected.

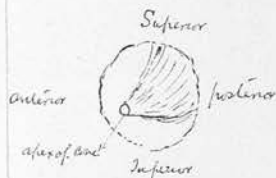
Since the discharge commenced, treatment has been regular, and consisted of daily syringing with boracic lotion, followed by insufflation of boracic acid powder. About three weeks ago, severe pain commenced in the affected ear, and a painful swelling commenced behind it over the mastoid region, which soon became red. During the last few days, the pain swelling and redness has been less marked.

Present condition 10/11/00. There is a copious foul-smelling discharge from the right ear, but no pain is complained of. The pus in the meatus obstructed the view until syringing had been done; since which the posterior wall of the meatus, is seen to be bulging into it in the form of a cone, as illustrated in the diagram.

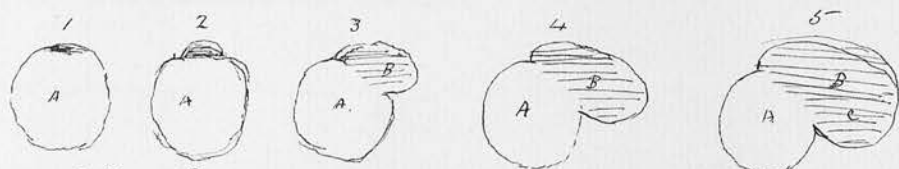
From the apex of the cone, pus was seen to be escaping, and into which it was possible to pass a small probe, and feel some bare bone. It is impossible to get a good view of the tympanic membrane, on account of this projection of the meatal wall. The parts about the mastoid are tender to touch, but

there is now very little swelling and no redness.

Operation 11/11/00. The usual mastoid skin incision was made, and the periosteum raised and stripped forward, and the bony external auditory meatus exposed. The tympanic membrane was found to be entirely gone. Stacke's director was passed into the tympanic attic, from the meatus and cut out with a chisel. This/



This director was next passed along the abscess, and chiselled down upon until it again came out. This was repeated several times until the mastoid antrum was reached.



A Position of Tympanum
B - Mastoid Antrum
C Cells

The above diagrams show the stages by which the aditus and antrum were laid open.

The gauge forceps for cutting bone were used to remove the rest of the antrum wall, and a dental bur was used to smooth off the ragged prominences of bone. The mastoid antrum was found of large size, and to contain cholesteatomatous masses and granulation. (Some of the latter were taken in the usual manner, for inoculation experiment).

The granulations were of medium size and red colour. They were scraped thoroughly from the cavity, which was then stuffed with cyanoid gauze. After treatment 13/11/00. The dressings had a disagreeable smell, consequently they were removed and the wound dressed.

16/11/00. The wound has been dressed every day since the last note was made, and is now quite sweet; and is hereafter to be dressed every second day.

4/12/00. The wound is still open, but is closing, and there is still some discharge from the meatus. The patient was discharged to attend as an out patient.

20/12/00. The patient was re-admitted to the Ward on the 18th, on account of a rise of temperature, which had occurred the previous night, and thought to be due to sepsis in the wound, but since coming into hospital, the temperature has been normal. There is a great deal of discharge from the ear and the wound, yet the latter looks fairly healthy. To be dressed daily.

26/12/00. There is still a free communication between the mastoid wound and the external auditory meatus; some/

some greyish pink, thick, sloughy looking matter was seen at the bottom of the mastoid wound, this was removed with a sharp spoon, and the cavity swabbed out and stuffed with gauze.

31/12/00 The wound has been dressed daily since the last note, and now looks quite clean, and there is no odour to the discharge, which is small in quantity.

2/2/01. The patient is again an out patient and attending daily, to have his ear dressed. The wound is still open and there is some discharge of pus, but it is not bad smelling.

5/2/01 The posterior wound, although open is very small, and as it is impossible to keep the deeper parts clean by swabbing, consequently syringing has had to be resorted to.

-----C-----

Case 17. Chronic suppurative otitis media of the left ear.

L.F. Age 3 years and 10 months. Admitted to Ward 38, Royal Infirmary, Edinburgh, 18/12/00.

Family History Her parents are healthy; there is one brother who is healthy; there are no other children in the family, and there is no history of tuberculosis.

History The birth was normal. The discharge commenced from her left ear when she was 1 year and 9 months old, it began as follows:- The patient became feverish and complained of pain in the left side of her head, and kept constantly putting up her hand to the left ear. These symptoms continued intermittently for three days, when the discharge commenced; after which the child seemed to suffer no more pain. From the first the discharge was yellow pus, and has been almost continuous ever since; the only period without it, being this summer for about two months, when spending a holiday in the country. She has never had Measles or Scarlet Fever but a few months ago she had Whooping Cough, from which she made a good recovery. Occasionally when she/

she starts coughing, she seems to suffer from spasmodic closure of the glottis, as her mother states that on these occasions she becomes very blue and loses complete consciousness from two to five minutes.

Ever since the commencement of the disease, the ear has been syringed pretty regularly with boric lotion. About every three months, she has had attacks of very severe pain in the left side of the head, lasting for a day or two. At these times, it has been noticed that the discharge has appeared, and that on the re-establishment of the discharge the pain disappeared. About three weeks ago she had an unusual attack of this kind, and the family doctor was called in at 10 p.m. when he stated that he found her temperature to be 100.2: On this occasion also, the discharge was absent, but reappeared in two days with subsidence of pain. During the last six months, she has disliked having her head washed or touched in any way, as it seems to cause her pain. Since the commencement of her pain, she has been a restless sleeper.

Present condition.- She is a pale, ill nourished child. There is a thick discharge of yellow foetid pus, which is rather watery sometimes; there is no external swelling behind the ear or over the mastoid region on the left side, nor any standing out of the left ear. No enlarged glands can be felt in any part of the neck. There is a small perforation at the lower posterior quadrant of the tympanic membrane. This membrane is a dull greyish white colour and thick and sodden looking: no granulations are seen. There is some bulging and reddening of the posterior meatal wall; the discharge is very free.

Operation. 23/12/00. The usual incision was made for the mastoid operation, and the mastoid antrum opened. It was found to contain nothing abnormal, there not being the slightest sign of granulations or pus. Lotion was syringed in by the wound, and came out by the meatus. The wound was dusted with iodoform and stuffed with gauze.

I was unable to obtain anything for inoculation, or examination. (On several occasions previous to the operation, I stained films of pus, taken from the/

Name

Leana F.

Age 3 1/2 yr

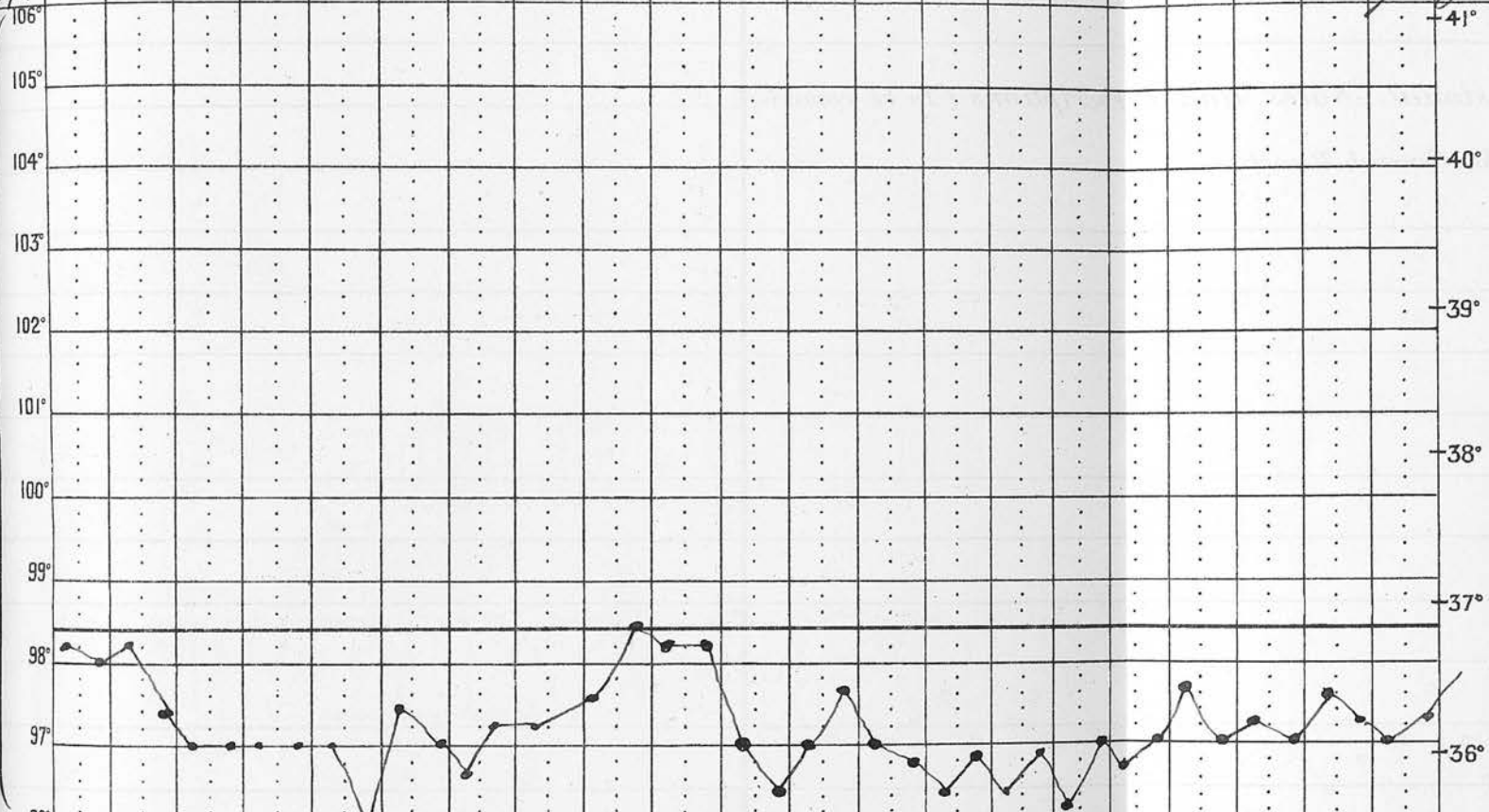
Disease Sapho Ditis Media

Result Case 17.

Date	18	19	20	21	22	23	24	25	26	27	28	29	30	31	1	2	3	4	5	6	7	Notes	
Dec 1900																						December 1900	
Jan 1901																							January 1901
Temp	98.1	97.9	98.1	97.2	96.9	96.9	96.9	96.9	96.9	96.9	97.3	98.3	98.1	98.1	96.9	96.4	96.9	97.5	96.9	97.1	97.0	97.5	
Pulse																							
Resp																							
Motions		1	0	0	0	3	1	1	2	2	1	2	1	1	0	2	0	1	2	2	2		
Urine, ozs.																							
Sp. Gr.																							
Reaction																							
Chlorides																							
Albumen																							
Day of Dis.																							

TEMPERATURE FARENHEIT SCALE

TEMPERATURE CENTIGRADE SCALE



Name

Lena J.

Age 3 1/2 yrs

Disease

Suffer Otitis Media

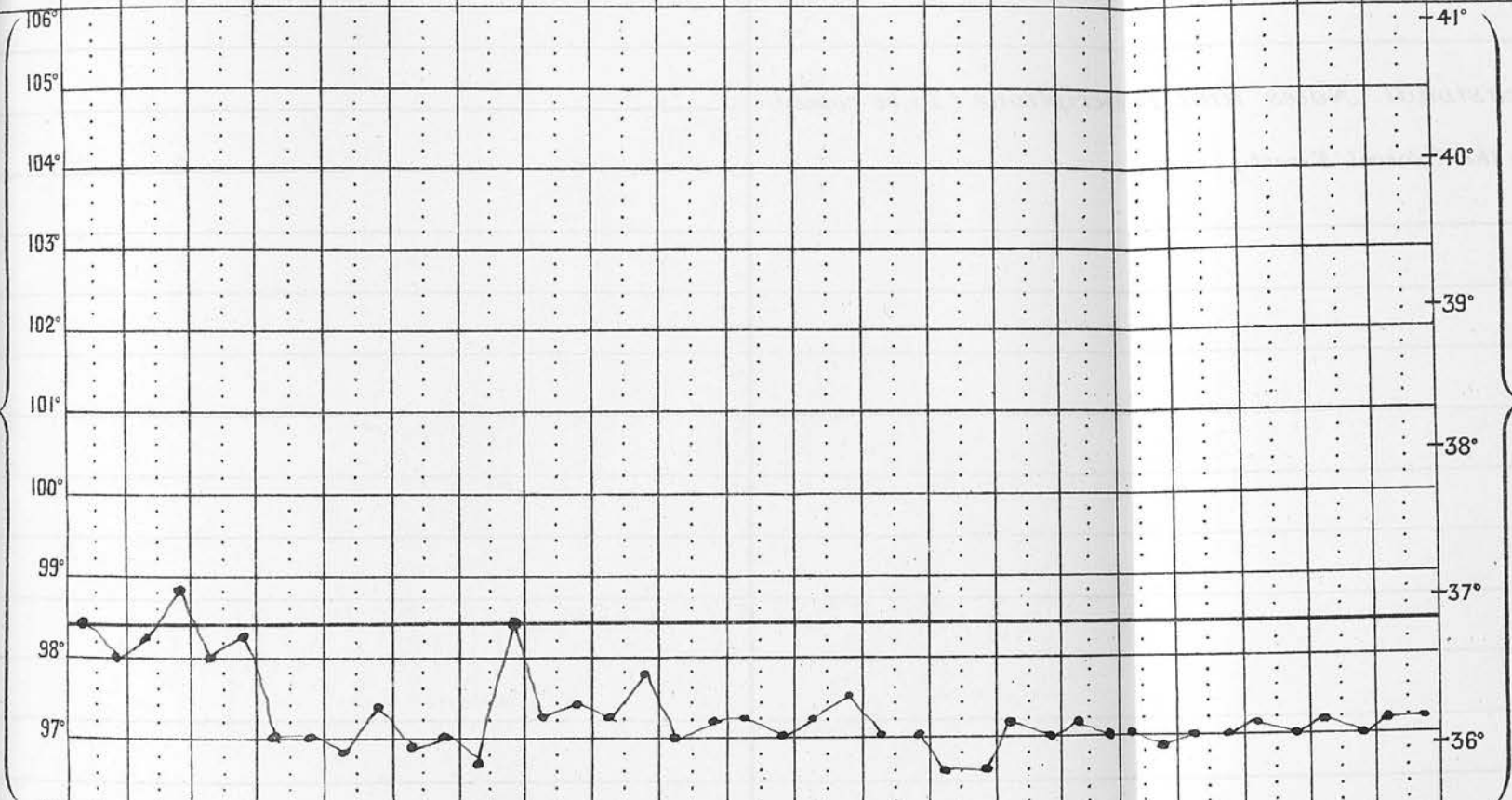
Result

Case 17.

January	8	9	10	11	12	13	14	15	16	17	18	19	20	21	22	23	24	25	26	27	28	
TEMPERATURE	98.3	97.9	98.1	98.6	97.9	98.1	96.9	97.2	97.3	97.1	97.7	96.9	97.1	97.1	96.9	97.4	96.9	96.9	96.8	97.0	97.1	97.2
Pulse	m	ε	m																			
Resp	ε																					
Motions	2	2	1	1	1	1	3	2	2	3	2	2	2	1	2	2	2	2	0	1	1	
Urine, ozs.																						
Sp. Gr.																						
Reaction																						
Chlorides																						
Albumen																						
Day of Dis.																						

TEMPERATURE FARENHEIT SCALE.

TEMPERATURE CENTIGRADE SCALE.



the surface of the drum at the perforation).

After History. 26/12/00. The wound was dressed for the first time, and looked very well; was syringed with boracic lotion and stuffed with gauze.

8/1/01. The right ear commenced to discharge to-day. The granulating surface in the left mastoid, looked rather flabby and over vascular, and was touched with solid cupric sulphate. Right ear is to be syringed night and morning.

16/1/01 The discharge continues profuse and foul-smelling from the right ear, notwithstanding frequent syringing. The granulations in the left mastoid wound are less flabby. Rectified spirit has been applied to them and to the meatus daily after the dressing, since making the last note.

26/1/01. A probe can no longer be passed into the mastoid wound, which now presents a healing appearance and is rapidly closing. The discharge still continues from both ears, but is not now bad smelling. Both ears are syringed twice daily.

2/2/01 The mastoid wound is now almost closed. Discharge still continues from both ears, but is less in quantity. Patient was discharged from Hospital to-day to attend as an out patient every other day, the mother to syringe the ears night and morning.

-----o-----

Case 18. Right chronic suppurative otitis media with acute mastoiditis.

A.R. (boy) Age 8½ years. Admitted to Ward 37, Royal Infirmary, Edinburgh. 16/1/01.

Family History. Both patient's parents are healthy and there is no history of tuberculosis, in any relatives. He has two brothers and three sisters living, both healthy; none dead.

History The patient has had a chronic discharge from the right ear for six years, following measles, the discharge has been intermittent; his father says the left ear has also discharged occasionally. A week ago a swelling rapidly appeared behind the right ear, which was larger then, than at present. The/

The patient says that he felt pain on the same day as the swelling appeared, but never previously. At three years of age, he had naso-pharyngeal adenoids removed, this was after the discharge from the ear commenced. Up till three years of age he was quite healthy, the delivery at birth being normal. When the discharge commences, for two or three days it is very profuse, it then grows less, and at the end of a week it stops and does not appear again for from four to eight weeks. Attacks of this kind have been recurring, since the first onset.

Present condition The right external meatus contains a considerable quantity of foul-smelling pus, thick in consistence, and of yellow colour, which when having been syringed away shows a tympanic membrane of purplish colour, with some whitish grey flakes upon it. No perforation is visible, although there is a suspicious area immediately in front of the umbo. There is no bulging of the posterior or upper wall of the meatus. Behind the right ear, over the mastoid, there is a large fluctuating swelling, rather larger than a five-shilling-piece, tender to the touch, but he does not complain of much pain unless the part is touched. There are no head symptoms.

19/1/01 The right tympanic membrane looks much less congested, and distinct pulsation is visible just in front of the umbo, showing the position of the perforation. He complains of no pain in the fluctuating swelling behind the ear.

The abscess was laid open by a Wilde's incision. There was an escape of about half an ounce of pus and sharp haemorrhage for a few moments. The cavity was stuffed with cyanoid gauze.

Operation 20/1/01. The previous incision was enlarged and the surface of the mastoid exposed, no supra meatal spine being present, the external auditory meatus was taken as the guide. The gauge was applied half an inch behind its upper margin.

When bone to the depth of about half an inch had been removed in this position, something soft was noticed in the bottom of the wound, which was smooth and unlike granulations. After a little more careful clearing, it was noticed to pulsate, and was at once/

Name

A.R.

Age 8 1/2

Disease Sapp's Otitis Media

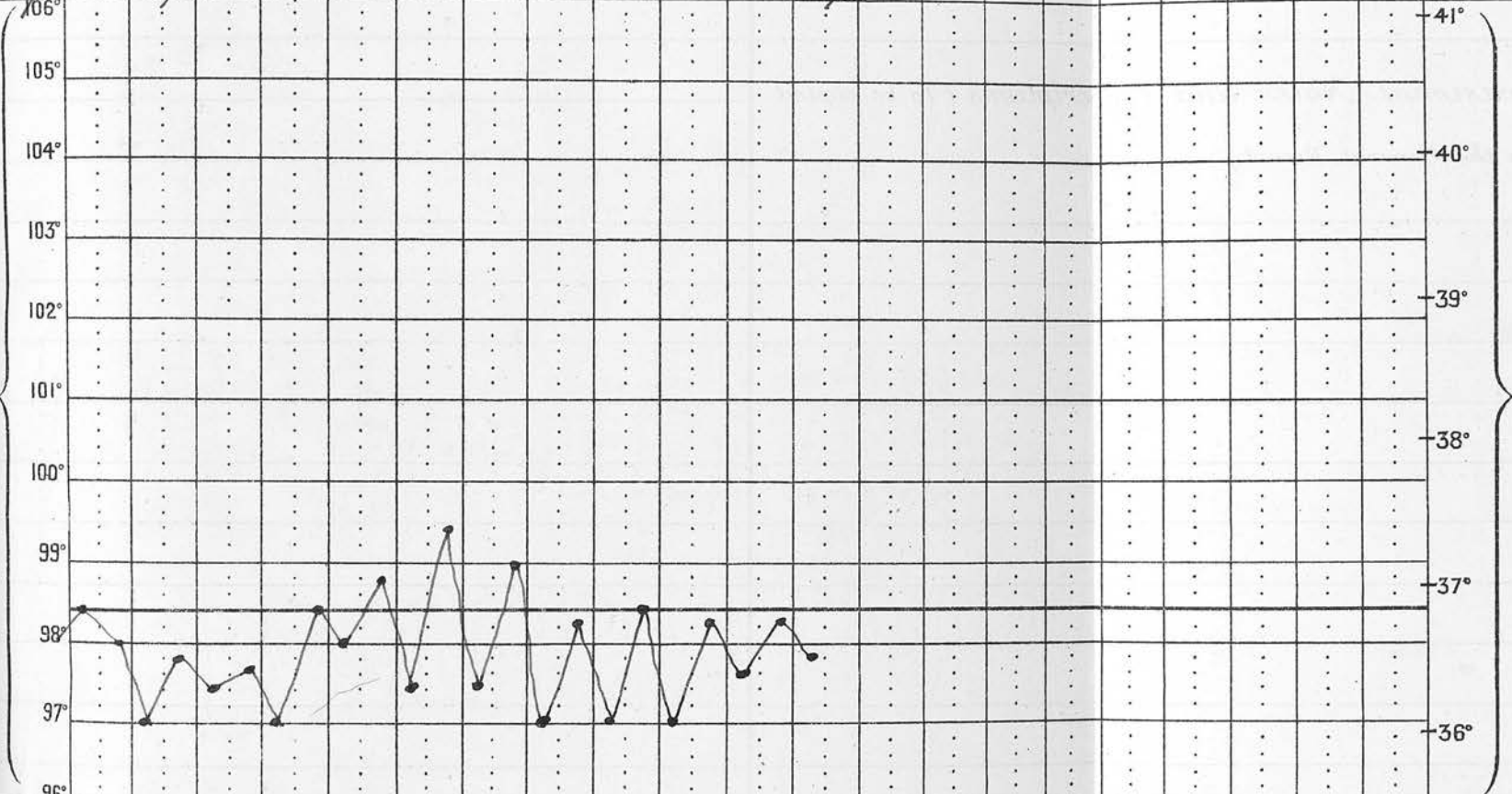
Result

Case 103

Temperature	16	17	18	19	20	21	22	23	24	25	26	27									
106°																					
105°																					
104°																					
103°																					
102°																					
101°																					
100°																					
99°																					
98°	98.3	97.9	97.7	97.5	97.5	98.3	97.3	99.3	97.3	98.8	96.9	96.9	98.1	96.9	96.9	98.3	97.5	98.1	97.7		
97°																					
96°																					
Pulse																					
Resp.																					
Motions																					
Urine, ozs.																					
Sp. Gr.																					
Reaction																					
Chlorides																					
Albumen																					
Day of Dis.																					

TEMPERATURE FAHRENHEIT'S SCALE.

TEMPERATURE CENTIGRADE SCALE.



once recognised as the wall of the lateral sinus. Its anterior edge was within half an inch of the external auditory meatus; being thus abnormally far forward. The mastoid antrum had been opened at the same time; a few granulations were found in it, these were cleared out and the cavity stuffed with cyanoid gauze.


27/1/01. The wound was dressed to-day for the first time and found quite sweet, and again stuffed with gauze.

31/1/01. The wound was dressed and found to be sweet, but large flabby granulations have formed on each side of the mastoid wound. The temperature has remained normal since the operation, and he has taken his food well, and his general condition has improved. The granulations were touched with red lotion, and the dressing applied.

(The granulations removed from the mastoid antrum at the operation, were placed in absolute alcohol and prepared for section cutting, as was also an enlarged gland, removed from over the mastoid process).

1/2/01. The wound was dressed and the granulations touched with rectified spirits.

4/2/01. The wound has been dressed daily since the last note and the granulations touched with solid sulphate of copper. The granulations are now beginning to look healthy and the wound is rapidly closing.



Case 19 Left acute suppurative otitis media followed by acute mastoiditis.

Mrs. W. Age 47 years. Admitted to Ward 38, Royal Infirmary, Edinburgh, 13/1/01.

History. Patient says she has never heard perfectly since an attack of measles, when she was a child, but beyond a dullness in hearing, until the present attack commenced, she had not suffered in any way from her ears. Ten days ago she was attacked with sudden pain in her left ear; previous to this she had suffered from a cold in her head for about a week. The/

The pain continued for two or three days, when she says she felt something burst in her ear, and she immediately afterwards noticed a red discharge coming from it. The onset of discharge did not result in relief of the pain, but the position of the pain changed from the ear to behind it, extending upwards over the head and downwards into the neck. The discharge since the onset has been continuous and profuse, consisting chiefly of thick yellow pus. There have been no rigors or vomiting. She has no tuberculous family history.

Present condition. The patient is a soft flabby looking woman, and has the appearance of a person addicted to the excessive use of alcohol. The temperature is normal, the pulse 75, weak and compressible. There is marked pain and tenderness over the left mastoid region, extending up over the temporal region and down at the neck. There is a profuse discharge of yellow pus from the ear: After gently syringing the meatus, there is seen, what looks like a congested bulging membrane. It is difficult to keep the membrane clean, owing to the rapid welling up of pus, but by wiping it carefully away, immediate inspection shows a large perforation situated in the anterior inferior quadrant, with thick oedematous edges. There is no apparent bulging of the meatal wall, and there is slight fullness over the mastoid process and region generally. The left auricle does not stand out more prominently than the right.

The patient can hear a voice in the affected ear, when it is raised a little above the ordinary conversational tone, at a distance of about one inch from the ear. The watch can only be heard in contact. The urine is normal.

Operation. 31/1/01. The usual mastoid incision was made behind the left ear, the periosteum divided and raised from the bone. This proceeding offered some difficulty, as the periosteum was very adherent to the bone. On chiselling away the cortical layer of bone just below the supra meatal spine, granulations were found about a quarter of an inch from the surface, and on going a little deeper, pus began to well up in small quantity. The mastoid cells were found/

1901.

Name *Wardlaw*

Age *47*

Disease *Sappurative Otitis Media* Result *Case 18*

July 1901		30	31	1	2	3	4	5	6	7	8	9	10	11	12	13	14	15	16	17	18	19	Jan. February		
TEMPERATURE FAHRENHEIT'S SCALE.																								TEMPERATURE CENTIGRADE SCALE.	
Pulse	m																							Pulse	m
Resp.	m																							Resp.	m
Motions	ε	2	2	3	3	0	6	0	6	3	4	0	2	1	1	2	0	3	0	0	3	1	Motions	ε	
Urine, ozs.																								Urine, ozs.	
Sp. Gr.																								Sp. Gr.	
Reaction																								Reaction	
Chlorides																								Chlorides	
Albumen																								Albumen	
Day of Dis.																								Day of Dis.	

Serous

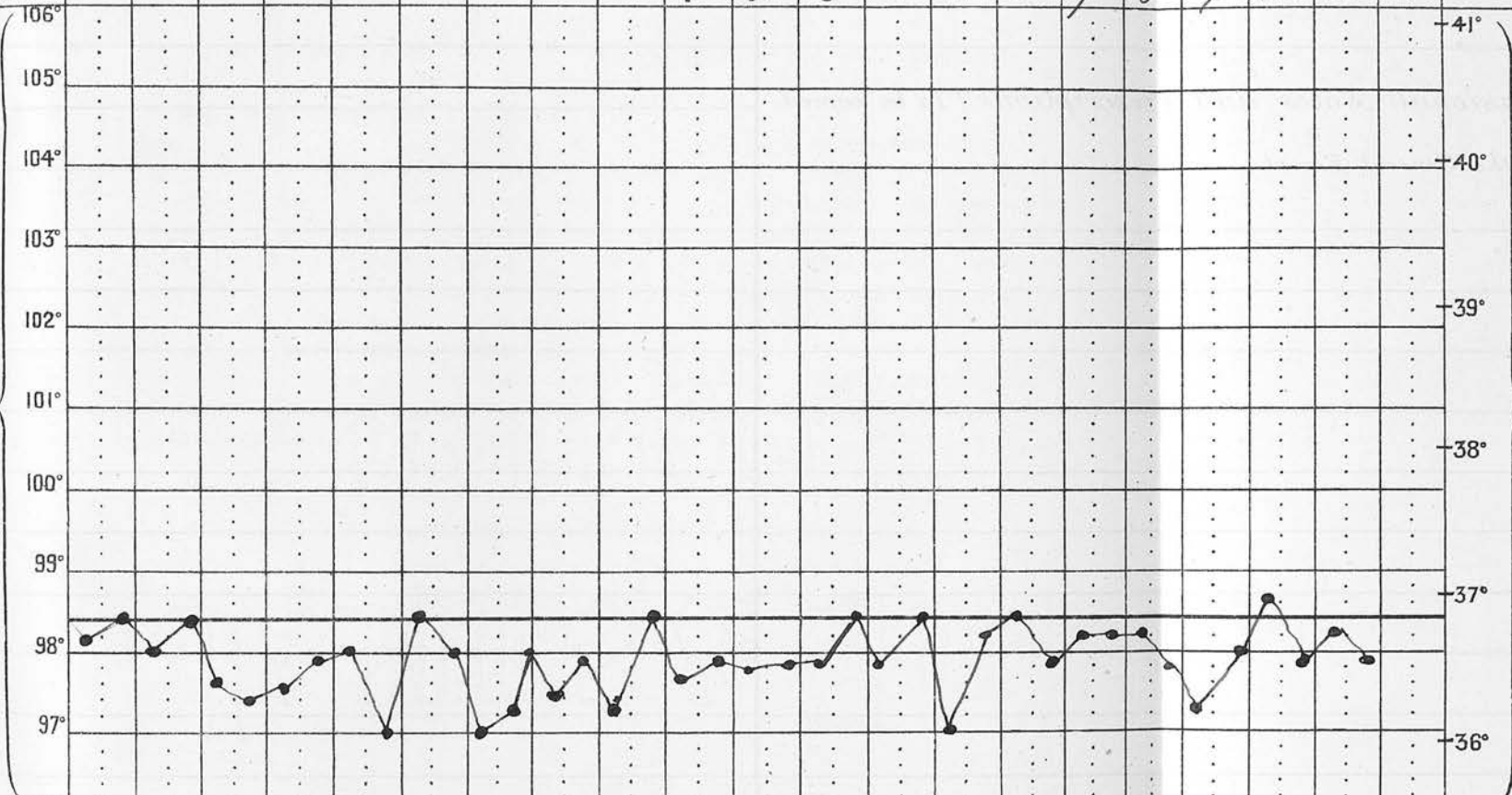
Serous

Name *W. W. Artlow* Age *47* Disease *Supp. Otitis media* Result *Case 18*

Mo	20	21	22	23	24	25	26	27	28	1	2	3	4	5	6	7	8	9	10	11	12						
Temp. Fahr.	98.1	98.3	97.9	97.5	97.8	97.9	96.9	97.8	97.4	97.7	97.7	97.7	97.7	97.7	97.7	98.1	98.3	97.8	98.1	98.1	98.1	97.7	97.9	98.6	97.8	98.1	97.8
Pulse																											
Resp.																											
Motions	2	0	1	1	0	1	0	1	1	0	1	0	1	1	0	2	1	8	0	1							
Urine, ozs.																											
Sp. Gr.																											
Reaction																											
Chlorides																											
Albumen																											
Day of Dis.																											

TEMPERATURE FAHRENHEIT'S SCALE.

TEMPERATURE CENTIGRADE SCALE.



found filled with granulations, no large antrum cavity was found, but the aditus was determined and a probe passed into it. All the granulations and pus were cleared out, and the cavity thus formed, stuffed with cyanoid gauze, as was the external auditory meatus. The posterior meatal wall was not in any way interfered with; (Granulations from the mastoid were taken under the usual sterile precautions for inoculation experiment, and others were taken for section cutting.)

After History. 2/2/01. The wound was dressed for the first time since the operation. Discharge was found free, but not bad smelling. The cavity was swabbed out with cyanoid gauze, and stuffed with the same, after iodoform and boracic acid had been well dusted in. The patient still complains of pain in the head, and seems very shaky, and she has a feeble pulse of irregular beat.

4/2/01. The wound was again dressed, and was found to be discharging freely. It was syringed with boracic lotion and stuffed with gauze.

-----oOo-----

To Dr. McBride I am indebted for the privilege of observing and studying cases 3, 4, 5, 6, 7, 10, 11, 12, 14, 16, 18, & 19, and the operations described as having been done on these cases, were done by him. In like manner I am indebted to Mr. Stiles for cases 1 & 2. To Dr. McKenzie Johnstone for cases 8, 15, & 17;; To Dr. Logan Turner for case 9, and to Dr. Hunter McKenzie for case 13.

I regret I have not been able to follow the After History of some of my cases that I had hoped to, owing to illness which has compelled me to remain in the Country under treatment for the last three months. For the same reason some points of research upon which I was engaged in connection with them at the Laboratory 2, Forrest Road, could not be completed.

M E T H O D S .

I N O C U L A T I O N M E T H O D .

Villimen in 1865 first described, subcutaneous inoculation of animals as a means for the detection of tubercle¹, while Cohenheim and Solomonsen in 1877 devised the plan of inoculation into the anterior chamber of rabbits². The method of inoculation for the detection of tubercle, is held by many competent observers, e.g. Arloing³, Leloir⁴, Verneuil, and Clado⁵, as giving the most reliable results, owing to the difficulty of demonstrating the tubercle bacillus in human tuberculous processes.

In selecting this method for investigation of my cases, and the guinea-pig as the animal to be experimented with, I have been influenced chiefly by the advice of Dr. Noël Paton, and by the results obtained by Milligan, who worked according to the inoculation method of Delépine; which is in reality only a modification of Villimen's method.

Delépine, after experimenting on a number of animals with tuberculous material, found that guinea pigs give by far the most reliable results⁶.

Delépine's conclusions⁵ regarding this method for the detection of tubercle, are as follows;-

- "1st.- The inoculation method is a method of diagnosis capable of giving results free from any ambiguity.
- "2nd. The negative results obtained by it are nearly as valuable as the positive results. 3rd. The positive results give more definite information than the discovery of the tubercle bacillus. 4th.
- "Results should be easily obtained within 2 or 3 weeks."

In carrying out my experiments, however, I have adopted the intra peritoneal method of inoculation, as usually carried out at the Laboratory of the Royal College of Physicians, Edinburgh, slightly modified, in preference to the subcutaneous method of Delépine.

The following are the details of the method employed, viz:- The specimen chosen for inoculation was, when possible, granulation tissue and a scraping of/

1.	Congre's	pour l'etude de la Tuberculose	1888	p.404
2.	do.	do.	do.	p.412.
3.	do.	do.	do.	p.415.
4.	^{Delépine} British Medical Journal,	23rd Sept.	1893.	p.665.
5.	do.	do.	do.	p.666.

of bone from the most actively spreading portion of a diseased part: On one occasion only, pus was used.

The specimen was taken by an instrument sterilised by boiling, and by being passed through the flame of a spirit lamp immediately before use. When it had been secured with this instrument, it was immediately placed in a sterilised bottle prepared by the method to be presently described, as that adopted for the sterilisation of the mortar pestle and syringe.

About two ounces of normal saline solution (i.e. 0.75% of sodium chloride) was taken in a small beaker and boiled for a minute or two and then allowed to cool. The mortar, pestle, syringe, and needle were sterilised by thorough washing, first in 2% lysol, then in methylated spirit, then in methylated aether, and finally in sterile salt solution. The tissue taken as above described (when solid) was shaken in sterile normal salt solution to remove any organisms that might be on its surface; it was then pounded in the previously sterilised mortar, with a little of the sterile salt solution, and when thoroughly rubbed up, the needle of the syringe was placed into it, and the more liquid portions drawn up into the syringe.

Two healthy guinea pigs were usually taken for each experiment, the second being used as a control. From the lower part of the abdomen of each guinea pig, the hair was cut short, and its surface well saturated with 1-1000 perchloride of mercury solution; then by the aid of an assistant, the guinea pig about to be inoculated, was held stretched out on its back, the whole thickness of the abdominal wall pinched up between the thumb and forefinger of the left hand, and the needle of the previously charged syringe plunged sharply into the peritoneal cavity, for about $\frac{3}{8}$ of an inch, and the syringe emptied.

When a second guinea pig was inoculated from the same specimen, or another specimen from the same case, this whole proceeding was gone over again, and the inoculation of it completed in the same way. The guinea pigs inoculated from the same case were always kept by themselves in one cage. Their weights were/

were taken at the time of inoculation, and again at intervals of a week or ten days, until they died or were killed, after a period of five or six weeks.

In the dissection made of the animal after dying, or being killed with chloroform, the abdomen was well saturated with 2% lysol solution, then, with a pair of scissors which were sterilized in a Bunsen flame, the abdominal wall was divided up its centre, laying open the abdominal cavity. The seat of inoculation was observed, as well as the peritoneum and all the abdominal organs, and their naked eye appearances carefully noted down; while all, or at least some, of the following organs and tissues were taken for microscopic examination, viz:- the great omentum, a mesenteric gland if enlarged, the spleen, a piece of liver, and a kidney. If any part of abnormal appearance in these organs was observed, that portion, especially, was secured for further examination. The thorax was then opened, and its glands and organs examined and dealt with as in the abdomen. On a few occasions the animal was opened, under the strictest sterile precautions, and a tuberculous nodule, if present in the omentum or spleen, was opened with the same care, and some of it inoculated on to a blood serum tube. Cover glass films were, on a few occasions, also made from a nodule, with strict sterile precautions.

Preparations of Specimens for cutting.
-----o-----

This was done by one of the three following common methods,- 1st. Corrosive method, in this the tissue was placed successively into (first) saturated solution of perchloride of mercury, (second) washed, (third) into a mixture of spirit and water, increasing in strength from 30% to 90% of spirit (fourth) absolute alcohol (fifth) cedar oil (sixth) soft paraffin (seventh) hard paraffin (eighth) imbedded in hard paraffin and thereafter cut with a Cambridge rocking microtome.

2nd./

2nd. Absolute Alcohol Method.- and that most frequently used, especially when looking for bacilli. With this method, the tissue was placed direct into absolute alcohol, and when sufficiently hardened, into cedar oil and the process completed as in the last method.

3rd. Formaline Method.- Here the tissue was first placed in 10% of formaline, or in a fluid in which formaline is the chief constituent, and after 24 hours or longer, was dehydrated with spirit and absolute alcohol, and the process completed as in the first and second methods.

The length of time the tissue was kept in each of the solutions mentioned, depended upon the kind and the size of the piece of tissue under examination.

After the blocks had been cut, as described, the sections were mounted on slides in the usual way, then placed in an incubator at about 30c. for an hour or two, by which time the sections were firmly fixed to the slide.

The slides I used, had previously been coated with egg albumen, by the following method of my own, which I found cleanly, convenient, and satisfactory. To 5cc' of white of egg, 50cc' of distilled water was added, and shaken together thoroughly, then filtered into a bottle, and 5cc' of absolute alcohol added, and kept tightly corked; all the utensils used being sterilised by the method before mentioned for sterilising the syringe &c.

The slides, before being coated, were cleaned in the same way, excepting that absolute alcohol was used instead of aether; the slides after being dipped into the egg albumen were placed in the incubator to dry, then stored in a clean vessel ready for use. The chief advantages I found in the egg albumen, prepared as I have described, were, 1st, it was not so sticky and dirty as that prepared with glycerine, and yet quite sufficiently adhesive to hold any specimen perfectly on a slide, including tissue fixed in formaline; 2nd, that it kept perfectly for months, and was always ready for use, thus being superior to egg/

egg albumen and distilled water alone, (Mann's method) which immediately becomes useless, and consequently has to be made fresh as required.

METHODS of STAINING.
-----oOo-----

1st. For Tubercle Bacilli.

A. In sections fixed by the absolute alcohol or corrosive method.

The paraffin was removed from the slide with benzole, and the latter washed off with absolute alcohol, which was in turn removed with water and then the sections stained with carbol-fuchsin and counter stained with methylene blue. The staining was carried out as follows:- either by placing the sections in cold filtered carbol-fuchsin (Ziehl Neelsen's stain) for 24 hours, or for 1 hour in the same stain in an incubator at 35c' then washed in water and decolourised in 25% sulphuric acid, until the section became a pale pink colour, then thoroughly washed in water and next in methylated spirit for five or ten minutes (the use of the spirit was to exclude the smegma bacillus which is decolourised by it) and again washed in water and counterstained with methylene blue for four or five minutes, washed, dehydrated with absolute alcohol, cleared in zylol, and mounted in balsam with No.1 cover glasses. Films were stained with carbol-fuchsin in a watch glass, heated until steam was given off, and afterwards allowed to stand for two minutes, washed, decolourised, counterstained &c., in the same way as sections.

B. In Sections fixed in Formaline.

The organs from four guinea pigs, which showed marked naked eye tuberculous infiltration, were fixed in Joel's Fluid, a preservative containing formaline. When the sections prepared in this way came to be stained by the ordinary carbol-fuchsin method, it was/

1. Muir and Ritchie Manual of Bacteriology page 102

was found that they took the stain badly, only a few bacilli took the stain, and although the character of the tissue could be made out to be tuberculous, its definition was cloudy and indistinct, in fact, in many of the sections, bacilli could not be demonstrated at all by this method; yet from the microscopic appearance of the tissue, one felt certain that they must be present (The Chief Laboratory Assistant and other experienced stainers also stained sections with exactly the same result as my own), consequently I came to the conclusion that the formaline in which the tissue was fixed, must in some way be interfering with the action of the stain. In discussing my difficulty with Dr. Paton, he suggested that the imperfect staining might be due to formic acid, and advised soaking the sections in some alkaline solution before staining, consequently, after removing the paraffin in the usual way, I placed the sections in 1 in 20 of liquor ammoniae in methylated spirit, and allowed them to remain there for half an hour, then washed them thoroughly and proceeded with the staining as before; the result was good, but only after from one to two hours of decolourisation with 25% sulphuric acid. Liquor sodae of a strength of 1 in 20 of methylated spirit also proved useful. After many experiments, the best results were found to be attained by putting the sections for 15 to 20 minutes in a solution of Liq. ammoniae, 1 in 40 of methylated spirits, and after the above treatment the time required did not exceed 5 minutes for decolourisation. By this modification of the carbol-fuchsin method, these formaline fixed sections could be perfectly stained, and made to show distinctly the structure of the tissue, the caseous nodules, and tubercle bacilli and epithelioid cells were also shown to be present in

2nd. For Tissue Elements.

This was done by the ordinary Haematoxylin and Eosin method.

THE MICROSCOPIC EXAMINATION OF SPECIMENS.

This was carried out with a one-fourth, a one-sixth and a one-twelfth (oil immersion) lenses; a mechanical stage being used.

The figures in red ink in the following pages indicate the numbers of the slides which illustrate the points observed & recorded in each particular case

MICROSCOPIC and INOCULATION EXPERIMENT REPORTS.

Case 1. M.W. The ^{left}mastoid gland and the granulations from the ^{left}mastoid antrum removed at the operation, 27/12/00, were prepared for section cutting by the absolute alcohol method, and the sections when cut and mounted were stained by staining method 1.A. (as were all specimens in this case).

Sections of the gland ^{show} numerous caseating areas in various degrees of advancement, a few giant cells, numerous epitheloid cells, and tubercle bacilli. The bacilli are most numerous in the more advanced ~~and~~ caseating areas; here the bacilli have mostly the beaded appearance.

The bacilli in and about the epitheloid cells are less numerous and do not present the beaded or spored appearance, being stained throughout their whole length. In several microscopic fields, with a one-twelfth inch oil immersion lens, between 20 and 30 bacilli were counted. Some portions of this gland present the normal lymphoid appearance, with no epitheloid cells or bacilli.

The granulations above mentioned were pale and flabby, and caseous looking points were visible in them. The caseating foci were very distinctly seen during the process of rubbing them up, in sterilized salt solution, in preparation for inoculation into the guinea-pig: The residue in the mortar having an appearance closely resembling grated cheese. (The naked eye appearance of the other specimens is given in the Post Mortem Report and immediately after it). Microscopic sections of these granulations ^{2.2.} show much the same appearance as that seen in the gland just described; there being caseating areas and epitheloid cells, and tubercle bacilli, but no giant cells. In one field more than sixty of these bacilli were counted, and as in the last specimen, they are most numerous in the caseating areas, where most of them show the beaded appearance.

An emulsion of some of the granulations was made in sterile salt solution, strained through sterilized muslin, centrifugularised, and films made from/

1. See Micro Photograph No 1. which was made from a section of this gland
2 " " No 2 " " " " " " " " these granulations

show caseating nodules, epithelioid cells, and bacilli. In those of the great omentum,¹⁰ a few giant cells are seen as well. Glands near the right and left eustachian tube¹¹, and a gland¹⁷ from under the sterno mastoid¹² show tuberculous infiltration, caseation, epithelioid cells, and bacilli in great number.

Sections of the left eustachian tube at different levels, show the whole mucous membrane and the submucous layer of adenoid tissue beneath it, infiltrated with tubercle: In fact nearly all the adenoid tissue normally present in children in this situation, has been replaced by granulation tissue, which in many parts has undergone tuberculous degeneration.

The tissues around the submucous adenoid layer are only slightly infiltrated at their junction with the latter. Bacilli are seen in considerable number throughout the mucosa and the submucous layer, but not beyond it. In a gland¹³ shown in the same section, and about $\frac{1}{4}$ of an inch from the eustachian tube,

advanced caseation and bacilli in great number are found. In one microscopic field, between three and four hundred bacilli were counted, but they were so numerous, that it was impossible to count them accurately. The tissue between the submucous and this gland, show no sign of tuberculous involvement.¹⁶ A gland situated near the right eustachian tube, shows a very similar appearance to the corresponding one on the left side. The cartilage around the left tube, the muscular and fatty tissues, and the mucous glands situated in the immediate neighborhood have not been attacked.

Sections from the pia mater¹⁶ and from the left temporo sphenoidal lobe¹⁷ of the brain, immediately over the tympanic roof in the middle cranial fossa, show no evidence of tubercular involvement, neither does the tissue from the pharyngeal wall in the immediate neighborhood of the adenoid tissue, which has been previously described as showing such advanced tuberculous change.

Haematoxylin and eosin stained sections of the right eustachian tube¹⁸ and carotid artery¹⁸ in the bony portion of the canal, show the mucosa of the eustachian tube/

13.	See microphotograph	No 8	from section of left Eustachian Tube
14.	"	"	7.
15.	"	"	9 " gland near right
16.	"	"	10 " under left Steno mastoid sinus etc
17.	"	"	11

tube much thinner and less involved than in the car:
:tilagenous portion of the left tube. The adven:
:titia of the right corotid^{is} much thickened, but
otherwise unaltered.

Granulations from the mastoid antrum, removed
at the operation, 27/12/00, were prepared and inocu:
:lated the same day into guinea-pig No.25: Its
weight was then 712grms., and on 21/1/01 675 grms.,
and on 29/1/01, 530 grms. It was killed on this
date, and on dissection showed the following:- the
prietal peritoneum was thickly studded with caseous
tubercles, as was also the great omentum, the spleen,
and the anterior mediastinal glands. The liver and
lungs appeared to be free.

A piece of omentum and the spleen were taken
and prepared for section cutting by the alcohol
method, and cultures were made on glycerine agar from
nodules in the spleen, peritoneum and a mesenteric
gland.

Microscopic sections of the spleen¹⁹ and great
omentum,²⁰ show caseating areas, epitheloid cells, and
tubercle bacilli.

-----o-----

Case 2. M.McI. Granulations, including some bone
tissue, were obtained from the left mastoid in the
usual way at the operation, 4/10/00. These were
prepared and inoculated into guinea-pig No.17 on the
same day; its weight then being 610 grms. On the
15/11/00 it weighed 460 grms (i.e. 32 days after
inoculation), it was then killed and dissected, and
showed a caseous nodule at the site of inoculation,
numerous tubercles in the great omentum, lumber glands
spleen, one or two on the liver, but none in the
lungs or kidneys.

Films²¹ were made from caseous nodules in the
spleen, great omentum, and site of inoculation, but
none of them show tubercle bacilli. The spleen,²²
great omentum²³ and a lumber gland were prepared for
section cutting by the absolute alcohol method.
The/

1. See Micro Photograph No. 12.
- 2 " " " 13

The sections chosen for staining were those passing through a nodule; these were stained by the ordinary method described for the detection of tubercle bacilli and they all show typical tuberculosis, caseous degeneration, epitheloid cells, and tubercle bacilli, but no giant cells. Two films were also prepared from a piece of granulation from the mastoid, and stained, but show no tubercle bacilli.

-----o-----

Case 3. A.H. Granulations were taken from the wall of the cavity in which the sequestrum was found, on 21/10/00. They were prepared as usual, and inoculated into guinea-pig No.20, 22/10/00, which then weighed 528 grms. It died on 23/11/00 (31 days after inoculation), its weight being 392 grms.


On dissection, adhesive peritonitis was found between the lower portion of the ascending colon, a few coils of small intestine, and the anterior abdominal wall on the right side. Throughout these adhesions were scattered caseating nodules. The lumbar glands were enlarged on the right side and presented caseous points. Caseous nodules were also visible in the great omentum, the spleen, mesenteric glands, and also at the site of inoculation. The kidneys, the heart, the lungs, the suprarenal bodies and the pancreas seem not to have been involved. The spleen, great omentum, the seat of inoculation, and a lumbar gland were prepared for section cutting by the alcohol method. Films were made from caseous nodules in the omentum, seat of inoculation, and anterior mediastinal gland. Sections prepared from the spleen²⁴ and the lumbar gland²⁵, stained for tubercle by Staining method No.1 A., show numerous caseous nodules and with the one-twelfth-inch lens, degenerative changes, epitheloid cells, and tubercle bacilli are found in considerable number, but no giant cells.

A film³ prepared from a nodule in the spleen²⁶, at the time of dissection, and stained as above, shows tubercle bacilli. None were found in several other films/

1. See Micro photograph No. 14.
- 2 " " " 15.
- 3 " " " 16.

films examined.

The largest of the sequestra, removed at the operation, was placed in Pereny's Fluid for decalcification, and subsequently dehydrated and fixed in absolute alcohol and prepared for section cutting. When cut and stained for tubercle²⁷, they show caseous looking areas and numerous large cells, but no tubercle bacilli. (The absence of bacilli may be due to their not taking the fuchsin stain, after being in Pereny's Fluid).



Case 4. E.E.M. The granulations and a scraping of bone, which were taken from the mastoid during the operation on 22/5/00, were prepared and inoculated into guinea-pigs Nos.13 and 14, by the usual method, on 25/5/00. (The delay in making the inoculations in this case and the next, was owing to the impossibility of obtaining guinea pigs sooner.)


At the time of the inoculations, the guinea-pigs weighed 527 and 490 grms. respectively. On 3/6/00 502 and 470 grms., on 10/7/00, No.13 died, it then weighed 330 grms. On dissection it showed general tuberculosis. Most of the numerous tuberculous nodules were caseating. The whole guinea-pig was placed in Joel's Fluid.

On the 13/7/00, No.14 was killed with chloroform, it then weighed 343 grms: When dissected it showed tuberculous nodules all over the peritoneum, in the spleen, great omentum, mesenteric glands, liver, one or two on the surface of the kidney, and in the mediastinal glands, lungs &c. This guinea-pig was also placed in Joel's Fluid. After allowing these guinea-pigs to remain in this fluid for two weeks, the liver, spleen, and the great omentum were taken from each, and prepared for staining by method No.3

When sections had been cut and stained by staining method No.1A^{28, 29, 30, 31, 32, 33}, it was found that they had not taken the stain well, and although they show numerous caseating nodules, and epitheloid cells, only a few imperfectly stained bacilli are seen in some of the sections/

28a, 29a, 31, 31A, 32a.

sections. By soaking sections, in 1 in 40 liquor ammoniae (Staining method No.1 B.) before staining, as previously described under "Methods", they are made to show the tissues much better stained, as well as numerous bacilli, which have all the typical characteristics of tubercle bacilli.




Case 5. D.P. Granulations and bone scrapings were taken from the mastoid antrum, and also granulations from the walls of the suppurating cavity in the neck, on 23/5/00.

The solution prepared from the former, was inoculated into guinea-pig No.15 and that from the latter into guinea-pig No.16 on 25/5/00. No.15 then weighed 492 grms., and No.16 542 grms; On 3/6/00, they weighed respectively 480 and 526 grms., No.15 died on 13/7/00; it then weighed 322 grms. and on the same day, that is nine weeks after the inoculation, No.16 was killed; its weight being 360 grms.

Both these guinea-pigs on dissection showed general tuberculosis, the tuberculous nodules being most numerous in the mesenteric glands, the great omentum, the spleen, and the liver. Several nodules were cut open, and each was found full of a yellow caseating material. Both these guinea-pigs were put into Joel's Fluid, and two weeks later, the great omentum, spleen, a piece of liver, and other affected parts, were prepared for section cutting by Method 3.

Sections of these organs when stained by Staining Method No.1 A. show exactly the same imperfect results as the sections from guinea-pig Nos.13 and 14 similarly stained, but when treated with ammoniae solution, as in the previous two cases, Staining Method No.1, B. they show tuberculous degeneration, caseation, epitheloid cells, and tubercle bacilli in the most typical manner.

Guinea Pigs Nos.13, 14, 15, and 16 had each a large caseous nodule at the site of inoculation, on the 17th day.



Case/

- 1. See Micro photographs No 17.
- 2 " " " " " 18
- 3 " " " " " 19

Case 6. H.G. The granulations removed at the operation on the 17/10/00; from the cavity in which the sequestrum was lodged, were prepared for inoculation by the usual method, and on the same day were inoculated into guinea-pigs Nos.18 and 19. On 27/11/00, No.19 died, and on the 28/11/00, No.18 died.

On dissection, the stomachs of both were found much distended with haemorrhages into their walls. No other abnormal appearance was noticed. The great omentum and spleen of both guinea-pigs were prepared by the absolute alcohol method for section cutting, and sections were stained by Staining Method No.1A.

No degenerative changes could be found in any of these tissues, ^{37, 38, 39, 40} nor any other appearance indicating tubercle.

At the post mortem examination on the body of H.G., an enlarged mesenteric gland was taken and prepared for section cutting by the corrosive method. Sections ⁴¹ from it were stained by Staining Method No. 1 A., microscopically they show no degenerative changes, or other evidence of tubercle.

A portion of the right temporal bone, including a portion of the wall of the cavity in which the sequestrum was situated, and with the granulation tissue on its surface, was placed in Pereny's Fluid to decalcify. Microscopic sections prepared in the usual way and stained ² with Haematoxylin and Eosin shows bone of the cancellous variety, covered on one surface with granulation tissue. ⁴² and sections of it stained for tubercle. *Show neither giant cells nor tubercle bacilli*




Case 7. AR Granulations from the wall of the cavity in the temporal bone from which the sequestrum was removed on 4/11/00, were prepared and inoculated into guinea-pig No.21 on the 5/11/00. At the time of inoculation it weighed 488 grms; on the 27/11/00 it died, and then weighed 494 grms. On dissection it showed distention and congestion of the mucous membrane of the stomach; congestion of the great omentum and lungs, but no caseous nodules: the other organs/


- 1. See micro photograph 20.
- 2 21.

organs looked normal. The great omentum and spleen were taken and prepared for section cutting by the absolute alcohol method. Microscopic sections of these, ^{43, 44} stained for tubercle by staining method 1 A. show no evidence of tubercle. Several films ⁴⁴ of the pus from the right external auditory meatus taken on the 14/11/00 and stained for bacilli, show none.

The gland removed on the 22/12/00 was prepared for cutting by the absolute alcohol method, cut and stained for tubercle by staining method 1.A. Some of the sections ⁴⁵ show degenerative changes in the tissue in some places and also a considerable number of cells exactly like epitheloid cells, but there are no giant cells or bacilli.



Case 8. W.C. The granulations removed from the mastoid at the operation, 29/4/00, were prepared and inoculated into guinea-pig No.12 on the 30/4/00; it then weighed 580 grms., on the 10/5/00 594 grms., on the 20/5/00, 605 grms., on 19/6/00 650 grms. On this date it was killed and dissected, all its organs and glands were found normal. There was no sign of tubercle anywhere.




Case 9. A.T. From this case, pus was taken on a sterile swab from the surface of the right tympanic membrane. The pus on the swab was mixed with some sterile salt solution in a sterile dish and inoculated into guinea-pig No.4 in the usual way on 15/3/00. The weight of the guinea-pig at the time of inoculation was 620 grms; on the 19/3/00 622 grms., on the 29th 698 grms., on the 2/4/00, 564 grms; on the 11/4/00 it died, that is between five and six weeks after inoculation. The dissection showed no evidence of tubercle in any gland or organ, the only abnormality observed was some ecchymosed patches in the mucous membrane/

membrane of the stomach,

The spleen was prepared by the corrosive method, cut, and sections stained as usually done, some with staining method 2^{4c}, and others with method 1 A⁴⁷.

The microscopic inspection of these shows no degenerative changes.




Case 10. R.H. The scraping which was taken from the tympanum in this case, was prepared with sterile salt solution by the usual method and inoculated into guinea pig No.5 on 20/3/00; its weight then being 597 grms; on 2/4/00 it weighed 442 grms; and on the 8th of April it died, that is 19 days after inoculation. Dissection shows no evidence of tubercle in any part.



Case 11. W.McK A solution was prepared from the granulations from the mastoid in this case, and inoculated into guinea-pig No.6 in the usual way on 21/3/00. The guinea-pig then weighed 574 grms; on 2/4/00, it weighed 444 grms; on the 27/4/00, it died and was dissected. No evidence of tubercle was found in any of its glands or organs. Its spleen was prepared for cutting by the corrosive method; cut and stained by No.1 A staining method. Sections of it, microscopically, show nothing abnormal. Some granulations from the mastoid⁴⁸ were also prepared by the corrosive method, cut and stained as usual. They show ordinary granulation tissue in a few places some large cells, but no caseation or bacilli.

Guinea-pig No.7 was inoculated with a solution made from granulations taken from the wound on the elbow, previously mentioned. On inoculation the guinea-pig weighed 381 grms, four days later it died, and the dissection showed advanced tuberculosis in the spleen, liver, peritoneum, and under surface of the diaphragm, but no tuberculous nodule was found at the seat of inoculation.

It is evident from the advanced stage of tuberculosis found in the organs, that this guinea-pig was tuberculous at the time of inoculation: This opinion is supported by Delepine's researches.



Case/

Case 12. G.C. Granulations from the mastoid in this case, were rubbed up with sterile salt solution and inoculated into guinea-pig No.1 on the 12/3/00; according to methods described.

On this date the guinea-pig weighed 670 grms; on 16/3/00 it weighed 560 grms; on the 19/3/00, 640 grms; on 22/3/00 658 grms; 2/4/00, 547 grms; on 17/4/00 515 grms, and on the same day it was killed with chloroform and dissected. All the glands and organs were normal to naked eye appearance; Dr.Noel Paton also examined this guinea-pig and expressed the same opinion. Granulations from the abscess cavity over the mastoid were treated similarly, and the solution derived, inoculated into guinea-pig No.2 on 12/3/00, which then weighed 752 grms; on 16/3/00, 647 grms; 19/3/00, 727 grms; 22/3/00, 693 grms; 2/4/00, 547 grms. This guinea-pig died on the 7th April, 26 days after the inoculation: Dissection revealed no naked eye evidence of tubercle. The spleen and great omentum of both these guinea-pigs were prepared by the corrosive method and stained by Staining Method 1. A. They show no tuberculous changes in their structure.

Sections of the aural polypus removed from the patient, were also made. It was prepared for cutting by the corrosive method, and stained by the usual methods. Its structure is found consisting chiefly of granulation tissue which show no degenerative changes.



Case 13. G.D. The granulations removed from the mastoid were prepared by the methods before described, and inoculated into guinea-pig No.3 on the 15/3/00. The guinea-pig weighed on this date 717 grms; on 19/3/00 it weighed 737 grms; on the 29/3/00, 760 grms. on the 16/4/00 780 grms; it was killed on this date with chloroform: No evidence of tubercle was found in any of the glands or organs. Portions of the liver and spleen were prepared by the corrosive method cut and stained, and others with method 1 ^{Aug. 50.} A, Some of the sections were stained by Method 2 ^{51.52}, but none of them show any degenerative changes.

A/

A streak culture was made on agar agar from the pus taken as previously described: after 24 hours a whitish culture was found, which on microscopic examination proved to consist of small narrow bacilli, and some strepto cocci. These bacilli were readily decolourized by acid.

Some antral granulations were also prepared by the corrosive method, cut and stained. They showed microscopically ordinary granulation tissue, without degenerative change or bacilli. Several films of pus from the external ear were stained by Method 1 A. They showed numerous small bacilli, and various kinds of cocci, but no tubercle bacilli.

-----0-----

Case 14. A.M. ^{53 3u 5u.c.} Several films were prepared with the pus from the external auditory meatus; they each showed numerous chains of streptococci and a few groups of staphylococci, but no tubercle bacilli. During the operation on the mastoid, some pus was taken as it escaped from the mastoid wound on a sterile needle, and several cover glass films made. These were stained for the detection of tubercle bacilli by Method 1 A., but showed none, but there were, as in the previous films, cocci in chains (streptococci) and a few cocci in groups, arranged in a manner resembling staphylococci. ^{1.38}


Some granulations were taken with strict sterile precautions, and rubbed up with salt solution and inoculated into guinea-pig No. 24. ³⁶ Films were made from a little of the granulation solution: On staining they showed nothing but cocci in chain and groups as did the pus films.

The guinea pig in this case was inoculated on the 29/11/00, it then weighed 282 grms; on the 8/12/00, 260 grms. It died on the 18/12/00, 19 days after inoculation. The dissection of it showed no evidence of tubercle in any of its glands or organs. The spleen and great omentum were prepared for cutting by the absolute alcohol method, and sections ^{37, 38} were stained for tubercle by the usual method (1 A.) The microscopic/


1. See Microphotograph No. 22.

microscopic examination showed no evidence of degenerative changes or bacilli.


Granulations from the mastoid were also prepared by the absolute alcohol method, cut and stained: The sections⁵⁹ show young granulation tissue, but no degenerative changes, and nothing indicating tuberculous involvement.



Case 15. Mr.C. The granulations removed from the mastoid antrum at the operation, 11/11/00, were prepared and inoculated by the usual method into guinea pig No.22 on the same day; its weight then being .502 grms, 15 days after inoculation, on the 26/11/00 it died, its weight being 514 grms. The dissection showed distention of the stomach and great congestion of its mucous lining: In the peritoneum about the seat of inoculation, there was a small grey point of the size of a pin's head; five or six other similar points were found in the great omentum: From two of these films were made; the remainder with the great omentum were taken for section cutting. All the other organs and parts showed no abnormal appearance to the naked eye. The spleen was prepared, with the great omentum, by the alcohol method for section cutting, and sections^{60,61} and films⁶² were stained by Staining Method 1 A. None of them show anything indicating tuberculous involvement.




Case 16. C.S. Granulations taken from the mastoid at the operation on the 11/11/00, were prepared in the usual way and inoculated into guinea-pig No.23 the same day; this guinea-pig then weighed 445 grms. It died four days later, of what cause is unknown, as all its organs looked normal.



Case/

Case 17. L.F. On several occasions in this case, more than a dozen films ^{63, 64, 65} of the pus from the external auditory meatus were stained, which showed the following:- numerous groups of cocci arranged as are Diplococci, staphylococci and other forms, and also a large number of stout short bacilli, quickly decolorized by the 25% sulphuric acid, and also a great many small, thin, bacilli, which hold the red stain more strongly than the first described, but they in no way resemble tubercle bacilli.


At the operation, no granulation tissue or pus was found, consequently, nothing could be obtained for inoculation experiment.



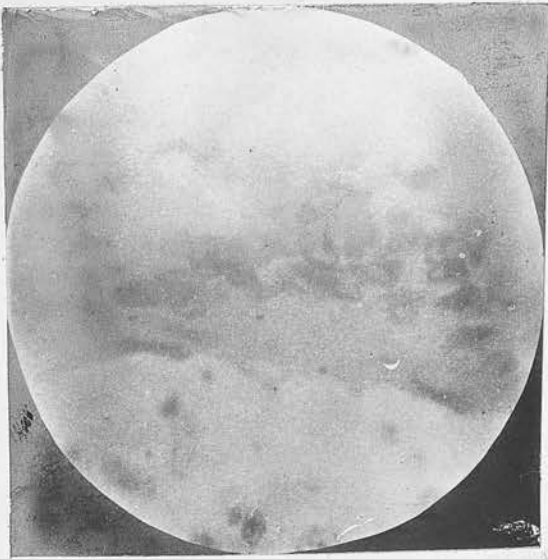
Case 18. A.R. The granulations removed from the mastoid antrum at the operation 20/1/01, were prepared by the absolute alcohol method, cut and stained by the ordinary No.1 A Staining Method. Microscopically, they ⁶⁶ show ordinary granulation tissue. There are no caseous areas, epitheloid cells or bacilli, neither do sections of the mastoid gland, ⁶⁷ which was also removed at the same time as the granulations, and prepared cut and stained in the same manner, show any degenerative processes or other evidence of tuberculous involvement.



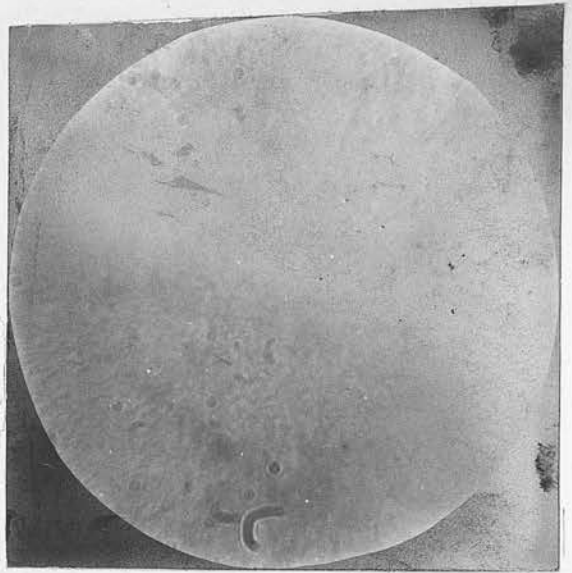
Case 19. Mrs.W. The granulations taken from the mastoid at the operation 31/1/01, were prepared and inoculated on the same date, in the usual way, into guinea-pig No.25a which then weighed 574 grms. On 21/3/01 it was killed, and then weighed 712 grms. The dissection showed it to be perfectly healthy, there being nothing resembling tuberculous deposits in any gland or organ.



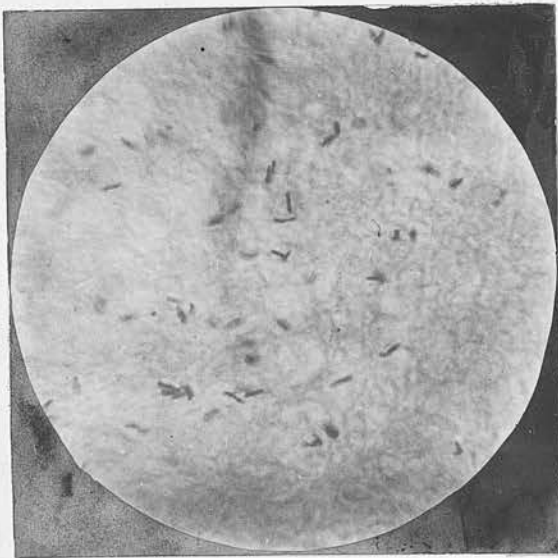
1.



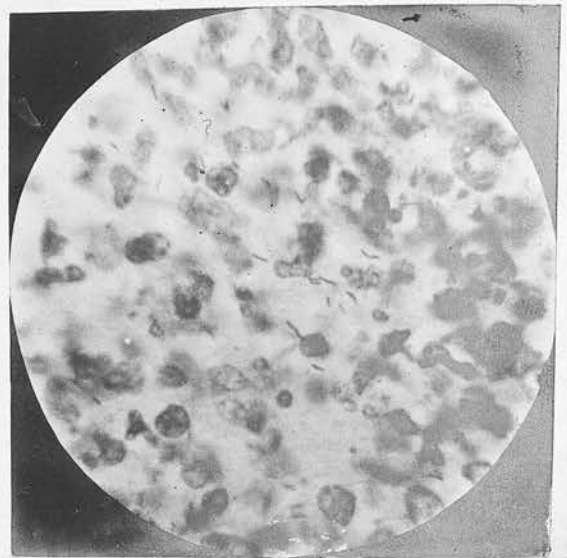
2.



3.




4.

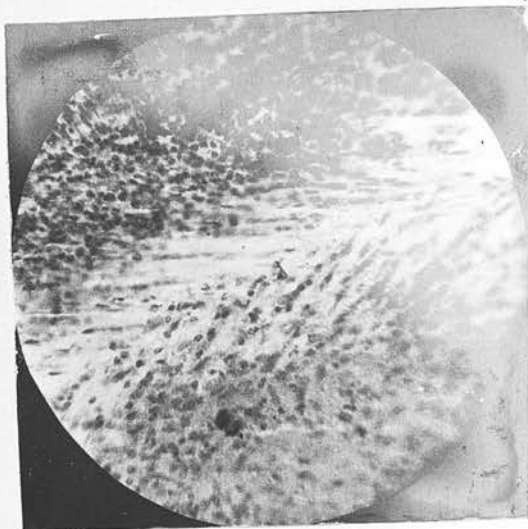


- | Slide | MicroPhotograph |
|-------|---|
| 1. | No.1. Shows a giant cell and three tubercle bacilli in it, in a microscopie section from the left maxillary gland Case 1. M. W. (Slide 1.) The bacilli are not very well shown in the photograph owing their <u>the whole length not being in focus at once</u> |
| 2. | No.2. Shows a few tubercle bacilli <u>imperfectly</u> in an M. Section of granulations from the left middle ear M. W. Case 1. (Slide No 2) |
| 3. | No.3. Shows a large number of tubercle bacilli in a M. Section from the Adenoid Tissue removed post mortem from the Naso Pharynx of M. W. Case 1. Slide No 3 |
| 4. | No.4. Shows a large number of tubercle bacilli in a M. Section of the Mucous Membrane of the right tympanum removed post mortem from M. W. Case 1. (Slide No.4) In this case the tympanic Membrane of the same ear looked normal to external inspection. |

5.



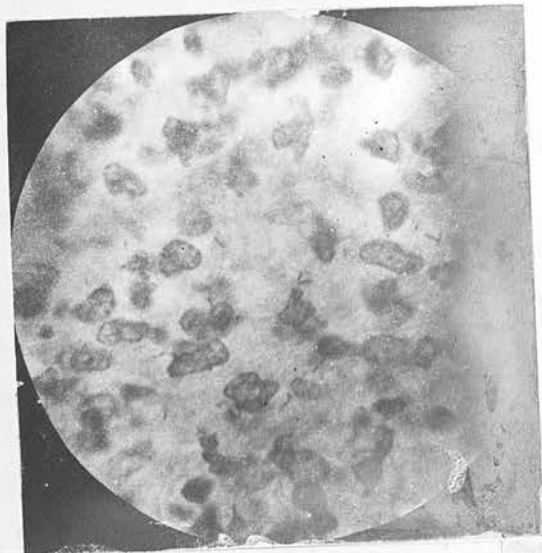
6



7.



8.



Slide

Micro-Photograph

5 →

No. 5. Is a low power photograph of the right tympanic membrane M.W. Case 1. (Slide 5.) The light line running through the photograph is the Membrana Fibrosa Propria being gradually eaten away by the advancing tubercle from the diseased Mucosa which is seen below it. This Mucosa is in an advanced stage of degeneration (tuberculous) & shows under high power numerous tubercle bacilli. The Demia's which is seen in the photograph above the light line (The Membr. Propria) was just beginning to show tubercular degeneration.

5 →

No. 6. Is a photograph of the same M. Section as No. 5 but under a higher power (Slide 5.)

14 →

No. 7. Is a low power photograph of the left Eustachian tube. The slightly darker area just around the central opening is the mucosa & lymphoid tissue layer in which tuberculous degeneration of tubercle bacilli are found present beyond this layer in the surrounding tissue tuberculous degeneration is not taking place.

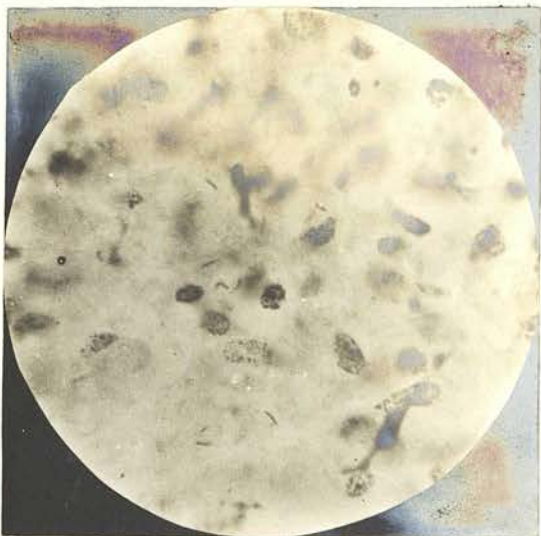
13 →

No. 8. Same M. Section as No. 7. under high power to show tubercle bacilli in the sub-mucosa of the left Eustachian tube. (Slide 13.)

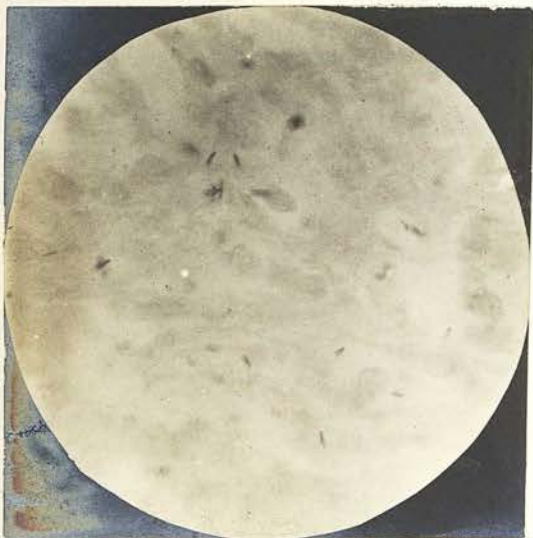9




10



11

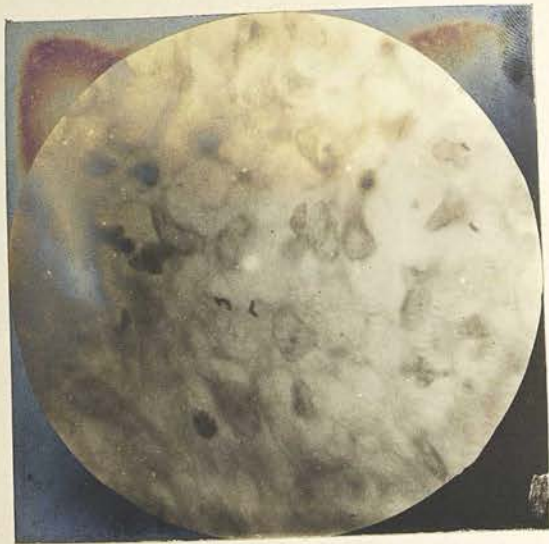

12

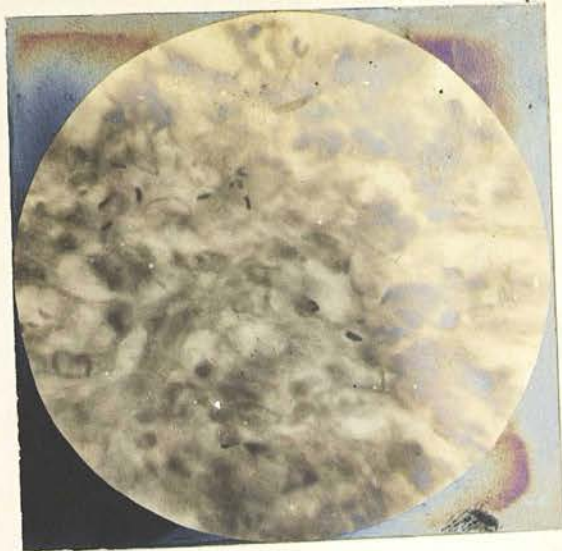

- | Slide | Micro-Photograph |
|-------|--|
| 13. → | No 9. Shows tubercle bacilli in M. section a gland near the left Pustachian Tube M.W. Case 1. (Slide 13.) |
| 11. → | No 10 Shows tubercle bacilli in M. section of a gland near the right Pustachian Tube M.W. Case 1. (Slide 11) |
| 12. → | No 11 Shows tubercle bacilli in M. section of a gland under the left sterno mastoid muscle M.W. Case 1. (Slide 12) |
| 18. → | No 12. Shows the right carotid artery near the right Pustachian Tube M.W. Case 1. (Slide No 18) |

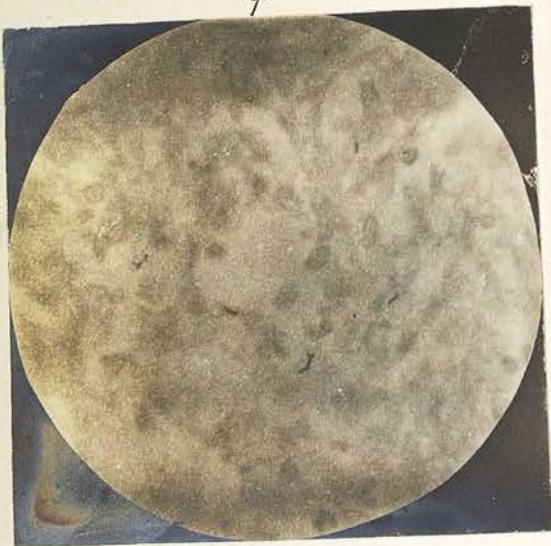17.



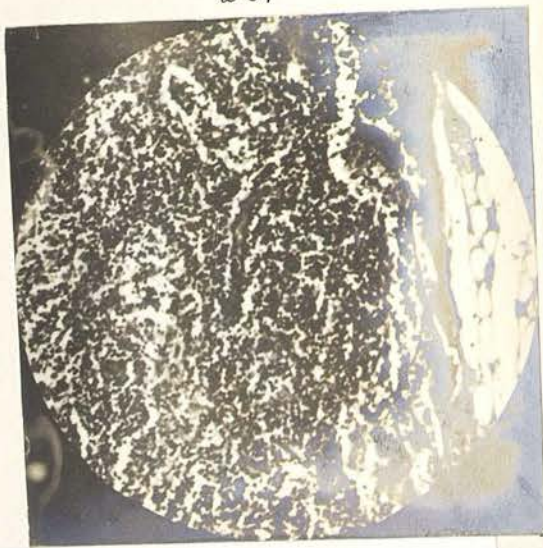18



19.




20.

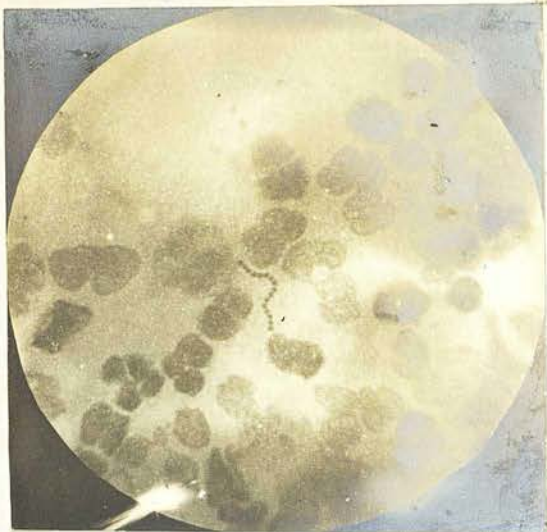

- | Slide | Micro Photograph | of | Observation |
|-------|------------------|--|---|
| 34 → | No 17. | Shows tubule bacilli in a M. Section | from <i>Gruera</i> fig No. 12. Case No 4. <u>E.E.M.</u> |
| 32A → | No 18 | " " " " " " " " | " Spleen " " 13 " No 4. <u>E.E.M.</u> |
| 35A → | No 19. | " " " " " " " " | " Mesenteric Gland Fig No 16 - Case 5. <u>D.P.</u> |
| 41. → | No 20 | " low power photograph of a mesenteric Gland removed at the post mortem in <u>H.B.</u> Case 6. (Slide #1) No degenerative changes as visible | |

No 21



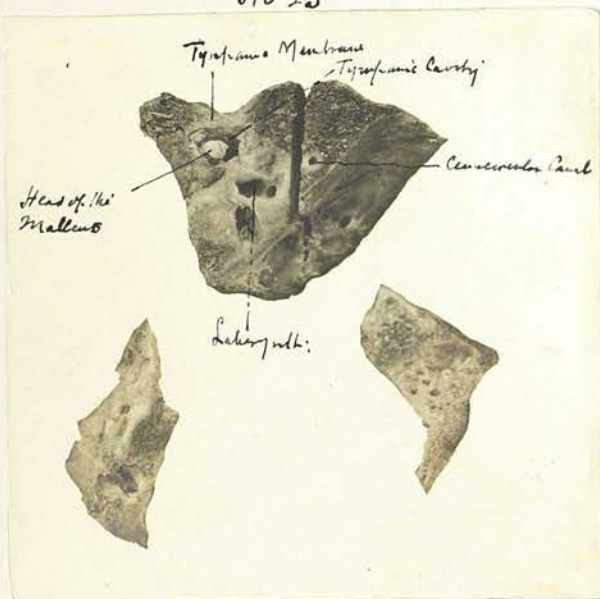
No 22



Slide 42 → Micro-Photograph No 21. Shows a M. Section of the Squamous covered with granulations removed at operation on ear of H. G. Case 6. (Slide 42-A)

55 → No 22. Shows a chain of Streptococci from a film of pus from Mastoid Antrum A.M. Case 14 (Slide 55)

No 23



No 23. Shows a photograph of the lower portion of the right tympanic cavity Case 6 M.W. The head of the malleus is seen in the center of the tympanic stock almost white in the photograph. The malleus membrane lining the tympanum is seen to be much thickened & more so in some places than others.

General Considerations of the results of
Investigations and conclusions.

-----0-----

Results of Case 1 specially considered

The results of the post mortem examination of M.W. (Case 1) are specially instructive and demonstrate that in a case of tuberculosis of the middle ear, tuberculous naso-pharyngeal adenoids of considerable size may have existed without giving rise to symptoms which caused their presence to be suspected, yet had an examining finger been passed into the naso-pharynx, they could scarcely have been overlooked, as the mass of lymphoid tissue found there, was about three quarters of an inch long and from a quarter to half an inch thick, and much lobulated. These facts indicate that in similar cases, such an examination should be made, and should any adenoids be found in the naso-pharynx, their removal and microscopic examination may give valuable indication as to the nature of the ear disease.

The advanced tuberculous degeneration present in the mucous membrane of the right tympanum and antrum, without producing any objective symptoms, is of great interest and importance. Here the most careful inspection of the outer surface of the right tympanic membrane, both antemortem and postmortem, revealed nothing abnormal beyond perhaps a slightly abnormal pallor, yet, when the tympanic cavity was laid open, post mortem, its mucosa was found much thickened, and studded with numerous elevated, grey, points (tubercles). From the naked eye and microscopic appearances, presented by the mucosa covering the inner wall of the tympanum, and that of the tympanic membrane and antrum, it is impossible to distinguish which was first affected, as the disease was equally far advanced in each of these positions, numerous caseating areas, epithelioid cells, and bacilli being present in all.

Interesting and important facts are also brought out by the microscopic sections of the tympanic membrane just referred to: In these sections, the whole/

whole of the stratum mucosum is in an advanced stage of tuberculous degeneration, while the fibrous membrana propria immediately external to it, is seen to be comparatively healthy, and is only being gradually eaten away by the advance of the disease, showing that this layer of the drum membrane, has offered a stubborn resistance to the spread of the disease. The erosion into this fibrous layer, is deeper in some positions than in others, and it may be assumed that the destructive process would have been completed first at the thinned places, with the result that perforation of the whole thickness of the membrane, would have been first completed at the corresponding sites, thus explaining the pathological processes at work in the formation of multiple perforations of the tympanic membrane - a symptom which is admitted by all authorities, to be highly suggestive of tuberculous origin. In what remains of the membrana propria no degenerative changes or epithelioid cells are seen, and only here and there a tubercle bacillus. These points indicate not only that this membrane resists, in a great measure, infiltration of its substance by tubercle, and that the bacilli are only able to find their way along the vessels which effect a communication between the vessels of the mucosa and those of the epithelial layer; and that it has been by this means that they have reached the latter.

In the epithelial layer of the membrane, the presence of epithelioid cells and a greater number of bacilli, in certain situations, show that the disease has here found a more favourable footing than in the membrana propria. The comparatively early stage of the tuberculous process in the epithelial layer, and the unperforated state of the fibrous layer, accounts for the absence of objective symptoms in this case. According to Brieger², a post mortem examination of a tuberculous middle ear, previous to perforation of the drum membrane, has very rarely been obtained, consequently the appearances observed, naked eye and microscopically, in this case, are of the greater interest. ^{importance} So far as can be gathered from a careful search of the available literature regarding early middle ear tuberculosis, the changes just described, have/

1. The layer of Cutis vera on the outer surface of the tympanic membrane is meant.

2. Transactions 6th International Otological Congress 1899 page 21.

have not previously been observed.

That fairly advanced tuberculous infiltration of the mucous membrane of a middle ear may occur, without producing any visible abnormal appearance in the outer surface of the tympanic membrane, is proved by the observations just recorded. How long this right middle ear had been tuberculous (in this case) must be a matter of conjecture, yet when one considers the comparatively slow progress of tuberculous infiltration and degeneration, as observed in tuberculous guinea pigs, it might be assumed that the disease had been present in the tympanum for quite two weeks. The appearances to be expected in the tympanum in the early stages of tubercle, are well illustrated by what was discovered in the right tympanum in this case, where the mucous membrane was found of a greyish colour and studded with grey raised points about the size of pins heads.

The path taken by the bacilli in finding their way to the tympanum in this particular case, was clearly by the eustachian tube, as they can be traced in their course from the tuberculous adenoids in the naso-pharynx along the mucous and adenoid tissue layers of the eustachian tube, as shown by the sections made from different levels of the tubes as already described, and this view is confirmed by the absence of tuberculous infiltration in the other tissues of the tubes, and right middle ear; other than their mucous membranes, which would have been infiltrated by the disease, had the bacilli found an entrance by the vessels from the general system, while the condition of the tympanic membrane proves that they did not find an entrance through it.

Although it cannot be proved that the first bacilli which reached the right tympanum did not get there mechanically, by means of a fragment of infected mucus from the naso-pharynx being forced up the tube by air pressure; it is much more probable that they entered by direct extension along the mucosa of the tube, since ^{my} microscopic investigations prove that tuberculous infiltration was present in the lining membrane of the left tube throughout its whole length, and in the upper portion of the right tube.

Microscopic/

Microscopic sections of granulations from the left middle ear, (Case 1) likewise show typical tuberculous degeneration, caseation, epithelioid cells and bacilli, and also that the glands along the eustachian tube, the mastoid glands, and other glands in the neck, may be similarly affected. Another point of interest observed was the great number of bacilli present, in the mucous membrane of the right and left middle ears, and in the glandular tissues along the tubes, as well as in the adenoid in the naso-pharynx. *{The Mastoid Gland and the granulations from the middle ear on the left side were examined and motion, consequently their microscopic examination may give an indisputable diagnosis}*

The free passage of blood down the eustachian tube during the operation on Case 1, supports Ostman's theory^h that in wasting diseases the eustachian tube becomes more patent. The extreme thinness of the left tegmen tympani, and the paleness of the dura mater over it, show that the disease was making its way towards the brain, and had the child survived longer, tubercular meningitis would probably have followed.



A n a l y s i s o f C a s e s .



The following facts and conclusions are brought out and deduced from an Analysis of the 19 cases of suppurative otitis media investigated:-

A satisfactory proof as to the presence or absence of tubercle was got in 18 of them, 5 being tuberculous and 13 non-tuberculous, while in the remaining case, although tubercle was not demonstrated, it cannot be held to have been excluded; thus, tubercle was the cause of the ear disease in 26.3% of all the cases. In 4 of the cases (6, 7, 10 & 11) or 21% in which inoculation experiment showed tubercle to be absent, each had some point or points in its history/

1. Wiener Medicinische Presse 1898. page 662.

history that might ^{have} lead to a suspicion of tubercle. The negative inoculation result was confirmed in two of these cases (6 & 11) by the microscopic inspection of sections from the mastoid granulations,

The ages of the 5 cases in which tubercle was proved, varied from 5 months to 7 1/2 years, three being under 1 year. The ages of the 4 suspected cases, which proved non-tuberculous, varied from 4 years to 39 years; two of these were under 10 and two over 30 years. The other 8 non-tuberculous cases ranged between 3 years and 10 months, and 38 years.

Of suppurative middle ear disease with bone lesion, in children under 1 year, a large percentage are tuberculous. Milligan's statement that "a large proportion of the cases of suppurative middle ear disease, with accompanying bone lesion, met with in practice, are tuberculous", unless we add to it "in children", is not supported by my experiments. Even Milligan's published statistics² do not bear out his statement, as the oldest of his 10 recorded cases is a patient of 19 years, and a child of 2 1/2 years, the oldest of his tuberculous cases. My examination of 18 cases shows, that 12 had marked destruction of bone in the neighborhood of the middle ear, and that only 5 or 41.6% of these were tuberculous, thus showing that great destruction of bone did not indicate tuberculosis in 50% of them. If we take the cases under 5 years of age, we arrive at a different result, for we find 80% of those with bone lesion, were tuberculous, while of those over 5 years, only 14% were tuberculous, consequently my results would confirm Milligan's if we modified his statement by adding to it "in children under 5 years of age".

Why suppurative otitis media in young children is so frequently tuberculous, I believe to be due, to bottle feeding with uncooked or unsterilised cows milk or cream: In two of my cases (Nos. 1 & 5) this was at least the probable cause of the ear disease.

Perforation of the inner wall of the mastoid process, near its tip (Betzold's Perforation) occurred in 20% of the tuberculous cases, and in 21.4% of the non-tuberculous, consequently, no inference as to/

1. Transactions 6th International Biological Congress 1899 page 35
2. British Medical Journal 16th November 1898 page 1224.

to the nature of the disease can be drawn from this symptom, but it points to considerable destruction of bone occurring in the non-tuberculous as well as in the tuberculous cases of middle ear disease.

Bare bone was felt through the meatus in 40% of the tuberculous cases, and in 21.4% of the non-tuberculous. The destruction of bone about the middle ear, ^{which was} chiefly ⁱⁿ the mastoid process, was great in all the tuberculous cases, and in 53% of the non-tuberculous.

The fact that great destruction of bone and hollowing out of the mastoid process is frequently found in tuberculous cases, with comparatively slight subjective and objective symptoms, seems due 1st. to the painless nature of tuberculous disease, generally, and 2nd to the fact that the mastoid process has a cortical layer of hard bone, which resists the advancing disease for a much longer time than the more vascular and cancellous bone ^{beneath} that makes up its greater portion.

Complete perforation of the outer surface of the mastoid process did not occur in any of my cases; but in all the tuberculous cases, the shell of bone was very thin which covered the diseased bone and granulation beneath, while in only 4 of the non-tuberculous was this the case: In 4 of these, this layer of bone was only slightly thinned, and in 2 it was thickened and sclerosed; In the remaining 3 cases, the mastoid was not opened.

In all the tuberculous cases, the diseased bone in the mastoid cavity, was soft, and consequently this symptom affords some indication as to the nature of the disease.

A sequestrum was found in 20% of the tuberculous cases, and in 15% of the non-tuberculous cases. Of these sequestra it cannot be said that any of them presented distinctive characteristics, excepting microscopically. *13. Cerebrating areas in the tuberculous. Sequestrum, these absent in the non-tuberculous*

In the five tuberculous cases, facial paralysis was present as the result of the disease in three, or 60%, and in each case, it appeared with, or very soon after the onset of discharge: In the 13 non-tuberculous cases, facial paralysis was present in 3 cases, or/

or 33%, and in only 1 of these (Case 7) did it come on soon after the discharge. In the other 2, the paralysis was not noticed until 1 year after it, in 1 case, and 13 years after it in the other; this shows that facial paralysis is more frequent in tuberculous cases, and that its early onset with, or soon after the discharge, is a symptom strongly indicating a tuberculous origin.

In the tuberculous cases, the discharge appeared first in the left ear in 60%, while in 40% of them, the other ear is known to have become tuberculous. In the 13 non-tuberculous cases, the left ear was affected in 7, - 53%, and suppuration subsequently appeared in the other ear in 26%. This observation indicates, that one ear is about as often affected as the other; but that the second ear becomes involved in the tuberculous cases more frequently.

The duration of discharge in the tuberculous cases, was from 10 weeks to 2 years and 9 months; in the non-tuberculous, from 4 days to many years; in one case 13 years. Thus the average in non-tuberculous, was much greater, and this ^{seems to} indicate a worse prognosis in the tuberculous cases. In none of the tuberculous cases did the discharge follow acute illness, and in 80% it commenced without any history of pain. In the one tuberculous case in which there is a history of pain preceding the discharge, at the time of investigation, the discharge had been present from both ears for more than a year, and since the patient had been living in a house, during that time, with two advanced cases of phthisis, it is conceivable that the tuberculous ear condition may have been a secondary infection, and not the primary disease.

In 7 or 53.8% of the non-tuberculous cases, the onset of discharge was associated with acute pain, and was associated with an acute illness. In 3 cases with Measles, (6, 13, & 18), in 3 ^{others} with acute Catarrh (12, 17, & 19), and in 1 with Influenza (14). In one case (11), the onset of discharge was painless, while with regard to the remaining 5 cases, no clear history was obtained as to this point. The absence of evidence of pain in the diseased ear, in the tuberculous/

1. This result ^{is} ~~is~~ Bernstein's (E) assertion that in tuberculous otitis the left ear is attacked by preference. Journal of Laryngology Rhinology & Otolary vol 7 1896 page 302.

tuberculous cases, was thus a marked symptom, while its presence was frequently observed in the non-tuberculous cases.

Evidence of tuberculosis in other organs, was obtained in one of the tuberculous cases, and in one of the non-tuberculous.

Enlarged glands in the neck occurred in all the tuberculous cases, while in only one of the non-tuberculous cases are they noted as having been present, *this is an important observation -*

and Cheyne¹ says in tuberculous middle ear disease, the chief complication related to the tuberculous nature of the disease, is the occurrence of tuberculous glands in the neck, and where these exist along with discharge from the middle ear, the mastoid antrum and process ought to be opened without delay, and the diseased bone removed. Each new case of the kind, I have been able to observe, impresses upon me more strongly than before the wisdom *in* this advice.

A sinus, from which came a discharge of pus, was situated in the immediate neighborhood of the affected ear in 4 or 80% of my tuberculous cases, but in only one or 7.6% of the non-tuberculous; while swelling over the mastoid process was present in 68.4% of the non-tuberculous. This denotes that in the tuberculous cases, owing to the absence of pain, the disease was allowed to progress, and treatment was not sought until the mastoid abscess had burst, while in the non-tuberculous, the great pain in the mastoid swelling drove the patients to seek treatment earlier, and consequently, these abscesses were met with at an earlier stage, and before they had time to burst, accordingly, the presence of a sinus or sinuses near a suppurating ear, especially if the granulations about its orifice are of a pale, oedematous, flabby type, may be taken as pointing to the probability of the ear disease being tuberculous.

The discharge from the ears of the five cases of tuberculous middle ear disease, was in each case a thick/

^{Text Book}

1. Cheyne.(Watson.) [^] Tuberculous disease of Bone and Joints. page 328

thick, yellow, creamy, foetid discharge, yet it cannot be said that that description of the pus is at all characteristic of tuberculous disease, because, in each of these cases, the discharge had been present for at least two and a half months, by which time a mixed infection must have been present, and must have altered the character of the pus. The pus in the non-tuberculous cases, was to naked eye appearance and smell, identical with that from the tuberculous cases, with the exception of two, namely, in Case 14, one of cholesteatoma where the pus contained cheesy particles; the other Case 9, where it was thin, and in which the nature of the disease is doubtful, as previously mentioned.

The naked eye appearance of the granulations offer a greater indication of the nature of the disease. In 80% of the tuberculous cases they were pale, oedematous, and flabby, while in one case, numerous caseating points were observed - especially was this noticeable on rubbing up the granulations with salt solution. In the remaining tuberculous case, they were flabby and red in colour. In 76.9 of the non-tuberculous cases, the granulations were dark red, and not flabby; in one they were flabby but of a dark red colour; In the remaining three non-tuberculous cases, granulations were not observed, consequently, it is evident that although pale, flabby oedematous granulations may not invariably point to the disease being tuberculous, their presence is strong presumptive evidence, and especially is palor in granulations, from the middle ear, suggestive of tubercle, while caseating points are ^{almost} absolute proof of a tuberculous origin. In so few of my cases was it possible to obtain a satisfactory view of the perforations in the tympanic membrane, or the remains of this membrane, that no conclusion can be drawn as to this point.

Of my 5 tuberculous cases, only one could be proved to be a secondary infection, because it alone came to a post mortem examination; in the other 4, no evidence was found of tubercle in other organs by clinical/

clinical investigation, yet it is doubtful, if on that account the ear should be considered the primary seat of infection, because in none of them, were tuberculous naso-pharyngeal adenoids excluded, and this I believed to be essential before concluding that the disease had its primary focus in the middle ear. To accomplish this, a digital examination of the naso-pharynx would require to be made in any suspected case, and should any hypertrophy be felt of the pharyngeal tonsil, this should be removed, and examined microscopically for tubercle. (In the cases described in this paper, an opportunity for carrying this procedure out, could not be obtained).

In the only one of my tuberculous otitis cases, in which the post mortem examination enabled this point to be cleared up, tuberculous adenoids were present, although they had been latent and had passed unobserved during life, and my microscopic sections of the eustachian tubes demonstrate, that the disease had reached the tympanic cavity by extension from these adenoids. As before stated, I believe an early examination of the naso-pharynx for hypertrophied adenoid tissue in suppurative otitis cases, is of the greatest importance, because, by so doing, latent tuberculous adenoids would not pass unobserved, as I believe is so frequently the case in cases of tuberculous otitis; (in some cases, at least, and probably in a large majority, especially in children, this would be the first available means of demonstrating the presence of tubercle), for hitherto it has not been the practice of otologists - as I contend it should be - to give this method of investigation any prominent place in investigating the pathological nature of the ear disease, unless the adenoids produce of themselves some noticeable symptoms. When one considers the intimate connection between naso-pharyngeal adenoid tissue, and the tissue in the sub mucous layer of the eustachian tube, it is clear that one of these tissues could not long be implicated with tuberculosis before it would appear in the other. Consequently, I contend that following the method suggested, would not only assist in arriving at an early diagnosis, but in cases in which latent tuberculous adenoids were found, their removal would get rid of a focus and breeding ground of this disease (which is specially liable to infect and reinfect the middle ear, and also to infect the lungs and alimentary track) and would produce a highly beneficial effect upon the whole future course of the case.

No aural polypi were found in any of the tuberculous cases, but they were present in 3 of the non-tuberculous

Other less important points brought out by the microscopic investigation of my cases are that in case I4, where streptococci and staphylococci were found in the pus, the symptoms were of an acute type; while in case I7, where acute attacks of pain in the ear with out discharge, alternated with longer periods of painless profuse discharge; staphylococci, diplococci, and a thin bacillus were found. In case I3, one of those complicated with cholesteatoma and acute mastoiditis, a thin bacillus, and streptococci were found in the mastoid antrum pus.

Granulation was much slower and weaker in the operation wounds of my tuberculous cases than in my other cases.

With reference to the point as to whether tuberculosis is ever associated with cholesteatoma my two cases of this kind (I3 & I6) both gave a negative result by inoculation experiment, and thus support Scheibe's observations. (he never found Koch's bacillus in cases of chronic purulent otitis with cholesteatoma.)

determining whether the animal has been rendered tuberculous by inoculation.

To avoid error in observation, from the guinea pig being tuberculous previous to inoculation, it is advisable to examine it thoroughly, before commencing the experiment, and also to inoculate a second, of a different strain, with some solution from the same specimen, as a control.

My experiments also demonstrate that where naked eye tubercle is not present in the great omentum or spleen of the guinea pig, three weeks after intraperitoneal inoculation, it is unnecessary to seek for it by microscopic inspection in sections of these tissues. While this point seems proved, the converse cannot be accepted as a positive proof of tubercle, for tissue, with structure resembling tubercle to the naked eye, cannot be assumed to be tuberculous, unless the characteristic degenerative processes and perhaps bacilli, have been demonstrated microscopically in it.

It is doubtful if the inoculation of a guinea pig intraperitoneally with pus suspected to be tuberculous in origin, is a reliable method of investigation, judging from the result obtained in Case 9, for here the clinical history and symptoms, pointed strongly to the ear disease being tuberculous, yet the inoculation experiment gave a negative result. Previous observers^{1,2} have shown that very few bacilli may be present in tuberculous pus, hence all this experiment proves, is, that tubercle bacilli were absent from the pus experimented with. The result of the experiment, nevertheless, is instructive, as it demonstrates one important fact, namely, that a guinea pig injected intraperitoneally with pus, necessarily develops septic peritonitis, for it lived twenty three days, and on dissection, showed neither peritonitis or tubercle, and the whole of my inoculation experiments tend to bear out the view that guinea pigs are but slightly susceptible to septic organisms, and are consequently suitable for the detection of tubercle when inoculated with granulations from a suppurating middle ear, for all such granulations/

1. Schlegendal quoted by Cheyne in his Work 'Tuberculous Disease of Bones & Joints' page 79.
2. Cheyne (W.) do do do page 80.

granulations are probably septic, previous to removal. This result is strongly opposed to Brieger's contention that "the frequency of mixed infection in tuberculous cases, generally causes a suppurative peritonitis when the guinea pig is inoculated intraperitoneally, (from mastoid granulations) and so prevents observations being obtainable regarding tubercle ^{owing to the dying evidence of tubercle has developed in it}"

Of the 26 guinea pigs inoculated by the intraperitoneal method, during my experiments, only one, that in Case 16, died before the seventeenth day, when tubercle, if present, would have been visible to the naked eye, according to Delepine's researches²; and after weighing the results of my experiments, I agree with Milligan's view³ that inoculation experiments offer the most reliable means yet known for the detection of tubercle in products from the middle ear.

G r a n u l a t i o n s .

A method of investigation which seems to hold out a promising result, in arriving at diagnosis, in a suspected case, is that of securing when possible, a granulation or a portion of the diseased mucous membrane from the middle ear, and examining microscopic sections of it for caseating areas, epithelioid cells, and bacilli. I was able to do this in only one of my cases, that proved to be tuberculous, Casel, but the changes found were so pronounced and definite, that they lead one to hope for similar results in other cases. Granulations were examined in a like way from the mastoids of several other cases (6, 11, 13, 14, & 18) with a negative result, and in each, the inoculation experiment confirmed the negative opinion formed from the microscopic appearance of these specimens.

F i l m s .

The staining for tubercle of films of pus from the/

1. Transactions International Otolological Congress 1899 p.32
2. British Medical Journal 23rd Sept. 1893 page 666.
3. Transactions 6th International Otolological Congress 1899 " 38.

the tympanum is an aid to diagnosis, but the small number of tubercle bacilli usually found in pus, renders this method very laborious as a means of demonstrating the bacillus. A dozen or more films made be stained for bacilli in a known tuberculous case, without giving a positive result, and in the case of guinea pigs, even when the films are made direct from a tuberculous nodule itself, my experience is, that this method is not very satisfactory, as not more than 15% of such films show the bacillus.

S e c t i o n s .

My experience points to the examination of microscopic sections from a tuberculous nodule, in the great omentum or spleen of a guinea pig, or of the tuberculous mucous membrane and granulations from the middle ear, as the easiest and most reliable means of demonstrating not only the bacillus tuberculosis, but also of showing the degenerative changes associated with it.

S t a i n i n g .

Ziehl Neelsen's method of staining modified, by the addition of decolourising the sections with methylated spirit, to exclude smegma bacillus, gives very satisfactory results in tissues fixed with corrosive sublimate and absolute alcohol, but is not so satisfactory where the tissue has been fixed in formaline: Here, however, an equally good result can be obtained by, previous to staining, soaking formaline fixed sections in one part of liquor ammoniac and thirty nine parts of spirit for fifteen or twenty minutes, as described in detail under 'methods'!

SUMMARY OF RESULTS OF PATHOLOGICAL
INVESTIGATIONS.



Results of Case 1 specially considered

Tuberculous naso-pharyngeal adenoids may be present in a case of tuberculosis of the middle ear without giving rise to any noticeable symptoms, e.g., Case 1, consequently, in cases of otorrhoea a digital examination of the naso-pharynx should be made, and any hypertrophied tissue found, should be removed and examined for tubercle, since valuable information regarding the ear disease may be gathered therefrom.

Advanced tuberculous degeneration of the mucosa of the middle ear may be present, without producing any objective symptoms in the tympanic membrane, e.g. Right tympanum, Case 1, where the post mortem examination revealed numerous grey elevated tubercles in the mucosa, notwithstanding ^{that} the external surface of the tympanic membrane looked normal both before and after death, and microscopic examination of this mucosa showed advanced tuberculous degeneration.

Microscopic sections of this tympanic membrane showed the whole of its stratum mucosum in an advanced stage of tuberculous degeneration, and that the membrana fibrosa propria next it, was not being infiltrated by the disease, but was gradually being eaten away in places, and in what remained of it, no epithelioid cells or degenerative changes could be seen. In a few places, tubercle bacilli were found, evidently in the course of its vessels, and some bacilli had found their way to the dermis along these vessels, where they found a more favourable soil for their development, as epithelioid cells were commencing to appear in several situations.

The fibrous membrana propria has the appearance of having offered considerable resistance to the spread of the disease, and the fact that it was being more quickly destroyed in some places, than in others, explains how multiple perforations of the drum, are caused in tuberculous cases.


A tuberculous tympanum, previous to perforation of its tympanic membrane, has very rarely been examined.

1. Brieger *Transactions 6th Otological (International) Congress 1899. p. 21.*

examined, and a tympanic membrane showing the changes observed in this case has not been previously described, consequently, these observations are of much interest and importance.

In this particular case (Case 1), I have shown that tubercle bacilli had found their way to the middle ear from the tuberculous adenoid tissue in the naso-pharynx by way of the mucosa, and the lymphoid tissue in the sub-mucosa, of the eustachian tube, as is demonstrated by my microscopic sections of these tissues and by the absence of tuberculous changes in the other tissues in their neighborhood. Microscopic sections of granulations from the left middle ear, and the mastoid gland on the left side, show caseating areas, epithelioid cells and bacilli in very great number. (These observations were made previous to the death of the patient, and they show the importance of examining microscopically, when possible, similar tissues as a means of establishing an accurate diagnosis in cases of chronic otorrhoea).

Although tuberculous change was not found in the brain or its membranes, the extreme thinness of the left tegmen tympani and the pale colour of the dura covering it, indicate that they would soon have become involved had the patient lived longer, and proves that tuberculous meningitis may be set up in this way.



A N A L Y S I S of C A S E S .

PERCENTAGE OF TUBERCULOUS CASES. 26.3% of the cases of suppurative middle ear disease which I investigated, proved to be tuberculous. In 21% of cases in which tubercle might have been expected, inoculation experiment proved it to be absent.

AGES. The ages of my five cases of tuberculous otitis, varied from 5 months to 7½ years, (of these 4 were under 5 years,) and in the 13 non-tuberculous, from 3 years and 10 months to 39 years. This result points/

ear disease is not tuberculous.

FACIAL PARALYSIS. Facial Paralysis was present in 60% of my tuberculous, and in 33% of my non-tuberculous cases, but the onset of the paralysis was at a much earlier stage of the disease in the tuberculous cases; appearing with, or very soon after the onset of the ear discharge, while in two-thirds of the non-tuberculous, it was a late symptom, appearing more than a year after the discharge commenced. This shows that facial paralysis is not only more frequent in tuberculous cases, but that when it is present as an early symptom, it strongly points to the ear disease being tuberculous.

EAR AFFECTED. In my cases, the left ear was affected first, slightly more frequently than the right, and this fact barely supports Bernstein's assertion that "the left ear is affected by preference". The other ear became involved more frequently in my tuberculous cases than in my non tuberculous cases.

DURATION OF THE DISCHARGE. The duration of the discharge on the average, was much greater in my non-tuberculous cases, which seems to indicate a worse prognosis in tuberculous cases.

PAIN. The evidence of pain was absent in 80% of my tuberculous cases from the first, and there was no history in any of them of the discharge having followed immediately on any acute illness, while in over 50% of the non-tuberculous cases, the onset of discharge was associated with great pain, and had immediately followed acute illnesses, as Measles, Chorea, and Influenza; thus showing that the absence of pain during the whole course of suppurative otitis, is strongly suggestive of its being tuberculous.

TUBERCULOSIS IN OTHER ORGANS cannot be said in my cases to have shown any reliable indication as to the nature of the ear disease.

ENLARGED GLANDS NEAR THE AFFECTED EAR were present in all my tuberculous cases, and in only one of my non-tuberculous cases, consequently, their presence suggests that the ear disease is tuberculous: while the presence of a suppurating sinus in the same position, especially when pale, flabby and oedematous granulations are found about its entrance, is a still

still stronger evidence of the ear disease being tuberculous (a discharging sinus was present near the ear in 80% of my tuberculous cases, and in only 7.6% of my non-tuberculous).

THE CHARACTER OF THE DISCHARGE from the ear was very similar in my tuberculous and non-tuberculous cases, excepting in two, - one a case of cholesteatoma, and the other (Case 9) which was of a doubtful nature, consequently, this symptom did not produce any evidence for or against the disease being tuberculous. This is probably due to the fact that at the time the cases were examined, the infection had become a mixed one.

THE GRANULATIONS removed by operation from the mastoid are a more important indication of the nature of ear disease, for in 80% of my tuberculous cases, they were pale, oedematous and flabby, and in 76.9% of my non-tuberculous, they were dark red in colour and not flabby. Caseating points are sometimes met with in tuberculous granulations - e.g., Case 1.

NATURE OF THE INFECTION. With reference to the question of whether tuberculosis of the middle ear is more frequently a primary or a secondary infection, my observations in the cases investigated, were unavoidably incomplete, for although no evidence of tuberculosis was present in any other organ in four of them, tuberculous naso-pharyngeal adenoids were not excluded; in the other case in which the post mortem examination enabled this point to be cleared up, tuberculous adenoids were present, although they had been latent and had passed unobserved during life, and my microscopic sections of the eustachian tubes demonstrate, that the disease had reached the tympanic cavity by extension from these adenoids.

As before stated, I believe an early examination of the naso-pharynx for hypertrophied adenoid tissue in suppurative otitis cases, is of the greatest importance, because, by so doing, latent tuberculous adenoids would not pass unobserved, as I believe is so frequently the case in cases of tuberculous otitis; (in some cases, at least, and probably in a large majority, especially in children, this would be the first available means of demonstrating the presence of tubercle), for hitherto it has not been the practice of otologists - as I contend it should be -

to/

to give this method of investigation any prominent place in investigating the pathological nature of the ear disease, unless the adenoids produce of themselves some noticeable symptoms. When one considers the intimate connection between naso-pharyngeal adenoid tissue, and the tissue in the sub mucosa layer of the eustachian tube, it is clear that one of these tissues could not long be implicated with tuberculosis before it would appear in the other. Consequently, I contend that following the method suggested, would not only assist in arriving at an early diagnosis, but in cases in which latent tuberculous adenoids were found, their removal would get rid of a focus and breeding ground of this disease (which is specially liable to infect and reinfect the middle ear, and also to infect the lungs and alimentary track) and would produce a highly beneficial effect upon the whole future course.

THE RELATION OF CHOLESTEATOMA TO TUBERCLE.

Inoculation experiment proved that the two cases of chronic suppurative otitis, complicated by cholesteatoma, which I investigated, were non-tuberculous, and thus supports Sheibe's observations.

GRANULATION OF THE OPERATION WOUND was noticeable slower and feebler in my tuberculous cases, than in my non-tuberculous.

SUMMARY OF RESULTS OF BACTERIOLOGICAL
DIAGNOSIS &c.

1. My observations point to a tuberculous nodule being present at the site of inoculation in guinea/

guinea pigs rendered tuberculous by this means by the seventeenth day, and hence, its absence in a tuberculous guinea-pig, would indicate that the guinea pig had become tuberculous in some other way.

2. If at the end of three weeks after intraperitoneal inoculation, naked eye examination of the guinea pig fails to indicate the presence of tubercle, microscopic examination gives negative results also.

3. The inoculation of a guinea pig with pus from a suppurating ear, is not reliable as a means of determining whether the case is one of tubercle or not.

4. My observations support Milligan's view that properly conducted inoculations of guinea pigs offer the most reliable means yet known for the detection of tubercle in products (Granulations) from the middle ear.

Granulations.

The microscopic examination of a granulation or a portion of a diseased mucous membrane from a middle ear, for degenerative changes and tubercle bacilli, will give definite results in many cases.

Films and Sections.

The staining of films for tubercle, of pus from a tuberculous middle ear, or those prepared from a tuberculous nodule in a guinea pig, is a laborious and unsatisfactory means of demonstrating the organism, while microscopic sections of tuberculous nodules and of tuberculous granulations, is an easy and a reliable method of demonstrating the bacillus, and tuberculous degenerative changes.

STAINING/

S t a i n i n g

The bacillus tuberculosis and degenerative tuberculous changes are well demonstrated by the Ziehl Neelsen method of staining, in corrosive and absolute alcohol fixed sections, but those fixed in formaline require soaking in 1 in 40 liquor ammoniae before staining, to give satisfactory results.

B I B L I O G R A P H Y



Koch. Berliner klinische Wochenschrift 1882.

Steinbrugge H. Archives of Otology (Knapp's) 1881.
Pages 31, 36, & 41.

Gottstein A. Archives of Otology (Knapp's) 1884.
Pages 225, 226, & 228.

Moose. Archives of Otology (Knapp's) 1887. Pages
31, 32, 33, 35, & 36.

Macfie & Newman. Transactions of the Glasgow
Pathological & Clinical Society 1886-91
Vol.3 Pages 71, & 73.

Eitelbery A. Archives of Otology (Knapp's) 1888.
Vol.18, Pages 236 & 238.

Milligan W. British Medical Journal 1895, 16th Nov.
Pages 1223 & 1224.

do. Manchester Medical Chronicle IV. 1895-6
Pages 254, 255, 256, 258, 259, & 260.

do. Transactions 6th International Otological
Congress 1899. Pages 35, 36, 37, & 38.

do. Encyclopedia Medica Vol.3, 1900 P.151.

Haenal W. Archives of Otology (Knapp's) 1897
Page 130.

Sheibe A. Archives of Otology (Knapp's) 1898
Pages 129, 130, 132, 133, & 134.

Lewis R. Jr. Archives of Otology (Knapp's) 1898
Vol.27 - Page 411.

Winkler E. Weiner, Medicinische Presse 1898,
Pages 662, 663, 715, & 718.

Brieger O. Transactions 6th International Otolog:
ical Congress, 1899 Pages 21-32.

Broca & Barbon. Mastoid Abscesses and their treatment
Tr. Curtis 1897. Page 184.

Bernstein E.J. Journal of Laryngology, Rhinology, &
Otology, Vol.2 1896 - Page 302.

Hartmann A. Diseases of the Ear Tr. Erskine, 1887.
Pages 180 & 181.

Gruber. Diseases of the Ear Tr. Law & Jewel 1890.
Pages 488 & 489.

Eschle. Deutsche Med. Wochenschrift, 30th Nov.
1883.

Roosa. Diseases of the Ear, 1892.

MacNaughton-Jones & Stewart Diseases of the Ear,
1892. Page 57.

Politzer/

- Politzer. Belenchtungsbilden des Trommelfells, 1865
Page 65.
- do. Diseases of the Ear, Ed. Dalby, 1894.
Pages 407, 408, & 501.
- Field Diseases of the Ear 1894, Page 376.
- Hovel M. Diseases of the Ear, 1894, Page 554.
- Shield M. Diseases of the Ear, 1895, Page 138.
- Barr R. Diseases of the Ear, 1896, Page 56.
- Dench E.D. New York. Diseases of the Ear, Pages 596,
and 597.
- Arloing. Congre's pour l'etude de la Tuberculose
1888 - Page 404.
- Leloir do. do. do. Page 412.
- Verneuil & Glado do. do. do. Page 415.
- Delepine S. British Medical Journal, 23rd Sept. 1893
Pages 665, & 666.
- Muir & Ritchie Manual of Bacteriology. Page 102
- McBride P. Diseases of the Throat, Nose & Ear, 3rd.
Ed. 1900. Pages 546, 547 & 548.
- Cheyne Watson. Tuberculous Disease of Bones & Joints. Pages 79, 80 + 328
