

1857.

UNIVERSITY
LIBRARY
EDINBURGH

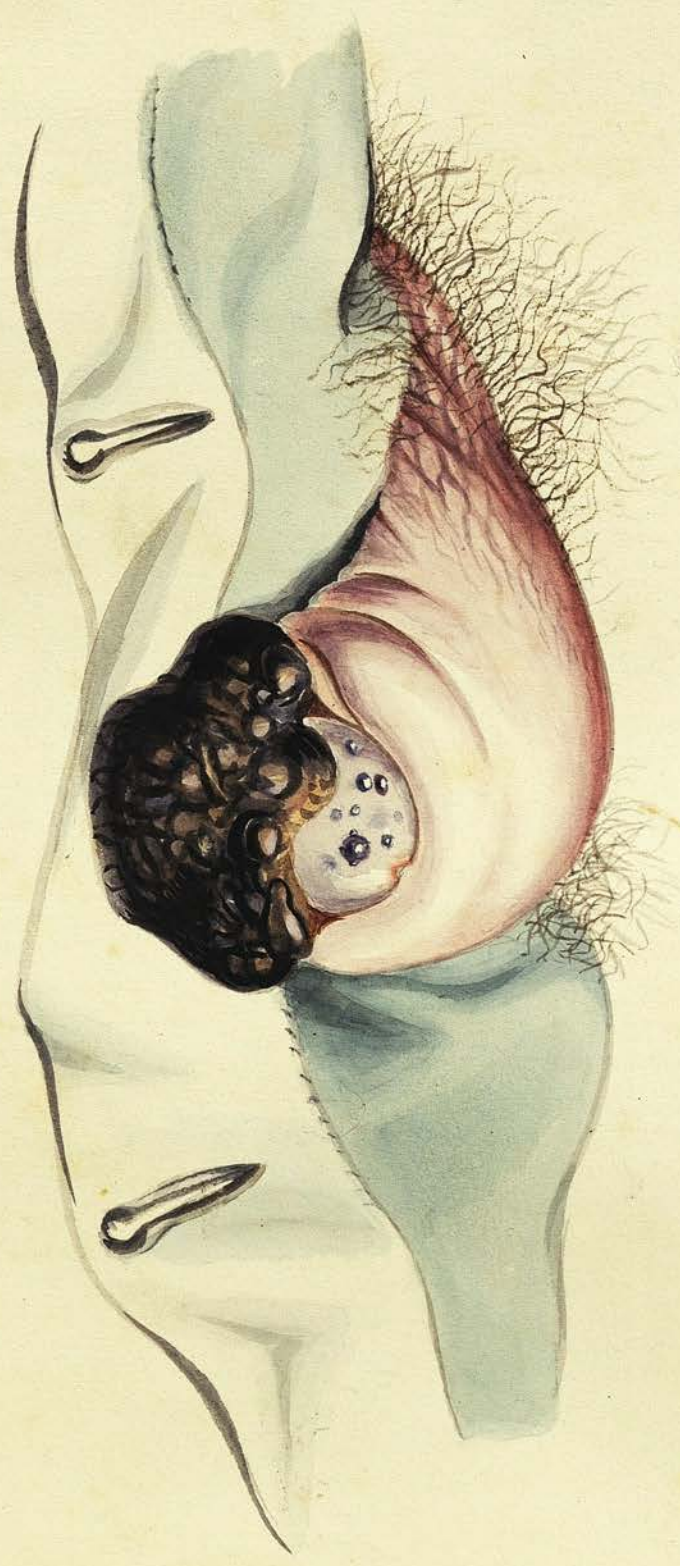



Plate XVII.

The drawing in this plate is intended to represent the Melanotic Cancerous Tumour of the Penis described in Observ. XLVII. — The Penis, which is considerably swelled, indurated, & congested is seen hanging over a fold of the patient's Trowsers. The Prepuce has been retracted in order to expose the glans, which is seen to be of small size, and partly occluded by the dark coloured tumour attached to the lower part of the prepuce and projecting over it. On the surface of the glans are seen a few small nodules, of the same nature as the mass of the large tumour.

Plate I.

Fig. 1. Appearance represented by the milky juice scraped from the section of the tumour of the Breast described in Obs. I. Magnified 280 diam^s. (Cancerous.)

Fig. 2. Section made with a Valentini's Knife of do.

Fig. 3. Juice from Tumour of the Mammary described in Obs. II. (Cancerous).

Fig. 4. Valentini's section of the same - Stroma composed of both yellow and white elastic tissue.

Fig. 5. Cells, Cholesteroline, &c. found in the juice of the Cancerous Tumour of the lower jaw described in Obs. III. (250 diam^s).

Fig. 6 Section made with a Valentini's Knife of the same.

Plate I.

Fig. 1.

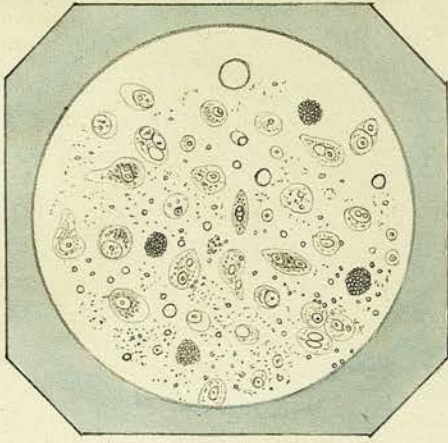


Fig. 2.

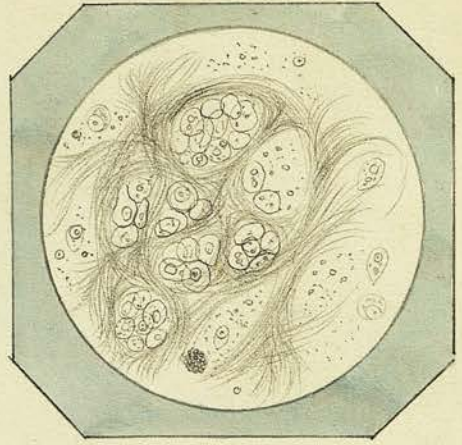


Fig. 3.

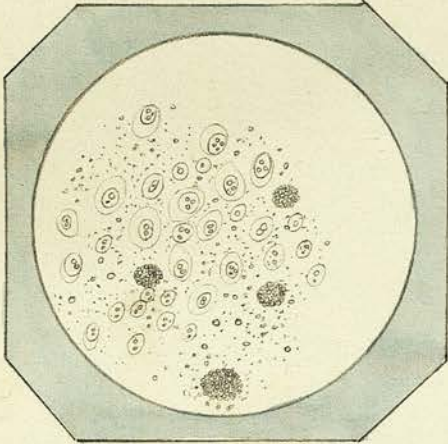


Fig. 4.

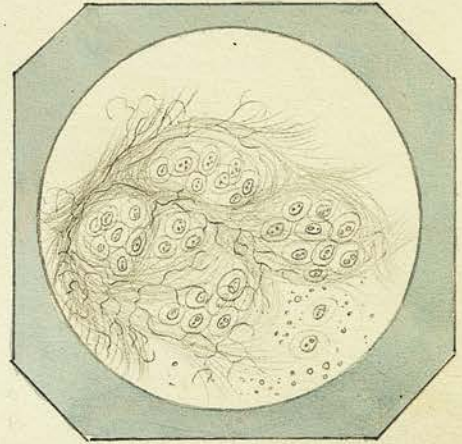


Fig. 5.

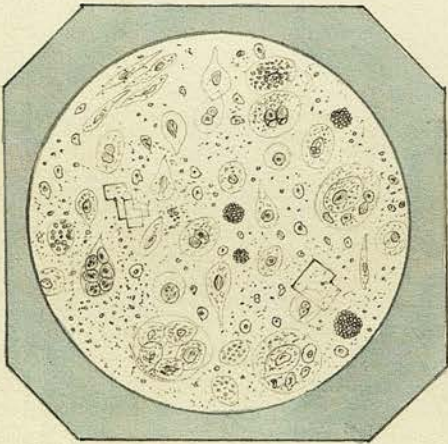


Fig. 6.

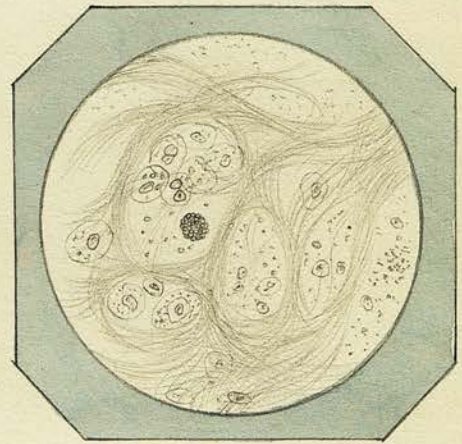


Plate II.

Fig: 7. From the Juice of the Cancerous tumour of the Jaw: (Obs. III) Taken from the junction of the tumour with the bone & straining the mineral granules out:
ter:

Fig: 8. Naked nuclei, granules &c. found in the juice of the Tumour of Testicle (Obs: IV) from grey part. After action of Acetic Acid (magn. 250 diam¹⁷⁹)

Fig: 9. Puriform fluid from brownish pink part of same tumour - Cells, nuclei, &c.

Fig: 10. Section made with Valentini's knife of greyish white part of Tumour of Testicle - (Acetic Acid added)

Fig: 11. Puriform Cancer cells, Epithelium Scales &c. found in the creamy juice obtained from the Cancerous tumour over Sacrum.

Fig: 12. Thin slice of same tumour, showing the arrangement of the cells & one of Bloodvessels.

Fig: 7.

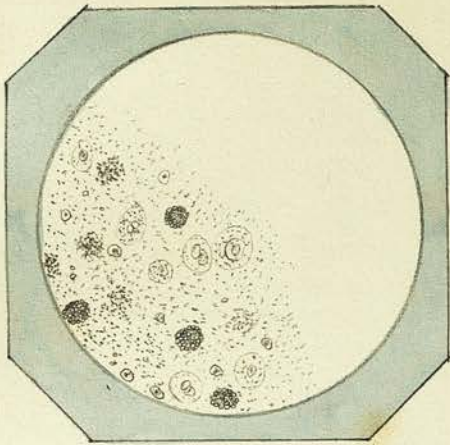


Fig: 8.

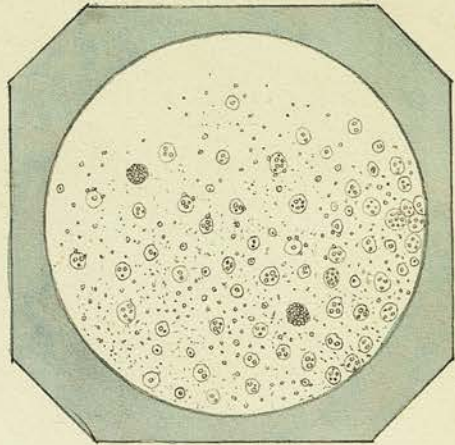


Fig: 9.

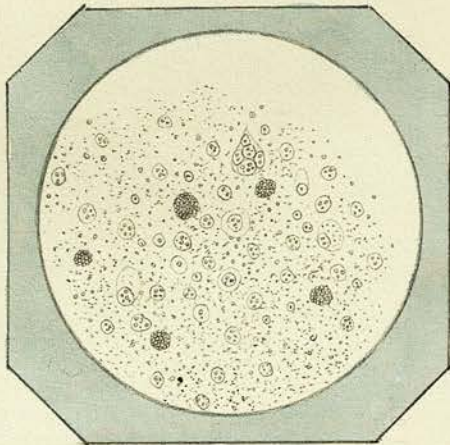


Fig: 10.

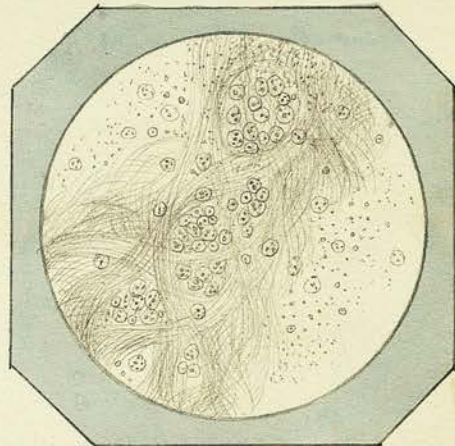


Fig: 11.

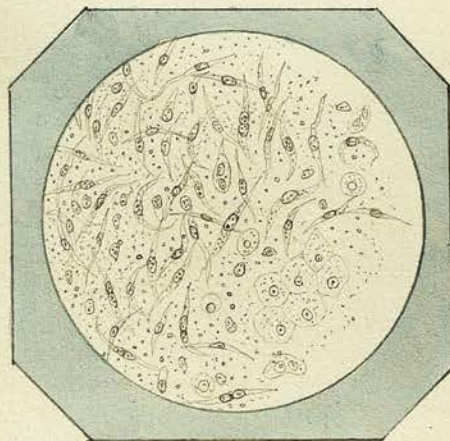


Fig: 12.

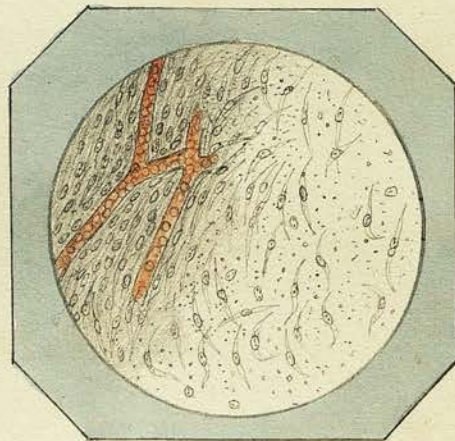


Plate III.

- Fig: 13. Contents of Atheromatous cyst described in *Observ.^{tu} VI.*
Cholesteroline. Oil-globules - Comp. granular Cells - Are of small cysts.
- Fig: 14. Contents of Encysted Tumour of Scalp - *Obs. VIII*
Cholesteroline - Oil-globules - granular matter - Compound granular
& nucleated cells -
- Fig: 15. Blood & Pus Corpuscles & des. albuminous granular Mat-
ter found in interior of Tumor described in *Obs. VIII.*
- Fig: 16. Epithelium? Cells & Composing Cancer like substance scrap-
ed from inner surface of wall of cyst. with a portion of
latter showing its fibrous structure.
- Fig: 17. Fat Cells, Oil globules, & White fibrous tissue from
fatty tumour of *Observ. IX.*
- Fig: 18. Pus Corpuscles, Cancer Cells, & granules Composing
discharge from ulcerated Cancerous tumour of *Obs. X.*

Fig: 13.

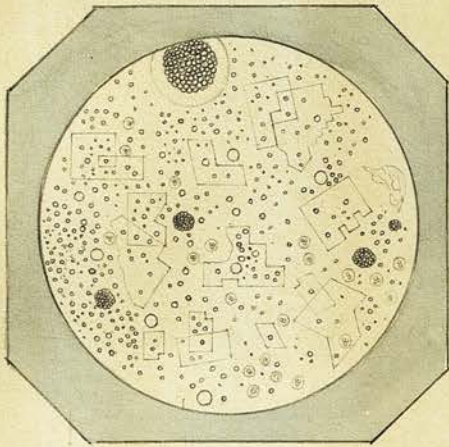


Fig: 14.

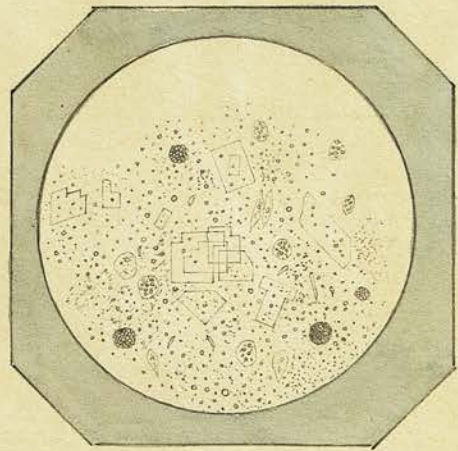


Fig: 15.

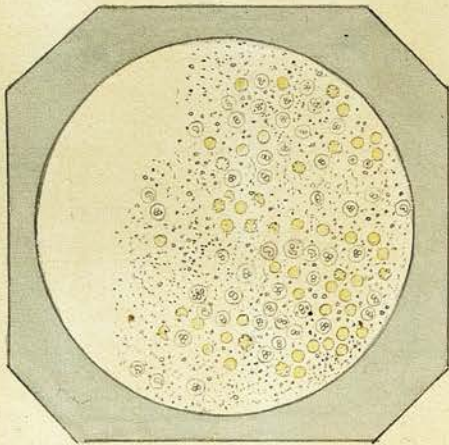


Fig: 16.

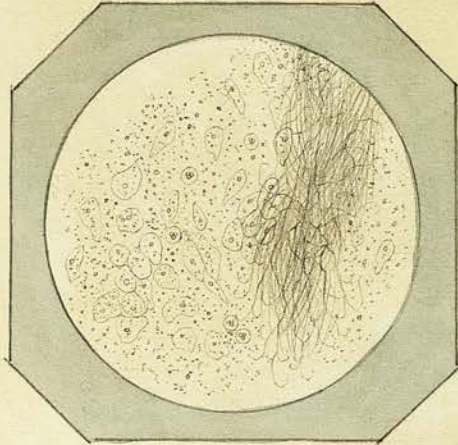


Fig: 17.

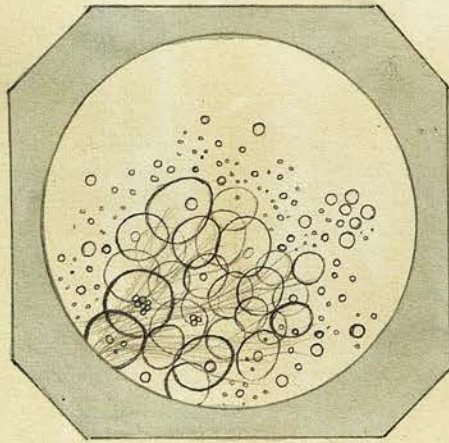


Fig: 18.

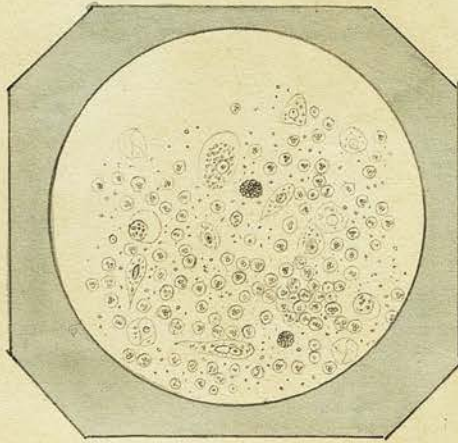


Plate IV.

Fig: 19. Epithelium cells &c. obtained from Warty Excrescence on Scrotum described in Obs. XI.

Fig: 20. Pus Corpuscles, Granular Matter, & Epithelial Scales scraped from ulcerated surface of growth on lower lip. Obs. XII.

Fig: 21. Epithelium & Fibro-plastic cells &c. from substance of the same.

Fig: 22. 1. Fibro-nucleated from Subcutaneous Scrofulous Tubercle.
2. Do. acted on by Acetic Acid. Obs. XIII.

Fig: 23. Epithelium cells &c. found in the soft matter situated underneath the horny shell of Obs. XIV.

One of papillae of Cutis vera seen at upper part of lip.

Fig: 24. Tubercle Corpuscles & granular Matter, composing softened portion of Tumour described under Obs. XV.

Fig. 19.

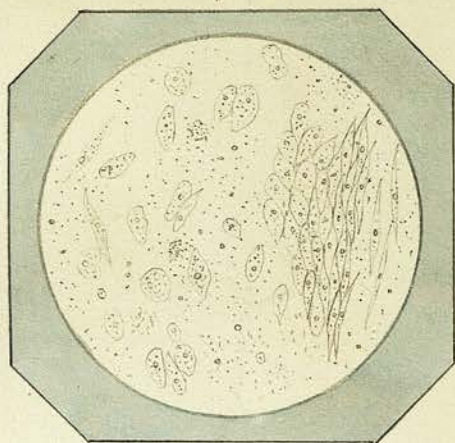


Fig. 20.

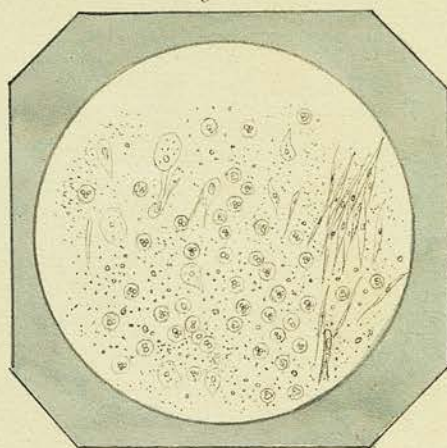


Fig. 21.

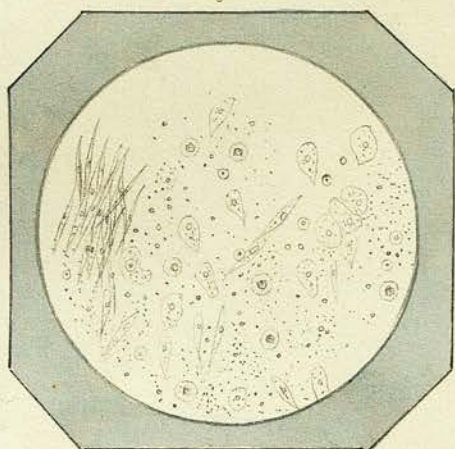


Fig. 22.

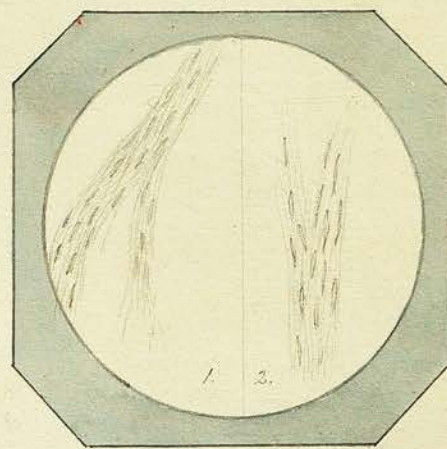


Fig. 23.

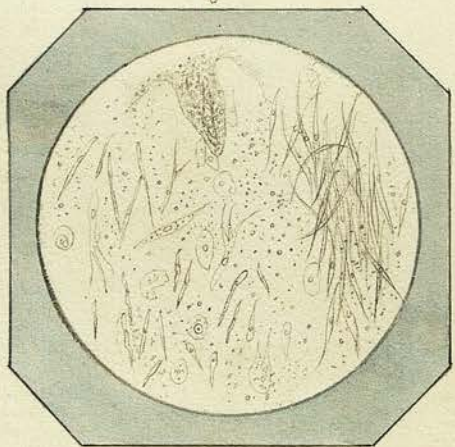


Fig. 24.

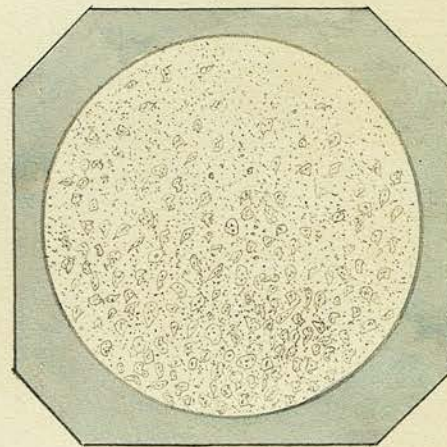


Plate V.

- Fig: 25. Nucleated Cells, oil globules, Blood Corpuscles &c found
in Juice, of Cancerous tumours of upper jaw. ^(Magn. 300 diam^{rs}) Obsv. XVI.
- Fig: 26th Section made with Valentini's knife through external
fibrous envelope and part of substance of same tu-
mour.
- Fig: 27th Pus Corpuscles, Comp. granular cells, oil globules & gran-
ular matter, from ulcerated surface of fatty tumour
described in Obsv. XVII.
- Fig: 28th Fat Cells & white fibrous tissue from substance of
same tumour.
- Fig: 29th Nucleated cells composing the gelatinous substance
of the Enchondroma described under Obsv: XVIII.
- Fig: 30th Pus Corpuscles, Nucleated cells, & oleo-albuminous
granular matter from the portion of the same
tumour in the immediate vicinity of the ulcerated
integuments.

Fig: 25.

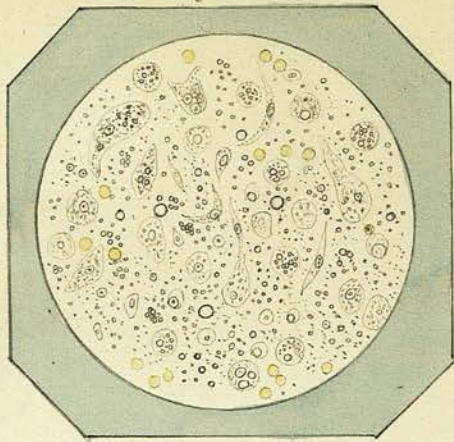


Fig: 26.

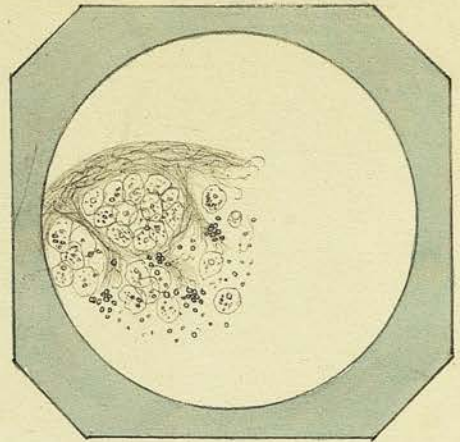


Fig: 27.

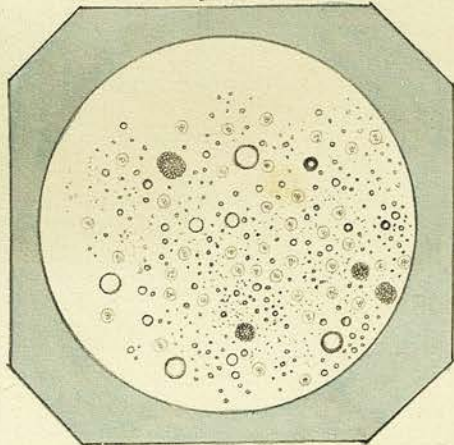


Fig: 28.

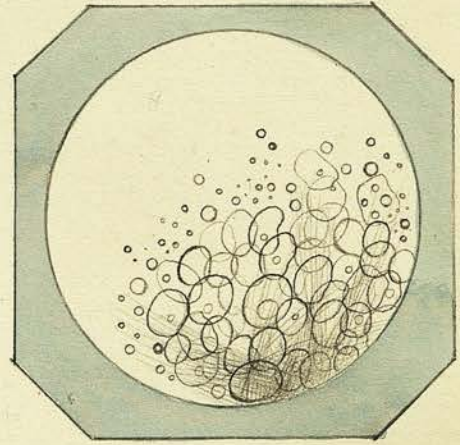


Fig: 29.

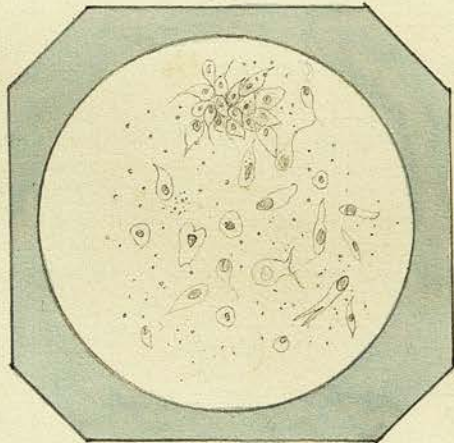


Fig: 30.

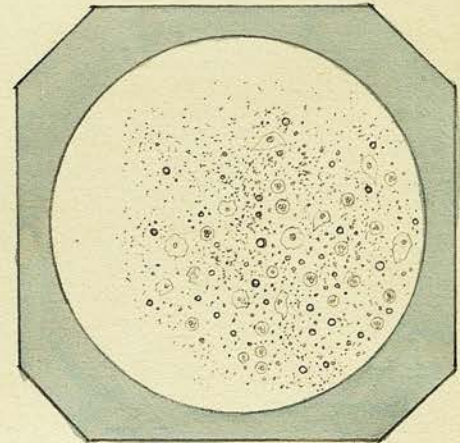


Plate VI.

- Fig: 31. Nucleated cells &c. from Echinodroma described in Ob-
servation XIX. (the gelatinous portion).
- Fig: 32. Transverse section through one of septa of the same
tumour, showing it to be composed of white & yellow
fibrous tissue.
- Fig: 33. Ciliated Epithelial scales & granules composing the
flaky substance scraped from the external surface
of gelatinous polypus described in Obs. XX.
- Fig: 34. Fibro-plastic, spindleiform cells, fibrous tissue, &
capillary blood vessel from substance of same polypus.
- Fig: 35. Scales of cholesteroline, nucleated & compound granular
cells, Blood Corpuscles, oil globules & granular matter
from contents of Men 1 described in Obs. XXI.
- Fig: 36. Nucleated & compound granular cells, Cholesteroline &c.
from Men 3 in Obs. XXI.

Fig: 31.

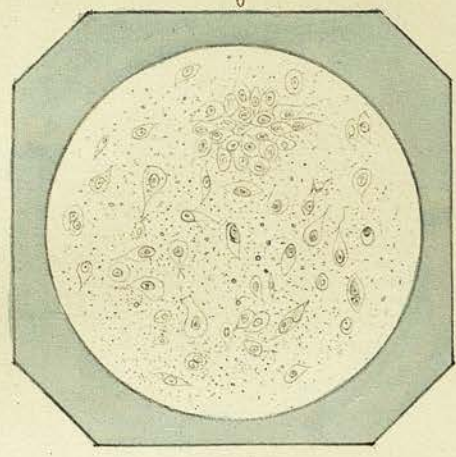


Fig: 32.

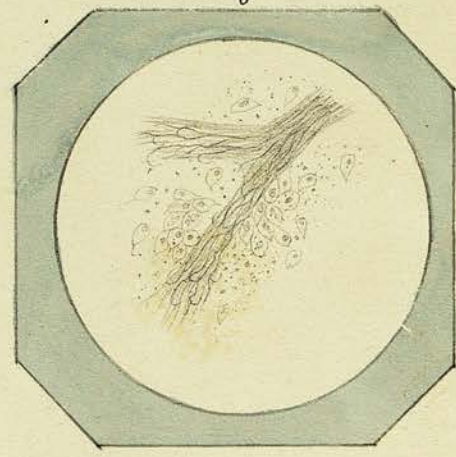


Fig: 33.

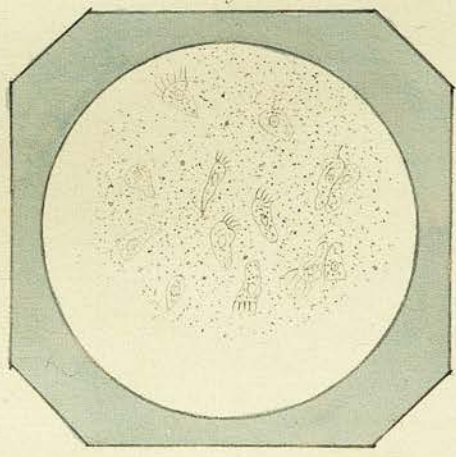


Fig: 34.

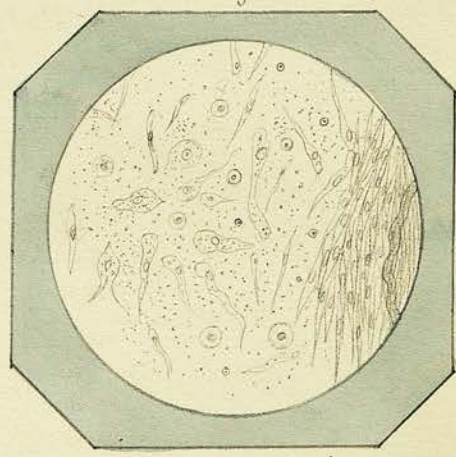


Fig: 35.

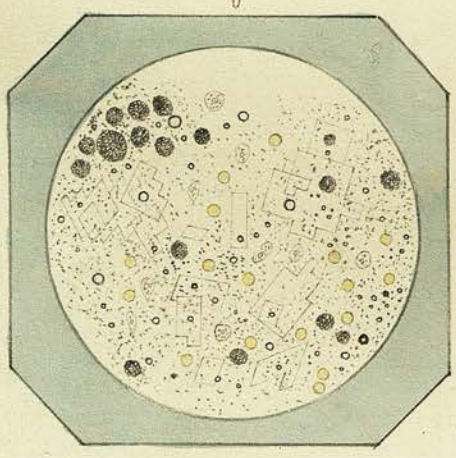


Fig: 36.

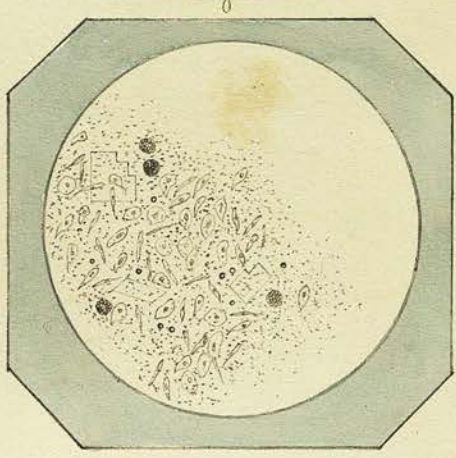


Plate VII.

Fig: 37. Shows a thin section made with a Valentini's Knife through the walls of one of the Encysted Tumours of the Scalp described in Obs. XXI. The gradual transition from nucleated Cells in the interior to fibrous tissue without.

Fig: 38. Fat Cells &c. from Adipose Tumour of Thigh - Obs. XXII.

Fig: 39. Epithelial Cells &c. from Wart, excrescence on lower lip - Obs. XXV.

Fig: 40. From milky juice of disintegrating Scirrhous Cancer of Mammary - Obs. XXVI.

Fig: 41. Thin section made with Valentini's Knife of same after addition of a drop of Acetic Acid.

Fig: 42. Thin section of Fibro-nucleated tumour from Mammary region - Obs. XXVII.

Fig: 37.

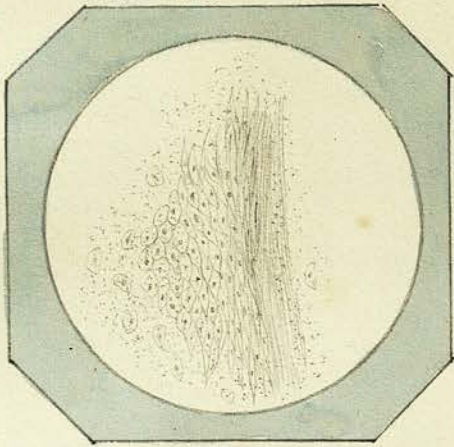


Fig: 38.

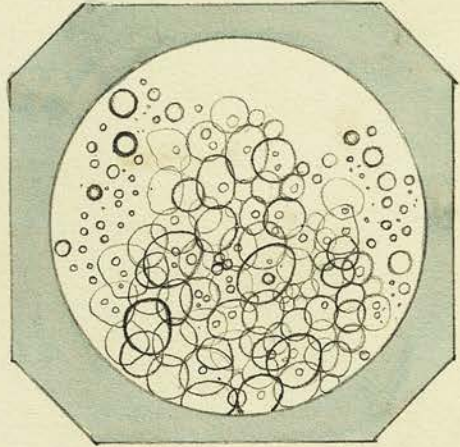


Fig: 39.

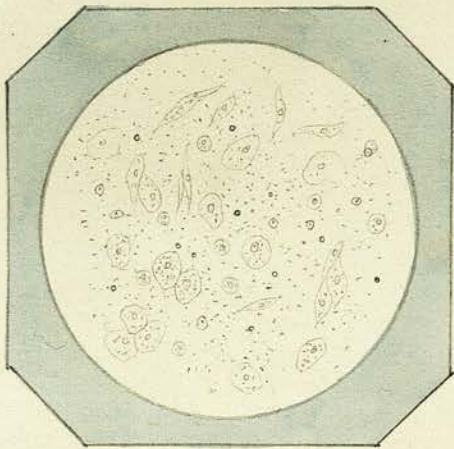


Fig: 40.

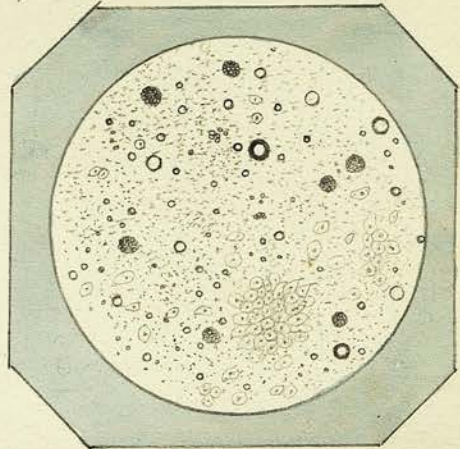


Fig: 41.

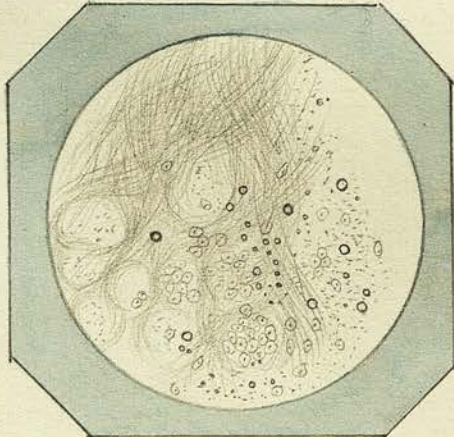


Fig: 42.

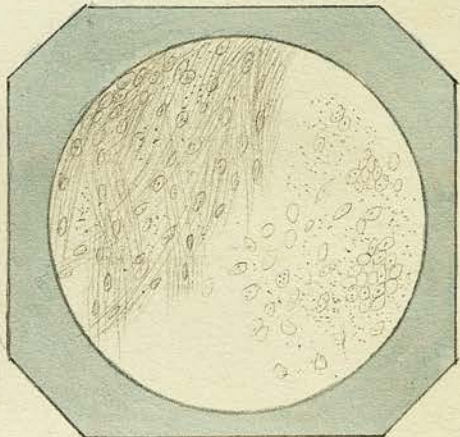


Plate VIII.

Fig: 43. Powder from Watery fluid of Tumour of Soft palate described in Obs. XXVIII.

Fig: 44. Section made with Valentini's Knife of same. (Acetic acid.)

Fig: 45. Cholesterol, nucleated, & compound granular cells, Blood Corpuscles, oil globules, & granules composing red dish brown fluid in one of the cysts of the tumour of the Mammary described under Obs. XXIX.

Fig: 46. Fibro-plastic fusiform cells and fine fibrous tissue from one of the cauliflower like excrescences growing into the interior of one of cysts of same tumour.

Fig: 47. Nucleated cells (Epithelia) & oil globules from tumour described in Obs. XXX.

Fig: 48. Yellow & white fibrous tissue from dense yellow portion of Tumour from Cheek. Obs. XXXI.

Fig: 43.

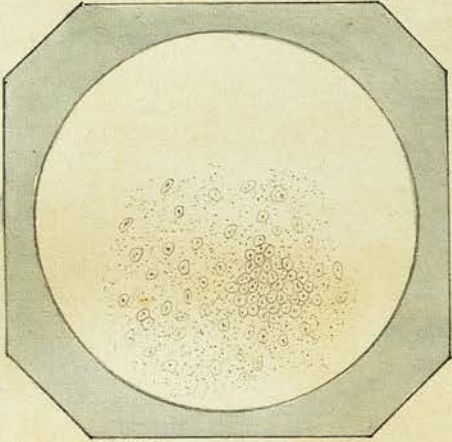


Fig: 44.

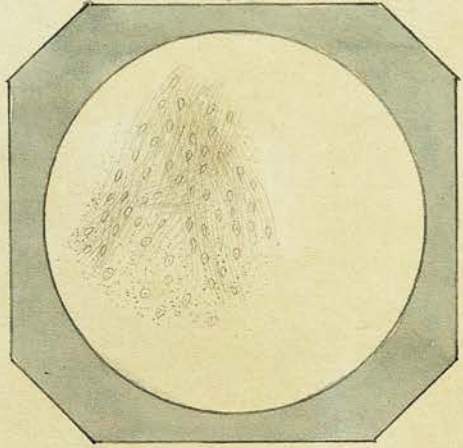


Fig: 45.

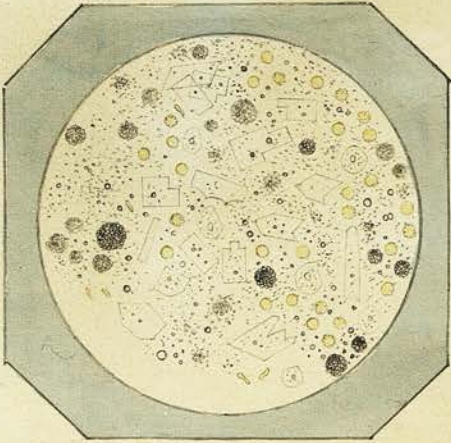


Fig: 46.

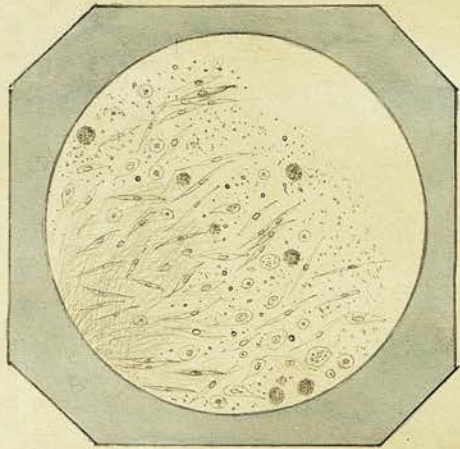


Fig: 47.

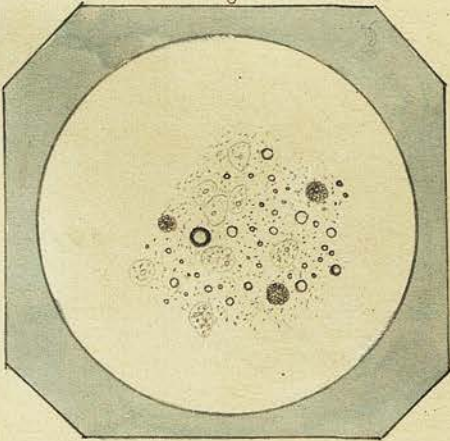


Fig: 48.

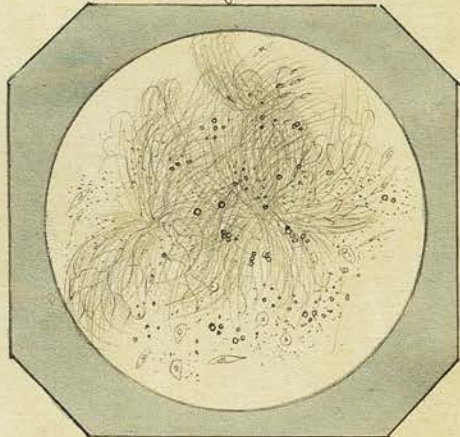


Plate IX.

Fig: 49. Nucleated Cells, fibrous tissue, oil globules &c. from soft portion of tumour described in Obs. XXXI.

Fig: 50. Spermatic Animalcules, and Epithelium Scales from a Spermatocele. Obs. XXXII.

Fig: 51. Blood & other Corpuscles from sanguineous tumour in Axilla. Obs. XXXIII. (magnified 350 diam^{rs}).

Fig: 52. Blood Corpuscles, Nucleated & Compound granular cells, oil globules & granular matter, comprising reddish brown fluid in one of cysts of Tumour of Mamma. Obs. XXXIV. (280 diam^{rs}).

Fig: 53. Nucleated cells &c. in transparent fluid from another cyst of same tumour.

Fig: 54. Fibro-plastic & fusiform cells, & fibrous tissue, comprising gelatinous mass in another cyst.

Fig: 49.

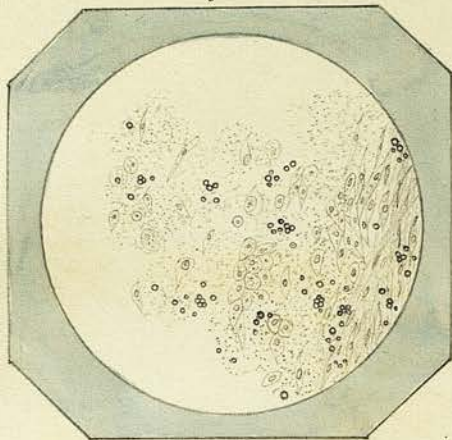


Fig: 50.

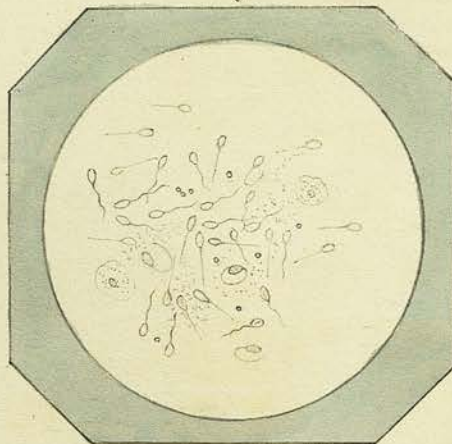


Fig: 51.

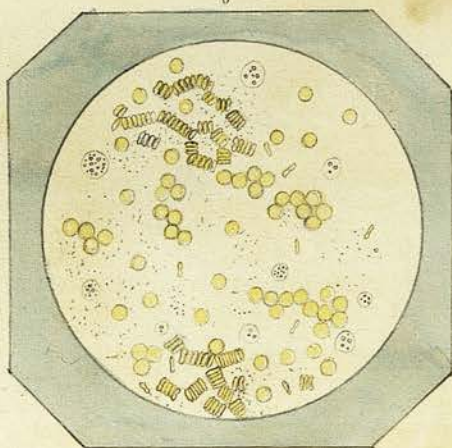
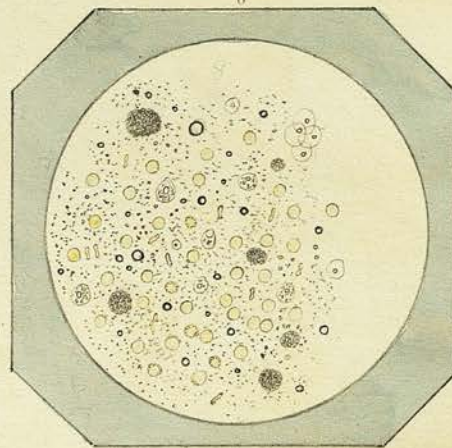


Fig: 51.



2 -

Fig: 53.

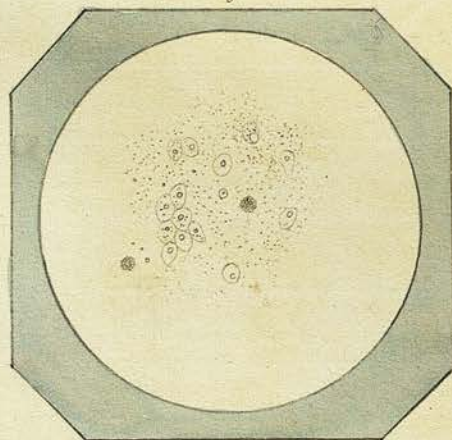


Fig: 54.

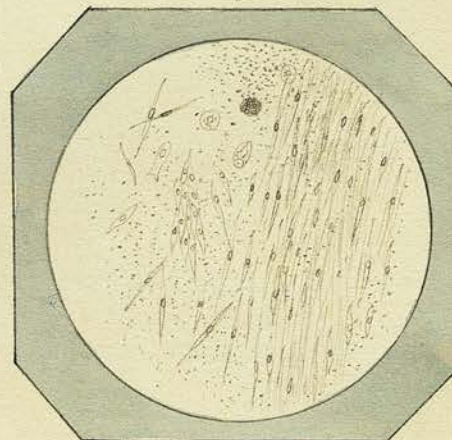


Plate. X.

- Fig: 55. Bodies found in the watery fluid squeezed from the solid portion of Tumour described in Obs. 34, which were infiltrated through a tissue of white & yellow elastic fibres.
- Fig: 56. Vascular spot in the semitransparent membrane of one of cysts - Obs. XXXIV. magn. 250 diam^{rs}.
- Fig: 57. Appearance presented by a drop of the fluid scraped from surface of softer portions of Tumour described in Obs. XXXV. (280 diam^{rs}).
- Fig: 58. Fibrous stroma of same tumour, showing one of the duct-like bodies described in Obs. 35.
- Fig: 59. Pus Corpuscle & Epithelium scales scraped from surface of "Epithelial Cancer" of Penis Obs. XXXVI.
- Fig: 60. A section through one of warty excrescences of same tumour. - Nucleated cells -
-

Fig: 55.

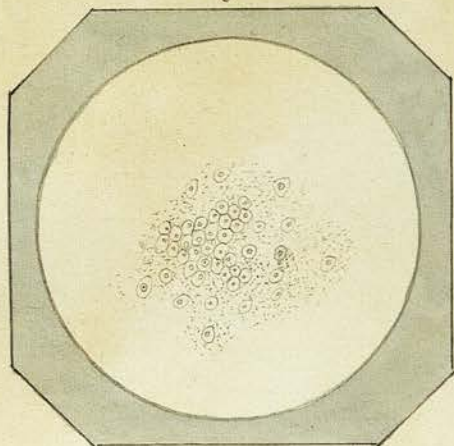


Fig: 56.

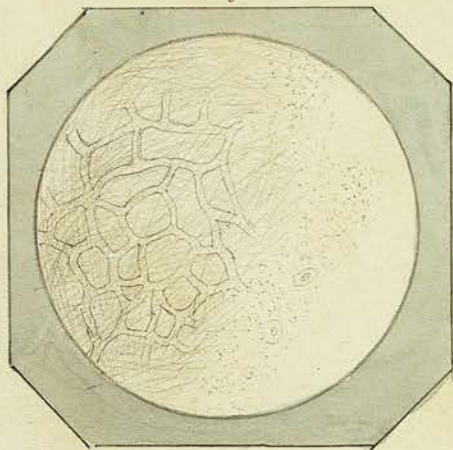


Fig: 57.

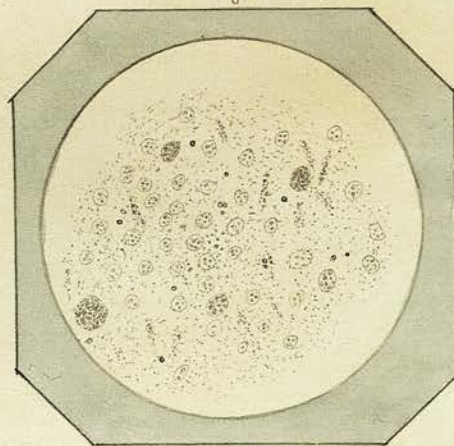


Fig: 58.

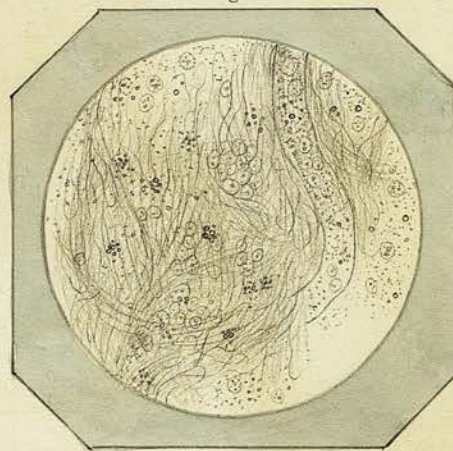


Fig: 59.

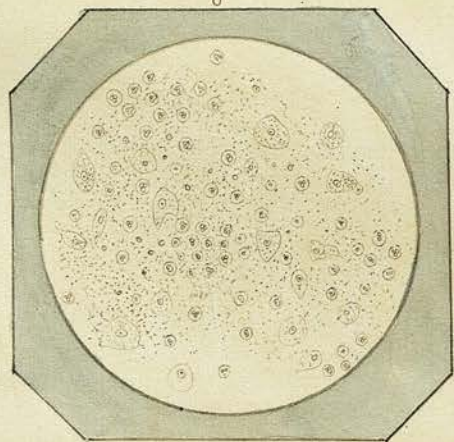


Fig: 60.

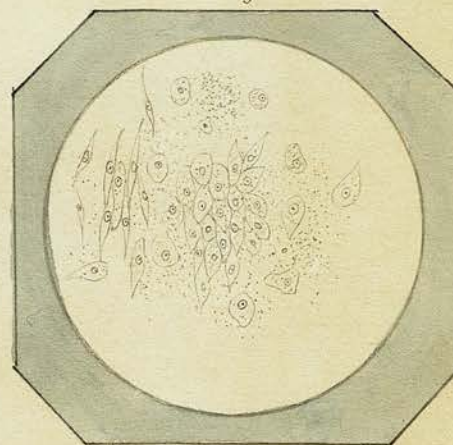
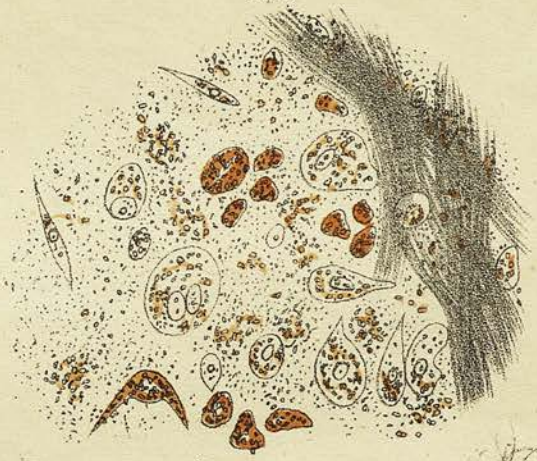

Fig. 2.

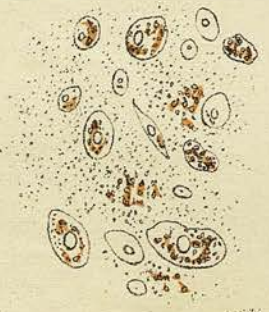

x 225

Fig. 1.

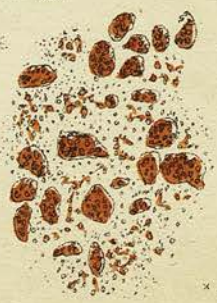

Fig. 3.



x 225

Fig. 4.



x 225

1000ths 1 x 225

Plate XI.

Fig: 61. Nucleated Cells and naked nuclei obtained from scraping
surface of section of tumour described in Obs: XXXVII.

Fig: 62. Portion of same tumour teased out with needles, showing
its fibro-nucleated structure.

Fig: 63. Epithelium Cells &c. from warty tumour of Labium.
Obs: XXXVIII.

Fig: 64. Nucleated cells from jelly like substance of Eucha-
drana described in Obs: XXXIX. - Some of the cells
seen imbedded in an amorphous matrix.

Fig: 65. Cells and oil globules from medullary substance
of phalanx from which above tumour was develop-
ed. (from immediate vicinity of substance of tumour)

Fig: 66. Cells and fine albuminous granules from turbid
fluid contained in a cyst of the mamma.
Obs. XI.

Fig: 61.

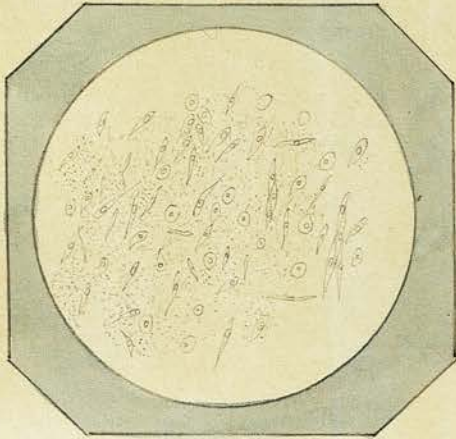


Fig: 62.

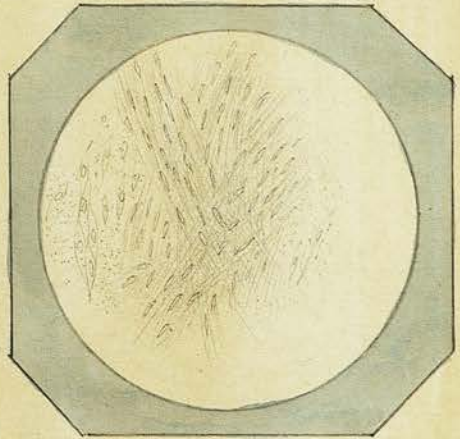


Fig: 63.

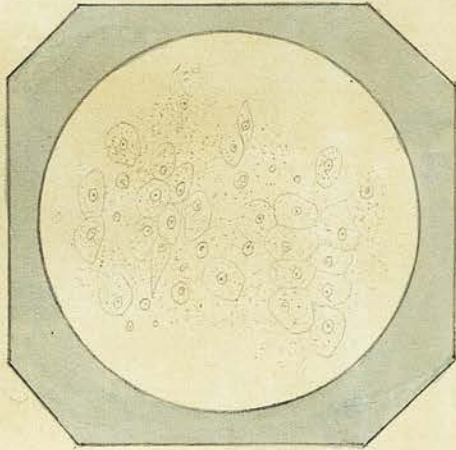


Fig: 64.

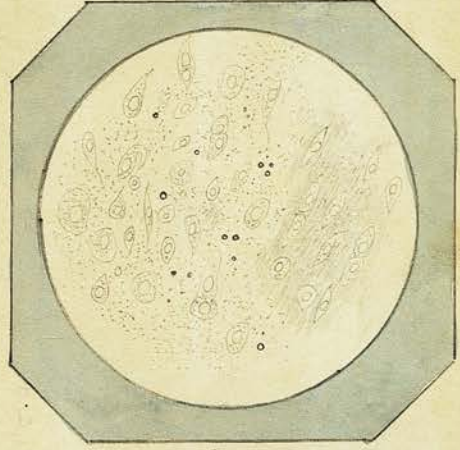


Fig: 65.

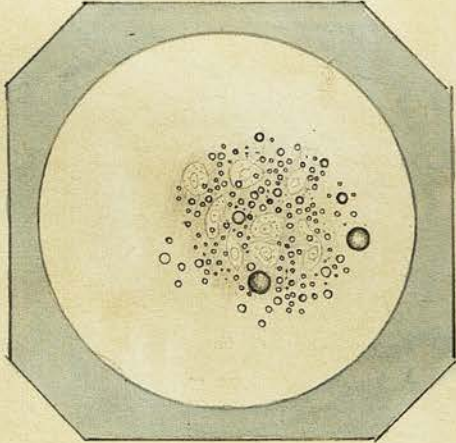


Fig: 66.

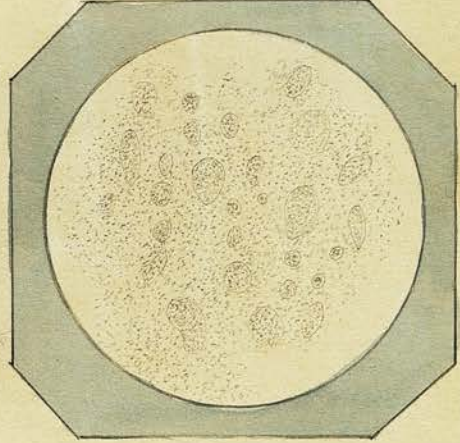


Plate XII.

- Fig: 67. Section made with a Valentini's knife through the walls of the cyst of mamma. Obs: XI. (its inner surface to the left. - Two or three of the cells represented in last figure, as seen when acted on by Acetic acid.
- Fig: 68. Nucleated cells, & granules from transparent glairy fluid contained in a cyst of the lower lip. Obs: XI. (250 diam.)
- Fig: 69. Portions of wall of same cyst. 1. when teased out with needles. 2. section through the same.
- Fig: 70. Cancer Cells &c contained in milky fluid scraped from surface of section of Scirrhus of mamma. Obs: XLII. (mag: 320 diam.)
- Fig: 71. Cancer Cells, Oil globules &c. from glands in axilla of same case.
- Fig: 72. 1. Struma of a portion of one of axillary glands after the milky fluid had been washed away with water. 2. Section made with a Valentini's knife through Scirrhous mass of mamma. Obs: 42.

Fig. 67.

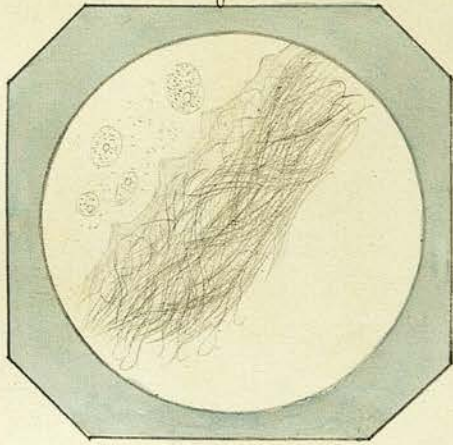


Fig. 68.

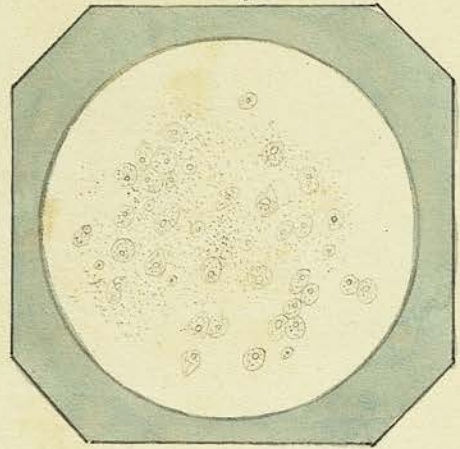


Fig. 69.

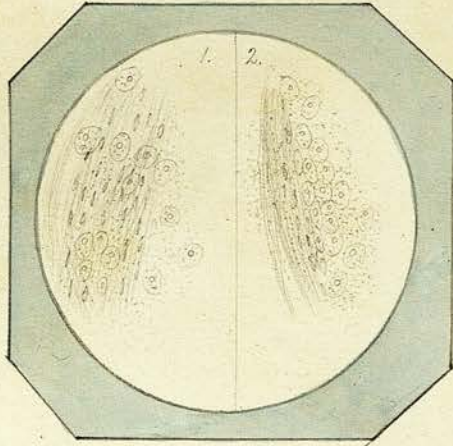


Fig. 70.

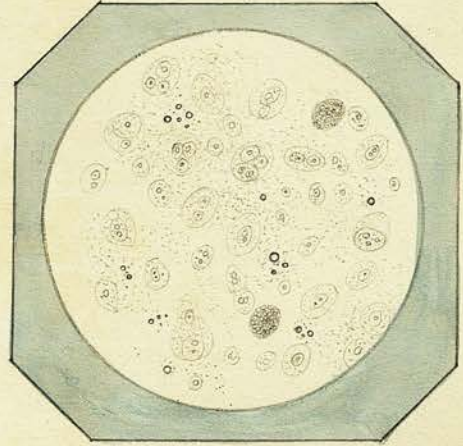


Fig. 71.

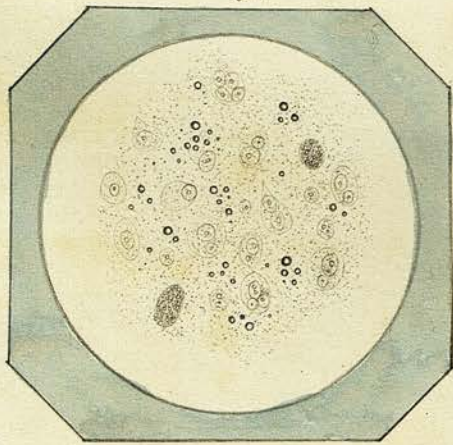


Fig. 72.

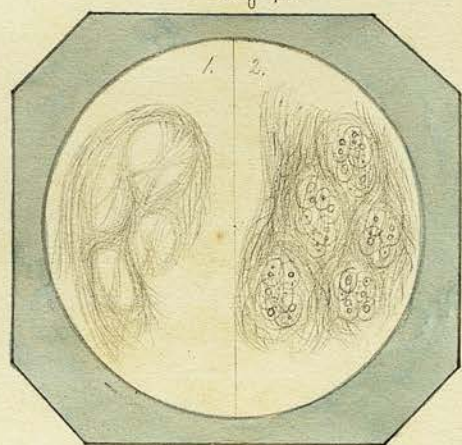


Plate XIII

Fig 73. Cancer Cells &c from milky juice of tumour of
Mamma - Obs. XIII. (280 diam^r)

Fig 74. Section of same tumour made with Valentini's knife
- treated with Acetic Acid.

Fig: 75. Nucleated cells &c from soft bulbous part of horn
described in Ob. XVI. One of cells seen marked
by a number of irregular concentric lines.

Fig 76. Elongated cells &c. from middle portion of same
horn

Fig 77. Striated appearance of substance at apex of
horn.

Fig: 78. Cancer Cells &c from milky juice of tumour
of mamma - Obs. XIV.

Fig: 73.

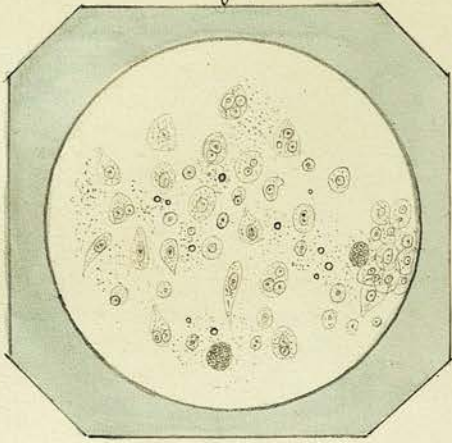


Fig: 74.

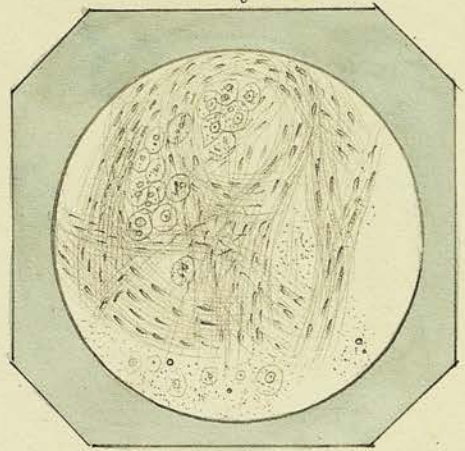


Fig: 75.

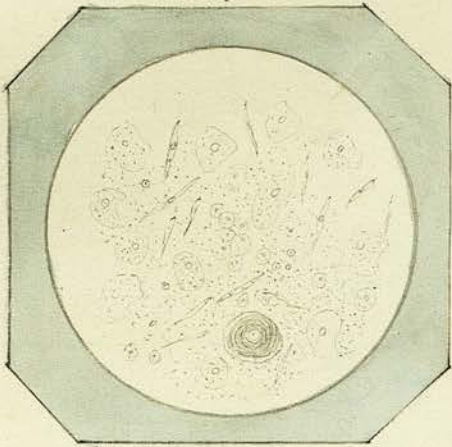


Fig: 76.

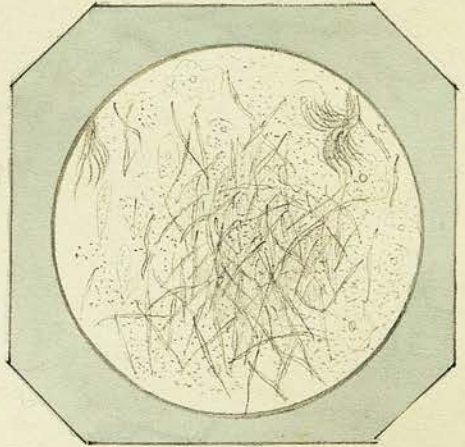


Fig: 77.




Fig: 78.

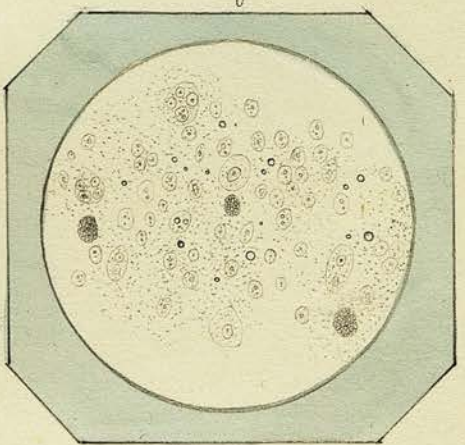


Plate XIV.

Fig: 79. Section made with Valentini's Knife of Tumour of
Mamma of Obs. XLV. treated with Acetic Acid
(280 diam.)

Fig 80. Pus Corpuscles &c from discharge scraped from
surface of Tumour of Penis, Obs. XLVI.

Fig 81. Pigment cells &c. from substance of same tumour. ^(280 diam.)

Fig 82. Fine fibrous stroma from same tumour.

Fig 83. Nuclei? contained in watery fluid scraped
from the surface of a section of a Fibro-nucleat-
ed tumour of Upper lip. - (320 diam.) Obs. 47.

Fig: 84. Fibrous stroma from same tumour.

Fig: 79.

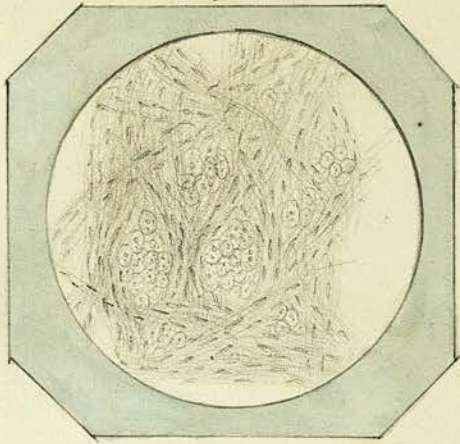


Fig: 80.

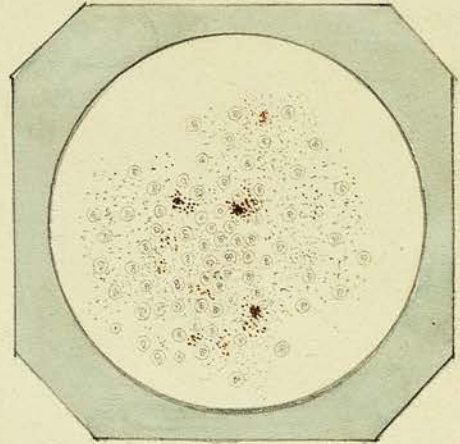


Fig: 81.

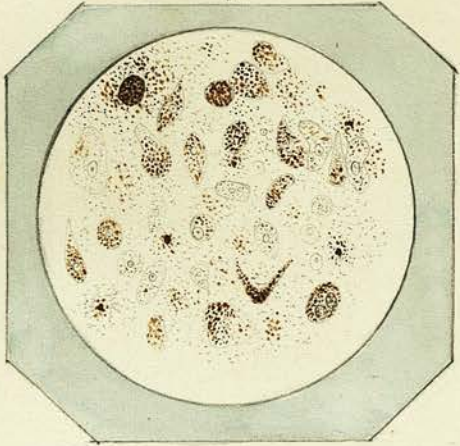


Fig: 82.

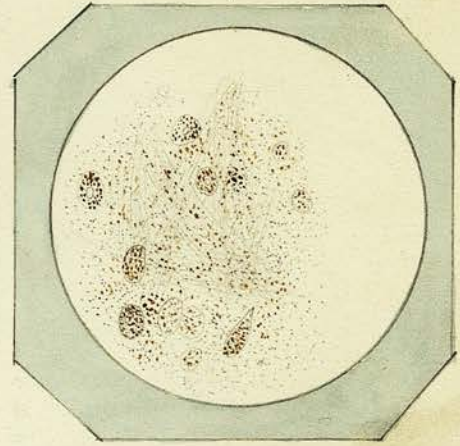


Fig: 83.

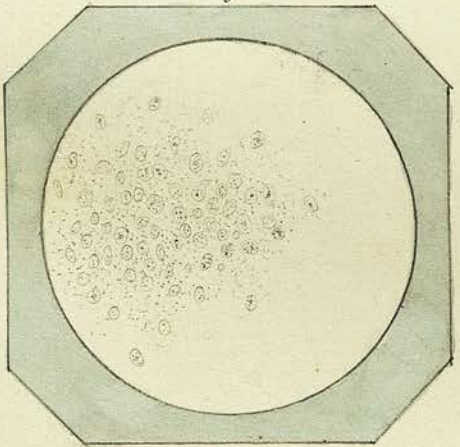


Fig: 84.

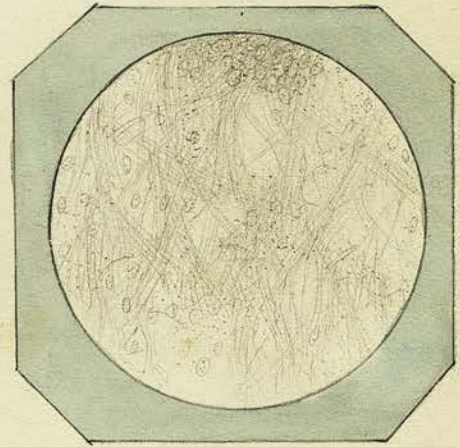


Plate XV.

Fig: 85. About the natural size - Shows two of the sides and the truncated extremity

Fig: 86. ^a A side view of the same - showing one side and the truncated extremity - b. A transverse section through centre of body, showing the cartilage laid on on one side of the bone. The fibrous shreds, by which probably the body had at one time been attached are seen hanging from the lower part.

Fig: 87. A thin slice of the cartilage - (Magn. 200 diam.) - nucleated cells imbedded in an amorphous mass.

Fig: 88. A thin section of the bony substance, showing Haversian Canals, lacunae, &c.

Plate XV.

Fig: 85.

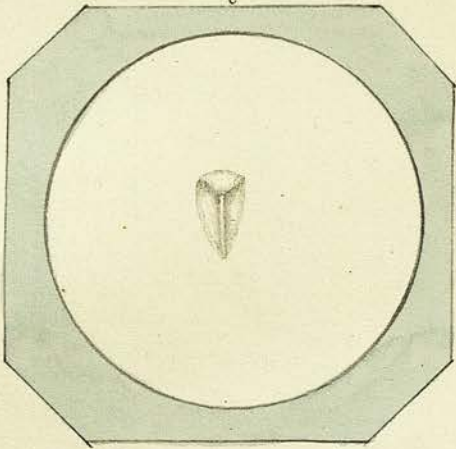


Fig: 86.

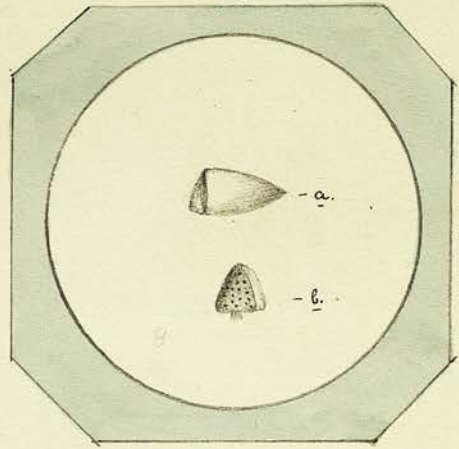


Fig: 87.

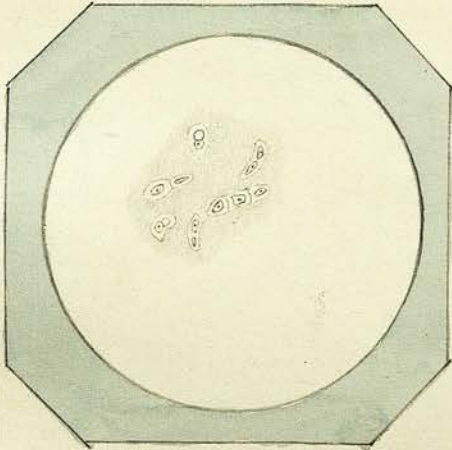


Fig: 88.

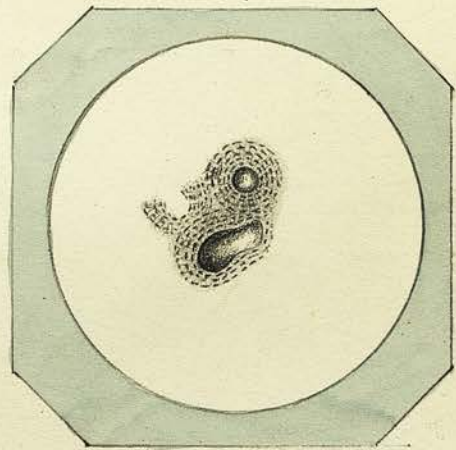


Plate XVI.

Fig: 89.

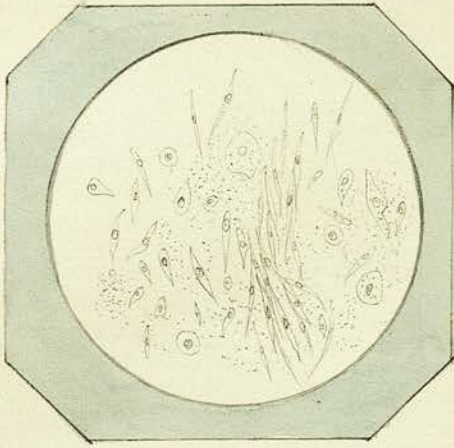


Fig: 90.

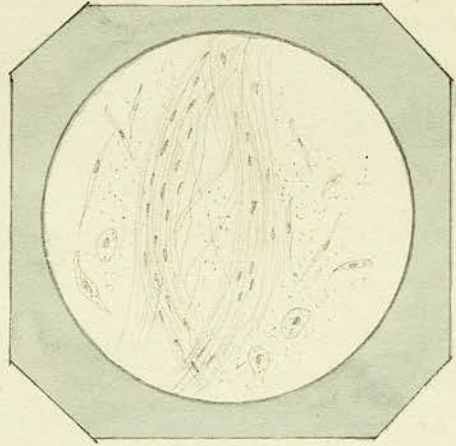


Fig: 91.

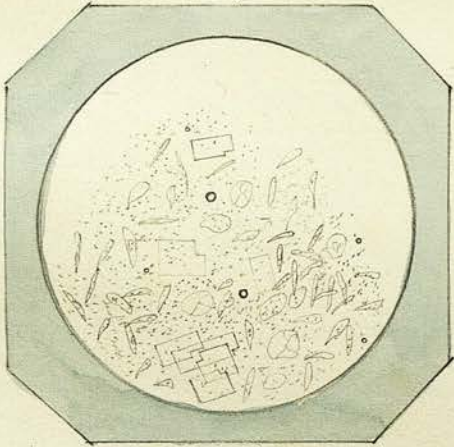


Fig: 92.

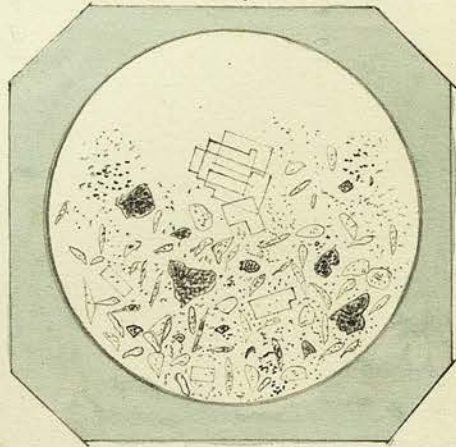


Plate XVI

Fig: 89. Nucleated Cells from one of white spots in tumour
of thigh described in Obser. XI. IX.

Fig: 90. Filaments nuclei and cells from another por-
tion of same tumour

Fig: 91. Cells, granules, Cholesteroline, & oil globules found
in contents of Encysted Tumour of scalp. Obser. I.

Fig: 92. Structures found in contents of another Encysted
tumour of scalp of same patient, containing in
addition to the above semi-crystalline Calcareous
masses -
