

WIGHTMAN PRIZE IN CLINICAL MEDICINE, 1956.

A SERIES OF SIX
CASE REPORTS

by

W.J. IRVINE, B.Sc.





DEPARTMENT OF MEDICINE
THE UNIVERSITY NEW BUILDINGS
EDINBURGH, 8

PROFESSOR OF MEDICINE
SIR STANLEY DAVIDSON
L. CANTAB., M.D., F.R.C.P. ED. & LOND.,
F.R.S.E., Q.H.P.
TELEPHONE 41001

4th June 1956.

SD/MMW

MISC. 12A

WARD 31

THE ROYAL INFIRMARY,

EDINBURGH 3 29th May, 56.

Dear Mr. Irvine,

I will be only too pleased to allow you to submit case reports on my patients for the Wightman Prize in Clinical Medicine.

K. Slater

Yours sincerely,

K. Slater.

Stanley Davidson

Name :- Hosmer, Charles
Rosyth.

Aged 32.

Occupation:- Store manager.

Date of Admission :- 12/11/55. Ward 31.

Recommended by Dr Currie of Rosyth.

Complaints :-

- 1) Increasingly tired and more than usually breathless on exertion.
- 2) Frequent attacks of epistaxis.
- 3) An undecipherable phrase passes through his mind as often as forty times a day.

History of the present illness.

1) Pallor, breathlessness and tiredness have progressed insidiously during the last four or five weeks. He noticed when cycling up a slight gradient that he became more breathless and exhausted than usual. This did not make him dismount. His increased pallor during the last few weeks has been commented on by his wife.

2) Since he was fifteen he has suffered from frequent attacks of epistaxis, and on this account has been a frequent out-patient at Maidstone Infirmary. His nose has been cauterised on several occasions, each time giving him relief for a month or so, but relapse invariably followed. The attacks of epistaxis have gradually become more frequent and now average once a day. Bleeding may occur from either nostril, and may last for thirty minutes. The patient was unable to estimate the blood loss in terms of portions of a cupful. The bleeding may be stopped by placing a plug of cotton wool in the appropriate nostril and pressing on the side of the nose, but if the bleeding is severe this method is ineffective and he resorts to hanging his head over a basin of water and waiting until the bleeding stops. Factors which precipitate epistaxis include stooping, lifting weights or anything that "increases the pressure in the head", leaving a hot room to go into the cold air etc. He has never wakened up in the night to find his bedclothes bloodstained. He does not bleed from any other site known to him, but during the last twelve months pin-head red spots have appeared on his face and were commented on by his wife as "the only things that gave his face any colour". Should he cut himself when shaving the bleeding readily stops.

3) About five weeks ago he began to suffer from an undecipherable phrase of five syllables passing through his mind at frequent intervals throughout the day. It is always the same phrase and his attention wanders for the moment the phrase lasts. These "mild attacks" have not shown any recent increase in frequency. There is no associated phantom smell or taste.

Since 1949 he has had four attacks of "epilepsy" (Sept. 1949, Sept. 1952, Jan. 1955, Sept. 1955.)

but had enjoyed good health.

Brother died at 25. This was thought to have been due to "meningitis" while he was being treated for a cold in the head. The duration of the illness was three days and he was known to suffer from ear trouble.

Another brother died in infancy from an unknown cause.

SOCIAL HISTORY.

An "out door type" in summer, reading a lot in winter. He is happily married and has good home conditions, but both he and his wife care little for Rosyth, and are nostalgic for the South of England. His job has never suffered seriously on account of his illness.

He is a light smoker (7-10 a day) and does not like Scottish pubs.

O/E.

GENERAL.

A bright and friendly individual originally from Kent. Except for his pallor he does not appear particularly ill. He looks no older than his years, and has no postural abnormality. His capacity as a witness is good.

Height 5'8", Weight 10 st. Average muscular development and good nutrition. Afebrile and no signs of cardiac failure. Pale mucous membranes.

EXAMINATION OF SKIN.

A few pin head telangiectases were observed on the skin of the face and upper chest, but not on the limbs. Telangiectases also present on mucous membrane of lips, wall of bucal cavity and tongue. These spots faded in response to pressure applied by a pencil point. At the inferomedial angle of the right external nares a large non-inflammatory haemorrhagic - looking swelling of the skin was observed.

C. V. S.

Examination of hands - No finger clubbing or koilonychia, cyanosis or capillary pulsation. Comfortably warm without sweating.

RADIAL PULSE. - 70/min.; regular in time and force, but of a collapsing character. Vessel wall impalpable. B.P.150/80.

NECK. No venous distension, but marked bilateral carotid pulsation. A bruit was heard over the right carotid artery at the base of the neck.

HEART.

Inspection - No subclavicular pulsation observed.

Palpation :- Apex beat in 5th intercostal space in the mid-clavicular line, tapping in character. No thrills.

Percussion :- Area of cardiac dullness present and normal in extent.

Auscultation :- Heart rate 70/min.; heart sounds of moderate strength in all areas. The first sound is replaced by a hard systolic murmur of low pitch and intensity which continued into the short pause. This murmur is heard in all areas, but is of maximal intensity in the pulmonary area. It is not propagated. The second sound is pure and closed in all areas with accentuation in the pulmonary area. A faint third heart sound is present in the long pause; it is protodiastolic and variable in intensity, disappearing in the upright posture.

Respiratory System.

Breathing. Costo-diaphragmatic regular at 16/min.

Chest.

Inspection. Well developed, symmetrical in form and movement.

Palpation: Expansion surprisingly poor ($33\frac{3}{4}$ " - 35").

Vocal fremitus unimpaired and equal throughout.

Trachea central, no enlargement of axillary or neck glands.

Percussion note equal and unimpaired in all areas except for area of cardiac and hepatic dullness.

Auscultation: Vesicular breathing with no accompaniments.

Vocal resonance unimpaired and equal throughout.

C.N.S. Alert and co-operative.. His speech is unimpaired as regards both the production of the spoken word and its interpretation. His memory is unimpaired. No lapse in his power of concentration could be detected. He is right handed. There are no signs of meningeal irritation.

Cranial Nerves: Each nerve was tested individually and all were found to be intact and functional. In particular the visual field is unimpaired and there is no retinopathy; the pupils are equal, of medium size and circular, reacting to both light and accommodation (direct and consensual). There is neither horizontal nor vertical nystagmus and diplopia is absent. Hearing is unimpaired as treated by wrist watch, Weber's and Rinne's tests.

Motor Functions: Normal muscle tone. No involuntary movements, clonus or inco-ordination.

Reflexes.

Biceps	Triceps	Supinator	Knee Jerks	Ankle Jerks	Plantar Responses	Abdominal.
+	+	+	+	+	↓	-
+	+	+	+	+	↓	-

Superficial and deep sensation unimpaired.

Alimentary System: Telangiectases present on lips, teeth, gums and wall of buccal cavity.

Tongue moist and of normal appearance - no atrophy or discoloration/

discolouration.

ABDOMEN - No obesity, scars or prominent veins. Moves easily with respiration.

PALPATION - No superficial guarding or tenderness. No deep tenderness or abdominal masses. Neither the liver nor spleen were palpable and the colon was not distended.

PERCUSSION - lower border of hepatic dullness at lower right costal margin.

FAECES - dark in colour but otherwise of normal appearance (patient was taking iron).

EXAMINATION OF BLOOD.

Before admission 11/11/55 Hb = 38%
R.B.C. = 4.33×10^6 /c.mm.
C. I. = 0.43
W.B.C. = 11,000/c.mm.

After admission 13/11/55 Hb = 40%
W.B.C. = 6,800/c.mm.
E.S.R. = 6mm/hr (Westergen)

Blood Film - microcytic hypochromic anaemia;
polychromasia. Platelets plentiful.
Reticulocyte count = 4%

EXAMINATION OF URINE

Yellow colour with no obvious deposit; S.G. = 1.020. Acid.

Sugar -ve
Ketone bodies -ve
Albumen -ve
Bile salts -ve
Bile pigment -ve
Urobilinogen -ve

Microscopic - No R.B.C, pus cells, epithelial cells, casts or organisms.

CLINICAL DIAGNOSIS

1) The tiredness, pallor and breathlessness are reflected in the blood examination; he has a severe hypochromic anaemia. There can be little doubt that frequent epistaxis is the basic cause, the associated iron loss making the anaemia hypochromic. The bone marrow has undergone compensatory hyperplasia as indicated by the raised reticulocyte count in the peripheral blood (4%).

2) His epistaxis could conceivably be due to one of the following types of defects -

- (a) Some defect in the intrinsic clotting mechanism,
- (b) A deficiency of platelets,
- (c) A defect of the capillary endothelium.

Since he has had all his upper teeth removed without gross haemorrhage and since bleeding is not prolonged should he cut himself while shaving, it is unlikely on clinical grounds that the primary defect lies either in the intrinsic clotting mechanism or in a deficiency of platelets. Moreover, the age of the patient and the long history of epistaxis argue against idiopathic or secondary thrombocytopenic purpura. Platelets were plentiful in the blood film.

This leaves the vascular purpuras in which the main lesion consists of damage to the capillary walls. The absence of fever indicates that his telangiectasia and epistaxis are not secondary to infection. There is no evidence that chemical agents are responsible and on account of his good nutrition it is doubtful if an avitaminosis can be present. The long and constant haemorrhage contra-indicates an anaphylactoid purpura, and since there is no evidence of renal or hepatic failure, the purpura cannot be metabolic in origin. His age discounts senile purpura.

Hereditary haemorrhage telangiectasis, however, receives much support from the clinical findings. The epistaxis began in adolescence before any cutaneous telangiectasis was noticed. The epistaxis has become more frequent and severe with advancing years. The distribution of the telangiectases about the face, nose and mouth but generally not on the trunk or limbs is characteristic. The blood appears to be normal except for the anaemia induced by the bleeding. Moreover, there is a suggestion of a family history. Not only did his father suffer from epistaxis, but the death of his brother from "meningitis" may possibly have been due to a subarachnoid haemorrhage associated with the familial condition.

The possibility of a bleeding polypus or a haemangioma of the nasal septum must nevertheless be borne in mind in spite of the fact that telangiectases are not of this character.

3) In spite of the grave disadvantage that no one has seen the patient in an epileptic seizure, the history of four fits which were heralded by crude auditory hallucinations together with the symptom of "frequently recurring phrase passing through the head" is indicative of a clinical diagnosis of temporal lobe epilepsy. Nevertheless, the facts that none of the attacks occurred during sleep or soon after waking

waking, that he never bit his tongue or injured himself and has never been incontinent of urine or faeces, suggest that his loss of consciousness may have some other aetiology.

A simple vaso-vagal attack is unlikely in view of his mild physical and mental state at the time of the onset of the fits, the absence of nausea and the apparently long duration of unconsciousness. An hysterical fit never occurs except in the presence of an audience. The recurring phrase does not have the characteristics of an obsessive-compulsive neurosis - the patient does not consider them absurd. They are very real to him.

Both the "severe" and the "mild" attacks will therefore be regarded as manifestations of temporal lobe epilepsy until proved otherwise.

The age of onset, the absence of family history, its focal nature and the distinctive character of the aura suggest that his epilepsy is symptomatic rather than ideopathic. It is very doubtful if the minor head injury in childhood is significant since the period of unconsciousness was short, and it preceded the first epileptic attack by as much as twenty years. He has no history of an inflammatory cause or of convulsive poisoning and there is no clinical evidence of a metabolic disorder. It is less easy to discredit the presence of a space occupying lesion such as a cerebral neoplasm, but a more likely possibility is some localised cerebro-vascular incident. This latter diagnosis would fit in well with the other aspects of his history and clinical findings, and his epilepsy might be expected to vary with the degree of cerebral anoxia as determined by the severity of his anaemia.

The more accurate localisation of the temporal lesion can only be deduced clinically from negative evidence. On account of the wide excursion which the optic radiation makes into the deep part of the temporal lobe (Meyer's bundle) in its course from the lateral geniculate body to the striate area of the occipital cortex, homonymous hemianopia of the upper quadrants, is very common in deep rooted lesions of the temporal lobes. The observation that there is no impairment of the field of vision of either eye indicates that the lesion must be confined to the more superficial parts of one or other of the lobes. This deduction is supported by the absence of hallucinations of taste and smell, the cortical representation of these sensations being in the uncinate and hippocampal regions of the temporal lobes. Hearing, taste and smell all have bilateral cortical representation, but the sensory speech area is confined to the temporal lobe of the dominant hemisphere which in this instance is the left hemisphere. The absence of any impairment in speech therefore suggests that the lesion is in the right temporal lobe. On the other hand it can be argued that in as much as the minor episodes involve speech symbols, the lesion is more likely to be in the dominant hemisphere. The present state of knowledge of cerebral localisation is insufficient to enable firm conclusions to be drawn.

4) The significance of the systolic murmur which is maxima in the pulmonary area and is not propagated is difficult to determine clinically

SUPPLEMENTARY INVESTIGATIONS

- 15/11/55 Bleeding time = 2 mins. (normal = 2-5 mins.)
Coagulation time = 4 mins. (normal = 4-8 mins.)
- 16/11/55 Capillary resistance test (Hess's method)- 8 tiny petechiae were counted within 1sq.inch in the ante-cubital fossa after the cuff was released whereas no spots were initially present. This may be considered to be within the range of normal.
- 17/11/55 E.N.T.Dept.- Several bleeding areas were observed in the nasal cavities in accord with the diagnosis of hereditary haemorrhagic telangiectasis.
- 23/11/55 X-Ray - Skull, No abnormality could be detected.
Chest, The pulmonary artery was slightly enlarged, but otherwise a normal X-Ray.
- 25/11/55 E.G.G. Normal sinus rythm rate 58/min. P.R. interval=0.18sec
The combined depth of the S wave in V1 and of the R wave in V5 measures 42mm and suggests that there may be left ventricular hypertrophy, although there is little other supportive evidence of this.
Lumber puncture.
C.S.F. protein = 132 mg/100mls (normal=15-50mg/100mls)
sugar = 62 mg/100ml
Cl = 706 (as NaCl) mg/100ml
WR = -ve
Cell count = 1/c.mm.
Gold Test = 000000000000
- 26/11/55 X-Ray Chest - There is slight prominence of the pulmonary conus and possibly a little left and right ventricular enlargement. The pulmonary vascularity is in the upper limit of normality. The appearances are not diagnostic and may indeed be consistent with a normal heart.
- 29/11/55 E.G.G - No unequivical abnormalities were recorded.
- 6/12/55 Eye Dept. Visual acuity and
Visual accommodation normal after correction.
Visual field (perimeter) no defect whatsoever.
- 20/12/55 Lumber puncture.
C.S.F. Protein = 61mg/100mls (normal = 15-50mg/100mls)
Other constituents (of 25/11/55) had not changed significantly.

TREATMENT AND PROGRESS NOTES

Before admission 11/11/55 Hb = 38%
RBC = 4.33×10^6 /c.mm.
C.I. = 0.43
WBC = 11,000 /c.mm.
Primidone ("mysoline") one tablet four times
a day after meals.

On admission 13/11/55 Bed Rest, blood groups determined and cross
matched. Sedation as required with Na amytal.
ESR = 6mm/hr (Westergen)
Hb = 40%
WBC = 6,800/c.mm.

Ferrous Sulphate tablets B.P. (0.2G) taken
t.i.d. after meals.
15/11/55 2 pints Packed Cells
16/11/55 Hb = 60%
19/11/55 2 pints Packed Cells
22/11/55 Hb = 80%

Much better colour and mucous membranes well
injected. Bleeding from nose once every day on
average, but very slight and quickly stopped by
putting the head back. The persistent undecipher-
able phrase still occurs with a frequency of
about 40 times a day - no change.

28/11/55 Up.
4/12/55 Troxidone ("tridione"), 0.3G t.i.d. by mouth.
7/12/55 The troxidone appears to have had little or no
effect. There are no unpleasant side reactions.
13/12/55 The frequency of the recurring phrase is now re-
duced to 5 per day. This is attributed by the
patient to the troxidone tablets.
Hb = 80%

24/12/55 Discharged with instructions to continue on
troxidone 0.3G t.i.d. and on Ferrus Sulphate
tablets 0.2G t.i.d. after meals.

Returning to R.I.E. (Ward 31 or 20) in January for cerebral arterio-
graphy with a view to possible removal of the cerebral telangiect-
asia.

9/5/56 He reported as an out-patient looking very well indeed. Since discharged from Ward 31 in December last year he has had little trouble from epistaxis. What was a large telangiectasia in the nose has spontaneously regressed until now it is quite small. The number of telangiectases on the face, however, show no change. One of them bleeds when provoked. He stopped taking the iron tablets at the end of February.
Hb = 95%.

The petit mal attacks of epilepsy occurred at a rate of approximately eight per day until suddenly in March they disappeared altogether and have not since recurred.

In view of his very satisfactory state it was decided not to admit him as had been previously arranged. Not only was admission at that time of doubtful necessity, but he would have stood to lose money by it.

13/5/56 Re- admitted.

At 9.30a.m. today (Sunday) he had another grand mal attack, very similar to these which he experience before. On this occasion, however, his wife witnessed the attack.

The aura (noises in the head) came upon him while he was in the kitchen peacefully occupied, and he at once made as quickly as he could for the bedroom, where he lost consciousness and fell upon the floor. His wife followed him and her description of the episode was that of a classical grand mal seizure. The tonic phase, initiated by a cry and accompanied by cyanosis, lasted for about 30 - 60 seconds. The lower limbs were extended, his right arm was between his legs and the wrist of left arm was beneath the dresser. The clonic phase followed and lasted for about a minute. The jerking movements were quite generalised, occurring in all parts of the body with no one sided predominance. The patient then passes into a placid stuporose state which lasted for about twenty minutes. During this phase his wife got him on to the bed. He did not injure himself during the attack, he did not bite his tongue and was not incontinent of either urine or faeces. There was no post-epileptic automatism. Upon regaining consciousness he developed a very severe headache.

On Examination:-

Nothing new was found. A bruit over the cranium was looked for but none was found.

Weight = 10st 5lbs.

B.P. = 150/70 mm.Hg.

Hb = 95%

WBC = 6,000/c.mm.

ESR = 4 mm./hr (Westergen).

Special Investigations:-

X-ray skull -ve.

E.E.G. -ve.

Dr Harris of Ward 20 was consulted and it was agreed that surgery is at present contra-indicated. Cerebro-angiography was therefore not performed.

26/5/56 Discharged home with instructions to take "tridione" (troxidone) 0.3G three times per day and phenobarbitone tablets, 30mgms, twice per day. He is to report periodically to Ward 31 as an out-patient.

COMMENTARY.

The supplementary investigations confirm the clinical diagnosis of hereditary haemorrhagic telangiectasia and his wife's description of a generalised grand mal attack confirms the diagnosis of epilepsy.

The pathology of multiple telangiectasis is a dystrophy of the capillaries; the telangiectases are masses of dilated capillaries or large sinusoidal spaces and are to be distinguished from the hyperplasia of a capillary haemangioma (Moore 1951; Boyd 1953; Price 1950). The spots fade on pressure since there is in the majority of cases no extravasation of blood. Since the capillary dystrophy is diffuse one cannot guarantee a good prognosis, let alone the fact that there is no curative treatment. Thus, although any blood loss can be made up by transfusions and treatment with oral ferrous sulphate and epistaxis can be temporarily arrested by cautery, one cannot be certain that other bleeding points will not appear - for example, in the alimentary tract, urinary system and particularly in other groups of cerebral capillaries. Should arteriography show a localised cerebrovascular lesion amenable to surgery his epilepsy might be cured until such time as another group of dystrophic capillaries succumb to the gradually mounting blood pressure of advancing years.

The significance of the pulmonary systolic murmur and collapsing pulse remain undetermined - there is little or no confirmatory evidence for a patent ductus or an arterio-venous fistula, both persisted after the correction of the anaemia and the heart is not greatly enlarged. It is possible that an arterio-venous fistula is present within the cranium and is responsible for his epilepsy. However, there is no other clinical evidence to support such a localisation. The occurrence of arterio-venous fistulae, particularly pulmonary, in association with hereditary haemorrhagic telangiectasis has been fairly frequently described.

The only positive factor among the special investigations that suggest a lesion of the C.N.S. is the raised C.S.F. protein level (132 mgs/100mls) of 25/11/55. When this was repeated on 20/12/55, however, the C.S.F. protein was down to 61mgs/100mls. Nevertheless, these negative results, including the negative E.E.G., do not refute the clinical diagnosis of temporal lobe epilepsy. According to Brain (1950) 10% - 20% of epileptics have a normal E.E.G. between attacks. The presence of a localised cerebrovascular incident is thought to be more likely than a neoplasm. Such a lesion could either be a cerebral arteio-venous fistula or a telangiectasia and one could only decide between these two by performing cerebral angiography.

Before committing the patient to the discomfort and not inconceivable risk of cerebral angiography (one may convert an able bodied man into a hemiplegic) one should be quite clear what one is going to do in the event of the lesion being operable. If it has been decided not to resort to surgery in any event, the test will not benefit the patient and the academic interest it may afford, although great, would not justify it. At present his epileptic symptoms are by no means disabling; he is not in danger of losing his job on account of his grand mal attacks and the frequently recurring phrase has disappeared

disappeared for the past two months. nevertheless, the patient is noticeably more anxious about his state than he was on first admission. He never knows when a grand mal attack may suddenly seize him and he is very much aware of his friends' perverted and anti-social feelings towards his condition. A likely and frequently fatal complication of a telangiectasis is a subarachnoid haemorrhage, whereas a likely complication of operative removal of such a lesion is grand mal epilepsy stimulated by the fibrous tissue of the cerebral scar. It is therefore, extremely difficult to decide whether to operate or not. Dr Harris from Ward 20 was consulted and it was agreed that operation would be inadvisable and that it would be better to treat him medically with troxidone (0.3G t.i.d).and phenobarbitone (30mgms. b.i.d). The troxidone is used prophylactically for the petit mal attacks, but it is uncertain whether the sudden disappearance of these minor episodes was due to the troxidone or whether it occurred spontaneously. The phenobarbitone may prevent further episodes of grand mal epilepsy and in any event will act as a mild sedative for an increasingly anxious patient.

Hereditary haemorrhagic telangiectasia is transmitted directly from generation to generation, affecting both sexes equally as a Mendelian dominant. Until such time as a curative treatment is available, the patient should be advised against having any more children.

This case shows very clearly how the occurrence and severity of the clinical features of anaemia are not only dependent upon the degree of anaemia, but also upon other rapidity of its development. The patient was initially admitted with a Hb of 40%, but with minimal subjective complaints.

FINAL DIAGNOSIS.

Hereditary multiple haemorrhagic telangiectasia with frequent epistaxis. A related cerebro-vascular lesion is the probable cause for the symptoms of temporal lobe epilepsy.

A CASE HISTORY OF
PEPTIC ULCER WITH HAEMORRHAGE

WARD 27, R.I.E.

(PROFESSOR SIR STANLEY DAVIDSON)

JANUARY 1956.

by

W.J. Irvine.

haemorrhage, and that he intended to treat her at home.

Next morning (Saturday) the doctor left a supply of "Nulacin" tablets for her to suck and an order to ring at once if the vomit was black. At 4.0pm the patient had her third copious haematemesis and arrangements were made for immediate hospitalisation. She had a further haematemesis in the ambulance.

Personal History :-

Some loss of weight and recent mild anorexia. Sleeps well. She tends to be rather constipated and requires cascara twice weekly. There has been no change in bowel habit. Her periods, which still persist, have been irregular of late and sometimes heavy. There is no breathlessness or swelling of the ankles, and she is quite capable of running up and down stairs. No cough or sputum.

Previous Health:-

- 1) German measles in childhood, but neither scarlet fever nor rheumatic fever.
- 2) "Frequent bilious attacks up to the age of twenty two.
- 3) Varicose veins in the legs were treated by ligation some ten years ago. They have given no trouble since.
- 4) Appendicitis six years ago.
- 5) A few years ago three cysts were removed from her breasts over a period of two years; two from the right breast and one from the left.
- 6) Two years ago she began to have persistent mild headaches which later became very severe. She was referred in the summer 1955 to the physiotherapy department for heat treatment and stretching exercises for her neck. This proved to be very successful. The symptoms are now beginning to recur and she was due at the time of admission for another period of treatment. The headaches are worst in the mornings, and she is in the habit of taking "Askit" every morning before rising.

Family History :-

Living Members	2 brothers 2 sisters	} generally healthy
	Husband 50	suffers from obesity, but otherwise well.
	Daughter 17	suffered from severe sinus trouble until she had an operation. Otherwise well.

Deceased Members

Father 60 Cancer of the liver, operated upon by Prof. Wilkie, who used to demonstrate him plus half his liver in a bottle as an example of an outstandingly successful surgical "cure" Unfortunately his patient took to drink and died, eight years after the operation.

Mother 70 Arteriosclerosis with cerebral symptoms.
No family history of dyspepsia, perforation or gastrointestinal haemorrhage.

Social History:-

One gets the impression of a very busy woman doing far too much, which for the most part is probably genuine. At various times she has run a small hotel, taken paying guests, organised a restaurant, and now restricts herself to a newsagent's business and running the home. Apparently the husband is a source of further worry and does not play a very active part in the family affairs. The daughter is more helpful. Unquestionably, the patient is the main drive behind the family. There is little doubt that she is very particular and fussy in keeping her home. A few years ago she had a difficult time nursing her mother who latterly suffered from cerebral arteriosclerosis. Last year she did not take a holiday at all. She neither smokes nor drinks.

On Examination :-

A pale lady who looks no older than her years. The mucous membranes were poorly injected but she did not appear to be markedly dehydrated. The tongue was moist, the eyes were not sunken, and the elasticity of the skin was not diminished. She lay still in a somewhat drowsy but afebrile state.

There was no engorgement of the neck veins nor any sacral oedema, or swelling of the ankles. The extremities were not cyanosed.

Although a little thin, her muscularity and nutrition were moderately good.

Alimentary System :-

The lips and buccal membrane were pale, the tongue was moist and slightly furred, the breath was mildly unpleasant but the gums were healthy. She wore dentures. The fauces were clear of infection.

Abdomen :-

Inspection :- Slightly sunken with prominent anterior superior iliac spines, moved freely with deep respiration and showed no abnormal local prominence, no restrictions and no visible veins. An appendix scar was seen in the left iliac fossa. Peristaltic movements could not be detected.

Palpation :-

Superficial - although there was no tenderness, there was a slight degree of guarding over the upper segment of the left rectus abdominus muscle. No inguinal glands could be palpated, and there was no evidence of hernia.

Deep :- There was some tenderness over the old appendix scar in the left iliac fossa, and the subjacent caecum could be palpated. The scar moved freely.

No abnormal masses could be felt, and no splashing could be elicited.

Neither the liver nor the spleen were clinically enlarged.
Percussion :- Confirmed the absence of hepatomegaly or splenomegaly.
Auscultation :- Normal peristalsis sounds.

Faeces :- A well formed, black tarry stool. ~~Stool Gregerson~~ +++.

CARDIOVASCULAR SYSTEM.

Radial Pulse :- 100/min., regular in time and force, but only moderate in volume. The pulse wave was normal in character and the vessel wall was not palpable.

B.P. :- 135/80.

Hands :- Moist, but not warm. No finger clubbing or koilonychia.
No cyanosis.

Heart :-

Inspection :- No subclavicular pulsations were seen.

Palpation :-

Apex beat in the 5th intercostal space in the mid clavicular

clavicular line; of moderate strength and tapping in character.
No thrills.

Percussion :-

Area of cardiac dullness present and normal in extent.

Auscultation :-

Heart rate 100/min.; both heart sounds were present; ^{in all areas} closed and of moderate strength without any abnormal accentuation ~~in all areas~~. There were no murmurs or adventitious sounds.

RESPIRATORY SYSTEM.

Breathing :- 16/min., costo-diaphragmatic, regular.
No cough or spit.

Chest :-

Inspection :- Symmetrical in form and movement with good expansion. The scars of the surgical removal of cysts were seen on the breasts.

Palpation :-

Good and equal expansion. The breasts were tender in the region of the scars.

Vocal fremitus unimpaired and equal throughout.

Trachea central.

No enlargement of axillary or supraclavicular glands

No thyroid enlargement.

Percussion :- Note unimpaired and equal in all areas.

Auscultation :-

Vesicular breathing with no accompaniments.

Vocal resonance unimpaired and equal throughout.

NERVOUS SYSTEM :-

Attentive, moderate power of concentration and emotionally stable. Her memory is somewhat poor. There is no abnormality of speech.

No evidence of meningeal irritation.

Each of the cranial nerves were tested individually; all were found to be intact and fully functional.

The pupils were central, circular, equal and of normal size.

They reacted to light (both directly and consensually) and to accommodation. There was no retinopathy.

Motor functions :- Normal muscle tone, no involuntary movement, good co-ordination.

Reflexes :-

Biceps	Triceps	Supinator	Knee J.	Ankle J.	Plantar Responses	Abdominal.	Right side
+	+	+	+	+	↓	-	Right side
+	+	+	+	+	↓	-	Left side

No clonus.

Superficial and deep sensation unimpaired.

Examination of the Blood :-

Hb = 70%
WBC = 11,200/c.mm.
ESR = 10mm/hr. (Westergen)
Group A; Rh negative.

Examination of Urine :-

Yellow colour, S.G. = 1.020; Acid reaction.
Albumen -ve
Sugar -ve
Acetone -ve
Urobilinogen -ve
Bilirubin -ve

Microscopic examination :- nothing abnormal seen.

CLINICAL DIAGNOSIS.

The most common causes of haematemesis and melaena are peptic ulcer (60%), bleeding oesophageal varices in portal hypertension (8%) and gastric carcinoma (5%). Most of the remaining 27% are of unknown aetiology, the lesion having healed by the time it is considered safe to perform diagnostic procedures.

In the present case the history conforms fairly well with that of peptic ulceration. She has had intermittent epigastric discomfort for about a year. This discomfort could be relieved by food or alkalis, and she could localise its position in the epigastrium with one finger. She has been occasionally sick and the act of vomiting seemed to relieve the discomfort. Although there is no family history of peptic ulcer, her driving and worrying personality and rather slender build conform with the recognised diathesis of that condition. On examination, although there was no tenderness, there was guarding of the upper segment of the left rectus abdominis muscle.

Massive bleeding of sudden onset may also arise from rupture of oesophageal varices such as occur in portal hypertension. However, there was no splenomegaly, no ascites, no abdominal veins or haemorrhoids, and the liver was not palpable.

Alimentary neoplasm, however, is less easy to exclude. There has indeed been some anorexia during the past few months with some loss of weight, but this has not been marked. To explain the copious haematemesis and the absence of dysphagia such a neoplasm would have to be gastric. However, the vomit has never previously been blood stained. Although she has been taking iron tablets in the past, her periods have not yet stopped and indeed have at times been heavy. A gentle trickle from a chronic ulcer would be equally effective in producing an iron deficiency anaemia as would a slow ooze from a gastric carcinoma. There is no history of intermittent vomiting to suggest pyloric obstruction and there is no splashing or visible peristalsis. No scars are palpable in the abdomen and there is no lymphadenopathy (e.g. of the supraclavicular glands). The erythrocyte sedimentation rate is not raised. In view of the year's history a gastric carcinoma would be expected to have presented more pronounced clinical features. The above arguments do not exclude a simple oesophageal, gastric or duodenal polypus.

The most likely diagnosis, therefore, seems to be peptic ulceration. From the length of the history the ulceration is more likely to be chronic rather than acute, but as to its site it would be rash to hazard a guess. The occurrence of heartburn on lying down is perhaps suggestive of regurgitation of gastric contents into the oesophagus. Symptomatic hiatus hernia (e.g. a sliding oesophagogastric hernia) has a frequent association with duodenal ulcer.

TREATMENT.

Before Admission :-

30/12/55

Rest in bed.
SC Injection of morphine.
"Nulacin" tablets s.o.s.

After Admission.

31/12/55.

Complete bed rest with initially only one pillow.
Patient was in a drowsy state not requiring any more morphine.
Immediately put on hourly pulse and B.P.
Blood grouped and Cross-matched. Hb estimated.
One pint whole blood at 10p.m.
Fluids - fruit juices, milk.
Magnesium Trisilicate Mixture B.P.C. 2 hrly.
24 hr. fluid balance estimation.

1/1/56.

One pint blood at 2a.m.
One pint glucose at 6a.m.
One pint glucose at 10p.m.
One pint blood at 12p.m.
One pint saline at 3p.m.
IM. sodium Luminal 0.9G at 12.45p.m.

2/1/56

IM. sodium luminal 0.9G at 9.50p.m.
No other sedative given hereafter.
Milk puddings, and on to Ulcer diet.

9/1/56

Ferrous gluconate tablets B.P.C. 3G. thrice daily.

20/1/56

Do quadriceps exercises for cramp in right leg.

21/1/56

Stop Magnesium Trisilicate Mixture B.P.C.
"Nulacin" tablets s.o.s.
Aluminium hydroxide mixture N.F. 8mls suitably diluted 2 hrly.

22/1/56

Keep right leg still; raise foot of bed.
(Thrombophlebitis diagnosed)

3/2/56

Transferred to Astley Ainslie for convalescence.

SPECIAL INVESTIGATIONS.

7/1/56.

Serum bilirubin	= 0.3mg./100ml.
C. C.F.T.	= negative.
Thymol Turbidity	= 1 unit.
Thymol Flocculation	= negative.
Serum Cholesterol	= 158mg./100mls.

Plasma albumen	= 3.9G/100ml.
Plasma globulin	= 1.6G/100ml.
Non - protein Nitrogen	= 47 mgm/100ml.

13/1/56.

Barium Meal:

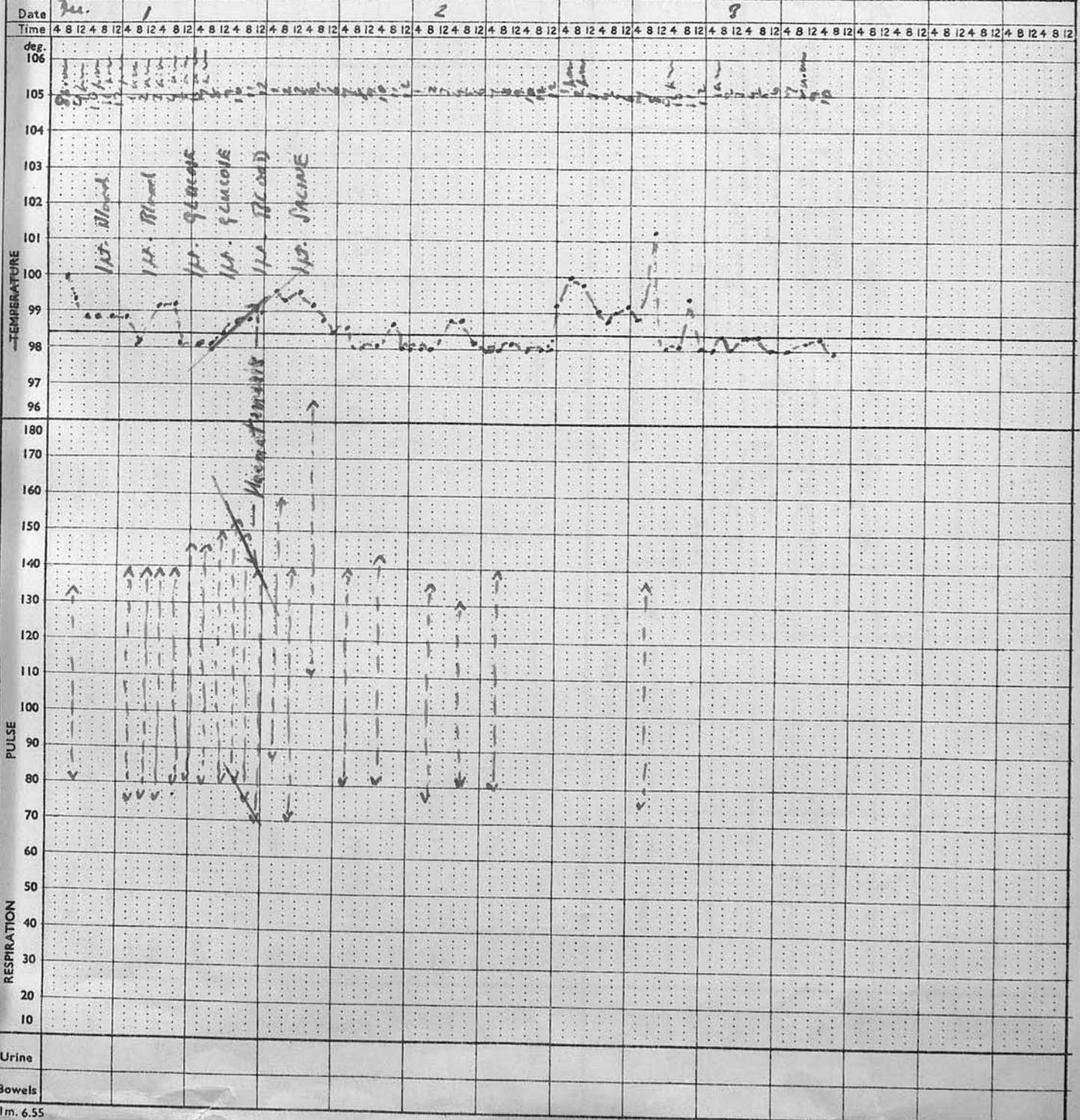
Oesophagus and stomach negative, apart from slight pylorospasm. The duodenal cap was difficult to fill completely and was slightly tender. An ulcer crater was not demonstrated.

SURNAME (Block Letters) Mr Mrs Miss DORRIS		CHRISTIAN NAME (Block Letters) MINNIE	AGE 53	RELIGION	CASE No.
---	--	---	------------------	----------	----------

DATE of ADMISSION	HOME DOCTOR and ADDRESS Dr KIRK, GLEN.
-------------------	--

Date	Height and Weight	Date	Diet and Medicines	Date	Diet and Medicines
10/1/56	Height : 5' 8" Weight : 8st. 4lbs Correct Weight :				
17/1/56	8st. 3 1/2lbs.				
21/1/56	8st. 4lbs.				

1st. **JAN 1956** 2nd 3rd



SURNAME: ^{MR} DOBIE }
^{MRS} MINNIE }

CHRISTIAN NAME: MINNIE

AGE: 53

CASE No.

DATE	R.B.C. x10 ⁶ /cmm.	Hb.	C.I.	P.C.V.	M.C.V.	M.C.H.C.	M.C.H.	Retic.	W.B.C. /cmm.	Neut. Polys.	Eos. Polys.	Bas. Polys.	Lymph. Mono.	Other Cells	Platelets /cmm.	Faeces Occult Blood	Urobilinogen		Therapy
																	Faeces	Urine	
31.12.55		70							11,200										
1.1.56		80							9,500										
3		78	3.32	1.18															
4		64	3.10	1.00				2.5%	4,000										
5																			
6		59	2.84	1.03	105	29			3,400	78	3		17	2		7/1/56 + + +			
7		77														19/1/56 —			
14		73	3.16	1.15	30%											19/1/56 —			
10		81														22/1/56 —			
		84																	

DATE	Platelets /cmm.	Bleeding Time (Mins.)	Capillary Fragility		Clotting Time (Mins.)	Miscellaneous Investigations	Bone-Marrow Films	Therapy
			Pos. Press	Neg. Press				
31.12.55						EPR = 10 mm /h. (Watson)		
3.1.56						Blood film :- some microcytosis with some Hemifid. Differentiated count normal	Polychromatinic microcytes. Platelets a few.	
4.1.56						Blood film :- some microcytosis tending Platelets normal.	to microcytosis. Some polychromatinic.	
17.1.56						Blood film :- some microcytosis tending	to microcytosis.	

SURNAME (Block Letters)

CHRISTIAN NAME

Fluid Balance Chart

Mr
Mrs
Miss
DOBIE

MINNIE

CASE No.

FLUID BALANCE CHART

DATE	Time	INTAKE				OUTPUT		
		ORAL		INTRAVENOUS		URINE	STOMACH	BOWEL
		Quantity	Nature	Quantity	Nature	Quantity	Quantity	Quantity
31/12/55	10 p.m.			540 ml.	Blood	1600 ml.		
	1 a.m.	120 ml.	Water	540 ml.	Blood			
	5 a.m.			540 ml.	Glucose			
	8.30 a.m.			540 ml.	Glucose			
	1 p.m.			540 ml.	Blood.			
	4 p.m.			240 ml.	Saline.			
1/1/56	7.30 p.m.	120 ml.	Water + Milk.					
		Total = 240 ml.		Total = 2940 ml.		Total = 1600 ml.		
		∴ Total Fluid Intake during 24 hrs. ending 10 p.m. 1/1/56 = 3,180 ml.				Total Fluid Output during 24 hrs. ending 1 a.m. 1/1/56 = 1600 ml.		

COMMENTARY.

Differential Diagnosis.

On barium meal examination the oesophagus and stomach were negative. No ulcer could be demonstrated in the duodenum. This was surprising because according to the clinical diagnosis the postulated peptic ulcer was to have been a chronic one. An experienced radiologist will miss very few ulcers on the lesser curvature or posterior wall, but may miss them in the antrum or near the cardia. In the duodenum, although it requires careful technique to demonstrate the niche, the cap will be distorted by spasm and, if the ulcer is of any size, healing and scarring will produce permanent deformity. The slight pylorospasm observed might indicate an ulcer somewhere near the pylorus. There were no filling defects to suggest gastric neoplasm. Oesophageal varices or oesophagitis are difficult to demonstrate radiologically. An acute gastric or duodenal ulcer may well have healed by the time the X-ray was done, but the history does not suggest its presence.

Further investigations should have been done; in particular, histamine gastric analysis. Hypochlorhydria would have been indicative of neoplasm, while hyperchlorhydria would have suggested a duodenal ulcer. Furthermore, the volume of the fasting juice would have given a clue to the degree of any pyloric obstruction that may have been present; while the character of the juice may have suggested its aetiology.

Depending upon the results of the gastric analysis, gastroscopy might well have been instructive in this instance. Indeed this procedure will be a virtual necessity if the patient has another haematemesis or melaena. By this method, oesophageal varices and acute ulcers can readily be seen.

As a point of interest rather than of practical application in the present case, Shiela Sherlock of London has recently developed the technique of portal venography in which an opaque dye is injected into the spleen. In this way oesophageal varices can be very clearly demonstrated.

A curious feature of this case is the tendency towards macrocytosis noted repeatedly in the blood film and confirmed by an MCV = 105 cu. microns. (Normal = 76-96 cu. microns.) The origin of this is not certain. No stress can be placed on the high values obtained for the colour index (1.18 - 1.03) since the Hb determinations are obviously inaccurate. In the absence of a blood transfusion it is quite impossible for a Hb = 59% on 6/1/56 to rise to 77% by 9/1/56. The determination of the RBC is inaccurate at the best of times, but the C.I must be virtually useless if the Hb determination is also grossly in error. Fuller investigation would involve the examination of the sternal marrow, fractional gastric analysis and possibly the uptake of cyanocobalamin and folic acid.

Liver function tests were normal except possibly for the lowish value /

value of 1.6 G/100 ml. for plasma globulin (Normal=1.6-3.1 G/100ml.)
Extra-renal factors are in all probability responsible for the
figure of 47mg% for the serum non-protein nitrogen (normal=22-35mg%).
The fluid balance chart, however, shows no abnormality.

In spite of the negative radiological report the diagnosis of
peptic ulcer is maintained by the history. This diagnosis, however,
is somewhat indeterminate and other investigations should have been
performed.

Aetiology of Peptic Ulcer:-

The exact aetiology of peptic ulcer is still obscure, but the central equation of ulcer aetiology seems to be:-

Acid-pepsin versus Mucosal Resistance.

The evidence that ulcers can only occur in the presence of acid and pepsin is strong. Thus, peptic ulceration has never been found in a case of pernicious anaemia, and if rigid criteria are used it is doubtful if an active ulcer has ever been known to occur in association with true achlorhydria. The rigid criteria comprise:-

- a) fluoroscopy to prove that the tube is in the stomach,
- b) the use of histamine of known pharmacological activity, in high dosage 0.6 mg histamine /10 Kg. covered by mepyramine, and
- c) continuous aspiration of gastric juice for an hour.

Again peptic ulcers are only found in those regions in the alimentary tract which are exposed to the action of acid : the lower end of the oesophagus, the stomach, the duodenum, the small intestine anastomosed to the stomach, or rarely, at the junction of a Meckel's diverticulum (which contains acid secreting mucosa) with the small intestine.

Peptic ulcers do not arise in the area of acid production, but are found immediately on the pyloric side of the varying acid line.

Although there is no evidence that the parietal cell in a case of duodenal ulcer secretes acid of a higher concentration than does a similar cell in the stomach of a normal person, in some cases of chronic duodenal ulcers there may be an excessive secretion of acid in response from an increased secretory cell mass to a meal, or a prolonged secretion during the interdigestive period. The amount of nocturnal interdigestive secretion can certainly be very striking. High acidity for long periods may possibly explain duodenal but not gastric ulcer. A biopsy taken through the gastroscope heals as quickly when the acidity is high and continuous as in cases of achlorhydria.

Moreover, hyperacidity is by no means a constant feature of all ulcer cases. There is the impressive experiment that when kidney or spleen with circulation ~~interest~~ is introduced into the stomach they are not digested, even when the cut surface is exposed to the gastric juice for weeks or months. Factors influencing the mucosal resistance to trauma and to acid-peptic digestion must therefore be seriously considered. The nature of these factors is unknown, but four possibilities include :-

- 1) Mucus, 2) Nutrition, 3) Blood supply, 4) Hormones.

Mucus.

This is secreted by the neck cells of the gastric mucosa, and is consequently in a good position to act as a first line of defence. Little is known, however, about its clinical constitution or what factors influence its secretion.

As it is slippery to the touch physiologists have maintained that mucin (the chief constituent of mucus) is a lubricant which assists the onward passage of food, and at the same time prevents damage to the mucosa from mechanical trauma. This seems to be reasonable.

Other/

Other protective functions, however, have also been assigned to mucin; in particular, the capacity to prevent the digestion of the stomach by the gastric juice. While there is no doubt that the stomach and upper part of the duodenum are more resistant to gastric juice than the rest of the intestine, it would appear that the part played by mucin in this resistance is generally misinterpreted. Thus, according to Florey (1954), there is at most 0.5% of mucin in pyloric and duodenal secretions and this possesses no appreciable buffering power against HCl. The buffering power of the juices appear to lie almost entirely in their content of bicarbonate, which is in all probability secreted by the same cells that produce mucin. Furthermore, it is commonly accepted doctrine that mucin inhibits peptic digestion (see Babkin 1950 for literature). This effect has usually been demonstrated using methods of pepsin estimation employing solid substrates (e.g. coagulated egg white, fibrin, the gelatin of photographic emulsions, etc) and no precautions were taken to exclude the possibility that the apparent inhibition might have been due simply to less efficient mixing of the substrate and enzyme in the presence of the viscous mucin. Heatly (1956) and Shock & Fogelsen (1942) before him determined the effect of mucin on peptic activity in a homogenous digestion mixture and found no such inhibitory effect. Mucin in the sol state does not interfere with the diffusion of HCl. The behaviour of mucin of pyloric and duodenal secretion is altered by change in pH. Whereas pig juice above pH circa 4.7 behaves as a viscous but true fluid, in more acid solution it becomes gelatinous, which may increase its mechanical efficiency.

Thus it would appear that mucus is secreted at least in part in a relatively freely flowing form which is gelled in contact with acid. Some of this material adheres to the surface of the mucosa and by virtue of its physical properties impedes the mixing which would otherwise bring the gastric juice in contact with the surface mucosa. By its lubricant properties it protects the mucosa from mechanical trauma. Though the mucoprotein itself has no buffering capacity nor does it inhibit peptic digestion, the bicarbonate ions secreted with it helps to neutralise the HCl and by so raising the pH makes the action of pepsin less effective. Beneath the surface layer of mucus, lies undischarged mucin in the continuous palisade of gastric surface cells, so that any protection afforded by secreted mucus is probably reinforced by the concentrated mucin contained in the underlying cells.

Nutrition:-

Although nutrition must be of the greatest importance in maintaining the health and secretion of the gastric mucosa, it is doubtful if malnutrition can be of much importance in peptic ulceration in this country.

Blood Supply:-

An attractive hypothesis is one which ascribes the lowering of mucosal resistance to poor blood supply. There seems no reason why thrombosis should not occur in the end arteries of the stomach in human/

human subjects with arteriosclerosis, and this would account for the ulceration seen in elderly patients with no previous history whatever of an ulcer dyspepsia. Characteristic of this type of ulceration is the sudden onset of symptoms, often dated to a day, and the rapid healing that follows. Burger (1947) has drawn attention to a close correlation between the incidence and growing frequency of angina pectoris and peptic ulcer.

This would not explain the occurrence of ulceration in younger age groups and is of doubtful application in the present case. Barclay & Bentley (1949), however, using an injection technique of radio-opaque material into the stomach vessels claim to have demonstrated the existence of an arterio-venous shunt in the submucosa which, when potent, might produce relative ischaemia of the overlying mucosa. If this shunt operates during life, and produces localised areas of ischaemia, conditions would exist for peptic ulceration.

Hormonal Factors:-

The striking sex difference in the incidence of duodenal ulcer and the observation that during pregnancy ulcers tend to heal only to break down again when pregnancy has ended both suggest that hormonal substance, may in some way be protective.

Experimentally, the influence of "hormonal factors" can be studied on dogs. Mann - Williamson (1923). Gastro-jejunosotomy with an anastomosis to the terminal ilium of the duodenojejunal segment, which contains the bile and pancreatic ducts, is performed. Almost 100% of dogs so operated die with a jejunal ulcer opposite the gastrojejunal stoma in an average of about 75 days, when an ordinary kennel diet is fed. Prolongation of life and prevention of occurrence of ulcer are the criteria used in assessing the value of treatment.

Intestinal extracts in the form of enterogastrone concentrates prepared from the small intestine of hogs were first administered IV (Hands et al 1942) to Mann - Williamson dogs in doses of 50 mg. three times a day, in the hope that this might inhibit gastric secretion sufficiently to prevent post-operative jejunal ulcer. As it happened, the gastric secretion was not significantly affected, but nevertheless jejunal ulcers developed in only six of the twenty five dogs during a one year period of treatment. This was subsequently confirmed by Ivy (1944). Since the active constituent appeared to be distinct from enterogastrone it was christened enteroantheone (anti-against, helckos-ulcer).

In human peptic ulcer patients Ivy et al (1949) used recurrence rate as a criterion of benefit, and found that the majority of forty six patients receiving enterogastrone concentrates intramuscularly three to six times weekly for one year experienced fewer recurrences during and after discontinuation of treatment than before beginning treatment. This finding, however, has not been universally confirmed (see Sandweiss et al 1948; Pollard 1948).

As already mentioned an amelioration of symptoms in peptic ulcer patients is frequently observed during pregnancy. This led Sandweiss et al (1938) to test the effect of various endocrine preparations on the/

the Mann - Williamson dogs. Among the hormones tested, chorionic gonadotrophin prepared from the urine of pregnant human subjects, was the only one which reduced the incidence of the ulcers. Subsequent studies by Sandweiss, however, revealed that the urine of non-pregnant women and therefore devoid of chorionic gonadotrophin, also exerted this beneficial effect, whereas urine from normal men was less effective, and that from patients with peptic ulcer was stated to be ineffective. Statistically, the difference between the rates of effectiveness of urine extracts from pregnant and non-pregnant females was not significant, nor was that of urine extracts from normal men and male peptic ulcer patients. However, the difference between urine extracts from females (pregnant or non-pregnant) and males (with or without ulcer) was highly significant. The active constituent of female urine was christened uroantheleone, but it is not known whether or not it is a distinct substance from urogastrone.

As far as I am aware, only one group of ulcer patients has been treated with injections of urine extracts (Sandweiss 1941). Only moderate improvement was noted, with no suppression of recurrences. However, only small doses were given intermittently for a short period.

Now, although it is convenient to distinguish the anti-ulcer from the anti-secretory action of intestinal and urinary extracts, it must be remembered that antheleone has never been clinically separated from urogastrone or enterogastrone and it is quite possible that a single substance in each of these extracts is responsible for both kinds of activity. Urinary and intestinal extracts, prepared in exactly the same way, as in making urogastrone and enterogastrone concentrates, are simply called antheleone preparations when they are used in the treatment of peptic ulcer.

The only alteration in peptic reaction which has been observed to result from the administration of enterogastrone concentrates to Mann - Williamson dogs is a reversion of the excessively prolonged secretory response to alcohol to a normal type of response. Whether this is the cause or the result of the therapeutic effect is not known. On histological evidence, Sandweiss (1945) proposed that antheleone stimulated the healing process in ulcers. Since, however, a very significant percentage of Mann - Williamson dogs treated with uroantheleone or enteroantheleone never develop an ulcer at all, it is doubtful if this can be the full explanation. The mechanism of action of antheleone remains entirely conjectural.

PAIN OF PEPTIC ULCER.

Before discussing treatment, which in the first instance is symptomatic, it is well to consider the aetiology of the presenting symptom - epigastric pain or discomfort. Three theories have been advanced; the "acid", "motility" and "inflammation" theories.

Although the acid theory has an obvious appeal and has been strongly upheld by Palmer in USA and Pickering in Britain, it has its weaknesses. Most of the evidence is derived from experiments in which HCL is introduced onto the stomach through a gastric tube. Palmer (1926) used 200mls. 0.5% HCL and repeated the dose after the first half-hour if the first injection failed to produce pain. This produced pain in 324 experiments, but failed to do so in another 119, 105 of which were conducted during distress-free periods. Strong criticisms of this experimental procedure are that 0.5% is about twice the physiological concentration of acid gastric juice and that the interval between the injection of acid and the onset of pain was in some cases as long as an hour or more. Many other reliable workers have failed to produce pain by this technique (e.g. Hurst 1940; Carlson 1918), but, although they used equally high concentrations of acid and even as high as 5%, they did not use so great a volume as 200mls. One observation of particular interest is that made by Wolf & Wolff (1947) on Tom: strong acid applied through the fistula to the inflamed and even eroded gastric mucosa did not cause pain. Furthermore, many people who have the typical pain of peptic ulceration are found to have no ulcer demonstrable by X-ray examination or even by direct examination at operation. Hordt (1918, 1922) has reported pain where there is no free acid in the gastric juice as tested by a *grass meal*. There is also the difficulty of explaining the rapid relief of symptoms on going to bed in spite of the fact that the hyperchlorhydria is unaltered and the ulcer unhealed.

According to the "motility" theory, ulcer pain is attributable to peristaltic contractions of the stomach or duodenum, or to local spasm. Peristaltic contractions may be painful in themselves or they may, like local spasm, cause pain by compressing the ulcer. The experimental basis for this theory was put forward by Cannon & Washburn (1912) who, by means of the balloon-kymograph technique, claimed to demonstrate that hunger pains in normal people coincided with vigorous gastric contractions. Carlson (1918) repeated these studies on a student who had a peptic ulcer and pointed out that the contractions which were associated with pain were no more vigorous than the hunger contractions which occurred in the normal individual. On the other hand, Patterson & Sandweiss (1942) made twenty one simultaneous recordings of gastric and duodenal motility and showed that ulcer distress occurred only when the duodenum was active. The stomach might or might not be active at the same time. If the patients experienced severe ulcer pain for 15 - 18 minutes, or more, the duodenal motility pattern became abnormal with increase in tone until a state resembling that of incomplete tetanus was reached.

reached. However, alkalis introduced into the stomach through a tube relieved the distress but did not alter the motility record.

The "inflammatory" theory emphasises the importance of pain threshold - the level of the intensity of a stimulus necessary to produce pain - and how that threshold might be altered by inflammatory change. An analogous example when the surface of the body is inflamed is the hyperalgesia of sunburn. If the sensitivity of the stomach to stimuli is largely dependent on the degree of inflammation present, this alteration in threshold might explain alterations of ulcer pain which occur without alteration in the size of the ulcer niche, or in the amount or quality of gastric secretion. Normally the mucosa of Tom's gastric fistula (Wolf & Wolff 1947) was insensitive to painful stimuli such as pinching or pricking, but on one occasion there was "complete herniation of the stomach lining following an injury at a football game". The mucosa became cyanotic and oedematous and remained so for 3 -4 hours. The pain was intense and the mucosa was markedly tender to the slightest digital pressure. Again, when the mucosa of the stoma became red and oedematous after the use of a coarse rubber tube for feeding, the slightest touch with the tube became painful. The importance of oedema and increased tissue tension is also indicated by the observation that pain can be produced by injecting normal saline into the bowel wall at a colostomy opening. Lastly, Dragstedt & Palmer (1931 - 2) have reported the experiences of a patient who had a duodenal ulcer and on whom a laparotomy was performed under local anaesthesia. Pinching of the ulcer area and traction on the scar of the ulcer visible on the enteral surface both caused pain. While traction was maintained, relief was produced by the injection into the duodenum of 20mls. of a 5% solution of NaHCO.

In conclusion it would appear that, although both acidity and motility may in varying proportions be ultimately responsible for the stimulation of pain receptors, the threshold for pain must be sufficiently reduced before the discharge from these receptors is sufficient to produce the sensation of pain.

TREATMENT.

The first line of treatment in a severe haematemesis such as the present one is to put the patient to bed in a quiet room and allay anxiety by subcutaneous injection of morphine, 10-15 mg. Some clinicians advocate not unreasonably that morphine may induce vomiting, and so disrupt the delicate clot that is preventing a further haematemesis. For this reason they prefer an intramuscular injection of sodium phenobarbitone, 0.2G. Although nausea may occur, vomiting is not a very common side-effect of morphine and there is at present no other drug quite as good as morphine in the relief from apprehension.

The initial decision of her family doctor to treat the "gastric haemorrhage at home" is very surprising. Any patient with a severe haematemesis, especially with a history of melaena, should be admitted to hospital as an emergency. Delay in treatment could well result in the development of irreversible shock. Once in hospital the immediate question is whether the patient requires an immediate transfusion. If the haemorrhage is a recent one the process of haemodilution will not have had time to take effect, so that an estimation of the haemoglobin is notoriously unreliable. A low haemoglobin, however, is very significant and suggests previous haemorrhage and the need for blood. The patient is put on a half hourly pulse and blood pressure chart. A rapid pulse and low blood pressure are indicative of a reduced effective circulatory volume. The appearance of the patient is all-important. In the present case she did not appear to be suffering from shock, or of being grossly dehydrated. She was pale and thirsty with a dry tongue, a Hb of 70%, a pulse rate of 100/min. and a history of repeated and considerable haematemesis. She was grouped and cross-matched, and two pints of blood were given during the night. There were no signs of high output cardiac failure. The intravenous drip was maintained with glucose saline in the event of a second haematemesis. It is the change in the pulse rate and the blood pressure that is important rather than their absolute values. A rise in pulse rate with a fall in blood pressure should be taken as a cry for blood. In fact, a second haematemesis did occur, and if the chart is examined closely a slight rise in pulse rate and fall in blood pressure does actually precede it. A third pint of blood was immediately given.

It is important in such a case as this, where the patient is getting beyond middle age and where repeated haematemesis is likely from the failure of sclerotic vessels to contract, to get a surgeon in on the picture at an early date. The mortality in gastro-duodenal bleeding is slight till after 55; well above this age, bleeding becomes a dangerous hazard. To operate on an elderly exsanguinated patient might be thought to be risky but experience has shown that it saves many lives. In the present case, however, the patient settled down without further trouble after the third pint of blood so that immediate surgery became unnecessary.

Milk, glucose drinks and fruit juices were allowed in liberal quantities during the first day, and milk pudding on the second day, and then within a few days on to a full ulcer diet.

Oral iron was not given until a week had elapsed since the last haematemesis as it is mildly irritant to the gastric mucosa. She will be kept on ferrous gluconate tablets B.P.C 0.3G three times a day until the Hb is restored to 100%

The remainder of the treatment concerns the underlying cause; the presumed peptic ulcer. The preceding long dissertation on the aetiology of peptic ulcer and its associated pain or discomfort may seem to some readers somewhat out of place and unnecessary, but it is well worth while to enquire into the fundamental disturbed physiology before accepting without question the value of present day therapeutic methods. Although much of the experimental work discussed has not yet found application in therapeutics, one has only to re-call the severe restriction of fluids of the bad old days to be reminded of the dangers of irrational empirical therapy.

It was clearly shown from the work of Wolf and Wolff (1947) that emotional stress is a powerful augmentor of vagal tone and therefore of acid secretion and gastric motility. Correspondingly, the most important single factor that can be prescribed is rest. The patient was kept in bed and given a mild sedative in the form of a barbiturate as required. The treatment of symptoms must not be confused with the healing of an individual ulcer, and if economically possible a period of bed rest of three weeks is very desirable. This was achieved with the present patient. An unfortunate but common complication of three weeks bed rest occurred in the form of thrombophlebitis. The right leg became swollen and painful with a strongly positive Homan's sign. On account of recent haemorrhage anti-coagulants were contra-indicated. The severity of the local reaction indicated that the infected thrombus would be firmly attached to its vein of origin and a pulmonary embolus unlikely. No such embolus occurred.

In order to both neutralise the gastric juice and to give "motor rest" to the stomach frequent small bland meals should be given. Empirical clinicians thought that to rest the stomach one should give it nothing to do, but experiment shows that to achieve this aim you must fill it. Uncooked fats are especially effective due to the subsequent release of enterogastrone from the duodenal mucosa. Excess gastric acidity can be neutralised between meals by antacids, such as the magnesium trisilicate mixture given here. "Nulacin", which was also given, consists of dextrinised milk (together with an assortment of antacids) so that, when sucked, it in effect gives a continuous milk drip. It is, however, difficult to correlate the clinical beneficial effect with the experimental findings, for it can easily be shown that hourly feedings of milk provide more acid secretion in the stomach than does the ordinary routine of four meals a day. Motility and acid secretion can also be diminished by atropine-like drugs, ganglion-blocking agents and by propantheline bromide (which is believed to combine the previous two types of action and be partially selective for the alimentary system) but were not used in the present case.

With the exception of the avoidance of roughage in the diet which might traumatise the delicate regenerating gastric epithelium, it is clear that virtually all present day therapy is directed against the left-hand/

left-hand side of our central equation of ulcer aetiology :-
Acid-pepsin versus Mucosal Resistance.

Finally there is the question of the ultimate treatment. The difficulty here is that whereas the clinical history is strongly suggestive of peptic ulceration such an ulcer has never been demonstrated radiologically. If haemorrhage should recur, gastroscopy would have to be carried out to determine the bleeding point with a view to operative removal. In the meantime the patient should be encouraged to adopt a more philosophical outlook on life, and realise that, while peptic ulcer may not be entirely a psychosomatic disease, her driving personality and materialistic ambitions are of considerable aetiological importance.

FINAL DIAGNOSIS.

Peptic Ulcer with haemorrhage.

REFERENCES.

- Barclay & Bentley (1949) : Brit. J. Radiol. 22, 62.
Cannon & Washburn (1912) : Amer. J. Physiol. 29, 441.
Carlson (1918) : Amer. J. Physiol. 45, 81
Dragstedt & Palmer (1931) : Proc. Soc. Exper. Biol & Med. 29, 753.
Florey (1954) : Proc. Roy. Soc. B. 143, 147.
Grossman (1950) : Physiol. Rev. 30, 33.
Hands et al (1942) : Endocrinology 30, 905.
Heatley (1956) : Q. J. Exper. Physiol. 41, 25.
Ivy (1944) : (i) Gastro enterology 3, 443.
 : (ii) Fed. Proc. 4, 222.
Ivy et al (1949) : Gastro enterology 12, 735
Mann & Williamson (1923) : Ann. Surg. 77, 409.
Palmer (1927) : Arch. Int. Med. 39, 109.
Patterson & Sandweiss (1942) : Amer. J. Digest. Dis. 9, 375.
Pickering (1952) : "Modern Trends in Gastroenterology"
Pollard (1948) : Arch. Surg. 56, 372.
Sandweiss et al (1938) : Amer. J. Digest. Dis. 5, 24.
Sandweiss (1941) : Amer. J. Digest. Dis. 8, 371.
Sandweiss (1945) : Gastro enterology 5, 404.
Sandweiss et al (1948) : J. Amer. Med. Ass. 138, 552.
Shock & Fogelson (1942) : Proc. Soc. Exper. Biol. N.Y. 50, 304.
Wolf & Wolff (1947) : "Human Gastric Function".

A CASE HISTORY OF

ADDISONIAN PERNICIOUS ANAEMIA.

WARD 27 R.I.E.

(PROFESSOR SIR STANLEY DAVIDSON.)

JANUARY 1956.

by

W. J. IRVINE, B.Sc.Hons.

Name:- Mrs Margaret Maley.

Aged 49, married, housewife.

Admitted:- 31-12-55, referred to Blood Clinics R.I. E. by
Dr Lamouri, Cambridge Street, Leith.

Date of examination:- 13-1-56.

Complaints:-

1. Tiredness and breathlessness on exertion since July 1955 with marked loss of weight, some anorexia and a mild degree of nausea and waterbrash.
2. Several attacks of nocturnal pain in the calf of the right leg during the last three months variously described as "pins and needles" or as cramp.
3. An unpleasant tongue and numbness in the tips of all fingers have developed during the last few weeks.

HISTORY OF PRESENT ILLNESS:-

Since the early summer of last year (1955) she has felt tired and "done out". She was readily exhausted and became breathless when going her messages or walking up a hill; but this was not associated with any cough or pain, nor with swelling of the ankles. She found it necessary to take two hours rest after lunch.

There was at the same time some disinclination for food; but she made the paradoxical statement that "although I didn't care for other meals, I always ate a good lunch". She made things for the family but had no wish to eat them herself. It was difficult to pin down any type of food which was specifically avoided, but fatty foods were generally not taken. There was no diarrhoea. The tiredness and anorexia have both persisted without remission.

She went to her doctor with the above story in July 1955 and he prescribed red tablets to be taken thrice daily. These tablets turned her stools a shiny black and she thought that they were responsible for the nausea and occasional waterbrash that later developed. She therefore cut her dose by half and then eventually stopped taking the tablets all together.

In September or thereabouts she noticed that her water was unusually dark, and she went so far as to show it to her sister-in-law; but her confidant did not think much of it. No change was noticed in the colour of the stools. She went back to her doctor, who was annoyed at her not taking the tablets and insisted on her continuing with them, saying that "they were the only things that would help her".

Before the onset of the present illness she weighed about 8st. 4lbs but when she weighed herself in Woolworths in September she was only 7st. 2lbs. This did not surprise her because she had noticed that clothes that had previously fitted were hanging loosely.

Her brother, who only visits her when on shore-leave, commented on her obvious loss of weight and also on her greyish-yellow colour. She herself thought she was somewhat jaundiced.

During the last three months she has suffered pain on several occasions in the right calf muscle variously described as "cramps"

"cramps" or as "pins and needles". The onset of this pain was unrelated to exercise; it came on in bed waking her from sleep. During the last four or five weeks she noticed that the tips of her fingers were "lifeless" and "numb", but at no time has she had pins and needles in her fingers. There has been no paraesthesia or numbness in her toes or feet. She has not noticed any unsteadiness on her feet even in the dark, and does not complain of any muscular weakness.

During the last three or four weeks her tongue has been dry and unpleasant on waking in the mornings, but it has never been painful. She has since adopted the habit of drinking a glass of warm water night and morning.

At no time has there been any abdominal pain, heart burn, dysphagia, vomiting, or any change in bowel habit. She has not noticed any change in her finger nails, and she has not been shedding hair.

She went back to her doctor in December for a fresh supply of tablets. He sent her to the R.I.E. blood clinic for investigation and was admitted to ward 27 two days later.

PERSONAL HISTORY:-

Loss of weight; although a little constipated, bowels moved without the aid of medicine; there has been no change in bowel habit, and in particular no periodic diarrhoea. No nocturia or polyuria. Periods stopped in 1946, sleeps very well, no cough or sputum.

PREVIOUS HEALTH:-

Scarlet fever at four years, during which she lost her hearing in the right ear.

Shortly after this she had her tonsils and adenoids removed. Otherwise she has never been in hospital before and has enjoyed good health. In particular she has had no abdominal operations. She has been aware of a lump in her right breast for many years but it has never caused her any trouble. She has never had rheumatic fever, nephritis, or previous jaundice and has never been abroad. No bones have been broken and there is no history of tetany. There is no history of any haemorrhagic tendency.

FAMILY HISTORY:-

Living members	Husband	
	Boy 13	Alive and well
	Girl 10	
	Brother 47	

Deceased members

Mother 48	"Heart attack"
Father 37	"Pneumonia".

There is no family history of anaemia.

SOCIAL HISTORY:-

Her husband works in Crawford's biscuit factory as a "packer". In spite of a fairly good income the four of them live in a cold and rather damp two-roomed apartment of a tenement block. She very rarely smokes or takes alcohol, but keeps the money for sweets and the "pictures".

PHYSICAL EXAMINATION.

General:-

The patient was a pale yellow sallow colour, but the cornea was not distinctly icteric. The mucous membranes were markedly anaemic. The skin was healthy and her hands were moderately warm but not moist. There was no finger clubbing. The nails appeared brittle, and were longitudinally striated but convex. Her hair was whitish-grey, of good texture, and without evidence of thinning. Likewise, there was no thinning of the eyebrows. She was small and slight of build, but had no gross postural abnormality, no swelling of the ankles or sacral oedema. No muscle wasting.

Although she had previously insisted that she was deaf in the left ear it was obvious that the deafness was in the right ear. Her speech was somewhat indistinct and her capacity as a witness was below average.

ALIMENTARY SYSTEM:-

The mucous membrane of the lips, gums and buccal cavity were uniformly pale, and without any abnormal pigmentation. There was no pyorrhea or ulceration. Dentures. No angular stomatitis. The tongue was a fairly moist reddish-pink, smooth, glassy, and unusually clean. No papillae could be detected for there was little or no atrophy of the tongue muscle. The fauces were free from infection and the breath was not offensive.

ABDOMEN:-

Inspection:- Normal in general and local form; it was not emaciated and there was no visible peristalsis or obvious mass present. There was no obesity, distension or retractions. No scars were visible. The abdomen moved freely with respiration.

PALPATION:- No superficial or deep resistance or tenderness. The inguinal lymph glands were small. No abnormal masses were palpated, and no splashing could be elicited.

The liver was readily palpated in the epigastrium and two finger's breadth below the right inferior costal margin.

The tip of the spleen was palpable on inspiration.

PERCUSSION:- Confirmed the hepatic and splenic enlargement. There was no free fluid.

AUSCULTATION:- Normal bowel sounds.

Rectal Examination:-

Faeces:- Well formed and of normal colour. No frank blood visible.
Occult blood ++.

NERVOUS SYSTEM:-

Attentive and co-operative and not of a neurotic disposition. Her memory was reasonable, but her speech was somewhat indistinct. There was no evidence of an aphasia.

No meningeal irritation.

The cranial nerves were tested for individually and all were found to be fully functional. The deafness in the left ear was determined by Rinne's and Weber's tests to be a middle ear deafness.

The pupils were of normal and equal size, central and circular. They reacted physiologically to light and accommodation (direct and consensual). There was no retinopathy and, in particular, there were no petechial haemorrhages.

MOTOR FUNCTIONS. :-

No involuntary movements of any kind were detected. Muscle tone was normal (no paralysis or spasticity), and the co-ordination tests were well performed. She was not ataxic when walking up the ward. There was no foot drop.

REFLEXES:-

	Biceps	Triceps	Supinator	Knee Jerks	Ankle Jerks	Plantar Response Babinski	Abdominal
Left	+	+	+	+	+	↓	-
Right	+	+	+	+	+	↓	-

There was no clonus.

SENSATION:-

Cutaneous sensation to touch (cotton wool) and to pain (pin prick) was very carefully tested in the extremities and on the face. Particular attention was paid to the toes and fingers. Deep sensation was tested with respect to vibration and proprioception. No superficial or deep sensory loss could be demonstrated.

The patient could not readily tell the difference between a halfpenny and a shilling when such a coin was placed unseen in her hand.

The calf muscles were not tender to pressure.

Romberg's test was negative.

CARDIOVASCULAR SYSTEM:-

Radial Pulse:- 64/min.; regular in time and force and of normal character. Vessel wall just palpable.

Blood Pressure = 140/70mm Hg.

Neck Vessels:- A large external jugular vein was noted to be pulsating (a, c and v waves) just above the left clavicle in posterior triangle of neck. Height of column of venous blood about 1cm. above sternal angle. There was no venous engorgement and the hepato-jugular reflux was absent.

Carotid pulsation not obvious.

HEART:-

Inspection:- Neither the apex beat or any other praecordial pulsation was visible.

Palpation:- The apex beat was feeble and diffuse, but appeared to be in the 5th intercostal space within the mid-claviclar line. No thrills.

Percussion:- No enlargement of the area of cardiac dullness was detected. The normal area of hepatic dullness was present.

Auscultation:- The heart sounds were faint and were only heard with difficulty in the aortic and pulmonary areas.

A soft short blowing systolic murmur beat heard in the mitral area replaced the first heart sound in that area, but was not propagated into the left axilla.

The second heart sound was closed in all areas and was not unduly accentuated. The long pause was free from adventitious sounds.

No signs of cardiac failure.

RESPIRATORY SYSTEM:-

Breathing:- 16/min., costo-diaphragmatic, regular in rhythm and of normal depth.

No cough or spit.

Chest:-

Inspection:- Symmetrical and well developed with good symmetrical expansion.

Palpation:- Good symmetrical expansion.

Vocal fremitus normal and equal throughout.

Neither the trachea nor the apex beat displaced.

No axillary, supraclavicular or submental lymph glands palpable. No thyroid enlargement.

Percussion:- Normal and equal percussion note elicited from all surfaces.

Auscultation:- Vesicular breathing in all areas with no accompaniments.

Vocal resonance normal and equal throughout.

EXAMINATION OF THE URINE:-

31/12/55. Output of 500 ml., yellow in colour, normal smell and no abnormal gross or microscopic deposit.

S.G. = 1:012, acid.

Albumen :

Sugar :

Ketone bodies :

Bile piments :

Urobilinogen +++.

} Negative.

EXAMINATION OF THE BLOOD:-

3/1/56 Hb = 39%
RBC = 1.75×10^6 /c.mm.
CI = 1.11
PCV = 19%
MCV = 108.6c.microns (Normal=78-94 cubic microns)
MCHC = 30.4 microgrms. (Normal=27-35 microgrms).
Film = macrocytic
Reticulocytis = 1.2%
WBC = 3,400/c.mm.
ESR = 60mm/hr. (Westergen).

CLINICAL DIAGNOSIS.

The clinical symptoms of anaemia - general lassitude, malaise, breathlessness on exertion, paresthesia etc - are confirmed by a Hb of 39%. The anaemia is probably also responsible for the variation in temperature with intermittent pyrexia. A low Hb and PCV together with a raised colour index and MCV makes the diagnosis of a macrocytic anaemia indisputable. Although the reticulocyte count is 1.2%, the leucopenia (WBC 3,400/c.mm.) suggests that there may be general involvement of the bone marrow. Involvement of the bone marrow would be one explanation for the discrepancy between the severity of the anaemia and the mildness of the jaundice.

While the most likely aetiology is a deficiency in the body of some essential erythropoietic factor, it is to be remembered that some cases of haemolytic anaemia, hepatic cirrhosis, myxoedema and leukaemia may show a macrocytic anaemia, and the only sign that is pathogenic of a vitamin deficiency macrocytic anaemia is a megaloblastic bone marrow. Clinically there is no ascites to suggest hepatic cirrhosis, no changes in the hair or subcutaneous tissues or enlargement of the thyroid to suggest myxoedema, and no lymphadenopathy or ulceration to suggest an aleukaemic leukaemia.

Of all the essential erythropoietic factors either vitamin B₁₂ (cyanocobalamin) and ~~for~~ folic acid (pteroyl glutamic acid) are the most likely to be deficient. Since the patient prior to the onset of the illness in July took a normal balanced diet, and catered for a normal healthy family of four it is improbable in the extreme that there was any dietary vitamin deficiency. The basic aetiology must therefore lie in the malabsorption of some essential erythropoietic factor and in the present circumstances the differential diagnosis is between Addisonian pernicious anaemia and the malabsorption syndrome (in this instance, idiopathic steatorrhoea or the very rare condition of diverticulosis of the small intestine).

Without the aid of special investigations it is difficult to differentiate between these two possibilities. No signs of subacute combined degeneration or peripheral neuritis, which would have virtually clinched the diagnosis in favour of Addisonian anaemia could be elicited. The marked loss in weight would favour the malabsorption syndrome, but the stools were well formed and of normal colour and were not offensive. A high ESR may be produced by any form of anaemia. The presence of occult blood in the stool suggests the possibility of an early gastric or intestinal neoplasm or perhaps a diverticulosis, but a past history of haemorrhoids is confusing. Should she have acid in the stomach there might be a peptic ulcer.

There was neither pain, discomfort or tenderness in the left iliac fossa or elsewhere to confirm a diverticulitis nor any change in bowel habit to confirm alimentary neoplasm, but there is marked loss of weight. At all events the blood loss has not been so marked as to produce a ~~hypochromic~~ **hypochromic** blood picture.

In summary the clinical diagnosis lies between Addisonian pernicious anaemia and the malabsorption syndrome with the possible complication of an alimentary neoplasm, but should the sternal marrow fail to be megaloblastic some other diagnosis must be found.

SPECIAL INVESTIGATIONS.

2/1/56 Serum bilirubin = 1.0mg%.

2/1/56 Alcohol test meal.

Time	Amount	Reaction
7a.m.	6ccs	Alkaline
	50cc alcohol 7%	
7.30a.m.	1cc	Alkaline
7.35a.m.	0.5mg Histamine SC.	
8.00a.m.	4cc.	Alkaline
8.30a.m.	2cc	Alkaline
9.00a.m.	2cc	Alkaline
Remainder	3cc	Alkaline

Conclusion:- No acid after 0.5mg. histamine.

2/1/56 Sternal puncture:- megaloblastic bone marrow.

5/1/56 Chest X-Ray :- negative.

6/1/56 Given radioactive B12. Subsequent report (18/1/56) stated that 95% of the radioactivity in the test done was recovered in the faeces.

18/1/56 Serum Iron Estimation

- 1) Before treatment with 200mg cyanocobalamin=95microgrms/100ml.
- 2) 48 hours after 200mg cyanocobalamin = 50.5 microgrms/100ml.

19/1/56 Faecal Fat(6 day collection).

Total fat in 3,672 G of wet specimen

= 42.2G in 6 day collection

= 7G per day. (upper limit of normal = 5.5G/day).

Conclusion :- a steatorrhea is present.

30/1/56 Barium Meal:-

A small diaphragmatic hernia.

No evidence of gastric or duodenal ulceration; there were no pitting defects and the mucosal pattern in the stomach and upper portion of the intestine was normal.

TREATMENT.

General:-

The patient was kept in bed but allowed to the toilet. She was put on a light and easily digested diet rich in protein, iron and vitamin C.

Specific :-

1) Once the diagnosis had been thoroughly established, cyanacobalamin was given intramuscularly in the form of "Cytamen".

9/1/56 200mg "Cytamen" IM.
11/1/56 }
13/1/56 }
15/1/56 } 100mg "Cytamen" on alternate days.
17/1/56 }
19/1/56 }

2) Intravenous Iron.

11/1/56 200mg. "Ferrivenin" IV.

PROGRESS.

Since admission her appetite has improved and she has become more cheerful. The response to cyanocobalamin is most gratifying and is shown here in tabular and graphic form.

Discharged home on 21/1/56

The ESR was reduced to 15mm/hr (Westergen) and the Stool Gregerson was negative. The urinary urobilinogen which was present in marked excess on admission was only slightly above normal. There has been no weight increase. To report back to the blood clinic in one month's time. Until then she is to receive 100 microgrms cyanocobalamin ("cytamen") weekly.

20/2/56 :-

Continues to respond satisfactorily to therapy with cyanocobalamin. Hb = 98%
Dose of "cytamen" reduced to 100 microgrms fortnightly.

She is to report back again in two month's time when the dose will probably be put on to a maintenance of 100 microgrm every three or four weeks as required to maintain her Hb at 100%.

Blood Picture :-

Date	Hb%	RBC	CI	PCV%	MCV	MCHC	Retic.%	WBC	ESR.
3/1/56	39	1.75	1.11	19	108.6	30.4	1.2	3,400	60mm/hr.
7/1/56	40								
9/1/56	44	1.93	1.14				1	4,200	
0/1/56							1		
1/1/56							2.8		
2/1/56	52	2.29	1.13				3.5	5,200	
3/1/56							9.5		
4/1/56							7.4		
6/1/56	64	3.03	1.06				3.4	5,600	
9/1/56									20mm/hr.

Faecal Occult Blood (Gregerson)

3/1/56 ++
19/1/56 ++

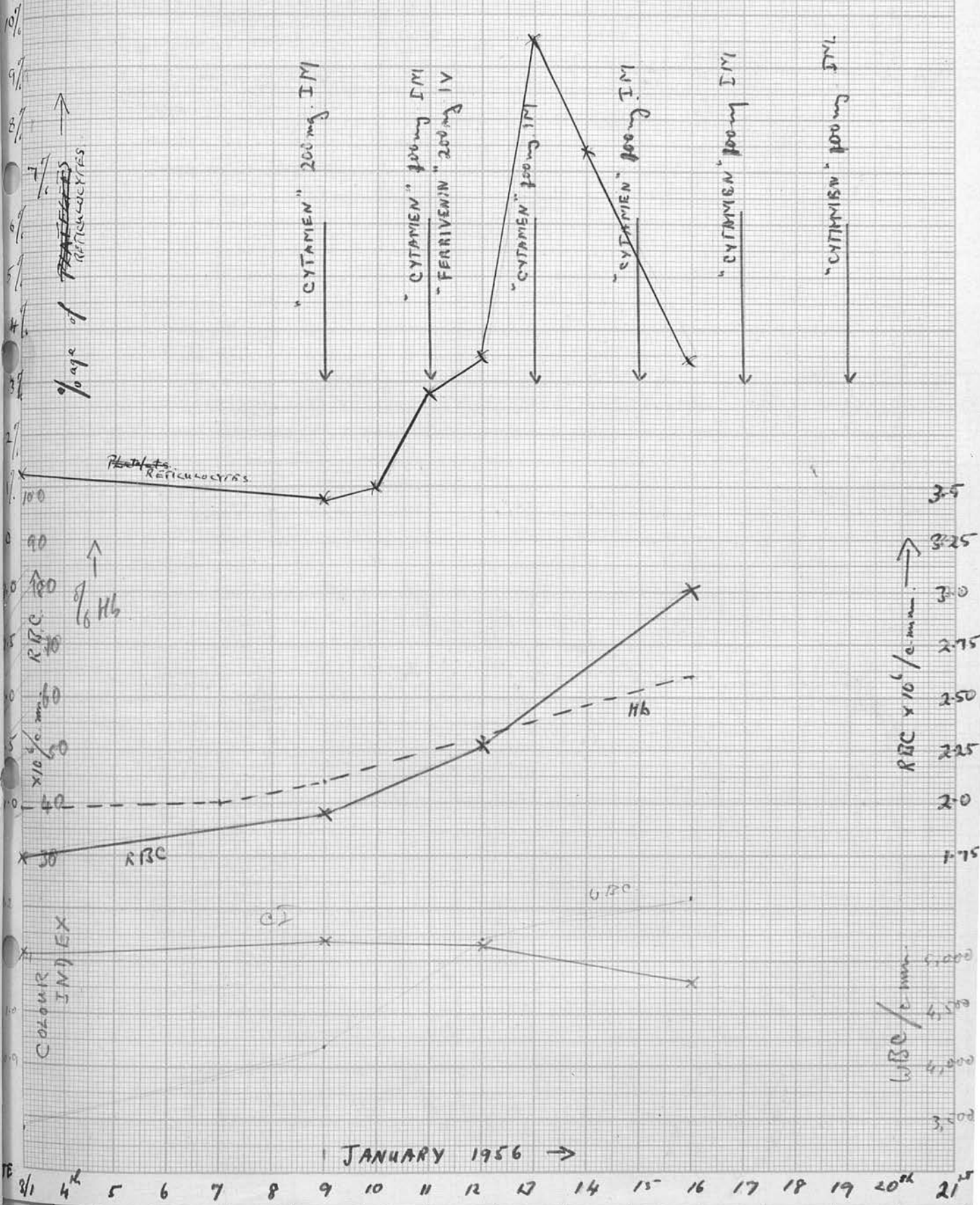
Urine

31/12/55.	Yellow colour; S.G. = 1.012; Acid Urobilinogen +++ Microscopic deposit = N.A.D.	Bile -ve Sugar -ve Acetone -ve Protein -ve
19/1/56	Yellow colour; S.G. 1.014; Acid. Urobilinogen + Microscopic deposit = N.A.D.	

Weight

31/12/55 6st. 9lbs.
10/1/56 6st. 10lbs

MALEY, Mrs Margaret. Act 49.

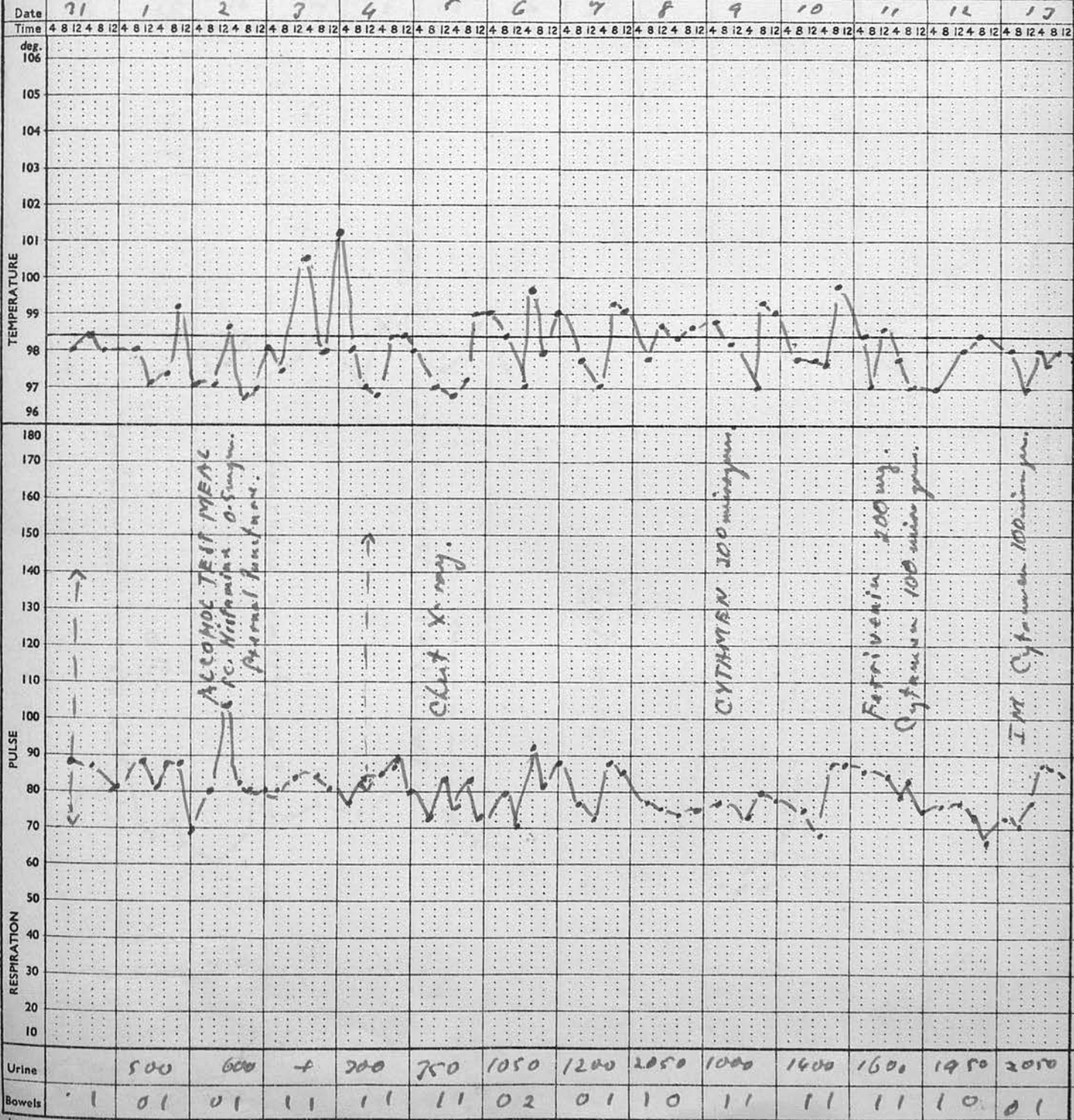


Sir STANLEY DAVIDSON

THE ROYAL INFIRMARY OF EDINBURGH

Temperature Chart

SURNAME (Block Letters) Mr Mrs Miss MALEY		CHRISTIAN NAME (Block Letters) MARGARET		AGE 49	RELIGION PROT	CASE No.
DATE of ADMISSION 31.12.55		HOME DOCTOR LAMBURK and ADDRESS Cambridge Street, Hill.				
Date	Height and Weight	Date	Diet and Medicines	Date	Diet and Medicines	
31.12.55	Height: 4' 10" Weight: 6st. 9lb Correct Weight: 8st. 10lb					
10.1.56	6st. 10lb					
Dec 1955 Jan 56						



Commentary.

Differential Diagnosis.

The megaloblastic bone marrow, the histamine-fast achlorhydria and the very poor absorption of radioactive cyanocobalamin are strong indications for the diagnosis of Addisonian anaemia, but they are not incompatible with the malabsorption syndrome. Moreover, there is a mild steatorrhoea.

It must be remembered, however, that the intestinal flora contribute to an unknown but probably significant degree to the normal faecal fat. Now the intestinal flora, on account of the absence of the protective mechanism of gastric hydrochloric acid which normally kills most bacteria and fungi before they enter the bowel, is liable to be altered in Addisonian anaemia, and it may be that the abnormal figure for faecal fat excretion is attributable merely to a change in the intestinal flora, and not to any gross change in intestinal digestion and absorption. Furthermore, the wet specimens of faeces apparently lie around the laboratory in a wide necked open container for up to a week or a fortnight. The consequent dehydration may be sufficient to produce results above normal limits.

Considering that the normal fat intake per day is approximately 100G, the extent of the true malabsorption of fat cannot be at all severe. However, the malabsorption syndrome is a multiple deficiency syndrome so that it is conceivable that the absorption of an essential erythropoietic factor is more seriously affected than the absorption of fat.

A histamine fast achlorhydria is uncommon in the malabsorption syndrome. Card, Marks and Sircus (1956), using continuous suction of juice and stimulating gastric secretion with a large subcutaneous injection of histamine (0.04mg/Killog.body weight) covered with mepyramine, have so far failed to find any instance of achlorhydria in a series of over 500 tests except in cases of Addisonian anaemia. The method of gastric analysis used in the present case, however, was much less drastic and therefore much less sensitive to small amounts of HCl which might be present, or could be produced if the mucosa was sufficiently stimulated.

The very poor absorption of cyanocobalamin is especially interesting. In Addisonian anaemia if a small amount of gastric extract containing intrinsic factor is given with the radioactive cyanocobalamin the absorption of cyanocobalamin is greatly improved, whereas in the malabsorption syndrome the improvement is less marked. This additional test was not performed. Another relevant investigation would have been

been to determine the effect of aureomycin on the absorption of cyanacobalamin. This has been found to enhance the absorption of the vitamin in cases of intestinal diverticulosis whereas it has little or no effect in cases of Addisonian anaemia or megaloblastic anaemia associated with idiopathic steatorrhoea. The mucosal pattern of the upper intestine seen on X-ray examination after a barium meal was normal with no evidence of a diverticulosis or of the "deficiency pattern" characteristic of the malabsorption syndrome. In spite of this it might have been worthwhile doing a glucose tolerance test; a normal curve would be expected in Addisonian anaemia while a flat curve would be expected in the malabsorption syndrome.

The additional investigations mentioned above would be for the most thorough investigation of the patient, and for most practical purposes it would be sufficient for the diagnosis of Addisonian anaemia to demonstrate a macrocytic anaemia with a megaloblastic bone marrow and a histamine fast achlorhydria, in the absence of gross "naked eye" steatorrhoea, pregnancy or infancy.

Witts has suggested that Addisonian anaemia can have one of two aetiologies. There is the commonly described idiopathic type in which there is often a family history of Addisonian anaemia and the onset of the condition is not preceded by a prolonged hypochromic anaemia. Secondly, Witts has suggested that some cases of Addisonian anaemia may be secondary to a prolonged hypochromic anaemia with chronic gastritis and ultimate atrophy of the gastric mucosa and in which no family history of Addisonian anaemia can be elicited.

In the present case, although there is no relevant family history, the duration of anaemia symptoms and anorexia (which would accompany a chronic gastritis) is short. This case is therefore probably idiopathic in origin.

Aetiology and Pathogenesis :-

Prior to the fortuitous discovery of the successful treatment with liver the number of red blood cells and the amount of haemoglobin in the circulating blood of patients with Addisonian anaemia, although approaching normal during remissions, invariably declined and lead irrevocably to the death of the patient. For this reason the disease was known as pernicious anaemia.

As a result of his plasmapheresis experiments on dogs Whipple (1925) found that the maximum regeneration of haemoglobin and red cells occurred when ox liver was fed. This suggested that liver may contain either some important precursor of haemoglobin or some factor which accelerates the process of erythropoiesis. Minot and Murphy (1926) fed liver to patients with pernicious anaemia and a dramatic improvement in their condition was produced, although it has subsequently been shown that the liver factor which hastens regeneration of blood in dogs made anaemic by bleeding is a different factor from that which alleviates pernicious anaemia in man.

As already mentioned, achlorhydria is virtually an invariable accompaniment of pernicious anaemia. The significance of this fact was demonstrated by Castle (1929) who found that the gastric contents/

contents of a normal person during the digestion of meat were curative when fed to a subject with pernicious anaemia. Administration of normal gastric juice alone, or beef alone, did not effect a cure, but if beef was incubated in vivo with normal gastric juice the resulting product was curative. Moreover, normal human gastric juice can produce full remission when given to patients who have taken beef, with or without prior digestion, immediately before hand. Further similar experiments showed that the active principle in gastric juice is not pepsin, hydrochloric acid, renin or lipase and is present only in the gastric juice and not in the duodenal juice. Castle interpreted these findings by suggesting that the erythropoietic factor is formed by the interaction of an extrinsic factor which is obtained from the food with an intrinsic factor secreted by the normal gastric mucosa.

The relation between cyanocobalamin, folic acid and Castle's extrinsic and intrinsic factors is debatable, but it seems likely that the extrinsic factor is either cyanocobalamin or some related compound. The function of the postulated intrinsic factor is apparently to facilitate absorption, but it must be emphasised that no one has ever isolated this factor or determined its precise chemical nature. It has however been prepared in a relatively pure and concentrated form and is believed to be a mucoprotein (Taylor, Turnbull & Witts 1955). Moreover, no one knows what conditions determine its secretion by the gastric mucosa, if in fact it is ever actively secreted at all. (Its presence in the gastric juice does not necessarily mean that it is actively secreted). Although the absorption of physiological amounts of cyanocobalamin seems to depend on the presence of intrinsic factor, detectable rises in the cyanocobalamin in serum and urine can occur when large doses are given by mouth without intrinsic factor, e.g. 1,000 microgrms. (Ross 1954). Haematological effects have been observed when smaller doses (e.g. 50mg) have been given daily to fasting patients. However, for the absorption of the minute amounts present in the diet the special mechanism of the intrinsic factor is necessary.

The basic pathology in pernicious anaemia is a chronic atrophic gastritis. The upper two thirds of the stomach show severe atrophy and in some cases, the wall may be no thicker than parchment paper. This atrophy involves all the coats of the stomach wall, and in the mucosa the specialised oxyntic and peptic cells disappear. An abrupt change to normal is classically described at the junction of the fundus with the pylorus.

Consequent to the gastric atrophy there is a deficiency of intrinsic factor, and hence a deficiency within the body of erythropoietic factor. All the remaining pathology in pernicious anaemia is secondary in this latter deficiency.

The normal maturation in the bone marrow of erythroblasts to normoblasts is interfered with and large primitive red cells (megaloblasts) are formed, some of which may be passed into the blood stream along with other immature forms of red cells. Reticulocytosis, polychromasia and possibly punctate basophilia are characteristically

characteristically seen in blood film, but in the present case the initial reticulocyte count was never greater than 1.2% in spite of the severe anaemia. The production of white cells is also depressed (WBC = 3,400/c.mm)

The diameter of the red cells according to the Price-Jones curve varies between about 3.75 and 13 μ , with an average of 8.3 μ .

Thus, not only are the peripheral cells larger than normal, but they also are variable in size. In addition they are of variable shape. A film of the patient's blood demonstrated clearly the presence of both anisocytosis and poikilocytosis. Poikilocytosis increases the fragility of the circulating cells so that they are mechanically more readily broken down by the reticulo-endothelial system, and for this reason increased levels of serum bilirubin with latent or clinical jaundice is often observed in pernicious anaemia. In the present case in spite of the severe anaemia the serum bilirubin was only 1.0mg%, the upper limit of normal. The excess urinary urobilinogen may have been due to cloudy swelling or fatty change in the slightly enlarged liver.

Whether or not the phagocytic activity of the reticulo-endothelial system is primarily increased is not clear. The observed splenic enlargement which is now a much less common finding than it used to be may conceivably have been due to some such reaction in the spleen, or perhaps to myeloid transformation of the pulp (a reversion in response to anaemia to a prenatal condition). Alternately the splenic enlargement may simply have resulted from congestion secondary to cloudy swelling or fatty change in the liver.

The anaemia which results from the defective formation and the increased destruction of erythrocytes stimulates the early unaffected stages of erythropoiesis, and the red bone marrow spreads into the shafts of the long bones. Fatty change is often prominent in the heart, and although this patient's heart was not clinically enlarged, the apex beat was feeble and the heart sounds were faint. The soft blowing systolic murmur in the mitral area is of doubtful significance it may be a haemic murmur. Fatty change is also no doubt responsible for the slight hepatic enlargement. Although the kidneys were not palpable they may have been similarly affected. There is incipient atrophy of the tongue with absence of papillae.

Subacute combined degeneration of the spinal cord occurs in about 5% of untreated cases (Davidson & Gullard). Its appearance bears no relation to the severity of the anaemia and it was not present in this instance.

The positive stool Gregerson which, in association with her very low weight, at first suggested the possibility of a neoplastic complication. On radiological examination the gastric mucosa was normal but a small hiatus hernia was reported. Although symptom free it would be quite adequate to explain the transient positive stool Gregerson.

Nevertheless neoplasm of the colon is still a possibility that has not been excluded.

TREATMENT

The rational treatment of pernicious anaemia would obviously be to provide the body tissues with adequate amounts of erythropoietic factor. The early dramatic success of oral liver therapy, however, was probably not primarily due to an increase in erythropoietic factor at all but to folic acid. Folic acid has a beneficial effect, at least temporarily, on the macrocytic anaemia; but it does not prevent and may even aggravate the condition of subacute combined degeneration if it is present. It is now a crime to give folic acid to a patient with pernicious anaemia, for not only is it ineffective in curing or preventing subacute combined degeneration, but it masks the diagnosis if this complication should later arise. Today a chemically pure preparation of cyanocobalamin is given by intramuscular injection in preference to liver extract, because:-

- 1) There is little doubt that it is the principal haemopoietic agent in refined liver extract.
- 2) It is very unlikely to give rise to allergic reactions.
- 3) There is no need for bioassay, and
- 4) It is cheapest.

In response to this treatment the bone marrow is converted from megaloblastic to normoblastic blood function. There is, so to speak, a release of inhibition on erythropoiesis and the first thing that appears in the blood, typically after a delay of one day, is a sudden increase in the reticulocyte count. This reaches a peak in about four days, and later subsides to normal values in about seven to ten days. The height of the reticulocyte response is approximately proportional to the initial severity of the anaemia. The present response is shown graphically and is quite characteristic, except that a higher peak might have been expected. In the wake of the rise in reticulocytes is a rise in the erythrocyte count and in the haemoglobin. An increase of 500,000 RBC/cm and 7% Hb can be expected per week after the initial sharp rise. A lot of iron will have to be incorporated into Hb before the normal blood levels of Hb is restored, and although iron has been stored in the body, even perhaps to the extent of siderosis, it may be necessary to give medicinal iron to ensure that the blood film will not become hypochromic as complete recovery is approached. For this reason 200mg. saccharated iron oxide ("Ferrivenin" were given. Since there is some dubiety concerning the absorption of oral iron in the presence of achlorhydria, the intravenous route was used. In practice, however, oral iron is usually quite adequate.

It is of the utmost importance that this patient should continue to receive regular doses of cyanocobalamin for the rest of her life. She will attend the blood clinic to get her injections every two weeks to begin with until the blood picture is normal, and subsequently perhaps once a month. The dose will be regulated so that the haemoglobin level is maintained at approximately 100% and the RBC at 5,000,000. By this measure alone will the complication of subacute combined degeneration of the cord be avoided. She should attempt to get her weight up to normal by eating a diet rich in proteins and vitamins. In this case it should be economically possible. If her

weight/

weight should continue to fall amore thorough investigation of the lower bowel would be advisable.

FINAL DIAGNOSIS.

Addisonian Pernicious Anaemia.

REFERENCES.

Badenoch, Bedford & Evans (1955) : Quart.J.Med. 24, 321.

Card, Marks & Sircus (1956) : "Observations on Achlorhydria"
J. Physiol.

Castle (1929) : "Observations on the Etiologic Relationship of
achylia gastrica to pernicious anaemia".

Minot & Murphy (1926) : "Treatment of Pernicious Anaemia by a
special diet".
J.Amer. Med. Assoc. 87, 470.

Whipple (1925) : "Favourable influence of liver, heart and skeletal
muscle in diet on blood regeneration in anaemia".
Amer.J. Physiol. 72, 408.

Witts (1956) : "B Vitamins in the blood and gastro-intestinal Tract"
Brit. Med. Bull. 12, 14.

A CASE HISTORY OF

- 1) IDIOPATHIC THROMBOCYTOPENIC PURPURA,
- 11) IDIOPATHIC ACQUIRED HAEMOLYTIC ANAEMIA.

WARD 27, R.I.E.

(PROFESSOR SIR STANLEY DAVIDSON.)

December 1955 - January 1956.

by

W. J. IRVINE, B.Sc.Hons.

Name :- Flett, Miss Margaret.
28 Mertoun Place, Edinburgh.

Aged 28.

Occupation :- Secretary.

Date of Admission :- 17/12/55.

Recommended by :- Dr Pole, Gilmour Place, Edinburgh.

Complaints :-

- 1) Unexplained bruising for six weeks (6/52) before admission.
- 2) Purpuric spots for two weeks (2/52) before admission.
- 3) Otherwise perfect health.

History of present illness :-

At the end of October (about six weeks prior to admission) this girl began to notice that she was bruising rather readily. The legs were the most affected, but bruises also appeared on the arms and later on the trunk. Bruises gradually accumulated, and people began to comment on their number and size. At that time, however, she was playing a lot of badminton, and naturally thought that the rough and tumble encountered in the game was responsible. Yet as the weeks past large bruises as big as a butter dish would appear without, as far as she knew, any antecedent injury. The bruising did not affect the face.

About four weeks after the onset of bruising red spots began to appear. They varied in size from that of a pin-head (petechiae) to small blotches (ecchymoses). Once again they were mainly on the legs, but were also present in fairly large and increasing numbers on the arms, neck and trunk. Each crop of spots seemed to persist for several days, turning a brownish-black before finally disappearing. At no time were the spots itchy, they were even with the surface of the skin, and they did not disappear when she pressed them.

Even at this stage she felt perfectly fit, and was playing as much badminton as well, and with the same enthusiasm as before. She did not feel tired and was never unduly breathless. Neither she nor anyone else noticed any change in her colour.

Eventually the spots appeared on her face, and it was this that sent her to her doctor. Two days later she was admitted to Ward 27.

Personal History :-

Her periods are regular, lasting five days every four weeks (5/28). The menstrual loss is average, and has shown no gross change in the last few months. Her last menstrual period at the end of November was only slightly heavier than normal, lasting three days with two to three pads daily. She has not had any nose-bleeds within recent memory, and has never spat or vomited blood. Bleeding from an accidental cut or scratch has never seemed to her to be unduly prolonged. Her stools are of a normal brown colour, and she has not noticed any darkening in recent weeks. The water has remained a normal pale yellow.

Her appetite has always been good, her weight has remained constant, the bowels are generally regular, but on rare occasions require the aid of purgatives. She has no trouble with micturition and in general sleeps well without the help of a hypnotic.

Her general health is good.

Previous Health :-

Measles and whooping cough in childhood; but no scarlet fever, rheumatic fever or nephritis. No history of peptic ulcer or tuberculosis.

She has suffered for some years from mild hay fever, urticaria and eczema, but does not take any drugs for these conditions. The hay fever seems to be an allergy to dust, but she has not had an attack recently.

During 1953-55 she suffered from "nerves" for which she used to take phenobarbitone morning and night. Eventually she took five weeks off work for a rest-cure holiday. She maintains that she has completely got over this and has stopped taking phenobarbitone for some six or seven months.

Over three years ago she took iron tablets for a short time to "boost her blood".

Tonsillitis two months before the onset of bruising, but this was not associated with any marked fever and she did not go to bed. She was treated with penicillin lozenges, but not sulphonamides. She cannot remember when she was last fevered.

For an occasional headache she takes 1-2 tablets Codeine Co.B.P.

For occasional constipation she takes "Ex-lax", but the last time she took this was in the summer.

She has never had a blood transfusion, and has never been in hospital before. Except for the five weeks rest-cure she has never been off work. She has not been X-rayed recently, and has not been exposed to radioactive substances.

Family History :-

Living. Mother (54) Both well with no history of any blood disorder;
Sister (25) both still possess a spleen.

Deceased Father (50) Died from "angina".

No remote history of any similar disorder.

Social History :-

She is unmarried and lives at home.

As a secretary to an attorney she claims to be content with her work. Her main recreation is badminton, which she plays about three nights a week. She neither drinks nor smokes.

On Examination :- A bright, healthy-looking but rather nervous girl. Small, but of good development, muscularity and nutrition. She looks as if she might play good badminton. Afebrile. Her capacity as a witness is good when she feels inclined.

Skin :- Many obvious and large bruises were seen on all parts of the body except the face. The bruising was most marked on the legs,

legs, almost the whole of her thumb and thenar eminence of her right hand was dark black.

Red unelevated spots (petechiae and ecchymoses) were diffusely spread over the body. Again, they were mostly on the legs but large numbers were also on the face, arms and neck. The spots did not disappear on pressure.

Otherwise the skin was healthy.

Lymph Glands :-

Small, firm, mobile, non - tender lymph glands were palpated in the cervical region. Similar small glands were found in the axilla and groin. No significant difference could be detected between the glands of either side.

Alimentary System :-

There was no ulceration of the lips, tongue or buccal mucous membrane. The tongue was of normal appearance, but her teeth showed a few caries. The gums were healthy, and the tonsils were small and clear of infection.

Abdomen :-

Inspection :- Good shape and moved freely with respirations. There were no abnormal prominences, retractions scars or veins.

Palpation :- No superficial resistance or tenderness and the inguinal orifices were normal. On deep palpation no tenderness was detected, nor any abnormal mass.

The spleen could not be palpated, nor could the liver. The colon was not distended.

Percussion :-

confirmed that neither the spleen nor the liver were enlarged.

Auscultation :-

Normal bowel sounds were heard.

Faeces :- Well formed, of normal colour and no trace of frank blood.
Stool Gregerson +ve.

Cardiovascular System :-

Radial Pulse :- 80/min., regular in time and force, of good volume and normal in character. The vessel wall was not palpable.

Blood Pressure :- 138/80. mm.Hg.

Hands :- Warm but not moist. No finger clubbing or koilonychia.

Neck :- No venous distension or abnormal pulsations.

The thyroid gland was not enlarged.

Heart :-

Inspection :- Neither the apex beat nor any other pulsation could be detected.

Palpation :- The apex beat was in the 5th intercostal space within the mid clavicular line. It was of a normal tapping character. No

No thrills were present.

Percussion :- The area of cardiac dullness was within normal limits.

Auscultation :-

Both heart sounds were clear and closed in all areas, and there was no irregularity of rhythm. Both the short (systole) and the long (diastole) pauses were silent :- i.e. no murmurs or adventitious sounds were present.

Respiratory System :-

Breathing :- 15/min., costo - diaphragmatic and regular in rhythm.
No cough or spit.

Chest :-

Inspection :- Well developed and symmetrical with good expansion.

Palpation :- Expansion of three inches. Vocal fremitus normal and equal throughout. Trachea central.

Percussion :- A normal and equal percussion note was obtained in all areas.

Auscultation :- Vesicular breathing throughout in all areas with no accompaniments. Vocal resonance normal and equal throughout.

Nervous System :-

An alert and intelligent girl with a goodish memory and no abnormality of speech. Emotionally, however, she was not very reliable.

No signs of meningeal irritation either by the chin-en-chest or by Kernig's test:

The cranial nerves were treated individually, but no abnormality was detected except for a slight deafness in the right ear. Weber's and Rinne's tests indicated a middle - ear rather than a nerve - deafness.

The pupils were circular, central and equal; they reacted physiologically to light (both directly and consensually) and accommodation.

There was no retinopathy and in particular no petechial haemorrhages were seen.

Motor Functions :-

No involuntary movements or any abnormality of muscle tone. There was no ataxia on walking or rombergism on standing; the co-ordination tests were perfectly performed. Her posture was good,

Reflexes :-

	Biceps	Triceps	Supinator	Knee Jerks	Ankle Jerks	Plantar	Resp	Abdn.
R/side	+	+	+	+	+	-	↓	-
L/side	+	+	+	+	+	-	↓	-

No clonus.

No thrills were present.

Percussion :- The area of cardiac dullness was within normal limits.

Auscultation :-

Both heart sounds were clear and closed in all areas, and there was no irregularity of rhythm. Both the short (systole) and the long (diastole) pauses were silent :- i.e. no murmurs or adventitious sounds were present.

Respiratory System :-

Breathing :- 15/min., costo - diaphragmatic and regular in rhythm.
No cough or spit.

Chest :-

Inspection :- Well developed and symmetrical with good expansion.

Palpation :- Expansion of three inches. Vocal fremitus normal and equal throughout. Trachea central.

Percussion :- A normal and equal percussion note was obtained in all areas.

Auscultation :- Vesicular breathing throughout in all areas with no accompaniments. Vocal resonance normal and equal throughout.

Nervous System :-

An alert and intelligent girl with a goodish memory and no abnormality of speech. Emotionally, however, she was not very reliable.

No signs of meningeal irritation either by the chin-on-chest or by Kernig's test:

The cranial nerves were treated individually, but no abnormality was detected except for a slight deafness in the right ear. Weber's and Rinne's tests indicated a middle - ear rather than a nerve - deafness.

The pupils were circular, central and equal; they reacted physiologically to light (both directly and consensually) and accommodation.

There was no retinopathy and in particular no petechial haemorrhages were seen.

Motor Functions :-

No involuntary movements or any abnormality of muscle tone. There was no ataxia on walking or rombergism on standing; the co-ordination tests were perfectly performed. Her posture was good,

Reflexes :-

	Biceps	Triceps	Supinator	Knee Jerks	Ankle Jerks	Plantar	Resp	Abdn.
R/side	+	+	+	+	+	-	↓	-
L/side	+	+	+	+	+	-	↓	-

No clonus.

CLINICAL DIAGNOSIS.

A history of unexplained bruising with the subsequent appearance of large numbers of purpuric spots virtually necessitates a consideration of all the haemorrhagic diseases.

There might for example be a deficiency in the intrinsic clotting mechanism. If haemophilia was present it would have been obvious at an earlier age. Hypoprothrombinaemia occurs in gross hepatic disease or as the result of certain anti-coagulant therapy, neither of which is at present relevant. A deficiency of plasma fibrinogen may arise as a congenital abnormality or, again, as a result of severe liver disease, and can therefore be excluded on account of the age of the patient and the negative clinical findings.

Defects of the capillary endothelium could very well explain the purpura and spontaneous bruising. In particular anaphylactoid purpura (simplex, Henoch's or Schonlein's) must be considered. Her occasional mild hay fever and urticaria indicate that she is liable to hypersensitivity reactions, but the absence of a current bacterial infection makes purpura simplex unlikely and the absence of toxæmia, joint pain and tenderness argues against a diagnosis of Schonlein's purpura. Although the stool Gregerson is positive there appears to be no serious effusion and no abdominal cholic. Moreover, in Henoch's purpura, which chiefly occurs in children, the spots have a characteristic distribution which is not shown in the present case.

A wide variety of infection may exert a toxic action on the capillary endothelium, but her last noticeable infection was a month or so prior to the onset of symptoms. The infection (tonsillitis) was not severe and the present haemorrhagic symptoms were insidious in onset rather than acute.

There is no history of the consumption of organic or inorganic poisons such as sulphonamides, arsenical or gold preparations, atropine, ergot, iodides, phenytoin, quinidine, quinine. She has not taken phenobarbitone since the summer, and takes only an occasional tablet of Tab. Codeine Co. B.P. for headaches. Whether or not "ex-lax" could give rise to such a condition is not recorded to my knowledge. The appearance of the patient is not in keeping with a chronic nutritional disturbance or a state of cachexia, and there is no history of frequency and no hypertension to suggest chronic nephritis.

The third group of possibilities involves a deficiency of blood platelets. This deficiency could either be primary or secondary. Her abundant good health and enthusiasm for badminton cast doubt on a primary disorder of the bone marrow. Her negative drug and fever histories likewise do not support a secondary thrombocytopenia. She has not been X-Rayed recently nor has she been exposed to radio-active substances. Clinically there is no splenomegaly to incriminate hypersplenism. If there is a thrombocytopenia it would therefore appear to be idiopathic in origin.

In fact her platelet count on admission was 70,000/c.mm.-i.e. there is a very severe thrombocytopenia with a prolonged bleeding time (21+mins), and positive Hess's Test. The normal clotting time excludes any defect in the intrinsic clotting mechanism while the thrombocytopenia/

thrombocytopenia adequately accounts for the condition without postulating any defect in the capillary endothelium. A normal haemoglobin and white count confirm the absence of any primary disorder of the bone marrow, at least in regard to the red and white cell series.

The final diagnosis is, therefore, that of an Idiopathic Thrombocytopenic Purpura.

SUPPLEMENTARY INVESTIGATIONS.

19/12/55

Chest X-ray:-

Calcified focus in the right hilum.
Otherwise negative.

3/1/56

CO₂ combining power = 31.7 m.equiv./litre
Blood urea nitrogen = 17 mg./100 mls.
Serum Na⁺ = 139.5 m.equiv./l
Serum K⁺ = 4.08 m.equiv/l
Serum Cl⁻ = 95.8 m.equiv/l

6/1/56

Electrolytes :-

Within normal limits.

TREATMENT.

17/12/55 Full diet with low sodium content (=3G/day)
 19/12/55 * "Delta cortril" 15mgms. daily
 21/12/55 "Delta cortril" 15mgms b.i.d.
 21/12/55 Potassium Citrate 1g t.i.d.
 23/12/55 "Delta cortril" 15mgms 8 hourly.
 25/12/55 "Delta cortril" 15mgms 6 hourly.

14/1/56 TRANSFERRED TO WARD 8.

Very low salt diet (=1g/day)
 "Delta cortril" 15mgm 6 hourly.

17/1/56 Splenectomy.

Operation:- Mid-line upper abdominal.
 Findings :- Liver appeared normal. Spleen was not
 enlarged and was not mobile.
 No accessory spleen
 Surgeon :- Sir James Learmonth.

23/1/56 TRANSFERRED BACK TO WARD 27

"Delta cortril" 15mgms 6 hourly.
 Moderately reduced salt intake.

25/1/56 Reduce "Delta cortril to 10mgms 6 hourly.
 27/1/56 : : : : : 8 hourly.
 29/1/56 : : : : : 12 hourly.
 30/1/56 : : : : : 15mgms /day.
 31/1/56 : : : : : 5mgms 12 hourly.
 1/2/56 : : : : : 5mgms /day.
 1/2/56 I.M.I. AACTHI. Gel. 40 units.
 2/2/56 : : : : : 30 units.
 3/2/56 : : : : : 20 units
 4/2/56 : : : : : 20 units

Discharged.

THE ROYAL INFIRMARY OF EDINBURGH

Sir STANLEY DAVIDSON

Weight Chart

SURNAME (Block Letters)

CHRISTIAN NAME

CASE No.

Mr
Mrs
Miss
FLETT

MARGARET

(28)

WEIGHT CHART

Dec. 1955

Jan 1956

DATE 20 21 22 23 24 25 26 27 28 29 30 31 1 2 3 4 5 6 7 8 9 10 11 12 13 14 15 16 17 18 19 20 21 22 23

Height = 5' 0"

Correct Weight = 8 st. 6 lbs

7 lbs

Stone

7 lbs

Stone


7 lbs

Stone

7 lbs

Stone

8



SURNAME **FLETT** CHRISTIAN NAME **Margaret** AGE **28** CASE No.

DATE	Hb.	R.B.C. $\times 10^6$ / cmm.	C.I.	P.C.V. M.C.V. M.C.H.C. M.C.H. Retic.	W.B.C. /cmm.	Neut. Polys.	Eos. Polys.	Bas. Polys.	Lymph.	Mono.	Other Cells	Platelets /cmm.	Faeces Occult Blood	Urobilinogen		Therapy
														Faeces	Urine	
16/1/56	100				10,000							100,000				"Delta control 15 mgm 664. + Low Salt Diet.
12-15 p.m.												202,000				
4.0 p.m.												198,000				
17/1/56				SPLENECTOMY in the morning.								250,000				Splenectomy.
18/1/56												204,000				
20/1/56	96	4.88	1.02		12,400							402,000				
23/1/56	96	4.78	1.00		11,400							420,000				
26/1/56												385,000				
30/1/56												375,000				"Pitche out."
31/1/56	102	5.20	0.98		19,000	76%	6%	17%	17%	4%						

DATE	Platelets /cmm.	Bleeding Time (Mins.)	Capillary Fragility		Clotting Time (Mins.)	Miscellaneous Investigations	Bone Marrow Films	Therapy
			Pos. Press	Neg. Press				
16-1-56								
12-15 p.m.	202,000	5 1/2						
4.0 p.m.	198,000	2 1/2						
18/1/56	250,000	5						
						Hear's Test		
						17/12/55 ++		
						29/12/55 ++ (50 plate / sq. mm)		
						13/1/56 +	17/1/56	
						27/1/56 -		
						3/2/56 -		

PROGRESS.

Within a few days of the commencement of treatment with deltacortisone the patient noticed that her cheeks were becoming "fat" and that both her hands were beginning to swell slightly. At about the same time she came out in quite a large number of spots all over the body, including the face and upper chest. These spots were a whitish pink and raised above the level of the skin. (acne)

The bruises and petechiae gradually decreased in number so that after a fortnight only a few spots and bruises remained. Indeed she banged her hand accidentally against the bedside locker without any consequent bruising. Hess's test at this time, however, was still strongly positive with a count of 50 petechiae in one square inch.

On 7/1/56 and again on 8/1/56 she had a slight epistaxis. The first one was initiated by blowing her nose, but the second was spontaneous. They each lasted for one to two hours, with blood slowly dripping down the nasopharynx. Her stool benzidiae, which was worth two pluses (++) on 17/12/55 and again on 26/12/55 was reduced to one plus (+) on 4/1/56.

Thus although the patient was "clinically cured" in so far as the spots and bruises had disappeared, yet in spite of maximal deltacortisone therapy the platelet count remained very low and even tended to fall further. After three weeks treatment the platelet count was only 20,000/c.mm. Splenectomy was therefore seriously considered, and on 14/1/56 was transferred to ward 8 for that purpose. The spleen was removed ^{without} incident by Sir James Learmonth on the morning of 17/1/56. However, the day before splenectomy the platelets began to show a decided rise. This rise continued after splenectomy eventually reaching the order of 400,000/cmm. six days after the operation. This level has since been maintained. Coincident with a normal platelet count Hess's test became negative (27/1/55).

Eight days after splenectomy the dose of delta cortisone was gradually reduced until on 31/1/56 it was 5 mgm 12 hourly. She suddenly developed a severe headache, anorexia, marked nausea and some vomiting, but was not restless and had no joint pains. It is quite probable that her sickness and the low deltacortisone dosage are correlated, her own cortex not yet being able to produce a normal amount of cortisone. No one else had similar symptoms in the ward and she herself could not account for it. Improvement occurred shortly after 40 units ACTH gel were given intramuscularly. (IM)

It is interesting to note the change in mental outlook of the patient, possibly caused by the influence of cortisone. When taking the history I got the impression that she had prior to treatment a rather adverse attitude towards other people, but after a few weeks of treatment I disregarded my first impressions as being quite erroneous. To my surprise, however, she commented on this very change in outlook a few days later without any provocation whatever. When her dosage had been low for a few days she became unco-operative and difficult.

Delta cortisone had no deleterious effect on the healing of the operation wound and the stitches were removed on 31/1/56, a fortnight after the operation. The serum electrolytes after three weeks treatment were within normal limits. Surprisingly the weight has shown a fall rather than an increase. The blood pressure remained constant. Hirsutism did not develop. Potassium citrate was given orally (1G t.i.d) to combat the increased urinary excretion of potassium induced by cortisone therapy.

Fortunately none of the serious complications of the disease occurred; in particular, there was never any clinical evidence for a subarachnoid haemorrhage. A positive stool benzidine test on admission indicated that some haemorrhage was occurring into the alimentary tract probably from lesions similar to these seen in the skin. The later epistaxis emphasises the tendency for haemorrhage.

Follow up :-

19/3/56 ; Feeling perfectly fit. She has had a normal menstrual period since discharge from hospital, and is not showing any further bruising or purpura.

Hb = 91%

Platelets = 535,000/c.mm.

Bleeding Time = 3 mins.

To report back to Blood Clinic in two months time.

12/5/56 Her condition is entirely satisfactory.

Hb = 97%

Platelets = 460,000/c.mm.

Bleeding Time = 1 min.

To report back to Blood Clinic in two months time.

AETIOLOGY :-

Some 40% of cases of idiopathic thrombocytopenic purpura (ITP) occur before the age of puberty, and at this age the sex evidence is equal. After puberty females preponderate in the proportion 5:1. Exacerbation by menstruation and pregnancy has been commonly described and the possible importance of endocrine factors is also suggested by the frequent co-existence with thyrotoxicosis.

In these few cases which have been traced to an idiosyncrasy for certain drugs, e.g. sedormid or quinidine, a "platelet "crises" is induced in the susceptible individual within a few hours of taking the offending drug. Another group of cases occurs from one to three weeks after an infection such as tonsillitis, and these cases may be due to the infecting organism or its products. Although the patient had recently had tonsillitis, the throat infection preceded the onset of symptoms by as much as two months. Like the majority of similar cases the present one remains unexplained.

Nevertheless, evidence has recently been accumulated that at least in some cases a disturbance in auto-immune mechanisms is an important component of the disease. Thus according to Harrington et al (1953) platelet agglutinins have been demonstrated in vitro in the plasma of many patients where thrombocytopenia was of the idiopathic variety and, secondly, a factor presumably identical to this platelet agglutinin is capable of inducing thrombocytopenic purpura and altering megalocaryocytes in normal recipients of this plasma.

The rapidity with which ITP patient's plasma causes thrombocytopenia when transfused into normal recipients is dramatic, and the fast rate at which transfused normal platelets disappear from the circulation of patients known to have the thrombocytopenic factor also tends to be convincing. In the former instance the entire pattern of abnormal reactions of laboratory tests characteristic of thrombocytopenic purpura is induced: prolonged bleeding time, increased capillary fragility, decreased clot reaction, decreased prothrombin consumption and morphologic changes in the bone marrow megalocaryocytes so that very little platelet formation could be seen. The depressed platelet level would persist for from four to seven days. These experiments on man confirm earlier work on animals.

The fact that not all patients with ITP seem to possess this thrombocytopenic factor or platelet agglutinin does not necessarily detract from the importance of such a platelet agglutinin. It suggests that ITP may not be a specific disease but a syndrome which may develop as a consequence of more than one abnormal mechanism. Thus in some instances the disorder may be due to a deficiency of a factor/s necessary for platelet formation, while in other instances it may be due to a suppression of platelet production by metabolic or splenic dysfunction. In yet other instances there seems to be good evidence for an excessively rapid platelet destruction. The main obstacle to progress in this field at the moment is the great need for better methods for studying rates of platelet formation and destruction.

The treatment adopted in this case of idiopathic thrombocytopenic purpura/

purpura is discussed later along with that of the following case of idiopathic acquired haemolytic anaemia.

Name :- Mentiplay, Miss Helen. Aged 24.
71, Shearer Square, Dunfermline.
Occupation :- Unqualified nurse in Northern Hospital Dunfermline;
subsequently a silk weaver in a Dunfermline factory.
Date of Admission :- 9/10/55 from the Northern Hospital Dunfermline.

Complaints :-

Before admission to Northern Hospital Dunfermline there was a history of 2½ weeks of "pumping noise in the head", headache, irritability and vague ill-health, preceded by darkening of the urine and accompanied by pallor.

History :-

Until the end of August 1955 this girl appears to have been perfectly fit when she noticed that her urine was becoming "darker and stronger". This in itself did not cause her much concern, but she was aware of becoming irritable and easily tired. Some days later she developed noises in her ears which she described as like "blowing up a bicycle pump". On direct questioning she said that, like a bicycle pump, the noises were not continuous, but regular in frequency and seemed to keep time with the pulse (she was a nurse). Thinking she needed her ears washed out she went to her doctor for that express purpose. The doctor, no doubt influenced by her biased story, could find no wax and concluded that there must be inflammation of the ear. Two days later she returned to her doctor to tell him "he would have to do something more about it". He prescribed some pills, the character of which is not known to the patient.

At the time her mother noticed that the patient was becoming rapidly pale, lethargic and very irritable. Eventually she could no longer go to work. She did not feel giddy, and her vision was unimpaired. There was no tingling or pins and needles in the fingers or toes. Her appetite was not too bad. She did not have marked palpitation, and did not exert herself sufficiently to become breathless. One evening after taking the pills she was violently sick and took to her bed in a collapsed state. Immediate admission to the Northern Hospital Dunfermline was arranged.

Although she was at once put on high doses of cortisone, jaundice developed in a few days and her condition did not improve. On account of the collapsed state of the veins they had to cut down in order to give a blood transfusion. The addition of ACTH to the cortisone therapy made little difference so that urgent splenectomy was seriously considered. The patient by this time, however, was no longer a good surgical risk, and the assistance of Sir James Learmonth was sought. She was rushed to the R.I.E. but it was then decided to try and build her up prior to operation, and for that purpose she was admitted to Ward 27 on 9/10/55.

Personal History :-

There has been no change in weight, her appetite has remained good. There has been no indigestion, and the bowels have remained slightly sluggish. She has not noticed any change in the colour of the stools. Other than the darkening of the water, she has had no trouble with micturition. The periods have remained regular, persist for five

five days with an average blood loss which has not recently increased. She has always slept well and has no cough or spit.

Previous Health :-

- 1) A vague blood disorder at birth with jaundice -? erythroblastosis fetalis.
- 2) Apart from a rare cold she will admit to none of the common childhood ailments -scarlet fever, rheumatic fever, measles, chicken pox, mumps or whooping cough.
- 3) She has never previously been off work and never before been in hospital as a patient.
- 4) Her only travel abroad was to Montreal (Canada) in 1954 where she stayed for one month.
- 5) No history of fever, septicaemia or malaria, and she is not subject phenomena such as hay fever, urticaria or asthma.
- 6) The question of taking numerous drugs was enquired into assiduously and exhaustively. This included :-
Phenylhydrazine, naphthalene, benzene, nitrobenzene, promin, arsenic, lead, sulphonamides, quinine, pamaquin, para-aminosalicylic acid, phenylsemicarbazide, phenothiazine, neorsphenamine, benzedrine, mesantoin, and antihistamines.

The various diseases for which these drugs are used were also inquired into, but with no positive result.

The only drugs she has taken are :-

ASA

Cod liver oil

Codeine tablets (Tab. Codeine Co./B.P.)

Aspirin

Unknown tablets taken for tinnitus (Ferrous sulphate)
(Penicillin)

Family History :-

Living :- Father (48) ; quite healthy.

She has no brothers or sisters.

Deceased :- Mother (44) from Rheumatic Carditis.

No history of anaemia or any blood disorder.

Social History :-

Lives at home in Dunfermline with her father. She is clearly not inwardly content; she has changed her job as an unqualified nurse to a silk weaver in a factory, she went to Montreal with the intention of emigrating, but gave it up after a month and paid her own fare home. She is unmarried.

She used to smoke about five cigarettes per day, but has stopped since going on cortisone. More or less teetotal.

ON EXAMINATION:-

Except for her pale and slightly icteric appearance and her marked tiredness this girl appeared fairly healthy. The mucous membranes were poorly injected. There was no purpura or rash; there was no venous engorgement, sacral oedema or swelling of the ankles. She was afebrile and of good development, muscularity and nutrition. Her capacity as a witness, however, was not very commendable.

CARDIOVASCULAR SYSTEM:-

Radial Pulse = 95/min., regular in time and force, and of moderate volume. The character of the wave was normal and the vessel wall was impalpable.

Blood Pressure = 130/60.

Examination of hands :- Not excessively warm, but rather moist.
No finger clubbing or koilonychia.

Neck vessels :- No venous engorgement or abnormal pulsations.

Heart :-

Inspection :- No subclavicular pulsations were seen.

Palpation :- Apex beat in mid-clavicular line. No other pulsations were present, and there were no thrills.

Percussion :- Areas of cardiac and hepatic dullness present and within normal limits.

Auscultation :- A soft blowing systolic murmur replaced the first heart sound in all areas. This murmur was best heard in the mitral area, and was propagated into the left axilla. The second was clear and closed in all areas, and was nowhere abnormally accentuated. The long pause was silent. There were no adventitious sounds.

RESPIRATORY SYSTEM :-

Breathing :- 18/min., regular and costo diaphragmatic.
No cough or spit.

Chest :-

Inspection :- Well developed and symmetrical in form and movement.

Palpation :- Good and equal expansion (3")
Vocal fremitus unimpaired and equal throughout.
Trachea central.
No supraclavicular, submental or axillary glands were palpable. There was no thyroid enlargement.

Percussion :- normally resonant and equal throughout.

Auscultation :- Vesicular breathing in all areas with no accompaniments.
Vocal resonance unimpaired and equal throughout.

ALIMENTARY SYSTEM. :-

The lips were pale but there was no angular stomatitis or any evidence of glossitis. Some gingival infection was present and the teeth were carious, but the breath was not offensive.

Abdomen :-

A little plump but not markedly obese; it moved freely with respiration, and showed no scars or veins or local prominences.

Palpation :-

There was no resistance (superficial or deep) or tenderness. Only a few inguinal nodes were palpated, and they were soft, non-tender, mobile and present on both sides.

Neither the spleen nor the liver could be palpated. The kidneys likewise could not be felt. There were no abnormal masses.

Percussion :-

Confirmed the absence of clinical splenomegaly or hepatomegaly.

Auscultation :-

Normal bowel sounds heard.

Faeces :- Well formed and slightly better pigmented than normal.

NERVOUS SYSTEM :-

She tended to be depressed, and when so, had rather limited power of concentration. Her memory was quite good, however, and she had no trouble with her speech.

There was no evidence of meningeal irritation (Chin-on-chest and Kernig's Tests).

Each of the cranial nerves were treated individually, and all were found to be intact and fully functional. The pupils were circular, central and of moderate and equal size. They reacted to light both directly and consensually and to accommodation.

There was no retinopathy.

No involuntary movements could be detected and muscle tone in all limbs was normal. The co-ordination tests were well performed.

Reflexes :-

Biceps	Triceps	supinator	Knee J.	Ankle J.	Babinski	Abdominal
+	+	+	+	+	↓	+ +
+	+	+	+	+	↓	+ +

No clonus.

Both superficial and deep sensation (touch, pain, vibration and proprioception, respectively) were unimpaired. Stereognosis was faultless.

EXAMINATION OF URINE :-

Yellowish brown in colour, with no obvious deposit :

S.G. = 1.018 acid.

Urobilinogen = ++

Bile Pigments = +ve

Bile salts = -ve

Albumen = -ve

Bile Sugar = -ve

Acetone = -ve

Microscopically- No RBC, pus cells, casts or organisms present.

EXAMINATION OF THE BLOOD :-

Hb = 21%

RBC = 1.1M

CI = 0.35

Reticulocytes = 15.4%

WBC = 24,270./cmm.

EPR = 164 w/h. at Dimpfunda

CLINICAL DIAGNOSIS.

When the girl presented herself to her general practitioner she complained solely of noises in the head which she felt sure were due to inflammation or wax in the ear. Although he could not have found any good reason for it on auroscopic examination, the doctor prescribed penicillin tablets. By her second visit a few days later the demanding tone of her voice ("you'll have to do something more about it") and her increasing pallor and lethargy must have underlined the symptoms of anaemia. Now, since the commonest cause of anaemia in a woman of child-bearing age is a post-haemorrhagic anaemia consequent to excessive menstrual loss, it is perhaps understandable why iron tablets were prescribed. However, there was no history of dysmenorrhoea and the doctor failed to enquire specifically as to whether there had been any change in the colour of the urine or stools - his one guiding symptom in this case to the correct diagnosis. She herself had no doubt at all about the early darkening of her urine, and simply did not mention it to the general practitioner because she thought it irrelevant and ("he didn't ask, so why should I?")

Two very simple tests - the determination of the blood haemoglobin and urinary urobilinogen - could quite easily have been carried out by the practitioner in the first instance and this might have avoided to some extent the development of such a collapsed state before a diagnosis was made.

The haemoglobin on admission was 21%.

There is nothing in the history to suggest an acute blood loss, while the observation that the colour index is within normal limits contra-indicates the occurrence of a chronic blood loss. The anaemia might therefore be due either to hypoplasia of the bone marrow (primary or secondary) or it could be due to the excessive breakdown of erythrocytes within the body. The presence of jaundice with an excess of urobilinogen in the urine point to a haemolytic anaemia, while the reticulocyte count of 15.4% refutes any possibility of a bone marrow hypoplasia.

A diagnosis of ^{congenital} haemolytic anaemia is opposed by the age of the patient (24), the absence of a family history of anaemia or jaundice, and by the absence of any clinical splenomegaly. No spherocytosis was seen in the blood film. No history could be elicited of a preceding bacterial infection (e.g. haemolytic streptococci, staphylococci, clostridium welchii) nor of any protozoal infection (e.g. malaria). An exhaustive investigation into the consumption of any one of numerous drugs and poisons was made without avail. It would therefore seem that the haemolytic anaemia is not due to any infective or toxic factor.

The patient has never previously been transfused. There is no history of skin rashes or joint pains to suggest syphilis, and on clinical examination there was no evidence of cirrhosis of the liver, nor any chest, alimentary or renal signs to suggest tuberculosis. The patient is too young for malignant disease to be likely. The high white count (WBC = 24,270/c.mm) would be indicative of leukaemia.

leukaemia if it were not for the high reticulocyte count. The present haemolytic anaemia does not, therefore appear to be symptomatic in origin. A paroxysmal haemoglobinuria is contra-indicated by the occurrence of jaundice and the presence of excess urobilinogen in the urine.

By the process of exclusion there remains the diagnosis of idiopathic (acquired) haemolytic anaemia.

TREATMENT AND PROGRESS.

At the Northern Hospital Dunfermline.

1) Cortisone, rapidly stepping up to full dosage

Her Hb failed to respond:-

34%, 30%, 33%, 29%, 26%, 27.5%.

Reticulocyte Count:-

11% - 26%.

2) Reinforcement of the cortisone with ACTH appeared to make no difference, and there was a further fall in Hb.

3) Blood Transfusion, but experienced difficulty in getting a vein, eventually cutting down.

4) Splenectomy was urgently considered, but owing to the poor state of the patient the assistance of Sir James Learmonth was sought and she was rushed to the R.I.E.

At the R.I.E.

It was decided to try and build her up prior to operation.

	<u>Treatment</u>	<u>Progress</u>
10/10/55	2 pts Packed Cells Cortisone 100mg.	For blood picture and biochemistry see adjoining charts. 1) Gradual development of "moon-face" and purpura, mainly on her arms and legs. 2) Persistent mild jaundice 3) Wt changes shown in adjacent chart.
11/10/55	Cortisone 200mg.	
12/10/55	3 pts Packed Cells Cortisone 300mg.	
13/10/55	Cortisone 300mg daily.	
1/11/55	Cortisone 200mg daily.	
10/11/55	Cortisone being reduced.	
16/11/55	Cortisone 75mg/day.	
7/12/55	Cortisone 50mg/day.	
14/12/55	Discharged on Cortisone 50mg./day.	

The patient continued to feel weak and fatigued and soon relapsed with the return of "the pumping noise in the ears", jaundice, headache, irritability, increased fatigue, and darkening urine.

20/12/55. Readmitted.

O/E. Obviously jaundiced, pale mucous membranes and obvious facial oedema of cortisone therapy.

She was irritable and depressed.

No lymphadenopathy.

Alimentary System:-

Similar to 10/10/55 and in particular the spleen was not palpable

Cardiovascular System:-

Radial pulse 80/min, regular in time and force, of moderate volume and normal character.

B.P. = 120/70 No change in hands or neck vessels.

Heart:- Apex beat is still in the mid clavicular line, and there is no change in the character of the heart sounds. No signs of cardi failure.

Respiratory System:- Breathing regularly at 16/min.

No cough or spit.

Vesicular breathing throughout with no basal crepitations or dullness.

Hb = 42%

RBC = 2.17×10^6 /cm.

Reticulocytes = 18%

C I = 0.97

WBC = 20,700/cmm.

Serum bilirubin = 5.6mg./100mls.

Urinary urobilinen = +++.

	<u>Treatment</u>	<u>Progress</u>
20/12/55	3pts.packed cells. Cortisone 100mg./day.	
27/12/55	Splenectomy Ward 8 1 pt. blood at operation 2 pts. blood slowly that night.	
4/1/56.	Packed RBC.	
5/1/56.	Readmitted to Ward 27 from ward 8.	"Delta cortril"
14/1/56	"Delta cortril" 25mgm 8hrly	still mildly
17/1/56 15mgm 6hrly	jaundiced and
	Stitches out.	somewhat depressed.
	Delta cortril 50mgm daily	
20/1/56 10mgm 6 hrly.	
23/1/56 10mgm 8hrly	
26/1/56 25mgm daily	
28/1/56	<u>Discharged</u> fully ambulant, cheerful, and optimistic. The scar had healed well, but the sclera were still noticeably icteric.	

The following therapeutic programme was arranged:-

28/1/56	25mgs "delta cortril"	
29/1/56	20mgs /day	
2/2/56	15mgs	
6/2/56	Report to Blood Clinic R.I.E.	

INVESTIGATIONS CARRIED OUT AT THE NORTHERN HOSPITAL, DUNFERMLINE.

Hb	25%
RBC	840,000/c, mm
WBC	17,200/c. mm.
ESR	164mm/hr.
PCV	14%
MCV	166/c. micron ?
MCHC	25%
Differential Count	Normal
Reticulocyte Count	33%
Sternal marrow	Normoblastic hyperplasia.
MSU	No pus, blood, casts or organisms.
Fractional Test Meal	Within normal limits
Serum bilirubin	2mgms%
Direct van den Bergh	-ve.
Coomb's Test	Strongly positive
Red cell fragility	Resists 0.45% saline.

FURTHER INVESTIGATIONS CARRIED OUT AT THE R.I.E.

- 12/10/55 Chest X-ray :- -ve.
W.R. -ve.
- 13/10/55 A trace of Corproorphyrin (types 1&2) was detected in the urine, Uroporphyrin was not detected.
- 15/10/55 R.B.C. fragility test :- normal
- 17/10/55 Paul Bunnel Test:- There was agglutination of *def* R.B.C up to and including a serum dilution of 1/16.
- 4/11/55 E.N.T. department:-
O/E both drumheads were normal; hearing on each side good.
Tonsils buried and nasopharynx clear.
Nose healthy with no discharge.
The anaemia from which she suffers could easily explain her tinnitus.

BIOCHEMICAL INVESTIGATIONS.

Serum Protein

Date	Total Protein	Albumin	Globulin								NPN
			α ₁		α ₂		β		γ		
	g/100ml	g/100ml % of total	g/100ml	% of total	g/100ml	% of total	g/100ml	% of total	g/100ml	% of total	
10/10	4.5 g/100ml	2.8 63%	0.3	6%	0.2	5%	0.4	8%	0.8	17%	
11/12	6.6 -	3.5 53%	0.4	6%	0.5	7%	0.5	8%	1.7	26%	
12/12		3.99	← 1.7 g/100ml →								30 mg?
1/1	6.1 -	3.7 61%	0.3	5%	0.4	6%	0.5	7%	1.2	20%	

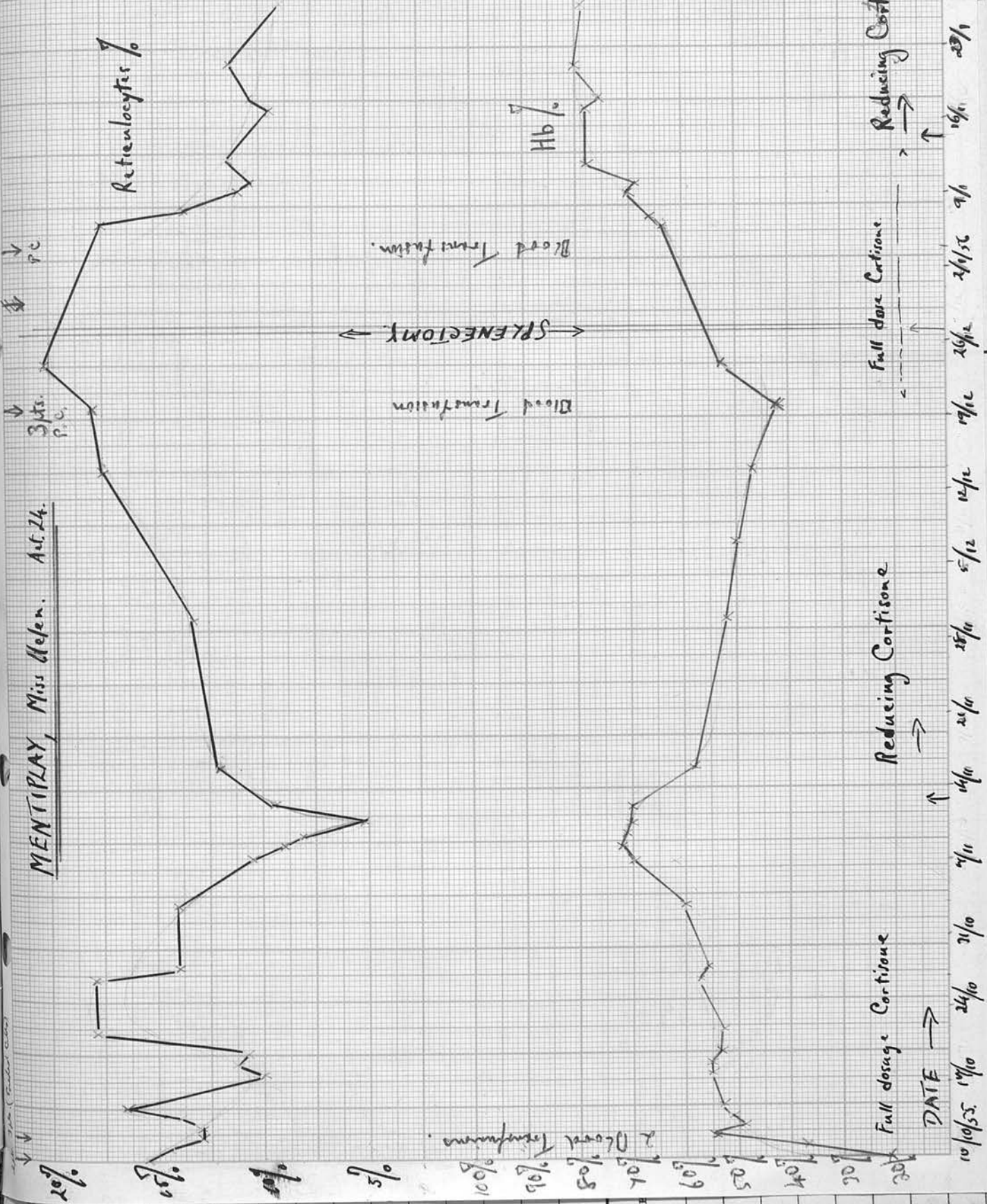
Electrolytes

Date	Na ⁺	K ⁺	Cl ⁻	CO ₂
10/10/55	134.8	3.57	97.2	31.2
16/10/55	145.7	3.26	101.9	31.2
11/12/55	136	4.86	100.2	26.8

Bile Pigments

Date	Serum Bilirubin	Faecal Stercobilinogen	Urobilinogen
10/10/55	2.1mg/100 ml.		
16/10/55			1.1mg/100 or 19.8 mg/24 hrs
4/11/55		62.7mg in 24hrs.	
23/12/55	5.6mg/100 ml.		
9/1/56			1.6mg/100 ml or 19.2mg/24hrs
20/1/56	2.0mg/100		
24/1/56			0.74mg/100 or 12.6mg/24hrs

MENTIPLAY, Miss Helen. Aut. 24.



Sir STANLEY DAVIDSON

THE ROYAL INFIRMARY OF EDINBURGH

Weight Chart

SURNAME (Block Letters)

CHRISTIAN NAME

CASE No.

Mr
Mrs
Miss
MENTIPLAY

HELEN

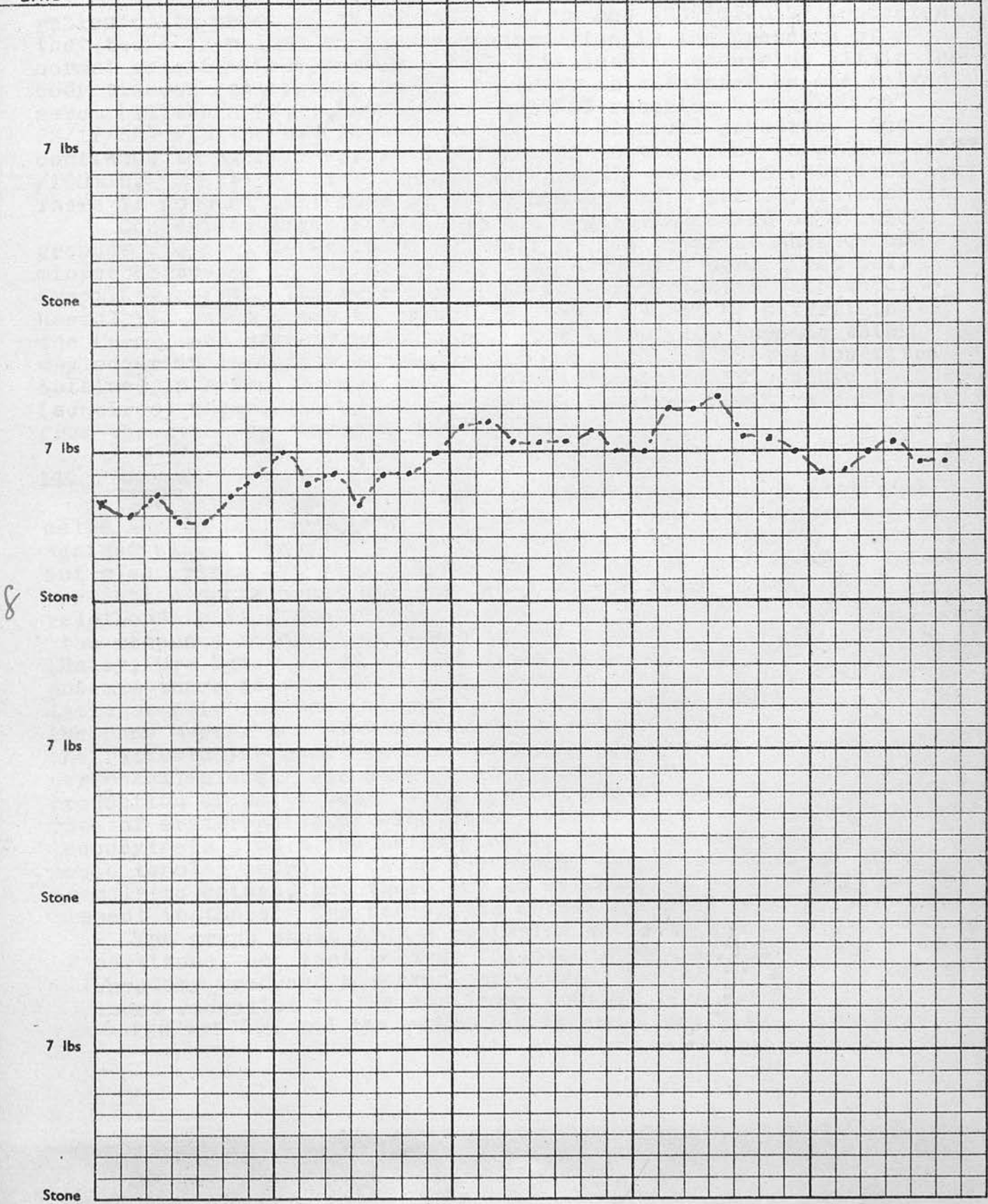
WEIGHT CHART

October

November

DATE

9 10 11 | 30 31 1 2 3 4 5 6 7 8 9 10 11 12



8

COMMENTARY.

1. Differential Diagnosis.

A normoblastic hyperphasia of the bone marrow with a reticulocyte count of 15.4% and a low Hb and RBC (CI=0.9) indicates that there is a loss of formed erythrocytes in the presence of a normal reactive bone marrow. That this loss is occurring within the body tissues rather than to the exterior is witnessed by the raised serum bilirubin (2.1mg/100mls on 10/10/55 reaching 5.6mg/100 on 23/12/55) and the development of obvious clinical jaundice. She continued to excrete excess urobilinogen in the urine (e.g. 1.1-1.6mg/100mls). Faecal stereobilinogen was greatly raised (62.7mg in 24 hrs). There is no doubt therefore of the diagnosis of a haemolytic anaemia.

Congenital haemolytic which was contra-indicated on clinical grounds was finally excluded not only by the repeated absence of microspherocytes in the blood film but also by a normal red cell fragility curve. The rare condition of porphyrinuria with which a haemolytic anaemia may be associated was excluded by determining the faecal and urinary porphyrins. The haemolytic anaemia which may occur in infective mononucleosis was excluded by the low titre obtained in a Paul Bunnell Test. The diagnosis of idiopathic (acquired) haemolytic anaemia, however, received positive confirmation from the strongly positive Coombs' Test.

11. Progress

The patient responded well to blood transfusions with packed cells and to full dosage of cortisone. The graph of reticulocytes against blood haemoglobin not only displays the patient's progress, but also brings out very clearly the reciprocal relationship between the reticulocyte count and the level of the blood haemoglobin. This relationship is diametrically opposite to that seen at the start of the response to cyanocobalamin in the case of pernicious anaemia (Maley, Mrs Mgt.) which is also presented. In the case of pernicious anaemia there is abnormal erythropoiesis whereas in acquired haemolytic anaemia the bone marrow is reacting normally to anoxia. Indeed the bone marrow has been sufficiently stimulated that not only is the reticulocyte count raised but a few normoblasts are seen in the peripheral blood. For some unknown reason there is also an increased production of white cells - in sympathy, as it were, to the augmented rate of erythropoiesis. The blood picture shows a polymorphonuclear leucocytosis plus a few metamyelocytes and even some myelocytes. Acute tubular necrosis is an occasional complication of an acute haemolytic crises, but there was no evidence of renal damage in the present instance. The haemolytic crises was more chronic than acute.

The graph shows that a remission was obtained with full dosage of cortisone, but that relapse followed when this dosage was reduced. Splenectomy produced a marked improvement in that relapse no longer followed reduction in the cortisone dosage. The haemoglobin on discharge was 79% and the reticulocyte count was 9.2%. Excess

excess urobilinogen was, however, still present in the urine. The rationale of cortisone and splenectomy in this condition is discussed later.

Miss Mentuplay suffered from much the same side effects of cortisone therapy as did Miss Flett (ITP), except that in the case of Miss Mentuplay the moon face was more obvious, and there was a decided weight increase. This is probably explained by the fact that Miss Mentuplay was on cortisone for the greater part of her treatment while Miss Flett was on delta-cortisone, an analogue of cortisone which is supposed to have less effect on the retention of electrolytes. Both patients developed the typical spots (acne), but Miss Mentuplay never developed anything resembling the temporary euphoric attitude of Miss Flett. Miss Mentuplay had no cortisone withdrawal symptoms. Neither patient showed any evidence of hirsutism or upset in menstrual cycle.

Follow up at Blood Clinic :

7/2/56 Hb = 85%
RBC = 4.26M
C.I. = 1.0

Reduce deltacortril to 10 mgms./day.

16/2/56 Leg swollen for one day during last week, but claimed to feel quite well and there was no clinical evidence of jaundice.

Hb = 71%
RBC = 4.16 M.
Retics = 5.8%
Continue on 10 mgms deltacortril /day.

22/2/56 Hb = 82%
RBC = 4.33 M
CI = 0.95
Retics = 6.5%
WBC = 16,400 /c.mm
Continue deltacortril.

8/3/56 Feeling very well and has not suffered any toxic symptoms from her deltacortril.

Hb = 68%
Retics = 1.4%
Continue 10 mgms deltacortril /day.

14/3/56 Came with a letter from her doctor saying she had been jaundiced and not feeling well. She was re-examined but nothing fresh was found. She thinks that her anaemia may have been produced by a home perm outfit she was using; this is unlikely, but she was advised not to use it again.

Hb = 52%
RBC = 2.75 M
Retics = 22%
WBC = 23,600 /c.mm.

- 21/3/56 Hb = 61%
Continue deltacortril.
Recommended to get a sitting job.
- 28/3/56 Hb = 51%
Retics = 44%
- 4/4/56 Hb = 59%
Retics = 36%
RBC = 2.91 M
WBC = 23,000 /c.mm.
- 20/4/56 Looking better
Hb = 68%
RBC = 3.09 M
CI = 1.1
WBC = 20,400 /cmm.
Retics = 13.0%
All treatment stopped and asked to report back in one week.
- 25/4/56 After stopping cortisone she came out in a very itchy papular rash on the face and neck. Slight icteric tinge in sclerae. Nevertheless, feels well generally and there has been no increase in breathlessness or tiredness. She is able to climb two flights of stairs without breathlessness.
Hb = 65%
RBC = 3.00 M
CI = 1.08
WBC = 16,400 /c.mm.
Retics = 31.5%
The rise in the reticulocyte count may have been slightly influenced by the occurrence of two days menstruation, but this cannot be the whole explanation. Urinary urobilinogen was moderately positive; bile was absent.
Recommended to try another week without cortisone.
- 7/5/56 She has noticed no deterioration in her own condition and in fact has remarkably few symptoms.
Hb = 54%
RBC = 2.12 M
Retics = 23%
Recommended to re-start cortisone (10 mgm delta cortisone twice a day).
- 23/5/56 Looking better
Hb = 59%
RBC = 2.44M
C.I. = 1.20
Retics = 17%
Continue delta cortisone 10 mgm twice a day.

SUMMARY OF PROGRESS :-

Miss Mentiplay's progress since discharge was initially very encouraging, but has since proved disappointing.

Until 14/2/56 10mms. delta cortisone (prednisone) was adequate and gave rise to no toxic symptoms. Jaundice suddenly developed, the Hb and RBC fell markedly and the reticulocyte count rose sharply. Clearly a mild haemolytic crises had occurred. Improvement later occurred with the same dose of cortisone, but when cortisone was removed altogether signs of impending relapse were again apparent.

The prognosis in this case is poor, splenectomy having failed to effect a lasting cure. We can only hope that the haemolytic tendency can be kept in abeyance by subtoxic doses of cortisone.

AETIOLOGY and PATHOGENESIS.

Acquired haemolytic anaemia is associated with the presence of a circulating antibody, active at 37°C, though in a small proportion of cases activity only occurs when the blood in some part of the circulation is cooled below the normal temperature. The antibodies concerned are auto-antibodies to which the patient's erythrocytes are susceptible. Red cells from patients with this disease can be shown by the anti-globulin test to be coated with antibody, whose existence in the plasma also can be shown by indirect antiglobulin tests or the use of enzyme treated cells. It has been demonstrated (Dacie and Mollison 1943, Brown et al 1944, Mollison 1947) that if patients with acquired haemolytic anaemia are transfused with normal red cells these cells are rapidly eliminated. More recently, Selwyn and Hackett (1949) have shown that prior to their elimination the normal corpuscles may also be coated with antibody, and so react with antiglobulin serum. On the other hand, apart from an initial phase of increased destruction the red cells of the patient are eliminated from the circulation of a normal recipient at a normal rate.

In spite of the fact that antibodies capable of producing haemolysis in vitro are difficult to demonstrate, it seems reasonable on the above evidence that the presence of auto-antibody plays an important part in the pathogenesis of acquired haemolytic anaemia. Thus it could be that the blood cells of the patient might be slightly altered by contact with some extraneous substance, drug, viral or bacterial enzyme and so trigger off a process of auto-immunisation with the production of auto-agglutinins and haemolysins. Whether or not acquired haemolytic anaemia arises in this way is not proven. An alternative mode of production of the auto-antibodies may be as the result of a primary abnormality of the plasma-protein and antibody-forming mechanism. The problem is a very complex one and although fascinating it would not be profitable to explore it further at this juncture. Unfortunately, in the present instance no attempt was made to demonstrate the auto-antibodies described above.

Some workers are of the belief that the haemolytic crises that are characteristic of AHA may be due to a sudden arrest of the hyperplastic erythropoietic process superimposed upon excessive haemolysis.

TREATMENT OF IDIOPATHIC THROMBOCYTOPENIC PURPURA (ITP) AND ACQUIRED HAEMOLYTIC ANAEMIA (AHA).

The treatment of the two conditions is so similar that they will be considered together.

1) Transfusion :-

Blood transfusion was not necessary in the case of ITP since there was no severe haemorrhagic loss, but repeated transfusions of packed cells were required to sustain life in the case of AHA. Packed cells were given slowly in order to avoid precipitating failure in a heart with an already augmented output on account of anaemia. The pulse rate prior to transfusion was rapid (95/min), ~~and~~ the apex beat was in the mid clavicular line, and there was a soft blowing systolic murmur. Much care had to be taken in the blood typing since reactions are particularly liable to occur in AHA.

2) Cortisone :-

"In most patients with acquired haemolytic anaemia or ITP remissions can be induced by the administration of ACTH or cortisone. The importance of adequate dosage is to be stressed. Remissions can often be maintained for long periods by the continued administration of these cortical steroids" (M.R.C. Report: 1955).

Cortisone appears to have two more or less separate effects in the condition of ITP; an effect on the clinical bleeding and capillary resistance may be independent of an effect on the platelets. The dissociation of these two effects is well seen in the present case. The bruises and purpura disappeared in response to delta cortisone, and Hess's test showed some improvement although it was not restored to normality before splenectomy was performed. The amount of occult blood in the faeces showed some decrease. There was, therefore, a virtual clinical cure in spite of the fact that the platelet count remained very low.

According to the literature this arrest of clinical bleeding and improvement of the capillary resistance is a constant finding, while a rise in the platelet count is frequently not elicited. In the present case delta cortisone in high dosage was given for three weeks without there being any rise in the platelet count. On the day prior to operation, however, a slight rise did occur which may or may not be significant. Although this absence of a platelet response is the more usual finding with cortisone therapy, in some cases the platelet count has been reported to have risen shortly after the onset of treatment. The duration of this platelet response is variable, a short course of treatment has been followed by a permanent remission, while in other cases relapse occurred on cessation of the drug. The natural history of the disease confuses the evaluation of cortisone therapy for in the absence of treatment the condition may remit spontaneously or may pursue a cyclic course, or it may persist.

If we accept that cortisone may directly influence the platelet count, it is probably operative through modifying antigen-antibody reactions of the type described under the aetiology of the condition.

condition. Indeed, Stefani (1955) has reported that ACTH or cortisone significantly decrease the blood titre of platelet agglutinin. It has been emphasised, however, that not all patients with ITP harbour Harrington's platelet agglutinin, and that the condition of ITP may not be a specific disease at all but a syndrome of multiple aetiology and pathogeneses. Consequently the variation in the platelet response to cortisone may perhaps be understandable.

The subject is further complicated by the absence of platelet budding from marrow megalocaryocytes in patients with ITP. This suggests that myeloid stimulation may be a significant factor in effecting a platelet response.

When ACTH or cortisone is given to patients with AHA, it has reported that the changes that occur in the antibody titre do not vary directly with change in haemolytic activity. Indeed, Meyers et al (1952) report a case in which a marked rise in the titre of auto-immune bodies occurred at a time when clinical and haematological remission was evident. This would suggest that the administration of these steroids may restore haemopoietic equilibrium through a combination of effects, including modification of antigen-antibody reactions, diminished red cell destruction by the reticulo-endothelial system, and myeloid stimulation. In the present case there was remission with full dosage of cortisone, but when the cortisone was reduced a relapse occurred.

In summary it is quite clear that the use of cortisone or delta cortisone in these two haematological disorders is at the moment quite empirical.

Delta cortisone is preferred to cortisone since it is about five times more active (so that 75mg./day is a full dosage) and is thought to be less liable to produce fluid retention.

SPLENECTOMY :-

Among the physiological activities of the spleen are included reservoir function and sequestration of erythrocytes, haemopoietic activity at certain phases of life, phagocytic and reticulo-endothelial activity, possibly hormone production, and capacity to elaborate antibodies. A number of these functions may be of importance in the two disorders under consideration, either through a primary functional derangement or through the operation of a normal physiological mechanism on unduly susceptible cells.

Since Kaznelson first reported the successful effects of splenectomy in idiopathic thrombocytopenic purpura in 1916, the role of the spleen in this condition has been much debated. One hypothesis was that the excessive destruction of platelets took place in the spleen, while a second hypothesis contended that the spleen exercised an inhibitory action on the maturation of the megalocaryocytes and on platelet formation in and release from the bone marrow. Histological evidence of increased platelet destruction in the spleen is not usually found in idiopathic thrombocytopenic purpura, although it has been observed by some workers (Nickerson & Sunderland 1937; Wiseman et al 1949). In vivo studies of splenic activity have likewise yielded discrepant results.

On the other hand, the early observations of Frank (1915, 1925) that marrow megalocaryocytes were normal or increased in number in idiopathic thrombocytopenic purpura, but showed defective granularity, and platelet formation has frequently been confirmed in recent years. After splenectomy a rapid change occurs in the marrow and the megalocaryocytes become surrounded by large masses of platelets. Numerous cells with Howell-Jolly bodies were seen in the blood film of the patient with AHA after splenectomy, but not in the film of the patient with ITP. Showers of nucleated cells and cells with Cabot rings are also frequently described after splenectomy, but were not seen in the present cases. However, the evidence for the inferred splenic hormone is entirely indirect and observations before and after injecting extracts from normal and pathological spleens into animals have been equivocal and inconsistent.

The recent concept of auto-immune idiopathic thrombocytopenic purpura is based on a firmer experimental evidence (Harrington 1951 : 1953). In those cases to which this concept is applicable it seems the splenic functions involved are these of sequestration and destruction of platelets rendered susceptible by antibody sensitisation, together with possible initial contribution to the formation of the antibodies. Stefanini (1955) has recently shown that although splenectomy does not apparently influence the titre and activity of platelet antibodies, the thrombocytopenic effect of injected ITP plasma in experimental animals is greatly reduced by previous splenectomy or ligation of the splenic artery in the recipient. This perhaps suggests that the splenic contribution to antibody formation in idiopathic thrombocytopenic purpura is not of great importance, but that it is the thrombocytolytic role of the spleen which is prominent. Many more observations on this point are necessary, however, before any confident conclusion can be made.

The association of circulating auto antibodies with acquired haemolytic anaemia at once suggests that the spleen may be the major site for the production of these auto antibodies. Splenectomy in this condition is sometimes followed by a sharp reduction in the level of auto-antibody, but in other patients the reduction may be slight, or may not occur at all (Dacie 1954). Thus it is probably fair to conclude that although the spleen may be a site of ante-antibody production, it is not the only site. Since splenectomy is in fact successful in improving the condition substantially, or even in producing a clinical cure, in about 50% of cases (including the present one) it seems likely that some other splenic function is also involved.

Cell sequestration and concentration in the splenic sinuses perhaps augmented in acquired haemolytic anaemia by erythrocyte agglutination due to the action of the circulating ante-antibodies, is probably of great importance. Sequestration may lead to local spherocytosis with an increased fragility, and therefore susceptibility to haemolysis. Congestion and haemosiderosis are usually prominent features of splenic histology in acquired haemolytic anaemia, which indicates that erythrostatic and phagocytic activity within that organ must be considerable.

considerable.

In both idiopathic thrombocytopenic purpura and in acquired haemolytic anaemia it would seem that the success of splenectomy in many cases may be attributable chiefly to the removal of a major site of cell sequestration and concentration and their phagocytic sequelae. Some confirmatory evidence for this hypothesis is to be found in the vascular anatomy of the mammalian spleen. Kinisely (1936) demonstrated that blood from the Malpighian bodies passes through arterioles and arteriolar capillaries into venous sinuses from which further circulation into the collecting venules is controlled by an efferent sinus sphincter. Closure of this sphincter leads to gross distension of the venous sinuses and the wall of the dilated sinus comes to act as a filter which allows plasma to escape into the splenic pulp but retains the erythrocytes and platelets. Although Kinisely's conception is now widely accepted and suits our present purpose, it must be remembered that it is but one of several views on the complex subject of the splenic circulation which has been extensively reviewed by Bjorkman (1947).

The mere aggregation of red cells in packed masses may be followed by anoxic degenerative changes, with the production of metabolites possessing osmotic activity which tend to give rise to haemolysis. Selweyn and Dacie (1954) postulate a degenerative change in the cell membrane as the factor of prime importance in lysis and no doubt several mechanisms are potentially available in the spleen whereby the red cell membranes may be weakened. Nevertheless, the spleen does not appear to be by any means the only organ of red cell destruction for under normal conditions the life-span of erythrocytes after splenectomy is not significantly increased.

In conclusion a substantial number of cases of both idiopathic thrombocytopenic purpura and acquired haemolytic anaemia seem to be immuno-allergic in origin. The success of cortisone and delta - cortisone is most probably due to their effect in modifying antigen-antibody reactions, although in idiopathic thrombocytopenic purpura these drugs have the additional effect of increasing the capillary resistance. The success of splenectomy in some cases probably lies mainly in the removal of a site of increased erythrocyte or platelet destruction, the result not necessarily of a primary disorder of splenic function, but rather of the operation of a possibly normal splenic function on sensitised blood elements.

PROGNOSIS IN ITP. & AHA.

The amelioration of symptoms observed in both cases subsequent to splenectomy may be due either to the removal of one of the main sites of antibody-formation, and/or of increased lysis. The spleen, however, is not the only organ that performs these functions. Moreover, splenoculi have been described which may undergo hyperphasia following splenectomy so that in the course of time the patient may once again have a normal or greater than normal amount of splenic tissue.

It is not surprising, therefore, that both these conditions may relapse. Thus, while there is no doubt that Miss Flett has responded extremely well to splenectomy, it is quite probable that thrombocytopenia may return within a year or two. Indeed, I have seen several cases in Ward 27 (e.g. Mrs Flynn) in whom the condition of ITP has taken just that course. The rate of relapse in ITP may be as high as 50% if the patients are followed up over a number of years. It is for this reason that she is asked to report back to the blood clinic at two monthly intervals.

The prognosis in AHA is even less favourable. Not only may antibody production and lysis return to their initial rate but with advancing years the bone marrow can no longer maintain the extreme hyperplasia that is indicated by Miss Mentiplay's frequently high reticulocyte count. Once exhaustion hypoplasia of the bone marrow occurs the outlook is hopeless. The patient, however, may die in one of their frequent acute haemolytic crises, which may be due to a temporary but severe hypoplasia of the bone marrow.

REFERENCES.

- Bjorkman, S.E. (1947) *Acta. med. scand.*; Suppl. 191, 1.
Dacie, J.V. (1954) "The Haemolytic Anaemias", London.
Davis, L.J. et al (1952) "The haemolytic Anaemias of various types treated with cortisone & ACTH".
Glasg. med. J. 33, 263.
Harrington et al (1953) *Ann. Int. Med.* 38, 433.
Knisley (1936) *Anat.* 65, 23.
Medical Research Council Reports (1952) *B.M.J.* 1, 1261.
Meyers et al (1952) "The use of ACTH & cortisone in ITP & AHA!"
Ann. intern, Med. 37, 352.
Mollison (1947) *Clin. Sci.* 6, 137.
Nickerson & Sunderland (1937) *Amer. J. Path.* 13, 463.
Selweyn & Dacie (1954) *Blood* 9, 414.
Stefani (1955) *Sang* 26, 83.
Zarafonietis et al (1954) "Compds. E & F, and ACTH in the management of ITP"
Amer. J. med. Sci. 228, 1.

A CASE HISTORY OF

CHRONIC CHOLECYSTITIS.

WARD 27, R.I.E.

(Professor Sir Stanley Davidson.)

January 1956.

W. J. IRVINE, B. Sc. (Hons. Physiol.)

Name:- Brennan, Mrs Elizabeth.

5, Craigmillar Castle Gardens, Edinburgh 9.

Aged 53. Married. Housewife.

Date of admission:- 14/1/56.

Recommended by Dr Stewart, 31 Northumberland Street.

Date of examination :- 16/1/56.

Complaints :-

(1) A vague intermittent gripping pain in the right lumbar region for the past year. Avoidance of fatty foods and some loss of weight.

(2) Since 8/1/56 (6 days before admission) she has had a severe, intermittent, sharp gripping pain with a residual gnawing ache, mainly over and below the lower ribs in the back on the right side; but later radiating to the front. Subsequent tenderness, vomiting and complete anorexia.

History:-

For the past year the patient has had an intermittent pain in the right lumbar region which she attributed to "rheumatics". It never amounted to very much, and was associated with a vague history of shoulder pain. She has deliberately avoided fatty foods for the past year and attributes a general disinterest in food to having to do so much cooking. She has lost some excess weight since the summer (10st- 8st 9 $\frac{3}{4}$ lbs). There is no history of flatulence.

A fortnight ago she noticed that her urine was unusually dark and there has been some frequency with nocturia (2-3 times in the night). She could not recall any change in the colour of the stools.

While dressing early in the morning of Sunday 8th January she felt a "catching" pain in the back, on the right side just under the ribs, but this did not prevent her from dressing. The pain gradually increased in severity and when she walked it seemed to go down into the groin. It later developed into a constant gnawing pain, but intermittently gave way to spasms of a sharp "gripping" pain that lasted for a few minutes, and was so severe that it made her feel sick. Her breath caught on deep inspiration, but otherwise the pain was unrelated to breathing. There was no shoulder pain. She did not go to bed.

The spasms and residual ache persisted all day Sunday, but with a hot water bottle next to the painful part she managed to sleep that night only to wake at 3a.m. violently sick. The pain, which was severe and sharp, had moved centrally to the region of the umbilicus. The vomit at first contained food (although she had not eaten anything since the previous morning), and later became "green and acid". She vomited at frequent intervals all day Monday and retched between times with shivering and a profuse sweat. The abdomen became tender in the region of the gall-bladder. A neighbour saw her on Monday and commented on her "jaundiced" colour, while her eldest daughter thought her colour "queer".

The doctor made an initial diagnosis of "gastric 'flu", and

and provided six powders, one to be taken every two hours. He told her to stay in bed till Friday. The powders, however, made her sick and did not ease the pain.

Her condition remained much the same over the next few days; sleeping poorly and feeling cold, shivering and miserable, with no appetite whatsoever. The sickness stopped on Thursday, but was replaced by constipation and extreme thirst. She drank lots of lemon squash with water - the only thing that would stay down. Spasms of pain still occurred but they were now less frequent. The constant gnawing ache persisted in the right lumber region.

On Friday the doctor arranged for her admission to the R.I.E.

Personal History:-

Some loss of weight and a slight deterioration in appetite during the past six months. Although recently constipated, her bowels previously moved regularly without the aid of purgatives. Her periods stopped 3 years ago. She has no cough or sputum, but is breathless on exertion, and has noticed some swelling of the ankles, which is relieved on resting. Sleep has been rather poor during the last few years. Otherwise she enjoys good general health.

Previous Health:-

- (1) Measles, whooping cough and chickenpox in childhood, but not rheumatic fever. No history of diabetes.
- (2) Sinus trouble for past 15 years, and as a result is slightly deaf in right ear. On occasions she suffers from severe headaches between the eyes, precipitated by a cold in the head. She attends the radio therapy department for treatment.
- (3) Nasal polyp removed 5 -6 years ago.
- (4) Vague history of "rheumatic pains" in muscles and joints, including the right lumbar region and shoulder joint.
- (5) Two attacks of pleurisy in the (L) lung 6 years ago.
- (6) The last two births were by Caesarian section; one of these being precipitated by a fright due to a rat in the bed.
- (7) Strangulated right - sided hernia in 1949 operated on as an emergency in ward 14.

Family History:-

Living Members:-

Husband	57	"Perfectly healthy".
Son	27	Rheumatic fever in childhood. Tuberculosis 10 yrs ago.
"	25	} Alive and well.
"	23	
"	16	
Daughters	29	}
"	20	
"	18	Rheumatic fever in childhood and has an "enlarged heart"
"	14	} Alive and well.
"	10	

Deceased :-

Mother	In childbirth	}- Both died between 40 and 50 }- when the patient was young.
Father	?	
Daughter	7 weeks	Pneumonia
Son	11 months	"took fits".

Social:-

Although she was brought up in Ireland she has lived 25 years in Edinburgh. Before moving into a corporation house 15 years ago, she and her large brood lived in a cold and damp two roomed house, seemingly infested with rats, and no doubt other vermin. As a sequel to the rat scare and subsequent Caesarian section, the 9 of them plus the husband's nephew moved into their present house, which comprises of three bedrooms, living room, bathroom and scullery. She has "five beds to wash for". All except the youngest two are out working, yet she does not consider herself financially well off. The house is a bit "rowdy" for her liking. Some of its members smoke and drink but she participates in neither.

On Examination:-

A moderately obese woman who does not look very ill, but is somewhat pale. The mucous membranes, however, are well injected. The sclera may have a slight icteric tinge. Afebrile and of good nutrition. Height= 5'1 $\frac{3}{4}$ " Weight= 8st9 $\frac{3}{4}$ lbs.

She was co-operative in giving the history and during the examination.

Her capacity as a witness was moderate.

Alimentary System:-

The tongue is moist and shows no signs of inflammation or atrophy. The lips are not pale or cyanosed. Dentures. Her breath was not offensive.

Abdomen:-

Inspection:- Slightly obese, moves freely with respiration and shows no retractions or prominent veins. There are two median Caesarian scars and a scar of strangulated hernia in the right iliac fossa. No abnormal masses are prominent, and there is no visible peristalsis.

Palpation:-

There is an area of mild superficial tenderness, but this is not associated with muscle guarding. No abnormal masses were detected on deep palpation. No splashing.


The edge of the liver was palpated 1 -2 fingers' breadths below the lower right costal margin. Her breath "caught" on deep inspiration. The gall bladder could not be palpated and neither the spleen nor the kidneys were palpable.

Percussion: Confirmed the absence of fluid or splenomegaly and the presence of slight hepatomegaly.

Auscultation:- Normal bowel sounds.

Faeces:- Well formed and of normal colour.

Vomited matter:- She has not vomited since admission.



Cardiovascular System:-

Radial Pulse:- 75 /min, regular in time and force and the wave is normal in character. The vessel wall was not palpable.

B.P. = 140/90

Hands:- No finger clubbing or koilonychia. The hands were not unusually warm or moist, but the skin of the forearm was dry and scaly.

Neck:- No abnormal pulsations were observed and there was no venous engorgement.

Heart:-

Inspection:- No subclavicular pulsations could be seen.

Palpation:- The apex beat is feeble, in the 5th intercostal space and within the mid clavicular line. There are no thrills.

Percussion:- The extent of cardiac and hepatic dullness is within normal limits.

Auscultation:- Both heart sounds could be heard; they were normal in character and closed in all areas.

There were no accompaniments.

There is no sacral oedema or swelling of the ankles.

Respiratory System:-

Breathing:- 15/min., costo-diaphragmatic and regular in depth and rhythm.

No cough or spit.

Chest:-

Inspection:- Veins were seen running horizontally across the upper chest, the blood flowing from left to right.

(The patient claimed that they had always been there).

The chest was symmetrical in form and movement.

Palpation:- Good and equal expansion.

Vocal fremitus equal on both sides.

Trachea central.

No axillary or supraclavicular glands could be palpated, and there is no enlargement of the thyroid.

Percussion:- Normally resonant and equal throughout.

Auscultation:- Vesicular breath sounds without accompaniments.

Vocal resonance normal and equal throughout.

Nervous System:- Attentive and kept to the point. Her memory was good and she is not of a neurotic disposition.

No evidence of meningeal irritation (Chin-on-chest; Kernig's sign). The cranial nerves were tested individually but no abnormality

abnormality could be detected, except mild deafness in the right ear. According to Rinne's and Weber's tests this deafness is a middle-ear rather than a nerve deafness.

The pupils were circular, central and equal. They responded physiologically to light and (directly and consensually) and to accommodation. There was no retinopathy.

Muscle power good and co-ordination was unimpaired.

No involuntary movement or abnormality of muscle tone.

Reflexes :-

	Biceps	Triceps	Supinator	Knee Jks	Ankle Jks	Abdominal	Plantar Response
Left	+	+	+	+	+	-	↓
Right	+	+	+	+	+	-	↓

No clonus.

There was no abnormality in cutaneous sensation to touch and pain and both vibration and proprioception sense were good.

Stereognosis was faultless.

Examination of the Urine :-

14/1/56 Pale yellow, S.G. = 1.018, acid.

Albumen } - ve
Sugar }

Acetone + ve

Urobilinogen - ve Bile -ve.

Microscopic Deposit :- No pus cells, R.B.C., casts or motile organisms

Examination of the blood :-

14/1/56 Hb = 80%
WBC = 9,600/cm.
ESR = 29 mm / hr (Westergren)

CLINICAL DIAGNOSIS.

The History of severe abdominal pain, sharp, gripping, intermittent, and localised, of relatively sudden onset, associated with marked anorexia, nausea and vomiting strongly suggests a diagnosis of colic rather than any other form of upper abdominal pain, such as perforation of a peptic ulcer, a myocardial infarction or an acute pancreatitis. Moreover, at no time after admission did the patient look ill. There was no history of epigastric pain or discomfort, and the blood pressure and pulse pressure were well within normal limits. There was no tachycardia or arrhythmia and the pain was quite unrelated to exercise.

An inflamed retrocecal appendix is less difficult to exclude, but unless the caecum was high (which is uncommon) it would be unlikely to give rise to acute tenderness at the lower border of the liver. Furthermore, an appendix pain (which is seldom so severe) usually starts centrally, and only subsequently moves into the right half of the abdomen. Salpingitis is unlikely to present with upper abdominal tenderness.

Although the pain was in the region of the right kidney there is no history of dysuria or stragury, nor any marked and precipitant fever to substantiate a diagnosis of acute pyelonephritis. The urine was never cloudy and on admission contained neither cells (RBC or WBC) nor organisms. The kidneys were not palpable. No high remittent fever to suggest a perinephric abscess.

The pain of pleurisy, which could quite easily have been referred to the area, does not have the gripping character described in the present case. There were no respiratory symptoms or signs. Localisation of the pain was not sufficiently good for a Herpes Zoster, and the history of the pain exceeds its incubation period.

The differential diagnosis is therefore between biliary colic, renal colic and intestinal colic. An intestinal colic is unlikely in view of the fairly localised nature of the pain and area of tenderness, and of the later development of constipation and the absence of diarrhoea. The constipation is adequately explained as being secondary to the complete anorexia.

Lumbar pain with radiation into the groin is indicative of renal colic, but although the pain was present on admission no red blood corpuscles could be found in the urine. Admittedly there was a recent history of mild frequency with nocturia two to three times each night, but its onset preceded the recent pain, and it is very doubtful if it was marked enough to support a diagnosis of renal colic. The loin was never tender.

The fact that the patient was female, had been a little overweight, had had nine children and was of late middle age, places biliary colic as by far the most likely diagnosis. The localisation of pain in the back radiating later to the front is not atypical of that condition, while tenderness in the vicinity of the gall bladder is characteristic. The avoidance of fat for the past year and a slightly/

slightly diminished appetite, the recent darkening of the urine and suggested transient jaundice are all in favour of an acute episode of a mild chronic cholecystitis. A history of flatulent dyspepsia is an almost constant feature in chronic cholecystitis, and its absence in the present case must be noted as an atypical feature of the symptomatology. The "rheumatism" in the right loin may or may not have been due to a grumbling infected gall-bladder, and the relationship of the shoulder pain is even less clear.

SUPPLEMENTARY INVESTIGATIONS.

- 20/1/56 :- X-ray. Plain film of chest and abdomen.
Heart has undergone aortic change. The transverse diameter was within normal limits, and the lung fields were clear.
- 25/1/56 :- Cholecystography.
The gall bladder was reasonably functional, showing quite a good concentration of the dye. The gall bladder was set rather low in the abdomen and was not greatly enlarged.
Multiple small circular translucences were seen in the fundus of the gall bladder. None were seen in the neck of the bladder, cystic duct or common bile duct.

TREATMENT AND PROGRESS.

- 14/1/56 1) Bed Rest.
2) Non-fat diet.
3) Sulphadimidine 1G 6 hourly to clear up the infection in the gall bladder.
4) The acute pain returned on the second and third day after admission and intramuscular methadone (physeptone) was used for its relief.

15/1/56 IM "physeptone" 10 mgms. at 8pm.
16/1/56 : : 10 : : 6.30pm.

- 5) Sedation was encouraged by giving quinalbarbitone "(Seconal") 0.2G orally every evening.

There was no more pain from the third day after admission. The appetite gradually returned and within a few days was back to its previous level. There was no vomiting and the initial slight icteric appearance rapidly disappeared.

18/1/56 Hb = 102%
RBC = 5.17 10/c.mm Polymorphs = 45%
CI = 0.99 Eosinophils = 1%
WBC = 3,200 /c.mm Lymphocytes = 46%
Blood film normal. Monocytes = 8%

19/1/56 Up
22/1/56 Sulphadimidine stopped.
27/1/56 Discharged to convalescent home for one week.

2/3/56 Since discharge there has been some slight recurrence of pain in the right hypochondrium, which has been worse in the last day or two. The urine has been dark.
Admitted to Ward (Mr K. Paterson Brown) on the recommendation of Ward 27. A provisional diagnosis was made of an acute exacerbation of chronic cholecystitis. The acute phase was allowed to resolve before proceeding to cholecystectomy. Since there had been a history of frequency and pyelitis in her last two pregnancies her urinary function was investigated in the pre-operative interval.

Catheter specimen urine = sterile
Urea range = normal
Intra venous Pyelogram = some deformity of renal pelvis which was thought to be due to displacement of kidney rather than to intrinsic disease.
Retrograde Pyelography = arranged for 29/3/56.

13/3/56 Cholecystectomy, from which she made an uneventful recovery, and was discharged home on 15/3/56.

COMMENTARY.

Diagnosis:-

The demonstration by choecystography of the presence of stones in the gall-bladder confirms the clinical diagnosis of an acute episode of a chronic cholecystitis.

The fact that the gall stones were translucent and multiple suggests that they are pigment stones, cholesterol stones usually occurring singly. Bile-pigment stones are, however, comparatively rare. Mixed stones are the commonest type and are composed of cell debris, cholesterol, bile pigment and calcium salts. They are usually multiple and a considerable proportion do not contain enough calcium to make them radio-opaque. It is very probable that the present stones are of the mixed type.

Aetiology :-

Cholecystitis is a common condition and is particularly so in obese middle aged women who have born many children. Although the aetiology of gall stones is still unsettled, the three chief factors concerned in their production seem to be :-

- a) stasis or stagnation of the bile,
- b) the composition of the bile and
- c) bacterial infection of the gall bladder.

Biliary stasis is produced by atony of the gall bladder and it is believed by some that this is favoured by conditions causing pressure on the gall bladder. Thus it is liable to occur in stout women, during constipation and during pregnancy. The present patient was not grossly obese, and claimed not to be constipated, but she had been unquestionably fertile. An additional, and probably the main factor which is operative in pregnancy is a general relaxation of smooth muscle induced by the placental hormones. The observation that in pregnancy the gall bladder generally does not empty in response to a fat meal is in support of this theory. Moreover, gall stones are 3 - 4 times more common in women who have borne children than in those who have not.

Biochemical analysis shows that the cholesterol content of the blood is increased in pregnancy and obesity as well as in other conditions which are not at present relevant (e.g. diabetes, myxodema). The cholesterol is secreted by the liver in the bile where it is held in solution by the action of the bile salts. If present in excess and especially if there is an associated biliary stasis, the cholesterol is liable to crystallise out, and in a sterile gall bladder a solitary cholesterol stone may result. On the other hand, the excess cholesterol may be absorbed by and deposited in the gall bladder mucosa to produce the condition of cholesterosis. This condition may or may not be associated with chronic inflammation of the gall bladder wall. Pedunculated mucosal folds containing cholesterol may be pinched off and form the nuclei of stones. Regrettably a serum cholesterol was not determined.

A rather different aetiological mechanism might be responsible if/

if there had been any antecedent obstruction of the common bile duct. In this event the liver would continue to secrete bile for quite a period and the gall bladder would continue to concentrate it. Multiple fine bile pigment stones might be the result. Bile pigment stones are common in chronic forms of haemolytic anaemia. In the present case, however, haemolytic anaemia is excluded on account of the absence of anaemia, reticulocytosis and urobilinogenuria.

Whatever its mode of origin the presence of a gall stone pre-disposes to inflammation of the gall bladder mucosa, and this results in an increased reabsorption of water and bile salts from the lumen. Indeed, the ratio of bile salts to cholesterol which is normally 20 : 1 may fall to 6 : 1. This favours the crystallisation not only of cholesterol but also of bile pigment and calcium, probably derived from the inflammatory exudate. In the present case the deposition of calcium has been slight and not sufficient to produce an opacity on straight X-ray. Infection also produces a deposition of fibrous tissue in the gall bladder wall. This is the rational basis of Courvoisier's law which states that in jaundice due to pressure on the common bile duct from without (e.g. by cancer of the head of the pancreas) the gall bladder is greatly distended, whereas in jaundice due to impaction of a stone in the common duct the gall bladder is not distended to such an extent that it can be detected clinically on account of the preceding chronic cholecystitis.

Unfortunately, I did not see the present case at the time of admission, but was informed by the house physician that a rounded mass was palpable in the right hypochondrium, and that the jaundice was slight or absent. It might therefore be concluded that the fibrosis of the gall bladder wall was not gross, and that either a small gall stone had become impacted in the common bile duct producing partial obstruction, or that the stone had become impacted in the cystic duct producing complete obstruction of that duct with a resultant mucocele or hydrops of the gall bladder together with exacerbation of the previous low grade infection due to associated stasis. Regrettably, a serum bilirubin estimation was never done so that it is impossible to say whether or not there was a latent jaundice, and therefore impossible to decide between the two alternative sites of impaction.

The initial treatment is rest in bed and the relief of pain. S Since the pain was severe a strong analgesic was required. Both morphia and pethidine, ~~however~~, have the undesirable effect of stimulating the contraction of the sphincter of Oddi. Methadone, however, has a minimal action in this respect and yet possesses the same analgesic effect as the same dose of morphine.

Sulphonamides, such as sulphadimidine, are freely excreted in the bile and are concentrated by the functional gall bladder, but their bacteriostatic effects may be reduced to some extent if their access to the gall bladder is restricted by the blockage of the cystic duct, or if the organisms (B.coli, enterococci, etc.) are insensitive. In the present case, however, sulphadimidine was effective; there was no more pain after the first three days and the rounded mass together with the tenderness and muscle guarding rapidly subsided.

The/

The diet was initially restricted (in accord with the desire of the patient) to fluids. The extreme thirst mentioned in the history is no doubt due to a state of dehydration consequent to persistent vomiting; but as soon as the acute exacerbation was over the patient was put on a full diet with a low fat content. Fats are avoided since they stimulate contraction of the gall bladder through the release of cholecystokin from the intestinal mucosa, and thus encourage the discharge of gall stones into the cystic and common bile ducts. Also, in chronic cholecystitis there may well be some obstruction to the liberation of bile salts into the duodenum so that fats are poorly tolerated. Indeed, she gives a year's history of avoidance of fats.

The most common complication of chronic cholecystitis is an obstructive jaundice with consequent damage to the liver parenchyma eventually leading to biliary cirrhosis and terminal hepatic failure. In the present case, however, the slight enlargement of the liver is probably not significant; the lower border of the liver did not feel unduly firm, or tender and jaundice was never marked. Empyema of the gall bladder might occur during an acute exacerbation with possible perforation. Infection may spread along the biliary passage to give rise to a cholangitis and even multiple abscesses in the liver. A large gall stone may ulcerate its way through the gall bladder wall into the duodenum and subsequently undergo impaction (usually in the region of the ileo-caecal valve) to produce intestinal obstruction, either directly or by irritation.

For these reasons cholecystectomy must be seriously considered in all cases of chronic cholecystitis with demonstrable gall stones. The patient is at present 53 and a good surgical risk. Multiple gall stones are present so that the probability of further acute exacerbation is high, and even if none of the more dramatic complications ensue parenchymal liver damage is cumulative.

On the other hand this patient's symptoms and signs have not been very severe. Her first unmistakable attack of biliary colic was just prior to her admission to Ward 27, it was doubtful if she had ever been jaundiced and her gall bladder was reasonably functional. Treated on conservative lines, with the avoidance of fatty food and the reduction of obesity, further recurrences might be avoided. In spite of such measures, however, the patient experienced recurrent bouts of pain in the right hypochondrium within a month after discharge from Ward 27. Although she did not become jaundiced, the urine became dark and it is probable that small stones or portions of them were being periodically passed into the cystic duct and common bile duct giving rise to pain and mild obstructive symptoms. Further persistence in medical treatment was unlikely to be effective, and surgery was recommended. The patient agreed and made an uneventful recovery from cholecystectomy.

Final Diagnosis

Chronic Cholecystitis.