

A report and commentary on 5 cases from
Wards 28 and 29 of the Royal Infirmary
published by R. J. Henderson and entered
for the Wightman Prize competition. The
cases are published with the permission of
Dr. Chalmers Watson.



A CASE OF PRIMARY LUNG CANCER.

PHILIP SMITH.

Age 37.

Address. 76 Kirkgate, Leith.

Occupation. Marine Fireman. Admitted. 7th August 1922

Complaint.

- (a) Pain in right side of chest and neck. - 4 months.
- (b) Loss of weight and increasing weakness - 4 months.
- (c) Cough and Sputum. - - - - - 10 days.
- (d) Anorexia. - - - - - 3 months.
- (e) Loss of power in right arm. - - - 4 weeks.

History of Present Illness.

The patient had an attack of "Influenza" about 8 months ago and he never seemed to recover completely from it. He was not as fit for his work as he had been previously. About 4 months ago the patient consulted his doctor because he had developed a sharp stabbing pain when he coughed. The pain was localised about the region of the spine of the right scapula. It was then discovered that he had lost about a stone in weight. Coincident with the onset of the pain the patient had been conscious of a feeling of increased weakness. As time went on the distribution of the pain began to spread so that it radiated down the right arm and up the right side of the neck to the occiput, ear and face. This pain could be induced by coughing. Although he had a cough at that time he had no sputum but 4 months ago he had had a small haemoptysis. Shortly afterwards the cough subsided and did not return until/

until 10 days ago and at the present time he coughs frequently and expectorates about 2 ozs. of mucoid sputum daily. During the last 8 weeks he has been a patient in Leith Hospital during which time his condition has become steadily worse. He has lost a great deal of the power of his right arm. The right supraclavicular fossa has filled up and now there is a prominent swelling. During the past few days he has been conscious of the condition spreading to the other side of the neck. Altogether he has lost 3 stones in weight and is feeling very weak and exhausted. His appetite has been very poor for about 3 months.

Previous Illnesses.

Patient had diphtheria when a child and measles when 8 years of age. In neither case were there any complications. Influenza and tonsillitis 8 months ago. As a young man he was always robust and healthy.

Personal and Family History.

He has shown no indications or symptoms suggesting status lymphaticus. The secondary sex characters developed when 15 years old. Patient's father died suddenly, aged 47, of pneumonia. His mother is alive and well aged 70. He has 2 brothers and 3 sisters alive and they are well with the exception of one brother who suffers from gastric ulcer. He had 10 brothers and sisters who died at birth or shortly afterwards.

He/

He works in an engine room where gas and oil are used as fuel and the conditions are very unhealthy, the atmosphere being laden with gas and oil fumes. He is down in the engine room for long periods at a time, a minimum of 8 hours. His meals were regular but not very varied and his dietary was generally as follows:-

Breakfast: Porridge, tea; Bread and butter;
Bacon and eggs on occasion.

Dinner: Stew, meat, potatoes, Rice puddings.

Tea: Tea, bread and butter.

Supper: More meat, Bread and butter, Tea.

General Condition.

The patient looks much older than he is. His nutrition is very poor and there are signs of recent loss in weight. His complexion is grey and sallow and he has a tired and worried expression. The gravity of his condition is suggested by his appearance and by the presence of a unilateral right-sided exophthalmos. He has a frequent cough and expectoration of muco-purulent sputum.

Temp:- 98⁰. Pulse:- 96. Respirations:- 24.

Weight:- 9 st. 4 lbs.

CLINICAL EXAMINATION.

Respiratory System.

Patient has a hard, painful cough with mucopurulent sputum, 2 ozs. per day. Small haemoptysis 4 months ago. Pain in right side of neck. Not much difficulty in breathing. Slight cyanosis.

The skin of the chest is poor in texture and there is evidence of loss in weight. The ribs are very prominent but the shape of the chest is quite good. The superficial veins are prominent. The respiratory rate is 24. There is a marked fullness in both sides of the neck, but it is more marked on the right side and the skin over the upper part of the right supraclavicular fossa and lower part of the neck is very congested. The expansion is equal on both sides but limited. On palpation no definite glandular swelling can be made out, but there is a soft tender swelling in the right fossa. On percussion both apices are dull and this impairment extends to below the third rib on the right side and to the second rib on the left side. Below this dullness the percussion note is boxy. Over the rest of the lungs no impairment can be detected. On auscultating over the apices fairly loud breath sounds are heard, medium pitched bronchial in character. There are no accompaniments. Elsewhere the breath sounds are vesicular. Over the dull areas vocal fremitus and resonance are increased.

Circulatory System./

Circulatory System.

No palpitation, faintness or giddiness. Dyspnoea is very slightly present and not increased by exertion. There is slight cyanosis. No pain over the praecordium.

Pulse - Rate 96. Regular in time and force. The wave is poorly sustained and both rises and falls sharply. The artery wall is thickened. BP $\frac{124}{76}$. On inspection the apex beat is visible in the 5th left interspace 4 inches from the midline. The beat is not very forcible when palpated and on percussing the left border the heart seems somewhat enlarged. It may be displaced as the right border does not extend beyond the sternum. On auscultation at the mitral area the heart sounds are heard but they are weak. The first sound is superimposed by a soft systolic murmur. The second sound is closed. At the pulmonary, tricuspid and aortic areas both sounds are closed.

Nervous System.

There is no headache, insomnia or loss of memory. There is no impairment of the higher cerebral functions. No aphasia. There is pain radiating from the right supra clavicular fossa up to the occiput, through the shoulder to the scapula and across to the other side. It also radiates frequently down both arms.

Sight is unimpaired and the fields of vision are normal. Ocular movement is unaffected. The right pupil/

pupil fails to react to light or accommodation. The left pupil is moderately contracted but reacts quite well. The right eyelid is retracted and exophthalmos of the right eye is present. The retinae and optic discs are normal. The facial muscles are not interfered with, neither are those supplied by the 5th nerve. Sensation of the face is unaltered. The tongue is protruded in the mid line. The trapezius and sternomastoid muscles function perfectly. There is loss of power of the right arm involving all the muscle groups and also impairment of sensation to light touch. Motor power is very slightly impaired in the left arm but sensation is unaltered. The tendon reflexes of both arms are normal. Motor power and sensation are unaltered in the lower limbs and trunk. The reflexes, organic, tendon, and superficial are unimpaired.

Alimentary System.

Anorexia for 3 months. No abdominal pain, no actual sickness. No flatulence or water brash. No indigestion.

The abdomen is poorly clad and hardly moves on respiration. There is no obvious irregularity of outline. The skin is coarse and grey. On palpation there is no tenderness or increased resistance and no swellings. On percussion the liver dulness extends to 1 inch below the costal margin. The upper border is at the 5th rib in the mid-clavicular/

clavicular line. The spleen is not enlarged by percussion. There is no evidence of fluid in the peritoneal cavity.

Genito-Urinary System.

There is no pain in the kidney region. No anuria polyuria, or dysuria.

No tenderness over kidney region or bladder. Percussion reveals no enlargement of bladder.

Examination of Urine. Specimen is acid.

Specific Gravity 1020. Amber in colour. Deposit of mucus. Trace of Albumin. FEHLING'S solution slightly reduced. BENEDICT not reduced. No acetone bile or blood. Microscopically there are seen a few degenerated pus and renal cells. A few uric acid crystals. No casts.

Haemopoietic System.

No anaemia - no tenderness over the long bones. Spleen not enlarged.

Blood count. RBC 3,800,000.. HB 60%, C.l. .8
WBC 8,000. Film normal.

Integumentary System.

No subjective phenomena. The skin is very poor in texture, greyish in colour and the subcutaneous fat has all gone giving evidence of loss in weight.

Locomotory System.

Considerable weakness of right arm and very slight weakness of left.

Endocrine System./

Endocrine System.

Both subjective and objective examinations are negative.

SPECIAL INVESTIGATIONS.

Faeces. A specimen examined shows no evidence of constipation. There are no scybala, no faecal sand or mucus. Odour is not grossly offensive. The second return of a double washout is approximately clear.

X-Ray. Films taken of the chest when in Leith Hospital show an opacity of the upper lobe of the right lung. The opacity is uniform with a fairly well defined margin which is irregular in outline. The density is most marked towards the hilum. The rest of the lung fields are clear.

Wasserman. Negative.

Sputum. No tubercle bacilli. Catarrhal organisms present. No disintegrating lung tissue.

Differential Diagnosis.

The swelling in the neck, the exophthalmos and the radiating pain had lead the investigators in Leith Hospital to suspect an intrathoracic condition and accordingly the chest was X-Rayed. The X-Ray picture shows an opacity of the right upper lobe.

The most probable cause of this opacity is a malignant growth and to support this view are:-

- (1) The insidious onset with no previous history of lung trouble, except influenza.
- (2) Gradual increase of the severity of the symptoms and progressive loss in weight.
- (3) The neuralgic pain radiating into the neck, face and occiput.
- (4) X-Ray findings.

Other possible conditions.

- (1) Tuberculosis. No T.B. in sputum, no temperature, no history of night sweats. The X-Ray shadow is too large - homogeneous and dense for a tuberculous focus.
- (2) Fibrosis. Against this are the history and the progressive condition.
- (3) Unresolved pneumonia gives a very similar picture, perhaps less opaque and not so well defined. No history of pneumonia.
- (4) Benign Tumour. These are uncommon but if they present similar shadows they do not give rise to such severe symptoms.

(5)✓

- (5) Gumma of a bronchus. This usually gives a coarse irregular fan-shaped shadow spreading out from a bronchus. It is usually small and does not involve an entire lobe. There are no other signs of syphilis and the Wasserman test is negative.
- (6) Aneurysm. Such a condition could quite easily give a shadow like this. Other signs are lacking such as endocardial murmurs or a difference in the pulses. The physical signs in the chest exclude aneurysm.
- (7) Other pulmonary conditions such as abscess, bronchiectasis, interlobular effusion. Bronchiectasis is usually in the lower lobe and unless there is gross sacculation with filled cavities there is no dulness on percussion. The breath sounds are not bronchial and there are nearly always coarse crepitations. An abscess would not give signs such as are present in this case. An effusion might be confused on an X-Ray but the systemic disturbance is too severe to be caused by such an effusion. The physical signs also exclude this possibility.
- (8) As rare but possible conditions one must include hydatid cyst and actinomycosis. The latter might give as severe symptoms but no clinical evidence has been found of such a condition. The sputum shows no sign of spores. The X-Ray picture does not definitely indicate whether/

whether the growth is sarcomatous or carcinomatous in origin and whether it arises from the lung substance, the bronchi, or the mediastinum. Its edge is quite well defined and it seems to be confined to the right upper lobe. Its denseness suggests a very solid growth and probably involvement of the whole lobe.

There is a slight rise in temperature this evening but the patient is not feeling any marked diminution of his appetite. He is not, however, any worse. The cough is somewhat troublesome at night and last night he had to have oxygen or to let him sleep. The analgesic pain has also been troublesome.

12: 31: 33.

The patient is having exposures every day. His temperature is stable every night. The analgesic is the work is less tense. The pain is relieved considerably, although it is still induced by coughing. He is getting better daily for the cough. The dullness over the right upper lobe has not increased. His general condition is good and his appetite is appreciably so.

13: 31: 33.

Patient is still having exposures. There appears to be a slight reduction in the size of the swelling. The cough is very troublesome at night and he has to have oxygen or to let him sleep. He is getting on. 5 cm. of oxygen which allows him to sleep.

14: 31: 33.

PROGRESS.

Admitted to the ward 7th August 1932.

The patient is to receive Deep X-Ray therapy in an effort to arrest and possibly cause regression of the tumour mass in the lung.

9: 8: 32.

Patient had first X-Ray exposure to-day. There is a slight rise in temperature this evening but the patient is not feeling any immediate amelioration of his symptoms. He is not, however, any worse. The cough is somewhat troublesome at night and last night he had to have omnopon gr. $\frac{1}{6}$ to let him sleep. The neuralgic pain had also been troublesome.

12: 8: 32.

The patient is having exposures every day. The temperature is rising every night. The swelling in the neck is less tense. The pain is relieved considerably, although it is still induced by coughing. He is getting codeine jelly 3 i for the cough. The dullness over the right upper lobe has not increased. His general condition is poor and his appetite is appreciably so.

15: 8: 32.

Patient is still having daily exposures. There appears to be a slight reduction in the size of the swelling. The cough is very troublesome at night and the pain also. He is getting gr. $\frac{1}{6}$ Omnopon which allows him to sleep.

23: 8: 32./

23: 8: 32.

X-Ray Therapy continues daily. During the last week the pain has been slightly better. The trace of sugar is still present in urine. Albumin is also present.

31: 8: 32.

Still getting X-Ray treatment. He has been more comfortable during the last week as both the pain and cough have been less troublesome. He has been sleeping well with the help of gr. x Veronal nightly. There is no change in the size of the swelling in the neck.

6: 9: 32.

The patient has had no X-Ray treatment since the 31: 8: 32. The Radiologist reports that the lesion is progressive and that further exposure may be harmful and cannot possibly arrest the advance of the tumour. On these grounds also he thinks that the lesion is carcinomatous in origin and not sarcomatous. The patient however is certain that the pain in his arm has been worse since the cessation of therapy and has been enquiring as to the reason for the stoppage. Hitherto he has been hopeful as regards the prognosis but now it is possible that he may worry a great deal.

4: 10: 32.

Patient is not looking so well and is getting weaker. The pain in the right side of the neck and in the right arm is getting worse. There is no improvement clinically. He has developed a sharp pain/

pain in the right side on coughing. The dullness on percussion on the right side has taken the place of normal lung resonance from the apex down to the liver. The patient has required Morphine gr. $\frac{1}{4}$ every night. He is also getting a laxative every night as the drug is producing severe constipation.
5: 10: 32.

Examination of the chest reveals marked pleural friction on the right side, in the axilla and front of the chest. Antiphlogistine is to be applied to relieve the pain. It is getting more difficult for him to swallow his food. The dysphagia is probably arising from pressure on the oesophagus.

1: 11: 32.

The patient's condition varies. He feels better in the morning than in the evening but his general appearance is very much worse. His colour is getting greyer and cyanosis is appearing in the lips and cheeks. Dyspnoea is becoming more marked. He gets relief from this by sitting up.

4: 11: 32.

Patient is losing ground. The pain is constant when not relieved by morphine. There is a progressive oedema of the right arm. He is scarcely able to take any nourishment now as his appetite has gone entirely. X-Ray shows a marked advance in the condition. The right lung field is completely obliterated and the trachea and heart are pushed far over to the other side. The opacity is also present on the other side and only a very small area/

area of the lung field is clear. The morphine is increased to gr. $\frac{1}{2}$ morning and evening. The patient is now almost completely under morphine, day and night. The patient died on the morning of the 12:11:32.

POST MORTEM REPORT.

The right pleural sac contained a large amount of clear fluid in which there was a quantity of shreddy fibrin. The left sac had no fluid but the pericardial sac also contained some similar fluid and fibrin. On examining the right lung it was found that the lower parts were collapsed and airless. The upper lobe was almost entirely replaced by a solid mass of whitish tumour tissue. The tumour extended anteriorly through the chest wall and pectoral muscles to infiltrate the subcutaneous tissue of the right breast. It also extended back being firmly adherent to the posterior part of the bony thorax. There was gross involvement of the tissues of the posterior mediastinum and marked infiltration through all coats of the oesophagus. This latter infiltration extended throughout the oesophagus as far down as the cardiac orifice. The mediastinal, upper abdominal, para-aortic, and sub-clavicular lymph glands on both sides were involved. There was also extension into the pericardial sac with the presence of small secondary nodules on the epicardium.

The left lung was congested and oedematous but showed no signs of malignant involvement.

The heart was atrophic and showed a good many epicardial tumour nodules.

The liver was markedly displaced downwards. Its upper border was about 1 inch above the costal margin/

gin. It showed no gross tumour involvement, there being only one small doubtful secondary.

The kidneys were congested and oedematous and in the left kidney there was a small tumour nodule about 1 cm. in diameter.

The stomach, intestines and spleen showed nothing of note.

Microscopic Examination.

System of primary cancer - small-cell carcinoma. The cells are small, round, with scant cytoplasm and hyperchromatic nuclei. The cells are arranged in nests and cords, separated by a thin layer of connective tissue. The cells are arranged in a solid pattern, with a narrow zone of necrosis in the center. The cells are arranged in a solid pattern, with a narrow zone of necrosis in the center. The cells are arranged in a solid pattern, with a narrow zone of necrosis in the center.

In other areas there was evidence of metastatic disease. The cells are small, round, with scant cytoplasm and hyperchromatic nuclei. The cells are arranged in nests and cords, separated by a thin layer of connective tissue.

COMMENTARY.

Description of the Neoplasm.

The growth was very large, as it replaced the whole of the upper lobe of the right lung. It was firm in consistence throughout and whitish in colour. It had infiltrated and become firmly attached to the anterior and posterior walls of the chest. It had extended medially and involved the mediastinum grossly. The oesophagus and trachea were surrounded by the mass. There were no areas of softening, in any part of the growth, nor any bronchiectatic cavities. It had infiltrated the glands adjacent to it but the only secondary growths at any distance were those in the pericardial sac and doubtful ones in the liver and kidney.

Microscopic Examination.

Section of Primary Growth - stained Eosin-Methylene Blue. Low Power. Great variation in structure is seen. In some parts there is definite arrangement of cells in groups, with a narrow stroma separating the groups, the whole resembling an effort on the part of acinar formation. The cells at the periphery of the group have a columnar appearance. In other parts the stroma is much more marked and appears as broad bands with a definite connective tissue appearance giving off branches which encircle masses of cells.

In other areas there has been no attempt at differentiation and the cells are massed together. There are very/

very few blood vessels present. Those present are surrounded by stroma with a narrow wall of small cells. On the whole the acinar elements predominate.

High Power.

The cells vary a great deal in appearance. Where they are in masses with no acinar formation they are somewhat rounded with a faintly staining cytoplasm and they are not marked off clearly from their neighbours. The nuclei are large and occupy more than half the cell area. They are sharply marked off from the rest of the cytoplasm.

When the acinar groups are examined the majority of cells are seen to be definitely columnar. The nuclei are either at the base or middle of the cells. It is very seldom however that a perfect acinus is seen, more often there is just a tendency to a clearing of the centre of the group of cells.

The stroma also varies in appearance, in some places it is an ordinary connective tissue and in others it is formed of long narrow cells with long nuclei, placed close together. Towards the edge of the section aberrant types of cells are seen. Many are very large with a pale cytoplasm, some have no nuclei at all, while others have 2, 3 or 4 nuclei. The cells are sometimes triangular and often many sided, while some in the acini show definite cilia formation.

Section/

Section of Lymph Gland.

The section shows the Gland to be invaded by the same type of growth as the primary. There is not the same variation in the shape of the cells and there are fewer acini, but where they are present they are better shaped than in the primary. The major part of the section shows masses of shapeless cells with a pale cytoplasm and sharply defined nuclei. The lymphatics are all filled with plugs of cells. These are small and poorly stained and form irregular groups.

Section of Oesophagus.

Plugs of cells can be seen in the lymphatics between the muscle bundles. There are also masses of cells invading the wall between the outer longitudinal and inner circular muscle coats. There is no attempt at acinar formation and where the cells are grouped together there is no stroma.

It was impossible to show definitely where the tumour growth had arisen, but it had most probably begun in the epithelium of one of the larger bronchi of the upper lobe. The predominance of the acinar elements pointed to its epithelial origin.

The usual types of neoplasm in the lung.

The type in this case is a very common variety. They arise near the hilum in a bronchus, and spread through the lung by infiltration and also extend into the mediastinum. Other types are the squamous celled variety/

variety which grows slowly, is circumscribed and metastasis occurs late. It is this type which is favourable for operation. There is a pleural type also which grows extensively along the pleural surface and may extend into the lung tissue. Microscopically they are divisible into three groups.

In the first one finds masses of epithelial cells, flattened cuboidal or cylindrical in shape, and they may form psuedo alveoli from central necrosis. The cells are poorly differentiated, and great variations in size are seen, due to unequal division. Giant cells are common.

In the second type, the cells are cylindrical or cuboidal, but the nuclei are shrunken and stain deeply. There is no gland formation. This type forms the variety known as the "oat" celled cancers and are now recognised as cancers and not, as was previously thought, mediastinal sarcomata or lymphos arcomata.

The third division comprises the adenocarcinomata. They may arise from the mucous glands of the bronchi but one does not often find them forming true gland shapes but a mixture rather of atypical glands and masses of undifferentiated cells. If these latter parts predominate, and the cells are usually of the "oat" type then the growths may resemble sarcomata. The majority of lung cancers are of this last mixed type and it is into this category that the case under discussion falls.

When the growth is of the "oat" cell type the consistence is softer than the others and necrosis occurs readily/

readily in the centre of the tumour.

These "oat" celled types are now recognised as carcinomata because of the epithelial elements which are constantly present in them and vice versa because often one finds in well recognised carcinomata areas of "oat" cell formation. Of the other malignant growths in the lung, with the elimination of these "oat" celled types, very few true sarcomata are met with. When present they are generally fibro-sarcomata.

As regards pleural growths many lung tumours which have spread along the pleural surface have been reported as pleural in origin but probably they are very rare. No doubt they can arise in the pleura as well as in the peritoneum, but when the lung is much invaded it is impossible to tell where the growth started.

Complications of lung Cancer.

The pleura is affected in the majority of cases, a dry pleurisy eventuates, which later in the majority of cases goes on to an effusion which may be clear, purulent or sanguinous. In this case the pleura had been attacked at an early stage and there was a large amount of clear fluid in the pleural cavity and it contained a quantity of shreddy fibrin.

The occlusion of a main bronchus takes place in a great number of cases and this may be partial or complete. Collapse of that lobe occurs with ensuing fibrosis. If the occlusion is slow and partial bronch-pneumonia is common and bronchiectatic cavities are/

are also formed. Abscesses may ensue which originate in these cavities. Gangrene may occur. As an early complication bronchitis is nearly always present. In this case the massive involvement of the upper lobe had caused complete collapse of the lower lobe and there was a compensatory emphysema of the other lung. There was also an accompanying bronchitis.

Extension of the cancer is seen in many ways. It often proceeds along the lymphatic channels to the pleura and it may also extend along the bronchi for some distance without breaking through the mucosa. It may extend and often does extend into the mediastinum and grows into and about the pericardium, great vessels, nerves and other structures. The oesophagus is infiltrated and occluded. In this case the neoplasm had infiltrated the oesophageal wall down to the cardia. There had also been along with the mediastinal extension gross involvement of the anterior and posterior chest wall, pectoral and scapular muscles and the subcutaneous tissue.

Metastases are found according to figures compiled by investigators of this subject in 50% of cases, but many of these are discovered at post mortem and it is impossible to say how early in the disease they occur. The figures also show that metastases are found most often in the regional lymph glands, next the liver, then the suprarenal glands, pleura - vertebrae and other bones - brain, in that order. Least common are the heart and pericardium and other abdominal/

abdominal viscera. Lung cancers are the principal source of supply of metastases to bones according to these figures. The large number of cerebral metastases are probably due to the fact that the circulation proceeds to the brain from the lungs after passing through the left heart. In many cases the metastases in the bones gives the first evidence of the condition. It is interesting to note that in this case although there was gross disease there was one doubtful secondary in the liver and some nodules in one of the least common sites namely the epicardium. The regional glands, however, the mediastinal, para-aortic, supraclavicular and upper abdominal were extensively involved.

Symptoms of Lung Cancer.

Observers are varied in their placing of the different symptoms as they arise. Some say there is pain first and then cough. Others say dyspnoea first then the cough later. The onset may be insidious or it may be abrupt. It may come on in an apparently healthy individual or it may appear as an exaggeration of an already existing lung condition such as Chronic Bronchitis. There may be a sudden attack of dyspnoea followed by the coughing up of a piece of tumour tissue or there may be haemoptysis as the initial indication of the condition.

Many cases have been diagnosed following investigation of symptoms arising through metastases to distant/

distant parts such as the femur, vertebrae or brain.

In this case the first symptom was pain in the back of the chest and cough appeared later. The cough, however, subsided and reappeared 3 months later. Haemoptysis had occurred once, about the same time as the onset of the pain but had been very slight. Weakness and loss in weight had appeared gradually following the primary symptom.

Cough is a fairly constant initial symptom and is usually dry and paroxysmal in type. It is generally due to an associated bronchitis but if it is accompanied by dyspnoea it is due to pressure on a large bronchus or on the trachea. Sputum appears sooner or later and resembles that of chronic bronchitis. It is unusual to get cells in it. In this case, sputum was excessive especially in the later stages and it was frothy and muco-purulent in character. Haemoptysis does not occur often considering the large number of tumours which invade the bronchi and become necrotic.

Pain is also a constant feature and may be very severe. It is very varied in type but commonly it resembles that of a dry pleurisy. Thus it may be in any part of the chest and may radiate to the shoulder, arm, around the costal margin or to the flank. It may be sharp and stabbing or dragging in character. In this case it radiated up into the neck and back of the head indicating reflex irritation/



irritation in the cutaneous distribution of the cervical plexus. Here it was always aggravated by coughing except in the later stages when it was constant and very severe.

The wasting which accompanies these cases comes on early or late and is accompanied by other signs of cachexia such as anorexia and weakness. When the patient first went to his doctor it was found that without being aware of it he had lost a stone in weight and as the disease progressed his emaciation became extreme.

Dyspnoea is generally a late manifestation unless it is due to an effusion which may come on quite early in the disease especially if it is a pleural growth. It may be severe if a large part of the lung is involved but it is usually due to collapse of one or more lobes due to occlusion of the bronchi. Accompanying bronchitis or broncho-pneumonia are also causes of dyspnoea. Asthma-like attacks signify vagal involvement. Pyrexia according to statistics occurs in about 50% of cases and may be remittent, intermittent or continuous in type.

Quite often the patient runs a temperature like that of a phthisical patient. Here the temperature varied, as long bouts of a remittent type were followed by subnormal intervals. It is, of course, influenced largely by the various complications which may arise.

Late symptoms and signs are cyanosis, oedema of the neck/

neck or upper extremities, dilated veins and hoarseness. The cyanosis is due to the extent of lung involvement and to associated bronchitis, broncho-pneumonia or collapse of the lung. The oedema may be caused by involvement of the great veins in the mediastinum.

In this case together with the cough, pain and wasting such as have been described there was a group of symptoms and signs due entirely to pressure of the growth on structures in the mediastinum. The right cervical sympathetic was undergoing irritation due to the pressure and although the pupil was not dilated there was exophthalmos and sweating and flushing of the right side of the face. There had been increasing dysphagia during the terminal part of the illness due to pressure on the oesophagus. There was also evidence of involvement of the recurrent laryngeal nerve in quite a marked hoarseness, which had also supervened late in the illness. The other manifestations were due to pressure on the subclavian vein, as shown by oedema of the right arm, and on the brachial plexus. This latter condition had resulted in weakness of the arm, which was an early symptom, pain, which had also arisen early, and wasting of the muscles which had eventuated as a late feature.

Physical Signs.

In this case, at an early stage tubular breathing, increased vocal resonance and fremitus and dullness in percussion were present at the upper lobe of the right lung. There were no accompaniments/

accompaniments. Below this the vocal resonance and fremitus were again increased with faint bronchial breathing, but these signs disappeared low down and signs of fluid were present. The signs of the effusion appeared much later however. In general the signs are those of a varying degree of bronchial obstruction. There is massive dullness with weak or absent breath sounds due to collapse of the lung. The signs may be altered by effusion or cavitation. The heart and mediastinum are generally not displaced.

Aids to Diagnosis.

The X-Ray picture is the best means of diagnosing the condition but as was described earlier difficulty may arise in connection with some conditions. The commonest appearance is that of an ill defined mass near the hilum. Less often is seen a coarse nodular mass in the middle of a lung or a diffuse infiltration of one or more lobes. If a main bronchus is stenosed there may be a diffuse homogenous opacity of a lobe, clearly defined by the interlobular fissure, and produced by the absence of air in the lobe.

Bronchoscopy may be of value when a small growth, not yet visible in the X-Ray picture is projecting into a bronchus. The variations in texture and mobility of the trachea and main tubes may be seen and attempts may also be made at removal by this method.

Cytology/

Cytology of the effusion. According to the statistics an effusion is present in 30% of cases and in 30% of these it is sanguineous. The commonest cell change is that of a lymphocytosis of the effusion but this is not constant enough to be a means of diagnosis.

Blood Count - All cases generally have a leucocytosis of 12,000 upwards but again a diagnosis could not be made on this.

Treatment of Lung Cancer.

Deep X-Ray therapy is not proving of much value since by far the greater number of lung malignant growths are carcinomata which are not responsive to the rays in the way that sarcomata are. Some observers report that its greatest value lies in relieving the pain which it certainly did in this case and for this reason alone it should be continued.

Any attempts at removal of a part of the lung have usually resulted in operation deaths, although small bronchial growths may conceivably be removed through a bronchoscope.

The main treatment is symptomatic in order to relieve the cough, pain and to ensure sleep. In this case, on admission veronal grs. X, given at night ~~were~~ was sufficient. Later this had to be changed to omnopon gr. $\frac{1}{6}$. During the last two months morphine had to be given in doses increasing from gr. $\frac{1}{4}$ at night to gr. $\frac{1}{2}$ morning and evening.

Prognosis/

Prognosis.

The prognosis is hopeless, death ensuing in usually 6 months time. It may run a much shorter course and on the other hand patients have lived for 1 or 2 years after the initial symptoms.

Aetiology.

Observers agree that there has been a great increase during the last 10 or 15 years of lung cancer. Whether this is real or only results from more searching examination and better methods of diagnosis it is difficult to say. It is generally held that the increase is connected with an increased prevalence of chronic lung disease which has also become apparent during the last 20 years or so. Especially the conditions associated with epithelial hyperplasia due to air laden with irritants such as tar, exhaust from motor cars, coal, silica, mineral and vegetable dust. The great influenza pandemic of 1918 has also been an important factor in the production of chronic pulmonary disease during the years following it. It is important to note that statistics show that there are 5 cases of lung cancer in males for every 1 in females. There is no evidence to show that one lung is affected any oftener than the other.

(1) Influenza. In 1918 it was observed that there was hyperplasia of the bronchial epithelium in many cases of influenza. Shortly afterwards the statistics showed the increase in lung cancer, and it was suggested that the hyperplasia was pre-cancerous/

cancerous in origin and led to the development of cancer in susceptible individuals. Influenza however does not explain why there is such a preponderance of male cases. Also in many cases there is no antecedent history of influenza. However it does not follow that because influenza is not the solution that chronic pulmonary disease should be left out of the aetiological factors.

- (2) Inhaled irritants. It has been found by experiment that when rats are painted with tar in some cases they developed lung cancer before skin cancers. Experiments causing the rats to inhale gasoline fumes also showed that they might develop lung cancer. But again these irritants do not explain the preponderance in males. It is significant that the patient of this case worked in an engine room for years, exposed to air laden with oil fumes and coal dust. One can only say that coincidentally with a great increase in tar and exhaust gases in the inspired air there has been a similar increase in lung cancers and tar has been shown to be an aetiological factor in the initiation of lung cancers in rats and mice.
- (3) Dusts and Pneumokoniosis. Any favourable evidence in this direction has been that in the selection of cases by different authors, the incidence of these occupations in the aetiology has/

has been noticeable. It has been noted that in the cobalt, arsenic and nickel mines in Saxony the incidence of lung cancer is rather heavy and has always been a source of evidence for investigators. A wide investigation in Manchester showed that the incidence was greatest amongst outside transport workers and the theory was put forward that Bronchial Catarrh was the main feature in the aetiology.

- (4) Tuberculosis and Syphilis. The evidence in favour of Tuberculosis is divided, some claiming that a great many cases show Tuberculous lesions and others claiming that there is no connection between the two. There is no evidence that Syphilis plays any part in the aetiology. Tobacco smoke and trauma have been cited but again they have been merely expressed as opinions.

From the evidence brought forward by different investigators it is quite probable that chronic pulmonary disease, or irritants in the shape of fumes or dusts do play an important part in the production of lung cancer, but the fact that so many people are exposed to the same difficulties and yet remain healthy points to the importance of the personal factor in the prevention of cancer of the lung and indeed cancer of any tissue. It seems that these chronic diseases or irritants produce the cancer only in susceptible people, when the tissues are unhealthy and the individual cells are weakened by faulty/

faulty nutrition, and retention of wasteproducts of metabolism through faulty elimination.

A CASE OF ACUTE HAEMOLYTIC ANAEMIA.

A CASE OF ACUTE HAEMOLYTIC ANAEMIA.

Jessie McTaggart.

Age. 17. Occupation. Typist.

Address. Priestfield Road, Edinburgh.

Admitted. 25. 7. 32.

Complaint.

1. Excessive tiredness - - - 2 weeks duration.
2. Marked pallor - - - 2 " "
3. Thirst - - - 4 days "

History.

Until recently the patient has been a singularly healthy girl. She was a typist and worked from 8.30 a.m. to 5.50 p.m., with 1½ hours off for lunch. The office is not well ventilated and as it is poorly situated her access to sunshine is limited. She was fond of dancing and went out two nights in the week. She also was addicted to reading until the early hours of the morning and as a result of these two bad habits her hours of sleep were continually encroached upon. Thus she was never able to get much fresh air. For the past 5 weeks her work at the office has been very strenuous owing to the staff being shorthanded and her hours being longer. About 2 weeks ago she began to feel very tired and on getting home after a day's work she did not have the energy to do anything and went straight to bed. As her lethargy progressed it became more difficult for her to do her work and she eventually had/

had to give it up 10 days ago. She then took to her bed and had her doctor to see her for the first time. Her pallor has become much more intense during the past two weeks. She has not complained of any marked breathlessness and her appetite has always been good even up to admission to hospital. During the past 4 days she has been very thirsty and continually asked for something to drink. The bowels for sometime past have tended to be very sluggish. She has had no urinary trouble except for some frequency during the day or two prior to admission. There has been no noticeable loss in weight.

Personal History.

The menarché appeared at 14. Periods have been regular and of a $\frac{4}{28} - \frac{5}{}$ day type. There has been no menorrhagia, dysmenorrhoea or leucorrhoea.

Previous illnesses.

Whooping cough, aged 4, and measles in the same year, neither being followed by any complications. Shingles on the right side aged 13 and when 14 she had to lie up for a short time owing to being "run down". Latterly she has been subject to colds and sore throats.

Diet.

Breakfast. 7.30 a.m. Fish or egg. White bread and
and butter, Tea.

10 a.m. Tea and biscuit.

Dinner/

Dinner. 1 p.m. Soup, meat, potatoes, cauliflower, cabbage, beetroot, pudding and stewed or tinned fruit.

Tea. 6.30 p.m. Tea, fish, bread and butter, pastry.

Supper. 10 p.m. Cocoa, often fruit.

Environment.

Until May she lived in a 3 roomed house with 5 inmates. Very little sunlight, but it was airy and dry. In May the family removed to a modern Bungalow which was hygienic except for its damp walls. Her conditions at work have been described.

Family History.

Mother and father alive and well. 2 sisters alive and well. No deaths in the family. No history of anaemia in any member of the family.

General Condition.

She is a well nourished girl, of rather large build and good development. She is extremely pale and her skin is tinged a definite lemon yellow, more marked in the sclera. She is extremely exhausted and lies limp in bed taking no interest in her surroundings. Her intellect is not dulled so that she gives a fair history.

Temperature 101.6°. Pulse 126. Respirations 24.

Clinical Examination.

Haemopoietic System.

Slight breathlessness on exertion. Excessive tiredness on exertion. No giddiness or fainting.

She shows no pain or tenderness over the long bones and the spleen is not enlarged on palpation or percussion. The blood on examination is pale and watery and the counts are as follows:- R.B.C. 730,000. W.B.C. 8,800. Haemoglobin 20%. Colour Index 1.4. Reticulocytes. 30%. A film showed the presence of megaloblasts and normoblasts. Anisocytosis and poikilocytosis of the red cells were observed.

Cardio-Vascular System.

Slight breathlessness on exertion. No cyanosis, palpitation or pain.

Pulse. Rate 124, regular in time and force. The wave is weak and poorly sustained. The blood pressure is 104/70, the arterial wall is not thickened. The heart is not enlarged. There is no dullness to the right and the apex beat is palpable in the 5th left intercostal space $3\frac{1}{2}$ inches from the mid line. On auscultation the heart sounds are as follows.

Mitral Area. The first sound is superimposed and followed by a harsh systolic murmur. Second sound pure and closed.

Aortic Area. First sound superimposed by a very soft systolic murmur. Second sound closed but a little weak.

Pulmonary/

Pulmonary Area. First sound superimposed by a very soft systolic murmur. Second sound closed but weak.

Tricuspid Area. First sound superimposed by a soft systolic murmur. Second sound is closed and pure.

Alimentary System.

Appetite good and no history of indigestion. No nausea or sickness. No pain before or after food. No acidity, flatulence or waterbrash.

The lips are dry, the tongue is tonic but dry and furred. The teeth are in exceptionally good condition. The gums are pale and there is no pigmentation of the mucous membranes. The fauces are healthy.

The abdomen is well clad and moves moderately with respiration. No obvious abnormality of contour, swellings, hollows, etc. On palpation there is no tenderness or rigidity. The liver and spleen are not palpable.

On percussion the liver dullness reached $\frac{1}{2}$ an inch below the costal margin and its upper border is in the 5th intercostal space. The spleen is not enlarged on percussion.

Respiratory System.

No dyspnoea, no cough, expectoration, haemoptysis or pain.

The chest is well developed with equilateral expansion/

expansion.

The percussion note is resonant all over. Vocal fremitus unaltered. Breath sounds are vesicular and there are no accompaniments. Vocal resonance is unaltered.

Nervous System.

There had been a certain amount of sleeplessness and headache. Cerebration is unaffected, the patient's mental faculties being perfectly clear.

The pupils are round and react equally to light and accommodation. Ocular movement is excellent. No nystagmus. The functions of the other cranial nerves are unimpaired. There is a general impairment of motor power. There is no sensory disturbance. The superficial and tendon reflexes are unaltered.

Genito-Urinary System.

Slight frequency of micturition. No dysuria, polyuria. No pain in kidney region.

Urine analysis.

Specimen is dark amber in colour, acid, specific gravity 1005. Tests for albumin, sugar, blood, bile are negative. A strong Ehrlich's aldehyde reaction is obtained indicating the presence of excess of urobilin. A microscopic examination shows epithelial and renal cells and organisms present./

present. No pus cells or casts.

Special Examinations.

Faeces. A colonic washout shows scybalous masses, faecal sand and a small quantity of mucus. Odour markedly offensive.

Vomit. Congo red paper applied to the vomitus shows the presence of free H Cl in the gastric secretions.

Wasserman. Negative.

Differential Diagnosis.

In the accompanying chart there will be seen drawn up the various diseases which come before one's mind in considering the diagnosis. The salient features of these diseases are compared with the corresponding findings in the clinical examination of the patient. It will be seen that two diseases resemble the patient's condition closely, namely acute febrile anaemia and an unknown subacute haemolytic process. They are alike in rapidity of onset, age incidence and blood picture. Urobilin is excreted in the urine in each condition and each is accompanied by a rise in temperature. No doubt many cases which are labelled febrile anaemia are due to an unknown haemolytic process and it seems certain that the cause of death in this case was some obscure toxæmia resulting in a widespread, malignant haemolysis.

Progress.

26:7:32.

The patient has remained in very much the same condition as on admission. She was given a blood transfusion this afternoon, consisting of 8 ozs. of blood made up to a pint with normal saline. Her pulse has improved appreciably after the transfusion. Her colour is also much better. She says she does not feel any immediate benefit.

27:7:32.

The patient slept well last night and says she is feeling a little stronger. There is a slight increase of colour. R.B.C. 1,100,000.

28:7:32.

Patient slept well again last night. She says she is feeling much better today, not so tired. Colour is still improving.

29:7:32.

Patient is not so well this morning. Her colour is falling off again. She is inclined to be restless. The blood picture still shows a great many normoblasts and some megaloblasts. The reticulocytes are 60%. Fragility test. Laking commenced at .45% of saline as compared with the control (R.I.H.) at .4%. Temperature is still raised. The pulse is weak and rapid. Respiratory rate is rising. At lunch to-day she was given liver extract but vomited it and following this she appeared to become definitely worse..

The/

The vomitus gave a strong H Cl reaction .

30:7:32.

Last night the patient developed signs of air hunger. The pulse became very weak. She complained of a feeling of intense tiredness. She was very restless. A glucose saline ($\frac{1}{2}$ pint) was given into the sub-mammary tissues at 1.30 a.m. Her general condition improved slightly after this and she got a little sleep. This morning air hunger is much more marked and her general condition worse. Incontinence of urine is present. Her skin is more lemon yellow in colour and her mucous membranes very pale. The tongue is fairly moist. Pulse is rapid and feeble. She is complaining of intense weakness. The urine now contains a small amount of albumin and gives a strong urobilin reaction to Ehrlich's aldehyde reagent. Bowel washout also gives an intense reaction. The spleen appears to be a little enlarged on percussion but is not palpable. Very great difficulty was experienced in obtaining compatible blood for a transfusion. A pproximately 62 donors were typed with her serum and all except one gave a very strong agglutination of cells.

At 3 p.m. a second transfusion was given consisting of 14 ozs. of blood and 10 ozs. of glucose saline. She showed immediate improvement during the transfusion. A pink glow was observed to develop in her cheeks and she was rapidly transformed from her intensely lethargic state into a condition of increased vitality/

vitality so that at the end of the procedure she was actually laughing and talked of again dancing at the Palais.

This evening her colour is very much improved. She is much more alert and she says she is feeling stronger. The temperature has dropped slightly. The pulse is stronger and signs of air hunger have vanished.

31:7:32.

She has had a very restful night. This morning the temperature is normal, the first time it has been so since admission. The pulse is stronger, rate 100, and respirations 24. Colour and general condition are very much improved. The urine still contains albumin but no blood. The urobilin reaction is very strong. Microscopically there are no cells but large numbers of coliform bacilli.

This evening the satisfactory progress continues. Her colour remains considerably improved and her expression brighter. The pulse is steadier and stronger. The systolic murmurs in all areas of the heart are less harsh than when she was admitted. Spleen remains I.S.Q. Liver dullness just below the costal margin. Her tongue remains fairly moist. She is taking plenty of fluids, mainly irradiated milk and orange juice. She has a complete amnesia for the transfusion yesterday. Otherwise her mental processes seem to be normal and rational, although sluggish.

1:8:32.

General condition I.S.Q. She had a fairly restful night/

night. Temperature has risen to 102° . Pulse and respirations are rising. A count shows, R.B.C. 1,240,000. W.B.C. 18,800. Haemoglobin 29%. Colour Index 1.2. Reticulocytes 50%.

2:8:32.

Patient is very much improved in every way. Vitality increased, mental processes much more alert. Her colour is good and her appetite is returning. Pulse is strong, rate 100, and her blood pressure has risen. The haemic murmurs are the same. The spleen is not palpable although percussion dulness suggests enlargement. She has been reading all day, and taking an active interest in her surroundings.

3:8:32.

She has had a fairly comfortable night. General improvement continues. Satisfactory urinary output. The urine still has albumin and gives a strong urobilin reaction.

A count shows, R.B.C. 1,106,000. W.B.C. 12,800. Haemoglobin 25%. Colour index 1.1.

4:8:32.

Patient became suddenly worse about midnight last night, she was very restless and she said she was very tired. This morning she is definitely worse. Her tongue is dry, her temperature is rising. This afternoon she got another transfusion, 1 pint of blood and saline. She improved after it but not so markedly as before and her mental processes have dulled. This evening her temperature has risen to 102° /

102°, her pulse is very rapid and poor and her respirations 30. She is very restless and cannot sleep.

(The donor was a polycythaemia, in indifferent health, aged about 55. The cells remained distinct for 10 minutes after which they agglutinated.)

5:8:32.

Her condition this morning is still poor. She has hardly slept all night. Her temperature is 101°, and her pulse poor and rapid. Professor Wilkie had seen her on the 4:8:32 and as splenectomy had been decided upon she was transferred to his ward early in the forenoon of the 5th. The operation was carried out late in the forenoon of the 5th. Chloroform and ether were administered and to minimise shock the peritoneal tissues were infiltrated with novocaine. The spleen was somewhat enlarged and of a deep purple colour typical of haemolytic anaemia. (Wilkie).

In the afternoon she was given another transfusion consisting of 10 ozs. of blood and 10 ozs. of glucose saline. For the rest of the day she remained asleep.

6:8:32.

She slept well last night but this morning her condition has not improved. Her pulse is rapid and weak. She is almost comatose and does not recognise anyone nor take any interest in what is going on around. This evening her condition is getting desperate and it seems that she is not going to pull through. Air hunger is very marked.

7:8:32/

7:8:32.

During the night she had slept in bouts and when not asleep murmured in a low delirium. This morning she was able to take some milk and fruit juice and was given sub-mammary glucose saline, 8 ozs. For the rest of the day she lay almost comatose and did not recognise her parents.

This evening she is no better and her pulse is almost imperceptible.

8:8:32.

Air hunger was very marked during the night and again the patient had a low muttering delirium. She was very low in the morning and died shortly after 9 a.m.

Post-Mortem Report.

At Post Mortem the following report was drawn up. The body was well clad and in fact showed rather an excess of adipose tissue. Post-Mortem lividity was well marked.

On opening into the abdomen the blood was seen to be pale and watery. There was a little blood stained fluid in the peritoneal cavity. The liver was purplish in colour but not enlarged. The rest of the abdominal viscera were healthy. The thoracic viscera also were perfectly healthy except that the heart showed "Thrush-Breast" mottling in the endocardium of the left ventricle. The mitral valve showed a few small vegetations which seemed to be fairly recent in origin. The brain and meninges were perfectly healthy.

The liver on section and treated with the Prussian Blue reagents did not give a very strong reaction. The kidneys gave a fair reaction chiefly in the medullary zone.

There were one or two enlarged lymph glands in the mediastinum which were discreet and which were thought possibly to be of lymphadenomatous origin. On microscopic examination it was later shown that they were tuberculous glands of bovine type.

A portion of bone from the femur was removed and the pulp was seen to be red and active looking.

The stomach was not dilated and held some bile stained fluid. The mucous membrane was apparently healthy. Microscopic sections of the bone marrow, spleen, liver and/

and kidneys were examined. The bone marrow tissue was very active, there being very few fat cells. There was a lot of bile present, both in large endothelial cells and deposited in the intercellular spaces. Many normoblasts were seen. Not many white cells were seen, only a few leucocytes and myelocytes, but there were also a large number of megaloblasts. The liver showed signs of cloudy swelling and fatty degeneration to a marked degree among the polygonal cells which were also heavily laden with bile pigment. In the prussian blue section the iron was seen to be deposited mostly at the periphery of the lobules although the endothelial cells and Kupffer cells of the capillaries contained a great deal of iron.

The spleen unfortunately had been put after removal at operation into unsuitable fixing agents and the slide was not a very good specimen. It showed proliferation of the pulp cells and a large amount of cellular debris. Some doubt was expressed as to whether or not the spleen had not assumed the function of making blood. There were a great number of megaloblasts and normoblasts present. Some of the megaloblasts were seen to be in a state of division. There was much small celled infiltration of the pulp present.

The kidneys showed marked cloudy swelling in the tubules and these cells had also a strong deposit of iron as shown by the prussian blue reaction.

On/

Commentary.

Physiological Haemolysis.

Before considering the unnatural haemolytic processes which may be present in this case it is necessary to review the natural process of physiological haemolysis. The life of the red blood cell in the body is short and as a result of this inherited brevity of existence the cell at an early stage begins to show degenerative changes. It is now of no further use to the body and is therefore removed from the circulating blood. A fresh cell is being regenerated to take its place, so there must be a natural mechanism to destroy the old cell and get rid of the debris.

Ranvier was the first to describe the clasmatocyte, a branched cell which he noted in connective tissue generally, more so in the peritoneum and to which he attributed active phagocytic and food carrying properties. The true properties of these scattered cells were determined by Ehrlich who injected dyes into the body cavities of experimental animals and he showed that these cells were capable of picking up fine granular forms of these colloid particles. No doubt other cells when stimulated will take up these particles, but only those cells with a primary avidity for these particles were included. They were the cells of the splenic pulp, the spleen sinuses, and cells lining the channels of lymph glands, bone marrow capillaries and liver capillaries. Not only the/

the endothelial cells but other cells with a fibrillar protoplasm found in these places were singled out and Ehrlich designated them the reticulo-endothelial system. It is obvious that the degeneration of red blood cells and the disintegration of their substance will be followed by the passage of haemoglobin into solution where it will be dealt with by the reticulo-endothelial cells.

As to the reason why the red cells should be broken down and haemolysed it seems that it is the natural fate of the old degenerated cells. The old cells are only too readily seized and destroyed by the phagocytes and their haemoglobin is then carried off. The organs where most active destruction of the red cells takes place are the spleen, bone marrow and liver. Such destruction of cells is important in that first, a satisfactory number of red cells is kept circulating in the blood stream and secondly because haemoglobin is the only source of bile pigment. How this latter process goes on is as follows.

After the red cells are destroyed by the reticular elements of the spleen, bone marrow and liver, the haemoglobin is converted by the reticular cells into bilirubin which is then set free to circulate in the blood. This it does but it is firmly bound to serum proteins, and it is this combination which causes serum to give an indirect Van den Bergh reaction. Further it is not excreted by the kidneys but as it passes through/

through the liver it is extracted from the blood vessels by the polygonal cells, split by them from its protein combination, passed on to the bile capillaries and excreted in the bile. The bile pigment is broken down in the intestine by bacterial fermentation into urobilin and its precursor urobilinogen. These are absorbed into the circulation and a very small amount of urobilin is excreted in the urine. The rest is reconverted in the liver cells to bilirubin and biliverdin.

When excessive haemolysis is going on as in haemolytic anaemias, the reticular cells form more pigment than the polygonal cells can deal with and it passes into the blood stream and produces jaundice. In obstructive jaundice the bile pigment is absorbed from the bile ducts and also gives rise to jaundice. In this latter condition bile appears in the urine as soon as the renal threshold for bile is exceeded but in haemolytic anaemias there may be a high blood content of pigment but none appears in the urine. In these cases, however, the urinary urobilin content is high and it is not unreasonable to assume that in these cases the bile pigment is being excreted as urobilin.

Haemolysis in pathological conditions.

While physiological haemolysis is carried out as part of the daily metabolic routine there are conditions in which this is either excessive or replaced by/

by an entirely different process.

Pernicious anaemia and acholuric jaundice.

It will be advantageous to consider these conditions together as they are both diseases in which excessive haemolysis is present due to abnormal development of the red blood cells. Previously pernicious anaemia was thought to be due to an excessive intravascular haemolysis by a toxin of intestinal origin. Now it is recognised that owing to the absence of a maturing factor the red cells in this disease are liberated into the circulation in a premature state and are therefore more prone to destruction by the reticulo-endothelial system. This haemolysis is purely secondary to the abnormal state of the bone marrow and is merely an exaggeration of the normal process, the reticular cells carrying out their work by destroying the abnormal corpuscles.

In acholuric jaundice a hereditary taint causes the red cells to be abnormally fragile and so liable to excessive destruction. In a normal person the red cells resist laking by hypotonic saline down to a strength of 0.45%. In acholuric jaundice lysis results at concentrations between 0.6% and 0.7% of saline. The spleen is far more active in destroying the abnormal cells in this disease than any other part of the reticular system, as is shown by the beneficial results of splenectomy. The corpuscles, however, remain fragile but their destruction is very much reduced.

Non/

Non Specific Haemolysis.

Here we have a group of haemolytic agents at work which will cause haemolysis of the blood of animals in general. Most important are the bacterial haemolysins, such as streptolysin, tetanolysin, staphylolysin etc. Such haemolytic organisms having gained access to the blood, issue a toxin which is capable of dissolving the red cells. A haemolytic toxin may be shown to be present by experiments in vitro, but its mode of action on the cells is uncertain. Little is known of the physical properties of the toxins except that, streptolysin is much more resistant to heat than staphylolysin. They have been described as specific fat complexes of the bacteria in a colloid state which act by dissolving the envelope of the corpuscles.

Another group is the saponin group. About 40 plants have juices which is introduced into the blood stream dissolve the corpuscles by either combining with or dissolving their lipoids. It has been noted that saponin + blood + cholesterol produces no haemolysis but that saponin + lecithin is intensely haemolytic. This has some bearing on the next group of the haemolysins, the snake venoms. Snake venom, notably cobra venom, is extremely haemolytic again acting in virtue of its power to dissolve the cell envelope. The haemolytic action of cobra venom + lecithin was found to be inhibited in the presence of excess of cholesterol, and further observations showed that when in combination with the unsaturated fatty acids/

acids such as oleic acid haemolysis was much more marked than when in the presence of saturated fats. It is considered that the combination of cobra venom and lecithin is haemolytic especially when the cholesterol content is low and that it is activated by the amount of unsaturated fatty acid present in the blood.

It will be noted that this type of haemolysis occurs as a result of the dissolution of the cell envelope and is quite different from normal phagocytic haemolysis.

Specific haemolysis.

Bordet in 1898 first demonstrated the existence of specific haemolysis by showing that the serum of a guinea pig which had previously received intraperitoneal infections of rabbit corpuscles, was able to lyse the rabbit cells. Something had been formed in the pig's serum capable of dissolving the rabbit corpuscles and moreover it was specific for that animal and its close relations. Bordet also found that the serum lost this property from age or by heating and could be reactivated by addition of fresh untouched serum. It was concluded therefore that another substance, "complement", was present in normal serum and necessary for the haemolysis of the corpuscles. Bordet postulated that the haemolysin sensitises the cells and renders them susceptible to the direct action of complement.

The/

The haemolysis is essentially a splitting or dissolving of the lipoids out of the erythrocytes.

It is interesting to note the existence of an autohaemolysin. That is to say in the serum of some individuals there exists a haemolysin for their own corpuscles. When the body temperature is low enough this haemolysin sensitizes the corpuscles so that when the normal temperature is regained, haemolysis occurs. This is the explanation of paroxysmal haemoglobinuria, and it is suggested that trauma, cold and passive congestion lead to excessive acidity in the tissues and the organic acids formed are the haemolytic agents. On the other hand the haemolysin, may like the snake venom, be complemented by lecithin or fatty acid or by some other unknown factor.

Malaria.

Here one is dealing with yet another type of haemolysis, namely destruction of cells by parasites. The parasite develops and divides inside a corpuscle and at a certain stage in the cycle the cell is ruptured and the contents set free. If the attack is severe the patient becomes very anaemic as there is a rapid dissolution of red blood corpuscles going on.

Black Water Fever.

In this condition the blood destruction is so great that the urine is literally darkened by the red cells, haemoglobin and debris. Gulland and Goodall/

Goodall think that the haemolysis is merely an expression of an extreme degree of malarial haemolysis. Thompson suggests that the cells altered by repeated attacks of the plasmodium falciparum are acted upon by a specific autolytic substance produced in the plasma. In this disease then the intravascular destruction of red cells is so great as to cause an extreme degree of haemoglobinuria.

Considering then these different aspects of haemolysis is it possible to explain why in some cases haemoglobinuria occurs while in others there is instead an increased excretion of urobilin. Gulland and Goodall do so by dividing haemolytic processes into two classes.

1. In conditions such as streptococcal septicaemia and blackwater fever there is a toxin strong enough to directly dissolve the corpuscles and as a result the blood stream contains large quantities of red cell debris and haemoglobin. The kidneys are unable to cope with the excess of debris and the urine is thus literally darkened with cells, fragments of cell envelopes and haemoglobin.

2. (a) The toxic agent is not so strong and merely poisons the cells thus rendering them more liable to phagocytosis by the reticulo-endothelial system. For example splenic anaemia and probably this case.

- (b) The cells are premature as in pernicious anaemia or inherently weak as in acholuric jaundice and as/

as a result are specially liable to early phagocytosis. In both (a) and (b) the haemoglobin is carried to the liver by the reticular cells. The polygonal cells are unable to deal with the excess of material, it is passed on into the blood stream and is excreted in the urine as urobilin.

What is the essential process in this case.

The fragility test showed that there was no inherent weakness of the cells but one must recognise the fact that in acquired acholuric jaundice there is often no demonstrable fragility of the cells. Therefore this condition cannot be dismissed too lightly. One is quite definite that this is not an intravascular haemolysis because of the absence of haemoglobinuria. The condition then probably comes under the category of group 2 of Gulland's classification. One must then find an agent which has poisoned the cells rather than dissolved them. The possibility must also be kept in mind that this may have been a nutritional disorder causing faulty haemogenesis. The patient had been very constipated previous to the illness, she had had a faulty dietary and irregular meal hours and she had suffered under the strain of over work. She had also deprived herself of fresh air, sunlight and exercise.

One of the very early theories of the cause of pernicious anaemia, namely that of an intestinal toxæmia was supported by the following observation.

Tyramine/

Tyramine when injected in to the experimental animal produced a hyperchromic anaemia and it was also found that tyramine could be produced by the action of B.Coli on cheese. It was then suggested that if by stagnation the flora of the small intestine could approach that of the colon, then an anaemia like pernicious anaemia would result. This stasis was produced in dogs by operative stricture and the anaemia resulted. It is quite reasonable to suppose that in this case the haemolysis was brought about by the absorption of tyramine like bodies from the small bowel where they had been produced by constipation and faulty digestion.

One can also consider the possibility of an excessive hypocholesteraemia. Cholesterol in the presence of excess of unsaturated fatty acid, inhibits the haemolytic action of snake venom + lecithin. Was it possible that like Evan's theory of pernicious anaemia there was some toxic product of metabolism present which united with the lecithin of the cells, weakened them and rendered them liable to phagocytosis? That an abnormal state of the cholesterol and fatty acids was present is quite conceivable in the presence of the faulty metabolism.

Lastly there is the possibility that the condition resembles that of serum haemolysis. When an animal is immunised against foreign corpuscles, the serum acquires the power of rapidly haemolysing those corpuscles. However if very small quantities are injected/

jected, then only poisoning and excessive phagocytosis of the cells results. Cederberg noted that some animals dying of an anaphylactic shock showed this type of haemolysis and it is quite conceivable that this disease was in the nature of an anaphylactic reaction. The toxin or exciting agent was some foreign protein absorbed from the bowel or more likely arising in the blood from the faulty metabolism. The toxin was akin to the small doses of serum injected into the experimental animal and the poisoning of the cells and destruction by the phagocytes ensued. To support this were the presence of a temperature and the sickness which the patient developed, these being common features of anaphylaxis. That this was a sudden fierce anaphylaxis was unlikely as shown by the comparatively lengthy illness and the lack of haemoglobinuria. If it had been a sudden anaphylaxis one would also have expected a sharp onset, a higher temperature and other manifestations such as a rash.

Other interesting features of this case.

1. Failure of splenectomy to benefit the patient.

Splenectomy is performed as a routing therapy in three diseases.

A. Acholuric Jaundice where both in the chronic type and more especially in the acquired type its removal is a curative measure. In the latter type where the patient may be reduced to a grave condition in a few days, with temperature, jaundice/

jaundice and profound anaemia, the rapid improvement within a few days is very striking.

B. Purpura Haemorrhagica. In the acute stage it is doubtful if any therapy is useful but in the chronic type its removal seems to cure the condition.

C. Splenic Anaemia. - here and according to so great an authority as Moynihan its removal is necessary to save life and more so before any signs of hepatic cirrhosis have developed.

In the first condition the spleen removes the abnormal cells and keeps up the anaemia and in the second it is also probable that the spleen destroys the blood platelets. In the third the spleen is probably issuing a cell poison, but in these definite conditions its removal is necessary because one is aware of the organ that is at fault, and results amply justify the procedure. In this condition however the whole of the reticulo-endothelial system was destroying the red cells and as probably the bone marrow and Kupffer cells in the liver were just as active as the spleen the rationale of the operation was not obvious, and we see it was quite ineffective. In fact it is quite possible that the spleen here was regenerating blood as from the microscopic appearances it appeared so and that far from benefiting the patient possibly harm was done.

2. Difficulty of finding compatible Blood Donors.

In/

In all no fewer than sixty donors were tried for the first two transfusions. The corpuscles of her parents and nearest relatives were rapidly agglutinated by the patient's serum. Eventually two people were found whose cells were not agglutinated so rapidly as the others and they were used. It was quite possible that the abnormality of the patient's blood was responsible for the unusual agglutination. Again it may have been due to faulty technique, but it was much more likely that some iso-agglutinin had arisen in the serum possibly in the same manner as the haemolytic agent.

A CASE OF ANGIOBLASTIC LEUKAEMIA.

A CASE OF AURICULAR FLUTTER.

David Simpson.

Age. 66. Address. 6 Crown Terrace, Prestonpans.

Married. Coal Mine Engineer. Admitted 4/7/32.

Complaint.

- | | |
|---|--------------------|
| 1. Breathlessness. | Duration 2 months. |
| 2. Swelling of ankles and feet. | " 2 months. |
| 3. Sleeplessness. | " 2 months. |
| 4. Cough. | " 20 years. |

History of Present Illness.

Previous to two months ago the patient enjoyed excellent health. Two months ago he had an attack of shingles and was confined to bed for a fortnight. The eruption extended over the upper and outer aspect of the left arm. After convalescence he had a short holiday in order to recuperate and it was then that he found that he was becoming unduly breathless especially when he underwent any exertion such as walking uphill or climbing stairs. He resumed his work and carried on for some weeks but it became increasingly difficult for him on account of the breathlessness. Two weeks ago his ankles and feet began to swell and he noticed that this was most marked at night and that the swelling was very much less in the morning. The breathlessness increased to such an extent that during the past week he has had difficulty even while lying at rest in bed. He continued at his work nevertheless until the day of admission. 20 years ago he had an empyema of the left side of the/

the chest and ever since he has had a cough. At present he brings up a lot of frothy white sputum. Sleeplessness has also troubled him for the past two months causing him to lose an hour or two every night.

Previous Illnesses.

Measles, whooping-cough, scarlet fever, diphtheria, as a child. Operation for left-sided empyema, aet 46. Operation for "adhesion of bowels" aet 58. Appendectomy at same time. He is subject to sore throats and colds, but has never had influenza.

Personal and Family History.

When a young man he drank heavily for about 3 years but he gave that bad habit up fortunately and since then his drink has been moderate in amount. Previous to two months ago he used to smoke 30 cigarettes a day but since his shingles he has limited this to 5 a day. His bowels are regular but this he says is due to regularly taking medicine. He has been putting on weight lately.

His mother died aet 54, cause unknown. Father died aet 84 - senility. One sister is alive and well. Another sister died aet 15 of typhoid. His wife is alive and well. He has one son alive and well. He had 2 daughters, one was still born and the other died aet 10 from "inflammation of the lining of the heart".

Home Conditions.

His house has 5 rooms and a scullery. 2 inmates. It is/

is dry and airy, it is situated about 50 yards from the sea and it gets plenty sunshine.

Diet.

Breakfast.	9.30 a.m.	Boiled egg - white bread and butter, tea.
Dinner.	1 p.m.	Broth, meat, potatoes, cabbage, pudding.
Tea.	4.30 p.m.	White bread, butter, cheese, tea.
Supper.		Nil. Moderate amount of fruit.

General Condition.

He is very well nourished but he looks his years. He has an unhealthy sallow complexion and is cyanosed. It is prominent in the lips, ears and malar regions. He is propped up in bed and is obviously breathing with difficulty. He is of average intelligence and pleasantly disposed.

Temp: 97°F. Pulse 108. Respirations 26.

Weight 14 stone 2 lbs. Height 5 feet 9½ ins.

Clinical Examination.

Circulatory System.

Orthopnoea is present. There is definite cyanosis. There is no pain in the praecordium, no palpitation, no dizziness, headache or throbbing in head. There is marked oedema of legs.

Pulse is 110, regular in time and force. The upstroke is fairly slow but the wave is not well sustained and falls suddenly. The vessel wall is just palpable, indicating slight thickening. The blood pressure is 150/90.

Apex beat is neither visible nor palpable. There is no visible pulsation in the neck.

On percussion the superficial cardiac dullness extends 5 inches to the left from the mid line and 1 inch to the right.

On auscultation the heart sounds are as follows:-

Mitral Area. First sound is muffled. Second sound, closed and pure.

Pulmonary Area. Again the first sound is muffled. The second sound is accentuated.

Aortic Area. First sound is muffled. Second sound slightly accentuated.

Tricuspid Area. Both sounds are closed, the second is slightly accentuated.

Respiratory System.

Chronic cough, white frothy expectoration. Cyanosis is marked. Orthopnoea is present. No pain in chest.

The/

The chest is well formed and well clothed. The respiratory excursion is poor but expansion is equal on both sides. On palpation expansion is equilateral and vocal fremitus is unaltered. On percussion the note is good all over. On auscultating the chest the breath sounds are vesicular. There are a few medium pitched rhonci heard and crepitations both fine and medium are heard all over. Vocal resonance is unaltered.

Alimentary System.

No indigestion, no flatulence or waterbrash, no vomiting, bowels regular. No difficulty in swallowing.

The tongue is large, dry and slightly furred. The teeth are all artificial and the gums are healthy. The pharynx and fauces are slightly congested. The abdomen is large and well clothed. Poor respiratory movement. There is a mid line scar 4 inches in length above the umbilicus. On palpation there is slight tenderness in the epigastric region. The liver dullness extends to about $1\frac{1}{2}$ inches below the costal margin. The edge is regular. No obvious splenic enlargement.

Nervous System.

No aphasia. No loss of memory. No headaches, giddiness or fits. Insomnia for about 2 months. No blindness, or diplopia. No paralysis or weakness of the limbs.

Pupils/

Pupils are equal in size, regular in outline and react sluggishly to light and accommodation. Ocular movements good. No nystagmus. Abdominal reflex is absent on both sides. Plantar reflex is doubtful but probably flexor. Wrist and elbow jerks present on both sides and brisk. Knee jerks are present. Ankle jerks are not present. No ankle or knee clonus. No sensory alteration.

Genito-Urinary System.

No pain in back. No frequency of micturition. No dysuria, polyuria or anuria. No haematuria.

Palpation. Neither kidney felt. No tenderness over kidney or bladder. No enlargement of bladder.

Specimen of Urine. Straw colour. Specific Gravity 1015. Acid, no deposit. Trace of albumin.

Sugar -ve. Blood -ve.

Microscopically there are a few granular and hyaline casts. There are pus cells and a few renal and epithelial cells present.

Endocrine, integumentary and locomotory systems have nothing to note.

Special Examination.

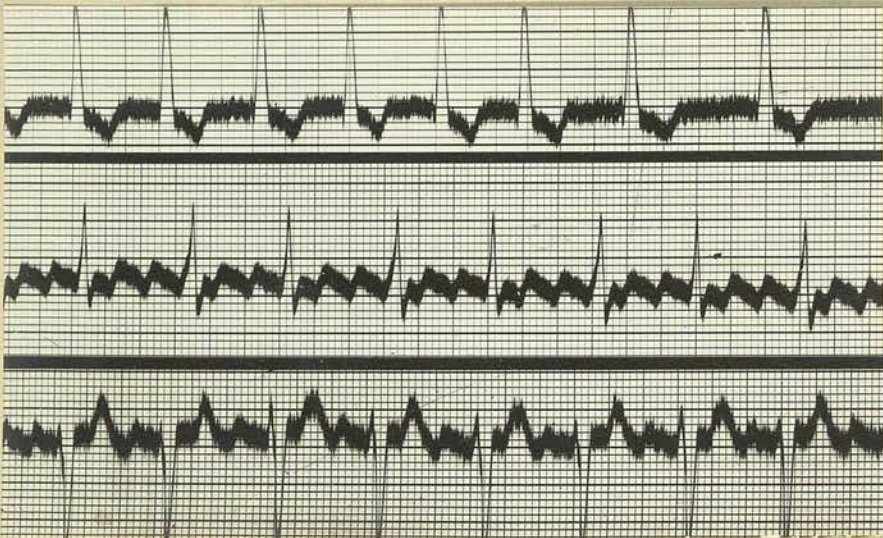
An electrocardiogram showed the presence of auricular flutter. A 3:1 heart block is present but the ventricular response is regular. There is also a left ventricular preponderance present.

Diagnosis.

This patient presented the symptoms of cardiac failure. The breathlessness was very marked, and while previously it had been present only on exertion, now it was severe when lying in bed. Oedema of the lower extremities was also present and had come on gradually over a period of 2 weeks. The pulse showed a rate of 110 beats per minute but it was regular in time and force. On examination there were no visible pulsations in the neck and the apex beat was not visible. On auscultation at the mitral area the first sound was muffled and the second sound was slightly accentuated. The commonest causes of heart failure, namely auricular fibrillation and valvular disease were eliminated first by feeling the pulse and then auscultating. Fibrillation was not present as the pulse was perfectly regular and as there was no indication of a water-hammer element present aortic incompetence was also eliminated. This, and the possibility of mitral disease, were also excluded by auscultation as no murmurs were heard at any area. The less common conditions had to be next considered, and as the heart was on percussion found to be somewhat dilated, fatty disease was suspected. Fatty infiltration was hardly conceivable as the patient was not an excessively stout man and was not given to over indulgence in food, but the attack had commenced after shingles which had possibly acted as an acute infection on the heart. One would have expected, however, /

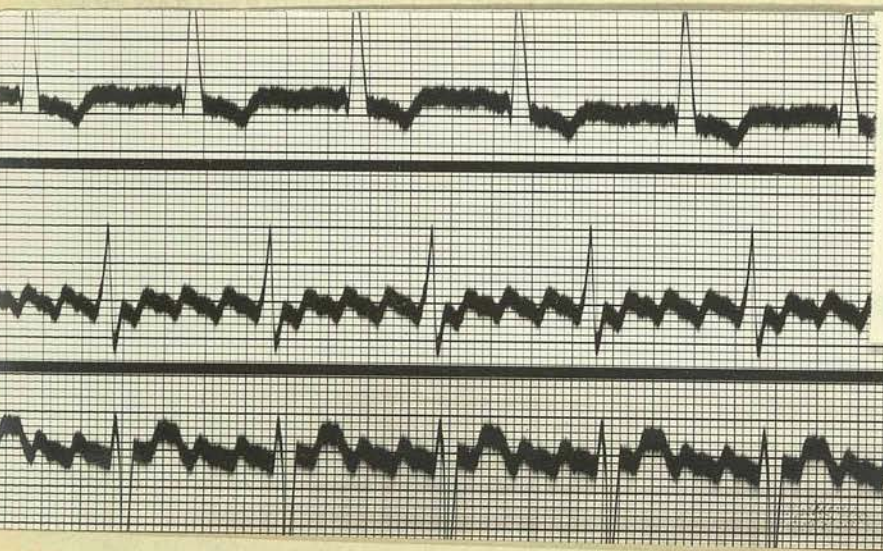
however, in this condition very weak heart sounds and a more rapid pulse. Chronic interstitial myocarditis if present would give symptoms such as the patient showed but there was no indication of any coronary disease present. Nor did one suspect gummatous deposits in the heart wall and there had been no long standing hypertension or venous congestion such as might have resulted in the present condition.

The other conditions which have to be considered are bundle branch block and auricular flutter. The first of these is a severe condition which presents symptoms of cardiac failure but which one cannot diagnose without the aid of the electro-cardio-graph. Flutter, on the other hand, can often be fairly accurately diagnosed by its clinical symptoms. It was suspected in this patient by the regularity of the pulse and the severity of the heart failure. Another sign may be present, namely a rapid pulsation in the side of the neck. The pulse is generally somewhat faster, about 150 beats per minute as the auricles are contracting at a rate of about 300 or so per minute and there is present usually a 2:1 block. In this case, however, as was shown definitely by means of an electro-cardiogram, flutter was present with a 3:1 block, giving a pulse rate of about 110 beats per minute.



4.7.32
3:1 FLUTTER
REGULAR VENTRICULAR
RESPONSE.

L. VENTRICULAR
PREDOMINANCE.



7.7.32
4:1 RHYTHM
REGULAR V. RESPONSE
AFTER 18cc DIGIT.

Progress and Treatment.

1678
137
Treatment started 4.7.32. The patient was put to bed and propped up in the orthopnoeic position. He was put on a milk diet and elimination from the colon was ensured by a dose of 3 grains of calomel to be followed by washouts. An electrocardiogram was taken and showed that the condition was auricular flutter with a 3:1 rhythm giving a regular ventricular response. The pulse at the time of recording was 108. It was decided to give the patient 2 c.c. of digitalis t.i.d. to start with.

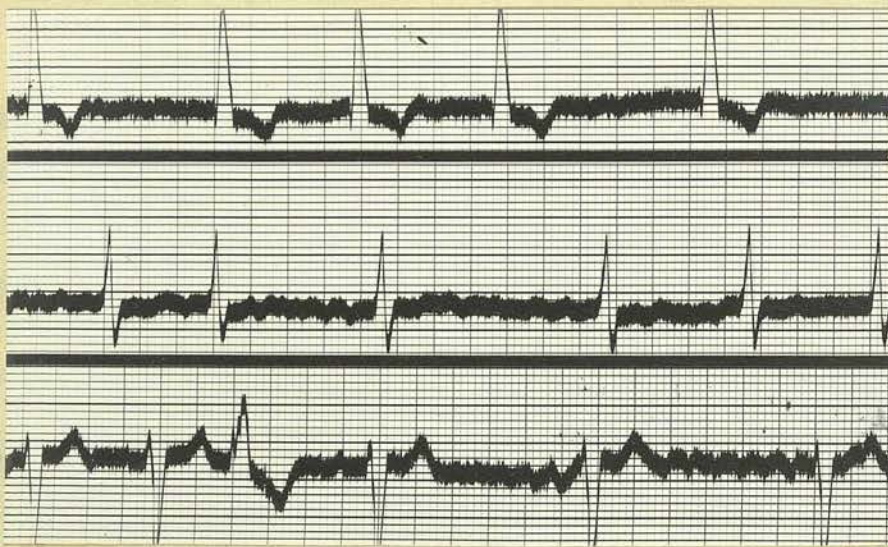
5:7:32.

The patient has been fairly comfortable although he is still breathless. Slept well last night.

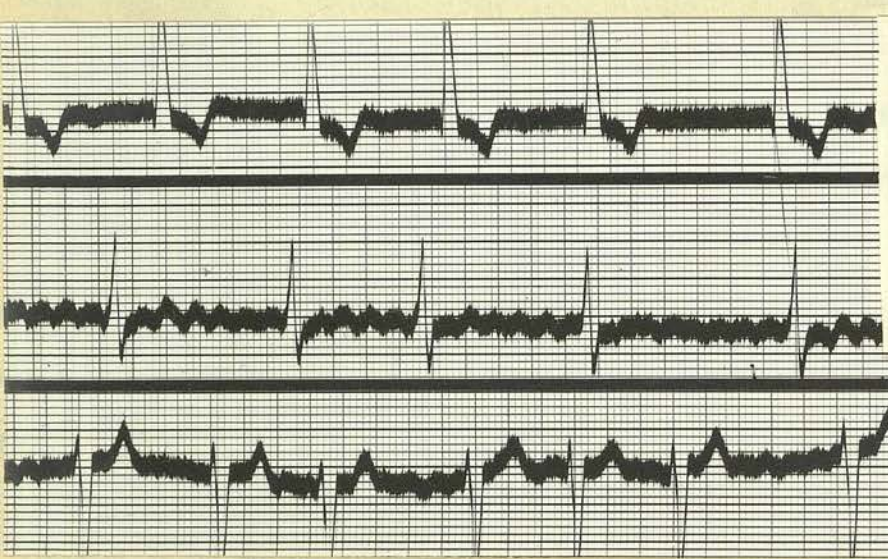
7:7:32.

1678
16-7-
Last night the patient's breathing was of the Cheyne-Stokes type but this only lasted for about 4 hours and the breathing gradually returned to normal with a respiratory rate of 34. During the past two days he has been fairly comfortable. The pulse has been varying between 90 and 100 and has been regular. The urinary output has doubled itself and remains about 100 ozs. per day. The oedema has not markedly changed. To-day's electrocardiogram shows a 4:1 rhythm and a regular ventricular response. Up till the recording he has had 18 c.c. of digitalis. He is to continue with 3 c.c. daily from to-morrow.

12:7:32/



13.7.32.
FIBRILLATION
PRESENT.
PROBABLY BEGAN ON
12.7.32
AFTER 33cc DIGIT.
PULSE 64.
DIGITALIS STOPPED.



16.7.32.
IMPURE FLUTTER.
PULSE 65.

12:7:32.

The pulse to-day is slightly irregular and the rate is down to 80. The urine is also down to 70 ozs. Respirations have fallen to about 26. The oedema is decreasing, especially in the legs. The patient has been very comfortable and sleeps well. On the 10th. his feeding was changed from the milk regime to a light diet.

13:7:32.

To-day's electrocardiogram shows that the patient is now fibrillating. This probably began yesterday. The urine is decreasing and the average daily output is about 70 ozs. The pulse to-day is down to 64 and the digitalis will be discontinued from to-morrow.

16:7:32.

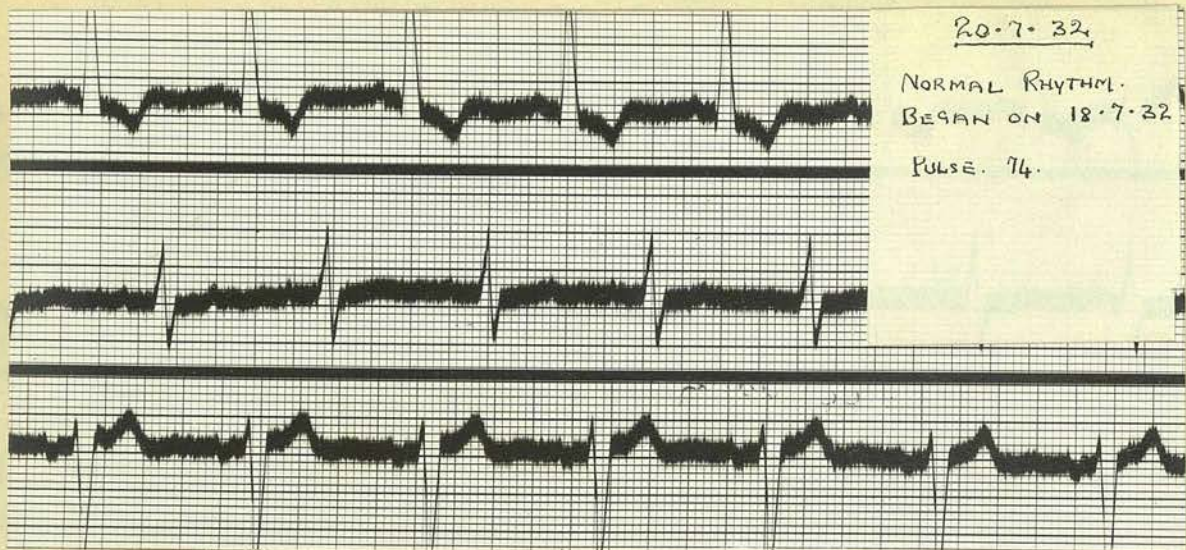
For the last 3 days the pulse has been below 65 but irregular and the respirations have been just over 20. The urinary output is down to just over 50 ozs. per day. The patient is very comfortable. He is not breathless at all now and the oedema has almost disappeared, especially from his legs. An electrocardiogram taken to-day shows fibrillation but small peaks are visible giving a picture of impure "Flutter".

18:7:32.

Pulse is regular to-day except for a very occasional irregular beat.

20:7:32.

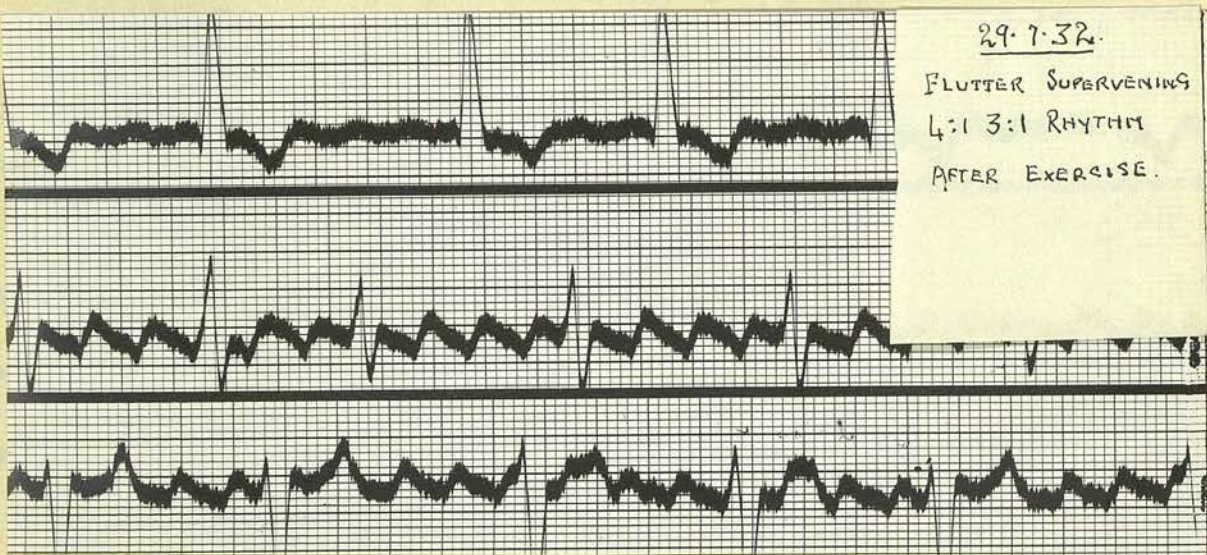
Pulse has been regular since the 18th with a rate of about 80 beats per minute. To-day's electrocardiogram/



20.7.32.

NORMAL RHYTHM.
BEGAN ON 18.7.32

PULSE. 74.



29.7.32.

FLUTTER SUPERVENING
4:1 3:1 RHYTHM
AFTER EXERCISE.

gram shows practically normal rhythm.

25:7:32.

Pulse rate to-day is 74 and has been regular since the 18th. The patient is very comfortable and sleeps well. His appetite is good. The urinary output has been below 40 ozs. since the 19th.

26:7:32.

Pulse to-day is slightly irregular. Rate is 78. The irregularity is irregular. General condition has not changed.

28:7:32.

Patient got up to-day for half an hour and walked a little. He feels very well after it. The irregularity is still present in the pulse.

29:7:32.

To-day's electrocardiogram shows that the patient has returned to flutter. It is mainly a 4:1 rhythm but 3:1 groups are seen and it is this interspersing of the groups that is giving the irregularity to the pulse. No more digitalis is to be given but the exercise will increase daily. The patient was up to-day for 1 hour. He is feeling quite strong. The respirations are 20 to the minute. The breathlessness and oedema have both disappeared.

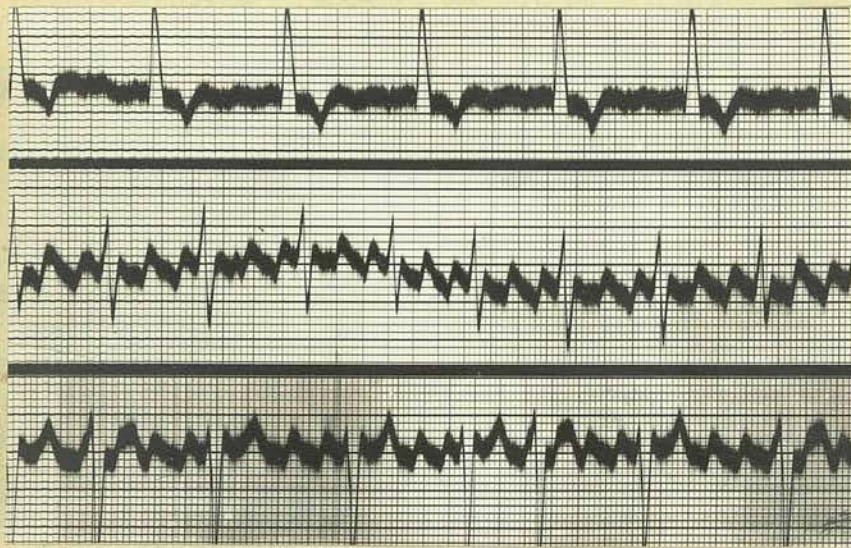
4:8:32.

The pulse to-day is 56. It is still irregular however.

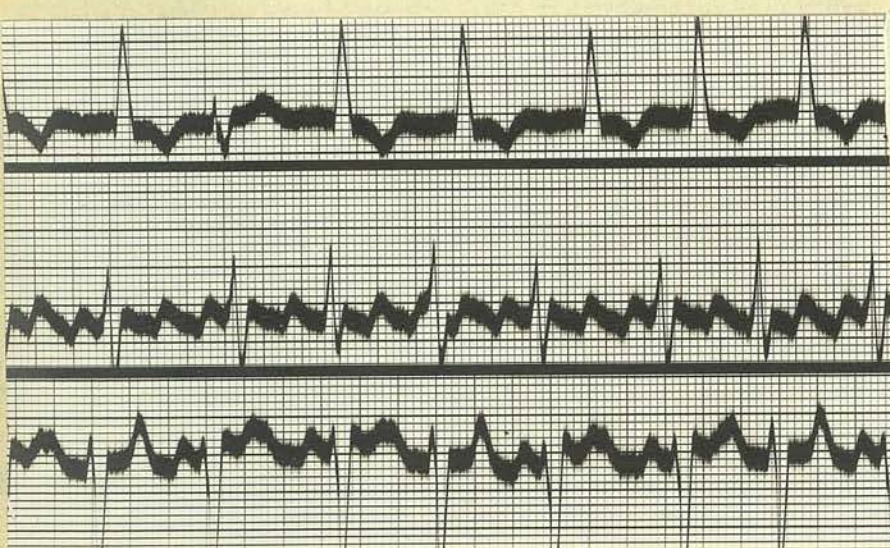
8:8:32.

The electrocardiogram to-day shows almost a regular 3:1 flutter. The patient is up for nearly all the afternoon now.

The/



8.8.32.
A. FLUTTER.
3:1 RHYTHM.



24.8.32
A. FLUTTER.
2:1 3:1 RHYTHM.

The patient was discharged on the 17th. The flutter had continued but the pulse when he went out was 70 beats per minute and he felt strong and fit. The pulse had continued to be regular.

He reported on the 24/8/32 and said that he had been very well, his appetite had been good and that he was sleeping well. He was soon to resume work. An electrocardiogram showed that the flutter was still present with a varying 2:1, 3:1 rhythm.

Commentary.

Auricular flutter is a condition in which the auricle contracts roughly at a rate of 300 contractions per minute. The ventricle of course can not respond to this so that there is always a degree of heart block present. Usually there is a 2:1 block. This will result in a ventricular rate of 150 beats per minute. Not nearly so common as this is a 4:1 block and one also may meet with a 3:1 variety. Very often these variations are met with in the same individual, groups of 3:1 contractions may be followed by 2:1 groups and possibly between these may be interspersed some 4:1 types. If these variations occur at regular intervals then the pulse will have a regular though abnormal rhythm, usually however the ventricular response is irregular. The patient under consideration showed on admission a 3:1 block with a regular ventricular response.

In 1887 this condition was first introduced by McWilliam who produced a rapid contraction of the auricles in dogs by faradisation and also an irregular condition akin to fibrillation. These did not result immediately the current was applied, but followed it, i.e. a spontaneous after result.

Ritchie drew attention to the same condition in 1905 and recognised the essential similarity to McWilliam's flutter. He was able to observe auricular contractions at the rate of 275 per minute. In 1909 by the aid of the electro cardiograph he identified
a/

a condition clinically in which the auricles were contracting at a similar rate and named the condition auricular flutter.

Since this discovery much research has been carried out on the subject of flutter and fibrillation and following experiments in which a continuous wave of contraction is made to travel round a ring of muscle, much light has been thrown on the passage of the wave of contraction in the auricles in these conditions.

In the normal heart the passage of the stimulus is from the S-A node to the A-V node. In doing so, after being received at the S-A node it spreads over the auricle causing it to contract and when the stimulus has reached the A-V node the contraction dies away and the auricle is quiescent until reactivated by a fresh stimulus. The impulse is passed through the auricle by means of a special property of auricular muscle, namely its conducting power. Each muscle fibre on contracting causes its neighbour to contract and as long as that property of the muscle is not interfered with then the normal passage of the stimulus will ensue. The other property of auricular muscle which plays an important part in the production of these conditions is the refractoriness of the muscle, that is, the period after contraction during which the muscle fibre rests and will not contract even though receiving a stimulus. In flutter it seems that instead/

stead of this normal passage of an impulse from the one node to the other with the refractory period ensuring a rest after the contraction, there is a continuous wave of contraction circulating round the auricle. This wave has a fixed path which includes the orifices of the superior and inferior caval veins. Thus no regard is paid to the orderly flow of impulses generated at the S-A node and impulses are literally showered down on the A-V node usually with a deleterious effect on the ventricular contractions. This circular wave of contraction however is fixed and constant and quite unlike that of a fibrillating auricle in which there is also a circular wave but which follows a much shorter path and which gives off side shoots and is forever deviating in different directions. The individual fibres thus contract independently and inco-ordinately.

The manner in which this circulating impulse was discovered is quite interesting and in the tissues used for the experiment a circulating wave was actually produced which could be kept going for a considerable length of time. Mayer in 1908 cut a ring of tissue from the umbrella of a jelly fish and applied an electrical stimulus at one point. A wave of contraction started at that point and proceeded round the ring in two directions, and both waves met at the other side and mutually extinguished each other. He now applied cold to a part of the ring and the wave of that side stopped there as the conduction of the muscle/

muscle had been interfered with. The other wave, travelling round the ring was also held up there. The next step was to withdraw the cold immediately after the stimulus was applied and although the one wave was stopped, by the time the other wave came round the muscle had recovered and the wave went on and so back to where it had started. Thus he had produced a one way wave and he next showed that if the ring was large enough and the point of stimulation was not refractory when the wave came round then it would go on round and round for hours or even days. Mines experimented after this and used the hearts of large rays but he produced his ring by applying stimuli in rapid succession and he offered the suggestion that it was the rapidity of the stimuli which was the factor responsible for the continued wave of contraction.

The results of these experiments were employed in an effort to understand the fundamental condition of the auricle in both flutter and fibrillation and the theory of circus movement was evolved. This meant that, as has been previously described, there is a wave of contraction circulating round the auricle in both these conditions. While in flutter the path is fixed, in fibrillation it takes any direction open to it. In flutter the time required by the wave to travel its circular course is greater than is required by it to recover from its refractoriness and so it goes on. Thus there is as it were a gap between the head/

head and tail of the wave in which the muscle is refractory, the circular path followed by the wave being large enough to allow of this gap. It is this ring of contraction then that circulates round the auricle at a rate corresponding to 300 circulations per minute and which causes it to contract at the same rate giving rise to the condition known as auricular flutter.

The condition gives a characteristic electrocardiogram. The auricular contractions are recorded, and are known as flutter peaks, the upstroke of one contraction beginning immediately at the termination of the previous one. These peaks are not often visible in lead I but in leads II and III are usually quite obvious. In each lead however if they appear they are constant and rhythmic. When a case of flutter is undergoing a change, either to normal rhythm or to fibrillation, the peaks become much smaller and interspersed with little oscillations similar to those produced by a fibrillating auricle and the name of "impure flutter" is now given to the electrocardiographic appearance. Throughout the tracings of this case these characteristics were noted. There is no indication in lead I except the absence of the normal P deflection. In lead II there is a typical picture in most of the examples. Lead III varies, as while in some especially the 4:1 rhythms it is well marked, in others it is not so obvious. During the treatment one of the tracings shows/

shows an example of what is meant by impure flutter. Throughout the series there is also seen evidence of a left ventricular preponderance but this probably is quite apart from the condition of flutter.

The aetiology of the condition is probably nearly identical with its much commoner companion disease, fibrillation. It is a disease of late middle life, much commoner in males than females and is associated with myocardial degeneration most commonly rheumatic in origin. Cardiac enlargement is an important feature in the aetiology and very often the cases showing this feature are not those which have resulted from high blood pressure. On looking over the patient's history one can find no indication of rheumatism which was actually known of, but he was very subject to sore throats and colds. In his childhood he also had more than his share of the infectious diseases. As regards heredity his family history shows no known evidence of heart disease, with the possible exception of his mother whose death resulted from an unknown cause. He worked as a coal mine engineer which is not laborious work has probably not played any part in the production of the necessary cardiac weakness. One notes that for 3 years the patient was a heavy drinker and that previous to his shingles he smoked heavily. The patient possibly had an inherent susceptibility to toxic conditions as is evidenced by his infections when very young, empyema in early middle life, appendicitis probably several times and, later on, shingles. It is quite possible/

possible that his circulatory system has long suffered under the strain of these attacks and also the strain of faulty elimination from the bowel, as is noted from the history and that the acute attack of herpes has precipitated a severe heart failure.

The diagnosis of auricular flutter would be very difficult were it not for the ease in which the condition is revealed by the electrocardiograph. It is always to be considered when there is cardiac failure, with a rapid regular pulse, or a slow pulse which has a regular though abnormal rhythm. When the pulse is irregular it is almost impossible to differentiate the condition from fibrillation apart from electrocardiographic methods. The observation of a fullness in the veins of the neck or a rapid pulsation might help to put one on the track of flutter. Transient attacks of flutter should always be suspected whenever an individual is conscious of a rapid heart or attacks of palpitation. Heart failure resulting from flutter is also apt to come on much quicker than failure from other causes and this diagnosis is suggested when failure results from apparently no cause especially when the rhythm is regular.

The prognosis of auricular flutter on the whole is not good. The attack may last for a few moments and disappear never to return. On the other hand it may last for years and above all there is a definite tendency for it to recur. It probably accounts/

accounts for many cases of paroxysmal tachycardia and if these are few and far between then they are not of much significance but a flutter sustained for any length of time is a sign of a damaged myocardium. If the ventricular rate is high and the myocardium weak, very rapid cardiac failure results with cyanosis and dropsy and the prognosis is guarded. It is rendered grave in the presence of frequent attacks, damaged valves and unhealthy vessels. Much also depends on the treatment by digitalis and whether or not it is possible to restore normal rhythm.

Treatment. The treatment of auricular flutter becomes necessary when heart failure dominates the picture and in this case the routine procedure was carried out. The drug used is digitalis and this was exhibited along with the other measures necessary in heart failure cases viz. - bed, propping up of the patient, milk diet, and the ensuring of free elimination by the bowel. The preparation of choice is the tincture and this was given, 2 c.c. three times in the day. The guides which one follows in the administration of the drug are the pulse, the patient's appetite or rather its effect on the gastrointestinal tract, and the amount of the drug given. When the pulse drops down to about 60 as it did here about the 10th day of treatment the digitalis must be stopped. By this time the patient had received about 35 c.c. as the drug had been reduced to half the dose after three days. Allowing about 10/

10 c.c. for elimination over that period the patient received about 25 c.c. or in other words was fully digitalised. The electrocardiograms showed that the heart had responded long before that amount had been given. Why is digitalis used and what is its action? It is known that there is a circus movement in the auricle with a gap between the head and tail of the wave of contraction. The action of digitalis is mostly through the vagus and here it acts in two ways. It either shortens the refractory period and so lengthens the gap or it improves conduction and so tends to shorten it. The sum of these two actions is that the speed of transit of the wave is increased. The circus being thus quickened tends to take a shorter path if one is open and the next step is that the auricle is found to be fibrillating. In a large number of cases if this is allowed to continue for a short time and then the digitalis stopped the fibrillation stops and the heart resumes normal rhythm. This is what was aimed at in this case and as was seen in the electrocardiograms these different stages under the influence of the drug were reached but unfortunately after a very short interval of normal rhythm the auricles returned to their state of flutter. Digitalis was not resumed as the patient was doing very well after the rest even though he was still fluttering and it was decided to get him under observation later and again try/

try digitalis medication. Quinidine is the other drug which is used in the treatment of flutter and it also acts through the vagns but unlike digitalis it depresses. On the whole however most authorities do not use quinidine as a routine drug on account of its toxic properties and its liability to increase the ventricular rate.

Digitalis gives the most satisfactory results generally as it rapidly improves the symptoms of heart failure. In this case in a few days the oedema had visibly lessened, the urinary output had increased and the appetite and a feeling of well-being had returned. If it is not possible to ensure a return to normal rhythm the pulse must be kept about 70-80 and and sometimes it is found that these patients are better kept fibrillating as they get about better this way and can be kept permanently under control.

On the whole this was quite a satisfactory case because although normal rhythm was not maintained the patient was very much improved and it is hoped that he may have further medication later with a view to restoring possibly the normal state of affairs.

1925

1926

1927

1928

1929

1930

1931

1932

1933

1934

1935

1936

1937

1938

1939

1940

1941

1942

1943

1944

1945

1946

1947

1948

1949

1950

1951

1952

1953

1954

1955

1956

1957

**TWO CASES, MYELOGENOUS LEUKAEMIA and
LYMPHADENOMA illustrating the use of
X-Ray Therapy.**

James Turnbull. Aged 28. Occupation. Packer.

Address. 20 Parson's Green Terrace, Edinburgh.

Admitted. 29:10:32.

Complaint.

Pain in back and chest.	10 months duration.
Weakness.	15 " "
Swelling in neck.	15 " "

History.

Fifteen months ago the patient noticed a swelling in the left side of his neck and as it was getting larger he consulted his doctor about it. His doctor sent him to the Surgical Out-Patient Dept. of the R.I.E. and he was referred from there to Ward 10. He was examined there and recommended to see Dr. Chalmers Watson in Ward 28. On examination there it was found that he had enlarged glands in both sides of the neck, most marked on the left side, and also slight swellings in both axillae. A biopsy was done and a piece of the gland tissue of the neck was examined. It was found to be a gland affected by Hodgkin's disease and the patient was admitted to the ward for treatment. He was given X-ray therapy about once a week and after five weeks treatment he was sent to the Astley Ainslie Institute. After spending some time there he was readmitted to the ward for a further fortnight's treatment. When he was discharged the swelling of the glands had been reduced/

reduced greatly. He was asked to report once a month to the X-ray Dept. for observation and treatment. For a year after his discharge he was able to do light work but for the last nine or ten months he has had to go to bed early at night and remain in bed over the week ends on account of pains in the back and chest. The pain in the back was sharp and stabbing in character while that in the chest was much more of an ache. The pain was always worse at night and much easier in the morning. The pain gradually increased in severity and as it was preventing him from using his arms while working he gave up his work three weeks ago. He reported at the ward and was sent out to the Astley Ainslie Institute for rest and treatment but he was sent back to the ward very soon on account of the severity of the pain. Since the commencement of the illness the patient has lost a few pounds in weight. His appetite varies considerably. He has a short irritable cough which is most troublesome when he lies on his left side or suddenly changes position.

Personal and Family History.

Father died aet 34 - cerebro-spinal meningitis. Mother is alive but bedridden with rheumatoid arthritis. Wife is alive and well and he has one boy alive and well. He has three sisters alive and well.

Habits./

Habits.

He lives in a comfortable, airy, dry house. His diet consists of:-

Breakfast. 7 a.m. Tea, eggs, ham, fish, bread and butter.

Dinner. 12 a.m. Meat, potatoes, soup, pudding, tea.

Tea. 5.30 p.m. Tea, bread, butter and meat.

Supper. Tea, a little milk and fruit.

He does not drink but smokes twelve cigarettes daily.

Previous Illnesses.

Measles in childhood. Influenza when aged 14.

Condition on Admission.

Patient is thin and undernourished. His complexion is pale and white rather than sallow. There is a slight pink flush in both cheeks. His expression and attitude are remarkably bright. He is of average intelligence.

Pulse. 90. Temp. 99.5⁰. Respirations. 22.

Weight. 9 st. 3 $\frac{1}{4}$ lbs. Height 5 feet 8 ins.

Clinical Examination.

Haemopoietic System.

Considerable degree of weakness. No marked breathlessness.

Enlargement of the lymphatic glands at the root of the neck on both sides, most marked on the left. Enlargement of posterior auricular and occipital glands. Enlargement of the axillary glands on each side and also of the glands above and below the inguinal ligament on both sides. All these glands are firm and rounded and are not tender with the exception of the inguinal glands which are very tender. Splenic dulness extends to 3 inches below the costal margin, where the lower pole of the spleen is palpable. The lower border of the liver is 2 inches below the costal margin.

Blood examination. R.B.C. 4,150,000. W.B.C. 16,200.

Haemoglobin. 75%. C.I. 9.

Differential Count. Polymorph leucocytes. 84.5%.

Lymphocytes. 12.5%. Mononuclears 1.5%.

Eosinophils. 1%. Basophils 0.5%.

A film showed normal red cells. Some of the large lymphocytes had the appearance of and possibly were Hodgkin cells.

Cardio-vascular System.

Pain in back and chest. No palpitation. Considerable weakness. No dyspnoea. Short irritable cough.

Pulse/

Pulse. Rate 90, regular in time or force. The wave is not well sustained and the upstroke and downstroke are both fairly rapid. B.P. 130/80. Vessel wall is not palpable.

Heart. Apex beat is visible in the 5th left interspace $2\frac{1}{2}$ inches from the middle line.

Palpation. The beat is also felt in the same spot.

Percussion. The left border is only $2\frac{1}{2}$ inches from the mid line and the right border one inch.

Auscultation. Sounds closed and pure in all areas.

Respiratory System.

Short cough on changing position or lying on left side. Pain in back and chest. No haemoptysis. No marked breathlessness. No sputum.

The chest is narrow and poorly clad. Expansion is equal on both sides but poor. Palpation. Vocal fremitus is increased all over. Percussion note is impaired all over but notably at the bases.

The front and back of the right side of the chest is also markedly dull.

Auscultation. Breath sounds are bronchial in character and deeply pitched. A few rhonchi are present posteriorly and the breath sounds are less intense at both bases. Vocal resonance is increased especially at the apices.

Alimentary System.

Appetite varies. No marked thirst. No indigestion, pain, flatulence, acidity. No vomiting.

Bowels/

Bowels not constipated.

Tongue is dry and covered with a thin white fur. Teeth are comparatively good. Fauces healthy. No difficulty on swallowing. Abdomen is poorly clad, the muscles are held tightly and respiratory movement is poor. Palpation. There is some tenderness and resistance over both liver and spleen. Percussion. The lower border of the liver extends to 2 inches below the rib margin. The spleen dullness extends down for 3 inches.

Nervous System.

Patient is of average intelligence and memory is unimpaired. No hallucinations, delirium, drowsiness, aphasia. The pupils are round and react to light and accommodation. Ocular movements are excellent. Considerable loss of power in arms. No sensory disturbance. No loss of power or sensation in lower limbs.

The abdominal reflex is present and the plantar response is flexor.

The tendon jerks at the elbow, wrist, knee and ankle are somewhat brisk. No clonus.

Genito-Urinary System.

No pain or discomfort in lumbar region. No pain over bladder. No frequency. No dysuria, anuria or polyuria.

Examination/

Bowels not contracted.

Tongue is dry and covered with a thin white fur.

Teeth are comparatively good. Gums healthy.

No difficulty on swallowing.

Abdomen is poorly distended, the muscles are held tightly

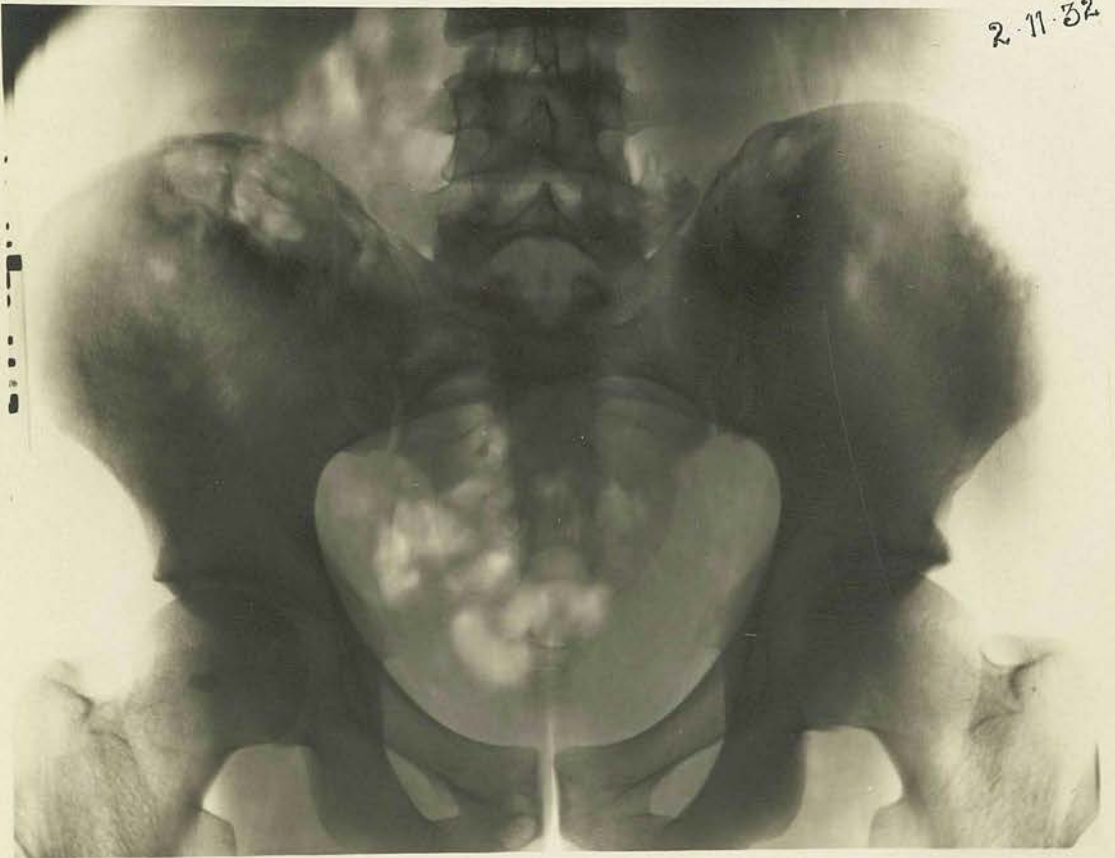and respiratory movement is poor.

Pulsation. There is some tenderness and resistance

over both liver and spleen.

Parasitism. The lower border of the liver extends

2-11-32



Genito-Urinary System.

No pain or discomfort in lumbar region. No pain

over bladder. No frequency. No dysuria, smegma or

prolapse.

Examination

Examination of Urine.

Specimen is amber in colour, specific gravity 1025.

Deposit of urates.

No pus, blood, albumin or sugar. No acetone or bile.

Microscopically there are seen some amorphous urates.

Bence-Jones proteose not present.

Beyond some wasting in the subcutaneous tissue and the weakness of the upper limbs there is nothing to note in the integumentary and locomotory systems.

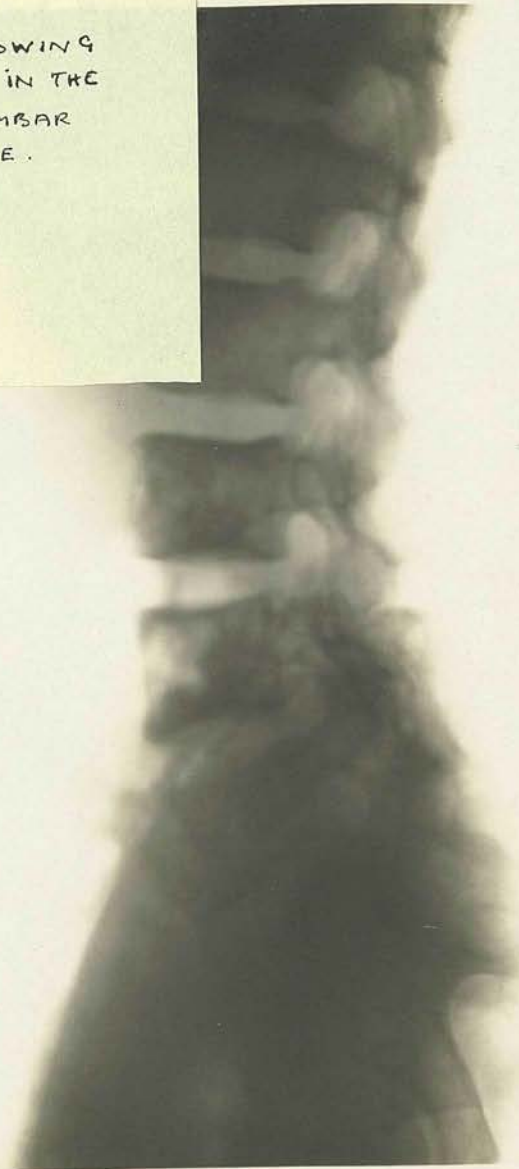Special Examinations.

X-Ray Report. There is a right pleural effusion. In the descending ramus of the right pubis and in the posterior parts of both iliac bones there are more or less circular defects in the bone structure each surrounded by a sclerotic zone.

Wasserman. Negative.

14-11-32.

X-RAY SHOWING
METASTES IN THE
LOWER LUMBAR
VERTEBRAE.



Progress.

The patient was put to bed and put on a light diet.

2:11:32.

A blood examination showed R.B.C. 4,100,000.

W.B.C. 22,000. Hb. 80%. C.I. 1. The patient is feeling quite well and the pain is not quite so bad.

7:11:32.

Patient is still feeling better but has had wheezing attacks during the night. W.B.C. are up to 25,000.

10:11:32.

Right side of chest was tapped on the 9:11:32 and 54 ozs. of fluid removed. It was yellow and turbid. The patient complains of much pain in the right side of the chest near the costal margin this morning. Percussion note has improved over the anterior part of the right side of the chest.

14:11:32.

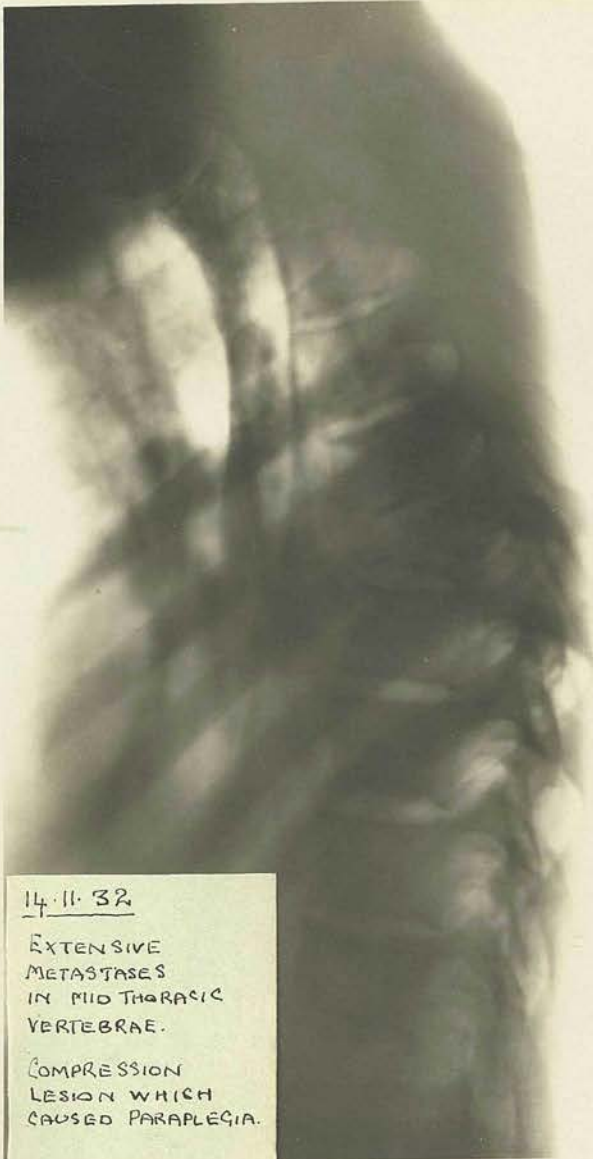Further 44 ozs. of fluid were removed from the right side of the chest on the 13th. It was similar in appearance to the fluid removed on the 10:11:32. He complained of severe coughing following the operation. This morning he complains of pain down the right side of the chest and in left hypochondriac region.

16:11:32.

The Bacteriologist's report on the pleural fluid is as follows. No tubercle bacilli. Some R.B.C.'s lymphocytes/

14.11.32

14.11.32



14.11.32

EXTENSIVE
METASTASES
IN MID THORACIC
VERTEBRAE.

COMPRESSION
LESION WHICH
CAUSED PARAPLEGIA.

16.11.32

16.11.32

lymphocytes and endothelial cells.

This morning the patient complains of pain down the left side which has been present since the 14th.

20:11:32.

Patient not so well. Feels weaker and complains of pain between the shoulder blades. The pain in the left side is still present.

24:11:32.

Pain in back and side is still severe. The glands in the groin are enlarging and are tender. X-ray shows secondary deposits in some of the dorsal and lumbar vertebrae.

Since a day or two after admittance the patient has been getting omnopon gr. $\frac{1}{6}$ at night and at mid-day. It has been necessary to control the pain.

30:11:32.

The pain is intense across the back and the patient is unable to sit up. Morphine gr. $\frac{1}{4}$ is being given at night, sometimes twice, and through the day also. Fluid is accumulating in the right side of the chest again.

5:12:32.

The patient cannot bear any movement on account of the pain. Breathing is difficult. He is receiving 4 c.c. of collosol intravenously every third day.

The pathologist reports on a gland taken from the axilla as follows:- Hyperplasia of the lymphoid tissue/

tissue with many giant cells of the Hodgkin type present. Many show mitosis and are irregular in shape and size and suggest extreme malignancy.

12:12:32.

During the past week the patient has developed paralysis first of the lower limbs, and now the upper limbs. The trunk is also paralysed. There is defective sensation extending up to the costal margin, the patient being unable to appreciate light touch or the difference between sharp or blunt points. There is some degree of urinary and rectal incontinence. The abdomen is very tight and painful. Both wrist joints are very swollen and painful.

20:12:32.

Bacteriologist's report:- The guinea pig inoculated with the pleural fluid on 5:11:32 has been killed and shows no sign of tubercle. The patient is requiring morphine gr. $\frac{1}{2}$ twice daily to control the severe pain in the back. The swelling of the wrists which have been treated with local heat has gone. Paralysis and sensory loss is still present.

27:12:32.

The condition is progressing. The pulse is becoming weaker and more rapid. Bed sores appeared a few days ago and are troublesome to treat. He has still the pain in the back which appears to be at the junction of the paralysed and non-paralysed areas. Strangely enough his appetite is quite good./

good.

10:1:33.

Patient is very much worse. He is very pale and takes no interest at all in anything around except that he takes food all right. He has developed some cyanosis and his breathing is difficult, especially at night.

13:1:33.

Patient died this morning after being completely comatose for some hours.

Diagnosis. Lymphadenoma.

When the patient was seen early in 1931 he had an enlargement of the cervical glands in both sides of the neck. There was also swelling of the axillary glands. The only way to settle the diagnosis then was to do a biopsy and examine the gland tissue microscopically. The overgrowth of the endothelial elements and the increase of fibrous tissue characteristic of the condition were seen. Many of the multinucleated endothelial cells, which are described as Hodgkin cells, were also seen. The condition was undoubtedly one of lymphadenoma. When undergoing treatment in the ward, a guinea pig was twice inoculated with material taken from a pleural effusion which had supervened. No evidence of tuberculosis could be made out. A further biopsy of the axillary glands showed definite lymphadenomatous change. The report this time contained the remark that the cells showed extreme malignancy.

Mrs. Annie Leslie.

Aged 42.

Address. 5 Parkside Terrace, Edinburgh.

Admitted. 11:2:31.

Complaint.

1. Swelling and tenderness
of abdomen.- - - - 2 months duration.
2. Weakness and lethargy. - 2 years "
3. Breathless on exertion
and palpitation. - - 6 months "
4. Profuse nocturnal per-
spiration. - - - - 2 months "
5. Loss of weight and ap-
petite.- - - - 6 months "

History.

About 2 years ago the patient felt that she was run down and she was unable to cope with her household duties. Since then her weakness and lethargy have progressed until recently she has been unable to do any housework and has had to stay in bed in the mornings. About 6 months ago she noticed that she became very breathless and had palpitation when climbing stairs or on similar exertion. Now mere walking about induces these symptoms. During the last 6 months she has lost $1\frac{1}{2}$ stones in weight. Coincidentally with this her appetite has gradually failed so that now she is satisfied with a few mouthfuls of food at each meal. 5 months ago tenderness appeared in the left hypochondrium and 2 months ago she noticed a small firm swelling below the left costal margin and since/

since then the swelling has grown rapidly. Her colour has faded and during the past 2 months her pallor has been a noticeable feature. During the same period she has been perspiring freely at night and when she awakes in the morning her periorbital tissues are usually swollen. She has had an irritating throat cough for two months but has no sputum.

Personal History.

Menarché appeared at 14. Periods were regular, 7/28 day type until 6 months ago. Now menstruation is very irregular, 7/10-21 day type. There is pain for 2 days preceding the onset of the periods. No leucorrhoea.

Previous Illnesses.

Measles as a child. Septic throat when 14 years old. No growing pains. Nervous breakdown with slight jaundice when 38. One year ago she was seized with severe abdominal pain, and was admitted to Mr. Chiene's ward. She was treated for pyelitis for 10 days. For the past 2 years she has suffered from intermittent severe headaches.

Diet.

Breakfast. 8 a.m. Porridge, milk, egg, 1 slice
white or brown bread, butter,
marmalade. Tea, 1 cup.

11 a.m. 1 cup cocoa made with water.

Dinner. 1 p.m. Meat soup, meat or fish, vege-
table every day with pudding
or stewed fruit.

Tea./

Tea. 5.30 p.m. Fish and salad. Bread,
scones or cake. Tea.
Supper. 10.30 p.m. Slice of bread, butter,
tea.

Environment.

The home conditions are excellent, plenty of
sunshine and fresh air. No dampness.

Family History.

Father aged 65, alive and well. Mother died
aged 60. Gallstones and a weak heart. 2 bro-
thers alive and well. Husband has an excellent
position and is in constant employment. 1 child
died of influenza aged 3. 5 children alive and
well. No miscarriages.

General Condition.

Patient is a fairly well preserved woman but she
shows signs of recent loss in weight. She is of
moderate build and musculature. She has an un-
healthy pallid complexion with a slight malar
flush. The lips are pale. Her hair is black
but dull and lustreless. Her expression is weary
and tired.

Temperature 98.4⁰. Pulse 88. Respirations 22.
Weight 7 stones 12 lbs.

Clinical Examination.

Haemopoietic System.

Marked breathlessness on exertion. Excessive weakness and lethargy. Marked pallor.

No enlargement of lymphatic glands. The spleen is enlarged to beyond the umbilicus. It is tender and the margin is firm and well defined. Liver is 2 inches below the costal margin.

Blood examination. R.B.C. 3,570,000.

W.B.C. 276,000. Haemoglobin 58%. Colour Index. 0.83. A film showed that the white cells are mostly myelocytes and there are relatively very few fully mature leucocytes.

Circulatory System.

Breathlessness and palpitation on exertion. Slight throaty cough. No praecordial pain.

Pulse rate is 88 beats per minute and it is regular in time and force. The pulse wave is normal and the blood pressure is 120/80. The arterial wall is not palpable.

On inspection of the precordium the apex beat is not visible. There are no extra-cardiac pulsations. When palpating the apex beat is difficult to locate and there is no thrill. On percussion the right border is 1 inch from the mid line and the left reaches out to $3\frac{1}{2}$ inches.

On auscultating the heart, the sounds are very faint. The first sound at the mitral and aortic areas is superimposed by a very soft systolic murmur/

murmur. Second sound in both areas is closed and pure.

At the pulmonary area there is a soft systolic murmur replacing the first sound almost entirely. Second sound is closed and pure. The sounds at the tricuspid area are closed and pure.

Alimentary System.

Progressive loss of appetite. Feeling of fullness after eating. No actual sickness. No pain after food.

The teeth are well worn down, but are not carious. Some are artificial. The lips are pale. The tongue is bright red, clean, moist and tonic. Fauces are healthy. The bowels move regularly every day. The abdomen on inspection shows an obvious swelling below the left costal margin extending down to the umbilicus. The skin is dry and lax. There is scanty subcutaneous fat. The respiratory excursion is limited. The swelling is due to enlargement of the spleen which is firm with definite serrated margins. The liver extends 2 inches below the rib margin and is soft with a regular margin.

Respiratory System.

Slight throaty cough. No sputum. No haemoptysis. No pain. No cyanosis. Marked breathlessness on exertion.

The respiratory rate is 22 and the breathing is regular and not laboured when lying quietly in bed. The nares, pharynx, etc., show nothing abnormal. On inspection/

inspection of the chest, the shape is quite good and expansion fairly good and equilateral. The vocal fremitus is unaltered. The percussion note is resonant all over. The breath sounds are vesicular and there are no accompaniments. Vocal resonance is unaltered.

Nervous System.

Patient is of average intelligence, but is somewhat highly strung. There is no insomnia, or any other impairment of the higher cerebral functions. No impairment of speech.

The pupils are round and equal in size and react equally to light and accommodation. Ocular movement is unimpaired.

The facial muscles function perfectly. Tongue is protruded in the mid line. No disturbance of the actions of the sympathetic.

Superficial and deep reflexes are normal. Sensation is unimpaired. Considerable general muscular weakness.

Genito-Urinary System.

Frequency of micturition present. No dysuria. No pain or discomfort in kidney region. Menorrhagia and slight dysmenorrhoea complained of.

Examination of urine.

Specimen is acid. Cloudy amber in colour. Specific gravity 1014. Thin white deposit with mucus. Albumin +

Tests/

Tests for sugar, blood, bile, acetone are negative.
Microscopically there are seen large epithelial cells.
No casts or pus cells present.

Locomotory, Endocrine and Integumentary Systems have
nothing abnormal to note.

Special Investigations.

Wasserman. Negative.

Faeces. A colonic washout revealed a turbid
fluid with a heavy deposit of faecal
sand and debris. Acid reaction and
markedly offensive.

Diagnosis.

Myelogenous leukaemia.

The diagnosis was made from the symptoms of increasing lassitude and breathlessness, the swelling of the abdomen due to the splenic enlargement and the blood picture. Typical of the condition were the insidious onset and the progressive anaemia. As was to be expected the patient experienced considerable discomfort after meals and had a very poor appetite. This is commonly found in this condition. The splenic enlargement, which is almost diagnostic, nearly filled the abdomen, reaching down beyond the umbilicus and its firm margin was distinctly notched. In a typical case the W.B.C. count is usually about 400,000 of which 200,000 are myelocytes. In this case the W.B.C. count was 270,000 and practically all the cells were myelocytes. The R.B.C. was nearly what is usually found, 3,500,000, and the haemoglobin and colour index also were typical being respectively 58% and 0.8.

and cannot finish her supper.

11:30.

Second episode to-day. No other effects. Slept well last night. Spleen softer. W.B.C. 316,000.

23:30.

W.B.C. 174,000.

14:30.

No reaction after 1-day. Uricar improving. Improved appetite for dinner to-day. W.B.C. 215,200.

14:30.

Severe flatulence following vegetable pie for lunch.

No/

Progress and Treatment.

The patient was kept in bed and put on the Gerson regime of diet. This at first consisted mainly of water and orange juice but very soon additions were made in the shape of fresh irradiated milk, lactic milk, vegetable juices, fresh butter, egg, meat, wholemeal bread. The characteristics of the diet are its simplicity and the freshness of its constituents.

Deep X-Ray therapy is to be employed to reduce the activity of the myeloblastic tissue.

18:2:31.

By this date the patient has already improved. Night sweats still present. Spleen I.S.Q.

19:2:31.

W.B.C. 248,000. R.B.C. 3,420,000. Hb. 60%.
C.I. 0.7.

20:2:31.

X-Radiation begun to-day. Patient has a headache and cannot finish her supper.

21:2:31.

Second exposure to-day. No after effects. Slept well last night. Spleen softer. W.B.C. 246,000.

23:2:31.

W.B.C. 196,000.

24:2:31.

No reaction after X-Ray. Colour improving. Had an appetite for dinner to-day. W.B.C. 213,200.

26:2:31.

Severe flatulence following vegetable pie for lunch.

No/

No reaction after X-Ray. W.B.C. 202,400.

28:2:31.

Severe indigestion for past 2 days but looking quite well. W.B.C. 230,000. Spleen I.S.Q.

1:3:31.

W.B.C. 142,400.

2:3:31.

No appetite for tea or supper but otherwise feeling very well. Spleen has diminished by $1\frac{1}{2}$ inches since treatment began and is much softer and not so tender.

W.B.C. 100,000. R.B.C. 3,480,000. Hb. 55% C.I.

0.8.

3:3:31.

Now getting up for half an hour daily.

8:3:31.

The patient is looking very much better and is feeling much stronger. The spleen is gradually diminishing in size and is much softer. Blood film shows that the white cells are mostly all fully formed polymorphs. W.B.C. 85,600.

15:3:31.

W.B.C. 30,000.

19:3:31.

R.B.C. 3,540,000. Hb. 60%. C.I. 0.8. W.B.C.

20,000. Last X-Ray exposure to-day. Colour still rather pallid. Says she has not felt so well for 4 years. Appetite excellent. Weight increasing slowly. Bowels satisfactory. Still some albuminuria.

26:3:31/

26:3:31.

W.B.C. 8,800. R.B.C. 4,410,000. Hb. 61%. C.I. 0.7. Spleen is only $1\frac{1}{2}$ inches below costal margin. There is very little change, however, in the liver enlargement. Abdominal swelling has gone. No abdominal tenderness. She can walk for a considerable distance and climb stairs without suffering from any breathlessness or palpitation. She still has soft blowing murmurs superimposed on the first sound in the aortic, pulmonary and mitral areas. The albuminuria has almost gone. The general well-being of the patient is very marked.

27:3:31.

Discharged.

Following discharge from the ward, the patient attended the X-Ray department for observation and further therapy every fortnight until the end of the year and thereafter once a month. In March 1932 she went for a holiday to West Linton where for no apparent cause she had an attack of severe diarrhoea and vomiting. During the first 24 hours of this illness the spleen enlarged at an incredible rate and reached the appendicular region. She was very collapsed, almost moribund, but she gradually rallied and during the next month which she spent in bed the spleen gradually regressed until it reached the umbilicus where it has remained. While at West Linton her night sweats, absent for over a year, returned and have been very profuse. Her energy has also failed and she is now very weak. On coming up to the ward on the

18:5:32/

18:5:32 her W.B.C. were 140 and she was now looking well at all. It was considered advisable to get her into Hospital for more X-Ray treatment. She had developed a cold as a result of getting chilled following her profuse perspirations, and her cough is troublesome, keeping her awake at night. She spends the greater part of the day in bed as she is too weak to get about. Her condition is much the same as when she was admitted in February 1931.

14:6:32.

Readmitted. R.B.C. 3,570,000. Hb. 60%. C.I.O.85.
W.B.C. 141,000.

22:6:32.

Improved after a week's rest. Her cold has improved and the night sweating has decreased. The spleen is the same size and approximately of the same consistence as on admission. W.B.C. 170,000.

27:6:32.

Improvement is maintained but the W.B.C. have risen to 213,500. The spleen has increased in bulk but has not extended any further downwards. To-day the first dose of X-Rays is to be applied.

28:6:32.

Immediately after the therapy the R.B.C. were raised by 800,000 and there was a slight decrease in the W.B.C. Drowsiness and a feeling of nausea came on about 2. hours after the radiation. She was very uncomfortable after supper and the nausea became intense during the night. Soon after midnight she vomited

2/

2 ozs. of greenish material. She was given some soda bicarb. but vomited again. She had only about one hour's sleep that night.

29:6:32.

Not looking so well to-day. Yesterday anorexia was marked and the patient had nausea all morning. There was a temperature of 101° in the evening. Slept badly again last night.

30:6:32.

Appearance slightly improved to-day. Last night had griping pains all over the abdomen. W.B.C. 156,000.

3:7:32.

All reaction after X-Rays has gone. The spleen is not perceptibly reduced in size but it is much softer and less tender. Patient is sleeping well but is still perspiring freely. W.B.C. 125,000.

6:7:32.

Yesterday patient had the second application of X-Rays. After it she felt drowsy and doped all afternoon. She took her lunch, tea and breakfast this morning without any nausea or anorexia. She slept well last night and awoke this morning feeling very refreshed.

7:7:32.

Patient received further X-Ray treatment to-day. She has had no reaction after it but has again experienced the drowsy feeling which she had after the last dose 2 days ago. Has also developed marked thirst following the application. This was also present for some 12 hours following each of the last 2 applications.

8:7:32/

8:7:32.

Except for this feeling of drowsiness the patient is very well. W.B.C. have dropped by $\frac{1}{2}$ in the last day or two. Now the count is 67,000.

10:7:32.

The patient is keeping very well but the night sweating is persistent and very troublesome. The albumin in the urine is reduced to a trace and the spleen has also decreased 1 inch in size. W.B.C. 43,000.

12:7:32.

Further X-radiation to-day. W.B.C. 38,800.

18:7:32.

No reaction at all after the therapy. Patient feeling very fit. Got up on 14th for a short time and on each of the last 4 days she has been up sitting in the sun and getting a little exercise. Spleen is reduced in size by over 2 inches. W.B.C. 18,000. The night sweating has almost disappeared.

By the 23rd. the patient was so well that it was unnecessary to keep her in hospital and she was discharged for the second time. The R.B.C. were 3,500,000 and the W.B.C. down to 9,000. The spleen was barely showing below the costal margin and the blood film showed few myelocytes. The albuminuria had disappeared and the haemic heart murmurs were much less obvious. She was instructed to report as before, regularly, for observation.

31:8:32.

Patient had enjoyed excellent health and had been holidaying in Oban. She had gained 7 lbs. in weight.
On/

On the 16th the W.B.C. had been 41,000 and by the 23rd. had increased to 60,000. By the 31st the spleen had enlarged slightly so it was decided to radiate the spleen again.

7:9:32.

On the day after the exposure she developed nausea and vomited. She went to bed and remained bilious for 3 days. She got over this and by the 7th had regained her previous well-being. W.B.C. 52,800.

13:9:32.

Patient got further therapy on the 8th but there was no reaction after it. W.B.C. 23,800.

6:10:32.

All this time the patient has been at home and able to do practically all her household duties. Her general health has been excellent and the W.B.C. have been kept at a figure between 20,000 and 40,000.

:10:32.

X-Ray exposure. No reaction. W.B.C. 45,000.

20:10:32.

Further radiation. Fairly marked reaction. Nausea and vomiting. It appears that when the anterior part of the spleen is irradiated the reaction follows but that no reaction appears when the posterior part is treated. Following the sickness the patient again was drowsy and had a fairly severe headache.

11:11:32.

It is 3 weeks since the reaction after the exposure of the 20th and it is only now that the patient is looking/

looking better. She remained in bed for nearly a fortnight. She had X-radiation on the 3rd but no reaction followed. W.B.C. 35,000.

25:11:32.

X-radiation on 12th but only a slight reaction followed. The spleen is 3 inches below the costal margin.

20:12:32.

By the 13th of December the spleen had enlarged again to the umbilicus and the W.B.C. had risen to 93,000. She had two exposures on successive days, 15th. and 16th., and there was no reaction.

16:2:33.

Following the last 2 exposures she was to have been treated again in a fortnight but she took a cold in the chest and remained in bed for a month.. At the beginning of February she looked pale and tired, had lost weight and the spleen had enlarged beyond the umbilicus. 3 doses were given to the spleen on alternate days. After the first two she complained of nausea, lethargy and weakness. After the third, after leaving the department she almost collapsed. She managed to stagger up the drive and got into a taxi and reached home in a fainting condition. She was so collapsed that her family doctor was sent for. She was advised to come into the ward again.

25:2:33.

She was admitted looking a little better but still very much below par. The spleen is enlarged beyond the umbilicus/

umbilicus and the liver is also greatly enlarged.

W.B.C. 35,000. R.B.C. 3,560,000. Hb. 67%.

C.I. 0.9.

5:3:33.

Personal condition has improved greatly over past week. Urine contains Albumen++ and has a persistently low specific gravity, never above 1010. A few granular and hyaline casts are present..

W.B.C. 30,000.

14:3:33.

Patient has started to go back again. There is an evening rise in temperature and the night sweats are very distressing. W.B.C. have risen to 55,000.

17:3:33.

Progress still in retrograde direction. Albuminuria is increasing. Exposure to-day at noon. No nausea or vomiting followed, but only a feeling of drowsiness. W.B.C. 59,600.

18:3:33.

Further exposure to-day. Again no adverse reaction but the patient experienced the same drowsiness, especially towards evening. W.B.C. have risen to 91,400.

19:3:33.

Again an exposure. No reaction.

20:3:33.

These 3 exposures on successive days have evoked no reaction except for the drowsiness felt on the 17th. The W.B.C. count to-day is 54,400. R.B.C. 3,210,000. Hb. /

Hb. 64%. The general condition of the patient is excellent.

At the time of writing this case the patient has had 3 exposures on the 23rd, 25th and 27th. These were followed by no reaction of any sort. As a result of these 6 exposures in the last 10 days the W.B.C. count has dropped from 91,000 to its present figure of 20,000. The R.B.C. count is still rather low 3,610,000 and the haemoglobin is 64%. The spleen extends for about $1\frac{1}{2}$ inches below the costal margin but the liver is still about 1 inch beyond also. She is to have no further therapy for at least 2 weeks.

Commentary.

In both of these cases X-Rays were used in an attempt to check growth of tissue which was proving disastrous to the good health of the two patients. Both are fairly typical examples of the results which are obtained nowadays in this particular type of therapy. In the case of lymphadenoma, while the visible signs of the disease, the enlarged glands, were quite readily controlled, yet the progress of the disease in the deeper tissues was entirely unassailable. In the case of leukaemia, the control of the spleen, and as a result of that apparently, the W.B.C. count and the condition of the patient were really striking.

It is only comparatively recently that X-Rays began to be used for therapeutic purposes and at the present time radiologists have only advanced a very small way towards a full knowledge of X-radiations. For the treatment of practically all the conditions coming within the scope of this therapy the technique does not vary a great deal. An X-ray tube is used which will give off a radiation with a wave length somewhere between 0.05 and 10 A° units. The wave length is varied by altering the voltage applied to the tube and this is only important because there are two types of ray which are used. One is a soft ray which acts mostly on the skin and superficial structures, because it is absorbed there. The hard ray on the other hand penetrates, and is used for the treatment/

treatment of the deeply lying structures such as the mediastinum. It is almost impossible to have a completely hard or soft ray so that one cuts out the undesired element by the use of filters.

Many ways have been devised for measuring the ray qualitatively and quantitatively and the way commonly used in Edinburgh is to establish a dose according to the erythema it produces on the abdominal skin within a specified time. Thus an erythema dose will be an exposure to the rays for half an hour or one hour followed in 7 to 21 days by erythema and subsequent desquamation.

In the treatment of the case of lymphadenoma the patient was referred for radiation as soon as the diagnosis was made. An area was mapped out circumscribing the enlarged glands and following the usual technique the rest of the head and neck was protected by rubber mats. An exposure of about 20 minutes equalling $\frac{1}{3}$ of an erythema dose was given and this was repeated on each of the next two days. When seen one month later the masses on the neck had disappeared but enlarged axillary glands were palpable. There were given daily exposures of the same strength for 6 days. A definite scheme was drawn up so that on one day the cervical glands were radiated the next day the right axillary glands, next day the left axillary glands and the same order followed in the next 3 days. In 3 weeks time, the enlargement had subsided, but while under observation

3 months later it was found that the inguinal glands had enlarged bilaterally. Four exposures were given on successive days to these areas. Again in 3 weeks time the swellings had gone but yet again within 3 months the cervical glands became enlarged. This time they formed a mass in the left supra-clavicular region, and the axillary glands had also enlarged. This time the dose was increased to $\frac{1}{2}$ an erythema dose and one area was irradiated daily for 6 days. For the next 2 months there was not an enlarged gland to be palpated but, unfortunately, meanwhile changes had occurred in one of the lungs. This was not due to the X-rays at all and no further treatment was given as there was no evident superficial or mediastinal glandular involvement.

For the treatment of the leukaemic case the rays were directed first towards the spleen and the shafts of the long bones. In the later stages of the treatment it was found unnecessary to irradiate the bones and instead the different aspects of the spleen were irradiated in turn. In this case the dose was much smaller, at first only that equal to $\frac{1}{10}$ th of an erythema dose being used. From the 20th February 1931 to the 20th March 1931 the patient received a daily exposure. Each day a different part was irradiated and the order followed was, spleen, right and left humeri, right and left femora, spleen, right and left tibiae, right and left ribs posteriorly. By the end of the treatment the W.B.C. count/

count had dropped from 248,000 to 20,000 and the patient had been transformed from her state of weakness and extreme dyspnoea into that of perfect health and fitness. She then reported for observation and from March 1931 to March 1932 the W.B.C. count was maintained at about 40,000 by exposures at fortnightly or monthly intervals of $\frac{1}{6}$ of an erythema dose.

Owing then to injudicious adaptation to her circumstances the patient had a relapse and the W.B.C. count rose to 250,000. This time only the spleen was irradiated but different aspects were irradiated in turn. Thus first the anterior, then the lateral, and then posterior aspects were treated. Only 4 exposures in this manner, with $\frac{1}{3}$ of an erythema dose were given from May 1932 to July 1932 and once more the W.B.C. count was reduced to 20,000 and even less.

Since then, up to the present, the patient has had exposures of a similar strength on 15 occasions at roughly monthly intervals. The W.B.C. count has never risen beyond the 90,000 figure and the spleen has been maintained at a reasonable size. On some occasions two or even three exposures on successive days have been necessary to keep the white cell figure low but it is quite evident that two things are happening. One is that the dose is increasing and the other is that the interval between the doses is lessening.

From/

From these two examples it can be seen that the effect of X-radiations on lymphadenomatous enlargement of glands is to reduce these glands to normal within 2 or 3 weeks. When a spleen enlarged as a result of leukaemia is irradiated the spleen shrinks and softens and the W.B.C. count is reduced. These two conditions illustrate the action of X-radiation on morbid growth at its best and the reason is seen if the pathology of the two conditions is studied. Quite early in the history of X-radiations it was known that a cell which was premature or which belonged to a tissue in which mitosis of cells occurred frequently was peculiarly susceptible to the rays. Thus the more active tumours are the most radio-sensitive. The fact that immature cells are very sensitive is seen strikingly in leukaemia. When the blood pictures are studied it will be seen that in the myelogenous type the cells which are first to disappear following irradiation are the primitive myeloblasts and myelocytes.

It was previously thought that cells were most sensitive during the mitotic stage. Alberti and Politzer following experiments on salamander larvae, showed that cells which at the moment of irradiation had already started off into mitosis completed the process normally. The cell varies in susceptibility with its cycle and apparently the most sensitive time is just before beginning mitosis. Applying this to the two conditions under consideration it is no/

no wonder that the enlarged glands subside. A lymphadenomatous gland shows great proliferation of the endothelial and reticular cells and these are often multi-nucleated and show aberrant shapes as a result of their premature state. They are thus very sensitive to radiations and more so because they are on the surface and offer ready access to the rays. In leukaemia the enlargement of the spleen is mostly due to the packing of the sinuses with myeloblasts and myelocytes and these are premature leucocytes. When X-Ray therapy is employed in leukaemia inhibition of the formation of these cells is brought about. They disappear from the peripheral circulation and the spleen shrinks in size. After irradiation there is a great increase in pigment in the spleen, the follicles are reduced in size and large inter-cellular spaces appear.

This action of irradiation on active tissues is also seen very strikingly in sarcomatous growths. Tumours of this type have been known to disappear so rapidly that toxic effects have ensued which have been due to the rapid disintegration of the tissue. Applying this also to normal tissues it is found that the tissues of the body vary in their susceptibility to radiations. The most sensitive tissues are the lymphoid structures and the leucocytes. After moderate doses there is a rapid fall in the white cell count which may continue for 2 or 3 weeks. Next are the ovaries and testes, and their sensitiveness is due to the rapid mitosis of cells in their structure/

structure. The skin, mucous membranes and glands come next and lastly come the nervous system and nerves. This last can be appreciated owing to the permanent state of the cells and relative absence of active mitosis.

An important fact which was always evident when studying the histological effects of X-radiations upon tissues was as follows - When mitosis had been arrested by irradiation unless the dose had been very great, far greater than has been ever given to a patient, it became re-established sooner or later. This enables one to give an accurate prognosis of most of the conditions treated by X-Rays. A permanent cure cannot be guaranteed. All that can be done is to procure temporary remissions, maintain them for varying intervals but over a space of time which is inevitably limited. Thus in cases of lymphadenoma the glandular enlargement in one area may be reduced only to be followed by enlargement in another area. This in its turn is reduced and then there is a recurrence in the first site. When the primary growth is in the retro-peritoneal region or in the mediastinum a penetrating ray is used, which operates from different angles so as to ensure a cross-fire. The effect on deeply situated glands is not so marked or so easily controlled as that on superficial glands. In leukaemia, as is strikingly illustrated in the case described, the spleen is reduced in size and the patient kept in good/

good health for as long as a year but sooner or later a relapse occurs. Again therapy relieves the condition but as time goes on the intervals between the relapses lessen and the dose has to be increased. Eventually the X-radiations have no effect. In many cases it is doubtful if life is prolonged, and the only benefit is that instead of being bedridden for a year or two prior to death, the patients are enabled to go about their daily work.

The specific effect of X-radiation on tumour tissue is something which is quite obvious but even to-day it is far from being understood. While rays are known to inhibit actively growing tissues in selected areas, it is well known that a general effect upon the whole body is produced and very little is known of what action the rays may have in the tissues around the tumour. Patients undergoing treatment by X-Rays frequently improve markedly in health. They gain in weight, they improve in colour and if the blood picture is examined definite improvement is noted and not necessarily only in cases of leukaemia. It is quite logical to suppose that the temporary improvements in Mrs. Leslie's good health was not entirely due to the reduction in the W.B.C. count. While a general beneficial effect is noted there are also severe reactions which follow exposure to X-Rays. In the case described these took generally three types. Many of the exposures were followed by drowsiness which usually persisted until the patient went/

went to sleep at night. The other symptoms were nausea and vomiting. This usually came on within an hour or two of exposure and in many instances lasted until the next day. These reactions were not constant in their appearance but after many months of treatment it was noticed that radiation of the anterior surface of the spleen was followed by sickness more often than after exposure of the other splenic surfaces. The radiation of the long bones did not often give rise to a reaction. These findings are in accordance with the general experience of radiologists and it is stated that the toxic results are due to changes in the chemical constituents of the plasma appearing as a fall in the chloride content.

There is yet another effect of radiations on tissues, an indirect or remote effect which has been noted. This is possibly part of the improvement in the general health which is often seen. Thus in irradiating a growth of the breast, glands in the axilla and other areas may be reduced in size. Changes may and have been noted to take place, after irradiation, which could not have been due to the direct action of the rays, all of which are put down to a remote or indirect effect.

In summing up therefore after discussing these few aspects of X-radiation upon these two conditions it will be seen that the action of the rays is indeed complex. It is very doubtful even if the rays are being/

being used in the best way and with the maximum of advantage. So far as is known no beneficial effects can be produced by the use of X-rays upon the healthy organism. It will therefore be clear that in applying them to the treatment of disease we have to rely upon the greater sensitivity of the morbid as compared with the healthy tissues in an effort to obtain a cure. The difficulty then arises that morbid tissues, even of an apparently identical nature, differ greatly in radio-sensitivity. It is common to get two growths of apparently similar nature responding differently as far as can be judged to precisely similar conditions of rays and dosage. There then enters into consideration the remote or indirect effects which have been mentioned.

One must also realise the fact that the normal tissues play an important part in the effects produced when a morbid condition is treated by X-Rays. It is known that animal tumours when infected into irradiated animals do not grow so easily as in the ordinary animal. Further a malignant growth in a healthy vigorous adult is much more resistant to treatment than an apparently similar growth in an elderly patient. In the same way the atrophic scirrous cancer in elderly patients is one of the most responsive varieties. However this by no means contra-indicates the effort to improve the general condition of the patient so that his natural powers of resistance to the disease may be increased.

Then/

Then further, the minimum amount of radiation should be sought and the best technique developed in order to use that dose to its best advantage. Thus a certain technique pushed to the limit of safe dosage may produce little or no effect on a malignant growth while yet another method, differing perhaps in the wave length of the rays or the intervals between the doses, may lead to satisfactory results. At the present time however radiologists are tending to place less and less reliance upon what may be termed the lethal effect of radiation. Instead of a destructive effect upon a malignant growth being sought it is much more rational to attempt to control growth. Tissue response to an irritant is a neoplastic change which exhibits no defensive property. Normal cells surrounding a growth are actively defensive. If there could be obtained a balancing of these defensive properties, and a control of the morbid cells, this would be much more satisfactory than a crude lethal attack on the malignant tissue. Perhaps in time an understanding of the remote or indirect effects may come about and those marked constitutional changes which cannot be explained by the direct action on the tissues will be made clear. The idea then of harnessing these effects may come into operation and irradiation of the whole body will be the method of treatment in the future.

A point of special interest regarding the case of lymphadenoma was the occurrence of secondary deposits in the bones. About 3 months before the fatal termination a pathological appearance was seen in an X-Ray film of the bones of the pelvis. This was followed by a similar defect in the dorso-lumbar spines. The deposits in the spines grew and ultimately caused necrosis of the lower lumbar vertebrae leading to a paraplegia. At post mortem, examination of the deposits showed that they were composed chiefly of sarcomatous tissue, but lymphadenoma cells were also present. The conclusion was drawn that sarcomatous degeneration had taken place in the original new growth. That the original condition was one of Hodgkin's Disease one is fairly certain, from the report of expert pathologists. On several occasions samples of gland tissue taken at biopsy proved that this was the case.

The X-radiation which this patient received was intensive. On one occasion 6 daily exposures were given. It is open to speculation whether under intensive radiation lymphadenomatous tissue will take on a more active form and become a lympho-sarcoma giving rise to metastases.