

GENETIC AND MORPHOLOGICAL STUDIES OF GENES  
AFFECTING HAIR GROWTH IN MICE

by

JOHN P. FLANAGAN,  
B.Agr.Sc., National University of Ireland.  
Dip.Anim.Gen., Edinburgh.

Thesis presented for the Degree of Doctor of Philosophy of the University  
of Edinburgh in the Faculty of Science.

Institute of Animal Genetics, Edinburgh.  
October, 1964.



## CONTENTS.

	Page
CHAPTER I <u>INTRODUCTION</u>	1
(a) Hair Development in the mouse	
(b) The role of genetic factors in hair development.	
(c) The present investigation.	
CHAPTER II <u>STUDIES OF SHAVEN</u>	19
1. Genetics.	19
2. Morphology	30
(a) Homozygous shaven mice	
(b) Heterozygous shaven mice	
3. Skin histology	40
(a) Homozygous shaven mice	
(b) Heterozygous shaven mice	
4. Skin histochemistry	50
5. Discussion	54
6. Summary	64
CHAPTER III <u>STUDIES OF NUDE</u>	66
1. Genetics	66
2. Morphology	77
3. Skin histology and histochemistry	88
4. Liver histology	93
5. Discussion	96
6. Analysis of the pleiotropy	99
7. Summary	112
CHAPTER IV <u>GENERAL DISCUSSION</u>	114
CHAPTER V <u>GENERAL SUMMARY</u>	119
ACKNOWLEDGEMENTS	
REFERENCES	

## CHAPTER I INTRODUCTION.

Knowledge concerning the effects of a gene in higher organisms is derived from the fact that at any particular locus a gene may occur in more than one form each with different properties and potentialities. These alternate genes produce deviations in the series of developmental processes leading to the visible character and so phenotypic differences between individuals are observed.

In the mouse, known genetic differences between individuals have been exploited in order to translate the static concept of the Mendelian character into the concept of dynamic processes following a definite sequence during development. With this object in view, the present study seeks to explain in histological terms two newly discovered autosomal non-allelomorphic genes each causing hairlessness in the mouse. In addition to the defect in hair growth both genes show certain other interesting peculiarities. Thus, it will be shown that one of them is very closely linked to a well known gene which also causes hairlessness while the other mutant has associated with it a liver disease which develops in the adult animal and results in death.

There are three main reasons why the developmental mechanisms of mutant genes should be examined: (a) the mutants may serve as tools for the causal analyses of embryonic processes and mechanisms which are not readily accessible by other means; (b)/

(b) they may be employed to elucidate the nature of gene action; (c) gene controlled pathological development in mammals offers suitable material for investigation of inherited abnormalities in man. On these grounds, many authors have analysed both genetically and morphologically numerous inherited abnormalities of the mouse (see especially Gruneberg 1963). These investigations have demonstrated the complex problem of the nature of gene action and it will be interesting to discuss later the interpretations based on the results of such studies. But first of all, it is necessary to recall the major events which happen during the normal development of the pelage in mice. This will then lead on to a review of the significant role of genetic factors in the development of the coat and an attempt will be made to fit the gene controlled errors of hair growth into the framework of physiological genetics.

a. Hair development in the mouse.

The embryology and development of hair follicles and fibres in the mouse has been described by Dry (1926) and Chase (1954). For convenience three phases are recognised: anagen, catagen and telogen.

Anagen: The first indication of follicle formation is cell proliferation in the Malpighian layer of the epidermis which results in an invagination of cells into the dermis.

(Fig. 1) These follicle primordia are first visible in mouse embryos/

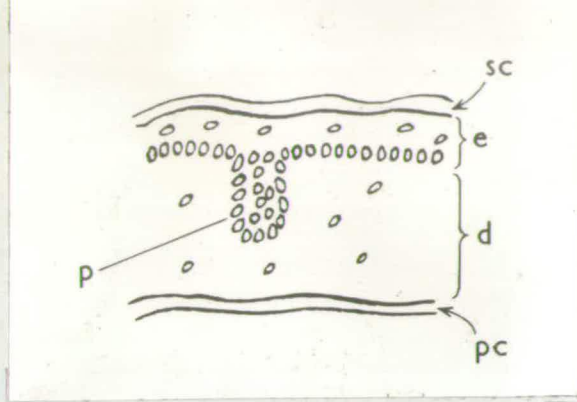


Fig. 1. A follicle primordium is formed by a downgrowth of epidermal cells into the dermis.

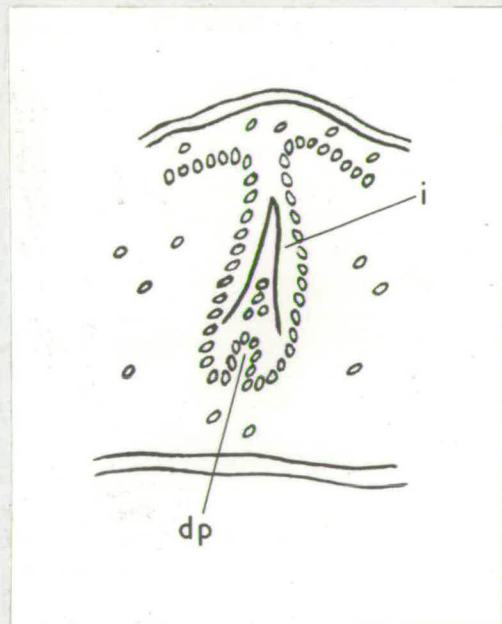


Fig. 2. The base of the invagination expands into a bulb and the dermal papilla and inner root sheath are formed.

Abbreviations.

a = adipose layer  
 b = bulb matrix  
 ca = capsule  
 c = hair cuticle.  
 co = hair cortex  
 d = dermis

dp = dermal papilla  
 e = epidermis  
 h = hair  
 hc = hair club  
 i = inner root sheath  
 me = medulla

o = outer root sheath.  
 p = follicle primordium  
 pc = panniculus carnosus  
 s = sebaceous glands.

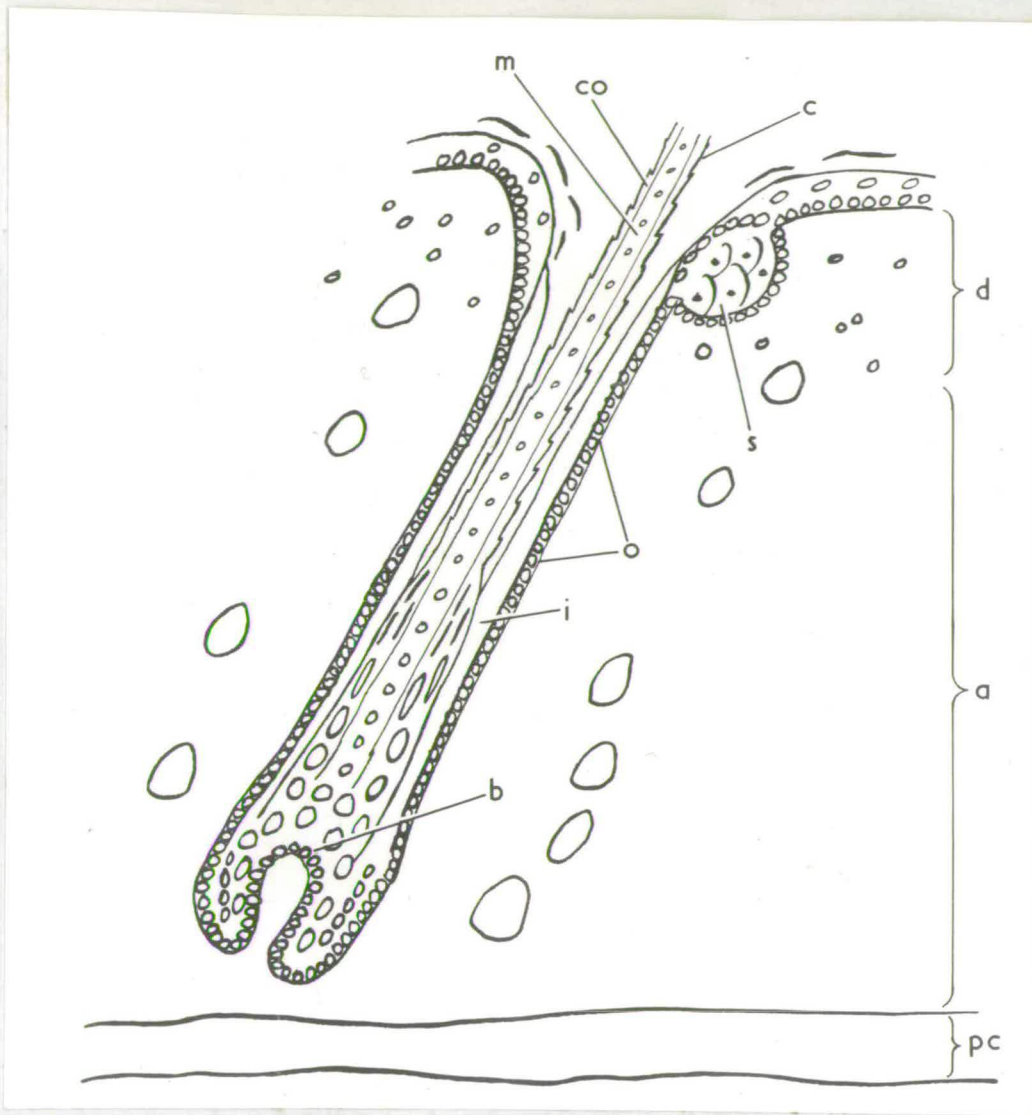


Fig. 3. The skin thickens considerably. The hair erupts and the follicle attains maximum size.

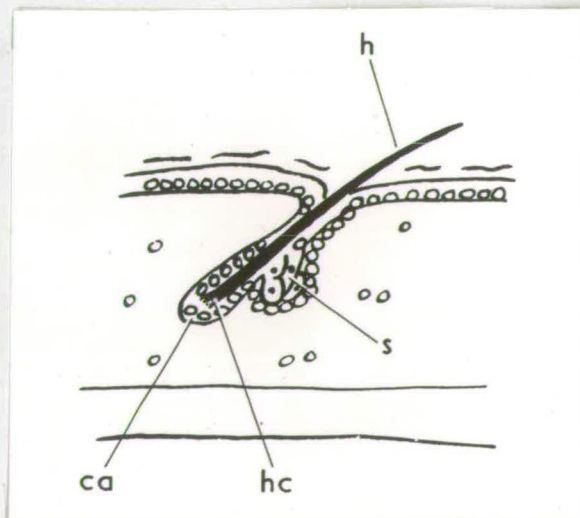


Fig. 4. The telogen stage of the hair follicle. The skin has decreased in thickness.

embryos, at 14 days of gestation. At the lower end of the invagination a "dimple" forms enclosing a cluster of dermal cells which form the dermal papilla. A thin partially keratinized dome appears within the invagination. This is the beginning of the inner root sheath. (Fig. 2). Intensive mitotic activity causes the cord of epidermal cells to elongate downwards into the adipose layer. The base of the cord expands into a bulb and the basal layer of the bulb produces a matrix of cells responsible for the differentiation of the inner root sheath and hair. The walls of the invagination form the external root sheath. The inner root sheath projects upwards through the external sheath as more cells from the bulb become keratinized. Pigmentary dendritic cells in the bulb inoculate granules of pigment into the passing stream of future cortical and medullary cells.

The follicle continues to grow in length. The sebaceous glands differentiate when cells of the external sheath in the upper third of the follicle grow out into the dermis. Inside the inner sheath, cells pass upwards from the apical region of the bulb and become keratinized to form the young hair. The inner sheath forms a vanguard for the hair and terminates as a free edge at the sebaceous gland level. At this point the hair penetrates the inner sheath and emerges through the follicle opening. Hair emergence occurs at about 8 days after follicle initiation. The base of the hair shaft consists /

consists of a medulla, cortex and cuticle but the hair tip consists of cortex and cuticle only. Three layers constitute the inner sheath, an inner layer of cuticle, Huxley's layer and Henle's layer in that order. Henle's layer consists of elongated cells of hyaline cytoplasm. Large eosinophilic trichohyaline granules are present in the lower part of Huxley's layer and the upper part consists of hyaline. The follicle has now reached maximum size (Fig. 3) and hair growth continues for the following 8 or 9 days.

Catagen: This is the transition stage between the growing and resting conditions. At about 17 days post-natal age cell division in the bulb ceases. A club of keratinized cells is formed at the base of the hair shaft. Brush-like in appearance, the club is surrounded by a capsule of partially keratinized cells and serves as an anchor for the hair. The follicle shortens from the base upwards until the club takes up a position just proximal to the sebaceous gland ducts. The inner sheath disintegrates. A few cells of the former bulb matrix remain to form the germ which lies just below the club. In the succeeding hair generation, cell division appears first in the germ. The duration of the catagen stage is normally two days.

Telogen: The resting follicle is entirely within the dermis (Fig. 4). Telogen lasts for about ten days in young mice but with increasing age it may persist for months. /

The hair types: The structure of the mouse coat has been examined by Dry (1926) and Fraser (1951). In addition to those of the snout, a number of vibrissae can be identified on each side of the head. There are two supra-orbital, one post orbital and two post oral vibrissae. (Dry 1926). The body hairs are recognised on the basis of the number of bends along the fibre and the number of rows of air cells in the medulla. There are four types of body hairs. Guard hairs, which form only 2% of the coat, are long straight fibres projecting above the rest of the coat. They have two rows of air cells in the medulla and a long fine tip. Awls comprise about 28% of the coat and are straight hairs about two-thirds the length of guard hairs. They possess at least two rows of air cells and frequently four rows are present. Auchenes are of similar length to awls and have a bend at about two-fifths of the fibre length from the apical end. Two rows of air cells are usually present. The remaining 70% of the coat consists of zig-zag hairs. A zig-zag has three to five bends spaced along its length and only one row of air cells.

Hair structure: The hair fibre is composed of a cuticle, cortex and central medulla. The cuticle consists of thin horny scales overlapping one another in the direction of the apical end. The cortex is made up of elongated fusiform shrunken cells rigidly fused together into a homogeneous hyaline mass/

mass. The medulla consists of air spaces separated by a meshwork of cell walls representing cornified epithelial elements.

b. The role of genetic factors in hair development.

(i) Differentiation and morphogenesis: During the development of an organ or tissue such as the hair follicle, perhaps one of the first points to notice is that a particular structure does not arise directly from the genes themselves. Specific substances are synthesised at specific times and segregate out into well defined regions of the developing organism. Examples of this type of event are the migration of the pigment cells from the neural crest to the epidermis (Rawles 1947) and the localisation and concentration of sulphhydryl (-SH) groups in tissues undergoing keratinization. In organisms other than the mouse, Ebert (1953) has shown that cardiac myosin of the chick embryo cannot be detected before a certain stage of development. It is then distributed throughout the embryo but later becomes progressively localised in the prospective heart forming areas. New cellular environments are continuously being created and the effective action of any gene in a cell is influenced by the substrates already present. A series of interrelated processes intervenes between the gene, on the one hand, and the definitive phenotype, on the other.

Not only is the path from the gene to the phenotype a complex one but different levels of organisation are observed. Firstly/

Firstly, there is the morphological level at which the differentiated cells are organised or localised into aggregations to form organs and tissues. Secondly, at the physiological level, these structures have specific functions and the tissue cells metabolize characteristic substances. Thirdly, at the level of cellular biochemistry, analyses of enzyme systems in certain organisms have shown that the presence of a gene may be related to the presence of a specific enzyme in the cells. Studies at each level of enquiry are aimed at elucidating one primary problem, i.e., how the genotype is causally related to the developed character. In attempting to answer this question, we are led to trace the differences between specific phenotypes such as those associated with the genotypes AA, Aa and aa back towards their origin, in ontogeny.

By such a procedure a number of hereditary defects of the mouse coat have been investigated by various workers. Certain steps among the processes of follicle initiation, differentiation and keratinization are affected and the result is partial or almost complete nakedness. Also, a group of independent genes produces a strongly waved pelage while one gene manifests itself by causing an otherwise normal coat to be greasy. For illustrative purposes, the hair mutants are classified in Table I on the basis of the structures and mechanisms involved. There are a number of conditions of genetic hairlessness which have not been sufficiently studied in detail in order to be classified in the manner set out in the Table and these have been excluded from the survey.

Table I./

Table I: Classification of selected examples of hair mutants.

<u>Abnormal structure or mechanism</u>	<u>Hair Mutants</u>
1. Follicle initiation and differentiation	ragged, opossum, crinkled, tabby.
2. Keratinization of hair fibres	naked, matted, bare.
3. Keratinization of hair club and regeneration cycle	hairless, rhino, bald.
4. Wavy coat	caracul, rex, waved-1, waved-2, wellhaarig.
5. Greasy hairs	rough.

Those mutants which lead to a complete absence or loss of certain hair types are included in the first group. Ragged Ra produces almost complete nakedness in homozygous RaRa mice and a sparse pelage in heterozygotes Ra+ (Slee 1957 a, b). Most RaRa mice die as embryos or at birth. The skin of viable adults contains incompletely formed follicles lacking external and internal root sheaths. The coat of Ra+ mice is less dense than normal because many zig-zags are missing. Opossum Ra<sup>op</sup> is a semi-dominant lethal and is an allele of Ra (Green and Mann 1961). Heterozygous Opossum Ra<sup>op</sup>+ mice resemble Ra+ individuals in that many follicle primordia fail to differentiate so that the adult coat is sparse. The coat of crinkled crcr mice lacks guard hairs and zig-zags and all the hairs resemble awls (Falconer, Fraser and King 1951). There is no follicle initiation in the 14 to 17 day embryo or during the post-natal period. It is only between 17 days of gestation and time of birth that follicle primordia are laid down and these all produce /

produce awls. It appears that, normally, guard-hairs are produced from those follicles initiated between 14 and 17 days of gestation and that zig-zags are formed in follicles initiated after birth. The chief interest of the crinkled gene lies in the hierarchy of physiologically related abnormalities, the initial cause being a defect in the epidermis and the effects in other tissues being secondary. This is consistent with the principle of the unity of gene action (Gruneberg 1938). This principle will be discussed more fully later.

A pronounced abnormality in the keratinization of the hair fibres occurs in the mutants listed in the second group of Table I. A typical example is naked N which causes the hairs of homozygous NN mice to break off at the skin surface as they emerge (David 1932). Most NN mice die before 10 days of age. Heterozygous N+ mice have hairs that break only at weak points after emergence. Follicle initiation and cyclic activity are unaffected. The gene matted ma causes the body hair to be brittle due to faulty keratinization so that breakage of the fibres occurs (Jarrett and Spearman 1957). In bare bebe mice, keratinized globular masses are present in the follicles instead of straight hairs (Randelia and Sanghvia 1961).

Mutants in which hair loss takes place by shedding of entire fibres are represented in group (3). The hairless gene hr, and also its alleles rhino hr<sup>rh</sup> and bald hr<sup>ba</sup> results in a failure of the follicle to shorten properly during the catagen/

catagen stage (Fraser 1946, Garber 1952). The anchoring club fails to keratinize so that the entire fibre falls out in contrast to the naked phenotype in which the hair breaks off at the skin surface. Also, the hr gene disrupts the cyclic activity of the hair follicles and the claws are excessively long.

A number of mutant genes produce wavy hairs and mimic one another in their effects. Little is known about how the curvature is produced. In waved - 1 and waved - 2 mice, David (1937) reports that most of the follicles are curved so that the keratinized fibres erupt as waved hairs. The members of this group of mutants resemble one another closely but Carter (1951) has examined phenotypic interactions between rex Re, waved - 1 wa-1, waved - 2 wa-2, and demonstrated that six genotypes (ReRe; Re+; Re+, wa-1wa-1; wa-1wa-1; Re+, wa-2wa-2; wa-2wa-2) can be distinguished from one another phenotypically, the chief criteria of classification being the shape of the vibrissae and the grade of waving pattern in the coat.

The last category of this organisational scheme contains only one mutant, namely rough ro. In this phenotype the hairs tend to stick together in bundles so that the pelage has an untidy appearance (Falconer and Snell 1952). The internal structure of the hair is abnormal in two respects: the air spaces of the medullae are smaller than normal and a high proportion/

proportion of them is filled with fluid.

The general picture which emerges from the foregoing discussion is that the differentiation, morphogenesis and growth of the hair follicle depends on the collaboration of many genes. At each step in the sequence of developmental events, e.g., follicle initiation, keratinization of hair fibre, there is a number of genes acting. These genes come into action when prompted by specific processes and follow one another in their effects.

Pleiotropy: The concept of pleiotropy is important in deciding whether a gene can exert only one type of immediate effect in a tissue or whether a single gene can play different roles in different tissues. A number of mutations in the mouse and in *Drosophila* have been analysed and in no case was clear evidence found for more than one type of gene action, the final effects of the gene being the direct or indirect results of a single defect of development. From these findings, Gruneberg (1938, 1943, 1948) has developed the principle of the unity of gene action. According to this principle, the observed pleiotropy is spurious/

spurious and is to be distinguished from genuine pleiotropy in which a gene would be performing different roles in different tissues. The principle receives strong support from the two different genes, crinkled and tabby (Ta Falconer 1953), both of which produce exactly the same syndrome. If each abnormality was caused by a separate reaction of the gene, it is difficult to visualise how such a parallelism could arise unless crinkled and tabby were identical genes which the genetical evidence proves them not to be.

There are, however, cases of complex phenotypes in which it does not seem to be possible to relate the pleiotropic effects to a single initial cause in development. The mutants, dominant spotting W, and its viable allele, W<sup>v</sup>, produce blood, gonad and pigment changes in the mouse which have not been shown to be causally related. The pleiotropic pattern beyond a certain point is irreducible. The failure to reduce the whole series of changes to a single primary defect raises a number of questions. Is it because the morphological and embryological methods employed are insufficiently sensitive? It is not unlikely that more refined methods will detect a single process connecting the macrocytic anaemia with gonad defects and abnormal pigmentation. Or is it because the gene actually does different things in different tissues? Another possibility is that different tissues use the same gene product for different "purposes", i.e. different pathways leading to different specific proteins.

Mimic genes /

Mimic genes.

Non-allelomorphic genes can often be grouped together on the basis of phenotypic similarity. The genes naked, bare, and hairless mimic one another in causing hairlessness and the basic defect in each case is faulty keratinization. But, as stated previously, the mechanisms by which the hairlessness is brought about can be seen to be different. These mimic genes illustrate the fact that although various mutants are alike in producing a common end result, in this case hairlessness, the same kind of deviant phenotype can arise from different developmental causes.

(ii) Physiological aspects.

A deeper penetration towards an understanding of the metabolic processes underlying the morphological changes may be obtained by physiological examination of the phenotype. Very few hair mutants have been investigated in such a way. Fraser (1946) found that normal skin transplanted to rhino hosts behaved autonomously and grew a normal coat. But rhino implants on normal hosts gave a somewhat different result. The rhino skin showed depilation in the middle but in the peripheral zones the rhino hair persisted. This suggests that normal skin produces a diffusible substance which is absent from rhino, but the rhino cells are capable of utilising it when it is supplied from neighbouring normal follicles. To digress for a moment from skin transplantations, the body growth and sterility of pituitary dwarfism in the mouse can be corrected by normal pituitary implants. There is a gene controlled error of synthesis of a specific substance in a particular organ, i.e., failure of the pituitary gland to produce growth/

growth hormone. Such physiological analyses help to bridge the gap between events at the morphological level and those occurring at the intra-cellular level.

(iii) Biochemical aspects.

Ultimately, one must seek an explanation of gene action in chemical terms. Detailed investigations of the biochemistry of individuals with known gene substitutions may give a clue to the specific manner in which these individuals differ from one another metabolically. From this one may expect to reach certain conclusions regarding the fundamental nature of the action of the gene. The hair mutants in mice have not been investigated on such a basis and to emphasise the salient features of biochemical genetics it is necessary to consider examples from other sources. Individuals homozygous for the alcaptonuria gene in man are unable to oxidise homogentisic acid and so it is excreted in the urine (Garrod 1923). Normally the oxidation is accomplished under the influence of an enzyme which appears to be absent from alcaptonurics. The normal allele of the alcaptonuric gene is essential for the production of this particular enzyme.

Many similar cases have been discovered in micro-organisms. In each instance there is a block at some point in the normal metabolic pathway. Such a block can be attributed to the deficiency of a specific enzyme and this in turn can be accounted for in terms of a single gene substitution. This has led to the one gene-one enzyme theory which supposes that genes operate through the medium of enzymes and that each gene controls the synthesis/

synthesis of one and only one enzyme. The theory derives its support almost entirely from studies of micro-organisms and does not allow for the whole range of phenomena involved in morphogenesis.

Summarising the situation we see that underlying morphological differences between genotypes are physiological ones and underlying these are modifications of enzymes within the cell. Since chemical changes may ante-date morphological changes, the point in the developmental sequence at which a gene appears to act depends on the method of investigation and different methods give different answers. But before the fundamental processes of gene action are exposed, it is necessary to examine the morphological effects of the gene. Techniques of anatomy and histology reveal certain tissue relationships and enable comparisons to be made between embryonic rudiments and structures amongst individuals with known genetic differences.

### C. The present investigation.

The two new mutants which form the subject of this investigation differ from previous cases of hereditary hypotrichosis in certain respects. One, found by Dr. Kirkham and Dr. Bell (Endocrinology Dept., Edinburgh) is partially dominant and is designated shaven, symbol Sha. Young homozygous shaven ShaSha mice fail to grow a first coat. Their viability is normal. Adult ShaSha mice are very sparsely covered with short brittle hairs. They are fully fertile. The coat of heterozygous shaven Sha+ mice is of normal length and density but is greasy, and/

and closely resembles the rough roro phenotype. The other mutant is recessive and is called nude, symbol nu. The original nude mice were obtained from Dr. N.R. Grist, of the Virus Laboratory, Ruchill Hospital, Glasgow. The mutant was said to have arisen "in a private stock of white mice, which have not been sib-mated". Many nunu mice die within a few days of birth and viable young mice never grow a first coat. Adults are rarely fertile; they develop a liver disease, become weak and die.

The second chapter of this thesis deals with the formal genetics and the morphological and histological effects of the Sha gene. As new genes in the mouse come to the attention of investigators, the chromosome map is continually being revised. This results in better mapping of the chromosomes and increases the value of the animal as material for basic genetic research. The new genes are fitted into place and the additional information is brought to bear on linkage relationships already established. Linkage tests have been made with respect to the Sha gene and it will be shown that it has a characteristic linkage relationship with another gene causing hairlessness.

Following on from the formal genetics, the homozygous shaven and heterozygous shaven phenotypes are described. This leads on to the main features of the skin histology of these animals. The failure of ShaSha mice to grow a first coat could be attributed to one of two possible causes:

- (a) There may be no follicle initiation or differentiation.
- (b) /

(b) Follicle initiation and differentiation may occur but the follicles may not produce hairs.

Each possibility has been investigated in order to decide if the developmental mechanisms underlying the deviant phenotypes are essentially different from those underlying previous conditions of hereditary hairlessness, as outlined in the last section. If the hairlessness is due to complete failure of follicle initiation in embryonic and post-natal skin then, clearly, ShaSha mice would represent a new type of hereditary hypotrichosis. Alternatively, if the follicle primordia are laid down but the follicles fail to produce hair, then the Sha gene would be an additional example of that group of hairless genes typically represented by N.

Semi-dominant genes causing hairlessness exhibit dosage effects, the lack of hair being more extreme in homozygous mice than in heterozygotes, e.g., ragged and naked. This does not apply to shaven mice. The presence of the Sha gene in single dose Sha<sup>+</sup> causes a greasy coat but has no effect on hair length or density. An attempt has been made in the present study to relate the greasy pelage of Sha<sup>+</sup> mice to the hairlessness of ShaSha individuals.

The main interest of the nu gene rests in the variety of morphological and histological abnormalities which it produces. The third chapter is concerned with these abnormalities. The reasons for studying the genetics and the histology of the hairlessness were the same as those mentioned above in connection with Sha. One of the abnormalities caused by the nu gene is an unfamiliar liver disease which has fatal consequences in all nunu/

nunu adults. According to Gruneberg's principle of the unity of gene action, there should be a causal connection between the failure of hair growth in young nunu mice and the liver disease which develops in the adults. The problem has been examined on this basis but not much progress towards a solution has been found, beyond the exclusion of certain possibilities.

CHAPTER II. STUDIES OF SHAVEN.

This chapter is concerned with the genetics of the shaven gene and with the morphology and skin histology and histochemistry of homozygous and heterozygous shaven mice. The first section deals with the segregation and linkage data obtained from the breeding experiments. The second section describes the gross morphology of homozygous and heterozygous shaven animals and an account of the skin histology of both phenotypes is given in the third section. In the fourth part, the relevant histochemistry of the skin of homozygous shaven mice is examined. Finally, all the results of these investigations are discussed in the fifth section of the chapter.

1. GENETICS.

The original hairless specimen was outcrossed to normal mice and all the  $F_1$  animals had a fully grown coat but they were distinctly greasy. It was supposed that the shaven gene was partially dominant and this supposition was confirmed by intercrossing the  $F_1$  animals. Three phenotypic classes were obtained: hairless, greasy coated, and normal mice in the ratio 1:2:1. All the hairless mice were proved to be homozygous for the shaven gene; when the hairless females were mated to the hairless males, all the offspring were also hairless. The greasy coated animals were proved to be heterozygous for the shaven gene; when crossed to the hairless animals, half the offspring were hairless and half were greasy coated. Homozygous shaven mice ShaSha are recognisable at birth by the paucity and waviness of the vibrissae./

vibrissae. Heterozygous shaven mice Sha<sup>+</sup> cannot be classified with certainty before 12 to 14 days, but during the third week the greasy coat becomes clearly noticeable and the vibrissae are usually wavy. The three phenotypes ShaSha, Sha<sup>+</sup>, ++, are compared in fig. 5.

Segregation data.

When the original ShaSha mouse was outcrossed to an unrelated agouti black laboratory strain, a stock heterozygous for the Sha gene was established and the gene was kept segregating by means of intercross matings. Segregation data obtained from different types of matings are given in Table 2. The progeny of intercross matings

Table 2: Segregation of shaven

Type of mating.	No. of matings	Progeny			Total	$\chi^2$	P
		ShaSha	Sha <sup>+</sup>	++			
<u>Sha</u> <sup>+</sup> x <u>Sha</u> <sup>+</sup>	33	230	482	214	926	2.11	>0.30
<u>ShaSha</u> x <u>Sha</u> <sup>+</sup>	62	831	822	0	1653	0.05	>0.80
<u>Sha</u> <sup>+</sup> x ++	46	0	558	593	1151	1.06	>0.30

Sha<sup>+</sup> x Sha<sup>+</sup>, were always classifiable into three phenotypes; hairless, greasy and normal. These three classes represented the genotypes ShaSha, Sha<sup>+</sup> and ++, respectively. The segregation data from intercross matings are in satisfactory agreement with expectation, verifying that Sha is a semi-dominant gene. Backcross breeding data from ShaSha x Sha<sup>+</sup> matings are close to the expected 1:1 ratio. The other backcross, Sha<sup>+</sup> x ++, gave a slight excess of ++ mice. This appears to be due to normal overlapping. It was sometimes noted that when /

when Sha<sup>+</sup> animals from the shaven stock were outcrossed to ++ animals from an unrelated stock, the manifestation of the Sha gene was considerably diminished, as judged by the reduced greasiness of the coat, so that Sha<sup>+</sup> animals were phenotypically similar to normal animals. It appears that the expression of the Sha gene, in heterozygous animals, is subject to modification by the genetic background.

#### Tests for Allelism.

The hairlessness of ShaSha mice and the greasy coat and wavy vibrissae of Sha<sup>+</sup> mice suggested that Sha might be an allele of hr, ro, or cw. ShaSha mice were mated to hrhr animals, and also to roro and to cwcw individuals. All the F<sub>1</sub> mice were fully coated but greasy. The absence of interaction between Sha and hr was presumptive evidence against Sha and hr being alleles, since the fully coated animals so produced would have to be Sha/hr on the hypothesis of allelism. Conclusive evidence against allelism was obtained when the doubly heterozygous F<sub>1</sub> animals, Sha +/+ hr, were backcrossed to + hr/+ hr animals. Normal mice were recovered in the progeny and there was no evidence of linkage. Similarly, no evidence of allelism was obtained in the tests against ro and cw.

#### Linkage tests.

Linkage tests were carried out to identify the linkage group of Sha. The Sha gene was tested against the five multiple linkage testing stocks described by Carter and Falconer (1951). Two additional stocks were also used. The stocks were as follows:

<u>Stock Number.</u>	<u>Markers present</u>
I	Va Sd Ra
II	Wh T N
III	p se fz v
IV	s wa-2 ln b a
V	ru je f c <sup>e</sup>
VI	Re w <sup>v</sup>
VII	Os So Sl

The tests required two generations in all cases. The first consisted of outcrossing a ShaSha animal to an animal from each stock. The multiple heterozygote, whose gametic constitution was tested for evidence of linkage, was recovered from the F<sub>1</sub> generation. The second generation was obtained by backcrossing the multiple heterozygote of the F<sub>1</sub> to the multiple recessive. The offspring of this backcross were examined and the deviation of Sha from independent segregation calculated.

It was soon obvious that Sha was either allelic or closely linked to N, in linkage group VI. All other linkage tests were immediately terminated. The linkage test with N consisted of a backcross of Sha +/+ N mice to + +/+ + mice. The other marker genes of stock II, Wh and T, were also segregating in the backcrosses, but these were gradually eliminated. From the backcrosses, 43 classified progeny were obtained and no cross-over was found. At the 5% probability level, no cross-over in 46 progeny gives a recombination value of not more than 7.7%. It was thought likely that Sha and N might be alleles, since both genes cause hairlessness. Further data, however, showed that the two genes are not allelic but are closely linked. The evidence was obtained /

obtained from three types of backcross matings, as follows:

- (a) Sha +/+ N x + +/+ +  
 (b) Sha +/+ N x Sha +/Sha +  
 (c) Sha N/+ + x Sha +/Sha +

The details will be given under separate headings.

(a) Sha +/+ N x + +/+ + The first type of backcross involved the mating of a double heterozygote to normal mice. Sha +/+ N mice are phenotypically indistinguishable from + +/+ N mice, as the Sha gene does not interact with N. Doubly heterozygous animals lose their first coat at 14 days of age and the pattern of cyclic hair regeneration in the adults is similar to that of + +/+ N animals. The progeny of the backcrosses were classified at 14 to 16 days of age. The backcross data are given in Table 3. Since Sha +/+ N mice are indistinguishable from + +/+ N animals, the progeny of the backcross

Table 3. Sha +/+ N x + +/+ + matings. Data showing linkage between Sha and N

Parents	<u>Sha</u> +/+ <u>N</u> x + +/+ +			
	non cross-overs		cross-overs	
Progeny	<u>Sha</u> +	+ <u>N</u>	<u>Sha</u> <u>N</u>	+ +
Phenotype	greasy	Semi-hairless		Normal
No. observed	40	41		0
Ratio	1	2		1
No. expected	20.25	40.50		20.25

matings were classifiable into three groups only, as shown in the table. On the basis of independent segregation of Sha and N, a 1:2:1 ratio was expected. But out of 81 classified offspring no /

no normal mice were observed, indicating that Sha and N were allelic or closely linked. Since one of the cross-over classes, Sha N, is confounded with one of the non cross-over classes, + N, all semi-hairless mice were tested for the presence of Sha by mating with Sha +/Sha + animals. One semi-hairless mouse, so tested, gave 17 offspring, 7 of which were completely hairless. This semi-hairless mouse was thus proved to carry the Sha gene, and its genotype was Sha N/+ +. In the light of this new information, obtained after test mating, the data in Table 3 may be re-arranged, as in Table 4.

Table 4. Sha +/+ N x +/+ + matings. Data of Table 3 reclassified after testing all semi-hairless mice.

Parents	<u>Sha +/+ N</u> x +/+ +			
Progeny	<u>Sha +</u>	+ <u>N</u>	<u>Sha N</u>	+ +
No. observed	40	40	1	0
Total	81			
Recombination %	1.2			

It is seen that the percentage recombination is 1.2.

(b) Sha +/+ N x Sha +/Sha +. The second type of backcross involved matings of double heterozygotes to Sha +/Sha + animals. Since classification of the offspring was simplified somewhat, backcrosses of double heterozygotes to Sha +/Sha + mice supplanted the previous type (a) backcross. Once again, only three phenotypic classes were distinguishable in the progeny. The linkage data are shown in Table 5.

Table 5. Sha +/+ N x Sha +/Sha + matings. Data showing linkage between Sha and N

Parents	<u>Sha +/+ N x Sha +/Sha +</u>			
	non cross-overs		cross-overs	
Progeny	<u>+ N</u>	<u>Sha +</u>	<u>Sha N</u>	<u>+ +</u>
Phenotype	semi-hairless	hairless		greasy
No. observed	543	460		5
Ratio expected	1	2		1
No. expected	252	504		252
Total		1008		
Recombination %		0.9		

One of the cross-over classes, Sha N, is indistinguishable from one of the non cross-over classes, Sha +, because the N gene carried by a Sha N animal cannot manifest itself in a completely hairless phenotype. The hairless offspring were not test-mated to see if they carried the N gene. For the purpose of estimating recombination, only 2 classes can be compared, + N and + +. Out of 548 progeny, 5 were recombinants. This gives a percentage recombination of 0.9.

It is apparent that there is a deficiency of hairless mice when the litters are classified at 14 days of age. Sometimes, Sha +/+ N and Sha +/Sha + mothers have a limited milk supply and the hairless offspring may have difficulty in competing successfully for food with their partially coated littermates.

(c) Sha N/+ + x Sha +/Sha + It will be recalled that one recombinant was obtained from the type (a) backcross. This animal had the Sha and N genes in coupling and was back-crossed to Sha +/Sha + animals. Excluding crossing-over, the hairless offspring /

offspring were Sha N/Sha + and these were in every way similar to Sha +/Sha + animals.

As before, the offspring from this type of backcross were classifiable into three phenotypes only. The relevant data are given in Table 6. Comparison between the classes + + and

Table 6. Sha N/+ + x Sha +/Sha + matings.  
Data showing linkage between Sha and N.

Parents	<u>Sha N/+ + x Sha +/Sha +</u>			
Progeny	Non cross-overs		cross-overs	
	+ +	<u>Sha N</u>	<u>Sha +</u>	+ <u>N</u>
P Phenotype	greasy	hairless	semi-hairless	
No. observed	480	402	3	
Ratio expected	1	2	1	
No. expected	221.2	442.4	221.2	
Total		885		
Recombination %		0.6		

+ N shows that there are 3 recombinants out of 483 mice, indicating a percentage recombination of 0.6%.

There is no appreciable heterogeneity between the various types of backcross matings. The data from the three types of backcrosses are pooled in Table 7. In backcross (a), it is seen that, after testing the offspring, there is one recombinant out of 81 mice. In backcrosses (b) and (c), the offspring were not test-mated and comparisons between the two phenotypic classes, + N and + +, show that there are  $5 + 3 = 8$  recombinants out of  $543 + 3 + 480 + 5 = 1031$  mice. Summing the data, there are 9 recombinants out of a total of 1112 mice, which gives a percentage recombination of 0.8% at/

Table 7. Pooled results of two point tests  
between Sha and N

<u>Type of mating</u>	<u>+ N</u>	<u>Progeny</u>		
		<u>Sha +</u>	<u>Sha N</u>	<u>+ +</u>
1. <u>Sha +/+ N</u> x <u>+ +/+ +</u>	40	40	1	0
2. <u>Sha +/+ N</u> x <u>Sha +/Sha +</u>	543	460		5
3. <u>Sha N/+ +</u> x <u>Sha +/Sha +</u>	3	402		480
Recombination %		0.8		
5% Fiducial limits		0.37	—	1.54

at the 5% level, the fiducial limits range from 0.37% to 1.54% (Table VIII, Fisher and Yates 1948).

Thus, it is seen that Sha and N are closely linked. There was no sex difference in the frequency of recombination.

The next step was to determine the linear order of the Sha and N genes in relation to a third marker gene on the chromosome. The additional marker chosen was Ca. It was known that the percentage recombination between N and Ca is 2 (Burdette 1963), and, since the recombination value between Sha and N has been shown to be 0.8%, it was thought unlikely that Ca is located between Sha and N. Thus, two possibilities were considered:

- (a)        N ——— 0.8% ——— Sha ——— 1.2% ——— Ca  
 (b)        Sha ——— 0.8% ——— N ——— 2% ——— Ca

In order to decide between these alternatives, three point tests were carried out by crossing Sha N +/+ + Ca mice with normal + + +/+ + + mice. Sufficient data to enable definite conclusions to be made are not yet available but the tests are being continued. The results obtained so far are shown in Table /

Table 8. The classes of progeny from the three point tests are

Table 8. Results of three point tests Sha N +/+ + Ca x + + +/+ + +. Classes of progeny are arranged in pairs according to cross-over type.

Cross-over type.	Classes of progeny.	No. of progeny observed.	No. classified with certainty in each cross-over type.
1. Non cross-over	<u>Sha N +</u> <u>+ + Ca</u>	493 515	515
2. <u>Sha</u>	<u>+ N +</u> <u>Sha + Ca</u>	(-) 1	1
3. <u>N</u>	<u>+ N Ca</u> <u>Sha + +</u>	(-) 9	9
4. <u>Ca</u>	<u>Sha N Ca</u> <u>+ + +</u>	(-) 0	0
Total		1018	525

arranged in pairs according to cross-over type. There are 4 types of cross-over as outlined in the first column of the table. After classification of the progeny, the rarest class will represent double cross-overs, by means of which the central of the three loci is exchanged by the homologous chromosomes. Complete classification of the progeny, however, is very difficult, if possible at all. Sha cannot be definitely recognised in the presence of N. Thus, in the second column of the table, the classes of progeny which carry N are phenotypically similar and are confounded. These classes are indicated by brackets in the third column. The last column of the table gives the number of progeny which were classified with certainty in each type of cross-over. The 3 recombination percentages are:

N — Ca	$\frac{9}{525}$	=	1.7%
N — Sha	$\frac{10}{525}$	=	1.9%
Sha — Ca	$\frac{1}{525}$	=	0.2%

Since  $1.7\% + 0.2\% = 1.9\%$ , it appears that the order of the 3 loci is as follows:

$$N \text{ — } 1.7\% \text{ — } Ca \text{ — } 0.2\% \text{ — } Sha$$

The three point test data indicate also that alternative (a) above is possible, and that alternative (b) is ruled out.

The three point test data are not in agreement with the two point test data. The recombination value of 1.9% between Sha and N is considerably higher than the value of 0.8% obtained from the two point tests. Also, the three point tests suggest that Ca is located between N and Sha, whereas the two point tests indicate that Ca is not the central locus. Further data from the three point tests are awaited.

Summary of linkage tests. From two point tests, the percentage recombination between Sha and N was 0.8%, with 5% fiducial limits of 0.37% to 1.54%. The recombination value obtained from the three point tests was higher, being 1.9%. The two point tests suggested that Ca is not the central of the 3 loci but the three point tests contradict this and indicate that Ca is located between Sha and N.

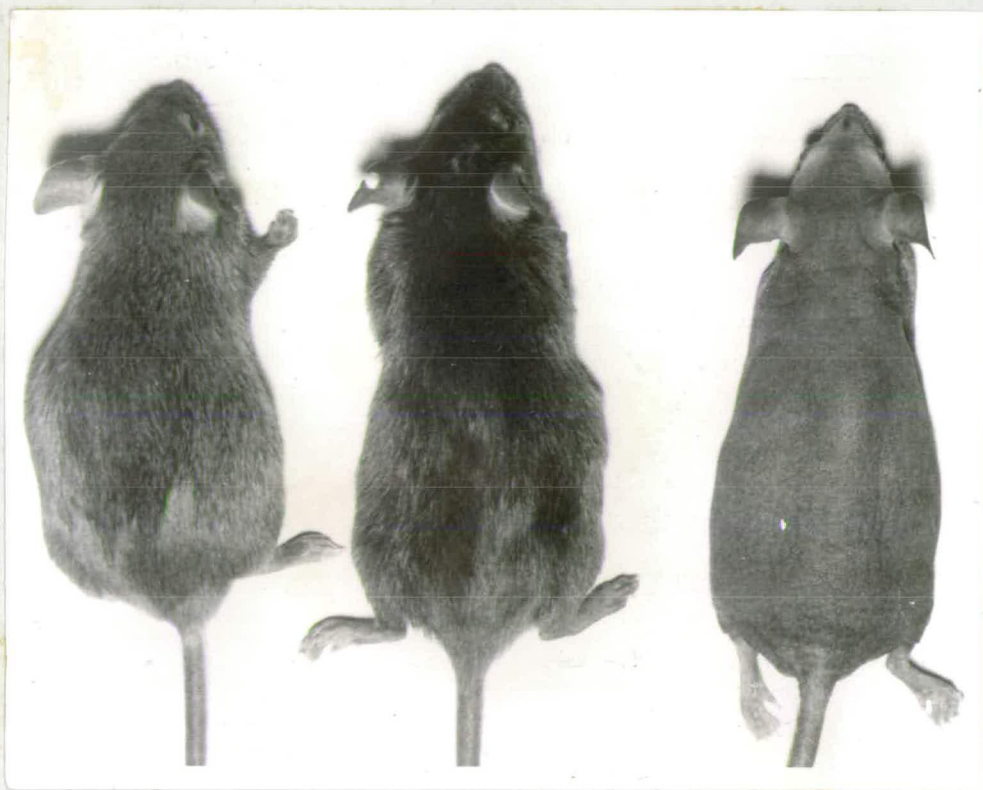

Fig. 5. Left to right: ++, Sha+, ShaSha mice. All are agouti black animals. The greasy hairs of Sha+ mice are illustrated in the text. The ShaSha mouse is completely hairless.

2. MORPHOLOGY.

In this second section of Chapter II the gross morphological abnormalities caused by the Sha gene in the homozygous and heterozygous conditions will be described. The Sha gene was kept segregating by means of intercross matings, so that ShaSha, Sha+, and ++ mice were available for comparison in the litters. The three phenotypes are compared in Fig. 5 .

(a) Homozygous shaven mice (ShaSha).

External appearance. At birth ShaSha mice can be distinguished from their Sha+ and ++ sibs by the paucity and waviness of the vibrissae. Usually 3 to 7 waved vibrissae are observed on each side of the snout. The supra-orbital, post-orbital, and post-oral vibrissae are rarely discernible and only vibrissae stubs are present. All the vibrissae follicles are present on the snout and head.

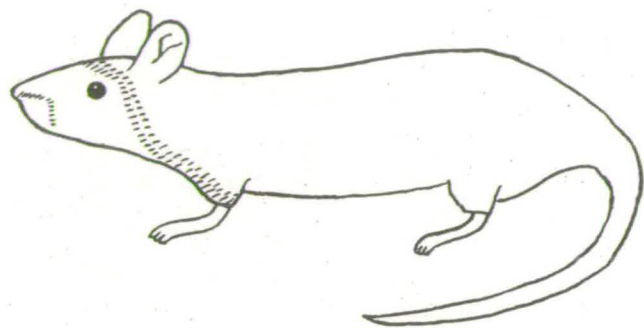
The second criterion for the classification of ShaSha mice is the absence of the first coat at 6 days of age. On normal mice of this age, numerous hairs have erupted on the dorsum but in ShaSha specimens no hairs have emerged from the skin, although there is no delay in the thickening or pigmentation of the integument. The hairlessness is most obvious in 10-day old animals, and the skin is coarsely wrinkled. ShaSha mice are smaller than their normal littermates at this time.

Macroscopic/

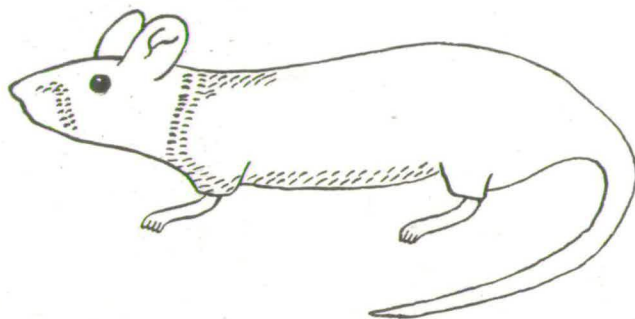
Macroscopic examination reveals hair stubs scattered on the dorsum of 2-week old ShaSha mice. The hair stubs indicate that a few follicles, at least, are present in the skin and that the hairs fragment into minute pieces as they erupt. The skin of agouti animals is intensely pigmented and appears black. A few short fine hairs are observed on the head, feet, and tail.

During the third week there is a pronounced reduction in skin thickness. This corresponds to the catagen stage of normal skin. At three weeks of age the dorsum is still wrinkled, and the smutty appearance is maintained. ShaSha mice sometimes appear to be in poor condition at weaning, but this is misleading as they are robust and thrive during the post-weaning period. The absence of the first coat is a striking feature.

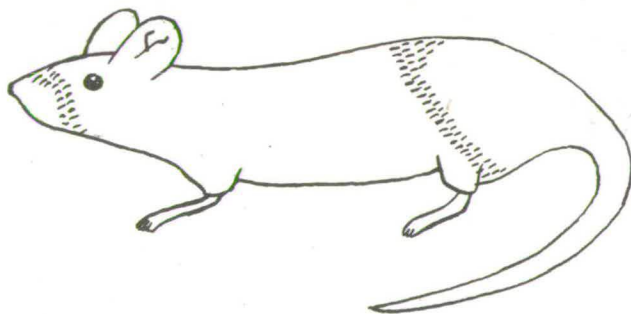
The first indication of hair growth on the main body area of ShaSha mice is manifested between 28 and 34 days of age. The wrinkling disappears from the dorsum, the skin thickens, and sparse fuzzy hairs averaging about  $\frac{1}{8}$ " in length erupt on the head, anterior dorsum, shoulders, and Ventrums. At this age, normal littermates are entering the second growth cycle. The short fuzzy hairs gradually become established on the mid-dorsum and lateral trunk regions, but as the fibres appear on the posterior regions, those of the anterior areas are shed, the hairs breaking at the skin surface. Thus, an irregular band of sparse short hair moves in a cephalo-caudal /



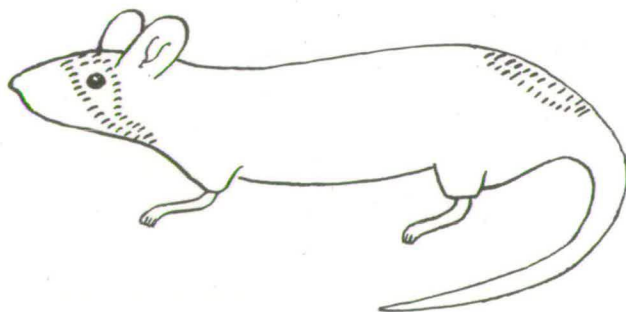
80 days



85 days



90 days



95 days

Fig. 6. Drawings of an adult ShaSha mouse, made at 5 day intervals illustrating the regeneration of short sparse hair.

caudal direction, and most of the hairs are lost before 6 weeks of age. The skin decreases in thickness once more.

The integument of ShaSha adults resembles that of NN animals. ShaSha adult mice undergo cyclic regeneration and loss of short fuzzy hair. The manifestation of a band of newly initiated hair growth on a ShaSha adult specimen is shown in Fig. 6. Each wave of hair regeneration is preceded by thickening and intense pigmentation of the skin.

With progressing age, ShaSha mice may remain completely hairless for long periods. Skin pigmentation is considerably diminished.

Vibrissae. Although a few wavy vibrissae are observed at birth, these soon break off as they erupt. The supra-orbital, post-orbital, and post-oral vibrissae are usually present at birth but they are short and fragment at 2 to 3 days. Consequently 10-day old ShaSha mice lack vibrissae. Most adult ShaSha mice show repeated regeneration and loss of short wavy vibrissae.

Nails and teeth. The toe-nails of ShaSha mice are generally normal in shape and length and remain so with increasing age. Excessive nail length as found in hrhr mice is not observed in ShaSha animals. A few ShaSha mice, however, were found in which one or two toe-nails of each mouse were malformed, the nails being normal in length but spirally shaped. But these malformations are not at all common. The teeth appear normal.

Mortality and fertility. The mortality of ShaSha mice is rather greater than normal during the suckling period because hairless /

hairless specimens sometimes have difficulty in competing with the normal sibs for milk. After weaning, mortality is similar to that of normal mice. ShaSha adults are fully fertile and the mothering ability of females is not much inferior to that of normals.

#### Hair morphology.

The short sparse hairs of ShaSha mice are not classifiable into the four standard types, i.e., guard hairs, awls, auchenes, and zig-zags. Diagrams of normal and ShaSha fibres are presented in Fig. 7. ShaSha hairs generally do not exceed  $\frac{1}{8}$ " in length, and a continuous gradation ranging from straight coarse fibres to fine twisted fragments is observed. Three general fibre types may be recognised:

- (a) Short straight fibres with stout bases and twisted tips; these fibres faintly resemble awls.
- (b) Short thin fibres with one or two bends along their lengths; these hairs are probably segments of zig-zags.
- (c) A transitional series of short, straight or curved fibres, with long coiled tips.

The majority of ShaSha fibres fall into the third category.

Microscopic examination of whole fibre mounts reveals several anatomical defects of ShaSha hairs. Drawings of the internal morphology of normal and ShaSha fibres are presented in Fig. 8, and microphotographs are shown in Figs. 9 and 10. Fibre diameter varies considerably and when focussed under the high power the hair shaft /


Normal fibres




Guard hairs



Awls



Auchenes



Zig-zags

ShaSha fibres



Awl-like hairs



Transitional hairs



Zig-zag-like hairs

Fig. 7. Camera lucida drawings of hairs of ++ and ShaSha mice.

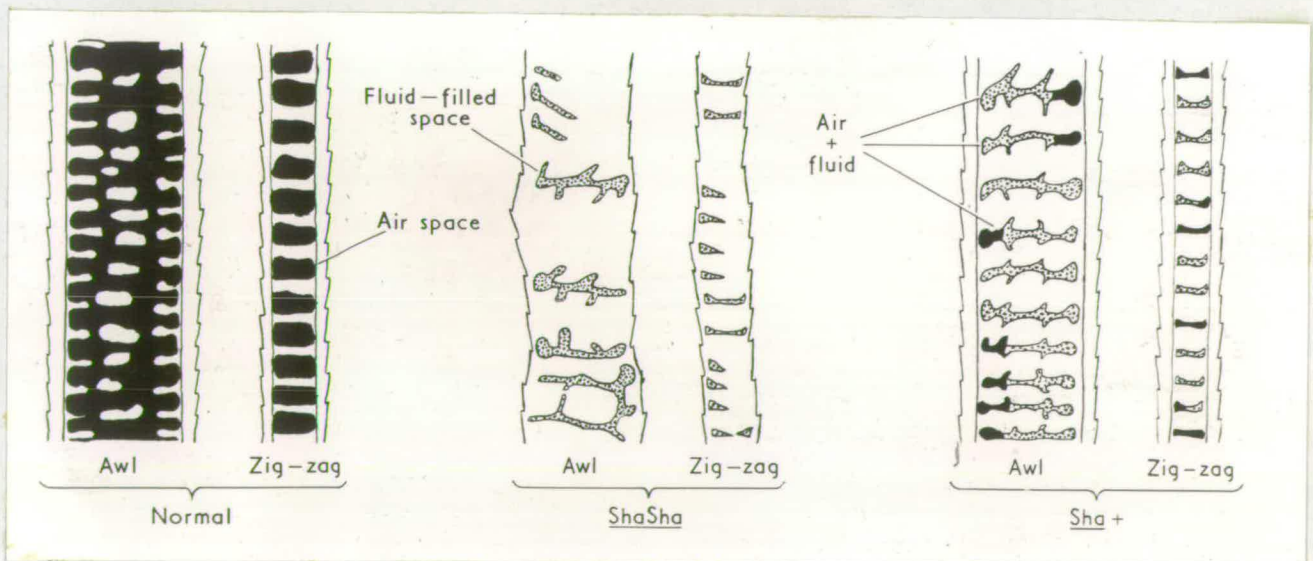


Fig. 8. Camera lucida drawings of hairs of ++, ShaSha, Sha+ mice, to illustrate the internal morphology of the different types. The air spaces are black and the fluid-filled spaces are stippled.




Fig. 9. Microphotograph of ++ fibres showing air spaces (black) and cross-septa in the medullae. X190.

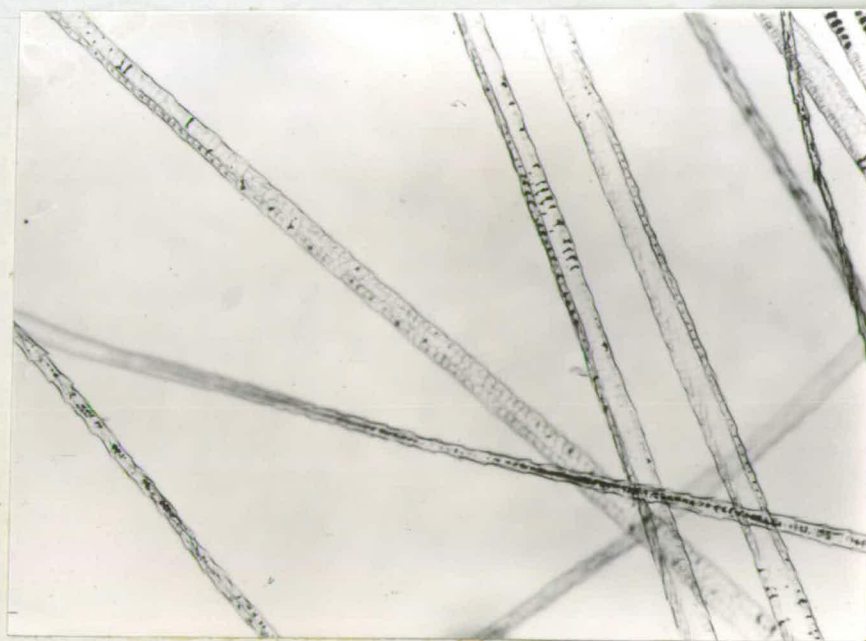


Fig. 10. Microphotograph of ShaSha fibres. The medullae are not regularly septate and the air spaces contain fluid. X190.




Fig. 11. Microphotograph of Sha+ fibres. The medullae are regularly septate but most of the hair spaces contain fluid. X190.

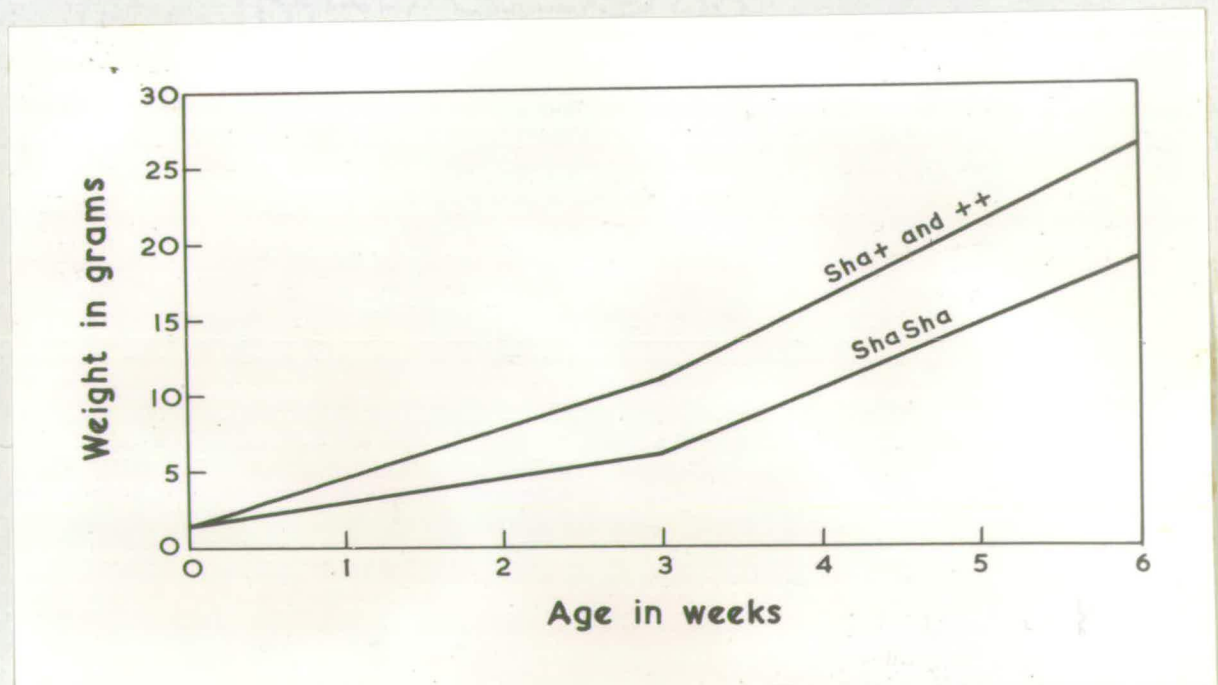


Fig. 12. Growth of ShaSha and [Sha+ and ++] mice.

shaft is often spirally twisted. Almost all the hairs possess a normal cuticle and the cuticular scales appear structurally sound. The cortex is thin in most hairs and in some fibres it is non-existent.

The medulla is strikingly abnormal. In the normal hair the medulla is regularly septate. Between the septa are air cells which appear black when examined by reflected light. In ShaSha hairs the normal ladder-like arrangement of septa and air cells is absent. The septa are very thick and the air spaces are narrow and compressed between the septa. Most of the air spaces, however, are clear and glassy rather than black, and appear to contain liquid rather than air, when viewed by reflected light. The significance of these glassy spaces will be referred to in more detail later.

#### Body growth.

The absence of a pelage and competition from normal littermates for food are partially responsible for ShaSha mice being smaller than coated individuals at 3 weeks of age. For the purpose of obtaining an objective assessment of this difference in growth rate, a random sample of litters from intercross Sha+ x Sha+ and backcross Sha+ x ShaSha matings were weighed at birth, at 3 weeks and, frequently, at 6 weeks of age. Within each litter, the mean weight of each phenotypic class was recorded. The means were summed over all the litters, and the mean of means, together with its standard deviation, were calculated for each phenotypic class. Since Sha+ and ++ mice have similar growth rates, these two types have been combined in the analysis. The results are given in Table 9.

Table 9. The mean weights of ShaSha and [Sha+ and ++] mice at birth, 3 weeks, and 6 weeks of age. The differences indicate the reduced growth rate of ShaSha mice.

	No. of mice	Mean $\pm$ S.D.	Weighted difference (g)	Sha+ and ++ heavier in %	S.E. of difference	Significance
	143	1.6 $\pm$ 0.21	—	—	—	—
and ++ weeks.	172	1.6 $\pm$ 0.23	—	—	—	—
	91	6.2 $\pm$ 1.9	4.9	45.0	0.60	P < 0.001
and ++ weeks.	150	10.9 $\pm$ 2.7	—	—	—	—
	49	18.6 $\pm$ 3.7	7.0	27.1	1.00	P < 0.001
and ++	78	25.8 $\pm$ 2.6	—	—	—	—

There was no difference in birth weight between the two groups, but at 3 weeks and at 6 weeks the body weight of ShaSha individuals was reduced considerably. The differences are significant at the 0.1% level. The growth curves are shown in Fig. , and they illustrate the slower growth of ShaSha mice compared with normals.

The results show that the Sha gene, when homozygous, exercises an appreciable influence on body growth. Since the chief function of the coat is the conservation of body heat, it is reasonable to suppose that heat loss from the body surface is greater in ShaSha mice than in coated animals. In order that the increased heat loss may be balanced by increased heat production, it seems likely that ShaSha mice utilise considerable amounts of energy, which in normal circumstances would be converted into muscle and fat.

Despite the reduced growth rate before 6 weeks, ShaSha mice eventually reach a mature body size which is not much smaller than that of normals. The percentage difference in body weight between ShaSha and coated animals is reduced from 45.0% at 3 weeks to 27.1% at /

at 6 weeks (Table 9), and general observations on the animals indicated that ShaSha mice grow and mature steadily between 6 and 10 weeks of age.

(b) Heterozygous shaven mice (Sha+).  
External appearance.

Heterozygous shaven mice are entirely different in appearance from ShaSha animals and resemble rough homozygotes (roro). The vibrissae are normal at birth, there is no delay in hair eruption during the post-natal period, fibre growth and density are normal, and at 2 weeks of age the coat is fully established. Hair loss or fibre breakage never occurs.

The most reliable characteristic for the classification of Sha+ mice is the greasiness of the coat at 2 weeks of age. The hairs tend to stick together in bundles so that the coat looks somewhat ruffled. Frequently, the tips of the guard hairs do not project above the rest of the coat as in normal mice, but lie flat against the underfur. When the dorsum is stroked in the posterior direction with the fingers, the hairs remain flat along the back and do not become erect as rapidly as normal hairs. Pigmented and non-pigmented animals are equally affected.

The greasiness of the coat of Sha+ animals is variable. This variability is genetically controlled. Whereas Sha+ animals derived from the initial shaven stock are distinctly recognisable, outcrossing Sha+ mice to unrelated strains, e.g., some of the linkage stocks, decreases the expression of the Sha gene, so that /

that normal overlapping may occur. The unrelated mice provide a genetic background in which the dominance of shaven over its normal allele is almost suppressed and this results in diminished greasiness of the coat.

Most Sha+ animals exhibit variable degrees of vibrissae waviness at 2 weeks of age, but in some animals the vibrissae are not sufficiently abnormal to make this characteristic a reliable criterion for classification. The waviness is not as pronounced as that of the caracul, rex, or waved - 2 phenotypes.

Adult Sha+ mice exhibit greasy coats, although the defect is sometimes less obvious than on 2-week old specimens. A few Sha+ adults were observed to replace their initial wavy vibrissae with normal ones. In such cases, vibrissae waviness is a transient abnormality.

#### Hair morphology.

Macroscopic examination showed that the hair of Sha+ mice can be classified into the four standard types of fibre: guard hairs, awls, auchenes and zig-zags. The Sha+ fibres are of normal dimensions and form when compared with normal hairs.

The internal morphology of Sha+ hairs resembles that of rough roro hairs. Diagrams of Sha+ hairs are shown in Fig. 8, and may be compared with the normal hairs. A photomicrograph of Sha+ hair is shown in Fig. 11. The medullary septa of Sha+ hairs are thick and the air cells are reduced in size. With the ordinary /

ordinary light microscope, most of the air spaces appear clear and glassy rather than black, and seem to contain liquid rather than air.

The greasy appearance of the coat suggested that the glassy spaces of the medullae might contain a fatty substance. This suggestion was supported by observations when samples of hair from Sha+ and normal mice were stained with Herxheimer's solution (Sudan III and IV in equal parts of 70% alcohol and acetone), and washed briefly with 70% alcohol. The medullae of Sha+ hairs contained many sudanophilic spaces, whereas the medullae of normal hairs remained unstained. The cuticle, cortex and cross-septa of Sha+ hairs were Sudan negative; only the glassy spaces gave a positive reaction.

Further evidence for the presence of a fatty substance in the medullary spaces of Sha+ fibres was obtained from the following observations. When hair samples from Sha+ and normal littermates were washed thoroughly in ether and allowed to dry over phosphorous pentoxide, many of the glassy spaces of Sha+ fibres contained air. The ether dissolved out much of the fatty substance. The normal hairs were unaffected. When the Sha+ hairs were then stained with Herxheimers solution, the medullary spaces were only mildly sudanophilic. Thus, the intensity of the Sudan reaction was reduced after washing the fibres in ether.

The fact that hairs of the Sha+ coat tend to stick together  
in /

in clumps implied that there might also be external fatty substances adhering to the cuticular scales of the fibres. No fatty material was observed on the external surfaces of the hairs; the cuticular scales were not stained with Sudan.

The Sha gene does not exhibit a dosage effect. In this respect, there is a striking contrast between Sha and other semi-dominant genes causing hairlessness, e.g., N, Ra. There is no hair loss in heterozygous shaven mice, and at the macroscopic level, there is no structural relationship between the greasy coat of Sha<sup>+</sup> animals and the short sparse hairs of ShaSha adults. However, comparisons between the internal morphology of Sha<sup>+</sup> and ShaSha fibres reveals one defect common to both phenotypes, namely, the clear glassy spaces present in the medullae. It has been mentioned before that such spaces are found between the septa of ShaSha fibres. The detection of this common feature suggested that ShaSha hairs might also contain a sudanophilic substance in the medullae. This belief was confirmed by a pronounced Sudan positive reaction obtained after staining the ShaSha fibres with Herxheimers solution. Thus, it was shown that a sudanophilic substance was present in the glassy spaces of both Sha<sup>+</sup> and ShaSha fibre medullae.

If one can imagine hair regeneration taking place on ShaSha mice in such a manner that dense waves of long fibres are produced instead of short sparse bands, it is not unreasonable to assume that such a hair covering would be greasy in a similar fashion to that of Sha<sup>+</sup> animals. The validity of this assumption was tested by examining /

examining the fibre medullae of 5-week old N+ mice. At this age, the regenerated hair growth covers most of the main body area of N+ specimens. It was found that many N+ fibres contain clear spaces in the medullae, and they present an appearance similar to the clear spaces of Sha+ and ShaSha fibre medullae. After staining with Herxheimers solution, the clear spaces of N+ fibre medullae were Sudan positive. N+ hairs were also examined by Jarrett and Spearman (1957) and they reported the presence of anatomical defects along the hair shaft, but did not specifically mention the glassy spaces of the medullae. The presence of a sudanophilic substance in the medullae of both ShaSha and N+ fibres suggests that the substance may be a by-product of incomplete keratinization. The finding of such a substance in Sha+ hairs is difficult to explain since the keratinization of these hairs appears normal in all respects. This point will be enlarged on later.

### 3. SKIN HISTOLOGY.

#### (a) Homozygous shaven mice.

In studying the histology of ShaSha mice the aim was to determine whether the failure of the young animals to grow a coat was due to the absence of follicle initiation or to the inability /

inability of the follicles to produce hair. In this section, the development of the hairlessness is followed and explained in terms of the underlying histological abnormalities of the skin.

#### Methods.

Since the macroscopic appearance of the main body area of ShaSha mice appears normal at birth, and since the hairlessness is most obvious at 10 days of age, serial skin sections of animals between 0 and 10 days of age were examined in order to trace the development of the defect. Intercross matings Sha+ x Sha+ gave ShaSha and coated animals in the ratio 1:3; a ShaSha, Sha+, ++, classification could not be made since Sha+ and ++ mice are indistinguishable before 14 days of age. Within each litter, then, the coated mice, which were genetically Sha+ and ++, acted as controls for ShaSha animals, and it will be convenient to refer to the coated animals as normals, when referring to hair growth. All the coated mice were similar as regards stage of hair eruption, rate of hair growth, and hair density.

Skin samples were taken from the mid-dorsum of ShaSha and normal littermates at birth and at 3, 6, 9 days of age. When 14-day old litters were fully classified, skin samples were taken from ShaSha, Sha+, ++ littermates at 14, 17, 20 days of age. At each age, 1 or 2 mice of each phenotype were sampled. Skin samples were fixed in Bouins fixative, dehydrated, cleared in methyl benzoate and 7 $\mu$  serial paraffin sections were obtained. The sections were stained with haematoxylin and eosin.

#### Results. /

## Results.

Follicle initiation and differentiation. There is no histological abnormality in the dorsal skin of ShaSha mice at birth. Normal and ShaSha skin sections are compared in Figs. 13 and 14. The epidermis, dermis and panniculus carnosus are clearly differentiated in ShaSha skin. The cells of the malpighian layer of the epidermis proliferate upwards to form the other layers of the epidermis as follows:

- a) The stratum intermedium, which contains 2 to 5 rows of polyhedral cells.
- b) The stratum granulosum, which contains basophilic keratohyaline granules.
- c) The stratum corneum, which is desquamating at the surface.

The hair follicles are at different stages of development. Most of the follicle primordia consist merely of aggregations of Malpighian cells but a few possess a bulb and a papilla. On occasional guard hair follicle is found which has grown downwards to the panniculus carnosus.

At 3 days of age, the skin is expanding in thickness and many follicles extend to the muscle layer. Within the differentiating inner root sheath, the cells which have migrated up from the bulb are keratinized to form the young hair. Normal and ShaSha skin sections at 3 days of age are compared in Figs. 15 and 16. There is no difference between the number of follicles per microscopic field in normal/

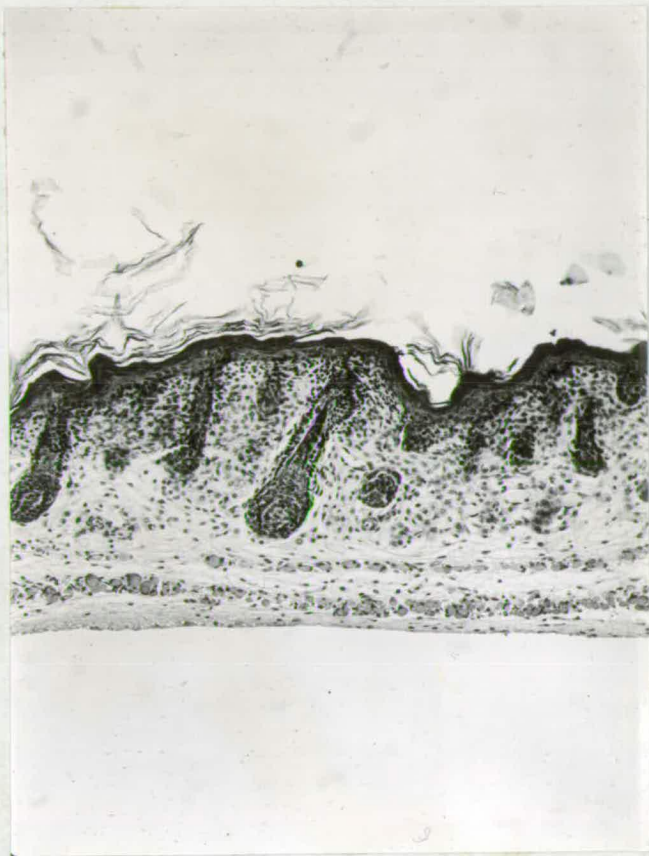

Fig. 13.

Normal skin at birth showing a guard hair follicle and several primordia. X115.

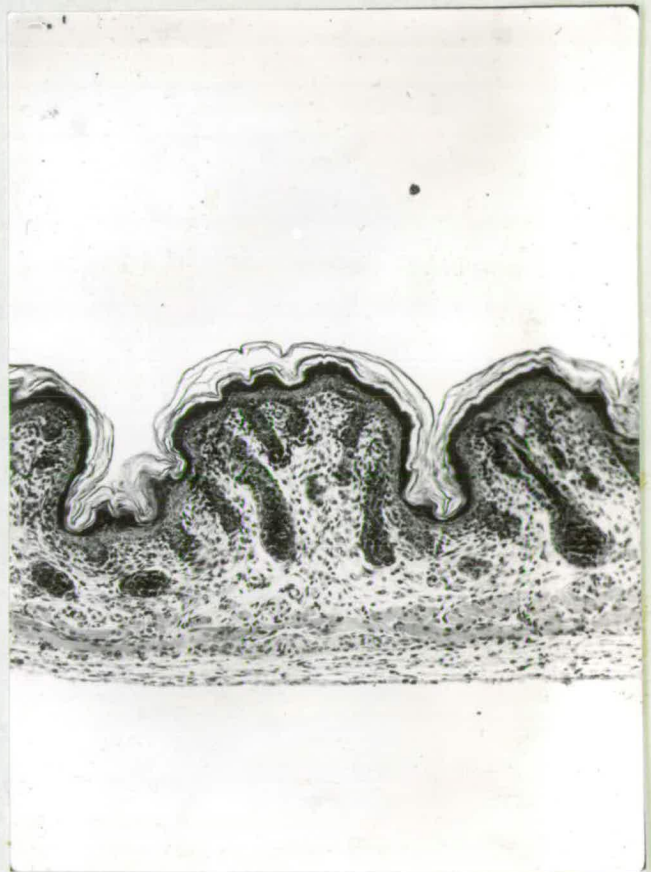

Fig. 14.

ShaSha skin at birth showing a guard hair follicle and several primordia. X115.

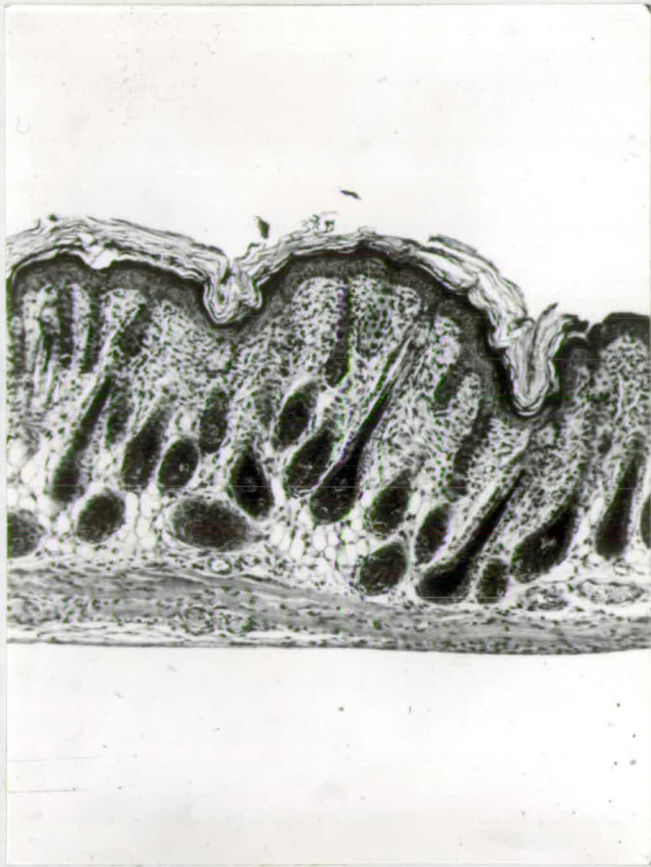


Fig.15. Normal skin at 3 days showing downgrowth of follicles into the dermis. X115.

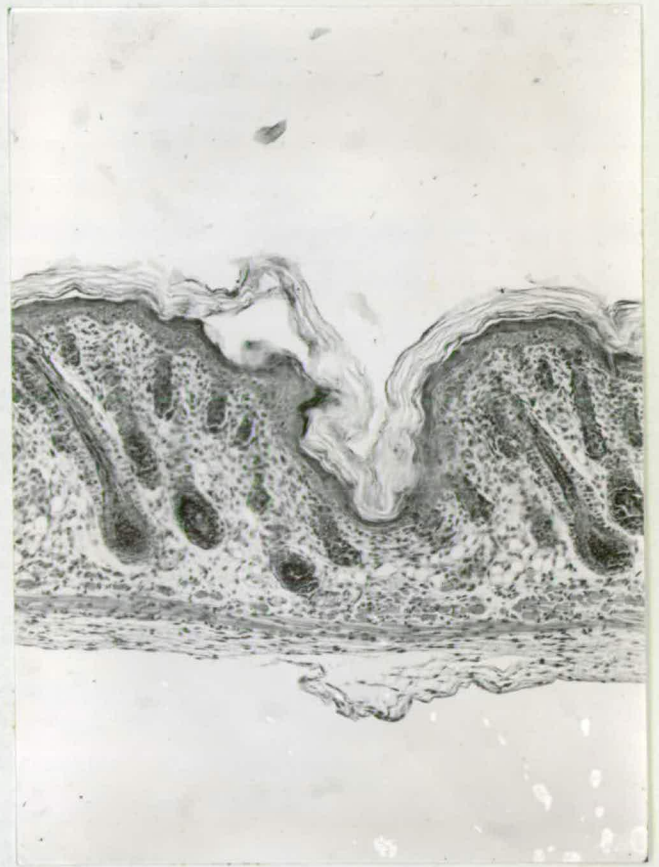


Fig. 16. ShaSha skin at 3 days of age showing downgrowth of follicles into the dermis. X115.

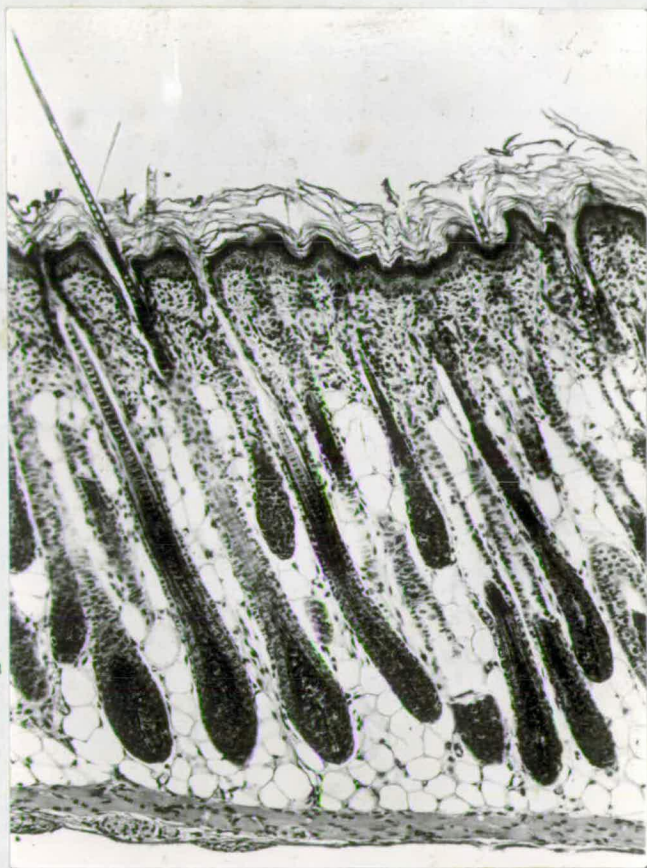


Fig. 17. Normal skin at 6 days showing follicles with fully keratinized hairs. X115.

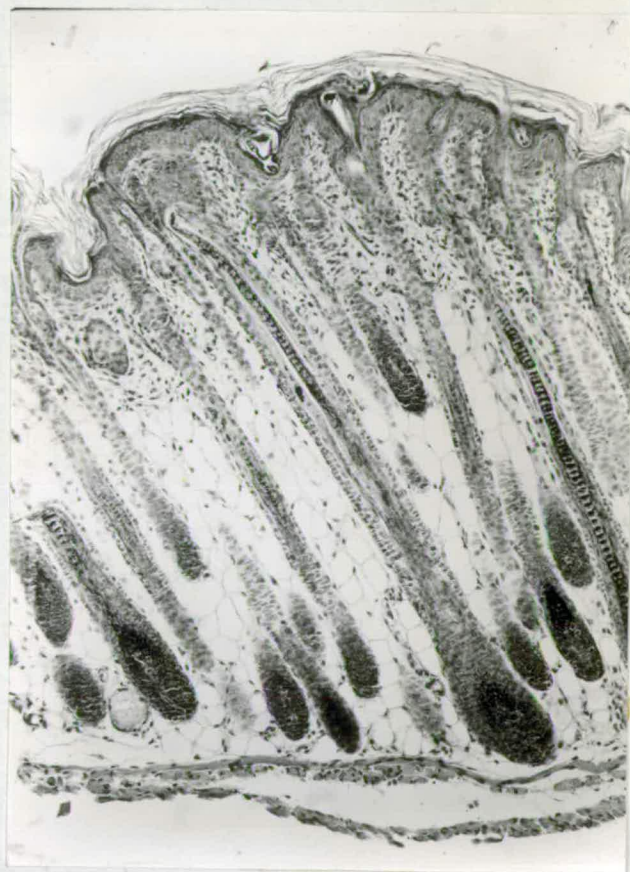


Fig. 18. ShaSha skin at 6 days showing follicles with poorly keratinized hairs. X115.

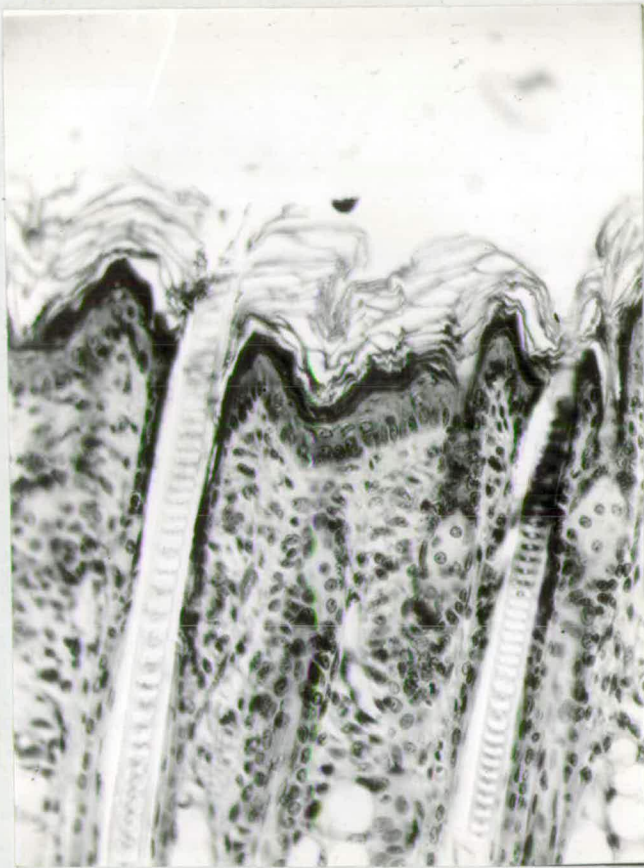


Fig. 19. Upper follicle region of normal skin showing hair eruption X210.

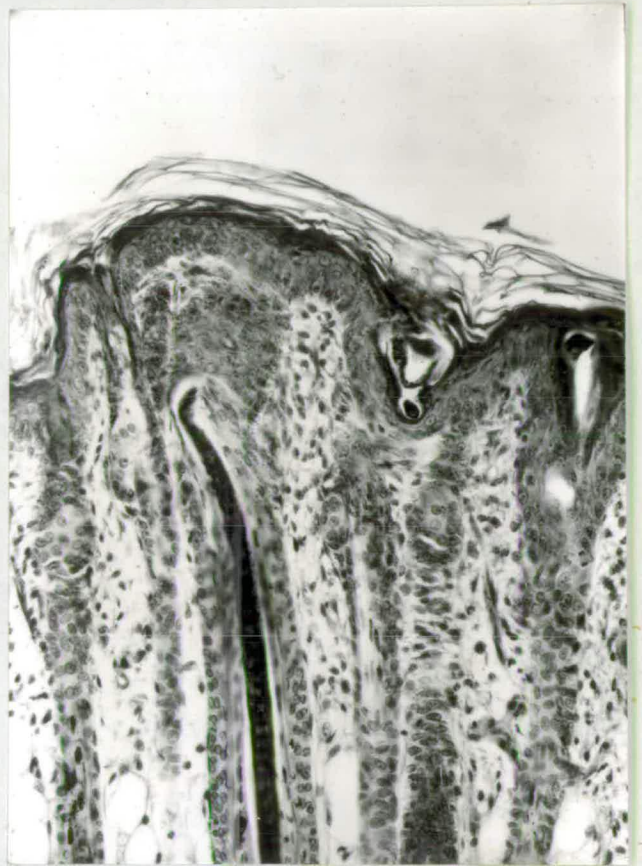

Fig. 20. Upper follicle region of ShaSha skin showing bending of hair. X210.

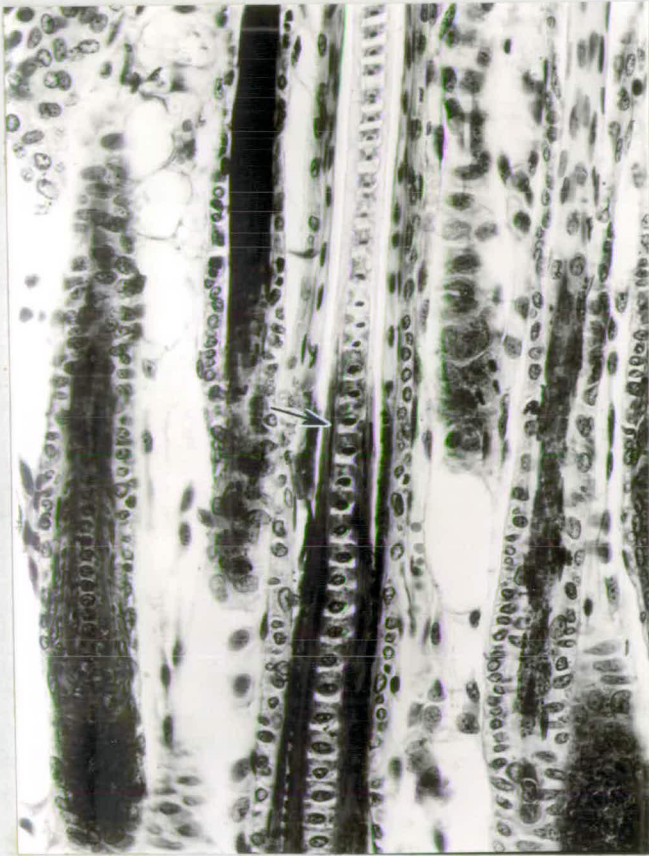


Fig. 21. Mid-follicle region of normal skin showing fully differentiated hair cortex and medulla. Note condensed rod-like nuclei of cortex (arrow). X325

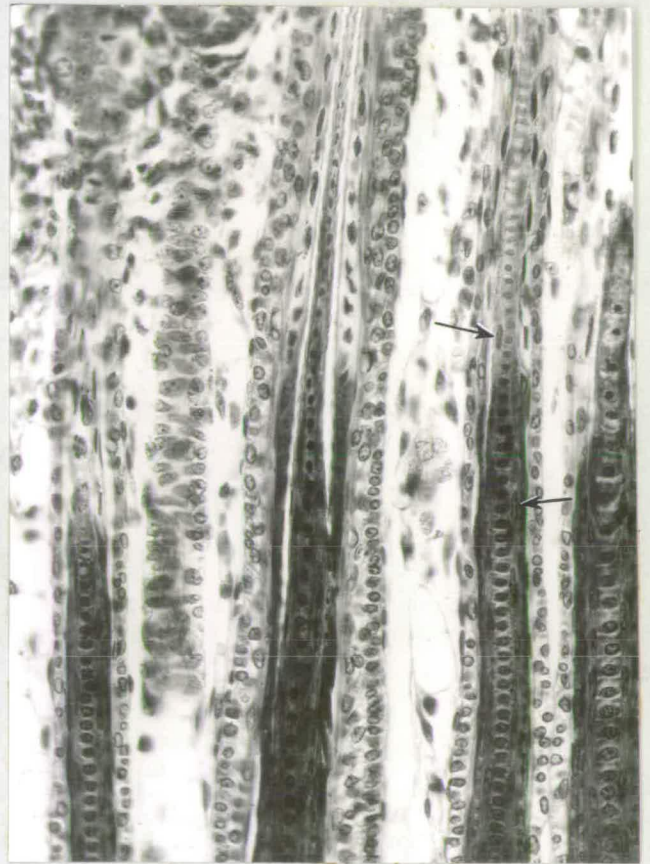

Fig. 22. Mid-follicle region of Shasha skin showing the hair cortex and medulla. Note uncondensed nuclei of cortex (arrow). X325.

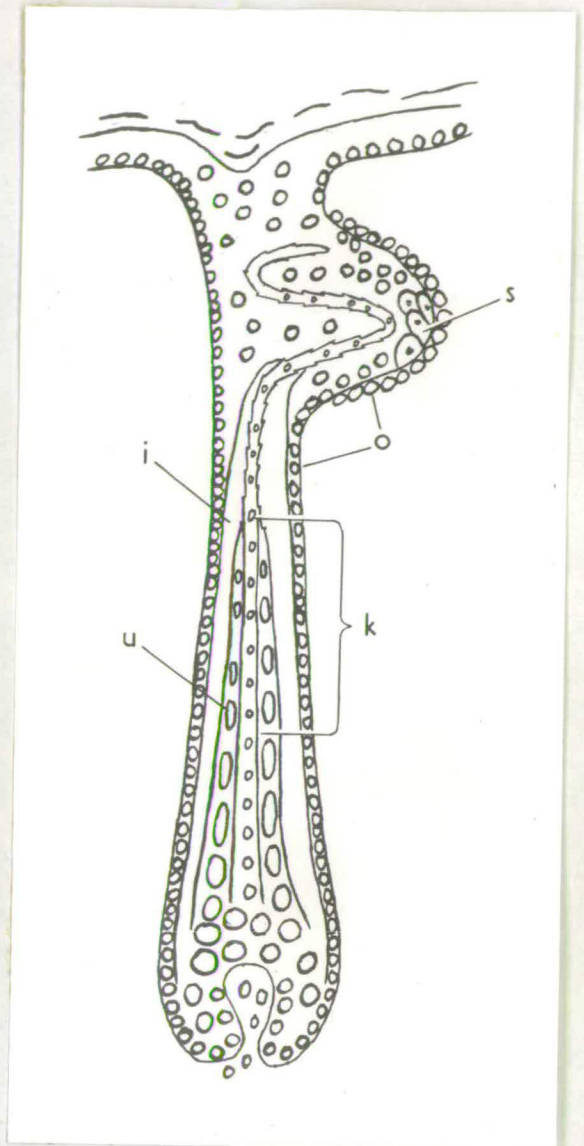
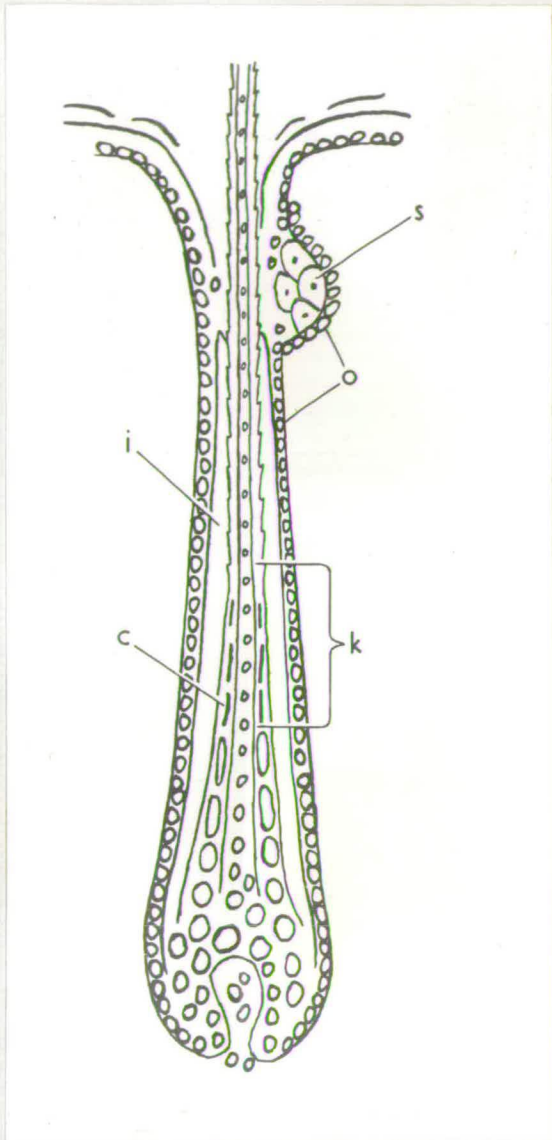


Fig. 23. Diagram of follicle of normal skin showing rod-like nuclei in the keratogenous zone of the cortex.

Fig. 24. Diagram of follicle of ShaSha skin showing abnormal differentiation of the hair cortex. In the keratogenous zone the nuclei of the cortex remain ovoid.

Abbreviations.

c = condensed rod-shaped nucleus  
 i = inner root sheath  
 k = keratogenous zone

o = outer root sheath  
 s = sebaceous gland.  
 u = uncondensed nucleus.

normal and ShaSha skin at birth and at 3 days of age.

Non-eruption of hair.

Morphological defects are unmistakably visible in ShaSha skin as soon as the hair penetrates the distal end of the inner root sheath. Instead of erupting, the hair tip bends at the sebaceous gland level. The abnormalities become more pronounced as follicle growth proceeds and they are rather similar to those of NN mice. Skin sections of normal and ShaSha mice at 6 days of age are compared in Figs. 17 and 18. Whereas the hairs have erupted in normal skin, the hairs of ShaSha skin become coiled at the epidermal-dermal junction, and they are string-like and degenerate. In normal skin, the hair shaft is basophilic in the mid-follicle region and picrophilic in the upper follicle region. This is not so in ShaSha skin; the hair shaft is basophilic in the mid-follicle region but is eosinophilic in the upper follicle with a poor affinity for picric acid.

All the layers of the skin, including the stratum corneum are normal in thickness. The sebaceous glands are fully differentiated. There is no deficiency of pigment in ShaSha follicles.

The upper follicle region. Examination of the upper follicle region under high power shows that the hair of ShaSha mice is of irregular diameter and consists of a cuticle, cortex and/

and medulla. The cuticle is picrophilic and appears normal. In contrast to the cuticle, the cortex is eosinophilic and consists of a narrow layer of hyaline. The medulla is mildly eosinophilic and is not clearly differentiated into septa and intercellular spaces. The spaces are small and compressed between the thickened septa. The medulla diameter varies according to the fibre diameter.

The different conditions found in the upper follicle region of normal and ShaSha skin are shown in Figs. 19 and 20. The weak hairs become entangled in the Malpighian layer and outer root sheath cells. These cells are stimulated to proliferate and aggregations of daughter cells may contain hair fragments.

The mid-follicle region. The lack of a rigid picrophilic cortex in the hair can be traced to a deficiency of cortical elements in the middle third of the follicle. This region corresponds to the keratogenous zone. In the keratogenous zone of the normal follicle, the cells of the hair cuticle, cortex and medulla are keratinized to form the hair. The keratogenous zones of normal and ShaSha follicles are shown in Figs. 21 and 22.

In the normal follicle, the cells of the cortex have attained a high degree of elongation in the keratogenous zone. At the lower end of the zone the cell nuclei are fusiform, and at the upper limit of the zone, they are highly condensed/

condensed elongated rods. The cells contain numerous refringent parallel fibrils in the cytoplasm and these fibrils are a prominent feature of the keratogenous zone. The nuclei and fibrils are basophilic. The keratogenous zone of a normal follicle is shown diagrammatically in Fig.23 . At the distal end of the zone the cortical cells become rigidly fused together, the nuclei and fibrils suddenly disappear, and the homogeneous refractile layer of the cortex is formed. Coinciding with the disappearance of nuclei and fibrils, there is a sharp change from the basophilic reaction to the picrophilic staining of the hair cortex. The cells of the cuticle also elongate and become keratinized to form the hair cuticle. The cells of the medulla are keratinized slowly, and even at the sebaceous gland level degenerating nuclei may be observed in the medulla. Thus, there are three hair keratins: cuticle, cortex and medulla. Another feature of the zone is the sudden keratinization of Huxleys layer of the inner sheath from eosinophilic into basophilic hyaline. Also, the trichohyaline granules disappear completely. Henles layer is keratinized, not in the keratogenous zone, but in the bulb region where the ovoid cells are transformed into a narrow sheet of hyaline.

In Shasha skin, the cortical cells of the keratogenous zone lack rod-like nuclei and fibrils(Fig.22). The cell nuclei are not sufficiently elongated and they are hydrated rather/

rather than being condensed. There is a marked deficiency of fibrils in the cytoplasm, which is granular instead of being longitudinally refringent. Because of the lack of fibrils, the cortex becomes very narrow at the distal end of the keratogenous zone and it is eosinophilic throughout the upper regions. The keratogenous zone of the upper regions. The keratogenous zone of a ShaSha follicle is shown diagrammatically in Fig.24 .

The cuticle of ShaSha hairs is normally keratinized in the keratogenous zone. The medullary cells, however, are not regularly differentiated into septa and intercellular spaces, the septa being thicker than usual and the spaces consequently smaller.

Both Henles and Huxleys layer are fully keratinized in ShaSha follicles. The former is uniformly hyaline and the latter contains normal amounts of trichohyaline in the lower regions.

The lower follicle region. No histological defects are apparent in the lower region of ShaSha follicles which may be responsible for the abnormal keratinization of the hair. The papilla is typically lanceolate and frequent mitoses are found in the bulb. The bulb contains all the concentric layers of undifferentiated cells that normally form the strata of the upper follicle. At the neck of the bulb, the nuclei of the cortical cells elongate and the cortical/

cortical tissue appears normal in consistency. But at the base of the keratogenous zone, the defects described above become apparent.

Different forms of keratin. It will be useful to enumerate the keratinized structures of the skin. In the epidermis there is the stratum corneum, and its precursor, keratohyaline. There are three hair keratins: cuticle, cortex and medulla. The eosinophilic Henles layer is considered to be a form of keratin. The basophilic hyaline of the upper region of Huxleys layer is a form of keratin, of which the trichohyaline, in the same layer is a precursor. In ShaSha mice, only the keratins of the hair cortex and medulla were found to be abnormal.

Hair growth after the first anagen phase. Concomitant with the accumulation of twisted hairs in the upper follicle regions during the first anagen phase, there is extensive hyperplasia of outer root sheath and Malpighian layer cells so that the dermis is compressed. Growth pressure from beneath causes the coiled hairs to force an exit through the epidermis. This results in malformation of the hair canal.

During catagen, the follicles of ShaSha mice shorten in a normal manner but the hair club is imperfectly keratinized. The telogen stages of 21-day old normal and ShaSha mice are shown in Figs. 25 and 26. The sebaceous glands are abnormally located either at the base of the hair canals or/

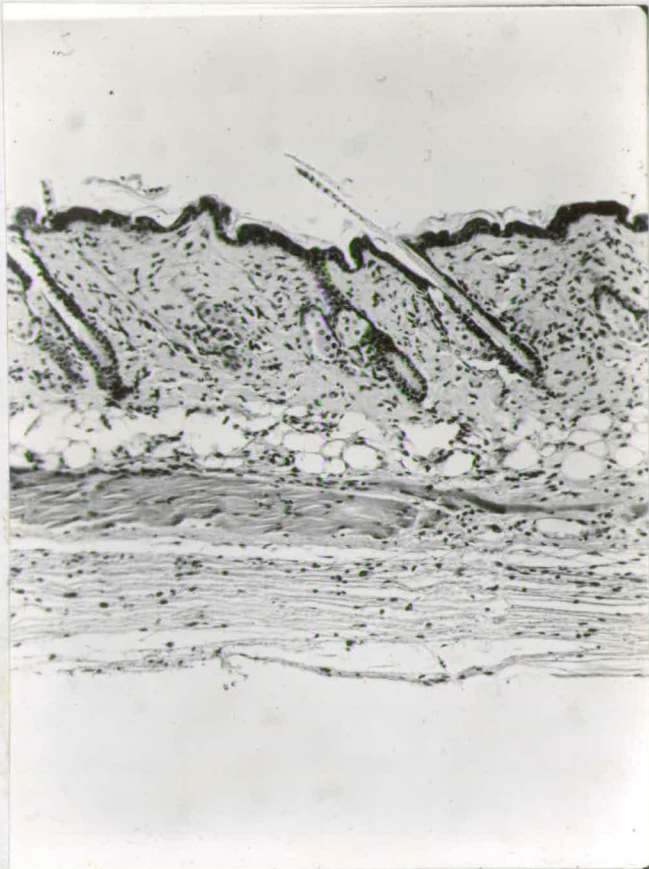


Fig. 25. Normal skin at 21 days of age. X115.

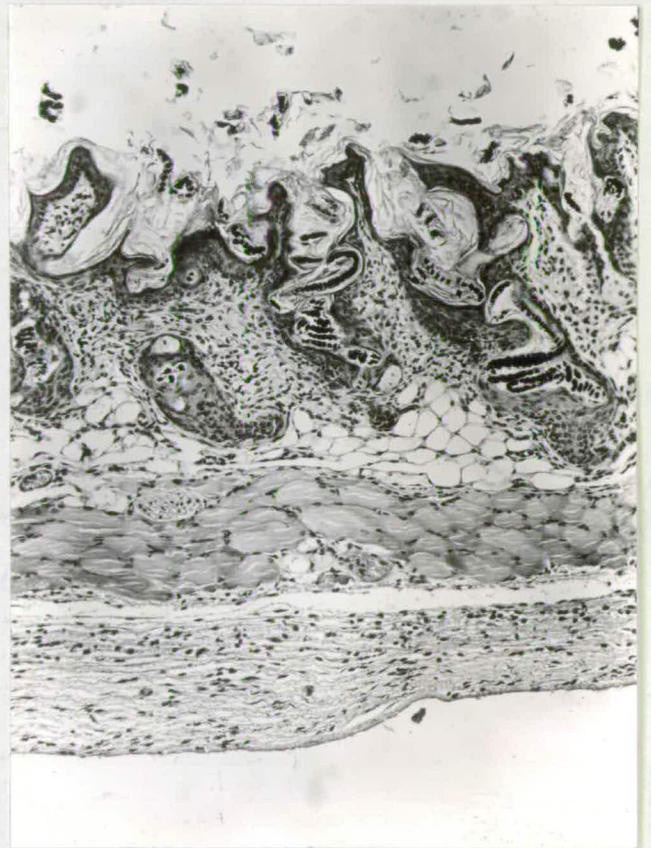


Fig. 26. ShaSha skin at 21 days of age showing distended hair canals with coiled hairs. X115.

or associated with hair fragments in the centre of the dermis. The distended hair canals containing coiled hairs are a striking feature of ShaSha skin during telogen.

With the growth of sparse hairs on 28 to 34-day old ShaSha mice, the hair masses in the hair canals are gradually eliminated. The removal of the obstructions enables the fragile hairs of the second anagen phase to erupt. The follicle morphology is similar to that of the first anagen and degenerate hairs lacking in cortex are produced. The ability of ShaSha adult mice to initiate follicles is maintained throughout life. The sebaceous glands do not become cystic.

(b) Heterozygous shaven mice.

Two conditions of coat greasiness have been reported previously. Rough rore mice have greasy hairs and the air space in the fibre medullae contain fluid (Falconer and Snell 1959). In the guinea pig, Herbertson, Skinner and Tatchell (1959) report that the gene "sticky" causes an extremely greasy coat with enhanced waviness. Rough and sticky animals never show baldness.

It has been shown that the hairlessness of ShaSha mice is due to abnormal keratinization of the hair cortex, and that the greasy coat of Sha+ mice is caused by a sudanophilic substance in the fibre medullae. The question which requires an answer is, how is it that in 2-week old mice, the shaven gene in single dose ensures the development of a coat which, except for the greasy hairs, is normally grown./

grown, while the Sha gene in double dose causes complete hairlessness? Normally, the fatty substances are excreted by the sebaceous glands, and the keratinization of the hair occurs in the keratogenous zone of the follicle. The recognition of a sudanophilic substance in the medullae of ShaSha hairs, however, indicated that the abnormal keratinization might be responsible for the deposition of an unknown sudanophilic material in the medullary spaces of these hairs. If this is true for ShaSha hairs, the sudanophilic substance of Sha+ hairs may be derived, not from the sebaceous glands, but from the medullary cells in the keratogenous zone of the follicle. The present investigation was carried out in order to determine whether the sebaceous glands are morphologically abnormal or whether accumulation of lipid material was present in the follicle strata.

#### Methods.

Skin samples were obtained from normal and Sha+ littermates at 14, 17 and 20 days of age. Bouin fixed, paraffin wax sections were stained with haematoxylin and eosin. To investigate lipid content, the skin samples were fixed in 10% formol saline and frozen sections were stained with Herxheimers solution (Sudan III and IV in equal parts of 70% alcohol and acetone). Sections were also stained with Sudan black.

#### Results./

## Results.

The results were negative. The histology of H and E stained Sha+ skin sections contained no detectable abnormalities at 14, 17 and 20 days of age. There was no difference between the size and shape of the sebaceous glands of Sha+ and normal mice. The differentiation of the hair medullae into cross-septa and intercellular spaces was complete.

There was no excess lipid material in Sha+ skin and the intercellular spaces of the fibre medullae were Sudan negative.

The moderately positive Sudan reaction of the sebaceous glands of Sha+ skin was normal when compared with normal skin.

### 4. SKIN HISTOCHEMISTRY.

#### Homozygous shaven mice.

In the last section, it was mentioned that the cellular elements of the hair cortex are derived ultimately from the bulb matrix. The cells of the bulb matrix and those at the neck of the bulb are bathed in a fluid plasma of nutrient substances, they are rich in nucleic acids and are the sites of extensive protein synthesis (Hardy 1952). Regarding the differentiation and growth of the cortical cells, the problems are to identify the more important substances that are the precursors of hair keratin and to determine the sites at which these substances are synthesised. One such substance has been recognised and consists of a complex of sulphhydryl groups (-SH) (Rothman 1954).

An/

An important feature of keratinization is the concentration and localisation of -SH groups in the hair cuticle and cortex of the keratogenous zone (Giroud and Bulliard, 1930; Eisen et al., 1953). During keratinization, the -SH groups of cysteine residues are oxidised to form disulphide bonds (-S-S-) of cystine; the keratinized hair contains no free -SH groups and is rich in cystine. The -SH group in the keratogenous zone react intensely with-SH reagent (Eisen et al. 1953). The reaction increases in intensity from the neck of the bulb to the keratogenous zone. At the distal end of the zone, the reaction ends suddenly and the fully keratinized hair is unreactive. The abrupt change in reaction indicates that all the -SH groups have been oxidised. The disulphide cross-linkages bind the polypeptide chains of the keratin molecule and are mainly responsible for the resistance of keratins to chemical disruption. (Rothman 1954).

The distribution of -SH groups in the skin follicles of hairless mice has not previously been reported. Jarrett and Spearman (1957) examined the brittle hairs of matted mice but failed to demonstrate free -SH groups in the aberrantly keratinized fibres. In the present study, the distribution of -SH groups in ShaSha follicles was compared with that of normal follicles. The purpose was to determine whether the ShaSha follicles were deficient in -SH groups, or whether a normal concentration of -SH groups was present but aberrantly distributed/



distributed over the follicle strata. The first alternative would indicate that the Sha gene when homozygous, causes the synthesis of inadequate amounts of keratin precursor, and the second hypothesis, if true, would suggest that ShaSha mice are capable of synthesising normal quantities of precursor but are unable to convert such precursor to hair keratin.

#### Methods.

The method of Bennett (1951), as modified by Mescon and Flesch (1952), was employed for the detection of -SH groups. Skin samples from 6-day old ShaSha and normal littermates were fixed in 10% neutral formaline and 6  $\mu$  paraffin sections obtained. After dewaxing and immersion in absolute alcohol, the sections were stained for 24 hours in 80% alcoholic solution of -SH reagent. The reagent used was a red compound with the chemical constitution 1-(4-chloromercuriphenylazo)-naphthol - 2.

#### Results.

ShaSha mice show a deficiency of -SH groups in the keratogenous zone of the hair follicle. The distribution of -SH groups is normal and ShaSha skin is shown in Figs. 27 and 28. It is seen that in the follicles of normal skin, the positive reaction begins above the neck of the bulb and increases in intensity at successively higher levels. It attains maximum intensity in the keratogenous zone. The intensity of the reaction decreases suddenly above the zone. A similar intense/

intense reaction of -SH groups is not found in the follicles of ShaSha skin; the keratogenous zone is only weakly reactive throughout its length. Sometimes the cortex above the keratogenous zone is weakly reactive, indicating the presence of free -SH groups in a part of the fibre from which they should be absent.

With the exception of the keratogenous zone the distribution of -SH groups in the skin of ShaSha mice is similar to that of normal skin. The stratum corneum is weakly reactive; the Malpighian layer, outer root sheath and Henle's layer are unstained; Huxley's layer is moderately reactive. The keratohyaline granules of the epidermis and the trichohyaline granules of Huxley's layer react negatively.

Under the high power, the fibrillar nature of the hair cortex in the keratogenous zone can be readily observed (Fig.29). The fibrils give the strongest reaction. The hair cuticle also stains intensely but, since this layer is thin, the details are not obvious. The reaction of the medulla is somewhat variable; in general it is weakly reactive, but occasionally it is strongly reactive, though never as intensely as the cortex or cuticle. The fibrillae are absent from the cortex of ShaSha follicles (Fig.30). The cortex is thinner than normal and contains only traces of -SH groups. The deficiency of -SH reactive fibrils is striking. The cuticle is intensely reactive and is similar to that of normal follicles in all respects. The medulla shows traces of -SH groups, as is/

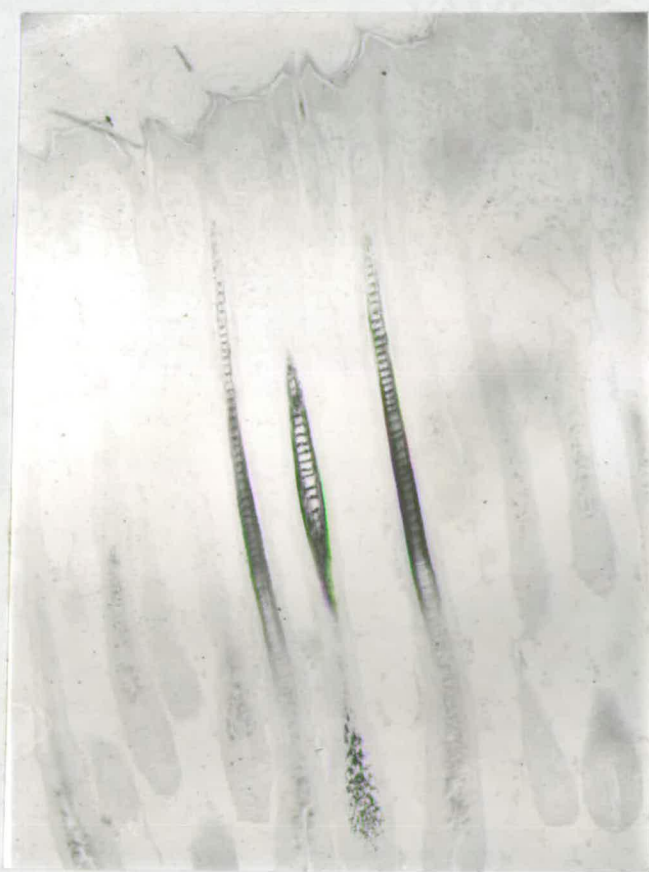

Fig. 27. Normal skin at 6 days  
The keratogenous zone of the  
follicle reacts intensely with  
-SH reagent. The reaction ends  
above the zone. X130

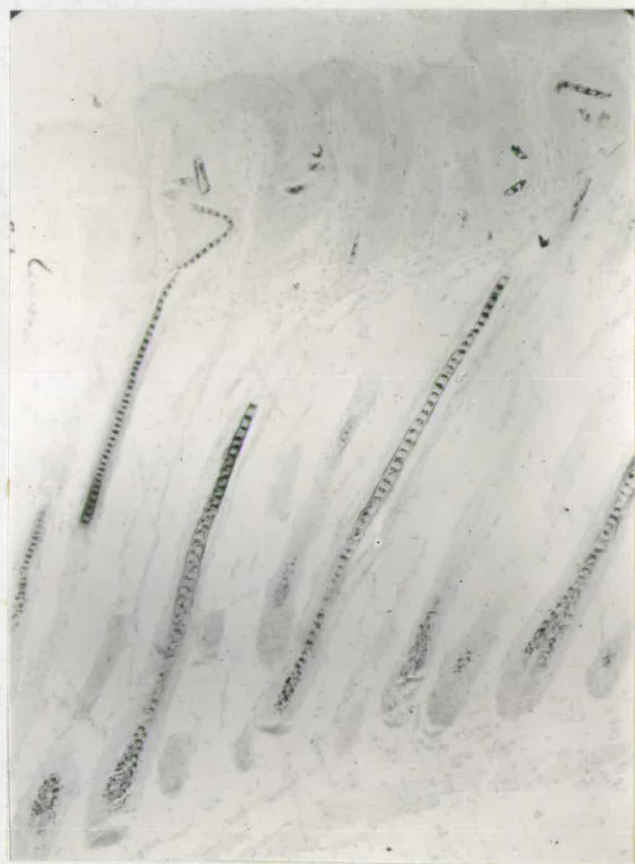

Fig. 28. ShaSha<sup>skin</sup> at 6 days  
showing weak -SH reaction  
of the keratogenous zone  
of the follicles. X130.

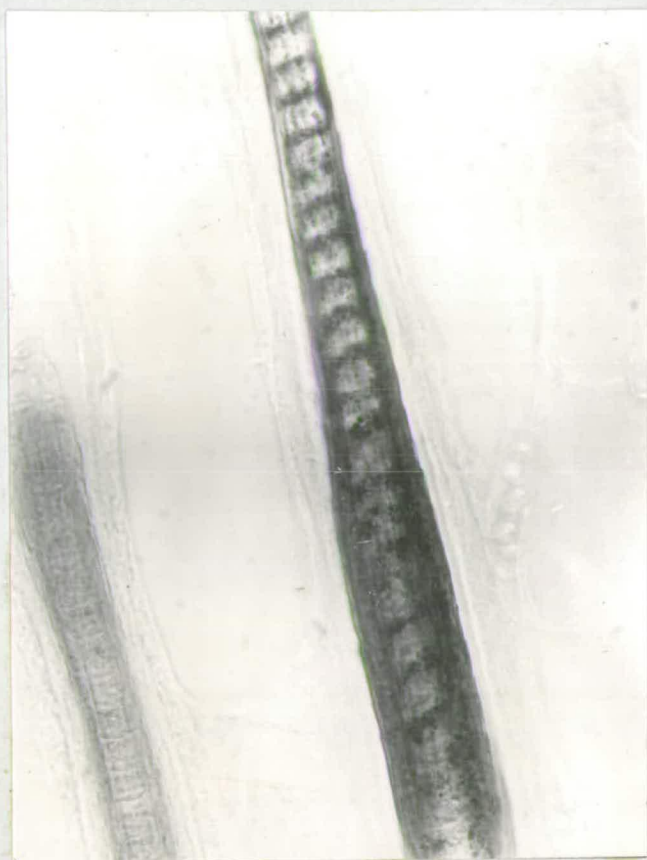


Fig. 29. Normal skin at 6 days showing intense -SH reaction of cuticle and cortex in the keratogenous zone. X600

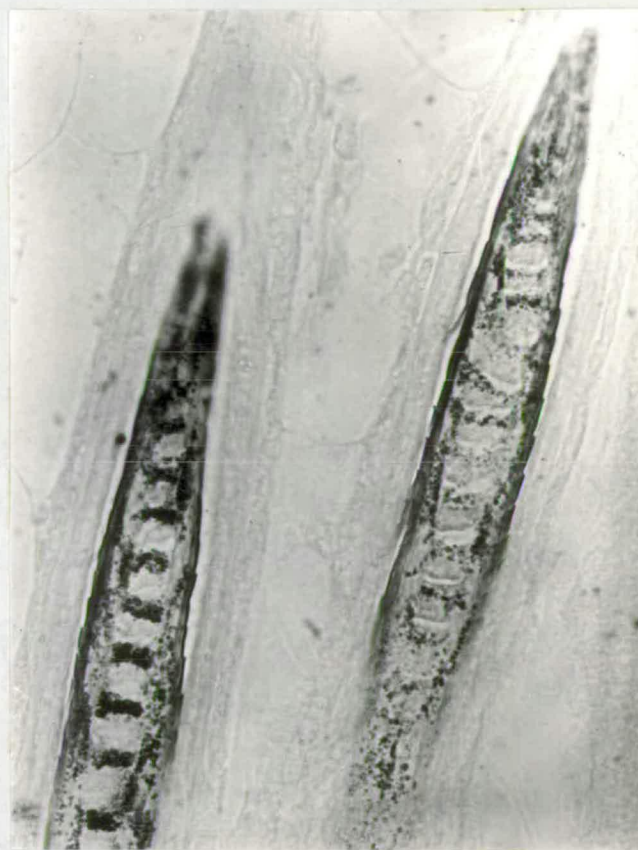


Fig. 30. ShaSha skin at 6 days showing weak -SH reaction of cortex and intense reaction of cuticle in the keratogenous zone. X600.

is normal.

## 5. DISCUSSION.

### (a). The genetics of shaven.

Homozygous shaven mice are phenotypically similar to homozygous naked mice and the two loci, Sha and N, are closely linked. This is the third example in the mouse of a phenomenon in which adjacent loci have similar phenotypic effects. The other cases are: (a) patch Ph and dominant spotting with macrocytic anaemia W, W<sup>V</sup>, in linkage groups III (Gruneberg and Truslove 1960); (b) the brachyury T, fused Fu, and anury t, series of mutations in linkage group IX (Dunn and Caspari 1942). The questions which arise are whether Sha and N are mutations in repeated loci, similar to the doublets in *Drosophila*, or whether they are different mutational sites within one gene, or whether the close proximity of Sha and N is merely a matter of chance.

To prove that the Sha and N mutations represent the replication of a chromosomal segment requires both cytological and genetical evidence. Cytological evidence of adjacent gene repetitions in *Drosophila* has been given by Bridges (1935), who demonstrated the double structure of certain bands of salivary gland chromosomes. The doublet structures were correlated with similarity of effect on the phenotype, and this led to the conclusion that the repeated loci were derived from one original locus. Similar cytological evidence is not available/

available from the mouse, and it is not possible to say whether or not Sha and N are derived from a single locus. The genetical evidence is partially consistent with the repeat hypothesis. The Sha and N genes are similar in function and the two loci are definitely separable by crossing-over. Mutations at repeated loci are expected to act in similar ways during development, and this expectation is realised in the case of ShaSha and NN mice. In both cases the hairlessness is due to abnormal keratinization of the hair shafts in the follicles during anagen. But there is also the problem of the dissimilar phenotypes of the heterozygous shaven and naked animals. Although ShaSha and NN mice are mimics, Sha+ and N+ mice are entirely different in appearance, and the greasy fully grown coat of Sha+ animals contrasts with the semi-hairlessness of N+ specimens. In the double heterozygote, Sha +/+ N, the Sha and N genes are not complementary. The greasy defect is obscured by the semi-hairlessness, and Sha +/+ N animals have a typical N+ phenotype. The question whether Sha and N are mutations at duplicated loci remains unanswered.

The second possibility, that Sha and N form a complex gene with different mutational sites, must be considered in the context of the traditional views regarding gene structure in the mouse. The fact that Sha and N are separable by crossing-over proves that they are non-allelic; 9 recombinants were obtained during gametogenesis of 1031 double heterozygotes/

heterozygotes in the two point tests (Table 7). Position effects are not found and Sha +/+ N mice are indistinguishable from Sha N/+ + mice. These observations indicate that Sha and N should be regarded as two distinct loci which are closely linked.

But is the occurrence of two mutations, which cause similar developmental defects and which show approximately 1% recombination, merely a coincidence? The increasing frequency of such cases as Sha and N, Pb and W<sup>V</sup>, etc., suggest that close linkage and similarity of effect are not a matter of chance alone. It is likely that further examples in the mouse will be discovered as more gene loci come to the attention of investigators. The old rules that gene loci are scattered throughout the chromosomes irrespective of developmental effects and that adjacent loci which are seldom separable by crossing-over need not have similar phenotypic effects, will probably remain true but explanations in terms of chromosomal organisation and gene structure are required whenever cases such as those mentioned are encountered.

(b). The skin histology and histochemistry of homozygous shaven mice.

The hypotrichosis of ShaSha mice is due to the inability of the follicle population to produce fully keratinized hairs, and not to a failure of follicle initiation. The abnormality is similar to that produced by the naked gene. It will be convenient to discuss the histology and histochemistry of ShaSha skin under separate headings.

Follicle initiation./

Follicle initiation. ShaSha mice are capable of initiating follicle primordia in the skin in a normal manner. There is no difference between ShaSha and normal mice in the number of follicle primordia and number of guard hair follicles per microscopic field at birth, at 3 days, and at 6 days of age. This shows that the germinative property of the Malpighian layer is not diminished by the Sha gene. In this respect, ShaSha mice differ from RaRa, Ra+ and crcr animals.

Follicle differentiation. There is no obvious histological abnormality in the follicles until the young hair passes the distal end of the inner root sheath. The hair bends at the epidermal-dermal junction, and this explains the non-eruption of the coat at 5 to 6 days of age. The pertinent question is whether the bending of the hair is due to an abnormal epidermis or to a defect of the hair. Examination of the epidermis shows that it is normally differentiated and the stratum corneum is normal in thickness. Observations indicate that the resistance of the epidermis to the erupting hair is unaltered in ShaSha skin. On the other hand, the weakness of the hair is suggested by its thin eosinophilic cortex. The absence of a rigid microphilic cortex is a manifestation of a keratinization defect in the lower follicle regions.

The hyperplasia of Malpighian layer and outer root sheath cells in the sebaceous gland regions exemplifies the pluripotentially of these cells. Since the hair canal is normally/

normally straight, any hair which does not conform to its shape presumably acts as a stimulating agent on the surrounding tissues. The proliferation of the epidermal cells appears to be a response to such a stimulus.

The keratinization process.

The hairlessness of Shasha mice can be traced to an aberrant cortex in the keratogenous zone of the follicle. The cell nuclei are not elongated and they remain uncondensed. The cells are deficient in fibrils. The hydrated nuclei and granular cytoplasm give the impression that the follicles of Shasha mice are unable to orientate the fibrils in a longitudinal direction. In contrast to the cortex, the cuticle is a rigid picrophilic layer, and its keratinization is not affected by the Sha gene. The medulla is not grossly abnormal in the keratogenous zone and the only defects are smaller intercellular spaces and rather thickened septa. These defects are more extreme at the epidermal level. Consequently, in the keratogenous zone the keratinization defect is confined chiefly to the cortex.

Scrutiny of the bulb and supra-bulbar region of the follicle does not reveal any mechanism which might explain the abnormally shaped nuclei and deficiency of fibrils in the keratogenous zone. All the concentric layers of cells which are destined to form the hair, are clearly defined in the bulb, and the frequency of mitotic figures is not subnormal.

The/

The fact that the Sha gene, when homozygous, causes abnormal keratinization of the cortex and medulla, and does not appear to affect the keratinization of other epidermal or follicle layers, suggests that the type of keratin which is produced by each cell layer is genetically predetermined. There are about seven keratins which differ in chemical composition: the stratum corneum, Henle's layer, Huxley's layer, the hair cuticle, cortex, medulla, and the keratin of the nails. The cuticle keratin differs from cortical keratin (Geiger 1944), and the medulla contains only small amounts of keratin (Stoves 1946). The various forms of keratin illustrate the different biological capacities of the cell layers. In ShaSha skin, it is chiefly that cell layer which forms the hair cortex that deviates from the normal sequence of developmental events.

Genetic specificity of the type of keratin synthesis in a given cell layer is indicated also by other genes causing hairlessness. In N+ mice, David (1932) found that the hair cuticle was deficient in the lower follicle region but the other follicle strata were normal. The defect is more extreme in NN animals; not only is the hair cuticle absent, but the cortical and medullary elements are reduced and Huxley's layer is unkeratinized. In hrhr mice, keratinization of the hair club at the end of anagen, is abnormal (David 1932), Jarrett and Spearman (1957), however, failed to note any histological defect/

defect which might account for the brittleness of the hairs in matted mama mice.

It is seen, then, that the development of the hair cortex in the follicles of ShaSha skin, proceeds normally up to a certain stage. Then, in the keratogenous zone and without any reason detectable histologically, the differentiation of the cortex fails to reach completion. After pinpointing the histological basis for the incomplete keratinization, other methods of investigation must be employed if any further progress towards a solution is to be made.

Other methods of analysing the keratinization defect of ShaSha mice. Electron microscopic studies have yielded valuable data concerning the structure of wool keratin. It has been shown that the cortical cells of wool keratin are connected together by interlocking and protruding fibrils (Alexander and Hudson, 1954). It would be interesting to examine the cortical cells of ShaSha follicles and to compare the fine structural details with those of normal cortical cells. Such studies might also reveal whether ShaSha follicles are completely lacking in fibrils or whether fibrils are present but are not properly orientated. The information obtained, however, would be essentially morphological.

In seeking an underlying physiological explanation for the keratinization defect of ShaSha mice, two methods of investigation may render useful information. The first procedure concerns the distribution of sulphhydryl groups in ShaSha /

61.

ShaSha follicles. Details of such an investigation have already been given and will be discussed later. The second likely method for studying the relevant metabolism of ShaSha follicles involves the use of radioactive isotopes. Hair keratin is rich in sulphur and the sulphur metabolism of hair follicles has received much attention from various workers. Bern et al. (1955) and Ryder (1958) injected mice with cystine, labelled with sulphur-35, and noted the sulphur concentration in different regions of the follicles. Comparisons between ShaSha and normal follicles with respect to the development of peaks of activity along the follicle axis would indicate any abnormal sulphur metabolism which might be present in ShaSha follicles. Autoradiographic techniques were not used in these investigations but the sulphur metabolism of ShaSha follicles was examined by observing the concentration of sulphhydryl groups in the keratogenous zone, and comparing the abnormal follicles with normals.

The distribution of sulphhydryl groups in the follicles of ShaSha skin. A high concentration of sulphhydryl groups was found in the keratogenous zone of normal follicles and this observation agrees with the findings of previous authors. The strongest reaction was found in the fibrils of the cortex. The -SH reactive fibrils are "hardened" by the formation of -S-S- bonds, and the fully keratinized hair cortex is devoid of free -SH groups. In ShaSha follicles the cortex is deficient in -SH reactive fibrils. Yet the cuticle is intensely reactive/

reactive. It appears that the cortical cells of ShaSha follicles are unable to synthesise normal amounts of cysteine residues which are necessary for oxidation to cystine, and that the cuticular cells retain this capacity. The failure to synthesise -SH reactive fibrils partially explains, in physiological terms, the inability of ShaSha follicles to produce fully keratinized hair. It appears that the Sha gene in the absence of its normal allele, interferes with the synthesis of keratin precursor in the cortex of the follicles and that the keratin precursors in the other layers are normally synthesised.

(c). The skin histology of heterozygous shaven mice.

With the techniques used, no histological defects were detected in Sha+ skin which might be associated with the greasy condition of the coat. The abnormal accumulation of sudanophilic material in the medullae of Sha+ fibres is difficult to reconcile with the normal distribution of lipids in Sha+ skin. Nevertheless, a tentative explanation may be offered as follows:

In the normal follicle the sebaceous gland ducts open into the hair canal at a higher level than that at which the fibre is fully keratinized. Consequently, the fatty secretions of the glands are applied only to the outer surface of the hair. Any substance present in the medulla must ultimately be derived from the plasma of the follicle bulb or by penetration of the gland/

gland secretions through the fully keratinized hair cuticle and cortex. The latter possibility is very unlikely because the cuticle and cortex are rigid structures and may be considered impenetrable by large fatty molecules. Also, no sebaceous gland excretions were found adhering to the external surfaces of Sha<sup>+</sup> hairs. The other alternative, i.e., that the sudanophilic substance of Sha<sup>+</sup> fibre medullae is derived from the lower follicle regions, is more likely, but its plausibility was not sustained by the Sudan negative reaction of the hair medullae in histological sections. It is possible, however, that the Sudan reaction was not as efficient in penetrating the interior of densely packed follicles of frozen sections as in penetrating the medullary spaces of plucked hairs.

In the light of the observations on ShaSha and Sha<sup>+</sup> skin the presence of the Sha gene in double dose may be considered to cause a specific physiological process, i.e., synthesis of inadequate amounts of cysteine residues in the hair cortex, to exceed a certain threshold, so that almost complete hairlessness results. In the heterozygote, one normal allele appears to be sufficient to produce normal amounts of the keratin precursor, but it is possible that the Sha allele has an undetectable residual effect on the keratinization of the medulla, causing the deposition of sudanophilic material in the air spaces and so accounting for the greasiness of the coat. This possibility remains to be proved.

Another/

ShaSha follicles. Details of such an investigation have already been given and will be discussed later. The second likely method for studying the relevant metabolism of ShaSha follicles involves the use of radioactive isotopes. Hair keratin is rich in sulphur and the sulphur metabolism of hair follicles has received much attention from various workers. Bern et al. (1955) and Ryder (1958) injected mice with cystine, labelled with sulphur-35, and noted the sulphur concentration in different regions of the follicles. Comparisons between ShaSha and normal follicles with respect to the development of peaks of activity along the follicle axis would indicate any abnormal sulphur metabolism which might be present in ShaSha follicles. Autoradiographic techniques were not used in these investigations but the sulphur metabolism of ShaSha follicles was examined by observing the concentration of sulphydryl groups in the keratogenous zone, and comparing the abnormal follicles with normals.

The distribution of sulphydryl groups in the follicles of ShaSha skin. A high concentration of sulphydryl groups was found in the keratogenous zone of normal follicles and this observation agrees with the findings of previous authors. The strongest reaction was found in the fibrils of the cortex. The -SH reactive fibrils are "hardened" by the formation of -S-S- bonds, and the fully keratinized hair cortex is devoid of free -SH groups. In ShaSha follicles the cortex is deficient in -SH reactive fibrils. Yet the cuticle is intensely reactive/

reactive. It appears that the cortical cells of ShaSha follicles are unable to synthesise normal amounts of cysteine residues which are necessary for oxidation to cystine, and that the cuticular cells retain this capacity. The failure to synthesise -SH reactive fibrils partially explains, in physiological terms, the inability of ShaSha follicles to produce fully keratinized hair. It appears that the Sha gene in the absence of its normal allele, interferes with the synthesis of keratin precursor in the cortex of the follicles and that the keratin precursors in the other layers are normally synthesised.

(c). The skin histology of heterozygous shaven mice.

With the techniques used, no histological defects were detected in Sha+ skin which might be associated with the greasy condition of the coat. The abnormal accumulation of sudanophilic material in the medullae of Sha+ fibres is difficult to reconcile with the normal distribution of lipids in Sha+ skin. Nevertheless, a tentative explanation may be offered as follows:

In the normal follicle the sebaceous gland ducts open into the hair canal at a higher level than that at which the fibre is fully keratinized. Consequently, the fatty secretions of the glands are applied only to the outer surface of the hair. Any substance present in the medulla must ultimately be derived from the plasma of the follicle bulb or by penetration of the gland/

gland secretions through the fully keratinized hair cuticle and cortex. The latter possibility is very unlikely because the cuticle and cortex are rigid structures and may be considered impenetrable by large fatty molecules. Also, no sebaceous gland excretions were found adhering to the external surfaces of Sha<sup>+</sup> hairs. The other alternative, i.e., that the sudanophilic substance of Sha<sup>+</sup> fibre medullae is derived from the lower follicle regions, is more likely, but its plausibility was not sustained by the Sudan negative reaction of the hair medullae in histological sections. It is possible, however, that the Sudan reaction was not as efficient in penetrating the interior of densely packed follicles of frozen sections as in penetrating the medullary spaces of plucked hairs.

In the light of the observations on ShaSha and Sha<sup>+</sup> skin the presence of the sha gene in double dose may be considered to cause a specific physiological process, i.e., synthesis of inadequate amounts of cysteine residues in the hair cortex, to exceed a certain threshold, so that almost complete hairlessness results. In the heterozygote, one normal allele appears to be sufficient to produce normal amounts of the keratin precursor, but it is possible that the Sha allele has an undetectable residual effect on the keratinization of the medulla, causing the deposition of sudanophilic material in the air spaces and so accounting for the greasiness of the coat. This possibility remains to be proved.

Another/

Another causal relationship between the hairlessness of ShaSha mice and the greasy coat of Sha+ mice would need to be proved if it was established that the sebaceous glands were responsible for the greasiness of Sha+ hairs. In such a case, an investigation of the epidermal cells during follicle initiation and differentiation would be required, since the glands and hair shaft are essentially epidermal in origin.

#### 6. SUMMARY OF SHAVEN.

- (1). The gene shaven Sha is a new gene causing hairlessness in the mouse, and it differs phenotypically from all previous hairless genes. It is semi-dominant. ShaSha mice never grow a first coat, and Sha+ mice have a fully grown coat which is greasy.
- (2). ShaSha mice can be classified at birth by the paucity and waviness of the vibrissae, and at 5 days by the absence of the first coat. Sha+ mice are not classifiable until about 14 days of age when the greasy coat becomes noticeable.
- (3). Sha is closely linked to N in linkage group VI. The percentage recombination estimated from two point tests was 0.8%.
- (4). Five-week old ShaSha animals grow a few short malformed hairs which are not classifiable into the standard types.
- (5). The body growth rate of ShaSha mice is subnormal.
- (6). The failure of ShaSha mice to grow a coat is due to abnormal keratinization of the hair. The skin histology is rather similar to that of NN mice.
- (7). There is a deficiency of sulphhydryl groups in the follicles of ShaSha skin.
- (8). The greasiness of the Sha+ coat is due to the presence of a sudanophilic substance in the fibre medullae. A similar substance/

substance was found in the fibre medullae of ShaSha and N+ mice. The possibility that the sudanophilic material may be a by-product of abnormal keratinization is discussed.

(9). The keratinization defect of ShaSha skin is discussed in histological and histochemical terms.



Fig. 31. Normal and nude adult mice. Both are agouti black animals. The nude animal is completely hairless and the skin on the posterior dorsum is losing its pigmentation.

CHAPTER III. STUDIES OF NUDE.

The gene nu also causes hairlessness in mice but differs phenotypically from the hairless genes previously discovered. In addition to the hairlessness, the nu gene causes a number of other abnormalities including reduced growth rate, infertility, high mortality of young mice, and 100% mortality of the adults as a result of a liver defect. This chapter is divided into five sections which deal with the various topics in the following order: the genetics of the nu gene, the gross morphological abnormalities of nunu mice, the skin histology, the liver defect, a discussion of the skin and liver histology, an analysis of the pleiotropy, and finally, a summary. Normal and nunu mice are shown in Fig. 31 .

I. GENETICS.Stocks.

The mice obtained from Glasgow consisted of one hairless male and one phenotypically normal male thought to be heterozygous for the nu gene, together with one phenotypically normal female also thought to be heterozygous for the nu gene. The hairless male died without producing offspring. The remaining pair were mated and produced 2 litters of 23 mice but no hairless specimens were obtained. The progeny were intercrossed at random and one mating produced hairless animals. Thus, two heterozygous parents were identified, and they produced 8 litters.

None of the hairless specimens survived but the normal offspring,  $\frac{2}{3}$  of which were expected to be heterozygous for the nu

nu gene formed the basis of the nu stock.

Segregation data.

It was assumed that nu is a recessive gene, and this assumption was confirmed by the segregation data presented in Table 10. Nude mice can be classified with accuracy at

Table 10. Segregation of nude

Type of Mating	No. of matings	Progeny +	nu	Total	$\chi^2$	P
<u>+nu</u> x <u>+nu</u>	122	3890	1349	5239	1.59	0.20
<u>nunu</u> x <u>+nu</u>	4	16	14	30	0.13	0.70

birth by the absence of vibrissae. This fact has provided more accurate records of segregating litters than would otherwise be possible, since many nunu mice die within a few days of birth and are eaten by the parents. Nude animals are rarely fertile and all adults die, usually between 5 and 14 weeks. Because of infertility, the segregation data is derived mainly from intercross +nu x +nu matings. The data <sup>are</sup> ~~is~~ biased towards an excess of nunu animals as no mating is included unless it has produced at least one nunu offspring. Matings between heterozygotes which, by the chances of sampling, produced no abnormal young have not been considered. The observed segregation of nu does not differ significantly from expectation. Four matings, in which one of the parents was homozygous nude and the other heterozygous nude, produced offspring. The segregation of nu was in good agreement with the expected 1:1 ratio. Nude was thus proved to be a recessive gene.

Linkage tests.

Nude was tested for linkage with all the marker genes contained in the stocks described previously in connection with shaven. It was realised that the practical value of nu as a marker would be almost negligible on account of the infertility of nunu mice and of the lethality of the gene in the adults. Nevertheless, it was considered interesting to identify its linkage group and to establish its relationship, if any, with the other genes causing hairlessness.

The stocks used were as follows:

<u>Stock No.</u>	<u>Markers present</u>				
I	Va	Sd	Ra		
II	Wh	T	N		
III	P	se	fz	v	
IV	S	wa-2	ln	b	a
V	ru	je	f	c <sup>e</sup>	
VI	Re	WV			
VII	OS	So	Sl		

The methods for testing nu for linkage with the marker genes were essentially different from those testing shaven. Nude is recessive and in addition, the animal, used for outcrossing to the marker stock must be a heterozygote +nu, since homozygotes nunu are rarely fertile. Consequently, only half the  $F_1$  mice will carry the nu gene, and these can be identified only after testing them against known +nu animals. The procedure was as follows:

In all cases, a known +nu animal was outcrossed to any animal from each stock. The next step depended on whether the marker gene, against which nu was being tested, was dominant or recessive/

recessive. When nu was being tested against dominant markers, i.e., those of stocks I, II, VI and VII, the  $F_1$  multiple heterozygotes were mated to known +nu mice and one mating in two was expected to produce nunu offspring. In this way, multiple heterozygotes which carried the nu gene were identified. Continued mating of such animals to known +nu mice yielded the pertinent linkage data. These linkage tests were mixed crosses, being backcrosses for the dominant markers and intercrosses for nu. For example, let A be a dominant marker, then the test was  $A +/+ \text{ nu} \times + +/+ \text{ nu}$ . The deviation of nu from independent segregation with each dominant marker was then estimated.

When nu was being tested against recessive marker genes of stocks III, IV and V, there was a choice of two procedures. The mice might have been tested against known +nu mice to see if they carried nu. Those  $F_1$  animals which were proved to carry nu might then have been intercrossed to produce the  $F_2$  generation, from which the relevant linkage data would be obtainable. The second system might consist merely of intercrossing all  $F_1$  mice at random, and one in four matings would be expected to produce nunu offspring in the  $F_2$ . The second procedure was adopted since it is more straightforward. It is seen that the linkage tests between nu and recessive markers were intercrosses, e.g., if y is a recessive marker, the test was  $y +/+ \text{ nu} \times y +/+ \text{ nu}$ .

The results of the linkage tests are summarized in Table II.

The/

Table II. Results of linkage tests with nude

Gene tested	Linkage group	Phenotype of progeny				Total	Independence		Recombination	
		x +	+ nu	+ +	x nu		$\chi^2$	P	%	S.E.
Va	XVI	29	6	23	6	64	0.19	0.70	45	10.8
Sd	V	24	10	33	9	76	0.16	0.70	54	9.9
Ra	V	79	67	94	-	240	1.25	0.25	63	11.2
Wh	XI	54	19	59	14	146	0.23	0.70	47	7.1
T	IX	48	19	59	12	138	0.24	0.70	46	7.4
N	VI	79	32	69	-	180	0.75	0.30	39	12.8
p	I	34	37	107	11	189	0.03	0.90	49	5.5
se	II	24	14	84	6	128	0.48	0.50	55	6.6
fz	XIII	55	60	128	-	243	2.50	0.10	35	9.0
v	X	30	18	79	3	130	1.23	0.25	43	6.6
s	III	11	23	67	4	105	0.00	0.98	50	7.3
wa-2	VII	22	30	58	-	110	0.25	0.70	43	14.3
ln	XIII	19	30	56	-	105	0.00	0.98	49	14.6
b	VIII	11	10	33	2	56	0.28	0.60	45	10.0
a	V	18	22	40	-	80	1.10	0.30	33	16.7
ru	XII	37	35	125	17	214	2.00	0.20	57	5.1
je	XII	24	15	57	5	101	0.25	0.60	46	7.5
f	XIV	40	41	111	13	205	0.12	0.75	48	6.2
ce	I	23	28	77	2	130	2.88	0.10	39	6.6
Re	VII	94	56	60	-	210	7.36	<0.01	18	11.9
WV	III	71	37	103	26	237	0.00	0.98	50	5.6
Os	XVIII	36	20	67	13	136	0.25	0.60	54	7.4
So	XVIII	48	34	39	-	121	0.90	0.30	35	15.7
Sl	XIX	32	22	56	8	118	0.90	0.30	42	8.0

The mixed crosses are in coupling, that is, both dominant genes entered the tests from the same parent. The intercrosses are in repulsion. The marker genes, Ra, N, fz, wa-2, ln, a, Re, So, are indistinguishable from their normal alleles in nude mice. Consequently, only three phenotypes are recognisable in the offspring of tests between nu and these markers. This lessens considerably the amount of information per individual in the tests. The deviation from independent segregation of nu with all markers and the percentage recombination together with its standard error were estimated by the method of Carter and Falconer (1951) which is based on the methods of Mather (1935), Finney (1943) and Fisher (1946). Scoring coefficients and amount of information per individual were fitted to the data. The recombination fraction of nu with each marker was obtained by dividing the total score by the total amount of information, and adding the fraction so obtained to  $\frac{1}{2}$ .

The number of offspring obtained from the tests ranged from about 60 to 240. Analyses of the data showed that Re was not segregating independently of nu. It is seen from the table that the deviation from independent segregation was significant at the 1% level, and the recombination value of 18% differed from 50% by more than twice the standard error.

The/

The number of matings in the test was then increased in order to obtain further evidence of linkage between Re and nu. The complete results are given in Table 12. The data show that nu is linked with Re in linkage group VII.

Table 12. Results of linkage tests between nu and Re

---

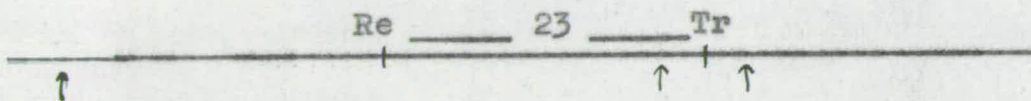
Parents	<u>Re</u> +/+ <u>nu</u> x +/+ + <u>nu</u>
Progeny	<u>Re</u> + + <u>nu</u> + + <u>Re nu</u>
No. observed	623      383      407      -
Total	1413
Recombination	19.4% ± 4.6%
$\chi^2$	44.0 $P < 0.001$

---

The percentage recombination was  $19.4 \pm 4.6$ . The closest admissible linkage at the 5% probability level was 10.2 but, also, the linkage might be as loose as 28.6.

Localization tests were then initiated in order to determine the linear order of Re and nu with respect to a third marker in this linkage group. The third marker chosen was Tr. The location of/

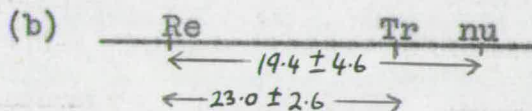
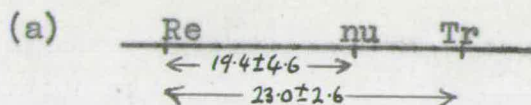
of Re and Tr in linkage group VII is shown below:



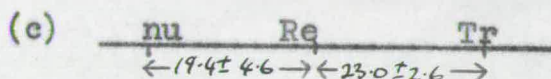
The percentage recombination between Re and Tr, as estimated by Falconer and Sobey (1953) is  $23.0 \pm 2.6$  and it has been shown that the recombination value between Re and nu is  $19.4 \pm 4.6$ . Thus there are 3 possible positions of nu, as indicated by the arrows in the diagram. In order to discriminate between these three possibilities three point tests were carried out by crossing Re Tr  $+/+$   $\times$  nu  $+/+$   $\times$  nu mice. The location of the nu gene can then be determined, since the rarest phenotype will represent the double cross-over. The method, however, is slow, since for obvious reasons Tr and nu are difficult genes to use in linkage tests. Sufficient results are not yet available to enable definite conclusions to be made. The three point crosses are being continued and the data will be published later.

Two point tests between nu and Tr were also carried out, since this procedure is more straightforward than the three point crosses, although the amount of information obtainable is very much reduced. Tr  $+/+$  nu females were mated to  $+/+$  nu males. If nu and Tr show little recombination, it may be concluded that nu is located near Tr and that the order of the genes is not nu \_\_\_ Re \_\_\_ Tr. The arrangement of the genes and the recombination frequencies between them would be one of two alternatives as follows:-

(a)/



But if the frequency of recombination between nu and Tr in the two point tests approaches 40% the order of the genes and the estimates of recombination between them would be as shown in the diagram below:



In this case, another 19 units would be added to linkage group VII.

The results of the two point tests between nu and Tr are shown in Table 13. It is apparent from the data that nu and Tr show fairly close linkage.

Table 13. Results of two point tests between nu and Tr

Parents		Progeny				Total
		<u>Tr</u> +	+ <u>nu</u>	+ +	<u>Tr nu</u>	
$\frac{\text{Tr} +}{+ \text{nu}} \text{♀}$	x $\frac{+ +}{+ \text{nu}} \text{♂}$	81	42	27	1	151
Recombination %		8.6 ± 7.0				

The standard error is large on account of the reduced amount of information obtained per individual in the mixed cross. The percentage recombination of  $8.6 \pm 7.0$  strongly points to order (c) above being excluded. It is, however, worth while to examine this/

this conclusion more critically. The alternative diagrams, a, b, and c above may be discussed separately:

(a) From the two point test data, the frequencies of recombination are as follows:

$$\begin{array}{c} \text{Re} \leftarrow 19.4 \pm 4.6 \longrightarrow \text{nu} \leftarrow 8.6 \pm 7.0 \longrightarrow \text{Tr} \\ \leftarrow 23.0 \pm 2.6 \longrightarrow \end{array}$$

The observed recombination values add up to a value of 28.0 between Re and Tr compared with the value of  $23.0 \pm 2.6$  obtained by Falconer and Sobey (1953). The difference between the two estimates is 5.0 and, in order to test the significance of this deviation, the variance of the difference is equal to the sum of the individual variances,  $(4.6)^2 + (7.0)^2 + (2.6)^2 = 76.9$ . When the difference between the two estimates is compared with its standard error,  $5.0 \pm 8.7$ , it is seen that the difference is not significant.

(b) Suppose that the order of the 3 loci is Re - Tr - nu. Then, from the two point test data, and including the estimate of recombination of  $23.0 \pm 2.6$  between Re and Tr obtained by Falconer and Sobey (1953), the frequencies of recombination between the 3 genes are as follows:

$$\begin{array}{c} \text{Re} \leftarrow 23.0 \pm 2.6 \longrightarrow \text{Tr} \leftarrow 8.6 \pm 7.0 \longrightarrow \text{nu} \\ \leftarrow 19.4 \pm 4.6 \longrightarrow \end{array}$$

When the estimates of recombination of the two individual segments are summed, the recombination value between Re and nu is 31.6, compared with the observed estimate of 19.4 obtained from the two point test data. The difference of 12.2 has a variance of 76.9, as before. The difference between the two estimates, when compared/

compared with its standard error,  $12.2 \pm 8.7$  is not significant at the 5% probability level.

(c) Finally, if the order of the 3 loci is nu - Re - Tr, the estimate of recombination may be arranged as follows:

$$\begin{array}{c} \text{nu} \leftarrow \text{-----} 19.4 \pm 4.6 \text{-----} \rightarrow \text{Re} \leftarrow \text{-----} 23.0 \pm 2.6 \text{-----} \rightarrow \text{Tr} \\ \leftarrow \text{-----} 42.4 \text{-----} \rightarrow \end{array}$$

When the recombination values of the two individual segments are summed, the estimate of recombination between nu and Tr is 42.4, compared with the observed estimate of 8.6 obtained from the two point tests. Comparing the difference with its standard error,  $33.8 \pm 8.7$ , it is seen that the difference is greater than twice the standard error and must be considered significant at the 5% probability level. Hence, the recombination value 42.4, which is the result of addition of two other estimates is incompatible with the observed recombination value,  $8.6 \pm 7.0$ , between nu and Tr.

From this analysis, it may be stated that, after allowing for experimental error, alternatives a and b are much more likely than c. The gene nu is probably located near Tr but in the absence of three point test data it cannot be decided whether nu is positioned to the right or left of the Tr locus. The three point test data will be available later.

Summary of linkage tests. The gene nu is linked to Re in linkage group VII. The recombination value obtained from two point tests was  $19.4\% \pm 4.6\%$ . Tests between nu and Tr gave a recombination value of  $8.6\% \pm 7.0\%$ . The order of the 3 loci appears to be either/

either Re - nu - Tr or Re - Tr - nu. The two point tests indicated that the order of the genes is not nu - Re - Tr.

## 2. MORPHOLOGY.

In this second section of Chapter III, an account is given of the abnormalities caused by the nu gene. The complex of abnormalities is dealt with as follows: the external appearance of nunu mice, hair morphology, body growth rate, infertility of both sexes, mortality and, finally, the incidence of liver necrosis in moribund or dead nunu animals.

### External appearance.

The integument of young nunu mice resembles except for a few details, that of ShaSha animals. These differences will be pointed out in due course.

Nude specimens are classifiable at birth by the absence of vibrissae. All the vibrissae follicles are present on the snout and on the head, but they contain vibrissae stubs only. Many nunu mice die within a few days of birth.

Viable young animals fail to grow a first coat. At 6 days no hairs have erupted on the dorsum and the skin becomes wrinkled. At about 10 days of age a few hair stubs are found scattered on the dorsum, and a few fine hairs are present on the head, feet and tail. Otherwise, the animals may be said to be completely hairless.

Three-week old nunu mice are smaller than normal mice, and they are often in poor condition. Those animals, which survive the weaning period show signs of hair growth at about 5 weeks of age. The skin becomes thickened and intensely pigmented and fragments of malformed hairs emerge on to the skin surface. Some nunu mice grow/

grow short fuzzy hairs similar to ShaSha mice, and the limited growth proceeds in a cephalo-caudal direction. The hairs soon break off and depilation is complete at 6 weeks.

Healthy adult mice show thickening and pigmentation of the skin at regular intervals. In most cases only excrescences of hair fragments are found on the integument. A minority of nunu animals show regeneration of sparse fuzzy hairs, but these bands disappear before reaching the posterior dorsum. Stunted nunu mice do not show cyclic skin thickening and eruption of fuzzy hairs and the skin remains thin throughout life.

With the onset of illness, usually between 5 and 14 weeks of age, there is wastage of the subcutaneous fat. The skin loses its pigmentation completely and becomes transparent.

Vibrissae. In contrast to ShaSha mice, nunu animals show partial growth of vibrissae during the preweaning period. Although the vibrissae are absent at birth, 10-day old individuals usually have 10 to 12 vibrissae, about  $\frac{1}{2}$ " long. The supra-orbitals, post-orbitals, and post-orals, have also erupted at this time. At weaning it is apparent that some whiskers have broken off but the remainder have reached  $\frac{1}{2}$ " in length. All vibrissae are shed at about 4 weeks. Older nunu mice show repeated growth and loss of short wavy vibrissae.

Nails and teeth. Nude mice also differ from ShaSha mice in that the nails are usually malformed. At weaning the nails are distinctly shorter than normal. This underdevelopment is more obvious in adults. The central nails of each foot are often constricted and show a spiral formation. The outer nails are not malformed. There is/




Fig. 32. Microphotograph of hairs from nude mice. The hairs vary in diameter and are twisted. A few small air spaces are present in the medulla and some of them contain fluid. X190

is no excessive elongation of the claws as in hrhr mice. The teeth appear normal.

#### Hair Morphology.

The macroscopic appearance of the fibres of those nunu animals which show hair regeneration is similar to that of ShaSha mice, and the nunu fibres may be grouped into the same three categories. The internal morphology of nunu fibres is similar to that of ShaSha fibres (Fig. 8), and a microphotograph is shown in Fig. 32. The only difference between nunu and ShaSha hairs is that the former lack a cuticle. The cortex is very thin or non-existent and in the bulbous expansions of the hair shaft the cortex may be splintered. The medulla contains clear glassy spaces similar to those of ShaSha, Sha+ and N+ fibre medullae. When nunu fibres are stained with Herxheimers solution, the glassy spaces of the medullae are Sudan positive. The common occurrence of the sudanophilic material in the medullary spaces of abnormally keratinized hairs suggests that this substance is a by-product of incomplete keratinization.

#### Body growth rate.

The growth of nunu mice which survive the suckling period, is very much retarded. Nude and normal animals were weighed at birth, 3 weeks, 6 weeks of age. The results are given in Table 14. The nunu mice are compared with normals on a within-litter basis. It is seen that nunu animals have a normal birth weight but they grow at a very reduced rate, so that at 3 weeks they are little more than half the weight of normals. After weaning the surviving nunu mice grow slowly and adults weigh, on the average, 14.3 g/

Table 14. The mean weights of nude and normal mice at birth, 3 weeks and 6 weeks of age. The differences indicate the reduced growth rate of nude mice.

Age	No. of mice	Mean $\pm$ S.D. (g)	Weighted difference	Normal mice (g) heavier in %	S.E. difference	Significance
<u>Birth</u>						
Nude	258	1.6 $\pm$ 0.60	—	—		
Normal	731	1.6 $\pm$ 0.66				
<u>Three weeks</u>						
Nude	78	5.8 $\pm$ 1.67	4.5	42.1%	0.43	P < 0.001
Normal	276	10.7 $\pm$ 2.30				
<u>Six Weeks</u>						
Nude	25	14.3 $\pm$ 4.13	11.1	44.2%	1.44	P < 0.001
Normal	58	25.1 $\pm$ 3.26				

14.3 g compared with the normal average of 25.1 g. The size of adult nunu mice varies from runtéd animals to specimens about  $\frac{2}{3}$  the normal size. The growth curves of normal and nunu animals are given in Fig. 33 . Although the growth of nunu mice is much reduced, it follows a similar course of <sup>to</sup> that of normals.

#### Fertility.

Although nunu mice are generally infertile, there are occasional exceptions. Details of matings involving nunu mice are given in Table 15. It is seen that matings between nunu females and nunu males, and between nunu females and normal males, rarely produced offspring. Only 4 out of a total of 46 such matings, in which the female parent was nunu, were successful. Each of the four matings produced only one litter. In a few cases male nunu mice were fertile; out of 70 matings between nunu males and normal females, 18 produced offspring. Almost all the matings produced only one litter, but from one mating four litters were obtained. The average litter size of nunu mice, irrespective of mating type, was significantly abnormal.

Nude mothers are unable to suckle mice of their own genotype or any other genotype, but nunu mice have been successfully fostered on to normal mothers. Vaginal smears indicate that the oestrus cycle of adult nunu females is irregular and many exhibit continuous dioestrus or metoestrus phases. Six adult females were dissected and in each case the ovaries were much reduced in size. Five seven-week old females, all in fairly good condition, were injected with 4 I.U. of P.M.S. and, 40 hours later, with 2 I.U. chorionic gonadotrophic hormone, in order to induce ovulation. About 42 hours after the second injection, the animals were dissected and the number of eggs shed was counted.

The/

Table 15. Details of matings involving nude and normal mice

Type of mating	nunu♀ x nunu♂	nunu♀ x nu♂	+nu♀ x nunu♂	+nu♀ x +nu♂
Total No. of matings	20	26	70	444
No. of fertile matings	2	2	18	435
Average no. of litters per type of mating	1.0	1.0	1.6	5.0
Av. litter size ± standard error	7.0 ± 2.00	5.0 ± 0.00	6.7 ± 0.70	10.2 ± 0.54
Litter size of nude parent less than normal	3.2 P < 0.001	5.2	3.5	—
Significance of reduced litter size	P < 0.001	P < 0.001	P < 0.001	—

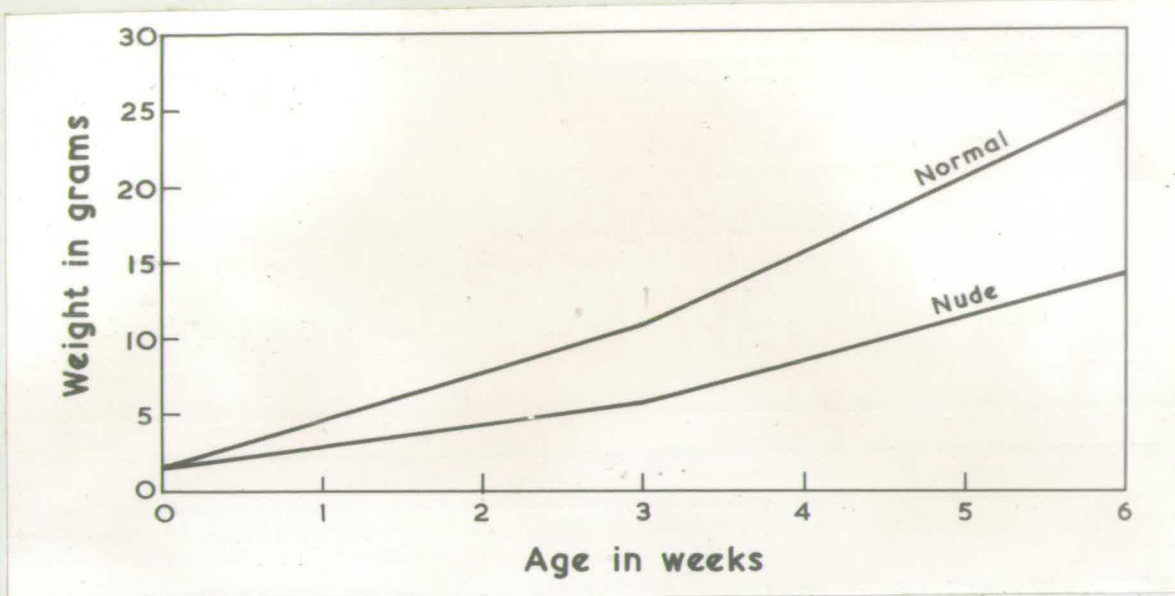

Fig. 33. Growth curves of normal and nude mice.

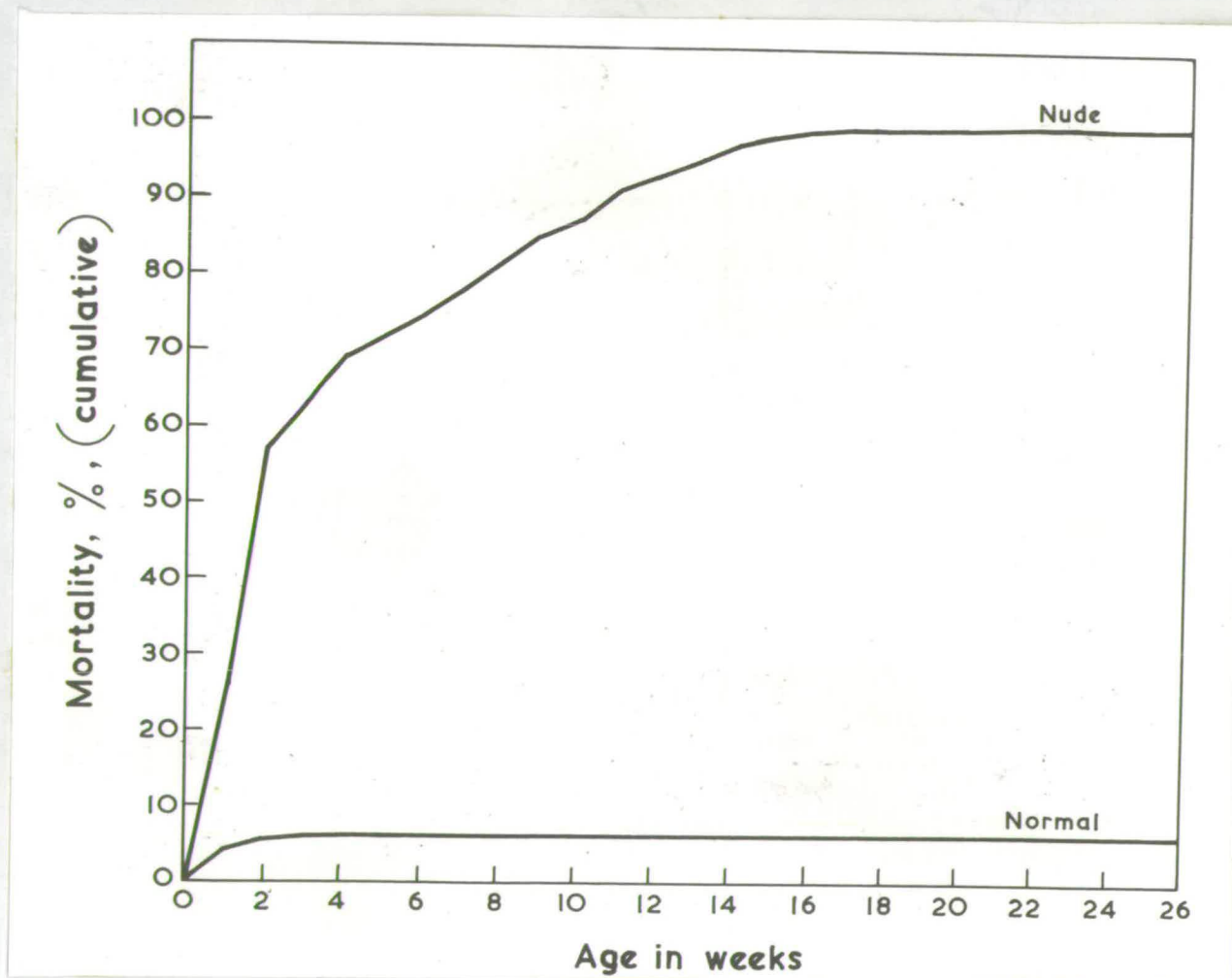


Fig. 34. Mortality curves of normal and nude mice.

The ovaries of all 5 specimens were considerably reduced in size. Three mice shed no eggs; one animal shed 4 eggs in the left ovary and none in the right, and one shed an egg in each ovary. Lack of a regular oestrus cycle, undersized ovaries and reduced number of eggs are responsible for the infertility of female nunu mice.

Evidence of copulation between nunu males and normal females was provided by the finding of vaginal plugs. Only a small proportion of copulations results in pregnancy. Microscopic examination of the sperm of nunu males showed that many sperm were non-motile and had coiled tails. These observations account for the infertility of male nunu mice.

It appears that the infertility of nunu mice is due to specific defects in the reproductive system and not merely to general weakness of the entire body.

#### Mortality.

There is no evidence of increased prenatal mortality of nunu mice compared with normals. This evidence is based on data obtained from the segregating litters which were classified at birth. The segregations from intercross matings + nu x + nu gave 3890 normals: 1350 nunu mice which is in agreement with a 3:1 ratio.

The majority of nunu mice die within two weeks after birth. Prior to death, the animals lose weight rapidly and in the more pronounced cases a typical emaciation occurs. Many of the survivors are sluggish and may become moribund at any time. Some nunu mice live on for a considerable period. Data concerning the mortality of nunu and normal mice are presented in Table 16. Mortality records were maintained on 486 nunu mice. Similar records/

records were kept on 1393 normal littermates up to six weeks of age, at this stage many normals were discarded intentionally but mortality amongst the

Table 16. Mortality of nude and normal mice at different ages.

Age	No. of deaths		% Mortality (cumulative)	
	Nude	Normal	Nude	Normal
Birth to 1 week	130	58	26.7	4.2
1 to 2 weeks	145	18	56.5	5.5
2 to 3 weeks	29	4	62.5	5.8
3 to 4	31	3	68.9	6.0
4 to 5	12	1	71.4	6.1
5 to 6	15	0	74.5	"
6 to 7	17	0	78.0	"
7 to 8	17	0	81.5	"
8 to 9	17	0	85.0	"
9 to 10	11	0	87.3	"
10 to 11	19	0	91.2	"
11 to 12	10	0	93.3	"
12 to 13	8	0	94.9	"
13 to 14	12	0	97.4	"
14 to 15	5	0	98.4	"
15 to 16	0	0	99.2	"
16 to 17	4	0	99.6	"
17 to 18	2	0	99.6	"
18 to 19	0	0	99.6	"
19 to 20	0	0	99.6	"
20 to 21	0	0	99.6	"
21 to 22	1	0	99.8	"
22 to 23	0	0	99.8	"
23 to 24	0	0	99.8	"
24 to 25	0	0	99.8	"
25 to 26	1	0	100.0	"
<b>Total deaths</b>	<b>486</b>	<b>84</b>	<b>100%</b>	<b>6.1%</b>

remainder was zero. Data on the deaths of nunu and normal mice in the linkage tests was not included, since such information is confounded with the lower viability of the linkage stocks, and since many segregating litters were killed after classification.

The table shows that out of 486 nunu mice, 275 or 56.5% died within two weeks after birth. Only 76 out of 1393 normal mice, or 5.5% failed to survive this period. There was appreciable mortality/

mortality of nunu mice around three weeks, due partly to weaning stress. Between 4 and 14 weeks of age the mortality rate remained steady, until 15 weeks when 98.4% of nunu mice had died. Eight animals were viable at 15 weeks and one specimen attained the age of 26 weeks before dying. The mortality of normal mice up to 5 weeks of age was 6.1% and afterwards it was zero. Graphs of the mortality of nunu and normal mice are compared in Fig. 34. It is shown that the mortality of nunu mice during the pre-weaning period is very high and that, afterwards, it eventually reaches 100%. It is shown, also, that the mortality of normal mice is no greater than can be expected under standard laboratory conditions.

#### The incidence of liver necrosis.

After the first few months of breeding experiments, the failure to obtain viable adult nunu mice prompted postmortem examination of a few carcasses. All had a severe liver necrosis. During the remaining breeding experiments, all nunu mice which were found moribund or dead in the cage were dissected and the livers were scrutinised. Table 17 gives the frequency of necrotic livers in moribund or dead nunu mice at different ages. Nude mice which died before weaning could not always be examined as they were often eaten by the parents. But out of 56 observations during this period, one case of liver necrosis was found between 2 and 3 weeks of age, or more precisely, at 20 days of age. For two weeks after weaning a number of stunted nunu mice were found dying from general weakness, and only some of these individuals had liver necrosis, 3 out of 12 mice had developed the disorder between 3 and 4 weeks and 6 out of 12 mice had the defect between

Table 17. The frequency of liver necrosis in moribund or dead nude mice at different ages.

Age.	No. of moribund or dead mice at each age.	No. of moribund or dead mice with necrotic livers at each age.
Birth to 1 week	27	0
1wk " 2 wks.	16	0
2 " " 3 "	13	1
3 " " 4 "	12	3
4 " " 5 "	12	6
5 " " 6 "	7	7
6 " " 7 "	12	12
7 " " 8 "	11	11
8 " " 9 "	17	17
9 " " 10 "	10	10
10 " " 11 "	10	10
11 " " 12 "	5	5
12 " " 13 "	5	5
13 " " 14 "	10	10
14 " " 15 "	2	2
15 " " 16 "	2	2
16 " " 17 "	0	0
17 " " 18 "	0	0
18 " " 19 "	0	0
19 " " 20 "	0	0
20 " " 21 "	0	0
21 " " 22 "	0	0
22 " " 23 "	0	0
23 " " 24 "	0	0
24 " " 25 "	0	0
25 " " 26 "	1	1

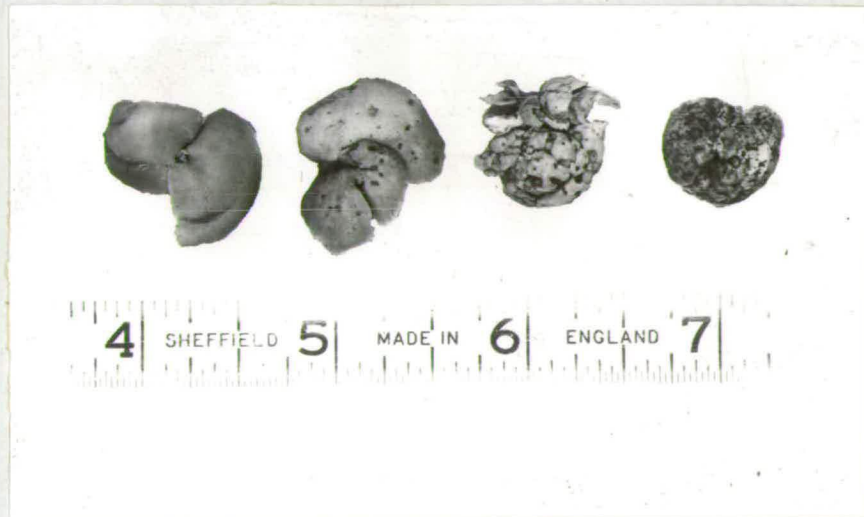

Fig. 35. Progressive liver degeneration of nude mice; from left to right;-

- (a) normal liver;
- (b) small round open lesions scattered uniformly over the lobes;
- (c) advanced stage, with normal hepatic tissue interspersed between large open scars;
- (d) atrophied liver from a moribund nude mouse; no normal hepatic tissue remains.

4 and 5 weeks. Afterwards, all the carcasses had necrotic livers. Thus, the defect appeared to be very rare before weaning but after about 5 weeks it was a characteristic abnormality of all nunu mice.

The severity of the liver necrosis at the time of death is variable. The condition ranges from a few small open lesions scattered on the lobes, in some animals, to a complete degeneration of all hepatic tissue, in other animals. Fig. 35 shows the degrees of severity of the necrosis. The milder form of necrosis (Fig. 35b) consists of small round reddish perforations scattered on the lobe surfaces. In a more severe form (Fig. 35c), the liver has larger open sores, with normal hepatic tissue interspersed between the sores. The sores are roughly circular, reddish, and gorged with blood. In the most extreme form (Fig. 35d), the liver has no normal tissue, the lobes are atrophied and the whole organ is scarred. As mentioned above, all degrees of severity have been found in dead nunu mice.

The symptoms associated with the liver abnormality are also rather variable. The following symptoms are typical of most nunu mice. The animals may be healthy for a variable number of weeks after weaning; then they become lethargic in movement, the backs become arched, partial closure of the eyes occurs, accompanied by retinal degeneration. During the following two weeks or so, the animals lose weight rapidly and a typical emaciation sets in. Subcutaneous fat is absorbed and there is wastage of the muscles on the dorsum and legs. Very occasionally, paralysis of the hind legs occurs. Ascitic tumors are not found. The emaciated specimens have completely degenerate livers, as shown in Fig. 35d. The necrosis develops insidiously and if the animals are killed at the first signs of illness, the necrosis is already well established, and 6 to 8 lesions may be scattered throughout the lobes.

Although the majority of nunu mice lose weight and become emaciated over a 2 to 3 week period, some specimens show a more acute form of the disease and may die within 3 to 5 days of becoming ill. The apparently healthy animals suddenly become ill and lose weight through severe emaciation is not observed as the animals die off quickly. Very rarely, ascitic tumors are found. In this acute form of the disorder, all degrees of severity of liver necrosis, as illustrated in Fig. 35, are discernible.

The coated littermates of nunu mice never show any signs of illness or develop necrotic livers. Normal littermates of nunu mice were killed intentionally at various ages but all the livers were normal.

In addition to necrosis of the liver, other tissues also show degeneration in nunu mice. In particular, the subcutaneous fat is absorbed, the muscles on the dorsum and legs waste rapidly and the retina frequently degenerates. With the exception of the liver, the other internal organs of nunu mice, including the lungs, heart, spleen and kidneys, remain macroscopically normal.

Histological details of the liver degeneration, and the possible causes of the defect will be discussed later.

### 3. SKIN HISTOLOGY AND HISTOCHEMISTRY.

In the third section of this chapter the histological defects of the skin of nunu mice are described. In addition to conventional haematoxylin and eosin skin sections, the distribution of sulphhydryl groups in the skin was also examined.

The/

The basic premises for analysing the histology and histochemistry were essentially the same as those already outlined in connection with ShaSha skin. Suffice it to say that the effects of the nu gene on hair growth are rather similar to those produced by the Sha gene in homozygous condition.

#### Methods.

The macroscopic appearance of the skin on the main body area of nunu mice is normal at birth and the hair follicle rudiments are visible externally as pimple-like thickenings of the skin. Consequently, embryonic skin was not examined but dorsal skin samples were obtained from normal and nunu littermates at 0, 3, 6, 9, 17, and 20 days of age. Paraffin wax sections were obtained by the methods already mentioned in connection with shaven mice. The distribution of sulphhydryl groups in the skin of 6-day old normal and nunu mice was examined by the method of Bennett (1951), as modified by Mescon and Flesch (1952).

#### Results.

Histology. Like ShaSha mice, nunu<sup>animals</sup> show no histological abnormalities of the skin at birth (Figs. 36 and 37). The size and shape of the follicle primordia, number of follicle primordia per a microscopic field, and thickness of epidermis and dermis are normal in nunu skin.

As the follicles continue to grow downwards and as the inner root sheath reaches the epidermis, histological abnormalities become obvious (Figs. 38 and 39). Although the outer root sheath, inner root sheath, sebaceous glands, bulb and dermal papilla are normally differentiated, the hair is extremely degenerate and it bends in the sebaceous gland region. The hair consists merely of /

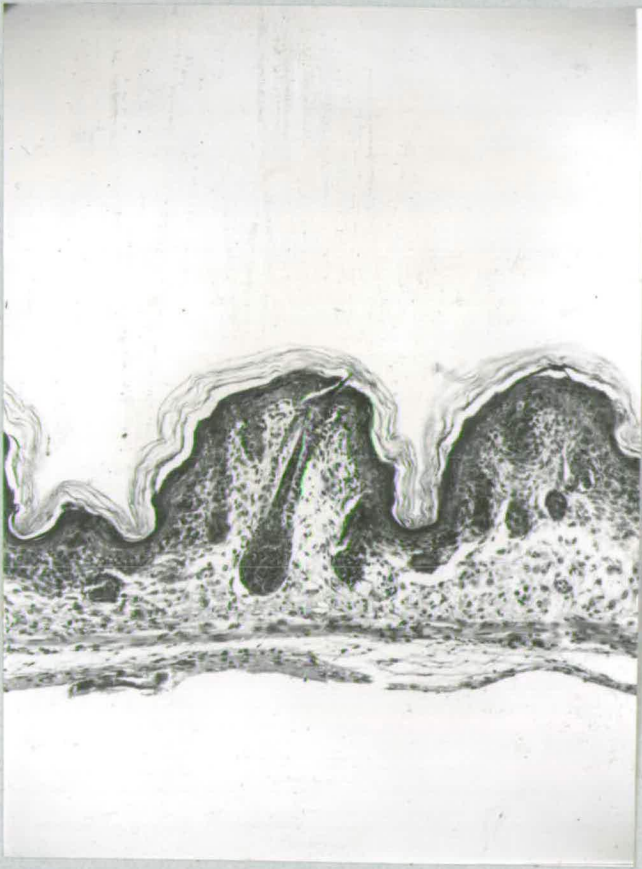


Fig. 36. Normal skin at birth showing a guard hair follicle and primordia. X115.

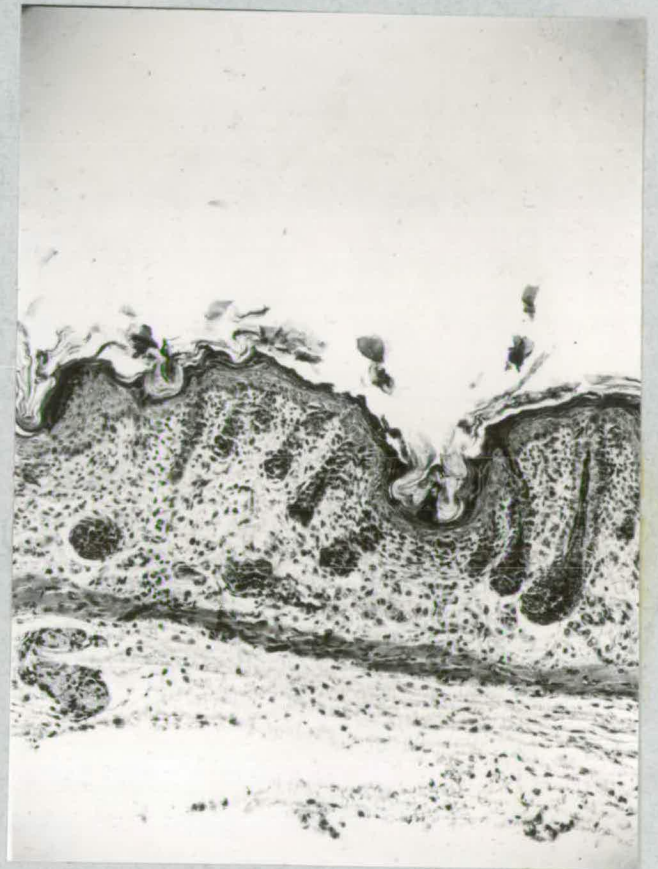

Fig. 37. nunu skin at birth showing a guard hair follicle and primordia. X115.

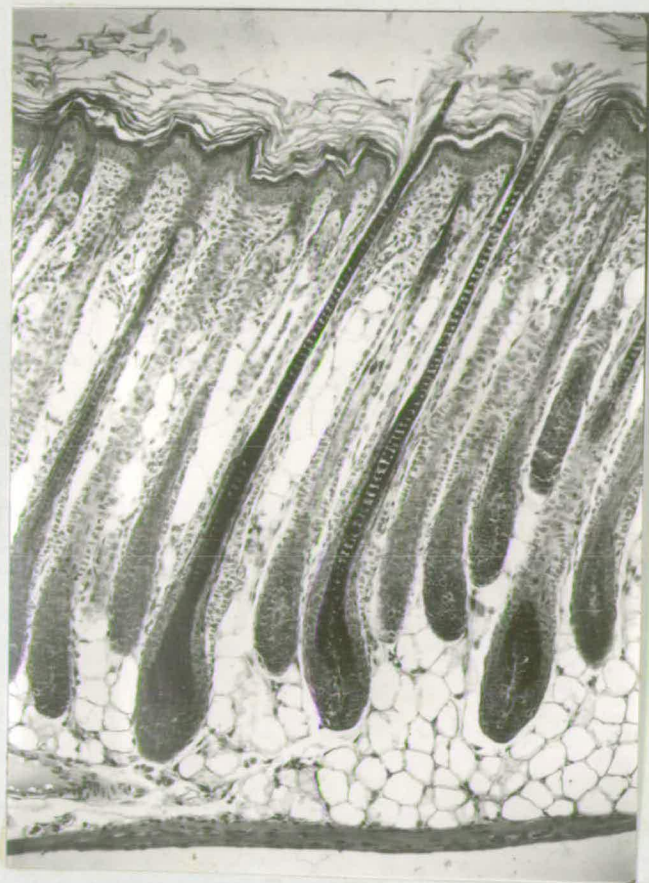

Fig. 38. Normal skin at 6 days showing follicles with fully keratinized hairs. X115.

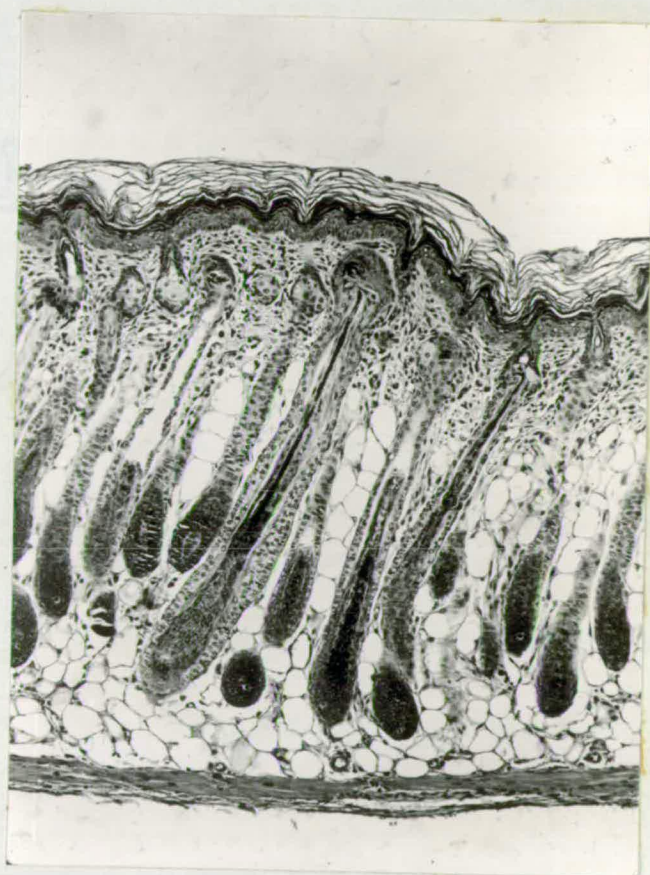


Fig. 39. nunu skin at 6 days showing follicles with strands of hair substance. X115.

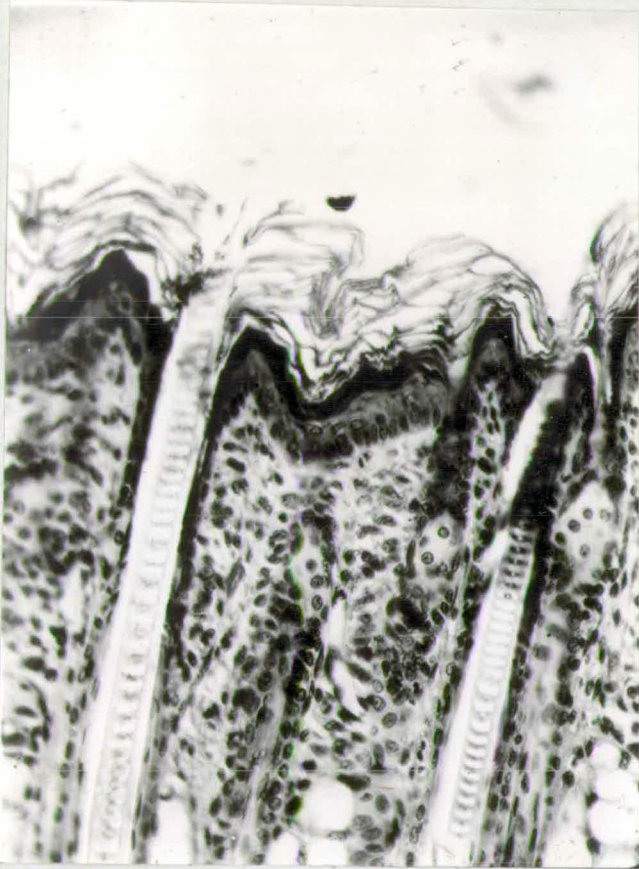


Fig. 40. Upper follicle region of normal skin showing hair eruption. X210

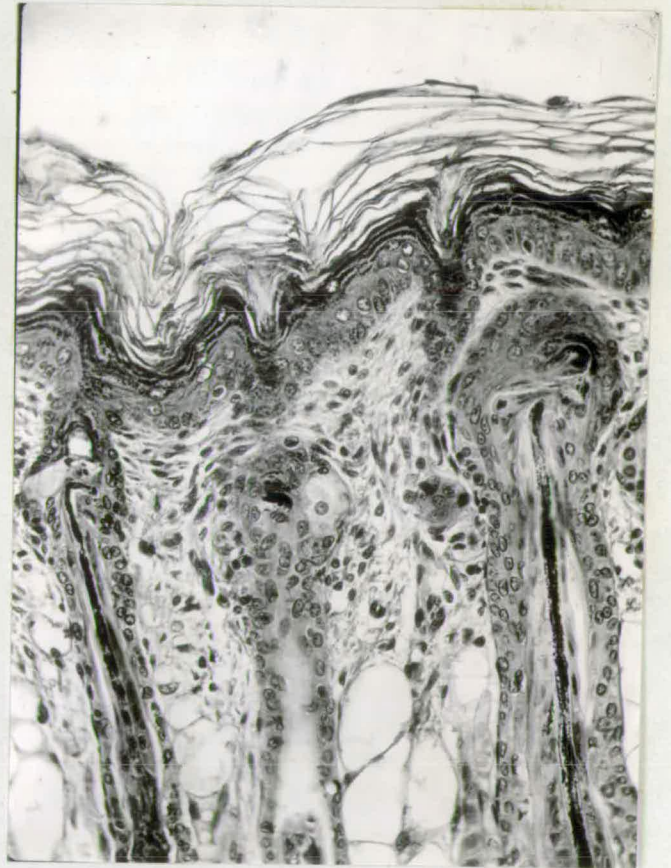


Fig. 41. Upper follicle region of nunu skin showing bending of hair strands. X210.

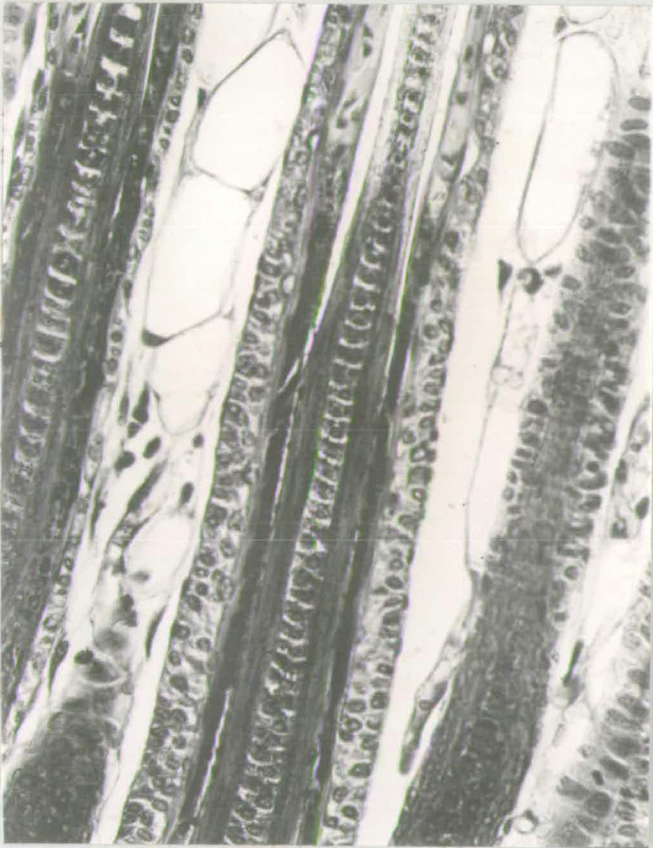


Fig. 42. Mid-follicle region of normal skin. The hair cortex and medulla are fully differentiated. During keratinization, the basophilic cortex becomes picophilic (upper part of photo). X325.

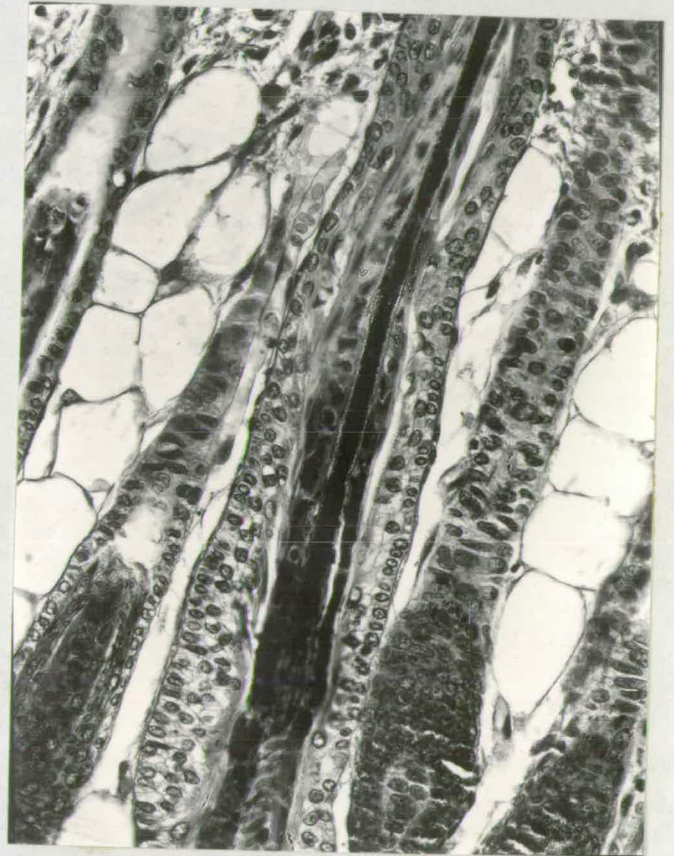


Fig. 43. Mid-follicle region of nunu skin. The hair cortex is absent and the medulla is not fully differentiated. X325.

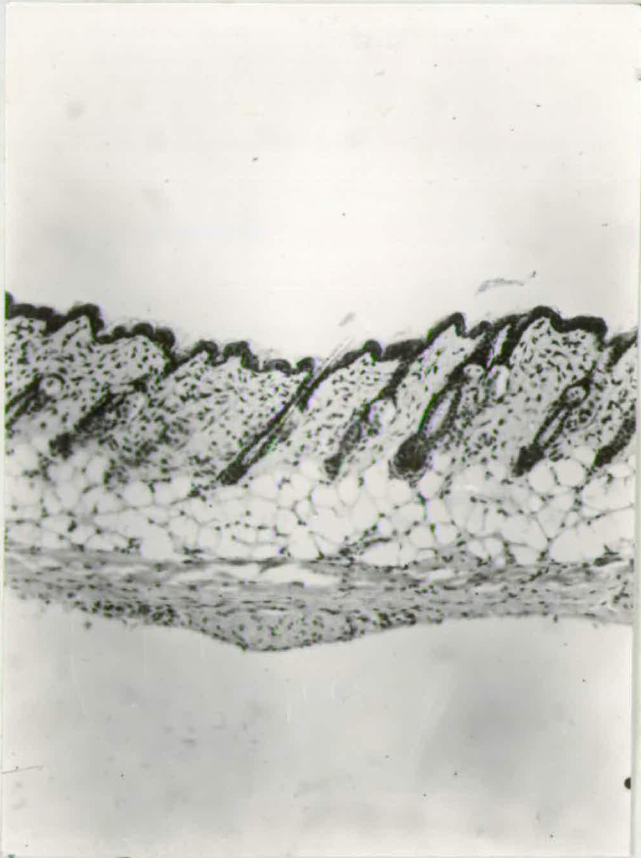


Fig. 44. Normal skin at 21 days of age, telogen stage. X115.

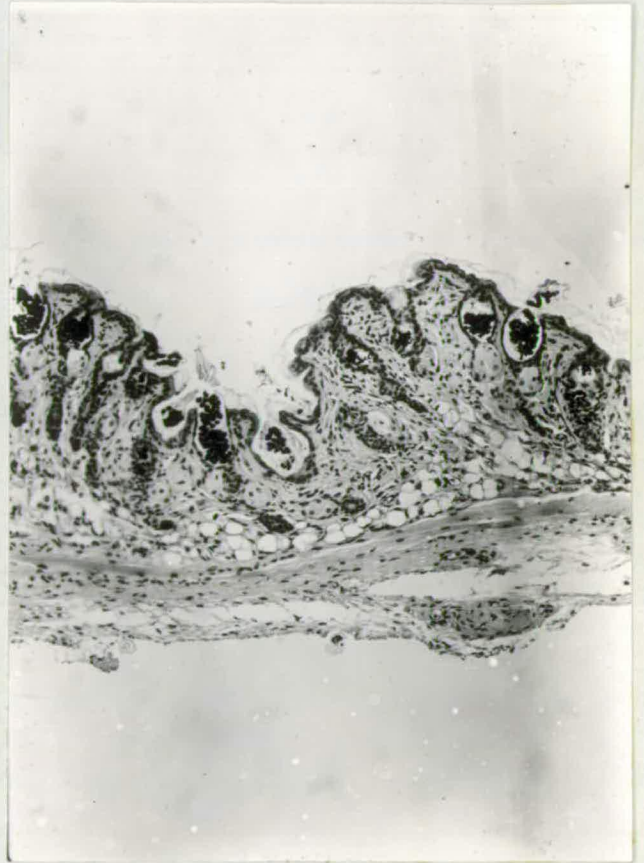


Fig. 45. nunu skin at 21 days of age, telogen stage. X115.



Fig. 46. Normal skin at 6 days  
The keratogenous zone of the  
follicle reacts intensely with  
-SH reagent. The reaction  
ends above the zone. X130.

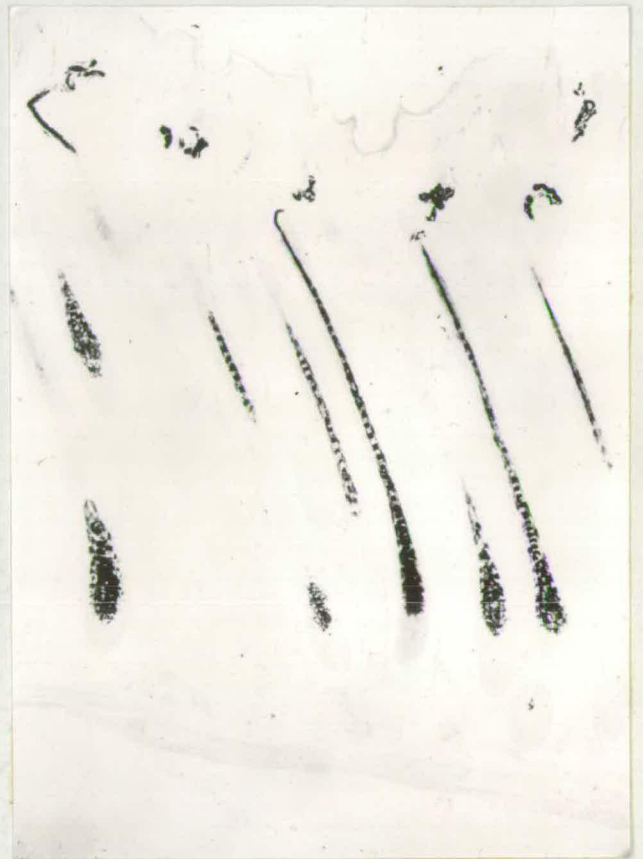

Fig. 47. nunu skin at 6 days  
showing negative reaction of  
the follicles to -SH reagent.  
The strands of pigment indicate  
the outline of the follicles.  
X130.

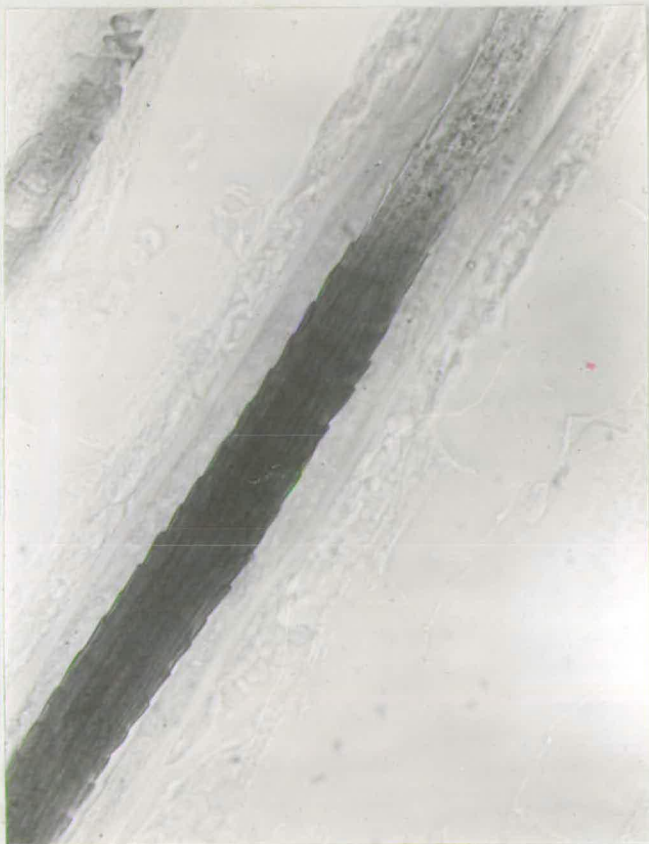


Fig. 48. Normal skin at 6 days showing intense reaction of cuticle and cortex to -SH reagent. Note fibrillar nature of cortex. The reaction ends sharply above the keratogenous zone. X600.

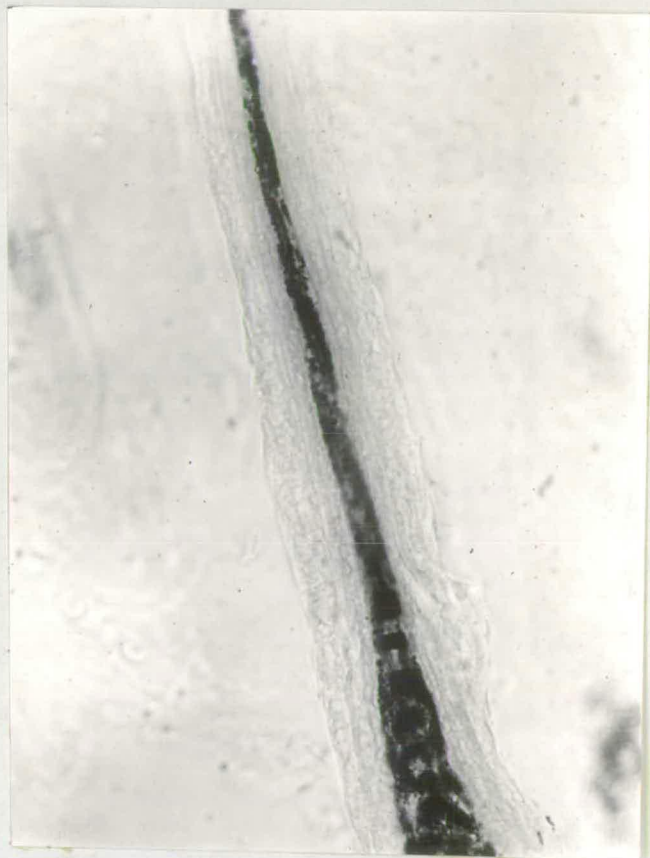

Fig. 49. nunu skin at 6 days showing negative -SH reaction of the keratogenous zone. The cuticle and cortex are absent and the hair consists of medulla only. X600.

of a strand of medullary substance and, in agouti black animals, it is heavily pigmented throughout its length. The hair strand is eosinophilic and never picrophilic. The hair follicles have grown downwards to the panniculus carnosus level at 6 days of age.

Unlike ShaSha mice, the strands of hair material produced by the follicles of nunu mice lack a cuticle completely and most hairs lack a cortex. The hairs consist solely of medullary substance. The conditions prevailing in the upper follicle regions of normal and nunu skin are shown in Figs. 40 and 41. The coiled strands of hair cause hyperplasia of the outer root sheath cells. All the layers of the epidermis appear to be fully differentiated, and the stratum corneum is normal in thickness.

The keratogenous zone of the follicles of nunu skin is grossly abnormal. Figs. 42 and 43 show the structure of the keratogenous zone of normal and nunu follicles. The hair cuticle is absent and the cortex is either very thin or non-existent consequently the inner root sheath lies closely adjacent to the hair strand. Instead of the hair strand undergoing picrophilic transformation in the keratogenous zone, it acquires a strong affinity for eosin. The medulla is not differentiated into cross-septa and intercellular spaces and is uniformly pigmented throughout.

The other follicle strata in the keratogenous zone are normal. The outer root sheath is 2 to 4 cells thick, the inner root sheath may be rather thinner than usual but it is normally keratinized.

The lower/

The lower region of the follicle in nunu skin contains no obvious histological abnormalities. The bulb matrix contains much cytoplasm, and the common occurrence of mitotic figures indicates that cell division is not reduced. All the concentric layers in the bulb are normally aligned. But in that region of the follicle above the neck of the bulb in which the cuticle and cortical cells normally become elongated, the cell nuclei are reduced in size and remain ovoid, rather than becoming narrow.

From these observations, it is seen that the follicles of nunu mice are unable to form any of the hair keratins. The cuticle and cortex are completely absent and the medulla is not normally differentiated. The other forms of keratin appear to be fully synthesised by nunu mice. These include the stratum corneum, and its precursor keratohyaline, the eosinophilic Henle's layer, the basophilic Huxley's layer together with its precursor trichohyaline.

During the first anagen phase, the string-like hairs aggregate in the upper dermis and eventually they are forced on to the skin surface. During catagen, the follicles shorten but the hair club is abnormally keratinized. During telogen, the distended hair canals contain accumulations of hair material. Telogen follicles of normal and nunu mice are shown in Figs. 44 and 45. In Fig. 45 the sebaceous glands are abnormally located at the base of the hair canals or in the centre of the dermis.

At/

At about 4 weeks of age, the follicles of nunu mice enter a second anagen phase but, as before, the hair strands lack a cuticle and cortex. As the follicles develop, the various histological abnormalities outlined above are manifested once more.

Histochemistry. There is a general deficiency of -SH groups in the keratogenous zone of the follicle in nunu skin. The distribution of -SH groups in normal and nude skin is shown in Figs. 46 and 47. Whereas the -SH reaction begins above the neck of the bulb in normal follicles and reaches maximum intensity in the keratogenous zone, a similar -SH reaction in the follicles of nunu mice is not found. Under the high power objective, the intense reaction of the cuticle and the fibrous nature of the cortex can be easily recognised in normal follicles (Fig. 48). The sudden termination of the -SH reaction is also obvious. In nunu follicles, the cuticular scales and cortical cells are completely absent from the keratogenous zone (Fig. 49).

With the exception of the hair itself, the distribution of -SH groups in nunu skin is similar to that of normal skin. The stratum corneum is weakly reactive and the follicle strata are unreactive.

It will be more convenient to delay discussion of the histology and histochemistry of nunu skin until the development of the liver necrosis has been traced.

#### 4. LIVER HISTOLOGY.

##### Introduction.

Hereditary liver necrosis in mice has not previously been reported. Bagg (1925) observed haemorrhagic lesions of the liver in a myencephalic blebs stock, but the abnormality occurred only very rarely in this stock.

A prerequisite for attempting to identify the causative agent of the liver necrosis is the determination of the course of events in the hepatic tissue leading up to the final form of the necrosis. After distinguishing the anatomical form of the initial lesions and the subsequent reaction of the hepatic tissue, it may then be possible to reduce tentatively the number of causative agents. The reasons for examining the histology of the liver necrosis of nunu mice were those just mentioned. Other reasons were, to find a unifying factor relating the liver necrosis to the keratinization defect of the integument, and to see if the disorder resembled any of the familiar liver defects of man.

##### Methods.

In the early stages the necrosis of nunu mice develops insidiously and, in order to obtain a clear picture of the initiation of the lesions, apparently healthy nunu mice must be sacrificed. Random samples of healthy, mildly ill, and emaciated nunu mice were dissected, and the livers graded in order of severity of the necrosis. For each nunu animal, a normal littermate was also dissected, but no normal littermate had any trace of necrosis.

Formol /

Formol saline fixed paraffin wax sections were stained with haematoxylin and eosin and with basic fuchsin. Fixed frozen sections were <sup>stained</sup> fixed with Herxheimer's solution in order to determine whether fatty infiltration occurred. Silver impregnation of reticulin fibres (Pearse 1960) was also carried out to observe whether extensive fibrosis became established, and if so, the nature of its distribution.

### Results.

Initially, the necrosis of the liver is localised and consists of inflammatory reactions at widely separated points throughout the lobes. Fig. 50. shows the lobular arrangement of normal liver, and Fig. 51a. illustrates an incipient necrotic lesion in the liver of an apparently healthy nunu mouse. Another incipient lesion in the liver of a healthy nunu animal is shown in Fig. 51b. The first sign of inflammation is the appearance of polymorphonuclear leucocytes and monocytes in the centre or towards the periphery of a lobule. The parenchymal cells degenerate and the necrosis rapidly spreads until most of the lobule is destroyed. Islets of normal cells survive in the midst of the necrotic area, and these islet cells regenerate. The tissue surrounding the necrotic area is entirely normal.

With progressive necrosis, the lobules are destroyed and the lesions begin to link up (Fig. 52). The anatomical form of the lesion appears to be massive, as whole lobules are involved and surrounding tissue remains normal. The periportal areas are often gorged with blood cells, /

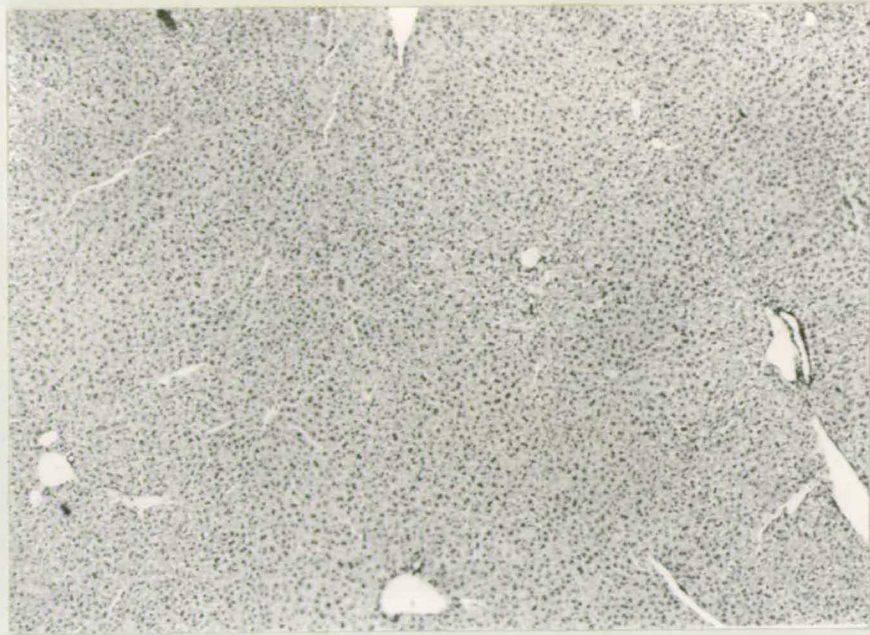


Fig. 50. Section of normal liver showing central veins and portal tracts of the lobules. Parenchymal cells constitute the liver lobules. X63.

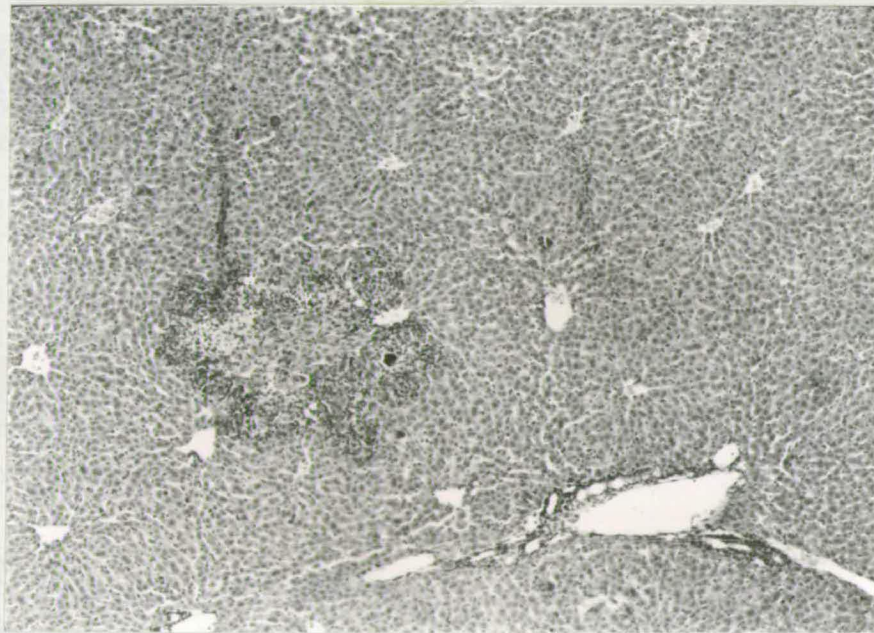


Fig. 51a. Section of liver from an apparently healthy nunu mouse. An inflammatory reaction involving 2 to 3 adjacent lobules is observed. The parenchymal cells are undergoing necrosis. X63.

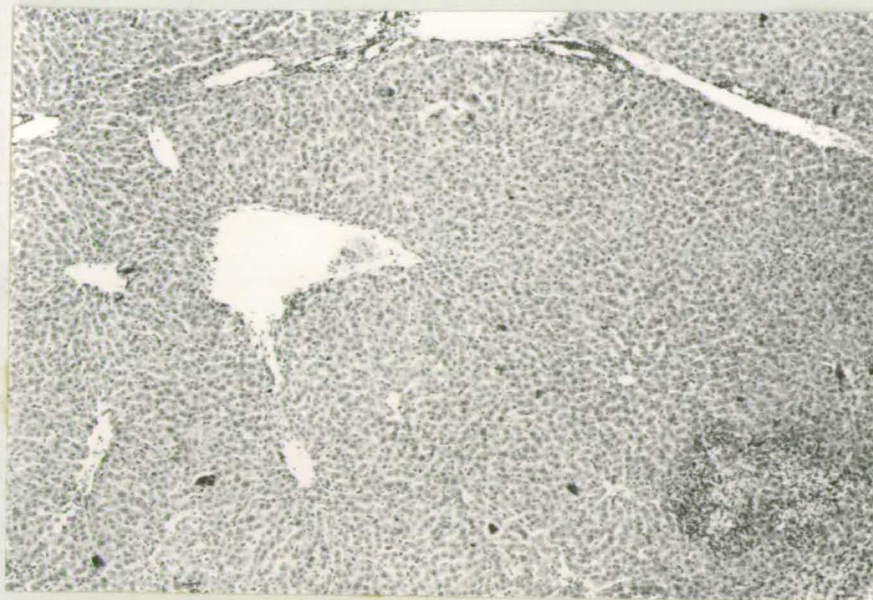


Fig. 51b. Section of liver from an apparently healthy nunu mouse. Cellular degeneration is localised (upper left) and the surrounding hepatic tissue is normal. X63.

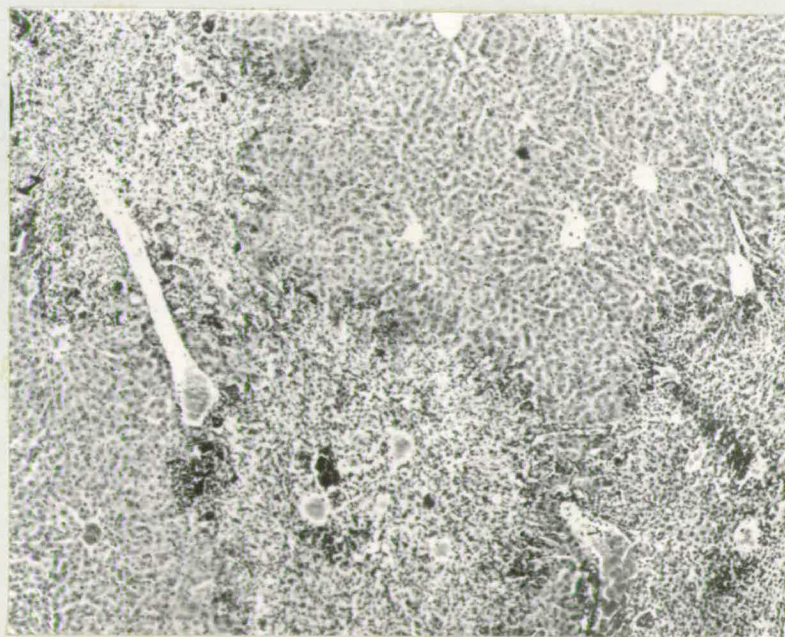


Fig. 52. Section of liver from nunu mouse showing areas of necrosis linking up. Whole lobules are involved in the cellular degeneration while adjacent lobules remain normal. X63.

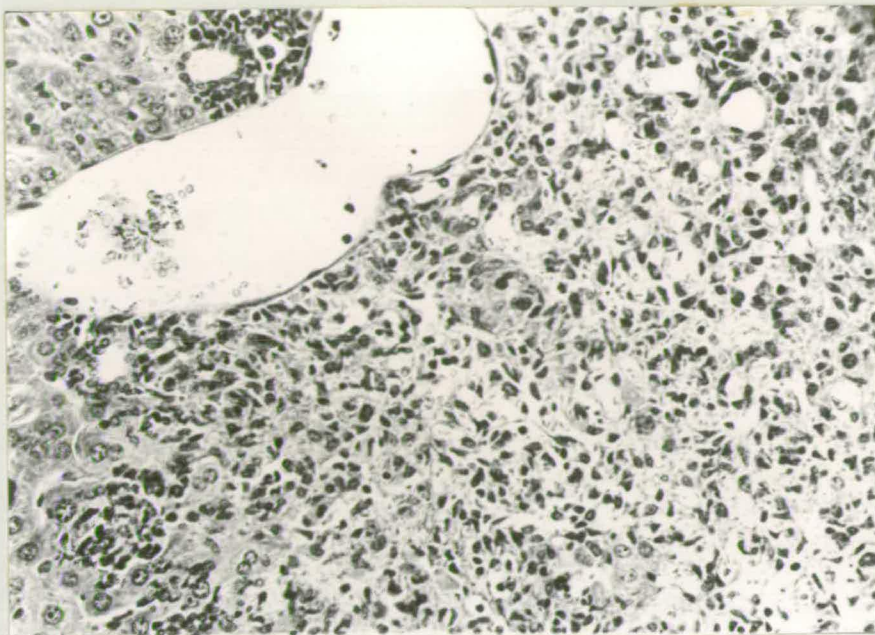


Fig. 53. Section of liver from nunu mouse showing cellular degeneration and phagocytosis around a portal tract. There is extensive infiltration with polymorphonuclear leucocytes and monocytes. X250.

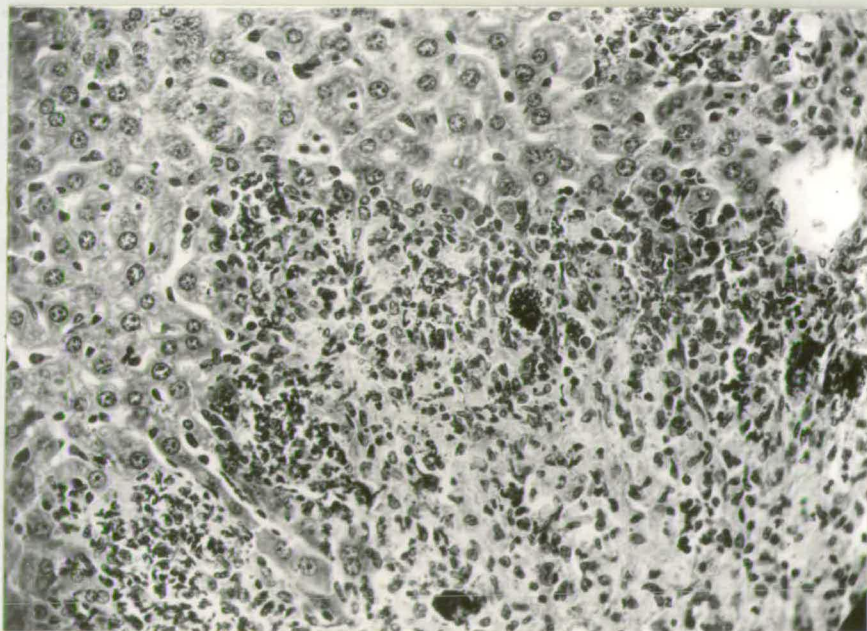


Fig. 54. Section of liver from nunu mouse showing "balloon" cells with basophilic bodies in a necrotic area (centre and lower parts of picture). The parenchymal cells adjacent to the degenerating tissue are normal. X250.

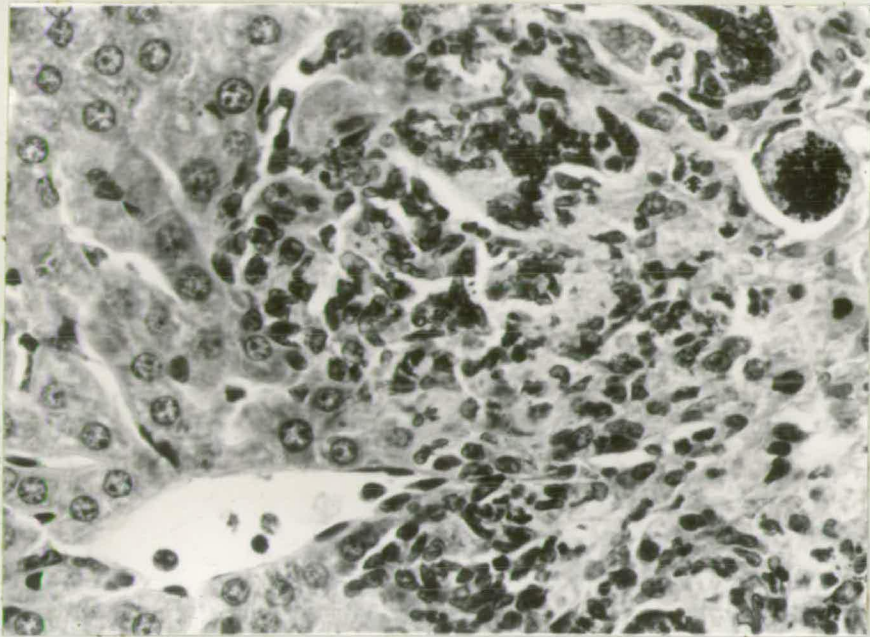


Fig. 55. Section of liver from nunu mouse showing a "balloon" cell with numerous basophilic bodies. The cell is distinct in outline and is situated in an open space (upper right). X520

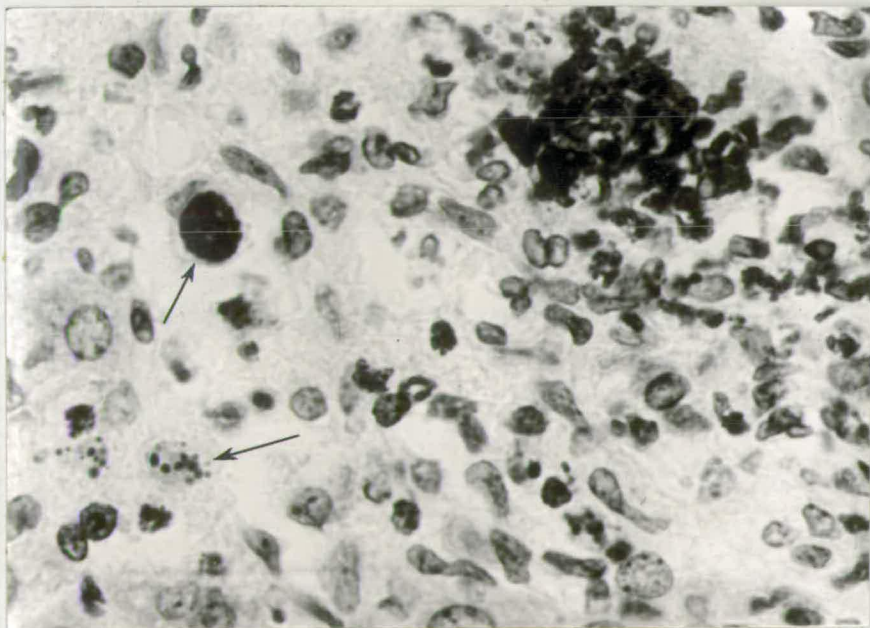


Fig. 56. Section of liver from nunu mouse showing cells containing round Feulgen positive bodies (arrows). Feulgen reagent stain. X920.

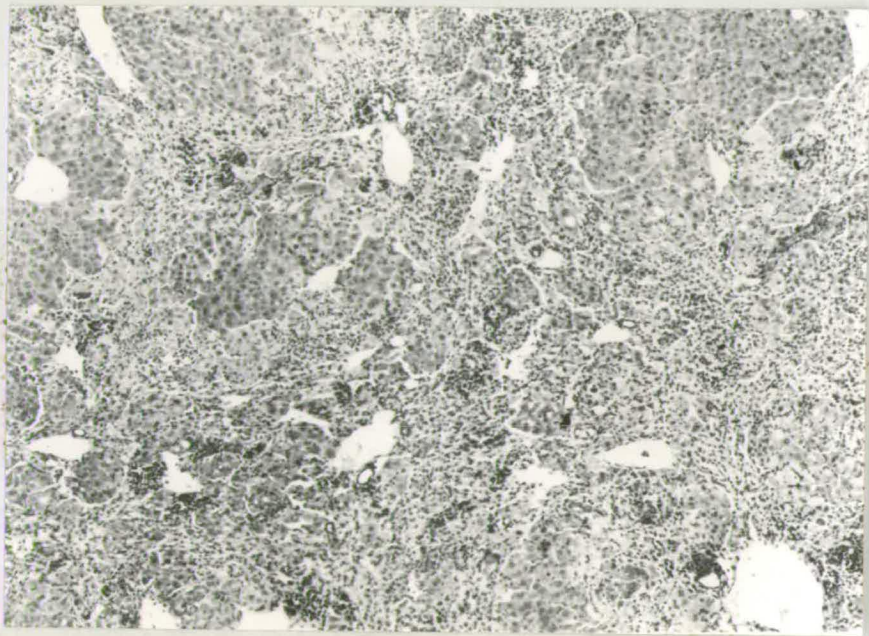

Fig. 57. Section of liver from nunu mouse at time of death. Very little normal tissue remains. X63.

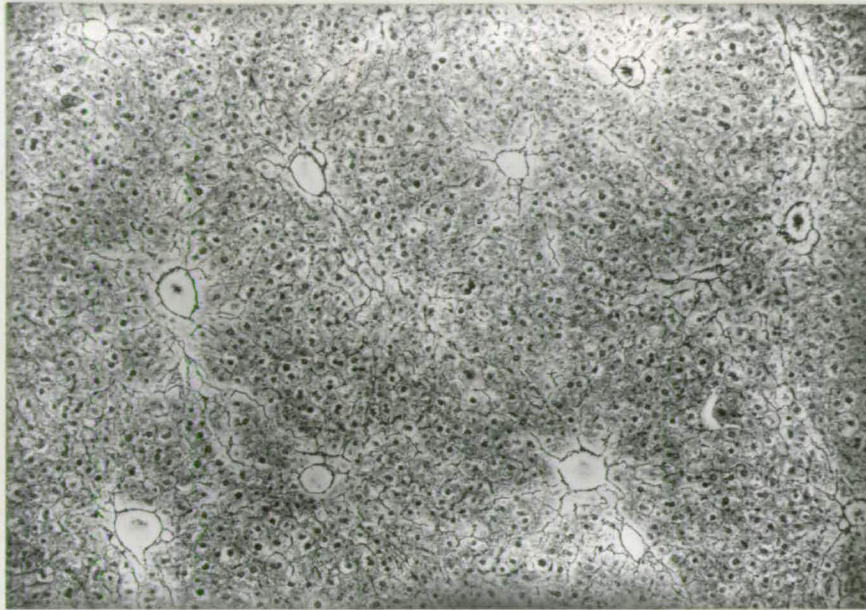


Fig. 58. Section of normal liver showing fine reticulin fibres traversing the lobules. Silver impregnation. X100.

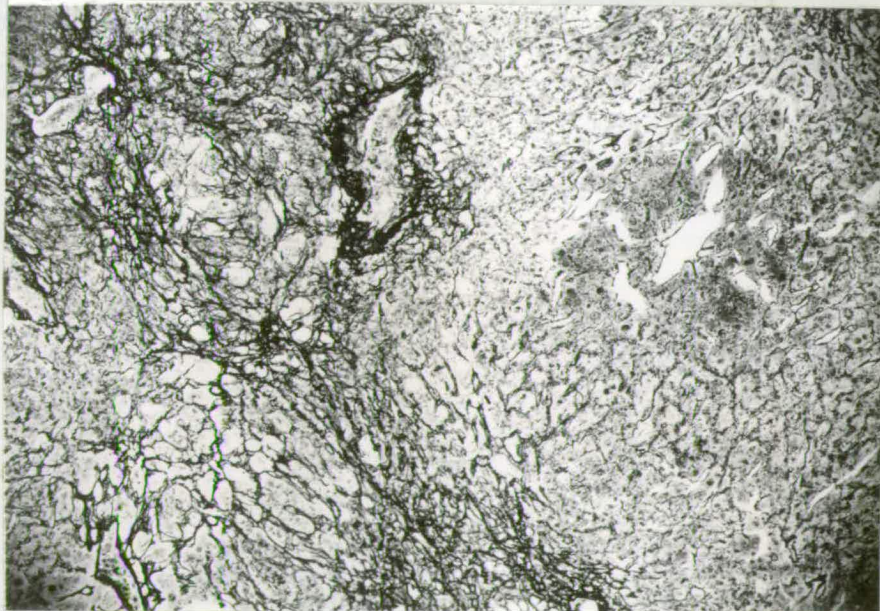


Fig. 59. Section of liver from nunu mouse with advanced liver necrosis showing fibrous reaction of the degenerating tissue. Silver impregnation. X100.

cells, and there is extensive infiltration with leucocytes and monocytes (Fig. 53), which engulf the debris of the necrotic cells.

Eventually, the centre of the lesion assumes a glassy appearance, as phagocytosis has reached an advanced stage. At the lesion margins, necrosis continues; many cells are vacuolated and the nuclei are disintegrating. Balloon cells and acidophilic bodies are frequently found. One of the most striking features of the lesions is the common occurrence of balloon cells containing strongly basophilic bodies (Fig. 54). Some of the balloon cells are irregularly shaped and have cytoplasmic processes to which the basophilic bodies are attached. Other balloon cells are distinctly circular; they have a regular outline and all the basophilic bodies are clearly within the cell (Fig. 55). All the balloon<sup>cells</sup> containing basophilic bodies are situated in open spaces. The basophilic bodies are numerous; they vary in shape and size and they are Feulgen positive, (Fig. 56).

The necrosis of the hepatic tissue proceeds until, inevitably, little normal tissue remains (Fig. 57). A few islets of cells remain; these regenerate and are very much enlarged. In the degenerated tissue, large masses of cytoplasm devoid of nuclei are found.

Extensive thickening of reticulin fibres develops simultaneously with the necrotic lesions. The fine network of reticulin fibres in normal /

normal liver and the fibrous reaction of the necrotic liver are contrasted in Figs. 58 and 59, respectively. Coarse bands of fibres traverse the necrotic areas.

There is no fatty infiltration of the liver of nunu mice. At all stages of the necrosis, the lipid content was similar to that of normal liver.

### 5. DISCUSSION.

The most interesting aspect of the nu gene is the variety of abnormalities which it produces. The mortality, reduced growth rate, and infertility of males and females, have already been outlined. It is appropriate at this stage to discuss briefly the skin and liver histology before attempting to analyse the pleiotropy.

Skin histology. It has been shown that the hairless condition of nunu mice is due to the failure of the follicles to produce fully keratinized hairs, and is not due to a failure of follicle initiation. The follicle primordia are all laid down by the Malpighian layer in the usual fashion. In these respects the nu gene resembles Sha and N.

The initial histological abnormalities become noticeable as the hairs attempt to erupt. The hairs consist solely of eosinophilic strands of medullary substance, and the keratinization defect can be traced to the keratogenous zone. Here, the hair cuticle and much reduced cortex suddenly disappear, so that the hair strand lacks rod-like nuclei and fibrils.

No histological defects are noticeable in the bulb which might account for the failure of the cuticular and cortical cells to differentiate into scales and fibrils respectively. The nude phenotype is another example in which specific tissues, in this case, the hair cuticle, cortex and medulla, develop normally up to a certain stage and then, unaccountably, the differentiation fails to reach completion.

The incomplete differentiation of the cuticle, cortex, and medulla, appears to be associated with a gross deficiency of -SH groups in the keratogenous zone of the follicle. The -SH reactive cuticular scales and cortical fibrils are absent and the follicles of nunu mice are unable to synthesise adequate amounts of keratin precursor for conversion to keratin or, in other terms, they are unable to metabolise normal amounts of cysteine for oxidation to cystine.

Liver histology. The liver necrosis of nunu mice is remarkable in a number of ways. Firstly, the co-existence of the hairless condition and a liver abnormality in an individual as a result of a single genetic change is very surprising. In the course of the breeding experiments, the hairlessness and liver necrosis never became dissociated during segregation. Yet it is difficult to explain how the liver damage is related to the abnormal synthesis of keratin, and ultimately to a specific defect of an epidermal structure, i.e., the hair follicle. Secondly, to use the principle of the unity of gene action as a guide, the liver defect appears to be a secondary effect of the hairlessness. The liver defect in

in the majority of nunu animals is not manifested until a considerable period of time has elapsed after the initial hair defect. Whereas the keratinization defect may be observed as early as 3 days of age, the majority of necrotic livers are found between 5 and 14 weeks of age. Thirdly, the balloon cells with basophilic bodies are a characteristic feature of the necrotic areas. When the liver sections were first examined, these balloon cells were considered to be macrophages engulfing chromatin debris. The idea that they represented an infectious agent was not entertained for two reasons:

- (a) The basophilic bodies vary considerably in size and shape.
- (b) If an infectious agent was responsible for the necrosis, it seemed very likely that the coated littermates of nunu mice, kept in the same cages, would also be similarly affected with the liver disorder. Normal littermates of nunu mice never show liver necrosis and the balloon cells with basophilic bodies have never been found in their livers. Consequently, it was concluded that the liver necrosis of nunu specimens was not due to a pathogenic organism. It will be shown later, however, that there are doubts about the validity of this conclusion.

The histology shows the anatomical form of the liver disorder. The necrosis appears to be massive in type, rather than zonal, as large areas of tissue degenerate, while immediately adjacent to such areas, extensive tracts of normal tissue remain. Once a region becomes necrotic there is no recovery and the necrosis progresses very rapidly towards /

towards an inevitable conclusion, i.e., death of all the liver tissue. The development of fibrosis as a result of the necrosis leads to scarring. The absence of fatty infiltration is rather expected since such infiltrations are associated with long term liver disorders.

## 6. ANALYSIS OF THE PLEIOTROPY.

### Introduction.

The range of abnormalities produced by the nu gene may be briefly stated as follows:

- (a) Hairlessness, which is associated with gross deficiency of sulphhydryl groups in the follicle, and which may be observed as early as 3 days of age.
- (b) Reduced growth rate.
- (c) Infertility, which is caused by reduced ovary size, reduced number of eggs shed, and irregular oestrus cycle, in the females; in the males, infertility is due to non-motile sperm.
- (d) High mortality during the suckling period, and death of all animals which survive weaning as a result of liver necrosis.

To use the theory of the unity of gene action as a guide, the reduced growth rate, infertility and liver necrosis, appear to be secondary effects of the initial primary defect, hairlessness. The most significant of the secondary effects is the liver necrosis, as all previous forms of hairlessness have never been associated with abnormalities of the viscera or with such fatal consequences as the liver /

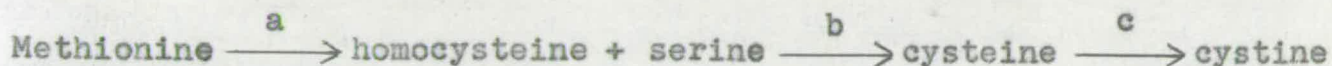
liver defect of nude mice. On account of the joint segregation of the hairlessness and liver defect, as a result of a single gene substitution, it was considered important to reduce the two abnormalities to a single unifying anomaly during development. However, it will be seen that, with the techniques used, the investigation failed to reduce the pleiotropy to one initial cause.

Since the hairlessness is associated with a deficiency of sulphhydryl groups in the follicles, the liver abnormality was examined to see whether it can be shown that this defect is also associated with abnormal sulphur metabolism in the parenchymal cells of the hepatic tissue. The amino-acids methionine, cysteine, and cystine are particularly relevant to this study.

Sulphur metabolism.

Methionine cannot be synthesised by the animal body from the constituents of the diet and must be present in adequate amounts in the food for the promotion of growth and maintenance of nitrogen balance in adults. Methionine alone can satisfy all the sulphur requirements of the body, since it is readily converted into cystine. This reaction occurs in liver tissue. Methionine forms an amino-acid homocysteine, which then condenses with serine to form cysteine. The cysteine is converted to cystine. The sequence of reactions is illustrated in simplified form as follows:

Methionine /



It seemed possible, in view of the deficiency of cysteine and cystine in the hair follicles, and also on account of the much reduced growth rate, that the nu gene may interfere with one of the steps of the metabolic pathway whereby methionine is converted to cystine. Also, it has been shown experimentally that cystine deficiency causes massive hepatic necrosis (Glynn et al. 1945). The one gene - one enzyme theory suggests that the nu gene may be responsible for the liver cells being unable to perform one of the reactions indicated by the letters a, b, c, in the diagram above.

Amino-acid supplements, methionine, cysteine and cystine were added to the diet of nunu mice. If the biosynthetic pathway is blocked at a, b, or c, then feeding cystine should ameliorate the necrosis. If the reaction sequence is blocked at steps a or b, feeding cysteine should ensure continued health of the hepatic tissue. In the case of a block at step a, the provision of adequate amounts of homocysteine and serine would prevent liver degeneration, but such a provision was not attempted in the experiment.

Fifty-one nunu mice were divided into five groups. Four groups each received an amino-acid supplement of methionine, cysteine, cystine, and cystine plus methionine, while the remaining group received no supplement. The supplement groups, with the exception of that group receiving methionine plus cystine, had a control group of normal mice receiving /

receiving similar amino-acid supplements. In each group, the amino-acid supplement comprised 0.8% of the diet, as recommended by Long (1961).

The amino-acid supplements failed to ameliorate the necrosis. Details of the feeding experiment are set out in Table 18. All the nunu mice died after a variable number of weeks and all normal

Table 18. Results of feeding supplements of methionine, cysteine, cystine to nude mice. All nude mice died after a variable number of weeks. Control groups of normal mice received similar supplements; since they showed no ill-effects, the normals are not included in the table.

	Group 1 No supplement	Group 2 Methionine	Group 3 Cysteine	Group 4 cystine	Group 5 Methionine + cystine
No. of Mice	12	15	7	11	6
Age at start of experiment	28 days	30 days	24 days	28 days	28 days
Amount of supplement as % of diet	-	0.8%	0.8%	0.8%	0.8%
Length of survival on diet.	12 weeks	8 weeks	8 weeks	16 weeks	8 weeks.

mice lived indefinitely without showing any ill-effects. The livers of all nunu mice had necrotic lesions, some livers were more severely affected than others. The normal mice were killed intentionally but none showed any trace of liver necrosis.

It is seen, therefore, that supplements of sulphur-containing amino-acids failed to improve the viability of nunu mice. Since cystine was supplied in adequate amounts, the results suggest that the liver necrosis is not caused by cystine deficiency but is probably due to some other aspect of amino-acid metabolism. Consequently another attempt to analyse the liver defect was made by obtaining urine chromatograms and amino-acid analyses of liver extracts.

Urine /

Urine chromatography and liver extract analyses.

If nunu mice suffer from a renal abnormality, vital amino-acids, such as methionine and cystine, may be excreted in the urine, thus precipitating gross protein deficiency and consequent necrosis of the liver. Such pathological excretion of amino-acids should be detectable on chromatograms. If the metabolic defect is not due to a renal abnormality but to a block in some amino-acid sequence in the liver, such a block should result in deviant concentrations of one or more amino-acids in the liver tissue. These alternative possibilities were investigated by the following methods:

One ml. urine samples were collected from normal and nunu mice over a 24 hr. period and passed through a cation exchange column consisting of N.HCl - washed Amberlite 1R 120 resin. The column was washed with distilled water to remove anions and neutral compounds. The amino-acids were then displaced by washing down with 2N.NH<sub>3</sub> and the first effluent collected. Samples of 50 $\mu$ l. of effluent were applied to the chromatography papers, which were then developed in a 4:1:5 N-butanol-acetic acid-water system. For amino-acid analyses of the liver, 4 week old normal and nunu mice were dissected and the wet weight of the livers noted. The nunu mice had healthy livers. Each liver was homogenised in 10 ml. 3% sulphosalicylic acid, centrifuged and freeze dried. One ml. of distilled water was added to the dried liver extract and the solution was diluted in series. That dilution /

dilution which gave the most suitable peaks on the autoanalyser chart was used in the test. A sample of 0.5 ml. of solution was made up to 1 ml. by adding 0.1 ml. N.HCl., 0.1ml.  $\alpha$ - amino  $\beta$  - guanidino propionic hydrochloride, and 0.3 ml. distilled water. One liver extract from a normal mouse and two liver extracts from nunu mice were run through the autoanalyser.

The results of the two experiments were negative. The chromatograms did not reveal pathological excretion of amino-acids in nunu mice, as the concentration was similar to that of normals. Also, there was no difference between normal and nunu mice in the positions of the amino-acids on the papers. In the amino-acid analyses of liver extracts, there was no difference, qualitatively or quantitatively, between the series of peaks produced by the normal and nunu specimens. In particular, the peaks of methionine, cysteine, cystine and serine were not abnormal in nunu mice.

#### Familial skin-liver syndromes in man.

The negative results obtained from the feeding experiment, chromatograms, and liver extract analyses prompted a survey of skin and liver syndromes in man, and these may be usefully summarized at this stage to see if any of them resemble the hypotrichosis - liver defect of nunu animals. Haemochromatosis is caused by an inborn error of iron metabolism and is characterised by extensive skin pigmentation, liver cirrhosis and storage of large amounts of iron in the tissues. Affected individuals survive for many years. No iron /

iron deposits were observed in the hepatic tissue of nunu mice. A familial form of xanthomatosis occurs in man, in which nodular lesions of the skin are associated with enlarged liver and spleen. But no liver necrosis occurs. There are two further familial conditions which affect the liver but do not involve the skin. Wilson's disease is due to abnormal copper metabolism and is characterised by basal ganglion degeneration, liver cirrhosis and amino-aciduria. Copper is deposited in the brain and liver, and the latter becomes nodular. The liver of nunu mice was examined for copper deposits by staining with rubeanic acid (Pearse 1960) but the reaction was negative. The syndrome known as the de Toni-Fanconi syndrome is another complex of abnormalities characterised by rickets, massive necrosis and amino-aciduria. The syndrome appears to depend on an enzymatic disturbance. Prolonged protein deficiency in the diet causes a syndrome known as Kwashiorkor, usually in tropical countries. Various dermatoses and a grossly fatty liver result.

All these syndromes differ from the hypotrichosis and liver necrosis of nunu mice in one or more respects. Nude mice do not accumulate the noxious factors, iron and copper, in the hepatic tissue; the liver does not become enlarged or fatty over a long period; on the contrary the liver necrosis of nude mice proceeds rapidly; nunu animals do not show amino-aciduria or rickets. Thus, it appears that the skin-liver syndrome of nunu mice is not analogous to any of the common skin-liver syndromes of man. The liver degeneration caused by the nu gene offers suitable /

suitable experimental material for studying the pathology of hepatic diseases since the progress of the hepatic tissue injury and the reaction of the parenchymal cells to such injury can be readily witnessed.

Discovery of a pathogenic organism in nude mice.

In a renewed effort to solve the liver necrosis, attention was focussed on the frequent occurrence of balloon cells, containing basophilic bodies (Figs. 54 and 55). The original belief that they did not represent a pathogenic organism was revised, since the general appearance of the balloon cells gave the impression that they might possibly be cysts containing infectious organisms. It was difficult to understand how an infectious agent could affect the liver of nunu mice while normal littermates in the same cages were unaffected. Nevertheless, three moribund nunu mice were handed to Dr. J.G. Campbell, British Empire Cancer Campaign, Poultry Research Centre, Edinburgh, and the carcasses were examined. The presence of a protozoan, Toxoplasma gondii, was demonstrated histologically in a number of tissues. The balloon cells were interpreted as pseudo-cysts, containing large numbers of this parasite. The cysts were also present in the brain. The free form of the organism was demonstrated in the skeletal muscle and duodenum.

The discovery that a parasite was associated with the liver necrosis of nunu mice was very surprising, in view of the fact that neither pseudo-cysts or liver necrosis were ever found in normal /

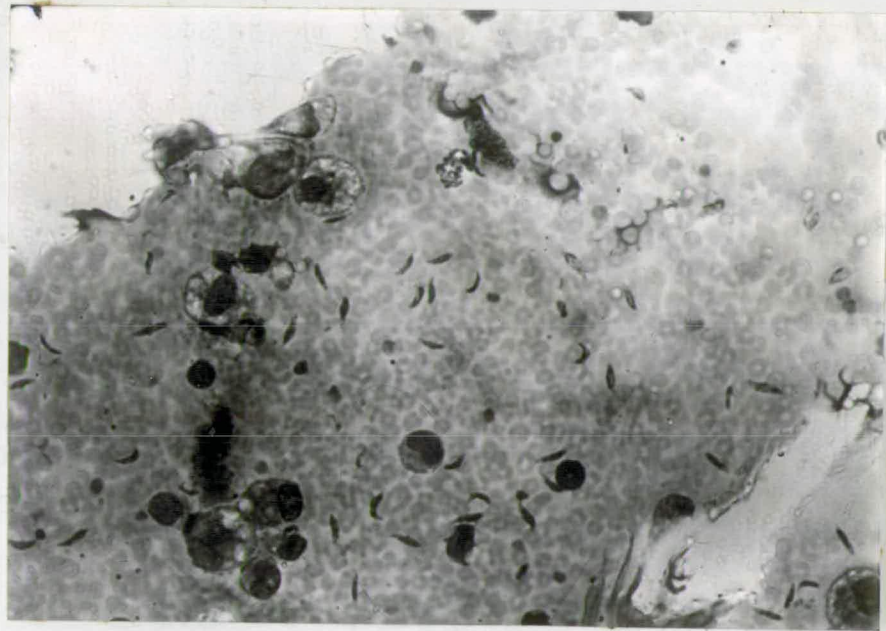


Fig. 60. Blood smear of necrotic liver of nunu mouse showing banana shaped organisms, Toxoplasma gondii. Wrights blood stain, Oil immersion.

normal cage-mates. It is not within the scope of this study to outline the pathogenic manifestation of Toxoplasma but a brief description of its more important characteristics is relevant to the liver problem of nunu animals.

Toxoplasma gondii is a protozoan which is harboured by many species. It is found in a latent form in mice, guinea pigs, cat, dog, sheep, swine and humans (Jacob 1953). The organism is banana shaped, being 4 to 7 microns in length. In tissue sections, the organism is shrunken by fixation procedures. In chronic infections, the organisms are present in pseudo-cysts, which lie dormant in the tissues (Frenkel 1953). The characteristic location of the pseudo-cysts is the brain, but they are also found in the liver. After initial infection, animals develop immunity and survive in a healthy condition for life. If infection is acute, e.g., infection produced by intraperitoneal inoculation, ascitic tumors develop and death occurs within 9 to 10 days. The free form of the organism is readily recognised in smears of peritoneal fluid. Inoculation of the peritoneal fluid into disease-free stocks ensures transmission of the parasite.

Intra-uterine infection is the only natural mode of transmission of Toxoplasma which is known with assurance. The organism can be transmitted across the placenta from a chronic tolerant carrier to the foetus (Weinman 1952). The congenital toxoplasmosis may result in death /

death of the foetus, or the foetus may be born but has various abnormalities such as hydrocephalus and chorioretinitis, or the foetus may be normal at birth and the individual may remain normal for weeks or months before certain structural changes result (Feldman 1953). Other methods of infection are thought, though not proven, to be ingestion of infected carcasses and shedding of the organism in the faeces. In general, the pseudo-cysts are resistant to chemical therapy.

In nunu mice it is apparent that infection is chronic rather than acute. Although the pseudo-cysts were demonstrated in all necrotic livers, the free form of the organism was rarely observed. Smears of necrotic liver fluid of 20 nunu mice were stained with Wright's blood stain but the free organisms were observed in only one instance (Fig. 60). This one instance, however, is unequivocal evidence that nunu mice are infected with Toxoplasma, since it is more easily recognised in the free state than in histological sections. Attempts to isolate the organism by passage through disease free stocks were unsuccessful. Necrotic liver extracts were injected into disease free mice, kindly donated by Dr. J.M.K. Mackay, Animal Diseases Research Association, Moredun Institute, Edinburgh. These mice were confidently regarded as being free from Toxoplasma infection. Thirty mice were divided into 5 groups of 6 mice each. The 5 groups were injected intraperitoneally with liver extracts obtained from 5 nunu mice suffering from liver necrosis. Only one mouse developed illness. This animal died 9 days after inoculation /

inoculation without developing the characteristic ascites. The liver was completely necrotic and resembled the necrotic liver of nunu mice. But the free Toxoplasma organisms were not found on smears of liver and other tissue fluids. The absence of ascites and of free organisms on the smears raises the question whether the animal died of Toxoplasma or of some other cause. The result of the inoculation experiment is puzzling and needs to be repeated before any conclusion can be made.

#### Discussion.

In addition to the hypotrichosis-liver abnormalities of nunu mice, the presence of pseudo-cysts of Toxoplasma creates new problems. In order to determine the relationship between Toxoplasma and the liver necrosis three hypotheses may be proposed:

1. Nude mice may be specifically infected with the parasite, while the normal mice are completely free from infection. The specific affinity of nunu mice for the organism may result in liver necrosis.
2. The organism may be present in a latent form in both normal and nunu mice but the hairlessness may reduce the natural resistance of nunu animals in such a way that the parasite becomes more virulent in these specimens. Since the liver is the seat of extensive metabolic activity, toxins liberated by the increasingly virulent parasite /

parasite may cause necrotic lesions in the liver. Normal coated animals may develop an immunity to the organism so that no cellular degeneration occurs.

3. The organism may be present in a latent form in both normal and nunu mice and it may be in no way responsible for the liver necrosis. It may be sufficient to postulate that a defect in the intermediary metabolism of nunu mice results in the development of liver necrosis. With progressive necrosis, the organism may proliferate and find expression as pseudocysts in the liver and other tissues.

No experiments have yet been designed to decide which interpretation is the correct one. But the alternatives may be discussed on the merits of the previous observations. The first suggestion mentioned above appears unlikely. In view of the <sup>ubiquitous</sup> nature of the organism it seems probable that both normal and nunu mice carry the organism. Evidence that the organism is not confined specifically to the nunu animals was obtained as follows: A heterozygous nude  $+nu$  male was crossed with a homozygous normal  $++$  female, which was obtained from a different laboratory stock. The  $F_1$  animals were mated at random and some matings gave nunu mice in the  $F_2$ . These nunu individuals had pseudo-cysts in the necrotic livers. This implies that the normal mice of the  $F_1$  generation carried a chronic infection and that this infection was transmitted to the offspring and had deleterious effects on nunu animals only. Histological demonstration of the dormant pseudo-cysts in the brains of normal mice would disprove this first hypothesis.

Although /

Although it is not inconceivable that the Toxoplasma is directly responsible for the liver necrosis, some circumstantial evidence suggests that it is not the cause of the necrosis. Necrotic lesions of the type described are not usually associated with infections of Toxoplasma. Typically, the pseudocysts lie dormant in the tissue, but the inflammatory reactions and intensive monocytic infiltrations in the livers of nunu mice are most exceptional. If the pseudo-cysts were the cause of the liver defect, they should also be responsible for psychomotor disturbances in the brain. Such disturbances have not been observed.

The third hypothesis, that the liver abnormality is due to an inborn error of metabolism and that the presence of Toxoplasma is ancillary, appears more probable than the two previous suggestions. Evidence would be forthcoming if chemical therapy was successful in eliminating the organism. Elimination of the organism without any concomitant affect on the liver necrosis would confirm the belief that the occurrence of the organism is subsidiary to the liver defect.

Further research on the whole problem of the hypotrichosis, liver necrosis, Toxoplasma complex association of nunu mice is necessary. Probably the first step would be the demonstration of the organism in normal mice by histological examination of the brain. Next, the eradication of the organism might be accomplished, if recent methods of therapy have been successful. Amelioration of the necrosis would then suggest that the organism is a causative agent of the defect.

Support for/

for the belief that the liver necrosis is due to a metabolic disturbance and not to Toxoplasma may be obtained from experiments on embryos. Since infection via the uterus during pregnancy is the only mode of transmission that has been definitely established, transplantation of nunu eggs into females which are known to be free from Toxoplasma may produce nunu mice which are free from infection. If these nunu specimens develop liver necrosis it would be reasonable to suppose that the necrosis arises independently of Toxoplasma infection. The questions raised regarding the liver necrosis - parasite relationship must remain open for the present.

From the results of the various experiments it is seen that, with the techniques used, the pleiotropic effects of the nu gene have not been traced back to a single defect during development. The various abnormalities of the skin, reproductive system and liver have been outlined in this chapter, but the action of the nu gene at the morphological level of enquiry does not appear to be tissue specific. The pleiotropy is complicated by the presence of a pathogenic organism in the tissues. It is clear that biochemical and pathological techniques are required in order to continue the analysis of the pleiotropy.

## 7. SUMMARY OF NUDE.

1. The new hairless gene nude nu is recessive and linked to rex in linkage group VII. The percentage recombination between nude and rex was  $19.4 \pm 4.6$ . Three point tests to determine the linear order of the genes nu Re Tr are being carried out.
2. Nude mice can be classified at birth by the absence of vibrissae and at 5 days by the non-eruption of the first coat. The hair-

hairlessness is due to very poor keratinization of the hairs in the follicles and histochemical examination shows that the follicles are deficient in sulphhydryl groups.

3. The nu gene differs from all other hairless genes.

In addition to hairlessness, the gene causes high mortality of young mice, slow body growth and very poor fertility of survivors, and death of all adults as a result of a liver defect.

4. No morphological abnormalities, other than hairlessness, were found in nunu mice which die during the suckling period. It appears that young nunu mice die of starvation and general body weakness. Only one nunu specimen, at 20 days of age, was found to have a defective liver before weaning.

5. Nude mice which survive the pre-weaning period usually die between 3 and 14 weeks of age.

6. The livers of dead or dying nunu mice show degeneration of the hepatic tissue and the severity of the condition is variable. The histology of the defect is outlined in the text.

7. Attempts to relate the sulphhydryl group deficiency of the integument to abnormal sulphur metabolism in the liver were unsuccessful.

8. Pseudo-cysts of a protozoan, Toxoplasma gondii, were identified in the liver, and in one case, the free form of the organism was obtained in a stained smear.

9. The possible relationships between the liver necrosis and the presence of the pathogenic organism are discussed.

CHAPTER IV GENERAL DISCUSSION.

The two new mutants Sha and nu may be added to the sizeable list of genes causing hairlessness in the mouse. Furthermore, Sha and nu belong to that group of hair mutants characterised by abnormal keratinization of the hair shaft in the follicle, as exemplified by N.

Mutant genes which cause abnormal keratinization of the hair shaft have not been extensively investigated for the purpose of elucidating the underlying physiological basis of the defect. Since the strength of keratin depends largely upon the conversion of sulphhydryl groups to disulphide bonds, Jarrett and Spearman (1957) examined the hairs of matted mama mice for the presence of free sulphhydryl groups, but no abnormality was found. In the present investigation it was shown that the follicles of ShaSha mice are deficient in sulphhydryl groups in the cortex of the hair in the keratogenous zone, and that only traces of sulphhydryl groups are discernible in the follicles of nunu mice. Thus, it appears that the follicles of ShaSha and nunu mice are unable to metabolize adequate amounts of the keratin precursors, cysteine residues.

In addition to the hairlessness, both mutants have characteristic features. It is generally true that genes are located throughout the chromosome complement without regard to their phenotypic effects. But the close linkage of Sha and N is the third example in the mouse of adjacent loci having similar phenotypic manifestations. The question is, what does the close linkage between Sha and N mean when considered in the light of the random distribution of the other hairless genes over /

over the chromosomes? There is no satisfactory answer at present. Perhaps a consideration of the mimics cr and Ta may be helpful. In view of the similar pleiotropic patterns produced by these two mutations, it seems likely that the same type of change in a chromosome element may be repeated in widely separated parts of the chromatin. This may also apply to the waving mimics Re, Ca, wa-1, wa-2. If these specific chromosomal changes are replicated at widely separated sites, they may also be replicated in close proximity to one another and thus be responsible for close linkage and similarity of effect, such as Sha and N. The chance of such an event occurring is very small but the possibility exists. More likely explanations in terms of intra-chromosomal re-arrangements and gene structure are required.

The Sha gene is also characterized by the peculiar manifestation of dominance over its normal allele. In the presence of a normal allele, the Sha gene never causes hairlessness but causes the fully grown coat to be greasy. At the N locus, the N+ heterozygote is semi-hairless and the NN homozygote is hairless. At a glance, it is difficult to see how the greasy coat of Sha+ mice can be physiologically related to the hairlessness of ShaSha animals. But it has been mentioned that the greasy appearance of the Sha+ coat is due to the presence of a sudanophilic substance in the hair medullae and that a similar substance is also present in the short hairs of ShaSha mice. Also, it has been suggested that this sudanophilic material may not originate from the sebaceous glands but from the bulb or keratogenous zone of the follicle. It is likely that /

that the sudanophilic material in ShaSha hairs is a secretory product of abnormal differentiation of the medulla. If so, it is possible that a similar substance may be secreted in Sha+ hairs as a result of some anomaly during the differentiation of the medulla cells. The Sha gene may cause minor undetectable keratinization defect in the medulla, in the presence of a normal allele. It has been shown that the Sha gene causes abnormal keratinization of the cortex and medulla when its normal allele is absent. In this way, the Sha+ and ShaSha phenotypes may be related.

Although the follicles of nunu mice are grossly deficient in sulphhydryl groups, the main interest of the nu gene lies in the multiple pattern of morphological abnormalities which it causes. The most interesting and significant defect of the pleiotropic system is the liver necrosis, from both genetical and pathological viewpoints. Analyses of pleiotropic patterns in the mouse have shown that if one original mass of tissue is abnormal all the developmental features which depend upon it will also be abnormal. This applies at both morphological and physiological levels of investigation. The initial change in the range of abnormalities observed in nunu mice is abnormal keratinization of the hairs in the follicles. The reason why the initial change occurs at all appears to be due to a deficiency of sulphhydryl groups in the follicles. The problem of the liver necrosis which usually occurs after 4 to 5 weeks of age, was investigated on the basis/

basis that the sulphur metabolism of the liver may be aberrant. The methods used, however, left the pleiotropy irreducible to a unifying cause.

This means that other methods of investigation must be employed. Since the nu gene is responsible for the synthesis of inadequate amounts of sulphhydryl groups in the follicles, an enzyme system involved in sulphur metabolism may be defective. Techniques of biochemistry and enzymology would appear to be the most likely means of seeking an explanation to the liver necrosis. The one gene - one enzyme theory suggests that the nu gene may cause a block in a biosynthetic sequence of reactions in the parenchymal cells of the liver. But another surprising aspect of this investigation must be considered when seeking an explanation for the liver defect.

The unexpected finding of a parasitic protozoan, Toxoplasma in nude mice complicates the issue. Certain suggestions regarding the relationship between the liver defect and Toxoplasma have already been made. The immediate problems are to decide if normal littermates of nunu mice carry the parasite, and if the organism causes the liver necrosis of nunu mice. If the organism is not responsible for the liver necrosis, then a solution to the problem will probably be obtained by the techniques of biochemical genetics. Alternatively the organism may be confined to nunu mice and be absent from normals. This would be an example of a specific genotype parasite relationship. The whole problem of the liver abnormality of nunu mice remains open for further investigation.

It/

It is seen, then, that the Sha and nu genes add a variety of problems to those already existing from previous studies of hairless mutants. The main genetical, and morphological features of the two new mutants have been clarified, though a few details remain to be completed. But there is much work on a biochemical plane to be undertaken before a deep and penetrating understanding of the mode of action of the Sha and nu genes can be obtained.

CHAPTER V GENERAL SUMMARY.

The genetics, morphology, and histology of two new hair mutants which are phenotypically different from previous forms of hairlessness in the mouse, have been investigated.

One of the new hairless genes is semi-dominant and is called 'shaven', Sha. ShaSha mice do not grow a first coat and the adults grow sparse short hairs at regular intervals. Sha+ mice are very different in appearance from ShaSha animals: they grow a full coat and never show baldness, but the coat is greasy. Thus, the Sha gene differs from other semi-dominant hairless genes in that it does not show a dosage effect. Sha is closely linked with naked N in linkage group VI. The percentage recombination was 0.8 with 5% fiducial limits of 0.37 to 1.54. This is the third example in the mouse of adjacent loci having similar phenotypic effects. The hairlessness of ShaSha mice is not caused by a failure of follicle initiation but is due to the inability of the follicle population to produce fully keratinized hairs. The follicles metabolize sub-normal amounts of the keratin precursors sulphhydryl groups. The greasy coat of Sha+ animals is due to the presence of a sudanophilic substance in the air spaces of the fibre medullae.

The other new hair mutant is recessive and is called nude, nu. Nude nunu mice never grow a first coat and only hair fragments erupt on the adults. Again, the hairlessness is caused by/

by abnormal keratinization of the hairs during anagen. The defect is associated with deficiency of sulphhydryl groups in the follicle. The nu gene causes a number of other abnormalities: high mortality of young nunu mice, reduced growth rate, infertility and death of all the adults, usually between 5 and 15 weeks of age. Death is due to degeneration of the liver tissue. An attempt to relate the abnormal sulphur metabolism of the skin to a similar defect of the hepatic tissue was unsuccessful. A surprising outcome of the study of nunu mice was the discovery of a parasitic protozoan, Toxoplasma gondii, in the liver. The implications of this observation are discussed.

The histological studies showed that the genes Sha and nu may be added to that group of hairless genes which cause aberrant keratinization of the hairs in the follicles and which is typically represented by the gene N.

### ACKNOWLEDGEMENTS.

I am very grateful to Dr. D.S. Falconer for his advice and guidance given throughout this study. I am indebted to Professor C.H. Waddington for laboratory facilities.

I wish to thank Dr. K. Jones, Dr. J.M.K. Mackay, Dr. J.G. Campbell and Mr. C. Curtis for helpful discussions, and Mr. R.B. Land for injecting the mice. Thanks are also due to Mr. J. Isaacson and his staff for technical assistance in looking after the mice. The valuable help of Mr. D. Pinkney and Mr. E.D. Roberts in preparing the figures is much appreciated.

I am indebted to The Agricultural Institute, Dublin, for financial support throughout these studies.

## REFERENCES.

- Alexander, P. and Hudson, R.F. (1954). Wool, its chemistry and physics. Chapman and Hall Ltd., London.
- Bagg, H.J. (1925). Hereditary abnormalities of the viscera. 1. A morphological study with special reference to abnormalities of the kidneys in the descendants of X-rayed mice. Amer.J.Anat. 36.275-311.
- Bennett, H.S. (1951). The demonstration of thiol groups in certain tissues by means of a new coloured sulphhydryl reagent. Anat. Rec.110.231.
- Bern, H.A., Harkness, D.R. and Blair, S.M. (1955). Radioautographic studies of keratin formation. Proc.Nat.Acad. Sci. 41. 55-60.
- Carter, T.C. (1951). Wavy coated mice: Phenotypic interactions and linkage tests between rex and (a) waved-1, (b) waved-2. J. Genet. 50.268-276.
- Carter, T.C. and Falconer, D.S. (1951). Stocks for detecting linkage in the mouse and the theory of their design. J. Genet. 50.307-323.
- Chase, H.B. (1954). Growth of the hair. Physiol.Rev.34.113-126.
- David, L.T. (1932). The external expression and comparative dermal histology of hereditary hairlessness in mammals. Z. Zellforsch. U.Mikroskop. Anat. 14.616-719.
- Dunn, L.C. and Caspari, E. (1942). Close linkage between mutations with similar effects. Proc.Nat.Acad.Sci. 28.205-210.
- Ebert, J.D. (1953). An analysis of the synthesis and distribution of the contractile protein, myosin, in the development of the heart. Proc.Nat.Acad.Sci. 39.333-344.
- Eisen, A.Z., Montagna, W. and Chase, H.B. (1953). Sulphydryl groups in the skin of the mouse and guinea pig. J.Nat.Cancer Inst. 14.341-348.
- Falconer, D.S. (1953). Total sex-linkage in the house mouse. Zeitschrift für indukt. Abstammungs-und Vererbungslehre, 85.210-219.
- Falconer, D.S., Fraser, A.S. and King, J.W.B. (1951). The genetics and development of "crinkled", a new mutant in the house mouse. J.Genet. 50.324-344.
- Falconer, D.S. and Snell, G.D. (1952). Two new hair mutants, rough and frizzy, in the house mouse. J. Hered. 43.53-57.

- Falconer, D.S. and Sobey, W.R. (1953). The location of Trembler in linkage group VII in the house mouse. *J. Hered.* 44. 159.
- Feldman, H.A. (1953). The clinical manifestation and laboratory diagnosis of Toxoplasmosis. *Amer.J.Trop.Med. and Hygiene.* 2.420-428.
- Finney, D. (1943). The determination of linkage VII. Combination of data from matings of known and unknown phase. *Ann.Eng.,London.* 12.31-43.
- Fisher, R.A. (1946). A system of scoring linkage data with special reference to the pied factors in mice. *Am.Nat.* 80.568-578.
- Fisher, R.A. and Yates, F. (1948). Statistical tables for biological, agricultural and medical research. 3rd. Ed. Oliver and boyd. London and Edinburgh.
- Fraser, A.S. (1951). Growth of the mouse coat. *J.Exp.Zool.* 112. 15-30.
- Fraser, F.C. (1946). The expression and interaction of factors producing hypotrichosis in the house mouse: histology and experimental results. *Canad. J. Res. D,* 24.10-25.
- Frenkel, J.K. (1953). Host, strain and treatment variation as factors in the pathogenesis of Toxoplasmosis. *Amer. J. Trop.Med. and Hygiene.* 2.390-415.
- Garber, E.D. (1952). "Bald", a second allele of hairless in the house mouse. *J. Hered.* 43.45-46.
- Garrod, A.E. (1923). In-born errors of metabolism. 2nd.Ed. Ox. Univ. Press.
- Giroud, A. and Bulliard, H. (1930). La keratinization de l'epiderme et de phaneres. Genese des substances soufrees de la keratins. *Arch.Morph.Gen.Exper.* 29.1-83.
- Glynn, L.E., Himsworth, H.P. and Neuberger, A. (1945). Pathological states due to deficiency of the sulphur containing amino-acids. *Brit. J. Exp. Path.* 26.326.
- Green, E.L. and Mann, S.J. (1961). Opossum, a semi-dominant lethal mutation affecting hair and other characteristics of mice. *J. Hered.* 52.223-227.
- Gruneberg, H. (1938). Analysis of the pleiotropic effects of a new lethal mutation in the rat. *Proc.R.Soc. (B), No.838,* 125.123-144.

- Gruneberg, H. (1943). Congenital hydrocephalus in the mouse, a case of spurious pleiotropism. *J.Genet.* 45.1-21.
- (1948). Genes and pathological development in mammals. *Symp.Soc.Exp.Biol.* No. 2, Growth.
- (1963). The pathology of development. A study of inherited skeletal disorders in animals. Oxford: Blackwell Scientific Publications.
- Gruneberg, H. and Truslove, G.M. (1960). Two closely linked genes in the mouse. *Genet.Res.* 1.69-90.
- Hardy, M.H. (1952). The histochemistry of hair follicles in the mouse. *Amer.J.Anat.* 90.285.
- Herbertson, B.M., Skinner, M.E. and Tatchell, J.A.H. (1959). "Sticky", a new mutant in the guinea pig. *J.Genet.* 56.315-324.
- Jacob, L. (1953). The biology of *Toxoplasma*. *Amer.J. of Trop. Med. and Hygiene.* 2.365-389.
- Jarrett, A. and Spearman, R.I. (1957). The keratin defect and hair cycle of a new mutant (matted) in the house mouse. *J. Embryol. exp.Morph.* 5.103-110.
- Long, C. (1961). *Biochemists Handbook*. Spon Ltd., London.
- Mather, K. (1935). The combination of data. *Ann.Eng.*, London. 6.399-410.
- Mescon, H. and Flesch, P. (1952). Modification of Bennetts method for histochemical demonstration of free -SH groups in skin. *J.Invest.Derm.* 18.261-266.
- Pearse, A.G.E. (1960). *Histochemistry*. 2nd. Ed. Churchill Ltd. London.
- Randelia, H.P. and Sanghvi, L.D. (1961). "Bare", a new hairless mutant in the mouse, genetics and histology. *Genet. Res.* 2.283-289.
- Rawles, M.E. (1947). Origin of pigment cells from the neural crest in the mouse embryo. *Physiol.Zool.* 20.248-266.
- Rothman, S. (1954). *Physiology and Biochemistry of the Skin*. University of Chicago Press.
- Ryder, M.L. (1958). Investigations into the distribution of thiol groups in the skin follicles of mice and sheep and the entry of labelled sulphur compounds. *Proc.Roy.Soc. Edin. (B)* LXVII (1), p.65.

Slee, J. (1957a). The morphology and development of Ragged, a mutant affecting the skin and hair of the house mouse. 1. Adult morphology. J.Genet. 55.100-121.

(1957b). The morphology and development of Ragged, a mutant affecting the skin and hair of the house mouse. 11. Genetics, embryology and gross juvenile morphology. J.Genet. 55. 579.

Stoves, J.L. (1946). The chemistry of animal hair. In: fibrous proteins. Sympos.Soc.Dyer. and Col. 58-66.

Weinman, D. (1952). Toxoplasma and toxoplasmosis. Ann. Rev. Microbiol. 6.281-298.