STUDIES ON SEXUAL PHYSIOLOGY
OF THE MOUSE.

By

Y. TAMURA.

Presented to the Faculty of Science of the
UNIVERSITY of EDINBURGH
as a
THESIS for the DEGREE of Ph.D.

July 1926.

CONTENTS.

A HISTOLOGICAL STUDY OF OVARIAN GRAFTS
IN THE MOUSE.

By

Y. TAMURA.

Animal Breeding Research Department, Edinburgh University.

Thesis for the Degree of Ph. D.

CONTENTS.

I. Introduction.

II. Material and Methods.

III. Description of Cases.

IV. Discussion.

V. General Conclusions.

VI. Summary.

VII. References.

VIII. Description of Figures.

§ 1. Introduction.

During recent years a great deal of attention has been given to the effects upon the body of the host of the physiological activities of implanted gonadic tissues. The coincident effects of such implantation upon the engrafted tissues have not received the same attention. The rabbit, guinea pig, and rat have been the animals used by the great majority of investigators in this field. Schultz (1900 and 1902), however, used the mouse and recorded that in this animal implantation of ovarian tissue into the male was unsuccessful. Since there was reason to assume that possibly this failure was due to imperfection in the technique, it was decided to repeat and extend his work.

§ 2. Material and Method.

The experimental material consisted of 31 male mice, varying in age from 8 to 20 weeks at the time of operation.

Table I.

Age at operation in weeks	Nomenclature.	No. of operated animals
8	A_1 A_2 A_3 A_4 B_1 B_2 C_1	7
12	D_1 D_2 D_3 D_4 D_5 D_6	6
14	E_1 E_2 F_1 F_2	4
15	G_1 G_2 G_3 G_4 G_5 H_1 H_2 H_3 H_4 H_5 H_6 H_7	12
20	I_1 I_2	3
		Total 31

Offspring of the same litter have identical initial letters.

Three of the males were mated at different times after the operation and proved to be fecund.

Stringent antiseptic precautions were taken during the operations. The male was etherised and an area of skin round the site of the operation shaved and painted with iodine. An incision was made just posterior to the last rib, exposing a fatty mass (capsula adiposa) and the kidney. The kidney was carefully detached from the abdominal wall and an incision made in the tunica fibrosa which was folded back. At this stage the wound was covered with a piece of gauze moistened with an antiseptic solution. The female supplying the graft was then etherised, and the ovary removed and transferred to the male, the peritoneal capsule of the ovary being removed before implantation. The surface of the kidney beneath the incised tunica fibrosa was slightly injured and the ovary placed in the wound. The lips of the tunica fibrosa were pulled together as far as possible to cover the graft and the

capsula/

capsula adiposa replaced. The abdominal muscles as well as the skin were then sutured and the wound again painted with alcoholic solution of iodine.

The experimental animals were killed for examination at periods varying from 10 to 35 days after operation. The grafts were removed immediately post mortem and fixed in Allen's modification of Bouin's fluid. Serial sections 10 in thickness were cut and stained either with Delafield's haematoxylin or Heidenhain's Iron Alum Haematoxylin.

§ 3. Description of Cases.

G_1. 15 weeks old at the time of operation. Killed 10 days after operation. (Fig. 3).

Histology of the graft. The graft has persisted but is highly necrosed and the central region consists mainly of a mass of inflammatory tissue. The peripheral region is somewhat more free from inflammatory lesions but isolated groups of lymphocytes and granulocytes are met with. All the follicles in the body of the graft are highly degenerate and are represented by hollow vesicles containing fluid following resorption of the oocyte and of the cells composing the stratum granulosum. The germinal epithelium is apparently healthy and numerous mitotic figures are present. Immediately below the germinal epithelium numerous (about 900) small immature oocytes are found embedded in the stroma. The majority of these are encapsuled by a single layer of epithelial cells; although most of them appear to be normal and healthy, it is estimated that about one third show some signs of the onset of degenerative changes, such as a marked irregularity in the shape of the nuclei and the failure of the chromatin in the nucleus to retain the stain.

Successive stages in the new formation of oocytes from the cells of the germinal epithelium leave little doubt that the numerous young oocytes present in the graft were derived from a post-operative proliferation from the germinal epithelium.

G_2. 15 weeks old at the time of operation. Killed 10 days after operation,

Histology. As in the case of G_1 the graft has persisted but necro-

:tic/

:tic changes are more widely spread. The graft is surrounded by a sheath of fibrous connective tissue except in one restricted region where alone the germinal epithelium has remained intact. There appears to be little doubt that this fibrous tissue is derived from a proliferation of the subepithelial strands of connective tissue following upon the degeneration or breaking down of the germinal epithelium in this area. It is noteworthy that where the germinal epithelium persists there is no proliferation of the underlying fibrous connective tissue elements (basement membrane, tunica albuginea). It is only in the small area covered by normal germinal epithelium that the graft retains a more or less healthy appearance. The bulk of the graft is heavily infiltrated by masses of lymphocytes and granulocytes. All the follicles are highly degenerate and their outlines only can be determined, all normal histological details being lost.

In the small area of apparently normal ovarian tissue numerous young oocytes are found (about 500). There is some activity of the germinal epithelium in this region,(although it is not so marked as in the previous case),indicating the new formation of oocytes.

A_1. Operated at 8 weeks old. Killed 12 days after operation. Histology. The graft has become attached to the tissues of the host and shows no evidence of gross degenerative changes although the surrounding tissues is heavily infiltrated by masses of granulocytes. An outgrowth from the surrounding tissue encapsules the graft. Five large follicles, varying in diameter from 0.37 mm. to 0.32 mm. are present and some of them are in the early stages of follicular atresia. A few smaller follicles

(under/

(under 0.25 mm. in diameter) are present in the cortical stroma while just beneath the germinal epithelium at least 600 primary oocytes were counted. As in the case of the larger follicles it was observed that many of the medium sized follicles showed early signs of follicular atresia, e.g. fatty infiltration of the cells of the stratum granulosum.

As previously described, new formation of oocytes from the germinal epithelium was observed.

A_2. Case history the same as that of A_1.

Histology. The graft is almost completely enclosed in a fibrous connective tissue sheath which, however, is not in direct contact with the graft except at the point of attachment. The graft has retained the typical ovarian structure and there is no evidence of widespread inflammatory changes.

Six large follicles 0.38 mm. in diameter) are present but most of them show signs of the onset of degenerative changes. In the case of the most advanced stage degeneration is evidenced by the irregularity in the shape of the follicles and degeneration of the cells of the membrana granulosa which lie scattered in the liquor folliculi; the failure of the chromatic elements in the nuclei of the ova to retain the stain; and irregularity in the shape of the ova.

Numerous small oocytes are present and the majority of these are localised in the peripheral region. It was noted that follicles of intermediate size (0.15 mm. to 0.35 mm. in diameter) were absent. The occurrence of many anovular follicles and the presence of a series of intermediate stages in the formation of such atypical follicles show that there are two alternative modes/

:des of origin, namely (1) the onset of degenerative changes which result in the breaking down and resorption of the ovum; or (2) the non-inclusion of the ovum in the formation of the primary follicle.

Abundant subepithelial primary follicles are found but the activity of the germinal epithelium at the time of examination is only slight as is evidenced by the fact that very few mitotic figures are observed.

A_3. 8 weeks old at the time of operation. Killed 14 days after operation. (Fig. 4).

<u>Histology</u>. The graft is composed of two distinct portions : gonad and Fallopian tubes area, and is completely enclosed by fibrous connective tissue; it forms a solid mass in which the Fallopian tubes are embedded but there is only a thin capsule over the gonadic portion which is only at some points in direct contact with the latter.

The central region of the gonadic portion of the graft consists of a mass of hyaline fibrous connective tissue and scattered degenerate nuclei. There has been considerable hypertrophy of the ovarian stroma. In the peripheral area five small apparently normal follicles are found but medium and large sized follicles are absent; numerous primordial follicles are present. As in the previous cases new formation of oocytes from the free margin of the germinal epithelium is observed. Some of these are found rather deeply embedded in the stroma and this was found to be due to a folding-in of the germinal epithelium in this region caused possibly by shrinkage following degeneration of the central area of the graft and subsequent absorption of necrosed tissue/

tissue. Anovular follicles are commonly met with.

A_4. 8 weeks old. Killed 14 days after operation. The ovarian tissue used for grafting in cases A_3 and A_4 was taken from the same litter sister. (Fig. 5).

Histology. This graft is the most successful of the series. It is encapsuled by a fibrous outgrowth from the base of its attachment. The typical ovarian structure has been retained with only a slight evidence of degenerative changes. The medullary region of the graft consists of numerous cysts embedded in a connective tissue stroma.and representing the ultimate stage in follicular atresia.

Twelve large follicles (0.22 mm. to 0.30 mm. in diameter) and about fifty smaller ones (0.11 mm. and under) are present in the stroma of the central region in addition to the very numerous primary follicles found at the periphery, just beneath the germinal epithelium. Six of the large follicles show signs of incipient atresia in that the ova are prematurely entering into the maturation division; in two of these the first polar body has become constricted off and the ova are in the early anaphase stage of the second mitotic division. These ova have become detached from the stratum granulosum and are lying free in the liquor folliculi. Such abnormal follicles are commonly met with in the normal functioning ovary. The germinal epithelium retains its normal structure.but there is no marked activity of the component cells.

H_1. 15 weeks old at the time of operation. Killed 14 days after operation.

Histology/

Histology. The graft is highly necrosed, the central region consisting of a mass of pale staining cell debris through which isolated pycnotic nuclei are scattered. Nearer the periphery the degenerative changes are not so marked and typical ovarian stroma is present through which extensive erythrocyte extravasation has occurred. The germinal epithelium in contradistinction to the rest of the graft shows few or no signs of degenerative changes and the presence of several mitotic figures in different regions of the epithelium gives evidence that this structure is functioning normally.

The presence of a few small follicles in an early stage of follicular atresia was noted but most of the follicles originally present in the graft have completely degenerated and all traces of their characteristic histological features have been destroyed. Several apparently healthy primary follicles were observed.

H_2. 15 weeks old at the time of operation. Case history as in H_1.

Histology. Although the graft has persisted, wide spread necrotic changes have occurred, particularly in the central area which consists of a scanty framework of connective tissue with masses of lymphocytes, granulocytes and degenerating cells scattered throughout it. One or two large blood vessels permeate this region. The degenerative changes are less marked towards the periphery of the graft. No follicles of any size are present and in only one instance has the outline of the follicle been retained. Small follicles are present embedded in the peripheral stroma but are apparently unhealthy, as the chromatin threads of the ova fail to retain the stain.

The/

The germinal epithelium, which has for the most part retained its normal structure, shows only slight activity.

H_3. 15 weeks old at the time of operation. Case history the same as that of his litter brothers.

Histology. Although the graft has persisted, degenerative changes are wide spread and the original histological features have become almost obliterated. There has been a practically complete degeneration of the **Graafian** follicles which are represented only by a persisting fibrous capsule derived from the thecae of the follicle ; the central cavity has been invaded by lymphocytes and leucocytes and the ovum and follicular cells have been completely absorbed. There has been considerable hypertrophy of the ovarian stroma and the continued activity of the stroma cells is evidenced by the presence of abundant mitotic figures.

Invasion of inflammatory tissue has taken place throughout the graft but is greater in the medullary than in the cortical region. The germinal epithelium, if present, could not be identified with certainty.

H_4. 15 weeks old at the time of operation. Case history as that of litter brothers.

Histology. Although the medullary region of the graft is composed almost entirely of inflammatory tissue, such degenerative changes are not so marked in the cortical region, where several follicles (0.16 mm. to 0.10 mm. in diameter) are found embedded in the rather dense and actively proliferating stroma. Some of these follicles are in the early stages of atresia, as is shown in one case by the early onset of the maturation processes, the

ovum/

ovum being in the early anaphase stage of the first mitotic division. The original large follicles of the graft have completely broken down and all definite histological follicular features have disappeared.

The germinal epithelium has retained its normal structure and signs of cell activity are marked. Just below the germinal epithelium, embedded in the peripheral stroma, many young oocytes were found.

Considerable ingrowth of fibrous tissue is noticeable in one region of the graft.

H_5. 15 weeks old at the time of operation. Case history as that of litter brothers.

Histology. The graft exhibits gross degenerative changes which have greatly modified the typical ovarian structure. It consists of two portions : an area containing Fallopian tubes deeply embedded in a dense fibrous stroma, and a gonadic area loosely enclosed by a fibrous sheath. Large vascular spaces are present between the graft proper and the fibrous capsule. The grafted Fallopian tubes have undergone considerable degenerative changes. The epithelial lining is very scanty and is not folded and the cavity of the tubes contains a mass of cell debris derived from desquamated degenerative epithelial cells.

The medullary region of the gonadic portion consists of a mass of degenerated cells supported by a loose framework of connective tissue. Liquefaction and absorption of the degenerating tissue is actively progressing. The remains of degenerated Graafian follicles are represented by scattered cysts full of fluid and containing scattered degenerated nuclei.

The/

The peripheral stroma contains no follicles of any size but about 100 very young oocytes were counted. Active hypertrophy of the stroma is evidenced by the presence of many cells undergoing mitosis.

The germinal epithelium could not be identified with certainty.

H_6. 15 weeks old. Case history the same as that of litter brothers. (Fig. 6).

<u>Histology</u>. As with the other members of this group considerable necrosis of the implanted tissue has occurred. The graft may be divided into two distinct portions separated by a wide band of fibrous tissue : (1) an area embedded rather deeply into the tissue of the kidney, consisting of large distended Fallopian tubes; these are lined by a single somewhat flattened layer of epithelial cells of unhealthy appearance and are embedded in a fibrous stroma which is heavily infiltrated by leucocytes, granulocytes and lymphocytes; (2) an area of gonadic tissue projecting above the surface of the kidney and internally coming into contact with the Fallopian tube area. The graft has retained the histological character of an ovary to a greater extent than in the preceding case. Although the cortical region is almost as completely degenerate the cortical zone still contains a number of Graffian follicles which have not yet undergone the extreme degeneration noted previously. One large follicle (0.40 mm. in diameter) in atresia was seen in which the ovum had broken down and was partially absorbed. Degenerative changes in the follicular cells are confined to the innter layers while the peripheral layers are apparently normal and many of their cells are in mitosis.

A/

A dozen small follicles (less than 0.10 mm. in diameter) are present, many of them in early stages of atresia. The ovarian stroma is somewhat dense and hypertrophy of the constituent cell elements is in progress. In the stroma just beneath the surface of the graft numerous apparently healthy developing oocytes are found. The outer surface of the graft is covered by the germinal layer, many of whose constituent cells are in varying phases of mitosis. Intermediate stages in the neoformation of primary oocytes from this active layer are observed.

H_7. 15 weeks old. Case history the same as that of the other members of group D^1.

Histology. Of all the grafts of group D^1 this one has undergone the greatest modifications. The medullary region consists of a mass of inflammatory tissue. The cortical region is composed of a fairly dense stroma, many of the cells of which are showing mitosis and are heavily impregnated with masses of leucocytes, granulocytes, and lymphocytes. There is no trace of any of the definitive female sex cells or follicular structures. The germinal epithelium has retained its structure and the cells are actively proliferating but only intermediate stages in the neoformation of oocytes from the epithelium were encountered.

D_1. 12 weeks old at the time of operation. There was no operative interference with the male genital organs. Killed 16 days after operation. (Figs. 1 and 7).

Histology. The graft has survived without any gross alteration from the normal ovarian structure. More than a dozen comparatively large Graafian follicles (maximal diameter 0.35 mm.) are present, some of which are in the early stages of follicular degeneration/

:neration with desquamated cells of the granulosum and irregular:ly-shaped ova floating in the liquor folliculi. Five follicles (diameter 0.38 mm.) were found in which extravasation of blood into the follicular cavity had occurred; in these incipient sta:ges in the degeneration of the ovum and the epithelial lining of the follicles were seen (so-called blood follicles). Several small and numerous primary follicles are present.

The medullary region is heavily infiltrated by masses of lymphocytes.

Follicles with a diameter ranging from 0.35 mm. - 0.15 mm. are extremely rare. The germinal epithelium possesses the nor:mal structure. Although there are no signs of cell activity newly formed oocytes are found in clusters just beneath the germ:inal epithelium.

D_2. 12 weeks old at the time of operation. Case history the same as D_1. (Fig. 2).

Histology. The graft is composed of two distinct portions, Fallo:pian tube and gonadic, and is partially embedded in the tissue of the kidney which in the immediate neighbourhood of the graft consists of degenerating tubules and areas of inflammatory tis:sue. The Fallopian tube region consists of large swollen ve:sicles filled with fluid and containing a few degenerate cells and embedded in an inflammatory connective tissue stroma. The absence of folds in the walls of the grafted Fallopian tubes is due to the distension of the tubes by accumulated fluid. This area occupies about two thirds of the graft.

The outer surface of the gonadic portion of the graft is closely applied to the fibrous tissue sheath which covers the entire/

entire graft but enlarged vascular vesicles are present at frequent intervals between the two tissues. The histological structure of the graft approximates that of the normal ovary except that the ovarian stroma is more dense owing to (1) hypertrophy of the stroma elements; (2) heavy infiltration of inflammatory tissue, particularly marked in the medullary region, and the higher frequency of follicular degeneration. Numerous follicles in the later stages of atresia, consisting of a cyst filled with fluid and cell debris, are found; their occurrence is due to a break-down and absorption of both the ovum and the cells of the stratum granulosum.

The ovarian tissue adjacent to the large vascular spaces shows least evidence of degenerative changes and 14 follicles (diameter varying from 0.35 mm. to 0.25 mm.) are found, either apparently normal or exhibiting only early stages in atresia. In this region numerous apparently healthy small and primary follicles are also found.

Although identification of a continuous germinal epithelium surrounding the graft was difficult, cellular activity at the periphery was noted and aggregates of young oocytes appear to indicate that active proliferation of oocytes from the germinal epithelium is in progress.

D_3. 12 weeks old at the time of operation. Case history as that of his litter brothers. Killed 16 days after operation.

Histology. The basal portion of the graft is embedded in the tissue of the kidney. There is a sheath of fibrous tissue surrounding that portion of the graft which is projecting from the surface of the kidney. However, the sheath is not in direct con-

:tact/

:tact with the germinal tissue, owing to the intervention of large blood lacunae. The graft has retained the typical histological structure of an ovary. Several normal large follicles (0.41 mm. in diameter) are encountered as well as eight comparatively large follicles in early atresia, in some of which the ovum is absent. However, there where the ovum is still present it is mostly undergoing abnormal maturation, the nuclei being in the early anaphase stage of the first or second mitotic division. This abnormality is commonly met with in the normal functioning ovary and is an early sign of the onset of follicular atresia.

In some cases the process of follicular degeneration is more advanced as is exhibited by the sloughing off of cells from the stratum granulosum into the follicular cavity.

About a dozen medium-sized follicles (0.20 mm. - 0.26 mm.) are present. Fatty infiltration of the cells of the stratum granulosum in some of these is indicative of follicular atresia.

In this graft young oocytes are most abundant and are restricted to a definite area. As in the previous cases, considerable activity of the cells of the germinal epithelium and intermediate stages in the formation of oocytes from this structure were noted.

D_4. 12 weeks old at the time of operation. Killed 18 days after operation.

Histology. The graft is enveloped by a connective tissue sheath which, however, is not in direct contact with the graft at all points owing to the intervention of large blood lacunae. The graft present the typical ovarian structure. Eight large normal follicles (0.32 mm. - 0.37 mm.) are present. Seven comparative:ly/

:ly large atretic follicles were encountered; in three of them the ova are undergoing abnormal maturation processes, the nuclei are in the anaphase stage of the first or second mitotic division. In the others follicular degeneration is more advanced; the ova have completely broken down and the typical histological appearance of the membrana granulosa has almost disappeared owing to the desquamation of the cells into the follicular cavity.

Medium and small-sized follicles are present some of which are in early stages of atresia; this is shown by fatty infiltration of cells of the stratum granulosum although the ova show no signs of degeneration. In other cases the degenerative changes are more marked owing to a more extensive infiltration of the follicular cells and the ova have completely degenerated.

The central medullary zone of the graft consists of numerous cysts embedded in a fibrous stroma which is somewhat heavily infiltrated by lymphocytes. In the peripheral area numerous young oocytes are present embedded in the stroma. The germinal epithelium presents a normal appearance and activity of the component cells is evidenced by the presence of numerous mitotic figures. Intermediate stages in the development of primary oocytes from the cells of the germinal epithelium are encountered.

D5. 12 weeks old. at the time of operation. Killed 18 days after operation.

Histology. As in the preceding case, the graft is enclosed by a sheath of fibrous tissue which is separated from the body of the graft by enlarged blood-filled lacunae. Gross alterations from the typical structure of the functional ovary are observed. No large follicles are present. The bulk of the graft consists of

a/

a loose framework of connective tissue scattered through which there are numerous epitheloid cells with degenerating nuclei and lymphocytes. The epitheloid cells are derived from the strata granulosa of the degenerated follicles following the disruption of the theca. The accumulation of these epitheloid elements is more marked in the peripheral region of the graft, the medullary tissue being more open.

Towards the outer edge of the graft two small follicles (0.12 mm.) apparently normal, several small follicles in atresia, and numerous young oocytes are found embedded in the dense stroma. Various stages in follicular atresia, as previously described, were observed.

Some activity of the cells of the germinal epithelium is noted. It is more marked in those regions below which the stroma contains numerous young oocytes.

D_6. 12 weeks old. at the time of operation. Killed 18 days after operation.

Histology. The graft is rather deeply embedded in the substance of the kidney. The gross histological structure shows no marked deviation from that of the normal ovary. The medullary zone contains numerous thin-walled cysts embedded in a fibrous stroma. Large numbers of follicles of varying size are met with throughout the graft but most of them are in a more or less advanced stage of atresia. There are eight large follicles (0.35 mm. in maximum daimeter), all of which are undergoing atresia. Towards the periphery of the graft many apparently healthy small follicles and young oocytes are present.

The germinal epithelium, where it is not in direct contact with the fibrous sheath covering the graft, retains its typical structure/

structure and the activity of the cells is evidenced by the presence of mitotic figures. In this region the neoformation of oocytes from the cells of the germinal layer is observed.

B_1. 8 weeks old at the time of operation. There was no operative interference with the male reproductive glands. Some time after the operation the animal was mated to a litter sister and the mating proved fertile. Killed 20 days after operation.

Histology. The graft encapsuled by a sheath of fibrous connective tissue is embedded in the substance of the kidney. The medullary region shows widespread degenerative changes, the fibrous stroma being heavily infiltrated by masses of lymphocytes. In the centre of the graft a very large haemorrhagic vesicle is present. The cortical stroma is extremely dense and in addition to the elements normally present in this region slight infiltration of lymphocytes is noticed. The presence of mitotic figures among the stroma cells leads one to the conclusion that the denseness of the stroma is to be attributed to an abnormal activity of the component cells. It was shown in two previous cases (D_5 and D_6) that abnormal density of the stroma may be due to the setting free of the follicle cells following the breakdown of the thecae of the follicles. Several degenerated and anovular follicles are present as well as fourteen apparently healthy follicles varying in diameter from 0.15 mm. to 0.32 mm.

In one region of the graft there is present a relatively enormous vesicle with thickened fibrous walls occupying about one third of the total area of the graft. The cavity is filled with fluid in which lymphocytes and debris of degenerated cells are found.

Where/

Where the germinal epithelium remains unmodified no activity of the constituent cells is seen although the presence of numerous young oocytes situated somewhat deeply in the stroma (0.3 mm. from the periphery) was noted.

B_2. 8 weeks old at the time of operation. Subsequent to the operation the animal was mated to a litter sister and this mating proved fertile. Killed 20 days after operation.
Histology. The graft has retained the characteristic structure of the ovary but evidence of degenerative changes is given by the occurrence of a wide spread infiltration of lymphocytes and leucocytes, particularly marked in the fibrous medullary region. The cortical stroma is dense and consists of proliferated connective tissue elements, some infiltration of leucocytes and lymphocytes and large isolated epitheloid cells with a large round nucleus and granular cytoplasm (interstitial tissue).

Numerous follicles (about 40 were counted), the majority of which are apparently healthy, with a diameter ranging from 0.32mm. to 0.12 mm. were found. A few of these are in the early stages of atresia, incipient degeneration of the ovum, the stratum granulosum,or of both being present. As in the case of the normal ovary some follicles (three) are undergoing premature maturation process.

A typical germinal epithelium surrounds the graft but only a slight activity of the constituent cells is observed. Numerous young oocytes are found just below the surface of the epithelium.

C_1. (Fig. 8) 8 weeks old at the time of operation. Post-operative mating of the animal proved fertile. Killed 20 days after/

:er operation.

Histology. The graft has persisted and shows few or no signs of degeneration. However, extensive necrosis of the adjacent kidney tissue is evident. The kidney tubules in this area consisted of thin-walled cysts distended with colloid; there is considerable hypertrophy of the intratubular connective tissue elements and at the region of attachment of the graft large masses of lymphocytes.

Many large follicles (0.6 mm. to 0.35 mm.) are present embedded in the cortical stroma which is somewhat more dense than in a typical normal ovary. Two of the largest follicles (0.6 mm.) have completed their development, the nucleus of the ovum being in the metaphase stage of the first maturation division. It is approximately at this stage in the case of the normal ovary that the follicle ruptures and the ovum is extruded. An unusual feature met with in the graft is the presence in the follicular cavity of two medium-sized Graffian follicles of extravasated blood. Although the other histological features are those typical of the healthy follicles, small and primary follicles of healthy appearance are abundant.

Many of the constituent cells of the germinal epithelium of the graft are undergoing mitosis and successive stages in neoformation of oocytes from the germinal layer are observed.

I_1. 20 weeks old at the time of operation. Killed twenty days after operation.

Histology. The graft is clearly divisible into two distinct portions : (1) Fallopian tube area, and (2) gonad. The Fallopian tubes are embedded in a dense fibrous stroma in which large aggre-

:gates/

:gates of infiltrated lymphocytes are found. The gonadic portion of the graft is rather deeply embedded in the kidney tissue which in the vicinity of the graft is somewhat necrosed and inflammatory tissue is abundant. The gonadic portion is at several points in direct contact with the covering fibrous capsule but, as in the previous cases, large haemorrhagic lacunae occur at frequent intervals.

The medullary area of the graft consists, as in the normal ovary, of numerous vesicles embedded in a loose stroma of connective tissue. An abnormal feature, however, is the presence of aggregations of infiltrated lymphocytes. The peripheral region of the graft, though not so heavily infiltrated by these cells, is atypical in that the stroma is somewhat more dense than that of the normal ovary.

Three large almost mature follicles (0.45 mm. in diameter) are present, one of them showing early signs of atresia. Many small follicles are embedded in the peripheral stroma and some of them are undergoing degeneration. No medium-sized follicles are present.

The germinal epithelium covering the graft retains its normal structure even in that region where the degenerative processes in the sub-epithelial tissue are most marked.

Numerous mitotic figures are found both in the cells of the epithelium and in the peripheral stroma. Evidence of the neoformation of oocytes was educed from the sections.

I_2. 20 weeks old at the time of operation. Case history as in I_1.

Histology. On examining the sections of the graft it is found that/

that all histological features of the original ovarian implant have disappeared and have been replaced by ingrowth of fibrous connective tissue and the infiltration of large numbers of lymphocytes and leucocytes. Only occasionally can the remnants of degenerated follicles be seen. These occur as small vesicles scattered through the fibrous tissue, with only a few cells lining the limiting membrane, the cavity being filled with a mass of broken down cell constituents. In a few instances isolated ova are found with no trace of follicular cells or thecae. In these cases the type of degeneration is not characteristic in that it is commonly found that the ovum is more susceptible to the onset of degenerative changes than the follicular and thecae cells.

G_3. 15 weeks old at the time of operation. Killed 21 days after operation.

Histology. The graft, clearly separated into two distinct portions, is enclosed by a thick connective tissue sheath. Degenerative changes are well advanced in one area, where no typical ovarian features can be identified, the whole of the tissue being inflammatory. The other region although markedly degenerate retains its original ovarian structure, more or less modified by the presence of infiltrated masses of leucocytes, lymphocytes, and granulocytes. Embedded in the stroma five follicles (0.21 mm. in maximal diameter) are found, in which degenerative changes are exhibited in the ovum, although the cells of the membranum granulosum are normal. In addition to these, several small and primary follicles, apparently healthy, are found embedded in the stroma. The germinal epithelium covering the graft/

graft could not be identified with certainty.

E_1. 14 weeks old at the time of operation. Killed 21 days after operation. The grafted ovary had become absorbed.

E_2. (fig. 9). 14 weeks old at the time of operation. The ovary was taken from a litter sister in an early stage of pregnancy. Killed 21 days after operation.
<u>Histology</u>. The graft, almost completely separated into two portions by an invading band of fibrous tissue, is enveloped by a thick connective tissue sheath which, however, is in direct contact with the graft only at a few points, the intervening spaces being filled with blood. The graft retains the typical ovarian structure. No signs of wide spread degeneration are in evidence but small restricted areas of inflammatory tissue are present in some regions. Nine large healthy Graafian follicles (0.5 mm.), several medium-sized and numerous primary follicles are found embedded in the stroma, which contains in addition to the usual stroma elements large masses of interstitial tissue bundles separated from each other by strands of fibrous connective tissue. Some of the smaller oocytes show signs of incipient degenerative changes, partial atrophy of the ovum and fatty infiltration of follicular cells.

The germinal epithelium retains for the most part its structure apparently unchanged although only slight activity is evidenced by the presence of a few mitotic figures; at some points the germinal epithelium has become flattened. Further evidence of the derivation of the new oocytes from the epithelium, as previously described, was obtained from this graft.

G_5/

G_5. (fig.10). 5 weeks old at the time of operation. Killed 28 days after operation.

Histology. The graft is encapsuled by fibrous connective tissue and the gross histological appearance has not been affected. Many Graafian follicles of varying size (maximal diameter 0.51 mm) apparently normal, are found embedded in the dense stroma which, in addition to its normal constituents, contains areas of interstitial cell tissue and masses of infiltrated leucocytes, granulocytes and erythrocytes. In addition six large follicles (0.64 mm.) in atresia are present, in two of which the follicular cavity is filled with extravasated blood and degenerative changes in the ovum are evident. In the others desquamation and absorption of the cells of the stratum granulosum is taking place. In the peripheral region several small thin-walled cysts filled with fluid represent the ultimate stage of follicular atresia. Many primary oocytes are found both singly and in small aggregates near the surface of the graft. The germinal epithelium could not be identified as the fibrous sheath was closely applied to the external surface of the graft. A large cyst filled with fluid which at its widest diameter occupies about one half of the graft is found embedded in its substance at one extremity. At the outer surface it is lined by a single layer of flattened epithelial cells outside of which there is a thin fibrous capsule. Internally, however, the connective tissue strands and the epithelial lining have broken down and the cavity of the cyst is in direct association with the ovarian stroma. In the fluid contents of the cyst aggregates of granulocytes and cell debris are found suspended.

It is suggested that this large cyst was derived from a de-

:generate/

:generate Graafian follicle, gradual accumulation of fluid distending the degenerating follicle until rupture occurred. This would be followed by the formation of cysts and absorption of the ovarian stroma at the site of the rupture.

F_1. (fig.11). 12 weeks old at the time of operation. Killed 35 days after operation.

Histology. The graft persisted without any material alteration in the structure of the grafted tissue. It is divided into two portions : (1) an area of dense fibratic stroma in which Fallopian tubes are seen in section; the tubes are typical in appearance and structure and the folded epithelial lining shows no sigsn of cell degeneration. (2) a gonadic area which retains the histological features characteristic of the normal functioning ovary. The graft is surrounded by a sheath of fibrous tissue which over the greater part of the surface of the graft is separated from it by large lacunae filled with blood; here the germinal epithelium retains its typical structure without modifications. Centrally the graft consists of a collection of empty cysts supported by a framework of fibrous tissue. The cortical stroma is, as in the normal ovary, rather scanty, though in it masses of interstitial cell tissue are located.

Two large Graffian follicles are found in the corticall zone (0.58 mm.), the ovum in each of them showing signs of degeneration. They are irregular in shape and hypochromatic. Many medium-sized and small follicles are present, some of them apparently healthy, others showing evidence of degenerative changes, namely fatty infiltration of many of the cells of the strattum granulosum. Two large follicles 0.8 mm.) the follicular cavity of/

of which is filled with extravasated blood were noted.

The most striking feature of this graft is the presence of four corpora lutea which from their histological appearance date the rupture of the ripened follicle to about 5 days previous to the killing of the animal for examination. The corpora lutea are essentially similar histologically both in structure and appearance to those found in the normal functioning ovary. It was impossible to identify a continuous germinal epithelium at all regions of the graft but where it could be identified no activity of the component cells was noted although the sub-epithelial stroma contained numerous young oocytes and primordial follicles

F_2. 12 weeks old at the time of operation. History as in F_1
Histology. The medullary region of the graft consists of(a)loose framework of connective tissue supporting numerous thin-walled cysts; their cavity is.filled with fluid in which a few degenerated nuclei and erythrocytes are found; (b) blood vessels; (c) degenerate cell masses and aggregates of leuco- and lymphocytes.

The cortical zone in this graft is interesting in that the ovarian stroma in which the Graafian follicles are embedded also contains abundant interstitial tissue. These cells occur either singly or in elongated bundles separated by connective tissue strands. It is possible to trace the formation of typical bundles of interstitial cells from the sub-epithelial primary follicles. The ovum degenerates and fatty infiltration of the single layer of follicular cells takes place. The cells gradually increase in size, obliterating the follicular cavity.

Typical cytological changes are observable in the nucleus which becomes hyperchromatic and irregular in outline. As the

cells/

cell mass sinks deeper into the stroma it becomes somewhat elongated owing to lateral pressure.

Although no definite evidence as to the origin of the isolated interstitial elements could be deduced, it seems probable that they are derived from the breaking-down of the bundles of interstitial cells mentioned above. Scattered through the stroma there are isolated patches of leucocytes and lymphocytes.

Two large follicles (0.3 mm.) are present; in both cases no trace of an ovum can be discerned although the stratum granulosum retains a healthy appearance. Numerous small follicles are observed many of which show definite evidence of degenerative changes such as breaking down and partial or total absorption of the ovum in conjunction with fatty infiltration of the cells of the stratum granulosum.

The germinal epithelium retains for the most part its typical structure but shows signs of cellular activity.

Many primary oocytes are found in the sub-epithelial stroma.

§ 4. Discussion.

(1) Germinal epithelium.

Herlitzka (1900) examined the ovarian grafts in individuals of both sexes of the guinea pig 4-50 days after implantation, and recorded that there was no difference between the fate of the graft in the female and of that implanted into the male. According to his description, the grafted ovary underwent progressive degeneration; the germinal epithelium remained intact until the 4th to 9th day, but after 10 days degenerative changes set in and at 35 days no trace of germinal epithelium could be identified, except in 2 cases examined at 42 and 46 days respectively after the operation where the germinal epithelium presented a more or less normal appearance. This was specially marked in the case of an ovary grafted into a male at 46 days, where he recorded a normal appearance with a healthy germinal epithelium and follicles. He concluded that in the guinea pig the germinal epithelium of the ovary remains intact if the peritoneal capsule enveloping the ovary is included in the transplant. Schultz (1900), however, observed normal germinal epithelium in an ovary grafted into the male guinea pig as early as 8 days and as late as 117 days after transplantation. Marshall and Jolly (1907) stated that in their experiments "the germinal epithelium had always become absorbed". Moore (1921), who worked on the rat, did not refer to the germinal epithelium in his paper, but he found primary follicles in the graft 232 days after transplantation. More recently Voss (1925) reported that in ovarian transplantations in the guinea pig the germinal/

germinal epithelium persisted in most cases.

In the present series of experiments the germinal epithelium remained intact in the majority of cases, although in some it was impossible at the time of examination to identify a continuous germinal epithelium (especially when the grafted ovary contained numerous large follicles).

As stated above in cases G_1, G_2, A_3, H_2, and H_7, the germinal epithelium remained intact and active, as was shown by the presence of plentiful mitotic figures, notwithstanding the fact that the central medullary zone had undergone severe necrosis which was spreading towards the peripheral region. The presence of mitotic figures in the germinal epithelium was also reported by Schultz (1900) in the grafted ovary 8 days after transplantation. Figs. 12-20 show the successive stages of mitotic division in the cells of the germinal epithelium. These are identical with the mitotic figures described by Allen (1923) as characteristic of oogenesis during sexual maturity. According to Allen proliferation of the germinal epithelium occurs in the ovary of the mouse after sexual maturity.

Young oocytes and successive stages of neoformation of the oocytes from the cells of the germinal epithelium were also observed in the present series. Schultz (1900) likewise recorded the presence of young oocytes in his cases and maintains that these were newly formed ones, The results of the microscopical examination demonstrates that according to the histological structure of the grafts the cases are capable of classification as shown in Table II. At 10-16 days and again at 35 days after transplantation (groups B and C) the medium sized follicles were absent or exceedingly rare, whereas the germinal epithelium was/

TABLE II.

Histological condition.	Individuals	Age at operation (weeks)	Time of killing after operation. (days)
I. Typical ovarian structure:			
(a) Follicles of all sizes are present	B_1 B_2 C_1	8	20
	D_2 D_3	12	16
	D_4 D_5 D_6	12	28
	E_2	14	21
	G_3	15	21
	G_5	15	28
	I_1	20	20
(b) Only primary and large but no medium follicles are present.	A_1 A_2	8	12
	A_4	8	14
	D_1	12	16
	F_1	14	35
(c) Only primary follicles are present.	A_3	8	14
	F_2	14	35
	G_1 G_2	14	10
	H_1 H_2 H_4 H_5 H_6 H_7	15	14
II. The graft is highly degenerate and the typical ovarian structure cannot be identified.	E_1	14	21
	G_4	15	14
	H_3	15	21
	I_2	20	20

was active. On the other hand, at from 16-35 days follicles of all sizes were present, including 4 corpora lutea found in one graft at 35 days after transplantation, and the degree of activity of the germinal epithelium varied. At 16-20 days it showed activity, but at from the 21st-35th day it was either inactive or could not be identified with certainty. According to these facts it may be assumed that the fate of the original follicles of all sizes present in the graft is as follows. The large follicles begin to degenerate soon after transplantation; the medium sized and the small follicles develop for a certain period of time but afterwards also undergo degeneration. This process terminates at about the 16th day after transplantation. A new proliferation of young oocytes occurs sometime before the 10th day and the oocytes develop and become medium sized follicles at the 14th day. Proliferation continues until about the 20th day. When the graft attains the stage at which it was at the time of transplantation, the activity of the germinal epithelium ceases until the second proliferation Allen maintains that "a cyclic proliferation of the germinal epithelium gives rise to a new addition of young ova to the cortex of the adult ovary at each normal œstrous period, 4-6 days". The conditions found in the ovarian grafts in the present series can be interpreted if it is assumed that in the ovary grafted into the male cyclic proliferation of the germinal epithelium occurs, the rhythm of which is less rapid than that of the normal œstrous cycle of the female.

If the graft possesses many various sized follicles embedded partially in foreign tissues or is enclosed by a thick connective tissue capsule which is in direct contact with the graft in most parts/

parts, the germinal epithelium is not active, as is seen in Figs. 10 and 11 (G_5 and I_1). On the other hand, even though the graft possesses follicles of all sizes but the connective tissue sheath is not in direct contact with the graft, the germinal epithelium retains its activity, as shown in Figs. 5, 7, 8 and 9 (cases A_4, D_1, C_1, and E_2). These facts indicate that the enlargement of the graft through the development of the component follicles is of necessity inhibited by the enveloping capsule, pressure causing the growing follicles (mostly the large ones) to become irregular in shape (Fig. 11) and the germinal epithelium to become flattened or to exhibit degenerative changes. The degeneration of the component follicles causes a partial shrinkage of the graft and the germinal epithelium again becomes active and gives rise to a second proliferation. It is of importance to note that the most active germinal epithelium is found in those cases where it is not compressed in direct and close contact with the capsule; this point was also emphasised by Herlitzka.

Finally, in cases H_3, H_5, and A_3 the germinal epithelium could not be identified with certainty at the time of examination but abundant mitotic figures in various stages were observed in the stroma. These may have been due to the abnormal proliferation of the stroma elements. In cases H_5 and A_3 abundant young oocytes were found embedded in the peripheral stroma. Their origin could not be traced though it is possible that they are derived from the cells of the germinal epithelium which have migrated into the stroma following upon the shrinkage of the surface of the graft.

(2) Graafian follicles.

(a) Follicular atresia. Schultz (1900) gave no detailed

description/

description of atretic follicles, stating only that at 117 days after transplantation the ovum in the large follicles had degenerated and follicular cells were undergoing transformation into connective tissue. According to Herlitzka (1900) the ova degenerate before the other structures of the ovary and this writer assumes that the ovum is the most specilised element and that it is the most specialised element which is the first to suffer in a strange environment. In the cases described in this paper, in the small follicles in early stages of degeneration fatty infiltration was observed in the stratum granulosum but the ovum was apparently healthy; in more advanced stages, although the fatty infiltration affected the ovum itself, yet, as described in case I_2 (Fig. 34) an isolated ovum with no traces of follicular cells or thecae could be found. Fig. 35 provides further evidence of this kind of atresia; the ovum has remained in the cavity while no definite follicular cells can be identified. This type of atresia, the ultimate stage of which is a hollow vesicle, is common in small and medium sized follicles.

Another process of atresia is that in which the degeneration first affects the ovum and thereafter the follicular cells. There would appear to be two types of this process : (1) in which the stratum granulosum remains in an active condition after the degenerated ovum has become absorbed; in this case the atretic follicle retains its structure during a certain period as an anovular follicle (League and Hartman, 1925; Tamura, 1926), thereafter either undergoing lypolitic degeneration or becoming transformed into other ovarian tissue, such as interstitial tissue. (2) The second type of atresia is that in which the degeneration of/

of the follicular cells follows that of the ovum; the follicular cells desquamate and disappear. These two types of atresia are more common in the medium and large sized follicles.

According to our observations, abnormal maturation processes occur not only in the large follicles but also in the medium-sized ones. Figs. 29-32 show such processes in medium sized follicles. These processes are very common even in the normal functional ovary and present evidence of some degenerative changes. However, when the maturation division is found in large follicles, it is often very difficult to determine whether the process is a normal or an abnormal one. Opinion is divided on this point especially as regards the time at which the formation of the polar body occurs in the mouse (Sobotta, 1875; Kirkham, 1907; Gerlach, 1906; and recently Frankenberger, 1926). It certainly is a fact that the appearance of the maturation division in the nuclei of the ovum marks the end of its development and the ovum is then either extruded or else undergoes atresia.

Haemorrhagic follicles are common among the large ones; the origin of the blood in the follicular cavity was described in detail by Heape (1905). This type of atretic follicles is found after 3 weeks and never before 18 days subsequent to transplantation. Typical haemorrhagic follicles are shown in Figs. 10 and 11 (28-35 days after transplantation).

Finally, small and large cysts are found in some of the grafts; these cysts are derived from degenerated Graafian follicles.

(b) Interstitial tissue. In almost every graft interstitial tissue was present, but the most typical interstitial cells appeared/

appeared at about three weeks after transplantation. Moore (1921) observed such cells in ovarian grafts several months after transplantation and states that "from about the stage of maturation the follicles undergo atresia, the ovum fragments and disappears and the cells of the stratum granulosum are converted into interstitial cell masses." According to our observations, these changes are more common in the small and medium sized atretic follicles than in the large ones. Fig. 36 shows anovular atretic follicles in which the cells of the granulosa are exhibiting activity. Though mitosis is not clearly seen in the illustration, two mitotic figures were observed in the original preparation. These cells of the stratum granulosum will be transformed into interstitial tissue subsequent to the degeneration of the theca.

The interstitial cells are more commonly derived from primary atretic follicles as shown in Fig. 25. One primary follicle is present immediately beneath the germinal epithelium, a few primary anovular follicles, formed following absorption of degenerate ova or developed as anovular follicles from the germinal epithelium are seen, and mitotic figures are observed in the component cells. It can be concluded that the interstitial cell masses are formed by (1) the transformation of the follicular cells of the stratum granulosum in various sized follicles undergoing atresia; (2) by transformation of cells directly proliferated from the germinal epithelium, as suggested by Ochoterna and Ramirez (1920); or, more probably, (3) by transformation of either the follicular cells of primary anovular or of medium sized anovular follicles. Isolated interstitial cells originate from degeneration of bundles of interstitial tissue.

§ 5. General Conclusions.

The results of the present study demonstrate that transplantation of ovary into the male was successful in 90 per cent.of cases and in almost all these cases the germinal epithelium had remained intact. Since the germinal epithelium exhibited activity and successive stages of mitoses were found, it has been suggested that there exists a cyclic rhythm at which proliferation occurs, the first proliferation taking place at 16-20 days and the second sometime about the 35th day after transplantation. It is next suggested that the potentiality of the grafted ovarian tissue in the male body depends primarily upon its vascularisation and secondarily upon the activity of the germinal epithelium. If the graft establishes vascular connections soon after transplantation and under favourable conditions, it retains the original ovarian structure for a certain period of time - about 16 16;20-28 ? days after transplantation - (Table II), and during this period a new proliferation of the cells of the germinal epithelium occurs and gives rise to young oocytes. Even under less favourable conditions, if some degenerative changes set it, the graft will retain the ovarian structure for a varying period of time, provided vascularisation is established before the whole graft undergoes necrosis and while the germinal epithelium is still active.

On comparing the amount of the germinal epithelium of a grafted with that of a normal functioning ovary, it becomes obvious that in the former case it is reduced in area. This is due to (a) the fact that it becomes flattened owing to the pressure of foreign tissue, and (b) degenerative changes. Schultz (1900)

and/

and Moore (1921) had observed that the grafted ovary was reduced in size at 117 and 152 days respectively, and while the former worker reported the presence of distinct germinal epithelium, the latter did not mention it at all but reported the presence of primary follicles. The decrease of the ovarian graft in size is a sequence either of the absorption of the necrosed medullary region of the graft or more probably of a reduction in the area occupied by the germinal epithelium (vide supra).

According to Herlitzka (1900) and to Foa (1900) the graft is more likely to persist if the operation is carried out at an early age. Moore also used young animals for his experiments. However, Lipschütz's school, using a special technique, recently succeeded in transplanting adult ovarian tissue, and the present writer also obtained successful results with the transplantation of ovarian tissue on to the surface of the kidney of the host. It is assumed that the favourable time for ovarian transplantation would be in the case of the mouse from the onset of sexual maturity, i.e., about 8 weeks, to 12 weeks.

It is seen that the female sex gland can persist and develop in the male body, as is the case with an ovarian graft in the female (Foa, 1900). In agreement with the results of Schultz (1900), Herlitzka (1900), Basso (1905), Moore (1921), it was found that the presence of the testis did not interfere with the vitality of the ovarian tissue.

§ 6. Summary.

I. A series of experiments is described in which ovaries from litter sisters at the age from 8 to 20 weeks old, were grafted on to the surface of the kidney of male mice.

II. The grafts were examined at periods varying from 10-35 days after operation. It was found that in the majority of cases the graft had retained the typical ovarian structure, in one case corpora lutea being present (35 days after transplantation).

III. It is suggested that the survival of the graft is dependent primarily upon its vascularisation and secondarily upon the degree of activity of the germinal epithelium at the time of operation.

IV. It is assumed that if the germinal epithelium is unimpaired it proliferates; the first proliferation occurs sometime before the 10th day and continues until the graft has attained the stage at which it was at the time of operation.

V. The original large follicles begin to degenerate soon after transplantation; the medium sized and small ones develop for a certain period of time but afterwards also undergo degeneration.

VI. Graafian follicles undergo degeneration at various stages of development.

VII. Interstitial tissue appears to be derived from the follicular cells of the atretic, or more probably, of the primary and medium sized anovular follicles.

VIII. It is concluded that the presence of the testis does not affect the vitality of the ovarian graft.

§ 7 . References.

ALLEN, E., (1922). The Œstrous Cycle in the Mouse. Amer.Jour. Anat., vol. 30, pp. 297-371.

" (1923). Ovogenesis during Sexual Maturity. Ibid., vol. 31, pp. 439-482.

BASSO, G. L., (1905). Über Ovarientransplantation. Arch. f. Gynäk., vol. 77, pp. 851-861.

FOA, E., (1900). La greffe des ovaires en relation avec quelques questions de biologie générale. Arch. Ital. d. Biol., vol. 34, pp. 43 - 73.

FRANKENBERGER, Z., (1926). Über die Entwicklung des Eies der weissen Maus. Biol. General., vol. 2, pp. 21-62.

GERLACH (1906). Über die Bildung der Richtungskörper bei Mus Musculus. Weisbaden. (cited from Marshall's "Physiology of Reproduction").

HEAPE, W., (1905). Ovulation and Degeneration of Ova in the Rabbit. Proc. Roy. Soc. B., vol. 76, pp. 260-268.

HERLITZKA, A., (1900). (1) Recherches sur la transplantation. (2) Quelques remarques à propos de la transplantation des ovaires. Arch. Ital. d. Biol., vol. 34, pp. 84-110.

KIRKHAM, W. B., (1907). Maturation of the Mouse Egg. Biol.Bull., vol. 12, pp. 259-265.

LAMS and DOORME, (1907). Nouvelle recherches sur la maturation et le fécondation de l'oeûf des mammefères. Arch. d. Biol., vol. 23, pp. 259-336.

LEAGUE, B., and HARTMAN, C. G., (1925). Anovular Graafian Follicles in Mammalian Ovaries. Anat. Rec., vol. 30.

LIPSCHÜTZ, A., (1925). Experimenteller Hermaphroditismus und der Antagonismus der Geschlechtsdrüsen. I. Die intrarenale Ovarientransplantation. Die Indikatoren des weiblichen und männlichen hormonalen Effekts beim Meerschweinchen. Plfüg. Arch., vol. 207, pp. 548-562.

MARSHALL, F. H. A., (1922). The Physiology of Reproduction. 770 pp., London.

" and JOLLY, W. A., (1907). Results of Removal and Transplantation of Ovaries. Trans. Roy. Soc. Edinb., vol. 45, pp. 589-599.

MOORE, C. R., (1921). On the Physiological Properties of the Gonads as Controllers of Somatic and Psychical Characteristics III. Artificial Hermaphroditism in Rats. Jour. Exper. Zool., vol. 33, pp. 126-171.

MOORE, C. R., (1921). IV. Gonad Transplantation in the Guinea-pig. Ibid., pp. 365-389.

OCHOTERENA and RAMIREZ, (1920). The Origin and Evolution of the Interstitial Cells and of the Ovary, and the Significance of the Different Internal Secretions of the Ovary. Endocrin., vol. 4, p. 541.

SCHULTZ, W., (1900). Transplantation der Ovarien auf männliche Tiere. Zentrabl. f. allg. Path., vol. 11, pp. 200-202.

SOBOTTA (1895). Die Befruchtung und Furchung des Eies der Maus. Arch. f. mikr. Anat., vol. 45, pp. 15-92.

VOSS, H. E. V., (1925). Condition de la greffe ovarinne intra-:testiculaire. C. R. Soc. Biol., vol. 93, pp. 1066-1071.

§ 8 . Description of Figures.

Fig. 1. D_1. Graft 16 days after transplantation.

" 2. D_2. The same.

" 3. G_1. Ovarian graft 10 days after transplantation, showing four necrosed Graafian follicles in the stroma and several young oocytes in the peripheral region. × 50

" 4. A_3. Ovarian graft 14 days after transplantation. In the centre is the gonadic portion where one small follicle is seen. × 25

" 5. A_4. Ovarian graft 14 days after transplantation. × 25

" 6. H_6. Ovarian graft 14 days after transplantation. The lower half is occupied by the Fallopian tube area and the upper half is the gonadic portion where a small follicle is seen. × 25

" 7. D_1. Ovarian graft (cf. Fig. 1) 16 days after transplantation. × 25

" 8. C_1. Ovarian graft 20 days after transplantation, showing large follicles. × 25

" 9. E_2. Ovarian graft 21 days after transplantation × 25

" 10. G_5. Section of the ovarian graft 28 days after transplantation. Two so-called "blood follicles" and a mature sized follicle are seen. × 25

" 11. F_1. Section of the ovarian graft 35 days after transplantation. Two so-called "blood follicles", two mature sized follicles, and three corpora lutea are seen. × 25

" 12. G_2. Section through the germinal epithelium with cell in early prophase. × 1200

" 13. A_3. Section through the germinal epithelium with cell in metaphase (polar view) × 2000

" 14.
" 15. } G_1. Section through the germinal epithelium with cell in metaphase (polar view). × 1200
" 16.

" 17. G_1 Section through the germinal epithelium with cell in metaphase (side view) × 1200

" 18. G_2: Section through the germinal epithelium with cell in metaphase (side view). × 1200

" 19/

Fig. 19. G_1. The same, with cell in anaphase (polar view) × 1200

" 20. G_2. The same, with cell in late anaphase (polar view) × 1200

" 21.
" 22. } A_3. Section through the peripheral region of the graft, showing young oocytes. × 750
" 23.

" 24. B_1. Section showing young oocytes in the stroma, 0.3 mm. from the periphery. × 750

" 25. E_2. Section showing young oocytes, primordial anovular follicles, and interstitial cell masses × 480

" 26. E_2. Section showing interstitial cell masses × 480

" 27. F_1. Section showing corpus luteum (Fig. 11) × 50

" 28. G_2. Germinal epithelium has remained intact, notwithstanding the necrotic change spread widely to the peripheral region × 370

" 29. D_4. Section through a medium sized follicle whose ovum has a clear nucleus. × 280

" 30. The same. Section through a medium sized follicle; the nucleus of the ovum is in the metaphase stage × 280

" 31. The same. The nucleus is in the early anaphase stage × 280

" 32. The same. Section through a medium sized follicle, showing polar body and second maturation spindle. × 55

" 33. The same. Section through a medium sized follicle, showing the early stage of haemorrhage. × 55

" 34. B_1. Section showing two atretic follicles; on the right the follicular cells have degenerated and are being absorbed, leaving the degenerated ova in the cavity. × 55

" 35. I_2. Section through a small atretic follicle; the degenerated ova has remained in the cavity but the follicular cells have disappeared. × 55

" 36. H_2. Section through an anovular follicle, the follicular cells of which are undergoing transformation into interstitial tissue.

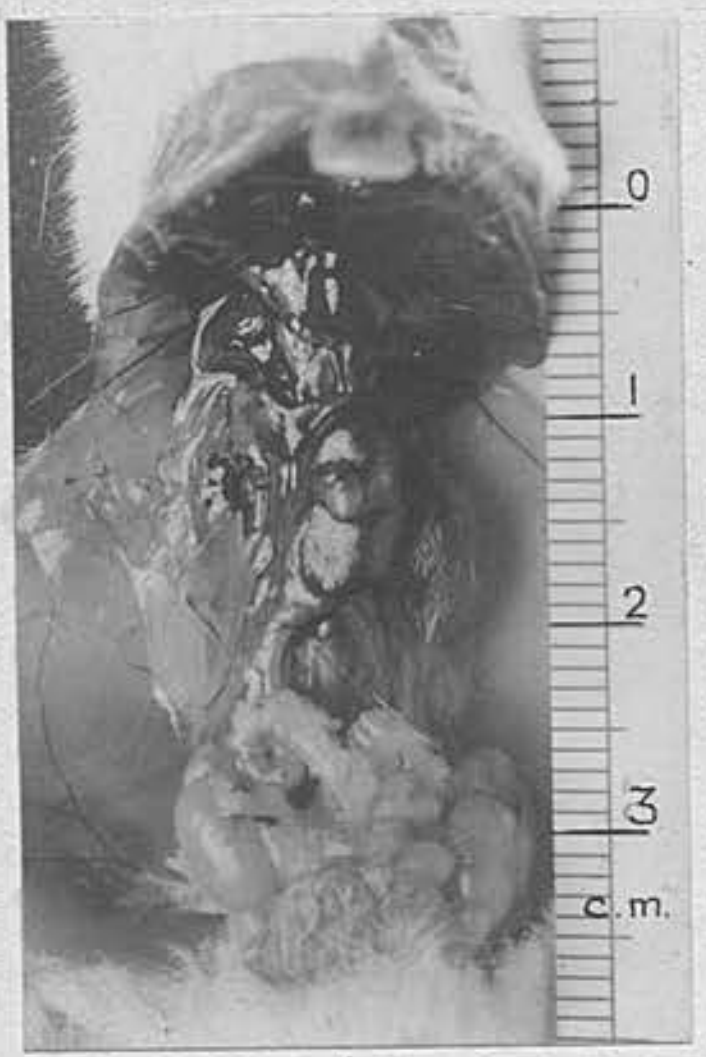

1

2

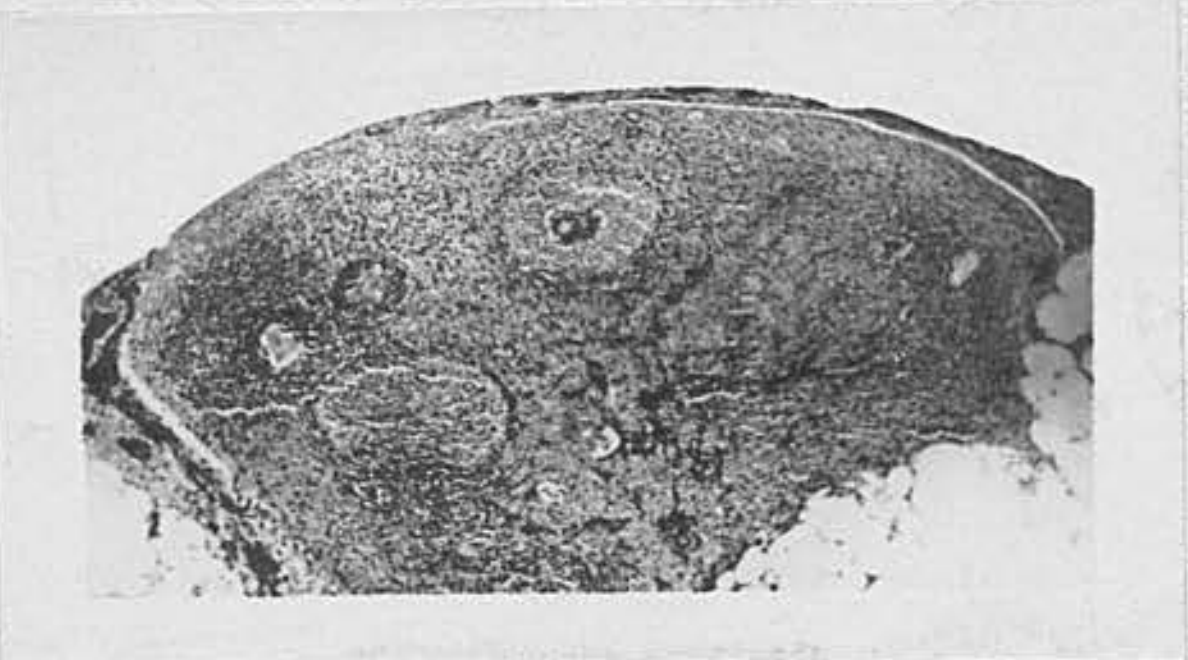

3

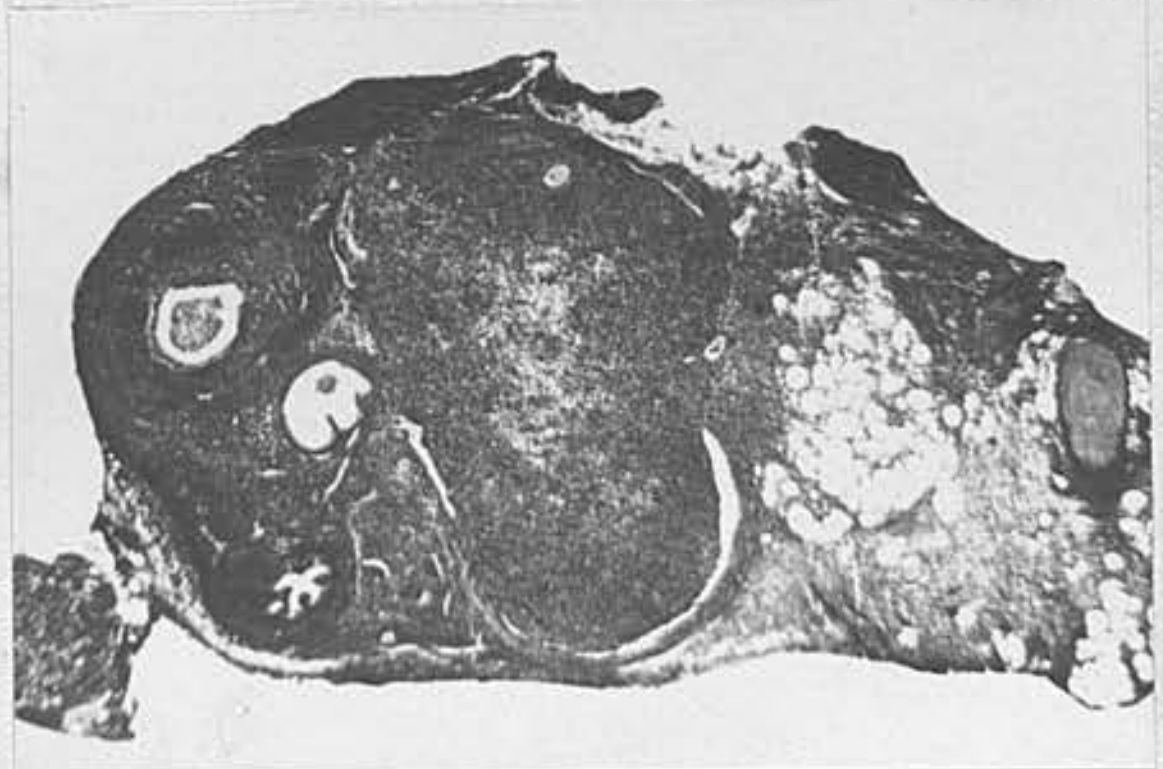

4

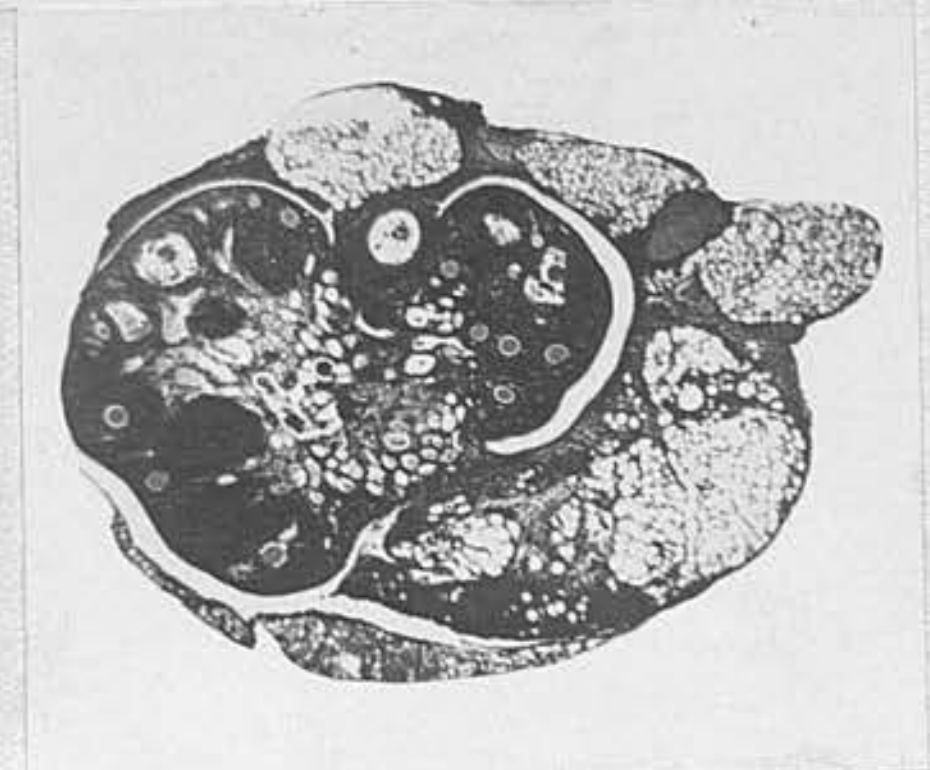

5

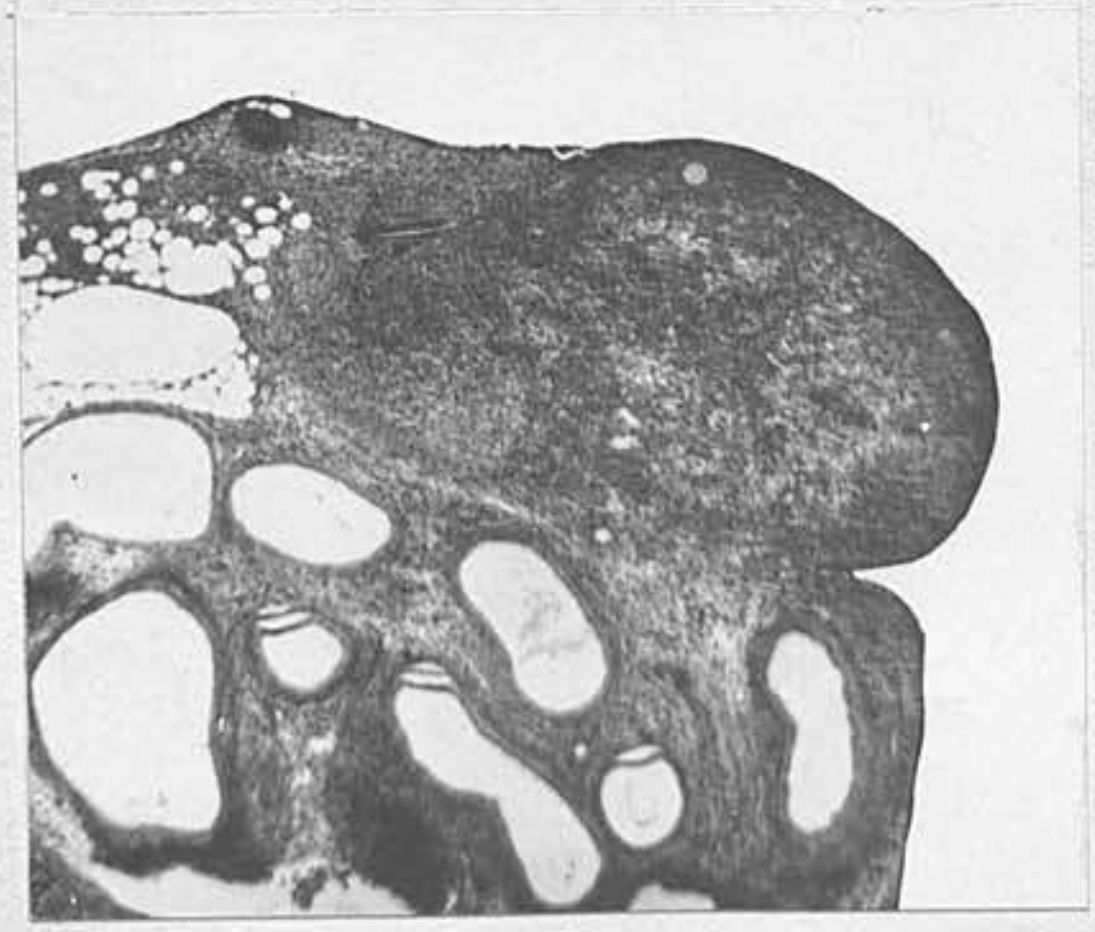

6

7

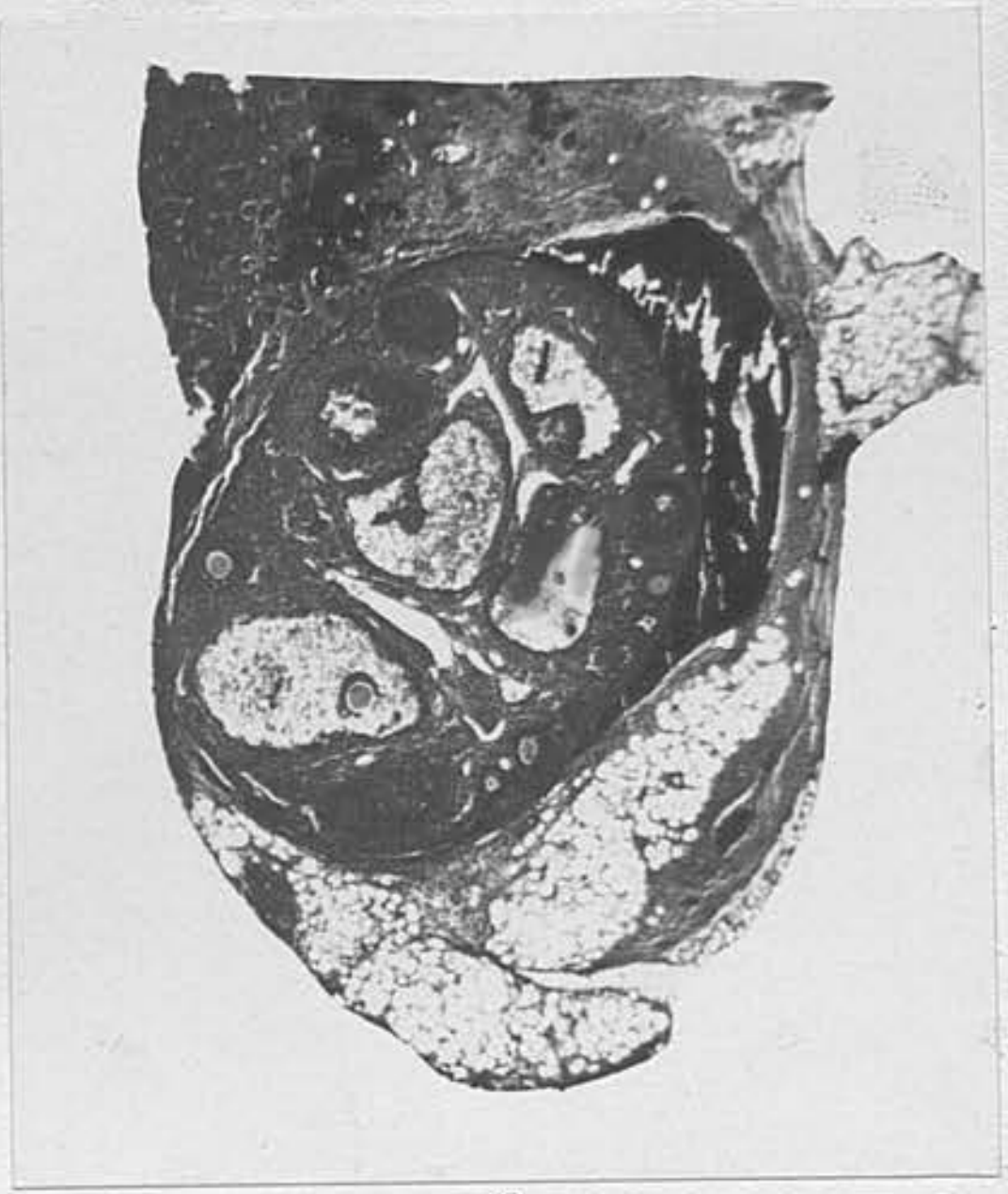

8

9

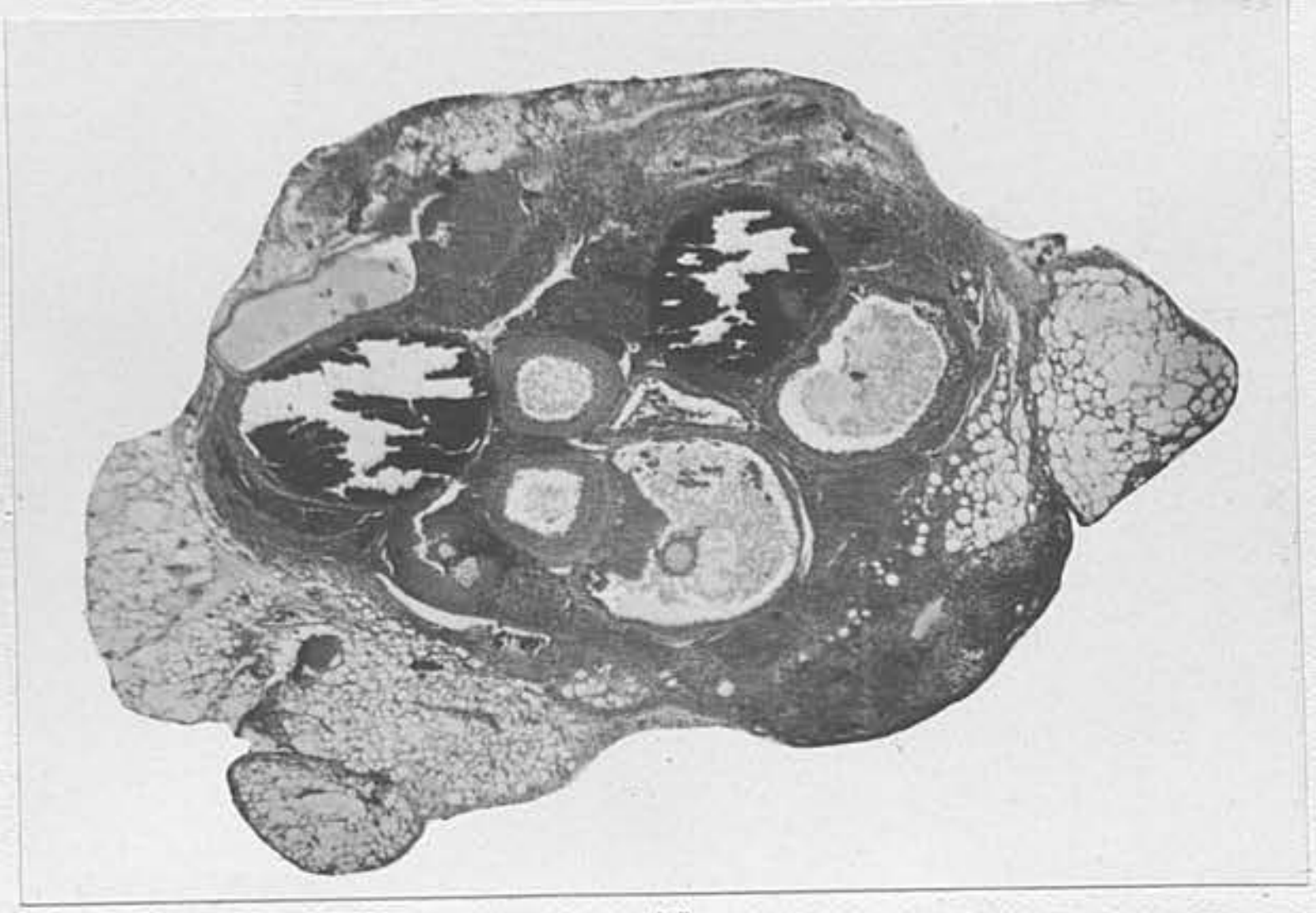

10

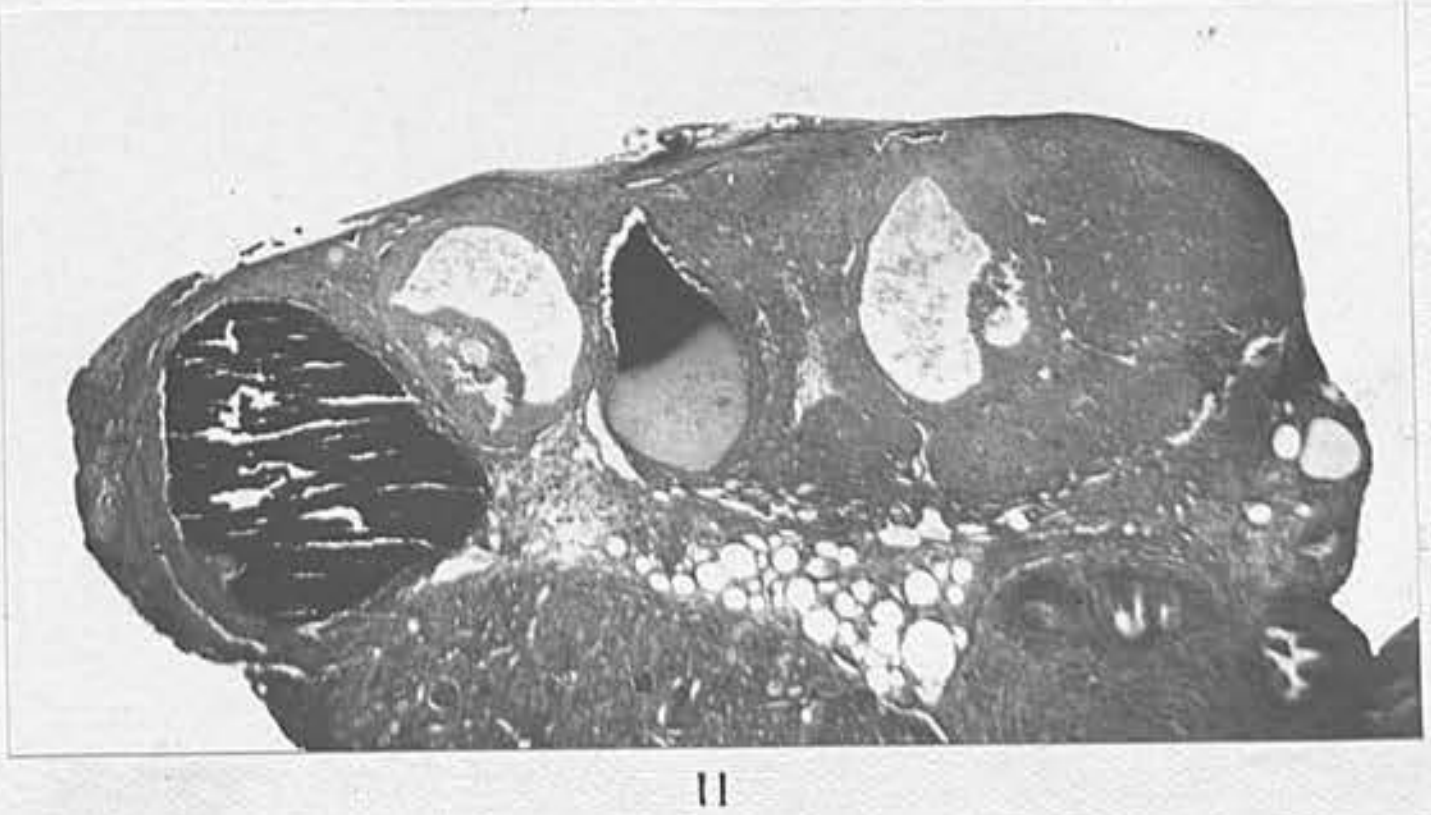

11

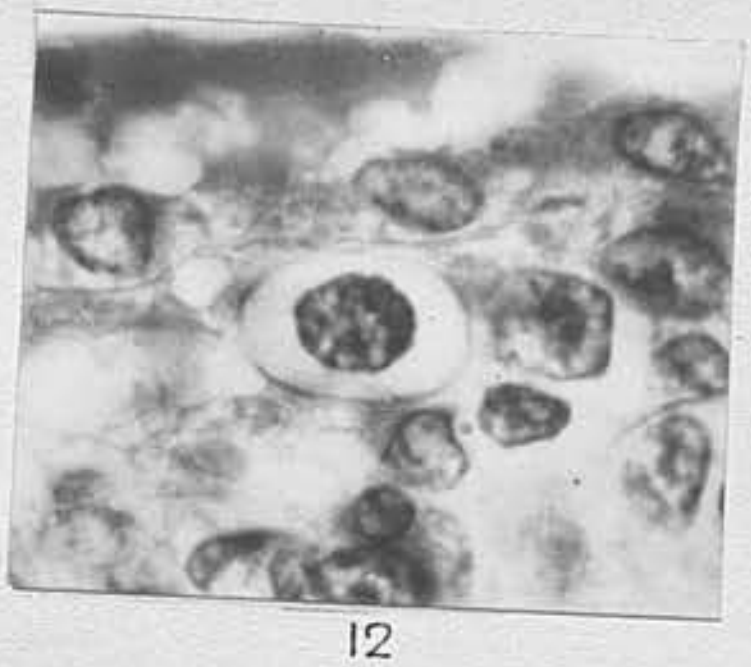
12


13


14


15

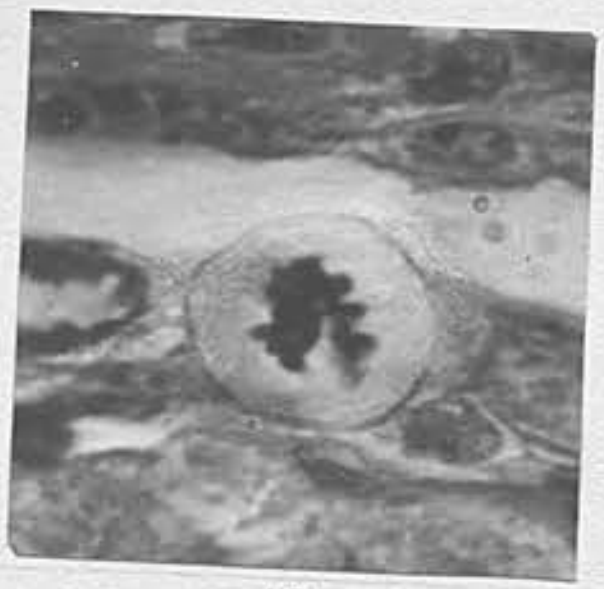
16

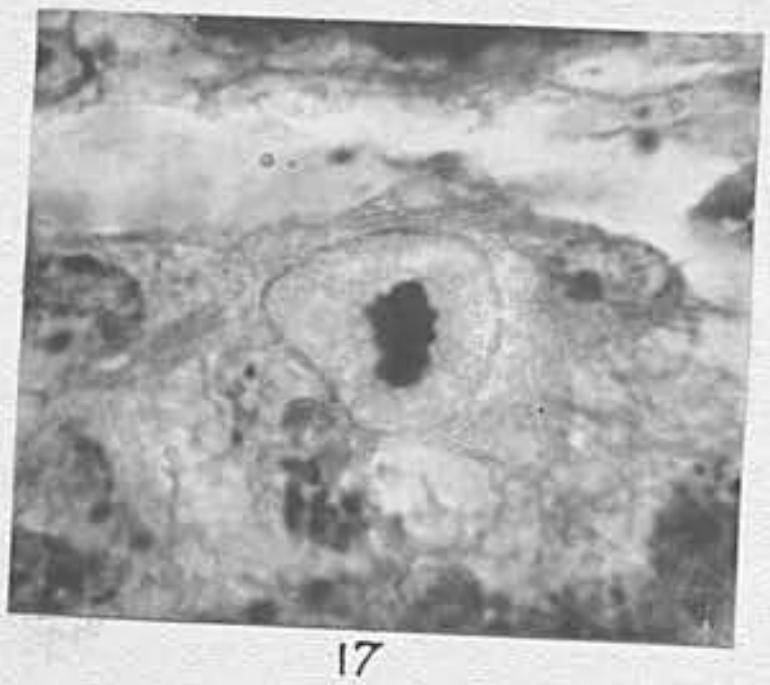
17

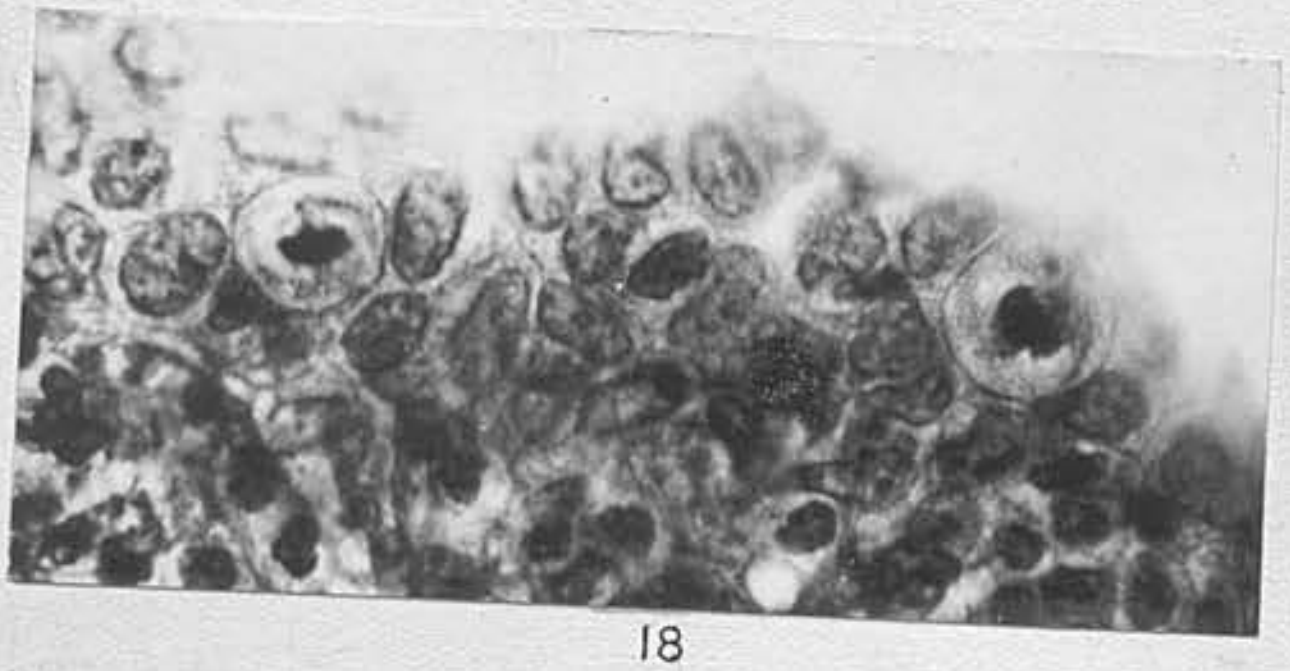
18


19

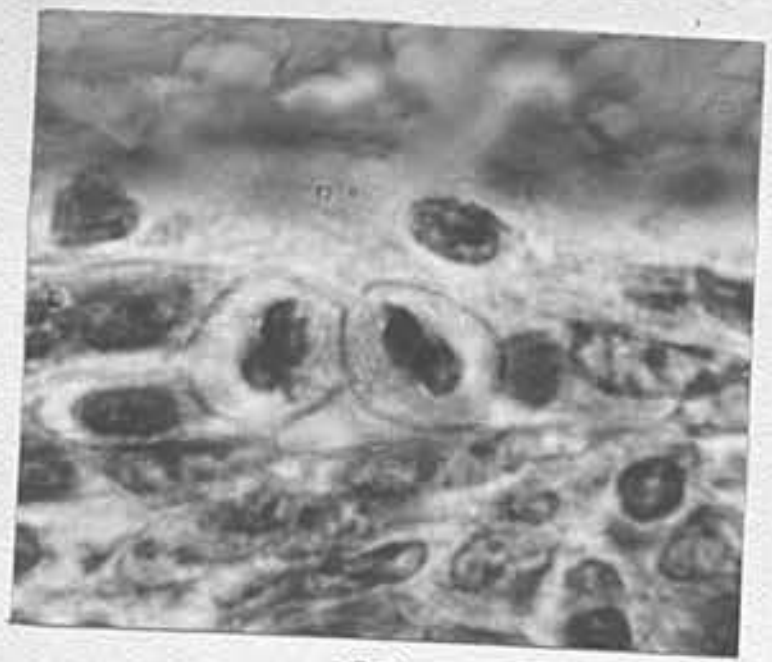
20


21

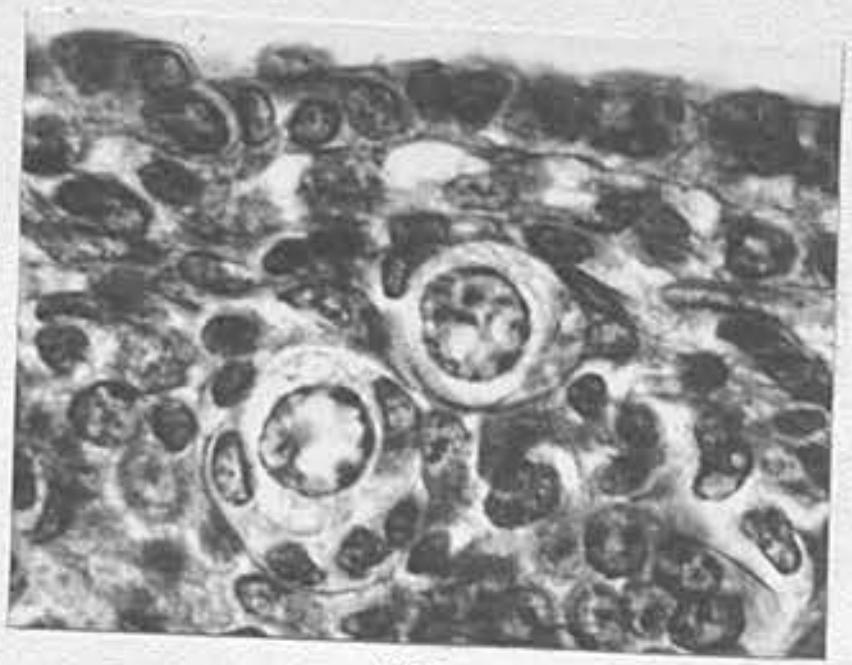
22


23


24

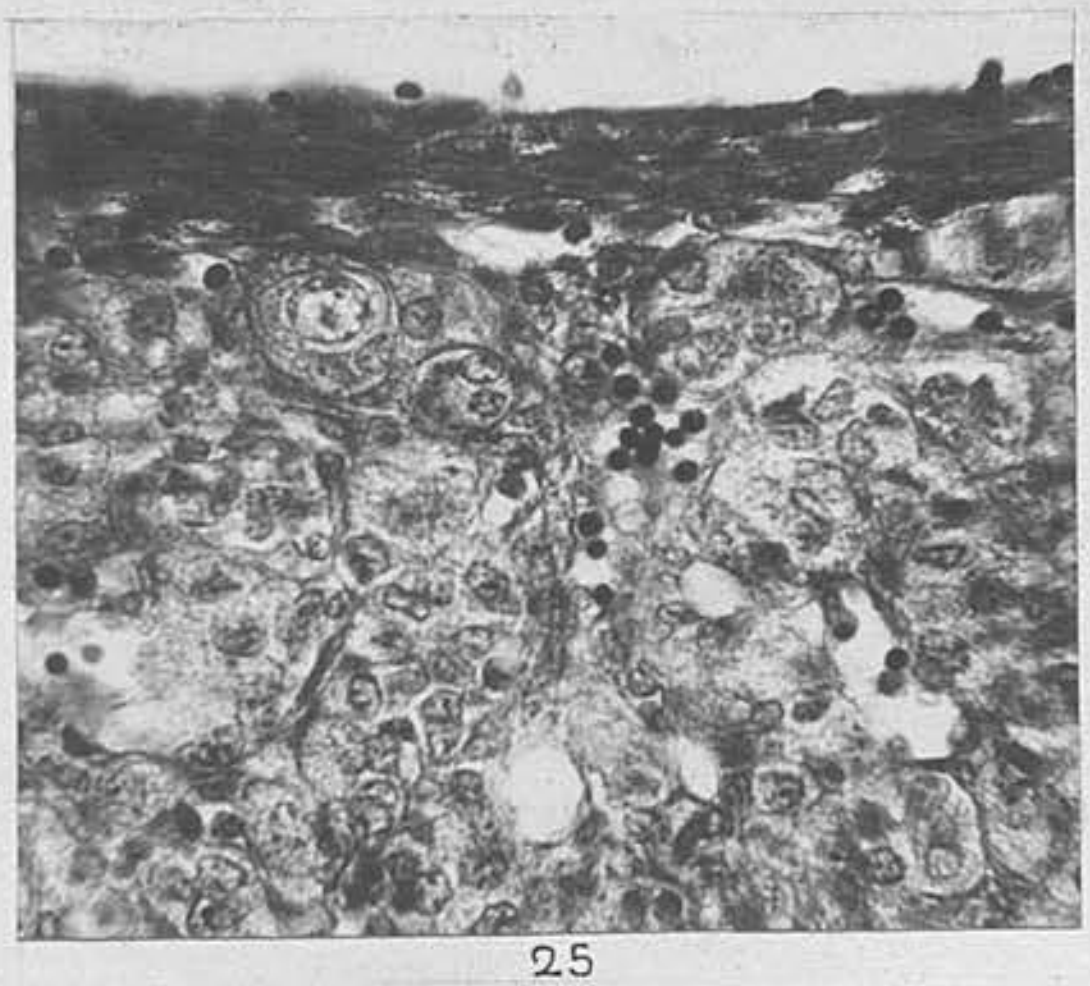

25

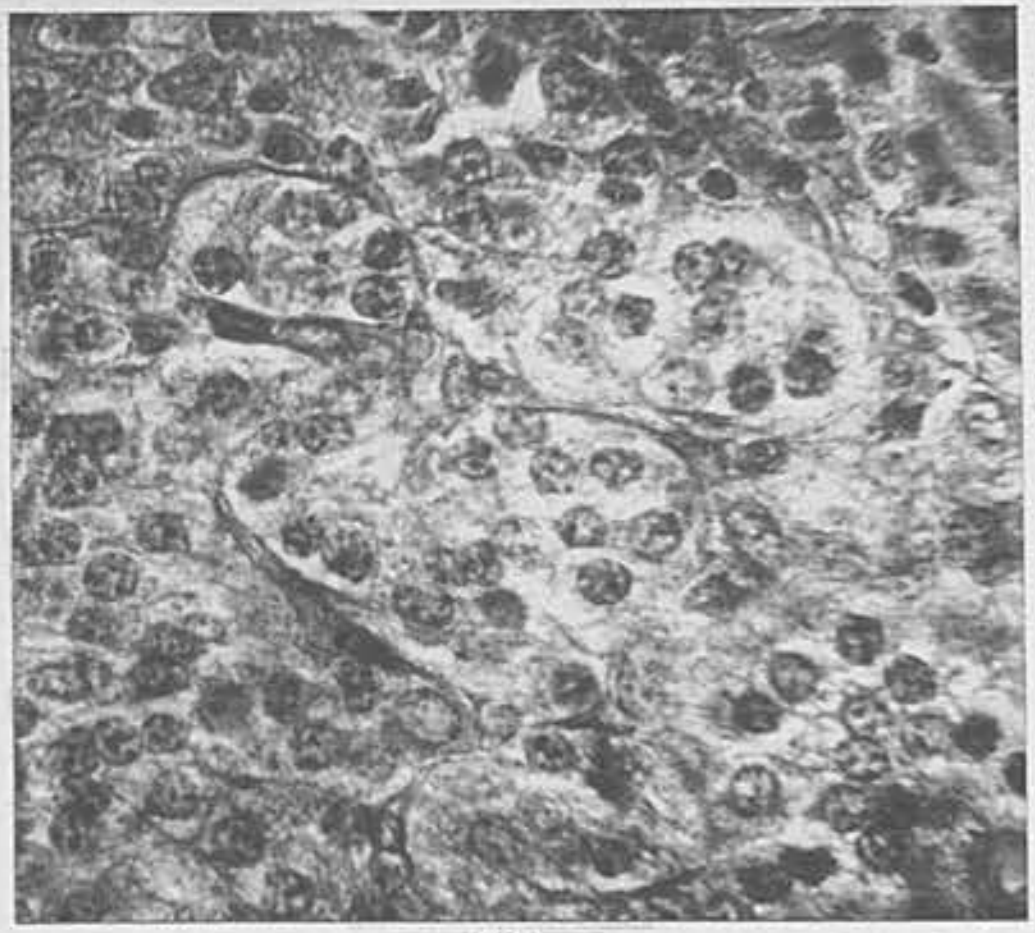

26

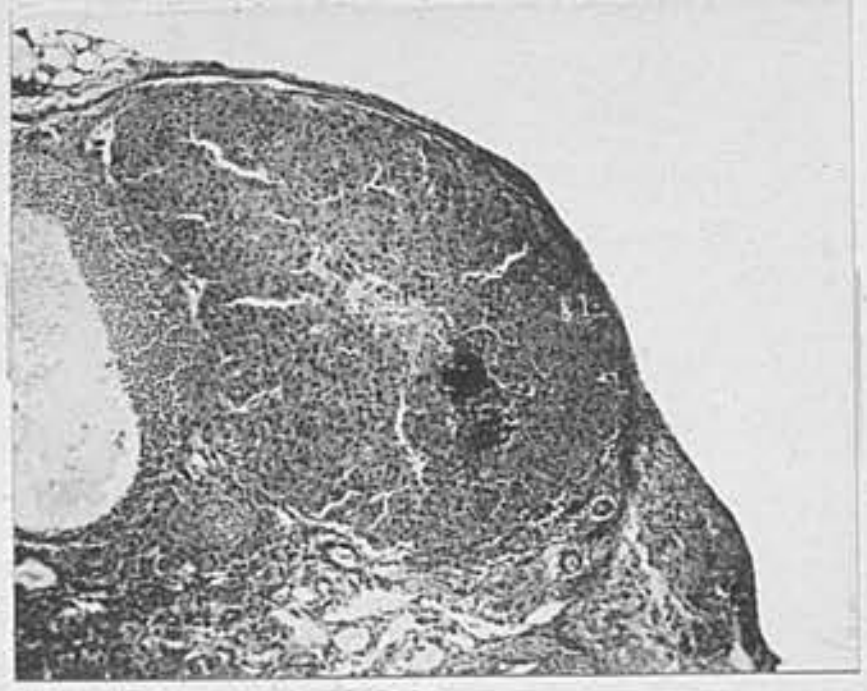

27

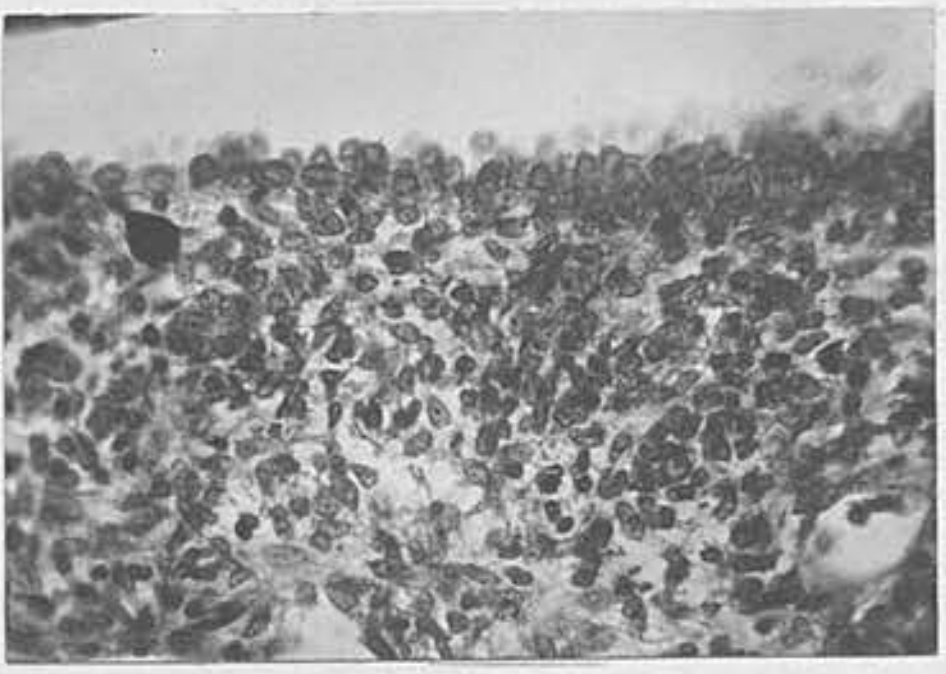

28

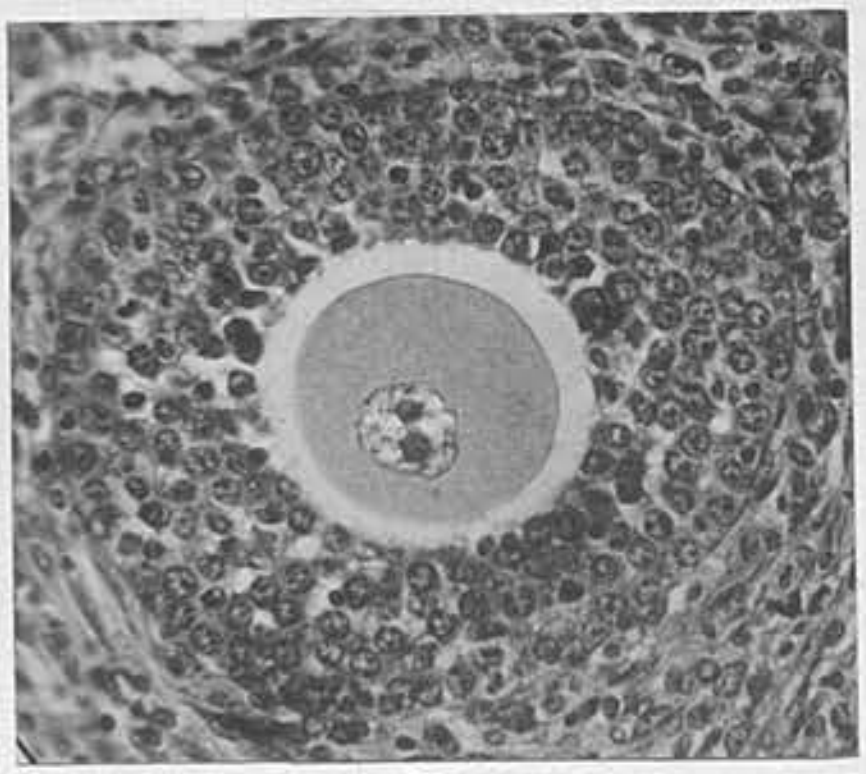

29

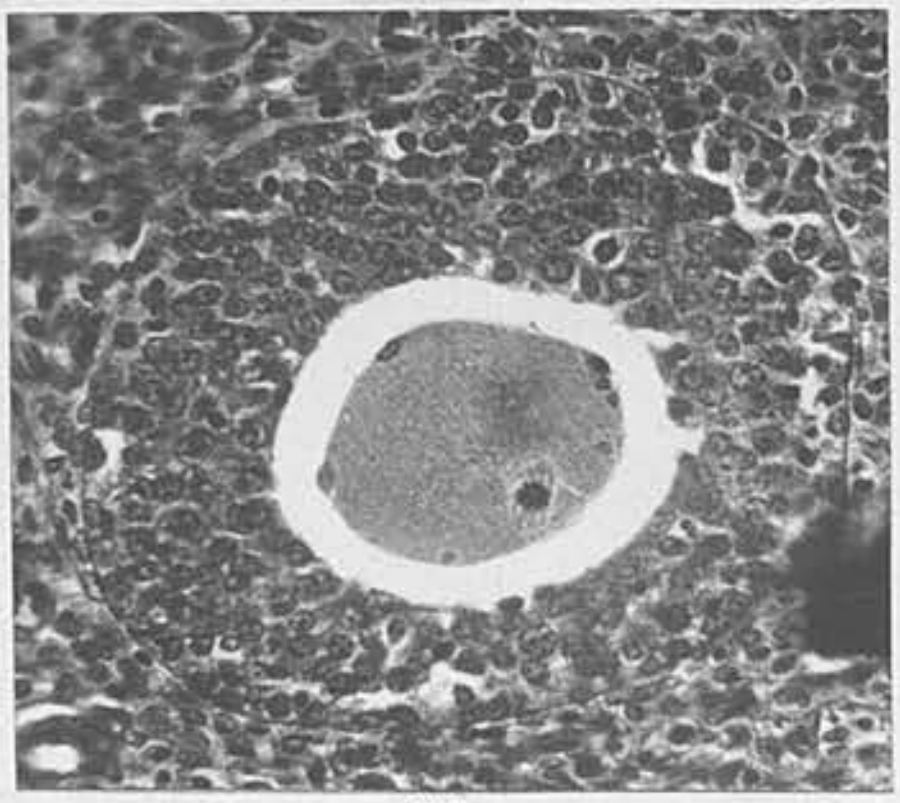

30

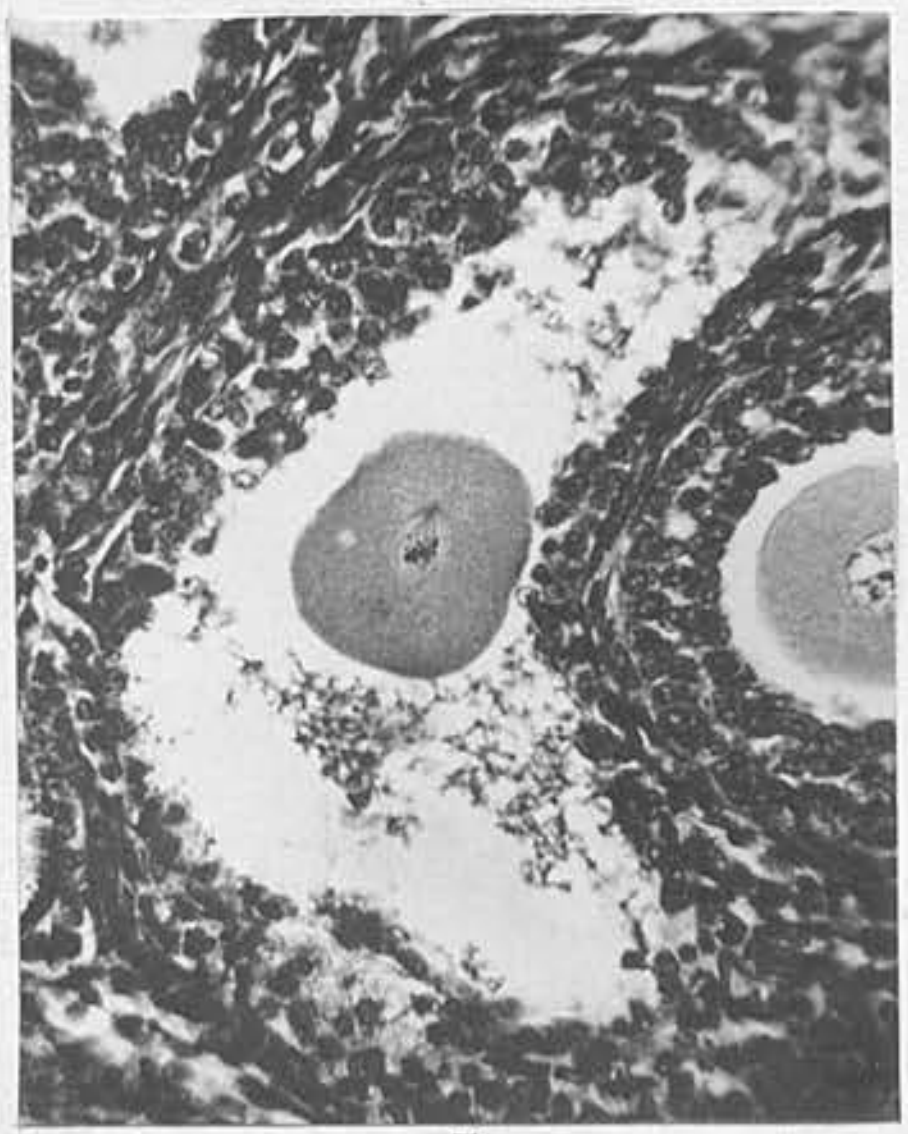

31

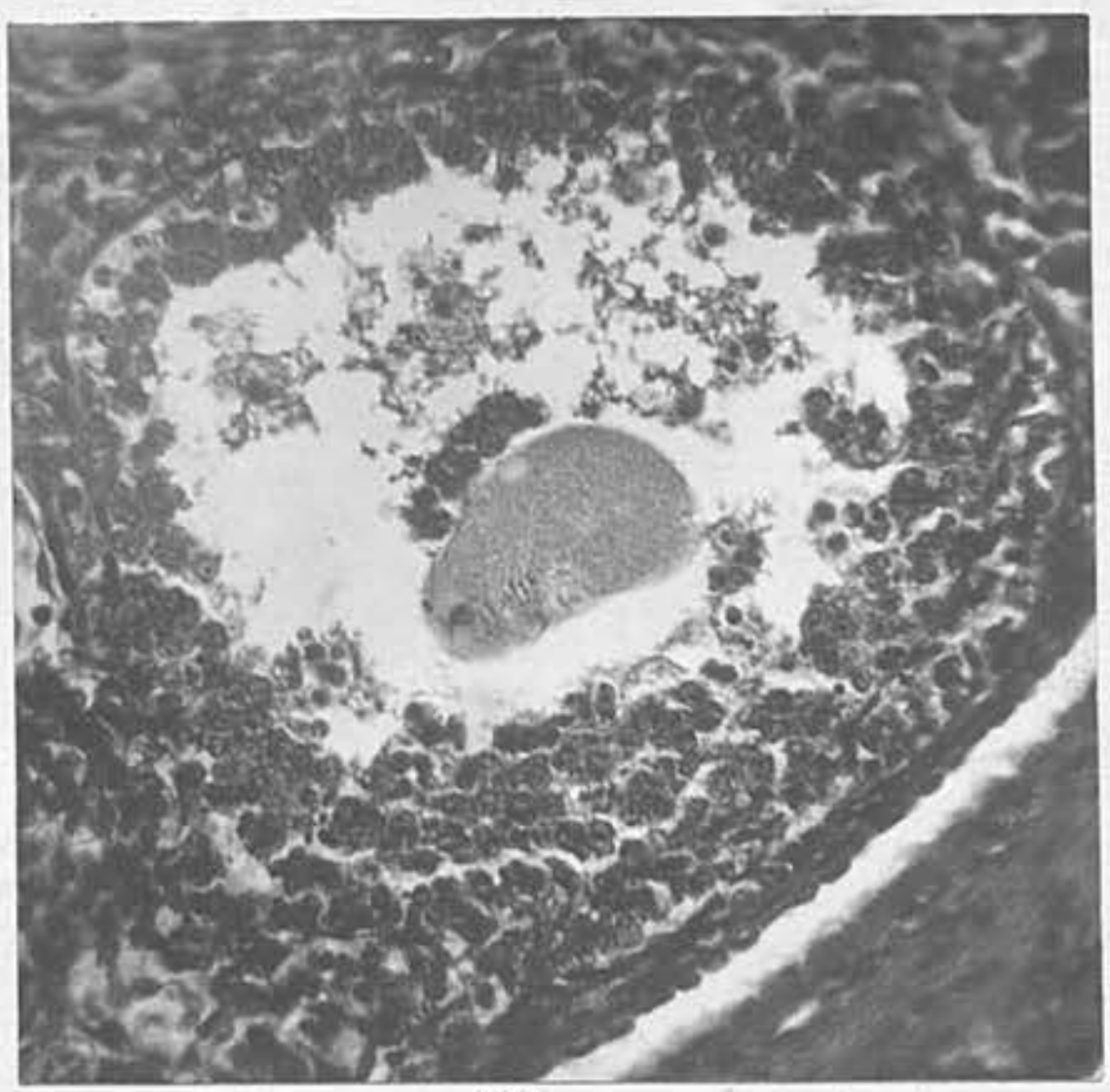

32

33

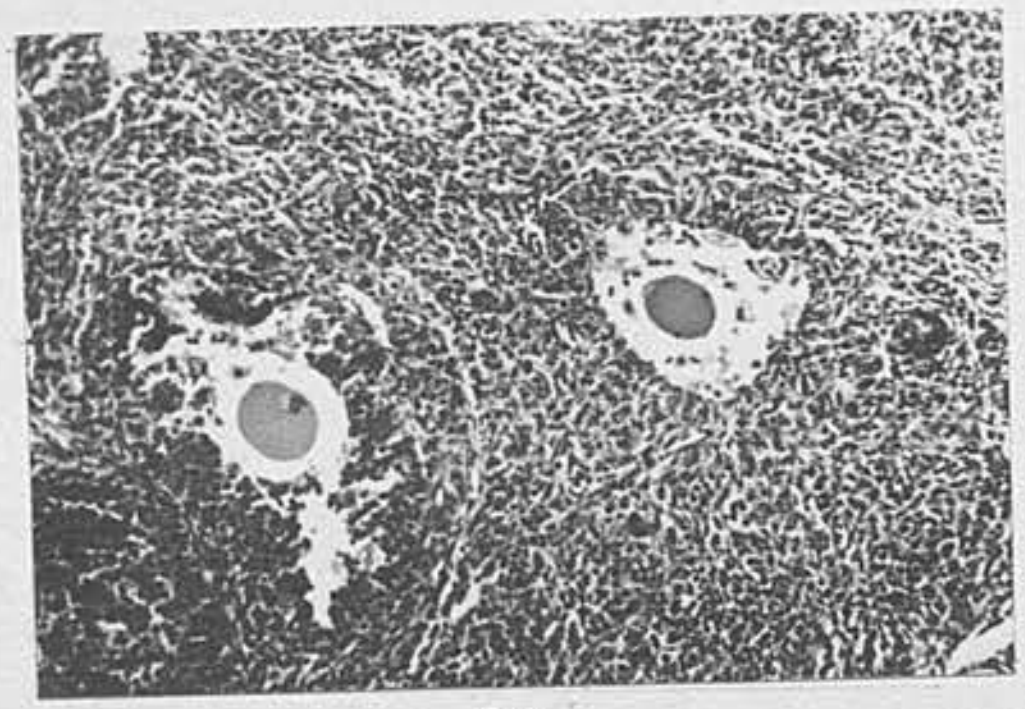

34

35

36

STRUCTURAL CHANGES IN THE SUPRARENAL OF THE MOUSE DURING PREGNANCY

by

Y.TAMURA

Animal Breeding Research Department, UNIVERSITY of
EDINBURGH.

In the Press. Brit. Journ. Exper. Biol. 1926.

STRUCTURAL CHANGES IN THE SUPRARENAL OF THE MOUSE DURING PREGNANCY.

CONTENTS.

I. INTRODUCTION.

GUIEYSSE (1899) observed that the suprarenal gland of the guinea pig underwent enlargement during pregnancy, this increase chiefly affecting the zona faciculata. This observation was confirmed by KOLMER (1912) and extended to the case of the rabbit by KOLDE (1913) and others. According to GUIEYSSE, the hypertrophy of the zona faciculata in the guinea pig is due to an enlargement of the cells themselves and not to an increase in their number. He also states that there is no enlargement of the zona glomerulosa or of the medulla.

An increase in the weight of the suprarenal in the rat during pregnancy was noted by HERRING (1920), and in the guinea pig by VERRDOZZI (1917) and CASTALDI (1922). DONALDSON states that there is no change in the weight of the adrenal in the healthy albino rat during the phase of pregnancy-lactation. MASUI and TAMURA (1924) have shown that the suprarenal of the mouse increases in size at the beginning of pregnancy, but that at the same time degeneration of the zona reticularis sets in and proceeds until this zone has completely disappeared, so that towards the end of pregnancy the gland as a whole is greatly reduced/

reduced in size, although the zona faciculata itself has increased slightly.

The present work was undertaken in order to examine the effect of unilateral ovariotomy on the suprarenal. Observations were made on unilaterally ovariotomised mice during pregnancy. The results obtained show that unilateral ovariotomy is not followed by any change in the histological structure of the adrenal (apart from that variation which is also found in normal non-pregnant females), and that during pregnancy in the unilaterally ovariotomised female both adrenals undergo similar modifications in structure identical with those that occur in the normal pregnant female.

II. MATERIAL AND METHODS.

Ordinary mixed tame mice were used as material. Each experimental group was composed of individuals from one and the same litter and virgin females from a few litters were kept as controls. Unilateral ovariotomy was performed under ether anaesthesia at three, five, seven and eight weeks after birth. The operated and control animals from each experimental group were kept in the same box. The ovariotomised animals/

animals were mated at nine weeks and killed with chloroform at the first, second or third pregnancy. They were weighed and measured immediately after killing, the ovaries and other endocrine organs were removed and fixed. Allen-Bouin, Regaud and Chura's solutions were used as fixitive agents. The last solution gave good results for the purposes of examination of mitochondria, granules and chromosomes. The thickness was six μ for structure and three μ or four μ for granules examination. The stains used were Delafield and Heidenhein's Haematoxylin for structure, Champy-Kulle's acid-fucsin-toloidium-Aurantia for mitochondria and granules, and osmic acid for lipoid and fatty substances. The uterus and its contents were weighed, then all foetuses were weighed and their measurements taken. It is impossible by examination to determine with exactitude the stage which pregnancy has reached in the mouse. If the length of the foetus is used as a standard for classification, the whole period of pregnancy may be conveniently divided into the following five stages:-

STAGE I. Before the formation of the placenta, i.e., the stage of fixation of the fertilised egg, or the coelomic stage.

STAGE/

STAGE II.	From the formation of the first traces of placenta to the stage when the length of the foetus is 5 mm.
STAGE III.	The length of foetus from 6 to 12 mm.
STAGE IV.	The length of foetus from 13 to 20 mm.
STAGE V.	The length of foetus from 21 mm. and over.

In order to determine the range of variation in the length of the foetus during Stage V, measurements were taken of young at birth and lengths from 21 mm. to 27 mm. were obtained. To determine the relative sizes of the different areas of the adrenal, a drawing was made of the largest section (fixed in Allen-Bouin solution for as short a time as possible in order to prevent shrinkage, and stained with ordinary Delafield haematoxylin) and the outline of each zone was traced with the aid of a planimetre.

My thanks are due to Dr. F.A.E Crew for providing accommodation and the experimental material and also for his valuable help and constructive criticism during the course of this study.

III. DESCRIPTION OF EXPERIMENTS.

MASUI and TAMURA (1924) have described in

detail/

detail both histologically and cytologically the structure of the suprarenal-cortex; it is not necessary, therefore, in this paper to deal specially with this. The changes in the histological structure of the adrenal during pregnancy will be described with reference to the five stages which have been defined.

STAGE I. (Figs.1, 2, and 3.) During this stage no change in the relative sizes of the areas of all zones either in the cortex or in the medulla is to be observed, as is shown in Tables I and II. The histological structure of the zones, however, shows modification, that of the zona reticularis to the greatest extent, and that of the zona faciculata to the least.

The cells of the zona glomerulosa have become active, some showing mitosis, others becoming enlarged in size, whilst minute granules are present as in the glands of the normal non-pregnant female. In the zona faciculata two types of cells appear. One is the typical vacuolated faciculata cells (Figs. 11 and 21) and these are present in large numbers throughout the zone; the others are much smaller, clear non-vacuolated cells which lie at the border line between this zone and the zona reticularis/

reticularis. These cells are similar in structure to those of the zona reticularis. Signs of mitosis are visible in their nuclei. The region of these cells will be termed zona gestationis.

The zona reticularis shows a remarkable change due to a rapid degeneration of the tissues (Fig. 10). This degeneration begins along the whole of the border-line of the zona faciculata and proceeds centripetally; at an early stage of degeneration a layer composed of contracted cells, packed closely together, can be seen between the two zones (Figs. 2 and 3). In some cases this process is far more advanced than in others; the zona reticularis has for the most part degenerated into large vacuoles or connective tissue and is represented by a thin layer of cells adjacent to the medulla, which still retain the original characters. The cells of this layer are reduced in size and have irregularly shaped nuclei with one or more very clear nucleolui and a small quantity of chromatin granules. Cells containing secretory granules are, when present, very few in number and the size of the granules is smaller than that of those in the non-pregnant female. Thus, although at this period the zona reticularis is present, the/

the characteristic reticularis cells are almost absent, this finding being in agreement with that of M MASUI and TAMURA.

In the medulla a few mitotic figures are present, but no other changes can be seen.

STAGE II. (Fig. 4). The total area of the section is reduced by about 18 per cent and a remarkable change in the relative sizes of the zona faciculata and reticularis has occurred; the latter zone is much reduced in size owing to the absorption of the tissue which is the principal cause of the shrinkage of the section as a whole. In the zona glomerulosa no change is to be observed, as is shown in Tables II and III. The area of the zona faciculata shows an absolute increase by about 20 per cent, i.e., a relative increase (estimated in relation to the total area of the cortex) or about 56 per cent. On the other hand, the area of the zona reticularis decreases by 84 per cent in absolute, and 78 per cent in relative value.

Notwithstanding the remarkable change in the relative size of the area, the histological structure of the zona glomerulosa and faciculata is almost the same as in the former stage. The smaller clear/

clear and non-vacuolated cells (zona gestationis) of the zona faciculata have increased in number towards the periphery, among them small cells having large clear nuclei and a relatively scanty protoplasm are also visible. The zona reticularis has either almost or entirely disappeared and is replaced by connective tissue. When the zona reticularis has degenerated, it does not surround the medulla as in the normal gland, but becomes compressed along the abcissa of the section and accumulates in elongated processes at each side of the medulla along its ordinate. No noticeable change has occurred in the medulla, although its area has increased slightly. Several mitotic figures are observed as in the former stage.

STAGE III. (Fig. 5). There is no observable change in the relative sizes of the different zones when compared with those of the previous stage (see Tables III and IV); the zona reticularis has increased by 37 per cent; this is caused by the presence of large vacuoles (the so-called zona spongiosa). On histological examination, the zona glomerulosa is seen to be still developing and mitotic figures in considerable numbers are visible, mostly in cases when the length of the foetus is 8 mm. and over/

over. Granules, which were described in the previous stage are again found, though they are now of varying sizes.

The structure of the zona faciculata in this stage may be of two different types; in one type, almost the whole of the area is occupied by typical vacuolated faciculata cells (as in the former stages) and the vacuoles near the centre are smaller than those in the peripheral region. In the second type, the central portion is occupied by the clear cells (Fig. 16) described in the previous stage, which are now more numerous. A few mitotic figures at varying stages are found.

It is noteworthy that when these latter cells are present, the vacuolated cells in the peripheral portion are polyhedral in shape and the nuclei in some cases show degeneration. The relative size of the area of the medulla in this stage shows a decrease which, being but slight, may be due to fluctuation. Mitotic figures are more numerous, being from about 8 mm.

STAGE IV. (Figs. 6, 7 and 8). There is no observable change in the relative size of the zona faciculata, while that of the zona glomerulosa has increased by about 26 per cent, as compared with that of former stages and that of the zona reticularis by about/40 per cent.

about 46 per cent.

On microscopical examination, it is seen that the zona glomerulosa is remarkably changed. During the previous stage the minute granules were seen to be increasing in size; at this stage, mostly at from about 16 mm., they are seen to be typical secretory granules (Figs. 14 and 15) having a structure identical with that described by MASUI and TAMURA (1924) in the cells of the zona reticularis. The maximal secretory activity is found at about 17 mm. As observed in the zona reticularis of the normal, non-pregnant, very big vacuoles or a network of connective tissue (Fig. 13) in the cells are also found, the nuclei in these cases are similar to those of the secretory cells. As shown in Table IV, the area of this zone takes up on an average about 21 per cent of the cortex and at its maximal 36 per cent.

In the zona faciculata at this stage the new clear cells (Fig. 12) mentioned above appear in all cases, although their number varies. In some cases they occupy the whole area of this zone, and in others they press the vacuolated cells towards the periphery, so that the latter become diminished in/

in size and rectangular or elliptical in shape, and their nuclei are irregularly shaped.

Some of the new clear cells, mostly those situated in the peripheral region, show (Figs. 18 and 19) "siderophile bodies" (secretory granules) and contain granules of various sizes, while those situated in the central portion do not contain any granules or mitochondria.

At this stage the size of the zona reticularis varies very considerably; in one case it was equal to that of the zona faciculata (Fig. 8), though it consisted of nothing but big vacuoles and a network of connective tissue. In another case it occupied but 1 per cent of the cortex (Fig. 7) and had the form of a thin line of connective tissue.

No marked change is found in the medulla as regards its microscopical structure; its area is found to be increased by about 6 per cent. The mitotic figures are still increasing in number.

STAGE V. (Fig.9) At this stage the relative size of the areas of the zona glomerulosa, faciculata, and reticularis have decreased by 17, 5, and 56 per cent respectively. On histological examination the secretory activity in the zona glomerulosa is not/

not visible, although in a few cases secretory granules are still observed. Likewise, in the zona faciculata a remarkable change has occurred. In cases there the typical faciculata vacuolated cells have been pushed towards the periphery remain, they become enlarged. In other cases where no faciculata cells were present, they appear and the zona gestationis is seen to unuergo degeneration. (Fig. 9). Its cells become greatly vacuolated, in some instances the entire cell protoplasm being reduced to a network. The degeneration proceeds from the periphery. In some cases the zona gestationis disappears entirely and typical faciculata cells occupy the whole area. The proportion of the area of the medulla increases by 14 per cent in absolute, and by 30 per cent in relative value to the entire area of the gland.

IV. DISCUSSION.

(1) HYPERTROPHY OF THE ZONA FACICULATA.

GUIEYSSE stated that in the guinea pig the hypertrophy of the zona faciculata is the result of an enlargement of the cells themselves and not of an increase in their number. However, in the mouse two types of hypertrophy may be observed. One is similar to/

to that described by GUYEISSE in the guinea pig. It takes place at a very early period of pregnancy and the cells increase in diameter by about 38 per cent, the largest cell increasing from 16 to 22. GUIEYSSE maintained that hypertrophy implies hyperfunctioning of the zona faciculata, even though he was unable to demonstrate how this occurred. However, it is reasonable to assume that this hypertrophy is only compensatory following a shrinkage caused by rapid degeneration and complete disappearance of the zona reticularis.

An examination of Tables 2, 3, 5, and 6 will show that the average area of the zona faciculata in stage 2 shows a very great increase as compared with Stage I; and that in Stage V a decrease, as compared with Stage IV. However, the initial increase is much greater than the subsequent decrease. This is probably due to the fact that the increase in size in the zona faciculata is permitted by a very rapid degeneration of the zona reticularis and is thus a process of compensatory hypertrophy. In the later stage (V), when the zona gestationis has ceased to develop and begins to degenerate, this process is slow and therefore the increase in the area of the typical/

typical vacuolated faciculata cell is very gradual.

Another type of the hypertrophy of the zona faciculata is that caused by the development of the zona gestationis within the zona faciculata. The new zone increases gradually in size and in Stage IV occupies almost the whole area of the zona faciculata; in Stage V it ceases to develop and begins to degenerate and consequently the area of the zona faciculata becomes reduced. As shown in Table V, the area of the zona faciculata is greatest at Stage IV.

(2) THE ZONA GESTATIONIS.

Origin. As stated above, when at an early period of pregnancy, the zona reticularis begins to degenerate, there appears on the border line between it and the zona faciculata a layer of degenerated cells, which clearly separates these two zones. At the same time, one can identify at the inner margin of the zona faciculata clear cells which increase gradually in number and in the third quarter of pregnancy (i.e., 17 mm. in length) occupy almost the whole area of the zona faciculata, while during the last quarter they become reduced in number. As stated above, the vacuoles of the cells in the inner portion/

portion of the zona faciculata are smaller in size than those of the outer one. Mitotic figures are present in the cells up to the middle of pregnancy.

From these facts it is seen that the zona gestationis arises on the border line between the zona faciculata and the zona reticularis. Normally, these cells, whose structure cannot be distinguished from those of the zona reticularis, lie at the border of this zone and the zona reticularis, but the occurrence of pregnancy stimulates their activity and produces structural changes.

Structure. At the early period of pregnancy the cells do not show any signs of secretory activity and have a very clear protoplasm and nucleus (Fig. 10). Some of them show mitotic figures which increase gradually in number up to the beginning of Stage IV, when minute granules appear which are arranged irregularly around the nucleus (Fig. 17); at the 17 mm. stage some cells show typical secretory granules (Figs. 18 and 19), while in Stage V (21 mm. and over), the granules change into vacuoles (Fig. 20) which are similar to those of typical faciculata cells. It is noteworthy that the change begins along the whole outer margin of the zone and proceeds inwards./

typical vacuolated faciculata cell is very gradual.

Another type of the hypertrophy of the zona faciculata is that caused by the development of the zona gestationis within the zona faciculata. The new zone increases gradually in size and in Stage IV occupies almost the whole area of the zona faciculata; in Stage V it ceases to develop and begins to degenerate and consequently the area of the zona faciculata becomes reduced. As shown in Table V, the area of the zona faciculata is greatest at Stage IV.

(2) THE ZONA GESTATIONIS.

Origin. As stated above, when at an early period of pregnancy, the zona reticularis begins to degenerate, there appears on the border line between it and the zona faciculata a layer of degenerated cells, which clearly separates these two zones. At the same time, one can identify at the inner margin of the zona faciculata clear cells which increase gradually in number and in the third quarter of pregnancy (i.e., 17 mm. in length) occupy almost the whole area of the zona faciculata, while during the last quarter they become reduced in number. As stated above, the vacuoles of the cells in the inner portion/

(4) ZONA GLOMERULOSA.

According to GUIEYSSE, no hypertrophy occurs in this zone. However, in the course of this investigation it was observed at certain periods of that an enlargement of this zone occurred resulting from an increase in number of the constituent cells and a heightened activity. During Stage IV there is an average hypertrophy of about 20 per cent, with a maximum of 80 per cent.

The presence of mitotic figures was noted by KOLMER (1912). In the course of the present investigation these were observed at an early period of pregnancy, mostly at the beginning of Stage IV, while no mitotic figures are visible at Stage V. As stated previously, cells of the zona glomerulosa are most active during the closing period of Stage IV.

(5) MEDULLA.

According to GUIEYSSE, there is no hypertrophy in the medulla of the guinea pig during pregnancy. MASUI and TAMURA reported that it atrophied in the mouse at the closing period of pregnancy. In the present investigation a marked increase of the area of the medulla was observed, this process is slow in certain stages, but towards the end of pregnancy/

pregnancy there is a sudden acceleration, so that in certain cases the medulla occupies as much as 26 per cent of the total area, thus representing an increase of 46 per cent over that which obtain at the beginning of pregnancy when the medulla is but 16 per cent of the whole area of the gland. A few mitotic figures were observed during Stage II, and a considerably larger number in Stage IV. This suggests that there occurs a hypertrophy of the medulla during Stages IV and V.

(6) AREA.

In a recent paper, DONALDSON (1924) comes to the conclusion that "there is no change in the weight of the adrenal of the healthy albino rat during the pregnancy lactation period", although he observed a slight increase in weight in the first quarter, an observation also made by VERDOZZI and CASTALDI in the case of the guinea pig. Similarly HERRING (1920) observed in the rat an increase in the weight of the adrenal at the close of pregnancy. It is not reasonable to hold that there must be a correlation between the size of the gland and the degree of its functional activity as suggested by RIDDLE (1923) in the pigeon especially, as in the case/

case of the suprarenal gland of the mammal there are several distinct zones.

There can be no doubt that the zona reticularis during pregnancy in the mouse is composed of nothing but connective tissue or big vacuoles in which fatty substances are present. Thus the increase in the weight of a gland cannot be considered as indicative of an increase in its functional activity. A gland may have a very large total area, yet if the area taken up by the degenerated zona reticularis is deducted from it, it will be seen that the area occupied by functional tissues is actually smaller than in the normal gland.

(7) FUNCTIONAL ACTIVITY.

GUIEYSSE, who observed vacuoles and siderophile bodies in the adrenal of the guinea pig, regards them as signs of secretory activity of the gland. He suggests that in the guinea pig the secretory activity is cyclic, increasing till the middle of pregnancy, and followed by a resting stage until parturition.

But in the present investigation vacuoles are present in great numbers in Stage I; in Stage II they are reduced in number and are replaced by the cells of the zona gestationis which at this stage showed no sign of secretory activity. As stated above/

above, this process is very gradual. During Stage IV the vacuoles are almost absent. The cells of the zona gestationis as well as those of the zona glomerulosa, exhibit the maximal degree of secretory activity, containing large numbers of siderophile bodies (referred to by MASUI and TAMURA as secretory granules).

MAHNERT (1920) assumed that during pregnancy the suprarenal is in an exhausted condition. In explanation of this assumption he says, "Geht aus der Lipoidverarmung dieser organe bei den Schwangerschaftstoxikosen". On histological examination there can be no doubt that the lipoids are scanty throughout pregnancy, except at a very early stage, so that the assumption of MAHNERT is probably true. If the functional activity during pregnancy is noted, it will be seen to increase slowly until the third quarter and to decrease during the last quarter.

WATRIN (1914, 1919) attempted to discover the cause of the hypertrophy of the suprarenal in the rabbit and after numerous experiments concluded that hypertrophy is due to the presence of the fertilised ovum before fixation and of the foetal placenta. The results of the present investigation are such as tend to/

to corroborate this suggestion.

MAHNERT considers that during pregnancy the suprarenal is functioning abnormally and that this disfunctioning (or malfunctioning) of the endocrine organs during pregnancy is caused by the toxins of the foetal elements of the placenta. Further, he agrees with others that the disfunctioning of the ovary is primary and that of the adrenal secondary.

Current opinion concerning the relationship of the suprarenal ovary can be as follows:-

1. The zona reticularis is hyperfunctioning at the period of "heat" (MASUI and TAMURA)
2. During pregnancy, when the ovary and adrenals are in the disfunctioning stage, the zona reticularis degenerates and disappears. (TAMURA in this paper).
3. The zona reticularis reappears when the ovary regains its normal functioning. (MASUI and TAMURA).
4. In the blood of the gonadectomised female there is present an enzyme which stimulates the development of the ovary. (LONG and EVANS and GOTO).
5. Complete gonadectomy in the female has no effect/

effect on the structure of the suprarenal. (MASUI and TAMURA).

The results of the present investigation are such as tend to confirm MAHNERT'S first suggestion, but in them there is no evidence which permits a decision as to whether the disfunctioning of the suprarenal in relation to that of the ovary is primary or secondary.

V. SUMMARY.

1. In the mouse there is no correlation between body weight, body length, and the size of the suprarenal gland. The size of this gland is not always indicative of its functional activity.
2. Unilateral ovariotomy has no effect on the functional activity of the suprarenal gland.
3. During pregnancy the gland becomes reduced in area.
4. The hypertrophy of the zona glomerulosa occurs during pregnancy and at 17 mm. stage it reaches the maximal secretory activity.
5. Observations on the hypertrophy of the zona faciculata are in agreement with those of other workers. This hypertrophy may be caused by either an enlargement of cells or an increase of their number. In the latter case it is due to the appearance of a new zone, zona gestationis. This zone reaches its maximal activity at about 17 mm., and at this stage so-called siderophile bodies (secretory granules) are visible in great numbers.
6. Zona reticularis degenerates rapidly at an early period (before formation of placenta) of pregnancy/

pregnancy, and at the middle of pregnancy the site of this zone is occupied by vacuoles.

7. The hypertrophy of the medulla occurs at the closing period of pregnancy.
8. Mitotic figures were observed in every zone except zona reticularis at an early period of pregnancy.
9. The secretory activity of this gland increases slowly and reaches its maximum at about the third quarter of pregnancy, followed by a partial decrease during the last quarter.

VI. REFERENCES.

CASTALDI, (1922) Arch.d.fisiol., 20, p.33. (quoted after DONALDSON)

DONALDSON, J.E. (1924) "The Influence of Pregnancy and Lactation on the Weight of the Adrenal Gland in the Albino Rat" Amer.Jour.Physiol., 68, 517-522.

GOTO, N., (1923) "Studies on the Internal Secretion of Ovary applying to Parabiose in the Albino Rat." I. Japan.Jour.Gynaec., 18, p.3.

" " (1923) II. Ibid.,

GUIEYSSE, M.A. (1899) "La capsule surrénale chez la femelle du cobaye en gestation" C.R.Soc.Biol., 51, 898-900.

" " (1901)"La capsule surrénale du Cobaye" Jour.d'anat.& de physiol., 37, 312-435.

HERRING, (1920) "The Effect of Pregnancy on the Various Organs of the White Rat." B.M.J., pt.2, 886.

KOLDE, W., (1913) "Veränderungen der Nebenniere bei Schwangerschaft und nach Kastration" Arch.f.Gynäk., 99, 272-283.

KOLMER, W. (1912) "Beziehungen von Nebennieren und Geschlechtsfunktion." Pflüg.Arch., 144.

LONG, J.A. and EVANS, H.M., (1922) "The Oestrous Cycle in the Rat and its Associated Phenomena." Mem.Univ.Calif. No.16.

MAHNERT, A. (1920) "Weitere Beiträge zum Studium der Dysfunktion endokrinern Drüsen in der Schwangerschaft." Arch.f.Gynäk., 113, 472-489.

MASUI, K. and TAMURA, Y. (1924). "The Effect of Gonadectomy on the Structure of the Suprarenal Glands of Mice, with Special [illegible]

Special Reference to the Functional Relation between this Gland and the Sex Gland of the Female." Japan.Jour.Zootech.Sci.,1, 55-79

RIDDLE, O. (1923) "Studies on the Physiology of Reproduction in Birds. XIV. Suprarenal Hypertrophy coincident with Ovulation." Amer.Jour.Physiol., 66, 322-339.

VERDOZZI, C. (1917) "Capsules surrénales et allaitement." Arch.ital.biol., 66, p. 121. (quoted after DONALDSON)

WATRIN, J. (1914). "L'hypertrophie des capsules surrénales au cours de la gestation, est-elle sous la dépendance du corps jaune ?" C.R.Soc. Biol., 77, 142-143.

" " (1914) "Le corps jaune sensibilise les capsules surrénales à l'action des facteurs qui déterminent leur hypertrophie gravidique." Ibid., 207-209.

" " (1914) "L'oeuf fecondé conditionne, avant sa fixation, l'hypertrophie des capsules surrénales chez la lapine." Ibid., 321-323.

VII. Description of Figures.

Fig. 1. Adrenal of the mouse at a very early stage of pregnancy (Stage I).

Figs. 2 & 3. The same. (Stage I).

Fig. 4. The same (Stage II), showing degenerated zona reticularis.

Fig. 5. The same during Stage III.

Fig. 6. The same at the beginning of Stage IV.

Fig. 7. The same, showing zona gestationis occupying the entire site of zona fasciculata and vacuoles in zona glomerulosa.

Fig. 8. The same, showing large vacuoles in the site of zona reticularis.

Fig. 9. The same during Stage V.

Fig. 10. Degenerating cells in zona reticularis during Stage IV (from fig.7).

Fig. 11. Typical vacuolated cells of the zona fasciculata.

Fig. 12. Cells of zona gestationis (from fig.7)

Fig. 13. Cells of zona glomerulosa during Stage IV (from fig.7)

Fig. 14. & 15. A cell of zona glomerulosa showing granules.

Fig. 16. A cell of zona gestationis during Stage III.

Figs. 17, 18 & 19. A cell of zona gestationis during Stage IV.

Figs. 20 & 21. The same during Stage V.

TABLE I.

CONTROL

AREA IN MM.^{2}

	ZONA GLOMERULOSA	ZONA FACICULATA	ZONA RETICULARIS	MEDULLA	TOTAL
Ex.6 No.3	0.224	0.926	0.354	0.227	1.731
Ex.37 No.2	0.178	0.531	0.422	0.204	1.335
Ex.9 No.2	0.184	0.540	0.529	0.289	1.542
Ex.9 No.3	0.224	0.473	0.302	0.210	1.289
Ex.26 No.2	0.132	0.526	0.473	0.250	1.381
No.1 ♀	0.166	0.611	0.710	0.178	1.665
No.2 ♀	0.145	0.881	0.342	0.289	1.657
No.3 ♀	0.118	0.382	0.480	0.191	1.171
No.4 ♀	0.132	0.625	0.454	0.184	1.395
No.5 ♀	0.132	0.395	0.381	0.154	1.065
AVERAGE	0.164	0.589	0.445	0.217	1.423

TABLE II.

STAGE I (0-5 mm.).

GROUP I.

	AREA IN $MM.^2$				
	ZONA GLOMERULOSA	ZONA FACICULATA	ZONA RETICULARIS	MEDULLA	TOTAL
No. 16 ♀ p.	0.191	0.395	0.572	0.183	1.341
No. 21 ♀ p.	0.151	0.526	0.552	0.224	1.453
Ex. No.2	0.193	0.531	0.569	0.246	1.539
No.17 ♀ p.	0.229	0.611	0.270	0.302	1.412
No.10 ♀ p.	0.176	0.658	0.549	0.192	1.575
Ex.23 No.3	0.183	0.532	0.433	0.168	1.316
Ex.31 No.1	0.256	0.639	0.354	0.263	1.512
Ex.16 No.3	0.168	0.526	0.270	0.256	1.220
Ex.21 No.3	0.214	0.736	0.339	0.282	1.571
AVERAGE	0.196	0.573	0.434	0.235	1.438

TABLE III.

GROUP 2.

	AREA IN $MM.^2$				
	ZONA GLOMERULOSA	ZONA FACICULATA	ZONA RETICULARIS	MEDULLA	TOTAL
Ex.19 No.5	0.217	0.921	0.105	0.420	1.663
No. 6 ♀ p.	0.097	0.471	0.036	0.270	0.874
Ex.21 No.4	0.121	0.710	0.050	0.256	1.137
No.11 ♀ p.	0.210	0.556	0.060	0.180	1.006
Ex.21 No.2	0.159	0.774	0.085	0.215	1.223
AVERAGE	0.161	0.686	0.067	0.268	1.182

TABLE IV.

GROUP 2.

AREA IN $MM.^2$

	ZONA GLOMERULOSA	ZONA FACICULATA	ZONA RETICULARIS	MEDULLA	TOTAL
No. 9 ♀ p.(6)	0.215	0.826	0.109	0.254	1.404
No.18 ♀ p.(6)	0.151	0.610	0.172	0.198	1.131
No. 1 ♀ p.(7)	0.132	0.634	0.046	0.232	1.044
Ex.19 No.6(8)	0.209	0.834	0.088	0.414	1.545
Ex.31 No.2(8)	0.179	0.460	0.095	0.192	0.926
No. 8 ♀ p.(9)	0.167	0.823	0.060	0.351	1.401
No. 2 ♀ p.(9)	0.132	0.584	0.060	0.164	0.940
No.13 ♀ p(10)	0.171	0.640	0.197	0.211	0.219
No.12 ♀ p(10)	0.122	0.547	0.091	0.249	1.009
No.22 ♀ p(10)	0.221	0.711	0.113	0.290	1.335
No.23 ♀ p(10)	0.158	0.434	0.243	0.151	0.986
No.11$_2$♀ p(10)	0.070	0.682	0.028	0.206	0.986
No. 7 ♀ p(11.5)	0.121	0.806	0.085	0.360	1.372
Ex.34No.4(12)	0.295	0.864	0.101	0.261	1.501
Ex.21No.1(12)	0.235	0.809	0.114	0.289	1.447
AVERAGE	0.171	0.684	0.107	0.255	1.213

TABLE V.

STAGE IV (13 - 20 mm.).

	AREA IN MM.^{2}				
	ZONA GLOMERULOSA	ZONA FACICULATA	ZONA RETICULARIS	MEDULLA	TOTAL
Ex.22 No.3(12.5)	0.233	0.622	0.114	0.280	1.249
Ex.21 No.5(13)	0.158	0.539	0.127	0.189	1.013
No.25 ♀ p.(13)	0.224	0.848	0.105	0.309	1.486
No.26 ♀ p.(13)	0.212	0.557	0.184	0.250	1.203
Ex.19 No.3(14)	0.195	0.707	0.264	0.225	1.391
Ex. 8 No.1(14)	0.213	0.579	0.239	0.151	1.182
No.15 ♀ p.(14)	0.114	0.546	0.080	0.257	0.997
Ex.34 No.2(16)	0.296	0.940	0.155	0.299	1.690
Ex. 6 No.12(16)	0.229	0.794	0.189	0.274	1.486
No. 4 ♀ p. (17)	0.352	0.822	0.016	0.368	1.558
Ex.53 No.2 (17)	0.191	0.555	0.555	0.247	1.548
Ex.30 No.2(17.5)	0.343	0.559	0.046	0.389	1.337
No.27 ♀ p. (18)	0.178	0.592	0.506	0.302	1.578
Ex.16 No.1 (20)	0.284	0.988	0.201	0.261	1.734
AVERAGE	0.230	0.689	0.198	0.272	1.389

TABLE VI.

STAGE V (21 mm. and over).

AREA IN MM.^{2}

	ZONA GLOMERULOSA	ZONA FACICULATA	ZONA RETICULARIS	MEDULLA	TOTAL
No. 3 ♀ p. (21)	0.100	0.534	0.020	0.374	1.028
Ex.16 No.2 (21)	0.234	0.518	0.066	0.266	1.084
Ex.10 ♀ p. (21)	0.321	0.902	0.197	0.513	1.933
Ex. 9 No.1 (24)	0.218	0.658	0.068	0.300	1.244
Ex.25 No.4 (24)	0.163	0.602	0.155	0.192	1.112
Ex.14 ♀ p. (24)	0.167	0.596	0.063	0.298	1.124
No. 5 ♀ p. (24)	0.220	0.676	0.075	0.307	1.278
No. 5_2♀$_2$ (24)	0.101	0.736	0.070	0.408	1.315
Ex. 6 No.2 (24)	0.189	0.639	0.070	0.193	1.091
AVERAGE	0.190	0.651	0.087	0.317	1.245

1

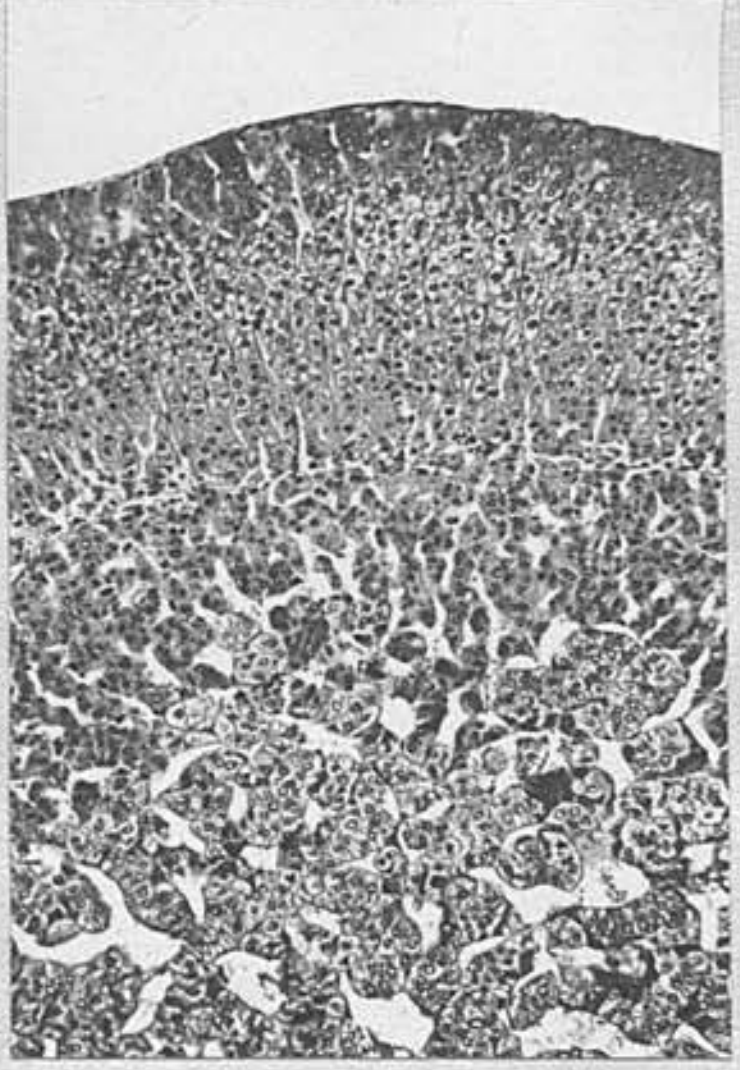

2

3

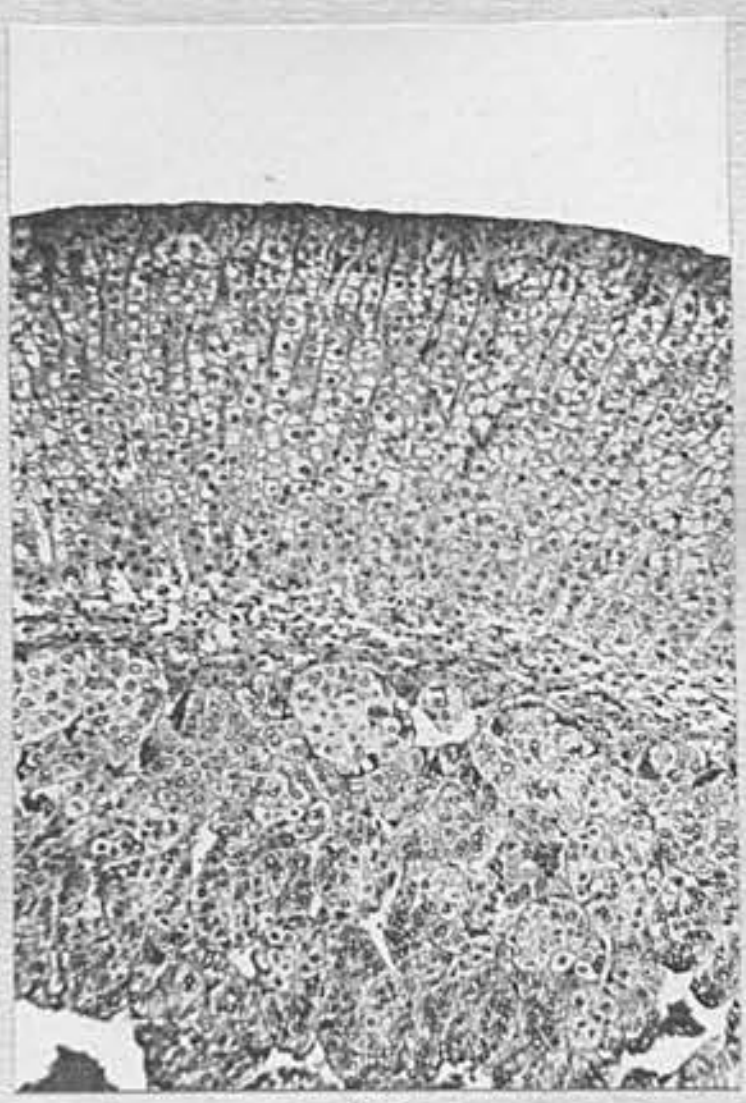

4

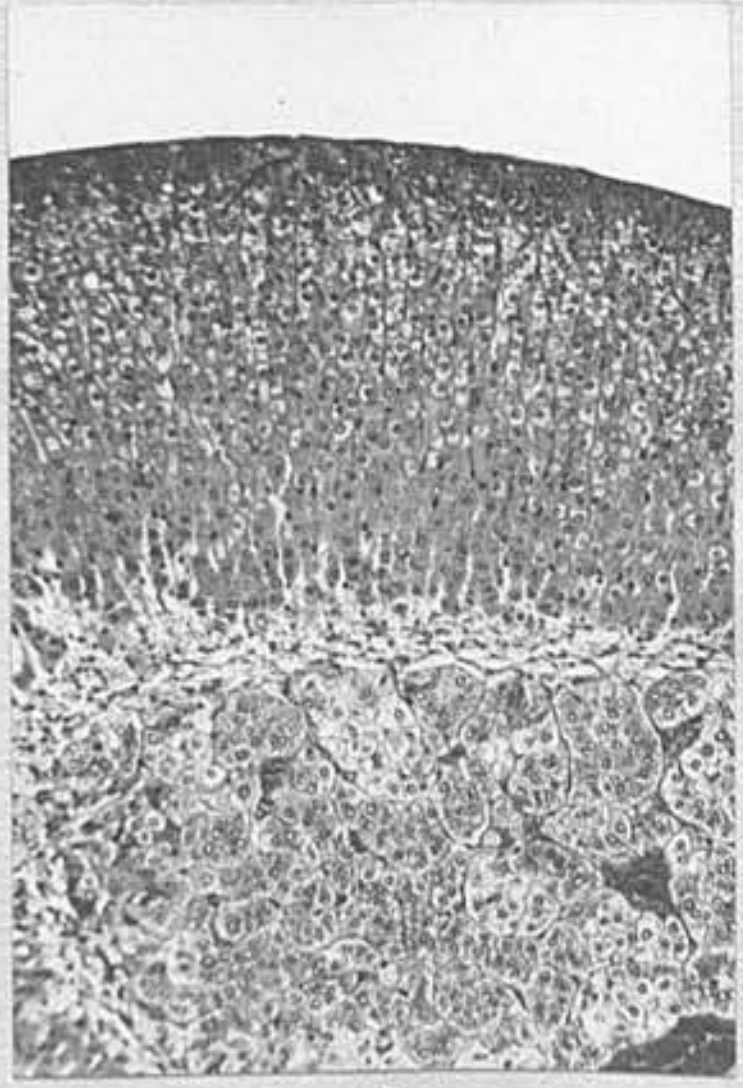

5

6

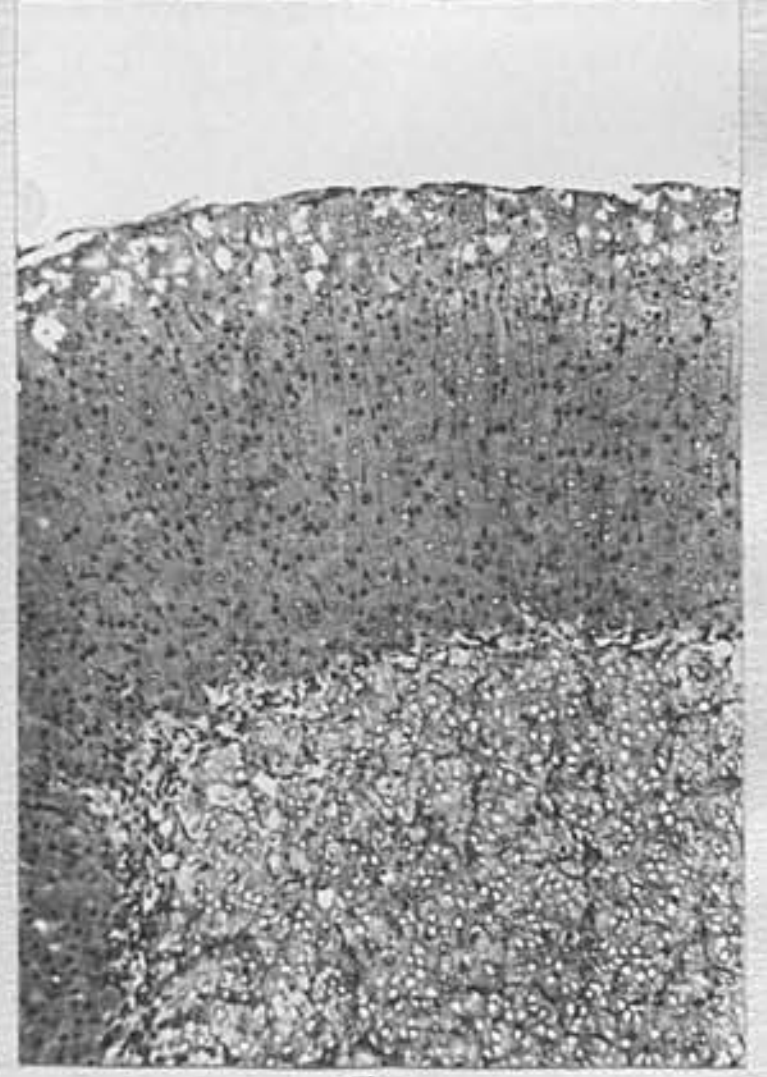

7

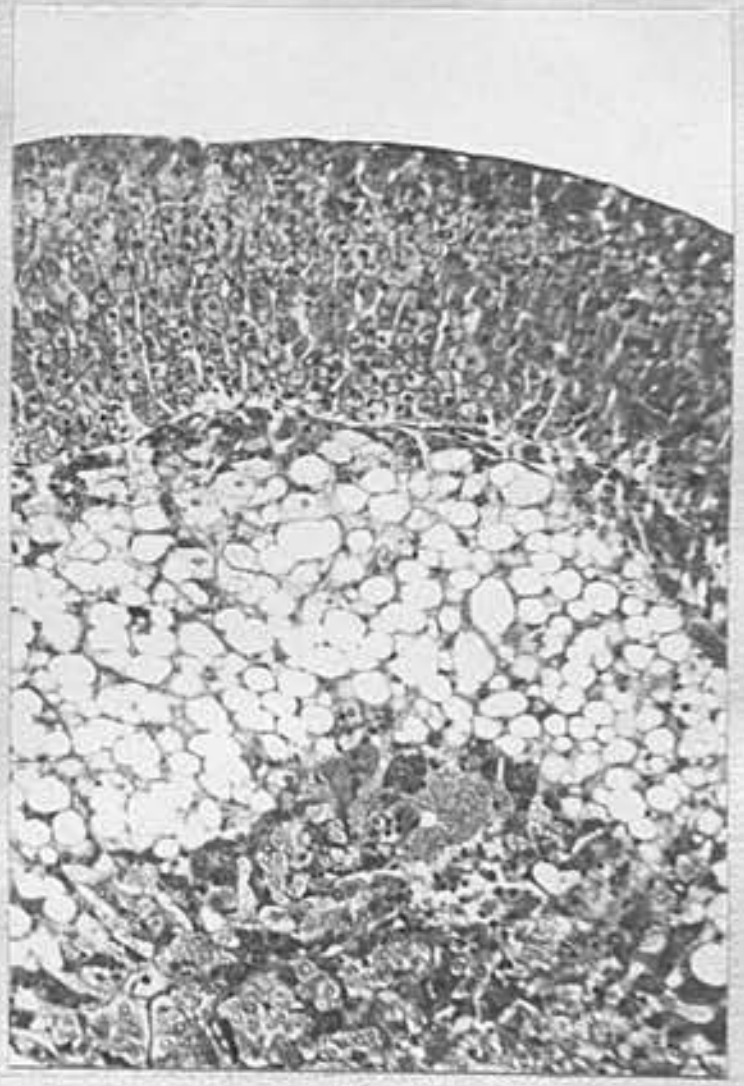

8

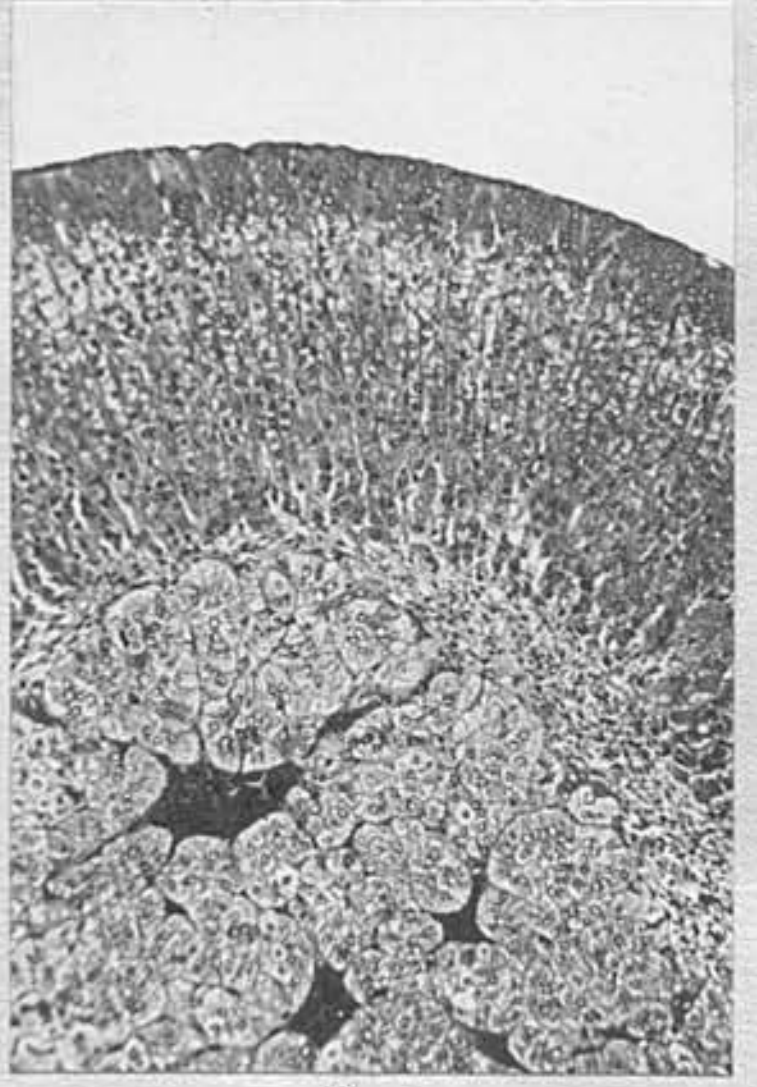

9

10

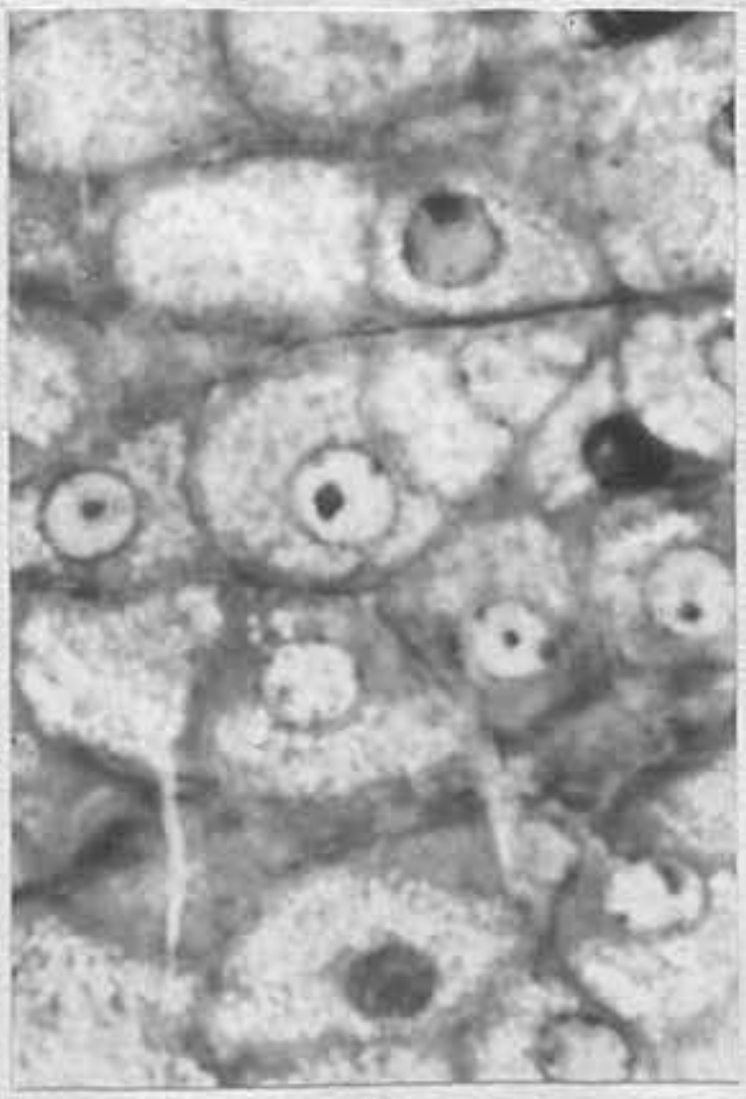

11

12

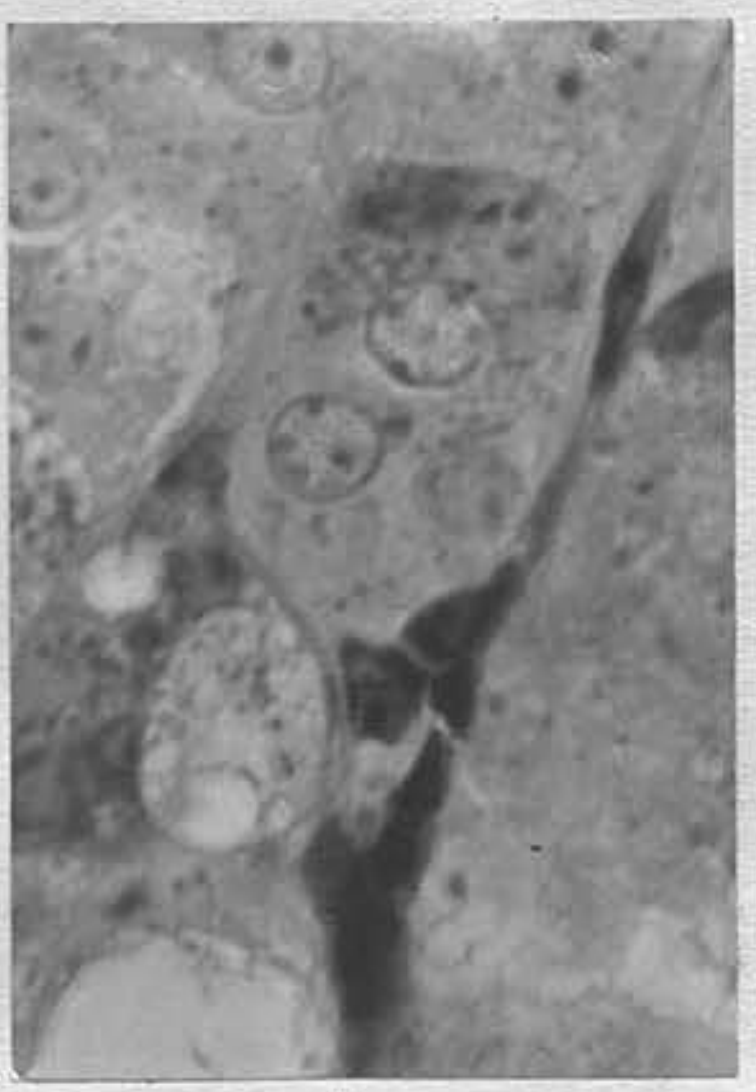

13

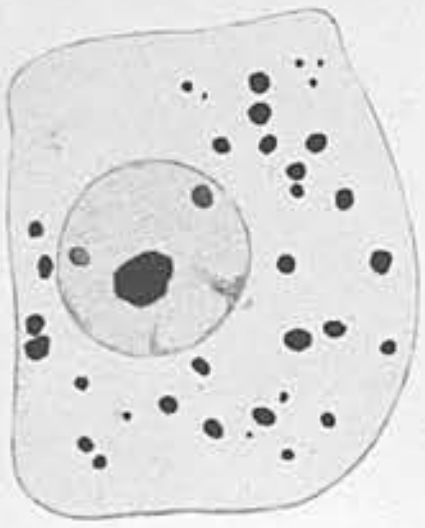

14

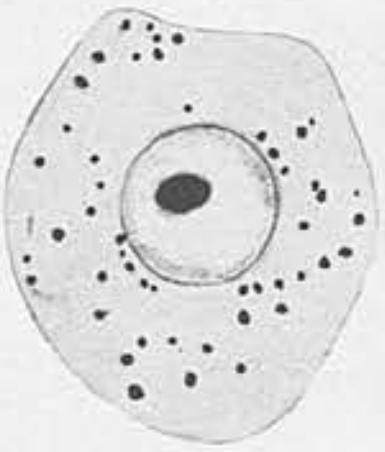

15

16

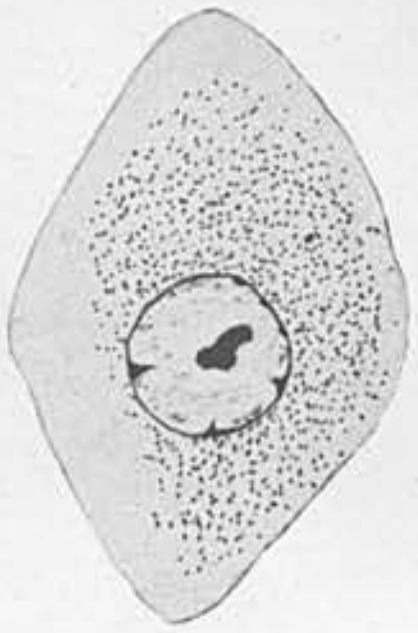

17

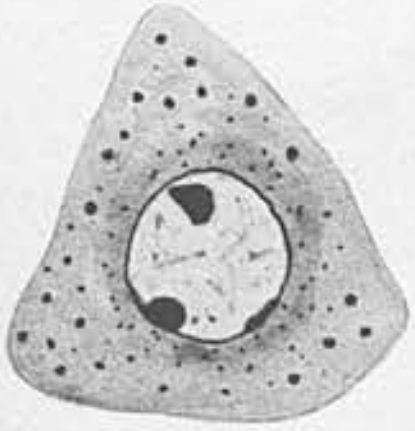

18

19

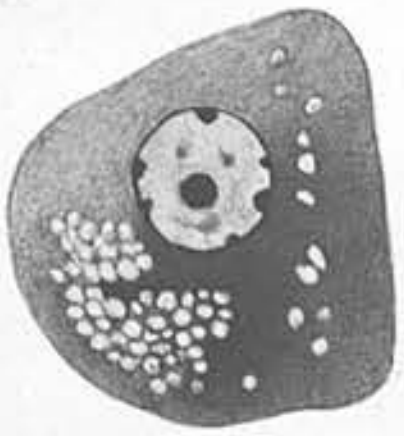

20

21

A HISTOLOGICAL STUDY
of the
ANOVULAR FOLLICLE in the DINGO & the MOUSE.

BY

Y. TAMURA.

In the press. Journ.Anat. 1926.

A HISTOLOGICAL STUDY of the ANOVULAR FOLLICLE in the DINGO & the MOUSE.

by

Y. TAMURA.

LEAGUE and HARTMAN (1925) have recently reviewed the literature relating to anovular follicles in the mammalian follicles possessing normal granulosa, basement membrane, and theca interna, but devoid of eggs in the armadillo, opossum, and rhesus monkey. They distinguish, chiefly on the basis of size, three types of anovular graafian follicles, viz:- primordial, medium and mature. In their opinion primordial anovular follicles are usually of approximately the same size as primordial ova and consist of granulosa cells only, loosely arranged within a basement membrane; as suggested by Gérard (1920) they arise from Pflüger's egg tubes and are simply groups of epithelial cells that have failed to become associated with ova. They concluded that in the opossum these primordial anovular follicles may undergo cell division and enlarge to form 'medium' anovular follicles consisting of many compactly massed granulosa/

In the press. Journ.Anat. 1926.

granulosa cells, as REGAUD and LACASSAGNE (1913) maintain to be the case in the rabbit. Another type of anovular follicles is that which arises by death and resorption of the ovum, or more rarely by the migration of the ovum out of the membrana granulosa. LEAGUE and HARTMAN hold that in the opossum this type gives origin to the mature anovular follicles whose structure has the appearance of a syncytium and whose nuclei are mostly peripherally arranged, with a scattering of several nuclei near the centre.

They concluded also that the identity of the origin of the normal and the anovular follicles is evidenced by their association together in similar stages of development. Two follicles, one normal, the other abnormal, may be surrounded by the same theca interna. They hold that the anovular follicle undergoes chromatolytic and lipolytic degeneration and present evidence to show that the granulosa is able to maintain its integrity for some time after the egg has disappeared. REGAUD and LACASSAGNE (1913) state that the anovular follicles are to be found only in young animals and that their number decreases with the age of the individual. On the other/

other hand, Gerard states that in the case of GALACO the anovular follicles are few in number in the young and numerous in the adult, and LEAGUE and HARTMAN maintain that the anovular follicles are not limited to young animals.

The present writer, in the course of an examination of sterile dingoes and of mice during their sixth pregnancy for other purposes, took the opportunity of looking for anovular follicles. The ovarian tissue was fixed in ALLEN'S BOUIN and FLEMMING and stained with DELAFIELD and HEIDENHAIN'S haematoxyline. Serial sections of eight were examined. In certain details the results of this study agree with the conclusions of LEAGUE and HARTMAN, while in others they do not.

In the case of the adult sterile dingo bitches, numerous primordial follicles were found; while most of them showed degeneration of the contained ovum, and a few were normal, the primordial anovular follicles described by LEAGUE and HARTMAN were exceedingly rare, and in contradistinction to the findings of the above authors. No signs of mitotic figures were to be found. Mitotic figures in/

in early stages, however, were found in the primordial follicles in which the ovum had already degenerated or resorbed, and which had a normal active membrane granulosa.

The most common type of anovular follicles in the dingo is that whose structure is very similar to the structure of the "mature" anovular follicles described by LEAGUE and HARTMAN. However, they are found to vary greatly in size, ranging from 0.069 mm. to 0. 19 mm. in diameter in the largest section (Fig.I) No follicles resembling in structure the so-called "medium" anovular follicles of LEAGUE and HARTMAN could be identified, and no evidence could be gleaned that would support the contention of the above authors and of REGAUD and LACASSAGNE (1913) that such medium anovular follicles had in the case of the dingo bitches developed by cell division from the primordial epithelial cells. The condition found suggested that these anovular follicles in the dingo had resulted from the absorption of the ova and preservation of membrane granulosa at a stage when the follicle was of the size that it exhibited at the time of examination. Various stages of mitotic figures were found in the follicles in which the ovum had degenerated or already become resorbed/

resorbed while their membrane granulosa corresponded with that of normal follicles at a similar stage of development. In some cases the granulosa projects into the human and mitotic figures in early stages are still showing and in the case of a more advanced stage of degeneration the granulosa cells are scattered loosely in the lumen, and there is an indication of an antrum in the centre of the follicle, as described by LEAGUE and HARTMAN in the case of mature anovular follicles. In other cases the anovular follicles in the course of formation become compressed from both sides and elongate taking on a tubule-like appearance. (Fig.2). Structures identical in appearance with the 'medium' follicles of LEAGUE and HARTMAN and surrounded by a well-developed theca interna were present, but on careful examination of the serial sections these were found to be merely parts of a normal medium sized follicle.

Careful examination of serial sections failed to reveal the presence of two follicles, one normal and the other anovular, in association as described by LEAGUE and HARTMAN. On the other hand, there was plentiful evidence to show that such an apparent combination was obtained when sections were cut/

cut from a single follicle which had become diminished in size, for what seems to be two follicles when followed through, was found to be but one. (Fig.2).

The fate of these anovular follicles was typical lipolytic degeneration; several single anovular follicles of varying size underwent lipolytic degeneration here and there, but it was found that the great majority migrated to one area of the ovary which consisted of nothing else but follicles in some stage of degeneration. (Fig.3).

In the left ovary of one of the dingoes masses of tissue closely resembling seminiferous tubules were found invading the connective tissue. (Fig.4.). It was not possible to decide with confidence what this tissue actually was. No signs of spermatogenesis could be identified, but the structure was very similar to that of the testis of the immature male and very different from that of the anovular follicle. The theca of the abnormally large atretic follicles, particularly when contorted and enclosing a lumen lined with degenerated granulosa, presented an appearance very suggestive of this seminiferous tubule-like tissue, but it is impossible to decide whether the seminiferous tubule-like tissue had its origin in this.

It is of interest to note that HAMMOND

(1925)/

(1925) describes a very similar embryonic seminiferous tubule-like tissue in the ovaries of infecund rabbits. His figures (Plates XII, Fig. 2, and XIII, Figs. 3 and 4) present features that are very similar indeed to anovular follicles found in the dingoes.

In the case of the old pregnant mice, numerous anovular follicles were found in the ovaries, (Fig. 5) whereas in the case of younger mice pregnant for the first or second time, no such follicles were present. In the mouse it would seem that the number of anovular follicles increase with age after a certain age. This is not in agreement with the conclusions of REGAUD and LACASSAGNE. In structure these follicles were as the primordial and medium anovular follicles described by LEAGUE and HARTMAN.

Since in the experience of the writer these anovular follicles are more frequently found in old, sterile, or pregnant individuals, it seems reasonable to suggest that their development is determined by nutritional agencies, and that when nutrition or the hypothetical "generative ferment" of HEAPE is inadequate, it may result in the failure of many of the constituent follicles of the ovary to attain their normal development and the appearance of anovular follicles/

follicles. It is probable that in this matter one or more members of the endocrine chain are involved. In the case of the dingoes examined the individuals were infecund and examination of the endocrines revealed the fact that all were abnormal (TAMURA, 1926). However it is impossible to say definitely that nutritive supply or the "generative ferment" has its origin in the endocrine organs, but it may be assumed that, as suggested by HAMMOND (1925), endocrine organs have a very important role in the normal development of the ovary.

It is still questionable whether it is the gonads or the endocrine organs that are the first to be affected by environment. However, GLYNN (1921) MASUI and TAMURA (1924) have presented evidence which demonstrates the intimate interrelationship of the adrenal and ovary, and MACCARRISON (1917) of the thyroid and the gonad. Therefore it may be suggested that the formation of anovular follicles may be the sequel to a malfunctioning of some member of the endocrine chain caused by an inadequate nutrition or "generative ferment".

In conditions of inadequate nutrition fewer primordial follicles continue their development to

become/

become medium sized follicles than in conditions when nutrition is in every way adequate and similarly fewer medium sized follicles continue their development to become large sized follicles and further, fewer of these proceed to complete development. The result is, therefore, that in such a case, fewer ripe ova are elaborated and this is evidenced by the fact that very few corpora lutea are found on examination. In the case of the dingoes, there were no corpora lutea.

I am greatly indebted to Dr. F.A.E. CREW for the material supplied and also for much constructive criticism during the course of this study. I also wish to thank Dr. A.W. GREENWOOD for his valuable help.

REFERENCES./

REFERENCES.

GERARD. POL., 1920. Contribution à l'étude de l'ovaire des mammifères. L'ovarie de Galago mossambicus (Young) Arch. d. Biol., 30, 357-392.

GLYNN

HAMMOND. J., and MARSHALL. F.H.A., 1925. Reproduction in the Rabbit. Biological Monographs and Manuals. Oliver and Boyd.

LEAGUE. B., and HARTMAN. C.G., 1925. Anovular graafian follicles in mammalian ovaries. Anat. Rec., 30, 1-9.

McCARRISON. R., 1917. The thyroid gland in Health and Disease. Balliere, Tindall, & Co.

MASUI. K., and TAMURA. Y., 1924. The effect of Gonadectomy on the structure of the Suprarenal Gland of Mice, with special reference to the Functional Relation between this gland and the Sex Gland of the Female. Jap. Jour. Zootech. Sci., I, 55-79.

REGAUD. C., and LACASSAGNE. A., 1913. Les follicles anovulaires de l'ovaire chez la lapine adulte. C.R. Assoc. Anat., 15th. meeting, Lausanne, 15-27.

TAMURA. Y. 1926. Sterility in a Dog x Dingo Cross. Veter. Jour., 82.

DESCRIPTION of FIGURES./

DESCRIPTION of FIGURES.

Fig. 1. Shows various sized anovular follicles the structure of which is the same as that of "mature" anovular follicles of LEAGUE and HARTMAN. Note few normal small sized follicles in the peripheral region.

Fig. 2. Shows two follicles surrounded by the same theca interna, and an elongated anovular follicle.

Fig. 3. Shows a group of anovular follicles which are undergoing hypolytic degeneration.

Fig. 4. Shows a seminiferous tubule-like mass which is found in the left ovary of a dingo bitch.

Fig. 5. Shows anovular follicles found in a pregnant mouse.

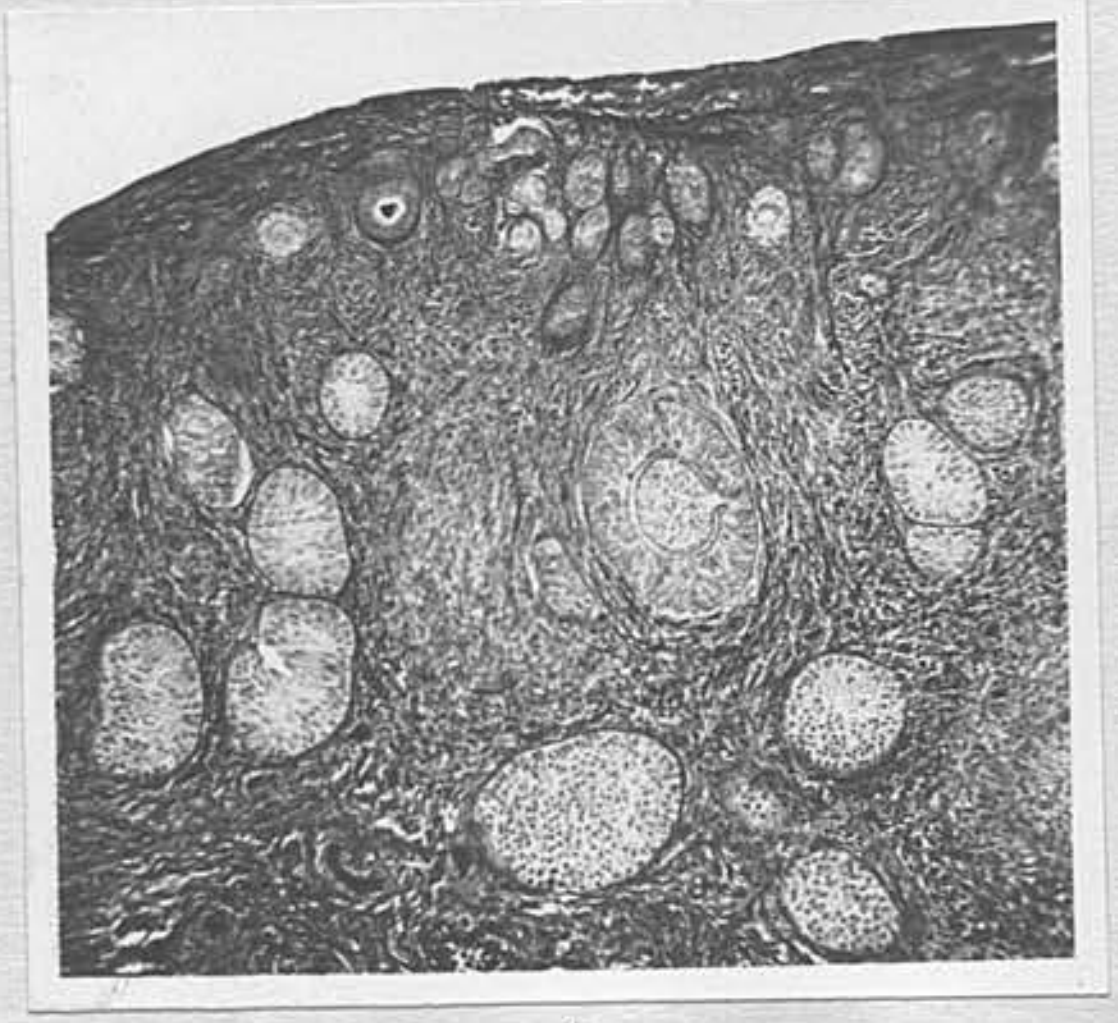

1

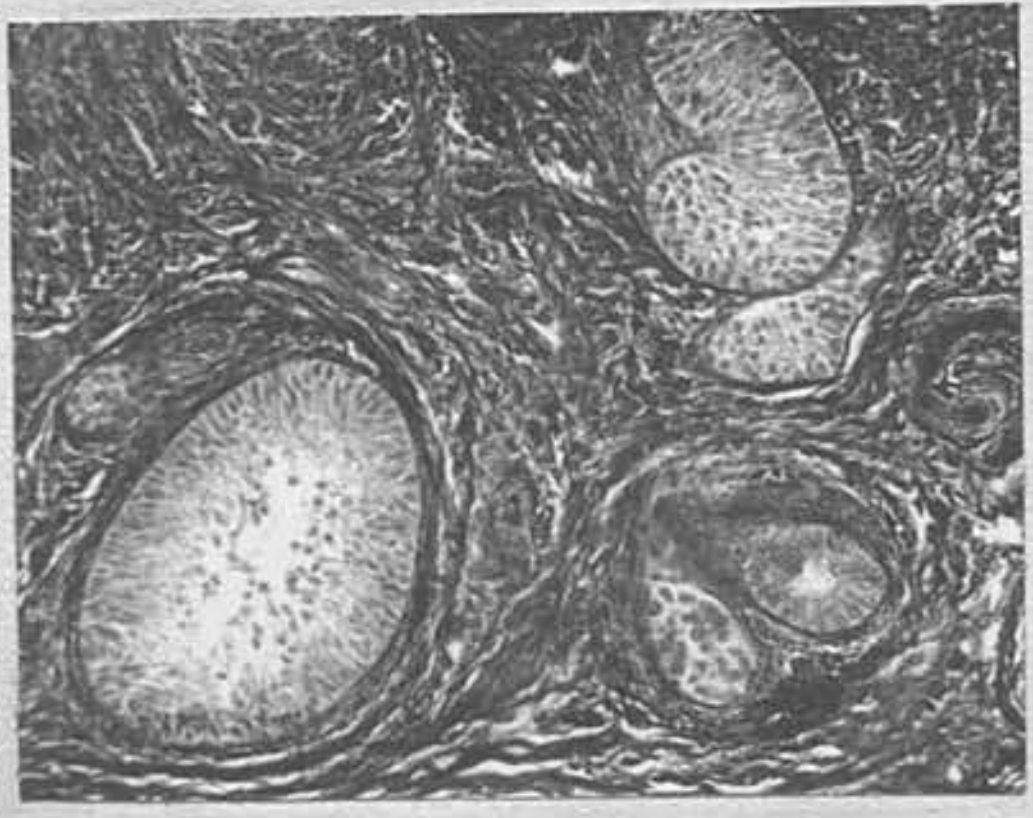

2

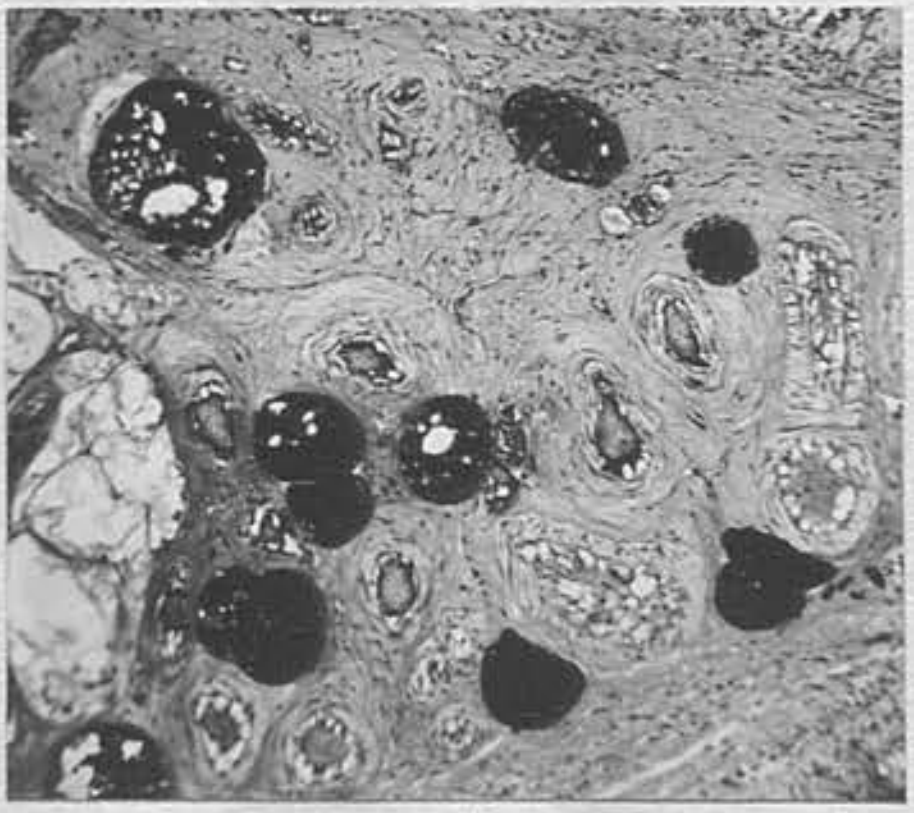

3

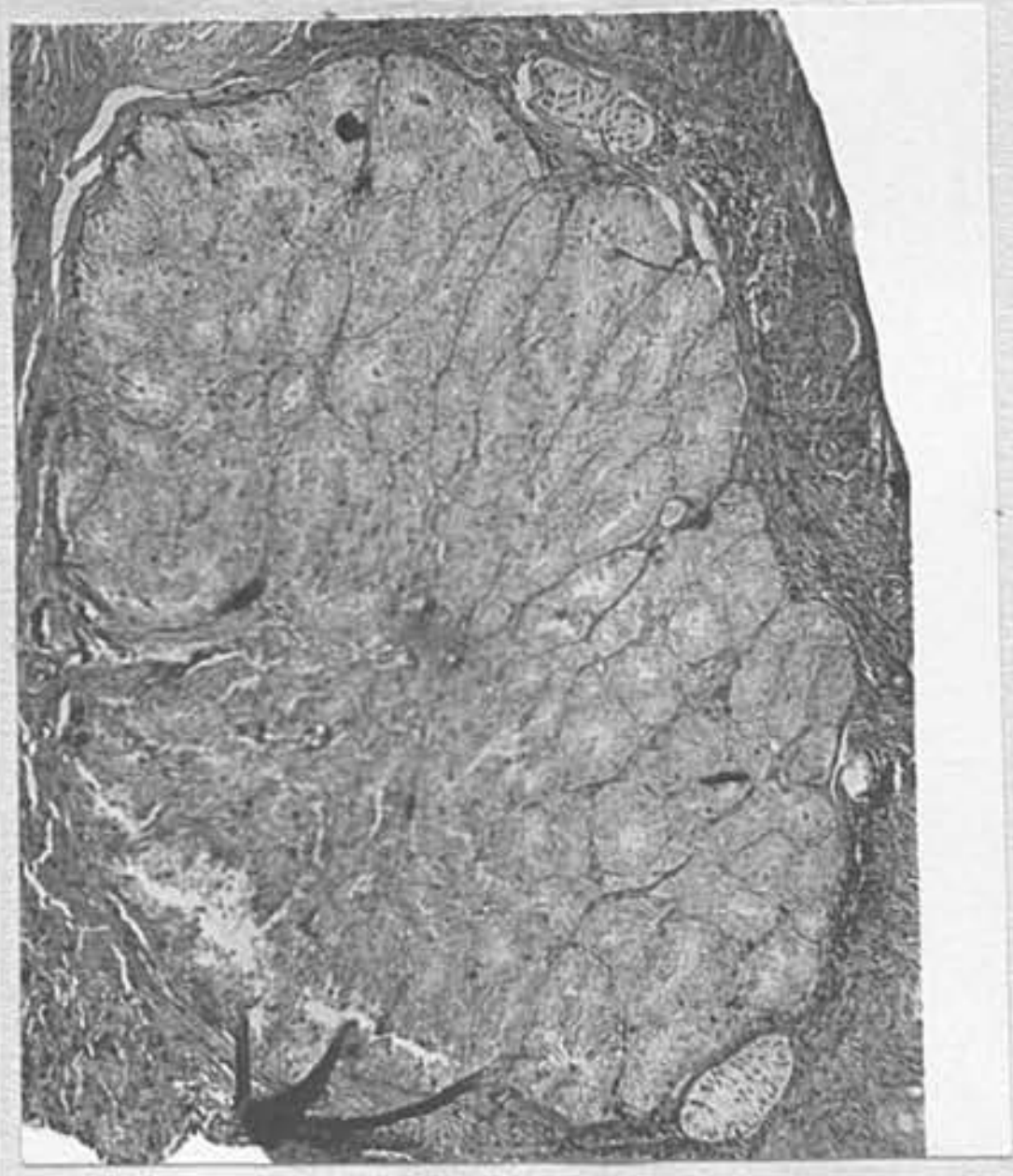

4

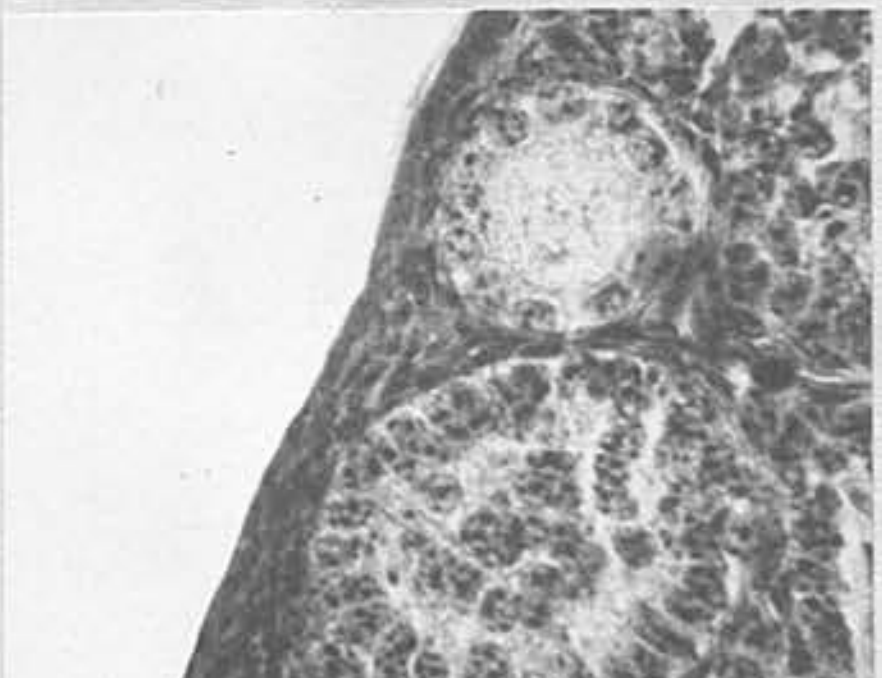

5

THE EFFECT of GONADECTOMY on the WEIGHT of the KIDNEY, THYMUS, and SPLEEN of MICE.

By KIYOSHI MASUI,

Anat. Lab. for Vet. Science. Faculty of Agric.,
Imperial University of Tokyo,

and

YASUSIGE TAMURA,

Animal Breeding Research Department, The University,
Edinburgh.

THE EFFECT of GONADECTOMY on the WEIGHT of the KIDNEY, THYMUS, and SPLEEN of MICE.

By KIYOSHI MASUI,

Anat. Lab. for Vet. Science, Faculty of Agric.,
Imperial University of Tokyo,

and

YASUSIGE TAMURA,

Animal Breeding Research Department, The University,
Edinburgh.

CONTENTS.

PAGE.

The British Journal of Experimental Biology, Vol.III;
pp. 207-223.

I. INTRODUCTION.

The effects of gonadectomy on the size of the body and of the various organs, especially of the endocrine glands, have been studied by several investigators who, however, record very different results. According to HATAI (1915), the result of castration in the rat is considerably to increase the weight of the suprarenal, hypophysis, and thymus. On the other hand MOORE (1922) found that in the castrated guinea-pig the suprarenal and hypophysis are considerably lighter than in the normal males.

In a previous study (1924) we demonstrated that in the mouse there exists a distinct sexual difference in respect of the size of the suprarenal, this gland being considerably larger in the female than in the male. This size difference is due to differences in the degree of development of the zona reticularis, which is well developed in the female, whereas in the mature male it has almost entirely disappeared. In castrated males, when compared with the normal, the suprarenals show an enlargement which likewise, is for the most part due to an increase in the size of the zona reticularis. On the other hand, ovariotomy in the female is not followed by any increase in the size of the zona reticularis, and consequently/

consequently the size of the gland as a whole remains unchanged.

The present paper deals with similar sexual differences in the weight of the kidney, thymus, and spleen of the mouse and with the effect of gonadectomy.

We wish to express our thanks to Prof. C. Ishikawa, Prof. R.Goldschmidt, and Dr. F.A.E.Crew for their help during the course of this study. The expenses of the investigation were defrayed by a grant from "Keimeikwai" (an association the object of which is to give pecuniary assistance to scientific investigations), to which we also wish to extend our cordial thanks.

2. MATERIAL and METHODS.

The animals used in the present study were reared in the Anatomical Laboratory for Veterinary Science, University of Tokyo. In the majority of cases they were operated on at the age of twenty days, though in certain cases the operation was delayed until thirty or forty days, in order that the effect of age on the results of gonadectomy could be examined. Individuals belonging to the same litter were divided into two lots, viz. operation and control;/

control; but in order to avoid variation in external conditions, operated mice were kept in the same cages as the controls, but any litter of more than six individuals was divided into two cages. When ninety days old all mice were weighed and killed with chloroform, the organs being removed and weighed immediately.

In his investigation HATAI divided a litter into two lots, one for operation the other for control; and comparison was made between the two lots. He used this method because he believed that variability of body weight in a litter is only about one half that in the total population. MOORE, however, holds a different opinion as regards the guinea-pig; he says: "Comparison of animals of the same litter "does not afford more convincing argument in favour "of weight comparison". It must, however, be noted that in his experiments on gonadectomy MOORE used only 46 animals.

In analysing our data it was found that even in the same litter there is considerable variation as regards body weight. It is reasonable to postulate that size in animals is the expression of the interaction of a number of factors (three or more). If so many factors are concerned in the production of one character, it may be assumed that only in/

in extremely rare cases can a homozygous race be obtained. It is, therefore, probable that the animals used in the present experiment differed considerably with regard to their genetic constitution, and consequently it becomes difficult to obtain reliable results, especially if only a limited number of animals is concerned. Comparison of animals of the same litter does not afford any more reliable results, because, as stated above, each animal may belong to a different genotype. In view of these facts, and in order to determine exactly the existing sexual differences with regard to certain characters and also the results of gonadectomy in the two sexes, it was found necessary to use a large number of animals and to make a statistical analysis of the data collected.

3. DESCRIPTION of EXPERIMENTS.

a. BODY WEIGHT. Male mice are on the average about 7·5 per cent heavier than female. When the mean value of the body weight of the males is compared with that of the females, the difference is found to be approximately 7·6 times its probable error: M (o) = 22·70 ± 0·085; M (♀) = 21·11 ± 0·19 (Table I).

EFFECT of CASTRATION. When the average body weight of normal and castrated males is compared, it is found that the difference is but slight, the/

the castrated being only 1·3 per cent. heavier. Thee difference of mean values of body weights between normal and castrated males (Mo) = 22·99 ± o·126), as seen in Table I., is smaller than twice its probable error and may be regarded as insignificant. It can thus be concluded that castration in the male has no effect upon body weight.

EFFECT of SPAYING. When the average body weight of normal females is compared with that of ovariotomised animals, it is seen that the latter are about 7·34 per cent. heavier than the former. The difference of the mean values for the body weights of normal and spayed females ($\overset{\phi}{+}$=22·66±0·242) is approximately five times its probable error. This is significant, indicating that spaying has a definite effect upon body weight (Table I.)

b. BODY LENGTH. In the rat HATAI found that the body length is absolutely less in castrated than in the normal animals, and concluded that castration embarrasses growth of body length. MOORE obtained similar results in the guinea-pigs. In the case of the mouse, however, it was found that castrated males are considerably longer than the normal.

TABLE I./

SEXUAL DIFFERENCE. Comparing the average body length of females with that of the normal males it is found that it is about 1·2 per cent greater in the former; thus the difference is very slight. Statistical analysis shows that the difference of the mean values for body length between the males and females (M (o) = 6·085 ± 0·0072; M $(\overset{o}{+})$ = 6·156±0·018) is approximately 3·7 times as large as its probable error, i.e. not so significant as to warrant grouping into different classes.

CASTRATION. Comparing the average body length of normal males with that of the castrated, it is found that the body length of the latter is about 1.9 per cent. greater than that of the former. The difference of mean values for body length in the two classes is approximately eleven times as large as its probable error (M(o) = 6.085 ± 0·0072: M $(\not{o})$ = 6·198 ± 0·0058), and is therefore significant (Table II.). It is reasonable to attribute this increase in body length to the effects of castration.

SPAYING. When the average body length of spayed females is compared with that of the normal, it is evident that the difference is very slight, the latter being only 0·36 per cent. greater than the/

the former. The difference of mean values for body length in the two classes (Table II.) is approximately equal to its probable error ($M(\overset{o}{+})=6\cdot156\pm0\cdot018$; $M\ (\overset{\varnothing}{+})=6\cdot134\pm0\cdot0165$), i.e. it is not significant.

In the guinea-pig MOORE found that the average body length of the normal female is slightly greater than that of the spayed. In the rat different results were obtained by **HATAI**, who concluded that the absolute body length is slightly greater in spayed females. It is, however, unjustifiable to attribute such slight variation to the effects of gonadectomy.

c. WEIGHT of the KIDNEYS. As far as we know no one has previously described the effects of gonadectomy on the weight of the kidney. It will be shown that the weight of the kidney in the mouse differs according to the sex of the individual, it being considerably heavier in males than in the females. Since the kidney is a most important excretory organ, it is very probable that it has some important relation to the metabolism of the body. Moreover, it is reasonable to assume that the weight of an organ is correlated with its functional activity, i.e. the functional activity may increase in proportion to the weight of the organ. Since the male kidney is heavier/

heavier than the female, it can be argued that the metabolic activity of the male is higher than that of the female.

SEXUAL DIFFERENCES. On comparing the average weight of the kidney of the male with that of the female, it is found that the former is considerably heavier. The difference (about 45 per cent.) is so great that the statistical method of comparison is not necessary in this case (M(o)=0·418 ± 0·00303; M (♀)=0·289 ± 0·0024. It is, of course, true that with the increase of the body weight the weights of the various organs likewise increase. But since the average body weight of the normal males is only 7·3 per cent. greater than that of the females, it is evident that the difference in the weight of the kidney in the two sexes is significant (Table IV.).

CASTRATION. When the average weight of the kidneys of castrated males is compared with that of normal ones, it is found that the latter is about 53 per cent. heavier. As this difference is even greater than that existing between the weights of kidneys of normal males and females, it is clear, even without a statistical analysis, that it cannot be due simply to variation (M(o)=0·418±0·00303; M(ø)=0·274 +0·0024). As stated above, castrated males are slightly heavier than normals, and thus the difference/

difference of the relative weights of the kidneys is greater than that of the actual weights (Table IV.) Hence it may be concluded that castration inhibits the growth of the kidney to a remarkable extent.

SPAYING. Comparing the average weight of the kidneys of spayed females and that of the normal it is seen that the latter is about 8·6 per cent. greater ($M(\overset{o}{+})=0{\cdot}289 \pm 0{\cdot}0024$; $M(\overset{\text{ø}}{+})=0{\cdot}266 \pm 0{\cdot}0016$). As stated above. spayed females are considerably heavier than normal, and accordingly the difference of relative weights between them is greater than that of actual weights (Table IV.).

It is seen that the difference in weight of the kidneys of the two sexes disappears after gonadectomy, when the weight in either sex approaches that of the female. Tables I. and II. demonstrate the differences of the actual and relative weights of the kidneys in normal and operated individuals. It is of importance to note that as the result of gonadectomy in the male the kidney becomes greatly decreased in weight, while in the spayed female it undergoes but a slight diminution in weight (Figs. 3 amd 4). On the basis of what has been said above in respect of the metabolic activity of the two sexes, we may infer that castrated males approach the female type of metabolism, while in spayed females/

females only a slight change occurs. The metabolic changes of the castrate are caused by the absence of the internal secretion of the testis. The very considerable reduction of the weight of the kidney after castration may be one of the most important signs of the depression of the metabolic activity.

d. WEIGHT of the THYMUS. Sexual differences. It has been stated that gonadectomy is followed by a considerable increase in the size of the thymus in both sexes, but no previous investigator has recorded the fact that there exists a sexual dimorphism as regards the weight of the thymus. In the mouse the thymus is considerably heavier in the female than in the male (Fig.5), the difference being on the average 81 per cent. (M(o)=0·021 ± 0·00035; $M(\overset{o}{+})$=0·038 ± 0·00073). Since the body weight of the male is about 7·5 per cent. greater than that of the normal female, it is evident that the difference of percentage weights of the thymus between the two sexes is greater than that of absolute weights. (Tables VI., VII., VIII.).

CASTRATION. When the average weight of the thymus of castrated males is compared with that of the normal, it is found that there is a marked difference, namely an excess of about 146 per cent. in/

in favour of the castrates ($M(o)=0{\cdot}021\pm0{\cdot}00035$; $M(\not{o})=0{\cdot}00518\pm0{\cdot}00066$). The difference is manifestly greater than that existing between the weight of the thymus of normal males and females; thus it follows that as the result of castration the thymus becomes greatly enlarged (Tables VI., VII.). This conclusion is in agreement with that of other investigators who used different material.

SPAYING. The average weight of the thymus of spayed females is about 3·7 per cent. greater than that of the normal: ($M(\overset{o}{+})=0{\cdot}038 \pm 0{\cdot}00073$: $M(\overset{\not{o}}{+})=0{\cdot}051 \pm 0{\cdot}00049$). It will be remembered that the body weight of the spayed female is considerably greater than that of the normal; the difference of the relative weights, as shown in Table VII., is also found to be considerably greater. It has, however, to be noted that the difference of mean values of the weights of the thymus in the normal and the spayed females is but 3.5 times its probable error (cf. Table VIII.); it cannot therefore be stated definitely whether this is a case of enlargement of the thymus as a result of gonadectomy, or merely a case of fluctuating variation.

As seen in Fig.5, the frequency distribution of the thymus weight of the castrated males and/

and spayed females is very similar to that of the normal females. This is even better shown by a statistical calculation (Table VI.). The same relation is seen on comparing the relative weight of this organ. It can thus be concluded that as the result of castration the weight of the thymus becomes greatly increased, approaching almost that of the female, while in the spayed female the increase in weight of the thymus is not so striking.

Thus, as in the case of the kidney, the castrated males, the normal and the spayed females display a great similarity in respect of the weight of the thymus. This fact leads us to the conclusion that there is an intimate functional relation, either direct or indirect, between the testis and the thymus; while no close association can be seen between the thymus and the ovary.

e. WEIGHT of the SPLEEN. As far as could be ascertained, MOORE is the only investigator who has observed the functional relation existing between the spleen and the sex glands. He recorded (1922) that in the guinea-pig there is a slight sexual dimorphism as regards the weight of the spleen which is greater in the female; and that in the castrated male there occurs a slight increase, in the spayed female, a slight decrease in weight.

SEXUAL DIFFERENCE. In the house there exists a sexual dimorphism with regard to the weight of the spleen, that of the female being on an average 6·5 per cent. heavier than that of the male (M(o) = 0·081 ± 0·0023; M(♀) = 0·134 ± 0·0058). As the body weight of the male is about 7·5 per cent. greater than that of the female, it will become obvious that the difference of the relative weights of the spleen (in relation to body weight) is greater than that of the absolute weights. Hence it is evident that there is a distinct sexual difference in the weight of the spleen.

CASTRATION. The weight of the spleen of the castrated males is on an average much greater than that of the normal, there being an increase of 54 per cent. (M(o) = 0·0081 + 0·0023; M(ø) = 0·125 ± 0·0033). Since the body weight of the castrated male is about 7·5 per cent. greater than that of the normal, the relative weight of the spleen of the castrated individual is also considerably greater than that of the normal. Statistical calculation shows that the difference of mean values of the castrated and the normal males is approximately eleven times its probable error (Fig.8). It is thus seen that the spleen of the castrated male is strikingly heavier than that of the normal, and is in this respect/

respect similar to the spleen of the normal female. This relationship is clearly illustrated in Fig.8.

SPAYING. On comparing the average weight of the spleen of the spayed and the normal female, it is found that the former is somewhat lighter than the latter. However, the difference is only about 3·9 per cent. ($M(\overset{o}{+}) = 0{\cdot}134 \pm 0{\cdot}0058$; $M(\overset{\not{o}}{+}) = 0{\cdot}129 \pm 0{\cdot}005$), and since the difference in body weight between the normal and the spayed female is also very slight, there is no marked difference between the actual and the relative weight of the spleen (Table XI).

Thus, as in the cases of the thymus and the kidney, castration results in an enormous increase in the weight of the spleen, which approaches that of the female; while spaying produces no change in the weight of the organ. Also, the normal and the spayed females and the castrated males show great similarity as regards the weight of the spleen, a result which is in strict conformation with that obtaining in the cases of the kidney and the thymus.

4. CONCLUSIONS.

According to LIPSCHÜTZ (1924) "by castration the sexually differentiated type, i.e. the male or female, loses more or less its sexual character/

character and shows a tendency to become a sexually indifferent form common to both sexes". Further, he says: "There can be no doubt that in the mammal there is no development of characters characteristic of the other sex after castration". The results of the present study do not conform with LIPSCHÜTZ'S hypothesis of the 'asexual type': as the result of gonadectomy in the male the weight of the kidney, thymus, and spleen approaches that of the female, i.e. a character develops which is typical of the opposite sex. This observation is completely in accord with the results of our previous study on the suprarenals of the mouse.

5. SUMMARY.

1. There is a distinct sexual difference in the body weight of the mouse, the males being considerably heavier than the females. As the result of gonadectomy in the male there occurs no change in the body weight, while in the female it increases rapidly after spaying.

2. A slight sexual difference is seen to exist in the body length, the females being longer than the males. Body length increases slightly after castration, while spaying produces no effect.

3. There is a distinct sexual difference in the weight of the kidney, it being strikingly heavier in the male. The kidney of the castrated male becomes greatly reduced in weight and approaches that of the female kidney; in the spayed female only a slight reduction in the weight of the kidney may be observed.

4. The thymus of the female is considerably heavier than that of the male. As in the kidney, castration is followed by a striking increase in weight which approaches that of the female thymus; spaying has but little effect.

5. There is a distinct sexual difference in the weight of the spleen, it being considerably heavier in the female. The results of castration and of spaying are the same as in the case of the thymus.

6. The results of the present study do not agree with LIPSCHÜTZ'S hypothesis of an 'asexual' type, for as the result of gonadectomy in the male the weight of the kidney, thymus, and spleen approaches that of these organs in the female, or, in other words, gonadectomy is followed by a development of the characters typical of the opposite sex.

6. REFERENCES.

HATAI, S. (1915) "The Growth of Organs in the Albino Rat as affected by Gonadectomy", Journ.Exp.Zool., 18,1-67.

LIPSCHÜTZ, A. (1924), The Internal Secretion of the Sex Glands, Cambridge.

MASUI, K., & TAMURA Y., (1924), "The Effect of Gonadectomy on the Structure of the Suprarenal Glands of Mice, with Reference to the Functional Relation between this Gland and the Sex Gland of Female", Jap.Journ.Zootech.Sci.I. 55-79.

MOORE, C.R., (1919), "On the Physiological Properties of the Gonads as Controllers of Somatic and Psychical Characteristics" II. "Growth of Gonadectomised Male and Female Rats," Journ.Exp.Zool., 28, 459-67.

" " (1922) V. "The Effect of Gonadectomy in the Guinea-pig on Growth, Bone Length, and Weight of Organs of Internal Secretion", Biol.Bull. 43, 285-312.

STOTSENBURG, J.M. (1913), "The Effect of Spaying and Semispaying Albino Rats (Mus norvegicus albinus) on the Growth in Body Weight and Body Length", Anat.Rec.17 183-194.

" " (1917), "Observations on the Influence of Isolated Ovaries on the Body Growth of the Albino Rat" (Mus norvegicus albinus), Anat.Rec., 12, 259-263.

TANDLER, J., and GROSSZ, S., "Die biologischen Grundlagen der sekundären Geschlechtscharaktere, Berlin.

TANDLER, J., & KELLER, K., (1911), "Die Körperform der weiblichen Frükastraten des Rindes", Arch. Entw.Mech., 31, 289-306.

TABLE I.

	$M_1 - M_2$.	$\pm\sqrt{m_1^2 + m_2^2}$.	
♂ ♀	1·59	± 0·209	7·6 ×
♂̸ ♂	0·29	± 0·156	1·9 ×
♀̸ ♀	1·55	± 0·306	5·0 ×
♂̸ ♀	1·88	± 0·230	8·2 ×
♂̸ ♀̸	0·33	± 0·273	1·2 ×

TABLE II.

	$M_1 - M_2$.	$\pm\sqrt{m_1^2 + m_2^2}$.	
♀ ♂	0·071	0·0190	3·7 ×
♂̸ ♂	0·100	0·0093	10·8 ×
♂̸ ♀	0·042	0·0189	2·2 ×
♀ ♀̸	0·022	0·0244	0·0
♂̸ ♀̸	0·064	0·0175	3·6 ×

TABLE III.

	$M_1 - M_2$.	$\pm\sqrt{m_1^2 + m_2^2}$.	
♂ ♀	0·129	± 0·0039	33·0 ×
♂ ♂̸	0·144	± 0·0039	37·0 ×
♀ ♂̸	0·015	± 0·0034	4·0 ×
♀ ♀̸	0·023	± 0·0029	8·0 ×
♂̸ ♀̸	0·008	± 0·0029	2·8 ×

TABLE IV.

	M.
♂	1·77 ± 0·0052
♀	1·30 ± 0·0018
♂̸	1·11 ± 0·0150
♀̸	1·12 ± 0·0180

TABLE V.

	$M_1 - M_2$.	$\pm\sqrt{m_1^2 + m_2^2}$.	
♂ ♀	0·486	± 0·0187	25·0 ×
♂ ♂̸	0·66	± 0·0159	42·0 ×
♀ ♂̸	0·186	± 0·0235	7·9 ×
♀ ♀̸	0·180	± 0·0254	7·0 ×
♀̸ ♂̸	0·012	± 0·0228	− 1·9 ×

TABLE VI.

	$M_1 - M_2$.	$\pm\sqrt{m_1^2 + m_2^2}$.	
♀ ♂	0·0172	± 0·00081	21·0 ×
♂̸ ♂	0·0305	± 0·00075	40·7 ×
♂̸ ♀	0·0133	± 0·00098	13·5 ×
♀̸ ♀	0·0125	± 0·00080	15·6 ×
♂̸ ♀̸	0·0008	± 0·00082	0·0 ×

TABLE VII.

	M.
♂	0·0795 ± 0·0021
♀	0·188 ± 0·0080
♂̸	0·185 ± 0·0061
♀̸	0·228 ± 0·0082

TABLE VIII.

	$M_1 - M_2$.	$\pm\sqrt{m_1^2 + m_2^2}$.	
♂ ♀	0·109	± 0·0083	13·0 ×
♂̸ ♀	0·106	± 0·0065	16·0 ×
♀̸ ♀	0·040	± 0·0115	3·5 ×
♀ ♂̸	0·003	± 0·0100	− 3·0 ×
♂̸ ♀̸	0·043	± 0·0102	4·2 ×

TABLE IX.

	$M_1 - M_2$.	$\pm\sqrt{m_1^2 + m_2^2}$.	
♀ ♂	0·054	0·0062	8·7 ×
♂̸ ♂	0·045	0·0040	11·0 ×
♀̸ ♀	0·005	0·0077	− 1·54 ×
♀ ♂̸	0·009	0·0067	1·3 ×
♀̸ ♂̸	0·004	0·0042	0·0

TABLE X.

	M.
♂	0·329 ± 0·0063
♀	0·487 ± 0·0170
♂̸	0·472 ± 0·0134
♀̸	0·479 ± 0·0150

TABLE XI.

	$M_1 - M_2$.	$\pm\sqrt{m_1^2 + m_2^2}$.	
♀ ♂	0·149	± 0·0180	8·2 ×
♂̸ ♂	0·143	± 0·0150	9·5 ×
♀ ♀̸	0·001	± 0·0027	−2·7 ×
♀ ♂̸	0·006	± 0·0024	2·5 ×
♀̸ ♂̸	0·007	± 0·0200	−3·5 ×

FIG. 1.—Frequency distribution of body weight.

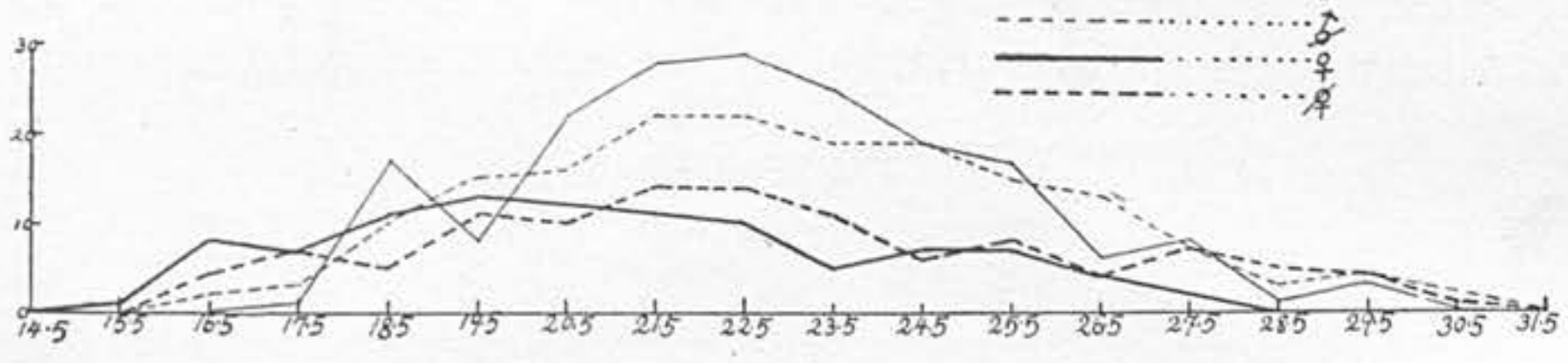

W. in gms.	15·5.	16·5.	17·5.	18·5.	19·5.	20·5.	21·5.	22·5.	23·5.	24·5.	25·5.	26·5.	27·5.	28·5.	29·5.	30·5.	Total.
Freq.																	
♂	...	...	1	17	8	22	28	29	25	19	17	6	8	1	3	...	184
♂̸	...	2	3	10	15	16	22	22	19	19	15	13	7	3	4	2	172
♀	1	8	7	11	13	12	11	10	5	7	7	4	2	...	...	...	98
♀̸	...	4	7	5	11	10	14	14	11	6	8	4	7	5	4	1	111

FIG. 2.—Frequency distribution of body length.

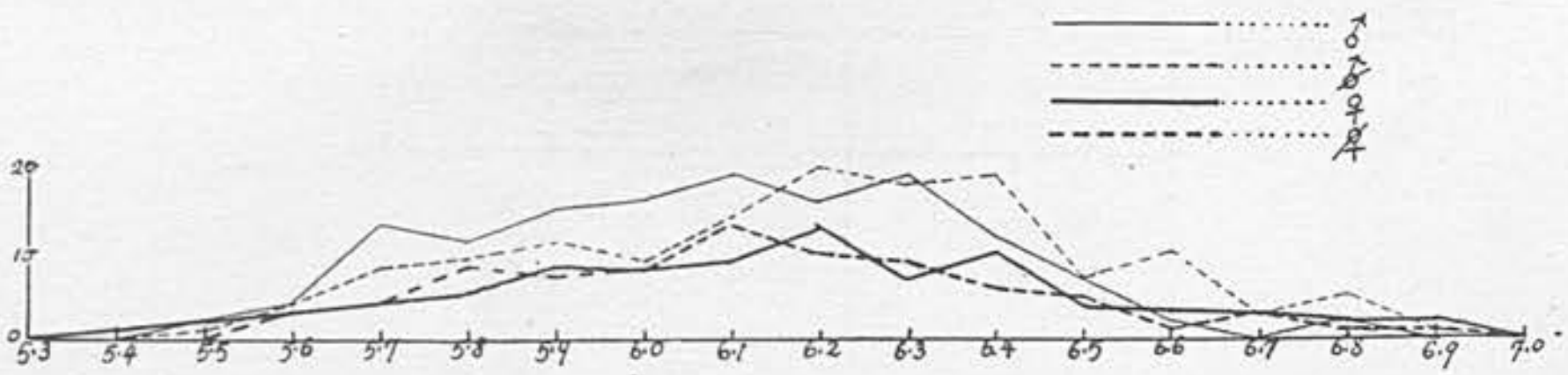

L. in cm.	5·4.	5·5.	5·6.	5·7.	5·8.	5·9.	6·0.	6·1.	6·2.	6·3.	6·4.	6·5.	6·6.	6·7.	6·8.	6·9.	Total.
Freq.																	
♂	...	2	4	13	11	15	16	19	16	19	12	7	2	...	2	...	138
♂̸	...	1	4	8	9	11	9	14	20	18	19	7	10	3	5	1	139
♀	1	2	3	4	5	8	8	9	13	7	10	4	3	3	2	2	83
♀̸	...	...	3	4	8	7	8	13	10	9	6	5	1	3	1	1	79

FIG. 3.—Frequency distribution of weight of the kidneys.

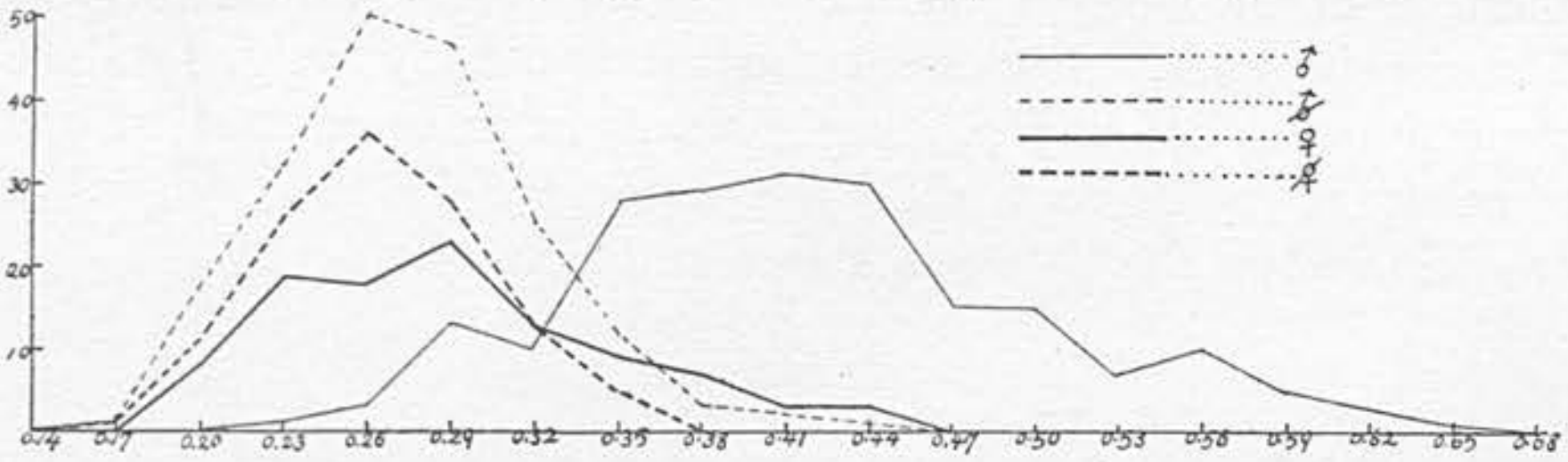

W. in gms.	0·17.	0·20.	0·23.	0·26.	0·29.	0·32.	0·35.	0·38.	0·41.	0·44	0·47.	0·50.	0·53.	0·56.	0·59.	0·62.	0·65.	Total.
Freq.																		
♂	...	...	1	3	13	10	28	29	31	30	15	15	7	10	5	3	1	201
♂̸	1	18	32	50	47	25	12	3	2	1	...	...	...	...	...	...	...	191
♀	...	8	19	18	23	13	9	7	3	3	...	...	...	...	...	...	...	103
♀̸	1	11	26	36	28	13	5	...	...	...	...	...	...	...	...	...	...	120

FIG. 4.—Frequency distribution of percentage weight (to the body weight) of kidneys.

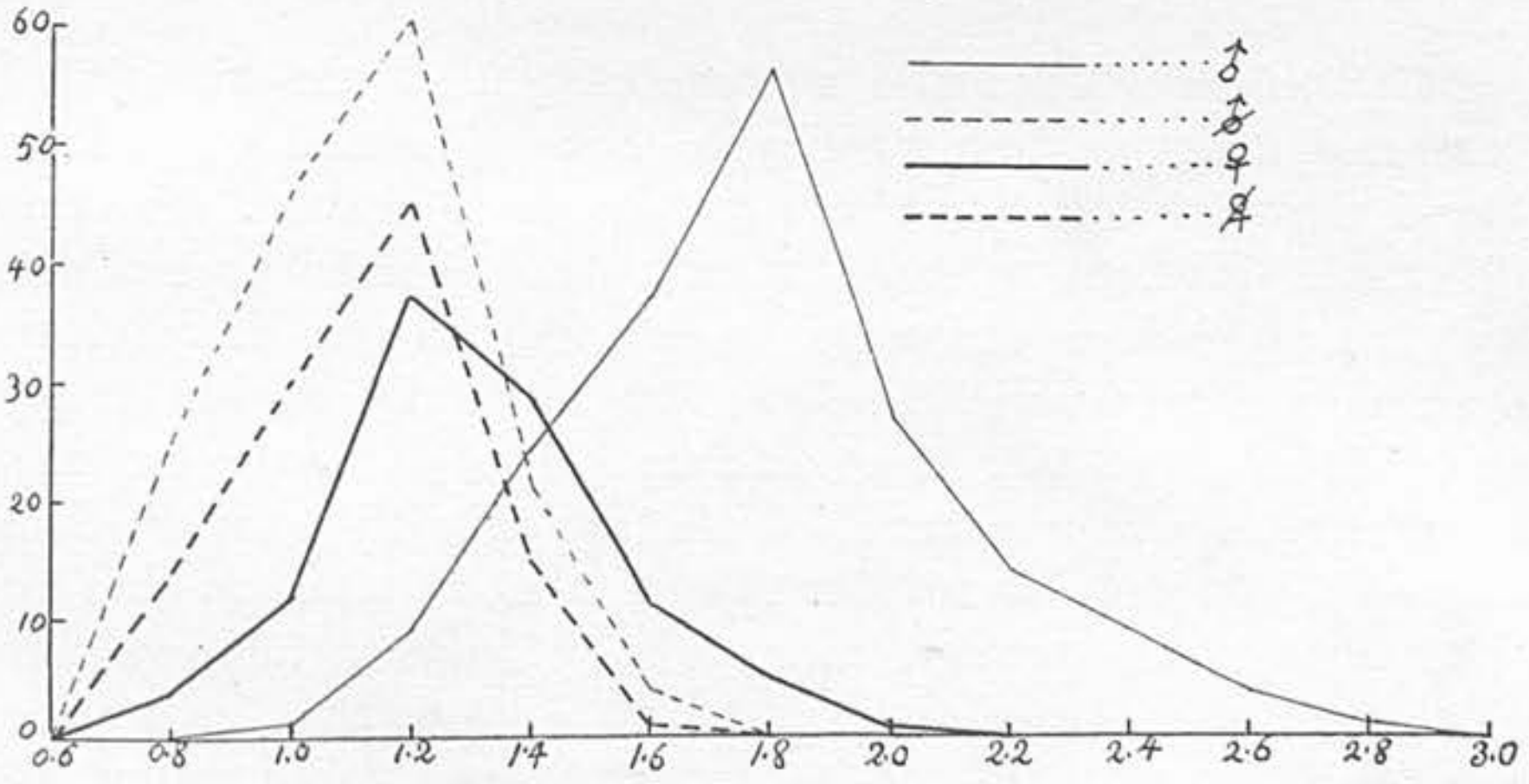

Per cent. W.	0·8.	1·0.	1·2.	1·4.	1·6.	1·8.	2·0.	2·2.	2·4.	2·6.	2·8.	Total.
Freq.												
♂	...	1	9	24	37	56	27	14	9	4	1	182
♂̸	25	46	60	21	4	...	...	...	...	...	...	156
♀	4	12	36	28	11	5	1	...	...	...	...	97
♀̸	14	30	45	15	1	...	...	...	...	...	...	105

FIG. 5.—Frequency distribution of weight of the thymus.

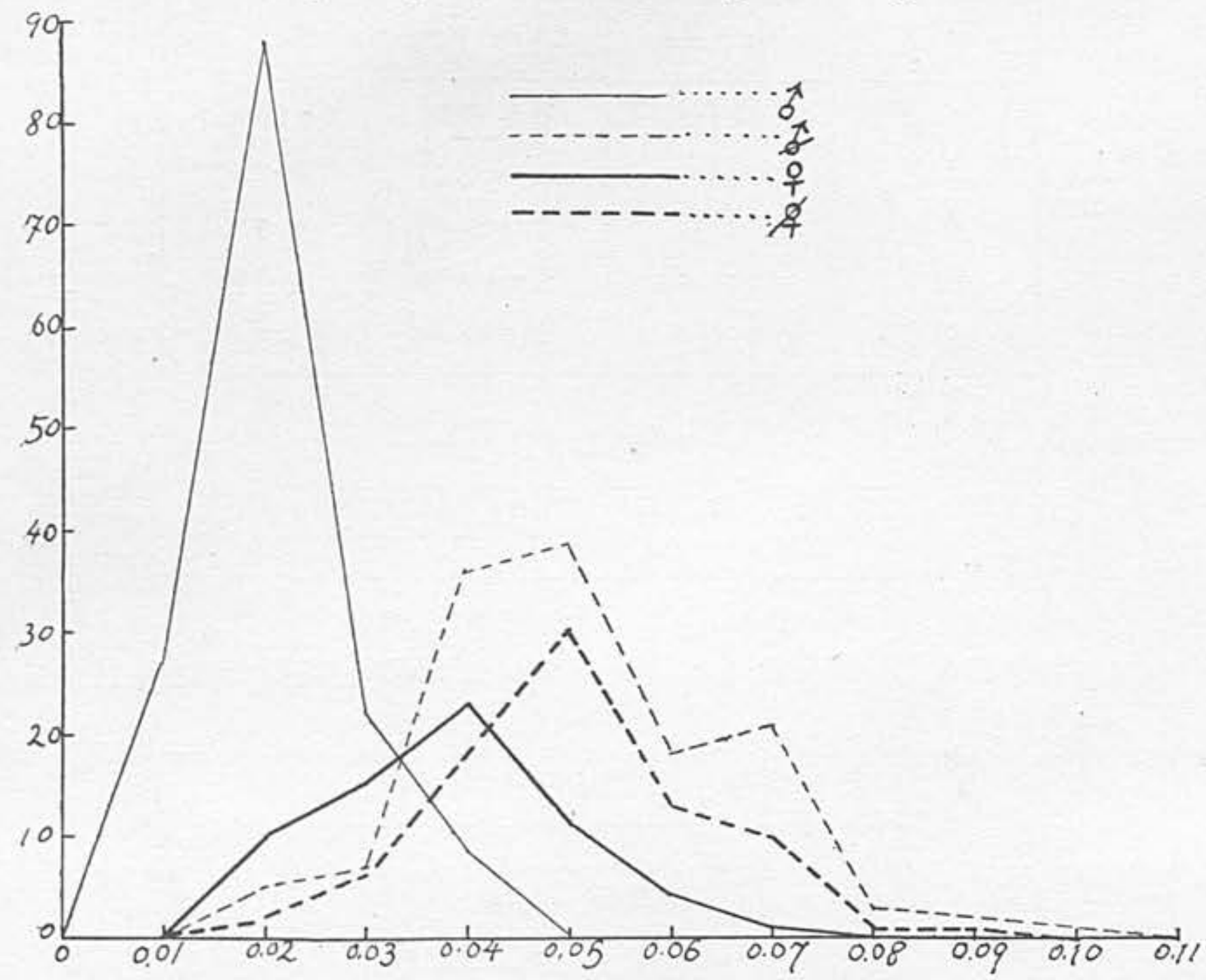

W. in gms.	0·01.	0·02.	0·03.	0·04.	0·05.	0·06.	0·07.	0·08.	0·09.	0·10.	Total.
Freq.											
♂	27	88	22	8	...	...	...	...	...	...	145
♂̸	...	5	7	36	39	18	21	3	2	1	132
♀	...	10	15	23	11	4	1	...	...	...	64
♀̸	...	2	6	18	30	13	10	1	1	...	81

FIG. 6.—Frequency distribution of percentage weight (to the body weight) of the thymus.

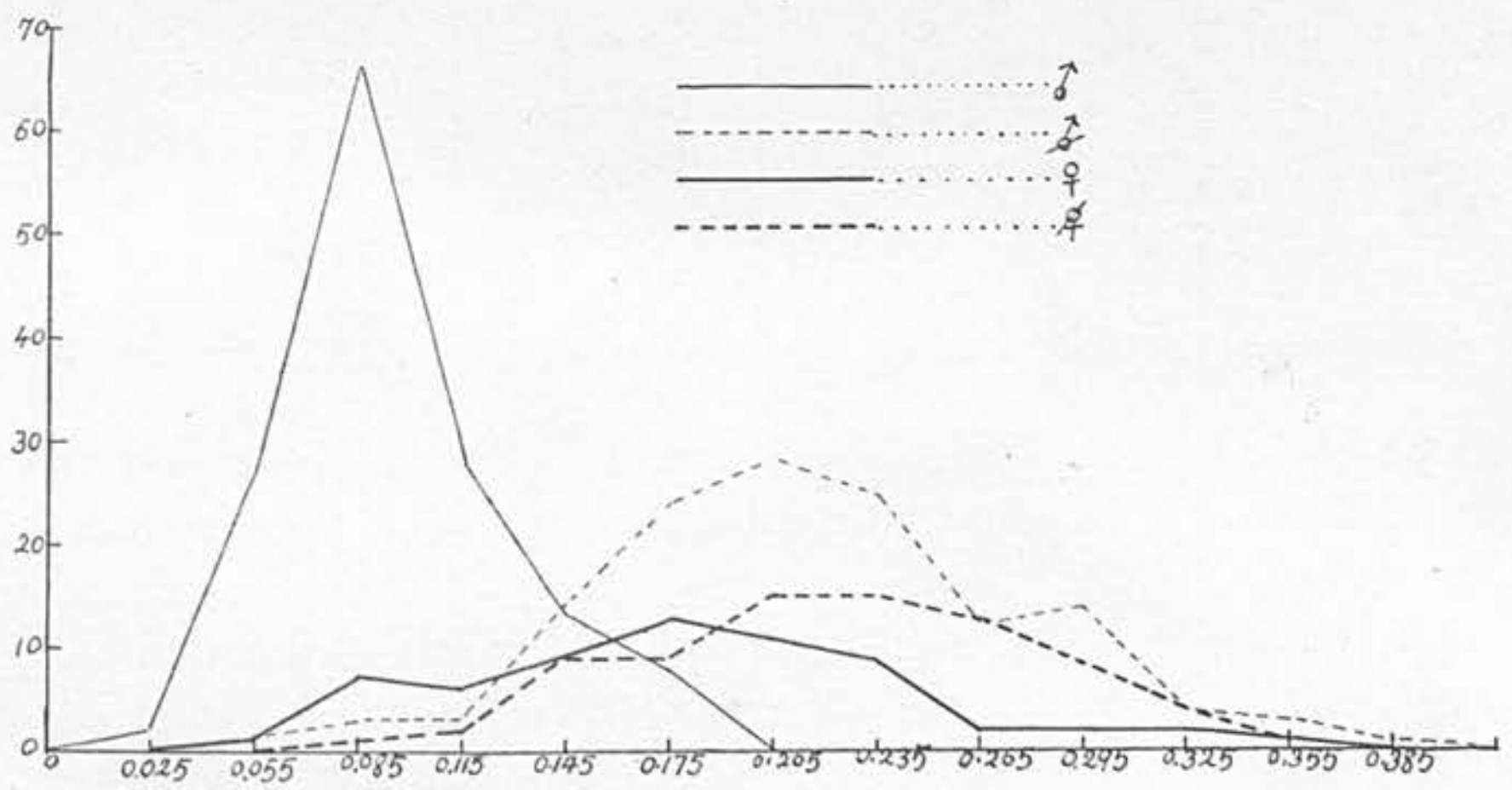

Per cent. W.	0·025.	0·055.	0·085.	0·115.	0·145.	0·175.	0·205.	0·235.	0·265.	0·295.	0·325.	0·355.	0·385.	Total.
Freq.														
♂	2	27	66	28	13	8	...	...	...	...	...	...	...	144
♂̸	...	1	3	3	14	24	28	25	12	14	4	3	1	132
♀	...	1	7	6	9	13	11	9	2	2	2	1	...	63
♀̸	...	...	1	2	9	9	15	15	13	9	4	1	...	78

FIG. 7.—Frequency distribution of weight of the spleen.

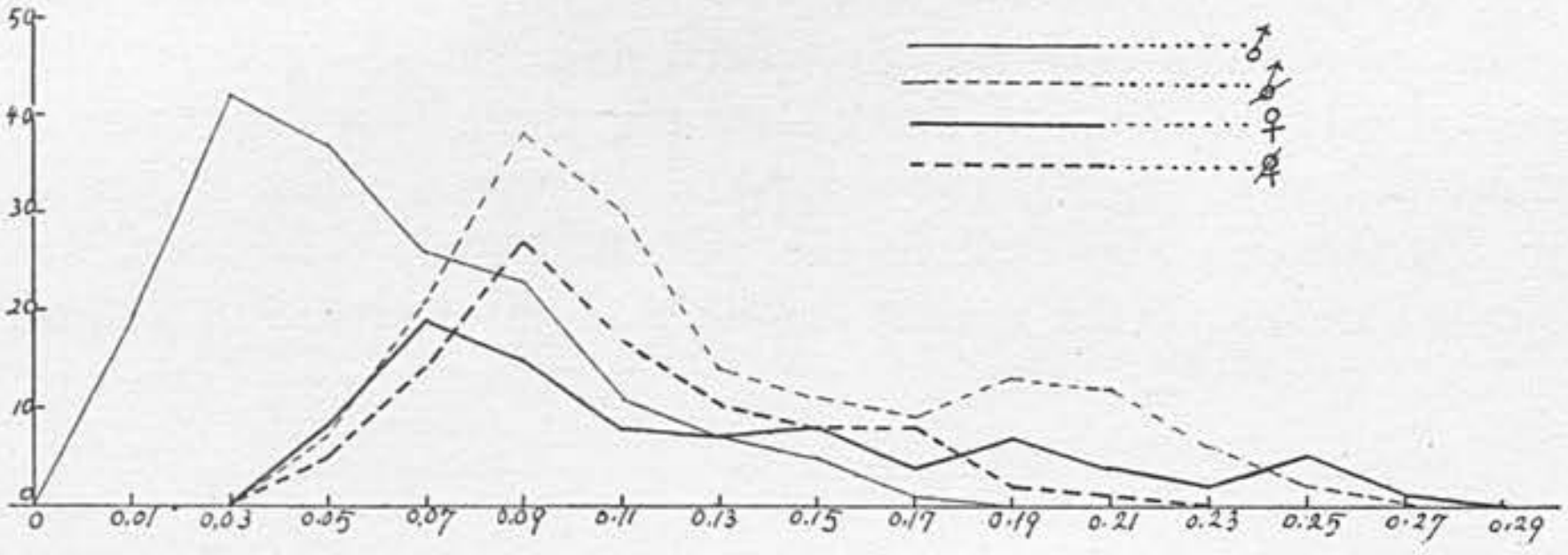

W. in gms.	0·01.	0·03.	0·05.	0·07.	0·09.	0·11.	0·13.	0·15.	0·17.	0·19.	0·21.	0·23.	0·25.	0·27.	Total.
Freq.															
♂	19	42	37	26	23	11	7	5	1	...	...	...	...	...	171
♂̸	...	...	7	21	38	30	14	11	9	13	12	6	2	...	163
♀	...	...	8	19	15	8	7	8	4	7	4	2	5	1	88
♀̸	...	...	5	14	27	17	10	8	8	2	1	...	...	...	92

FIG. 8.—Frequency distribution of percentage weight (to the body weight) of the spleen.

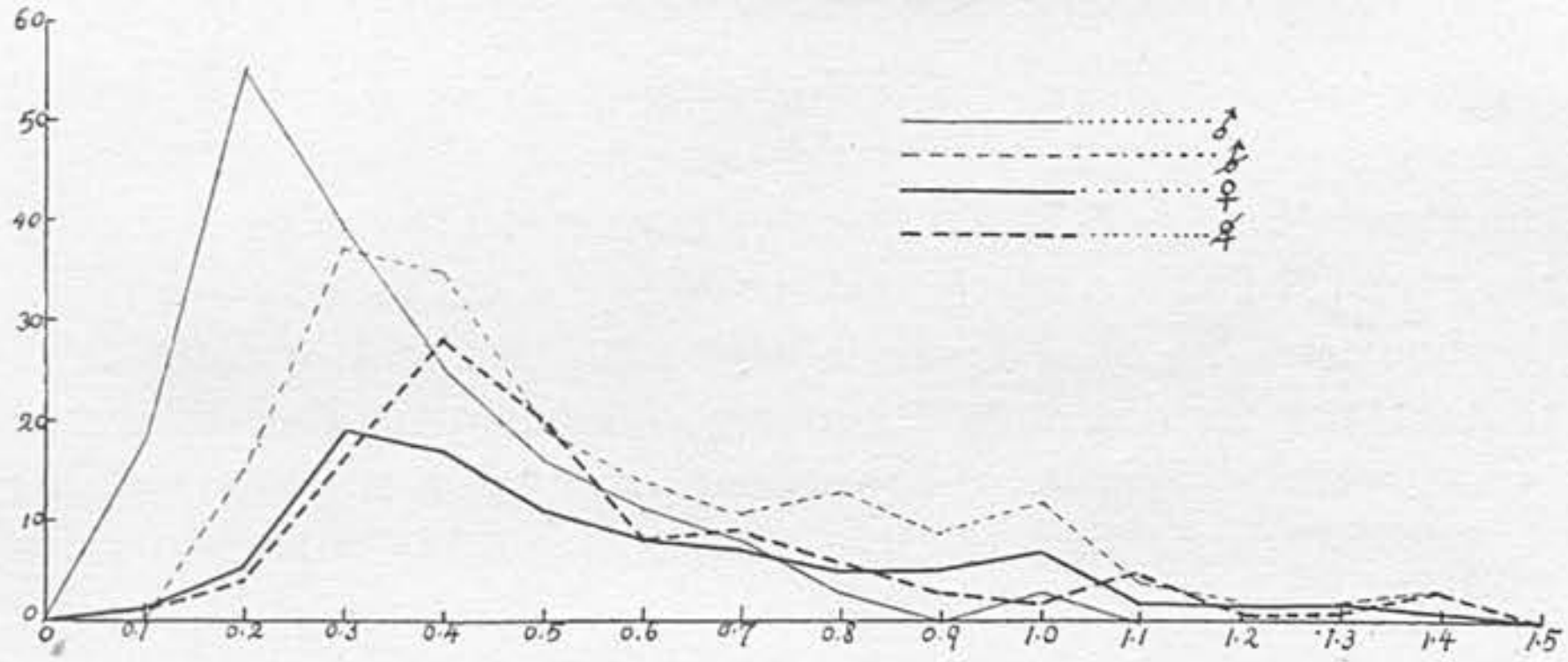

Per cent. W.	0·1.	0·2.	0·3.	0·4.	0·5.	0·6.	0·7.	0·8.	0·9.	1·0.	1·1.	1·2.	1·3.	1·4.	Total.
Freq.															
♂	18	55	39	25	16	11	8	3	...	3	...	...	...	...	178
♂̸	...	15	37	35	19	14	11	13	9	12	4	2	2	3	176
♀	1	5	19	17	11	8	7	5	5	7	2	2	2	1	92
♀̸	1	4	16	28	20	8	9	6	3	2	5	1	1	3	107

ON the EFFECTS of VASECTOMY and of EPIDIDYMO-DEFERENTECTOMY. in the MOUSE.

BY

Y. TAMURA and F. A. E. CREW,

Animal Breeding Research Department, University of Edinburgh.

In the press. Proc. Roy. Soc. Edin., 1926.

INTRODUCTION.

The recorded results of the STEINACH operation on animals including man, and their interpretation, demand that there shall be made available accurate information concerning the effect upon the testis of vasoligation or of vasectomy. The STEINACH school holds that following such operative interference, there is a definite degeneration of the germinal epithelium of the gonad and submits that the rejuvenescent effects which it claims to have produced are to be interpreted as the result of the post-operative hyperplasia of the interstitial tissue, this increase in bulk being associated with a corresponding augmentation in the amount of the internal secretion elaborated. OSLUND (1924), however, has brought forward evidence which points to the conclusion that uncomplicated vasectomy is not followed by degeneration of the germinal epithelium and maintains that when such degeneration is present it is due to the fact that one sequel of the operation is an artificial cryptorchism, this condition and not the operation of vasectomy or of vasoligation being the actual cause of the degeneration. VAN WAGENEN (1924) on the/

the other hand, has shown that such degeneration does indeed follow the operation of epididymo-deferentectomy or of ligation of the efferent ducts. It seemed desirable to repeat and extend these observations because of the manifest difference in opinion.

MATERIAL and METHODS.

Tame mice, albinos, blacks, chocolates, and chocolate and whites of no special breeding from the general laboratory stock were used. Ether was employed as a general anaesthetic, all antiseptic precautions being taken, an incision was made alongside the penis, special care being taken not to injure the inguinal canal and the vas was exposed and traced up to its connection with the epididymis. In those cases in which vasectomy or vasoligation was performed the vas was cut or tied near its junction with the epididymis: in those in which epididymo-deferentectomy was carried out the epididymis was carefully dissected from the testis and removed together with a portion of the vas. The blood and nerve supply of the testis was not disturbed and every care was taken to guard the testis itself against exposure and injury. Finally, having seen that the testes were within/

within the scrotum, the incision was sutured in two layers. All the experimental animals were kept together along with a number of controls and examined at intervals in order to decide whether or not the testes were still within the scrotum. The controls were tested for fecundity at the age of nine weeks and all matings involving these proved to be fertile. When the mice were killed the testes were removed immediately, cut into three pieces, and fixed in Allen's modification of Bouin, Flemming or Chura's solution, sections 5-12 were stained with Delafield, and Heidenhain's iron alum haematoxylin. In all cases the testes of the experimental animals were compared with those of the controls of the same age and killed at the same time (spermatogenesis is normally exceedingly active).

RESULTS.

In certain cases the testis had become intra-abdominal following the operation. When examined histologically its structure was that of the typical cryptorchid as described by OSLUND (1924) and others. Though mice of different ages (3,5, and 7 weeks old at the time of operation) were used, the results were similar/

similar in all cases, and it was found that though in certain of the cases the operation had been performed on sexually immature animals, this did not prevent the testis from continuing its development.

A. Bilateral vasectomy or vasoligation. Operation performed when the mouse was 3 weeks old, 13 cases; when 5 weeks old, 11 cases; and when 7 weeks old, 8 cases.

(1). <u>The testis examined 70-90 days after the operation</u>. The testes present the normal structure; all stages of spermatogenesis are present and spermatozoa are abundant. The epididymis is relatively greatly increased in size, the epithelial lining of the epididymal tubes present a normal histological structure with cells in all stages of mitosis. Within the epididymis there are plentiful sperm and there is nowhere any evidence of degeneration (Fig.1). These findings are in agreement with those of OSLUND, MOORE and QUICK.(1924).

(2). <u>The testis examined 150-250 days after the operation</u>. In the majority of cases the structure of the testis is quite normal. In quite a number, however, many of the seminiferous tubules include degenerated germinal cells (Fig.3). The epididymis is still/

still further increased in size, often being more than three times the size of the normal, and in several instances a yellowish area of degeneration can be seen on its surface. Within the epididymal tubules are numerous spermatozoa and degenerated testicul products (Fig.2), the amount of these varying greatly and being dependent upon the extent of the area of degeneration within the testis. The epithelial lining of the epididymal tubules is greatly attenuated in those parts in which the tubules are distended with testicular detritus.

These observations point to the conclusions that degeneration of the germinal epithelium is a sequel of uncomplicated vasoligation or vasectomy and that the difference in opinion on the question is due to the fact that in different cases the examination of the gonad has been made at different intervals of time following the operation. It is probable that, in these cases the arrest of spermatogenesis is caused by the backward pressure on the testis following an accumulation of testicular products within the seminiferous tubules or more probably by the action of toxic substances elaborated by the disintegrating cell and sperm débris. The highly organised/

organised cells nearer the lumen are the first to be affected but on those regions in which the accumulation of cell detritus is greatest all cell elements are involved and only the fibrous basement membrane of the tubule remains.

B. Bilateral epididymo-deferentectomy. Operations performed at three weeks, 16 cases; at 5 weeks, 11 cases; and at 7 weeks, 7 cases.

(1). The testis examined 70-90 days after the operation. In every case there is definite degeneration of the germinal epithelium, this degeneration being restricted to the central region of the gonad. In a typical case in which the operation had been performed when the mouse was 3 weeks old and in which the animal had been killed 90 days after the operation, the testes, scrotal in position, were normal on inspection. Histological examination, however, shows that though the greater part of the gonad preserves a normal structure, all stages of spermatogenesis being found, in the region of the rete testis the seminiferous tubules exhibit marked degenerative changes and contain within their lumen abundant degenerate sperm-detritus (Fig.5). Around this area/

area of extreme degeneration the neighbouring tubules show evidences of definite but less severe degeneration, the spermatogenial being normal and spermatogenesis, though embarrassed, still continuing, but the tubules contain quantities of disintegrated epithelial cells. Many of the tubules are distinctly larger in diameter than the normal and the germinal epithelial is reduced in thickness to about two-thirds of the normal.

It is clear that degeneration, equivalent in every way to that which follows simple vasectomy, follows the operation of epididymo-deferentectomy after a shorter interval of time (about 70 days instead of about 200) although this degeneration is localised to the region of the rete testis.

(2). <u>The testis examined 150-250 days after the operation</u>. In a typical case in which the operation was performed at 5 weeks and the mouse killed 259 days thereafter, histological examination of the scrotal testes revealed all stages of active spermatogenesis although the spermatozoa were distinctly reduced in number. The area of degeneration in the region of the rete has become greatly enlarged and contains/

contains sperm and degenerate seminal products. In the tubules adjacent to this large area of degeneration spermatogonia are abundant but spermatocytes and spermatids cannot be identified. Primary spermatocytes in division are loose within the lumen of the tube and are degenerating. The thickness of the germinal epithelium is no more than from two to four cell layers, so that the tubules appear to have increased in diameter (Fig.7). In other cases, these degenerative changes involve the greater part of the testis, degenerated and disintegrated germinal cells filling the lumen of the tubules. Primary spermatocytes in division are seen, but no normal spermatids or spermatozoa are present. With the increase in the post-operative interval before examination there is an increase in the area of degeneration.

These results are in agreement with those of VAN WAGENEN and the technique we have employed is not open to the same criticism as that made by MOORE and QUICK (1924) upon the method of ligation of the efferent ducts employed by VAN WAGENEN for epididymo-deferentectomy can be performed without injury to the testis or to its trophic supply. Spermatogenesis is not completely arrested during the period of experimentation/

experimentation, even though severe degenerative changes widely affect the gonad. We agree with KUNTZ (1921) that in cases of testicular degeneration the spermatid is first to be affected, then the spermatocyte, and finally, in advanced cases, the spermatogonium. It is seen that the spermagonial cell is involved only rarely following epididymo-deferentectomy and never following vasectomy.

C. Unilateral vasectomy together with unilateral epididymo-deferentectomy . In these cases the two sides reacted to the different operative interference quite independently presenting the typical effects of vasectomy and of epididymo-deferentectomy respectively.

SUMMARY.

1. Degeneration of the germinal epithelium of the testis invariably follows the operation of vasoligation or of vasectomy in the mouse, but does not become evident until a considerable period of time has elapsed.

2. Similar degeneration follows the operation of epididymo-deferentectomy but after a much shorter interval/

interval of time.

3. This degeneration is caused perhaps by the pressure within the seminiferous tubules exerted by the accumulation of seminal products or more probably by the action of toxic substances liberated from the disintegrating cell and sperm debris.

REFERENCES./

REFERENCES.

KUNTZ. A. (1921) Degenerative Changes in the Seminal Epithelium and Associated Hyperplasia of the Interstitial Tissue in the Mammalian Testis. Endocrin, 5 190-204.

MOORE. C.R. (1924) Properties of the Gonads as Controllers of Somatic and Psychical characteristics. VI. Testicular Reactions in Experimental Cryptorchidism. Amer. Jour. Anat., 34, 269-316.

" (1926) Biology of Mammalian Testis and Scrotum. Quart. Rev. Biol. I 1-50.

" and QUICK. W.J. (1924) Properties of the Gonads as Controllers of Somatic and Psychical Characteristics. VII. Vasectomy in the Rabbit. Amer. Jour. Anat., 34, 317-336.

" and OSLUND. R. (1924) Experiments on the sheep testis. Cryptorchism, Vasectomy, and Scrotal insulation. Amer. Jour. Physiol. 67, 595-607.

OSLUND. R. (1924) A Study of Vasectomy on Rats and Guinea-Pigs. Amer. Jour. Physiol. 67, 422-443.

WAGENEN. VAN. C.T. (1924) Degeneration of the Germinal Epithelium in the Testis of the Rat as a result of Efferent Duct Ligation. Anat. Rec., 27, 189.

" (1925) Changes in the Testis of the Rat following Ligation of the <u>Ductuli efferenti</u>. Anat. Rec., 29, 399.

DESCRIPTION OF FIGURES.

FIG. 1. Epididymis of the mouse. 70 days after Vasectomy; shows normal apithelial lining of the epididymal tubules and plentiful sperm. x 130.

" 2. Epididymis of the mouse. 175 days after vasectomy; shows degenerated testicular products in the epididymal tubules. Note the enlargement of the tubules as compared with that in Fig. 1. x 130.

" 3. Degenerated part of the Testis. 160 days after vasectomy; a few tubules have degenerated and some include degenerated germinal cells. x 70.

" 4. Testis of the mouse. 150 days after vasectomy. x 48.

" 5. Testis of the mouse. 90 days after epididymo-deferentectomy; shows degenerated seminal tubule which is greatly increased in size contains degenerated sperm-detritus. x 48.

1

2

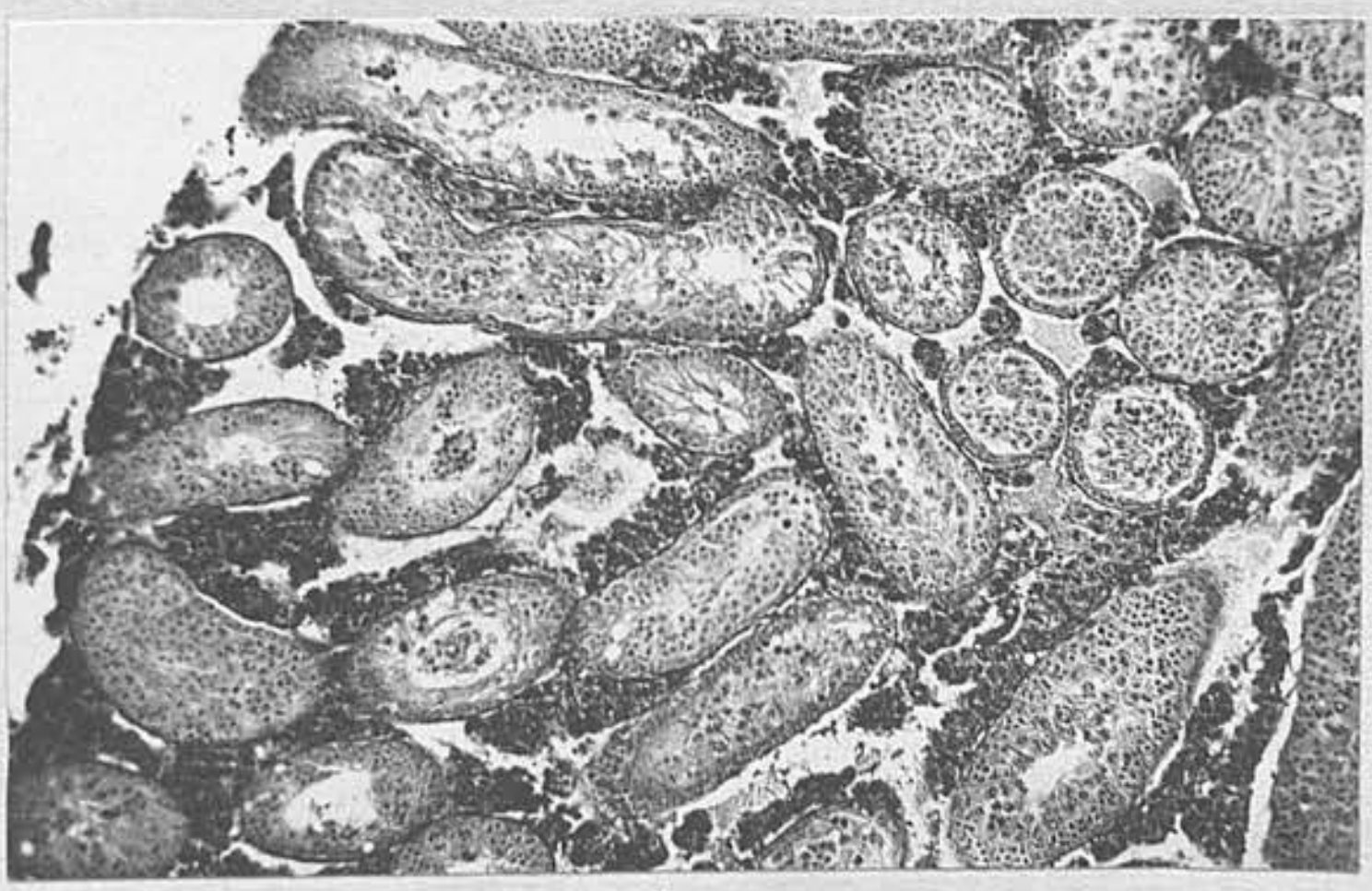

3

4

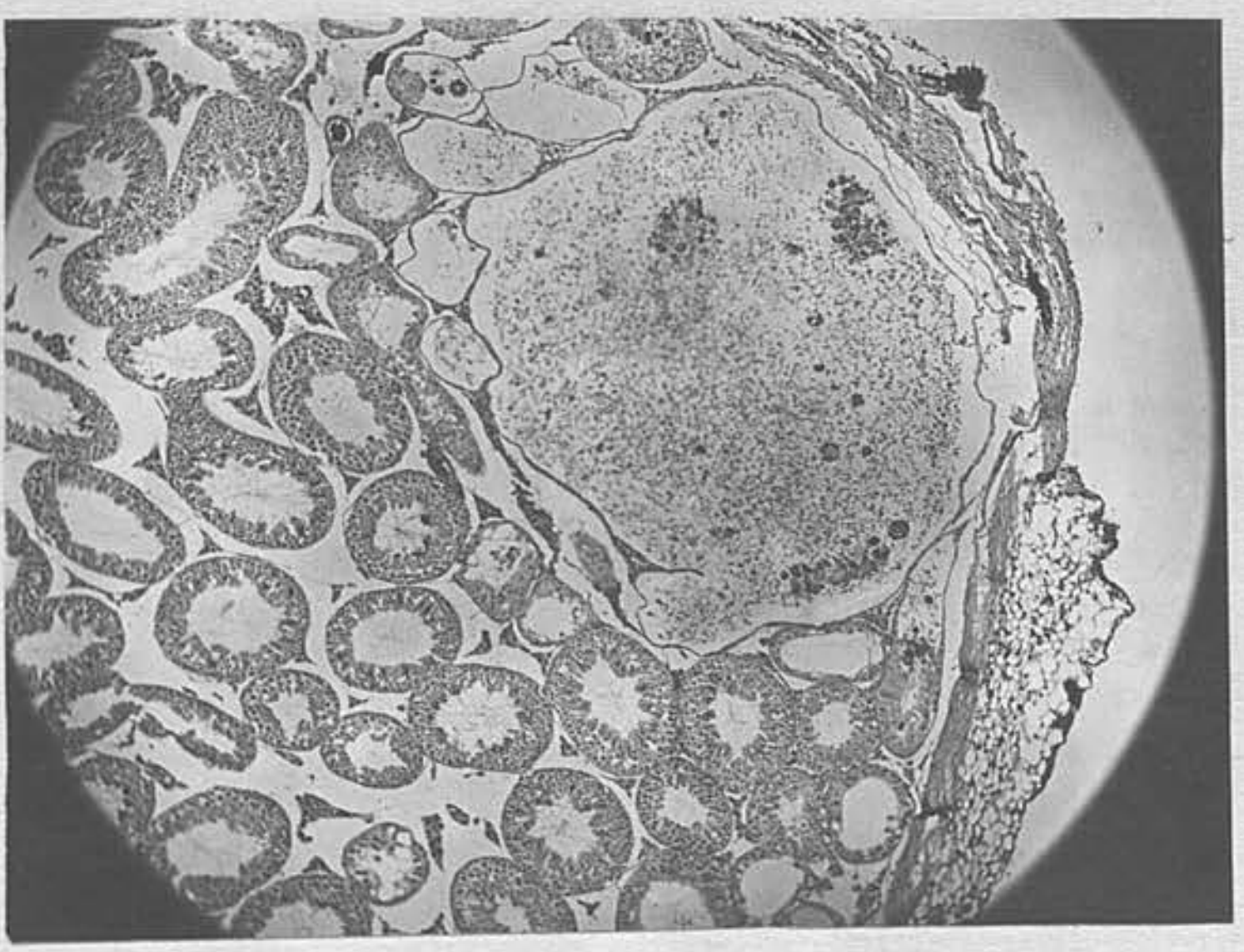

5