

ABNORMALITIES AND DISEASES
OF THE OESOPHAGUS.

With special reference to their
X-Ray appearances.

Thesis presented for Gunning Prize
in Radiology

by

R. Morrison, M.B., M.R.C.P.



ANATOMY.

The oesophagus traverses the lower part of the neck, the entire length of the thorax, to join the stomach in the abdomen.

It extends from the termination of the pharynx at the lower border of the cricoid cartilage opposite the 6th cervical vertebra to the cardiac orifice of the stomach opposite the 11th Thoracic Vertebra.

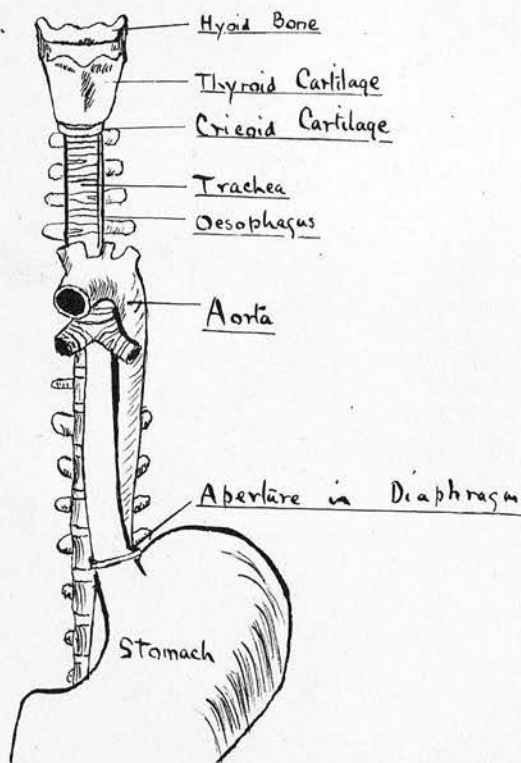
It is curved in an antero-posterior direction to correspond to the antero-posterior curvatures of the vertebral column. It is also slightly curved in a lateral direction, - in the lower part of the neck the oesophagus deviates to the left for about $\frac{1}{4}$ ". It returns to the median plane at the level of the 4th Dorsal Vertebra behind the aortic arch.

Lower down it again leaves the median plane at the 7th Dorsal Vertebra, passes to the left and forwards to reach the oesophageal opening of the diaphragm $1'' - 1\frac{1}{2}''$ in front of the vertebral body. It crosses in front of the aorta at the 8th Dorsal Vertebra.

RELATIONS.

Radiologically, some of the relations of the oesophagus are of importance. In the thorax it passes behind the aortic arch separated from it by the trachea. It descends in posterior mediastinum at first to right of the descending aorta then in front and slightly to its left. In front, at the level of the 5th Dorsal Vertebra, the left bronchus crosses it, and below this it is in relationship with the pericardium and the left auricle. On both sides are the respective pleural cavities.

Fig. 1.



Showing Relations of Oesophagus to Trachea and Aorta.

NERVES.

The two vagus nerves after forming the pulmonary plexuses descend to the oesophagus where they unite with the sympathetic fibres to form the anterior and posterior oesophageal plexuses. Lower down the left nerve winds round to the anterior while the right turns to the posterior surface of the oesophagus. In this relationship they pass through the diaphragm to the walls of the stomach.

→ The length of the oesophagus is 10". With the exception of the pylorus it is the narrowest part of the alimentary tract.
(Hence/

(Hence if an F.B. gets through to the stomach it will in all probability be able to go through the entire length of the remaining part of the Alimentary Canal without difficulty).

CONSTRICTIONS.

The oesophagus has four distinct constrictions:-

1. At its beginning at the cricoid sphincter.
2. At the level of the aortic arch.
3. Where it is crossed by the left bronchus.
4. At the cardiac sphincter.

These are also the sites at which carcinoma is liable to develop, where diverticula are seen, and where strictures tend to develop.

VEINS.

Veins form a plexus on the exterior of the oesophagus. At the lower end of the oesophagus the veins of the stomach which drain to the portal system are in communication with the veins of the oesophagus which drain to the systemic system (vena azygos and vena cava). In obstruction to the portal system these veins become dilated and may rupture.

LYMPHATICS.

The lymphatics form two networks: one in the submucous, and one in the muscular coat.

The lymph vessels of the oesophagus form a free anastomosis. They pass from the cervical part to the inferior set of deep cervical glands in the neck; from the thoracic part to the posterior mediastinal glands; from the abdominal part to the glands round the coeliac axis.

STRUCTURE OF THE OESOPHAGUS.

The oesophagus is one of the most muscular parts of the Alimentary Canal. The muscle fibres are in two layers - an inner circular layer and an outer longitudinal layer. Longitudinal fibre layers run the entire length of the oesophagus and are continuous with the longitudinal fibres of the stomach.

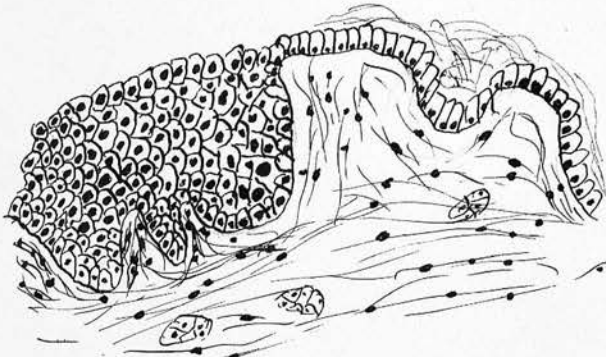
The circular fibres are not so well developed as the longitudinal fibres.

At first the musculature is striped muscle but as we pass down unstriped appears, and the relative proportions to unstriped decreases. In the lower half the musculature is all unstriped.

This oesophageal muscle is surrounded by an outer layer of areolar tissue. Within, a submucous areolar layer of tissue connects the mucous membrane loosely to the muscular coat. In this layer are the numerous racemose glands.

The mucous membrane is composed of thick stratified squamous epithelium on the surface of which open the numerous glands. There is a distinct irregular line which runs round the lower end of the oesophagus and which indicates the junction between the oesophageal mucous membrane and the columnar epithelium of the stomach. (Fig. 2.)

Fig. 2.



Drawing from slide showing
abrupt change from stratified
epithelium of oesophagus to columnar
epithelium of stomach.

(from Schäfers Histology).

RADIOLOGICAL EXAMINATION.

The Radiological examination of the oesophagus consists in observing under the screen the passage of barium along its lumen. Films are taken for record. As the majority of cases coming for examination suffer from dysphagia it may sometimes be difficult to induce the patient to try to swallow barium.

The chest and abdomen are usually screened first before the patient is rotated to the right oblique position. He is then asked to swallow a mouthful of barium cream and its course is/

is observed. In certain cases such as diverticula and cardio-spasm the postero-anterior, the left oblique and the lateral positions may be of value.

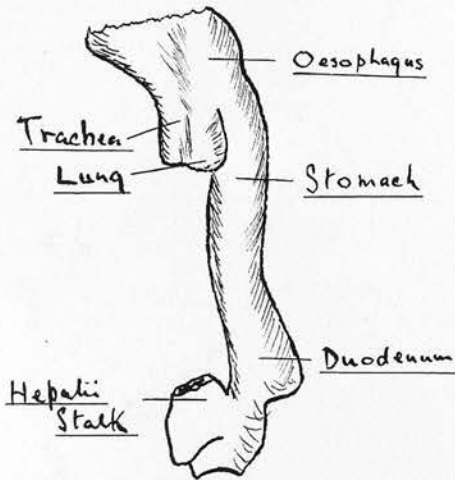
In the right oblique position the barium is seen to pass down the oesophagus in a rapid peristalsis^c wave. Its rate depends on the position of the patient and the consistency of the medium. The supine position and thick barium slow up the rate. Behind and separated by a clear space which is widest at the lower end lies the dorsal spine. In front the impressions of the aortic arch, the left bronchus and the left auricle are seen.

To demonstrate the upper and the lower limits of a lesion such as Carcinoma, the Double-Swallow Method is employed. The patient is asked to swallow some thin barium cream and he is then turned over on his back, his head at a lower level than his feet. In this position he is asked to swallow more barium. Regurgitation of barium from the stomach outlines the lower margin of the lesion while the upper limit is demarcated by the barium swallowed.

Alternate drinks of barium cream and water have been recommended to outline radiotranslucent foreign bodies.

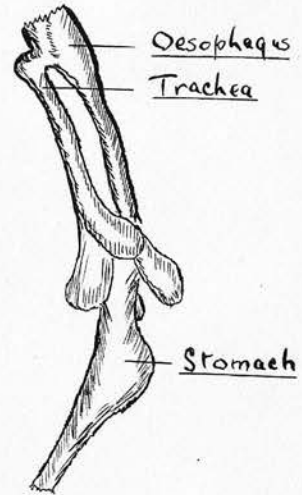
DEVELOPMENT.

The oesophagus is developed from the foregut.



Foregut in 4th week
of Development

Fig. 4



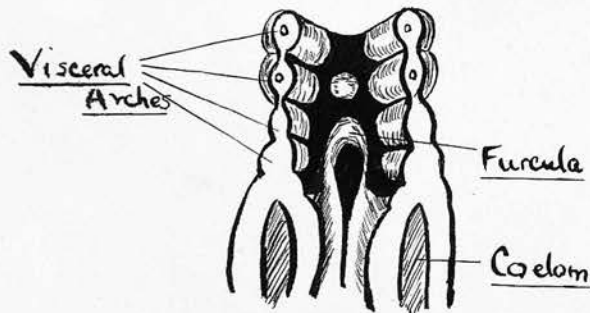
Foregut at end of 5th
week of development
showing elongation of
oesophagus

At the 4th week of embryonic life the future oesophagus resembles that of a fish. It is scarcely 2 m.m. long and merely forms a sphincter between pharynx and stomach. (Fig. 3)

From a diverticulum on the ventral wall of the foregut develops/

develops the rudimentary respiratory system. This diverticulum is in the form of a longitudinal groove and is bounded at its cranial end and laterally by an elevated ridge called the furcula. (Fig. 5)

Fig. 5



View of Floor of Primitive Pharynx
showing the Furcula with the groove
from which the Respiratory System arises.

The caudal end of the groove ^{becomes} dilated into a pouch from which are developed lung buds.

In the 5th week two lateral septa grow in from the sides and fuse together giving rise to trachea in front and oesophagus behind. Fusion takes place from above downwards and the last parts to fuse are the lowest parts of the two septa.

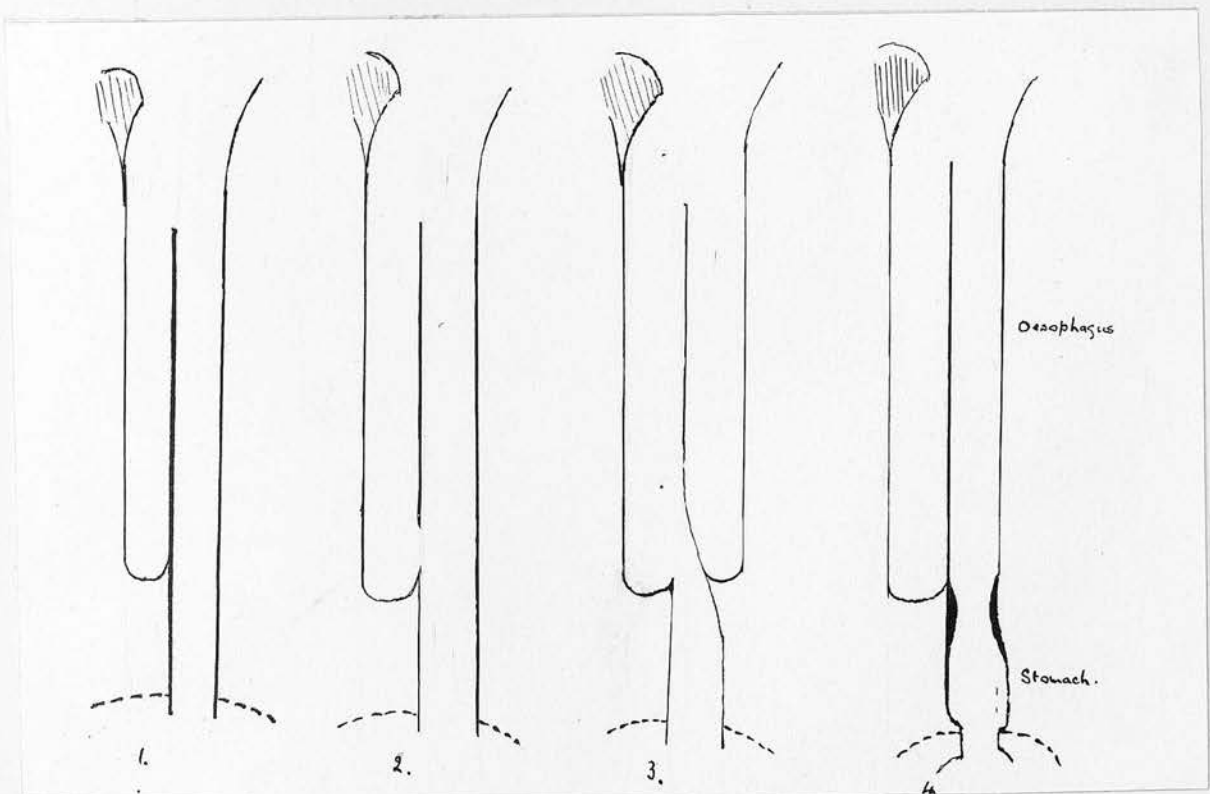
During the 6th and 7th weeks the head is being separated from/

from the thorax, and lungs and pleural cavities are also developing. The stomach is forced backwards and the oesophagus undergoes rapid elongation. (Fig. 4)

At first the oesophagus is lined by columnar epithelium but during the second month as it elongates, the epithelium proliferates forming several layers which occlude the lumen of the tube.

At a later stage this again becomes canalised to form a tube.

ABNORMALITIES OF DEVELOPMENT OF OESOPHAGUS.



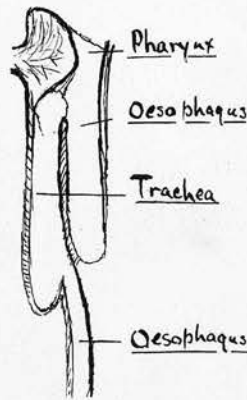
Congenital Abnormalities of Oesophagus - diagrammatic

1. Normal condition of Oesophagus and Trachea
2. Oesophago-Tracheal Fistula
3. Fistula with upper part shut off from lower part.
4. Congenital Short Oesophagus.

A. Defects in Septum Formation.

1. If the two ingrowing lateral septa fail to fuse in the last part a communication exists between oesophagus and trachea. (Fig. 6.)
2. Another abnormality of the lower end of this septum occurs when the processes do not fuse in the proper plane, but incline backwards at their lower ends and come into contact with the posterior wall of the oesophagus with which they fuse. As well as fistula formation the upper and lower parts of the oesophagus are cut off from each other.

Fig. 7



Irregular separation of Trachea and Oesophagus

The upper part of Oesophagus forms a blind sac.
The lower part passes from the Trachea to the Stomach.

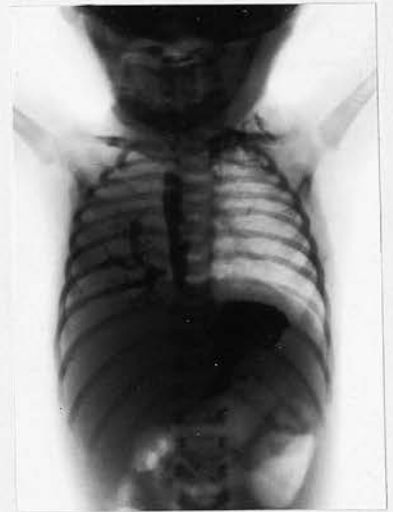


Fig. 8 Shows barium entering R. lung and stomach. The R. lung is collapsed.

This child died after 2 days from Broncho-pneumonia. At P.M. the upper part of oesophagus was a blind sac - the lower part arose from trachea.

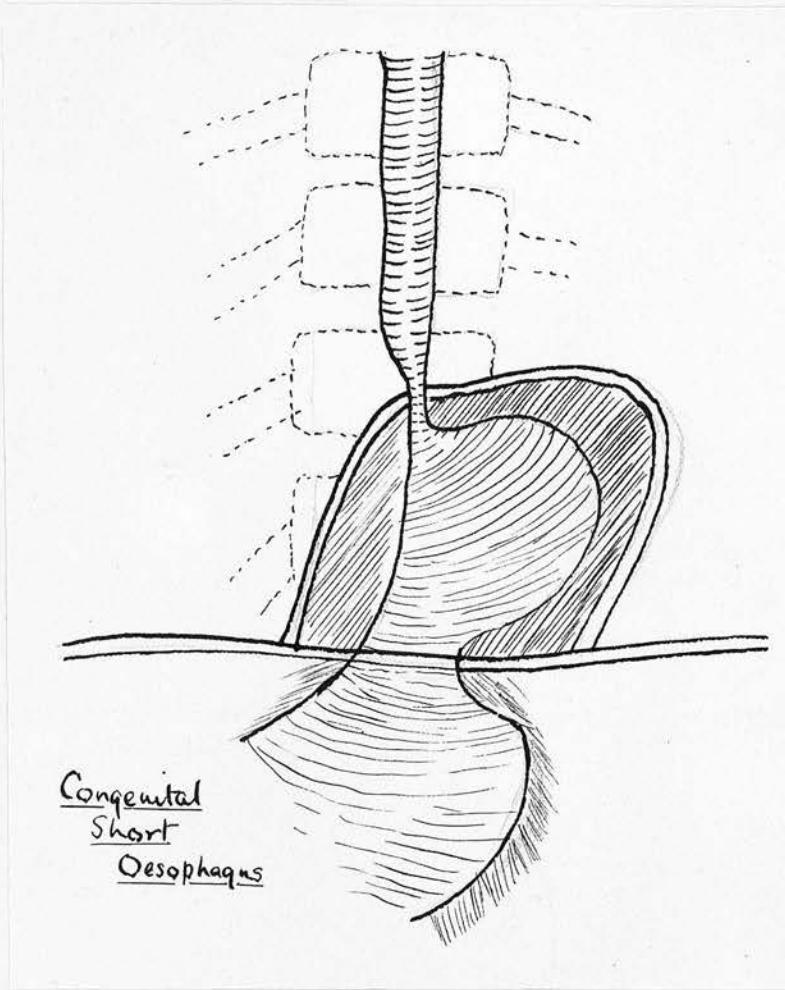
B. Failure of Elongation Process.

The oesophagus is congenitally short.

(Fig. 9)


Fig. 9

from picture
in Journal of
— article by
— Mas Dunhill.)



The result is that the cardia and portion of the stomach lie in the thorax, a hernial sac existing. Frequently such a condition is associated with congenital stenosis of the oesophagus.

The condition may be symptomless but more commonly, sooner or later, symptoms make their appearance.



Congenital Short Oesophagus -
 Thoracic Segment small.
 Axis of oesophagus and stomach
 normal



- Congenital Short Oesophagus -
 Thoracic Segment larger
 Stomach is rotated.

Fig. 11

As the diaphragmatic opening becomes more dilated more of the stomach comes to occupy the thorax. When this happens the stomach tends to rotate on its own axis so that the greater curvature is uppermost. The stomach may be angulated across the diaphragmatic opening, and distension of the thoracic sac will be increased, perhaps pressing on the oesophagus causing dysphagia or on the pericardium causing dyspnoea and distress. (Fig. 11)

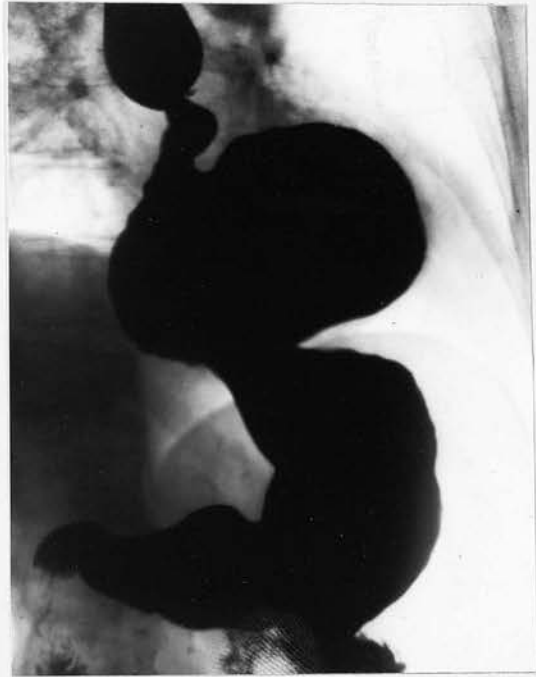
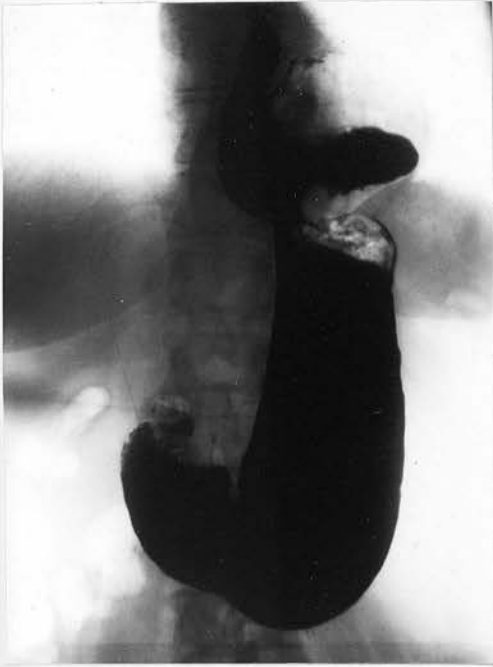
Fig. 12 Case of Congenital Short Oesophagus.
On the left the part of the stomach above the diaphragm
 is not filled out.
On the right this part is shown filled out with barium.

At the point of constriction at the diaphragm ulceration tends to develop and granulation tissue forms, giving rise to symptoms similar to those of gastric ulcer.

On X-Ray examination a portion of the cardiac end of the stomach stays above the diaphragm. The longitudinal rugae markings of the gastric mucous membrane are seen in the part above the diaphragm. In repeated studies there will be no variation in the part above the diaphragm and no alteration with posture.

The/

The oesophagus must be too short to reach the level of the diaphragm. It is seen as a straight tube that is neither tortuous nor angled.

The true capacity of the part above the diaphragm will only show itself when the part below is filled up. Clerf and Manges recommend examination of the patient in the R. oblique prone position to demonstrate it.

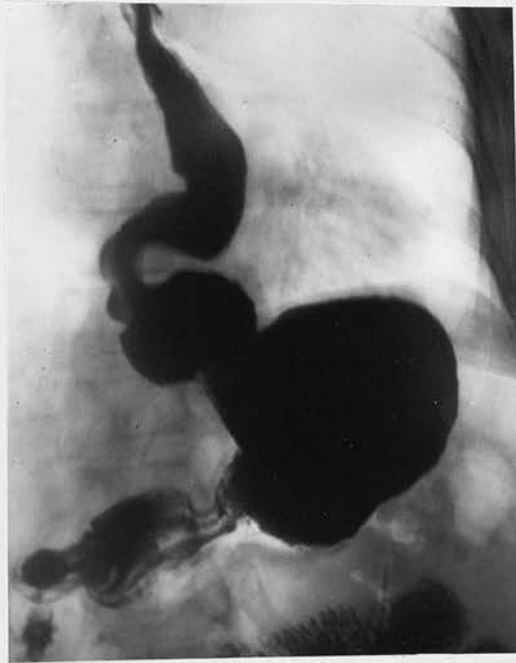

Fig. 13 Appearances are against this being a case of congenital short oesophagus. because of the tortuous oesophagus. They rather suggest that the cardiac end of the stomach has herniated through the hiatus into the thorax.


The differential diagnosis must be made from:-

1. Diaphragmatic hernia.
2. Paraesophageal hernia.

In both of these conditions the length of the oesophagus is normal.

In Diaphragmatic Hernia which is due to non-development of the diaphragmatic curve, there is a large gap in the diaphragm. This defect is shown in diagram. The stomach is free to move up and down and usually comes to lie in the posterior mediastinum. The oesophagus is of normal length.

Fig. 14



In Para-oesophageal Hernia the hiatus in the diaphragm is dilated and a hernial sac passes out through it lying beside the oesophagus. It may become adherent to lung or pericardium.

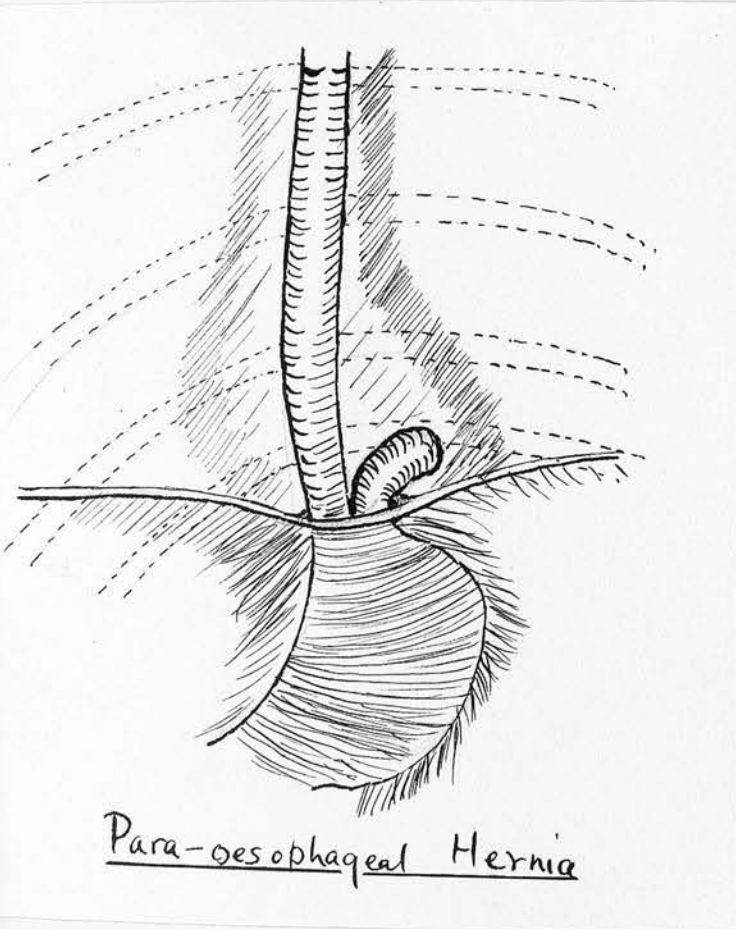
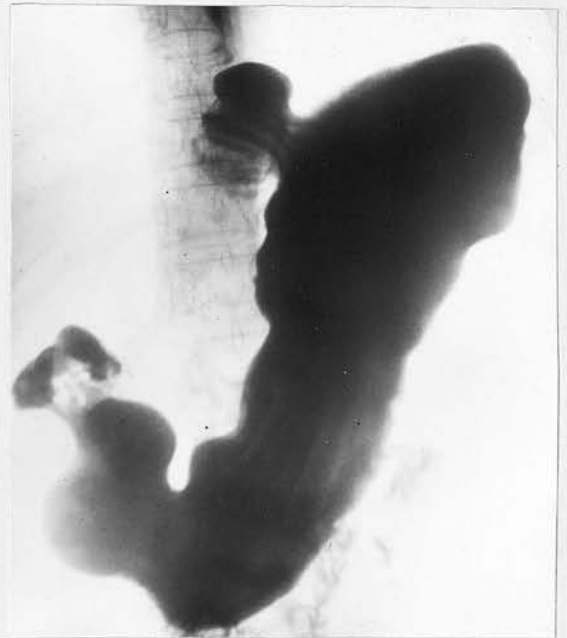

Fig. 16 Paraoesophageal Hernia
Mucous membrane pattern
is seen within the
herniated portion of
stomach.



Treatment.

No radical cure of this condition has as yet been attempted surgically.

C. Failure of Recanalisation Process.

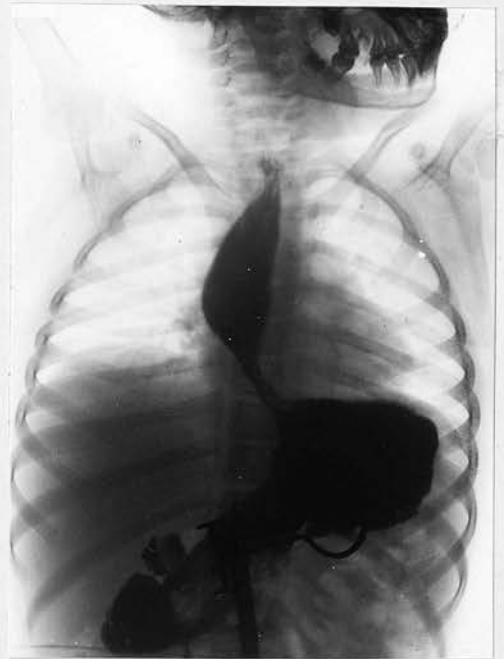
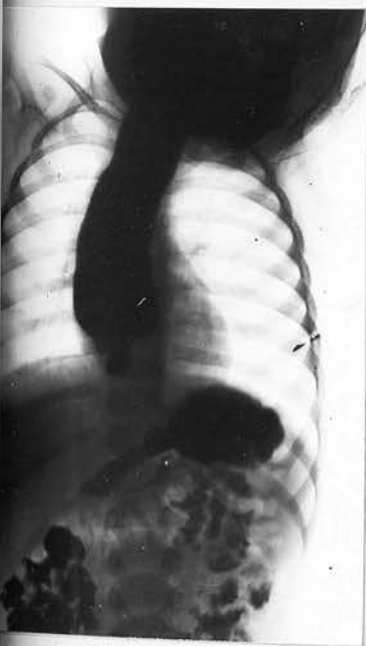
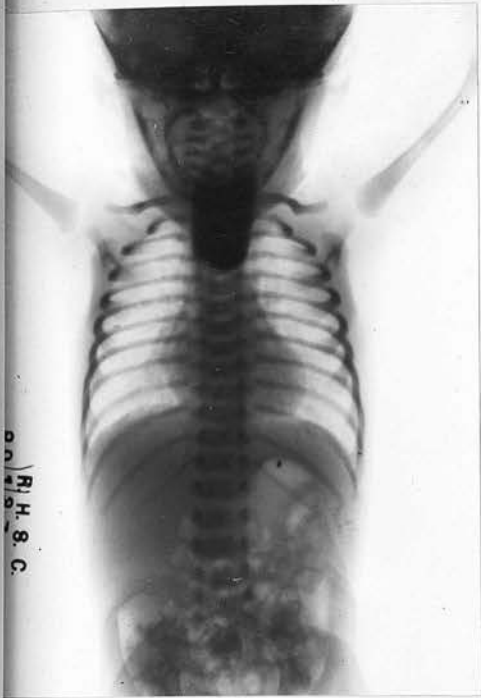
During the process of recanalisation, failure may take place over a limited area. Where a few layers of cells have failed to canalise a membranous diaphragm stretching across the lumen of the oesophagus remains.

On the other hand a considerable length of the oesophagus may fail to develop a lumen. Occasionally cases are described where the upper and lower parts are normal but in between merely a cord of fibrous tissue exists. In other cases there may be obliteration below the level of bifurcation of the trachea. (Fig. 18.)

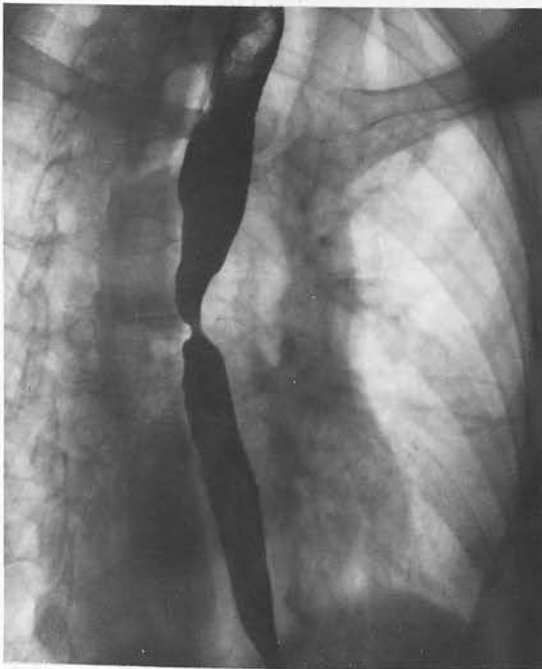

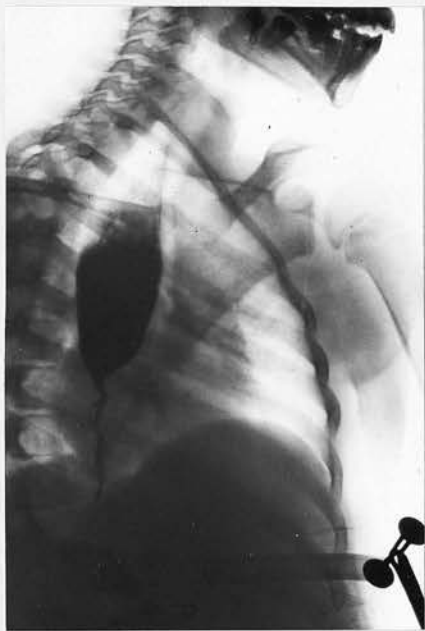Fig. 17 Structure of Oesophagus in its middle third. This was of congenital origin and represented an area of imperfect canalisation at the level of the left bronchus.

Fig. 18 The oesophagus ends blindly in the upper part of the thorax. The remainder was represented by a fibrous cord. The child lived only 5 days.



19. Congenital Stricture involving 3 cms. of lower end of oesophagus. The oesophagus above is dilated. A certain amount of barium has got through stomach and intestine

Figs. 20, 21. These films were taken after gastrostomy. Previous to the operation patient could eat little, was weakly and underdeveloped.

After operation she improved greatly and managed to eat semi-solid food. The stricture does not appear to be so tight.

The re-canalisation process may be imperfect, producing a degree of congenital narrowing of the oesophagus. This may be seen over its entire length or merely limited to a segment of the organ.

OESOPHAGEAL DIVERTICULA.

Oesophageal Diverticula are very rare. When present they are often associated with diverticula lower down in the Alimentary Canal. They are usually symptomless so that their discovery is, as a rule, merely accidental during barium examination of the Gastro-Intestinal Tract. However when symptoms do occur they often simulate common diseases.

Diverticula are frequently described as belonging to one of 3 types:-

1. Congenital.
2. Traction.
3. Pulsion.

It would seem unlikely however that one single factor is solely responsible for their production. Thus, a congenital area, weak in muscle, will be liable to develop a pulsion diverticulum from the increased intra-oesophageal pressure during swallowing. Similarly, if one considers an area of the oesophageal wall involved in an inflammatory process and now adherent to tracheal and bronchial glands. Movements of deglutition day by day will cause/

cause traction till a little pouch is formed. This pouch becomes continually enlarged by food and a diverticulum develops by a combined traction-pulsion mechanism.

A congenital abnormality predisposing to diverticulum formation is Leugart's ledge. This is a band of fibrous tissue sometimes present, passing from the left bronchus to the side of the vertebra. It causes a temporary halt in the descent of large particles of food. A little bulging of the wall may increase in size till a little pit is formed. Gradually a small diverticulum is seen prolapsing across the ledge. If this explanation of its formation is correct it will be of the pulsion variety. It is seen between the left bronchus and the arch of the aorta. This diverticulum is sometimes known as Leugart's Pouch.

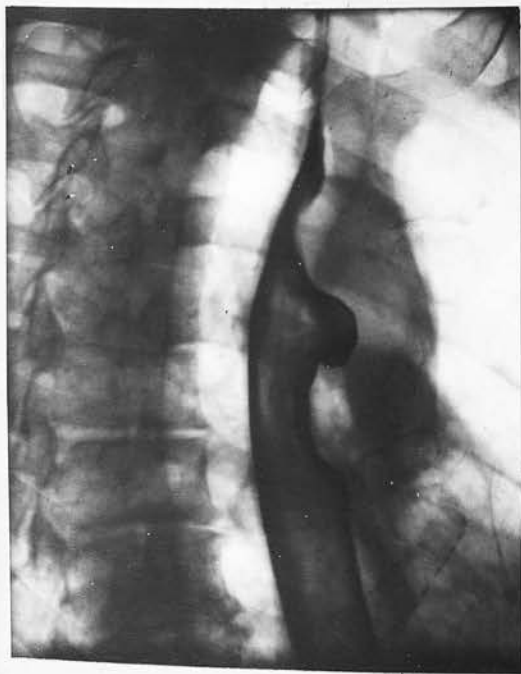

Fig. 22 Oesophageal Diverticulum

This is in the nature of a Leugart's pouch.

The impressions of the aortic arch and the left bronchus are seen with diverticulum in between.

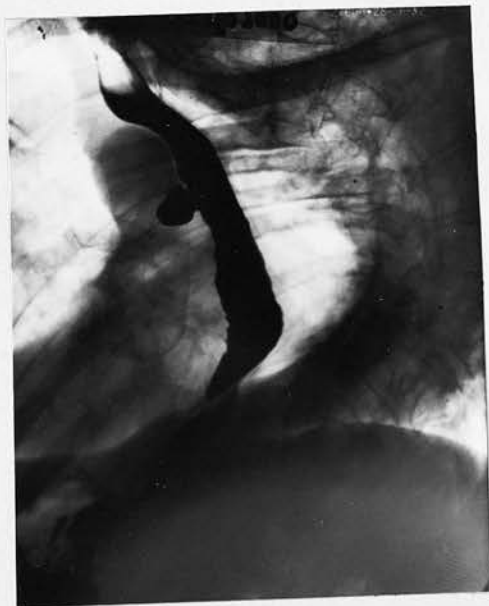

Fig. 23. A similar type of diverticulum. There is marked Kyphosis.

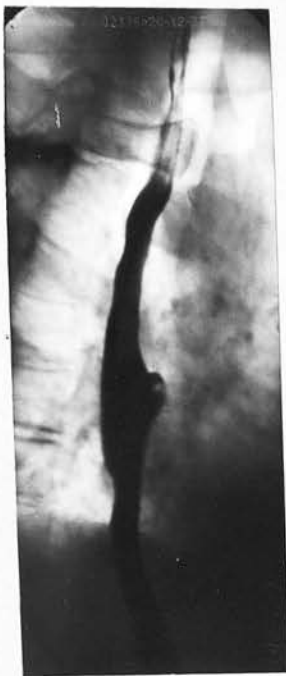
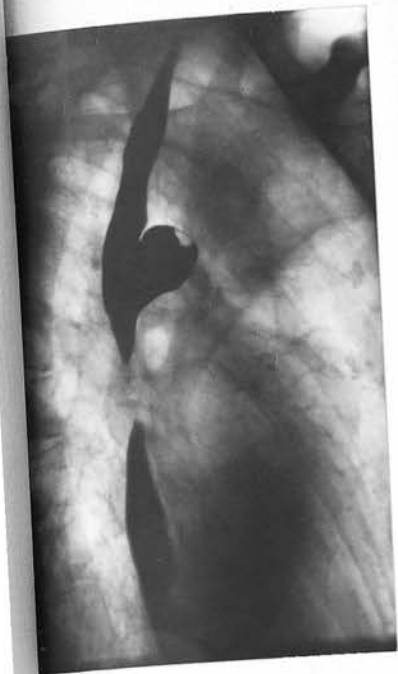
Fig. 25 Diverticulum of traction-pulsion type containing an air-bubble. This patient had no symptoms referable to the diverticulum.

24. Unusual diverticulum
traction-pulsion type
The fundus of the diverticulum appears to be drawn probably by fibrous tissue and there is narrowing at a lower level.

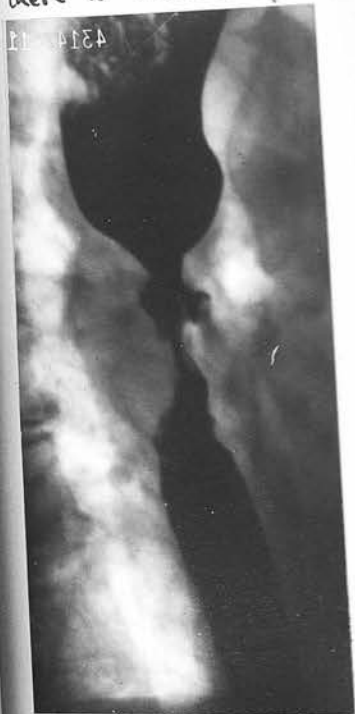

Fig. 26 Appearances of a diverticulum
seen in a carcinoma of the
esophagus.

The epiphrenic diverticulum is regarded by some as atavistic in origin. They say that it is similar to the fore-stomach in ruminants. Most observers however regard it as similar in origin to the other diverticula. It is probably an area of the oesophagus that is deficient in muscle fibres. The increase of pressure during swallowing have gradually produced a diverticulum. It is noteworthy that this condition is often present in cardiospasm where the pressure at the lower end of the oesophagus is increased. (Fig. 27)

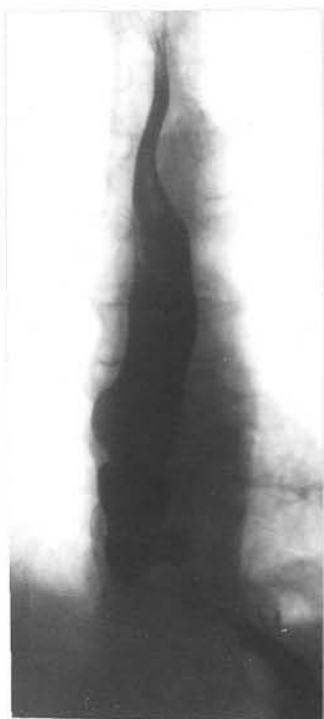

Fig. 27 Epiphrenic Diverticulum
occurring in an early case
of cardiospasm.

Probably one factor in its
production is the increased
pressure in this part of
the oesophagus during
swallowing movements.

In 26 cases examined by Wallace 10 had symptoms such as dysphagia, pain behind sternum, or haematemesis. He reproduces a series of drawings of the 27 diverticula ^(See Fig 28) indicating those that had symptoms and those that were symptomless. No relationship

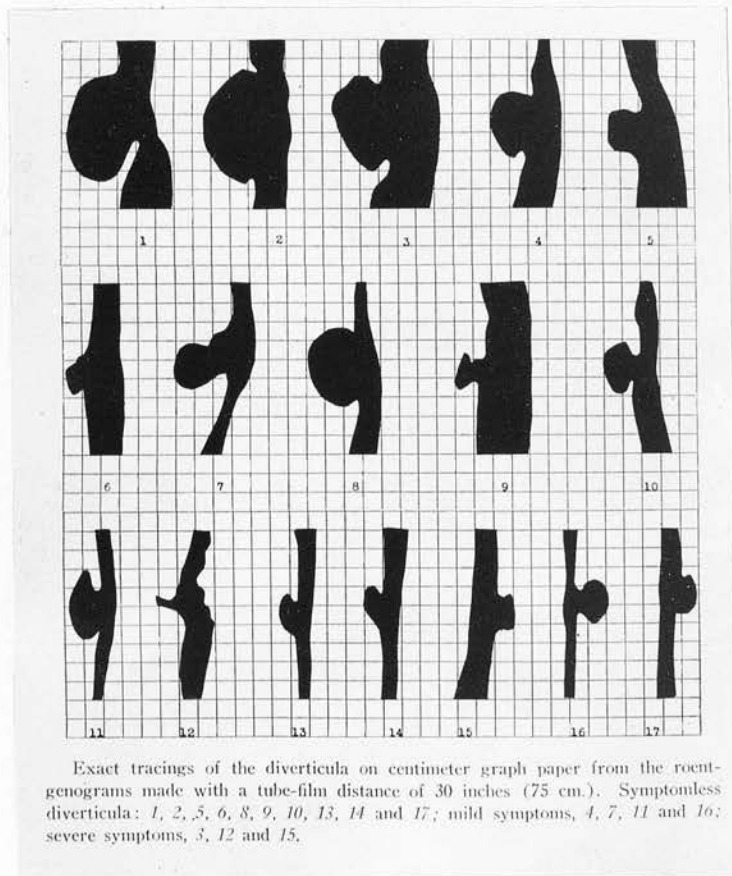


Fig. 28 Reproduction of tracings by Wallace.
 showing there is no relationship between size, shape and occurrence of symptoms with oesophageal diverticula.

between size, shape and occurrence of symptoms could be found. Several of the smallest sacs were noted in patients with the most severe symptoms and a number of the largest sacs produced no symptoms whatever. In a few the symptoms were chronically present but in the majority a period of comfort separated the attacks.

The morbid changes that are liable to develop in diverticula (e.g. the changes seen in Meckel's diverticula) are rarely seen with oesophageal diverticula probably because they have a wide mouth and the fundus is drawn to a higher level than the orifice, so that food cannot lodge in the diverticulum. Inflammatory changes have been described occurring in the diverticula however, and at P.M. gangrene and perforation to the pleural cavity have been noted.

ULCERS OF THE OESOPHAGUS.

Acute oesophagitis with ulceration may occur at all ages and from a variety of causes. In infants acute ulceration of the oesophagus may give rise to fatal melaena. The swallowing of boiling fluids or corrosives may cause ulceration. It frequently occurs after prolonged vomiting, such as may occur in hyperemesis gravidarum or in pyloric obstruction. It has also been noted to occur with anaesthetic vomiting and even sea-sickness.

A further cause is local suppuration due to a foreign body. Apart from this last cause, such conditions rarely call for X-Ray examination.

The lower end of the oesophagus may however be the seat of peptic ulceration. It is only within the past 10 years that attention has been drawn to this condition. As yet, both the X-Ray and the clinical picture are incomplete. Sir Arthur Hurst has described 6 cases. Chevalier Jackson has seen 21 active ulcers and scars of 67 healed ulcers in 4000 endoscopic examinations of the oesophagus.

Histologically, the ulcers are similar to chronic gastric and duodenal ulcers and are often associated with them.

In cases which have come to P.M. areas of heterotopic gastric mucous membrane are found similar to the areas of heterotopic mucous membrane occasionally found in a Meckel's diverticulum. This mucous membrane consists of columnar and oxyntic cells.

It secretes acid gastric juice which tends to collect in the lower end of the oesophagus above the closed sphincter. In time, an erosion, and later an ulcer develops similar to the peptic ulcer described in a Meckel's diverticulum. Another predisposing factor is excessive regurgitation from the stomach as seen in pyloric obstruction.

Ulcers occur in the lower third of the oesophagus and often extend into the stomach. They are most common on the posterolateral wall.

The condition occurs between the ages of fifty and seventy.

Symptoms/

Symptoms are often erroneously interpreted as gastric. There is substernal discomfort and pain whilst eating solid food, usually relieved by liquid food and alkalies. Patients may be afraid to eat because of severe spasmodic dysphagia. In consequence they lose weight and become emaciated. Thus the condition may be impossible to diagnose from carcinoma clinically.

As with peptic ulcers elsewhere, the disease has remissions.

The only X-Ray evidence of this condition may be spasm or irritability of the area involved. This spasm may produce slight delay in the emptying of the oesophagus. An ulcer crater may be seen and pain experienced as barium passes over it. When the rest of the oesophagus is empty a small fleck of barium may remain in the crater.

Jackson says that X-Ray examination in many of his cases was negative and he recommends oesophagoscopy in doubtful cases.

After a few weeks of medical treatment the appearances may entirely disappear.

Peptic ulcer of the oesophagus is liable to cause haematemesis. Perforation to the pleura or peritoneum, when it occurs, is nearly always fatal. After the ulcer heals stricture formation may take place.

STRICTURE OF THE OESOPHAGUS.

Any inflammatory lesion of the oesophagus severe enough to cause destruction of mucosa and invasion of muscular wall may be followed by stricture formation. Consequently stricture follows peptic ulceration and swallowing of caustics. Stricture is liable to develop at the narrow parts of the oesophagus because here the caustic has been in contact with the mucous membrane for a longer period of time.

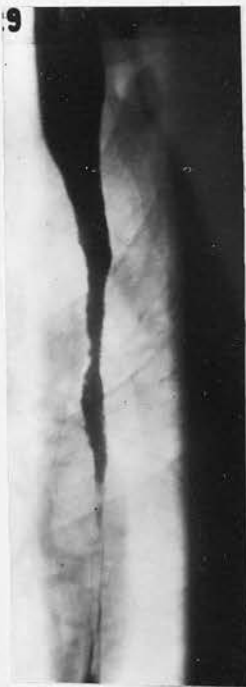

Fig. 29 Stricture of oesophagus
and oedema.

This patient swallowed and accidentally 14 days prior to this X-Ray film being taken. To a level 3 cm. below the arch of the aorta, the oesophagus normal. Below this level for 9 cms. there was marked constriction probably due to oedema and scarring.

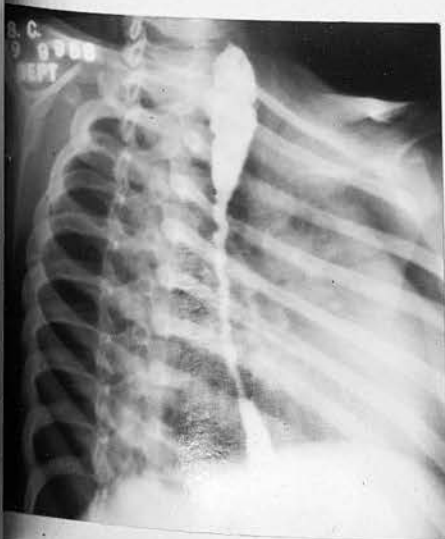

Fig. 30 This film is of a boy who suffered with progressive difficulty in swallowing. 2 months previously he drank sulphuric acid from an accumulator.

ACHALASIA OF THE CARDIA.

The condition has been defined by Sir James Walton as "dilatation and hypertrophy of the oesophagus where on P.M. examination no obstruction can be found distal to the dilatation" - the dilated oesophagus will not hold water. Thus whatever be the cause of the obstruction it ceases to act after death.

A rare type of condition simulating achalasia has been described but it differs from achalasia in that there is muscular hypertrophy of the cardia sphincter similar to that seen in congenital hypertrophic pyloric stenosis. In these cases the obstruction persists after death.

Apart from a few workers including Chevalier Jackson who believes that inco-ordination of the normal movements of the diaphragm during deglutition is the causative factor, the majority of people now consider that the condition is due to inco-ordination of the nervous mechanism supplying the lower end of the oesophagus. The original view put forward by Mickulicz was, that the condition was due to spasm of the circular fibres at the lower end of the oesophagus. Hurst observed that hypertrophy of the cardiac sphincter, such as one might expect in a condition of spasm, was never present. He put forward the view that the condition was due rather to non-relaxation of the sphincter because the opening mechanism was paralysed and he it was who introduced the term achalasia. Walton notes however that there may be spasm without producing hypertrophy of the muscle and he sites cases of pylorospasm/

pylorospasm. He thinks that the cardiospasm probably dates from birth. In early life while the muscle is healthy the obstruction can be overcome. As the patient gets older the muscle fails to overcome the obstruction and symptoms develop with stagnation, and as inflammation sets in, the action becomes further impaired. This explanation would certainly account for cases that come on suddenly after an acute infection when the muscle would be in a weaker state.

Recently Knight has studied the innervation of the oesophagus experimentally in cats. He found that the inter-diaphragmatic and intra-abdominal portion of the oesophagus function as a true sphincter. The sphincter receives its sympathetic supply from the coeliac plexus - the fibres following the course of the left gastric artery and its oesophageal branch. The parasympathetic supply of the sphincter comes from the vagi. Stimulation of the sympathetic causes the sphincter to contract whilst vagal stimulation causes it to relax. Excision of the vagi nerves produces a condition similar radiologically to Achalasia - the sphincter fails to relax. If however the sympathetic fibres were excised at the same time no obstruction resulted at the cardia and there was a loss of tonus of the cardiac sphincter.

In cats in which achalasia of the cardiac sphincter had been produced by vagal section subsequent coeliac sympathectomy resulted in relief of the condition. Coeliac sympathectomy has been successful in a percentage of cases in human beings.

So far as treatment is concerned, it does not matter whether one/

one subscribes to the views of Hurst or of Walton. In both cases there is a relative increase in the sympathetic activity and its removal should afford relief.

While Walton maintains that at operation there is marked spasm of the cardiac sphincter, the finger or bougie being tightly gripped as it is in anal spasm, Hurst says that his mercury tube passes easily, by reason of its weight. It may be that the condition can be divided into 2 groups:-

1. Those cases of contraction of the sphincter - Cardiospasm.
2. Those cases of vagal failure or achalasia.

In support of the view of vagal failure Rake has been able to demonstrate lesions of a subacute inflammatory nature involving Auerbach's plexus (the vagal fibres have been shown by Gaskell to terminate in this plexus.). He found the ganglia to be infiltrated with lymphocytes and increased in size. Some cells were in a state of degeneration and were undergoing phagocytosis. At a later stage there was disappearance of the ganglion cells and fibrosis of the plexus. When traced upwards from the cardiac end these changes became less marked. The cause of this inflammatory and destructive change is not known. Syphilis has been blamed but the Wassermann reaction in most cases was negative. Some have suggested that the inflammatory process spreads from the oesophagus but the oesophagitis is a secondary occurrence to the achalasia. Others have suggested ganglionitis due to virus infection similar to herpes zoster, while others have suggested a peripheral neuritis as one finds following diphtheria.

Pathology:

Achalasia at first produces hypertrophy of the circular muscle wall of the oesophagus above the sphincter. This hypertrophy continues to increase so long as it becomes sufficient to overcome the obstruction and during this time there are no symptoms. However, sooner or later, hypertrophy fails and secondary dilatation appears.

The degree of dilatation is much greater than that found in strictures even of long standing, and is comparable to the dilatation one sees in the colon in Hirschsprung's disease and also in idiopathic dilatation of the ureter and it has been suggested that the pathology of these diseases is similar. In advanced cases the lumen of the oesophagus commences to dilate just below its origin. The dilatation ends usually at the diaphragm although it may end just above the diaphragm or more frequently extends through the diaphragm to end within the abdomen.

With increase in width there is also increase in length and this forces the oesophagus to take a tortuous course through the chest. The normal convex curve to the right becomes exaggerated and the dependent part rests like a sac on top of the diaphragm. Food and saliva stagnate in this sac the contents of which may amount to several hundred c.cs. and will readily become infected. Fermentation gives rise to oesophagitis with ulceration of the mucosa. Ulceration may in turn lead to hyperkeratosis and leukoplakia and as a final change a squamous celled carcinoma may develop.

The/

The disease comes on slowly and lasts with intermissions for years. From the clinical standpoint these are the important points in the Differential Diagnosis from Carcinoma:-

1. The duration of the condition.
2. Intermissions.

On the X-Ray screen one sees the violent peristaltic waves which are continuing throughout the day. The peristaltic waves are unable to overcome the obstruction because the dilatation is so great that the waves are not deep enough to obliterate the lumen. They merely churn the contents of the lower end of the oesophagus. The resistance of the unrelaxed sphincter can be overcome by a head of 8" of water and hence when a meal is taken nothing enters the stomach until the contents of the oesophagus form a column 8" high. A tube loaded with mercury may pass into the stomach because of its weight and hence this method is used to/

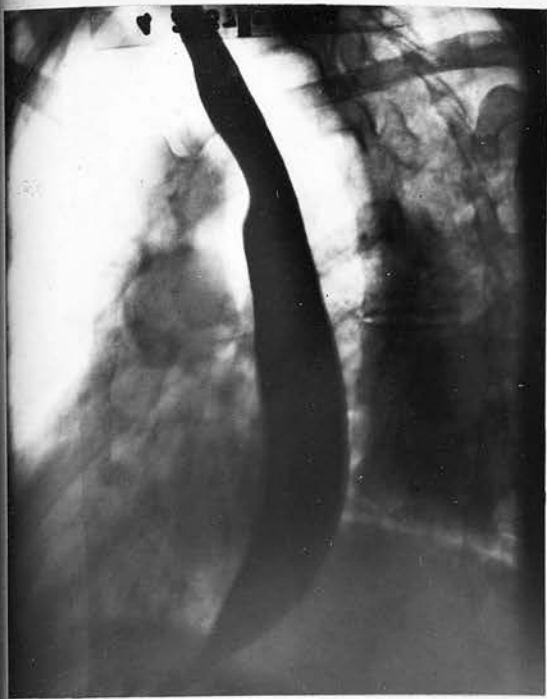

Fig. 31 An early case of Achalasia showing slight dilatation at the lower end of oesophagus.
(This film has been photographed the wrong way round)

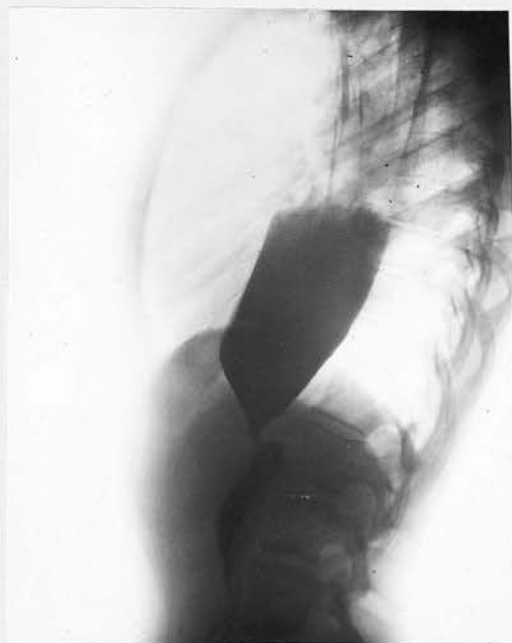
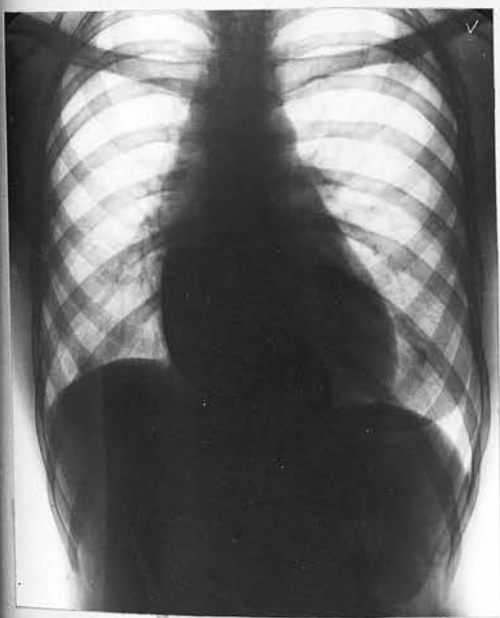


Fig. 32 Advanced Case of Achalasia

The mediastinal shadow is broadened by the dilated oesophagus which is seen to contain a head of barium. In cases such as this a ~~Ryle's~~ ^{Hurst's} tube merely curls up at the lower end.

to treat early cases. Where the dilatation is gross the tube tends merely to become turned back on itself at the lower end.

As the barium is swallowed it slowly sinks to the bottom of the stagnating fluid and outlines the cardiac orifice which is not dilated. Barium is seen to enter the stomach in small spurts - an important point in differentiating the condition from carcinoma where the barium tends merely to trickle through. In advanced cases the right margin of the dilated oesophagus may extend to the right of the spine and cause a wide mediastinal shadow. Examination of the stomach is difficult because of the small quantity of barium getting through.

VARICES OF OESOPHAGUS.

It was not till 1928 that Wolf first demonstrated this lesion radiographically and described its appearances.

At the lower end of the oesophagus the veins of the stomach which drain to the portal system are in communication with the oesophageal veins which drain to the vena azygos and vena cava. These communications are of importance in cases where the portal vein is obstructed e.g. cirrhosis of the liver. The veins become grossly enlarged and varicose and cause widening of the lumen of the oesophagus. Occasionally one of the dilated veins ruptures and causes severe haematemesis which is often fatal. Berg states that 5% of Gastro-intestinal haemorrhages occur from varices generally in consequence of portal cirrhosis.

In/

In cases of bleeding from the digestive tract where X-Ray examination of the stomach give negative results varices of the oesophagus should be looked for especially if the spleen is enlarged or ascites be present. On occasion the diagnosis can be made before clinical symptoms appear. Berg goes as far as to say that X-Ray diagnosis is without error and is more convincing than biochemical tests of liver function.

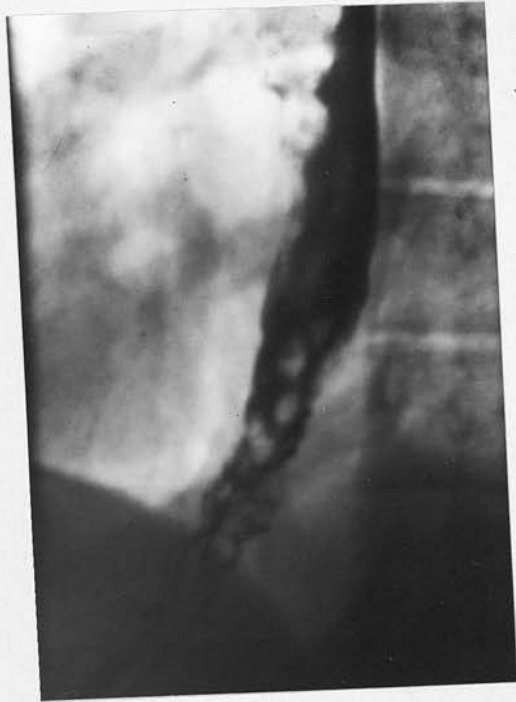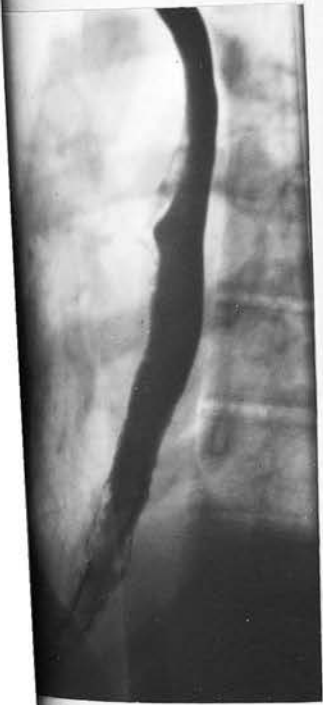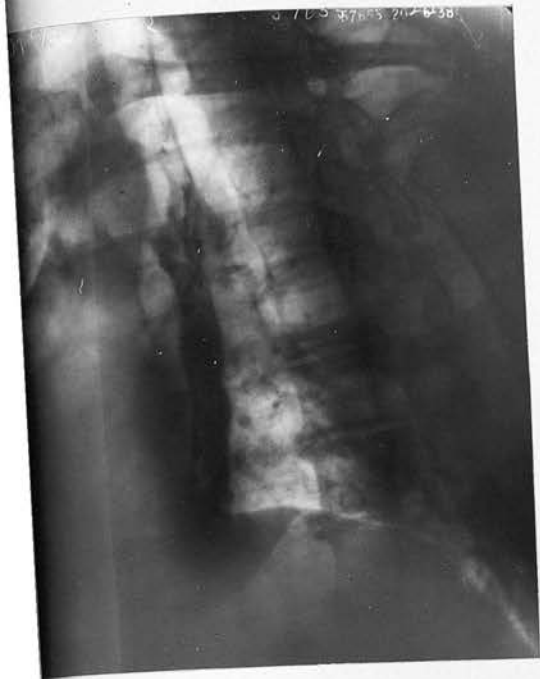Varices are best seen with patient lying horizontally and rotated towards the left. Thick barium with drinks of water may be given. The veins may be seen to extend fully half-way up the oesophagus. In some of the illustrations shown by Hjelm the varices are seen extending up as far as the level of the clavicles. The peristaltic wave squeezes the blood from the veins but they rapidly refill and the normal mucosal folds are replaced by the irregular shadows of the tortuous veins.

Films should be taken with as short an exposure as possible after the patient has swallowed two or three mouthfuls of thick barium.

Some recommend giving atropine before the examination to keep the mucosa dry and allow the barium to adhere better.

Fig. 33 Varices.

This was a case of Haemochromatosis
that had multilobular cirrhosis of liver.

Fig. 34 Varices.

This was the film
of a woman who
had splenic anaemia.
Irregularity of mucosal
folds is seen.

CARCINOMA OF OESOPHAGUS.

Carcinoma of the oesophagus occurs with about one-third of the frequency of carcinoma of the stomach. It accounts for 5% of cases of malignancy. Men are affected in approximately three-quarters of the cases and they are usually over the age of 55. The average age of patients coming for treatment at the Infirmary is 61 years. In the series investigated by Clayton the average age at the time of death was 60.5 years.

The sites at which the disease is liable to develop are the anatomical narrow points namely:-

1. The arch of the aorta.
2. The point where the Left bronchus crosses.
3. The lower end.

These three points are also the sites at which diverticula tend to form. Primary carcinoma in the cervical portion is rare, but an extension from a pharyngeal carcinoma is common in women.

Histological variations which may be important predisposing factors in the development of carcinoma.

1. In some cases the mucous membrane is interrupted here and there by islands of mucous glands. They are especially well seen towards the cardiac end of the stomach. They probably represent irregular development of oesophageal epithelium. The sudden transition of epithelial types offers a predisposing factor for development of epithelioma. These islands are said to give origin to the mucoid and adenoid varieties of carcinoma.

2. Ewing draws attention to another anomaly which probably arises from incomplete separation of trachea from oesophagus in embryonic life. It is the presence of small canals lined by cubical or squamous epithelium lying in the submucosa of the oesophagus, or even extending through its muscle coat to the trachea and forming a small fistula.
3. A further point is the sudden transition from squamous epithelium of the oesophagus to the columnar epithelium of the stomach. At this edge carcinoma tends to develop.

Other Contributing Factors.

Alcohol, tobacco, oral sepsis and drinking of hot fluids have been put forward as contributing factors. Excessive indulgence in alcohol leads to a chronic oesophagitis, and it has been noted that carcinoma is especially liable to develop in men such as brewers, barmen and cellarmen engaged in the alcohol trades.

The factor of Leukoplakia.

As in the tongue leukoplakia has been regarded as a pre-cancerous condition. It is often observed in old people and in the neighbourhood of a carcinoma.

Pathology.

Tumour may be:-

1. Flat infiltrating ulcer.
2. A bulky polypoid mass.
3. or rarely a diffuse infiltration.

The ulcerative type grows round the lumen of the oesophagus, and constricts and obstructs it. It gradually occludes the tube but it may not be till the lumen is only $\frac{1}{2}$ cm. that increasing difficulty is experienced in swallowing first with solids and later with liquids. The initial lesion is small and from the X-Ray film one is inclined to picture the condition as a local one involving merely the wall of the oesophagus. The lesion however rapidly spreads and at an early stage invades the surrounding structures.

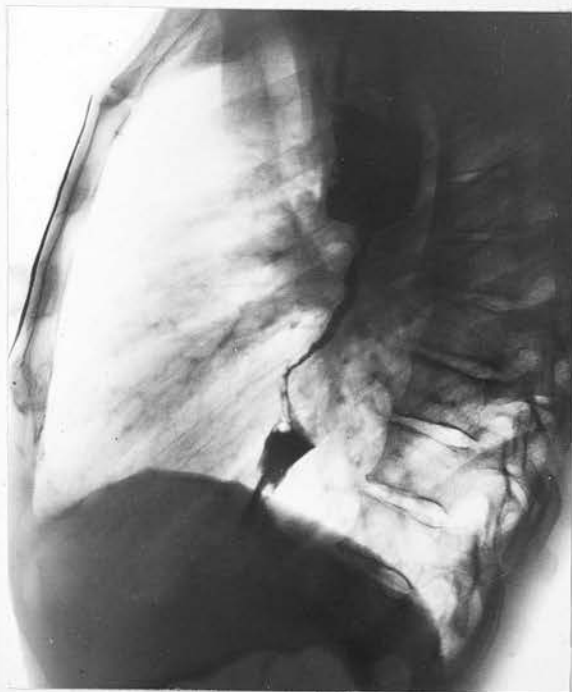

Fig. 35 Carcinoma involving a considerable length of the oesophagus and almost completely occluding lumen. This patient complained of progressive dysphagia for 2 years before this film was taken. She died 6 months later.

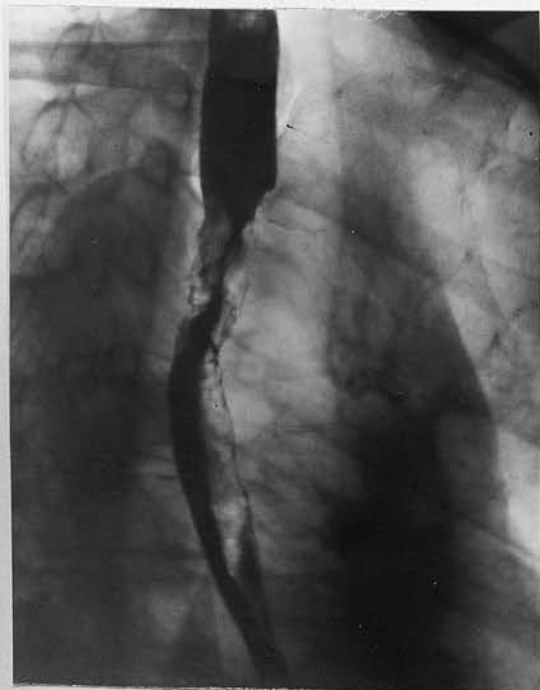


Fig. 36 Flat ulcerating type of carcinoma involving middle third of oesophagus and causing annular constriction over several cms.

The bulky tumours are usually of the adenocarcinomatous type. They form large irregular growths within the lumen. This type is most frequently found at the lower end.

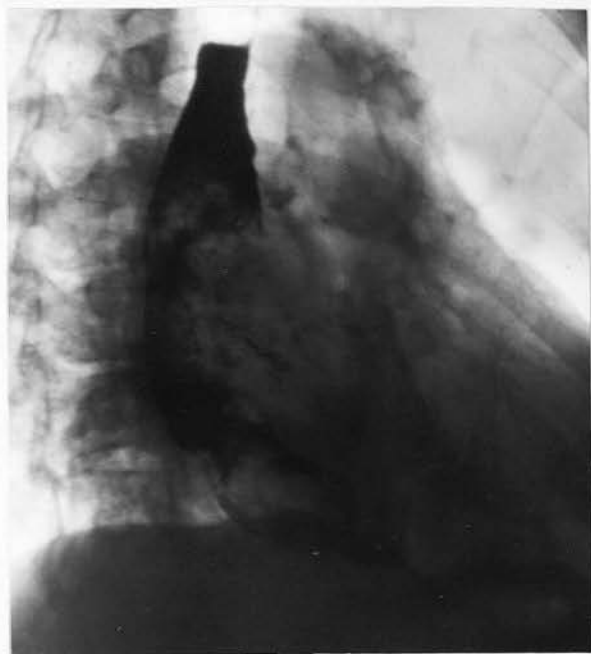

Fig. 37 large polypoid
carcinoma of oesophagus
distending the oesophagus and
partially blocking it.

Sometimes a type of Carcinoma is seen where there is diffuse infiltration of a segment of the oesophagus.

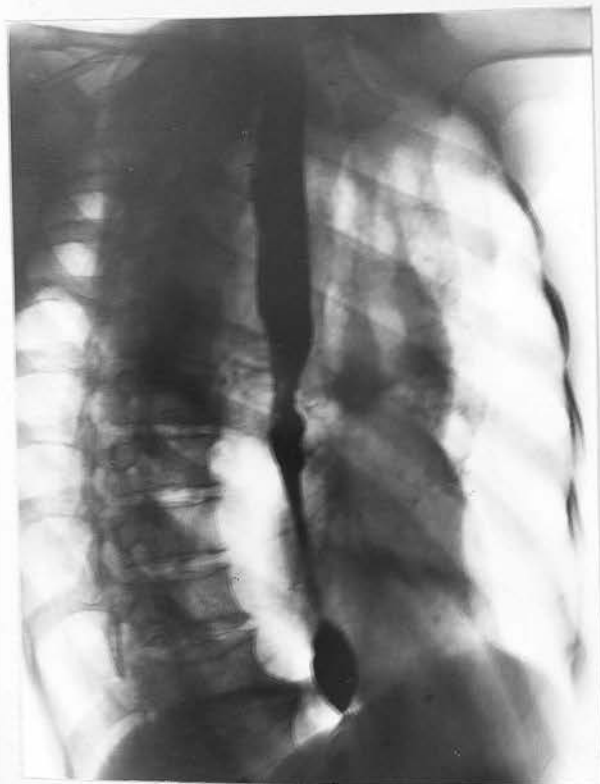


Fig. 38 This tends to be
of the diffuse scirrhous
type. There was
dysphagia only with solids.

Carcinoma of the Oesophagus invades the surrounding structures at an early stage. There is a wide submucous lymphatic plexus and spread along the lumen is therefore easily explained. Once the tumour has penetrated the outer fibrous wall of the oesophagus its growth through lymph vessels and by direct spread is very rapid. It is this fact which makes cure of Carcinoma of the Oesophagus by resection almost impossible and also may be the cause of failure of many cases treated by radiotherapy. It would certainly explain the failure of treatment by radium.

A further fact which makes treatment difficult is that Carcinoma of the Oesophagus does not cause recognisable symptoms till the disease is already well advanced. The organ does not possess sensory fibres and therefore the earliest symptoms are reflex in character - several writers have noted substernal discomfort and spasm as the earliest symptoms.

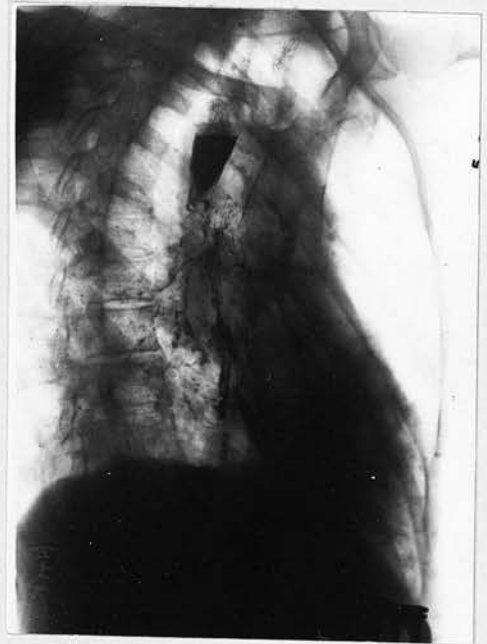
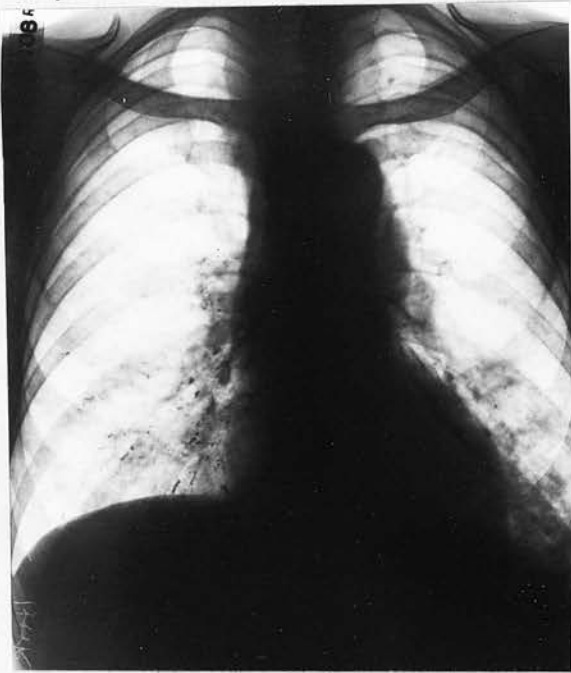
The oesophagus is a dilatable tube, and the food may pass although a large growth is present. By the time there is difficulty in swallowing the lesion has probably metastasised or spread beyond its walls.

Chevalier Jackson believes that when obstruction ensues the lesion has been present for at least a year and Grey Turner noted in his cases that the average time between onset of symptoms and investigation was 15 weeks. This knowledge emphasises the imperative necessity and importance of skilled examination by methods of precision the moment symptoms are complained of.

Trachea/

Trachea, bronchus, lung and mediastinum may be involved. With involvement of trachea or bronchus fistula formation may occur and death soon follows from septic aspiration pneumonia. 75% of cases terminate with Broncho-Pneumonia. A film is shown where the bronchial tree is outlined by barium through a fistula.

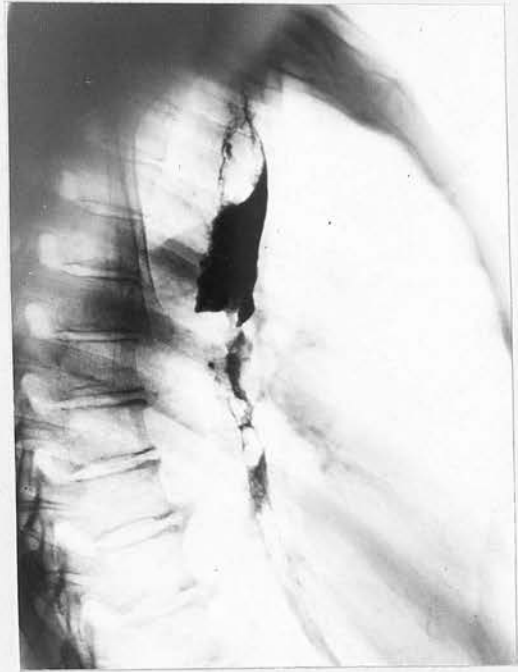
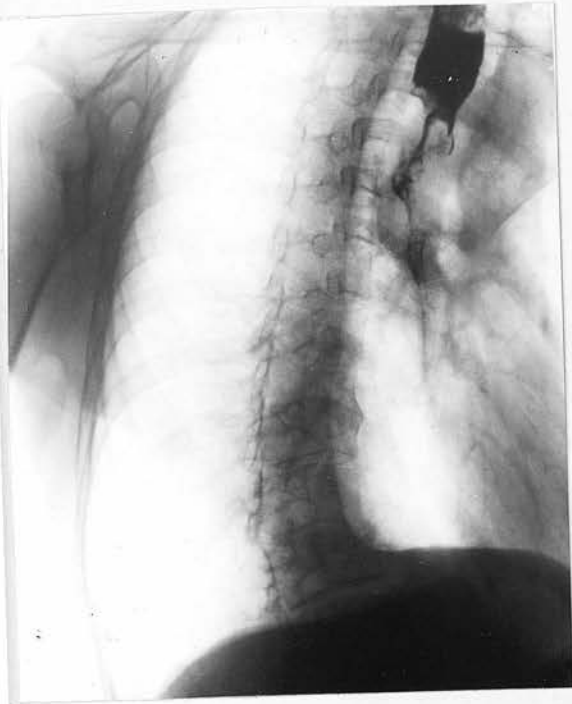
Fig. 39. Showing bronchial tree outlined with barium. This case was treated with radium.



When mediastinum is involved mediastinitis develops and if the pleural cavity be invaded a pleural effusion or empyema may be present.

Death from haemorrhage due to erosion of vessels is uncommon.

The lymph glands involved are those in the supraclavicular area, the mediastinal glands and the glands round the coeliac axis. They may be extensively involved with a very small primary tumour which causes no symptoms. Spread by blood stream is uncommon.



Figs 40 Carcinoma Oesophagus.

There is a sharp line of demarcation between apparently normal oesophagus and the carcinoma in both cases.

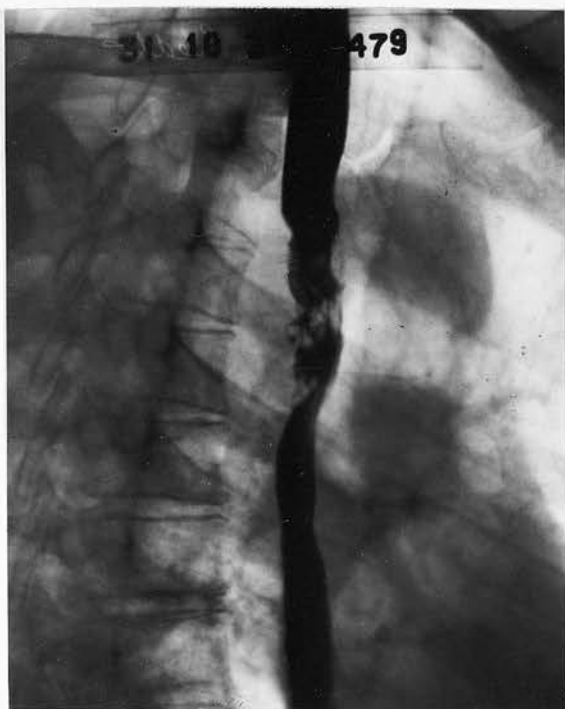

Fig. 41 Carcinoma Oesophagus.
 in middle third causing
 irregularity of mucous
 membrane pattern.

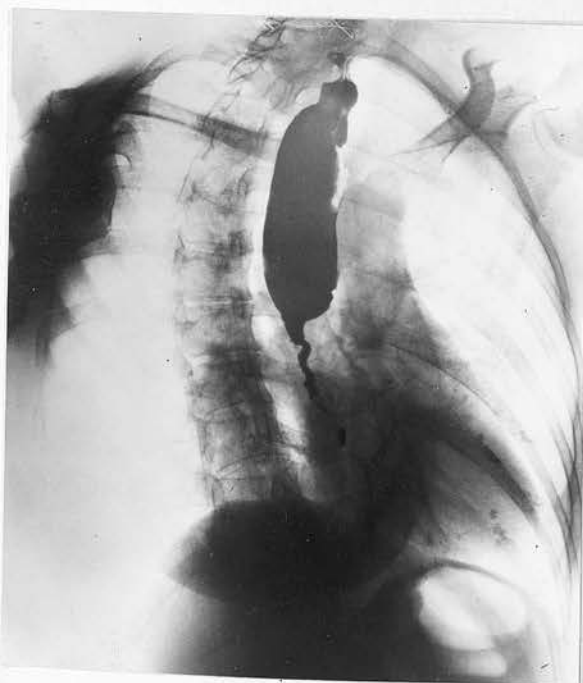
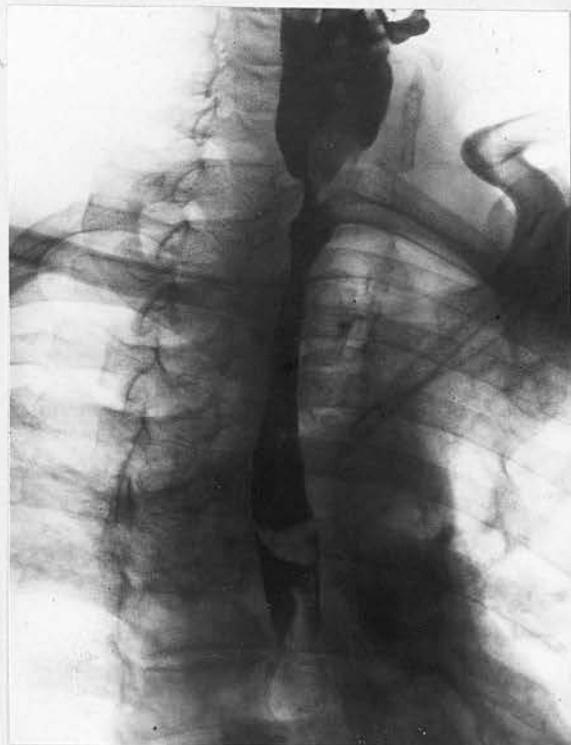
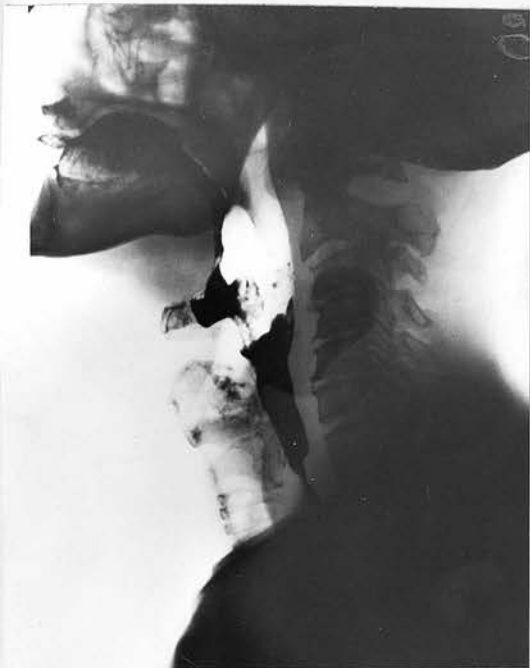

Fig 42 Large Carcinoma
involving 8 cm. of
oesophagus and almost
 completely occluding lumen.
 Although this film was
 taken in August 1938
 when the patient complained
 of Dysphagia and loss of
 weight, so far as is known
 he is still alive.



Figs. 43. An unusual site of Carcinoma of Oesophagus.

The cervical part was involved over 8 cms.
Patient died 9 months from time of first
Symptoms.

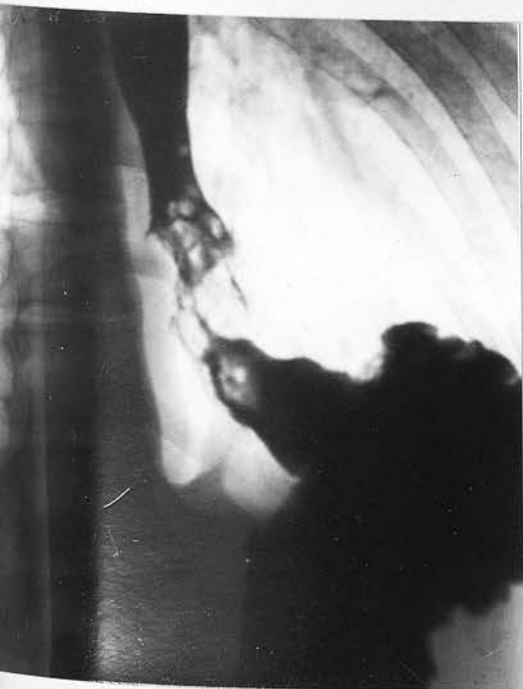

Fig. 44 Carcinoma of
cardiac end of stomach
spreading up and
involving oesophagus.

My thanks are due to Dr McWhirter who has given me every help and facility. I am also indebted to him for permission to use X-Ray films and lantern slides from his collection.

I am also grateful to Dr Allan for allowing me to use some of his films of congenital abnormalities.

Mr Martin and radiographers of the Infirmary have given me a great deal of valuable help with the photographic work.

References:-

- ABEL, A.L.: B.M.J. 1928 Vol.II, p.47.
- AURELIUS, J.R.: 'Peptic Ulcer of the Oesophagus'. American Journal of Roentgenology Vol. 26, p.697.
- BARRETT, N.R.: 'Diverticula of the Thoracic Oesophagus'. Lancet 1933 Vol. I, p.1009.
- BEUTEL, A.: 'Acta Radiology' Vol. 13, p.527.
- BRITISH AUTHORS: 'Text-Book of Radiology'.
- CUNNINGHAM: 'Text-Book of Anatomy.'
- EWING: 'Neoplastic Diseases.'
- HILL, W.: 'Pharyngeal and Oesophageal Diverticula'. B.M.J. B.M.J. 1926, Vol. 2, p.1163-1169.
- HJELM, R.: 'Acta Radiology' 1935, Vol. 12, p.146.
- HURST, A. and RAKE, G.: Quarterly Journal of Medicine 1929-30, Vol. 23, p.491.
- JACKSON, CHEVALIER: 'Peptic Ulcer of the Oesophagus.' Journal of American Medical Association 1929, Vol. 92, p. 369-372.
- JACKSON, CHEVALIER and SHALLOW, T.A.: 'Diverticula of the Oesophagus, pulsion, traction, malignant and congenital.' Annals of Surgery 1926. Vol. 83, p.1-19.
- KNIGHT, G.C.: 'The Relation of Extrinsic Nerves to Functional Activity of Oesophagus.' B.J.S. 1934, Vol. 22, p.155.
- 'Sympathatomy in the Treatment of Achalasia', B.J.S. 1935, Vol. 22, p.864.

- MANGES, L.H. and CLERF, W.F.: 'Congenital Abnormalities of the Alimentary Tract.' Amer. Jour. Roentgenology, Vol.33, p. 657.
- 'The Congenital Short Oesophagus'. Journal of the American Medical Association 1934, Vol. 102 p. 2008-2012.
- MOYNIHAN, B.: 'Diverticula of the Alimentary Canal'. Lancet 1927. Vol. I, p.1061.
- PATERSON, R.S.: British Journal of Radiology, 1929, Vol.2, p.331.
- RAVEN, R.W.: 'Pouches of the Pharynx and Oesophagus. B.J.S. 1933, Vol. 21. p.235.
- STEWART, M.J. and HARTFALL, S.J.: 'Chronic Peptic Ulcer of the Oesophagus'. J. Path. 1929. Vol. 32, p.9-14.
- STURTEVANT M, SHAPIRO, L.L. and WALLACE, R.: American Journal of Roentgenology. Vol. 27, p.187.
- TURNER, GREY: Lancet 1936, Vol. I, pp.67 and 130.
- SCHATZKI: Acta Radiology 1933. Vol. 18 Supplement.
- WALTON, J.: 'Surgical treatment of Cardiospasm.' B.J.S. 1925, p.701.
-