

Thesis submitted for the Ch.M. Degree. Edinburgh University.

March 1913.

61743

CONGENITAL DILATATION AND HYPERTROPHY
OF THE COLON AND RECTUM

by

L. E. BARRINGTON-WARD.

M.B. Ch.B. F.R.C.S.Edin. F.R.C.S.Eng.



The first full description of this disease was given by Hirschsprung in 1886, and it has been customary to associate his name with the condition. It had, however, been recognised before that date, and according to Jayle, Ruyson in the 17th century described a fairly typical case in a girl of 5 years. Parry in 1825, Billard in 1829, Von Ammon in 1842, published undoubted cases which were followed by several others before Hirschsprung's paper appeared. (Finney).

The disease when developed presents such a striking picture that it is not surprising to find that observers hasten to put their experiences on record, and the literature of the condition is considerable.

Finney in a comprehensive survey of the literature discovered 206 references up to January 1908, and gave an excellent summary of the chief points of the condition. I have found his paper of considerable value in the preparation of this thesis and have read all those articles which influence the point of view from which I am approaching the subject, and all other accessible communications which have been made up to the present date.

The clinical features are well known and I do not propose to deal with that section at any length. The etiology and treatment offer a wider scope.

For the purpose of enquiring into the etiology I have taken the Post-Mortem records of all the cases of this nature at the Hospital for Sick Children, Great Ormond Street.

Inasmuch as in the records the old nomenclature of sigmoid colon and rectum was used, I have thought it advisable to avoid confusion to retain this description of the large bowel as far as possible, in preference to the newer division into iliac and pelvic colon and rectum.

It is undoubtedly common to label as Hirschsprung's disease many conditions which are not so. I would exclude cases of simple atresia of the rectum where the rectum is neither dilated nor hypertrophied but merely stenosed. Treves' celebrated case in which he excised the colon, rectum and anus appears to me to belong to that class. Many of the recorded cases, especially of elderly males, are probably instances of an advanced degree of faecal stasis. I have seen two instances of a condition in infants in which fissures about the anus caused a reflex spasm of the sphincters and prevented defaecation. With the onset of abdominal distension and vomiting the diagnosis of Hirschsprung's disease was suggested. Treatment viz. dilation of the sphincter, ^{at} once differentiated this spurious form from the true variety. Post-mortem

examination or operation is a certain test and I have accordingly limited myself to cases verified by these means.

What is the best treatment to employ is still an unsettled question. I propose to give in some detail the treatment of ⁴ recent cases for which in ³ instances I was partly responsible, and in which the results have surpassed any others that have been treated at the Children's Hospital, Great Ormond Street.

Definition: The disease is perhaps most generally known by the name of Congenital Idiopathic Dilation of the Colon. By the term Idiopathic little is meant except complete absence of knowledge as to how the condition arises.

All cases where any form of obstructing agent is demonstrable should be excluded. In its most typical form congenital enlargement of the colon is manifested by progressive constipation and intestinal distension dating from birth. A form of the disease was described by Hirschsprung which occurs in later years and has been given the misnomer of pseudo-megacolon. Many of the cases described as such are not true examples of congenital enlargement but are due to a variety of kinds of mechanical obstruction and some to simple stasis. That the true congenital disease may occur in later life must be admitted, but such instances

are rare and are in every way comparable to the occasional appearance of apparently typical cases of congenital pyloric obstruction in adult life.

Emphasis is usually laid on the dilatation of the intestine. The hypertrophy, however, is no less striking a feature and has been described as present at birth. (Billard. Joukovsky.) If this is a secondary hypertrophy it is necessary to assume that there is an intra uterine factor at work. Further attention will be paid to this point in discussing the etiology.

It is described as a disease of the colon and the sigmoid colon has attracted most attention. The huge sigmoid is undoubtedly a feature of the condition but I shall hope to show that it is not necessary in the colon that the most marked changes are found.

It is the function of the sigmoid to act as a reservoir for faeces and in virtue of its wide mesenteric ~~attachment~~ its capacity for distension in the normal is considerable. Therefore in any distension affecting the large bowel as a whole the change will be most marked in the sigmoid.

Observations as to the condition of the rectum proper in these cases are often incomplete. Of 15 of my cases in which a definite examination of this part was made at autopsy, in 13 cases the rectum was

noted as dilated and hypertrophied to within a few inches of the anus. In 3 cases during life this has been suggested by radiograms after Bismuth meals and has been verified at operation.

It must therefore be conceded that the term congenital dilatation of the colon is hardly correct in that it does not express the hypertrophy that so constantly accompanies the dilatation and does not include the rectum which in many of these cases shows the most interesting changes. Congenital Enlargement of the Rectum and Colon more accurately expresses the condition of affairs.

Etiology: Finney has made a complete collection of the numerous theories that have been put forward in explanation of this disease. They may be classified under the headings of mechanical, neuropathic, inflammatory, and congenital. To say that the condition is congenital is of little assistance: it merely means that it is an error of development which our present knowledge of pre-natal pathology is insufficient to explain. Yet it will be of some assistance to determine whether the disease can come under this heading or whether it is due to some factor acting post-natally which may be controlled by the methods at present at our disposal.

A. Mechanical

It has been suggested that the cause is:-

- (1) an abnormally long mesentery permitting torsion of the sigmoid. (Barth)
- (2) increased length of the intestine especially the sigmoid which throws the bowel into loops and causes kinking and obstruction (Marfan. Neter.)
- (3) atresia of the rectum and anus. (Treves)
- (4) valve formation. (Perthes. Roser)
- (5) distension of pelvic colon with meconium at birth and valve action. (Wilkie)

B. Neuropathic.

- (1) Neuromuscular defect of a segment of the intestine. (Hawkins)
- (2) Paralysis of a segment of intestine. (Pennato.)
- (3) a lesion of the sympathetic (Bing)
- (4) reflex spasm of the sphincters due to anal fissures. (Fenwick)

C. Inflammatory.

Colitis becoming chronic.

D. Congenital.

- (1) anomaly of development - dilatation and hypertrophy congenital. (Hirschsprung)

(2) dilatation congenital, hypertrophy secondary.

(Mya. Concetti.)

(3) hypertrophy congenital, dilatation secondary.

(Fenwick. Genersich.)

I propose to consider these theories in the light of this series of cases.

I will briefly summarise the main points discovered at Post-mortem examination.

Between the year 1868 and 1912 Post-mortem examinations were made at the Hospital for Sick Children on 19 undoubted cases of Hirschsprung's disease.

16 of these were males and 3 were females. The youngest was 3 weeks, the oldest 12 years old. 10 of them were 1 year of age and under, and 6 were between 1 and 5. 13 had received medical treatment: 6 had undergone surgical operations.

In all cases it was noted that the sigmoid colon was hypertrophied. In 12 cases the rectum was affected, either hypertrophied or dilated or both. In 2 cases it was said to be normal. In 5 cases no statement was made as to the condition of the rectum. In no case was any mechanical obstruction to be found, though in one case the bowel was said to be kinked as it turned into the pelvis.

I would lay particular stress on the condition of the rectum in these cases. In many of the reported

cases the rectum is said to be normal but in the routine autopsy the bowel is not dissected out entire down to and including the anus but is cut across at an accessible point in the pelvis. In this manner hypertrophy of the rectum without much dilatation could easily be overlooked.

In 10 of this series it is definitely stated that the hypertrophy of the rectum extended down to the anal canal or within 4" from the anus. These are independent observations of a number of different pathologists extending over a period of 44 years. Assuming this to be a common feature it at once excludes many of the suggested theories. In several of the cases it is stated that the thickening of the walls of the gut became progressively greater towards the anus. No external or internal factor of any kind was found to act as an obstructing agent. The fault must have been in the wall itself. The anus was in every case normal. In 3 cases a thickening was to be felt just above the anal canal and the observers likened it to the feel of a congenital hypertrophic pylorus. In these circumstances any theory which blames a mechanical cause whether it be kinking of the gut, torsion of the sigmoid from an abnormally long mesentery or from abnormal length of the gut itself is untenable. The last part of the rectum takes a practically straight course before

passing into the anal canal, and in none of these cases was any abnormality to be discovered in the valves of Houston.

The neuropathic theories are difficult to prove or disprove. Histological changes in the sympathetic are not easy to show, ^{but} ~~the~~ Finney states that in 2 cases he found apparently healthy ganglion cells in both Meissner's and Auerbach's plexuses.

The age, the marked sex preponderance, the history that in all but 3 of the cases - (the time of onset in these cases was 2 months, 6 months, and 3 years 9 months) - constipation had dated from birth appear to my mind as almost conclusive proof that the condition is for want of a better term a congenital one. Finney brings forward from the literature strong evidence in favour of Hirschsprung's conception of the disease. Several cases are on record of its being present at birth. Joukovsky describes a case which is I believe the key to the whole question. It was that of a new born child with ectasia of the large intestine, with hypertrophy of the whole of the intestinal tract, and with stenosis of the duodenum.

If such an error can take place in the development of the whole of the intestine, it is not unreasonable to assume that it may with more frequency affect only a part of the intestine. Errors of development

are especially prone to occur in the region of the junction of the proctodaeum and hind gut and the junction of the fore and mid gut. In this connection the similarity of congenital pyloric stenosis to congenital disease of the colon and rectum is striking. According to R. S. Frew in a work shortly to be published and which I am permitted to quote, he has found in a series of microscopical studies that the hypertrophy and thickening so obvious in the pylorus are always associated with hypertrophy of the duodenum also as far as the middle of the second portion - that is to say, the posterior end of the fore-gut. In the comparatively thinned walled duodenum this hypertrophy is not very noticeable to the naked eye and is overshadowed by the thickness of the normally thick pylorus. Similarly in the lower end of the hind-gut any hypertrophy and dilatation will show itself much more readily in the capacious sigmoid.

The close similarity of the age of onset, the sex incidence, and the histology well deserve examination. Both conditions may be present at birth. I have seen a perfect example of hypertrophic stenosis of the pylorus in a male infant of 3 days. The case was admitted to the Hospital for Sick Children under the care of Mr. Tyrrell Gray, on September 20th, 1912, with the history of persistent vomiting. The diagnosis of a high intestinal obstruction or atresia

was made and at operation a markedly thickened and stenosed pylorus was discovered. The infant succumbed and at the autopsy this condition was verified.

Characteristic symptoms of pyloric stenosis occur at about 4 to 6 weeks after birth and the symptoms are probably due to the associated gastritis from gastric stasis and fermentation, and it is not until infection of the mucous membrane occurs that vomiting becomes a feature. Successful medical treatment - lavage - is directed to the cure of the gastritis.

In the case of Hirschsprung's disease at first the symptoms are of constipation only and little harm results. It is with the onset of colitis at about the second or third month that characteristic and harmful symptoms develop. Fermentation changes increase the abdominal distension which as a rule attracts attention at about this time.

Again, in both conditions symptoms may be delayed to later life. Barling has reported instances of apparently true congenital hypertrophic stenosis of the pylorus in 2 patients aged 17 and 27 years. In neither case had symptoms been shown in childhood.

Congenital disease of the pylorus and colon may be theoretically explained by assuming a nerve lesion which places a block on the intestinal canal in these regions, but in view of the condition having been found at birth it is necessary that movements of the

intestinal canal should have been active for some time prenatally. The nerve lesion if there is one is more likely to be of a trophic nature in the failure of regulation of the growth of the parts. We know so little of the control of the development of the body that it is perhaps idle to speculate.

Gigantism or a symmetrical overgrowth of the extremities and different parts of the body has long been recognised and there seems no reason why such prenatal overgrowths or potential overgrowth should not be allowed in the case of the intestine. Finney in the description of his own case draws attention to the large size of the blood vessels and lymphatics and compares it to a lymphangiectasis such as is met with elsewhere.

Most observers are agreed on the histological changes. In those of the present series which were submitted to histological examination the hypertrophy and hyperplasia of the muscular coats especially the circular were the characteristic features. Changes in the submucosa and the mucosa were of the nature of round celled infiltration such as would be expected from the generally associated colitis.

A satisfactory theory that will explain all the cases that have been reported as instances of congenital megacolon is impossible. Many of these cannot properly be classified as congenital colon disease

at all.

I believe the theory that best explains this series of cases is as follows:-

There is a congenital abnormality in the lower end of the hind gut which takes the form of a muscular hyperplasia. It usually involves the rectum and extends for a varying distance up the pelvic and iliac colon. It may be that the whole of the hind gut is affected. In some cases there is a definite localisation of the change, e.g. cases 2, 12 & 14, where the hyperplasia has affected a segment of the intestine chiefly. The hyperplasia of the muscle gives rise to both thickening of the walls and increase of the lumen. The physiological functions of the intestine are in abeyance, a block is produced, and the bowel behind for a varying distance depending on the extent and duration of the condition dilates and hypertrophies. This faecal stasis in time produces inflammatory changes in the mucosa and an ulcerative colitis occurs which is the cause of death in most instances.

The Clinical Features are distinctive. The salient points are intractable constipation and enlargement of the abdomen. The constipation in 15 out of 18 cases dated from birth. In one case no note as to this fact was made. The enlargement

of the abdomen has been met with at birth. In these cases it was most commonly noted between the 2nd and 4th month, that is to say, at a time when the colitis was appearing. If the child survives to any age, the distension may assume enormous proportions. The literature abounds in examples of prodigious enlargement.

In a few cases compensation may be established and the symptoms are not sufficient to bring the patient under medical observation until some years have elapsed.

Of 19 cases 10 were 1 year of age and under and 6 were between the ages of 1 year and 5 years.

As a rule diarrhoea begins sooner or later and alternates with the constipation. Some cases remain comparatively well for periods between attacks of constipation and diarrhoea. It seems that compensation can break down and yet again be re-established. Any one of these attacks may be fatal. However well they appear between the attacks purgative medicines and enemata are always required. Long intervals of time may elapse between the actions of the bowels. In one of my cases 3 weeks was the usual interval but many more striking instances have been recorded.

Abdominal pain sometimes occurs but generally not until the later stages.

Vomiting is not a common feature but one of these

cases died from incessant vomiting at the age of 3 weeks.

The general features of auto-intoxication are well marked. Staining of the skin, emaciation, lethargy, foulness of the breath, a low blood pressure, and coldness of the extremities are present in every case of any standing.

The distended intestines produce pressure effects on the abdominal contents, and oedema of the legs, ascites, and collapse of the bases of the lungs result. One case had hydronephrosis.

The abdomen is tense, the abdominal wall has a glazed appearance and is marked by dilated veins.

Peristalsis, especially in infants, is generally obvious. On palpation the tension may be such that nothing definite can be felt or the faecal masses may be distinctly palpable and may give rise to the erroneous diagnosis of abdominal tuberculosis. In favourable cases the distended segment of the intestine may be actually palpated.

On rectal examination the anus and sphincters are normal. In 3 cases which I have had the opportunity of performing this examination, the examining finger easily palpated the distended lower part of the rectum which was filled with tenacious faecal material. I was unable to satisfy myself that I could feel any thickening of the rectal wall. In one

case later autopsy revealed enormous thickening of the rectal wall right down to the anus. (Photograph) A

The Diagnosis is easy in typical cases. Stress should be laid on the history, the constipation, the abdominal enlargement.

A digital examination of the rectum and anus will exclude spasm of the sphincters, and simple atresia of these parts.

The matted form of abdominal tuberculosis bears at times a superficial resemblance.

Excellent confirmatory evidence is obtained by examination with the X rays after a Bismuth meal. Appended are radiograms of the pelvic colon and rectum in 3 cases. (Vid B.C.D.)

That the treatment of this disease has been unsatisfactory is shown by the variety of the methods that have been employed from time to time.

In the first place it is necessary to decide the relative value of medical and surgical treatment.

The concensus of opinion seems to be that surgical treatment offers greater hope. If the condition is at all established, it is difficult to see how medical measures can help. Drugs rapidly lose all their power on the inert bowel; enemata are generally retained or returned without effect. The rectal tube is uncertain in its action and can only be a temporary expedient.

In 2 cases I gave courses of Pituitary extract (hypodermically), Hormonal (Splenic extract), and Suprarenal extract without the least effect.

Several writers have collected figures showing the relative mortality of cases treated medically and surgically.

Duval gives a mortality of 74% with medical and 34% with surgical treatment.

Lowenstein in 59 cases treated on medical lines found the mortality 66%, whereas of 44 cases treated by surgery the mortality was 48%. Terry collected 110 cases treated surgically with a mortality of 26%.

One is therefore justified in saying that surgery holds out better prospects of recovery than medicine and a fair estimate of the surgical mortality would appear to be about 36%.

If the condition is a congenital malformation medical measures can hardly have any curative effect. Cathartics may by irritation cause occasional evacuations: enemata may wash out any faecal material lying in the lower part of the rectum, but neither cathartics nor enemata can restore the hyperplastic and hypertrophic bowel to its normal size or reinitiate the normal peristalsis. The prolonged use of drastic purgatives especially in infants is dangerous. Many of the cases of this series were

brought up to hospital by the parents because of abdominal enlargement and constipation. They were in other respects fairly well. After a few days in hospital their condition became suddenly worse, diarrhoea set in, and collapse and death followed. This was in all probability due to the efforts of the physicians to clear the bowels with purgatives which incidentally set up a fatal colitis. Post-mortem in these cases ulceration of the mucosa was found.

Other measures such as massage, dieting, electricity, can only have a temporary effect on cases of undoubted Hirschsprung's disease: they may have a curative effect on the simple constipation of children.

The surgical treatment has been most varied. Cheadle claimed to have cured a case by simple puncture of the colon through the abdominal wall. The method is not likely to commend itself to most surgeons. Simple laparotomy has been performed and the contents have been squeezed out of the anus with temporary relief. This procedure has a field of usefulness as a preliminary to other treatment but cannot be considered as a curative measure. Colostomy has been a favourite mode of treatment but young children stand colostomy badly and it is open to question whether death would not be preferable to an artificial anus acting throughout adolescence

and adult life. Colostomy has been of use as a preliminary to other measures. Appendicostomy has not been followed by permanent good results.

Colopexy, coloplasty, colonplication, have all been attempted and have been abandoned. The basis of this form of treatment is founded on an incorrect idea of the pathology.

Intestinal exclusion by a short circuiting operation is an excellent temporary and preliminary form of treatment.

The ideal form of treatment is the removal of the whole of the affected bowel down to the anus. Treves made a complete excision of the anus, rectum, and descending colon and brought the transverse colon to the perineum. He hoped that control would be regained later. The operation is rendered easier if the last part of the rectum is retained and the final results justify its retention.

As the problem of treatment is frequently presented in the first few years of life, such heroic measures would be doomed to failure. In young children the operation should be performed in two stages. At the first operation the ileum is divided and implanted as low down in the rectum as possible. The open pelvis of the child permits the junction to be made at a lower level than would be possible in the

adult. The junction has to be made with the greatest care as the tissues of the rectum do not lend themselves to ready manipulation and the risk of leakage and peritonitis is considerable.

This operation may give the patient relief for several months. The fluid contents of the ileum find a ready exit through the shortened rectum and the blocking of the colon and rectum above prevent regurgitation to any harmful extent. The child's strength improves and at a favourable opportunity some months later the large bowel above the anastomosis is excised.

The operation may be a very simple one. This is especially the case if the gut is large and is provided with a distinct mesentery and the vessels can be controlled in a series of pedicles. The operation is more difficult if the huge size of the bowel has encroached on the mesenteric interval.

The operation leaves the patient with the ileum entering the dilated terminal ^{portion} of the rectum. It is true that this must be considered a theoretical disadvantage but in practice we have found that the fluid contents of the small intestine do not tend to lie in the rectum to any extent, the control is good, and the bowels move normally after this operation. If the faeces do tend to collect, which is rare, it is an easy matter to wash out the relatively small cavity left so near the anus. (See Photo A)

None of the cases treated are of sufficient standing to decide positively whether the ileum will dilate above the new anastomosis but with constant care to keep the rectal sac empty this should not occur.

In some favourable cases it may be more satisfactory to complete the operation in one stage. More particularly will this be the case when the patient is of some age and in good condition and when the size of the colon is such that the reposition of the abdominal contents would be difficult and would waste valuable time. The secret of success in these operations is speed. The shock is surprisingly small and varies directly with the exposure of the patient and the amount of anaesthetic employed. Open Ether anaesthesia should be used in all cases.

Saline subcutaneous infusion during the operation and for 36 hours afterwards is invaluable.

Treatment on the lines indicated has been employed by Mr. Arbuthnot Lane on 4 patients during the last year. Three have made perfect recoveries and the fourth died as the result of an unfortunate accident, namely the slipping of a ligature, but for which I believe he would have made a good recovery. Their ages were 6 (2), 10 $\frac{1}{2}$, and 12 years and they were all instances of the disease in an extreme form and they had all failed to react to medical treatment employed over long periods. (Photo F)

It may be objected that these 4 cases were of an age suitable for operative measures and that the means employed could not cope with the condition in infants. Unfortunately no opportunity has presented itself for employing this method on younger children. The youngest child on whom I have seen ileo-colostomy performed was 2 years and the operation caused no anxiety whatever and the child made a perfect recovery.

The advances recently made in the treatment of congenital pyloric stenosis have shown that gastro-enterostomy can be borne by exceedingly feeble infants. It is reasonable to expect that an ileo-colostomy could be performed with even greater safety, as patients with congenital colon disease do not as a rule present serious symptoms until rather later in life and they are never so feeble as the infant with pyloric stenosis, provided that medical treatment has not been persisted in too long. I believe that an ileo-colostomy would give temporary relief and tide the patient over for 1 or 2 years until the radical operation could be performed.

I append a table shewing the chief findings at the post-mortem examination of 19 cases, and a short account of the cases treated by Mr. Arbuthnot Lane by anastomosis and resection.

I am much indebted to the Medical Committee of the Hospital for Sick Children, Great Ormond Street, London, for permission to publish these cases.

Case	Sex	Date of onset of symptoms.	Age at death	Treatment.	Condition of colon	Condition of sigmoid	Condition of rectum
1. L.G. 1868	M	Birth	4*	Medical	'Con- tracted'	Dilated & Hyper- trophied.	Not stated
2. H.J.D. 1891	M	Birth	3 mths.	Medical	Hypertro- phied & Dilated.	Hypertro- phied & Dilated. Ulcerated	Thickened & narrowed. 2" above anus cir- cular thickening 1/8" in extent.
3. F.S. 1894	M	Birth	3	Medical	Distended	Distended	Distended to 3" from anus.
4. T.S. 1895	M	Birth	5 mths	Medical	Hypertro- phied & Distended	Hypertro- phied & Distended Kink at pelvic brim.	Normal.
5. C.F.C. 1895	F	Birth	4 mths	Medical	Dilated & slightly hypertro- phied.	Elonga- tion of Mesentery	Not stated.
6. C.F.G. 1897	M	Aged 6 mths	3 yrs 9 mths	Medical, Colos- tomy.	Distended & slightly hypertro- phied	Distended Hypertro- phied. Ulcerated	Distended & Hyper- trophied to anus.
7. H.F. 1899	M	Birth	4 yrs 9 mths	Medical	Dilated & Hypertro- phied. Ulcerated	Ditto.	Much hyper- trophied down to anus
8. S.H. 1899	M	Birth	4 mths	Medical	Dilated & Hypertro- phied	Dilated & phied. Thick- ness increased progressive- ly towards	Hypertro- phied. Thick- ness increased progressive- ly towards rectum.
9. H.L. 1904	M	Birth	3 wks	Medical	Dilated & Hypertro- phied	Dilated & Hypertro- phied.	Not stated
10. A.R. 1905	M	Birth	10 wks	Medical	Slightly dilated	Dilated, Thickened Ulcerated.	Dilated & Thickened

Case	Sex	Date of onset of symptoms.	Age at death	Treatment	Condition of colon	Condition of sigmoid	Condition of rectum.
11. C.B. 1905	M	Not	10 mths	Died on admission	Dilated	Dilated	'Ballooned'
12. A.S. 1905	F	Birth	1 yr 3 mths	Ileum anastomosed to rectum	Hypertrophied.	Hypertrophied.	2" from anus circular band $\frac{1}{4}$ " thick.
13. J.S. 1908	M	Birth	2 mths	Medical	Hypertrophied	Hypertrophied	Last part of rectum quite thickened.
14 V.R. 1908	F	Aged 2 months	4 mths	Died on admission.	Enlarged	Much enlarged.	Hard & thickened in lower part. Hypertrophy of circular coat.
15. F.C. 1908	M	Birth	11 mths	Colostomy Ileo-sigmoidostomy.	Dilated & Thickened	Dilated & Thickened	Dilated & Thickened to 4" from anus.
16. I.R. 1909	M	Birth	2 yrs 7 mths	Resection of 1 ft. of sigmoid	Distended Thickened	No	note
17. D.S. 1910	M	Birth	3 yrs 8 mths	Appendicostomy	Dilated and Hypertrophied.		Normal
18. E.H. 1911	M	Aged $3\frac{1}{2}$	4 yrs	Medical	Distended	Greatly distended & some hypertrophy.	Greatly hypertrophied.
19. R.L. 1912	M	Birth	12	Resection of colon	Dilated and hypertrophied	Hypertrophied	Very dilated and hypertrophied to anus.

Case 1. R.L. M. aged 12 was admitted to the Hospital on August 18th 1912. He had had difficulty with his bowels all his life and had never had a motion without medicine and injections. The abdomen had gradually become more distended. He occasionally had abdominal pain. 3 weeks was the usual interval between the motions. He was a well developed but thin boy with the usual signs of intestinal toxæmia. The abdomen was very large and was so tense that nothing definite could be palpated. On rectal examination the finger passed into a huge cavity filled with faeces. Enemata produced no result. A bismuth meal and radiograms showed enormous distension of the colon and rectum. *Photo B.*

On October 1st Mr. Lane operated. On opening the abdomen the pelvic colon 8" in diameter presented. The ileum was divided and the proximal end implanted low down into the beginning of the rectum. The pelvic colon was then cut across above the junction and the entire large bowel removed. The vessels of the colon were of a remarkable size. The operation had practically been completed and had been exceedingly well sustained when an alarming haemorrhage took place from slipping of the ligature on the left colic artery. It was controlled with great difficulty and the patient lost much blood. His condition became at once grave, but improved with intravenous saline.

Unfortunately he never rallied from the severe haemorrhage and died on the 3rd day following operation. Post-mortem there was no peritonitis. All the parts were healing satisfactorily. The rectum was found to be enormously hypertrophied, more so than the pelvic colon. (see photo ~~A~~)

Case 2. E.W. M. aged 6 was transferred from a medical ward on Oct. 24th 1912. He had been constipated since birth but symptoms had only become more troublesome during the past year. Medical measures had failed to relieve him at all. His abdomen was distended. The enlarged colon and rectum could be palpated and were rendered evident by bismuth radiograms. On October 25th Mr. Lane divided the ileum and implanted the proximal end into the upper end of the rectum. He was greatly relieved by this operation and for some time passed normal stools but the tendency to constipation returned and on February 4th 1913 the entire large bowel down to the rectum was excised. There was practically no shock and he made a perfect recovery. His bowels have been acting normally since the operation.

Case 3. H.B. M. aged 10½ was admitted on January 3rd 1913. He had always been constipated. He had never had proper control of his bowels since infancy. At

times the abdomen was very large. The abdomen was exceedingly tense and protuberant. There was tenderness in the left iliac fossa. On rectal examination a very dilated rectum was palpated. The bismuth radiogram confirmed this and showed great enlargement of the transverse, descending, and pelvic colon. On February 28th Mr. Lane excised the large intestine and implanted the ileum into the rectum. Recovery was excellent and 1 month after operation defaecation was normal.

Case 4. I am unable to give the notes of this case.

It was that of a boy aged 6 with well marked symptoms of Hirschsprung's disease. In November of last year at Toronto Mr. Lane performed a similar operation to the one above described, excising the whole of the colon. An excellent recovery was made and 4 months after the operation I was informed that his condition was excellent.

REFERENCES.

- | | |
|---------------------|---|
| Hirschsprung | Jahrb. f Kinderheilk. 1888. |
| Jayle | Presse Med. Paris. 1909. XVII. 813. |
| Finney | Surg.Gyn.Obstet. 1908 VI. 6. |
| Treves | Lancet. 1898. I. 276. |
| Wilkie | Ed.Med.Jl. 1909 ii & Oct. 1910. |
| Fenwick | B.M.J. 1900 ii 564 |
| Barling | Lancet. 1913 i. 231 |
| Duval | Revu de Chirurg. Paris. 1909 XL. 506 |
| Lowenstein | Centralb. f Allg. Path. 1907 XVIII. 929 |
| Terry | Jl.Am.Med.Assn.Chicago. 1911. LVII 731 |
| Cheadle | Lancet. 1898 i. 399 |
| Fletcher & Robinson | B.M.J. 1907 i. 370. |

A.

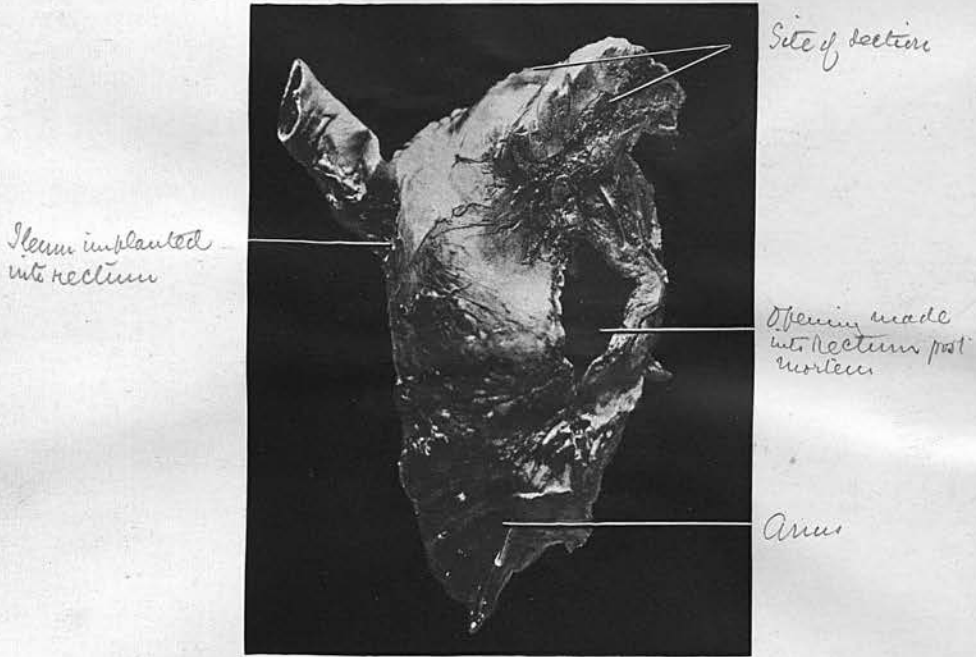
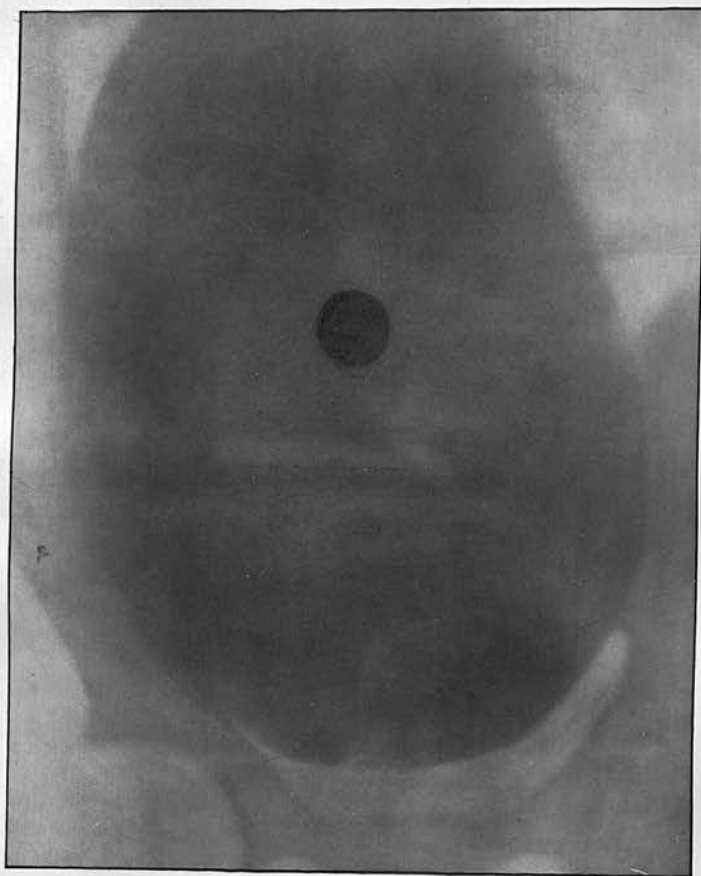
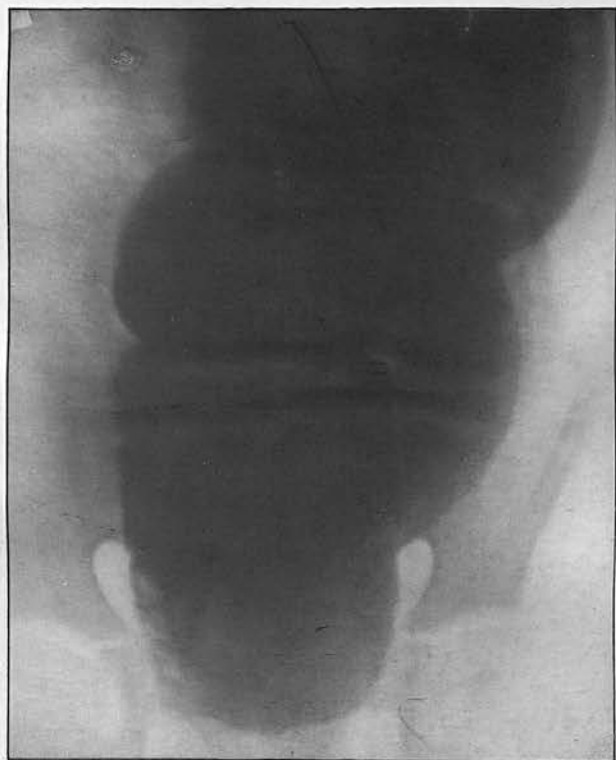

Fig 02 - Specimen

B

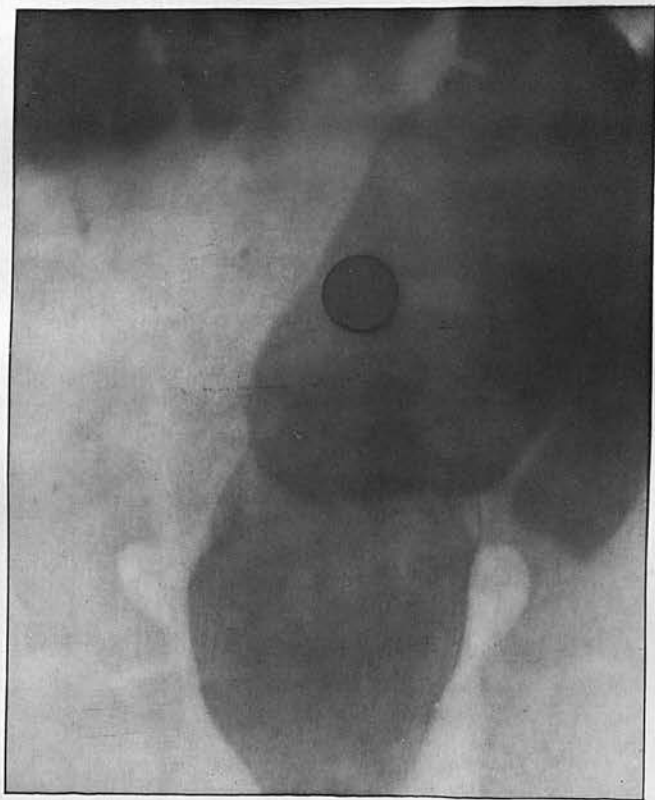


C



8

D



E

