

PHOTOGRAPHS AND PHOTOMICROGRAPHS

illustrating the Thesis on

CHOLESTEROSIS OF THE GALL-BLADDER;

A Clinical and Experimental Study.

---

Presented for the Degree of

M.D.

by

C.F.W. ILLINGWORTH,

M.B., Ch.B., F.R.C.S.E.

---



VOLUME II.

---

Fig. 1.

Photograph of a "Strawberry" Gall-bladder (Sir Harold Stiles's case). The ridges in the mucous membrane are seen to be very extensively loaded with masses of yellow lipoid. In this case the whole of the surface of the gall-bladder is affected. At the commencement of the cystic duct, however, the infiltration stops abruptly; the duct itself is free from lipoid.

---

Fig. 2.

Photograph of the same case, somewhat more highly magnified. The ridges or "villi" of the mucosa are seen raised up and distended by masses of lipoid.

---

Fig. 3.

Photograph of another "Strawberry" Gall-bladder (Professor Wilkie's case). In this case the lipoid infiltration is not so extensive or so massive. Delicate, prominent mucous ridges at the fundus and over the body of the gall-bladder contain yellow lipoid. The infiltration diminishes in extent towards the neck and is absent from the cystic duct.

---

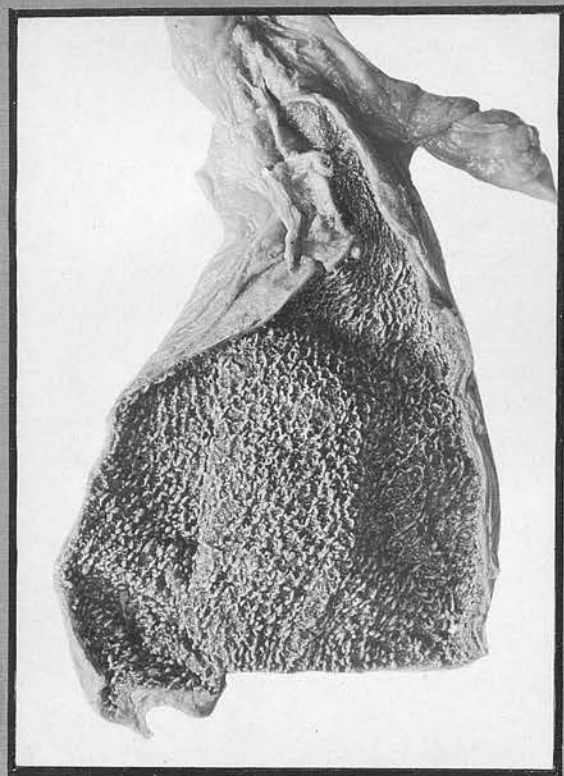


Fig. 1.

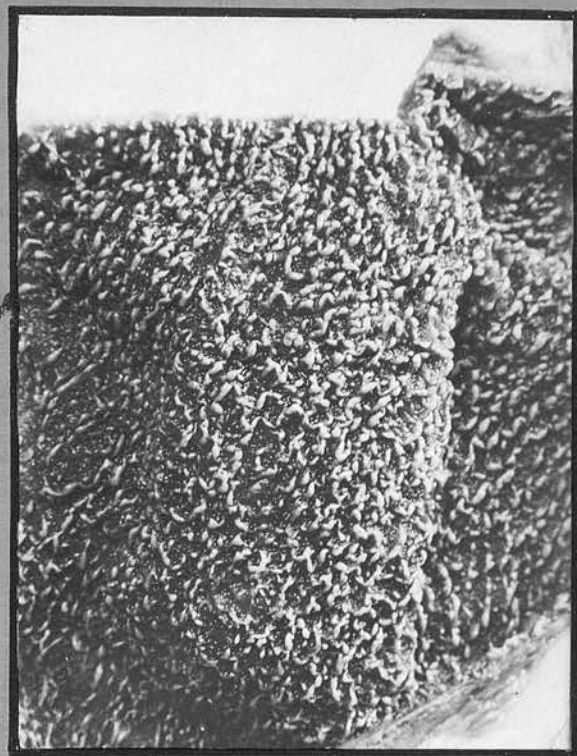


Fig. 2.

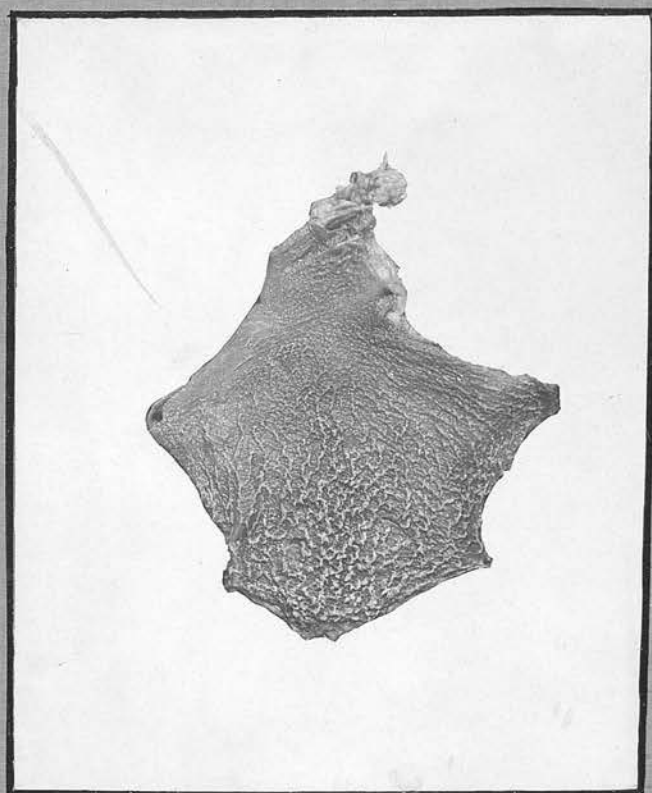


Fig. 3.

Fig. 4.

Photograph (from a painting) of a "Strawberry" Gall-bladder. Over the somewhat congested mucous membrane of the mid part of the gall-bladder are scattered numerous tiny yellow specks, like the "seeds" of a strawberry. In addition, one large pedunculated "Cholesterol polypus" is present (towards the left of the specimen).

---

Fig. 5.

Photograph of a "Cholesterol Polypus". This polypus, which is approximately 0.5 cm. in length, is attached to the subjacent mucous membrane by a very delicate thread of tissue. It is lobulated, and consists almost entirely of yellow lipid material. The remainder of the wall of the gall-bladder appears healthy.

---

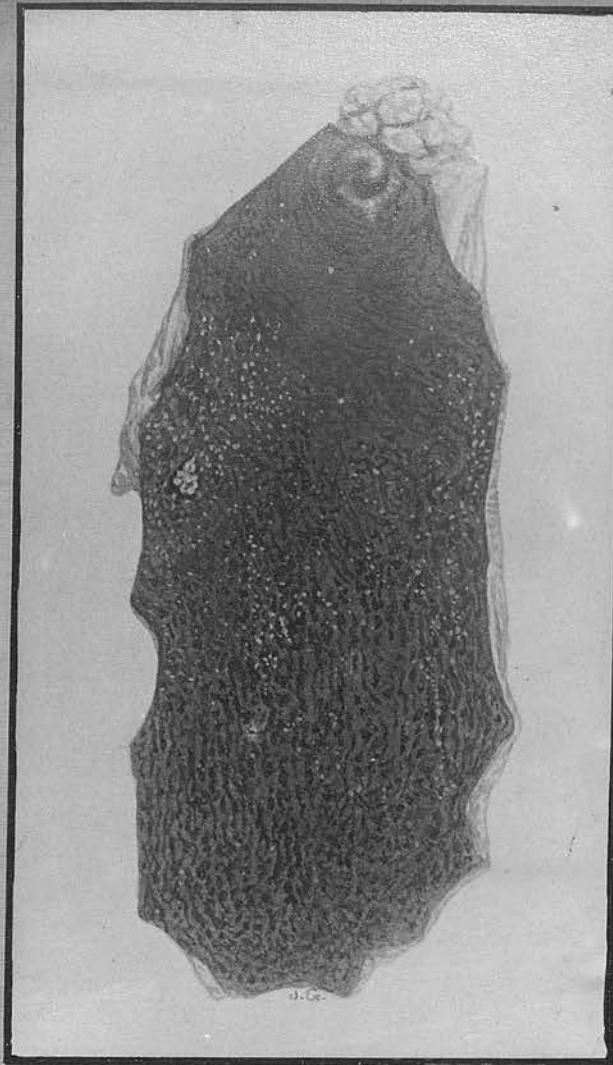


Fig. 4.




Fig. 5.

Fig. 8.

Photomicrograph of a Section of a "Strawberry" Gall-bladder (Paraffin Section, stained H. and E.).

Low Power View. The ridges or "villi" of the mucosa are raised up and swollen out, so that they almost look like air balloons attached to the subjacent wall by delicate strands of tissue.

---

Fig. 9.

Photomicrograph from the same section as in Fig. 8.

High Power View. Note the intact, healthy epithelium, and the large pale foamy cells of the stroma. (The multi-nuclear area on the left represents a tangential section of a portion of the epithelium.)

---

Fig. 10.

Photomicrograph of another "Strawberry" Gall-bladder (Paraffin Section, stained H. and E.). In this case, in addition to lipoid infiltration, there is an extreme epithelial hyperplasia. This appears to be a manifestation of a mild inflammation and not directly related to the cholesterol deposition.

---

Fig. 11.

Photomicrograph from the same section as in Fig. 10. A leash of foamy cells is seen extending down the base of a villus and at one part (on the left) penetrating between the muscular bundles.

---

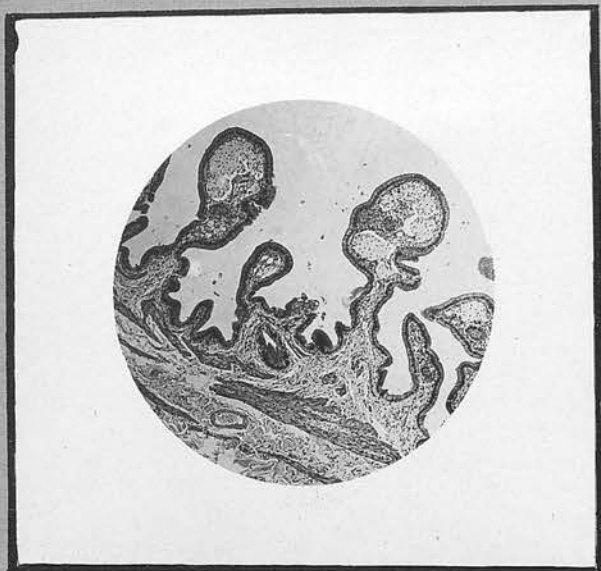

Fig. 8.

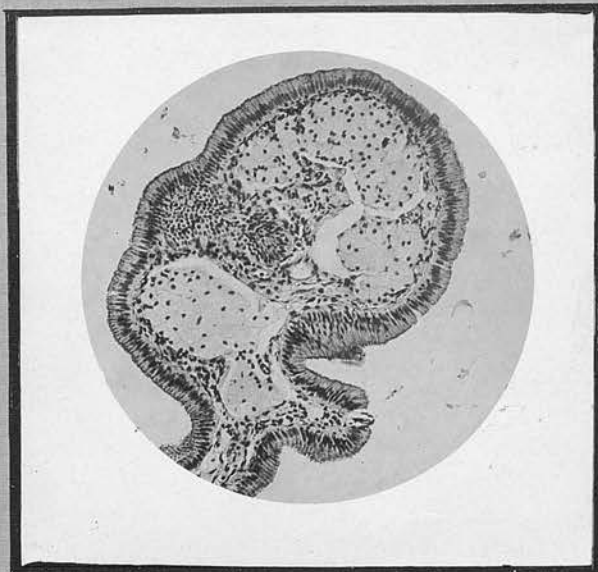

Fig. 9.

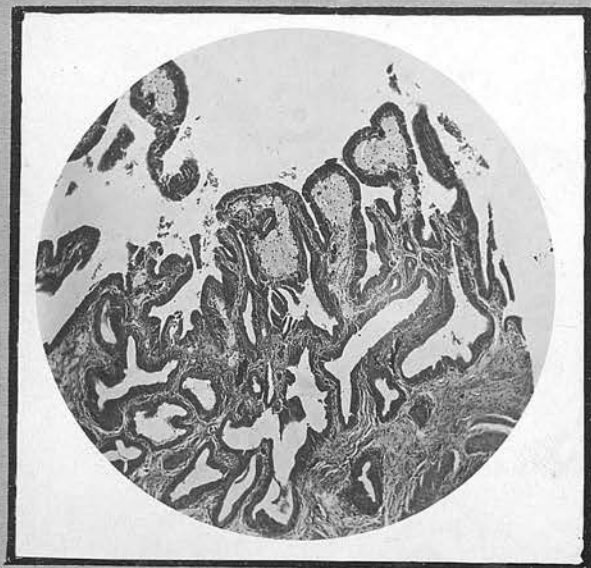


Fig. 10.

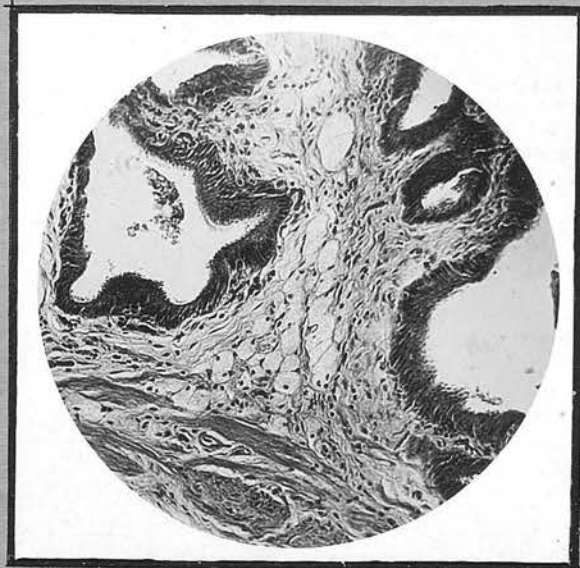

Fig. 11.

igs. 17, 18 and 19.

Photomicrographs of a section of a "Cholesterol Polypus" (Paraffin Section, stained Haematoxylin and Eosin).

Fig. 17. (Low Power)

There is a very marked epithelial hyperplasia affecting the adjacent mucous membrane. The Polypus, consisting almost entirely of large fat-laden cells, is seen attached to the subjacent mucosa by a delicate stalk.

Figs. 18 and 19. (Higher Power)

These show the characteristic histological features of the polypus. It is mainly composed of a mass of foamy cells, supported in a loose connective tissue reticulum and with extremely scanty blood vessels. The epithelium is largely desquamated.

---




Fig. 17.

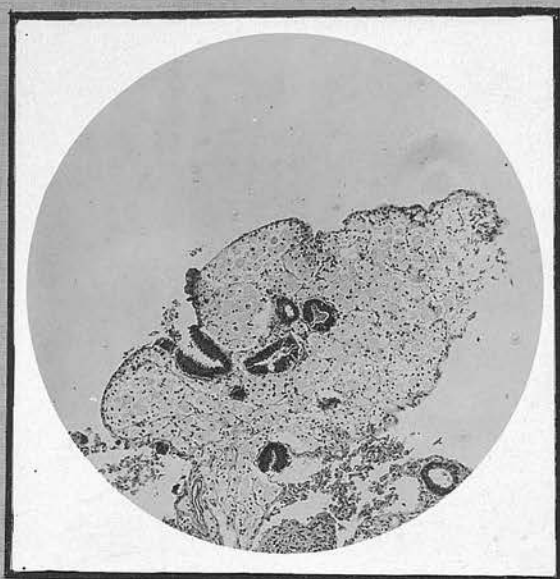


Fig. 18.

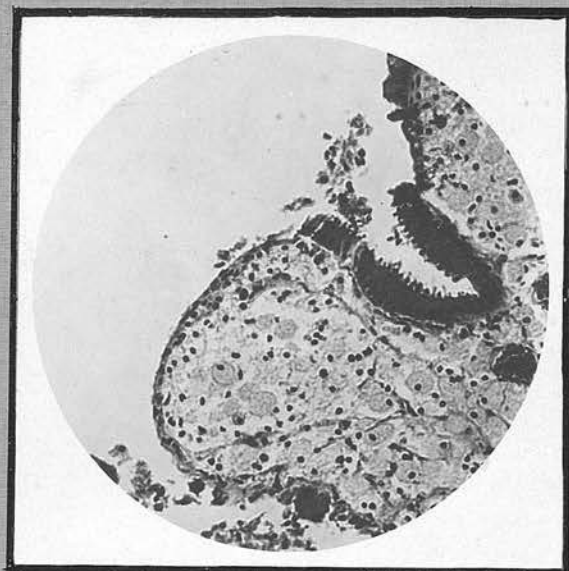


Fig. 19.

Fig. 20.

Photomicrograph from a Section of a "Strawberry" Gall-bladder (Paraffin Section, stained Haematoxylin and Eosin).

In sections from this case there is no trace of evidence of chronic inflammatory changes. In spite of large collections of lipoid-containing cells, the wall of the gall-bladder is extremely thin and appears healthy.

---

Fig. 21.

Photomicrograph from same section as in Fig. 20.

Note how foamy cells occupy the whole stroma of the villus, with very scanty vascular supply and no inflammatory infiltration.

---

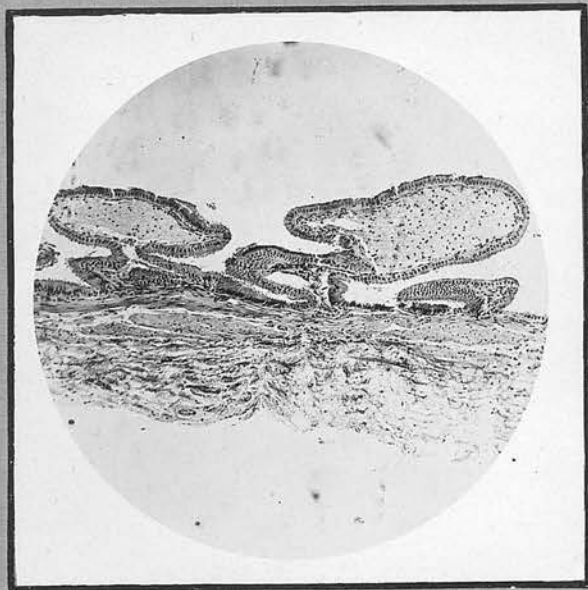


Fig. 20.

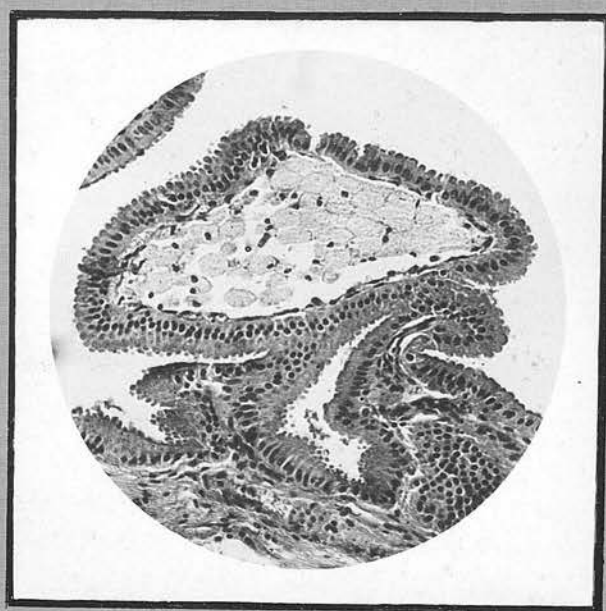


Fig. 21.

Figs. 24 and 25.

Photomicrographs of Lung of a Cat.  
(Paraffin Section, stained Haematoxylin and Eosin).

These sections illustrate a remarkable degree of atheroma in pulmonary arteries of a cat, which for a prolonged period had been fed with cholesterol.

Numerous foamy cells have appeared in the intima, encroaching upon the lumen and eventually (Fig. 25) almost occluding it completely. In Fig. 24 disintegration of the internal elastic lamina is clearly seen.

It is interesting to note that pathological change in the lungs of the cat was entirely confined to the vessels. No cholesterol deposits were observed in the bronchial walls and the parenchyma was unaffected.

---

Fig. 26.

Photomicrograph of the Spleen of the same Cat.  
(Paraffin Section, stained Haematoxylin and Eosin).

Foamy cells containing lipid are seen in small numbers situated close to the capsule of the spleen.

---

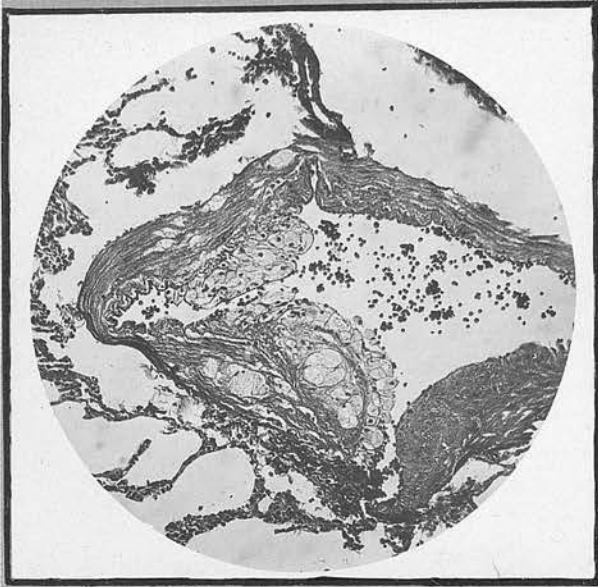


Fig. 24.

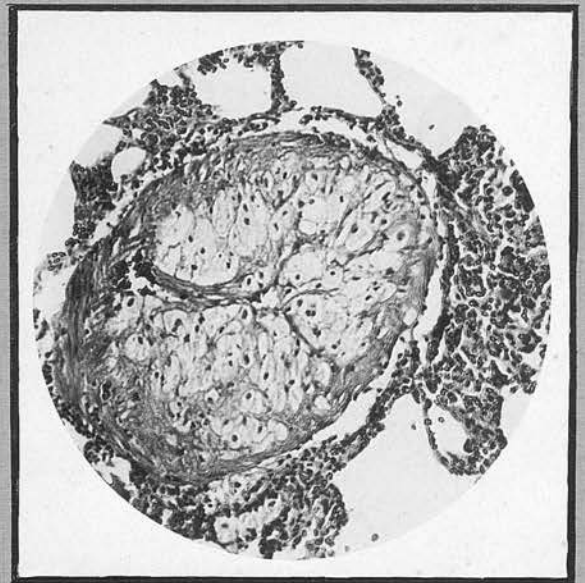


Fig. 25.

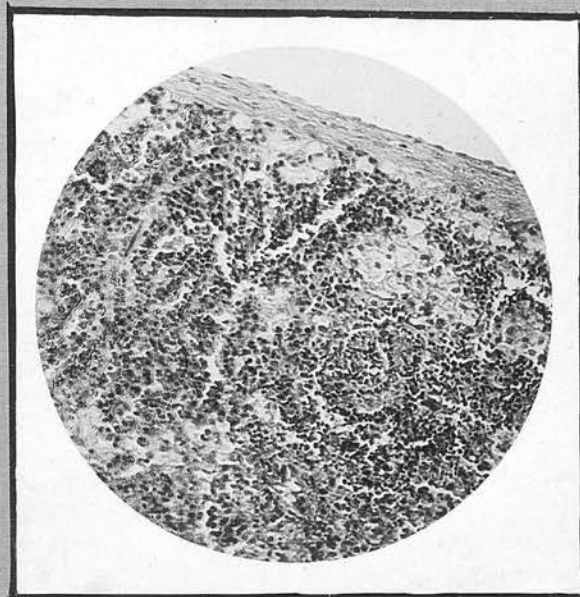


Fig. 26.

Fig. 29.

Photograph of the Gall-bladders of two Rabbits.

That on the left is a normal rabbit's gall-bladder, photographed for comparison.

That on the right illustrates the experimental production of Cholesterosis. Cholecystitis was induced in a hypercholesterolaemic cat by the introduction, into the layers of the wall of the gall-bladder, of a suspension of avirulent streptococci. The photograph shows how greatly the prominent yellow ridged mucosa resembles that of a "strawberry" gall-bladder.

---

Fig. 30.

Photograph from a coloured drawing of a section from the same gall-bladder. (Frozen Section, stained Sudan IV.).

Masses of scarlet lipid (anisotropic cholesterol esters) are present in the epithelial cells and the stroma of the villus.

---

Fig. 31.

Photomicrograph of Section of the same Gall-bladder (Paraffin Section, stained Haematoxylin and Eosin).

Note prominent villi distended by numerous foamy cells. There is a mild round-celled infiltration and some fibrosis of the fibromuscular and subserous coats of the gall-bladder wall.

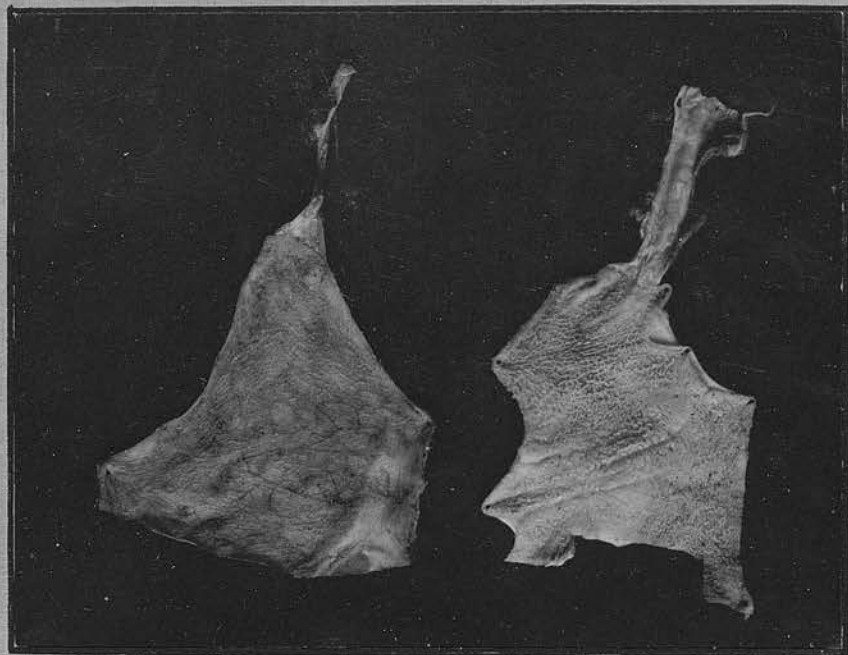


Fig. 29.

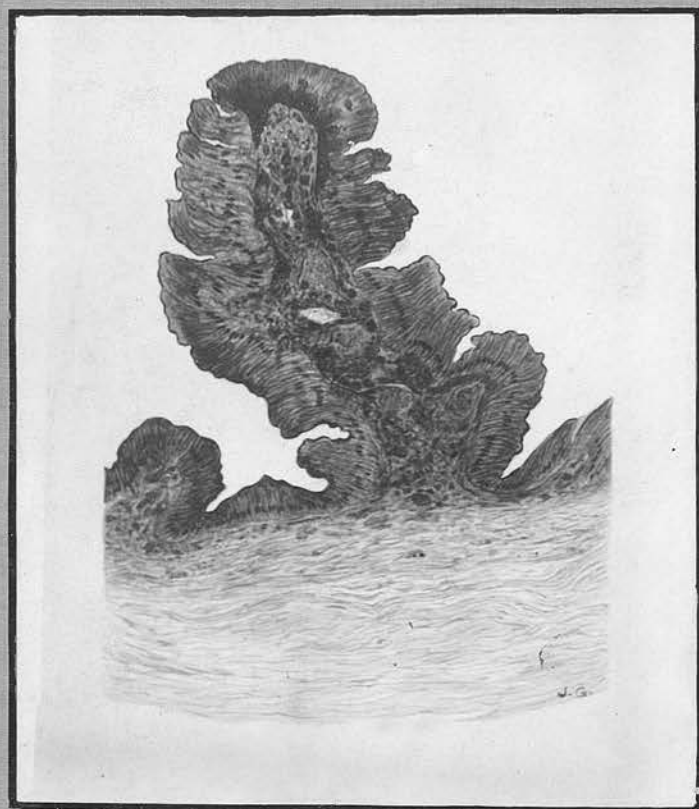


Fig. 30.

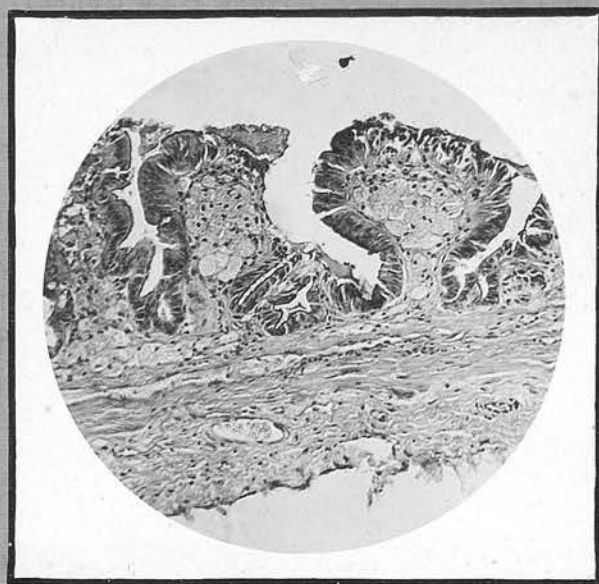


Fig. 31.

Fig. 32.

Photomicrograph of the Gall-bladder of a Cat  
(Frozen Section, stained Sudan IV.)

This photograph and the next demonstrate the absorption of fatty substances from the bile by the mucous membrane of the gall-bladder. In this case the gall-bladder was filled with oleic acid, the cystic duct being ligated to prevent emptying. In the section of the gall-bladder, removed two days later, large amounts of scarlet-stained fatty acid were seen in the epithelial cells of the mucous membrane, having obviously been absorbed from the lumen. In control experiments, in which no oleic acid was placed in the lumen, no fatty absorption was seen.

---

Fig. 33.

Photomicrograph of the Gall-bladder of a Cat.  
(Frozen Section, stained Sudan IV.).

This illustrates an experiment somewhat similar to that shown in Fig. 32. In this case, however, butter was injected into the gall-bladder, and the common bile duct was ligated. Large masses of fat are seen to have been absorbed into the epithelial cells.

---

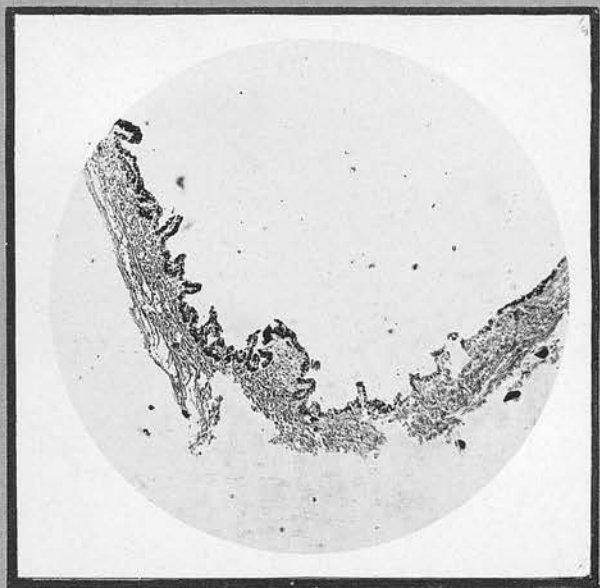


Fig. 32.



Fig. 33.