UNIVERSITY OF EDINBURGH.

THESIS FOR THE DEGREE OF D. Sc.

Part II.

ON THE DEVELOPMENT OF THE HIND-BRAIN OF THE PIG.

By O. Charnock Bradley. M.B., Ch.B. (1900).
Research Student in the University of Edinburgh
during Winter Session 1900-1901; Summer
Session 1901 and Winter Session
1901-1902.

ON THE DEVELOPMENT OF THE HIND-BRAIN OF THE PIG.

By O. Charnock Bradley.

Probably because the description given by the late Professor Wilhelm His of the development of the human hind-brain was so clear and detailed, only a comparatively small number of investigators, during the past twenty years, have turned their attention to this province of mammalian embryology. Nevertheless, in the somewhat sparse literature which does exist, several questions of importance have been raised, and conflicting opinions expressed. To mention only one point of surpassing interest and importance, all are not agreed as to the formation, degree of development and histogenetic function of a rhombic lip (Rautenlippe) in the embryos of mammals other than Man. There are those who are not satisfied as to its formation even in the human embryo.

In the conviction that the examination of even isolated species of mammals may afford additions to the sum of facts from which valuable generalisations may be deduced, it was decided to investigate some of the steps of the development of the hind-brain of the pig.

In most cases two embryos, of equal size, were chosen from the same litter; the one being sectioned in a sagittal, the other in a coronal direction. In the case of the younger material more than two embryos were examined.

With the exception of two embryos, where such a proceeding was not deemed necessary, models were made, according to Born's wax-plate method, of the hind-brain of all the different stages herein described. In many instances it was considered advisable to make two models from the same embryo; one of the whole hind-brain, and another of part of this organ under greater magnification. By this means, it is hoped, greater accuracy of description has been attained.

The following table shows the material employed in the research:-

	Age of embryo.	Length of embryo.	Models.
1.	19 days.		(1) x 50. (2).x 100
2.	22 days.	8 m.m.	(1) x $41\frac{2}{3}$ (2) (part) x $83\frac{1}{3}$
3.	25 days.	15 m.m.	(1) x $41\frac{2}{3}$ (2) (part) x $83\frac{1}{3}$
4.	28¼ days.	23 m.m.	(1) x $27\frac{7}{10}$ (2) (part) x $83\frac{1}{3}$
5.	30 days.	25 m.m.	(1) x 18 (2) (part) x $35\frac{5}{7}$
6.	35 days.	32 m.m.	(1) x 18 (2) (part) x $35\frac{5}{7}$
7.		37 m.m.	
8.		43 m.m.	
9.	40 days.	52 m.m.	(1x $35\frac{5}{7}$
10.	48 days.	80 m.m.	x $26\frac{6}{7}$
11.	55 days.	100 m.m.	x $35\frac{5}{7}$
12	70 days.	150 m.m.	(part) x $71\frac{3}{7}$

Although the "age" of the different embryos is given above, it is not intended that this should signify more than the length of time which elapsed between the time of coition and the time when the mother was destroyed. An examination of Keibel's Normentafel (1) shows that coition and fertilisation of the ovum are not by any means contemporaneous, or even approximately so in the pig. In embryos taken from two litters, it not infrequently happens that those which should be farther advanced in development, judging from the period which has elapsed since sexual congress took place, are as backward as, or even more backward than those of the "younger" litter.

GENERAL DESCRIPTION.

19 days embryo.

In the embryo pig taken from the uterus 19 days after coition the hind-brain is still in a rudimentary condition. The Fissura rhombo-mesencephalica (Kupffer) is distinct, and the cervical flexure is well marked; but the pontine flexure has only begun to be formed (Fig. 1). The hind-brain, as a whole, is in the form of a slightly bent tube, the calibre of which is greatest at about the junction of the anterior third with the posterior two-thirds. The roof of the tube is membranous from the cervical flexure to within a short distance from the constriction which marks the anterior limit of the hind-brain. The cerebellum is very rudimentary and indeed is difficult of accurate definition. Immediately behind the Fissura rhombo-mesencephalica there is a short non-membranous dorsal union between the two halves of the neural tube; but, with the exception of this the primitive Anlagen from which the future cerebellum arises are only connected by the Membrana obturatoria quarti ventriculi (Kölliker) (Fig.9).

Transverse sections taken anywhere, except at the most anterior part of the hind-brain, present a remarkable similarity, whether they are from the medulla or the region of the cerebellum. It is noteworthy that, though alar and basal laminae are clear and distinct in the spinal cord and in the mid-brain, it cannot be said that they are precisely defined in any part of the hind-brain. In fact the hind-brain at this stage consists of two lateral plates (Fig. 10), diverging from each other more and more as the widest part of the neural tube is approached, but joined ventrally at an acute angle which is indicated on the surface of the model by a median ventral ridge, which, though more pronounced in the region of the future pontine flexure, can be readily traced all the way from the cervical to the cephalic flexure.

From the above it will be seen that there is practically a uniformity of construction of the whole of the hind-brain at this period of development.

In this embryo there are seven neuromeres lying between the cephalic and cervical flexure (Fig. 2). Attention has been called to these structures elsewhere (2). It is, therefore, unnecessary to give more than a brief account of them here.

The interior of the neural tube presents seven grooves, of unequal extent and depth, corresponding to elevations on the exterior. Following the lead of previous observers, these grooves, with the external elevations produced by them, are held to indicate the presence of neuromeres. Longitudinal sections show that the height of the ridges separating the neuromeral grooves are often disproportionate to the depth of the constrictions between the external elevations (Fig. 11).

The first neuromere is large and from it the cerebellum arises, as has been shown by Orr (3), Hill (4) and Kupffer (5). The seventh neuromere is second in point of size and has a deep and extensive internal depression. Whether it is a neuromere of the hind-brain or of the spinal cord may be open to question, since Hill, after careful examination of the neuromeres of fishes and the chick, has announced it as his conviction that there are never more than six neuromeres in the rhombencephalon.

22 days embryo.

In the hind-brain of an embryo 22 days old the cervical flexure is more abrupt, and the pontine flexure is better marked than in the 19 days embryo (Fig.3). The two lateral parts of the cerebellum have increased in size,and their median connection is more extensive. As a consequence of these developments, the outline of the membranous roof of the ventricle (Rautenfeld) has changed. Those lateral borders of it which lie in front of the greatest transverse width of the rhombencephalon are now convex towards the middle line, instead of concave as previously. This, and the subsequent changes in the outline of the "Rautenfeld", are similar to those figured by Grönberg as occurring in Erinaceus (6).

The distinction between alar and basal laminæ can now be traced from the spinal cord into the medulla, but only for a short distance. The median ventral ridge, spoken of in connection with the younger embryo, is now confined to the district occupied by the pontine flexure and the isthmus rhombencephali, but in this situation it is even better marked than previously.

Seven neuromeres can still be detected (Fig. 4). Their internal depressions are deep and very clear, but the corresponding external elevations and the intervening constrictions have become very faint. The seventh depression is more shallow than before, and the sulcus between the alar and basal laminae (Sulcus limitans) is continued into it.

This embryo taken in connection with the younger one shows, in a very clear manner, the nerve-connections of the neuromeres. Stated briefly these are as follows. The N. trigeminus arises primarily from the second neuromere, but establishes a secondary connection with the third also. The acustico-facialis root-complex is associated with the fourth neuromere; and the glossopharyngeus and vagus with the sixth and seventh neuromeres respectively. The nerve-relationship, as here stated, is almost in entire accord with the description given by Prenant (7) of the condition found by him in a 14 m.m. pig embryo.

In the 22 days embryo the otic vesicle lies opposite the fifth and the greater part of the sixth neuromere. In the 19 days embryo it did not extend so far backwards, and it is, therefore, concluded that the real relationship of the vesicle is with the fifth neuromere; the association with the sixth being merely the result of expansion of the vesicle.

A more detailed description of the neuromeres is given in the paper already published.

Grönberg (6), in his description of the development of the brain of the hedgehog, attaches great importance to the appearance of two longitudinal grooves, lateral to the sulcus centralis, in the anterior part of the floor of the ventricle in the earlier stages of development. The more lateral of the two he considers to be the true Sulcus limitans. The more ~~lateral~~ central he holds to be only a secondary structure, and names it the Sulcus intermedius. This sulcus intermedius, however, he avers is equivalent to what His has recognised as the Sulcus limitans of the human embryo. Thus Grönberg desires to shift the sulcus between the alar and basal laminae into a more lateral position.

A comparison of Fig. 14 (transverse section through the hind-brain of a 22 days pig embryo) with Grönberg's Fig. 59 (Taf. 18) reveals a strong likeness. Grönberg's figure is from a hedgehog embryo of about the same stage of development as the 22 days pig; and the section is from about the same level as that from which Fig. 14 was taken. Both figures show two apparently longitudinal grooves; but the model of the pig embryo discloses the neuromeral nature of the grooves. Is there not a possibility that the grooves in Grönberg's illustration, and called by him Sulcus limitans and Sulcus intermedius, may bear a like interpretation? This is merely a query, not an assertion. Nothing short of making reconstruction-models of the hind-brain of hedgehog embryos would justify one in saying that Grönberg's reading is not the correct one. At the same time it is strange that the two figures should be so much alike.

15 m.m embryo.

In an embryo 15 m.m long (25 days old) the pontine flexure is well marked (Fig. 5). This, in association with the increased size of the cerebellar lamina, has produced a great alteration in the shape of the outline of the Rautenfeld. It is now in the form of a triangle whose base, directed forwards, consists of a median notch flanked on each side by a convexity produced by the lateral portions of the posterior border of the cerebellum. Its posterior angle no longer quite reaches the cervical flexure; and, since the lateral recesses are beginning to form, its lateral angles are curved slightly forwards.

In addition to the increased antero-posterior dimensions of the lateral parts of the cerebellum, there has also been an augmentation of their thickness. The inner surface of each half is now convex; but this is not entirely due to an increase in thickness , for there has been a concomitant production of an external concavity. The median part of the cerebellum has begun to develope a marked convexity in the sagittal and also in the lateral direction; a condition of some moment, as subsequent development will show.

Immediately behind the posterior edge of the cerebellar lamina a choroidal fold has begun to form. This begins laterally in the neighbourhood of the incipient lateral recess, and is continued for more than two-thirds of the distance between this point and the middle line. Something less than the median third of the border of the lamina shows no sign of folding.

The median ventral ridge, present in the earlier stages, has entirely disappeared, and has given place to a shallow groove continuous with the ventral groove of the spinal cord. This groove extends forwards to a level with the origin of the N. Trigeminus. Anterior to the origin of the N. acustico-facialis there is a low rounded ridge running along the floor of the groove.

Alar and basal laminæ can now be followed from the spinal cord into the medulla for about half the length of the ventricle, i.e. nearly to the most anterior root of the IX and X cranial nerves (Fig.16). Of the neuromeral grooves five are still evident(Fig. 6). The first, however, is shallow. The second is of good depth, and the ridge between it and the first is very prominent. The five grooves now present have the same nerve-relations as had the most anterior five of the seven in the earlier stages. The sixth and seventh neuromeres have, therefore, lost their internal grooves, and it appears that this has resulted from an anterior extension of the inter-zonal sulcus (Sulcus limitans). In support of this supposition may be cited the fact that the sulcus is much wider in the position of the former sixth and seventh neuromeres.

The fact that alar and basal laminae cannot be distinguished in the early rhombencephalon, and that, as growth proceeds, they gradually extend, as recognisable entities, farther forwards, appears to justify emphasis.

23 m.m. embryo.

The pontine flexure is so pronounced in this embryo that the floor of the ventricle slopes gently downwards and forwards from its posterior end to opposite the lateral recess (Fig. 7). Anterior to this it is inclined steeply upwards and forwards.

The lateral recess is now deep and clearly bounded. Its posterior limit has been defined partly as a consequence of the increase of the pontine flexure which has caused the ventricle to suddenly assume a much greater transverse diameter in front of the N. acustico-facialis; but partly, also, as the result of intrinsic development in this region. The cerebellum, because of its increase in size, and its greater backward projection produced by the accentuation of the pontine flexure, now completely roofs in the lateral recess.

The increase in the thickness of the floor of the ventricle has caused the distinction between alar and basal laminæ to become a matter of difficulty. But there is still a faint groove visible opposite the fasciculus solitarius.

It will be noticed that, in the pig, definite alar and basal laminæ separated from each other by a Sulcus limitans, have not been met with in the anterior part of the rhombencephalon. The farthest anterior point at which they can be distinguished is about the middle of the length of the ventricle, and this only in an embryo of 15 m.m. In younger material they cease to be obvious at a more posterior level.

Although the indications of neuromeres are generally held to disappear at a comparatively early period, there are grooves in this and older embryos which it is difficult not to consider as the direct descendants of the neuromeral grooves of younger embryos. A comparison of Figs. 6 and 7 will demonstrate the grounds for supposing that the grooves persist for a much longer time than is generally supposed. That grooves do exist in a 23 m.m. embryo is shown in Fig. 7, and these grooves- four in number -have the same topography as similar depressions in Fig. 6. If the grooves in the older embryo are not the descendants of those in the younger, it is strange that they should be so very similar in position and relations. Until the contrary is shown to be the case, the depressions in the 23 m.m. and older embryos will be described as being identical with those of the smaller embryos.

The first and second depressions are partly combined, i.e. they are now included in one large concavity; but their individuality is not completely lost: the grooves which extend laterally from them into the lateral recess of the ventricle are quite distinct from each other. The second depression is much deeper than the first.

At this period of development the third groove has gained the supremacy so far as depth is concerned. There is still a fourth depression, shallow and indistinct; and into it runs the possible representative of the Sulcus limitans. Microscopic sagittal sections suggest the presence of even a fifth depression but concerning this there is some room ~~of~~ for doubt.

25 m.m embryo.

In an embryo only 2 m.m longer than the one just described (25 m.m., 30 days old) the pontine flexure has attained its maximum curvature. From this time onwards the flexure gradually becomes more obtuse. The extreme degree of the flexure at this period produces a great exaggeration in the depth of the median fissure of the ventricle on a level with the lateral recesses. These latter are now very definitely bounded; above by the cerebellum, and below in a manner presently to be described (Figs. 38 and 39).

The connection between the two halves of the cerebellum has increased in thickness in its anterior portion. Posteriorly it gradually thins away. The lateral halves of the cerebellum are still concave on their outer surface; this being in striking contrast to a convexity occurring in the median region (Fig. 39).

By this time the choroid plexus is well formed, and is disposed in a curve whose concavity looks forwards.

Of the depressions considered in the last embryo as vestiges of the neuromeral grooves, four can still be distinguished. Internal to the opening from the body of the ventricle into the lateral recess, the first and second grooves are more blended than in the 23 m.m. embryo. But into the recess itself they can readily be traced as separate entities (Figs. 40 and 41).

Their relative position, however, has been altered owing to the increase of the pontine flexure. The first groove now lies at a higher level than the second, instead of being directly anterior to it (Fig. 41).

The third groove is still deep in the body of the ventricle, but it is with difficulty followed into the recess (Fig. 43). The fourth groove is faint and indistinct, and can only be satisfactorily demonstrated in sagittal microscopic sections.

32 m.m embryo.

The rhombencephalon of this embryo shows several features of interest. The pontine flexure is less abrupt. The transverse and vertical diameters of the medulla are much greater than those of the spinal cord, the change occurring rather suddenly at the cervical flexure. The fourth ventricle fails to reach the cervical flexure; that is the intercalated portion of the medulla (His' Schaltstück) has definitely begun to form. The dorsal median fissure of the spinal cord is continued into this part of the medulla, but becomes gradually shallower as it passes forwards. A short distance behind the posterior tip of the ventricle the bottom of the dorsal median fissure developes a ridge to which attention will directed later (Fig.44

Viewed from the surface, the two halves of the cerebellum do not meet at so sharp an angle as formerly. The outer surface of each half has still a slight concavity about its middle (Fig. 52), but its posterior portion is decidedly convex (Fig. 51). The external convexity of the median region of the cerebellum, which has made its appearance in the previous embryos, is now very prominent, but does not extend backwards as far as the posterior border of the cerebellum (Figs. 51, 52 and 53). Viewed from the inside, the two halves of the cerebellum are separated by a median sagittal fissure which is very deep on a level with the external convexity just mentioned (Fig. 53). This fissure has taken the place of a wide groove, previously present, corresponding to the thin median connection of the two moieties of the cerebellum. The change from a fairly wide groove into a contracted cleft has doubtless been due to two factors. In the first place, the outward bulging of this part of the cerebellum, without a commensurate increase in vertical thickness, must have contributed to the deeping of the groove. Secondly, the lateral walls of the groove have become steeper and taller because of the increase in thickness of the lateral halves of the cerebellum, and the resulting increase in the internal convexity of these parts.

In the posterior part of the cerebellar lamina, and in the wider part of the fissure just described, a prominent ridge has made its appearance (Fig. 51). This, however, disappears as the deeper, more anterior, portion of the fissure is approached. The occurrence of this ridge is no doubt associated with the initiation of the process of filling up of the fissure. It is of interest to note that Schaper (8) figures a similar, if larger ridge at the bottom of the "Medianfurche" (ventral surface of the "Deckplatte) in trout embryos (cf., for example, his figure 28). It may be remarked that a similar ridge is present (and was also visible in the 25 m.m. embryo) at the bottom of what may for convenience be called the ascending (anterior) portion of the median fissure (Sulcus centralis) in the floor of the ventricle (Fig. 53). Even in the 23 m.m. embryo the precursor of this ridge can be detected (Fig. 28).

It should be here noted that, at no time in its development, does the cerebellum of the pig present the internal features described by Kölliker (9) as occurring the the rabbit. Kölliker remarks that frontal sections reveal, on the under (inner) surface of the developing cerebellum, a deep median fissure and two lateral fissures. This surface, therefore, he says, has four longitudinal ridges running along it; of these the more lateral are the largest. This declaration is supported by the figure of a frontal section (Fig. 338) through the cerebellum of a 16 days rabbit embryo. In its lack of the lateral fissures, the pig resembles the sheep (cf Kuithan's figures).

The general character of the lateral recess has not altered materially, though its roof and floor are nearer together owing to the increase in thickness of the cerebellum by which the roof is formed. Owing to a diminution in the transverse diameter of the ventricle just behind the opening into the recess, the isolation of the latter is rendered more conspicuous.

In the body of the ventricle there is one shallow depression occupying the same relative position as the first and second grooves described in preceding paragraphs as neuromeral in origin. From this depression a deep furrow runs outwards into the lateral recess, in the outer and anterior part of which it divides into two, thus, possibly, indicating its duplex constitution. The third groove is of great depth in the body of the ventricle, and can readily be followed into the lateral recess.

52 m.m. embryo.

In the next older embryo (40 days) the intercalated part of the medulla has materially increased in extent. The cerebellum has developed rapidly and, examined from the exterior, now shows a division into an elementary vermis and two lateral hemispheres. The vermis is most markedly developed anteriorly, where it forms a rounded projection overlying the rudimentary anterior medullary velum and extending for some distance in front of the anterior limit of the hemispheres. This early indication of a vermis seems to militate against Bolk's contention that such a part of the cerebellum is not a fundamental division (10).

There can be little doubt that the vermis has sprung directly from the median convexity present in the earlier embryos; thus the median thin portion of the cerebellum only produces a very small part of it; almost the whole of it being developed from the more mesial parts of the lateral halves of the cerebellar lamina.

The transverse measurement of the cerebellum is much greater than that of the underlying portion of the rhombencephalon (Figs. 67 and 68). The sulcus, which has been previously described elsewhere (11) as demarcating the nodulus and flocculus from the rest of the cerebellum, is now present. The deep sagittal median fissure found on the inner surface of the cerebellum in the previous embryo has become a veritable cerebellar ventricle (Fig. 68), such as has been already described in mammalian embryos by Blake (12). This narrow cavity extends forwards into the anterior projection of the vermis, so that its communication with the rest of the fourth ventricle is directed downwards and backwards, as Figs. 68, 69 and 70 would lead one to conclude. In the depths of this cerebellar ventricle there is still a trace of the median ridge already mentioned.

The under surface of the anterior medullary velum is marked by a sagittal furrow which may be looked upon as a shallow forward continuation of the fissure out of which the cerebellar ventricle has developed (Fig. 70).

It is perhaps worthy of remark that, where the cerebellum joins the floor of the fourth ventricle, a ridge has made its appearance (Fig. 70).

In the posterior part of the floor of the fourth ventricle the lateral halves of the medulla are inclined to each other at a very acute angle, a condition which has been gradually evolved since the earlier stages. A ridge can still be distinguished at the bottom of the median fissure in the anterior part of the ventricle (Figs 66, 67 and 68), but this is the oldest embryo in which such a feature was found.

The depression occupying the position of the first and second neuromeral grooves is becoming very indistinct. The third groove, on the other hand, is still deep and very evident in the body of the ventricle, and is continued into the lateral recess as a conspicuous furrow.

The opening from the ventricle into the lateral recess has become both relatively and absolutely narrower.

80 m.m. embryo.

The cerebellum in an 80 m.m. embryo (48 days) has an unmistakable vermis and two lateral hemispheres. Fissures are beginning to separate its lobes: the nodulus and flocculus being already completely isolated from the rest of the cerebellum. The cerebellar ventricle has, to a large extent, become filled up, but it is not as yet completely obliterated. Where the cerebellum meets the floor of the ventricle there are now three short ridge-like elevations in the place of the one in the younger specimen.

The groove occurring on the under surface of the anterior medullary velum is now very shallow.

The floor of the ventricle has altered scarcely at all in the interval between 40 and 48 days. The third neuromeral groove is still represented by a deep depression in the body of ventricle; but it now lies at a level slightly in front of the opening into the lateral recess, whereas, formerly, it was on a level with this opening. This change of position is to be associated with a backward growth of the anterior wall of the recess, rather than to a forward movement of the depression. The subsequent history of the third neuromeral groove shows that there is little reason to doubt that it becomes the anterior fovea of the floor of the fourth ventricle. And it may be again repeated that, if the depression is not really a persisting neuromeral groove, there is nothing in the series of embryos examined which militates against the contention that it is so.

100 m.m. embryo.

The third neuromeral depression io still deep and occupies a position considerably anterior to the opening into the lateral recess, into which no continuation of ~~it~~ can now be demonstrated.

The three ridge-like eminences at the junction of the cerebellum with the floor of the ventricle are more prominent than in the earlier stage. The anterior medullary velum is thin; its ventricular surface showing a median sagittal keel, corresponding to a dorsal furrow. There is still a trace of the cerebellar ventricle.

THE RHOMBIC LIP.

In 1888 His (13) called attention to a folding over of the dorsal edge of the alar lamina which he named the "Rautenlippe" and to which he attached great importance as a factor in the development of certain portions of the medulla, and especially of the cerebellum of man. He stated that this rhombic lip begins to form, in the human embryo, at the beginning of the fifth week, and that it extends from the cervical flexure to the isthmus rhombencephali; in some places being larger, in others smaller.

Since the publication of His' paper several observers, working at the development of the hind-brain in different mammals, have arrived at diverse conclusions as to the formation and significance of the rhombic lip. Herrick (14) figures it as of extensive development in the guinea-pig, and dilates upon its high position as an agent in the formation of the cerebellum.

Dexter (15), on the other hand, avers that, in the rabbit, there is no trace of it. Kuithan (16) also, after following the development of the cerebellum of the sheep, expresses himself as doubtful of the occurrence of a rhombic lip.

Blake (12), in 1900, claimed that it is present in several mammals -pig, sheep, cat and rat- and gave an illustration of a transverse section through the hind-brain of an embryo rat (3 m.m. long) which certainly closely resembled some of the figures given by His. Blake stated that "hitherto it has not been demonstrated in the lower mammalia", and suggested that this omission may be due to the fact that "it is probably extremely transitory in an unfused condition".

Grönberg (6), writing still ~~some~~ more recently, and basing his statement on the examination of Erinaceus embryos, speaks in no uncertain voice against the occurrence of a rhombic lip. Not only does he deny its presence in hedgehog embryos, but he even seriously questions its formation in Man.

So far as Man is concerned, the occurrence of a rhombic lip may be assumed to be proved. In regard to its presence in the embryonic brain of the lower mammals, there is not yet sufficient evidence to prove that it is universal, or even common. For this reason considerable attention has been paid to the condition of the dorsal border of the alar lamina in the hind-brain of the pig embryos employed in this research. And the following has been found to obtain.

In the youngest embryos the edge of the alar lamina passes in a simple manner into the membranous roof of the ventricle. No indication of an outward folding is to be observed in any part of the rhombencephalon of the 19 and 22 days embryos. In the next older embryo (15 m.m.) there is a considerable difference. In the most posterior part of the medulla the upper border of the alar lamina is no longer thin, but has become thick and rounded, forming an apparent equivalent to

His' "Flügelwulst"; along the lateral margin of which the memmranous roof of the ventricle is attached (Fig. 16). When sections are followed forwards it is found that, not only is the border of the lamina rounded, but there is also the appearance of an outward bending. That is to say, there is distinct evidence of the formation of a rhombic lip, with a well-marked outer, and a shallow inner, "Lippenfurche". This is well seen on a level with the otic vesicle (Fig. 17). Towards the anterior limit of the vesicle the folding over almost entirely disappears, to be again well developed as soon as the vesicle is completely passed. On a level with the origin of the root-complex of the N. acustico-facialis there is a slight diminution in the size of the lip; a diminution doubtless associated with the exit and entrance of nerve-fibres at this point (Fig. 18). Immediately in front of this root the lip assumes its maximum development; both its outer and inner "Lippenfurchen" being deep (Fig. 19). The root of the N. trigeminus is connected with another diminution in the size of the lip; which is once more clearly marked externally in the region of the lateral recess, the outer "Lippenfurche" being continued slightly beyond the anterior limit of the recess (Figs 5 and 20).

The neuromeral grooves cross the "Flügelwulst", so causing the production of a number of rounded eminences.

With certain reservations, it may be said that, so far as concerns the rhombic lip, sections through the hind-brain of this embryo bear a marked resemblance to the figures given by His of a five weeks human embryo. There is, however, none of that flattening of the medulla, at the widest part of the ventricle, so conspicuously present in Man. There is, further, as has been previously stated, no clear distinction of alar and basal laminae in the widest part of the medulla.

It is not possible to follow the rhombic lip for even the shortest distance onto the cerebellum in this stage.

A considerabe advance has been made in the growth of the rhombic lip between the 15m.m. and the 23 m.m. stages. In a 23m.m. embryo the lip is again poorly developed in the posterior part of the medulla; and fusion is apparently taking place between it and the wall of the brain-tube (Figs. 25 and 26). Opposite the anterior part of the otic vesicle it would be difficult to say that a rhombic lip had ever existed where it not for the evidence afforded by the younger embryo. In connection with the lateral recess, on the contrary, the lip has grown considerably and now forms a substantial floor to the recess (Figs. 30 and 31). This region obviously corresponds to the district in which the lip was greatest in the 15 m.m. embryo.

At this stage there are unmistakable traces of a folding of the edge of the cerebellar lamina; but in no part is it so well marked as was formerly the case in the medulla.(Fig. 32). A cerebellar rhombic lip can be detected in both transverse and sagittal sections, the latter showing that it is best marked in the region of the lateral recess. As sections are followed towards the middle line the lip becomes gradually less and less, but does not entirely disappear until the median plane is closely approached.

In the posterior part of the medulla of a 25 m.m. embryo there is a thickened hem appended to the border of the former alar lamina, and to it the membranous roof is attached. This hem is sharply marked off from the rest of the wall of the ventricle by an internal furrow, above which a rounded ridge-like prominence (Figs 36 and 37). The furrow began to appear in the 23 m.m. embryo (cf. Fig. 25), and it does not seem altogether unreasonable to compare it with a groove figured by His (Fig. 18 (13)) as being present in a five weeks human embryo internal to the "Flügelwulst". If such a comparision be allowed, then the rounded ridge above it must be the remains of the "Flügelwulst". However this may be, the hem itself may be considered the representative of the rhombic lip; Blake having shown that, in the lower animals, it has such an appearance.

In connection with the latersl recess the rhombic lip continues to grow both in thickness and also in an outward direction (Figs. 38 and 39). Attention has already been called by Blake to the important role played by the lip in the formation of the recess, and the material at present described lends support to his statement. It should be added that the N. acustico-facialis has established a close connection with the ventral wall of the recess so formed (Fig. 39).

There is still a slight trace of a rhombic lip in connection with the cerebellum in the 25 m.m. embryo, but this is the latest stage in which it can be detected.

As has been previously stated, the most posterior portion of the medulla has become "closed" in the 32 m.m. embryo; this "closed" segment being provided with a dorsal median furrow. Just before the central canal opens up into the ventricle, a ridge makes its appearance in this furrow (Fig. 44). If this be followed forwards it is found to be continuous with rhombic lips such as were described in the 25 m.m. embryo (Figs. 45 et seq.). That is to say, the closure of the medulla has been caused by the fusion of the lips of the two sides. From this point the rhombic lip can be easily followed forwards. It presents an appearance not unlike that of the next younger specimen, and gradually increases in size as the entrance to the lateral recess is approached (Figs. 48 and 49).

A slight exaggeration in the thickness of the lip is shown in Fig. 49. This follows upon a narrowing of the roof of the ventricle just behind the opening into the recess, which causes the lip to incline inwards and forwards. Sections of it, therefore, are cut somewhat obliquely. The obliquity of section, however, does not account for more than a comparatively small part of the width of the lip as illustrated.

That part of the rhombic lip which is associated with the lateral recess has increased in thickness as well as in lateral dimensions. Consequent upon the addition to its width, the lip is now folded farther over the side of the medulla; but there is still no very remarkable degree of fusion between the medulla and the lip. The independence of the two structures is well shown in Figs. 49 and 50. Fig. 49 also demonstrates that the lateral recess is growing backwards beyond the level of its aperture of communication with the body of the ventricle, and that the N. acustico-facialis is now closely associated with the rhombic lip.

The "closed" part of the medulla has increased in length in the 52 m.m. embryo. As in the younger specimen, there is a dorsal median fissure in this region. And, again, before the central canal opens out into the fourth ventricle, a low rounded ridge appears in the fissure, thus materially reducing its depth (Fig. 54).

In transverse sections there is an area of tissue, differing structurally from that adjacent to it, stretching from the surface of the medulla down to the central canal, and corresponding in lateral extent to the width of the ridge at the bottom of the dorsal fissure (Fig. 54). This has evidently been produced by the fusion of the rhombic lips; for the examination of serial sections shows a continuation of this area with lips such as were seen in the 32 m.m. embryo (Figs. 54 and 55).

The disposition of the epithelium over the rhombic lip in the neighbourhood of the posterior end of the ventricle is noteworthy. Immediately upon the opening up of the central canal to form the fourth ventricle, i.e. as soon as the area of fusion of the rhombic lips is past, the epithelium, though of the same thickness over the greater part of the wall of the ventricle as in the central canal, becomes remarkably thin over the lips (Figs. 55, 56 and 57). This peculiarity is retained for some distance forwards. Afterwards the lip carries as thick an epithelium as the rest of the interior of the ventricle.

Just as the opening into the lateral recess is being arrived at, there is again a conspicuous increase in the size of the rhombic lip (Fig. 65), a condition not demonstrable in older embryos. That part of the lip which assists in bounding the recess is beginning to lose its hitherto remarkable independence.

The series of figures, 72 to 77, illustrates the appearance of the central canal in an 80 m.m. embryo. About the junction of the spinal cord and the medulla the canal is of fair width, and, judging from the arrangement of the epithelium, is undergoing constriction by fusion of its wall both dorsally and ventrally. If the canal be followed forwards, it is first observed to narrow (Fig. 74); and then its lateral walls appear to fuse about their middle, thus producing the appearance of two canals - a dorsal and a ventral (Fig. 75). Into the dorsal canal projects a slight dorsal ridge of epithelium. Still farther forwards the dorsal canal enlarges -the ridge of epithelium being still present- and finally appears to form the single central canal which opens into the ventricle. Though this is the appearance presented by sections, it is very doubtful if there is even an attempt at fusion of the lateral walls of the canal. Some sections, which had doubtless been rather roughly handled in preparation, show the walls separated from each other by a very narrow chink.

This condition of the central canal would not have been so fully described were it not that Balfour (17) was originally of opinion that diminution in the size of the cent~~ar~~ral canal of the cord was produced by a median coalescence of its walls. It was thought that here was possibly an appearance similar to that which led Balfour to his conclusions.

A dorsal median fissure in the "closed" part of the medulla is not present in the 80 m.m. embryo. Its place is taken by a triangular area of tissue, scantily provided with nuclei, which represents the fused rhombic lips (Fig. 77). At the apex of the ventricle the lips no longer project from the edge of the medulla; but their extent is determinable as a sparsely nucleated area continuous with the similar field just mentioned as occurring in the "closed" segment of the medulla (Fig. 78).

In veiw of the condition exhibited by the older material, it is well here to call attention to the fact that there is a manifest thickneing of the epithelium about the lower limit of the fused rhombic lips (Fig. 78 and 79). Over the major part of the lip the epithelium is almost as thin as was found to be the case in the next younger embryo.

On passing forwards the pale area gradually disappears, and the rhombic lip forms a projection such as has been ~~nees~~ seen previously (Figs. 80 and 81).

Fusion between the lateral recess and the medulla still goes on, but there is no difficulty in seeing the line along which it has taken place (Figs 82 and 83).

In the embryo 100 m.m. in length there is again a trace of a dorsal median groove in the most posterior part of the medulla (Fig 84). As stated above this was not to be found in the 80 m.m. embryo. It appears possible, therefore, that it is a new formation produced by inequalities in the rate of growth of different parts of the medulla. As the groove runs forwards it becomes obliterated by the presence of a pale triangular area such as was seen before (Fig. 85). Careful measurements show that the area increases in both its lateral and vertical dimensions as it is followed forwards. Its continuity with the rhombic lips is as it was in the younger embryo (Figs 85, 86 and 87). Contrary to the condition present in younger material the bulk of the rhombic lip diminishes as the opening into the lateral recess is approached (Figs. 87 and 88).

The character of the central canal in the 100 m.m. embryo, and its modifications as it opens into the ventricle, seem worthy of note. Some little distance (less than 300 μ) before the canal reaches the ventricle, it has the form of a moderately wide vertical slit with a median constriction, but no approximation of its lateral walls such as was seen in the last embryo (Fig. 84.). (The constriction is greater in a section 140 μ farther forwards than the one from which this figure was made). This constriction produces the appearance of two dilatations in the canal. Nextly the slit is elongated by the occurrence of a third dilatation dorsal in position (Fig. 85). Lastly a cleft sunders the two halves of the pale area which represents the fused rhombic lips. At the upper edge of the third dilatation, and about the lower limit of the rhombic-lip-area is a thickened patch of epithelium such as was seen before (Fig. 86).

The manner in which the central canal comes to an end differs somewhat in a 150 m.m. embryo. In this specimen the pale triangular area is present on a level at which the canal is still small; that is, the third dilatation mentioned in the preceding paragraph has evidenly been obliterated by the coalescence of the dorsal part of the walls of the canal. The area itself is even more obvious than before, on account of its marked vascularity. (Blake has directed attention to the fact that the extent of the fused rhombic lips can be determined by the greater vascularity of the area of tissue so produced). In addition it forms a prominent dorsal projection in transverse sections (Figs. 93 and 94). In this specimen the antero-posterior diameter of the area is absolutely less than it was in the 100 m.m embryo. In the latter it measured 252µ from its most posterior recognisable limit to the point of separation of the two rhombic lips. In the 150 m.m. embryo it only measures 204µ between similar points. This circumstance indicates a gradual loss by the area of its distinctive histological characters; this change occurring first posteriorly and advancing towards the apex of the ventricle. The area clearly forms the obex of the adult brain.

As the central canal is entering the ventricle it shows the constriction noted in the 100 m.m. embryo; but the third -most dorsal- dilatation is replaced by a rounded ridge on each side of the canal. This is the funiculus separans of Retzius (Fig. 8); and the two funiculi blend posteriorly in such a manner that there is a slight backward prolongation of the ventricle above them (Figs. 8 and 94). The more dorsal of the two dilatations of the central canal is continued into the ventricle as the ala cinerea (Fig. 8). The rhombic lip passing forwards from the obex forms the area postrema, which becomes gradually smaller and more and more separated from the bulk of the medulla. A little behind the opening into the recess it is very small and forms a narrow projecting lip; and just as the opening is reached it can hardly be said to be present at all.

That the rhombic lip is an important factor in the formation of the tuberculum acusticum has been claimed by Blake. The present research lends support to this claim (Figs. 97 and 98).

From what has been said above, it follows that the rhombic lip of the pig differs somewhat from the like structure in Man. From the time of its earliest appearance it is much more perfectly formed in the region of the lateral recess. In the posterior part of the medulla the lip is small in the younger material, but attains a good development later. In the middle district of the medulla there is an imperfect development of the lip during the whole embryonic life. Immediately behind the opening into the lateral recess the lip is large enough to be remarkable during the earlier stages covered by the material at present considered; but later this comparative prominence is lost (cf. Figs. 65 and 88). At no period is the folding over of the lip so great as has been described by His as occurring in the human embryo. There is never even an approach to the condition as depicted in His' Fig. 16 (18). It is difficult to imagine that the rhombic lip of the pig froms the olivary bodies &c.; at any rate in the manner as related by His. It seems more probable that the fasciculus solitarius becomes buried as the consequence of migration of neuroblasts independent of the formation of a rhombic lip. This would harmonise with the inability of Grönberg and Dexter to find the lip in the hedgehog and rabbit.

Further, it cannot be claimed that the lip plays more than a very small part in the formation of the cerebellum of the pig. The cerebellar rhombic lip appears later than the medullary lip; is very much smaller; does not reach the middle line; and all traces of it are soon lost.

It must be concluded, therefore, from these observations on the pig, and from the published results of other investigations, that a rhombic lip is not invariably present in mammals, and, when present, is not so important a factor in the development of the medulla as it is in man. In connection with the cerebellum its morphologic value is small.

THE CEREBELLUM.

Since the earliest observers were of the opinion that the hind-brain presented a yawning cleft in its roof during the first stages of its development, it was natural that they should conceive the cerebellum as arising from a pair of lateral Anlagen which, gradually growing towards each other, ultimately fused in the middle line. This view originated, according to Mihalkovics, with Fracassati (19), and was acquiesced in by all subsequent writers up to the time of the appearance of the first edition of Kölliker's Embryology (9). Tiedemann (20), Serres (21), v. Baer (22), Valentin (23), Schmidt (24) and Kollmann (25) were of this opinion.

Kölliker gave pause to the prevailing theory when he described the cerebellum as developing as a thickening of the roof of the most anterior part of the hind-brain; the thickening soon attaining the form of a transverse plate. Mihalkovics (26) followed Kölliker in considering the cerebellum to grow out of a transverse curved "Kleinhirnlamella". Lahousse (1888, (27)) and Hertwig (1893 (28)) are examples of moderns who hold with an unpaired cerebellar Anlage.

Most recent writers, however, describe a pair of lateral Anlagen. Goronowitsch (29) so represents the development in Acipenser. Schaper (8) believes that the cerebellum of Teleosts springs from a bilaterally symmetrical Anlage.

Stroud (30) doubts whether the cerebellum as a whole grows out of a thickening occurring in the roof of the hind-brain at the constriction of the isthmus. If this transverse plate is the cerebellum, he asks "Where is the valvula?". He appears to incline to the view that the cerebellum proper developes from a pair of Anlagen which appear posterior to the thickening; summing up by saying, "The mammalian cerebellum is developed from the caudal part of the epicoelian roof".

Kuithan (16), fiom his observations on the sheep, is of the opinion that the embryonic cerebellum has at first an upaired Anlage; but later it passes through a stage in which paired Anlagen can be detected. Prenant (31) joins the ranks of those who adhere to the opinion that there are originally two lateral structures from which the cerebellum arises; and Grönberg (6) is led to the same conclusion by his examination of hedgehog embryos.

There appears to be sufficient justification for the assertion that the cerebellum of the pig developes from a pair of lateral Anlagen. The median connection present in the youngest embryo examined (19 days) is so thin that there appears to be no reason for considering it of more importance than the Deckplatte of the spinal cord. It is merely a connecting-link between the alar laminae of opposite sides of the rhombencephalon. Further, the connection so established is of short sagittal extent only.

The rudiments of the cerebellum which are present in the 19 days embryo are not marked off from the medulla by anything more than the occurrence of a maximum width of the brain tube. The main connection of the two halves of the organ is the thin membranous roof of the ventricle; each half having a median border which slopes gradually inwards as it is followed forwards. Speaking generally there is an interval between the two parts of the cerebellum in the form of a moderately elongated isosceles triangle whose base is formed by a line drawn transversely to the long axis of the rhombencephalon on a level with its widest part, and whose apex points forwards.

As development proceeds, the superficial area of the two moieties of the cerebellum increases; and their median connection is extended antero-posteriorly from an extension of their line of contact. The median connection, though gradually becoming thicker, does not do so in proportion to the increase in its sagittal extent. The consequence being, that, for a long time, the two halves of the cerebellum are joined to each other by a remarkably thin bridge, internal to which is a longitudinal fissure whose relative depth increases, rather than diminishes, up to a certain stage in development. How the fissure developes into a cerebellar ventricle, and how this is not entirely obliterated even in a 100 m.m. embryo, have been related.

Concerning the manner in which the originally thin median portion of the cerebellum increases in thickness, with a concomitant diminution in the depth of the internal longitudinal fissure, there has been some divergence of opinion. Kuithan inclines to the view that there is approximation of, and, finally, fusion between the two walls of the fissure. Grönberg, on the other hand, holds that Erinaceus embryos do not exhibit any fusion of the ependyma. Schaper, as the result of his investigations into the development of the cerebellum in teleostean fishes, concludes that the connecting lamina between the two lateral halves does not develope into typical cerebellar tissue.

The question is evidently not one to which a satisfactory answer can be readily found. In the embryo of the pig there is certainly some thickening produced by proliferation of cells within the median part of the cerebellum itself. But there is the possibility that these cells have migrated thither from more lateral areas. It is not without interest to note that a ridge is present, in certain embryos, at the bottom of the internal median fissure of the cerebellum (Figs. 51 and 68), not altogether unlike that which appears in the depths of the sulcus centralis of the floor of the ventricle.

The extraordinary uniformity in the architecture of the whole of the hind-brain in the youngest embryo recalls the question as to whether a division of the rhombencephalon into two distinct segments, as originally suggested by v. Baer, is based upon altogether good morphological grounds.

Edinger's assertion that the cerebellum is, in the highest probability, one of the oldest segments of the brain (32) does not remove the impression, gained from an examination of the literature, that the cerebellum is fundamentally merely a continuation of the posterior part of the rhombencephalon. Or, as Spitzka has expressed it, a dorsal hypertrophy of the hindbrain.

That the cerebellum in the lower animals is mainly, if not entirely commissural has been shown by the researches of Burckhardt (on Protopterus (33)), Osborn (on Cryptobranchus and Amphiuma (34)), Fish (on Desmognathus (35)), Kingsbury (on Necturus (36)) and others. This leads to the deduction that originally the cerebellum was not an important nerve-centre: its subsequent attainment to a high morphological position being due to an augmentation in volume and an elaboration of structure rendered necessary by physiological specialisation.

The structural continuity of medulla and cerebellum lends support to the hypothesis that they are merely different parts of the same brain segment. In 1888, Goronowitsch (29) made the statement that, in Acipenser, the molecular layer of the cerebellum (with cells of Purkinje) is continued over the tuberculum acusticum as a crest to which he gave the name of "Cerebellarleiste". A like condition has been found to obtain in Amia (Kingsbury (37)), Acipenser rubicundus (Johnston (38)), Mustelus (Houser (39)) and Petromyzon (Johnston (40)). Johnston, in particular, is very earnest in his insistence upon "the morphological unity of the dorsal horn, acusticum and cerebellum": a unity rendering a dividing line between the cerebellum and tuberculum acusticum an impossibility.

The relationship beween the tuberculum and the cerebellum is further shown by the fact that the N. acusticus has an end-station in both. This has been demonstrated by a multiplicity of observations upon all classes of animals. Of those to whom we owe knowledge of this fact may be mentioned Mayser (41), Goronowitsch (29), Johnston (38 and 40), Köppen (42), Edinger (43) Sala (44), Brandis (45), and Wallenberg (46). Even in Man himself, in whom the cerebellum has become most highly specialised, the vestibular nerve sends fibres into the cerebellum.

In view of the facts which have been accumulated, and which are still rapidly accumulating, there seems good reason for considering the cerebellum and medulla as parts of one and the same segment of the brain; even if we do not go so far as to say, with Haller (47), that beyond doubt the "Cerebellarleiste" and its associated cerebellum have developed from the outer sensory region of the medulla oblongata; thus reducing the cerebellum to the level of a mere appendage to the medulla. That even the latter, and more extreme conclusion is justified by some -not to say many- facts, may, however, be readily contended.

The problem being one of much complexity, and further evidence being still needed for its solution, it may be well to suspend judgement, and await further developments; concludind with Wilder (48) that there is no reason why we should not go on "entertaining and employing, *as a convenient "working hypothesis"**the interpretation made by v. Baer, and accepted by the majority of later authorities upon the subject", at the same time remaining alive to the possibility that the division of the rhombencephalon into two segments, though convenient, may not be strictly scientific.

---

*The italics are not in the original.

THE FORAMEN OF MAJENDIE.

A figure give by His (Fig. 33 (49)) shows the roof of the embryonic fourth ventricle to be of the same thickness throughout. In the process of development a relative thinning takes place, and it seems probable that, in some mammals at least, this continues until an actual break occurs at certain points of the roof, whereby the cavity of the ventricle is placed in communication with the subarachnoid space. That such a connection is established in man and the higher apes, at least, appears to have been proved beyond doubt by careful work recently undertaken. Whether all the apertures found in man occur with the same regularity in all mammals has not been so clearly demonstrated. The older methods of research were not such as lent themselves to proving or disproving the existence of small openings in so delicate a membrane as that which closes in the fourth ventricle. So long as the only method employed was that of ordinary dissection, it was only natural that different observers should arrive at different conclusions; the amount of tension requisite for the production of an artificial opening being so very small. Even when the process of embedding and cutting section in paraffin or celloidin is used the results may be untrustworthy if there has been any roughness indulged in during extraction of the brain from the cranium.

The only way by which all danger of producing artifacts can be obviated is by embedding and cutting the whole head: a matter of obvious difficulty in the case of larger animals. Embryos lend themselves much more readily to this method than do adult animals. But in the case of the use of embryonic material negative evidence is of greatly less value than positive. / If there be no opening found in the embryo it does not follow that there should also be none in the adult. It is easily conceivable that an intercommunication between the ventricle and the subarachnoid space may be formed after birth. If, however, an opening is found to be present in the embryo there is a strong probability of its being present in the adult also.

In the early part of last century, Burdach (50) described the hinder end of the roof of the fourth ventricle as being perfectly closed. But, in 1842, Majendie (51) pointed out that there is normally and constantly an opening in the roof of the human ventricle; this foramen being bounded by the choroid plexus and the posterior medullary velum, and its size differing very much in different individuals.

Since 1842 conflicting opinions have been expressed as to whether the Foramen of Majendie is an entity or a chimera. Virchow (52) denied the existence of any connection between the ventricle and the subarachnoid space. Luschka (53) succeeded in finding an opening in the Tela choroidea inferior in man; but added that in many animals the ventricle is closed. In 1861, Reichert (54) averred that the foramen is only produced during the process of removal and manipulation of the brain; whereas, in the same year, Kollmann (25) not only described the opening as being natural, but also stated in what manner it is bounded.

Quincke (55) saw in the foramen a very variable and not always demonstrable opening in the connective tissue of the roof of the ventricle. Key and Retzius (56) examined 100 human brains, and found a foramen of Majendie in 98 of them. Sée (57) declared himself on the side of those who denied the existence of the foramen, and stated reasons for his attitude. It is exceedingly easy, he said, to tear the fine membranous roof of the ventricle during the removal of the brain; in several animals, e.g. horse, goat &c, it has been shown that the ventricle is closed; and the overfilling and distension of the ventricle, as the consequence of pathological conditions, is not reconcilable with the acceptance of the presence of an opening. Kölliker (9) held that there is complete closure of the ventricle in the embryo, and that this is the rule in the adult also. The foramen of Majendie, when present, he said, is no regular structure.

In 1885 the problem was attacked by Hess (58). He examined the brains of 30 adult human beings, 10 new-born children and 7 embryos of different ages. In only one instance did he fail to find an opening. He came to the conclusion, therefore, that the foramen is constant in man. He thought that it is possible that there is always an opening in the roof of the embryonic ventricle, since at five months the aperture is wide. He also found a foramen in the embryo of the cat.

Later observations by Wilder (59), Morton (60), Jacobi (61), Kohlmann (62) and others appear to indicate that the foramen as described by Majendie is a natural opening in man at least. Cannieu (63) is not so sure of the presence of a normal opening in the lower mammals.

The subject has received very careful attention at the hands of Blake (12), whose results were published in 1900. He describes a protrusion of the roof of the ventricle in the form of a glove-finger-like projection, which remains closed in the majority of mammals, but becomes an opening in man and the anthropoid apes.

In the pig there is little that is remarkable in the changes which occur in the roof of the ventricle before the embryo has attained a length of 50 m.m. The only points which needs mention is the relative thickness of the roof in different regions. In all the younger embryos (except that of 19 days) an oval patch of the membranous roof differs from the rest in being noticably much thinner. This occurs about the centre of the "Rautenfeld", and can be distinguished as early as the 22 day. It is not due to a reduction in the number of the layers of cells forming the membrane, but rather to a flattening of the individual cells; for the zone immediately surrounding the patch is provided with no more than one layer of cells, as is the patch itself.

Transverse sections through the "closed" part of the medulla of an 80 m.m. embryo show a backward extension of the cavity of the ventricle into a membranous cul-de-sac, which lies on the dorsal surface of the medulla. At this stage the cul-de-sac is applied closely and is adherent to the medulla. Its extent, in a sagittal direction partly, and in the lateral direction entirely corresponds to the triangular area formed by the fused rhombic lips (Fig. 77). A younger embryo (52 m.m.) shows the commencement of this condition. It is evident that, as the rhombic lips fuse, there is not a corresponding diminution in the antero-posterior diameter of the roof of the ventricle; the "closed" medulla rather, in a sense, burrowing under the roof, and so causing the cul-de-sac.

The backward prolongation of the cavity of the ventricle is very definite in an 100 m m. embryo. It has assumed the form which may well be likened to that of the finger of a glove. It extends farther back than the caudal limit of the triangular area produced by the fusion of the rhombic lips.And it is now free; its caudal extremity being some distance removed from the surface of the medulla (Fig. 84).

A 150 m.m. embryo shows the same kind of protrusion, but now much better developed. It extends backwards almost to a level with the most caudal part of the cerebellum, and is, posteriorly, in even closer relation with the cerebellum than with the medulla. Although the walls of this caudal protrusion are thin, there is no indication of a foramen of Majendie.

The embryo of the pig, therefore, corroborates the statements made by Blake. And, it may be added, a careful examination of the adult brain leads one to assert that the protrusion never becomes an opening.

OPENINGS IN THE LATERAL RECESSES.

Although Bockdalek (64), in 1849, stated that the choroid plexus lies free under the arachnoid mater in the region of the "Füllhorn", the description he gave was not such as to cause modern morphologists to associate his name with the openings in the lateral recesses of the fourth ventricle.

Luschka (53), some years after the publication of Bockdalek's paper, described the outer angle of the ventricle as standing in connection with the subarachnoid space, and the lateral part of the choroid plexus as lying free under the arachnoid. This, however, was not supported by Reichert (54), who, after a minute description of the choroid plexus, concluded with the declaration that there is a membranous closure of the lateral recesses of the ventricle.

There seems little doubt that to Key and Retzius (56) should be given the credit of having provided the first clear and detailed description of the connection of the cavity of the ventricle with the subarachnoid space. Out of 100 human brains examined by them the communication was found in all but three.

Kölliker (9) expressed himself as convinced that the openings are even less of regular structures than the foramen of Majendie, which, as previously mentioned, he held to be usually absent. Hess (58) concluded that the apertures are constant in man. Bland Sutton (65) attached great importance to the openings, and stated it as his opinion that their complete absence, or their closure either before or after birth, leads to pathological results.

Morton (60) and Jacobi (61) have averred that the openings are normal and always present; whereas, Cannieu (63) casts doubt on their natural occurrence in the lower animals.

Blake (12) included the consideration of the occurrence of these openings in the paper to which reference has already been made. The results of his investigations are of great interest, since they indicate that the openings are always present in mammals, and are even larger in the lower animals than in man. It would appear that there is a kind of compensatory development. When the foramen of Majendie is absent the openings in the lateral recess are larger than when the foramen is present.

The first rudiments of lateral recesses occur in the 15 m.m. embryo of the pig, i.e. the same specimen in which a rhombic lip is first to be observed. From this stage onwards the recess is bounded ventrally by the rhombic lip. Its caudal boundary is very indefinite in the 15 m.m. embryo, but in the next older specimen (23 m.m.) this limit is clearly formed, for now the recess has a greater antero-posterior diameter than has its opening into the body of the ventricle. It extends farther back, as well as farther forwards, than the level of the bounds of the opening into it. There has been, therefore, a bulging backwards of the caudal wall of the recess. This disparity between the antero-posterior measurements of the recess and of its opening into the ventricle becomes exaggerated as development proceeds.

As early as the 23 m.m. stage the choroid plexus has invaded the recess (Fig. 30). In the 25 m.m. embryo that part of the plexus which invaginates the outer wall of the recess is more anterior in position than the portion of it which belongs to the body of the ventricle. Later the median part of the plexus grows at a greater rate than the lateral portion.

A very important process begins in the 80 m.m. embryo. The most posterior part of the recess in this specimen has very thin walls, consisting solely of very thin epithelium, which, over blood-vessels especially, can scarcely be said to be perfectly continuous (Fig. 81). There is, however, as yet no definite discontinuity of the epithelium. The rest of the wall of the recess is composed of thick nervous tissue except along the line of invagination produced by the choroid plexus (Figs. 82 and 83).

In the 100 m.m. embryo there is a wide area in the most lateral part of the posterior end of the recess from which the epithelium has entirely disappeared. In Fig. 88 the termination of the epithelium is shown to occur abruptly, the contour of the recess remaining imperfectly preserved by loose and delicate connective tissue. In some sections this tissue is more scanty and interrupted than is the case in the section from which the figure was made.

The break in the wall of the recess is complete in the 150 m.m. embryo (Fig. 97) and the communication between the cavity of the ventricle and the subarachnoid space is fully established. Sections taken farther back than the one illustrated in the figure show the choroid plexus lying free in the subarachnoid space at some little distance posterior to the caudal end of the recess. It seems worthy of not that the break in the wall of the recess does not occur along the line of invagination of the choroid plexus. Both Fig. 88 (100 m.m. embryo) and Fig. 97 (150 m.m. embryo) show that the opening has been produced by the thinning of the lower part of the outer wall of the recess.

The embryo of the pig, then, lends confirmation to the statement as made by Blake that, while a foramen of Majendie is wanting in the lower animals, openings of large size exist in the lateral recess.

REFERENCES.

A list of papers dealing with Neuromeres is given in the communication on the "Neuromeres of the Rhombencephalon of the Pig" (2).

(1). KEIBEL. F. Normentafel zur Entwicklungsgeschichte des Schweines. Jena. 1897.

(2). BRADLEY. O.Charnock. Neuromeres of the Rhombencephalon of the Pig. Rev. Neurol. & Psych. Vol. 2. 1904.

(3). ORR. H.B. Contribution to the Embryology of the Lizard. Journ. Morph. Vol. 1. 1887.

(4). HILL. C. Developmental History of the Primary Segments of the Vertebrate Head. Zool. Jahrb. Abth. f. Anat. U. Ontogenie. Bd. 13. 1900.

(5). v. KUPFFER. C. Die Morphogenie des Centralnervensystems. Handbuch der vergleichenden und experimentellen Entwicklungslehre der Wirbeltiere. Herausgegeben von Dr. O. Hertwig. Jena. 1903. Lief. 14-15 and 16.

(6). GRÖNBERG. G. Die Ontogenese eines niederen Säugergehirns. Zool. Jahrb. Abth. f. Anat. U. Ontogenie. Bd. 15. 1902.

(7). PRENANT. A. Note sur l'existence des replis médullaires chez l'embryon du porc. Bull. de la Soc. d. Sc. de Nancy. Ser. 2. T. 9. 1889.

(8). SCHAPER. A. Die morphologische und histologische Entwicklung des Kleinhirns der Teleostier. Morph. Jahrb. Bd. 21. 1894.

(9). KÖLLIKER. A. Entwicklungsgeschichte des Menschen und der höheren Thiere. Leipzig. 1861. 2te. Aufl. Leipzig. 1879.

(10). BOLK. L. Hauptzüge der vergleichenden Anatomie des Cerebellum der Säugetiere mit besonderer Berücksichtigung des menschlichen Kleinhirnes. Monatsch. f. Psych. u. Neurol. Bd. 12. 1902.

(11). BRADLEY. O.Charnock. On the Development and Homology of the Mammalian Cerebellar Fissures. Journ. Anat. & Phys. Vol. 37. 1903.

(12). BLAKE. J.A. The Roof and Lateral Recesses of the Fourth Ventricle. Journ. Comp. Neurol. Vol. 10. 1900.

(13). HIS. W. Zur Geschichte des Gehirns. Abhandl. d. math-phys. Classe d. k. sächs. Gesell. d. Wissen. Bd. 14. 1888.

(14). HERRICK. C.L. Illustrations of the Archetectonic of the Cerebellum. Journ. Comp. Neurol. Vol. 1. 1890.

(15). DEXTER. F. Ein Beitrag zur Morphologie der verlängerten

Markes beim Kaninchen. Arch. f. Anat. u. Phys. 1895.

(16). KUITHAN. W. Die Entwickelung des Kleinhirns bei Säugetieren. Münchener Medic. Abhandl. 7 Reihe. 6 Heft. 1895.

(17). BALFOUR. F.M. Comparative Embryology. Vol. 2. 1881.

(18). HIS. W. Die Entwickelung des menschlichen Rautenhirns vom Ende des ersten bis Beginn des dritten Monate. Abh. d. math-phys. Classe d. k. sächs. Ges. d. Wissen. Bd. 17 1891.

(19). FRACASSATI Epistola de cerebro ad M. Malpighium. Opera omnia Malpiphi. T. 11. (Quoted by Mihalkovics).

(20). TIEDEMANN. Fr. Anatomie und Bildungsgeschichte des Gehirns im Foetus des Menschen. Nürnberg. 1816.

(21). SERRES. E.R.A. Merkel's Archiv. Bd. 1. 1815.

(22). v.BAER. K.E. Ueber Entwicklungsgeschichte der Thiere. Beobachtung und Reflexion. Königsburg. 1828.

(23). VALENTIN. G. Handbuch der Entwicklungsgeschichte des Menschen. Berlin. 1845.

(24). SCHMIDT. F. Beiträge zur Entwickelungsgeschichte des Gehirns. Zeitschr. f. wiss. Zool. Bd. 11. 1862.

(25). KOLLMANN. Entwicklung der menschlichen Adergeflechte. Leipzig. 1861.

(26). v. MIHALKOVICS. V. Entwicklungsgeschichte des Gehirns. Leipzig. 1877.

(27). LAHOUSSE. E. Recherches sur l'ontogenèse du cervelet. Arch. de Biol. T. 8. 1888.

(28). HERTWIG. O. Lehrbuch der Entwicklungsgeschichte des Menschen und der Wirbelthiere. 3 Aufl. Jena. 1893.

(29). GORONOWITSCH. N. Das Gehirn und die Cranialnerven von Acipenser ruthenus. Morph. Jahrb. Bd. 13. 1888.

(30). STROUD. B.B. The Mammalian Cerebellum. Part I. The Development of the Cerebellum in Man and the Cat. Journ. Comp. Neurol. Vol. 5. 1895.

(31). PRENANT. A. Éléments d'Embryologie. Paris. 1896.

(32). EDINGER. L. Bau der nervösen Zentralorgane. Leipzig. 1904.

(33). BURCKHARDT. R. Das Centralnervensystem von Protopterus annectens. Berlin. 1892.

(34). OSBORN. H.F. A Contribution to the Internal Structure of the Amphibian Brain. Journ. Morph. Vol. 2. 1888.

.. Preliminary Observations upon the Brain of Amphiuma. Proc. Philadelphian Acad. Nat. Sci. 1893.

(35). FISH. P.A. The Central Nervous System of Desmognathus fusca. Journ. Morph. Vol. 10. 1895.

(36). KINGSBURY. B.F. On the Brain of Necturus maculatus. *Journ. Comp. Neurol.* Vol. 5. 1895.

(37). KINGSBURY. B.F. The Structure and Morphology of the Oblongata in Fishes. *Journ. Comp. Neurol.* Vol. 7. 1897

(38). JOHNSTON. J.B. Hind-Brain and Cranial Nerves of Acipenser. *Anat. Anz.* Bd. 14. 1898.

.. The Brain of Acipenser. *Zool. Jahrb. Abth. f. Anat. u. Ontogenie.* Bd. 15. 1902.

(39). HOUSER. G.L. The Neurones and Supporting Elements of a Selachian Brain. *Journ. Comp. Neurol.* Vol. 11. 1901.

(40). JOHNSTON. J.B. The Brain of Petromyzon. *Journ. Comp. Neurol.* Vol. 12. 1902.

(41). MAYSER. P. Vergleichend-anatomische Studien uber das Gehirn der Knockenfische mit besonderer Berücksichtigung der Cyprinoiden. *Zeitsch. f. wiss. Zool.* Bd. 36. 1881.

(42). KÖPPEN. M. Zur Anatomie des Froschgehirns. *Arch. f. Anat. u. Phys.* Anat. Abth. 1888.

(43). EDINGER. L. Ueber Ursprungsverhältnisse des Acusticus und die directs Kleinhirnbahn. *Neurol. Centralbl.* 1886.

.. Das Cerebellum von Scyllium canicula. *Arch. f. mikrosk. Anat.* Bd. 58. 1901.

(44). SALA. L. Ueber den Ursprung des Nervus acusticus. *Arch. f. mikrosk. Anat.* Bd. 42. 1893.

(45). BRANDIS. F. Untersuchungen uber das Gehirn der Vogel. II Th. Ursprung der Nerven der Medulla oblongata. *Arch. f. mikrosk. Anat.* Bd. 41 u. 43. 1893-1894.

(46). WALLENBERG. A. Die secundäre Acusticusbahn der Taube. *Anat. Anz.* Bd. 14. 1898.

(47). HALLER. B. Vom Bau der Wirbelthiergehirns. I.Th. *Morph. Jahrb.* Bd. 26. 1898.

(48). WILDER. B.G. Do the Cerebellum and the Oblongata represent two Segments or only one? *Proc. Amer. Ass. Adv. Science.* Vol. 33. 1884.

(49). HIS.W. *Die Entwickelung des menschlichen Gehirns während der ersten Monate.* Leipzig. 1904.

(50). BURDACH. *Bau und Leben des Gehirns.* Leipzig. Bd.II. 1822. Bd.III. 1826.

(51). MAJENDIE. *Recherches anatomiques et physiologiques sur le liquide céphalo-rachidien.* 1842.

(52). VIRCHOW. *Handbuch der speciellen Pathologie und Therapie.* 1854.

(53). LUSCHKA.H. Die Adergeflechte des menschlichen Hirns. 1855.

(54). REICHERT. C.B. Der Bau des menschlichen Gehirns. Leipzig. 1861.

(55). QUINCKE. Zur Physiologie der Cerebrospinalflüssigkeit. Arch. v. Reichert u. du Bois-Reymond. 1872.

(56). REY & RETZIUS. Studien in der Anatomie des Nervensystems. Stockholm. 1875.

(57). SÉE. M. Sur la Communication des Cavités ventriculaires de l' encéphale avec les Espaces sousarachnoidiens. Revue Mensuelle. II (1878) III (1879).

(58). HESS. C. Das Foramen Magendie und die Öffnungen an den Recessus lateralis des IV Ventrikels. Morph. Jahrb. Bd. 10. 1885.

(59). WILDER. B.G. The Foramen of Magendie in Man and the Cat. N.Y. Med. Journ. Vol. 39. 1884.

.. Note on the Foramen of Magendie in Man and the Cat. Journ. Nerv. & Ment. Diseases. Vol. 13. 1886.

.. The Metapore (Foramen of Magendie) in Man and an Orang. Medical News. 1893.

(60). MORTON. C.A. The Pathology of tuberculous Meningitis with reference to its treatment by tapping the Subarachnoid. Brit. Med. Journ. 1891. II.

.. The Opening between the Fourth Ventricle and the Subarachnoid Space. Brit. Med. Journ. 1893. I.

(61). JACOBI. G.W. Lumbar Puncture of the Subarachnoid Space. N.Y. Med. Journ. 1895.

(62). KOHLMANN. J. Lehrbuch des Entwicklungsgeschichte des Menschen. Jena. 1898.

(63). CANNIEU. A. Note sur le Trou de Luschka Journ. de. med de Bordeaux. 1897.

.. Contribution a l'étude la voute du quatrieme ventricule chez les mammiféres. Ibid.

.. Recherches sur la voute du quatrieme ventricule des vertebres. Les trous de Magendie et de Luschka. Bibliogr. Anat. T. 6. 1898.

(64). BOCKDALEK. Neue Beobachtungen im Gebiet der physiologischen Anatomie. Präger Vierteljahrschr. 1849.

(65). SUTTON. J.Bland. The Lateral Recesses of the Fourth Ventricle. Brain. Vol. 9. 1887.

EXPLANATION OF FIGURES.

The outline of all the figures representing sections were made by means of a Leitz camera lucida.

The following objectives and oculars were used in drawing the various figures:-

Leitz Obj. 7.	Oc. 1.	Fig. 28.
.. .. 3.	.. 3.	Fig. 32.
.. .. 3.	.. 1.	Figs. 9-20, 22-27, 29 and 30.
.. .. 3.	.. 0.	Figs. 56-64, 73-78, 84, 85 and 88.
.. .. 1*.	.. 3.	Figs. 21, 31, 33-53.
.. .. 1*.	.. 1.	Figs. 54, 55, 65-72, 79-83, 86, 87, 89-98.

The following reference-lettering is common to all the figures:-

a.= the part of the cerebellum from which the nodulus and flocculus develope.

a.c. = ala cinerea.

al. = alar lamina.

a.m.v. = anterior medullary velum.

a.p. = area postrema.

b. = backward projection of the roof of the fourth ventricle.

bl. = basal lamina.

bl. vs. = blood vessels.

cb. = cerebellum.

c.c. = central canal.

c.v. = cerebellar ventricle.

ch. pl. = choroid plexus.

d. m. = dura mater.

floc. = flocculus.

f. s. = fasciculus solitarius.

f. sp. = funiculus separans.

fw. = Flügelwulst.

G. g. = Gasserian ganglion.

h.b = hind-brain

l. r. = lateral recess.

m. b. = mid-brain.

nX. &c. = nucleus of X &c. cranial nerves.

ob. = obex.

o. v. = otic vesicle.

pfl. = paraflocculus.

p. m. v. = posterior medullary velum.

rec. lab. = recessus labyrinthi.

r. l. = rhombic lip.
s-a. s. = subarachnoid space.
1, 2, &c. = 1st, 2nd &c neuromeral grooves.
V &c = V &c cranial nerves.

Fig. 1. 19 days embryo. Model of the hind-brain. Exterior.
.. 2. .. .. Interior.
.. 3. 22 days embryo. Model of the hind-brain. Exterior.
.. 4. .. .. Interior.
.. 5. 15 m.m. embryo. Model of the hind-brain. Exterior.
.. 6. .. .. Interior.
More than half of the brain has been modelled. the cut surface, therefore, is greater than it would be in the middle line.
.. 7. 23 m.m. embryo. Model of the region of the lateral recess. Interior.
.. 8. 150 m.m. embryo. Model showing half of the most posterior part of the fourth ventricle and the central canal. From within and in front.
Figs. 9 and 10. 19 days embryo. Horizontal sections through the hind- and mid-brain.
Fig. 11. 19 days embryo. Sagittal section, to the left of the middle line, through the hind-brain.
Figs. 12-15. 22 days embryo. Transverse sections through the hind-brain.
.. 16-22. 15 m.m. embryo. Transverse sections through the hind-brain.
.. 23 and 24. 15 m.m. embryo. Sagittal sections of the hind-brain.
.. 25-35. 23 m.m. embryo. Transverse sections through the hind-brain. Fig. 28 illustrates the arrangement of the cells, and the incipient ridge, at the bottom of the median fissure. Fig. 32 shows the amount of the development of the rhombic lip of the cerebellum in the neighbourhood of the lateral recess.
.. 36-41. 25 m.m. embryo. Transverse sections through the hind-brain.
.. 42 and 43. 25 m.m. embryo. Sagittal sections.
.. 44-53. 32 m.m. embryo. Transverse sections through the hind-brain.
.. 54-70. 52 m.m. embryo. Transverse sections through the hind-brain. Figs. 56-64 illustrate the form

and dimensions of the rhombic lip at different levels.

Fig. 71. 52 m.m. embryo. Sagittal section in the region of the lateral recess.

.. 72. 80 m.m. embryo. Transverse section of the "closed" portion of the medulla.

Figs. 73-76. 80 m.m. embryo. Illustrate the changes in the shape of the central canal.

.. 77-83. 80 m.m. embryo. Transverse sections through the hind-brain.

.. 84-91. 100 m.m. embryo. .. ..

.. 92-98. 150 m.m. embryo. .. ..

①

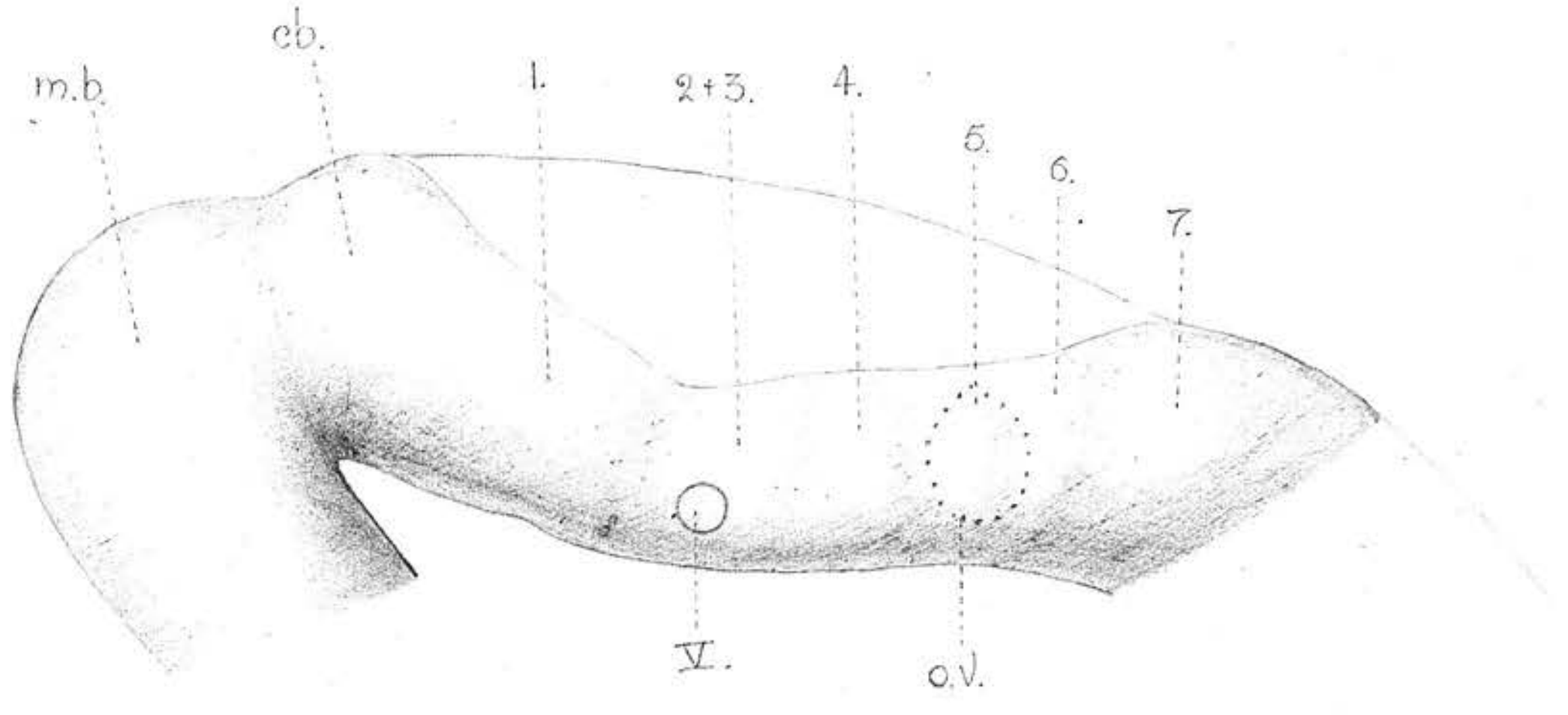

Fig: 1.

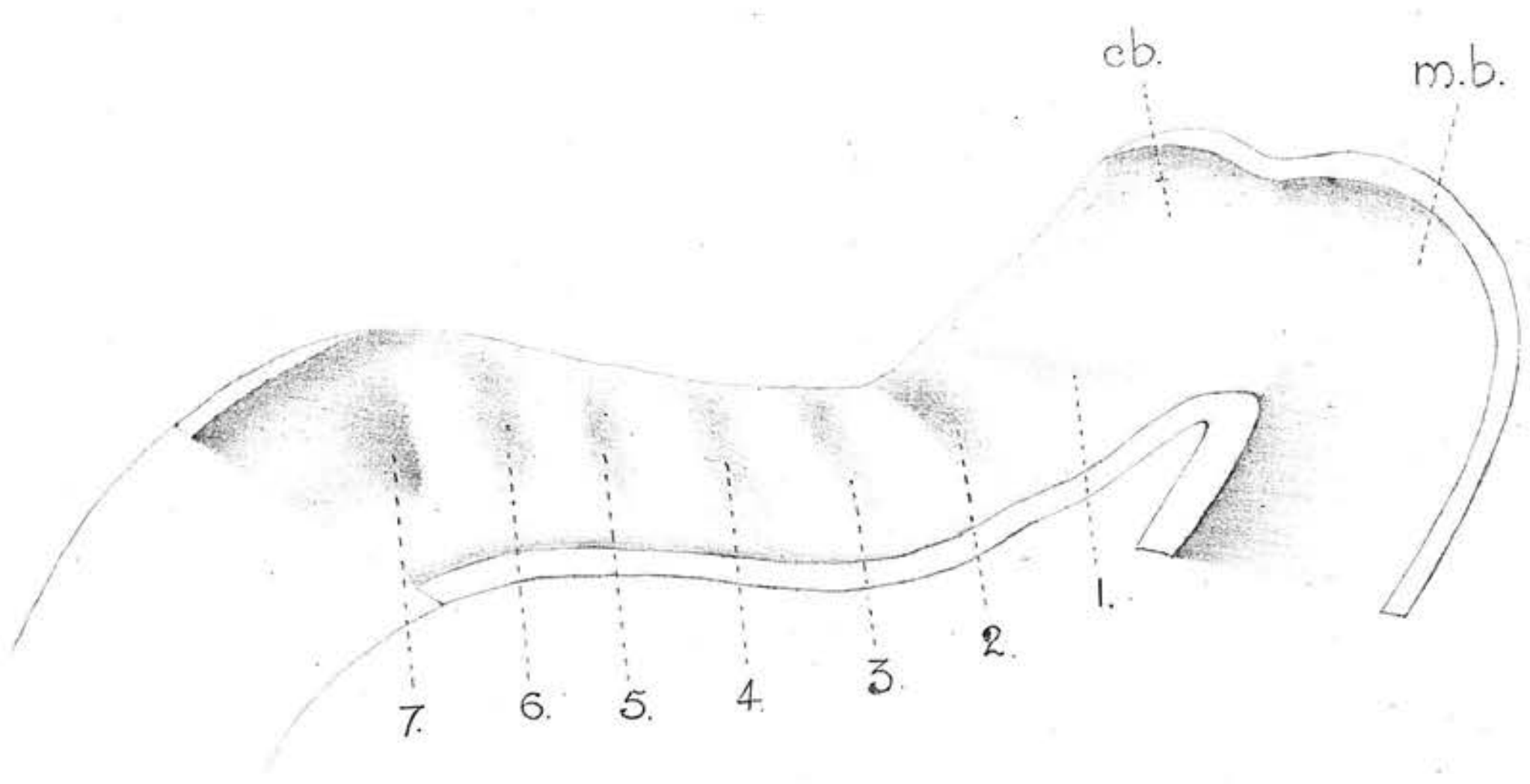

Fig: 2.

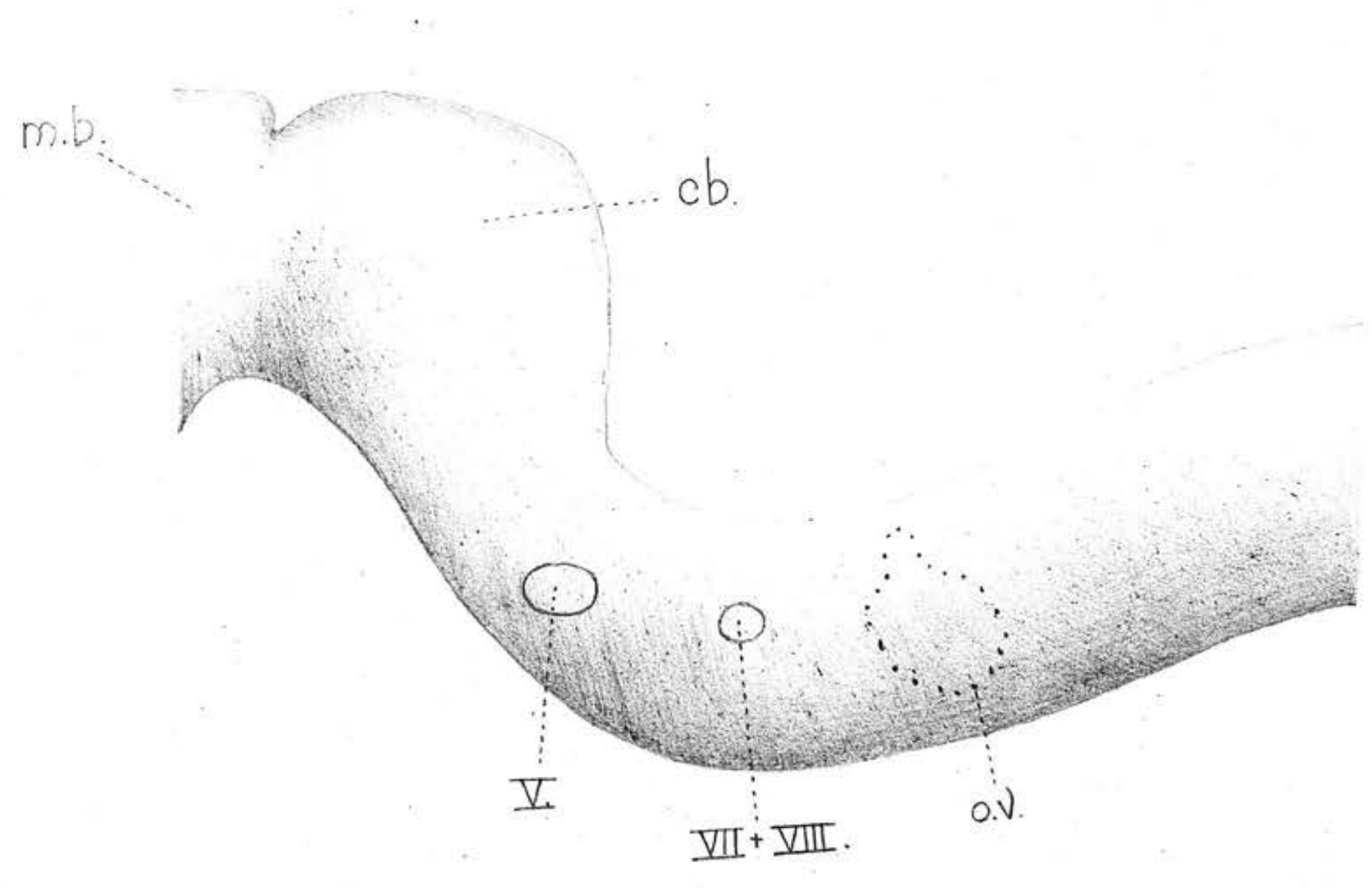

Fig: 3.

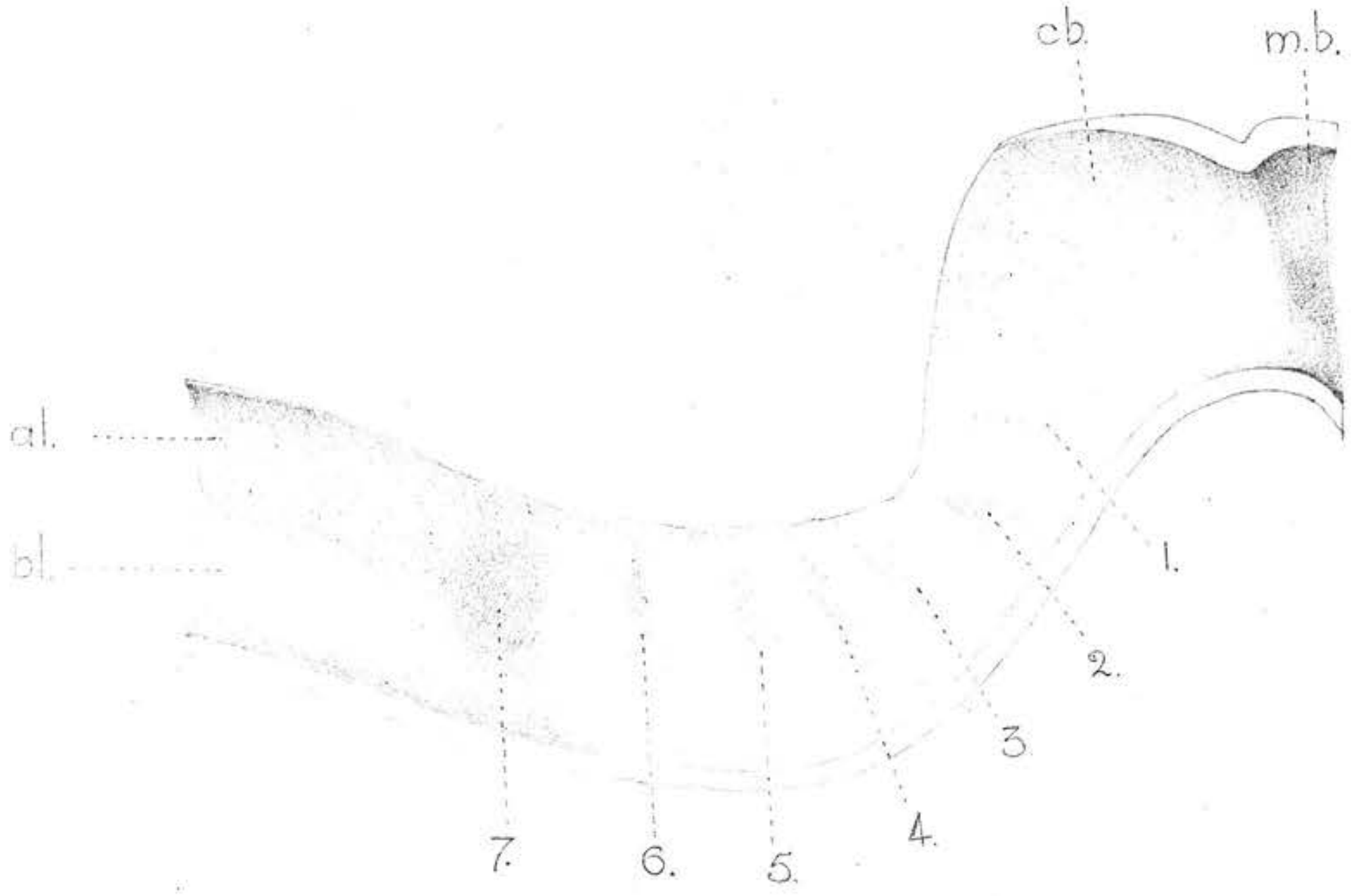

Fig: 4.

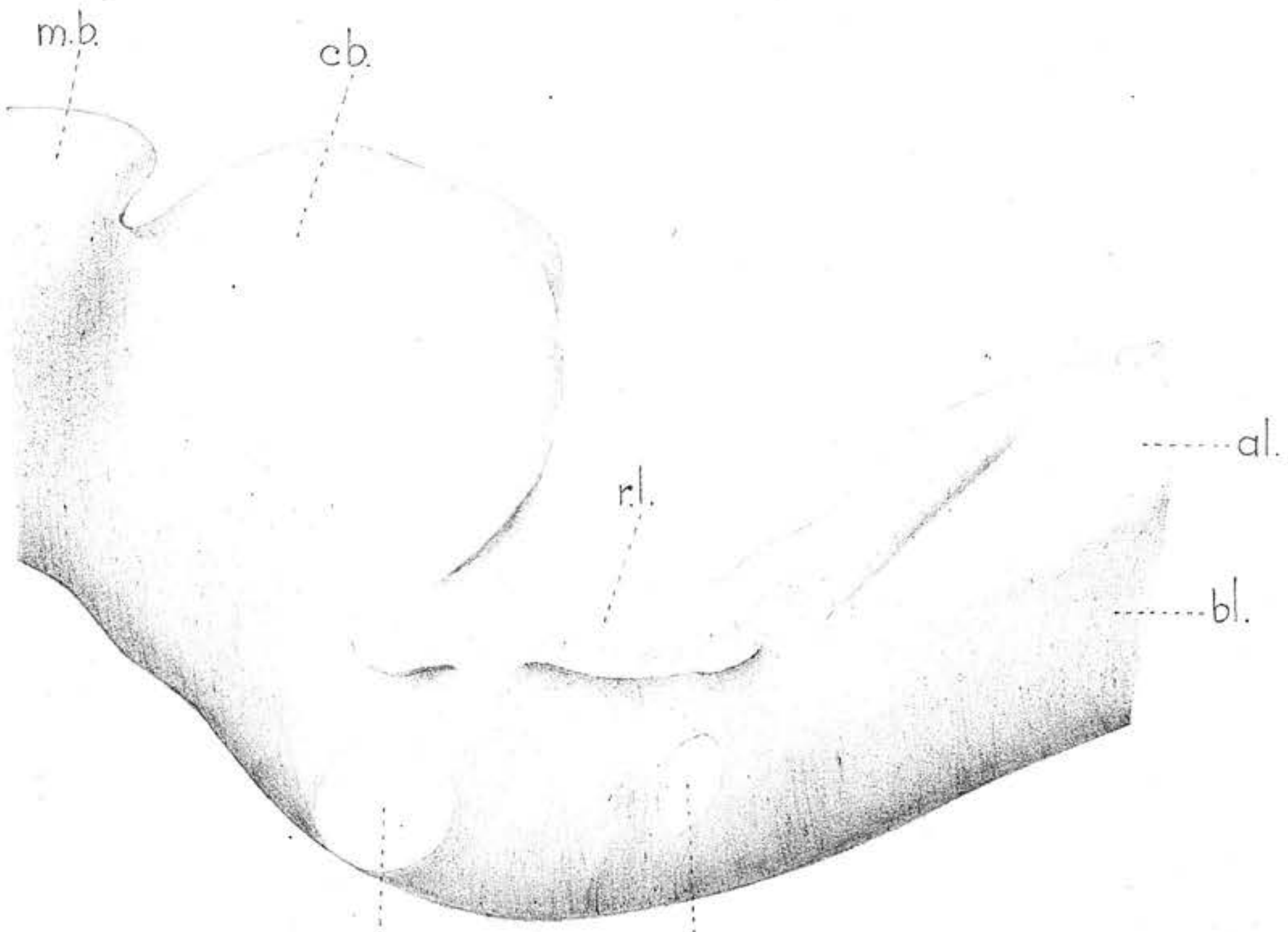

Fig: 5.

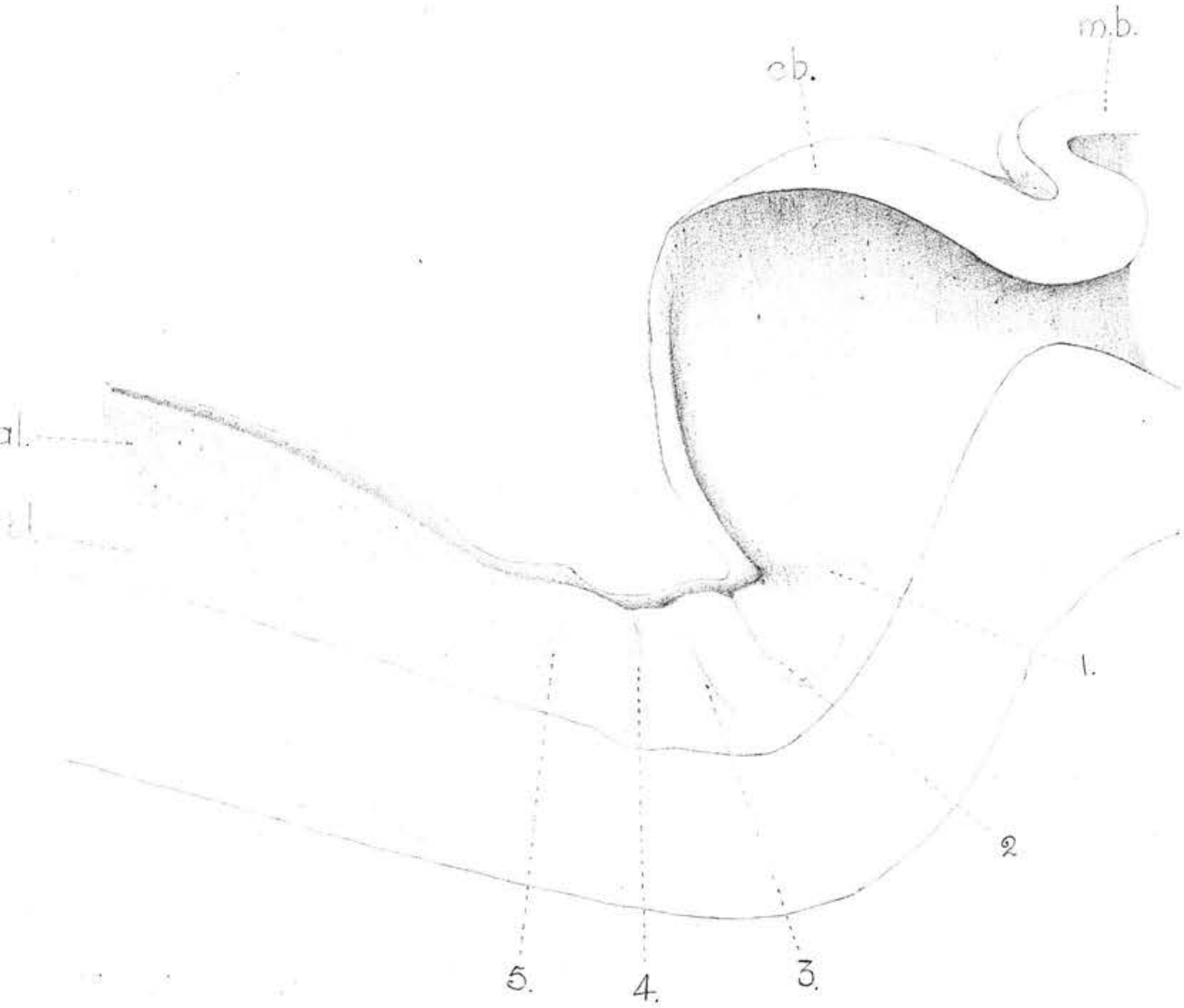

Fig: 6.

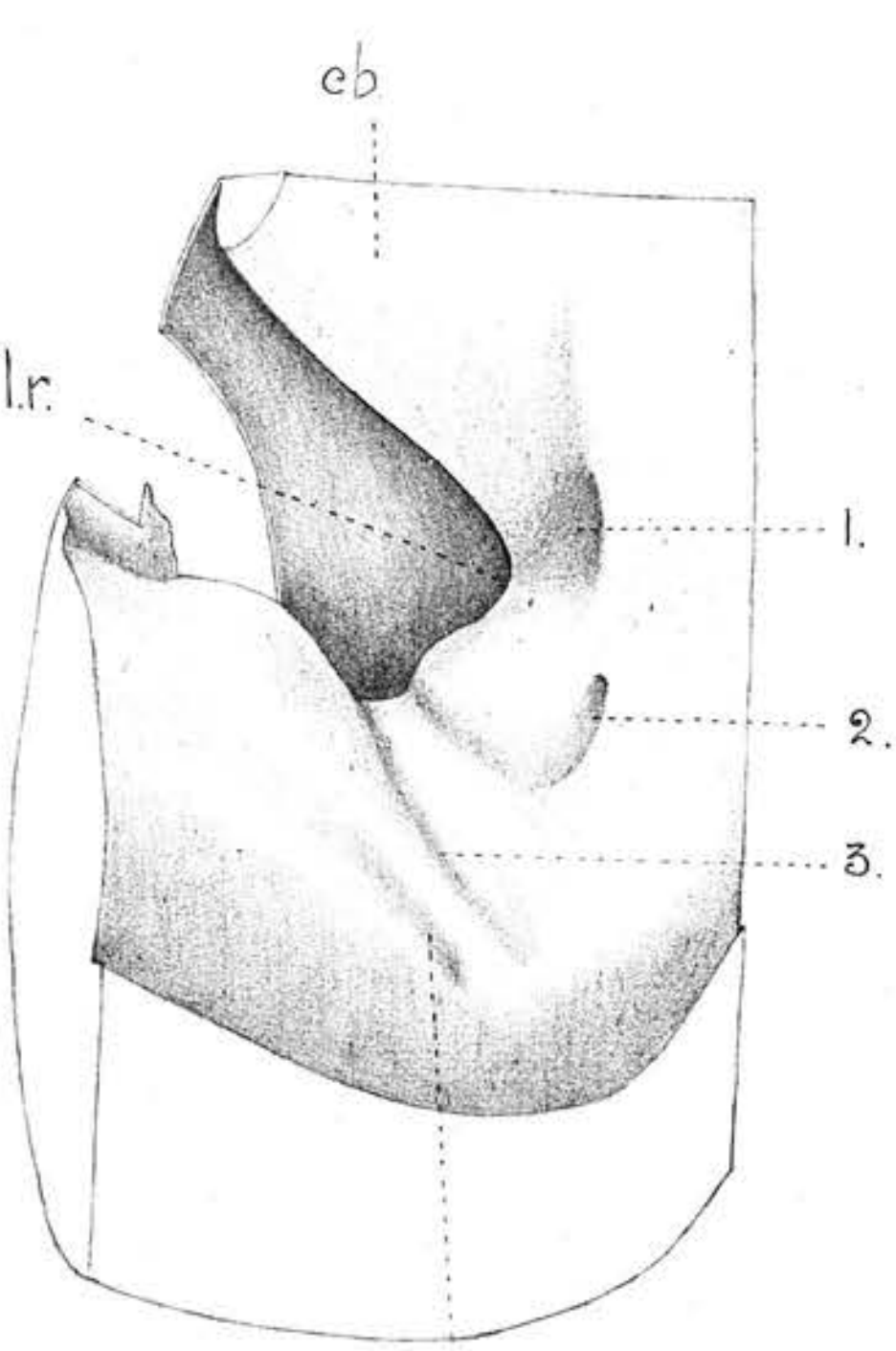

Fig: 7.

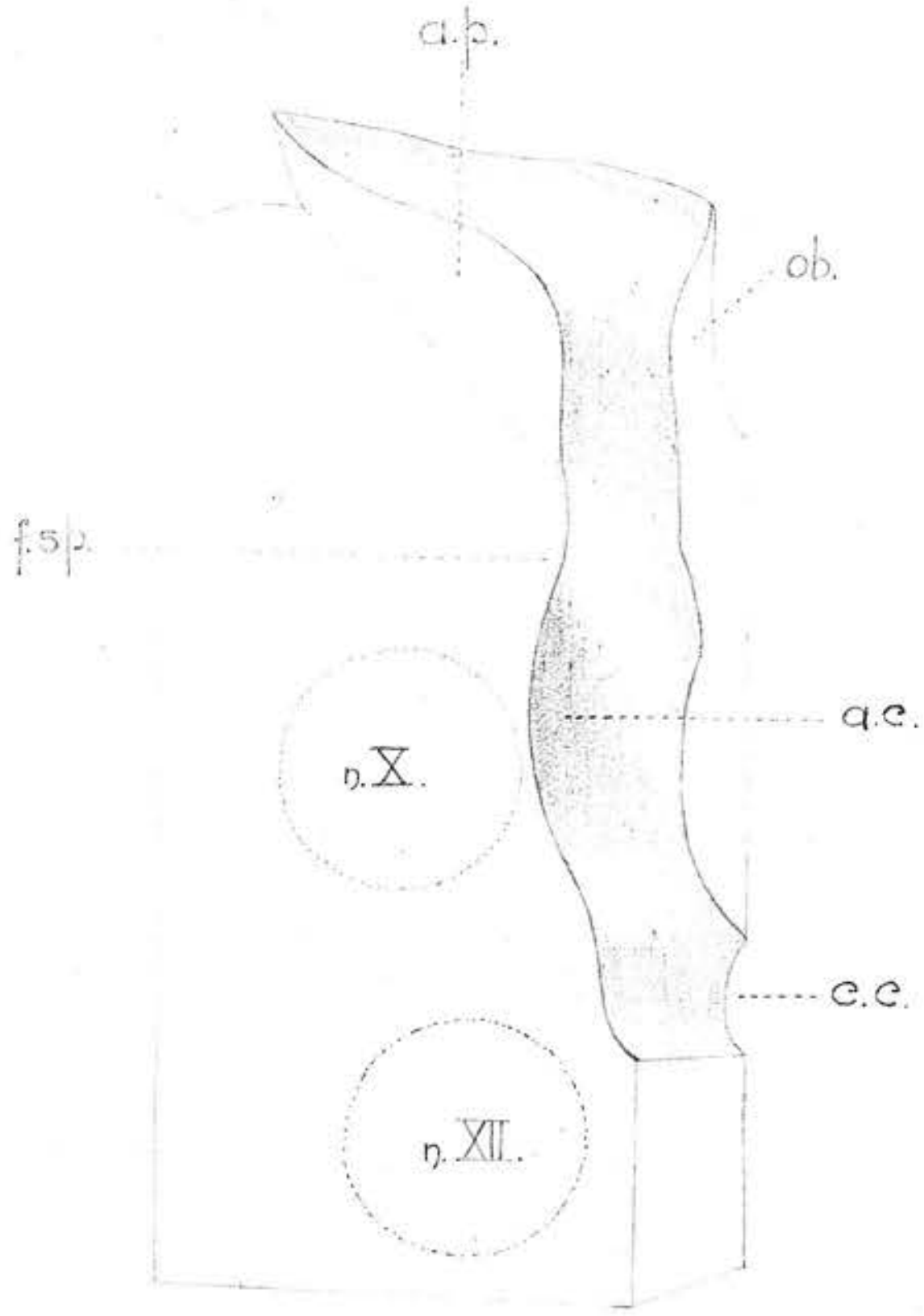

Fig: 8.

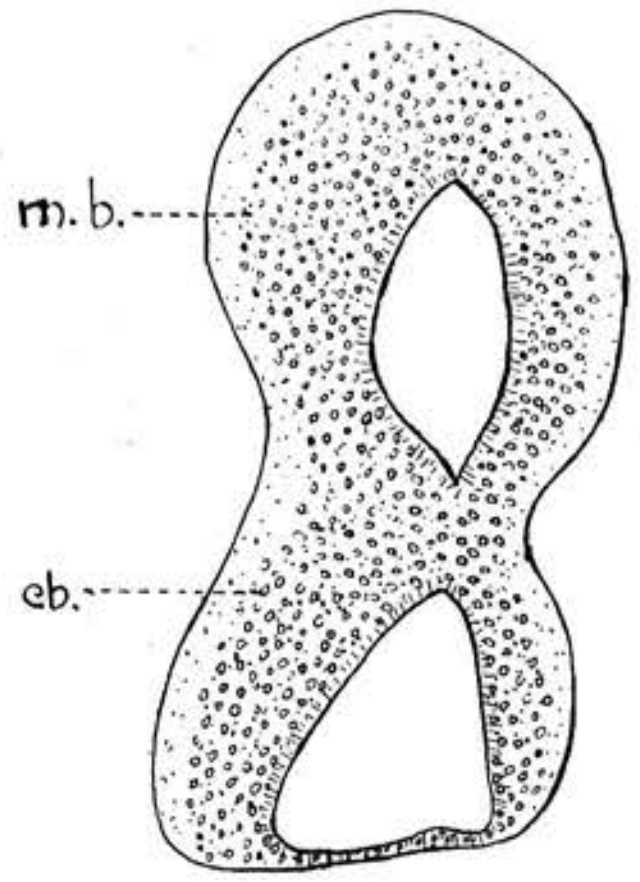

Fig: 9.

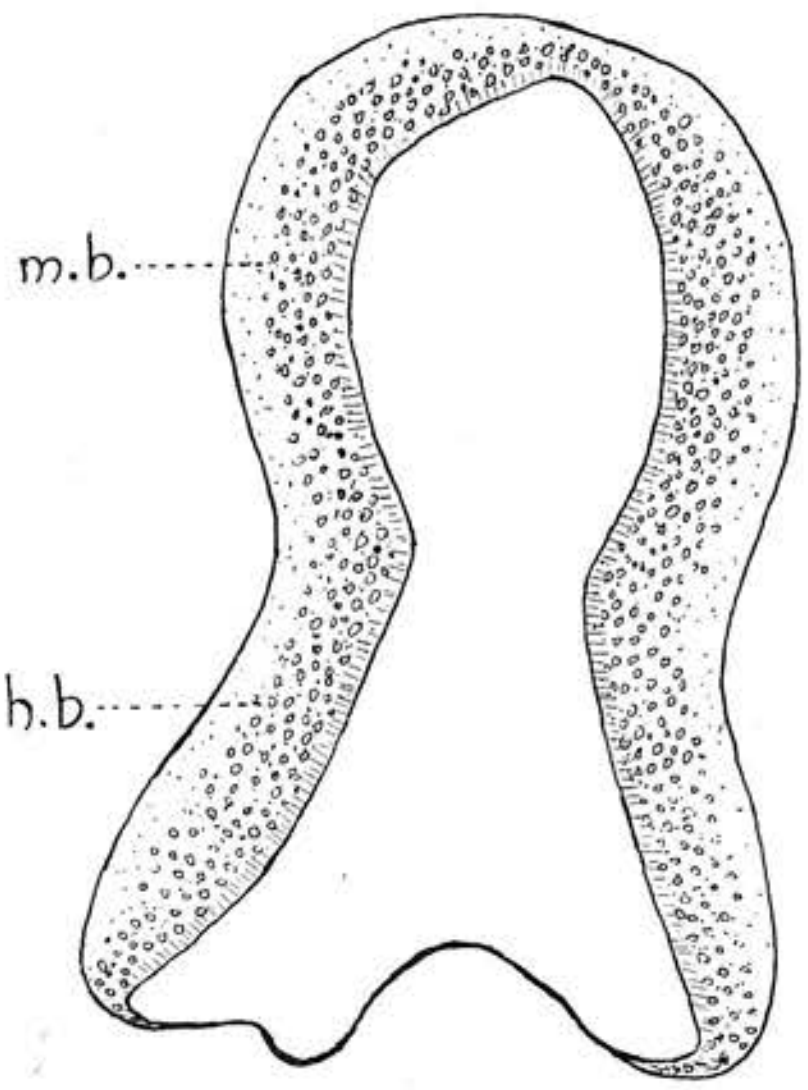

Fig: 10.

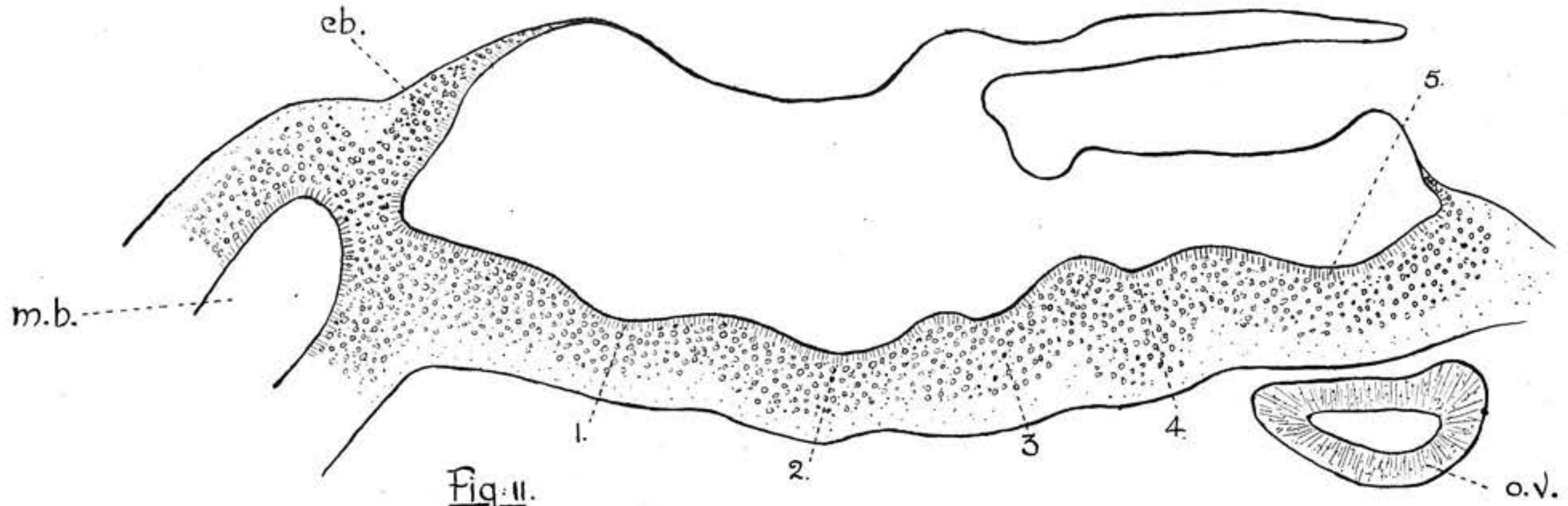

Fig: 11.

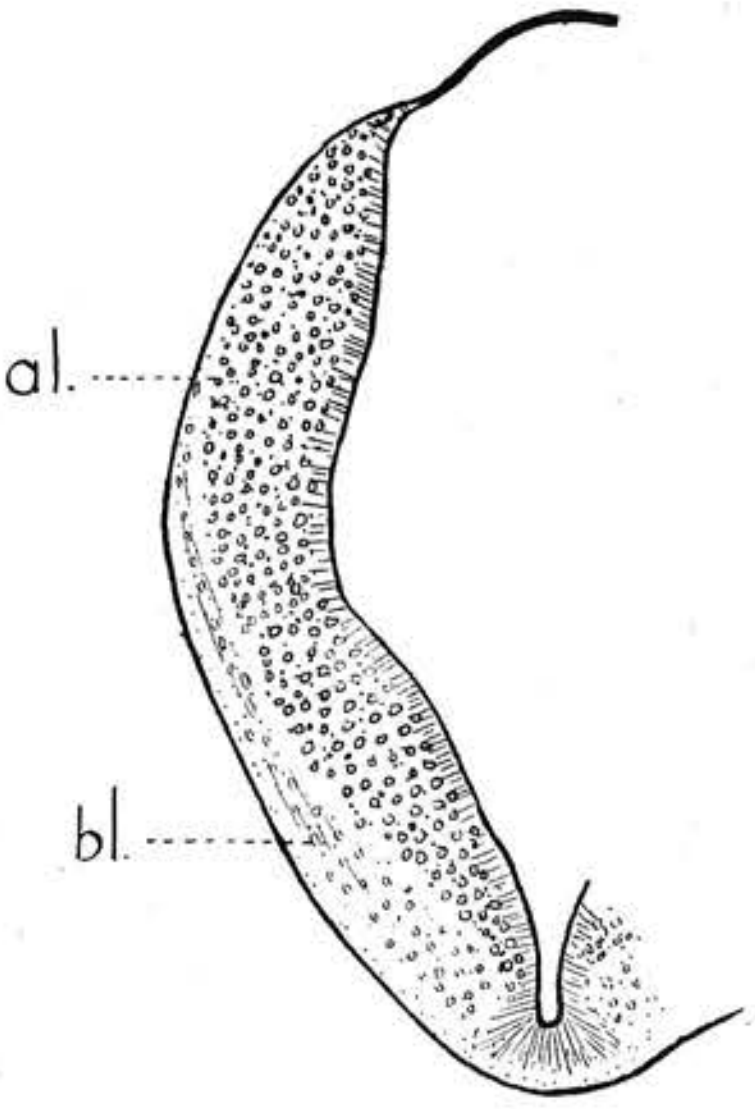

Fig: 12.

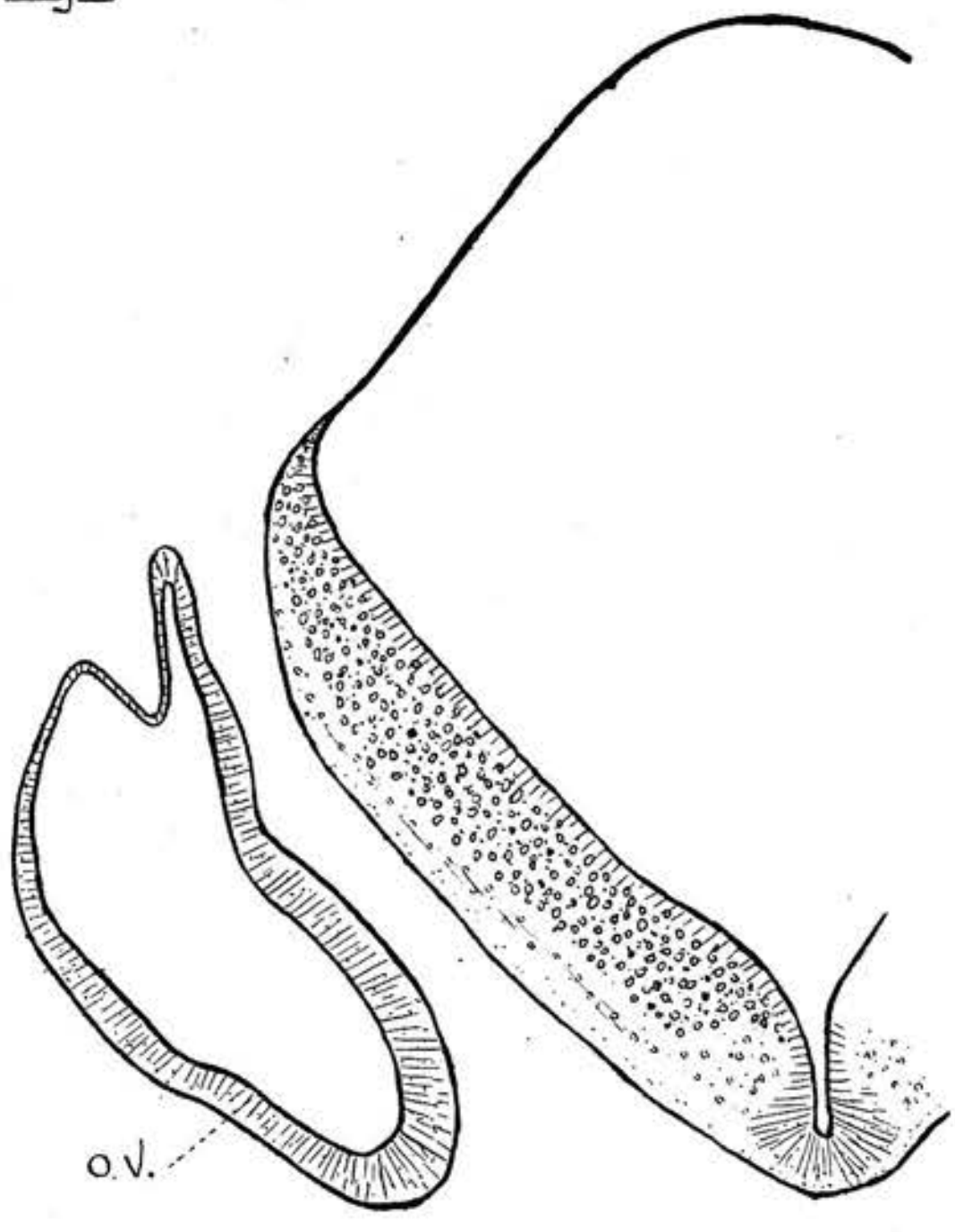

Fig: 13.

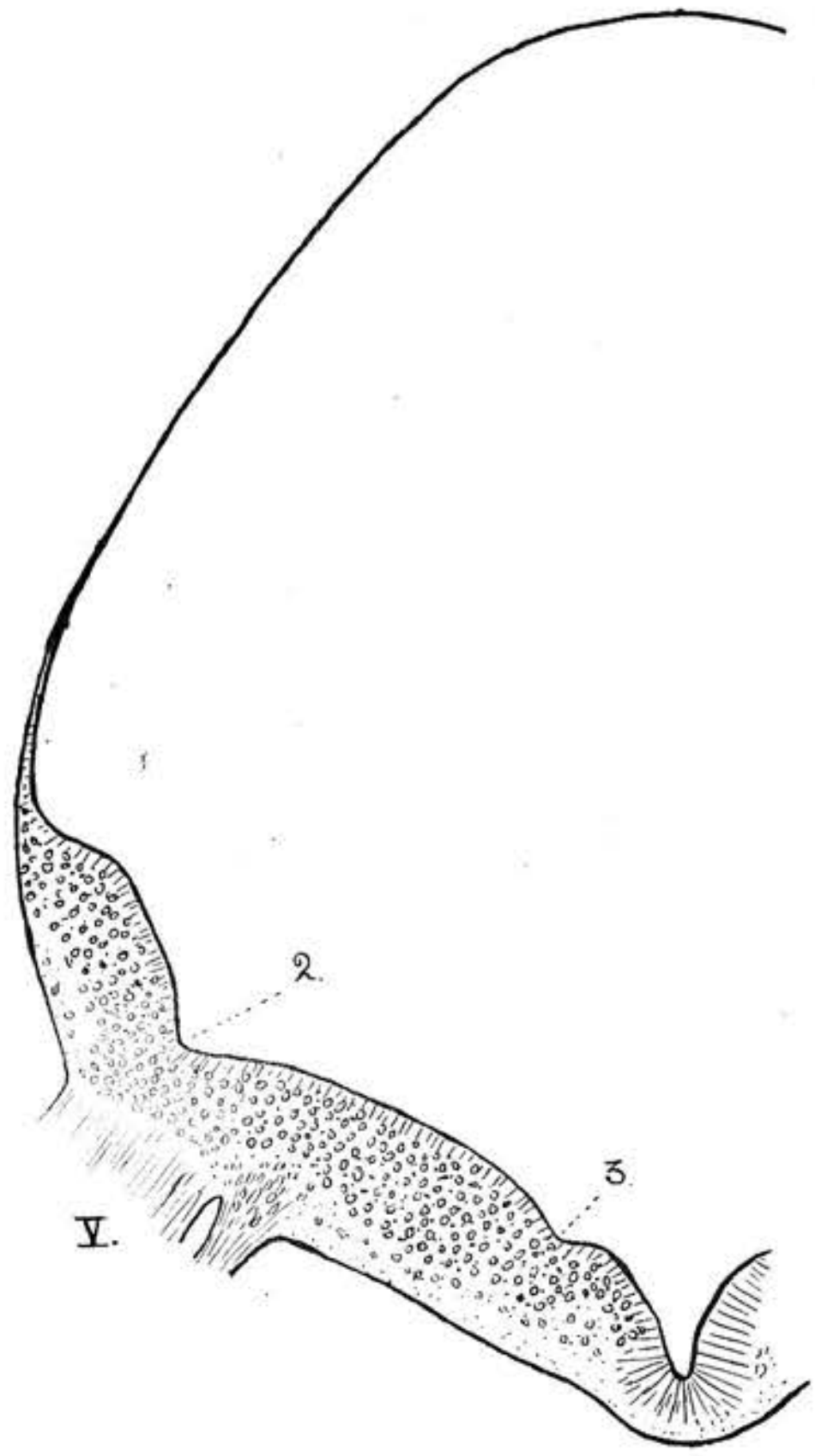

Fig: 14.

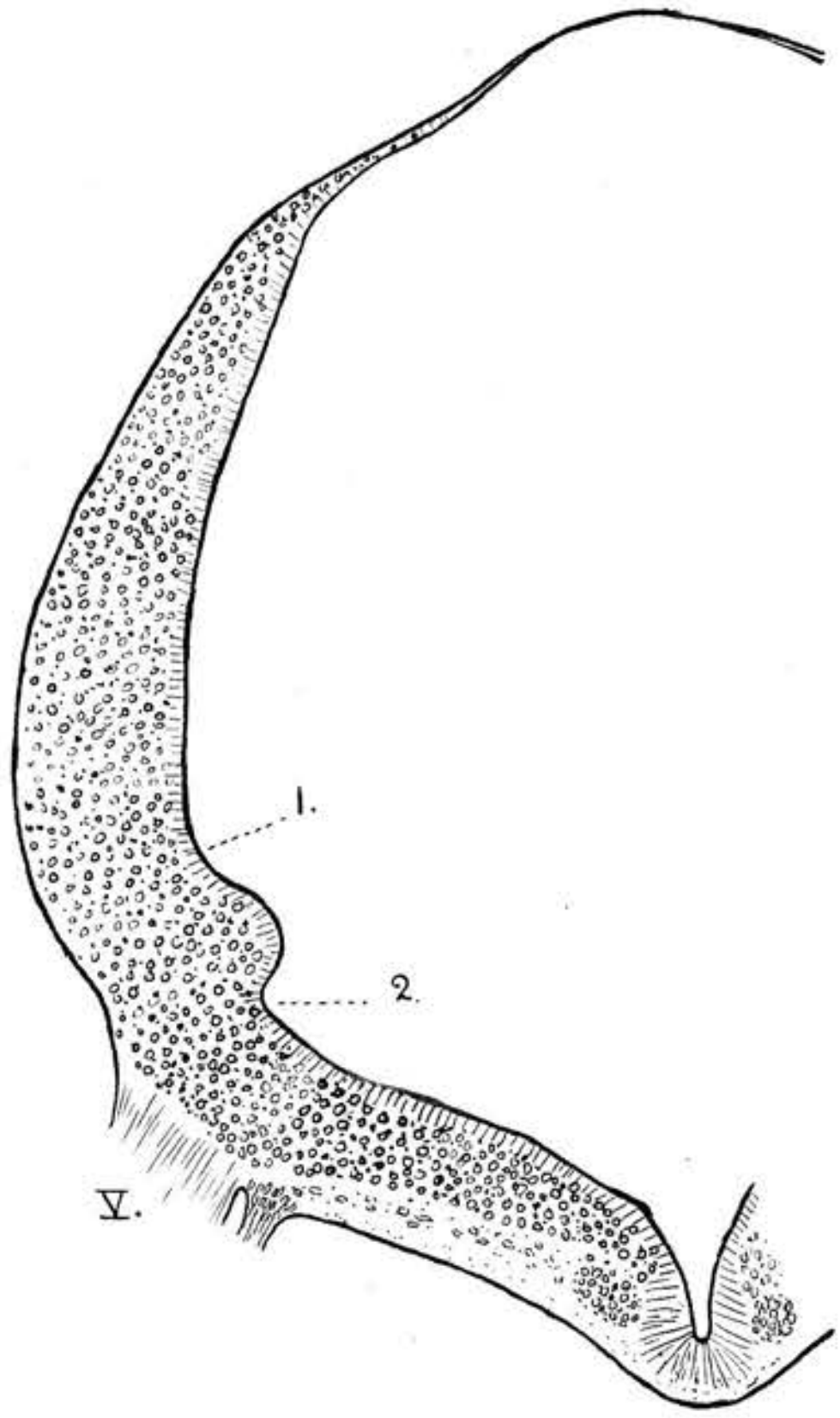

Fig: 15.

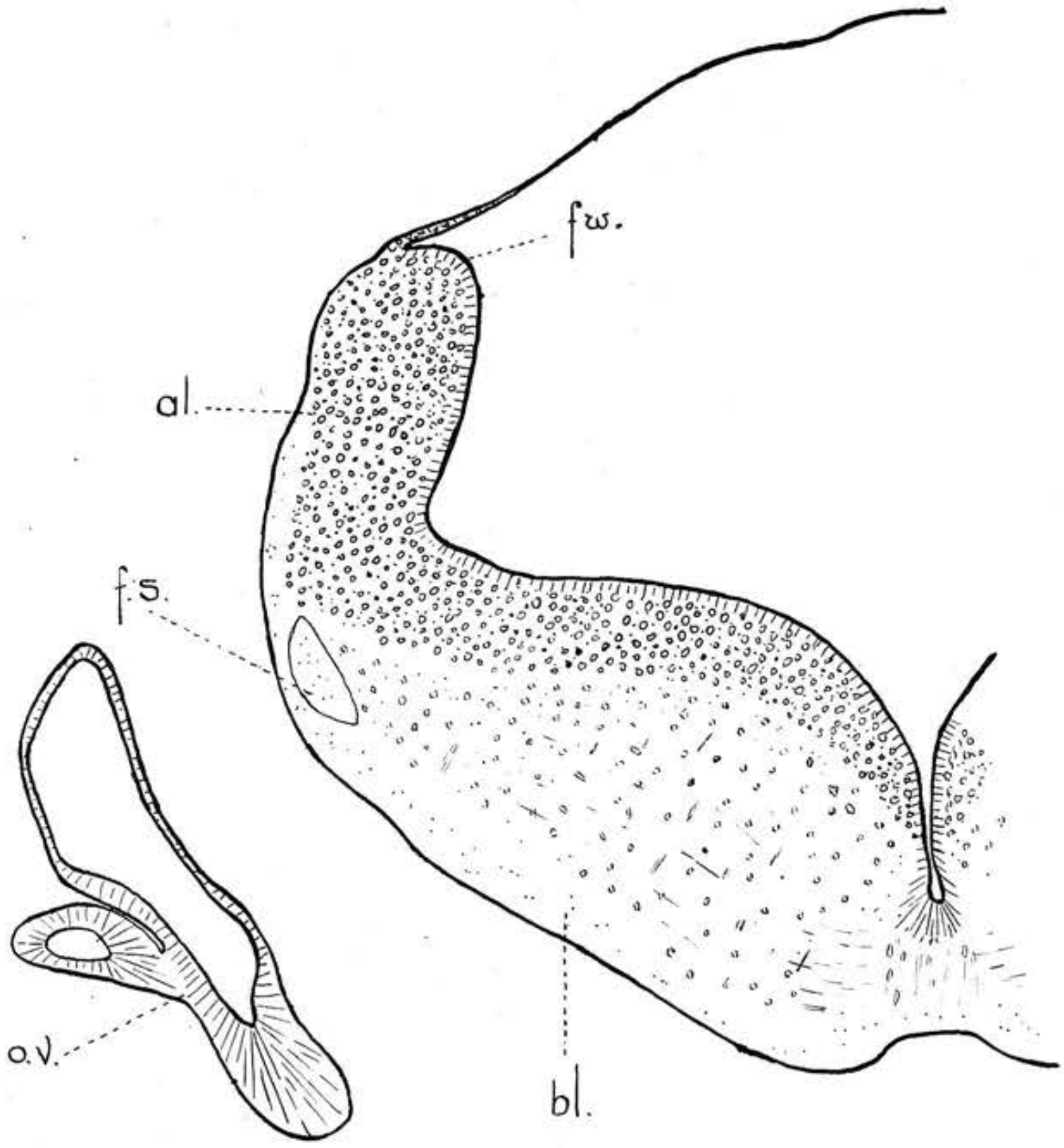

Fig: 16.

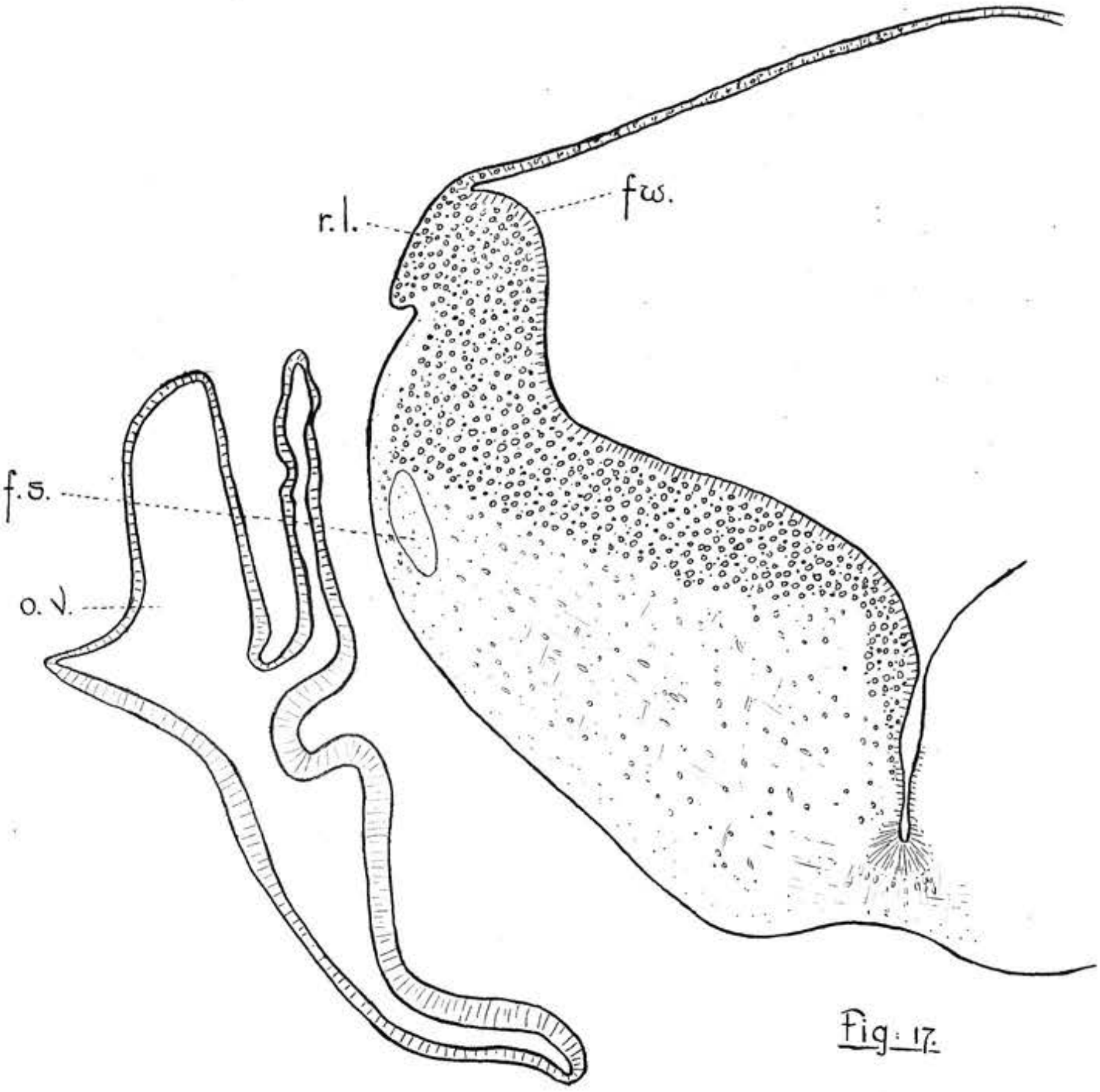

Fig: 17.

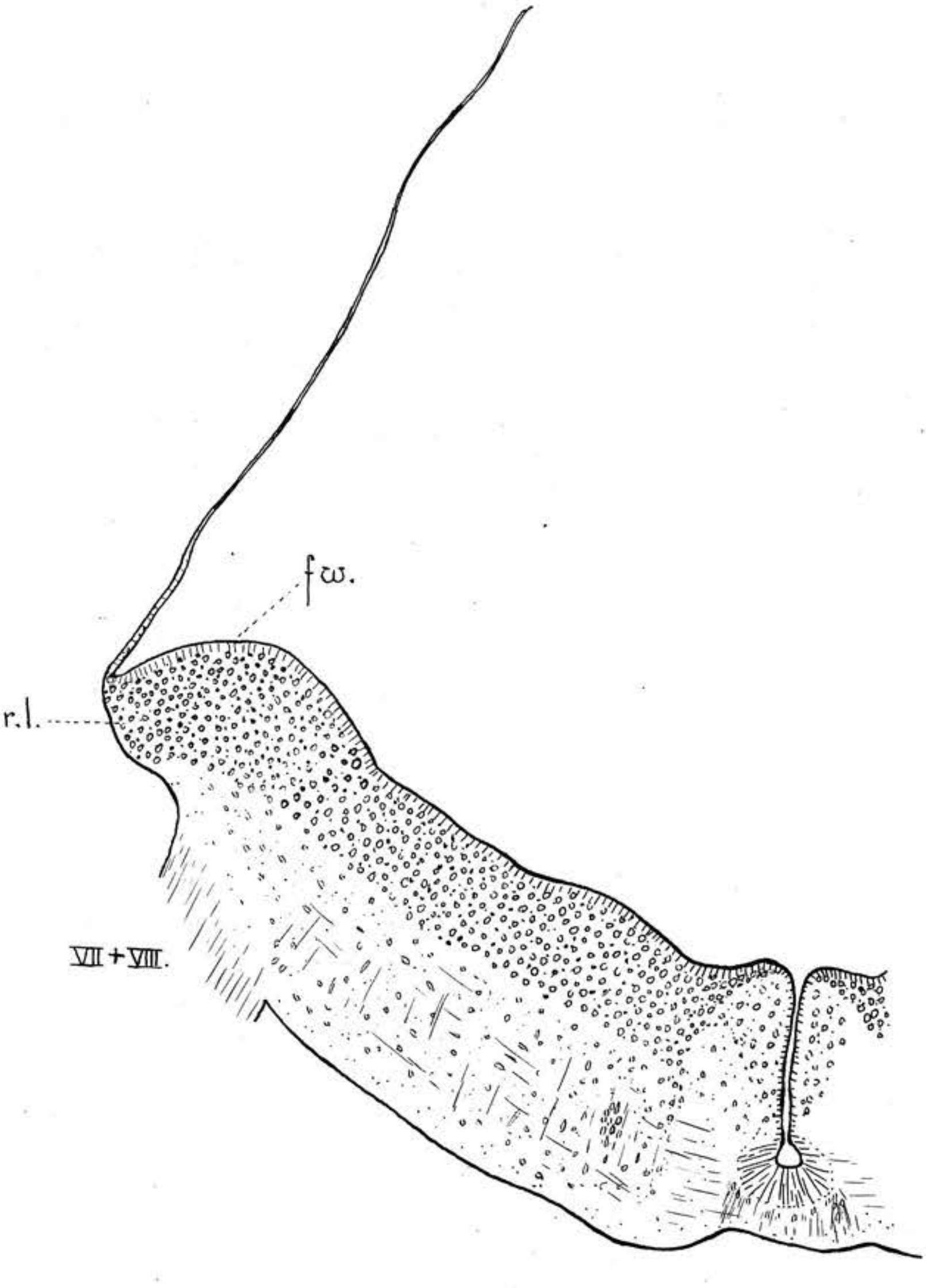

Fig: 18.

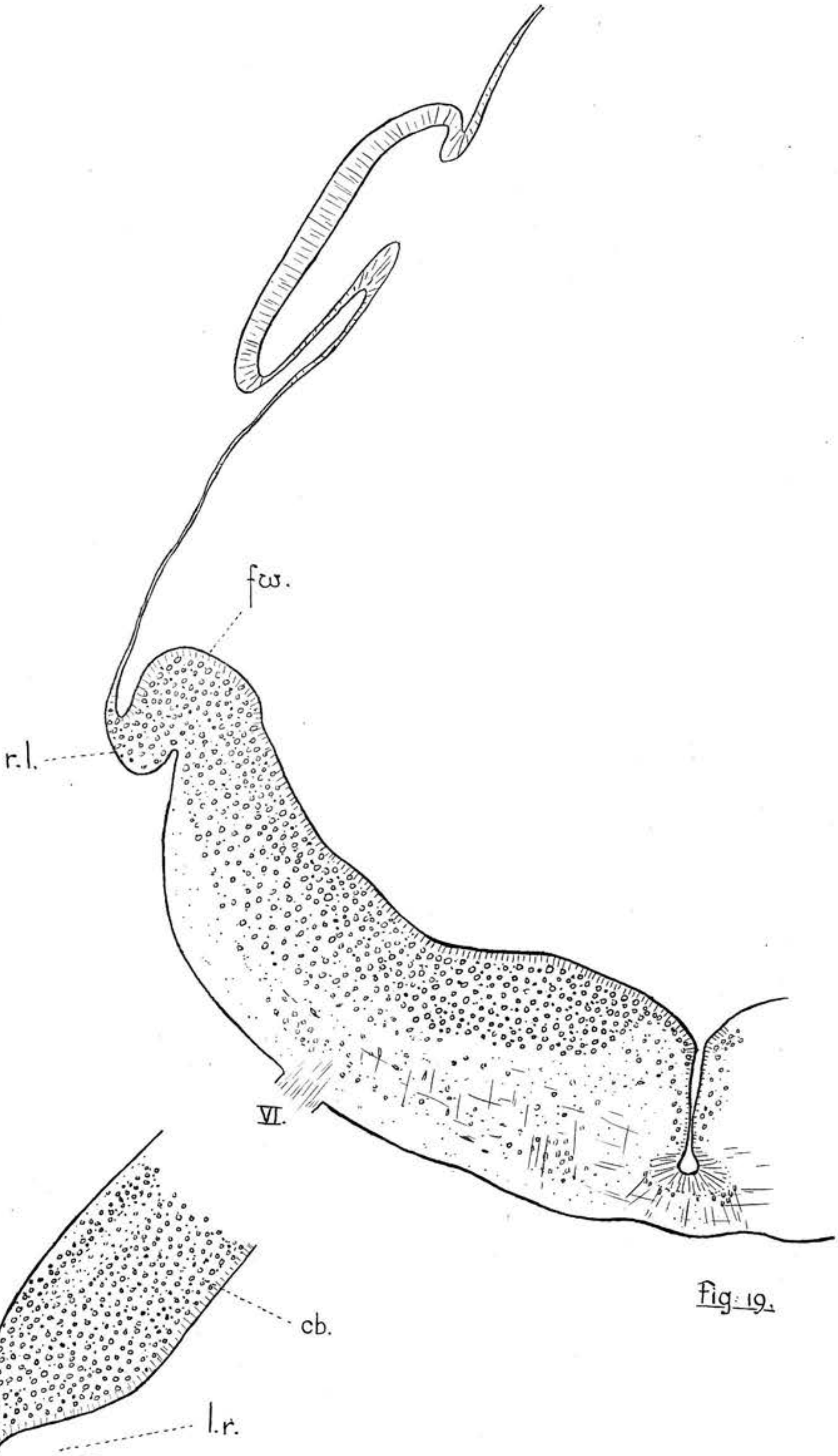

Fig: 19.

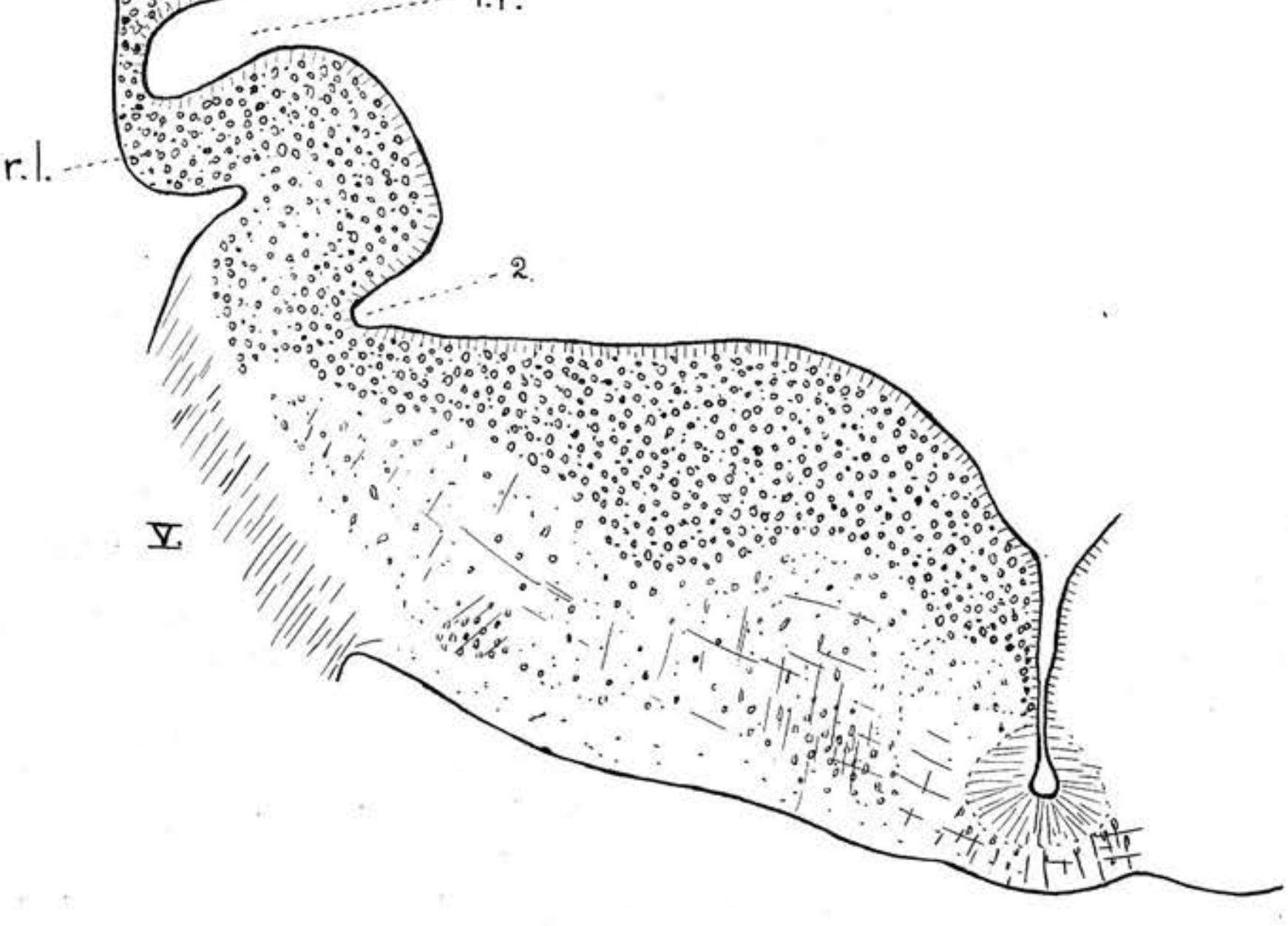

Fig: 20.

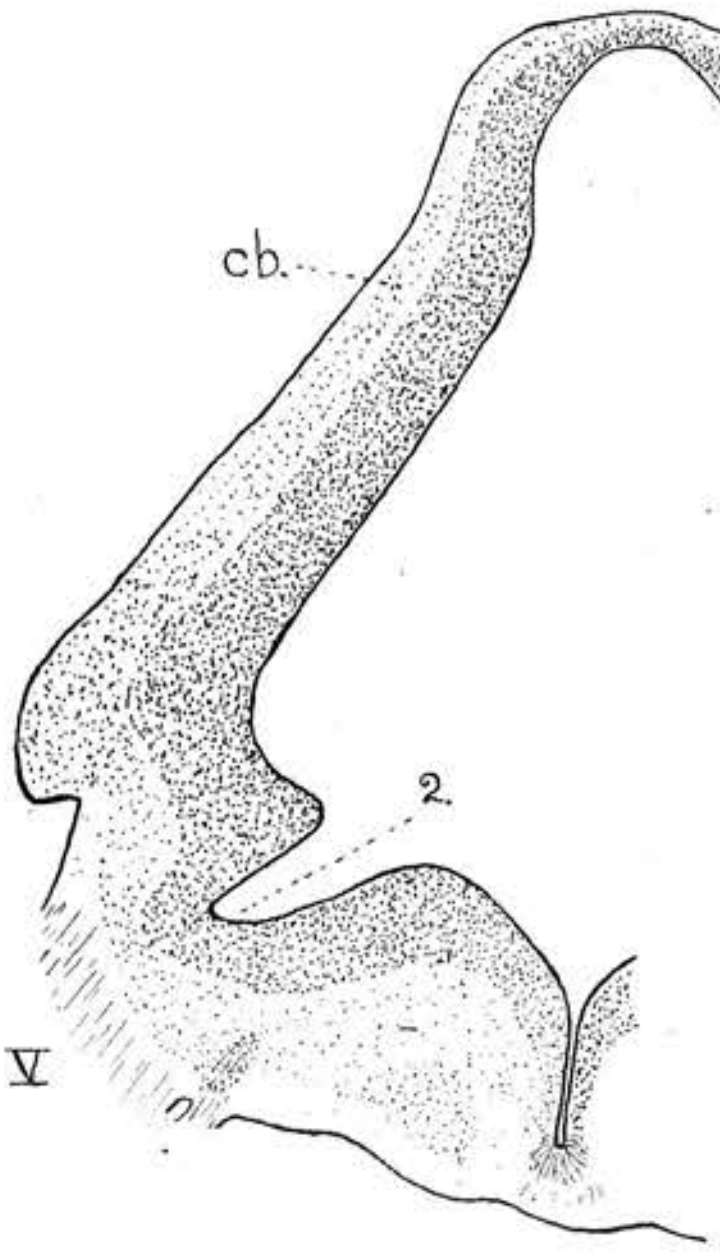

Fig: 21.

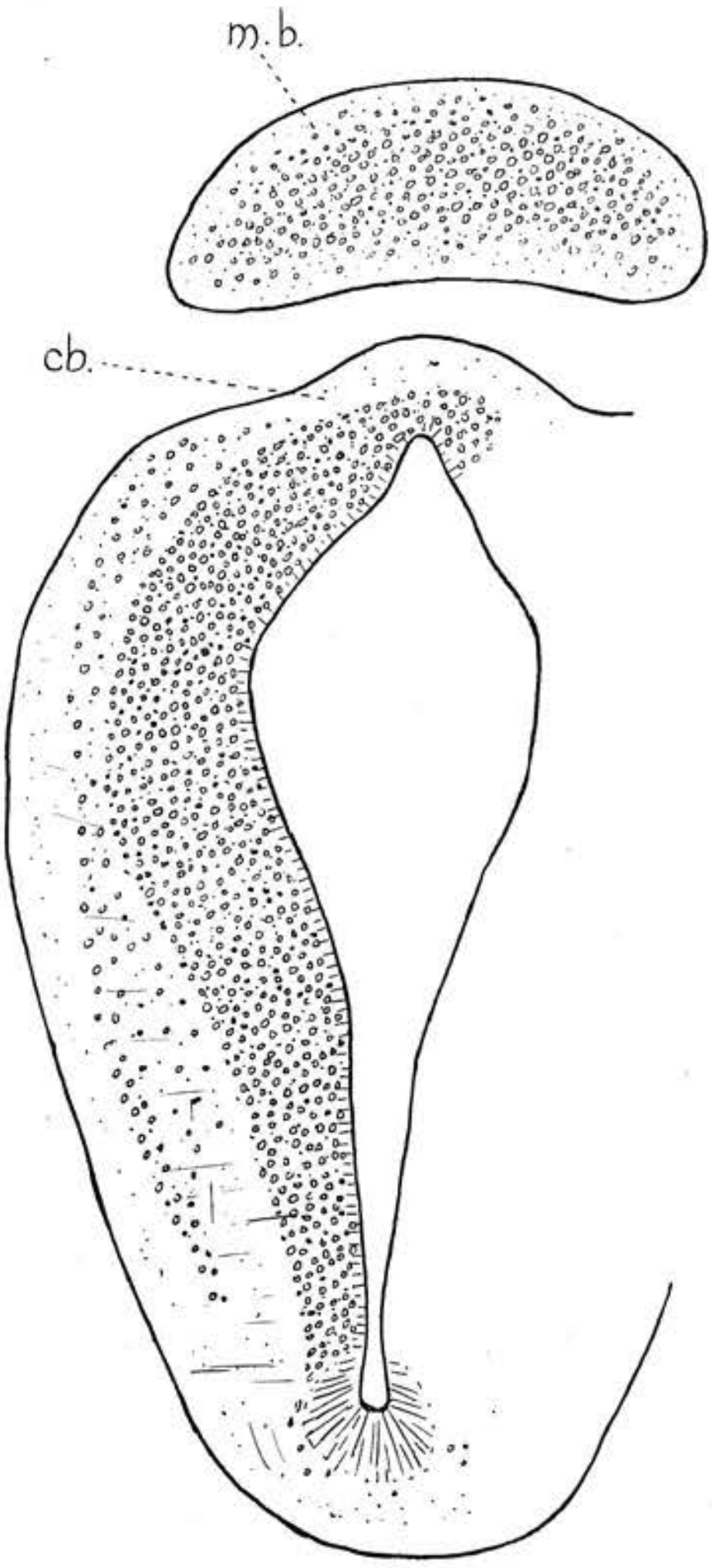

Fig: 22.

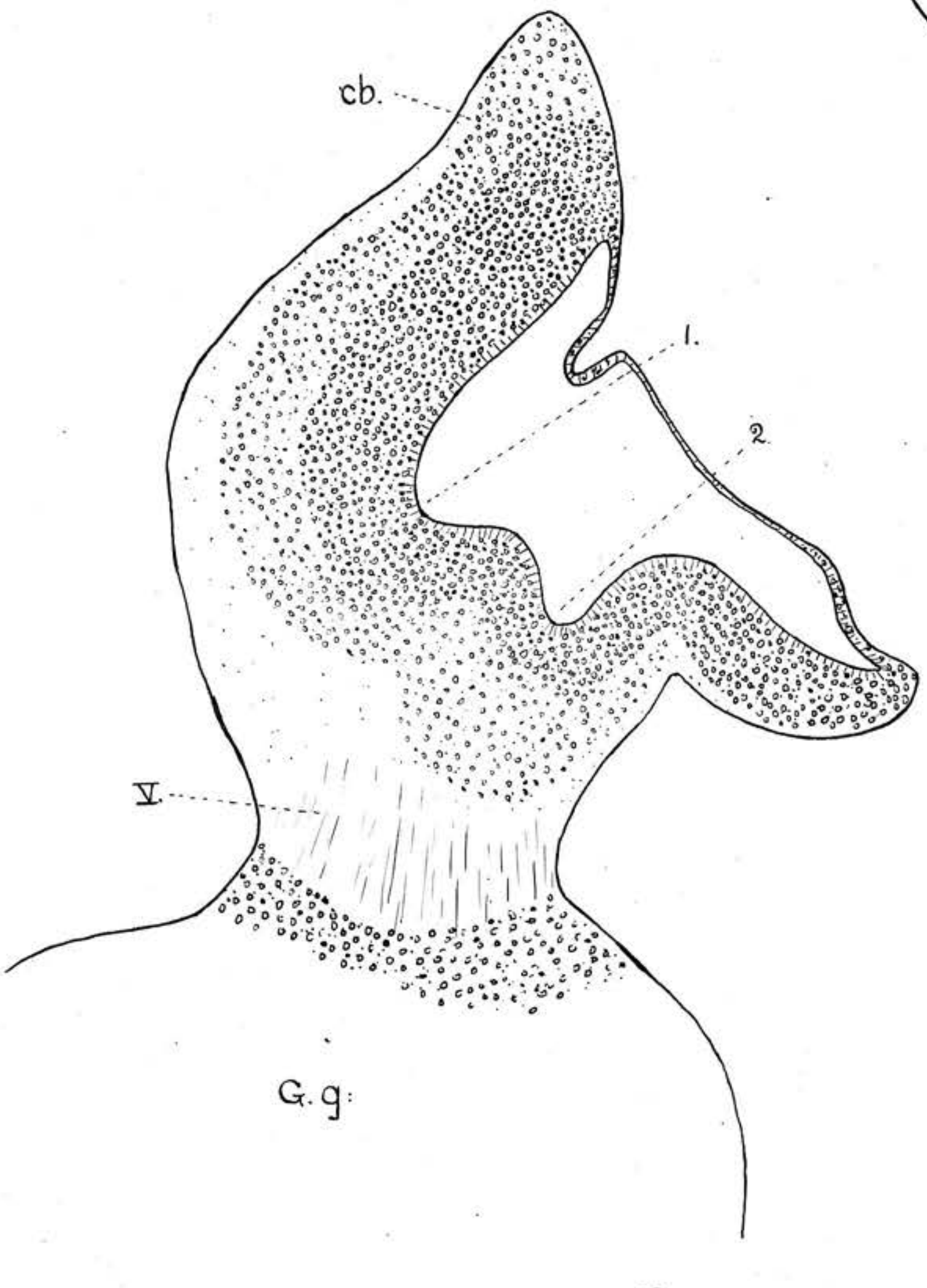

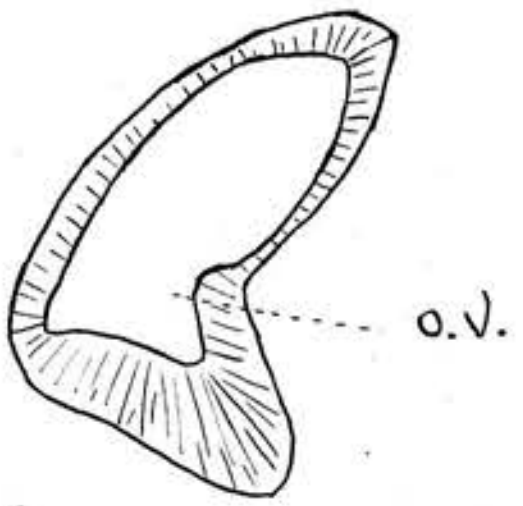

Fig: 23.

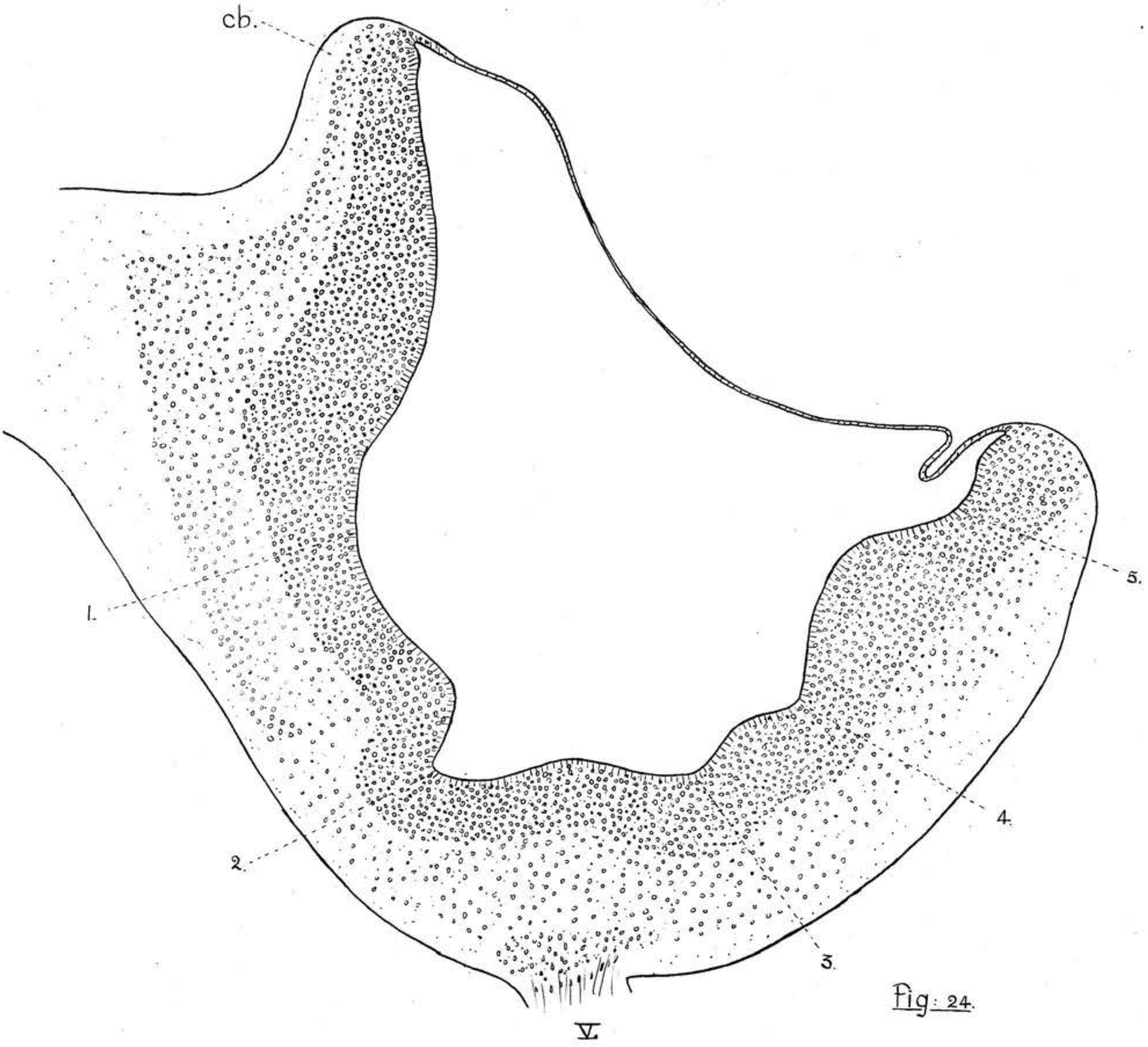

Fig: 24.

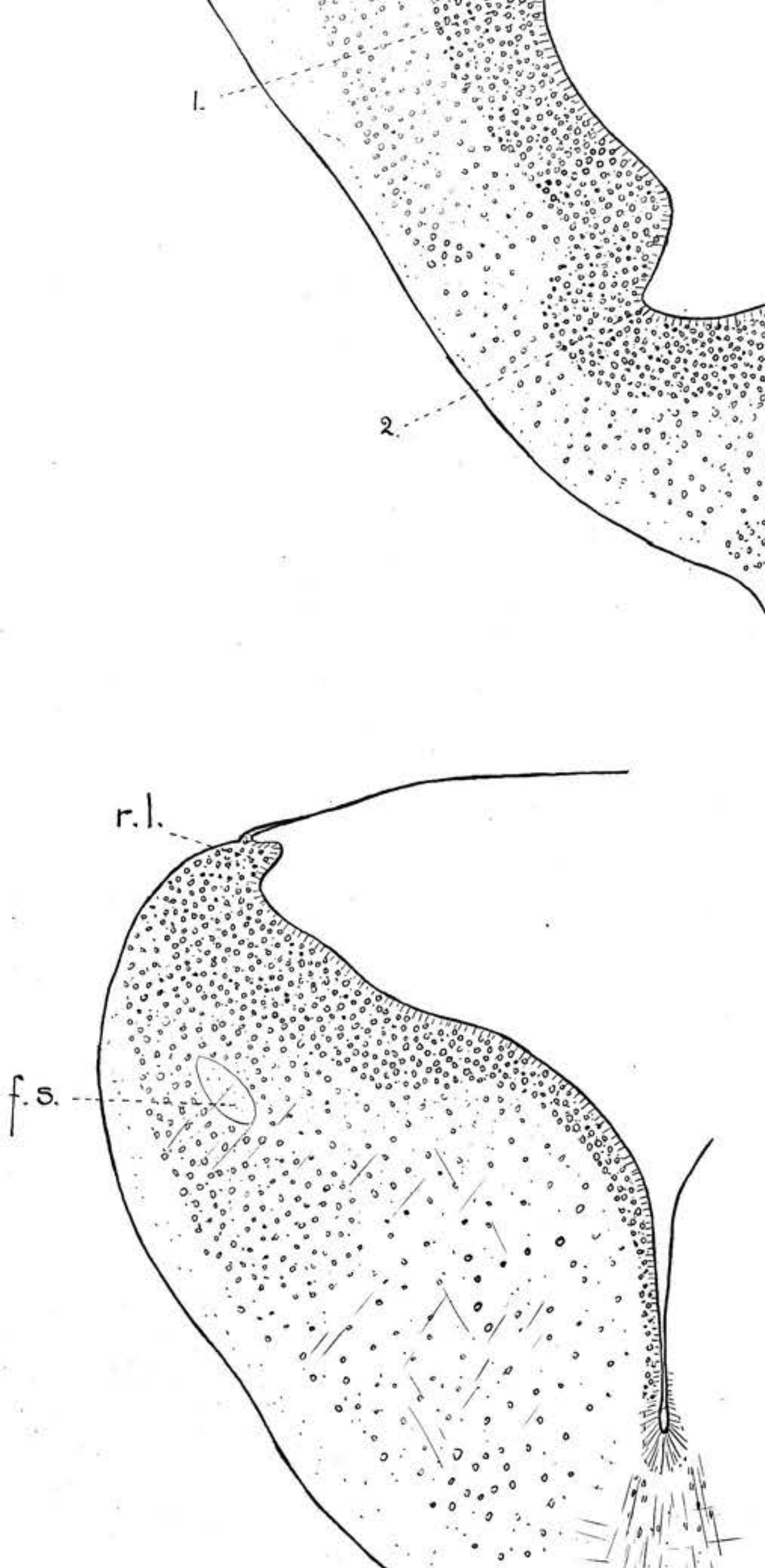

Fig: 25.

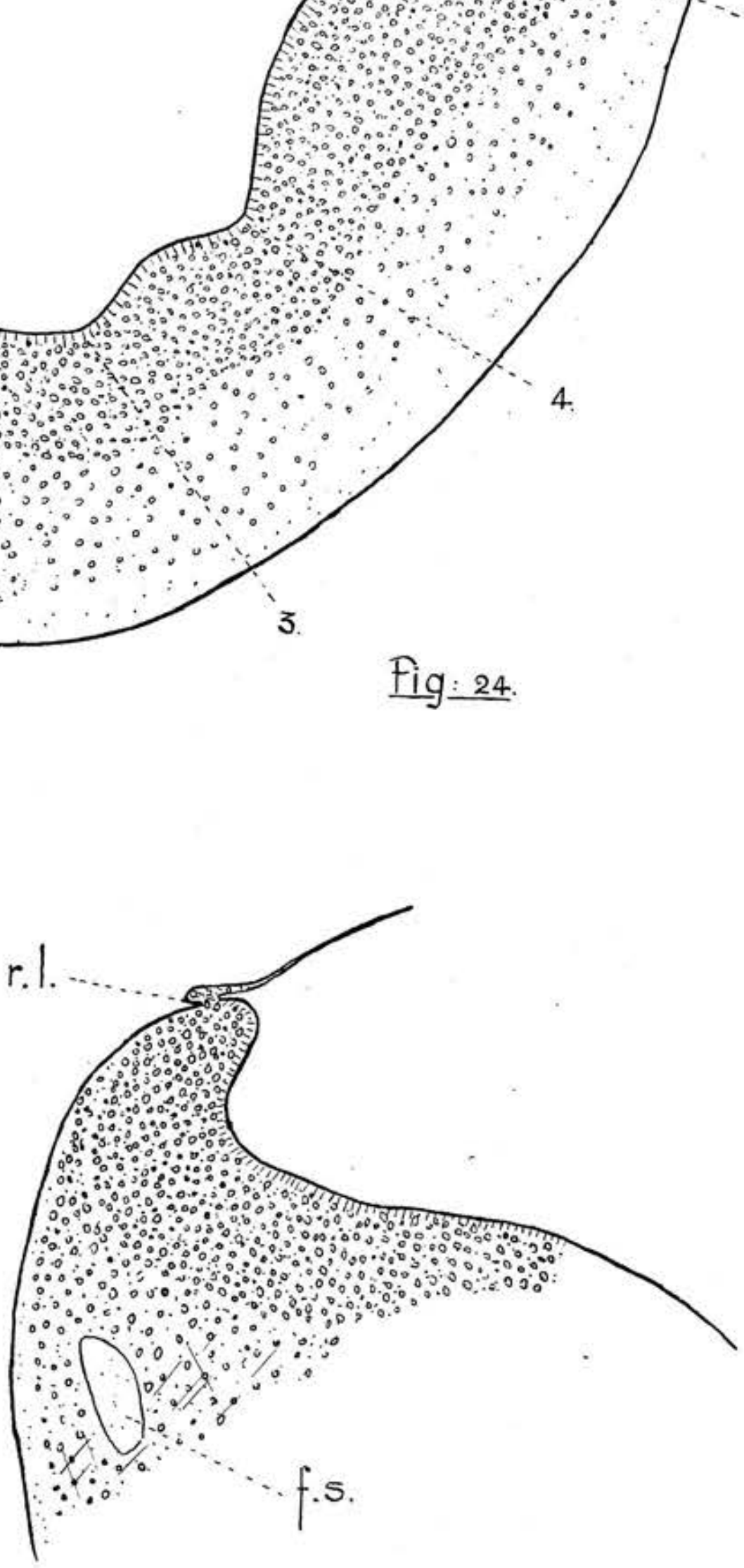

Fig: 26.

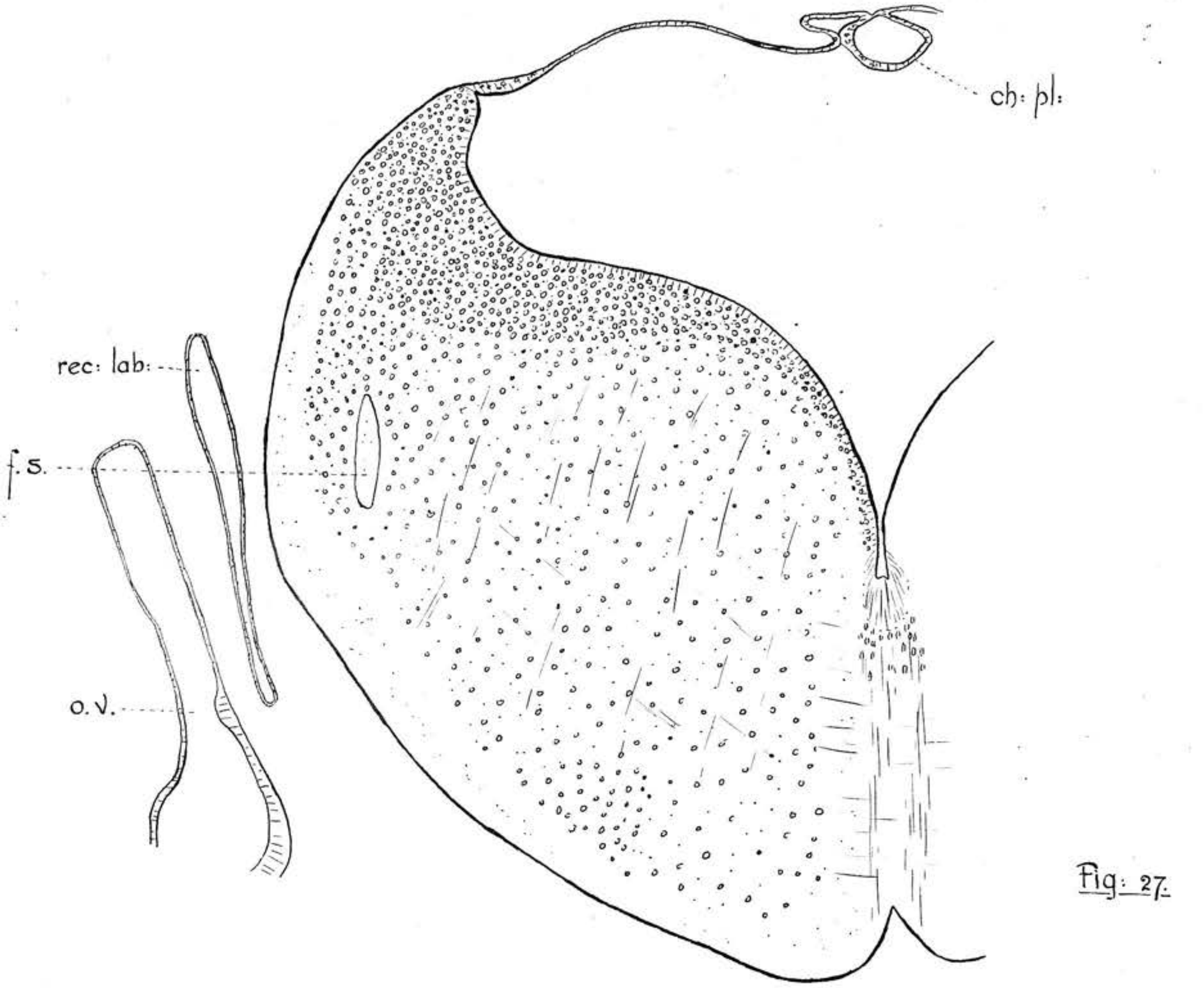

Fig: 27.

Fig: 28.

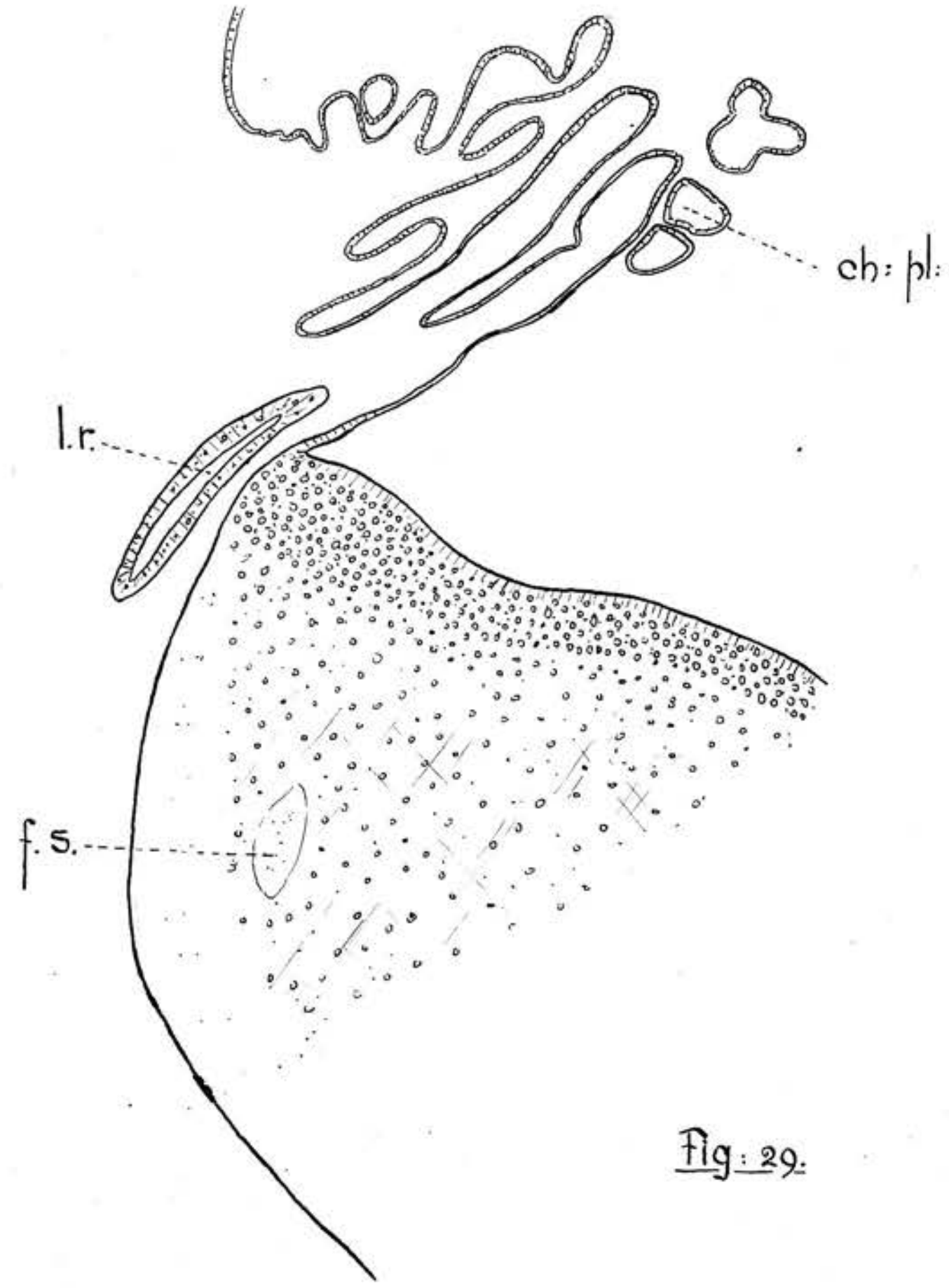

Fig: 29.

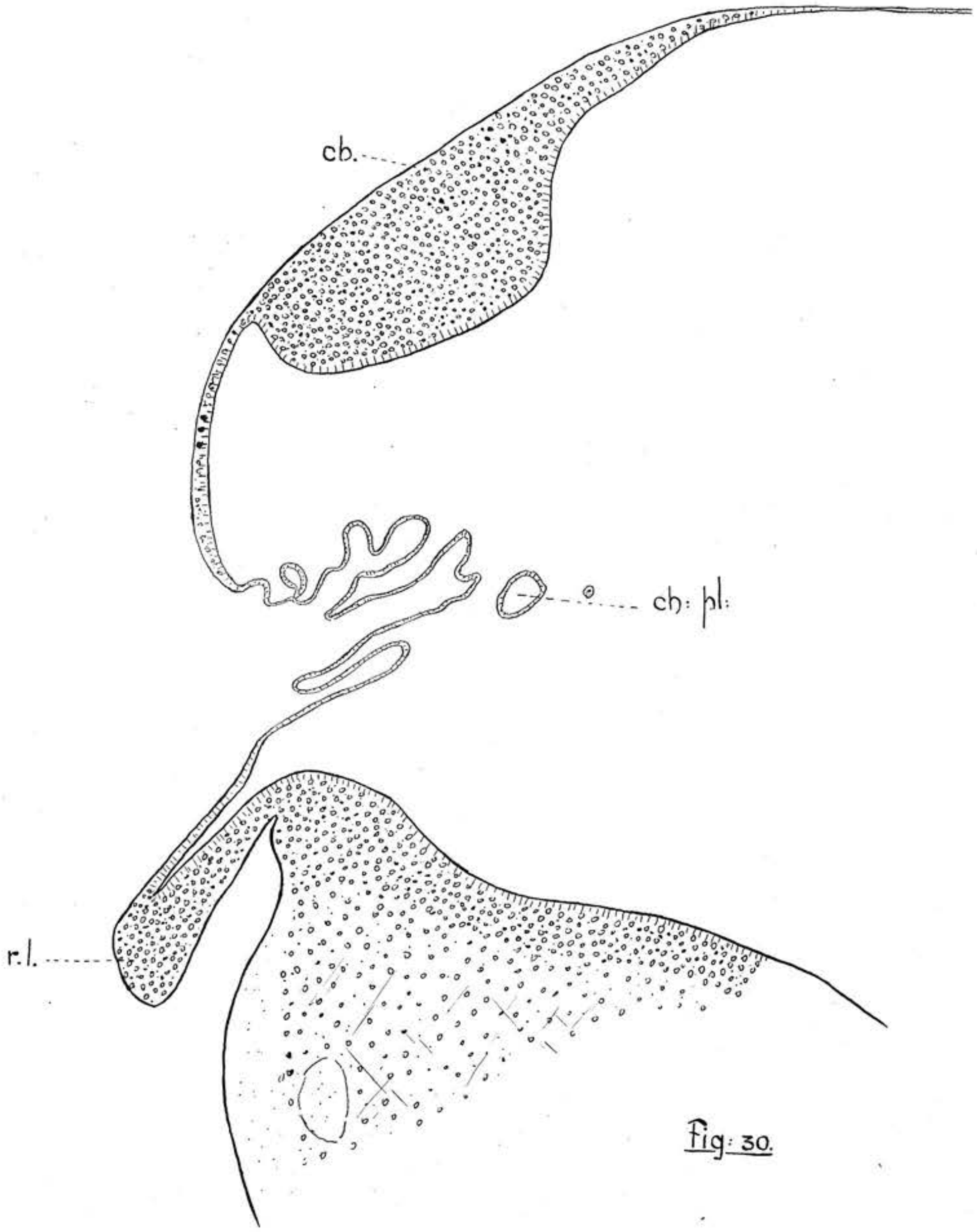

Fig: 30.

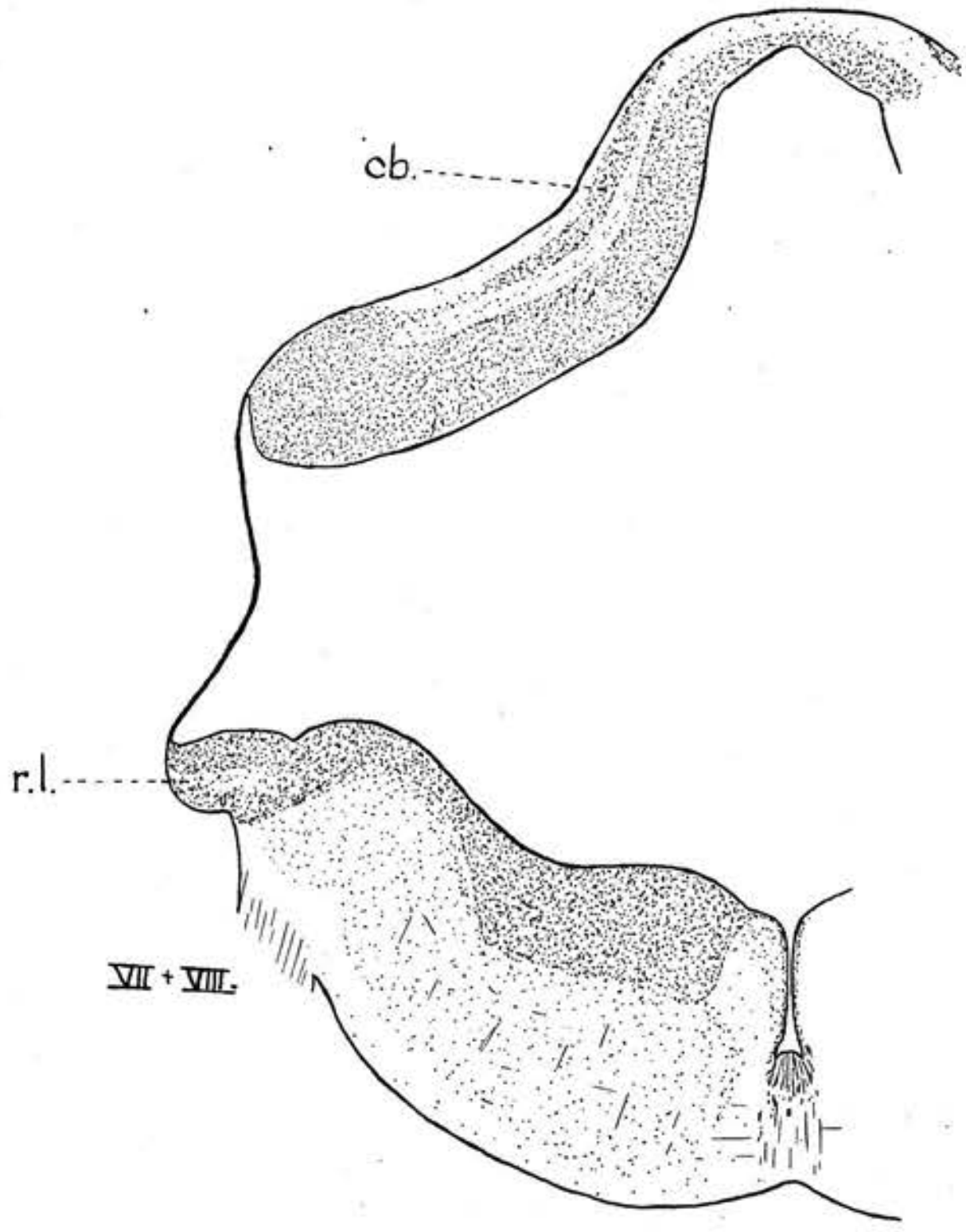

Fig: 31.

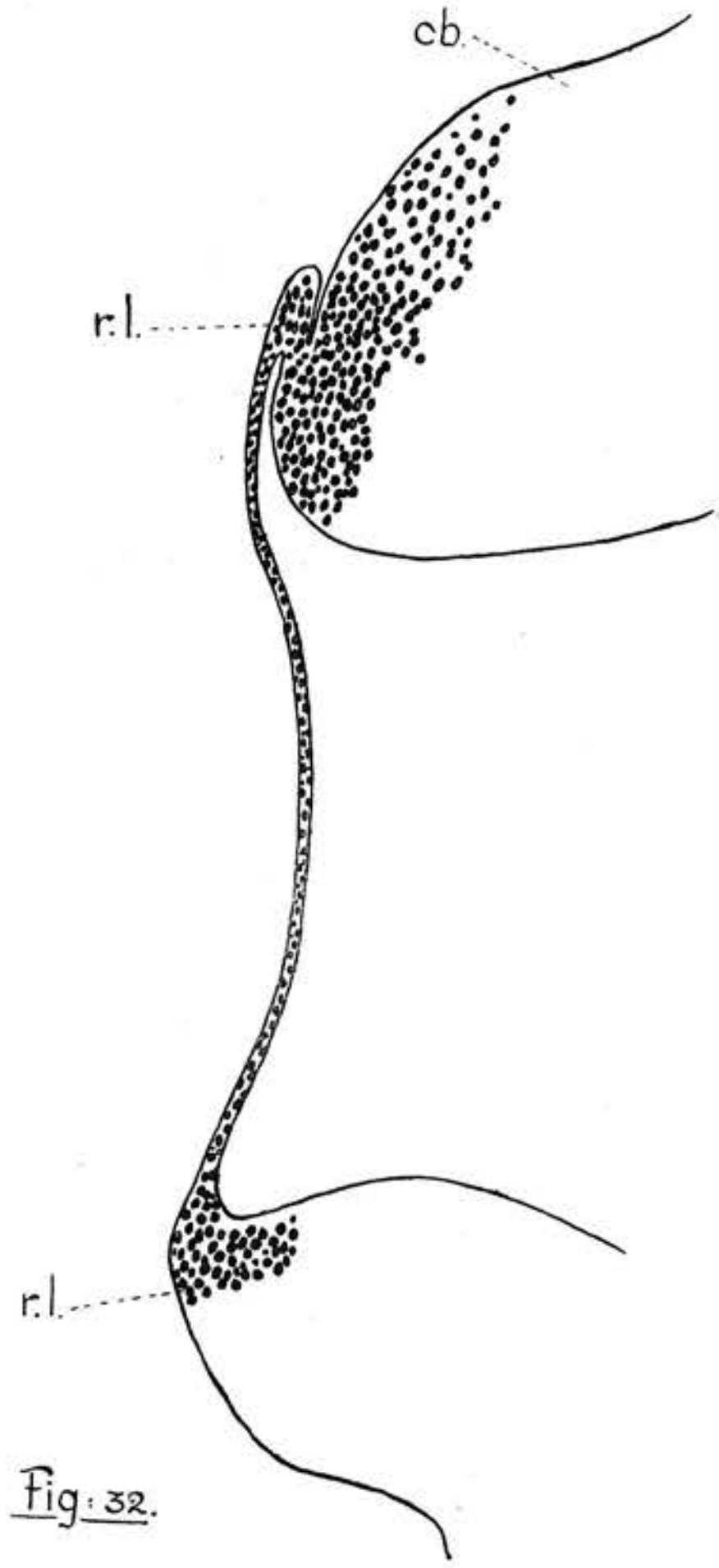

Fig: 32.

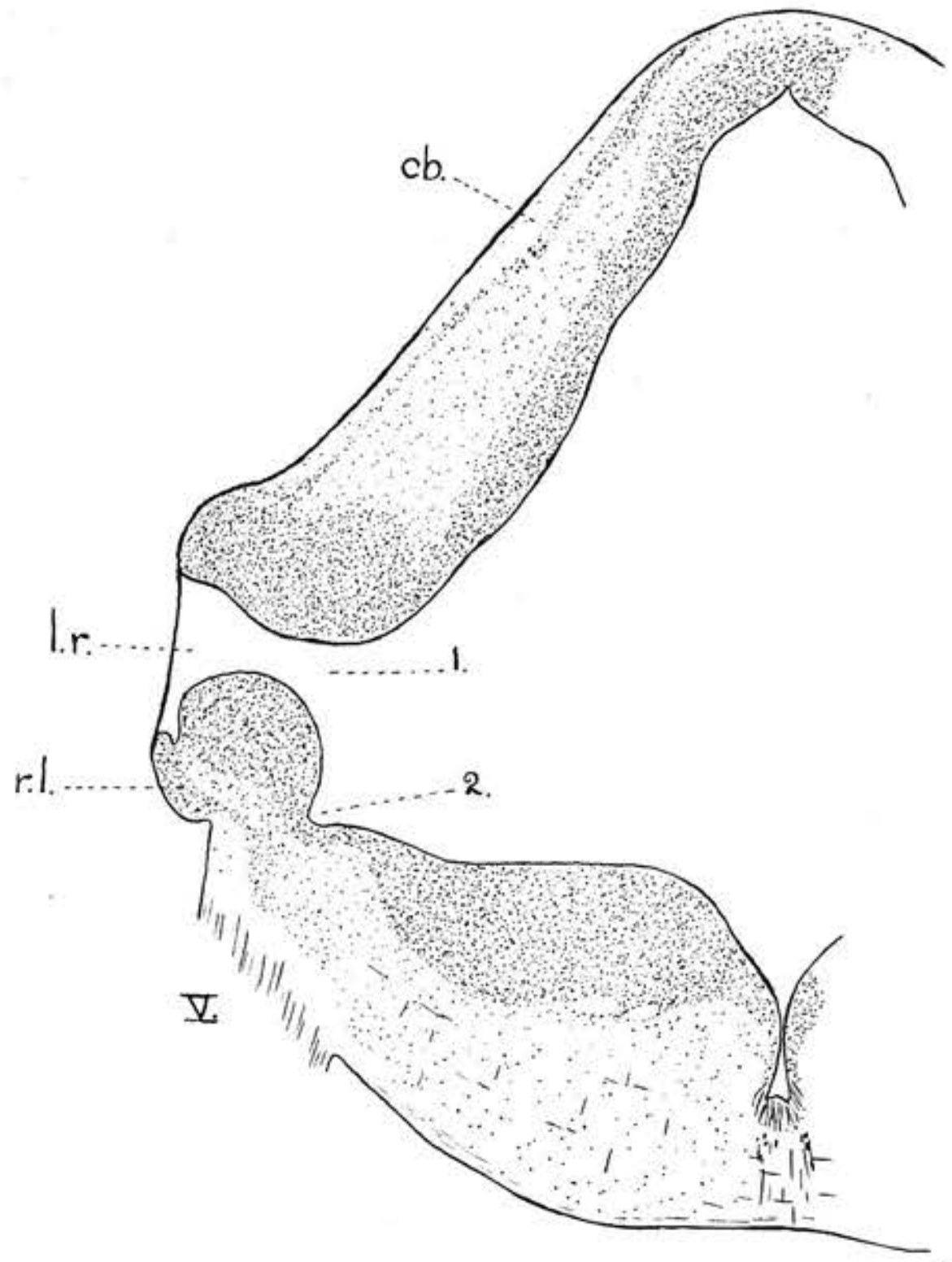

Fig: 33.

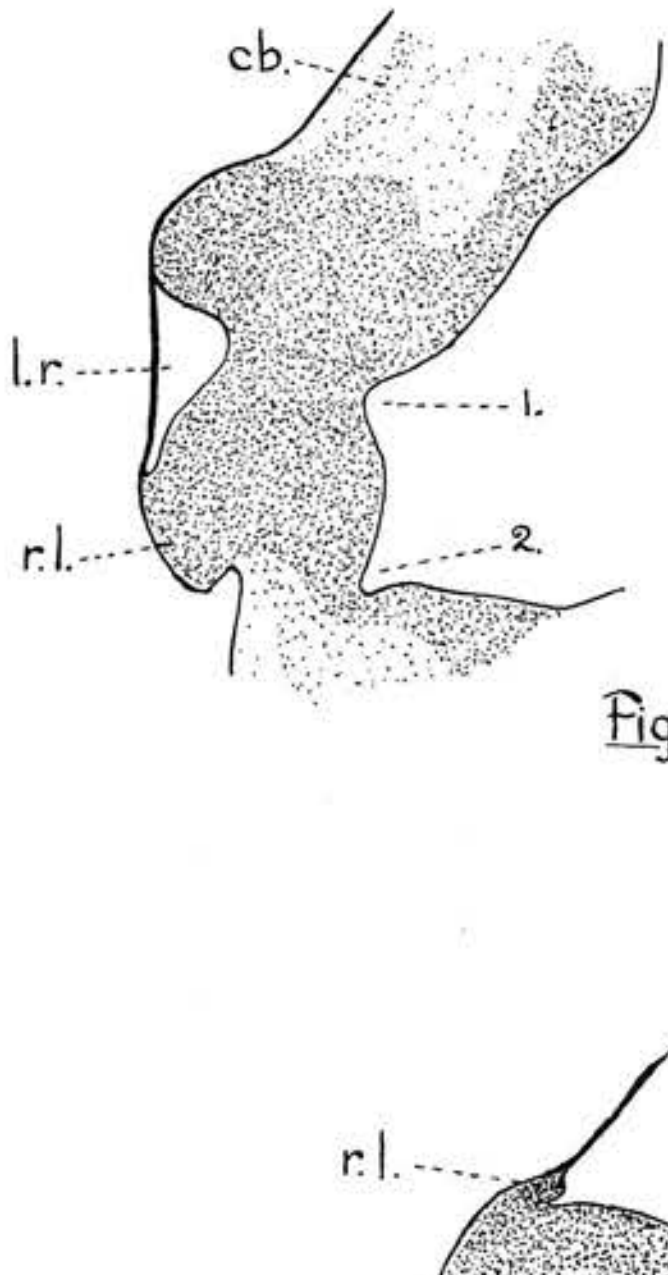

Fig: 34.

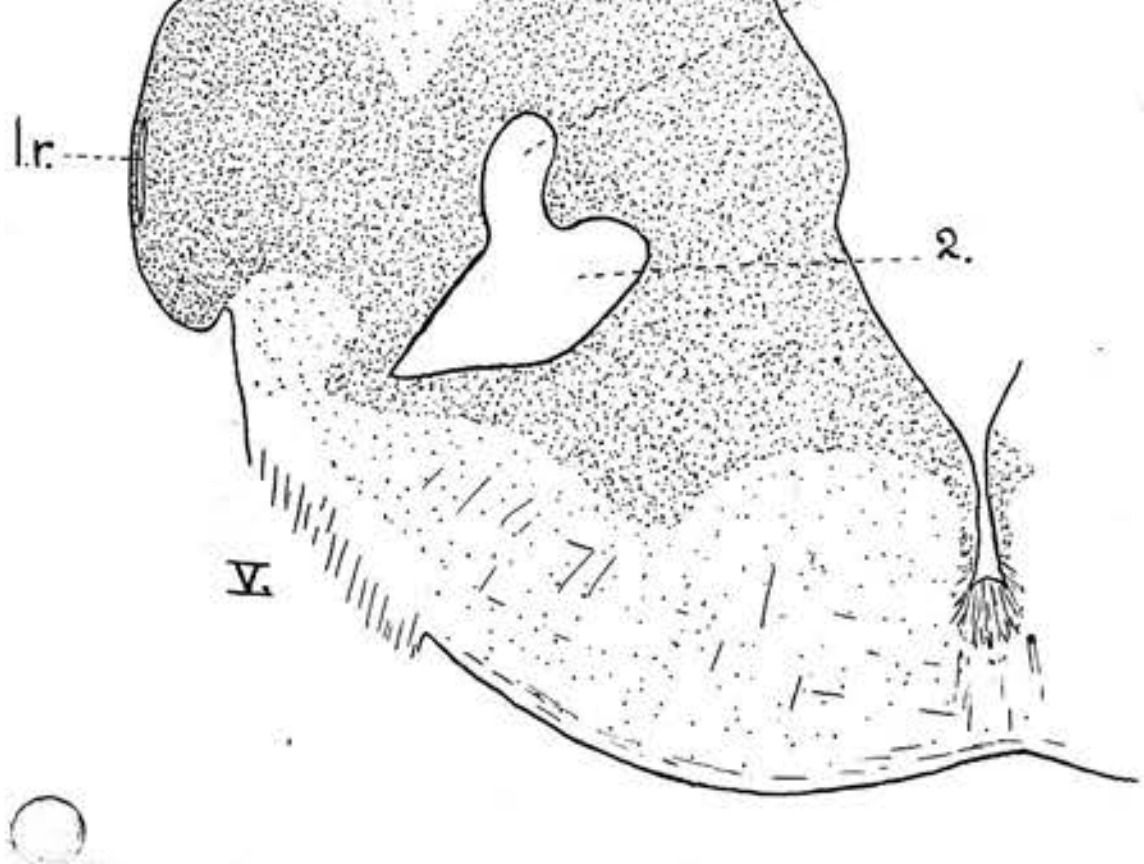

Fig: 35.

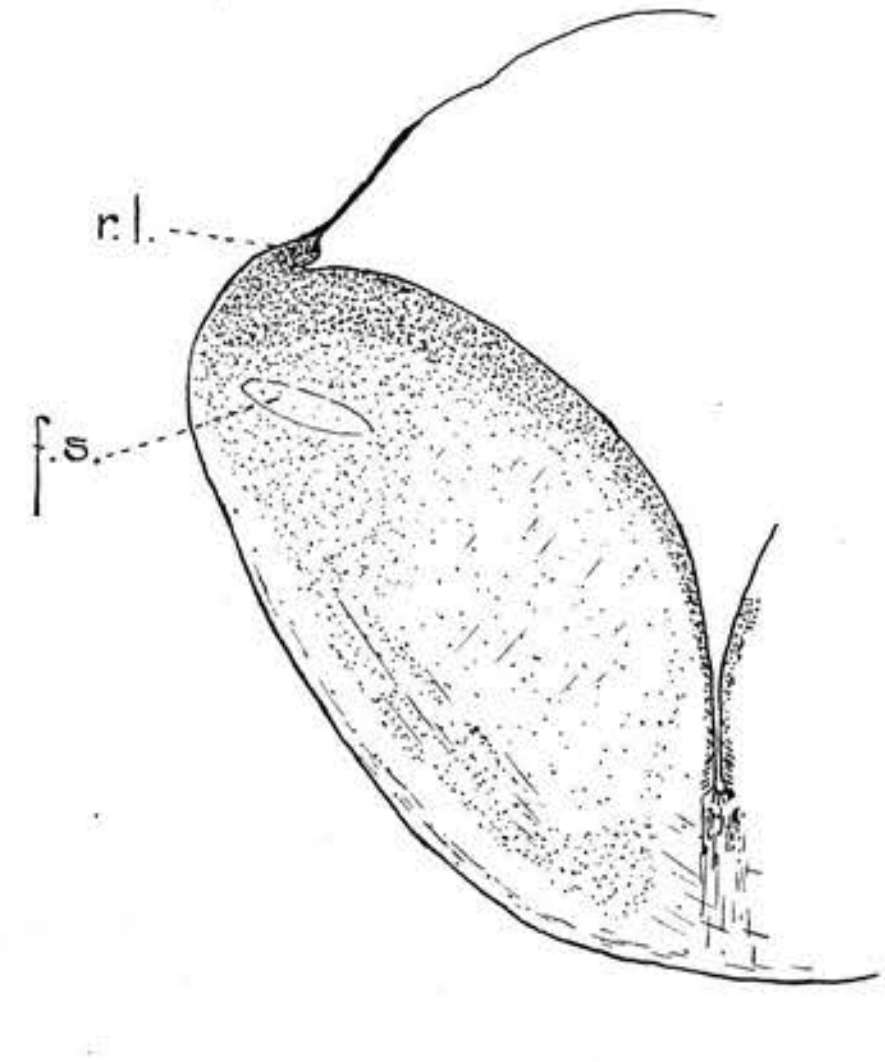

Fig: 36.

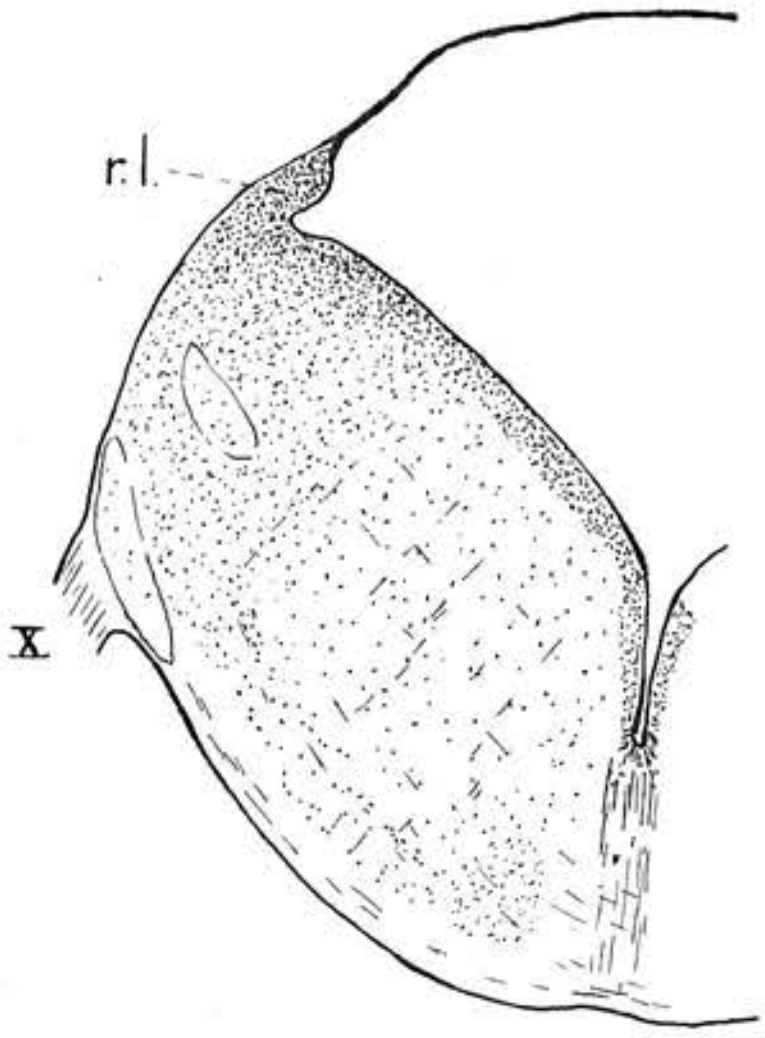

Fig: 37.

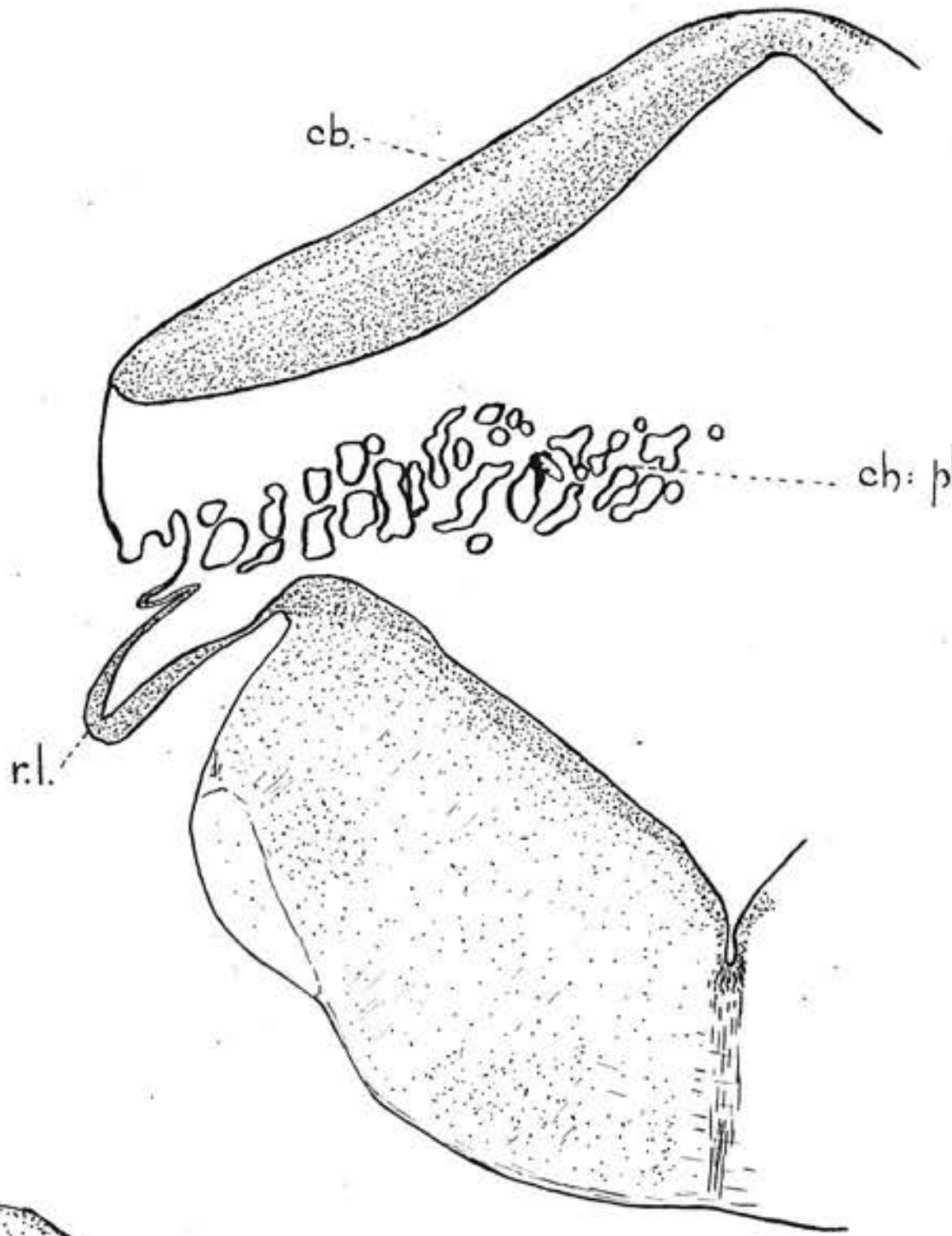

Fig: 38.

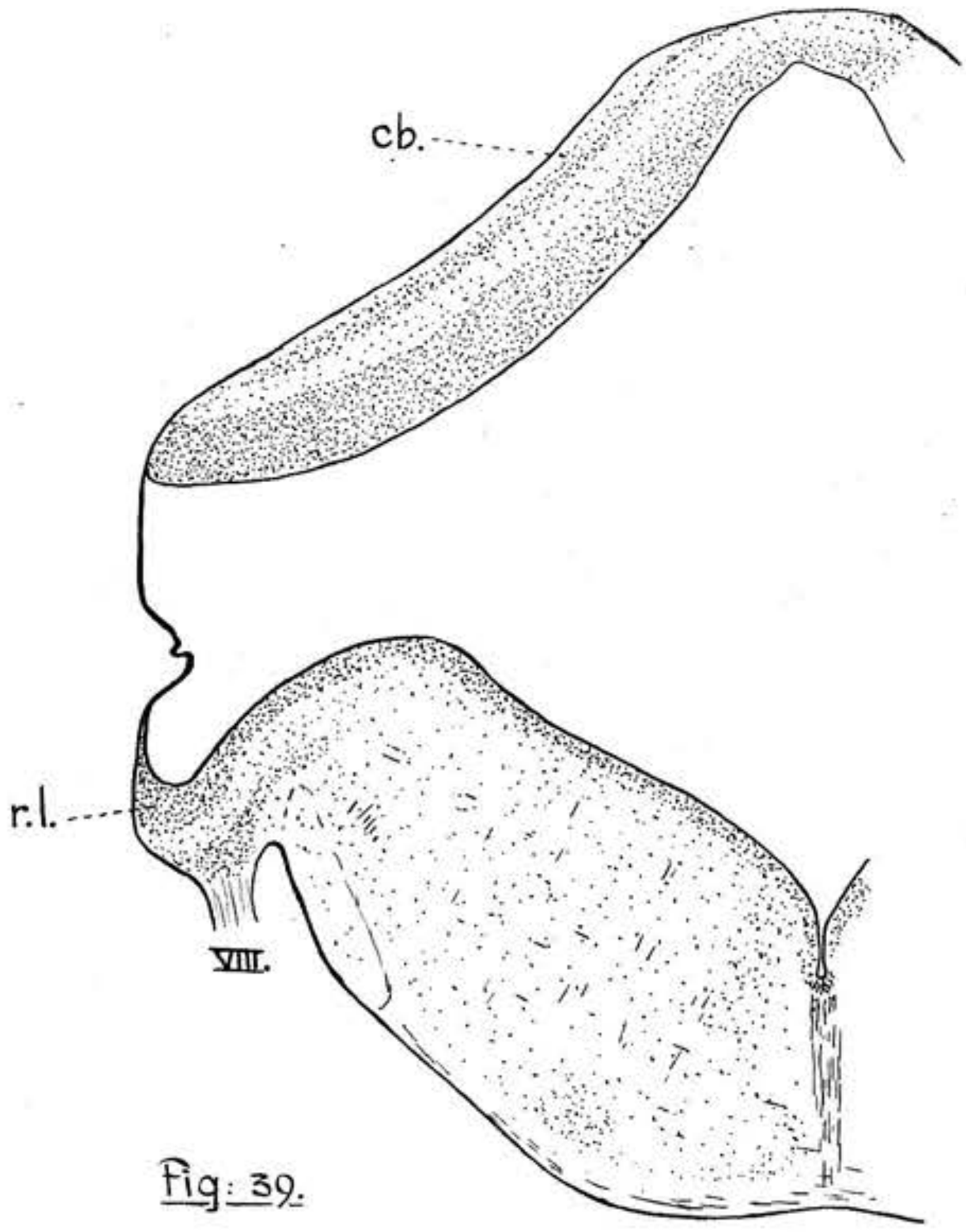

Fig: 39.

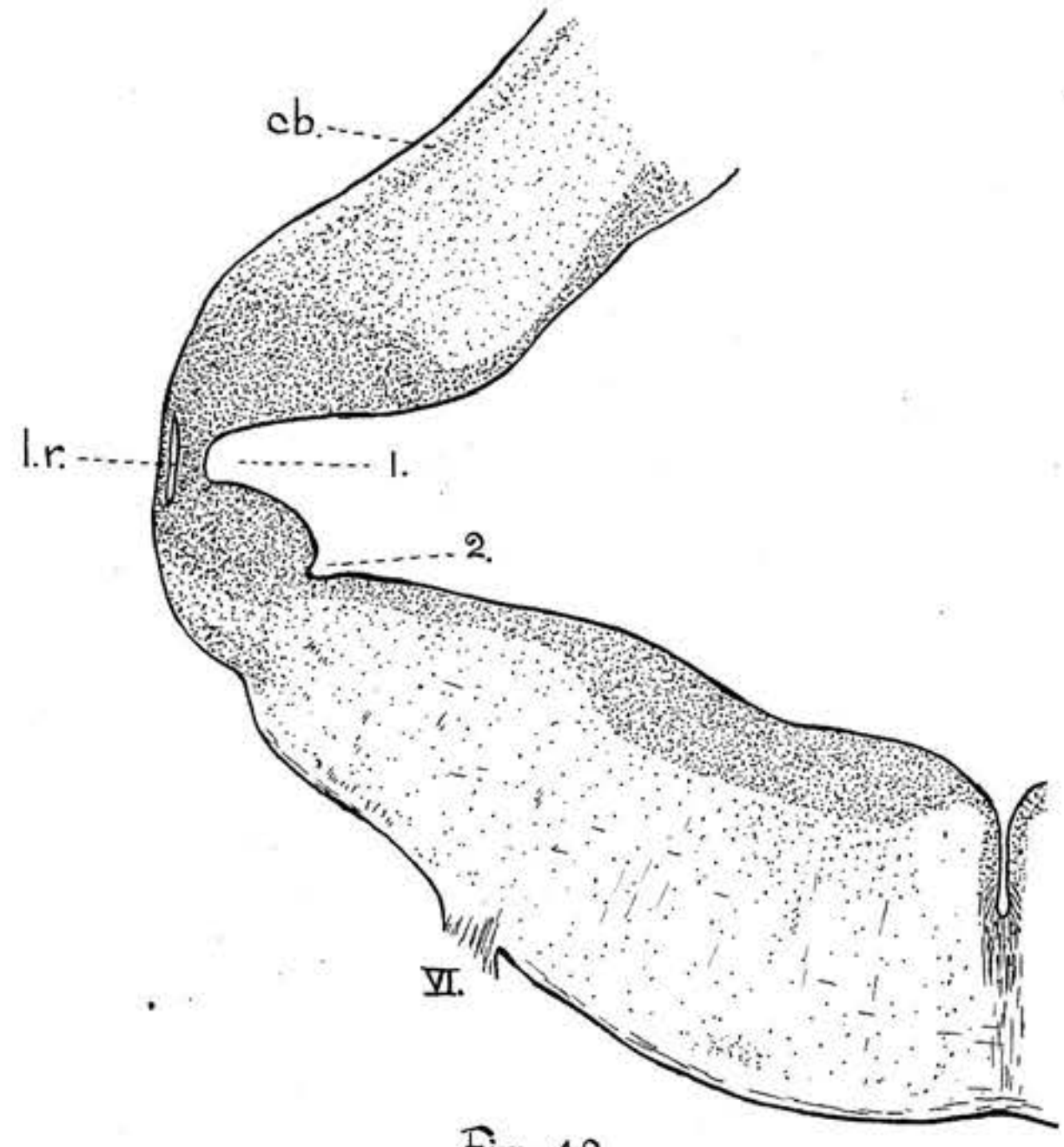

Fig: 40.

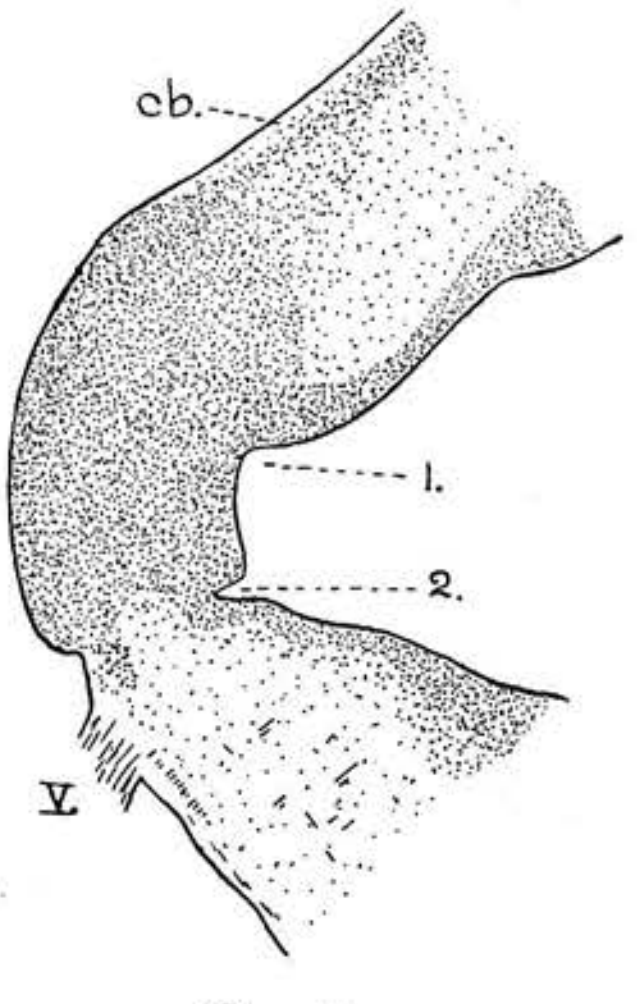

Fig: 41.

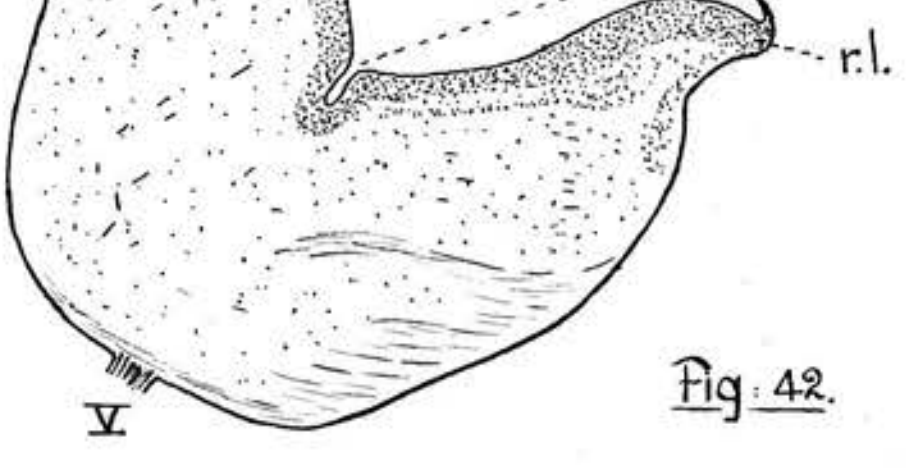

Fig: 42.

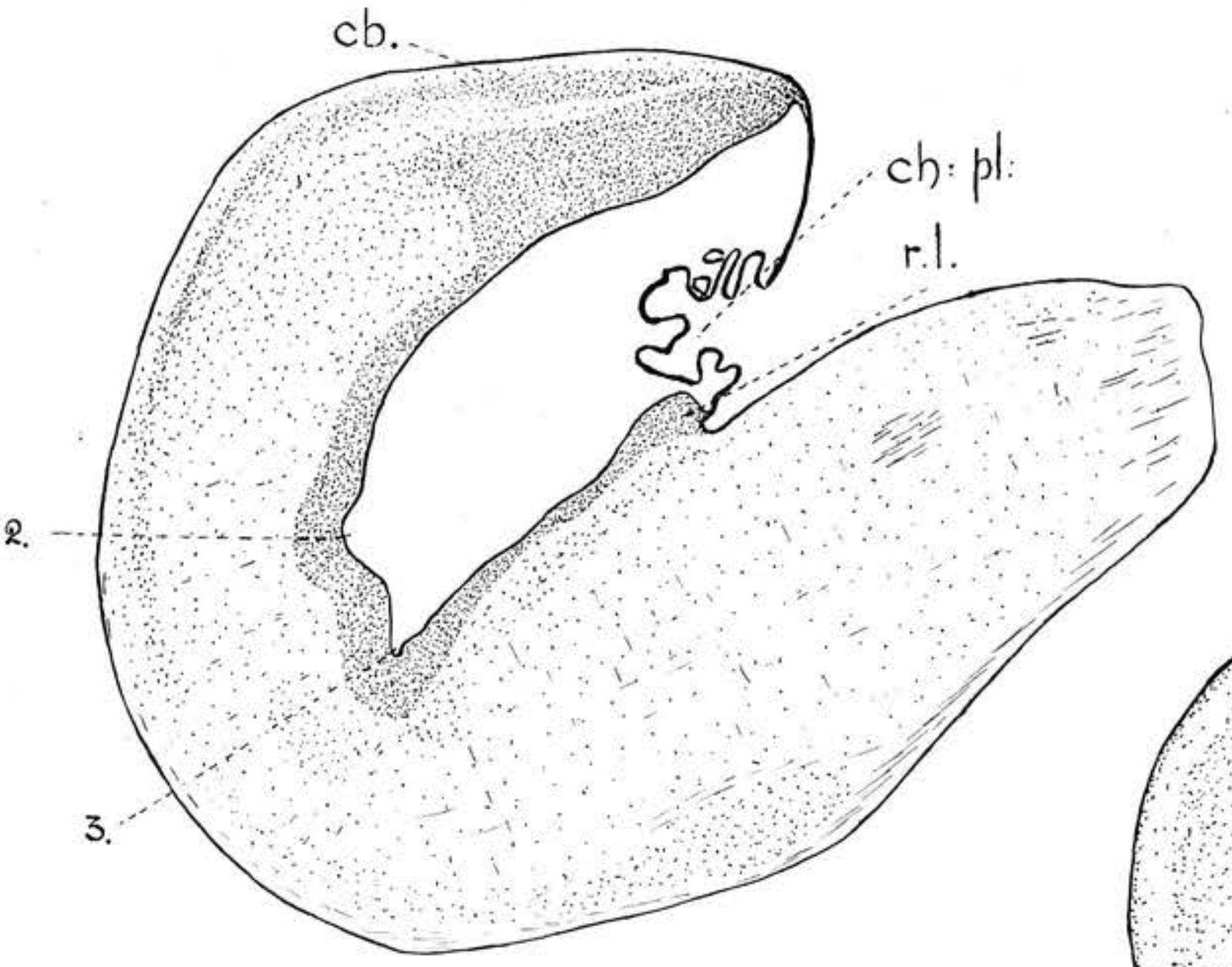

Fig: 43.

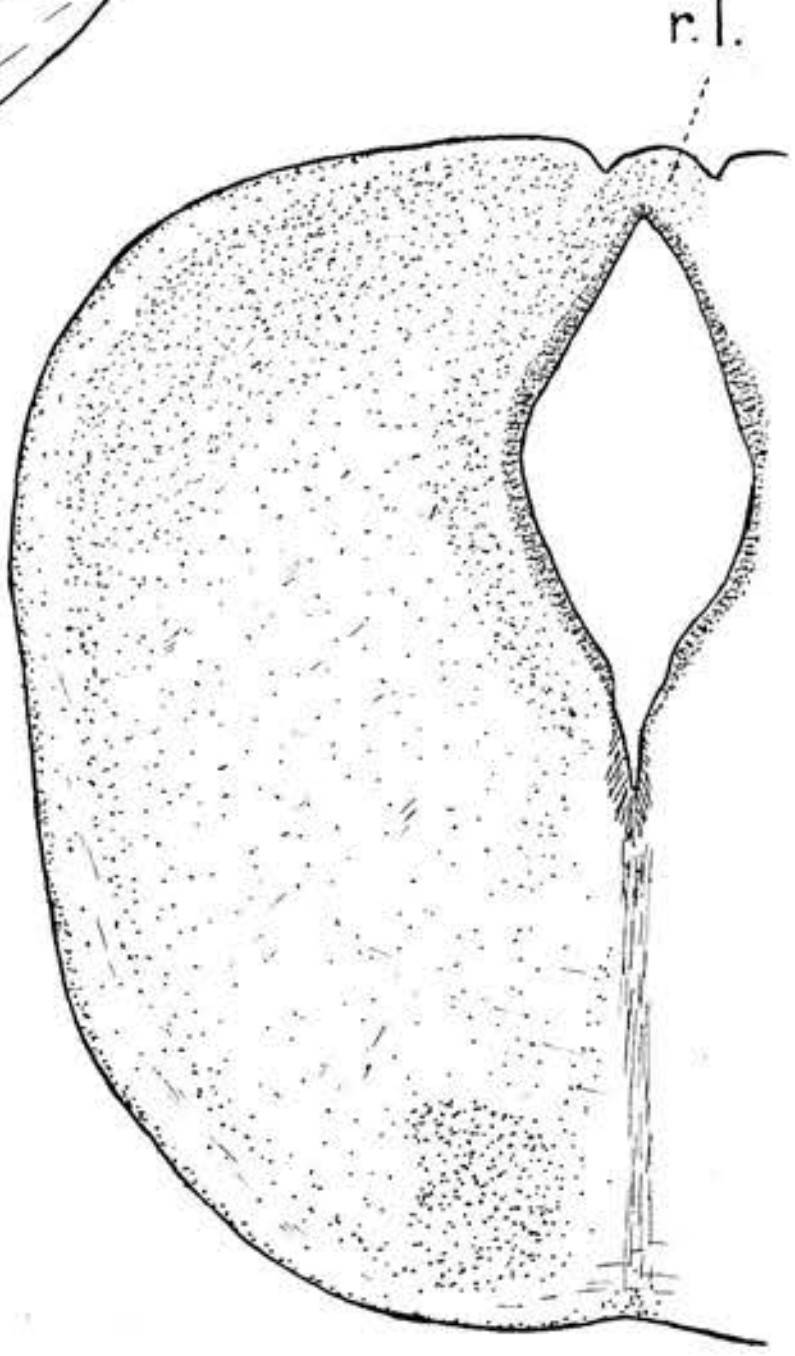

Fig: 44.

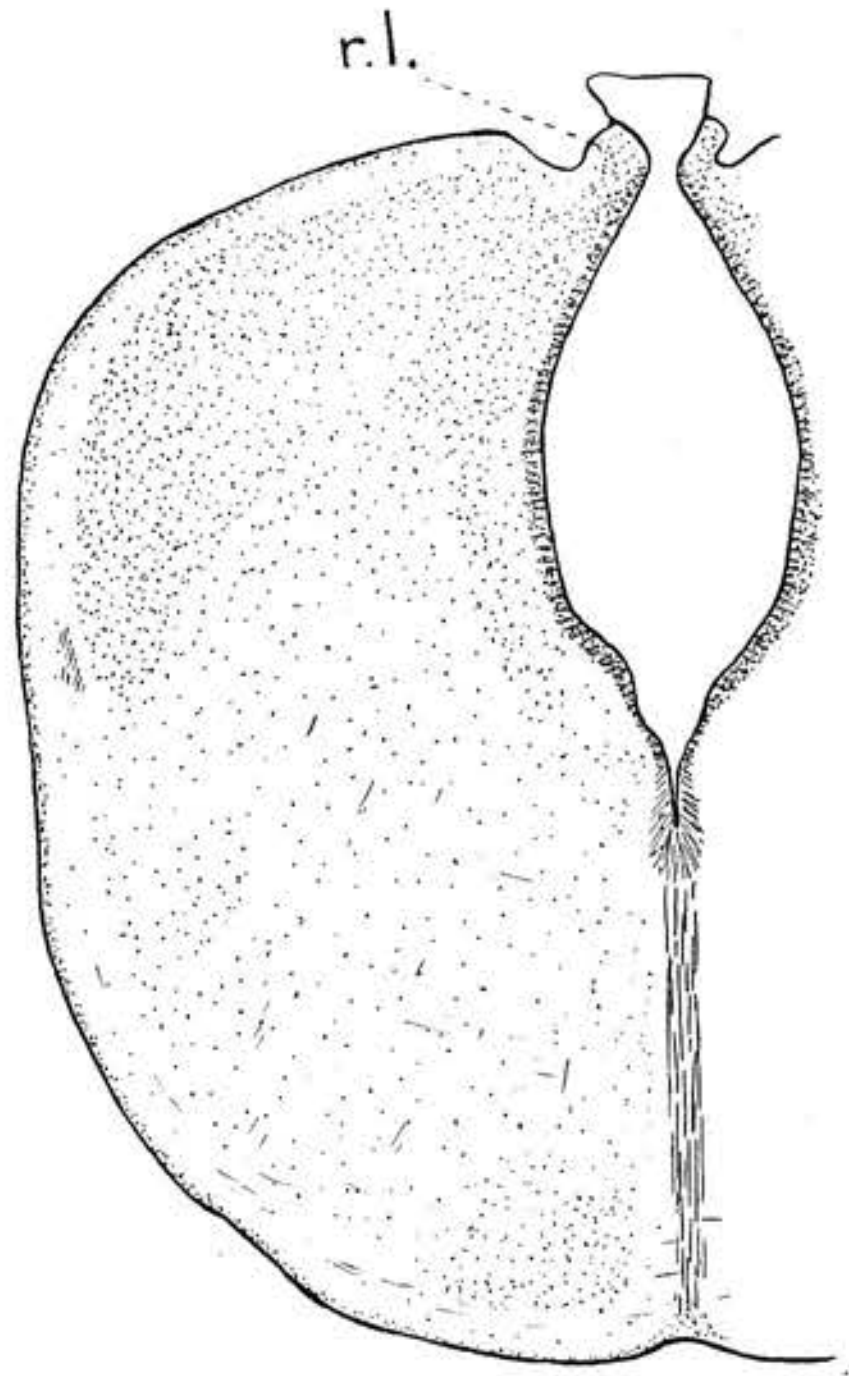

Fig: 45.

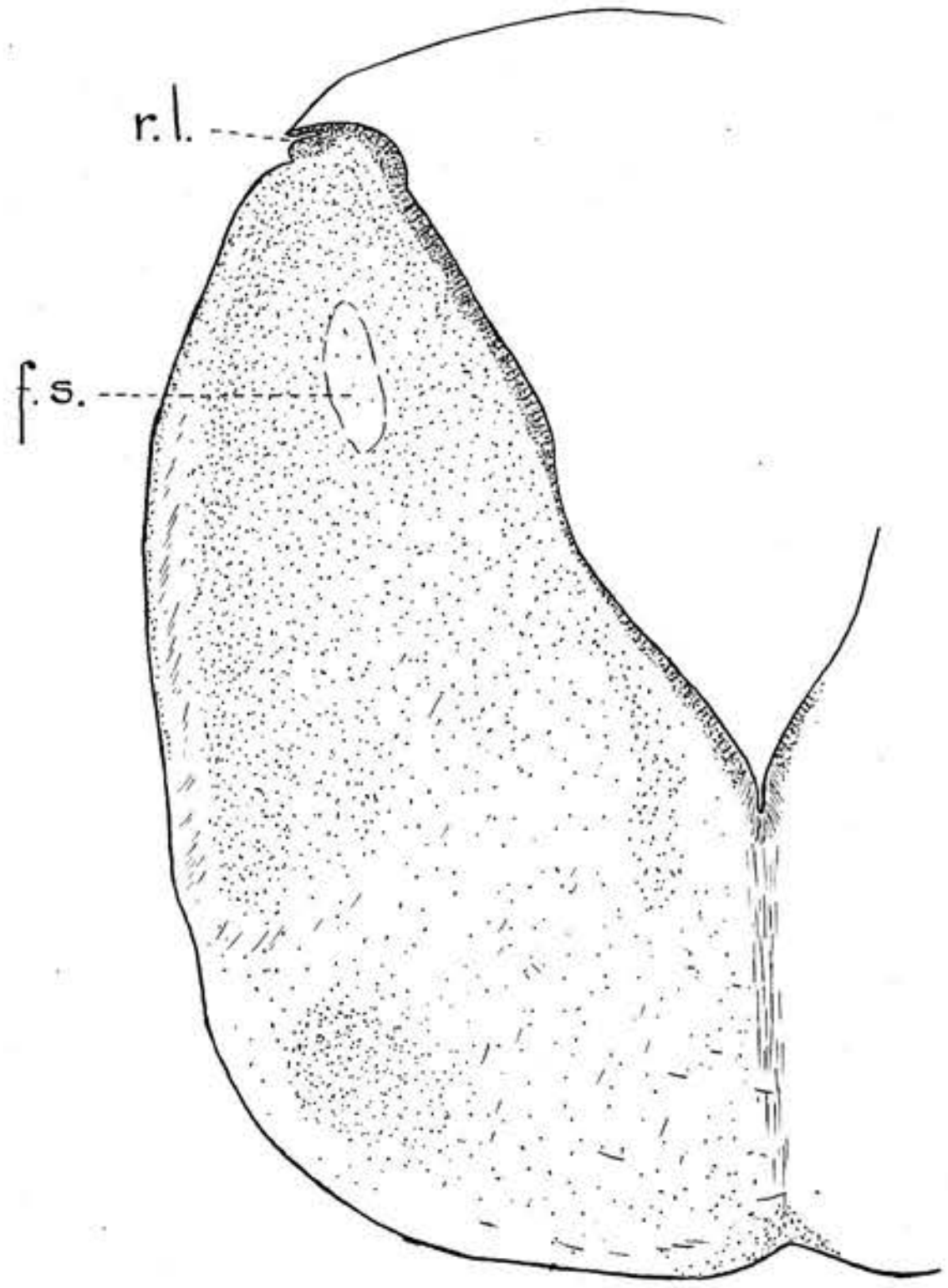

Fig: 46.

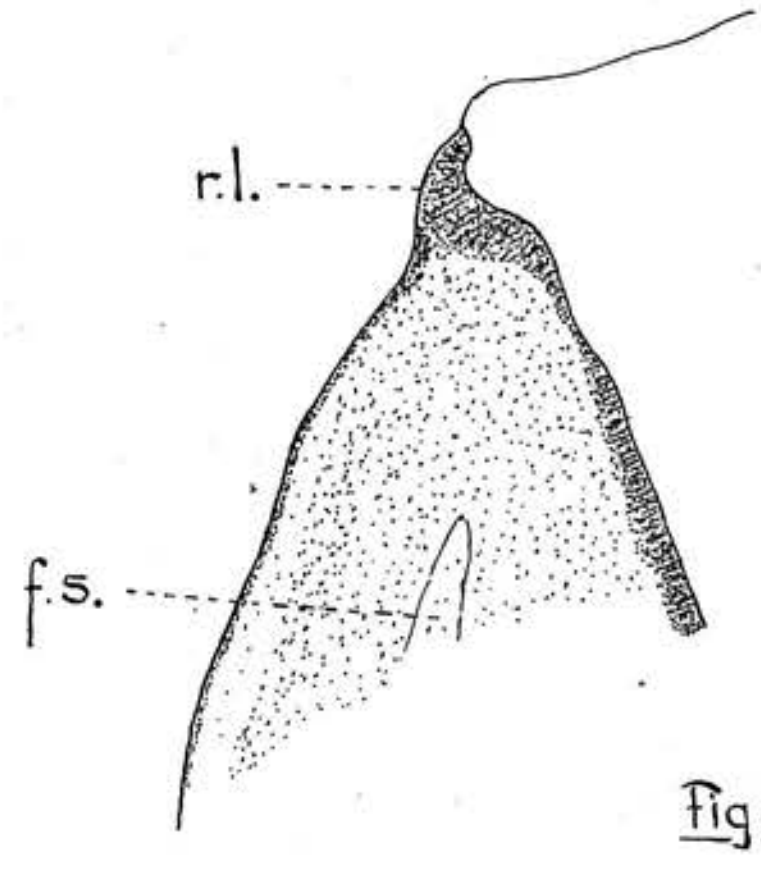

Fig: 47.

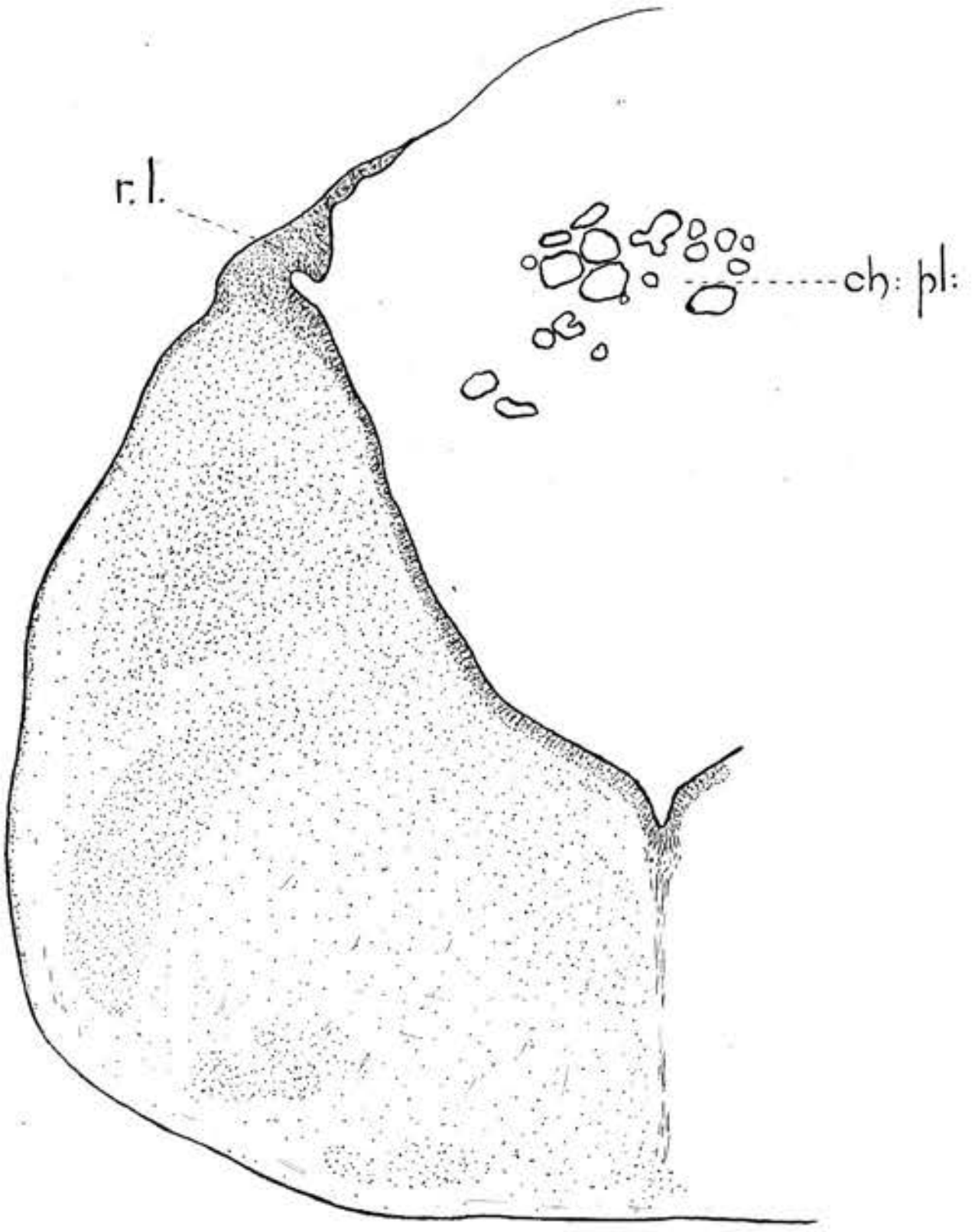

Fig: 48.

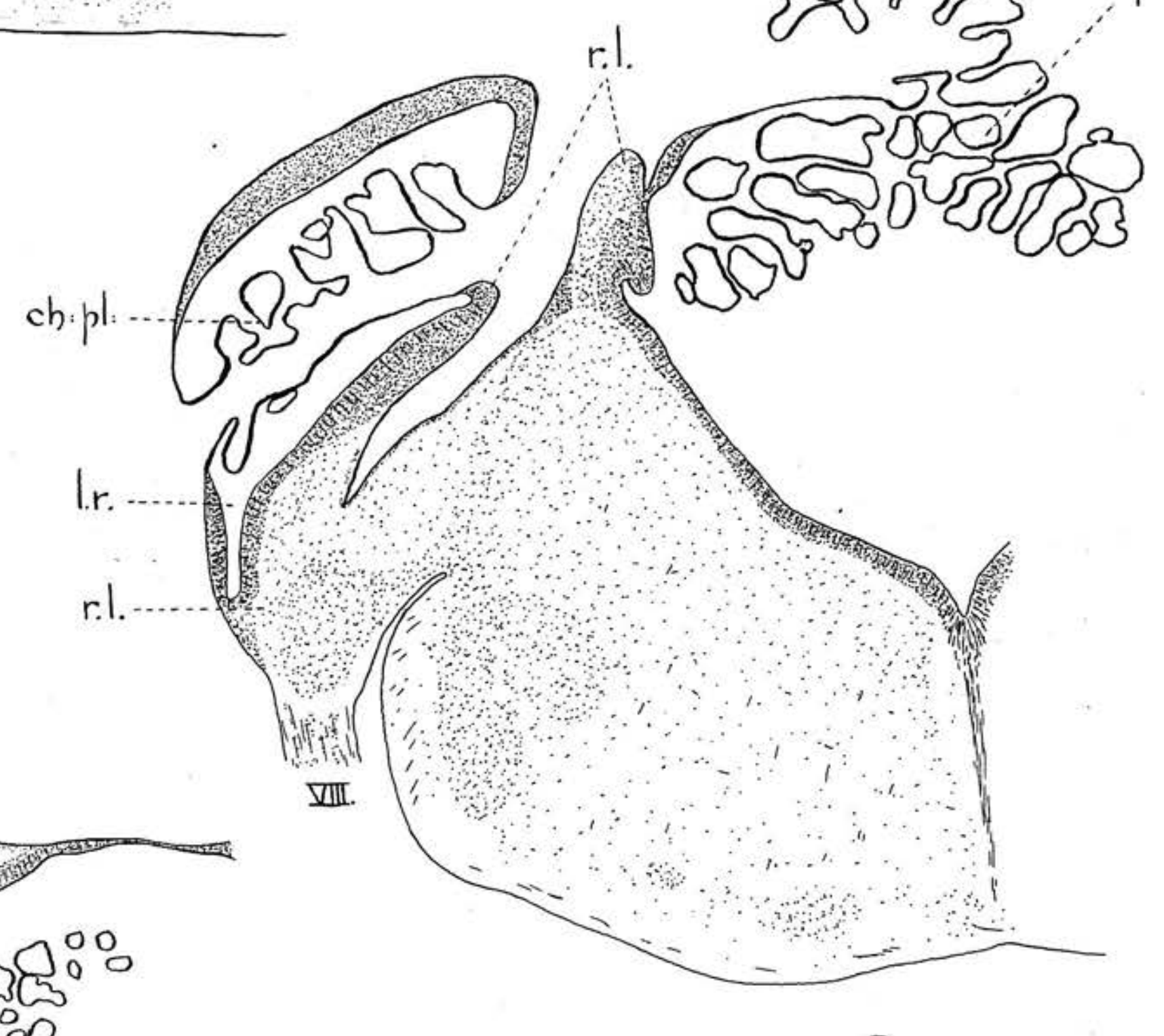

Fig: 49.

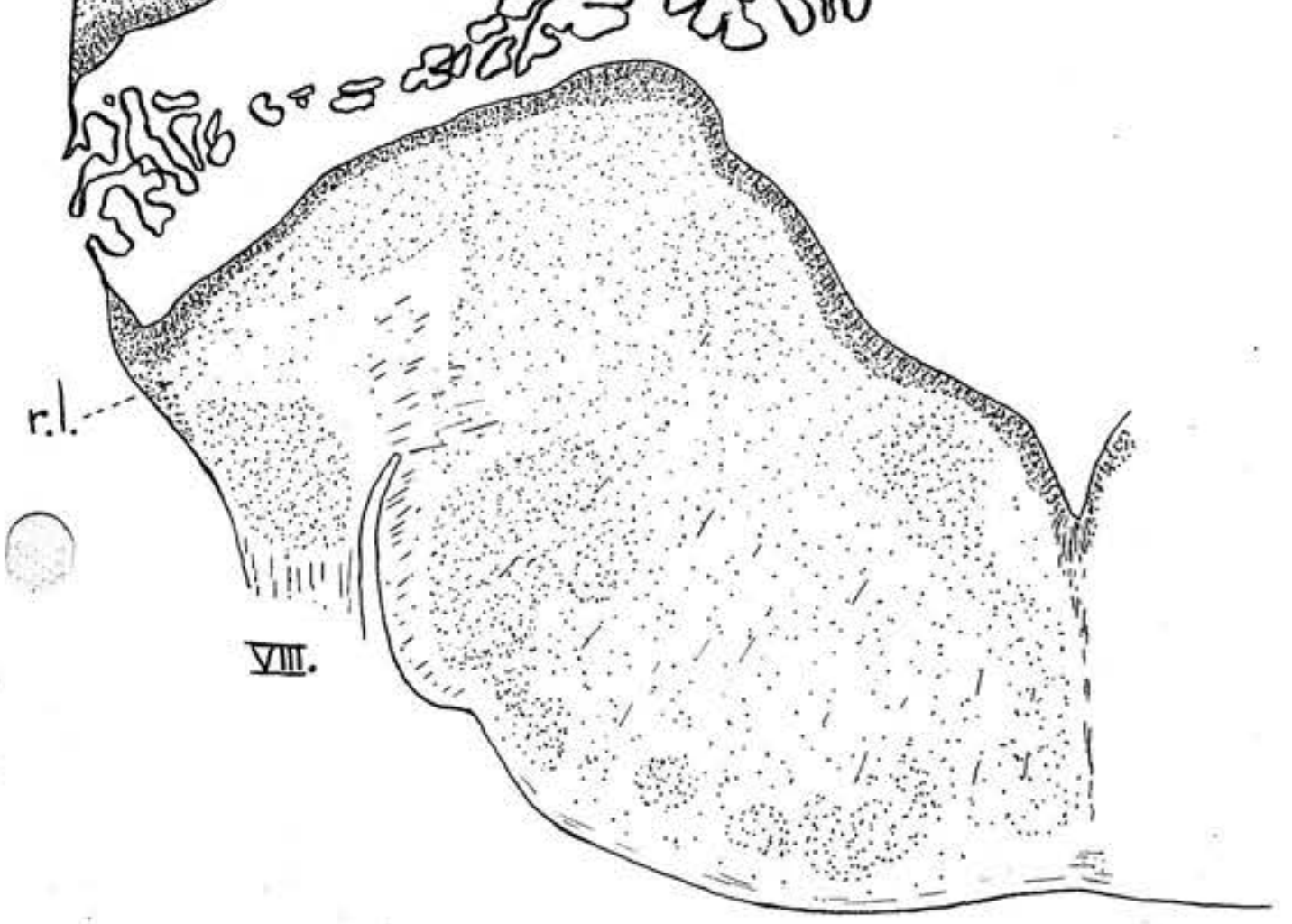

Fig: 50

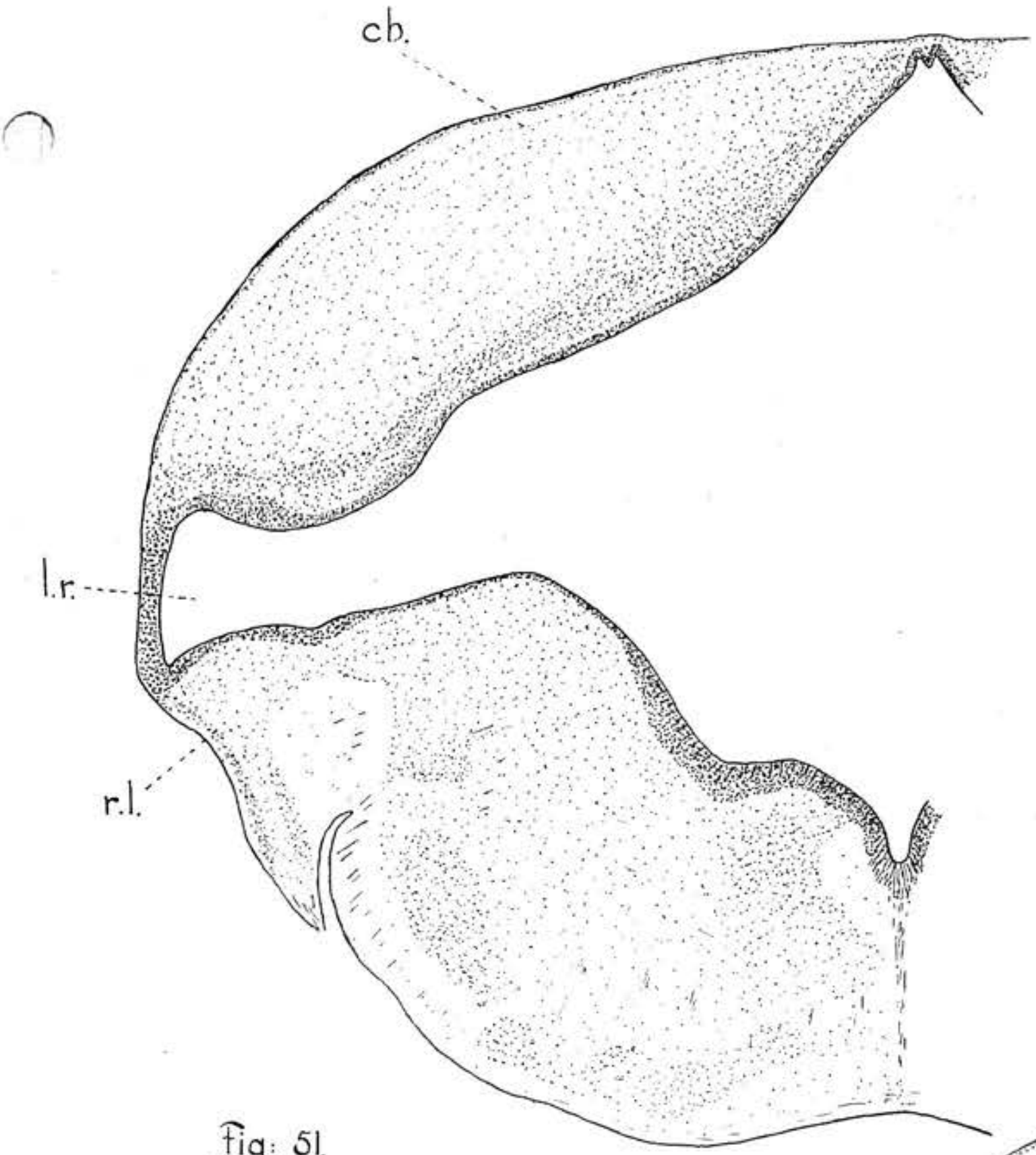

Fig: 51.

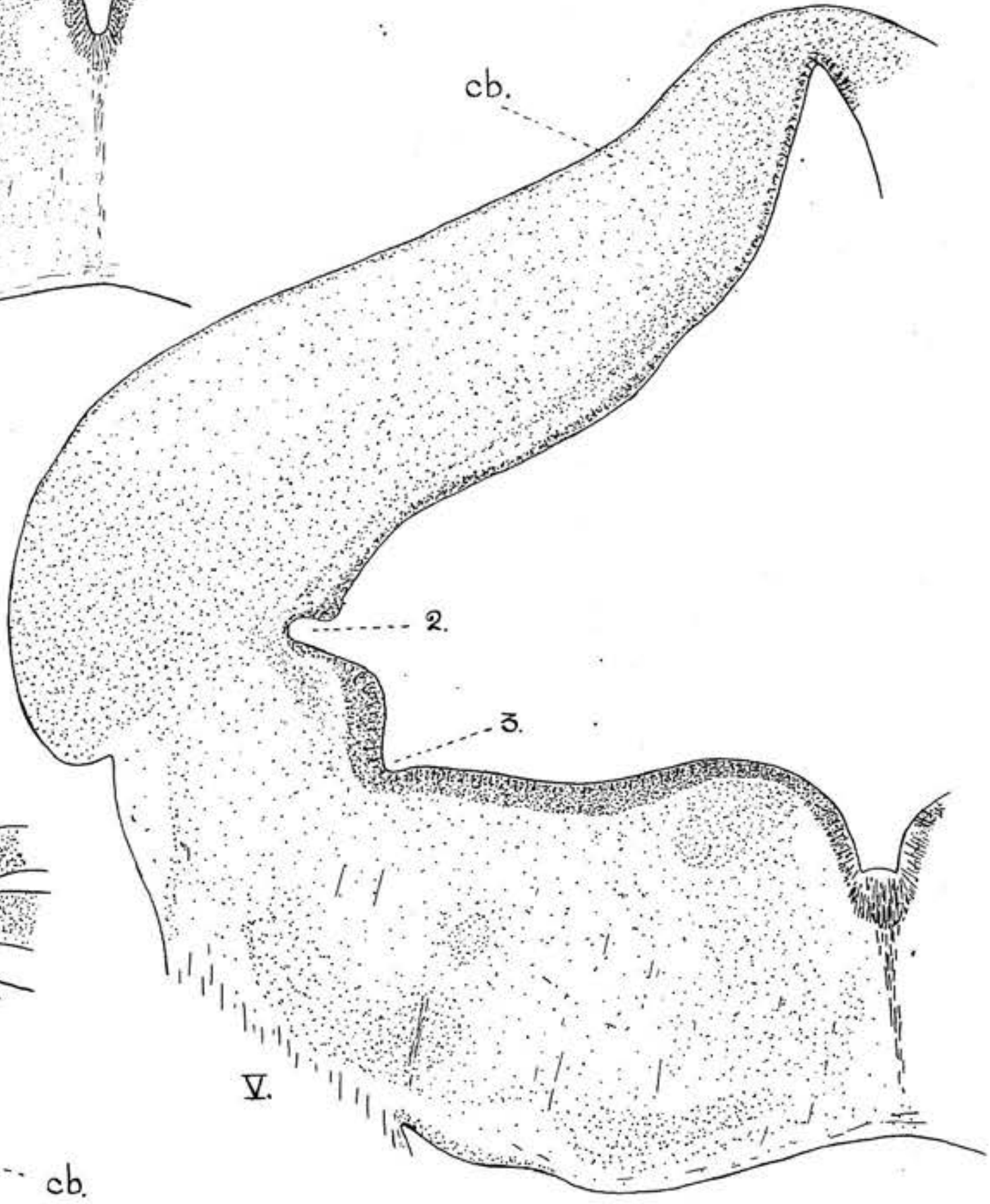

Fig: 52.

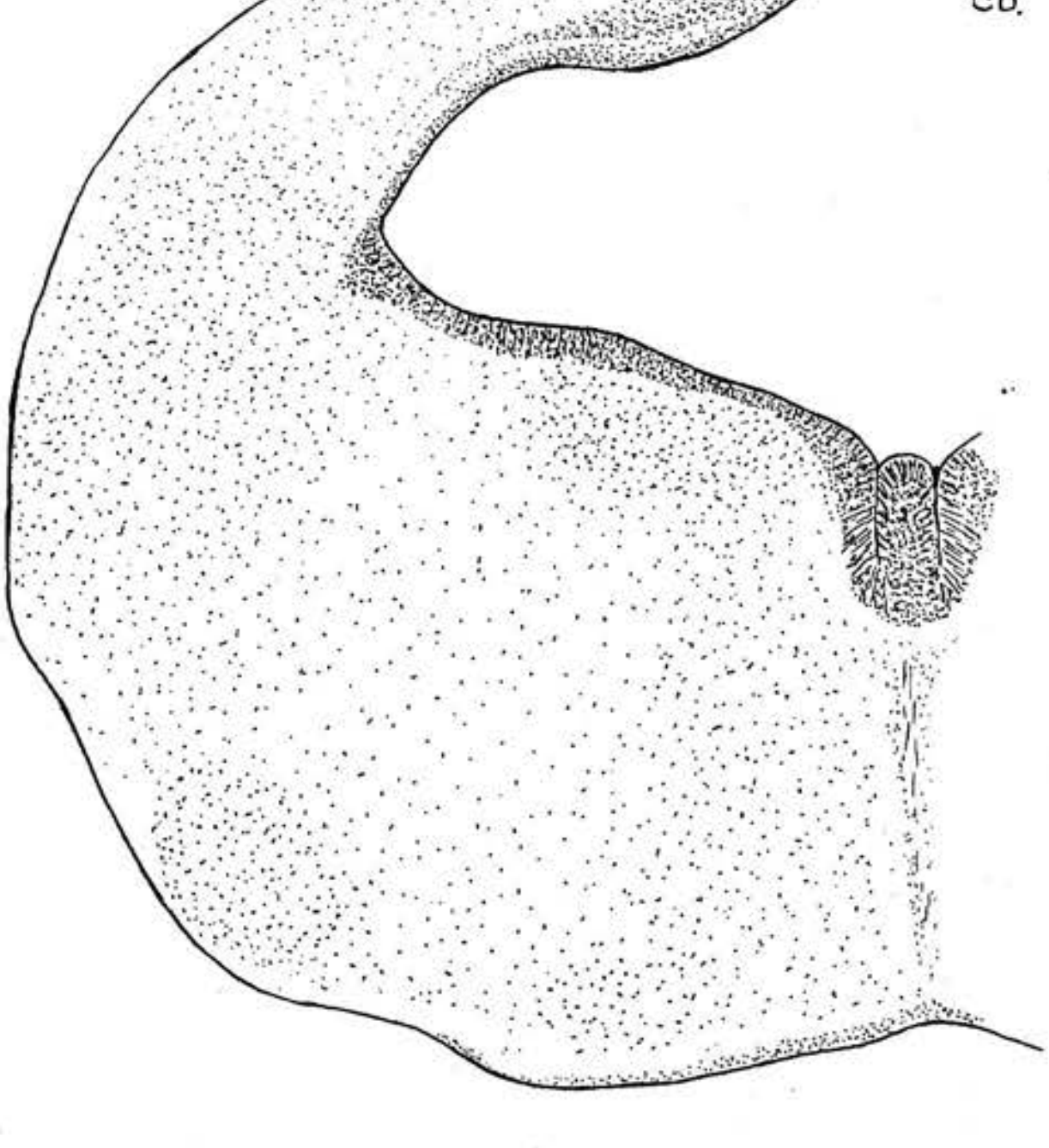

Fig: 53.

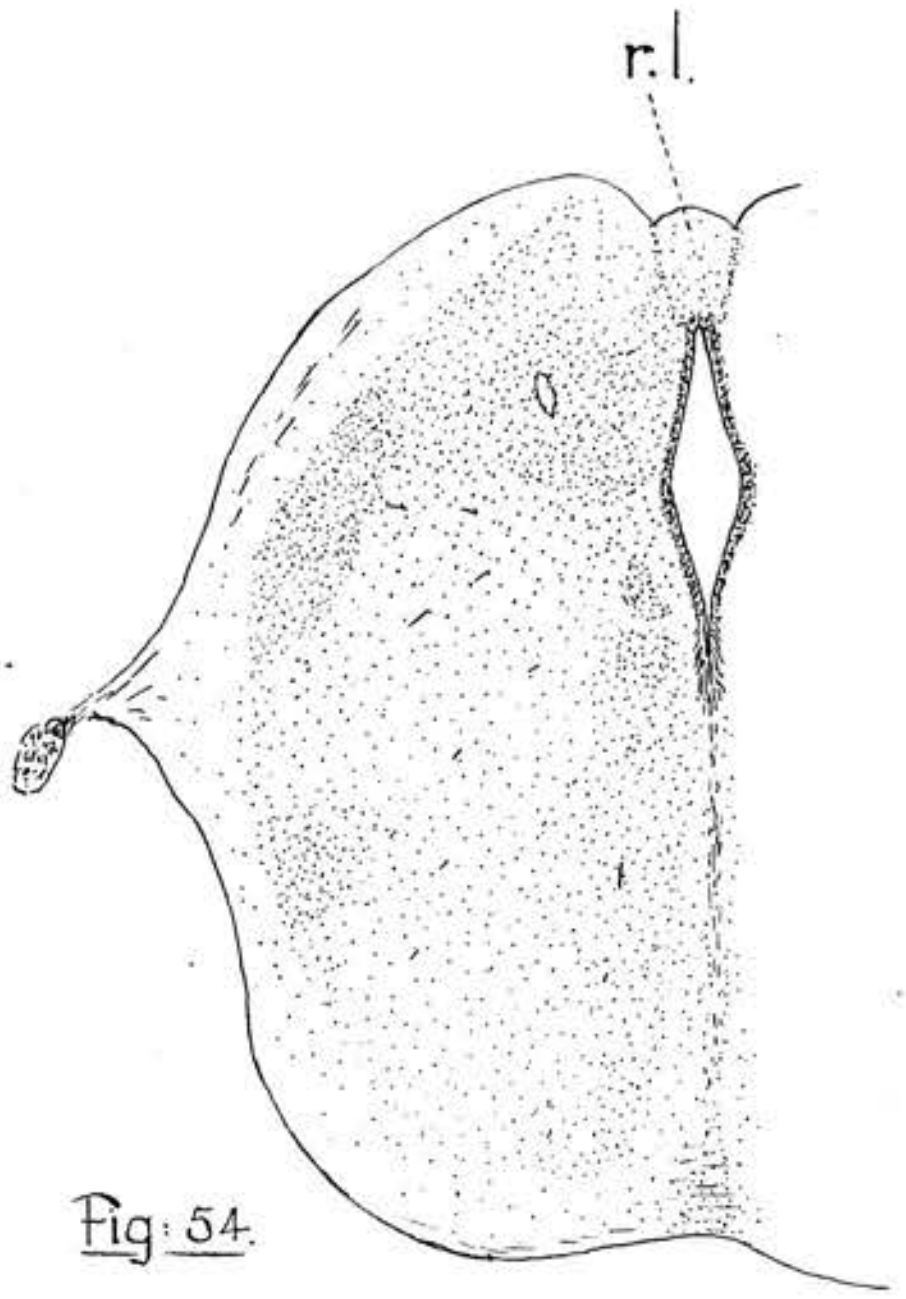

Fig: 54.

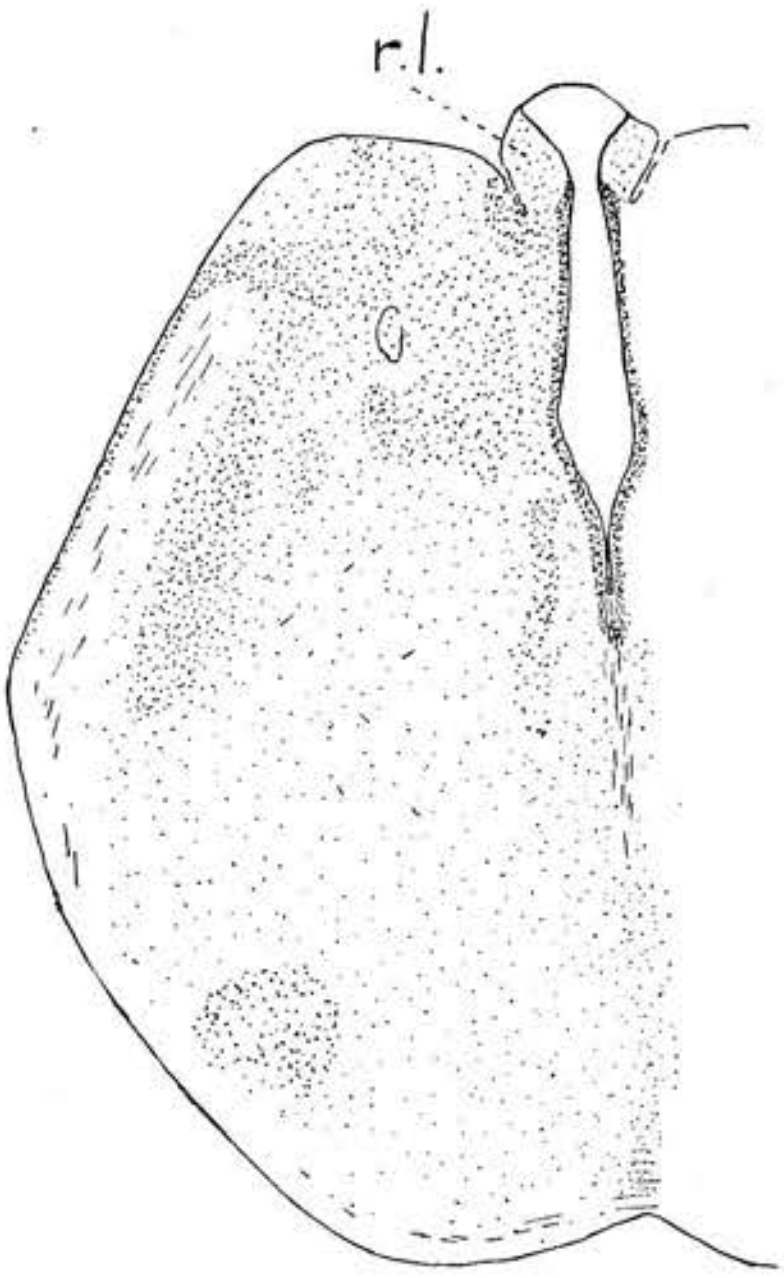

Fig: 55.

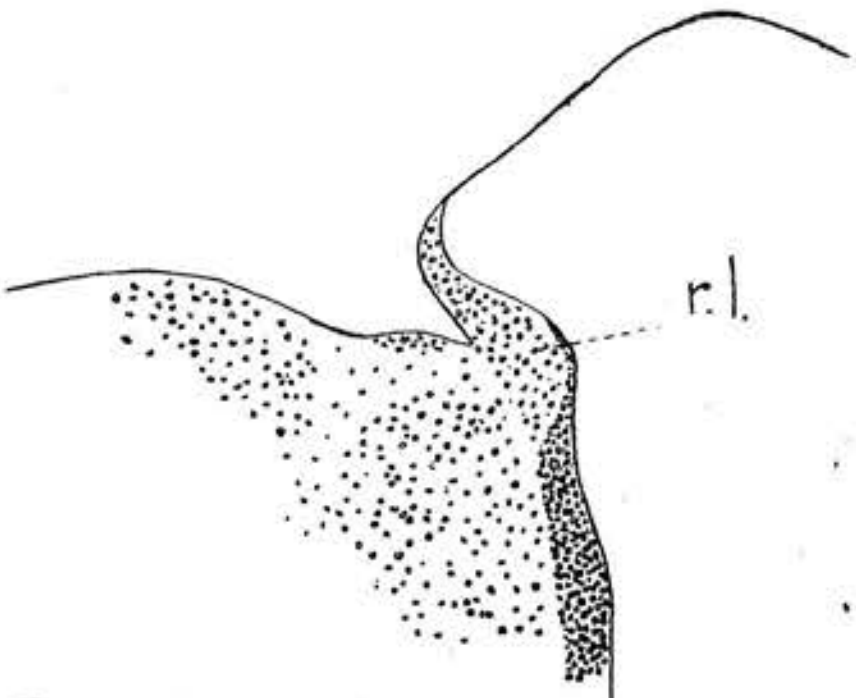

Fig: 56.

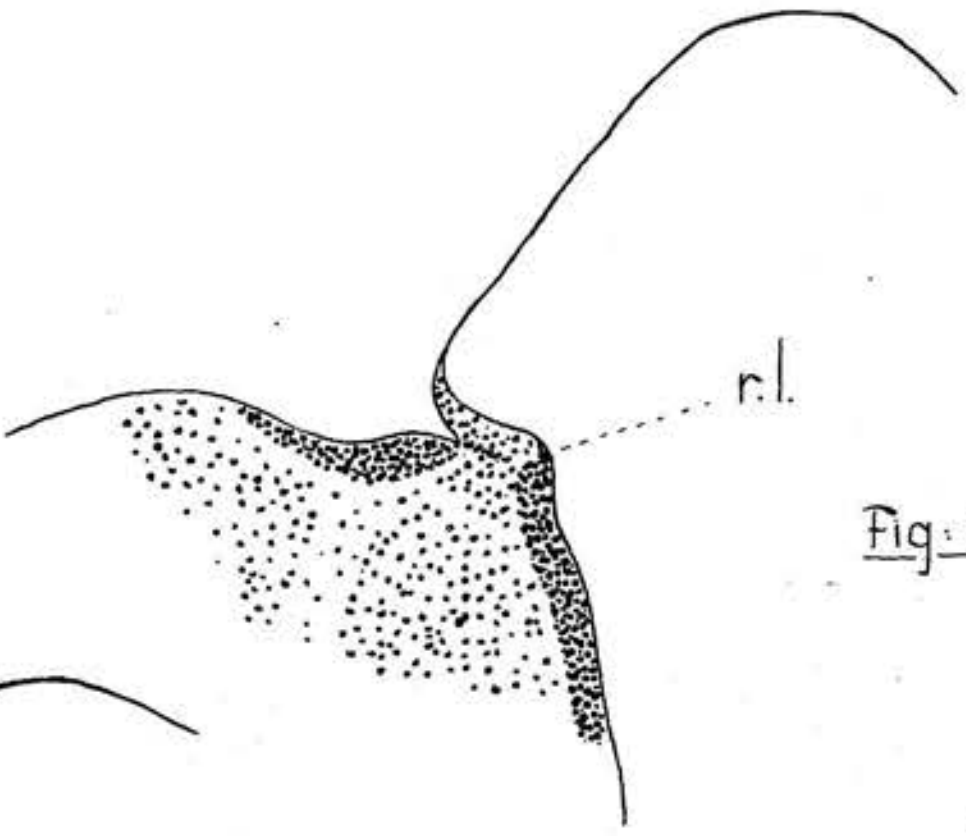

Fig: 57.

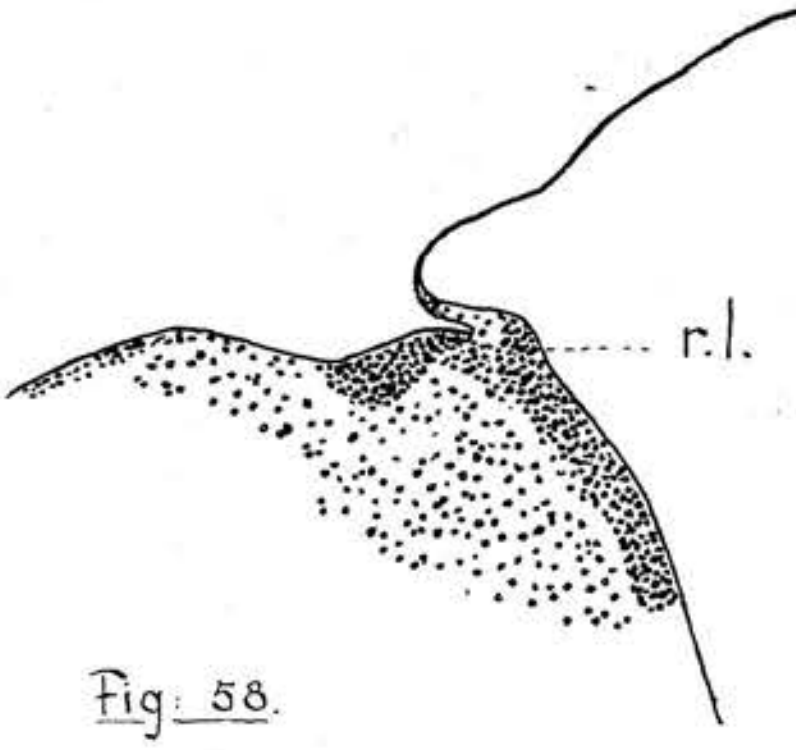

Fig: 58.

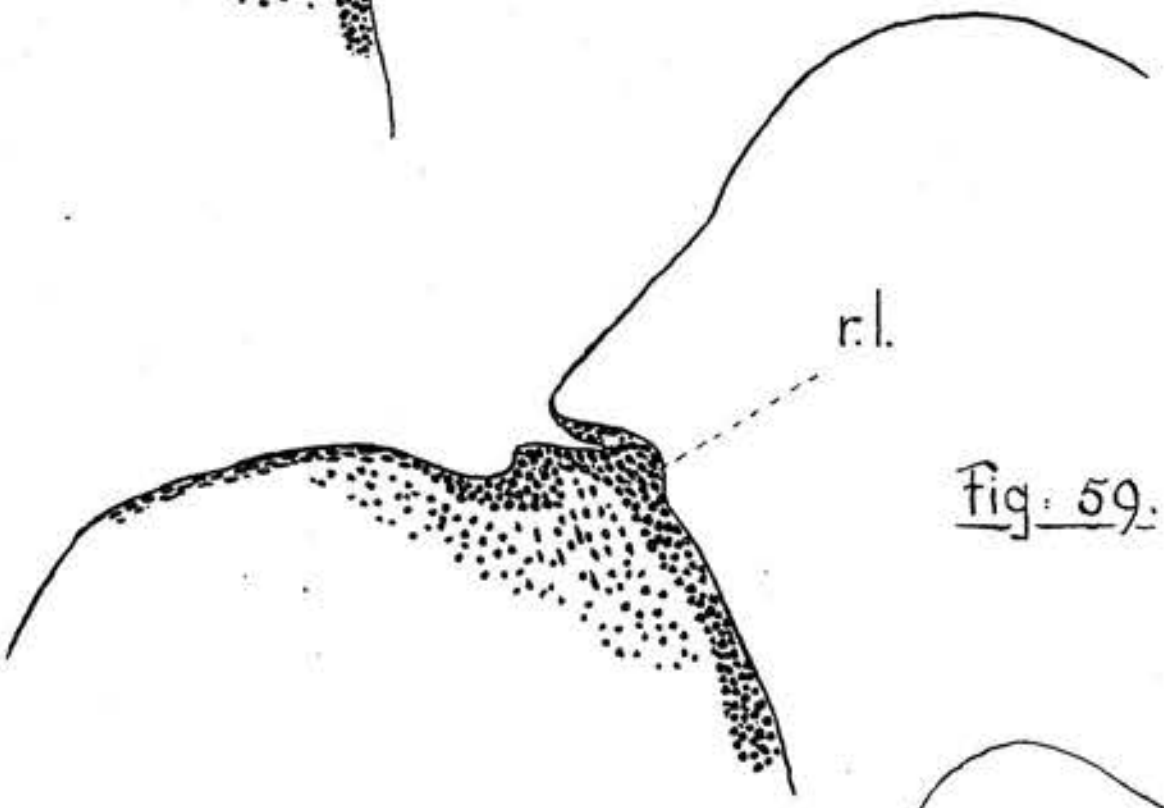

Fig: 59.

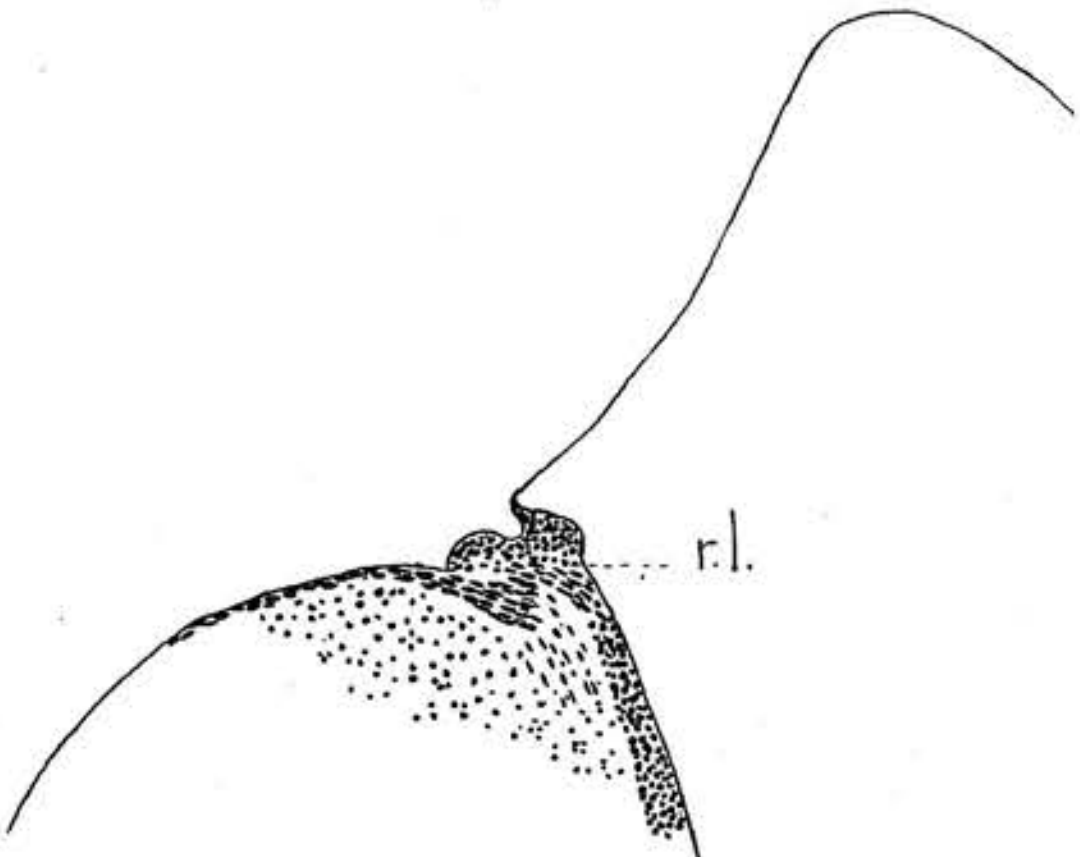

Fig: 60.

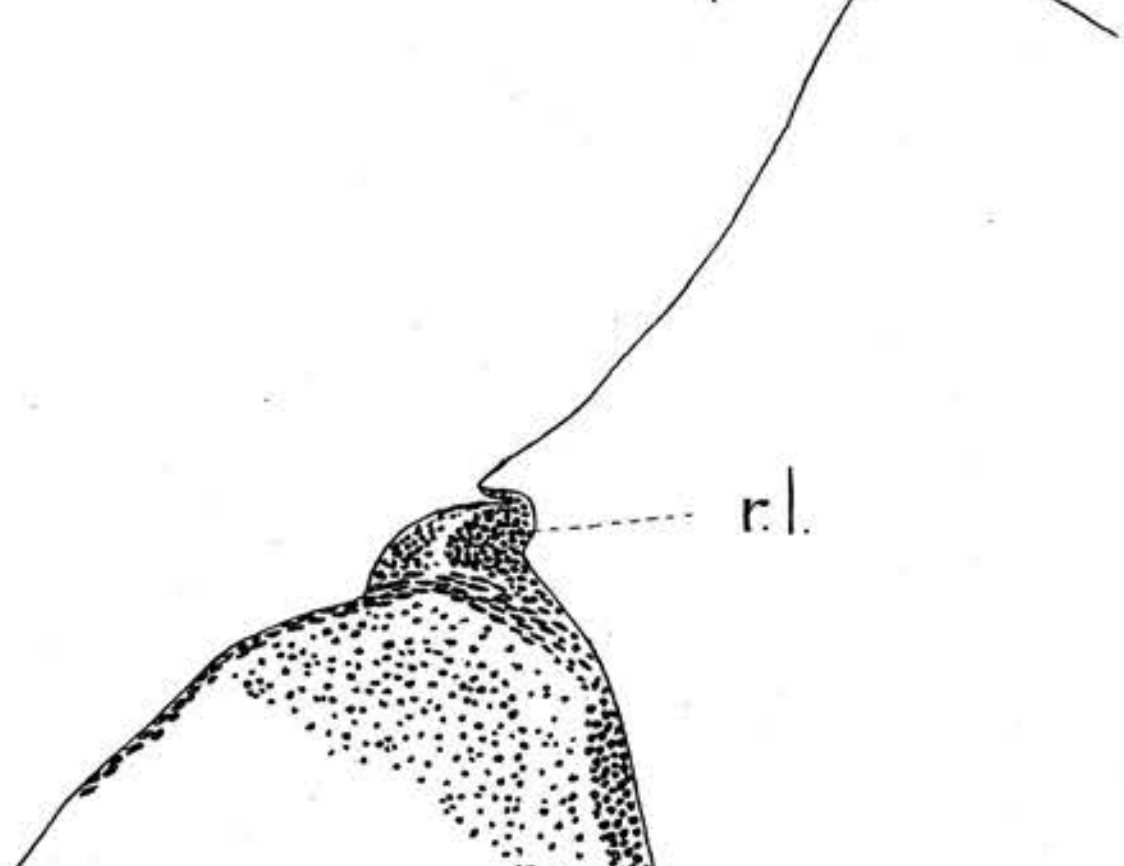

Fig: 61.

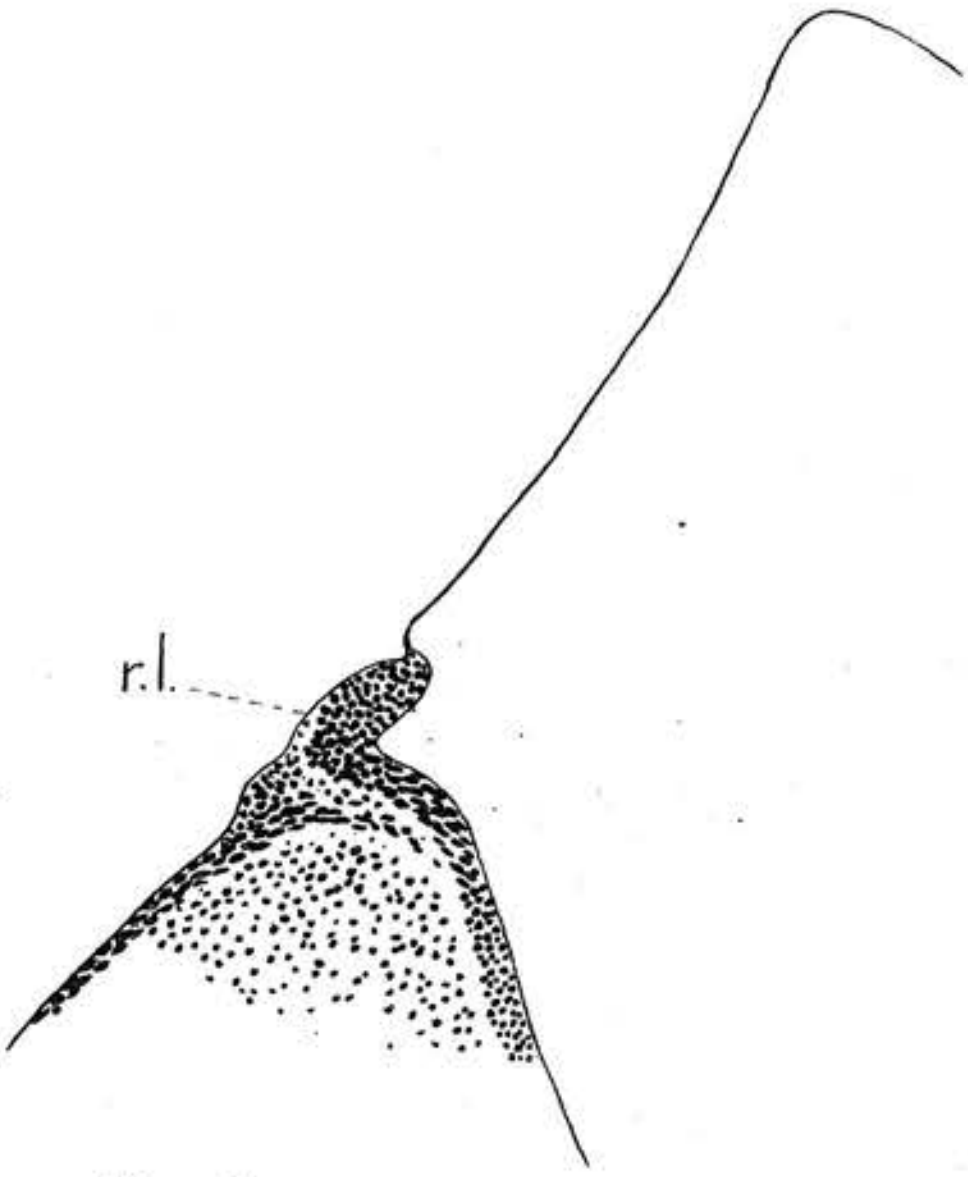

Fig: 62.

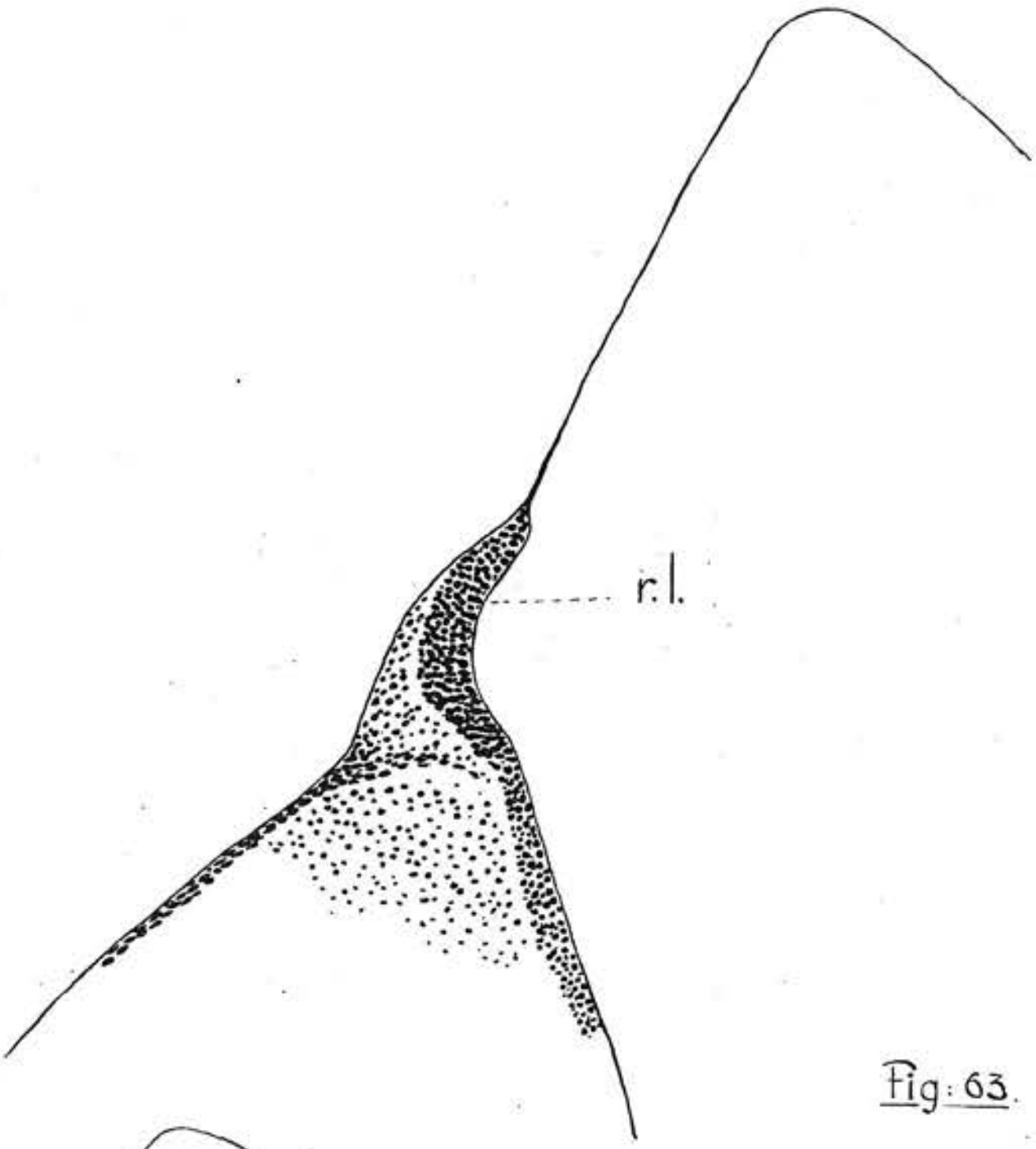

Fig: 63.

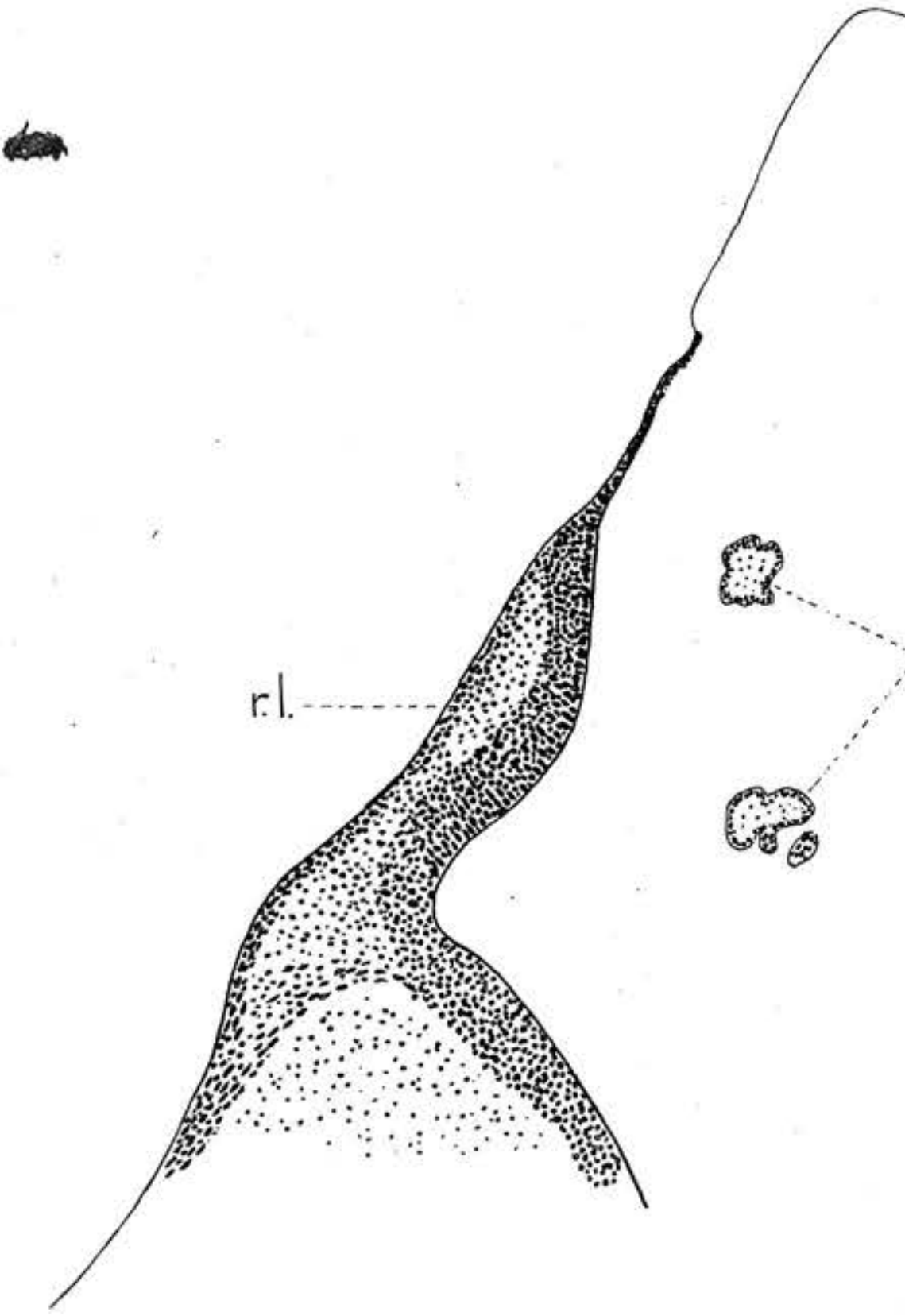

Fig: 64.

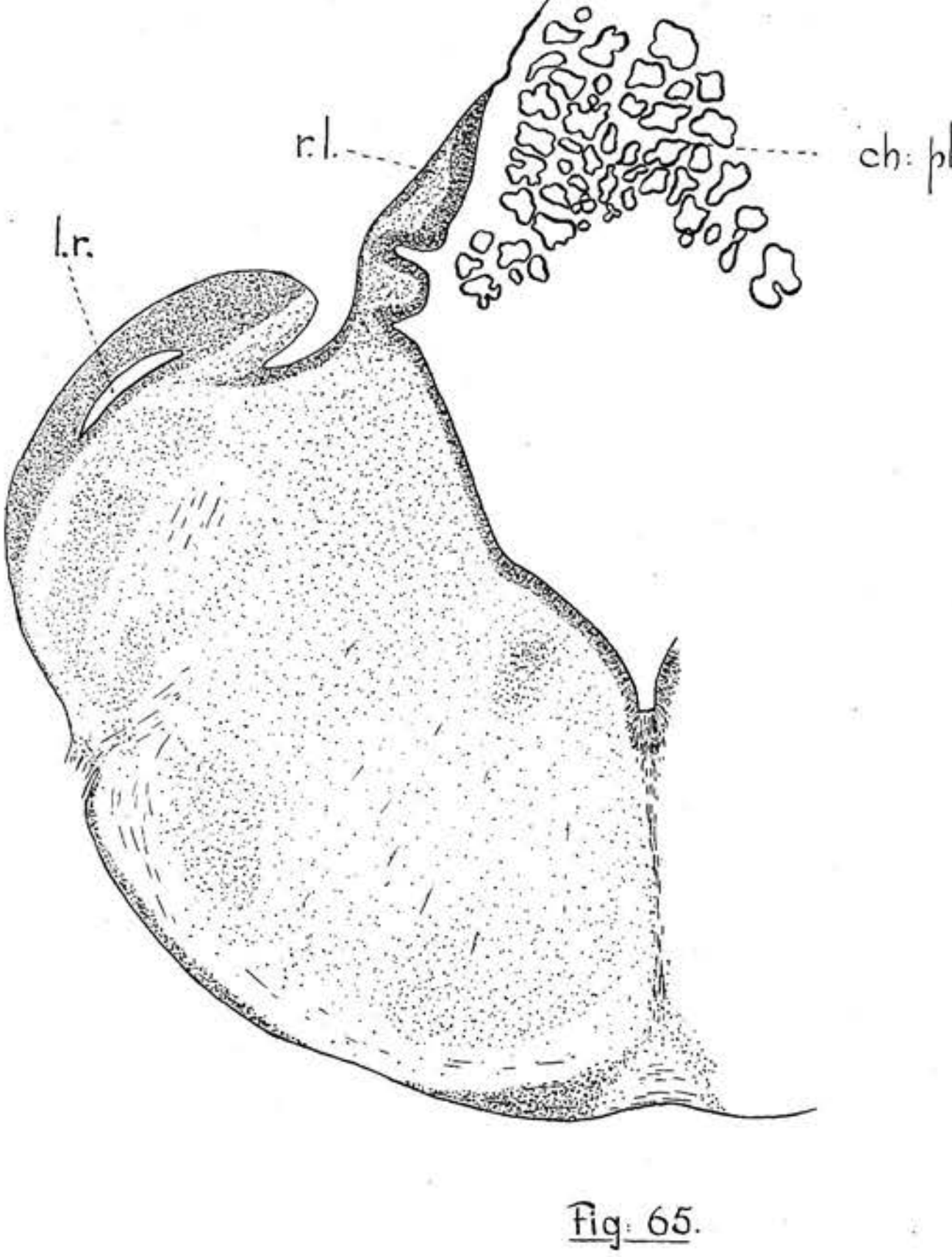

Fig: 65.

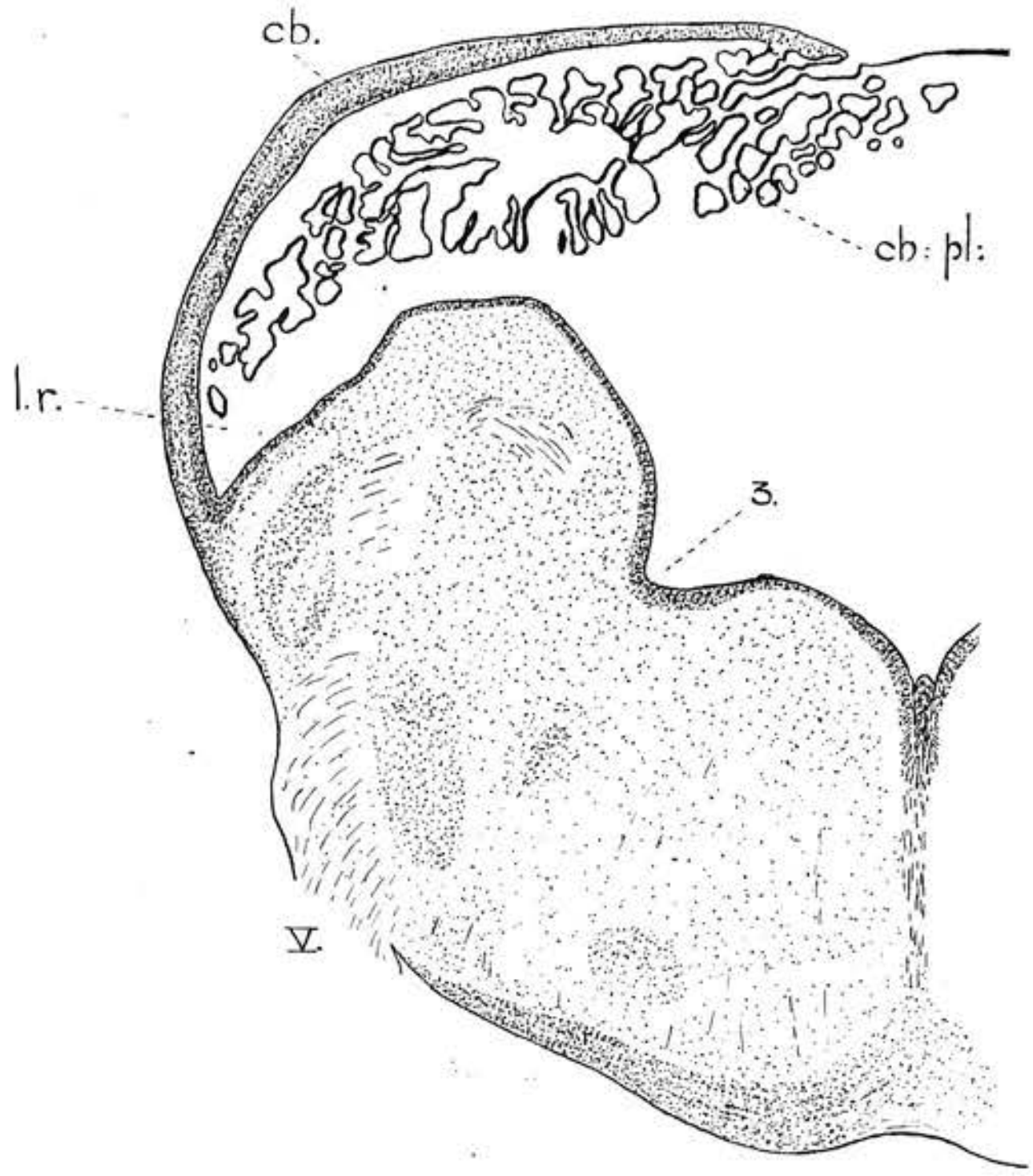

Fig: 66.

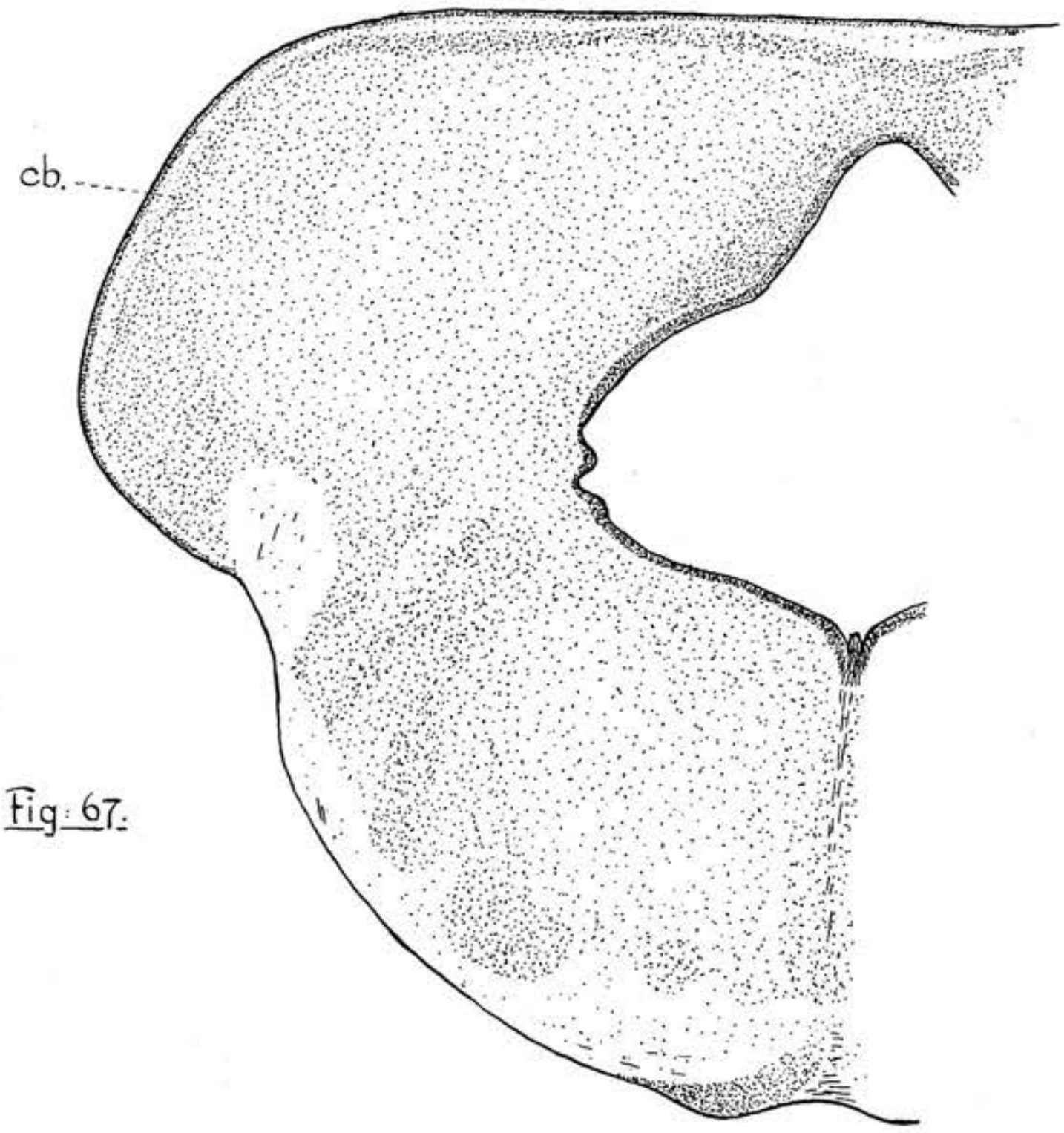

Fig: 67.

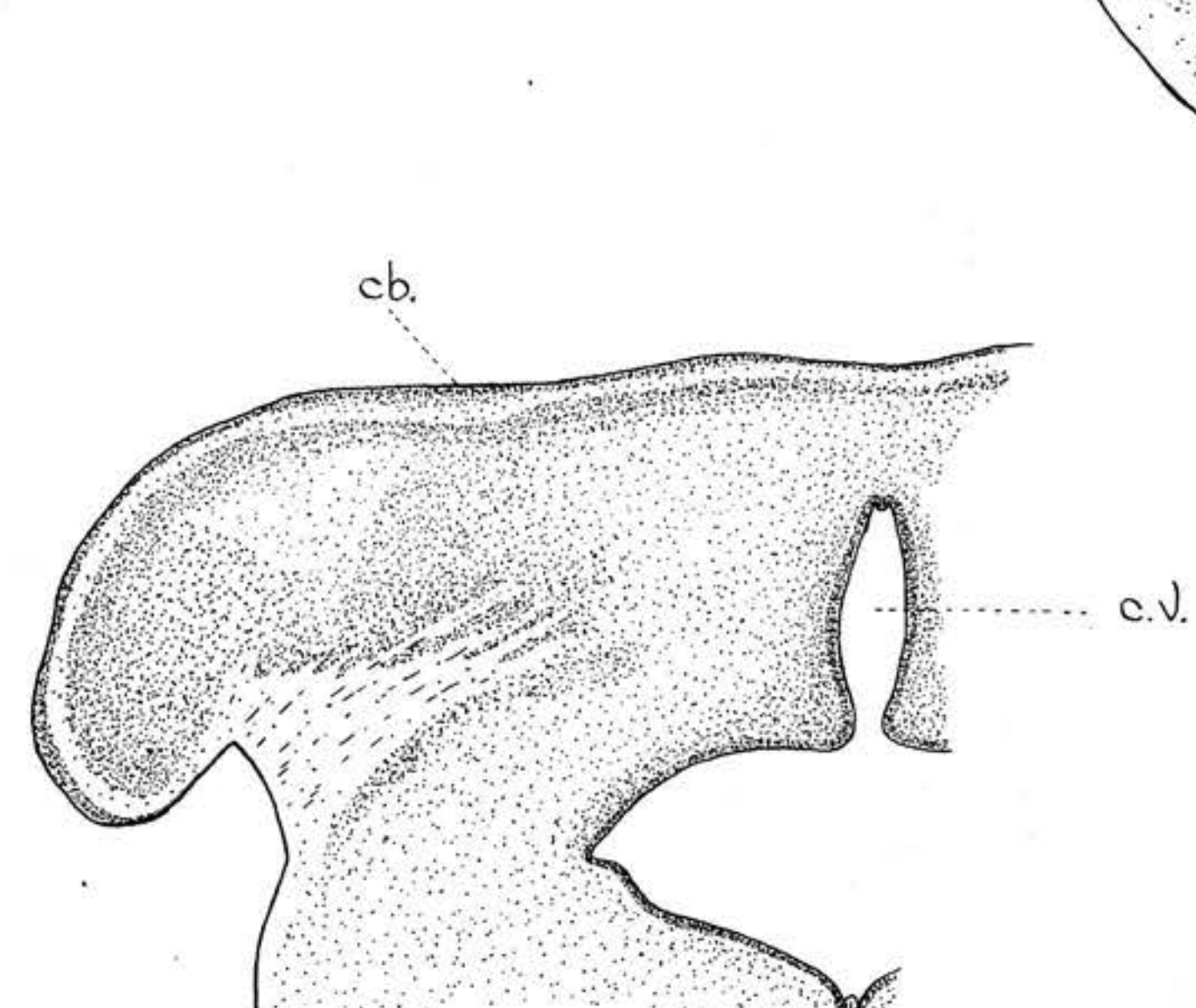

Fig: 68.

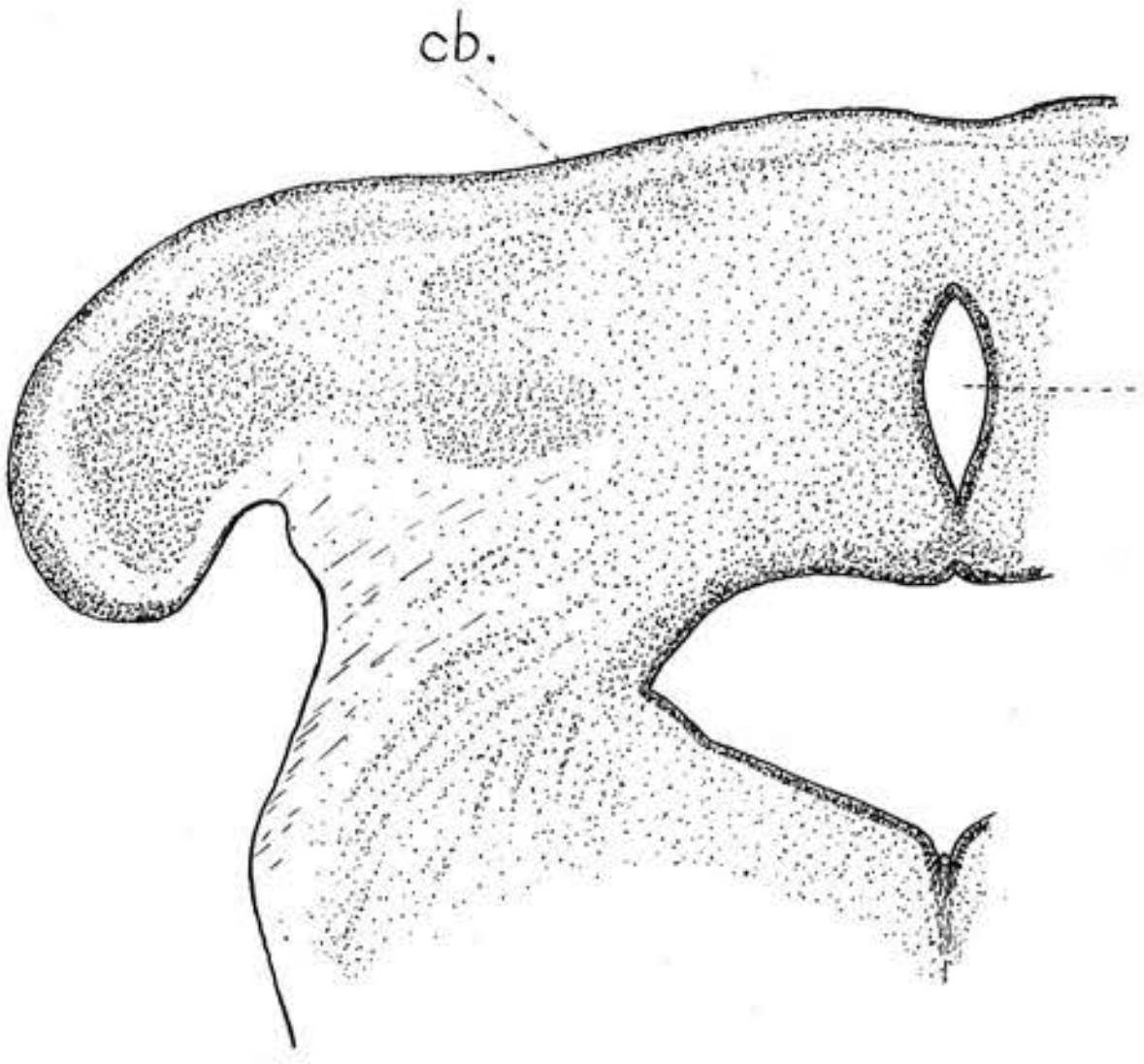

Fig. 69.

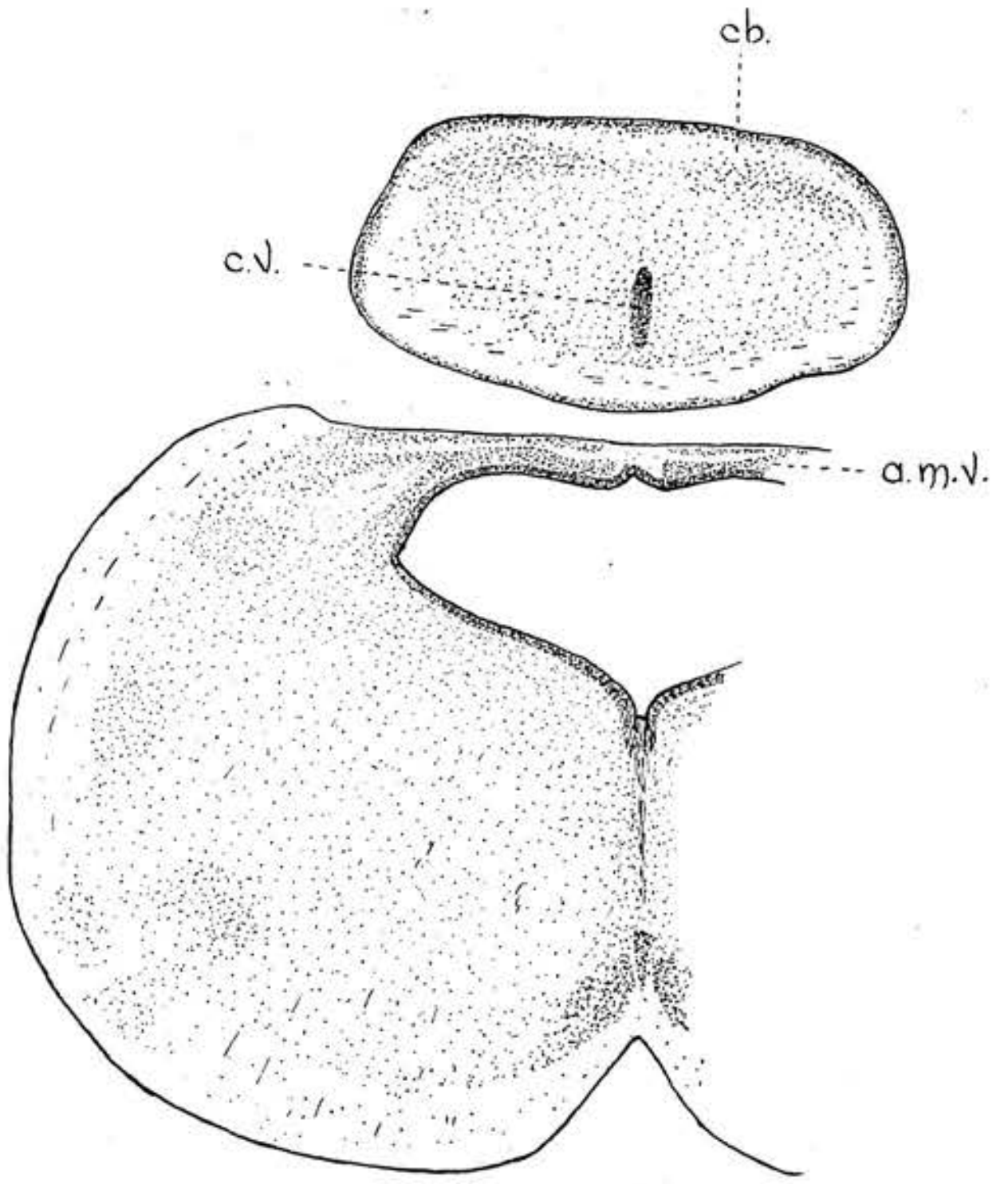

Fig: 70.

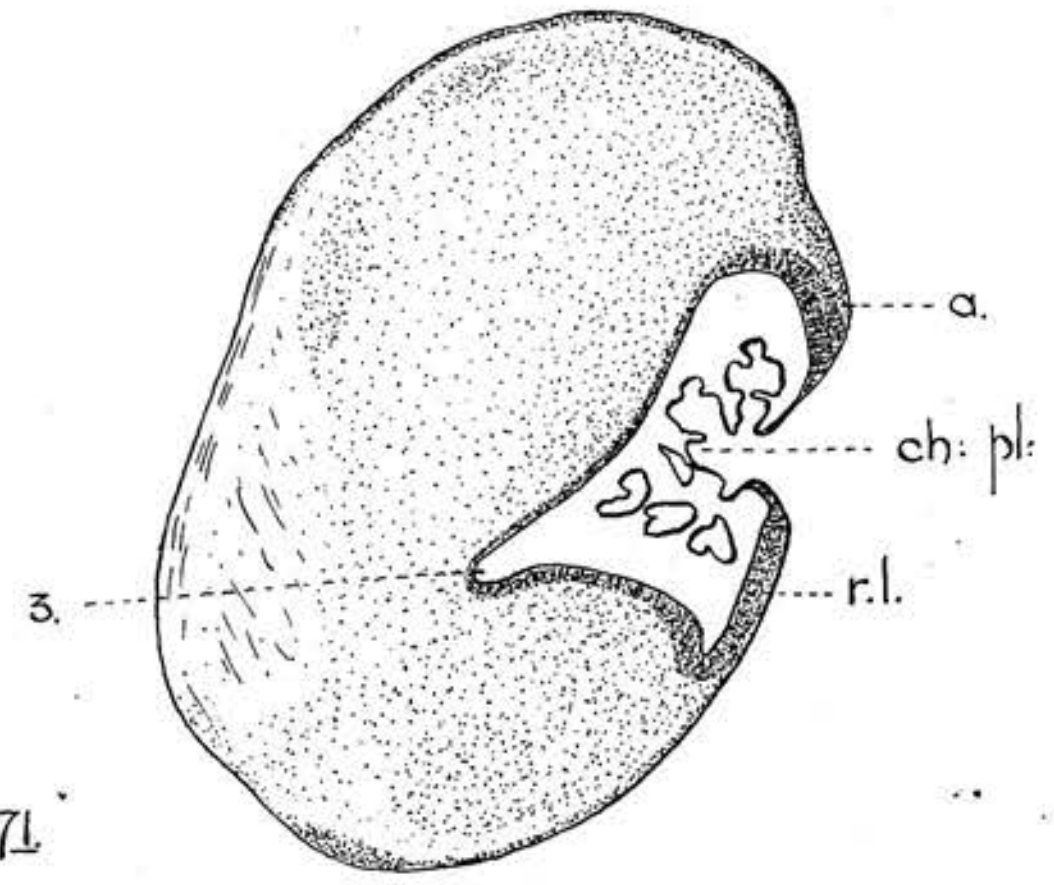

Fig: 71.

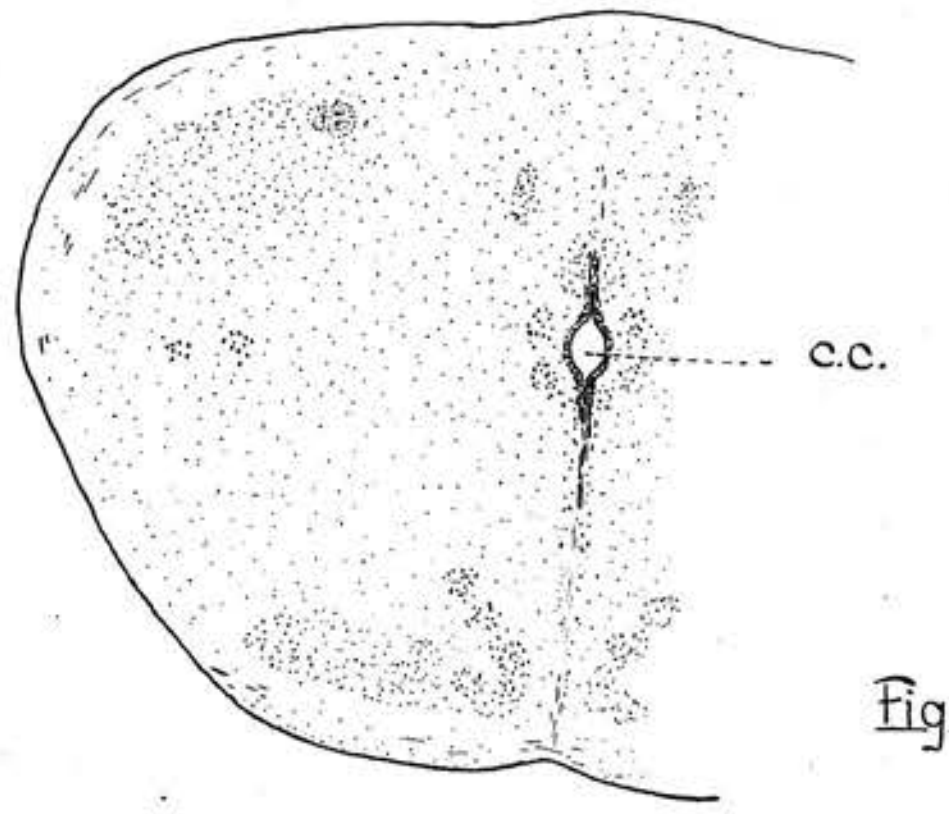

Fig: 72.

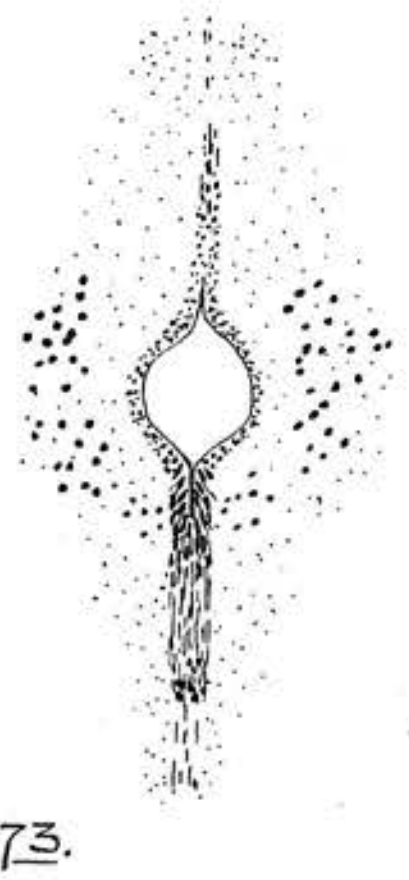

Fig: 73.

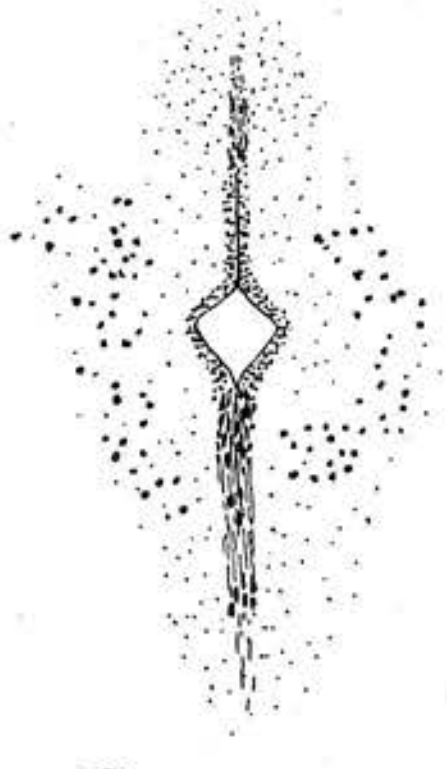

Fig: 74.

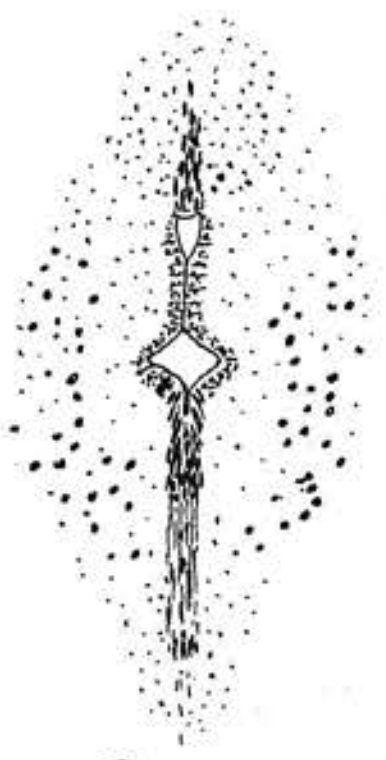

Fig: 75.

Fig: 76.

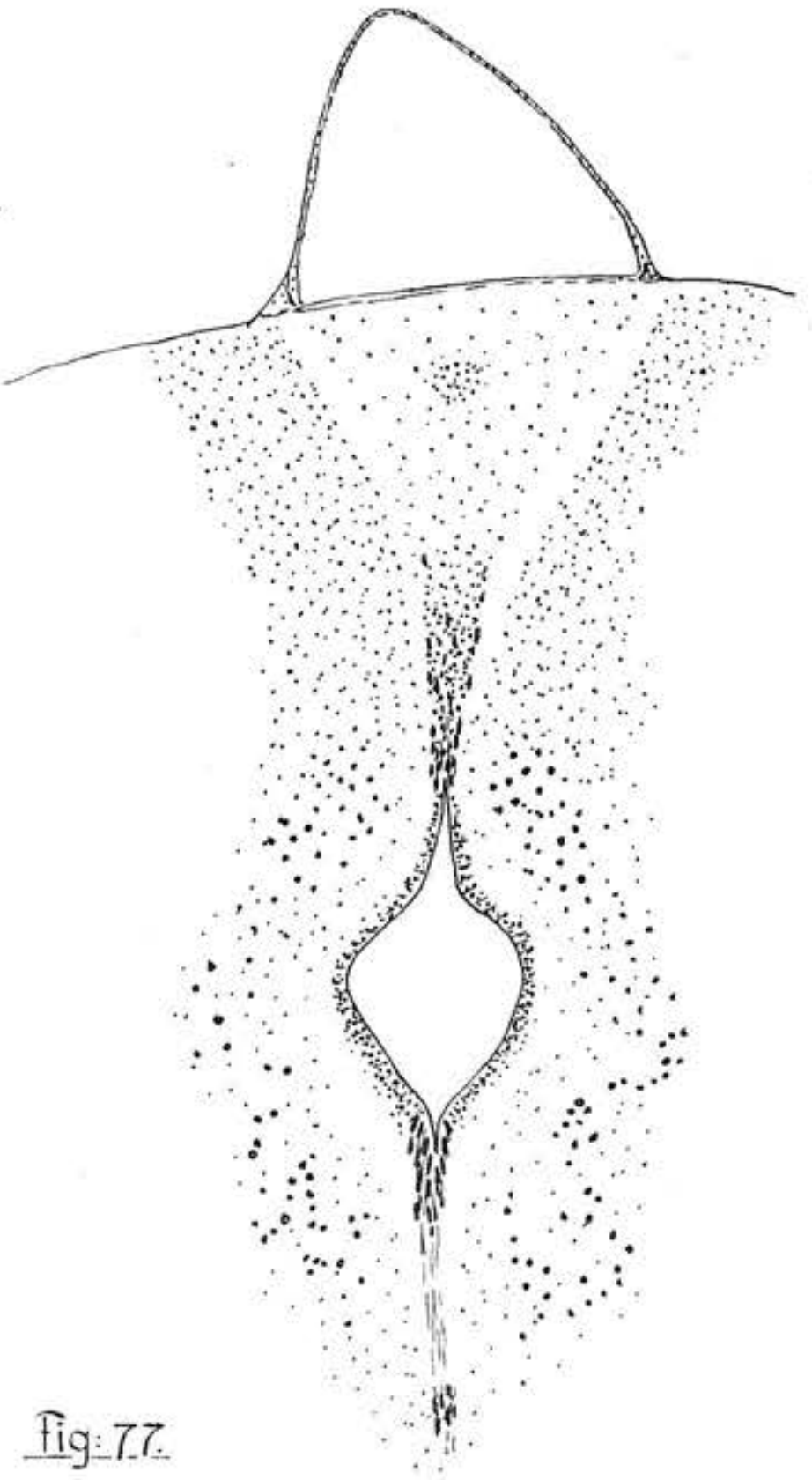

Fig: 77.

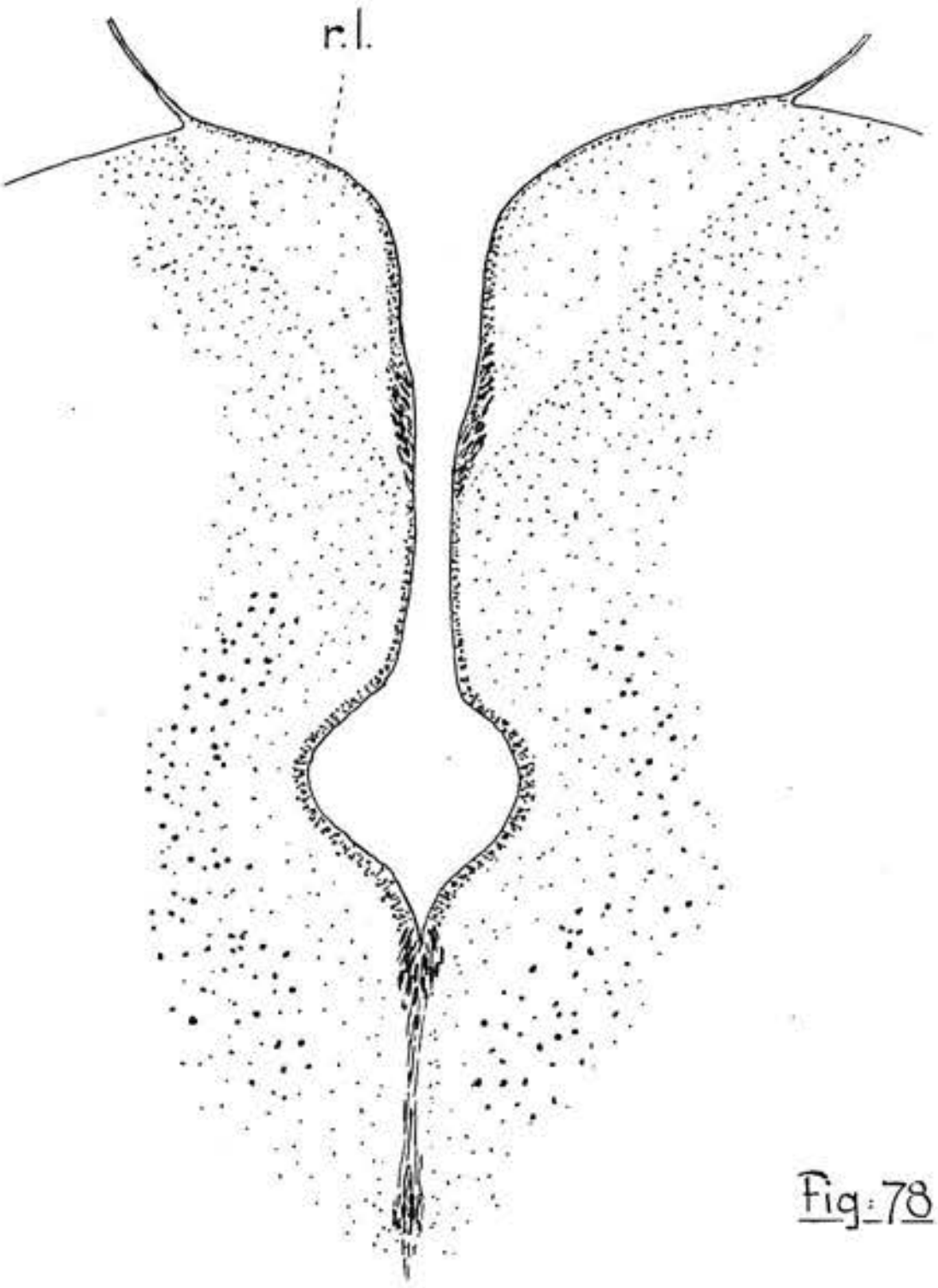

Fig: 78.

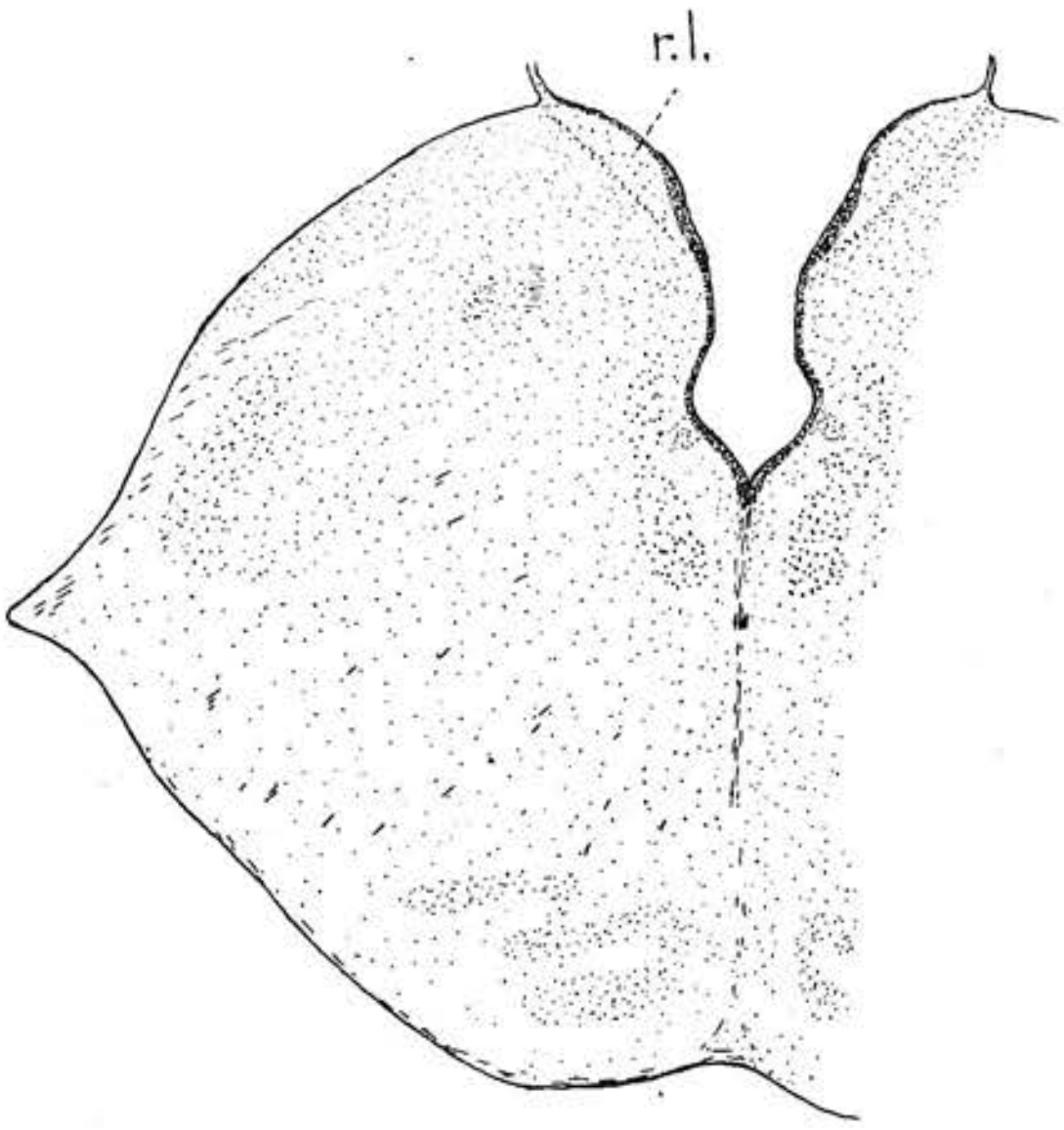

Fig: 79.

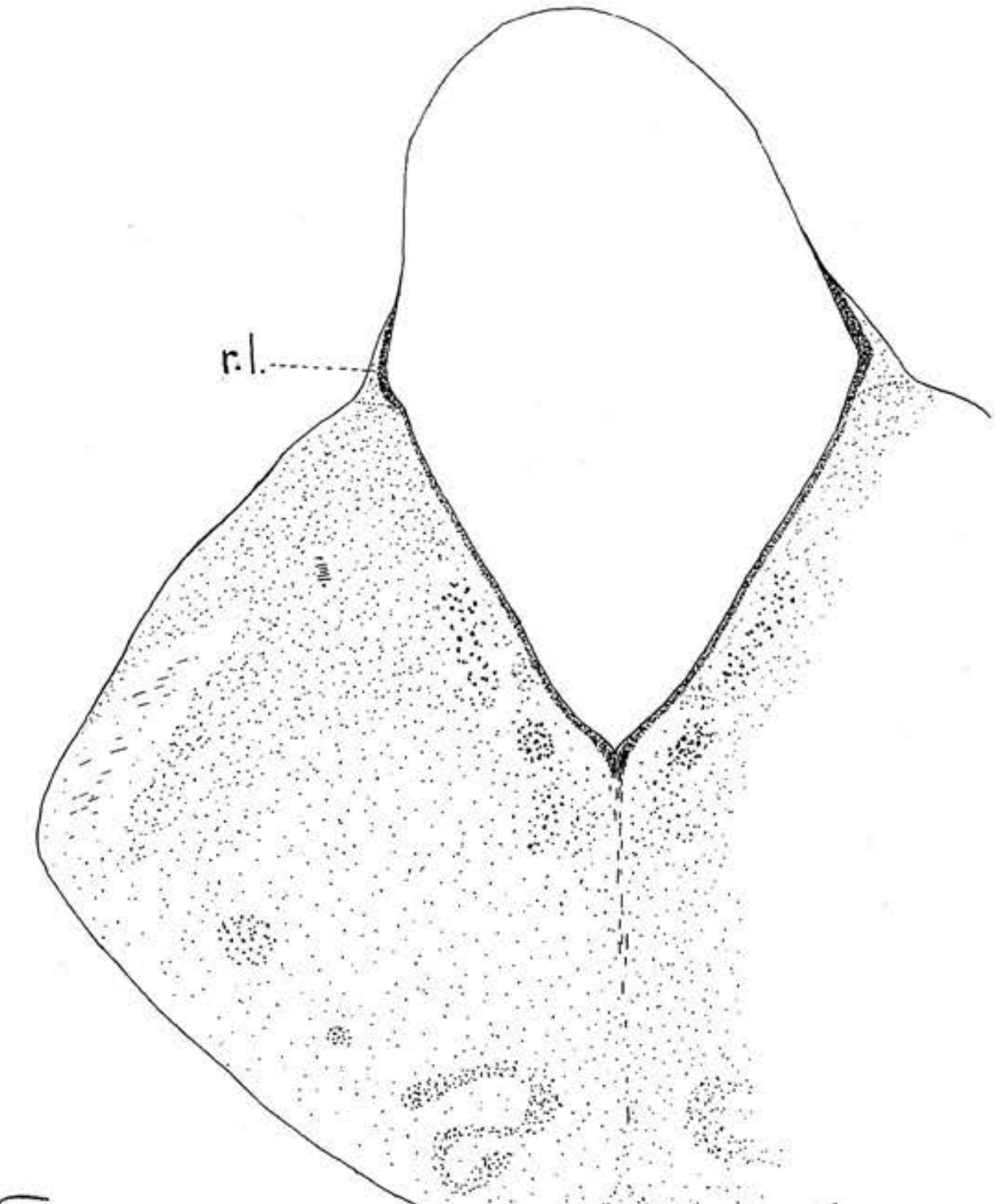

Fig: 80.

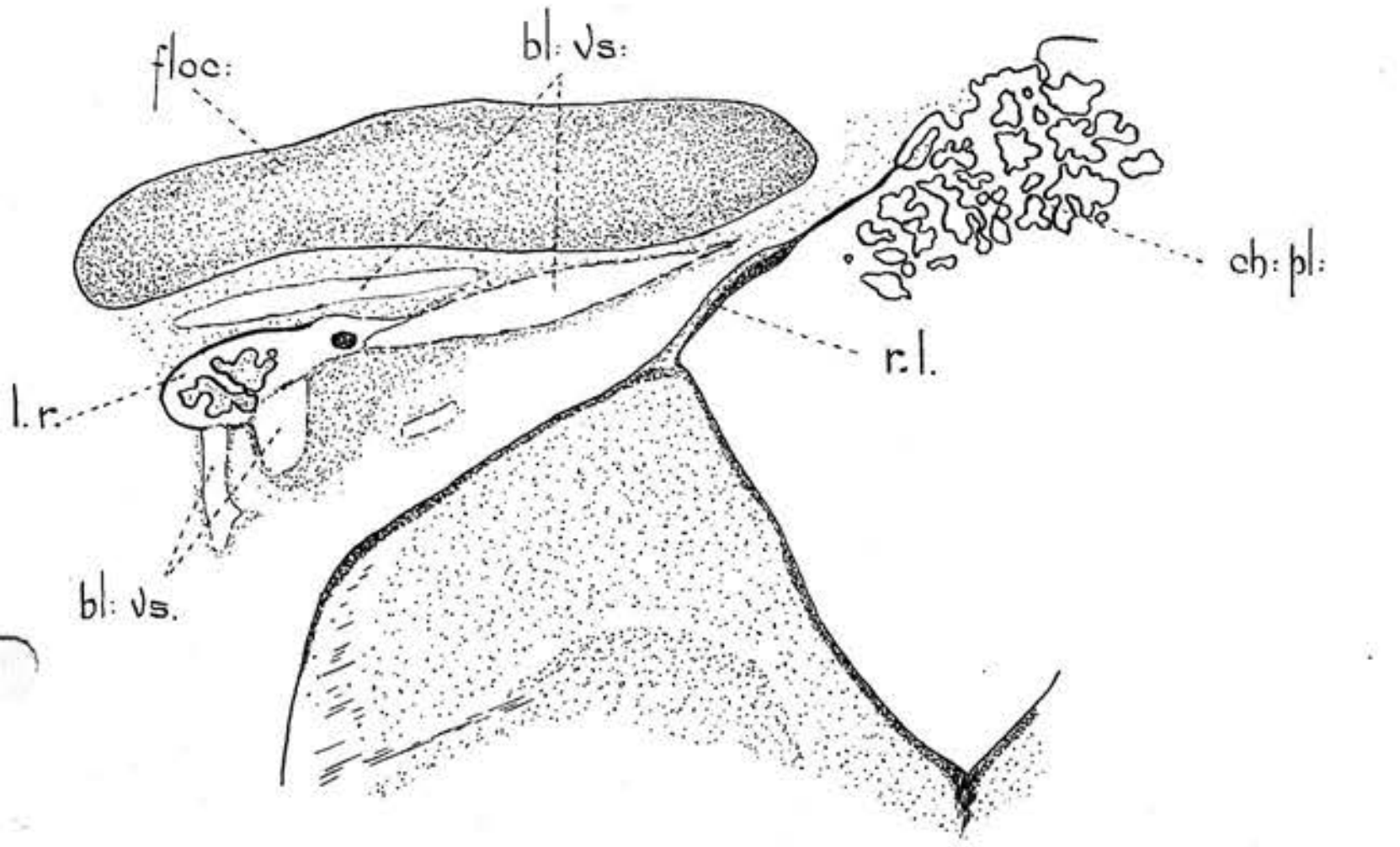

Fig: 81.

㉓

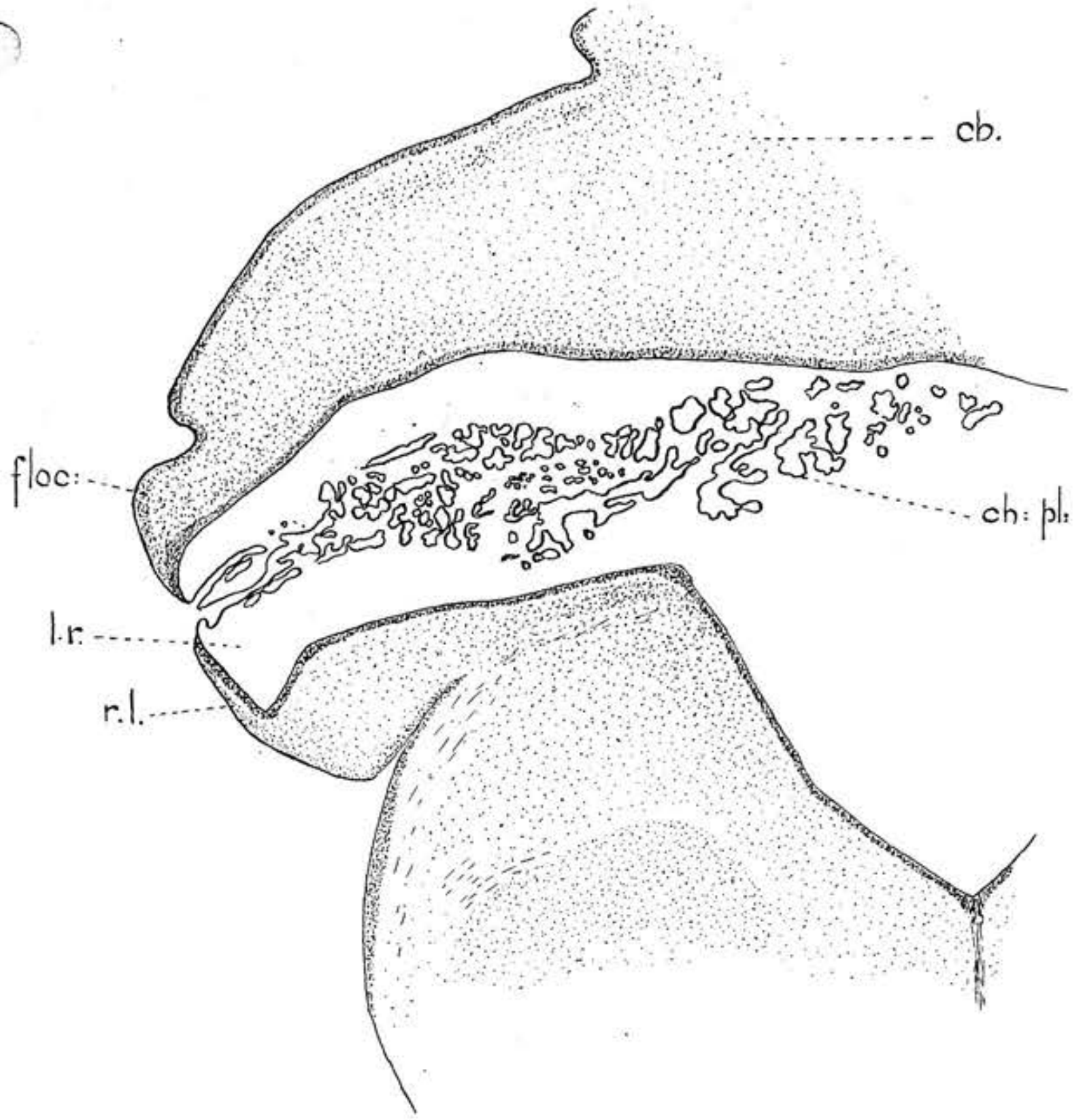

Fig: 82.

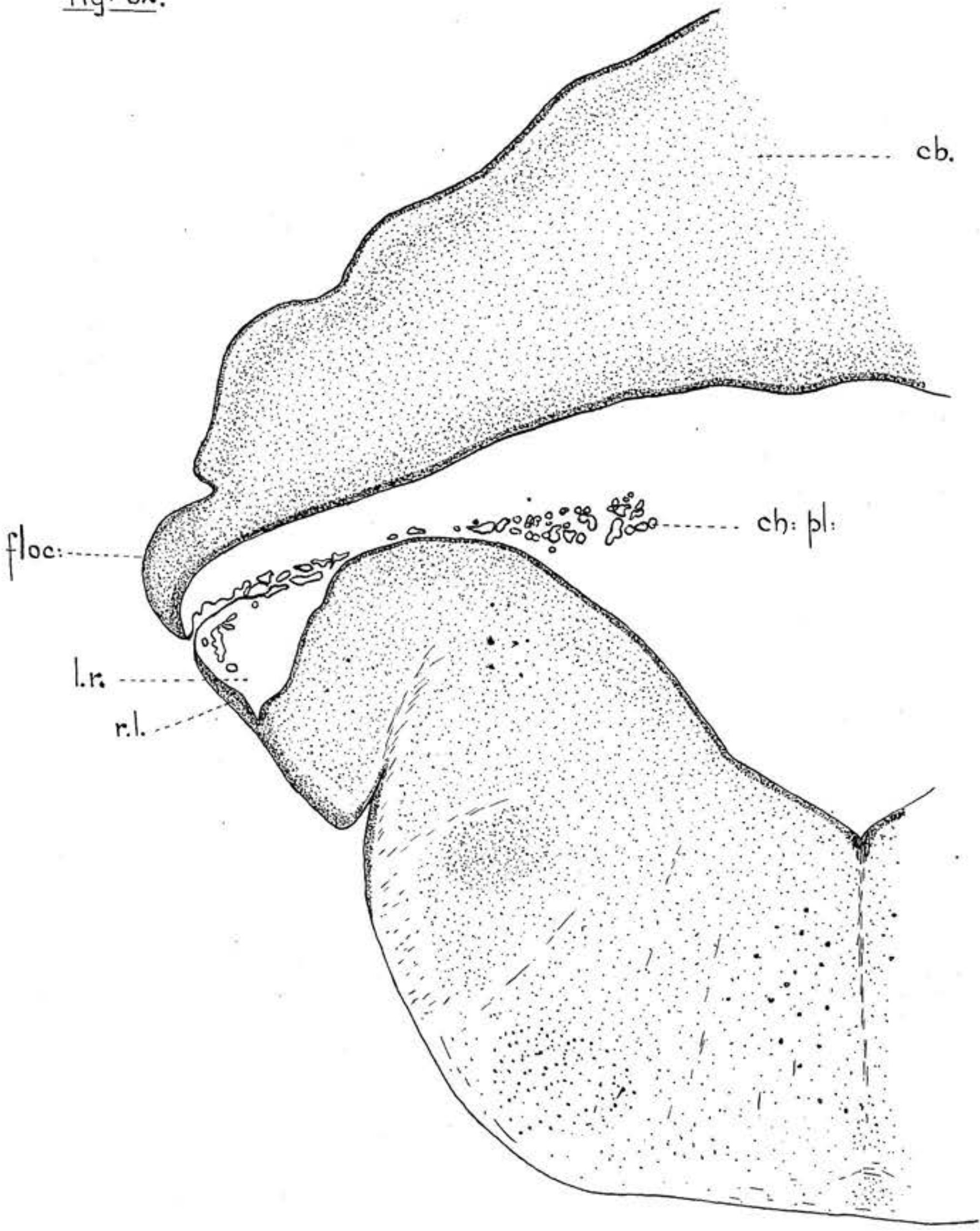

Fig: 83.

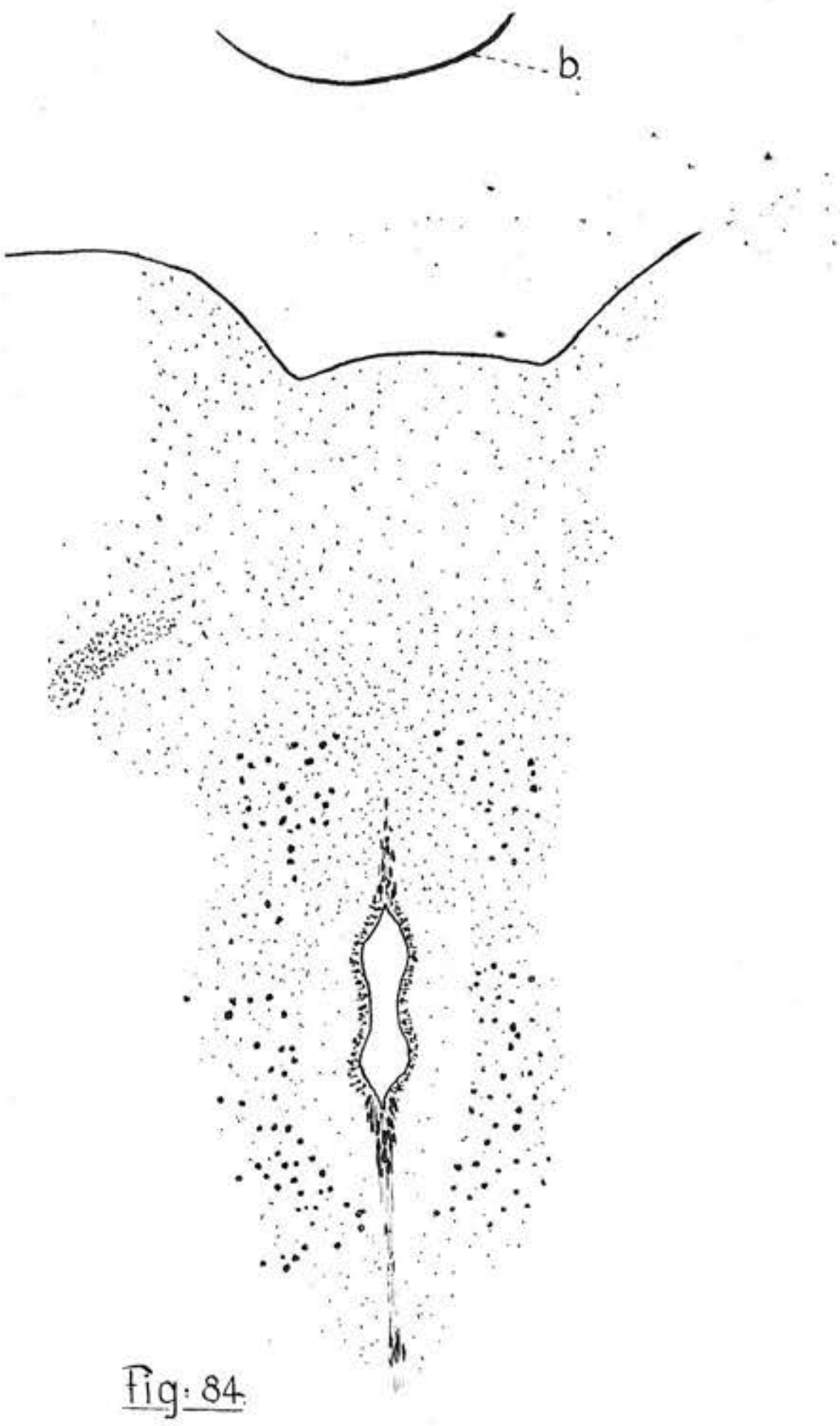

Fig: 84.

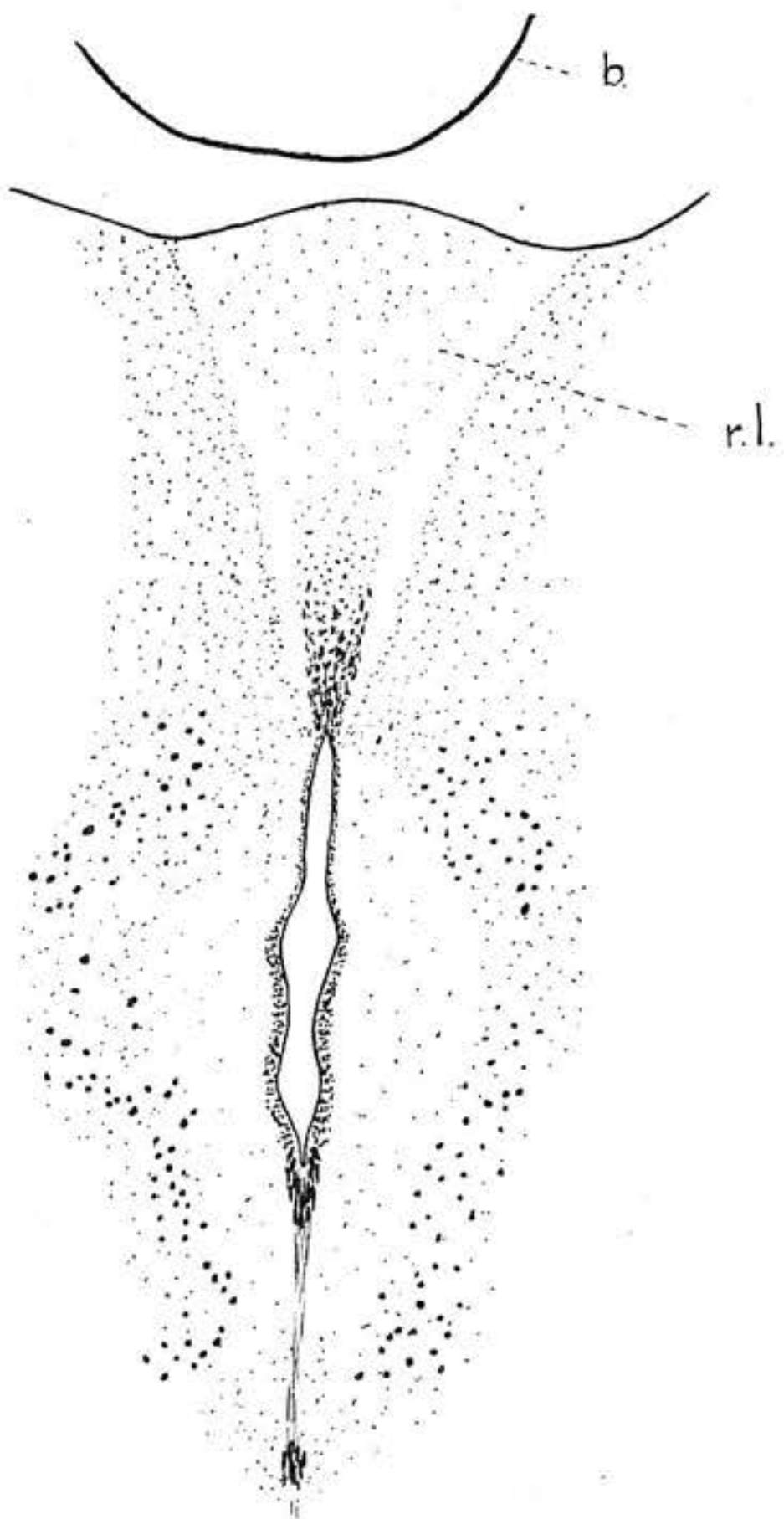

Fig: 85.

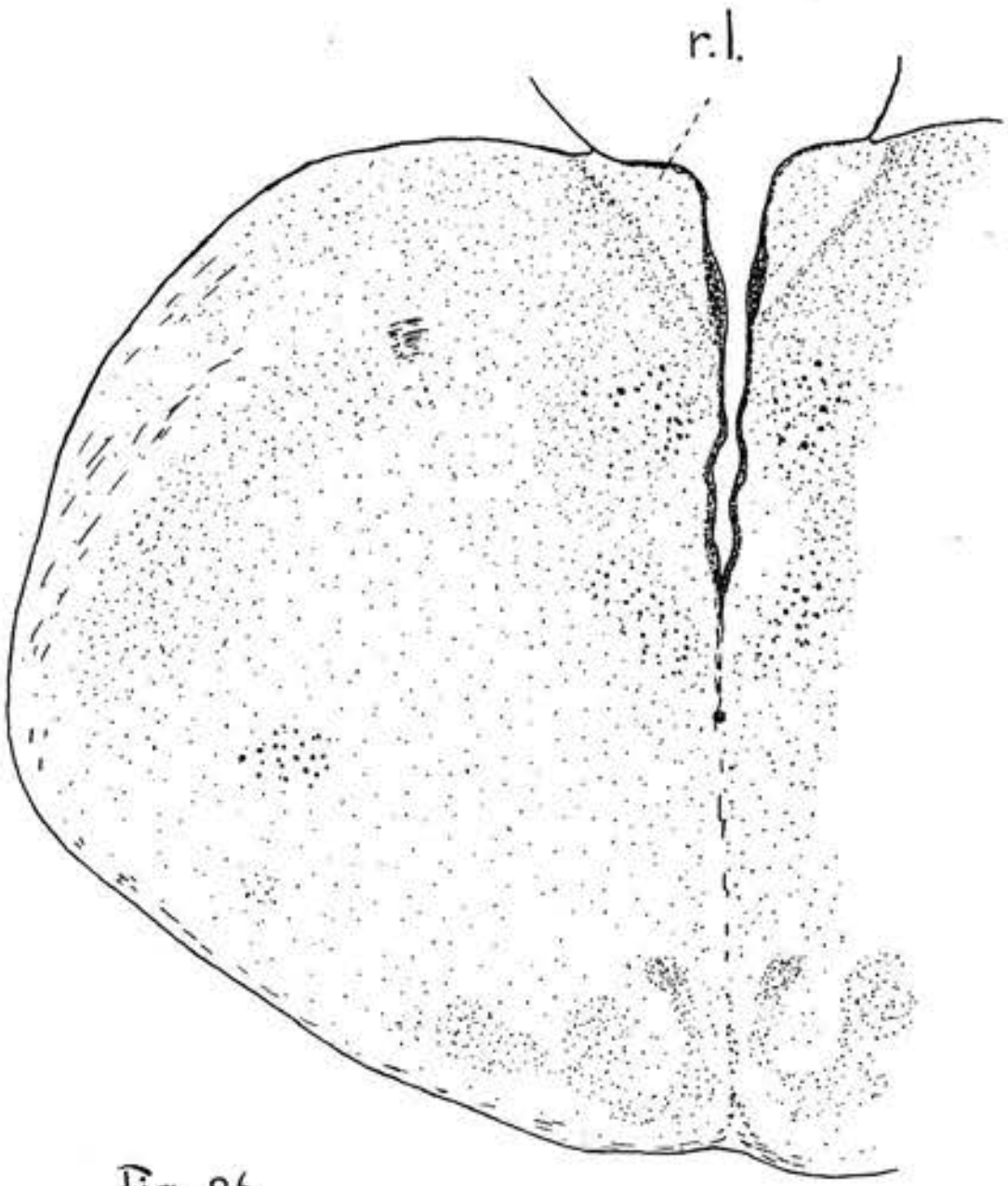

Fig: 86.

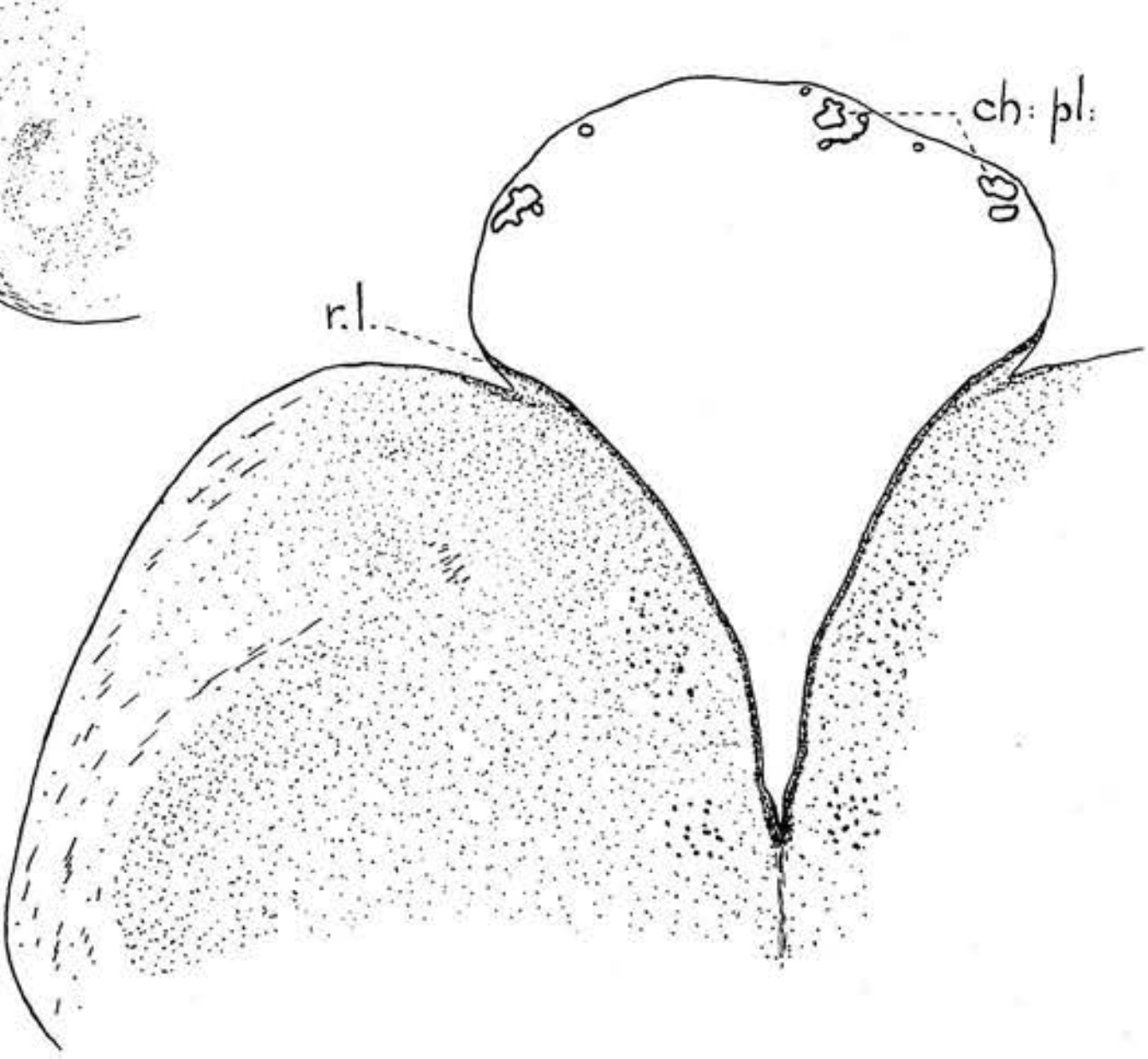

Fig: 87.

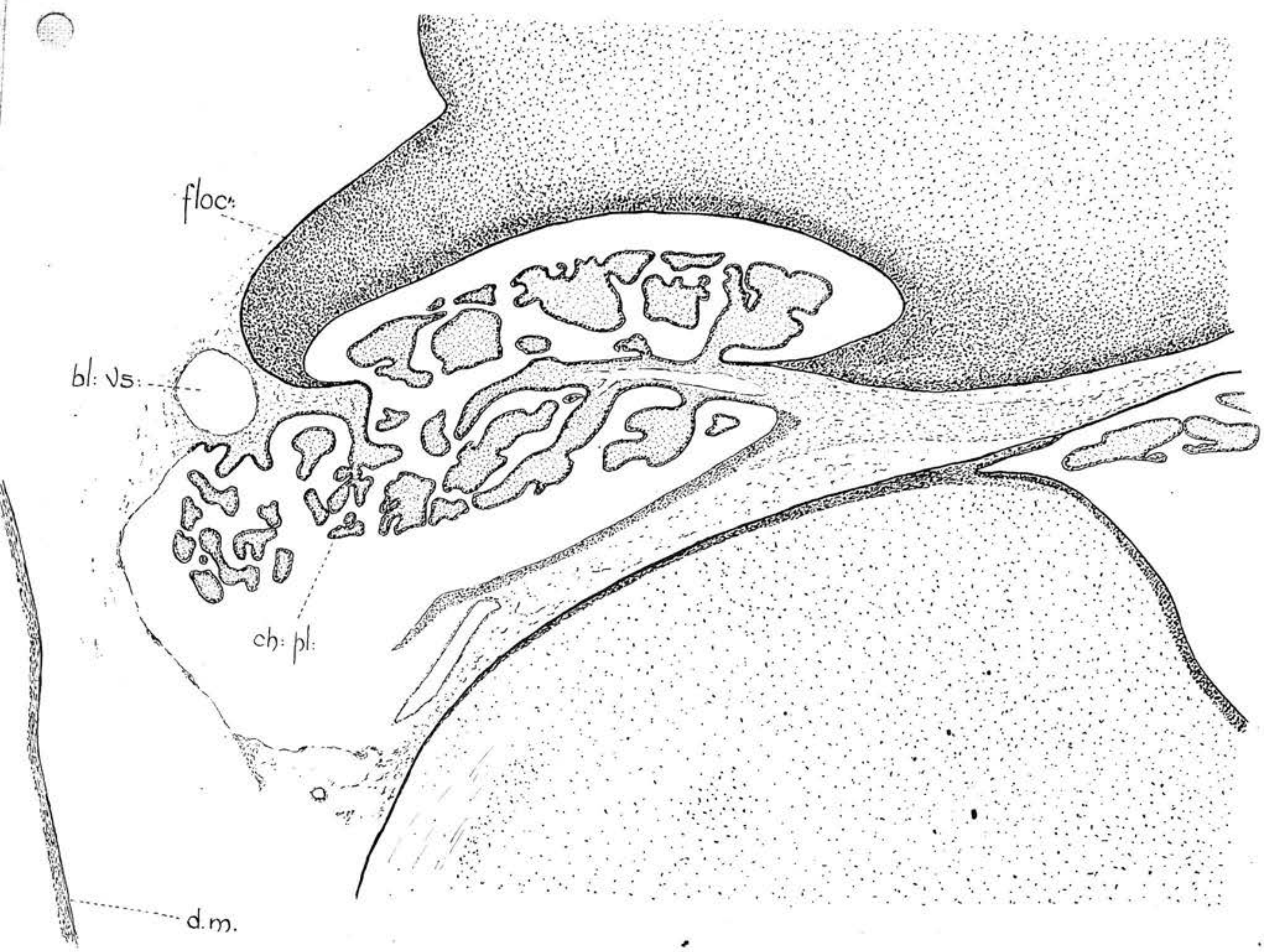

Fig: 88.

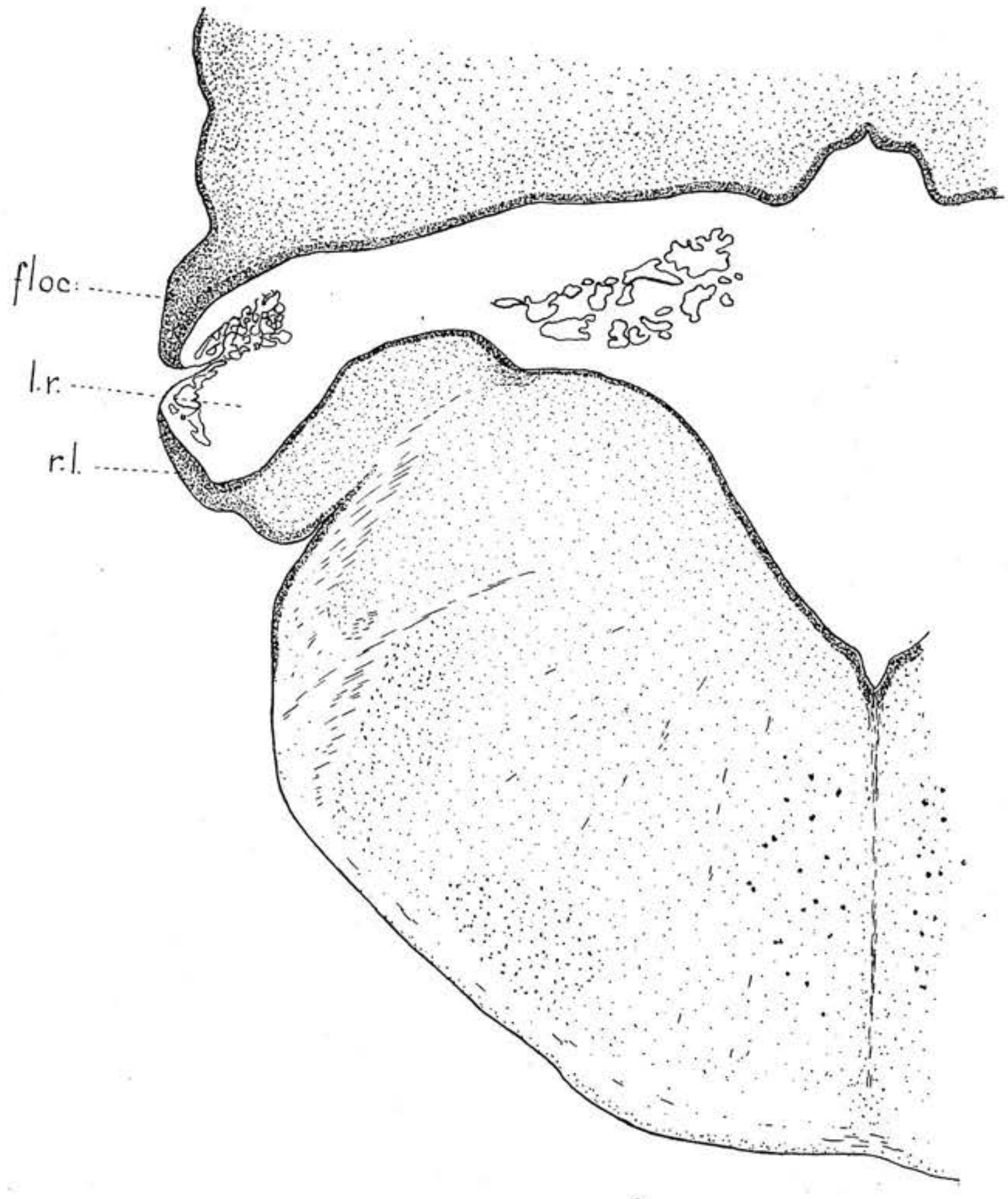

Fig: 89.

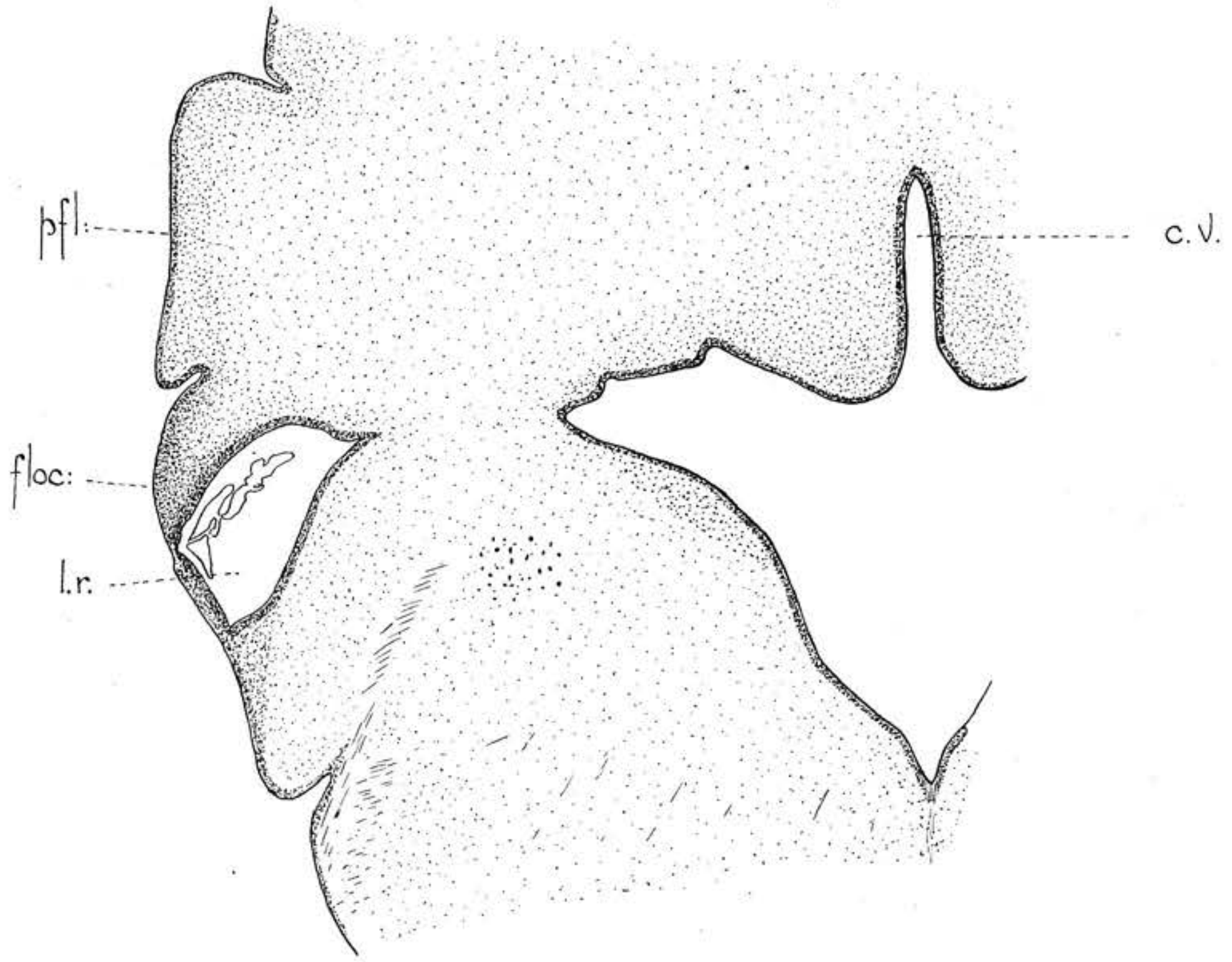

Fig: 90.

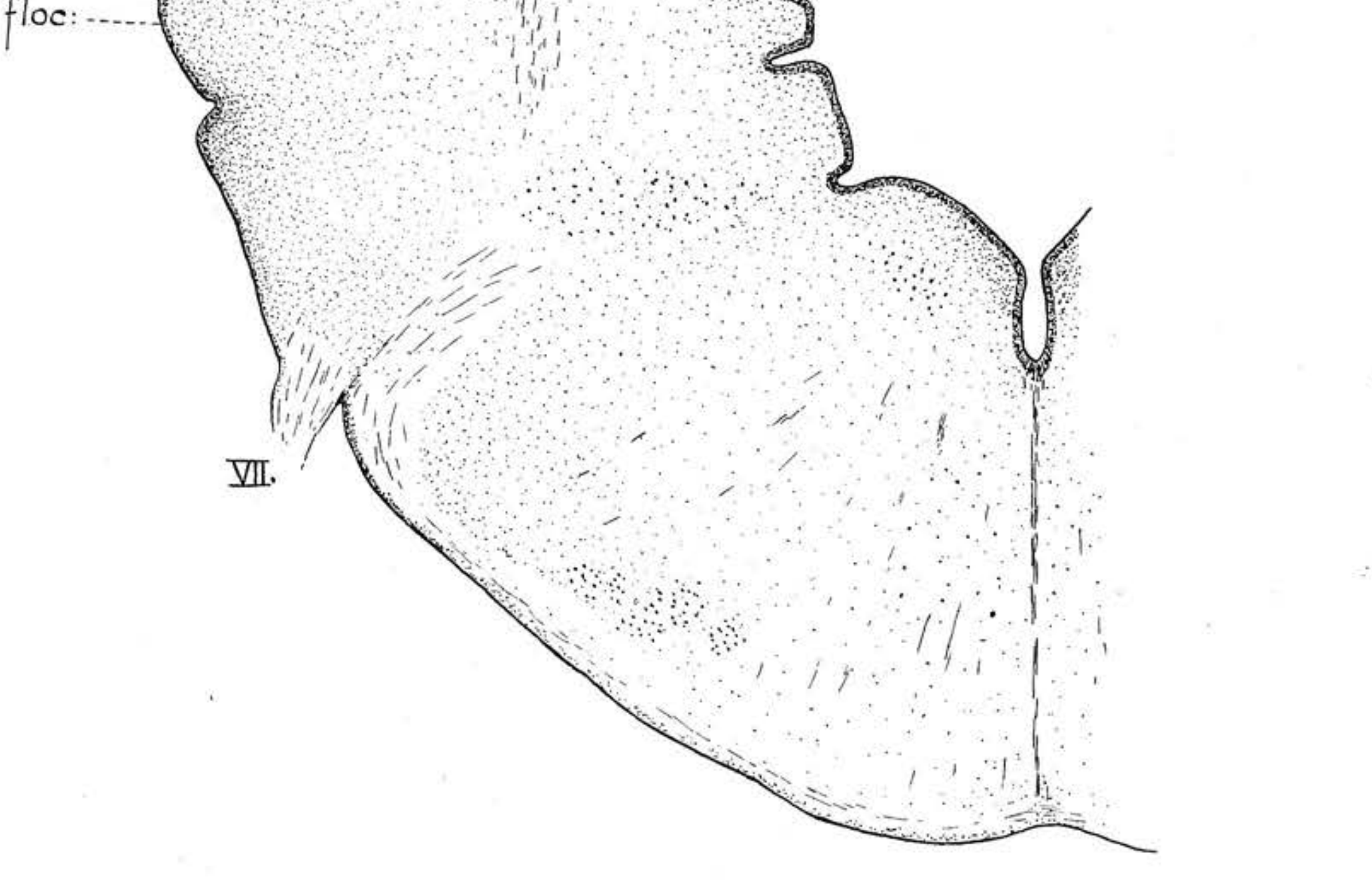

Fig: 91.

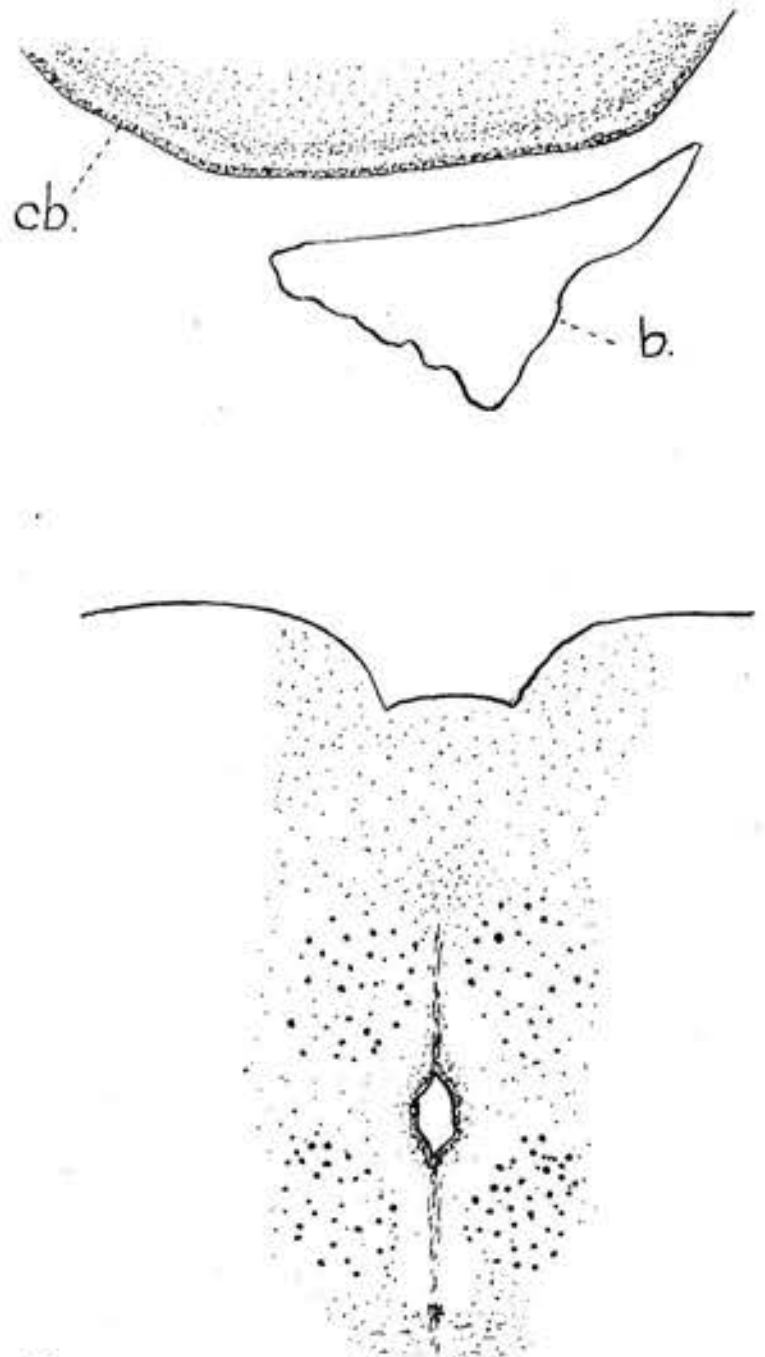

Fig. 92.

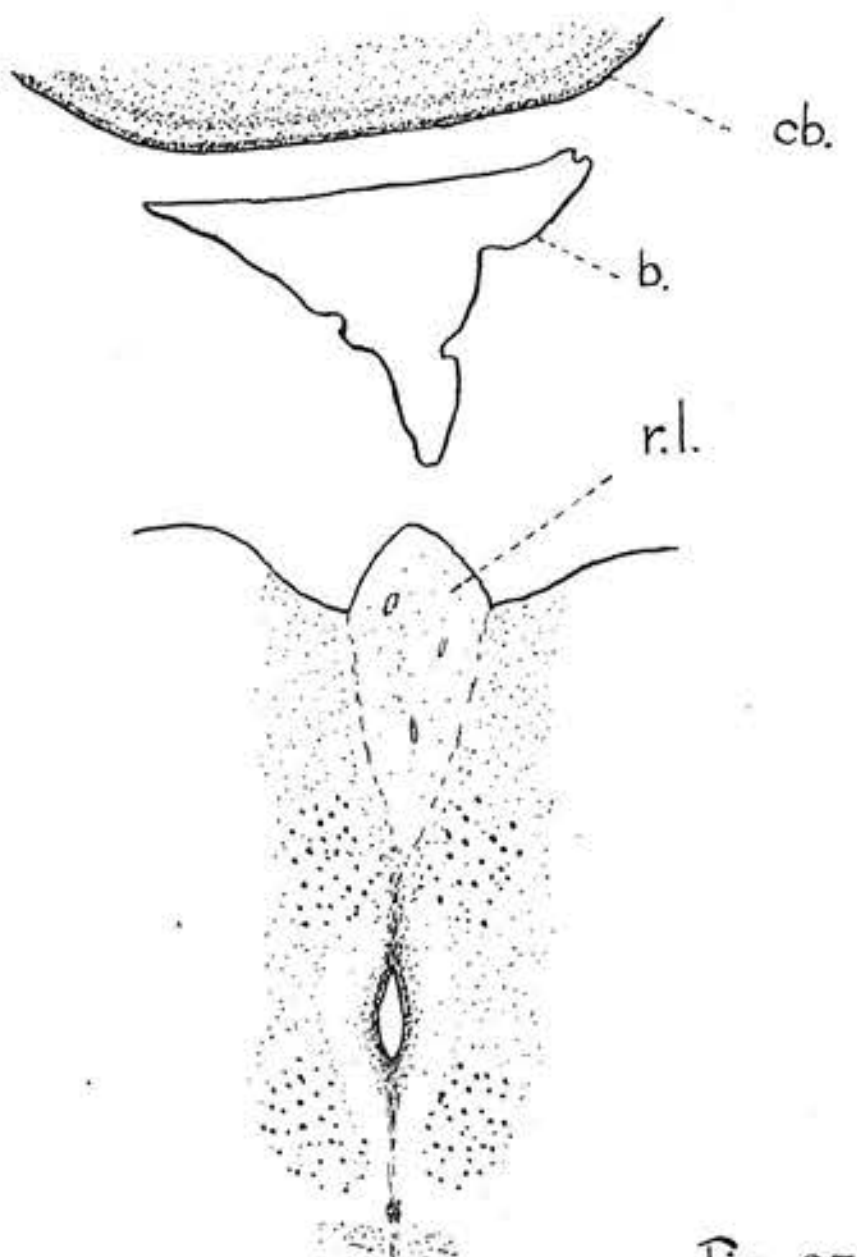

Fig. 93.

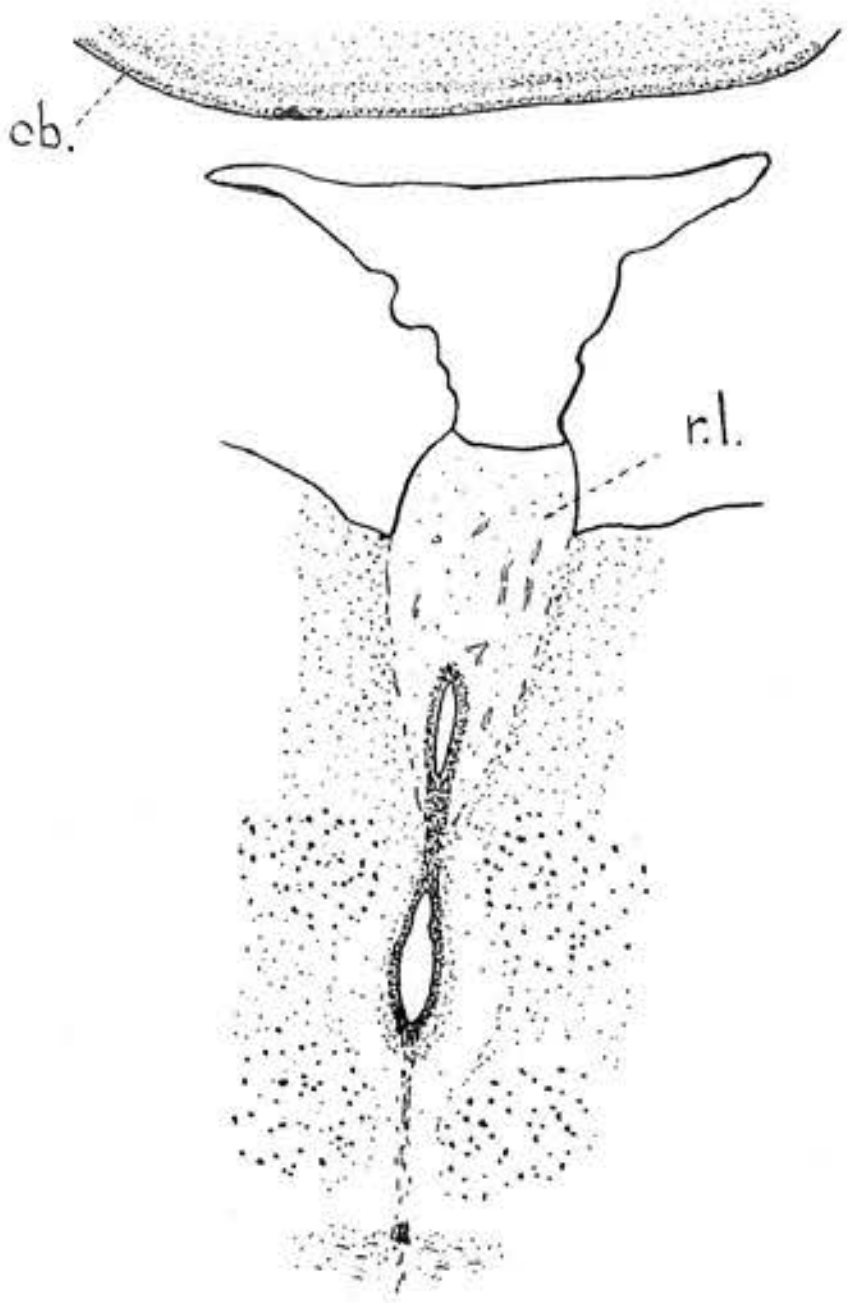

Fig. 94.

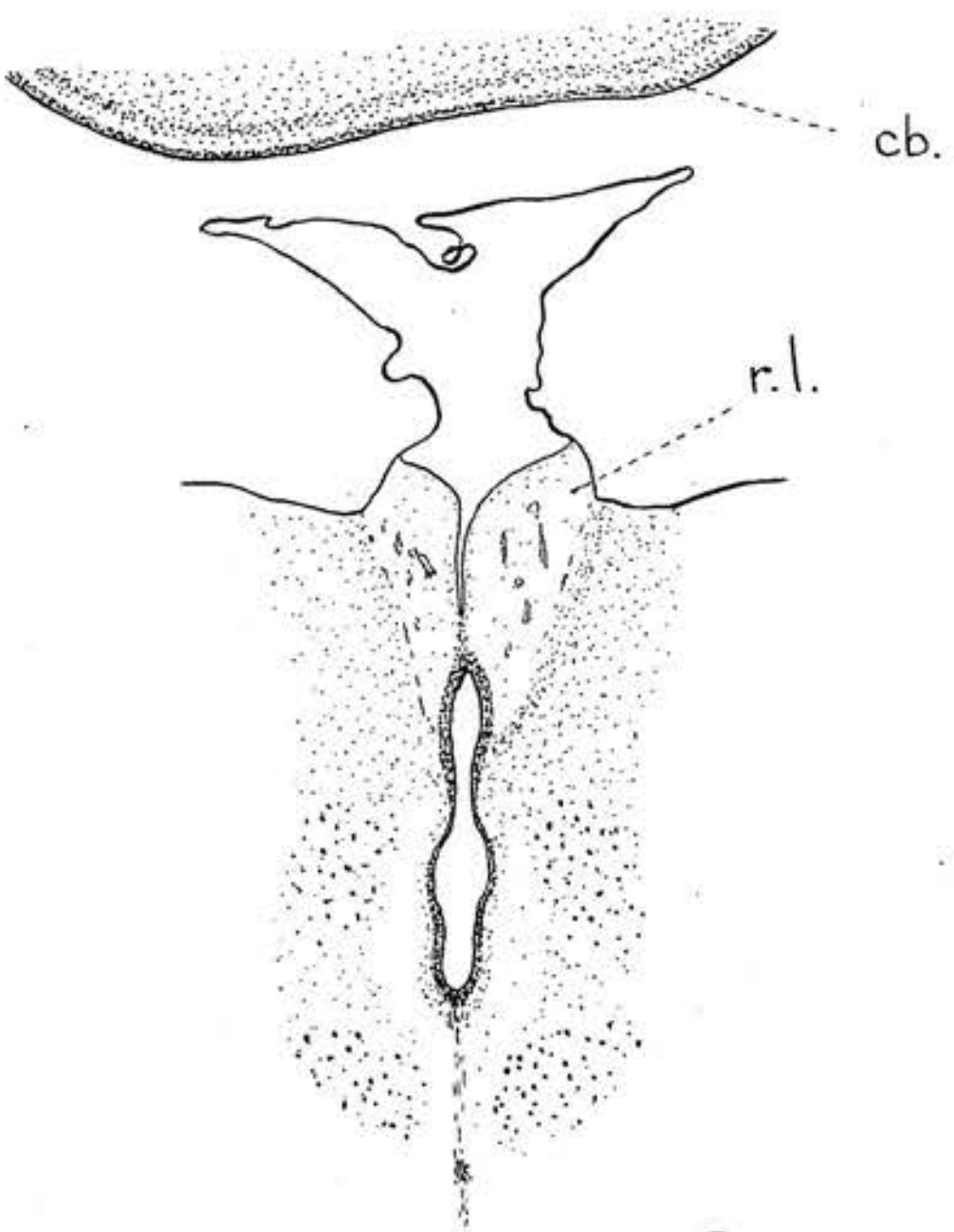

Fig. 95.

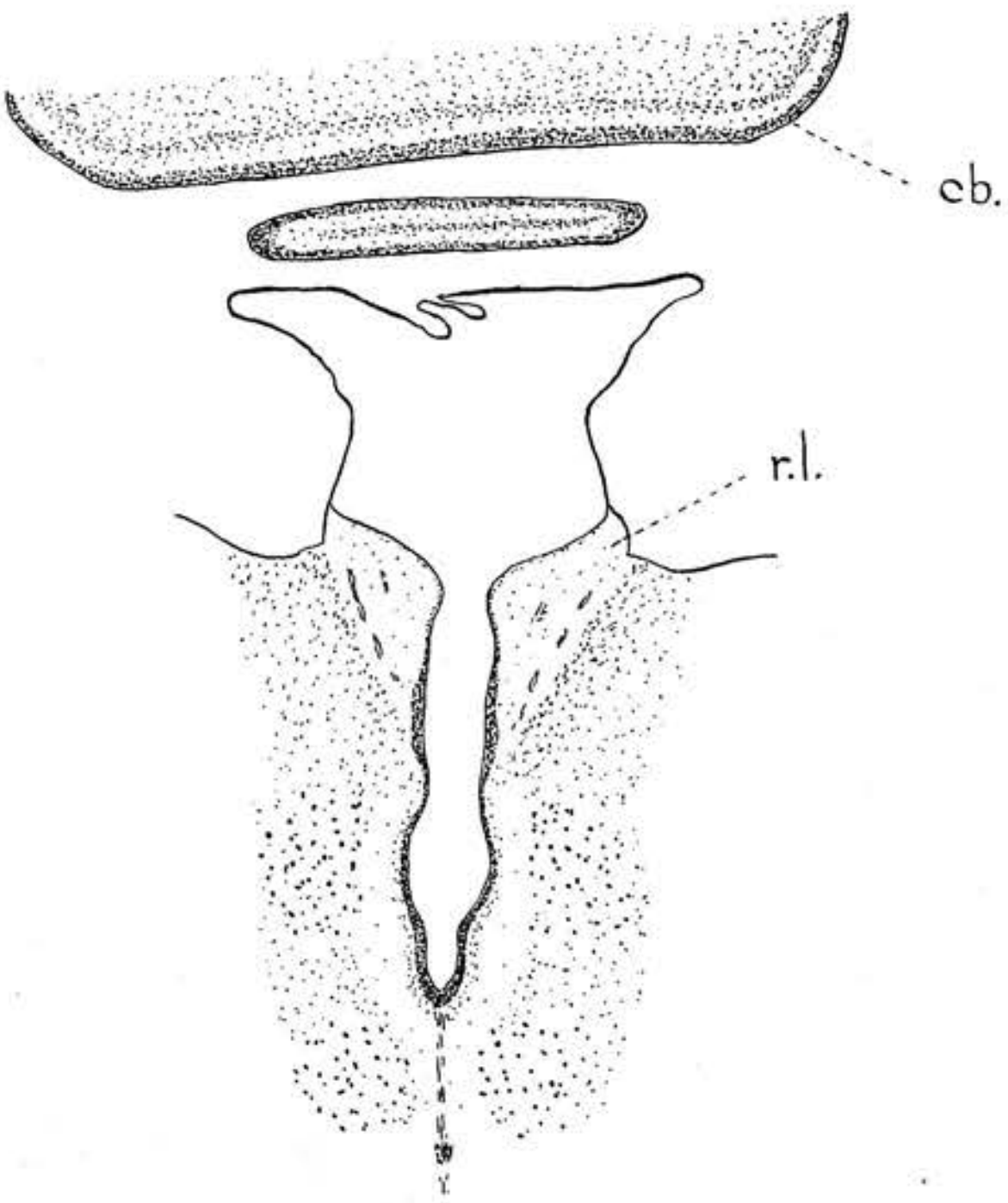

Fig. 96.

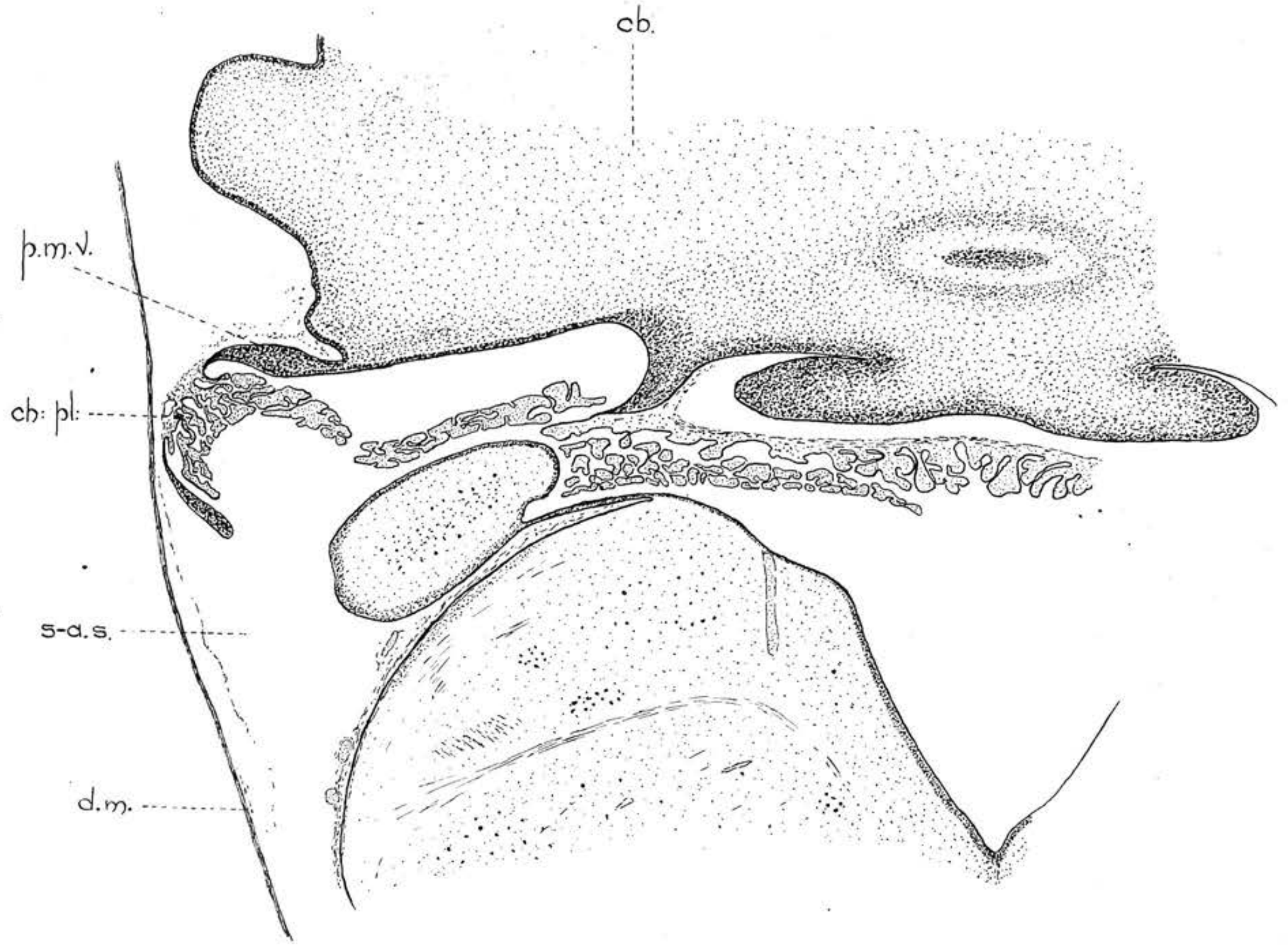

Fig: 97.

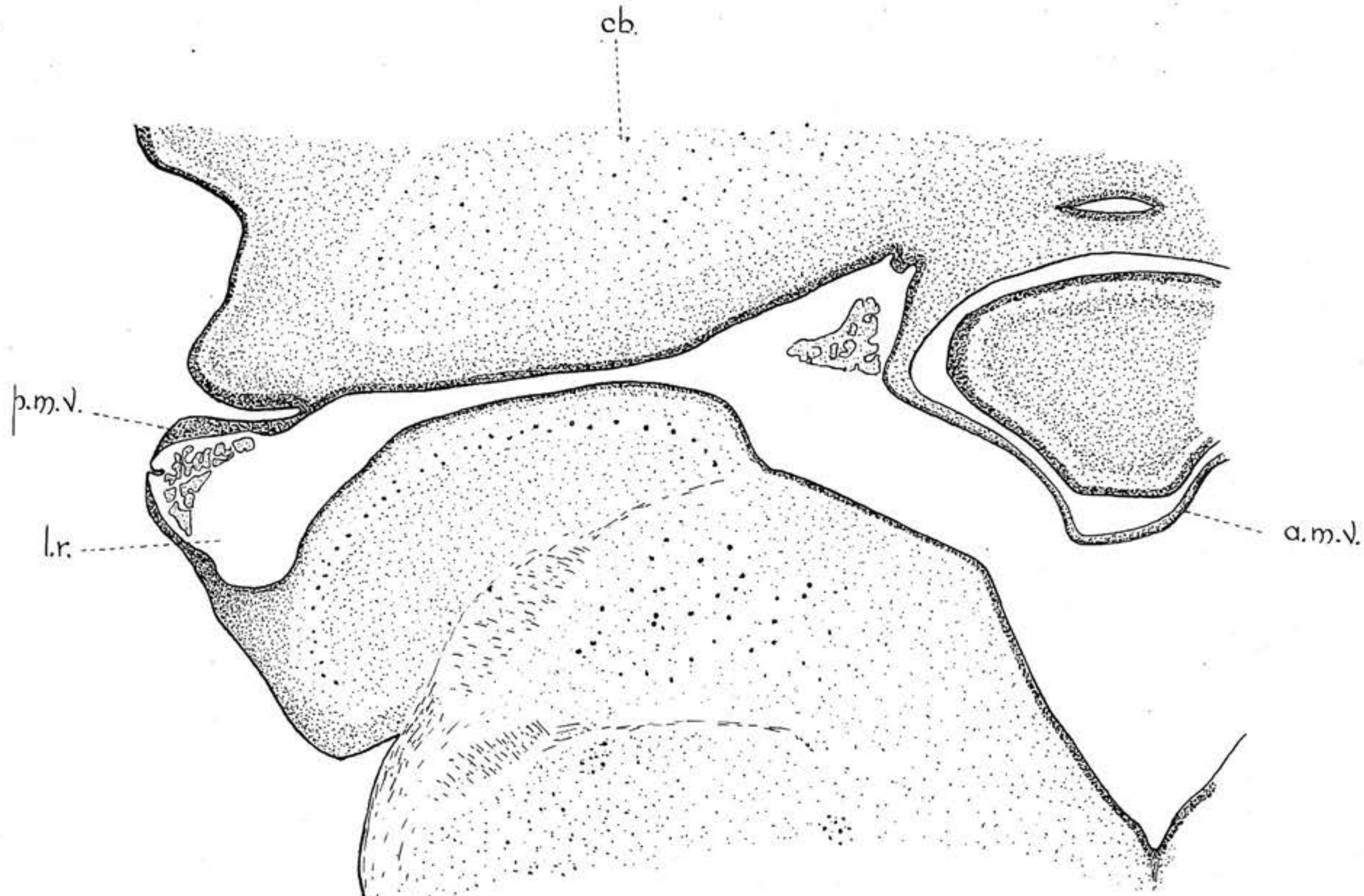

Fig: 98.