

INTRACARDIAC AIDS TO DIAGNOSIS IN INFANCY

by

HAMISH WATSON

M. B. , Ch. B. , M. R. C. P. E.

A thesis submitted to the Faculty of Medicine of the  
University of Edinburgh for the degree of Doctor of Medicine.

To my only son Michael, who was born too soon  
to share the fruits of these and others' labours.

Kinnaird, September, 1962.

## INTRODUCTION

"Accurate diagnosis will become progressively more important as surgical skill becomes better able to correct or compensate for the various malformations."

Helen B. Taussig, June 1947.

The wisdom of these prophetic words has become increasingly apparent in recent years, for though it had been said that when surgeons could open up the heart and have a really good look at it, there would be little need for elaborate and time consuming pre-operative investigations, exactly the opposite has proved to be true. As cardiac surgery becomes daily more complex its continuing success clearly depends on accurate diagnosis and close co-operation between all concerned. This clear need for detailed pre-operative assessment and study of the effects of operative treatment on the functional efficiency of the heart has in fact revolutionised cardiological thought and lead to the development of a whole new field of investigative medicine. Cardiac catheterisation, first accomplished by Forssmann in 1929, has played a vital role in this new cardiology. Developed as a clinical

tool by Cournand and Ranges, their paper "Catheterisation of the right auricle in man" published in 1941 was the first of the now almost innumerable accounts of its various uses. Its value in the diagnosis of congenital heart disease was reported by Brannon et al. in 1945, Baldwin et al. and Dexter et al. in 1946, Bing et al. in 1948 and summarised by Cournand and his associated in 1949. Initially used for probing, measuring pressures and obtaining samples of blood for gas analysis, catheters were soon being used to determine cardiac output by McMichael and Sharpey-Schafer in 1944; to record electrocardiograms inside the heart by Lenègre and Maurice in 1945, to study coronary blood flow and myocardial metabolism by Goodale et al. in 1947, to inject contrast medium into the heart for selective angio-cardiography by Chavez et al. in 1947, to measure shunts, flows, pulmonary vascular resistance and to estimate valve areas by Gorlin and Gorlin in 1951, to detect shunts by dilution curves after the injection of dye by Swan et al. in 1953 or by selective blood sampling after the inhalation of gases by Morrow in 1955, to record intracardiac phono-cardiograms by Yamakaw et al. and Soulié in 1954 and to study the

pharmacological action of injected drugs by Wood and Besterman in 1956. These and many other methods of venous catheterisation have been used extensively to explore the right side of the heart and the pulmonary arterial tree from the antecubital fossa or the groin. Information about the other side of the heart has been more slowly acquired, for though pressure measurements made during operations had been reported by Munnell and Lam in 1951 and it had been demonstrated by Epps and Adler in 1953 that human left atrial and pulmonary arterial wedge pressures and wave forms were similar, access to the left heart was found to be difficult and hazardous unless it could be reached through septal defects as described by Cournand et al. in 1947. The logical sequence of events was retrograde arterial catheterisation and this was reported by Zimmerman et al. and Limon Lanson et al. in 1950. It involved surgical exposure of a peripheral artery and the catheter had to be passed through the aortic and mitral valves against the blood flow with the risk of damaging the valve cusps or occluding a coronary artery on the way. Though somewhat simplified by Seldinger's method of percutaneous insertion of the catheter, it got a

bad reputation and has never become widely used except for aortography. About this time attempts at left heart puncture were being made and in 1951 Ponsdomenech and Nunez claimed to have carried out the first successful left ventricular angio-cardiography using a trochar and an epigastric paraxiphoid approach. Other reports of needle puncture of the left heart and great vessels soon followed. A transbronchial approach to the left atrium and later to other chambers was described by Facquet et al. in 1952 and by Allison and Linden in 1953 and 1954, Radner reported successful aortic puncture through the suprasternal fossa in 1953 and later extended this technique to the left atrium and other heart chambers and great vessels in 1954 and 1955, and direct puncture of the heart through the chest wall using a right paravertebral approach was described by Björk et al. in 1953. In a very short time the left heart was being catheterised through such needle punctures, a variety of routes being used to insert the catheter into the left atrium - the posterior trans-thoracic by Björk et al. in 1954 and by Fisher in 1955, the transbronchial by Braunwald in 1957 and the suprasternal by Fox in 1959. Direct ventricular puncture,

though less popular, was further developed by Cregg et al. in 1955 and by Lehman et al. in 1957 for radiological purposes and used by Brock et al. in 1956 for catheter studies in aortic stenosis.

These methods, however, were not without risk and none has become as universally adopted as right heart catheterisation. This well tried procedure, long acknowledged to be safe when in good hands, could well provide the answer for the technique of transeptal puncture first described by Ross in 1959 may yet prove that the safest approach to the left side of the heart is from the right.


The purpose of this thesis is to illustrate techniques which I have developed during the last five years and applied to the investigation of babies and very small children. For, in spite of continued surgical progress, the high mortality from congenital heart disease in the first year of life remained a challenge and it was clear that diagnostic methods required some modification to select not only those for whom operative treatment was already possible, but also those for whom it might soon be.

With this in mind, the information obtained from the electrocardiograms recorded inside the heart during cardiac catheterisation in 500 consecutive cases has been analysed and is presented with special reference to the value of intracardiac electrography as a routine procedure in infancy and the neo-natal period.

Angiocardiography plays an important part in the investigation of children in this age group since it is not always possible to make an exact diagnosis by cardiac catheterisation when complex lesions are present. A technique of selective cine-angiocardiology has been developed using image intensification and cine-photography whereby films can be taken at any stage of the procedure. This method has increased the accuracy of diagnosis by making study of the actual intracardiac circulation possible, while at the same time reducing the total length of the investigation and the radiation of both patients and staff. The successful development of cine-radiography has of course involved a great deal of technical skill and I would like to take this opportunity of paying tribute to my friend and colleague Dr. C. Pickard who has devoted so much of his time and skill to this end.

Intracardiac electrography and selective cine-angiocardiology will each be illustrated in separate sections and their combined value when taken in conjunction with careful analysis of pressure pulse recordings will be demonstrated in the step by step analysis of the nature of the obstruction to the out flow of blood from the right ventricle in severe isolated pulmonary valvular stenosis and by a study of the altered pressure flow relationships in this condition.

Work of this type does not lend itself to the compilation of tables and statistical analyses. My aim has been to evaluate which intracardiac procedures give most information while involving the patient in the least possible risk, and my object to adapt them to babies and very small children whose investigation presents special problems to the cardiologist.



Department of Medicine.  
University of St. Andrews.

## SECTION 1

### INTRACARDIAC ELECTROGRAPHY IN THE INVESTIGATION OF CONGENITAL HEART DISEASE IN INFANCY AND THE NEO-NATAL PERIOD

The first electrocardiograms ever to be recorded inside the heart with a cardiac catheter were obtained in dogs by Luisada et al. in 1937, and the earliest account of human intracardiac electrography, by Lenègre and Maurice, did not appear until 1945. Using a No. 13 ureteric catheter with a fine gold wire in its lumen and a soft tin electrode at its tip, they were able to record electrical potentials from the cavities of the right atrium and right ventricle and suggested that "our knowledge of the timing and the pathway of the intra-cardiac excitation" could be extended in this way. During the next few years there were reports by Hecht in 1946, Battro and Bidoggia, and Sodi-Pallares et al. in 1947, Duchosal et al., Kossmann et al., Schlesinger et al., and Sodi-Pallares et al. in 1948, Kert and Hoobler, Kossmann et al. and Levine et al. in 1949 and by Kossmann, Kossmann et al. and Levine and Goodale in 1950, which described various techniques of obtaining intracardiac electrograms by venous catheterisation and the complexes found at

different sites in the heart and great vessels. These early records were obtained with catheters specially modified for the purpose. In most cases a small round or ovoid electrode was fitted onto the distal end and acted as an exploring electrode. This was connected to a central terminal by a steel, silver or copper wire threaded through the lumen of the catheter, which was therefore of little use for anything else. Intracavity potentials from the left side of the heart were first described by Sodi-Pallares et al. and Duchosal et al. in 1948 and by Kert and Hoobler in 1949 in cases where catheters had crossed from right to left through septal defects. These were later confirmed and augmented during retrograde left heart catheterisation by Zimmerman and Hellerstein, Coelho et al., and Steinberg et al. in 1951 and by Mas et al. in 1952.

Most of this work was fairly academic in nature and much of it was concerned with fundamental theories of electrocardiography. The course of action currents and the spread of activation through the myocardium were studied and the effects of bundle branch block analysed. In addition geographical maps were made showing the morphology of the intracardiac complexes which were compared with those obtained from the epicardial surface

of the heart by Grödel and Borchartd in 1948. These investigations provided valuable evidence that many of the observations which had been made on animals by Wilson and others, since Lewis' classical experiments, were also applicable to the human heart. The potential variations recorded by these early electrode catheters confirmed the basic concepts of the origin, spread and distribution of action currents within the human heart upon which our present day interpretation of electrocardiograms depends.

These important studies were however somewhat esoteric and intracardiac electrography failed to catch the imagination of the host of busy investigators who were working on more practical aspects of cardiology. Few reports of its clinical application have appeared in the literature - even to this day. Goodale et al. in 1949 noted that it helped to determine the position of the catheter tip in the coronary veins, and its possible value in the analysis of complex arrhythmias was pointed out by Ferrer et al. in 1949 and by Steinberg et al. in 1952, Emslie-Smith, reporting the early experience from this Department in 1955, suggested that it might have a wider use in cardiac catheterisation and the following year with Lowe and Hill illustrated its value as an aid in the local-

isation of pulmonary stenosis. In 1956 Sodi-Pallares indicated that it could be helpful in the diagnosis of Ebstein's anomaly and this was confirmed by Hernandez et al., and by Yim and Yu in 1958. Several papers on various aspects of "électrocardiographiques endocavitaires" have been written during the last ten years by an active French group headed by Giraud and a monograph summarising their experience in the subject was published by Latour and Puech in 1957. In three recent papers Dickerson and Caris, Testelli, and Bertrand et al., have re-emphasised its usefulness during both right and left heart catheterisation, and Watson has demonstrated its value in the investigation of congenital heart disease in infancy and the neonatal period.

This section will be devoted to the clinical application of intracardiac electrography to diagnosis in very small children because in these cases, where catheterisation tends to be a little more difficult than usual, it is particularly useful. I agree with Ziegler (1954) that when a serious lesion is suspected, the sooner an exact diagnosis is made the better, and with Sones (1955) that no child should be denied the opportunity because he is too small or too ill. A full investigation at this stage may save the lives of some babies, spare others from unnec-

essary operations and result in better advice being given to parents, paediatricians and family doctors. In addition, essential information is obtained that helps to fill the gaps in our knowledge and understanding of the natural course of events in different types of congenital heart disease. It has been found, for example, that ventricular septal defects, though commonly discovered during routine examinations in symptomless children, often cause serious trouble in infancy. A few babies born with this lesion soon die from heart failure and some, failing to thrive, can be tided along with careful medical treatment only to succumb to intercurrent infections. Many, however, after a bad start, seem to adapt themselves quite well to their Eisenmenger reaction and grow big enough for operation only to find it hazardous or even contra-indicated because of their altered pulmonary haemodynamics.

There seems little doubt that before long the challenge of this and other conditions which cannot as yet be treated surgically will be met, and that when a suitably sized pump-oxygenator becomes available, the high mortality from congenital heart disease in the first year of life will be considerably reduced. It is not always possible to make an exact diagnosis at the bed side




FIGURE 1

in very small children, and clearly our diagnostic methods require to be modified and adapted to select not only those infants for whom surgical treatment is already possible, but also those for whom it soon will be. Many of them are ill or have heart failure and present special problems to the anaesthetist and cardiologist. Intracardiac manipulations have to be very gentle in such cases - the heart being only about the size of a walnut and often extremely irritable during cardiac catheterisation. As the investigation may have to be abandoned at any stage, speed is essential and it is also wise to record every piece of information as it becomes available, because for a variety of reasons it may not be again. A catheter which has taken an unusual route, for example, may have to be withdrawn somewhat hastily before pressures or oxygen saturations can be recorded and in these and other circumstances the routine use of intracardiac electrography can be most helpful.

#### METHODS AND MATERIAL

Electrode catheters are now easily obtained from the United States Catheter and Instrument Corporation. The standard production model, shown in Figure 1, is exactly the same as the single lumen Cournand catheter,

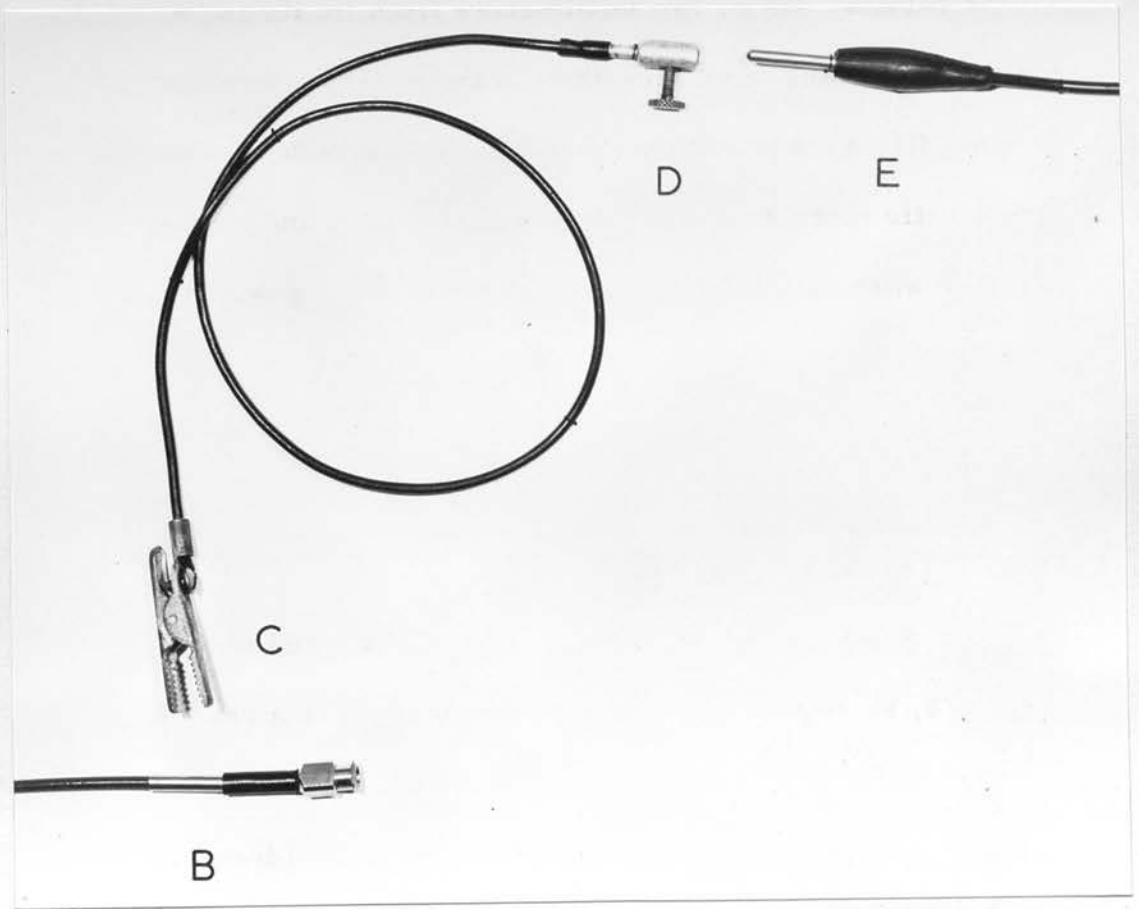


FIGURE 2

except for its electrode, and can be obtained in all sizes from 5F to 14F and 50, 100 or 125 centimetres long. They will also supply any of their other catheters with electrodes or make up special types to order. The exploring electrode (A), a small nickel silver ring, is flush with the surface of the catheter one or two millimetres from its tip and a spiral conducting wire runs down in the wall to a terminal contact (B) at its proximal end. These electrode catheters are a little more expensive than ordinary ones and have a shorter working life because twisting and turning during use tends to crack them along the line of the spiral wire lying under the outer cover. With careful handling however each can be used many times and the extra information acquired is cheaply bought.

Some simple device such as is illustrated in Figure 2, is required to connect the electrode to a recorder, a bulldog clip (C) grasps the terminal contact (B) and leads to a female socket (D) into which the V lead terminal (E) from the electrocardiograph can be fitted. It is then possible to make simultaneous recordings from the terminal electrode and the catheter tip knowing that both have the same location in the heart. A special catheter is therefore no longer required to record electrocardiograms inside the heart and the presence of an electrode at its

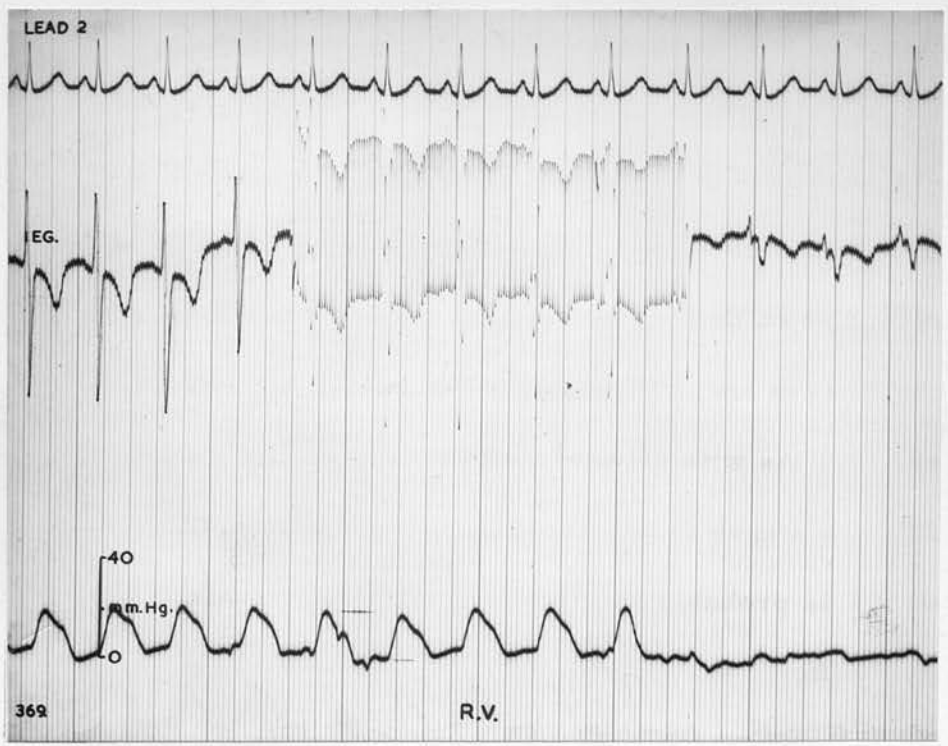

FIGURE 3

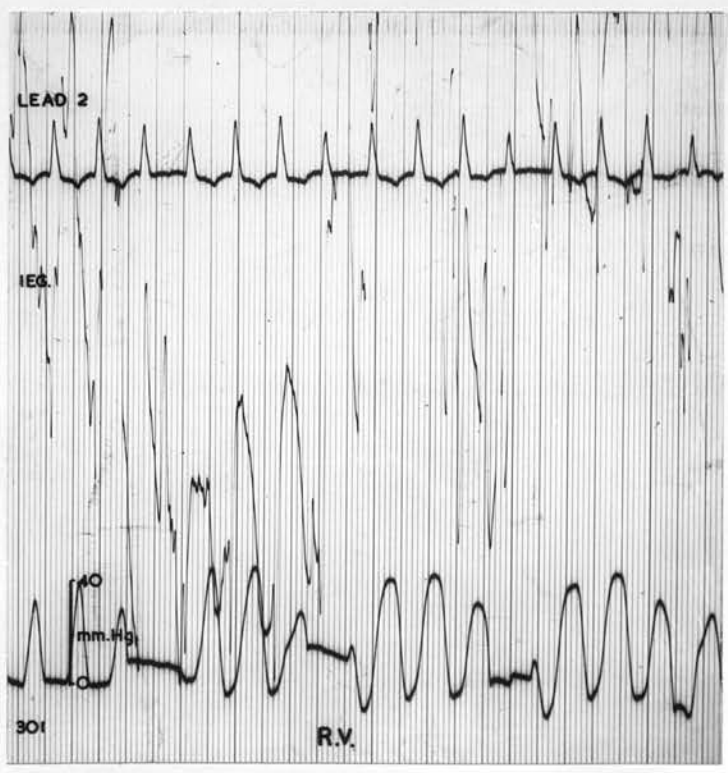


FIGURE 4

tip in no way interferes with its other functions.

In spite of this, intracardiac electrography has never received the attention it deserves and it seems a pity that such a valuable technique is not in more general use. One of the reasons is perhaps that many who have tried it have been disappointed and put off by their early results. As with all new methods many small technical difficulties have to be overcome and of these A.C. interference is probably the most troublesome. This is always difficult to suppress in cardiac theatres because of the close proximity of the X-ray apparatus and the multiplicity of electrical appliances, switches and wires which criss-cross the room, and the host of nurses, technicians, radiologists, anaesthetists and visitors who tend to gather round them - much of the time in the dark!

Figure 3 shows how records can be spoiled if one of them inadvertently touches the patient - in this instance an anaesthetist about to count the temporal pulse. It is also most important to maintain a completely dry field throughout the entire investigation since damp terminals cause faulty connections and result in poor quality tracings of the type seen in Figure 4, where the intracardiac lead is unstable, contributes nothing and may even spoil the record.

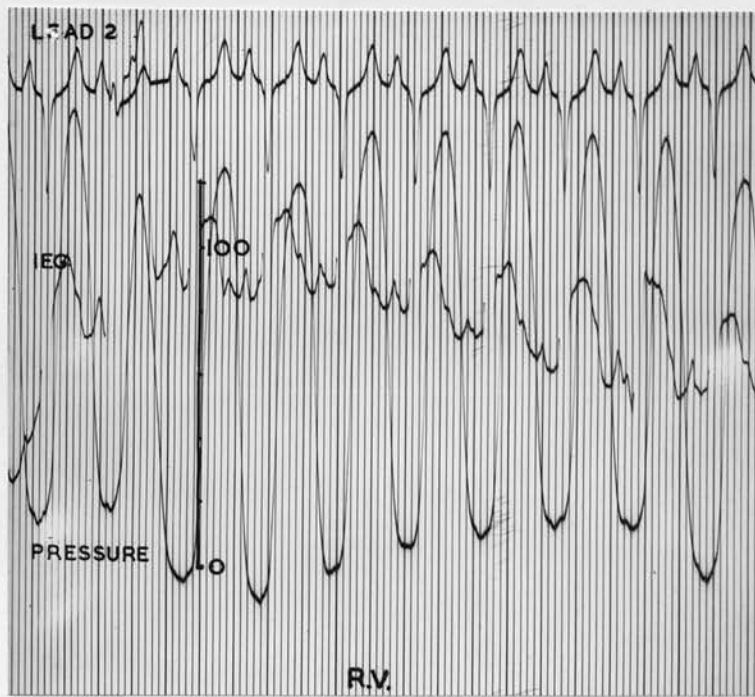


FIGURE 5

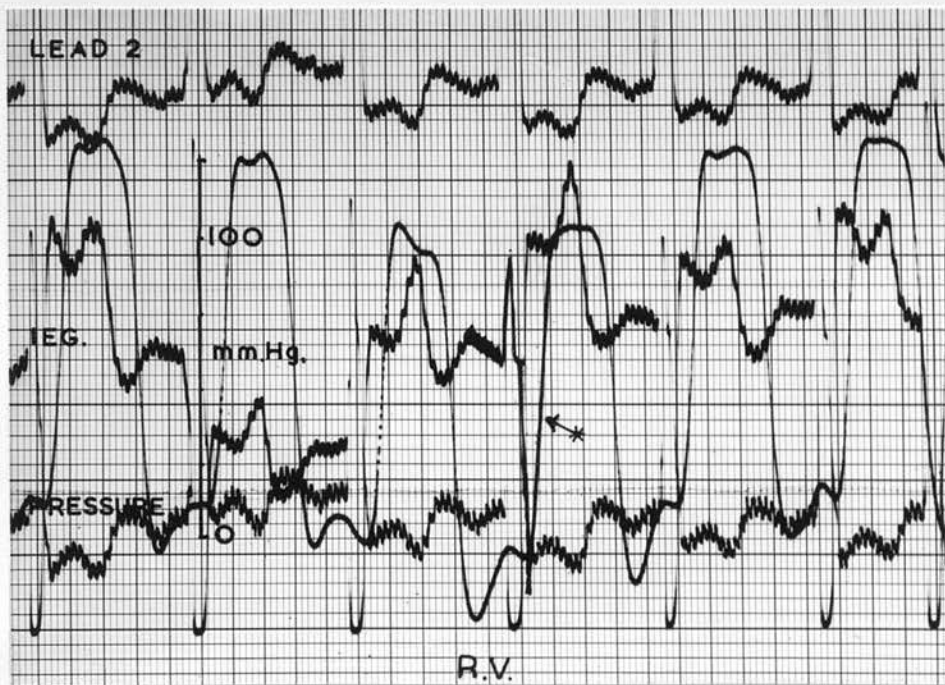


FIGURE 6

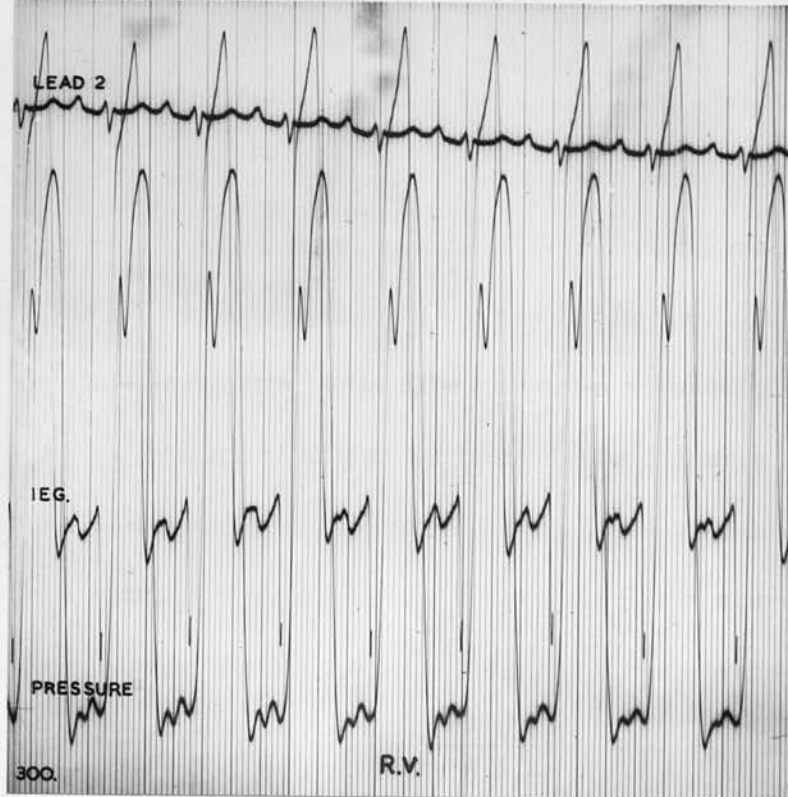


FIGURE 7

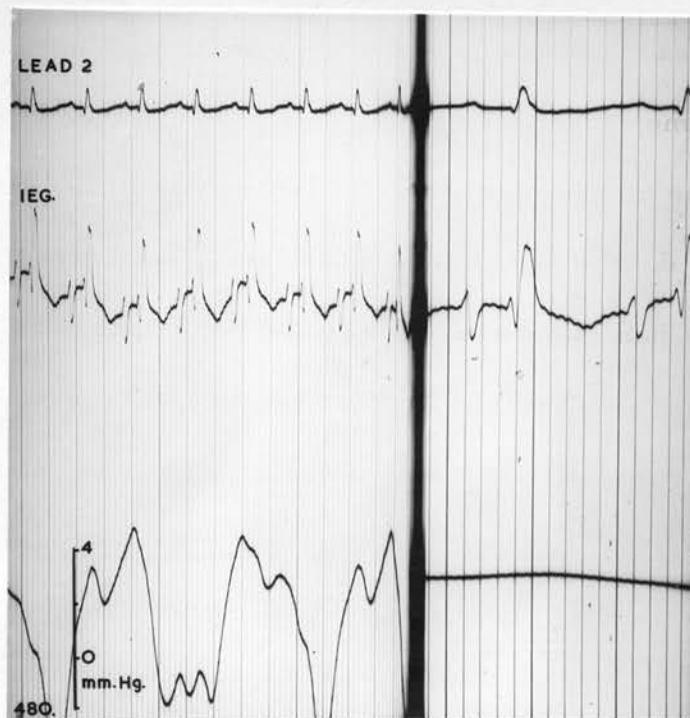


FIGURE 8

A good multichannel photographic recorder is essential for the successful reproduction of intracardiac potentials which are often of high voltage. As at least one surface lead must be included for reference, wide paper is required to ensure that the complexes do not cross or become mixed up with other simultaneously recorded signals, which must be carefully spaced out to avoid the confusion seen in Figure 5 or the misinterpretation seen in Figure 6, where the negative deflection of the cardiogram has been continued into the upstroke of the pressure pulse "for clarity's sake" before it was put out in a demonstration. Since the amplitude of the signals to be recorded is constantly varying, their standardisation requires frequent adjustment. For routine use the intracardiac lead is probably best standardised at 2 millivolts per centimetre deflection and this can be reduced to increase the size of low voltage complexes when necessary. For huge deflections, such as those seen in Figure 7, it should be increased still further and the output from the pressure channel halved to make the record legible. Fast paper speeds are necessary for the detailed study and timing of deflections in individual complexes (Figure 8), and a good light and some magnification helps with the analysis of high speed deflections, many of which may

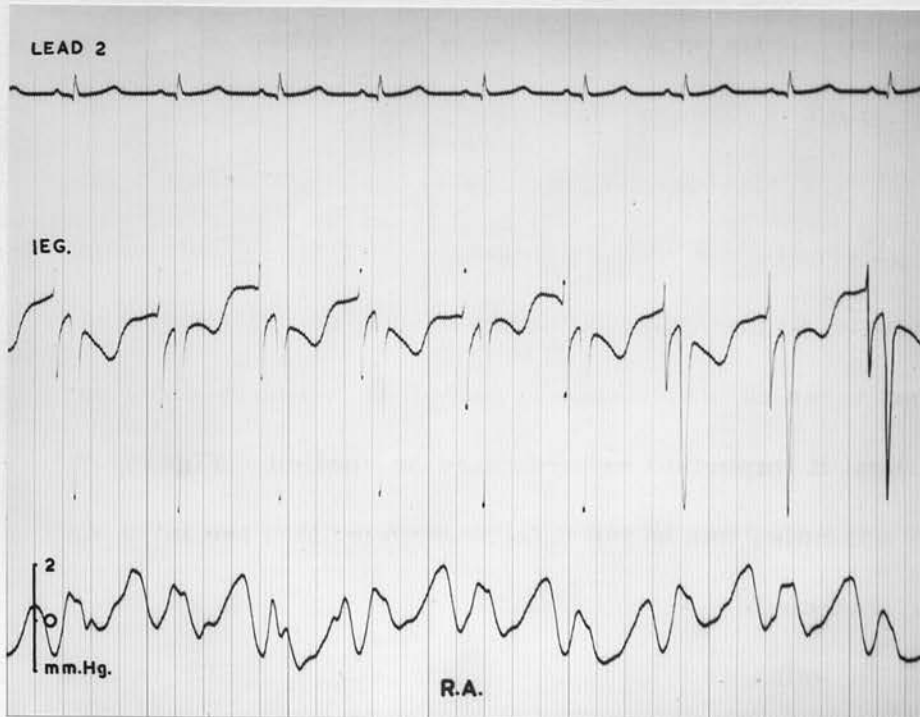


FIGURE 9

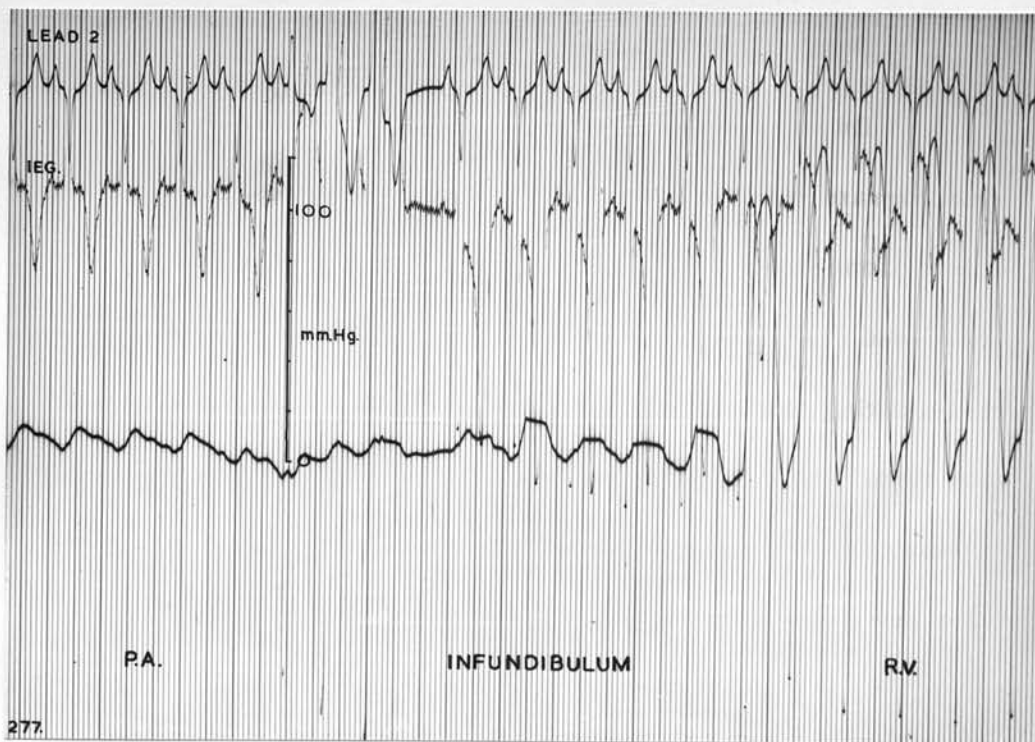


FIGURE 10

require a little emphasis to make them visible in illustrations (Figure 9).

If high quality tracings are desired such things as galvanometer mirrors require precise setting and the intensity of the light source must be accurately adjusted. Good technical assistance is therefore indispensable, for without it important records may be spoiled - Figure 10, for example, one of the first to confirm that the intracardiac lead could identify infundibular stenosis, is so poor that its valuable information is all but obscured. An experienced hand is therefore required at the controls to maintain the equipment and to make the rapid changes, which are so often necessary, as the catheter moves about inside the heart and great vessels.

During cardiac catheterisation the intracardiac electrogram may be monitored on an oscilloscope, either alone or with simultaneously recorded pulse pressures, and it also assists when the photographic records made during the investigation are being analysed and reported. Complexes may be recorded either when the catheter is stationary or as it is being withdrawn slowly from one place to another. The morphology of these complexes indicates the site of the tip or the route it has taken, and much time and trouble can be saved if full use

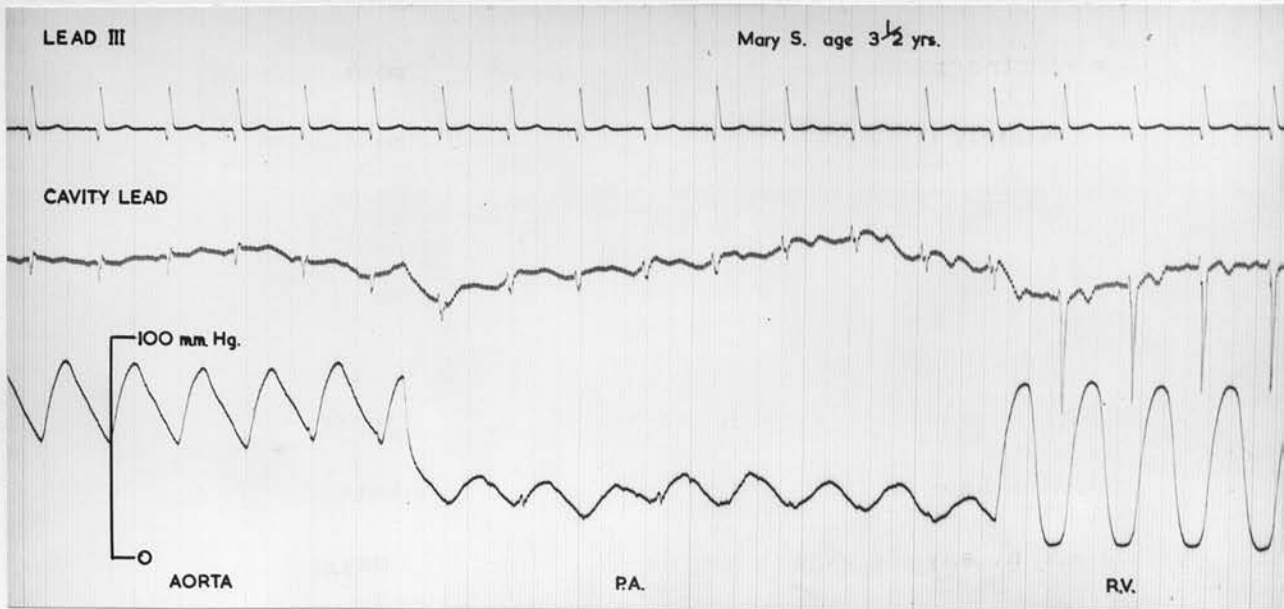


FIGURE 11

is made of this during catheterisation.

Figure 11, for instance, is a record made as a catheter was withdrawn from the supracardiac area in a rather puzzling case which turned out to be one of Fallot's Tetralogy with a large patent ductus arteriosus. The route - aorta, patent ductus, pulmonary artery, right ventricle - has produced an unusual pressure pulse tracing and is confirmed by the intracardiac lead. The low voltage electrograms in the great vessels change from qr to rs immediately the tip comes through the ductus from aorta to pulmonary artery, and a great increase in voltage is seen whenever it passes back through the stenosed pulmonary valve from the thin walled pulmonary trunk into the thick muscular walled right ventricle. Such complexes may also help during blood sampling when a catheter placed in, say the right ventricle, to determine oxygen saturations has to be moved about before a sample can be withdrawn. The intracardiac electrogram will show whether or not it is still in the right ventricle when the blood is obtained and so avoid the inconvenience of stopping to check the pressure pulse.

The characteristic changes that occur in the electrogram as the catheter tip moves from one site to another can assist with many difficult manoeuvres,

which are often associated with damped pressure pulses, in much the same way as radar helps to steer through the fog. The facility has even been used by some as an alternative to X-ray control, Dickerson and Caris having cut down their radiation time in this way from 10-15 to as little as 1 or 2 minutes and only screening when stuck or in difficulties.

While there is no doubt that intracardiac electrography reduces the length of fluoroscopy required, it must be used as a supplement and not as a substitute for it. Except during slow withdrawals, the Golden Rule for safe cardiac catheterisation should be that no catheter is ever moved about inside the heart without X-ray control. When combined with simultaneously recorded pressure and electrocardiographic signals from inside the heart, this gives triple visual control and increases the safety factor considerably. Thus, when a catheter lying in the coronary sinus appears to have entered the right ventricular outflow tract and, as sometimes happens, the pressure pulse seems to confirm this - the characteristic intracardiac electrogram will immediately give warning of the true state of affairs and prevent dangerous attempts to advance it into the pulmonary artery.

Hazards may be further minimized by keeping a

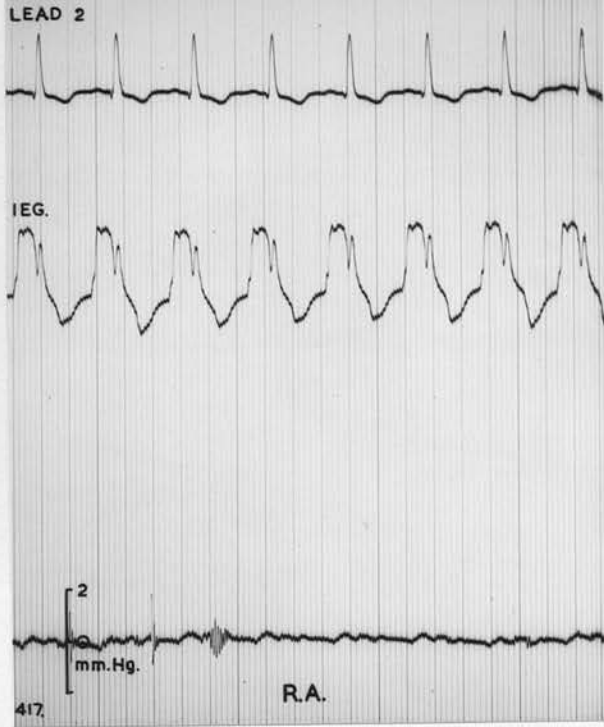


FIGURE 12

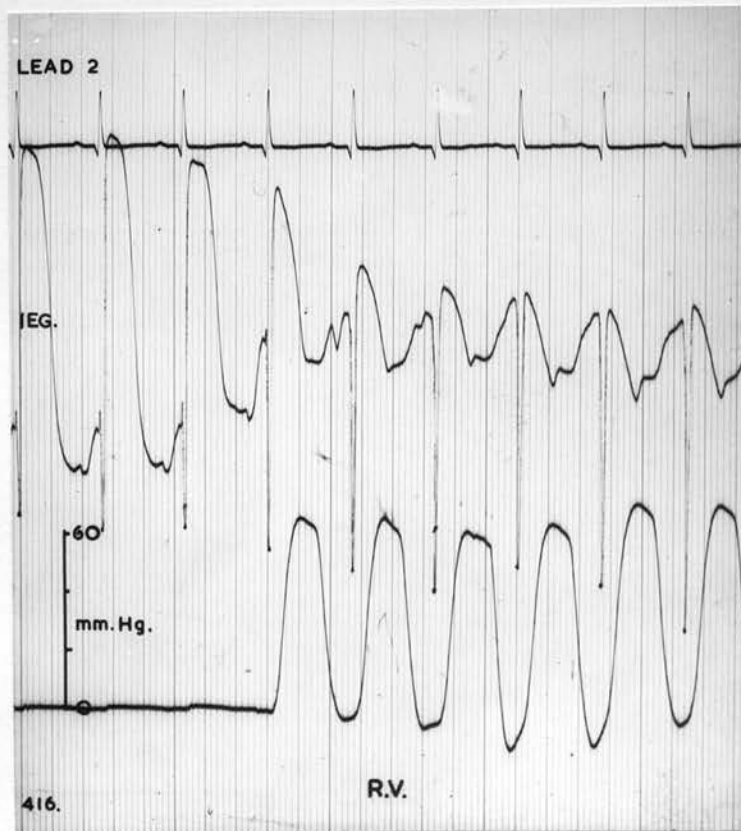


FIGURE 13

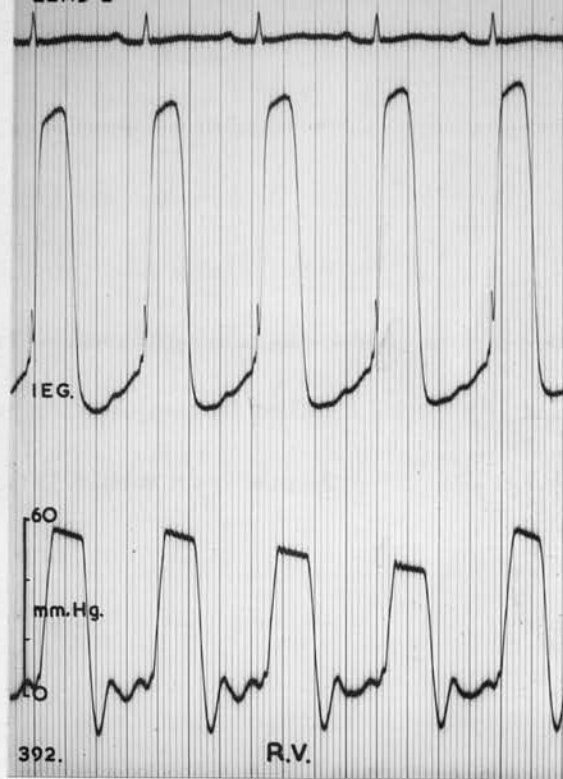


FIGURE 14

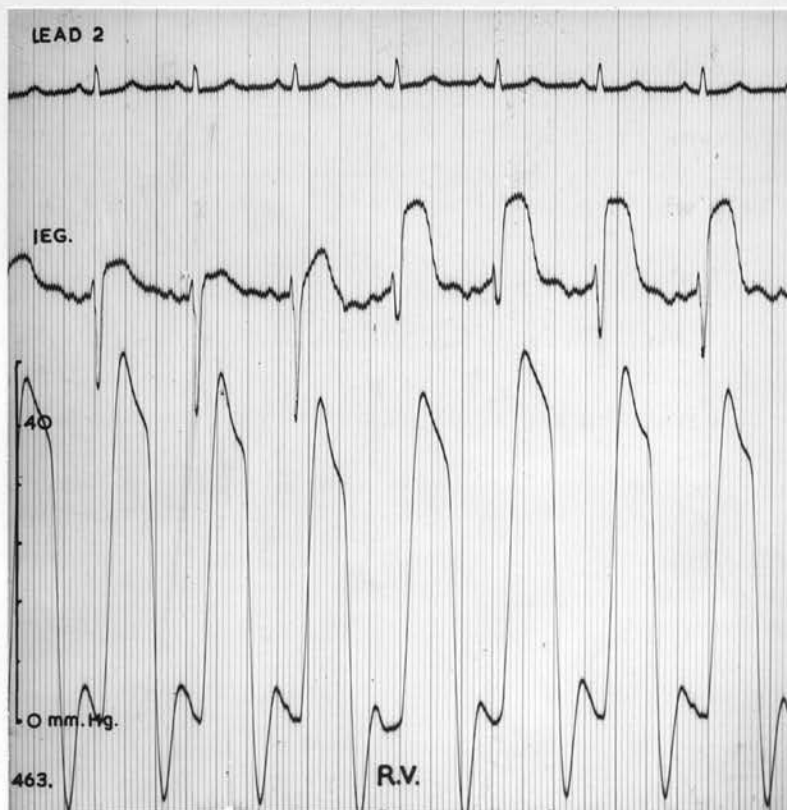


FIGURE 15

careful look out for the ST or PT elevations which occur when the intracardiac electrode is pressed against the endocardium. These so called injury deflections would be better named contact currents, since no injury is likely to take place unless their presence is ignored. They can be of diagnostic value when studied in conjunction with damped pressure pulses which by themselves would fail to indicate their site of origin. The large PT elevations in Figure 12, for example, indicate that the pressure pulse is absent because the end of the catheter has been pressing against the atrial wall, and a similar effect is seen in the ventricle in Figure 13. In this instance, though no pulse is recorded initially, when the catheter is withdrawn a little, contact is lost, the ST elevation subsides, and the pulse waves re-appear. Such contact or injury currents also help when recorded pressures are not true - the gross ST shifts in Figure 14 confirming that the somewhat flat tops of the pulse waves were artefacts which in this case had reduced the ventricular pressure by as much as 25 mm. of Hg. It must be remembered however, that as the electrode is on the side of the catheter and about a millimetre from its tip, ST shifts may occur in the absence of pressure damping, and this is illustrated in Figure 15, where the electrode has merely come in contact with the

side wall of the ventricle during recording without affecting the pressure pulse.

While giving invaluable assistance in these and other circumstances, the intracardiac lead is not really suitable for routine monitoring during catheterisation as recommended by Emslie-Smith. Ordinary catheter manipulations cause it to wander over and off the oscilloscope, while ectopic beats and ST shifts frequently produce gross deflections. In the dark theatre the whole picture, with its afterglow, tends to look rather wild and alarming, and rhythm is much better and more accurately monitored on an ordinary standard lead.

The actual catheterisation is best done from the groin, and though the jugular and even the umbilical vein (Furman, 1951) have been used for the purpose, the saphenous is by far the most satisfactory. It is easily found on a line mid way between the femoral artery and the pubic tubercle about half an inch below the inguinal ligament. The right side should be chosen if possible, as the junction of the internal iliac veins with the inferior vena cava is sometimes T rather than Y shaped and may be difficult to pass if approached from the left. Some special little instruments make the operation easier and the two

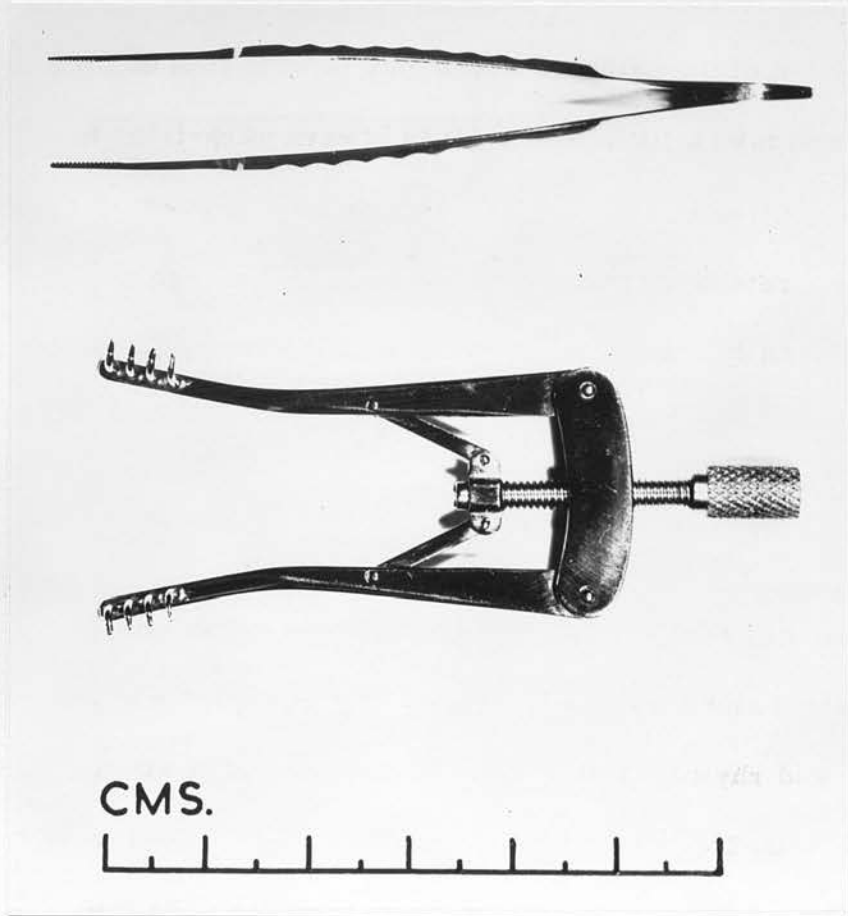


FIGURE 16

pictured in Figure 16 are especially helpful. Alm's self-retaining retractor, designed for finger surgery, from Down Bros., Mitcham, Surrey, and the Manchester-pattern eye capsule forceps made by Weiss of London are just the right size. The latter are invaluable during insertion of the catheter which may on occasion be difficult and take a little time. It is always surprising how even the tiniest vein will dilate up to take what often seems to be a relatively enormous catheter, and though very occasionally a femoral vein may have to be used, so far no case has been encountered, even in the new born, which would not take at least a No. 5.

The actual catheterisation presents no serious problems, though careful and gentle manipulations are required and a close watch should be kept on the heart rate and rhythm throughout. I disagree most strongly here with Ziegler who states that continuous electrocardiographic observations are not necessary and then goes on, in the same paragraph, to describe a case of fatal ventricular tachycardia.

A few tricks must be learned in this as in other procedures and practice is required to get a catheter through the tricuspid and pulmonary valves when approached from the groin. Exploration of the septum,

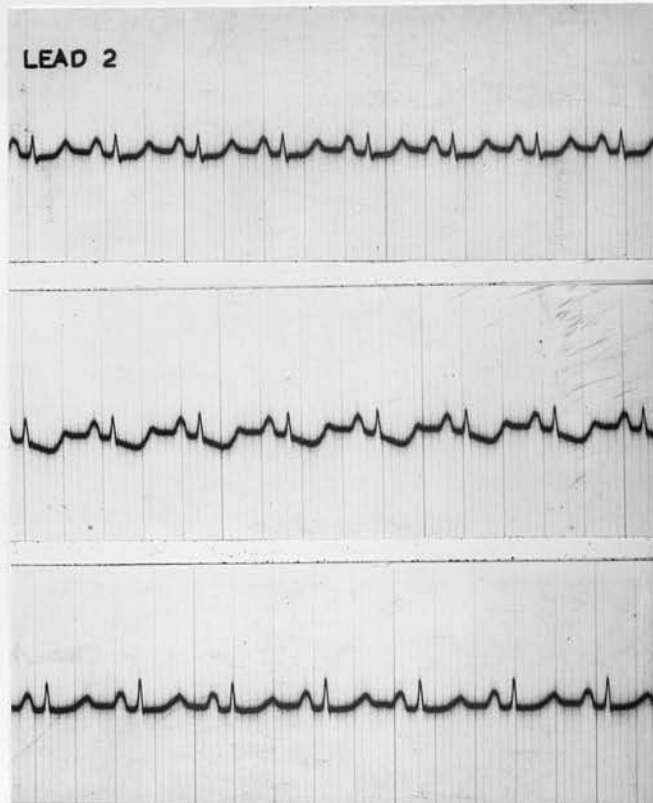


FIGURE 17

however, and of the left heart too, if a defect is present or foramen ovale is patent, is so much easier from the leg than from the arm that it should be the route of choice for all cardiac catheterisation.

It almost goes without saying that these operations demand the skill of an experienced anaesthetist, for they are always difficult and often hazardous especially in cases with failing hearts or severe cyanosis. Here again the electrocardiogram may be of considerable assistance both during and after intubation since ST-T wave changes are commonly the first signs that all is not well. The signs of myocardial anoxia come and go with surprising rapidity and must be carefully and continuously watched for. This is demonstrated in Figure 17 where an attempt was made to use a normal atmospheric oxygen concentration in a severely ill baby. The changes seen in the middle strip of lead 2 developed almost immediately and had disappeared again after breathing 100% oxygen for only 3 minutes.

Authoritative statements have been made by many writers on intracardiac electrography with surprisingly little experience to back them and with few exceptions the number of cases studied is remarkably small. Lenègre and Maurice's report was on only 3,

Levine's on 21, Hecht's on 5, Sodi-Pallares' on 6, Kossmann's on 14 and Battro and Bidoggia's on 23. Some later reviews have certainly been more comprehensive, Bertrand with 136 and Dickerson with 150, but as recently as April 1959, Testelli filled 15 pages of The American Journal of Cardiology with his experience of 15 cases.

The following examples, chosen to demonstrate its diagnostic application, have been selected from nearly 500 cases who have had intracardiac electrograms recorded during cardiac catheterisation. The illustrations are reproductions of photographic records made with New Electronic Products equipment, and the layout of each is the same - a standard scalar electrocardiographic lead at the top for reference, a unipolar intracardiac lead in the middle and the pressure pulse tracing at the bottom. Many of them are withdrawal tracings, so it is important to remember that catheterisation has been from the groin in every case and that the withdrawals are in that direction.

### NOMENCLATURE

A variety of names has been used to designate the various deflections recorded by the intracardiac electrode in different parts of the heart and even a common

name for the subject is lacking. Some use such titles as endocardiac or intracardiac electrocardiography, intracavitary electrography or endoelectrography, while others simply talk of endocardiac, intracardiac or intracavitary potentials.

The Editor of the British Heart Journal has recently ruled that Intracardiac Electrography, and thus Intracardiac Electrogram, are correct and these terms will be used in this thesis.

Confusion has also arisen because some authors have used the words auricular and ventricular to designate atrial and ventricular activity wherever it happens to be recorded, others to mean the total electrical activity in either of these chambers. A ventriculogram may thus be either the QRS complex anywhere in the heart and great vessels, or the whole P, QRS and T wave complex recorded inside the ventricle itself.

Here, the terms atriogram and ventriculogram are used to refer to the whole sequence of electrical events recorded during the cardiac cycle in the atrium and ventricle respectively.

#### ATRIOGRAMS

Because the heart is small, it is not always easy

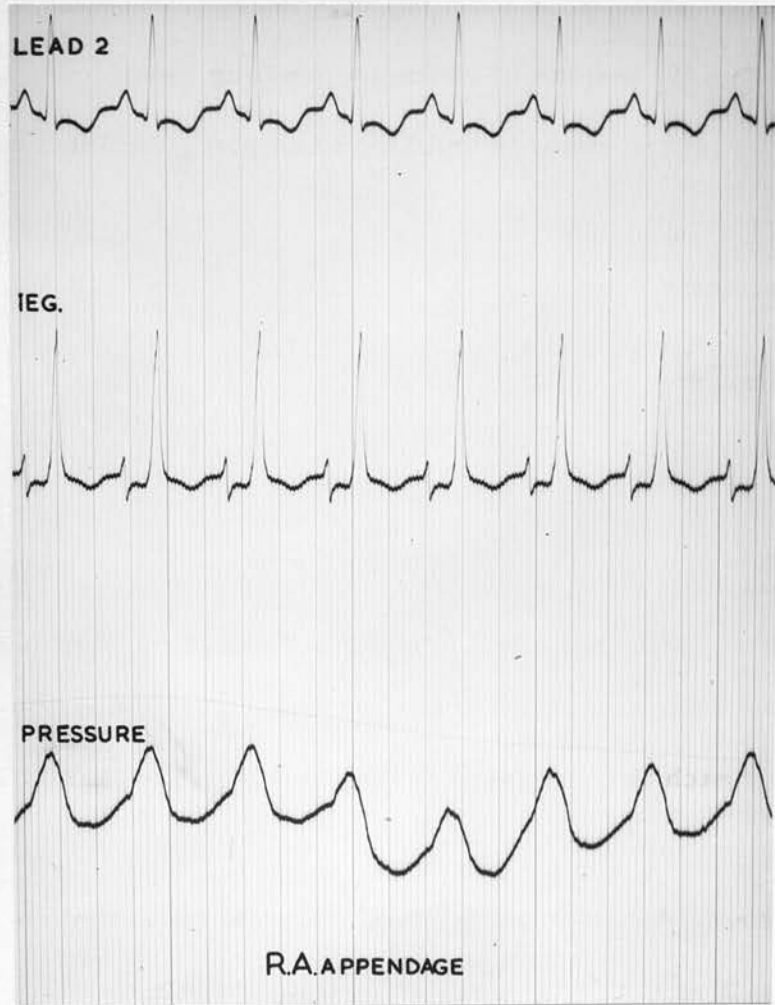


FIGURE 18

to tell with fluoroscopy alone exactly where the catheter is. The tip often crosses the mid-line fairly high in the right atrium, for instance, and when it will not pass easily into a pulmonary vein and it is not certain whether the left atrium has been entered or not, much time can be saved if, instead of continued probing or stopping to take pressure records and blood samples, the intracardiac electrogram is inspected on the oscilloscope. Often the characteristic complexes illustrated in Figure 18 will be seen, the tall R as the sole deflection and an inverted T wave indicating that the electrode is in the right atrial appendage, which is often very mobile in infants and can be moved far from its normal anatomical position by a catheter in its apex. So, while attempting to pass a catheter through an atrial septal defect, it is possible to tell each time whether the tip has been successfully advanced into the left atrium or merely into the right auricle. As many parts of the heart have fairly distinctive electrograms, an assistant can watch the intracardiac lead on the oscilloscope and in this way help the operator with his manipulations under the X-ray screen; such reports as 'coronary sinus', 'right ventricle', 'pressing up under pulmonary valve cusps' or 'just through into pulmonary trunk, making many

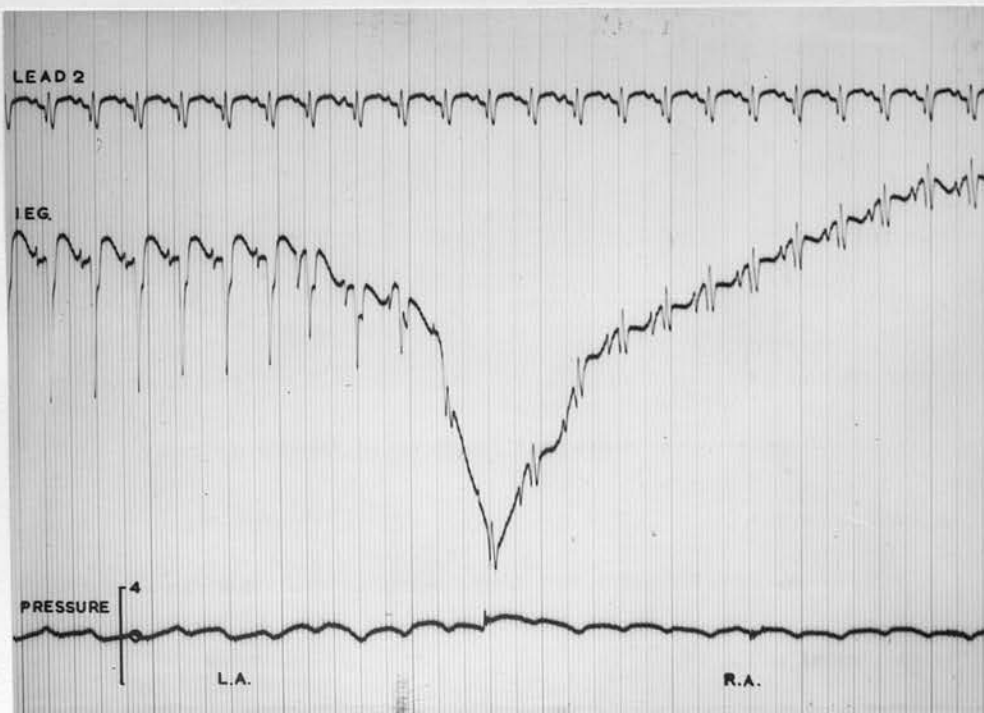


FIGURE 19

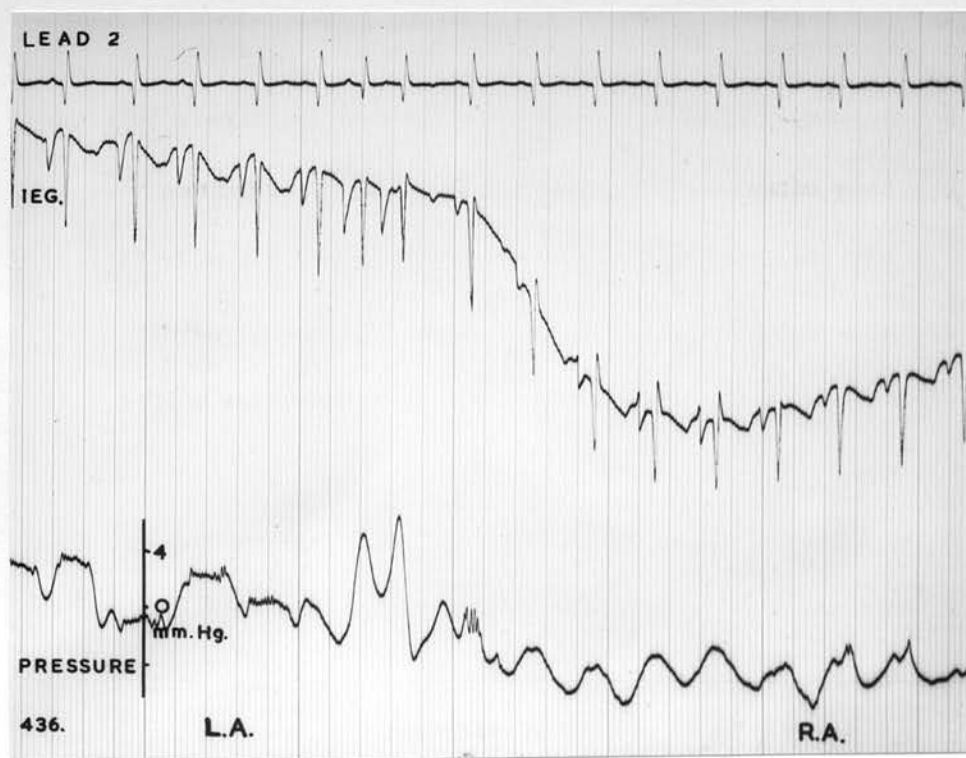


FIGURE 20

manoeuvres much easier and less time consuming than they would otherwise be.

As well as helping with their catheterisation, the intracardiac lead can also confirm the presence of defects in the interatrial septum, for the sudden movement seen in the base line of the intracardiac electrogram in Figure 19 is a very constant feature of tracings made as a catheter tip is withdrawn slowly from left to right atrium. It is of course an artefact, caused by the sudden movement of the catheter tip as it comes across the edge of the defect; just as would be seen in a strip of standard lead 2 if the patient moved his right arm during the recording. This figure has been selected for demonstration purposes from a case where the left and right atriograms are very different. Where they are similar, and they often are (Figure 20), this flip is evidence that the catheter tip has in fact crossed from right to left atrium, especially, if as in Figure 19, there is little difference in the pressure pulses on either side of the septum. When there is, it provides confirmatory evidence as will be seen in Figure 20, where a quick withdrawal had to be made before there was time for blood sampling or exploration of what was thought to be the left side of the heart.

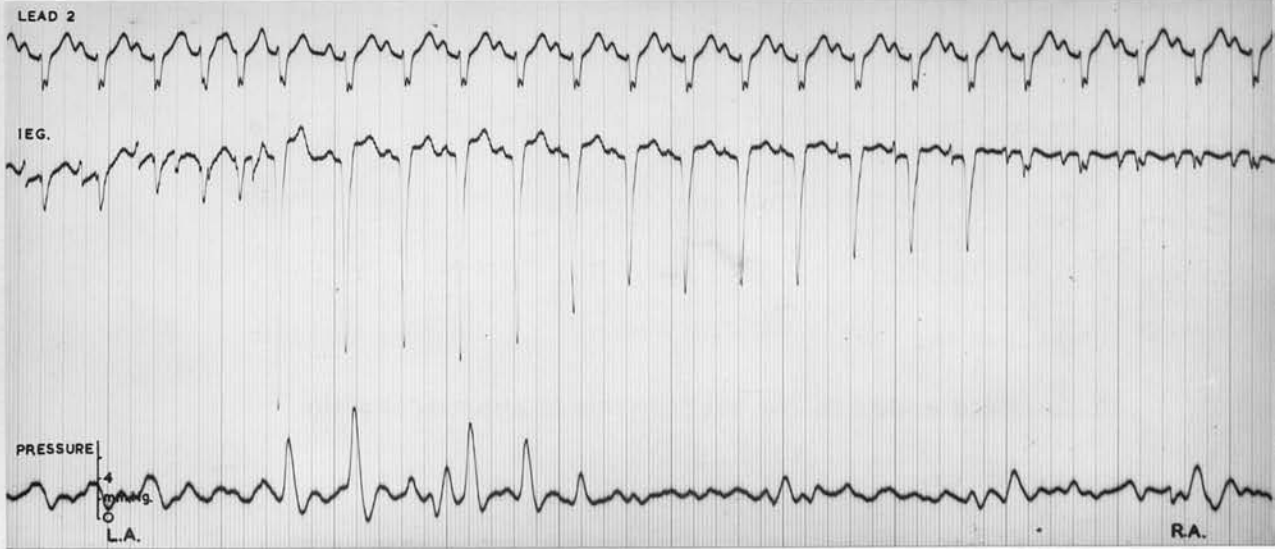


FIGURE 21

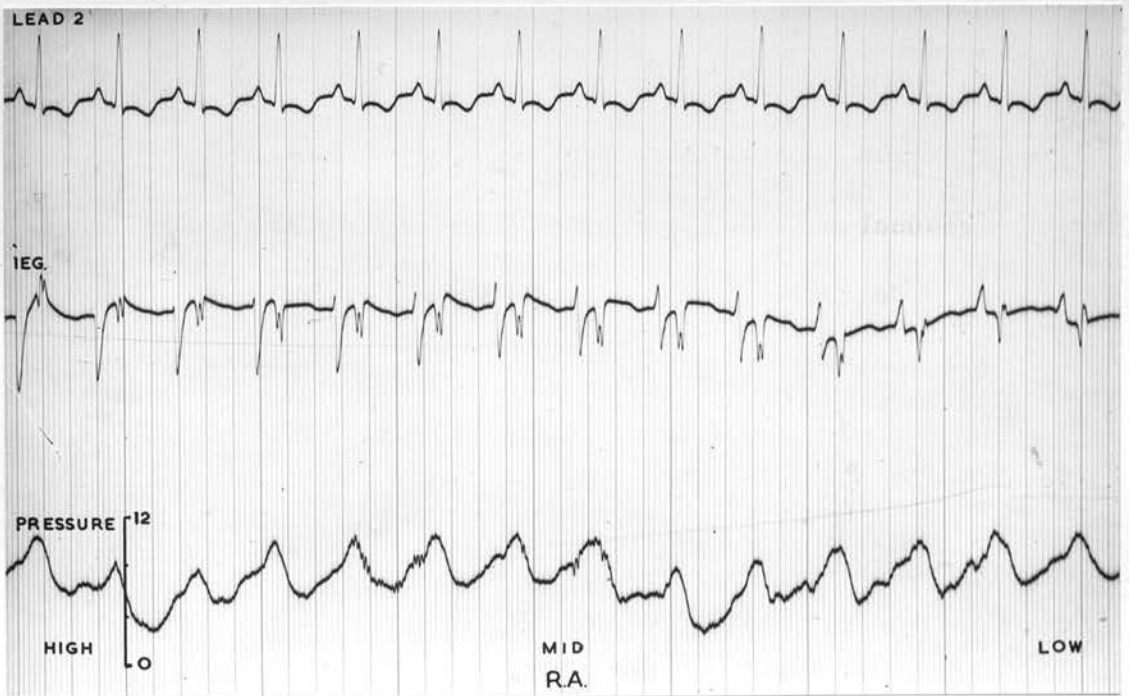


FIGURE 22

Catheter flip is nearly always present when withdrawal is from the groin and its great value is that it pin-points the site of the defect on the records. It is seldom seen when withdrawal tracings are made from the arm. Figure 21 is such a tracing, when there was no doubt that the catheter tip started off well out in the left atrium and ended in the right. As it approaches the septum it crosses the mouth of the mitral valve picking up high voltage from the cavity of the left ventricle with its electrode and "valve slap" on its pressure channel. After this however, it would be difficult to tell from the pressures or the electrograms exactly where, or even if, it had crossed through the septum.

When an electrode passes down through the right atrium from superior to inferior vena cava, there is a gradual and constant change in the polarity of the P waves. In sinus rhythm they are negative high in the atrium, become diphasic in mid cavity and positive low in the chamber as can be seen in Figure 22. This normal feature of atrial potentials can be used in conjunction with the catheter movement artefact just demonstrated to give some indication of the site of defects in the interatrial septum. This is illustrated in Figure 23, a recording made as a catheter was withdrawn

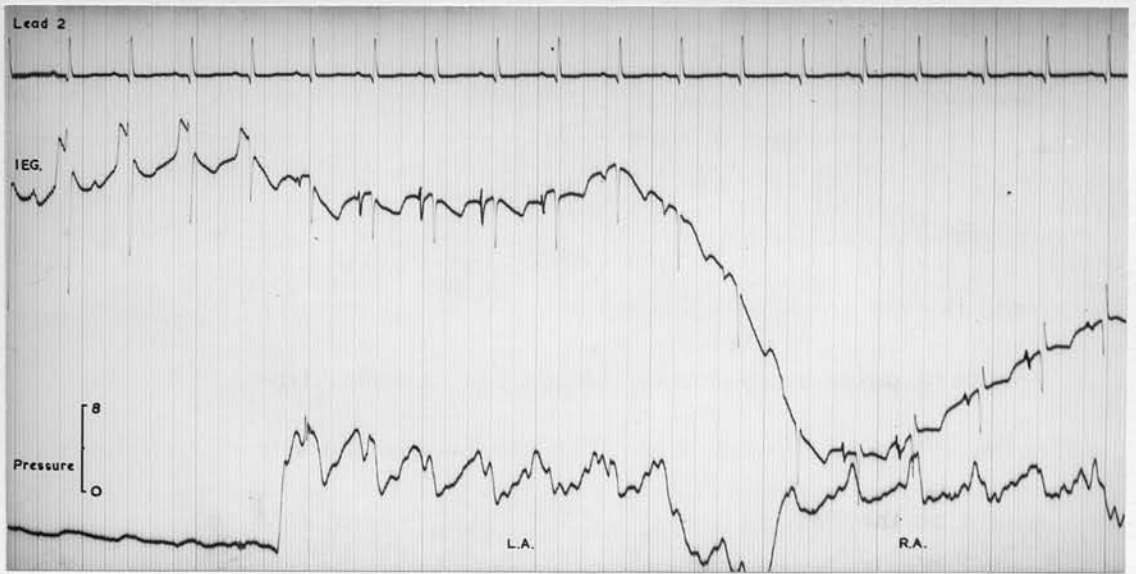


FIGURE 23

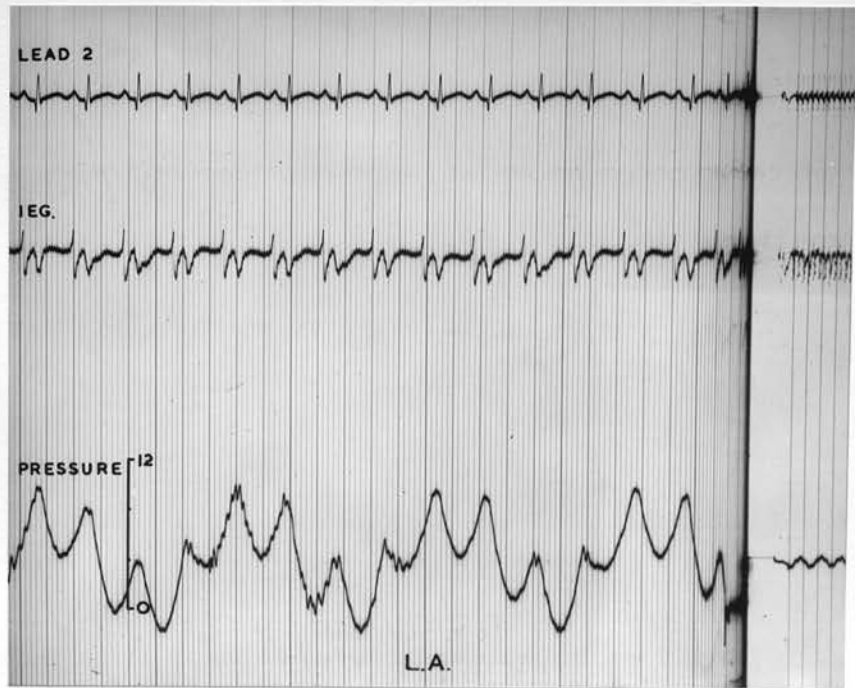


FIGURE 24

from left to right atrium through an atrial septal defect. Initially the tip of the catheter has been pressed against the lateral wall of the left atrium producing left atrial injury or contact currents with consequent damping of the pressure pulse tracing. As withdrawal begins, contact is lost, the PT elevation disappears and the left atrial pressure pulse reappears. When the catheter tip moves from left to right atrium the flip pin-points the site of the defect on the record and the P waves on either side of it can then be studied. In this case they are biphasic in the left atrium and biphasic in the right atrium - suggesting that the catheter tip has crossed from left to right in the mid septal area, through a secundum type defect.

In infants it is the rule rather than the exception for the catheter to cross into the left atrium and it nearly always does so through a foramen ovale rather than through a true septal defect. This method of analysis gives valuable confirmatory evidence that the route has been via the foramen ovale and an almost constant pattern is produced on withdrawal tracings. In Figure 24 for example, the catheter tip has initially been screened into mid left atrium, where pressures and oxygen saturations have been recorded, the position

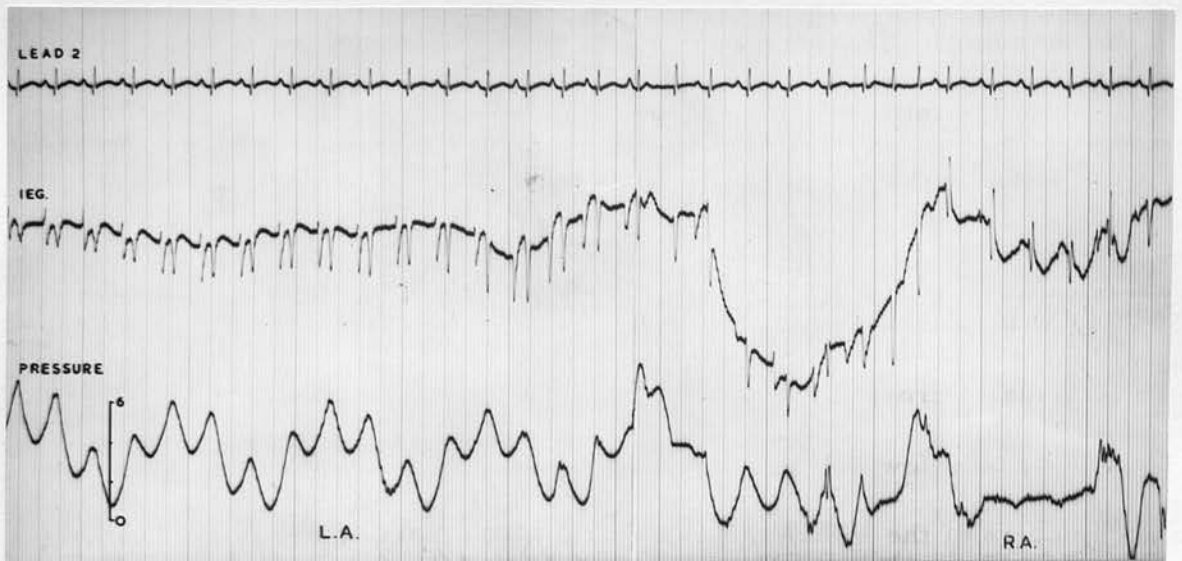


FIGURE 25

being confirmed by the biphasic nature of the P waves in the atriogram. Figure 25 shows the withdrawal from left to right atrium, and the catheter which has pushed its way through a foramen ovale fairly high in the septal wall, has to come back up into the upper part of the left atrium again on its way out - the P waves changing as it goes from the biphasic ones of the mid cavity to the wholly negative ones in the upper part of the chamber. The catheter then slips back through the foramen into the right atrium and the catheter flip produces the usual baseline movement. Because of this wandering of the iso-electric line it is impossible to say much about the nature of the deflections as the catheter actually cross the septum and, at this time too, there may be a few atrial ectopic beats which obscure the true nature of the P waves on the right atrial side of the defect. If several slow and careful withdrawals are made however, there is nearly always one which is free of such interference.

This is, of course, not a specific diagnostic test but merely an additional piece of useful information which should be considered with the other evidence obtained by catheterisation - the ease with which the defect can be found, the impression formed about its size and

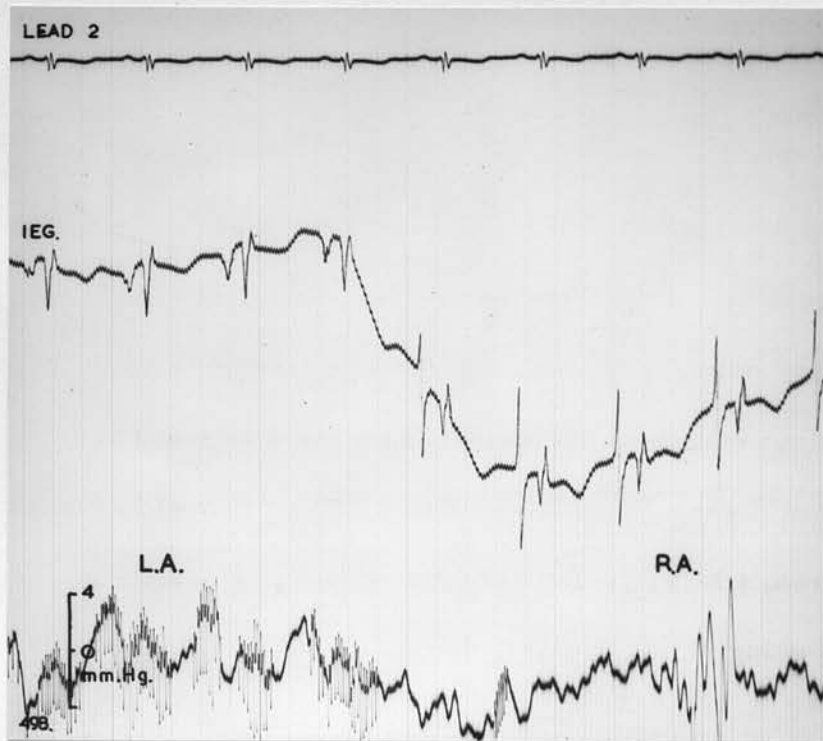


FIGURE 26

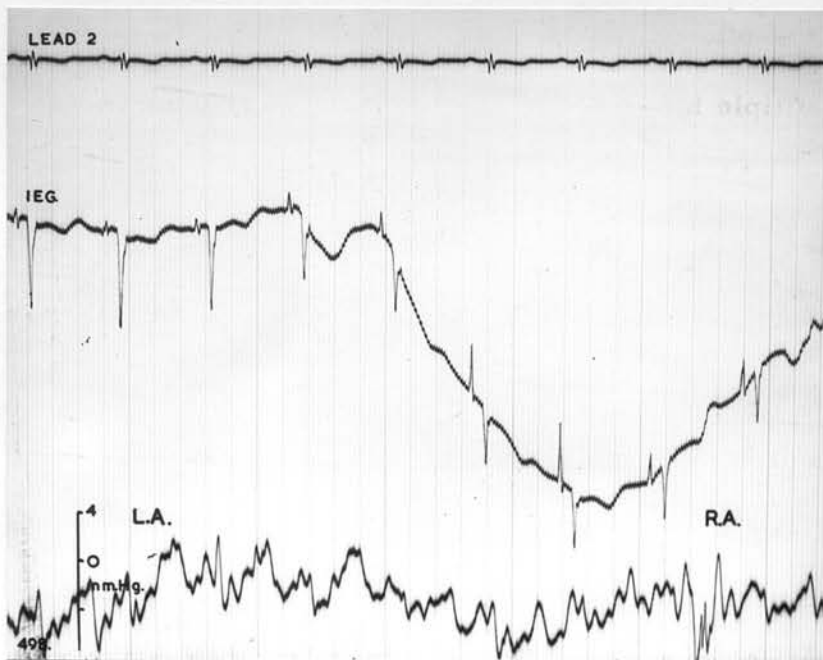


FIGURE 27

shape during probing or pushing a loop of the catheter through it, multiple blood samples etc. etc. Figures 26 and 27, for example, were recorded during catheterisation of what was thought to be a large hole in the septum. In Figure 26 the catheter was withdrawn from a right superior pulmonary vein, and the electrograms show that it has come through the defect from the upper left atrium in the mid septal area. In Figure 27, where withdrawal was from a left inferior pulmonary vein, it is seen to be crossing very low in the septal wall. These findings were confirmed at operation when a large lozenge shaped defect was found stretching down from high mid septum almost to the mouth of the inferior vena cava.

When a catheter passes out into a pulmonary vein it is often difficult to tell, even with careful screening and multiple blood sampling, whether it has done so from left or right atrium. The origin of the vein is usually well inside the edge of the heart shadow and the site of the transition from vein to atrium impossible to determine. If the catheter is not withdrawn far enough the blood still comes from the pulmonary vein and, mistaken for a left atrial sample, an anomalous vein may be missed. If, on the other hand, it is withdrawn a little too far, in cases where the atrial septum lies obliquely, the tip may pass

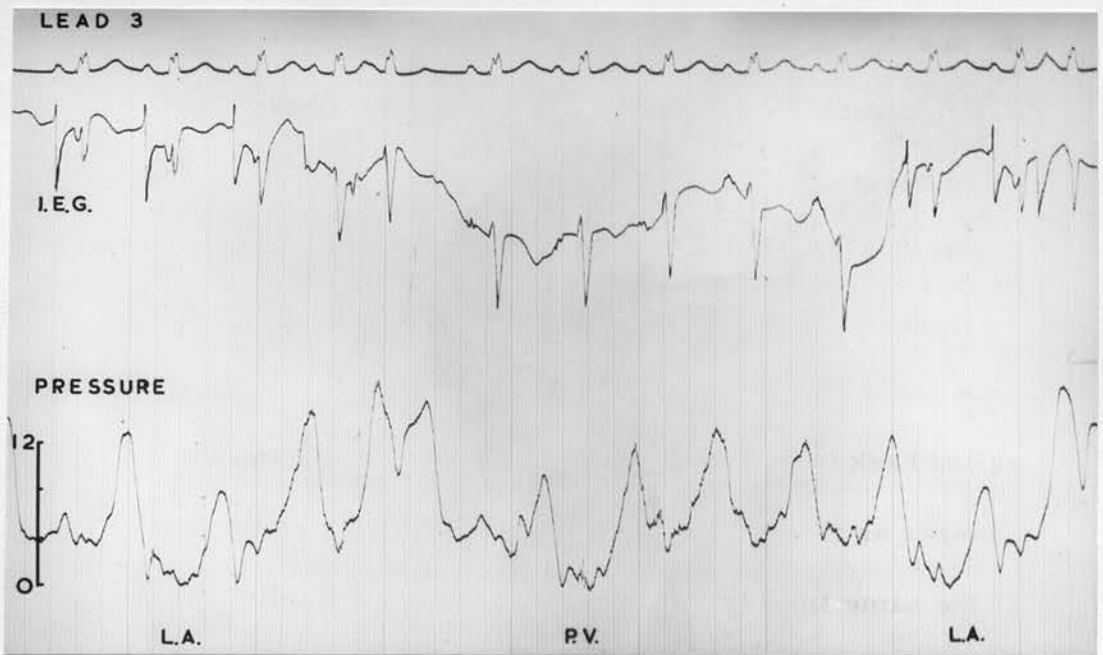


FIGURE 28

unwittingly from left to right atrium and a normally sited vein may be thought to be anomalous. The nature of the complexes recorded from the electrode at the tip of the catheter sometimes helps on these occasions because the venogram and atriogram are often different and, if the withdrawal is carefully monitored, it is easy in such cases to spot the first complex recorded inside the heart. A blood sample taken there and the nature of this complex when the record is analysed leave little doubt about the site of origin of the vessel. Figure 28 illustrates the change which takes place in an intracardiac electrogram as a catheter is pushed out of the heart from the left atrium into a pulmonary vein and then pulled back in again. The morphology of the complexes changes as the catheter passes from one to the other and at the same time there is movement of the baseline as the catheter tip flips over the edge of the atrial wall at the mouth of the vessel.

It is important to realise that it is impossible to tell from which atrium an isolated complex has been recorded as neither the atrial nor the ventricular components of the atriogram are in any way specific for the right or left atrium. In this illustration for example, the intrinsic deflection of the P wave occurs early in the P

wave component of the simultaneously recorded standard lead 2, and though in the left atrium this deflection is often late, it is frequently no later than the initial deflection in the right atrium. Similarly though the ventricular component in the left atrium usually picks up a Q from the cavity of the left ventricle, it is in no way unusual for it to have an initial positive deflection or for Q waves to be recorded in the right atrium. It is only possible to be certain where a complex was recorded when it is studied in detail along with the other records made during the catheterisation.

### VENTRICULOGRAMS

No attempt will be made to discuss or interpret the variations which occur in the magnitude of ventricular potentials in different conditions. This is an important field for study but is presently difficult to pursue in human subjects. From the inverse square law we know that the amplitude of a deflection is dependent upon the square of the distance between the exploring electrode and the source of the electrical potentials. It is very simple to locate the electrode by X-rays, pressure pulses and intracardiac electrograms and it is easy to tell from pressure damping and contact currents when it is actually

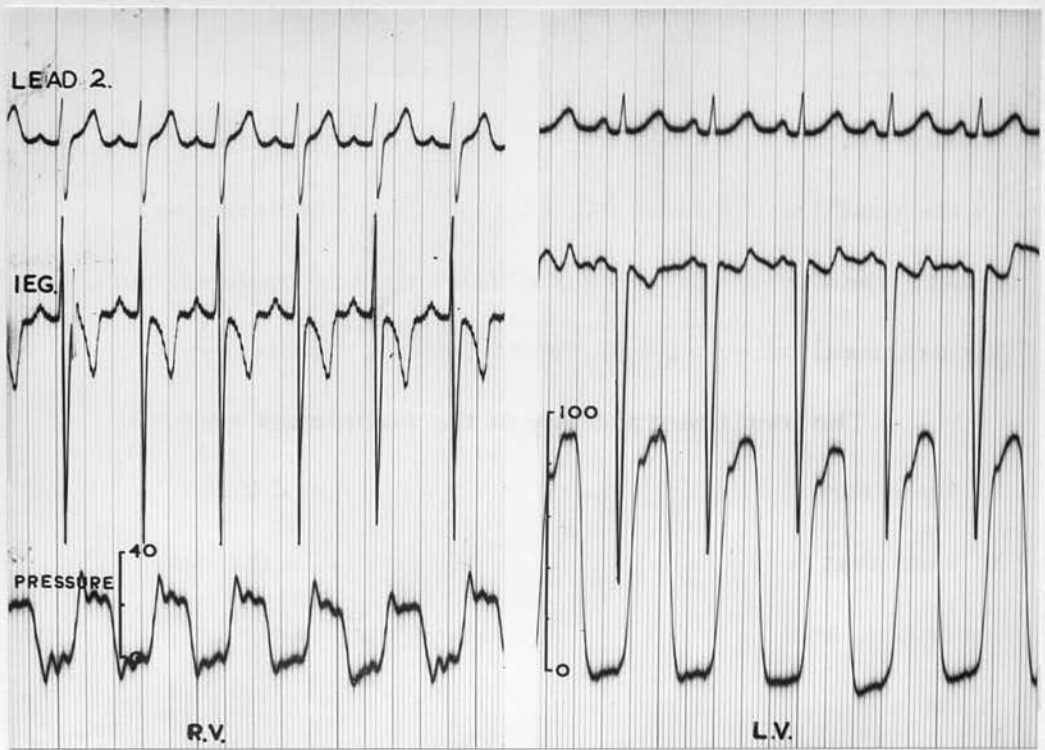


FIGURE 29

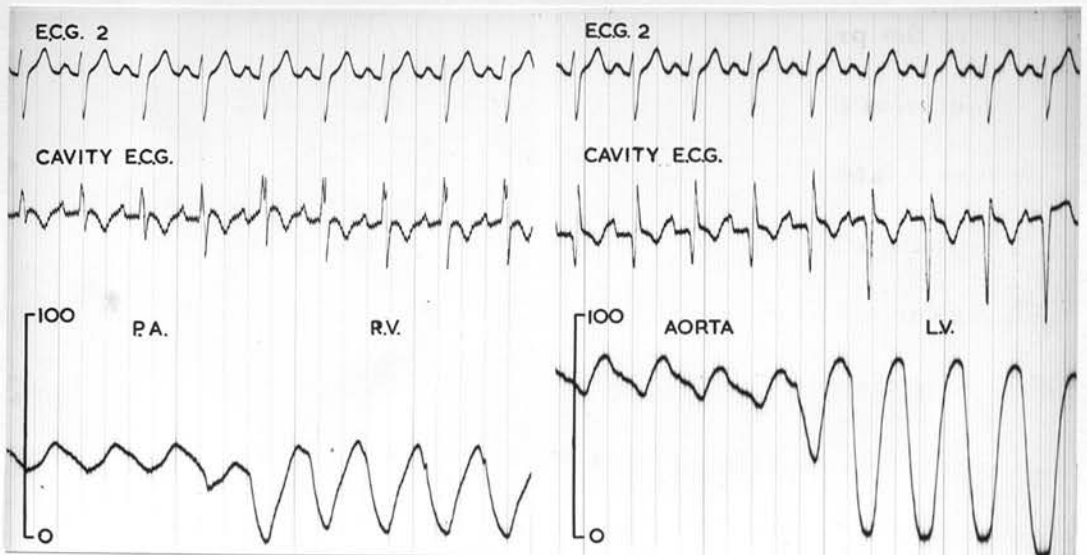


FIGURE 30

touching the heart wall, but it is usually quite impossible to determine its exact distance from the endocardium. During systole however, the ventricular cavity is small, so the possible variations in this distance can never be great, when compared with the high voltages involved, and for practical purposes will not affect this thesis.

The usual morphology of the complexes recorded in the ventricles is illustrated in Figure 29 and it will be seen that there is normally an rS pattern in the right ventricle, and a deep Q is as a rule the sole deflection in the left. When withdrawals are made from pulmonary artery to right ventricle and aorta to left ventricle this polarity is usually maintained (Figure 30). The height of r in the right ventricle however, is variable and it may even be absent altogether in some cases - especially where the pressure is high. On the other hand it is sometimes the main deflection in the outflow tract, where a late R may be seen close to the pulmonary valve. Too little attention has been paid to the varying electrical forces in the right ventricular outflow tract and they will be fully discussed in Section IV.

In Fallot's Tetralogy it is not uncommon for the deflections to remain negative when the catheter is withdrawn from the over-riding aorta into the right ventricle

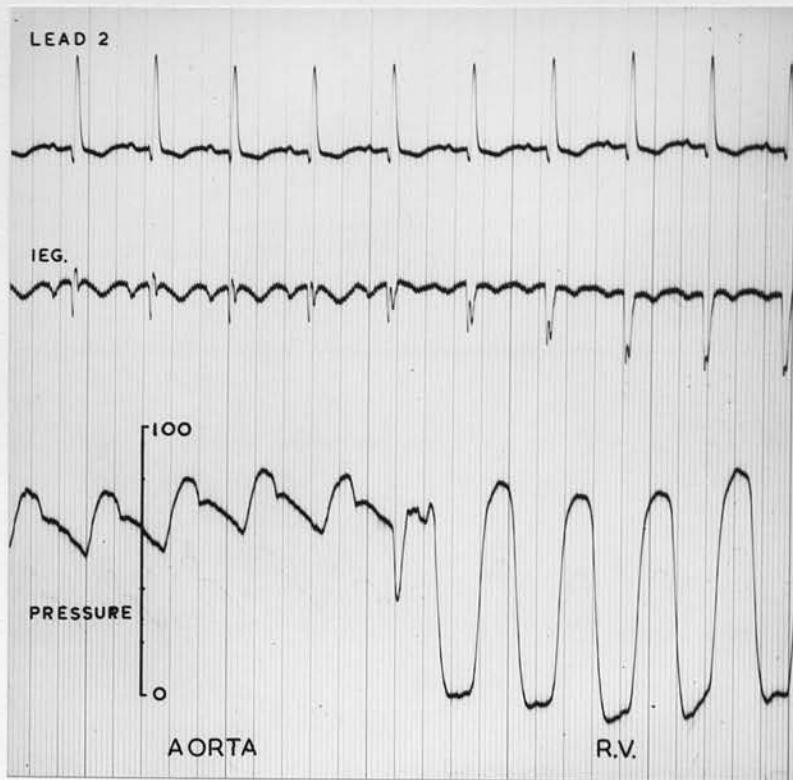


FIGURE 31

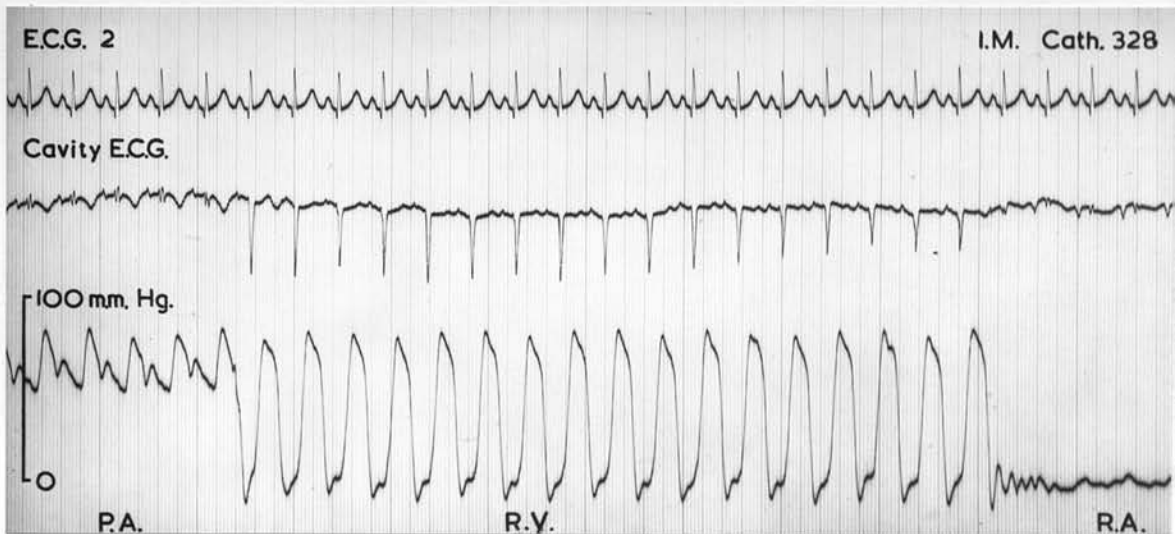


FIGURE 32

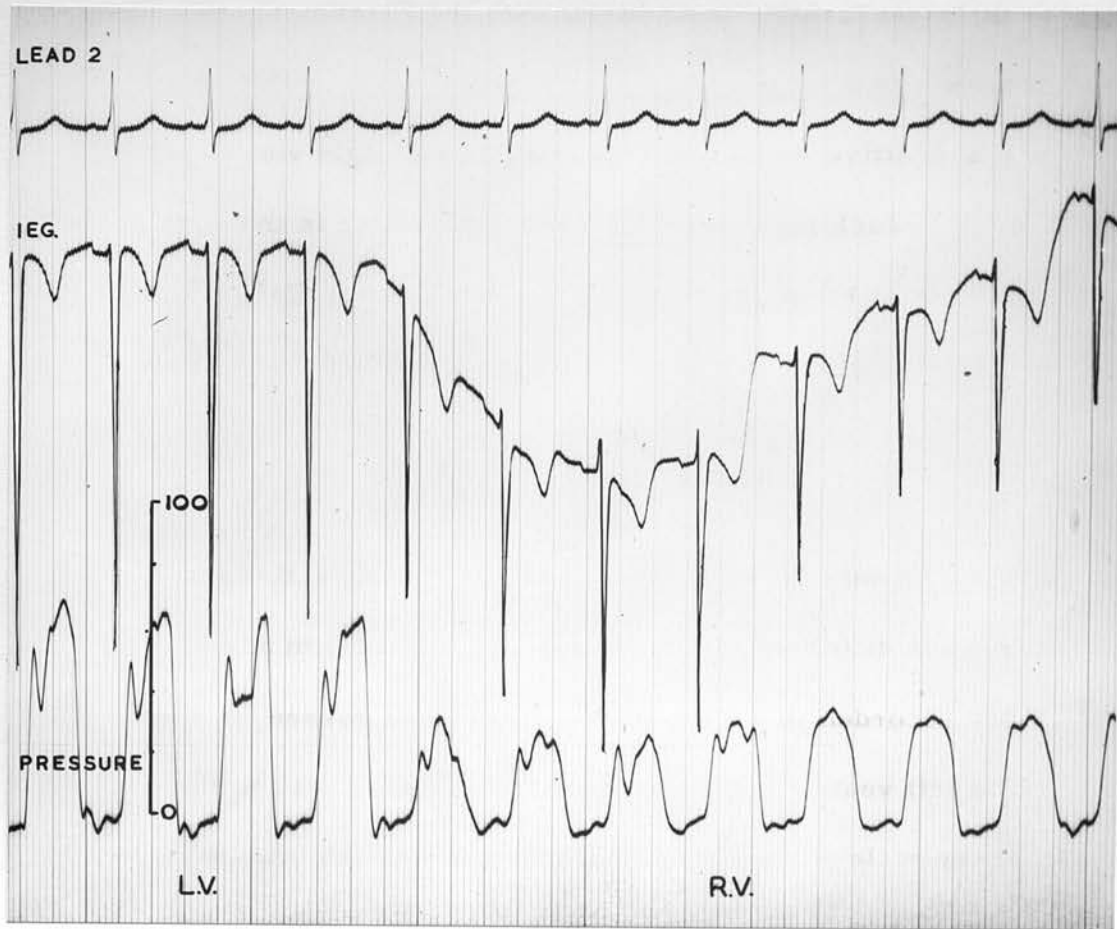


FIGURE 33

and Figure 31 shows the W shaped complexes sometimes seen in the outflow tract in this condition. Occasionally, r waves are almost completely absent on the right side of the heart, and in Figure 32, a catheter has been withdrawn slowly all the way from the pulmonary artery to the right atrium, in an infant with the Eisenmenger response to a large ventricular septal defect, without a single positive deflection appearing in the right ventricle.

Much less commonly r waves appear in the left ventricle. First reported by Zimmerman and Hellerstein in 1951 and since by Coelho et al., and Mas et al. in 1952, Latour and Puech in 1957 and Testelli in 1959, they are rare and unexplained in the absence of bundle branch block. It may be that once begun, islands of activation spread in different directions through the septum, and those recorded in Figure 33 were certainly picked up close to its left ventricular surface. The catheter was in the left ventricle when withdrawal began and a flip, similar to those seen in defects of the atrial septum, is synchronous with the pressure gradient between the two ventricular cavities. This unpublished tracing is, as far as I know, the only one of its kind.

Many babies requiring investigation already have a fully developed Eisenmenger reaction so that there is

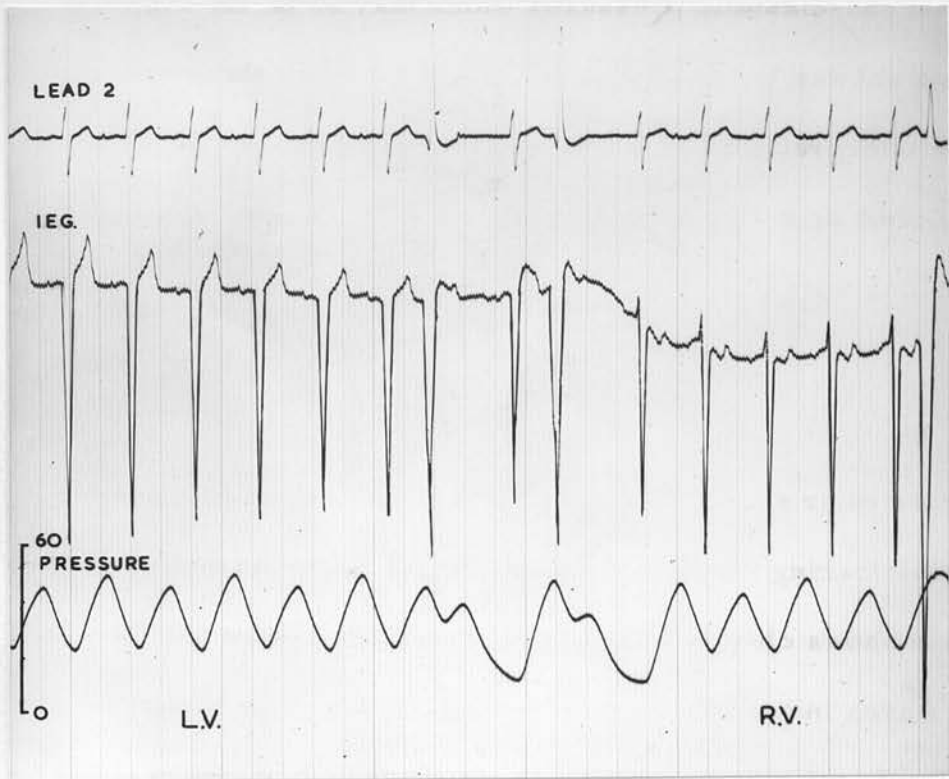


FIGURE 34

little difference between the systolic pressures in the right and left ventricles, or in the pulmonary artery for that matter if there is no pulmonary stenosis. Because these pressures are high, the heart rate rapid and the catheter size necessarily small, there is often considerable damping of the recorded pressure pulses, particularly of end-diastolic pressures which may be on the high side anyway because of a failing heart. For these reasons the interpretation of pressure pulse tracings can be difficult or even misleading and simultaneously recorded intracardiac electrograms can be most helpful.

Figure 34 is a record made as a catheter tip is withdrawn from left to right ventricle through a ventricular septal defect. Though the damped pressure-pulse tracing gives no indication of this, the intracardiac lead shows clearly what has happened, for there are deep Q waves in the left ventricular cavity, a couple of extrasystoles as the catheter tip scrapes through the defect, and the appearance of initial r waves immediately the right ventricle is entered.

It is often impossible to catheterise the right or left pulmonary arteries from the groin in small children. The catheter lies pointing upwards in the upper part of the cardiac silhouette and it is difficult to be sure

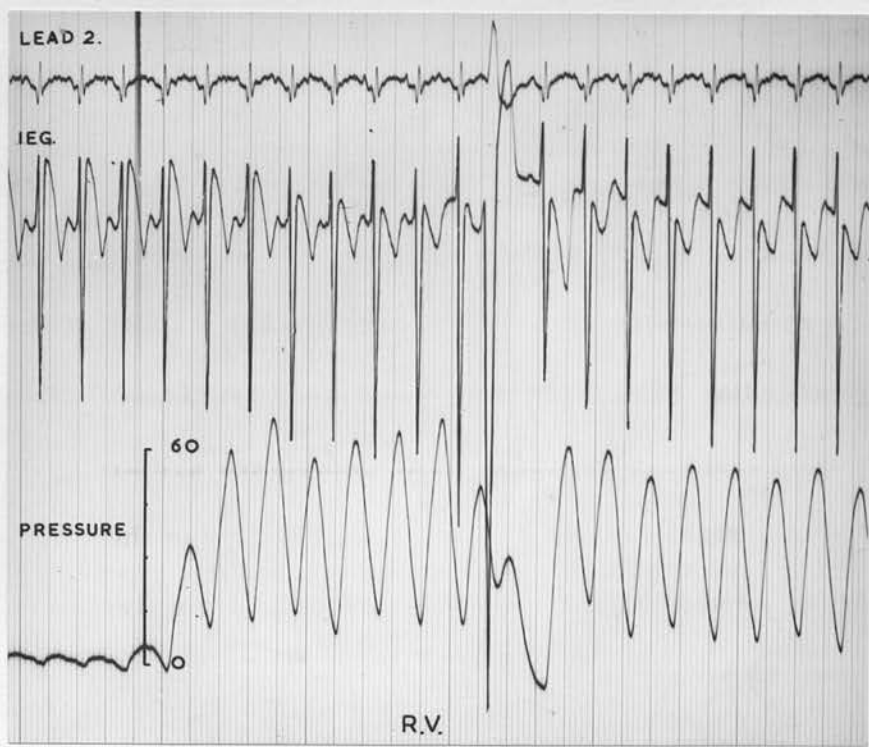


FIGURE 35

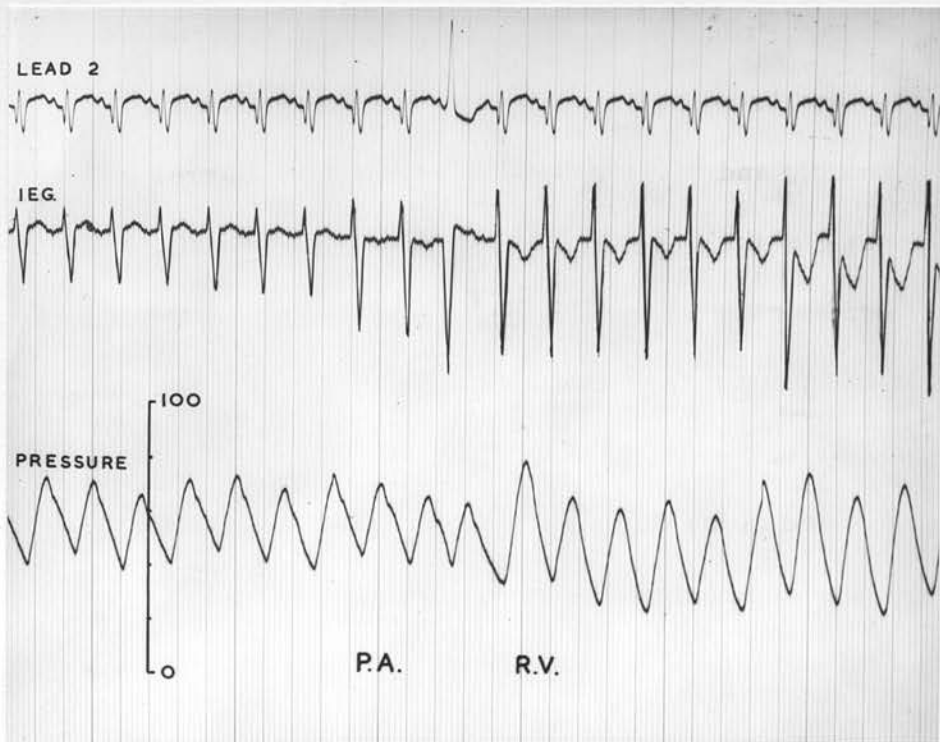


FIGURE 36

on the X-ray screen whether the tip has actually passed through the pulmonary valve or merely lies in the upper part of the right ventricular outflow tract. When a withdrawal tracing is made the pressure pulse may suggest severe pulmonary stenosis (Figure 35) but a study of the intracardiac electrogram demonstrates conclusively that no such lesion is present. The complexes are all typically right ventricular and it is clear from the ST shifts, or ventricular contact currents, in the first part of the record, that the catheter tip has been pushed up under the pulmonary valve cusps causing pressure damping which disappears when contact is lost and simulates pulmonary stenosis.

Pressure damping may also obscure the diastolic gradient between the pulmonary artery and the right ventricle and Figure 36 illustrates a case where, without the aid of the intracardiac lead, it would be difficult to be certain from the withdrawal tracing that the catheter had in fact passed from the pulmonary artery into the right ventricle. The transition from the low voltage complexes recorded in the thin walled great vessel to the high voltage and obviously right ventricular complexes in the thick muscular walled chamber dispels any doubts about the route taken by the catheter and confirms the absence

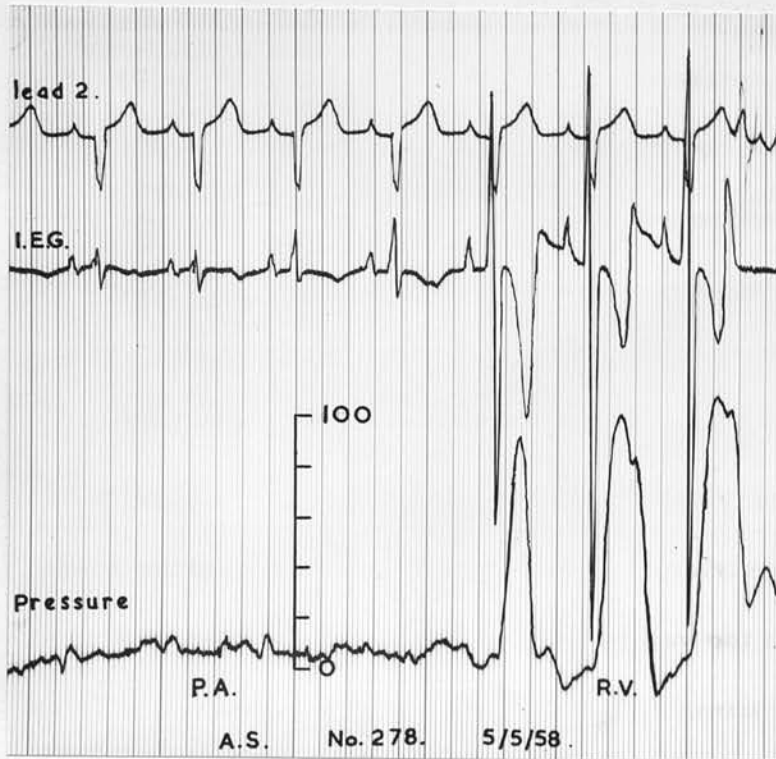


FIGURE 37

of pulmonary stenosis in such cases.

Where this lesion is present, on the other hand, the striking change in morphology which usually takes place as the catheter passes back from the pulmonary trunk into the right ventricle has proved of great value. Because the electrode is at the very end of the catheter, any alteration in electrical potentials which it picks up can be precisely related to the pressure at its tip. When the two are simultaneously recorded, the correlation between changes in the intracardiac electrogram and the pressure pulse pattern is most instructive. In Figure 37, a sudden and dramatic change takes place in both. The low voltage aVR-like complexes recorded in the pulmonary artery change to high voltage and typically right ventricular ones as the catheter tip moves back through the valve, and simultaneously a pressure gradient of approximately 100 mm. of Hg. is revealed. Thus the intracardiac electrogram confirms the presence of valvular pulmonary stenosis in such cases.

The fact that it can pin-point the site of the valve in this way means that it is possible to delimit the outflow tract with some accuracy on records made as a catheter is withdrawn from the pulmonary artery into the right ventricle. In Figure 38 there is a change from pulmonary

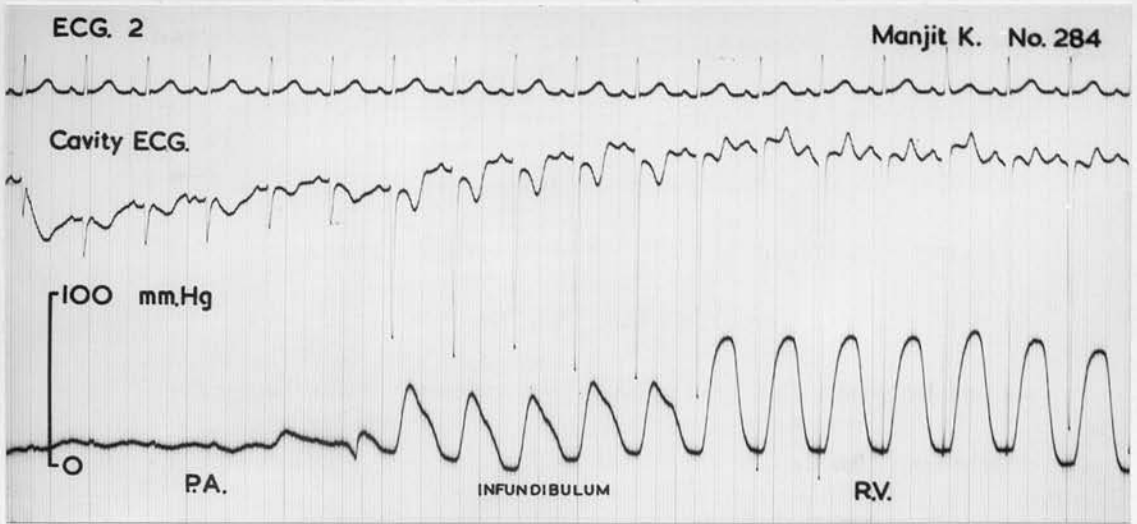


FIGURE 38

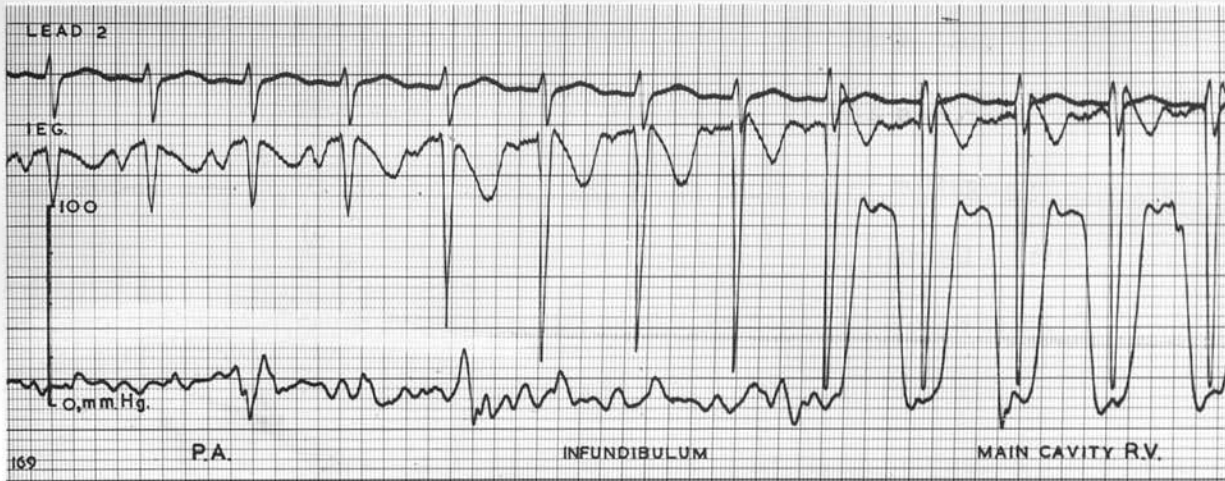


FIGURE 39

artery to right ventricular type complexes as the electrode comes through the valve. This electrocardiographic change is synchronous with the first pressure pulse gradient, indicating valvular stenosis and marking the site of the valve on the record. The intracardiac electrogram remains right ventricular throughout the remainder of the tracing and confirms that the intermediate pulse waves between the two pressure gradients have been recorded as the catheter tip passed slowly down through the right ventricular outflow tract. This record was made during cardiac catheterisation of a little girl with Fallot's Tetralogy, who afterwards had a successful transarterial pulmonary valvotomy and in this case the nature of her pulmonary stenosis could fairly easily have been foretold from the pressure pulse tracing alone. Figure 39, however, was also recorded during the pre-operative investigation in a case of Fallot's Tetralogy and here though the pressure suggests valvular stenosis, the intracardiac electrogram demonstrates quite clearly that it is infundibular, there being no pressure gradient where the complexes change at the site of the valve and therefore no valvular stenosis. This diagnosis was confirmed at autopsy some years later, when the boy died of a cerebral abscess.

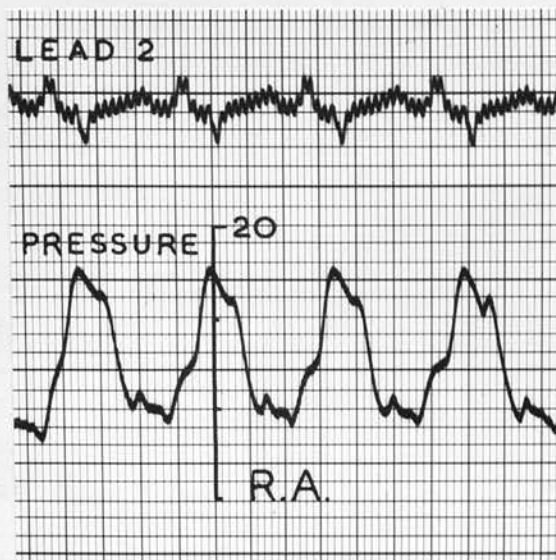


FIGURE 40

This ability to differentiate between valvular and infundibular pressure gradients has proved of great value, not only in the diagnosis of the various types of pulmonary stenosis, but in studies which have gone a long way to clarify our understanding of their effects on right ventricular haemodynamics.

### ANGIOCARDIOGRAPHY

In these days of selective angiocardiology when contrast medium is injected directly into the heart under high pressure, it is most important to be quite certain where the tip of the catheter is before the injection is made. If it is not in exactly the right place, the desired films may not be obtained and serious damage may be caused to the heart, either by the force of the jet of contrast, the sudden distension caused by injection into a confined space or the whip back of the catheter itself. The usual practice is to position the catheter by X-ray screening and then check its site by examination of the pressure pulse. In the tense moments before an angiocardiology is fired the wave form may easily be misinterpreted and a pressure pulse of the type seen in Figure 40, which on careful analysis is obviously a giant "a" wave, could under such circumstances, easily be mistaken for a ventricular one.

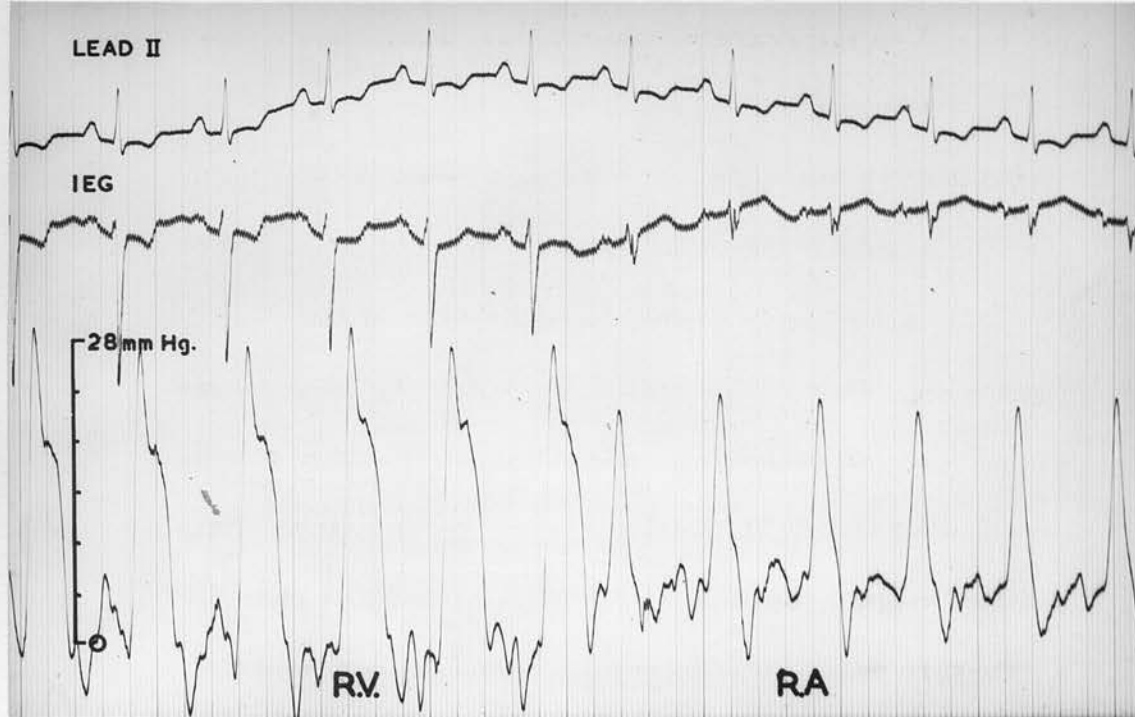


FIGURE 41

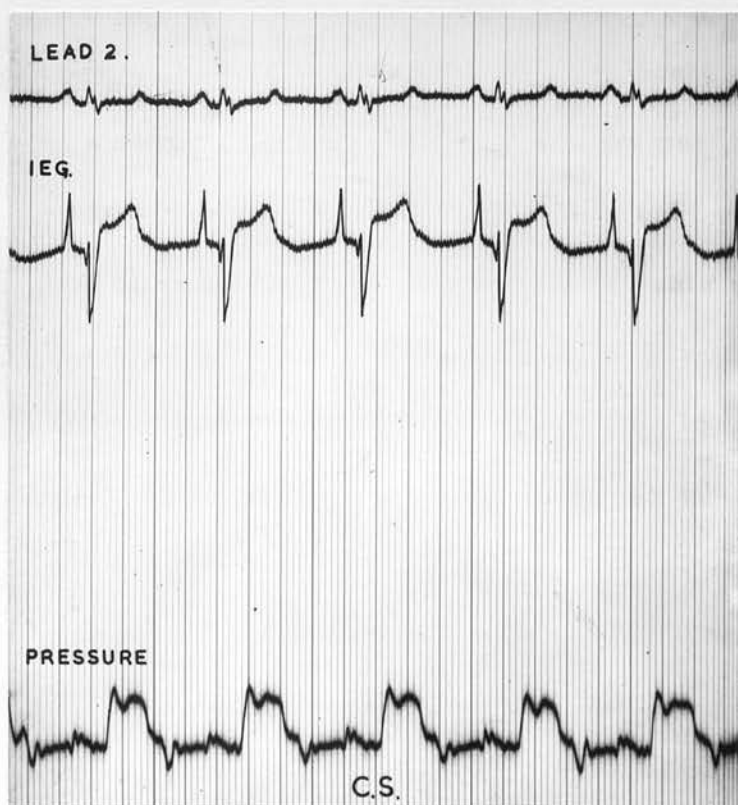


FIGURE 42

The intracardiac electrogram should always be inspected to avoid the possibility of such errors, and had it been in this case, it would have been obvious that the catheter was in the atrium, where the complexes are quite different from those usually seen in the ventricle. This is illustrated in Figure 41, from a case of tricuspid stenosis which shows that even where the right ventricular and right atrial pressure pulses are of similar magnitude, it is easy to tell from which chamber a pressure pulse comes when there is a simultaneously recorded electrogram.

Perhaps the greatest danger is from injections of contrast medium under high pressure into the coronary sinus and here too the pressure pulse may closely resemble a right ventricular one. Such a case is seen in Figure 42 which also demonstrates that the coronary sinus electrogram is so characteristic that such errors should easily be avoided if the intracardiac lead is used routinely, as well as the pressure pulse, to check the site of the catheter tip before injections are made.

In the early days there were one or two rather alarming experiences when, because of the high pressure required to force contrast medium through

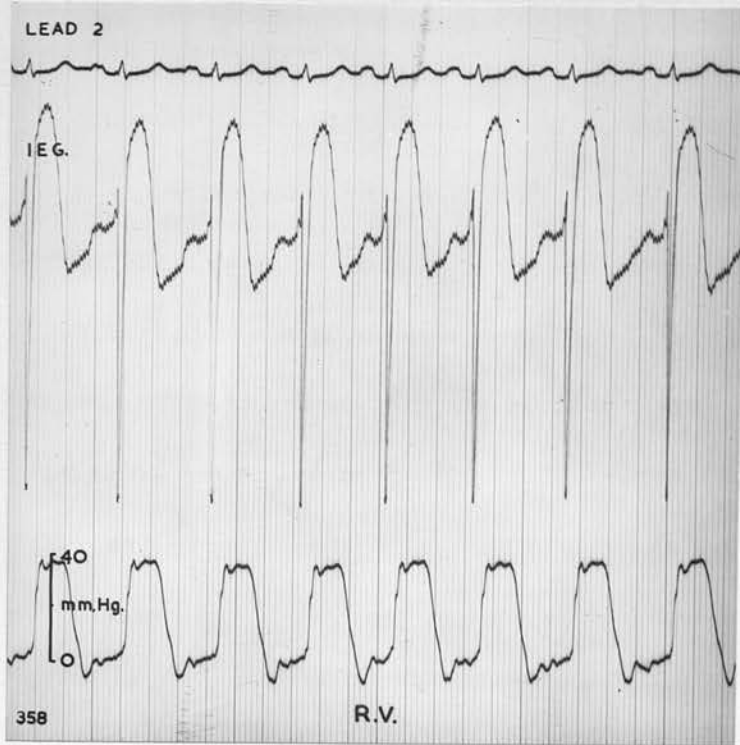


FIGURE 43

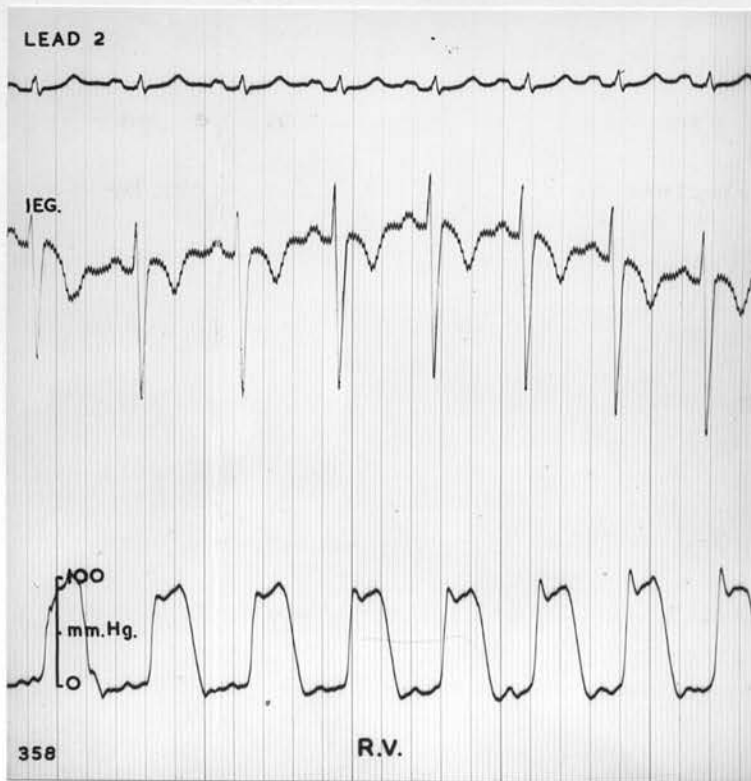


FIGURE 44

small lumen catheters, some of it was forced under the endocardium. Fortunately, none proved fatal and the position of the catheter is now checked very carefully before injections are made by examining the complexes of the electrogram for contact currents. If these are present it means that the tip is either pressed against the ventricular wall or buried in the columnae carneae as shown in Figure 43, where there are gross ST elevations in the ventriculogram. The catheter is withdrawn until they disappear and normal right ventricular complexes (Figure 44) return to the oscilloscope, signifying that contact has been lost and that the tip of the catheter now lies free in the ventricular cavity, where injection may be more safely made.

From these illustrations it will be apparent that an electrode at the tip of the catheter can be of the greatest possible assistance during the investigation of congenital heart disease, and the routine use of electrode catheters makes cardiac catheterisation in infants and the new born quicker, safer and more informative. If time is limited and it is decided that selective cineangiocardiology will be of more assistance than continued catheterisation, then here too intracardiac electrography will help with the correct

positioning of the catheter and ensure that the maximum amount of information is obtained in the safest possible way.

In this age group the size of catheters that can be used is strictly limited and difficulties arise if the same catheter has to be used for both intracardiac electrography and selective angiocardiology. Because of their viscosity the new less toxic tri-iodide contrast media are hard to inject through standard size small catheters and with electrode catheters this problem is accentuated because the thickness of wall required to incorporate the spiral wire necessarily reduces their internal diameter.

During such investigations it is usual to change catheters and pass a thin walled angiocardiological one after the haemodynamic data has been obtained. This practice has however certain disadvantages in babies and very small children, since having once got a catheter into the heart, one is, for obvious reasons, sometimes reluctant to remove it. Again, if the catheter is changed, the advantages of the electrode at its tip are not available - siting is more difficult and an important safety factor is lost.

Because it is desirable to perform the whole operation with one catheter in situ, a special catheter has been designed for the purpose and is being made with the assistance of the United States Catheter and Instrument Corporation. A ribbon electrode has been developed to replace the wire and so increase the bore without increasing the external diameter. Two types have been made, one with an end hole and two laterally opposed side holes, the other with two pairs of laterally opposed side hole and a closed end. The electrodes are between the orifices which are sited within 5 or 8 millimetres of their respective catheter tips.

Recent developments have still further increased the versatility of these catheters by substituting platinum for the nickel silver electrodes. These, when used in conjunction with injections of ascorbic acid solutions, can detect the presence of intracardiac shunts (Nixon et al. 1962). This technique has certain advantages over dye dilution methods since the indicator solution does not interfere with the determination of oxygen saturations, and can therefore be carried out at any stage of the procedure - a point of some importance in babies where time is important and maximum information must be collected as

the investigation proceeds.

This new wide bored platinum electrode catheter has therefore great potentialities as a multi-purpose clinical tool, for in addition to fulfilling all the usual functions of a cardiac catheter, it can be used for intracardiac electrography, shunt detection, and selective angiocardiology as well. Though not yet in commercial production it will soon be available from the U.S.C.I. Corp. in New York.

## SECTION II

### SELECTIVE CINE-ANGIOCARDIOGRAPHY WITH IMAGE INTENSIFICATION

As long ago as 1897, only one year after the discovery of the roentgen ray, MacIntyre made a motion picture. He did this by taking a number of single X-rays of a frog's hind leg in different positions and by arranging them in sequence was able to simulate movement. The quest for rapid filming thus began very early in the history of radiology and by 1909 Kaestel et al. had managed to expose as many as 13 films in 22 seconds. It is also interesting to note that in the earliest attempts at angiocardiology, the contrast medium was introduced directly into the heart (Forssmann, 1931; Perez Ara, 1931 and Moniz et al. 1931). Though unsuccessful, they obviously appreciated the importance of delivering the contrast as close as possible to the part they wished to see opacified.

Angiocardiology has been of great value in congenital heart disease and has provided a degree of accuracy in diagnosis which was unobtainable by any other method. It has developed steadily since 1923, when Sicard and Forestier injected iodized poppy-seed oil into an antecubital vein and watched it flowing through the right

side of the heart on an x-ray screen. Many technical difficulties had to be overcome before it blossomed forth as a routine diagnostic procedure in 1937. In that year Castellanos, Pereira and Garcia reported that satisfactory opacification of the heart chambers was possible in children and this was confirmed a year later by Robb and Steinberg, who showed that equally successful results had been obtained in adults.

Intravenous injection was the route chosen by these workers and it became the standard practice until a reliable method of direct intracardiac angiocardiology was described by Chavez, Dorbecker and Celis in 1947. After this, much thought was given to methods for rapid and safe intracardiac injection of contrast medium (Jönsson et al., 1949; Dorbecker et al., 1954; Gidlund, 1956; and Rodríguez-Alvarez and de Rodríguez, 1957) and selective injection is now in routine use.

A great deal of work was also put into the development of suitable X-ray apparatus and eventually Elema produced a roll film unit which could take 12 full size plates per second in two planes and had an excellent programme selector switching unit. This was probably the ultimate standard X-ray machine and though still widely used is being superseded by image intensification

in much the same way as the piston engine is giving way to the jet.

The introduction of image intensification by Teves and Feddema in 1953 started off a new era in diagnostic radiology and the combination of the intensifier with a cine-camera provided an instrument that was particularly suited to angiocardiology. The 5 inch intensifier developed and introduced by Philips (Radiological) Ltd., the first of its kind, was used in all the early work done in Scandinavia and in this country. Lind and Wegelius (1954, 1955 and 1957), working under considerable difficulties, pioneered cine-angiocardiology. They did so in the face of many vested interests, for there were those who were not keen to see older methods and equipment too rapidly replaced, and they had to take their intensifier from Sweden to Denmark to get much of their early clinical material.

The method was further developed by Astley (1955 and 1956), Stauffer et al. (1955), Pickard and Watson (1957), and Watson et al. (1958) and though off to a slow start, it is now rapidly coming into general use, several large manufacturers having introduced standard production models in the last year or two. Most now have 9 or 10 inch fields and some are being developed for

bi-plane work and television viewing. When used in conjunction with a good technique of selective injection, the films made can be studied either in motion, at normal or slow speeds, or projected as serial stills, and this results not only in more accurate diagnosis but allows detailed study of the actual intracardiac circulation. In addition the comparatively small radiation rates used (Feddemma, 1953; and Lind et al., 1955) means much greater safety for both patients and staff - a factor now rightly considered of the utmost importance.

#### EQUIPMENT AND METHODS

These studies have mostly been done with one of the first 5 inch Philips intensifiers which has now been dismantled and is being replaced by two of their new 9 inch models, each of which has both television and cine-cameras. This unit, one of the first of its kind, has taken rather longer to instal than had been anticipated and though our early experience with it is encouraging, it is as yet too soon to present results. The illustrations in this section have therefore been prepared from records made with our original intensifier which is seen, ready for use, in Figure 45, and for comparison Figure 46 is a




FIGURE 45




FIGURE 46

picture of the Elema unit in the Karolinska Institute in Stockholm.

The intensifier unit consists of a tilting table with a mobile top. The undercouch tube is a Super Dynamax with a 1 mm. focal spot, and the focus is 24 inches (60 cm.) from the skin surface. The operator controls the beam delineation by a double diaphragm which affords full protection. Power is supplied to the tube from a Watson cine-generator and, as the H. T. cables are long, no further stabilization is required with low continuous tube currents. The explorator has been replaced by a Philips 5-inch (12.5 cm.) intensifier which can be used with a fluorescent tunnel, a direct lens system, or a 35-mm. cine-camera. Standard fluorescent screen examination is also possible over a 12 inch (30 cm.) square area, and spot films can be taken if required.

The control of the exposure for cine-radiography is now standard. A micro-voltmeter is in circuit and arbitrary figures have been established that correlate the size and thickness of patient, the speed of the camera, and the radiographic output from the tube. This system has been satisfactory for all the speeds so far used. At lower speeds radiographic factors of the order of 65KV and 1 MA are utilized, but at higher speeds, 100 KV and

5 MA are required. A stationary grid has been found an advantage and the filtration of the tube varies from 0.5 to 3 mm. depending upon the KV applied. As the period during which cine-cardiography is in operation does not usually exceed 12 seconds, it has not been found necessary to involve complicated switching devices. During the preparation of the installation, much detailed work was carried out on the photographic aspects of this technique, and after experimenting with a variety of methods, HPX or Scopix G. 35 mm. film, processed under standard conditions with standard solutions, has been found satisfactory for most cases, the master film being available for preliminary examination within a few hours.

The main disadvantage of this intensifier is the small size of the screen, and this rather limits its usefulness. The investigation of congenital heart disease is however largely confined to children, and a 5 inch (12.5 cm.) field is less restrictive than would at first sight be imagined. It does mean however, that great care must be taken with the positioning of both the patient and the catheter if satisfactory results are to be obtained. When only able to film in one plane, the left anterior oblique view is used, and, when varied to suit the lesion present, gives good visualization of the heart chambers and

great vessels. In infants and young children, where the size of the screen is no problem, this represents a good compromise in the absence of the usual biplane photography and gives satisfactory results. When it is not possible to get the whole heart on the screen, the field is centred on the particular area that will give most help in the diagnosis and future surgical treatment, though of course with a 9 inch intensifier this is no longer necessary.

If in addition to diagnosis and pre-surgical evaluation, the intracardiac circulation is to be studied, it is essential that the injection be truly selective. To make certain of this is by no means easy because the action of the heart, the rotation of the patient into the desired position, and the force of the injection itself, all tend to produce movement of the catheter tip and may cause it to change position. If, for example, the right ventricular outflow tract and pulmonary valve are to be studied, the contrast medium is injected into the apex of the right ventricle so that ventricular contraction will distribute it into the infundibulum. If the catheter moves up or points up into the outflow tract during the injection, a pulmonary arteriogram will result and neither the filling mechanism nor the anatomy will be demonstrated. On the other hand, should the force of the injection push

the tip of the catheter back into the right atrium, only the initial opacification takes place in the ventricle, and very quickly the unwanted right atrial shadow obscures the detail of the outflow tract and pulmonary valve.

The size of the catheter used varies and is not necessarily the largest one possible. When selecting it, the size of the heart, as well as the size and age of the patient, have to be considered carefully and in the light of previous experience, if good pictures are to be obtained. For babies a No. 5 catheter is used and the injection given as rapidly as possible, but with larger catheters in older children the force of the injection is varied to suit the problem that is being investigated.

When angiocardiograms are studied in motion, opacification is much more obvious than it is on still pictures, and can be seen where, on stills, there would be some doubt as to whether or not faint delineation is present. Ultra-rapid injection is not always required, and the aim should be to produce adequate opacification over several cardiac cycles and thus demonstrate the intracardiac circulation. Since delineation is fairly obvious at rapid film speeds, two or more small injections may be given in different planes and still keep the total amount of contrast substance

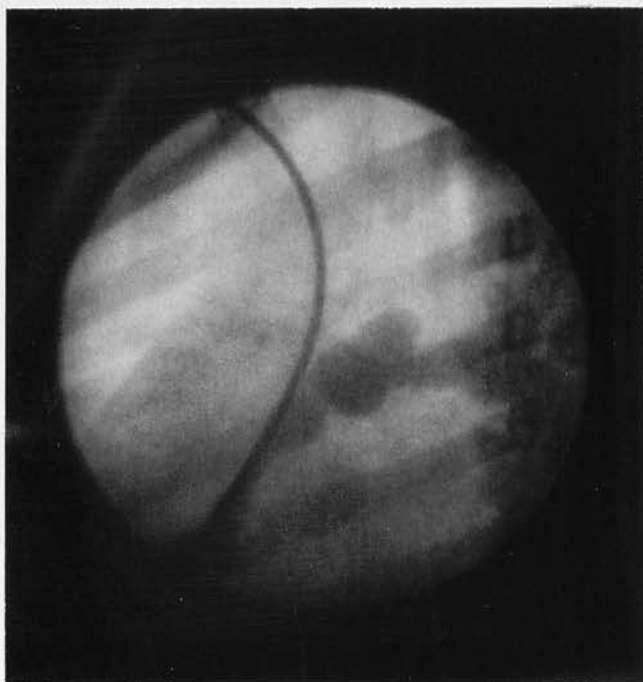


FIGURE 47

within reasonable limits. When this is done it is essential for the opaque medium to enter the heart as a bolus and the object is to catch at least one complete cardiac cycle showing the initial opacification. The tip of the catheter is shaped and fixed to match the size of the heart and the site of injection in each case. A leg vein is used for the catheterisation for two reasons: firstly because in babies and very small children it is easier, and secondly because we have found that if an arm vein is used and films are taken in oblique positions, the catheter may obscure structures to be visualized. This is illustrated in Figure 47, where it lies along the line of the outflow tract and valve in a case of pulmonary stenosis and spoils the film. When the catheter is in the desired position, it must be securely anchored to the skin of the limb so that the force of the injection will not cause it to change position, and the use of catheters with lateral holes near the tip does much to reduce recoil during the injection.

Not only the choice of the site of the injection, but also the means used to ensure that the contrast substance is in fact delivered there, have an important effect on the value of what is eventually seen on the cinematograph screen. As the field to be photographed

can be seen through a lens or tunnel in full lighting, it is a simple matter to check the position of the patient and the site of the catheter tip right up to the moment of injection.

The problem of correlating angiocardiographic films with events in the cardiac cycle is one that has in the past received surprisingly little attention, perhaps because it is not vitally important in many cases with slower film speeds. With cine-photography accurate timing is of first importance if the intracardiac circulation is to be studied in detail, but is by no means easy to achieve. Ideally it should be built into the intensifier, though so far the manufacturers have not been able to do so - perhaps because of technical difficulties, but more likely because of the absence of consumer demand.

Originally a simple device producing automatic exposure marking on a synchronous electrocardiographic record devised by Lind et al. was modified for this purpose. It consisted of a make-and-break spindle in the camera shutter and a device which automatically indicated the duration of the injection on the recording paper. By this means the electrocardiogram, X-ray pictures and injection of contrast medium could be

correlated. As it was soon found wise to make certain that the camera was running correctly before injection began, this correlation was far from exact. A machine has now been constructed which amplifies an electrocardiographic signal, such as the top of an R wave, to move a small radio-opaque pointer placed on the edge of the intensifier field, so making a permanent record of the heart cycle on the film.

One of the first major difficulties which had to be overcome was how to present the results of cine-angiocardiology for analysis. In the early days various possibilities were tried and discussed (Campeti et al. 1955; Greenwood, 1956) and the method we adopted was to process the master film, approximately 80 - 100 feet, examine it for possible faults and then send it away for professional copying. Because we think analysis is easier when the contrast appears black, and as the safety regulations in this country make it difficult to project 35 mm. film, a positive 16 mm. copy is made from the original 35 mm. negative. Detailed examination is not carried out until the prints are available, and though this means a certain amount of delay, the master film is protected from wear and tear and filed for future reference.

It takes time to adapt to this new method of presentation, and the eye accustomed to conventional angio-cardiography finds the speed of events a little confusing. When running the film through as serial stills it has to be constantly borne in mind that the time interval between pictures is very small, otherwise a false impression of persistent opacification in this or that chamber or vessel will be created. Slow motion projection is really essential for detailed study. This is at present hard to achieve since the maximum camera speed commonly in use is only about 50 frames per second, which is of course, not fast enough for genuine slow motion projection. It can however be simulated by individual film multiplication during printing and though this is most effective, it is also very expensive. Camera speeds will have to be increased until slow motion projection is possible and with this in mind we have produced satisfactory films at up to almost 100 frames a second in babies. The difficulty is that with present equipment the radiation factors have to be increased considerably to get the brightness required at very fast rates when patients become older, thicker and more dense. It has been suggested that image persistence will be troublesome at higher speeds and though this may

well be a problem in future, it has not appeared so far.

Much talk is heard, usually be it said from those not yet using intensifiers, about the lack of definition in cine-angiocardigraphic films. We have always found it adequate, not only for diagnostic purposes, but also for detailed functional studies and it is some examples of these which will be illustrated in this section. While there is no doubt that beautiful pictures can be obtained by other methods, they are relatively few in number and taken at the expense of high radiation rates. It is not uncommon for does of 20, 30, 40 or even 50 roentgens to be given when exposing up to 12 plates per second in two planes, and even then the number of films in each phase of the cardiac cycle is small - particularly in children whose heart rates tend to be rapid. When studying the opacified right ventricular outflow tract in pulmonary stenosis, for example, the momentary phase of relaxation may easily be missed and difficulty experienced in distinguishing between muscular contraction and true organic obstruction. The main problem facing those interested in angio-cardiography has therefore been how to get increased film speeds without raising the already high radiation rates. With an intensifier, we can now take 200 or 300 pictures per

roentgen and the infundibulum can be studied in all phases of the cardiac cycle. So in a child the total radiation of cardiac catheterisation and an angiocardiographic film containing about 1000 pictures may only be in the region of 5 or 6 roentgens (Watson et al., 1958 (b)).

Routine interpretation is made easier by having this large number of frames to project as serial stills, and by the pattern of movement which one comes to associate with various lesions after some experience of watching contrast circulating through congenitally deformed hearts. Detailed studies of the intracardiac circulation have also lead to a much clearer understanding of the abnormal mechanisms involved and some of these will be illustrated in this section. In each case the injection has been made into the apex of the right ventricle through a cardiac catheter passed from the groin, and the patient is lying in the left anterior oblique position.

#### CINE-ANGIOCARDIOGRAPHIC STUDIES OF THE INTRA- CARDIAC CIRCULATION IN THE TETRALOGY OF

#### FALLOT

Though attempts have been made to define the Tetralogy of Fallot and which cases should rightly be grouped under this title (Goodwin and Hollman, 1960) consideration of the various views expressed suggests that the exact sequence

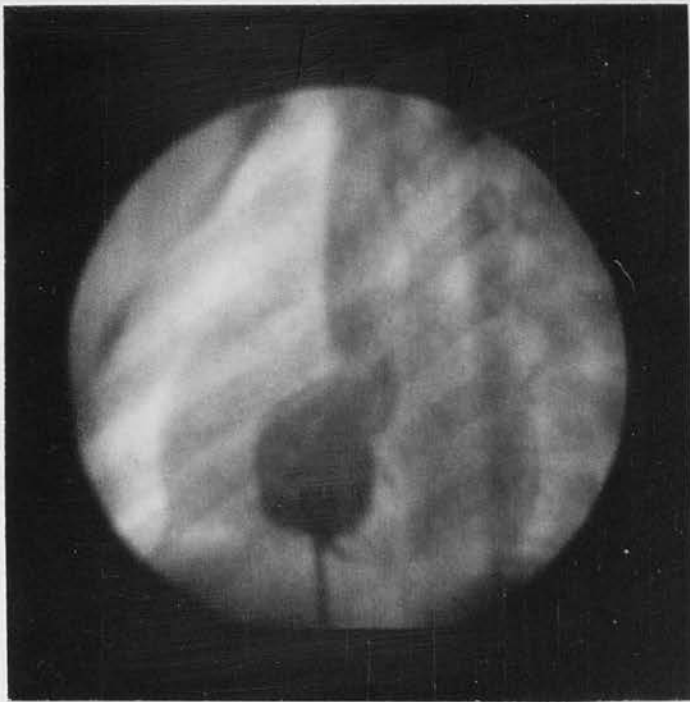


FIGURE 48

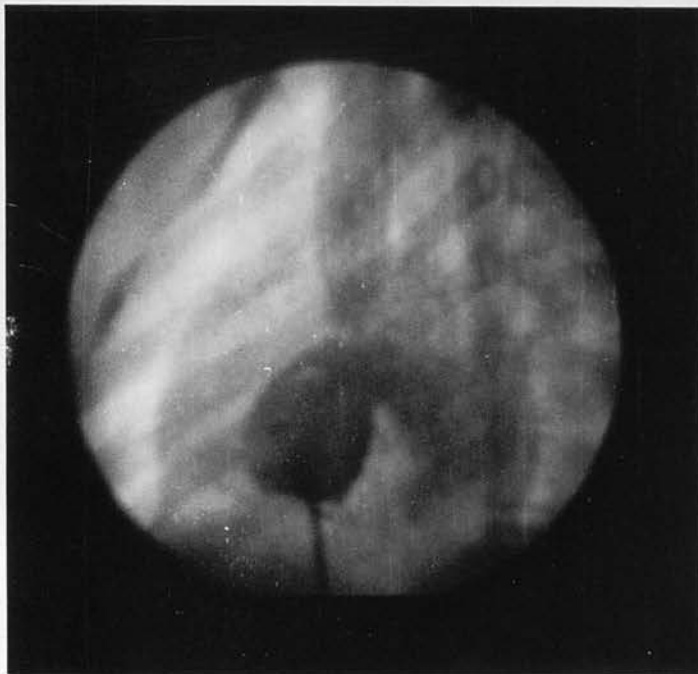

FIGURE 49

of events which takes place inside the heart during each cardiac cycle is not generally appreciated. Wood (1956), for example, says that the shunt is at ventricular level, but then goes on to state that it is "not a matter of the right ventricle expelling part of its contents directly into the over-riding aorta", and Hollman (1960) agrees with this view. Figure 48, however, shows that this is how the right ventricle does get rid of much of its content; it would be difficult for it to do so in any other way, since its own outflow tract is obstructed and there is a systemic pressure in the left ventricle.

In 1954, Hilario, Lind and Wegelius did find angiographic evidence of right to left shunting between the two ventricles but, even using exposures of 1/300 second and filming at the then rapid rate of 10 pictures per second in two planes, were unable to determine its exact timing. They emphasised at that time, that if functional as well as anatomical studies were to be made, enough films must be taken to visualize all phases of the cardiac cycle.

There is a right to left shunt at ventricular level as well as a direct discharge into the over-riding aorta in Fallot's Tetralogy, and this is illustrated in Figure 49 where both ventricles, the defect between them and the over-riding aorta are opacified - the characteristic "water-wings" pattern seen when patients with this lesion lie in

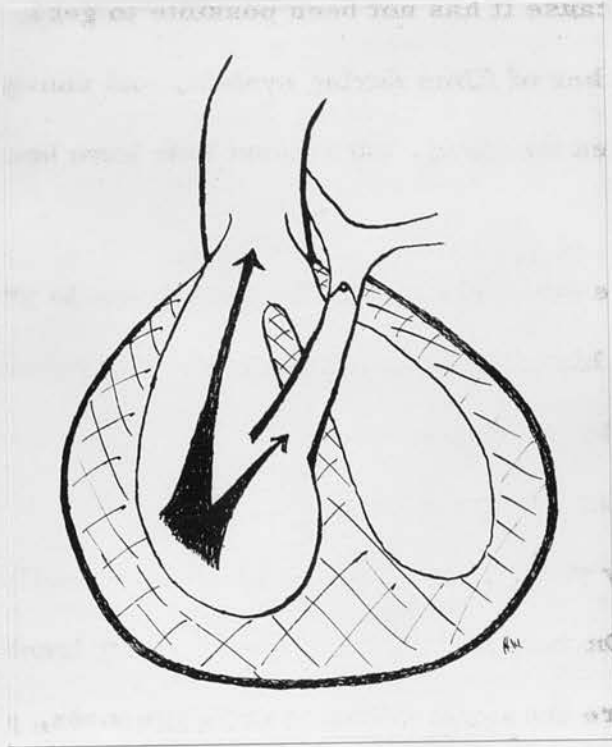


FIGURE 50

the oblique position during filming. Both these shunts occur in systole and Figures 48 and 49 are classical cine-angiocardiographic appearances in different phases of this part of the cardiac cycle. Confusion has arisen in the past because it has not been possible to get a sufficient number of films during systole, and sometimes one, sometimes the other, but seldom both have been visualized.

At the onset of systole, the resistance to pulmonary flow is so high that the right ventricle discharges some of its blood into the over-riding aorta and for most of this phase of the cardiac cycle there is flow through both aortic and pulmonary valves, as is shown diagrammatically in Figure 50. On very fast films, the pulmonary trunk opacifies just before the aorta and as systole proceeds, pulmonary flow appears to diminish. This is probably due to narrowing of the right ventricular outflow tract by systolic contraction of the infundibular muscles, and there is some evidence, though not yet proof, that the dilation of the ascending aorta which takes place when both ventricles expel their contents into it, may further impede the passage of blood into the lungs.

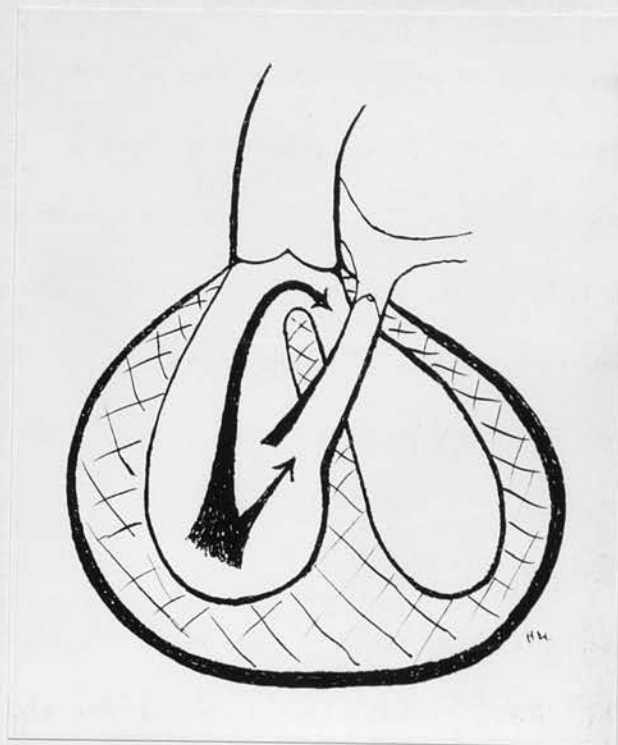


FIGURE 51

In Fallot's Tetralogy the right ventricle has more blood to discharge than the left, since it takes the whole systemic venous return, whereas its neighbour gets only what blood passes through the lungs and the little that shunts from right to left across the ventricular septal defect. Right ventricular systole, therefore, lasts longer than left ventricular systole and continues after the left ventricle is empty. When the systolic pressure in the right ventricle falls below aortic diastolic level, the aortic valve closes and since right ventricular outflow remains obstructed, venous blood is shunted across the ventricular septal defect into the left ventricle (Figure 51).

Kjellberg et al. (1959), using 12 per second bi-plane films found that they were unable to be certain of the timing of this shunt because injection into the right ventricle might artificially raise the pressure there and cause some opacified blood to spill over the septum. They also thought that its angiocardigraphic interpretation could be falsified by the heavy mixture of blood and contrast medium running through a posteriorly placed defect when a patient was lying in the recumbent posture. Lind and Wegelius (1953) were the first to suggest that a

high pressure injection inside the right heart could, by producing momentary shunt reversal, help to demonstrate septal defects, and this has been confirmed many times since. (Dotter, 1959; Jefferson et al. 1959). On the other hand Herbst showed in 1954, that when high pressure injections are made at some distance from the heart, the pressure alterations so caused are completely balanced by the elasticity of the venous system.

The patients in this study have all lain in the left anterior oblique position, so it is unlikely that gravitational flow has falsified the pictures, and though the contrast is routinely injected into the apex of the right ventricle, the effects illustrated in Figure 49 are constantly present even when the injection is made into the inferior vena cava, well below the diaphragm. The right to left interventricular shunt is always a late systolic event, results from inco-ordinate ventricular action and only takes place once left ventricular ejection is completed.

The whole sequence of events that takes place during systole in Fallot's Tetralogy is illustrated in Figure 52, which is a series of twelve consecutive

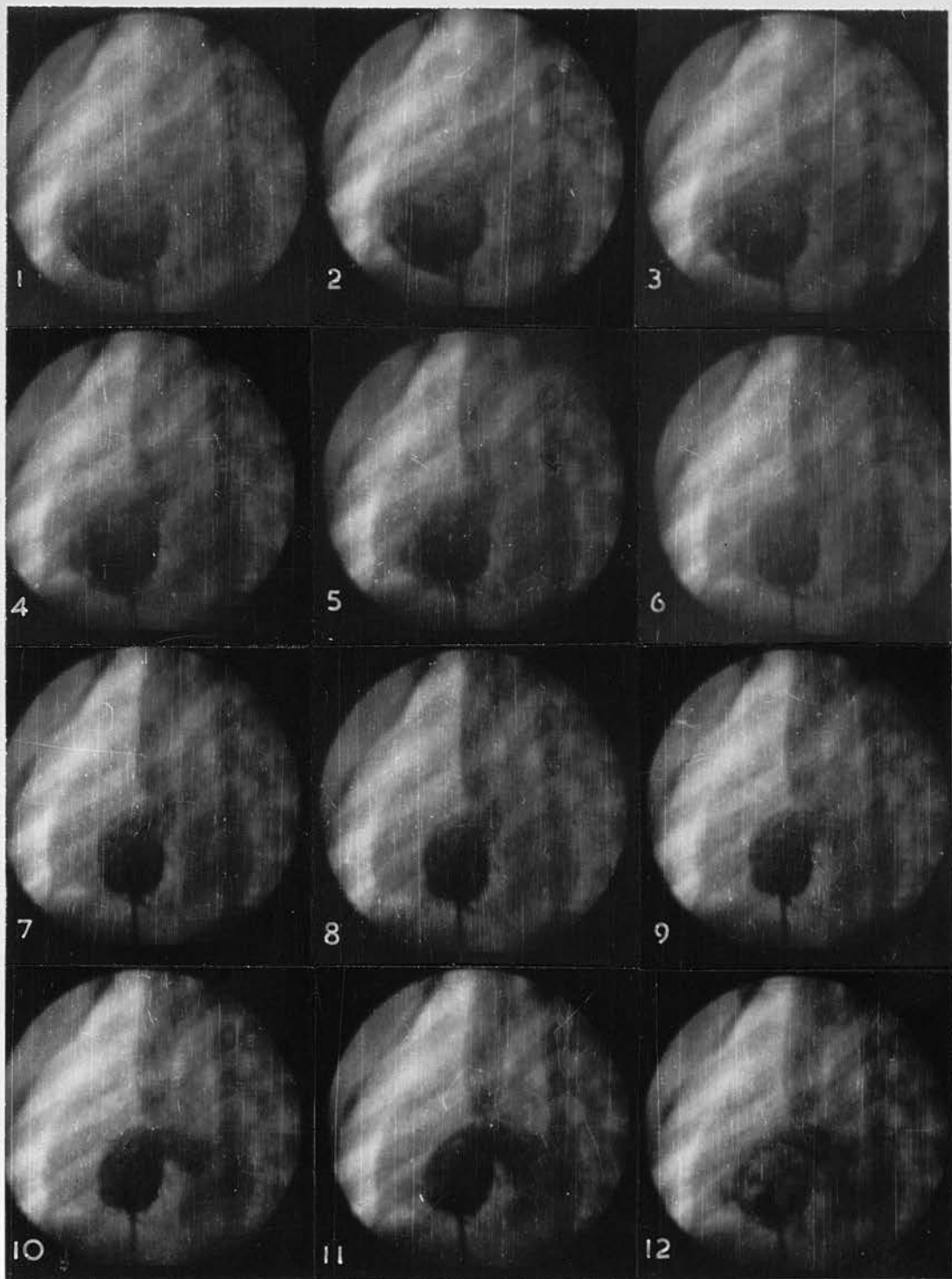


FIGURE 52

pictures taken at approximately 50 frames per second. They have been excerpted from the middle of a selective cine-angiographic film where injection lasted through several cardiac cycles, so some opacification is already present in the ventricles and great vessels in the first few frames which show the late stages of diastole. With the onset of right ventricular contraction, Nos. 3 and 4, opacified blood is expelled directly into the overriding aorta and, as will be seen in Nos. 5 - 8, this right to left shunt persists throughout most of systole. Towards the end of this phase of the cardiac cycle when the left ventricle is already almost empty, the pressure in the right ventricle falls below systemic diastolic level, and the aortic valve shuts (Film 9). As venous blood can now no longer escape into the aorta, it spills over the septum into the left ventricle and this late systolic interventricular shunt is clearly visible in 9, 10 and 11 immediately before diastolic relaxation appears in 12.

CINE-ANGIOCARDIOGRAPHIC STUDIES IN THE EISEN-  
ENMENGER SYNDROME

This method of investigation has also been of assistance in cases with the Eisenmenger syndrome (Wood 1952) in whom it has not been possible to determine by clinical examination or cardiac catheterisation the lesion responsible for this reaction. The films not only make its diagnosis possible but, by showing the intracardiac circulation, demonstrate once again that the timing of events in the cardiac cycle is perhaps not always as would be expected. Shunting of blood within the heart in either direction, tends to be thought of almost subconsciously in terms of systolic ejection, but cine-angiographic studies have shown that this is far from being the whole story as will be seen in the following illustrations.

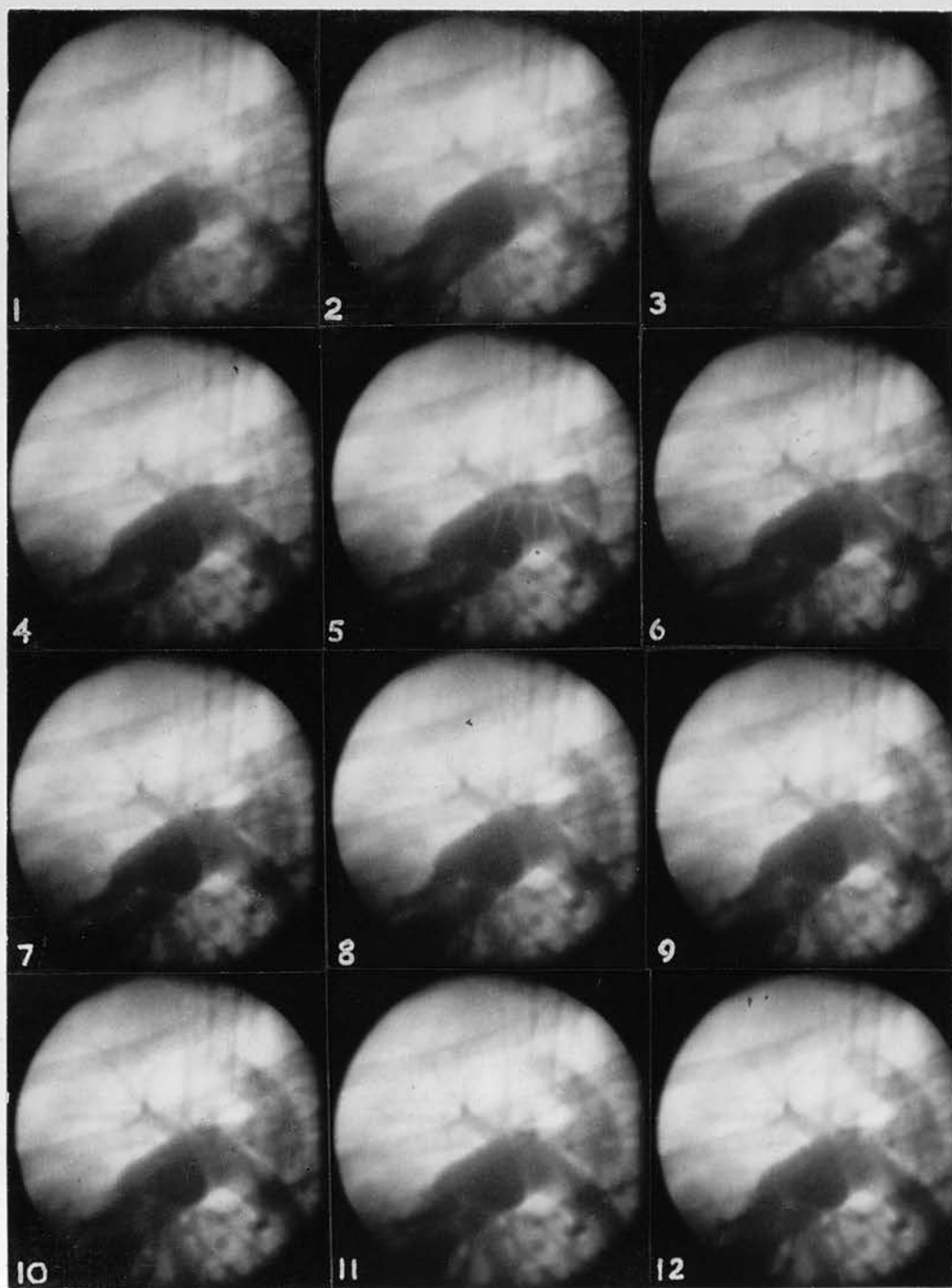
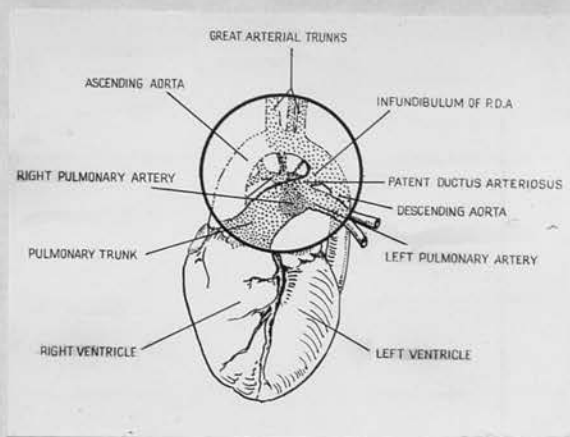


FIGURE 53



Figures 53 and 54 are two sets of 12 consecutive pictures taken at 50 frames per second in an eight year old girl, who presented as a case of the Eisenmenger syndrome, and in whom previous investigation had failed to differentiate between a ventricular septal defect and patency of the ductus arteriosus.

In Figure 53 the diagnosis is immediately obvious, for in pictures 1 - 6 the initial opacification of a patent ductus arteriosus is seen developing, and in 7 its infundibulum (Steinberg et al. 1943; Jönsson and Saltzman, 1952) is clearly defined. Thereafter retrograde opacification of the first part of the descending thoracic aorta takes place and confirms the right to left shunting which had previously been noted in this case. As the film progresses, an interesting fact about the timing of the shunt emerges - which will be apparent from a study of Figure 54.

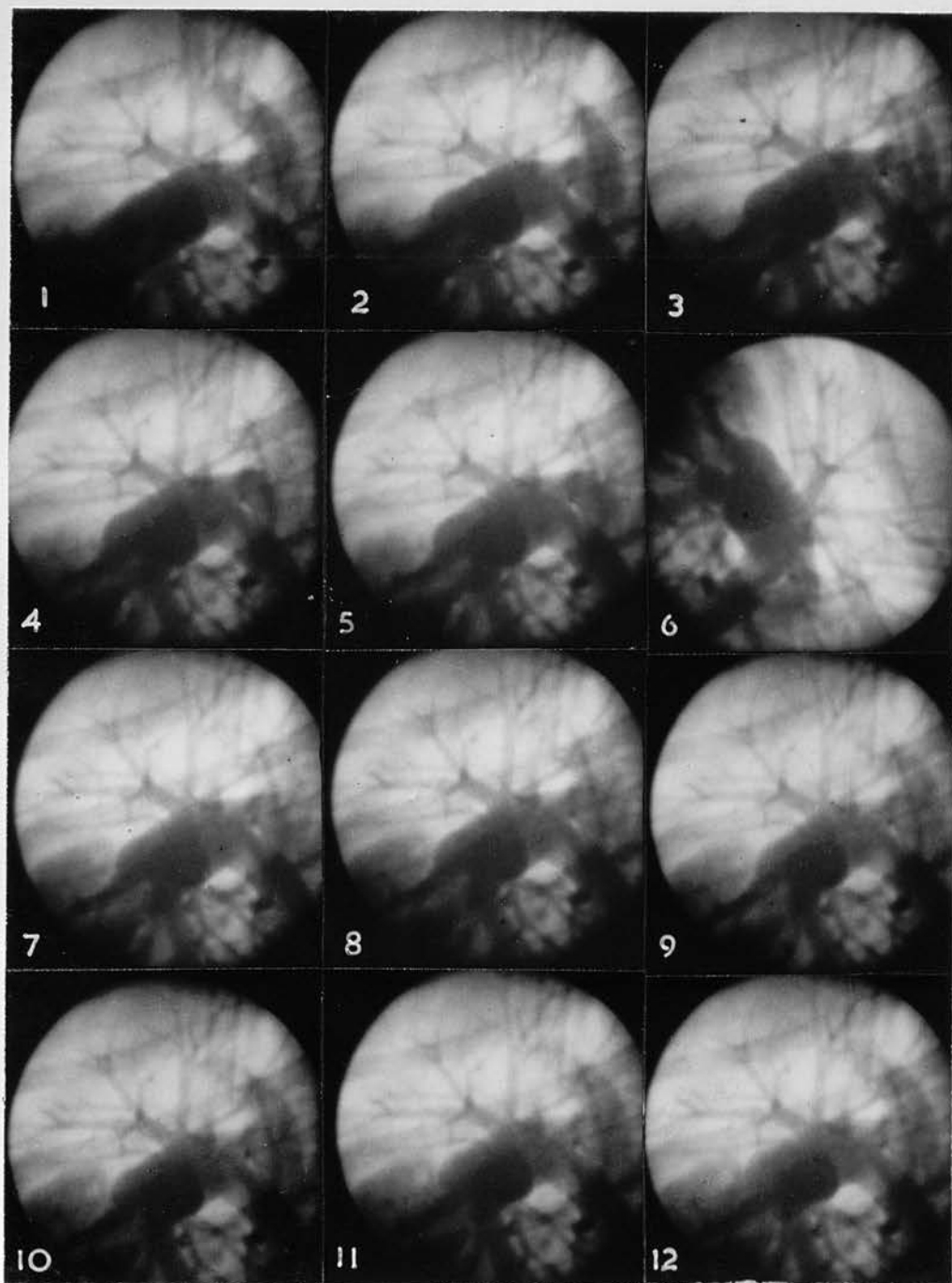
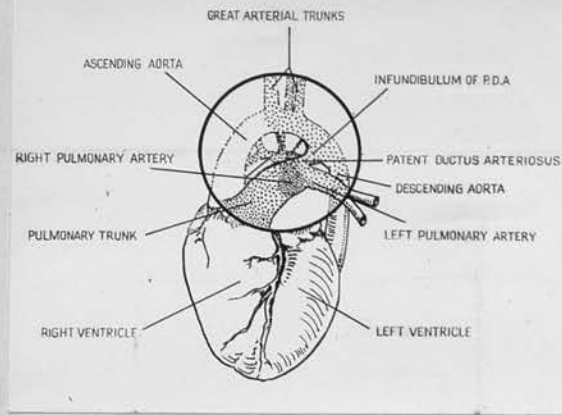


FIGURE 54



The first picture in this illustration is taken at the end of diastole and shows that by then, the innominate artery and the distal half of the aortic arch have become opacified. In the second picture systole begins and the non-opacified blood from the left ventricle proceeds to wash the contrast out of the aorta down to the level of ductal entry (2 - 7). During this time right to left shunting of opacified blood across the ductus continues, and with the onset of diastole retrograde opacification of the aorta begins once more, progressing rapidly upwards and continuing throughout this phase of the cardiac cycle.

Reversed shunting through a patent ductus arteriosus in systole is often referred to as a right ventricular safety valve and it is now clear from such films that the flow continues throughout diastole as well - the pulmonary arteriolar resistance not only making it difficult for the right ventricle to pump blood through the lungs, but

forcing it back out of the pulmonary arterial tree across the ductus and into the aorta after the pulmonary valve has closed. The profound and usually fatal haemodynamic upset which follows surgical closure of the ductus in such cases may well be due to the fact that this blood must then be retained in the lungs.

CINE-ANGIOCARDIOGRAPHIC STUDIES OF THE  
RIGHT VENTRICULAR OUTFLOW TRACT IN ISOLATED  
PULMONARY VALVULAR STENOSIS

There has been much confusion and misunderstanding regarding the nature of the obstruction to the outflow of blood from the right ventricle in patients with pulmonary stenosis. This obstruction may be due to an abnormal pulmonary valve as in pulmonary valvular stenosis, or to a variety of congenital infundibular lesions such as are commonly seen in Fallot's Tetralogy. A combination of these valvular and infundibular lesions is often found, and there may even be obstruction due to constriction in the pulmonary arterial tree - the rare supra-valvular pulmonary stenosis. Lastly, and perhaps the most intriguing and controversial aspect of the subject, is the acquired infundibular obstruction seen in response to severe valvular stenosis and which is due to hypertrophy of the muscles in the outflow tract. Examples of the cine-angiocardio-

graphic studies which have helped to resolve the complex nature of this functional disorder (Watson et al., 1960 (a)) will be discussed and illustrated in some detail in the following pages.

The concept that muscular hypertrophy might of itself cause obstruction has been suggested by some workers who have studied right ventricular dynamics in pulmonary valvular stenosis with intact ventricular septum (Kirklin et al., 1953; Swan et al., 1954; Brock 1955; Blount et al., 1957; McGoon and Kirklin, 1958; Engle et al., 1958; Johnson, 1959) and rejected by others (Bing et al., 1954; Kjellberg et al., 1954). Hitherto most views on the subject have rested on haemodynamic considerations, for in severe pulmonary valvular stenosis with right ventricular hypertrophy there is usually a systolic pressure gradient at the valve site only and though the infundibular lumen may be narrowed, the high pressure seems uniformly distributed throughout the ventricular cavity. Following successful valvotomy however, an infundibular systolic pressure gradient may become evident and presumably the narrowing of the infundibular lumen remains the sole obstruction to rapid outflow of blood. This pressure gradient can be reduced immediately by infundibular resection but, if this part of the operation is not carried out, cardiac catheterisation at a later date may show

regression of the infundibular pressure gradient, presumably due to involution of the hypertrophied infundibular muscles (Engle et al., 1958; Johnson, 1959).

Surgeons in the past have been divided in opinion about whether or not infundibular resection is required after successful pulmonary valvotomy and though some still do so if the right ventricular pressure remains high, most now hold the view that it is no longer necessary.

We have been interested in this problem for some years now and initially used intracardiac electrography to help in locating the site of the obstruction as has been illustrated in Section I. In cases with withdrawal tracings like the one illustrated in Figure 37, it seemed almost certain, from both the pressure pulse and the electrogram, that the stenosis was an isolated valvular lesion and we were often puzzled and disappointed to be told by the surgeons, that though this diagnosis was correct, there was infundibular stenosis present as well.

It seemed that selective cine-angiocardiology might help to solve this problem and using the image intensifier it was possible to get a sufficient number of pictures in all phases of the cardiac cycle to see the outflow tract in all stages of contraction and relaxation, and to judge whether true organic obstruction was present or not (Watson et al. 1958). In severe cases of

pulmonary valvular stenosis, as judged by the height of the right ventricular pressure, relaxation was found to be a momentary event and a characteristic picture, which fitted in very well with the information obtained from the intracardiac electrogram and the pressure records, emerged. The operative findings still suggested additional infundibular stenosis, and it was slowly realised that the clinical diagnosis and the operative findings were each compatible with a diagnosis of severe isolated pulmonary valvular stenosis. Further cine-angiocardiographic studies have confirmed this and helped to unravel the complex secondary changes which take place in the right ventricle when its outlet is obstructed.

To understand the intracardiac circulation in congenital heart disease it is essential to decide first of all what abnormality was present at birth and what has developed as a result of it. In pulmonary stenosis, the great majority are born with valvular stenosis and as the right ventricle hypertrophies to do the work which the valvular obstruction imposes upon it, there is simultaneous hypertrophy of the muscles in the outflow tract. If the stenosis is severe and the hypertrophy is gross, a stage is reached when the infundibular muscles encroach on the lumen to such an extent that this constitutes an added obstruction.

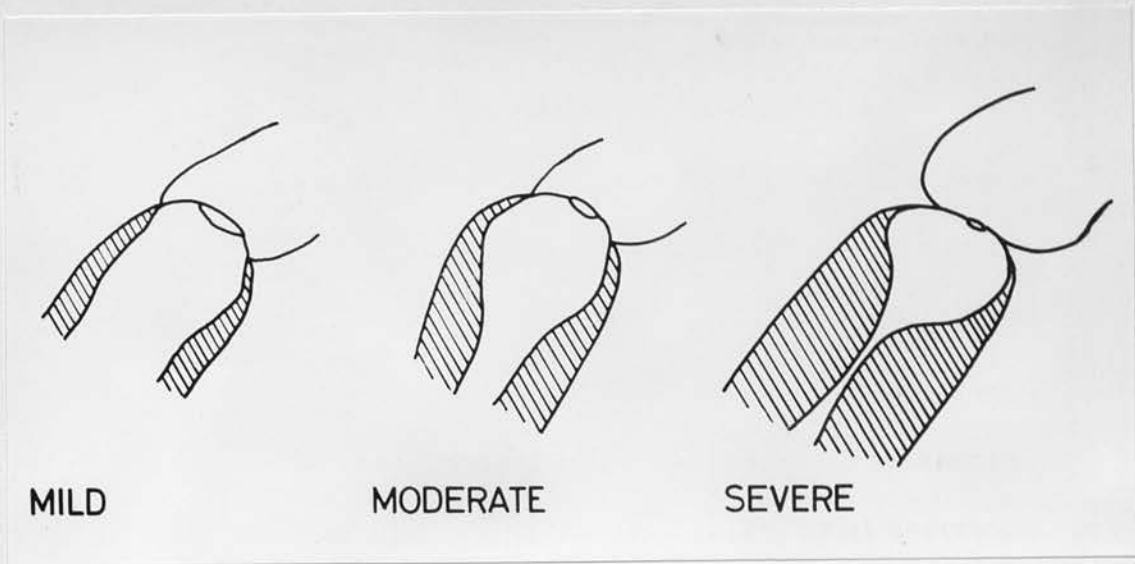


FIGURE 55

to the outflow of blood, and because they too contract during systole, it becomes increasingly difficult for the chamber to expel its contents into the pulmonary artery. The valvular obstruction alone makes this difficult, but when the two parts of the ventricle start to work against each other as it were - a vicious circle is set up which places a great load on the already severely taxed ventricular muscle.

This concept is demonstrated in Figure 55, where with examples of mild, moderate and severe pulmonary valvular stenosis it is shown diagrammatically that as the stenosis becomes more severe, the muscular hypertrophy increases and the width of the outflow tract decreases. The following illustrations have been excerpted from cine-angiographic films taken in cases of mild, moderate and severe isolated pulmonary valvular stenosis, as judged by the height of the right ventricular pressure. It will be seen that the degree of narrowing of the infundibular lumen is roughly proportional to the degree of stenosis present and the duration of the dilated phase in diastole seems almost inversely proportional to the severity of the lesion.

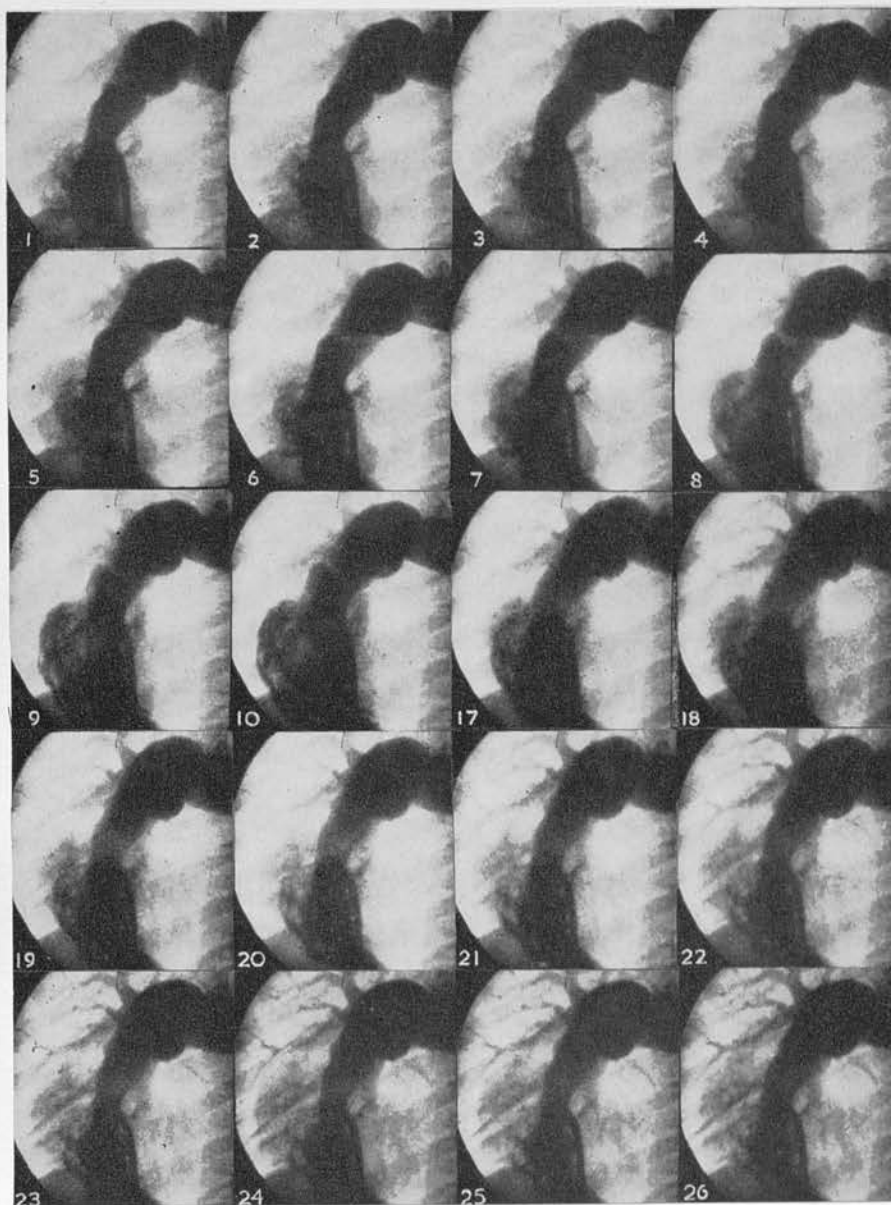


FIGURE 56

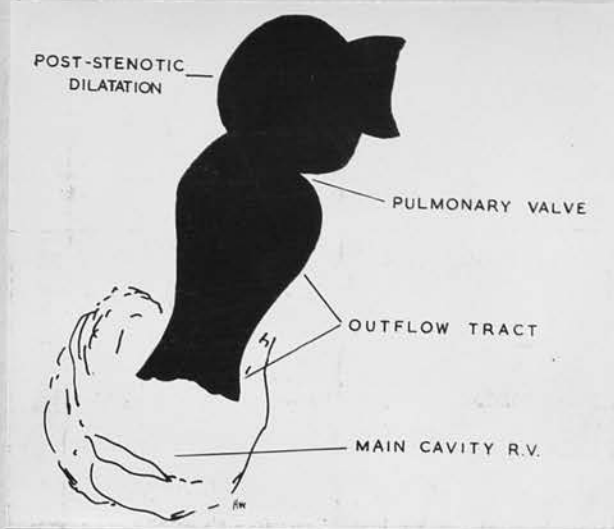


Figure 56 is from a case of mild pulmonary valvular stenosis in a four year old girl whose right ventricular pressure was 46/0 mm. of Hg. It was taken at approximately 70 frames per second and Nos. 11 - 16 of the 26 consecutive frames have been removed since they merely repeat the picture of the fully dilated phase seen in 10 and 17.

This excerpt shows only the post-stenotic dilation of the pulmonary trunk, but in an earlier part of the film an obvious jet can be seen issuing from the stenosed pulmonary valve during the initial opacification. There is slight systolic narrowing throughout the whole length of the outflow tract which is widely dilated during diastole, and the appearance of this infundibulum is in fact almost within normal limits.

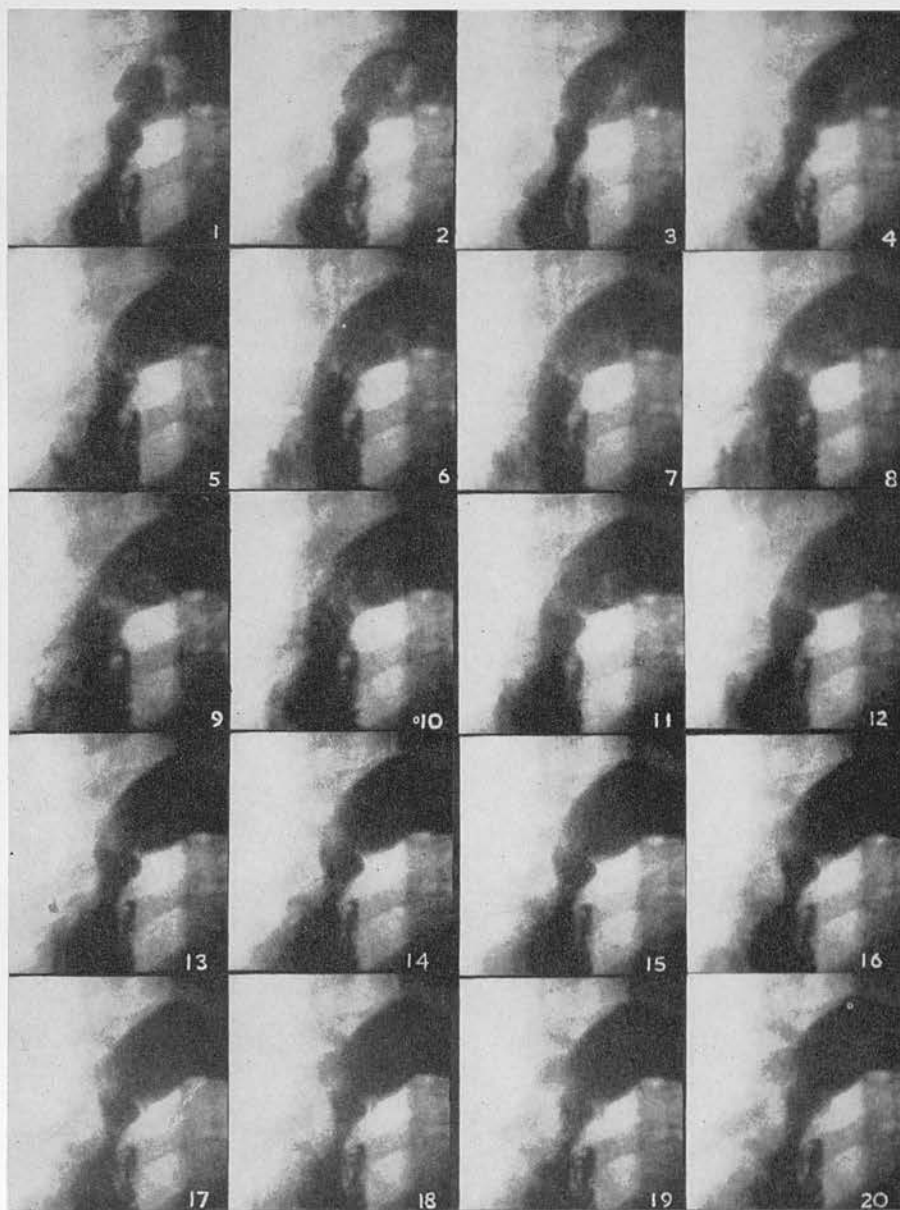


FIGURE 57

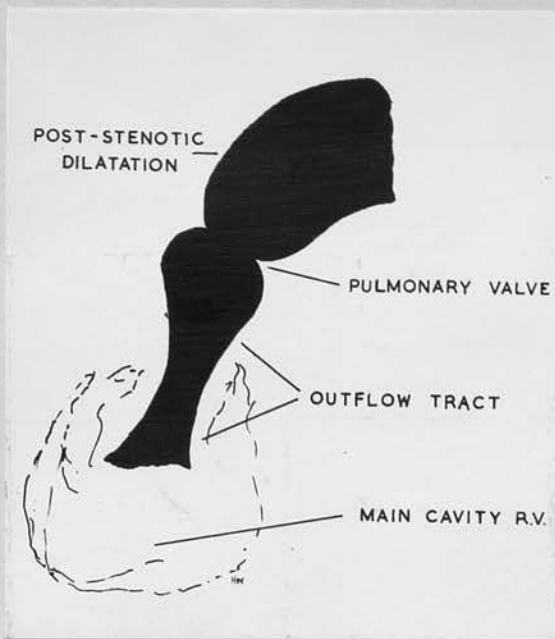


Figure 57 is excerpted from a cine-film taken at approximately 65 frames per second in a nine year old girl with moderate isolated pulmonary valvular stenosis, whose right ventricular pressure was 73/0 mm. of Hg. These are 20 consecutive frames and show a complete cardiac cycle.

In this case a jet at the valve and turbulence in the post-stenotic dilatation can be seen in the first few pictures. The outflow tract is significantly narrowed throughout its whole length and though obviously still capable of fairly wide dilatation, the duration of this phase is short. Its lumen is reduced in calibre for the greater part of the cardiac cycle and shows marked constriction during systole.

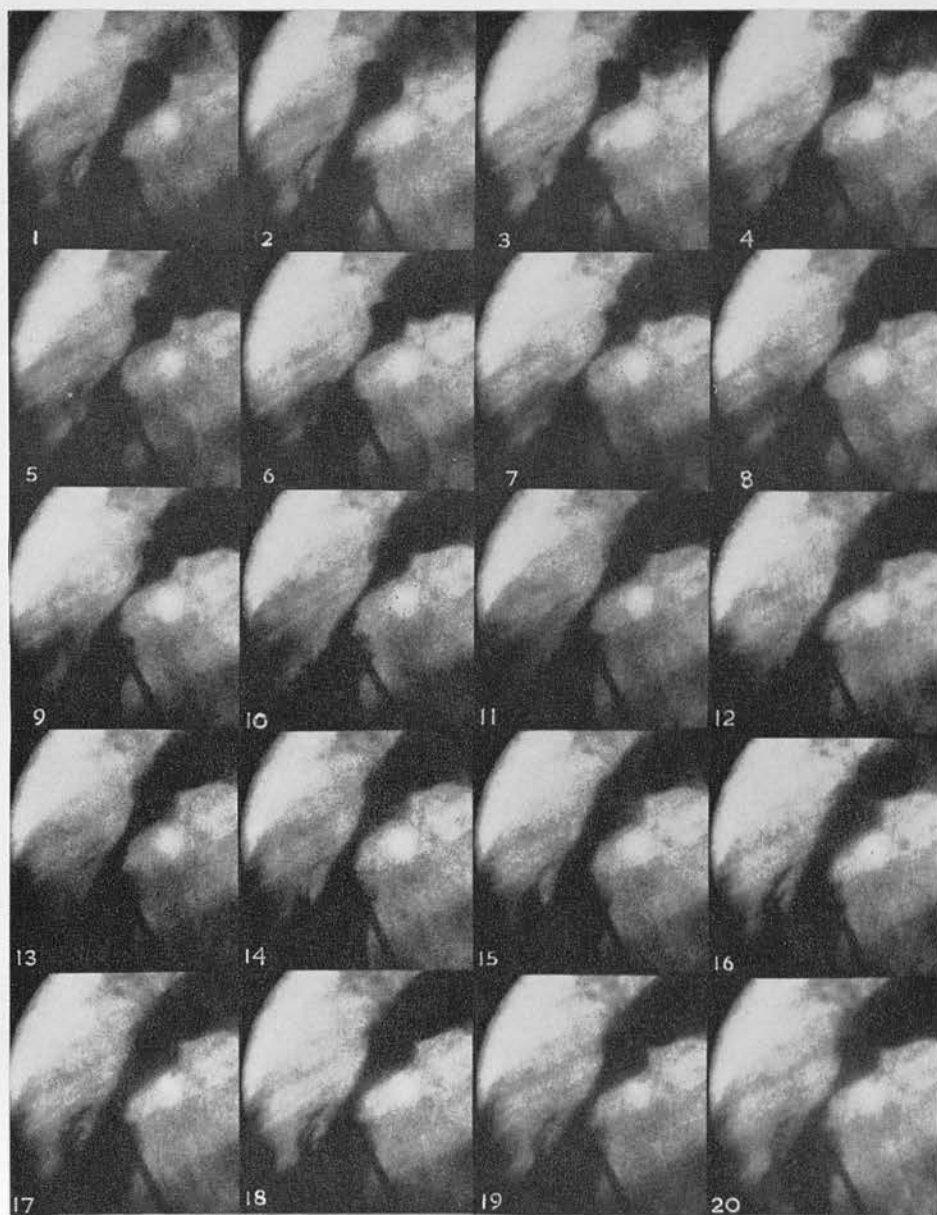


FIGURE 58

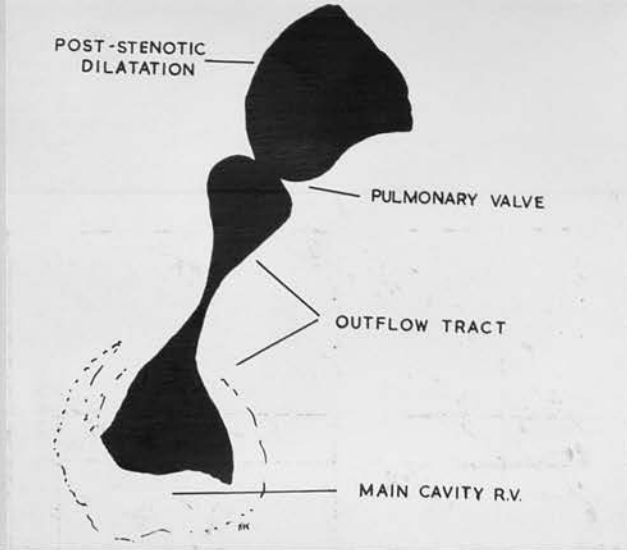


Figure 58 shows the characteristic cine-angiographic picture of severe isolated pulmonary valvular stenosis. In this case, a nine year old boy whose withdrawal tracing was used in Figure 37, the right ventricular pressure was 110/0 mm. of Hg. and the diagnosis was confirmed at operation. These 20 consecutive pictures were taken at approximately 50 frames per second and 16 frames represent a cardiac cycle.

There is gross narrowing of the lumen of the outflow tract and this persists throughout the greater part of the cardiac cycle. Dilatation is a momentary event in such cases and in this instance is seen in only three frames - Nos. 15, 16 and 17. In the remaining 12 pictures it shows constriction and in many of them, this is of extreme degree.

Looking at a film like this it is not hard to imagine the hypertrophied infundibular muscles bulging into the lumen of the outflow tract and to see how this constitutes an added obstruction to right ventricular emptying. The Oxford English Dictionary defines muscle-bound as "with muscles stiff and inelastic through over-exercise" and this is the cine-angiographic appearance of the muscle-bound right ventricular outflow tract in severe isolated pulmonary valvular stenosis.

-----

These examples of selective cine-angiography have been chosen to illustrate not only its value in diagnosis, but the part it has to play in much more fundamental studies. It is, of course, difficult to demonstrate the merit of motion pictures with still films, and the cine-film accompanying this text shows, in a much more vivid way, how detailed study of the intracardiac circulation leads to a better understanding of the abnormal mechanisms involved.

The patients have been filmed in the left anterior oblique position and the contrast has been injected through a cardiac catheter passed from the groin into the apex of the right ventricle.

Each sequence commences with a still of the structures to be visualized already fully opacified, so that the viewer may become familiar with the anatomy before movement begins. The cine-angiocardioqram is seen at normal speed and the same picture is then repeated in slow motion.

The first part of the film, Fallot's Tetralogy though now rather scratched, has been included in preference to one of better quality because of its historical interest. It was the first film of its kind ever shown at a scientific meeting.

I had hoped to put a sound track on to the film since the various points can only be demonstrated adequately by a spoken commentary. As this was unfortunately not possible, I will be very glad to come and speak to it when the examiners are viewing it.

VENTRICULAR PRESSURE FLOW RELATIONSHIPS IN  
ISOLATED PULMONARY VALVULAR STENOSIS

"Intracardiac electrocardiography may be used increasingly often, not only as a protective measure during cardiac catheterisation, but also in the assessment of right ventricular function." - Annotation, Lancet 26.9.59.

When this editorial comment appeared in the Lancet, the assessment of right ventricular function reported in this section was already well under way, for once it was realised that the infundibular obstruction so often associated with severe pulmonary valvular stenosis was due to muscular hypertrophy, it soon became obvious that a more critical appraisal of right ventricular haemodynamics was required. The outflow of blood from the right ventricle has in the past been considered too much in terms of anatomical obstructions and the pressure gradients across them, and too little thought has been given to the pressure flow relationships involved. The combined use of various techniques already illustrated, has played an important part in this study of what has always been the enigma of acquired infundibular stenosis - the presence of an obstruction to the outflow of blood in the absence of a demonstrable pressure gradient.

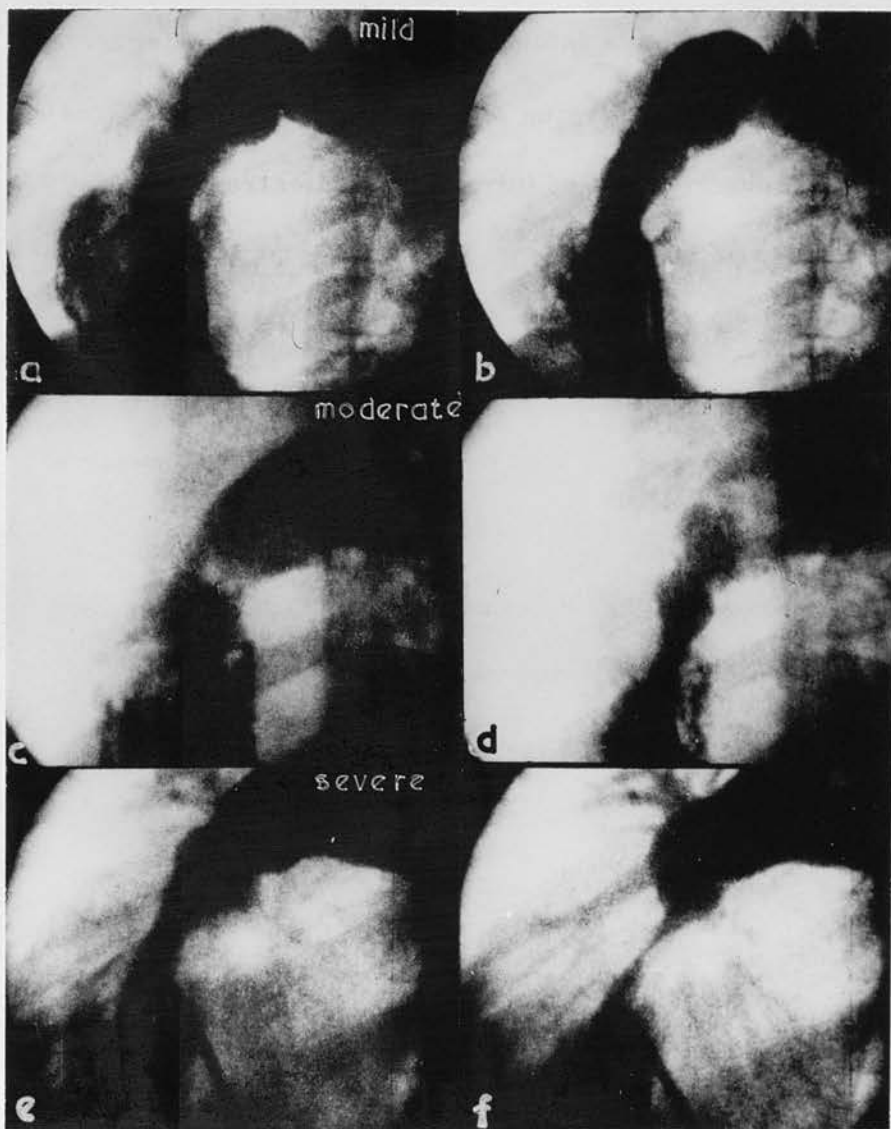


FIGURE 59

CINE-ANGIOCARDIOGRAPHY

As has been seen in Section I, differentiation between valvular and infundibular pressure gradients can be simplified by using an electrode catheter and making simultaneous records of intracardiac electrograms and pressure pulses as it is withdrawn from the pulmonary artery into the right ventricle. By this means the pressure pulses recorded in the outflow tract can also be located and compared with those recorded in the main cavity.

Cine-angiocardio-graphic studies of the opacified right ventricular outflow tract have demonstrated that there is progressive narrowing of the infundibulum as the severity of the valvular stenosis increases, and Figure 59 is a composite illustration made up from the examples of mild, moderate and severe stenosis in Section II. It shows the outflow tract fully expanded on the one hand and in maximum systolic contraction on the other. In the severe case it remains narrow even during its brief phase of relaxation, and it will be obvious from Figure 58 and from the cine film which accompanies this text, that in such cases the infundibulum is a narrow and almost rigid tube.

Though there now seems no doubt that secondary hypertrophic infundibular stenosis does constitute an added obstruction to the outflow of blood from the right ventricle (Swan, 1960, Brock, 1961), the absence of a demonstrable infundibular systolic pressure gradient in such cases has hitherto been somewhat puzzling. There is usually an obvious systolic pressure gradient only at the pulmonary valve, and though the lumen of the whole outflow tract is narrowed, the high pressure seems to be uniformly distributed throughout the right ventricle.

It is not easy to study the right ventricular outflow tract in pulmonary stenosis on account of its irritability, and usually during cardiac catheterisation there are frequent ectopic beats or short bursts of ventricular tachycardia when it is stimulated by the catheter tip. It is sometimes difficult to pass a catheter even once through the stenosed valve into the pulmonary artery and often difficult to do so several times if the records are being spoiled by arrhythmia in this way. As a result, many withdrawal tracings show at best only one or two genuine right ventricular pressure pulse waves and the electrograms recorded under the pulmonary valve

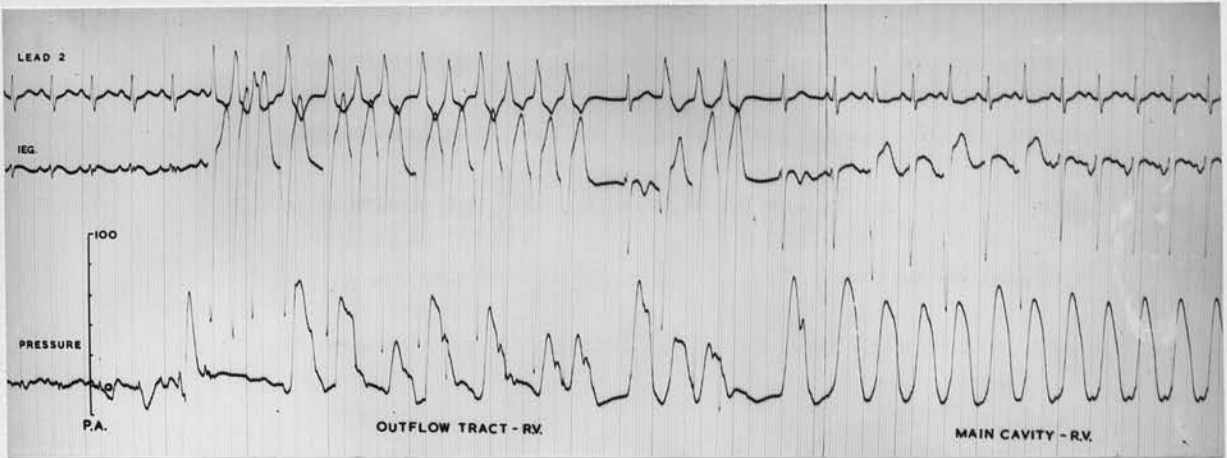


FIGURE 60

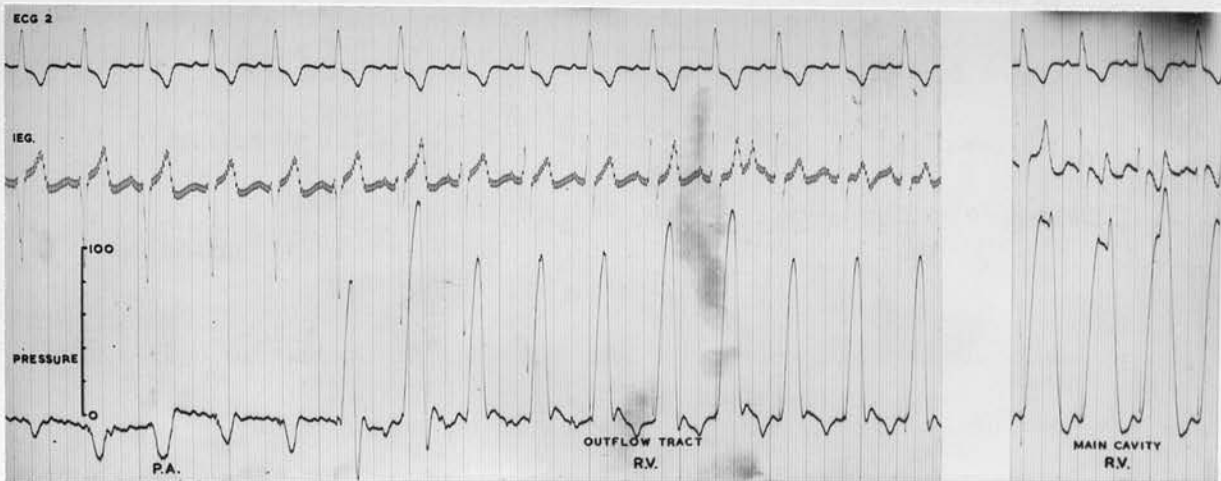


FIGURE 61

and in the infundibulum are bizarre, returning to the usual pattern only when the main cavity of the ventricle is reached. Thus, as will be seen in Figure 60, the true nature of the pressure and electrocardiographic wave forms in the infundibulum may not be demonstrated.

On the other hand, when tracings are not being spoiled by arrhythmias in this way, it often happens that ventricular outflow tract pressure pulses are the only ones recorded, because after a systolic pressure gradient has been observed and the pulse waves are obviously right ventricular, withdrawal has been stopped before the main cavity is reached and recording has ended with the catheter tip still lying in the outflow tract. Many published tracings are of this type and Figure 61 shows the change from pulmonary artery to infundibular pressure pulses during such a withdrawal and also the rather different type of right ventricular pressure pulse recorded later in mid-cavity.

All those familiar with cardiac catheterisation know how rapidly a catheter can on occasion change its location inside the heart, whipping from one place to another almost quicker than the eye can follow it. It may thus traverse the outflow tract without recording any true pressure pulses there or, at most, only one or two

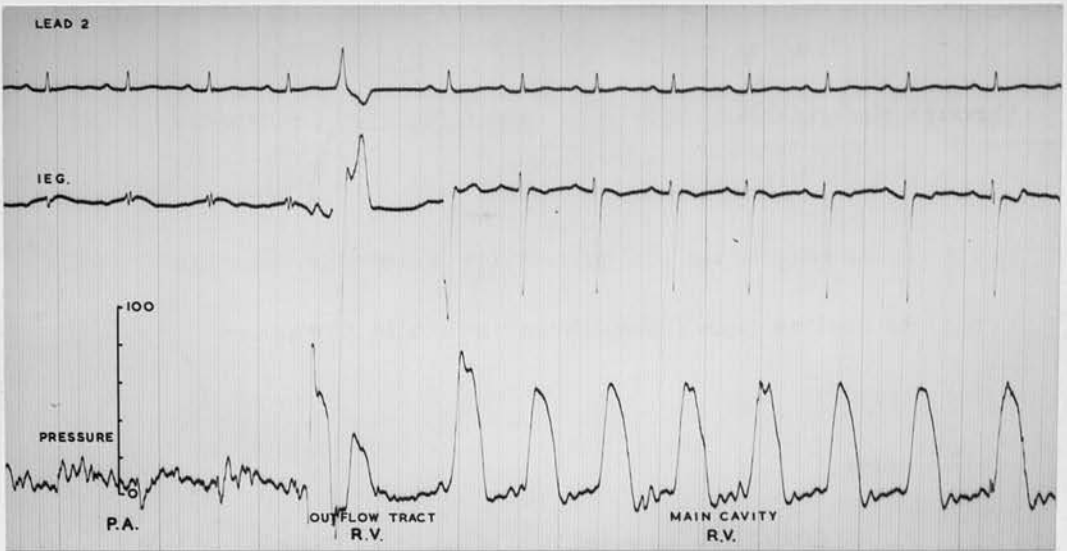

FIGURE 62

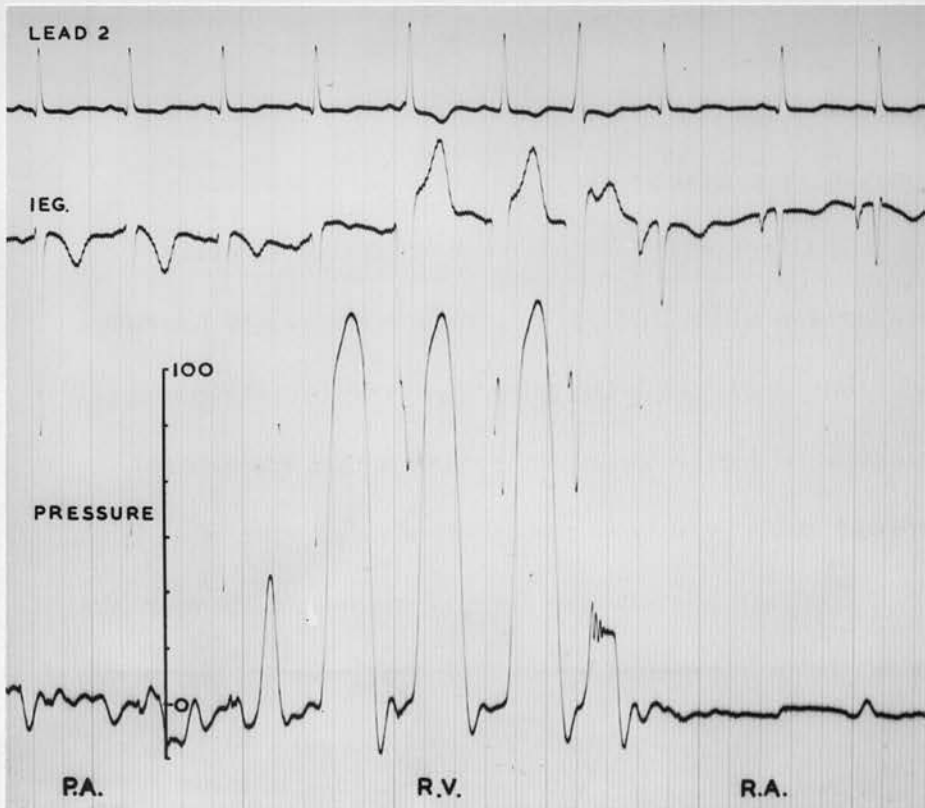


FIGURE 63

spoiled ones. This is illustrated in Figure 62, a withdrawal tracing in which the catheter tip has passed through the pulmonary valve in systole, thence rapidly through the outflow tract recording only two ectopic beats on its way from the pulmonary artery to the right ventricle and no true infundibular systolic pressure pulse waves for comparison with those recorded in the main cavity.

On occasion too, the catheter will pass very quickly from pulmonary trunk to right atrium with only a few damped or atypical pressure pulses recorded during its whole course through the right ventricle. Such a withdrawal is seen in Figure 63, where though the pulmonary stenosis is proved, detailed analysis of the ventricular pressure pulse waves is not possible.

Circumstances may thus combine to make comparison of the infundibular and main cavity pressure pulse waves difficult or impossible and thereby prevent detection of the obvious differences which may exist between them in severe cases of valvular stenosis.

Study of pressure flow relationships in man has always been hampered by the fact that most of the physical laws relating to such matters are concerned with steady flows, and nearly all of them are applicable only to rigid

tubes. For example Poiseuille's Law,  $\Delta P = \frac{8L \times V \mu}{R^2}$   
- (P = pressure drop, L = length, R = radius, V =  
velocity and  $\mu$  = viscosity) which deals with streamlined  
flow of viscous fluids, cannot be applied quantitatively  
under normal conditions to the circulatory system because  
the radius and length of the blood vessels are constantly  
altering during each cardiac cycle and therefore the  
pressures and tube dimensions are not independently  
variable (Rushmer, 1961). It has been shown by cine-  
angiocardiology however, that the hypertrophied out-  
flow tract in severe pulmonary valvular stenosis appears  
to be almost rigid and that its radius and length change  
little, once systolic contraction has taken place. Moreover,  
the fact that blood is not truly viscous and homogeneous  
fluid is probably only of importance when considering  
flow through small vessels, and it seems obvious from  
Poiseuille's equation that in severe stenosis of the  
pulmonary valve, where the radius of the outflow tract  
(R) is greatly decreased and the velocity (V) is therefore  
greatly increased, we have two factors which will cause  
the infundibular pressure to fall during systole, while the  
pressure in the main cavity of the right ventricle  
remains high in order to expel its contents past the  
obstruction.

Even when the whole length of the outflow tract is not uniformly narrowed we know from Bernoulli's Theorem,  $p/w + \frac{V^2}{2g} = \text{a constant}$  (  $p = \text{pressure}$ ,  $w = \text{density}$ ,  $v = \text{velocity}$  and  $g = \text{acceleration due to gravity}$ ) that when fluid flows along a rigid tube of varying calibre, the lateral pressure of the fluid at any point varies with the cross-sectional area or inversely with the velocity. The principles of the Venturi pump and flowmeter are, in fact, based on this theorem and the term "Venturi effect" has come to be used in haemodynamics to describe the drop in pressure which occurs as blood flows rapidly from a high pressure right ventricle through a stenosed pulmonary valve (Sobin et al 1954, Bouchard and Cornu, 1954). A similar though less marked paradoxical systolic pressure drop has been described in patients with atrial septal defects, where greatly increased blood flow through normal pulmonary valves results in relative pulmonary valvular stenosis (Jonsson, 1957).

When considering the hypertrophied muscular infundibulum and the changes in its calibre, which had been so clearly demonstrated by cine-angiocardiology, it was obvious that in dealing with pulsatile flow through a non-rigid tube of complex shape whose lumen was reduced in size during ejection, the mathematics

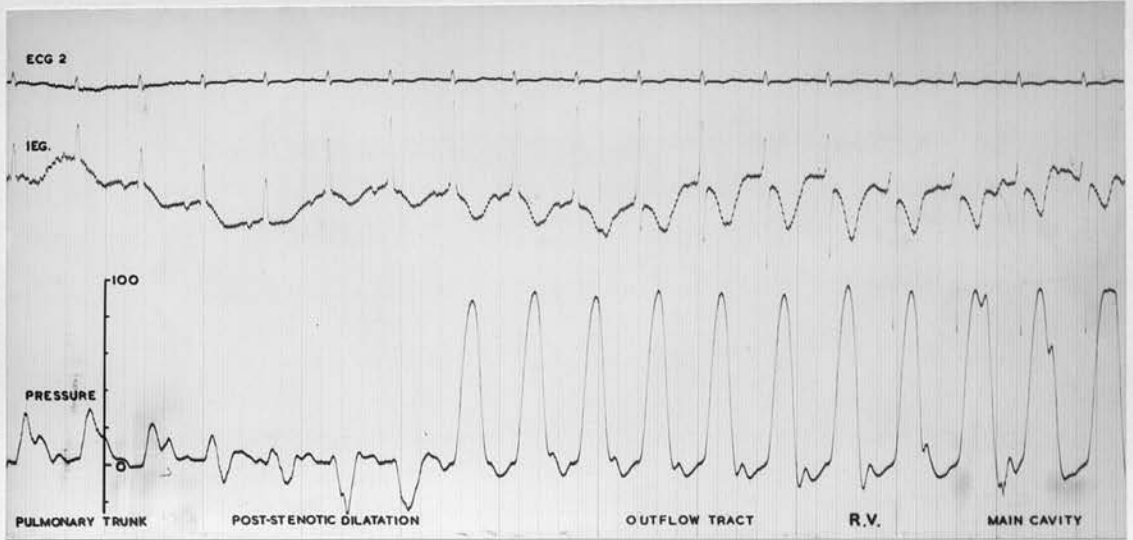


FIGURE 64

of the pressure flow relationships would be somewhat complicated. Nevertheless the fact that the lumen was narrowest when the rate of blood flow was maximum made it clear that a pressure drop was to be expected there during systole. With this in mind, cardiac catheterisation data in cases of pulmonary stenosis was re-appraised, and a fall in pressure was found during systole in the outflow tract.

Though the pulmonary artery Venturi effect is now a well recognised phenomenon, few appear to have appreciated the significance of this infundibular effect which is illustrated in Figure 64. This is a recording made as an electrode catheter was withdrawn slowly from the pulmonary trunk, through a severely stenosed pulmonary valve and thence down a grossly hypertrophied outflow tract into the main right ventricular cavity. As the catheter tip approaches the pulmonary valve the amplitude of the positive pressure pulse waves gradually decreases and the Venturi effect appears, so that the last two complexes recorded in the pulmonary artery are negative systolic pressure pulse waves. It then slips back through the valve into the outflow tract and the large systolic pressure gradient confirms the presence of severe pulmonary valvular stenosis. In

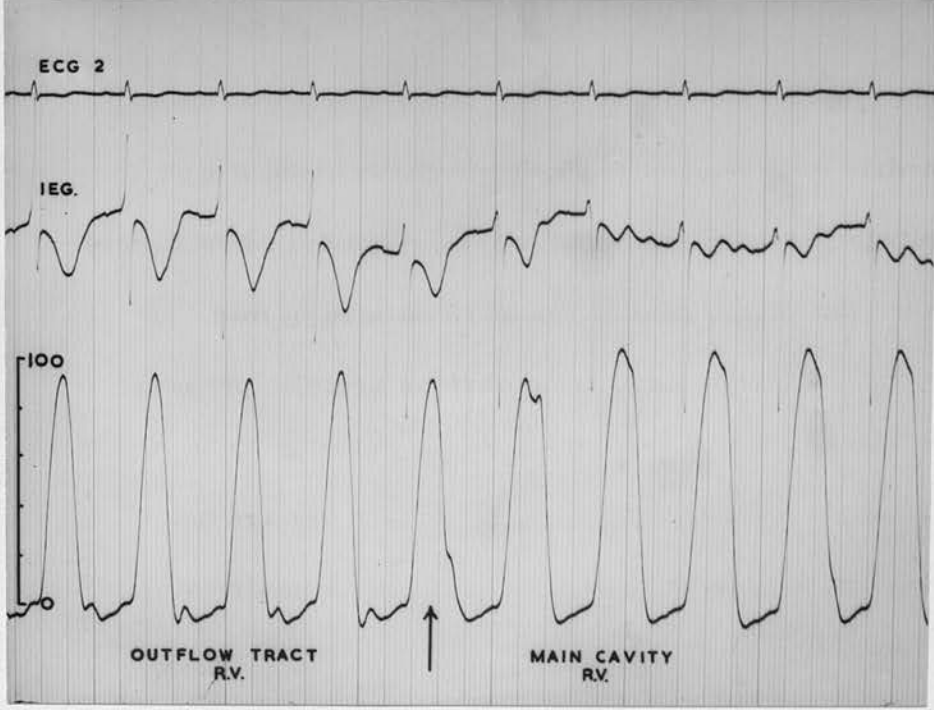


FIGURE 65

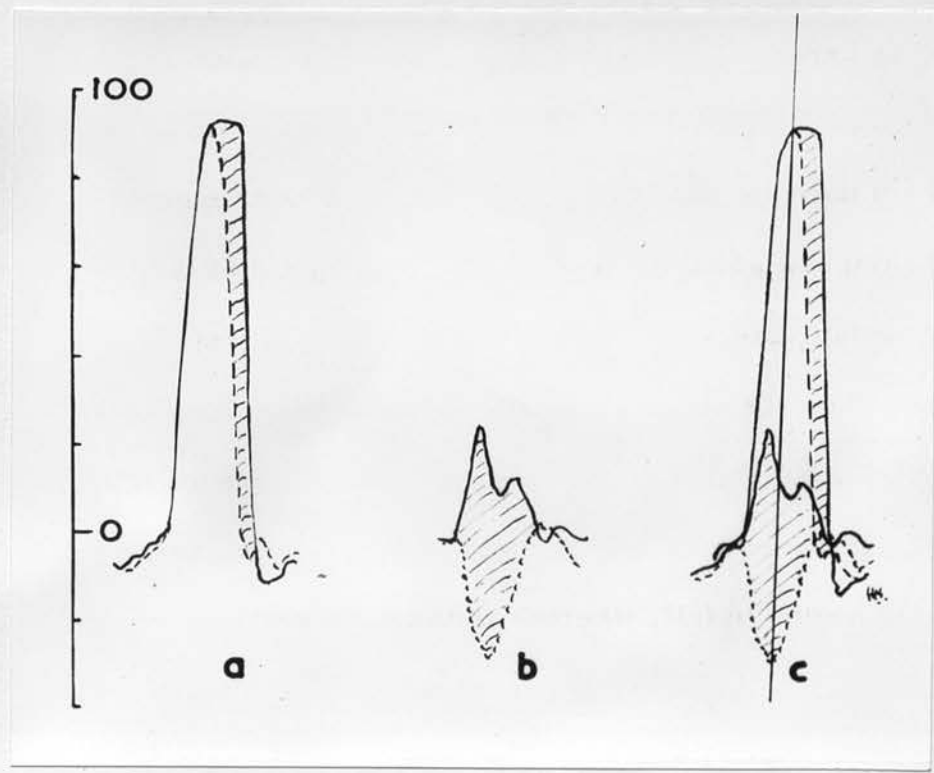


FIGURE 66

this case the course of the catheter through the infundibulum can be clearly seen on the tracing because the intracardiac electrogram changes gradually from a high voltage late intracardiac R wave, recorded immediately under the valve, to the typical rS pattern of mid cavity. Though there is no obvious systolic pressure gradient present, inspection of the pressure pulse waves shows that those in the outflow tract are not identical with those recorded in the main cavity of the right ventricle.

This is seen more clearly in Figure 65 which is an enlargement of the transition from infundibulum to main cavity, and where the transitional pulse is marked by an arrow. The two types of right ventricular pressure pulse can be seen clearly on either side of it. When they are superimposed, using the scalar electrocardiogram to ensure correct timing, Figure 66 (a), important differences between them are apparent. Both show the same initial rise in pressure during early systole, but then as blood begins to flow at high velocity through the ever narrowing outflow tract the pressure there begins to fall, whereas in the main ventricular chamber it remains high throughout systole to force blood past the obstruction. During the remainder of

systole the contraction of the hypertrophied infundibular muscles causes further reduction in the lumen of the outflow tract, thereby increasing the velocity of the blood flowing through it and consequently decreasing the pressure which falls away rapidly towards zero.

The behaviour of these two pressure pulses is as would be expected from consideration of the physical laws referred to above - narrowing of the bore of the outflow tract causes the blood to flow through it with increased velocity and at decreased pressure. The intraventricular pressure drop is represented by the shaded area in Figure 66 (a), and similarly the superimposed pulmonary arterial pressure pulses in Figure 66 (b) show the depressor effect which the high velocity jet of blood issuing from the stenosed valve has on the pressure at the valve and in the immediate post-stenotic region. All four pressure pulse waves have been superimposed in Figure 66 (c) to show their time relationship to each other more clearly.

The pressure flow relationships are therefore broadly speaking as could be predicted and this fall in systolic pressure in the infundibulum will usually be found when there are true records of both outflow tract and main cavity pulse waves. It may vary at different levels in

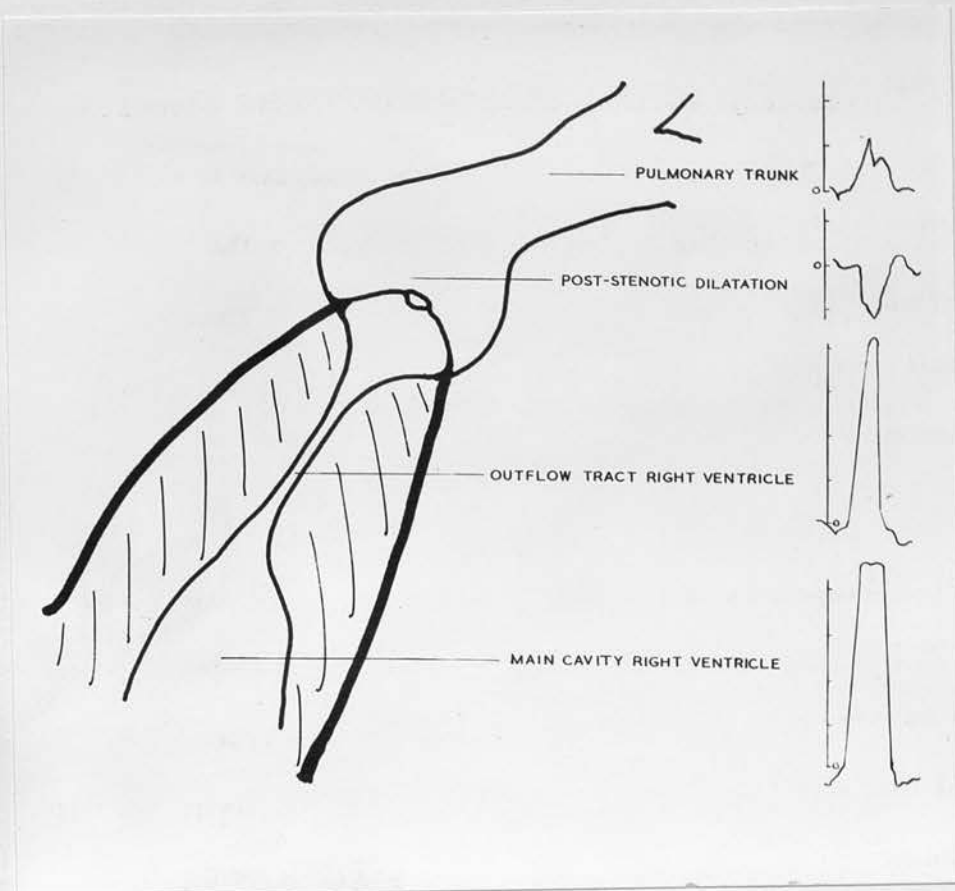


FIGURE 67

the infundibulum since its lumen may be conical or irregular in shape, but the sequence of pressure pulses will conform to the general patterns seen in Figure 67 which is a composite diagram showing the main right ventricle, outflow tract, post-stenotic dilatation and pulmonary trunk with their corresponding pressure pulse waves.

The nature of such drops in pressure as occur at sites of narrowing during systole depends on the Length/diameter ratio of the obstruction. Thus, where this ratio is small, as at stenosed pulmonary valve or a localised infundibular obstruction, the fall in pressure is a simple Venturi effect; where it is large, as in the hypertrophied infundibulum, the situation is more complex and depends mainly on viscous resistance to flow through a narrow bore tube. It will be appreciated from Figure 67 that when flow from the main ventricular cavity begins, there will be initially a small Venturi effect as the cross sectional area is suddenly reduced. Then, since  $\text{flow rate} = \text{cross section} \times \text{velocity}$ , the blood will flow at high velocity in the narrow bore outflow tract where, since the length/diameter ratio is high, the fall in pressure along it will be mostly a fluid resistance effect.

There seems little doubt that insufficient attention has been paid to the nature of the wave forms recorded during cardiac catheterisation, and that unusual patterns have all too often been branded as artefacts of one sort or another. Many abnormal pulses recorded in the infundibulum have, for example, been wrongly attributed to mechanical damping or to movement of the catheter tip backwards and forwards through the pulmonary valve in response to the heart's action. This latter seldom, if ever, happens in pulmonary stenosis and though one has indeed to be wary of artefacts when interpreting catheter data, they should not be troublesome if a good optical recording system is used and scrupulous attention is paid to technical details.

The interpretation of the nature of the systolic pressure drop seen at the pulmonary valve and in the outflow tract of the right ventricle has depended on the study of infundibular pressure pulse waves and the data for this analysis has been collected over a number of years. This better understanding of right ventricular haemodynamics in pulmonary valvular stenosis has therefore been acquired slowly and has been greatly assisted, not only by cine-angiocardiology, but also

by the routine use of electrode catheters. These not only locate the site of the tip but, by recording injury currents, indicate when it is in contact with or pressed against intracardiac tissues and therefore likely to record damped pulse waves or artefacts.

Rodbard and his colleagues describing a somewhat similar phenomenon in Fallot's Tetralogy in 1956 and 1957 stated that such right ventricular and infundibular pressure tracings are not uncommon in the literature and that their significance had not previously been commented upon. A similar effect had in fact been illustrated by Kjellberg et al. in 1954 and referred to briefly in a case of isolated infundibular stenosis as "the depressor effect of the pressure of velocity".

The only other published reference to the nature of these infundibular pressure pulse waves appears in a discussion on functional infundibular stenosis (Johnson, 1959) for though withdrawal tracings showing them have been published from this Department, they were not commented on at the time. (Emslie-Smith et al., 1956 - Figure 7, complexes 6 and 7; Watson et al., 1960 - Figure 1, complex 5).

The realisation that muscular hypertrophy is responsible for the infundibular stenosis so often seen in severe pulmonary valvular stenosis has gone a long way to rationalise surgical treatment, and even the vexed question of whether or not to resect it after successful valvotomy appears to be resolving. As Brock in his recent review of the subject has said "nothing continues as simple as it at first appears to be, and this has proved to be so with valvotomy for pulmonary stenosis." These words could well be echoed in relation to its diagnosis, for the absence of some sort of pressure gradient between the right ventricle and its outflow tract in such cases has long been a puzzle. A study of the physical laws concerned has shown that complex pressure flow relationships are involved which result in a fall in pressure during systole both at the valve and in the outflow tract, and suggest that a more careful analysis of the haemodynamics in other lesions may increase our understanding of their effects upon the heart and circulation.

## SUMMARY AND CONCLUSIONS

Despite continued technical progress the high mortality from congenital heart disease in the first year of life remains a challenge, and though diagnosis is often difficult in very small children it is clear that our methods must be modified and adapted to select not only those for whom treatment is already possible but also those for whom it soon may be. The investigation of such cases is, often a matter of urgency, since many are ill or in heart failure and anything that shortens intracardiac procedures, makes them more informative or less hazardous is of obvious value.

With these points in mind the electrocardiograms recorded inside the heart in 500 consecutive cases have been analysed with a view to assessing their value in infancy and the neo-natal period. It has been found that the nature of the complexes in the various cavities quickly confirms the location of the catheter tip during sampling, probing and pressure recording, helps determine the course of withdrawal tracings and the siting of injections, The characteristic changes that occur in the electrogram as the catheter tip moves about inside the heart assists many difficult manoeuvres and when studied in conjunction

with pressure pulse records helps to avoid misinterpretations caused by artefacts. It is concluded that intracardiac electrography has an important part to play in the investigation of congenital heart disease in children of this age group and that the routine use of electrode catheters makes cardiac catheterisation in babies and very small children safer, quicker and much more informative.

Many complex lesions are seen in this age group and good angio-cardiographic facilities are often required to reach a firm diagnosis. A method of selective cine-angiocardiology has been developed using image intensification and cine-photography whereby it is possible to switch from screening a catheter in the heart to photographing contrast media injected through it at any stage of the investigation. This has greatly increased the accuracy of diagnosis in young children and for the first time has visualised the actual intracardiac circulation in congenital heart disease. The relative merits of various methods have been discussed and the potentialities of high speed selective cine-angiocardiology have been illustrated in the text and demonstrated by a 16 mm. film which accompanies it.

These aids to diagnosis have also contributed

to other more fundamental studies, and this has been exemplified in the step-by-step analysis of isolated pulmonary valvular stenosis. Intracardiac electrography has been used to locate the site of stenosis and delimit the infundibulum, selective cine-angiocardiology to demonstrate the function of the right ventricular outflow tract and the information thus obtained has helped to solve what has always been the enigma of acquired infundibular stenosis - the presence of an obstruction to the outflow of blood in the absence of a demonstrable pressure gradient.

As future emphasis shifts towards the correction of malformations in ever younger children, accurate diagnosis has become progressively more important and these intracardiac aids have helped surmount many of the special technical problems associated with the investigation of congenital heart disease in very small patients.

## REFERENCES

ALLISON, P. R. and LINDEN, R. J. (1953) - The Bronchoscopic measurement of left auricular pressure.

Circulation, 7 : 699.

ALLISON, P. R. and LINDEN, R. J. (1955) - Bronchoscopic approach for measuring pressures in the left auricle, pulmonary artery and aorta. Lancet, 1 : 9.

ASTLEY, R. (1955) - Cine-radiography with an image amplifier: a practical technique. Brit. J. Radiol., 28 : 221.

ASTLEY, R. (1956) - Cine angiocardiology. Brit. J. Radiol., 29 : 556.

BAHNSON, H. T. and ZIEGLER, R. F. (1950) - Consideration of causes of death following operation for congenital heart disease of cyanotic type. Surg. Gynec. Obstet., 90 : 60.

BALDWIN, E. de F., MOORE, L. V. and NOBLE, R. P. (1946) - The demonstration of ventricular septal defect by means of right heart catheterisation. Amer. Heart J., 32 : 152.

BATTRO, A. and BIDOGLIA, H. (1947) - Endocardiac electrocardiogram obtained by heart catheterisation in man. Amer. Heart J., 33 : 604.

BERTRAND, C. A., ZOHMAN, L. R. and WILLIAMS, M. H. (1959) - Intracardiac Electrocardiography in Man. Amer. J. Med., 26 : 534.

BING, R. J., VANDAM, L. D. and GRAY, F. D., Jr. (1947) - Physiological studies in congenital heart disease - (I) Procedures (II) Results of preoperative studies in patients with tetralogy of Fallot. Bull. Johns Hopk. Hosp., 80 : 107 and 121.

BING, R. J., REBER, W., SPARKS, J. E., BALBONI, F. A., VITALE, A. G. and HANLON, M. (1954) - Congenital pulmonary stenosis. J. Amer. Med. Ass., 154 : 127.

BJÖRK, V. O., MALMSTRÖM, G. and OGGLA, L. G. (1953) - Left auricular pressure measurements in man. Ann. Surg., 138 : 718.

BJÖRK, V. O., BLAKEMORE, W. S. and MALMSTRÖM, G. (1954) - Left ventricular pressure measurements in man. Amer. Heart J., 48 : 197.

BLOUNT, S. B. , Jr. , Van ELK, J. , BLACHUM, O. J.  
and SWAN, H. (1957) - Valvular pulmonary stenosis  
with intact ventricular septum. Clinical and physiologic  
response to open valvuloplasty. Circulation, 15 : 814.

BOUCHARD, F. and CORNU, C. (1954) - Etude des  
courbes de pressions ventriculaire droit et arterielle  
pulmonaire dans les rétrécissements pulmonaires.  
Arch. mal. coeur, 47 : 417.

BRANNON, E. S. , WEENS, H. S. and WARREN, J. W.  
(1945) - Atrial septal defect. Study of haemodynamics  
by the technique of right heart catheterisation.  
Amer. J. Med. Sci. , 210 : 480.

BRAUNWALD, E. , TANENBAUM, H. L. and MORROW,  
A. G. (1957) - Dye-dilution curves from left heart and  
aorta for localization of left-to-right shunts and  
detection of valvular insufficiency. Proc.  
Soc. exp. Biol. (N. Y.). , 94 : 510.

BROCK, R. C. (1955) - Control mechanisms in the outflow  
tract of the right ventricle in health and disease.  
Guy's Hosp. Rep. , 104 : 356.

BROCK, R. , MILSTEIN, B. B. and ROSS, D. N.

(1956) - Percutaneous left ventricular puncture in the assessment of aortic stenosis. Thorax, 11 : 163.

BROCK, R. (1961) - Surgical treatment of pulmonary stenosis. Brit. Heart J. , 23 : 337.

BURCHELL, H. B. , PARKER, R. L. , DRY, T. J. ,

WOOD, E. H. , PENDER, J. W. , and PUGH, D. G.

(1948) - Cardiac Catheterisation in the diagnosis of various cardiac malformations and diseases.

Proc. Mayo Clin. , 23 : 481.

CAMPETI, F. , GRAMIAK, R. , WATSON, J. S. ,

RAMSEY, G. H. and WEINBERG, S. (1955) -

Visualisation of the coronary sinus in cine-angiocardiology. Circulation, 12 : 199.

CASTELLANOS, A. , PEREIRA, R. and GARCIA, A.

(1937) - La angio-cardiografia radio-opaca. Arch. Soc. estud. clin. Habana, 31 : 523.

CHAVEZ, I. , DORBECKER, N. and CELIS, A. (1947) -

Direct intracardiac angiocardiology: its diagnostic value. Amer. Heart J. , 33 : 560.

COELHO, E. , FONSECA, J.M. NUNES, A. , PADUA, F.  
and PEREIRA, J. S. (1951) - Les potentiels intra-  
cavitaires due coeur gauche de l'homme dans differentes  
cardiopathies. Arch. mal. coeur, 44 : 961.

COOKSON, B. A. , NEPTUNE, W. and BAILEY, C. P.  
(1952) - Intracardiac surgery with hypothermia, J.  
Int. Coll. Surg., 18 : 685.

COURNAND, A. and RANGES, H. A. (1941) - Catheter-  
ization of right auricle in man. Proc. Soc. exp. Biol.  
(N. Y.). , 46 : 452.

COURNAND, A. , MOTLEY, H. L. , HIMMELSTEIN, A. ,  
DRESDALE, D. and BALDWIN, J. (1947) - Recording  
of blood presauere from the left auricle and pulmonary  
veins in human subjects with interauricular septal  
defect. Amer. J. Physiol. , 150 : 267.

COURNAND, A. , BALDWIN, J. S. and HIMMELSTEIN, A.  
(1949) - Cardiac catheterisation in congenital heart  
disease: A Clinical and Physiological Study in Infants and  
Children. New York, Commonwealth Fund, 1949.

DEXTER, L., BURWELL, C.S., HAYNES, F.W. and SEIBEL, R.E. (1946) - Venous catheterisation for the diagnosis of congenital heart disease. Bull. New Eng. Med. Cent., 8 : 113.

DICKERSON, R.B. and CARIS, R.N. (1959) - Supplemental value of the intracavitary electrocardiograph in cardiac catheterisation. Circulation, 22 : 928.

DORBECKER, N., RODRÍGUEZ-ALVAREZ, A. and CELIS, A. (1947) - II Congreso de Cardiología SIBIC - Acapulco, Mexico.

DOTTER, C.T. (1959) - Personal communication.

DUCHOSAL, P.W., FERRERO, C., DOËT, J.P., ANDEREGGEN, P. and RILLIET, B. (1948) - Les potentiels intra-cardiaques recueillis par catheterisme chez l'homme. Cardiologia, 13 : 113.

EMSLIE-SMITH, D. (1955) - The intracardiac electrogram as an aid in cardiac catheterisation. Brit. Heart J., 17 : 219.

EMSLIE-SMITH, D., LOWE, K.G. and HILL, I.G.W. (1956) - The intracardiac electrogram as an aid in the localization of pulmonary stenosis. British Heart J. 18:29.

ENGLE, M. A. (1954) - Ventricular septal defect in infancy. *Pediatrics*, 14 : 16.

ENGLE, M. A. , HOLSWADE, G. R. , GOLDBERG, H. P. , LUKAS, D. S. and GLENN, F. (1958) - Regression after open valvotomy of infundibular stenosis accompanying severe valvular pulmonic stenosis. *Circulation*, 17 : 862.

EPPS, R. G. and ADLER, R. H. (1953) - Left atrial and pulmonary capillary venous pressures in mitral stenosis. *Brit. Heart J.* , 15 : 298.

FACQUET, J. , LEMOIN, J. M. ALHOMME, P. and LEFEBVRE, J. (1952) - La mesure de la pression auriculaire gauche per voie transbronchique. *Arch. mal. coeur*, 45 : 741.

FEDDEMA, J. (1955) - Some possible diagnostic applications of cine-radiography. *Brit. J. Radiol.* , 28 : 217.

FERRER, M. I. , HARVEY, R. M. WEINER, H. M. , CATHCART, R. T. and COURNAND, A. (1949) - Haemodynamic studies in two cases of Wolf-Parkinson-White syndrome with paroxysmal A-V nodal tachycardia. *Amer. J. Med.* , 6 : 725.

FISHER, D. (1955) - The use of pressure recording obtained at transthoracic left heart catheterisation in the diagnosis of valvular heart disease. J. thorac. Surg., 30 : 379.

FORSSMANN, W. (1929) - Die sonderrung des rechten Herzens. Klin. Wschr. 8 : 2085.

FORSSMANN, W. (1931) - Ueber Kontrastdarstellung der Hohlen des lebenden rechten Herzens und der Lungenschlagader. Munch. med. Wschr., 78 : 489.

FOX, S.M. (1959) - Pretracheal left heart catheterisation a difficult technic with some advantages. Circulation, 20 : 696.

FURMAN, R. A. , HELLERSTEIN, H. K. and STARTZMAN, K. V. (1951) - Electrocardiographic changes occurring during the course of replacement transfusion. J. Pediat., 38 : 45.

GIDLUND, A. (1956) - Development of apparatus and methods for roentgen studies in haemodynamics. Act. Radiol. Suppl., 130.

GIRAUD, G. , LATOUR, H. , LÉVY, A. et PUECH, P.  
(1951) - L'electrocardiographie endocavitare. Montpellier  
méd. , 94 : 487.

GOODALE, W. T. , LUBIN, M. , ECHENHOFF, J. E.  
and HAFKENSCHIEL, J.H. (1947) - Coronary sinus  
catheterisation technique for studying coronary blood  
flow and myocardial metabolism in vivo. Proc. Soc.  
exp. Biol. (N. Y.). , 66 : 571.

GOODALE, W. T. , LEVINE, H. D. , BING, R. J. and  
HACKEL, D. B. (1949) - Electrocardiographic control  
of coronary venous catheterization in dogs and man  
and simultaneous measurement of coronary blood flow,  
cardiac work and efficiency. Nat. Meet. Amer. Fed.  
Clin. Res. , Atlantic City.

GOODWIN, J. F. and HOLLMAN, A. (1960) - The Defini-  
tion and Management of Fallot's Tetralogy. Brit.  
Heart J. , 22 : 587.

GORLIN, R. and GORLIN, S. E. (1951) - Hydraulic  
formula for calculation of the area of stenotic mitral  
valve and other cardiac valves, and central circulatory  
shunts. Amer. Heart J. , 41 : 1.

GREENWOOD, F.G. (1956) - The clinical applications of image intensification. Brit. J. Radiol., 29 : 544.

GROEDEL, F.M. and BORCHARDT, P.R. (1948) - Direct electrocardiography of the human heart. Brooklyn Med. Press, New York.

HECHT, H.H. (1946) - Potential variations of the right auricular and right ventricular cavities in man. Amer. Heart J., 32 : 39.

HERBST, M. (1954) - Experimental investigations concerning the pressure in the right heart during rapid injection of fluids into the inferior vena cava. Arch. Kreisl. - Forsch, 21 : 323.

HERNANDEZ, F.A., ROCHKIND, R. and COOPER, H.R. (1958) - The intracavitary electrocardiogram in the diagnosis of Ebstein's anomaly. Amer. J. Cardiol. 1 : 181.

HILARIO, J., LIND, J. and WEGELIUS, C. (1954) - Rapid bi-plane Angiocardiography in the Tetralogy of Fallot. Brit. Heart J., 16 : 109.

HOLLMAN, A. (1960) - Personal communication.

HOWARTH, S., McMICHAEL, J. and SHARPEY-SHAFER, E.P. (1947) - Cardiac catheterisation in cases of patent interauricular septum, primary pulmonary hypertension, Fallot's tetralogy and pulmonary stenosis. Brit. Heart J., 9 : 292.

JEFFERSON, K., LEATHAM, A. and SLOMAN, G. (1959) - The diagnosis of small ventricular septal defects. Brit. Heart J., 21 : 580.

JOHNSON, A.M. (1959) - Functional infundibular stenosis: its differentiation from structural stenosis and its importance in atrial septal defect. Guy's Hosp. Rep., 108 : 373.

JOHNSON, A.M. (1959) - Hypertrophic infundibular stenosis complicating simple pulmonary valve stenosis. Brit. Heart J., 21 : 429.

JONSSON, B.J. (1957) - Influence of pressure loss of velocity on pulmonary arterial pressure recorded through a heart catheter. Scan. J. Clin. Lab. Invest., 9 : 249.

JÖNSSON, G., BRÖDÉN, B. and Karnell, J. (1949) - Selective angiocardiology. Acta. Radiol., 32 : 486.

JÖNSSON, G. and SALTZMAN, G.F. (1952) - Infundibulum of patent ductus arteriosus studied by thoracic aortography  
Acta Radiol., 37 : 445.

KEASTLE, C., RIEDER, H. and ROSENTHAL, J.  
(1909) - Ueber kinematographisch aufgenommene rontgenogramme der inneren organe des menschen.  
Munch. med. Wschr., 56 : 280.

KEITH, J.D. (1956) - Congestive heart failure.  
Pediatrics, 18 : 491.

KEITH, J.D. ROWE, R.D. and VLAD, P. (1958) -  
Heart disease in infancy and childhood. The  
Macmillan Co., New York.

KERT, M.J. and HOOBLER, S.W. (1949) - Observations on the potential variations of the cavities of the right side of the human heart. Amer. Heart J., 38 : 97.

KIRKLIN, J.W., CONNOLLY, D.E., ELLIS, F.H., Jr., BURCHELL, H.B., EDWARDS, J. E. and WOOD, E.H.  
(1953) - Problems in the diagnosis and surgical treatment of pulmonic stenosis with intact ventricular septum.  
Circulation, 8 : 849.

KJELLBERG, S.R., MANNHEIMER, E., RUDHE, U.  
and JONSSON, B. (1954) - Diagnosis of Congenital Heart  
Disease. The Year Book Publishers Inc., Chicago.

KOSSMANN, C.E., BERGER, A.R., BRUMLIK, J. and  
BRILLER, S.A. (1948) - An analysis of causes of right  
axis deviation based partly on endocardial potentials of  
the hypertrophied right ventricle. Amer. Heart J.,  
35 : 309.

KOSSMANN, C.E., BERGER, A.R., BRUMLIK, J.,  
BRILLER, S.A. and RADER, B. (1949) - Variability  
of endocardial potentials of the right ventricle. Amer.  
Heart J., 37 : 644.

KOSSMANN, C.E., BERGER, A.P., RADER, B.,  
BRUMLIK, J., BRILLER, S.A. and DONNELLY, J.H.  
(1950) - Intracardiac and intravascular potentials  
resulting from electrical activity of the normal human  
heart. Circulation, 2 : 10.

KOSSMANN, C.E. (1950) - Unipolar electrocardiography,  
including intracardiac leads in the diagnosis of myo-  
cardial disease. Bull. N.Y. Acad. Med., 26 : 20.

LATOUR, H. and PUECH, P. (1957) - Electrocardiographie Endo-cavitaire, Masson, Paris.

LEHMAN, J.S., MUSSER, B.G. and LYKENS, H.D. (1957) - Cardiac ventriculography. Amer. J. Roentgenol., 77 : 207.

LENÈGRE, J. and MAURICE, R. (1945) - La dérivation directe, intracavitaire des courants électriques de l'oreillette et du ventricule droits. Paris Méd., 35 : 23.

LENÈGRE, J. and MAURICE, P. (1945) - De quelques résultats obtenus par la dérivation directe intracavitaire des courants électriques de l'oreillette et du ventricule droits. Arch. mal. coeur., 38 : 298.

LEVINE, H.D., HELLEMS, H.K., WITTENBORG, M.H. and DEXTER, L. (1949) - Studies in intracardiac electrocardiography in man. I. The potential variations in the right atrium. Amer. Heart J., 37 : 46.

LEVINE, H.D., HELLEMS, H.K., DEXTER, L. and TUCKER, A.S. (1949) - Studies in intracardiac electrocardiography in man. II. The potential variations in the right ventricle. Amer. Heart J., 37 : 64.

LEVINE, H.D. and GOODALE, W.T. (1950) - Studies in intracardiac electrocardiography in man. IV. The potential variations in the coronary sinus. Circulation, 2 : 10.

LEWIS, F.J. and TAUFIC, M. (1953) - Closure of atrial septal defects with the aid of hypothermia: Experimental accomplishments and the report of one successful case. Surgery, 33 : 52.

LEWIS, T. (1910) - Galvanometric curves yielded by cardiac beats generated in various areas of the auricular muscle. The pacemaker of the heart. Heart, 2 : 23.

LEWIS, T., MEAKINS, J. and WHITE, P.D. (1914) - The excitatory process in the dog's heart. I. The auricles. Phil. Trans. B., 205 : 375.

LEWIS, T. and ROTHSCHILD, M. (1951) - The excitatory process in the dog's heart. II. The ventricles. Phil. Trans. B., 206 : 181.

LIMON, LANSON, R., RUBIO ALVAREZ, V. and  
BOUCHARD, F. (1950) - El cateterismo intracardiaco  
V. Cateterizacio de las cavidades izquierdo en el hombro.  
Arch. Inst. Cardiol. Mexico, 21 : 271.

LIND, J. and WEGELIUS, C. (1953) - Atrial septal  
defect in children; an angiocardigraphic study.  
Circulation, 7 : 819.

LIND, J., WEGELIUS, C. and LICHTENSTEIN, H.  
(1954) - The dynamics of the heart in complete A-V  
block. Circulation, 10 : 195.

LIND, J., WEGELIUS, C. and BOESEN, I. (1955) -  
Recent developments in Angiocardiology. Henry Ford  
Symposium on Cardiovascular Surgery, Detroit.

LIND, J., ROCHA, M. and WEGELIUS, C. (1957) - The  
value of fast angiocardiology in the early diagnosis of  
patent ductus arteriosus. Amer. J. Roentgenol., 57 :  
235.

LUISADA, A.A., RUBINO, A. and CANELLA, C.  
(1937) - The electrocardiogram of the right atrium and of  
the S-A node. Cardiologia, 1 : 28.

McGOON, D.C. and KIRKLIN, J.W. (1958) - Pulmonic stenosis with intact ventricular septum. *Circulation*, 17 : 180.

McMICHAEL, J. and SHARPEY-SCHAFFER, E. (1944) - Cardiac output in man by a direct Fick method. *Brit. Heart J.*, 6 : 33.

MAS, S., SLONINSKY, T. and MOLINS, M.E. (1952) - Electrocardiograma normal intraaortico y intraventricular izquierdo humano. *Medicina (B. Aires)*, 12 : 224.

MILLER, B.J. GIBBON, J.H., Jr., and GIBBON, M.H. (1951) - Recent advances in the development of a mechanical heart and lung apparatus. *Ann. Surg.*, 128 : 843.

MILLER, B.J., GIBBON, J.H., J.R., GRECO, V.F., SMITH, B.A., COHN, C.H. and ALLBRITTEN, F.F., (1953) - The production and repair of interatrial septal defects under direct vision with the assistance of an extracorporeal pump-oxygenator circuit. *J. thorac. Surg.*, 26 : 598.

MONIZ, E., de CARVALHO, L. and LIMA, A. (1931) - Angio-pneumographie. *Press méd.*, 39 : 996.

MORROW, A.G. (1955) - New Techniques in the diagnosis of interatrial septal defects. Proc. Symp. Cardiovasc. Surg.; Henry Ford Hosp., Philadelphia; Saunders.

MUNNELL, E.R. and LAM, C.R. (1951) - Cardiodynamic effects of mitral commissurotomy. Circulation, 4 : 321.

NIXON, P.G.F., HAY, G.A., HEPBURN, F., SNOW, H.M. and ADDYMAN, R. (1962) - An amperometric technique for recording ascorbate dilution curves and blood flow pulses. Brit. Heart J., (in press).

PEREZ ARA, A. (1931) - El sondaje de corazon derecho; su tecnica y aplicaciones. Rev. Med. Cir. Habana, 36 : 491.

PICKARD, C. and WATSON, H. (1957) - Proceedings of The British Cardiac Society, May 1957. Brit. Heart J., 19 : 585.

PONSDOMENECH, E.R. and NUNEZ, V.B. (1951) - Heart puncture in man for diodrast visualization of the ventricular chambers and great arteries. Amer. Heart J., 41 : 643.

RADNER, S. (1953) - Method of recording aortic pressure pulses. Scand. J. clin. Lab. Invest., 5 : 129.

RADNER, S. (1954) - Suprasternal puncture of the left atrium for flow studies. Acta med. Scand., 148 : 57.

RADNER, S. (1955) - Extended suprasternal puncture technique. Acta med. Scand., 151 : 22.

ROBB, G.P., and STEINBERG, I. (1938) - A practical method of visualisation of the chambers of the heart, the pulmonary circulation and the great vessels in man. J. clin. Invest., 17 : 507.

RODBARD, S. and SHAFFER, A.B. (1956) - Muscular contraction in the infundibular region as a mechanism of pulmonic stenosis in man. Amer. Heart J., 51 : 885.

RODBARD, S. and REKATE, A.C. (1957) - Direct evidence of supraventricular sphincter action as a mechanism of pulmonic stenosis. Exp. Med. Surg. 15 : 317.

RODRÍGUEZ-ALVAREZ, A. and de RODRÍGUEZ, G.M. (1957) - Studies in angiocardiology. Amer. Heart J., 53 : 841.

ROSS, J., Jr., (1959) - Catheterisation of the left heart through the interatrial septum: a new technique and its experimental evaluation. Surg. Forum, 9 : 297.

RUSHMER, R. F. (1961) - Cardiovascular Dynamics  
2nd Ed., W.B. Saunders Co., Philadelphia.

SCHLESINGER, P., BENCHIMOL, A.B. and COTRIM, M.R. (1948) - Electrocardiograma precordial atipico na hipertrofia ventricular direita. Arch. clin. (Rio de J.) 6 : 3.

SEALY, W.C., BROWN, I.W., and YOUNG, W.G. (1958)  
- A report on the use of both extracorporeal circulation and hypothermia for open heart surgery. Ann. Surg. 147 : 603.

SELDINGER, S.I. (1953) - Catheter replacement of the needle in percutaneous arteriography. Acta Radiol., 39 : 368.

SICARD, J.A. and FORESTIER, G. (1923) - Injections intravasculaires d'huile iodee sous controle radiologique C.R. Soc. Biol. (Paris), 88 : 1200.

SOBIN, S.S., CARSON, M.J., JOHNSON, J.L. and  
BAKER, C.R. (1954) - Pulmonary valvular stenosis  
with intact ventricular septum. Amer. Heart J., 48 : 416.

SODI-PALLARES, D., VIZCAINO, M., SOBERON, J.  
and CABRERA, E. (1947) - Comparative study of the  
intracavity potential in man and in dog. Amer. Heart  
J., 33 : 819.

SODI-PALLARES, D., THOMSEN, P. and SOBERON, J.  
(1948) - New contributions to the study of intracavity  
potentials in cases of right bundle branch block in the  
human heart. Amer. Heart J., 36 : 1.

SODI-PALLARES, D. (1956) - New basis of electrocardio-  
graphy. C.V. Mosby, St. Louis.

SONES, F.M., Jr., (1955) - Heart Catheterization in  
infancy. Physiological studies. Pediatrics, 16 : 544.

SOULIE', P. (1954) - Paper presented at International  
Congress of Cardiology, Washington, D.C.

STAUFFER, H.M., MORTON, J., OPPENHEIMER,  
M.J., STEWART, G.H., and BLACKSTONE, A.W.,  
(1955) - Practical image amplifier technics.  
Radiology, 65 : 784.

STEINBERG, M. F., GRISHMAN, A. and SUSSMAN, M. L.  
(1943) - Angiocardiography in congenital heart disease.  
II - Intracardiac shunts. Amer. J. Roentgenol., 50 :  
306.

STEINBERG, M. F., SELIGMANN, A., KROOP, I. G.  
and GRISHMAN, A. (1951) - Catheterization of the left  
ventricle in man. Study of right bundle branch block by  
simultaneous intracardiac electrocardiography of both  
ventricles. Circulation, 3 : 198.

STEINBERG, M. F., KROOP, I. G. and GRISHMAN, A.  
(1952) - Value of intracardiac and esophageal leads in  
analysis of complex arrhythmias. J. Mt. Sinai Hosp.,  
18 : 337.

SWAN, H., CLEVELAND, H. C., MUELLER, H. and  
BLOUND, S. W., Jr. (1954) - Pulmonic valvular  
stenosis; results and technique of open valvuloplasty.  
J. Thorac. Surg., 28 : 504.

SWAN, H. (1960) - In discussion of Gerbode et al. -  
"Surgical treatment of Pulmonary Stenosis using  
extra-corporeal circulation." Surgery, 48 : 58.

SWAN, H.J.C. and WOOD, E.H. (1953) -

Localisation of cardiac defects by dye-dilution curves recorded after injection of T 1824 at multiple sites in the heart and great vessels during cardiac catheterisation. Proc. Mayo Clin., 28 : 95.

TAUSSIG, Helen B. (1947) - Congenital Malformations of the Heart. Commonwealth Fund, New York, 1947.

TESTELLI, M.R. (1959) - Intracardiac electrocardiography. Observations during left heart catheterization in man. Amer. J. Cardiol., 3 : 495.

TEVES, M.C. (1955) - Image intensification. Brit. J. Radiol., 28 : 216.

WARDEN, H.E., COHEN, M., READ, R.C. and LILLEHEI, C.W. (1954) - Controlled cross circulation for open intracardiac surgery. J. Thorac. Surg., 28 : 331.

WATSON, H., PICKARD, C., LOWE, K.G. and HILL, I.G.W. (1958) - (a) - Selective Cine-angiocardiology with image intensification. Brit. Heart J., 20 : 459.

WATSON, H. , PICKARD, C. and HILL, I.G.W. (1958)

(b) - Le cine-angiocardigraphie selecteur utilisant  
l'intensification d'images dans les cardiopathies  
congenitales. III Congrès mondial de Cardiologie,  
Brussels.

WATSON, H. , PICKARD, C. , LOWE, K.G. and HILL,  
I.G.W. (1960) (a) - Cine-angiocardigraphic studies of  
the outflow tract in isolated pulmonary valvular stenosis.  
Brit. Heart J., 22 : 706.

WATSON, H. , PICKARD, C. , LOWE, K.G. and HILL,  
I.G.W. (1960) (b) - Acta Tertii Europaei de Cordis  
Scientia Conventus, Rome.

WATSON, H. (1962) - Intracardiac electrography in the  
investigation of congenital heart disease in infancy  
and the neonatal period. Brit. Heart J., 24 : 141.

WILSON, F.N. , HILL, I.G.W. and JOHNSON, F.D.  
(1934) - The interpretation of galvanometric curves  
obtained when one electrode is distant from the heart and  
the other near or in contact with the ventricular surfaces.  
II. Observations on the mammalian heart. Amer.  
Heart J., 10 : 163.

WOOD, P. (1952) - "Pulmonary hypertension".

Brit. med. Bull., 8 : 348.

WOOD, P. (1956) - Diseases of the Heart and Circulation

2 ed. p. 433, Eyre and Spottiswoode, London.

WOOD, P., BESTERMAN, E.M., TOWERS, M.K.

and McILROY, M.B. (1957) - The effect of

acetylcholine on pulmonary vascular resistance and

left atrial pressure in mitral stenosis. Brit. Heart

J., 19 : 279.

YAMAKAWA, K., SHIONOYA, Y., KITAMURA, K.,

NAGAI, T. and YAMAMOTO, T. (1954) - Intracardiac

phonocardiography. Amer. Heart J., 47 : 424.

YIM, B.J.B. and YU, P.N. (1958) - Value of an

electrode catheter in the diagnosis of Ebstein's disease.

Circulation, 17 : 543.

ZIEGLER, R.F. (1954) - Clinical cardiac catheterisation

in infants and children. Pediat. Clin. N. Amer., 1 : 93.

ZIMMERMAN, H.A., SCOTT, R.W. and BECKER, O.N.

(1950) - Catheterisation of the left side of the heart in

man. Circulation, 1 : 2.

ZIMMERMAN, H.A. and HELLERSTEIN, H.K. (1951)

- Cavity potentials of the human ventricles. *Circulation*,

3 : 95.

INDEX

INTRODUCTION	Page	1
SECTION I, Intracardiac electro- graphy in the investigation of con- genital heart disease in infancy and the neonatal period.	"	8
SECTION II, Selective cine- angiocardiology with image intensification.	"	74
SECTION III, Ventricular pressure flow relationships in isolated pul- monary valvular stenosis.	"	118
SUMMARY and CONCLUSIONS	"	138
REFERENCES	"	140