

HISTOLOGICAL CHANGES IN THE KIDNEY.

Produced By

THE ACTION OF DRUGS.

Thesis submitted for the Degree of

DOCTOR OF MEDICINE

in the University of Edinburgh

by

William Kinnear M. A. (St. And.) 1884.

M. B. C.M. (Edin.) 1888.

1901.



HISTOLOGICAL CHANGES IN THE KIDNEY

PRODUCED BY

THE ACTION OF DRUGS.

Introductory.

Apart from physiological investigations numerous re- searches both pathological and pharmacological have been made on the action of drugs on the kidneys. These organs, being the main excretory glands of the body, occupy a peculiar position with regard to the action of drugs. Every or nearly every substance ab- sorbed into the blood is excreted wholly or in part by them, consequently they are not unfrequently act- ed upon, and, if the substance be present in large amount, they may undergo considerable change.

Some particular drugs, especially of the irrit- ant class, have a marked influence, and in large doses cause congestion and inflammation; but others, whose predominant action is elsewhere, frequently affect the kidneys also. It is not difficult to understand why this is so. At the present day the tendency is to regard the action of drugs, broadly speaking, as a general one, and doubtless in the maj- ority of instances this is in the main correct; for once a drug is in solution in the blood it bathes all tissues alike, and the difference between the fund- amental living basis of different cells is not so great that the majority of drugs can demonstrate it.



obtained from the animal killed with strychnine
 In other words the selective action of most drugs
 Urethans.

simply means preponderating effect. When excessive

It is not always the cells of the convoluted
 doses of drugs are given their action becomes widely
 tubules that are mainly affected. The glomeruli in
 diffuse, they tend to become protoplasmic poisons and
 some cases are the parts that have undergone the most
 affect most of the tissues. The kidneys owing to
 marked change, while in chronic intoxications, as in
 their position are readily affected; but it must be
 plumbism, alcoholism, etc., the interstitial tissue is
 admitted that they possess a peculiarly resistant
 the most obviously affected. To a certain extent
 structure. The renal cells may however, if

the changes produced are dependent upon the dose and
 Albrechts'¹ investigations are correct, be modified

the length of time the kidney is acted upon.
 by comparatively simple means, for after the inject-
 Santaridin,² for instance, in large doses rapidly
 ion of strong saccharine solutions into the intestine
 produces a glomerulitis, while in small continued
 he found distinct changes in the renal cells on the
 doses it produces distinct interstitial changes.
 following day.

Other drugs -- e.g. Bichromate of Potassium³ -- pro-

PATHOLOGICAL CHANGES PRODUCED BY DRUGS IN THE KIDNEY.

ated tubules also produce interstitial changes when

Speaking generally the pathological change produced
 by poisons in the cells of the kidney is [^] necrosis;
 cloudy and fatty degeneration, hitherto believed to be
 common, are comparatively rare or late in appearing.
 The renal cells lose their contour, the protoplasmic-
 contents--especially around the nucleus--break up and
 disappear, the nucleus itself diminishes in staining
 power and becomes eccentric in position, and later
 the whole cellular contents decompose and disappear.

In my own investigations these changes are most
 obvious in the Digitalis specimens, and they are also
 to be seen in their very early stages in the specimen

in and its hydroxyl-derivative Naphthol

especially powerful in causing
 (The numbers refer to references at the end).

obtained from the animal killed with Ethylidene urethane derivatives found in some vegetable purgatives.⁴ Urethane.

The so-called blood poisons, too, seem to have some influence on the kidney but it is doubtful if this is tubules that are mainly affected. The glomeruli in independent of their purely irritant action.

some cases are the parts that have undergone the most

marked change, while in chronic intoxications, as in effects of the action of drugs on the kidney has been plumbism, alcoholism, &c., the interstitial tissue is possible. In the main this is probably due to the the most obviously affected. To a certain extent

absence of special investigations in this department the changes produced are dependent upon the dose and for although much work with single drugs has been the length of time the kidney is acted upon.

done by pharmacologists and pathologists the question Cantharidin,² for instance, in large doses rapidly of dose and other conditions in the separate invest- produces a glomerulitis, while in small continued -ations are too varied to serve for this purpose. doses it produces distinct interstitial changes.

One thing however is apparent and that is that sub- Other drugs -- e.g. Bichromate of Potassium³-- pro- stances closely allied chemically may produce very ducing primarily changes in the cells of the convol- different effects upon the kidney. Besides the in- uted tubules also produce interstitial changes when tammatory changes -- the glomerulitis, the necrotic given in small doses over a long period. Others changes in the cells, and the interstitial changes again -- e.g. Aloin⁴-- seem to act upon the three -- the kidney may undergo others, thus Phosphorus parts in a more uniform manner.

poisoning produces fatty degeneration of the renal The number of substances producing changes in cells, and as a result of Oxalate poisoning crystals the kidney is large. All the heavy metallic salts⁵ of Calcium Oxalate may be deposited in them. But in toxic doses produce kidney lesions, some of them perhaps the most interesting is the calcification re- of a more or less specific character and the large salting from the administration of certain salts -- class of irritants is especially active in causing mercury, Bismuth, and Chromium -- and also occurring, inflammation of this organ. Of these the volatile a solid, after Aloin and Glycerin. This subject oils and the allied resins are of most importance.⁵

has been of considerable interest and has been Many substances belonging to the simpler members of it has been investigated by Lockley and the aromatic group are also fairly active, -- Naphtha- independently. lin and its hydroxyl-derivative Naphthol seem to be especially powerful in causing acute nephritis when

administered for some time,⁶ as are also the anthracene derivatives found in some vegetable purgatives.⁶

The so-called blood poisons, too, seem to have some influence on the kidney but it is doubtful if this is independent of their purely irritant action.

Hitherto no classification of the pathological effects of the action of drugs on the kidney has been possible. In the main this is probably due to the absence of special investigations in this department for although much work with single drugs has been done by pharmacologists and pathologists the question of dose and other conditions in the separate investigations are too varied to serve for this purpose. One thing however is apparent and that is that substances closely allied chemically may produce very different effects upon the kidney. Besides the inflammatory changes -- the glomerulitis, the necrotic changes in the cells, and the interstitial changes it has also been found in man. Prevo¹⁴ in a fatal case of poisoning by Mercuric Nitrate in a man aged 73 found it in the straight tubules of the kidney and afterwards he obtained the same result experimentally in various animals. -- He lays great stress on the effect of Mercury on the bones in which the metal resulting from the administration of certain salts -- Mercury, Bismuth, and Chromium -- and also occurring, it is said, after Aloin and Glycerin. This subject has excited considerable interest and quite recently it has been re-investigated by Dockray and Karvonen independently.

It was thus thoroughly established that mercury produced a calcareous deposit in the kidney.

CALCIFICATION OF KIDNEY. -- HISTORY.

The subject was first noted by Pavy⁷ in 1861, and later was investigated by Saikowsky⁸ who found that after doses of Corrosive Sublimate an infiltration of the straight tubules with a deposit of calcareous salts took place. He also found that hypodermic injection of the poison gave the best results and that the longer the animal lived the greater was the calcareous deposit.

For many years afterwards the action of Mercury in this direction was almost alternately denied and confirmed. Rosenbach⁹ produced calcification in only about one-third of his experiments; Balogh,¹⁰ Lazarevic,¹¹ and Schlesinger¹² failed to produce it at all; Heilborn¹³ found it in the straight tubules, as also did Jablonowsky,¹⁴ and Doleris and Butte¹⁵. It has also been found in man. Prévost¹⁶ in a fatal case of poisoning by Mercuric Nitrate in a man aged 73 found it in the straight tubules of the kidney, and afterwards he obtained the same result experimentally in various animals. He lays great stress on the effect of Mercury on the bones in which the metal was nearly always found and in some investigations *with* Frutiger¹⁷ he says that the weight of the bones was notably diminished. He therefore concluded that the lime salts found in the kidneys were derived from the bones.

It was thus thoroughly established that Mercury produced a calcareous deposit in the kidney and it

finally resulted in necrosis of the cells, this was now became the object of investigations to determine accompanied by a calcareous deposit commencing in the cause and nature of the process. As early as 1880 Litten¹⁸ produced calcification of the kidney by spreading to the convoluted tubules. He held that ligature of the renal artery, which was removed after two hours. The sudden anaemia produced by the ligation of the Mercury upon them while they were excreting caused necrosis of the cells and then the removal of the ligature allowed blood and lymph to be freely supplied to those cells and thereby it was thought calcification was produced. He maintained that as long as the cells were alive no calcification could occur; he also affirmed that only in cells killed by anaemia could calcification take place. These experiments were confirmed by Grawitz and Israel,¹⁹ and by Von Werra.²⁰

Kaufmann²¹ in giving the results of his experiments accepted Litten's theory. He said that Mercury first produced a necrosis of the epithelium of the convoluted tubules which was due to an arterial anaemia caused by the formation of thrombi in the capillaries, and that after the cells were necrosed they retained the lime salts contained in the blood and lymph passing through them; he thus disagreed with Prévost's theory that the lime salts were derived from the bones and were altered as regards their lime-secreting power. He attributed the irregular manner in which the deposits occur to the supposition that they were in the areas supplied by the thrombosed capillaries.

Klemperer²² altogether disagreed with Kaufmann's anaemic necrosis theory. He found that Mercury quickly produced an inflammatory process which

finally resulted in necrosis of the cells, this was accompanied by a calcareous deposit commencing in but still living cells which remain attached to the casts filling up the straight tubules and gradually spreading to the convoluted tubules. He held that the necrosis of the cells was due to the direct action of the Mercury upon them while they were excreting it. Round the necrotic areas the epithelium was not detached from the basement membrane and either lies normal, as one would expect under the anaemic necrosis free in the lumina of the tubules or run together to form a second set of lime casts. thrombosis was never observed. Klemperer also dis-

agreed with Prevost's theory of the origin of the deposit of lime as he could find no marked increase of degenerative changes are due to the direct action of the mercury on the individual cells. Heidenhain²² has shown that the convoluted tubules are the active secretory portion of the kidney; the mercury is probably excreted by their cells, and hence is due, changed the constitution of the epithelium in such a way that it allows more lime to be diffused than before and subsequent calcification in the cells of these "pore".

Falckenberg²³ and Leutert also rejected Kaufmann's theory. Leutert²⁴ in a long and elaborate paper expressed his views as follows:-

- (I) That calcification is a pathological process which may occur in necrobiotic or necrosed cells or tissues, provided that they are supplied with a nutritive fluid of one kind or another which contains lime salts in solution;
- (II) The calcareous changes are due to an impregnation of lime salts and not to an increased discharge of lime from any other part of the body e.g. the bones. This process of calcification, or more correctly speaking, calcareous impregnation, consists of a precipitation of these salts, previously held in solution, by a physico-chemical change supervening in the cell protoplasm;

(III) Part of the lime is deposited in the altered but still living cells which remain attached to the basement membrane, part is secreted in the lumina of the tubules and is precipitated on the various organic casts there, being unable to escape.

(IV) If the living calcified cells die they become detached from the basement membrane and either lie free in the lumina of the tubules or run together to form a second set of lime casts.

Dockray²⁵ who made many experiments on rabbits and rats, is also strongly of opinion that the primary degenerative changes are due to the direct action of the mercury on the individual cells. Heidenhain²⁶ has shown that the convoluted tubules are the active secretory portion of the kidney; the mercury is probably excreted by their cells, and hence is due, Dockray thinks, the preponderating amount of necrosis and subsequent calcification in the cells of these tubules.

His general conclusions are:-

(I) That calcification is a pathological process which may occur in necrobiotic or necrosed cells or tissues, provided that they are supplied with a nutritive fluid of one kind or another which contains lime salts in solution;

(II) That this process of calcification, or, more correctly speaking, calcareous impregnation, consists of a precipitation of these salts, previously held in solution, by a physico-chemical change supervening in the cell protoplasm;

(III). That a chemical change has occurred is proved by the alkaline reaction of the cell, and this alkalinity is probably due to the diminution or absence of metabolism setting free an insufficient amount of Carbonic Acid; and ion of the kidney preceded by

(IV). That whilst this physico-chemical change will elucidate many points in connection with this process of calcification, yet it will not explain all the facts, and we must still admit that death involves the loss of many vital functions of which as yet we know nothing.

Karvonen's²⁷ experiments with mercury gave similar results; he found that there was first a necrosis of the cortical tubules, especially of the convoluted ones, with abundant formation of casts, and then calcification of the tubular epithelium and of these casts; interstitial nephritis was usually also present.

I have already stated that other substances besides Mercury have been shown to produce calcification of the kidney. Litten¹⁷ caused it by ligature of the renal artery. Kabierske³ found crystals in the kidney -- probably composed of salts of lime -- after the administration of Potassium Bichromate; this was also observed by Neuberger²⁸. Leu Gottschalk²⁹ found that aloes produced changes similar to those caused by mercury. -- first necrosis and then calcification of the convoluted tubules chiefly; this was again confirmed by Neuberger²⁸.

the cells have an alkaline reaction.

Cohn⁴ and Mürset⁴ also noticed epithelial necrosis after aloes but do not mention the presence of calcification.

Bismuth Subnitrate was observed by Langhans³⁰ to produce calcification of the kidney preceded by glomerular nephritis; Neuberger²⁸ has also observed this.

Affanassiew³¹ by injecting glycerin directly into the kidney of a rabbit succeeded in producing calcification. Robert³² after very chronic poisoning with Manganese lasting several months found calcification of the kidneys.

Charcot and Gombault³³ experimenting with lead, found in acute cases both in the convoluted and in the straight tubules a cloudy swelling of the protoplasm along with a proliferation of the nuclei, and in these altered cells calcareous matters were present. In chronic cases interstitial changes were far more marked. Prévost and Binet³⁴ repeated and corroborated these experiments.

Phosphorus was found by Ziegler and Oblonowsky³⁵ to produce fatty degeneration of the epithelium of the convoluted tubules, but they saw no calcification. This however has been observed after phosphorus poisoning by Paltauf³⁶, Neuberger²⁸, and Leutert²⁴ who again saw no fatty degeneration. And this coincides with what Dockray and other observers have pointed out, namely that fatty degeneration cannot co-exist with calcification because in the latter condition the cells have an alkaline reaction.

Calcification requires some time for development but although comparatively common it does not always follow that a substance which produces necrosis of the secretory cells will produce calcification also. In the only case of subacute poisoning (viz. digitalis) I have investigated, although there was necrosis of the cells no trace of calcification was to be seen.

ERRATIC DISTRIBUTION OF PATHOLOGICAL LESIONS.

A marked peculiarity of the action of drugs upon the kidney is the somewhat erratic distribution of the pathological areas in certain cases. This is mainly seen when the substance has been acting for a short time only. Certain areas of the kidney seem to be more affected than others and this has been attributed to differences in the blood supply -- some of the smaller arteries being more contracted than others and thus leading to a lessened supply of the poison to these parts. Whether this is the primal cause or not it appears to be due to a difference in functional activity of different parts of the kidney at one and the same time. The condition is well seen in the arrangement of the calcified parts of one of Dockray's specimens in the possession of Professor Marshall which I have examined. It is also noteworthy in one of my specimens, -- the kidney of a guinea-pig subjected to ~~chronic~~ poisoning with digitalis. (Fig. 1.). This is interesting in that the poisoning was what we might term chronic --

digitalis in large doses had been repeatedly given -- and not acute. Chronic poisoning in the great majority of cases gives rise to a more uniform appearance in the pathological changes. Professor Marshall, St. Andrews University. Nearly all of them were obtained from animals poisoned by large doses (acute) of drugs. After death the kidneys and other tissues were hardened in Müller's fluid or in alcohol, and were subsequently cut on a freezing microtome or after embedding in paraffin. As staining agents Hemalum and Eosin or Orange were used and in the Müller-hardened specimens Oxalic acid was also employed.

DIGITALIS.

The largest number of experiments were made on digitalis poisoned animals to some of which nitro-glycerin had also been given as an antidote. Although this ~~was~~ substance probably has an action on tissues apart from its special effect on blood vessels it did not seem likely that the doses given in these experiments, being very small and in all except a few cases given once only, would exert much influence in this direction, and this proved to be the case. The tissue changes found in the number examined showed a marked similarity whether nitro-glycerin had been given or not. Professor Marshall tells me however that in experiments where the urine was being collected immediately after the injection of the drugs - as

PERSONAL EXPERIMENTS.

The kidney specimens I have examined were kindly placed at my disposal by Professor Marshall, St. Andrews University. Nearly all of them were obtained from animals poisoned by large doses (acute) of drugs. After death the kidneys and other tissues were hardened in Müller's fluid or in alcohol, and were subsequently cut on a freezing microtome or after embedding in paraffin. As staining agents Haemalum and Eosin or Orange were used and in the Müller-hardened specimens Osmic acid was also employed.

DIGITALIS.

The largest number of experiments were made on digitalis poisoned animals to some of which nitro-glycerin had also been given as an antidote. Although this ~~the~~ substance probably has an action on tissues apart from its special effect on blood vessels it did not seem likely that the doses given in these experiments, being very small and in all except a few cases given once only, would exert much influence in this direction, and this proved to be the case. The tissue changes found in the number examined showed a marked similarity whether nitro-glycerin had been given or not. Professor Marshall tells me however that in experiments where the urine was being collected immediately after the injection of the drugs - as

when a cannula was introduced into the bladder -- blood tended to appear more abundantly when a vasodilator like nitro-glycerin was given with or before the digitalis than when the digitalis was given alone. Perhaps this may be explained by the fact that the dilated vessels allowed a greater quantity of digitalis to pass through the kidney and act as an irritant. But whatever the explanation may be, the real changes were undoubtedly due to digitalis poisoning and not to nitro-glycerin.

The preparation used in the experiments was French digitalin on account of its purity and because it is more soluble in weak alcohol than is digitoxin.

History.

I have been unable to find any literature bearing upon this subject. In 1897 Hare³⁷ and Coplin investigated the changes produced in the pig's heart by means of long continued administration of small doses of digitalis but this has no bearing upon my own research.

EXPERIMENTS.

Experiment I. Guinea-pig, 480g.

.4 c.c. 2% digitalin (.83g. per Kg. bodyweight) +
1 c.c. 1 in 500 nitroglycerin + 6 c.c. H₂O injected
into right side.

After 25' weakness noticed which gradually increased
After 45' respirations deeper with tonic convulsions.
After 62' the breathing having almost stopped, 1 c.c.

1 in 500 nitroglycerin was injected; breathing improved for $\frac{1}{2}$ ' being patchy. Some tubules were distinctly stained. Died in 64'. In the unstained tubules nuclei irregular; protoplasm granular. Halo around nucleus.

P. M.

Heart. Auricles and right ventricle dilated; left ventricle contained blood. distinct granulation of protoplasm. Other organs apparently normal. nuclei which are

Microscopic Examination of Kidneys.

Well marked patchy staining. In the unstained tubules no definite formation to be made out at all, nuclei in them slightly stained. Stained tubules

Experiment III. Guinea-pig. 462g.
 .4 c.c. 2% digitalin (.8g. per Kg body weight) + 4.6 c.c. H₂O injected.

less distinctly so than in subsequent specimens. After 14' weakness and tremors noticed, weakness gradually increased. Blood corpuscles not markedly shrivelled.

Experiment II. Guinea-pig, 560g. 14th uncountable pulse

.47 c.c. 2% digitalin (.8g per Kg body weight) + 1.53 c.c H₂O injected into left side. but an occasional

After 25' weakness noticed, gradually increasing.

After 30' inspirations fuller, passing into inspiratory dyspnoea after 60'.

Heart. Auricles and right ventricle dilated; left ventricle slightly dilated.
 Died after 82'.

P.M.

Heart. Auricles dilated; ventricles contained blood. Rest of animal apparently normal.

Microscopic Examination of Kidneys.

Staining patchy. Some tubules more distinctly stained than adjoining ones. Most of the nuclei irregular; protoplasm granular. Halo around nucleus in a few instances in the badly stained patches. In the well stained patches no distinct granulation of protoplasm is shown; no halo round nuclei which are somewhat irregular.

Degenerative changes of the cells not so marked as in subsequent specimens. . *See Fig. I. p. 37.*

Experiment III. Guinea-pig. 462g.

.4 c.c. 2% digitalin (.87g. per Kg body weight)+4.6 c.c. H₂O injected.

After 14' weakness and tremors noticed, weakness gradually increased.

After 30' heart beats irregular with uncountable pulse; respirations gasping.

After 34' respiration stopped, but an occasional heart beat.

After 36' heart stopped.

P. M.

Heart. Auricles and right ventricle dilated; left ventricle slightly dilated.

Other organs apparently normal.

Experiment V. Guinea-pig, 462g.

Microscopic Examination of Kidneys

2 c.c. 2% digitalin + 4.6 c.c. H₂O injected.

Some of the tubules totally denuded of their cells
After 45' considerable weakness noticed with somewhat
with nothing but basement membrane left.
laboured respiration.

Very marked cellular degeneration.

After 85' slight clonic convulsions.

Glomeruli markedly wrinkled but not contracted.

After 90' pulse very irregular, breathing irregular

Experiment IV. Guinea-pig, 462g.

and slow conjunctival reflex gone.

.4 c.c. 2% digitalin (.87g. per Kg. bodyweight) + 4.6

After 91' breathing stopped.

c.c. 1 in 1000 nitroglycerin injected.

After 93' Heart stopped.

After 14' weakness noticed.

P. M. Heart. All the chambers, especially the right

After 17' rigors with head on one side.

ventricle, dilated.

After 25' dyspnoea; 5 c.c. 1 in 1000 nitroglycerin

intestine. Half of small intestine pink and filled

injected; heart irregular, beating in periods of 5,

with slightly red gelatinous mass.

with 2 - 4 beats missed.

Other organs apparently normal.

Died after 30'.

Microscopic Examination of Kidneys.

P. M.

Heart. Auricles and right ventricle much dilated

left ventricle fairly so. pig. 461g.

Other organs apparently normal. 1 in 1000 nitroglycerin

Microscopic Examination of Kidneys.

A Marked degeneration of cells. Cells and nuclei

present a somewhat coagulated appearance. Tubules in

some places represented only by a network, while ad-

acent tubules are practically unaffected. Glomeruli

somewhat shrivelled. occasionally made a rush.

After A preparation, stained with Hoemalum only, shows

dilatation of capillaries in parts, with the blood

corpuscles wrinkled and contracted.

Pulse now beating in groups of 3 - 4.

After 106' pulse irregular, beating 8-10 times

then an interval; breathing led.

Experiment V. Guinea-pig. 452g.

.2 c.c. 2% digitalin + 4.8 c.c. H₂O. injected.

After 45' considerable weakness noticed with somewhat laboured respiration.

After 85' slight clonic convulsions.

After 90' pulse very irregular, breathing irregular and slow, conjunctival reflex gone.

After 91' breathing stopped.

After 93' Heart stopped.

P. M. Heart. All the chambers, especially the right ventricle, dilated.

Intestine. Half of small intestine pink and filled with slightly red gelatinous mass.

Other organs apparently normal.

Microscopic Examination of Kidneys.

See next case.

Experiment VI. Guinea-pig. 451g.

.2 c.c. 2% digitalin + 4.8 c.c. 1 in 1000 nitroglycerin injected.

After 45' slight weakness noticed which increased until after 60' the animal was quite collapsed and 5 c.c. 1 in 1000 nitroglycerin were injected.

After 65' it was better, though weaker than before the injection, and occasionally made a rush.

After 72' it fell off the table. It then got gradually weaker and after 95' lay flat on venter but still tried to walk.

Pulse now beating in groups of 3 - 4.

After 106' pulse irregular, beating 8-20 times and then an interval; breathing bad.

After 110' pulse very irregular and feeble; gasping breathing. 2 hours the animal began to get stronger. Died after 117'. quite well.

P. M. afterwards. .175 c.c. 2% digitalin + 4.825 c.c. 1 in 1000 atropine injected.
Heart dilated.

Intestine. First half of small intestine pinkish and filled with yellow gelatinous stuff. After 25' shivering and weakness noticed, the weakness increasing.

Other organs seemed normal.

After two hours heart irregular and some inspiratory Microscopic Examination of Kidneys.

In these last two cases the conditions were very much alike. After 24 hours heart began to beat more forcibly, though irregularly, and the strength to improve till Glomeruli wrinkled and contracted. Very marked degeneration of tubular cells, in parts nothing of

Next day. .175 c.c. 2% digitalin in 2 c.c. saline them remains but a coarse network. Nuclei shrivelled and embedded in the protoplasm remaining at the base of the cells; they present a somewhat coagulated appearance, chromatin being collected peripherally. Two days afterwards. .175 c.c. 2% digitalin + 1.50 c.c. saline solution injected.

Blood vessels dilated. Animal a little out of sorts but never really bad. Quite well after 3 hours. what coagulated appearance, chromatin being collected peripherally. Two days afterwards. .175 c.c. 2% digitalin + 1.50 c.c. saline solution injected.

Experiment VII. Guinea-pig. 546g. Next day the same amount of digitalin and saline solution was injected with the result that the animal This had practically no effect was merely a little weaker than it was the day before

Four days afterwards. .15 c.c. 2% digitalin + 4.85 c.c. H₂O injected. For the next 14 days the same dose was repeated daily each day with less effect. After 1 hour appreciable weakness noticed which gradually increased for another hour; the animal then got gradually stronger until 3 hours after the injection it was quite well again.

Then after a day's interval .15 c.c. 2% digitalin was injected. Next day. .175 c.c. 2% digitalin + 4.825 c.c. H₂O injected.

After 50' weakness noticed which gradually increased, but after 2 hours the animal began to get stronger again and became quite well.

Six days afterwards. .175 c.c. 2% digitalin + 4.825 c.c. 1 in 1000 nitroglycerin injected.

After 25' shivering and weakness noticed, the weakness increasing.

After two hours heart irregular and some inspiratory dyspnoea.

After 2½ hours heart began to beat more forcibly, though irregularly, and the strength to improve till after 5 hours the animal was pretty well.

Next. day. .175 c.c. 2% digitalin in 2 c.c. saline solution injected.

Weakness after 1 hour, but animal could move about.

Quite well after 3 hours.

Two days afterwards. .175 c.c. 2% digitalin + 1.5 c.c. saline solution injected.

Animal a little out of sorts but never really bad.

Next day the same amount of digitalin and saline solution was injected with the result that the animal was merely a little weaker than it was the day before.

For the next 40 days the same dose was repeated daily, each day with less effect.

Then for two days it got .18 c.c. 2% digitalin each day, and for another two days .19 c.c. each day with very little effect.

Then after a day's interval .2 c.c. 2% digitalin was injected.

Bladder Contracted.

Brain etc.

After 20' animal perceptibly weaker and cyanosed.

After 40' still weaker but could run about.

After 1 hour it could walk but was shivering and remained about the same all day.

Next day. .21 c.c. 2% digitalin + saline sol. to 2 c.c. were injected and the animal died in 12 hours.

This animal had digitalin injected 17 times during a period extending over 27 days.

P. M.

Weight now 460g.

Experiment VIII. Guinea-pig 505g.

Absence of fat in body cavities.

Heart. Right ventricle dilated; left ventricle midway between diastole and systole; dilatation of auricles doubtful.

Lungs. Congested in places.

Liver. Dark in colour; gall-bladder contained pale bile.

Spleen. Contracted and bloodless.

Stomach. Fairly distended with flatus and a pale

yellow shreddy material in a pale acid fluid; on

emptying and washing out there were long shreds of

mucous membrane. Punctiform haemorrhages on lesser

curvature. Large portion of greater curvature devoid of mucous membrane.

Intestines. Duodenum normal.

Jejunum. Upper portion congested.

Ileum and large intestine normal.

Kidneys. Pale. Left injected, small haemorrhage on surface. Right congested.

Bladder. Contracted.

Brain etc. Normal.

Microscopic Examination of Kidneys.

Glomeruli contracted. Vacuolisation of cells everywhere very well marked, the protoplasm being almost entirely gone. Nuclei small and somewhat irregular in contour. These changes in the cells more marked along the straight tubules. ? Blood pigment in lumen. Marked dilatation of larger vessels in some parts. A few apparent haemorrhages.

See Fig. II.

Experiment VIII. Guinea-pig 505g.

.1 c.c. 2% digitalin + 4.9 c.c. 1 in 1000 nitroglycerin injected. This produced no effect.

Four days afterwards .15 c.c. 2% digitalin + 4.85 c.c. 1 in 1000 nitroglycerin injected.

After 1 hour weakness observed, but after another hour the animal began to improve and after 3 hours was quite well.

Next day. .175 c.c. 2% digitalin + 4.825 c.c. 1 in 1000 nitroglycerin injected.

After 50' weakness observed which gradually increased

After 2°5' heart irregular; convulsions.

Died after 2°23'.

P. M.

Heart. Auricles dilated; ventricles moderately so, the left being the more contracted.

Mesenteric veins dilated.

Other organs apparently normal.

After 30' animal very ill

After 35' tetanic convulsions

Died after 40'.

Microscopic Examination of Kidneys.

Glomeruli present a slightly shrivelled appearance but no distinct contraction.

Nuclei generally slightly contracted and show a slight halo round them.

A few dilated vessels.

Experiment IX. Guinea-pig. 176g.

.63 c.c. 2% digitalin injected.

After 19' feeble tremors noticed.

After 41' strong action of bowels.

After 48' tetanic spasm of hind legs; pulse irregular.

Died after 67 minutes.

P. M. Haemorrhagic congestion at point of injection.

Heart. Left ventricle in systole.

Lungs. Pale.

Spleen. Very pale

Liver. Somewhat pale. Blood from liver showed irregularities in contour of red blood corpuscles, many being mulberry-like.

Stomach. Pale.

Kidneys. Rather pale if anything.

Microscopic Examination of Kidneys.

Some glomeruli contracted, some dilated.

Nuclei somewhat irregularly shaped.

Experiment X. Guinea-pig. 162g.

.56 c.c. 2% digitalin + .5c.c. 1% Caffein injected.

After 16' very feeble tremors with irregular pulse.

After 30' animal very ill and could not move.

After 35' tetanic twitchings of hind legs.

Died after 40'.

P. M.

Slight haemorrhage at point of injection.

Organs anaemic except liver and kidneys.

Blood corpuscles markedly crenate.

Microscopic Examination of Kidneys.

Glomeruli contracted in many places.

General mass of tubular epithelium not markedly altered.

No distinct lumen in most tubules and cell borders not well defined. Tendency to vacuolisation in cells, especially round nuclei which are mostly irregularly shaped. Nuclei and basement membrane distinct. A few tubules unstained and yellowish, fairly sharply marked off from surrounding tubules. Many vessels distended with blood; small haemorrhage in one part.

Microscopically there have been observed extensive cloudy swelling of the epithelium, the nucleus still retaining its staining power; necrosis of the epithelium, valvular infarction of the convoluted tubules; most part, of the glomerular tufts with peculiar shrivelling; degeneration, and in many cases disintegration, of the cells of the convoluted tubules, the protoplasm, especially round the nucleus, tending to break up and in some cases to disappear entirely, and the nuclei to lose their contour and become irregularly shaped. The cells of the straight tubules are not usually distinctly affected. The blood vessels apart from the glomerular tufts, are dilated in most parts of the kidney and occasionally slight haemorrhages are to be seen.

In one case (Experiment VII) curiously enough it was found that repeated dosage of nearly toxic amounts day by day did not lead to death; on the contrary by gradual increments the toxic dose was slightly exceeded before death occurred. In this case exactly similar changes were found in the Kidneys to those in the others and not to an appreciably greater extent.

Being distinctly abnormal.

Microscopic Examination SULPHONAL.

Similar capsules History.

It has been found that prolonged administration of this drug often causes albuminuria with tube casts, and after a few doses haemorrhages in the kidney have been noticed.

Microscopically there have been observed extensive cloudy swelling of the epithelium, the nucleus still retaining its staining power; necrosis of the epithelium; calcareous infarction of the convoluted tubules; yellow pigment flakes particularly in the straight tubules but also in the convoluted tubules, and white and disintegrating red corpuscles in them.

Haematoporphyria, so frequently obtained in man, does not usually occur in animals poisoned by Sulphon-al; Neubauer³⁸ however found it in rabbits after large doses, and Stokvis³⁹ also obtained it, but Kast and Weiss⁴⁰ did not.

and adjacent part of lower lobe.

Other distinct macroscopic change.

Experiment XI. Rabbit, 1460g.

4.3g. sulphonal (3g. per Kg. body weight) suspended in mucilage injected into stomach.

After 30' slight depression observed, quickly becoming more marked.

After three hours corneal reflex still present.

Died during the night.

P. M.

Nothing distinctly abnormal.

Microscopic Examination of Kidneys.

Glomerular capsules well filled.

Some vascular dilatation, but less than that observed after chloral.

Cells of convoluted tubules slightly swollen in parts, nuclei large and rounded.

urochloralic acid.

Experiment XIII. R. TETRONAL. 40g.

1g. chloral solution History. body weight injected

The effects produced by this drug have been found to be almost identical with those produced by sulphonal.

Experiment XII. Rabbit 1990g.

5.97g. tetronal (3g. per Kg. body weight) suspended in mucilage injected into stomach.

After 30' slight weakness and depression noticed, which gradually increased.

Died after 45 hours.

P. M. Haemorrhagic infiltration of upper lobe of left lung and adjacent part of lower lobe.

No other distinct macroscopic change.

Other organs apparently normal.

Microscopic Examination of Kidneys.

Cortex markedly congested. A few slightly
 Glomerular capsules well filled.
 Renal cells in some parts swollen, and in a few
 Capillaries markedly dilated all over; some appear to
 have burst into the interstitial tissue. Ed and well
 marked.

CHLORAL HYDRATE.History.

The kidney has been found to undergo the same degener-
 ative changes as the rest of the tissues after the
 continued administration of this drug. An explanat-
 ion of these has been sought for in the increased
 acidity of the urine, chloral being excreted as
 urochloralic acid.

Experiment XIII. Rabbit, 1260g. animal lay on
 lg. chloral solution per Kg. body weight injected
 into stomach. animal became weaker and died after
 After 9' signs of intoxication on movement.

After 16' asleep.

Heart markedly dilated.
 After 30' completely under the influence of the drug;
 Stomach. Severe inflammation with hemorrhagic in-
 conjunctival reflex gone.

After 18½ hours markedly comatose with an occasional
 Internal organs (liver, spleen, &c.) dark and congest-
 respiratory gasp (7-8 per minute).

Died after 20 hours.

Microscopic Examination of Kidneys.

P. M. not congestion practically all over.

Stomach somewhat congested, with 3 or 4 small
 Glomerular capsules very well filled.
 ecchymoses.

Renal cells swollen, hardly any lumen to be seen in
 Other organs apparently normal.
 some of them.

Microscopic Examination of Kidneys.

Glomerular capsules well filled, a few slightly contracted. No previous history found.

Dilatation of vessels in many parts, and in a few places small haemorrhages into the surrounding tissue. No definite cellular change; nuclei rounded and well marked.

After 30' asleep.

After 2 hours corneal reflex disappeared.

Died after 9 hours. BROMAL HYDRATE.

History.

I have found no previous record of the effect of this drug on the kidneys.

Experiment XIV. Rabbit 870g.

.44g. bromal hydrate (.5g per Kg bodyweight) given in water per os.

After 45' slight weakness noticed; animal lay on venter. Generally speaking rather swollen; examined

No distinct narcosis but grew weaker and died after 140'. Congestion, especially around the nuclei.

P. M.

Heart markedly dilated.

STOMACH. Severe inflammation with haemorrhagic infiltration. No previous history found.

Internal organs (liver, spleen, &c.) dark and congested.

Microscopic Examination of Kidneys.

Distinct congestion practically all over.

Glomerular capsules very well filled.

Renal cells swollen, hardly any lumen to be seen in some of them.

ETHYLIDENE URETHANE.

P. M.

No obvious changes. History.Microscopic No previous history found.Experiment XV. Rabbit 720g.

1.8g. ethylidene urethane (2.5g per Kg bodyweight)

suspended in mucilage injected into stomach.

After 15' weak and depressed.

After 30' asleep.

After 2 hours corneal reflex disappeared.

Died after 9 hours. History.

P. M.

Bladder has numerous small petechiae, and urine
contains blood corpuscles.

Other organs apparently normal.

Microscopic Examination of Kidneys.

Marked congestion.

Glomerular capsules full.

Cells generally speaking rather swollen; examined

with oil immersion they show a curiously vacuolated

appearance, especially around the nuclei.

After 4' pupils contracted, slight tremors which soon

ETHYL LACTATE.

After 12' dyspnea mostly inspiratory; pupils less

History.

No previous history found.

Experiment XVI. Rabbit, 570g.

2.3g (4g per Kg bodyweight) ethyl lactate in 15 c.c.

H₂O given per os.

After 1 hour weak and apparently sleepy.

After 1°20' fell on its side when it attempted to move.

Died after 2 hours.

P. M.

No obvious changes.

Microscopic Examination of Kidneys.

Slightly contracted glomerular tufts.

Capillaries dilated towards medulla and outlet of tubules.

Cells swollen.

PILOCARPINE.

History.

No changes in the kidney, as far as I am aware, have been described, notwithstanding the large amount of histological work done in connection with this drug.

Experiment XVII. Rat.

.02g pilocarpine (as NO_3) (3 c.c. .66% pilocarpine) solution injected into peritoneal cavity.

After 2' weakness and depression, with deeper respiration noticed.

After 3' distinct salivation, gradually increasing.

After 4' pupils contracted; slight tremors which soon became more marked.

After 12' dyspnoea mostly inspiratory; pupils less contracted.

After 32' salivation very marked, respirations deeper and slower; lay with chin on ground.

After 52' somewhat better.

After 67' salivation less; dyspnoea passing away.

After 92' no salivation; very much better.

After 142' almost normal. Killed.

P. M.

Submaxillary glands pale and enlarged.

Microscopic Examination of Kidneys. *pathol.*

Gesellsch. Nothing abnormal.

2. Brovian: Centralblatt f. die medic. Wissenschaften

1879 p. 143.

The substances investigated in these experiments are not linked by any chemical or therapeutical connection but have been taken as types of drugs in constant use. The experiments show that in doses just toxic most of the substances exert a distinct action on the kidney, thus supporting to some extent the view of a general action of poisons. *Jan 1880.*

Of the drugs investigated digitalis produces the most marked effects and these have been sufficiently described. From its composition we might expect ethylidene urethane to produce kidney lesions but it would have been difficult to conjecture the influence of the bromal hydrate except from its somewhat irritant effect. The negative result from pilocarpine is probably due to the fact that, notwithstanding the comparatively large dose, the effect was slight and transient and the animal was not killed until an hour after the symptoms had passed away.

It is perhaps necessary to add that microscopic examination of the kidneys of normal animals was made and that in all cases normal and pathological tissues were compared.

References.

1. Albrecht. Verhandl. d. deutsch. pathol. Gesellsch. 1900 II. s.462.
2. Brovicz: Centralblatt f.die medic. Wissenschaften 1879 p. 145.
- Aufrecht: Centralblatt f.die medic. Wissenschaften 1882 p. 849.
- Dunin: Virchow's Archiv. vol. 93 p. 316.
- Eliaschoff: Virchow's Archiv. vol. 94 p. 323.
- Steiger: Virchow's Archiv. vol. 104 p. 122.
3. Kabierske: "Die Chromniere" Inaugur. Dissert. Breslau 1880.
- Weigert: Virchow's Archiv. vol. 70 u. 72
- Posner: Virchow's Archiv. vol. 79
4. Cohn: "Ueber die Wirkung der Aloe" Berlin. Klin. Wochensch 1882 Nr. 5.
- Mürset: "Untersuchungen uber Intoxication-nephritis" Archiv. f. exp. Path. u. Pharm. , Vol.19 1885 p. 311.
5. Kunkel: "Handbuch der Toxicologie" erste haelfte. Jena. 1899 p. 67.
6. Cushny: Text Book of Pharmacology and Therapeutics 2nd. Edit. p. 397: p. 99.
7. Pavy: Guy's Hospital Reports, 1861.
8. Saikowsky: "Ueber einige Veränderungen welche das Quecksilber im thierischen Organismus hervorrufft". Virchow's Archiv. Vol. 37. 1866.

9. Rosenbach: Zeitschrift f. rat Med., 3 R XXX., 1868. X
10. Balogh: "A higanyhalvag hatásáról". Orvosi Hetilap. 51, 1875.
11. Lazarevic: "Experimentelle Beiträge zur Wirkung des Quecksilbers". Inaugur. Dissert., Berlin, 1879.
12. Schlesinger: "Experimentelle Untersuchungen über die Wirkung lange Zeit fortgegebener kleiner Dosen Quecksilbers auf Thiere". Archiv. f. exper. Path. u. Pharm. Vol. 13, 1881.
13. Heilborn: "Experimentelle Beiträge zur Wirkung subcutaner Sublimat-Injectionen". Archiv. f. exper. Path u. Pharm., Vol. 8, 1878.
14. Jablonowsky: "Ueber die Einwirkung des Quecksilbers auf den thierschen Organismus". Inaugur. Dissert., Berlin, 1885.
15. Doleris et Butte: "Recherches experimentales sur l'intoxication par le sublimé corrosif". Nouv. Archiv. Obstetr. et Gynéc., Paris 1886.
16. Prévost et Eternod: "Etude expérimentale relative à l'intoxication par le mercure". Revue médicale de la Suisse romande, 1882-83.
17. Prévost et Frutiger: "Etude expérimentale relative à l'intoxication par le mercure. Calcification des reins parallèle à la de calcification des os". Revue médicale de la Suisse romande. 1883.

- 18.Litten: "Untersuchungen über der haemorrhagischen Infarct. u. über die Einwirkung arterielle Anaemie auf das lebende Gewebe". Zeitsch. f. Klin. Med., Vol.I., 1880.
- 19.Grawitz und Israel: Virchow's Archiv., Vol. 123.
- 20.Von Werra: "Ueber die Folgen des vorübergehenden u. dauerenden Verschluss der Nierenarterie". Virchow's Archiv., Vol.88, 1882.
- 21.Kaufmann: (I). "Die Sublimat-intoxication; Beiträge zur Geschichte Klin. u. path. Anatomie derselben nebst experimentelle Untersuchungen zur Theorie ihres Wesens." Habilitationsschrift, Breslau, 1888.
- (II). "Neuer Beitrag zur Sublimat-intoxication nebst Bemerkungen über die Sublimat-niere". Virchow's Archiv., Vol.117, 1889.
- 22.Klemperer: "Ueber die Veränderung der Nieren bei Sublimat-vergiftung". Virchow's Archiv., Vol. 118 1889.
- 23.Falckenberg: (I) Inaugur. Dissert., Marburg, 1890.
- (II). Virchow's Archiv., Vol. 123, p. 567.
- 24.Leutert: "Ueber die Sublimatintoxication." Forschritte der Medicin., 1895.
- 25.Dockray: "Dissertation on Experimental Calcification". Victoria University, Manchester, 1898.
- 26.Heidenhain: Studien des Physiol.-Instit. zu Breslau 1861-1868.

27. Karvonen: "Ueber den Einfluss des Quecksilbers auf die Nieren". Berlin, 1898.
28. Neuberger: "Ueber Verkalkungen in den Nieren".
Archiv. f. exper. Path. u. Pharm., Vol. 27
1890.
29. Gottschalk: "Ueber die Einwirkung des Aloins auf den Körper speciell auf die Nieren". Dissert
Leipzig, 1882.
30. Langhans: "Path. anatom. Befunde bei mit Bismuthum subnitricum vergiftung Thieren".
Zeitsch. f. Chirurgie, Vol. 22, 1885.
31. Affanassiew: "Ueber die pathologische anatomischen Veränderungen der Nieren und der Leber bei einige mit Haemoglobinurie oder Icterus verbundenen Vergiftungen." Virchow's
Archiv., Vol, 98, 1884.
32. Kobert: Lehrbuch der Intoxicationen. Stuttgart
1893. p. 296.
33. Charcot et Gombault: "Note relative à l'étude anatomique de la néphrite Saturnine expérimentale". Archiv. de physiol. norm. et path., 1881, series 2, vol. 8, p. 126.
34. Prévost et Binet: "Recherches expér. sur l'intoxication Saturnine". Revue médicale de la Suisse romande, 1889.
35. Ziegler und Oblonowsky: "Experimentelle Untersuchungen über die Wirkung des Arseniks u. des Phosphors auf die Leber u. die Nieren."
Beitrag z. path. Anat. u. Physiol. von
Ziegler u. Nauwerk, Vol 2, heft 3, 1888.

36. Haltauf: "Ueber Phosphorvergiftung".

Wiener Klin. Wochensch. 1888.

37. Hare: Therapeutic Gazette, 1897, p. 800.

38. Neubauer: Archiv. f. exp. Pathol. u. Pharmacol.

Bd. XLIII. S 456.

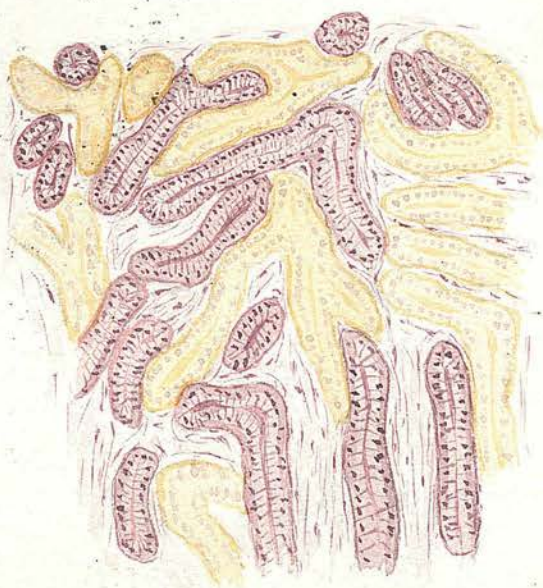39. Lewin: Lehrbuch der Toxikologie 2 Aufl. p 466.

40. Kast und Weiss: Berlin Klin, Wochensch. 1896 p.

621. (cf. also Vanderlinden et De Buck:

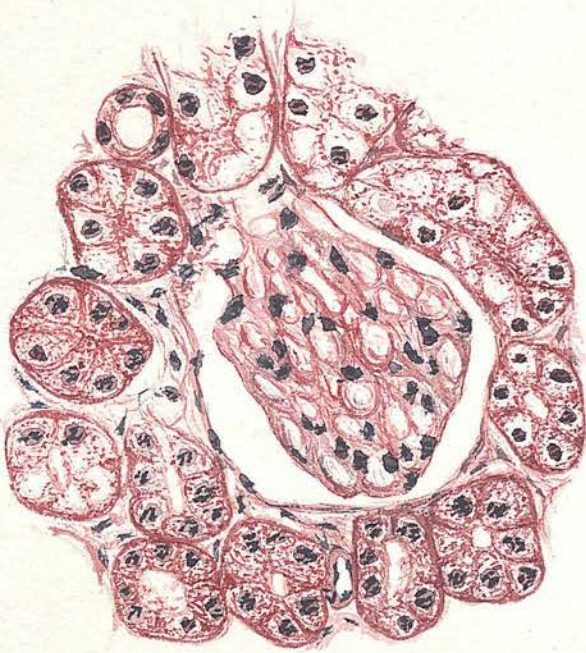
Arch. de Pharmacodyn: Vol. I p. 431.)

Fig. I.



Drawn with the Abbe camera from guinea-pig
(Experiment II.). Leitz objective $\frac{1}{4}$;
ocular III. (X 110)

Fig II.



Drawn with Abbe camera from guinea pig
(Experiment VII). Leitz objective $\frac{1}{6}$;
ocular III. ($\times 390$).