

TABLE OF CONTENTS

PREFACE

Part I. INTRODUCTION AND REVIEW

RADIOLOGY IN DECOMPRESSION SICKNESS

OBSERVATIONS ON COMPRESSED AIR WORKERS AT THE CLYDE TUNNEL

(a) Clinical Features .. .. .	17
(b) Management .. .. .	19
(c) Pathology .. .. .	20
<u>Radiotherapy</u>	
(a) Bone Abscess (Avascular Necrosis) .. .. .	21
(b) Fracture Healing .. .. .	25
(c) Miscellaneous Radiological Features .. .. .	32

Part II. OBSERVATIONS ON COMPRESSED AIR WORKERS AT THE CLYDE TUNNEL

JOHN K. DAVIDSON,

M.B., Ch.B., M.R.C.P. (Edin.), F.F.R.

The Clyde Tunnel Project .. .. .	37
Working Conditions .. .. .	39
Medical Aspects .. .. .	43

2. PHYSICAL SURVEY

Thesis submitted to the University of Edinburgh .. .. .

for the Degree of Doctor in Medicine .. .. .

1964

Illustrative .. .. .	49
Discussion .. .. .	74



3. AVASCULAR NECROSIS OF BONE

<u>Radiographic Survey</u>	
(a) Object .. .. .	86
(b) Method .. .. .	87

## TABLE OF CONTENTS

<u>PREFACE</u>	..	..	..	..	..	1
<u>Part 1.</u>	<u>INTRODUCTION AND REVIEW</u>					
Definitions	..	..	..	..	4	
Decompression Sickness						
(a) Historical Development	..	..	..	..	8	
(b) Aetiology	..	..	..	..	13	
(c) Clinical Features	..	..	..	..	17	
(d) Management	..	..	..	..	19	
(e) Incidence	..	..	..	..	20	
Radiology						
(a) Bones and Joints (Avascular Necrosis)	..	..	..	..	21	
(b) Pulmonary Features..	..	..	..	..	28	
(c) Miscellaneous Radiological Features	..	..	..	..	32	
<u>Part 11.</u>	<u>OBSERVATIONS AT THE CLYDE TUNNEL</u>					
1.	<u>INTRODUCTION</u>					
The Clyde Tunnel Project	..	..	..	..	37	
Working Conditions	..	..	..	..	39	
Medical Aspects	..	..	..	..	41	
2.	<u>PULMONARY FEATURES</u>					
Radiographic Survey						
(a) Object	..	..	..	..	44	
(b) Method	..	..	..	..	45	
(c) Result	..	..	..	..	47	
(d) Effect on Incidence of Decompression Sickness	..	..	..	..	48	
Illustrative Cases	..	..	..	..	49	
Discussion	..	..	..	..	56	
Conclusion	..	..	..	..	62	
3.	<u>AVASCULAR NECROSIS OF BONE</u>					
Radiographic Survey						
(a) Object	..	..	..	..	66	
(b) Method	..	..	..	..	67	

CONTENTS

(c) Classification of Radiographic Features .. ..	71
(d) Result .. ..	112
(e) Frequency of Lesions .. ..	112
(f) Site of Lesions .. ..	113
(g) Clinical Features .. ..	118
(h) Relation of Age to Bone Lesions .. ..	121
(i) Relation of Occupational History to Bone Lesions .. ..	122
Illustrative Cases .. ..	131
Discussion .. ..	158
Conclusion .. ..	205

ACKNOWLEDGEMENTS

REFERENCES

APPENDIX 1 - Review of published cases of avascular necrosis of bone in compressed air workers and divers.

PREFACE

It is the purpose of this thesis to record my observations, as a Diagnostic Radiologist, on a group of men who have worked in compressed air during the construction of the Clyde Tunnel.

The first part concerns the radiographic appearances that may be demonstrated in the lungs in acute cases of decompression sickness. The possible connection between decompression sickness and pulmonary disease is discussed and an attempt has been made to assess the value of a chest radiograph in men before exposure to compressed air.

The major part of the thesis deals with avascular necrosis of bone, which is a complication of decompression sickness, and the radiological features are discussed. The radiographic survey of selected bones and joints is of particular interest and helps to throw some light on the problem of avascular necrosis.

The radiological features of any condition form only part of the complete picture, and are fully appreciated when considered with the other features of the disease. Consequently, in introducing this thesis, due attention has been paid to the nature of decompression sickness and the use of compressed air in civil engineering. The accepted theory of bubble formation is described.

While much has been done to reduce the dangers to which these hard working men are exposed, very little is known of the late complication of bone necrosis; any evidence, if only confirmatory, may help to prevent the onset of this crippling condition.

In recent years there has been considerable interest in the surgical application of oxygen at hyperbaric pressures. Under these conditions, staff are exposed to an increased pressure of

air, often for long periods; these people require decompression and consequently are liable to develop decompression sickness. Some of the observations in this thesis are pertinent to those who work in these pressure chambers.

decompression sickness

The symptoms and signs, which occur in people who return to normal atmospheric pressure after working at high pressure or who are exposed to low pressure after having received normal atmospheric pressure, are collectively referred to as decompression sickness.

PART 1. INTRODUCTION AND REVIEW

The word "decompression sickness" is a term which may be called "the bends", caisson disease, compressed air illness, diver's paralysis, "air embolism", pulmonary barotrauma and cerebral edema. However, decompression sickness is not the accepted general term.

Some authors distinguish between decompression sickness and "air embolism", or pulmonary barotrauma (Dovey 1967, Milne 1962). The former condition results from bubbles arising in supersaturated tissues, while the latter is the result of lung damage from sudden expansion with associated breaks in the alveolar membrane. In the latter condition, air, absorbed in large quantities, may enter the interstitial tissues, the pleural cavity, or the pulmonary veins and so reach the systemic circulation.

In this thesis, the term decompression sickness includes what is known as "air embolism" and pulmonary barotrauma. The associated lung disease and decompression sickness will be discussed at a later stage.

In most circumstances, the primary symptom producing factor is believed to be the presence of gas bubbles in both the intravascular and extravascular tissues. Decompression will relieve the symptoms as the bubbles will pass back into solution.

Recently the Decompression Sickness Panel of the Medical Research

## DEFINITIONS

### Decompression Sickness:

The symptoms and signs, which develop in people who return to normal atmospheric pressure after working at high pressure or who are exposed to low pressure after having been at normal atmospheric pressure, are collectively referred to as decompression sickness.

The condition may arise in a variety of circumstances and may be called "the bends", caisson disease, compressed air illness, diver's paralysis, "air embolism", pulmonary barotrauma and aero-embolism of aviators. However, decompression sickness is now the accepted general term.

Some authors distinguish between decompression sickness and "air embolism", or pulmonary barotrauma (Dewey 1962, Miles 1962). The former condition results from bubbles arising in supersaturated tissues, while the latter is the result of lung damage from sudden expansion with associated breaks in the alveolar membranes. In the latter condition, air, sometimes in large quantities, may enter the interstitial tissues, the pleural cavity, or the pulmonary veins and so reach the systemic circulation.

In this thesis, the term decompression sickness includes such terms as "air embolism" and pulmonary barotrauma. The association of lung disease and decompression sickness will be discussed at a later stage.

In most circumstances, the common symptom producing factor is believed to be the presence of gas bubbles in both the intravascular and extravascular tissues. Recompression will relieve the symptoms as the bubbles will pass back into solution.

Recently the Decompression Sickness Panel of the Medical Research

Council (Campbell Golding et al 1960) have classified their cases into type 1 or "the bends", and type 2 or the more serious acute cases of decompression sickness.

Type 1 - "the bends" - this can be defined as pain, varying intermittently from a "nagging ache" to a very severe pain, usually described in or around a joint. In the majority of cases, the lower limbs only are affected. Occasionally the upper limb or both the upper and lower limbs are involved. The pain usually comes on three hours after decompression but the time of onset varies considerably. All cases respond to recompression. Sometimes there is a history of bruising, sprain or excessive use of the limb in the area where the pain arises.

Type 2 - the more serious cases - these cases are defined as patients who present with symptoms other than pain or with abnormal physical signs, such as: vertigo, "shock", (pale, clammy thready pulse, hypotension), visual disturbance, paralysis of limbs, dyspnoea, speech defect. The symptoms usually begin after decompression and often within the first hour. In general, these cases react favourably to recompression and more quickly than type 1 cases.

#### Avascular Necrosis of Bone

This can be defined as the necrosis of bone which follows the interruption of the blood supply to an affected area in patients who return to normal atmospheric pressure after working at high pressure or, less commonly, in those who are exposed to low pressure after having been at normal atmospheric pressure. The condition has been called caisson disease of bone, caisson hip, pressure induced osteoarthropathy,

barotraumatic osteoarthropathy, aseptic necrosis of caisson workers, barotraumatic arthrosis.

In this thesis, the term "avascular necrosis of bone" refers to those patients with bone necrosis and who have been exposed to either increased or reduced atmospheric pressure. If the necrosis results from some other cause, such as trauma, then this will be stated.

Avascular necrosis of bone is a complication of decompression sickness and is recognised by characteristic radiographic and clinical features in certain bones, which appear at a later date. These will be described subsequently.

#### Compressed Air Workers:

When a man is in a working chamber, either in a tunnel or a caisson, and the pressure of air within that chamber is higher than the normal atmospheric pressure, he is said to be in compressed air. If the pressure of air exceeds twice that of the normal atmosphere and the man is exposed to this increased pressure for three or four hours, then decompression sickness is liable to appear when the man returns to normal atmospheric pressure. The fact that the pressure of air must exceed twice that of the normal atmosphere, before symptoms occur, will be discussed at a later stage.

At sea level, the atmospheric pressure is 14.7 lbs. per square inch (p.s.i.), and if the pressure in the working chamber is raised by 20 lbs. p.s.i., then the ABSOLUTE pressure is 34.7 lbs. p.s.i. If the pressure in the chamber is raised by 14.7 lbs. p.s.i., or one atmosphere absolute, then the absolute pressure is 29.4 lbs. p.s.i. and this can be referred to as two atmospheres absolute.

In civil engineering practice, the absolute pressure is disregarded and reference is made to the GAUGE pressure. If the

pressure of air in the working chamber is raised by 20 lbs. p.s.i. - then the pressure is referred to as 20 lbs. per square inch gauge or 20 lbs. p.s.i.g. or just 20 lbs. p.s.i.

It is important to avoid confusion between the ABSOLUTE and GAUGE pressures. In this thesis, the suffix p.s.i. will refer to gauge pressures, and the term absolute will be used to indicate an absolute pressure.

#### Divers and Underwater Swimmers

The risk of decompression sickness occurs among service and commercial divers, underwater swimmers and in men learning to escape from submarines. For every 33ft. ( $3\frac{1}{2}$  fathoms), in depth of water, the pressure increases by one atmosphere or 14.7 lbs. p.s.i. Thus the diver, as he descends, is exposed to an increasing pressure of air and is subsequently decompressed when he ascends. Symptoms of decompression sickness are liable to appear following decompression from a depth exceeding 33 ft. when the pressure exceeds twice the normal atmosphere. Too rapid decompression, as in an emergency escape from a submarine, sometimes called an "explosive decompression", may result in a severe form of decompression sickness. It is in this group that pulmonary changes are common.

#### Aviators

Decompression sickness among aviators results from men being exposed to low pressure. The condition may arise when flying at great heights, on being exposed to low pressure in an altitude decompression chamber, and has been described in experiments with a two-man space cabin (Morgan 1962). The clinical features in these circumstances are similar to the decompression sickness following exposures to high pressures; however, permanent sequelae are rare. One question, which has never been clarified, is that of the absolute

minimum height at which decompression sickness may occur. One clear cut case has been described at 18,500 ft. following an exposure for nine hours, but the majority of cases occur at altitudes of 25,000 to 30,000 ft. A height of 20,000 ft. is equivalent to 0.50 atmospheres absolute (Miles 1962) and if a height of 20,000 ft. is exceeded, then the equivalent pressure would be less than half the normal atmospheric pressure. Symptoms of decompression sickness would be liable to appear at these heights as the pressure difference is greater than two to one. A guiding principle which has been taught to air crews with excellent results is that "the occurrence of any abnormal sensation at an altitude in excess of 18,000 ft. in the absence of readily demonstrable anoxia should be regarded as decompression sickness and treated by immediate descent" (Fryer 1962).

#### DECOMPRESSION SICKNESS

##### (a) Historical Development

The first account of bubble formation was that given by Sir Robert Boyle in 1670 in the proceedings of the Philosophical Society. (Fig. 1) While experimenting with his newly invented evacuation pump, he found among other things that a bubble had formed in the eye of a snake which had been placed in the vacuum. Boyle also suggested that the 'premortal agony' of an animal could result from bubble formation. In this way, he gives a modern interpretation of the condition which we now refer to as decompression sickness.

There are few, if any, references to decompression sickness in compressed air workers until 1839. In this year Triger was the first man to use compressed air for sinking a mine shaft and since then, the basic principle of civil engineering in waterbearing ground, whether in a tunnel or a caisson, has changed very little. In 1871

(2011)

Numb. 62

# PHILOSOPHICAL TRANSACTIONS.

August 8. 1670.

## NEW PNEUMATICAL EXPERIMENTS about RESPIRATION.

*These Experiments, made by that Indefatigable Benefactor to Philosophy, the Honourable Robert Boyle, in order to bring some more Light to the Doctrine of RESPIRATION, as well as to minister occasion to Inquisitive Naturalists to make farther Researches into the same, were by their Noble Author communicated to the Publisher of these Papers; who esteem'd it more convenient to make them a part of these Tracts (they taking up the room but of a few Sheets) than to publish them any other way.*

*Note, that the two foregoing Experiments were made with an Eye cast upon the inquiry, that I thought might be made; Whether, and how far the destructive operation of our Engin upon the included Animal, might be imputed to this, that upon the withdrawing of the Air, besides the removal of what the Airs presence contributes to life, the little Bubbles generated upon the absence of the Air in the Blood, juyces, and soft parts of the Body, may by their Vast number, and their conspiring distension, variously streighten in some places, and stretch in others, the Vessels, especially the smaller ones, that convey the Blood and Nourishment; and so by choaking up some passages, and vitiating the figure of others, disturb or hinder the due circulation of the Blood? Not to mention the pains that such distensions may cause in some Nerves, and membranous parts, which by irritating some of them into Convulsions may hasten the death of Animals, and destroy them sooner by occasion of that irritation, than they would be destroyed by the bare absence or loss of what the Air is necessary to supply them with. And to shew, how this production of Bubbles reaches even to very minute parts of the Body, I shall add on this occasion (hoping that I have not prevented my self on any other,) what may seem somewhat strange, what I once observed in a Viper, furiously tortured in our Exhausted Receiver, namely that it had manifestly a conspicuous Bubble moving to and fro in the waterish humour of one of its Eyes.*

Fig. 1. First account of bubble formation by Sir Robert Boyle in 1670.

the Hudson river tunnel was completed, the first tunnel to be built using compressed air. Today, work in compressed air in civil engineering is carried out extensively throughout the world.

In 1841, Triger reported to the Academy of Science in Paris that certain labourers were suffering from severe limb pains arising about half-an-hour after leaving compressed air. In 1854, Pol and Watelle published an account of sixteen cases of severe illness and two fatalities among compressed air workers at Lourches.

In these early days many explanations were given for decompression sickness, but, most of them such as carbon dioxide concentration, cold, foul air, oxygen poisoning etc. were soon discounted, largely by the fact that the symptoms developed following decompression.

There have been many publications on the various aspects of decompression sickness since these dates. Among the most significant and well known are those by Haldane (1908, 1922, 1935). Professor Haldane stated that significant bubble formation would not occur unless the tissue partial pressure of nitrogen is more than twice that of the surrounding atmosphere. The theory of stage decompression is based on this principle and rapid decompression to half the absolute pressure would enable the men to get rid of excess nitrogen through the lungs far more rapidly than if they were decompressed at an even rate. The danger lay in the last stages of decompression and still exists at this point.

A very complete review of decompression sickness is given by Behnke (1945) and this gives incontrovertible evidence of bubble formation. Behnke and his associates determined, among other things,

that the elimination of all excess nitrogen after complete saturation of all the tissues requires approximately twelve hours; and 75% is removed in the first two and a half hours.

In more recent years in this country, Paton and Walder (1954) reported, from the Tyne Tunnel, a marked decline in the incidence of decompression sickness with the number of shifts worked and stated that men appear to develop acclimatization to the condition. In 1957, Hempleman, while working in the Royal Naval Physiological laboratory, confirmed the assumption by Haldane and his colleagues that the pressure ratio is the governing factor in satisfactory decompression procedures. In 1960 the Decompression Sickness Panel of the Medical Research Council published an excellent report from the Dartford Tunnel. They divided their cases into Type 1 - "the bends", and Type 2 - "the more serious cases" and mentioned the variation in susceptibility to decompression sickness. They also indicated that it is not possible to identify these men prior to working in compressed air.

#### Diving and Underwater Swimmers

It has been known for centuries that sponge and pearl divers are liable to certain types of illness and even "the bends". In 1869, Le Roy Mericourt and later, 1888, Catsaras recorded forty-eight cases with severe neurological disorders among sponge divers in Athens, when the annual death rate was as high as twelve.

More recently, Miles (1962), gives a comprehensive review of all the aspects of decompression sickness. He indicates that the incidence of this condition in naval divers and in men learning to escape from submarines is declining. In contrast, Dewey (1962) reports that decompression sickness is the most frequent serious

complication in underwater swimmers ('scuba' divers - self-contained underwater breathing apparatus). From all causes of accidental death among 'scuba' divers, decompression sickness ranks second after drowning. Ten years ago, civilian diving casualties comprised only 1 to 2% of the total number of cases treated by recompression in the U.S. Navy Decompression Chambers and these consisted primarily of commercial divers such as the abalone fishers in the Pacific area. To-day, approximately eight out of ten serious diving casualties are civilian and the majority are recreational 'scuba' divers.

#### Aviators

Observation in subatmospheric pressure was first carried out by Bert in 1874, who subjected himself to a pressure reduction equivalent to 29,000 ft., breathing oxygen, without ill effect. Other similar experiments were carried out by Von Schrötter in 1906 and Boycott and Haldane in 1908.

During the first World War, it was realised that decompression sickness might be encountered among fliers operating military aircraft. In 1917, Yandell Henderson, a physiologist and an authority on decompression sickness, pointed out that aviators would have to ascend rapidly to at least a height of 20,000 ft., when the atmospheric pressure would be almost half that of sea level, before symptoms would arise.

However there appears to have been extreme reluctance to accept the possibility of decompression sickness at altitude, even when limb pains were being reported by personnel in altitude decompression chambers carrying out research for the R.A.F. in 1935 (Fryer 1962). It took the occurrence of paraplegia at 35,000 ft. in the American

physiologist, Dr. Heim, in 1938, to convince the world that there was a risk of a condition similar to that affecting compressed air workers and divers (Boothby and Lovelace 1938).

(b) Aetiology

There are many theories on the aetiological factors involved in decompression sickness and these are documented by Fulton (1951).

The accepted theory

The accepted theory of the processes taking place during compression and decompression is as follows. At normal atmospheric pressure, there is an equilibrium between the gases in the lung alveoli, of which the air is composed, and those dissolved in the blood stream and tissues. As air is a mixture of gases, mainly nitrogen and oxygen, the amount of each gas dissolved in the blood stream or tissues will depend on the individual or "partial pressure" of that gas. In keeping with the laws of partial pressure, the amount of a given gas that will dissolve in a solution is determined by the percentage of that gas in the total mixture and the pressure of that mixture.

With an increase in the atmospheric pressure, the pressure of air within the lung alveoli is also increased and there will be a pressure gradient driving each gas across the alveolar membrane into the blood stream. After an interval, the exact time as yet undetermined, an equilibrium will be established between the undissolved gases in the lung alveoli and those dissolved in the blood stream and saturated tissues.

Of major importance is the fact that nitrogen is an inert gas and when the body tissues are saturated or in equilibrium with the surrounding atmosphere, the partial pressure values of nitrogen in

the alveolar air, venous and arterial blood and in the tissues are identical. Oxygen and carbon dioxide, on the other hand, are actively involved in metabolic processes and are of small consequence in bubble formation.

Another important fact is that, when the atmospheric pressure is increased, nitrogen does not dissolve in all the body tissues at the same rate or in the same amounts. Tissues rich in blood supply will reach equilibrium or become saturated much more quickly than those with a poor circulation. Nitrogen is known to be five times more soluble in fat than in water (Vernon 1907) and consequently tissues with a high lipid content, such as the spinal cord, bone marrow and fat deposits, will contain a greater amount of nitrogen before equilibrium or saturation is reached. Fatty tissues often have a poor circulation and although the amount of dissolved nitrogen is high, it takes longer to reach equilibrium.

When the pressure of air is decreased, as occurs when a compressed air worker is decompressed, then the pressure within the lung alveoli is reduced while the partial pressure of gas within the blood stream temporarily remains raised. Thus the pressure gradient across the alveolar membrane is reversed. Nitrogen then leaves the tissues for the blood, and crosses the alveolar membrane to the air. Provided the decompression is well controlled, that is sufficiently slow, then the blood and circulation will be able to remove the excess nitrogen from the tissues. The slowest tissues to give up their nitrogen will be those with a slow circulation or a high lipid content.

Behnke (1945) stated that the elimination of all excess nitrogen after complete saturation of all the tissues requires approximately

twelve hours, and that 75% of the nitrogen is eliminated in the first two and a half hours. He also stated that the following nine and a half hours are required to remove the remaining 25% nitrogen which is found in the fatty tissues. However, these statements are not based on sound experimental evidence. (Walder 1964)

Bubbles are liable to form if the pressure is reduced too quickly and a 'steep' pressure gradient is created which will drive the gas out of solution. Under these conditions, the rate of diffusion of nitrogen from the tissue via the blood and alveolar membrane to the air is too slow to cope with the volume of nitrogen evolved. Thus gas will come out of solution in the form of bubbles. Symptom producing bubbles will only develop if the tissue partial pressure of nitrogen is more than twice that of the surrounding atmosphere. Once this 2:1 pressure gradient has been exceeded, the number and size of symptom producing bubbles will be directly proportional to the margin and disparity between the two partial pressures.

The actual initiation of the bubble is not completely understood. Many theories have been discussed (Newton Harvey 1951). Some suggest that, as "the bends" often affect the most exercised part, carbon dioxide may form the initial microscopic bubble. Whatever the initial cause, the bubble must soon consist of carbon dioxide, nitrogen and water vapour in proportion to their partial pressures.

#### Possible Association with Pulmonary Disease

Recently the possible association between pulmonary disease and the more serious form of decompression sickness (type 2), has been discussed (Campbell Golding et al 1960, Walder 1963). It has been

known for some time (Behnke 1945) that, if an individual holds his breath while ascending rapidly to the surface in a submarine escape training tank, the intra-pulmonary pressure becomes higher than the surrounding hydrostatic pressure. This difference in pressure over-distends the lungs, the tissue is stretched and breaks will occur in the continuity of the alveolar membrane. Air may thus enter the blood stream, and there will be an interstitial emphysema and possibly an associated pneumothorax. Walder (1963) discusses the possibility that gas trapped in a pulmonary air cyst may burst into the pulmonary circulation during decompression. This could happen if a partial or complete obstruction of a bronchus or bronchiole occurred when the subject was in compressed air. In such circumstances, during decompression, a cyst could form and would expand as the surrounding pressure falls. Abnormal transfer of the trapped gas across the cyst wall could occur, or the cyst might rupture and the gas be discharged into the pulmonary circulation. In either case decompression sickness might be produced.

However, it is most probable that bubbles, both intra- and extra-vascular, caused by super saturation of tissues, or by some other means, are the cause of the signs and symptoms of decompression sickness.

Paton (1954) in a paper on the medical aspects of decompression sickness states "evidence that bubbles are the cause of bends is circumstantial but there is no other reasonable explanation and it accounts for the effectiveness of recompression". Behnke (1945) states "it is an indisputable fact that denitrogenisation (by inhalation of oxygen) prevents altitude decompression sickness".

Further evidence that nitrogen is the dangerous element in the bubble is given by Donald (1955). In a series of experiments on goats, which suffer decompression sickness under similar conditions to men, Donald demonstrated that, when eight goats breathed 65% oxygen at a pressure equivalent to 150 ft. of sea water for one hour and then were rapidly decompressed, six of them developed evidence of decompression sickness which cleared spontaneously in five minutes. This recovery would never occur if a significant amount of nitrogen had formed within the bubbles.

Attempts have been made at various times (Fulton 1951) to use helium and other gases to reduce the incidence of decompression sickness. However, practical application in civil engineering has not proved successful.

#### (c) Clinical Features

These are fully described in standard textbooks (Hunter 1963) and in various publications (Behnke 1945, Fulton 1951, and Campbell Golding et al 1960).

The commonest symptom is a dull throbbing pain frequently felt in the legs. Less commonly the arms and shoulders may be involved. The associated joint is held in a semiflexed position and, for this reason, these pains are often referred to as "the bends". The pains vary in intensity and can be very severe. Sometimes there is a history of excessive strain, swelling or bruising around the affected joint. Many suffer an indefinite but similar type of pain-"the niggles" - which is usually ignored.

An interesting sign is the occurrence of purplish patchy discolourisation of the skin. This disappears on local pressure and the area most commonly affected is the upper abdomen, but occasionally

it is seen spreading to the back and down the limbs. This mottling may be associated with skin irritation and is sometimes known as the "itch".

Symptoms and signs of a more serious import are dyspnoea associated with paroxysmal bursts of coughing and cyanosis - sometimes known as "the chokes". This may progress to peripheral circulatory failure with a fine thready pulse, hypotension and a pale clammy skin. Three cases with radiographic evidence of pulmonary changes are described in a subsequent section.

Neurological changes may be present. Vertigo is a common symptom. Loss of consciousness, visual upsets and speech defects may occur and these may be evidence of cerebral air embolism. If bubbles develop in the spinal cord during decompression then paralysis of a limb or limbs may occur; these features may be referred to as "the staggers". Paralysis only occurs when there has been a rapid decompression and the normal slow procedure has been ignored. The neurological symptoms are rare and appear to be more common in divers or underwater swimmers. However, they have been described in tunnel workers (Paton and Walder 1954) and in aviators (Boothby and Lovelace 1938).

Recently, the Decompression Sickness Panel of the Medical Research Council, in their investigation into decompression sickness during the construction of the Dartford Tunnel, found that of a total of six hundred and eighty-five cases of decompression sickness, type 1 cases - "the bends" - usually presented about three hours after decompression and that in 85% of these cases the lower limbs only were affected. They found a good response to recompression and record such predisposing factors as injury, fatigue, ischaemia, and

long exposures. On the other hand, the thirty-five type 2 cases, usually presented about fifty minutes after decompression. The most common symptom was vertigo occurring in sixteen cases, dyspnoea occurring in four cases and temporary paralysis of the limbs in five cases. In addition to these thirty-five cases, some men volunteered information about symptoms for which they had not requested treatment; ten men reported a brief attack of "shortness of breath" on the way home. Two cases are of interest, as the management proved difficult, and in both these cases lung cysts were demonstrated radiologically. The Panel suggested that they may be the cause of type 2 decompression sickness (Campbell Golding et al 1960).

(d) Management

If any of these symptoms arise, immediate recompression is carried out in a separate medical recompression chamber, the pressure being raised until the symptoms disappear, when the bubbles will be dissolved. The pressure is then lowered at a steady rate, unless symptoms recur, when the patient is immediately recompressed. If the symptoms are severe and in particular if paralysis is present, then rapid recompression must be carried out if the patient's life is to be saved and permanent paralysis avoided. The pulmonary lesions can present a therapeutic problem and the recommendations by the M.R.C. Decompression Sickness Panel are of significance. "In the first place, the cyst cavities, being organised structures, cannot be made to disappear by high pressure or by prolonged treatment as can a bubble. Secondly, it is usually supposed that bubble formation will not occur in the body until a large pressure change is experienced, but in the event of occlusion of a bronchus, small pressure changes

are likely to cause trouble. It is advisable that in any atypical or serious case of decompression sickness the possibility of a cyst or of occlusion of a bronchus be borne in mind and two general principles followed: extremely slow rates of therapeutic decompression should be used and, should symptoms recur, no attempt must be made to dissolve a bubble by recompressing the patient to high pressures, the pressure should be raised just sufficiently high to relieve the symptoms. When this has been achieved then slow decompression can be resumed." (Campbell Golding et al 1960.)

(e) Incidence

In assessing the incidence of this disease, one must consider the air pressures to which the men are exposed and the length of each exposure or working shift. The 'Work in Compressed Air Special Regulations' 1958 require that, for pressures over 18 lbs. p.s.i. or exceeding two atmospheres absolute, accurate records are maintained of each man's exposure to compressed air. The number and length of each exposure and the time taken to decompress each person is recorded. At the same time, records are maintained of the symptoms treated by recompression. From these figures, the "bends rate" is calculated and this is expressed as a percentage of all compressions over 18 lbs. p.s.i.

At the Clyde Tunnel, the "bends rate" was 0.31%, and there has been one fatal case of decompression sickness. This is a satisfactory record, particularly when the "bends rate" for other tunnels is considered.

When compressed air was first used in tunnel construction in New York in 1889, men were dying at the rate of 25% of the labour

force per annum (Haxton 1958). Fortunately this callous disregard of life did not continue and conditions have shown progressive improvement. During construction of a caisson (Lewis and Paton 1957) a "bends rate" of 4% was recorded. At the Tyne Tunnel, three cases of paraplegia occurred, and the "bends rate" was 0.87% (Paton and Walder 1954). At the Dartford Tunnel, the Decompression Sickness Panel of the Medical Research Council recorded a "bends rate" of 0.55% for pressures up to 28 lbs. p.s.i. and no fatalities or cases of permanent disability.

#### RADIOLOGY

In decompression sickness, one tends to think that the radiographic changes are found only in association with avascular necrosis of bone. However, in addition to bones, radiographic changes have been demonstrated in the lungs and in the periarticular soft tissues.

##### (a) Bones and Joints (Avascular Necrosis)

The first report of avascular necrosis of bone in a compressed air worker was that described in Australia by Twynam in 1888. He reported a case who suffered from pain and swelling above the right knee leading, two months later, to abscess formation and drainage. A drainage sinus persisted for two years and because of this, an amputation was performed through the lower third of the femur. The shaft of the bone was found to be necrotic, and it was suggested that the primary lesion had been necrosis of the shaft of the femur with secondary infection. However the necrotic bone could easily

have resulted from the infective process and not from the exposure to an increased pressure of air.

The first recorded cases of bone necrosis being demonstrated radiographically in compressed air workers were those by Bornstein and Plate (1911-12) and Bassoe (1913). These authors independently described cases of chronic joint disease as a late complication of decompression sickness due to avascular necrosis of bone. The former reported the radiographic appearances of lesions affecting the shoulder and knee joints in three tunnel workers.

The pathology of this condition was first described by Kahlstrom, Burton and Phemister (1939) who reviewed the previous cases and added four of their own. Their description and correlation of the pathological and radiographic features is fascinating and of a very high quality. Other good pathological descriptions are given by Swain (1942) Catalano (1954) DeSèze et al (1951). As these lesions are usually an incidental finding at autopsy, one rarely has the opportunity of studying the exact pathological change.

Over the years there are many reports of bone necrosis amongst compressed air workers either individually or as small collections of three to six cases. In the British literature such reports include those by Walker (1940), McCallum et al (1954), Thomson and Young (1958), and Bucky (1959). In the American literature one finds similar reports by Coley and Moore (1940), Rendich and Harrington (1940), Kahlstrom (1942), and Poppel and Robinson (1956); in the Continental literature - from France, Wertheimer and Mansuy (1939), Alameroy (1945), Charles et al (1948), Bourret et al (1948), Fischgold et al (1948), Raymond (1948), Lazard et al (1949),

Bétoulières, P. and Boulouys, J. (1952), Guitard (1953), Ravault et al (1953), Roche and Rayneau (1953), Baillargé and Merer (1953), Chaumont and Blittersdorf (1953), Bureau et al (1955), Tara (1956), Champeux et al (1958), Fournier and Julien (1959), Tara and Françon (1959), Raymond (1960), Nicolet et al (1961); - from Italy, Ugolotti (1940), Balestra and Molfino (1949), Angei and Cossu (1954), Garavaglia (1958), Mauro (1958), Mauro and Saggese (1959), Francia and Quaglia (1959) and Molfino (1961); - from Germany, Plate (1928), Christ (1934), Franck (1935), Seifert (1936), Prezzolini (1936), Franck and Knoflach (1938), Rettig (1951), Leiss (1956), Schröder (1956), Fründ (1956), Déak and Rózsahégyi (1956). Other publications include those by Horvath (1958) and Kaczurba (1962). The publication by Rózsahégyi (1956) gives us a thorough and complete view of avascular necrosis of bone.

The classification of these publications, shown in Appendix 1, demonstrates that the lesions are usually localised to the proximal end of the humerus and to the proximal and distal ends of the femur, the lesions being situated either in the bone ends or in the shafts. There is a remarkable similarity in the radiographic features. The lesions are frequently bilateral and there is always delay before symptoms occur. Symptoms are only present if the articular surface of the joint is involved. The lesions usually follow work at pressures above two atmospheres absolute pressure. Some of the cases with radiographic evidence of bone necrosis had experienced acute episodes of decompression sickness while others had not. Baillargé and Merer (1953) and Jaffres et al (1955) suggest that a joint doing the greatest work is the one which is most frequently involved. They indicate that changes are seen most frequently in the left hip

and the right shoulder joint.

Two publications from the French literature are of interest - that by Reboul et al (1955) demonstrates beautifully the value of macroradiography in showing the early lesions of bone necrosis, while Roche et al (1956) clearly demonstrates the value of tomography in the early stages. Similarly Suntych and Suntychova (1961) from Czechoslovakia stress the value of tomography. Jaffres et al (1955) give a good review of bone necrosis and compare the similarity with osteochondritis dissecans.

The medico-legal aspects of avascular necrosis of bone following work in compressed air are discussed in the French literature by Julien et al (1954), Mosinger and Julien (1961) and Gaultier et al (1962). These authors stress the difficulty in differentiating the long standing changes of bone necrosis in the head of the femur with secondary osteoarthritis following work in compressed air from osteoarthritis of other causes. They give their views on the differential diagnosis, and these will be discussed later in the light of the present findings.

Several papers demonstrate the similarity of the radiographic changes of bone necrosis following decompression sickness and that following other causes. Taylor (1944) reported a series of fifty patients, of whom thirty-nine were male and eleven were female. Eleven of the males gave a history of continued exposure to high atmospheric pressure. In one patient there was but a single exposure. Joint and shaft lesions were present in twelve individuals who had never worked in compressed air and in these no aetiological factor is apparent. Taylor also records a case who demonstrated no radiographic abnormality and this man had

experienced "the bends" and had worked in compressed air for eight years.

Kahlstrom, Burton and Plemister (1939) in their second paper described bone necrosis in people who had never been in compressed air. Bucky (1959) reported similar cases in his paper.

The possibility that a single exposure to compressed air may produce severe bone necrosis has been raised from time to time. Usually a compressed worker migrates from one contract to another and it is very difficult to obtain an accurate history of work in compressed air. Barbara and Isola (1939) describe bone necrosis developing in the head of the femur and in the heads of both humeri in a man of thirty-two, after one exposure to four atmospheres absolute pressure for four hours. Guillain and Grossiord (1943) record a case of bone necrosis after a single exposure of four hours. Taylor (1944) mentions that in one of his cases there was only one exposure to compressed air. James (1945) described three of the five survivors from the submarine H.M.S. Poseidon which sank in 1931 in 120 ft. of water. Twelve years later these three men were found to have avascular necrosis in the left humerus in one, in both femora in the second and medullary infarcts were present in the left hip and shoulder in the third. These cases are of particular interest as the changes followed a single exposure to compressed air of approximately four hours.

#### Incidence of Bone Necrosis

From the published literature, it is impossible to assess the incidence of avascular necrosis of bone among compressed air workers. For this reason, the survey carried out at the Clyde Tunnel and reported in this thesis is of particular interest. This is the first

occasion than an attempt has been made to relate the history of work in compressed air to the radiographic evidence of bone necrosis in a large group of workers. The review by Bell, Edson and Hornick (1942) appears to be one of the earliest radiographic surveys of compressed air workers. These authors carried out a radiographic examination of the hips, shoulders, knees, skull, one elbow, and a wrist and hand in a group of thirty-eight workers who were attending the medical division of a New York Labour Department. A total of 75% of the men showed evidence of bone necrosis and many of these had symptoms. It is interesting to note that, even in the presence of this high incidence of bone necrosis, the radiographs of the skull, elbow, and wrists and hands were normal. It is clear that there must have been some indirect selection of these men to explain the high incidence of necrosis. The bone lesions were confined to the heads and shafts of the femora and the heads of both humeri and were frequently bilateral. No attempt was made to relate the bone necrosis with exposure to compressed air or to acute episodes of decompression sickness.

Nicholas (1949) states that one in twenty compressed air workers showed radiographic evidence of bone necrosis. Cavigneau et al (1949) found that the radiographs of forty-eight out of one hundred and twenty-five caisson workers showed a deviation from normal and this would represent an incidence of 38.4%. Many of the positive cases show features which one would hesitate to define as evidence of bone necrosis. Mungo and Sessa (1958), in a review of forty-seven compressed air workers, examined the radiographs of the hip, shoulder and knee joints. Fourteen men were found to be abnormal, an incidence of 34.25%. The quality of radiographs reproduced in their

report was very good and inspection reveals that many of the positive cases closely resembled bone islands, and the changes are more indefinite than one would accept. At the Dartford Tunnel, the Decompression Sickness Panel of the M.R.C. (Campbell Golding et al 1960) found a 10% incidence of avascular necrosis amongst eighty-three men, all of whom had suffered from an attack of "the bends". Minor changes were found in three out of twenty men who had suffered "the niggles" and had been recompressed. The radiographic changes in many cases were early and minimal and it was pointed out that the extent to which bone changes occur in men without symptoms has scarcely been explored. Rozsahegyi and Freid (1963) in a study of fifty-four compressed air workers, who had been involved in the construction of the Budapest underground, found an unexpectedly high incidence of 22% of avascular necrosis of bone. All but two of these men were symptom-free. They found no connection between an acute episode of decompression sickness and the late bone changes apart from stating that "the greater the frequency of bends, then the more likely is bone necrosis".

Avascular necrosis amongst divers is described much less frequently. Ronald (1953) described a case in this country. Herget (1948) however found avascular necrosis in thirteen divers from a total of forty-seven who were examined. The lesions have the same features as those following work in compressed air and appear to be more common in the heads of the humeri. Further cases of bone necrosis occurring in divers are recorded by Grützmacher (1941), Sartor (1947), Dale (1952), Slørdahl (1953), Pirastu and Perra (1960).

Amongst aviators, avascular necrosis of bone is rarely recorded. Ratnoff (1943) could find no radiographic evidence of bone necrosis

in the hip joints of twenty-one men who had been exposed intermittently to simulated altitudes of 35,000 ft. or higher in low pressure chambers. The duration of exposure varied between a total of five and a hundred hours. The first exposure to low pressure varied between three months and two-and-a-half years before the radiographic examination. Coburn (1956) however found a 17.5% incidence of bone necrosis in forty low pressure chamber operators of the U.S. navy and the changes are reported to be similar to those found following exposure to compressed air. Coburn explains this high incidence by saying that "many of the men had much longer exposures to lower pressures than the other series that have been reported" (1963). Berry and Hekhuis (1960) in a radiographic survey of five hundred and seventy-nine low pressure chamber operators in the U.S. air force could find no evidence of bone necrosis in the shoulders, hips or knee joints. Approximately half of these men had experienced decompression sickness. The length of exposure and the time interval between the first exposure and radiographic examination is not stated.

(b) Pulmonary Features

Any of the following features have been demonstrated on a chest radiograph: a bulla or cyst, a pneumothorax, interstitial and mediastinal emphysema, distension of the proximal pulmonary vessels with other radiographic signs of left ventricular failure.

Campbell Golding et al (1960) were the first to describe abnormalities on a chest radiograph of men who had been exposed to compressed air. Two patients with type 2 decompression sickness at Dartford were shown to have lung cysts, but these may have been present prior to work in compressed air. One patient developed paralysis of

his bladder and both lower limbs, which was relieved by recompression. Subsequent decompression was slow and required prolonged equilibration, and it was nine and a half days before the patient returned to normal atmospheric pressure. The other patient lost consciousness immediately following decompression and subsequently developed a spastic paralysis of both arms and legs. Recovery was complete following recompression, the subsequent decompression was slow.

Nashimoto and Furushashi (1961) described a patient who developed a violent cough with chest pain and dyspnoea immediately following a normal decompression, after working for four hours at a pressure slightly over two atmospheres absolute. A chest radiograph demonstrated a pneumothorax and subsequent radiographs, following repeated aspiration of the pleural air space, demonstrated bullae in the left upper lobe. The exposure to compressed air, with possible air trapping on decompression, probably caused the rupture of a bulla and the pneumothorax.

In a series of experiments on guinea pigs, Walder (1963), by producing generalised bronchial obstruction, was able to demonstrate that "air trapping" with subsequent alveolar rupture led to wide spread intravascular air bubbles. He suggested that this might be a cause of type 2 decompression sickness.

Prior to this, there are many reports of "air embolism" in men learning to escape from submarines. These emboli result from the trapping of air in the lungs with subsequent bulla formation, rupture of the alveolar membrane, and interstitial and mediastinal emphysema.

Kinsey (1954) describes four cases of "air embolism", two of which were fatal. In all four cases, the symptoms developed at

once; one patient was found to have subcutaneous emphysema of his neck and supraclavicular fossa, his voice developed a noticeable nasal quality, and a radiograph of his chest showed mediastinal emphysema which subsequently cleared. The second patient developed loss of power and numbness of his left arm which disappeared on recompression. Subsequent radiographs of his chest also showed mediastinal emphysema. In the two fatal cases, autopsy revealed widespread air bubbles in the cerebral arteries, in the heart and elsewhere. In both cases, there was evidence of subpleural blebs, with mediastinal and subcutaneous emphysema. In neither case could rupture of the alveolar membrane be demonstrated, even on repeated sections of the lungs.

Liebow et al (1959) describe two patients in whom the trapping of air in the lungs was thought to be the cause of "air embolism" in men learning to escape from submarines. In one fatal case, autopsy revealed a bronchololith in the superior segmental bronchus of the left upper lobe, with air trapped beyond it. There was extensive interstitial and mediastinal emphysema. It was thought that air had entered the pulmonary arteries, veins and interstitial tissues. The other case developed loss of consciousness shortly after surfacing, with flaccid paralysis of the legs. The man was successfully treated by immediate recompression, however, like the case described by Campbell Golding et al (1960), the subsequent therapeutic decompression was prolonged and lasted thirty-seven hours twenty-seven minutes. Radiographic examination of the chest, following decompression, demonstrated a large pulmonary cyst in the left lower lobe which disappeared spontaneously.

Case and Haldane (1941) suggest the rupture of a cyst or bulla

in their patient with a pneumothorax following decompression. Collins (1962) describes in detail several episodes of type 2 decompression sickness, with symptoms suggesting cerebral air embolism, in a naval man gaining diving experience. These symptoms developed after two rapid ascents from a depth of 50 ft. of water. He was treated successfully by recompression. The patient's original chest radiograph was normal while a radiograph, taken one hour after decompression following the last incident, showed multiple cystic areas in the upper lobe of the left lung.

The incidence of decompression sickness among men learning to escape from submarines is very low, and Miles (1962) records that in the British Training Tank there had been twenty-five incidents of decompression sickness in fifty thousand ascents. Of these incidents, there were nineteen cases of cerebral air embolism, four cases with emphysema, including one with an associated pneumothorax, and two with no definite abnormality. All twenty-five cases responded to treatment and recovered completely.

Among aviators, the presence of abnormal air containing spaces within the thorax of an air crew member, is considered a significant occupational hazard. The principle of expansion of trapped gases within a body space during ascent to altitude are well known to aviation medical specialists, and the danger of rupture of these spaces is the principle reason for not allowing air crew members with such lesions to fly (Parker and Stonehill 1961). Such abnormal expansion of air spaces within the lungs has been recorded on three occasions (Holter and Horwitz 1945, Amdur 1956, Berry and King 1959).

The report by Yanda et al (1963) presents an interesting sidelight on the connection between pulmonary disease and exposure

to compressed air. While studying the clinical applications of hyperbaric conditions, ten male cases with emphysema were submitted to a pressure of two atmospheres absolute. Great care was taken to avoid any possibility of air trapping and liberal use was made of theophylline and pseudo-ephedrine, in conjunction with a very slow decompression procedure. There was no evidence of an abnormal increased hazard to these patients, and three were found to show improvement in both their residual volume and clinical condition for a period varying between two-and-a-half days and four weeks.

### (c) Miscellaneous Radiological Features

#### The Soft Tissues

These changes are usually described in aviators and people subjected to low pressures (Boothby, Lovelace and Benson 1940, Evelyn 1941, Webb et al 1944, Thomas and Williams 1944, Ivy 1944, Bromley and Harvey 1944, Henry 1956).

The lesions are of two types: 1) Discrete round gas bubbles in the periarticular tissues above the knee joint, usually seen just behind or lateral to the distal end of the femur in the popliteal fat, and 2) longitudinal streaking in the popliteal fossa which appears to be distributed along the tendon or muscle bundles. Stereoscopic studies reveal them to be wide, flat, ribbon-like shadows presumably of finely dispersed gas particles. The bands appear to lie in the fascial planes.

These lesions may be associated with "bends" pain in the knees but may be found in a painless knee. While Webb et al (1944) found a high association of radiographic change with "bends" pain, the studies of Thomas and Williams (1944) and Ivy (1944) did not

reveal the same high association. The changes can be demonstrated at an altitude of 35,000 ft. and all evidence of crepitus and radiographic lesions will disappear on recompression to ground level. However, upon immediate reascent, both the crepitus and radiographic lesions will reappear, indicating that free gas is compressed but not completely reabsorbed until some time after descent to the ground (Fulton 1951).

Similar changes in a compressed air worker are described by Gordon and Heacock (1940). However, there was an associated fracture involving the articular surface of the knee, and "a vacuum phenomenon" from forced traction may have accounted for the linear translucencies.

#### Sinuses

An investigation by McGibbon (1944) suggests that the cause of pain in sinus barotrauma is possibly a submucosal haemorrhage within the affected sinus. The haemorrhage results from engorgement of the mucosa on descent from altitude. Bromley and Harvey (1944), on the other hand, give an interesting report on the radiographic appearances of sinuses and other organs at simulated altitude. They found that the radiographic appearance of the sinus bore no relation to the presence or absence of pain.

#### Alimentary System

It is known, from studies on subjects at simulated altitude, and from wartime experience in transporting patients with abdominal wounds by air, that intestinal gas expands at altitude.

Bromley and Harvey (1944), in a series of radiographic experiments at simulated altitude, demonstrated that the colon showed the greatest distention and the passage of barium through both the

small and large bowel was delayed at altitude.

PART II. OBSERVATIONS OF THE LATER STAGES.

PART 11. OBSERVATIONS AT THE CLYDE TUNNEL

1. INTRODUCTION

THE CLYDE TUNNEL PROJECT

The twin tunnels, which together constitute the Clyde Tunnel, have been built at Whiteinch to relieve traffic congestion in the Clydeside conurbation and are situated five miles down river from the most westerly point at which it has been possible to cross the river by road. The river at this point is 400 ft. wide, and the total length of each tunnel, including the sloping approaches at each end, is approximately half a mile. Each tunnel lies about 21 ft. below the bed of the river, in strata which consists of sandstone and shale overlain by variable glacial and alluvial deposits (Figs. 2 and 3).

Since construction commenced, 1,362 men have been at risk, some having worked only for short periods while others, in addition to being employed on this contract, have had many years of experience in compressed air. Tunnel construction was completed in January 1963, when the second tunnel reached the opposite bank.

During the construction of these tunnels in water-bearing ground under the river Clyde, compressed air was required to prevent water seeping through the surrounding strata and so flood the workings. The pressure of air has varied slightly with the type of strata through which the tunnel was passing and almost directly with the 'head' of water above the workings; approximately 1 lb. p.s.i. for every 2 feet of water. During the period from April 1958 to August 1962, the pressure of air was over 18 lbs. p.s.i. but has not exceeded 34 lbs. p.s.i. or approximately  $3\frac{1}{2}$  atmospheres absolute.

In practice, a pressure of 50 lbs. p.s.i. is usually considered the maximum that should be used, and, in tunnelling, modern methods of ground preparation have assisted the civil engineers in avoiding

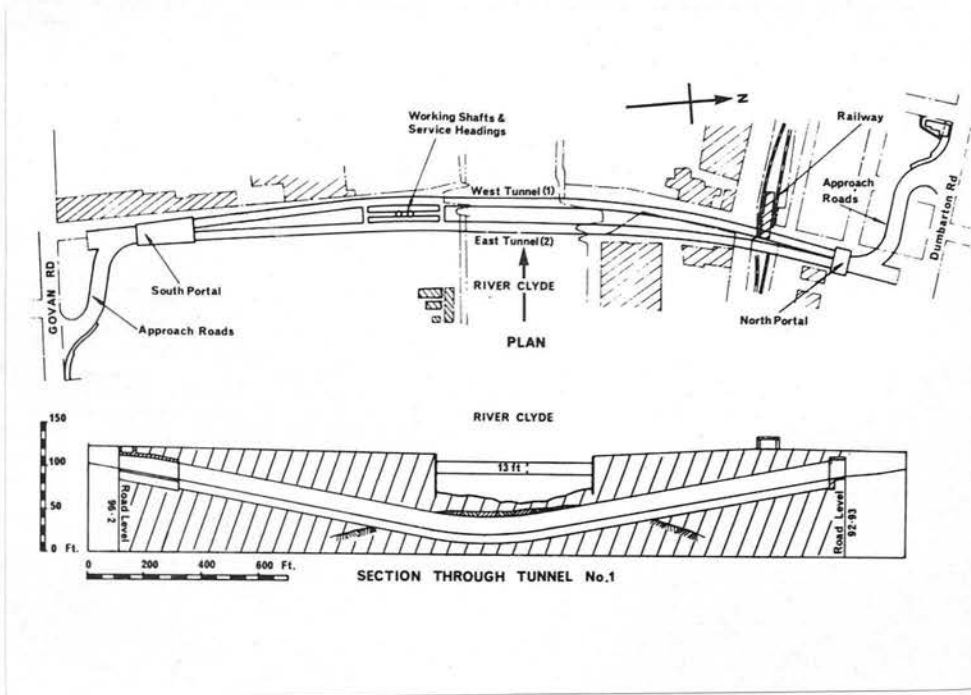


Fig. 2. Diagram showing position of Tunnel.




Fig. 3. Tunnel under construction.

the high pressure of air.

Divers can work for a short period at very high pressures and Behnke (1945) has indicated that the living animal is unaffected by a short exposure to 200 lbs. p.s.i.

In this country, the civil engineering contractors, using compressed air, are required to comply with the precautions laid down by the Minister of Labour and National Service in 'The Work in Compressed Air Special Regulations, 1958', as these affect any workman employed by them. These Regulations ensure that adequate precautions are taken to prevent undue danger to the workman, and these Regulations have been followed throughout the construction of the Clyde Tunnel.

#### WORKING CONDITIONS

The men entered the tunnel by descending the shaft and then entered the man-lock or chamber where they were rapidly compressed to the working pressure. At this stage the men were liable to suffer some ill effects from compression, such as, if a Eustachian tube was not patent, pain over the cranial sinuses or teeth, and a temporary vertigo if compression was too rapid. Regulations require that the rate of compression should not exceed 5 lbs. in the first minute and 10 lbs. a minute thereafter (Fig. 4).

At the end of a working shift, which was usually eight hours, the men re-entered the man-lock and were decompressed to normal atmospheric pressure. During decompression, the men sat on benches on either side of the chamber, which was heated to minimize

discomfort when the temperature suddenly fell below the normal  
point of decomposition. The men were controlled by a  
competent lock-attendant, who was required to keep accurate  
records of all persons who entered the lock and  
ensuring the safety of the men. The rate  
of decompression was controlled by the lock-attendant.

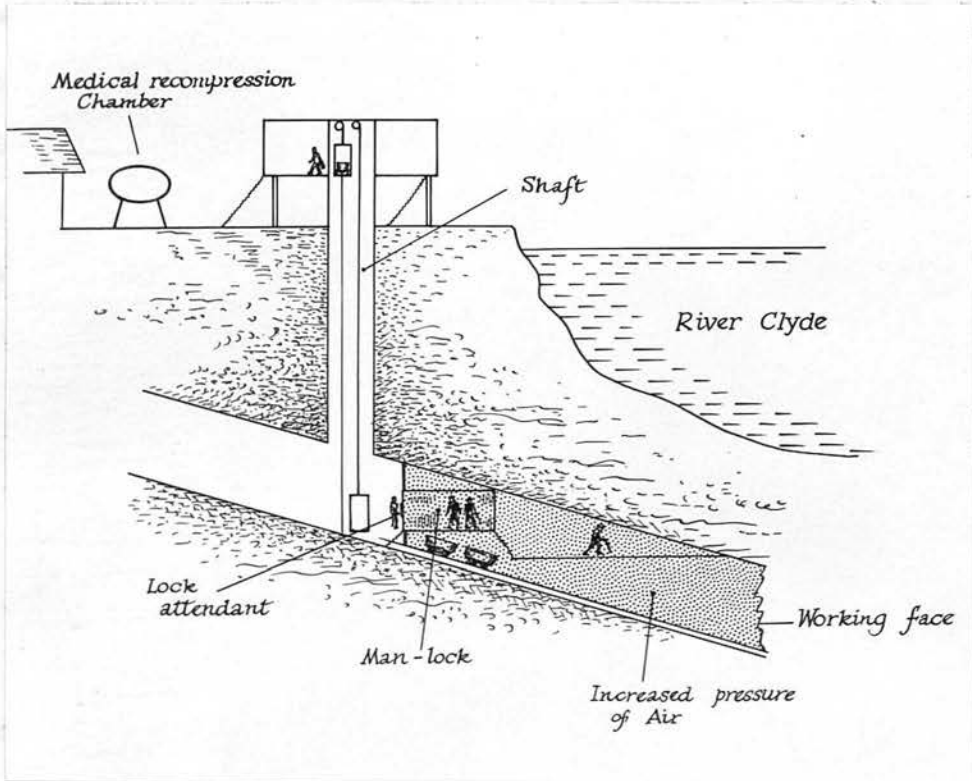


Fig. 4. Sketch demonstrating the principal features  
of construction using compressed air.

Each man was supplied with an emergency medical kit containing  
stitch and gauze which could be taken to the working face  
work. Facilities were provided at the lock for washing and  
changing and drying wet clothes. The men were encouraged to use  
the lock pass during the first hour following decompression and

discomfort when the temperature suddenly fell during the rapid phase of decompression. The locks were controlled by a competent lock-attendant, who was responsible for keeping records of all persons entering and leaving the tunnel and ensuring that they received the correct decompression. The rate of decompression was phased and was prolonged with a higher pressure of air and long exposure. The procedure followed the precautions laid down in 'The Work in Compressed Air Special Regulations, 1958'. At the end of decompression, the men remained on the site for an hour, as it is in this period that the signs and symptoms of decompression sickness are most likely to develop.

#### MEDICAL ASPECTS

Before a man was considered fit for work in compressed air at pressures exceeding 18 lbs. p.s.i., the Regulations required that he should be examined by an appointed Factory Doctor and, as long as he was exposed to compressed air, should have further medical examinations every four weeks and after any incidental illness. These medical examinations were carried out by a local general practitioner, who was an appointed Factory Doctor.

Each man was supplied with an advisory leaflet containing advice and precautions which could be taken in connection with his work. Facilities were provided at the tunnel site for washing and changing and drying wet clothes. The men were encouraged to use the Rest room during the first hour following decompression, and

were paid during this hour.

If symptoms of decompression sickness developed, either at the tunnel site or at home, the man reported back to the medical recompression chamber. This chamber was always ready for immediate use and constantly manned by a first aid attendant trained in the use of compressed air. The man was examined by the attendant and, if necessary, immediate therapeutic recompression to the working pressure was carried out. At the same time, the appointed Factory Doctor was notified.

Records were maintained of the number and length of each exposure to compressed air and of any case of decompression sickness treated by recompression. During the period from April 1958 to August 1962, when the pressure of air was over 18 lbs. p.s.i. or two atmospheres absolute pressure, there were four hundred and sixty-nine recompressions and the "bends rate" was 0.31% of all compressions. Of these four hundred and sixty-nine cases of decompression sickness, three hundred and ninety-eight cases were classified as type 1 and seventy-one cases were classified as type 2. There has been one fatal case of decompression sickness.

In the first instance, the... of... of...  
... of... of... of...  
... of... of... of...  
... of... of... of...  
... of... of... of...  
... of... of... of...

In a final case of the... of... of...  
... of... of... of...  
... of... of... of...

2. PULMONARY FEATURES

... of... of... of...  
... of... of... of...  
... of... of... of...

In view of the possible... of... of...  
... of... of... of...  
... of... of... of...  
... of... of... of...  
... of... of... of...

... of... of... of...  
... of... of... of...

It was found to... of... of...  
... of... of... of...  
... of... of... of...  
... of... of... of...

In... it is... of... of...  
... of... of... of...  
... of... of... of...

It has been pointed out that the occurrence of bronchial obstruction in workers suffering from bronchitis, or some similar condition causing bronchial obstruction, might be a factor in causing cyst formation or rupture of the alveolar membrane and so account for cases with type 2 decompression sickness (Campbell Golding<sup>et al</sup> 1960).

In a fatal case at the Clyde (Case 1 T.R.), a large bulla was found with extensive interstitial and mediastinal emphysema, and widespread intravascular bubble formation. The bulla was demonstrated on a post mortem radiograph and it appeared likely that it had developed during decompression, ruptured and caused the intravascular bubbles.

In view of the possible connection between pulmonary disease and decompression sickness, and as a result of the fatal case, it was decided, in July 1960, to radiograph the chest of all the compressed air workers already employed at the Tunnel and each new starter as he entered work in compressed air.

#### RADIOGRAPHIC SURVEY

##### (a) Object

It was hoped to reduce the incidence of type 2 decompression sickness and to prevent any further fatal cases, by excluding from work in compressed air all those with radiographic evidence of pulmonary disease.

As work in compressed air would continue for a further eighteen months, it was decided to repeat the chest radiographs of

those employed regularly in compressed air after one year. If any of the men with a normal chest radiograph subsequently developed a pulmonary cyst, this would suggest that exposure to compressed air might be an aetiological factor in the development of lung cysts.

(b) Method

During the months of July, August and September 1960, - a total of three hundred and ninety employees had a full sized chest radiograph. These men had been working regularly in compressed air for periods between six months and two and a half years at pressures up to 34 lbs. p.s.i. but averaging at  $24\frac{1}{2}$  lbs. p.s.i.

Between July 1960 and January 1963 - a total of five hundred and thirty-one new entrants had a full sized chest radiograph.

When a man applied for work at the Tunnel, he was interviewed by a supervisor before having his medical examination. The medical examination was carried out by an appointed Factory Doctor employed by the firm. If the man had an unsuitable physique, or his medical examination was unsatisfactory and especially if there was a history of pulmonary disease, then he was not considered for work in compressed air and did not attend for a chest radiograph. Only those with a satisfactory interview and medical examination attended for the chest radiograph.

A postero-anterior (P.A.) radiograph of the chest was taken in all cases. This was viewed by a Radiologist and an interim report was given before the man returned to the Tunnel. Occasionally the initial examination was supplemented by a right

or left lateral radiograph, or an apical view. Tomography was only carried out at a later stage and only if the man required accurate assessment prior to treatment for pulmonary disease. At this stage the man would have been excluded from further work in compressed air.

A final report of the radiograph was issued during the same afternoon and the majority of these were given by myself. The remainder were given by two other Radiologists, and the radiographs were subsequently reviewed by myself.

In September 1961 - two hundred and ninety-three employees had a repeat chest radiograph on hundred millimetre film. All these employees were known to have a normal chest radiograph. The follow-up P.A. radiographs of the chest were taken by a mass radiographic unit on one hundred millimetre film situated at the Tunnel. These radiographs were reviewed by myself.

At the outset, it was decided to exclude from work in compressed air all those with radiographic evidence of pulmonary disease, especially emphysema, a bulla or cyst, or small fibrotic scars, whether tuberculous or non-tuberculous in origin, which would almost certainly be associated with a small bulla. Radiographic evidence of emphysema was considered to be present if the diaphragm was low and flat, with generalised or localised hypertranslucency of the lungs, prominence of the proximal pulmonary vessels and diminution or attenuation of the peripheral vessel pattern, associated with a small heart shadow. Chronic bronchitis was usually diagnosed at the initial medical examination. Evidence of emphysema with small fibrotic scars and isolated tubular shadows of bronchiectasis would suggest the diagnosis of

chronic bronchitis (Simon 1959). Bullae and bullous areas are visible as hypertranslucent avascular areas surrounded by a fine linear opacity, representing compressed lung or pleura.

All those with a history of acute or chronic bronchitis were excluded from further exposure to compressed air.

(c) Result

Of the three hundred and ninety employees examined radiographically during the months of July, August and September 1960, seven men showing evidence of emphysema, bullae with associated fibrotic scars, or tuberculous disease were excluded from further work in compressed air. Five showed evidence of past tuberculous disease and two showed radiographic evidence of emphysema. Only one of these men had suffered from type 2 decompression sickness. His history is interesting in that he collapsed with pains in his chest and loss of power in both legs following a decompression at the end of a shift from  $24\frac{1}{2}$  lbs. p.s.i. This man recovered fully following recompression. The other six men had never had decompression sickness, although they had worked in compressed air for periods of three to fourteen months.

Of the total of five hundred and thirty-one new entrants examined radiographically between July 1960 and January 1963, eighteen men were rejected as unsuitable for work in compressed air because of evidence of pulmonary disease. This figure corresponds with those published in the reports of the Glasgow Mass Radiography Survey (1961 and 1962).

No pulmonary cyst or bulla developed in the two hundred and ninety-three men who had been working in compressed air for

periods of six months to a year, and were known to have a normal chest radiograph.

(d) Effect on Incidence of Decompression Sickness

This radiographic screening test appears to have had no definite effect in reducing the incidence of decompression sickness.

Table 1

Monthly Figures for "Bends Rate"

June 1959	0.90%	before chest X-Ray survey
June 1960	0.40%	
-----		
June 1961	0.34%	after chest X-Ray survey
June 1962	0.31%	

The steady reduction in the decompression sickness rate shown by these figures (Table 1) is that which would be expected as the men became acclimatized to work in compressed air (Paton and Walder 1954).

As already stated in this thesis during the period from the beginning of April 1958 to the end of August 1962 when the pressure of air was over 18 lbs. p.s.i., there were four<sup>↑</sup> hundred and sixty-nine recompressions. From a study of the records maintained by the medical attendant and the safety officer, it has been possible in retrospect to classify these cases of decompression sickness. Three hundred and ninety-eight cases or 85% can be classified as type 1, and seventy-one cases or 15% can be classified as type 2.

To determine if there has been any reduction in the incidence

of type 2, as a result of the radiographic screening test, it was decided to count the number of type 2 cases of decompression sickness in the period of eighteen months immediately before 1960, when the chest radiographic examinations were instituted, and to compare this figure with the number of type 2 cases in the following eighteen months (Table 2). The number of men at risk was approximately equal during both periods.

Table 2

Number of Cases of Type 2

Jan. 1959					
to	-	25 cases	-		before chest
June 1960					X-Ray survey
-----					
July 1960					after chest
to	-	35 cases	-		X-Ray survey
Dec. 1961					

This simple screening test has had no effect in reducing the incidence of type 2 decompression sickness. At the same time, it should be remembered that, following the fatal case in July 1960, the medical attendants were aware of the potential dangers of pulmonary disease and those men with an upper respiratory tract infection, or 'bronchitis' were prevented from work in compressed air.

ILLUSTRATIVE CASES

Three cases are now described, who developed type 2 decompression sickness with acute pulmonary changes.

Case 1. T.R.

This patient worked in compressed air at pressures up to 34 lbs. p.s.i. for eleven weeks. He had two previous attacks of "the bends", the first being characterised by severe pain in both knees, and the second by pain in his right knee. Recompression gave complete relief on each occasion. No previous chest radiograph.

On the day before his fatal illness, the patient complained of breathlessness following decompression, but no abnormality was found on clinical examination. The following day, the patient worked a shift of eight hours at a pressure of 34 lbs. p.s.i. About one hour following a normal decompression, he collapsed. He was recompressed immediately to  $31\frac{1}{2}$  lbs. p.s.i. in the medical recompression chamber. Artificial respiration was given, and shallow spontaneous respiration commenced. Thirty minutes later the patient died.

At autopsy, a radiograph taken prior to opening the chest (Fig.5) demonstrated a large translucent area lying medially in the right lower lobe. This subsequently proved to be a bulla.

Palpation of the anterior chest wall gave an impression of subcutaneous emphysema. On opening the body, large quantities of small air bubbles exuded both from the cut vessels and the subcutaneous tissues. The lungs showed a very marked degree of interstitial emphysema and congestion. A large collapsed subpleural bulla was present close to the hilum of the right lung, mainly involving the medial segment of the right lower lobe. Histological studies of the bulla were not carried out.

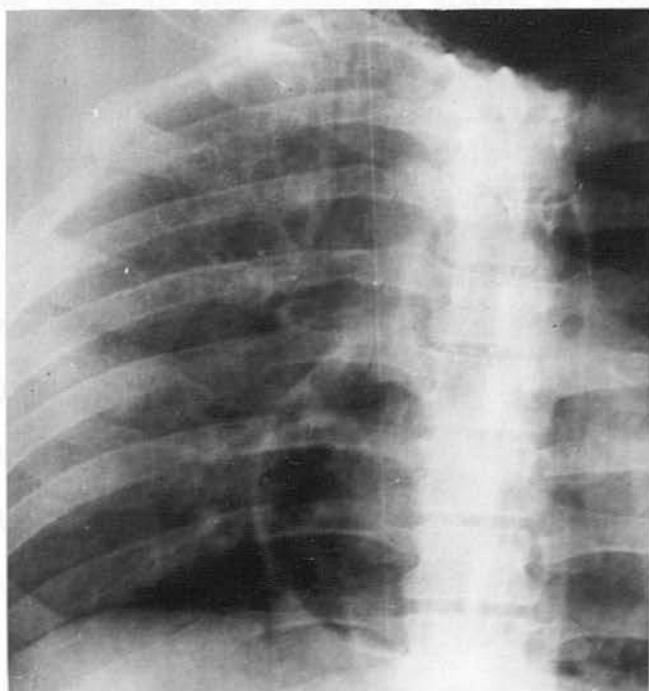


Fig. 5. (Case 1 - T.R.) - Post-mortem Radiograph. Large translucency medially in the right lower lobe, found to be a lung cyst. Extensive mediastinal emphysema.



Case 2. H.L.

This patient had worked regularly in compressed air at pressures up to  $24\frac{1}{2}$  lbs. p.s.i. for a year, and his chest radiograph was normal. About one hour following decompression from an eight hour shift at 27 lbs. p.s.i. he began to have recurrent spasms of coughing. He was admitted to hospital where it was thought he was slightly cyanosed. Chest examination revealed scanty crepitations throughout both lung fields but no other abnormality was noticed.

A chest radiograph taken twenty-four hours after decompression (Fig. 6a) showed fine linear opacities throughout both lung fields and the proximal pulmonary vessels were enlarged. Small transudates were noted at the costophrenic sinuses. At this time the patient felt well, there was no pyrexia, Hb., E.S.R. and W.B.C. were normal. His pulse, blood pressure and repeated E.C.G. examinations were normal. There were no signs of cardiac failure.

Serial chest radiographs over the next few days showed progressive improvement, and after seven days, the lung fields were clear (Fig. 6b).

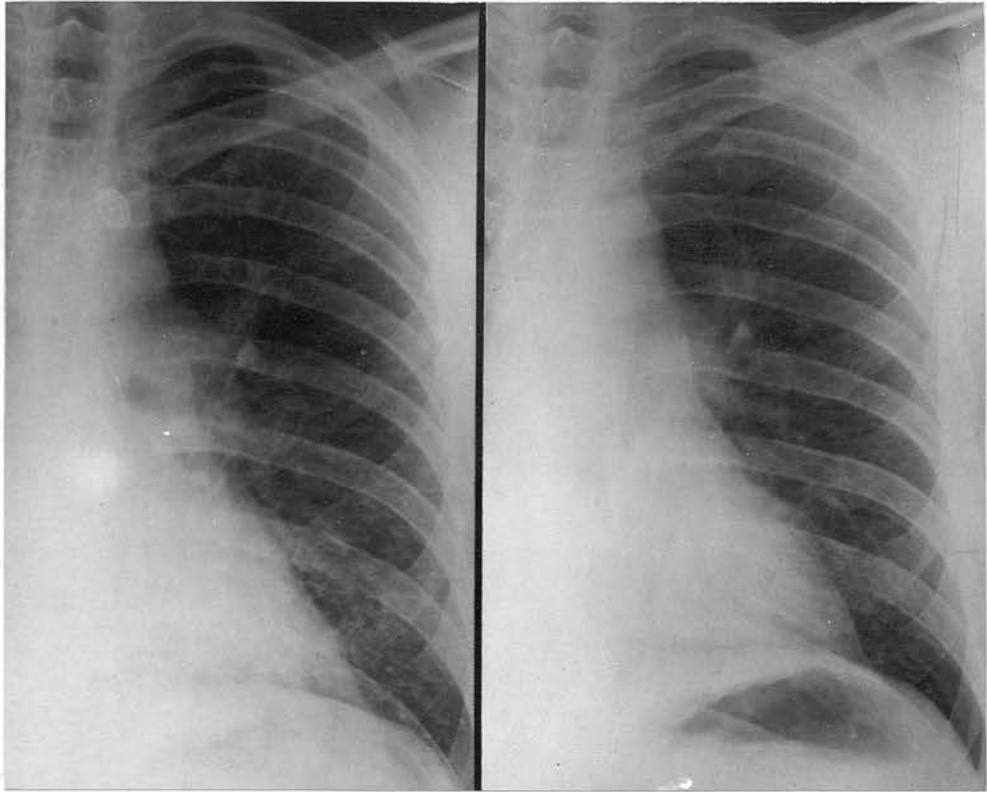


Fig. 6(a)

Fig. 6(b)

Fig. 6(a) (Case 2 - H.L.) - Fine linear opacities throughout lungs, slight distension proximal vessels, twenty-four hours after decompression.

Fig. 6(b) - Lungs now clear, seven days later.

Case 3. W.C.

This patient had worked in compressed air for seven months at pressures up to 34 lbs. p.s.i. and his chest radiograph was normal.

About one hour following normal decompression from an eight hour shift at 30 lbs. p.s.i. he started to cough and felt breathless.

On admission to hospital, two-and-a-half hours after decompression, he complained of severe breathlessness and precordial pain radiating down both arms. His respiration was shallow and rapid, cyanosis was present with widespread rhonchi were noted throughout both lung fields. E.C.G. examination was normal.

A chest radiograph (Fig. 7a), three hours and forty minutes after decompression, showed small ill defined nodular opacities in both lung fields. The proximal pulmonary vessels were enlarged and their peripheral branches were prominent.

The following day clinical recovery was complete and a chest radiograph (Fig. 7b) showed minimal transudates at both costophrenic sinuses. The lung fields were clear. The chest radiograph (Fig. 7c) one week later was normal.

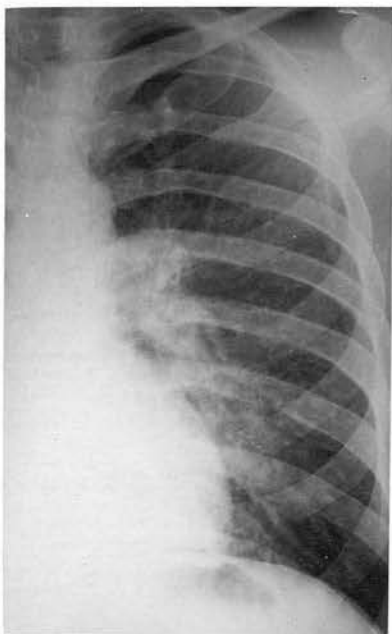

Fig. 7(a) (Case 3 - W.C.)

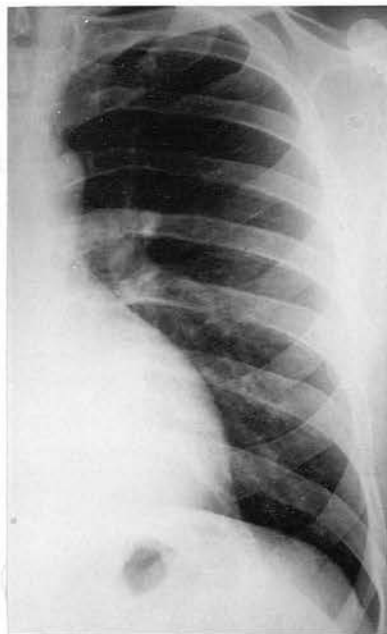

Fig. 7(b)

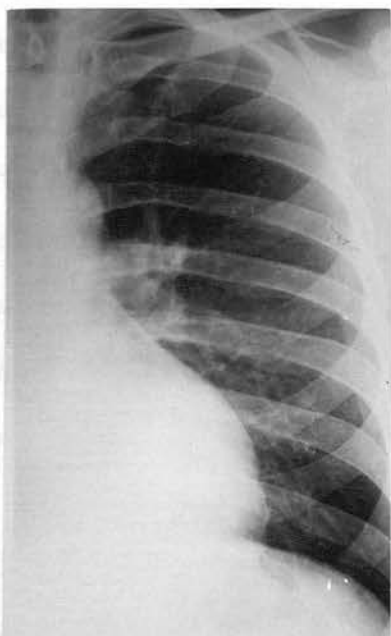


Fig. 7(c)

7(a) - Small ill-defined nodular opacities throughout both lungs, slight distension proximal vessels, three hours forty minutes after decompression.

7(b) - Minimal basal transudates, lung fields clear, twenty-four hours later.

7(c) - Lungs clear, seven days later.

DISCUSSION

In all of the three patients described the symptoms developed at about one hour after normal decompression. Dyspnoea was present in three cases, and in two, there were recurrent spasms of coughing and cyanosis. All three men were healthy prior to their illness. While it has not been possible to obtain a chest radiograph of Case 1, prior to working in compressed air, it seems likely that the cyst in this patient's chest developed rapidly during decompression either on the day prior to his fatal illness, accounting for his dyspnoea, or on the day of his death. This cyst probably resulted from bronchial obstruction and presumably ruptured into the pulmonary circulation, resulting in the wide distribution of gas bubbles.

The details of Case 1 are very interesting, as this is one of the few instances where an autopsy has confirmed the presence of extensive bullae, subcutaneous and interstitial emphysema, and intravascular air bubbles in a fatal case of type 2 decompression sickness in a compressed air worker.

Similar fatalities have been described in men learning to escape from submarines. (Kinsey 1954, Liebow et al 1959). The mechanism of air trapping in the lungs with subsequent bulla formation, rupture of the alveolar membrane, and interstitial and mediastinal emphysema is probably the same in these recorded cases, as in this fatal case in the compressed air worker.

Unfortunately the autopsy was carried out by a pathologist unfamiliar with the problem and adequate histological studies of the lungs were not carried out. Consequently an occluded bronchus or rupture of the alveolar membrane was not demonstrated.

Liebow et al (1959) described a bronchololith in the superior segmental bronchus of the left upper lobe with air trapped beyond it and rupture of the alveolar membrane in a fatal case. Kinsey (1954) was unable to demonstrate rupture of the alveolar membrane in two fatal cases even on repeated section of the lungs. In both cases there was evidence of subpleural blebs with mediastinal and subcutaneous emphysema.

The radiographic appearances of Case 2 probably result from the centrilobular transudates in the interlobular septa, even in the absence of other signs of cardiac failure. The small transudates at both bases and distension of the proximal pulmonary vessels would fit this picture of left ventricular failure.

In Case 3, an ill defined nodular pattern replaces the linear pattern of Case 2. There is distension of the proximal pulmonary vessels and the peripheral branches are prominent. Small transudates are present at the bases. This ill defined nodular pattern would not occur in any form of emphysema and is more consistent with pulmonary oedema. In both cases the radiographic appearances were normal after a few days. Neither case was recompressed or given specific treatment.

The nature of the changes in both Case 2 and Case 3 is difficult to explain, it appears likely that the radiographic features result from left ventricular failure. Possibly a gas bubble has entered the coronary circulation to cause the myocardial failure and this is supported in Case 3 by the history of precordial pain of anginal type. However, in neither case is there evidence of subsequent myocardial ischaemia. The cause of the gas bubbles has not been demonstrated.

The radiographic features of Cases 2 and 3 have not previously been described in compressed air workers. Ferris and Engle (1951) report a detailed case of decompression sickness in a man exposed to a simulated altitude of 35,000 ft. in a high altitude decompression chamber. This man experienced severe pain in both knees, a sensation of substernal distress, a frequent cough and slight dyspnoea. On return to normal atmospheric pressure the pain subsided but the substernal distress and paroxysmal coughing persisted. Subsequently he became pale and dizzy and was found to have a mild tachycardia and hypotension. His lungs were clear on clinical examination and the E.C.G. was normal.

A radiograph of the chest at this time, and reproduced in the report, showed evidence of 'pulmonary congestion' with enlargement of the proximal pulmonary vessels and generalised increased prominence of the peripheral vessels. The condition of the patient had improved by the following day without any specific treatment, and a radiograph of the chest was normal. Subsequent review of the chest radiographs, one taken prior to exposure to high altitude and the two consecutive radiographs taken during the acute episode of decompression sickness, showed that the radiographs were comparable and that the heart size was normal. The pulmonary vessels were enlarged on the day of the illness and returned to normal size on the following day.

In a subsequent discussion on the nature of decompression sickness, Ferris and Engle mention that some observers had described the development of pulmonary changes with rales and radiographic evidence of pulmonary congestion. The symptoms may persist for twelve to forty-eight hours and gradually subside in intensity.

It is interesting to note that both Cases 2 and 3 recovered without any specific therapy over twenty-four to seventy-two hours. The radiographic appearances in both cases were normal within one week.

Just recently two cases of post 'decompression sickness shock' were reported and both showed an appreciable decrease in plasma volume and responded to plasma infusion. The loss of plasma into the extravascular space was attributed to a widespread disturbance of capillary permeability, resulting possibly from small gas emboli damaging the capillaries. A chest radiograph in both cases was normal (Brunner et al 1964).

It may well be that a widespread disturbance of pulmonary capillary permeability may have occurred in Cases 2 and 3 and so explained the extravascular transudates of centrilobular and pleural distribution.

In the two cases reported by Campbell Golding et al (1960), radiographic examination of the chest demonstrated lung cysts, and this is the first occasion that such a lesion had been demonstrated in compressed air workers. Unfortunately, neither case had a radiograph of the chest taken prior to exposure to compressed air. The authors discuss the mechanism of bronchial obstruction and expansion of the cyst during decompression. They suggest "this would lead, at least, to an abnormal gas exchange through the wall of the cyst and possibly to rupture of the wall and discharge of gas into venous channels" and go on to say "but the problem remains as to why, if the men have had cysts for some time, they did not experience trouble earlier; or, if the cysts were a result of damage to the lungs, how such well defined cavities were produced, quite

unlike the rents observed with lungs burst by raised intrapulmonary pressure". Such cases can present an interesting therapeutic problem and the authors urge that extremely slow rates of therapeutic decompression be used, and if the symptoms recur the pressure should be raised just sufficiently high to relieve the symptoms.

In the case described by Nashimoto and Furushashi (1961) the pneumothorax probably developed from rupture of a bulla during decompression. In this case there may have been occlusion of a connecting bronchus and the pressure within the bulla would remain at the high working pressure while the surrounding ambient pressure returned to normal. In this way the bulla could easily rupture.

It is clear that the possibility of pulmonary disease must be kept in mind in all atypical or serious cases of decompression sickness. The correct diagnosis and treatment will be greatly facilitated if a chest radiograph can be taken at once or an X-Ray unit is available at the site where large numbers of men are working in compressed air.

Obviously the cases with lung cysts require careful slow therapeutic decompression and this feature is emphasized in several reports of decompression sickness in men learning to escape from submarines. Liebow et al (1959) described a therapeutic decompression lasting thirty-seven hours twenty-seven minutes in a man who was found to have a large pulmonary cyst. Collins (1962) records a case with type 2 decompression sickness and symptoms suggestive of cerebral air embolism. Subsequent recompression was successful and the therapeutic decompression was prolonged. The patient recovered completely.

The report by Yanda et al (1963) on the clinical application of hyperbaric conditions to patients with emphysema is interesting, especially their liberal use of theophylline and pseudoephedrine in the prevention of air trapping, these drugs being used in conjunction with a very slow decompression procedure. The use of bronchodilators has been considered by those concerned in the prevention of decompression sickness during tunnel construction and their general application is considered impractical.

### Survey

This is the first time that use has been made of routine chest radiography in workers who are exposed to compressed air. It is disappointing that the incidence of type 2 decompression sickness has not been reduced, and, while the classification into type 1 and type 2 has been a retrospective study, it must be accepted, that the routine radiographic examination of the chest of men before exposure to compressed air, is of no value in reducing the incidence of type 2 decompression sickness. In addition it should be remembered that from July 1960 onwards, when the chest radiographic survey was commenced, there was an increasing awareness by the medical staff of the potential danger of pulmonary disease in these men and that any man with suggestive symptoms was excluded from work in compressed air.

There were no fatal cases of decompression sickness following the radiographic survey.

It is interesting that there was no radiographic evidence of a pulmonary cyst or bulla developing in men who had been working in compressed air for six months or a year, and who were known to have a normal chest radiograph. It may be that such cysts or bullae could only be demonstrated if it were possible to radiograph the lungs of a

patient in the recompression chamber during an attack. In this way an advance might be made in the prevention of decompression sickness particularly of its more serious forms (Campbell Golding et al 1960).

### CONCLUSION

Until recently the possible connection between pulmonary disease and decompression sickness has been disregarded. It is suggested that some cases of type 2 decompression sickness in compressed air workers may result from air trapping within the lungs during decompression. Such cases will arise even after a short exposure and in spite of correct therapeutic decompression procedures.

The radiographic appearances of centrilobular and pleural transudates with prominence of the proximal pulmonary vessels, may be more common than is generally realised, and might be demonstrated if facilities were available for radiographic examination of the chest at the tunnel site. The explanation of the radiographic appearances of centrilobular and pleural transudates is more difficult. It may be that a bubble has entered the coronary circulation or, alternatively, the appearances may result from multiple small gas bubbles causing increased capillary permeability.

Valuable information might be obtained from a chest radiograph taken before recompression of those patients with decompression sickness, since air cysts or other pulmonary disease may only be

detectable at this time.

The use of routine radiographic examination of chest of men before exposure to compressed air is of no value in reducing the incidence of type 2 decompression sickness. In Los Angeles and in Glasgow, where experience is being gained in the surgical application of oxygen at hyperbaric pressures, great care is taken to avoid any danger to patients and staff. In Los Angeles, particular attention is paid to a slow decompression procedure, the rate being determined by the results of pulmonary function tests, the liberal use of systemic and topical (aerosol) bronchodilator drugs, and the assessment of those patients with possible pulmonary disease.

Nevertheless until the connection between pulmonary disease and decompression sickness is clarified, every man should have a chest radiograph before exposure to compressed air, and careful enquiry should be made for a history of pulmonary disease. Men with an acute upper respiratory tract infection, acute bronchitis, or chronic bronchitis and emphysema and with radiographic evidence of pulmonary disease, especially a cyst, bulla or emphysema, should avoid work in compressed air.

Further investigation should be made into the use of bronchodilator drugs during decompression procedures in civil engineering practice. At the same time it would be advisable to consider the possibility of assessing pulmonary function in compressed air workers.

In this way some of the severe type 2 or fatal cases of decompression sickness might be avoided.

The radiographic diagnosis of avascular necrosis of bone  
 must be based primarily on the radiographic appearance  
 density of the affected area, and this may be relative or  
 absolute. With a relative increase in density the structure  
 of bone in the affected area is unchanged while the surrounding  
 bone undergoes a progressive first stage. The absolute increase  
 in density is caused by an increased quantity of bone structure  
 and this is

**3. AVASCULAR NECROSIS OF BONE**

... the first stage of the bone of the foot... In  
 absolute increase in density is the usual radiographic appearance  
 of the bone following exposure to compressed air. However  
 it is not until at least before this absolute increase in bone  
 density becomes apparent, and during the early period, necrosis  
 may be fully established and active. In several cases,  
 where the lesion was found in the distal end of the long bones,  
 the increased radiographic density results from calcification  
 in the margins of the necrotic area.

The changes are usually confined to the head and neck of the  
 humerus. The head and neck of the femur, the distal ends of the  
 radius and the distal ends of the ulna. The lesions tend to  
 be multiple and symmetrical, those involving the head of the  
 humerus and the femur tend to involve the articular surface and so  
 cause synovitis. The radiographic picture of the femur is more  
 involved and includes the shaft of the femur, the head and neck  
 and the articular surface of the epiphysis.

Patient's experience of pain and stiffness in the shoulder and hip  
 joints and their symptoms are associated by the characteristic  
 radiographic features of bone necrosis involving the distal ends.

The radiographic diagnosis of avascular necrosis of bone from any cause is based primarily on increased radiographic density of the affected area, and this may be relative or absolute. With a relative increase in density the structure of bone in the affected area is unchanged while the surrounding bone undergoes osteoporosis from disuse. An absolute increase in density is caused by an increased quantity of bone structure and this results, during the process of reossification, from the laying down of new bone on the dead trabeculae. An absolute increase in density is the usual radiographic appearance found in necrosis following exposure to compressed air. However it is six months at least before this absolute increase in bone density becomes apparent, and, during the early period, necrotic bone is indistinguishable from living bone. In several cases, where the lesions are found in the diaphysis of the long bones, the increased radiographic density results from calcification in the margins of the necrotic area.

The changes are usually confined to the head and neck of the humerus, the head and neck of the femur, the distal shaft of the femur and the proximal shaft of the tibia. The lesions tend to be multiple and symmetrical, those involving the head of the humerus and the femur tend to involve the articular surface and so cause symptoms. The articular surface of the knee is never involved and lesions of the shafts of the long bone some distance from the articular surface are symptomless.

Patients complain of pain and stiffness in the shoulder and hip joints and these symptoms are accompanied by the characteristic radiographic features of bone necrosis involving the joint surface.

If the necrotic area does not involve the joint surface, then these areas will remain symptomless, and will only be demonstrated at a radiographic examination for some other purpose.

### RADIOGRAPHIC SURVEY

#### (a) Objects

The objects of the radiographic survey were to determine the incidence of avascular necrosis of bone in a large group of men who had been exposed to compressed air during tunnel construction and to demonstrate the site and frequency of the lesions. The history of exposure to compressed air and of any acute episode of decompression sickness would be obtained and this information was related to the results of the radiographic examination.

In this way, it was hoped to show whether or not there was any relation between bone lesions and work in air pressure particularly at the higher end of the normal working range, and to the total amount of time spent on compressed air work at any pressure in excess of normal. Another matter of great interest is the possibility of a relationship between the site of type 1 decompression sickness - "the bends" - and the site of the bone lesions.

A further object was to follow-up both the positive and negative cases by radiographic examination at yearly intervals. In this way further information might be obtained of the natural history of bone necrosis in compressed air workers. At the outset, it was realised that this follow-up would be incomplete as the

majority of the men would leave the district in search of work at other civil engineering contracts. This follow-up is being continued at the moment and observations are not included in this thesis.

(b) Method

The contractors - Messrs. Charles Brand and Co. - readily agreed to co-operate in this survey and arranged to extract the relevant information of each man's exposure to compressed air and subsequent decompression, maximum pressure of air to which he was exposed, and each episode of decompression sickness.

The contractor's agent and a member of the Medical Research Council Decompression Sickness Panel explained to the men the purpose of this radiographic survey, and they were also given a leaflet with a short statement to the effect that the investigation was part of a medical research project to prevent disease in tunnel workers. It was also explained that, if anything of note was found, the patient himself would be informed and arrangements made for him to see a doctor if he wished.

The radiographic survey included views of both shoulders, hips and knee joints in each of the men, as it is known from published cases, that these sites commonly demonstrated evidence of bone necrosis. The Department of Radiodiagnosis at the Southern General Hospital had already conducted a radiographic examination of the chests of these men employed at the Clyde Tunnel, and being situated at a short distance, it was decided that the Department could handle this extensive survey.

The investigation commenced at the end of November, 1962 and at this time many men had worked at the Clyde Tunnel since April,

1958 when the use of compressed air began. It was decided to examine as many men as possible, and only to exclude those who worked for very short periods in compressed air and who were known to have bone necrosis and still continued to work at the tunnel although not exposed to an increased pressure of air. By January, 1963, when tunnelling was completed and the labour force disbanded, a total of two hundred and forty-one men had been examined. Only six men refused to take part.

### Radiographic Technique

Initially the examination included antero-posterior and axillary projections of each shoulder joint and antero-posterior and lateral projections of each hip and knee joint. In general the radiographic technique followed those described in the standard textbooks (Meschan 1951, Clark 1956). A brief description of the principal points is as follows.

#### The Shoulder Joint

Antero-posterior projection (A.P.) - the patient was rotated approximately 15 degrees so that the shoulder being examined was flat against the table, and the opposite shoulder was slightly raised. With the hand supine the X-Ray beam was centred on the coracoid process.

Axillary projection (Ax.) - with the patient standing, the arm was abducted and kept level with the trunk, displaced neither forwards nor backwards. The position of the hand was standardised by ensuring that the thumb pointed upwards. The cone of the X-Ray tube was placed in the axilla being examined and the cassette was held

by the patient on the deltoid surface. (Campbell Golding 1961).

#### The Hip Joint

Antero-posterior projection (A.P.) - with the patient supine and the foot slightly internally rotated, the central beam of the X-Ray passed through a point one inch below the inguinal ligament.

Lateral projection (LAT.) - with the patient supine the thigh was erected by placing the heel of the side being examined against the opposite knee joint. The X-Ray beam was centred to the same point as in the antero-posterior projection.

#### The Knee Joint

Antero-posterior projection (A.P.) - the patient was sitting with the back supported. Slight rotation was sometimes necessary to centralise the patella on the femur. The X-Ray beam was centred immediately below the distal pole of the patella.

Lateral projection (LAT.) - the patient was turned on the side being examined and the limb was flexed at the hip and knee joint. The other leg was brought well forward and raised on a sandbag. The X-Ray beam was centred over the anterior border of the medial tuberosity of the tibia.

Every effort was made to ensure that adequate protective measures were taken against ionising radiation, particularly by the use of gonad shields and fast intensifying screens.

After examining eighty men, it became clear that the examination could be modified by excluding the axillary projection of the shoulder and the lateral projection of the hip. By modifying the examination in this way, the radiation hazard and the time involved in each examination was reduced without loss of information. In each case the projection of the radiograph ensured that a large part of the diaphysis was included without detracting from the quality of the radiograph by creating too great a radiographic field.

Many of the men with positive or doubtful radiographic evidence of bone necrosis were recalled for an axial projection of the shoulder and a lateral projection of the hip joint, if this had not been included at the original examination. In some cases the radiographic examination was supplemented by tomography in an attempt to demonstrate the ill defined lesions more clearly. Occasionally it was not always possible to carry out an additional examination as a few of the men had left the contract soon after the radiographic survey in search of other employment.

#### Analysis of Radiographs

Each man, examined in the radiographic survey, was given a separate number followed by the suffix 'S', indicating Survey, and the radiographs have been read repeatedly to reduce observer variation and have been classified as doubtful, positive or negative.

In the cases with positive changes, the radiographic features were those of avascular necrosis of bone following exposure to compressed air and in the following section there is a detailed description of the radiographic features.

Difficulty was experienced in classifying a group of cases with doubtful changes. In many instances, the changes closely resembled slight variations of bone trabeculae which are found in normal subjects and these were subsequently classified as normal. In other cases, there were dense areas of varying size and shape with irregular margins. Those areas which were round or oval were difficult to distinguish from bone islands. Irregularity of the margins tended to favour a diagnosis of bone necrosis. Sometimes the dense areas, with an irregular outline, assumed a more linear pattern following the line of the trabeculae. In these cases the trabeculae appeared thickened and fused. The radiographic changes of small dense areas with irregular margins and thickening of the trabeculae have been described earlier by Reboul et al (1955), Fournier and Julien (1959) and Mosinger and Julien (1961). These authors interpreted the features as evidence of bone necrosis. In many cases tomography was useful to confirm and demonstrate more clearly the features of the dense areas, and in particular to demonstrate the irregular outline.

Many of the radiographs with doubtful changes were studied on several occasions. In some cases it was impossible to be certain whether the appearance was normal or not and these were finally classified as doubtful. It may be that, on subsequent follow-up of these cases, the true nature of the appearances will become more clear.

### (c) Radiographic Appearances

In this section, the forty cases demonstrated during the survey and the eleven illustrative cases, who presented at various hospitals in Glasgow, are included in the description of the radiographic

appearances. In this way it is hoped to give a more complete account of the radiographic appearances in avascular necrosis of bone following exposure to compressed air.

The lesions were divided into two broad radiographic groups:-

1. 'Articular' lesions, these involve the articular surface directly, or, by their proximity, weaken the articular cortex which is then liable to collapse into the underlying bone.
2. 'Shaft' lesions, which are situated at a distance from the articular cortex and are likely to remain symptomless.

This decision was made at the time of reading the radiographs. A simple classification is given below: this is followed by a detailed description with reproductions of each radiographic feature.

### 1. 'Articular' Lesions

Lesions are seen in the shoulders and hip joints and may be bilateral.

#### A. Dense areas with an intact articular cortex

These changes are adjacent to an intact articular cortex, and may appear as small dense spots with irregular margins. These are more common in the head of the humerus and are demonstrated on the axillary projection.

#### B. Dense curvilinear layer - 'snow-cap'

The dense areas may assume a typical distribution forming a dense layer in the head of the humerus and less commonly in the head of the femur.

The margins extend to the articular surface and the involved area covers a third or two thirds of the bone end.

C. Translucent subcortical band

A fine translucent band immediately below the articular surface indicates that the weakened cortex is broken and increased density may be present in the adjacent bone. This is seen more commonly in the head of the humerus.

D. Collapse of the articular cortex

With weight bearing or repeated minor trauma, a segment or segments of the weakened articular cortex collapse into the subcortical bone. This is usually associated with increased density of a large area of adjacent bone.

E. Sequestration of part of the cortex

Occasionally a portion of the articular cortex appears separated and slightly displaced from the adjacent bone. This is a late sign and involves the head of the humerus or femur.

F. Secondary osteoarthritis

With a long standing bone lesion, evidence of secondary osteoarthritis will develop.

## 2. 'Shaft' Lesions

Some of the 'shaft' lesions that were uncovered by this investigation bore little resemblance to those which are illustrated in the literature. The reason being that none of the men had complained

of symptoms, and therefore constituted a group, most of whom would not probably have had a radiographic examination. These lesions are multiple, bilateral and often associated with articular lesions at other sites.

A. Dense areas at a distance from the articular cortex

These areas are very similar to those already described, they vary considerably in size usually being small, ill defined, and demonstrated more clearly by tomography.

B. Irregular calcified areas

These are usually found in the distal shaft of the femur, and the proximal shaft of the tibia and may form a coarse network or assume a more linear distribution.

C. Translucent areas with sclerotic margins

Occasionally a translucent area, as much as two centimetres in diameter, may be found in the neck of the femur or the neck of the proximal shaft of the humerus. This area may be surrounded by a fine sclerotic margin.

'ARTICULAR' LESIONS

A. Dense areas with an intact articular cortex

These lesions are demonstrated at the initial examination and are commonly found in the head of the humerus, and less frequently in the femoral head. They are often bilateral and multiple. Symptoms are absent with this type of lesion.

The lesions appear as small dense sclerotic areas adjacent to and often abut on the intact articular cortex. Their margins are irregular and, when the lesion lies on the line of the trabeculae these appears to be thickened or fused. The irregular outline helps to distinguish the lesions from bone islands. The surrounding bone is normal. The abnormality is demonstrated more clearly on an axillary or lateral projection of the involved joint or by tomography.

It is thought that the dense sclerotic area represents an absolute increase in bone density resulting from the laying down of new bone during attempted revascularisation of ischaemic bone.

(Fig. 8 - 17)

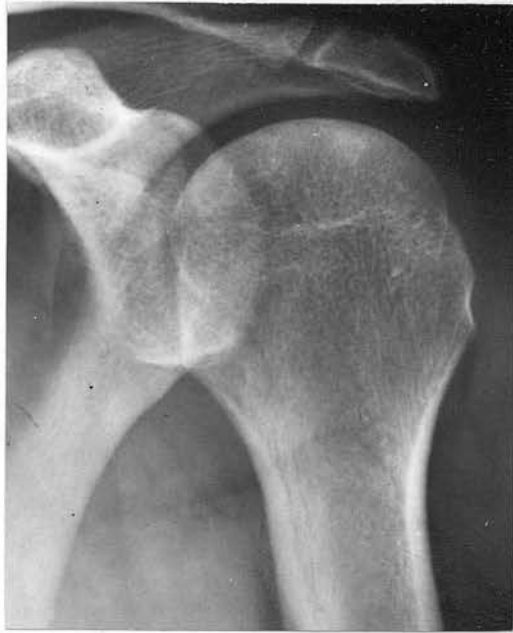

Fig. 8 (No.140S) - Dense areas lie adjacent to intact articular surface in head of left humerus. No symptoms.

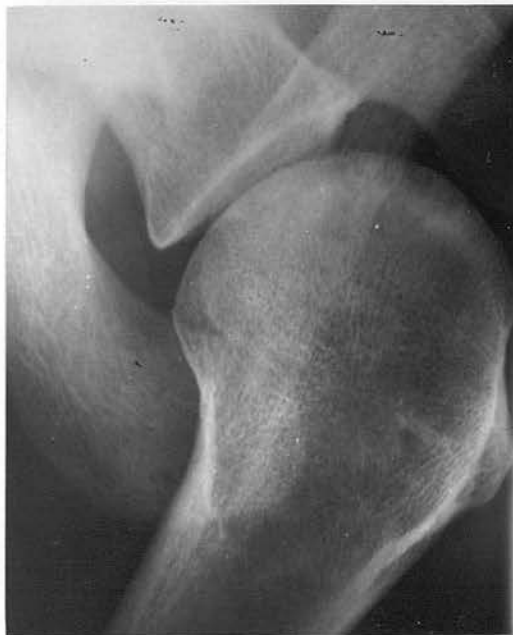

Fig. 9 (Case 10 - W.D.) - Axillary projection of right shoulder showing dense areas adjacent to articular cortex. No symptoms.

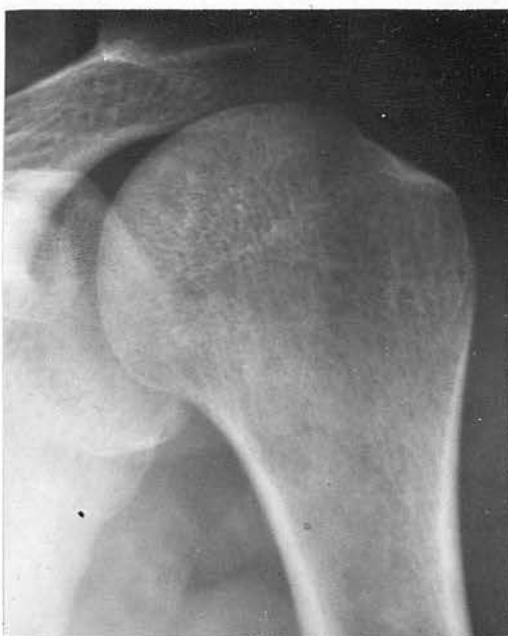

Fig. 10(a) (42S) - Ill defined dense areas in head of left humerus. No symptoms.

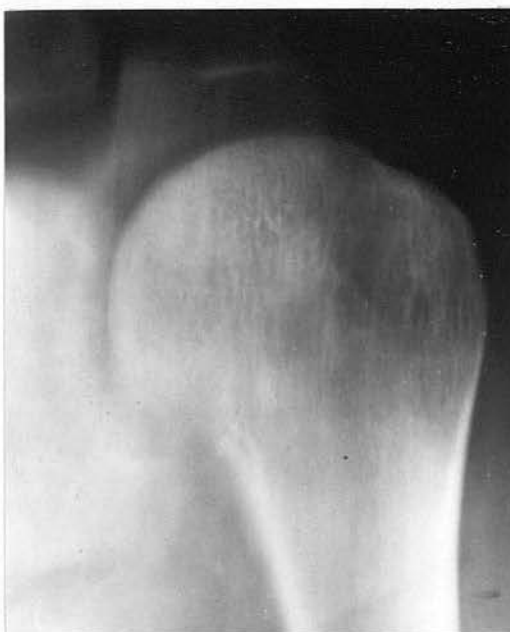

Fig. 10(b) (42S) - Tomography shows lesions more clearly.

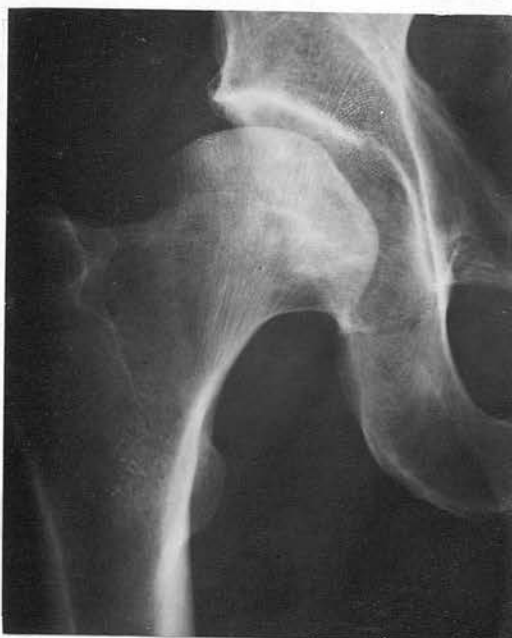

Fig. 11(a) (16S) - Ill defined dense areas in head of right femur. No symptoms.

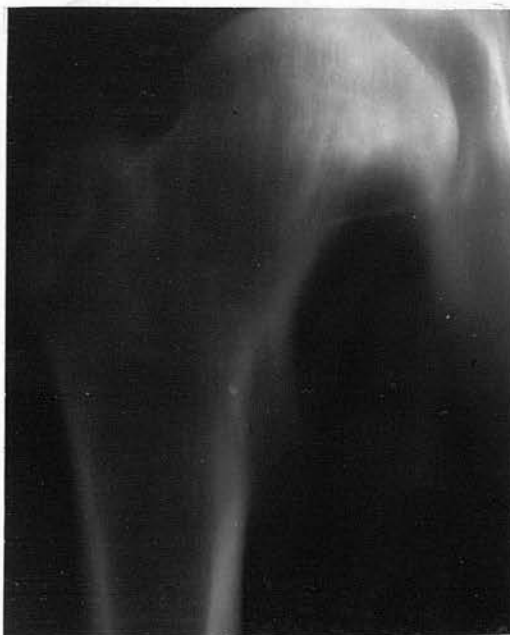

Fig. 11(b) (16S) - Tomography demonstrates the lesion adjacent to the intact cortex and in the neck of the femur.

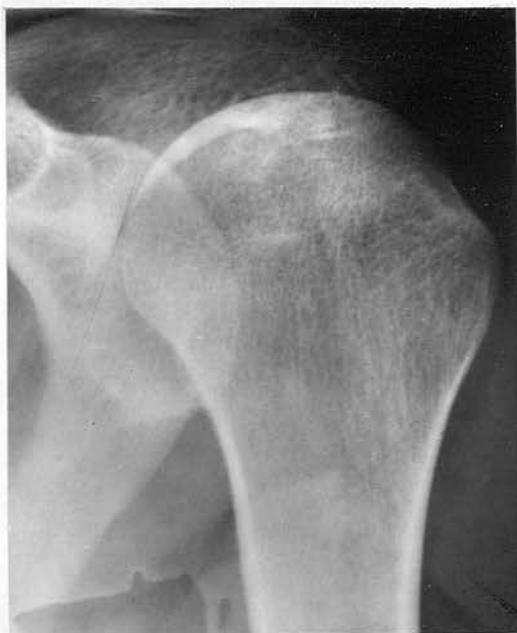

Fig. 12 (9S)

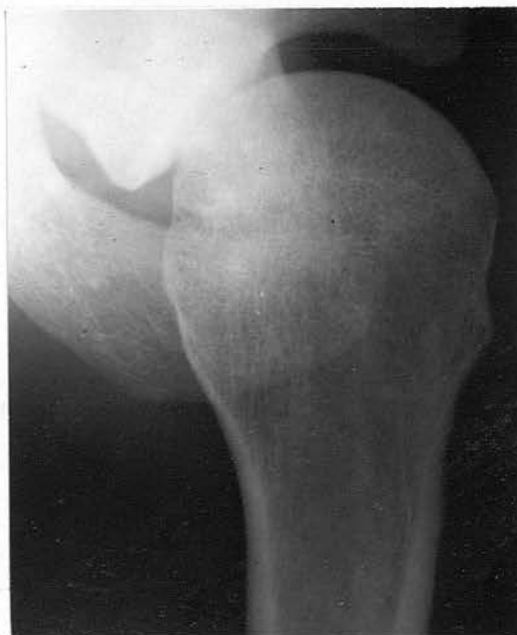

Fig. 13 (131S)

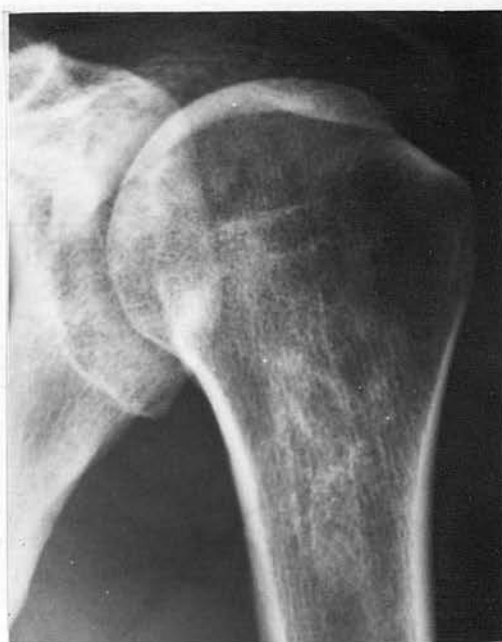

Fig. 14 (135S)

12 - Dense areas in head of left humerus, some adjacent to articular surface. No symptoms.

13 - Axillary projection of right shoulder. Dense areas present. Articular surface intact. Symptoms absent.

14 - Dense areas of varying size in head and proximal shaft of left humerus. No symptoms.

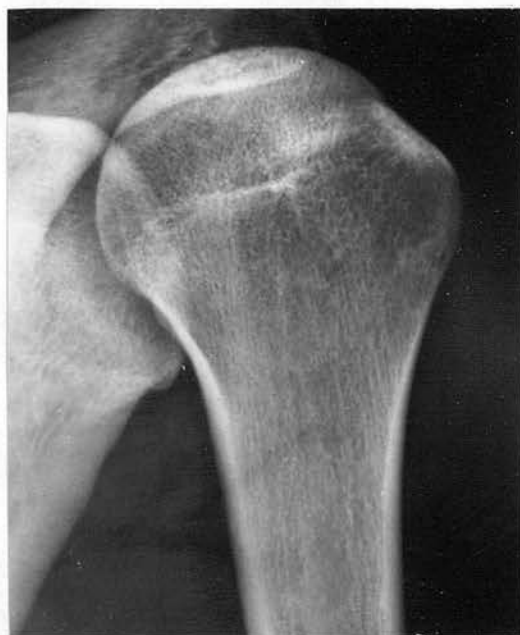

Fig. 15(a) (174S)

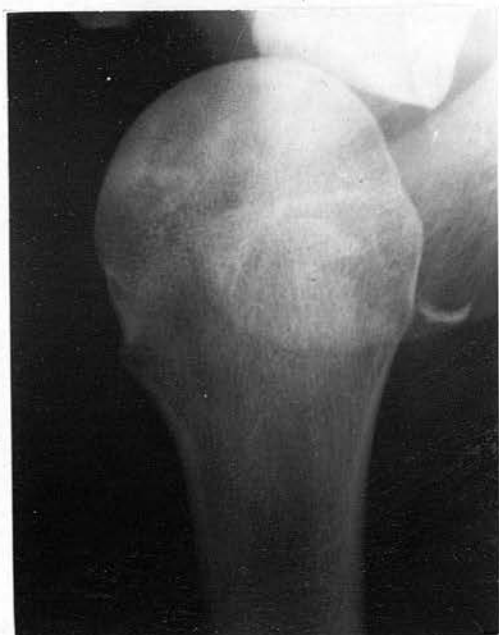

Fig. 15(b) (174S)

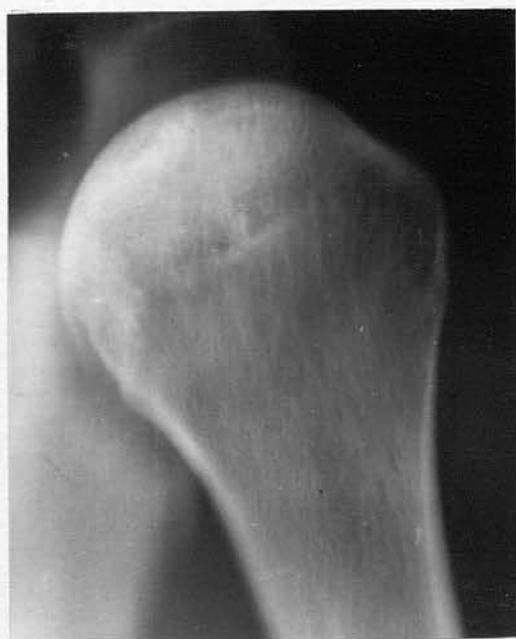

Fig. 15(c) (174S)

15(a) - Dense areas adjacent to intact articular surface. No symptoms.

15(b) - Axillary projection demonstrates dense areas.

15(c) - Tomography shows the lesions to form a rough curvi-linear layer.

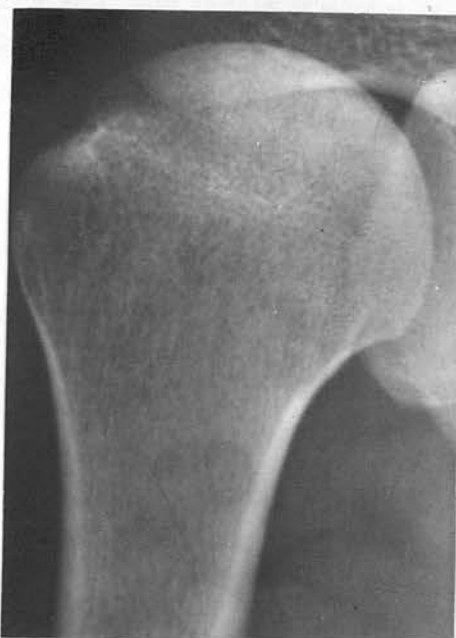

Fig. 16(a) (141S)

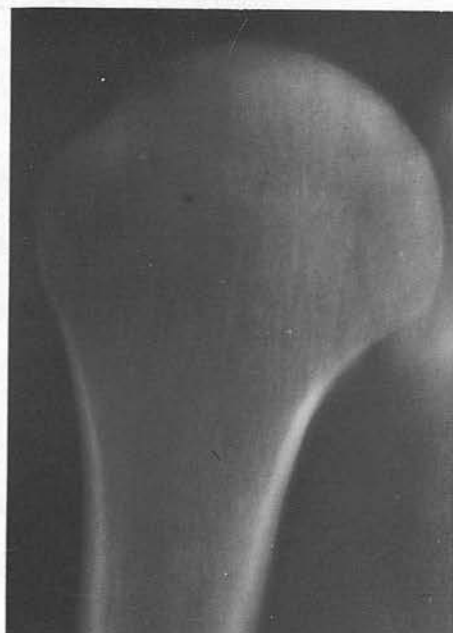

Fig. 16(b) (141S)

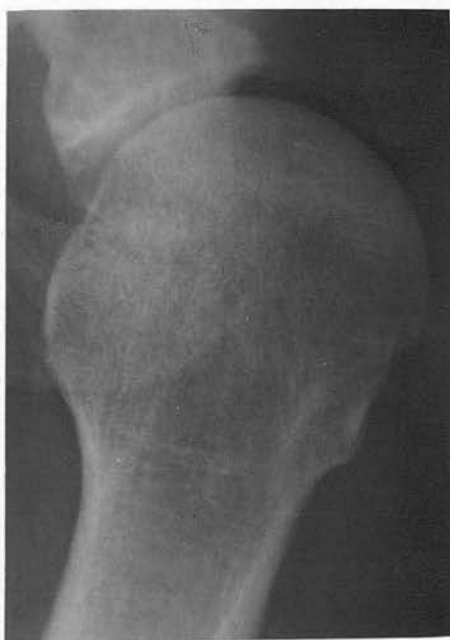

Fig. 17 (154)S.

16(a) - Dense areas in head of right humerus. No symptoms.

16(b) - Tomography confirms the presence of the lesion.

17 - Axillary projection showing large ill-defined dense areas close to an intact articular cortex.

'ARTICULAR' LESIONS

B. Dense curvi-linear layer - 'snow-cap'

This lesion found at the initial examination, is commonly demonstrated in the head of the humerus and only rarely in the femoral head. It may be that the overlying shadow of the acetabulum obscures bone detail and tomography would demonstrate the lesion more clearly. The lesion may be bilateral. Symptoms may be present and are of short duration.

The lesion appears as a dense sclerotic curvi-linear layer, varying in thickness from 2 mm. to a 'hair line'. The margins extend to the articular cortex on each side and enclose as much as two-thirds of the articular surface. The lesion has been described as a 'snow-cap' by Poppel and Robinson (1956). The bone between the dense layer and the articular cortex may show some decrease in density. The remaining bone may be of either normal density or show small sclerotic areas.

The dense curvi-linear layer represents a zone of reossification advancing into the necrotic bone and the increased density results from the laying down of new bone. The articular cartilage may be necrotic.

(Fig. 18(a) - 23(b))

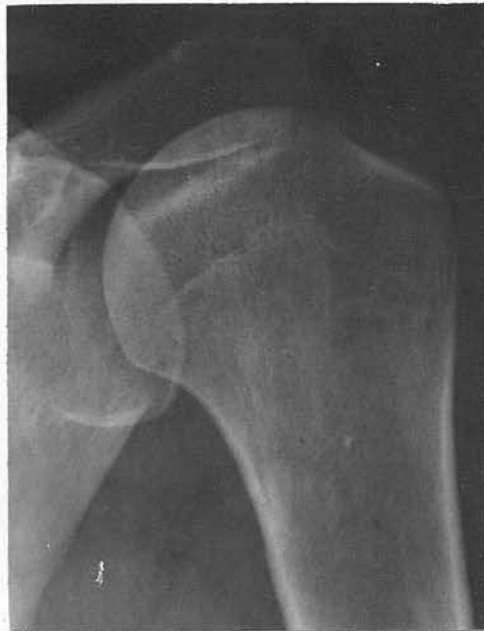

Fig. 18(a) (41S) - Dense curvi-linear layer or 'snow-cap' in head of left humerus. 'Painful arc' present on abduction.

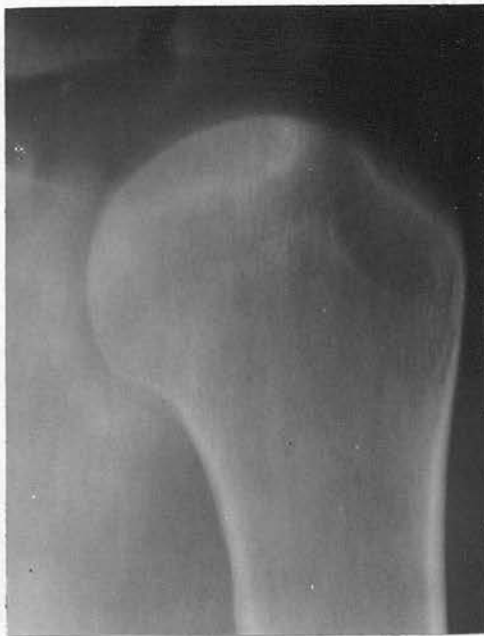

Fig. 18(b) (41S) - Tomography demonstrates the lesion clearly.

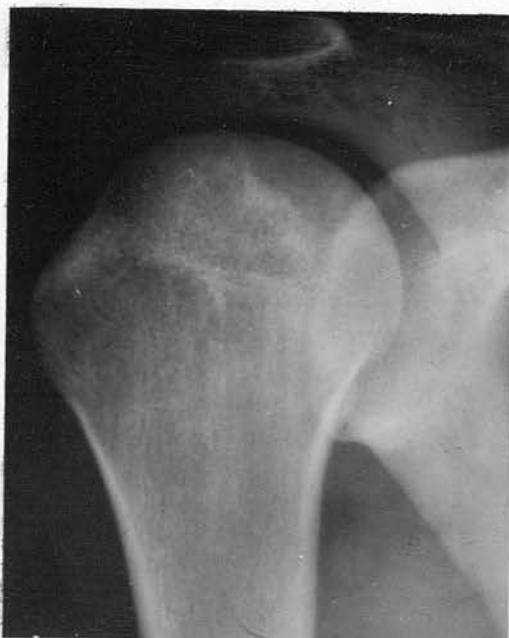

Fig. 19(a) (174S) - Dense curvi-linear layer in head of right humerus. No symptoms.

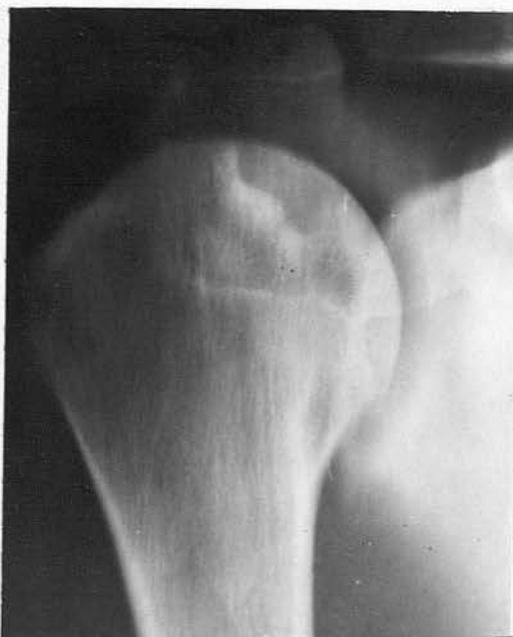

Fig. 19(b) (174S) - Tomography shows possible decrease in bone density between lesion and the articular surface.

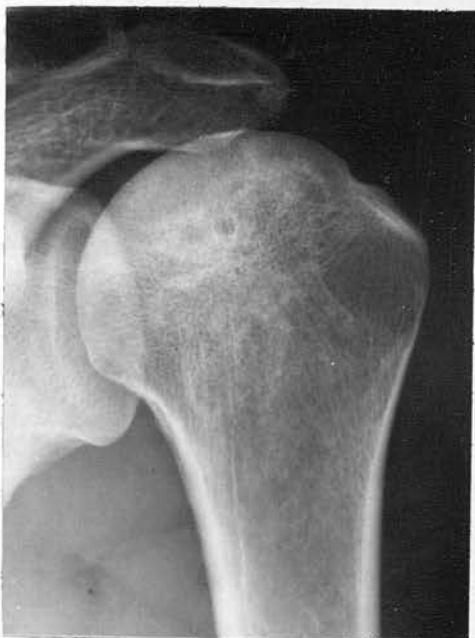

Fig. 20 (65S)

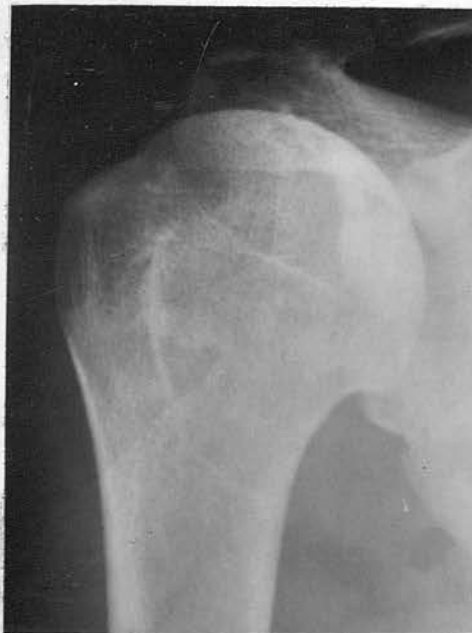
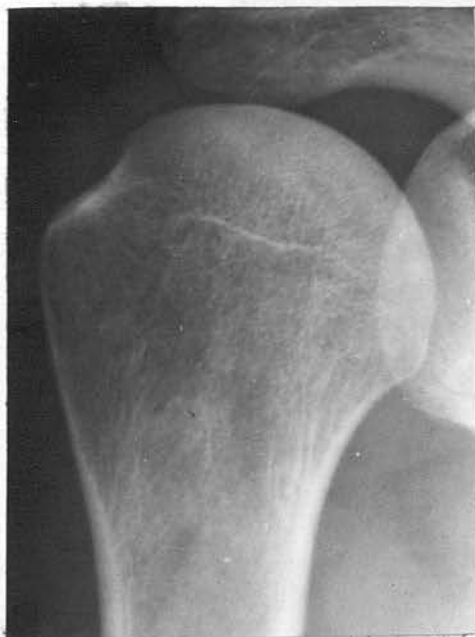
Fig. 21 (54S)



x Fig. 22 (104S)

20 - Dense curvi-linear layer situated 1.1 cm. from the intact articular cortex. No symptoms.

21 - Wide curvi-linear layer in head of right humerus.

22 - Fine curvi-linear layer with intact articular surface. No symptoms.

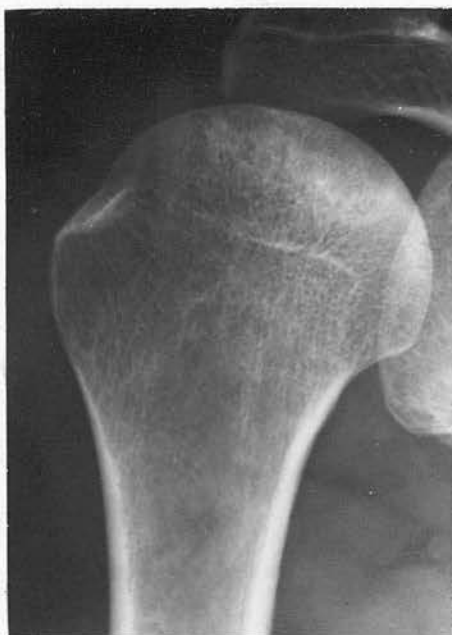

Fig. 23(a) (12S) - Dense curvi-linear layer  
in head of right humerus.

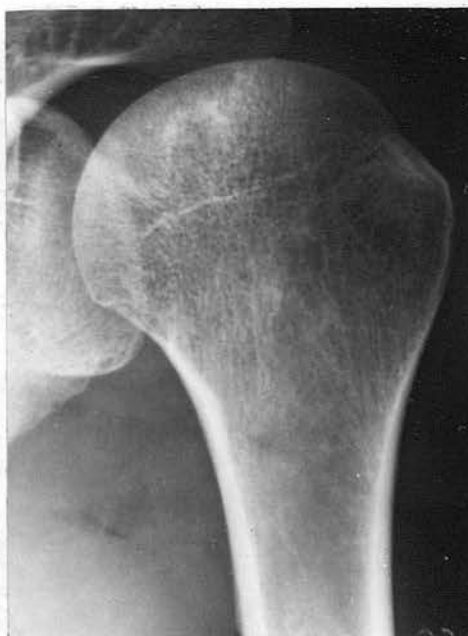

Fig. 23(b) (12S) - Similar lesion in head  
of the left humerus. No symptoms  
in either shoulder joint..

'ARTICULAR' LESIONS

C. Translucent subcortical band

This lesion is an early radiographic manifestation of bone necrosis and symptoms are of short duration. It is found in the head of the humerus and in the femoral head.

The lesion appears as a thin translucent line or band immediately below the articular surface, which otherwise appears intact. The translucency may extend over as much as two thirds of the bone end. Macroradiography helps to demonstrate the appearance more clearly (Reboul 1955). The adjacent bone may be of normal density and may contain small areas of increased bone density.

The translucency probably results from a zone of fibrous tissue within the necrotic area. Alternatively the band may represent a fracture line, indicating that the weakened articular cortex has broken. The surrounding area of increased density indicates that necrotic areas of bone are being revascularised.

(Fig. 24(a) - 27)

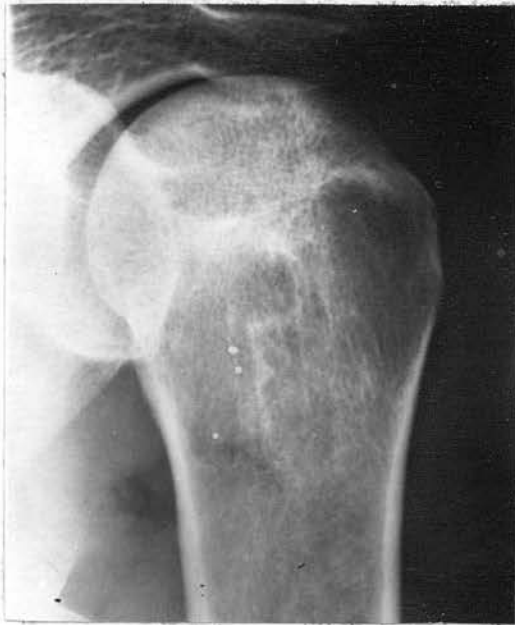

Fig. 24(a) (213S)

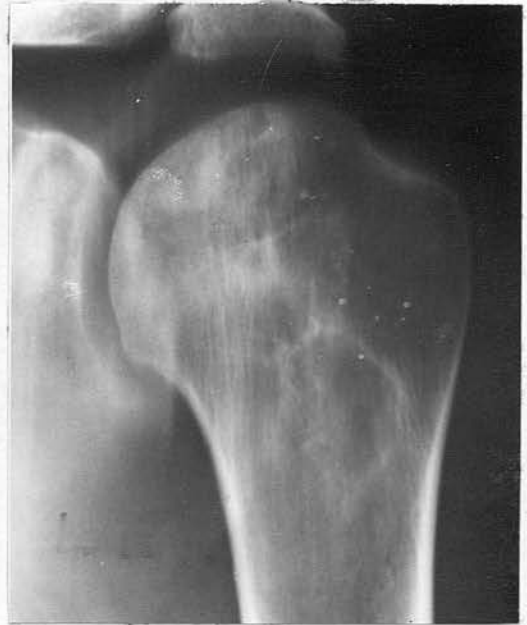

Fig. 24(b) (213S)

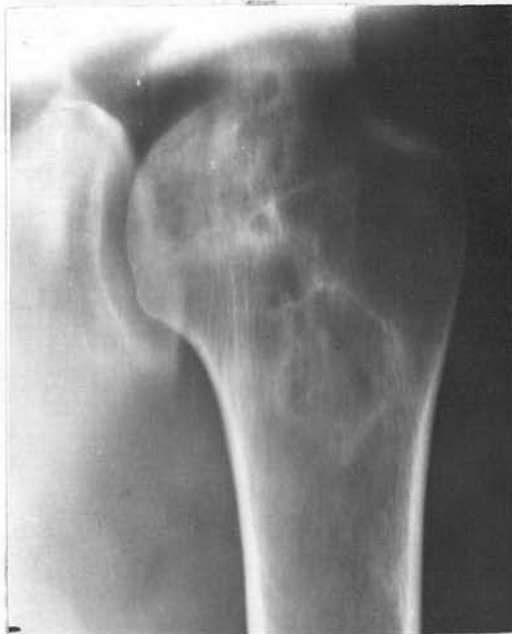

Fig. 24(c) (213S)

24(a) - Probable lesion in head of left humerus. Pain and limitation of movement in left shoulder joint.

24(b) - Tomography demonstrates a translucent subcortical band with several dense and translucent areas extending in an apex towards the proximal shaft.

24(c) - Tomography section more anterior shows a large translucency with a fine sclerotic margin.

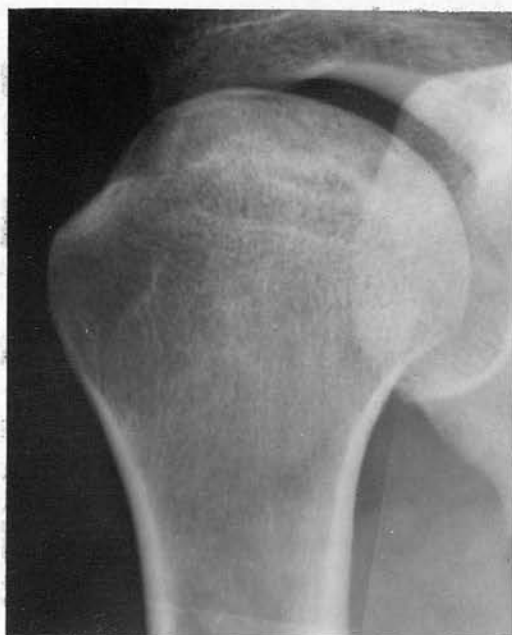

Fig. 25 (61S)

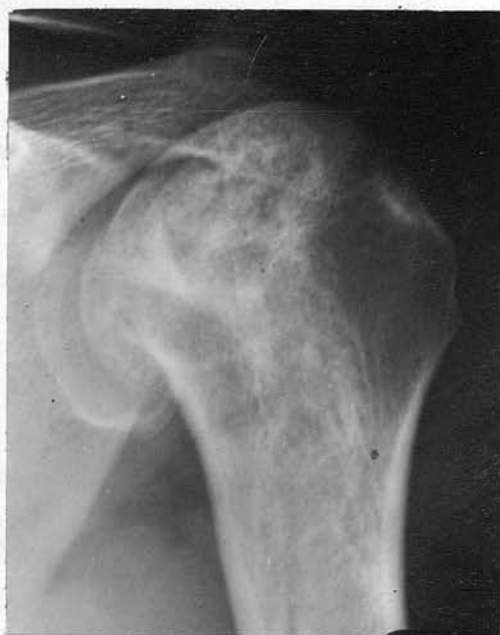

Fig. 26 (125S)

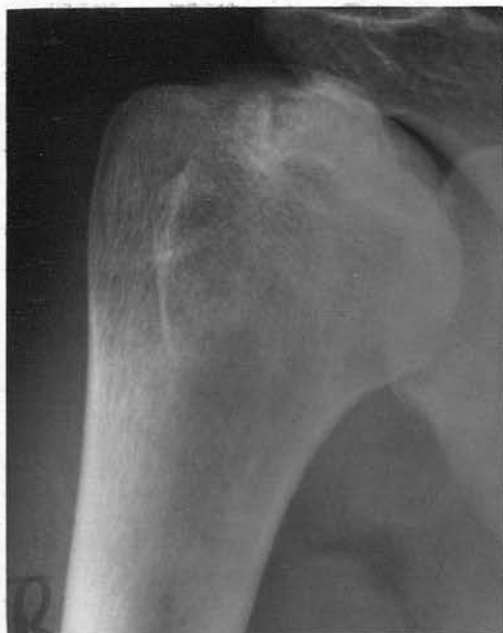

Fig. 27 (Case 11 J.McG)

- 25 - Fine translucent subcortical band in the head of the right humerus with dense areas in the adjacent bone. Symptoms present.
  
- 26 - Fine translucent band and possible collapse of the articular cortex. Large dense area involves the head of the left humerus. Symptoms present.
  
- 27 - Translucent subcortical band and large dense area in head of right humerus. Symptoms present.

'ARTICULAR' LESIONS

D. Collapse of the articular cortex

This radiographic sign is a late manifestation, symptoms having been present for some time. The lesions involve the middle third or two thirds of the articular surface of the head of the humerus, or the head of the femur when up to halve of the articular surface in the posterior or 'weight bearing' area may be depressed. The lesions may be bilateral.

The radiographic appearances show that a large intact segment or several small fragments of the articular cortex have sunk or collapsed into the subcortical bone. There is a clear 'step formation' at the junction with the normal articular cortex. The lesions are seen more clearly on a lateral or axillary projection of the involved joint and on tomography. Frequently there is a large area of increased radiographic density in the adjoining bone and this extends in an apex as far as the proximal shaft of the bone.

With weight bearing and repeated minor trauma, the weakened and infRACTED articular cortex will sink into the head of the femur or the humerus. In the shoulder, the middle third or two thirds of the head of the humerus is involved - the segment in contact with the glenoid when the arm is abducted and heavy activity presumably causes this portion of the weakened articular cortex to collapse. The large area of increased density in the surrounding bone suggests that the initial ischaemic episode resulted in a large segment of necrotic bone. (Fig. 28(a) - 32)

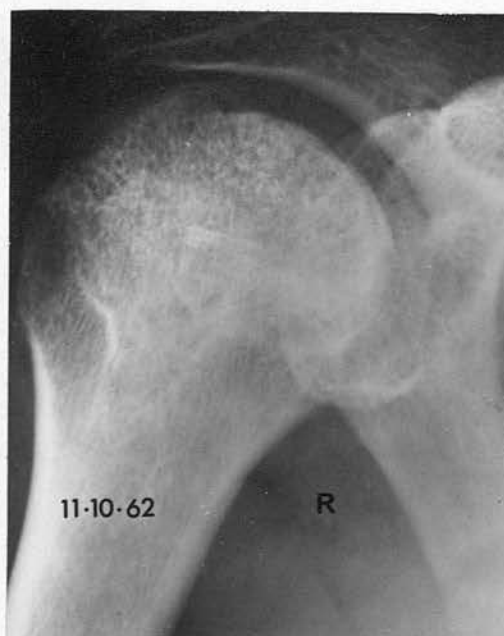


Fig. 28(a) (Case 5 - J.McV.) - Depression of segment of articular cortex. Dense areas involve a large segment of head of right humerus and extend towards the shaft.

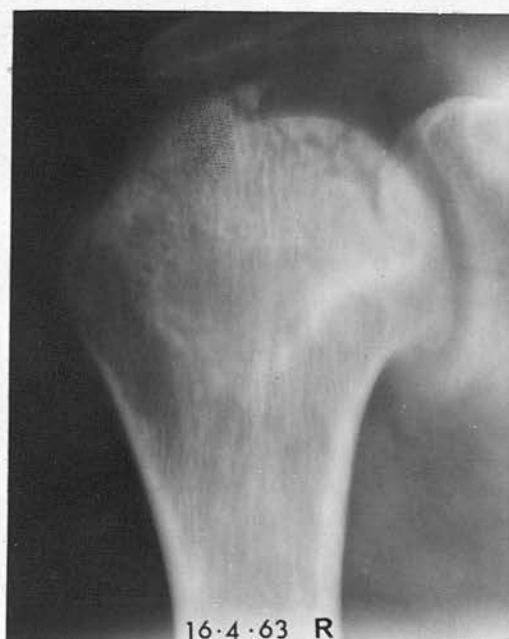
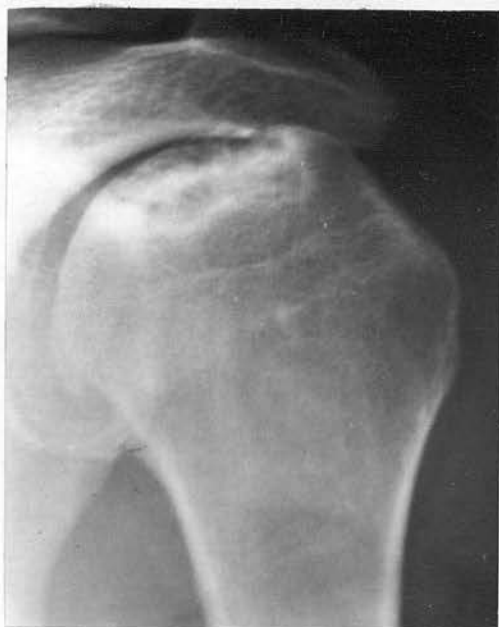
Fig. 28(b) (Case 5 - J.McV.) - Tomograph several months later shows that several fragments of articular surface have collapsed into the subcortical bone.



29 - Depression of a large segment of the articular surface in the left humerus. Wide curvi-linear layer present.

30(a) - Large dense areas in right humeral head, extending towards proximal shaft.

30(b) - Axillary projection demonstrates depression of articular surface more clearly.

Fig. 29 (46S)

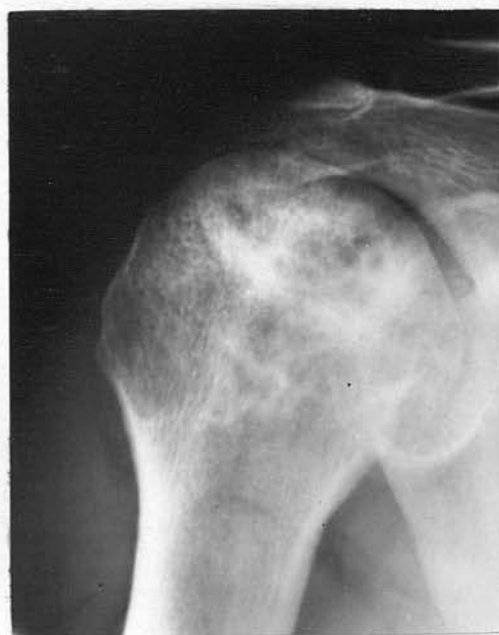

Fig. 30(a) (125/)

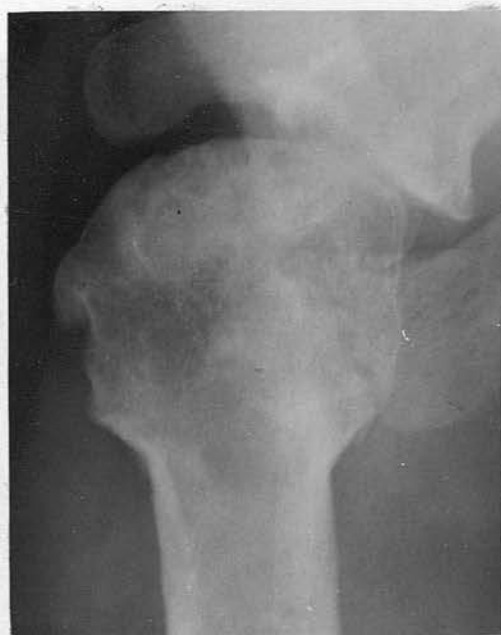

Fig. 30(b) (125S)

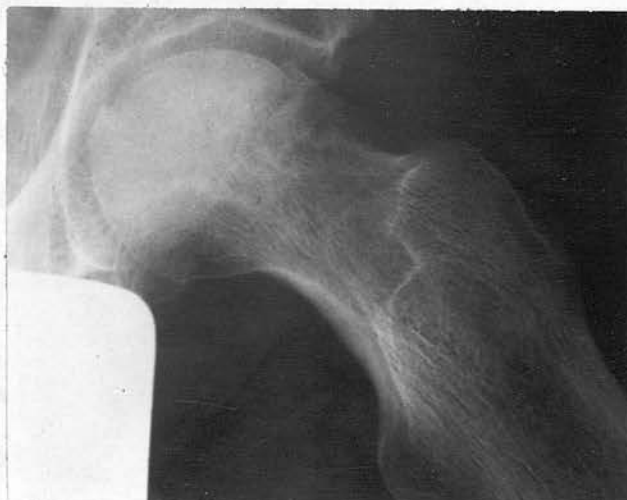

Fig. 31 (Case 6 - J.C.) - Lateral projection left hip showing collapse of large segment of articular surface in 'weight-bearing' area.

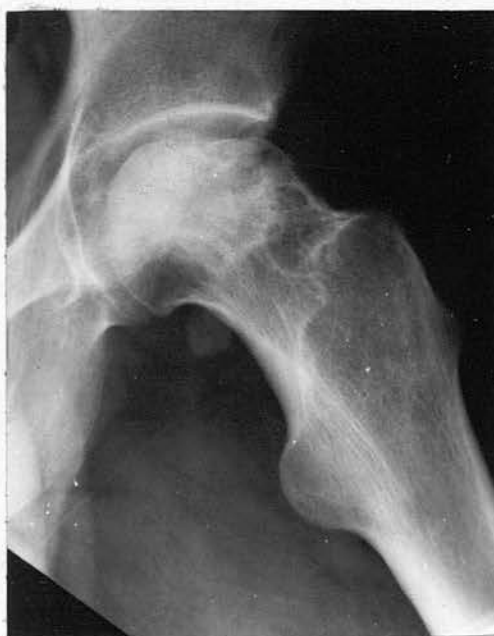

Fig. 32 (Case 4 - H.R.) - Lateral projection left hip showing collapse and irregularity of articular surface in 'weight-bearing' area.

'ARTICULAR' LESIONS

E. Sequestration of part of the cortex

This is a late manifestation of bone necrosis and the lesions are situated in the head of the femur or the humerus.

A large segment of the articular cortex, involving either the middle third or two thirds of the head of the humerus or the posterior area of the femoral head, appears separated from the adjacent bone by a translucent band. The translucency lies at some distance from the articular cortex. The sequestered segment is slightly displaced from the adjacent bone but is not depressed into the subcortical area. Occasionally small fragments of bone will be sequestered. The surrounding bone may be normal or show considerable increase in density.

The sequestered segment usually consists of necrotic bone, and, when the affected joint is explored, can be lifted out without much difficulty.

(Fig. 33(a) - 37(b))

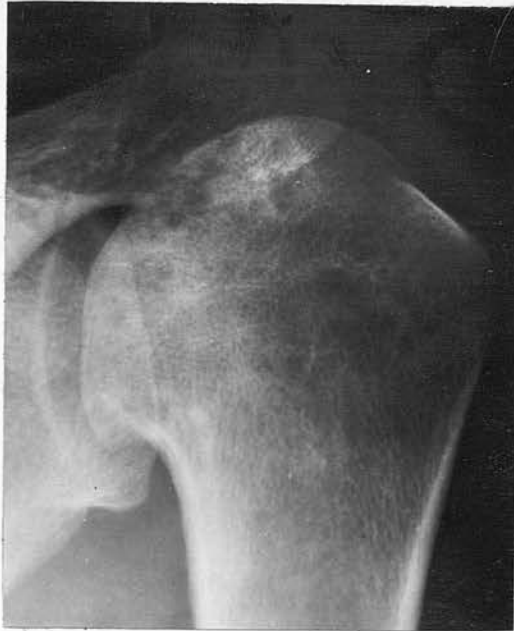

Fig. 33(a) (Case 10 - W.D.) - Dense areas in head of left humerus with irregularity of the articular surface.

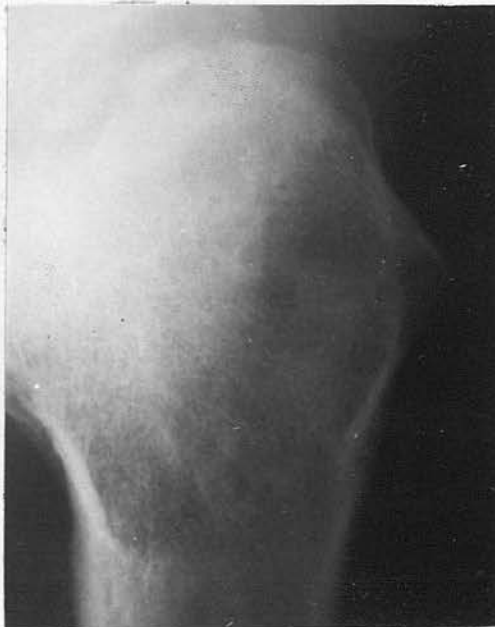

Fig. 33(b) (Case 10 - W.D.) - Axillary projection shows probable sequestration of the articular surface.

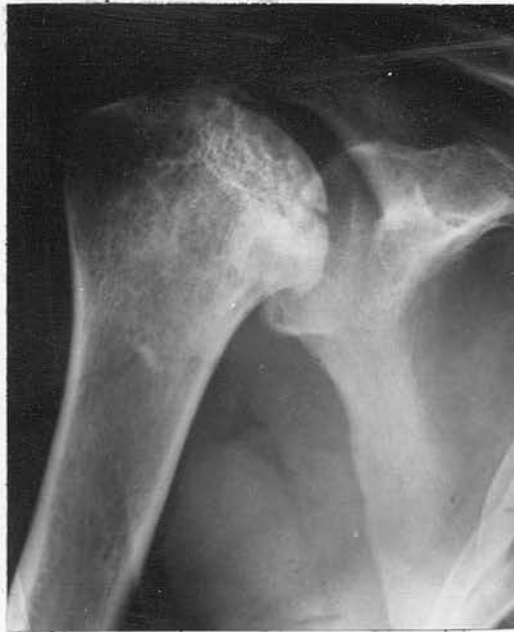

Fig. 34 (Case 12 - E.S.) - Probable sequestration of a large segment of the articular surface. Dense areas in the adjacent bone.

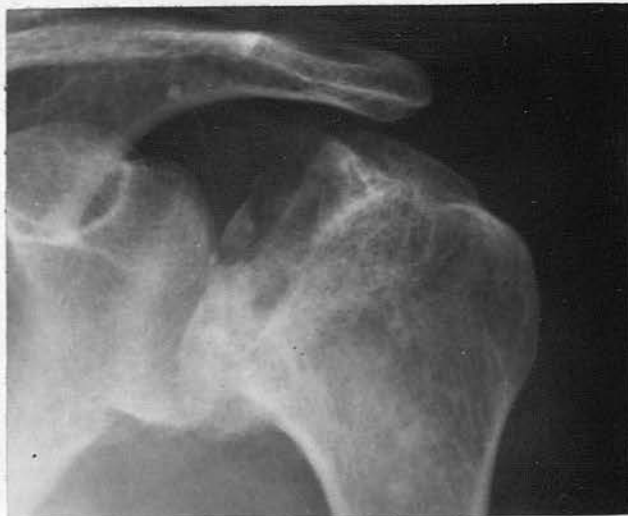
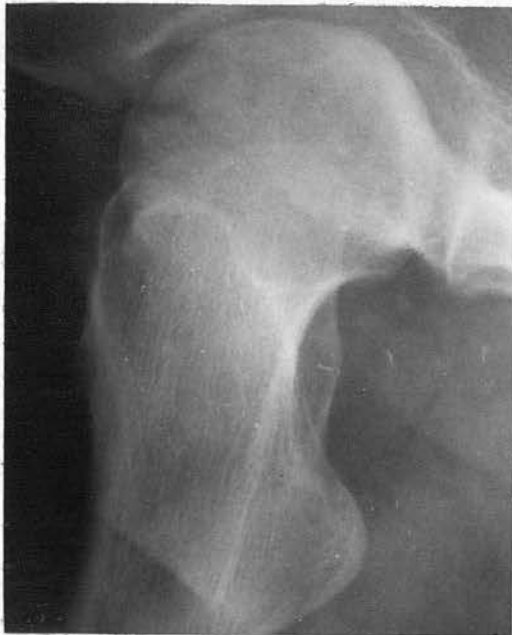
Fig. 35 (Case 8 - T.D.) - Considerable deformity with sequestration of several fragments.



36 - Lateral projection right hip with sequestration of 'weight-bearing' area.

37(a) - Lateral projection of right hip with sequestration of cortex and translucent area in the head and neck. See also Fig. 60(b).

37(b) - Sequestration present in head of left femur.

Fig. 36 (Case 13 - A.L.)

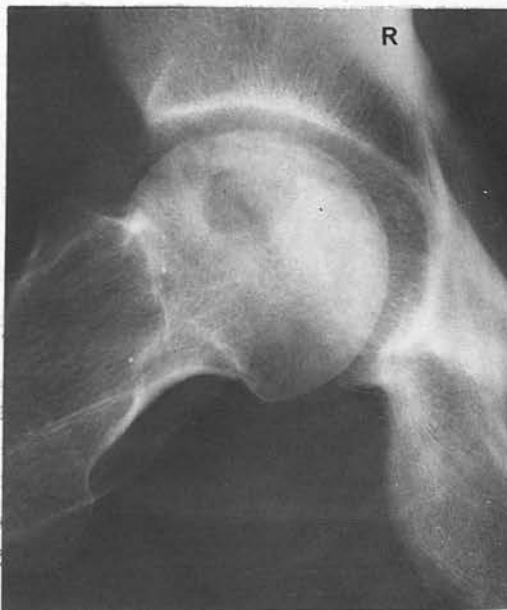

Fig. 37(a) (Case 7 - J.P.)

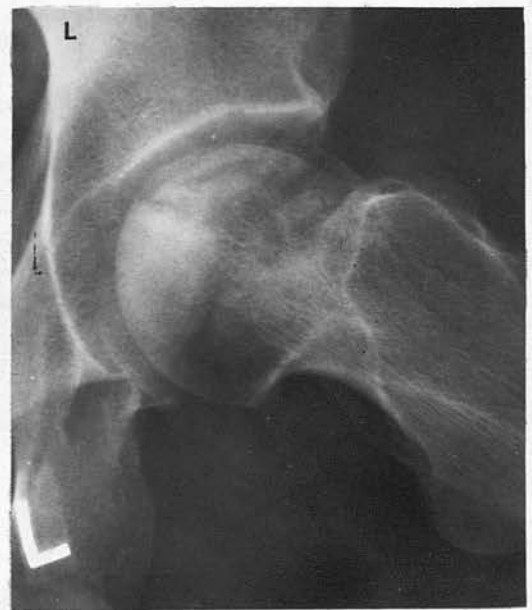

Fig. 37(b) (Case 7 - J.P.)

'ARTICULAR' LESIONS

F. Secondary osteoarthritis

This is a late complication of bone necrosis and symptoms will have been present for many years. The lesions may involve the head of the femur or the humerus.

The appearances are those of severe bone necrosis with dense sclerotic areas, infraction and possible depression or sequestration of the articular cortex. In addition there is osteophyte formation at the margin of the articular surface. In the two cases reported here the joint space is well preserved, and there is little evidence of osteoarthritis in the acetabulum or the glenoid.

The changes are those of osteoarthritis secondary to bone necrosis involving an articular surface. It is interesting to note that the joint space is preserved, in contrast to osteoarthritis resulting from articular degeneration.

(Fig. 38(a) - 39)

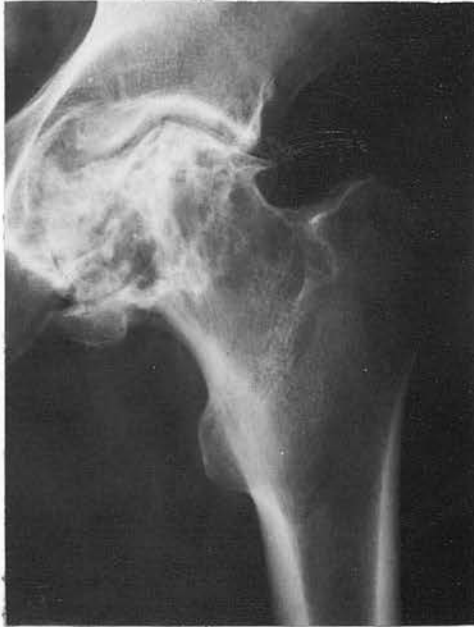

Fig. 38(a) (127S)

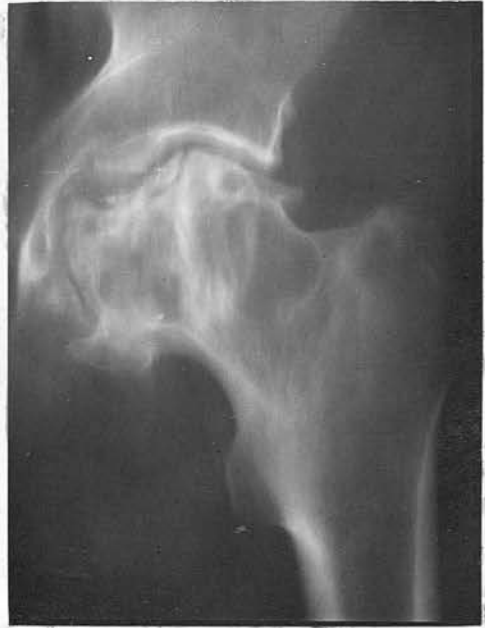

Fig. 38(b) (127S)

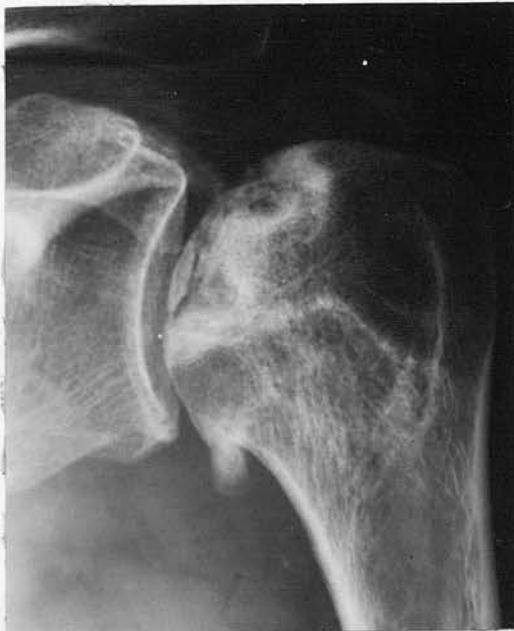

Fig. 39 (Case 14 - J.McA.)

38(a) - Severe osteoarthritis, probable separation of fragment of articular surface. Increased density of the femoral head.

38(b) - Tomograph confirms the osteophyte formation and demonstrates large translucent areas with fine sclerotic margins in head and neck of left femur.

39 - Long standing bone necrosis, with sequestration of articular cortex and marginal osteophytes.

'SHAFT' LESIONS

A. Dense areas at a distance from the articular cortex

These lesions are commonly found in the head, neck and proximal shaft of the femur and the humerus. Less commonly they are present in the distal shaft of the femur or proximal shaft of the tibia. The lesions are commonly multiple and bilateral, and are demonstrated at the initial radiographic examination.

The appearances are very similar to those already described in the 'Articular' section, the difference being that the lesions are situated at some distance from the articular cortex. Tomography helps to demonstrate the lesions more clearly. Occasionally a large area of bone may be involved.

The radiographic appearances probably result from re-ossification of a necrotic area of bone.

(Fig. 40(a) - 47)

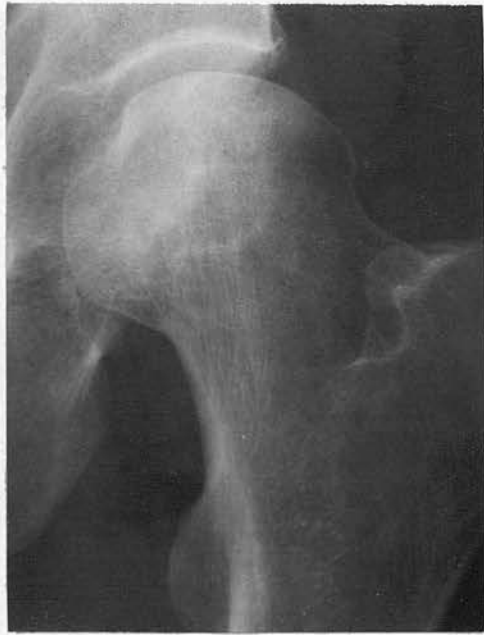

Fig. 40(a) (97S) - Small ill-defined dense areas in head and neck of right femur.

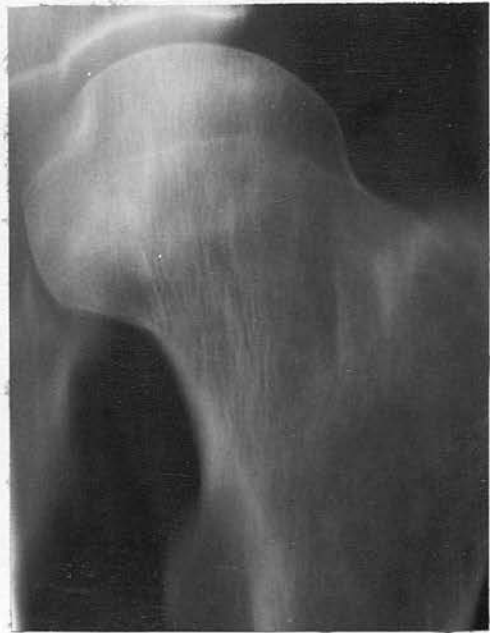

Fig. 40(b) (97S) - Tomograph demonstrates lesions more clearly.

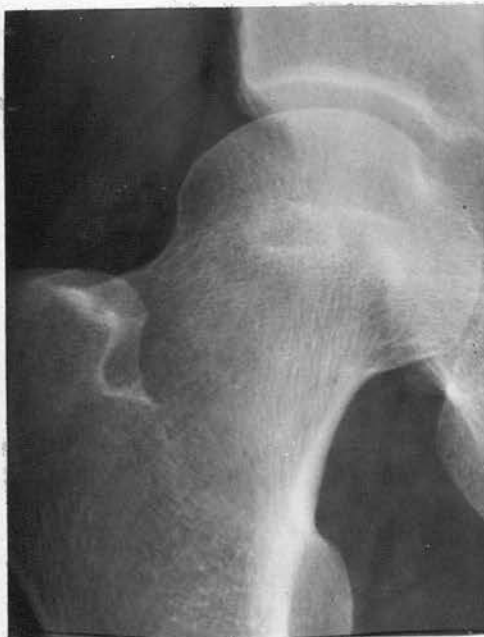

Fig. 40(c) (97S) - Small dense areas in neck of left femur.

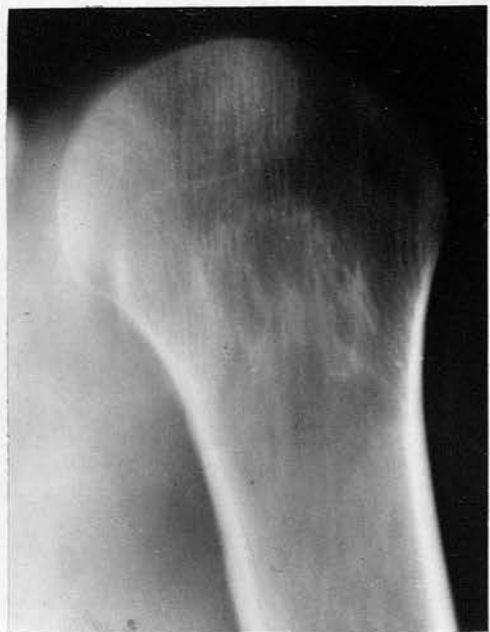
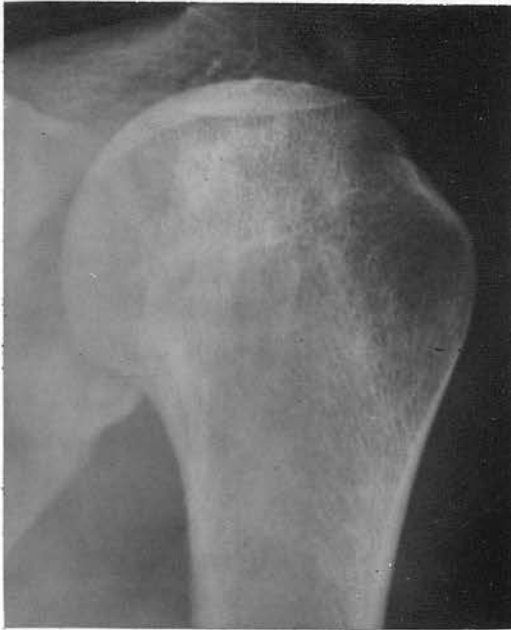
Fig. 40(d) (97S) - Tomograph demonstrates large irregular dense areas in proximal shaft of left humerus.



41 - Ill defined dense areas in head and neck of left humerus.

42(a) - Dense area in proximal shaft of right humerus.

42(b) - Similar lesion in left humerus.

Fig. 41 (54S)

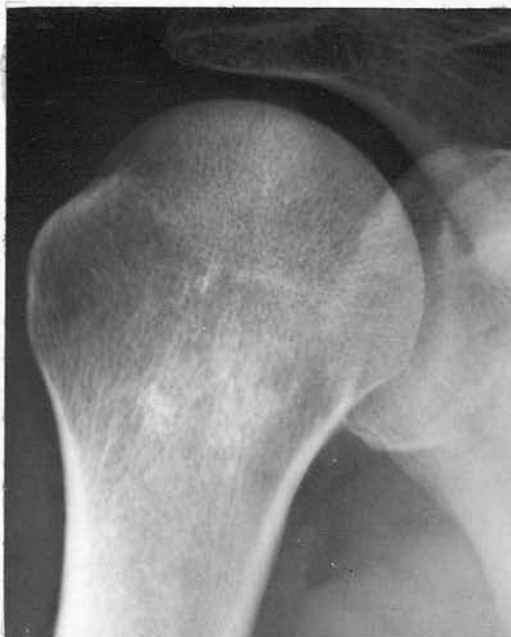

Fig. 42(a) (109S)

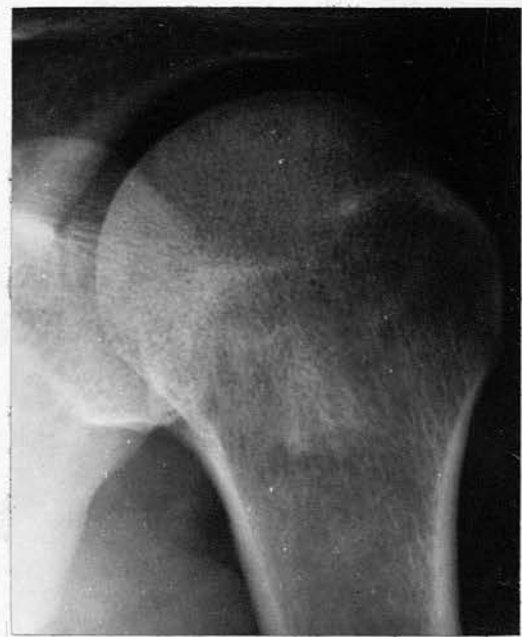

Fig. 42(b) (109S)

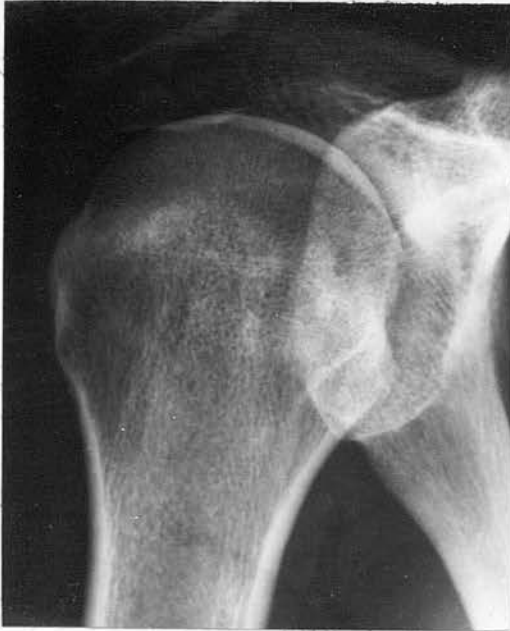

Fig. 43(135S)

43 - Small ill-defined dense area in neck of humerus

44(a) - Ill-defined dense area in neck of left femur.

44(b) - Tomograph shows irregular margins.

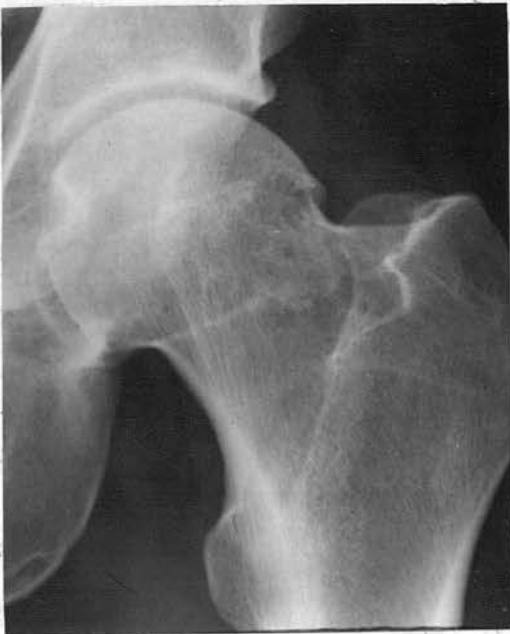

Fig. 44(a) (41S)

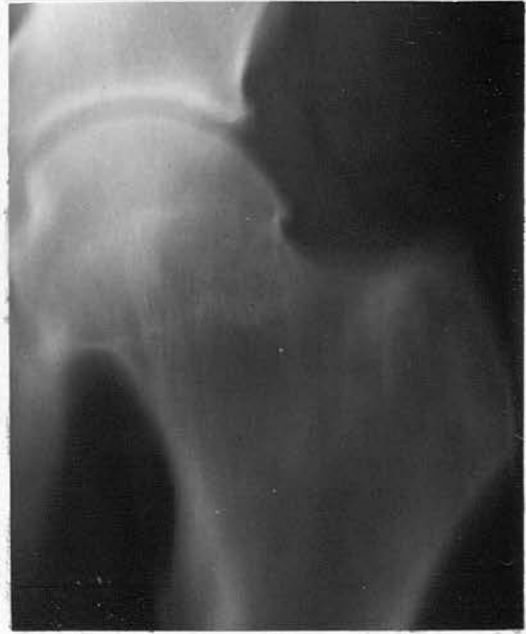

Fig. 44(b) (41S)

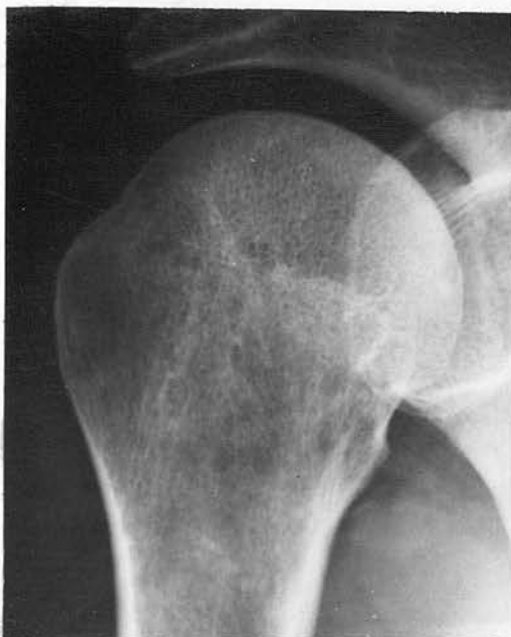

Fig. 45(a) (127S) - Small dense area in proximal shaft.

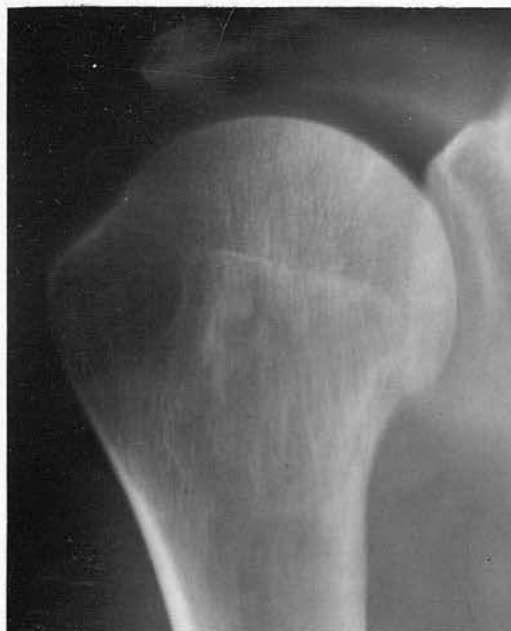

Fig. 45(b) (127S) - Tomography shows lesion.

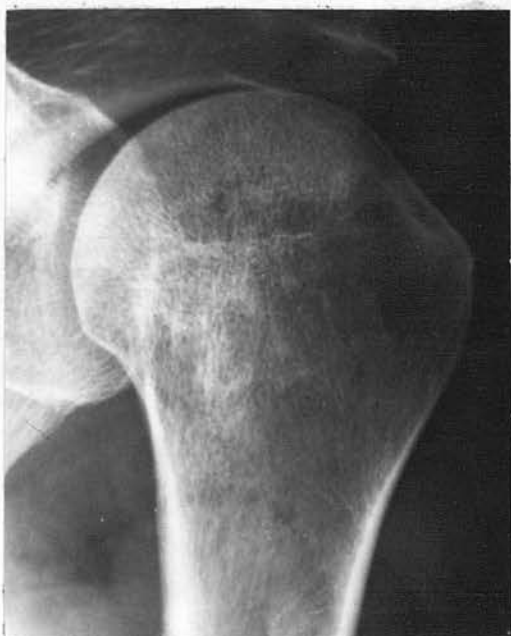

Fig. 45(c) (127S) - More definite dense areas in head and neck.

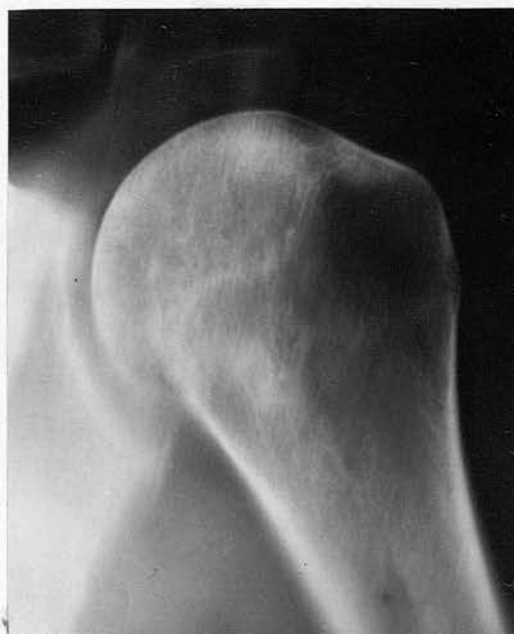

Fig. 45(d) (127S) - Tomography demonstrates more clearly.

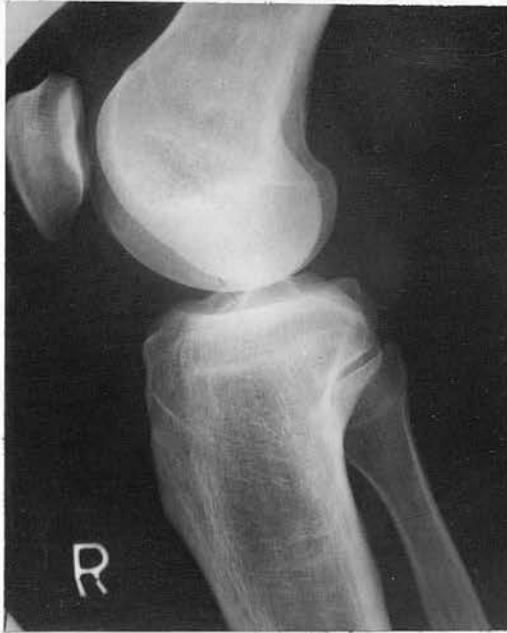

Fig. 46(a) (54S)

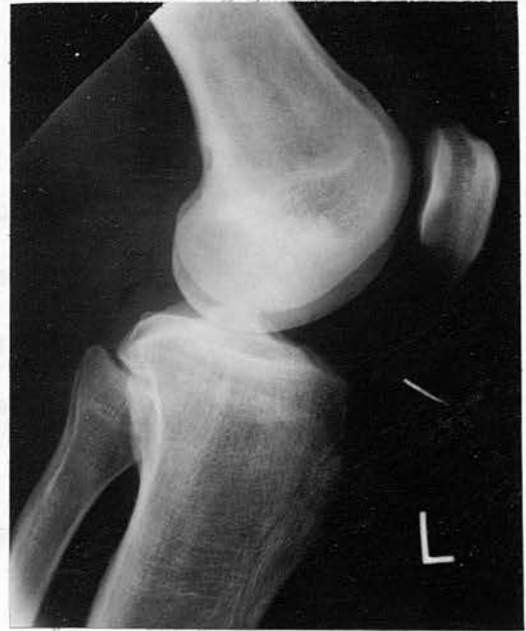

Fig. 46(b) (54S)

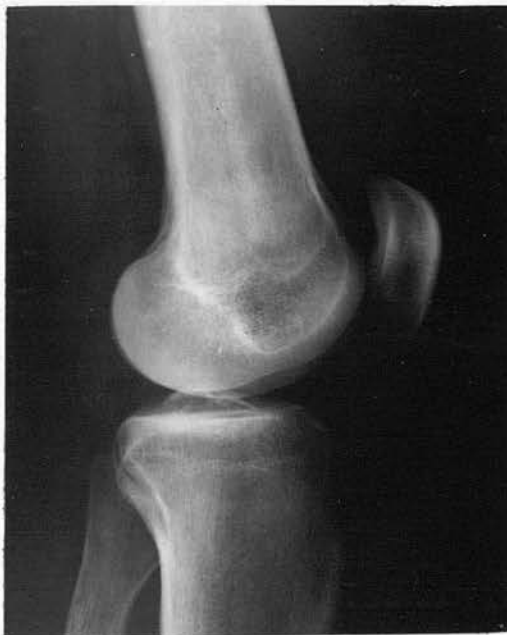

Fig. 47 (229S)

46(a) - Dense areas with 'mottled' appearance in distal shaft of right femur.

46(b) - Similar changes in left femur.

47 - Ill defined dense areas in distal shaft of right femur.

'SHAFT' LESIONS

B. Irregular calcified areas

These lesions are commonly situated in the distal shaft of the femur, in the proximal shaft of the tibia, and may be present in the proximal shaft of the humerus. The lesions are frequently bilateral and multiple.

The calcified areas can be of varying size and distribution. Occasionally they form a circular cluster of calcified lesions, or may form a continuous linear band extending for several centimetres. The lesions appear irregular and lie within the medulla of the bone. The cortex is not involved.

The radiographic appearances result from calcium being laid down in the fibrous tissue layer surrounding the necrotic area of bone.

(Fig. 48(a) - 51)

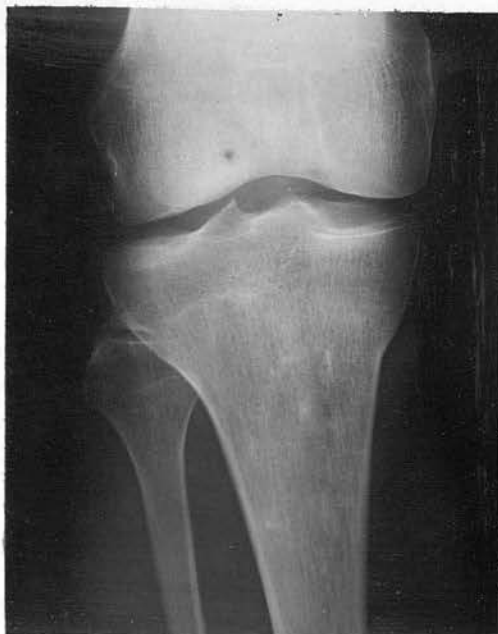

Fig. 48(a) (168S)

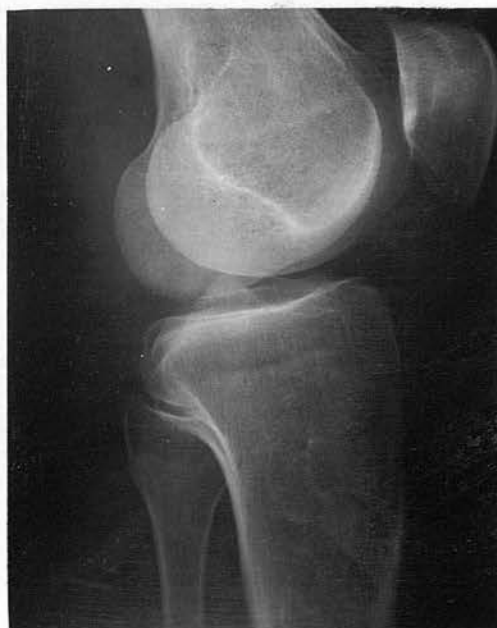

Fig. 48(b) (168S)

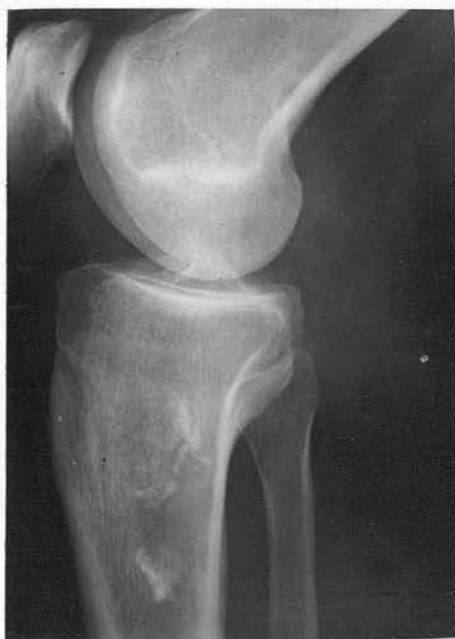

Fig. 49 (64S)

48(a) - Irregular calcified area in proximal shaft of right tibia.

48(b) - Lateral projection shows lesions more clearly.

49 - Large calcified area in proximal shaft of left tibia.

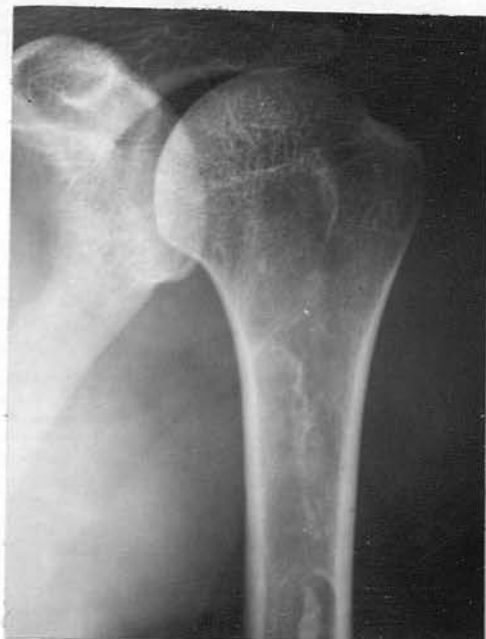

Fig. 50(a) (68S)

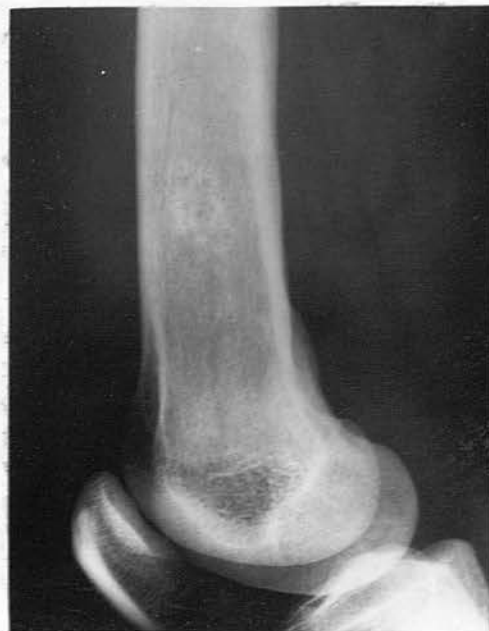

Fig. 50(b) (68S)

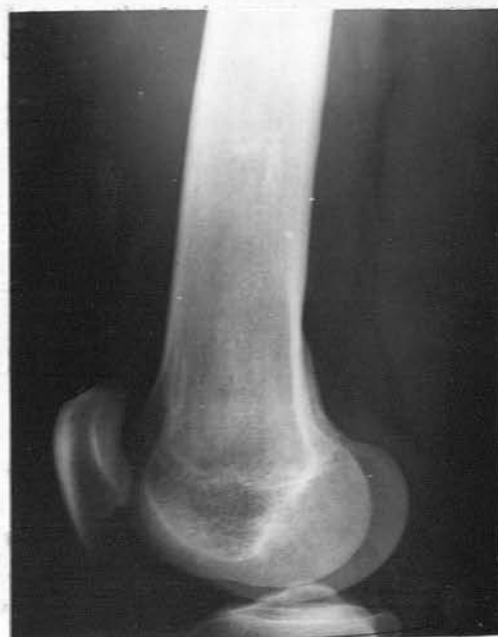

Fig. 51 (229S)

50(a) - Linear calcification in proximal shaft of left humerus.

50(b) - Small cluster of calcified areas in distal shaft of left femur.

51 - Calcification in distal shaft of femur.

'SHAFT' LESIONS

C. Translucent areas with sclerotic margins

This is an uncommon lesion and only a few examples have been seen in this study. The lesions are situated in the neck of the femur or in the head and neck of the humerus.

The translucent area can be of varying size, being as much as 2 cms. in diameter. The area is usually surrounded by a thin sclerotic margin. Tomography demonstrates the radiographic appearances more clearly. The lesion, situated in the head of the humerus, appears oval and follows the shape of the bone.

(Fig. 52(a) - 53(b))

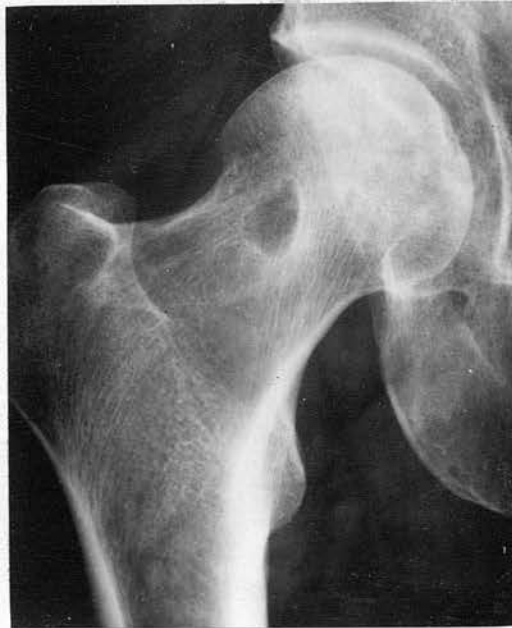

Fig. 52(a) (127S) - Translucent area (1.5 cm. in diameter) in neck of right femur.

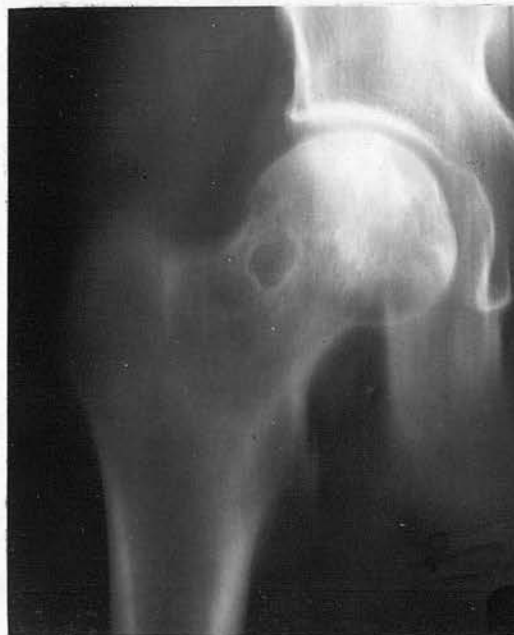

Fig. 52(b) (127S) - Tomograph shows translucency and the sclerotic margin.

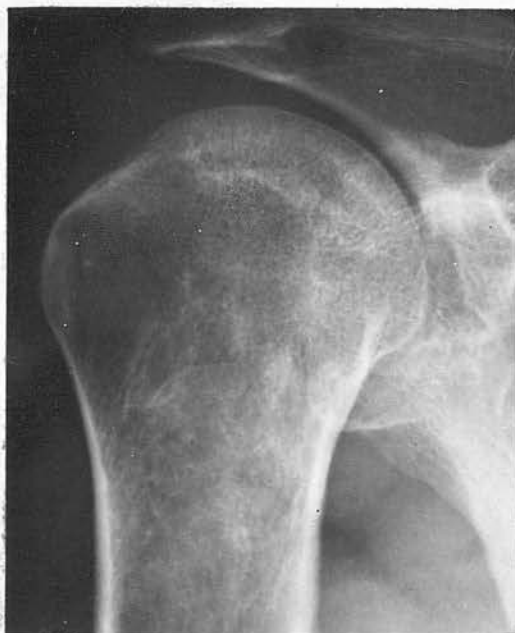

Fig. 53(a) (97S) - Large translucency with fine sclerotic margin follows the contour of humeral head.

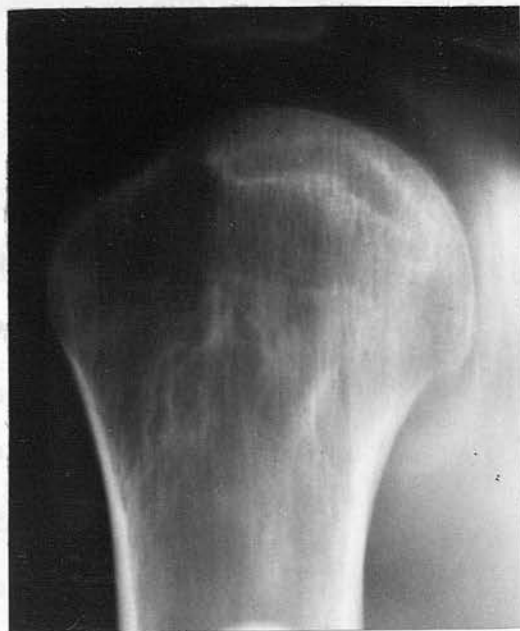

Fig. 53(b) (97S) - Tomograph shows lesion more clearly.

(d) Results

In this survey of two hundred and forty-one compressed air workers who had a radiographic examination of both shoulder joints, hip joints and knee joints, the following results were obtained.

Radiographic evidence of avascular necrosis of bone	- 40 men - (16.5%)
Doubtful evidence only	- 7 men - (2.9%)
No radiographic abnormality	- 194 men - (80.6%)

In ten of the above forty cases, the radiographic diagnosis was based solely on the presence of either dense sclerotic areas or ill defined calcified areas, there being no other radiographic evidence of the accepted change of bone necrosis. As these dense sclerotic areas frequently appear in the other thirty cases, where there is accepted evidence of bone necrosis, it is thought that these dense areas represent positive evidence of bone necrosis. This point will be developed in the discussion. The remaining thirty men had the classical radiographic changes of bone necrosis, which represents 12.4% of the total number who were examined.

(e) Frequency of lesions

The radiographs were reviewed and the number of the various types of lesions were assessed. The grouping of 'articular' lesions and 'shaft' lesions was made in order to have some idea of the frequency of those lesions which could give rise to symptoms. In many instances both 'articular' and 'shaft' lesions were present in the same case.

The results are as follows.

'Articular' Lesions

Dense sclerotic areas with intact articular cortex	- 9
Dense curvi-linear layer - 'snow-cap' All in the head of the humerus, except one - in the head of the femur.	- 13
Translucent subcortical band	- 7
Collapse of the articular cortex	- 2
Sequestration of part of the cortex	- 0
Secondary osteoarthritis	- 1
	<u>32</u>
TOTAL	<u>32</u>

'Shaft' Lesions

Dense areas at some distance from the articular cortex	- 24
Calcified areas of varying size	- 21
Translucent areas with sclerotic margins	- 3
	<u>48</u>
TOTAL	<u>48</u>

In assessing the frequency of lesions only those cases demonstrated in the radiographic survey were included and none of the illustrative cases were added. As expected, it has been shown that there is a high number of 'shaft' lesions in this survey of symptomless men. It will be shown subsequently, that of those men examined, eight were found to have symptoms resulting from their 'articular' lesions.

(f) Site of Lesions

The radiographs were again reviewed and, as in assessing the frequency of lesions, only those cases from the radiographic survey

were included. In this way it was hoped to show where the lesions would occur in a large group of men who were thought to be symptom free.

Table 3  
Number of 'Articular' and 'Shaft' Lesions  
in 47 Compressed Air Workers

Only cases from the Radiographic Survey are included.

	<u>Right</u>	<u>Left</u>	<u>Bilateral</u>	<u>Total Lesions</u>
Humerus				
(proximal)	7	11	11	40
Doubtful	4	5	1	11
Femur				
(proximal)	5	4	4	17
doubtful	3	4	0	7
Femur				
(distal)	6	3	5	19
doubtful	4	3	0	7
Tibia				
(proximal)	2	0	1	4
doubtful	1	0	0	1

Bone lesions are found to be multiple, and forty-seven men have positive or doubtful radiographic evidence of bone necrosis at a hundred and six different sites. A high proportion of these lesions are bilateral, and in fact, 41.5 per cent of all the lesions show bilateral involvement at the affected site. The other interesting and unexpected feature is the high frequency of lesions in the proximal end of the humerus, fifty-one lesions out of a total of a hundred and six, and that these are commonly bilateral.

As a basis for comparison a review was made of the published reports of bone necrosis occurring in compressed air workers and divers. The sites of these lesions are recorded in Appendix 1.

The results show that a hundred and fifty-three compressed air workers had a total of three hundred and seventy-nine bone lesions and that 37.5 per cent of these were bilateral. The site of these lesions has been summarised in Table 4.

Table 4  
Number of 'Articular' and 'Shaft' lesions in  
the published reports of Bone Necrosis  
in 153 Compressed Air Workers.

	<u>Right</u>	<u>Left</u>	<u>Bilateral</u>	<u>Total Lesions</u>
Humerus (proximal)	28	37	23	111
Femur (proximal)	38	44	26	134
Femur (distal)	11	5	12	40
Tibia (proximal)	10	8	14	46

Femur diaphysis included with distal femur. Tibia diaphysis included with proximal tibia. Proximal epiphyseal and metaphyseal areas of femur included with proximal femur. Proximal epiphyseal and metaphyseal areas of humerus included with proximal humerus. Diaphysis and distal ends of humerus, distal end of tibia, fibula not included.

The radiographic examination in the majority of these case reports, only included the known sites of bone necrosis, while in others the examination was more extensive.

Table 4 shows that the proximal ends of the femur and humerus are the most common sites of bone lesions and that the lesions are

multiple and frequently bilateral. Other sites may show evidence of bone necrosis and these include the shaft and distal end of the humerus, the proximal and distal ends and shaft of the fibula, the distal end and shaft of the tibia, the ischio-pubic rami, the acetabulum, the ilium and the clavicles.

Table 5

Number of 'Articular' and 'Shaft' lesions in  
the published reports of Bone Necrosis  
in 26 Divers.

	<u>Right</u>	<u>Left</u>	<u>Bilateral</u>	<u>Total Lesions</u>
Humerus (proximal)	5	5	12	37
Femur (proximal)	2	1	2	7
Femur (distal)	2	0	2	6
Tibia (proximal)	0	0	1	2

A similar analysis of the figures for divers in the review shows that twenty-six divers have a total of forty-nine bone lesions and that 69.4 per cent of these are bilateral. Table 5 shows a high proportion of these to be in the proximal end of the humerus. The radiographic appearances of these lesions are identical with those found in compressed air workers.

In view of the likelihood that lesions involving or adjacent to the articular cortex might be liable to cause symptoms, it was decided to analyse and tabulate the sites of such 'articular' lesions, in the present series.

Table 6

Number of 'Articular' Lesions at each site

Only cases from the Radiographic Survey are included

	<u>Right</u>	<u>Left</u>	<u>Bilateral</u>	<u>Total Lesions</u>
Humerus				
(proximal)	3	6	6	21
doubtful	0	3	0	3
Femur				
(proximal)	2	3	3	11
doubtful	1	2	0	3
Femur				
(distal)	0	0	0	0
doubtful	0	0	0	0
Tibia				
(proximal)	0	0	0	0
doubtful	0	0	0	0

Twenty-six men out of a total of forty-seven men i.e., - 55 per cent - have evidence of thirty-eight lesions which could be classified as 'articular' lesions. It is seen that there is a high frequency of lesions in the head of the humerus and these are commonly bilateral. Many of the 'articular' lesions are combined with 'shaft' lesions at other sites.

Table 7

Number of 'Shaft' Lesions at each site

Only cases from the Radiographic Survey are included

	<u>Right</u>	<u>Left</u>	<u>Bilateral</u>	<u>Total Lesions</u>
Humerus				
(proximal)	4	5	5	19
doubtful	4	2	1	8
Femur				
(proximal)	3	1	1	6
doubtful	2	2	0	4
Femur				
(distal)	6	3	5	19
doubtful	4	3	0	7
Tibia				
(proximal)	2	0	1	4
doubtful	1	0	0	1

Thirty-seven men out of a total of forty-seven, i.e., - 78 per cent - have evidence of sixty-eight lesions. The sites most commonly affected are the proximal shaft and neck of the humerus and the distal shaft of the femur. Many of the lesions show bilateral involvement at the affected site. Many of the 'shaft' lesions are often combined with 'articular' lesions at other sites.

A large number of 'shaft' lesions have been uncovered by this investigation, the explanation being that none of the men had complained of symptoms. They therefore constituted a group, most of whom would probably not have had a radiographic examination.

(g) Clinical Features

Forty-seven men with radiographic evidence of a positive or doubtful lesion were informed that the examination was "not entirely normal" and were advised to attend for further examination. Of the

thirty-eight men who attended for clinical examination, thirty-two men were known to have definite radiographic evidence of bone necrosis, while six had only doubtful evidence. All the men were examined by Professor Roland Barnes of the Orthopaedic Department in the Western Infirmary, Glasgow, and I am grateful for his permission in allowing me to study and report his clinical findings.

In reviewing the findings, it was found that there were sixteen men with 'shaft' lesions alone and these men had no symptoms or signs referable to their radiographic abnormality. All the joints had a normal range of movement.

A further sixteen men had radiographic evidence of an 'articular' lesion, either involving the articular cortex directly or close to the cortex which would be liable to become infRACTED. Many of these men had additional 'shaft' lesions.

Eight of the sixteen men were found to have symptoms referable to the radiographic abnormality at the affected joint.

Table 8

Relation of Radiographic Abnormality  
to the Clinical Findings

<u>Radiographic Lesion</u>	<u>No. of Lesions</u>	<u>No. with Symptoms</u>
Dense areas with intact articular cortex	6	0
'Snow-cap'	7	3
Translucent subcortical band	4	3
Depression of articular cortex	1	1
Sequestration of articular cortex	0	0
Secondary osteoarthritis	1	1

Symptoms and signs were absent in all the cases where the dense areas were close to the intact articular cortex.

Three out of the seven 'snow-cap' lesions gave rise to symptoms, in all three cases the lesions were in the head of the humerus and the articular cortex appeared intact on the radiographs. The symptoms were of occasional pain and stiffness in the affected shoulder joint varying in duration from two months to a year. The pain was present on abducting the arm, giving a painful arc, and when working above shoulder level. In one case, the pain caused the man to wake at night. All cases showed a normal range of movement of the affected joint, in one case, however, slight discomfort was noted in holding the right shoulder in abduction against strong resistance. The patient with bilateral 'snow-cap' lesions had noticed occasional pain on abduction of his left arm about a year before and this had subsequently disappeared. Two other patients with 'snow-cap' lesions were found to be free of symptoms. The presence of symptoms and signs in these three cases is thought to be evidence of damage to the articular cartilage.

Symptoms were present in three of the five cases where the radiographic lesion appeared as a translucent subcortical band. The pain was of sudden onset in one case, developing after lifting a heavy bag of tools. All patients had difficulty in abducting the arm and one noticed pain when working at a height above shoulder level. Examination of the affected joint demonstrated difficulty in abducting the arm over  $90^{\circ}$  and in one case, a scapular movement completed the last  $60^{\circ}$  of full abduction. All cases showed limited internal rotation of the arm.

When there was depression of the articular cortex, the patient had experienced comparatively severe pain for four to six months and this was aggravated by heavy work. The patient could not recall if the pain had been of sudden onset. Examination revealed a 'painful arc' of movement from 90° abduction up to a maximum of abduction which was 15° less than normal. A similar 'painful arc' was present on forward elevation. Discomfort was noted at extreme internal rotation of the arm. There was no muscle wasting or tenderness.

The patient with severe osteoarthritis of his left hip joint had experienced pain for twenty-six years. A limp was present on the left side and the joint was held in a position of abduction and flexion. Muscle wasting was noted with marked limitation of movement.

(h) Relation of Age to Bone Lesions

The age of all the compressed air workers was studied.

Table 9

Age of 241 Compressed Air Workers

		<u>Men with bone lesions</u>
15 - 19 years	6 men	0
20 - 24 years	39 men	4
25 - 29 years	53 men	9
30 - 34 years	53 men	9
35 - 39 years	42 men	7
40 - 44 years	26 men	4
45 - 49 years	7 men	2
50 - 55 years	3 men	2
Over 55 years	6 men	3

Six ages not available.

Study of these figures (Table 9) shows that most of the two hundred and forty-one compressed air workers were between twenty and forty years of age. The incidence of bone lesions is much higher in the men over forty-five years of age, the majority of whom are long term compressed air workers.

(i) Relation of Occupational History to Bone Lesions

A record of the maximum pressure of air within the tunnel, decompressions, and attacks of decompression sickness (type 1 and 2) during construction of the Clyde Tunnel, and a history of previous work in compressed air was obtained for each man with the help of the contractors - Messrs. Charles Brand and Co.

The information, together with the results of the radiographic examination, was abstracted on to a record sheet from which it was transferred to a punched tape for analysis by a Pegasus Computer. All forty-seven cases with positive and doubtful radiographic evidence of bone necrosis were counted as bone lesions. This work was done in conjunction with Mr. D. N. Walder in the University of Durham, Newcastle upon Tyne, and I am grateful to be allowed to reproduce Tables 10(a) to 13(b). The interpretation and conclusions are my own.

One of the important problems requiring solution was the relationship, if any, between the length of time at any pressure in excess of normal and the presence of bone lesions. It became clear that it would be impractical to extract the exact number of hours which each man had spent in compressed air at varying pressures. However each man, who had been exposed to a pressure in excess of 18 lbs. p.s.i., would be decompressed in accordance with the Regulations. Therefore it was decided to relate the

total number of decompressions for each man with the presence of absence of bone lesions. Those with the larger number of decompressions would have the longer experience in compressed air. The total number of workers was further divided into a group of two hundred and twenty-three men who worked at an increased pressure of air for the first time at the Clyde Tunnel, and a second group of eighteen men who had previous experience of this type of work. The majority of the latter group were key members of the Company who had worked for many years in tunnel construction.

Table 10

Relation of Decompressions to Bone Lesions

(a) No previous experience.

Number of decompressions (any pressure)	<u>without lesions</u>	<u>with lesions</u>
0 - 74	10	1
75 - 149	12	1
150 - 224	15	2
225 - 299	16	1
300 - 374	10	0
375 - 449	13	3
450 - 524	12	0
525 - 599	15	1
600 - 674	8	2
675 - 749	9	2
750 - 824	7	1
825 - 899	10	3
900 - 974	3	5
975 - 1049	7	2
1050 - 1124	5	2
1125 - 1199	5	1
1200 - 1274	2	1
1275 - 1349	9	3
1350 - 1424	3	2
1425 - 1499	3	1
1500 - 1574	1	2
1575 - 1649	3	1
1650 - 1724	7	1
<u>Total No. of men</u>	<u>185</u>	<u>38</u>
Average number of decompressions	646 <sup>±</sup> 34	908 <sup>±</sup> 72
Difference	262 <sup>±</sup> 81 - significant at 1% level	

(b) Previous experience.

	<u>without lesions</u>	<u>with lesions</u>
Number of men	9	9
Average No. of decompressions	1090	1156
Range of No. of decompressions	498 - 1652	662 - 1536
Difference between average number of decompressions		66 $\pm$ 173 n.s.

Summary of Table 10(a)

<u>Number of decompressions</u>	<u>Total men</u>	<u>with lesions</u>	<u>% with lesions</u>
0 - 299	58	5	8.8
300 - 599	54	4	7.4
600 - 899	42	8	19.0
900 - 1199	30	10	33.3
1200 & over	39	11	28.2
Total	<u>223</u>	<u>38</u>	17.0

As the number of decompressions rises there is a corresponding rise in the proportion of men with bone lesions. If a man is employed for a year in tunnel construction, he will work for approximately three hundred shifts and each shift is followed by a decompression. It can be assumed that the majority of men are employed on a working shift of eight hours and each shift is then counted as one decompression. The percentage of bone lesions increases from 8.6 per cent in men who worked for less than a year, having experienced less than three hundred decompressions, to 33 per cent in men who have worked for over three years.

Only a small proportion of men require to enter and leave compressed air on several occasions during a working shift. These men, having frequent short exposures and numerous decompression, are included in the group of one thousand two hundred decompressions and over (Table 10(a) Summary). Further analysis was not possible in this group, this is unfortunate as valuable information might have been obtained of the effect of short exposures to compressed air of four hours and less on the incidence of bone lesions. It may be that the incidence of lesions would decrease if the period of exposure was reduced.

In the men with previous experience of this type of work, there is a 50 per cent incidence of bone lesions. These men tended to be in the older age group and have had up to twenty-six years experience in compressed air. The average number of decompressions, Table 10(b), indicates that these men have been employed throughout most of the contract at the Clyde.

It appears from the analysis of the men with no previous experience in compressed air, that the incidence of bone lesions increases with the length of time in compressed air, and this is supported by the high incidence - 50 per cent - of bone lesions, who had worked at increased pressure of air, often for many years, before coming to this contract.

#### Relation of Air Pressure to Bone Lesions

Another point of interest was the possible relationship between the maximum pressure of air to which each man was exposed and the number of bone lesions.

Table 11

Relation of Maximum Pressure to Bone Lesions

(a) No previous experience.

Max. pressure (lbs. p.s.i.)	18	25	30	34	Total
With lesion	1(6%)	3(10%)	10(11%)	24(29%)	38(17%)
Without lesion	17	27	83	58	185
Total	18	30	93	82	223

There is a significant association between lesion and pressure  
 $(\chi^2 = 14.0, D.F. = 3, P \text{ is less than } 0.01)$

(b) Previous experience.

Max. pressure (lbs. p.s.i.)	30	34	Total
With lesion	3	6	9
Without lesion	3	6	9
Total	6	12	18

This demonstrated a significant incidence of bone necrosis - 29 per cent - at pressures over 30 lbs. p.s.i. in those with no previous experience of this type of work. No similar association is demonstrated in the men who have worked at an increased pressure of air before coming to the Clyde (Table 11(b)). Their <sup>previous</sup> history of exposure and maximum pressure are not known.

Relation of Type 1 and Type 2 Decompression Sickness to Bone Lesions

A study of the relation between the episodes of type 1 decompression sickness - "the bends" - and the presence of bone lesions was carried out in both those without and with previous

experience, Tables 12(a) and (b). A similar study showed the relation between episodes of type 2 decompression sickness and the presence of bone lesions in the two groups of men, Table 13(a) and 13(b).

Table 12

Relation of Type 1 - "the bends" -  
to Bone Lesions

(a) No previous experience.

					<u>With</u> <u>lesions</u>	<u>Without</u> <u>lesions</u>
Men with no Type 1					21 (55%)	160 (86%)
"	"	1	"	"	8	11
"	"	2	"	"	7	7
"	"	3	"	"	1	2
"	"	4	"	"	1	2
"	"	5	"	"	0	1
"	"	8	"	"	0	2
					—	—
					<u>38</u>	<u>185</u>

Of those men with lesions, significantly more have experienced at least one incident of type 1 - "the bends".

$$(x^2 = 18.1, \text{d.f.} = 1, P \text{ is less than } 0.001)$$

(b) Previous experience.

					<u>With</u> <u>lesions</u>	<u>Without</u> <u>lesions</u>
Men with no Type 1					4	4
"	"	1	"	"	4	3
"	"	2	"	"	0	2
"	"	7	"	"	1	0
					—	—
					<u>9</u>	<u>9</u>

Study of those men with no previous experience in compressed air (Table 12(a) ) shows that 45 per cent of those with a bone lesion had experienced type 1 decompression sickness - "the bends" - and of those whose bones were normal, only 14 per cent had experienced type 1 decompression sickness.

Analysis of these figures suggests that the greater the frequency of type 1 decompression sickness, then the more likely is bone necrosis.

Type 1 - "the bends" occurred most frequently in three men. The two men who had experienced eight episodes of type 1 and had no previous experience to compressed air, both had no bone lesions. While the third man with seven episodes of type 1, and a history of previous exposure to compressed air, had a bone lesion.

Among the men with previous experience in compressed air, Table 12(b) - there was no significant relation between the episodes of type 1 decompression sickness and the presence or absence of bone lesions.

Table 13

Relation of Type 2 to Bone Lesions

(a) No previous experience.

	<u>With</u> <u>lesions</u>	<u>Without</u> <u>lesions</u>
Men with no Type 2	36	178
" " 1 " "	2	5
" " 2 " "	0	2
	—	—
<u>Total</u>	<u>38</u>	<u>185</u>

(b) With no previous experience

	<u>With lesions</u>	<u>Without lesions</u>
Men with no Type 2	3	6
" " 1 " "	4	2
" " 2 " "	2	1
	-	-
<u>Total</u>	<u>9</u>	<u>9</u>

Study of the relation between type 2 decompression sickness and the presence of bone lesions, (Tables 13(a) and 13(b) ), shows that type 2 lesions are infrequent and there is no tendency to associate with bonelesions.

At this stage it is important to realise that a man was recorded as having type 1 or type 2 decompression sickness if he reported his symptoms and these were treated by therapeutic recompression. Many men experienced a similar, less severe pain-"the niggles" - and did not report their symptoms. Consequently these untreated "bends" are not recorded, and the incidence of type 1 or type 2 decompression sickness may be artificially low.

Although the site of the type 1 lesion was recorded, it was not possible to relate this site with the subsequent site of the bone lesion.

In conclusion, there is a 17 per cent incidence of both positive and doubtful lesions in two hundred and twenty-three men who had worked at an increased pressure for the first time at this tunnel. Approximately half of the men had worked for less than two years. In the eighteen men who had previous experience of this type of work, there is a 50 per cent incidence of positive

and doubtful bone lesions.

There is good evidence to state that the greater the number of shifts a man works in compressed air, the higher the risk of acquiring a bone lesion, and that such lesions are more liable to occur with work at pressures above 30 lbs. p.s.i.

There is a significant increase in the incidence of type 1 decompression in those men with bone lesions, and it is possibly true to say that the greater the frequency of type 1 or "the bends", the more likely is the possibility of a bone lesion.

ILLUSTRATIVE CASES

The following eleven illustrative case reports are of men who had worked in compressed air during construction of the Tunnel and had left employment, for one reason or another, before the radiographic survey commenced.

All the men presented because of symptoms and signs of avascular necrosis of bone involving the hip or shoulder joint. Four men, who were experienced compressed air workers, probably had bone necrosis before coming to the Clyde. Seven men worked in compressed air for the first time at this tunnel and their symptoms commenced about two years after exposure to compressed air.

Only two of these men were examined at the Southern General Hospital and the remainder were seen at the Diagnostic Radiology, Orthopaedic, and Surgical out-patient Departments of several hospitals in Glasgow and the West of Scotland. I am indebted to many colleagues who have kindly allowed me to study and report on their findings. In some cases it was not possible to include tomography or special projections at the radiographic examination.

Case 4 H.R. 21 years.

This patient worked regularly in compressed air for the first time at pressures up to 27 lbs. p.s.i. for four months from 2nd February to 5th June, 1961. He did not experience type 1 or type 2 decompression sickness.

He presented two years later with a history of pain and stiffness in his left hip of one years duration. On examination he was found to have limitation of flexion of the left hip. External rotation was considerably reduced and internal rotation was absent.

Radiographic examination revealed avascular necrosis of bone involving the head of the left femur with collapse and depression of the articular cortex posteriorly (Figs.54(a) and (b) ). A large part of the femoral head showed considerable increase in density and several translucent areas were noted. Radiographs of the right hip, both shoulders and knee joints were normal.

An arthrodesis was carried out on the left hip and several fragments of bone were removed and replaced by bone chips. Histological study revealed the articular cartilage to be viable, the underlying subchondral bone was necrotic, and revascularisation was noted at several sites with laying down of new bone on the dead trabeculae.

Case 4 H.R.

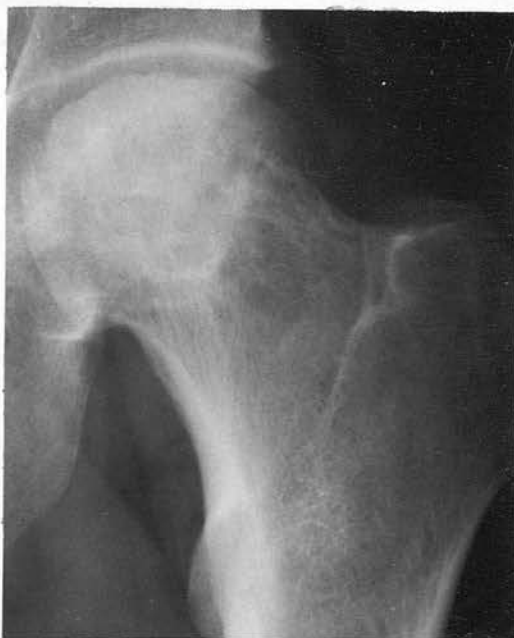

Fig. 54(a) - Increased density of left femoral head and neck with irregularity of the cortex.

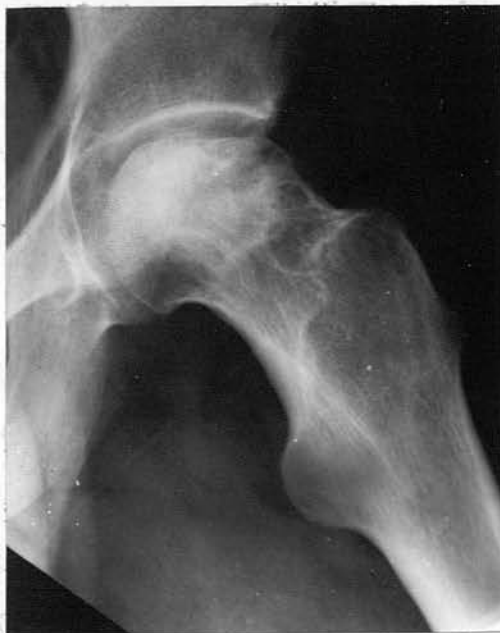

Fig. 54(b) - Lateral projection showing collapse and irregularity in 'weight-bearing' area.

Case 5 J.McV. 29 years.




This patient worked in compressed air for the first time on the 5th and 6th July, 1960 at pressures of  $24\frac{1}{2}$  lbs. p.s.i. for eight hours. On each occasion he had a severe attack of type 1 decompression sickness characterised by severe pain in the right shoulder and both knees. He was treated by recompression. Following this, he continued work at the tunnel, but was excluded from compressed air.

On 6th July 1962, he presented with a history of progressive pain and stiffness in his right shoulder of nine months duration. He remembered twisting his shoulder and had felt a "click" in September 1961 when cranking a heavy engine. On the right side abduction was possible to  $90^{\circ}$  with slight pain, and the arm could not be externally rotated. Similar less marked symptoms were present in the left shoulder. Slight restriction of abduction was noted on the left side.

Radiographic examination showed typical changes of avascular bone necrosis involving the heads of both humeri. On the right side there was increased density of the head of the humerus, with irregularity of the articular cortex, (Fig. 55(a) ), this is confirmed on the axillary projection (Fig. 55(b) ). Tomography of the right shoulder (Fig. 55(c) ), several months later, clearly demonstrated that several fragments of the articular cortex had sunk into the subchondral bone. The dense sclerotic areas involved the entire head of the humerus and extended into the shaft. On the left side there is similar increased density of the head of the humerus, with probable sequestration (Fig. 56(a) ). This is more clearly seen on the axial projection (Fig. 56(b) ), and on tomography (Fig. 56(c) ).

A chest radiograph in July 1962 (Fig. 57) demonstrated

fibrotic scars and bullae in the apical segment of the left upper lobe. Radiographs of both hip and knee joints were normal.



Case 5 J.McV.

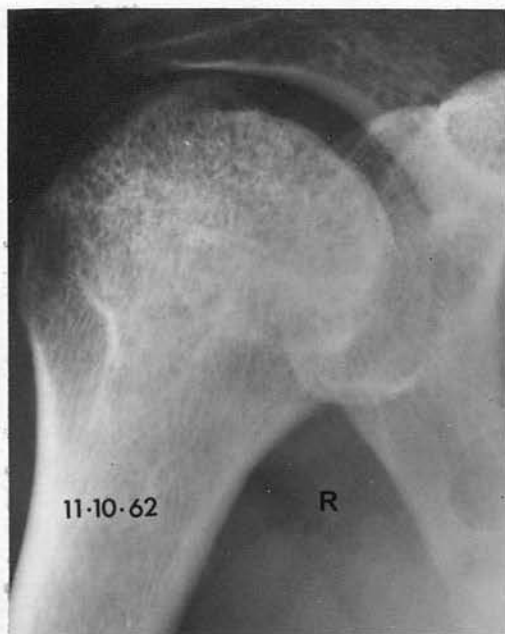


Fig. 55(a)

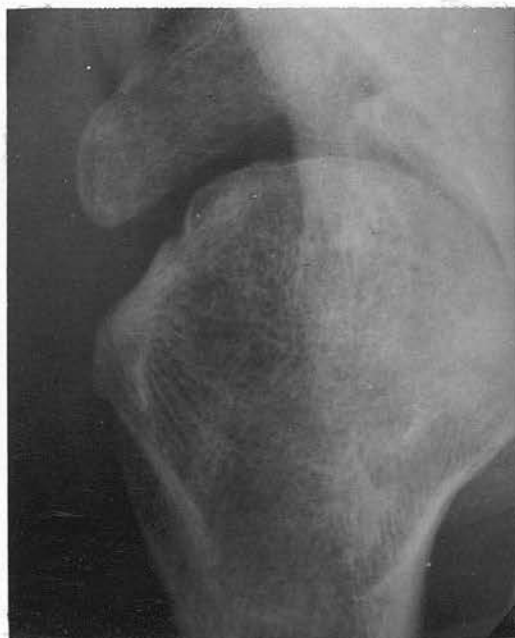

Fig. 55(b)

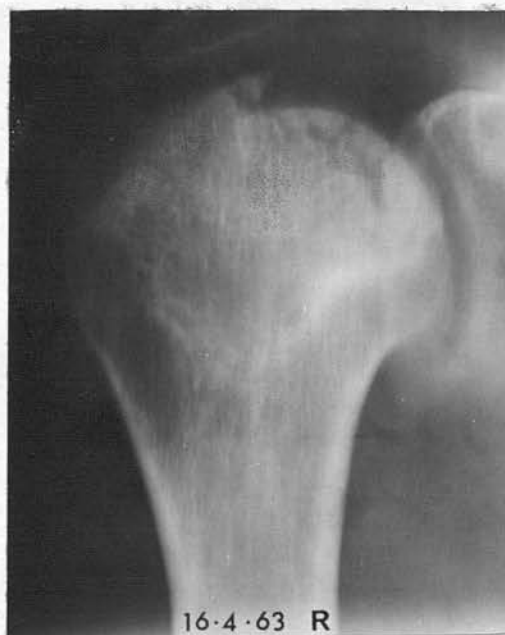

Fig. 55(c)

55(a) - Depression of segment of articular cortex. Dense areas involve head and extend to proximal shaft.

55(b) - Axillary projection demonstrates irregularity of articular surface.

55(c) - Tomograph several months later shows that several fragments have sunk into subcortical bone.

Case 5 J.McV.

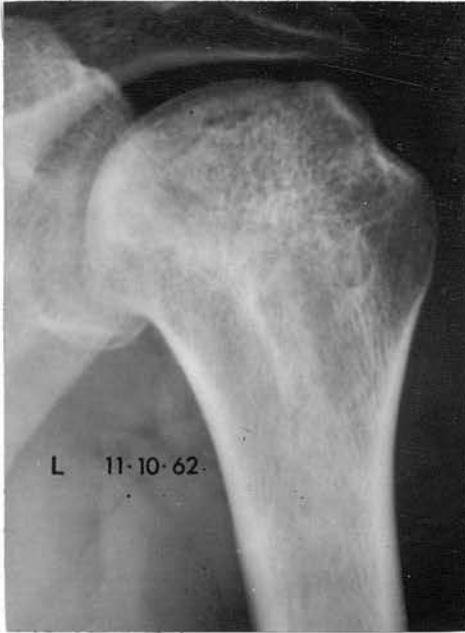

Fig. 56(a) - Increased density of left humeral head extending towards proximal shaft.

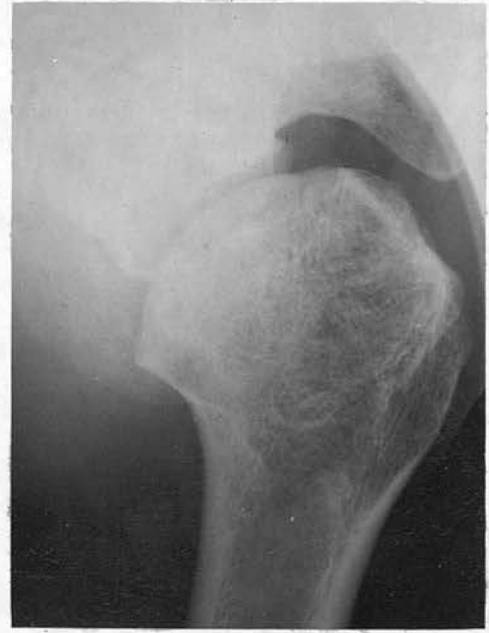

Fig. 56(b) - Axillary projection demonstrates probable sequestration.

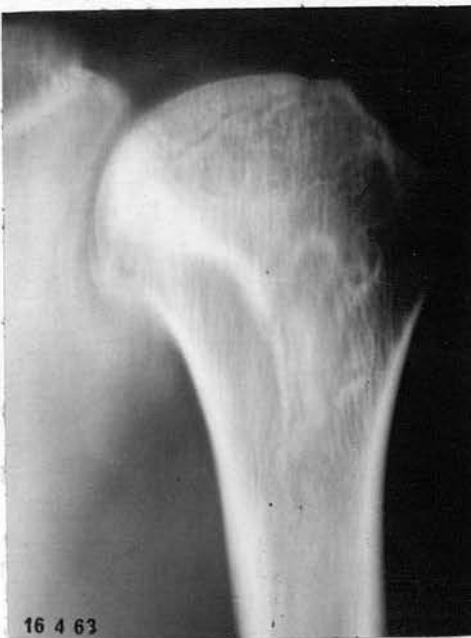

Fig. 56(c) - Tomograph confirms likelihood of sequestration and shows extent of dense areas.

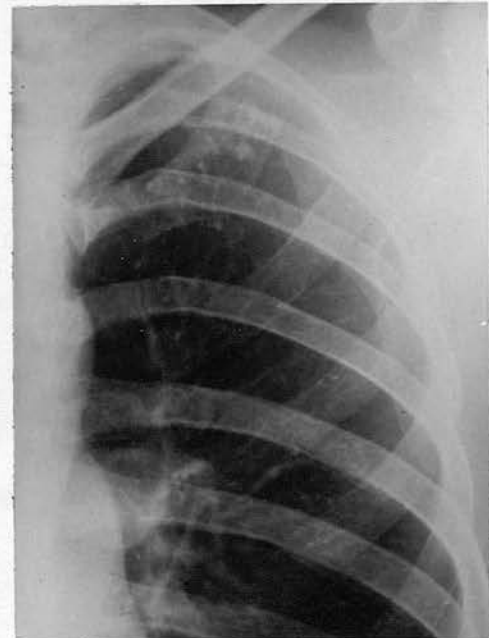

Fig. 57 - Calcified foci with probable bullae in left upper lobe.

Case 6 J.C. 33 years.

This patient had not previously worked in compressed air. On the 9th and 10th May 1959 he was subjected to pressures of 30 lbs. p.s.i. for four and a half hours and seven hours respectively. After the second shift, he required recompression for paralysis of both legs (type 2). On the 9th August 1959 he again worked at  $25\frac{1}{2}$  lbs. p.s.i. without any further trouble, but was not subsequently exposed to compressed air. A radiograph of his left hip (Fig. 58(a) ), taken on 29th November 1960, showed typical changes of bone necrosis with infraction of the articular cortex involving over half the area of the left femoral head.

Subsequent radiographs (Fig. 58(b) ) on 29th January 1962 showed progressive sclerosis of the left femoral head with some associated areas of translucency. The deformity of the femoral head persisted.

Bone necrosis was also present in the head of the right humerus (Fig. 59). Radiographs of other joints were normal.

Case 6 J.C.

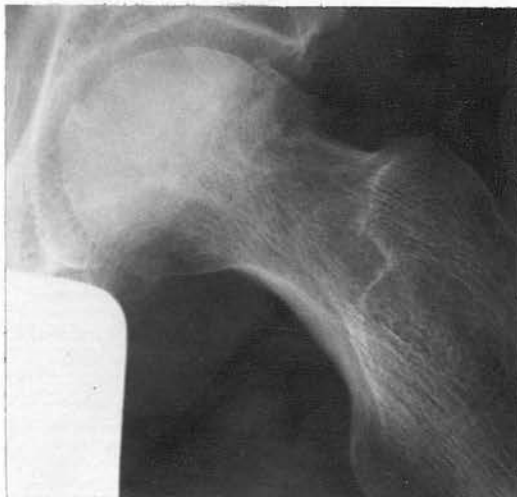

Fig. 58(a)

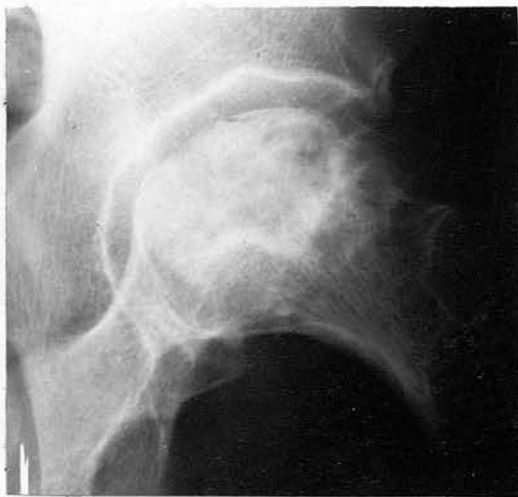

Fig. 58(b)

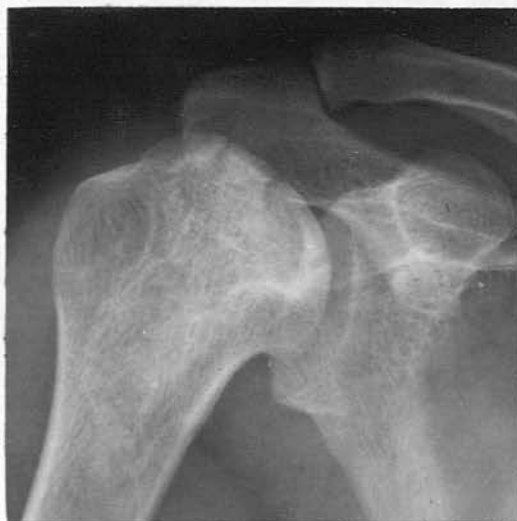

Fig. 59.

58(a) - Lateral projection left hip - 21st Nov. 1960 - infraction and collapse of posterior area of femoral head.

58(b) - Same projection - 29th Jan. 1962 - progressive increase in density from revascularisation. Deformity of the head persists and several translucencies are present.

59 - Bone necrosis in head of right humerus with partial depression of several fragments.

Case 7 J.P. 45 years.

This patient worked in compressed air for the first time at pressures up to a maximum of 32 lbs. p.s.i. from 30th August 1959 to 3rd July 1960. He was successfully recompressed on one occasion on 8th September 1959 following an attack of type 1 decompression sickness affecting both lower limbs.

He presented in May 1961 with a history of intermittent pain of increasing severity radiating down both lower legs for the past year.

Examination of both hips showed limitation of flexion, and internal rotation was more limited than external rotation. The disability was more severe on the left side.

Radiographic examination of both hips showed advanced bone necrosis in the heads of both femora. A large part of the articular cortex, involving the 'weight bearing' area was sequestered on both sides (Fig. 60(a) and 60(b) ). Increased areas of density were present in the femoral heads, and on the right side a large translucent area was noted in the head of the femur (Fig. 60(c) ). Increased density is noted in the head of the left femur (Fig. 60(d) ).

Because of persistent pain and the degree of disability in the left hip, surgical exploration was carried out. Several cartilaginous loose bodies were noted within the joint capsule. The articular cartilage covering the anterior and superior aspects of the femoral head was fragmented and necrotic. Cores were taken from the head of the femur and the naked eye appearance indicated that the first  $\frac{1}{4}$ " below the

cortex was necrotic, and the remaining bone showed a normal vascularity. A large cavity about 2 cms. in diameter, lay under the articular cartilage on the superior aspect of the left femoral head. This cavity contained a little fluid and was lined by granulation tissue. The area was packed with cancellous bone chips.

The extent of the damage to the cartilage was surprising. The impression was formed that the hip joint would eventually require an arthroplasty.

Histological examination of the fragments revealed that the majority of the articular cartilage was viable, and zones of attempted revascularisation were noted in the necrotic areas of bone.

Case 7 J.P.

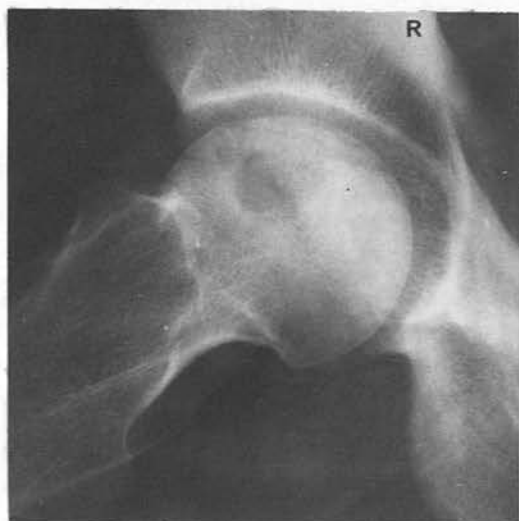


Fig. 60(a) - Lateral projection right hip showing sequestration of 'weight-bearing' area.

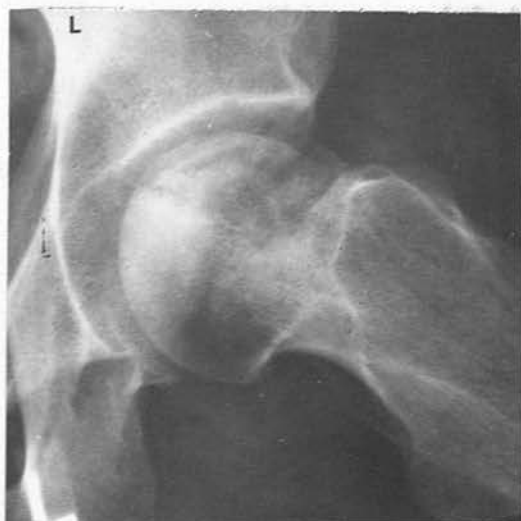

Fig. 60(b) - Same projection left hip showing sequestration.

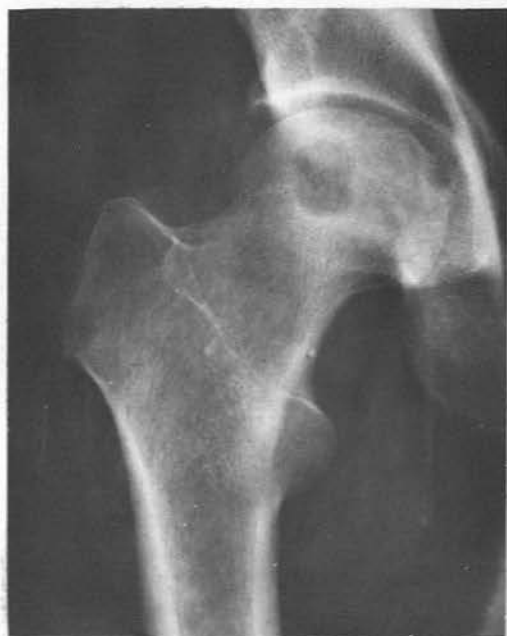

Fig. 60(c) - A.P. right hip, 2 cm. translucent area in head and neck of femur with sclerotic margins. Sequestration not seen.

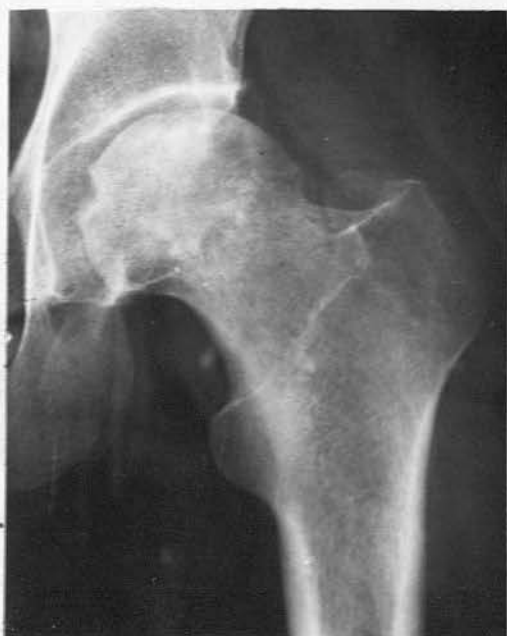

Fig. 60(d) - A.P. left hip, dense areas involve femoral head, Sequestration not seen.

Case 8 T.D. 40 years.

This patient worked regularly in compressed air for eleven months from 8th September 1960 to 24th August 1961, mostly at a pressure of 24 lbs. p.s.i. and occasionally at 28 lbs. p.s.i. During this time he did not suffer from either type 1 or type 2 decompression sickness and was never recompressed. This was his first experience in this type of work.

On 20th December 1962, he presented with symptoms in both shoulders and both hips and was found to have advanced avascular necrosis affecting these joints.

Radiographic examination of the right hip showed increased density in the head of the femur with irregularity and depression of a large segment of articular cortex (Fig. 61(a) ). The lateral radiograph (Fig. 61(b) ) confirmed these appearances and revealed that the posterior half of the femoral head was partially depressed into the subchondral bone with the possibility of sequestration. Similar and less marked radiographic appearances are present in the head of the left femur (Fig. 61(c) and 61(d) ).

The heads of both humeri showed advanced radiographic changes of bone necrosis. Dense sclerotic areas involved the heads of both bones and these appeared to extend to the proximal end of the shaft. On the right side there is slight depression of several fragments of the articular cortex and the presence of a translucent subchondral band (Fig. 61(e) ). On the left side the disorganisation of the articular cortex is more marked with sequestration of several fragments of the cortex and depression of others (Fig. 61(f) ).

Further information is not available on this case.

Case 8 T.D.

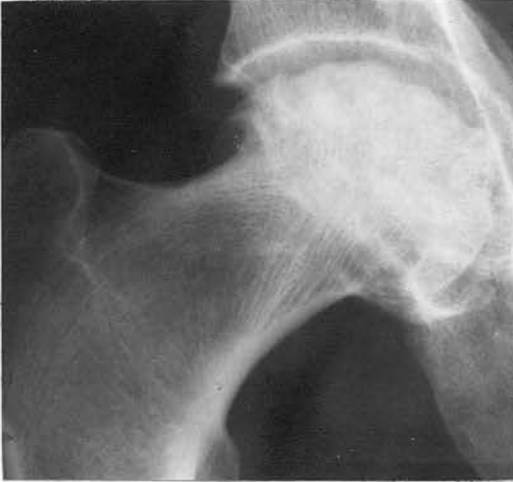

Fig. 61(a) - Increased density of femoral head with irregularity of articular surface.

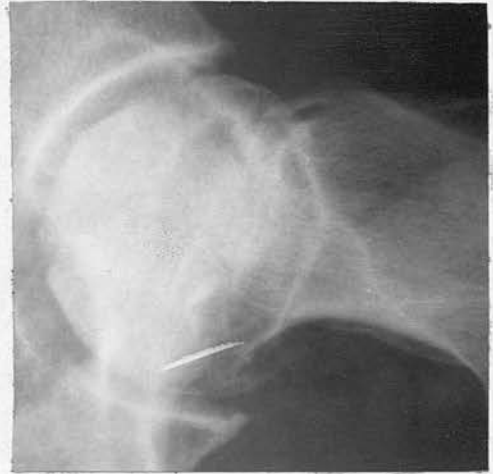

Fig. 61(b) - Lateral projection of (a) showing infraction of articular surface.

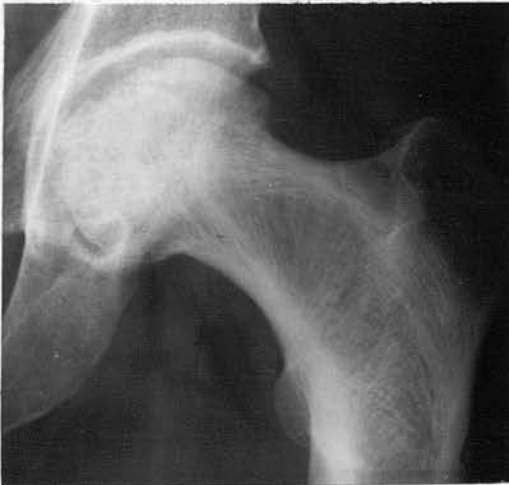

Fig. 61(c) - Left femoral head is similar in appearance to the right (Fig. 61(a)).

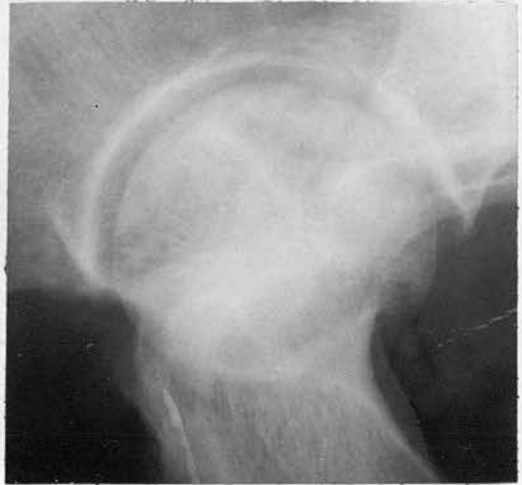

Fig. 61(d) - Lateral projection of (c) showing infraction of articular surface.

Case 8 T.D.

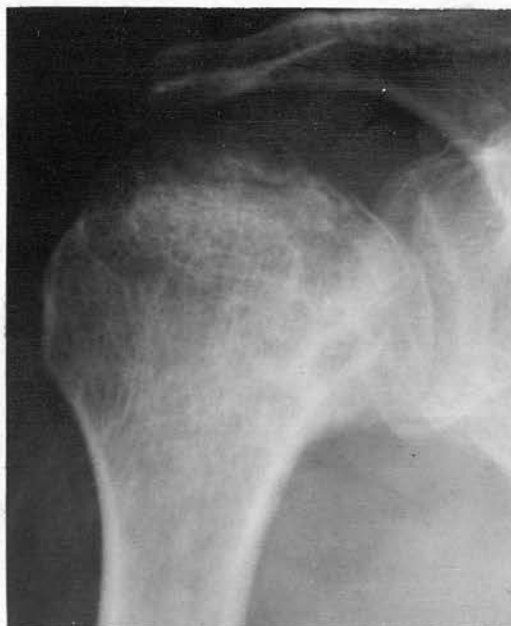

Fig. 61(e) - Translucent subcortical band in head of right humerus with increased density.

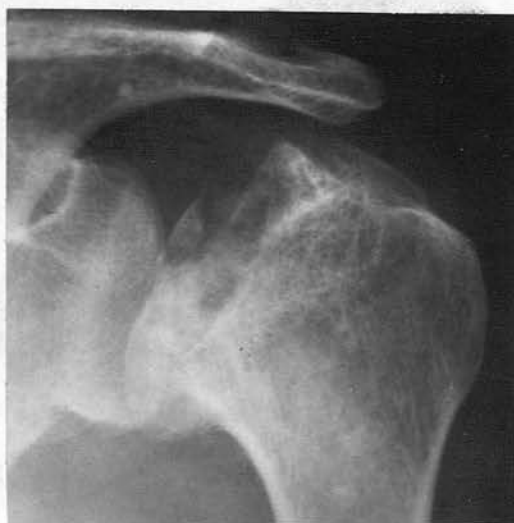

Fig. 61(f) - Considerable deformity of head of left humerus with sequestration of several fragments.

Case 9 D. McD. 43 years.

This patient had worked in compressed air before coming to the Clyde. From 28th April 1958 to 26th June 1959 he worked at pressures up to a maximum of  $32\frac{1}{2}$  lbs. p.s.i. During this time he did not suffer from type 1 or type 2 decompression sickness.

In February 1960, the patient presented with a history of pain in his right hip joint. This pain had commenced in December 1958 and had gradually increased in severity over the next fourteen months.

On examination he was found to have pain and limitation of flexion and internal rotation of his right hip.

Radiographic examination showed considerable increase in density involving most of the head of the right femur, extending into the neck (Fig. 62(a) ). The lateral projection showed infraction and irregularity of the articular cortex (Fig. 62(b) ).

In April 1960 a fusion operation was carried out. Radiographic examination of the right hip in the following July (Fig. 62(c) ) showed slight generalised decrease in density of the bone, presumably resulting from disuse, and that the increased density of the femoral head was unaltered.

Shortly after this operation the patient transferred to another hospital and no further information is available.

Case 9 D.McD.

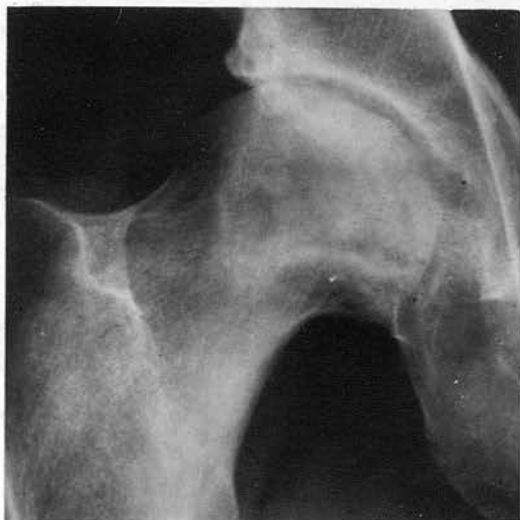

Fig. 62(a)

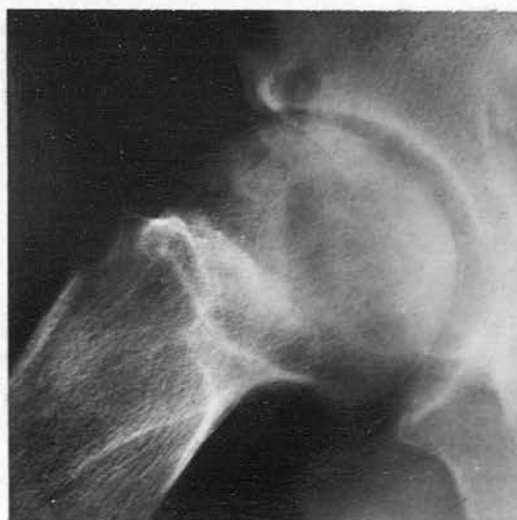

Fig. 62(b)

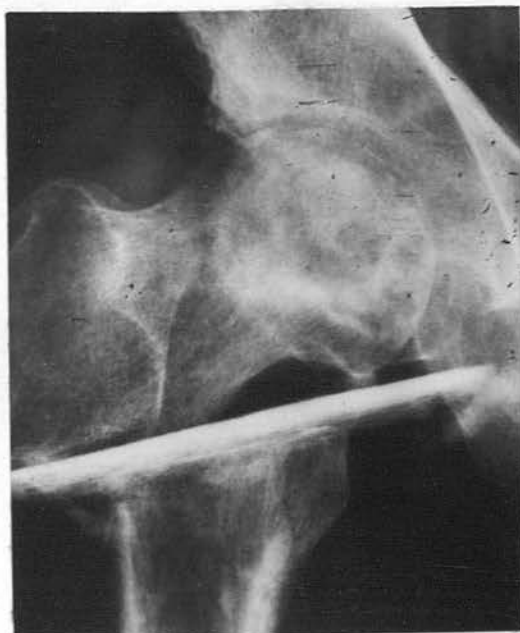

Fig. 62(c)

62(a) - Extensive bone necrosis in head of right femur extending in an apex towards the proximal shaft.

62(b) - Lateral projection of right hip showing translucent subcortical band and increased density.

62(c) - Radiograph of right hip following fusion.

Case 10 W.D. 38 years.

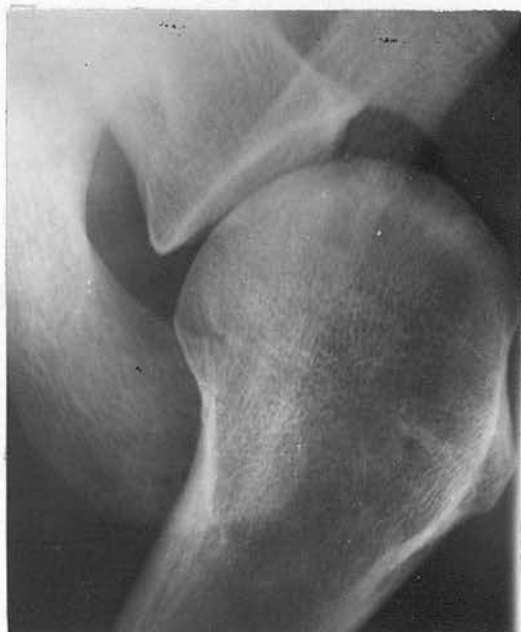This patient had worked regularly in compressed air for two and a half years at pressures up to  $34\frac{1}{2}$  lbs. p.s.i. and required recompression on 5th May 1960, 16th February 1962 and 14th May 1962. On the last occasion he collapsed with loss of consciousness (type 2) and was found to have "paralysis of all four limbs". He was treated successfully on each occasion, but after the third incident he was suspended from work in compressed air.

He presented on 4th December 1962 with pain in his left shoulder of ten months duration. On examination there was restriction of abduction and forward elevation of his left shoulder, with slight restriction of internal and external rotation.

Radiographic examination of both shoulders showed typical changes of advanced bone necrosis in the head of the right humerus (Fig. 63). Dense areas were present in the head of the left humerus, lying adjacent to the intact articular cortex (Fig. 64 and 65).

As his symptoms persisted and became more severe, the left shoulder joint was explored. The central part of the articular surface of the head, measuring 3 cms. by 2 cms., was of a dull yellow colour. This cartilage was removed as it was impossible to repair it, and it clearly could not have been dealt with in any other way. The underlying tissue was completely avascular. Histological study of the fragment showed necrotic bone.

Case 10 W.D.



63 - Axillary projection right shoulder showing dense area adjacent to intact articular cortex.

64 - Dense areas involve head of left humerus with irregularity of cortex.

65 - Axillary projection left shoulder showing probable sequestration.

Fig. 63

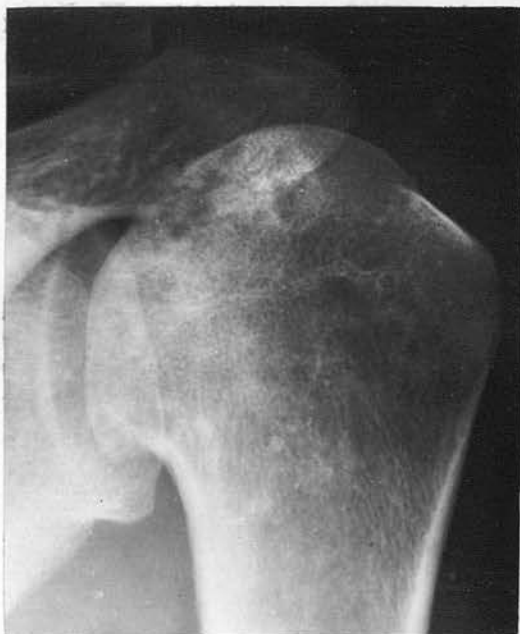

Fig. 64

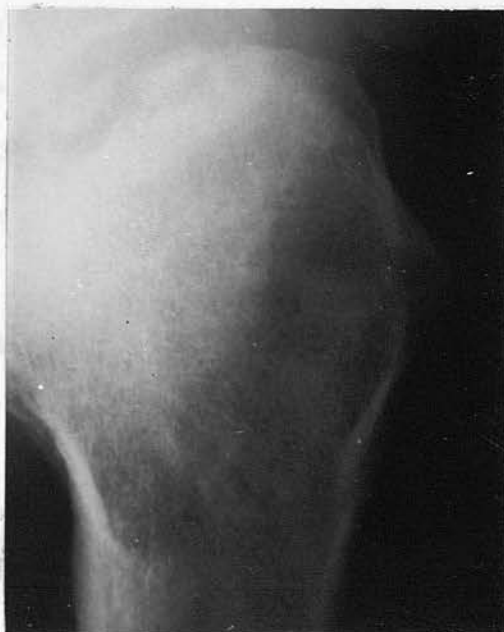

Fig. 65

Case 11 J. McG. 33 years.

This patient was known to have worked in compressed air before coming to the Clyde. At this tunnel he worked in pressures up to  $28\frac{1}{2}$  lbs. p.s.i. from 22nd August 1959 to 18th July 1961. He did not suffer from type 1 or type 2 decompression sickness while employed at the Clyde.

Examination on 16th August 1962 showed marked limitation of abduction and internal rotation of the right shoulder joint. Radiographic examination revealed bone necrosis, with increased density of the head of the right humerus adjacent to the articular cortex, and the presence of a translucent band in the subchondral bone (Fig. 66). Radiographs of the left shoulder, both hips and both knee joints were normal.

Shortly after this examination the patient left the area.

Case 11 J.McG.

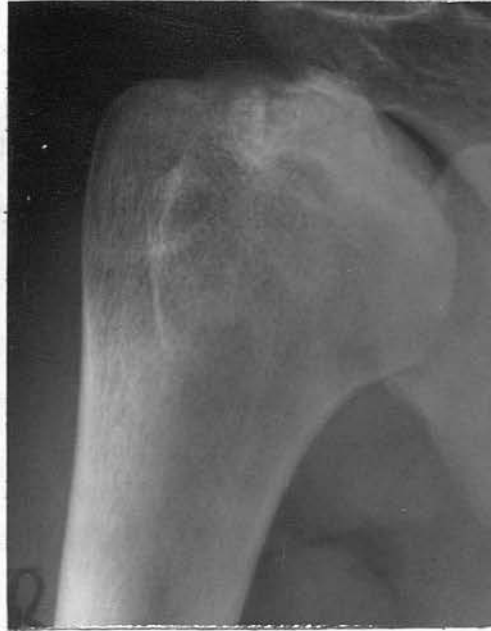

Fig. 66 - Bone necrosis in head of right humerus with translucent subcortical band.

Case 12 E.S. 31 years.

This patient had worked in the tunnel at pressures up to 34 lbs. p.s.i. for a period of four months. He had never required recompression. This patient had a long experience of work in compressed air.

He presented on 21st March 1961 with a history of progressive pain and stiffness in the right shoulder, and was found to have limitation of abduction with a painful arc.

Radiographic examination of his right shoulder (Fig. 67) showed sclerotic areas, infraction of the articular cortex, and partial separation of a bone fragment. Ill defined sclerotic areas were also present in the shaft.

The patient left the area shortly after his initial examination.

Case 12 E.S.

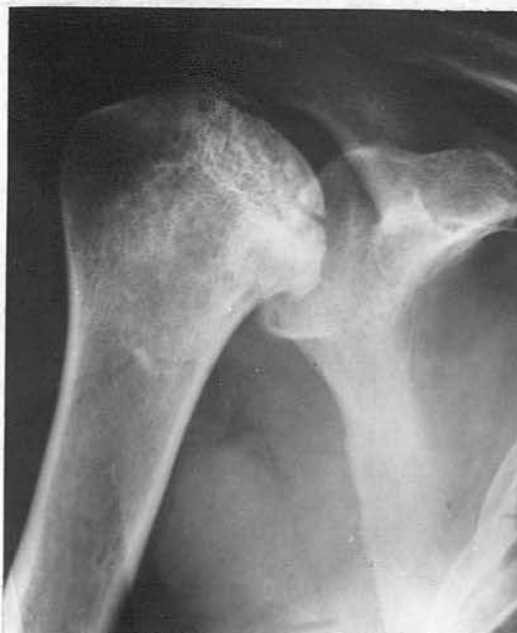

Fig. 67 - Probable sequestration of a large segment of articular surface. Dense area in adjacent bone.

Case 13 A.L. 30 years.

This patient worked for the first time in compressed air for six weeks from 8th May to 17th June 1961 at pressures up to  $28\frac{1}{2}$  lbs. p.s.i. He did not suffer from type 1 or type 2 decompression sickness.

He presented on 1st May 1964 with a history of having fallen and twisted his knee five months before. A slight pain had developed in his right hip six weeks later and this has persisted.

On examination he was found to have limitation of flexion and of both internal and external rotation at the right hip.

Radiographic examination (Fig. 68(a) ) demonstrated bone necrosis in the head of the right femur with dense sclerotic areas involving a large area of the head. A lateral radiograph (Fig. 68(b) ) demonstrated probable sequestration of the posterior or 'weight bearing' area of the femoral head. Tomography (Fig. 68(c) ) confirmed the increased density of the femoral head and reveals a translucent area laterally and close to the inflected articular cortex.

Radiographs of the left hip, both shoulders and both knee joints were normal.

Case 13 A.L.

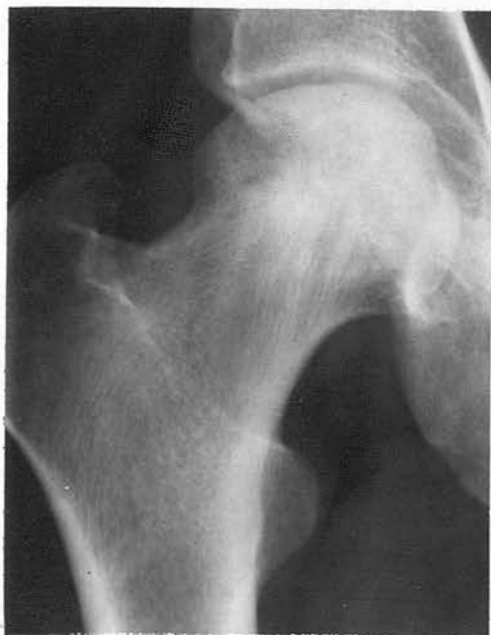

Fig. 68(a)

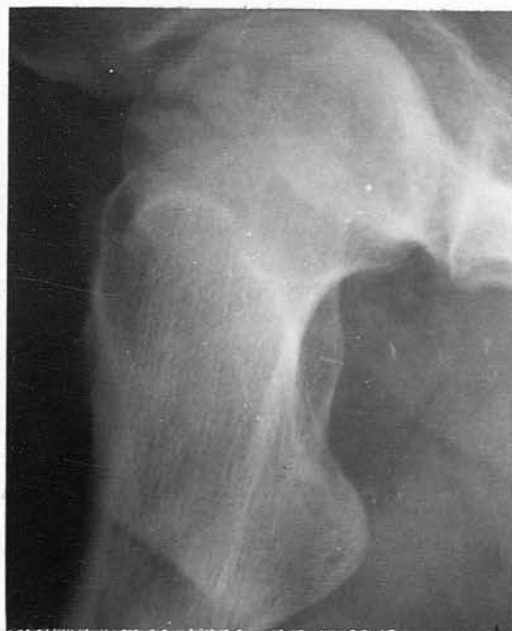

Fig. 68(b)

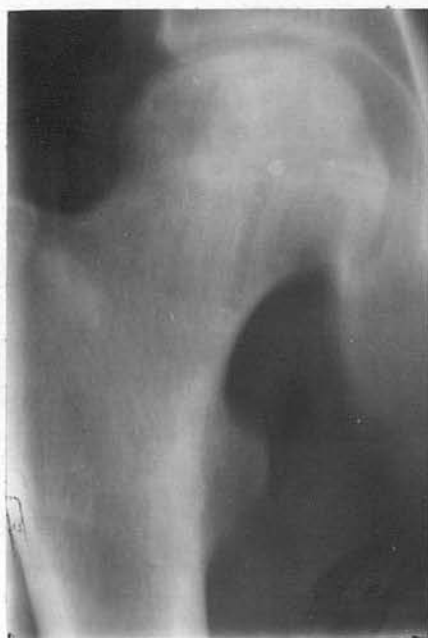

Fig. 68(c)

68(a) - Bone neerosis in head of right femur.

68(b) - Lateral projection right hip showing sequestration of articular surface posteriorly

68(c) - Tomograph confirms increased density, translucent area and infraction of the cortex.

Case 14 J. McA. 34 years.

This patient had worked in compressed air for many years before coming to the Clyde. At this tunnel he worked at pressures up to a maximum of 30 lbs. p.s.i. from 13th October 1959 to 15th January 1962. He did not experience type 1 or type 2 decompression sickness. However, he reported a persistent pain in his left shoulder joint and because of this he was considered unfit for further work.

At examination on 12th February 1962, he was found to have pain and marked limitation of abduction and both internal and external rotation in his left shoulder. The left hip also showed marked limitation of movement. No symptoms were present at the right shoulder.

Radiographic examination showed sequestration of a portion of the articular cortex with associated dense areas involving a portion of the head of the left humerus. Marginal osteophytes are present inferiorly (Fig. 69(b) ). In addition dense areas of bone necrosis are noted in the head of the right humerus with an intact articular cortex (Fig. 69(a) ). Advanced bone necrosis is present in the head of the left femur with collapse of the articular cortex (Fig. 69(c) ).

Case 14 J.McA.

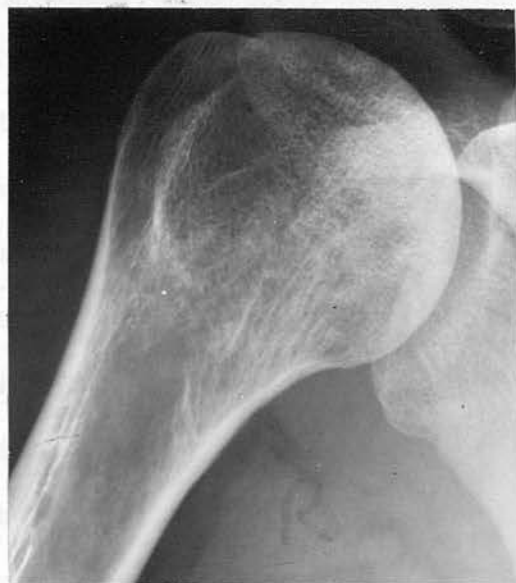

Fig. 69(a)

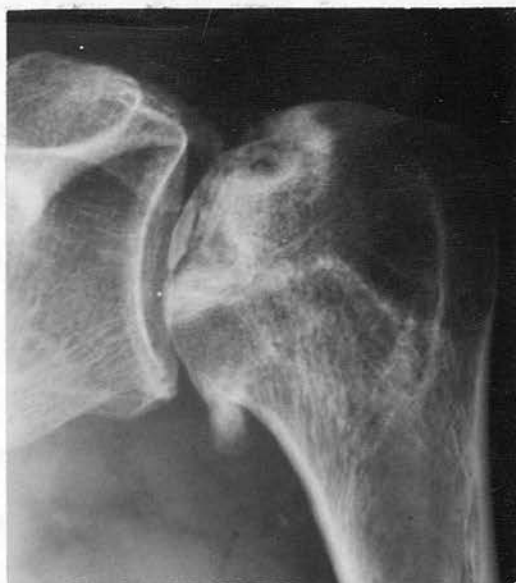

Fig. 69(b)

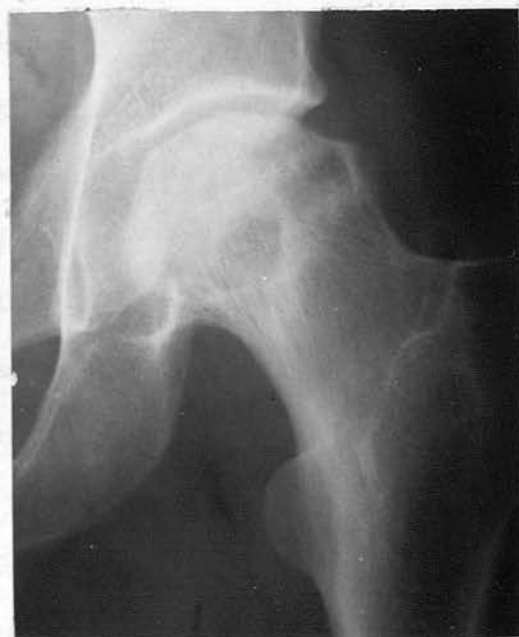

Fig. 69(c)

69(a) - Small dense areas in head of right humerus with intact articular surface.

69(b) - Long standing bone necrosis, with sequestration of articular surface and marginal osteophyte formation.

69(c) - Increased density in head of left femur with translucent areas and marginal osteophyte formation.

DISCUSSION

Avascular necrosis of bone is a hazard amongst compressed air workers. In a civil engineering contract lasting two or three years, a large number of men will be at risk. At Dartford, for example (Campbell Golding et al 1960), between 1957 and 1959, although only two hundred and fifty to three hundred and twenty men were at work in compressed air at one time, twelve thousand men were actually employed during the whole contract. During the construction of the Clyde Tunnel, while two hundred and forty to two hundred and eighty men were employed at one time, the total labour force was thirteen hundred and sixty-seven men. It is apparent, that avascular necrosis of bone, if it affects the shoulder or hip joint, is a potentially disabling condition and must be considered one of the most serious forms of decompression sickness.

In earlier surveys the incidence of avascular necrosis varies; - Bell, Edson and Hornick (1942) record a 75% incidence in thirty-eight workers in New York, however some selection must have been present to explain both the high incidence of bone lesions and the frequency of symptoms amongst the men. Cavigneau et al (1949) and Mungo and Sessa (1958) record an incidence of 38.4% in one hundred and twenty-five workers and 34.2% in forty-seven workers respectively. In both these reports, the reproductions of many of the positive cases show features which we would hesitate to define as evidence of bone necrosis. A more recent survey at Dartford demonstrated a 10% incidence of avascular necrosis amongst eighty-three men, all of whom had suffered 'the bends'. The radiographic changes in many cases were minimal. An interesting survey is that reported by Rózsahegyzi and Fried (1963) where

fifty-four symptom-free men, who had worked in compressed air on the construction of the Budapest Underground Railway between three and six years before, were found to have a 22% incidence of unsuspected avascular necrosis of bone.

These surveys are the few that have been done and no attempt has been made to relate the length of exposure to compressed air and the maximum pressure to the incidence of bone necrosis. All the surveys state that a large proportion of the men were long term compressed air workers usually of several years duration. In assessing the significance of the incidence of bone necrosis from the published surveys, the possibility of indirect selection of men who are likely to have bone lesions must be considered. In the same way, due attention must be paid to the interval between the dates of exposure to compressed air and the radiographic examination. It is known that bone necrosis does not become apparent on a radiograph until six months at the earliest, and usually a year, after the ischaemic episode. Therefore the longer the interval, up to two or three years, between the exposure to increased air pressure and the radiographic examination, the greater the incidence of bone lesion.

A feature of this survey is the incidence of 16.5% of bone necrosis in a group of two hundred and forty-one compressed air workers, who were thought to be symptom free. Although thirteen hundred and sixty-seven men were employed in compressed air during construction of the tunnel, many of them worked only for a few months in the tunnel and then left for another job. The group of two hundred and forty-one men represents 17.6% of the total number at risk and this is a biased sample, the majority of men

having a long exposure in compressed air and approximately over half had worked for longer than two years. The investigation was conducted at the completion of a four year contract in compressed air. In all cases, the interval between the first exposure to an increased air pressure and the radiographic examination was at least six months.

Of the two hundred and twenty-three men who had worked in compressed air for the first time at this tunnel, thirty-two or 13.7% were found to have positive evidence of bone necrosis, and amongst the eighteen men, who had been exposed to an increased pressure of air before coming to the Clyde, there is a 44% incidence of bone necrosis. The overall incidence of bone lesions is 16.5% amongst the two hundred and forty-one men, and this figure is reduced to 12.5% when only the accepted or classical radiographic evidence of bone necrosis is considered. These figures were higher than expected, if it was possible to repeat the examination in the same group of men at yearly intervals over the next three years without further exposure to compressed air, it might well be that the incidence of bone lesions would rise as the ischaemic areas have time to revascularise and so become evident on a radiograph. This point will be brought out when the pathological changes are discussed.

It is probably opportune to mention at this stage that twenty-six men or 55% had positive or doubtful evidence of bone lesions, either involving or adjacent to an articular surface, and these would be liable to cause symptoms. A high proportion of the men attended for clinical examination, thirty-eight men out of the forty-seven who were notified, and eight men, or 3.3% of the total number who were examined, were found to have symptoms referable to

their radiographic abnormality. One man is included who admitted having experienced symptoms before coming to the Clyde.

The remaining twenty-one men or 45% with positive or doubtful evidence of bone lesion at some distance from the articular surface were all free of symptoms.

When the relation of bone lesions is compared with the number of shifts worked in compressed air, the incidence of bone necrosis increases with a corresponding rise in the length of exposure. In addition there is a significant increase in the proportion with bone lesions in men who are exposed at one time or another to pressures over 30 lbs. p.s.i.

A single exposure to compressed air may produce severe bone necrosis and has been recorded on four occasions (Barbara and Isola 1939, Guillain and Grossiord 1943, Taylor 1944, James 1945). The last publication (James 1945) is a most interesting account of three of the five survivors from the ill-fated submarine H.M.S. Poseidon. These men were trapped in the partially filled escape hatch for approximately four hours at pressures probably just less than four atmospheres absolute, and had only been exposed to an increased pressure of air on this one occasion. Twelve years later these three men were found to have severe bone necrosis; in the left knee in one, in both femora in the second, and medullary infarcts were present in the left hip and shoulder in the third.

One of our illustrative cases - (Case 5 J.McV) - was only exposed to 24 lbs. p.s.i. for a total of eleven hours on two successive days. Symptoms developed about a year later and two years after the original exposure, he was found to have severe bone necrosis in the heads of both humeri. Another case

(Case 6 J.C.) - was only exposed to compressed air on three separate days for four hours at pressures not exceeding 30 lbs. p.s.i. and he subsequently developed bone necrosis in the left shoulder and left hip eighteen months later.

Thus a single exposure to compressed air probably of four hours or more, and a limited number of exposures can produce severe bone necrosis but the possibility is very remote.

It appears from the analysis that the greater the frequency of type 1 decompression sickness - "the bends" - then the greater the likelihood of a bone lesion. This would suggest that the type 1 lesion is a likely precursor of bone necrosis. However, this radiographic survey has demonstrated a high frequency of bone lesions in the head of the humerus, while type 1 decompression sickness most commonly affects the lower limbs. Several cases of bone necrosis are recorded in this thesis with severe radiographic changes, who have not experienced type 1 decompression sickness. In addition, it is known that many men, having become acclimatized to type 1 - "the bends", may only experience a similar mild pain - "the niggles". Observation over many years suggests that almost every shift worker has experienced "the niggles", which is not sufficiently severe to make him return for therapeutic recompression and consequently such cases are not recorded. In these circumstances no workman may be regarded as having been free from this mild form of pain - "the niggles". This being so, analysis of data becomes very difficult unless the type 1 case is regarded as being a much more likely precursor of bone necrosis than the mild case. This assumption would lead to the expectation of a significant difference in the incidence of bone necrosis between those with type 1

decompression sickness and those with "the niggles". Evidence from the Dartford investigation was insufficient to lend any support to such a hypothesis (Campbell Golding et al 1960). A possible way to ascertain whether bone necrosis is related either to the type 1 cases or "the niggles" is to examine the evidence from exposure of under four hours duration. Here the type 1 incidence is also relatively small, so that there is a distinct possibility of finding a sufficient number of men for investigation who have never had "the niggles".

An important point at issue is to establish whether there is a relationship between type 1 decompression sickness and the frequency of bone lesions. Under present conditions, the adequacy of decompression schedules is measured by the "bends rate" and, at the Clyde, this rate is 0.31% of all compressions, one of the lowest on record. It is recalled that the "bends rate" measures the incidence of the acute cases of decompression sickness, of which 85% are type 1. While these schedules have reduced the incidence of decompression sickness to a very low level, it appears that they are unable to prevent the onset of avascular necrosis of bone.

Another problem which still has to be answered is the identification of those men who are possibly susceptible to bone necrosis. In two of our cases - Case 5 J.McV. and Case 6 J.C. - advanced bone necrosis developed after a very short exposure. Some men develop bone lesions after several months in compressed air, while others, with many years experience including those who had worked in compressed air before coming to the Clyde, had no radiographic abnormality. At one time, some said that necrosis

was more common in those men who control decompression themselves and 'cut corners', but the bones of such men have been examined and no radiographic abnormality has been found.

### Pathological Features

When considering the significance of the radiographic features it is important to understand the underlying pathological changes associated with bone necrosis and repair. Unfortunately there are few published descriptions of the histology of bone necrosis in compressed air workers. Presumably because many of the necrotic areas demonstrated radiographically are symptomless, and are not examined histologically.

### Bone necrosis and repair

Detailed study has been made of avascular necrosis of bone occurring in the head of the femur following a fracture of the femoral neck and in avascular necrosis from other causes (Phemister 1940, Sherman and Phemister 1952, Bonfiglio and Bardenstein 1958, De Haas and McNab 1956, Barnes 1964, Patterson et al 1964). Avascular necrosis of bone means that the bone tissue has lost its blood supply and no longer survives.

As a result of interruption to the blood supply a wedged-shaped area of necrosis develops in the head of the femur, and a reparative process begins in which vascular fibrous tissue, or granulation tissue, advances from the edge of the living marrow into the intertrabecular spaces of the dead bone. As this vascular fibrous tissue advances, it ensheaths the necrotic trabeculae in its path with new bone, and if the process was not disturbed, it presumably would replace all the necrotic bone and marrow with living

tissue. However, this does not occur. For reasons unknown, after this vascular fibrous tissue has advanced for a certain distance, it changes into a primarily fibrous zone which has little or no reparative ability. The progress of the fibrous tissue then ceases, and it becomes a dividing line between dead and living bone.

Examination of an involved femoral head shows that the articular cartilage over the necrotic bone may be viable or dead. In advanced cases the subchondral bone may collapse producing cracks in the cartilage. Sagittal section through the centre of an involved head shows three definite zones - necrotic, fibrous and viable. (Figs. 70a and b).

The necrotic bone is located usually in the superior segment or 'weight bearing' portions of the femoral head. This zone has a wedge-shape with the apex pointing towards the centre of the head and the widest part abutting the articular cartilage and involving the subchondral bone. Osteocytes are absent in this zone and there is evidence of marrow necrosis. This wedge-shaped zone appears dense on the radiograph and the increased density results mainly from superimposition of new bone formation in the surrounding viable zone and also results from small areas of calcification within the necrotic bone. Occasionally a fracture line is noted in the necrotic bone and this appears on the radiograph as a translucent subchondral band. In addition, with repeated weight bearing, segments of the articular cortex may collapse into the necrotic bone causing progressive deformity of the femoral head.

The fibrous zone surrounds the necrotic area and is composed primarily of fibrous tissue. This may be demonstrated radiographically

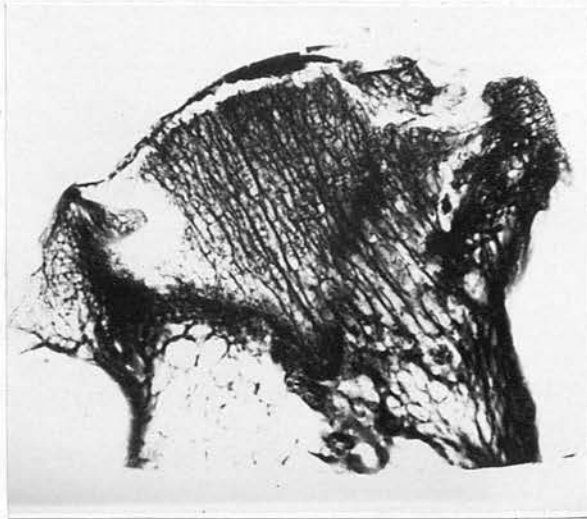


Fig. 70(a) - Radiograph of bone segment from an excised necrotic femoral head. Zone of reossification appears dense.

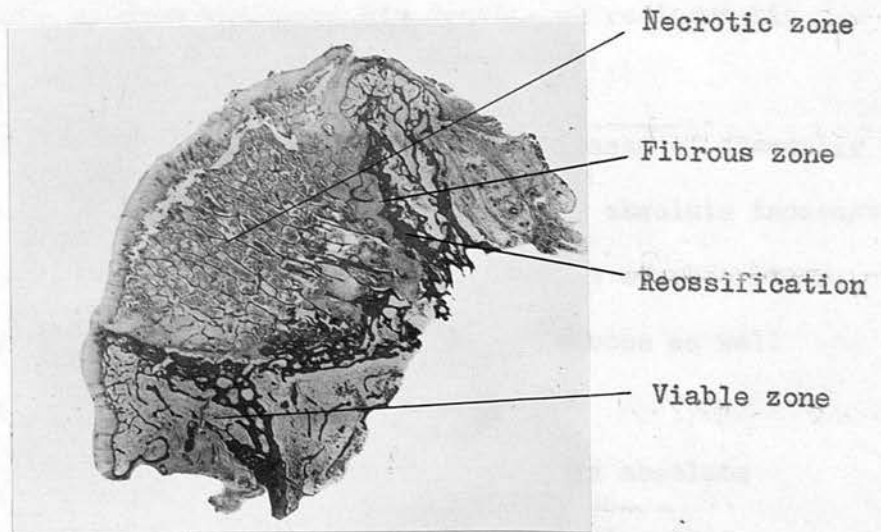


Fig. 70(b) - Histological section of same femoral head showing collapse of 'weight-bearing' segment. Zone of reossification is darkly stained.

when it will appear as a translucent band surrounding the necrotic zone. The appearances may suggest that the proximal necrotic bone is free and about to fall into the cavity of the joint.

The viable zone has a normal trabecular pattern. In the area adjacent to the fibrous zone, new bone formation is noted on the trabeculae of dead bone. This increased quantity of bone structure causes an absolute increase in radiographic density. Histological examination of such an area of increased density, in a tunnel worker with bone necrosis (Fig. 73c) revealed similar new bone formation in the area of reossification.

#### Radiographic Appearances of Bone Necrosis

The traditional view has been expressed that the increased radiographic density of avascular bone was only relative and was secondary to hyperaemic decalcification of adjacent viable bone (Jones and Roberts 1934). This was based on the assumption that the avascularity of the dead fragment prevented it from either gaining or losing calcium and hence its density on radiographic examination must remain unchanged.

But careful study of the radiographs in most cases of avascular necrosis shows that the "dead" bone may undergo an absolute increase in density in addition to other less marked changes of absorption, so that it may become denser than the surrounding bone as well as denser than it was to begin with.

However, it is six months at least before this absolute increase in bone density becomes apparent, and, during this early period, necrotic bone is indistinguishable from living bone.

Recently Coleman and Compere (1961) have had an opportunity of studying both the pathological and radiographic features of

sixty femoral heads which demonstrated avascular necrosis following a fracture of the femoral neck. These authors concluded that alteration in radiographic density was difficult to determine and could occur as early as two months after the fracture. Any increase in density could be relative or absolute or both, and overlapping shadows of the acetabulum added to the difficulty of interpretation.

Bobechko and Harris (1960) produced avascular necrosis of the femoral head in rabbits experimentally and subsequently studied both the histological and radiographic changes. Necrotic bone, which was not reossified or altered in any way showed no change in density on radiographic examination. Areas of necrotic bone, which was being revascularised with the formation of new bone, showed an absolute increase in density on the radiograph. On this basis, increasing radiographic density of bone suspected of being dead is a sign of reossification rather than of necrosis. In the rabbit an absolute increase in density was noted after eight weeks and the authors concluded that it would be six months to a year for a similar absolute increase in density to take place in the adult human femoral head.

The following two cases are of interest as the progressive radiographic changes of bone necrosis and repair are demonstrated.

Case 15 R.H. 16 years.

Crack fracture of the neck of the left femur without displacement. Treatment by traction without weight-bearing.

Serial radiographs (Fig. 71(a), (b) and (c) ) show the progressive radiographic change of bone necrosis

over eighteen months and that the early changes of sclerosis are evident in the femoral head as early as six months after the traumatic episode. In the lateral projection (Fig.71 (d), (e) and (f) ), serial radiographs show collapse of the posterior or 'weightbearing' surface with associated irregularity of the cortex, part of which has sunk into the subchondral bone.

From this case it is clear that radiographic evidence of bone necrosis was not present until six months after the original incident. However, the bone was necrotic immediately after the fracture, and radiographic changes only became evident with attempted revascularisation of the necrotic area and the laying down of new bone.

Case 16 Mrs. M.F. 70 years.

Cervical fracture of the neck of the left femur with insertion of a Smith Petersen pin.

Serial radiographs (Fig.72 (a),(b) and (c) ) show progressive radiographic evidence of bone necrosis over a two year period. In the lateral projection, there is collapse of the articular surface posteriorly.

In this case almost two years elapsed before there was radiographic evidence of bone necrosis.

It is unusual to find that the head of the femur returns to normal bone density and this will only happen after a number of years. More often the radiographic appearances tend to remain static.

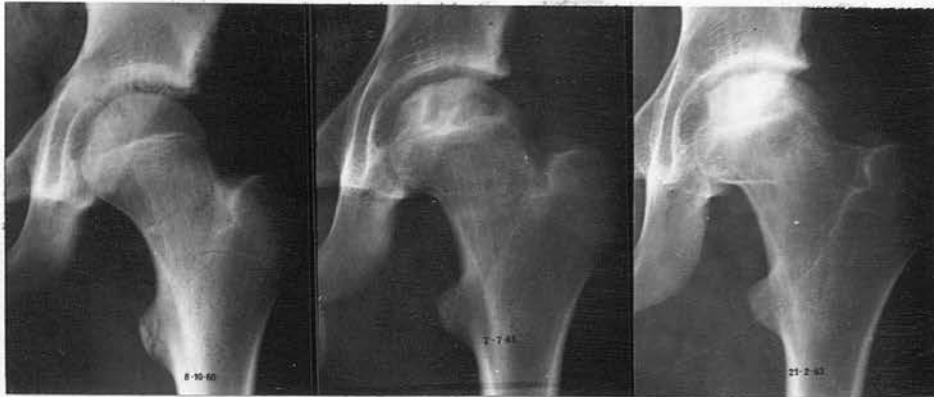

Fig. 71(a), (b), (c) - Crack fracture of the femoral neck.  
Progressive radiographic evidence of bone necrosis in  
head of femur over 18 months.

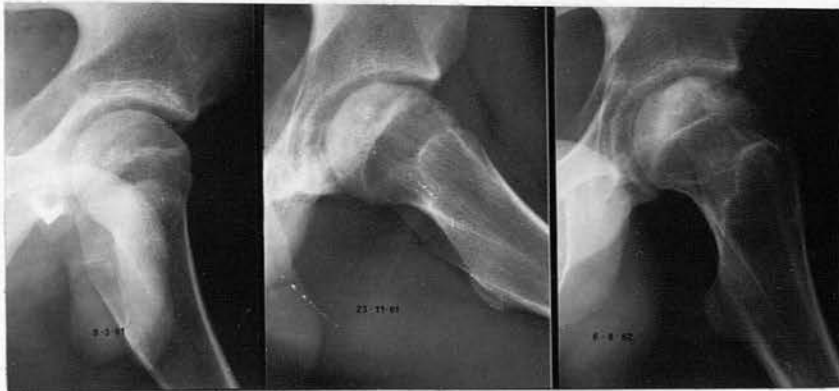

Fig. 71(d), (e), (f) - Lateral projection showing collapse of  
posterior or 'weight-bearing' area of the articular  
surface.

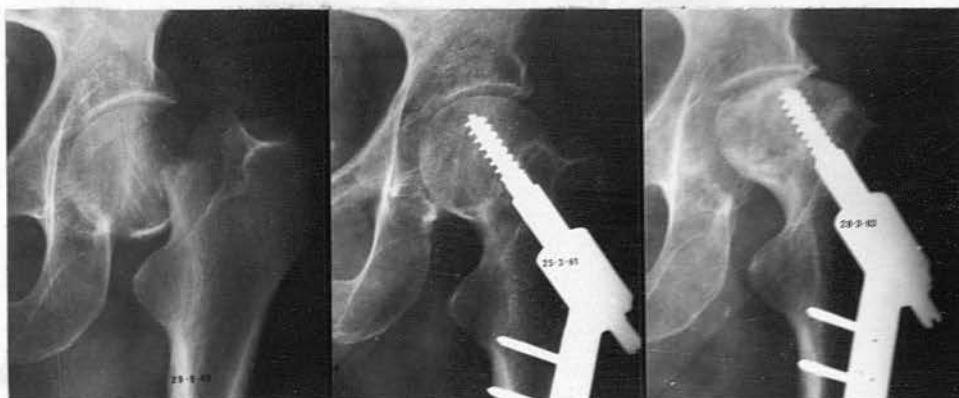


Fig. 72(a), (b), (c) - Transcervical fracture of the left femoral neck with internal fixation. Radiographic evidence of bone necrosis developing in head of left femur between 25.3.61 and 28.3.63.

Medullary infarcts are usually demonstrated in the distal shaft of the femur and can occur in the shaft of the tibia, humerus or fibula. Characteristic lesions are usually situated in the centre of the medullary cavity and rarely, if ever, enter the bone end. They appear radiologically as irregular calcified areas, of varying size and shape.

Excellent descriptions have been given of the pathological and radiographic features of calcified medullary infarcts, both as a complication of decompression sickness and from other causes and the similarity of these features is remarkable. (Kahlstrom, Burton and Plemister 1939, Plemister 1940).

The central necrotic area can be of varying size and consists of amorphous debris with calcified granules. This is surrounded by a dense fibrous tissue layer which is heavily calcified. This calcification accounts for the radiographic appearance and the size and shape varies with the extent of the necrotic area. Evidence of bone necrosis and repair may be present in the adjacent bone cortex.

The calcified areas usually remain static on serial radiographs and Kahlstrom, Burton and Plemister (1939) suggest that repair of the larger area comes to a standstill after the normal strength of bone has been returned.

#### Bone Necrosis in Compressed Air Workers

One of the first publications appeared in February 1939, when Kahlstrom, Burton and Plemister reported four cases of avascular necrosis of bone occurring in men who had been exposed to compressed air during tunnel construction. The necrotic areas were situated

in the head of the femur, in the head of the humerus and around the knee joint in addition to the distal tibia and fibula. In March 1939 they added three similar cases of bone necrosis of undetermined aetiology in persons who had not worked in compressed air, and who gave no history of "the bends". The radiographic features and histological findings are identical in all cases, the only differentiating point between the two series was the occupational history. In the absence of any explanation for the areas of infarction, there is always the possibility that bone infarcts in men working in compressed air may have antedated the occupation and may bear no relation to it.

Other publications by Lichtenstein and Zeitlin (1936), Swain (1942), Kahlstrom and Phemister (1946) and Catalano (1954), are of considerable interest.

Swain (1942) gives an excellent report on avascular necrosis affecting the heads of both humeri in an experienced compressed air worker who died from a coronary thrombosis. Accurate correlation was obtained of the radiographic and pathological appearances. Radiographic examination showed a large segment of the head of the right humerus to be sequestered and a dense curvilinear layer or 'snow cap' was present in the head of the left humerus. Pathological examination revealed an irregular area of pale devitalised cartilage covering two-thirds of the head of the right humerus. This area presented a mosaic appearance, with irregular fissures which divided its surface into small white areas. At its upper edge the necrotic area was in the process of separation from the underlying living bone and here it could be sprung in and out by the application and release of pressure.

In the head of the left humerus, the radiographic changes were typical of a 'snow cap' lesion and an irregular depressed area of devitalised cartilage covered about one-third of the head of the humerus. Wedge section and histological studies through the diseased area revealed that the necrotic area extended to about half-an-inch below the articular cortex. There was no evidence of osteoclastic activity in the centre of the necrotic area. The line of demarcation between necrotic and viable bone was translucent on the radiograph and consisted of fibrous tissue extending gradually to the articular cortex. Histologically the cartilage was healthy. In the viable bone, new bone formation was noted close to this layer of fibrous tissue and layers of new bone was deposited on the trabeculae of dead bone, forming the dense curvilinear layer or 'snow cap' on the radiograph.

In a case reported in this thesis (Case 17 W.C. - Fig.73 (a),(b),(c),(d) and (e) ) the opportunity has been taken to study and correlate the radiographic and pathological changes of bone necrosis in the head of the humerus and in the femur. This man, who had worked in compressed air for fourteen years, had not been employed at the Clyde, and died shortly after decompression at another tunnel. Autopsy revealed numerous subcutaneous and intravascular air bubbles and, in view of the terminal respiratory symptoms, it was thought that these may have resulted from rupture of a pulmonary bulla or cyst. However, such a bulla or cyst was not demonstrated histologically. The lung fields were not examined radiographically. Radiographic examination of the shoulder and hip joints at autopsy revealed evidence of bone necrosis.

The opportunity was taken for detailed histological studies of these involved segments and I am indebted to Dr. Catto for the findings.

In the head of the humerus, the radiographic lesion is seen to be a dense curvilinear layer - a 'snow cap'- and the margins extend to the articular cortex which is intact. (Fig. 73 (a) ). Histological examination of the section shows that this dense layer consists of viable bone with new bone formation and this surrounds the necrotic zone (Fig. 73 (b) ). New bone is being laid down on the trabeculae of dead bone and this is clearly shown on the sections which have been reproduced. The total increase in the amount of bone explains the dense curvilinear layer (Fig. 73 (c) ). The necrotic zone shows no definite change in its radiographic density, and the trabecular pattern is normal. The articular cartilage is necrotic on its inner surface adjacent to the bone cortex. It is interesting to recall that of the seven men who attended for clinical examination with this type of radiographic lesion, three were found to have symptoms of a painful arc on abducting the arm. The symptoms probably resulted from necrosis of the articular cartilage.

Similar histological and radiographic changes are found in the head of the femur. The dense layer at this site is formed, as in the head of the humerus, by a zone of viable bone with new bone formation, and this layer surrounds the necrotic bone.

Histological studies of the bone fragments removed from the joint surface of the head of the humerus (Case 10 W.D. ) and the head of the femur (Case 7 J.P. ) shows the articular cartilage to

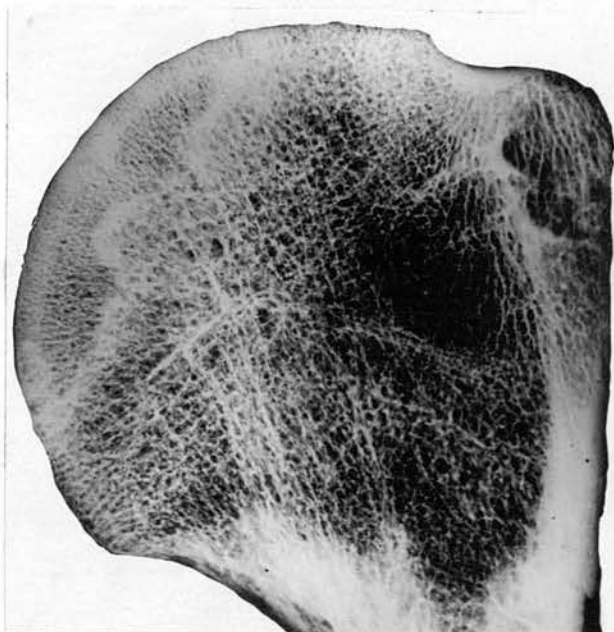


Fig. 73(a)

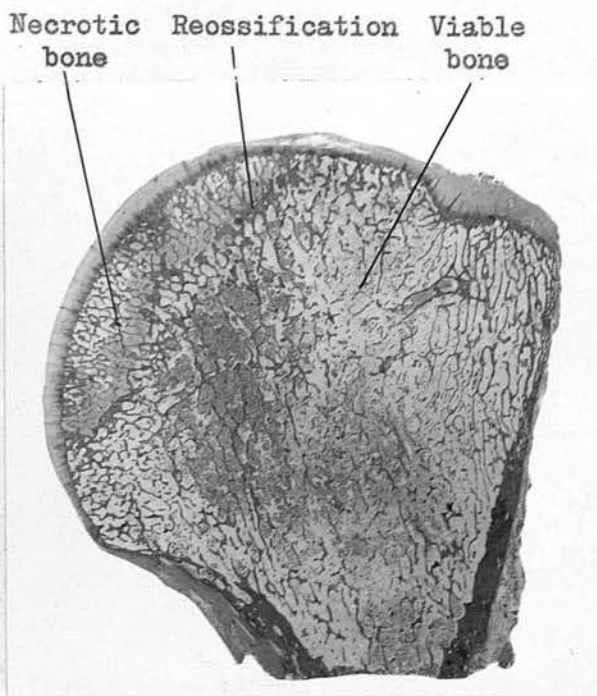


Fig. 73(b)

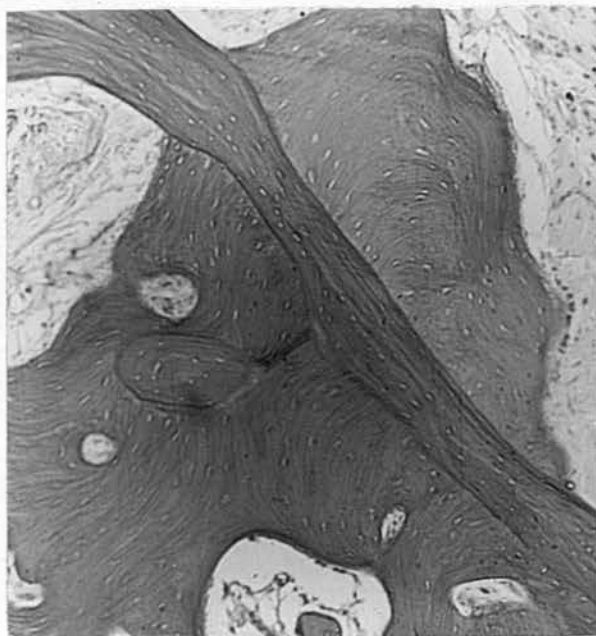


Fig. 73(c)

73(a) - Radiograph of excised head of humerus showing dense curvi-linear layer. Necrotic bone proximal to the layer is indistinguishable from viable bone.

73(b) - Section showing the dark stained zone of reossification.

73(c) - High power section from zone of reossification showing new bone being laid on necrotic trabeculae. Osteocytes are absent in dead bone. Bulk of bone is increased.

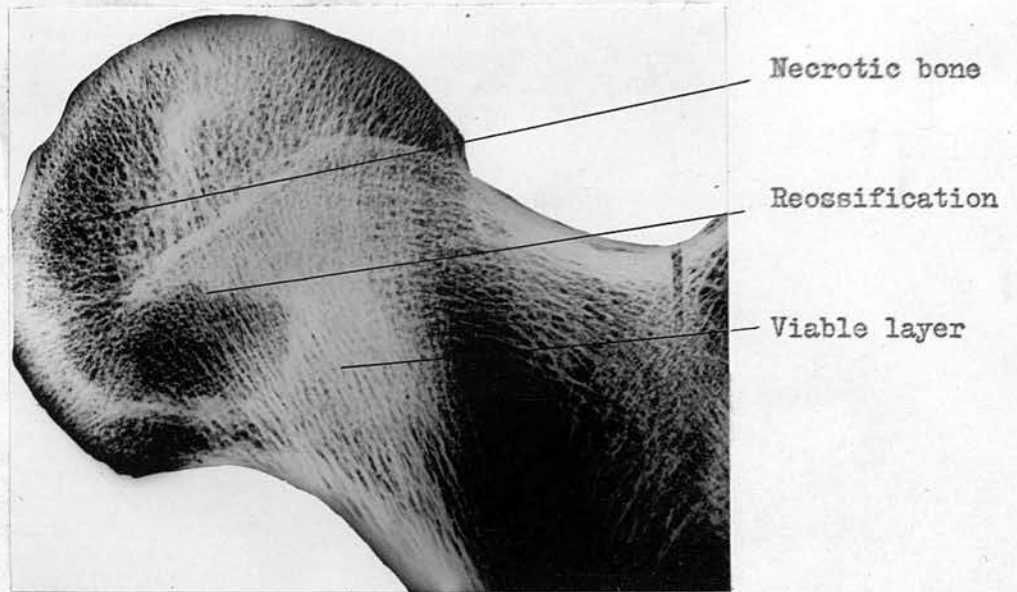


Fig. 73(d) - Radiograph of excised head of femur, same case as Fig. 73(a), showing dense zone forming a rough curvi-linear layer.

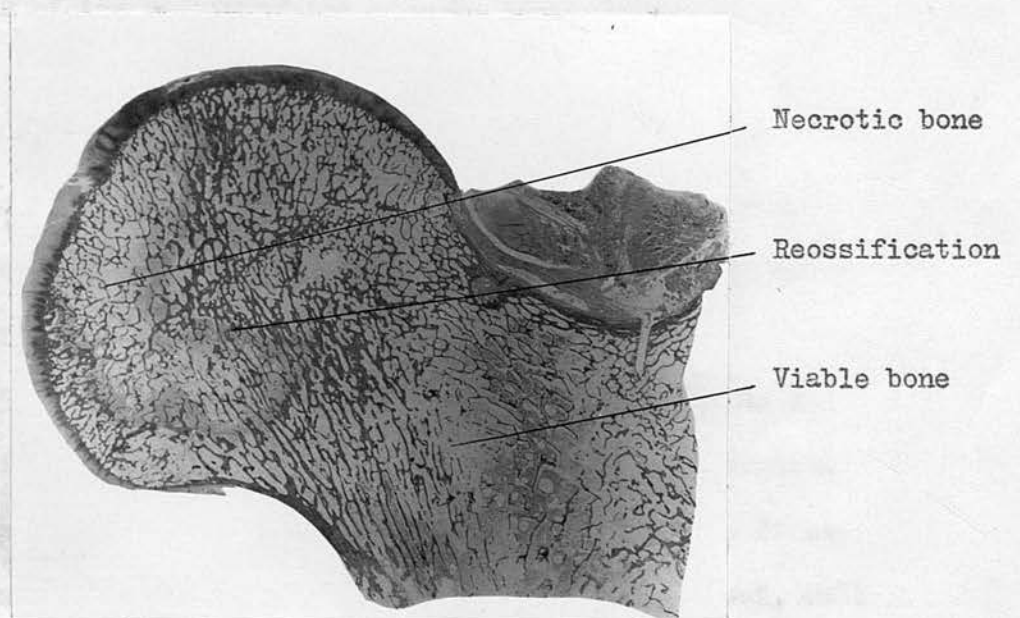


Fig. 73(e) - Section showing the dark stained zone of reossification.

be viable with underlying necrosis of bone. These fragments were almost separated from the underlying bone and could be picked out without much difficulty. At some sites new bone formation was noted on the trabeculae of dead bone. It is interesting to find that the translucent area in the head of the left femur was a large cavity, containing a little fluid and lined by granulation tissue. Studies of the bone fragments in Case 4 H.R. show a similar appearance of new bone formation in the involved area and presumably this accounts for the increased radiographic density of the femoral head.

#### Radiographic Features of Bone Necrosis in Compressed Air Workers

It is not possible to give an accurate histological interpretation of the radiographic appearances from study of the radiographs alone. However from the review of the published cases and the observations reported here a reasonable assumption can be made of the nature of the changes demonstrated on the radiograph.

It is very likely that the initial disorder is one of ischaemia of the affected area of bone. This bone rapidly becomes necrotic and for a long time, probably six months at least, no radiographic abnormality is evident.

Case 5 J.McV. is particularly interesting as there is a definite time interval between the probable date of infarction and the onset of symptoms fourteen months later. At the first examination, exactly two years after the original incident, well marked radiographic changes were demonstrated in the heads of both humeri. This man had not worked in compressed air before and it is reasonable to assume that the bone was normal at that

time. This time interval is rarely established with any degree of certainty. In another of our illustrative cases (Case 6 J.C.) there is an interval of eighteen months between the first exposure to compressed air and the initial radiographs showing marked infarction of the articular cortex in the posterior or weight bearing area of the head of the femur. In five other illustrative cases the men worked in compressed air for the first time at this Tunnel and symptoms, with radiographic changes, did not develop until approximately two years later.

### 1 - 'Articular' Lesions

The initial radiographic examination may demonstrate collapse of the articular cortex when a segment of the weakened joint surface sinks into the necrotic bone. These changes occur in the posterior or 'weight bearing' area of the head of the femur or in the middle third or two thirds of the head of the humerus. Collapse of the articular cortex is accompanied by a sudden onset of pain and this may be associated with lifting a heavy weight or heavy muscular activity. In the great majority of cases it is not possible to establish a clear cut time interval between the ischaemic episode and the onset of symptoms or radiographic change. Very often the men have worked in compressed air for many years and present with quite severe symptoms of several months or years duration and marked radiographic change (Case 7 J.P., Case 12 E.S., Case 14 J.McA.). In one of the cases (Figs. 38 (a) and (b) ) the man had experienced pain and symptoms for many years and had decided for himself that very little could be done.

The appearance of dense sclerotic areas of varying size and shape is one of the earlier radiographic changes of bone necrosis

(Figs. 8 to 17). It is likely that these dense areas result from attempted revascularisation of a necrotic area and is associated with the laying down of new bone. The size and shape of these dense sclerotic areas presumably depends on the extent of the initial ischaemic areas. Tomography often demonstrates the extent of the lesion more clearly and frequently demonstrates the irregular outline.

The dense areas may form a dense curvilinear layer or 'snow cap' which is more common in the head of the humerus, and the margins extend to the articular cortex on each side (Figs.18(a) to 32(b) ). From histological studies it appears that this layer or 'snow cap' is a zone of revascularisation which is probably advancing into the necrotic area. The segment of bone beyond the dense line is probably necrotic and radiographic assessment of the viability of this area is unreliable. Other dense sclerotic areas may abut on the articular cortex and this may collapse at a later date.

The radiographic appearances of a translucent subcortical band are usually associated with dense sclerotic areas in the adjacent bone. The translucent band may result from a zone of fibrous tissue or may represent a fracture line, indicating that the weakened cortex has partially separated from the underlying bone. The dense areas are evidence of revascularisation.

Depression of several fragments of articular cortex is probably a change of some duration. The fragments of bone are probably necrotic and sequestered (Figs.28(a) to 32). The increased density of the underlying bone probably results from the zone of revascularisation with new bone formation and possibly

small areas of calcification within the necrotic trabeculae. It is interesting to see that the dense area involves almost the entire head of the humerus or femur and often extends down into the proximal shaft of the humerus or femur, suggesting that a large segment of the bone was involved in the initial ischaemic episode.

Sequestration of a large portion of the head of the humerus or femur is also a change which is likely to be of some duration (Figs. 33(a) to 37(b) ). In the cases where the joint was explored a fragment of the articular cortex separated from the underlying bone without much difficulty, and in the case recorded by Swain, the large sequestered fragment of the head of the humerus could be sprung on pressure.

In long standing cases, osteophytes develop at the margins of the articular surface and the appearances are those of osteoarthritis (Figs. 38(a) to 39). Several authors have commented on the fact that, while marked changes of osteoarthritis are present in the femoral head, the acetabulum is comparatively normal and this may help in the differential diagnosis.

## 2 - 'Shaft' Lesions

When the shaft of a long bone is involved, the radiographic changes are usually seen in the distal medulla of the femur, and can occur in the tibia or humerus. Characteristic lesions are situated in the centre of the medullary cavity towards the end of the bone; they are recognised by an area of increased bone density with an irregular outline (Figs. 40(a) to 47). These lesions are very similar to the dense sclerotic areas adjacent to the articular cortex which have been already described, and are more

clearly demonstrated on tomography.

Often calcified areas are present in the medulla, these vary in size and shape (Figs. 48(a) to 51). This calcification appears to be laid down in the layers of fibrous tissue which surround a necrotic area of bone. These areas tend to remain static over many years. The areas can be large and Bucky (1959) showed a striking example which was wedge-shaped with the base of the wedge close to the scar of the old epiphyseal line.

Occasionally a translucent area is demonstrated in the shaft of the bone (Figs. 52(a) to 53(b) ). This may be associated with a fine sclerotic margin. The hip joint was explored in Case 7 J.P. and the translucent area was found to be a cavity containing clear fluid, and lined by granulation tissue. There are no comprehensive histological studies for this type of lesion.

#### Site and Frequency of Lesions and Clinical Features

The facts emerging from this radiographic survey show that forty-seven men were found to have a total of a hundred and six lesions and that 41% of these lesions were bilateral (Table 3). The head and neck of the humerus was most frequently involved, fifty-one out of one hundred and six lesions of avascular necrosis of bone being present at this site and 47.1% of these lesions were bilateral. 55% of the men or twenty-six out of forty-seven, were found to have definite radiographic evidence of a bone lesion involving or close to an articular cortex. The head of the humerus again was involved most frequently and, in fact, 63% of the lesions were found at this site or twenty-four out of the thirty-eight lesions.

'Shaft' lesions were present in 78% of the men or thirty-eight

out of a total of forty-seven. These were usually situated in the distal shaft of the femur and the proximal shaft of the tibia or the proximal shaft of the humerus. These lesions were frequently bilateral. A survey of symptom free men is likely to demonstrate such a high proportion of 'shaft' lesions. It is unlikely that these will ever cause symptoms.

When other publications are studied, this frequency of involvement of the head of the humerus is not borne out. In fact, Baillarge and Merer (1953) and Jaffres et al (1955) suggest that a joint doing the greatest work is the one which is most frequently involved and in their series they point out that the left hip and the right shoulder joint are most frequently involved. However, this finding is not confirmed in our series.

In the review of the site of bone lesions in the published reports of a hundred and fifty-three compressed air workers (Appendix 1 and Table 4), the hip joint is involved slightly more often than the shoulder joint. In the published reports, the bone lesions are seen again to be multiple and 37.5% are bilateral. Of course it must be remembered that when a large number of published reports of this type are studied, the majority of men will have presented with symptoms, and the hip joint was frequently involved. Further study of Appendix 1 shows that the bone lesions can occur at other sites - in the shaft and distal end of the humerus, the shaft and distal end of the tibia, throughout the fibula, in the acetabulum, the ischio-pubic rami and the clavicles. Lesions at these other sites are uncommon and are unlikely to cause symptoms. The review by Bell, Edson and Hornick (1942) indicates that even with a 75% incidence of bone necrosis, the

radiographs of the skull, the elbows and the wrists are normal.

Study of the published reports reviewing the findings in large numbers of compressed air workers shows a varying frequency of lesions at different sites. Bell, Edson and Hornick (1942) in their report on thirty-eight men with positive bone lesions found that the knee was the most common site. Poppel and Robinson (1956) found in their series of a hundred and ninety men with positive radiographic evidence of bone necrosis that the order of frequency was as follows: the distal shaft of the femur, the proximal shaft of the tibia, the heads and necks of the humerus and of the femur. They state that lesions have not been seen in the ribs, the spinal column or the 'miniature long bones'. Baillarge and Merer (1953), Mungo and Sessa (1958), Raymond (1960), and Rózszahegyi and Fried (1963) in reviews of twenty cases, fourteen cases, twenty-eight cases and twenty-four cases respectively found the heads and necks of the humerus and of the femur were involved in roughly an equal number of occasions. The head and neck of the femur was most frequently involved in the series of forty-eight men reported by Cavignaux et al (1949) and of twenty-five men reported by Jaffres et al (1955).

The review of published reports of bone necrosis occurring amongst twenty-six divers (Table 5) shows that the lesions are identical with those found in compressed air workers. Likewise the lesions are multiple, bilateral and the head of the humerus is most frequently involved. Many of the reports are from Scandinavian countries where the divers attain great depths when diving off the coast.

The survey at the Clyde has demonstrated that the shoulder

joint is more frequently involved than the hip. The reason for this is not at all clear. One wonders if the high frequency of involvement of the shoulder joint is because men were decompressed in the sitting position and if gas bubbles did form within the shaft of the bone then they would rise to the uppermost point. However the same theory might apply to the tibia, with the man in the sitting position the tibia would be more or less vertical and bubbles would rise to the proximal end of the tibia. However radiographic lesions are uncommon at this site. The aetiology of bone lesions is not clear and various theories will be discussed later.

In studying those cases who attended for clinical examination it was found that thirty-two men of a possible forty-seven came forward for examination. Eight men, or 25% were found to have symptoms referable to the radiographic evidence of bone necrosis. In seven cases the shoulder joint was involved and the hip joint was involved in one case. Symptoms varied from two months to a year's duration and consisted of a painful arc on abduction. More severe changes were limitation of movement and persistence of pain. Twenty-four men, or 75% were symptom free. The interesting point, in this part of the investigation, is that patients with radiographic incidence of an intact articular cortex should have symptoms and this in fact is evidence of damage to the cartilage. The other interesting feature is the man with evidence of a translucent subchondral band who was found to be symptom free. Repeated weight bearing and muscular activity may cause collapse of the weakened cortex with recurrence of symptoms. Similar symptoms and signs were present in the illustrative cases

who presented outwith the survey. Seven of these cases worked in compressed air for the first time at this tunnel for periods varying between several months and a year. These men presented with bone necrosis about two to three years later, symptoms having developed about one year after exposure to air. In general, the more severe the radiographic change, the greater the disability. The shoulder joint showed various degrees of limitation of abduction, internal and external rotation, and the hip joint shows similar limitation of function in flexion and and movement in rotation.

In studying the age of those men with positive radiographic evidence of a bone lesion, the highest incidence is found in men over 45 years of age, the majority of whom are long term compressed air workers. Study of the ages in the published reports (Appendix 1) also shows that many are between 35 and 45 years of age.

There are very few published reports with 'follow up' of the radiographic lesions. We have one example - Case 6 J.C. - where 'follow up' over two years shows increased density of the head of the femur, presumably being evidence of progressive revascularisation with laying down of new bone. In addition there is further translucency which may represent bone absorption. Rózsahegyi and Fried (1963) have published reproductions of the radiographs in twelve cases of bone necrosis followed up over a seven year period. These indicate that the dense sclerotic areas in the head of the humerus with an intact cortex tend to remain static. Only one case out of the six showed progression of the radiographic change. The hip joints, on the other hand, usually showed involvement of the cortex and four out of six cases showed

progressive change with an increase in the radiographic density and further collapse of the cortex. Further publications showing progressive radiographic changes are those by Dale (1952), Raymond (1960), Suntych and Suntychova (1961), Kaczurba (1962). From all these publications it is apparent that the development of progressive radiographic changes is slow and is probably more common in the hip than in the shoulder. The radiographic changes consist of progressive increase in bone density, slight further collapse of the articular cortex and probably the late onset of osteoarthritis.

#### Differential Diagnosis

Avascular necrosis of bone from other causes will give a similar radiographic appearance in the heads of the humerus and the femur and around the knee joint.

#### 'Articular' Lesion

Fracture of the femoral neck is a common cause of avascular necrosis in the head of the femur. Two representative cases of avascular necrosis developing in the head of the femur following a fracture of the femoral neck have already been described.

One case of an adolescent with a crack fracture (Fig. 71 (a) - (f) ) and the other following internal fixation of the fragments (Fig. 72(a) - (c) ). Necrosis is more common in adolescents (McDougall 1961).

Traumatic dislocation of the hip is an uncommon injury and necrosis of the femoral head may be sequel to this serious injury:

#### Case 18 G.M.

Dislocation of the right hip with a fracture of the posterior rim of the acetabulum following a serious fall. (Fig. 74(a) ). Shortly after the

injury, the patient, for personal reasons, was transferred to another hospital. A radiograph two years later (Fig. 74(b) ) showed marked necrosis of the femoral head.

In all these cases the radiographic appearance of bone necrosis is remarkably similar to those developing following exposure to compressed air where there is a history of severe trauma to the hip and the radiographic appearances are not complicated by the presence of marked secondary osteoarthritis involving the articular cortex of the femoral head, the differentiation from necrosis following work in compressed air will be comparatively easy.

Secondary osteoarthritis of the hip from some cause other than bone necrosis can present similar clinical and radiographic features to secondary osteoarthritis associated with necrosis of the femoral head following work in compressed air. Differentiation between the two conditions can be very difficult and has posed many medico-legal problems (Jullien et al 1954, Gaultier et al 1962). At this tunnel, there is only one case, (Fig. 38(a) and 38(b) ) showing advanced osteoarthritis in his left hip. This man has worked for many years in compressed air and has evidence of necrosis at other sites. Exposure to compressed air and the absence, prior to this type of work of conditions associated with osteoarthritis, such as obesity, congenital abnormalities, repeated trauma and atherosclerosis, should lead one to favour a diagnosis of bone necrosis following exposure to compressed air. Similarly this diagnosis will be supported when a younger age group is involved and if there is

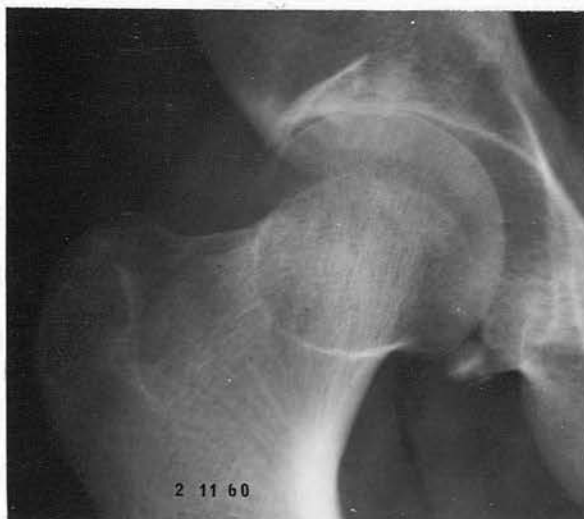

Fig. 74(a) - Dislocation of right femoral head with fracture of posterior rim of acetabulum.

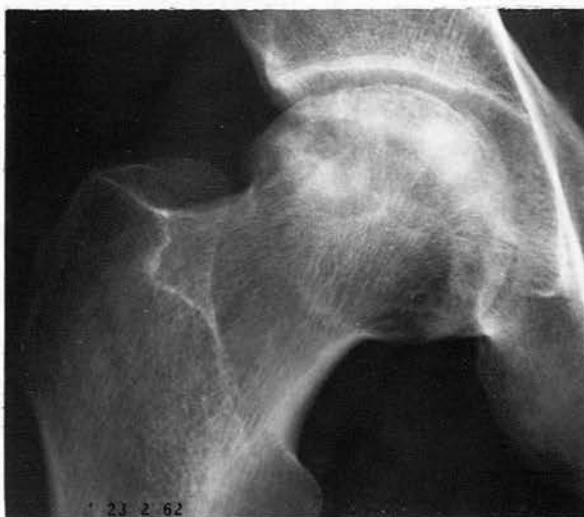

Fig. 74(b) - Bone necrosis in femoral head 2 years later.

a history of sudden onset of pain, from collapse of the articular surface. However many years may have elapsed, since the onset of pain, so that it is difficult for the patient to remember. In compressed air workers, the lesions are more likely to be bilateral and several joints may be involved. Calcification may be present in the shaft of the femur or tibia. In osteoarthritis, the joint space may be more diminished and there may be evidence of osteoarthritis in the acetabulum. The main difference being that the cartilage is primarily involved in osteoarthritis, while in bone necrosis, following work in compressed air, the articular change is secondary to necrosis of the underlying bone.

In the shoulder joint, (Fig. 39) the radiographic evidence of osteoarthritis secondary to bone necrosis is similar to osteoarthritis from other causes. However other forms of osteoarthritis are very rare. In a compressed air worker, the presence of dense areas in the head of the humerus, possible sequestration of a fragment of cortex, and marginal osteophytes should favour the diagnosis of bone necrosis following exposure to compressed air.

Osteochondritis dissecans involving the head of the femur can give a similar radiographic picture to that found in bone necrosis following decompression sickness. Case 7 J.P. (Fig. 60(a) and (b) ) is an example of this. Osteochondritis is uncommon in the adult, affecting males slightly more than females in the age group from six to forty years. Smillie (1960) in his excellent monograph describes only five examples involving the femoral head in three hundred and twelve cases. Other features to be considered in the differential diagnosis are the absence, in a radiograph, of dense

areas in the adjacent metaphyseal bone and the presence of further evidence of osteochondritis dissecans at the elbows, ankles or shoulders (Jacobs 1962). In this condition, as in osteoarthritis, a significant occupational history should favour the diagnosis of avascular necrosis of bone following exposure to compressed air.

Gaucher's disease can give rise to avascular necrosis of the femoral head. This is a rare familial disorder, more common in Jewish patients. The sex incidence is equal and the age group is from eighteen to forty years. Splenomegaly, hepatomegaly, pingueculae and skin pigmentation are often found. Radiologically the most common finding is widening of the distal shafts of the femora, the so called Erlenmeyer flask deformity, usually bilateral and symmetrical. Irregular areas of rarefaction and cystlike spaces may be present in the humerus, tibia, fibula, ulna, ribs and clavicle. Avascular necrosis of the femoral head is uncommon and differentiation from necrosis following work in compressed air is easy when these points are considered.

Radiotherapy, a number of years ago, was a cause of necrosis of the head of the femur or the humerus (Truelson 1942, McDougall et al 1950, Samuel 1957). The condition is believed to result from an endarteritis and symptoms do not appear until one or two years following the treatment. Fortunately, with improved methods in radiotherapy, this complication is now rare.

Sickle cell anaemia gives rise to bone necrosis, and Macht and Roman (1948), in a review of forty-eight cases, describe a twenty-seven year old coloured male who suffered frequent crisis since childhood and had multiple bone lesions. The radiographs of his femoral head show marked bone necrosis, with irregularity of the

cortex and secondary osteoarthritis. The tibia shows a typical calcified medullary lesion. Both lesions are similar to those found following exposure to compressed air. Sickle cell anaemia occurs in fairly well defined racial groups and principally affects infants and children. Recurrent exacerbation of joint and limb pains and splenomegaly are the common features. Laboratory tests will reveal sickling of erythrocytes, increased hemolysis, a raised reticulocyte count and a low erythrocyte sedimentation rate. Electrophoretic analysis of the blood will separate and identify the haemoglobins (Middlemiss 1958).

Idiopathic bone necrosis can present many difficulties in diagnosis. The term should be confined to cases where none of the known diseases associated with bone necrosis can be demonstrated. Among the more significant communications on this subject are those by Serre and Simon (1961), D'Aubigné (1964), Patterson et al (1964). The patient presents with pain and limitation of movement of the affected joint which may be of sudden onset. The condition is more common in males, between thirty and sixty years of age and there is frequently a history of repeated minor trauma to the affected joint, with a history of excessive strain at the onset of pain. Congenital abnormalities may also be present. About 17% are, by loose definition, alcoholic. D'Aubigné states that 36% of his cases had previously received steroid therapy. The condition is not rare and D'Aubigné describes one hundred and four cases over a period of seven years. However he includes osteochondritis dissecans in the idiopathic group.

Steroid therapy may be associated with bone necrosis and several cases have now been published (Serre and Simon 1960), Herman and

Freibergen 1960, Sutton et al 1963). Sutton describes eight patients all of whom had received systemic steroid therapy and in only one case had the normal dose been exceeded. The drugs had not been given intra-articularly. In all cases, the femoral head was involved, the changes were bilateral in five, and in one case the head of the humerus showed evidence of bone necrosis. Symptoms commenced between two and forty months after therapy began and the radiographic changes were present between eight and forty-four months from the commencement of therapy. It has been postulated that cortisone increases blood viscosity and so promotes relative vascular stasis and a tendency to thrombus formation. McFarland and Frost (1961) demonstrated 'micro' cracks on the surface of the femoral head which they suggest will not heal when cortisone is exhibited.

Case 19 Mrs. A.B. 48 years

A history of psychotic episodes was successfully managed by largactil in moderate dosage for a number of years. In May 1961, she presented at another hospital with a sore throat, septic lesions, and an agranulocytic anaemia which was thought to result from the largactil. This was controlled with systemic penicillin and prednisolone. Exact dosage not known now.

In August 1963 over two years later, she presented complaining of pain and limitation of movement in her right hip and stated that this pain had commenced suddenly a year before, following a heavy lift. This had progressed gradually since that time with increasing difficulty in movement in

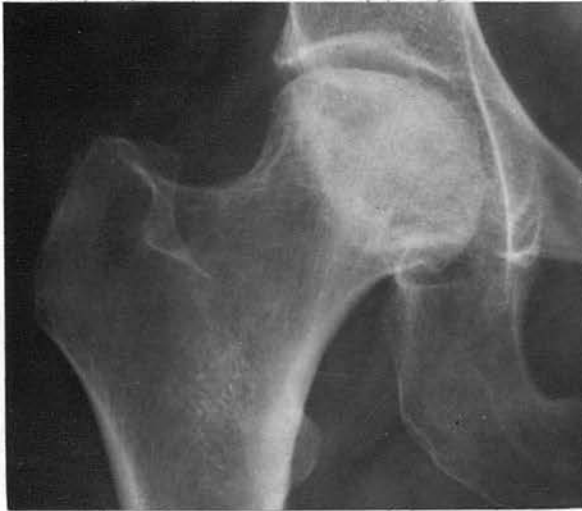

Fig. 75(a) - Bone necrosis in head of right femur.

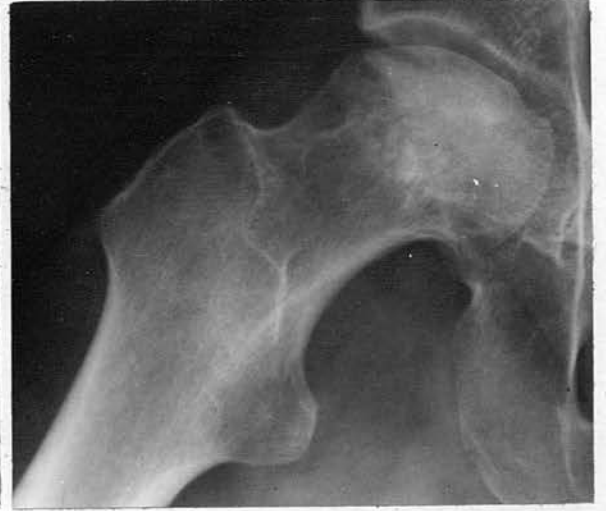

Fig. 75(b) - Lateral projection right hip showing collapse of articular surface.

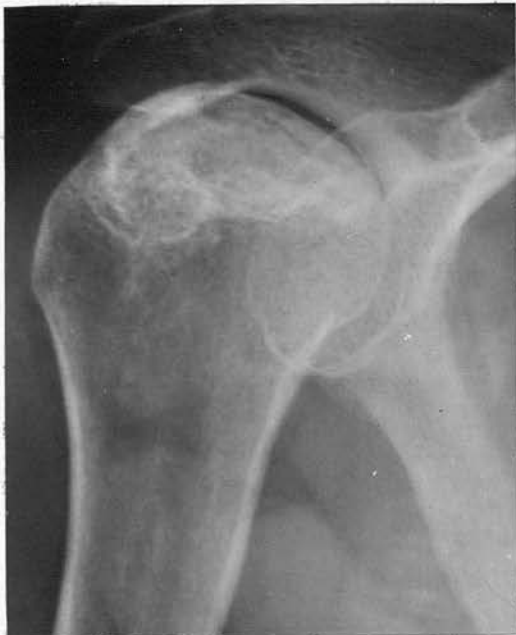

Fig. 75(c) - Bone necrosis in head of right humerus defined by a dense line.

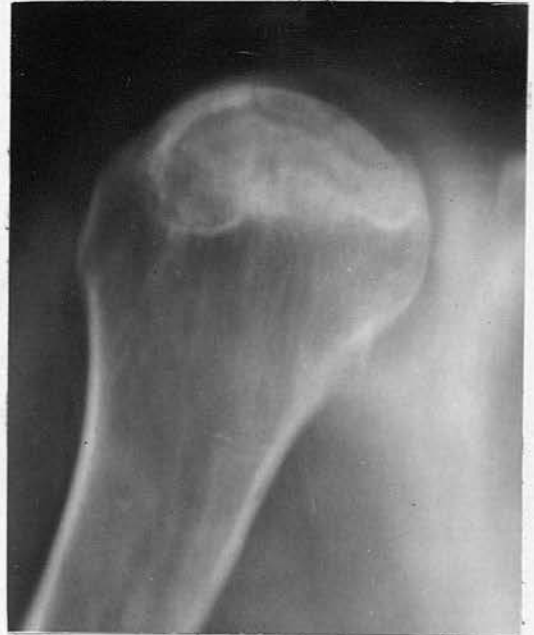

Fig. 75(d) - Tomograph right shoulder showing necrosis more clearly and probable sequestration.

the last three or four months. On examination there was marked limitation of movement in the right hip and in the right shoulder.

Radiographic examination showed typical changes of avascular necrosis of bone in the head of the right femur and in the head of the right humerus.(Fig. 75(a) - (d) ).

It is difficult to assess the significance of the connection between steroid therapy and bone necrosis. Many patients have received steroid therapy for one reason or another, and very few have developed bone necrosis.

Bone necrosis has also been recorded in association with rheumatoid arthritis, systemic lupus erythematosus, gout, subacute bacterial endocarditis; many of these cases had received steroid therapy.

#### 'Shaft' Lesions

Symptomless medullary infarcts are usually an incidental finding. If these calcified areas are demonstrated in men who have been exposed to compressed air, this is usually accepted as the cause.

Such calcified areas may be associated with extensive atherosclerosis or embolism of cardiac origin. In many instances the aetiology is unknown (Kahlstrom, Burton and Plemister 1939, Taylor 1944) and careful pathological studies have failed to reveal any evidence of athero-sclerosis in the intramedullary vessels even at the most extensive examination.

A heavily calcified enchondroma may be confused with a calcified

infarct, but evidence of erosion of the cortex and biopsy, if required, will indicate the correct diagnosis.

In some instances, as already indicated, difficulty is experienced in differentiating the small dense sclerotic areas from bone islands.

When the dense area follows the line of the trabeculae and have an irregular outline, sometimes confirmed on tomography, then the appearances favour a diagnosis of avascular necrosis of bone (Reboul 1955, Fournier and Julien 1959, Mosinger and Julien 1961). On the other hand, in several cases, it is impossible to distinguish the appearances from a bone island. This point has already been discussed in the thesis.

#### Treatment

Very few people have had any significant experience in the treatment of avascular necrosis of bone in compressed air workers. Manfredi (1956) gives a review of the treatment of twelve cases and having had experience of the administration of radiotherapy and physiotherapy, he considers that the optimum results are obtained by removing the necrotic areas of bone and replacing these with bone grafts, in an attempt to increase the vascularity of the area and the strength of the bone. Pachner (1955) suggests the use of cup athroplasties but this, to a certain extent, has gone out of favour in recent years.

In 1953, Baillargé and Merer reported very good results following the injection of Priscol at the stellate ganglion or at the lumbar sympathetic chain. These authors were of the opinion that one of the aetiological factors in bone necrosis was

a disturbance of the autonomic nervous system. Consequently areas of bone with a poor blood supply would be vulnerable. A subsequent paper by Bureau et al (1955) seriously contested the value of this form of treatment.

Surgical intervention depends on the severity of symptoms, at the moment the replacement of necrotic bone by grafts appears to be the most satisfactory method.

Obviously it is impractical to advise prolonged bed rest in those cases with articular damage. However it is important that these men should avoid heavy muscular work, especially above shoulder level, and should be encouraged to find light employment.

Treatment is lengthy and often unrewarding and it is of importance to know if these lesions can be prevented.

#### Aetiology of Avascular Necrosis of Bone in Decompression Sickness

Uncertainty still prevails as to the aetiology of this condition. Various theories have been put forward and some experimental work has been reported. While much work has been done to induce bone necrosis experimentally (Phemister 1940 and others), only a few attempts have been made to study the effect on bone of rapid changes in atmospheric pressure.

Kahlstrom, Burton and Phemister (1939) attempted to produce bone necrosis in seven dogs by injecting air into the abdominal aorta at the level of the bifurcation. Between 7 to 10 ml. per kilogram of body weight were injected and the femur and tibia were excised between seven and one hundred and fifty-five days later. There was no radiographic or histological evidence of bone necrosis.

Gersch (1945) studied the effect of decompression on the bone

marrow of guinea pigs. Only under severe conditions of pressurisation did extravascular gas bubbles appear, together with a large number in arteries, sinusoids and veins.

Colonna and Jones (1948) subjected animals to 55 lbs. p.s.i. air pressure and then rapidly decompressed them to sea level. Pathological examination of the animals, which died immediately, showed numerous cavities in the medulla of the long bones. These hollow spaces were interpreted as being gas bubbles. Animals sacrificed one month following decompression, showed large macroscopic cavities in the bone marrow, as well as typical microscopic changes of bone necrosis. However, their communication does not state conclusively that bubble formation was present in the marrow cavity.

Pirastu and Perra (1960) exposed ten rabbits and dogs to five or six atmospheres absolute repeatedly and no evidence of bone necrosis was noted over nine months.

Various attempts have been made to study the pressure within the medullary cavity of bone. Larsen (1938) studied the intramedullary pressure in the long bones of eight dogs and concluded that the total medullary capacity is fixed by inexpandible cortex except as modified by growth and disease. Moreover, excluding the marrow vessels, the medullary cavity is occupied by relatively incompressible material. Intramedullary tension must therefore be dependent on intravascular tension. Likewise any increase in the relative volume of extravascular tension can occur only at the expense of the volume of blood in the vascular bed.

More recently Rasgon et al (1951) found that the average systolic pressure of the marrow was 50 mm. mercury and similar pressures were obtained during simultaneous measurement in both

femora and in a femur and humerus. They concluded that the bone marrow is physiologically a closed cavity and that the changes of intramedullary pressure are dependent upon the volume of blood in the marrow cavity.

Kalser et al (1951) in a series of experiments on twenty-one dogs exposed the animals to a simulated altitude pressure of 40,000 ft. for periods varying between five and sixty minutes. The dogs were then recompressed to ground level. Simultaneous measurements were taken of the intramedullary pressure and the intravascular pressure in the carotid artery. While no change in the systemic blood pressure was found during decompression, the main intramedullary pressure fell from 52/41 to 44/41 mm. mercury at 40,000 ft. They found that there was direct correlation between altitude and fall in bone marrow pressure. This change in pulse pressure may be the result of intravascular gas emboli, however the authors favour the theory that the pressure changes result from vaso-constriction.

Swindle (1937) noted severe agglutination of red cells in decompression sickness and thought that this might predispose to vascular occlusion and so infarction. However, Behnke (1945) points out that this is not a true agglutination but a phenomenon that occurs under a variety of circumstances associated with slowed circulation, plasma loss and cell packing.

The following formulation of the factors involved is suggested. The radiographic abnormality is one of avascular necrosis of bone and this has been confirmed on pathological studies of a few cases. The lesions are confined to the head and neck of the humerus and the femur and to the distal shaft of the femur and the proximal shaft of

the tibia. Occasionally the distal shaft of the humerus or the radius and the ulna may be involved. The lesions tend to form a common radiographic pattern. The 'snow-cap' lesions are very common and the distribution of many of the small dense areas involving or adjacent to the articular cortex resemble the 'snow-cap' type of lesion. Occasionally the dense areas involve almost the entire end of the bone and extend down towards the proximal shaft. This indicates that quite a large area of bone is involved in the ischaemic process.

The large articular surfaces of the shoulder and hip joints do not receive an additional blood supply from the periosteal vessels and consequently these areas will be more vulnerable to an ischaemic process. However the same reasoning could apply to the knee joint and, while lesions are found in the shaft of the femur and tibia around the knee joint, the articular cortex is never involved.

We know from comments already made in this thesis of the incontrovertible evidence of bubble formation in decompression sickness and that these bubbles can occur both in the intravascular, usually venous, and extravascular tissues. The bubble contains a high proportion of nitrogen which has a high affinity for the lipid rich tissues of white matter in the spinal cord and in the bone marrow.

Slow release of nitrogen from the fatty tissues of the bone marrow could result in bubble formation in the extravascular tissues. These bubbles, being contained in the rigid structure of bone trabeculae, cannot expand freely and so would cause extravascular pressure on blood vessels.

Fatty marrow is not plentifully supplied with blood, and the

vessels, as described by Laing (1956) appear particularly vulnerable to occlusion by compression and distortion. In particular, that branch of the nutrient artery which ascends the humerus, that which descends the femur and that which ascends the tibia are sharply kinked after their origin from the main arteries because the latter enter the medullary cavity obliquely in the opposite direction. These branches often have a long course through the fatty marrow and show corkscrew twists.

Trueta and Harrison (1953) have demonstrated the blood supply to the femoral head and have shown numerous end arteries, and these would be liable to occlusion.

Intravascular bubbles, on the other hand, might easily arise in the sluggish circulation of the venous sinusoids of the red marrow (Trueta and Harrison 1953, Campbell and Hill 1933). This will result in stasis, both in the venous and arterial vessels. Stasis on the arterial side could well provoke bubble formation from saturated tissues. In either situation vascular occlusion could be produced.

The presence of either intravascular or extravascular bubbles slows or occludes the circulation and this is further aggravated by the possibility of vaso-constriction with altered intramedullary pressure.

Once an intraosseous bubble has formed, whether intravascular or extravascular, it may persist for several hours or longer, possibly increase in size, and probably does not give rise to an immediate symptom. Consequently such a bubble will be unrecognised and the patient will not have a therapeutic recompression.

Another factor which should perhaps be considered while

discussing the aetiology of necrosis of bone following decompression sickness, is the high incidence of alcoholism among compressed air workers. It has been pointed out that alcoholism is common among those with idiopathic necrosis of bone but the connection is not clearly established.

It is possible that a compressed air worker, who develops avascular necrosis of bone, may experience several symptomless ischaemic episodes, and that the bone infarcts, demonstrated on a radiograph, is the result of several different incidents.

#### Prevention of Bone Necrosis

Hitherto bone necrosis amongst compressed air workers has been disregarded and, in this country, attempts have been made only in recent years to study the incidence of bone lesions and their characteristics. No mention is made of bone necrosis in the 'Work in Compressed Air Special Regulations' 1958 and the men themselves are comparatively unaware of the condition. Obviously bone lesions are more common than is generally realised and, affecting the shoulder or hip joint, are a potentially disabling condition and must be considered one of the most serious forms of decompression sickness.

While the acute forms of decompression sickness, as judged by the "bends rate", is now reduced to very low figures. The present decompression schedules do not appear to prevent the prevalence of bone lesions. As already stated an important point at issue is to establish whether there is a relation between type 1 decompression sickness and bone lesions and in this way assess the value of the present decompression schedules. Consideration must also be given to any possible benefit of reducing the exposure time.

to four hours or less at the higher range of pressures.

In a recent report from Leningrad, Aver'ianova and Mikhailov (1962) stress the importance of immediate therapeutic recompression for the type 1 case and state that in this way bone necrosis will be prevented. This opinion follows experimental exposure of eight dogs to three atmospheres absolute pressure over a period of fifteen to ninety-one weeks, and is based on the fact that only one showed doubtful radiographic evidence of bone necrosis. However, from the review of the few experiments that have been done, we know of the difficulty in producing bone lesions. The majority of the type 1 and type 2 cases at the Clyde did have an immediate therapeutic recompression.

In most American states, men are exposed to compressed air for shorter periods at pressure, usually with a short interval between shifts. This means an increased number of decompression and Duffner (1962) feels that the incidence of bone necrosis would be reduced if the shifts were lengthened and the number of decompressions reduced. At the Clyde the working shift lasted eight hours and was longer than in the States at an increased pressure of air.

Further work and study is required to reduce the number of bone lesions. If bone lesions could be produced experimentally then various modifications of decompression schedules could be employed. The incidence of bone lesions, amongst those who are exposed for short periods with frequent decompression, should be more closely analysed.

For the present, it is advisable that all men should have radiographic examinations of the shoulder, hip and knee joints at yearly intervals. Those with evidence of bone necrosis and symptoms of

articular damage should be prevented from further exposure. Those with a lesion at some distance from a joint surface should have the significance of the lesion explained to them and be permitted to work in compressed air only at their own wish. The possibility of bone lesions occurring in this type of work should be more widely known, and it is important that the men themselves should be aware of the potential danger.

CONCLUSION

Avascular necrosis of bone amongst compressed air workers is more common than is generally realised.

This radiographic investigation of the shoulder, hip and knee joints shows, that in a group of two hundred and forty-one compressed air workers at the end of a four year contract, there is at least a 12.4 per cent incidence of bone lesions and probably a 16.5 per cent incidence when more indefinite evidence is included. Eight out of the two hundred and forty-one men or 3.3 per cent had symptoms, and this includes one man who admitted having experienced symptoms before coming to the Clyde. In addition, an analysis of the site of all bone lesions shows that 55 per cent of the lesions involve or are adjacent to a joint surface and so liable to produce symptoms. This group of two hundred and forty-one men only represents 17.6 per cent of the labour force, a total of thirteen hundred and sixty-seven men having been exposed to compressed air at one time or another during the contract and all these men are liable to develop avascular necrosis of bone. In fact another eleven cases of bone necrosis have presented at Hospitals in Glasgow and the West of Scotland over the past three years. All these men had worked at the Clyde Tunnel and had left employment before the survey commenced. Seven of the men had worked in compressed air for the first time at this tunnel.

The radiographic diagnosis of avascular necrosis of bone is based primarily on an absolute increase in radiographic density of the affected area. This increase in density results from the process of revascularisation of necrotic bone, and it has been shown during this process that new bone is laid down on the trabeculae of

dead bone. This process is usually seen at a bone end and takes some time to develop. It is six months at least, usually a year, before an increase in radiographic density becomes apparent and during this period necrotic bone is indistinguishable from living bone. In the shaft of the long bones, the increase in radiographic density results from calcification in the margins of the necrotic area. A similar period of time must also elapse before this calcification becomes evident on a radiograph. Consequently it is clear that the radiographic abnormality requires time to develop and it is suggested that the incidence of bone lesions is probably higher. This could be demonstrated if it was practical to examine the same group of men at yearly intervals over the next three years.

The initial radiographic changes are dense sclerotic or calcified areas of varying size with an irregular outline. Sometimes these dense areas are demonstrated more clearly on tomography or by macroradiography. These dense areas may assume a more linear outline following the line of the trabeculae, which then appears thickened and fused. Care must be taken to avoid confusion of this type of lesion with a bone island or variation in the normal trabecular pattern. These dense areas are believed to be evidence of revascularisation of an ischaemic area. The lesions are common and may be situated adjacent to the articular cortex or at some distance from it usually in the head and neck of the femur or of the humerus. Examination of all the affected men shows that these dense areas did not give rise to symptoms.

Another common radiographic feature was the presence of a dense curvilinear band or 'snow-cap' lesion usually in the head of

the humerus and occasionally in the head of the femur and often bilateral. This type of lesion is seen more clearly on a tomograph. The dense curvilinear band has been shown to be a band of revascularisation, laying down new bone, and advancing into the necrotic bone. Three out of seven men with this radiographic abnormality were found to have signs of a 'painful arc' on abduction. This sign is thought to be evidence of articular damage. When the arm is abducted the damaged area is brought into contact with the glenoid cavity and so will produce symptoms.

The presence of a translucent subchondral band also indicates that the lesion is of several months duration. This band, seen more clearly on tomography, lies immediately under the articular cortex and dense sclerotic areas are often associated. The lesion occurs in the head of the humerus and often shows symmetrical involvement. Signs of a 'painful arc' on abduction and limitation of movement may be present. In one case the symptoms had regressed after a few weeks, and would probably return with repeated weight-bearing or muscular activity.

Occasionally the initial radiographic examination may demonstrate collapse of a segment of the weakened articular cortex, and the neighbouring bone is of normal radiographic density. This is seen to involve the posterior or 'weight-bearing' area of the head of the femur. Symptoms are usually of sudden onset, and the patient may recall lifting a heavy weight or having muscular activity at the time of onset of the pain.

Other radiographic abnormalities consist of sequestration or depression of a section or fragment of the articular cortex. This is usually associated with an increase in radiographic density often

involving a large portion of the head of the humerus or femur and extending into the proximal end of the shaft. Evidence of secondary osteoarthritis is present in long standing cases. It is interesting to note how often the same area of the articular cortex is involved. Study of the radiographs shows that it is either the middle third or the middle two-thirds of the articular surface of the head of the humerus, and this feature may help to throw some light on the aetiology or the blood supply within the head of the humerus.

Symptoms and signs of pain and limitation of movement of an affected joint varied with the extent of the radiographic abnormality. Seven of the eleven illustrative cases worked for the first time in compressed air at this tunnel and presented about two years later.

This large survey of symptom free men has demonstrated many bone lesions which are situated at some distance from an articular cortex; these 'shaft' lesions do not give rise to symptoms. Irregular dense sclerotic areas of varying size similar to those already described, are a common feature. Irregular calcified areas of varying size are also present and these are usually situated in the distal shaft of the femur and occasionally in the proximal shaft of the tibia or the proximal shaft of the humerus. Symmetrical involvement is also a feature of these calcified lesions. Published reports indicate that this calcification is laid down in the fibrous capsule enclosing a necrotic area within the medulla of the bone. A less common lesion is the presence of a translucent area with a fine sclerotic margin. Surgical exploration of such an area indicated that this is a cavity lined with granulation tissue and new bone formation is probably present within the wall.

In the differential diagnosis of this condition, due

consideration must be given to a variety of conditions; these include trauma or previous dislocation of the head of the femur, osteochondritis dissecans either in the head of the femur or in the head of the humerus. Less common conditions such as Gaucher's disease, sickle cell anaemia and post irradiation necrosis should be considered especially when the head of the femur is involved.

Idiopathic necrosis of bone can present many difficulties in diagnosis and this term should be confined to those cases where none of the known diseases associated with bone necrosis can be demonstrated. The fact that steroid therapy may sometimes be associated with bone necrosis should be borne in mind.

Advanced secondary osteoarthritis of the hip joint, or less commonly the shoulder joint, can present similar clinical and radiographic features to those found associated with long standing bone necrosis in a compressed air worker. Exposure to compressed air and the absence, prior to this type of work, of conditions associated with osteoarthritis, such as obesity, congenital abnormalities, repeated trauma, atherosclerosis, lead one to favour a diagnosis that the bone lesion is a late complication of decompression sickness.

Bone lesions situated at some distance from the joint surface may pose some problems in the differential diagnosis. However, as these lesions are always symptomless, there is not the same urgency in the diagnosis and the question of compensation is not likely to arise. A calcified enchondroma may resemble a calcified bone infarct and this may be associated with endosteal erosion of the bone. Calcified bone infarcts are known to be present in the bones of those who have never been exposed to an increased pressure of air. The aetiology of these infarcts is not at all clear. Occasionally.

emboli or atherosclerosis have been suggested as the diagnosis.

A history of work at an increased pressure of air should lead one to favour that this exposure has been the cause of bone necrosis. In the present state of our knowledge the man should be given the benefit of any doubt, particularly in view of the prevalence of bone lesions amongst compressed air workers.

Bone lesions are multiple and often show symmetrical involvement at an affected site. The head of the humerus is most frequently involved and the lesions are commonly bilateral. Correspondingly, symptoms are more common in the shoulder joint than in the hip joint. The articular surfaces of the knee joint are never involved.

In a review of the published reports of a hundred and fifty-three compressed air workers, the head and neck of the femur was most frequently involved. This review also shows that lesions are multiple and symmetrical. Other reports of a large number of cases of bone necrosis shows variation in the frequency of the type of radiographic change and the site of the bone lesions. Some reports are confined to the examination of long term compressed air workers and others did not include a full radiographic study of all the joints. Only a few reports indicate the alteration that may occur in the radiographic appearances over a number of years. It appears that the lesions involving the articular cortex of the head of the humerus and femur are progressive. These lesions usually become more dense with increasing revascularisation of the necrotic area. Nearly all such reported cases develop evidence of secondary osteoarthritis after a number of years.

The published reports of divers show that the bone lesions are identical with those found in compressed air workers. The lesions are

multiple, symmetrical, and the head of the humerus is most frequently involved. Only one report indicates that bone lesions may develop following exposure to a reduced pressure of air in a high altitude decompression chamber. Several reports, on the other hand, have shown no radiographic abnormality in the study of a large number of men who operate low pressure chambers.

Relation of the occupational history with the bone lesions of all the men who were examined radiographically at the Clyde, shows that bone lesions are more common at the higher end of the normal working range - that is above 30 lbs. p.s.i. The risk of developing a bone lesion increases with the length of exposure to compressed air. The possibility that a single exposure to compressed air may produce severe bone necrosis has been established and two of the cases reported in this thesis had a very limited exposure. This raises the question if certain men are more susceptible to bone necrosis and if these men can be identified.

The cause of the bone lesions is not at all clear. Experimental work has been largely unsuccessful in producing bone lesions. Possibly the presence of intravascular gas bubbles developing on the venous side, may cause vascular occlusion. It is likely that those men with bone necrosis may have experienced several symptomless ischaemic episodes.

Treatment of the condition is lengthy and largely unrewarding. Only a few people have a limited experience in managing this type of problem. At the moment, removal of the necrotic bone and replacement by bone grafts appears to be of some value in promoting further revascularisation and strengthening the necrotic bone. Surgical intervention depends on the severity of symptoms.

Management should include the avoidance of heavy manual labour.

With such a prevalence of bone lesions, some of which are liable to cause symptoms, and as the treatment is lengthy and so unrewarding, it is obviously important to investigate any possible way that these lesions can be prevented. An important point is to establish the relation, if any, between the existing decompression schedules, as judged by the "bends rate" and the presence of bone lesions. At the Clyde, this rate was one of the lowest on record and yet bone lesions are unexpectedly frequent. It is known that many men with a mild pain - "the niggles" - do not return for treatment, and consequently the "bends rate" may be artificially low.

It is advisable that all men should be recompressed immediately a type 1 lesion develops, and that the men and contractors should be made more aware of the problem of bone necrosis. It is important that men should have a radiographic examination of the hip, shoulder and knee joints before exposure to compressed air. Those with evidence of a lesion involving or adjacent to a joint should be prevented in working in compressed air. Others with a 'shaft' lesion should be told of the nature of the abnormality and that while the lesion will not give rise to symptoms, a further exposure to air may cause other lesions which could give rise to a disabling condition.

Radiology has an important role to play in demonstrating those cases with avascular necrosis of bone and on studying the natural history of this disorder over a number of years.

of Glasgow is an acknowledged authority in the subject of bone pathology and she has been of great help in studying the histological appearances in four of the cases.

## ACKNOWLEDGEMENTS

It is a pleasure to acknowledge the help given to me by so many people.

Most of all, I am indebted to my colleagues on the Decompression Sickness Panel of the Medical Research Council for the knowledge and guidance that I have gained from them at our monthly meetings and during private discussion with individual members.

D. N. WALDER, M.D., F.R.C.S. - Chairman - Department of Surgery,  
The University of Durham, Newcastle upon Tyne.

PROFESSOR ROLAND BARNES, B.Sc., F.R.C.S. - Department of Orthopaedics,  
Western Infirmary, Glasgow.

WING COMMANDER D. I. FRYER, B.Sc., M.B., B.S. - Institute of  
Aviation Medicine, Farnborough.

F. CAMPBELL GOLDING, Ch.M., F.R.C.P., F.F.R. - Department of  
Diagnostic Radiology, The Middlesex Hospital, London.

P. D. GRIFFITHS, B.A., M.D., - Medical Officer - Blackwall Tunnel.

H. V. HEMPLEMAN, M.A., Royal Naval Physiological Laboratory,  
Alverstoke, Hampshire.

R. I. McCALLUM, M.D., M.R.C.P., - Nuffield Department of Industrial  
Medicine, The University of Newcastle upon Tyne.

Many Radiologists and Orthopaedic Surgeons in Glasgow and the West of Scotland have been generous in allowing me to reproduce the radiographs and clinical findings of their cases.

Dr. Mary Catto of the Department of Pathology in the University of Glasgow is an acknowledged authority in the subject of bone pathology and she has been of great help in studying the histological appearances in four of the cases.

The Civil engineering firm, which built the Clyde Tunnel, - Messrs. Charles Brand and Co. Ltd., - have been most helpful and co-operative. In particular, Mr. A. F. Haxton, a Director, Mr. H. E. Whyte, the Agent, and Mr. Mitchell, the Safety Officer, have been both painstaking and patient in supplying much necessary information.

I am indebted to Mr. Gabriel Donald and his staff in the Department of Medical Illustration at the University of Glasgow for his guidance and help with the numerous illustrations.

## REFERENCES

- ALAMERCY, D. (1945). Les ostéo-arthropathies des ouvriers travaillant dans les caissons à air comprimé. M.D. Thesis, Lyon. Cited by RÓZSAHEGYI, I. (1956). Arch. Gewerbepath. Gewerbehyg., 14, 483-510.
- AMDUR, R.D. (1956). Recurrent spontaneous pneumothorax caused by aerial flight: report of a case. J. Aviat. Med., 27, 456-459.
- ANGEI, A. COSSU, R. (1954). Infarto osseo. (contributo clinico-radiologico). Arch. Radiol. (Napoli), 29, 20-30.
- AVER'IANOVA, V.A. MIKHAILOV, P.M. (1962). On the cause and prevention of osteoarticular disorders in decompression (caisson) disease. Gig. Tr. Prof. Zabol., 6, 25-30.
- BAILLARGÉ, J. MÉRER, P. (1953). Contribution à l'étude des ostéo-arthropathies des caissons. Arch. Mal. prof., 14, 225-229.
- BALESTRA, G. MOLFINO, F. (1949). Le alterazioni ossee ed osteoarticolari nelle malattie dei cassoni. Radiol. med. (Torino), 35, 987-988.
- BARBARA, M. ISOLA, A. (1939). Accad. med., 7, 607. Cited by ROCHE, L. RAYNEAU, G. (1953). Arch. Mal. prof., 14, 233-240.
- BARNES, R. (1964). The unsolved fracture. Scot. med. J., 9, 45-57.
- BASSOE, P. (1913). Late manifestations of compressed air disease. Amer. J. med. Sci., 145, 526-542.

- BEHNKE, A.R. (1945). Decompression sickness incident on deep sea diving and high altitude ascent. *Medicine (Baltimore)*, 24, 359-402.
- BELL, A.L.L. EDSON, G.N. HORNICK, N. (1942). Characteristic bone and joint changes in compressed air workers: a survey of symptomless cases. *Radiology*, 38, 698-707.
- BERRY, C.A. HEKHUIS, G. L. (1960). X-Ray survey for bone changes in low pressure chamber operators. *Aerospace med.*, 31, 760-765.
- BERRY, C.A. KING, A.H. (1959). Use of altitude chamber in the diagnosis and disposition of problem aero-medical cases. *J. Aviat. Med.*, 30, 258-267.
- BERT, P. (1878). *La Pression Barometrique*. Paris: Masson.
- BÉTOULIÈRES, P. BOULOUYS, J. (1952). Trois cas d'infarctus osseux au cour de la maladie des caissons. *Presse Méd.*, 60, 344.
- BOBECHKO, W.P. HARRIS, W.R. (1960). The radiographic density of avascular bone. *J. Bone Jt. Surg.*, 42B, 626-632.
- BONFIGLIO, M. BARDENSTEIN, M.B. (1953). Treatment by bone-grafting of aseptic necrosis of the femoral head and non-union of the femoral neck (Phemister technique). *J. Bone Jt. Surg.*, 40A, 1329-1346.
- BOOTHBY, W.M. LOVELACE, W.R. (1938). *Oxygen in Aviation*. The necessity for the use of oxygen and a practical apparatus for its administration to both pilots and passengers. *J. Aviat. Med.*, 9, 172-198.

- BOOTHBY, W.M. LOVELACE, W.R. BENSON, O.O. (1940). High altitude and its effect on the human body. *J. aero. soc. Amer.*, 7, 1.
- BORNSTEIN, A. PLATE, E. (1911). Über chronische Gelenkveränderungen, entstanden durch Presslugterkrankung. *Fortschr. Röntgenstr.*, 18, 197-206.
- BOURRET, M. FRAISSE, P. FRAISSE, H. (1948). La maladie des caissons: contribution à l'étude des lésions osteo-articulaires des tubistes. *Arch. Mal. prof.*, 2, 309-311.
- BOYCOTT, A.E. DAMANT, G.C.C. HALDANE, J.S. (1908). Prevention of compressed air illness. *J. Inst. Hyg.*, 8, 342-443.
- BOYLE, R. (1670). New pneumatic experiments about respiration. *Philos. Trans.*, 5, 2011-2058.
- BROMLEY, J. HARVEY, W. (1944). Radiology at Simulated High Altitudes. Flying Personnel Research Committee. Report No. F.P.R.C. 626.
- BRUNNER, F.P. FRICK, P.G. BÜHLMANN, A.A. (1964). Post-decompression shock due to extravasation of plasma. *Lancet*, 1, 1071-1073.
- BUCKY, N.L. (1959). Bone infarction. *Brit. J. Radiol.*, 32, 22-27.
- BUREAU, R. HOREAU, LEMEILLET, (1955). A propos de quatorze observations d'arthroses barotraumatiques. *Sem. Hôp. Paris*, 31, 2342-2344.
- CAMPBELL, J.A. HILL, L. (1933). Studies in saturation of the tissues with gaseous nitrogen. 1. Rate of saturation of goat's bone marrow in vivo with nitrogen during exposure to increased atmospheric pressure. *Quart. J. exp. Physiol.*, 23, 197-210.
- CAMPBELL GOLDING, F. GRIFFITHS, P. HEMPLEMAN, H.V. PATON, W.D.M. WALDER, D.N. (1960). Decompression sickness during construction of the Dartford Tunnel. *Brit. J. industr. Med.*, 17, 167-180.

- CAMPBELL GOLDING, F. (1961). The shoulder - the forgotten joint.  
Brit. J. Radiol., 35, 149-158.
- CASE, E.M. HALDANE, J.B.S. (1941). Human physiology under high pressure. 1. Effect of nitrogen, carbon dioxide and cold.  
J. Hyg. (Cambridge), 41, 225-249.
- CATALANO, D. (1954). L'infarto osseo. (Descrizione di un caso con il reperto anatomico). Radiol. med. (Torino),  
40, 180-189.
- CATSARAS, M. (1888). Recherches cliniques et expérimentales sur les accidents survenant par l'emploi des scophandriers.  
Arch. Neurol., 16, 145-194, 346-395.
- CAVIGNEAUX, C. CHARES, A. FUCHS, T.S. TARA, M.S. (1949). Les lésions osseuses ignorées des tubistes. Arch. Mal. prof.,  
10, 359-361.
- CHAMPEUX, J. MORY, F. THEVENOUX, R. (1958). Intérêt de l'examen radiographique systématique du squelette chez les ouvriers travaillant dans l'air comprimé. Arch. Mal. prof., 19,  
396-398.
- CHARLES, A. CAVIGNEAUX, C. FUCHS, T.S. TARA, M.S. (1948). L'ostéo-arthrite évolutive de la hanche chez les "tubistes".  
Arch. Mal. prof., 9, 428-435.
- CHAUMONT, A.J. BLITTERSDORF, A.M. (1953). Un cas d'ostéopathie des caissons; aspects radiologiques. Med. Usine, 15,  
198-200.
- CHRIST, A. (1934). Über caissonkrankheit, mit besonderer berücksichtigung einer typischen erkrankung des hüftgelenks.  
Dtsch. Z. Chir., 243, 133-146. Cited by RÓZSAHEGYI, I. (1956).  
Arch. Gewerbepath. Gewerbehyg., 14, 483-510.

- CLARK, K.C. (1956). Positioning in radiography, London: Heineman.
- COBURN, K.R. (1956). Preliminary investigation of bone changes associated with decompression sickness. *J. Aviat. Med.*, 27, 163.
- COBURN, K.R. (1963). Personal communication.
- COLEMAN, S.S. COMPERE, C.L. (1961). Femoral neck fractures. Pathogenesis of avascular necrosis, non-union and late degenerative changes. *Clin. Orthop.*, 20, 247-265.
- COLEY, B.L. MOORE, M. (1940). Caisson disease with special reference to the bones and joints. *Ann. Surg.*, 111, 1065-1075.
- COLLINS, J.J. (1962). An unusual case of air embolism precipitated by decompression. *New Engl. J. Med.*, 266, 595-598.
- COLONNA, P.C. JONES, E.D. (1948). Aeroembolism of bone marrow. *Arch. Surg.*, 56, 161-171.
- DALE, T. (1952). Bone necrosis in divers. (Caisson disease). *Arch. Surg. Scand.*, 104, 153-156.
- D'AUBIGNÉ, R.M. (1964). Idiopathic necrosis of the femoral head in adults. *Ann. roy. Coll. Surg. Engl.* 34, 143-160.
- DEÁK, P. ROZSAHEGYI, I. (1956). Osteoarthropathie der caissonarbeiter (Befunde der ersten fünf jahren). *Fortschr. Röntgenstr.*, 84, 312-320.
- DEWEY, A.W. (1962). Decompression sickness, an emerging recreational hazard. *New Engl. J. Med.*, 267, 759-765.
- DONALD, K.W. (1955). 'Oxygen bends'. *J. appl. Physiol.*, 1, 639-644.

- DUFFNER, G.J. (1962). Decompression sickness and its prevention among compressed air workers. Report prepared for the Municipality of Metropolitan Seattle, Washington, U.S.A.
- EVELYN, K. (1941). The effect of simulated high altitudes on human subjects. Canada, N.R.C.C. Associate committee on aviation medical research, Proc, 9th meeting, Appendix A. Cited by FERRIS, E.B. ENGLE, G.L. (1951). in Decompression Sickness. Edited by J.F. Fulton. Philadelphia: Saunders.
- FERRIS, E.B. ENGLE, G.L. (1951). Clinical nature of high altitude decompression sickness. In Decompression Sickness. Edited by J.F. FULTON. Philadelphia: Saunders.
- FISCHGOLD, H. COVILLE, R. DOASSANS, P. (1948). Alteration chronique des épiphyses dans la maladie des caissons. J. Radiol. Électrol., 29, 230-231.
- FOURNIER, A.M. JULIEN, G. (1959). Aspect radiologiques de la maladie des caissons. J. Radiol. Électrol., 40, 529-534.
- FRANCIA, A. QUAGLIA, C. (1959). Il contributo roentgenologico alla conoscenza ed all' interpretazione della manifestazione osteoarticolari dei cassonisti. Minerva ortop. (Torino), 10, 105-112.
- FRANCK, A. KNOFLACH, J.G. (1938). Knochenveränderungen bei caissonkrankheit. Röntgenprax., 102, Cited by RÓZSAHEGYI, I. (1956). Arch. Gewerbepath. Gewerbehyg. 14, 483-510.
- FRANCK, H. (1935). "Caissonkrankheit" der hüftgelenke. Münch. med. Wschr., 457. Cited by RÓZSAHEGYI, I. (1956). Arch. Gewerbepath. Gewerbehyg., 14, 483-510.

- FRUND, R. (1956). Caissonkrankheit im schultereckgelenk. Z. Orthop., 87, 571-575.
- FRYER, D.I. (1961). Pathological findings in fatal sub-atmospheric decompression sickness. Medicine, Science and the Law, 2, 110-123.
- FRYER, D.I. (1962). Observations concerning the mechanism of sub-atmospheric decompression sickness. Unpublished data. Institute of Aviation Medicine, Scientific Memo. 42.
- FULTON, J.F. (1951). Decompression sickness. Caisson sickness, diver's and flier's bends and related syndromes. Philadelphia: Saunders.
- GARAVAGLIA, C. (1958). Le alterazione scheletriche nella malattia dei cassoni. Minerva med. (Torino), 49, 172-175.
- GAULTIER, M. FOURNIER, E. GERVAIS, P. RACT, A. (1962). A propos de deux cas d'osteo-arthrite baro-traumatique à révélation tardive. Imperfection de la législation actuelle. Arch. Mal. prof., 23, 32-38.
- GERSH, I. (1945). Gas bubbles in bone and associated structures, lung and spleen of guinea pigs decompressed rapidly from high pressure atmospheres of oxygen, helium-oxygen, argon-oxygen and air. J. cell. comp. Physiol., 26, 101-113.
- GLASGOW MASS RADIOGRAPHY SURVEY (1961) and (1962). Annual reports of the medical officer.
- GORDON, J.O. HEACOCK, C.H. (1940). Roentgenologic demonstration of localised gas in caisson disease. J. Amer. med. Ass., 114, 570-571.

- GRUTZMACHER, K.T. (1941). Veränderungen am schultergelenk als  
fulge von drucklufferkrankung. Röntgenprax., 13, 216.  
Cited by RÓZSAHEGYI, I. (1956). Arch. Gewerbepath. Gewerbehyg.
- GUILLAIN, G. GROSSIORD, A. (1943). L'ostéarthrite de la maladie  
des caissons. Paris méd., 329-333. Cited by BAILLARGÉ, J.  
MÉRER, P. (1953). Arch. Mal. prof., 14, 225-229.
- GUITARD, J. (1953). Considerations sur les signes de debut des  
osteoarthrites baro-traumatiques. Arch. Mal. prof.,  
14, 230-232.
- HAAS, W. De, MACNAB, I. (1956). Fracture of the neck of the femur.  
S. Afr. med. J., 30, 1005-1010.
- HALDANE, J.S. (1922). Respiration. New Haven: Yale University Press.
- HALDANE, J.S. PRIESTLEY, J.G. (1935). Respiration. New Haven: Yale  
University Press.
- HARVEY, E.N. (1951). Animal experiments in bubble formation. In  
Decompression Sickness. Edited by J.F. FULTON, Philadelphia:  
Saunders.
- HAXTON, A.F. (1958). Compressed air tunnelling, health, safety and  
welfare. J. Engin. Guild, 5, 289.
- HEMPLEMAN, H.V. (1957). Investigation into the decompression tables.  
Royal Naval Personnel Research Committee. Report No. R.N.P.  
57/896. Cited by FRYER, D.I. (1962). Institute of Aviation  
Medicine. Scientific Memo. 42.
- HENDERSON, Y. (1917). Effect of altitude on aviators. Aviat.  
Aeronaut. Engin., 2, 145-147.
- HENRY, F.M. (1956). J. Aviat. Med., 27, 250-259.

- HERGET, R. (1948). Neuere beobachtungen über chronische gelenkveränderungen bei tauchern durch drucklufteinwirkung. Arch. Langenbechs u. dtsh. z. Chir., 281, 330-360. Cited by RÓZSAHEGYI, I. (1956). Arch. Gewerbepath. Gewerbehyg.
- HERMAN, W.G. FREIBERGEN, R.H. (1960). Avascular necrosis of the femoral and humeral heads after high dosage corticosteroid therapy. New Engl. J. Med., 263, 672-675.
- HOLTER, H.V. HORWITZ, O. (1945). Spontaneous pneumothorax produced by ascent in airplane. J. Amer. med. Ass., 127, 519-520.
- HORVATH, F. (1958). Caisson - betegség okozta sinlyosis elváltzozások a combfejden. Mag. Radiol., 11, 92-94.
- HUNTER, D. (1963). The diseases of the occupations. London: English Universities Press.
- IVY, A.C. (1944). Personal communication. Cited by FERRIS, E.B. ENGLE, G.L. (1951). in Decompression Sickness. Edited by J.F. FULTON. Philadelphia: Saunders.
- JACOBS, P. (1962). Osteochondritis dissecans of the hip. Clin. Radiol., 13, 316-323.
- JAFFRÈS, R. MERER, P. NICOLET, L. (1955). Les ostéoarthroses barotraumatiques. Étude particulière des lésions de l'épaule. Relations avec l'ostéochondrite disséquante (maladie de Koenig). Rev. Rhum., 22, 722-734.
- JAMES, C.C.M. (1945). Late bone lesions in caisson disease. Three cases in submarine personnel. Lancet, 2, 6-8.
- JONES, R.W. ROBERTS, R.E. (1934). Calcification, decalcification and ossification. Brit. J. Surg., 21, 461-499.

- JULLIEN, G. LEANDRI, M. DESANTI, E. (1954). A propos des images radiologiques ostéoarticulaires consécutives au travail dans l'air comprimé et leur importance médico-légale. *Ann. Méd. lég.*, 34, 180-185.
- KACZURBA, A. (1962). Martuice kostne w przebiegu choroby kesonowej. *Pol. Przegl. radiol.*, 26, 9-26.
- KAHLSTROM, S.C. BURTON, C.C. PHEMISTER, D.B. (1939). Aseptic necrosis of bone. *Surg. Gynec. Obstet.*, 68, 129-146, 631-641.
- KAHLSTROM, S.C. (1942). Bone infarct. *Amer. J. Roentgenol.*, 47, 405-416.
- KAHLSTROM, S.C. PHEMISTER, D.B. (1946). Bone infarct. Case report with autopsy findings. *Amer. J. Path.*, 22, 947-964.
- KALSER, M.H. IVY, H.K. PEVSNER, L. MARBARGER, J.P. IVY, A.C. (1951). Changes in bone marrow pressure during exposure to simulated altitude. *J. Aviat. Med.*, 22, 286-294.
- KINSEY, J.L. (1954). Air embolism as a result of submarine escape training. *U.S. armed Forces med. J.*, 5, 243-255.
- LAING, P.G. (1956). The arterial blood supply of the adult humerus. *J. Bone. Jt. Surg.*, 38A, 1105-1116.
- LARSEN, R.M. (1938). Intramedullary pressure with particular reference to massive diaphyseal bone necrosis. Experimental observations. *Arch. Surg.*, 108, 127-140.
- LAZARD, F. CAVIGNEAUX, C. FUCHS, T.S. TARA, M.S. (1949). L'évolution accélérée des ostéo-arthrites des "tubistes". *Arch. Mal. prof.*, 10, 150-152.
- LICHTENSTEIN, B.W. ZEITLIN, H. (1936). Caisson disease: histologic study of late lesions. *Arch. Path. (Chicago)*, 22, 86-98.

- LIEBOW, A.A. STARK, J.E. VOGEL, J. SCHAEFFER, K.E. (1959).  
Intrapulmonary air trapping in submarine escape training casualties. U.S. armed Forces med. J., 10, 265-289.
- LISS, G. (1956). Knochen - und gelenk - veränderungen bei der caisson - krankheit. Fortschr. Röntgenstr., 84, 472-477.
- LEWIS, H.E. PATON, W.D.M. (1957). Decompression sickness during the sinking of a caisson; a study of some factors in the pathogenesis of caisson disease. Brit. J. industr. Med., 14, 5-12.
- MACHT, S.H. ROMAN, P.W. (1948). Radiologic changes in sickle cell anaemia. Radiology, 51, 697-707.
- MANFREDI, L. (1956). L'osteoartrosi cronica da malattia dei cassoni. Riv. Infort. Mal. prof., 43, 746-753.
- MAURO, M. (1958). Le lesioni ossee ed articolari da malattia dei cassoni. Contributo clinico. Folia med. (Napoli), 42, 288-326.
- MAURO, M. SAGGESE, V. (1959). Contributo allo studio clinico e radiodiagnostico delle lesioni osteoarticolari da malattia dei cassoni. Atti Accad. Stor. Arte sanit., 4, 1-7.
- MCCALLUM, R.I. STANGER, J.K. WALDER, D.N. PATON, W.D.M. (1956). Avascular necrosis of the femoral heads in a compressed air worker. J. Bone. Jt. Surg., 36B, 606-611.
- MACDOUGALL, J.T. GIBSON, A. WILLIAMS, T.H. (1950). Irradiation necrosis of the head of the femur. Arch. Surg., 61, 325-345.
- MACDOUGALL, A. (1961). Fracture of the neck of the femur in childhood. J. Bone Jt. Surg., 43B, 16-28.
- McFARLAND, P.H. FROST, H.M. (1961). A possible new cause for aseptic necrosis of the femoral head. Henry Ford Hosp. Bull., 9, 115.

- McGIBBON, J.E.G. (1944). Nasal sinus pain caused by flying (dyndrome of sinus barotrauma); analysis of cases. *J. Laryng.*, 59, 405-427. Cited in *Aviation Medicine*. Edited by K.G. BERGIN, Bristol: Wright.
- MERICOURT, le R. De (1869). Considerations sur l'hygiène des pêcheurs d'éponges. *Ann. Hyg. publ. (Paris)* 31, 274-286. Cited by FRYER, D.I. (1961), *Medicine, Science and the Law*, 2, 110-123.
- MESCHAN, I. (1951). An atlas of normal radiographic anatomy. Philadelphia: Saunders.
- MIDDLEMISS, J.H. (1958). Sickle-cell anaemia. *J. Fac. Radiol. (Lond.)*, 9, 16-24.
- MILES, S. (1962). *Underwater Medicine*. London: Staples Press.
- MOLFINO, F. (1961). Le artropatie barotraumatiche. *Minerva med. (Torino)*, 52, 247-253.
- MORGAN, T.E. ULDEVAL, F. WELCH, B.E. (1961). Observations in the SAM two-man space cabin simulator. II Biomedical aspects. *Aerospace med.*, 32, 591-602.
- MOSINGER, M. JULLIEN, G. (1961). L'expertise des ostéo-arthroses consécutives aux accidents de décompression. *Ann. Méd. leg.*, 41, 597-601.
- MUNGO, A. SESSA, G. (1958). Alterazione radiologiche dello scheletro nei lavoratori dei cassoni. *Folia med. (Napoli)*, 41, 819-836.
- NASHIMOTO, I. FURUSHASHI, M. (1961). Un cas de pneumothorax spontané chez un travailleur en caisson. *Maroc méd.*, 40, 522-525.

- NICOLAS, M. (1949). Notions nouvelles sur la maladie de l'air comprimé et son traitement dans le travail en tube ou caisson. *Méd. Usine*, 11. Cited by RÓZSAHEGYI, I. (1956). *Arch. Gewerbepath. Gewerbehyg.*, 14, 483-510.
- NICOLET, L. MERER, P. JAFFRES, R. (1961). De l'existence de manifestations neurologiques chez des travailleurs en caisson présentant des lésions osteoarticulaires barotraumatiques. *Rev. Rhum.*, 28, 241-245.
- PACHNER, E. (1955). Autotrapianto osseo endocefalico del femore per bonifica di osteonecrosi asettica in malattia dei cassoni. *Minerva ortop. (Torino)*, 6, 283-285.
- PARKER, G.W. STONEHILL, R.B. (1961). Further considerations of roetgenologic evaluation of flying personnel at simulated altitude. *Aerospace Med.*, 32, 501-504.
- PATON, W.D.M. WALDER, D.N. (1954). Compressed air illness - an investigation during the construction of the Tyne Tunnel. 1948 - 1950. *Spec. Rep. Ser. med. Res. Coun. (Lond.)*.
- PATTERSON, R.J. BICKEL, W.H. DAHLIN, D.C. (1954). Idiopathic avascular necrosis of the head of the femur. *J. Bone Jt. Surg.*, 46A, 267-282.
- PHEMISTER, D.B. (1940). Changes in bones and joints resulting from interruption of circulation. *Ann. Surg.*, 41, 436-472.
- PIRASTU, E. PERRA, L. (1960). Contributo clinico-sperimentale allo studio dell'infarto osseo e della malattia dei cassoni. *Rass. med. Sarda*, 62, 819-842.
- PLATE, E. (1928). Arthritis deformans des hüftgelenksestaden durch presluftwirkung nebst betrachtungen über das zustandekommer solcher erkrankungen. *Arch. f. Orthop.*, 26, 201.

- POL, B. WATELLE, J.J. (1854). Mémoire sur les effets de la compression de l'air appliquée au creusement des puits à houille. Ann. Hyg. publ. (Paris), 1, 241-279. Cited by FRYER, D.I. (1961). Medicine, Science and the Law, 2, 110-123.
- POPPEL, M.H. ROBINSON, W.T. (1956). The roentgen manifestations of caisson disease. Amer. J. Roentgenol., 76, 74-80.
- PREZZOLINI, (1936). Cited by RÓZSAHEGYI, I. (1956). Arch. Gewerbepath. Gewerbehyg., 14, 483-510.
- RASGON, I. VATER, G. MARBARGER, J.B. (1951). Unpublished data. Cited by KALSER, M.H. et al (1951). J. Aviat. Med., 22, 286-294.
- RATNOFF, O.D. (1943). The absence of roentgenographically demonstrable bony changes at the hip joint in subjects exposed to simulated high altitudes. U.S., A.A.F. School of Aviation Medicine, Project No. 217, Report No. 1.
- RAVAULT, P. MERER, P. ROCHE, L. RAYNEAU, G. (1953). Les ostéoarthropathie des caissons dues au travail en air comprimé. Rev. Rhumat., 20, 587-599.
- RAYMOND, M.V. (1948). Les ostéoarthrites pneumatiques. Lésions osseuses des tubistes et des scaphandriers. Arch. Mal. prof., 9, 437-442.
- RAYMOND, M.V. (1960). Arthroses baro-traumatiques. Arch. Mal. prof., 21, 609-621.
- REBOUL, J. DELOS, J. DELORME, G. GROG, J. De, BORDRON, H. CARRAZE, G. (1955). Radiodiagnostic des complications ostéoarticulaires de la maladie des caissons. J. Radiol. Electrol., 37, 685-694.

- RENDICH, R.A. HARRINGTON, L.A. (1940). Roentgen findings in caisson disease of bone. *Radiology*, 35, 439-448.
- RETTIG, H. (1951). Caissonnekrose an hüftkopf. *M Schr. Unfallheilk.*, 54, 338-341.
- ROCHE, L. RAYNEAU, G. (1953). Les ostéo-arthropathies chez les ouvriers travaillant en air comprimé. *Arch. Mal. prof.*, 14, 233-240.
- ROCHE, L. DEVIC, M. GENEVOIS, M. MARIN, A. (1956). La tomographie osseuse dans l'ostéoartropathie des caissons. *Arch. Mal. prof.*, 17, 597-601.
- ROCHE, L. MOURGUES, G. De, VEDRINNE, J. VITANI, C. (1963). A propos d'un cas d'ostéo-arthropathie des caissons - traitement chirurgical. *Lyon méd.*, 209, 1587-1594.
- RONALD, J. (1953). Aseptic necrosis of bone in caisson disease. *Lancet*, 2, 855-858.
- ROZSAHEGYI, I. (1956). Die chronische osteoartropathie der caissonarbeiter. *Arch. Gewerbepath. Gewerbehyg.*, 14, 483-510.
- ROZSHEGYI, I. (1962). Untersuchungen über die späteren folgen der dekompensionskrankheit. *Arch. Gewerbepath. Gewerbehyg.*, 19, 165-174.
- ROZSAHEGYI, I. FRIED, L. (1963). Untersuchungen über die entstehung und dynamik der chronischen osteoartropathie der caissonarbeiter. *Z. ges. Hyg.*, 9, 915-924.
- SAMUEL, E. (1957). Post-irradiation infarction of the femoral head. *S. Afr. med. J.*, 31, 841-842.

- SARTOR, E. (1947). Skelettförändringar vid tryckluftsjuka.  
Nord. Med., 35, 1551-1554.
- SCHRÖDER, G. (1956). Klinisch-röntgenologischer beitrag zum  
problem des knocheninfarkten bei caissonarbeitern.  
Mschr. Unfallkeilk., 59, 161-167.
- SCHRÖTTER, H. Von (1906). Der Sauerstoff in der prophylaxe und  
therapie der luftdruckerkrankungen. Cited by BOYCOTT, A.E.  
et al (1908). J. Inst. Hyg., 8, 342-443.
- SEIFERT, E. (1936). Seltene hüftglenkserkrankung. Zbl. Chir.,  
63, 2318.
- SERRE, H. SIMON, L. (1961). The role of corticotherapy in primary  
osteonecrosis of the femoral head in the adult. Presse  
méd., 69, 1995-1998.
- SÈZE, S. De, DURIEU, J. BRUX, J. De, GUEGUÉN, Y. WELFING, (1951).  
A propos d'un cas de "maladie des caissons". Rev. Rhumat.,  
18, 469-475.
- SHERMAN, M.S. PHEMISTER, D.B. (1947). The pathology of ununited  
fracture of the neck of the femur. J. Bone jt. Surg.,  
29, 19-40.
- SIMON, G. (1956). Principles of chest X-Ray diagnosis. London:  
Butterworth.
- SLØRDAHL, J. (1953). Aseptisk bennekrose ued dykkerske. T. norske  
Laegeforen, 73, 300-304.
- SMILLIE, I.S. (1960). Osteochondritis dissecans. Edinburgh:  
Livingstone.
- SUNTYCH, G. SUNTYCHOVÁ, M. (1961). Knochenveränderungen bei der  
caissonkrankheit. Radiol. Diagn. (Berlin), 4, 397-404.

- SUTTON, R.D. BENEDEK, J.G. EDWARDS, G.A. (1963). Aseptic bone necrosis and corticosteroid therapy. Arch. intern. Med., 112, 594-602.
- SWAIN, V.A.J. (1942). Caisson disease (compressed air illness) of bone with report of a case. Brit. J. Surg., 29, 365-370.
- SWINDLE, P.F. (1937). Occlusion of blood vessels by agglutinated red cells, mainly as seen in tadpoles and very young kangaroos. Amer. J. Physiol., 120, 59-74.
- TARA, M.S. (1956). Lésions ostéoarticulaires retardées des tubistes Arch. Mal. prof., 17, 477-478.
- TARA, M.S. FRANÇON, F. (1959). Lésions des tibias et des femurs par maladie des caissons sans atteinte articulaire. Rev. Rhum., 26, 142-147.
- TAYLOR, H.K. (1944). Aseptic necrosis in adults - caisson workers and others. Radiology, 42, 550-569.
- THOMAS, S. WILLIAMS, O.L. (1944). High altitude joint pains: their radiographic aspects. U.S., N.R.C., C.A.M. Report No. 395. Cited by FERRIS, E.B. ENGLE, G.L. (1951). in Decompression Sickness. Edited by J.F. FULTON. Philadelphia: Saunders.
- THOMSON, J.D. YOUNG, A.B. (1958). Aseptic necrosis of bone in caisson disease. Brit. J. industr. Med., 15, 270-272.
- TRIGER, (1841). Mémoire sur un appareil à l'air comprimé, pour le percement des puits des mines et autres travaux, sous les eaux et dans les sables submergés. C.R. Acad. Sci. (Paris), 13, 884-896. Cited by FRYER, D.I. (1961). Medicine Science and the Law, 2, 110-123.

- TRUELSON, F. (1942). Injury by roentgen treatment of carcinoma of uterine cervix. *Acta Radiol.*, 23, 581.
- TRUETA, J. HARRISON, M.H.M. (1953). The normal vascular anatomy of the femoral head in adult man. *J. Bone Jt. Surg.*, 35B, 442-461.
- TWYNAM, G.E. (1888). A case of caisson disease. *Brit. med. J.*, 1, 190-191.
- UGOLOTTI, F. (1940). La forma osteoarticolare della malattia dei cassoni e sua interpretazione medico-legale. Cited by KAHLSTROM, S.C.(1942). *Amer. J. Roentgenol.*, 47, 405-416.
- VERNON, H.M. (1907). The solubility of air in fat and its relation to caisson disease. *Proc. roy. Soc. B*, 79, 366-371.
- WALDER, D.N. (1963). A possible explanation for cases of severe decompression sickness in compressed air workers. In *The Regulation of Human Respiration*. Edited by D.J.C. CUNNINGHAM and B.B. LLOYD. Oxford: Blackwell.
- WALDER, D.N. (1964). Personal communication.
- WALKER, W.A. (1940). Aseptic necrosis of bone occurring in caisson disease. A case report. *J. Bone Jt. Surg.*, 22, 1080-1084.
- WEBB, J.P. RYDER, H.W. ENGEL, G.L. ROMANO, J. BLANKENHORN, M.A. STEVENS, C.D. (1944). Radiographic studies of the knee during bends. U.S., N.R.C., C.A.M. Report No. 305. Cited by FERRIS, E.B. ENGEL, G.L. (1951). in *Decompression Sickness*. Edited by J.F. FULTON. Philadelphia: Saunders.
- WERTHEIMER, P. MANSUY, L. (1939). Troubles trophiques des orteils, arthrite chronique de la hanche et maladie des caissons. *Lyon chir.*, 37, 26-29.

YANDA, R.L. MOTLEY, H.L. SMART, R.H. (1963). The effects of pressure upon lung volumes of pulmonary emphysema patients and upon normal individuals. In Clinical Application of Hyperbaric Oxygen. Proceedings of First International Congress. Amsterdam.



APPENDIX I

COMPRESSED AIR WORKERS																							
AUTHORS	PUBLIC- ATION	SITE	WITH SYMPTOMS				SYMPTOMLESS												OTHER SITES				
			HEAD OF HUMERUS		HEAD OF FEMUR		HUMERUS				FEMUR				TIBIA					FIBULA			
			PATIENT	AGE	R	L	R	L	DIAPH.	EPI. & META		DIAPH.	EPI. & META		DIAPH.	EPI. & META		DIAPH.		EPI. & META			
						R	L	R	L	R	L	R	L	R	L	R	L	R	L				
CHARLES, CAVIGNEAUX FUCHS, TARA	1948	B. A.	27																				
		G. R.	38																				
		M. P.	45																				
		R. R.	49																				
		P. E.	43																				
MOLFINO, BALESTRA	1948	B. B.	46																				
		G. M.	39																				
		M. B. P.	41																				
		L. T.	46																				
		A. B.	40																				
		P. B.	46																				
		B. M.	43																				
		G. M.	51																				
		V. P.	58																				
		G. P.	41																				
		FINCHGOLD, COVILLE, DOASSANS	1948	M. B.	39																		
LAZARD, CAVIGNEAUX, CHARLES, FUCHS, TARA	1949	A. R.	35																				
NICOLAS, CAVIGNEAUX, CHARLES, FUCHS, TARA	1949		34																				
DE SÈZE, DORSEU, BRUX, GIBOUEN, WELPING	1951		42																				
DEAN & BÓCSASZGYI	1951	G. C. S.	37																				
		J. K.	35																				
		I. M.	43																				
		M. S.	29																				
		I. B.	23																				
		J. B.	47																				
RETTIG	1951	R. R.																					
GUITARD	1952	T. G.	30																				
		J. L.	29																				
ROCHE, RAYNEAU	1953	L. C.	30																				
		A. T.	44																				
		L. C.	27																				
		L. B.	44																				
GUITARD	1953	R. V.	32																				
		M. W.	25																				
		Y. C.	26																				
		R. G.	27																				
CHAMMONT, BLUTTERBACH, RASKALIT, WEINER	1953	M. A. A.	35																				
MCALLUM, STANGER, WALDEH & PATON	1954		30																				
ROSDENHORN	1955	G. C.	37																				
		J. K.	35																				
		I. W.	43																				
		M. S.	29																				
		I. B.	23																				

Right radius  
left ulna (P. B.)  
Both ischio-  
pubic rami (V. P.)

Left clavicle (A. R.)

L. scapula neck (A. T.)



APPENDIX I

COMPRESSED AIR WORKERS																								
AUTHORS	PUBLIC- ATION	WITH SYMPTOMS										SYMPTOMLESS								OTHER SITES				
		SITE		HEAD OF HUMERUS		HEAD OF FEMUR		HUMERUS				FEMUR				TIBIA					FIBULA			
		PATIENT	AGE	R	L	R	L	DIAPH.	EPI. & META		DIAPH.	EPI. & META		DIAPH.	EPI. & META		DIAPH.	EPI. & META						
						R	L	R	L	R	L	R	L	R	L	R	L	R	L					
SUNTYCH & SUNTYCHOVA	1961	Z.S.	27																					
		Z.K.	32																					
		J.K.	38																					
		S.R.	41																					
		Z.C.	31																					
		H.W.	40																					
GAULTIER, FOURNIER, GERVAIS, RACHT	1962	L.H.	41																					
		R.G.	43																					
ROCHE, DE MOURGUES, VEDRINNE, VITANI	1963	R.M.B.	43																					
DIVERS																								
GRUTZMACHER	1941	O.B.	37																					
SARTOR	1947		40																					
HERGET	1948	G.G.	58																					
		A.P.	41																					
		H.M.	58																					
		K.D.	31																					
		F.L.	72																					
		A.A.	36																					
		E.K.	39																					
		H.B.	41																					
		W.A.	58																					
		J.B.	43																					
		RONALD	1953	H.S.	37																			
P.L.	47																							
ANGEI & COSSU	1955	K.S.	59																					
			62																					
SLØRDAHL	1953		25																					
			45																					
DALE	1952	E.H.	46																					
		J.S.	55																					
		E.H.	38																					
PIRASTU & PERRA	1960		62																					
			35																					
		M.V.	38																					
	31																							
	33																							

153 compressed air workers have a total of 379 bone lesions 37.5% are bilateral (see table 4)  
 26 divers have a total of 49 bone lesions 69.4% are bilateral (see table 5)

Left radius (45)