

GENITAL TUBERCULOSIS

A Clinical and Pathological Study of
Uterine and Adnexal Tuberculosis.

by

D. S. Cownie, M.B., Ch.B.

Submitted for

the Degree of M.D. (Edin.).

April, 1938.



I N D E X.

Page.

Volume I.

INTRODUCTION 1

ETIOLOGY;

Routes of Infection 7

Routes of Infection with special
reference to the part of the
Genital Tract affected.-

 I. The Fallopian Tubes .. 22

 II. The Ovaries .. 26

 III. The Body of the Uterus .. 28

 IV. The Cervix .. 32

Contributory Causes to Infection
in Lesions of the Uterus and
Adnexa 35

PATHOLOGY:

The Fallopian Tubes 46

The Ovaries 94

The Body of the Uterus . .. 113

The Cervix 148

Volume II.

SYMPTOMS and SIGNS: 164

SYMPTOMS.- The Fallopian Tubes 170

 The Uterus . .. 182

 The Cervix . .. 188

 General 191

SIGNS 193

	<u>Page.</u>
<u>DIAGNOSIS:</u>	
The Fallopian Tubes	197
The Uterus	212
The Cervix	219
 <u>THE COURSE and PROGNOSIS</u>	 225
 <u>TREATMENT:</u>	 230
Conservative	234
Operative	240
X-ray	250
 <u>SUMMARY and CONCLUSIONS</u>	 259
 <u>Bibliography</u>	 265
 <u>SUMMARY of CASES</u>	 Appendix.

INTRODUCTION.

Tuberculosis of the female genital tract is not common but it must not be regarded as being of extreme rarity. Moreover, when cases do occur, they are of considerable importance, from the diagnostic problems which they present and from the point of view of treatment.

The Continental literature contains numerous original accounts dealing with this condition. More recently, a considerable amount has been written in America. In this country, however, it has received comparatively little attention. One or two reviews have been published and certain aspects of tuberculosis in this situation have been fully dealt with but no account of the disease, based upon a series of cases, appears to have been published.

My purpose in this thesis is to make a comprehensive survey of certain forms of genital tuberculosis in the female. This will be based as far as possible on the information obtained from the study of a series of 69 cases. Lesions of the vagina and the vulva were not represented in the cases and these forms will not be dealt with. Otherwise, all aspects of tuberculosis of the uterus and adnexa will be considered. The

routes of infection, the pathology, the symptoms and signs, the obstacles to diagnosis, the question of treatment and the end results of treatment will be described and discussed.

Historical Survey. The first account of uterine and adnexal tuberculosis was that of Morgagni in 1744. In his De Sedibus et Causis Morborum, he gave an account of an autopsy on a girl of twenty who had died of tuberculous peritonitis. He found that the tubes and uterus were filled with caseous material and expressed the opinion that the infection of the peritoneum was secondary to the pelvic disease. The condition apparently received no further notice for nearly a hundred years but since about 1830, numerous reports have appeared and knowledge has steadily accumulated. The first description of tuberculosis of the cervix was probably that of Lisfranc in 1842. The credit of first discovering the tubercle bacillus in the genital tract goes to Babès (1883) but a tuberculous ulcer of the vagina was present, accompanied by a recto-vaginal fistula. One of the first accounts published in this country appears to be that of Berkeley (1903).

The subject continues to receive the greatest attention from Continental authors. Within the last eight years, however, two monographs have been published

in America, that of C. C. Norris in 1931 and that of E. M. Jameson in 1935.

In this thesis, free reference will be made to the literature but there will be no attempt to make a complete review.

Frequency of occurrence. Information regarding this is rendered uncertain principally by the difficulty of diagnosis. The only reliable figures are those which are obtained from pathological reports. These do not include those cases not subjected to operation and those in which there was no operative interference with the genital tract. For example, a certain number of cases of generalised tuberculous peritonitis in women originate in the pelvic organs and in these cases it is unusual for any portion of them to be removed.

The frequency of tuberculosis as a gynaecological disorder was estimated by Spalding (1922) as 2% and by Kermauner (1930) as between 1% and 2% of cases. The 200 cases of tuberculous salpingitis collected by Greenberg (1921) were all those occurring in the Gynaecological service of the Johns Hopkins Hospital over a period of thirty years and they formed .83% of the patients treated during that time.

The cases in this series were admitted to the

three Gynaecological Wards of the Royal Infirmary, Edinburgh, over a period of twelve years. During that time, the specimens found to be tuberculous represented approximately .6% of those received from the three wards.

If due allowance is made for cases which are treated conservatively, the suggested frequency of about 1% does not seem unduly high.

Method of Investigation.

Note was made of the cases in which tuberculosis had been found to be present. Full abstracts of the information contained in the case records were then made. The slides of the sections prepared for microscopic examination were also obtained from the Laboratory. These were available in cases 1 to 25 and 27 to 51.

It was desired to restrict the cases as far as possible to those in which the presence of tuberculosis in the genital tract was proved. Four cases have been included in which this was not done. These were cases of generalised tuberculous peritonitis in which the appearance at operation made it practically certain that the genital tract was involved.

An attempt was made to follow up all the cases. Those with an address in or near Edinburgh were visited.

In this way 16 patients were successfully traced, either personally or from information received. To those living at a distance a letter was sent and replies were received from 25. Three cases died in hospital and the remaining 24 cases could not be traced either by visit or by letter. In 14 of these, however, the case reports gave records of attendance at hospital after operation for periods varying from 3 months to $3\frac{1}{2}$ years. Thus only 10 cases or 14.5% were completely untraced from the time of operation.

In the letter which was written to the patients the following questions were asked:

1. Are you now in good health?
2. Have you had any serious illnesses since you were discharged?
3. Have you any pain?
4. Have you any discharge?
5. Have you put on weight?

Those in whom an artificial menopause had not been produced were asked:

6. Are your periods regular?
7. Do you lose too much?
8. Have you any pain with the periods?

Two further questions were addressed to those in whose case pregnancy was possible:

9. (If you are now married) Have you any children?
10. Have you had any miscarriages?

In some cases additional information with regard to further treatment, healing of the wound, etc., was requested. Those patients who were interviewed were questioned on similar lines.

The patients were first treated during the years 1923-34 and the greatest part of the follow-up was carried out in the year 1935.

ETIOLOGY.

THE ETIOLOGY OF UTERINE AND ADNEXALTUBERCULOSIS.ROUTES OF INFECTION.

It was formerly the custom to describe lesions of those portions of the genital tract which are under discussion as primary or secondary. The term primary must mean a lesion which is the first to be established within the body, whatever the portal of entry of the bacillus. It has frequently been loosely used as synonymous with an ascending infection. The absolute proof of a primary lesion would demand the most minute autopsy and is practically impossible. It is preferable to describe the infection as ascending or descending.

I. ASCENDING INFECTION.

Ascending infection - that is direct infection from without - may be (a) direct or (b) by the lymphatics from the vagina. The first suggestion of such a route of infection is attributed to Cohnheim, who suggested, in 1879, infection at coitus. Since that time, the possibility of its occurrence and its frequency, have been matters of dispute.

Coitus is usually considered the most frequent

means whereby the bacilli may be introduced into the vagina, usually in the semen. A case believed to be due to ascending infection has been reported in which sputum, found to contain tubercle bacilli, had been regularly used as a lubricant at coitus. Tubercle bacilli may also be introduced on the finger, on instruments and by douching.

A form of ascending infection, known as "primary-secondary" infection, has been suggested (Williams, 1894), due to contamination in a patient with, for example, positive sputum. It is also conceivable that tubercle bacilli might reach the vagina and cervix from infected urine or faeces.

Some gynaecologists have in the past denied the possibility of ascending infection and a few - Solomons (1923) quotes Müller - still uphold this view. The majority, however, consider that such infection can occur but that it is rare. The evidence on which this conclusion is based is both clinical and experimental. A number of cases have been reported in which the lesion, usually of the cervix, was held to be "primary", i.e. due to ascending infection. (Gruenstein (1932), White (1929), Misset (1929), Bottaro and Pavlovsky (1923), Diethelm and Ramsay (1935), Murphy (1903), Vineberg (1908) et al.) Some

of these cases were not subjected to autopsy and in very few is an examination of the husband reported. In none of the case reports was there absolute proof of ascending infection, although in a few the presumptive evidence was strong. Hirsch and Hoffmann (1933) state that no absolutely certain case of primary genital tuberculosis has ever been reported. Williams (1894) pointed out that in any given case it is almost impossible to exclude infection by the blood stream.

1. Results of Animal Experiments. A number of animal experiments have been carried out on guinea-pigs and rabbits. The usual technique has been either to insert virulent tubercle bacilli into the vagina of female animals, or to inject bacilli into the genital tract of male animals which were afterwards allowed to mate. The earlier results were not definitely conclusive. Among those who succeeded in producing lesions, Jameson (1935) quotes Jung, Bennecke and Baumgarten, while Cornil and Porowitz were unsuccessful unless the vagina was traumatised. Murphy (1903) quotes a large number of experiments, among them that of Gärtner, who injected bacilli into the testes of male rabbits and guinea-pigs. Of 65 female guinea-pigs fertilised, five died from tuberculosis starting in the vagina, and of 59 rabbits, eight or nine

developed uterine tuberculosis. Menge was also successful in a similar experiment and suggested that the tubercle bacilli were carried by the active movements of the spermatozoa. Bakács (1927) suggested that many of the older experiments were fallacious. In four female rabbits he got, respectively, no lesion; glandular lesions; vaginal, glandular and pulmonary lesions; vaginal, uterine, renal and pulmonary lesions. There were no cervical or general lesions. He concluded that a morbid condition of the vagina is necessary and that a healthy uterus prevents the ascent of infection which is always by the lymphatics and never intracanalicular.

Norris (1933) summarises the results of animal experiments as follows. Ascending infection seldom if ever occurs from a normal adult vagina, but may occur if the vagina is traumatised, mechanically or by inflammation, while pregnancy and the puerperium predispose to infection. Lesions may be local, distant or general, the last two occurring with or without local lesions. Infection ascends by the lymphatics usually involving the pelvic glands and local lesions occur in a minority. Infection is more likely to result if the bacilli are deposited in the uterus and young animals are slightly more susceptible than old.

One of the most recent experiments is that of Jameson (1935). This experiment takes into account both the state of the animal in relation to oestrus and the difference in "sensitised" and "unsensitised" animals. This latter, most important, factor, as he points out, seems to have been entirely ignored in previous experiments. The vast majority of experiments appear to have been carried out on "unsensitised" or "normal" animals. In his experiments, in the first series of animals, vaginal inoculation on a gauze swab was with a strain of tubercle bacilli tending to produce localised, non-progressive lesions. After an interval averaging eighty-seven days, ten out of eleven animals showed a positive reaction to old tuberculin. Autopsy was carried out on the hundredth day and in five of the eleven animals, tuberculous lesions were discovered. These were commonly in the form of lymph node involvement in the iliac and inguinal regions. In addition, one animal had tubercles in the cervix.

This experiment showed that infection can be obtained simply by placing bacilli in contact with the vaginal mucosa. Most of the animals were inoculated during oestrus but this factor did not seem to be of importance.

Jameson (1935) states that an injection of the organism used in the first series will produce local lymphatic lesions and that spontaneous recovery takes place. At the end of six months, only local lesions remain. Accordingly, in the second series, the animals were thus sensitised with an injection in the axillary region.

The bacilli used for vaginal inoculation were of a virulent human strain and the results were strikingly different. Of fifteen animals, nine showed vaginal, four cervical lesions and one a tuberculous abscess in the uterus. Ten showed lymph node involvement and in some the lungs and spleen were involved. Although serial sections were made in some cases, no break of the lining epithelium of the vagina was found, penetration and formation of submucous lesions having apparently taken place in spite of an intact surface. The cervical lesions did not involve the glands and were localised to the deep tissue. In the animal showing a uterine lesion, generalised tuberculosis was present. Jameson concludes that the results obtained in this experiment could only be explained on the basis of spread by the lymphatics. He believes that the rarity of lesions of the upper genital tract in ascending infection, and their unusual form when so produced,

indicates that, when such lesions are found, they are seldom, if ever, due to an ascending infection.

It can now be taken as definitely proved that ascending infection can be produced without difficulty in the experimental animal. Local lesions of the genital tract appear to be more frequent in the sensitised animal. Antecedent trauma does not appear to be necessary and the infection almost certainly spreads upwards via the lymphatics.

2. Position with regard to Cases in Human Subjects.

Some degree of caution should be exercised in applying these results, in their entirety, to human cases. It seems very probable, however, that ascending infection can occur in the human female. The proof of its occurrence must be, however, a matter of great difficulty. Ascent of the bacilli by the lymphatics disposes of theoretical objections such as the non-motility of the tubercle bacillus, the downward flow of the secretions and the effect of menstruation. Apart from auto-infection in a tuberculous individual, infected semen is usually considered the most important infecting agent. Useful information might be obtained if the husband's semen could be examined in all cases in which ascending infection was suspected. Conflicting opinions have been expressed regarding the frequency

with which tubercle bacilli may be present in the semen. Moore (1919) and also Dupeux (1933) stated that tubercle bacilli have never been found in the semen in such cases, in spite of much careful search. Goodall (1907) quotes Gärtner, who found tubercle bacilli in the seminal fluid of 16% of men suffering from tuberculosis, not necessarily genital. Other authorities give a much smaller figure.

It is impossible to estimate the relative frequency of ascending infection. There seems to be no reason to suppose that it is other than very rare, which is the general opinion. For this, and other reasons, its importance when considering treatment is negligible. Jameson's (1935) second experiment shows that the resulting lesion need not be primary. Solomons (1923) considers that it might be of importance in advising a tuberculous individual as to the advisability of coitus. Norris (1931) and Jameson both point out the extreme rarity of genital tuberculosis in the wives of men with genital or urinary lesions. It has been pointed out that care should be exercised to prevent auto-infection in tuberculous women. The practical importance of ascending infection, therefore, bears rather on prophylaxis than on treatment.

II. DESCENDING INFECTION.

Secondary infection - that is infection from a focus elsewhere by spread within the body - is accepted by the great majority as the usual occurrence in lesions of the ovaries, tubes and uterus. Some writers make an exception in the case of the cervix but even in this situation, most consider that infection is usually from lesions elsewhere. There are three possible routes:- (a) by the blood stream; (b) by the lymphatics; (c) by direct spread.

(a) Infection by the blood stream. Of all the possible routes whereby the tubercle bacillus may reach the genital tract, this is considered to be by far the most frequent in occurrence. Comparison is suggested with the male genital tract, the kidney and the bones. In the years before puberty, caseating glandular foci are common and metastatic lesions may occur (Muir, 1929). The tendency to remain latent, which is characteristic of tuberculous lesions, as Norris points out, makes investigation of this route of infection difficult. This undoubtedly helps to explain why an active lesion elsewhere is not more frequently demonstrated. Moulonquet (1933), who considers that infection is usually by the blood stream, thinks that it usually

takes place in the early years of life and remains latent until activated.

Lusmann (1929) mentions the analogy drawn between the haematogenous dissemination of tuberculosis and the secondary stage of syphilis. He points out the rather frequent association of tuberculosis of the external jugular or intercostal lymph nodes and genitourinary tuberculosis in cases, usually with advanced pulmonary tuberculosis. In cases where active pulmonary disease is present, Berkeley (1903) points out that the absence of lesions of the intestine or peritoneum is strong presumptive evidence of blood spread.

Those who do not agree that the blood stream is the usual route of infection point out that a bacillaemia is extremely difficult, if not impossible to demonstrate in all except military forms of the disease. Against this objection is the fact that blood infection of other organs does undoubtedly occur. Another argument is that only in extremely few instances has blood-borne infection of the genitalia been produced experimentally. Bakács (1927) failed to produce infection of the uterus, even after trauma, by the intravenous injection of bacilli. In their experiment, however, Hirsch and Hoffmann (1933) obtained haematogenous spread after injection into the inguinal or mesenteric

lymph nodes.

(b) Spread by the Lymphatics. This is usually considered to be much less frequent than infection by the blood stream. Jameson points out that it is necessary to postulate a retrograde extension, which is unlikely. Some consider that infection by this route is exceptional. In the experiment mentioned above, Hirsch and Hoffmann (1933) injected tubercle bacilli into the lymph nodes at the base of the mesentery in four guinea-pigs and into the inguinal nodes in two. In all six, haematogenous dissemination occurred. In five there was localised peritoneal tuberculosis with tubercles on the surface of the uterus. In two, isolated tubercles were found in the region of the abdominal ostium of the tube. They consider that these were derived either from the blood stream or direct infection from the peritoneal cavity. They found no basis for supposing that spread by the lymphatic channels took place but they do not deny its possibility.

The same authors report the examination of the genitalia of eleven female infants who died in the Lübeck disaster. Infection was due to injection of virulent bacilli and the primary lesions were in the intestine. The ileo-caecal region was commonly involved and the severity of the infection was shown by

the frequency of multiple lesions. The genitalia were involved in nine cases but the tubal mucosa in only five. They remark on the frequency - eight cases - with which the connective tissue surrounding the genitalia was affected and consider this evidence of haematogenous or lymphogenous spread. They conclude that retrograde spread by the lymphatics is a possibility in the presence of a disturbance of lymph drainage, and that infection of the female genitalia may be by the blood stream or by the lymphatics, transtubal, intracanalicular infection being much less frequent. In an earlier, similar experiment, Bakács (1927) obtained similar results from which he concluded that retrograde lymph spread was of great importance as the most frequent route of infection.

(c) Direct Spread of Infection. This route includes the passage of tubercle bacilli from the peritoneal cavity by the abdominal ostium and spread by continuity from lesions of neighbouring organs. Infection from the peritoneum is the most important. It seems probable that a distinction should be made between the transmission of tubercle bacilli and infection from a tuberculous peritonitis. As regards the first, Pinner's experiment is much quoted. He injected powdered cinnabar into the peritoneal cavity of rabbits

and dogs and later recovered particles from the vaginal secretion. Williams (1894) quotes Jani, who found tubercle bacilli in the normal tube in a woman dead of pulmonary and intestinal tuberculosis, without peritoneal lesions. Jameson (1935) states that Weigert found that, while a large number of bacilli introduced into the peritoneal cavity caused a generalised peritonitis, a relatively small number tended to gravitate to, and remain localised in, the pelvis. The possibility of this route of infection is thus established by experimental evidence. It is, therefore, probable that infection via the abdominal ostium can also occur in the early stages of tuberculous peritonitis.

The question of infection in peritonitis is complicated by the frequency with which peritonitis accompanies tubal lesions. Osler considered that 30-40% of cases of peritoneal tuberculosis in the female are due to infection from the tubes. In peritonitis, early closure of the abdominal ostium may prevent the spread of infection to the tubes. This question is discussed more fully under the etiology of the tube.

Direct spread from neighbouring organs does not appear to be of great importance. Berkeley (1903) quotes a case reported by Kraus, in which the right tube and ovary were infected from the appendix. Cases

have been reported of direct spread from the bowel, mostly gross lesions. An extremely small number of cases have been reported in which the urinary tract appeared to be responsible. The term "genito-urinary tuberculosis" is certainly not applicable to female cases.

Evidence from Cases.

In this whole series of cases the following facts may be mentioned as bearing on etiology. In two cases, active pulmonary lesions were present, and in two cases pulmonary lesions which appeared to be quiescent. One case gave a definite history of pulmonary tuberculosis and three cases a strongly suggestive previous history. In addition, one of these cases had had an operation on one hip in late childhood.

Thus in eight cases, or 11.6%, there is a definite or presumptive association with pulmonary tuberculosis. In 200 cases of tuberculous salpingitis, Greenberg (1921) found 25% with pulmonary tuberculosis. Peterson (1924) in 100 cases of all forms of genital tuberculosis found exactly the same percentage. In Smith's (1928) series of 63 cases, 19% had pulmonary lesions. The number in this series appears to be low but the figures are based on purely clinical evidence.

In case 9 there was a previous history of a nephrectomy for renal tuberculosis ten years previously. On the second admission, examination revealed no evidence of tuberculosis of the urinary tract. The infection of the tubes in this case may have come from the urinary tract but it is much more probable that both lesions were secondary to a focus elsewhere.

A definite previous history of abdominal tuberculosis was given in one case and a strongly suggestive history in four. There was no evidence in these cases as to the priority of the genital or peritoneal lesions. In another case it was stated that the appearance at operation suggested the ileo-caecal junction as the point of origin. No details were given. In the remaining 53 cases there was no definite evidence with regard to a possible primary focus of infection.

ROUTES OF INFECTION
WITH SPECIAL REFERENCE TO THE PART OF
THE GENITAL TRACT AFFECTED.

I. THE FALLOPIAN TUBES.

The routes by which the tubercle bacillus reaches the Fallopian tubes are of special importance, not only because of the comparative frequency of tubal lesions but because these are, in the great majority of cases, the initial lesions in the genital tract.

1. Ascending Infection. Ascending infection from without the body has been suggested as a possible route but it is doubtful if this ever occurs. Murphy (1903-04) reported a case in which the husband was suffering from tuberculosis of the uro-genital system with tubercle bacilli in the semen and urine. After seven months, the wife became ill and was found to have tuberculosis of the tubes and pelvic peritoneum. However suggestive these findings, there is no proof that this was an example of ascending infection. In this series, seven cases date their symptoms from shortly after marriage but at least one of them had a previous history of tuberculosis and there is no exact information with regard to their husbands. On ex-

perimental evidence Jameson (1935) concludes that infection of the tubes is seldom or never an ascending infection.

2. Primary Infection. It has been suggested that the tubal lesion may represent the primary localization of the disease within the body. Macnaughton Jones (1907) has reported three cases which he believed to be primary. The difficulty of arriving at definite proof of such an assumption has already been mentioned. Apparently complete cure by surgical removal does not constitute sufficient evidence as the primary focus may have healed.

3. Infection from the Uterus. It has been suggested that infection may extend upwards to the tubes from the uterus. This view receives very little support. From the results of animal experiments, Jameson believes that uterine tuberculosis is always due to a descending infection. He points out, however, that interference with normal drainage from the uterus might render possible an ascent of infection to the tubes.

4. Descending Infection. The usual source of infection is a focus elsewhere in the body and the infection is usually carried by the blood stream. It

has been pointed out that the blood supply to the ampullary portion of the tube is from the anastomosis between the uterine and ovarian arteries and that this would be a favourable situation in which infected emboli might lodge. In nearly every case the lesion is first situated in the ampulla of the tube. In cases where the primary lesion is distant, it is almost certain that haematogenous spread accounts for the tubal lesion. It does not account for the frequency of bilateral disease but, in such cases, the disease is usually more advanced on one side than the other. Pulmonary tuberculosis is usually considered to be the commonest form of such a distant primary focus.

The importance of infection by the lymphatic channels is difficult to assess but there is almost universal agreement that it is much less frequent than haematogenous spread. The fact that such an extension implies a retrograde travel, has already been pointed out. The investigations carried out by Hirsch and Hoffmann (1933) Bakács (1927) have already been mentioned. Where infection derives from lesions of the intestine, the possibility of retrograde lymphatic spread cannot be denied but the experimental evidence does not suggest that it takes place with any frequency.

The operation report in case 37, which stated that infection appeared to have reached the tubes from the ileo-caecal junction, was the only evidence in this series to suggest a spread from the alimentary tract.

The situation of the tubes in relation to the peritoneal cavity, raises the question of direct spread of infection. In the majority of cases, the peritoneum is involved to some extent. In this series there were adhesions in 88% and tubercles on the peritoneum in 27%. There is no doubt that the peritoneal cavity can be infected from the tubes. It is not possible to say with equal certainty that the reverse may be true and that tuberculous endosalpingitis may be due to infection from the peritoneal cavity.

Mention has been made in the general discussion on routes of infection, of experiments and observations which prove that bacilli may reach the lumen of the tube via the abdominal ostium. The experiment of Weigert, who showed that a small number of bacilli are more likely to reach the tube than a large number, which tend to cause a general peritonitis, must be stressed. There is general agreement that in primary generalised tuberculous peritonitis, true involvement of the tubes is infrequent. McCann (1908), reporting

a case in which he believed that the peritoneal involvement was secondary to the tubal disease, because only the lower part was affected, noted this fact and stated that he had seen several cases. In the discussion on the case reported by Brown (1931), Moench stated that he had found peritonitis secondary to tubal tuberculosis, but that if the peritoneum was involved first, the tubes remained free. In the same discussion, Baumgarten stated that this was due to the fimbriae becoming glued together causing early closure of the abdominal ostium and thus preventing infection.

Thus, if a small number of bacilli are discharged into the peritoneal cavity, infection of the tubes by the direct route may occur. It is impossible to state the frequency with which this takes place.

II. THE OVARIES.

Only two routes of infection need be considered - infection by the blood stream and direct spread from neighbouring structures. It may be possible for infection to reach the ovary by the lymphatics.

The so-called primary ovarian tuberculosis, where the disease in the genital tract is confined to the ovaries, is a result of infection by the blood stream. Cases are so rare that exact information is difficult

to obtain but it is said that most cases occur before or shortly after puberty. It may be, therefore, that infection by this route usually or always occurs before the ovary assumes its more active function.

Direct spread from the neighbouring Fallopian tube accounts for the usual form of tuberculosis of the ovary. It is also possible that infection might reach the ovary from the peritoneum. Involvement of one or both ovaries occurs in 20-30% of cases of tubal tuberculosis. Taking into account the situation of the ovary in close proximity to the tube and the frequency with which it is involved in adhesions, its frequent escape is surprising. The explanation seems to be the relative impermeability of the tunica albuginea and it is certain that the ovarian stroma is highly resistant to infection. This was well illustrated in cases 33 and 44 of this series.

The usual means whereby the substance of the ovary becomes involved is held to be infection of a recently ruptured Graafian follicle resulting in a lesion of the subsequent corpus luteum. Jameson (1935) illustrates an extremely good example of this from a fatal case of tuberculous peritonitis.

In case 32 of this series, a few tubercles were present in the region of the hilum of the ovary. The

tube was grossly diseased. It is possible that these tubercles represented a lymphatic spread of infection.

III. THE BODY OF THE UTERUS.

Since infection of the myometrium without the endometrium is rarely if ever present, the routes of importance are those to the endometrium. It is usual for the endometrium to be involved first and then for infection to spread into the myometrium, probably in the lymphatics.

1. Ascending Infection. It has already been conceded that infection of the cervix from material deposited in the vagina is a possibility. Two of the cervical cases in this series showed that infection may pass the so-called barrier of the internal os in a downward direction. Presumably it may, therefore, pass in the reverse direction also. Infection ascending by the lymphatics would, to a large extent, escape the effects of menstruation. In spite of these considerations, direct, ascending, or "primary" infection of the body of the uterus must be extremely rare, if it ever does occur. In Jameson's experiment, only one animal showed lesions in the uterus and generalised tuberculosis was also present. He is of the opinion

that uterine tuberculosis is seldom, or never, an ascending infection.

2. Direct Secondary Infection. The possibility of infection by the blood stream cannot be denied. In cases which are not secondary to tuberculosis of the tubes, it is the most probable route of infection, from foci elsewhere in the body. It is extremely doubtful whether lymphatic extension ever takes place from organs outside the genital tract. As Jameson points out, however, it is probably the most important means of spread between the different portions of the genital tract.

In cases of peritoneal tuberculosis, tubercles may be present on the peritoneal surface of the uterus. This is an example of direct spread but it is not an example of true uterine tuberculosis. The question arises, however, as to whether such an infection can penetrate into the substance of the organ. Murphy (1903) stated that such penetration had been obtained in experimental infection of monkeys but that he was unable to find an instance in human cases. In case 61 of this series, tubercles were described on the peritoneal surface of the uterus but the myometrium and endometrium were reported to be free from disease. In case 44, a section right through the uterine wall

was available. This showed extensive infection of the peritoneum and two small tubercles were present in the inner third of the myometrium. The tubercles in the peritoneal coat did not show any tendency to penetrate the muscular wall, in the section examined. A tubal lesion was present and the endometrium may have been involved, though no tubercles were present in the small portion seen. Infection from the tube to the uterine wall, by the lymphatics or by way of the endometrium, seems more probable, in this case, than spread from the peritoneum.

3. Descending Infection from the Tubes. Infection extending from tubal lesions, by direct continuity or by the lymphatics, is the usual means by which the disease becomes established in the uterus. Some maintain that such extension accounts for all cases of uterine tuberculosis. Brown (1931) considers that involvement of the uterus is usually secondary to disease of the tubes but that infection may be blood borne from distant foci. Norris (1933) states that uterine tuberculosis is almost always secondary to a primary focus in the tubes. He has never seen a case without concomitant infection of the tubes. Bush (1933) goes further and is of the opinion that one can say positively that the tubes are involved in every

case. In his 15 cases, 14 had definite tubal lesions and one was doubtful.

Whether infection spreads from the tube by direct continuity or by the lymphatics does not seem to be of great importance. Lymphatic spread is a possibility in cases such as 44 in this series and that reported by Brown (1931), in which no lesion was discovered in the endometrium. Norris (1933) favours direct continuity and both he and Murphy (1903) refer to the fact that early lesions are most frequently found in the region of the uterine cornu. Heinrich (1932) reports two cases and Goodall (1907) three cases out of five in which the tubes were involved and in which the tubercles in the endometrium were limited to the region of the cornu or fundus of the uterus.

Of the 25 cases of tuberculosis of the body of the uterus in this series, lesions of the tubes were proved to be present in 15. Such lesions were not excluded beyond doubt in any of the remaining cases. In case 3, the uterine appendages were involved in dense adhesions. The portion of the tube examined showed no evidence of tuberculosis but this does not rule it out. In case 66 also, there was evidence of chronic inflammation of the tubes but there was no histological report. In the remaining cases the abdomen was not opened but in

one the tubes were closed to insufflation and in two examination suggested the presence of an inflammatory condition. Unfortunately there is no record, in this series, of the position of lesions in the endometrium relative to the tubal openings.

In cases 11 and 16 the cervical lesions were obviously secondary to the uterine disease.

IV. THE CERVIX.

1. Ascending Infection. By reason of its anatomical position the cervix is more exposed to ascending infection than the body of the uterus and tubes. Nearly all the cases reported as "primary" are cases of cervical tuberculosis and most of what has been written on ascending infection is in reference to lesions of the cervix. Ascending infection has been demonstrated in animal experiments but its occurrence has never been satisfactorily proved in the human subject. From an analysis of all the cases in the literature, Morillo (1935) concludes that in none was the evidence sufficiently strong. Its possibility as a mode of infection cannot, however, be denied and in some cases the evidence, though not conclusive, is suggestive.

In case 8 of this series, certain features were

present which suggest that the lesion may have been due to an ascending infection. The tubercles were present only beneath the squamous epithelium, none being above its junction with the columnar epithelium. The tubercles were most numerous in the superficial layers of the fibro-muscular tissue. None were seen in relation to glands. (In four guinea-pigs infected by vaginal inoculation, Jameson states that the cervical lesions were localised to the deep tissues and did not involve the glands.) Complete removal of the uterus and appendages was carried out and no other evidence of tuberculosis was found. The patient was a married woman with one child, 6 years old. The husband and the child were apparently healthy. She was in good health nine months after the operation.

This case is not offered as a definite example of ascending infection. The evidence is incomplete as the upper genital tract was not examined minutely, employing multiple sections. Also, no source of infection was disclosed.

2. Descending Infection from the Genital Tract

Above. In cases of isolated lesions it is possible that infection has reached the cervix by the blood stream from foci at a distance. In the majority, if not all cases, however, lesions are present in the

genital tract above. Norris (1933) and Watson (1934) both state that such lesions are found in 75-80% of cases. In twenty cases from the literature, the upper genital tract was known to be involved in eleven. Gupta (1928) reported six cases in four of which the genital tract above was involved.

Spread from lesions of the body of the uterus is the usual course of events in cervical tuberculosis. Norris (1931) states that the more thoroughly cases are examined, the more frequently are corporeal lesions found. In cases 11 and 16 of this series, the cervical lesions were secondary to tuberculosis of the body of the uterus. In both cases the myometrium was involved as well as the endometrium. Spread may have been direct or by the superficial lymphatics.

These two cases prove that infection can pass the internal os in a downward direction. It has been stated that infection of the uterus rarely spreads downwards past this point.

Cases have been reported, such as that of Bishop (1930), in which the cervix and tubes were involved without demonstrable lesions of the body of the uterus.

V. CONTRIBUTORY CAUSES TO INFECTION IN LESIONS OF THE UTERUS AND ADNEXA.

Pregnancy and the puerperium, menstruation, sexual activity, infection, especially gonorrhoea, local trauma, operative interference and hypoplasia have all been cited as predisposing causes. Berkeley (1903) quotes Merletti as one of the first to suggest hypoplasia and a number of other authors mention it. Mayer (1911), in a small series of 40 cases, found an infantile condition of the uterus frequently present and attributed it either to atrophy or pre-existing hypoplasia. In fourteen cases of women dead of pulmonary tuberculosis Jameson (1935) found that the average size of the uterus was less than normal but admits that the number of cases is too small to warrant a statistical conclusion. Norris (1931) does not consider it of importance. It has been impossible to find any other definite evidence in the literature of the frequent occurrence of such a condition associated with tuberculous infection of the genitalia. In this series of cases, there is no record, based upon measurements, of its having been present in any. The statement that it is a predisposing cause does not seem to be fully supported by facts.

1. Activation of Latent Infection. In discussing

predisposition to infection, the suggestion that the disease may be established at an early age must be remembered. It will be seen at once that the other causes listed above are just those which might be expected to induce activity in a quiescent lesion. Moulonguet (1933), who believes that infection is usually established in the very young, cites these as activating causes, stressing especially sexual activity. He compares this to the course of events accepted in cases of pulmonary tuberculosis. In a small number of cases established lesions have been demonstrated in infants, showing that infection can take place in extreme youth. Further proof is lacking but there is no contradictory evidence and the possibility of this course of events should certainly be taken into consideration.

2. Pregnancy. The association of a certain number of cases with pregnancy, childbirth or abortion, proves that these may be contributory causes. In Greenberg's (1921) 200 cases, 12% attributed the onset of the trouble to one or other of these events. In this series the percentage was 8.7. Case 14 was five and a half months pregnant; case 38 had an abortion two months before admission and cases 16, 44, 34 and 28 dated some or all of their symptoms from the birth

of the last child. The intervals before admission in these four cases were respectively, one and a half, four, four and a half and twelve years. In all except case 28 the association seems quite definite. Case 16 gave, also, a previous history of pulmonary tuberculosis. In cases 38 and 44 the history and findings suggest the activation of a latent lesion rather than a recent infection. Bernardbeig et al (1936) report a case occurring in the puerperium which they believe to be an example of activation of a latent lesion. In this series of 69 cases, only fourteen had been pregnant. In Smith's series of 63 cases, 19 had been pregnant. Thus while childbearing is undoubtedly important it cannot be described as a frequent contributory cause. This is most probably due to the frequent association of sterility with genital tuberculosis.

In a recent debate (B.M.A. Annual Meeting, Oxford, 1936) the influence of pregnancy on pulmonary tuberculosis was discussed. It must be accepted (Young, Cohen) that, in certain cases at least, exacerbation of the disease may occur, usually following labour. This may be accompanied by spread of infection and at such a time the genital tract would be especially liable to infection.

3. Marriage. It is interesting to note that two cases in this series, 27 and 46, date their symptoms from what appears to have been a pseudocyesis. One patient, case 46, was married because she believed herself pregnant and the other, case 27, was admitted for one night to the Royal Simpson Maternity Hospital. Case 27 had a previous history of bilateral pleurisy on two occasions and the false pregnancy followed immediately after marriage. These two cases should be considered together with those whose onset followed marriage.

Accepting marriage as an index of increased sexual activity, it is found in this series that seven cases date some or all of their symptoms from marriage or shortly afterwards. In case 2 the period was ten years since the first symptom but a curettage had been carried out four years after marriage for sterility. In case 64 the previous history suggests the possibility of a pulmonary lesion. The symptoms date from her first marriage and were made much worse by a second marriage. In case 4 there was a history of tuberculous peritonitis two years before marriage and in case 32 the previous history of pleurisy, etc., is suggestive. The other cases were Nos. 17, 19 and 58. These cases, together with the two false pregnancies,

represent 13.0% of the whole series. In Greenberg's (1921) cases, 4.5% attributed the onset to marriage. Although the number dating symptoms from marriage is small, it is worthy of note that in this series 78.2% were married women and in Smith's (1928) series 87.3% were married.

4. Menstruation and Previous Infection. With regard to menstruation and infection, especially gonorrhoea, it is less easy to obtain exact figures. Greenberg found that 11% of his cases dated their symptoms from a menstrual period. In this series one case, 29, appears to have had gonorrhoea previously or coincidentally and also had a triple positive Wassermann reaction. One case, 67, with a history of symptoms for sixteen years, had what was probably a Bartholinian abscess twenty years before admission. In one case the gonococcal fixation test was weakly positive, and in one negative. In six cases the Wassermann reaction was negative.

5. Other Factors. In case 24 the onset definitely followed a Gilliam's operation and in cases 25 and 35, symptoms followed appendicectomy. This represents 4.3%. In Greenberg's series the figure was 2% following operation and 2% following injury. Only one case in this series, 7, ascribed her symptoms to an

injury, three months previously.

The occupation is stated in 45 cases, 34 of these being housewives or engaged in domestic work. The remainder were miscellaneous: no importance appears to attach to the occupation.

In case 60 it is specifically mentioned that the onset of symptoms was preceded by a period of some months' heavy work. This case gave a previous history very suggestive of a tuberculous peritonitis three years previously. This raises a most important point which is seldom emphasized. Lowering of the general resistance by minor degrees of ill-health, overwork, bad feeding and bad hygienic conditions must be a most important contributory factor. These facts are often difficult to elicit, which probably accounts for the rarity with which they are mentioned in case histories. Paucot (1935) stresses this factor and states that he saw more cases about the years 1917 to 1920 than in the whole of the rest of his experience.

In the remaining cases of this series, representing a large majority, no contributory or predisposing causes are apparent in the history.

In considering the figures given in this section, it must be remembered that they are based on the presence of symptoms. They cannot, therefore, be regarded

as strictly accurate since symptoms may be absent completely or for long periods.

IN LESIONS OF THE FALLOPIAN TUBES.

This is the most frequent situation in which unsuspected lesions, without symptoms or signs, are discovered. It is here, therefore, that activation of a dormant lesion is the most probable explanation when the onset of the illness has a definite starting point. This conclusion must be applied with caution, however, in cases dating from a pregnancy, since bilateral lesions of the tubes are frequently, if not always, accompanied by sterility. It is very rare for a woman in whom tuberculosis of the tubes has been proved, to become pregnant. Pregnancy may, however, act as a predisposing cause first by activating the primary lesion and then by creating a condition of the genital tract which favours infection.

The general statement which has been made with regard to contributory causes applies fully to lesions of the tubes. The case following, and apparently activated by, a Gilliam's operation has been mentioned. Salmond (1930) reports a case in which a few minute tubercles were noted on the Fallopian tubes at operation for a dermoid cyst and six weeks later the

remaining tube was found to be extensively involved with recent adhesions and general peritoneal tuberculosis.

IN LESIONS OF THE BODY OF THE UTERUS.

Dormant lesions of the body of the uterus alone are very rare. The main contributory cause here is an active lesion of the Fallopian tubes. In all the four cases dating from the birth of the last child in this series, the uterus was involved. The tubes were known to be involved in three and suspected in the other. It has been suggested that the raw area left in the uterus following parturition provides a favourable site for infection. The evidence of these few cases is not in favour of this and it is held that the general systemic effect of pregnancy is of much greater importance.

The influence of menstruation on tuberculosis of the uterus will be discussed later. There was no evidence, in this series, of any connection between menstruation and the onset of symptoms.

Jameson (1935) suggests that stasis within the uterus may predispose to infection. He considers that this is a factor in almost every case. This point is discussed more fully later in relation to the

severity of the lesion. It will be seen that in some of the more advanced cases a possible cause of stasis was present, while in the less severe cases no such condition appeared to exist. While it is not certain that stasis was present in any case, it is possible that the initial establishment of infection in the uterus and its subsequent progress may have been thus influenced. The evidence of these cases does not support the contention that its presence is almost a necessity before the disease can be established in the uterus.

IN LESIONS OF THE CERVIX.

The rarity of tuberculosis of the cervix is due to the natural resistance in this situation. The tissues composing the cervix are not those in which tuberculous lesions are most commonly established. It has also been suggested that the cervical secretion exerts a bactericidal action (Douglass and Ridlon, 1929; Veyrassat, 1934).

Of causes predisposing to infection, the most important is, undoubtedly, lowered general resistance in the presence of disease of the upper genital tract, especially of the body of the uterus. This was well illustrated in case 16 of this series, where the cause

of the lowered resistance was a pregnancy. Finlaison (1936) reports a similar case. Injuries to the cervix resulting from childbirth have been suggested as a predisposing cause but, as in the case of the uterus, it is the general and not the local effects of pregnancy which are important.

Pre-existing inflammation is said to be a predisposing factor. This may have some influence but its importance is doubtful and evidence is difficult to obtain. In cases 8 and 16 of this series the tubercles showed no relationship to the areas in which there was evidence of inflammation. This does not disprove that the entry of the bacilli had been facilitated by the inflammatory change.

PATHOLOGY.

THE PATHOLOGY
OF TUBERCULOSIS OF THE FALLOPIAN TUBES.

Tubal tuberculosis is the commonest and most important form of genital tuberculosis.

The figures given by various authorities for the frequency of tuberculosis in inflammatory conditions of the tubes, vary.-

TABLE I.

Author.	No. of Cases.	No Tuberculosis.	per cent- age.
Solomons (1923)	590	-	14
Daniel (1933)	266	-	10.7
Norris (1933)	-	-	5-10
Moulonguet (1933)	-	-	8
Williams (1894)	-	-	7.7
Greenberg (1921)	-	200	6.76
Taylor (1915)	-	-	5
Farr-Findlay (1929)	545	-	4.7
Bush (1933)	1987	51	2.6
Smith (1928)	-	63	2.26

Figures which have been given vary from 1% to 18%. The only explanation which can account for such a wide variation is the relative care with which the

tubes were examined. The true frequency appears to lie between 5 and 10%.

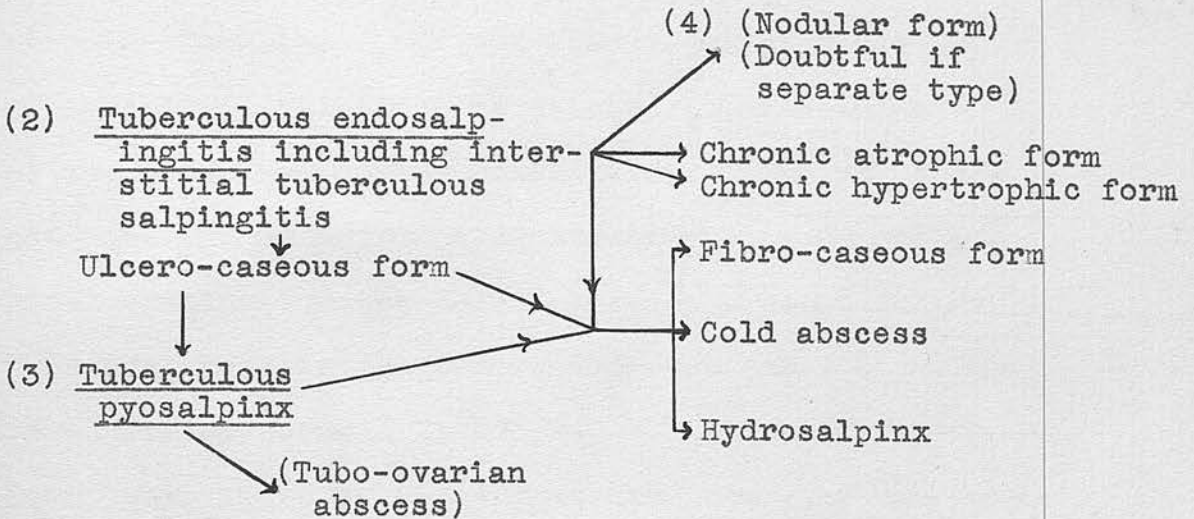
The same factor must account for the varying figures given for the frequency with which tubes are involved in genital tuberculosis. Jameson (1935) points out that one section is insufficient for diagnosis and that several sections or a sagittal section should be cut. He mentions that Höhne examined 160 sections in one case before finding typical tuberculosis. It is usually considered that the tubes are involved in about 90% of cases of genital tuberculosis. Norris (1931) considers that this under- rather than over-estimates the frequency.

In this series, there are 58 cases in 69, or 84%. The abdomen, however, was not opened in eight cases. Thus, the tubes were found to be involved in 95% of the cases in which the abdomen was opened. Of the remaining three cases, in one there was no histological report on the tubes, and in two only a single section was available for examination.

From the case reports, it is not possible to ascertain, in every case, whether one or both tubes were involved, but in only four does it appear that the lesion may have been unilateral. Greenberg (1921) states that the lesion is bi-lateral in 99% of cases.

As in the case of the cervix and of the body of the uterus, it is possible to divide tuberculosis of the Fallopian tubes into a number of different forms for convenience in description. The relative frequency of tubal lesions compared with those in other parts of the genital tract has led to a closer study of the pathology. In this situation, also, the disease is less influenced by factors such as secondary infection and cyclical changes which modify its course in the uterus and cervix. As a result, it tends to assume a greater variety of forms. Those which will be described are simply stages in the course of the disease, progressive or retrogressive, and are not rigidly differentiated types.

The classification followed by Jameson is on these lines and the diagram reproduced here is modified from that which he gives.

(1) Miliary serosal form.

1. The Miliary Serosal Form stands alone in the preceding diagram. It represents merely the incidental involvement of the surface of the tube in miliary peritoneal tuberculosis. The relationship of true tuberculous salpingitis to primary peritoneal tuberculosis has already been discussed. It has been shown that the weight of opinion, based on the available evidence, is against the possibility of spread to the tubes from the peritoneum, except in special circumstances.

Typical miliary tubercles are visible on the peritoneal surface of the tube, associated with tubercles elsewhere on the visceral and parietal peritoneum.

Associated with the general peritoneal reaction, there is some swelling and redness of the tube which affects also the fimbriae. If the disease attains any degree of severity, agglutination of the fimbriae and closure of the abdominal ostium takes place. The tubes are not adherent to surrounding structures. On histological examination the only tubercles present in the tube are those in the peritoneal coat and the picture is otherwise normal.

There is no evidence that the tubercles can penetrate to the wall or mucosa of the tube and this form is not believed to be a precursor of true tuberculous salpingitis. It is included here in order to make the classification complete.

Since salpingectomy would naturally not be carried out under these circumstances, no specimens are available for discussion, and there is only one case - No. 49 - which might be taken as an example of this form. As laparotomy only was carried out, the exact state of the tubes is not known. They were described as thickened and studded with tubercles. There was a general tuberculous peritonitis with matted coils of intestine and blood stained fluid. The nature of the condition was proved by biopsy.

2. Tuberculous Endosalpingitis. This is the true initial lesion in the tubes. In nearly every case, the ampullary portion of the tube is affected first. This fact has already been mentioned as evidence of the haematogenous nature of the infection. The lesion commences in, and is mainly confined to, the mucosa of the tube. In the early stages, or in mild, unprogressive cases, the tube appears normal to the naked eye and the condition is only diagnosed after histological examination.- Williams' (1894) "unsuspected" form of tubal tuberculosis. It was noted in this series that the tubes may appear healthy even when caseation is present in the lumen (Case 18). On the other hand, the tubes may show some swelling and congestion. Adhesions may be present, varying from a few in the region of the ostium, to dense bands firmly binding down the tubes to the pelvic organs. The fimbriae are usually thickened and matted together but the ostium may remain patent. The condition is almost always bilateral. In 200 cases, Greenberg (1921) found both tubes affected in 99%.

Histologically, tubercles are found to be present in the mucosa of the tube and there is usually some resulting distortion of the mucosal folds. There may also be some diffuse infiltration with endothelioid



cells and a degree of lymphocytic infiltration is the rule. A few miliary tubercles may be present in the wall of the tube. Side by side with this appearance, there may be evidence of a healing tendency in the shape of fibrosis and calcified tubercles.

(A) The ulcero-caseous form differs only slightly in degree from that just described. It is much less common for the tube to present a normal appearance, definite swelling and tortuosity usually being present. Dense adhesions are more frequent. Opinions vary as to the usual state of the abdominal ostium. Williams (1894) stated that it is always closed, Frank (1931) that it is closed in 50% of cases and Norris (1933) that it tends to remain open. Several authors have noted that the fimbriae tend to be adherent together rather than withdrawn within the peritoneal ring and this may account for the tendency of the ostium to remain patent. On histological examination, caseation and destruction of the mucosa is seen and caseous debris is present in the lumen.

(B) In the interstitial form dense adhesions are always present and these are frequently infiltrated with tubercles. In the tube, tubercles are present in the serous coat, the wall and the mucosa. Small

areas of caseation may be present in the wall. In the mucosa the condition may correspond to the miliary or ulcero-caseous form of endosalpingitis. The lumen may contain caseous debris or even pus.

Sections taken for microscopical examination from the same tuberculous Fallopian tube may show appearances which differ widely. For instance, a section cut from the undilated portion of a pyosalpinx may show only miliary tuberculous salpingitis. In all the cases of this series, the sections were taken primarily for diagnostic purposes and, therefore, are not always from the portion of the tube where the disease was most advanced. For this reason, the exact classification of these cases proved difficult as none of the gross specimens were available.

Cases of Endosalpingitis.-

Cases 10, 13, 15 and 48 have been taken as examples of tuberculous endosalpingitis of the early, miliary, or catarrhal form. Cases 10, 13 and 15 appear to be the earliest and most typical examples. In case 10, adhesions were present in the pelvis but the condition of the tubes was not noted. In case 13 the tubes were described as healthy but it was stated that there was evidence of tuberculosis in the pelvis. In case 15 one tube formed part of the pedicle of an

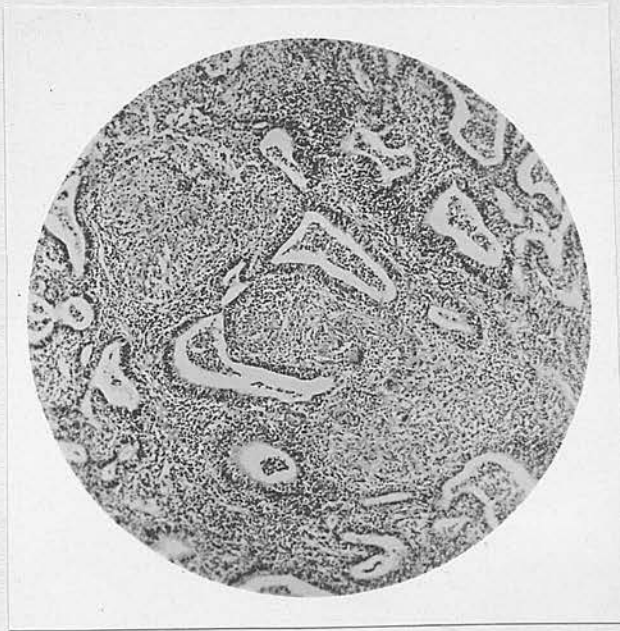ovarian cyst, the other showed what appeared to be a stricture and also some dilatation in the ampullary portion. The sections examined histologically all showed tubercles in the mucosa and there were no tubercles in the wall. In case 13 the tubercles were isolated and few in number. Some were recent, others were surrounded by dense fibrosis and two calcified tubercles were embedded in fibrous tissue which stretched across the lumen. In case 10, the tubercles were much more numerous, typical in appearance, and fibrosis was absent. In case 15 the process was more diffuse with numerous epithelioid and giant cells but few well-formed tubercles.

The tubercles were evenly distributed in the mucosa. The presence of tubercles and tuberculous tissue in the connective tissue of the plicae resulted in a certain amount of distortion and thickening. Especially in cases 10 and 13 there was some fusion of the tips of the plicae, producing a glandular appearance on section. In all three cases a tendency to hyperplasia of the epithelium was noted. Only in case 15 was there extensive desquamation of the epithelium. Changes similar to these were noted by Barbour and Watson (1911) in the undilated portions of pyosalpinges. A further feature which these authors

described was seen in case 10; that is, rupture of tubercles into the lumen and into the pseudo-glandular spaces. Some of the tubercles in these cases showed central caseation.

Illustration No. 1.

Tuberculous Endosalpingitis.



Case 10.

x 50.

Miliary form. Showing tubercles in connective-tissue stroma of plicae, with resulting distortion. The exudate present consists mostly of epithelial cells and lymphocytes but contains also a few red blood cells and polymorph leucocytes.

A slight catarrhal exudate was present in each of these cases, most marked in case 10. The presence of numbers of degenerate polymorph leucocytes in this case suggests that some secondary infection may have been present. It is very difficult, however, in cases of tuberculosis, to be certain on histological examination alone. Jameson states that although he was suspicious in several of his cases, he was never able to prove the existence of a secondary infection by the appearance under the microscope.

The classification of case 48 is difficult but the histological picture corresponds most closely to an endosalpingitis. Both tubes appeared to be slightly inflamed and tubercles were visible on one. The appearance of the sections was similar to those already described except that the tubercles were more numerous and showed slightly more extensive caseation. In two places, glandular tissue surrounded by tubercles appeared to be extending into the wall. This feature will be discussed later.

Cases of the Ulcero-Caseous Form.-

The ulcero-caseous form, which is a transition stage between miliary endosalpingitis and pyosalpinx, is represented in this series by cases 5, 7, 16, 18,

24, 37, 42, 55, 61, 64, 67 and 68. The usual description in the operation notes of these cases is that the tubes were thickened, dilated and adherent. In the majority, the adhesions were described as dense and involved the ovaries and other pelvic organs. In four cases tubercles were visible on the pelvic or abdominal viscera at operation. In a few cases the tubes felt firm and the presence of caseous material was suspected. In case 68 the condition found was described as a bilateral tubo-ovarian abscess containing caseous material but apparently no ovarian tissue was present in the sections examined. In case 18 the tubes were described as normal.

Sections were available for examination in cases 5 to 42. The appearance in the less advanced cases was similar to that of miliary endosalpingitis but the tubercles were more numerous, caseation was more extensive and ulceration and destruction of the mucosa were present to a varying degree. Tubercles in the wall of the tube were seen more frequently in these cases.

Case 16 differed very slightly from the cases of endosalpingitis described. There was some destruction of the plicae and considerable epithelial desquamation but caseation was slight. The tubercles in the wall

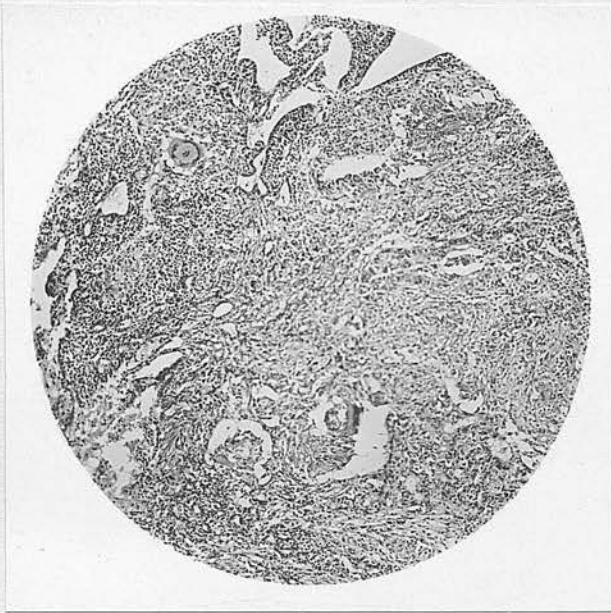
were more numerous towards the inner surface. Case 18, in which the tubes were described as normal, showed a similar appearance but the lesion was slightly more extensive. In case 7 the process appeared to be acute in character. There was widespread caseation in the mucosa, with considerable loss of surface epithelium and caseous debris was present in the lumen. Only a few well-formed tubercles were present. The appearance of a more chronic condition was seen in case 24. There were very numerous tubercles in the mucosa and tubercles were present in the wall. There were areas of calcification both in the lumen and the wall and some fibrosis was seen in the latter situation. In case 42, the stroma of the plicae was almost entirely replaced by tubercles, with miliary caseation and scattered areas of calcification. Round the periphery of the lumen the tubercles were much larger and confluent with surrounding caseation. In a few places tubercles could be seen invading the wall from the lumen. Caseous material and exudate containing cellular debris were present in the lumen.

Cases 5 and 37 showed a much more advanced condition, more nearly approaching a pyosalpinx. In these cases, the mucosa was almost entirely destroyed and the lumen was lined by loose granulation tissue

containing tubercles and the remnants of epithelium. The central part of the lumen was occupied by caseous debris. In case 37, the tubercles were few in number, there was considerable fibrosis, especially in the region of the wall, and there were several small areas of calcification. In this case also, tubercles were present throughout the wall.

Illustration No. 2.

Ulcerocaseous Tuberculous Endosalpingitis.



Case 42.

x 50.

Showing caseation and destruction of mucosa.

Cases of the Interstitial Form.-

In examining the cases of this series for examples of the interstitial form of tuberculous salpingitis, it was difficult to find cases which could be differentiated from ulcero-caseous lesions and early pyosalpinges. In the ulcero-caseous cases tubercles were present in the wall in at least seven out of twelve, being most numerous in the most advanced cases. In most of the cases of pyosalpinx, tubercles were present in the wall. It is, perhaps, wrong to classify the interstitial form as a variety of endosalpingitis and the study of these cases suggested that its occurrence is an accompaniment of certain endosalpingeal forms rather than a separate entity, as Jameson (1935) describes it.

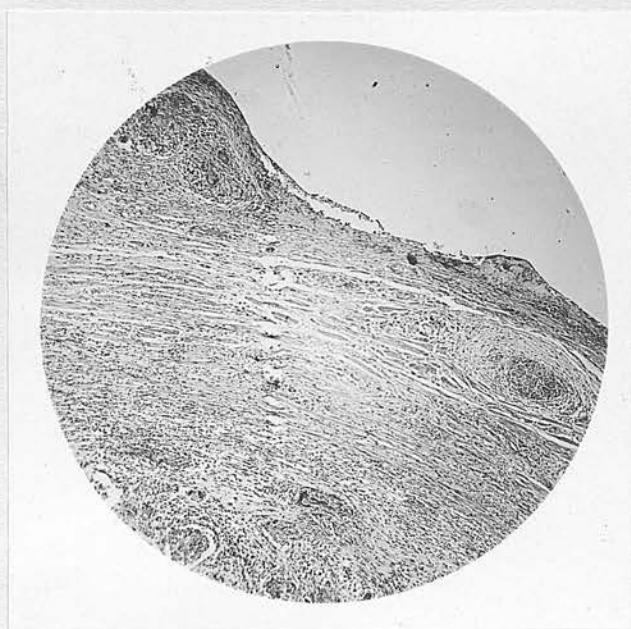
The three cases which have been taken as examples were chosen because the tubercles in the wall were especially numerous and involved the whole thickness of the wall, including the serous coat. In all three cases the tubes were surrounded by dense adhesions which were described as "filling the pelvis". In case 36 tubercles were not mentioned but in cases 33 and 44 tubercles were present on the tubes, in the pelvis and throughout the abdomen.

On histological examination the section of the

tube from case 44 showed very numerous tubercles in the serous coat. These varied in size from large masses containing numerous tubercles to single minute tubercles. Adhesions to the surface were present and these contained tubercles. Scattered tubercles were present in the muscular coat. A few small tubercles were present in the tissue of the broad ligament. The condition in the lumen corresponded to an advanced ulcero-caseous lesion, being similar to case 37. The appearance in this section did not suggest a spread through the wall to the serous coat but rather a superimposed peritoneal infection which probably spread from the tube via the abdominal ostium.

Illustration No. 3.

Interstitial Tuberculous Salpingitis.



Case 44. x 30.
Showing tubercles in lumen, muscular tissue
and serous coat.

In case 33 the wall, which showed some fibrosis, was densely infiltrated with tubercles. These were spreading from the lumen and in places approached close to the surface. In some areas the fibro-muscular tissue was almost replaced by tubercles. At the point where the tube wall was in contact with the ovary, the tubercles extended throughout the whole thickness. The mucosa was infiltrated with tubercles and largely destroyed, and pus was present in the lumen. In case 36, the infiltration of the wall was similar but less dense. No tubercles were seen on the serous coat but one was present on an adhesion. Within the tube, the picture was that of an advanced ulcero-caseous lesion with some calcification.

It seems that in some cases more than others, there is a tendency for the disease to spread outwards through the wall of the tube. It cannot be said, however, that any case in this series corresponds exactly to the description given for the interstitial form.

(C) The Chronic Atrophic Form. In the descriptions of the preceding cases, fibrosis and calcification have been mentioned. Under favourable circumstances these changes may come to dominate the picture,

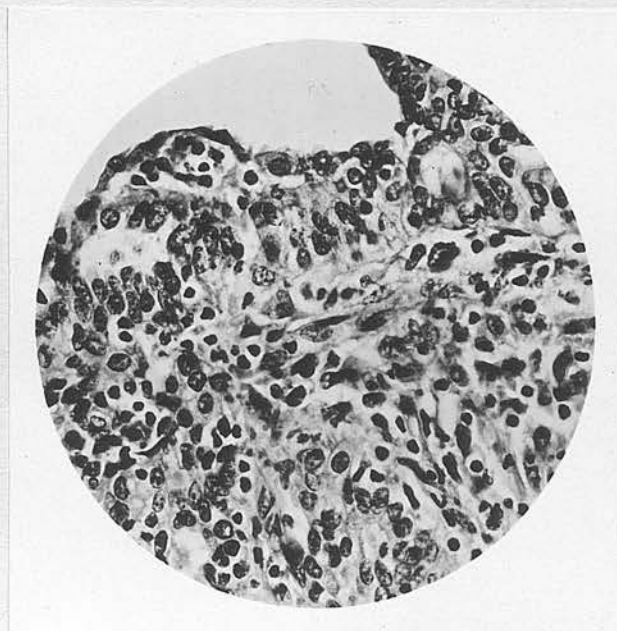
giving rise to one of the healing forms. These are seldom seen in their pure state, and it is more common to find a healing reaction and some evidence of activity, side by side.

The chronic atrophic and chronic hypertrophic forms are derived from the earlier stages of endosalpingitis. In the chronic atrophic form, fibrosis and calcification predominate. Cases 51 and 52 approach most closely to this conception. In case 51 there was a mass of adhesions in the pelvis between the uterine appendages, omentum and bowel. The tubes showed "evidence of long-standing chronic inflammation". On histological examination, the wall was found to be very thin and composed almost entirely of fibrous tissue. The lumen contained a few remnants of epithelial tissue but was largely occupied by tissue consisting of proliferated endothelioid cells with a few giant cells and a few lymphocytes. The appearance was very atypical but its tuberculous nature could not be doubted. In case 52, at operation, calcification was felt in the tube and in lymph glands, the situation of which was not stated. The tubes were not described but tubercles were present in the section examined. The operation was undertaken for a broad-ligament cyst and the patient was in good health.

(D) The Chronic Hypertrophic Form appears to be best represented in this series by case 21. In the section examined microscopically, the wall showed fibrosis. Fibrosis and areas of calcification were also present round the periphery of the lumen and in the plicae. In addition there was some lymphocytic infiltration, giant cells and small fibrotic tubercles. The most noticeable feature was marked proliferation and hyperplasia of the epithelium. In places the epithelial cells were heaped up and in places there was a tendency for solid plugs to penetrate the stroma.

Illustration No. 4.

Epithelial Hyperplasia.



Case 21. x 310.
Showing proliferation and heaping-up of epithelium and penetration of stroma by epithelial cells.

This case is not, however, a true example of the chronic hypertrophic form. Its main interest lies in the fact that the condition found at operation was typical of an ectopic gestation and the tube was, in fact, a haemato-salpinx. Examination revealed no evidence of gestation and the cause of the bleeding was not definitely established. The lumen of the tube contained red blood cells with a few leucocytes and epithelial cells. Macnaughton Jones (1907) reported the removal of a haemato-pyo-salpinx which was tuberculous in nature.

(E) The Fibro-Caseous Form. When caseation has taken place as in the ulcero-caseous and the interstitial varieties, healing is represented by the fibro-caseous form. Marked distortion of the tube and stricture formation may occur. In case 9, fairly thick adhesions were present and the tubes were nodular, with evidence of chronic inflammation. Two sections from this case show the wall replaced by fibrous tissue, lined by remnants of mucosa and the lumen occupied by caseous debris. Only one tubercle is present in each of these sections. In a further section, however, although there is extensive fibrosis, the mucosa is almost intact and widely infiltrated with tubercles.

3. Tuberculous Pyosalpinx.

The characteristic feature of this form is the distention of the tube by fluid or semi-fluid material. This may be semi-caseous, semi-purulent, or greenish-yellow pus or mucopurulent fluid. This represents a further stage of the ulcero-caseous form.

The size of the tubes varies. There may be a small swelling in the ampullary portion or the whole tube may be distended into a large, retort-shaped swelling. This may attain very large dimensions. Two of the cases reported by Barbour and Watson (1911) measured 13" x 10". Adhesions are usually present and may be dense. As in all forms of tuberculosis, both tubes are almost always affected, but one is usually larger than the other.

Tubercles may be present on the surface of the tube. Calcareous plaques may be visible on the surface or palpable in the wall.

Histologically, in the dilated portion of the tube, the wall is found to be largely or entirely replaced by fibrous tissue. This is lined by granulation tissue in which there may be some remnants of epithelial elements. At this stage, tubercles are frequently very scanty and may be absent altogether. The presence of the lining of granulation tissue

explains the appearance in the lumen of fluid containing leucocytes, with the resulting softening of the caseous material and formation of pus. An even more advanced condition is described by Barbour and Watson (1911) in one of their cases. The lumen, which contained glairy mucus, was lined by a single layer of flattened epithelium beneath which was healthy, newly forming tissue, containing a few tubercles. They suggest that the mucoid content in this case was due to increased and altered secretion from the hypertrophic epithelium.

A pyosalpinx may be associated with caseation and pus formation in the ovary, ultimately resulting in a tubo-ovarian abscess. Rupture of a pyosalpinx may take place into the abdominal cavity but is usually localised by adhesions to form a pelvic abscess. The uterus, bladder or colon may form part of the wall of such an abscess. Spontaneous fistula formation, into one of these organs or externally, has been reported.

(F) Cold Abscess. The form of tuberculous pyosalpinx known as cold abscess of the tube is not usually described separately in this country. According to Moulouquet (1933) it was first described by Faure in 1902. Nearly all the cases have been reported in the French literature.

The description of this form applies to cases in which the enlargement of the tubes attains a great size without giving rise to marked symptoms. The swelling of the tube is pear-shaped or retort-shaped and the contents are similar to those of a pyosalpinx. The serous coat of the tube is smooth and adhesions are absent. The histology is similar to that of a pyosalpinx, tubercles being few or absent. Such tubes may be prolapsed in the pouch of Douglas and may undergo torsion as in case 43.

The term, cold abscess of the tube, in fact, simply distinguishes a variety of tuberculous pyosalpinx in which the individual resistance is high or the infection is of attenuated virulence. Its claim to distinction as a separate form is doubtful. French authors do not restrict the term to cases which would conform to the above description. Delannoy (1935) reports three cases, in two of which adhesions were present. In his description, he stresses mainly the absolute absence of general disturbance and characterises the lesion as benign, limited and localised. Violet (1930) reported a case described as cold abscess in which external rupture in the left iliac region occurred spontaneously.

(G) Hydrosalpinx.

Tuberculous hydrosalpinx is not a common lesion. Like the last form described, it probably represents an attenuated form of pyosalpinx. The tube does not usually attain a great size and the wall does not become so thin as in the more common pathogenic form. The typical picture of tuberculous endosalpingitis is present in the undilated portion of the tube.

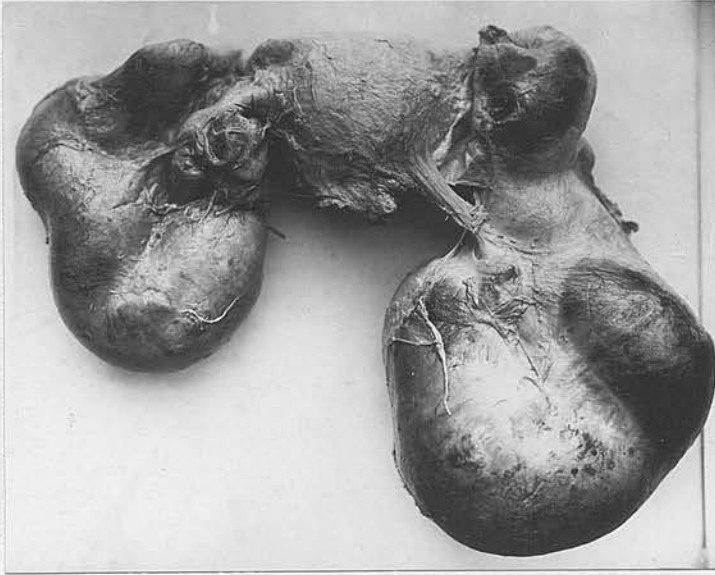
Cases of Pyosalpinx.-

There are sixteen cases in this series in which pyosalpinges were present. These were Nos. 2, 6, 11, 17, 20, 25, 34, 39, 50, 53, 54, 56, 57, 62, 65 and 69. Both tubes were affected in all these but in two cases - 20 and 25 - only one tube had progressed to the stage of pyosalpinx. The approximate size of the swelling is not stated in all the cases, but there was considerable variation. In some it is described merely as thickening. In case 65 the swelling is stated to have been the size of a duck's egg but in case 50 the tubes were apparently much larger than this. Dense adhesions between the tubes and the other pelvic organs were present in most of the cases. In some, however, the tubes were not so densely adherent and in cases 25 and 39 adhesions are not

mentioned in the description. Tubercles were visible in four cases - 11, 20, 53 and 56. There is no record of visible or palpable calcified areas in any of the tubes.

In case 54 it is noted particularly that the pelvis was filled with a very dense mass of adhesions. In cases 62 and 65 a similar condition was present and in these cases pus escaped when the adhesions were separated. The very large tubal swellings in case 50 were accompanied by an associated encysted peritonitis and free fluid was present in the peritoneal cavity. It seems almost certain that localised rupture had taken place in these cases. (This is borne out by the acute onset of symptoms a short time previously.) Slight torsion of one of the distended tubes was noted in case 53.

Illustration No. 5.
Tuberculous Pyosalpinx.



Showing the great size of the tubes, especially the right, and the dense character of the adhesions. Tubercles are visible on the surface of both tubes, the posterior surface of the uterus and the surface of the adhesions.

Specimen in Obstetrical and Gynaecological Museum, University of Edinburgh.

In nine of the cases, sections were available for examination under the microscope. The most typical picture was seen in case 50. One section in

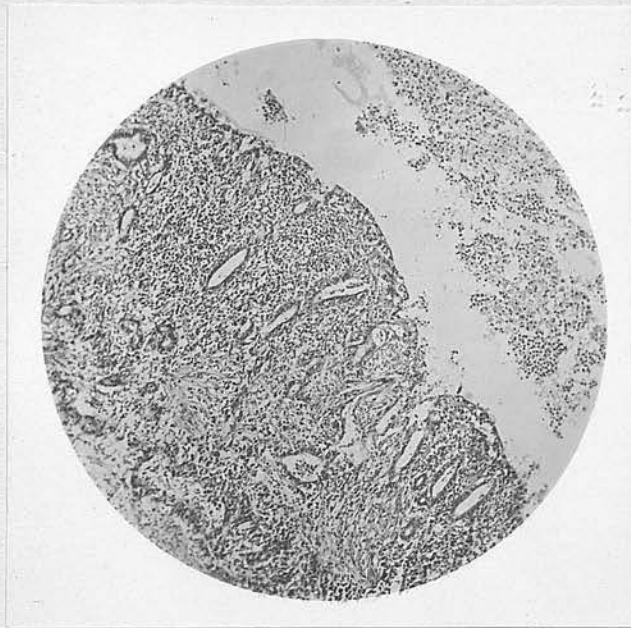
this case showed a portion of the wall of the most dilated portion of the tube. This consisted of rather poorly formed fibrous tissue infiltrated with lymphocytes. On the inner surface was a layer of granulation tissue with a shaggy edge, containing a few remnants of epithelial tissue and scanty but typical tubercles. The other two sections in this case had been taken from the undilated portion of the tube. The mucosa showed degenerative changes with some loss of epithelium, but some epithelial hyperplasia was present. There was one tubercle in the mucosa, near the centre of the lumen. The most interesting feature of these sections was an almost complete ring of dense infiltration with small round cells. This was situated in the inmost layers of the wall, close to the junction with the mucosa. It was accompanied by some destruction of tissue and contained a few tubercles.

In case 20 the section had been taken from a portion of the tube which was not grossly dilated. The appearance, nevertheless, was typical. The granulation tissue lining the lumen contained more remnants of epithelium than in the last case and was heavily infiltrated with lymphocytes and a few polymorph leucocytes. Some epithelioid cells and one giant cell were present. The lumen contained semi-caseous,

semi-purulent material containing numerous polymorphs. Further sections were cut and typical tubercles were found in some. The possibility of a degree of secondary infection cannot be ruled out in view of the histological appearance and might partly account for the absence of typical tubercles.

Illustration No. 6.

Pyosalpinx.



Case 20.

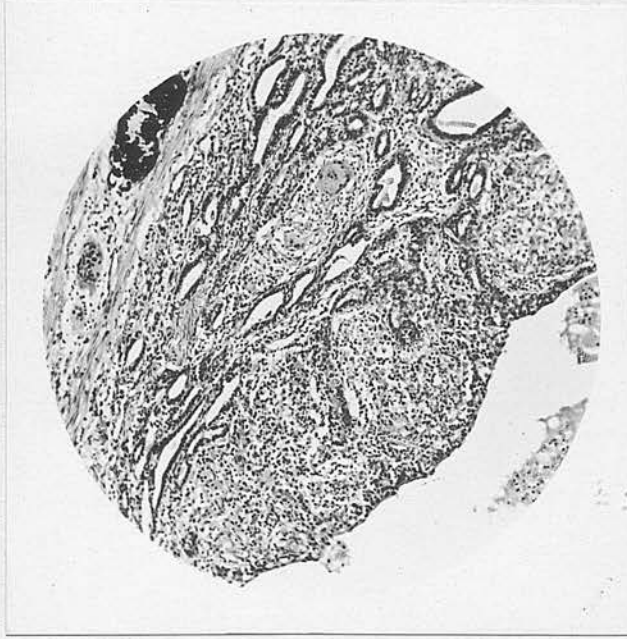
x 50.

Showing semi-caseous, semi-purulent contents. Lumen is lined by granulation tissue with marked cellular infiltration, containing remnants of mucosa and a single giant cell.

In cases 17, 25 and 34 the picture in the sections available was one of a less advanced lesion. There

was extensive infiltration with tubercles, which in two cases had invaded the wall. Areas of caseation were present and there was considerable destruction of the mucosa but this had not been replaced by granulation tissue. The contents were mostly caseous debris with some pus cells. A few red blood cells were also present in the lumen in case 34 and the whole appearance suggested an acute process.

In case 11 the portion of the tube seen in the section showed less destructive changes. Tubercles were present in the wall in the inner layers, close to the mucosa, and also a small area of calcification. The stroma of the mucosa was almost entirely replaced by tubercles and surface epithelium was absent. The lumen contained caseous debris and mucopus.

Illustration No. 7.Pyosalpinx.

Case 11.

x 75.

Showing advanced endosalpingitis with exudate in lumen and calcification in wall.

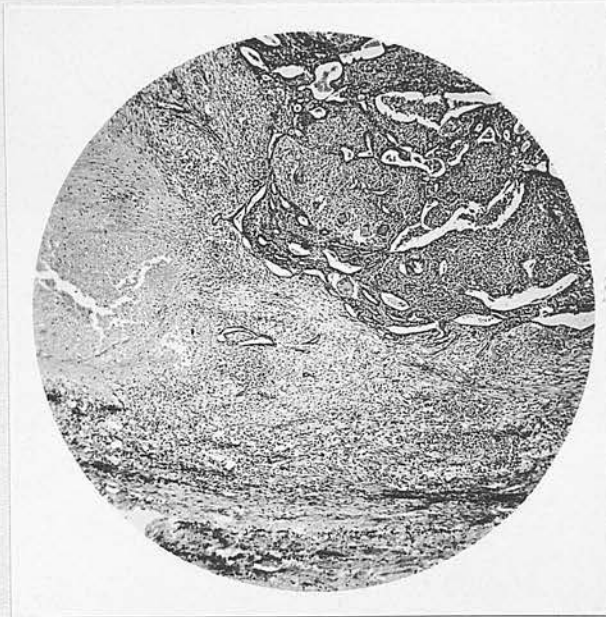The available sections in the remaining three cases showed merely advanced salpingitis. In all three a certain amount of debris and a number of polymorph leucocytes were present in the lumen. In case 2, the appearance was that of an ordinary salpingitis with very numerous tubercles evenly distributed throughout the mucosa. In cases 6 and 39 tubercles were present in the mucosa and the wall. In case 6 the

appearance suggested an acute process and polymorph leucocytes were especially numerous in the lumen. The tubercles were largest and most numerous in the mucosa close to the inner surface of the wall and in the bases of the plicae. In case 39 the condition was of longer standing and scattered areas of calcification were present. The distribution of the tubercles was very similar and, in this case, there was an area round the inner surface of the wall in which there was fairly extensive caseation with some fibrosis and calcification and a few tubercles. It has already been noted that in the sections from case 50, dense cellular infiltration was present in the same situation. Altogether eight cases in the whole series - 6, 9, 11, 17, 35, 39, 42 and 50 - showed the most numerous and largest tubercles in the mucosa adjacent to the wall and in the inner layers of the wall itself. In all these cases the section was from the undilated portion of the tube but in five of them the tube was the seat of a pyosalpinx, the remainder being, respectively, ulcero-caseous, fibro-caseous and hydrosalpinx. This must mean that this is the level at which infection spreads along the tube, presumably in the lymphatics. In their cases, Barbour and Watson (1911) noted that the tubercles were more numerous towards the tips of

the plicae. In this series, this distribution was found only in case 22.

Illustration No. 8.

Caseation in Inner Layers of Wall of Tube.



Case 39.

x 30.

Showing caseous area extending into mucosa from inner layer of wall. Tubercles are present in mucosa.

Cases of Tubo-ovarian Abscess.-

In cases 1, 23, 29, 45, 46, 58 and 60 the lesions of the tubes were accompanied by the formation of tubo-ovarian abscesses. As the tubes were involved, they must be mentioned here but they will be discussed more fully under the pathology of the ovary. With one exception, the portions of the tubes included in the sections showed changes typical of pyosalpinx. In case 46, the available section of the tube showed a condition of advanced endosalpingitis with considerable fibrosis.

Case of Cold Abscess.

Case 43 has been chosen to illustrate the form of pyosalpinx known as cold abscess of the tube. The right tube was described as enormously enlarged, coiled round behind the uterus and reaching to the umbilicus. There is no mention of adhesions. The left tube, which was almost as large, had undergone partial torsion and was densely adherent. The two sections examined showed the typical appearance of the wall of a pyosalpinx and a single tubercle was present in one.

There were no symptoms in this case prior to the acute illness of two weeks' duration, which was almost certainly due to the torsion of the left tube. The

patient eventually made a perfect recovery.

Cases of Hydrosalpinx.

In cases 22 and 35 the affected tubes were described as hydrosalpinges. In case 35 the hydrosalpinx of the left tube measured 4" x 6". In both cases very dense adhesions were present. The sections in both cases were taken from the undilated part of the tube and showed endosalpingitis with numerous tubercles present, the condition being more advanced in case 35.

(H) Cases of General Peritoneal Tuberculosis with Pelvic Lesions.

In two cases laparotomy only was carried out, the nature of the infection being established by biopsy of a portion of the peritoneum. These cases have been included here because there can be no doubt that the tubes were involved. In case 38 there was a mass in the left side of the pelvis and in case 40 the pelvic organs were matted together with dense adhesions. In both cases numerous tubercles were present throughout the abdomen and pelvis.

In case 14, the operation was an abdominal hysterotomy, to terminate a five and a half months pregnancy, and ligation of the tubes. The peritoneum

was found to be thickened and free fluid was present. Tubercles were present on the parietal peritoneum, omentum, bowel and pelvic organs. Both tubes were thickened and densely adherent in the pelvis.

In these cases, it is suggested that the infection had spread to the peritoneal cavity from the tubes, and, in case 14, that this spread was due to the pregnancy. In view of the frequency with which sterility is associated with tuberculosis of the tubes, it might be suggested that the tubes must have been involved after conception had taken place in case 14. It is difficult to be certain, however, as cases have been reported in which women have become pregnant in spite of the presence of tuberculosis. In this case an active primary focus was present in the chest. It illustrates to a marked degree the profound effect of pregnancy on the disease, which subsequently progressed to a fatal termination.

Nodular Salpingitis.

According to Jameson (1935), the nodular form of tuberculous salpingitis develops from the interstitial form. He describes the formation of caseous or fibro-caseous nodules in the wall of the tube giving rise to a nodular aspect which was formerly considered to be

pathognomonic of tuberculosis. Some cases in this series showed areas of caseation and fibrosis in the walls of the tubes on histological examination, and in others the tubes were described as nodular. In no case, however, did it appear that the nodular condition of the tube was due to areas of caseation in the wall, as far as could be judged from the available material.

The study of these cases, however, led to the consideration of certain other conditions which give rise to the formation of nodules in the Fallopian tube. In several of the cases mentioned above, the tube was described as being the seat of Salpingitis Isthmica Nodosa. This name implies the presence in the tube of nodules composed of a fibro-muscular stroma in which gland-like spaces, lined with epithelium, are present. While the exact nature of this condition is still in some dispute, it has, in the past, been associated with tuberculosis and is, therefore, of interest here.

Nodules in the isthmic portion of the tube and at the junction of the tube with the cornu of the uterus, varying in size from that of a pea to a hen's egg, and having the histological structure mentioned above, were first described in the year 1887. The condition was believed to be inflammatory in origin and was given

the name of Salpingitis Isthmica Nodosa. Later, it was suggested that some, or all, of the cases were due to neoplastic change, as the names of adenomyoma, adenomyosis and endosalpingiosis, imply. An origin from Wolffian relics was suggested by von Recklinghausen. Rabinowitz-Robinson (1913) believed that the condition was due to inflammation and suggested the name of adenomyosalpingitis. He found, in ten cases, that two were due to tuberculosis. Stewart and Oldfield (1932) distinguish this condition from endometriosis and suggest that it is usually due to chronic inflammation which is frequently tuberculous. In the isthmic portion of a tuberculous pyosalpinx, Barbour and Watson (1911) described extension into the wall of the hyperplastic epithelium, resulting in the formation of gland-like spaces.

Graves (1933) states that it should be discussed with endometriosis and divides the condition into four types:- (1) Due to inflammatory irritation, which may be tuberculous in nature: (2) due to non-inflammatory ingrowth of mucosa: (3) representing an extension of diffuse adenomyosis from the uterine mucosa: (4) developing in the scar of a salpingectomy. Watkins (1933) considers that it is most frequently the result of inflammation and that the gland-like spaces result

from the epithelialisation of healed abscess-cavities in the wall of the tube. Watkins and Menne (1930) showed, by bismuth injection and radiography of specimens, that the gland-spaces in the wall are almost always connected with the lumen.

The presence of a cytogenous mantle surrounding the epithelium is usually accepted as an indication that it derives from the endometrium (Sampson). It has also been suggested that this appearance may be due to metaplasia of the stroma. Douglass (1929) mentions this theory and states that cyclical changes are rarely seen in the epithelium.

Cases of Nodular Salpingitis.

In this series there were five cases which appeared to have sufficient of the characteristics described to justify their inclusion under this heading. These were cases 12, 31, 32, 59 and 63. Of case 59 it can only be said that the tubes were described as showing Salpingitis Isthmica Nodosa to a marked degree and on section, the fibro-muscular wall showed numerous gland-like spaces. Tuberculous infection was present, mainly in the fibro-muscular wall and involving many of the pseudo-glandular spaces.

In case 12 the right tube was described as

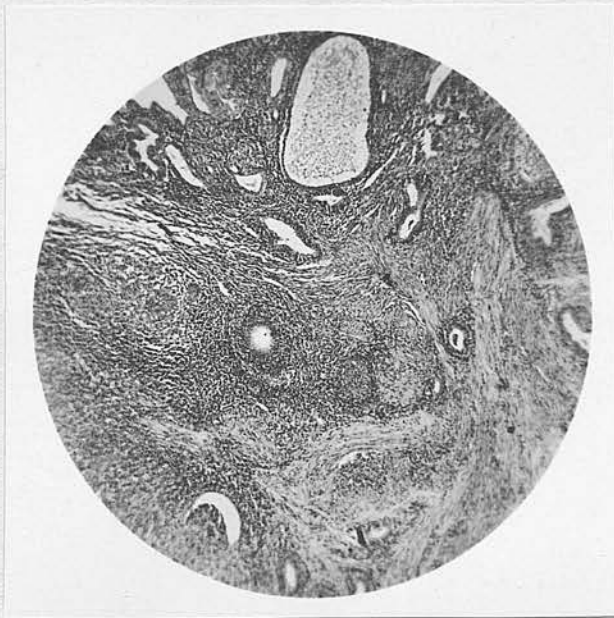
thickened and nodular as in Salpingitis Isthmica Nodosa. Microscopically the section examined showed thickening of the wall. In the fibro-muscular tissue of the wall, and especially numerous to one side of the lumen, were gland-like spaces lined with cuboidal epithelium which showed marked degenerative changes. In this case the epithelium was set directly on the muscle and there was no surrounding cellular stroma or cytogenous mantle. A few tubercles were present in the sub-epithelial stroma of the lumen itself. The majority, however, were in the wall and were all situated in relation to the gland-like spaces.

In the other two cases the tubes were not described as being nodular but the histology was similar. In case 31 the lumen could not be distinguished. The section showed a mass of fibro-muscular tissue containing irregular spaces, lined with columnar epithelium. Around some of these a cytogenous mantle appeared to be present. Tubercles were numerous, mostly related to these spaces but some were isolated in the fibro-muscular tissue. In case 32 the fibro-muscular tissue containing gland-like spaces was surrounded by the wall, or part of the wall of the tube. A cytogenous mantle could be recognised around the epithelial lining of some of the spaces. It was possible to

identify the true lumen and in it, hyperplasia of the epithelium was a very marked feature. The tubercles in this case were not numerous and were surrounded by well-marked fibrosis.

Illustration No. 9.

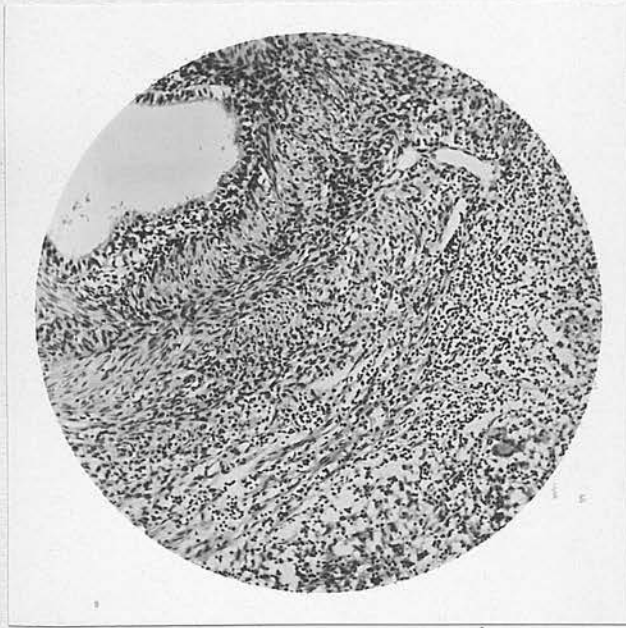
"Salpingitis Isthmica Nodosa"



Case 12.

x 30.

Showing spaces, lined with epithelium, in wall of tube adjacent to lumen. Part of the lumen is shown in the photograph. Tubercles are seen to be present in close relation to the gland-like spaces.

Illustration No. 10."Salpingitis Isthmica Nodosa"

Case 31.

x 80.

Showing portion of gland-like space set in fibro-muscular tissue. A small area of loose, cellular, sub-epithelial stroma is present. Part of a small collection of tubercles is also seen with surrounding infiltration by lymphocytes. In the section these did not appear to be related to any of the spaces lined with epithelium.

In case 63 an adenomyoma infected with tuberculosis was present in the uterus. In his report of this case Professor Johnstone (1924) gives a full description of the tubes: "Both tubes are thickened throughout and present nodular thickenings in addition

which are most marked at the cornu on each side. Other minor thickenings in the isthmus and ampulla of each tube can be felt between the fingers better than they can be seen. Tubercles are present in the cornual swelling of the left tube which presents many cystic spaces lined with glandular epithelium, but with little or no cellular stroma around them. This is characteristic of Salpingitis Isthmica Nodosa and also, according to Sampson, of adenomyoma of the tubal angle. The two conditions are probably often confused. Sections of one of the thickenings of the right tube in the outer isthmic region show one or two cystic spaces in addition to the tube lumen."

Varying degrees of the changes which have just been described, both naked-eye and microscopical, were noted in certain of the cases which have already been mentioned under other headings. In cases 2, 9, 25 and 58, one or both tubes were described as being either nodular or the seat of Salpingitis Isthmica Nodosa. The sections examined, however, did not show any corresponding histological changes. In cases 52 and 55 the pathologist's report mentions tuberculous salpingitis associated with Salpingitis Isthmica Nodosa. The tubes in case 24 were described as being the seat of nodular salpingitis. The section examined

showed an area, separate from the lumen, of tissue which was mostly fibrous and with a whorled arrangement round spaces which were lined with epithelium. This appeared to be definitely tubal epithelium. No tubercles were present in this area. In the lumen, an early ulcero-caseous lesion was present and some epithelial hyperplasia was noted. The section examined in case 51 was similar to that already described in case 31 but no tubercles were present.

A single nodule was present at the cornual junction of one tube in case 15. On section, this tissue presented the usual appearance but in the stroma, the muscular element predominated. Nowhere did the epithelium lining the spaces show any trace of a cytogenous mantle. No tubercles were present. The tube, however, was the seat of a tuberculous endosalpingitis.

If all these cases are accepted, the condition was present in 14 out of 58 cases of tuberculous salpingitis, i.e., 24%. The cases proved histologically number 10, giving a percentage of 17.3. It is not possible to give corresponding figures for tubes removed in other forms of salpingitis, but Culbertson (1924), in 282 cases of salpingitis, found it present in both tubes in 10% and in one tube in 12%. It is possible that the figure of 17% represents a greater

frequency than that usually found in association with all forms of salpingitis. The exact frequency of the condition is, however, unknown and the number of these cases is too small to warrant any definite conclusion.

Sections were examined in six cases and in case 63 a full description was available. In five of these cases, tubercles were present in the affected area. In all, an inflammatory process was present and one which is known to be associated with hyperplasia of the tubal epithelium. A typical cytogenous mantle or sub-epithelial stroma, present in cases of endometrioma was not seen, and the epithelium appeared to be tubal in all the cases.

If the condition is due to previous inflammation, it is possible that this state of affairs may predispose the tube to infection with tuberculosis. In cases 15 and 24, the appearance suggested rather an adenomyomatous condition and in these cases, no tubercles were present in affected area. Parsons and Glendinning (1909-10), however, report a case in which tubercles were present in what they describe as an adenomyoma which was situated in a tuberculous tube. While in some cases the condition is purely adenomyomatous in character, in many inflammation plays a

part in its causation. Tuberculosis is an inflammatory condition and one which is commonly accompanied by hyperplasia. It is, therefore, possible that tuberculosis is a causal factor in some cases.

The Peritoneum in Tuberculous Salpingitis.

In only 9 of the 58 cases were adhesions not mentioned in the operation reports, so that they were present in at least 49, or 84.5% of the cases. There is good reason to believe that adhesions were present in a number of the other cases, although they were not specifically mentioned in the operation reports. In the majority of cases, the description stressed particularly the dense nature of the adhesions. This is a characteristic feature of tuberculous adhesions. In only one case - No. 15 - were they described as filmy. In six cases the adhesions were not confined to the pelvis, bowel or omentum being involved.

More or less generalised tubercles throughout the peritoneal cavity were noted to be present in 12 cases. In four further cases tubercles were present on the surface of the tubes and uterus. This is an incidence of 27.6% of cases in which tubercles were present on the peritoneum. Greenberg (1921) found peritoneal

involvement in 63% of 200 cases, but he does not state whether this implies the presence of tubercles or of adhesions only. In 100 cases Peterson (1922) found a similar figure of 66%.

"Pseudo-tuberculous Salpingitis".

A condition which the authors named "pseudo-tuberculous salpingitis" has been described by Denton and Dalldorf (1930). The condition is referred to as a foreign body type of inflammatory process which they believe has been frequently confused with tuberculosis. Out of 78 tubes reported as tuberculous, they found foreign material present in 34 and thought that altogether 57 cases were deficient in the morphological characteristics of tuberculosis.

In the examples which they describe, the lesions were limited to the serous and mucous coats, and consisted of focal collections of small giant cells with nodular and diffuse endothelioid proliferation. The outline of the plicae was well retained. Particles of foreign matter were present in approximately half the cases. There was some fibrosis and epithelial proliferation was well marked.

In comparison, they describe cases which appear to have been examples of advanced tubal lesions with

pelvic peritonitis.

The foreign body which was present in the tubes appeared to contain calcium and fatty acids. In the cases of this type, there was no evidence of tuberculosis elsewhere and the general condition of the patients was good.

The authors admit that there is no conclusive evidence that the condition is not tuberculous. They suggest, however, that further investigation is indicated. They consider that the absence of definite tuberculous granulation tissue, an obvious cause for the giant cells in the foreign material present, and the lack of clinical evidence of tuberculosis elsewhere, favour their view. They suggest that the condition may result from chronic inflammation.

There does not appear to be any other reference in the literature to this condition. The appearances described were all seen in various cases in this series, associated with lesions which were definitely tuberculous. The absence of clinical lesions elsewhere is a feature of tuberculous salpingitis. Further evidence is required before it is accepted that appearances such as were described, are not due to tuberculosis.

Frequency of Occurrence of Forms Described.

The relative frequency of the pathological types found at operation in this series of 58 cases was as follows:-

TABLE II.

	No.	Percent- age.	No.	Percent- age
1. Miliary serosal	1	1.7		
2. Endosalpingitis	4	6.9)		
Interstitial	3	5.2)		
Ulcerocaseous	12	20.7)		
Chronic atrophic	2	3.4 (23	39.6
Chronic hyper- trophic	1	1.7)		
Fibrocaseous	1	1.7)		
3. Pyosalpinx	16	27.6)		
Cold abscess	1	1.7)		
Hydrosalpinx	2	3.4 (26	44.8
Involved in tubo- ovarian abscess	7	12.1)		
Nodular	5	8.6		
Unclassified	3	5.2		

THE PATHOLOGY
OF TUBERCULOSIS OF THE OVARIES.

Ovarian tuberculosis is almost always found associated with tubal disease. Cases have been reported in which the ovary alone was involved but this must be regarded as a rarity. It is, therefore, the usual practice to state the frequency as a percentage of cases in which tubal lesions are present.

Moench (1923), who found it a rare lesion in his own experience, mentions figures varying from 4.1% to 60% of cases of genital tuberculosis. In cases in which the tubes were involved, Taylor (1915), Smith (1928) and Greenberg (1921) give the figures of 22%, 24% and 29.5% respectively, for cases in which tuberculosis was found in the ovaries. In this series, there were 14 cases and the figure is 20.3% for all the cases and 24.1% for those in which tubal lesions were known to exist.

Jameson (1935) holds that there is a possible source of error because the ovaries are not removed as a routine procedure. In operations for tuberculosis, however, it appears that it is almost a routine. In Greenberg's cases, oöphorectomy was carried out in 83% and of these ovaries 33.1% were the seat of tuberculosis,

a figure which does not differ ^{greatly} from that given above. In this series, one or both ovaries were removed in 93% of the tubal cases and the figure for ovarian involvement as a percentage of oöphorectomies rises to only 25.9%. The figures given by Bush (1933) are comparable with these - 51 cases with oöphorectomy in 48 - but the figure for ovarian involvement is higher - 39%.

In this series half the cases were between the ages of 21 and 30. The distribution of the cases in age groups was:- 20 and under - 2; 21 to 30 - 7; 31 to 40 - 1; 41 and over - 4. It is stated that lesions originating in, and confined to the ovary are most common before, or about puberty. If this fact can be substantiated it would be of some interest, because during active sexual life, the ovary appears to be strongly resistant to infection.

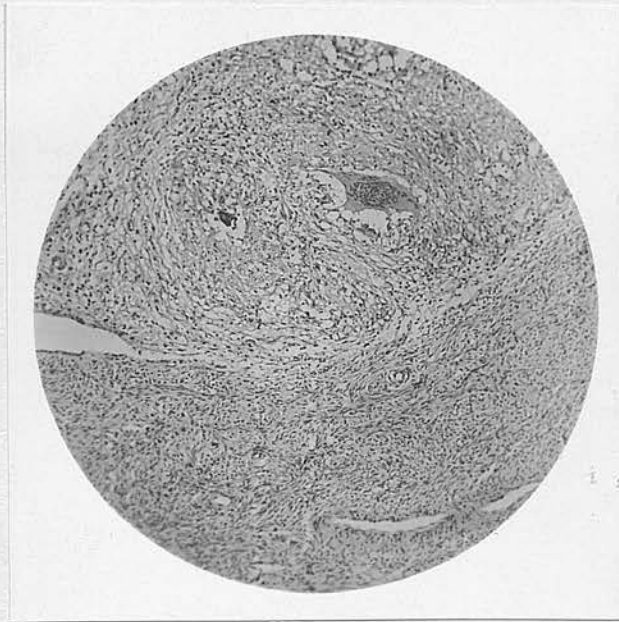
1. Peri-oöphoritis.

It is usually stated that the commonest form of ovarian tuberculosis is peri-oöphoritis. There were only five examples of this form in this series but in all these cases tubercles were present on the surface of the ovary. In a very much greater number of cases the ovaries were involved in adhesions. As no

tubercles were present, these could not be strictly defined as cases of peri-oöphoritis.

It is worthy of note that there were seven cases in which tubo-ovarian abscesses appeared to be present. In only two cases (in which slides were not available) the reports indicated a generalised infection without abscess formation. In other words, the intermediate stage between surface infection and complete, or almost complete destruction of the ovary, is poorly represented. This is due to the fact that the ovary presents an initially high resistance but when this is overcome, the progress of the lesion is rapid and its effects severe.

Cases of Peri-oöphoritis. The best example of peri-oöphoritis in this series was case 44. The right appendages were matted together by adhesions and studded with tubercles. On histological examination, the substance of the ovary was seen to be healthy. On the surface, two of the tubercles described at operation were seen. These were collections of typical microscopic tubercles and showed no tendency to penetrate the surface of the ovary. In addition, a single tubercle was present in one of the adhesions.

Illustration No. 11.Tuberculous Peri-oöphoritis.

Case 44.

x 50.

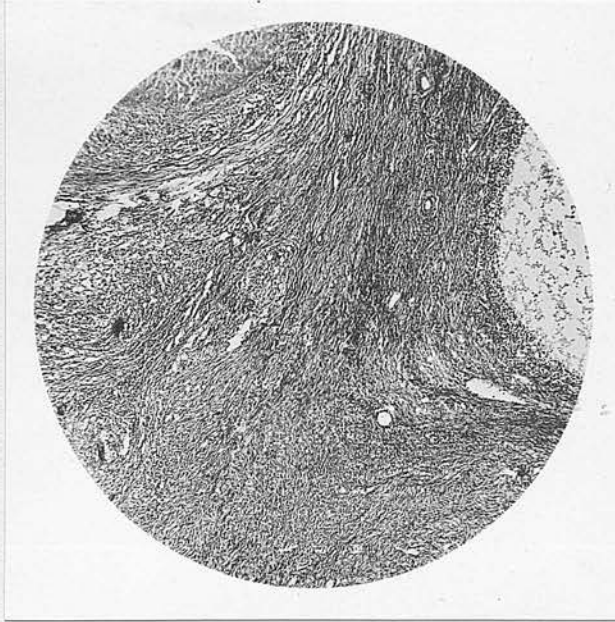
Showing tuberculous tissue on surface of ovary. There is no invasion of the substance of the ovary.

In case 33 both tubes were closely adherent to the ovaries. One section showed adhesions to the surface of the ovary. Tubercles in contact with the surface of the ovary were present in two of these. Another section showed a portion of ovary in close relation to the Fallopian tube. The area between the lumen of the tube and the ovary was occupied almost entirely by tubercles but there was no invasion of the

ovarian tissue.

Illustration No. 12.

Tuberculous Peri-oöphoritis.



Case 33.

x 30.

Showing tubercles in close contact with the ovarian cortex which is not being invaded.

In cases 9 and 12 one ovary was adherent to the corresponding tube. In the former a single small tubercle was present at the point of junction of an adhesion and in the latter three calcified areas and two fibrotic tubercles were present on the surface of the ovary. In case 23 it was stated that the left ovary was not adherent to the tube. A pelvic abscess

was present on the right side. The section of the left ovary showed, on the surface, two small and atypical tubercles.

2. Tuberculosis of the Substance of the Ovary.

In true ovarian tuberculosis, it is generally agreed that a recently ruptured follicle provides a portal of entry. As a result the lesion first becomes established in the consequent corpus luteum. None of the sections removed in this series showed a lesion at this stage. This is followed by rapid spread and involvement of all parts of the ovary. In cases 56 and 59, the case-reports indicate that a lesion at this stage was present. Unfortunately, sections were not available. In case 56 dense adhesions were present in the pelvis and there was a bilateral tuberculous pyosalpinx. Both ovaries contained numerous tubercles. In case 59 the tubes and ovaries were firmly bound down by adhesions. The right ovary was cystic, the left appeared to be healthy. One ovary, presumably the right, contained one or two tubercles and scattered caseous areas.

As the disease progresses, the caseous areas enlarge and become confluent. The ovary enlarges and adhesions, if not already present, form on the surface.

Jameson states that the first adhesions are usually attached to the fimbriae of the corresponding tube. If adhesions are not too dense and early rupture does not take place, the ovarian abscess may attain some size, the tube becoming stretched over the surface. This, however, is rare. Rupture may occur into the pouch of Douglas, the bladder or the pelvic colon, but only with extreme rarity. In the usual course of events the ovary is surrounded by dense adhesions which involve especially the neighbouring tube. Also, the ovarian tissue surrounding the abscess is not freely distensible. Rupture, therefore, usually occurs comparatively early and is localised by the adhesions. In the majority of cases the end-result is the formation of a tubo-ovarian abscess.

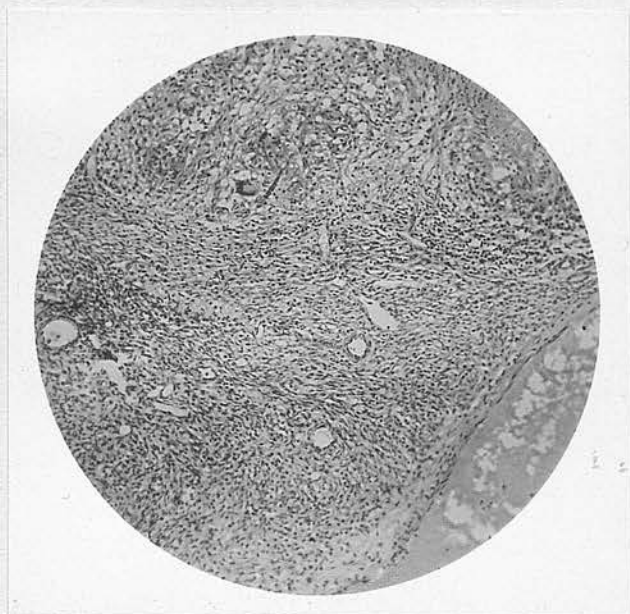
Cases of Tubo-ovarian Abscess. In this series a tubo-ovarian abscess was definitely present in four cases, and is presumed to have been present in three others. In case 1, there were dense adhesions and scattered tubercles throughout the abdomen. A large cystic mass on the right side of the pelvis, adherent to the pelvic colon and small bowel, contained creamy, greenish-white pus. (This had been aspirated through the vaginal fornix some three months previously.) The section examined showed the wall to be similar to that

of a pyosalpinx. It consisted largely of fibrous tissue in which was a portion of ovarian cortex and was lined by thick granulation tissue containing tubercles. Traces of caseo-purulent exudate were present. In case 45 there was a mass on the right side of the pelvis about the size of a grapefruit. This mass appeared to be partly within the broad ligament, the remains of the tube and ovary being posterior to it. The omentum and coils of intestine were adherent to the mass. It was found that the uterus had formed part of the wall of the abscess and that there was considerable destruction of the uterine wall. It seems possible that, in the absence of treatment, rupture would have taken place eventually into the cavity of the uterus. The section examined showed that the wall, from without inwards, consisted of ovarian tissue, fibrous tissue and tuberculous granulation tissue, within which was caseous debris. In case 29, the condition at operation was described as a left broad ligament cyst. This was adherent to the side wall of the pelvis, the small intestine and the bladder. After removal, it appeared as a cystic tumour, the size of a tangerine orange, one portion being thick walled and the other thin walled. The smaller, thick-walled portion contained pus. The section examined showed

an appearance very closely resembling that described in the last two cases. In case 23 a large mass was present in the pelvis and the uterus and tubes could not be identified. The omentum and bowel were not adherent. The mass was found to be friable and an abscess was found containing foul-smelling pus. In one section, the wall of the tube showed the usual appearance of a pyosalpinx. Another section was of an irregular fragment of ovarian tissue which had evidently formed part of the wall of an abscess. This was lined with thick tuberculous granulation tissue and contained caseous debris. This is the only section in which isolated tubercles were present in the stroma of the ovary. These were few in number and irregularly distributed. Some showed caseation.

Illustration No. 13.

Tuberculosis of the Ovary.



Case 23.

x 30.

Showing tubercles in ovarian cortex. A portion of a small caseous area can be seen, at top right-hand corner of photograph.

In case 46 bilateral tubo-ovarian cysts were described at operation and it was stated that there appeared to be no true ovarian tissue left. The pelvic organs were matted together by firm adhesions which involved the omentum and bowel. The section available showed only tube in a condition of advanced endosalpingitis. In case 58 both tubes and ovaries were extensively diseased and on the right side a tubo-ovarian

cyst, the size of a tennis ball, was present. In the report, it is stated that the ovarian tissue showed extensive fibrosis but no further description is given. Dense pelvic adhesions were present in case 60 and the tubes and ovaries were full of pus. The report describes the usual changes of pyosalpinx in the tubes and states that the ovaries showed signs of chronic inflammation without evidence of tuberculosis.

Case with Tubercles in Hilum. The remaining case does not represent any stage in the process which has just been described. In this case - No. 31 - both appendages were reported as grossly diseased and the tubes have been described under nodular salpingitis. The section of ovary examined showed a large blood cyst lined with lutein cells. No tubercles were seen on the surface or in the cortex. A number of small tubercles and a few calcified areas were present, however, in the hilum of the ovary. These were grouped together in the central part of the hilum, near the point at which it had been divided. Tubercles in this situation can only have spread by the blood stream or the lymphatics, more probably the latter. There was no evidence of the route followed in the section examined. The lesion appeared to be longstanding and not actively progressive.

There is no case in this series of the form of ovarian tuberculosis usually called primary. This is usually reported in cases about or shortly after puberty and is unaccompanied by tubal involvement. It is in this form that the ovarian abscess usually attains the largest size.

Ovarian Cysts and Tuberculosis.

Ovarian cysts were described at operation in cases 5, 15 and 67, and broad-ligament cysts in cases 8, 13, 35, 36 and 52. Only in case 15 was a section available for histological examination and this showed the cyst to be a typical pseudo-mucinous cystadenoma. The section showed no evidence of tuberculosis. Tuberculosis of ovarian cysts is of extreme rarity. Nielsen (1934) reported a case of tuberculosis in a multilocular ovarian cyst. The tubes and peritoneum were normal and the infection was believed to be haematogenous. This is apparently the only recorded case of isolated tuberculosis of an ovarian cyst. Jameson states that 55 cases have been reported in which ovarian cysts were involved in a secondary infection.

Changes in the Ovaries associated with Tuberculosis.

The question of changes in the ovaries associated with tuberculosis in the genital organs and elsewhere has received some attention in the literature. This is of interest because of the endocrine changes which may be associated, directly or indirectly, with tuberculosis and which may be shown by alterations in menstruation. Also, an attempt has been made to ascertain whether or not there is any characteristic pathology in the ovaries removed from tuberculous women.

While the ovaries removed from cases of extra-genital lesions, usually pulmonary tuberculosis, are free from the influence of local pelvic disease, it must be remembered that they are usually post-mortem specimens. Specimens are more frequently obtained at operation in cases of genital tuberculosis, but in these cases the disease is usually less severe and exerts a less profound general influence.

The feature to which most attention seems to have been directed is the occurrence of cystic change in the ovaries. Berkeley (1903) states that cystic degeneration is present in the ovaries in over 50% of cases of genital tuberculosis. Moench (1923), speaking of tuberculosis in general, notes a frequent association with cyst formation in the ovaries. From

a study of the ovaries of tuberculous women examined at autopsy, from the state of the ovaries described in reported cases of uterine and tubal tuberculosis, and from the examination of the ovaries of guinea-pigs showing no other lesions in the genital tract, Jameson (1935) is led to believe that a sclero-cystic condition with numbers of atretic and unruptured follicles is almost always present.

Description of the Ovaries in this Series.

In this series, the material which was available consisted of the operation reports in 60 cases in which the abdomen was opened, sections of one or both ovaries in 31 cases and the reports of histological examination of the ovaries in six cases. In 12 cases, one or both ovaries were described as cystic at operation. Follicular cysts and atretic follicles were seen, or reported to be present in the sections of ovary examined, in ten cases. The total number of cases in which definite micro-cystic degeneration may be said to have been present was 18 (30%). In five further cases one or two small cystic or atretic follicles were present. Although these figures are not complete and probably represent a minimum, they do not confirm the statement that in nearly every case of pelvic tuberculosis there is associated follicular cystic

degeneration of the ovaries. A comparable series of cases of other forms of pelvic inflammatory disease in the same age groups would almost certainly show at least an equal number of cystic ovaries. The usual causes of the formation of atretic follicles are probably pelvic inflammatory diseases, of which tuberculosis is one, and pituitary dysfunction. The latter may be one of the systemic effects of tuberculosis and may thus account for the occurrence of cystic degeneration in the absence of local lesions.

Influence on Endocrine Function.

The presence of cystic and atretic follicles in the ovaries may be associated with a hypersecretion of oestrin and this may in turn give rise to menstrual disturbances. The best example of this is the condition known as metrorrhagia haemorrhagica. It has been suggested that this may be the cause of the metrorrhagia and menorrhagia which is present in some cases of tuberculosis, both general and pelvic. There seems little doubt that an endocrine disturbance of this nature is a factor in some cases of pelvic tuberculosis with these symptoms. It has not been proved, however, and it is difficult to assess the relative importance and the exact relationship of the tuberculosis and the alteration of ovarian function.

In the above 18 cases where cystic degeneration of follicles was found to be present, the menstrual history was as shown in the following table. The number of cases with similar symptoms in the whole series is also given for comparison.

TABLE III.

	18 Cases with Cystic Ovaries.		Whole Series	
	No. of cases.	Percent- age.	No. of cases.	Percent- age.
Within the limits of "normal".				
Cases 2, 9, 10, 13, 23, 33, 42, 52, and 59	9	50.0	31	44.9
Definite Menorrhagia				
Cases 12, 22 & 68	3	16.7	14	20.3
Metrorrhagia				
Cases 3, 5 & 55	3	16.7	6	8.7
Menorrhagia & Metror- rhagia, including Epimenorrhoea				
Case 34	1	5.6	4	5.8
Amenorrhoea				
Case 11	1	5.6	9	13.0
Hypomenorrhoea				
Case 17	1	5.6	5	7.3

The relatively high incidence of metrorrhagia and

low incidence of amenorrhoea in the cases with cystic ovaries would have been of more significance if the number of cases had been greater. Actually, a little further investigation shows that the above figures convey a wholly erroneous impression. In cases 3 and 55 there had only been a single haemorrhage. In cases 25 and 34, the bleeding was of a type associated with a continued hypersecretion of oestrin and the appearance of the endometrium was not inconsistent with this but in both cases tuberculosis of the endometrium was present. Less can be said about the cases of menorrhagia but in case 22, the endometrium was densely infiltrated with tubercles.

Case 67 has not been included in the above 18 cases because there is no proof of follicular cystic change in the ovaries, though its existence must be strongly suspected. The patient's age was forty-one and menstruation previously $3/28$ had been $\frac{2-3}{14-21}$ for one year. The ovarian cyst described in the operation report was apparently a portion of dilated tube and the other ovary was enlarged but so densely adherent that it could not be removed. The pelvis and lower abdomen were filled with very dense adhesions. The history suggests a condition similar to metropathia haemorrhagica. The uterus was not removed and the

endometrium was not examined. If the cause of the epimenorrhoea was of this nature, it was a direct result of the dense adhesions surrounding the ovaries and preventing the normal rupture of Graafian follicles.

Poncet and Leriche, Violet and Polloson (cited by Mench (1923) and Jameson (1935)), have put forward a theory that the micro-cystic degeneration of the ovaries in these cases is actually a tuberculous process. This has been given the name of "tuberculose inflammatoire". They hold that this may, under certain suitable conditions, assume the typical and rapidly spreading form of the disease. This theory is not generally accepted and it is not supported by any of the known facts. Typical tuberculosis does occur in the ovaries and there is no reason to believe that the disease should also occur in such an atypical form. Microcystic degeneration, also, is frequently found in the complete absence of any evidence of tuberculosis.

The Ovaries in Extra-genital Tuberculosis.

In a study of the ovaries of women who had died of extra-genital tuberculosis, Petrova (1932) described the following changes. In 3.5% there was a complete lack of primordial or developing follicles. In 64% there was a comparative reduction in the number of

primordial follicles. In 32% there was a complete lack of ripening follicles. There was evidence of epithelial degeneration in the primordial follicles and the ova showed degenerative changes.

In this series, out of 36 cases below the age of 41, there were eight, or 21.6%, in which there was thought to be a diminution or absence of primordial and developing follicles. None of these cases had amenorrhoea, three were normal and five had menorrhagia. Cystic change was also present in four.

The ovaries examined in this series of cases did not show any constant change attributable to the presence of tuberculosis.

PATHOLOGY OF
TUBERCULOSIS OF THE BODY OF THE UTERUS.

Tuberculosis of the body of the uterus ranks next to the tubes in order of frequency. It is, however, far from being a common lesion. The frequency with which it is found as a gynaecological lesion is difficult to estimate, as few figures are available. In the examination of 1500 specimens of material removed by curettage, Martin (1935) found 22, or 1.4%, to be tuberculous. This figure may be rather low because the uterus is not examined in all cases of pelvic inflammatory disease. This fact must also be borne in mind in estimating the relative frequency with which the uterus is involved in genital tuberculosis.

Jameson (1935) suggests 50%. Norris (1933) 35-50% and Frank (1931) quotes White's figure of 53%. In Greenberg's (1921) series of 200 cases of tuberculous salpingitis, the uterus was involved in 45% of the whole but 72.6% of the hysterectomies. In a similar series of 52 cases, Bush (1933) found tuberculosis in 48% of the 31 uteri examined but he considers that the figure would have been higher had more uteri been examined.

In this series of 69 cases there were 25 examples of uterine tuberculosis, a percentage of 36.2. This

does not include four cases in which tubercles were present on the peritoneal surface, in three of which the uterus was not examined further. These would raise the percentage to 42. The uterus was removed or curetted in 45 cases and, of these, 25, or 55.5%, were proved histologically to be tuberculous. Thus, it seems safe to say that the uterus is involved in at least 50% of cases of genital tuberculosis. The 45 cases do not include case 2, in which the uterus was removed one year after the tubes because the second operation revealed no evidence of pelvic tuberculosis.

For purposes of description, tuberculosis of the uterus is usually divided into two forms - the miliary and the ulcero-caseous. These represent, in fact, different stages in the progress of the disease. A hypertrophic and an interstitial form have also been described.

1. The Miliary Form.

In the miliary form, tubercles are usually discovered only when histological examination is carried out. Occasionally, they may be visible to the naked eye, on section of the uterus. The lesion does not cause any alteration in the form or size of the organ. Tubercles are usually confined to the endometrium but

may be present in the myometrium also. Involvement of the myometrium without the endometrium is probably very rare, if it ever does occur. In discussing the spread of infection from the tubes, reference has already been made to the fact that the tubercles may be most numerous in the region of the uterine cornu.

On histological examination, the tubercles are usually found to be typical in form. In the endometrium they are situated in the interglandular stroma and may be closely related to the glands. The tubercles are usually most numerous in the functional layers but the whole endometrium may be involved. As a cause of the spread to the deeper layers, Jameson suggests stasis in the uterus, and Schröder (1921) suggests menstruation. If the disease is progressive, with confluence of the tubercles and widespread caseation, the condition assumes the ulcero-caseous form.

In addition to the presence of tubercles in the endometrium, there may be some hyperplasia and irregularity of the glands and some infiltration of the stroma with lymphocytes. The glandular epithelium may show marked degenerative changes.

Cases of the Military Form. In this series, 19 cases have been classified as belonging to the military form. In two cases, the classification was made on

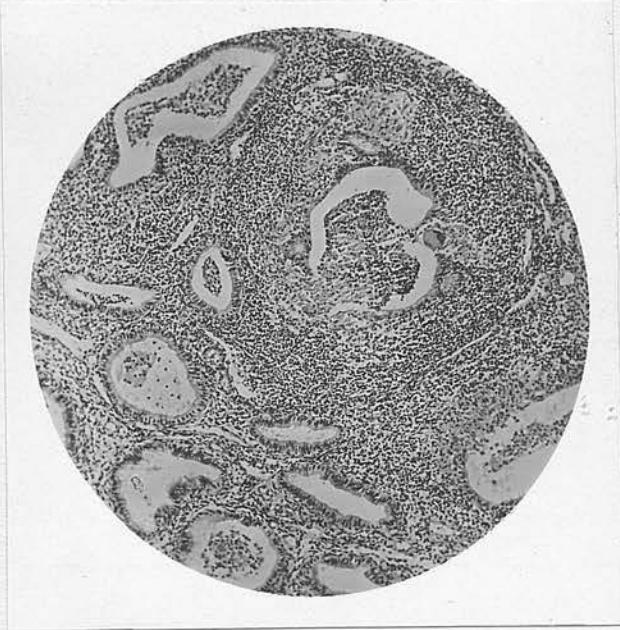
the pathologist's report, and in the remainder on the sections which were available for histological examination. In eleven of the cases the uterus was removed and in three of these, tubercles were found in the myometrium. In one of these, tubercles were not seen in the endometrium.

Excluding the two cases in which sections were not available, the 16 examples of miliary tuberculosis of the endometrium fall roughly into three groups. The largest of these, numbering eight cases, consists of all those in which the appearance of the endometrium was that of the proliferative, secretory or menstrual phases - Nos. 3, 19, 28, 30, 34, 41, 47 and 48. In all of these the infection was moderate in severity. In no case were the tubercles scattered diffusely throughout the endometrium but appeared to be gathered together in small groups. The tubercles were most numerous and largest in that part of the endometrium corresponding to the spongiosa. Those near the surface tended to be much smaller. In five of the cases some or all of the tubercles were definitely related to glands. In one or two instances the appearance was that of a gland in process of destruction, ringed round with tubercles, while in others the tubercles could be seen spreading in the long axis

of the gland.

Illustration No. 14.

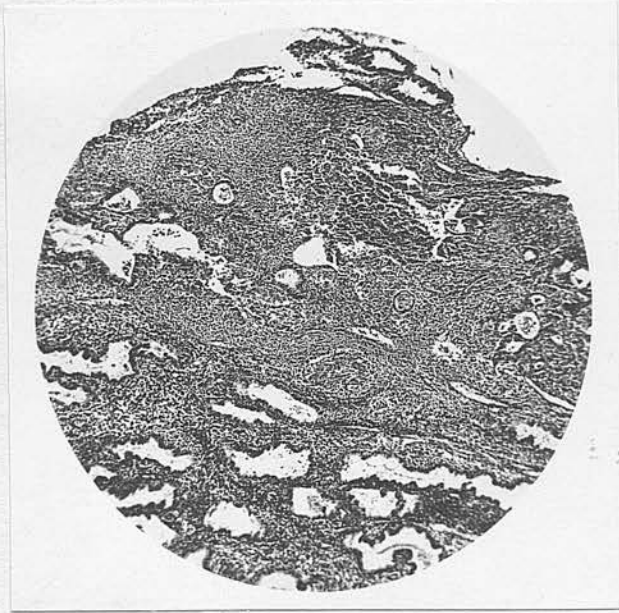
Miliary Tuberculosis of Endometrium.



Case 28.

x 60.

Showing tubercles surrounding gland which shows marked degeneration. Rupture has taken place into lumen. Secretory phase.

Illustration No. 15.Miliary Tuberculosis of Endometrium.

Case 3.

x 30.

Showing somewhat diffuse infiltration in long axis of gland. This consisted mostly of lymphocytes but contained a few epithelioid cells and giant cells. This was the only evidence of tuberculosis in the section. Secretory phase.

One case in this group was bleeding at the time of operation and the appearance was that of a menstrual endometrium. In the others, slight general lymphocytic infiltration, abnormal density of the stroma with patchy fibrosis and some epithelial degeneration

were noted. The general character of the endometrium in these cases is given in the table below, together with the form of menstruation at the time of operation.

TABLE IV.

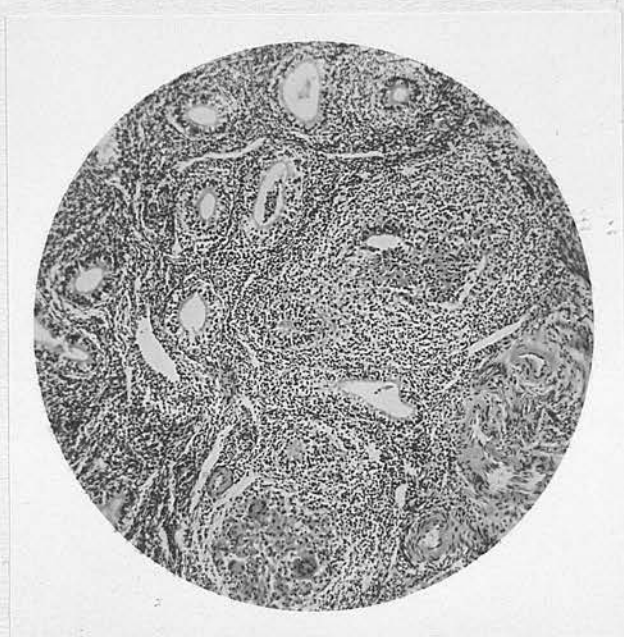
Case	Menstruation	Endometrium
30	Menorrhagia $\frac{7-10}{28}$	Early secretory phase but proliferative change well marked.
19	Menorrhagia $\frac{7}{14}$	Well marked proliferative phase.
34	Menorrhagia $\frac{9-10}{14}$ & Metrorrhagia	Late proliferative phase, well marked with recent interstitial haemorrhage. Last period 12 days previously.
28	Rather profuse $\frac{7}{26}$	Immediately pre-menstrual.
48	Scanty $\frac{7}{28}$	Early secretory phase with much recent interstitial haemorrhage.
3	Metrorrhagia	Premenstrual with fibrosis of stroma.
41	Rather profuse $\frac{4-5}{21}$	Stroma fairly dense and fibrotic.
47	Menorrhagia $\frac{5-14}{28}$	Menstrual.

In the second group, four cases - 6, 12, 17 and 36 - have been considered together because, in each, only one or two tubercles were present. The main interest lies in cases 12 and 17, because the specimens - uterine scrapings and section of uterine wall

respectively - were obtained immediately following a menstrual period. One or two small tubercles were seen in the material obtained by curettage from case 12 and the tubercles seen in case 17 are illustrated.

Illustration No. 16.

Miliary Tuberculosis of Endometrium.



Case 17.

x 60.

Tubercles in close proximity to myometrium.
Immediately post-menstrual endometrium.

These cases show that it is possible for infection of the endometrium to survive the changes of menstruation. The peri-glandular situation of the tubercles in certain of the cases already mentioned

might suggest spread from the basalis alongside the developing gland structure. On the other hand, the endometrium in those cases showed no tubercles in the basalis. It seems more probable that, in the majority of cases, a fresh surface infection from a diseased tube during the regeneration of the endometrium, may give rise to tubercles related to the glands.

In case 36, although not immediately post-menstrual, the single tubercle seen was in the basalis. The functional layers of the endometrium showed marked "toxic" change (see discussion later).

Of the other cases in this group, No. 6 is of interest, although the endometrium in the section examined contained only a single tubercle which was small and somewhat atypical. Menstruation was 7/28 and the last period was 25 days before operation but had come ten days early. Evidence of some premenstrual activity would have been expected but instead the endometrium was thin and showed marked interstitial fibrosis - "senile" appearance. The explanation lies in the clinical finding of severe bilateral tubal lesions, the illness being of fairly acute onset, and succeeded by amenorrhoea.

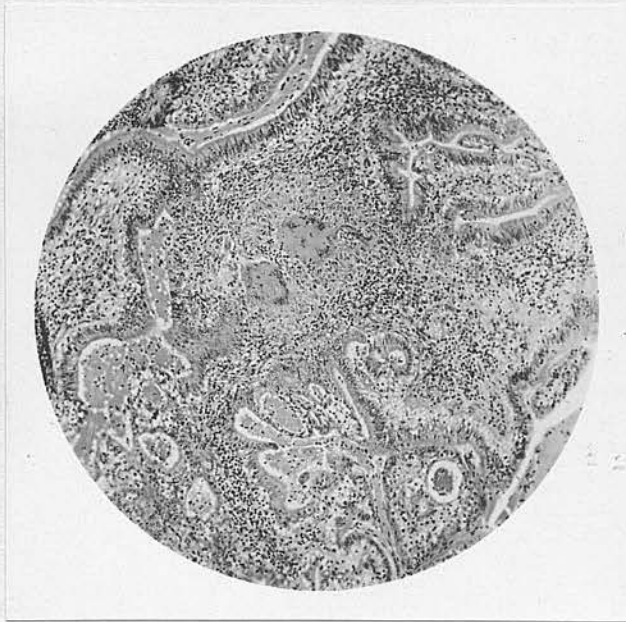
The remaining four cases which have been classed as miliary represent more extensive lesions, approaching

the ulcero-caseous form. One case - 25 - resembles those described in the first group, in that the tubercles were massed together and not scattered diffusely throughout. Some general lymphocytic infiltration was present. The dilated glands and the appearance of proliferation and epithelial hyperplasia are in accord with the metrorrhagia which was present.

There is a close similarity between the findings in the last three cases - Nos. 4, 11 and 27. In the first there was hypomenorrhoea and in the last two, amenorrhoea. In the sections from these cases the endometrium was thin and atrophic. There was general lymphocytic infiltration, interstitial fibrosis with inactive, and, in places, degenerated glands. In all three, there were widespread scattered tubercles. In case 4 these were small, while in case 27, they almost replaced the stroma in some areas. (This last case might possibly have been classed as ulcero-caseous.) From the description given, the endometrium in case 60 was similar in appearance. Amenorrhoea was also present in this case.

Illustration No. 17.

Miliary Tuberculosis of Endometrium.



Case 11.

x 60.

Showing atrophic endometrium with marked fibrosis, extensively infiltrated with lymphocytes and numerous tubercles.

The appearance of the endometrium in these cases was similar to that seen in case 6. It must be noted, however, that none of them was acutely ill and that in no case was an adnexal lesion of like severity present.

No slides being available, cases 54 and 50 have been placed in the miliary classification on the description given, the endometrium only being involved.

In cases 11, 44 and 48 tubercles were present in the myometrium. These cases will be discussed later.

The four cases in which tubercles were present on the peritoneal surface, and in which the uterus was not removed or found to be free from disease, have not been included. They do not represent true uterine tuberculosis.

2. The Ulcero-Caseous Form.

In the early stages minute ulcers appear on the surface of the endometrium. As the condition advances, the ulcers enlarge and become confluent. A stage may be reached in which the endometrium is almost completely destroyed and the uterine cavity occupied by caseous material. The ulcers have been described as round or ovoid, with an indurated edge and irregular base covered with caseous material. If the cervix becomes obstructed, pyometra may result.

Microscopically, the surface epithelium is seen to be lost and the surface covered with caseous material. The endometrium is more or less replaced by tubercles and tuberculous granulation tissue in which are the remnants of glands and stromal elements.

The myometrium is frequently involved in uterine lesions at this stage. One or two miliary tubercles

only, may be present or the wall may be extensively invaded by tubercles and caseation may occur. There is fairly general agreement that the tubercles in the myometrium usually derive from the endometrium via the lymphatics. On histological examination, isolated tubercles, typical in appearance, may be seen lying between the muscle bundles or there may be extensive direct invasion of the wall from the uterine cavity by tuberculous tissue. A few cases have been reported in the literature in which the uterine wall was distorted by the presence of a large cavity, filled with caseous material.

Cases of the Ulcero-Caseous Form. This series of cases contains one definite example of the ulcero-caseous form - case 7. Cases 16 and 22 have been tentatively placed in this category also, and case 26 on the description given as no sections could be obtained.

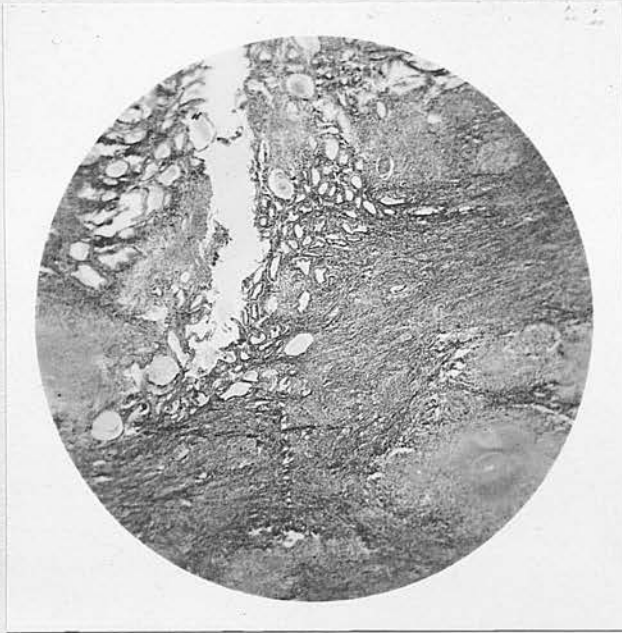
Cases 16 and 22 have been included because there appeared to be superficial ulceration of the endometrium in the sections examined. In case 16 the tubercles were grouped together in the deeper layers and the remainder of the endometrium showed marked "toxic" change. In case 22 the tubercles were more diffuse (see Illustrations Nos. 20 and 21). In both

cases, tubercles were present in the myometrium.

In case 7, the appearance of the endometrium closely conformed to the description given for the ulcero-caseous form. Tubercles and caseous masses were present in the myometrium. This case occurred in a woman past the menopause. Amenorrhoea had been present for seven years.

Illustration No. 18.

Ulcero-caseous Uterine Tuberculosis.



Case 7.

x 10.

Very low-power view showing destruction of endometrium and caseous masses in myometrium. Post-menopausal uterus.

Tuberculosis of the Myometrium, with Description of Cases.

The discussion of tuberculosis of the myometrium has been deferred so that all the cases could be considered together. The myometrium was involved in cases 7, 11, 16, 22, 44 and 48. Of these, cases 11, 44 and 48 were classified as miliary, the remainder as ulcero-caseous. Since the uterus was not removed in case 26, the myometrium was found to be involved in all the ulcero-caseous cases in which it was examined.

In the presence of widely scattered tubercles elsewhere, the calcified areas, with giant cells and lymphocytes, in case 11 were undoubtedly due to healed, or healing tuberculosis of the myometrium.

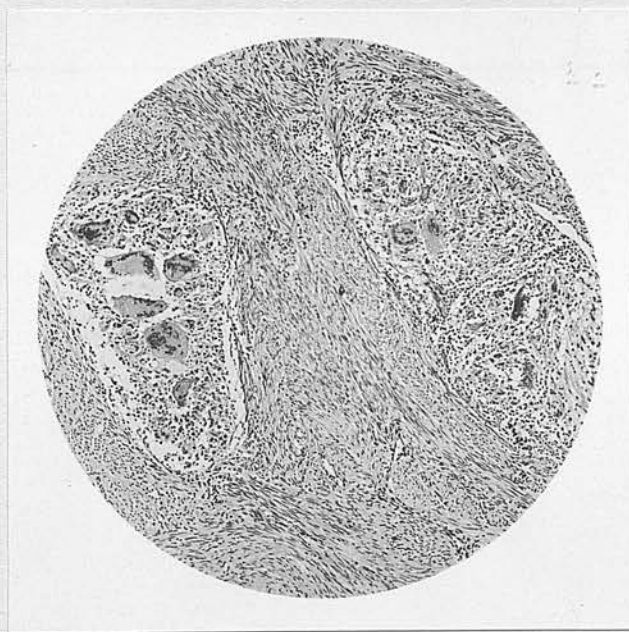
Two miliary tubercles were noted in each of the cases 22, 44 and 48. These were situated in the inner third of the muscular wall. Although tubercles were not present in the endometrium in the sections examined from case 44, the similarity in the position of the tubercles suggests that they were derived from the endometrium in the same manner as in the other cases. In case 16 the infection was much more extensive. Some of the tubercles were fairly large but no caseation was seen. In this instance, the tubercles were almost entirely confined to the inner half of the wall.

In one or two places, the tubercles could be seen spreading directly into the wall from the endometrium but the great majority were quite separate.

In case 7 the myometrium contained both scattered tubercles and caseous masses. Many of these had no visible connection with the lesions in the endometrium.

Illustration No. 19.

Tuberculosis of Myometrium.



Case 16.

x 60.

Showing two miliary tubercles in uterine wall.

Jameson states that distinct tuberculous nodules are not found in the myometrium. The tubercles in

these cases were, however, well-formed and typical. In his case, Brown (1931) noted that some of the tubercles in the myometrium were related to spaces lined with endothelium, which he thought to be lymphatics. Both Schütze (1907) and Kückens (1932) give a careful description of tubercles in close relation to the lymphatics in the myometrium. In cases 16, 22 and 44, the appearance of some of the tubercles was very similar to that described by these authors. It is generally agreed that infection of the myometrium spreads from the endometrium by the lymphatics in nearly every case. Cases such as number 44 in this series, in which the endometrium was not seen to be involved, suggest that infection may have been by another route. It is difficult, however, to be certain that the endometrium was free from disease. In case 44, there were tubercles on the peritoneal surface of the uterus but these showed no tendency to penetrate the muscular wall. It is probably possible for the disease to spread direct to the myometrium from the tubes via the lymphatics (especially if the tubal lesion is "closed"). Brown (1931) suggested that this occurred in the case which he reported. In this, there were bilateral hydrosalpinges and no tubercles were seen in the endometrium.

In this case, the tubercles were situated mainly in the outer two-thirds of the myometrium (cf. the cases in this series).

3 & 4. Hypertrophic and Interstitial Tuberculosis
of the Uterus.

3. The hypertrophic, (of which the first account was given by Babès (1926)). He described the presence of masses in the uterine wall, sometimes projecting on the surface or into the cavity and producing distortion of the organ. The stroma of these masses contains caseous foci and masses of tuberculous tissue. The disease is found mainly in the myometrium but may involve the endometrium.

Doubt has been cast on the existence of this form as a separate entity because the appearance described closely resembles that of adenoma and adenomyoma infected with tuberculosis. (Jameson (1935); Norris (1933).)

4. The interstitial form. This can only be recognised microscopically. The appearance described is a diffuse infiltration of the muscular wall with lymphocytes and giant cells, tubercles being small

and scanty. Jameson suggests that the appearance might be due to lymphatic invasion of the wall and that it should not be considered as a separate form.

In case 66 the description of the section of the uterine wall is similar to that given above, but specimens were not available for examination.

Effects of Menstruation on Tuberculosis of the Endometrium.

The characteristic function of the endometrium lends a special importance to tuberculosis in that situation. What are the effects of menstruation on the disease? These cases show that tubercles situated in the basalis may survive a menstrual period. Tubercles are not, however, commonly present in this situation unless the endometrium is extensively involved. The position of the tubercles in the less severe cases showed that they would have been largely, if not entirely shed, at the succeeding menstrual flow. The small number of cases showing tubercles in a post-menstrual endometrium might suggest that it is uncommon to find the disease at this stage in the cycle. Unfortunately, the total number of cases is too small to warrant such a conclusion.

In the less severe cases the whole, or nearly

the whole, of the diseased tissue must be shed at each menstruation. The importance of foci in one or both Fallopian tubes has already been stressed, and in such cases the disease in the endometrium must be maintained by a fresh infection after each period. It is possible that a permanently infected area may be present in the region of the tubal opening. It seems reasonable to suggest that in such cases, infection of the endometrium may be intermittent, a point of importance if diagnosis depends on curettage alone.

Effects on Menstruation.

It will be seen later that increased bleeding - menorrhagia and/or metrorrhagia - is more frequently associated with tuberculosis of the uterus than with lesions of the adnexa and is therefore accepted as a symptom of uterine involvement. It has already been seen that the appearance of the endometrium in one case suggested endocrine imbalance with a hypersecretion of oestrin and that in some others, proliferation was well marked. This, however, is a general effect and does not explain the association of increased bleeding with tuberculosis of the endometrium. The additional factor must be the local degenerative changes with fibrosis of the stroma. In very advanced

cases, where the endometrium is completely destroyed, amenorrhoea must be present. In such cases the amenorrhoea is associated with severe disease and is a cause rather than a result of the lesion in the endometrium.

Influence of Stasis.

It has been seen that the local effect of menstruation on the endometrium must be regarded as a check to the progress of the disease. The four cases in this series with amenorrhoea and the one with hypomenorrhoea all had severe disease of the endometrium. In the post-menopausal case the lesion was very advanced and extended into the myometrium. This case must be accepted as an example of the effects of stasis. In the others, it is not possible to be so certain of the local influence of the amenorrhoea because this symptom is itself an indication of the general systemic effects of severe disease.

Jameson (1935) maintains that before tuberculosis can become established in the uterus, there must be some interference with free drainage from the uterine cavity. These cases were carefully searched for any indication of a possible cause of stasis other than amenorrhoea. In the majority none could be found.

The degree of stasis, if any, in retroversion and retroflexion of the uterus is doubtful. It was the only possible cause found and it was present in four cases, in three of which the lesion was of the ulcero-caseous form and, therefore, comparatively severe.

There can be no doubt that any impairment of drainage from the uterine cavity will influence the progress of the disease and cause it to be more severe. Tuberculosis of the endometrium may, however, exist in the absence of any obvious degree of stasis.

Possibility of Healing. Severe and extensive involvement of the uterus is rare, in contra-distinction to the Fallopian tubes, where severe lesions are not uncommon. Except in the presence of much lowered resistance, the disease tends to remain stationary rather than to progress. It is probable that complete healing may occur, especially if the tubal focus is removed. The lesions of the endometrium may disappear completely. In no case was calcification seen in the endometrium, nor is its occurrence there to be expected. Tubercles in the myometrium may become calcified as in case 11.

The Effects of Curettage on the Endometrium.

The diagnosis of tuberculosis of the uterus is frequently established by curettage and the operation may, in some cases, be carried out for therapeutic purposes. The histological examination of specimens removed after curettage is therefore of interest as illustrating the results which may be expected. Six such specimens were available in this series.

In three cases, the time which had elapsed since the uterus had been curetted was short. In each case, the specimen consisted of a section of the uterine wall including the endometrial surface. In cases 3 and 34 the interval was six and five days respectively. Both showed a thin layer of endometrium in the early stages of repair. In both, there was a generalised infiltration with lymphocytes. In case 34 a number of these cells were grouped together round the base of a gland, but in neither case was there definite evidence of tubercle formation. In case 48 the interval was seventeen days. In spite of the longer interval the endometrium was very thin and showed little evidence of repair. There was lymphocytic infiltration but no tubercles were present.

In these three cases, the material removed at curettage showed a miliary lesion, in a pre-menstrual

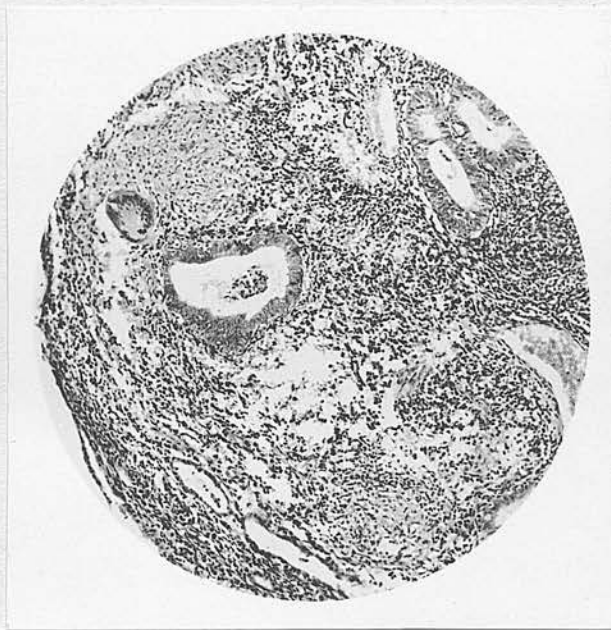endometrium. As far as could be judged from the sections examined, all the diseased tissue had been removed at the operation.

In three cases, the second specimen was obtained after a greater length of time.

It is only in case 22 that the first specimen was available. This showed an extensive infection, classed as ulcero-caseous, and the section which was obtained three and a half years later showed a state of affairs which was striking in its similarity.

Illustration No. 20.

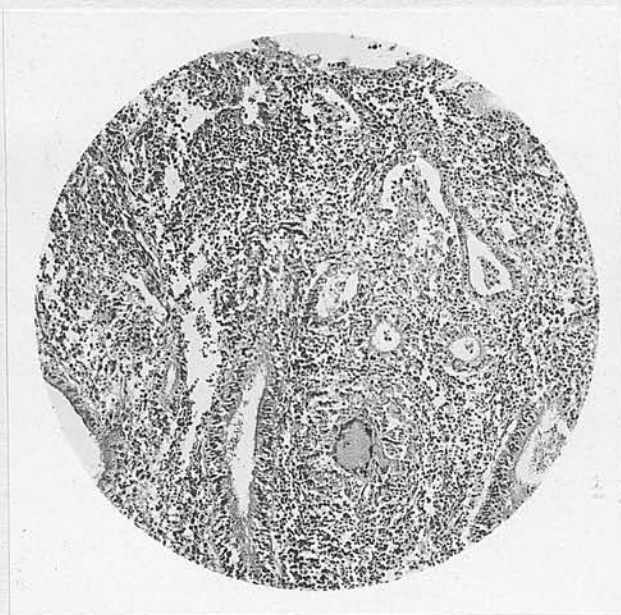Tuberculosis of Endometrium.



Case 22.

x 75.

Specimen obtained by curettage showing
ulcero-caseous lesion.

Illustration No. 21.Tuberculosis of Endometrium.

Case 22.

x 75.

Specimen from the same case obtained by hysterectomy, $3\frac{1}{2}$ years after the curettage, showing closely similar appearance to No. 20.

The remaining two cases had been curetted prior to admission and the condition present at the operation is unknown. Case 16 had been curetted about six weeks before the uterus was removed. The endometrium showed marked "toxic" change, with degeneration of the superficial layers, and it was noticeable that the tubercles were most numerous in the deeper layers. In case 34 it has already been mentioned that curettage showed a

miliary infection in a pre-menstrual endometrium. In this case, the uterus had been curetted one year prior to admission.

The immediate effect of curettage is to remove all, or the greatest part, of the diseased endometrium. It cannot be said that the whole of the infection is removed though no tubercles were visible in the post-operative specimens. In any case, the presence of a focus in the tube would nullify such a result, even if it were achieved. In case 16, the extensive involvement, especially of the deeper layers of the endometrium, was probably partly due to the operation. No other endometrium examined showed such a massive infection of the deeper layers.

Whatever may have been the immediate result of the first operation in case 22, the ultimate result was a return to the original state of affairs.

Changes in the Endometrium associated with Tuberculosis.

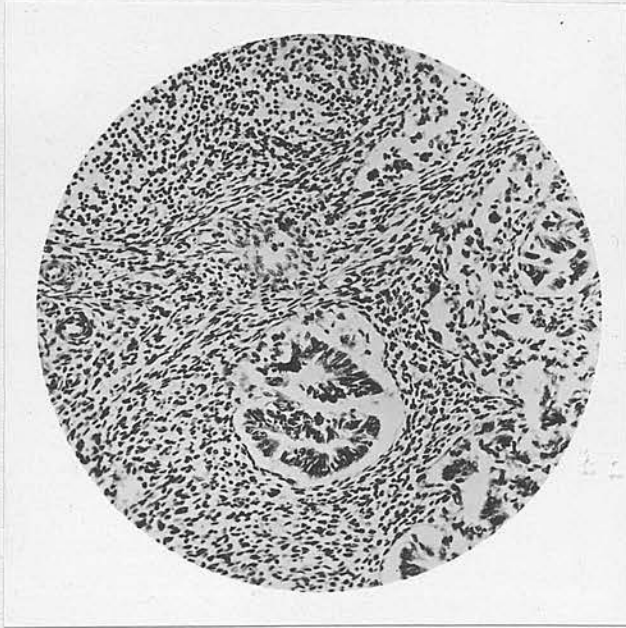
Seven cases in this series showed an appearance on histological examination of the endometrium which has been noted by Jameson (1935). These cases, Nos. 8, 16, 23, 33, 35, 36 and 46, showed marked degeneration of the glandular structures and, in the stroma, round-cell hyperplasia and fibrosis. Jameson states

that this appearance has been seen in the endometria of women dead of pulmonary tuberculosis and in infected guinea pigs, that it has been termed "toxic endometritis" for want of a better name, and that it may exist with or without infection of the genital tract, including the endometrium. In the cases mentioned above, there was evidence of pulmonary tuberculosis only in case 16. In cases 16 and 36 tubercles were present in the endometrium, in the others none were seen.

The condition is reported in association with severe pulmonary tuberculosis but, in this series, there was no apparent relationship between its existence and the severity of the disease. The appearance illustrated from a typical case is almost identical with that illustrated by Jameson from a case dead of tuberculous peritonitis and pneumothorax.

Illustration No. 22.

"Toxic Endometritis"



Case 23.

x 130.

Showing characteristic appearance of degenerate glandular epithelium and infiltration with lymphocytes.

The histo-pathology of the endometrium in such cases has been studied by Petrowa (1932). The changes which he noted were:-

1. Absence of a definite functioning layer.
2. Unusually strongly positive reaction of the basal layer glands to mucicarmine.
3. Marked hyperplasia of the basal layer in comparatively young women.

4. Sclerosis of the mucosa, and

5. Cystic degeneration of the basal layer glands.

He considered that the changes were due to general tuberculous toxæmia and disturbance of ovarian hormonal activity.

Adenomyomata of the Uterus and Tuberculosis.

Case in this series.- Of the various pathological conditions which may be found in association with uterine tuberculosis there is an example of one in this series. In case 63, the two adenomyomata present were found to be the seat of extensive tubercle formation. This case was fully reported at the time by Professor Johnstone (1924). There were two diffuse adenomyomata of the posterior wall of the uterus, the larger of which was about the size of a plum. Both tumours were infiltrated with tubercles. "The distribution of these appears to be mainly but not exclusively in the cellular mantle of the glandular elements. Both the glandular elements and the tubercles are most numerous in the left and larger tumour and the tuberculous infection is most noticeable in the part of the tumour nearest to the endometrium and the cavity of the uterus. The section, which includes part of the endometrium, shows clearly the inflowing of the endometrium

into the adenomyomatous tissue and proves clearly the endometrial origin of this adenomyoma." Tubercles were also present in the endometrium and the muscular wall. There were cornual swellings of both tubes and in that on the left side, tubercles were present.

No sign of peritoneal involvement was discovered and the infection appeared to be more advanced in the uterus than the tubes. The case was regarded as a probable example of blood-borne infection of the endometrium from a pulmonary focus. (The physical signs suggested an old, inactive lesion at one apex.) Spread to the uterine wall had then taken place. Aided by the glandular prolongations, the infection gained ready access to the tumour, which appeared to be an area of diminished resistance.

Professor Johnstone points out that, although adenomyomata are not protected by a capsule as is the case in fibromyomata, infection is of very rare occurrence. He describes six cases of tuberculous infection of adenomyomata in the literature. They were reported by von Recklinghausen (2 cases); Hösli, Lichtenstern, Archambault and Pearce (endometrium not involved), and Grünbaum (tubercles not found in tubes). In the last three of these cases, the tuberculosis was held to be secondary

to the tumour and in the last two it was regarded as a blood-borne infection.

Cases in the Literature.- Up to the present time, it has been possible to find the reports of eight other cases in the literature. Dickson (1906) states that no example of infection was discovered in 1800 myomata examined. He reports a case in which five myomata and one adenomyoma were present, all the seat of tuberculosis. Tuberculosis of the tubes and endometrium was present and he considered that the infection had descended from the tubes to the endometrium and had then reached the tumours via the lymphatics. In his case, Schütze (1907) noted tubercles in the walls of lymphatics in the myometrium. A case was reported by Heesch in 1928. Stewart and Oldfield (1932) reported a case in which a diffuse endometriosis was present, widely infiltrated with tubercles. They suggest that tubercles seen in the myometrium, apart from the glandular elements, were due to the plane of the section. The endometrium was also involved and an obsolete tuberculous salpingitis was present. The infection was obviously secondary to the presence of the tumour.

An apparently isolated infection of an adenomyoma of the posterior wall of the uterus was reported by

Vaux (1932). No tubercles were found elsewhere in the uterus, but the tubes were not completely removed. Kücken's (1932) case was a myoma in which he noted that tubercles were definitely related to lymphatics. The tube and endometrium were involved. He also reported an infected adenomyoma of the cervix. A case similar to that of Stewart and Oldfield was reported by Clara Stewart in 1933. The tubercles were related to the islets of glandular tissue and both the endometriosis and tuberculosis were most marked in the inner third of the myometrium. One discrete nodule of adenomyoma near the surface of the uterus also contained tubercles. Advanced disease of the endometrium was present.

Rigdon (1933) reported a case in which the uterus contained a fibroid and a large, diffuse adenomyoma. Almost all the adenomyomatous tissue contained tubercles situated around the glandular elements. There was extensive tuberculosis of the endometrium and the endometrium extended into the uterine wall in places. The tubes were also involved and he was of the opinion that this was the initial lesion, infection having reached the adenomyoma by direct extension in the endometrium and glandular tissue.

The most recent case was that reported by Lash (1934). Several adenomyomata containing tubercles

were present in the uterus. In a number of places the endometrium showed a marked tendency to penetrate deeply into the myometrium. Both the endometrium and several of these areas of diffuse adenomyosis contained tubercles. Advanced disease of the tubes was found and this was regarded as the initial lesion, spread having taken place to the endometrium and thence to the adenomyomata.

Relationship of the two conditions.- With regard to these cases, there has been some discussion as to which is the primary lesion, the tumour or the tuberculosis. In the tubes and cervix, tuberculosis is accompanied by a tendency to epithelial hyperplasia. In the endometrium this is a less prominent feature because of the cyclical change. It has been suggested, however, that the presence of the tuberculosis is the stimulus to the formation of the tumour. This seems most unlikely. The available sections of the junction of the endometrium and myometrium, in this series, were examined for evidence of penetration by the endometrium. In one or two cases this was present to a moderate depth and in a large number there was slight penetration. It was only in the post-menopausal case, however, that tubercles were associated with the penetrating glands. It is almost certain that, when tuberculous

infection of an adenomyoma is present, it is secondary to the presence of the tumour.

Tuberculosis usually, if not always, reaches the endometrium from lesions of the tubes and may spread thence to the myometrium, by the lymphatics. It is possible that, in a few cases, the myometrium may be involved by direct lymphatic spread from the tube. Normally, the myometrium is resistant to infection. If, however, it contains aberrant endometrial elements, whether diffuse or circumscribed, these provide areas of diminished resistance. Infection may reach these by direct or lymphatic spread from the endometrium, depending on their situation. Direct lymphatic spread from a tubal lesion might be considered in the absence of disease of the endometrium, but only if its absence both in the past and present, is beyond doubt. It is also possible that, in certain cases, infection of the adenomyomatous tissue may be from the blood stream. The fact that endometrial tissue is less resistant than myometrium is probably sufficient to account for the situation of the lesions in these cases. In addition, its resistance may be further lowered, in an abnormal situation, by defective circulation (Kückens, 1932) and impaired drainage.

Tuberculosis and Fibromyomata.

The association of fibromyomata and tuberculosis is probably accidental. The two conditions occur in similar age groups and fibromyomata are not uncommon. Of the 25 cases of uterine tuberculosis in this series, one had small multiple fibroids, one a small sub-peritoneal fibroid, and one had a fibroid the size of a pea. Tuberculous infection of fibromyomata is of extreme rarity.

Cetroni (1930) holds that the association of fibromyomata with tuberculosis of the genital tract is comparatively frequent and he considers that this is due to a hyperfunctional condition of the ovaries. In this whole series of 69 cases, fibromyomata were known to be present in nine cases.

PATHOLOGY OF
TUBERCULOSIS OF THE CERVIX.

Tuberculosis of the cervix is a very rare condition but the exact frequency with which it occurs is difficult to assess. The number of reported cases in the literature is not a reliable guide, because, with very few exceptions, these have been examples of the ulcerative or papillary forms which have been of clinical interest. Jameson (1935) believes that it is more frequent than is generally supposed. He points out that supra-vaginal hysterectomy is the operation usually performed for inflammatory conditions of the internal genitalia. He also considers that many cases are missed owing to the difficulty of histological diagnosis in the presence of a superimposed infection. Solomons (1923), White (1929) and Bishop (1930) also refer to this difficulty. It must be accepted, however, that tuberculosis is rare in this situation. In a thorough examination of 1200 cervixes removed, 777 of which showed inflammatory changes, Davis (1932) found one to be tuberculous. Spalding (1922) found one in 704 cervixes.

The cervix is involved in only a small percentage of cases of genital tuberculosis. In 74 tuberculous

specimens out of a total of 15,130 in the Obstetrical and Gynaecological Laboratory, University of Pennsylvania, Norris (1933) found the cervix involved four times. He quotes Späth, who found it involved six times in 119 tuberculous cases. From a series of autopsies, Berkeley (1903) gives a figure of 6.4%. In Greenberg's (1921) cases, the cervix was involved in 3.5%. In this series of 69 cases there are three examples, a percentage of 4.3. It must be noted, however, that the cervix was examined histologically in only six cases. The fact that 50% of the cervixes examined were found to be involved certainly suggests that a greater number might have been found to be tuberculous had more been examined. This gives support to Jameson's contention that the frequency is under-estimated.

The following pathological varieties of tuberculosis of the cervix are usually described:- (1) Miliary, (2) Interstitial, (3) Papillomatous, (4) Ulcerative. Other forms which have been described but are less generally accepted are: (5) Catarrhal, and (6) Inflammatory or para-tuberculosis. There is, however, a lack of uniformity in the descriptions applied to the various types.

1. The Military Form.

In the military form, the cervix may be normal in appearance or tubercles may be visible on the surface, which may be injected and may also show some tuberculous granulation tissue. On section, typical military tubercles are found and these may be situated in any part of the cervix. This form may be part of a generalised military tuberculosis or confined to the cervix.

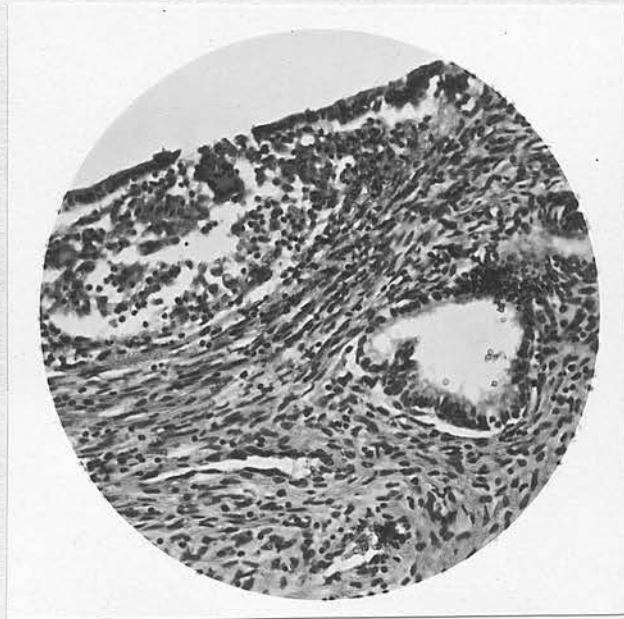
Moore (1919) apparently restricts the description of military to those cases showing tubercles on the surface, his description being based on his own case. Frank states that the earliest tubercles are always found beneath the epithelium, basing this statement on Cullen's (1916) case, in which a solitary tubercle was found in this situation. As Jameson (1935) points out, however, and as the following cases show, military tubercles may be found anywhere in the cervix and such cases must be described as military. This form represents the first stage of all cases in which typical tuberculous lesions are found in the cervix.

Cases of the Military Form. In this series, cases 11 and 16 are examples of the military form. In neither case is the naked-eye appearance of the cervix described, so there can have been no external evidence

of tuberculosis. The section of case 11 shows a tubercle near the surface, tubercles deep in interglandular stroma, and a tubercle about the mid-point of the muscular wall. In the sections of case 16 the tubercles are situated beneath the epithelium of the cervical canal. The illustration shows the smallest of these and the most superficial. The others were not in contact with the epithelium. The appearance in these sections is closely similar to that described and illustrated by Cullen (1916).

Illustration No. 23.

Miliary Tuberculosis of the Cervix.



Case 16.

x 140.

Showing tubercle beneath epithelium of cervical canal.

In both these cases lesions were present in the endometrium and myometrium. They prove that, in the secondary form at least, miliary tubercles may be found at any point in a cervix showing no gross evidence of disease. Both cases were unsuspected until histological examination was carried out.

Jameson believes that in this form, the disease is capable of undergoing resolution and healing. The histological appearance of the tubercles in case 11 indicated a tendency to fibrosis and healing. This is borne out by the clinical history. The patient had had fifteen months sanatorium treatment and made a good recovery after the operation, which included removal of a bilateral pyosalpinx. Had the cervix not been removed it would probably have healed completely.

2. The Interstitial Form.

The interstitial form of tuberculosis of the cervix represents a more advanced stage of the disease. Its only claim to be distinguished as a separate type from an advanced miliary lesion, lies in the alteration of the macroscopic appearance of the cervix. This is usually described as marked enlargement or hypertrophy, which may be regular and diffuse, or

irregular. The surface epithelium may remain intact (Frank, 1931), or tubercles may eventually appear, forming ulcers (Moore, 1919). Petit-Dutaillis (1913) holds that the appearance of the surface, "cet aspect mamelonné" is pathognomonic. Others (Norris, 1933) have described a form which commences as a single, deep, circumscribed nodule which eventually reaches the surface, with the formation of a single deep ulcer.

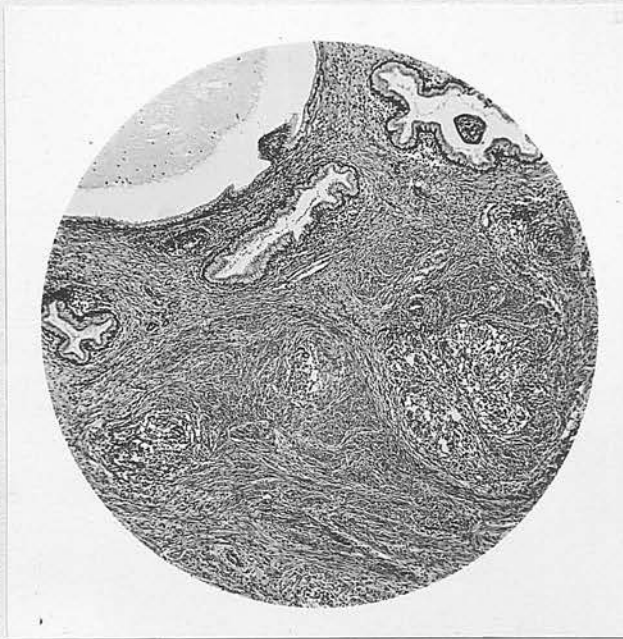
On histological examination, tubercles are found to be present, mainly in the muscular wall and deep in the sub-epithelial tissue. The tubercles tend to remain more or less discrete and may be diffuse throughout the cervix or confined to one or more circumscribed areas. Hyperplasia of the fibro-muscular tissue has been described as the cause of the cervical enlargement.

Case of the Interstitial Form. Case 8 has been taken as an example of the interstitial form. The gross hypertrophy of the cervix which was described and the surface changes may, however, have been due partly to chronic inflammation. It is interesting to note that the tubercles were in no way related to the area showing chronic inflammatory change, a fact which was also noted in case 16. The tubercles were most numerous in the more superficial layers of the fibro-muscular tissue and the appearance suggests that the

spread had been from this area, both deeply and towards the surface, one or two small tubercles being actually beneath the epithelium. The tubercles were diffuse, but, in the sections examined, were confined to that portion of the cervix covered by squamous epithelium. This case has already been mentioned as a possible example of ascending infection.

Illustration No. 24.

Interstitial tuberculosis of the Cervix.



Case 8.

x 30.

Showing tubercles in fibro-muscular tissue of cervix, not related to glands or Nabothian follicles.

Most of the cases reported in the literature belong to the ulcerative or papillary varieties. Some cases have been reported in which the two forms are combined. There are no cases of either form in this series.

3. The Ulcerative Form.

In the ulcerative form there may be a single ulcer or several. The ulcers may be small or there may be extensive destruction of the cervix, extending up to the internal os. In the earlier cases the ulcers are usually found in the region of the external os and extend on to the portio and into the canal. Ulceration is usually visible on the vaginal cervix but the process may be confined to the canal. In the case reported by Veyrassat (1934) there was a deep ulcer within the canal but the cervix was absolutely normal in appearance.

From the descriptions of this form and from individual case reports, it is difficult to find a description of the ulcers which can be accepted as typical. Some believe (Jameson, 1935) that tuberculous ulcers of the cervix have no characteristic appearance. The base is usually described as lightish in colour, grey or yellow, but it may be dark and beefy or red and

granular. The edges are usually sharp and may be undermined or swollen and irregular. Tubercles are only rarely visible on the base or at the edges. In what was evidently an early case of this form, Hauch (1934) described "pea-sized papules with ulcerated apices". The ulcers usually bleed easily but only slightly. The cervix is usually somewhat indurated but is said to lack the stony hardness and friability of carcinoma. At best, however, this is only relative and cases, such as Culbertson's (1924), have been reported in which the lesion was both stony hard and friable.

On histological examination, tubercles are found, usually in the tissue below the floor of the ulcer and, sometimes, round the edges. In the presence of secondary infection, the appearance may be quite atypical, and repeated examination may be necessary before the diagnosis can be established. The remaining portions of epithelium may show a tendency to hyperplasia.

4. The Papillomatous Form.

The papillomatous or papillary form also commences in the region of the external os, probably arising first in the lower part of the canal. It spreads within

the canal and on to the portio. It may appear as an erosion, the surface of which is papillary, or as a mass which may attain the size of an apple. The colour varies from pink to dark red and the surface may be covered with secretion or discharge. The mass may be cauliflower, polypoid or nodular. Rarely, the lesion may be confined to the canal. Moore (1919) states that pyometra may result from obstruction of the canal. The lesion is usually described as soft but not friable and bleeds easily to the touch. Moore describes a velvety feel and Watson's (1934) case felt almost diffluent. Cases have been described as tough, and some as definitely friable. Induration is not usually marked, but the remainder of the cervix may be enlarged and reddened. Ulceration may co-exist.

Microscopically, the stroma, within the papillae and around their bases, contains tubercles, which are usually typical unless secondary infection is severe. The glandular proliferation may result in an appearance resembling adenoma.

Condylomata of the Cervix.

In discussing condylomata of the cervix, Wharton (1921) describes a case due to tuberculosis. He quotes Maley, who states that it is the rarest form of

tuberculosis of the cervix. The cervix showed marked hypertrophy and the affected area was soft, not friable, felt like sarcoma and was tough to the curette. In Maley's case, the papillae were covered with cylindrical epithelium and in Wharton's, with stratified squamous epithelium. Beneath this was tuberculous granulation tissue which ended abruptly at a depth of 1.5 cm.

In the other two forms which have been described, typical tubercles were not found in the cervix and their existence is, therefore, open to question.

5. The Catarrhal Form.

The catarrhal form, described by Schütt, is said to be limited to the superficial epithelium and glands of the canal. In Schütt's case, the glands were filled with greyish masses, there was epithelial desquamation and sub-epithelial infiltration with lymphocytes. The case was diagnosed on the finding of tubercle bacilli in the tissue of the cervix (Moore, 1919). Only three other cases of this form have been reported.

6. The Inflammatory Form.

The inflammatory form, or para-tuberculosis of

the cervix, was described by Cotte. The cervix was hypertrophic with glandular hyperplasia, and showed no histological evidence of tuberculosis. According to Jameson, the diagnosis was established serologically, a method of which the accuracy is open to considerable doubt.

Details of Histology.

In the sections from these cases examined microscopically, the tubercles seen were typical and unmistakable. There is no basis for the statement that typical tubercles are not found in the cervix. In cases 8 and 16, the appearance in certain areas was typically that of a common inflammatory process, unconnected with the tuberculous infection. It has already been noted that tubercles were not present in the affected areas. It must be recognised, however, that severe secondary infection may so alter the histological picture that the presence of tuberculosis may not at first be recognised. Bishop (1930) reports a case in which the first biopsy was somewhat suspicious but inconclusive. It was only after the secondary infection had been cleared up that a second biopsy rendered the definite diagnosis.

In a cervix which is the seat of tuberculosis,

the glands commonly show a degree of hyperplastic change. This takes place in all forms of cervical tuberculosis and in this series was most marked in case 11. Moore (1919) states that the glands may become papillary, polypoid, or dendritic, and quotes Emmanuel, who states that the glands and stroma may hypertrophy, resembling adenoma. There is a suggestion of this appearance in case 11.

Douglass and Ridlon (1929) describe the changes due to tuberculosis in early cases as hypertrophic, proliferative, or vegetative, with only later the appearance of true tubercle formation. This statement cannot be accepted fully. If the cervix is, in fact, the seat of tuberculosis, tubercles will be present.

Frequency of different forms.

In cases 11 and 16, the miliary tubercles were intracanalicular, while in case 8, the interstitial lesion involved the vaginal portion of the cervix. In fourteen cases from the literature, where the position of the lesion was stated, the canal was involved in three, the vaginal cervix in two, and in nine both were involved or the lesion was stated to be at the external os. In an analysis of 68 cases from the literature, Beyea (1901) gives the following figures: canal, 6; portio, 19; and both, 43. While early

miliary tubercles seem to be most commonly found in the canal, it is probable that lesions of the ulcerative and papillary varieties usually start in the region of the external os. In advanced cases, combined involvement of both the vaginal cervix and the canal, is the most frequent finding.

Cases of the ulcerative and papillomatous forms of disease are of the greatest importance and clinical interest. It is, therefore natural that the majority of reported cases should be of these types. Cases of the miliary and interstitial forms are only likely to be discovered when operating for some other lesion. For these reasons, the figures usually given for the relative frequency of the different forms must be accepted with caution. In 22 cases from the literature there were: 1 miliary, 2 interstitial, 10 ulcerative, 8 papillomatous and 1 ulcerative and papillomatous. Chaton's figures are widely quoted. In 77 reported cases he found 7 miliary, 37 ulcerative, 22 papillary, 6 ulcerative and papillary, and 5 ulcerative and miliary. In a study of 106 cases, Norris (1931) found 7 miliary, 6 interstitial, 52 ulcerative and 41 papillary. He thinks, however, that, had the cases been examined earlier, the number of miliary, and perhaps of interstitial forms, would have been

increased.

Non-tuberculous cervices in this series.

In cases 2, 27 and 31, sections of the cervix were taken at the time of operation and these show no evidence of tuberculosis. In case 27, the only one of these in which the endometrium was involved, there is a suggestion of epithelial hyperplasia in the cervical glands.

In case 7, the cervical stump was removed eleven and a half months after the sub-total hysterectomy. The surface infection appeared to be of common type. The focal collections of lymphocytes which were present did not contain any epithelioid cells and there was no evidence of tuberculosis. This is of interest because the previous operation revealed advanced ulcero-caseous disease of the endometrium with tubercles in the myometrium.

Association of Tuberculosis of the Cervix with
Carcinoma.

In view of the hyperplastic and proliferative reaction which is shown in cervices which are the seat of tuberculosis, the association has aroused some interest. A few believe that tuberculosis predisposes

the cervix to malignant change. Gruenstein (1932) has reported a case in which tuberculosis was discovered by biopsy and treated by radium and X-rays. In six months time an inoperable carcinoma was found to be present. He considered that the carcinoma was secondary to the tuberculosis but, as Jameson points out, the carcinoma may have been present when the first biopsy was taken. Strachan (1924) believes that the association is accidental.
