

X RAYS AS A
DIAGNOSTIC AGENT
in
P H T H I S I S P U L M O N A L I S .

F. Gardiner, M.B., C.M., B.Sc.



This Thesis, which I present to the University of Edinburgh, for the degree of M.D., is the outcome of two different spheres of experience.

Being engaged in X Ray Work, as Clinical Assistant for a year in the Royal Infirmary, and at the same time at the Victoria Dispensary for Consumption and Diseases of the Chest, as Out-patient Physician, it was a natural sequence that I should think of the application of X Rays as a Diagnostic agent in Phthisis Pulmonalis. Gross Lesions were at once detected but soon it was observed that much more could be revealed - accordingly, for the last eighteen months, I have devoted a good part of my time to the subject.

APPARATUS.

As used in the Edinburgh Royal Infirmary. An Apps' Coil giving a 12 inch spark - with a Schall Motor Mercury Interruptor. These were worked by means of 10 storage cells charged by a Motor Transformer from the Edinburgh Main Current. Twenty-two Volts was thus generally available, and an Amperage of 18-20 on the Interrupted Current, was generally observed to be passing.

VACUUM TUBE.

For the first 6 months generally, a "Volt-Ohm" Tube supplied/

supplied by Isenthal of London, and latterly a "Hirschmann" Tube were used.

These tubes have generally a resistance equal to 5 or 6 inches of spark gap, and the X Rays produced, have great penetrating power- a desideratum in examining the Chest.

The whole Apparatus was in a darkened room, and 5 minutes at least was allowed to elapse before making any mental notes, as the tubes gradually improve after working for some minutes, and the eyes get accustomed to the darkness.

Beclère, in a paper read before the British Congress on Tuberculosis, 1901, recommends remaining ten minutes in the darkened room before starting observations.

I quite agree with him, and furthermore would like to emphasise the value of doing the work in the evening with the same end in view.

The Tube was fixed on the stand at the level of the patient's chest, and then the patient, having meanwhile been stripped to the waist, was placed right opposite its centre and an inch or two from it. The Reflector was then right opposite the middle line of the body.

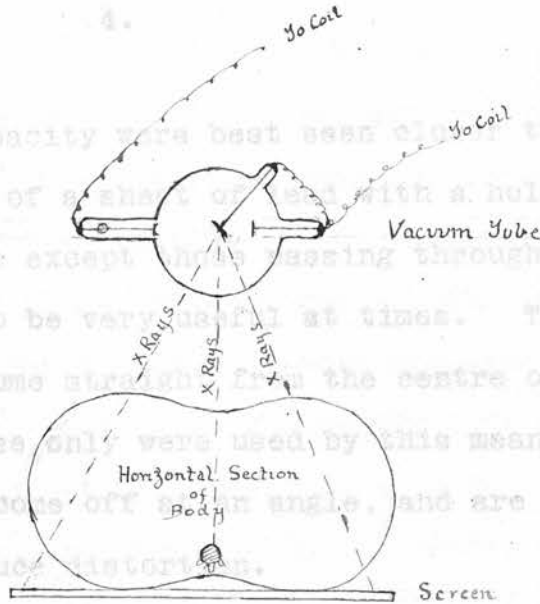
See/

Fisher/

3.

4.

See Diagram.



Another precaution found necessary, was to obliterate as much as possible, the shadow of the Scapula, by in-

The Screen was then placed flat against the chest, structuring the patient to hold his hands on his head, and the fluorescence and shadow were seen. Barium - and point the elbows anteriorly.

Platino - Cyanide was the fluorescent material used in after studying any opacities in the Lungs - the the screen.

Size, Position and Movement of the Heart was observed.

The posterior aspect of the Chest was first examined - and it occurred to me that a future field of research at various distances from the tube, and again with the might be, the watching the effect of Drugs on the Heart - tube at various levels. The anterior aspect was then giving these Drugs hypodermically.

examined similarly, so that all parts were gone over The slope of the Ribs on each side, and their move- seriatim.

ment when examined revealed in many cases, alterations

For a comparison of both Lungs from apex to base, accompanying diseased conditions of the lungs. the Tube was placed opposite the 4th Ribs, in the middle line, and the patient at 2 feet distance from it - this mostly, the movement of the Diaphragm was observed with a note of its position in rest. A degree of the throws the darker parts into greater relief as the light measurement of the movement as seen on the screen, with is weaker.

Finer/

Finer shades of opacity were best seen closer to the Tube, and the use of a sheet of lead with a hole in it, obscuring all rays except those passing through this hole, was found to be very useful at times. The most powerful X Rays come straight from the centre of the Reflector and these only were used by this means. The remaining X Rays come off at an angle, and are apt therefore to produce distortion.

Another precaution found necessary, was to obliterate as much as possible, the shadow of the Scapula, by instructing the patient to hold his hands on his head, and point the elbows anteriorly.

After studying any opacities in the Lungs - the Size, Position and Movement of the Heart was observed, and it occurred to me that a future field of research might be, the watching the effect of Drugs on the Heart - giving these Drugs hypodermically.

The Slope of the Ribs on each side, and their movement when examined revealed in many cases, alterations accompanying diseased conditions of the Lungs.

Lastly, the movement of the Diaphragm was observed with a note of its position in rest. A comparative measurement of the movement as seen on the screen, with the/

lying flat, either supine or prone
on the plate with Tube at some distance
above/

the patient at 2 feet distance from, and facing the Tube, was taken. The method adopted for this, was to mark in blue pencil on the Chest, the level at full inspiration and full expiration, and afterwards measure.

Thus in Routine Screen Examination I examined for

1. Loss of Translucency in any part of the Lung.
2. Alterations in the Heart.
3. Slope and Movements of Ribs.

At first 84. in Position and Movement of the Tube and the patient; but Diaphragm. working Tubes have been got, the distance has been increased to 18 inches with, I think, better results.

PHOTOGRAPHY

This was only used in some cases. special X Ray Plates POSITION OF PATIENT always used.

Two positions were at different times adopted - these again we (a) Patient sitting facing, or with film side (always kn back to the Tube, and the plate of the envelope) was pressed against the opposite aspect the X Rays acted on of the body, so that the rays had ARRANGEMENT OF TUBE to pass through the Chest wall to

This had to be the photographic plate. the centre of the Reflect (b) Lying flat, either supine or prone the body, and half was on the plate with Tube at some distance a/ above/

a weight and plumb above the patient. Latterly the
 Any displacement flat position with arms extended
 found to falsify the on either side of the head or
 DURATION OF EXPOSURE pointing out laterally, has been
 2½ - 3½ minutes always used. The arms were placed
 working state of the in the above position, to avoid as
 Chest. much as possible, the shadow of the

After exposure Scapulae were developed with
 DISTANCE OF TUBE the usual way, and fixed with Hyposulphite
 of soda. At first 6-8 inches was the space between the Tube
 and the patient; but as better working Tubes have been
 got, the distance has been increased to 18 inches with,
 I think, better results.

PLATESATIVE VALUE OF SCREEN AND PHOTOGRAPHIC PICTURE
 Edwards "Cathodal" or Lumieres Special X Ray Plates
 size 15 x 12 were always used. They are continually moving,
 and The Plates were enclosed in yellow envelopes and
 these again were placed inside black envelopes. The
 film side (always known by being opposite the flap of
 the envelope) was set next to the Chest wall so that
 the X Rays acted on it after going through the Chest.
 ARRANGEMENT OF TUBE developed and fixed, did not show, as
 accurate This had to be accurately placed with the centre
 of the Reflector, directly opposite the middle line of
 the body, and half way down the Chest, and to secure this

a//

a weight and plumb line were used. strongly upheld the

use of Any displacement to one side or the other was
found to falsify the result. later in a book on the

DURATION OF EXPOSURE published, Williams strongly states

his 2 $\frac{1}{4}$ - 3 $\frac{1}{4}$ minutes were allowed - depending on the
working state of the Tube, and the thickness of the
Chest. ular" of March 28th 1902 says:-

After exposure the Plates were developed with
Hydroquinone in the usual way, and fixed with Hyposulphite
of soda - the tendency being rather to over than under
develop, and this is a general experience. short exposures

"may avoid the faults due to respiratory movements,

"the disturbances due to the heart considerably lessen

COMPARATIVE VALUE OF SCREEN AND PHOTOGRAPHIC PICTURE the

"met During the two or three minutes of exposure the
Chest wall, Diaphragm and Heart are continually moving,
and consequently the outlines are more blurred than when
seen with the screen. For permanent records of the
grosser lesions the photograph may be useful; but for
immediate use the screen is preferable in Chest cases,
and in the majority of cases I have found that the
negative, when developed and fixed, did not show, as
accurately, the extent of the disease, as did the Screen.

Most observers are agreed on this point - in fact
the only dissentient voice that I have heard, is that
of/

of Mr Hugh Walsham of London, who strongly upheld the use of the Photographic Plate at the recent Tuberculosis Congress in London - yet still later in a book on the "Roentgen Rays" just published, Williams strongly states his preference for the Screen. time the patient held his Dr Haughton in an article in the "Medical Press and Circular" of March 26th 1902 says:- to two reasons - first "The fluorescent screen is infinitely preferable "to any photographic method for these reasons; the "cardiac movements disturb the lung tissue for a considerable area around, and, though very short exposures "may avoid the faults due to respiratory movements, "the disturbances due to the heart considerably lessen "the value of the examination. On the other hand, the "method by screen examination occupies a much shorter "time - a few seconds in some cases - and possesses "the further advantage, that with the eye one can "actually watch the movements of the heart and diaphragm, "as their position change". they should be examined in good day. I certainly must disagree with him as regards his statement of a Screen examination only taking a few seconds - ten minutes is what I find the minimum.

In the near future, I hope, that with better Coils, Interruptors, Tubes and Photographic Plates, the exposures may be shortened to seconds, and then the results may be/

be comparable to Screen examination. I have tried the Cadette X Ray Paper, and, combined with an intensifying Screen of Calcium Tungstate between the paper and the Chest wall, have taken Photographs in 35 seconds which showed the Ribs - during this time the patient held his breath, but still the results were not satisfactory. These unsatisfactory results I attribute to two reasons - firstly, an intensifying Screen gives a mottled print, and, secondly, the details are not well brought out.

Taking all these facts into consideration, I only present photographs of some cases, because, although eminently desirable as permanent records of cases, and records from which the personal element is to a great extent expunged, yet even to an inexperienced observer, the photographic print does not reveal as much as the Screen picture.

EXPLANATION OF PHOTOGRAPHS

In studying these skiagrams of Chests I should like to suggest strongly, that they should be examined in good daylight and at a distance of six feet, because then only, can the tout ensemble be taken in.

The various points may then be taken up as follow:-

1. The Shape of the Chest.
2. The Slope of the Ribs - often more acute/

outlines/

outlines of the ribs are entirely
obsoured.

3. The Shadow of the Heart is generally well seen either to the right or left of the mid-line, according as the anterior aspect or posterior aspect is shown: close to it is frequently seen, a faint line indicat-

Some investigators and Walsham of London, always being translucent bear this out. On fibrosis with distinct do not show marked

ing the Pericardium. Mr Hugh Walsham did some research to prove this point, his method being, to photograph a Cadaver by X Rays - removing different organs in the

A Tuberculous chest in place of the normal Lung is practically translucent from apex to base - this varies to a certain degree with the thickness of the Chest wall - thick muscles often cast a slight shadow. As far as my observation goes it also seems to be the case that with increase of age the Lungs are less translucent.

Where there is a more homogeneous The Photographs

1.
3.
3.

Corresponding interspaces should be compared and also upper and lower interspaces.

Where there is greater loss of translucency, the outlines/
noted

outlines of the Ribs may be blurred, and even entirely obscured.

Nodules may be seen in some cases.

In Cavities with walls not too thick, and comparatively free from secretion, abnormal translucency may be seen.

Some investigators, such as Immelmann of Berlin and Walsham of London, make a strong point of cavities always being translucent; but my experience does not bear this out. On the contrary, many cases of marked fibrosis with distinct physical signs of cavity formation, do not show marked translucency at the supposed site.

A Tuberculous Chest shows a mottled character in place of the normal clearness - this mottling, however, being more marked in the Photographic than in the Screen picture.

Where there is a thickened Pleura, one generally sees a more homogeneous shadow.

The Photographs are of:-

1. Normal Chests.
2. Phthisical Chests.
3. Post Mortem Photographs of Lungs.

The cases examined were got, chiefly from the Victoria Dispensary for Consumption, Edinburgh, - and were all examined by myself first and physical signs noted/

noted - then X Ray examination was carried out. These cases were also examined mostly by Dr Philip or Dr Gulland, by ordinary methods, and the results of their examination were open to me. A few cases were from the Infirmary wards - for which, as also for some pathological specimens, I express my indebtedness to Professor Greenfield. Other cases were from my own private practice.

The photographs of Normal Chests are sent in purely for purposes of comparison with Chests containing tuberculous Lungs.

Furthermore, notes as to the amount of Diaphragmatic Movement, with full inspiration and expiration, are appended to the Diagrams.

As a result of repeated examinations, I have found the average normal Diaphragmatic Movement, in the Adult, to be on the Right Side $2\frac{5}{8}$ inches, and on the Left Side $2\frac{7}{8}$ inches.

PHOTOGRAPHS OF NORMAL CHESTS.

METHOD OF RECORDING PHYSICAL SIGNS.

Both showing the posterior aspect.

(adopted for convenience).

NO. 1. is that of a female aged 23, the chest is rather a narrow one, and the case was examined, to see if any Pulmonary Tuberculosis was present. ~~The roentgen was anemic, but the ordinary~~ Indicates impaired note on percussion. physical examination revealed no abnormality in the chest, and X Rays corroborated.

The clear outline of the ribs, all the way down, is important, as any loss of translucency, at once blurs the outline of the ribs. dulness on percussion.

The Heart Shadow is not very distinct; but a slight shading is seen on each side, indicating the movement. ~~The Pericardial Shadow is not so~~ marked dulness on percussion. clear, as will be seen in other photographs.

Both apices are not so clear as the lower parts, and this is to be expected, considering the mass of muscle ~~and~~ crepitations. in these areas.

The right apex is, if anything, slightly less clear, than the left.

A slight bulging at the left side of the vertebrae, ~~mark~~ rhonchi. ~~cross~~, I attribute to the Aorta, as the spinal column has been slightly bent, by the patient altering the position of her head.

" friction.

PHOTOGRAPHS OF NORMAL CHESTS.

Both showing the posterior aspect.

NO. I. is that of a female aged 23, the chest is rather a narrow one, and the case was examined, to see if any Pulmonary Tuberculosis was present. The woman was anaemic, but the ordinary physical examination revealed no abnormality in the chest, and X Rays corroborated.

The clear outline of the ribs, all the way down, is important, as any loss of translucency, at once blurs the outline of the ribs.

The Heart Shadow is not very distinct; but a slight shading is seen on each side, indicating the movement. The Pericardial Shadow is not so clear, as will be seen in other photographs.

Both apices are not so clear as the lower parts, and this is to be expected, considering the mass of muscular tissue in these areas.

The right apex is, if anything, slightly less clear, than the left.

A slight bulging at the left side of the vertebrae, marked by a cross, I attribute to the Aorta, as the spinal column has been slightly bent, by the patient altering the position of her head.

NO. 2. is that of a youth aged 18, with good muscular development. There is markedly less clearness about this photograph, than NO. I., chiefly owing to the greater muscular clothing of the chest wall. The shape is much less narrow than NO. I., and the Heart Shadow stands out more clearly.

As additional, almost normal chests, those of Richard M. and Joseph L. may be taken.

I feel I cannot press, too strongly, the fact, that these photographs can only be fairly examined, at a distance of 6 feet or more, in a good light, and in a position where they appear free from any glaze. Afterwards they may be examined more closely if desired.

At the end of each case is a sheet with two charts - the upper refers to the results of ordinary examination, and the lower to X Ray Screen Examination.

The blue pencil shading only shows in a comparatively rough way the details of the shadow/

ARRANGEMENT OF CASES.

The first series of 19 cases which are all accompanied by photographs, are arranged, so that those showing early Phthisis come first, and the more advanced conditions are seen later.

The 26 cases unaccompanied by photographs, are purposely allowed to go in any order, to prevent monotony in reading.

The presence or absence of Tubercle Bacilli has not been mentioned in many cases, but the search for them has been a routine practice, and unless when expressly mentioned as not found - they were found in cases that had any sputum.

At the end of each case is a sheet with two charts - the upper refers to the results of ordinary examination, and the lower to X Ray Screen Examination.

The blue pencil shading only shows in a comparatively rough way the details of the shadow/

shadow, but the main points are brought out.

E.M. Female age 17, complained of bloodlessness

The term "loss of translucency" used so frequently is not meant to be absolute, but applies to any departure from the normal clearness.

Another sister suffers from Phthisis Pulmonalis.

RESPIRATORY SYSTEM

As regards the physical examination - details sufficient to show the extent of the disease have been given - other less essential points have been left out.

Pulse 103. Tension and Volume poor. (Temperature normal) No night sweats.

Other systems normal.

PHYSICAL EXAMINATION OF THE CHEST.

Breath sounds very faint over the upper part of the Chest front and back.

Anteriorly. No impairment of the note on percussion.

No increase of Vocal Fremitus.

Breath sounds normal but faint.

Posteriorly. Slight impairment of the note on percussion, over the left apex down to the 4th Rib.

Breath sounds vesicular, with prolonged expiration at both apices.

No accompaniments.

CASE.

E.M. female age 17, complained of bloodlessness lasting for a year. Previously she had enjoyed good health, except as a child, when she suffered from Bronchitis.

Another sister suffers from Phthisis Pulmonalis.

RESPIRATORY SYSTEM.

Loose cough. Thick blackish sputum. No Hoemoptysis. No pain in the Thorax. Dyspnoea on exertion. Larynx normal except for paller.

Pulse 102. Tension and Volume poor. (Temperature normal) No night sweats. Other systems normal.

PHYSICAL EXAMINATION OF THE CHEST.

Breath sounds very faint over the upper part of the Chest front and back.

Anteriorly. No impairment of the note on percussion.

No increase of Vocal Fremitus.

Breath sounds normal but faint.

Posteriorly. Slight impairment of the note on

percussion, over the left apex down to the 4th Rib.

Breath sounds vesicular, with pro-

longed expiration at both apices.

No accompaniments.

SCREEN/

SCREEN EXAMINATION.

Anteriorly. Opacity slight at both apices - most marked on the left side, where it extended to the 2nd Rib. On the right side it extends to the 1st Rib.

Posteriorly. Opacity extends on the left side down to the 5th Rib, and on the right side to the 4th Rib.

Diaphragmatic movement. At 2 feet distance $1\frac{1}{4}$ " on left side. 1" on the right.

PHOTOGRAPH.

Taken at 3" distance, with a Hirschmann Tube and Edwards Cathodal Plate.

When examined at 6 feet distance, it reveals an obvious loss of translucency at both apices, extending down to the 4th Rib.

On the left side it is somewhat darker, (the dark spot seen there, is from an air bubble fixing on the plate, when it was being developed.)

The Ribs on the left side seem, on the whole, to be placed at a more acute angle, than those on the right side.

The Heart is seen in the centre low down - with faint shadows of the Pericardium on either side, particularly on the right.

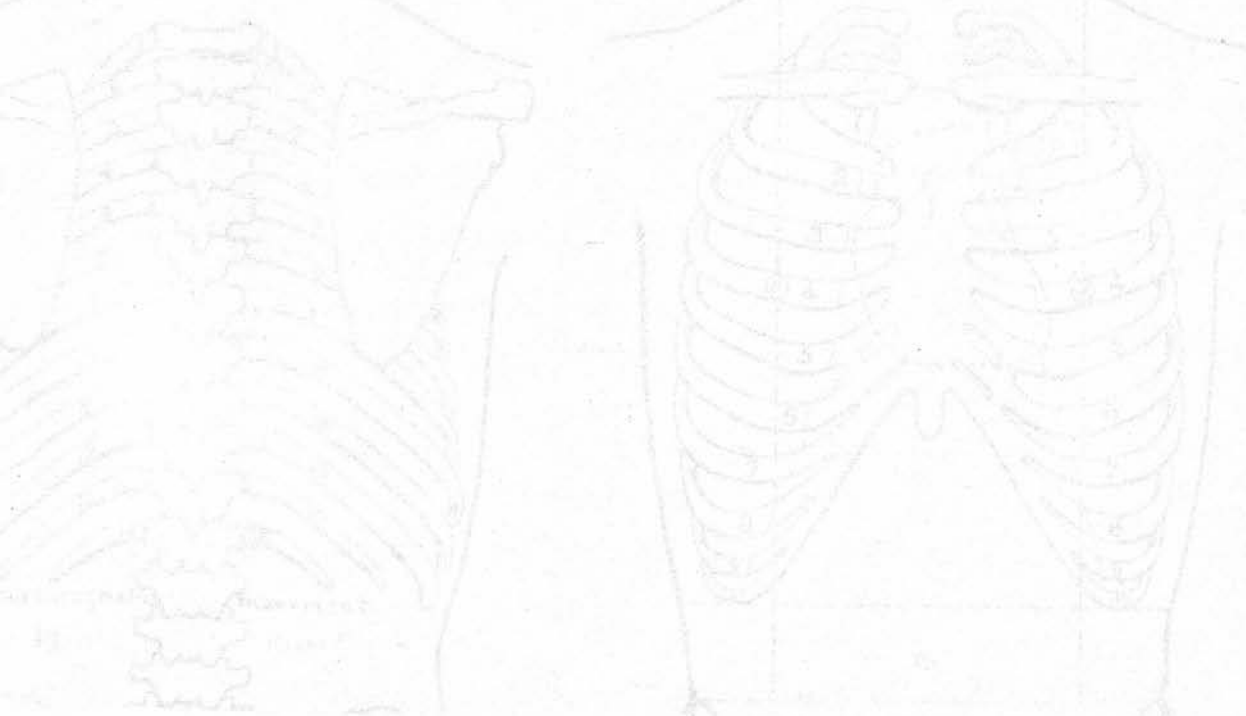This/

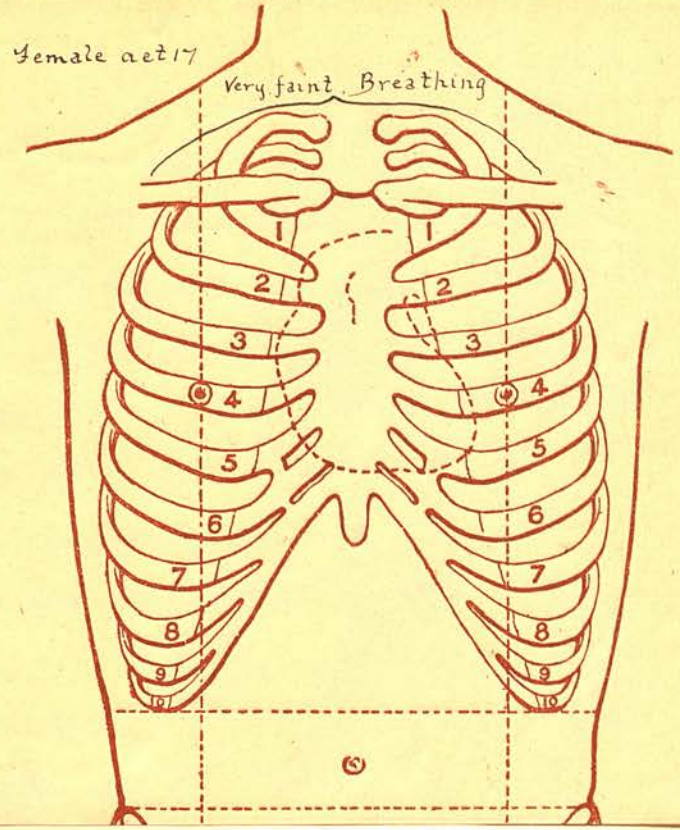
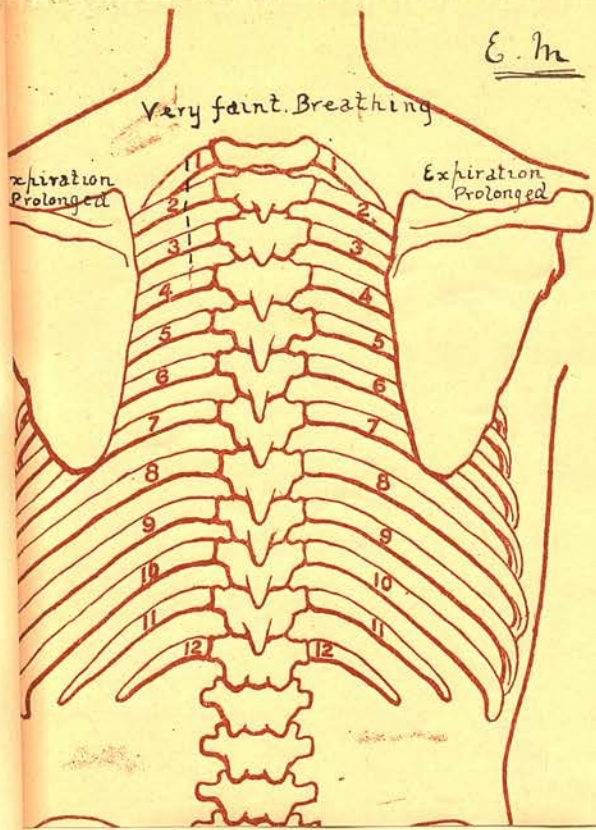
This case seems to show a distinct advantage of the X Rays over the usual Physical Examination.

The History is undoubtedly suspicious, and one might certainly be inclined to diagnose Phthisis from Physical Examination, even though, as in this case no Tubercle Bacilli were found in the Sputum; but the X Rays make one much more certain.

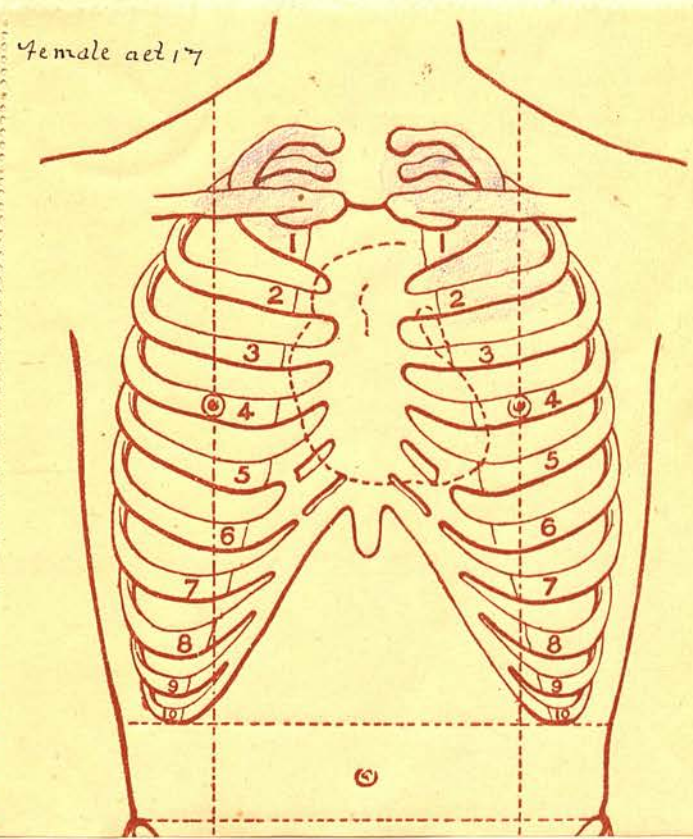
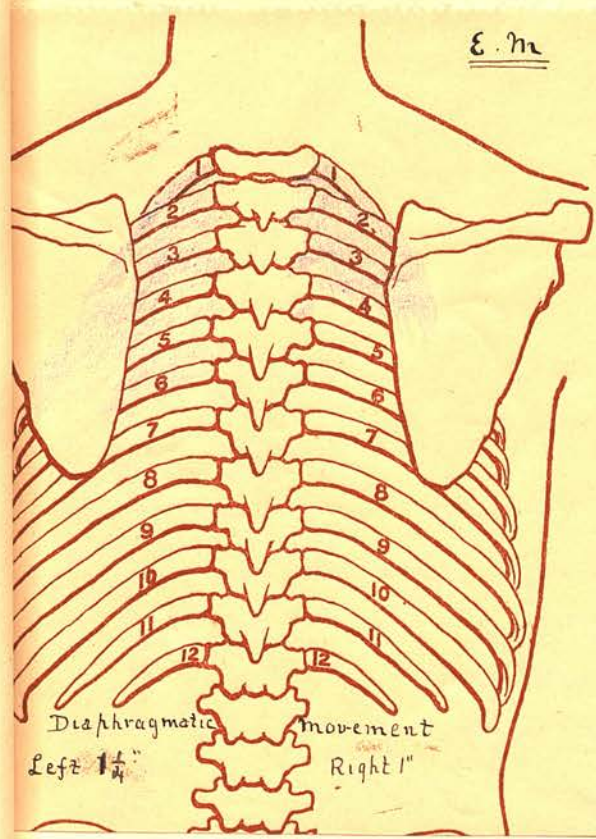
Accompanying are two diagrams - one showing the results of the customary physical examination, and the other the shadow as seen on the Screen.

These, when compared, indicate the fuller diagnosis thus obtained by the Screen.





AUSCULTATION OF THE HEART



Richard M. Age 14. Height 4 feet $10\frac{1}{2}$.
 Weight 5 stone $5\frac{1}{2}$. Complains of cough lasting for
 three weeks. Father suffers from Asthma. Patient
 had Rheumatic Fever when 4 years old, and has suffered
 from Malaria on several occasions. Cough loose with
 thin white sputum. No Hoemoptysis. Pain in front
 of the Chest at times. Dyspnoea on exertion.
 Tonsils enlarged and irregular. Enlarged glands on
 the right side of the neck.

Examination of the Lungs revealed no abnormality,
 except weak breath sounds at the right apex. On
 auscultation of the Heart, mitral and aortic stenosis
 was discovered. Pulse 102. Tension and Volume
 poor. No night sweats. No Tubercle Bacilli.

SCREEN EXAMINATION.

Anteriorly. Revealed slight loss of translucency
 in the first two interspaces, on
 the right side.

Posteriorly. Revealed slight loss of translucency
 in the first two interspaces, on
 the right side.

Diaphragmatic
 movement. This was of a peculiar jerky
 character, and the full extent of
 the movement, with the deepest
 breathing I could get the patient
 to take, was only 1" on either
 side, /

side, when examined at 2 feet distance from the tube.

PHOTOGRAPH.

Lumière Plate, Hirschmann Tube 20" distance.
Showing the posterior aspect.

The Chest has a good shape, but at the right apex an opacity is observable in the first two interspaces. Also the interspaces are narrower there, but the clavicles are not exactly sloping alike, so it is advisable not to lay too much stress on this. The enlargement of the Heart is quite noticeable.

In all probability, the Lung condition reveals a healed Phthisis at the apex - a condition which ordinary physical signs did not reveal in this case.

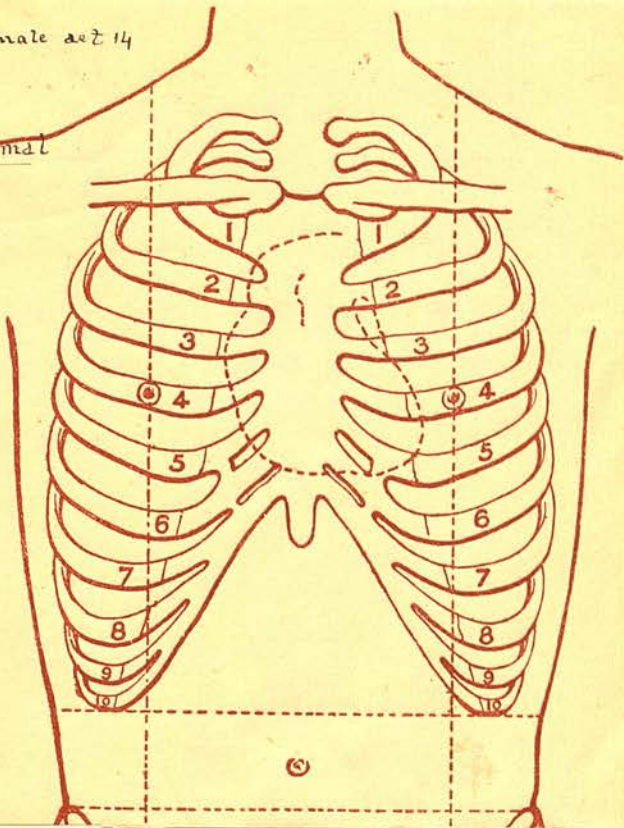
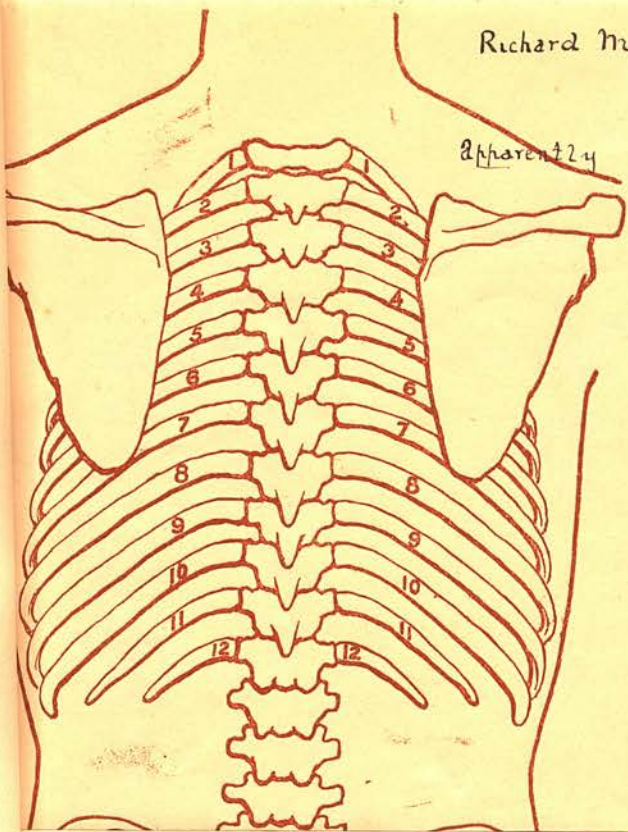
The enlarged glands mentioned above were high up, and none could be felt over the region of the opacity.

Richard M

male aet 14

apparent 24

normal

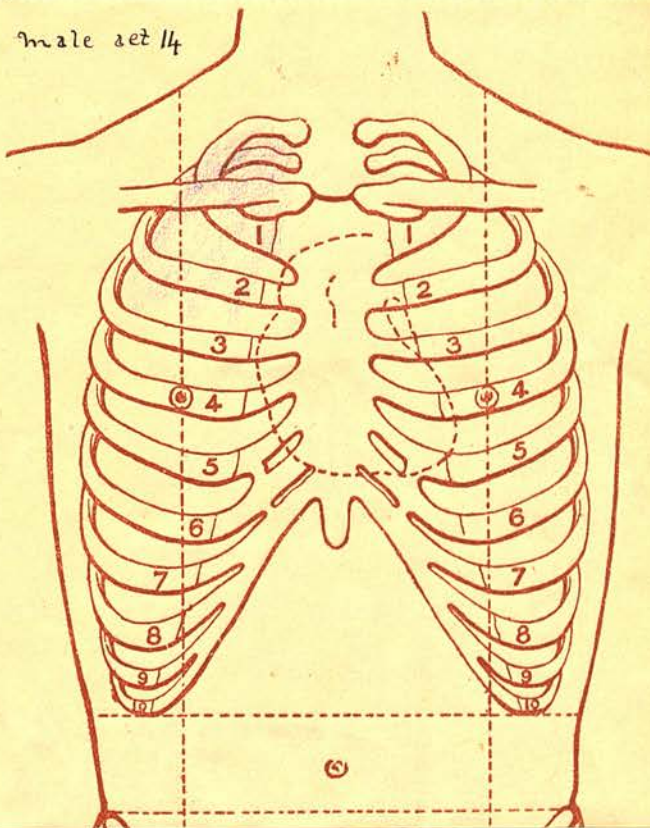
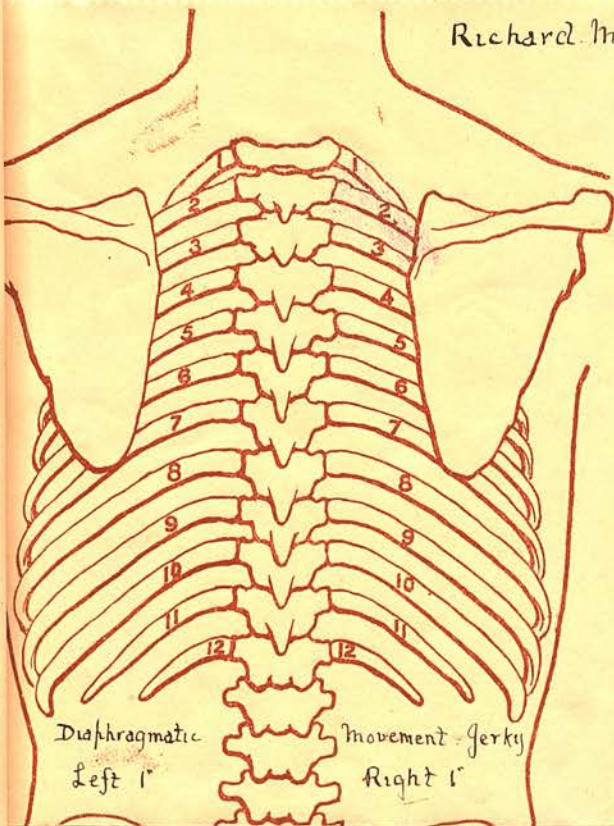


Richard M

male aet 14

Diaphragmatic
Left 1'

Movement - Jerky
Right 1'



Joseph L. Male, age 9. Height 5 feet $1\frac{1}{2}$ inches.
Weight 4 stone 1 lb.

COMPLAINT.

Severe cough lasting for four months. Previously he had been in good health. A sister died of Phthisis 9 months ago.

RESPIRATORY SYSTEM.

Cough troublesome mostly at night. Expectoration small in amount, and thin in character. No Hoemoptysis, Pain or Dyspnoea. Tonsils enlarged. Larynx healthy. No Tubercle Bacilli found in Sputum.

Patient has been losing weight, and the digestive functions are impaired. Pulse 90, with fair volume and tension. Night sweats profuse.

PHYSICAL EXAMINATION OF THE CHEST.

Revealed just a little dulness at the right apex, in front above the clavicle, and behind to the 3rd Rib.

On the left side the note is impaired posteriorly, above the Scapula, but normal in front.

Breath sounds are almost bronchial in character, at the right apex

posteriorly. Puerile breathing elsewhere/

elsewhere. No accompaniments to the breath sounds anywhere.

SCREEN EXAMINATION.

Anteriorly. Loss of translucency at the right apex, down to the 3rd Rib, - elsewhere translucent.

Posteriorly. Very slight opacity, extending to the 5th Rib on the right side, and on the left side, to the spine of the Scapula.

Diaphragmatic movement. At two feet distance is $1\frac{1}{4}$ " on each side, but on the right side the movement is of a jerky character.

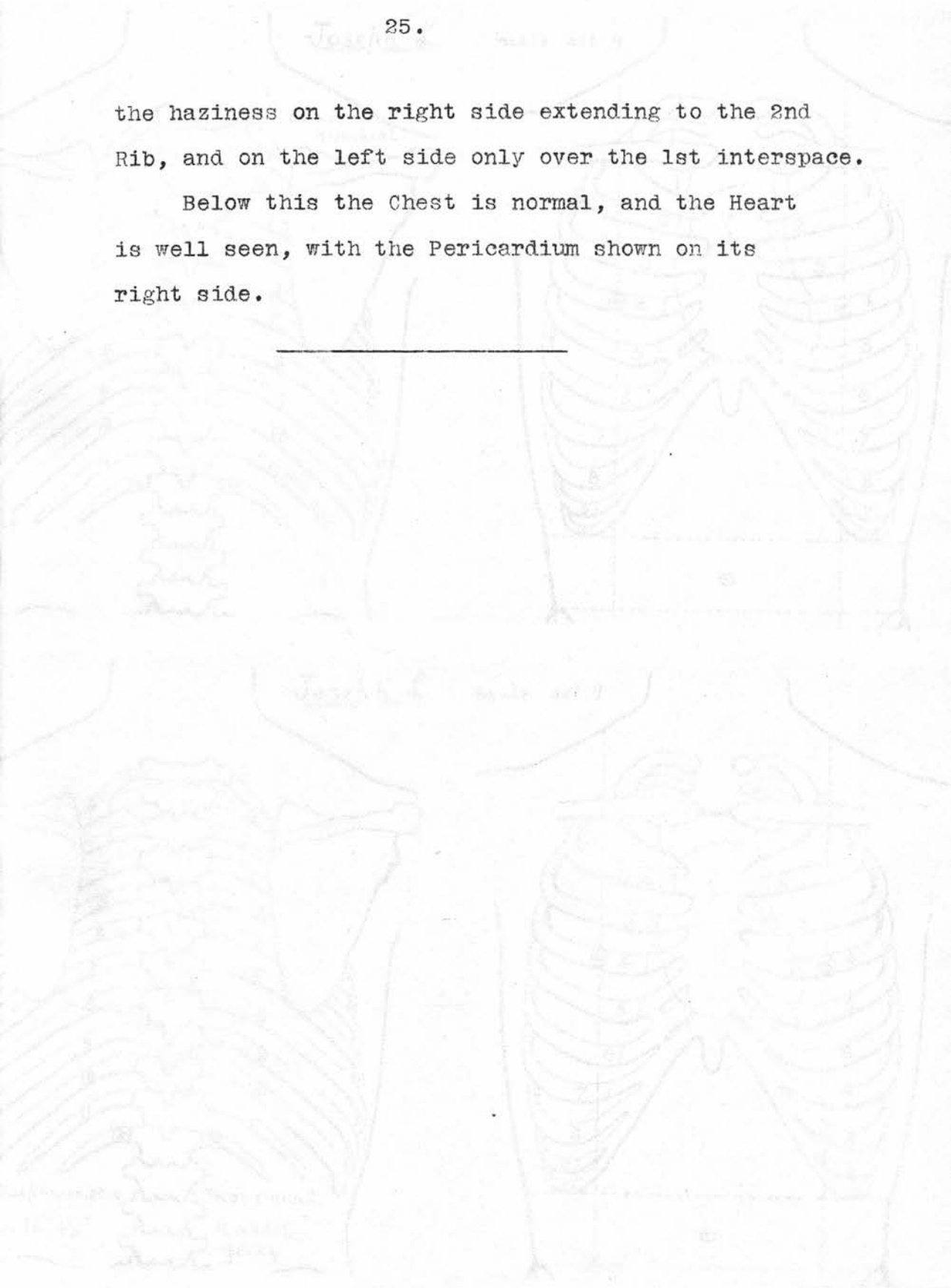
PHOTOGRAPH.

Taken on a Lumière Plate and showing the posterior aspect. The Hirschmann Tube was at 18" distance from the Chest wall, with the patient lying, and an exposure of $2\frac{1}{2}$ minutes was given. The print shows very little, and may be rather taken as an example of the failure of the photographic method, especially where one is dealing with faint loss of translucency. Still both apices are not as translucent as normal, especially considering the age of the patient.

The right apex is more affected than the left -
the/

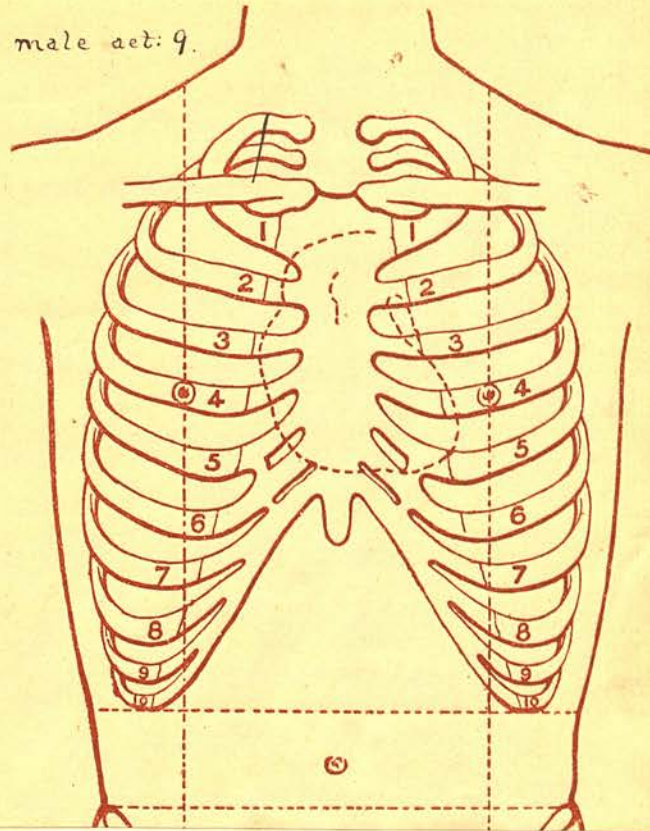
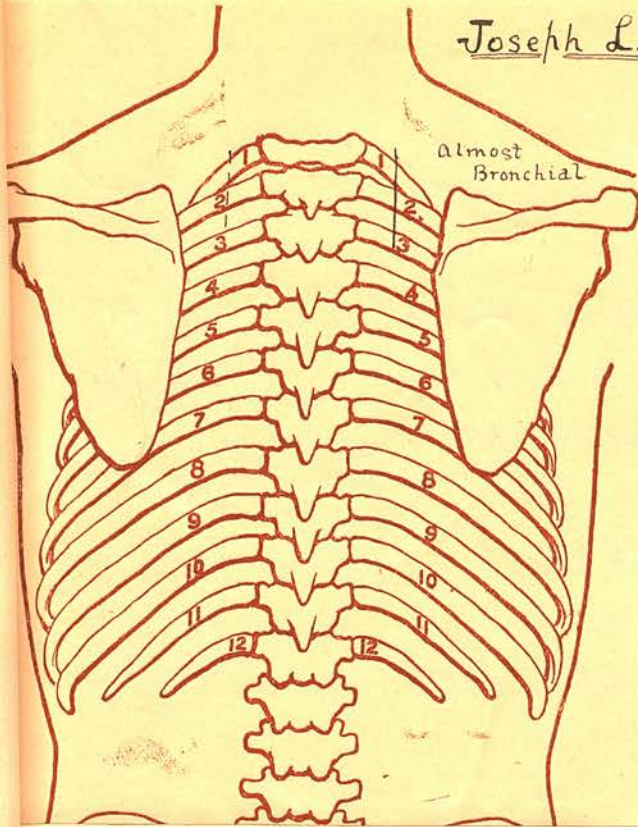
the haziness on the right side extending to the 2nd Rib, and on the left side only over the 1st interspace.

Below this the Chest is normal, and the Heart is well seen, with the Pericardium shown on its right side.



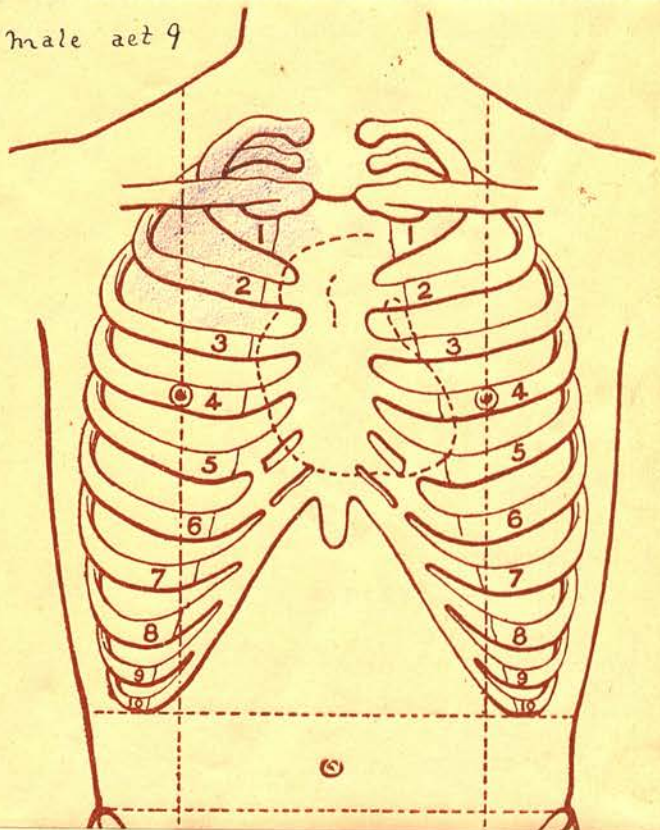
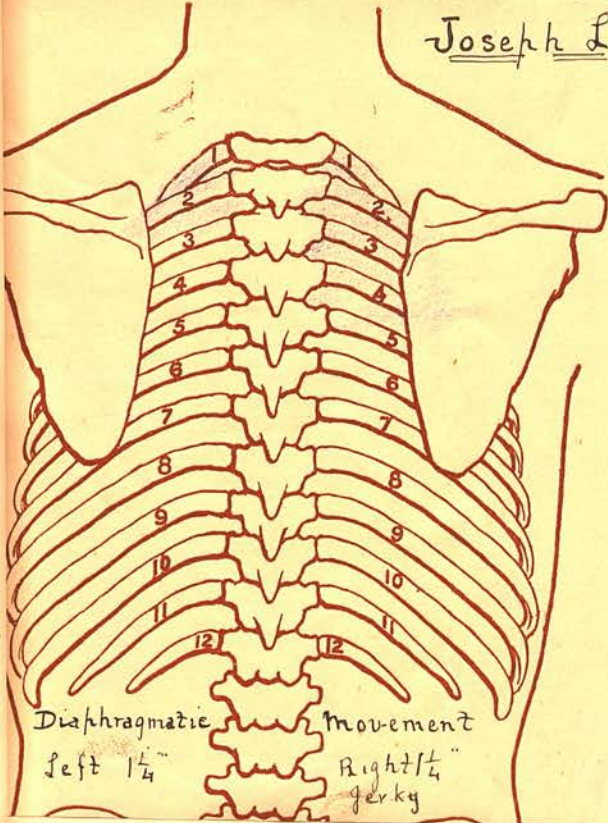
Joseph L.

male aet: 9.



Joseph L.

male aet 9



Andrew A. Male, age 35. Height 5 feet 6½".

Weight 10 stone 9½. Temperature normal.

COMPLAINT.

"Chest trouble" lasting for 4 years. Has had slight Hoemoptysis on 3 occasions. Distinct history of Consumption in the family.

RESPIRATORY SYSTEM.

Slight cough with bluish spit, in which Tubercle Bacilli were found. No pain in the Chest. Congestion of epiglottis and ary-epiglottidean folds, but vocal cords normal.— Occasionally suffers from Dyspepsia. Pulse 70. Tension and volume fair. No night sweats. Glandular enlargement in the neck of slight amount. Systems otherwise normal.

PHYSICAL EXAMINATION OF CHEST.

Anteriorly. Left side is dull on percussion, as far as the 2nd Rib, the breathing being bronchial in character above the Clavicle, and accompanied with crepitations.

Below the Clavicle, and down to the 2nd interspace, there is vesicular breathing with prolonged expiration.

On the right side, there is no dulness on percussion; but there is distinct prolongation of the expiratory/

expiratory murmur as far as the first interspace.

Posteriorly. On the left side, there is dulness on percussion to the spine of the Scapula, and over this area the breathing is bronchial, accompanied by crepitations. Below this there is vesicular breathing with prolonged expiration.

On the right side there is dulness down to the spine of the Scapula, and there is prolongation of the expiratory sound over this area.

SCREEN EXAMINATION AND PHOTOGRAPH.

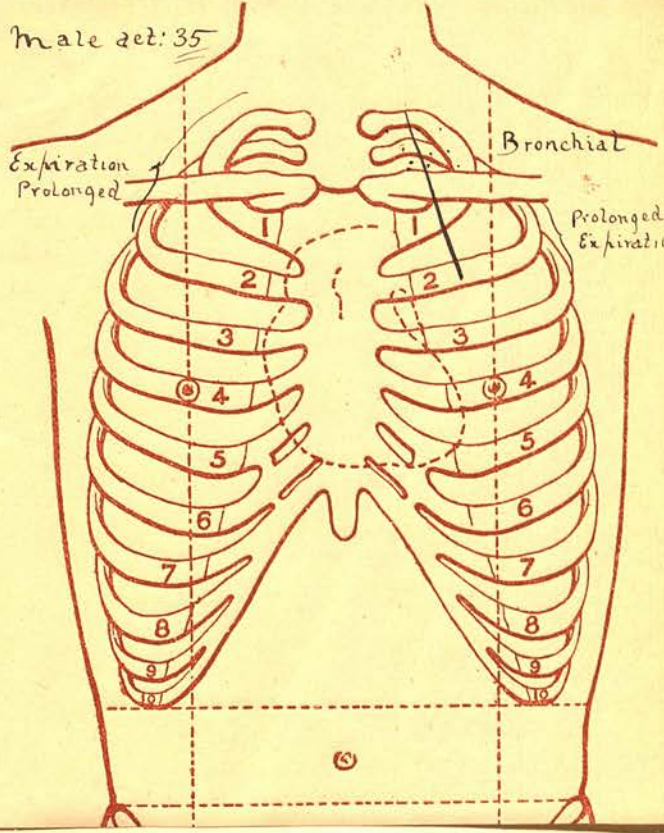
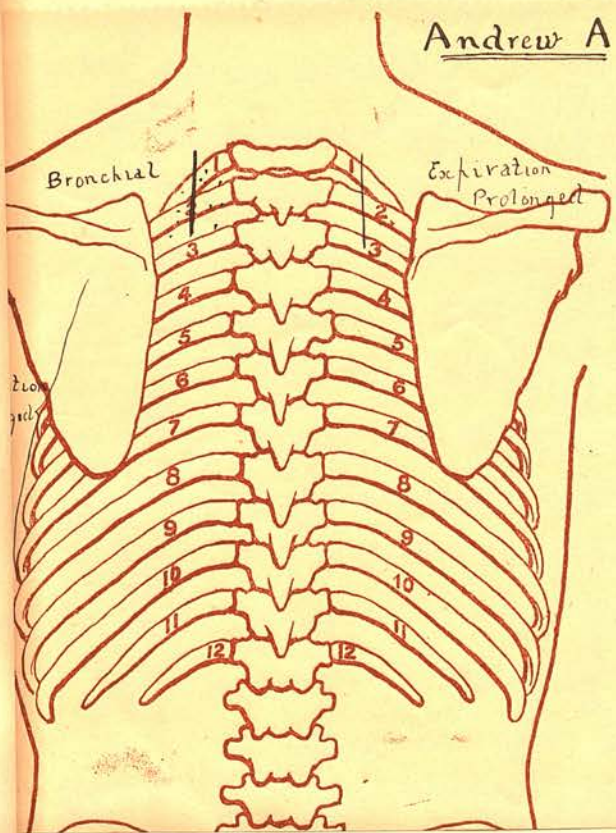
In this case these agree, so that no separate description is given.

Diaphragmatic movement. At two feet distance is $1\frac{3}{4}$ " on the left side, and $1\frac{1}{2}$ " on the right side.

PHOTOGRAPH. A.

Taken November 1900 with a Volt-Ohm Tube, at distance of 12" from the Chest of the patient, who was lying on his back. The plate was a "Cathodal" one, and the duration of exposure $3\frac{1}{4}$ minutes.

The Chest shows marked sloping of the Ribs on the/



PHOTOGRAPH. B.

Taken a little more than a year later, in December 1901, with patient in exactly the same position.

Photograph was same as Screen Examination

Diaphragmatic Movement

Left $1\frac{3}{4}$ "

Right $1\frac{1}{2}$ "

The only two changes being, that a Ward tube was used, and the "Volt-Unit" was unsatisfactory, and the distance from the patient was increased to 16".

The patient's condition was now much improved, his weight being over 11 stone; - cough absent almost, and no expectoration.

The physical examination of the Chest revealed more/

the right side, at the lower part. The Heart is seen, at the lower part, faintly. On the right side, there is loss of the normal clearness, though not great in amount generally, as far as the 5th Rib; but particularly interesting is the presence of nodular masses.

The best marked of these - Nodule 1 - is in the fourth interspace, and has a distinct round character - in the interspace above, and slightly internal to this, there is another marked patch, though not so definitely outlined. Nodule 2. On the left side, the loss of translucency extends over the first three interspaces, and above and below the 3rd Rib is seen, a faintly outlined nodular mass. Nodule 3.

PHOTOGRAPH. B. noticeable on the right side. This

Taken a little more than a year later, in part December 1901, with patient in exactly the same position as the above - the same kind of plate being used, and the same duration of exposure given.

The only two changes being, that a Hirschmann Tube was used - as the "Volt-Ohm" was unsatisfactory, and the distance from the patient was increased to 18".

The patient's condition was now much improved, his weight being over 11 stone; - cough absent almost, and no expectoration.

The physical examination of the Chest revealed more/

more marked dulness than formerly; but of the same extent: the breath sounds were more bronchial in their character, but there were no accompaniments.

The photograph shows an analogous picture to the former one, but there are very obvious divergences - if the two are placed alongside each other in good light, at 6 feet distance from the eye, they can be compared fully.

The Ribs, in the upper part of the Chest, slope much more rapidly in B, indicating a shrinkage of the Lungs there.

At the lower part, however, in B, the Ribs are more nearly at right angles to the Vertebrae; and the interspaces are somewhat wider than in A, - this being more noticeable on the right side. This I take it, shows greater expansion in the lower part than previously. The loss of translucency is about the same in extent, but more marked in the later photograph.

On the right side, Nodule 1 is again seen, but even though this is a darker print, the nodule, both at the periphery and centre, is paler than in photograph A.

Nodule 2 is almost in statu quo, but now the shadow of the inner end of the clavicle is well seen above/

above it. On H. main, Age 9 years. Height 3 Feet 7 1/2"
 Weight Some smaller masses are seen in the interspaces
 above. Last cough lasting for two months. When
 5 years On the left side Nodule 3 has become larger.
 Family Taking the history of the case, and all the
 points brought out in the two examinations, - the
 disease has evidently advanced somewhat especially
 on the left side, and since then, contraction of the
 Lungs at the apices has become more pronounced, and
 with it, collapse of the Ribs in the upper part.

On both sides, below, a condition of Compensatory
 Emphysema is well established, as evidenced by the
 less acute slope of the Ribs, the greater clearness
 of the Lungs in the lower central parts, away from
 the shadow of the muscles and Heart, and the fact,
 not already mentioned, that the Diaphragmatic move-
 ment has increased to 2" on each side. In dulness

The Photographs are fortunate in revealing many
 points which ordinary physical signs did not show,
 and still more are they valuable, as permanent records
 of the progress of a case. Scepticism, as to the
 nodular condition, might well be held with Photograph
 A; but when Photograph B, taken over a year later,
 corroborates it, any doubt is unjustified. That
 Phthisis exists is vouched for, by other observers,
 and also, by the fact, that Tubercle Bacilli were
 present in the sputum.

Gillon B. male, Age 9 years. Height 3 feet 7 $\frac{1}{2}$ "
 Weight 2 stone 13 $\frac{1}{2}$. Temperature normal. Complains
 of short cough lasting for two months. When
 5 years old he suffered from a Tubercular Knee.
 Family history of Tuberculosis is present.

RESPIRATORY SYSTEM.

Cough short. No sputum. No pain in Chest.
 Dyspnoea on exertion. Tonsils enlarged. Larynx
 shows some congestion.

ALIMENTARY SYSTEM.

Normal except for doughy enlargement of abdomen -
 probably Tabes mesenterica.

Pulse 120 with poor tension and volume. No
 night sweats.

PHYSICAL EXAMINATION OF CHEST.

Very thin but no marked sinking anywhere.

Anteriorly. On percussion, there is dulness
 on the Right Side extending down

Posteriorly. Loss of Translucency extends to
 to the 2nd Rib, and on the Left
 Side down to the 1st interspace.

Below on either side there is some
 hyperresonance.

On auscultation, there is
 Diaphragmatic movement.
 with deep breathing at 2 feet
 distance from the Tube. This was
 only

is/

is markedly increased, on the right side. Rhonchi are heard all over, on both sides; but no crepitations.

Posteriorly. On percussion, at both apices there is dulness to above the spine of the Scapula. The breath sounds are Bronchial over the dull areas, but normal - puerile in character below. Rhonchi are present here as in front.

Showing the position of the Hirschmann Tube with 19 inches from Tube exposure 2 minutes On examination 6 feet, the Chest SCREEN EXAMINATION OF CHEST.

Anteriorly. Loss of Translucency on left side, down to the 4th Rib and on the right side, down to the 3rd interspace. Most pronounced in both cases above above the Clavicles, and being slightly darker on the right side.

Posteriorly. Loss of Translucency extends to about the 6th Rib on each side, being greater above and tapering off below. The Right side is again slightly darker.

Diaphragmatic movement. With deep breathing at 2 feet distance from the Tube, this was only/

the/

only half an inch on either side,
 and this movement was irregular
 in its character - probably partly
 from nervousness.

PHOTOGRAPH.

Showing the posterior aspect. - Taken by a Hirschmann Tube with Lumière Plate, at a distance of 19 inches from Tube to front of Chest. Duration of exposure 2 minutes 10 seconds.

On examination of this photo at a distance of 6 feet, the Chest is seen to be fairly well shaped, with no marked disparity between the sides.

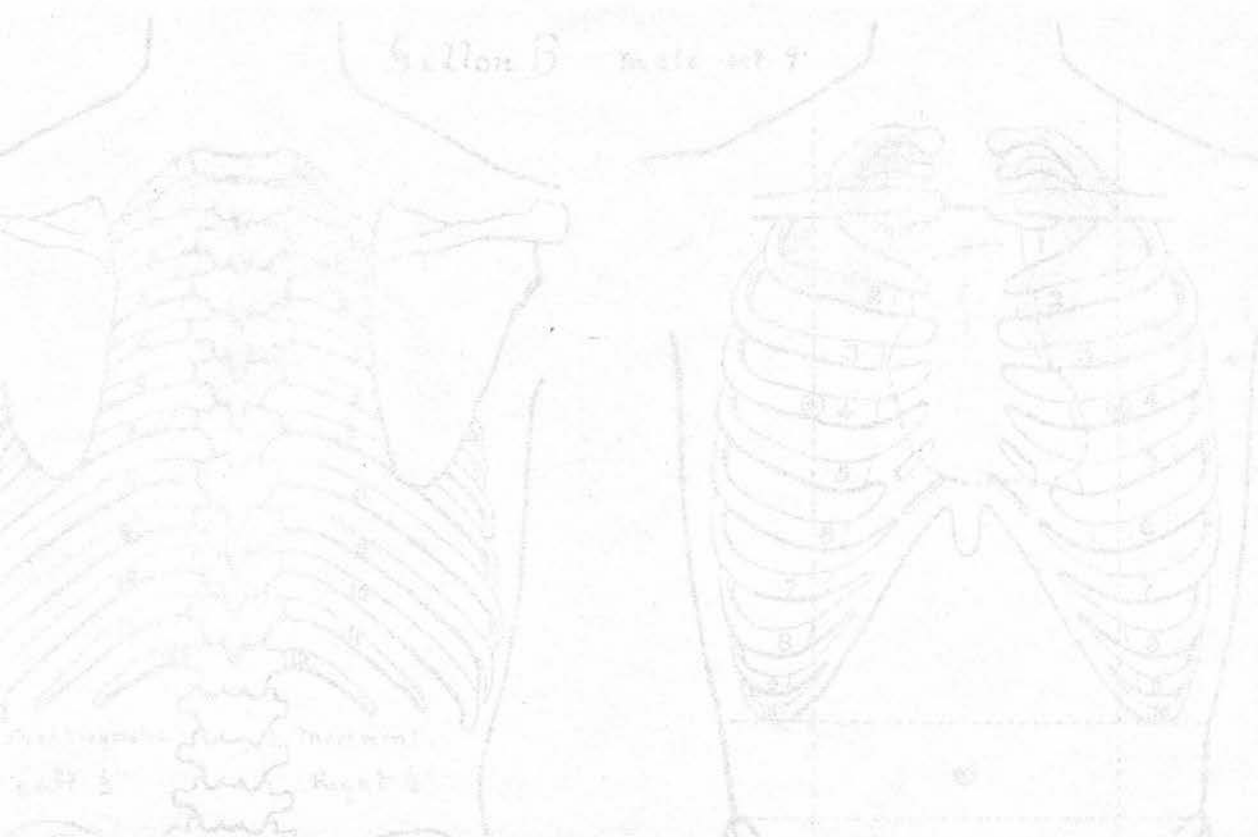
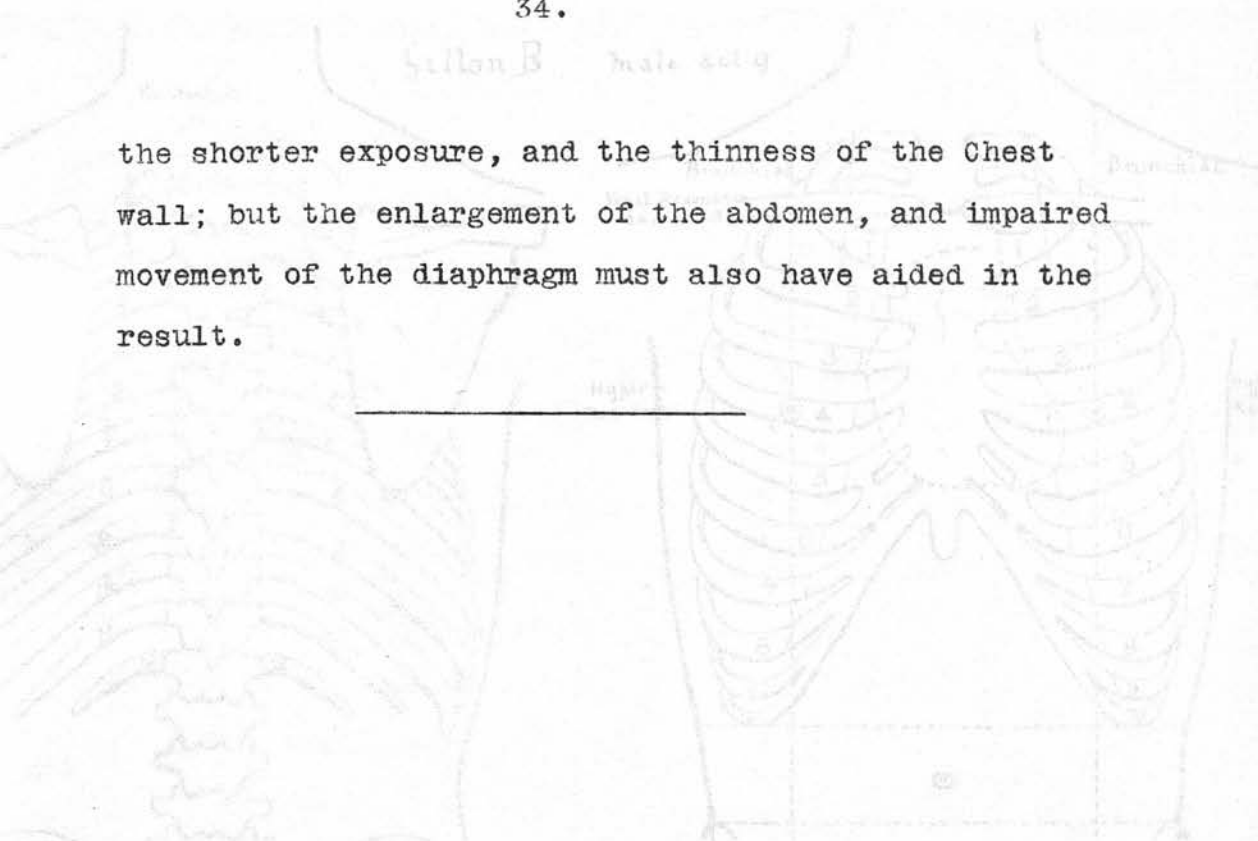
Both apices are markedly opaque, but the right is more so. Mottling extends on the right side, down to the 6th Rib, where it fuses on to the Pericardium. On the left side, mottling extends the same distance. Both Lungs also show a faint mottling lower down, which seems to indicate patches of disease in these parts.

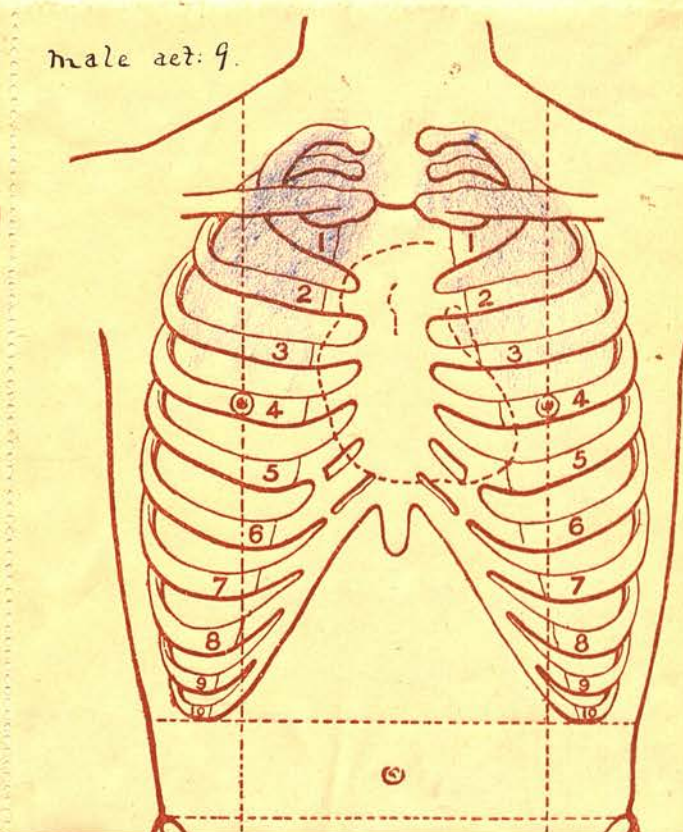
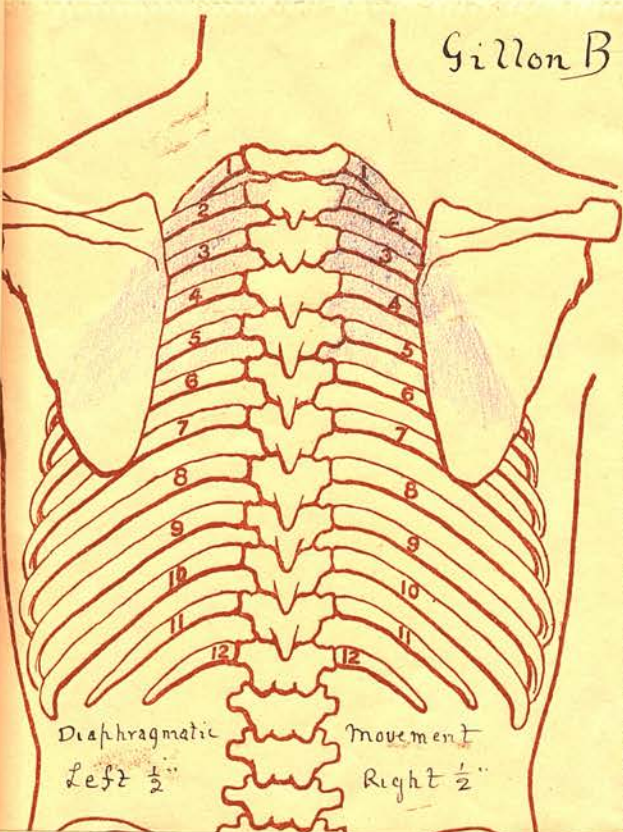
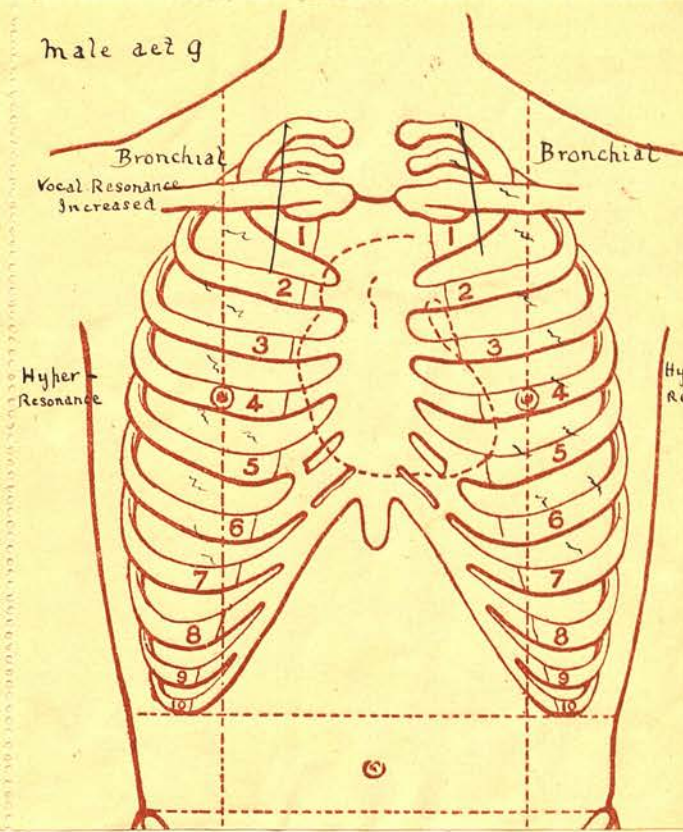
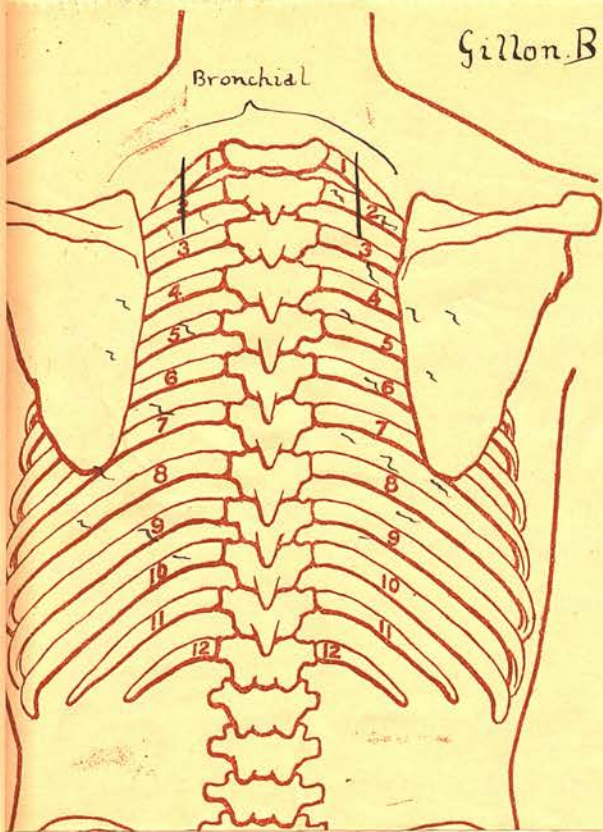
In this case, the ordinary physical signs were obscured by the presence of rhonchi; and I should fancy that many clinicians would be glad of the fuller knowledge, obtained from the X Rays in such a condition - a condition not unfrequently met with.

The Photograph gives here, apparently, a better result, than the screen, owing chiefly no doubt, to the/

Sillson B male set 9

the shorter exposure, and the thinness of the Chest wall; but the enlargement of the abdomen, and impaired movement of the diaphragm must also have aided in the result.





Magnus H. Grocer. Age 21. Height 5 feet $1\frac{1}{4}$ ".
 Weight 7 stone $10\frac{1}{2}$ lbs. Temperature normal.

COMPLAINT.

Pain on the right side and cough lasting for
 a year. Personal and family history good.

RESPIRATORY SYSTEM.

Cough hard, worst in morning. Thick yellow
 sputum. Slight Hoemoptysis, three months ago.
 Pain on right side, especially on full inspiration.
 Dyspnoea on exertion. Larynx shows pallor.

ALIMENTARY SYSTEM.

Tongue furred, appetite fair. Vomiting after
 coughing. Bowels regular.—Pulse 96. Tension
 and Volume fair.

PHYSICAL EXAMINATION OF THE CHEST.

Anteriorly. On the right side, dulness on
 percussion as far as the 4th Rib.

Posteriorly. Breathing bronchial to the 2nd
 Rib. Pleuritic friction heard
 from clavicle to 5th Rib.

On the left side, there is no
 dulness on percussion, but
 prolongation of expiratory murmur
 above the clavicle.

Posteriorly. On the right side, dulness on
 percussion/

PHOTOGRAPH. percussion over the first two
 showing areas Ribs, and again from the 3rd
 Wirschmann Tube at interspace to the fifth Rib.
 Plate. Exposure The breathing is accompanied by
 a pointed one, and crepitations down to the fifth
 be observed to six Rib, and pleuritic friction is
 The right apex is heard round the inferior angle
 left, and the char of the Scapula. ing can be observed
 extending down to On the left side, there is
 On the left side, impairment of the note over the
 interspace. first and second Ribs.

SCREEN EXAMINATION. ture shows more extensive disease
 than Anteriorly. There is loss of translucency
 than ordinary phys all down the right side, the shadow
 Diaphragmatic move being deeper at the apex. at
 any rate, no doubt On the left side, there is loss
 fainter shadow of of translucency down to the 2nd Rib.
 Posteriorly. On the right side, the translucency
 it is possible that is absent all down and again
 deeper lung disease the apex is more affected. ent
 anteriorly. On the left side, the loss of
 translucency extends down to the
 fifth Rib.

Diaphragmatic
 movement.

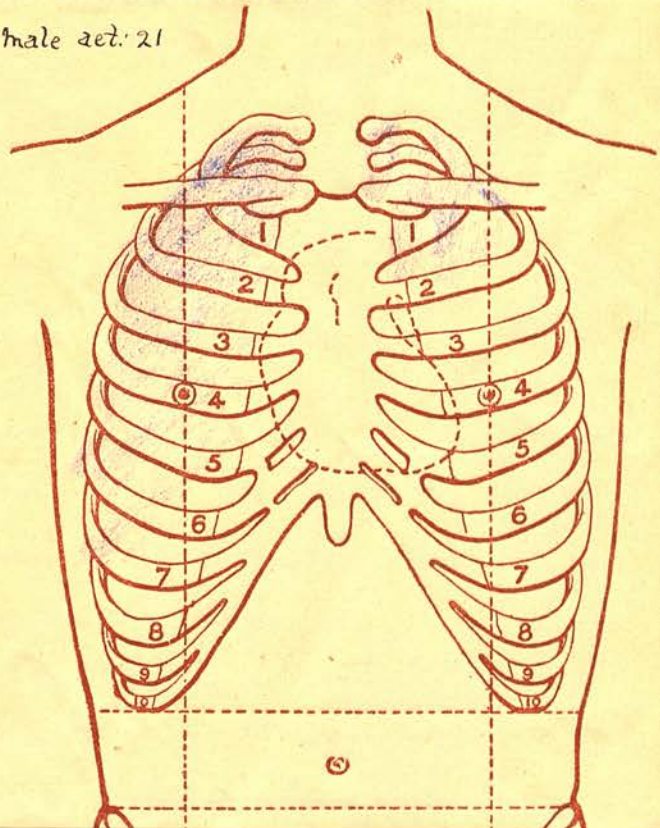
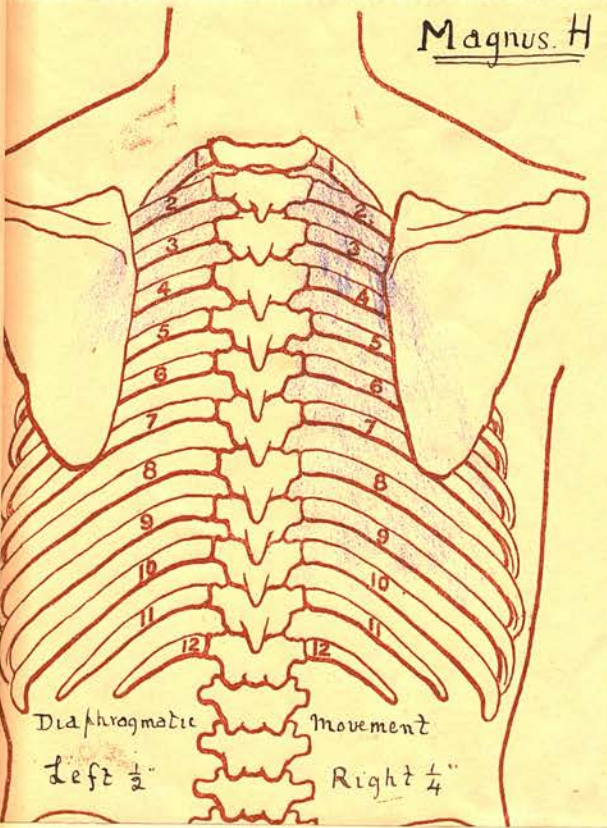
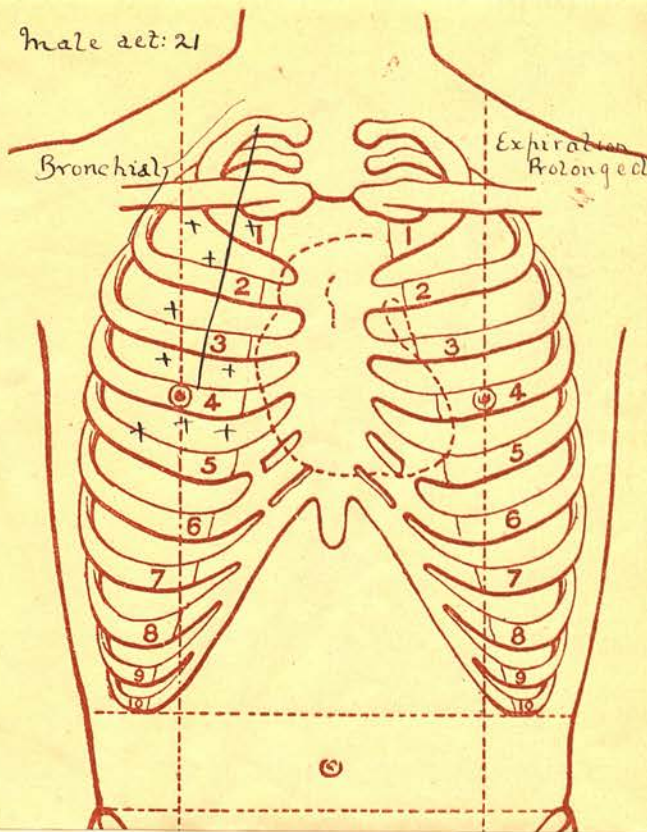
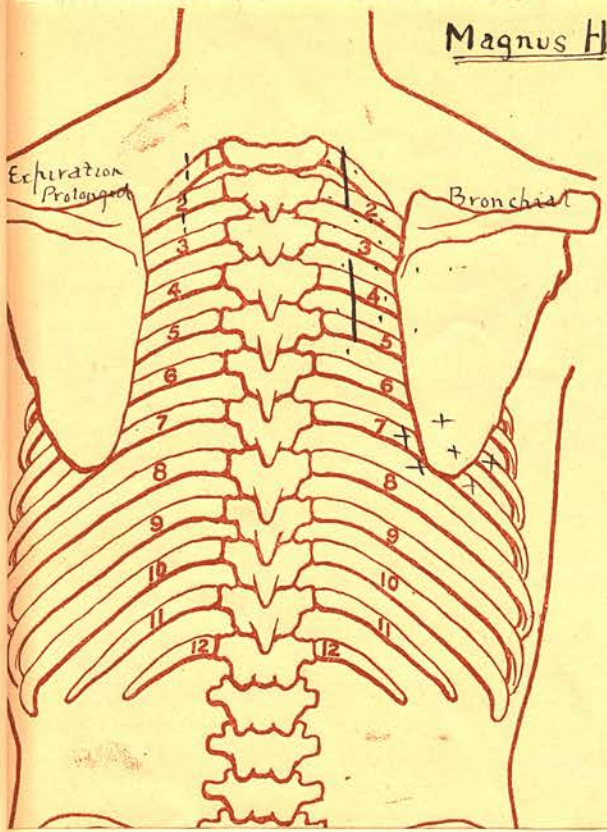
At two feet distance $\frac{1}{4}$ " on the
 right side, and $\frac{1}{2}$ " on the left.

PHOTOGRAPH/

PHOTOGRAPH.

Showing dorsal aspect, was taken by a Hirschmann Tube at 14" distance, with Cathodal Plate. Exposure 3 minutes. The Chest is rather a pointed one, and the Ribs on the right side can be observed to slope more acutely. The right apex is obviously more affected than the left, and the characteristic mottling can be observed extending down to about the 7th Rib. On the left side, the disease extends to the 4th interspace.

The screen picture shows more extensive disease than the photograph, and the latter more, again, than ordinary physical examination. The Diaphragmatic movement is very small in part at any rate, no doubt due to the Pleurisy. That the fainter shadow of the Pleurisy is not seen on the photograph, may be owing to its being recent and it is possible that the photograph shows here the deeper Lung disease, as distinct from the recent Pleurisy.



John C. Shop Porter, age 40. Height 5 feet 10. Weight 12 stone.

COMPLAINT.

Pain in the chest lasting for a fortnight. Has not been well for some time previously.

RESPIRATORY SYSTEM.

Short cough in the morning, with thick grey sputum. No Hoemoptysis. Pain referred to the right side of the Chest. Larynx congested but shows no lesion.

Pulse 102 slightly irregular. Other systems normal.

PHYSICAL EXAMINATION OF THE CHEST.

Anteriorly. On the right side, dulness on percussion to the 1st inter-space, with vesicular breathing, and prolonged expiration over this area. Below from 3rd to the 5th interspace, there is faint pleuritic friction.

On the left side, dulness on percussion to the 1st Rib, with prolongation of the expiratory murmur over this area.

Posteriorly. On the right side, dulness on percussion to the 4th inter-space, with bronchial breathing over/

At two feet distance. Right over the same area. Pleuritic side 18 inches. Left side friction is heard in the 7th and 8th interspaces.

PHOTOGRAPH.

On the left side, dulness on showing the posterior aspect, and taken with patient lying, Hirschmann Tube, Lumière Plate, top of the third Rib, over this distance 18 inches. Duration of Exposure three minutes. area there is prolonged expiration.

SCREEN EXAMINATION.

A very marked diseased condition is at once seen Anteriorly. On the right side, there is the ribs, at the upper parts, being almost obscured, - marked loss of translucency and a mottled condition all over the chest, being from apex to the 4th Rib, and present, - the only clear parts being at each side, tapering off for an interspace on a level with the heart, or two below.

The ribs slope more acutely on the right side. On the left side, marked loss of this can be best estimated over the clearer parts, translucency above the clavicle, just mentioned, - on the left side, the interspaces and to a much less degree as far will be observed to be much wider, in this region, as the 4th Rib.

The impaired expansion at the right base, as Posteriorly. On the right side, opacity down well as the greater limitation of the diaphragmatic movement, I attribute as due to the Pleurisy, to the 7th Rib, and slighter impairment of the translucency,

The heart shadow is distinctly seen, low down, for an interspace or so below. and the settling on each side, at the base, has been seen in other photographs, and ascribed to the On the left side, to the 5th Rib, there is loss of translucency.

Diaphragmatic At/
movement. right hand lower corner, are due

to/

At two feet distance.) Right
 side $1\frac{3}{8}$ inches.) Left side
 $2\frac{1}{8}$ inches. Pleurisy, which, as has
 PHOTOGRAPH.

Showing the posterior aspect, and taken with
 patient lying, Hirschmann Tube, Lumière Plate,
 Distance 18 inches. Duration of Exposure three
 minutes.

A very marked diseased condition is at once seen -
 the Ribs, at the upper parts, being almost obscured, -
 and a mottled condition all over the chest, being
 present, - the only clear parts being at each side,
 on a level with the heart.

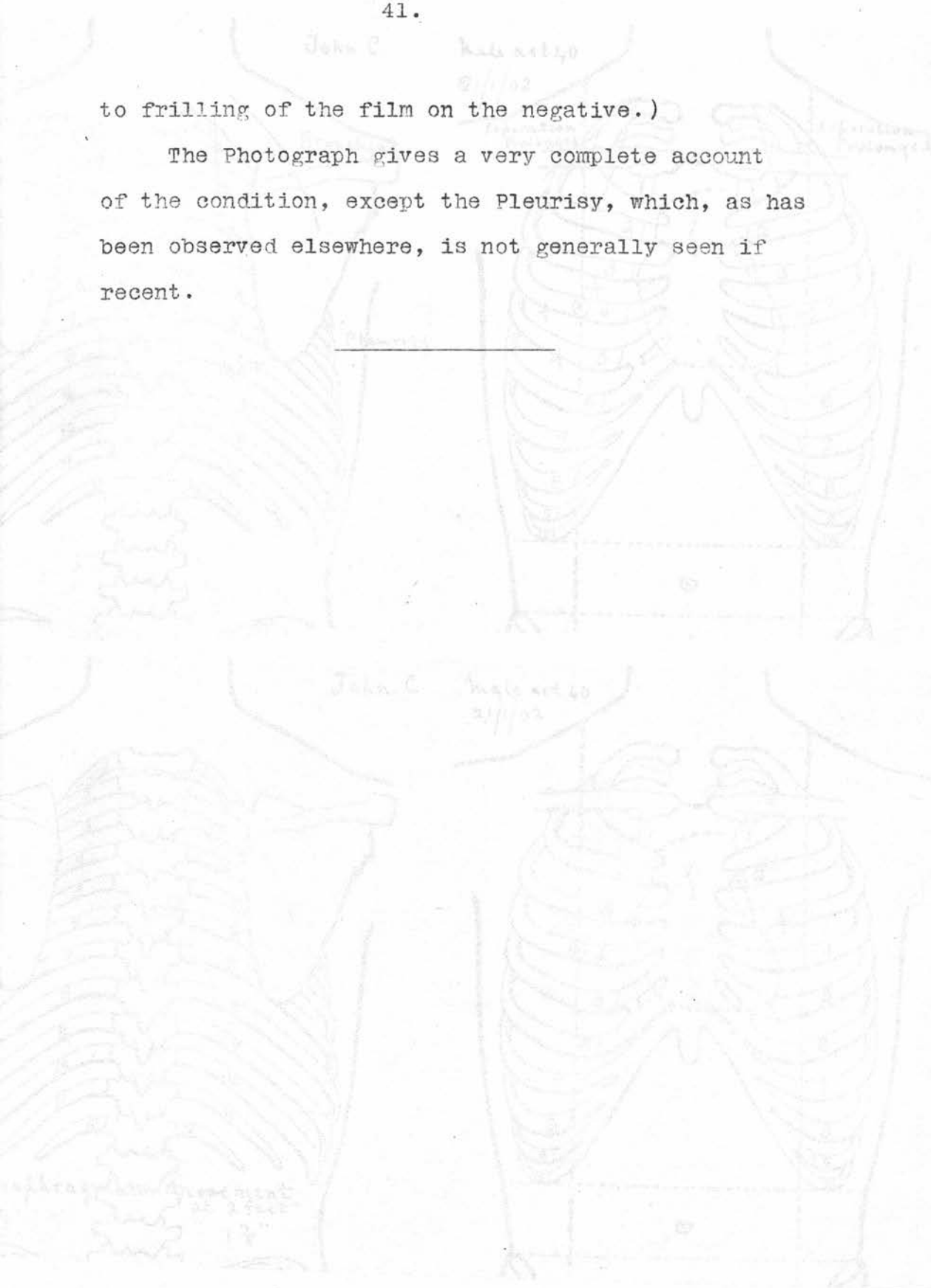
The Ribs slope more acutely on the right side, -
 this can be best estimated over the clearer parts
 just mentioned, - on the left side, the interspaces
 will be observed to be much wider, in this region.

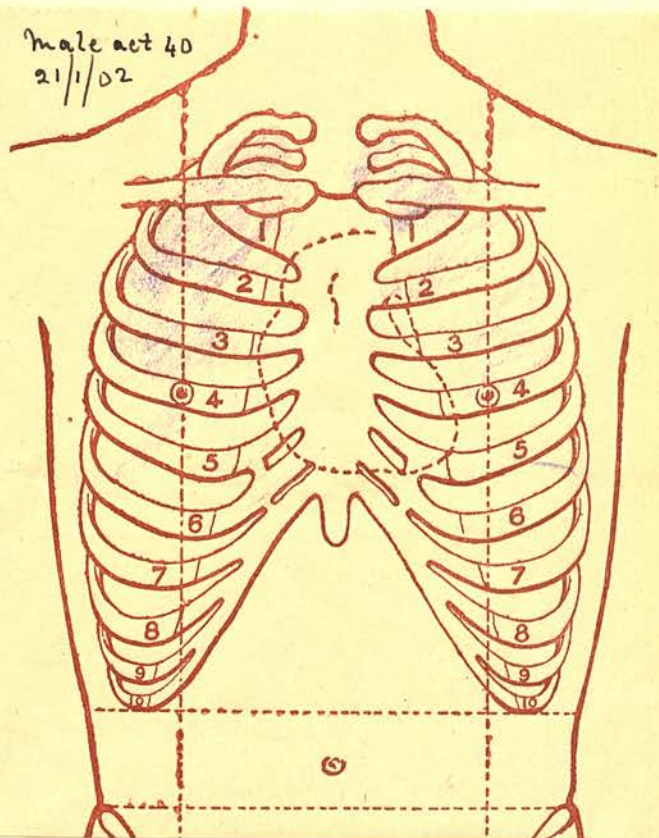
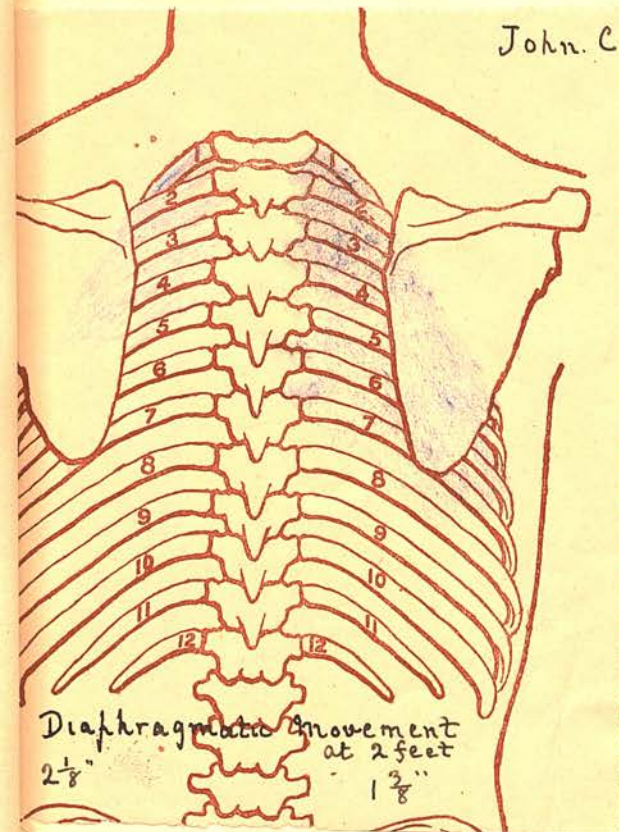
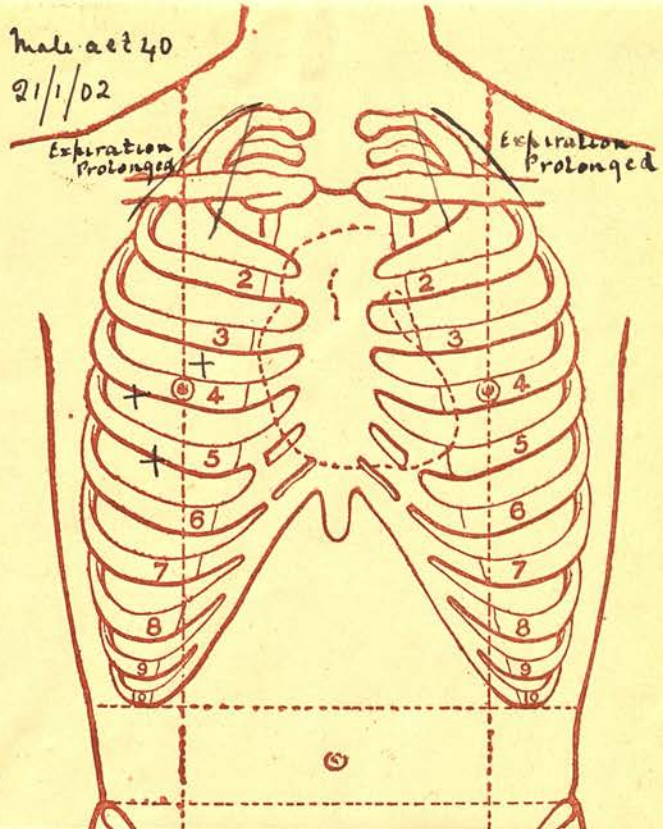
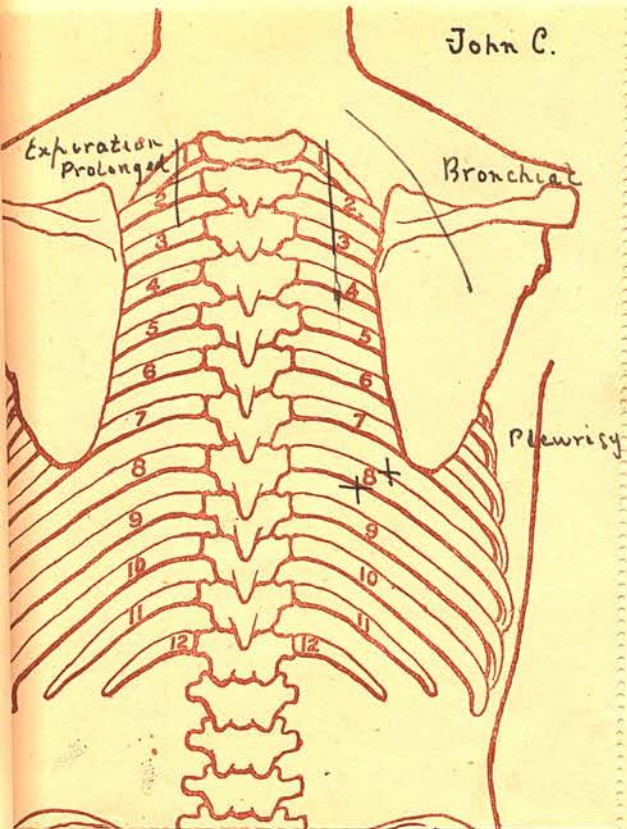
The impaired expansion at the right base, as
 well as the greater limitation of the diaphragmatic
 movement, I attribute as due to the Pleurisy.

The heart shadow is distinctly seen, low down,
 and the mottling on each side, at its base, has been
 seen in other photographs, and ascribed to the
 cardiac movement, or lymphatic spread. (The
 markings at the right hand lower corner, are due
 to/

to frilling of the film on the negative.)

The Photograph gives a very complete account of the condition, except the Pleurisy, which, as has been observed elsewhere, is not generally seen if recent.





B.G. Age 20, Composer. Height 5 feet 2 $\frac{1}{2}$.

Weight 9 stone 10.

COMPLAINT. Pain under the left shoulder blade.

DURATION. 5 weeks.

Father died of Phthisis 9 months ago, and was ill for some years. Patient had Rheumatism 6 years ago, but formerly was healthy.

RESPIRATORY SYSTEM.

Cough slight. Sputum thin white. No Hoemoptysis. Dyspnoea on exertion. The pain under the left shoulder blade is felt mostly, when taking a long breath. Tonsils enlarged. Larynx normal.

ALIMENTARY SYSTEM.

Tongue tremulous and flabby. Diarrhoea at present. Pulse 96. Temperature normal. No night sweats. Other systems normal, except for some enlargement of the Heart.

PHYSICAL EXAMINATION OF THE CHEST.

Anteriorly. On percussion, there is dulness on both sides to the 2nd Rib, with Bronchial breathing above the Clavicle.

Posteriorly. On the left side, the dulness on percussion extends to the 7th Rib, being most marked above. Crepitations accompany the breath sounds, all down this/

this side. Down to about the 4th Rib, the breathing is Bronchial, and below that it is Vesicular, with prolonged expiration.

PHOTOGRAPH.

Taken with a Roentgen Plate

Posteriorly. On the right side, the note is impaired to the 3rd Rib, and crepitations are present for that distance. Bronchial breathing is present above the Scapula, and Vesicular breathing, with prolonged expiration, for one or two interspaces below.

SCREEN EXAMINATION.

Anteriorly. Diminished translucency all down the left side, but most marked above.

On the right side, down to the 3rd Rib, there is also diminished translucency.

Posteriorly. The left Lung is opaque to the 4th Rib, and the loss of translucency below, though not so great, extends down to the diaphragm.

On the right side, there is loss of translucency down to the 5th Rib.

Diaphragmatic movement. This is also much impaired - at two feet distance the measurement with deep/

deep breathing was $\frac{1}{2}$ " on the left side, and 1" on the right side.

PHOTOGRAPH.

Taken with a Hirschmann Tube on a Lumière Plate at 18" distance, shows the posterior aspect.

A first glance at once reveals a marked difference between the two sides, the left showing a deep shadow all the way down.

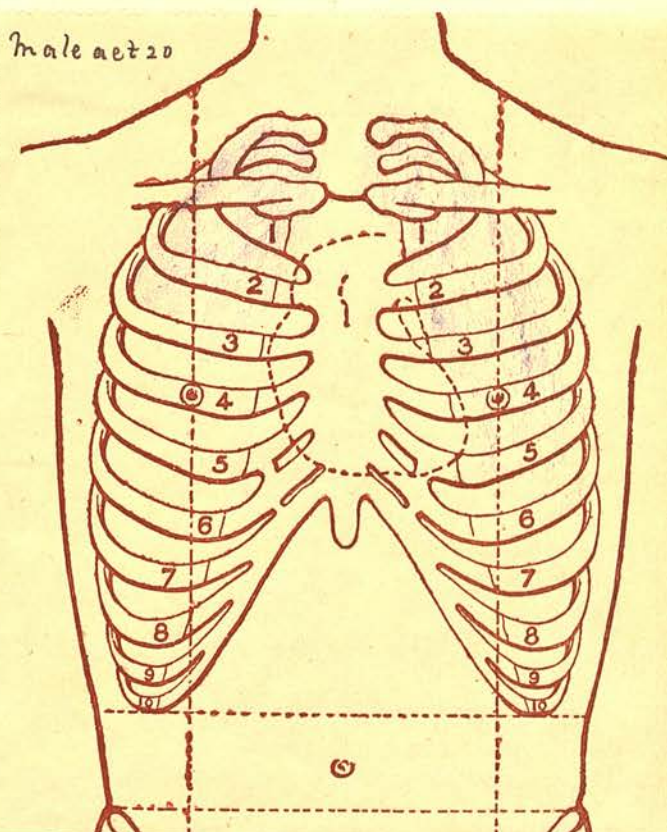
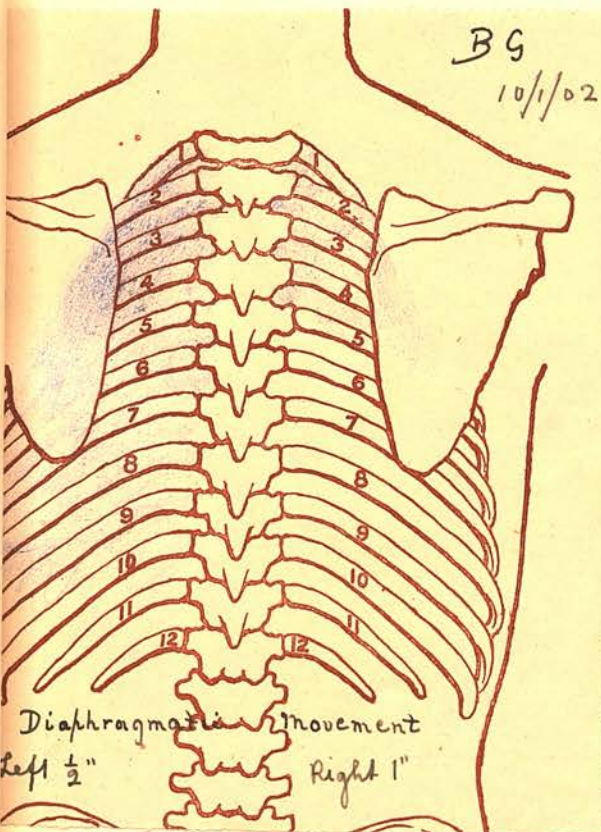
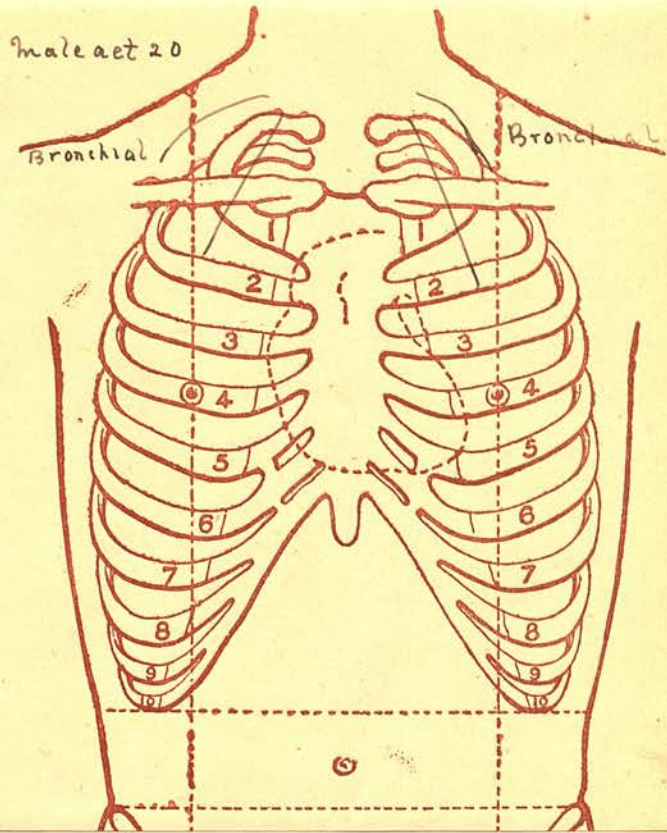
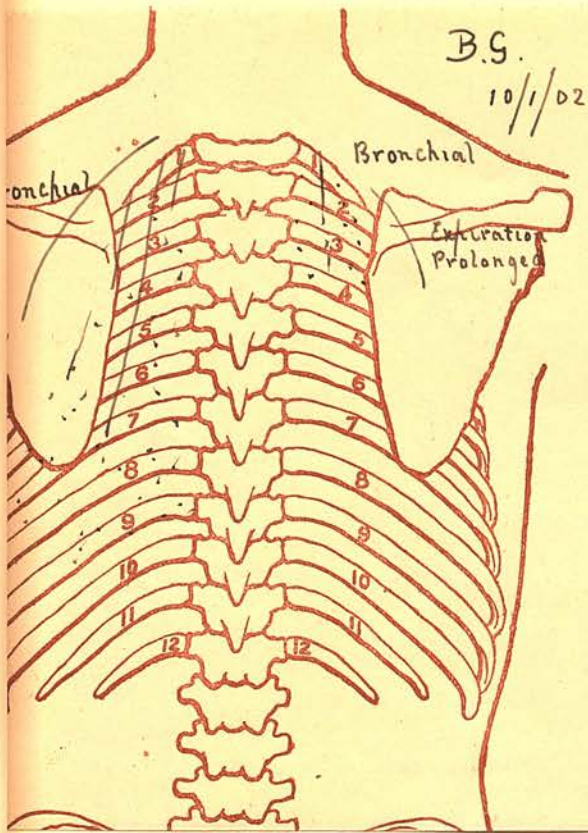
The shadow of the Hypertrophied Heart is well seen, encroaching on this side.

On the right side, the shadow extends to the 3rd Rib although not so dense, and at the lower part, there is abnormal clearness indicating a compensatory emphysema.

The shadow on the left side is not so mottled as in other cases, this being due to the thickened Pleura.

The Chest is fairly well shaped, but the interspaces will be noticed to be narrower on the affected side, at the lower part especially, and on this (left) side, the angle of the Ribs is more acute.

In this case, the photographic picture revealed more than I could find with ordinary examination; but still it is inferior to the Screen Examination.



John J. Scavenger. Age 52. Height 5 feet
6. Weight 9 stone 5. Temperature normal.

COMPLAINT.

Cough for two years; and recently he has been
spitting blood.

Previous history good.

Mother died of "Chest Complaint".

RESPIRATORY SYSTEM.

Cough very slight, with thick greenish sputum.

Frequently has slight attacks of hoemoptysis.

Larynx pale but no lesion.

Other systems normal.

Pulse 84 slightly irregular in time and force.

PHYSICAL EXAMINATION.

Anteriorly. On the right side, there is dul-
ness on percussion, above the
clavicle, and there the breathing
is almost bronchial.

No accompaniments. Normal below.

On the left side, a more marked
dulness above the clavicle, the
breathing being vesicular, with
prolonged expiration, as far as
the 1st Rib.

Posteriorly. On/

On the right side, there is dulness to the spine of the scapula, and impairment of the note, to the 5th Rib. An occasional crepitation is heard in this area, and the breathing is vesicular, with prolonged expiration to the 6th Rib. On the left side, there is marked dulness, above the scapula, where the breathing is Bronchial.

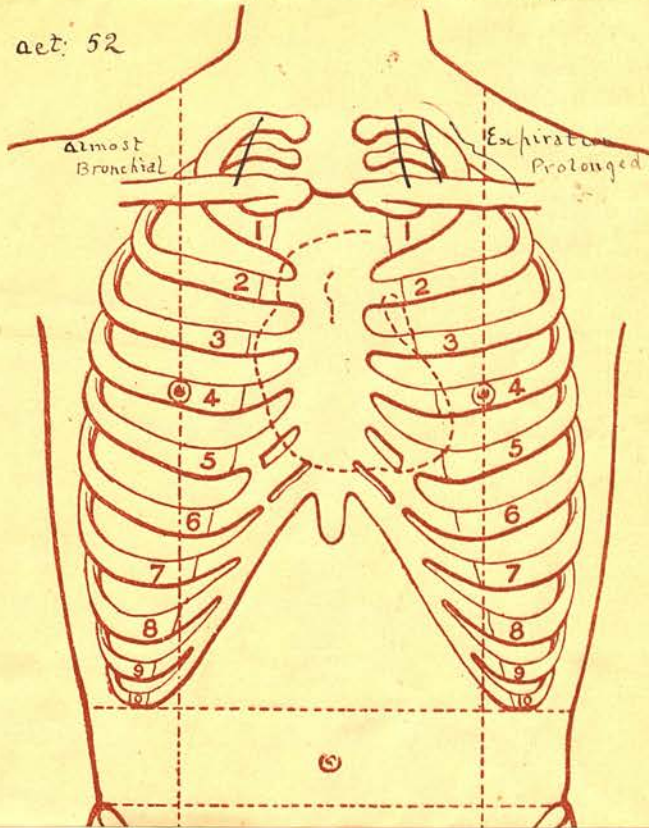
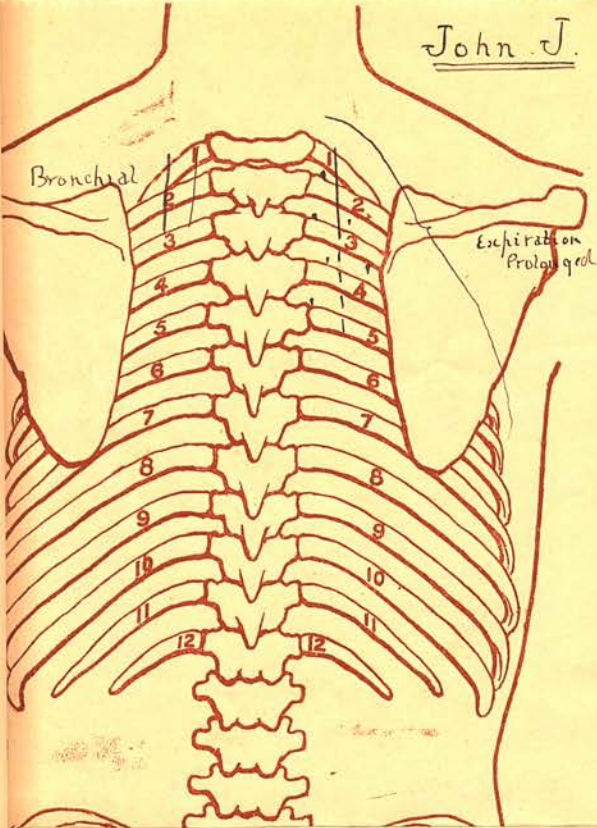
SCREEN EXAMINATION.

Anteriorly. On the right side, there is loss of translucency, marked to the 2nd Rib, and shading off, for one or two interspaces below. On the left side, - marked loss of translucency to the 2nd Rib, and shading off as on the right side.

Posteriorly. On the right side, there is very marked loss of translucency to the 4th Rib, and though/

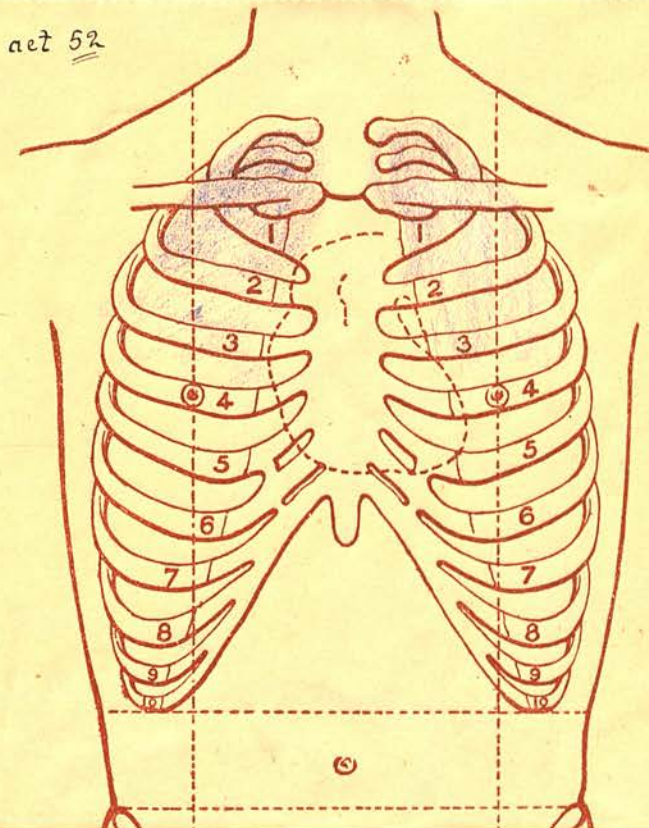
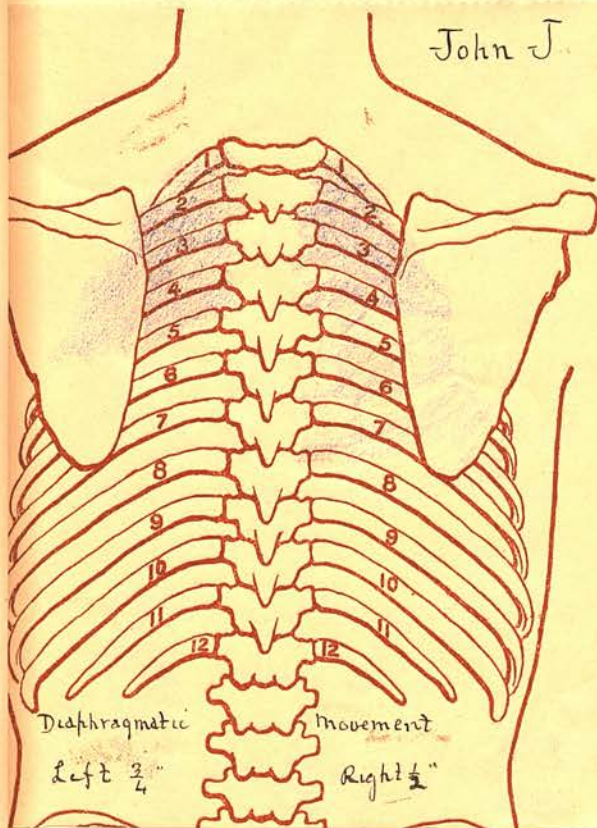
John J.

aet. 52



John J.

aet. 52



though not so marked, extends down to the 8th. On the left side, the loss of translucency extends down to the 5th Rib.

Diaphragmatic movement.

At two feet distance.

Right $\frac{1}{2}$ inch. Left $\frac{3}{4}$ inch.

PHOTOGRAPH.

Showing Posterior Aspect - taken with patient lying, and arms away from the sides.

Lumière Plate. Hirschmann Tube. Distance 18 inches.

Duration of exposure $2\frac{3}{4}$ minutes.

When examined at two feet distance, the marked affection of the apices is at once seen - the right being, if anything, more opaque.

The mottling extends down, on the right side, to the 7th Rib. On the left side, the extent seems pretty much the same, and in comparison with the right side, is more distinct at the lower part.

The Heart is seen at the lower part, and the mottled shadow of the Pericardium, apparently at its right side.

EXAMINATION THREE MONTHS LATER.

PHYSICAL EXAMINATION OF THE CHEST.

Anteriorly. On the right side, the dulness had extended to the 1st Rib, and/

and the breathing is distinctly bronchial. On the left side, there is creaking friction over the first 3 interspaces, and the prolonged expiration is heard, down to the 4th Rib.

Posteriorly. On the right side, there is dulness to the 7th Rib, and impairment of percussion note, to the 8th interspace: Vesicular breathing with prolonged expiration is heard over this area. Crepitations are heard, to the Spine of the scapula.

Posteriorly. On the left side, the dulness extends to the 4th Rib, and bronchial breathing is heard over there. Crepitations are heard down to lower angle of Scapula. Below the 4th Rib the breathing is vesicular with expiration prolonged.

SCREEN EXAMINATION. is not very slight - $\frac{1}{2}$ inch on

Anteriorly. On/ side, and being more transmitted/

on the right side, the only part clear is below the 5th Rib, at the outer end.

On the left side, there is deeper shadow now, from a chronic pleurisy; the Ribs slope much more acutely, and move less freely on this side, and the only part absolutely clear, is at the outer end, below the 6th Rib. A faint clearness is seen above the clavicle, indicating a cavity probably.

Posteriorly. The loss of translucency extends all down on the right side. On the left side, the loss of translucency extends to the 8th Rib, and there is a slight clearing over the 1st and 2nd interspaces, corresponding to the probable cavity seen in front.

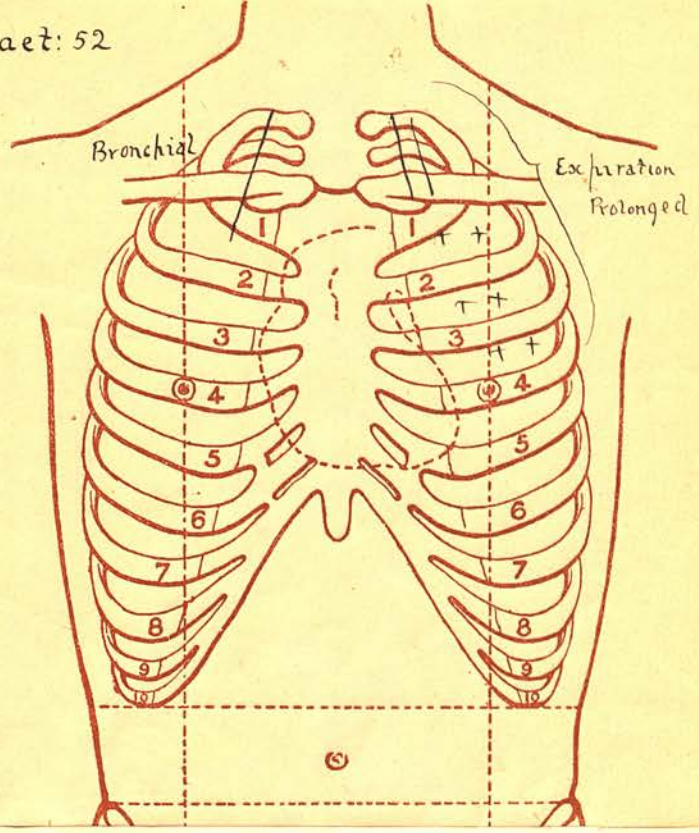
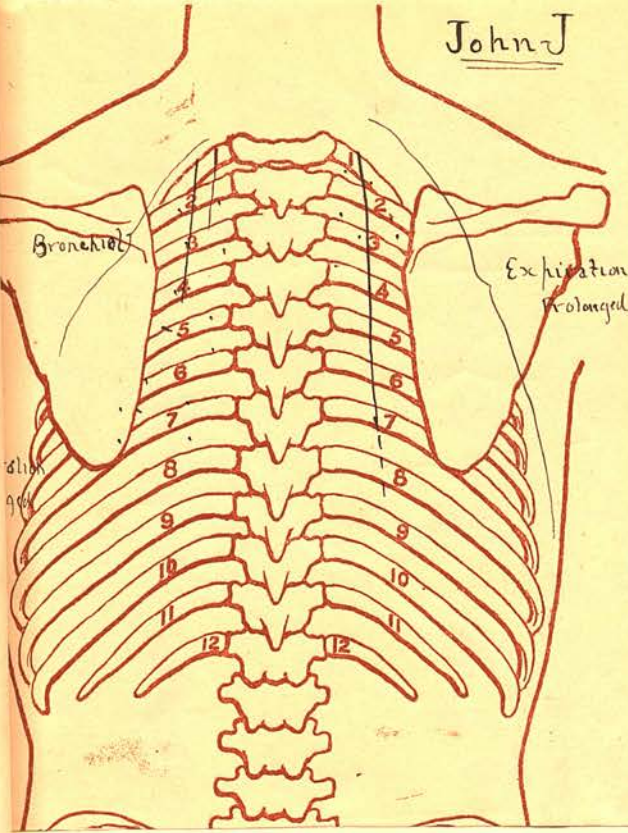
Diaphragmatic movement. Is now very slight - $\frac{1}{4}$ inch on each side, and being more a transmitted/

transmitted wavy motion, from side to side. The expansion of the Chest, seems to be, mainly, by movement of the Ribs. The case is one, in which, I have been able to trace the progress, and record it; but he would not submit to have a second photograph taken, as the lying down caused pain before. At both times, the X Ray examinations have given fuller details, than ordinary physical examination. Particularly interesting are, the appearance of a probable cavity later, when physical signs still did not show it, and the effect of the chronic pleurisy, in increasing the slope of the Ribs on the left side. The alteration of the Diaphragmatic movement is also noticeable.

Examination 3 months later

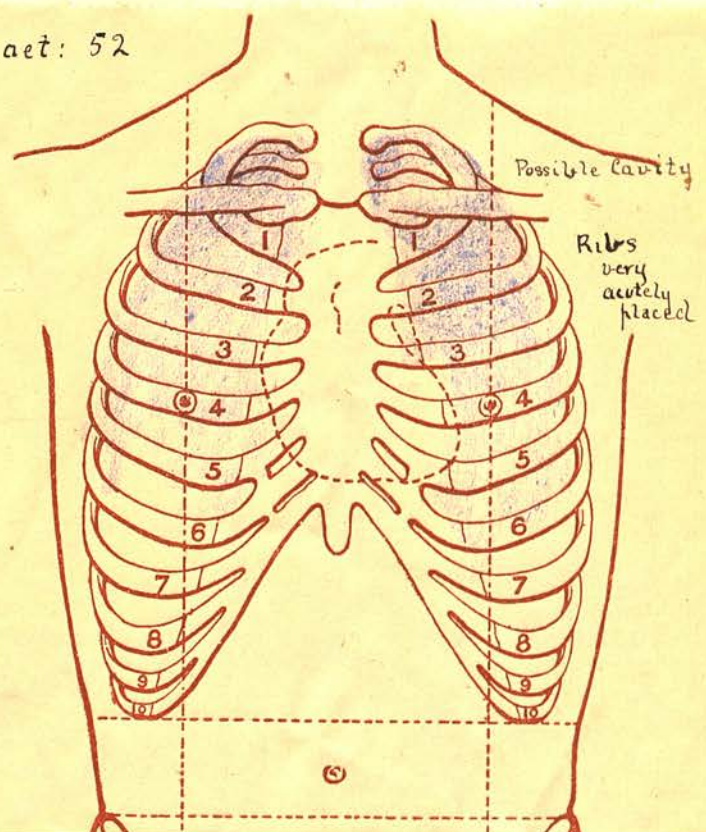
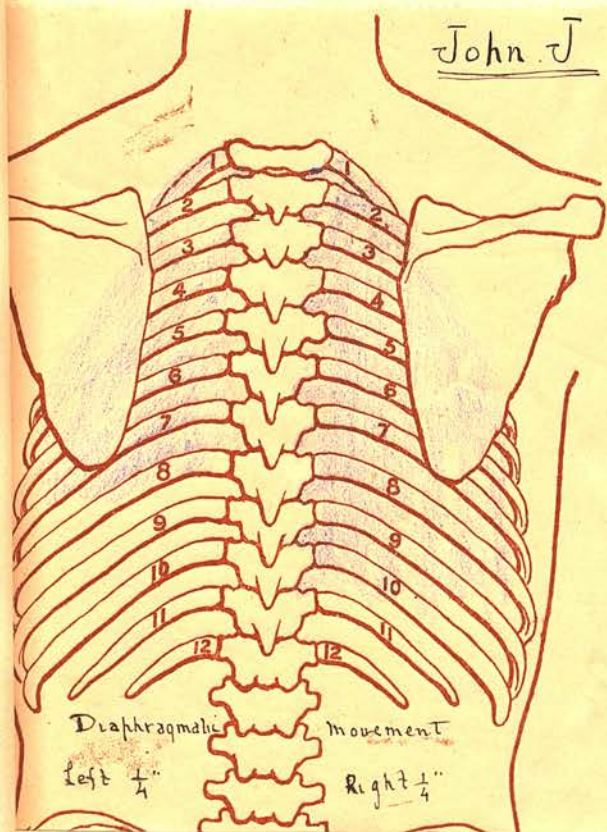
John J

aet: 52



John J

aet: 52



Thomas R. male. Basketmaker. Aged 38. Normal
 Height 6 feet $3\frac{1}{4}$ inches. Weight 13 stone $13\frac{3}{4}$ lbs.
 Temperature normal.

COMPLAINT.

Cough and spit for two years. Pleurisy, with effusion, two years ago. Brother died of Phthisis 18 years ago.

RESPIRATORY SYSTEM.

Cough hard - worst in morning. Sputum thick yellow, with occasional streaks of blood at times, for the last month. Dyspnoea on exertion. Larynx normal.—Patient has some dyspeptic symptoms; but no diarrhoea. Pulse 78. Tension and Volume fair. Night sweats at times. Has been losing weight.

PHYSICAL EXAMINATION OF THE CHEST.

Anteriorly. On the right side, dulness on percussion, to the 2nd Rib, with prolonged expiration, and vesicular breathing - almost bronchial in character. On the left side, dulness, on percussion, to the first interspace, over which there is vesicular breathing, with/

Posteriorly.



with prolonged expiration. Normal elsewhere.

Posteriorly. On the right side, dulness on percussion to the 4th interspace, with bronchial breathing over the first three Ribs, and prolonged expiration, with vesicular breathing, to the 5th interspace. On the left side, dulness on percussion to the 3rd interspace, with vesicular breathing and prolonged expiration, to the 4th interspace. Again, from the 8th Rib to the Diaphragm, there is a patch of dulness, and over this pleuritic friction, and crepitations are heard.

SCREEN EXAMINATION.

Anteriorly. On the right side, there is loss of translucency, down to the 4th Rib, and on the left side, to the 2nd Rib. More marked on the right side.

Posteriorly. On the right side, there is opacity to/

to the 6th Rib, tapering off below. On the left side, the loss of translucency extends from apex to the top of the 5th Rib, but is not so dense as on the right side. A nodular mass is present in the 7th interspace, $1\frac{1}{2}$ inches from the central line of the vertebral column, and about the size of a halfpenny.

From the 8th Rib to the base, another patch of dulness, more dense, is seen, corresponding to the pleurisy found in physical examination. The Ribs slope more acutely at the upper part, on the right side.

Diaphragmatic. At two feet distance. Right movement. side 1 inch. Left $\frac{3}{4}$ of an inch.

PHOTOGRAPH.

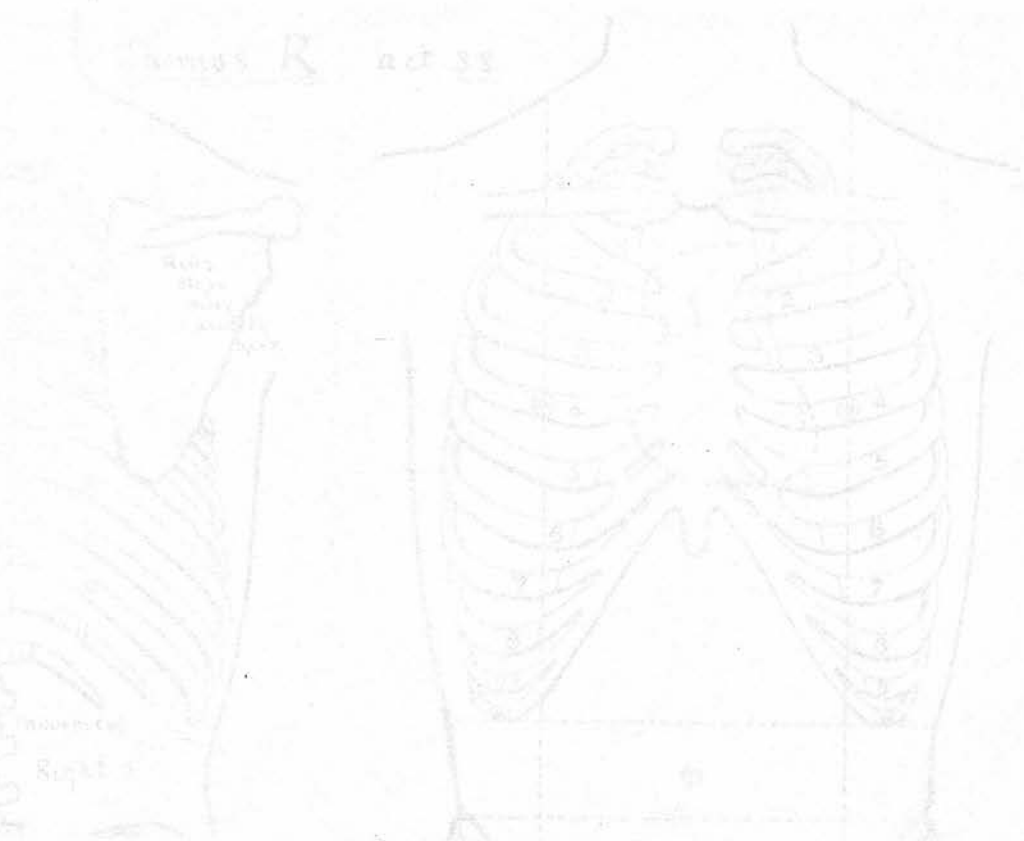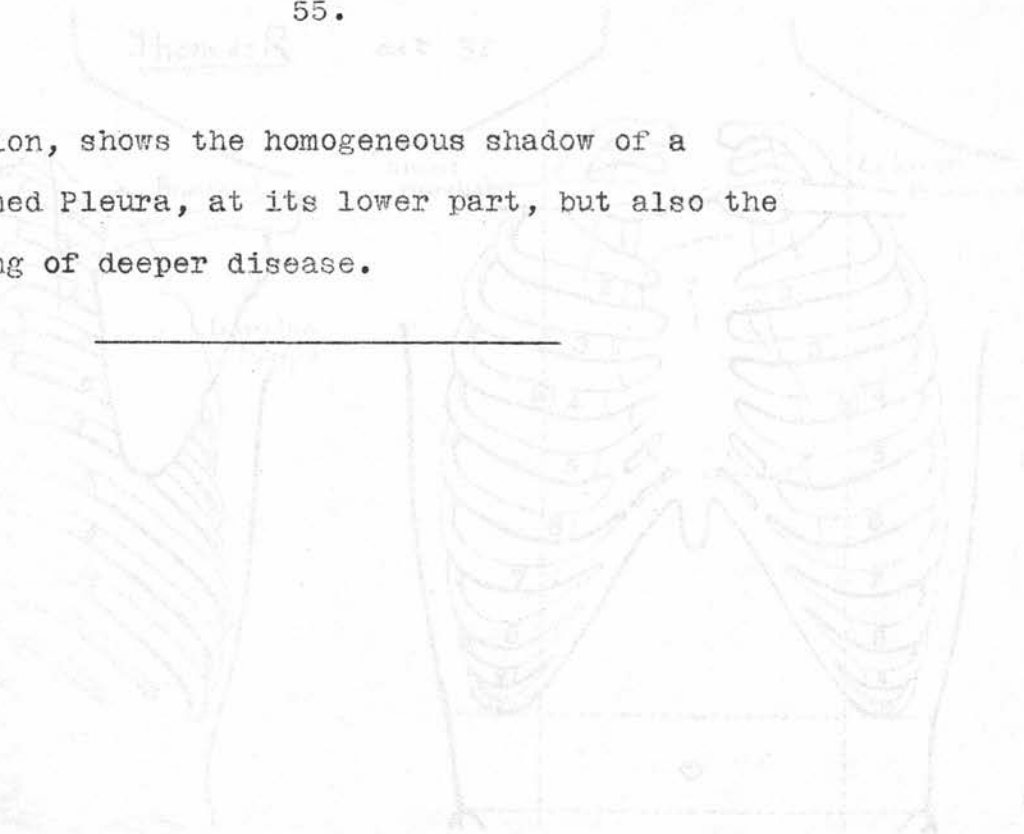
Showing the posterior aspect. Taken with patient lying. Lumière Plate. Hirschmann Tube. Distance 14 inches. Duration of exposure $3\frac{1}{4}$ minutes.

This/

This patient was a very muscular man, and consequently, there are dense shadows seen, especially at the sides, due to the muscles. The Ribs slope more acutely on the right side, especially at the upper part. Down to the 6th Rib, the right side is slightly more shaded than the left; but one must always take into account, the greater muscular development on this side, in a right handed man. Even allowing for this, there is a distinct mottling over the region mentioned. The left apex shows some faint patches, especially in the first interspace. At the left base, again, a shadow corresponding to the Pleurisy, is seen over the lower three interspaces. There is no definite sign of the nodule seen, unless the part marked by a cross indicates it - this, however, corresponds with the edge of the cardiac shadow, and if the screen examination had not attracted attention to it, no mention would have been made.

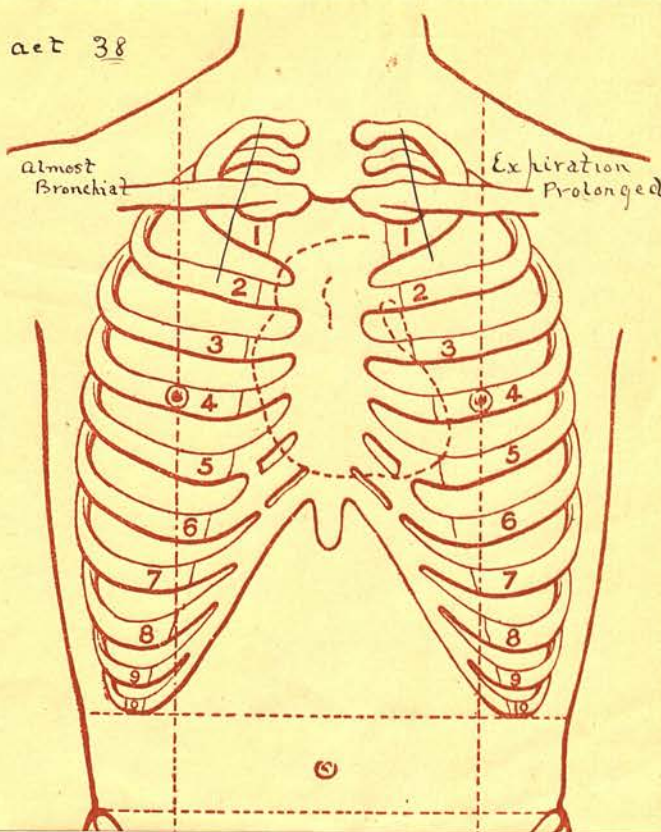
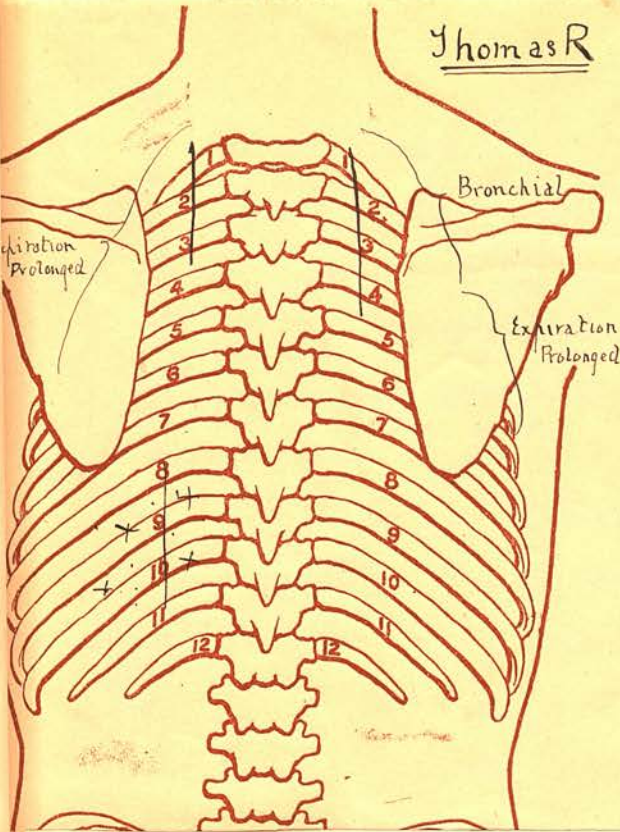
The Screen and Photograph both amplify the ordinary physical examination, and may be instructive, as showing the difficulties of diagnosis in a muscular individual; difficulties which are often met with, in ordinary physical examination. The Left Basal condition/

condition, shows the homogeneous shadow of a thickened Pleura, at its lower part, but also the mottling of deeper disease.



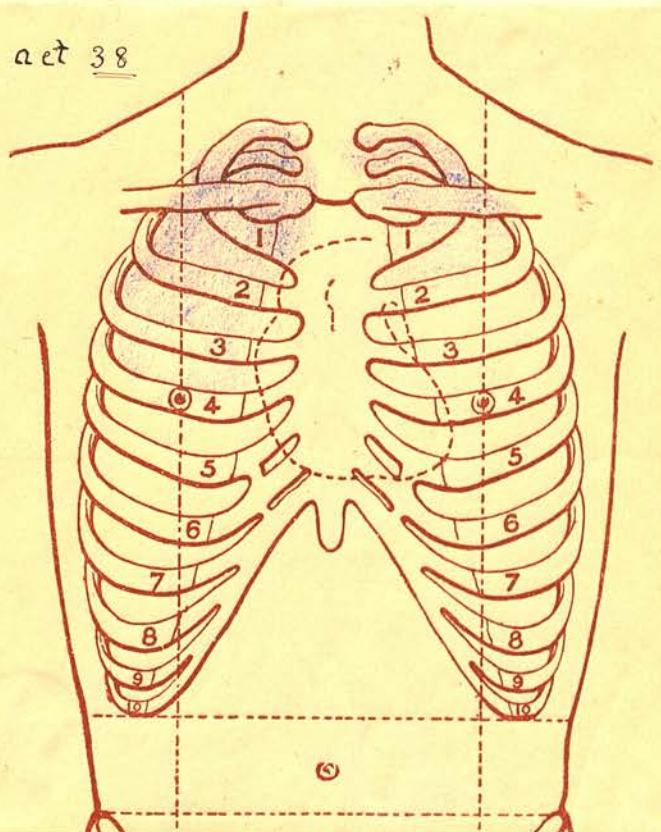
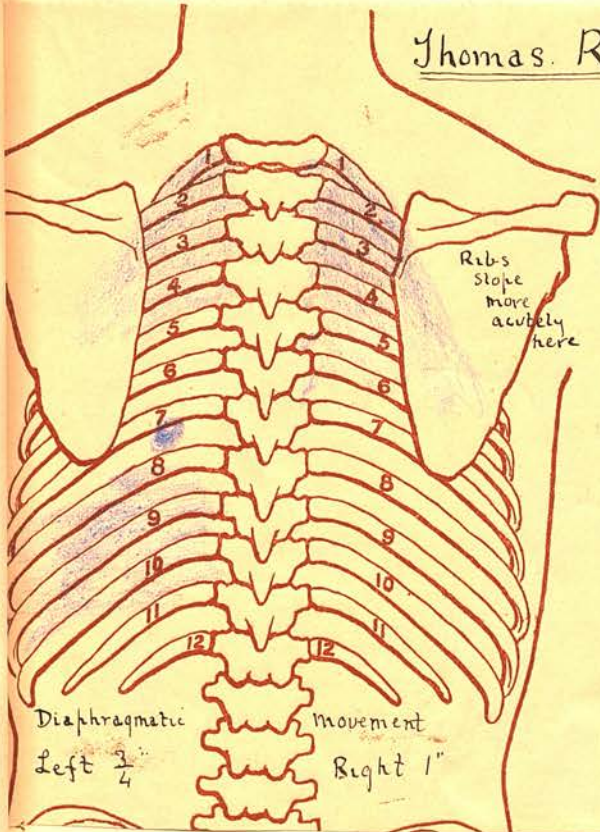
Thomas R

aet 38



Thomas R

aet 38



William G. Age 13. Height 4 feet $8\frac{1}{4}$ inches
Weight 4 stone 12 lbs. Temperature normal.

COMPLAINT.

Cough in the morning for the last 6 or 7 months.
Brother died of Phthisis 5 years ago.

RESPIRATORY SYSTEM.

Cough of a tickling nature in the morning,
with thick white sputum. No hoemoptysis.
Occasional pain in front of the Chest.
Dyspnoea on exertion. Larynx normal except for pallor.

ALIMENTARY SYSTEM.

Tongue furred. Appetite fair. Vomiting
after a fit of coughing. No diarrhoea. Has
been losing weight. Pulse 80. Tension and
Volume Poor. Night sweats.

PHYSICAL EXAMINATION OF THE CHEST.

Anteriorly. Slight dulness on percussion, on
the left side from apex to 1st
interspace. Vesicular breath-
ing with prolonged expiration
over this area.
Posteriorly. On the right side, an impaired
note on percussion, down to
the 5th interspace, with
bronchial breathing to the 2nd
Rib, /

Rib, and prolongation of the inches.

PHOTOGRAPH.

expiratory murmur to the 6th

Patient sitting Rib. On the left side, per-

the posterior aspect cussion reveals an impairment

and Cathedral Plate of the note, down to the 7th

exposure of 37 min interspace. On Bronchial Breath-

example of the point ing is heard to the 4th Rib. and

in Phthisis cases. Occasional crepitations accompany

well seen, and the the breath sounds, over the

on its right margin region of impaired percussion

consolidation, exc note, posteriorly. no apices,

especially the right.

SCREEN EXAMINATION.

Anteriorly. On the right side, loss of

the result is disap translucency to the 1st Rib, on

chiefly to the lung and on the left side, to the

distance of the Chest 2nd Rib, and more marked in

The photograph was character. beginning of 1901,

when I was especially not working regular

especially difficult translucency to the 3rd Rib, on

and on the left side to the examination fall and

5th Rib - again more marked on

this case: there may the left side. cause in the

Diaphragmatic At two feet distance - right

movement.

side/anything, but faulty

methods, and faults in the apparatus. I have tried

since to get the patient again, but have not been

successful so far.

side 1 inch. Left side $1\frac{1}{2}$ inches.

PHOTOGRAPH.

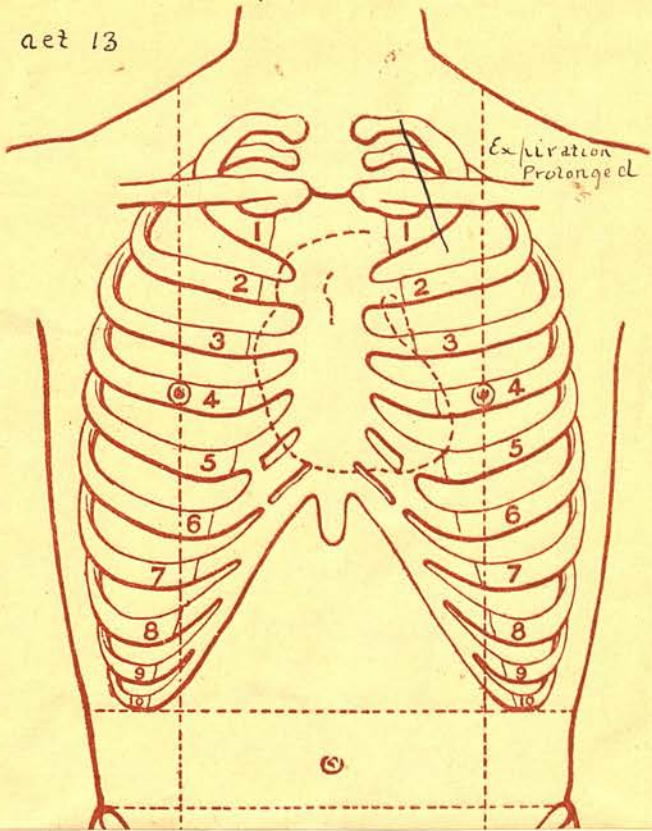
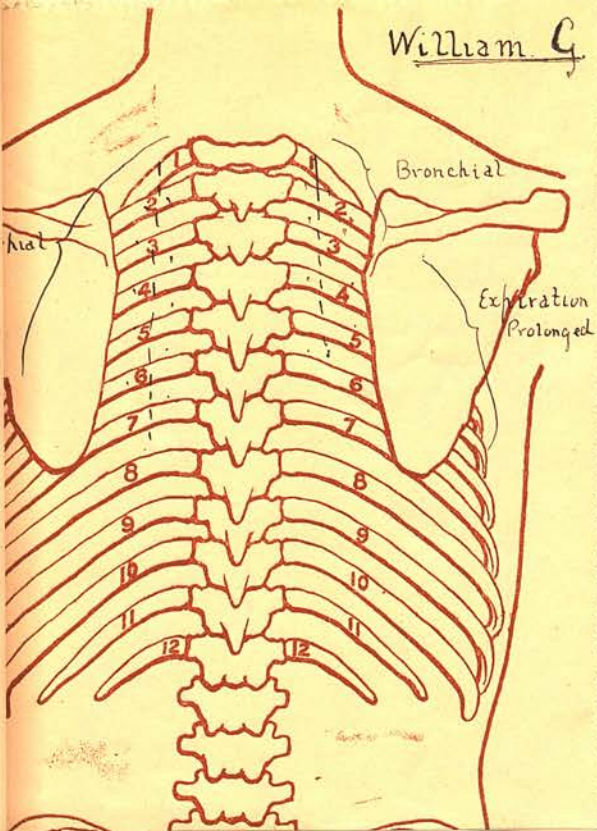
Patient sitting - arms hanging down - showing the posterior aspect. Taken with Hirschmann Tube, and Cathodal Plate, at 10 inches distance, with exposure of $3\frac{1}{2}$ minutes. The Chest is a typical example of the pointed and narrow character, found in Phthisis cases. The outline of the Heart is well seen, and the faint shadow of the Pericardium on its right margin, but practically no signs of consolidation, except a haziness at the apices, especially the right.

There was no doubt about the physical signs, and the result is disappointing, and may be attributed chiefly to too long exposure, and not sufficient distance of the Chest from the tube.

The photograph was taken at the beginning of 1901, when, unfortunately, the Infirmary Apparatus was not working regularly, and made screen examination especially difficult. Both photograph and screen examination fall short of ordinary methods, in this case: there may have been some cause in the character of the disease, which affected this; but I see no reason to blame anything, but faulty methods, and faults in the apparatus. I have tried since to get the patient again, but have not been successful so far.

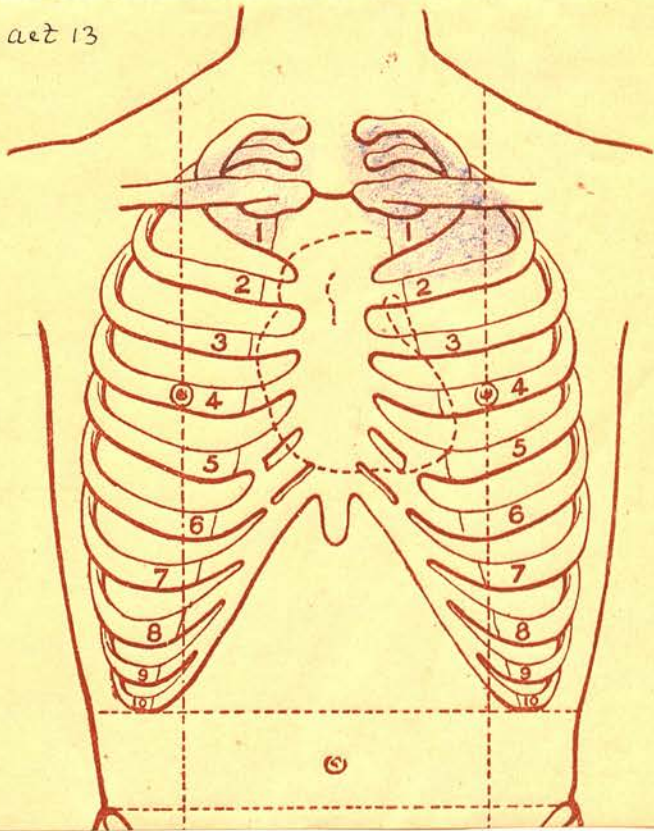
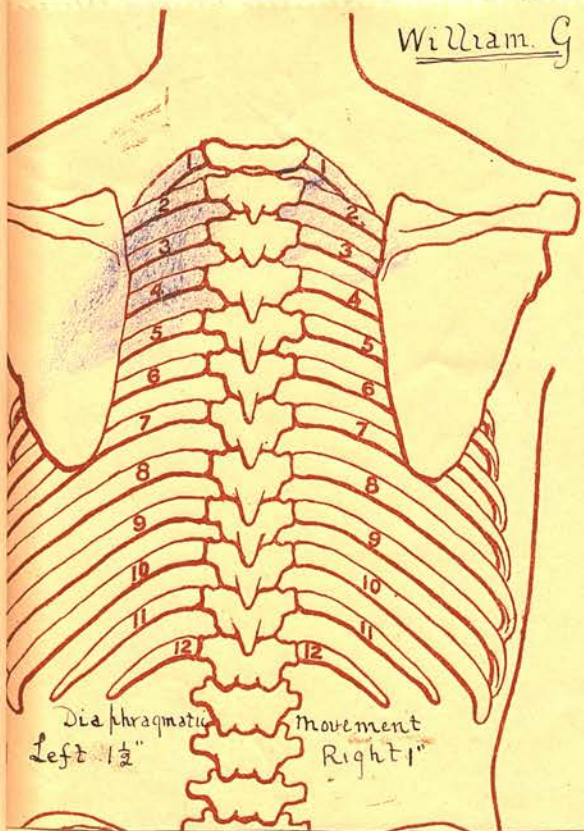
William G

aet 13



William G

aet 13



Jessie R. Age 10. Height 4 feet 5". Weight
3 stone $1\frac{1}{4}$ lbs.

COMPLAINT.

"Cough and spit" lasting for 18 months.

Family history of Phthisis.

RESPIRATORY SYSTEM.

Cough hard and very troublesome at night.

Thick white sputum occasionally tinged with blood.

Pain on the right side posteriorly. Tonsils enlarged.

Larynx very pale. Sputum when examined showed

Tubercle Bacilli.—Pulse 120. Tension and Volume

fair. Urine contains sugar. Suffers from night

sweats. Has been losing weight.

PHYSICAL EXAMINATION OF THE CHEST.

Anteriorly. No dulness on percussion. On

both sides, rhonchi and occasion-

al crepitations are heard, down

to about the 5th Rib.

Posteriorly. No dulness on percussion anywhere.

On the right side, the breathing

is bronchial to the 5th Rib, and

rhonchi and crepitations are heard,

almost all over.

On the left side, rhonchi and

crepitations are also present.

SCREEN EXAMINATION.

Anteriorly./

Anteriorly. On the right side loss of translucency to the 3rd Rib and on the left to the 2nd interspace. Denser on the left side. Heart shadow seems smaller than normal.

Posteriorly. On the right side loss of translucency to the 6th interspace, and on the left side, to 6th Rib, - denser on the left side.

Diaphragmatic movement. This is very jerky in its action; and only $\frac{1}{2}$ an inch on the right side and $\frac{5}{8}$ on the left.

PHOTOGRAPH.

Showing the posterior aspect - taken by a Hirschmann Tube at 18" distance from Chest wall. Cathodal Plate and 3 minutes exposure.

When examined, the photograph shows marked sloping of the Ribs, on the right side.

There is a general haziness all over, but the shadow is deeper at the upper parts, especially the left.

On the right side, there is, what looks like, a focus of disease near the base of the Heart - marked with a cross in the photograph.

On the left side, the shadow stops at the base of/
of/

of the Heart and just there, is a denser mass, marked with a cross, which may indicate lymphatic enlargement, or possibly the dilating auricle. Neither of these masses were seen on the screen.

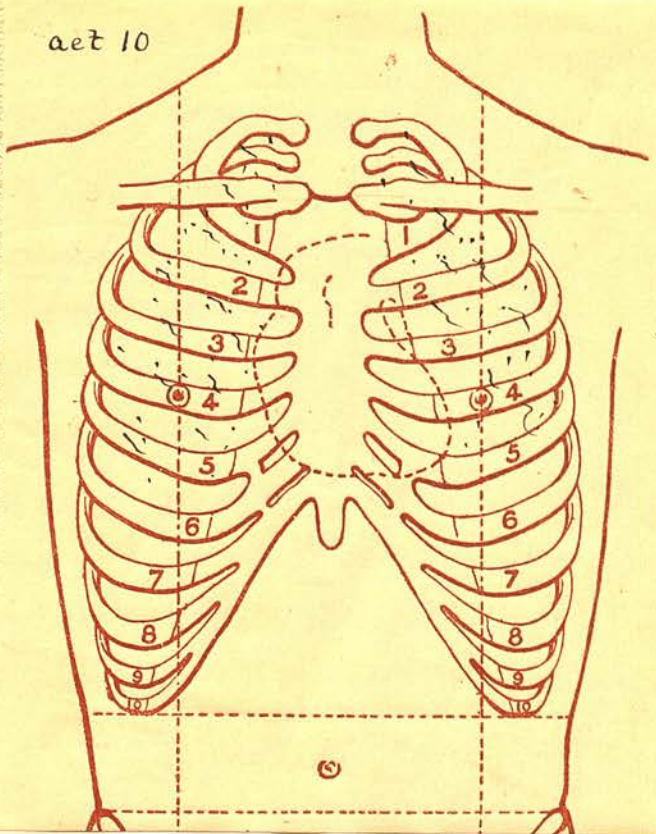
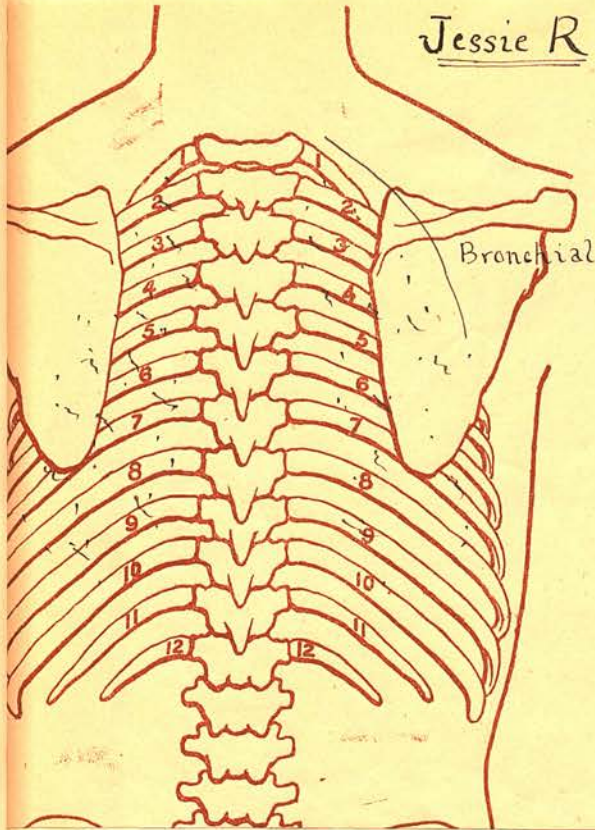
The photograph is not a very clear one, but indicates a more advanced condition, than the screen examination revealed.

The condition was complicated with so much Bronchitis, that ordinary physical signs were obscured; a state of matters in which I have found X Rays exceedingly helpful.

I heard recently that the patient died suddenly a few weeks after the above examination.

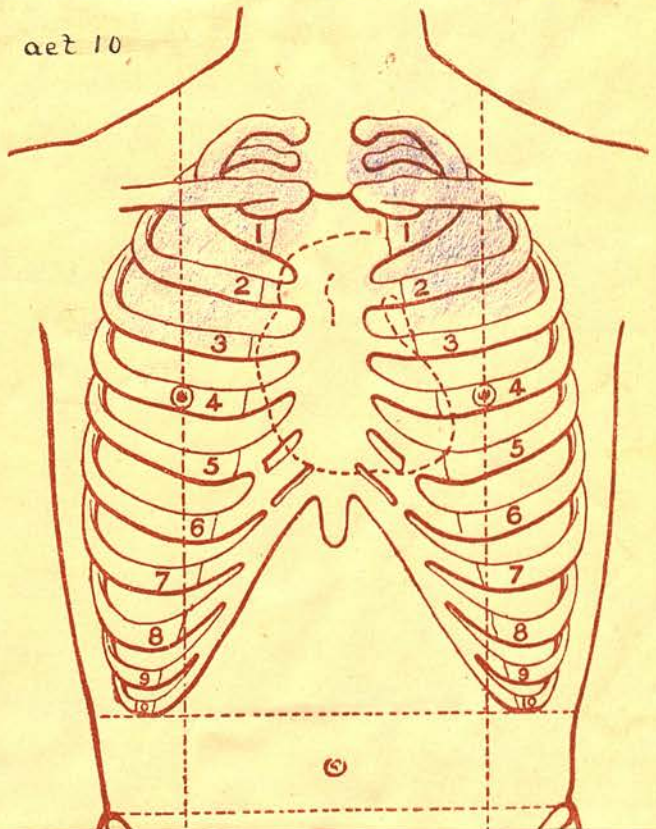
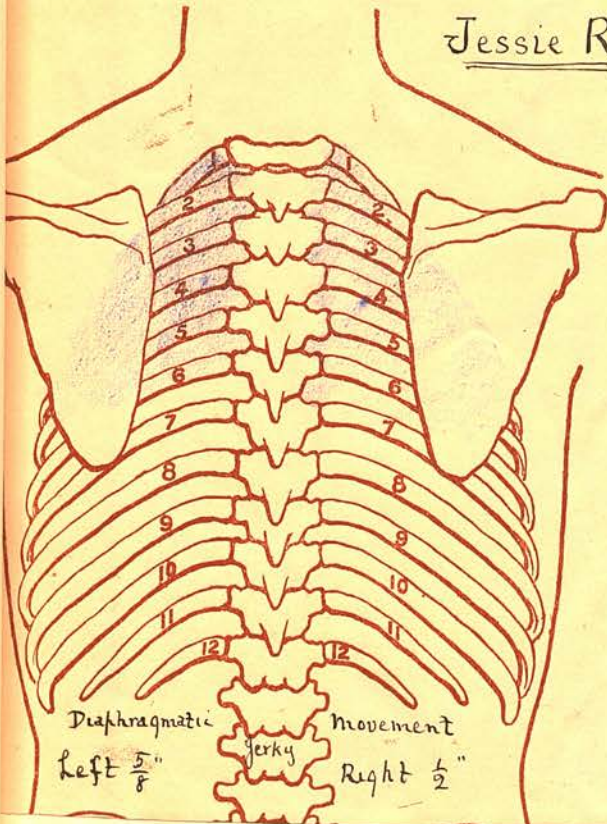
Jessie R

aet 10



Jessie R

aet 10



Mrs R. Housewife, age 36. Height 5 feet 8 inches. Weight 8 stone 11½ lbs.

Complaint - general weakness and cough; lasting for some years. Family history doubtful. Previously treated for Menorrhagia.

RESPIRATORY SYSTEM.

Cough sometimes severe, at other times absent. Yellowish expectoration, occasionally streaked with blood. Sometimes suffers from pain on right side of Chest. Dyspnoea on slight exertion. Larynx healthy.—Pulse 90; poor. Heart slightly enlarged. Miscarriage 6 years ago. Menstruation irregular. Otherwise normal.

PHYSICAL EXAMINATION OF CHEST.

Anteriorly. Slight dulness on percussion, at

Posteriorly. both apices, as far as the 1st Rib.

Breathing vesicular, with prolonged expiration over these areas.

Below the shadow of the scapulae, the Lungs are emphysematous condition. Hyperresonance on percussion, with harsh breathing below this, on both sides.

Posteriorly. On the right side, dulness on percussion, as far as the 5th Rib,

PHOTOGRAPH.

The Chest looks like a barrel chest. On the left side, with bronchial breathing above the spine of the Scapula, and vesicular breathing, /

side, at the lower part of the ribs approximately half as rapidly than they do at the upper part.

On the left side, dulness on percussion, as far as the 5th Rib, and impaired note to the 7th Rib. The breathing over this area is vesicular, with prolonged expiration and over the 4th and 5th and 6th Ribs, crepitations are heard.

Below these areas, on both sides, the note is hyperresonant.

SCREEN EXAMINATION.

Anteriorly. Loss of translucency extends to the 2nd interspace on the left side, and the 2nd Rib on the right side.

Posteriorly. On the right side, loss of translucency to the 4th Rib, and on the left side to the 7th Rib.

Below the shadowed areas, anteriorly and posteriorly, the Lungs are abnormally clear, indicating an emphysematous condition.

Diaphragmatic movement. At 2 feet distance from the Tube
 $1\frac{1}{4}$ " on each side.

PHOTOGRAPH.

The Chest looks barrel-shaped, and on the right side/

side, at the lower part, the Ribs approximate more rapidly than they do on the left side.

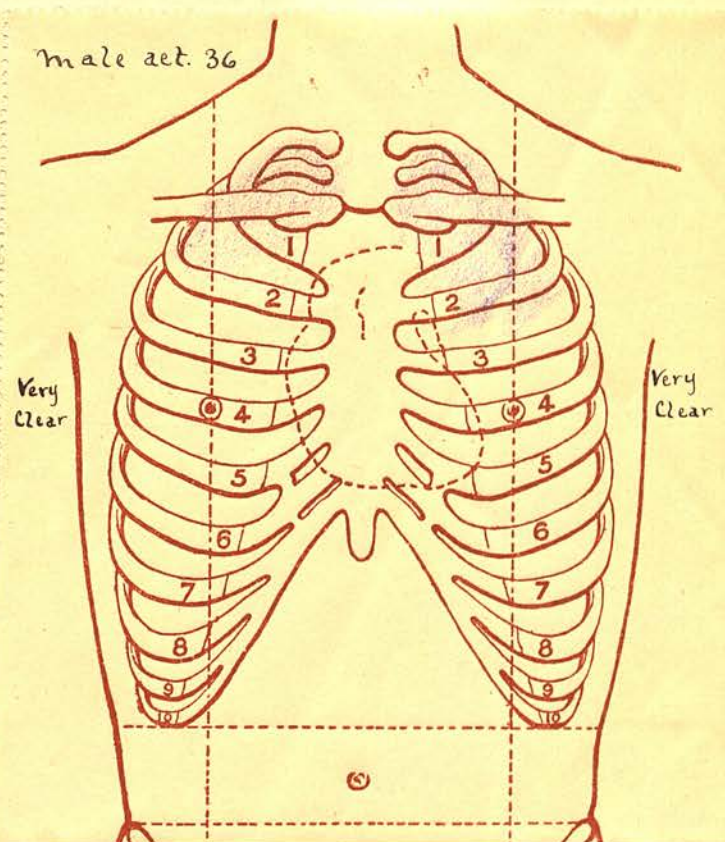
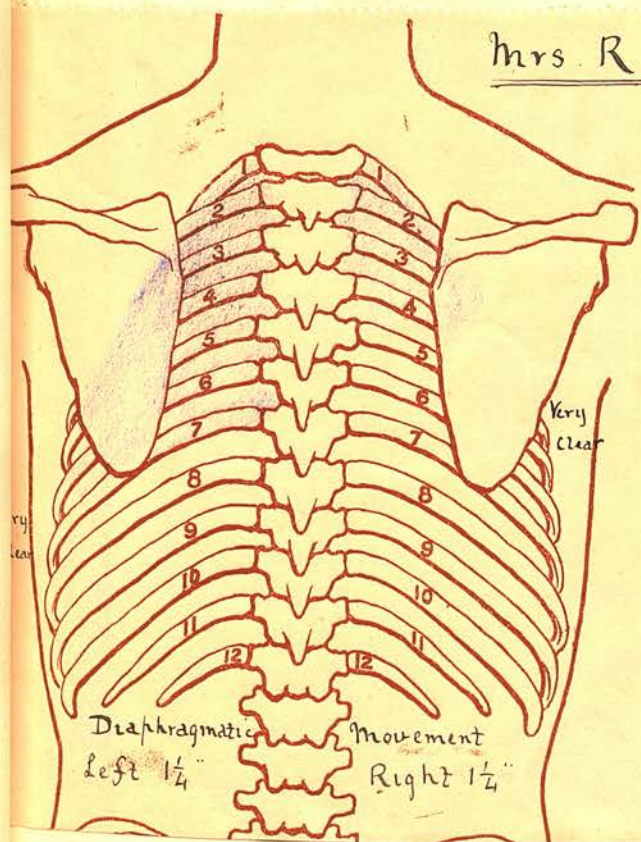
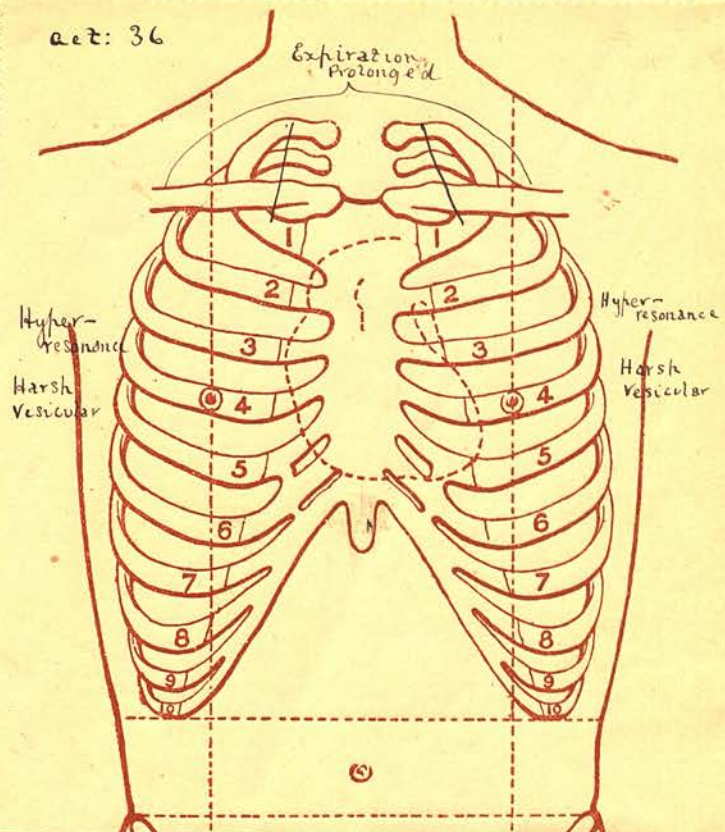
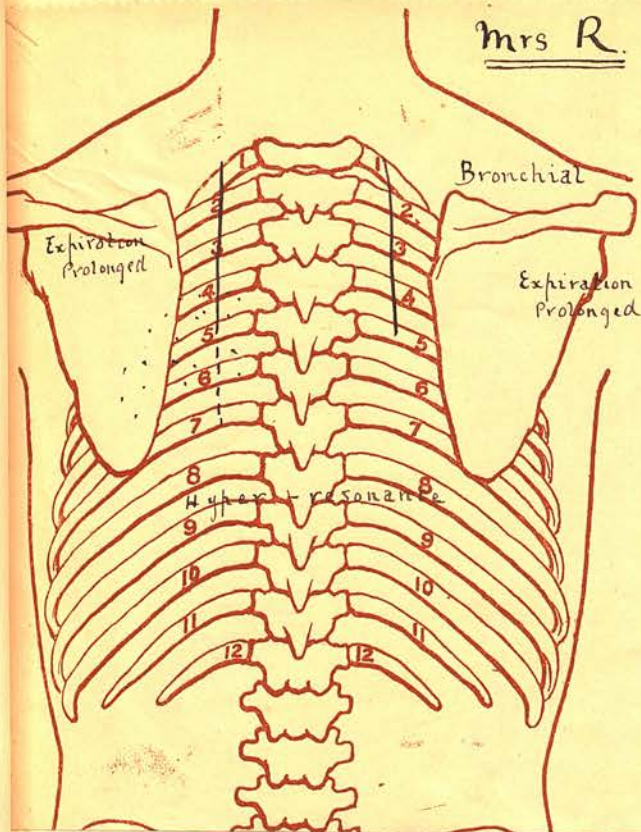
The enlarged Heart stands out prominently lower down, and about the region of the roots of the Lungs, two conspicuous opacities are seen, - the one on the left side being the larger - and these may indicate a mass of enlarged glands.

Mr Walsham of London has shown similar photographs, taking that view of the abnormality; but as yet there is no post mortem verification.

The right apex is more opaque than the left, and shows characteristic phthisical mottling, as far as the 5th interspace.

The left Lung shows the extent of disease from apex to the 7th Rib. The inner parts of both Lungs below these areas are very clear.

The disparity between the results of X Ray and Physical Examination, by ordinary methods, is in this case not great.



John McL. Painter, Age 25. Height 5 feet 3 inches. Weight 9 stone. Temperature normal.
COMPLAINT.

Pain on left side of chest which has lasted for a week. No Previous illnesses. Brother died of Phthisis Pulmonalis.
RESPIRATORY SYSTEM.

Slight irritating cough with small amount of bluish expectoration. No Hoemoptysis. The pain shoots through the left lung, especially when he is in bed. No Dyspnoea. Larynx shows congestion. Pulse 80 of good tension and volume. Tongue pale and furred. Other systems normal.
PHYSICAL EXAMINATION OF THE CHEST.

Anteriorly. Dulness on percussion as far as the first interspace on the right side - over this area the vesicular breathing has prolonged expiration, and below this, the Lung is apparently normal.

On the left side the dulness, although more definite in character, only extends to the Clavicle, and the breathing is vesicular, with expiration prolonged over this area, and normal below.

Posteriorly./

3 minutes.

Posteriorly. On the right side, there is dulness with prolongation of the expiratory murmur, as far as the 4th Rib. The dulness on the left side, extends only to the 3rd Rib; and another patch of dulness is present over the 7th, 8th, 9th and 10th Ribs. The expiratory sound is also prolonged at this apex, and accompanied by crepitations - otherwise the breath sounds are normal.

SCREEN EXAMINATION.

Anteriorly. Loss of Translucency is present on the right side, as far as the 3rd Rib, & on the left side, as far as the 2nd Rib.

Posteriorly. On the right side, the loss of translucency extends to the 5th Rib. The left apex shows marked opacity extending to the 5th Rib, and a fainter opacity over the 8th, 9th and 10th Ribs.

PHOTOGRAPH.

Lumière Plate, 18" distance showing the posterior aspect taken by a Hirschmann Tube with exposure of

3 minutes.

The Ribs on the right side seem to be much more collapsed than those on the left. There has been a slight inclination of the head to the right side, which may accentuate this more than normally. The mottling on the left side extends to the 5th Rib, and there is a slight mottling at the base over the lower two interspaces.

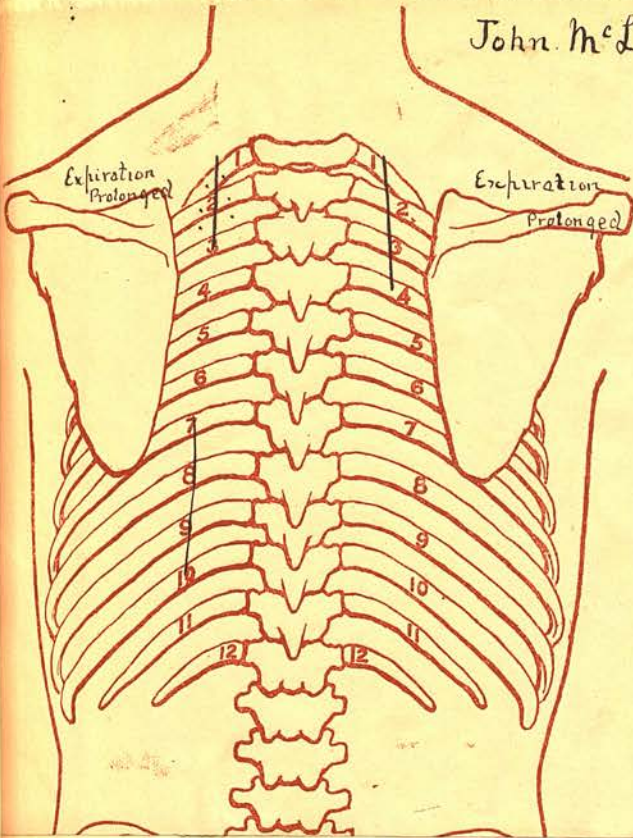
The mottled aspect on each side of the Vertebral Column, low down, is obviously from the Heart and Pericardium, and can be seen on some of the normal photographs.

On the right side, the normal translucency is affected as far as the 7th Rib, being much more pronounced at this apex.

In this case, the Photograph appears to have shown a fuller clinical picture than either the screen or the usual physical signs, with the exception of the condition at the left base.

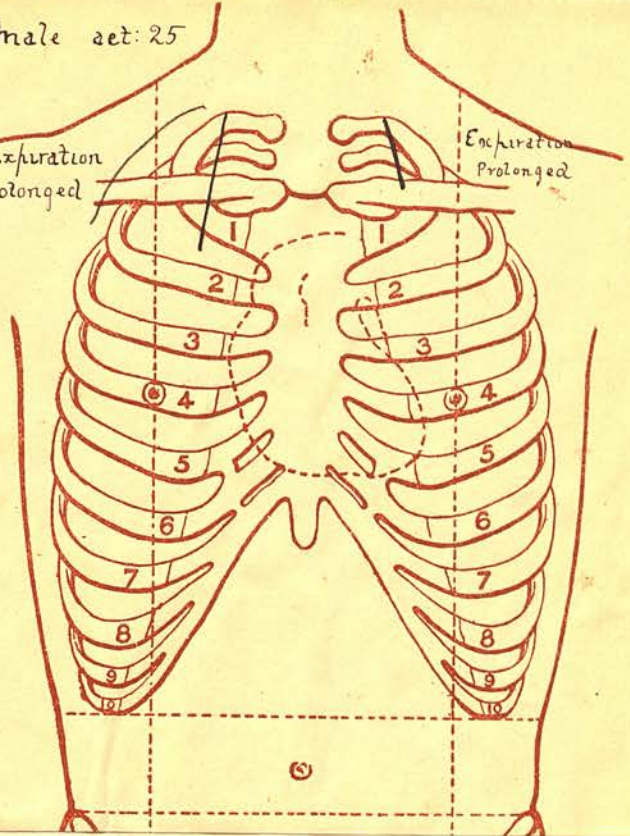
John McL.

male aet: 25



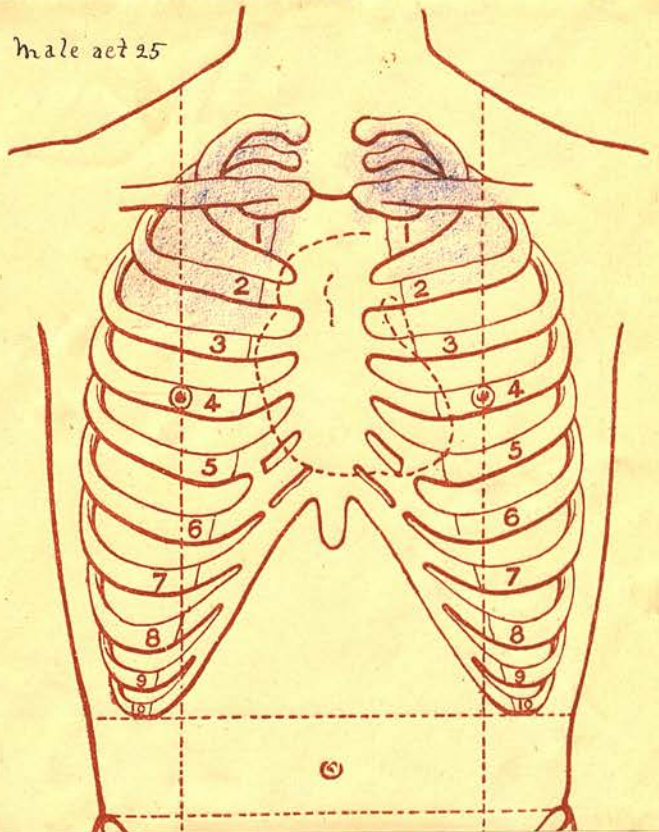
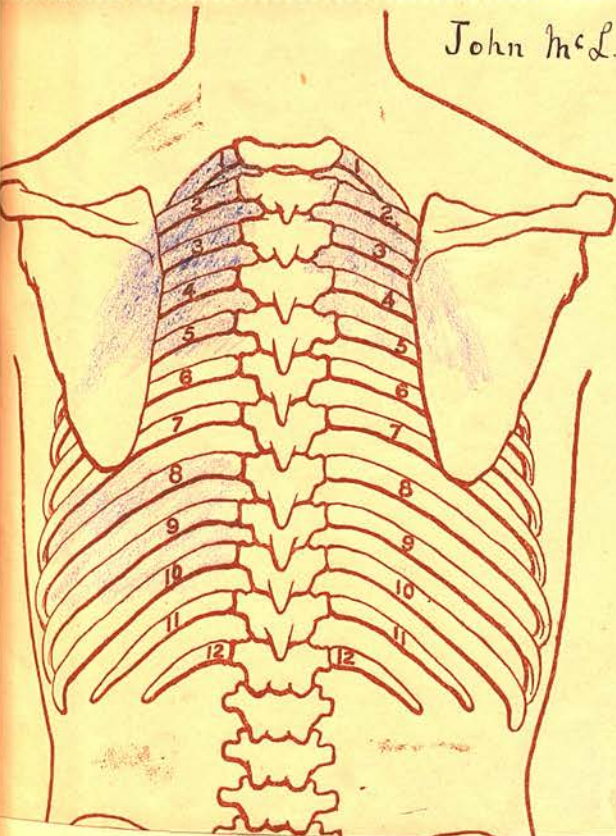
Expiration Prolonged

Expiration Prolonged



John McL.

male aet 25



Henrietta A. Female Rubber Worker, age 18.

Height 5 feet. Weight 5 stone 12 lbs. Temperature normal.

COMPLAINT.

Severe cough, lasting for about two years.

5 years ago suffered from diseased bone in big toe.

Family history good.

RESPIRATORY SYSTEM.

Cough hard, with thin white sputum (containing Tubercle Bacilli).. No Hemoptysis. No pain.

Pulse 112 weak. Menstruation irregular.

PHYSICAL EXAMINATION OF THE CHEST.

Anteriorly. On the right side, there is slight dulness on percussion, to the 6th Rib, with bronchial breathing to the third Rib, and occasional crepitations.

On the left side, dulness to the 6th Rib, with distinct signs of cavity formation, over the

first two interspaces. There

is bronchial breathing at the apex, and again from the 3rd, to the 6th Rib. Crepitations accompany the breath sounds, all down this side.

Below/

Below the 6th Rib, there is
Hyperresonance.

Posteriorly. On the right side, dulness on
percussion, over the first two
Ribs, and again over the 8th
and 9th. Bronchial breathing

is heard to the 3rd Rib.

Occasional crepitations are
heard, towards the lower part.

Hyperresonance is present,

between the two patches of dul-

ness. On the left side, there

is no distinct dulness anywhere,

and over the lower part, there

is hyperresonance. Bronchial

breathing is heard, as far down

as the 4th Rib, and rhonchi and

crepitations are heard at parts.

Pleuritic Friction is present,

near the 9th Rib.

SCREEN EXAMINATION.

Anteriorly. On the right side, there is faint

loss of translucency all down.

On the left side, there is great

clearness, corresponding to

the/

is more contracted the cavity just below the clavicle.

spaces, on a line. Marked opacity above and below
on this side. this to the 6th Rib, and again,

The Heart. below this, it is clearer over
direct contiguity the hyperresonance. at its base,

Posteriorly. On the right side, there is

The Right a loss of translucency over the the
way down, at first three, and again from the

base, which may 8th to the 10th Ribs. Between

diaphragm, partly these patches it is clearer

through from the than normal. On the left side

On the Left side the loss of translucency, though

interspaces, just not so marked as in front, is

to the cavity seen all down. Cavity not seen.

Diaphragmatic Not observed in this - an early
movement.

of the Heart and case. lower interspaces are clearer

PHOTOGRAPH. wider, indicating the Emphysema.

Taken with a Lumière Plate, and Volt-Ohm
The Case is an advanced one and the cavity
Tube, with exposure of $3\frac{3}{4}$ minutes. Distance
was confirmed by this means, - as also the dis-
12 inches. Showing the anterior aspect, and taken
generatory Emphysema.
with the patient sitting.

The Photograph lacks detail, being one of my earlier
attempts. The exposure was too long, and the tube
too near the Chest. The left side of the Chest

is/

is more contracted than the right, and the interspaces , on a line with the heart, are narrower, on this side.

The Heart, which appears smaller, is in direct contiguity to a dense fibrosis at its base, which stands out prominently.

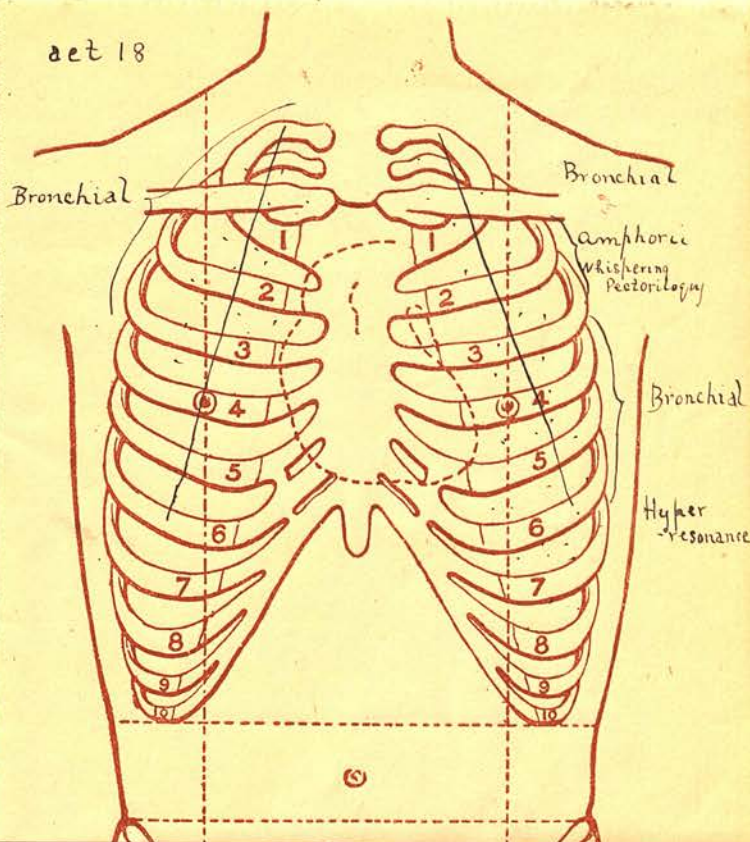
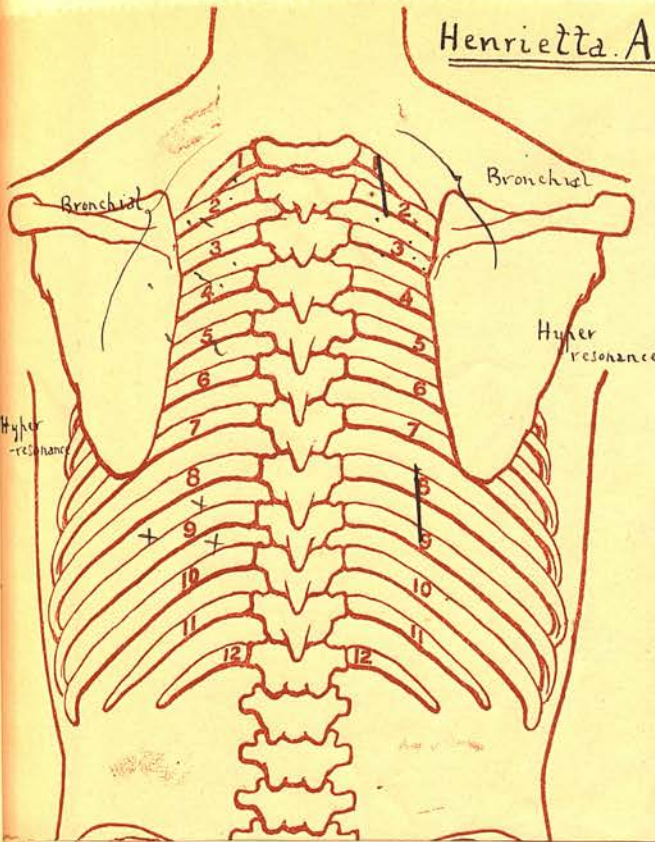
The Right side shows a faint mottling all the way down, at places, and a deeper shadow at the base, which may be from the movement of the diaphragm, partly; but also partly reflected through from the opacity, posteriorly.

On the Left side, there is a clearer part in the interspaces, just below the clavicle, corresponding to the cavity seen more distinctly by the screen; - a loss of translucency is seen all down the side of the Heart and the lower interspaces are clearer again, and wider, indicating the Emphysema.

The Case is an advanced one and the Cavity was confirmed by this means, - as also the Compensatory Emphysema.

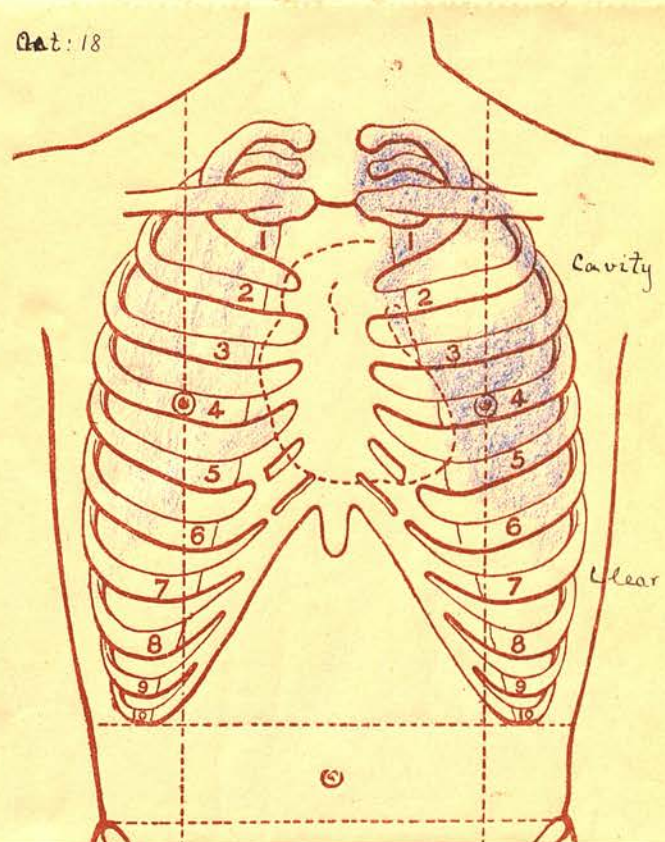
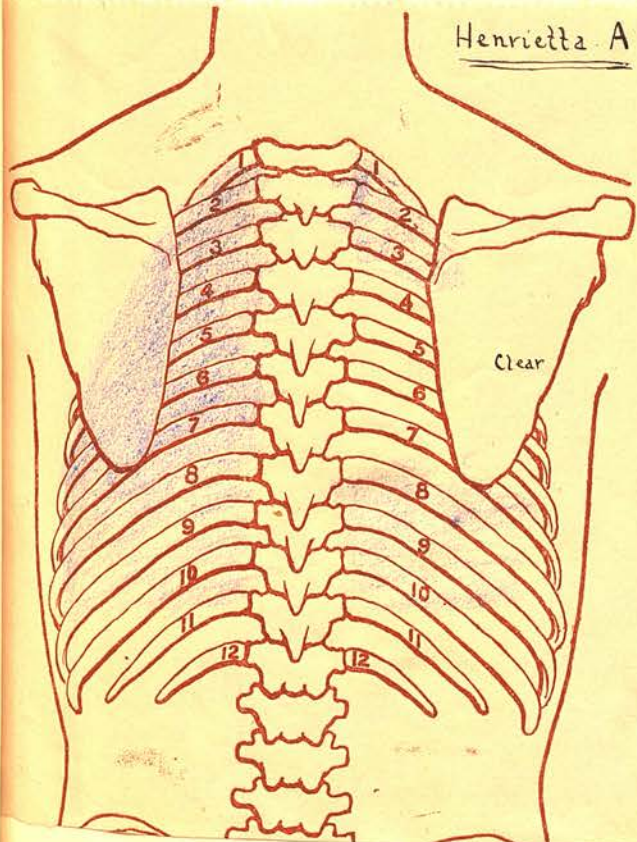
Henrietta A

aet 18



Henrietta A

aet: 18



William R. Labourer. Age 57. Height 5 feet 6.
Weight 10 stone $\frac{1}{4}$ lb. Temperature normal.

COMPLAINT.

A cough lasting 6 months.

History. - Was in Edinburgh Infirmary two months ago, and the Right Pleura was tapped, on three occasions for effusion. Family History good.

RESPIRATORY SYSTEM.

Irritating cough with thick whitish expectoration. Never had Hoemoptysis. No pain in Chest. Dyspnoea present. Throat congested.

Pulse 120 irregular in time and force. Tension and volume poor. Sleeps badly, and suffers from night sweats. Occasionally vomits after a fit of coughing. Other systems otherwise normal.

PHYSICAL EXAMINATION

Anteriorly. Dulness on percussion on the right side, as far as the 2nd Rib, and on the left side to the 3rd Rib. Bronchial breathing is present over the dull areas, and below this, the vesicular breathing is accompanied with prolonged expiration.

Posteriorly. Marked dulness on percussion all down the right side, with bronchial breathing/

breathing as far as the 4th Rib,
 and faint vesicular breathing
 with increased Vocal Resonance be-
 low.

On the left side, the dulness
 extends to the 4th Rib, and over
 this area bronchial breathing is
 heard; below this the breathing
 is harsh, but normal otherwise.
 All over the Chest the breath sounds
 are faint.

SCREEN EXAMINATION.

Anteriorly. Loss of translucency all down the
 right side, and on the left side
 as far as the 2nd Rib.

Posteriorly. There is loss of translucency all
 down the right side. On the left
 side there is loss of translucency,
 as far down as the 4th Rib; and
 again over the lower two or three
 interspaces.

Diaphragmatic movement. This was not extensive, but diffi-
 cult to ascertain, owing to the
 affection of the bases of both
 Lungs.

PHOTOGRAPH.

Showing/

Showing the posterior aspect, was taken with patient lying down, and Hirschmann Tube at a distance of 18 inches from the Chest wall. Cathodal Plate used with an exposure of 3 minutes.

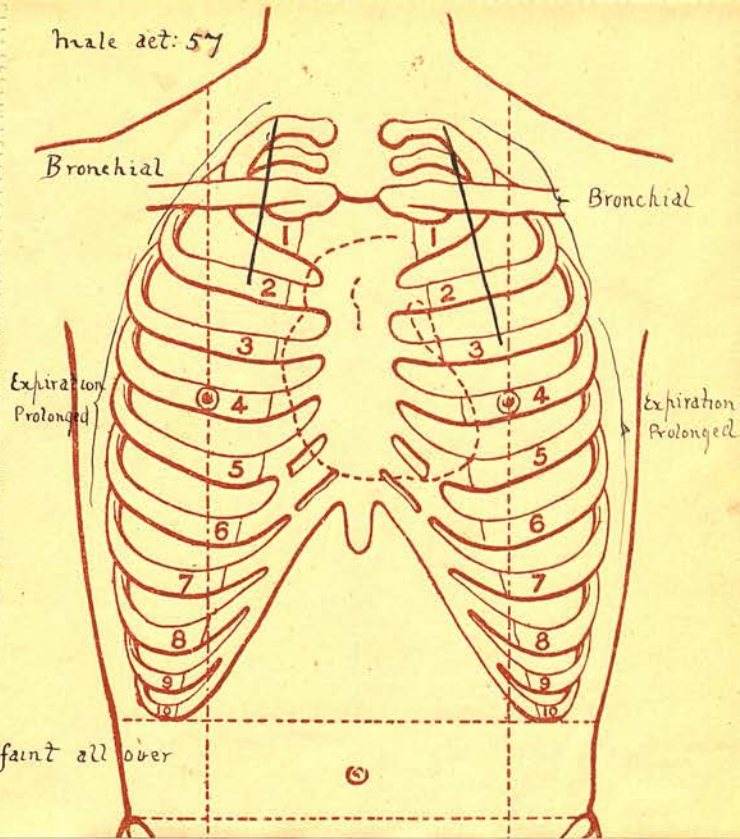
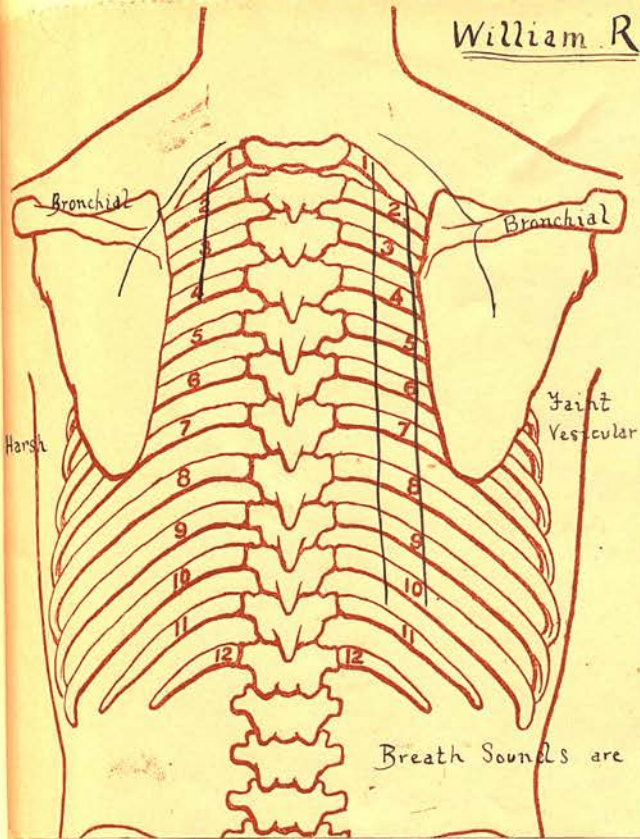
The right side is practically opaque all down, and the uniform character of the opacity is due to the thickened pleura. (No effusion could be found, by tapping, on one or two occasions.)

The left apex is opaque, over three interspaces, and opacity is also present at the base - the only clear part being in the centre, and this on the screen looked clearer than in the photograph, indicating an emphysematous condition. Even in this clear part, however, there is distinct mottling.

The photograph here, and still more the screen, shows both the thickened pleura, and the affected Lungs (as the mottling is even observed on the right side through the deep shadow) more fully than ordinary physical signs. The left basal condition had none of the ordinary physical signs, and was only observed by means of the X Rays.

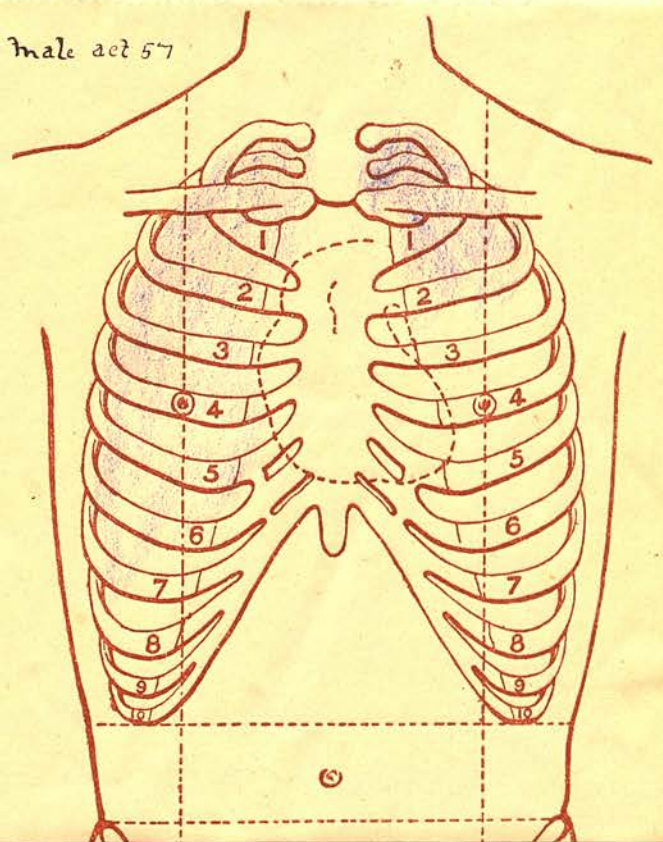
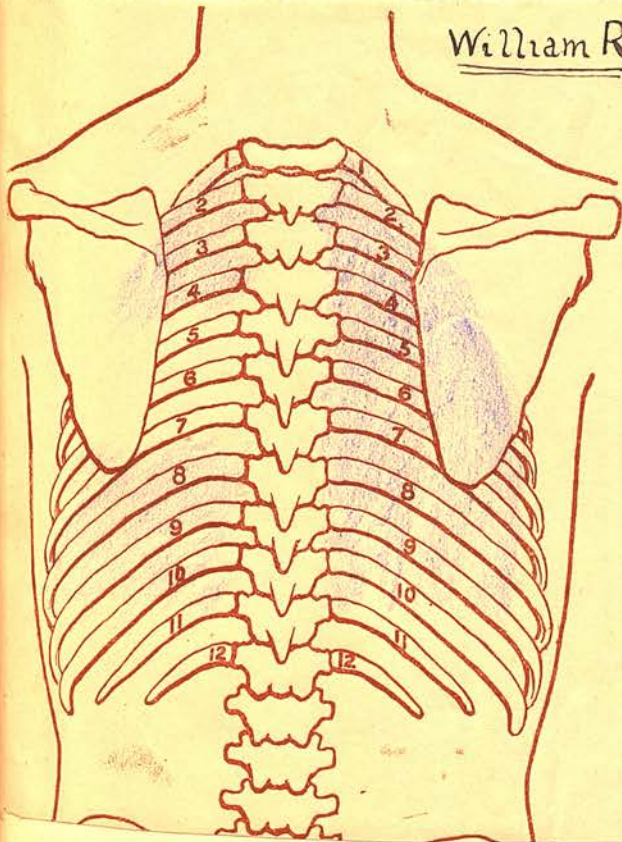
William R

male aet: 57



William R

male aet 57



David S. Male, age 18. Height 5 feet 5½. Weight 6 stone 12½ lbs.

Complains of "Cold in the Chest" lasting for two years. About a year ago he had slight Hoemoptysis; but apart from that, there is no distinct history of illness. Family History is good.

RESPIRATORY SYSTEM.

Cough is troublesome, especially at night and morning. Thick greenish sputum - has had slight, occasional hoemoptysis, for a fortnight. At present, he feels a pain in front of the left apex.

On examination of the Larynx, the epiglottis was seen to be markedly injected - as also the parts lower down, but otherwise no distinct lesion.

Pulse 114 of poor volume and tension. Other systems normal.

PHYSICAL EXAMINATION OF THE CHEST.

Anteriorly. Dulness on percussion on the left side, as far as the 5th Rib; and on the right side, as far as the 4th Interspace.

At the 2nd Interspace on the left side, there is a tympanitic note. The breath sounds are bronchial, as far as the 4th Rib on the right side, /

side, and accompanied with crepitations. Below this, the breathing is harsh vesicular.

On the left side, the bronchial breathing extends to the 5th Rib; and below this, the vesicular breathing has marked prolongation of the expiratory murmur.

Crepitations accompany the breath sounds, all down this side.

Posteriorly. The dulness on percussion extends, on the left side, as far as the 8th Rib; and on the right side, as far as the 6th Rib, being more pronounced at the apices.

Bronchial breathing extends on both sides, as far as the 6th interspace, and crepitations accompany the breath sounds, almost all over the back.

At the left base, there is Pleuritic Friction.

SCREEN EXAMINATION.

Anteriorly. There is loss of translucency on the right side, as far down as the 6th/

6th Interspace, and on the left side, as far down as the 6th Rib, except over the 2nd Interspace, where there is a clear space indicating a cavity. At both apices, the loss of translucency is much greater; but more especially the left.

Posteriorly. The loss of translucency extends on both sides, as far as the 9th Rib, being again more marked at the apices, especially the left. A clear space indicating another cavity, or an upward prolongation of the one seen anteriorly, is seen over the third interspace.

DIAPHRAGMATIC movement. At two feet distance this is $\frac{1}{3}$ " on the right and $\frac{1}{4}$ " on the left side.

PHOTOGRAPHS.

Two were taken in this case, one showing the front, and the other the back view. Both were taken with the patient lying on the couch, and the tube at 18" distance from the Chest wall. Lumière Plates were used, and the duration of exposure was two and a/

a half minutes in each case.

The test is a good one, and the one result tallies with the other.

Anteriorly. What at once strikes an observer, is the marked disparity between the size of the two sides, - the left Lung being much less expanded than the right. This is, in part, due to the more advanced thickening of the lung there; but no doubt also, to the fact, that the existing Pleurisy impaired its movement. On the right side, the Ribs go out almost at right angles, to the Sternum, and the interspaces are wide; while on the left side, the Ribs slope more, and the interspaces are narrower. The Heart, which is not enlarged, is well seen low down. The left Lung is very opaque at the apex, almost obscuring the shadows of the Ribs - below this, the mottling extends to an interspace above the Diaphragm. A clearer space marked by a cross, indicates/

indicates the position of the cavity, which was much better seen on the screen.

The right Lung shows mottling, practically down to the Diaphragm; but the apex is not so opaque as on the left side.

The screen showed the loss of translucency was practically the same in extent, on both sides, although a little more on the right side; and the marked difference between their extent on the photograph, I attribute to the disturbance of the Cardiac movement, affecting the left side more.

Posteriorly. Here again, the right side is more expanded than the left. The left Lung is very dark at the apex; the upper cross over the clearer part corresponds to the clear space, described as a cavity, in the screen description. A lower cross over a ring-like, slightly clearer part, corresponds to the cavity seen from the front. Mottling extends/

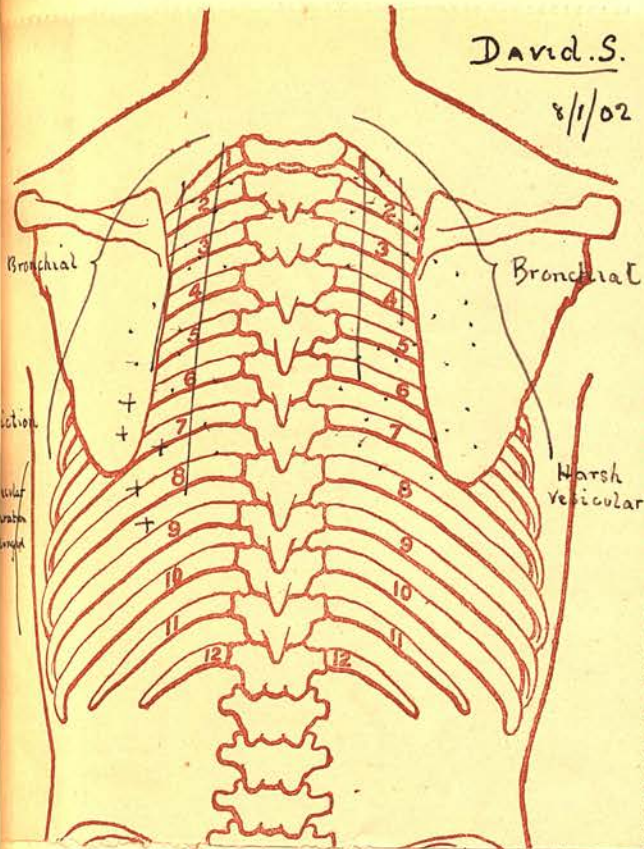
extends for a few interspaces below this.

The right Lung shows mottling, almost to the Diaphragm; but not so dense in the upper part, as on the left side. The absence of shadow, representing the Pleurisy at the left base, is probably due to the fact, that it was recent, and there was not much fibrous thickening; and also to the disturbance from cardiac movement.

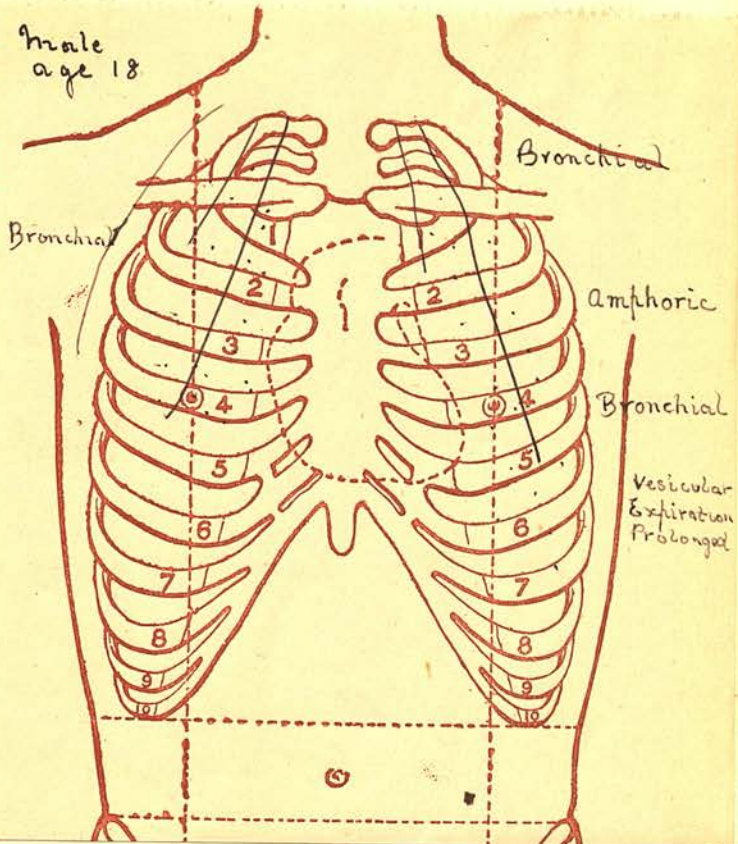
Both Photographs and Screen, in this case, give one a much fuller idea of the condition of the Lungs. What is specially interesting, is, the confirmation of the existence of a cavity, and the effect of Pleurisy, both on the movement of the Diaphragm, and the expansion of the Lung generally.

David.S.

8/1/02



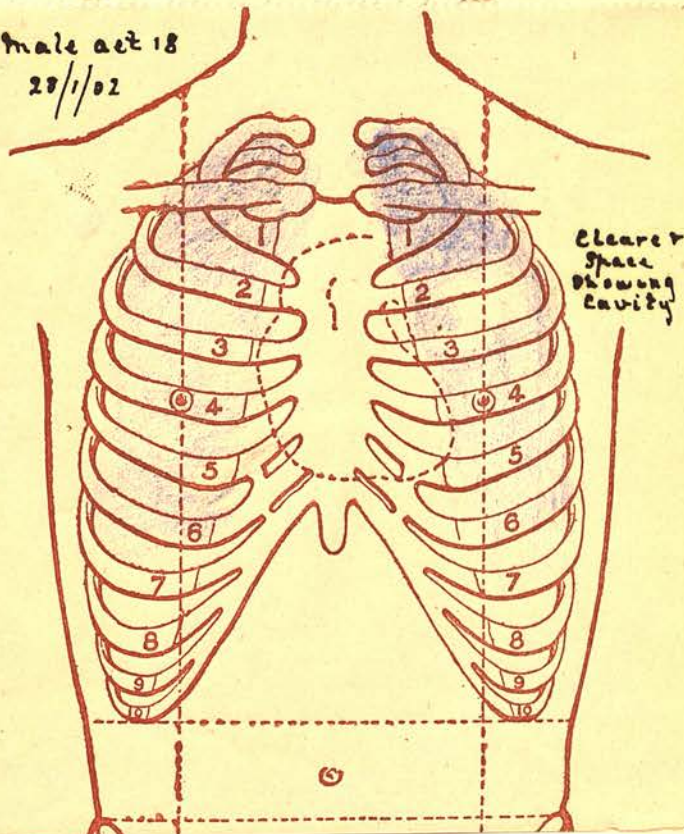
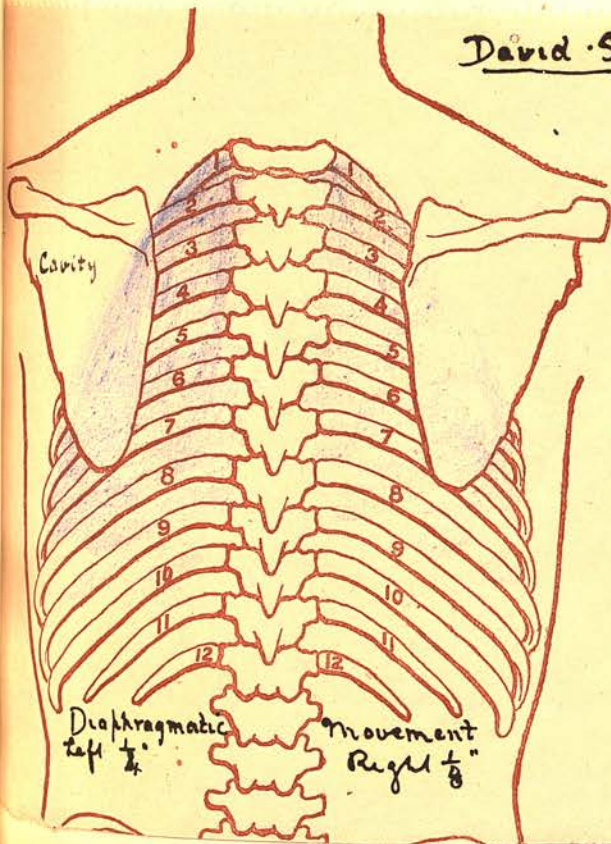
male age 18



David.S.

male age 18

28/1/02



Donald H. Age 37. Height 5 feet 3 $\frac{1}{2}$ inches.
Weight 8 stone 7 $\frac{3}{4}$ lbs. Temperature normal.

COMPLAINT.

Pains in Chest and Abdomen lasting for three months. Previous health good. Has been drinking to excess lately.

RESPIRATORY SYSTEM.

Cough troublesome in the morning. Thick clear sputum. Slight Hoemoptysis a year ago but none at present. Pain in front of the Chest. Dyspnoea on the slightest exertion.

Pulse 120. Tension and Volume poor. Suffers from Dyspepsia and Diarrhoea. Has been losing weight.

PHYSICAL EXAMINATION OF THE CHEST.

Breath sounds are weak all over.

Anteriorly. On the right side, dulness on percussion, marked to the 2nd Rib; but extending to the 4th.

Bronchial breathing, with crepitations, are heard to the 2nd Rib, vesicular, with prolonged expiration, to the 5th Rib, or harsh vesicular, below this.

On the left side, dulness on percussion to the 2nd interspace, with bronchial breathing to the 3rd/

3rd Rib. Harsh vesicular pro-
breathing below this. heard,
Posteriorly. On the right side, marked Rib,
dulness to the 4th interspace, is
and dulness to the 7th Rib.

SCREEN EXAMINATION

Bronchial breathing is heard,
Anteriorly. from apex to the 2nd interspace.

Amphoric breathing from 3rd to
the 4th Rib. Bronchial breath-
ing again to the 6th Rib, and
prolongation of the expiratory
murmur, with vesicular breathing

below this. Crepitations are
heard from the apex to the 5th
interspace, and are consonating
in character, over the region of

Posteriorly.

the amphoric breathing. On the
left side there is dulness from
the apex to the 5th Rib, more
marked from the 2nd to the 3rd
Rib. Prolongation of the
expiratory murmur is heard,
over the first two Ribs -

Diaphragmatic
movement.

below this to the 5th Rib, the
breathing is bronchial.

PHOTOGRAPH.

Vesicular/

Taken/

Vesicular breathing, with prolonged expiration is heard, from the 5th to the 8th Rib, and below this, the breathing is harsh vesicular.

SCREEN EXAMINATION

Anteriorly. There is marked loss of translucency at the right side, from the apex to the 4th Rib, and tapering off to the 5th interspace. On the left side, the

loss of translucency extends to the 7th Rib, being very dense over the 2nd, 3rd, and 4th Ribs.

Posteriorly. On the right side, there is loss of translucency down to about the 8th interspace, being denser above. No sign of cavity is

seen. On the left side, there is loss of translucency all down, - again being more marked above. acute slope of the Ribs.

The Diaphragmatic Not measured although small. by movement.

PHOTOGRAPH.

Taken/

Taken on a Cathodal Plate, with Volt-Ohm Tube, at a distance of about 9 inches - patient sitting. Exposure $3\frac{3}{4}$ minutes.

The Chest is a narrow pointed one, - the Ribs sloping acutely on both sides, but more so on the left. Marked mottling is observed, all down on both sides.

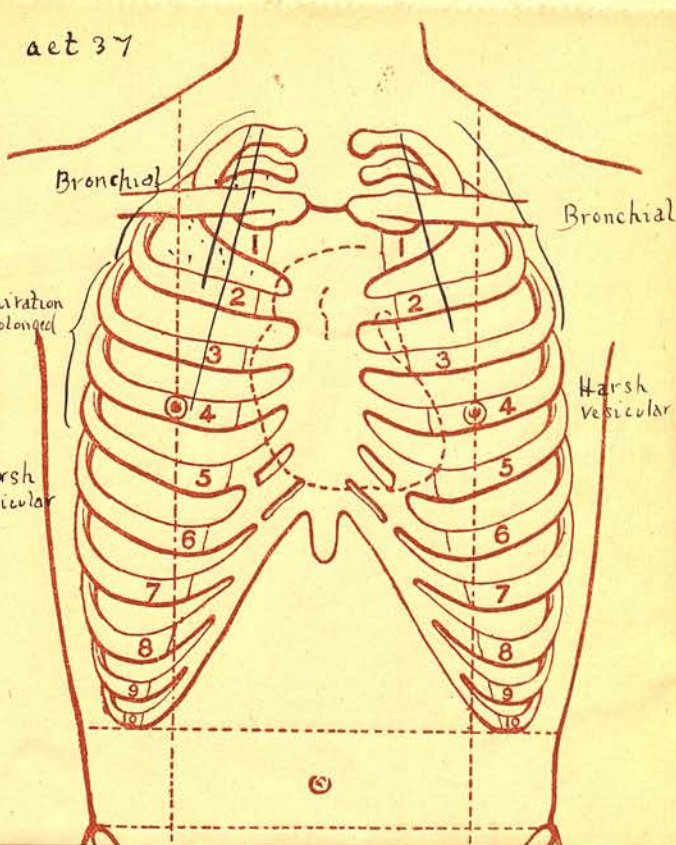
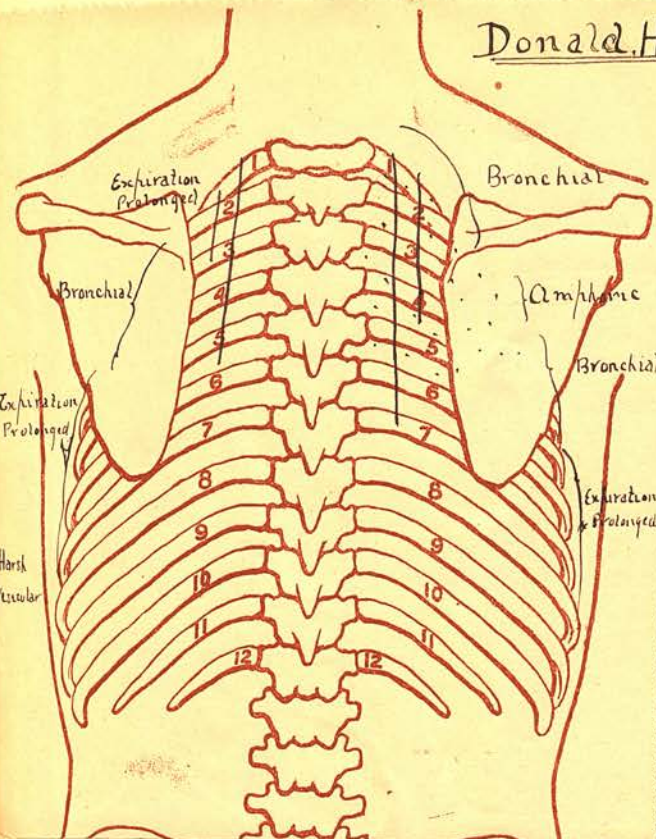
On the right side, the mottling is denser above; but the shadow of the scapula is also seen, as the patient kept his arms by his sides. The lower part is clearer.

On the left side, the shadow of the scapula again comes in, giving rise to a dense opacity at its vertebral border, and inferior angle; this is where it overlaps the Heart, and the general fibrosis, and shows the necessity of placing the patient's arms forward to avoid this shadow. The mottling is present all down, and the Heart shadow is faintly seen.

This case was one of the first examined, and it shows the necessity of care, in placing the patient correctly. The extensive character of the disease is well shown, as also the acute slope of the Ribs. The cavity is not seen and was probably obscured by secretion, /

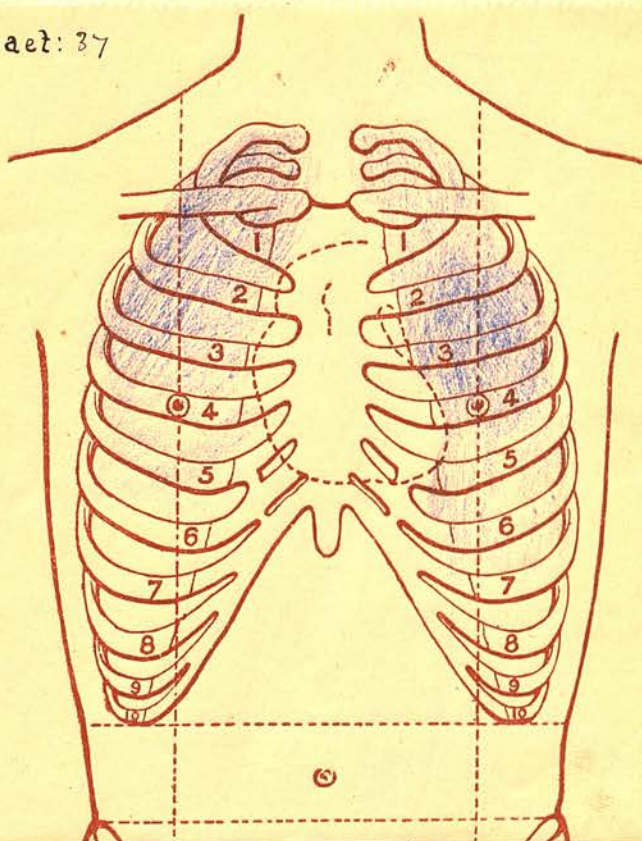
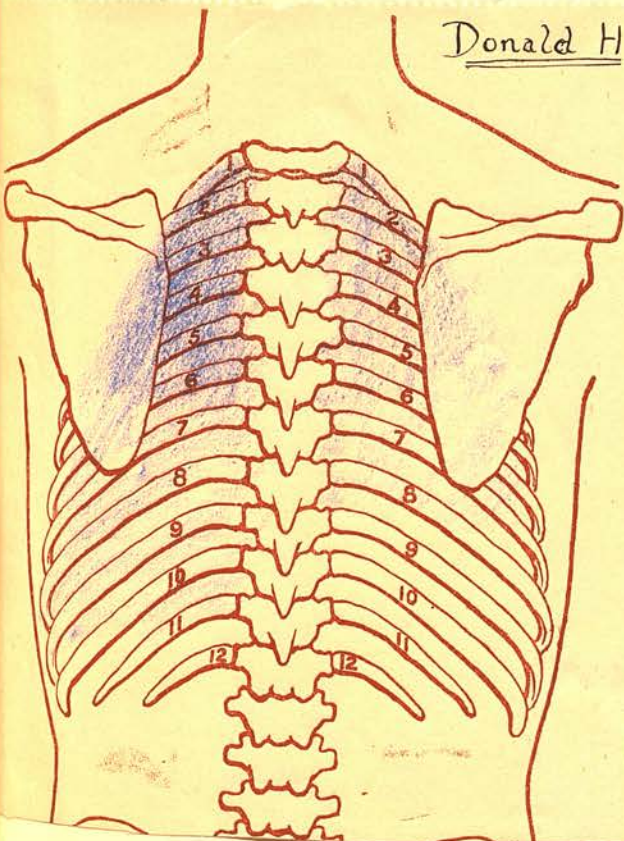
Donald H.

aet 37



Donald H

aet: 37



Euphemia S. Farm-labourer, age 26. Height 5 feet 2. Weight 7 stone $3\frac{1}{2}$ lbs. Temperature normal.

COMPLAINT.

Weakness, pain in the side, cough lasting for two years; but worse lately. Was perfectly healthy before this time. A sister and a brother died, in childhood, of "Diarrhoea".

RESPIRATORY SYSTEM.

Cough slight. Sputum thin, small in amount and containing numerous Tubercle Bacilli.

CIRCULATORY SYSTEM.

Pulse 100 regular. First sound weak in the Mitral area, second sound accentuated.

Has been losing weight. Amenorrhoea for two years.

PHYSICAL EXAMINATION OF CHEST.

Anteriorly. Slight indrawing, above and below the clavicles, on both sides.

Posteriorly. On the right side, above the clavicle, marked dulness; below the clavicle, near the sternum, the note is resonant, farther out, in the 2nd interspace, it is "boxy". Breath sounds are bronchial/

bronchial above the clavicle, and immediately below the clavicle, they have a cog-wheel character.

In the 2nd interspace in the mammary line there is cavernous breathing, with crepitations.

On the left side, dulness above the clavicle; below the clavicle to 2nd interspace, there is

cracked-pot sound. Expiration is prolonged above the clavicle, and coarse friction is heard.

Below the clavicle, in the 2nd interspace, there is cavernous breathing, with coarse metallic crepitations, and whispering pectoriloquy.

Posteriorly. There is marked dulness at the right apex, and resonance below. The breathing at the apex is bronchial, and harsh vesicular, over the rest of the Lung.

On the left side, there is a boxy note, above the spine of the left/

left Scapula, and also at 4th, and 5th Rib, - below this, dullness to 7th Rib, not so marked.

Breathing is bronchial, with numerous crepitations in the upper lobe.

Diaphragmatic movement.

At apex of lower lobe, the breathing is cavernous, and an occasional rhonchus is heard.

PHOTOCRAPE. SCREEN EXAMINATION.

Anteriorly. On the right side, marked opacity above the clavicle, - in the 1st and 2nd interspaces, there is a

clearness corresponding to the cavity, - below this, loss of difference, between translucency to 5th interspace.

On the left side, On the left side, opacity to top part, the ribs slope of 1st interspace, - below this, to the 2nd interspace, a clearness low in position of the I is a clearer part, over the cavity, and lower still, corresponding to the cavity. loss of translucency to the 6th Rib. observed, for a few interspaces below.

Posteriorly. On the right side, opacity to and below it, a slightly clear spot marked X, indicating position of cavity. Below this, a very again loss of translucency, to about/

about the 6th Rib.

On the left side, opacity to 2nd interspace; a clearness below this, to the 5th Rib, and marked loss of translucency almost to the base.

Diaphragmatic movement.

At two feet distance. Right side $\frac{1}{2}$ inch. Left side very slight about $\frac{1}{8}$ inch.

PHOTOGRAPH.

Showing Dorsal aspect, taken with patient lying. Hirschmann Tube used. Lumiere Plate. Distance of Tube 18 inches. Duration of Exposure $2\frac{3}{4}$ minutes.

It is slightly obliquely placed on the print, but when examined at 6 feet distance, a marked difference, between the two sides, is at once seen.

On the left side, especially at the lower part, the Ribs slope a little more acutely.

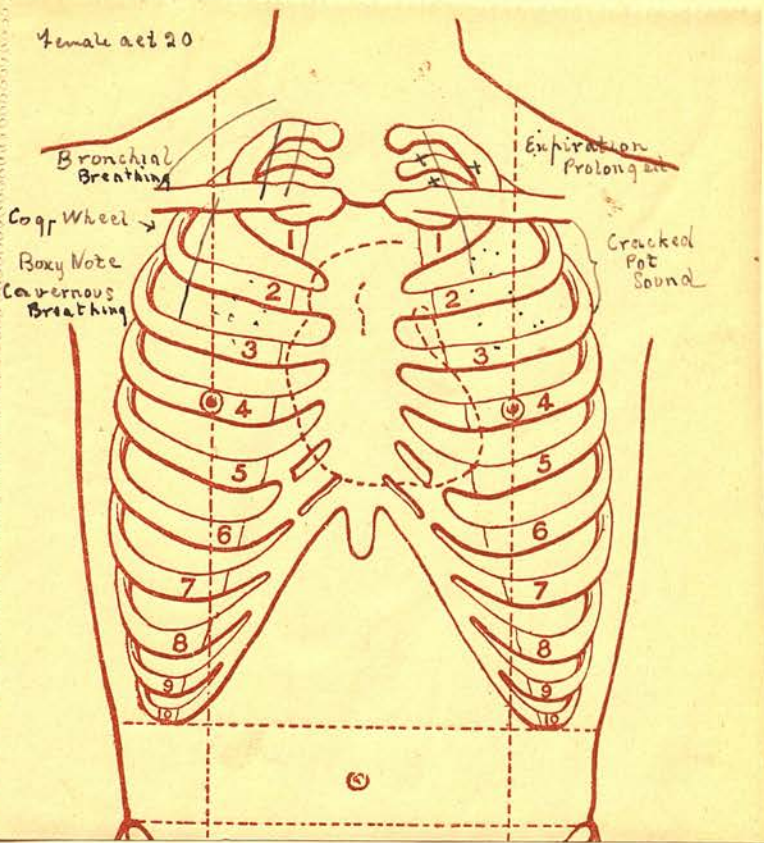
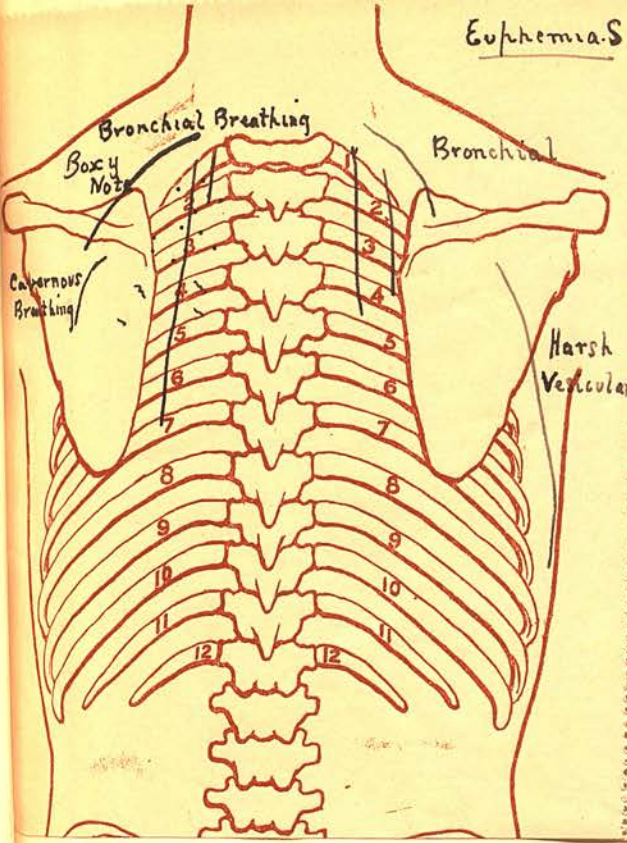
On the right side, the apex is opaque, and below in position of the X is a clearer part, corresponding to the cavity. Mottling is observed, for a few interspaces below.

On the left side, the apex is again opaque, and below it, a slightly clear spot marked X, indicating position of cavity. Below this, a very

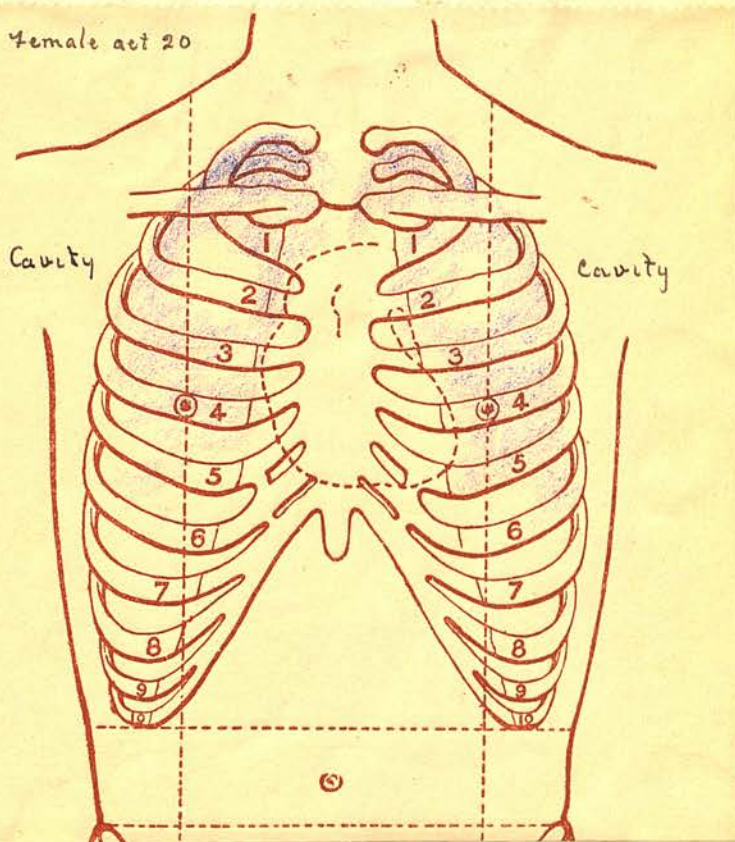
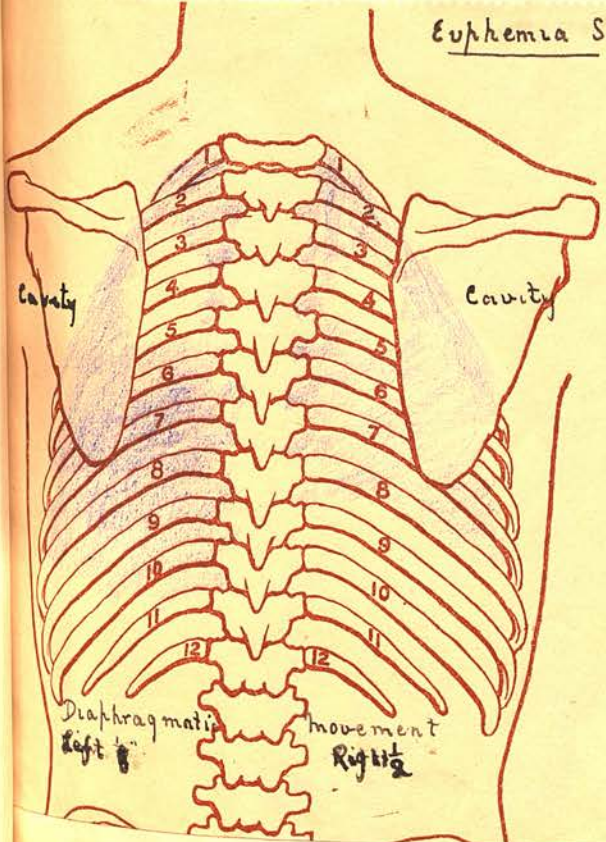
very dense mottling extends to the base, leaving only the outer end of an interspace, at all clear - the Heart shadow is practically obscured by it.

In this case, the Photograph and Screen Examination reveal a much more advanced condition, than physical signs indicated - particularly towards the left base.

Euphemia S. Female aet 20



Euphemia S Female aet 20



Thomas H. Shoemaker, Age 25. Height 5 feet 9 $\frac{1}{4}$ inches. Weight 11 stone 3 $\frac{1}{2}$ lbs. Temperature normal.

COMPLAINT.

"Cold in the Chest" lasting for a month. Six years ago had double Pneumonia, and for the last six months he has been feeling out of sorts. One brother died of Phthisis, six years ago.

RESPIRATORY SYSTEM.

Cough loose in character, and troublesome in the morning. Thick yellow expectoration. No Hoemoptysis. Pain in the front of the Chest. Dyspnoea on exertion. Pharynx - Fauces injected. Larynx shows general pallor. Inter-arytenoid folds are relaxed. Vocal cords healthy. — Tongue furred. Bowels regular. Has been losing weight. Pulse 78. Tension and Volume fair. Does not suffer from night sweats. Systems otherwise normal.

PHYSICAL EXAMINATION OF THE CHEST.

Anteriorly. On the right side, dulness on percussion above the clavicle. Breath sounds faint vesicular, with expiration prolonged, as far as the 2nd Rib. No accompaniments. Below this the breathing is normal.

On/

On the left side, there is dulness on percussion as far as the 2nd Rib, with faint breathing, vesicular in character, with expiration prolonged over the same area.

No abnormality below.

Posteriorly.

On the right side, the dulness on percussion extends to the 2nd Rib, and over this area there is faint bronchial breathing, without accompaniments.

On the left side, there is dulness as far as the 3rd interspace, and impairment of the percussion note to the 4th interspace.

Faint bronchial breathing is heard to the 2nd interspace, and vesicular breathing with prolonged expiration to the 5th Rib.

Elsewhere than in these parts the lungs are apparently normal posteriorly.

SCREEN EXAMINATION.

Anteriorly. On the right side there is loss of translucency to the first interspace, and on the left side,

to/

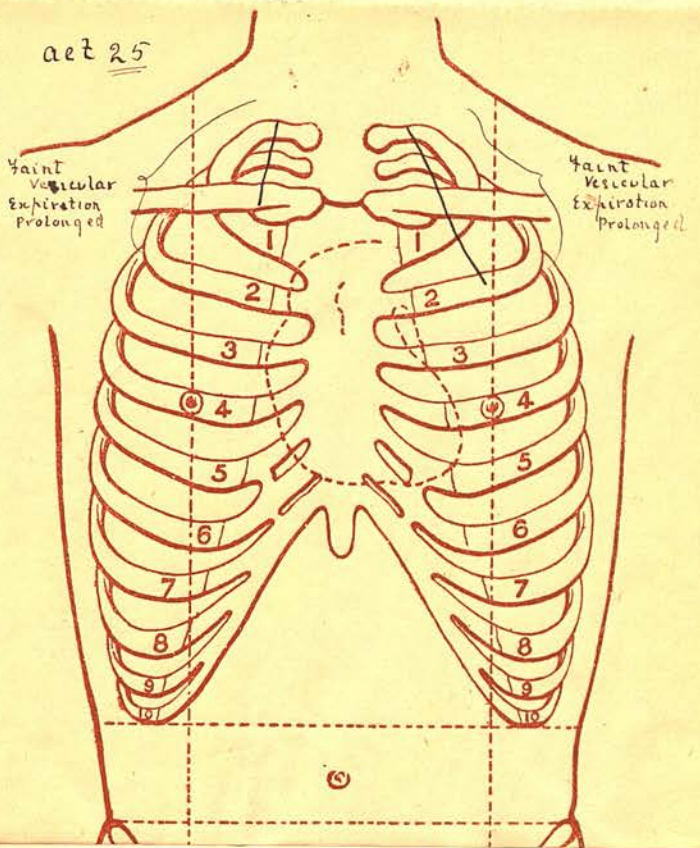
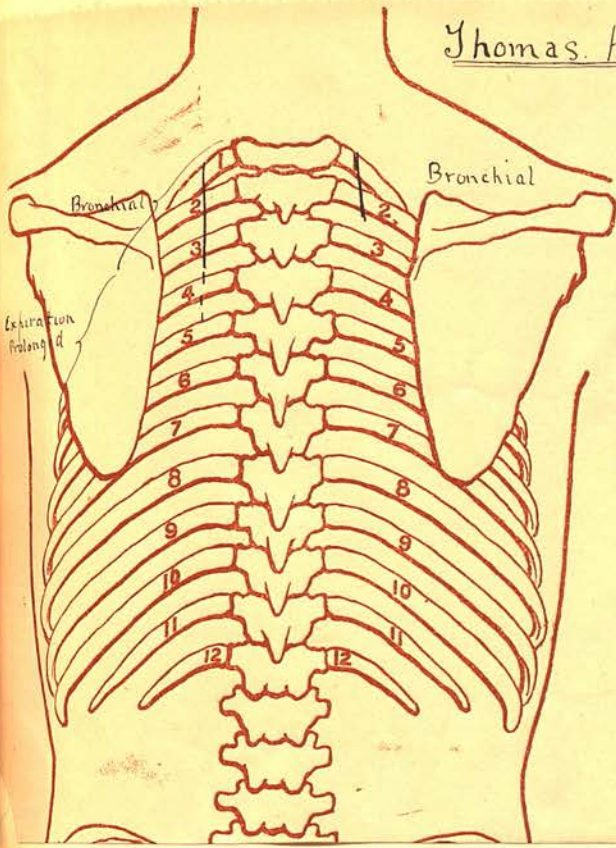
to the 2nd Rib to a greater degree.
Posteriorly. On the right side, there is loss
of translucency to the 3rd Rib,
and on the left side to the 5th
Rib.

Diaphragmatic movement. With full inspiration and
expiration. Right 1". Left $1\frac{1}{2}$ "

The corroboration of the physical examination,
by the screen picture, is full here, and it goes
further. Very noticeable is the diminution of the
diaphragmatic movement on both sides.

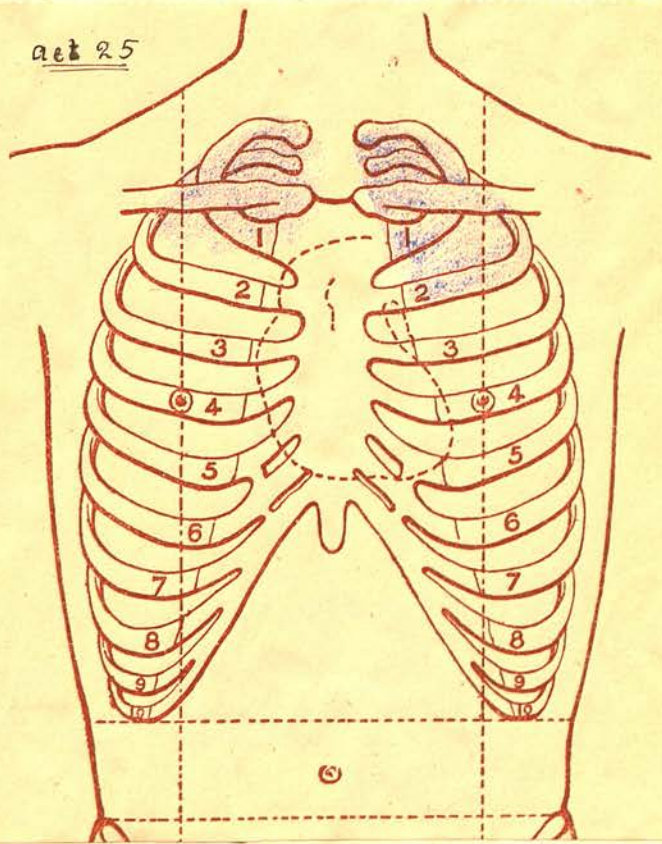
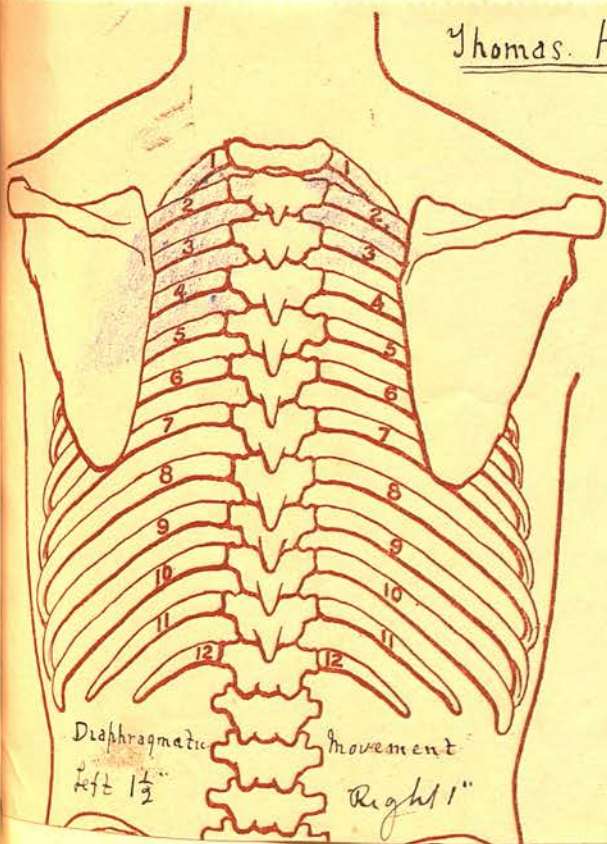
Thomas. H

aet 25



Thomas. H

aet 25



George S. Warehouseman. Age 56. Height
5 feet 7½ inches. Weight 9 stone 7½ lbs.

Temperature normal.

COMPLAINT.

A severe cold lasting for a fortnight. Had
Pneumonia of the left side, 5 years previously.
Family history good.

RESPIRATORY SYSTEM.

Cough - hard, worst at night. Spit thin
white. No hoemoptysis. No pain in the Chest.
Dyspnoea on exertion.

CIRCULATORY SYSTEM.

Pulse 102. Tension and Volume fair. Vessels
atheromatous. Heart shows mitral regurgitation
and possible Aortic Stenosis. Other systems
normal, except for night sweats.

PHYSICAL EXAMINATION OF THE CHEST.

Anteriorly. Dulness on percussion, on the
right side from apex to 1st Rib.
Breath sounds approach bronchial
character, in this region.
Elsewhere normal.

Posteriorly. On the right side, dulness on
percussion to the 3rd Rib, with
breathing almost bronchial.

Normal/

Diaphragmatic
movement.

Normal below. On the left side, dulness to the 2nd interspace, and again from the 5th to the 7th Rib. — Expiration is prolonged, over the upper patch of dulness. Cogwheel breathing is heard over the 5th Rib, and interspace. Bronchial breathing, at a patch over the inferior angle of the Scapula. The breath sounds are all very faint.

SCREEN EXAMINATION.

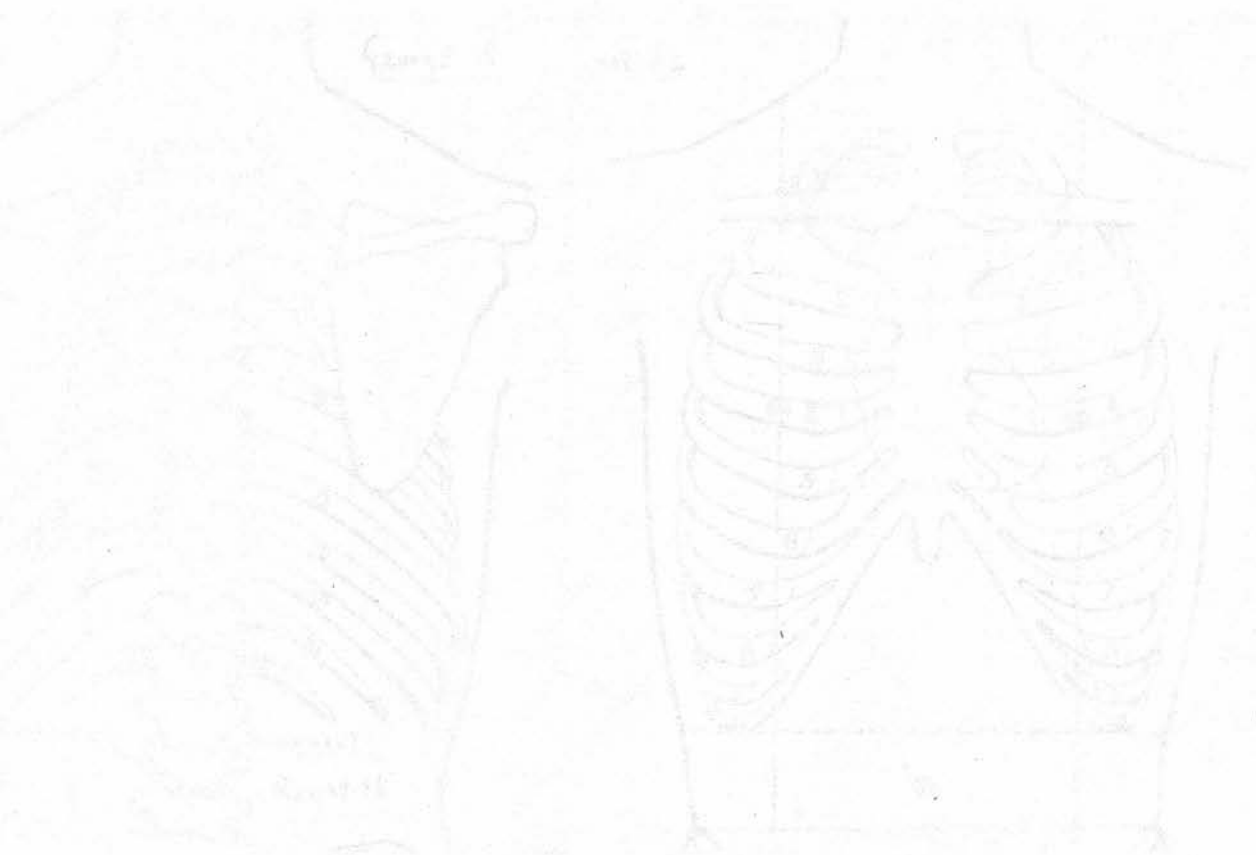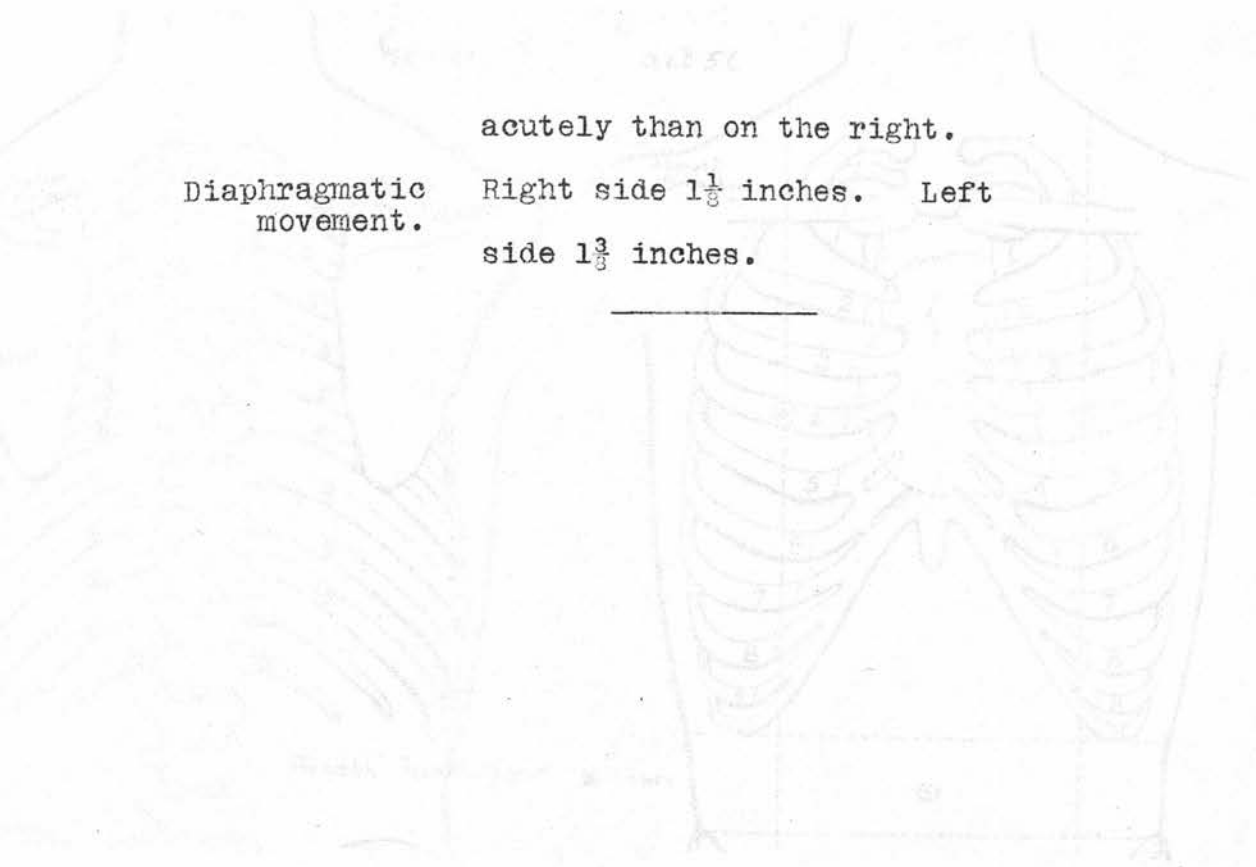
Anteriorly. There is loss of translucency on the right side from apex to the first interspace. On the left side, the loss of translucency extends from apex to 5th Rib.

Posteriorly. On the right side, the loss of translucency extends from apex to 6th Rib. On the left side, it is more markedly opaque, and extends from apex to the 9th Rib, being denser towards the foot of this patch. The Ribs on the left side slope more acutely /

Diaphragmatic
movement.

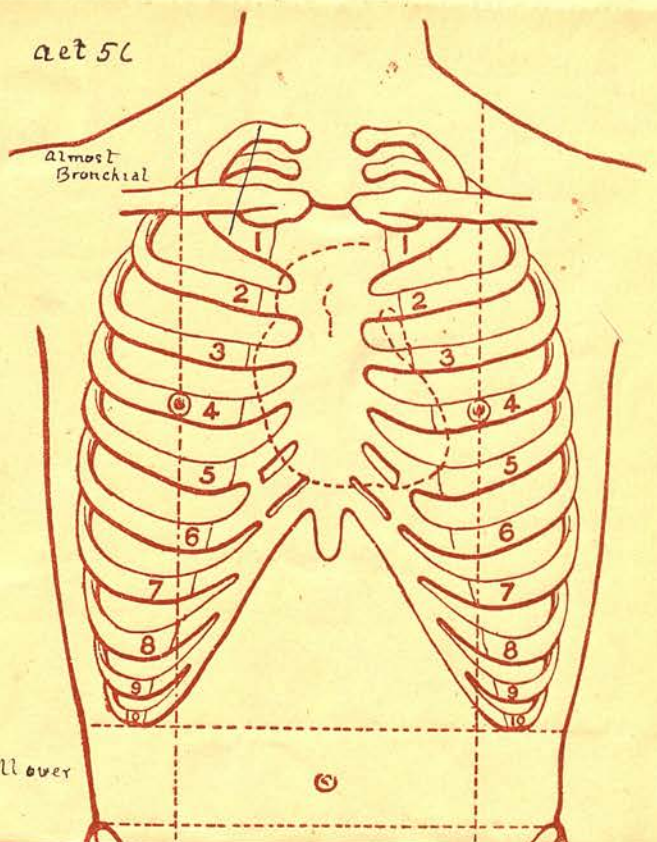
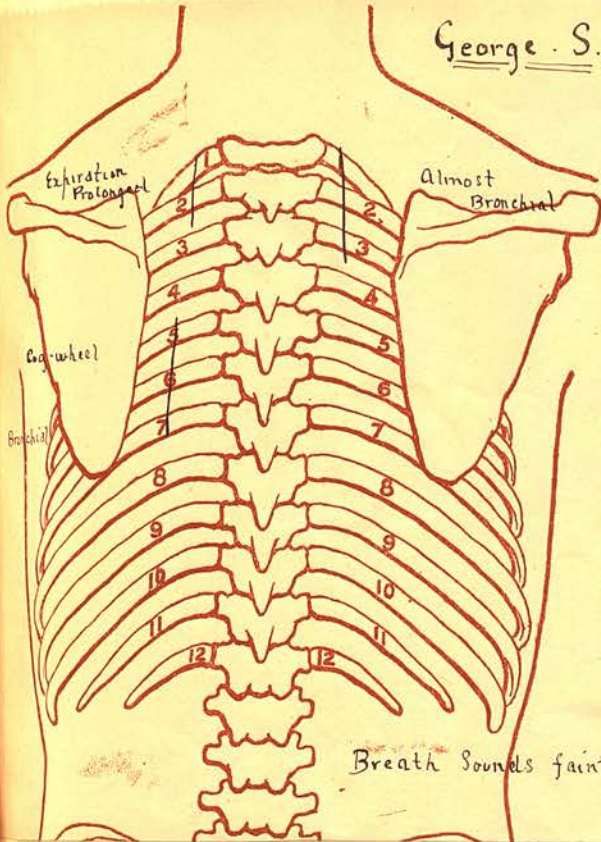
acutely than on the right.

Right side $1\frac{1}{8}$ inches. Left
side $1\frac{3}{8}$ inches.



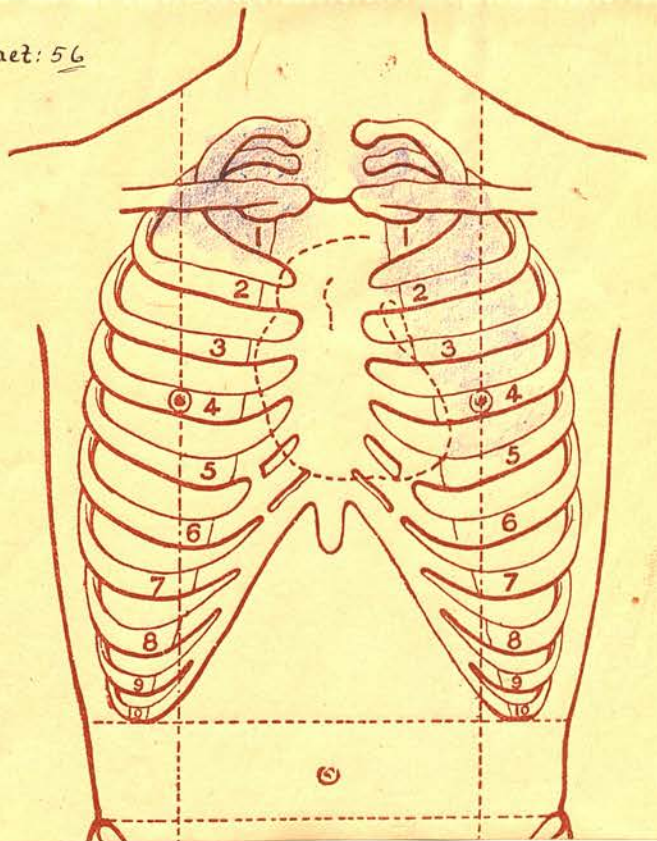
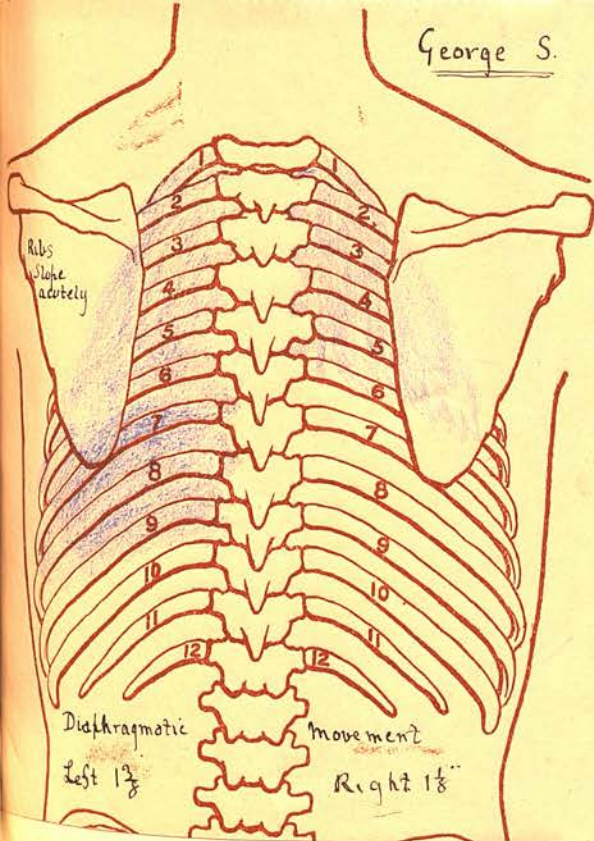
George S.

aet 56



George S.

aet: 56



Flora S. Rubber Worker. Age 17. Weight 9 stone. Height 5 feet 2 inches. Temperature normal.

COMPLAINT.

General weakness - lasting about a month. Has suffered from Anaemia for a year. Family history good.

RESPIRATORY SYSTEM. Normal.

Tonsils enlarged. Tongue furred, occasionally vomits her food. Bowels regular. Menstruation regular. Quantity scanty.

PHYSICAL EXAMINATION OF THE CHEST.

Lungs appeared healthy.

SCREEN EXAMINATION.

Anteriorly. Loss of translucency on the right side, slight above the clavicle, and on the left side, from the apex to the 1st inter-space.

Posteriorly. On the right side, loss of translucency to the 3rd Rib, and on the left side to the 2nd inter-space, though not so marked.

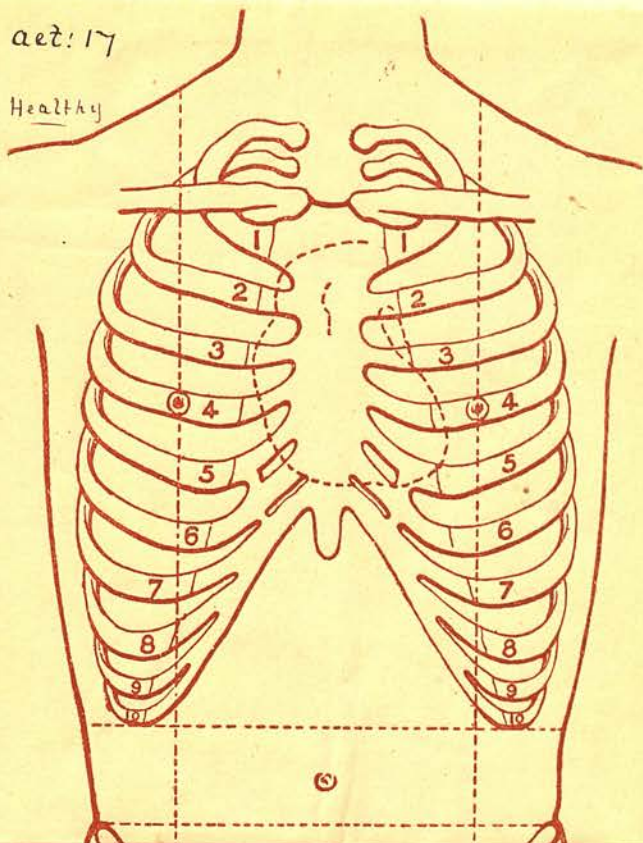
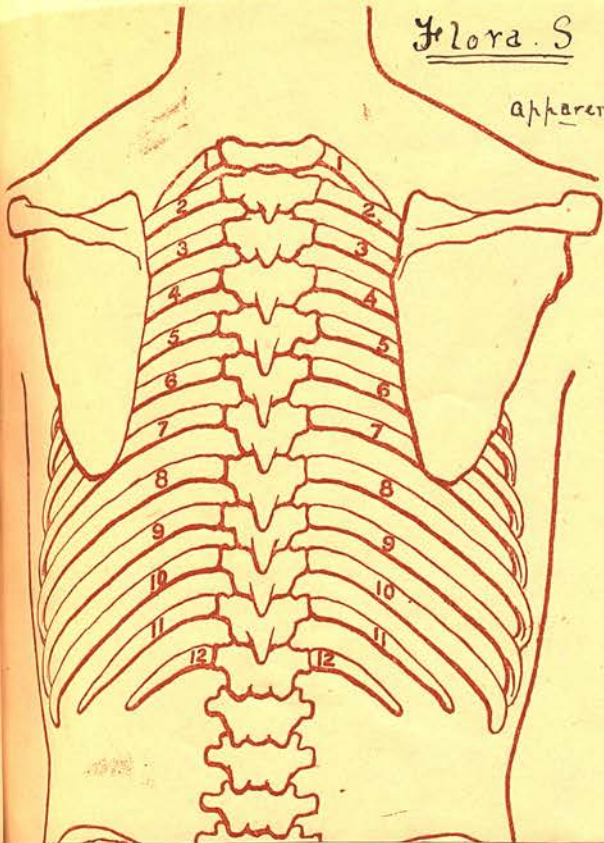
Diaphragmatic movement. Right 2 inches. Left $2\frac{1}{4}$ inches. The movement here is very good, and/

and the disease is in a very
early condition - a stage at
which X Rays gave some indication
and the ordinary physical ex-
amination none.

Flora. S

aet: 17

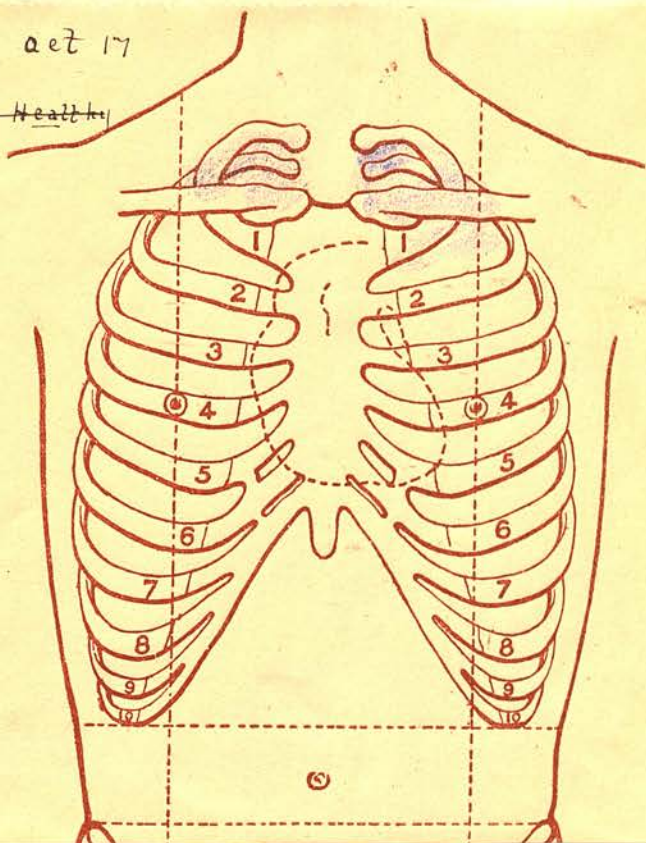
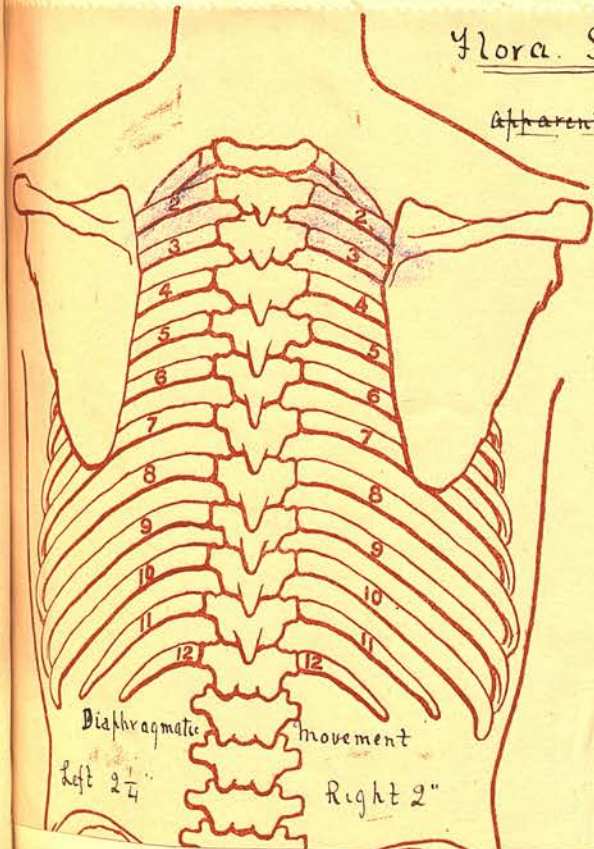
apparently Healthy



Flora. S

aet 17

apparently Healthy



Mrs L. Housewife. Age 25. Height 5 feet $3\frac{1}{2}$ inches. Weight 9 stone $6\frac{1}{4}$ lbs. Temperature normal.

COMPLAINT.

General weakness lasting for 9 months.

Previous history good. Husband has advanced Phthisis. No cough or Expectoration. Has been losing weight. Pulse 96. Tension and Volume fair. Menstruation irregular.

PHYSICAL EXAMINATION OF THE CHEST.

Anteriorly. There is a very slight impairment of the note, on the right side, above the clavicle. An occasional Rhonchus is heard, above the clavicle on the left side; otherwise the Lungs appear healthy.

Posteriorly. There is slight dulness to the top of the 4th Rib, on the right side, and over this area, the breathing approaches a bronchial character. No crepitations are heard, and otherwise the Lungs seem normal.

SCREEN EXAMINATION.

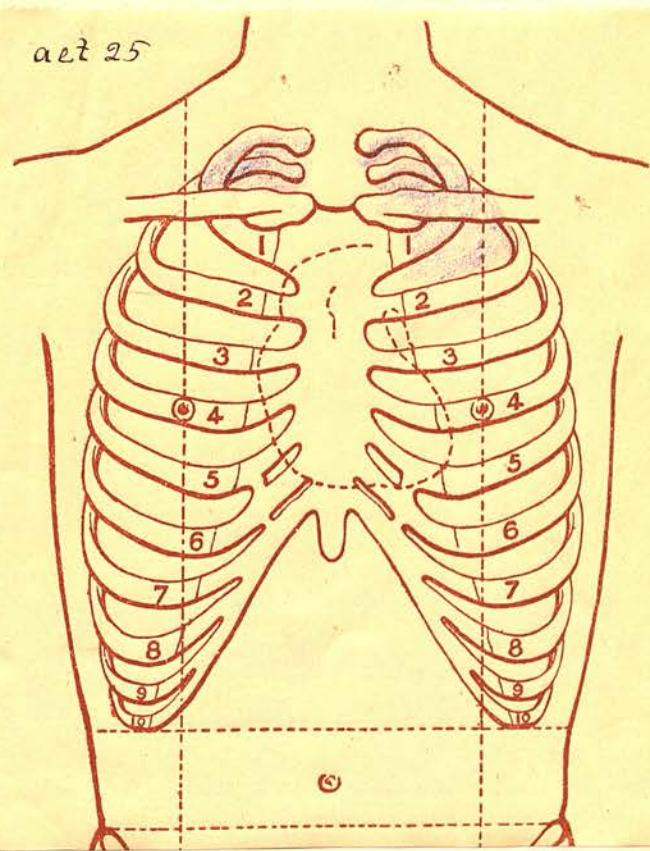
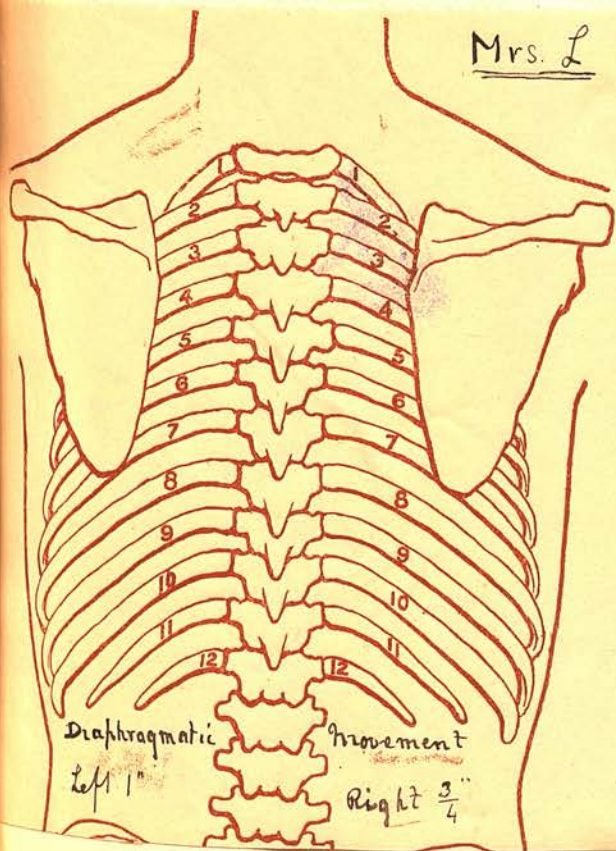
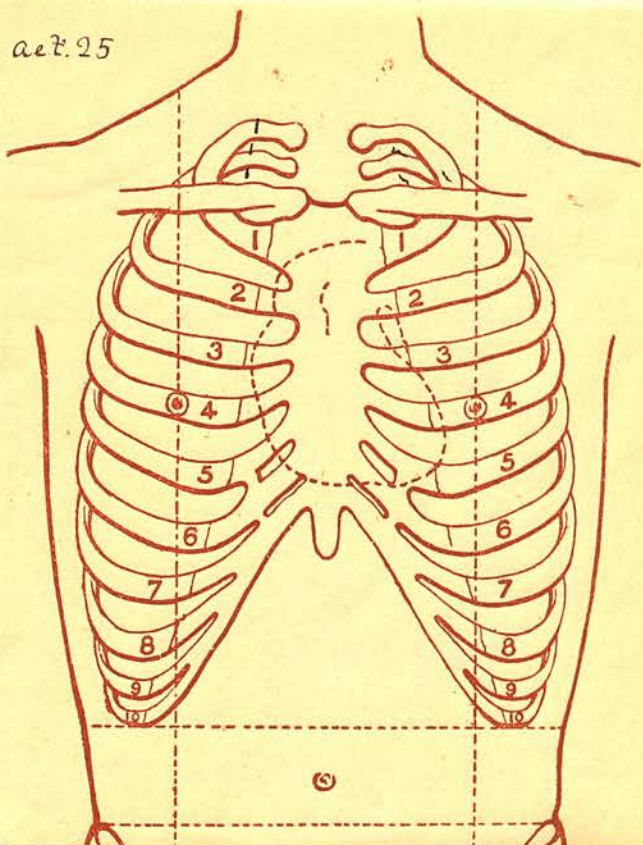
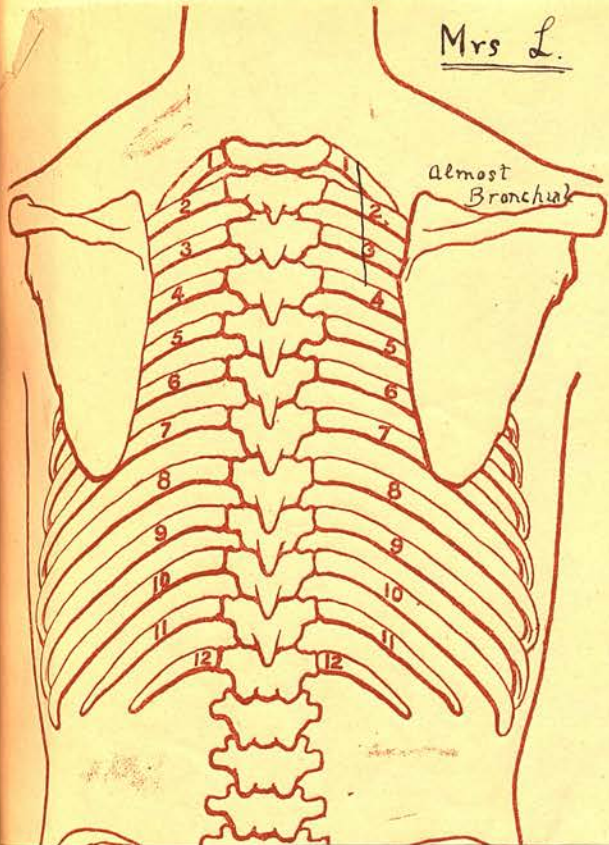
Anteriorly. There is loss of translucency on the/.

the left side, down to the 2nd Rib, and on the right side to the clavicle.

Posteriorly. On the right side loss of translucency to the 4th Rib.

Diaphragmatic movement. Right $\frac{3}{4}$ inch. Left 1 inch.

The Case is an early one, and it was doubtful whether the note over the right apex was more impaired than normal.



Jane T. Age 18. Height 5 feet $2\frac{1}{2}$ inches.

Weight 7 stone $12\frac{3}{4}$ lbs. Temperature normal.

COMPLAINT. HEMOPTYSIS. RISE ABOVE LEVELS OF BOTH SIDES.

Cough and spit lasting for 4 weeks. Has not been in good health for some months. Mother died of Phthisis twelve years ago.

RESPIRATORY SYSTEM. Intercostal, at the outer end,

Loose cough, especially in morning. Thick yellow Sputum in which Tubercle Bacilli were found. No Hoemoptysis.—Glandular swelling in neck. Sinus on left cheek. Menstruation irregular. No night sweats.

PHYSICAL EXAMINATION OF THE CHEST.

Anteriorly. Dulness on percussion, on both sides, as far as the 2nd Rib. Vesicular breathing, with prolonged expiration over the same areas. At the left apex a few crepitations, and Rhonchi are heard. Diaphragmatic movement.

Posteriorly. Dulness on percussion, to about the spine of the Scapula, on both sides. At the left apex, the breathing is bronchial, and at the right apex - vesicular, with/

with prolonged expiration.

No accompaniments.

SCREEN EXAMINATION. Ribs slope acutely on both sides.

Anteriorly. General haziness all over, but more marked on the left side. A nodule is seen in the first interspace, at its outer end, just below the clavicle on this side. On the right side, a triangular focus is seen, with its base, just at the axillary end of the 2nd interspace, and apex pointing inwards.

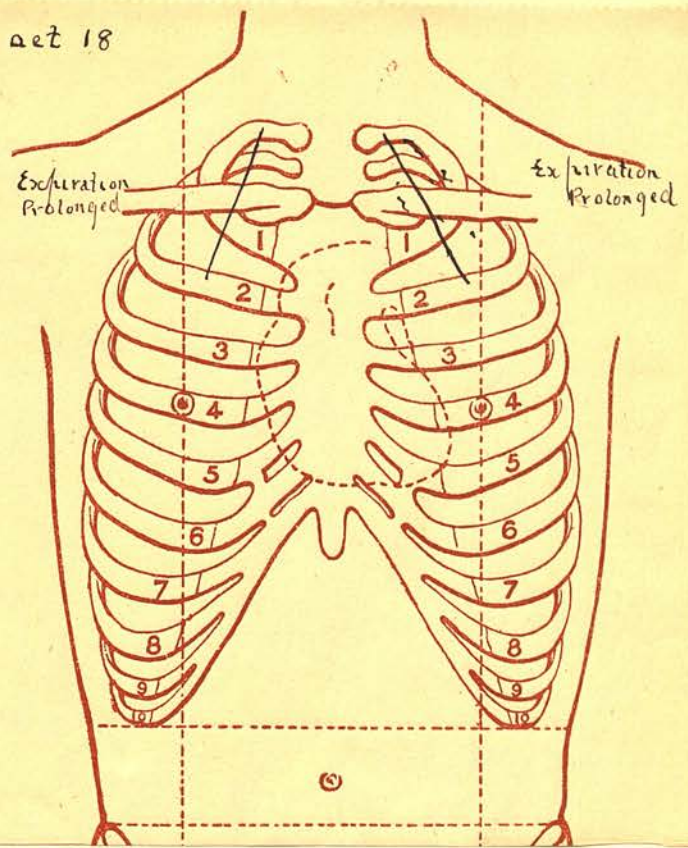
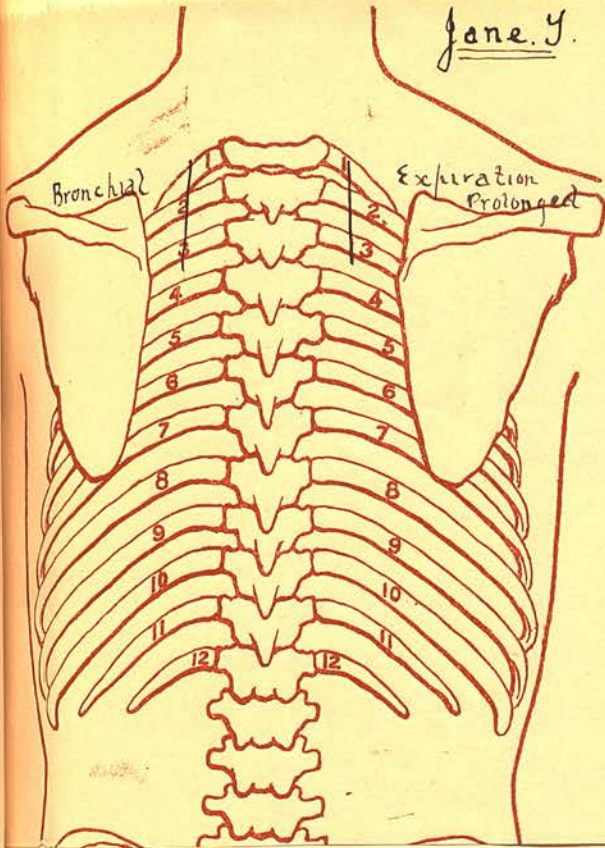
Posteriorly. Slight loss of translucency, almost all over, but deeper on the left side. On the right side, the triangular focus is again seen.

Diaphragmatic movement. Small. $\frac{1}{2}$ inch on the right side and $\frac{3}{4}$ inches on the left. The presence of distinct nodular foci, and the extensive, though slight loss of translucency, to which there were very few ordinary physical/

physical signs corresponding,
are the interesting facts in
this case.

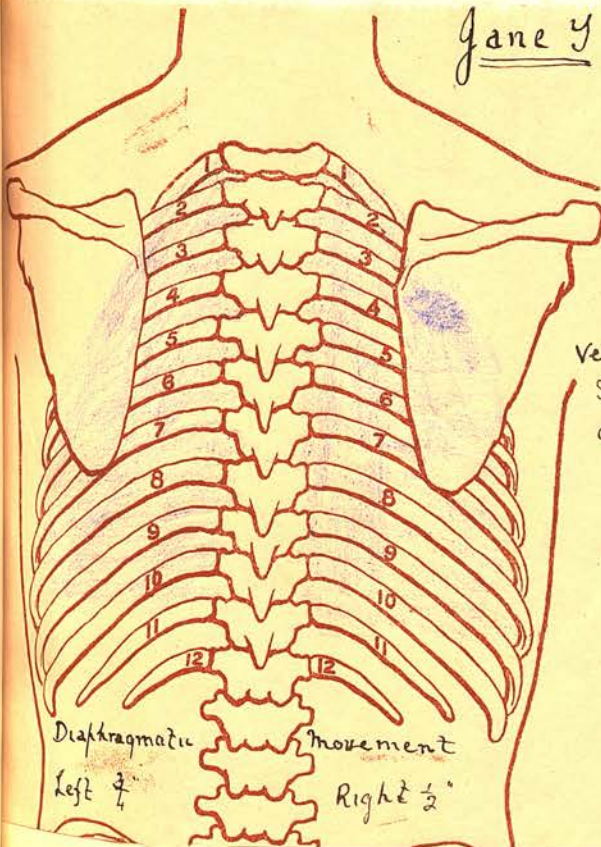
Jane Y.

aet 18

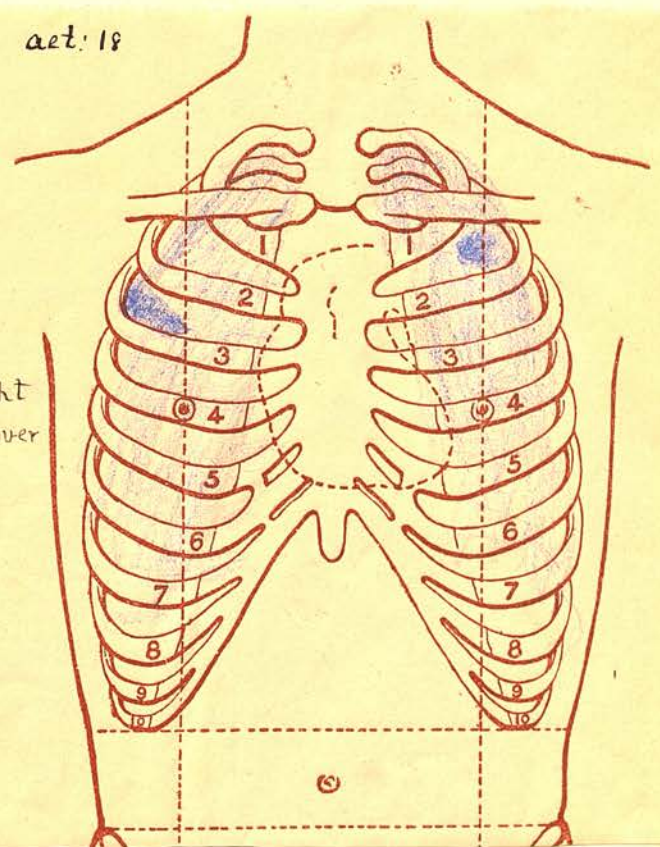


Jane Y

aet: 18



Very slight all over



John Mc R. Plumber. Age 44. Height 5 feet
 6½ inches. Weight 9 stone 6½ lbs. Temperature
 normal.

COMPLAINT

Weakness in the Chest, lasting for 9
 months. Personal and Family History good.

RESPIRATORY SYSTEM.

Cough hard, with thick yellow sputum, occasion-
 ally tinged with blood. Pain in front of the
 Chest. Dyspnoea at times.

ALIMENTARY SYSTEM.

Tongue furred. Appetite poor. Vomits
 occasionally after coughing. Suffers from
 constipation. Pulse 96 with poor tension and
 volume. Has been losing weight. Suffers occasion-
 ally from night sweats.

PHYSICAL EXAMINATION OF THE CHEST.

Anteriorly. On the right side, dulness on
 percussion to the 6th Rib: bron-
 chial breathing is heard all
 over this area, except over the
 3rd interspace, where the breath-
 ing is Amphoric. Crepitations
 are heard all down this side.

SURVEY EXAMINATION. On/

Anteriorly. There/

On the left side, dulness on percussion to the 2nd interspace, with prolonged expiration over this area. Crepitations accompany the breath sounds to the 4th Rib, and over the 6th and 7th Interspaces, in the Anterior Axillary Line, pleuritic friction is heard.

Posteriorly. On the right side, there is dulness on percussion right down to the 10th Rib, and very marked to the middle of the Scapula. Bronchial Breathing, and crepitations are heard all over this area. On the left side, there is dulness down to the 5th Rib, and down to the 4th Rib, the breathing is almost bronchial in character, - for the next three interspaces, the breathing is vesicular, with prolonged expiration. Crepitations are present down to the 6th Rib.

SCREEN EXAMINATION.

Anteriorly. There/

There is opacity all over the right side, with a denser patch over the 3rd, 4th, and 5th Ribs. On the left side, there is opacity to the 2nd Rib, and the loss of translucency tapers off to the 3rd interspace.

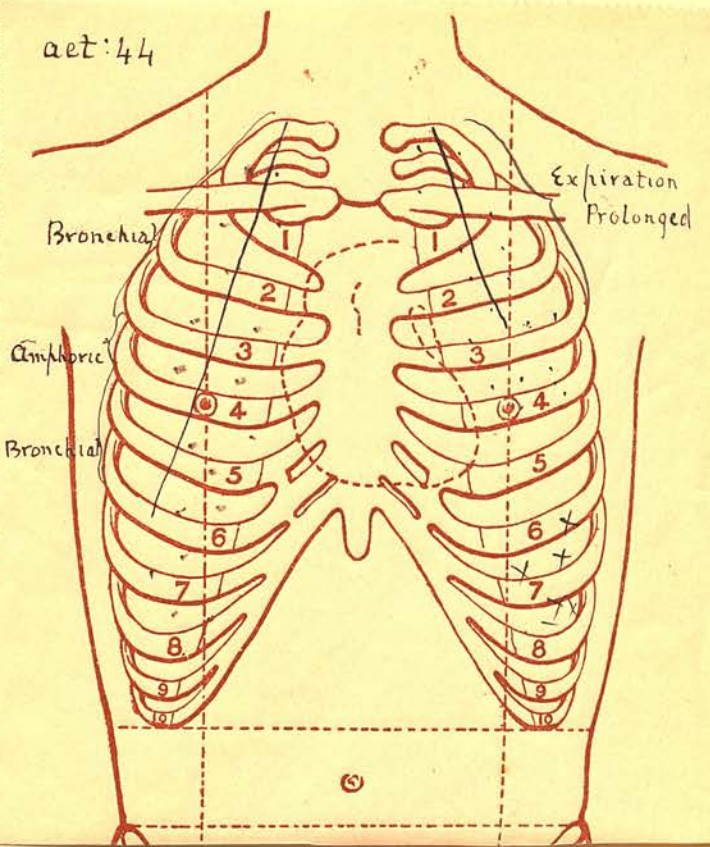
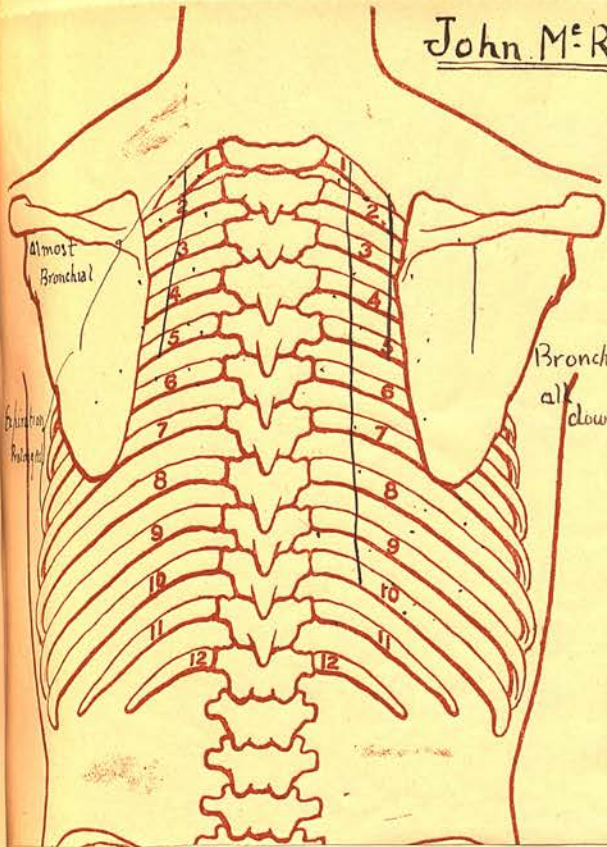
Posteriorly. On the right side, the Lung is again opaque all the way down, with a denser patch, corresponding to the 5th, 6th, 7th and 8th Ribs. On the left side, the opacity extends as far as the 6th Rib, tapering off slowly below this.

Diaphragmatic movement. Right $\frac{5}{8}$ of an inch. Left $1\frac{1}{8}$ inches.

In this case, the X Ray corroborates the ordinary physical examination; but no cavity formation was seen, although the Amphoric Breathing pointed to the possibility of it. The recent Pleurisy was not seen.

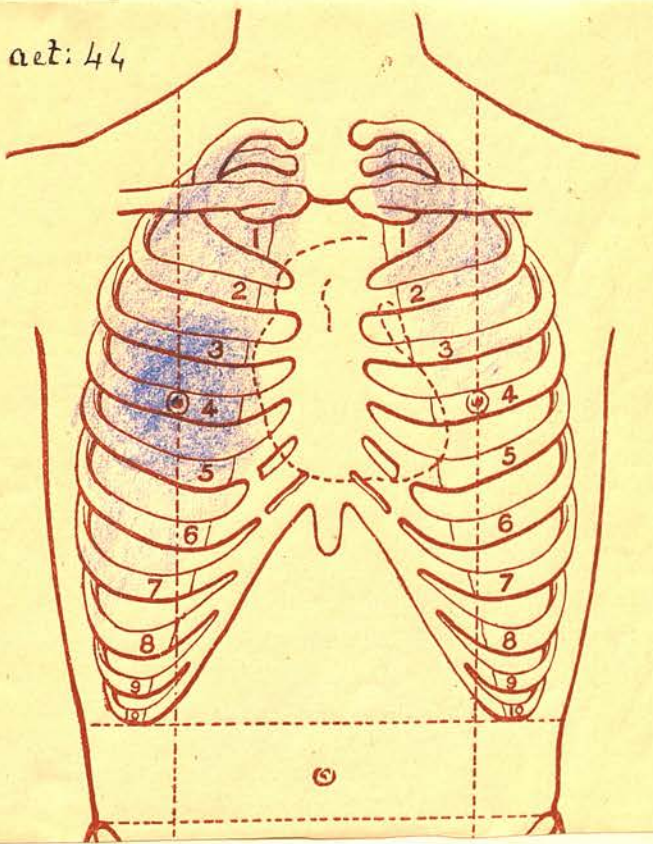
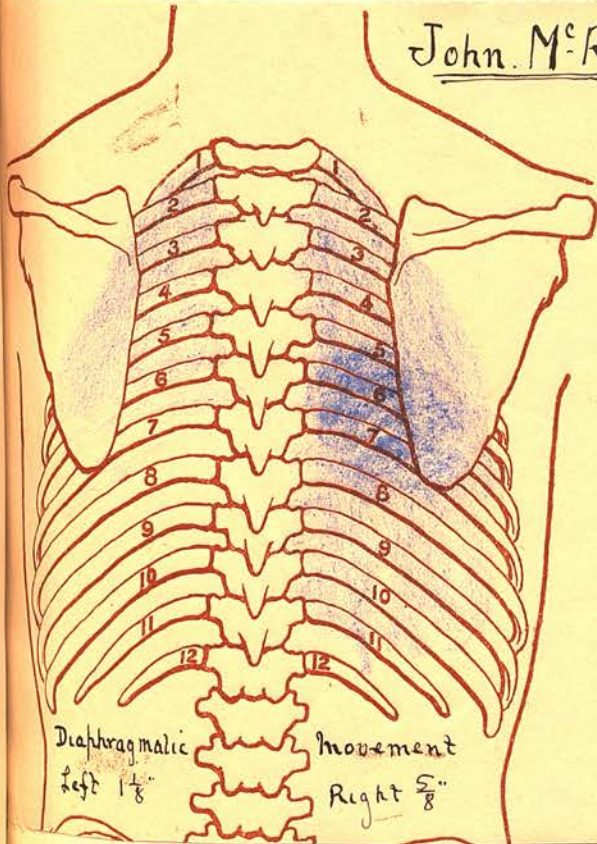
John M^cR

aet: 44



John M^cR

aet: 44



Jane G. Barmaid, age 38. Height 5 feet 3 inches. Weight 8 stone $3\frac{3}{4}$ lbs. Temperature normal.

COMPLAINT.

Pain in the back lasting for 6 weeks. Previous history good. Two cousins died of Phthisis.

RESPIRATORY SYSTEM.

Cough only severe at night. Sputum thick yellow. Hoemoptysis occasionally, during the last two months, but never severe. Pain in the back between the shoulders. Larynx shows pallor. Tongue furred. Appetite good. Vomits occasionally after coughing. Bowels regular. Frequently suffers from night sweats. Has been losing weight. Pulse 108. Tension and Volume fair. Systems otherwise normal.

PHYSICAL EXAMINATION OF THE CHEST.

Anteriorly. The note, on percussion, is impaired over the left apex above the clavicle. Otherwise normal.

Posteriorly. On the right side, there is dulness over the first three Ribs, and there the breathing approaches the bronchial character. On the left side, there is dulness over the first three Ribs, /

Ribs, with bronchial breathing over the first two ribs, and crepitations with the breath sounds as far as the fourth rib. A few crepitations are heard over the 8th and 9th ribs on the left side; but the breathing is vesicular. Elsewhere the lungs appear normal.

SCREEN EXAMINATION.

Anteriorly. On the right side, there is loss of translucency, as far as the 4th rib, and on the left side above the clavicle.

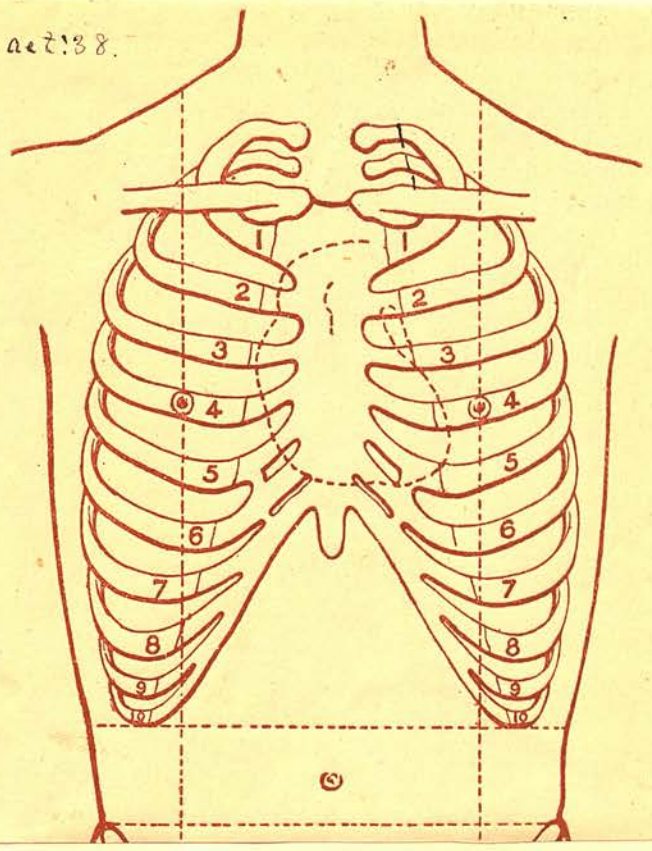
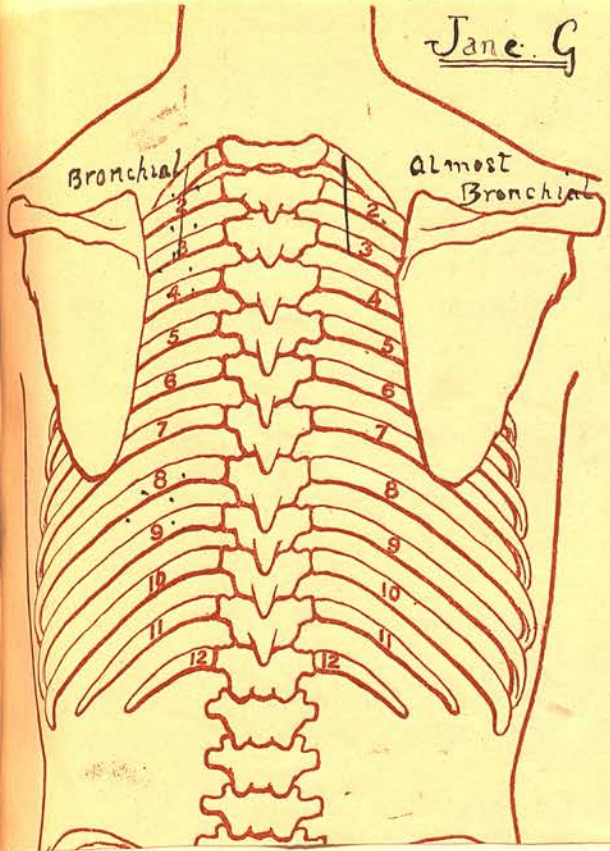
Posteriorly. On the right side, loss of translucency to the 3rd interspace, and on the left side to the 5th interspace.

Diaphragmatic movement.

This was difficult to measure as the patient would not breathe satisfactorily - but it was about $\frac{1}{2}$ an inch on the right side and 1 inch on the left.

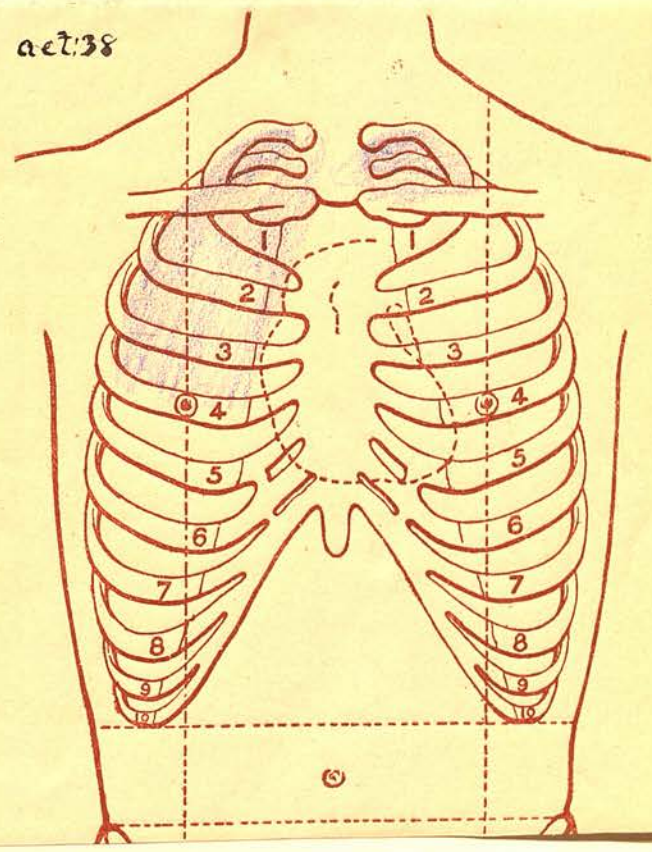
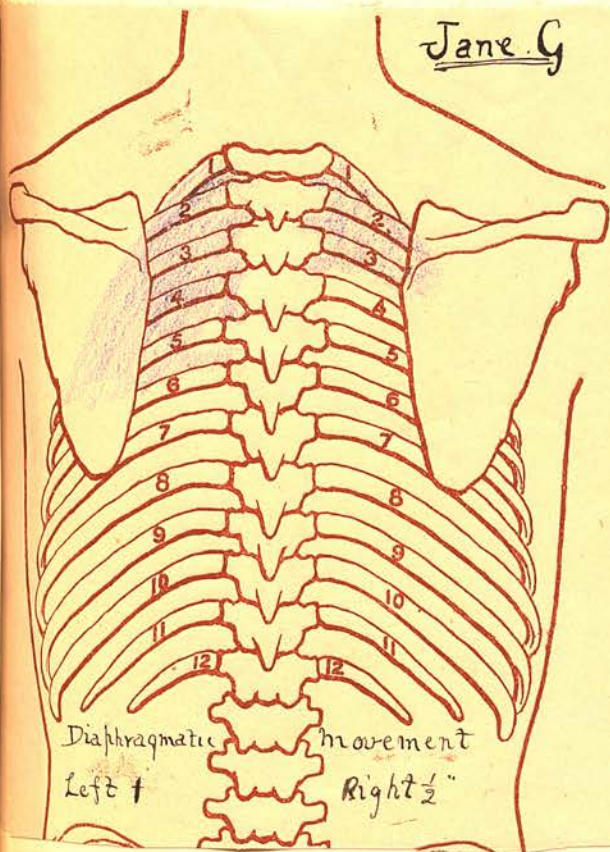
Jane G

aet: 38.



Jane G

aet: 38



Alfred C. Lamplighter. Age 34. Height
5 feet $3\frac{1}{4}$ inches. Weight 8 stone 13 lbs.
Temperature normal. *There is very slight loss of*
COMPLAINT. *translucency all over the*

Weak Chest, which has continued for 2 months.
Previous history good. One sister suffered from
Asthma. *left side clear.*

RESPIRATORY SYSTEM. *The right side shows*

Hacking cough, with very little sputum. No
Hoemoptysis. Dyspnoea in the morning. — Pulse
66. Tension and Volume fair. Other systems
normal. Has lost over a stone in weight, during
the last two months. No Tubercle found in Sputum.

PHYSICAL EXAMINATION OF THE CHEST, *chest, in which*

Anteriorly. No dulness on percussion.

Rhonchi are heard almost all
over. Breath sounds normal,
as far as can be made out.

Posteriorly. Slight impairment of the per-
cussion note over the first

four ribs, on the right side,
and over this area the Vocal
Resonance is increased. No
alteration in breath sounds.

Rhonchi are heard in both Lungs
posteriorly/

posteriorly.

SCREEN EXAMINATION.

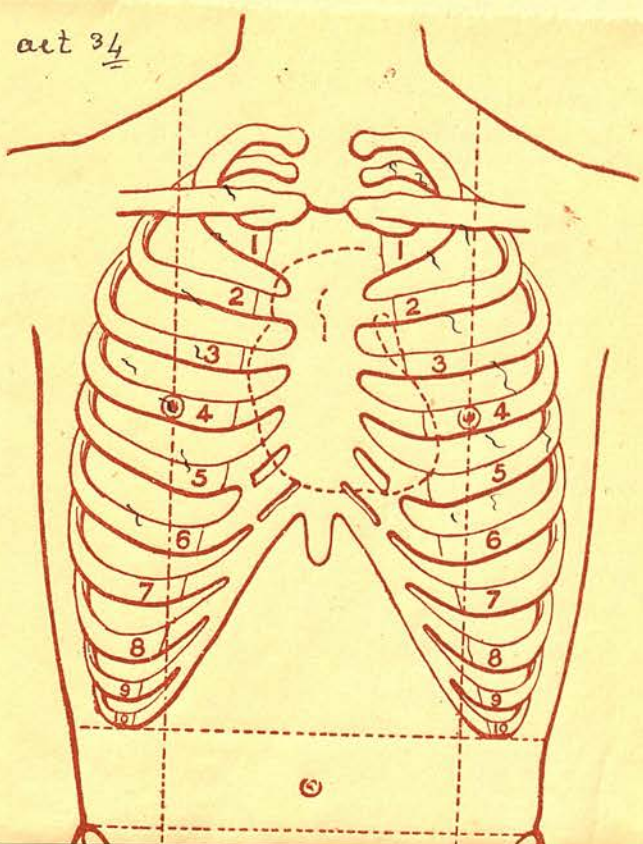
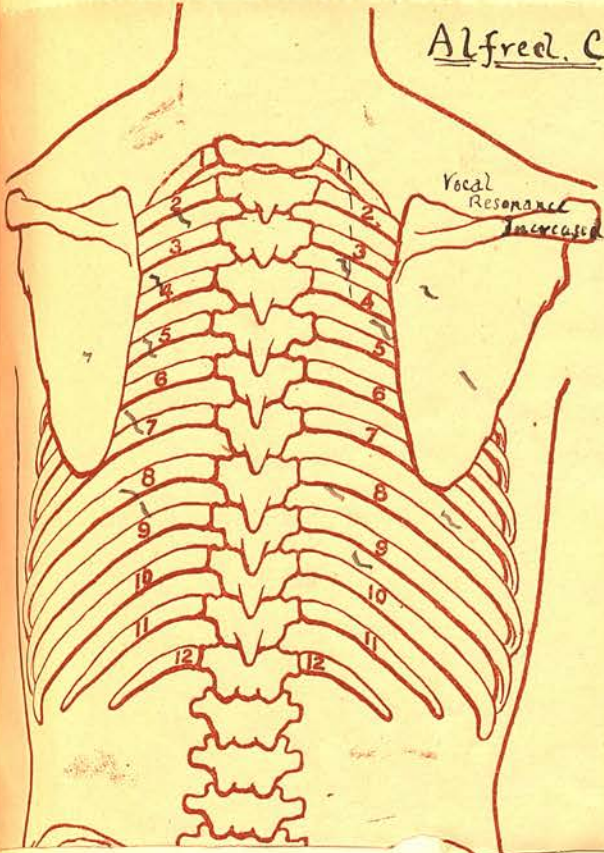
Anteriorly. There is very slight loss of translucency all over the right side, but more markedly so, as far as the 2nd Rib. The left side is clear.

Posteriorly. The right side again, shows slight loss of translucency over its whole extent, but more distinctly over the first four Ribs. Left side clear.

Diaphragmatic movement. Right 2 inches. Left $2\frac{1}{2}$ inches. This is another case, in which one finds X Rays valuable, as one often finds Rhonchi obscure the Lung condition.

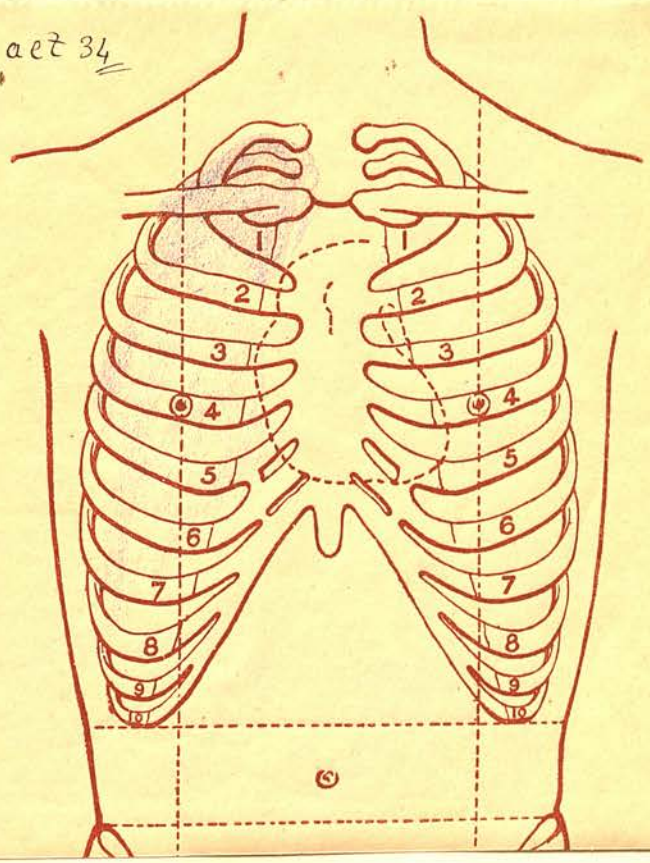
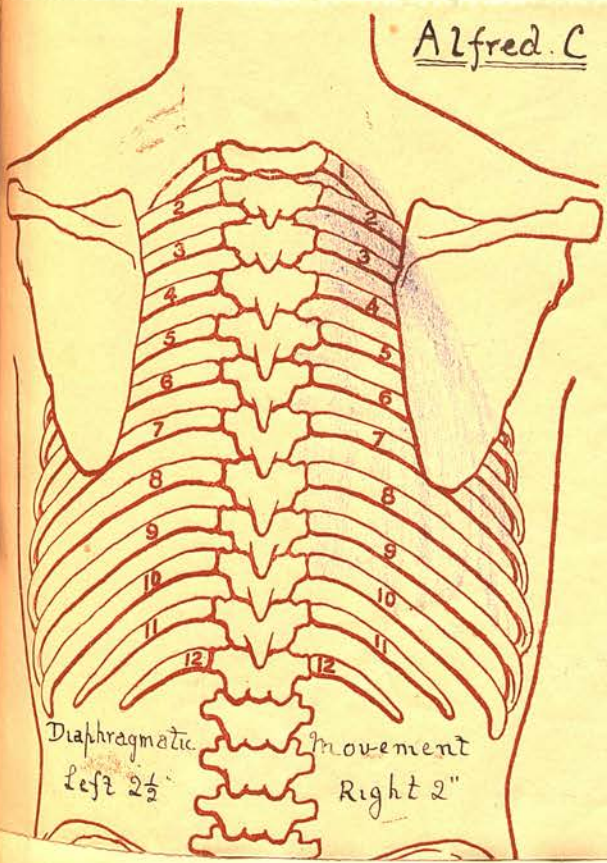
Alfred. C.

act 34



Alfred. C.

act 34



William D. Labourer aged 33. Height 5 feet 6 $\frac{1}{4}$ inches. Weight 9 stone 10 lbs. Temperature normal.

COMPLAINT.

Cough and spit lasting for three months.

Father died of Phthisis twenty years ago.

RESPIRATORY SYSTEM.

Slight cough. Thick clear sputum. No hoemoptysis. Dyspnoea at times. Larynx congested. Digestive system normal. Pulse 96. Tension and Volume fair. Glands swollen, on the right side of the neck.

PHYSICAL EXAMINATION OF THE CHEST.

Anteriorly. On the right side, impairment of the note on percussion down to the 1st Rib. Vesicular breathing, with prolonged expiration over this area. Harsh vesicular breathing over three interspaces

SCREEN EXAMINATION

Anteriorly.

below. On the left side, dulness on percussion down to the 1st Rib, with expiration prolonged and harsh vesicular breathing down to the 4th Rib. Below this area, the breathing is simply harsh vesicular.

Posteriorly. On/

Posteriorly. On the right side, no impairment of the note on percussion; but there is prolongation of the expiratory murmur down to the third Rib, and crepitations are occasionally heard, down to the 2nd interspace. On the left side, the note is impaired down to the 5th interspace. Down to the 2nd Rib, the breath sounds are almost bronchial in character, and down to the 6th Rib, there is vesicular breathing, with prolonged expiration. Over the 5th interspace, the breath sounds are jerky. Occasional crepitations are heard to the 4th Rib. Elsewhere the Lungs seem normal.

SCREEN EXAMINATION.

Anteriorly. On the right side, there is slight loss of translucency, above the clavicle, and on the left side, marked loss of translucency, down to the top of/

of the 4th Rib. The Heart is, apparently, smaller than normal.

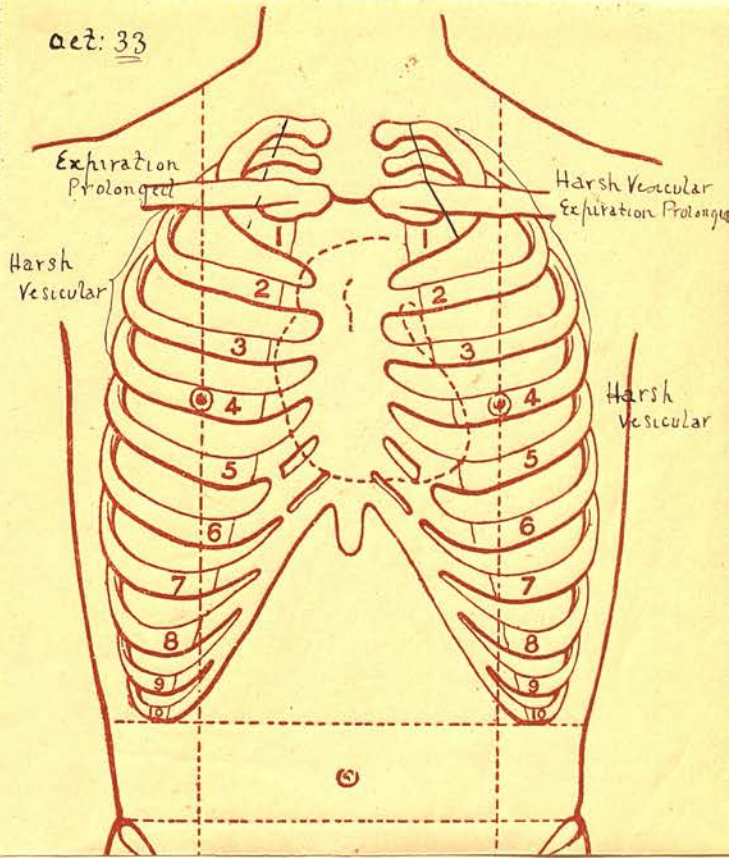
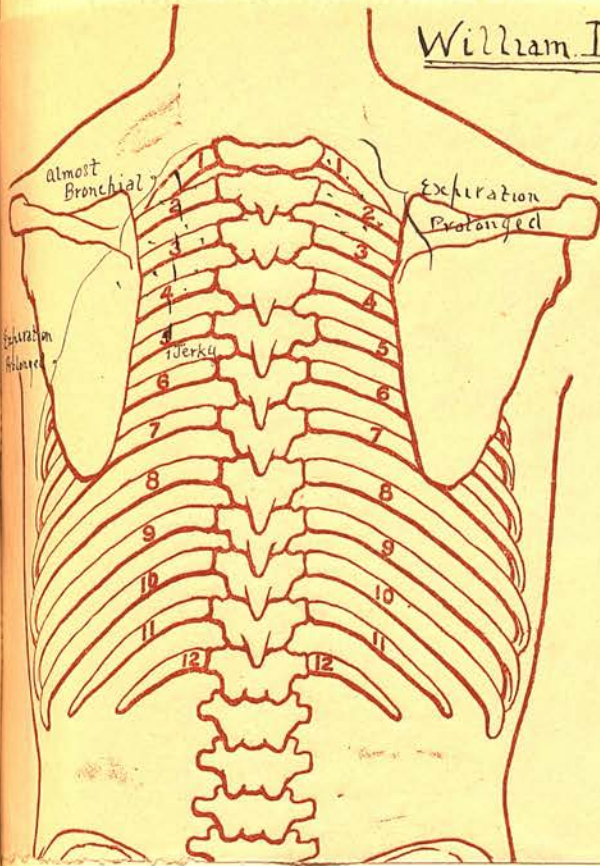
Posteriorly. On the right side, loss of translucency to the 4th Rib, and on the left side, it is again more decided, and extends to the 7th interspace.

Diaphragmatic movement.

At two feet distance. Right side 1 inch. Left $\frac{3}{8}$ of an inch. Thus the screen examination reveals a greater extent of disease, than does the ordinary routine physical examination.

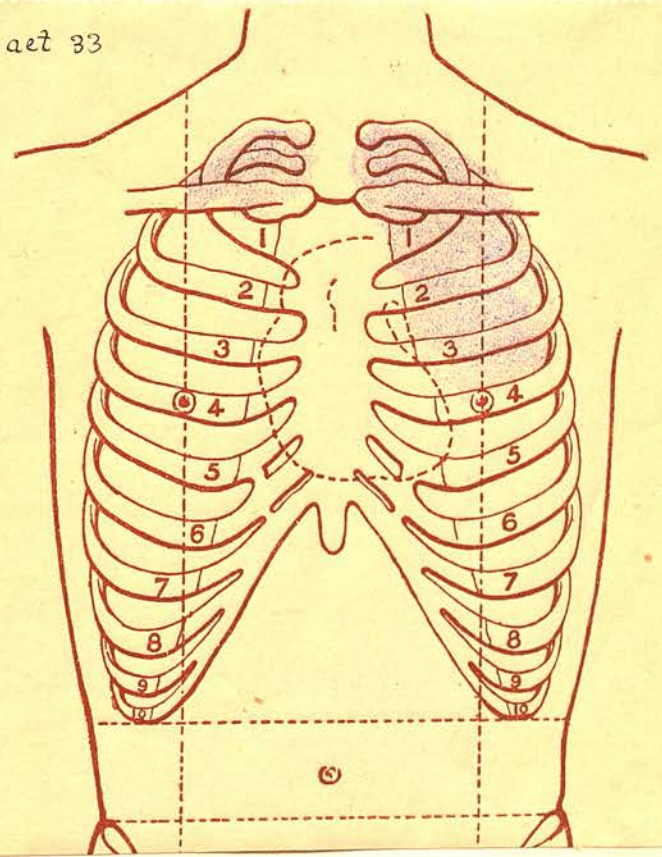
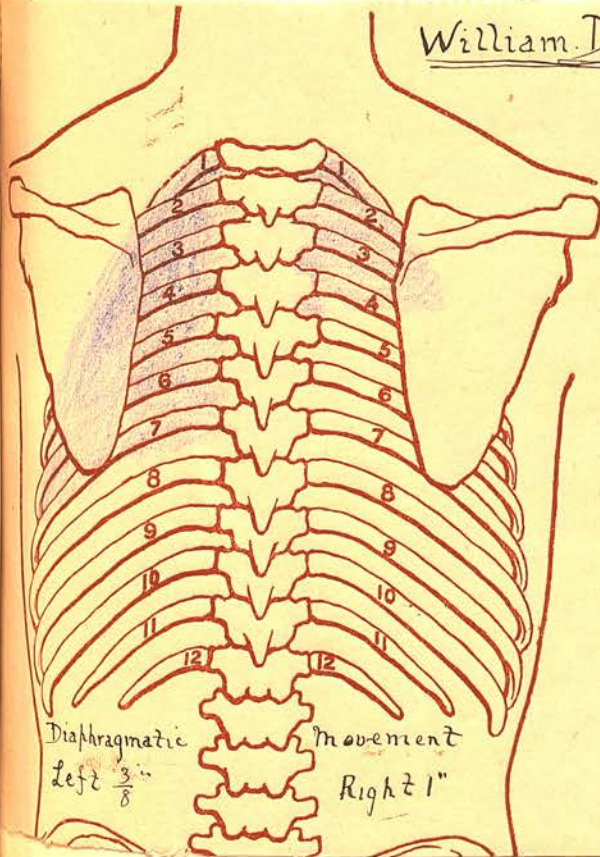
William D

aet: 33



William D

aet 33



Thomas M. Painter, age 19. Height 5 feet 8.
Weight 8 stone $6\frac{3}{4}$ lbs. Temperature normal.
COMPLAINT.

"Cough and Spit" lasting for 7 months. Had
Pneumonia as a child on two occasions. "Vomited"
blood 6 months previously, and again three months
ago. Uncle died of Phthisis.
RESPIRATORY SYSTEM.

Cough hard, worst in the morning. Thick
green sputum. No Hoemoptysis. Pain on the left
side at times. Examination of Larynx, reveals
ulceration of the left vocal cord. — Pulse 150.
Tension and Volume poor. Has Dyspeptic symptoms,
but no diarrhoea. Is losing weight. Suffers
from night sweats.
PHYSICAL EXAMINATION OF THE CHEST.

There is marked sinking in, of the Chest in front,
down to about the 2nd Rib, and posteriorly there
is a bulging.

Anteriorly. On the right side, dulness on
percussion, very marked to the
third rib - hyperresonance
below. Bronchial breathing
from Apex to the 2nd Rib, and
vesicular breathing, with pro-
longed expiration, to the 4th
Rib/

Rib. No accompaniments.

On the left side, marked dulness on percussion to the 4th Rib, with hyperresonance below - just below the clavicle, the note has a tympanitic character.

SCREEN EXAMINATION.

Anteriorly.

Bronchial breathing is heard all over the dull area, and is accompanied with occasional crepitations.

Posteriorly.

On the right side, the dulness is marked, to about the 8th Rib, - over the first four Ribs it is tympanitic, with amphoric breathing. Down to the 6th Rib, below this, the breathing has a bronchial character, - harsh vesicular to the 8th Rib.

On the left side, there is marked dulness on percussion, as far as the 7th Rib, - over the first

Posteriorly.

three Ribs, there is rather a tympanitic note, and here the breathing is amphoric. Down to the 5th Rib the breathing is bronchial, /

bronchial, and below that, to the 8th Rib, it is harsh vesicular, in character. A few crepitations are heard on this side, at the upper part.

SCREEN EXAMINATION.

Anteriorly. There is loss of translucency, on the right side, very marked to about the 4th Rib, and tapering off for one or two interspaces below. The lower interspaces are very clear, indicating Emphysema. Above and around the clavicle, the opacity is not so marked; but it is not specially clear.

On the left side, the loss of translucency is also marked, and extends to the 6th Rib - to the outer end of the first interspace, there is a clearer patch.

Posteriorly. On the right side, the loss of translucency extends to the 8th Rib - there being a well marked cavity over the 2nd and 3rd Ribs.

On/

Thomas M. Curtis

On the left side, the opacity extends to the 9th Rib, and is more marked than on the right side - a clearer part indicating a cavity is well seen over the first two Ribs.

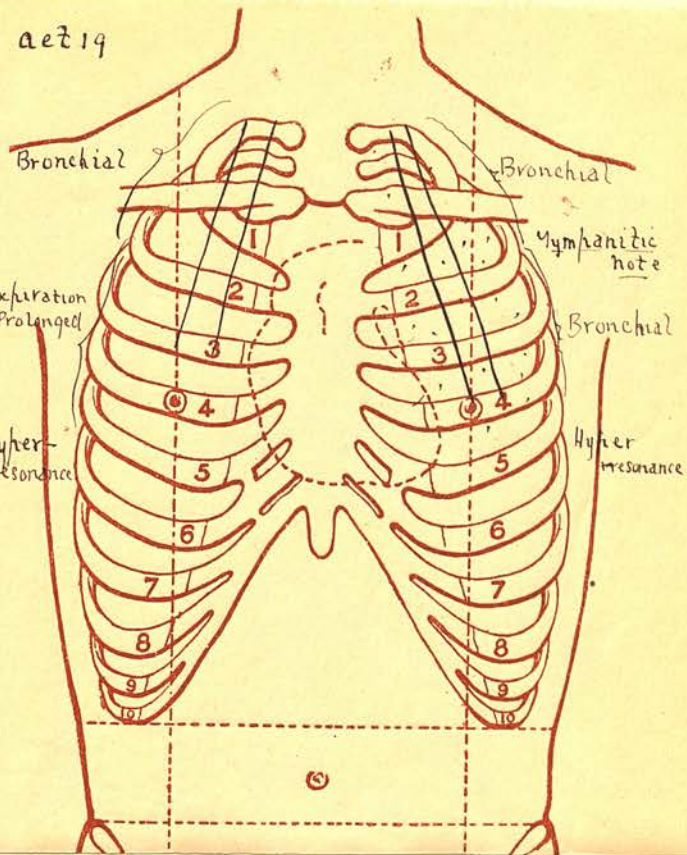
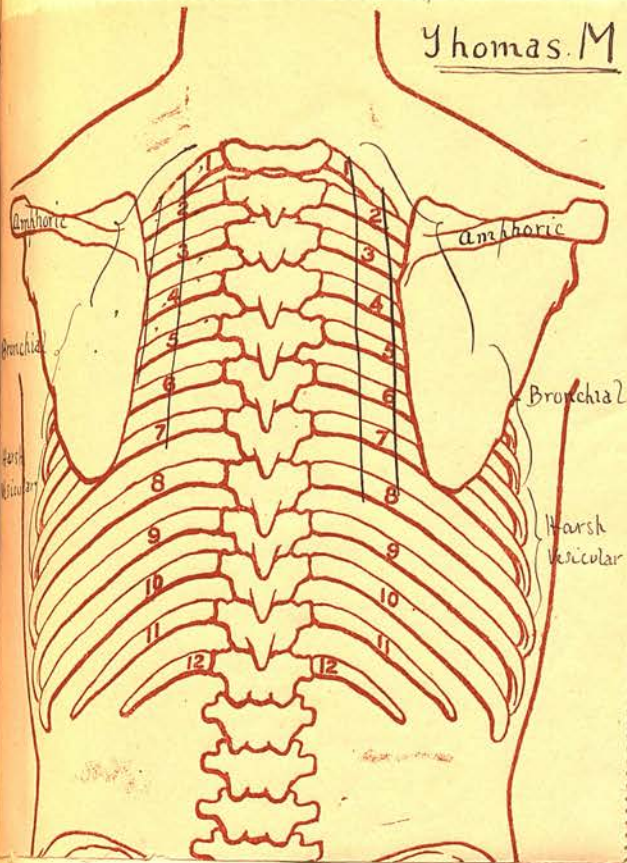
Diaphragmatic movement.

Very small; but not made out satisfactorily.

Thomas M. Curtis

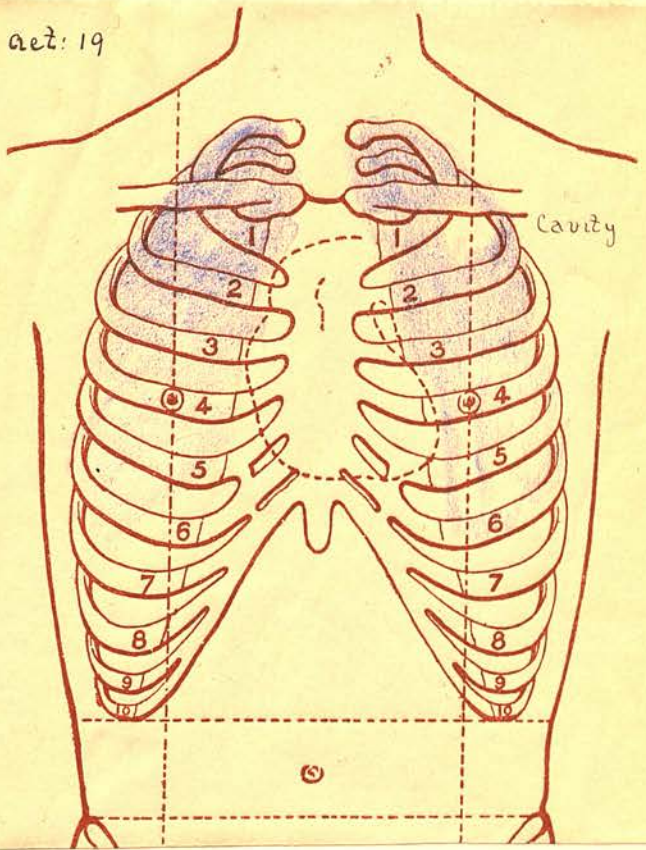
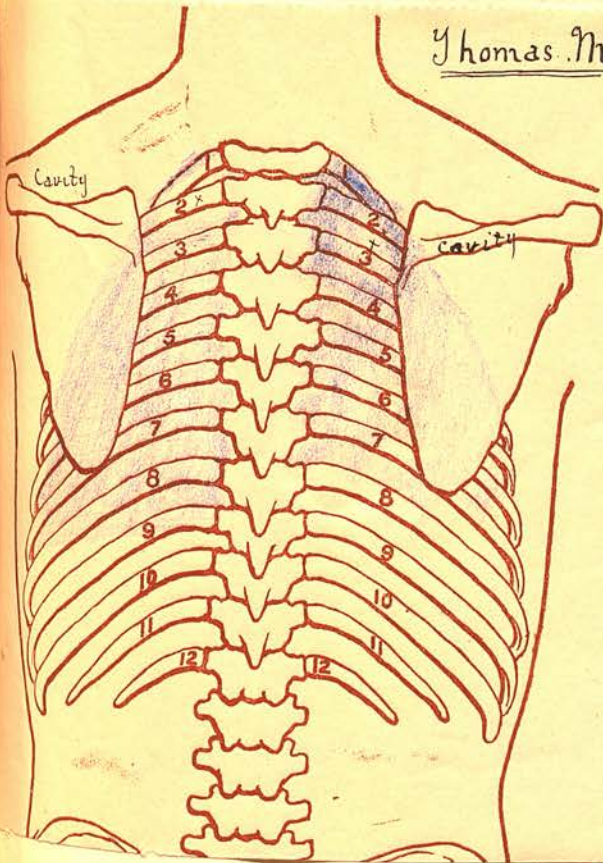
Thomas M

aet 19



Thomas M.

aet: 19



W. Reid. Brewer's Labourer, age 32. Height 5 feet 8. Weight 11 stone. Temperature normal.

COMPLAINT.

Cough, lasting for three years. 5 years of previously he had a bad attack of Influenza. Brother died of Phthisis. He is a well-developed muscular man.

RESPIRATORY SYSTEM.

Short slight Cough. Sputum thin white, containing Tubercle Bacilli. No Hoemoptysis. Occasional heavy feeling in the chest. Larynx normal.

Pulse 60. Tension and Volume fair. Other systems normal.

PHYSICAL EXAMINATION OF CHEST.

Anteriorly. Slight sinking in, above both clavicles.

Anteriorly. On the right side, dulness on percussion, to the 2nd Rib, and vesicular breathing, with prolonged expiration, down to the 2nd interspace.

Posteriorly. The left side shows exactly the same condition.

Posteriorly. On/

On the right side, dulness on percussion, to the 3rd interspace, and impairment of the percussion note, to the top of the 6th Rib. Expiration is prolonged, down to the 3rd Rib, and a few crepitations are heard to the 2nd interspace.

On the left side, dulness on percussion, to the 4th Rib, and slight impairment of the percussion note, as far as the 8th Rib, The breath sounds are bronchial to the 2nd Rib, and down to the 6th Rib, there is prolonged expiration.

SCREEN EXAMINATION.

Anteriorly. On the right side, loss of translucency, to the 3rd Rib; and on the left side, to the 4th interspace, being deeper in character above, on both sides.

Posteriorly. On the right side, loss of translucency, to the 7th Rib, and/

and on the left side, practically only the last interspace is clear.

The Ribs slope much more acutely on the left side.

Diaphragmatic movement.

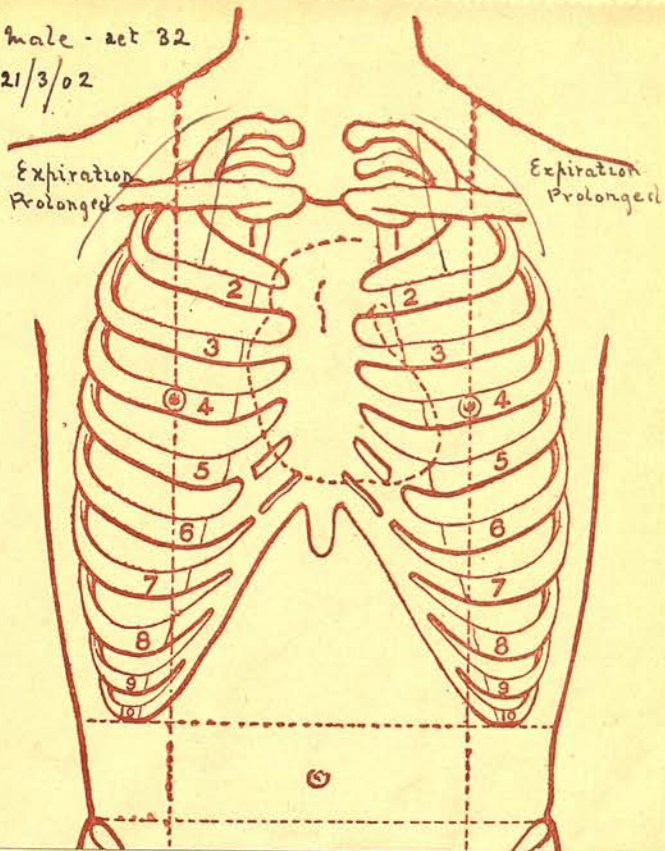
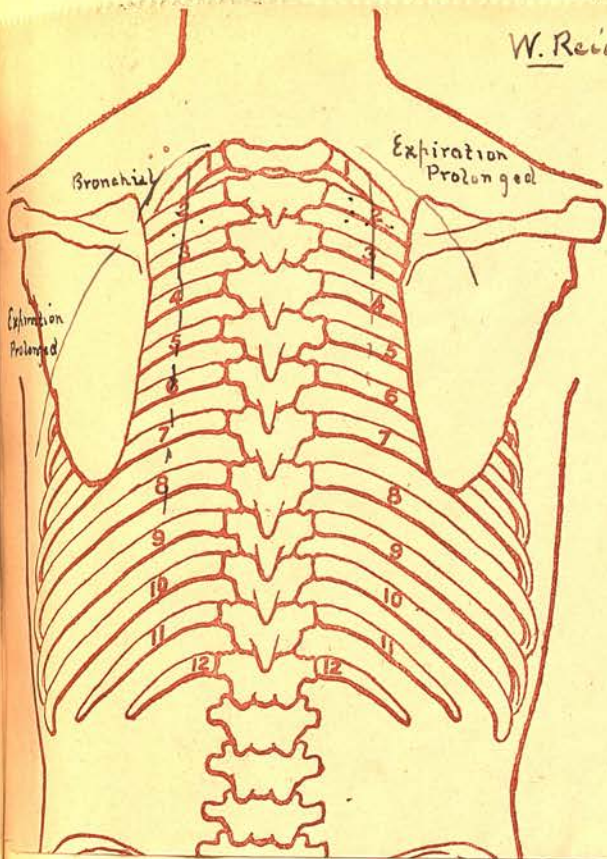
At two feet distance. Right $1\frac{3}{4}$ inches. Left $1\frac{1}{2}$ inches.

movement
Right $1\frac{3}{4}$

W. Reid

male - aet 32

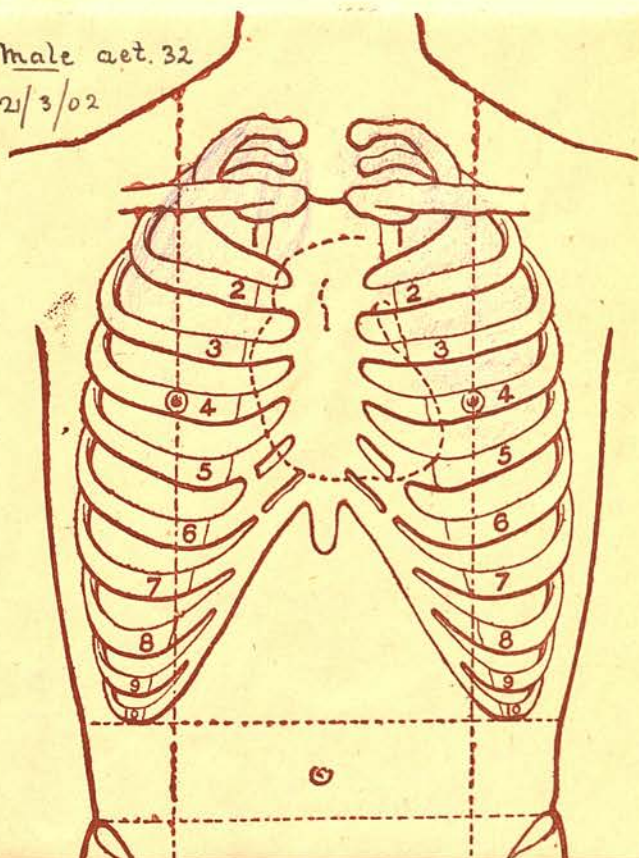
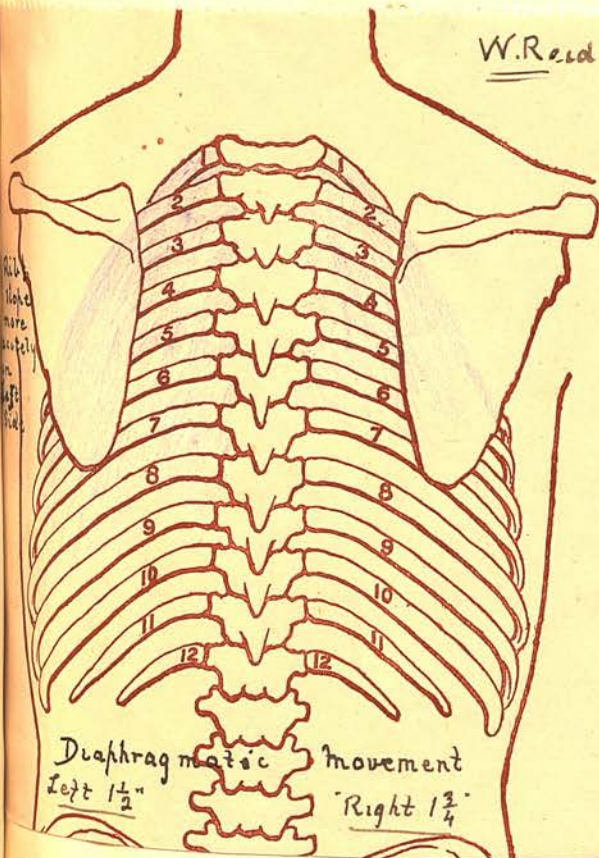
21/3/02



W. Reid

male aet. 32

21/3/02



Alexander A. Tinsmith, age 23. Height 5 feet 9. Weight 9 stone $3\frac{3}{4}$ lbs. Temperature 99.

Complains of Cough and spitting blood lasting for three weeks. Previous health good. Family history good.

RESPIRATORY SYSTEM.

Short cough - slight blood-stained sputum. No pain in chest. Larynx congested. Vocal cords injected. — Pulse 120, fairly strong and regular. Occasional night sweats. Other systems normal.

PHYSICAL EXAMINATION OF THE CHEST.

Anteriorly. On the right side percussion note is impaired as far down as the 2nd Rib; and on the left side as far as the 3rd Rib. Breath sounds approach bronchial character, above the clavicles, and prolonged expiration extends for a few interspaces below.

Posteriorly. On the right side, dulness on percussion as far as the 5th Rib - the breathing being bronchial over this area and accompanied by crepitations. Vesicular breathing below this.

On/

On the left side, the dulness on percussion, extends as far as the 7th Rib. Bronchial breathing extends down to the 5th Rib, and vesicular, with prolonged expiration, for two interspaces below. Amphoric breathing is heard, over the 3rd Rib interal to the Scapula. No accompaniments are present on this side.

SCREEN EXAMINATION.

Anteriorly. On the right side, the loss of translucency extends to the 4th Rib; but no-where is it satisfactorily clear.

On the left side, as far as the 4th Rib the Lung is very much less translucent, than normal.

Posteriorly. On the right side the loss of translucency extends to the 6th Rib, and on the left side to the 7th Rib.

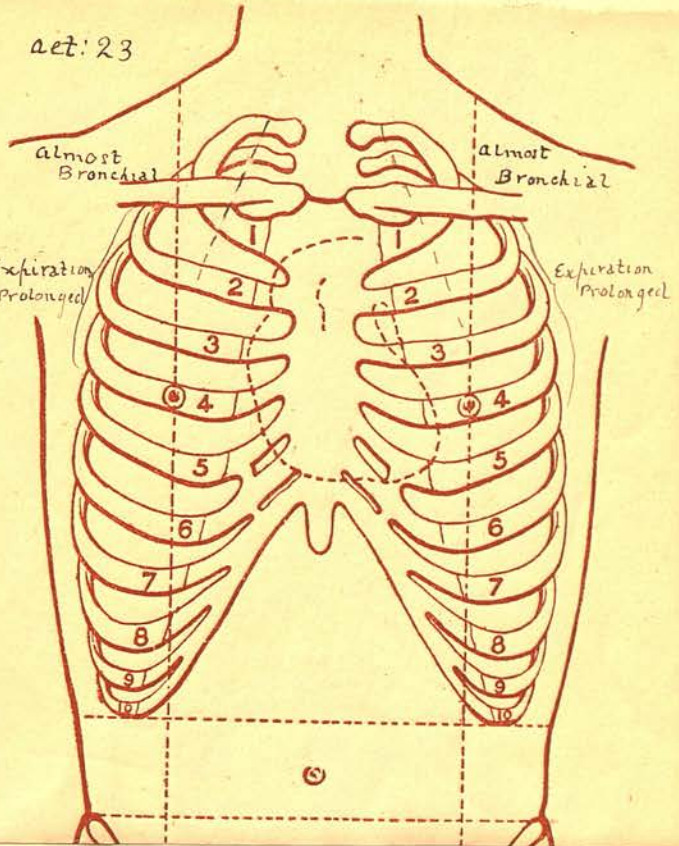
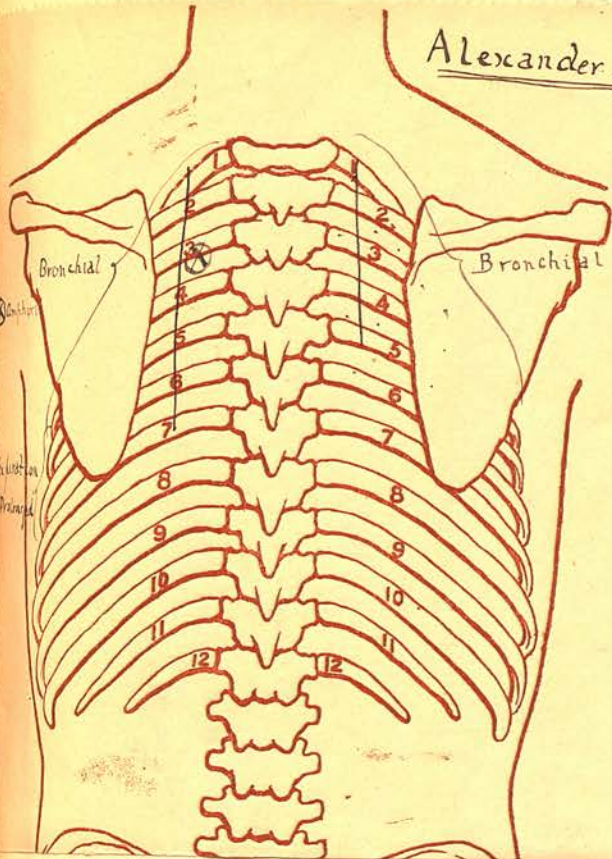
Diaphragmatic movement. Right side $\frac{3}{4}$ inches. Left 1 inch.

The difference between the two methods/

methods, is, here, not very
great; but the advantage un-
doubtedly lies with X Rays.
No signs of cavity were observed
by X Rays.

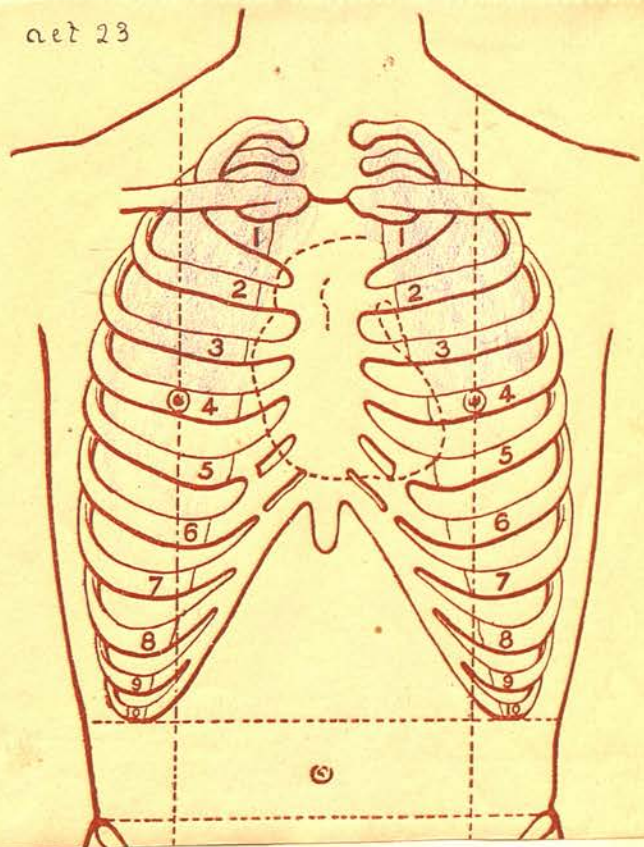
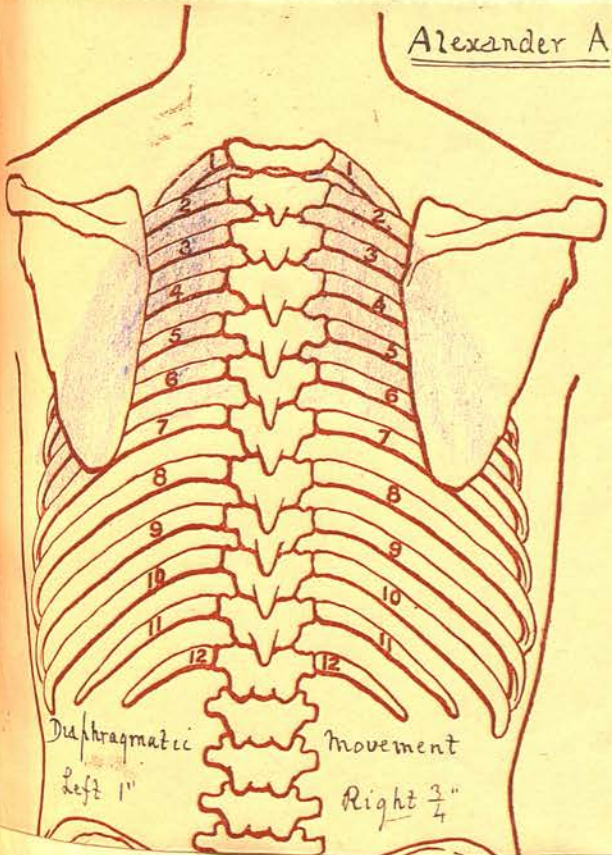
Alexander A

aet: 23



Alexander A

aet 23



Thomas C. Pavement Layer, age 32. Height 5 feet 8½. Weight 10 stone 7. Temperature normal.

COMPLAINT.

"Cough and Spit" lasting for three days; but he has been out of sorts for some time. Smokes 7 ounces of tobacco weekly. Had pleurisy ten years ago. Family history good.

RESPIRATORY SYSTEM.

Hacking cough with thick white sputum. No Hemoptysis. Pain in front of the Chest at times. Larynx - Vocal cords normal. Swelling of the posterior fold. — Pulse 102. Tension and Volume poor. Slight irregularity in time. Night sweats occasional. Otherwise the systems are normal.

PHYSICAL EXAMINATION OF THE CHEST.

Anteriorly. There is dulness on percussion, as far down as the 1st Rib on the left side. Breath sounds normal.

Posteriorly. On the right side, the note is impaired over the first two Ribs. Breath sounds normal. On the left side, there is dulness to the 4th Rib, and crepitations/

crepitations are heard over this area. No Bronchial breathing is heard anywhere, but prolonged expiration at the left apex.

SCREEN EXAMINATION.

Anteriorly. There is faint loss of translucency to the 3rd Rib, on the left side, and the 2nd Rib on the right side.

Posteriorly. On the right side there is loss of translucency to the 4th Rib, and on the left side to the 8th Rib.

Diaphragmatic movement.

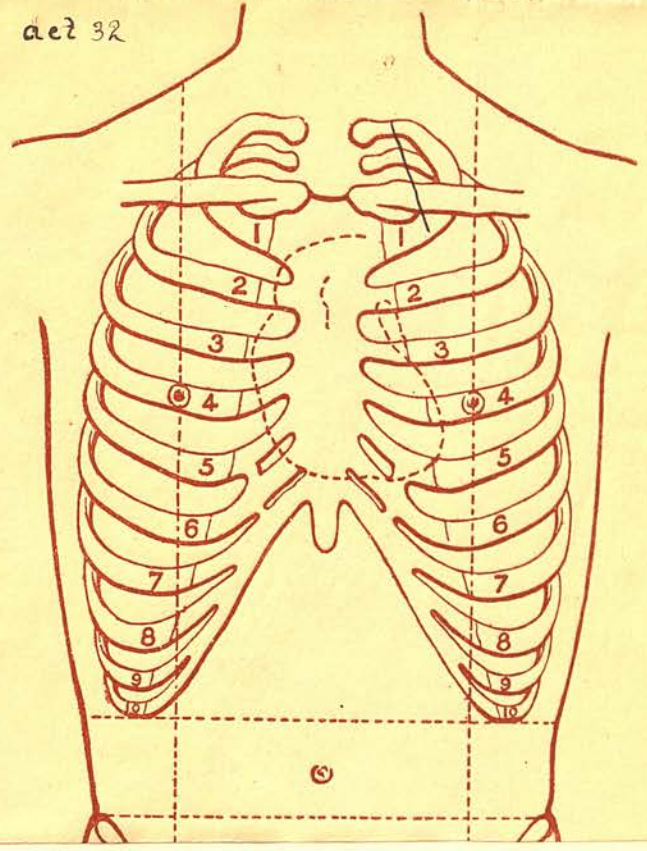
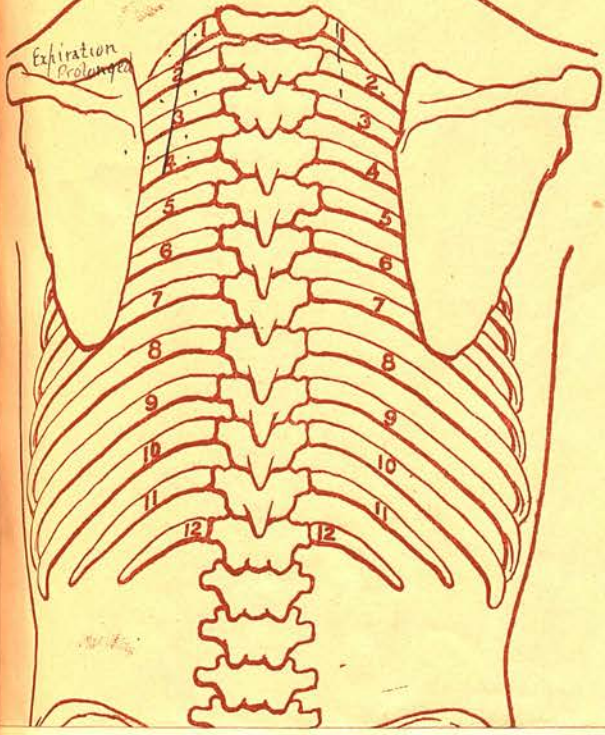
Right side $\frac{1}{2}$ inch. Left side $\frac{1}{4}$ inch.

The diminution is very pronounced here.

Thomas. C.

aet 32

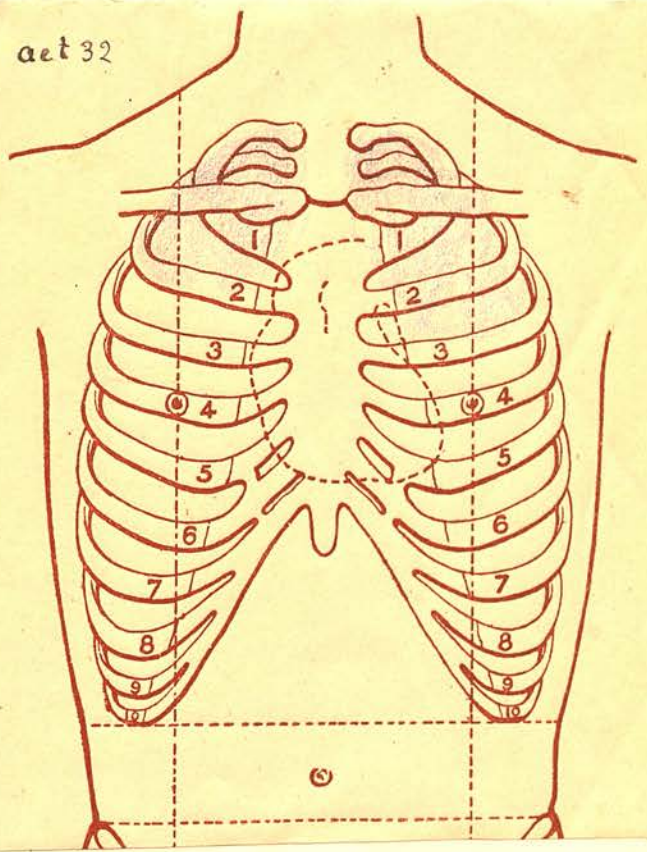
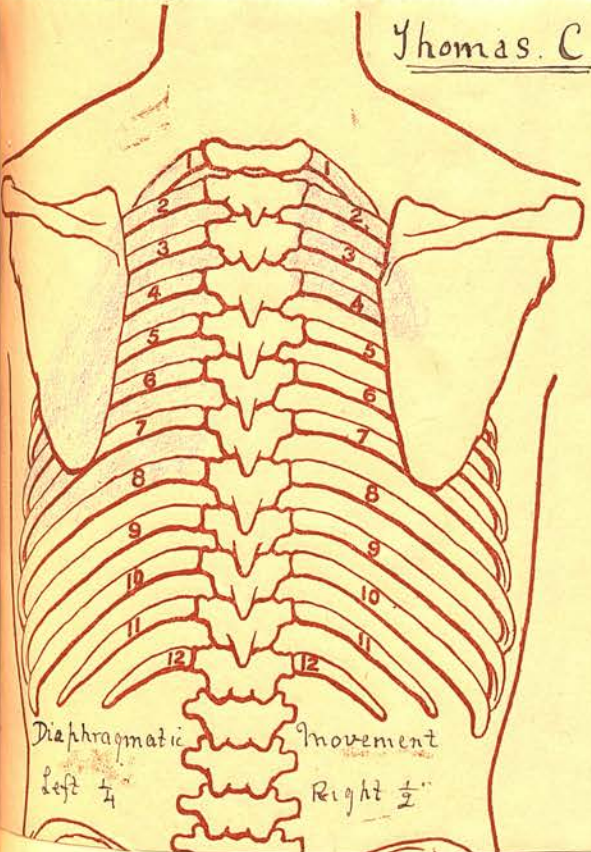
Expiration
Prolonged



Thomas. C.

aet 32

Diaphragmatic
Movement
Left $\frac{1}{4}$ " Right $\frac{1}{2}$ "



James S. Blacksmith, age 16. Height 5 feet 4.

Weight 8 stone. Temperature normal.

COMPLAINT.

Cough lasting for 6 months. Previous history good. Brother died of Phthisis 4 years ago.

RESPIRATORY SYSTEM.

Cough hard, worst at night. Sputum, thick-yellowish. No Hoemoptysis. No pain. Dyspnoea on exertion. Palate pale, with areas of injection. Ary-Epiglottidean folds swollen and red. Vocal cords grey and granular.

CIRCULATORY SYSTEM.

Pulse 126. Tension and Volume poor. Systolic murmur in the mitral area. 2nd sound reduplicated. Digestion good. Has been losing weight. Suffers from night sweats.

PHYSICAL EXAMINATION OF THE CHEST.

Anteriorly. Dulness on percussion on the left side, to the 2nd interspace, and over this area bronchial breathing is heard, accompanied by crepitations. Prolonged expiration, with vesicular breathing, for an interspace below. Elsewhere normal.

Posteriorly. On/

On both sides, dulness on percussion, to the 3rd Rib, with bronchial breathing faint in character, over the same areas. Elsewhere normal.

SCREEN EXAMINATION.

Anteriorly. A very slight loss of translucency, above the clavicle on the left side.

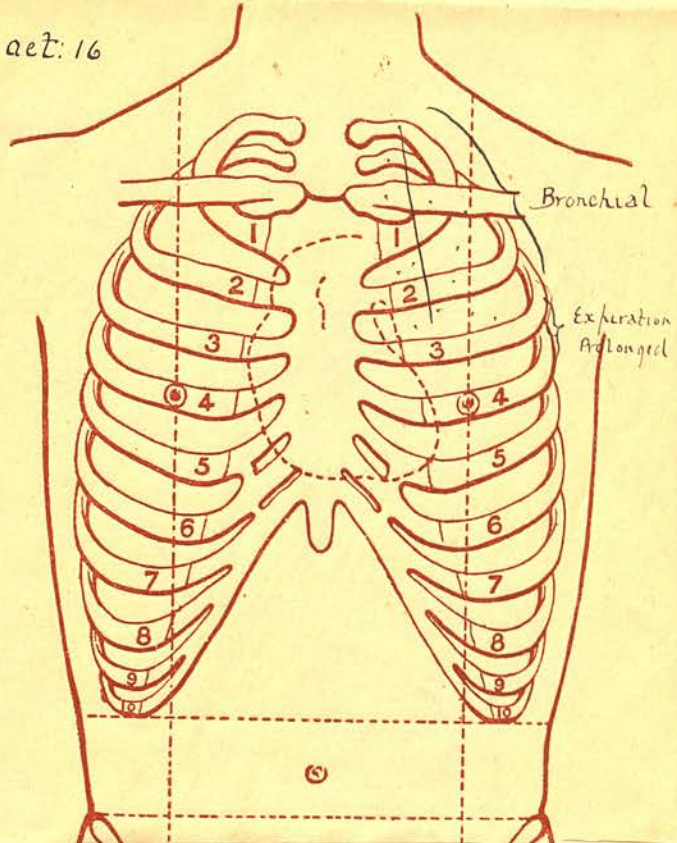
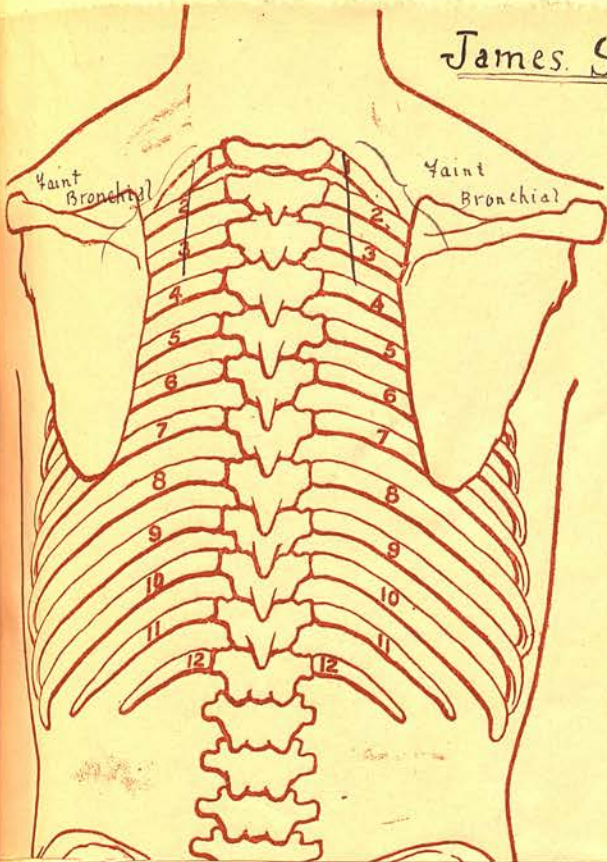
Posteriorly. On the right side, loss of translucency, to the 4th inter-space.

On the left side, the loss of translucency is not so marked, and only extends to the 3rd Rib.

This was one of my first examined cases, and the diaphragmatic movement was not measured. The Screen Examination corroborates the Physical examination, does not go so far in some respects, and in others goes further.

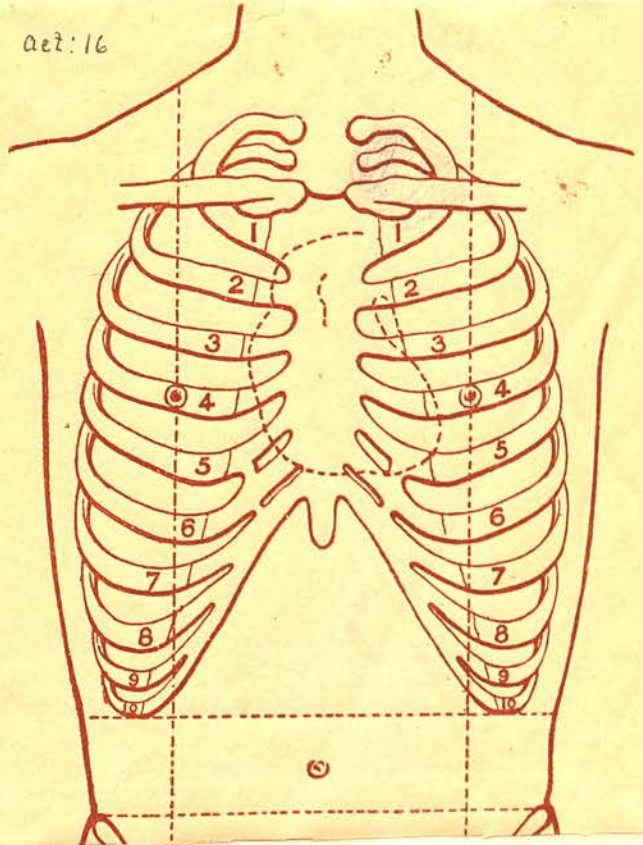
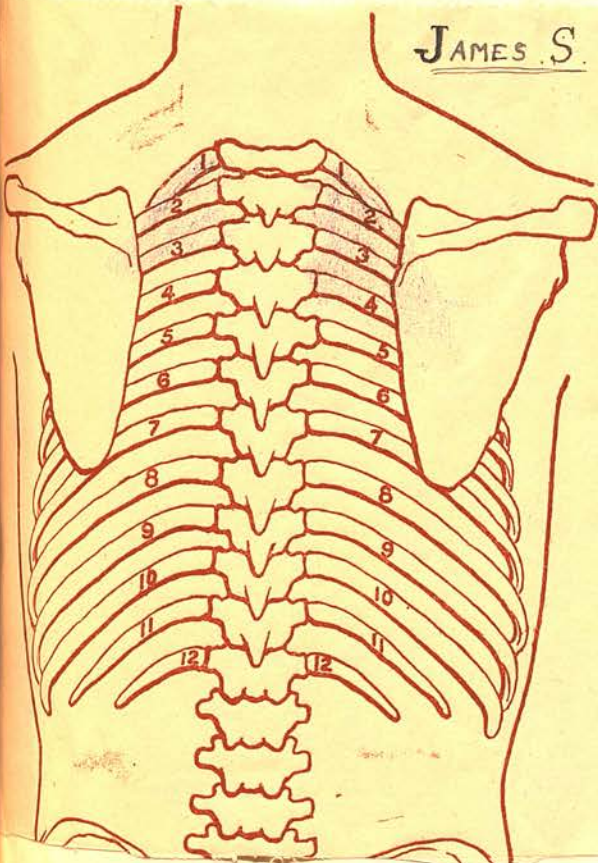
James. S

aet: 16



JAMES. S.

aet: 16



James Sv. Bookmaker. Age 33. Height 5 feet
5 inches. Weight 8 stone $11\frac{3}{4}$ lbs. Temperature
normal.

COMPLAINT.

Cough and general weakness lasting for a
fortnight. For the last 5 years he has been
troubled with a short cough. Mother died of
Phthisis 12 years previously.
RESPIRATORY SYSTEM.

Cough loose, worst in morning, with thick white
sputum. Slight hoemoptysis for 3 days.
Larynx congested; but no loss of substance.
Has been losing weight.

Pulse 84. Tension and Volume fair.

PHYSICAL EXAMINATION OF CHEST.

Anteriorly. Slight dulness on percussion on
left side, from apex to 1st Rib.
Bronchial breathing above the
clavicle. Elsewhere normal.

Posteriorly. On the right side, slight dulness
on percussion, over the first
two Ribs, and vesicular breathing,
with prolonged expiration, is
heard above the Scapula - this be-
ing more than is normally heard
at/

at the right apex.

Diaphragmatic
movement.

On the left side, dulness on percussion, very marked to the 4th Rib, and extending to the 6th. Bronchial breathing is heard, above the spine of the Scapula, and vesicular, with prolonged expiration, to the 7th Rib.

SCREEN EXAMINATION.

Ribs on the left side slope much more acutely, than on the right.

Anteriorly. On the right side, there is loss of translucency above the clavicle. On the left side, marked opacity from apex to 2nd Rib, and tapering off to the 4th Rib.

Posteriorly. On the right side, loss of translucency from apex to 4th Rib, and on the left side, it is more marked and extends from apex to the 8th Rib, - being denser to/

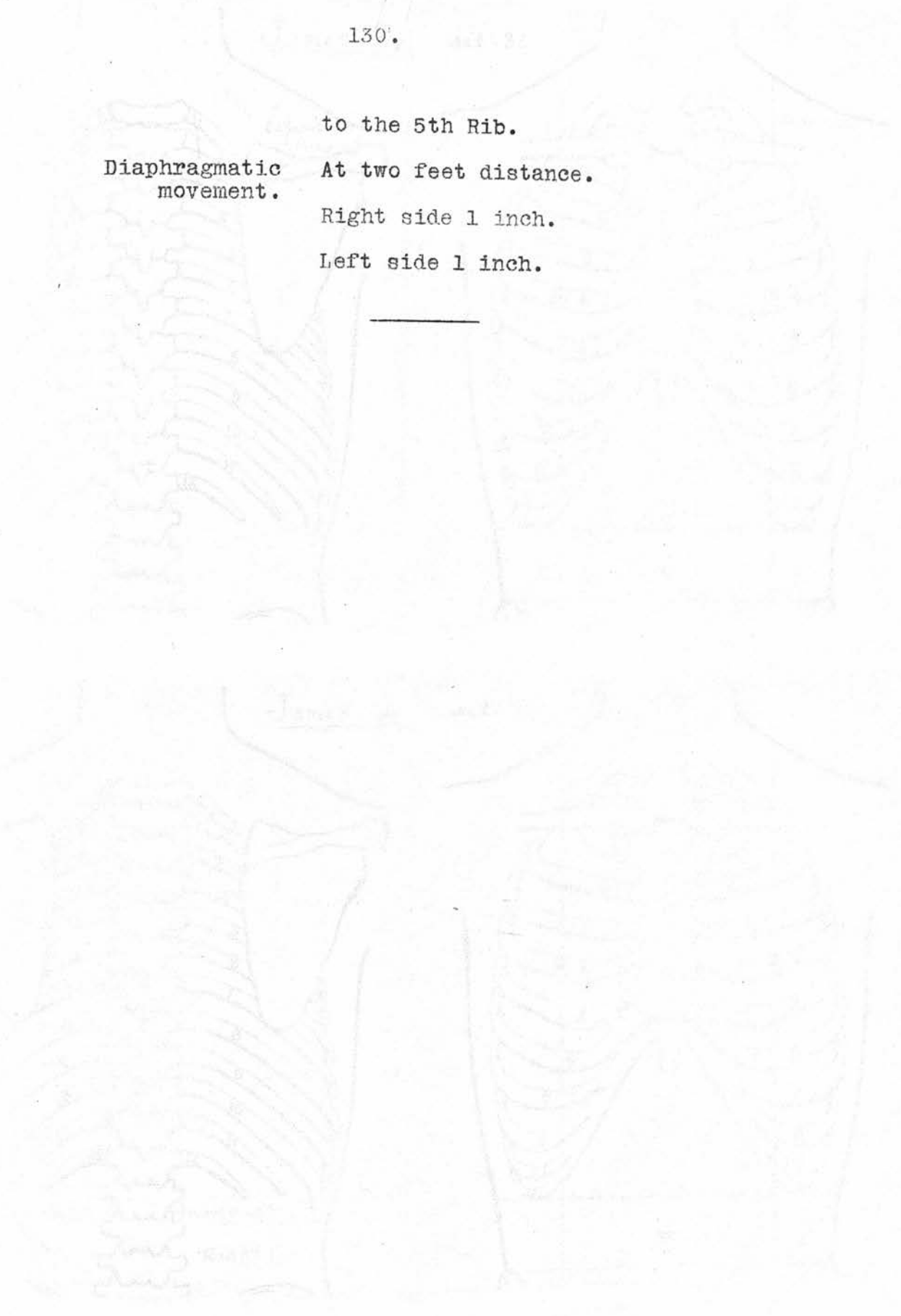
to the 5th Rib.

Diaphragmatic
movement.

At two feet distance.

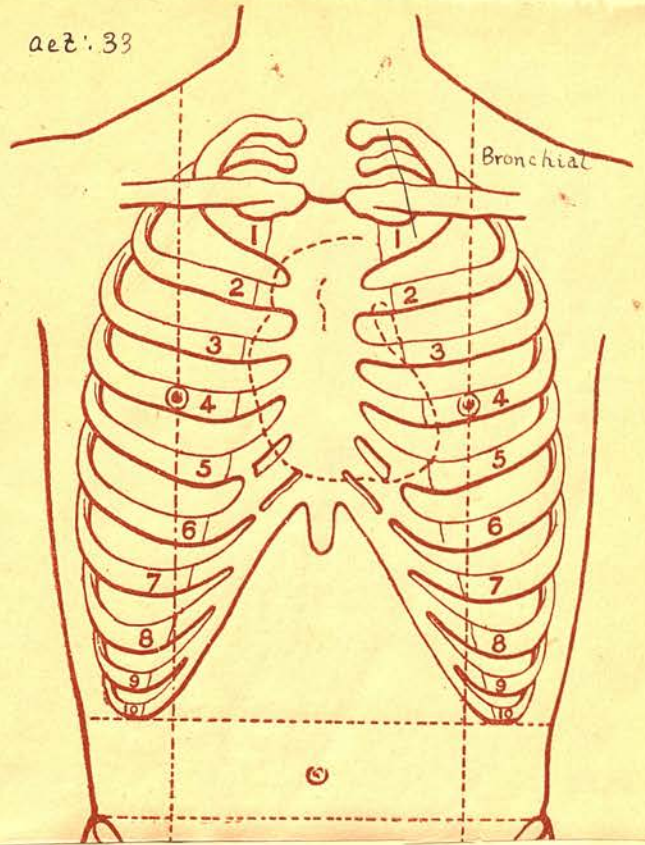
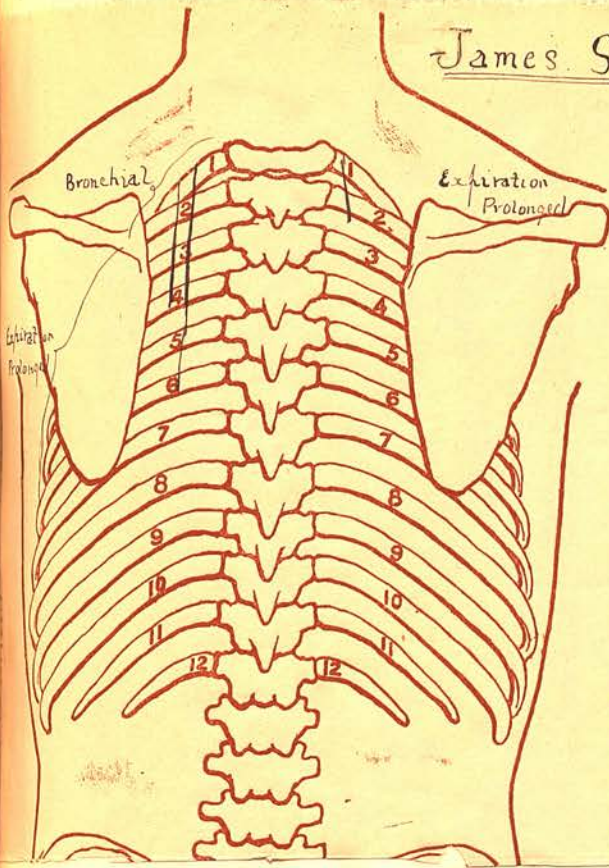
Right side 1 inch.

Left side 1 inch.



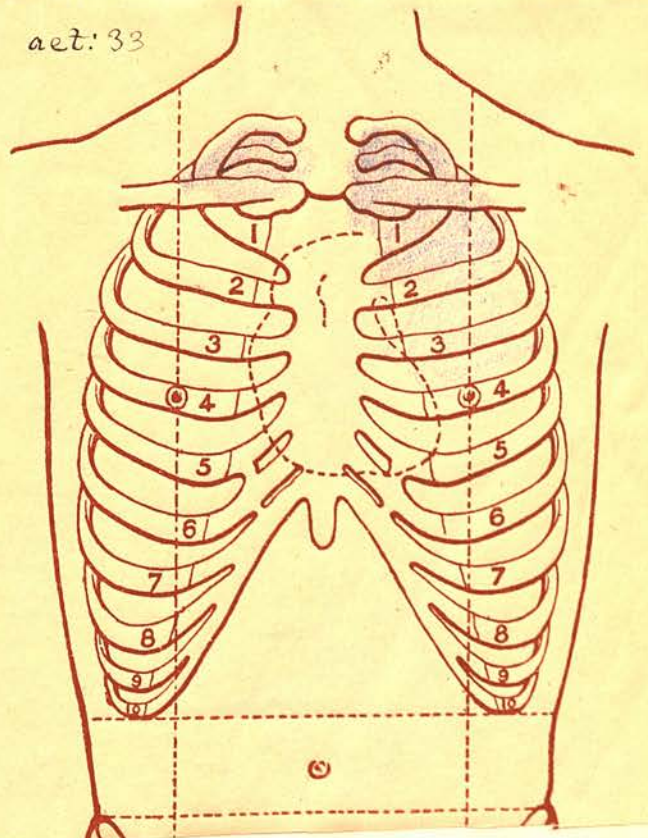
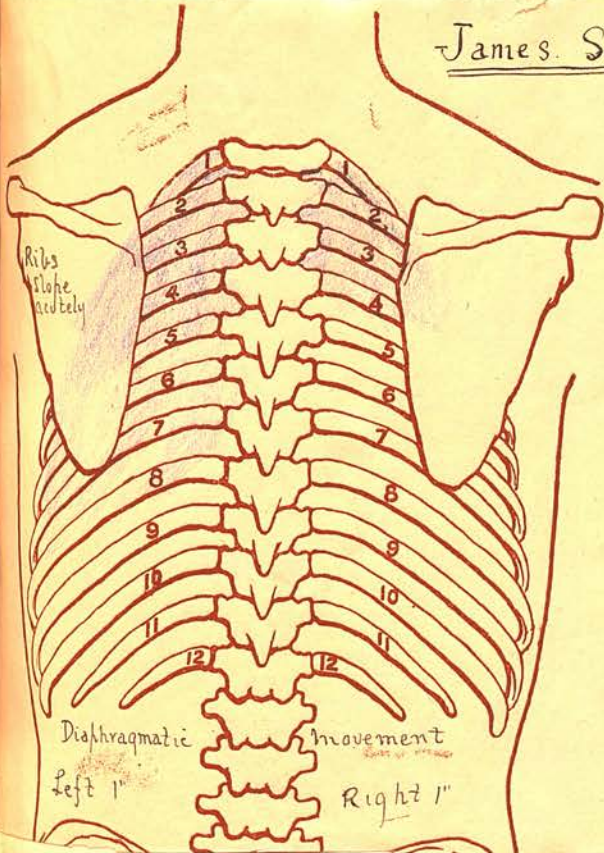
James Sr

aet: 33



James Sr

aet: 33



David T. Marine engine driver. Age 43. Height
5 feet 10 $\frac{3}{4}$ inches. Weight 10 stone 8 $\frac{1}{2}$ lbs. Tem-
perature normal.
COMPLAINT.

"Spitting Blood" for 5 weeks.
Two months previously, he had hoemoptysis, lasting
for 10 days, and accompanied by Pleurisy on the
right side. One sister died of Phthisis.
RESPIRATORY SYSTEM.

Cough dry, worst at night. Sputum thick
yellow, tinged with blood.
Throat - Fauces injected. Larynx normal.
Pulse 90. Tension and Volume fair. Suffers from
night sweats.
PHYSICAL EXAMINATION OF THE CHEST.

Anteriorly. On the right side, dulness on
percussion to the first Rib, with
bronchial breathing over the same

Anteriorly. On the left side, there
is great flattening at the
apex, and marked dulness on
percussion, from apex to the

Posteriorly. and prolonged expiration over
this area.

Posteriorly. On/

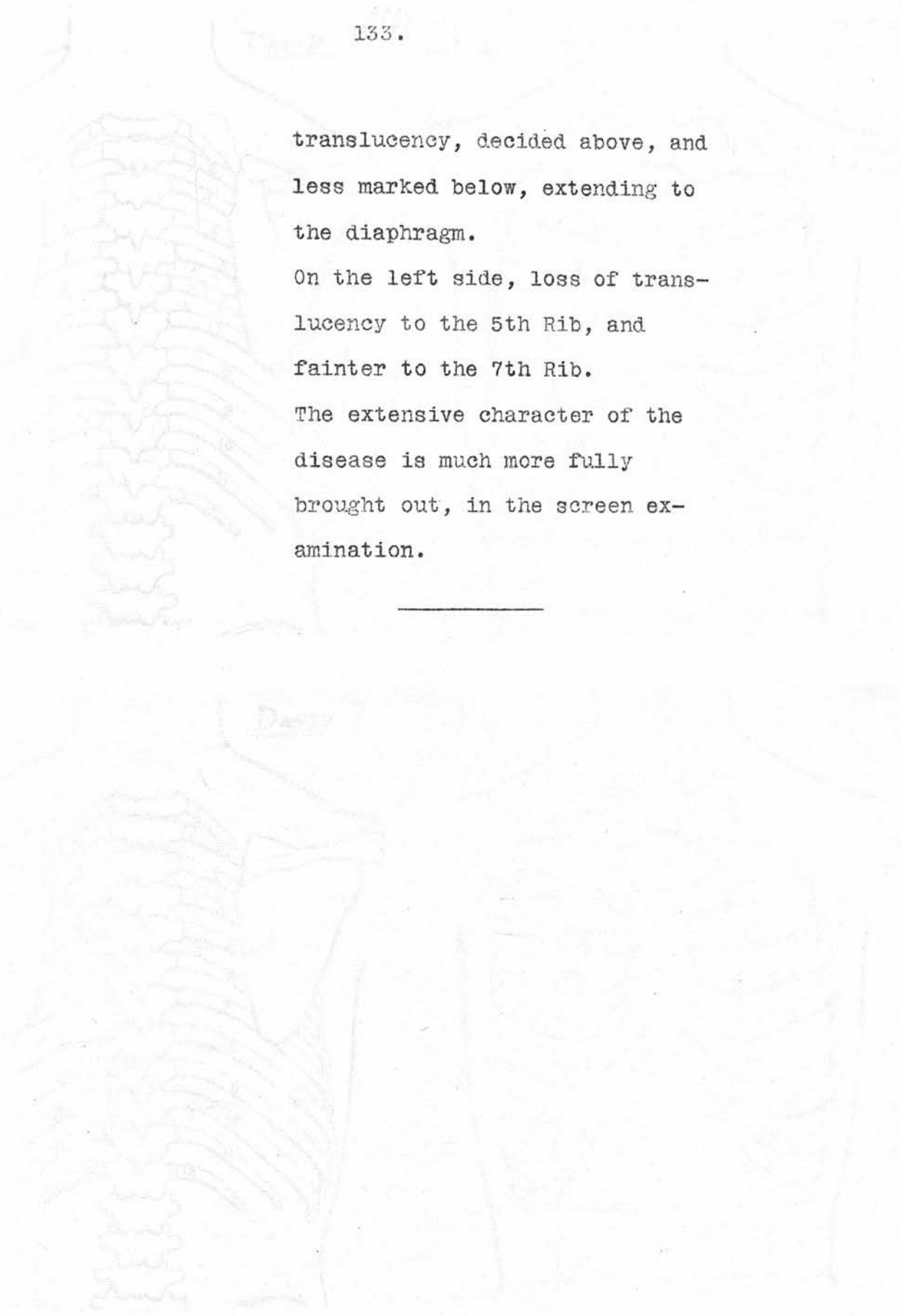
On the right side, dulness on percussion over the first four Ribs, and again a patch over the 6th and 7th. Bronchial breathing and crepitations are heard, from apex to the 4th Rib.

Over the 5th and 6th interspaces, pleuritic friction, and occasional crepitations are heard. On the left side, there is dulness on percussion to the 3rd interspace, and again, from 4th to 5th interspace. Bronchial breathing is heard, from apex to the 3rd Rib, and a few crepitations are heard in the lower area of dulness.

SCREEN EXAMINATION.

Anteriorly. On the right side, loss of translucency slight in character all down. On the left side, loss of translucency, to the third Rib.

Posteriorly. On the right side, loss of translucency/

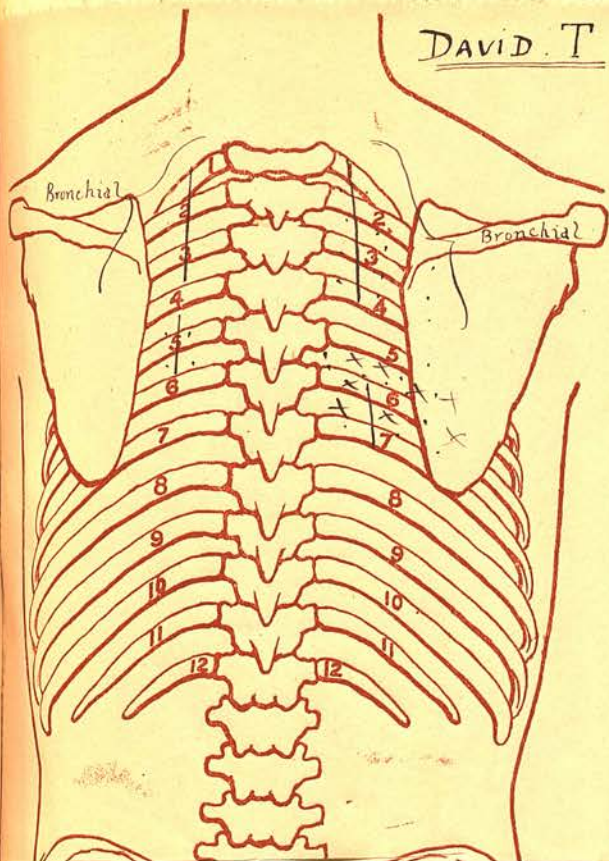


translucency, decided above, and less marked below, extending to the diaphragm.

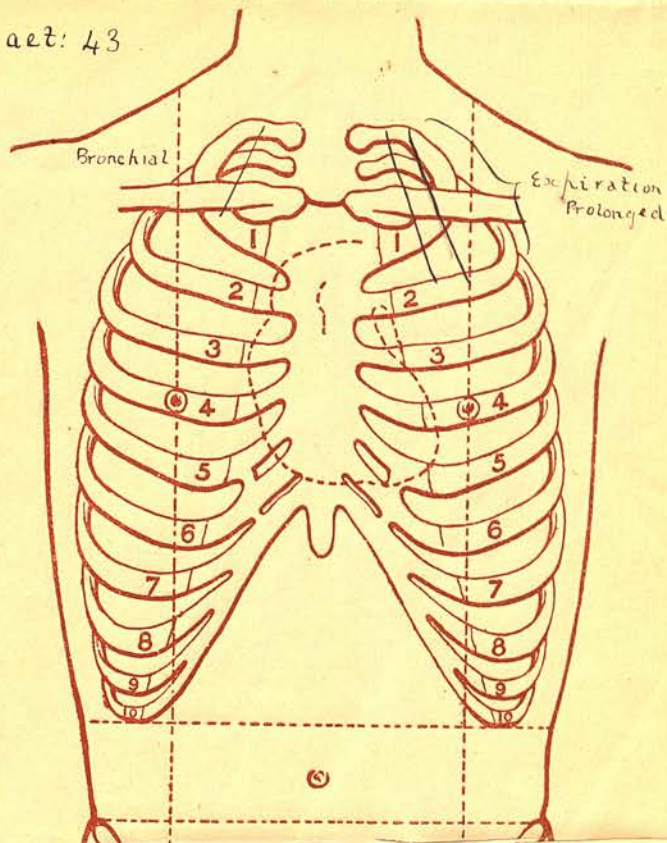
On the left side, loss of translucency to the 5th Rib, and fainter to the 7th Rib.

The extensive character of the disease is much more fully brought out, in the screen examination.

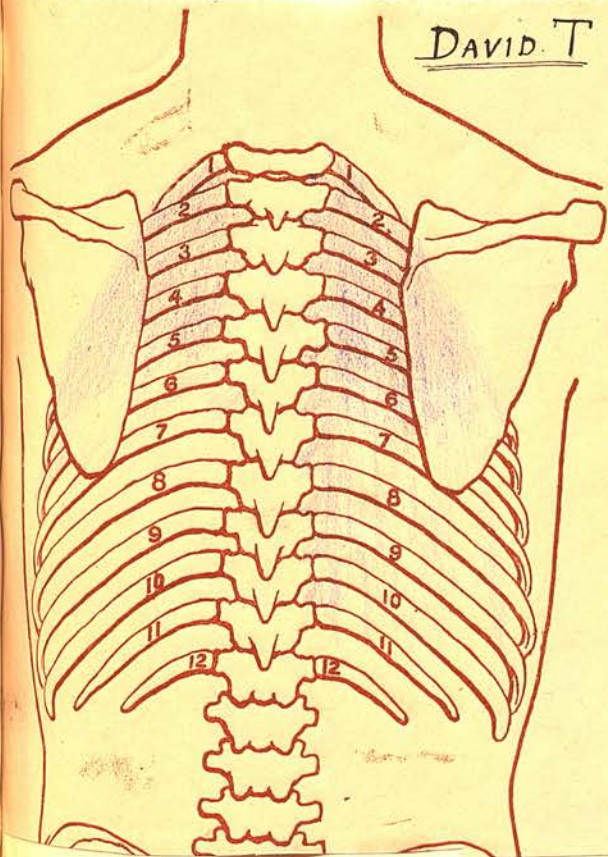
DAVID T



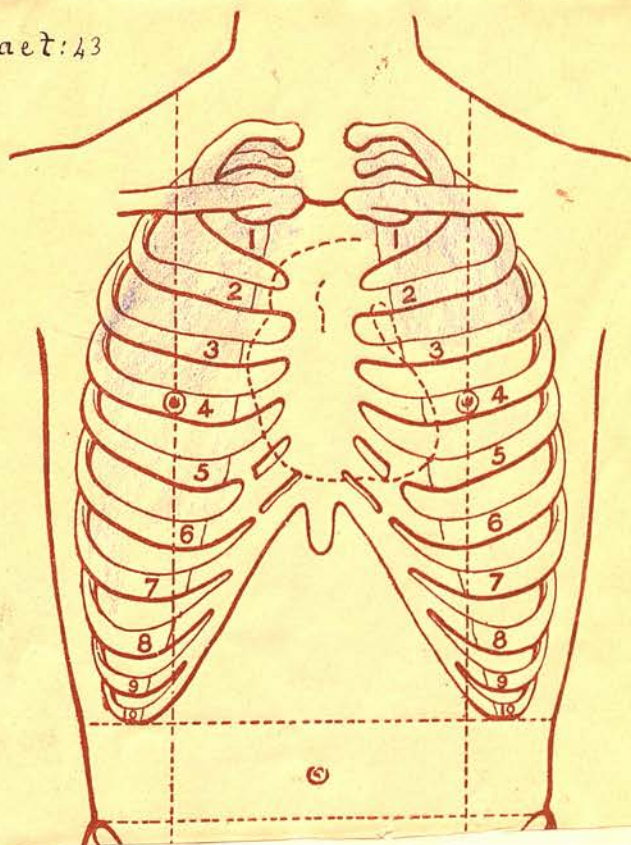
aet: 43



DAVID T



aet: 43



John Ar. Type-founder, Age 37. Height
5 feet 8 inches. Weight 10 stone. Temperature
99 degrees.

COMPLAINT.

"Weak Chest, with which he has been troubled
for a year, starting with Hoemoptysis then.

Father died of "Chronic Bronchitis" 25 years ago.

RESPIRATORY SYSTEM.

Cough - hacking in character. Thick yellow
sputum. No hoemoptysis, at present.

Pain in the front of the Chest, at times. Dyspnoea
on exertion. Larynx congested - yellow patch
on right vocal cord.

ALIMENTARY SYSTEM.

Tongue furred. Appetite poor. No vomiting.
Diarrhoea at present.

Pulse 102. Tension and Volume fair. Has been
losing weight. Suffers from night sweats.

PHYSICAL EXAMINATION OF THE CHEST.

Anteriorly. On the right side, dullness
on percussion to the 3rd Rib, with
bronchial breathing above the
clavicle, and vesicular
breathing with prolonged ex-
piration, to the 4th Rib.
Crepitations/

Crepitations are heard, from the apex to the 1st interspace.

On the left side, dulness on percussion, to the clavicle.

Posteriorly.

On the right side, dulness on percussion to the 9th Rib.

Bronchial breathing is heard from the apex, to the 5th Rib.

On the left side, the only patch of dulness is over the

Posteriorly.

4th, 5th, and 6th Ribs, internal to the scapula: and over this area cogwheel breathing is heard. Above this, the breathing is vesicular, with prolonged expiration.

No crepitations are heard particularly internal to the scapula.

On the left side, the breath sounds are very faint, loss of translucency is seen, all over.

SCREEN EXAMINATION OF THE CHEST.

Anteriorly. On the right side, there is loss of translucency all

Diaphragmatic movement.

down/ feet distance.

On the right side $\frac{1}{2}$ inch, and

down - very marked over the area, between the 1st, and 4th Ribs, and fading away below. On the left side, the loss of translucency is not nearly so great - is most definite from apex to the 2nd Rib, and is just made out, for a few Ribs below.

The Heart shadow is smaller than normal.

Posteriorly. On the right side, the loss of the normal translucency is again present all down - tapering off at the lower part, and from the 3rd, to the 7th Rib, there is a very dense opacity, particularly internal to the Scapula. On the left side, the loss of translucency is seen, extending from the apex to the 6th Rib, and a faint shading is observable, for a few interspaces below.

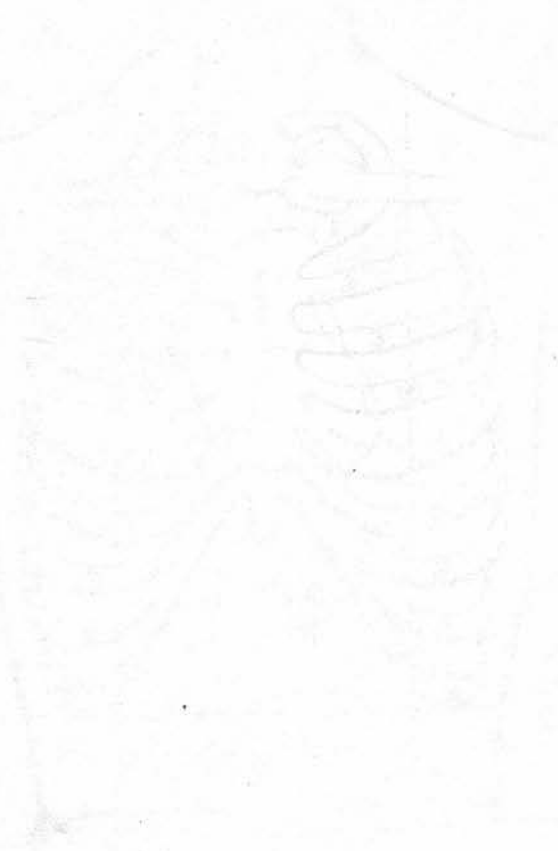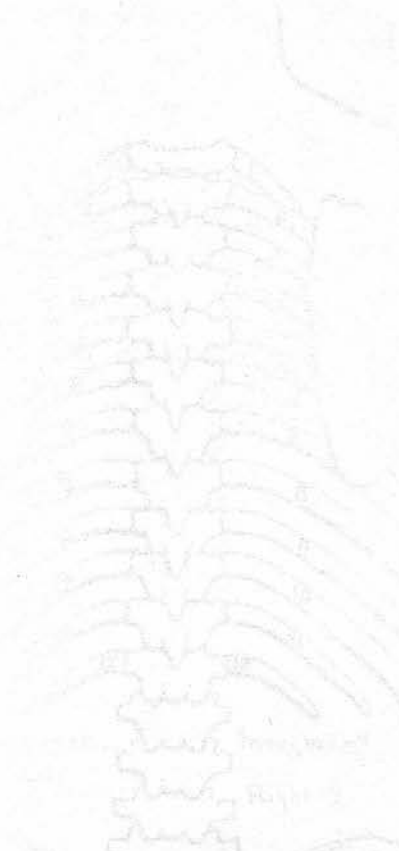Diaphragmatic movement.

At two feet distance.

On the right side $\frac{1}{2}$ inch, and on/

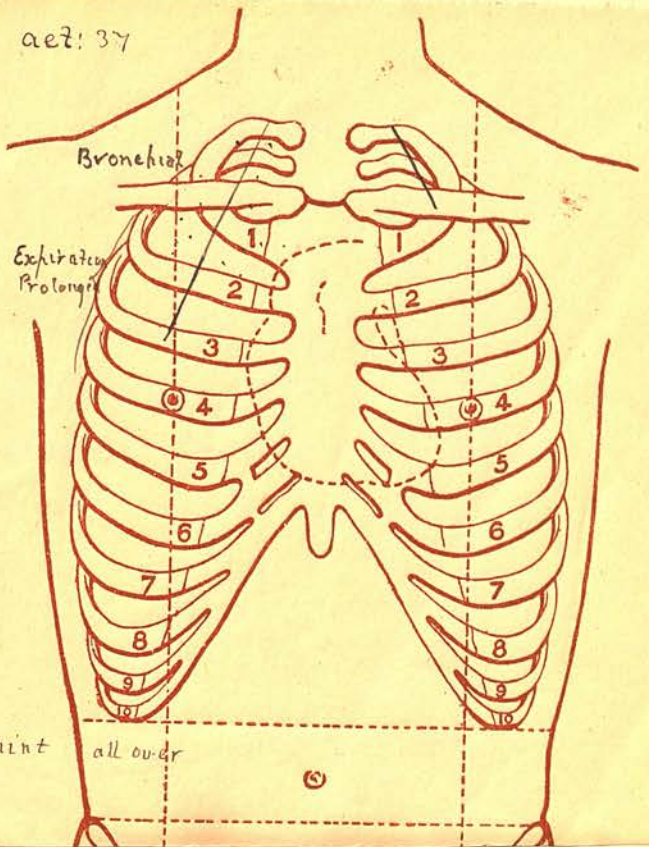
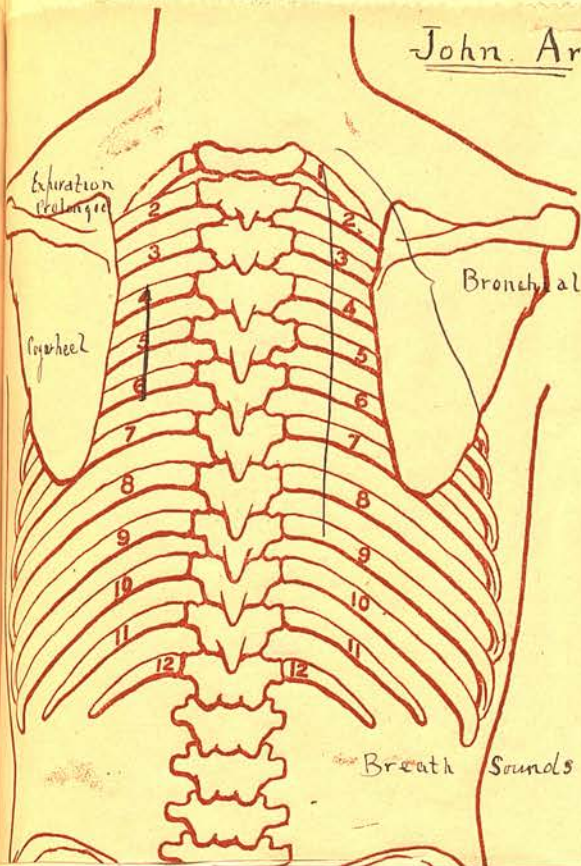
on the left side $\frac{3}{4}$ inches.

The special point in this case, in addition to fuller details, is the dense mass, apparently spreading from the root of the Lung. The Diaphragmatic movement is much impaired.



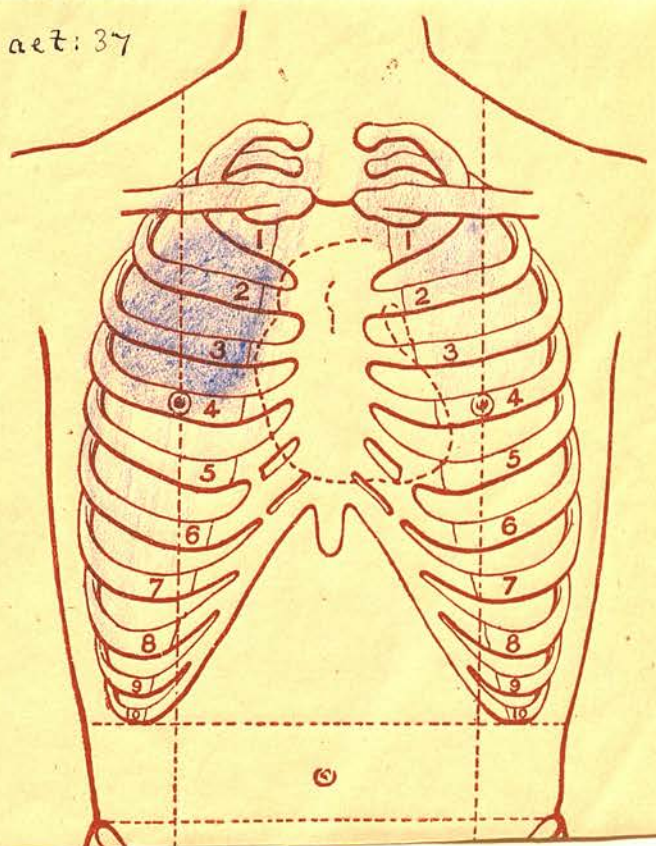
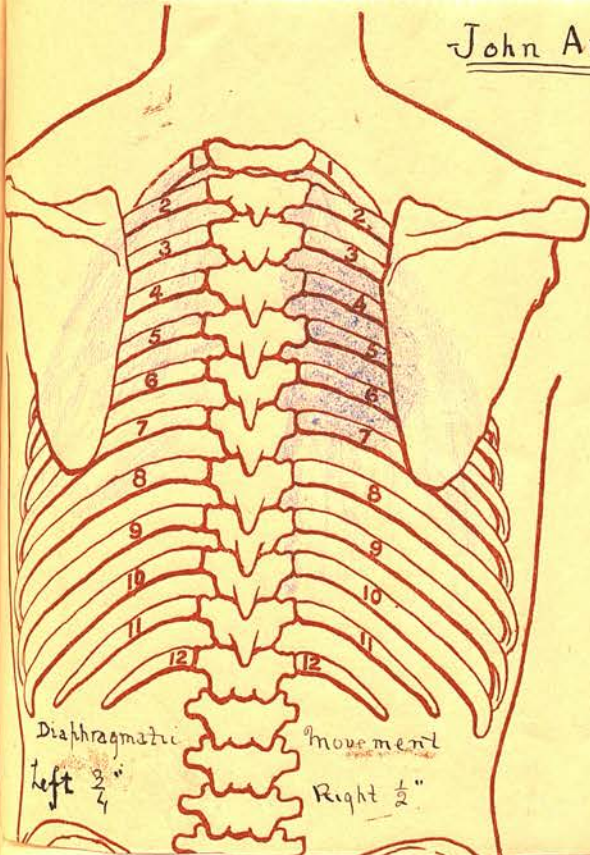
John Ar

aet: 37



John Ar

aet: 37



Jemima K. Housekeeper. Age 23. Height 4 feet
 $1\frac{1}{2}$ inches. Weight 6 stone $13\frac{1}{2}$. Temperature
 normal.

COMPLAINT.

A weak chest lasting for 5 months.
 Has not been well for two years. When 7 years
 of age she had Pneumonia.

RESPIRATORY SYSTEM.

Short cough. No Expectoration. No
 pain. Vocal cords lustreless, and covered with
 a grey secretion.

Has been losing flesh.

Pulse 114. Tension and Volume poor.

Other systems normal

PHYSICAL EXAMINATION OF CHEST.

Anteriorly. No abnormality is found, except
 faint breath sounds, at both
 apices.

Posteriorly. No dulness or impairment of
 note on percussion. On the
 right side, over the 1st inter-
 space, the breathing is almost
 bronchial, and down to the 4th
 Rib, it is vesicular, with
 prolonged/

prolonged expiration.

On the left side down to the 3rd Rib, the breath sounds are harsh vesicular, with prolonged expiration. The breath sounds are very faint in the upper parts, on both sides. No accompaniments anywhere.

SCREEN EXAMINATION.

Anteriorly. On the right side, there is slight loss of translucency, to the 3rd Rib, and on the left side to the 1st interspace.

Posteriorly. On the right side, the loss of translucency is marked to the 5th Rib, while on the left side, it is not so marked, and extends only to the 4th Rib.

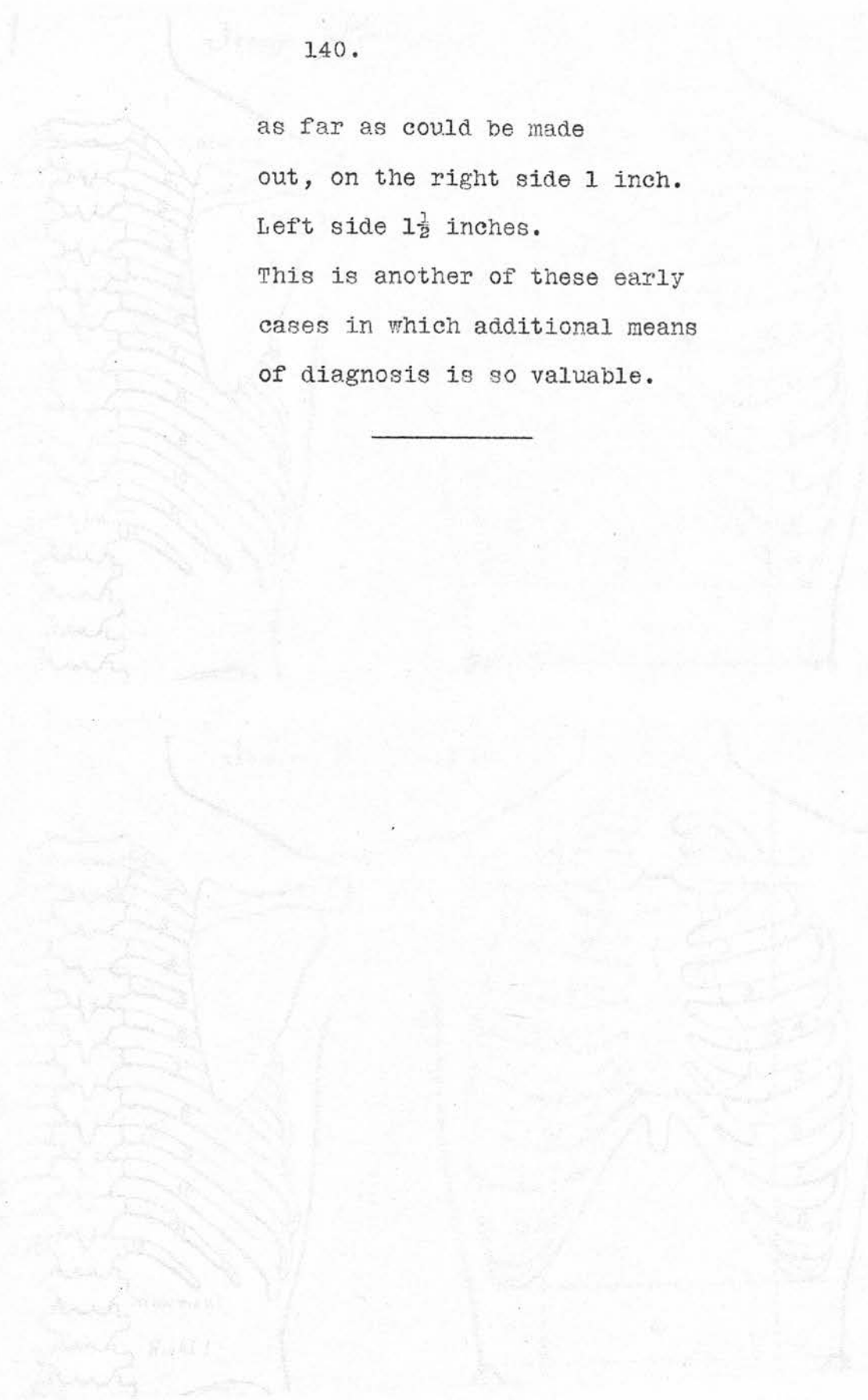
Diaphragmatic movement. At two feet distance, distinctly less on the right side, and as/

140.

as far as could be made
out, on the right side 1 inch.

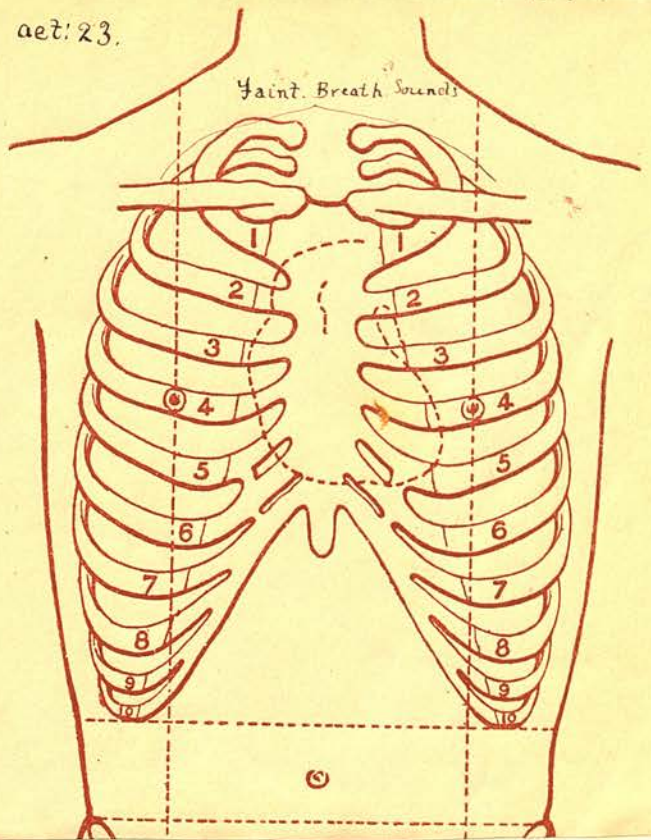
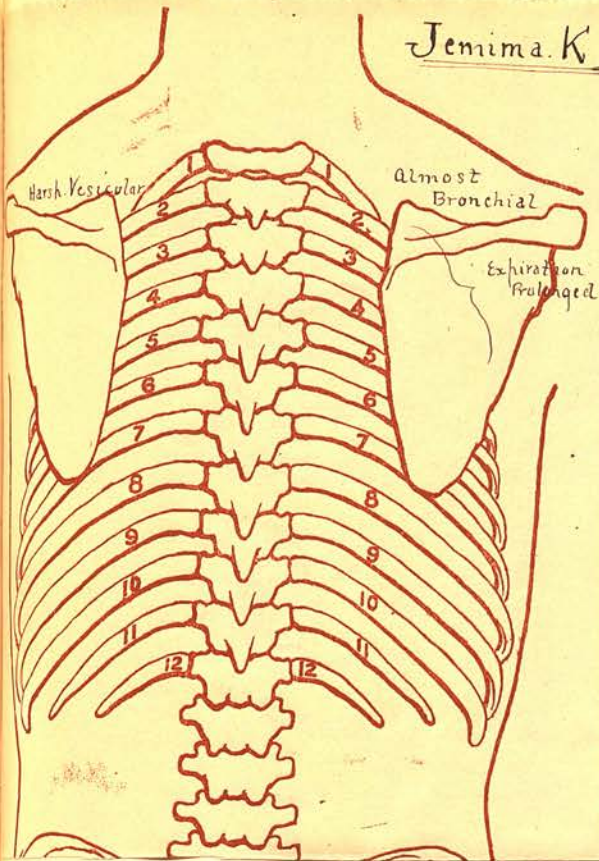
Left side $1\frac{1}{2}$ inches.

This is another of these early
cases in which additional means
of diagnosis is so valuable.



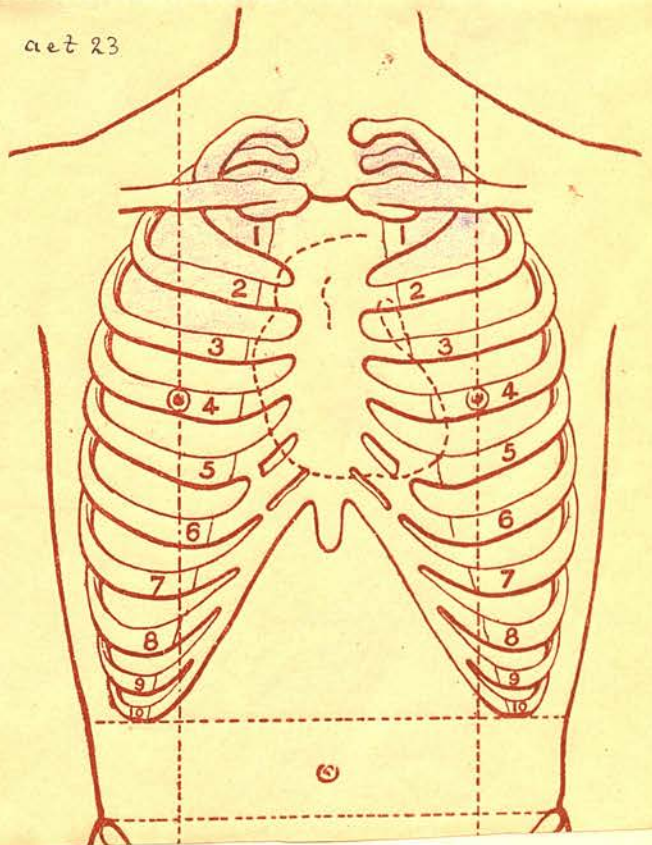
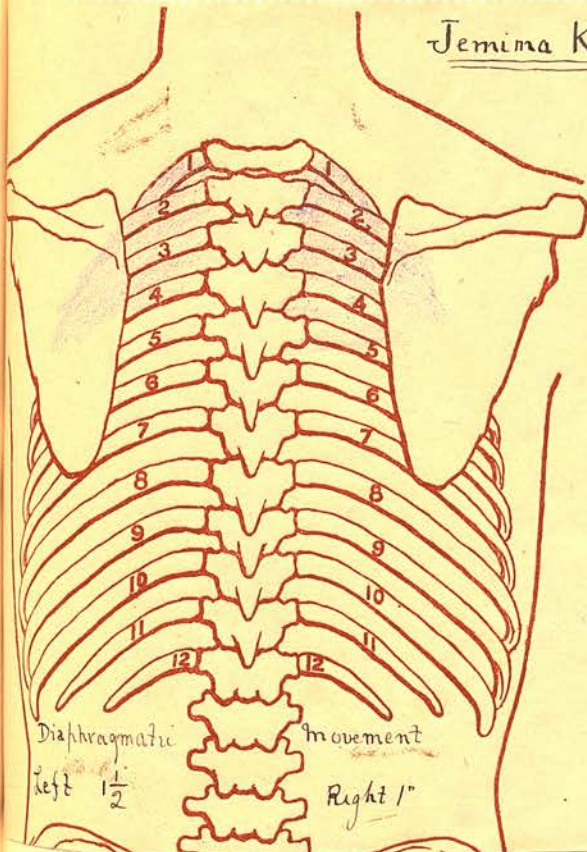
Jemima K

aet: 23.



Jemima K.

aet 23



Alfred C.V. Message Boy. Age 14. Height 5 feet 7 inches. Weight 8 stone 9½ lbs. Temperature normal.

COMPLAINT.

"Bronchitis and a weak Chest", from which he has suffered for a fortnight. Three years ago he had Bronchitis and Peritonitis.

RESPIRATORY SYSTEM.

Slight cough, with thick white sputum. No hoemoptysis. Larynx congested. Cords red, and lustreless. No Tubercle Bacilli found in Sputum. Pulse 102. Tension and Volume fair. Has been losing flesh. Other systems normal.

PHYSICAL EXAMINATION OF THE CHEST.

Breath sounds faint, front and back at upper parts.

Anteriorly. On the left side, there is dullness on percussion to the 1st Rib. Over the 1st interspace, cogwheel breathing is heard. Occasional crepitations are heard in this area. Elsewhere in front - no apparent change from normal.

Posteriorly. On/

On the left side, there is dullness on percussion, to the 4th Rib, and Vocal Resonance is increased over this area. No accompaniments, or alteration in the breathing.

SCREEN EXAMINATION.

Anteriorly. On the right side, faint loss of translucency to the 2nd rib, and on the left side, still fainter, and extending to the 1st interspace.

Posteriorly. On the right side, more marked loss of translucency to the 5th Rib, and on the left side, not so marked, to the 4th Rib. Heart shadow is smaller than normal.

Diaphragmatic movement.

At two feet distance.

Right side $\frac{3}{4}$ inches.

Left side 1 inch.

The results in this case conflict.

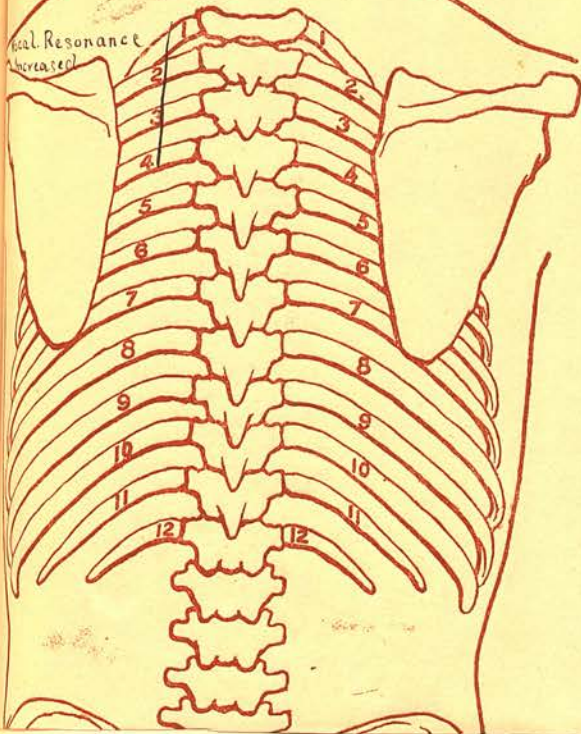
X Rays bring out a more marked condition on the right side than the left. The faintness of the/

Alfred Cu

aet: 14

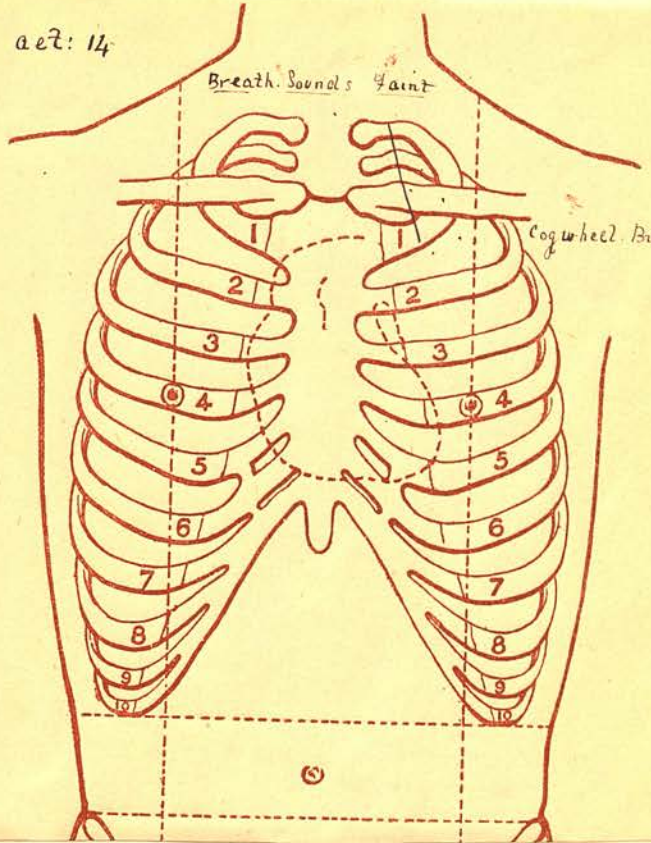
Breath. Sounds faint

Real Resonance
Increased



Breath. Sounds faint

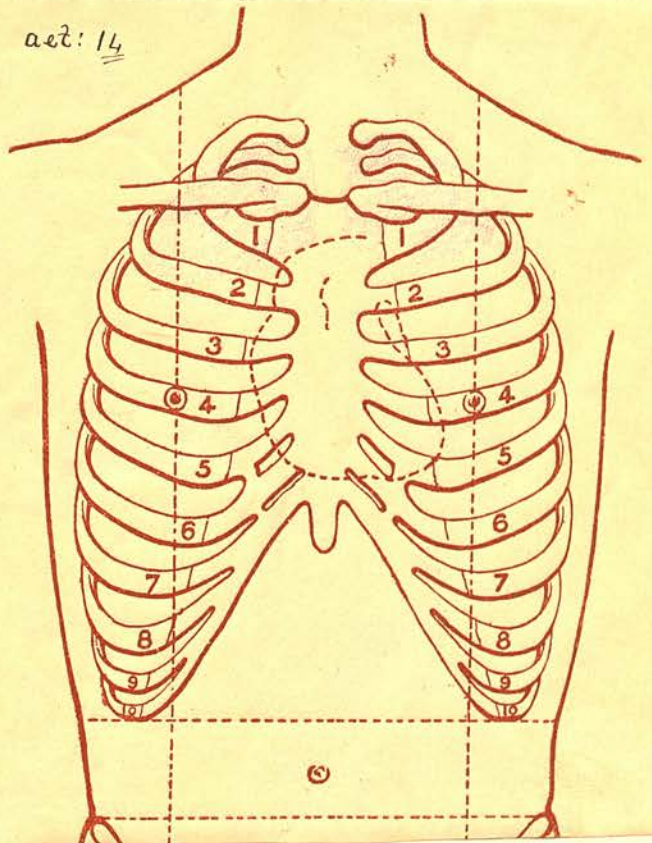
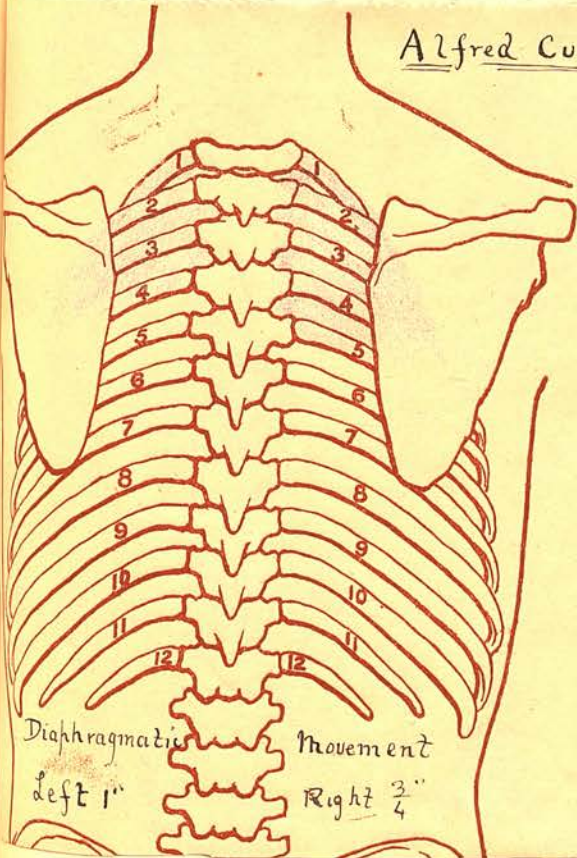
Cogwheel Breathing



Alfred Cu

aet: 14

Diaphragmatic Movement
Left 1" Right $\frac{3}{4}$ "



143.

Marian L. Housewife age 33. Height 5 feet 3 1/2 inches. Weight 10 stone 6 lbs. Temperature normal. the breath sounds may prevent one hearing their exact character.

COMPLAINT.

"Weak Chest" from which she has suffered for 9 months. Brother died of Phthisis 6 years ago.
RESPIRATORY SYSTEM.

Short cough, with thick white sputum. No haemoptysis. Larynx congested - no loss of substance. No Tubercle in Sputum.

Pulse 108. Tension and Volume Poor. 3 months pregnant. Other systems normal.

PHYSICAL EXAMINATION OF THE CHEST.

Anteriorly. There is slight dulness on percussion, on the right side, from apex to the 2nd rib. Bronchial breathing is heard above the clavicle. Elsewhere in front, normal.

Posteriorly. On the right side, there is bronchial breathing, over the first two ribs. On the left side, no dulness or alteration in breath sounds; but occasional faint/

Marian L. Housewife age 22. Height 5 feet 3½ inches. Weight 18 stone 6 lbs. Temperature normal. EXAMINATION.

COMPLAINT. Priorly. On the right side, slight loss

"Weak Chest" from which she has suffered for 9 months. Brother died of Phthisis 6 years ago.

RESPIRATORY SYSTEM. Loss of translucency, from apex

Short cough, with thick white sputum. No hoemoptysis. Larynx congested - no loss of substance. No Tubercle in Sputum.

Pulse 108. Tension and Volume Poor. 3 months pregnant. Other systems normal. and on the left

PHYSICAL EXAMINATION OF THE CHEST. of translucency

Anteriorly. There is slight dulness on diaphragmatic movement. percussion, on the right side, from apex to the 2nd Rib.

Bronchial breathing is heard above the clavicle. Elsewhere in front, normal.

Posteriorly. On the right side, there is bronchial breathing, over the first two Ribs. On the left side, no dulness or alteration in breath sounds; but occasional faint/

faint crepitations, from apex
to 7th Rib.

SCREEN EXAMINATION.

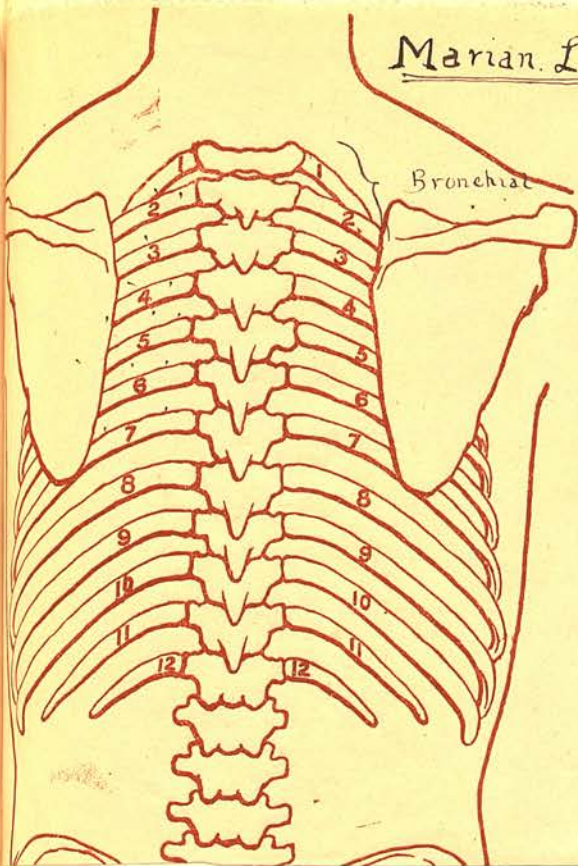
Anteriorly. On the right side, slight loss
of translucency, to the second
Rib. On the left side, faint
loss of translucency, from apex
to 6th Rib.

The Heart shadow is smaller than
normal.

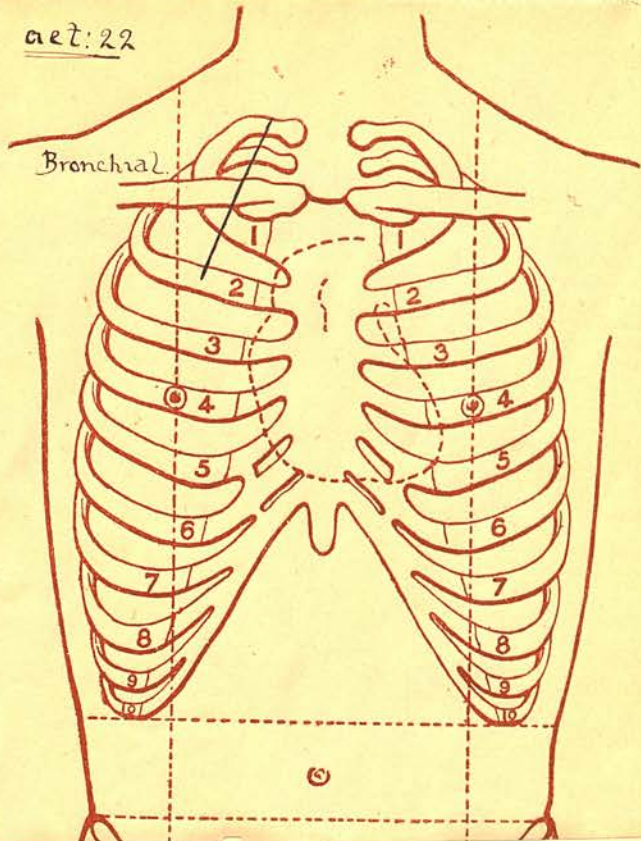
Posteriorly. On the right side, faint shading
to the 4th Rib, and on the left
side, faint loss of translucency
from apex to the 9th Rib.

Diaphragmatic movement. Not estimated.

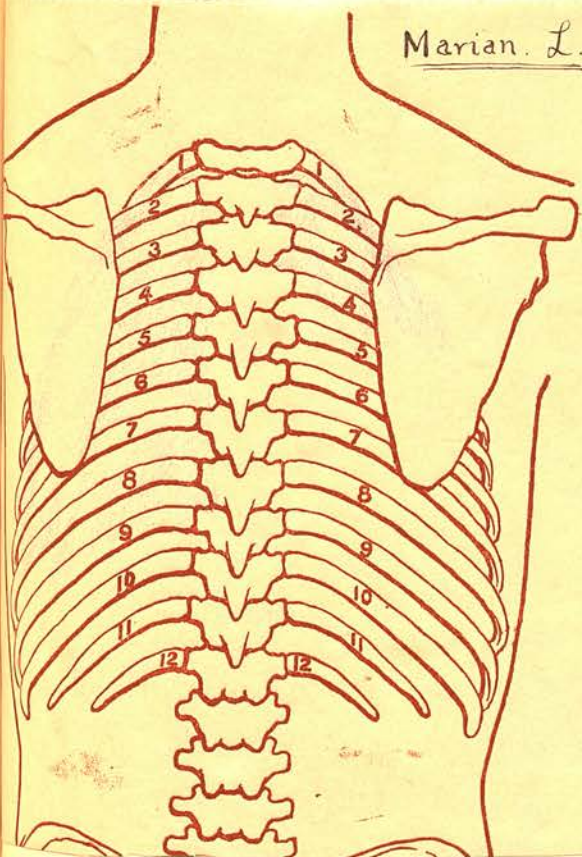
Marian. L.



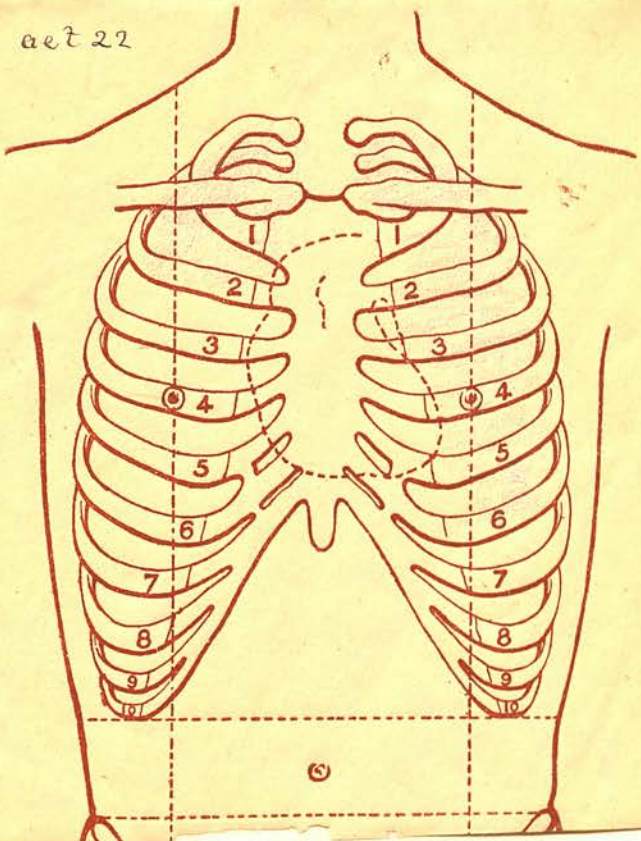
aet: 22



Marian. L.



aet 22



James B. Scavenger. Age 34. Height
5 feet 7 inches. Weight 11 stone. Temperature
normal.

COMPLAINT.

Cough and pain in Chest.

Four months previously, he had Pneumonia.

Family history good.

RESPIRATORY SYSTEM.

Cough hard, and troublesome at night. Thick
clear expectoration. No hoemoptysis. Pain at
the right side posteriorly. Laryngeal examination,
shows Vocal Cords swollen & reddened.

Has some Dyspeptic symptoms. No Diarrhoea.

Pulse 78 - slightly irregular in time. Suffers
from night-sweats.

PHYSICAL EXAMINATION OF THE CHEST.

Anteriorly. On the right side, dulness on
percussion, as far as the 2nd
Rib, with vesicular breathing,
and prolonged expiration over

SCREEN EXAMINATION.

Anteriorly.

this area. On the left side,
there is prolonged expiration,
and vesicular breathing above
the clavicle.

Elsewhere/

Elsewhere normal.

Posteriorly. On the right side, dulness on percussion, over the first two Ribs, Vesicular breathing, with prolonged expiration from apex to 4th Rib. Another patch of dulness is present, over 5th, 6th, 7th, and 8th Ribs. Friction is heard, at places, in this area. On the left side, slight dulness on percussion, above the Spine of the Scapula. Vesicular breathing, with prolonged expiration, heard all down this side.

Diaphragmatic movement.

No accompaniments are heard with the breath sounds anywhere, except the friction at the right base posteriorly.

SCREEN EXAMINATION.

Anteriorly. On the right side, there is loss of translucency to the 2nd interspace, distinctly marked.

On/

On the left side, the loss of translucency extends to the 2nd Rib, though not so marked.

Posteriorly. On the right side, there is loss of translucency to about the 4th Rib, and a fainter shading over the 5th, 6th, 7th, and 8th.

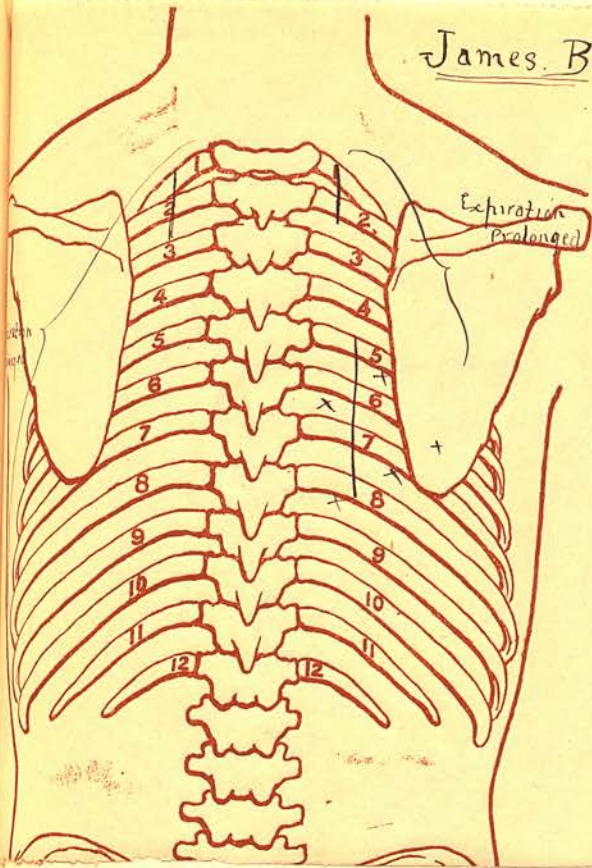
On the left side, there is loss of translucency all down, but most marked, as far as the 4th Rib. The Ribs slope much more acutely on the left side.

Diaphragmatic movement. At two feet distance.

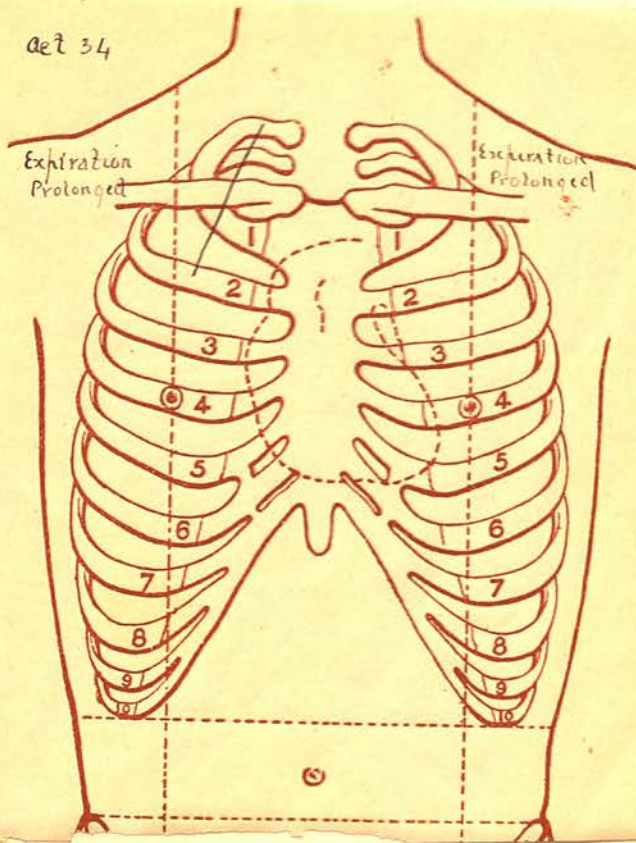
Right side 2 inches. Left $1\frac{3}{4}$.

This case shows a much more extensive disease, on the left side than was suspected by ordinary methods, - the pleurisy was very faintly brought out.

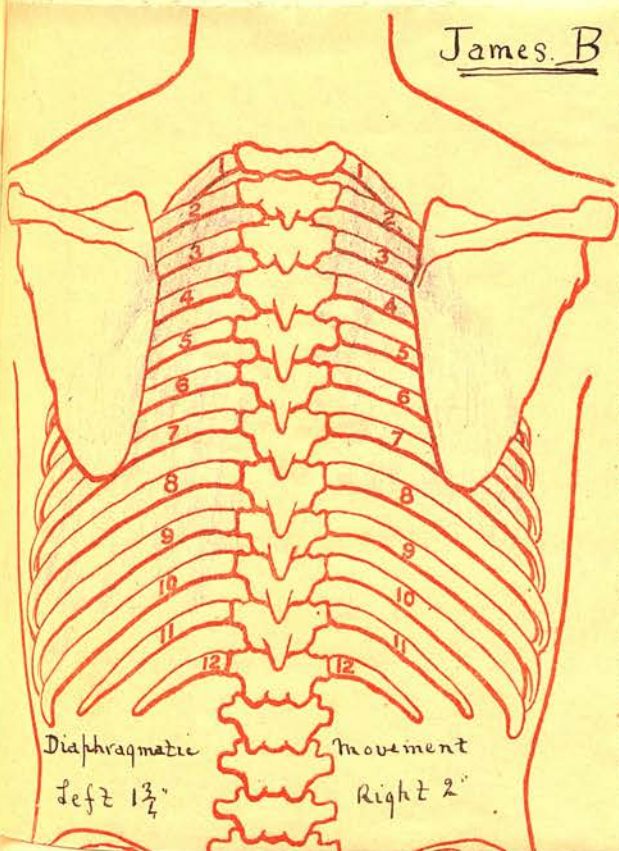
James. B



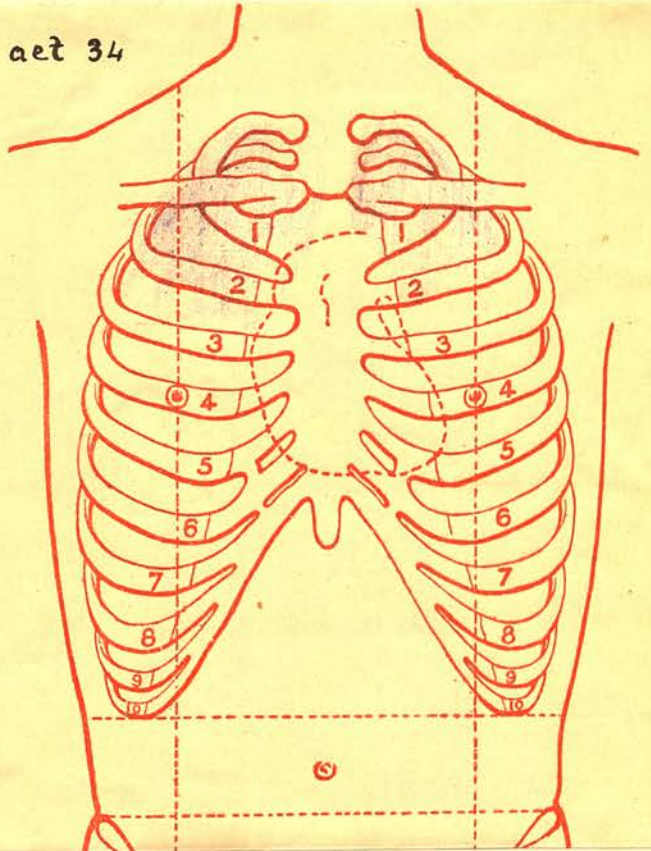
aet 34



James. B



aet 34



Margaret C. Age 12. Height 4 feet $4\frac{1}{2}$.

Weight 4 stone 12 lbs. Temperature 99.

COMPLAINT.

"Cough" for 6 weeks. She fell into a muddy stream, and swallowed a lot of water. Broncho-Pneumonia followed after this. Father died of Phthisis three years ago.

RESPIRATORY SYSTEM. At two feet distance. Right

Irritating cough, without expectoration.

Adenoids and enlarged tonsils.

Has been losing flesh. Pulse 120. Tension and Volume poor.

PHYSICAL EXAMINATION OF THE CHEST.

Anteriorly. Very slight impairment of note, above the clavicle, on both sides.

Posteriorly. Similar condition over both apices, for two interspaces. Breath sounds normal all over. No accompaniments.

SCREEN EXAMINATION.

Anteriorly. There is loss of translucency, slight in character, on the left side from apex to 2nd Rib; and on the right side above the clavicle./

clavicle.

Posteriorly. There is loss of translucency, on the right side, from apex to 5th interspace - this is also not very marked.

On the left side - the same condition is seen to the 3rd Rib.

Diaphragmatic movement.

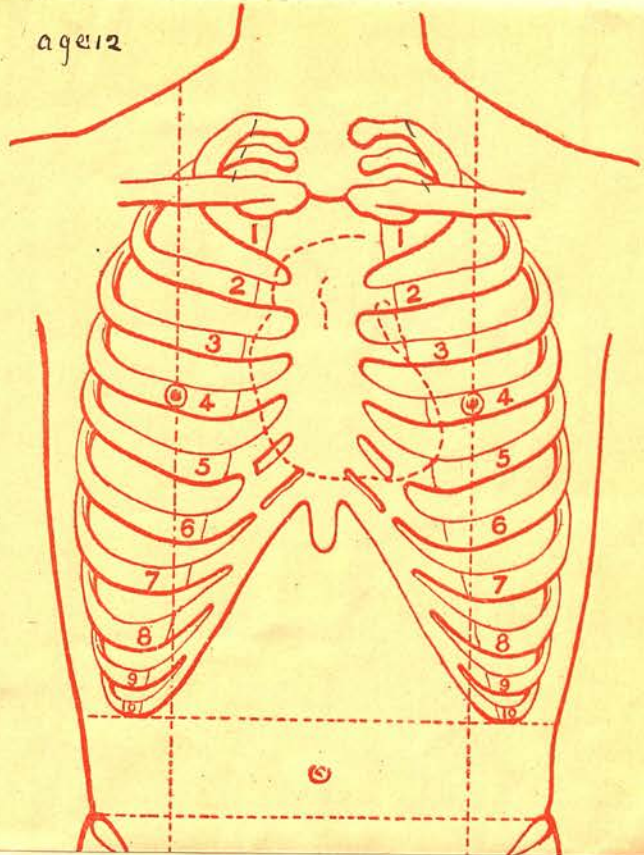
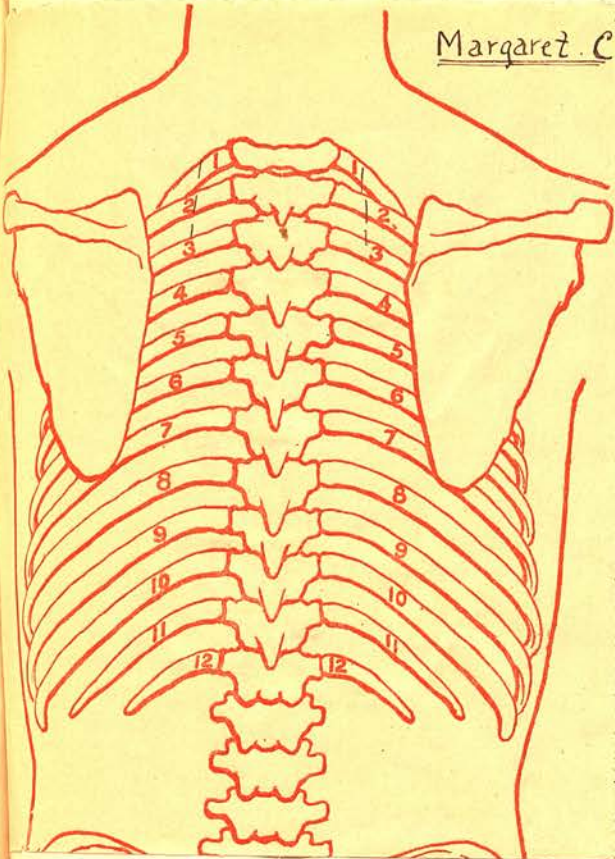
At two feet distance. Right side $\frac{5}{8}$ inch. Left $\frac{1}{2}$ inch.

This measurement is not very satisfactory, as the child was, obviously, very nervous.

The condition is an early one, and the screen examination confirms the suspicions, that physical examination, by ordinary methods gave rise to.

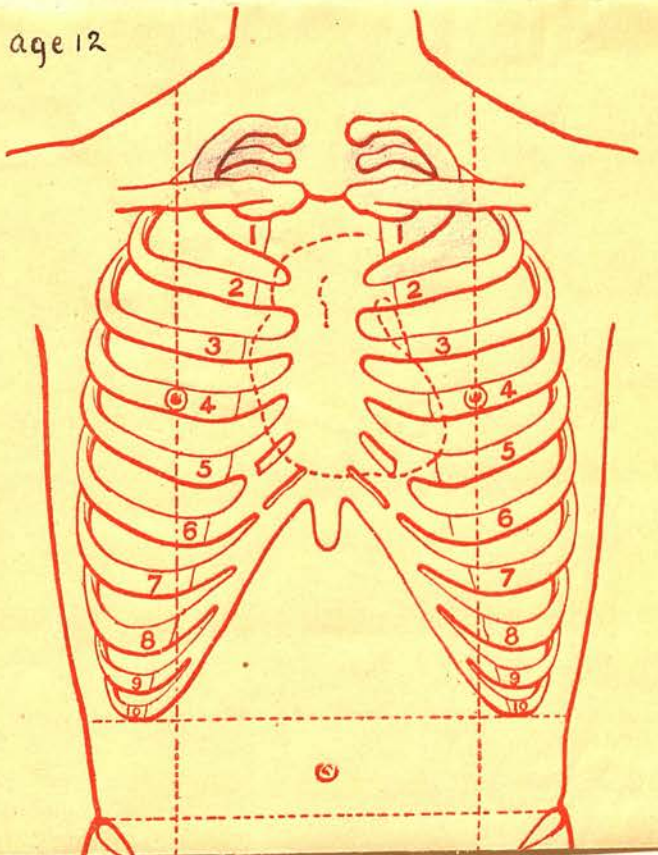
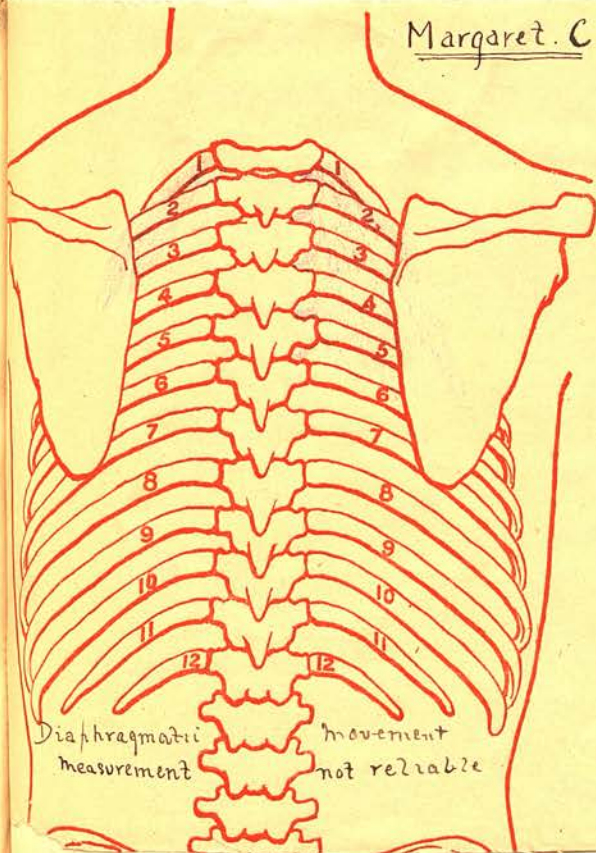
Margaret. C

age 12



Margaret. C

age 12



Diaphragmatic
measurement

movement
not reliable

William B. Blacksmith, age 18. Height 5 feet $7\frac{1}{4}$. Weight 7 stone $10\frac{3}{4}$. Temperature 99.8.

COMPLAINT.

Pain in side lasting for four days. Broncho-Pneumonia with Pleurisy as a child. For the last two winters, he has had a cough. No distinct family history of Phthisis.

RESPIRATORY SYSTEM.

Cough troublesome at night, and morning. Spit blackish-grey, occasionally stained with blood. Pain on the right side, when coughing. Larynx congested; but no lesion. Pulse 76. Tension and volume fair. Other systems normal.

PHYSICAL EXAMINATION OF CHEST.

Anteriorly. On the right side, dulness on percussion to the 4th Rib, with bronchial breathing, over this area. Crepitations are heard from apex to 6th Rib. On the left side, dulness on percussion, to the 3rd Rib, with bronchial breathing, above the clavicle. Crepitations, few in number, are heard from apex to//

Posteriorly.

to 5th Rib. *area is very opaque.*

Posteriorly. On the right side, dulness on percussion, all down, but very marked to the 4th Rib. Bronchial breathing is heard at the upper part, and lower down there is vesicular breathing, with prolonged expiration. Crepitations accompany the breath sounds, all over. *and the ribs show very*

Diaphragmatic movement.

On the left side, there is dulness on percussion, to the 5th Rib.

Bronchial breathing, and crepitations are heard in this area.

Below this, the breathing is vesicular, with prolonged expiration. *especially on the*

SCREEN EXAMINATION OF CHEST.

Anteriorly. On the right side there is marked loss of translucency above, and it is seen to less degree, extending to the diaphragm.

On the left side, the loss of translucency - not so marked - extends to the 6th Rib.

Posteriorly. The/

The right side is very opaque, all down - no signs of clearness are observed, and for the upper half, it is very dense.

On the left side, down to the 5th Rib, it is markedly less translucent, than normal; below this it is clear.

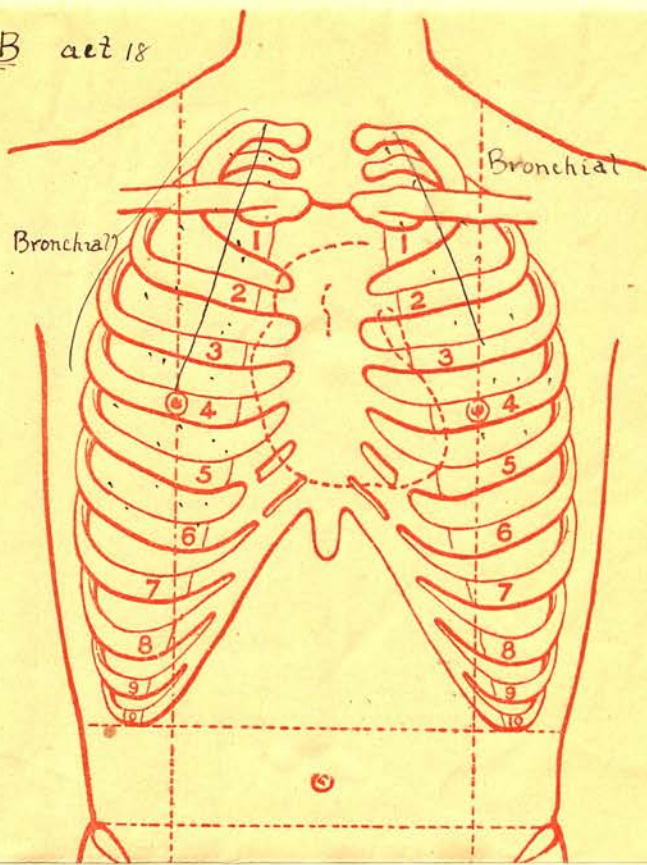
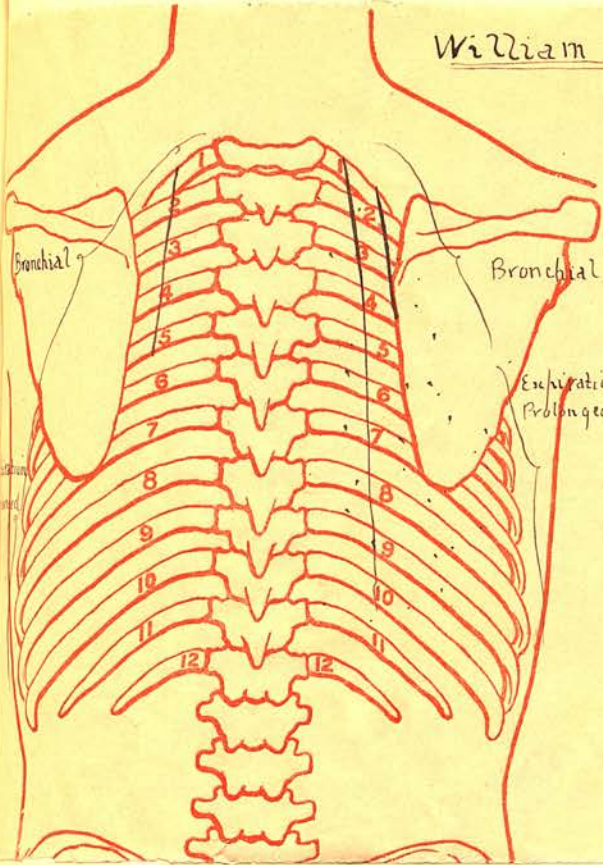
The Chest is a narrow pointed one, and the ribs slope very acutely, on the right side.

Diaphragmatic
movement.

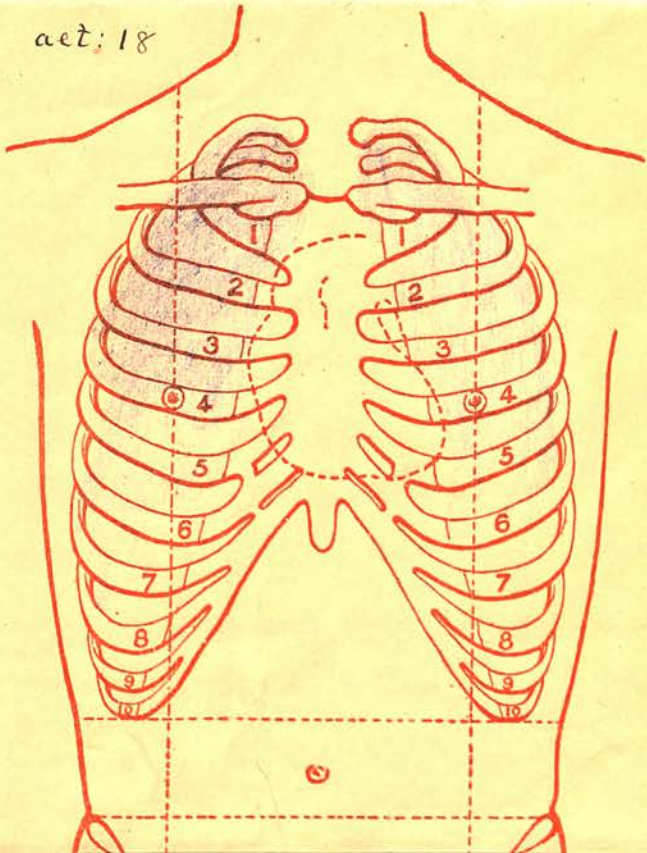
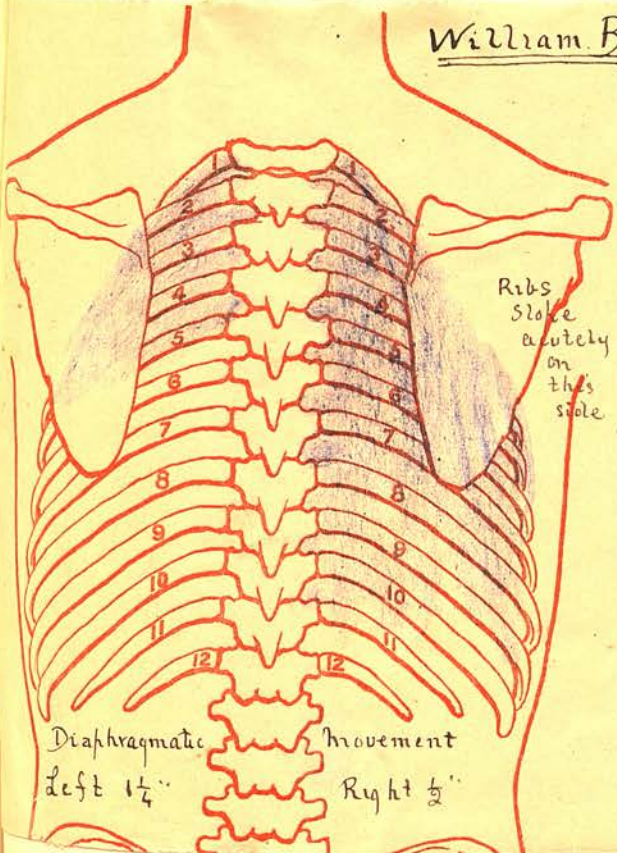
At two feet distance. Right side $\frac{1}{2}$ inch. Left side $1\frac{1}{4}$ inch.

This Screen examination gives a fuller picture of a collapsed Chest, with impaired Diaphragmatic movement, especially on the right side.

William B aet 18



William B aet: 18



James O. Traveller, age 24. Height 5 feet $3\frac{3}{4}$. Weight 8 stone 9. Temperature normal.
 COMPLAINT. percussion, to the 3rd Rib, and

"Cough and Spit" for last 2 years. Previous history good. Is a heavy cigarette smoker.

RESPIRATORY SYSTEM.

Cough slight in morning. Thin grey sputum. Pain in front of chest on coughing. No Hoemoptysis. No Tubercle Bacilli found in Sputum. Pulse 78, irregular and intermittent. Has Chronic Pharyngitis. Other systems normal.

PHYSICAL EXAMINATION OF CHEST.

Anteriorly. On the right side, there is impairment of note on percussion, from apex to 1st Rib; and over this area the breathing is vesicular, with prolonged expiration. Above the clavicles, on both sides, the breath sounds are very faint.

Posteriorly. On the right side, there is dullness on percussion, down to the 3rd Rib. The expiratory murmur is more prolonged than usual, even in this area.

On/

On the left side, there is very slight impairment of the note on percussion, to the 3rd Rib, and the breath sounds are, as on the right side.

SCREEN EXAMINATION.

Anteriorly. On the right side, loss of normal translucency from apex to 3rd Rib, and on the left side, though not so distinct, as far down as the first interspace.

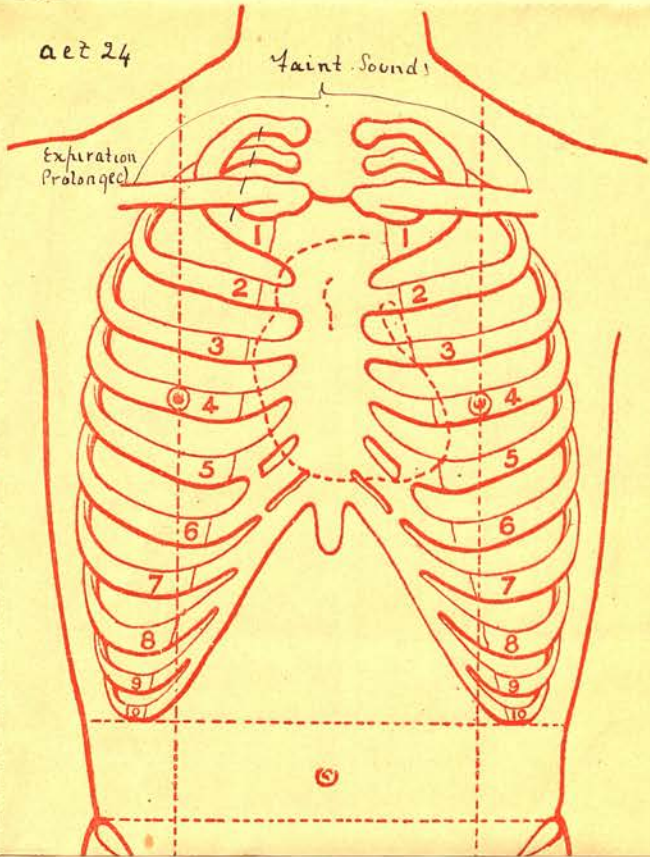
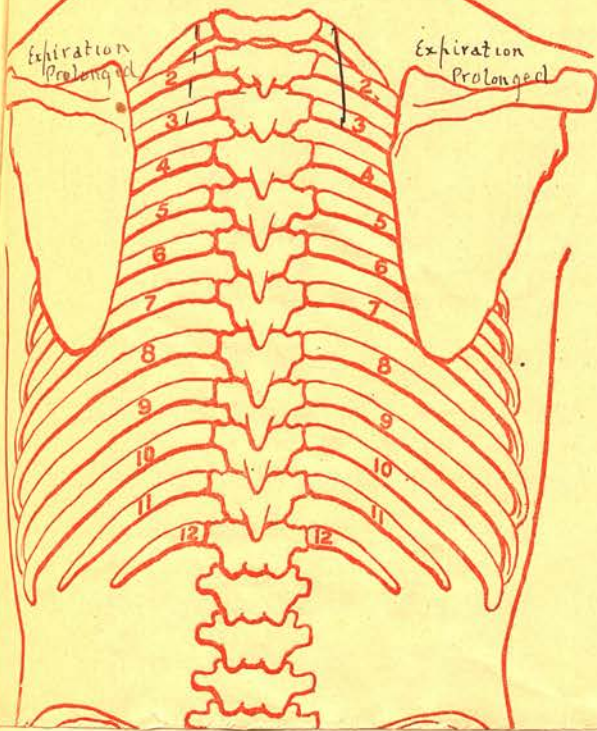
Posteriorly. On the right side, loss of translucency to the 6th Rib, while on the left side, it is fainter, and extends only to the 4th interspace.

Diaphragmatic movement. Right side $1\frac{3}{4}$ inches. Left 2 inches.

James O

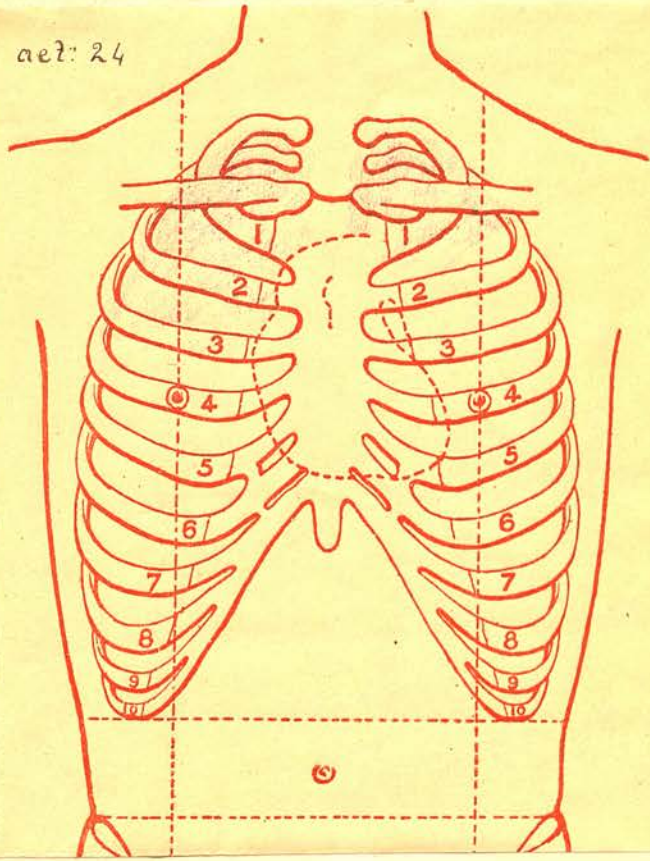
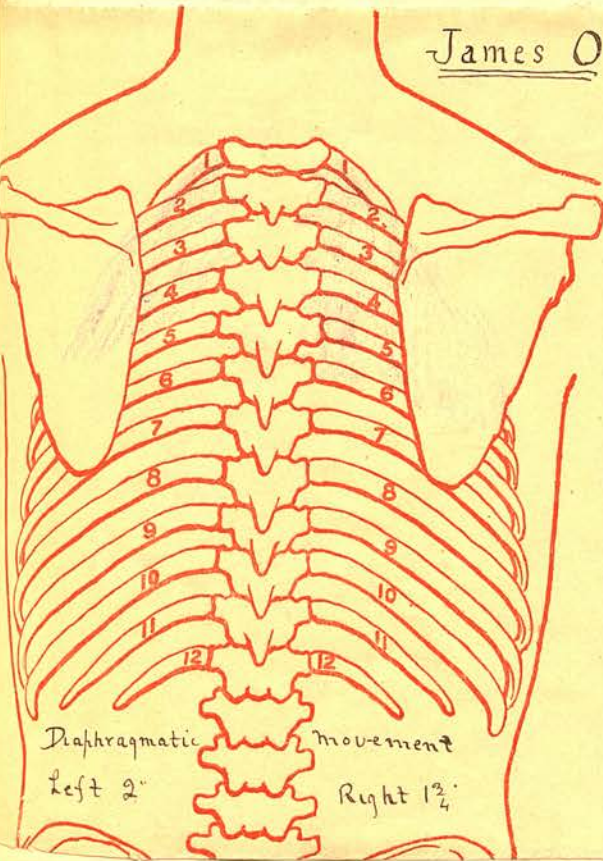
aet 24

Faint Sound!



James O

aet: 24



Jeannie M. Clerkess, age 26. Weight 7 stone $5\frac{1}{2}$.

Height 5 feet $3\frac{1}{2}$. Temperature normal.

COMPLAINT.

Affection of Lungs, lasting for a year.

Previous history good. Mother died of Phthisis, 11 years ago.

RESPIRATORY SYSTEM.

Cough troublesome at night. Thick yellow sputum. Pain on the right side posteriorly. Vocal cords lustreless, but no lesion.

CIRCULATORY SYSTEM.

Pulse 96. Tension and Volume fair. Mitral Stenosis.

Has been losing flesh. Amenorrhoea for 7 months. Suffers from night sweats.

PHYSICAL EXAMINATION OF CHEST.

Anteriorly. On the right side, dulness on percussion to the 4th Rib.

Crepitations are heard over this area, and Vesicular breathing, with prolonged expiration, is heard to the 5th Rib.

On the left side, dulness to 4th Rib, more marked in character. Crepitations/

Crepitations are heard in this area also, with prolonged expiration.

Posteriorly. Dulness on percussion, on the right side to the 6th Rib.

The breathing is harsh vesicular over this area, with whispering pectoriloquy at the 2nd inter-space. Crepitations accompany the breath sounds over this area also.

On the left side, dulness on percussion, to the 7th Rib - the breathing here is harsh vesicular, with crepitations, and rhonchi, most prominently, at the upper part.

SCREEN EXAMINATION.

The Chest is a narrow pointed one - on both sides the Ribs are acute, but more so on the left side.

Anteriorly. On the right side - there is marked opacity to the 4th Rib, and below, there is loss of translucency, extending down though/

though not so marked, - only the last interspace being absolutely clear.

On the left side, there is marked opacity to the 4th Rib, and loss of translucency below, though fainter all down.

Posteriorly.

On the right side, there is opacity, very marked above, and tapering off to a faint shade, to two interspaces above the Diaphragm. No signs of cavity.

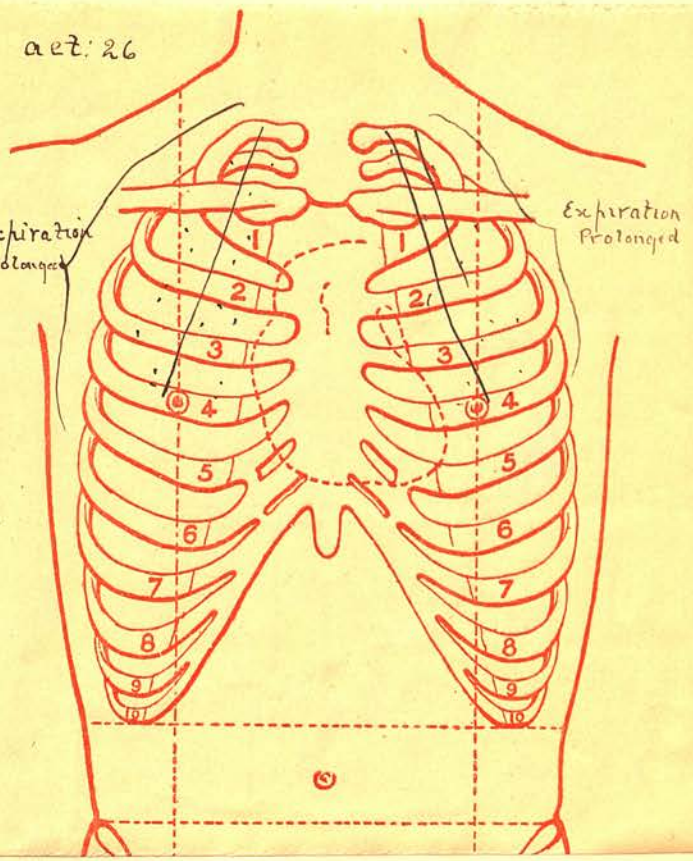
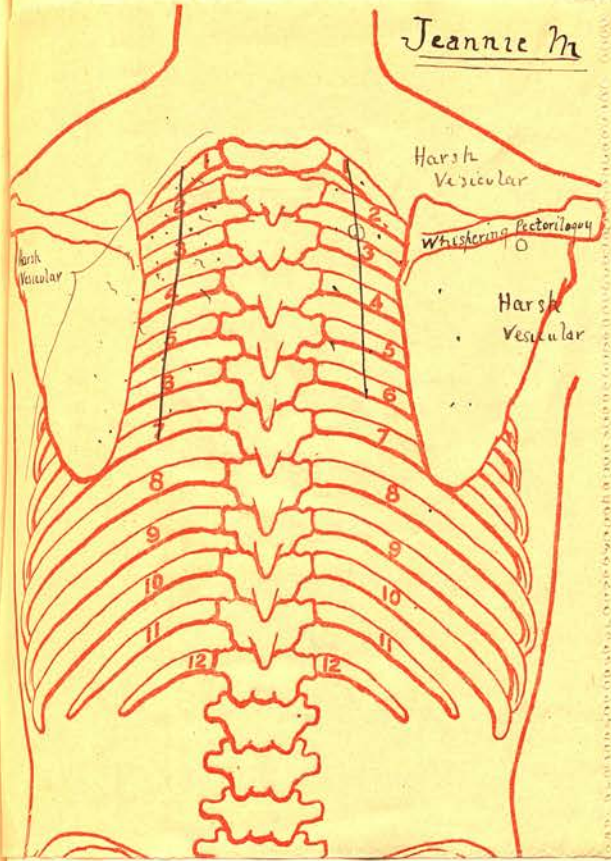
On the left side, there is opacity, dense to the 6th Rib, and loss of the normal translucency all down.

Diaphragmatic movement.

At two feet is very slight, - about $\frac{1}{2}$ inch on each side, and that of a very irregular character.

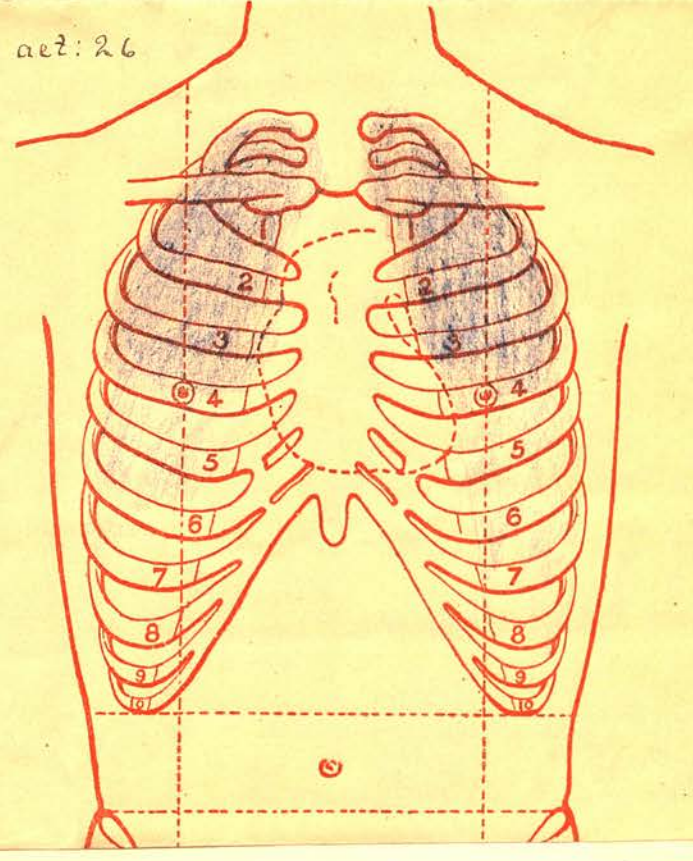
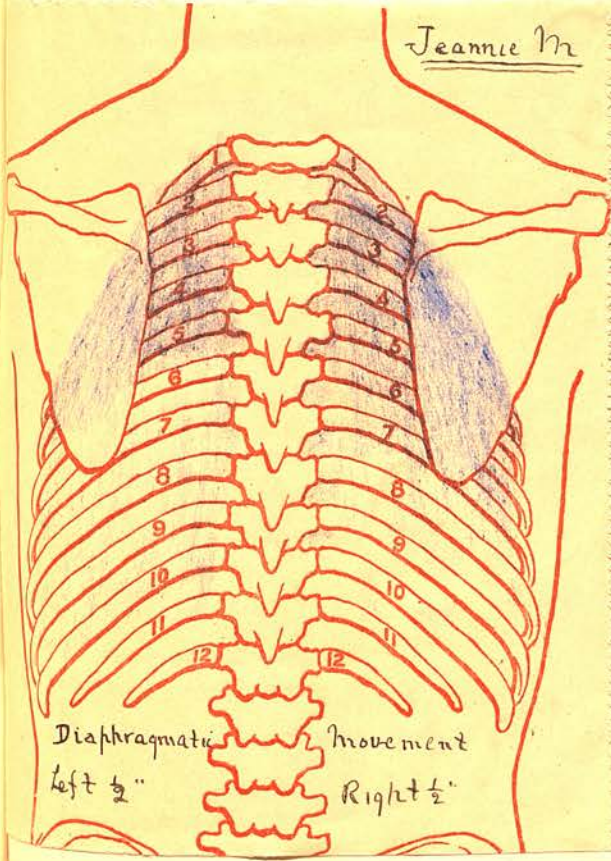
Jeannie M

aet: 26



Jeannie M

aet: 26



Mary F. Age 20. Height 5 feet 4. Weight 7 stone
 2½ lbs. Temperature normal.

COMPLAINT.

"Weight on Chest and Cough" - lasting for
 about a week. Previous health good.

RESPIRATORY SYSTEM.

Cough hard, worst at night and morning.

Thick yellow sputum, containing Tubercle Bacilli.

No Hoemoptysis.

Laryngeal Examination reveals relaxation of
 Inter-Arytenoid Folds, and grey appearance of
 Vocal cords.

Pulse 120. Tension and Volume poor.

Menstruation regular. Has been losing weight.

PHYSICAL EXAMINATION OF CHEST.

Anteriorly. On the right side, dulness on
 percussion, to the 2nd inter-
 space, Bronchial breathing above
 the clavicle - crepitations are
 heard to the 2nd Rib.

On the left side, dulness on
 percussion, above the clavicle,
 and crepitations are heard in
 this area.

Posteriorly. On the right side, dulness on
 percussion/

percussion to the 5th Rib.

Bronchial breathing is heard to the third interspace, - crepitations are occasionally heard, all the way down to the 7th interspace.

On the left side, dulness on percussion to the 4th Rib.

Bronchial breathing is heard over the 1st and 2nd interspaces, crepitations accompany the breath sounds to the 4th Rib.

SCREEN EXAMINATION.

Anteriorly. The Ribs slope, rather rapidly, down on both sides, and marked narrowing of the Chest, at the lower part, from corset tightening, is observed. The Heart appears smaller than normal. On the right side, loss of translucency to the 2nd Rib, and on the left side to the 5th Rib.

Posteriorly. On the right side, the loss of translucency extends all down, being very marked above.

On/

161.

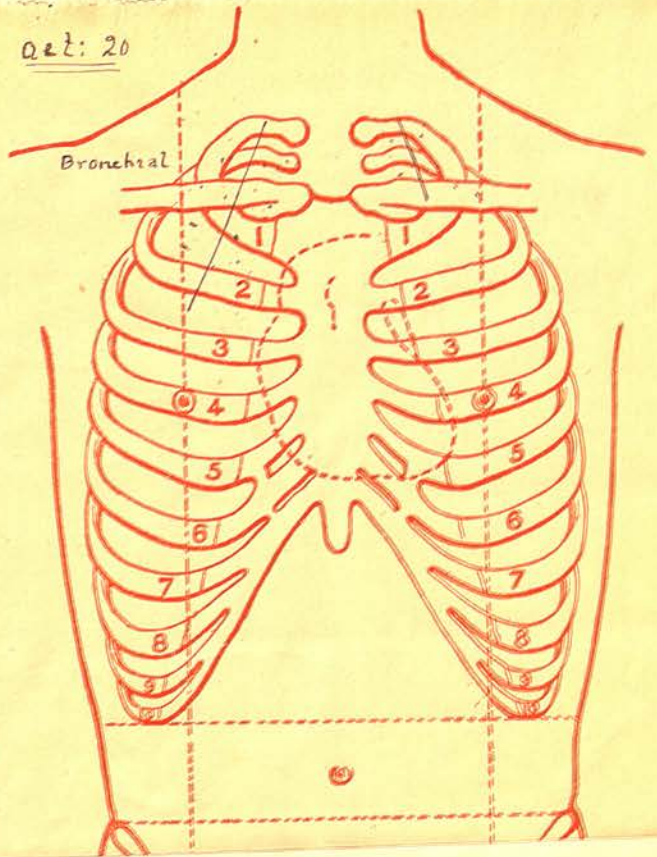
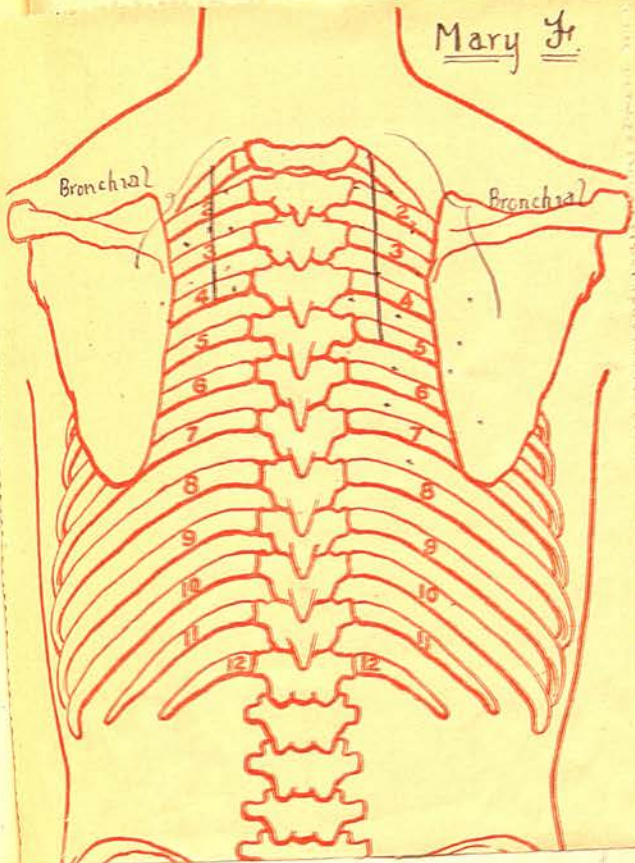
On the left side, to the 6th
Rib, there is loss of Translucency.

Diaphragmatic
movement.

At two feet distance. Right
side $\frac{1}{2}$ inch. Left $\frac{1}{4}$ inch.

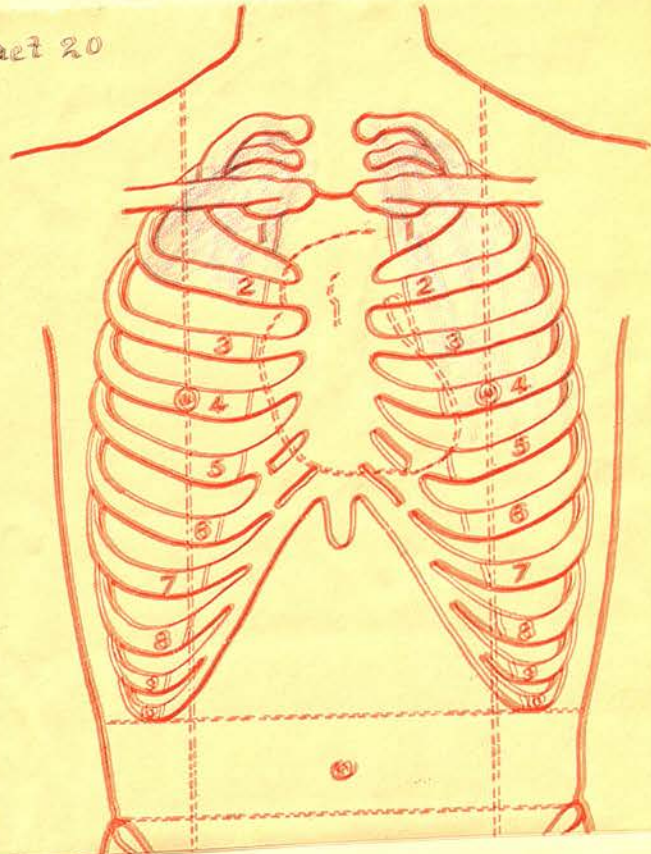
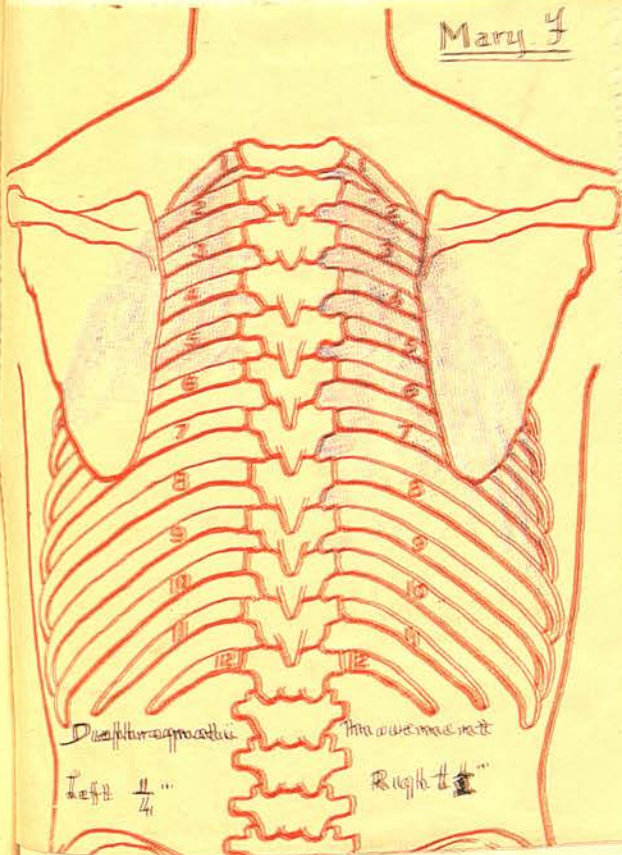
Mary Jr.

aet: 20



Mary Jr.

aet 20



Diaphragm approx. 11"

Intercostal space 1 1/4"

Left 1 1/4"

Right 1 1/4"

PHOTOGRAPHS OF POST MORTEM SPECIMENS.

It might have seemed a fitter arrangement, if X Ray examinations of post-mortem cases and specimens, had preceded the X Ray examination of Pulmonary Tuberculosis in the living body; but, unfortunately, when I first started the work, I was unable to obtain any facilities for doing so. As it is only recently, that I have got arrangements made to carry out this part, I have to offer these circumstances as apology, for the incompleteness of my Thesis, in this direction.

Here, undoubtedly, is a sphere, in which X Ray Photography is as good, at least, as screen examination, as the difficulty of movements continually going on, is not present to affect the result.

I hope, in the near future, to go much more completely into this aspect of the work; but meantime present the few photographs that I have taken.

NO. I

Taken on a Cathodal Plate - with Hirschmann Tube. Duration of exposure 35 seconds. Distance 12 inches, - is that of a Lung without any Tuberculosis, showing, simply Hypostatic Congestion, chiefly in the Lower Lobe.

The Lung is not clear, as the healthy Lung in life is, owing to the Congestion which is present all over, and also the collapse.

Faint traces of the Bronchi, are seen in the centre, and the fine network all through.

these are much clearer.

NO.II.

Taken on a Cathodal Plate, with Hirschmann Tube. Duration of exposure 35 seconds. Distance 12 inches. This is a vertical lateral section

showing This is a Lung still more congested, but again free from Tuberculosis. The main Bronchus stands out, very clearly, in the centre, and the lower lobe is again especially dark, from the congestion.

In this, and the preceding photograph, the edges of the Lungs were emphysematous at parts, and these are much clearer.

Below the sulcus, between this, and the convex exterior margin, are one or two clear spaces, which are small deep cavities.

Below the Sulcus, is an obvious cavity, which was only apparent on the surface. Between the two lines marked () the photograph reveals the spread internally.

The main bronchi and their divisions, are very well displayed, and along and around these, small clear patches, indicating cavities are seen.

NO. III.

Taken on a Cathodal Plate with Hirschmann Tube. Duration of exposure 30 seconds. Distance 12 inches. This is a vertical lateral section showing a half Lung which had been preserved in fluid, with cavity formation. The part below the projection. The Tuberculosis was spread, practically, all over the Lung; but, in addition the Lung was more consolidated than a fresh specimen, owing to the action of the preserving fluid.

At the apex, is a patch of Emphysema clearly seen, and this was only revealed afterwards, by cutting into the specimen: between this, and the convex exterior margin, are one or two clear spaces, which are small deep cavities.

Below the Sulcus, is an obvious cavity, which was only apparent on the surface, between the two lines marked () - the photograph reveals the spread internally.

The main bronchi and their divisions, are very well displayed, and along and around these, small clear patches, indicating cavities are seen.

NO. IV.

Taken as previous specimens, with exposure of 30 seconds duration.

This was It is a vertical lateral section of a preserved Lung, which also showed advanced tuberculosis, with cavity formation. The part below the projecting tongue, in photograph, was all that seemed clear of the disease, from surface examination. Smaller cavities, and a patch of Emphysema are seen and marked on the Photograph. Air divisions are well seen.

Some of the cavities are marked with crosses, but many more are present, and in places they appear to spread along the Bronchioles.

NO. V.

Taken as previous specimens, with Distance
Exposure of 40 seconds duration. e 50 seconds.

This was a preserved whole Lung cut down, and the
incompletely separated halves, were lying with cut
surface uppermost. This cutting gives rise to
the special clear line, down the centre Peri-
of the photograph. The whole Lung was affected
with Tuberculosis, with Cavity formation at parts.
no part w The Bronchi, and their divisions are
well seen. The Pleura was thickened slightly, but
more esp. Some of the cavities are marked with
crosses, but many more are present, and in places
they appear to spread along the Bronchioles.

In the right lung were a large, and
several small cavities at the apex, military
lymphatic spread over the whole lung, and marked
interstitial change on upper and middle lobe.

In the left lung there was a large cavity
at the apex, interstitial change at the upper lobe,
and military lymphatic spread all over.

(The streaks running across the photograph, are
due/

NO. VI.

due to drying the normal quickly, with the aid
of Methylated Spirit. — several very dark spots

seen, were caused by thickened secretion and blood
Lumiere Plate. Hirschmann Tube. Distance
getting between the plate and the specimen.
14 inches. Duration of exposure 60 seconds.

On examination, the trachea is prominently
This photograph of both Lungs and
seen, in the centre, dividing into the two main
Trachea, just after removal from the cadaver, was
Bronchi, — the right Bronchus, somewhat to
taken with the anterior surface lying on the plate.
general direction of the trachea, more than

the left. This is an interesting anatomical study:
cardium still left, and, unfortunately, the Lungs
and if the views of the older anatomists, as to the
were deeply incised and so distorted, although
direction of the Bronchi, had not been already
no part was removed.

The Pleura was thickened slightly, but
their views. The wider character of the right
more especially on the left side.
Bronchus is distinctly seen, and a faint trace of

Both Lungs were infiltrated, practically
its first branch, the apical Bronchus, is just
to the base.
made out.

In the right Lung were a large, and
Below the bifurcation of the Bronchi, a
several small cavities at the apex, miliary
darker shades, indicating the incised and dis-
lymphatic spread over the whole Lung, and marked
torted Pericardium is seen.
interstitial change on upper and middle lobe.

is observed, and its resemblance to the similar
condition in life, is evident.
In the left Lung there was a large cavity
at the apex, interstitial change at the upper lobe,
and miliary lymphatic spread all over.

on the right side, the apex is, un-
Fortunately, freely incised, but the remaining clearer
(The streaks running across the photograph, are
spots, show the site of the cavity. The
due/
darker part, below this, shows the interstitial
change./

due to drying the negative quickly, with the aid of Methylated Spirits. Several very dark spots seen, were caused by thickened secretion and blood getting between the plate and the specimen).

On examination, the Trachea is prominently seen, in the centre, dividing into the two main Bronchi, - the right Bronchus, continuing the general direction of the Trachea, more than the left. This is an interesting anatomical study; and if the views of the older anatomists, as to the direction of the Bronchi, had not been already confuted, would have been strong evidence against their views. The wider character of the Right Bronchus is distinctly seen, and a faint trace of its first branch, the Eparterial Bronchus, is just made out.

Below the bifurcation of the Bronchi, a darker shadow, indicating the incised and distorted Pericardium is seen.

All over both Lungs, the mottled character is observed, and its resemblance to the similar condition in life, is evident.

On the right side, the apex is, unfortunately, freely incised, but the remaining clearer spots, show the site of the cavity: the darker part, below this, shows the interstitial change./

change.

NO. VII.

On the left side, the apical cavity is better seen, and the general mottling as on the right side.

Taken as previous specimens, with 40 seconds exposure. Preserved specimen of Syphilitic Lung, with marked thickening of the Pleura.

The extent and character, of this thickening, is well brought out. At the apex, though the specimen is, as a whole, thinner, and pointed in this region, there is marked opacity, as the pleura was very thick.

The Homogeneous character of this opacity, is similar to that, seen in the photographs, of patients with thickened Pleura, which I have previously presented.

NO. VII.

Taken as previous specimens, with 40 seconds exposure. Preserved specimen of Syphilitic Lung, with marked thickening of the Pleura.

The extent and character, of this thickening, is well brought out. At the apex, though the specimen is, as a whole, thinner, and pointed in this region, there is marked opacity, as the pleura was very thick.

The Homogeneous character of this opacity, is similar to that, seen in the photographs, of patients with thickened Pleura, which I have previously presented.

172.

NO. VIII.

Taken as in previous specimens, with 35 seconds exposure. Preserved lateral vertical section of Lung, showing Grey Hepatisation stage of Pneumonia.

The upper lobe is completely opaque, and the definite lobar character, is well brought out, giving a clearer picture in some respects, than the specimen itself - the divisions of the bronchi are well brought out, especially in the upper lobe.

These photographs IX. of post-mortem specimens, though few in number, are sufficient to show, at least, that a normal lung is healthier than a

Another section of the same Lung, slightly diseased Lung: that cavities are observable by thinner, and, therefore, only exposed for 30 seconds. means of X Rays; that a thickened pleura gives a The same details are brought out, but in homogeneous shadow; and Tuberculosis in the Lung the upper lobe the divisions of the bronchi, are itself, a mottled appearance. even more clearly seen. In the lower lobe,

Specimens 3, 4, 5, 7, 8, and 9 are in the fibrous strands are prominently shown. possession of Professor Greenfield, who kindly

let me have the loan of them. Afterwards when the negatives were developed, he cut up some of them sufficiently to establish the facts, as regards the cavity formations.

The other specimens were also cut up, after X Ray examination, and the deeper parts examined.

An ideal series would be, to have an X Ray photograph of a case, just before death - then after death, and lastly of the lungs after removal, and before being examined.

It seems to me, that such a series could easily be obtained in a Lunatic Asylum, where so many patients die of Tuberculosis, and difficulties, sentimental and otherwise, do not often stand in the way/

These photographs of post-mortem specimens, though few in number, are sufficient to show, at least, that a normal Lung is healthier than a diseased Lung: that cavities are observable by means of X Rays; that a thickened pleura gives a homogeneous shadow; and Tuberculosis in the Lung itself, a mottled appearance.

Specimens 3, 4, 5, 7, 8, and 9 are in the possession of Professor Greenfield, who kindly let me have the loan of them. Afterwards when the negatives were developed, he cut up some of them sufficiently to establish the facts, as regards the cavity formations. The other specimens were also cut up, after X Ray examination, and the deeper parts examined.

An ideal series would be, to have an X Ray photograph of a case, just before death - then after death, and lastly of the Lungs after removal, and before being examined.

It seems to me, that such a series could easily be obtained in a Lunatic Asylum, where so many patients die of Tuberculosis, and difficulties, sentimental and otherwise, do not often stand in the way/

SUMMARY AND CONCLUSIONS.

way.

So far, little or nothing has been done, in this direction - at any rate, results have not been published.

of Pulmonary Tuberculosis.

As regards acute military Tuberculosis, I have had no opportunity of examining such a case by X-Ray. These foregoing photographs, were all taken, by placing a piece of jaconette over the envelope, containing the negative, and, on the top of this jaconette, placing the specimen. Jaconette being transparent to X Rays, does not mar the effect, and the negative is unaffected by the moisture.

The 28 cases only accompanied by screen examination, are made up of 8 in an early stage, and 18 in later stages.

In the early stages, I trust I have shown, that in most cases at least, this method is superior. The only other way, in which I could have more fully examined the cases, in this stage, was by the injection of Tuberculin. In America this test is carried out frequently; but it has not yet been proved, that it is harmless to the patient - in fact, opinions generally point the other way, and

SUMMARY AND CONCLUSIONS.

These 45 cases, of which I have recorded the results, are examples of the most common types of Pulmonary Tuberculosis.

As regards acute miliary Tuberculosis, I have had no opportunity of examining such a case by X Rays; but Dr Walsh of London, at a meeting of the British Medical Association, last year, showed a photograph, in which signs of this were observed.

Of the 19 cases photographed, 4 show the disease in an early condition, and 15 show different stages of advancement, from fibrosis to cavity formation.

The 26 cases only accompanied by screen examination, are made up of 8 in an early stage, and 18 in later stages.

In the early stages, I trust I have shown, that in most cases at least, this method is superior. The only other way, in which I could have more fully examined the cases, in this stage, was by the injection of Tuberculin. In America this test is carried out frequently; but it has not yet been proved, that it is harmless to the patient - in fact, opinions generally point the other way, and

I/

I had neither the facilities to enable me, nor the moral courage to allow me to use it.

Dr Harry Rainy, in the Scottish Medical and Surgical Journal of April 1902, makes the following statement;-

"In most cases, however, the presence of the disease can be discovered at an earlier period, by other methods, and radioscopy is only of value, where the lesion is suspected to lie so deeply, as to be beyond the reach of percussion, or, where, owing to the possibility of bilateral apical phthisis, further information regarding the two apices is desirable."

This statement I cannot class as anything, but entirely misleading, and can only ascribe it, as due to the fact, that the lungs in a child are much clearer than in an adult, and presume that Dr Rainy has drawn, mainly, on his experience in children.

Doctors Hugh Walsham of London, Espina Y. Capo of Madrid, Immelmann of Berlin, and Béclère of Paris - who are experts in Tuberculosis as well as X Rays - are unanimous in favour of the superiority/

superiority of X Rays, as a diagnostic agent in Pulmonary Tuberculosis, both in early and late cases.

The photographs and screen examinations I have shown, are evidence of its value in later stages, in bringing out details as to the topography of the disease, not discernible by ordinary means, even where the disease does not lie "so deeply as to be beyond the reach of percussion".

As regards the early cases, it may be said, and that justifiably, that another more experienced and better observer, would have found out details in the physical examinations that I omitted to find. The personal equation must always come in, and, as truly might it be said, that an expert radioscopist might have found out more details in the X Ray examinations, than I found.

I can only repeat, that I was at liberty to consult the records of Physical examination, by expert observers, and quote the experience I have had.

During my tenure of office, at the Victoria Dispensary for Consumption, which lasted for eighteen months, scarcely a day passed, without my/

to break up the blood corpuscles, afterwards washing out/

my examining three or four cases of Phthisis, and on many days, as many as 30 or 40 such cases, came under my observation, since then, I have continually kept in touch with cases of the kind.

At the X Ray Department in the Infirmary, where I was clinical assistant for a year, and since then at my own residence, where I have an X Ray installation fitted up; and through the kindness of Dr Dawson Turner at the Infirmary, I have gained experience in, and kept abreast of this method of examination, for fully two years.

I apologise for bringing in this personal note; but feel sure that the examiners of this thesis, will understand the reason of its introduction,

Three points are mentioned in these early cases:-
Loss of Translucency, Alteration in the Shape of the Chest, and Impaired Movement of the Diaphragm.

The first point, and the most important, viz:- Loss of Translucency, is due to the infiltration, and not the mere congestion. Dr Walsham experimented with a view to determine this point, by taking the Lungs from a case of Pulmonary Tuberculosis - soaking one in water for some hours, to break up the blood corpuscles, afterwards washing out/

out the vessels, till the water came away colourless, then skiagraphing both Lungs, with the result, that very little difference was observed between them. Faint loss of translucency, is, as may be imagined, very difficult to determine; and here, experience is the only guide. Lungs show less translucency with advancing years, and the apices, owing to the muscular clothing, and the smaller amount of Lung tissue, are not so clear as other parts. The right apex is, I think also, always slightly less clear than the left, as it has a slightly higher pitch on percussion, and more prolongation of the expiratory murmur in the normal Chest. Again the Chest is less translucent in a muscular, than a thin individual.

The second point - alteration in the shape of the Chest, is, in the nature of things, better examined by X Rays, as we can trace the direction of the Ribs no matter how muscular the individual is.

The third point, viz:- impaired movement of the Diaphragm, is a most important one. Dr Williams, in his book on the Roentgen Rays, lays great stress on it. An early affection, as will be/

be observed from the previous records, may be characterised by an impairment of an inch or more. In later cases the impairment is still greater, so much so, that the expansion of the Chest is observed to be mainly, by movement of the Ribs, and a comparison of the movement of the Diaphragm on the two sides, is, generally, an index of the amount of disease in each.

A peculiar jerky, and at times, a wave-like movement, was observed in some cases, which may have been due to faulty innervation; the result possibly, of reflex irritation, from a diseased lung. The position of the Diaphragm at rest, was not regularly observed, and I have not mentioned the results I have collected; but, undoubtedly, it occupies a higher position than normal, in a diseased chest generally. Photographs, as has been pointed out, do not give a true idea of this, owing to the convexity of the Diaphragm, unless the Tube is placed just at the level of its upper margin, it appears lower or higher than it really is. For instance, in the Photographs shown, the Tube was placed opposite the middle of the Chest, and the Rays formed a tangent, not with the top of the/

the Diaphragm, but the posterior aspect, to some extent - accordingly the position appears lower than it actually was.

It is especially in these early, or doubtful cases, that, for screen examination, the observer requires a faultlessly working apparatus; too great flickering, or an imperfect interruption on the coil, may absolutely prevent proper diagnosis.

The Schall Motor-Mercury Interruptor, which is still in use at the Royal Infirmary, was a great improvement on the Hammer Interruptor; but it has served its day. The Mackenzie-Davidson Motor-Interruptor, which I have used lately, is a great advantage, as, by its means, one can get an extremely regular and rapid interruption, owing to the speed at which the motor is driven, and a consequent steady light, in which the flickering is hardly perceptible.

One other point, as regards the Diaphragm, may be mentioned, although it does not, exactly, bear on the subject. Older physiologists at least, used to teach, that the Diaphragm flattened itself out, in inspiration; but on X Ray examination, one can observe it moving up and down, almost like

a/
Base Pulmonary Tuberculosis give a shadow,
peculiarly/

a piston, and preserving its curved contour all the time.

I have discussed the use of X Rays in early Phthisis, but, in later cases also, they are of much use. One could give a much better prognosis, in cases, where some parts are absolutely clear, than, where the loss of translucency, though faint, is very general. Again, in tracing the progress of the case, one can get fuller details, as to the healing and expansion of a Lung, or the reverse. If photographic methods should advance, as they will most certainly do, interesting clinical pictures, free from any bias on the observer's part, could be taken. With apparatus and methods at their present state of perfection, facts as to the slope of the ribs, presence of nodules, and almost immobility and irregular action of the Diaphragm, are brought out by this, as by no other method.

Pleurisy, unless chronic, is only faintly seen by the Screen; but its effect on the Diaphragmatic movement, and the expansion of the Chest generally, is distinct.

Does Pulmonary Tuberculosis give a shadow, peculiarly/

peculiarly its own? This is a natural question, which must, I fear, be answered in the negative, even with the mottled character seen in photo and screen. A Pulmonary Tumour and a thickened Pleura, both give homogeneous shadows, but so does a very advanced fibrosis in many cases. Pneumonia casts a shadow, which I have, unfortunately, not been able to test - and so does an effusion into the Pleural cavity, which I have seen.

This comes to the point which I want to lay stress upon, and that is, that X Rays are only an aid to Diagnosis. With this, as with every method, one desires as many details of history and symptoms as can be got, and then when ordinary Physical Examination and X Ray Examination:-

"These twain....."

Sit side by side full summ'd in all their powers." we may be able to study and treat this disease better than before.

Williams puts the point in very apt words:-

"We may by their use, not only
"control one method by another, but
"with the eye supporting the ear, we
"also control one sense with
"another."

greatly. A fair amount of literature, in the form, chiefly, of articles in journals, has appeared in recent months: and many little details are recorded, which I have not found to be regularly present, although existing in some cases. I mention them here with that reservation.

Firstly. "Smallness of the Heart" which Immelmann says is "characteristic of Phthisis" and Espina Y. Capo has also noted.

Secondly. The Ribs are said to be arranged like tiles.

Thirdly. Increased flexure of the clavicles, especially at their outer end.

Fourthly. Scapulae placed higher than normal.

In conclusion, I beg to tender my thanks to the University Court, for their kindness, in giving me a grant from the "Moray Bequest" which aided me in this research.

To Professor Greenfield, I again express my indebtedness, for the loan of specimens and supervision of the disposal of the grant.

Dr Philip, and Dr Gulland, helped me greatly/

greatly, in securing cases, and the former, more especially, with kindly suggestion.

Dr Dawson Turner first taught me the details of X Ray work, and since then, has allowed me to use the apparatus in the Infirmary, when I required to do so.

To Dr Bruce for a case, and to the Pathologists at the Royal Infirmary for three specimens, I express my gratitude.

"The Roentgen Rays" ———— Walsh.

"Archives of the
Roentgen Ray.
May 1900."

Articles by Dr Walsham

Reports of British
Congress on
Tuberculosis.

"Radiographie der
Brustorgane".

Dr Maximilian
Walzberger.

"Practitioner"
Tuberculosis
Number. 1901.

