



# THE UNIVERSITY *of* EDINBURGH

This thesis has been submitted in fulfilment of the requirements for a postgraduate degree (e.g. PhD, MPhil, DClinPsychol) at the University of Edinburgh. Please note the following terms and conditions of use:

- This work is protected by copyright and other intellectual property rights, which are retained by the thesis author, unless otherwise stated.
- A copy can be downloaded for personal non-commercial research or study, without prior permission or charge.
- This thesis cannot be reproduced or quoted extensively from without first obtaining permission in writing from the author.
- The content must not be changed in any way or sold commercially in any format or medium without the formal permission of the author.
- When referring to this work, full bibliographic details including the author, title, awarding institution and date of the thesis must be given.

**A PATHOLOGICAL, HISTOLOGICAL AND  
ULTRASTRUCTURAL STUDY OF  
DISEASED EQUINE CHEEK TEETH**

**IAN THOMAS DACRE**

**B.V.Sc. M.R.C.V.S.**

**Presented for the degree of Doctor of Philosophy**

**The University of Edinburgh**

**2004**

## ABSTRACT

The examination of 220 normal and 130 diseased equine (extracted) cheek teeth was performed using a variety of traditional and novel imaging techniques primarily to assess the aetiopathogenesis of the important dental disorders of apical infection and “idiopathic” dental fracture. Optimal settings for radiography and computer axial scanning of normal and diseased cheek teeth were determined. It was found that standard radiography of extracted cheek teeth was very poor at identifying intra-dental anatomical or pathological features, whilst computer axial scanning gave accurate information on both normal and abnormal radiographic features.

Newly established histological techniques allowed preparation of undecalcified sections of 4-6 $\mu$ m thickness, and undecalcified sections of 50-60 $\mu$ m thickness. The current classification of equine dentine was modified, with primary, regular secondary, irregular secondary and tertiary dentine all being categorised separately. Previously undescribed histological features of normal and diseased equine teeth were identified such as dentinal pearls, interglobular dentine, caries and the presence of pioneer micro-organisms.

The normal endodontic anatomy of all 24 cheek teeth was established, with individual pulp horns being identified using a unique numbering system. Anatomical parameters of dentine were established for normal cheek teeth, and these were compared to those of apically infected cheek teeth. A decreased presence of primary and secondary dentine, predentine and intertubular dentine was found in diseased teeth compared with normal cheek teeth, but increased number of resting lines were present in diseased cheek teeth.

Analysis of 50 individual apically infected cheek teeth showed anachoretic pulpitis to be the most common aetiology, with occlusal pulp exposure often being a secondary finding. Apical infection caused by periodontal disease or infundibular caries was uncommon finding. Fracture patterns to the clinical crown of equine cheek teeth were grouped, with most fractures involving the buccal pulp horns of both maxillary and mandibular cheek teeth.

## ACKNOWLEDGEMENTS

This work has been graciously supported by The Home of Rest for Horses, under the stewardship of Brigadier Paul Jepson.

I am enormously indebted to my principle supervisor, Professor Padraic Dixon, for his teachings, enthusiasm, guidance, patience and friendship throughout and beyond my period of study. I would also like to thank Mrs Anne Dixon and the Dixon family for their kindness and friendship.

I wish to express my sincere gratitude to Dr. Sue Kempson for her anatomical insights into equine dentition, her work in the revision of this manuscript and her enthusiasm in the arena of equitation in general.

Dr. Ario Santini and Dr. Howard Moody have given me great insight into the realms of human dental histopathology, for which I am extremely grateful.

I would like to thank Mike Hall (Department of Geology), for his great skill in cutting undecalcified dental sections; Neil McIntyre, Andrew Dawson and Sharon Moss and Gordon Goodall for preparing decalcified dental sections (Departments of Veterinary Pathology and Preclinical Veterinary Studies), and Professor Rod Else for use of facilities within the Pathology Department.

Many thanks go to Steve Mitchell and Nicola Cayzer for their help with all aspects of electron microscopy in this work, and additionally to Steve for his support, being a fellow 'equine dentistry student.' My thanks to Kirsty McLean and Dr Joe Brooks for assistance in the use of computer axial tomography, Rona Rae for standard radiography, and Joyce Wood and Ali Cannon in their handling of skulls used in this work. Photographic work has been greatly improved by contributions from Colin Warwick, Bob Munroe and Yvonne Cooper.

I would have been lost in the midst of numbers had it not been for early statistical advice from Dr. Gordon Scott and Dr. Denis Fielding in planning this work, and especially for help in the final analyses from Dr. Darren Shaw.

Many thanks go to Professor Joe Mayhew and all equine clinicians at the Easter Bush Veterinary Centre for having included me as one of their own throughout my time at the R(D)SVS. Particular thanks go to Professor Dixon, Safia Barakzai and Henry Tremaine for their reading of radiographs and enthusiasm for equine dentistry in general, along with veterinary equine dental practitioner Dr David Klugh from Oregon, USA.

Finally I would like to thank all my friends and family who have given me such wonderful support throughout.

## DEDICATION

To my mother Heather and my wife Kirstie – I could not even have hoped to have completed this work without your support and encouragement throughout my life.

# Contents

<b>DECLARATION .....</b>	<b>II</b>
<b>ABSTRACT .....</b>	<b>III</b>
<b>ACKNOWLEDGEMENTS.....</b>	<b>IV</b>
<b>DEDICATION .....</b>	<b>VI</b>
<b>CONTENTS .....</b>	<b>VII</b>
<b>ABBREVIATIONS.....</b>	<b>X</b>
<b>CHAPTER ONE: GENERAL INTRODUCTION .....</b>	<b>11</b>
<b>CHAPTER TWO: LITERATURE REVIEW .....</b>	<b>15</b>
2.1 INTRODUCTION.....	15
2.2 EVOLUTION OF EQUINE TEETH .....	15
2.3 FUNCTION OF THE MAMMALIAN ORAL CAVITY.....	19
2.4 EMBRYOLOGY OF EQUINE TEETH .....	19
2.5 MINERALISATION.....	23
2.6 GROSS ANATOMY.....	24
2.6.1 <i>Blood Supply</i> .....	29
2.6.2 <i>Innervation</i> .....	31
2.6.3 <i>Periodontium</i> .....	31
2.6.4 <i>Endodontic System</i> .....	33
2.7 HISTOLOGICAL FINDINGS ON EQUINE DENTITION.....	33
2.7.1 <i>Dentino-Pulpal Complex</i> .....	35
2.7.2 <i>Enamel</i> .....	40
2.7.3 <i>Cementum</i> .....	41
2.8 AGE RELATED CHANGES .....	43
2.9 DENTAL DISEASE AND PATHOLOGY .....	45
2.9.1 <i>Abnormalities of Dental Development and Eruption</i> .....	45
2.9.2 <i>Abnormalities of Wear</i> .....	51
2.9.3 <i>Acquired Disorders</i> .....	54
2.9.4 <i>Odontogenic Tumours</i> .....	65
2.9.5 <i>Odontogenic Cysts</i> .....	66
2.9.6 <i>Iatrogenic Dental Disorders</i> .....	67
2.10 DIAGNOSIS OF DENTAL DISORDERS .....	68
2.10.1 <i>Clinical Examination</i> .....	68
2.10.2 <i>Ancillary Diagnostic Aids</i> .....	69
2.11 <i>Conclusions of Literature Review</i> .....	70
<b>CHAPTER THREE: MATERIALS AND METHODS.....</b>	<b>71</b>
3.1 INTRODUCTION.....	71
3.2 INITIAL WORK.....	71
3.3 COLLECTION, CLASSIFICATION AND FIXATION OF TEETH .....	73
3.3.1 <i>Collection, Classification and Fixation of Normal Teeth</i> .....	73
3.3.2 <i>Collection, Classification and Fixation of Pathological Teeth</i> .....	76
3.4 RADIOGRAPHY .....	76
3.4.1 <i>Computer Axial Tomography</i> .....	77
3.5 GROSS PATHOLOGY.....	78
3.6 TEETH SECTIONING .....	78
3.7 DISSECTING MICROSCOPY .....	81
3.8 LIGHT MICROSCOPY.....	83
3.8.1 <i>Decalcification of Hard Tissues</i> .....	83
3.8.2 <i>Undecalcified Thin Sections</i> .....	88
3.9 SCANNING ELECTRON MICROSCOPY (SEM).....	90
3.9.1 <i>EM505 SEM</i> .....	91

3.9.2 XL30/CP SEM.....	92
3.10 TRANSMISSION ELECTRON MICROSCOPY (TEM).....	93
3.10.1 Preparation for Examination in a Philips EM400 TEM.....	93
3.10.2 Ion Thinning for Examination in a CM12 TEM.....	94
3.11 STATISTICAL TECHNIQUES.....	95
<b>CHAPTER FOUR: CONTROL CHEEK TEETH RESULTS .....</b>	<b>97</b>
4.1 INTRODUCTION.....	97
4.2 ENDODONTIC ANATOMY .....	97
4.2.1 Verification of Endodontic Anatomy.....	97
4.2.2 Endodontic Status.....	99
4.3 NORMAL HISTOLOGICAL STRUCTURE .....	102
4.3.1 Decalcified Histological Structure .....	102
4.3.2 Undecalcified Histological Structure.....	112
4.4 HISTOLOGICAL MEASUREMENTS .....	115
4.4.1 Repeatability.....	115
4.4.2 Decalcified Maxillary Cheek Teeth Histology .....	116
4.4.3 Decalcified Mandibular Cheek Teeth Histology.....	120
4.4.4 Undecalcified Cheek Teeth Histology.....	123
4.5 RADIOGRAPHY .....	125
4.5.1 Standard Radiography.....	125
4.5.2 Computerised Axial Tomography.....	125
4.6 SCANNING ELECTRON MICROSCOPY.....	128
4.7 DISCUSSION .....	128
4.7.1 General Characteristics.....	128
4.7.2 Endodontic Anatomy.....	129
4.7.3 Normal Histological Structure .....	132
4.7.4 Histological Measurements.....	133
4.7.5 Radiography.....	137
4.7.6 Scanning Electron Microscopy.....	138
<b>CHAPTER FIVE: EXAMINATION OF MAXILLARY AND MANDIBULAR CHEEK TEETH WITH APICAL INFECTIONS.....</b>	<b>139</b>
5.1 INTRODUCTION.....	139
5.2 CASE STUDIES.....	140
5.3 GROUPED ANALYSIS OF MAXILLARY CHEEK TEETH APICAL INFECTIONS.....	142
5.3.1 Gross Pathology .....	142
5.3.2 Radiographic Assessment.....	142
5.3.3 Histological Results.....	144
5.3.4 Electron Microscopy.....	149
5.3.5 Summary of Grouped Analysis of Maxillary Cheek Teeth Apical Infections Examined in Detail.....	157
5.3.6 Additional cases:.....	158
5.3.7 Statistical Analyses:.....	160
5.4 GROUPED ANALYSIS OF MANDIBULAR CHEEK TEETH APICAL INFECTIONS .....	160
5.4.1 Gross Pathology .....	160
5.4.2 Radiographic Assessment.....	161
5.4.3 Histological Results.....	163
5.4.4 Summary of Grouped Analysis of Mandibular Cheek Teeth Apical Infections Examined in Detail .....	168
5.4.5 Additional Cases.....	169
5.4.6 Statistical Analyses .....	170
5.5 DISCUSSION .....	171
5.5.1 History and Clinical Examination.....	171
5.5.2 Radiography and Additional in situ Imaging Techniques.....	174
5.5.3 Dissecting Microscopy.....	177
5.5.4 Histology .....	178
5.5.5 Electron Microscopy.....	182

5.5.6 General Conclusions on the Aetiology of CT Apical Infection .....	182
<b>CHAPTER SIX: IDIOPATHIC CHEEK TEETH FRACTURES.....</b>	<b>188</b>
6.1 INTRODUCTION.....	188
6.2 CHEEK TEETH CATEGORISATION AND FRACTURE PLANE CLASSIFICATION .....	188
6.3 HISTORY, GROSS EXAMINATION AND DISSECTING MICROSCOPY.....	192
6.4 HISTOLOGY.....	193
6.5 DISCUSSION .....	193
<b>CHAPTER 7: SUMMARY AND FUTURE WORK.....</b>	<b>198</b>
<b>REFERENCES: .....</b>	<b>203</b>
<b>APPENDIX 1: CASE REPORTS ON MAXILLARY CHEEK TEETH WITH APICAL INFECTIONS .....</b>	<b>228</b>
<i>Case 1: 99/998</i> <i>7 year-old Welsh pony, mare.....</i>	<i>228</i>
<i>Case 2: 99/558</i> <i>10 year-old Warmblood, mare .....</i>	<i>233</i>
<i>Case 3: 99/457</i> <i>3 year-old Welsh cross Arab, mare .....</i>	<i>237</i>
<i>Case 4: 98/019</i> <i>2 year-old Cob, gelding .....</i>	<i>243</i>
<i>Case 5: 97/777</i> <i>6 year-old Welsh pony, gelding.....</i>	<i>245</i>
<i>Case 6: 96/801</i> <i>6 year-old Cleveland bay, mare .....</i>	<i>248</i>
<i>Case 7: 96/148</i> <i>10 year-old Hanoverian, gelding.....</i>	<i>250</i>
<i>Case 8: 95/935</i> <i>5 year-old Thoroughbred, mare.....</i>	<i>253</i>
<i>Case 9: 95/301</i> <i>5 year-old Clydesdale, mare .....</i>	<i>256</i>
<i>Case 10: 94/282</i> <i>6 year-old Thoroughbred, stallion.....</i>	<i>259</i>
GROUPED EXAMINATION .....	261
<i>Group Seven: Cases 20, 101, 103, 107 and Control 50.....</i>	<i>261</i>
<i>Group Eight: Cases 17, 102, 106 and control 19 .....</i>	<i>269</i>
<b>APPENDIX 2: CASE REPORTS ON MANDIBULAR CHEEK TEETH WITH APICAL INFECTIONS .....</b>	<b>280</b>
<i>Case 23: 98/412</i> <i>4 year-old Welsh Pony, Gelding.....</i>	<i>280</i>
<i>Case 25: 97/1121</i> <i>6 year-old Hunter, Mare .....</i>	<i>285</i>
<i>Case 28: 95/889</i> <i>6 year-old Irish Draught, Mare .....</i>	<i>288</i>
<i>Case 21: 01/181</i> <i>9 year-old Pony, Gelding.....</i>	<i>293</i>
<i>Case 31: 93/586</i> <i>4 year-old Mare.....</i>	<i>296</i>
GROUPED EXAMINATION .....	299
<i>Group Seven: Cases 27 and 33, and Control CT 13.....</i>	<i>300</i>
<b>APPENDIX 3: CASE REPORTS OF IDIOPATHIC CHEEK TEETH FRACTURE IN DIFFERENT FRACTURE GROUPS.....</b>	<b>306</b>
<i>Group 1: Maxillary Buccal Slab Fractures.....</i>	<i>306</i>
<i>Group 2: Maxillary Infundibular Sagittal Fractures .....</i>	<i>311</i>
<i>Group 3: Miscellaneous Maxillary Fractures .....</i>	<i>315</i>
<i>Group 4: Mandibular Buccal Slab Fractures.....</i>	<i>317</i>

# Abbreviations

CAT	computer axial (assisted) tomography
C.E.	common era (c.f. A.D.)
CT	cheek tooth or cheek teeth
kg	kilogram
LM	light microscope
$\mu\text{m}$	micrometer
mm	millimeter
N	Newton
PDL	periodontal ligament
SEM	scanning electron microscope
TEM	transmission electron microscope
UK	United Kingdom
USA	United States of America

## Chapter One: General Introduction

Gross anatomical features of equine dentition have been recorded as far back as 600 C.E. (Kertesz 1993). These include eruption times of deciduous and permanent dentition, the presence of incisor ‘hooks’ and ‘grooves,’ and the presence of features such as the ‘dental star’ on the occlusal surface of incisors that were traditionally (but often erroneously) used to age horses. Sydney Galvayne claimed that **“there is no record of me having made a single mistake”** with respect to his ability to age horses based on examination of their incisor dentition (Galvayne 1912). Recent studies have shown many of these historical methods of ageing to be inaccurate ( Walmsley 1993; Richardson et al. 1994; Muylle et al. 1999a). It is evident that in the arena of equine dentistry there has been much dogma, that is now being questioned by an increasing amount of research in anatomical, pathological and clinical areas of equine dentistry (Dixon 1993).

A recently reported study on the ultrastructural anatomy of equine calcified dental tissues has highlighted the complex and varied nature of these tissues (Kilic *et al.* 1997a-d). Similarly, computer axial tomography with histological examination of corresponding sections of equine mandibular cheek teeth has partially revealed their endodontic anatomy, high-lighting its complexity and variability with age (Kirkland et al. 1996). It is a statement of the limitations of our current knowledge of equine dentistry that such critical and fundamental work is still being carried out in the third millennium.

Possibly due to the difficulties of performing a thorough dental examination of the equine oral cavity (prior to the introduction of modern sedatives), the horse was considered to have a relatively low incidence of dental disease compared with other species, and this may be one reason for the lack of research into this field (Uhlinger 1987).

Previous studies on equine dental pathology have concentrated on gross findings, with many of these studies performed on skulls collected from abattoirs, i.e. using animals with unknown dental histories ( Honma *et al.* 1962; Baker 1979a; Wafa 1988; Kirkland et

al. 1994). Even so, much useful data has been gained from these studies, importantly revealing that equine dental disorders are in fact common occurrences.

On examining 218 abattoir skulls, Baker (1970) recorded an incidence of 60% periodontal disease and 79% infundibular caries in animals aged over 15 years. A study by Honma *et al.* (1962) of 365 abattoir skulls revealed that 100% of animals identified as being 12 years or older had dental caries. In a study of 355 abattoir skulls, Wafa (1988) found 13% to have abnormalities of development or eruption; 17% to have wear abnormalities; 35% to have periodontal disease; 29% to have caries and 7% to have dental pulp exposure. He concluded this latter category was of greatest clinical significance and that **all of the periapical infections in his study were attributed to exposure of the dental pulp.**

Wafa's study contrasts with a clinical survey by Dixon *et al.* (2000a) of 400 referred dental cases of which 162 (41%) had '**primary**' apical abscessation (i.e. apical infections of unknown aetiology). Occlusal pulp exposure was only noted in two (3%) of the mandibular CT with primary apical abscessation, with none being recorded in maxillary CT. Dixon *et al.* conclude that "**such lesions may not be detected unless teeth are specifically examined for them, and it is possible that similar lesions were missed earlier in the study**".

Apical abscesses were also found to have arisen from concurrent dental disorders, such as periodontal disease, dental displacement or fracture (Dixon *et al.* 2000a). These were defined as '**secondary**' apical abscesses. In the series of four papers reporting this study by Dixon *et al.*, a detailed incidence of gross pathological dental conditions were noted in this referral population (Dixon *et al.* 1999a; Dixon *et al.* 1999b; Dixon *et al.* 2000a; Dixon *et al.* 2000b). Whilst the population was representative of referred cases within the region, their dental disorders were of a more severe nature than the dental disorders of the general population, being typical of any referral population.

A **clinical** survey of a general horse population by Uhlinger (1987) of 233 adult horses (aged 6-11 years) differs from the previously noted abattoir surveys, in that clinical histories were available. Of 150 horses with no signs of dental disease (including the owners' observations), 24% had one or more dental abnormality present. Soft tissue ulceration of dental origin was present in 8% of this category.

In the second group of 83 horses that were showing signs of dental disorders, 7% had fractured or missing teeth, 28% had soft tissue lacerations caused by dental overgrowths and 35% had no detectable dental abnormalities. This last figure may be over-estimated, possibly due to the owners' inaccurate reporting of clinical problems, or the intentionally extreme criteria used by Uhlinger to define dental abnormalities. It does highlight however the fact faced by the equine practitioner that not all suspected dental cases necessarily require dental treatment. Additionally, when we consider that 24% of horses that were reported to have no dental abnormalities did in fact have dental disorders present, it is apparent that **owners are poor at interpreting signs of dental disease in their horses, and/or that some horses are poor at showing signs of dental disease.**

Equine dental disorders are a major part of equine practice in the United Kingdom as indicated by a British Equine Veterinary Association (BEVA) survey that showed 10% of equine practice time was spent on dental-related work (BEVA 1965). More recently, a survey in the United States ranked dental disorders as the third most common equine medical problem encountered by large animal practitioners (Traub-Dargatz et al. 1991).

Despite its importance, the field of equine dentistry, both at the level of research and of clinical practice, not surprisingly lags far behind that of human dentistry, but also of small animal veterinary dentistry. In many ways the eminent 19<sup>th</sup> century veterinarian and founder of this veterinary school gave an apt and unfortunately still relevant summary when he wrote "**of the diseases of the teeth in the horse we know little**" (Dick 1862).

Recent progress has been made in both clinical examination of equine dentition (Uhlinger 1987; Mueller 1991; Easley 1999) and in the use of ancillary aids to image normal and diseased equine teeth (Tietje et al. 1996; Gibbs 1999; Weller et al. 2001; Simhofer et al. 2003). For equine dentistry to attain the standards of practice currently employed by small animal practitioners, this progress must be built upon by further research and development at both pure research and clinical levels (Dixon 1993; Schumacher 2001).

*The principle aims of this thesis are to:*

- *examine clinically normal equine cheek teeth (maxillary and mandibular) to further define their anatomical parameters, using dissecting and light microscopy, radiography and computer assisted tomography – developing or improving techniques for such imaging modalities where necessary*
- *define the endodontic anatomy of equine cheek teeth*
- *examine clinically diseased equine cheek teeth (maxillary and mandibular) having apical infections or idiopathic fractures, using gross pathology, radiography, computer assisted tomography, light microscopy, scanning electron microscopy and transmission electron microscopy*
- *to attempt to determine the pathological features, and from these findings, the aetiology and pathogenesis of the lesions observed in these cases*
- *to relate the detected pathological changes with the clinical signs shown by the patients*

*This thesis tests the hypothesis that the clinical signs and anamnesis of the cases examined will be reflected in the gross, radiographic, histological and ultrastructural changes observed in the diseased teeth examined. By more fully understanding the aetiology and pathogenesis of these conditions, we may then be able to make advances on their treatment and clinical prognosis.*

## Chapter Two: Literature Review

### 2.1 Introduction

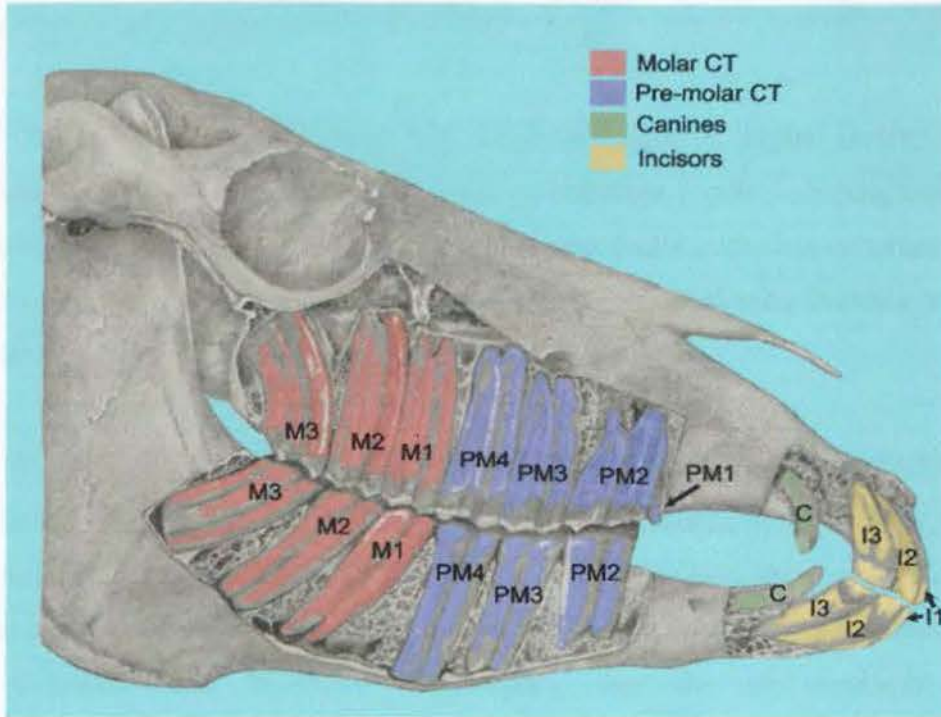
Until very recently there has been a paucity of literature on equine dentition, dentistry and dental pathology (Lowder 1997). This general literature review of equine dentistry concerns dental anatomy, pathology and touches on some aspects of current treatments. In addition, citations from relevant dental research in other species have been added, particularly where this knowledge is still lacking in the equine field. This review aims not only to give a general background in equine dentistry to readers of this text, but also act as a reference source for further equine researchers.

### 2.2 Evolution of Equine Teeth

Equine teeth have evolved considerably from those of the earliest mammals of the Jurassic period some 220 million years ago. These distant relatives had molars that cut like shears, ideally suited for slicing up insects. The development of the **tribosphenic** molar (found in Mesozoic mammalian fossils) allowed grinding between the pestle-like ‘cusp’ (protocone) on upper teeth and mortar-like ‘basin’ (talonid) of the lower teeth (Stokstad 2001). This action allowed tribosphenic mammals to crush seeds, fruit pulp and some succulent leaves.

The first member of the *Equidae* family, *Hyracotherium* (also known as ‘Dawn horse’ or Eohippus), was a small (*circa* 26” high), three-toed mammal found in South America during the Eocene period some 50-70 million years ago (Bennett 1992). It had shovel-shaped **brachydont** (short-crowned) incisors and muscular, prehensile lips to pluck and tear leaves from succulent plants. Seven premolars and molars were present, collectively termed **cheek teeth** (CT). Although having short crowns (i.e. were also brachydont), these CT were aligned to permit a more efficient lateral mastication of tough fibrous plant material, compared with the more vertical action of *Hyracotherium*’s predecessor,

*Phenacodus* which was present before the phylogenetic branching of the *Equidae* family (Getty 1975).



**Figure 2.1:** Lateral view of an equine skull with bone removed to reveal the reserve crowns and roots of incisor (I1-3), canine (C), premolar (PM1-4) and molar (M1-3) teeth. Note how pre-molars 2-4 and molars 1-3 are tightly packed together to act as a single grinding unit, as was also the case for *Hyracotherium*, the ancestor to the modern horse.



**Figure 2.2:** Close-up views of the occlusal surfaces of a maxillary (left) and a mandibular (right) equine cheek tooth when viewed from the bucco-occlusal direction.

The ridged (lophed) nature of the CT has been highlighted by lines indicating crests (red) and troughs (blue) being superimposed onto the occlusal surface.

The occlusal surface of *Hyracotherium's* CT (four pre-molars and three molars per quadrant) were also tightly compressed in a rostro-caudal direction, forming a battery of teeth to function as a single grinding unit (Figure 2.1).

Each of *Hyracotherium's* individual CT had three ridges or 'lophs' (lophodont teeth being ridged c.f. selenodont [crescent shaped] or bunodont [conical shaped] teeth) and it is upon this lophed pattern that all subsequent equine dental evolution occurred (Bennett 1992). At this early evolutionary point, maxillary CT had already become wider and squarer than their mandibular counterparts (Figure 2.2).

During the early Eocene era, *Hyracotherium* migrated from North America to Europe via the Greenland land bridge, however all its European descendants died out by the mid Oligocene period, during which the above noted land bridge also disintegrated. It was not until the late Oligocene period, with the re-opening of a second trans-continental land bridge (Alaska-Siberia bridge or 'Beringia'), that the chalicomorph browser *Anchitherium* travelled westwards to Europe. Its descendants diversified into many species in Eurasia and may have been the first equids to inhabit Africa (Churcher & Richardson 1978).

The genus *Hipparion* was the next equid to migrate from North America to Eurasia via Beringia (Bennett 1992) and it is from this genus that the modern horse *Equus caballus* evolved. As a consequence of major climatic and other environmental changes leading up to and during the Miocene period, such as the earth cooling and becoming drier, more fibrous plants replaced the previous more succulent types. This caused selection-pressure towards animals like *Hipparion* with teeth that were capable of grazing the coarser plants of the Savannahs, Steppes and Tundra (Kovacs 1971; Bennett 1992).

The principle dental adaptations to cope with this coarser herbivorous diet included the development of a more complex crown. For CT this included the development of complex enamel infoldings (as deep infundibular pits on the maxillary CT occlusal surface or infoldings on the sides of the principle crest), an increase in crown length with prolonged eruption (i.e. became **hypsodont** meaning 'tall teeth' with reserve crown development), and the presence of cementum peripheral to enamel (Kozawa et al. 1988; Bennett 1992).

The apposition of the three calcified dental tissues (cementum, dentine and enamel) with differential wear rates allowed these CT to 'self-sharpen' during mastication, with the harder enamel ridges protruding above the softer dentine and cementum on the occlusal surface (Bennett 1992; Kilic 1995). Additionally all the CT, except the first premolar, came into full apposition allowing an even more efficient lateral grinding type of mastication (Figure 2.1).

A further widening of the interdental space or 'bars' of the mouth caused the incisors and the grinding CT to form into separate uniform series or 'batteries' of teeth. This anatomical feature extended the jaw length, thus raising the height of the eye-level of these primitive horses whilst their head was lowered grazing, the effect of which was to improve their ability to detect predators while grazing. Their incisors became specialised for efficient cropping of grass during prolonged periods of grazing, of up to 16.5 hours per day (Capper 1992; Budiansky 1997).

Equidae increased in body height (and overall size) as they evolved, with a corresponding increase in the size of their teeth (Bennett 1992). To facilitate these dental adaptations, there was a compensatory lengthening and deepening of the jaws, and an increase in bulk of masseter and medial pterygoid musculature (Smith & Savage 1959).

In addition to efficiently grinding grass and other coarse forage, herbivorous mammals must also be able to digest it. Oreodonts and camelids were the first to evolve ruminant

digestion which still remains the most efficient means by which mammals can extract energy from cellulose (Bennett 1992). Equids evolved a more primitive hindgut fermentation digestive process, involving considerable enlargement of the caecum and colon, together with co-adaptation of commensal gut flora and fauna to digest cellulose. The evolutionary dental changes occurred concomitantly with these alimentary developments, as well as axial and skeletal limb modifications such as development of monodactyly, and the previously noted increase in body size. All these developments have been codified as the branching evolutionary story of the modern horse, *Equus caballus*.

### 2.3 Function of the Mammalian Oral Cavity

The fundamental function of the oral cavity in all mammals is the prehension and mastication of food. Teeth gather and prepare food for swallowing, although they also play lesser roles in grooming, defence and vocalisation, with much variation in the latter functions between different species.

When masticating hay, a horse chews 58-66 times per minute, approximating 4200 chews per kilogram of dry matter (Capper 1992). This compares to 100-105 chews per minute when at grass (Myres 1994). It has been calculated that horses in light work, or those being fed *ad libitum*, may consume 12.5kgs of hay (e.g. a 500kg horse), which may take up to 16 hours (Hollands 2004). This is thought to approximate the conditions under which modern horse evolved (Bennett 1992; Budiansky 1997).

### 2.4 Embryology of Equine Teeth

Tooth development or **dentogenesis** involves numerous biological processes including epithelial-mesenchymal interaction, growth, remodelling, and mineralisation. Mammalian teeth germs undergo a series of distinct consecutive events, namely the initiating, morphogenetic and cytodifferentiative phases of dentogenesis (Warshawsky 1983; Fortelius 1985; Boyde et al. 1988; Ten Cate 1998c; Dixon 1999). Compared with

brachydont teeth, hypsodont teeth have a delayed termination of these latter two stages to allow for the growth of their longer crowns.

Tooth development begins within the stomatodeum or embryonic mouth, initially by thickening of the oral epithelium into two horseshoe-shaped bands, called the **primary epithelial bands**. These bands subsequently invaginate into the underlying mesenchymal tissue forming two distinct ridges – the **vestibular** and **dental laminae**. The dental laminae are apparent in 25-day-old canine embryos (Noden & DeLahunta 1985). At approximately 100 days of gestation in equids, the dental lamina separates and forms individual ‘tooth buds’ (Lowder & Mueller 1998) and this is consequently termed the **bud stage** of tooth development. Both deciduous and permanent tooth buds form within a short time of each other, with the buds which form the permanent dentition arising directly adjacent to their corresponding deciduous bud. This is of importance when considering **oligodontia** (developmental absence of one or more teeth) and other developmental dental disorders in dentally immature horses (Section 2.8.1).

Mesenchymal cells then proliferate beneath the ‘hollow’ ectodermal tooth bud, which inverts into a cap-shaped structure called the **enamel organ**. This is termed the **cap stage** of dentogenesis. The mesenchymal cells continue to proliferate within the concave aspect of the enamel organ and eventually form the **dental papilla** that is responsible for the formation of the pulpo-dentinal complex. These mesenchymal cells extend peripherally to cover the enamel organ, forming the **dental sac** (or dental follicle), which protects and nourishes both the enamel organ and dental papilla until dental eruption (Brescia 1966; Berkovitz & Moxham 1981). The dental papilla, enamel organ and dental sac are collectively termed the **tooth germ**, and each of the structures is responsible for different aspects of dental development.

Deciduous teeth develop from the enamel organ of the dental lamina, with their permanent counterparts developing from a now separate, medially situated enamel organ, also of dental lamina origin (Ten Cate 1998c). Equine teeth with no deciduous precursors

(i.e. canines, first premolars and all molars) develop from individual enamel organs of the dentinal lamina (Dixon 1999).

The next stage of dentogenesis, termed the **bell stage** - due to the bell-like shape of the enamel organ- determines the overall shape of the fully developed tooth. Cells lying on the concave aspect of the enamel organ differentiate to become the internal enamel epithelium, whilst those on its convex aspect develop into the external enamel epithelium (Ten Cate 1998c). Between these two layers lie the cells of the **stellate reticulum** whose function is to provide nutrients and protection during early enamel development. This process is more extensive in equine (hypsodont) CT than in brachydont teeth, with infoldings that develop in the enamel organ at this stage later becoming the infoldings of peripheral enamel (Latshaw 1987). Additionally, the enamel epithelium of incisors and maxillary CT invaginates at the site of the future occlusal surface to become precursors of the cup-like infundibula, whose purpose is to increase the length of protruding enamel ridging on the occlusal surface once in wear (Kilic 1995; Lowder & Mueller 1998).

At the molecular level, ectodermal cells of the internal dental epithelium's basal membrane induce cytodifferentiation of the underlying mesenchymal dental papilla cells, prompting them to rapidly enlarge into **odontoblasts** (Fortelius 1985; Dixon 1999). The ectodermal cells on the concave surface of the internal enamel epithelium are reciprocally stimulated by dentine secreted by these newly differentiated odontoblasts to become **ameloblasts**, responsible for future enamel synthesis (Ferguson 1990).

The first dentine layer is laid down along a basal membrane between the two newly differentiated cell layers of odontoblasts and ameloblasts at the late bell stage of dental development. Subsequent disintegration of the basal membrane is the stimulus for overlying external enamel epithelial cells to differentiate into ameloblasts and then begin enamel production (Eisenmann 1998; Ten Cate 1998a).

Migrating away from an initially structureless enamel layer, the ameloblasts develop projections termed **Tomes' processes** at their distal surface that are responsible for secretion of both interprismatic enamel and enamel prisms (Suga 1979; Eisenmann 1998). The first radiographic signs of these mineralised stages of equine dentogenesis may be detected as early as 138 days into gestation and this mineralisation has been reported as complete in the deciduous equine CT by 240 days (Baker 1982; Soana et al. 1999)

Once the enamel layer within a dental crown has reached a genetically predetermined size and shape, the cells of the epithelial root sheath (formerly external and internal epithelial cells) break down and no further enamel will be produced, following what may be regarded as apoptosis (programmed cell death) of ameloblasts (Latshaw 1987; Eisenmann 1998; Ten Cate 1998c). Although death of the ameloblasts renders enamel non-vital and insensitive, with no means to repair or regenerate (in contrast to dentine and cementum), it is not completely inert as it still remains ionically active once exposed to the oral cavity – a feature that can predispose it to carious attack and partial remineralisation following such attacks (Ten Cate 1998d).

During dentine production (**dentinogenesis**), as the odontoblasts migrate into the former pulp cavities, their basal aspects become thinner, gradually forming long, thin, odontoblast processes that in turn secrete their own dentine matrix. Eventually these odontoblast processes become encased within their own **dentinal tubule**, whilst the cell body remains adhered to the pulp chamber wall. Histological images of fully formed dentinal tubules are present in Section 4.3.

Direct contact between dentine and the cells of the dental sac, at an area termed the **cemento-dentinal junction** triggers the mesenchymal cells of the dental sac to locally differentiate into **cementoblasts**. These cells will then produce cementum over the enamel surface prior to the tooth's eruption, and latterly assist the formation of the true roots (a region with no enamel present) (Brescia 1966; Warshawsky 1983). In horses,

cementum production begins at *circa* 210 days gestation (Baker 1985). The deposition of infundibular cementum is discussed in depth in Section 2.7.3.

As mentioned previously, calcification of the deciduous CT has been reported to be complete radiographically by 240 days gestation in horses. Permanent tooth buds remain dormant until the supporting bones have developed to a sufficient size for their development, with mineralisation of the first permanent tooth (1<sup>st</sup> molar or 4<sup>th</sup> CT) beginning around six months after the formation of deciduous CT is complete (Baker 1979a).

## 2.5 Mineralisation

As mentioned previously, the equine dental germ has been identified radiographically at 138 days gestation in equine foetuses (Soana et al. 1999). Even though their final structural forms may be quite different, there are many common features associated with mineralisation of all mammalian calcified tissues – be they enamel, dentine, cementum or bone (Ten Cate 1998d), although many of the mechanisms for such mineralisation remain unknown.

The development of enamel, cement and dentine occurs in two consecutive phases – the secretion of an extracellular matrix of mucopolysaccharides and organic fibres, and their subsequent mineralisation (Eisenmann 1998; Ten Cate 1998a; Ten Cate 1998d). For dentine and cementum, the fibre component within the organic matrix is principally type-1 collagen, while enamel contains a distinct family of enamel proteins, containing some collagen (Ten Cate 1998d). The synthesis of enamel matrix from rough-surfaced endoplasmic reticulum, through the Golgi apparatus and secretory granules into enamel has been demonstrated using autoradiography (Frank 1970; Slavkin et al. 1976).

In summary, the formation of enamel, dentine and cementum involves the secretion of an organic matrix by ameloblasts, odontoblasts and cementoblasts respectively. This matrix

is capable of accepting mineral - principally calcium hydroxyapatite ( $\text{Ca}_{10}(\text{PO}_4)_6(\text{OH}_2)$ ), aided by the action of the **alkaline phosphatase** enzyme family (Ten Cate 1998d).

Alkaline phosphatase is deeply involved in the production of any mineralised tissue, being found in the blood vessels and cell membranes of hard-tissue forming cells and also in the organic matrix (Ten Cate 1998d). 'Alkaline phosphatase' is a family of enzymes all of which act by cleaving phosphate ions from organic substrates in an alkaline pH. An unknown number of functions in the mineralisation of hard tissues may be attributed to this group.

The progressive attrition of equine teeth at a rate of *circa* 2-3 mm/year necessitates the continued deposition of secondary dentine to prevent pulpal exposure. This metabolically demanding process means a significant blood supply must be prolonged to the dentinogenic zone of the pulp cavity well into a horse's life (Dixon & Copeland 1993). In contrast, the apical foramina that carry the pulpar blood supply to brachydont teeth are narrowed by dentine deposition within the pulp canal, restricting maximal blood vessel diameter at a relatively early stage of the tooth's life (Berkovitz & Moxham 1981). If appropriately stimulated, odontoblasts may produce dentine throughout their lifespan (Fawcett 1987; Ten Cate 1998a).

Subgingival cementum is nourished by the periodontium and soon after this vascular supply is lost, following its eruption as clinical crown, cementum may be considered an inert tissue (Mitchell 2004). Within the alveolus and more especially in the sub-gingival region immediately above the alveolus, cementum is deposited throughout the life of the tooth, and cementoblasts can respond quickly to harmful stimuli with further rapid deposition (Jones 1981; Mitchell 2004).

## 2.6 Gross Anatomy

All domesticated mammals are **diphyodont** i.e. have two sets of teeth – one of which is termed deciduous (primary or temporary) and the other permanent (or secondary) (Noden

& DeLahunta 1985). **Elodont** teeth grow throughout the animal's lifetime, as opposed to **anelodont** teeth that have a limited growth period. Anelodont teeth are further subdivided into hypsodont (high-crowned) or brachydont (short-crowned) types. The horse has hypsodont teeth, although the vestigial first pre-molar may be anatomically considered as brachydont.

Adult equids have four basic types of teeth: incisors, canines, premolars and molars although both equine CT types (premolar and molar) have evolved to be similar anatomically (i.e. termed **molarisation** of the premolars). Their arrangement in a rostro-caudal direction in upper and lower arcades is shown in Figure 2.1 and is summarised with the following dental formula:

Equine dental formula:      Deciduous  $I_d$  3/3,  $C_d$  0/0,  $P_d$  3/3  
   Permanent I 3/3, C 0-1/0-1, P 3-4/3, M 3/3

It can be seen that there are a total of 24 deciduous and 36-44 permanent teeth. This latter variability arises from the irregular presence of the canine teeth in females, and the first premolar ('**wolf tooth**') in either gender. Colyer noted canine teeth to be present in 28% of 173 mare skulls, but only 6% had all four canines present (Miles & Grigson 1990).

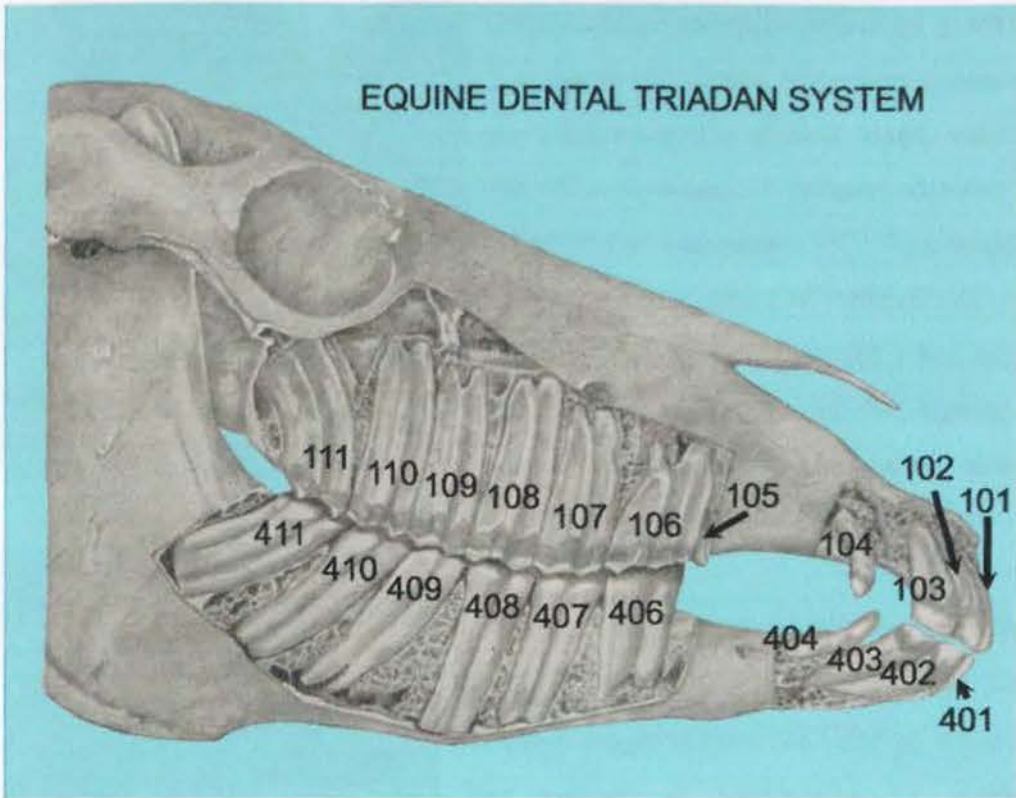
In the same 1906 study, Colyer found 16% of all 484 skulls examined to have 1<sup>st</sup> premolars present. This compares favourably with 13% incidence reported in another UK study (Baker 1979a). A study in Ireland however noted 28% of 355 skulls collected from an abattoir to have wolf teeth present, including 50% of all pony skulls (Wafa 1988). It is possible that some of the skulls in the above UK studies had their first premolars removed by natural or surgical means prior to post-mortem examination.

The use of traditional equine dental nomenclature may result in confusion (e.g. the 'first cheek tooth' may refer to either the 1<sup>st</sup> or 2<sup>nd</sup> premolar, while the '3<sup>rd</sup> molar', may be either the 4<sup>th</sup> premolar or the 6<sup>th</sup> cheek tooth). Likewise, clinical dental records may be

similarly inaccurate (Foster 1996). The introduction of the '**Modified Triadan**' system (adapted from human dentistry) for use in horses gave equine dental professionals a system of nomenclature to avoid such ambiguity (Floyd 1991; Foster 1996).

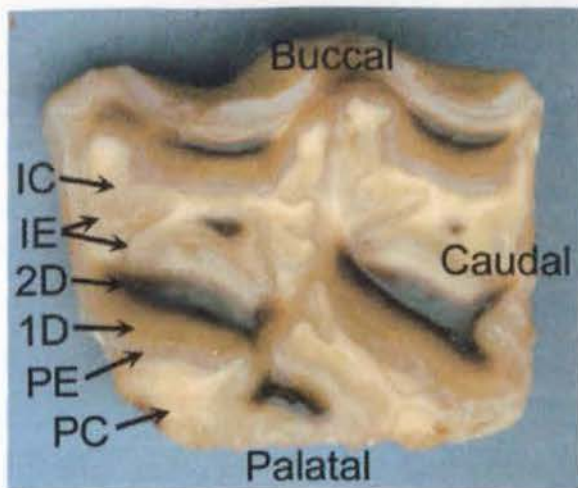
In the Triadan system, the teeth in each quadrant are numbered from one to eleven in a rostro-caudal direction. This number is preceded by a number (one to four) representing the quadrant the tooth is located in, with the horse's upper right dental quadrant being 'quadrant 1' (with the observer facing the horse) and with others following in a clockwise manner (Figure 2.3). For deciduous teeth, the quadrants are numbered from five to eight. This system is used whenever appropriate hereafter in this thesis.

In younger (4-8 year old) horses, the caudal 3-4 maxillary CT (Triadan 108-111, 208-211) have much of their reserve crown embedded in the rostral and caudal maxillary sinuses (Dixon 1999). The exact relationship between these teeth and their adjacent sinus was originally thought to follow the 'rule of two' with 106-107 and 206-207 not being within any sinus; 108-109 and 208-209 being within the rostral maxillary sinus and 110-111 and 210-211 being within the caudal maxillary sinus. Recent studies have shown this relationship to be much more variable (Perkins 2001). As these teeth erupt into the oral cavity, the residual sinus cavities increase in volume. This relationship has relevance when considering clinical signs of maxillary CT apical abscess formation as discussed in Section 2.9.3.3.

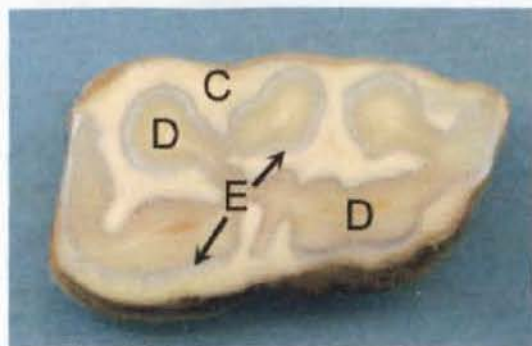


**Figure 2.3:** The right side of an equine skull identifying teeth by their Triadan position.

As discussed in Section 2.4, infoldings in the enamel organ during dentogenesis result in extensive enamel folding in mature equine teeth. These enamel folds are supported by dentine deposited on their inner surface and by cementum on their external aspects (Miles & Grigson 1990; Kilic 1995;). This folding arrangement is further enhanced in the maxillary CT by the presence of two infundibula (which have been described by Getty (1975) as to make the occlusal surface of these CT appear as a Gothic letter 'B'), with the infundibular cemental lakes lying within the two halves of the letter (Baker 1991a) (Figure 2.4). Mandibular CT have more infolding of their peripheral enamel than maxillary CT in compensation for having no such infundibula (Figure 2.5). Incisors have one short infundibulum present and no peripheral enamel folding (Muylle et al. 1999a).



**Figure 2.4:** Occlusal surface of a maxillary CT. Areas of stained secondary dentine (2D) are present in five distinct areas, surrounded by paler non-stained primary dentine (1D). Infundibular cementum (IC) lies within the two continuous rings of infundibula enamel (IE). Peripheral cementum (PC) lies outside a continuous ring of peripheral enamel (PE) where this has not been worn away by interdental attrition.



**Figure 2.5:** Sub-occlusal (section 2) transverse section of a mandibular CT. Dentine (D) lies within a single continuous band of enamel (E). The enamel is surrounded by supporting peripheral cementum (C).

Despite the lack of a distinctive 'neck' (due to prolonged tooth eruption) as commonly occurs in brachydont teeth, the hypsodont equine tooth is divided into **crown** (coronal) and **apical** regions. At the start of eruption, equine hypsodont teeth do not have **true roots** – being defined as an enamel-free area lying apical to the enamel-bearing crown (DeLahunta & Habel 1986; Miles & Grigson 1990). Once developed, the root will contain cementum, dentine and pulp (Figure 2.6). The crown may be categorised as either **clinical** crown (i.e. it has erupted into the oral cavity) or **reserve** (unerupted) crown. Reserve crown has recently been sub-divided into **gingival** and **alveolar** crown, with the more active cementum deposition occurring at the former site (Mitchell 2004). Muylle et al. complicate this nomenclature by referring to both a 'clinical root' and 'reserve crown' as being that part of the tooth embedded in a bony alveolus (Muylle et al. 1999a).



**Figure 2.6:** Longitudinal section in the bucco-palatal plane of a maxillary CT embedded in resin. The clinical crown (coloured yellow) lies beyond the gingival margin, within the oral cavity. In this young tooth the majority of the tooth is present as reserve crown extending from the clinical crown to the enamel-free, root area (coloured pink) as indicated by the red arrow. Pulp chambers 1 and 3 (numbered) extend occlusally from a common pulp chamber (C) and still contain pulp although this has become artefactually dehydrated and shrunk. The rostral infundibulum (I) extends apically from the occlusal surface.

### 2.6.1 Blood Supply

During early dentogenesis, the tooth is nourished from the blood supply of the dental sac (Dixon 1999). When the mineralisation of the enamel layer is complete, a vascularly impermeable barrier is placed between the developing external **periodontium** (Section 2.6.3) and the internal **dentino-pulpal complex** (Section 2.7.1) by the 'enamel shell'.

Little is known about the mechanisms of development of vascularisation and innervation to the periodontium. However, the highly vascularised periodontal ligament (PDL) later carries the blood supply to the cementoblasts that are responsible for future cementum deposition (Ten Cate 1998b). Its highly vascularised nature indicates the high nutritive demands of the cells contained within and adjacent to the PDL. In turn, the main PDL blood supply is from **alveolar arteries** that pursue an intra-osteal course, giving off alveolar branches that ascend within the bone as **interalveolar arteries**. Numerous branches arise from these vessels, termed perforating **arteries** in man (Freeman 1998) and run horizontally into the PDL space. Thereafter, vessels course in an apical-occlusal

direction with many transverse connections. Fenestrated capillaries are the terminal branching of these arteries before venous drainage is achieved by an apically directed network of venules. Lymphatic vessels tend to follow this periodontal venous drainage.

The blood supply to the dentino-pulpal complex arises from arteries entering through the tooth's apical region, which remains dilated (open) for much longer periods in hypsodont than brachydont teeth (Bishop & Boyde 1986; Dixon 1999). After entering the pulp, these arteries soon lose most of their muscular wall, becoming arterioles. Sensory and sympathetic nerves, and the draining venules usually accompany them at the apex, forming triad bundles (Jones 1990; Torneck 1998). In brachydont teeth, the number, size and distribution of these pulpar vessels varies both between individuals, individual teeth, and also changes with time throughout the life of the individual tooth. The passage of these arterioles through human pulpar tissue is disputed, with Hayward (1981) stating they proceed coronally along the periphery of the pulp while Torneck records their passage to be more centrally in the pulp (Torneck 1998).

Additional blood vessels enter the pulp laterally through small accessory canals in the root region of brachydont teeth, and such canals have recently been identified in equine incisors (Klugh 2003). It has not yet been identified whether nerves are also present within these accessory equine incisor canals, but nerves are absent at these sites in man (Jones 1990). The arterioles divide into pulpar capillaries, and the capillary blood drains into an extensive venous network, with the pulpar venules exiting the tooth following a much more tortuous path than their arteriole counterparts (Jones 1990).

Microcirculation studies of equine dental pulp have not yet been carried out, however studies in rats and dogs indicate that pulpal haemodynamics are regulated significantly by the sympathetic adrenergic system (Kim et al. 1989).

## 2.6.2 Innervation

In brachydont teeth, sensory pulpar nerves branching from the trigeminal nerve (5<sup>th</sup> cranial nerve) are found mainly in coronal dentine where they form the Plexus of Raschkow (Torneck 1998). Branches of the cervical ganglion (sympathetic) trunk innervate vascular smooth muscle to regulate pulpar blood flow (Hayward 1981; Torneck 1998). The actual mechanisms of periodontal and dentine sensation are discussed more fully in Sections 2.6.3 and 2.7.1.

## 2.6.3 Periodontium

The **periodontium** is defined as the supporting (peripheral cementum, periodontal ligament and dental alveolar bone) and investing (gingiva adjacent to the tooth) tissues surrounding teeth (Freeman 1998). **Cementum**, which is discussed in its own right in Section 2.7.3, also plays an integral role within the periodontium.

The **periodontal ligament** (PDL) lies between the peripheral cementum and alveolar bone. In man it is *circa* 0.2mm in thickness and shows a progressive thinning with age (Freeman 1998). Its principal functions are to support the tooth within the alveolar socket, flexibly attaching it to the surrounding bone and allowing it to withstand the considerable masticatory forces. It also acts as a sensory receptor – necessary for positioning of the jaws during mastication (Bonte et al. 1993).

Although inter-species differences have been reported, an anatomically similar pattern for PDL innervation is seen in many species, with periodontal fibres running occlusally from the apical region, being joined by fibres entering laterally through foramina in the alveolar wall (Byers & Holland 1977; Linden 1990; Freeman 1998). Four types of neural terminations have now been described in the PDL, with the most common having free nerve endings that end in a branch-like configuration and are thought to have both nociceptive and mechanoreceptor functions (Freeman 1998). Only one type of periodontal mechanoreceptor is present in the cat, and that receptor response is variable, depending

upon receptor position within the PDL (Linden & Millar 1988). In human beings, oral tactile sensibility is 60 times more sensitive when biting than chewing (Owall & Moller 1974). This is assumed to be caused by adaptation of mechanoreceptors situated in the periodontal membranes and mucosa, and modulation of the input from these receptors. No studies on PDL sensitivity have been carried out in the horse.

As with other connective tissues, the PDL consists of cells (principally **fibroblasts** with some undifferentiated mesenchymal cells and remnant epithelial cells), and an extracellular matrix of fibres and ground substance (Freeman & Ten Cate 1971; Ten Cate et al. 1976). Additional cells such as **cementoblasts** (cementum producing cells) and **osteoblasts** (bone producing cells) whilst technically within the PDL are considered with the hard tissues that they form (Section 2.7.3).

In human beings a mixture of **type-I and III collagen fibre bundles** dominate the PDL extracellular matrix, with their fibre diameters considerably smaller than that found in most human tendons or ligaments (50nm c.f.100-150nm) (Freeman 1998). This is thought to reflect the rapid turnover of such fibres, with little time for continuous assembly. Their appearance is that of spliced rope and in the human PDL, fibres are arranged into five anatomical groupings dependent on position. The embedded aspect of any PDL fibre that inserts into cementum is termed a **Sharpey fibre** (Jones 1981; Baker 1991a; Kilic et al. 1997d). These may be fully or partially mineralised. The formation and contraction of these fibres within the periodontium has been proposed as the most likely mechanism for dental eruption (Ten Cate 1998e).

**Alveolar bone** (or process) is the bone within the jaws that helps to retain the teeth. It consists of an outer cortical bone plate (associated with the maxilla or mandible); central trabecular or 'spongy' bone; and dense bone lining the alveolus, referred to as the 'cribiform plate', 'bundle bone', or the *lamina dentis dura* in human and veterinary dental radiology (Dixon & Copeland 1993; Gorrel 1998) and it is here that fibres of the PDL insert (Ten Cate 1998e).

## 2.6.4 Endodontic System

Baker (1970) reported the upper (cheek) teeth pulp cavity to have five main divisions within the folds of enamel and the lower (cheek) teeth to have two main divisions. Subsequent computer assisted tomography with examination of corresponding sections of some mandibular CT (Triadan 307-310 & 407-410) provided some further information of equine endodontic anatomy, high-lighting its complexity and variability with age (Kirkland et al. 1996) (Figures 3.5 & 3.6).

Equine incisors, canines and 'wolf teeth' have been reported to contain a single simple pulp chamber (Dixon et al. 1999a; Muylle et al. 2000a).

## 2.7 Histological Findings on Equine Dentition

The technical process of making histological dental sections is discussed fully in Chapter 3. To date, there has been limited work on the histology of equine dental tissues as evidenced by the sparse literature on this subject (Kilic 1995).

Decalcified human dental histological sections are routinely cut to *circa* 4-5 $\mu$ m thick, and undecalcified sections to 40-50 $\mu$ m thick, although more recently, sections containing both hard and soft tissues have been sectioned to 100 $\mu$ m thickness (Fawcett 1987). In human dental histology it is normal to examine both decalcified and undecalcified histological dental sections, as detailed examination of enamel features such as caries are best observed in undecalcified 'ground' sections - as being 98% mineral, enamel's structure becomes unrecognisable or completely absent in decalcified sections (Section 4.3). In contrast, features such as the true relationship of the dentino-pulpar complex are more readily observed in the thinner decalcified sections where soft tissue structure is preserved (Eisenmann 1998; Ten Cate 1998a; Ten Cate 1998c; Ten Cate 1998d; Ten Cate 1998g; Torneck 1998).

Previous attempts at equine dental histology have been made by two distinct groups of researchers. Since the 19<sup>th</sup> century, archaeologists have examined fossilised dental remnants in a field termed ‘**skeletochronology**’ (Coy et al. 1982; Hillson 1986). Cementum and dentine are both laid down progressively throughout the life of a tooth and may record events (physiological or pathological) that occur during the animals life (Coy et al. 1982). By examining bone or dental cementum **growth zones** (relatively thick, opaque layers of isotropic ‘summer’ or active cementum growth), **annuli** (narrower anisotropic bands of relatively translucent cementum deposited during periods of slow growth) and **lines of arrested growth (LAGs)** (thin chromophile discontinuities or ‘**resting lines**’ where cementum or bone growth has been completely stopped) the season of the animal’s death may be calculated, as well as its age (Peabody 1961; Castanet 1980).

More recently, histological sections of fossilised equine teeth have been compared with those of contemporary horses (Burke & Castanet 1995). Decalcified sections were cut to 18µm thickness using a freezing microtome and undecalcified sections (using a procedure similar to that detailed in Chapter 3) were ground and polished to around 40µm thick. Unfortunately the ages of the modern (control) horses were unknown and so it was not possible to assess the reliability of skeletochronology for age determination in that study. The date of death however was known for the control animals and indicated that the rate of cementum deposition in these Northern Hemisphere horses had slowed in November, when intermittent annuli or LAGs were observed, and fully ceased from December-April. It was not statistically possible to use the final growth zone’s thickness to assess time of death, other than grouping the animal’s death to be either during the ‘warm’ or ‘cold’ season.

The second smaller group of researchers, i.e. equine dental histologists, consist of researchers who have examined the normal anatomy and pathology of contemporary equine teeth. There have been two significant equine dental histology studies to date. In his thesis ‘Dental disease in the horse’, Baker (1979a) prepared histological sections of

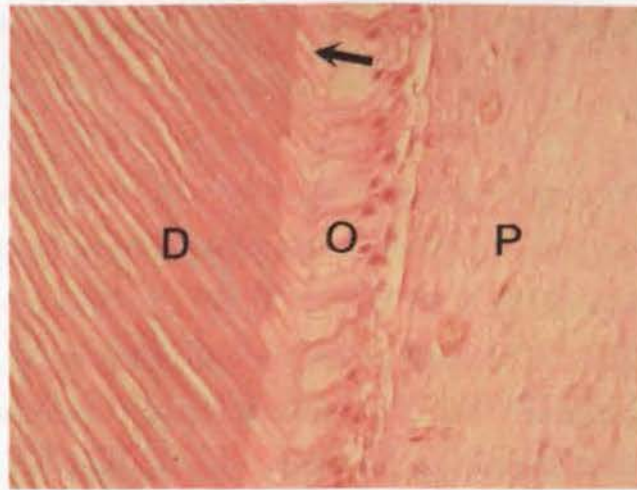
equine adult and foetal teeth, cutting sections 12µm thick in adult teeth, and 10µm in foetal dental material. Teeth taken from foetuses of less than 250 days gestation did not require decalcification.

In a later study 'A light and electron microscopic study of calcified dental tissues in normal horses' Kilic (1995) prepared both decalcified sections (10µm) and undecalcified sections (40-50µm) (see Section 3.8.1) of 50 normal teeth, including 46 CT and four incisors. This work and the four papers arising from it are the backbone to our current understanding of equine dental ultrastructure (Kilic et al. 1997a; Kilic et al. 1997b; Kilic et al. 1997c; Kilic et al. 1997d).

A third major contributor to the field of equine dental gross anatomy, histology and its ultrastructure is the Belgian anatomist Muylle, who has published over 10 papers on anatomical features of equine incisors during the past decade, including both light and electron microscopic studies (Muylle et al. 1999a; Muylle et al. 2000a; Muylle et al. 2000b; Muylle et al. 2001; Muylle et al. 2002).

### **2.7.1 Dentino-Pulpal Complex**

The dentino-pulpal complex is so termed because of the intricate association between the dental pulp and surrounding dentine (Jones 1990; Torneck 1998). The dental pulp consists of an intricate network of loose connective tissue supported on a fibrous skeleton containing blood vessels, lymphatics and nerves that enter and exit at the dental apex. The outermost layer of pulp consists of odontoblast cells, responsible for continuous dentine production, which begins immediately before the formation of the enamel 'scaffolding' within the dental sac, and continues throughout the life of the equine tooth (Ferguson 1990) (Figure 2.7).



**Figure 2.7:** Decalcified transverse section from a control CT showing odontoblast cells (O) withdrawing towards the centre of the pulp (P) whilst laying down a secretory matrix of predentine, i.e. the paler staining layer (←) adjacent to dentine (D). Odontoblast processes are present within the dentinal tubules. (H&E x400)

Odontoblast cells leave long tubular odontoblast processes within the dentine (dentinal tubules) as they retreat centrally into the pulp, with progressive deposition of dentine by these structures (Kilic et al. 1997c; Lowder & Mueller 1998; Muylle et al. 2001). Equine odontoblast processes extend horizontally to the amelodentinal junction and vertically to the occlusal surface of equine teeth (Kilic et al. 1997b; Kilic et al. 1997c). It is believed that odontoblast processes may transmit normal (physiological) stimuli from the occlusal or interproximal surfaces via changes in fluid pressure within the dentinal tubule and that this can regulate the rate of dentine deposition in the underlying pulp or transmit noxious stimuli (e.g. from physical, chemical or thermal trauma or caries) to initiate tertiary dentine production (Kempson et al. 2003).

### 2.7.1.1 Classification of Equine Dentine

There is some confusion concerning the classification of human dentine as being either primary, secondary or tertiary. Ten Cate (1998a) describes primary dentine as the dentine laid down until the external form of the tooth is completed, with secondary dentine being

laid down thereafter. Torneck (1998) however defines secondary dentine as that which develops after root formation has been completed.

Neither of these definitions are applicable to equine (hypsodont) teeth, with their prolonged deposition of peripheral cementum on the reserve crown and roots (Kirkland et al. 1996), thereby changing the external shape of the tooth (especially its apical aspect) throughout its life, possibly for up to 40 years (Dixon 1999). When discussing equine dentition it may therefore be most accurate to use a third definition of secondary dentine, which defines it as the dentine which is deposited once a tooth is in full occlusal contact (Kierdorf & Kierdorf 1992).

In equine **primary** dentine, the odontoblast processes are surrounded by dentinal tubules, which are filled with peritubular dentine (more precisely called **intratubular** dentine), the latter being present only in primary dentine (Figure 4.1) (Kilic et al. 1997c; Muylle et al. 2001). As intratubular dentine confers resistance to wear, it is unclear why it should be absent from secondary dentine. The mechanism of intratubular dentine formation is not currently understood. A thin layer of **intertubular** dentine (that has a honeycomb appearance when phosphoric acid-etched sections are viewed by scanning electron microscopy) in turn surrounds the intratubular dentine.

**Mantle** dentine is formed immediately following the differentiation of mesenchymal cells into odontoblasts. As it is the first dentine laid down by the tooth, it lacks the structural identity of regular primary or secondary dentine (Ten Cate 1998a; Torneck 1998). Instead, the first dental collagen secreted by the odontoblasts is secreted into the ground matrix of the dental papilla and these fibres are oriented almost parallel to the dentinal tubules that end in this mantle dentine. In man, mantle dentine is 10-15µm thick (Shellis 1981) but this value has yet to be established for equine teeth.

**Secondary** dentine is classified as being either **regular** or **irregular**, with irregular secondary dentine also being referred to as reparative, reactive or tertiary dentine (Kilic et

al. 1997c). Following dental eruption, regular secondary dentine is laid down by odontoblasts throughout most of the life of the tooth, with the odontoblast cells withdrawing centripetally (towards the centre of the pulp) from the previously laid down primary dentine (Figure 2.7). Secondary dentine is continuous with primary dentine, sharing the same odontoblast process within a continuation of the same dentinal tubule. Under normal circumstances, both in brachydont and hypsodont teeth, 'regular' secondary dentine will be laid down within the pulp chamber by the odontoblasts until the pulp chamber is almost completely occluded (Figure 4.2).

Irregular secondary (reparative, reactive or tertiary) equine dentine has previously been classified as being laid down in response to noxious stimuli (Muyllé et al. 2002). However this current work has shown irregular secondary dentine to be present in all (n=100) grossly normal equine teeth examined, with no evidence of prior exposure to noxious stimuli (Section 4.3). This secondary irregular dentine is laid down in the most central part of the pulp horn when this region is undergoing its final physiological stage of pulp replacement by dentine (Figures 4.4 and 4.6). The continued formation of both regular and irregular secondary dentine prevents pulpar exposure on the occlusal surface.

**Tertiary** (otherwise termed reactive or reparative) dentine is laid down **focally**, in response to specific local noxious stimuli (Ten Cate 1998a) (Figure 4.8). It may have some tubules that are continuous with those of secondary dentine; tubules that are sparse or distorted; or no tubules at all (Torneck 1998). Cells may be trapped within this rapidly laid down tissue and this type of dentine is termed **osteodentine**. Tertiary dentine may be further subdivided into reactionary or reparative dentine, with the former being laid down by pre-existing odontoblasts and the latter by newly differentiated odontoblast-like cells from within the pulp.

Where areas of dentine have failed to mineralise sufficiently, **interglobular** dentine will occur (Figure: 4.16). Being a failure of mineralisation rather than of matrix formation, the normal architectural pattern of the dentinal tubules is present, running through zones

where the globular calcospherites have failed to fuse into a homogenous mass within the maturing dentine. Interglobular dentine is thought to arise in human teeth due to vitamin D deficiency or following exposure to high fluoride levels at time of dentine formation (Torneck 1998).

**Sclerotic** dentine is formed when dentinal tubules become occluded with calcified material. The degree of dentinal sclerosis increases with age in human teeth that have no clearly identifiable external stimuli for this process, and this occlusion occurs by several different mechanisms. In horses, where dentine is exposed on the occlusal surface, we would expect the presence of a high degree of dentinal sclerosis to prevent bacterial invasion down such exposed dentinal tubules. Kilic (1995) and Kempson *et al.* (2003) demonstrated the presence of large numbers of odontoblast processes on the occlusal surface of equine dentine. It was suggested by Kilic that these processes were calcified (i.e. sclerotic remnants of odontoblast processes) however more recent work by Kempson *et al.* suggested there were viable odontoblast processes present at this site following recent dental rasping.

The presence of open dentinal tubules and odontoblast processes on the occlusal surface has been proposed to be part of a sensory mechanism to limit the stress applied to teeth (with fluid movement within dentine during tooth compression stimulating pulpar baroreceptors) and thus helping to facilitate discrimination of particle hardness during mastication (Paphangkorakit & Osborn 2000). This process was previously believed to be principally regulated via mechanoreceptors within the periodontal ligament.

Dentine is a sensitive tissue, and in a comparison of 40 contra-lateral pairs of human teeth, wet dentine exposed through grinding was found to be much less sensitive than recently exposed fractured dentine, or dentine that became dehydrated on exposure to air (Johnson & Brannstrom 1974). This, in part, may explain the absence of obvious pain during mastication in horses that have large areas of exposed dentine on their teeth.

As noted, numerous **incremental lines** are present in human dentine (as well as in enamel and cement) indicating the phasic nature of dental mineral deposition (Ten Cate 1998d). These lines may be seen on light microscopy of undecalcified (ground) and decalcified dental sections, reflecting their presence in both mineralised and matrix components respectively, in these hard tissues. A **neonatal line** occurs in human dentine reflecting stress on dentine production around the time of birth. Similar lines occur following febrile diseases in childhood. Such heamatoxyphilic lines in bone are found to contain less calcium and phosphate, but more sulphur than the surrounding bone.

**Reversal lines** are also seen in cementum and bone (but not in dentine or enamel - as these two tissues do not remodel) indicating a change from mineral deposition to resorption. Resting, reversal and incremental lines in dentine and cementum have been observed in equine dental histological sections, however their presence is not constant and not yet fully understood (Figure 4.4), despite their long-term use as archaeological tools for assessing factors such as seasonality of death in fossilised equine remains (Section 2.7).

Young equine teeth have minimal dentine but a large pulp cavity and blood supply, while old (>20 years old) teeth have little or no pulp cavity remaining, the pulp having been progressively replaced with dentine, with a corresponding decrease in pulp volume. Consequently dentine makes up the largest proportion of the dental tissues in older horses (Kilic et al. 1997c; Dixon 1999; Muylle et al. 1999b).

## **2.7.2 Enamel**

Enamel is the hardest substance in the body but is also very brittle (Kilic et al. 1997b). In both brachydont and hypsodont teeth it consists of 95-98% mineral by weight, being mainly composed of calcium hydroxyapatite [ $\text{Ca}_{10}(\text{PO}_4)_6(\text{OH}_2)$ ] crystals, although minute quantities of other (inorganic) salts are found within its matrix. In contrast however, Robinson *et al.* (Robinson et al. 1988) found mature enamel in deciduous bovine incisors

to contain 2-3% protein, 70-80% mineral and 20-30% water when they related both mineral and organic matrix concentrations to tissue volume, rather than to tissue weight.

### **2.7.2.1 Classification of Equine Enamel**

Enamel is the first of the calcified tissues to become mineralised (by ameloblasts) and Kilic *et al.* (1997b) defined three types of equine enamel according to the transverse appearances of their enamel prisms and the presence, amount and appearance of their interprismatic enamel.

Equine Type-1 enamel contains alternating rows of oval-shaped prisms and thick interprismatic enamel plates, and is found adjacent to amelodontal junctions. Equine Type-2 enamel consists of 'keyhole' to 'horseshoe' shaped prisms with little or no interprismatic enamel and is located adjacent to the amelocemental junctions. Three-dimensional prism decussation (interweaving) is present in equine Type-2 enamel, which is the main type of enamel in equine incisors. This makes it much more resistant to cracking and fracture than equine Type-1 enamel (Pfretzschner 1992; Rensberger 1992; Kilic *et al.* 1997b). Greater amounts of equine Type-1 enamel are present in maxillary than mandibular CT, with equine Type-2 enamel dominating mandibular CT.

Equine Type-3 enamel is inconsistently present as a thin layer at both the amelodontal and amelocemental junctions, where its interprismatic enamel forms a honeycomb like structure, with each 'cell' occupied by an oval shaped prism. It is less highly evolved than equine Type-1 and 2 enamel (Kilic *et al.* 1997b).

### **2.7.3 Cementum**

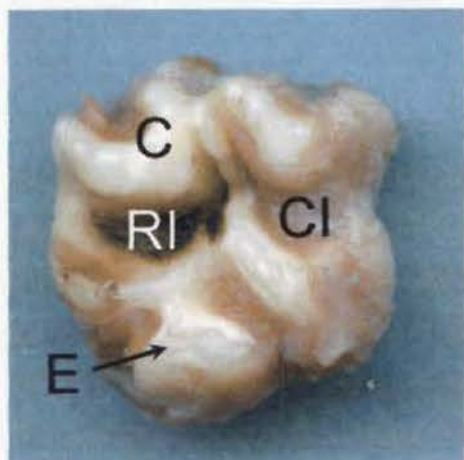
Cementum is the softest of the three calcified dental tissues, being approximately 65% mineral, 35% organic, with calcium hydroxyapatite crystals being the principle mineral present (Kilic *et al.* 1997d; Ten Cate 1998d). Irregularly spaced lacunae are found in both peripheral and infundibular cement, having a larger diameter in infundibular cement, yet having the same density (lacunae/unit area) in both areas (Kilic *et al.* 1997d). Peripheral

cement is deposited both directly and indirectly onto resorbed and unresorbed enamel, with a thin calcified layer interposed in areas of indirect mineralisation.

Cementum (cement) is a specialised calcified connective tissue that provides anchorage for the fibres of the periodontal ligament and also a means for dental eruption in both brachydont and hypsodont teeth. It's higher organic and water content confers some flexibility (like dentine) allowing it to give necessary support to the brittle adjacent enamel. In all horses (particularly as they become older), cementum also significantly structurally contributes to the size and strength of the crown and roots (Kilic et al. 1997d; Mitchell 2004).

### 2.7.3.1 Classification of Equine Cementum

Once the thin cemental covering is worn from the occlusal surface of hypsodont teeth, exposing the **secondary occlusal surface**, equine cementum may be grossly classified as being either peripheral or infundibular (Kilic 1995) (Figure 2.8 c.f. Figure 2.4).



**Figure 2.8:** The primary occlusal surface of a maxillary CT. The caudal infundibulum (CI) still has soft tissue present within its crypt, however food has already become impacted within the rostral infundibulum (RI). A thin layer of cementum (C) covers most of the exposed CT surface. However, where the tooth has come partially into occlusal wear, enamel (E) is already showing.

Cementum can be classified on three levels namely:

1. Time of formation, being either primary or secondary (c.f. dentine formation)
2. Presence or absence of cells within its matrix i.e. being either acellular or cellular

3. Whether fibres within the matrix are intrinsic (resulting from cementoblast deposition) or extrinsic (i.e. Sharpey's fibres incorporated from the PDL)

This results in five categories of cementum (Freeman 1998):

1. Primary acellular intrinsic fibre cementum
2. Primary cellular extrinsic fibre cementum
3. Secondary cellular intrinsic fibre cementum
4. Secondary cellular mixed fibre cementum
5. Acellular afibrillar cementum

Under polarised light, undecalcified (ground) transverse sections of equine CT show two distinct regions to be present in peripheral cementum. Adjacent to the peripheral amelocemental junction, the crystalloid nature of the cementum is observed to be irregular in hydroxyapatite crystal orientation. This is similar to maxillary CT infundibular cement. Beyond this, its nature changes to become regular, with crystals having a similar concentric orientation. It is in this zone that 'peripheral lines' may be observed in decalcified transverse sections. These two zones of regular and irregular peripheral cementum are more pronounced near the occlusal surface in sections of older teeth.

## 2.8 Age Related Changes

In 1873 Mayhew wrote **"by the time recognised as 'aged' in the equine species, the indications of the teeth do no more than tempt a guess."** The estimation of a horse's age by examination of the incisors has been well documented, with more recent studies agreeing with those comments of Mayhew over a century previously (Galvayne 1912; Mayhew 1873; ;Walmsley 1993; Richardson et al. 1994; Richardson et al. 1995a; Richardson et al. 1995b; Muylle et al. 1996; Muylle et al. 1999a;).

In one such study, age-related morphological characteristics were investigated in 948 equine incisors (Muylle et al. 1999a). They identified maximal length to occur at 2-3 years post-eruption, which was then maintained until the horses were 15-20 years old or even older. Muylle *et al.* suggest that incisor root formation is completed by 15-17 years

of age. This contrasts with the figures of 10-12 years (van Foreest 1995), and of 8 years (Latshaw 1987). Equally confusing in CT, the period of dental development (i.e. continued tooth 'growth') has been reported to stop at 6 years (Barone 1997), 8 years (Levine 1982), 12-14 years (Schumacher & Honnas 1993) or at 2-8 years post – eruption (Kirkland et al. 1996).

Using computer assisted tomography (CAT) scans, Kirkland *et al.* (1996) imaged 48 hemimandibles from horses aged 2-9 years old, and determined that the cranial and caudal pulp chambers were distinct entities by 5-6 years post eruption. Ageing in this study was calculated by incisor table wear rather than by patient records.

Following eruption, the coronal enamel and cementum are quickly worn away, exposing dentine. This is termed the 'secondary occlusal surface' and represents the true functioning occlusal surface of a hypsodont tooth.

In the incisors of young (<5 years old) horses, before true root formation has begun, the apical foramen of Triadan 01s is large (25-35mm<sup>2</sup>) and has a true apical position. This contrasts with old (>17 years old) horses where the apical foramen is said to be 'dot-like' in appearance and located 5-15mm occlusally from the dental apex (Muylle et al. 1999a). In many species a number of age-related changes occur within the dental pulp, including the pulp becoming less cellular, with a decrease also in the number and size of its blood vessels and nerves (Torneck 1998). The most important change however is due to the reduction in size and volume of the pulp chamber due to the continued laying down of secondary or tertiary dentine (Ten Cate 1998f). As noted there is also a tendency for increasing dentinal sclerosis as the tooth ages i.e. where the dentinal tubules become filled with mineral deposits and this partly explains why the rate of dental wear decreases with age (Stanley et al. 1983; Kirkland 1994).

## 2.9 Dental Disease and Pathology

As noted in the introduction (Chapter 1), the horse was previously considered to have a relatively low incidence of dental disease compared with other species (Uhlinger 1987). However this assumption has been shown to be incorrect with dental disease prevalence estimates ranging from 8%-80% of the equine population (Baker 1979a; Honma et al. 1962; BEVA 1965; Uhlinger 1987; Wafa 1988; Kirkland et al. 1994).

### 2.9.1 Abnormalities of Dental Development and Eruption

Although a number of different dental abnormalities are often present concurrently and may be inter-related in their pathogenesis, it is useful to classify them as being either **developmental** or **acquired** in origin. Those termed developmental disorders are present at the time of tooth eruption, while acquired disorders develop subsequently (Baker 1999a; Dixon et al. 1999b). The presence of developmental dental disorders may predispose to acquired disorders that may cause more severe clinical disease.

#### 2.9.1.1 Developmental Conditions Arising Prior to Eruption

**Polyodontia** is the presence of supernumerary permanent teeth and is thought to arise from the splitting of dental buds during dentogenesis. In horses it most commonly results in a supernumerary 7<sup>th</sup> (caudal) maxillary CT, which may be **connated** (i.e. consists of one or more conjoined teeth – often near the roots) (Dixon et al. 1999b). This disorder must be differentiated from the more common disorder of retained deciduous teeth, in particular for incisors.

In 1906 Coyler found 12 of 484 skulls (3%) to contain supernumerary teeth (Miles & Grigson 1990). In a more recent study of referred dental disorders, 3% of horses with CT disorders and 9% of horses with incisor disorders had supernumerary teeth (Dixon et al. 1999a; Dixon et al. 1999b). In contrast, neither Wafa (1988) in a study of 355 skulls, or Baker (1979a) in a study of 121 skulls reported any cases of polyodontia.

In human beings, the congenital absence of teeth may be referred to as **hypodontia**, **anodontia** or **oligodontia**, and may be **partial** or **total** (Soames & Southam 1993c). In horses, the term hypodontia has not been widely used. The term anodontia technically refers to complete absence of dental development, which does not appear to have been reported in horses. Oligodontia, referring to the congenital absence of one or more teeth, has been reported relatively frequently in horses (Baker 1999a; Dixon et al. 1999b; Ramzan et al. 2001). Oligodontia arises from failure of a dental bud (or buds) to develop for ensuing dentogenesis. Oligodontia may be considered physiological (i.e. normal) when horses fail to develop the first pre-molar (Triadan 05; 'wolf teeth'), or when mares do not develop canine teeth.

The few reported cases of true equine oligodontia have involved absence of multiple teeth, with dental **dysplasia** (abnormal growth or development) being present in some or all of the teeth that did develop (Ramzan et al. 2001). Oligodontia may also be associated with other epidermal defects such as poor development of coat and hooves, indicating a primary enamel developmental disorder caused the oligodontia and dysplasia.

Stewart and Genetzky (1984) and Dubielzig *et al.* (1986) report that dental **dysplasia** (being a malformation or absence of tissue) has been rarely described in the horse. Dysplasia of dental tissues may result in an irregularly shaped tooth that does not fit well in the dental row, with a potential for food pocketing and periodontal disease (Stewart & Genetzky 1984; Dubielzig et al. 1986).

**Hypohidriotic ectodermal dysplasia** is the most common form of human ectodermal dysplasia and is characterised by varying degrees of oligodontia and dental dysplasia, together with decreased sweating (hypohidrosis) and decreased hair development (hypotrichosis) (Tape & Tye 1995). Coat changes have been reported in cases of both equine oligodontia and dental dysplasia, suggesting similarities between these two conditions (Ramzan et al. 2001). Hypohidriotic ectodermal dysplasia in man is an X-

linked, recessive trait and carrier females may be asymptomatic. It is unknown if the above congenital dental disorders reported in horses are hereditary.

**Hypoplasia** (a decreased amount of normal tissue) of equine dental tissues is most commonly recorded in infundibular cementum. **Central infundibular cemental hypoplasia** is the most common equine dental developmental disorder (Kilic et al. 1997d) but it is often not possible to establish its presence by examining the occlusal surface of a young tooth. Baker (1974) reported that 43% of infundibula in erupted teeth contain connective tissue remnants at their apex. This disorder has been incorrectly referred to as infundibular *necrosis* and infundibular *caries* (Section 2.9.3.4). The process whereby infundibular cemental hypoplasia progresses to result in an apical abscess is discussed under **infundibular caries** (Section 2.9.3.4).

All incisors and maxillary CT have some degree of infundibular cemental hypoplasia that may predispose to cemental caries (Baker 1999a). Traditional anatomy describes the blood supply to infundibular cementum as only entering through the occlusal surface, with an intact enamel cup preventing any collateral blood supply more apically. However, additional vascular supplies to cementum through the apical area of some infundibula have been reported in a small number of maxillary CT (Dr Jack Easley, personal communication 2002). However for the majority of maxillary CT, premature eruption, premature removal of the overlying protective deciduous teeth ('caps'), or an otherwise compromised infundibular blood supply (e.g. excessive deposition of infundibular cementum near the occlusal surface constricting the blood supply to cementocytes deeper within the infundibulum) may all be reasons for inadequate cementum deposition (Baker 1974; Baker 1982; Kilic et al. 1997d). The resultant defect in the 'hypoplastic' infundibular region is then prone to packing with food material from the oral cavity and subsequent cemental caries (Figure 2.8).

In an ultrastructural examination of 46 equine CT, Kilic *et al.* (1997d) reported two types of cemental hypoplasia. Sixty-five percent of maxillary CT examined had one or more vascular channels in their infundibular cement, and some of these were termed to have ‘central infundibular hypoplasia.’ The defects were often porous, with large vascular channels in recently erupted teeth often containing connective tissue remnants. The number of vascular channels in cement ranged from 650-1300/mm<sup>2</sup> in normal infundibular cement and 750-1700/mm<sup>2</sup> in hypoplastic infundibular cement. The second type of cemental defect was termed ‘junctional cemental hypoplasia’ that was found near the amelocemental junction (ACJ) of both peripheral and infundibular cement, but was believed to possibly be an artefact.

Cementocytes can deposit peripheral cementum throughout the life of a tooth while the cement remains within the dental alveolus or gingiva (Mitchell 2004). They can respond quickly to harmful stimuli with further rapid deposition of cement when appropriately stimulated (Jones 1981).

The disorder termed **peripheral cemental hypoplasia** had not been reported in horses prior to this present study (Dacre & Dixon 2002), and this disorder is discussed in Chapters 5 and 6.

**Enamel hypoplasia** has been identified grossly in equine teeth (Baker 1979a). The condition also results in defective coronal cementum which will usually be laid over the enamel, however the disorder is thought not to be of any clinical significance (Baker 1999a). Baker (1999a) proposed that teratogenic drugs may be responsible for the formation of hypoplastic enamel, or that its occurrence may be idiopathic.

### **2.9.1.2 Developmental Disorders Arising at Eruption**

It is now generally accepted that the PDL is responsible for tooth movement including eruption and shedding (Ten Cate 1998e). Becker (1939) categorised dental eruption into six phases namely:

- Stage I: preparatory stage (opening of the bony crypt)
- Stage II: migration of the tooth toward the oral epithelium
- Stage III: emergence of crown tip into the oral cavity (beginning of clinical eruption)
- Stage IV: first occlusal contact
- Stage V: full occlusal contact
- Stage VI: continuous eruption and movement

Abnormalities of eruption may be traumatic, genetic, viral or teratogenic in origin (Shafer et al. 1983c; Shafer et al. 1983d; Shafer et al. 1983f; Baker1999a). It is believed that when there is excessive rostro-caudal compression within an equine CT row, a permanent tooth may become vertically **impacted** between the two adjacent (deciduous or permanent) CT. This frequently involves the Triadan 07's and 08's, these being the last permanent CT to erupt (Miles & Grigson 1990; Dixon et al. 1999b). Dixon *et al* (1999a) noted that 23% (5/22) of cases referred with primary incisor disorders had retained deciduous teeth (i.e. **retained "caps"**).

Mild impaction of either the erupting permanent CT or retained deciduous CT remnants may result in **eruption cysts** ('3 or 4 year-old bumps') bilaterally on the ventral mandible or on the rostro-dorsal aspect of the maxilla (Baker 1999a; Dixon et al. 1999b). Baker (1970) proposed that retained deciduous CT caused faulty positioning of the underlying permanent tooth and subsequent lack of mechanical pressure to promote root resorption of the overlying temporary tooth.

If over-crowding of a CT is severe and it becomes further impacted, this may result in a more pronounced and often unilateral swelling that may become hot and painful (Dixon et al. 2000a). During this time, the tooth and associated region are hyperaemic which may predispose to an **anachoretic pulpitis** (Shafer et al. 1983e). This process can occur when bacteria, carried in either the blood stream or local lymphatic system, lodge within an area of pulp that is already compromised by being mildly inflamed or oedematous (Gutman & Harrison 1991; Soames & Southam 1993d).

A **diastema** (pl. diastemata) may be thought of as being the opposite of an impaction, being a space between two adjacent teeth (Barakzai & Dixon 2003; Carmalt 2003). Developmental diastema result from teeth either having insufficient angulation to achieve good compression between adjacent teeth, or because the embryonic teeth developed too far apart. Voss (1937) noted that horse teeth taper towards their apices, and as they continue to erupt, the occlusal surface reduces in size, with resulting potential for acquired diastemata. Equine diastema have been functionally termed as either ‘open’ when they do not trap food, or ‘closed’ (or valve) diastema when they do (Carmalt 2003). Diastemata were reported to be present in 1% of 30,000 military horses examined by Becker (1962), 4% in Wafa’s (1988) abattoir study of 355 equine skulls and most recently 19% of CT in 400 cases of referred dental disorders by Dixon *et al.* (1999b).

Teeth may also become rotated or otherwise **displaced** due to developmental malpositioning of dental buds, or due to overcrowding before, during or following eruption (Baker 1979a; Wafa 1988; Miles & Grigson 1990; Dixon *et al.* 1999b).

Dixon *et al.* (1999b) found 87% of displaced CT to have concurrent secondary periodontal disease. Two different mechanisms were thought to be involved in equine CT displacements, with all maxillary and 67% of mandibular CT displacements appearing to be developmental in aetiology (often due to overcrowding). The remaining 33% of mandibular cases were believed to be acquired, possibly due to abnormal occlusal pressures. Overall Triadan 309-310 and 409-410 mandibular CT were most frequently displaced, with 306-308 and 406-408 being least often displaced as they erupted into the space of their deciduous precursors.

Miles and Grigson (1990) noted premature loss of a deciduous tooth with subsequent crowding of the replacement tooth’s space might result in its displacement. Additionally damage to or absence of a deciduous tooth bud may result in the absence of the permanent tooth (Lowder & Mueller 1998). Non-eruption of displaced teeth is also

possible if they are sufficiently displaced in a horizontal direction (Becker 1962; Edwards 1993).

## 2.9.2 Abnormalities of Wear

**Overgrowths** due to abnormalities of wear are a major cause of dental disorders in hypsodont species (Becker 1962). In a study of 355 skulls, Wafa (1988) noted that overall 17% had abnormalities of wear, rising to an incidence of 48% in skulls over 20 years of age. Dixon *et al.* (2000a) noted horses with disorders of wear exhibited the highest incidence (70%) of **quidding** (the dropping of feed during masticatory movements) of all dental diseases. Significant periodontal disease was also recognised in 73% of cases by the latter, a feature also noted by Wafa (1988), and this periodontitis may have been an additional source of oral pain, in addition to buccal or lingual trauma from the overgrown teeth.

The **anisognathic** nature of the equine jaw (being approximately 23% wider apart in the maxillary than mandibular jaw (Taylor 2001)) predisposes to additional wear on the palatal aspect of upper CT and the buccal aspect of the lower CT. As teeth are constantly erupting and being occlusally reshaped by the opposing teeth, any lack of symmetry in the teeth or jaw can lead to abnormalities of wear (Uhlinger 1990).

Studies by Leue (1941) showed how differing feed types alter the excursion of CT when masticating. Incomplete chew cycles, resulting from animals being fed high levels of concentrates or from altering their masticatory actions to avoid painful areas in the mouth can further promote wear disorders. Diets high in concentrates also greatly limit the length of time horses chew forage and so further predispose to overgrowths (Section 2.9.2.1) (Becker 1962; Capper 1992; Dixon 1999).

Although it has been argued that dental overgrowths are the result of abnormal masticatory movements due to periodontal disease, the absence of periodontal disease in

27% of cases reviewed with such overgrowths by Dixon *et al.* (2000a) does not support this hypothesis.

A set of descriptive terms has been used to describe and classify occlusal surface irregularities that develop in horse's teeth as a sequel to normal and abnormal wear. Their development is progressive and correlates with the time that the aetiological factors (anatomical, pathological or dietary) have been present (Baker 1999a).

#### **2.9.2.1 Enamel Overgrowths**

Enamel 'points' are overgrowths that develop on the buccal occlusal edge of maxillary CT and the lingual occlusal edge of mandibular CT because of: the anisognathic nature of the equine mouth; differing CT occlusal table widths; and the direction and force of the equine masticatory cycle. These overgrowths may be extremely sharp and cause laceration of adjacent soft tissues (Uhlinger 1990). These soft tissue lesions (associated with sharp enamel ridges) were present in 12% of horses examined by Uhlinger (1987). This is a much lower incidence than noted by Becker (1962) who recorded 79% of horses having buccal trauma, and 93% as having sharp enamel overgrowths. It has also been noted that many larger overgrowths may include dentine and cementum in addition to enamel (Dixon *et al.* 2000b).

#### **2.9.2.2 Focal Dental Overgrowths**

Focal dental overgrowths can occur in any position where there is incomplete occlusion between upper and lower teeth. Large focal dental overgrowths (variously referred to as 'beaks,' 'ramps,' or 'rostral or caudal hooks') commonly arise specifically on Triadan 106, 206, 311 and 411 and less frequently on 111, 211, 306 and 406. Their presence is caused by incomplete occlusal contact with the opposing teeth due to a partial disparity between maxillary and mandibular CT row occlusion (Becker 1962).

### **2.9.2.3 Shear-mouth**

Shear-mouth is an excessive (i.e.  $>25^\circ$ ) angulation of the occlusal surface of a CT row in a transverse plane and is caused initially by a lack of normal movement of the mandible in the transverse plane, leading to a more vertical masticatory action. Shear-mouth may later result in a self-propagating mechanical restriction to jaw excursion, due to the presence of tall CT with excessive occlusal angulation. The lingual aspect of maxillary, and labial aspect of mandibular CT can be worn to gum level in some cases (Wintzer & Jaksch 1986; Baker 1991b). A study by Becker (1962) showed the presence of shear-mouth in 0.3% of 30,000 cavalry horses.

### **2.9.2.4 Wave-mouth**

Wave-mouth is the presence of an undulating occlusal surface of the CT row in a rostro-caudal plane. Dixon *et al.* (2000b) proposes teeth with a diseased periodontium may erupt at a reduced rate and that this may contribute to wave-mouth formation. This is not the only aetiological factor however, as 49% of cases of wave-mouth observed did not have a significantly diseased periodontium. Another possible factor is the differential rates of eruption that occur in the CT (Kirkland *et al.* 1996) or delayed eruption of some CT with a resultant long-term overgrowth of its opposite tooth, as noted by Becker (1962). Scrutchfield *et al.* (1996) noted wave-mouth to be common in old horses, with the 4<sup>th</sup> and 5<sup>th</sup> mandibular CT tending to overgrow and the 3<sup>rd</sup> and 4<sup>th</sup> maxillary CT tending to shorten.

### **2.9.2.5 Step-mouth**

Supraeruptions (increased rate of eruption) of teeth opposite a missing tooth are thought to be the usual cause of step-mouth. They are classically defined as being rectangular overgrowths of individual CT, however Dixon *et al.* (2000a) noted 11 of 15 stepmouth cases were more triangular in shape when viewed laterally, resembling an exaggerated, localised wave-mouth. Additionally in four of these 15 cases, restriction of normal jaw movements had caused development of secondary shear-mouth and wave-mouth. Nine of

these 15 step-mouths (60%) had resulted from loss of the opposing tooth. The other six were caused by maleruptions of the opposing tooth.

#### **2.9.2.6 Smooth-mouth**

Smooth-mouth arises when most or all of the enamel has been worn away from the occlusal surface allowing the remaining dentine and cementum to be worn smooth, and is usually seen in older horses (Dixon, 2000a). Wafa (1988) noted smooth-mouth in 5% of 355 skulls of mixed ages, with 35% of skulls over 20 years having absence of enamel in some of their CT. Becker (1962) also noted that some affected teeth had a concave occlusal surface, a condition he termed 'senile excavation.'

### **2.9.3 Acquired Disorders**

#### **2.9.3.1 Pulpar Exposure**

To avoid pulpal exposure on the occlusal surface due to attrition, dentine is laid down by odontoblasts throughout the life of the tooth (Ten Cate 1998a). Excessive attrition of dentine with resultant pulpar exposure has been proposed as a route of infection into equine apical tissues ( Wafa 1988; Lane 1994; Kilic et al. 1997c). If dental attrition on the occlusal surface exceeds the rate of secondary dentine deposition, the pulp will eventually become exposed. The rate of dentine formation is dependent on intra-dental factors such as the stimulation and health of the layer of odontoblasts present at the periphery of the pulp, in addition to other extra-dental factors such as pulpar vascular supply, as discussed previously (Ten Cate 1998a).

'Spontaneous' pulpar exposure on the occlusal surface of equine CT was reported in three mandibular and one maxillary cheek tooth by Becker (1962), who also cited three previous authors as recording an incidence of 3-4% of this disorder in equine CT. In a survey of 355 abattoir skulls, Wafa (1988) found 7% of CT to have some dental pulp exposed. Dixon *et al.* (2000b) also clinically recognised pulpar exposure in some cases of

apical infection, but commented that such lesions are often subtle and may not be clinically detected unless teeth are specifically examined for them (Dixon et al. 2000a).

It has been proposed that as brachydont teeth have very fine vasculature at the apical foramen, traumatic inflammation or bacterial invasion following occlusal pulp exposure in adults is likely to result in pulpitis, with resultant compression of its fine blood vessels leading to pulp ischaemia and probable pulp death (Shafer et al. 1983e). Young equine hypsodont teeth may often resist such pulp ischaemia following exposure (Dixon 1999). This is due to the relatively large apical foramen and large vasculature present which allows pulpitis to occur without the resultant inflammation occluding pulpar blood supply with consequent ischaemic necrosis (Section 2.6.1)

#### **2.9.3.2 Pulp Stones**

Pulp stones, also termed denticles (i.e. concentric areas of calcified dentine), are thought to be evidence of prior pulp irritation or inflammation in brachydont teeth (Torneck 1998). Such inflammation may arise from focal areas of anachoretic pulpitis, or from other noxious stimuli including chemical, bacterial, vibrational (mechanical) or thermal stimuli (Shafer et al. 1983e).

#### **2.9.3.3 Apical Infections**

The terms ‘apical abscess’, ‘apical infection’, ‘periapical abscess’, ‘dento-alveolar infection’, ‘dental sepsis’ and ‘tooth root abscess’ have been used interchangeably in relation to equine CT, because none describes the disorder(s) fully (Mueller & Lowder 1998). The term ‘apical abscess’ more correctly refers to those abscesses resulting from acute ischaemic pulpar necrosis and subsequent abscess formation following vascular occlusion in the apical foramina of brachydont teeth. The use of the term ‘periapical’ to describe the condition excludes infection confined within endodontic tissues, and so may be inaccurate.

'Dento-alveolar' infection implies that both the tooth and the alveolar socket are infected, which may not be true in early cases. It does however accurately describe the extent of the tissues infected in advanced cases, especially in younger horses, when the supporting bones frequently become involved in hypsodont teeth (Miles & Grigson 1990). 'Dental sepsis' can loosely mean bacterial tooth infection, which might also include carious attack. 'Tooth root abscess' is also inaccurate because in horses apical infections may occur prior to the development of any true roots (i.e. apical areas without enamel), especially in younger mandibular CT.

Apical abscess formation constitutes a large percentage of the more serious equine dental disorders. Dixon's review of 400 cases referred with dental disease showed no less than 162 (41%) to be suffering from this disorder (Dixon et al. 2000a). The initial response of pulpal tissues to injury is inflammation and Baker (1999b) states that the equine pulpal tissues are in a constant state of low grade inflammation as shown by cell types persistent in 'normal' equine dental pulpar tissue.

The hypothesis that continued irritation of dental pulp tissue results in acute pulp necrosis secondary to hyperaemia, oedema, and the development of pressure necrosis within the confines of the pulp chamber has been refuted in the human dental literature (Soames & Southam 1993d) as discussed in Section 2.9.3.1. It is even less likely to occur in equine teeth due to the presence of very large open apical foramina, particularly as the condition of periapical abscess formation is most prevalent in younger animals when the apices are most open (Muyllé et al. 1996; Dixon et al. 2000a).

As noted, occlusal pulp exposure has been proposed as a major aetiopathological factor for the development of CT apical abscesses (Wafa 1988; Lane 1994; Kilic et al. 1997a). Many apical infections, especially of mandibular CT, occur soon after eruption when eruption cysts are present and an anachoretic pulpitis may be the cause of apical infections in this group (Dixon et al. 2000a).

The presence of food within hypoplastic infundibular cementum can promote infundibular caries which, depending on the type of bacteria; amount and type of food present, and the duration of lesion, has been proposed as another cause of apical infection (Baker 1974; Schumacher & Honnas 1993). If caries penetrates through the residual infundibular cementum, infundibular enamel, and into the dentino-pulpal complex, a bacterial pulpitis could result.

#### 2.9.3.4 Caries

Caries is defined as a disease of the calcified dental tissues resulting from the action of microorganisms on carbohydrates within the oral cavity, and is characterised by both demineralisation of the inorganic part, and subsequent destruction of the organic part of the tooth (Shafer et al. 1983b). It is a complex and dynamic physiochemical process involving the movements of ions across the dental-oral cavity interface (Figure 2.12), as well as biological processes between bacteria and host defence mechanisms (Soames & Southam 1993a).

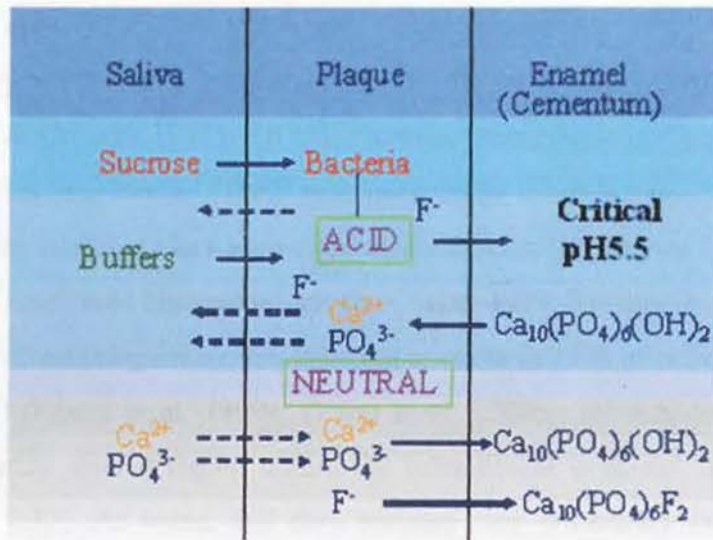
The generally accepted aetiology of caries has remained largely unchanged since first postulated (Miller 1891). Miller's **acidogenic theory** proposed that acid, resulting from the fermentation of dietary carbohydrates by oral bacteria, led to progressive decalcification of tooth substance with subsequent destruction of the organic matrix. Oral bacteria make up the bulk of dental **plaque**, where they are suspended in an amorphous matrix, incorporating salivary mucoids and extracellular bacterial polysaccharides (Budtz-Jorgensen et al. 1981; Shafer et al. 1983b). After cleaning, human enamel is covered within a few seconds by an adsorbed glycoprotein layer (the **pellicle**) from saliva onto which oral bacteria from the oral cavity adhere.

*Streptococci* bacteria are the first to colonise (within hours) the newly deposited pellicle and remain the dominant group of organisms in human plaque for around 7 days if left undisturbed. Thereafter, anaerobic bacteria begin to compete for nutrients, becoming the dominant group by 14 days (Soames & Southam 1993a). A thorough bacteriological

cataloguing of both commensal and pathogenic species in the equine oral cavity has yet to be undertaken.

Plaque on non-carious human teeth can have a neutral pH (i.e. pH 7.1). When dietary sugars are metabolised by bacteria to lactic acid (acetic and propionic acids may also be produced), plaque pH will fall, e.g. by two units within 10 minutes of sugar ingestion by humans (Critchley et al. 1967). When plaque pH reaches 5.5 or below, mineral ions are released from calcium hydroxyapatite crystals in mineralised dental tissues, and then diffuse into the adjacent plaque, and thereafter the oral cavity (Soames & Southam 1993a) (Figure 2.12). Such mineral loss principally occurs from teeth during prolonged acidic attacks.

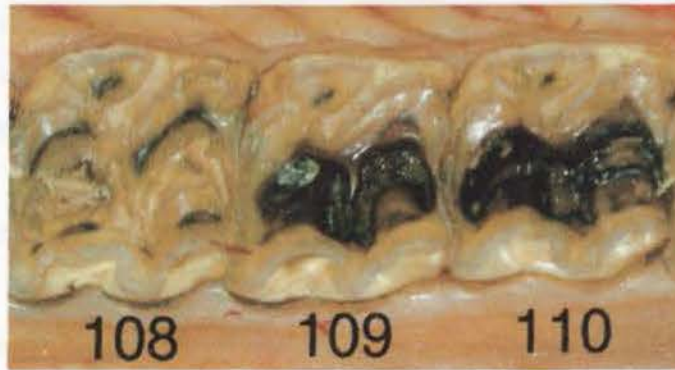Saliva will aid the tooth in buffering such acidic attack, and the plaque will eventually return to a neutral pH. At this point, the plaque may be supersaturated with mineral ions, some of which will re-precipitate back on to the tooth surface. Fluoride ions (usually present in higher concentration in plaque than saliva) aid in mineral re-precipitation, by forming fluorapatite when substituted by more soluble hydroxyl ions (Figure 2.12).



**Figure 2.12:** Diagrammatic representation of dental caries under acidic (pH<5.5) conditions (favouring caries) e.g. following degradation of carbohydrates (e.g. sucrose) and at a neutral pH e.g. following buffering by saliva. Incorporation of fluoride ions into the apatite crystal forms the caries resistant fluorapatite molecule, being less soluble than calcium hydroxyapatite (Soames & Southam 1993a).

Baker (1979a) demonstrated the presence of plaque on equine teeth using a disclosing dye, showing the principle areas of plaque formation to be at the gingival margin and interdental space in normal teeth, and occlusally in unopposed teeth. There has been little work since on the possible role of plaque in equine dental pathology.

In his thesis, Baker (1979a) states **the most common (equine dental) pathological conditions were periodontal disease and caries of cementum**. Early studies reported incidences of **infundibular caries** to be as high as 79-100% in certain ages of equine populations (Honma et al. 1962; Baker 1970). It is possible however that infundibular hypoplasia was incorrectly identified as infundibular caries in some of these studies. This may be one reason why Brigham and Duncanson (2000) reported a much lower incidence (12%) of caries in 50 skulls (Brigham & Duncanson 2000). Similarly, Colyer recorded the presence of caries in 13% of 484 equine skulls examined, noting them to only occur within maxillary infundibular cement, with CT 109 and 209 being most frequently affected (Miles & Grigson 1990). All these studies have recorded a significantly higher incidence of caries than Becker (1962) who only found 1% of horses affected in a study of 30,000 cavalry horses. It has been suggested the term 'caries' be avoided in equine dentistry unless confirmed histopathologically (Baker 1970; Rooney & Robertson 1996). More recently, infundibular caries was reported to occur in 12% of maxillary CT, but not in incisors (0%) (Dixon et al. 1999a; Dixon et al. 2000a). Infundibular caries grossly appears as a darkly stained region within the infundibular cemental lakes (Kilic et al. 1997d) (Figure 2.13). As noted, this dark staining may potentially extend beyond the infundibular cementum into both the enamel, and into adjacent dentine.



**Figure 2.13:** Infundibular caries is present in both the rostral and caudal infundibula of maxillary CT 109 and 110. The infundibula have not coalesced at this stage but infundibular enamel and dentine between the two infundibula is carious.

Honma (1962) described the following equine infundibular caries grading system:

- 1<sup>st</sup> degree caries: where the infundibular cement is affected
- 2<sup>nd</sup> degree caries: where the infundibular enamel is affected
- 3<sup>rd</sup> degree caries: where infundibular dentine is affected
- 4<sup>th</sup> degree caries: where the pulp of the tooth is affected
- 5<sup>th</sup> degree caries: where the teeth are completely missing due to caries or extraction

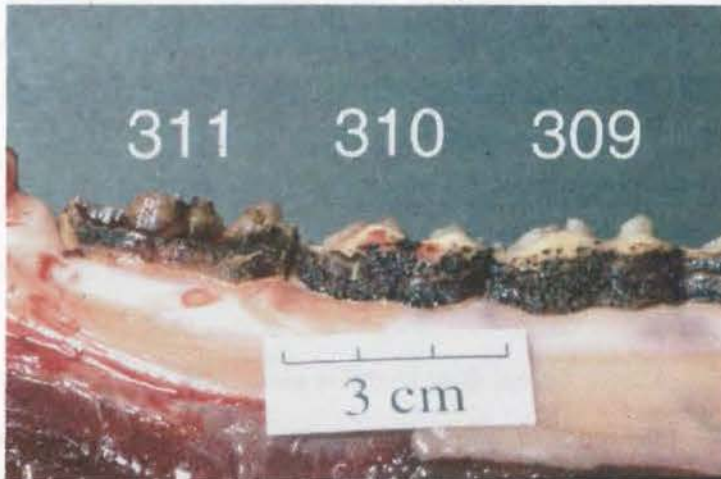The fifth category is considered redundant and a modified system based upon this of Honma's is proposed in this work.

**Modified Honma Classification:**

- 0 degree caries: no evidence of caries on a macroscopic level, but this grade can include hypoplastic tissue (i.e. central infundibular cemental hypoplasia)
- 1<sup>st</sup> degree caries: caries only affecting cementum – this may vary considerably from small darkly pitting superficial spots, to extensive destruction and loss of cementum. On this basis it may be divided into class 1 and 2 respectively
- 2<sup>nd</sup> degree caries: extends beyond cementum to affect adjacent enamel

- 3<sup>rd</sup> degree caries: extends beyond cementum to affect enamel and dentine
- 4<sup>th</sup> degree caries: where caries has progressed to affect the integrity of the entire tooth i.e. development of an apical abscess, or secondary tooth fracture

The above classification system is equally suitable for carious lesions found in peripheral calcified tissues, notably peripheral cementum. To date the pathological significance of **peripheral cemental caries** is unknown (Figure 2.14). By weakening and removing occlusal cementum that contributes considerably to equine CT clinical crown structure (Mitchell 2004), it may increase the rate of occlusal wear, or even to the development of diastema or periodontal disease. Removal of peripheral cementum also makes proud areas of brittle enamel on the occlusal surface more prone to fracture.



**Figure 2.14:** Peripheral cemental caries of mandibular CT 309-311. Note how the caries has removed much of the supporting lingual cementum of 311, making the exposed enamel more prone to fracture.

### 2.9.3.5 Dental Fractures

There are several classification systems for fractured teeth in human dentistry. One widely adopted is that of Ellis & Davey (1970), who graded traumatised teeth into nine classes:

Class1: Simple fracture of crown enamel, involving little or no dentine

- Class 2: Extensive fracture of crown, involving considerable dentine but not the dental pulp
- Class 3: Extensive fracture of the crown, involving considerable dentine and exposing the dental pulp
- Class 4: The traumatised tooth becomes non-vital, with or without loss of crown structure
- Class 5: Tooth lost as a result of trauma
- Class 6: Fracture of the root, with or without loss of crown structure
- Class 7: Displacement of the tooth, without fracture of crown or root
- Class 8: Fracture of the crown en masse and its replacement
- Class 9: Traumatic injuries to deciduous teeth

This classification system is a good starting point to classify equine dental fractures, however the more complex nature of equine teeth requires further details to be recorded. Apart from publications on the surgical repair of fractured teeth or jaws, there is limited literature on the incidence, histology, ultrastructural anatomy and pathogenesis of equine dental fractures. Becker (1962) reported an incidence of fractures in all equine teeth to be 0.7% in 30,000 cavalry horses, while Geres (1962) found radiographic evidence of fractures in 3.5% of 500 skulls, although this latter higher incidence may have been caused by post-mortem fractures.

The study by Dixon et al. of 400 cases referred with dental disorders found complicated **traumatic** fractures (i.e. with pulp exposure) of the incisors and /or their supporting bones in 25% of incisor cases and **idiopathic** (of unknown aetiology) incisor fractures in 7% of cases (Dixon et al. 1999a; Dixon et al. 2000c). Incisors were usually fractured in a transverse plane in contrast to CT fractures that were usually sagittal in nature. In the same study 8% of reported CT disorders were traumatic CT fractures, and 7% were termed idiopathic CT fractures.

Dental trauma is common in horses, as a result of kicks, biting inanimate objects, crib biting, and high-speed encounters with immobile objects (Hague & Honnas 1998). Of those CT categorised by Dixon of having suffered trauma, 71% were mandibular and 29% maxillary. Eleven of the 18 cases (61%) of mandibular CT trauma resulted from

external trauma (kicks most frequently), compared to 3 of the 8 (38%) maxillary CT cases (Dixon et al. 2000b). It was noted that iatrogenic fractures were more likely to occur in younger (age <8 years) teeth when molar-cutters were used by veterinarians or dental technicians to remove large overgrowths, as little secondary dentine has been laid down to protect the brittle enamel in these younger teeth (Section 2.9.6).

### 2.9.3.6 Periodontal Disease

Periodontal disease affects the tissues of the periodontium i.e. gingival mucosa, the PDL, and the alveolar socket lining (Shuttleworth 1948). Inflammation of these tissues is termed **periodontitis**, with other terms commonly used being ‘alveolar periostitis,’ ‘alveolar osteitis,’ ‘alveolar disease,’ ‘Rigg’s disease,’ ‘periosteitis,’ ‘pyorrhea alveolaris,’ ‘paradontal disease’ and ‘chronic ossifying alveolar periostitis’ (Wafa 1988; Miles & Grigson 1990).

Human periodontal disease has been classified into two categories – inflammatory (gingivitis, periodontitis) and dystrophic (gingivosis, periodontosis, atrophy and occlusal traumatism) (Shafer et al. 1983d). **Gingivitis** refers to inflammatory lesions confined to the marginal gingiva. It is generally accepted that some cases of gingivitis will progress to periodontitis. **Periodontitis** is present once lesions have extended beyond the gingiva to include destruction of the underlying periodontal connective tissue and loss of alveolar bone by resorption (Soames & Southam 1993b). **Dystrophic** changes are caused by degenerative, circulatory or mechanical influences, or other processes resulting in pathological changes to the periodontium (Shafer et al. 1983d).

Periodontitis is a complex disease process involving a combination of genetic, microbial, immunological and environmental factors that determine the risk of acquiring, and then of the progression of this disease (Shafer et al. 1983d). As with caries, formation of dental plaque is considered to be the main aetiological factor for periodontal disease in brachydont species. If unresolved, periodontal disease may lead to marked loss of alveolar bone, and if it extends to the apical region can cause invasion of periapical

tissue, septic pulpitis, and even eventual tooth loss (Crabill & Schumacher 1998). In severely affected equine cases (e.g. some cases of severe diastemata) the disease may progress to widespread osteomyelitis and even necessitate euthanasia of horses on welfare grounds (Dixon et al. 1999b).

In humans, cats, and dogs periodontal disease begins with a focus of gingivitis usually between adjacent teeth and proceeds to the formation of a triangular shaped pouch that fills with food from the oral cavity (Soames & Southam 1993b). As bacteria multiply and more food substrate is impacted into the defect, a vicious cycle is perpetuated resulting in progressive periodontium breakdown (Figure 4.23). When this pocket extends as far as the apical region, bacteria may directly invade the pulp chambers via apical foramina.

Periodontal disease is of major importance in man. In one survey, 50% of adults aged 55-64 years old had severe (>4mm periodontal attachment loss) periodontal disease (National Institute of Dental and Craniofacial Research 2003). Its much lower prevalence in 'lower animals' has been cited as one reason why research in this area of human medicine has been relatively unsuccessful to date (Shafer et al. 1983d).

Despite this observation, in 1906 Colyer described periodontal disease as the '**scourge of the horse**,' finding this disease present in approximately one third of 484 skulls examined (Miles & Grigson 1990). Baker (1970) recorded an incidence of 60% periodontal disease in horses aged over 15 years, and later developed a grading system for equine periodontal lesions from 1-4 (Baker 1979a). Wafa (1988) reported an overall incidence of 37% of periodontal disease in the abattoir specimens he examined, with 52% of animals showing concurrent periodontitis as their teeth were erupting. Again the disease was more prevalent in older animals, reaching a peak of 60% in horses over 20 years of age. In contrast to Baker's study however, Wafa found that misplaced or rotated teeth, or diastemata more commonly instigated secondary periodontitis than abnormalities of wear.

Primary equine periodontal disease, aside from the normal transient periodontitis of erupting teeth, is uncommon (Baker 1979a; Baker 1979b; Wafa 1988; Dixon 1992). In his study in 1970, Baker recognised 40% of immature horse skulls examined to have considerable periodontal inflammation associated with eruption of permanent dentition. Dixon found 7% of cases referred with incisor dental problems to be affected by primary periodontitis (Dixon et al. 1999a) and 4% of mandibular and maxillary CT cases to be similarly affected (Dixon 1992).

Hofmeyer (1960) claimed that periodontal disease was the major dental disease of South African horses, attributing a diet of coarse or chopped food as a predisposing factor. In contrast to most other reports, he stated that the maxillary CT rows were more commonly affected with periodontitis than mandibular CT rows (Hofmeyer 1960).

Diet has been implicated in the aetiology of equine periodontal disease (Becker 1962). Feeding of chaff, where small pieces of food can become impacted between teeth, is thought to initiate gingival damage either mechanically or through bacterial fermentation of these foodstuffs (Miles & Grigson 1990). The presence of diastemata increased the likelihood of interdental feed impaction, with a similar result on gingival tissues (Little 1913). The increased prevalence of diastema with age is attributed to the tapering of CT towards their apex (Voss 1937), thus with increasing age and wear there is a natural decrease in occlusal surface area and a resultant increase in the interdental space.

#### **2.9.4 Odontogenic Tumours**

A distinction is made in the human medical literature between odontomes and odontogenic tumours. **Odontomes** are non-neoplastic developmental anomalies or malformations that contain fully formed enamel and dentine. **Dental hamartomas** containing calcified dental tissues may therefore be considered as such (Soames & Southam 1993c).

Several histologically distinct types of epithelial odontogenic tumours have been identified in almost 250 cases reported in various species of domesticated animals (excluding horses) (Walsh et al. 1987). These are usually described as low grade malignancies which rarely metastasise (Thoma & Goldman 1960; Baden 1971). In their review of epithelial odontogenic tumours, Walsh *et al.* (1987) give a well referenced classification of odontogenic tumours of domestic animals, the most common being the ameloblastic odontoma of the maxilla (Baker 1991b). Pirie and Dixon (1993), Head and Dixon (1999) and Knottenbelt (1999) give thorough reviews of **equine** tumours of odontogenic origin and of the oral cavity and surrounding structures.

In the review of 400 horses referred for dental disorders, Dixon *et al.* (1999a, 2000b) found neoplasia in three out of 44 (7%) cases with incisor problems and in seven of 349 (2%) with CT problems. Both groups had a wide range in age of the affected horses (1-14 and 0.1-19 years respectively). Ameloblastomas, hamartomas, an osteosarcoma, and an osteoma were diagnosed on histopathology.

### 2.9.5 Odontogenic Cysts

There are six main categories of **odontogenic cysts** in man (Shafer et al. 1983a). The two main types of odontogenic cysts reported in equine literature (namely dentigerous and eruption cysts) are classified as having similarities to each other in the human medical literature (Shafer et al. 1983a).

A **dentigerous cyst** encloses part or the entire crown of an unerupted tooth. It is attached to the amelocemental junction and arises in the follicular tissues covering the fully formed crown of the unerupted tooth. An **eruption cyst** is a dentigerous cyst that arises in an extra-alveolar location.

However neither of these definitions is applicable to those cysts described in the equine literature. **Equine dentigerous cysts**, also called heterotopic polydontia or incorrectly

temporal teratomas, arise from displacement of dental germs of the first branchial arch during development, and are believed to originate from Hertwig's epithelial root sheath or its precursor (Baker 1991a; Mueller 1991). The cysts often appear in the region of the ear or temporal bone (Rashmir-Raven et al. 1990) or occasionally within the cranial vault or maxillary sinus (Hunt et al. 1991). One or several dental elements may be involved in these cysts that are usually diagnosed in young horses around the time their permanent teeth erupt. In the human medical literature such lesions have been reported to be precursors to ameloblastomas, however in horses they have not been shown to progress to neoplasia. Surgical excision is usually completely successful.

**Equine eruption cysts** are not true cysts, and as such have been discussed under developmental disorders of eruption (Section 2.9.1.2). To this author's knowledge only a single **intraosseous epidermoid cyst** has been reported in the equine literature (Camus et al. 1996).

### **2.9.6 Iatrogenic Dental Disorders**

In recent years there has been increased awareness of equine dental disease and an increase in the range of equipment to treat such conditions (Scrutchfield & Schumacher 1993) including manual, and adapted or equine-specific motorised dental equipment (Scrutchfield 1999b; Baker & Allen 2002; Dacre et al. 2002).

Prior to the increased availability of motorised equipment, large dental overgrowths were reduced manually and the use of 'molar cutters' or 'guillotines' for such purpose can result in teeth fracturing, shattering, and being cut too low or at an incorrect angle (Scrutchfield 1999b).

Aggressive dental treatments by some dental practitioners have resulted in removal of the normal CT occlusal table topography, to the point where it is flat (so-called 'flattening of

the table'). This procedure has been shown to reduce feed digestibility (Ralston et al. 2001) and decreases dental life.

Pulpal insults can be caused by heat, pressure, vibration, desiccation, chemical exposure, and bacterial infection (Shafer et al. 1983e). Heating of the pulp can cause various histopathological changes, such as burn reactions at the periphery of the pulp, including formation of 'blisters', protoplasm coagulation, and expansion of liquid contained in the pulp and dentinal tubules with resultant increased outward liquid flow from tubules (Castelnuovo & Tjan 1997). These reactions can lead on to vascular pulpar injuries with subsequent tissue necrosis (Raab 1992). The potential for thermal pulpar insult to be caused by modern motorised equine dental equipment has been studied *in vitro*, concluding that if used incorrectly, thermal trauma may occur to equine dental pulp (Baker & Allen 2002; Dacre et al. 2005).

Aside from the potential risks associated with thermal pulpar insult, aggressive dental reductions (that do not expose a pulp cavity) e.g. full 'bit-seating' (reducing and rounding off the rostral aspects of the 06s for allegedly better bit comfort), have the potential to expose sensitive dentine to the oral cavity (Kempson et al. 2003). In normal circumstances, dentine in contact with the oral cavity is sclerotic i.e. the dentinal tubules have been occluded either by calcification of the odontoblast process, or by the tubule being filled by a 'smear' layer (ground fine dental dust). Kempson *et al.* showed this sclerotic layer could be removed completely with modern dental equipment, exposing sensitive odontoblast processes.

## 2.10 Diagnosis of Dental Disorders

### 2.10.1 Clinical Examination

The practice of performing thorough dental examinations in horses has been rejuvenated within the last 15 years. To perform an examination correctly it is now recommended that a full mouth speculum must be used in conjunction with a good light source, mirror and

washing food out the mouth thoroughly (Dixon 1993; Scrutchfield & Schumacher 1993; Baker 1998; Easley 1999;). Currently sedation is used by veterinarians when performing dental examinations on animals that are difficult to handle or on those that require advanced dental treatment (Ramzan 2002), however its use is steadily increasing.

With these improvements in examination techniques, the recognition of dental abnormalities such as presence of caudal dental overgrowths, diastemata, CT fracture and occlusal pulp exposure is increasing (Easley 1999; Dixon et al. 2000b).

### **2.10.2 Ancillary Diagnostic Aids**

**Radiology** has been the most frequently used ancillary aid in the diagnosis of equine dental disease to date, as shown by the numerous reports on its use (Baker 1971; Baker 1972; Gibbs 1978; Wyn-Jones 1985; Mueller 1991; Dixon et al. 2000a; Barakzai & Dixon 2003). These reports have mostly been on clinical studies aimed at improving the diagnosis of dental disorders.

A major problem faced by standard radiography of equine dentition has been the overlapping nature of the opposite dental rows, facial bones and sino-nasal structures, and the complex radiological images of individual teeth, in particular of CT. For this reason use of radiography has leaned towards the diagnosis of dental disorders involving extra-dental features such as changes to the supporting bones or periapical tooth region (Dixon et al. 2000a; Barakzai & Dixon 2003).

Perhaps due to these limitations of equine dental radiography, clinicians have been keen to use other imaging modalities such as computer assisted tomography (Barbee et al. 1987; Tietje et al. 1996), magnetic resonance imaging (Tucker & Farrell 2001), and nuclear scintigraphy (Weller et al. 2001) to improve diagnosis. The principal drawbacks to all of these new imaging techniques for equine dental disease are their limited availability and cost. Due to the anatomy of the equine oral cavity, visualisation of equine

dental disorders has always been a major difficulty. However, the recent use of rigid endoscopy to improve visualisation of the clinical crown within the equine oral cavity has helped identify pathological features not previously recognised, such as the presence of fissures within CT occlusal dentine (Simhofer et al.2003).

## **2.11 Conclusions of Literature Review**

The review of the literature shows that the gross and microscopic anatomy of the normal equine cheek teeth has been well defined but there remains some confusion concerning the classification of irregular secondary dentine and tertiary dentine. The endodontic anatomy of equine cheek teeth also needs to be clarified. These two areas will need to be fully characterised to enable the proposed histopathological investigation of diseased CT, in particular, the histological examination of the dentino-pulpal complex, to be undertaken.

There have been very few and limited pathological and histopathological studies to date on the very significant disorder equine CT apical infection. In particular, the histopathological changes associated with this disorder have been poorly described. A variety of causes of equine CT apical infection have been proposed such as infundibular caries, occlusal pulpar exposure and anachoresis and there is much disagreement in the literature in this respect. Until a systematic study has been performed on the pathology of CT apical infections, the aetiopathogenesis of these lesions will continue to be conjecture.

Although idiopathic CT fractures can also cause major medical and welfare problems to horses, there appears to be no information available in the literature on their nature or cause. A systematic pathological evaluation of these lesions is also indicated to elucidate their pathogenesis.

## **Chapter Three: Materials and Methods**

### **3.1 Introduction**

Although many commonly used imaging techniques have been used in this current work, they have often been used in novel ways. For example although radiography is frequently used in horses in numerous ways to assess radiological features, this author is unaware of its use to assess extracted teeth on an individual basis – a technique commonly used in human dental research. Other techniques, such as processing of CT sections for decalcified and undecalcified histological sections, have required (sometimes extensive) modification of previously reported techniques. These techniques are reported here in a detailed manner to assist future research that requires the high quality imaging of equine dental material.

### **3.2 Initial Work**

All diseased teeth included in the study were previously extracted from clinical cases referred to the University Equine Hospital however; it was also necessary to establish an efficient and reliable technique to extract complete teeth from cadaver skulls for use as controls. Consequently 120 CT were extracted post-mortem from five horses that were euthanased on welfare grounds for non-dental disease at this institution. These control teeth were also used for pilot studies on new dental examination protocols.

Further fundamental reasons why normal CT needed to be examined are to define their gross endodontic anatomy and to clarify the differences between secondary and tertiary dentine. Such information is crucial to the examination of diseased CT because it is proposed that comparison of dentinal thickness between diseased CT with age and Triadan position matched control CT could be used to assess when dentine was ceased to be laid down. This information could be used to assess the duration of apical infection and thus the time of pulpar death. It is proposed that dentinal thickness measurements could also be used to in aetiological studies to assess if pulpar death preferentially

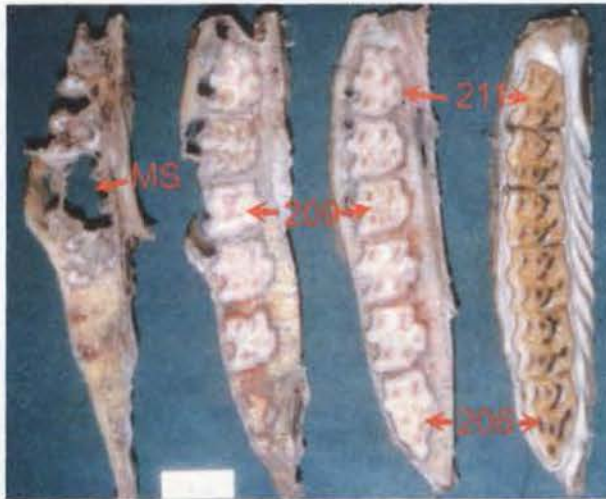
occurred in a single pulp chamber, i.e. indicating that pulpar exposure was the cause of the apical infection.

The 120 control CT extracted from these skulls were immediately placed into 10% buffered formalin (Genta Medical, Tockwith, Yorkshire, UK) for fixation. After 1-2 weeks fixation, the teeth were either: cut transversely into two or three sections using a Wadkin Bursgreen band saw (Wadkin Ltd., Leicester, UK); cut transversely into two or three sections using a standard hardened hacksaw blade; or fractured using a hammer. The first two methods were found to be unsuitable by causing too much damage to the tissues through heat generation and being unable to cut teeth accurately, and the last by causing uncontrollable, irregular fracture patterns. None of these methods were used beyond pilot studies. The dental sections and fragments were replaced into containers containing saline formaldehyde (Genta Medical, Tockwith, Yorkshire, UK) (50% of samples), 3% glutaraldehyde (Fischer Scientific UK Ltd, Loughborough, UK) (25% of samples) or buffered saline (Fischer Scientific UK Ltd, Loughborough, UK) (25% of samples) for further fixation.

To assess fixative efficacy, two weeks later four dental pulps from each fixative type were removed from the above cut or fractured specimens and were processed for histology. In addition, half the remaining samples were changed from their original fixatives to 'Gooding and Stewart's' decalcification solution (Culling 1974), to assess the speed with which this agent decalcified equine dental tissues at standard room temperature and pressure. Unless otherwise stated, all procedures were carried out under standard room temperature and pressure conditions.

During this period, a further two skulls were collected from the University's post-mortem room, from horses also euthanased on welfare grounds for non-dental disease. The skulls were trimmed using the band saw leaving only the upper and lower CT and their immediately surrounding bone, before these tissue blocks containing individual CT rows were transversely sectioned into 1-2cm thick slices (Figure 3.1).

In addition to processing the above control teeth, seven apically infected CT (from an original collection of nearly 400 extracted or repulsed teeth) deemed to be expendable as they had incomplete histories, were transversely sectioned using a water-cooled Logitech CS10 saw (Logitech Ltd, Glasgow, UK) with a 10" diamond blade (Malvern Lapidary, Malvern, Worcester, UK) at the Department of Geology, Edinburgh University. These were included in a subsequent pilot study involving a total of 16 apically infected maxillary CT.



**Figure 3.1:** Transverse sections of a left maxillary CT row from an eight year-old horse, with the most apical section on the left and occlusal section on the right. Some teeth are identified by their Triadan position, as is the maxillary sinus (MS).

### 3.3 Collection, Classification and Fixation of Teeth

#### 3.3.1 Collection, Classification and Fixation of Normal Teeth

Following the above pilot study, 100 control CT were extracted post-mortem from a further nine horses with no history of dental disease, that were euthanased on welfare grounds. These individual CT were grossly examined to confirm that no dental disease was present.

Throughout this study the **dental age** of teeth is given rather than the actual age of the horse from which the teeth were extracted. This is to take into account the staggered eruption times of teeth, and allows comparison of teeth relative to the length of time that they have been in occlusal contact (and hence having a stimulus for secondary dentine production). Dental age may be determined by subtracting the eruption age of the tooth (Getty 1975) from the actual age of the horse, as shown in Table 3.1.

The two inherent weaknesses still present when using this modified dental age are: that CT eruption time can be variable i.e. the eruption times given in the above table are not exact times for all horses (Dixon & Copeland 1993; Richardson et al. 1995c; Kirkland et al. 1996); and that the recorded age of a horse will (by tradition) only be given as the year in which it was born, rather than its actual birth date. As many normal teeth were included in this study as time and resources would allow, partially compensating for such variables. Details of these 100 control teeth are presented in Tables 3.2 and 3.3.

Triadan number	106/206 306/406	107/207 307/407	108/208 308/408	109/209 309/409	110/210 310/410	111/211 311/411
Eruption age (years)	2.5	3.5	4	1	2	3.5
Example: CT dental ages for a 5 year-old horse (years)	5.0 -2.5 = 2.5	5.0 -3.5 = 1.5	5.0 -4.0 = 1.0	5.0 -1.0 = 4.0	5.0 -2.0 = 3.0	5.0 -3.5 = 1.5

**Table 3.1:** Eruption times for equine cheek teeth with an example of dental ages for a five-year-old horse's cheek teeth.

Triadan No:	106 206	107 207	108 208	109 209	110 210	111 211	306 406	307 407	308 408	309 409	310 410	311 411	Total
Dental age (years):													
0-1	0	0	4	0	0	2	0	1	3	0	0	2	12
1.5-3	3	2	1	2	3	1	3	2	1	1	3	1	23
3.5-5	1	1	2	2	1	3	1	2	1	2	1	3	20
5.5-7	2	0	1	3	2	0	1	0	1	3	2	0	15
7.5-9	1	2	1	0	1	1	1	2	1	0	1	1	12
9.5-11	0	0	0	2	0	0	0	0	0	2	0	0	4
11+	0	1	0	0	0	0	0	0	1	0	0	0	2
<b>Total</b>	7	6	9	9	7	7	6	7	8	8	7	7	88

**Table 3.2:** Dental age (years post eruption) and Triadan position of 88 control CT cut in transverse section. Red numerals highlight the presence of multiple teeth in the same Triadan position and age group category.

Triadan No: Dental age (years):	108	109	408	409	Total
1	1	0	1	0	2
4	0	1	0	1	2
5	1	0	1	0	2
8	1	1	1	1	4
11	0	1	0	1	2
<b>Total</b>	<b>3</b>	<b>3</b>	<b>3</b>	<b>3</b>	<b>12</b>

**Table 3.3:** Dental age (years post eruption) and Triadan position of 12 control CT cut in longitudinal section.

Selection of the 88 CT to be examined in transverse section was biased to ensure that each of the six maxillary and mandibular Triadan positions (06-11) were represented by at least six CT, and that multiple CT of similar dental age and Triadan position were present in as many categories as possible. Fifty-three of the 88 (60%) transversely sectioned *control CT* were thus grouped with CT of similar dental age and same Triadan position - as highlighted by figures in red in Table 3.2. This enabled comparison of control CT by Triadan position and dental age, and also between different horses and corresponding contra-lateral teeth from the same horse.

Following extraction, all teeth were fixed in 10% buffered formalin, with this solution being replaced with fresh formalin after 48 hours. Twenty-three control teeth were placed intact in fixative and were only sectioned when required for dissecting microscopy, to simulate the fixation methods used for most of the pathological specimens collected, i.e. allowing fixation of pulp tissue only via the apical foramen (unless gross pathological disorders were present, such as dental fracture, occlusal pulp exposure or advanced caries). The remaining teeth were sectioned using a water-cooled Logitech CS10 saw with a 10" diamond blade within 24-48 hours of euthanasia before being placed in fixative. This was to investigate whether increasing fixative access to pulp tissue, improved fixation.

Twenty-four control CT from a five-year-old horse, and 42 CT from two eight-year-old horses were radiographed prior to sectioning (Section 3.5). Additionally, the 24 CT from the five-year-old horse and 21 CT from one of the eight-year-old horses were imaged with an X-ray computer axial tomography (CAT) scanner prior to sectioning (Section 3.4.1).

### **3.3.2 Collection, Classification and Fixation of Pathological Teeth**

From a pool of extracted diseased equine CT that had been collected at this University over the previous two decades, 70 CT that had been extracted from 68 horses on clinical grounds were selected. Twenty-eight of these were from cases of maxillary CT apical infection, 22 from cases of mandibular CT apical infection and a further 20 from cases of idiopathic CT fracture. These teeth were selected on the basis of having a complete dental history, and having the majority of the tooth present for evaluation. Excluded from these criteria were three cases of dental fracture where only the fractured portion of the CT was available for examination. Details of these CT are presented in Appendices 1-3. All CT underwent detailed radiological, histological and ultrastructural examination.

A further 60 CT from the collection that did not have a full dental history underwent gross pathological examination, but because of constraints of time and resources, were not examined beyond this level.

### **3.4 Radiography**

Twenty-four intact control CT from a five-year-old horse, and 42 CT from two eight-year-old horses were radiographed using a Gigantos 1012MP X-ray unit (Siemens AG, Munich, Germany) on CEA RP film (CEA AB, Strangnas, Sweden) with medium speed (200) Fast Detail rare earth Ultra Vision cassettes (Dupont, Newbury, Berkshire, UK). Exposures were varied from 5.0-8.0 MAs and 50-70 kV in order to gain optimal images.

These radiographs were digitised using a Fujifilm 6900Z digital camera (Fuji Photo Film Co. Ltd., Tokyo, Japan) whilst on standard radiographic viewing panels. These radiographs were used to establish radiological features of intact, control extracted CT.

The 70 diseased CT undergoing detailed examination were radiographed in latero-medial (bucco/palatal-lingual) and rostro-caudal planes using the above protocol. The radiographs were evaluated for exposure quality and then their normal anatomical and pathological features were documented.

Radiographs of eight maxillary and eight mandibular extracted CT with apical infections were selected at random from the above 50 apically infected CT. Four experienced equine clinicians viewed these radiographs 'blindly' and independently. Each was asked to identify the presence or absence of specified normal anatomical and pathological features. These results were then compared with those from the author's original radiological observations, and with features noted at gross pathological and dissecting microscopy examinations.

### **3.4.1 Computer Axial Tomography**

Nine diseased CT (eight maxillary and one mandibular) were imaged using a Somatom Plus 4 Volume Zoom computer axial tomograph (CAT) scanner (Siemens AG, Munich, Germany) at Middlesex Hospital, London, UK, and the data were analysed using Osiris 4 JPEG format software (University Hospital of Geneva, Geneva, Switzerland).

A further 46 control CT and 20 diseased CT were imaged with a Somatom Esprit CAT scanner (Siemens AG, Munich, Germany) available locally at the Scottish Agricultural College's CAT unit on the Bush Estate, Midlothian. A spiral series of images (1.5mm in depth with 0.75mm overlap) was taken of each tooth and the data stored on CD for later analysis using Syngo A40A software (Siemens AG, Munich, Germany).

As individual equine CT do not appear to have been CAT scanned in such detail in any previous study, normal anatomical details such as endodontic structure were recorded in both control and diseased teeth, as well as pathological features in the latter. A major benefit to the study was that areas of interest detected in these CAT scans of both normal and diseased CT could be accurately identified by non-invasive means for future histology. Subsequently, these CT images were used to select sites for sectioning in some diseased cheek teeth.

Once histological processing of these teeth had been completed, image data from these CAT scans was related to histological findings. Additionally, a database of reference values for Hounsfield units (reflecting tissue radiodensity from the CAT scan images) was cross-matched to the four tissue types (enamel, dentine, cementum and pulp) for future reference.

### **3.5 Gross Pathology**

Following sectioning, all diseased teeth were photographed prior to further fixation, as the formalin fixative bleached the colour from the soft tissue within a few days of immersion. This imaging was initially performed by the Department of Geology and by Easter Bush Veterinary Centre's photographic units within the University of Edinburgh, and latterly by use of digital cameras by the author. In addition, abnormal external features were noted and recorded in freehand drawings.

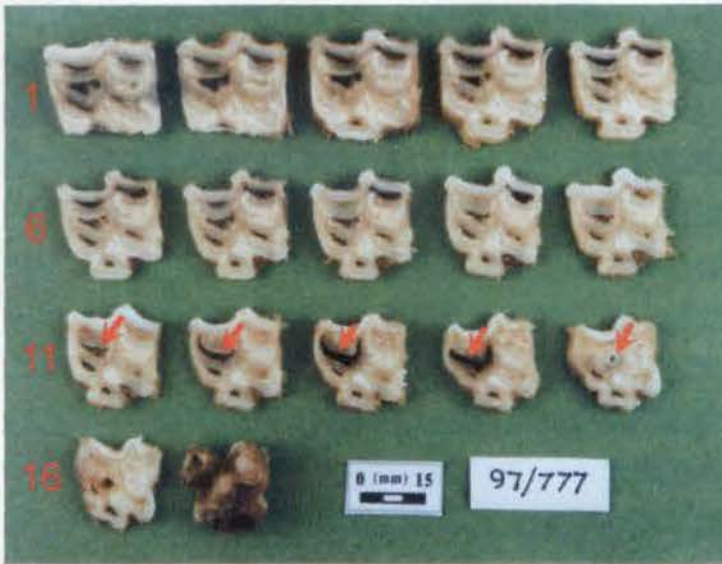### **3.6 Teeth Sectioning**

Twelve control CT were sectioned in a rostro-caudal plane, and 88 control CT in a transverse plane using a water-cooled Logitech CS10 saw with diamond blade. Thirty-six apically infected CT were also transversely sectioned using the above diamond saw. The remaining 14 apically infected CT were latterly transversely sectioned at Easter Bush Veterinary Centre using a 99-TS230M tile-saw (Buehler, Coventry, UK) with an 8" Thin CR diamond blade (Malvern Lapidary, Malvern, Worcester, UK). This saw was also used

for sectioning the 20 CT with idiopathic fractures and latterly CT examined with incomplete dental histories.

As CT often curve in three dimensions (x, y and z axes), sectioning them in a longitudinal direction with a rigid blade does not always allow the anatomical features of interest (e.g. infundibula or endodontic pulp chambers) to be followed for their full course. Consequently all quantitative measurements recorded from pathological specimens were taken from transverse sections and only qualitative assessments were made of longitudinal sections.

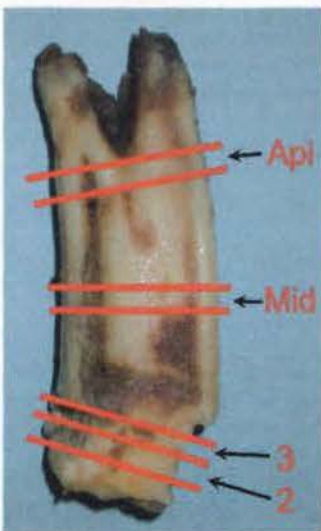In an initial pilot study of 16 maxillary-infected CT (seven of which were not included in final results as they had incomplete case histories – Section 3.2) the CT were transversely sectioned at 3mm intervals (with 1.0mm being lost with each saw cut), from the occlusal surface to the apical region. This produced up to 23 sections per tooth. Sections from each tooth were randomly assigned for light microscopy following decalcification (Section 3.8.1), undecalcified light microscopy (Section 3.8.2), scanning electron microscopy (Section 3.9) or transmission electron microscopy (Section 3.10).



**Figure 3.2:** Transverse sections from CT 108 from Case Five (97/777: Appendix 1). Sections are arranged with most occlusal section (section 1) being top left. Sections 1, 6,

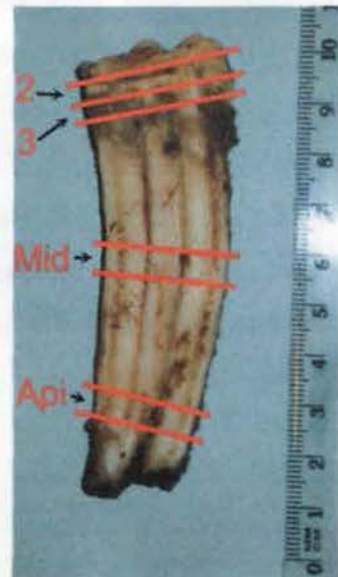
11 and 16 are numbered. Note the carious rostral infundibulum (arrow) that differs in size in the various sections.

This protocol was changed for examination of all (88) transversely sectioned control CT and the remaining 34 maxillary and mandibular CT with apical infections, as it was not thought practical or necessary to histologically examine this number of sections from every CT. Standardised measurements were made of diseased CT for comparison with similar sections of control CT, and areas of interest were investigated individually. Consequently, only four sections were cut per tooth unless otherwise indicated, namely the 2<sup>nd</sup> section (hereafter referred to as the sub-occlusal transverse section), 3<sup>rd</sup> section (immediately apical to 2<sup>nd</sup> section), a mid-section and an apical-section, each being 5mm in thickness, except for the 3<sup>rd</sup> section of 2mm thickness (Figures 3.3-4).



**Figure 3.3:** Maxillary CT (Case 103) with the transverse sectioning cuts superimposed (2= 2<sup>nd</sup> or the sub-occlusal section 5mm thick for decalcified histology; 3= 3<sup>rd</sup> section 2mm thick for undecalcified histology; Mid= middle section 5mm thick for decalcified histology; Api= apical section 5mm thick for decalcified histology). The super-imposed lines representing section cuts are intentionally thick to indicate that 1.0mm of tooth is lost with each cut made.

**Figure 3.4:** A mandibular CT (Case 32) with the sites of transverse sections superimposed (labeling as for Figure 3.3).



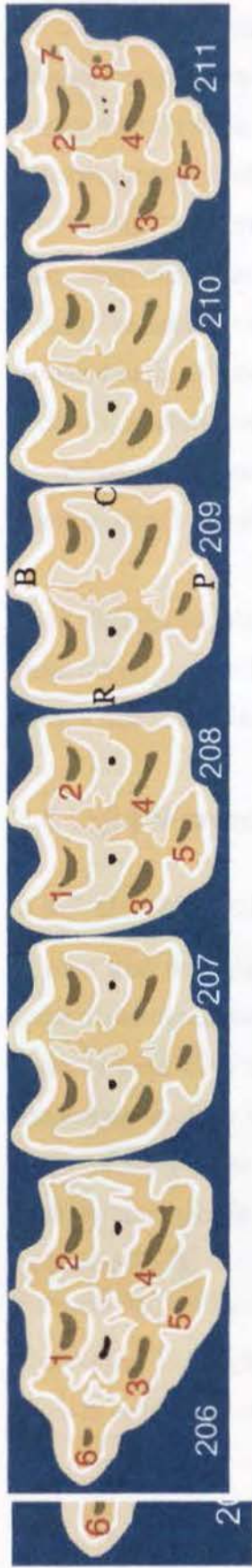The sub-occlusal (2<sup>nd</sup>), mid and apical sections were cut to 5mm thickness to improve tissue block handling and give greater support following their decalcification, prior to being mounted on slides (Section 3.8.1). The 2mm (3<sup>rd</sup>) sections were processed for undecalcified histology (Section 3.8.2).

All sections were placed in individual histokinette chambers (Simport Plastics, Beloit, Canada) before being returned to the formalin solution. In some cases, transverse sections of (the larger) maxillary CT were divided into rostral and caudal halves, in order to allow their placement into individual histokinette chambers.

### 3.7 Dissecting Microscopy

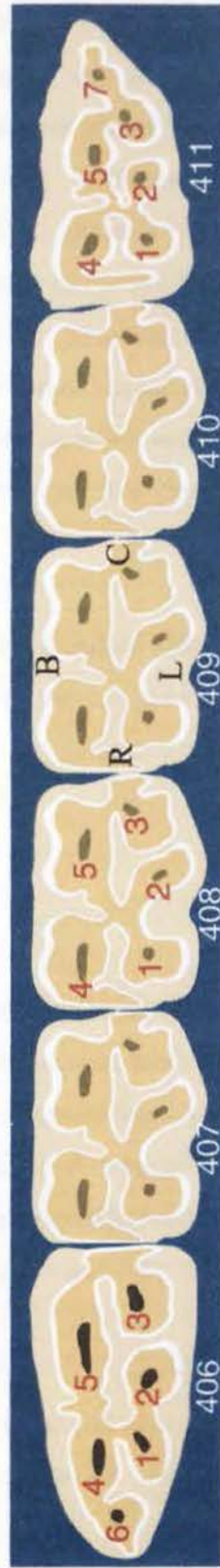
All cut surfaces of dental sections were examined using an SMZ10 binocular / stereo dissecting photomicroscope (Nikon UK Ltd., Telford, UK) at 4 - 40 times magnification. Areas of interest were initially photographed using slide film, however it was later found that digitally recording photographic images directly using a HP6800 flat bed scanner (Hewlett-Packard Company, Palo Alto, USA) gave superior results. In addition to these digitised images, diagrams of sections were drawn freehand to highlight areas of interest. Gross pathological data were tabulated and later compared to histological findings.

At this point of the study, an endodontic referencing system was proposed to facilitate recording of pathological features. All six maxillary and mandibular CT (Triadan 06-11) were proposed to consistently contain five *pulp horns* (the pulp within individual endodontic chambers or *horns* that develop in an occlusal sense, each arising initially in young horses from the common pulp chamber). In maxillary CT, these five pulp chambers were numbered from 1-5 with the rostro-buccal pulp horn being numbered 1, the caudo-buccal 2, rostro-palatal 3, caudo-palatal 4, and mid-palatal 5 (Figure 3.5). In mandibular CT rows, the rostro-lingual pulp horn was numbered 1, mid-lingual 2, caudo-lingual 3, rostro-buccal 4 and caudo-buccal 5 (Figure 3.6). In both cases numbering began at the highest rostral occlusal point, this being on the buccal aspect in extracted maxillary CT, and lingually in mandibular CT.



**Figure 3.5:** Diagrammatic representation of the occlusal surface of a left maxillary cheek teeth row. Pulp horn positions are indicated by the overlying secondary dentine (shown here as dark brown, with enamel being white, primary dentine tan, and cementum cream). Pulp horn numbers 1-8 are identified to the left of the pulp horn. Teeth 207, 209 and 210 all have similar pulp horn numbering to 208. Pulp horns 7 and 8 are not always present on tooth 211. (B) buccal; (P) palatal; (R) rostral; (C) caudal.

The right maxillary CT row is a reflection of this image.



**Figure 3.6:** Diagrammatic representation of the occlusal surface of the right mandibular cheek teeth row. Pulp numbering is the same as for Figure 3.5. (B) buccal; (L) lingual; (R) rostral; (C) caudal.

The first CT (Triadan 06) in all four rows had an additional smaller pulp horn, rostral to the others, which was numbered 6. The sixth *maxillary* CT (Triadan 111 & 211) had irregular caudal extensions to the second pulp chamber, and when distinct, this was numbered 7. In these teeth a further additional pulp chamber palatal to a caudal peripheral enamel infolding was numbered 8 when present. As the endodontic findings in the Triadan 11s were less consistent than the endodontic features present in other CT, nine additional control maxillary CT (Triadan 11) were examined from teeth gathered during the initial work (Section 3.2) in addition to the seven maxillary 11s already included in the 100 control CT (Section 3.3.1) in order to confirm the above findings. The sixth CT in mandibular rows (Triadan 311 & 411) had an additional caudal pulp horn, numbered 7, but no eighth pulp horn. The accuracy of this proposed endodontic nomenclature is verified later (Section 4.2.1).

Using this endodontic numbering system combined with standard anatomical directional terminology, it was hoped that an accurate location of any anatomical or pathological feature within a CT could be accurately recorded.

## 3.8 Light Microscopy

### 3.8.1 Decalcification of Hard Tissues

A pilot trial used eight diseased CT to prepare decalcified histological dental sections using histological techniques previously described for equine teeth (Kilic 1995). All sections were slide mounted in triplicate, as it was apparent from an early stage that processing artefacts were present in many of the sections. A total of 288 sections were cut, with many of the larger CT sections having to be quartered to facilitate handling. The sections could not be cut to less than 8-10 $\mu$ m in thickness using the techniques reported by Kilic (1995).

The manual histological processing technique used by Kilic was also used for assessment of fixative efficacy on dental pulps as discussed in Section 3.2. Because there were no

accompanying calcified tissues, results were superior to complete dental sections, achieving 6µm thick pulp sections that were relatively free from artefact.

The introduction of new histological processing equipment – namely a Shandon Pathology Centre automated tissue processor (Thermo-Shandon, Runcorn, UK) and the availability of a new decalcification agent, Surgipath Decalcifier II (Surgipath Europe Ltd., Peterborough, UK) in the histology laboratory at Easter Bush Veterinary Centre allowed a new technique to be developed for further decalcified equine dental histology.

A total of 464 transverse occlusal, mid or apical sections, 36 longitudinal tissue sections and 21 sections from fractured teeth in various orientations were processed using the technique described below.

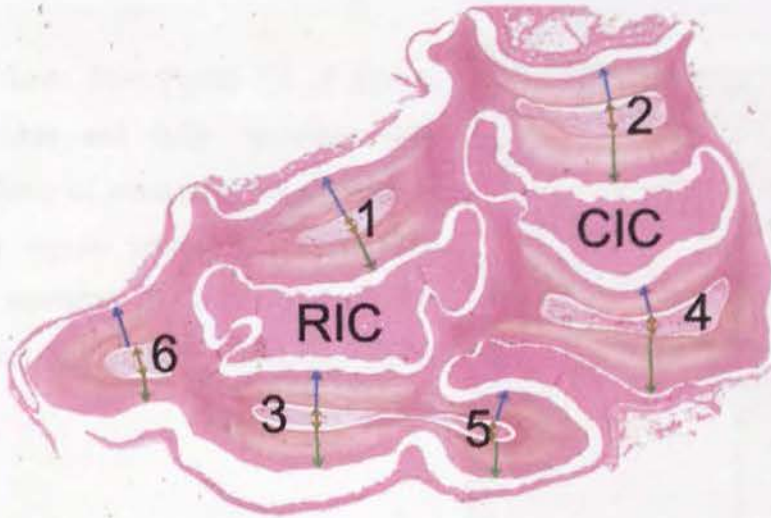
Following sectioning using a diamond saw, the CT sections were removed from fixative and washed under running, cold tap water for 20 minutes. They were then placed into Surgipath Decalcifier II solution (20x volume) for 3-4 days at 18°C, being examined every 12-24 hours to assess the level of decalcification by palpation. On removal from the decalcification solution, the samples were washed again in running, cold tap water for 20 minutes prior to being placed into a Shandon Pathology Centre automated tissue processor. This process first dehydrated the samples through a series of graded ethanol and xylene baths. The final stage of this automated processing was to impregnate the tissues in Paraplast Plus Tissue Embedding Medium (Oxford Labware, St. Louis, USA). The impregnated tissues were then cast into paraffin wax blocks.

The blocks were placed on ice one hour prior to sectioning on an automated RM2155 microtome (Leica Instruments GmbH, Nussloch, Germany). Sections were consistently cut 4-5µm thick and then mounted onto Biobond coated glass slides (BB International, Golden Gate, Cardiff, UK). The mounted sections were dried for 48 hours in an incubator at 37°C, before being stained with haematoxylin and eosin (Culling 1974). Following staining, cover-slips were placed over the sections.

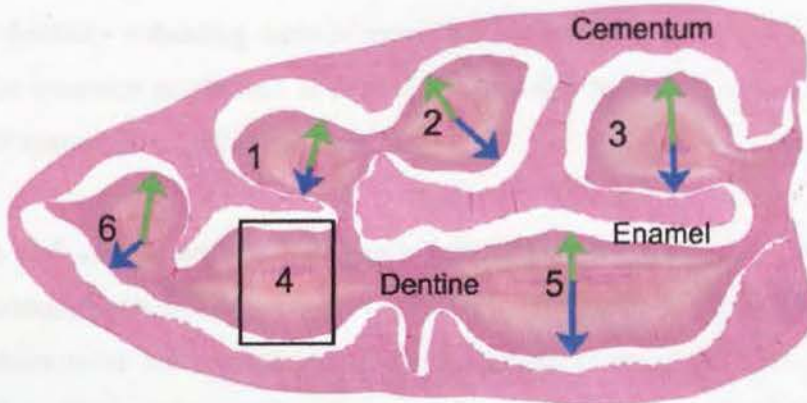
All transverse sections were examined under a BX41 light microscope (Olympus Corporation, Tokyo, Japan) on a quantitative and qualitative basis, with areas of interest being imaged using a Camedia C4040 Zoom digital camera (Olympus Corporation, Tokyo, Japan). For reasons already mentioned, all longitudinal sections were examined on a qualitative basis only. As these sections were decalcified, enamel (being ~98% mineralised) was usually absent, however some organic enamel components occasionally remained and if so, their presence was recorded.

Processing of the sections often resulted in peripheral or infundibular cementum being displaced, because the enamel that previously held it in position had dissolved. For this reason cementum was examined on a qualitative basis only.

Dentine, being laid down continuously throughout the life of a healthy tooth, was used as an indicator of the health status of the tooth itself, as noted in Section 2.7.1. Quantitative measurements of dentine were made for both control and diseased teeth as follows. The thickness of primary, secondary and tertiary dentine were measured in buccal and palatal (or lingual) directions, from where they radiated out from each individual pulp horn (when discrete) towards the amelodentinal junction (Figures 3.7 & 3.8). These distances were initially measured to 1.0 $\mu$ m limits, using an Image ProPlus (Media Cybernetics, Maryland, USA) computer image analysis system. Later, using a stage micrometer, these distances were measured to 50 $\mu$ m limits.

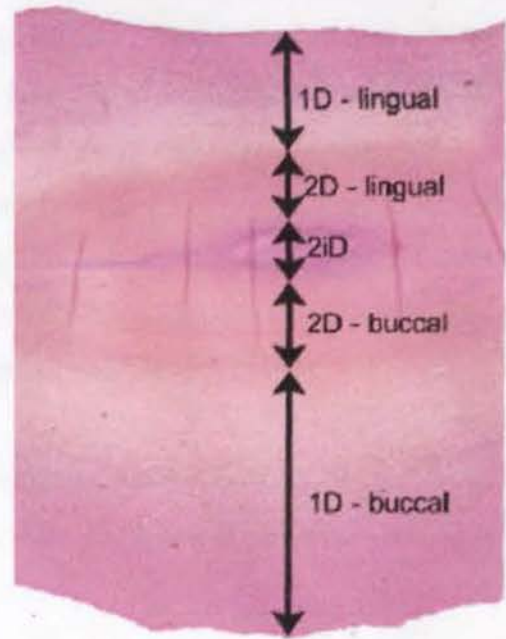


**Figure 3.7:** Decalcified transverse mid-section from a control CT 106 from a four-year-old horse. Green arrows indicate dentinal measurements made in a palatal direction, blue in a buccal direction, and brown for pulp diameter. Both rostral and caudal infundibular cementum is present (RIC and CIC respectively) and pulp chambers are numbered 1-6. (H&E x8)



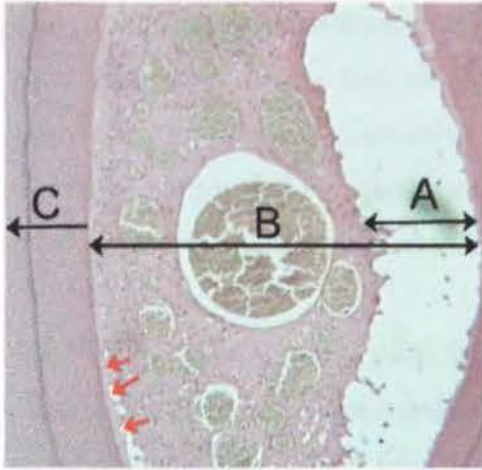
**Figure 3.8:** Decalcified sub-occlusal transverse section from CT 406 from a five-year-old control. Dentine and cementum are labelled, as are the six pulp chamber regions, all of which have been occluded by dentine. Green arrows indicate measurements made in a lingual direction, and blue for those in a buccal direction. An enlarged image of the boxed region surrounding pulp chamber 4 is presented in Figure 3.9. (H&E x8)

**Figure 3.9:** Insert from Figure 3.8 of dentine deposited within and fully occluding pulp chamber 4. Sites of measurements of primary dentine (1D), regular secondary dentine (2D) and irregular secondary dentine (2iD) are shown in both buccal and lingual directions. (H&E x128)



As well as measuring the thickness of the various types of dentine, the presence of intertubular dentine - indicating areas of more rapid or irregular dentine deposition - was recorded. The presence or absence of predentine was also recorded, as was the presence or absence of resting lines within the dentine.

Quantitative and qualitative measurements were taken for each pulp chamber area including measurements from the buccal to palatal (or lingual) side of each pulp chamber when chambers were still patent. Additionally, a measurement of the space present between pulp and dentine resulting from artefactual shrinkage was obtained (Figure 3.10). Qualitative records were made on the state of diseased pulps, such as where the pulp chamber had been filled with secondary or tertiary dentine, impacted with feed or if the pulp tissue was inflamed, necrotic or absent.



**Figure 3.10:** Transverse decalcified section through a control CT pulp chamber and adjacent dentine. Line 'A' is the distance of artefactual shrinkage of pulp, line 'B' is the complete palato-buccal pulp chamber diameter and line 'C' shows the transect line of the buccal dentine measurement. The red arrows indicate pale-staining predentine. (H&E x200)

These data were then compared between normal and diseased teeth of the same age, between differing age groups, between different teeth and between different endodontic regions within the same tooth and between teeth.

Although very little tissue was lost during processing in this study, one notable exception was the loss of 34 sections of fractured CT that were being prepared for decalcified microscopy. Having placed all of these sections in Surgipath Decalcifier II, all specimens were found to be destroyed by the solution when examined at their first examination, at 24 hours. Correspondence with the manufacturer revealed that the solution used on this particular occasion had been mixed to incorrect proportions and the batch was subsequently recalled.

However, undecalcified histological slides (Section 3.8.2) were available from all of these fractured CT to allow their examination, together with 13 decalcified sections processed in a later batch for decalcified histology.

### 3.8.2 Undecalcified Thin Sections

Eighty-eight control CT transverse (3<sup>rd</sup>) sections, 50 diseased CT transverse (3<sup>rd</sup>) sections and 21 sections from fractured teeth in various orientations, were dehydrated through a series of graded ethanol on a semi-automatic histokinette (Colombia Hendry, Slough,

UK). Following removal from ethanol, they were air dried at room temperature for 24 hours. The samples were then placed into a foil mould and cast into blocks using Epo-Thin resin (Buehler UK, Coventry, UK) - with 2% petropoxy blue dye (Buehler UK, Coventry, UK) added to help identify any remaining covering resin during the hand-grinding phase - and samples were left to set at room temperature for 24 hours.

Once set, samples were removed from the mould and excess resin was trimmed away using a diamond saw. The desired face of the sample was then hand ground, using a series of incrementally finer silicon carbide grit papers (240, 400, 800, 1200, 2500, and 4000 grit) (Buehler UK, Coventry, UK) to obtain a flat surface. Ilocut 430 (Castrol UK Ltd, Swindon, UK) was used as a non-water based lubricant for this and all further processing requiring cutting or grinding. Samples were then rinsed clean with acetone (VWR International Ltd, Poole, Dorset, UK).

The hand-ground surface was then bonded to a glass slide using Epo-Thin resin and left in a spring-loaded jig (Logitech Ltd, Glasgow, UK) for 24 hours. The samples were then removed from the jig and using a Petrothin cut-off saw (Buehler UK, Coventry, UK) with a diamond blade and vacuum mount, the mounted tissue blocks were cut to a thickness of 500µm. At this stage, the calcified tissues were already translucent to transmitted light and were checked for potential processing faults. In some cases it was necessary to re-mount the section, if bonding to the slide was thought inadequate to hold it through the remaining processing.

**Figure 3.11:** Logitech LP30 rotary lapping machine.



The 500 $\mu$ m thick sections were then placed onto a Logitech LP30 rotary lapping machine (Logitech Ltd, Glasgow, UK) (Figure 3.11) for 20 minutes with ethanediol as an initial lubricant, and 600 grit silicon carbide powder (Peter Wolters U.K. Ltd., London UK) with ethylene glycol constantly being drip-fed onto the contact surfaces. Following this, the sections were hand-lapped on a glass plate using 800 grit silicon carbide paper to give a fine finish and a final thickness of 60-70 $\mu$ m. The exposed surface was gently cleaned with acetone before being covered with a glass cover-slip using Eukitt adhesive (VWR International Ltd, Poole, Dorset, UK).

Dentinal measurements were made of 26 undecalcified control CT (3<sup>rd</sup> section) slides as described for decalcified slides (Section 3.8.1), and the results compared to the adjacent control decalcified (2<sup>nd</sup> section) transverse sections from the same CT. These data were correlated to the respective CAT scan image data when available. Control undecalcified slides were qualitatively assessed for artefact and any anatomical irregularities were recorded.

Undecalcified slides of apically infected CT and those with idiopathic dental fractures were examined under dissecting and light microscopy for any evidence of dental caries. The undecalcified slides from CT with idiopathic fractures had their fracture planes categorised, and any other pathological features recorded whilst being viewed under dissecting and light microscopy.

### **3.9 Scanning Electron Microscopy (SEM)**

Six of the 120 control CT initially collected to establish protocols for this study were used to gain experience at SEM processing before progressing to SEM of pathological specimens. No other control teeth were examined by electron microscopy in this study, this work having already been comprehensively performed at this institute by Kilic (1995).

A section from each of the 16 apically infected maxillary CT used in the initial pilot study (Section 3.6) was allocated to one of four groups, with each group then being randomly assigned for electron microscopy with either the EM505 SEM (Philips Electron Optics, Eindhoven, Netherlands); the XL30/CP SEM (Philips Electron Optics, Eindhoven, Netherlands); and either 'standard' or 'ion beam thinning' of specimens for viewing by the CM12 TEM (Philips Electron Optics, Eindhoven, Netherlands). Images from these four electron microscopic examinations were then compared.

### **3.9.1 EM505 SEM**

Following removal from 10% buffered formalin, dental sections were rinsed in tap water, before being acid-etched using 2.5M phosphoric acid (Fischer Scientific UK Ltd, Loughborough, UK) for 45 seconds to clear the surface of organic debris and to highlight remaining calcified features (Kilic 1995). The sections were then rinsed in running tap water for one minute before having 2% hypochlorite (Milton Chemicals, UK) dripped over the surface for 30 seconds. The sections were rinsed again under running tap water for 30 seconds, rinsed in distilled water for 30 seconds and then labeled, before being stored in sodium cacodylate buffer (Agar Scientific Ltd., Stanstead, UK). The samples were temporarily stored at 4°C until a batch was ready to undergo dehydration in a series of graded acetone (10 minutes each in 50%, 70%, 90%, and finally three 10 minute baths in 100% acetone) while being stirred with a magnetic mixer.

Following removal from acetone, samples were placed in wire baskets and critically point dried in preparation for sputter-coating using carbon dioxide in an E3000 SII Jumbo Critical Point Drying Apparatus (Polaron, Watford, Hertfordshire, UK). Upon removal from their baskets, samples were mounted on aluminium stubs (Agar Scientific Ltd., Stanstead, UK) with double-sided tape in correct orientation for viewing, and sputter coated with 20nm T8843 Gold (60) / Palladium (40) (Emtech Ltd., South Stour Avenue, Ashford, Kent, TN23 7RS, UK) in an SC500 sputter coater (EMScope Laboratories Ltd., Ashford, Kent, UK).

These pathological samples were viewed in the EM505 SEM and the appearance of the calcified dental tissues noted, with areas of interest being photographed. In addition to the maxillary CT sections imaged during the pilot study, 35 regions from the 20 CT with idiopathic fractures were examined using this same protocol and qualitative records and photographs were taken.

### **3.9.2 XL30/CP SEM**

Prior to processing the 16 maxillary CT samples from the pilot study, eight control CT from previous work (Section 3.2) were used to optimise a protocol for processing equine dental tissue for examination in a semi-environmental SEM.

Dental sections were removed from 10% buffered formalin and washed in tap water for 10 minutes before being placed on paper towels to air dry for 1, 24 or 120 hours. Half the sections were then dehydrated further through a series of acetone baths (20 minutes in 50% acetone; 20 minutes in 75% acetone; 20 minutes in 90% acetone and finally three 20 minute baths in 100% acetone while being stirred with a magnetic mixer), while the other half were dehydrated through a series of ethanol baths (20 minutes in 50% ethanol; 20 minutes in 75% ethanol; 20 minutes in 90% ethanol and finally three 20 minute baths in 100% ethanol).

Following dehydration, specimens were left to dry overnight and carbon-coated the following day in an Edwards High Vacuum Coater (BOC Group, Crawley, Sussex, UK) before being placed in the XL30/CP SEM (Philips Electron Optics, Eindhoven, Netherlands) for examination. Aside from being able to examine larger samples (<5cm c.f. <2cm in the EM505 SEM), the semi-environmental SEM was able to run semi-quantitative line-profile element analysis of these eight samples. In this pilot study a broad spectrum of elements were chosen including calcium, phosphorous, carbon, chlorine, nitrogen, oxygen, magnesium and silicone.

## 3.10 Transmission Electron Microscopy (TEM)

### 3.10.1 Preparation for Examination in a Philips EM400 TEM

Samples selected for TEM were not decalcified, as had been the case in previous studies (Kilic 1995). Areas of predominantly pulp, with a small amount of dentine attached were selected from 10 areas of four CT in this pilot study.

After removing the transverse sections from 10% buffered formalin, areas of interest were dissected using a diamond saw, before placing the tissue into 3% gluteraldehyde in sodium cacodylate buffer for a further week of fixation. The specimens were then removed from this fixative and after post-fixation with 1% osmium tetroxide (Johnson Matthey PLC, Royston, Hertfordshire, UK) in sodium cacodylate buffer, they were washed three times for 20 minutes in distilled water.

After washing, the specimens were dehydrated in a series of graded acetone and infiltrated with a mixture of dodecyl succinic anhydride (DDSA) (Agar Scientific Ltd., Stanstead, UK) and araldite CY212 (Agar Scientific Ltd., Stanstead, UK). An accelerator containing 67% dibutylphthalate and 33% dimethylaminomethyl (DMP)-30 (Agar Scientific Ltd., Stanstead, UK) was added to the DDSA / araldite mixture to harden it.

Once set, the resin block was trimmed with a hacksaw, prior to mounting on a Reichert Ultramicrotome OMU4 (Leica UK Ltd., Milton Keynes, UK). One-micrometer thick sections were cut using a glass knife, and were then stained with toluidine blue to allow areas for TEM examination to be selected under light microscopy. Using the above ultramicrotome, 60nm thick sections were cut and mounted on copper discs, stained with uranyl acetate LKB Ultrastainer (Leica UK Ltd., Milton Keynes, UK) and lead citrate and examined in the EM400 TEM.

### **3.10.2 Ion Thinning for Examination in a CM12 TEM**

To allow areas of undecalcified dental tissue (e.g. enamel) to be examined under TEM, an alternative to the above technique was assessed using the Department of Geology's ion thinning equipment.

Following removal from 10% buffered formalin, the sections were rinsed in tap water, and the viewing side of the section was hand-ground using Beuhler-Met metallographic grinding paper (400 grit paper followed by 800 grit paper) until score marks from the diamond saw were no longer visible. The sections were then air-dried, before being glued to glass slides with RS850-940 Quick Set Epoxy adhesive (R.S. Components, Corby, UK). The same procedure was then carried out to the reverse side, before sections were polished using a Lapmaster 15 lapping machine (Payne Products International, Ivybridge, Devon, UK) with a Hyprocel Pellon polishing cloth (Kemet International, Maidstone, Kent, UK) and a 0.3 $\mu$ m aluminium oxide particle suspension (Abralox, Peter Wolters U.K. Ltd., London UK).

Following the above double polishing, selected areas were mounted on 3mm copper discs with a central aperture 1000 $\mu$ m in diameter. An argon beam was focused onto the sample over this aperture, and the sample progressively thinned using an Atom-Tech ion mill (Ion-Tech, Teddington, UK). Once thinned, samples were carbon-coated and viewed in a EM400 TEM.

Areas that could be effectively examined using this technique were very limited and contained significant artefacts so this technique was discarded.

### 3.11 Statistical Techniques

Normally distributed data are presented as mean and standard deviation or mean and standard error of mean. These data were analysed using parametric techniques, usually analysis of variance (ANOVA) and Student's t-test.

Non-normally distributed data are presented as a median and range. Statistical comparisons were made using non-parametric statistical analysis, i.e. the Mann-Whitney test for comparing two groups, and the Kruskal-Wallis test for comparing more than two groups. Statistical calculations were made using Minitab 14 computer statistical package (Minitab Ltd., Coventry, UK) and GraphPad Prism version 4.00 for Windows (GraphPad Software, San Diego, California, USA).

## **Chapter Four: Control Cheek Teeth Results**

### **4.1 Introduction**

Although equine teeth have been closely examined through several millennia (Kertesz 1993), data regarding their endodontic anatomy and histological features is still incomplete. In addition to their principle role as control specimens to the pathological CT examined in this study, 100 clinically healthy CT (51 maxillary and 49 mandibular) were examined using gross anatomical, dissecting microscopy, histological and radiological techniques developed in this study. Using these previously described imaging techniques (Chapter 3), it was hypothesised that the nature, frequency and accurate quantification of numerous normal anatomical features, including endodontic arrangement and dentine classification, would be possible. These 100 control CT had a median dental age of four years (range 0-12 years). Fifty-six of these CT were measured and had a median length (occlusal to apical limits) of 85mm (range 38-102mm).

### **4.2 Endodontic Anatomy**

As noted, there has been incomplete reporting of the equine CT endodontic system to date. Whilst the mid-four CT (Triadan 07-10) have been reported as having five endodontic pulp chambers extending occlusally from a common pulp chamber (Baker 1970; Kirkland 1994), the anatomy of the Triadan 06 and 11 CT does not appear to have been reported, and so the proposed CT endodontic nomenclature (Section 3.7) was evaluated.

#### **4.2.1 Verification of Endodontic Anatomy**

Following transverse sectioning of 88 control CT at three levels (sub-occlusal, mid and apical; Figures 3.3 and 3.4), the sections were examined under a dissecting microscope and the position of each pulp chamber in each section was recorded. Firstly it was established if an endodontic system was present as described in Section 3.7, and secondly what the status of the endodontic anatomy was for a given tooth and a given dental age, i.e. if pulp chambers communicated, were single, or had been

present and then filled with dentine. This was determined at sub-occlusal, mid and apical levels. Results are presented in Tables 4.1-3.

Dental age (years):	Triadan No:	106	107	108	109	110	111	306	307	308	309	310	311	<b>Total CT Examined</b>
		206	207	208	209	210	211	406	407	408	409	410	411	
0-1				4/4			2/5		1/1	3/3			2/2	15
1.5-3		3/3	2/2	1/1	2/2	3/3	1/2	3/3	2/2	1/1	1/1	3/3	1/1	24
3.5-5		1/1	1/1	2/2	2/2	1/1	6/6	1/1	2/2	1/1	2/2	1/1	3/3	23
5.5-7		2/2		1/1	3/3	2/2		1/1		1/1	3/3	2/2		15
7.5-9		1/1	2/2	1/1		1/1	1/1	1/1	2/2	1/1		1/1	1/1	12
9.5-11					2/2		1/1				2/2			5
11+			1/1				1/1			1/1				3
CT In Agreement with Proposed Endodontic Anatomy		7/7	6/6	9/9	9/9	7/7	12/16	6/6	7/7	8/8	8/8	7/7	7/7	97 (88+9)

**Table 4.1:** The number of control CT for a given dental age and Triadan position whose endodontic anatomy was in agreement with the proposed CT endodontic system (Section 3.7) when the transverse sub-occlusal and mid sections were examined. Only the maxillary Triadan 11 CT were not in 100% agreement with the proposed endodontic anatomical system (red numerals).

It was found that all mandibular CT, and maxillary Triadan CT in Triadan positions 06-10 agreed with the proposed endodontic system as described in Section 3.7, i.e. that the middle four (maxillary and mandibular) CT (Triadan 07-10) consistently contained five pulp chambers arising from a common pulp chamber. The first CT (Triadan 06) in all four CT rows consistently had an additional smaller pulp chamber, rostral to the other five pulp chambers, and that the sixth mandibular CT (Triadan 311 & 411) had five pulp chambers with an additional caudal pulp chamber.

The maxillary Triadan 11 CT had pulp chambers 1-5 present consistently as proposed, however the two caudal horns (7 and 8) were present in the sub-occlusal section of only 12/16 (75%) maxillary Triadan 11 CT. In all four CT where pulp chambers 7 and 8 were not present, the tooth's dental age was less than three years. However, further examination of more apical sections of these four teeth using a dissecting microscope

and use of CAT scan examinations in three of these CT, identified that pulp chambers 7 and 8 were present in all four teeth.

In conclusion, the proposed equine endodontic CT anatomy was present in all teeth examined, but pulp chambers 7 and 8 in maxillary Triadan 11 CT were not present near the occlusal surface in young teeth (<3 years dental age).

## 4.2.2 Endodontic Status

### Sub-occlusal and mid transverse sections

Decalcified sub-occlusal and mid transverse CT sections were histologically examined to determine whether the pulps horns had been occluded (filled with dentine) or still contained dental pulp (Table 4.2). In only two maxillary CT of 88 control CT examined, was pulp absent in (two) pulp chambers within the mid transverse section. However, the presence of pulp was much more variable in sub-occlusal transverse sections.

Pulp chamber number	% of pulp chambers with pulp in sub-occlusal horn chambers (n)	% of pulp chambers with pulp in mid horn chambers (n)
Maxillary 1	40 (12/30)	100 (38/38)
Maxillary 2	38 (13/34)	100 (35/35)
Maxillary 3	16 (5/31)	95 (35/37)
Maxillary 4	19 (7/36)	94 (34/36)
Maxillary 5	30 (9/30)	95 (37/39)
Maxillary 6	0 (0/6)	100 (5/5)
Maxillary 7	50 (2/4)	100 (4/4)
Maxillary 8	50 (2/4)	100 (4/4)
Mandibular 1	24 (9/38)	100 (33/33)
Mandibular 2	17 (6/41)	100 (32/32)
Mandibular 3	21 (8/39)	100 (32/32)
Mandibular 4	5 (2/41)	100 (31/31)
Mandibular 5	12 (5/42)	100 (33/33)
Mandibular 6	50 (2/4)	100 (4/4)
Mandibular 7	50 (2/4)	100 (4/4)

**Table 4.2:** The percentage of pulp chambers with viable pulp tissue still present in sub-occlusal and mid transverse sections of 88 control CT.

Those sections containing pulp were also assessed as to whether they still communicated with any other pulp chambers, as shown in Table 4.3. Mid transverse sections of the 88 control CT showed communication between one or more pulp chambers in 7/45 (16%) of maxillary and 16/43 (37%) of mandibular CT. This difference was found to be statistically significant ( $\text{Chi}^2=26.4$ ;  $p<0.001$ ).

Maxillary CT most commonly had communications between pulp chambers 3 and 5 (6/7 CT), with these seven CT having a mean dental age of two years. Mandibular CT most commonly communicated between pulp chambers 3 and 5 (10/15) and these 15 CT had a mean dental age of 4.5 years. It should be remembered that these pulp chamber numbers refer to different pulp chambers for maxillary and mandibular CT (Figures 3.5 and 3.6).

Control Tooth Number	Triadan Number	Section	Communicating Pulp	Dental Age (years)
1	106	Mid	3 & 5	1.5
25	106	Mid	3 & 5	2.5
26	107	Mid	3 & 5	1.5
2	108	Mid	3 & 5	0
27	108	Mid	3 & 5	1
29	110	Mid	3 & 5	3
54	111	Mid	1 & 3; 2 & 7	4.5
11	306	Mid	1 & 6	1.5
31	306	Mid	1, 4 & 6	2.5
32	406	Mid	1, 4 & 6	2.5
75	406	Mid	1, 2 & 4	8.5
61	307	Mid	3 & 5	4.5
34	408	Mid	3 & 5	1
46	409	Mid	3 & 5	6
66	409	Mid	3 & 5	7
86	409	Mid	3 & 5	11
14	310	Mid	3 & 5	2
36	410	Mid	3 & 5	3
47	410	Mid	3 & 5	5
67*	410	Mid	Unavailable*	6
48	411	Mid	1 & 4, 3 & 5	3.5
65**	311	Sub-occlusal**	1 & 4	4.5
68	411	Mid	1 & 4, 3 & 5	4.5

**Table 4.3:** Details of seven maxillary and 16 mandibular control CT identified as having communicating pulp chambers. In CT 67\* it was not possible to identify pulp chamber communications in this section as the pulp chambers had abnormal positioning. In CT 65 \*\* pulp horns 1 and 4 were joined in the sub-occlusal section, with the tooth's endodontic system differing from the pattern usually seen in mid sections in all others.

### Apical transverse sections

Even though transverse apical sections were taken immediately above the root furcation, 92% of maxillary control CT had peripheral enamel present at this level, indicating this region to be reserve crown and not true root, i.e. an enamel free area.

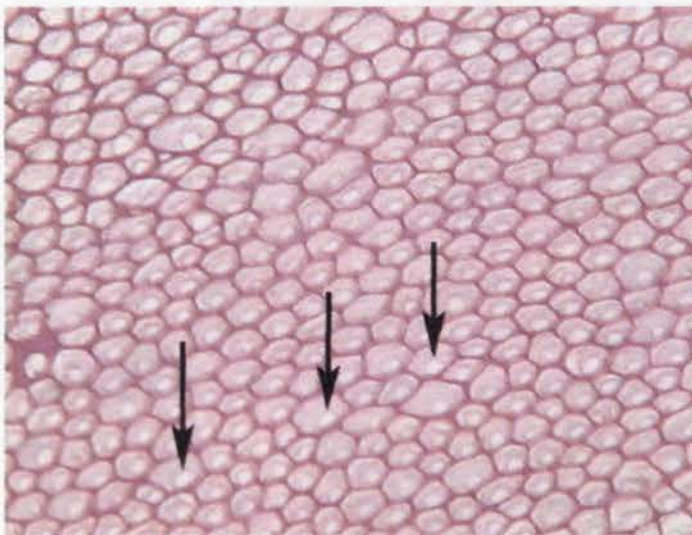
Thirty-one percent of maxillary sections had both of their infundibula present, 23% had one present, and 46% had both absent at this apical level. The endodontic features present in maxillary apical transverse sections were more irregular than those present in sub-occlusal or mid transverse sections. A single common pulp chamber was present in 13% of teeth, two in 13%, three in 27%, four in 26% and five in 21%.

Eighty-nine percent of transverse apical sections of mandibular CT sectioned immediately above their root bifurcation still contained (peripheral) enamel. Endodontic features were irregular, with 7% of mandibular apical sections having a single pulp chamber; 37% having a rostral and caudal pulp chamber; 33% having three canals (with the caudal pulp often dividing in two again having become single more occlusally); 13% with four canals; 7% with five canals; and 3% with six canals.

### 4.3 Normal Histological Structure

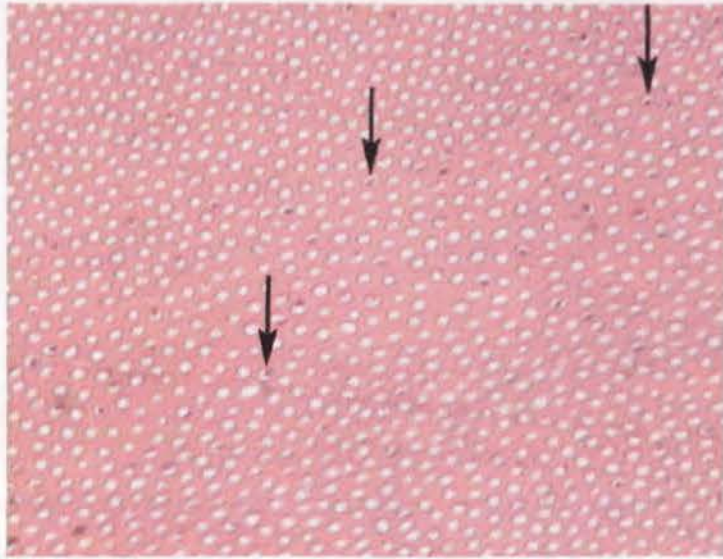
#### 4.3.1 Decalcified Histological Structure

Having improved on the previously described methods for histologically processing equine dental tissues (Section 3.8), images were of superior quality. The following are examples of undecalcified and decalcified equine dental histological sections from control CT.

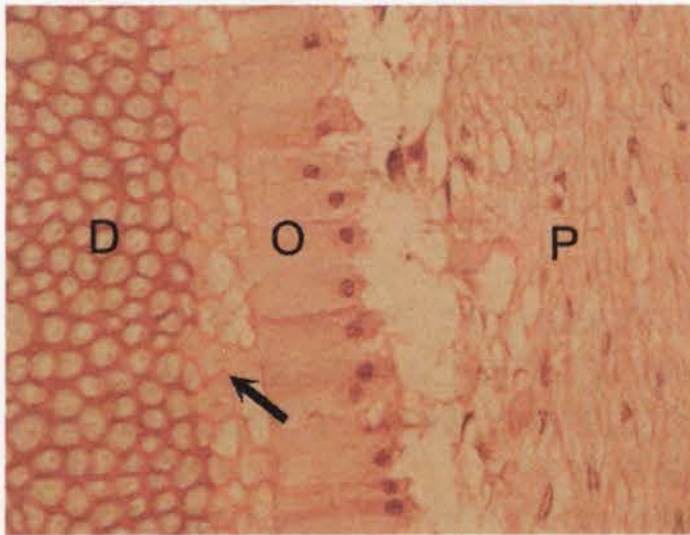


**Figure 4.1:** Normal equine primary dentine from a decalcified transverse section of a control CT, showing the typical honeycomb pattern of intertubular dentine. Within this network, lighter staining organic remnants of now demineralised intratubular (previously termed

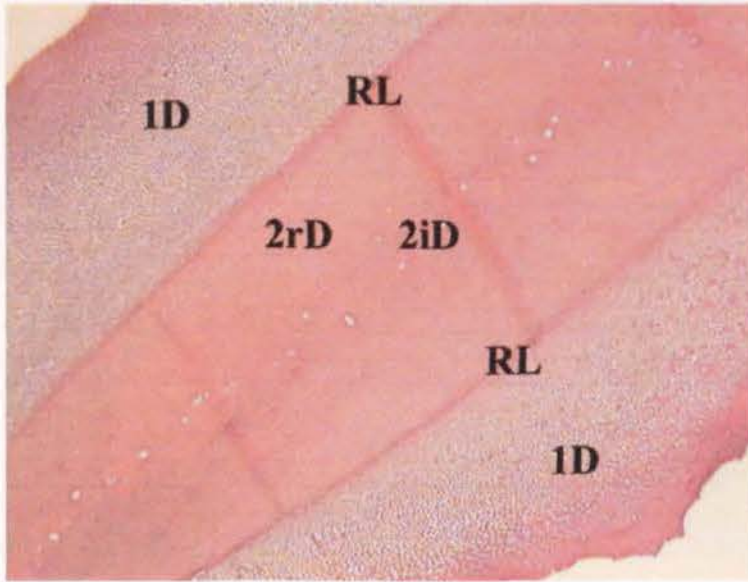
peritubular) dentine remain, with pale circular areas (↓) of the dentinal tubules, previously occupied by odontoblast processes still evident. (H&E x200)



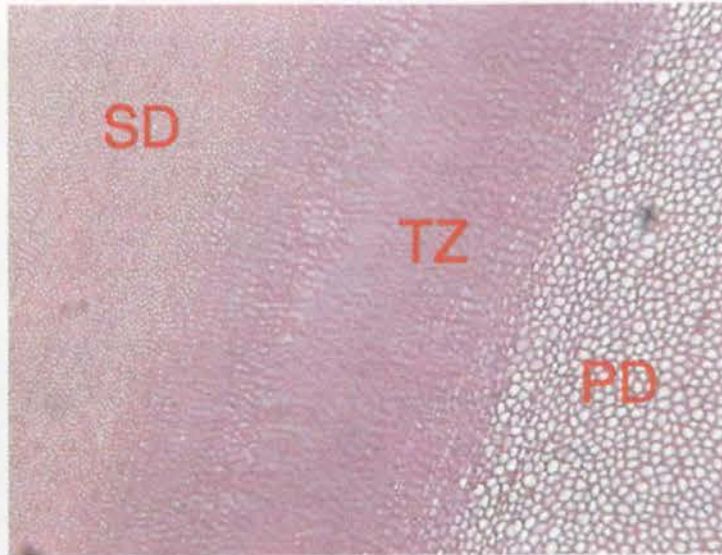
**Figure 4.2:** Normal equine regular secondary dentine in transverse section from a control CT. The absence of intratubular dentine and a greater proportion of intertubular dentine makes regular secondary dentine appear very different to primary dentine. Remnants of odontoblast processes still remain (following processing) in some of the dentinal tubules (↓). (H&E x200)



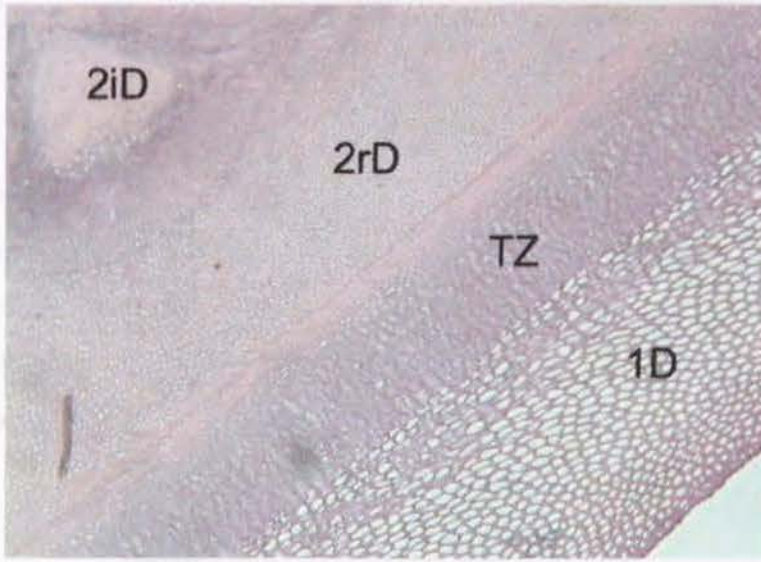
**Figure 4.3:** Decalcified transverse section from a control CT showing odontoblast cells (O) withdrawing towards the centre of the pulp (P) whilst laying down a secretory matrix of predentine i.e. the paler staining layer (←) adjacent to dentine (D). (H&E x400)



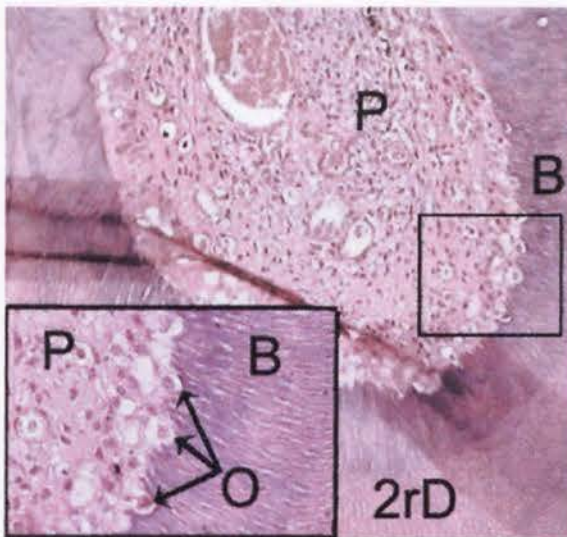
**Figure 4.4:** Decalcified, transverse histological section through a control mandibular CT pulp chamber that has become completely filled with secondary dentine. Primary equine dentine (1D) is positioned peripheral to the more centric regular secondary dentine (2rD) and irregular secondary dentine (2iD), with a resting line (RL) present between the primary and secondary dentine. (H&E x40)



**Figure 4.5:** Decalcified transverse section through a control mandibular CT. In contrast to Figure 4.4 this section shows a transition zone (TZ) between primary (PD) and secondary (SD) dentine and contains no resting lines. (H&E x100)



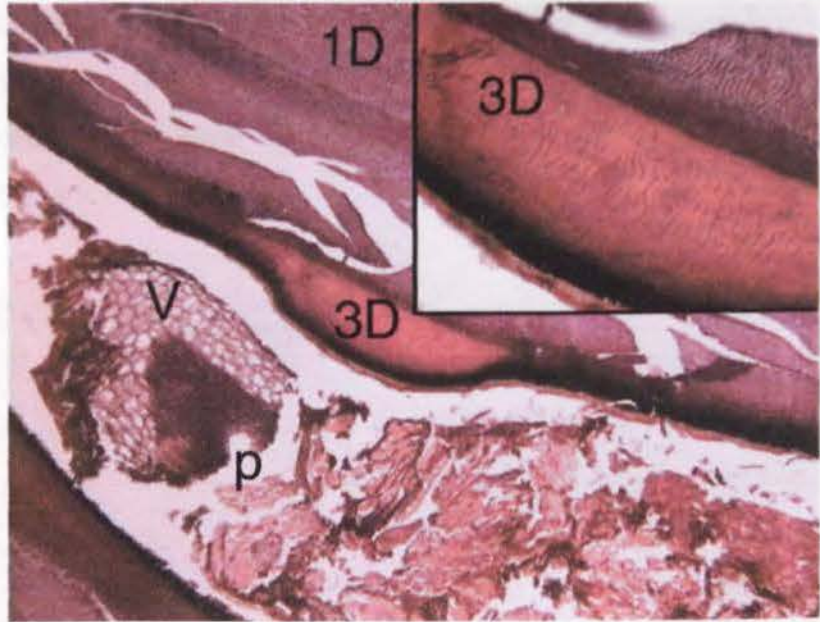
**Figure 4.6:** As odontoblasts retreat towards the centre of the pulp prior to eruption of the tooth, they lay down primary dentine (1D). They then deposit regular secondary dentine (2rD) after occlusal contact is made with the opposing tooth. Finally, irregular secondary dentine (2iD) occludes the pulp chamber completely under normal conditions. A transition zone (TZ) between primary and regular secondary dentine is present in this section. (H&E x100)



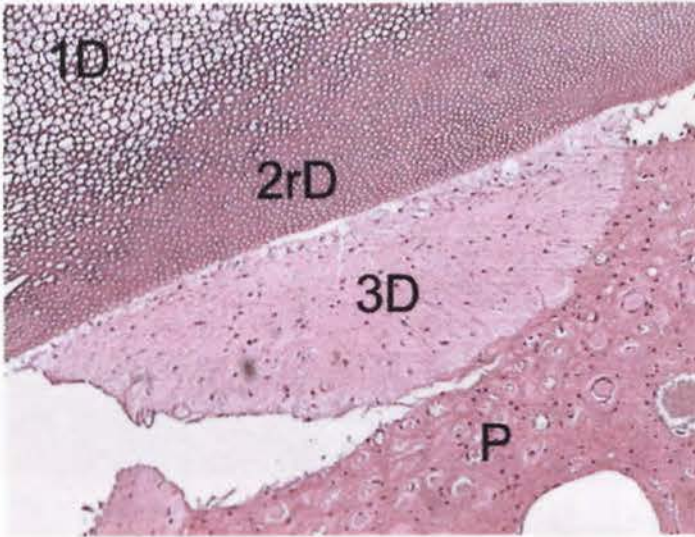
**Figure 4.7:** Decalcified transverse histological section through a control maxillary CT pulp chamber. A basophilic staining line (B) occurs where the dentine changes orientation from regular secondary dentine (2rD) to what will become irregular secondary dentine. Odontoblasts (O) are seen at the margin of the pulp (P) - as shown more clearly in the enlarged insert

(lower left). Note the change in orientation of the dentinal tubules within the basophilic line, as shown by their being sectioned in a more longitudinal plane. (H&E x100, insert x200)

**Figure 4.8:**  
Decalcified  
transverse  
histological section  
through a maxillary  
CT pulp chamber  
from a pathological  
specimen. This  
pathological  
specimen is  
included here to

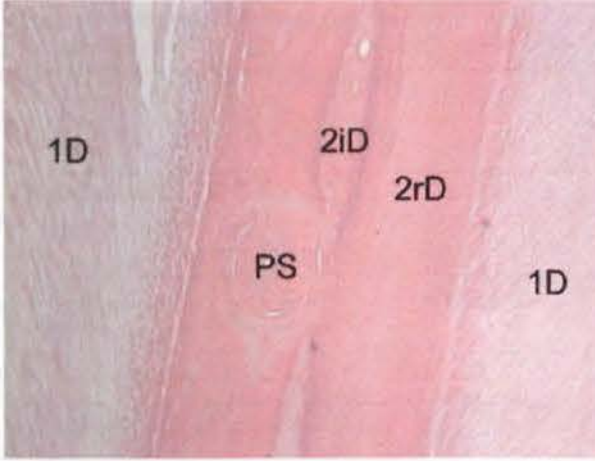


show an example of equine tertiary dentine. Tertiary dentine (3D) has been laid down within the pulp of this CT in response to focal noxious stimuli. As seen more clearly in the insert (top right), there is no continuity of dentinal tubules into this tertiary dentine (as occurs between primary and secondary dentine). In this diseased CT, the pulp (P) has become exposed on its occlusal surface through dental attrition, resulting in the pulp chamber filling with vegetable material (V) with subsequent infection and destruction of the remaining pulp. (H&E x40, insert x100)



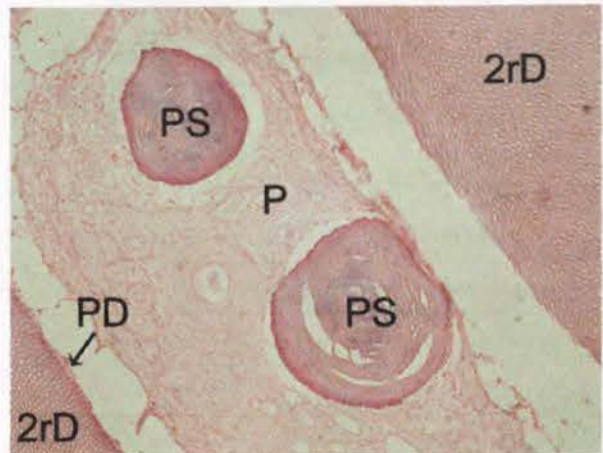
**Figure 4.9:** Decalcified transverse section from a diseased mandibular CT showing partially mineralised tertiary dentine (3D) being focally laid down adjacent to the pulp periphery (P), on previously deposited primary (1D) and secondary dentine (2D). (H&E x100)

True pulp stones contain dentinal tubules and may have an outer layer of predentine and odontoblasts (Soames & Southam 1993d). False pulp stones (as were present in this study) are composed of concentric layers of calcified material with no tubular structure (Figures 4.10 and 4.11).

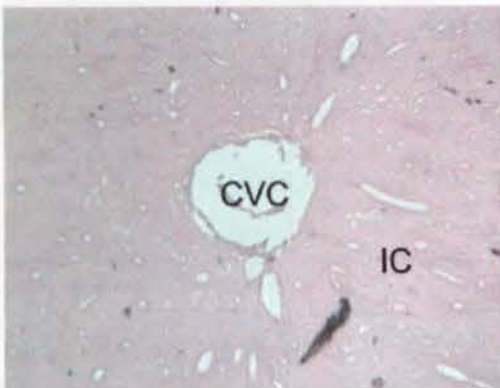


**Figure 4.10:** Longitudinal decalcified section from a control CT showing a pulp stone (PS) that has become surrounded by regular (2rD) and irregular (2iD) dentine. Primary dentine (1D) laid down before the tooth came into occlusal contact lies peripheral to the secondary dentine. (H&E x40)

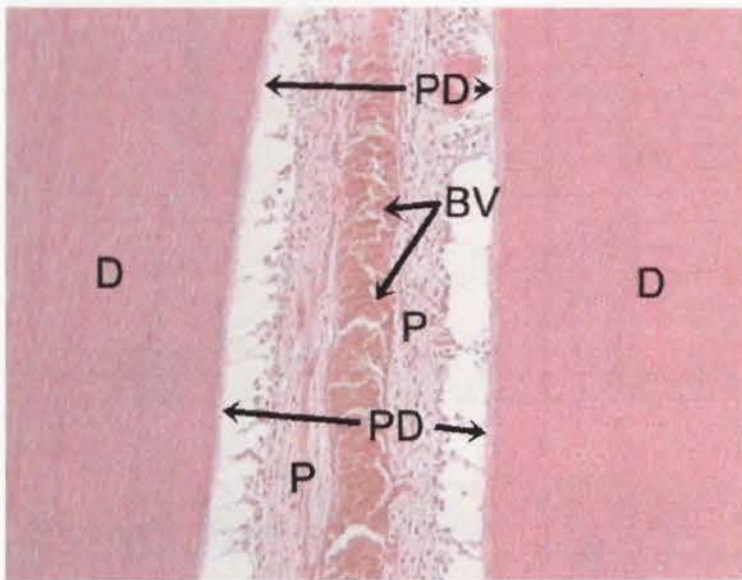
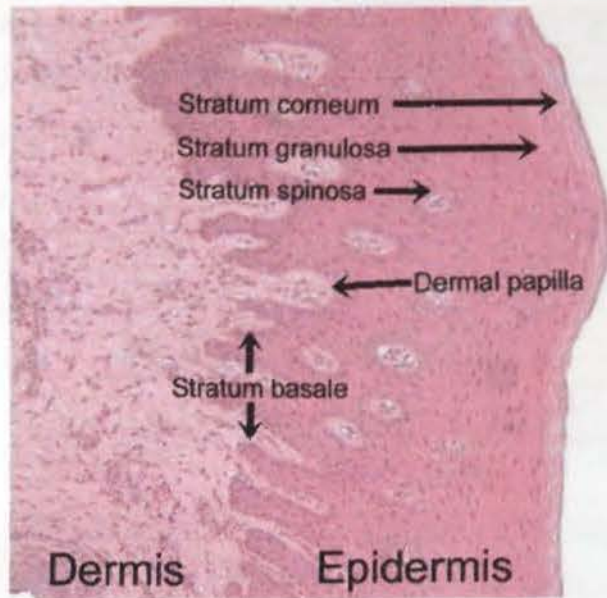
**Figure 4.11:** Transverse decalcified section from a control CT showing two pulp stones (PS) within a partially autolysed pulp (P). The pulp has shrunk (artefactually during specimen preparation) from the linear area of pale-staining predentine (PD) on the margin of fully mineralised secondary regular dentine (2rD). (H&E x100)



**Figure 4.12:** Decalcified transverse section of the infundibular cementum (IC) of a maxillary CT showing the central vascular channel (CVC) i.e. the central area of the infundibulum that was occupied by a blood vessel prior to eruption. (H&E x40)

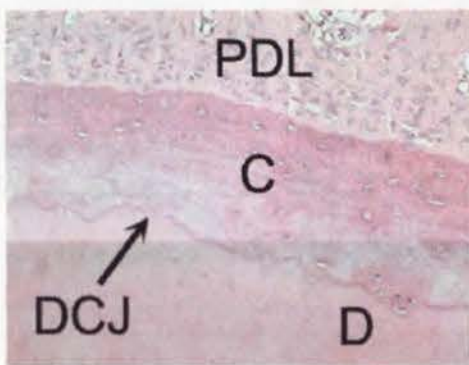


**Figure 4.13:** Transverse section of gingival tissue that was attached to a control CT. Zones of keratinised and non-keratinised epithelial cells make up the epidermis. Some of the paler staining underlying dermis is also present. (H&E x100)



**Figure 4.14:** Longitudinal decalcified section from a control maxillary CT. The pulp (P) within the pulp chamber has shrunk away from the predentine (PD) due to poor tissue fixation. A large blood vessel (BV) containing red blood cells is present


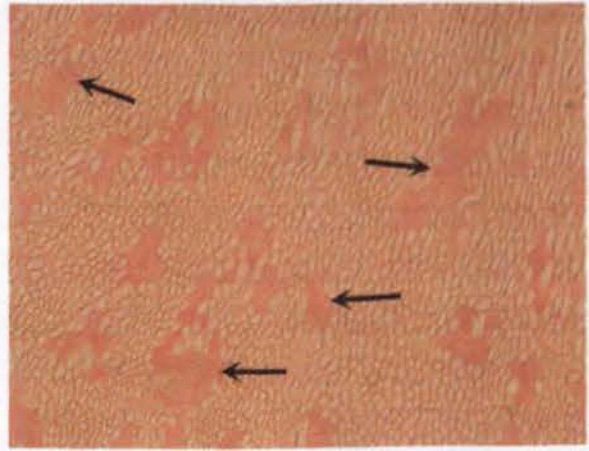
within the central region of the pulp (D=dentine). (H&E x100)



**Figure 4.15:** Decalcified transverse apical section from a control CT root showing the direct contact between dentine (D) and cementum (C) at the dentino-cemental junction (DCJ) (i.e. true tooth root dentine) and adjacent periodontal ligament (PDL). The lower third of the image is darker from artefact when the slide underwent digital scanning.

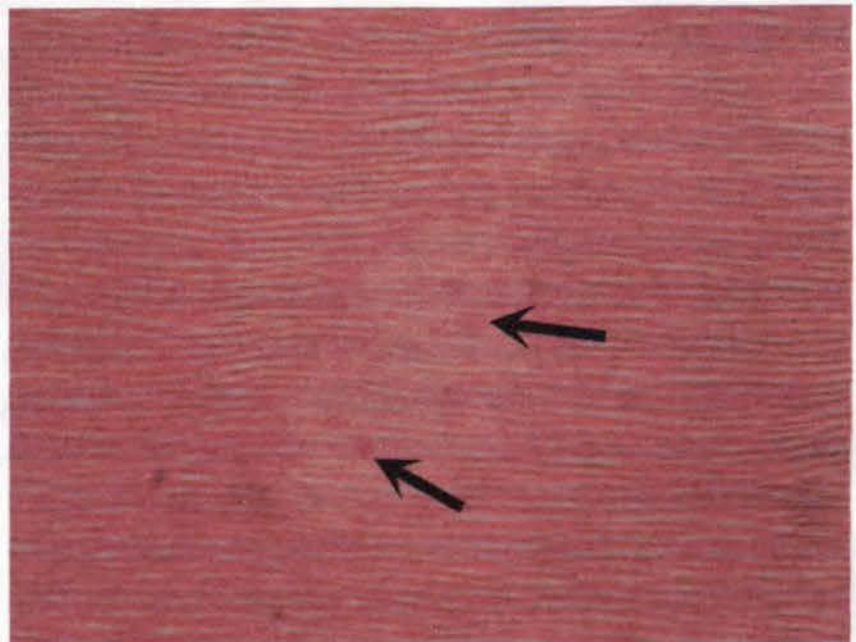
(H&E x200)

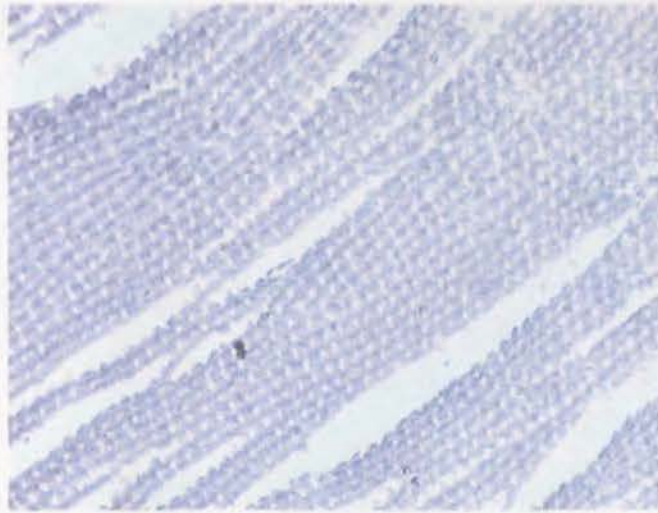
**Figure 4.16:** Decalcified transverse section from a control CT with areas of intertubular dentine (arrows) present within primary dentine. Such areas of intertubular dentine are associated with rapid dentine deposition. (H&E x200)



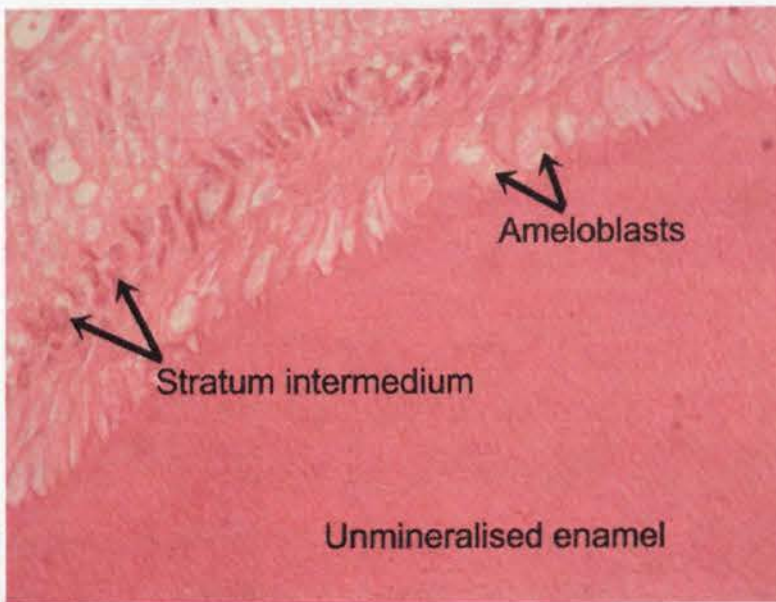
**Figure 4.17:** Decalcified longitudinal section from a control CT showing dentine with areas of partially mineralised interglobular dentine present (arrows). (H&E x100)

**Figure 4.18:** A higher magnification of a decalcified longitudinal section from a control CT showing areas of interglobular dentine. Individual mineralised calcospherites can be seen (arrows) in this section. (H&E x200)

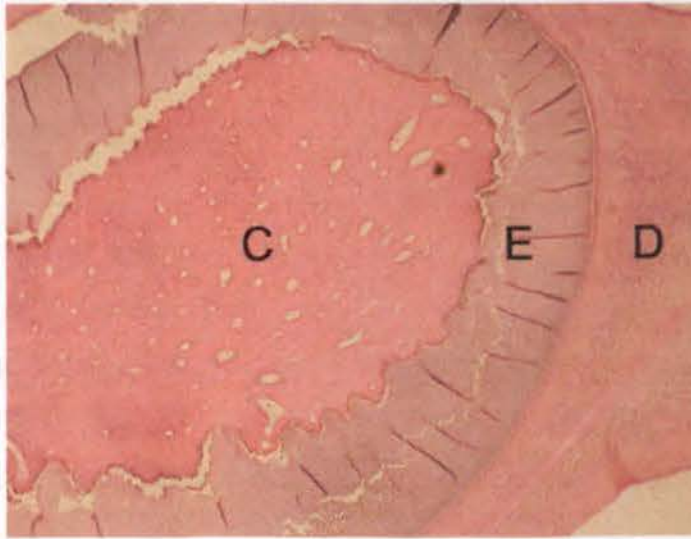




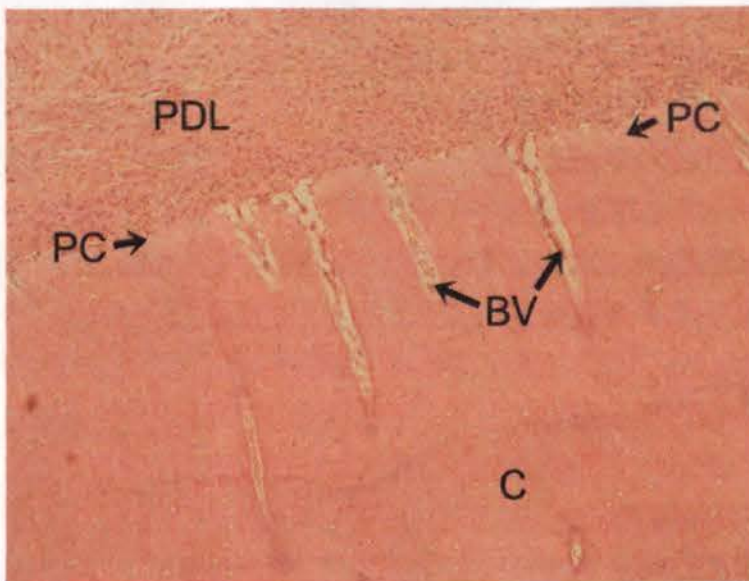
**Figure 4.19:** Decalcified transverse section from a control CT showing what are believed to be remnants of enamel rods present in equine type-1 enamel. These have been left after loss of the mineral portion (~98%) of the enamel during demineralisation, prior to the tissue being further processed for histological sectioning. (H&E x400)



**Figure 4.20:** An apical transverse decalcified section from a recently erupted 411 control CT. Developing, but not fully mineralised enamel is present, having been deposited by a row of ameloblasts that are now partially autolysed due to poor tissue fixation. The cell rich *stratum intermedium* lies between the ameloblasts and the rest of the pulp. (H&E x600)

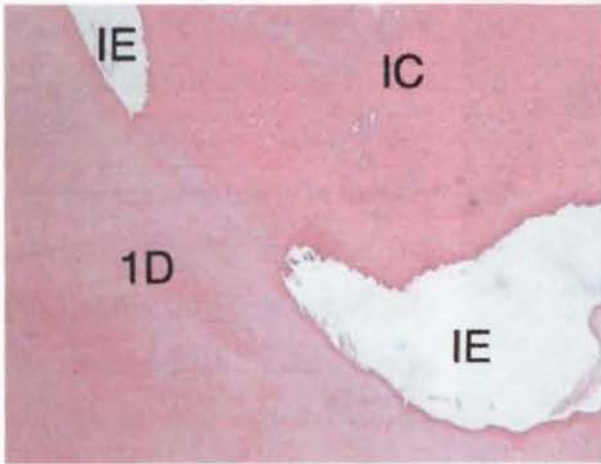
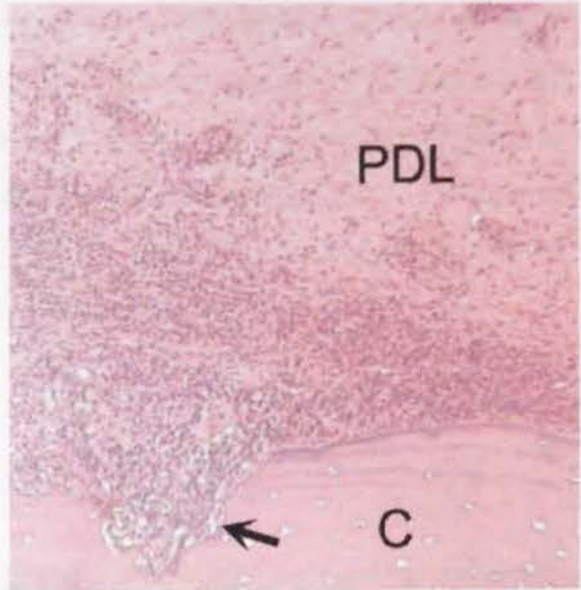


**Figure 4.21:** Decalcified transverse mid section from a control 310 CT, from a four-year-old horse. A band of enamel (E) remains between the cementum (C) and dentine (D). (H&E x40)



**Figure 4.22:** Transverse decalcified section from a control CT. A pale-staining layer of pre-cementum (PC) is present between cementum (C) and the periodontal ligament (PDL). At the periodontal margin, blood vessels (BV) are seen entering the cementum from the periodontal ligament. (H&E x100)

**Figure 4.23:** Transverse decalcified section from an (equine) cheek tooth with a localised periodontitis, as indicated by a neutrophilia, present within the periodontal ligament (PDL). The periodontal inflammation is adjacent to a defect (←) in the cementum (C) that may have arisen following carious attack. (H&E x100)

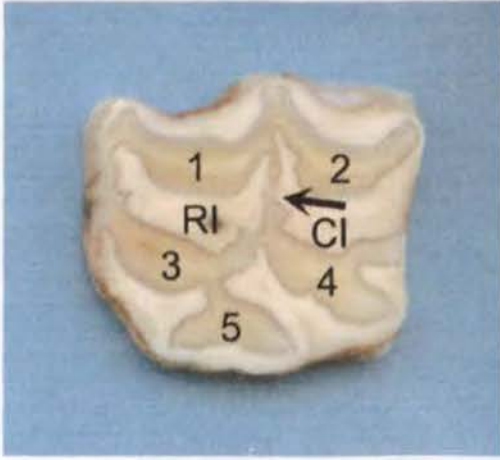


**Figure 4.24:** Decalcified longitudinal section of the apical aspect of a control maxillary CT infundibulum. The infundibular cementum (IC) is in direct contact with primary dentine (1D) because infundibular enamel (IE) has failed to develop at this local region i.e. localised enamel hypoplasia. As this

is a decalcified histological section, the region previously filled with (highly mineralised) infundibular enamel is empty. (H&E x200)

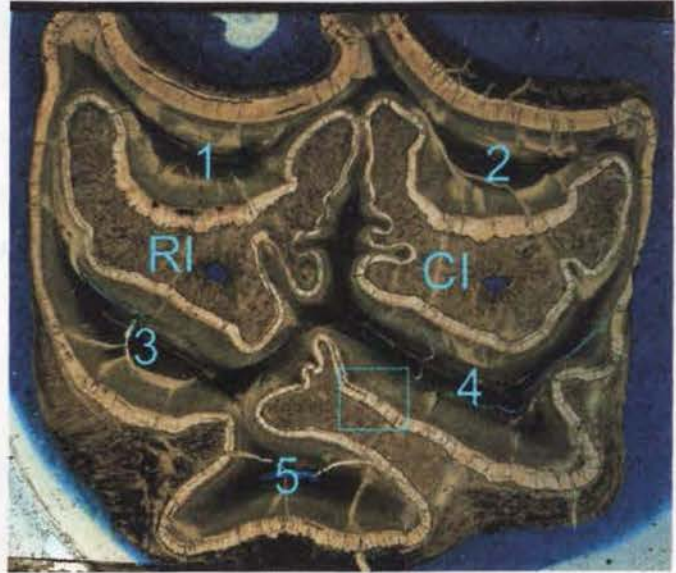### 4.3.2 Undecalcified Histological Structure

In one control maxillary CT (Triadan 108), the rostral and caudal infundibula were found to communicate in the occlusal third of the tooth (Figure 4.24). This feature was not observed in any other control or in any diseased specimen.




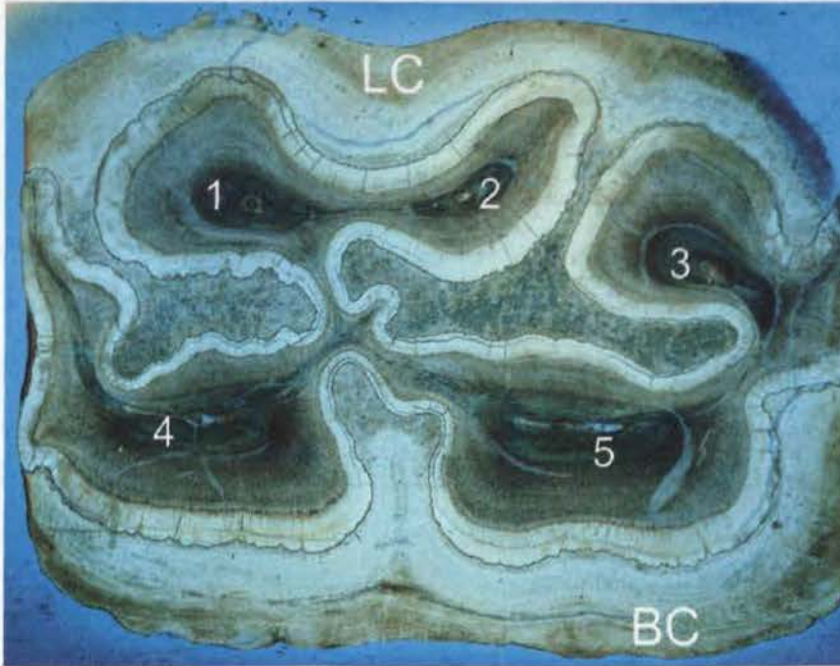
**Figure 4.24:** Transverse section from the occlusal third of a control maxillary 108 CT. Pulp chambers (1-5) have been occluded with secondary dentine. An arrow indicates where the rostral (RI) and caudal infundibula (CI) communicate.

**Figure 4.25:** Undecalcified transverse section 3 (i.e. sub-occlusal - Section 3.6) from a 14-year-old control horse, Triadan 109 CT. Pulp chambers 1-4 have become occluded with secondary dentine, and pulp chamber five has lost the small amount of pulp remaining within its horn during processing. The area within the inserted box is shown in Figure 4.26 below. (RI = rostral infundibulum; CI = caudal infundibulum). (Unstained, viewed under normal transmitted light, x6)

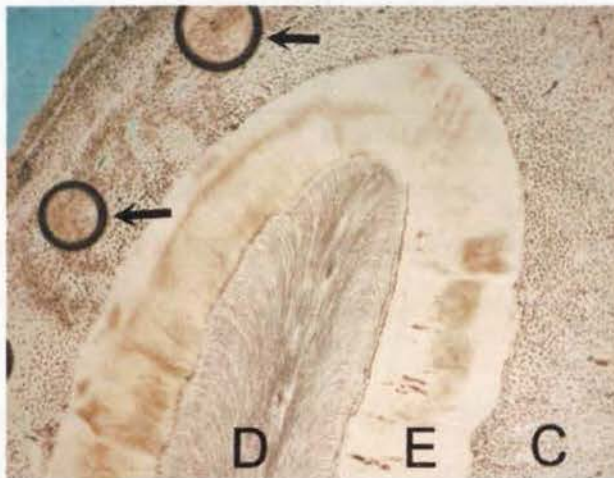


**Figure 4.26:** Magnified view of the highlighted area within Figure 4.25 showing enamel (E), dentine (D) and cementum (C). Artefactual fracture lines (arrows) have arisen in enamel and dentine during tissue processing. (Unstained x20)





**Figure 4.27:** Transverse undecalcified sub-occlusal section from CT 408 from a 16-year-old control horse. Pulp chambers are numbered (1-5). There is a greater amount of buccal cementum (BC) present than lingual (LC) as is often the case in mandibular CT at this level. (x6)



**Figure 4.28:** Transverse undecalcified section of Triadan 408 from a four-year old control horse. A band of enamel (E) lies between dentine (D) and cementum (C). Two air bubbles have become trapped when mounting the cover-slip (arrows). (x40)

## 4.4 Histological Measurements

### 4.4.1 Repeatability

Prior to establishing normal anatomical parameters for equine CT, the repeatability of linear histological measurements was established for two different measuring methods. Initially, histological measurements were made using the computer image analysis package Image Pro-Plus. Measurements of eight known anatomical positions from three transverse (decalcified) sub-occlusal sections, each from a different CT, were repeated five times. Results are shown in Table 4.4. The anatomical measurements taken are shown in Figures 3.7 and 3.8. Measurements using this system were recorded to 1 $\mu$ m accuracy.

Tooth No:	Measure -ment	1b dentine	1p dentine	2b dentine	2p dentine	4b dentine	4p dentine	5b dentine	5p dentine
5	Mean	1495	1461	1023	1687	1037	1347	1002	1551
	s.d.	17	22	32	20	22	33	18	30
9	Mean	1605	1730	1324	2207	1681	2023	1259	1927
	s.d.	32	24	17	21	27	25	16	32
21	Mean	974	2421	1076	2428	1325	2724	1249	1952
	s.d.	28	20	22	33	24	30	25	28

**Table 4.4:** Repeatability of anatomical measurements using the Image Pro-Plus computer image analysis programme for measuring anatomical distances in decalcified transverse dental sections as illustrated in Figure 3.7. (b = buccal; p = palatal; 1, 2, 4, 5 = pulp chamber; s.d.= standard deviation)

Having gained sufficient experience in reading and measuring equine dental histological slides, it was concluded that the above degree of accuracy (i.e. measuring to 1 $\mu$ m limits) was not required. Consequently, a stage micrometer was used to measure distance to 50 $\mu$ m accuracy. Measurements of the same eight known anatomical positions from three transverse undecalcified sections, each from a different CT were repeated five times. Results are presented in Table 4.5. The standard deviation for measurements made using a stage micrometer was within the accuracy of measurements being made (i.e. 50 $\mu$ m) in all cases.

Tooth No:	Measure -ment	1p	1p	2p	2p	4p	4p	5p	5p
		enamel	dentine	enamel	dentine	enamel	dentine	enamel	dentine
2	Mean	990	1320	980	2460	730	2520	800	1810
	s.d.	22	45	27	41	27	45	0	22
20	Mean	1070	2220	1070	2210	670	1030	2010	2400
	s.d.	45	27	27	22	27	28	41	25
39	Mean	2440	1010	2540	640	1550	840	2400	2010
	s.d.	22	22	22	22	0	22	0	22

**Table 4.5:** Repeatability of anatomical measurements using a stage micrometer for measuring distances in decalcified transverse CT sections. (p = palatal; 1, 2, 4, 5 = pulp chamber; s.d.= standard deviation)

A second worker (of veterinary undergraduate level experience in dental histology) was asked to read measurements from decalcified histological transverse systems using the same protocol. Categorisation of specialised tissue type (i.e. presence of predentine, intertubular dentine, resting lines, secondary dentine) was found to be 91% (n=265) in agreement with the author; measurements of anatomical distances to within 50µm had 68% agreement (n=210); anatomical distances to within 100µm, had 81% agreement (n=210), and anatomical distances to within 500µm had 98% agreement (n=210) with the author. It was usually evident upon re-examining slides where errors had occurred, which could explain the sometimes large discrepancies in results. Consequently, all readings from this worker were discarded from further use.

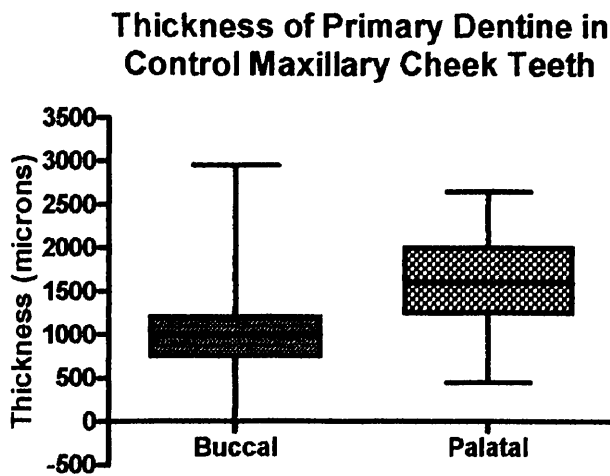
#### 4.4.2 Decalcified Maxillary Cheek Teeth Histology

Anatomical measurements (Figure 3.7) of individual pulps, together with their surrounding dentinal types were obtained from both the buccal and palatal sides of the pulp chamber. Dentine was classified by examining decalcified sub-occlusal and mid transverse CT sections (n=376). The results, with dental age taken into consideration, are shown in Tables 4.6 and 4.7.

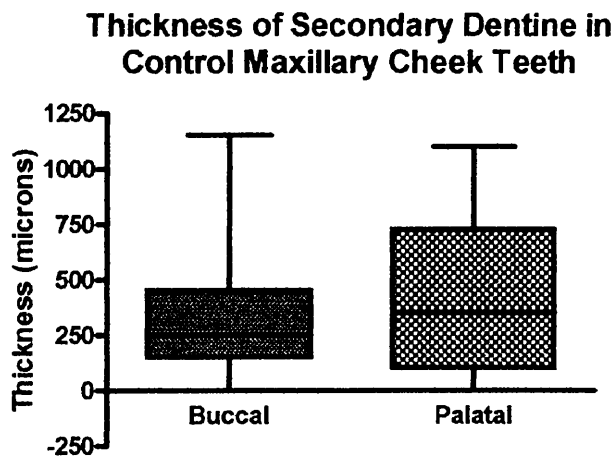
Dental age: years (section)		Pulp diameter ( $\mu\text{m}$ )	Secondary irregular dentine ( $\mu\text{m}$ )	Buccal primary dentine ( $\mu\text{m}$ )	Palatal primary dentine ( $\mu\text{m}$ )	Buccal secondary dentine ( $\mu\text{m}$ )	Palatal secondary dentine ( $\mu\text{m}$ )
<b>0-3 (Occ)</b>	Mean	358	203	1064	1574	328	429
	Std. Deviation	162	167	279	487	188	215
	Range	189-500	0-805	550-1990	463-2735	0-750	0-884
	N	4	57	54	52	57	57
<b>0-3 (Mid)</b>	Mean	949	4.14	1037	1615	126	166
	s.d.	288	22	305	499	139	221
	Range	300-2102	0-150	158-1921	546-2649	0-750	0-1196
	N	82	85	85	84	85	83
<b>3.5-7 (Occ)</b>	Mean	472	211	922	1749	458	590
	s.d.	241	247	291	576	213	223
	Range	97-1050	0-1626	400-1986	550-2950	0-1100	139-1100
	N	32	68	63	66	65	67
<b>3.5-7 (Mid)</b>	Mean	1007	8	1023	2035	277	421
	s.d.	533	62	594	581	185	274
	Range	200-2550	0-500	0-2950	500-2900	0-800	0-1100
	N	62	66	57	55	57	58
<b>&gt;7 (Occ)</b>	Mean	478	173	969	1627	465	622
	s.d.	196	144	219	400	191	170
	Range	250-900	0-477	500-1393	761-2652	150-1137	250-950
	N	13	40	40	39	40	39
<b>&gt;7 (Mid)</b>	Mean	900	16	984	1723	288	508
	s.d.	390	74	460	600	154	191
	Range	200-2200	0-400	250-2000	500-3058	100-697	275-986
	N	43	45	43	42	43	43

**Table 4.6:** The anatomical measurements of decalcified maxillary transverse CT sections in teeth of differing dental ages. (Occ = sub-occlusal section; Mid = mid section, n = number; s.d.= standard deviation)

A wide range was present for many of the measurements taken (e.g. the standard deviation exceeded the mean value for some parameters). This may have been due to the large number of variables present for each measurement i.e. differences in the dental age of tooth, Triadan position, pulp number, section measures (sub-occlusal or mid), and overall tooth size (as indicated by occlusal-apical length). Even so, the large number of measurements obtained did enable meaningful statistical analyses of these data to be carried out, once data for dentinal measurements were transformed by square root and log functions respectively, for primary and secondary dentine. These techniques normalised the data allowing more robust statistical analyses to be made.



**Figure 4.29:** Box plot graph showing mean, upper and lower quartiles, and 95% confidence levels for thickness of primary dentine on the buccal and palatal aspects of pulp chambers in control maxillary CT.



**Figure 4.30:** Box plot graph showing mean, upper and lower quartiles and 95% confidence levels for thickness of secondary dentine on the buccal and palatal aspects of pulp chambers in control maxillary CT.

A larger amount of palatal dentine compared to buccal dentine was present for both primary ( $F_{1,668}=366.7$ ,  $p<0.001$ ) and secondary dentine ( $F_{1,668}=7.08$ ,  $p=0.008$ )(Figures 4.29 and 4.30).

The thickness of dentine in maxillary CT were compared between three dental age brackets, i.e. from 0-3 years dental age, 3 ½ -7 years dental age and over 7 years dental age. There was no statistical difference in the amount of CT primary dentine present between these age groups ( $F_{2,667}=0.79$ ,  $p=0.46$ ) however there was a strong statistical difference between these groups in the thickness of secondary dentine, with (as expected) secondary dentine becoming thicker with increasing dental age ( $F_{2,667}=65.58$ ,  $p<0.001$ ).

There was no statistical difference in the amount of primary dentine present in sub-occlusal or mid transverse sections ( $F_{1,668}=0.55$ ,  $p=0.46$ ) but more secondary dentine was present in sub-occlusal sections than in mid sections ( $F_{1,668}=81.24$ ,  $p<0.001$ ).

When comparing the amount of dentine (in either buccal or palatal directions) around each individual pulp chamber (Section 3.8), there was a statistical difference in the amount of primary dentine surrounding each individual pulp chamber ( $F_{7,662}=6.45$ ,  $p<0.001$ ) but no statistical difference in the amount of secondary dentine present ( $F_{7,662}=0.86$ ,  $p=0.54$ ).

Dentinal pearls (pulp stones or denticles) were present in 5/51 (9.8%) control maxillary CT. Each of these five CT containing dentinal pearls was from a different horse, and the median dental age of affected CT was seven years (range 4-10.5 years). Two were from Triadan position 06 and three from Triadan 09.

Ninety-three percent (53/57) of pulp chambers in the sub-occlusal sections of maxillary control CT with dental ages from 0-3 years were occluded by secondary dentine, and only 3.5% (3/85) were occluded in the mid section. This compares with 53% (36/68) and 1.5% (1/65) respectively for maxillary CT aged from 3.5-7 years, and 68% (27/40) and 4.5% (2/45) for maxillary CT aged above seven years.

Dental age (years)	Section	Resting lines	Predentine (buccal)	Intertubular dentine (buccal)	Predentine (palatal)	Intertubular dentine (palatal)
0-3	Occ	13/57	1/57	4/57	1/57	1/57
	Mid	8/85	16/85	15/57	33/85	4/85
3.5-7	Occ	1/83	16/79	5/78	21/79	9/78
	Mid	3/84	23/82	17/80	54/83	9/81
>7	Occ	3/85	18/83	11/81	28/83	8/81
	Mid	2/85	19/82	15/81	43/83	10/81

**Table 4.7:** Incidence of resting lines, predentine and intertubular dentine in control maxillary cheek teeth.

The incidence of resting lines was significantly higher in 0-3 years dental age CT compared with older groups ( $\text{Chi}^2 > 10.8$   $p < 0.001$ ) and in this group, resting lines were more often present in sub-occlusal than mid sections ( $\text{Chi}^2 = 3.85$   $p = 0.05$ ). Predentine was less commonly present in sub-occlusal sections of younger (0-3 years dental age) CT compared with older groups ( $\text{Chi}^2 > 8.7$   $p < 0.05$ ). In mid sections, predentine was more commonly present on palatal than buccal aspects ( $\text{Chi}^2 > 7.3$   $p < 0.05$ ).

When comparing the incidence of intertubular dentine between the three age groups; between different sides of the pulp chamber (i.e. buccal or palatal); or between sections (sub-occlusal and mid), the only statistically significant findings were that the presence of intertubular dentine in sub-occlusal sections in young maxillary CT (0-3 years dental age) was less than occurred in mid sections ( $\text{Chi}^2 = 6.32$   $p = 0.01$ ) and similarly for CT aged from 3 ½-7 years dental age ( $\text{Chi}^2 = 6.07$   $p = 0.01$ ).

#### 4.4.3 Decalcified Mandibular Cheek Teeth Histology

Similar anatomical measurements were obtained from transverse, decalcified sub-occlusal and mid sections from 43 control mandibular CT ( $n = 184$ ) (Figures 3.8 and 3.9) and the results are presented in Tables 4.8 and 4.9.

As was found with maxillary CT, a wide range was present in many mandibular CT dentinal measurements in the transverse sections. The data were similarly transformed, being normalised by taking square-root values for primary dentine measurements and log values for secondary dentine measurements.

Dental age - years (section)		Pulp diameter* (µm)	Secondary irregular dentine (µm)	Lingual primary dentine (µm)	Buccal primary dentine (µm)	Lingual secondary dentine (µm)	Buccal secondary dentine (µm)
<b>0-3 (Occ)</b>	Mean	0	339	1247	1443	408	405
	Std. Deviation	0	146	438	782	241	238
	Range	0	100-730	300-2100	228-3069	0-1100	0-1000
	n	0	81	81	81	81	81
<b>0-3 (Mid)</b>	Mean	1166	8	1099	1290	131	159
	s.d.	416	72	542	741	154	179
	Range	250-2148	0-650	101-3600	73-2753	0-850	0-779
	n	83	82	81	80	81	80
<b>3.5-7 (Occ)</b>	Mean	386	221	970	1060	553	549
	s.d.	135	188	577	818	248	329
	Range	150-700	0-601	150-2600	100-3300	100-1250	0-1250
	n	31	81	77	81	77	81
<b>3.5-7 (Mid)</b>	Mean	792	0	1179	1331	297	404
	s.d.	310	0	801	1123	242	332
	Range	300-1550	0	400-3400	0-3850	50-1000	0-1400
	n	30	34	29	33	29	33
<b>&gt;7 (Occ)</b>	Mean	528	305	953	1229	541	607
	s.d.	0	125	546	772	325	333
	Range	528	0-600	92-2500	100-2797	100-1882	50-1271
	n	1	41	40	41	40	41
<b>&gt;7 (Mid)</b>	Mean	823	0	1099	1157	404	459
	s.d.	412	0	767	890	333	333
	Range	100-2055	0	211-3661	48-2967	44-1500	29-1361
	n	40	41	42	42	41	41

**Table 4.8:** Anatomical measurements of decalcified transverse control mandibular CT sections of differing dental ages. (Occ = sub-occlusal section; Mid = mid section, n = number; s.d.= standard deviation).

In contrast to maxillary CT, there was no statistical difference in the amount of primary dentine present between buccal and lingual (c.f. palatal) measurements in mandibular CT ( $F_{1,706}=1.84$ ,  $p=0.175$ ). Likewise, there was no difference between these two anatomical directions for secondary dentine thickness ( $F_{1,706}=0.51$ ,  $p=0.477$ ).

When comparing the amount of primary dentine within the three dental age brackets - as for maxillary CT - (i.e. 0-3 years; 3.5-7 years; >7 years) it was again found that secondary dentine was significantly thicker in younger than in older mandibular CT ( $F_{2,705}=11.79$ ,  $p<0.001$ ), but in contrast to maxillary CT, that this was also the case for primary dentine ( $F_{2,705}=8.78$ ,  $p<0.001$ ).

There was no statistical difference in the amount of primary dentine in sub-occlusal or mid transverse sections ( $F_{1,706}<0.001$ ,  $p=0.992$ ). In contrast to maxillary CT, there was also no difference between the amount of secondary dentine present at these two sites ( $F_{1,706}=0.48$ ,  $p=0.489$ ).

When comparing the thickness of dentine (in either buccal or lingual directions) around each individual pulp chamber (Section 3.8, Figures 3.8 and 3.9), there was a statistical difference in the amount of primary dentine, and also secondary dentine (unlike maxillary CT) around each individual pulp chamber (primary:  $F_{6,701}=40.43$ ,  $p<0.001$ ; secondary:  $F_{6,701}=38.77$ ,  $p<0.001$ ).

Only one (1/49) mandibular CT (Triadan 309) from a horse with a dental age of seven years was observed to have dentinal pearls present. This same horse also had dentinal pearls present in its Triadan 109 CT.

All (81/81) of the pulp chambers observed in the sub-occlusal sections of mandibular teeth with dental ages from 0-3 years were occluded with secondary dentine, with no pulp chambers (0/83) occluded in the mid section. This compares to 60% (46/77) and 0% (0/30), respectively, for teeth aged from 3.5-7 years, and 98% (40/41) and 0% (0/40) for CT aged above seven years.

Dental age (years)	Section	Resting lines	Predentine (lingual)	Intertubular dentine (lingual)	Predentine (buccal)	Intertubular dentine (buccal)
0-3	Occ	5/81	0/81	8/81	0/81	11/81
	Mid	1/81	22/81	15/81	24/81	11/81
3.5-7	Occ	5/84	11/84	2/84	12/85	8/85
	Mid	4/84	26/81	6/81	29/83	11/83
>7	Occ	10/82	4/83	1/83	4/84	9/84
	Mid	13/83	23/82	5/83	33/83	8/84

**Table 4.9:** Incidence of resting lines, predentine and intertubular dentine in control mandibular cheek teeth.

The incidence of resting lines was not significantly different between sections (sub-occlusal or mid); or age groups (0-3, 3 ½ -7 and >7 years dental age), except that there were significantly fewer resting lines in mid sections from young (0-3 years dental age) mandibular CT ( $\text{Chi}^2 > 4.3$   $p < 0.05$ ) compared to mid sections in older age groups.

Predentine was less commonly present in sub-occlusal sections, compared with mid sections in all age groups ( $\text{Chi}^2 > 7.5$   $p < 0.007$ ). There were no statistical differences in its presence between the buccal or lingual aspects of the CT.

On comparison of the presence of intertubular dentine between CT of different age groups; between sides of the pulp chamber (i.e. buccal or lingual); or between sections (sub-occlusal and mid), the only statistically significant finding was that intertubular dentine presence in young mandibular CT (0-3 years dental age) was greater than in older CT (>7 years dental age) on the lingual aspect ( $\text{Chi}^2 > 4.3$   $p < 0.04$ ).

#### 4.4.4 Undecalcified Cheek Teeth Histology

A section from each of the 88 transversely sectioned control CT was processed for undecalcified light microscopy. The principle role of this was to:

- Allow for improvement in the techniques being used, prior to processing pathological specimens
- Allow the operator to become familiar with the histological features of undecalcified (ground) histological slides of control equine CT

Artefactual micro fractures of enamel (Figure 4.26) were common in histological CT slides, although further experience in producing CT sections reduced the incidence of these artefacts. Enamel caries was not detected in any control CT section. Infundibular cemental hypoplasia was present in some sections, but because of time restraints this feature was not examined in depth, having been quantified in many previous studies (Baker 1979a; Kilic 1995).

As well as to help facilitate the above two functions, limited measurements were taken from six randomly chosen normal teeth to compare values of vertically adjacent decalcified and undecalcified sections (Table 4.10), and for later comparison with images from CAT scans of some control CT (Section 4.5.2).

As shown in Table 4.10, the differences in dentinal thickness in adjacent transverse sections were on average just outside the measurement accuracy of 50µm, and are not considered to be significant ( $t_{18}=-0.20$   $p=0.846$ ).

Tooth No.	Measurement	Decalcified (µm)	Undecalcified (µm)	
2	pc1 dentine (buccal)	1200	1300	-100
2	pc1 dentine (palatal)	2100	2450	-350
20	pc1 dentine (buccal)	2850	3050	-200
20	pc1 dentine (palatal)	2080	2200	-120
39	pc1 dentine (buccal)	2300	2450	-150
39	pc1 dentine (palatal)	2500	2550	-50
52	pc1 dentine (buccal)	1900	1850	50
52	pc1 dentine (palatal)	2700	2950	-250
52	pc2 dentine (buccal)	1500	1400	100
52	pc2 dentine (palatal)	3150	3050	100
87	pc1 dentine (buccal)	1350	1400	-50
87	pc1 dentine (palatal)	2350	2200	150
87	pc2 dentine (buccal)	1250	1400	-150
87	pc2 dentine (palatal)	2200	2300	-100
88	pc1 dentine (buccal)	2150	2150	0
88	pc1 dentine (palatal)	2750	2900	-150
88	pc2 dentine (buccal)	2050	1900	150
88	pc2 dentine (palatal)	3100	3000	100
		<b>Sum of differences</b>		<b>-1020</b>
		<b>Average</b>		<b>-56</b>

**Table 4.10:** Anatomical measurements from adjacent decalcified and undecalcified transverse CT sections.

## 4.5 Radiography

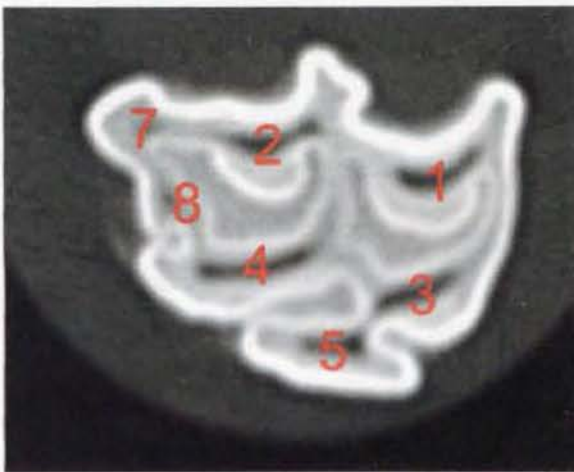
### 4.5.1 Standard Radiography

Twenty-four control CT from a five-year-old horse, and 42 CT from two eight-year-old horses were radiographed using a Gigantos 101 X-ray machine on CEA RP film with Ultra Vision cassettes with Fast Detail (speed 200) screens. To gain optimal images, exposures were varied from 5.0-6.5 MAs and 50-66 kV (Section 3.4). These radiographs were digitised using a Fujifilm 6900Z digital camera whilst on standard radiographic viewing panels. These radiographs were used to familiarise the observer with the normal radiological features of extracted equine CT.

### 4.5.2 Computerised Axial Tomography

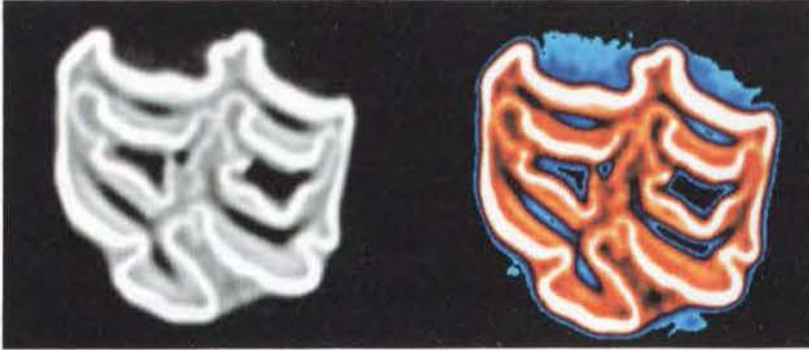Forty-six control CT were imaged with a Somatom Esprit CAT scanner and the images were stored on compact disc for later viewing and analysis using Osiris 4 JPEG format software.

The CAT technique recorded tissue radiodensity (Hounslow Units), and the range observed for the three mineralised equine dental tissues varied from 500-2400 units for cementum; 950-3000 units for dentine and 2000-3071 units for enamel, with the upper limit for enamel also being the upper limit for recording radiodensity, with the software programme used.



**Figure 4.31:** Transverse mid-tooth CAT slice through a control 211 CT showing seven pulp chambers as numbered (1, 2, 3, 4, 5, 7 and 8).

Once the images had been captured digitally, it was possible to assign differing radiodensities with differing shades of grey or colour to help identify different anatomical features.



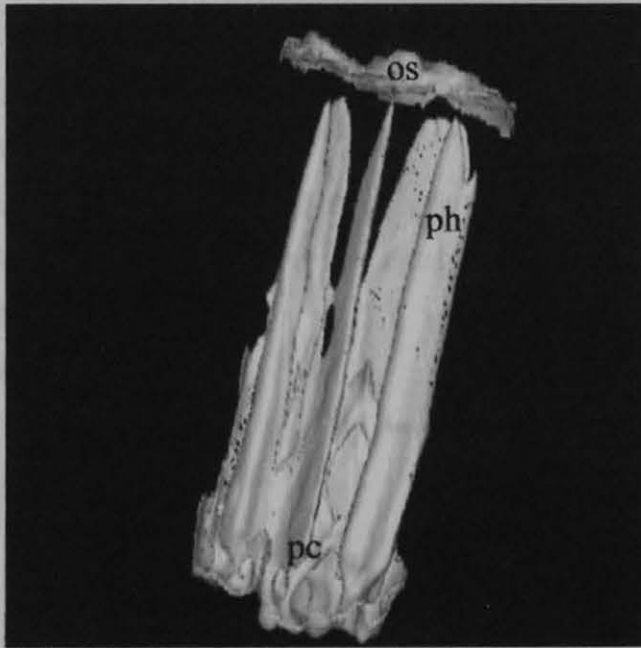
**Figure 4.32:** The same transverse section through a control maxillary CT (Triadan 108) when imaged using a Somatom Esprit CAT scanner (left) and when enhanced using Osiris software, assigning blue-black colours to the least radio-dense tissues (pulp, hypoplastic regions of cementum, and periodontal ligament) and white to the most radio-dense tissue, i.e. enamel. Red indicates intermediate levels of radio-density, including primary dentine, dense cementum and some areas of thin enamel.

Using the CAT scans in this way enabled areas of interest to be determined and these areas were later examined histologically to confirm which tissues were present. Of equal value was the ability to view the CT as video clips, looking at the change in endodontic anatomy of the CT progressively from occlusal to apical limits. Two examples are given as video files in the enclosed CD.

**Video 4.1:** Osiris 4 JPEG software converted to an avi video clip showing a Triadan 308 CT from an eight-year-old horse. The clip begins occlusally with the white radiodense enamel surrounding pulp chambers 1 and 2 appearing first. As the scan progresses apically, we see a series of transverse sections through the CT. All five pulp chambers are seen individually in the occlusal sections; however pulp chambers 3 and 5 merge halfway through the scan, later to be joined by pulp chamber 2. Pulp chambers 1 and 5 also merge more apically, creating a rostral and caudal pulp chamber where the CT bifurcates near the root region. Interestingly these rostral and

caudal endodontic canals divide once more as they progress apically before exiting through their apical foramen. (Video 4.1 in 'MS PowerPoint' format on CD enclosed)

**Video 4.2:** Osiris 4 JPEG software converted to a coloured avi video clip showing a Triadan 110 CT from a five-year-old horse. Beginning occlusally, all (five) pulp chambers are occluded with secondary dentine. As the scan progresses apically, pulp (green) is seen within the pulp chambers, with pulp chambers 3 and 5 communicating, before pulp chamber 1 also joins. Pulp chambers 2 and 4 communicate before all five pulp chambers become a common pulp chamber. The chamber then divides into three root canals. The rostral and caudal infundibula are also seen, with the infundibular cementum (red) becoming hypoplastic (yellow to green to blue) apically in both infundibula. Nearing the apical limit of the rostral infundibulum, infundibular cementum is seen to communicate directly with dentine (both being red) without any infundibular enamel (white) separating them, as would normally be the case.



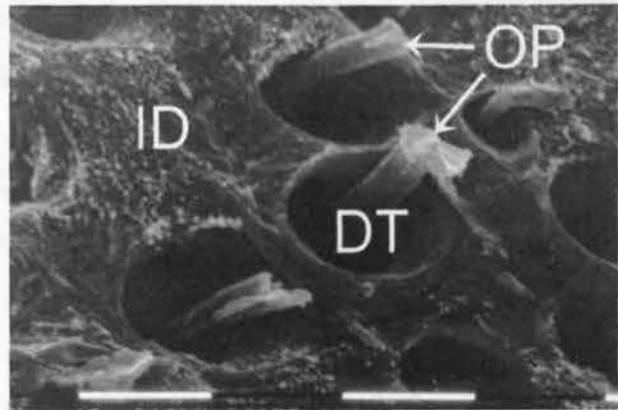
**Figure 4.33:** Computerised assisted tomograph (CAT) image of an intact mandibular CT, having removed the imaged cementum, dentine and enamel from the image (based on their radiodensity), thereby just leaving the image of the pulp horns (ph) extending from the apical common pulp chamber (pc), towards the remaining organic pellicle on the occlusal surface (os).

Infundibular cemental hypoplasia was evident in the apical third of the infundibulum in 16/25 (64%) of the CAT imaged maxillary CT. Additionally, enamel hypoplasia was identified in one maxillary and one mandibular CT.

## 4.6 Scanning Electron Microscopy

Six control CT were prepared for SEM (Section 3.9). This was to gain experience at processing and viewing subsequent pathological samples using SEM, as a study at this institute has already thoroughly described normal equine dental SEM anatomy (Kilic 1995). Some areas of interest were photographed during this initial SEM work.

**Figure 4.34:** Occlusal surface dentine of a control CT (Triadan 110). Odontoblast processes (OP) are seen emerging from dentinal tubules (DT) on the occlusal surface. Intertubular dentine (ID) lies between the dentinal tubules. It is assumed these odontoblast



processes are sclerotic, and that the large remaining space within the dentinal tubule was originally filled with highly mineralised intratubular dentine, that was removed by the acid etching of this section during processing for scanning electron microscopy. (1 bar = 10 $\mu$ m)

## 4.7 Discussion

### 4.7.1 General Characteristics

Equine dental anatomy has been described in many anatomical texts from as early as 600 C.E. (Galvayne 1912; Getty 1975; Kertesz 1993; Dixon 1999), and from archaeological, evolutionary and clinical perspectives (Levine 1982; Miles & Grigson 1990; Bennett 1992). A great deal of information however, still remains to be gained from detailed examinations of both normal and pathological equine dental specimens.

As Levine (1982) states however, many of the earlier studies have been “based upon an unsystematic collection of specimens.” One major inaccuracy of these studies has been the inconsistent determination of the age of examined dental specimens. The nine control horses in this study had a median age of four years (range 0-12 years) based on reliable medical records. This avoided ageing horses on dental wear or crown length, techniques that are now recognised to be inherently inaccurate, including factors such as individual variation, and differences in diet and breed (Levine 1982; Walmsley 1993; Richardson et al. 1995c).

The recorded age of a horse is usually only given as the year in which it was born, rather than its actual birth date, with horses being classified as being one year old during the full calendar year following their birth, irrespective of the time of year they were born. The proposed introduction of passports by DEFRA for all equids in the United Kingdom in February 2005 will allow future studies to have more accurate age records (DEFRA & Internet communication: [www.defra.gov.uk/animal/int-trde/default.htm](http://www.defra.gov.uk/animal/int-trde/default.htm) 2004).

Total CT length was measured in 56 control CT, with a median length of 85mm (range 38-102mm). The purpose of this measurement was to include a scalar measure estimating approximate size of the individual from which the tooth came. It may have been more useful to split this total occlusal-apical tooth measurement into true crown (containing enamel) and root lengths, to compare with data recorded by Kirkland (1994) and Levine (1982). However, as all *statistical* analyses were carried out on measurements from grouped teeth of mixed animal size, and not individual teeth, there was no need for such a linear comparison. Additionally, Levine (1982) states that the use of crown length measurements is inaccurate on an individual basis, and should be reserved for group comparisons.

#### **4.7.2 Endodontic Anatomy**

In her MSc thesis, Kirkland (1994) correctly stated “detailed, scientific information concerning the structure of the endodontic system, reserve crown, and roots of equine cheek teeth is unavailable”. Her study detailed the endodontic structure of mandibular

CT, only focusing on Triadan CT 07-10 in horses aged 2-9 years old. Although concentrating on these four CT positions, Kirkland reported computer assisted tomographic images revealed “5 or 6 long, thin, ribbon-like, tapering coronal extensions of pulp” however the current study only found five pulp chambers in these CT positions. As noted, a sixth pulp was always present in Triadan positions 06 and 11 (Section 4.2.1).

In describing equine maxillary CT endodontic anatomy, Baker (1970) found “in upper teeth the pulp cavity has five main divisions within the folds of enamel”. This description is not accurate for maxillary Triadan CT positions 06 and 11. Knowledge of endodontic status (including whether pulp has been replaced by dentine) is of importance to equine dentistry as it may give an indication of how much crown may be removed during treatment before encountering vital pulp. This is important in conditions such as step-mouth where large (>5mm) crown reductions may be necessary. Becker (1962) suggested that 10mm of secondary dentine is normally present between the occlusal surface and the coronal aspect of the pulp. The level of the sub-occlusal transverse section examined in the current study was between 2-6mm below the actual occlusal surface, with this variation being caused by natural transverse ridging of the CT occlusal surface. Vital pulp was present in 84/384 (21.9%) pulp chambers in sub-occlusal transverse sections from control CT (Table 4.2). As these sections were 2-6mm beneath the occlusal surface, the 10mm thickness of secondary dentine suggested by Becker would seem to be a gross over-estimation.

No pulp tissue was present in the 6<sup>th</sup> (rostral) pulp chamber region in sub-occlusal Triadan 106/206 CT sections (0/6), yet pulp was present in 50% (2/4) of mandibular 306/406 CT sub-occlusal sections. This finding has clinical significance considering the current practice of ‘bit-seating’ horses, i.e. grinding down the rostral aspect of Triadan 06 CT, purportedly to make the bit sit more comfortably in the horse’s mouth. Some authors have noted that bit-seating Triadan 306 /406 CT may involve reduction (removal) of clinical crown, beginning at the rostral gingival margin of the 06s, to half way along the occlusal aspect of these CT ( Scrutchfield et al. 1996; Easley 1998; Scrutchfield 1999a; Scrutchfield 1999b). In performing the more extreme type of bit seating, it is likely that not only sensitive dentine will become exposed (as shown in a

recent study examining the effect of dental rasping on the occlusal surface of CT (Kempson et al. 2003), but that pulp tissue itself may also become exposed.

In order to recognise the pathological features of diseased CT, a thorough knowledge of CT endodontic anatomy is required. Additionally, if performing clinical endodontic (i.e. pulp and pulp chamber) treatments, knowledge of the pulp chamber or horn anatomy must be known to improve the likely success of any such intervention. “The hard tissue repository of the human dental pulp takes on many configurations that must be understood before treatment can begin” (Burns & Herbranson 2002). This quote by Richard Burns, editor and author in ‘Pathways of the Pulp’, a text detailing the ‘art and science’ of human endodontics, may indicate why equine endodontic therapy currently yields poor results – with one recent study recording just 58% (11/19) of CT endodontic procedures to have short-term success (12 months post procedure) and 40% (6/15) having long-term success (>24 months post-surgery) (Schramme et al. 2000).

In performing endodontic treatments, the simpler the endodontic canal morphology, the easier the procedure (Burns & Herbranson 2002). Consequently, as fewer pulps were found to be communicating in transverse mid sections of control maxillary CT (7/45, 16%) than in mandibular CT (16/43, 37%) CT (Table 4.3), it may be more advisable to attempt endodontic procedures on upper rather than on lower CT.

As the size of pulp chambers decreases when more secondary dentine is laid down with increasing age (Kirkland et al. 1996; Kilic et al. 1997c; Ten Cate 1998a; Torneck 1998), pulp chambers are therefore less likely to communicate in older animals. When pulps did communicate in maxillary CT in this study, the average *dental age* was two years (c.f. 4 ½ years in mandibular CT). It is therefore more likely that maxillary endodontic canals are individual entities for most of their length at an earlier age than their mandibular counterparts. This is supported by the anatomical reason of rostral and caudal infundibula being present between the pulp chambers.

With the average *horse's age* suffering from apical infections being seven years in maxillary CT and five years in mandibular CT (Dixon et al. 2000a), we would expect even less pulpar communication to be present in the older horses with maxillary CT apical infection- and therefore it may be more logical to attempt endodontic treatment of apical infections in maxillary CT in preference to those in mandibular CT.

### **4.7.3 Normal Histological Structure**

The quality of equine CT histological sections obtained in this study has been stated to be the equivalent of those currently obtained in human dentistry (Dr A Santini and Dr H Moody – personal communications 2003). The large number of sections examined has identified histological dental features not previously reported in horses, such as dentinal pearls and interglobular dentine.

The identification of specific dentinal types, namely: primary, regular secondary, irregular secondary and tertiary dentine has also been possible, because of the large number of high definition slides obtained. Primary and secondary dentine have been previously described in both human and equine teeth (Kilic et al. 1997c; Ten Cate 1998a; Torneck 1998; Muylle et al. 2002). Secondary dentine is regarded as a continuation of primary dentine (i.e. with continuous dentinal tubules and odontoblast processes within), which is formed “once the normal anatomy of the tooth has been established” (Ten Cate 1998a). In human teeth, the main histological indications of change from primary to secondary dentine are an abrupt change in direction of dentinal tubules, along with the presence of a thick incremental line between the two dentine types (Jones 1990).

An incremental line between equine primary and secondary dentine was present in most sections, as seen in Figures 4.4 and 4.10. Occasionally, a transition zone is present between these two types of dentine (Figure 4.5), and in other sections, there is a gentle merging of the two dentinal types, as seen in Figure 4.9. Muylle (2002) reported “the only obvious feature characterising the transition between primary and secondary dentine in equine (incisor) teeth is the presence of peritubular dentine.” Torneck (1998) reported that secondary dentine has even been identified in unerupted

human teeth and this may be further evidence that the stimulus for change from equine primary to secondary dentine production is not as simple as the tooth erupting or coming into occlusal contact.

Although dentine has been classified into three main groups in this current work, other authors recognise only two groups (i.e. primary and secondary dentine), classifying tertiary dentine as reparative or reactionary secondary dentine (Kilic et al. 1997c; Muylle et al. 2002; Torneck 1998). Muylle describes dental stars on incisors as having “a central core of tertiary dentine” and that tertiary dentine “is produced in reaction to trauma, caries or restorative procedures.” In this work, the areas of dentine classified by Muylle as tertiary, were identified in *all* control CT, in the most central areas of *all* pulp chambers once they have been occluded by dentine (a process termed ‘pulp recession’ in human dentistry). With such a ubiquitous presence, these areas of dentine are much more likely to be physiologically normal and therefore the term irregular secondary dentine is much more appropriate to describe this type of dentine.

It is the author’s opinion that the term tertiary dentine should be wholly reserved for areas of dentine that are produced *focally* in response to specific noxious stimuli.

#### **4.7.4 Histological Measurements**

For research purposes, dentine may be regarded as a ‘living record’ of the history of an individual tooth because dentine is laid down throughout its lifetime (Ten Cate 1998a; Torneck 1998). Klevesal and Kleinenberg (1967) reviewed techniques for ageing mammals according to deposition of annual growth rings on bones and teeth (skeletochronology). Based on a study of teeth from 13 Asiatic wild asses, they concluded it would probably be possible to age their teeth based on counting the annual rings formed within dentine and cementum. Levine (1982) refuted this hypothesis however, arguing that if ageing was to be successful on this basis alone, a study needed to be carried out on animals of known age – which had not been done at that time. The field of skeletochronology has continued to develop, and cementum analysis has been reported as a means of determining the season of death in horses

found at archaeological sites (Burke & Castanet 1995). Currently there are even studies measuring the ratios of carbon and nitrogen isotopes in annual dentine layers of sperm whale teeth to determine their migratory history.

To test the hypothesis that a daily rate of dentine deposition might be calculated from measuring the amount of secondary dentine deposited within pulp chambers, calculations were made from dentinal thickness measurements from horses of known dental age. Rates of secondary dentine deposition within the pulp chambers measured varied from 0.5-10 $\mu$ m/day. This is comparable to values of 4.0 $\mu$ m per day for human coronal dentine deposition (Ten Cate 1998a). However Ten Cate also states that in humans, the rate of dentine formation will vary between individuals, between teeth from an individual, and with time within an individual tooth. So while the general principle that pulp recession will cause older teeth to have greater amounts of secondary dentine present is valid, there is considerable variation in this parameter in humans, as is also the case for horses.

Equine CT are obviously much larger than human teeth, and their hypsodont nature means that some of their tissues are also much more dynamic throughout their lifespan. These two factors, and the large number of measurements taken, have helped counteract the variability of dentine deposition and allowed meaningful statistical comparisons to be made within the control CT population. The amount of maxillary primary dentine did not increase significantly with increasing dental age ( $p=0.455$ ) with primary dentine deposition supposedly ceasing when teeth come into occlusion (if not before), it being remembered that all control CT in this study had erupted.

There was an age-related increase in the amount of secondary dentine present in both maxillary and mandibular CT ( $p<0.001$  for each). Surprisingly however, primary dentine in mandibular CT was also found to increase statistically ( $p<0.001$ ) with age, with the main increase occurring between the 0-3 years dental age group and the 3.5-7 years dental age group. As discussed previously (Section 4.7.3), there is evidence to show that the signal to change from primary to secondary dentine production is not necessarily as simple as having these teeth coming into occlusal contact. These results

suggest that the deposition of primary dentine continues in mandibular CT following eruption, and even following occlusal contact.

The masticatory chew cycle of the horse has been previously described, with the mandible dropping, moving laterally, and then coming up in a vertical crushing stroke before moving medially in a lateral crushing stroke (Capper 1992; Tremaine 1997; Baker 1999b; Dixon 2002). These movements place greatest lateral forces onto the palatal aspect of maxillary CT, and the buccal aspect of mandibular CT. The findings in this study support this apparent physiological need in maxillary CT, with palatal *dentine* (both primary and secondary) being thicker ( $p < 0.01$ ) than buccal dentine. However this pattern was not present in mandibular CT where no difference was observed in dentinal thickness between the different sides of individual teeth. Mandibular CT are narrower in a bucco-lingual direction than their maxillary counterparts (Dixon 1999) and this may partially explain the difference.

These findings contrast with the work of Kilic (1995) who found *enamel* to be thicker on buccal aspects of peripheral and infundibular enamel in maxillary CT, and Mitchell (2004) who found peripheral *cementum* was also thicker medially (palatally and lingually) than buccally. This may be an indication of the interactive supportive roles dentine and cementum play with respect to enamel.

Primary dentine was present in equal amounts in both sub-occlusal and mid sections, in both control maxillary and mandibular CT ( $p = 0.459$  and  $p = 0.992$ , respectively). Significantly less secondary dentine was present in mid sections than in sub-occlusal sections of maxillary CT ( $p < 0.001$ ). When considered with the finding that increased amounts of secondary dentine are present in older age groups of maxillary CT, this reinforces the concept that secondary dentine in maxillary CT becomes progressively thicker in an apical to occlusal direction, as odontoblasts withdraw circumpulpally and progressively as CT age, and the odontoblasts become closer to the occlusal surface from continued occlusal wear.

In contrast, there was no difference in the amount of secondary dentine present between sub-occlusal and mid sections in mandibular control CT ( $p = 0.489$ ). When

considered with the finding that there was no significant increase in secondary dentine with increasing CT age in mandibular CT, it appears that secondary dentine deposition occurs in a more generalised circumpulpal manner throughout the length of mandibular CT, and is not progressive in an apical to occlusal direction, as observed in maxillary CT.

Predentine was present more frequently in mid as compared to sub-occlusal sections for mandibular control CT in all age groups ( $\text{Chi}^2 > 7.5$   $p < 0.007$ ). This is because sub-occlusal pulp chambers had frequently become fully occluded with secondary dentine, and no pulp remained. There was no statistical difference in the presence of predentine between the buccal or lingual aspects of mandibular CT. However in mid sections of control maxillary CT, predentine was more commonly present on palatal than buccal aspects ( $\text{Chi}^2 > 7.3$   $p < 0.05$ ), supporting the finding of greater amounts of dentine being found on the palatal aspect of maxillary CT.

Intertubular dentine is present between the dentinal tubules of both primary and secondary dentine (Kilic et al. 1997c). It represents the primary secretory product of odontoblasts and consists of tightly woven type-1 collagen fibrils, with apatite crystals deposited within the fibre network. In some sections, patches of intertubular dentine were present, breaking up the usually orderly pattern of dentinal tubules. There was no pattern to the presence of intertubular dentine in the control CT specimens. Its presence is later compared to that found in diseased CT populations.

Dentinal pearls (denticles or pulp stones) were present in 5/51 maxillary CT and 1/49 mandibular CT. In human teeth dentinal pearls increase in prevalence with age and are believed to form around a focal point of dead or dying cells, blood thrombi or collagen fibres (Torneck 1998). Although they do not cause symptoms themselves in humans, their presence has been associated with neuralgic pain (Soames & Southam 1993d), and when present in large numbers, they may decrease the vascularity of the pulp thereby decreasing the tooth's ability to produce dentine (Torneck 1998). It is interesting that pulp stones were identified in nearly 10% of control maxillary CT, especially when it is remembered that only four transverse sections were usually

examined from the entire tooth, and so it is likely that an even higher incidence of pulp stones is present in equine CT pulp.

#### **4.7.5 Radiography**

Clinical radiography of equine CT has usually been concerned with detecting changes to the dental alveolus or to the overall appearance and position of CT, rather than identifying intra-dental pathology (Baker 1972; Dixon & Copeland 1993; Gibbs 1999).

Barbee et al. (1987) highlighted the advantages of computed tomographic examination of the equine head, because of its anatomical complexity, and resulting overlapping and superimposition of features, as compared to conventional radiological techniques. Since then, with the development of fourth generation computed tomography machines, scans of the distal extremities (limbs and head) of horses under general anaesthesia now have minimal artefacts and show precise detail. This has allowed various pathological changes to be accurately imaged and exact diagnoses achieved (Tietje et al. 1996; Tucker & Farrell 2001).

The scan protocol used in this present study, using a Somatom Esprit, allowed a 1.5mm spiral scan to be carried out with a 50% beam overlap. This gave such detail to two dimensional images and three-dimensional reconstructions that both pathological lesions and normal anatomical features of less than 1mm in size could clearly be identified. Secondary dentine in humans has been found to contain less calcium, phosphorous and collagenous matrix per unit volume, when compared to primary dentine, making it a more open, porous structure (Foreman & Soames 1989). This makes it less radiodense than primary dentine, a feature that is readily seen when imaging equine CT using CAT, as illustrated in Figure 4.31-33 and Videos 4.1-2. Care must be taken however not to confuse this decreased radiodensity with areas of mantle dentine (primary dentine found directly adjacent to the amelo-dentinal junction [Section 2.7.1]) which is also less mineralised and less radiodense (Ten Cate 1998a).

### **4.7.6 Scanning Electron Microscopy**

On SEM images, odontoblast processes were commonly seen on the occlusal surface of control CT (e.g. Figure 4.34). This feature was also recorded by Kilic (1995) and Kempson et al. (2003). Discussion has followed on whether these odontoblast processes are sclerotic, calcified, necrotic or viable, and if their exposure as a result of dental rasping (reductions) can cause pain.

The mineral content of intratubular dentine has been reported in humans to vary from 9% (Kvaal et al. 1994) to 40% (Ten Cate 1998a) more than intertubular dentine. This feature increases hardness and subsequently, resistance to wear (Kierdorf & Kierdorf 1992), but also results in exaggerated loss of intratubular dentine when acid etching dentinal surfaces prior to examination in a SEM. As seen in Figure 4.34, the odontoblast processes protrude from a wide dentinal tubule. The space surrounding each dentinal process was probably previously filled with intratubular dentine that was removed during the sample etching process (Muylle et al. 2001). In Figure 4.34, the odontoblast processes are seen to bend, where they extend beyond the limit of the dentinal tubule. This implies that these processes are still pliable and therefore either still viable or recently dead, rather than being sclerotic or dentine casts.

## **Chapter Five: Examination of Maxillary and Mandibular Cheek Teeth with Apical Infections**

### **5.1 Introduction**

Having established anatomical parameters for control equine CT, in particular for endodontic anatomy and for dentinal classification and thickness, (Chapter 4), 50 apically infected CT were examined, following extraction or repulsion at this institute from referred cases with full clinical histories. These examinations included visual assessment for gross pathological changes, dissecting microscopy, standard radiography, computer assisted tomography, histology and electron microscopy.

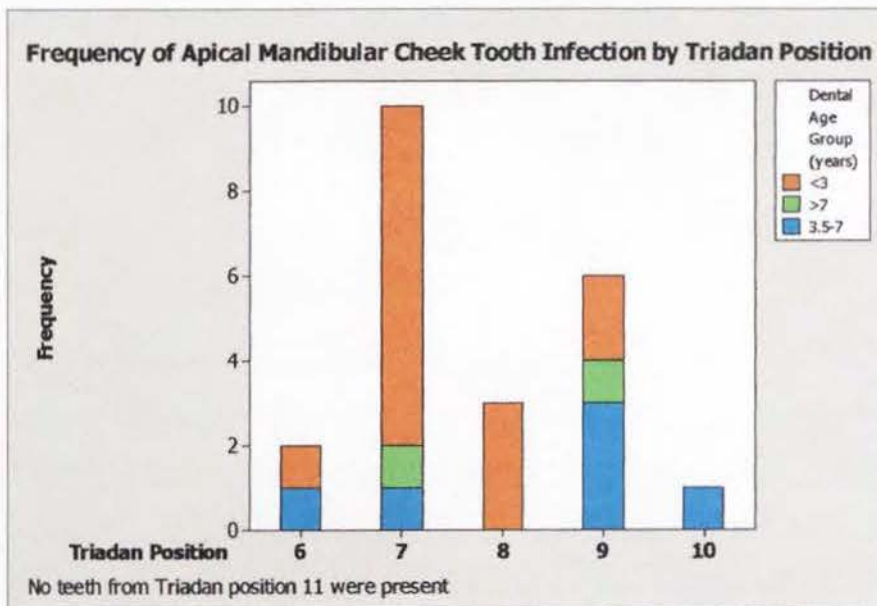
Using the enhanced imaging techniques previously described (Chapter 3) it was hypothesised that the nature and frequency of any pathological features present, and in particular the changes (both qualitatively and quantitatively) in present dentine could be accurately assessed. It was hypothesised that from these pathological observations a variety of aetiologies would be found for apical infection, including infundibular caries, periodontal spread and primary pulpar exposure. Thereafter, by a process of elimination, the remaining cases of apical infection could safely be stated to be due to anachoresis. Additionally quantitative data would be compared with the clinical history of each case (on an individual or grouped basis) to test the hypothesis that differences in dentinal thickness observed between both diseased and control CT, and between comparable diseased CT would be reflected in the duration of clinical signs.

Twenty-eight apically infected maxillary CT were examined. These permanent teeth had a median dental age of 3.5 years (range 1- 20 years). Seven CT were imaged using a CAT scan and eight were examined by scanning electron microscopy (SEM). An additional 31 maxillary CT (extracted because of apical infections but with incomplete clinical histories) were examined under dissecting microscopy only.

Twenty-two mandibular CT with apical infection were examined. These teeth had a median dental age of 1.75 years (range - 0.5 to 9 years). One CT developed an apical

infection prior to erupting, and was extracted at a dental age of -0.5 years (i.e. it was extracted six months before the standard eruption date for a tooth of this position) (Getty 1975). Ten of the 22 CT were from Triadan position 07 (Figure 5.1). Three mandibular CT were imaged using a CAT scan. An additional 19 mandibular CT extracted because of apical tooth infections, but with incomplete clinical histories, were examined under dissecting microscopy only, due to time constraints.

Variable amounts of damage were present on the apical region and clinical crown of CT as a result of extraction or repulsion procedures. Those CT that were extracted orally, frequently had crush marks in their cementum, but this type of artefact did not damage the adjacent enamel or dentine. Where noted, extractor forceps also iatrogenically fractured some CT, including their clinical crown, body or apex. Teeth repulsed into the oral cavity invariably suffered some degree of trauma to their apical region.



**Figure 5.1:** Frequency distribution of 22 mandibular CT with apical infections that were examined in detail.

## 5.2 Case Studies

Clinical, ancillary diagnostic and pathological details of 10 of the 28 apically infected maxillary CT examined are presented in detail in Appendix 1 to outline the range of

clinical, ancillary diagnostic and pathological findings in such cases. Two groups of four comparable (similar age and identical Triadan position) apically infected maxillary CT are also reported. Details of seven of the 22 apically infected mandibular CT examined are presented in Appendix 2. These detailed individual and two small group case analyses have been further condensed into the following group analysis results (Sections 5.3 and 5.4).

## 5.3 Grouped Analysis of Maxillary Cheek Teeth Apical Infections

### 5.3.1 Gross Pathology

Nine of 28 maxillary CT with apical infections examined in detail had been repulsed (the rest having been orally extracted) with all 9 repulsed CT having obvious iatrogenic apical fractures present. This damage ranged from having the calcified structures of the apical 5mm of tooth compressed, to the entire apical third of the tooth being shattered.

Infundibular caries of cementum extended to involve the infundibular enamel or dentine in three diseased maxillary CT (11%); being present in the rostral infundibulum in one case, the caudal infundibulum in another, and in both infundibula in the third case. The presence of tracts in the peripheral cementum, abnormalities of the periodontium, in conjunction with clinical history and clinical findings, identified periodontal disease as the likely route of apical infection in five cases (18%). Occlusal pulp exposure was present in six of the 28 CT (21%) examined and involved multiple pulp chambers in all cases where the full occlusal surface could be examined. A summary of these findings from all 28 CT is presented in Table 5.3.

### 5.3.2 Radiographic Assessment

#### 5.3.2.1 Clinical Assessment of Standard Radiography

Radiographs of eight maxillary CT with apical abscesses were selected at random from the 28 CT examined in detail. Four equine clinicians experienced at reading dental radiographs viewed the radiographs of extracted CT 'blindly' and independently, in order to assess intra-dental radiological features. The clinicians were asked to identify if the radiograph showed any of the following intra-dental radiological features:

- Changes to the apical third of the crown or roots of the tooth
- Changes within the central third (the crown) of the tooth
- Fractures within the body of the tooth
- Fracture to the clinical crown of the tooth
- Occlusal exposure of pulp
- Caries or hypoplasia of either the rostral or caudal infundibulum

- Caries of the peripheral cementum

The agreement between clinicians is shown in Table 5.1. On no occasion did all four clinicians agree on the presence (or absence) of any single radiographic feature in all eight radiographs. Three of the four clinicians identified the presence (or absence) of two radiological features in all eight radiographs. This was for presence or absence of a fracture within the clinical crown of the CT, and the presence or absence of caries in peripheral cementum. In these instances, the clinicians correctly identified the presence of fractured crown only in the two CT where this had occurred, however none identified the presence of caries present in peripheral cementum when it was present in two of the eight CT.

<b>Radiological factor</b>	<b>4/4 Clinician agreement</b>	<b>3/4 Clinician agreement</b>
Apical changes	5/8	7/8
Body changes	1/8	4/8
Body fracture	5/8	7/8
Clinical crown fracture	6/8	8/8
Caries / hypoplasia of rostral infundibulum	0/8	4/8
Caries / hypoplasia of caudal infundibulum	0/8	5/8
Caries of peripheral cementum	3/8	8/8
Occlusal pulp exposure	4/8	5/8

**Table 5.1:** Inter-clinician repeatability of reading 8 radiographs of extracted maxillary CT with apical infections.

### 5.3.2.2 Computer Axial Tomography

A total of 13 apically infected maxillary CT were scanned using a Somatom Esprit CAT scanner. A spiral series of images was taken of each tooth and analysed using Syngo A40A software. The principle use of these CAT scans was to identify areas of interest for future histology; however they were also useful for illustrating pathological changes of teeth, as shown in the video clips incorporated in Appendix 1.

### **5.3.3 Histological Results**

#### **5.3.3.1 Decalcified Histology**

A total of 160 decalcified transverse sections from 28 maxillary CT with apical infections were examined and anatomical measurements of individual pulp chamber diameters and their surrounding dentine were obtained (Section 3.8.1). The dentine was classified by histologically examining decalcified occlusal and mid CT transverse sections (n=132). Results are presented in Table 5.2. As noted for these same measurements of control CT (Chapter 4), a wide range and large standard deviation is often present for these parameters. This large variation results from normal anatomical variation between different pulp chambers being measured, and also from the health status of the pulp chamber throughout its dental life.

Twenty-eight transverse ‘apical’ sections were also examined. In cases where the CT had been repulsed, their apical regions were usually damaged and so sections were taken more occlusally. Areas of interest were photographed and have been included in these individual case studies (Appendix 1).

Data from mid-sections of maxillary CT with apical infections of over seven years dental age have not been included in Table 5.2 as only one section was examined in this category. Of the four maxillary CT that were in this category, two were considered too short in length to have occlusal sub-occlusal, undecalcified (3<sup>rd</sup>), mid and apical sections cut, and so it was elected not to take mid sections from these CT. Of the remaining two CT, a block from one would not decalcify sufficiently for cutting on the automated microtome and was eventually damaged beyond further use, leaving only one mid-section of CT of this age group examined.

Parameter	Pulp diameter (µm)	2iD (µm)	1D (buccal) (µm)	1D (palatal) (µm)	2D (buccal) (µm)	2D (palatal) (µm)
<b>Sub-occlusal section &lt;3 years old</b>						
(n)	80	60	40	38	40	40
Range	0-2650	0-540	463-1800	859-2450	0-600	0-800
Median	300	0	1000	1558	142	200
Mean (Std. Deviation)	415 (519)	85 (149)	1025 (312)	1600 (481)	152 (150)	237 (237)
<b>Mid section &lt;3 years old</b>						
(n)	48	38	27	27	27	27
Range	0-2400	0-1526	450-2200	684-2600	0-200	0-800
Median	1242	0	1000	1400	0	116
Mean (Std. Deviation)	1246 (613)	130 (376)	981 (401)	1556 (563)	50 (69)	153 (199)
<b>Sub-occlusal section 3.5-7 years old</b>						
(n)	116	122	56	51	56	52
Range	0-1400	0-1953	180-2900	142-2650	0-1000	0-1150
Median	356	0	928	1500	244	350
Mean (Std. Deviation)	393 (382)	198 (426)	1008 (518)	1425 (583)	302 (250)	373 (263)
<b>Mid section 3.5-7 years old</b>						
(n)	50	41	25	25	25	24
Range	0-1750	0-2785	264-1650	315-2400	0-1041	0-759
Median	1100	0	1200	1600	200	275
Mean (Std. Deviation)	1018 (447)	151 (608)	1087 (447)	1484 (680)	214 (228)	260 (227)
<b>Occlusal section &gt;7 years old</b>						
(n)	36	36	14	14	15	15
Range	0-1500	0-1100	550-1800	750-2550	150-850	150-1000
Median	150	300	1050	1950	300	500
Mean (Std. Deviation)	397 (490)	258 (291)	1089 (374)	1807 (489)	407 (200)	540 (262)

**Table 5.2:** Anatomical measurements of transverse sections at occlusal (section 2) and mid tooth levels from 28 maxillary CT with apical infections (1D=primary dentine, 2D=regular secondary dentine, 2iD=irregular secondary dentine).

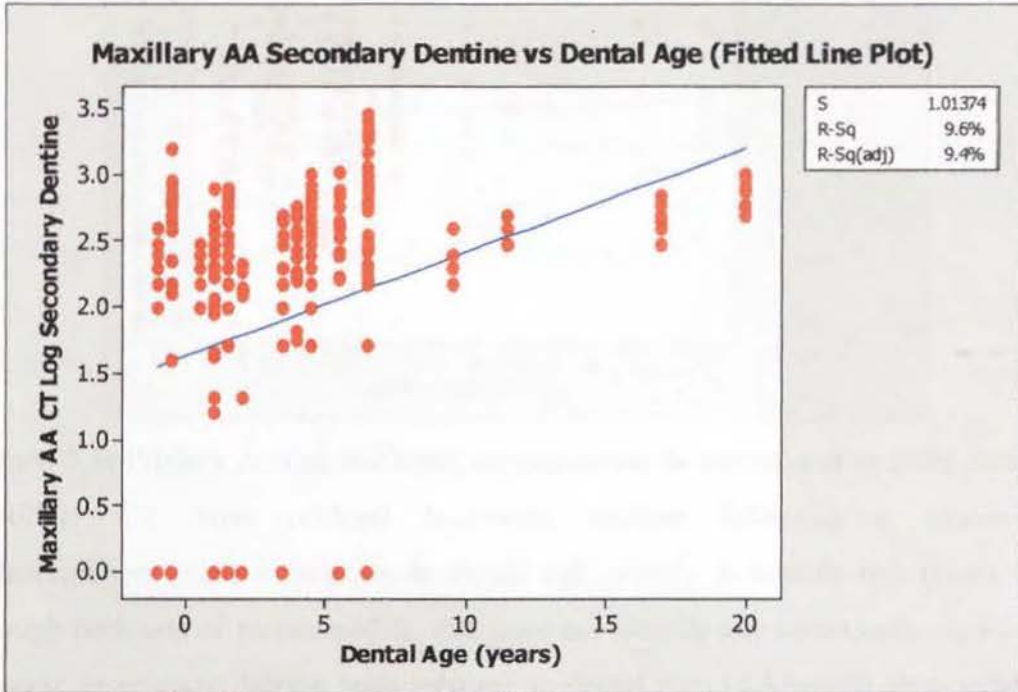
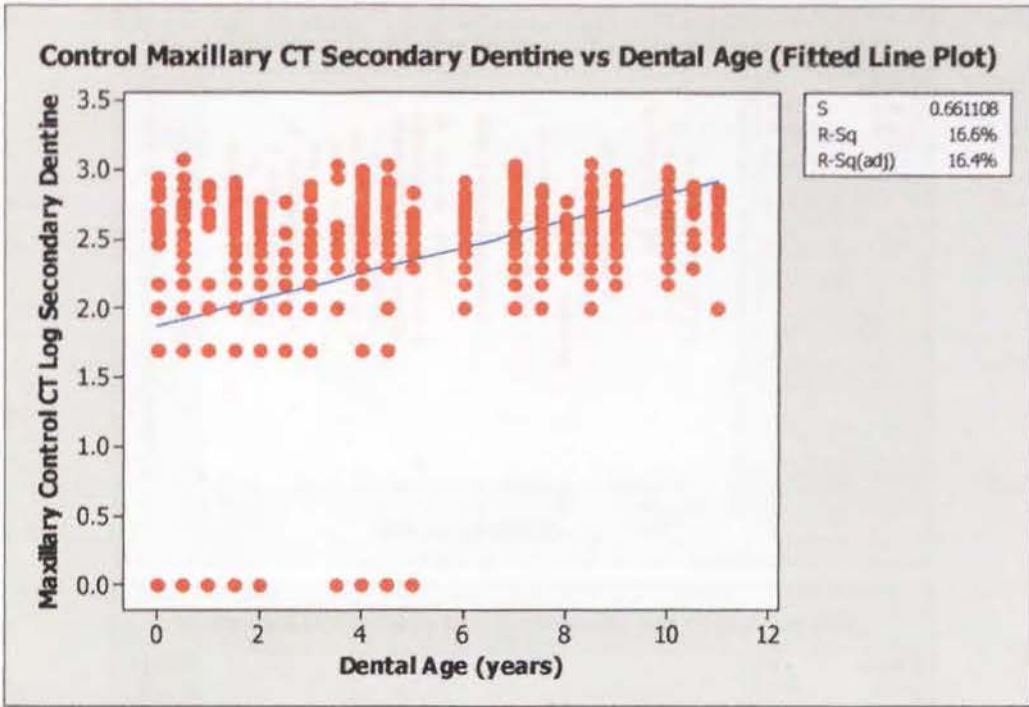
Data obtained from primary and secondary dentine measurements were transformed with square root or log transformations respectively in order to normalise their residuals, thereby allowing parametric statistical analyses to be performed.

When the transverse thickness of secondary dentine was examined with respect to dental age, this was found to significantly increase with increasing dental age, in both control and diseased CT ( $F_{1,692}=137.4$   $p<0.001$  and  $F_{1,347}=36.91$   $p<0.001$  respectively) (Figure 5.2). However on comparing the means of these two normalised data groups by Student's t-test, the control CT had more secondary dentine present than the diseased maxillary CT ( $t=-6.36$   $p<0.001$ ).

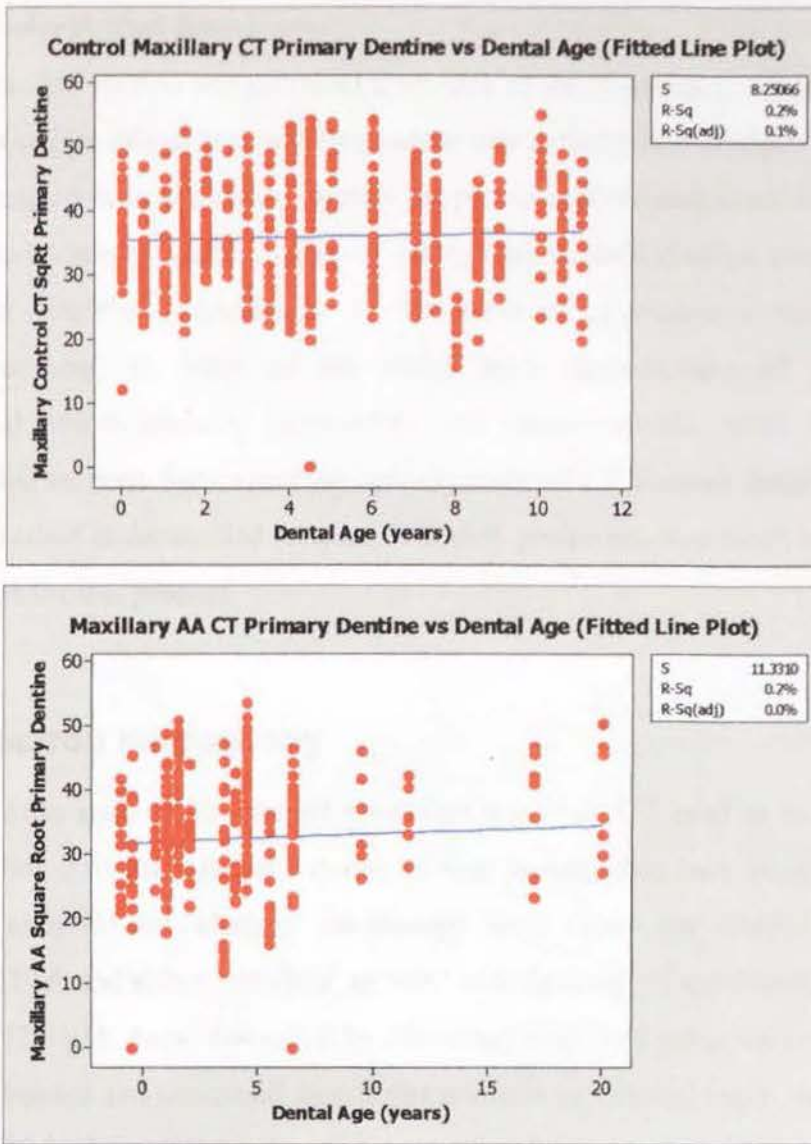
The thickness of primary dentine present was compared between control and apically infected CT in relation to their dental age (Figure 5.3). It was found that in both control and diseased maxillary CT, the amount of primary dentine present did not significantly change with increasing dental age ( $F_{1,678}=1.54$   $p=0.215$  and  $F_{1,345}=0.77$   $p=0.380$  respectively) as is represented graphically by the similar, non-sloping of the best-fit lines on the two linear regression graphs (control and diseased CT). On comparing the means of these two normalised data groups with a Student's t-test, the control CT had more primary dentine present than the diseased maxillary CT ( $t=-5.65$   $p<0.001$ ).

As with control CT, primary and secondary dentine was thicker on the palatal aspect of the pulp chamber than the buccal aspect ( $t=5.53$   $p<0.001$  and  $t=2.09$   $p=0.038$  respectively) in apically infected CT. Similarly, there was no statistical difference between the amount of primary dentine present between occlusal and mid transverse sections ( $F_{1,315}=0.0$   $p=1.00$ ), and a greater amount of secondary dentine was present in occlusal sections than in mid sections ( $F_{1,319}=36.44$   $p<0.001$ ) as with controls.

Again, following the same pattern as control CT, there was a statistical difference in the thickness of primary dentine of diseased maxillary CT surrounding individual pulp chambers ( $f_{1,311}=2.48$   $p=0.032$ ) but not secondary dentine ( $F_{1,315}=0.87$   $p=0.050$ ).



**Figure 5.2:** Secondary dentine thickness from occlusal transverse sections in control and apically infected maxillary CT following a log transformation ( $\log \mu\text{m}$ ) in relation to increasing dental age (years). A best-fit line (blue) runs through both sets of plotted points. (AA=apical abscess)



**Figure 5.3:** Primary dentine thickness measurements in control and apically infected maxillary CT from occlusal transverse sections following a square-root transformation ( $\sqrt{\mu\text{m}}$ ) in relation to dental age (years). A best-fit line (blue) runs through both sets of plotted points, that does not identify any statistically significant increase in primary dentine with increase in dental age. (AA=apical abscess/apical infection)

The incidence of resting lines present in apically infected maxillary CT was significantly higher than for control CT ( $\text{Chi}^2=27.31$   $p<0.001$ ). The incidence of predentine presence and enlarged areas of intertubular dentine were both lower in diseased CT than controls ( $\text{Chi}^2=46.53$   $p<0.001$  and  $\text{Chi}^2=14.15$   $p<0.001$ , respectively).

### **5.3.3.2: Undecalcified Histology:**


An undecalcified section was prepared from each of the 28 apically infected maxillary CT. The principle role of this was to examine any pathological changes to the CT in their mineralised state, such as to identify the presence of demineralised bands present during active carious attack. Areas of interest were photographed and have been included in case studies (Appendix 1). The presence of artefactual micro-fractures (from processing) in many of the slides made identification of pre-existing, pathological micro-fractures impossible. No measurements were made from undecalcified sections from maxillary apically infected CT because dentine was more readily classified in decalcified sections, and slide production was much more reliable and efficient for this process.

## **5.3.4 Electron Microscopy**

A section from each of 16 apically abscessed maxillary CT used in an initial pilot study (Section 3.6) was allocated to one of four groups, with each group then being randomly assigned for electron microscopy with either the EM505 SEM; the XL30/CP SEM; and either 'standard' or 'ion beam thinning' of specimens for viewing by the CM12 TEM. Areas that could be effectively examined using ion beam thinning were very limited and contained significant artefacts so this technique was discarded (Section 3.10.2). Images from the three remaining electron microscopic examinations were then compared.

### **5.3.4.1 Phillips EM 505 SEM**


Principle areas investigated in this pilot study were the dentine surfaces (primary and secondary) of pulp chambers from CT extracted with apical infections. As noted in the previous case studies, the contents of the pulp chambers varied considerably from frank pus to healthy pulp tissue. Figures 5.4-7 give examples of the effect these differing pulp chamber contents had on adjacent dentine.




**Figure 5.4:** Primary dentine lining pulp chamber 3 of CT 107 from Case 104. Vital pulp was still present within this pulp chamber at the time this CT was extracted, however pus was present in pulp chamber 4 as seen in Figure 5.5. Note how the intratubular dentine has

been removed from within the dentinal tubules (DT) during the etching of the sample in preparation for viewing. Organic material (OM) (thought to be remnants of a collagenous layer) still adheres to the primary dentine. (SEM 1bar = 0.1mm)

**Figure 5.5:** Primary dentine lining pulp chamber 4 of CT 107 from Case 104. Intertubular dentine (ID) has a more ragged appearance than that in pulp chamber 3, possibly due to caries. The organic material



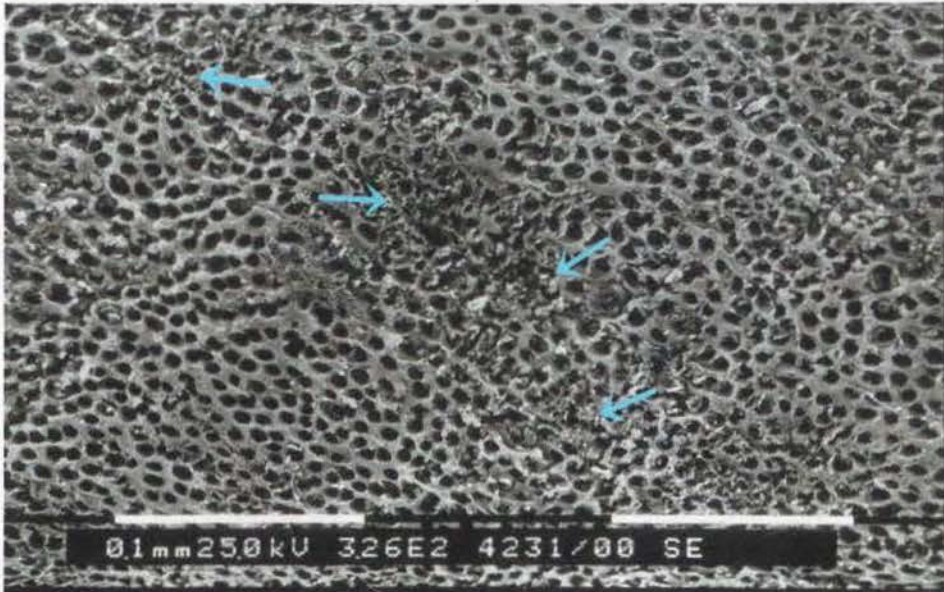
adherent to this primary dentine is more irregular than that present in pulp chamber 3. Again no odontoblast processes are present within the dentinal tubules (DT). (SEM 1 bar = 0.1mm)



**Figure 5.6:** Secondary dentine lining pulp chamber 2 from Case 202 (exact Triadan position unknown). Intertubular dentine (ID) is thicker in secondary dentine than primary dentine as is shown here. Odontoblast processes (OP) still lie

within dentinal tubules (DT), and the rounded nature of this dentino-pulpal interface (that odontoblast cells previously adjoined) is evident.

**Figure 5.7:** Secondary dentine lining pulp chamber 4 from Case 204 (exact Triadan position unknown).



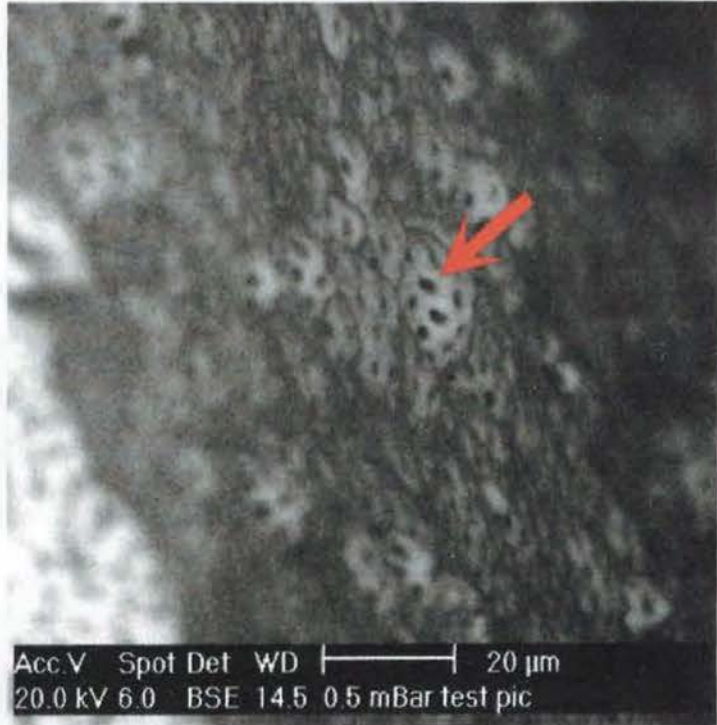There has been a loss of intertubular dentine integrity in many localised areas (identified by arrows). In this case the pulp within this chamber was necrotic and the partial loss of intertubular dentine structure may be due to carious attack. (SEM 1 bar = 0.1mm)

The gold-palladium sputter-coated samples viewed in the EM505 SEM could be seen to fissure whilst under vacuum. The surface of coated samples did not charge readily, in contrast to carbon coated samples viewed in the XL/CP30 SEM.

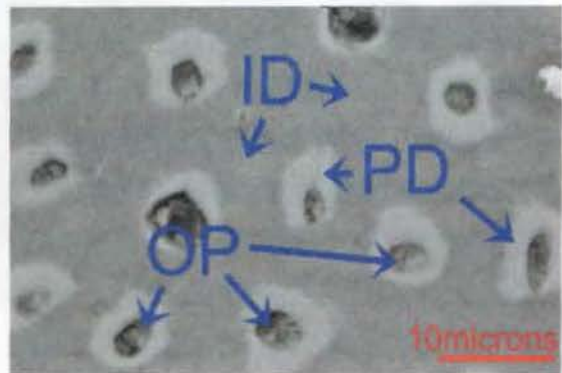
### 5.3.4.2 Phillips XL30/CP SEM

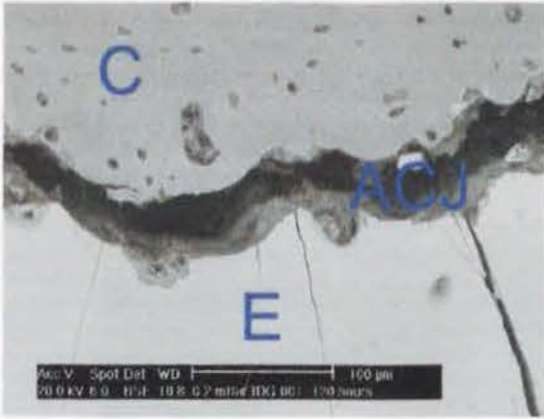
Carbon coated samples viewed in the XL30/CP SEM would frequently become charged when viewing using secondary electron imaging. This could be partially avoided by using a controlled low pressure (0.2mBar) and collecting images with 'back-scattered' electrons. The image quality of these carbon-coated samples was comparable to those gained using the gold / palladium sputter coating method for viewing in the EM505 SEM.

**Figure 5.8:** SEM of a mid transverse section from Case 217. The gently undulating surface of the dentine lining pulp chamber 6 is evident, as are openings for odontoblast tubules (arrow) that would have contained the odontoblast processes before the pulp was removed during processing.



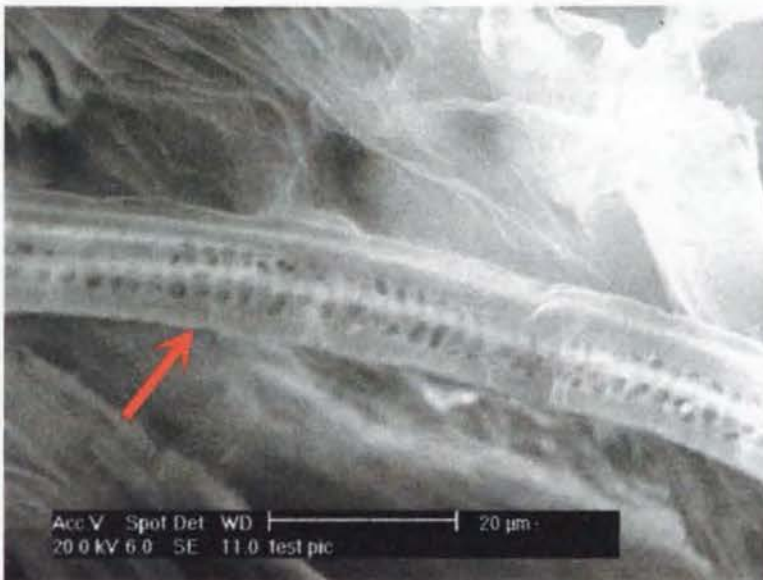
**Figure 5.9:** SEM of a sub-occlusal transverse section from Case 217 (exact Triadan position unknown). Odontoblast processes (OP) are present within a collar of peritubular dentine (PD), more recently referred to as intratubular dentine. Intertubular dentine (ID) present between the dentinal tubules (OP and PD combined).





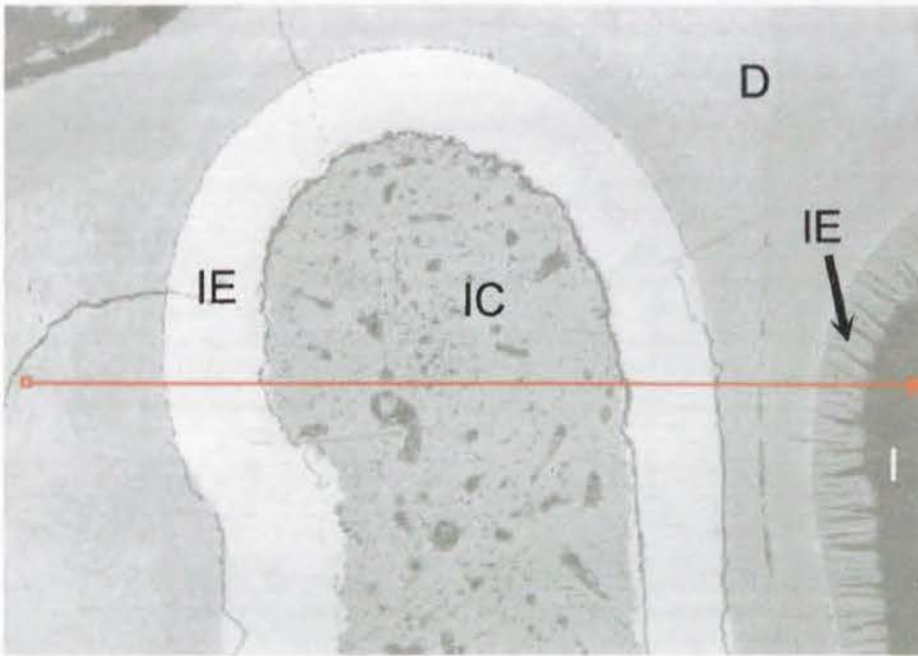
**Figure 5.10:** SEM of a sub-occlusal transverse section from Case 217 (exact Triadan position unknown) showing the scalloped nature of the amelocemental junction (ACJ) between enamel (E) and cementum (C). The space that has opened between these two calcified tissues is an artefact from the drying of the sample during preparation and imaging.

**Figure 5.11:** SEM of a sub-occlusal transverse section of peripheral enamel (e) from Case 205 (Triadan position unknown). Individual horseshoe-shaped enamel prisms can be seen (arrows), leaving a serrated edge where they have been dislodged along this artefactual fracture plane.



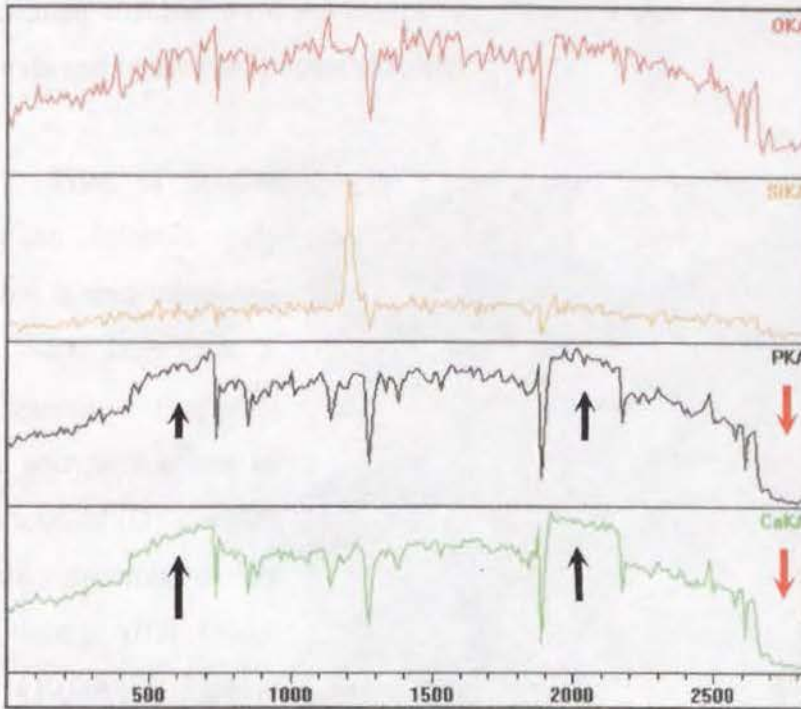
**Figure 5.12:** SEM of a sub-occlusal transverse section from Case 216 (Triadan position unknown) identifying the cellular nature of some fibrous vegetable material that has become impacted within the occlusally exposed pulp chamber 4 (arrow).

Semi-quantitative line-scans, to assess the proportions of key elements (namely calcium, phosphorus and carbon) were performed on polished transverse sections (Section 3.9.2). An example of such a line-scan for purposes of elemental analysis is seen in Figures 5.13 and 5.14.



**Figure 5.13:** SEM of a mid transverse section from CT of Case 216. The line scan (red) begins in on the left side in dentine (D), before passing through infundibular enamel (IE), infundibular cementum (IC) (caudal infundibulum), infundibular enamel again, dentine, carious enamel (arrow IE) of the rostral infundibulum and finally stops within the empty space of the rostral infundibulum (I) previously occupied by infundibular cementum.

Filename: D:\PGT Users\lan Dacre\13 August 2002\_68\_img1\_L01\_T01.lpa  
Number of Points: 248  
Line length: 2841.921  $\mu\text{m}$   
Point spacing: 11.459  $\mu\text{m}$



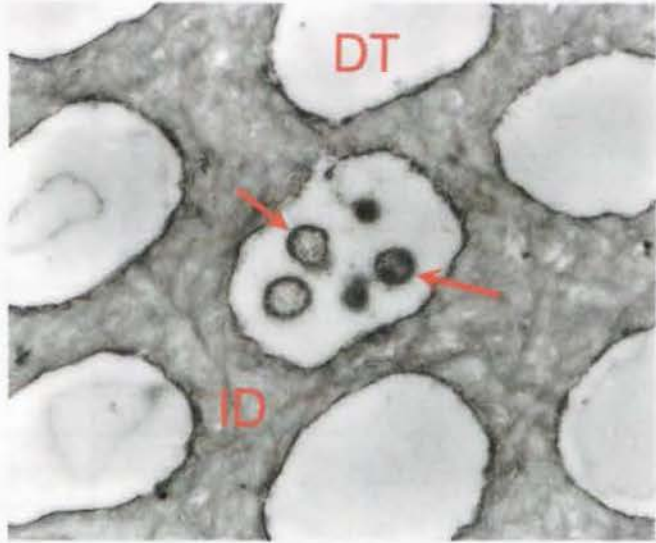
**Figure 5.14:** The trace print-out from the XL30/CP SEM of a line scan (Figure 5.56) performed on a transverse section from Case 216. The top two lines trace the relative abundance of oxygen (red) and silicon (yellow) as the line scan has passed from left to right across the sample as shown by the red line in Figure 5.56. The lower two lines represent the relative abundance of phosphorus (black) and calcium (green) present in the same line-scan. Black arrows highlight where the scanner was passing over areas of non-carious infundibular enamel or the caudal infundibulum, and the red arrow where it passed over carious enamel of the rostral infundibulum.

The line scan traces illustrate how calcium and phosphorus have been depleted in the carious rostral infundibular enamel compared to non-carious caudal infundibular enamel. Although this technique was used only once during this present study, it has obvious merits in the examination of calcified dental specimens.

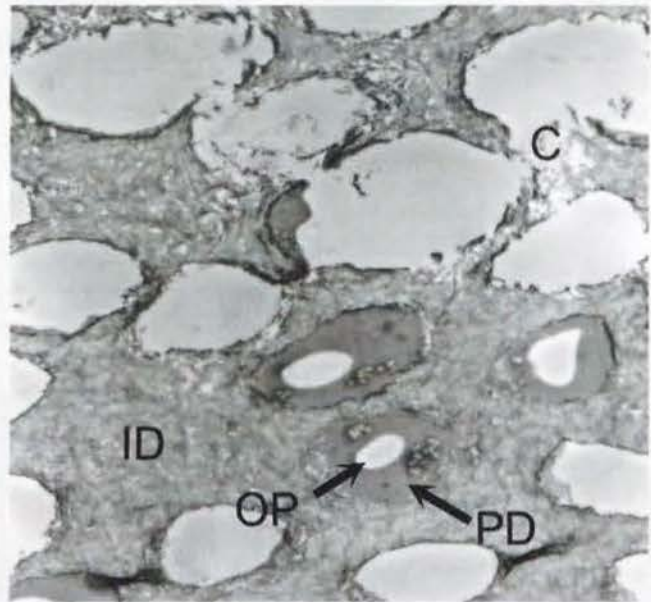
### 5.3.4.3 Philips EM400 TEM

Because of time constraints, only 10 areas of four CT (from 16 transverse sections allocated) were used in this pilot study. Areas of predominantly pulp with a small amount of dentine attached were selected. Even these few trial specimens however gave useful data and images as illustrated below.

**Figure 5.15:** TEM of dentine adjacent to an infected pulp chamber, from a mid transverse section of CT 207 from Case 3. Pioneer organisms (bacteria) (arrows) are seen within one of the dentinal tubules (DT), which are in turn surrounded by intertubular dentine (ID). (Non-stained x10,000; photo S.Mitchell)



**Figure 5.16:** TEM of dentine adjacent to an infected pulp chamber, from a mid transverse section of CT 207 from Case 3. The vacant space where an odontoblast process (OP) previously sat is surrounded by intratubular dentine, also referred to as peritubular dentine (PD). Intertubular dentine (ID) is present between these dentinal tubules (OP and PD) with some areas (C) having been destroyed either by carious attack, or tissue processing.



(Unstained x5000; photo S.Mitchell)

### 5.3.5 Summary of Grouped Analysis of Maxillary Cheek Teeth Apical Infections Examined in Detail

Table 5.3 summarises pertinent case history, gross pathology, dentine production and likely aetiology of the 28 maxillary CT with apical infections that were examined in detail. These are results are discussed in Section 5.5.

Case	Triadan	Dental age (years)	Duration of infection (months)	Antibiotics given (Yes/No)	CT extracted or repulsed	Occlusal pulp exposed (pulp chamber numbers)	Infundibular caries	Periodontal disease	Anachoretic pulpitis	Fracture	Decreased dentine	Developmental or Acquired origin
1	106	5.5	15	Y	E	1,2,3,4,5	Y	N	N	N	Y	-
2	207	6.5	24	Y	R	N	N	Y	N	N	N	A
3	207	-0.5	6	N	E	1,2,3,4,5	N	Y	Y	N	Y	A
4	106	-0.5	3	Y	E	N	N	N	Y	Y	Y	A
5	108	1	6	-	E	N	N	N	Y	N	Y	A
6	206	3.5	24	N	E	N	N	N	Y	N	Y	A
7	107	6.5	1.5	Y	E	N	N	N	Y	N	Y	A
8	209	4	4	Y	R	1,2,3,4,5	N	N	Y	N	Y	A
9	108	1	36	-	E	N	N	Y	Y	N	Y	D
10	108	2	3	-	R	N	N	N	Y	N	Y	A
11	108	1	6	Y	R	N	Y	N	N	N	Y	A
12	206	6.5	3	Y	R	N	N	Y	N	N	N	D
13	206	4.5	-	Y	E	1,2,4	N	N	Y	N	Y	D
14	208	20	-	N	E	N	N	Y	N	N	N	A
15	111	11.5	3	Y	R	N	N	Y	N	N	N	A
16	108	-1	-	N	R	N	N	N	Y	N	N	D
17	207	0.5	1	Y	R	N	N	N	Y	N	Y	D
18	206	-0.5	6	Y	R	N	N	N	Y	N	N	D
19	106	4.5	-	-	E	N	N	N	Y	N	Y	A
20	107	3.5	3	Y	E	3	N	N	Y	Y	Y	A
101	207	3.5	0.5	-	E	N	N	N	Y	N	N	A
102	107	1.5	36	-	E	1,2,3,4,5	N	N	Y	N	Y	D
103	207	4.5	3	-	E	N	N	N	Y	N	Y	A
104	107	1.5	1	-	E	N	N	N	Y	N	Y	D
105	207	9.5	-	-	E	N	N	Y	N	N	N	A
106/3										N		
9	107	1.5	1	Y	E	N	N	N	Y	N	N	A
107	107	4.5	1	N	E	N	N	N	Y	N	N	A
108	109	17	-	-	E	N	Y	N	N	N	N	A

**Table 5.3:** Classification of maxillary apically abscessed CT examined in detail.

(Y=yes or present; N=no or absent; E=extracted; R=repulsed; D=developmental origin; A=acquired origin; empty cell=information unavailable or not established).

### **5.3.6 Additional cases:**

An additional 31 maxillary CT extracted because of apical infection with incomplete or unknown histories were examined grossly and under a dissecting microscope. Histology or radiography were not performed due to time restraints. Eleven of the CT had been extracted orally, and 18 repulsed.

Ten CT had varying degrees of infundibular caries present, three of which had coalesced and the CT then fractured through the midline sagittal plane. The role of these carious infundibula in the aetiopathogenesis of the apical infection present in these CT could not be established in four of these 10 cases, given the limited examination performed. Infundibular caries was thought to be the most likely cause of the apical infection in the remaining six cases (19%). Periodontal disease was believed to have caused the apical infection in five CT (16%), but in three of these cases the periodontal disease was caused by the presence of adjacent dysplastic or supernumerary teeth with surrounding periodontal food pocketing, because these teeth did not fit correctly into their alveoli or the CT row. The remaining two cases with periodontal disease were from aged animals as judged by their CT length. The CT of eight of the 31 cases (26%) had pulp exposed on the occlusal surface through dental attrition, and another two had pulp exposure resulting from fracture to the clinical crown. Seven CT (23%) had fractures to the clinical crown, with three of these (10%) being midline sagittal fractures (through coalesced infundibula) in older teeth (based on CT length). One CT presented with a fracture within the body of the tooth that was non-displaced and appears to have deposited dentine and/or cementum to 'heal' the fracture.

A summary of the findings from these 31 CT is presented in Table 5.4. In cases with unknown histories, the CT examined often did not have its Triadan position recorded. By examining the occlusal table, the quadrant from which a CT originated can be established, and Triadan 06 and 11 positions recognised. Differentiating between Triadan 07-10 of CT from the same row however is uncertain, and for this reason exact Triadan position for several of these cases is not given.

Case	Triadan	Extracted / repulsed	Occlusal pulp exposed (numbers)	Infundibular caries	Periodontal disease	Fracture	Likely aetiology
201	207-10	E	N	Y	N	Y	Midline sagittal fracture
202	107-10	R	N	N	N	N	Anachoretic pulpitis
203	107-10	R	N	N	N	Y	Traumatic fracture
204	107-10	R	1,2,3,4	N	N	N	Pulp exposure
205	207-210	R	N	N	N	N	Anachoretic pulpitis
206	107-10	E	N	N	N	Y	Traumatic fracture healed
207	209	R	1,4	N	N	N	Pulp exposure
209	107-10	E	N	N	N	N	Anachoretic pulpitis
210	211-12	E	N	N	Y	N	Dysplastic / supernumerary
211	107-10	R	N	Y	N	N	Carious infundibulum
212	107-10	R	N	Y	N	N	Carious infundibulum
213	107	R	N	N	N	N	Anachoretic pulpitis
214	207-10	R	1,2,3,4	Y	N	Y	Traumatic fracture?
215	107-10	E	1	Y	N	N	Carious infundibulum?
216	207-10	E	1,2,3,4,5	Y	N	N	Advanced pathology
217	108	E	N	Y	N	N	Carious infundibulum?
218	207-10	E	N	N	N	N	Anachoretic pulpitis
219	207-10	R	N (1& 2 at fracture)	N	N	Y	Buccal slab fracture
220	107-10	E	N	N	Y	N	Periodontal disease
240	109	E	N	Y	N	N	Carious infundibulum
243	208	E	N	N	N	N	Occlusal caries extends to pulp chamber 4
246	107-10	E	N (2 at fracture)	N	N	Y	Pathological fracture
248a	110	E	N	N	Y	N	Associated periodontal disease
248b	111	E	N	N	Y	N	Dysplastic resulting in periodontal disease
249	107-10	E	5	N	N	N	Pulp exposure
251	207-10	E	N	Y	N	Y	Midline sagittal fracture
253	108	E	1	N	Y	N	Old CT periodontal disease
255	210	E	N	Y	N	Y	Midline sagittal fracture
256	107-10	R	N	N	N	N	Anachoretic pulpitis
257	107-10	E	N	N	N	N	Anachoretic pulpitis
260	207-10	R	4	N	N	N	Pulp exposure

**Table 5.4:** Summary of findings in 31 maxillary CT extracted because of apical abscess formation. As these CT had incomplete clinical histories, they have not been included in any statistical analyses. Only a 'most likely' aetiology could be given due to the limited history and examinations given for each case. (E=extracted, R=repulsed, Y=yes or present, N=no or not present)

### **5.3.7 Statistical Analyses:**

Chi-squared tests performed found no statistical differences between incidence of periodontal disease ( $\text{Chi}^2=0.01$   $p=0.94$ ), occlusal pulp exposure ( $\text{Chi}^2=0.09$   $p=0.76$ ), anachoretic pulpitis ( $\text{Chi}^2=1.72$   $p=0.19$ ) or infundibular caries ( $\text{Chi}^2=1.01$   $p=0.32$ ), between the 28 CT examined in detail and those ( $n=31$ ) without clinical histories.

The higher incidence of infundibular caries in the group with incomplete clinical histories (10/31), compared to the 28 maxillary CT examined in detail (3/28) may be a reflection of this second group containing older horses, as evidenced by their generally shorter occlusal-apical length (but with no case histories this could not be verified), and in any case this too was not statistically significant ( $\text{Chi}^2=2.82$   $p=0.09$ )

## **5.4 Grouped Analysis of Mandibular Cheek Teeth Apical Infections**

### **5.4.1 Gross Pathology**

Fifteen of the 22 mandibular CT examined in detail were orally extracted under standing sedation. The remaining seven CT were repulsed, with variable damage caused to the apical region. The median duration of apical infection before the CT was extracted for 19 CT with this information was three months (range 0-18 months).

Sinus tracts from the apical dental alveolus to the skin were present in 12 of 21 cases. Ten of 22 CT had pulp chambers exposed on the occlusal surface, although in four teeth, exposure had resulted from fracture (including the presence of a patent fissure fracture in Case 25), as opposed to attrition to the occlusal surface. Multiple pulps had been exposed in six of 10 cases. In two further cases, dental fracture to the apical tooth region following blunt trauma such as kicks was thought to be responsible for apical infection.

Periodontal disease was assumed to have been present when reactive changes to the cementum such as progressive tracts, areas of cemental reabsorption or cemental hyperplasia were present. Such changes were common, being present in 18/22 cases

examined. In most of these cases however such reaction by cementum was thought to be a secondary response following spread of apical infection to the dental alveolus. In two cases, descending periodontal disease (from gingiva to the apex) was thought to have been the primary cause of apical tooth infection (e.g. Case 33, Appendix 2).

Dentine production (usually only secondary dentine but in some cases, primary dentine also) was decreased in 16/22 infected CT. In all these cases an anachoretic pulpitis was believed to have been present that subsequently developed into an apical pulp infection. Four of these cases also had pulp chambers exposed on the occlusal surface and it is possible that this exposure may have resulted in the ultimate apical infection. However, the long standing changes in dentine formation present in these CT make it more likely that odontoblasts and their supporting pulp tissue were already compromised by an anachoretic pulpitis.

## **5.4.2 Radiographic Assessment**

### **5.4.2.1 Clinical Assessment of Standard Radiography**

As for maxillary CT (Section 5.3.2), radiographs of eight mandibular CT with apical abscesses were selected at random from the 22 CT examined in detail. The same four equine clinicians who were experienced at reading clinical dental radiographs viewed the radiographs of the extracted CT, 'blindly' and independently, in order to assess intra-dental radiological features. The clinicians were asked to identify if the radiograph showed any of the following intra-dental radiological features:

- Changes to the apical third of the of the tooth
- Changes to the middle third of the tooth
- Fracture to the clinical crown of the tooth
- Occlusal exposure of pulp
- Caries of the peripheral cementum

The agreement between clinicians is shown in Table 5.5.

<b>Radiological factor</b>	<b>4/4 Clinician agreement</b>	<b>3/4 Clinician agreement</b>
Apical changes	5/8	6/8
Changes in the middle third of CT	2/8	8/8
Clinical crown fracture	3/8	7/8
Caries of peripheral cementum	4/8	8/8
Occlusal pulp exposure	2/8	8/8

**Table 5.5:** Inter-clinician repeatability of reading 8 radiographs of extracted apically infected mandibular CT.

As found when examining radiographs of extracted maxillary CT, the clinicians did not agree in their interpretation of any one radiological features in the eight radiographs on a single occasion. Three of the four clinicians agreed on the presence (or absence) of apical changes, if there were radiological changes to the central third of the CT, whether pulps had been exposed occlusally and if caries of cementum was present in the eight radiographs assessed. Comparing the assessment of the three clinicians in agreement, to the findings from dissecting microscopy, there was 75% agreement on features present.

Given both inter-clinician variability in interpretation of this set of eight mandibular CT radiographs, and the poor correlation in their radiographic findings with the pathological changes actually present in the teeth (as assessed under dissecting microscopy) i.e. 75% correlation, it was concluded that radiography is insensitive in assessing intradental pathological changes.

#### **5.4.2.2 Computer Axial Tomography**

Three apically infected mandibular CT were scanned using a Somatom Esprit CAT scanner. A spiral series of images was taken of each tooth and analysed using Syngo A40A software. The principle use of these CAT scans was to identify areas of interest for future histology. Two video clips of diseased maxillary CT CAT scans formatted for inclusion in this work have been included on the CD enclosed with this work (Appendix 2).

## 5.4.3 Histological Results

### 5.4.3.1 Decalcified Histology

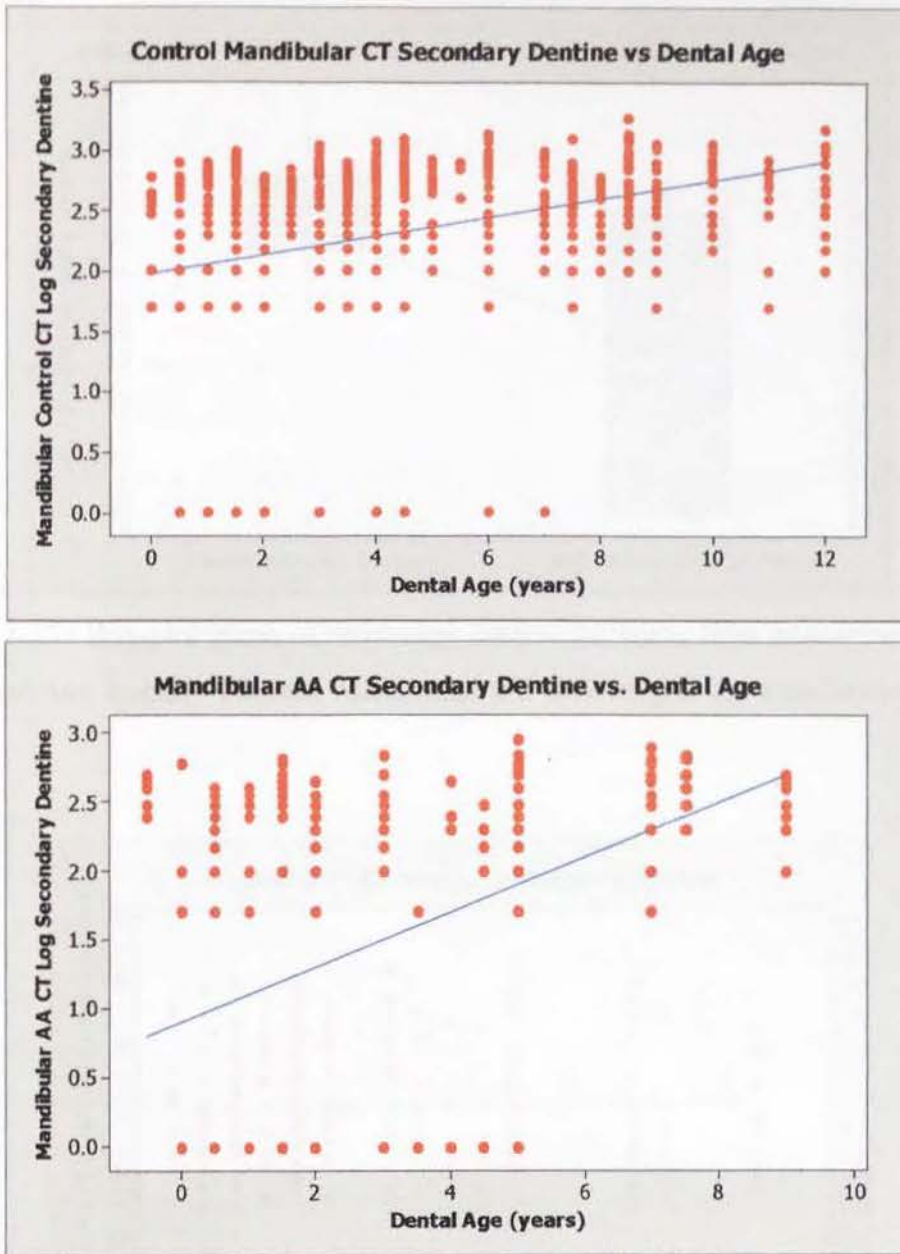
Sixty-one decalcified transverse sections from 22 maxillary CT with apical infections were examined and anatomical measurements of individual pulp chamber diameters and their surrounding dentine were obtained (Section 3.8.1). The dentine was classified by histologically examining decalcified sub-occlusal and mid transverse CT sections (n=42). Results are presented in Table 5.6. As noted for these same measurements in control CT (Chapter 4) and CT with maxillary apical infections (Chapter 5.3.3), a wide range and large standard deviation is often present for these parameters. Thirteen transverse 'apical' sections were also examined. In cases where the CT had been repulsed, apical regions were usually damaged and consequently apical sections were not cut. Areas of interest were photographed and have been included in case studies (Appendix 2).

Measurements of primary and secondary dentine (Section 3.8.1) were transformed with square root or log functions, respectively, in order to normalise their residuals, thereby allowing parametric statistical analyses to be performed. When the transverse thickness of secondary dentine was compared with respect to dental age, this was found to significantly increase with increasing dental age, in both control and diseased mandibular CT ( $F_{704}=86.23$   $p<0.001$  and  $F_{313}=64.84$   $p<0.001$  respectively) (Figure 5.17). On comparing the means of these two normalised data groups by Student's t-test, the control CT had more secondary dentine present than the diseased maxillary CT ( $t_{426}=12.86$   $p<0.001$ ) (Figure 5.18).

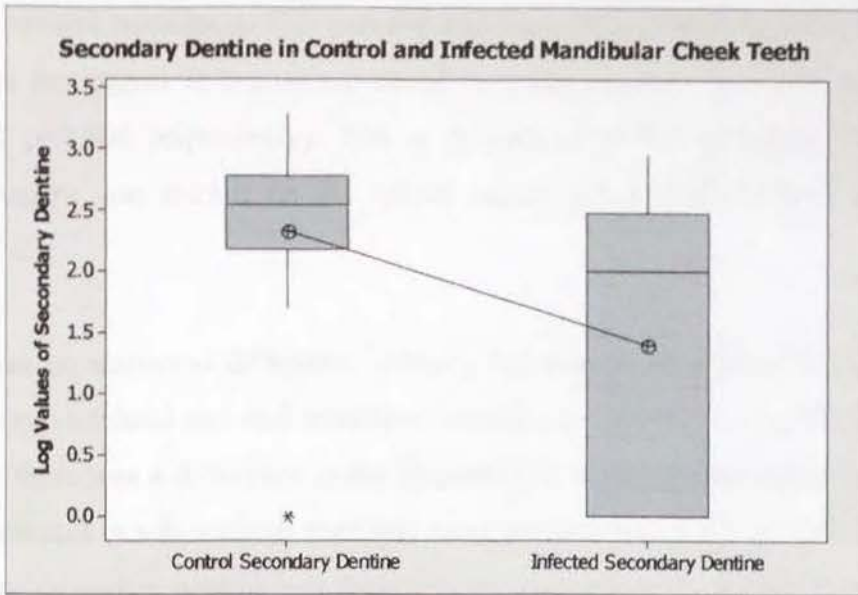
The thickness of primary dentine present was compared between control and apically infected CT in relation to their dental age (Figure 6.32). It was found that in diseased mandibular CT, the amount of primary dentine present did not significantly change with increasing dental age ( $F_{310}=0.06$   $p=0.80$ ) as is represented graphically by the non-sloping best-fit line on the linear regression graph. On comparing the means of control and apically infected mandibular CT normalised primary dentine data groups with a Student's t-test, the control CT had significantly more primary dentine present than the diseased maxillary CT ( $t_{539}=-3.21$   $p=0.001$ ).

Parameter	Pulp diameter ( $\mu\text{m}$ )	2iD ( $\mu\text{m}$ )	1D ( $\mu\text{m}$ )	2D ( $\mu\text{m}$ )
<b>Sub-occlusal section &lt;3 years old</b>				
(n)	98	108	101	104
Range	0-1800	0-700	200-2600	0-700
Median	0	100	1300	250
Mean (s.d.)	372 (537)	148 (170)	1316 (584)	240 (186)
<b>Mid section &lt;3 years old</b>				
(n)	88	102	90	100
Range	250-4000	0	50-2700	0-600
Median	1525	0	900	0
Mean (s.d.)	1735 (879)	0	1000 (558)	40 (97)
<b>Sub-occlusal section 3.5-7 years old</b>				
(n)	40	40	40	40
Range	0-2800	0-500	200-2800	0-900
Median	375	100	1000	100
Mean (s.d.)	888 (1002)	165 (185)	1106 (657)	254 (277)
<b>Mid section 3.5-7 years old</b>				
(n)	46	48	46	48
Range	350-3800	0	200-2450	0-650
Median	1000	0	800	150
Mean (s.d.)	1148 (679)	0	980 (663)	174 (161)
<b>Sub-occlusal section &gt;7 years old</b>				
(n)	1	1	2	2
Range	0	500	400-700	300-400
Median	0	500	550	350
Mean (s.d.)	0	500	550 (212)	350 (371)
<b>Mid section &gt;7 years old</b>				
(n)	14	14	13	13
Range	100-1950	0-100	300-2000	100-700
Median	700	0	800	300
Mean (s.d.)	779 (628)	14 (36)	989 (623)	350 (199)

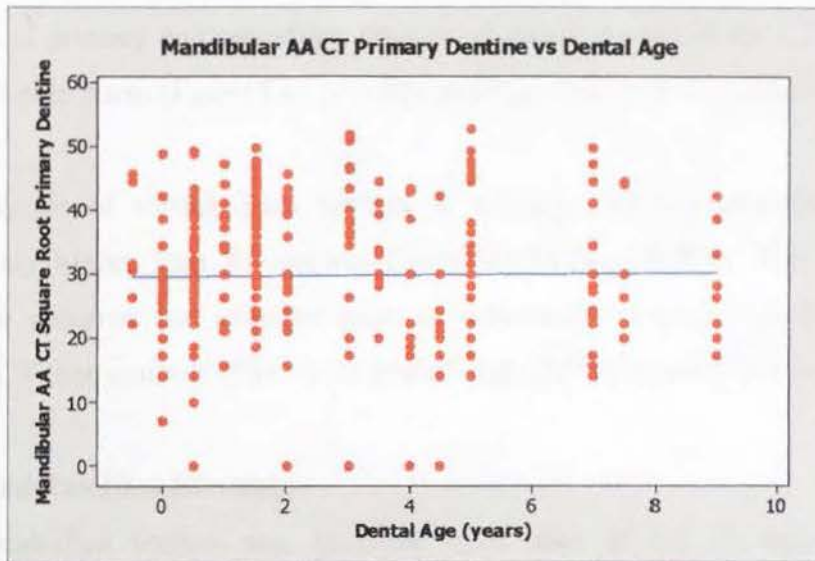
**Table 5.6:** Measurements of transverse sections at sub-occlusal and mid tooth levels from 22 mandibular CT with apical infections (1D= primary dentine; 2D= regular secondary dentine; 2iD= irregular secondary dentine; s.d.= standard deviation).



**Figure 5.16:** Secondary dentine thickness from transverse sections in control and apically infected mandibular CT following a log transformation ( $\log \mu\text{m}$ ) in relation to increasing dental age (years). A best-fit line runs through both sets of plotted points. (AA=apically abscessed, CT=cheek teeth)



**Figure 5.17:** Box-plot graph of secondary dentine thickness from transverse sections in control and apically infected mandibular CT following a log transformation ( $\log \mu\text{m}$ ).



**Figure 5.18:** Primary dentine thickness measurements in apically infected mandibular CT from transverse sections following a square-root transformation ( $\sqrt{\mu\text{m}}$ ) in relation to dental age (years). A best-fit line runs through the set of plotted points, which does not identify any statistically significant increase in primary dentine with increase in dental age. (AA=apically abscessed, CT=cheek teeth)

As with control mandibular CT, primary and secondary dentine was not statistically thicker at the lingual or buccal aspects of the pulp chamber ( $t_{292}=0.44$   $p=0.659$  and  $t_{312}=0.52$   $p=0.606$  respectively). This is in contrast to the maxillary CT findings, where dentine was thicker on the palatal aspect (c.f. buccal) in both control and diseased CT.

There was no statistical difference between the amount of primary dentine present between sub-occlusal and mid transverse sections in control CT ( $t_{622}=0.01$   $p=0.992$ ), however there was a difference in the diseased CT, with a greater amount of primary dentine present in sub-occlusal than mid tooth sections ( $t_{309}=3.73$   $p<0.001$ ). A greater amount of secondary dentine was present in sub-occlusal sections than in mid sections for both control and apically infected mandibular CT ( $t_{528}=8.86$   $p<0.001$  and  $t_{312}=6.03$   $p<0.001$  respectively).

Following the same pattern as control CT, there was a statistical difference in the thickness of primary and secondary dentine of diseased mandibular CT surrounding individual pulp horns ( $F_{305}=15.46$   $p<0.001$  and  $F_{308}=2.33$   $p=0.032$  respectively).

The incidence of resting lines present in apically infected mandibular CT was significantly higher than for control CT ( $\text{Chi}^2=74.74$   $p<0.001$ ). The incidence of predentine presence and enlarged areas of intertubular dentine were both lower in diseased CT than controls ( $\text{Chi}^2=3.82$   $p=0.05$  and  $\text{Chi}^2=9.56$   $p=0.002$  respectively).

#### **5.4.3.2 Undecalcified Histology**

An undecalcified section was prepared from each of the 22 apically infected mandibular CT. The principle role of this was to examine any pathological changes to the CT in their mineralised state. Areas of interest were photographed and the findings were similar to those included in maxillary case studies (Appendix 1).

No measurements were made from undecalcified sections from mandibular apically infected CT, because dentine was more readily classified in decalcified sections, and slide production was much more efficient for this process.

### 5.4.4 Summary of Grouped Analysis of Mandibular Cheek Teeth Apical Infections Examined in Detail

Table 5.6 summarises pertinent case history, gross pathology, dentine production and likely aetiology of the 22 mandibular CT with apical infections that were examined in detail.

Case Number	Triadan Position	Dental Age (years)	Duration of Infection (months)	Antibiotics Given Previously	CT Extracted or Repulsed (E/R)	Sinus Tract Present	Occlusal Pulp Chamber Exposure (pulp numbers)	Dental Fracture	Periodontal Disease	Anachoretic Pulpitis	Decreased Dentine	Developmental or Acquired Origin (D/A)	Likely Aetiology
21	310	7	8	-	R	+	-	-	-	+	+	A	AP
23	407	0.5	5	-	E	+	-	-	+	+	+	A	AP
24	407	1	U	-	E	-	-	-	+	+	+	A	AP
25	309	5	1	+	E	+	5	+	+	-	-	A	F
27	408	0	5	U	E	+	1,2,3,4,5	-	+	+	+	A	AP
28	309	5	5	+	R	-	1,2,3,4,5	-	+	+	+	A	AP
29	409	9	3	+	R	-	3,5	+	+	+	+	U	U
30	407	0.5	8	+	R	+	1,2,3,4,5	-	+	+	+	A	AP
31	307	0.5	12	+	R	+	-	-	+	+	+	U	U
32	309	2	2	+	E	-	-	-	-	+	+	A	AP
33	308	0	3	-	E	+	-	-	+	-	-	D	P
34	406	3.5	U	U	E	-	3,4,5,	-	+	+	+	A	OE/AP
35	407	-0.5	3	+	R	+	-	-	-	-	+	A	F/T
36	407	0.5	7	-	E	+	4	-	+	+	+	A	AP
37	407	4.5	2	-	E	+	-	-	+	+	+	U	U
38	409	4	U	U	R	-	1,4	+	+	+	+	A	F
39	307	1.5	U	U	E	-	-	-	+	+	+	A	AP
40	309	3	0	-	E	-	3	+	+	-	-	A	F
301	407	1.5	2	+	E	+	-	-	+	+	+	A	AP
302	307	7.5	18	U	E	-	+	-	+	-	-	A	OE/C
303	308	3	2	-	E	+	-	+	+	+	-	A	F/T
304	406	0.5	1	-	E	-	4,5	+	-	-	-	A	F

**Table 5.6:** Classification of 22 apically abscessed mandibular CT examined in detail.

E=extracted, R=repulsed, A=acquired, D=developmental, AP=anachoretic pulpitis, F=dental fracture, U=undetermined/unavailable, P=periodontal disease, OE=occlusal pulp chamber exposure, C=caries, + = present, - = absent.

### 5.4.5 Additional Cases

An additional 19 mandibular CT extracted because of apical infection (with incomplete or unknown histories) were examined grossly and under a dissecting microscope. No histology or radiography was performed. A summary of the findings from these CT is presented in Table 5.7.

Case	Triadan	CT Extracted or Repulsed (E/R)	Occlusal Pulp Chamber Exposure (pulp numbers)	Dental Fracture	Periodontal Disease	Likely Aetiology
208	307	E	0	0	0	AP
222	408	E	1,5	1	0	F
223	311	E	0	0	1	P
228	308	R	4,5	1	0	F
241	408	E	1,2,3,4,5	1	1	F
242	408	E	4	0	1	P
244	411	R	1,4	1	0	F
245	409-10	E	3,5	0	1	AP/OE
248	406	R	0	0	1	U
251	307	R	0	1	0	T/F
252	307-10	R	4,5	1	0	F
254	307-10	R	4,5	1	0	F
255	407-10	E	3,4,5	0	1	AP/OE
256	307-10	E	4,5	0	1	AP/OE
257	307-10	E	0	0	1	AP
258	307-10	E	0	0	1	AP
259	407-10	R	4,5	1	0	F
260	307	E	1,2,3,4,5	0	1	AP/OE
261	408	R	4,5	1	1	F

**Table 5.7:** Classification of 19 mandibular apically abscessed CT examined grossly.

E=extracted, R=repulsed, AP=anachoretic pulpitis, F=dental fracture, U=undetermined, P=periodontal disease, OE=occlusal pulp chamber exposure, 1=present, 0=absent.

As with the maxillary cases examined with unknown histories, mandibular CT examined often did not have their Triadan position recorded. Examination of the occlusal table however could establish the quadrant from which a CT originated, and Triadan 06 and 11 positions could always be recognised. Differentiating between Triadan 07-10 of CT from the same row however is uncertain, and for this reason the exact Triadan position for several of these CT is not presented.

All 19 mandibular CT had been collected on the basis of their having been removed from cases clinically diagnosed with apical infection. Eight of the cases had fractures involving their clinical crown. Four of these were small fractures or fissures extending into a pulp chamber. Four others were buccal slab fractures to the clinical crown running through pulp chambers 4 and 5. These four CT are discussed along with other CT having a similar fracture pattern in Chapter 6.

In the two cases where periodontal disease was associated with apical tooth infection, the CT had been grossly displaced, with adjacent deep periodontal pocketing. Rather than having reactive cemental hyperplasia, as seen in cases where apical infection spreads within the alveolus, the cementum in these two cases was hypoplastic adjacent to areas of periodontal disease.

A likely aetiology could not be determined in one case where the apically infected CT had yet to erupt, as it had been trapped beneath a deciduous CT, and no history was recorded as to whether periodontal disease had been present concurrently (c.f. Case 33, Appendix 2). Of the remaining seven cases, four CT had multiple pulp chambers exposed occlusally (through dental attrition), and six of the seven cases had changes to the cementum indicating infection of the periodontium. From experience gained examining previous cases in greater detail, it was felt that these cases were most likely to have had an anachoretic pulpitis leading to an apical infection.

#### **5.4.6 Statistical Analyses**

Prior to comparing the 19 CT with incomplete histories with the 22 CT examined in detail, seven CT with identifiable dental fracture patterns were removed (and are reported in Chapter 6), and one CT where a single likely cause for the apical infection could not be given were removed from the following analyses.

Chi-squared tests performed on the remaining cases (22 cases with and 11 cases without complete clinical histories) found no statistical differences between incidence of periodontal disease ( $\text{Chi}^2=0.05$   $p=0.83$ ), occlusal pulp exposure ( $\text{Chi}^2=0.06$   $p=0.87$ ), anachoretic pulpitis i.e. when either pulps were exposed from occlusal

attrition or absence of any other readily identifiable cause ( $\text{Chi}^2=0.04$   $p=0.84$ ), fissure fracture ( $\text{Chi}^2<0.01$   $p=0.95$ ) or apical tooth infection following traumatic apical dental fractures ( $\text{Chi}^2=0.26$   $p=0.61$ ).

## 5.5 Discussion

### 5.5.1 History and Clinical Examination

Along with the relatively recent increased awareness in equine dentistry (Schumacher 2001), there has been a recent increase in publications on how to perform and accurately record the findings of equine dental examinations (Scrutchfield & Schumacher 1993; Baker 1998; Easley 1999; Ramzan 2002). With this increased attention to accurate examinations by well-informed clinicians, and with well-designed dental charting systems now readily available to the profession, retrospective studies on both prevalence of disease and their clinical outcome will further increase our knowledge of equine dental disorders.

A series of this type of retrospective clinical reports by Dixon *et al.* (1999a,b, 2000a,b) has become the backbone to our current understanding of many common equine dental disorders. This present pathological dental study was possible because of the availability of a collection of extracted diseased cheek teeth, collected at this institution over the past two decades by the first author of the above papers. Approximately half of the teeth examined in the present study were from cases previously reported by Dixon *et al.*, with the additional teeth coming from cases treated subsequently.

The median horse age for CT extracted because of apical tooth infection that were examined in detail in the current study was 6.5 and 5 years of age, for maxillary and mandibular CT, respectively, which is similar to the values of 7 and 5 years, respectively, in the study of Dixon *et al.* (2000a). Teeth from Triadan 07 position were most commonly affected from both maxillary (39%) and mandibular (45%) CT (from 50 CT examined in detail) in this study, in comparison to 32% maxillary 07s and 31% mandibular 07s in the study by Dixon *et al.* (2000a). The histories and

clinical signs of affected horses are as expected, comparable to those previously reported by Dixon *et al.* (2000a).

Although there have been considerable improvements in recent years in both oral examination technique and charting of equine dental conditions as noted above (Scrutchfield & Schumacher 1993; Easley 1999), there are many areas of equine dentistry that still could improve. When dealing with dental disorders, the clinical history obtained should also include details of diet. Examination of such long term records may indicate if dental disorders such as caries are more likely to occur on certain potentially cariogenic diets, such as molasses, sugar beet or high starch content diets, as is well documented in man (Hartles & Leach 1975; Shafer *et al.* 1983b; Soames & Southam 1993a). Thirteen of the 59 (22%) maxillary CT with apical infections examined in this study had carious infundibula, with many maxillary and mandibular CT also having caries of peripheral cementum. It was not possible to establish a link between the presence of caries and diet, as dietary information from case notes was incomplete or absent.

Detailed dietary information may also reveal potential systemic mineral deficiencies, notably of calcium levels in growing animals, where developing teeth must compete with skeletal formation for a limited mineral supply. Enamel and cemental hypoplasia were present in some apically infected CT examined in this study. The exact mechanism by which these disorders arose has yet to be determined in horses, but severe nutritional deficiencies have been linked to enamel hypoplasia or hypomineralisation in humans (Soames & Southam 1993c). Similarly, some pet rabbits have been found to develop calcium deficiency, by selective eating of pelleted foods and this nutritional deficiency causes increased susceptibility to dental disease (Harcourt-Brown 1996).

It has been frequently proposed in this study that occlusal pulp exposure can result from odontoblast and pulp damage, e.g. following anachoretic pulpitis or thermal pulpar damage. Another possibility is that animals deficient in calcium are not able to deposit sufficient amounts of dentine within pulp chambers to prevent such occlusal pulp exposure. It was not possible in this study to determine if any animals suffering

CT occlusal pulp exposure were deficient in calcium prior to CT apical infection and subsequent dental extraction. In humans suffering from rickets, recently formed dentine is hypo-mineralised, with pronounced interglobular dentine present (Soames & Southam 1993c). Although in this study we have been able to identify the existence of interglobular dentine in horses, we have not linked its presence to intercurrent systemic disorders. It is the author's opinion from clinical experience, that occlusal pulp exposure is more frequently present in horses with a history of being "rescued" from circumstances where their dietary intake was inadequate, than in horses from the general horse population.

Another key area in the assessment of dental disorders is improvement in client education to allow them to identify when dental disorders may be present. Although the duration of dental related symptoms in cases of CT apical infection was recorded in this study directly from horse owners, the accuracy of this set of data must be questioned. Kirkland *et al.* (1994) found that approximately 24% of horses examined had dental disorders present that had not been reported by the owner. This indicates that horses are poor at demonstrating oral discomfort, which may be due in part to them being a prey species. With respect to an owner's or referring veterinarian's report on duration of apical infection prior to referral, these should be regarded as being the minimum time that a dental disorder has been present, and they should not be taken as an accurate record.

The disorder of head-shaking in horses needs to be re-examined with respect to dental disease. Previous studies have stated that oral examination has excluded the presence of dental disorders in such cases (Lane & Mair 1987; Mair 1999). At the time of these reports, recognition of subtle dental pathology (e.g. occlusal pulp exposure) during a routine dental examination was not common practice, as is today's standard. It may therefore be possible that some cases of head-shaking were suffering from undiagnosed dental disorders, and in fact the condition in some of these cases may have been a sub-clinical manifestation of apical infection.

## 5.5.2 Radiography and Additional *in situ* Imaging Techniques

Previous reports of diagnostic radiography in equine dental disease have focused on changes to the tooth apex (including the roots if developed), the surrounding alveolus and supporting bones and the periodontium (usually evaluating the width of the periodontal space and for loss of the lamina dura denta) with apical infections and other major abnormalities, such as gross CT displacement, oligodontia or presence of supernumerary teeth (Geres 1962; Baker 1971; Baker 1972; Gibbs 1978; Wyn-Jones 1985; Gibbs & Lane 1987; Lane et al. 1987a; Lane et al. 1987b; Lane & Mair 1987; May & Wyn-Jones 1987; Gibbs 1999; Tremaine & Dixon 2001; Barakzai 2004; Zaluski & Davis 2003).

Recently a technique has been developed to radiographically assess the clinical crown of CT to assist diagnosis of diastema, alveolar crest loss or crown fracture (Barakzai & Dixon 2003). Although this technique does allow assessment of changes in individual CT (i.e. presence of crown fracture or diastemata) there have been no studies to evaluate intra-dental tooth changes to CT with apical tooth infections.

This present work has described radiographic studies of extracted CT that were subsequently examined in detail at gross and histological levels. This allowed features that were identified radiographically to be directly correlated to unusual anatomical features or to pathological changes. When using conventional radiography to locate such features in extracted CT, the changes had to be advanced, e.g. presence of marked apical cemental remodelling, or fracture of the clinical crown, in order to be detected radiographically.

In the clinical situation, radiography is commonly undertaken to help determine if pathological changes indicative of apical infection are present in a cheek tooth. This situation was simulated in this study, with four clinicians 'blindly' reading radiographs of 16 extracted, apically infected CT (8 maxillary and 8 mandibular). On no occasion did the four clinicians fully agree as to the presence (or absence) of any major radiographic features (such as fracture of the clinical crown or apical changes) in the 16 radiographs. Overall, abnormal radiographic features were recognised by the

four clinicians in just 69% of CT; with 63% of maxillary CT radiographic features and 75% of mandibular radiographic features being identified.

Radiography of brachydont teeth is much more successful than above at identifying pathological changes, with radiography routinely employed to accurately identify the presence of caries; changes to the endodontic system and apex; and other subtle changes to calcified dental tissues in brachydont teeth (Stanley et al. 1983; Jones & Boydé 1987; Tohda et al. 1987; Leach et al. 1989; Obry-Musset et al. 1988; Ashley et al. 1998; Ingham et al. 2001).

This difference between the sensitivity of radiography of hypsodont and brachydont teeth is due to two main factors. Firstly, equine CT have very complex endodontic anatomy compared to brachydont teeth, containing multiple pulp canals and complex, variable infoldings of all three calcified dental tissues. This results in radiographic superimposition of the structures of the tooth itself. Secondly, most equine dental radiographs are taken extra-orally, with superimposition of numerous overlying anatomical features, e.g. nasal concha, maxillary sinuses or nasal septum (including the CT from the contra-lateral side of the head) on the dental image, which further complicates image interpretation.

Recently, a flexible intra-oral radiographic film and screen has been developed for taking intra-oral radiographs of equine CT (D.Klugh, personal communication 2003). The use of this technique will help reduce the superimposition of overlying structures. Nevertheless, radiography essentially remains a two-dimensional imaging of complex three-dimensional structures, and clinicians will continue to be faced by the two previous problems.

Given the limitations of standard radiography, clinicians are turning to newer imaging techniques for diagnosis of equine dental disorders. In a recent case examined at this institution which had bilateral, buccal slab fractures of the maxillary CT, the use of nuclear scintigraphy detected bilateral apical infection, when there was radiographic evidence of only unilateral apical involvement. A study comparing sensitivity and specificity of scintigraphy against that of standard radiography in the diagnosis of

equine dental disease found scintigraphy to be more sensitive than radiography (95.5% c.f. 51.5%) but less specific (86.4% c.f. 95%) (Weller et al. 2001). This increased sensitivity agrees with the findings in the above clinical case.

Computer axial tomography (CAT) has been used in horses for nearly twenty years (Barbee et al. 1987), however it is still unavailable to most equine clinicians due to the expense and thus scarcity of the equipment required. Previous studies have highlighted the quality and usefulness of images captured using CAT, particularly in anatomically complex regions such as the head (Tietje et al. 1996; Tucker & Farrell 2001).

Kirkland *et al.* (1996) used CAT scans to help determine the endodontic anatomy of normal equine mandibular CT 07-10 in 48 hemimandibles from horses 2-9 years old. The present study imaged extracted CT using a much higher definition CAT than previously used for equine dental imaging (Section 3.4.1). By imaging the extracted CT with an over-lapping spiral scan, a three-dimensional picture was gained of the individual teeth. Having captured this digital information, it is then possible to reconstruct images of the tooth, selecting radiodensity of tissue and tooth orientation as required. These spiral CAT images allowed clear identification of subtle changes in radiodensity, deep within the dental tissues that would not have been detected using standard radiography. With appropriate general anaesthesia facilities, it would be possible to gain this same level of image quality in anaesthetised clinical cases, and this would greatly enhance diagnosis in equine clinical dentistry.

The presence of the distinct radiodense layer of enamel between dentine and cementum is a useful radiological feature when reading CAT intra-dental images. When there was decreased radiodensity of the enamel layer on CAT scanning, subsequent targeted histological examination of the defective area was able to attribute such lesions to developmental (e.g. infundibular cemental hypoplasia) or acquired (e.g. caries) disorders. Other developmental disorders recognised using CAT were enamel hypoplasia; enamel aplasia; and enamel dysplasia with resulting dentine and cement dysplasia. A recent paper detailing the rate of equine enamel mineralisation (being completed 6-12 months post-eruption) has highlighted the need

to verify the radiological features present in CAT images with correlating histology (Hoppe et al. 2004).

Imaging a further 29 extracted CT with apical infection (Section 3.4.1), in addition to the 46 control CT previously scanned, confirmed that the endodontic morphology proposed in Section 3.7 was also valid in these diseased CT. In two cases of apical infection in mandibular CT that developed due to developmental enamel dysplasia, the pattern of pulp chambers could still be identified, and this anatomical information in fact assisted in the recognition of the dysplastic nature of enamel in these two CT.

### **5.5.3 Dissecting Microscopy**

Most previous equine dental pathology studies have examined teeth from cadaver skulls with no known clinical history, e.g. those obtained from knackeries or abattoirs (Honma et al. 1962; Baker 1974; Wafa 1988; Miles & Grigson 1990). The identification of dental lesions in these studies was based on recognising gross pathological dental changes. In the present study, maxillary and mandibular CT were examined in two groups – those with and those without complete clinical histories, in order to effectively try and correlate gross (e.g. occlusal pulpar exposure) and histopathological findings (e.g. presence and thickness of the different types of dentine, as compared to control teeth) with the clinical history, in particular with the duration of clinical signs. However, when the results of both groups were compared, there was no statistical difference in the likely aetiology of the apical infection between these two groups.

Although additional information can be gained from histological and ultrastructural evaluation of extracted CT, this study found that examination of CT at gross and dissecting microscopy levels (following careful sectioning, e.g. by using a diamond saw) yielded sufficient information to give a likely aetiology for the apical infection; with periodontal disease, infundibular caries, fractures and occlusal pulp exposure all being detectable on such examination. By a process of elimination of the above four potential routes of apical infection, the other major cause of apical infection, i.e. anachoresis could then be made with reasonable confidence.

Assessment of cheek tooth pulp chamber morphology (Chapter 4) has identified that the individual maxillary cheek teeth pulp chambers (5-7 in number) develop (from a common pulp chamber) in the occlusal half of the tooth at a younger dental age than occurs in their mandibular counterparts. This anatomical feature may allow a greater success in endodontic procedures carried out in maxillary CT than that achieved in the previous study by Schramme *et al.* (2000) where eight of 19 endodontically treated horses still had signs of infection 12 months post-intervention.

#### **5.5.4 Histology**

Although not within the intended remit of this study, some new histopathological features of normal equine CT have been identified, further confirming that the basic histological appearance of equine dentition is very different from human teeth (Moody and Santini, 2001; personal communications).

The first record of equine dental histology by a veterinary researcher appears to have been by Baker (1979a) at the University of Glasgow. In his thesis 'A study of dental disease in the horse', decalcified sections were cut to 12 $\mu$ m thickness, and "a limited number of ground transverse sections were prepared." Many of the decalcified histological sections were made from developing (i.e. not fully mineralised) teeth, which would have assisted in their processing to histological sections. Even so, this work is at the vanguard of equine dental histology.

Processing techniques for equine dental histology had improved little when Kilic (1995) completed his thesis "A light and electron microscopic study of calcified dental tissues in normal horses" at this University, with decalcified sections being cut to 10 $\mu$ m thickness. Kilic's work however, mainly focused on the use of electron microscopy to identify the normal ultrastructure of the mineralised equine dental tissues.

In the present work, decalcified equine dental sections were routinely cut to 4-5 $\mu$ m in thickness. This gave excellent image quality, greatly facilitating identification of known normal histological features, and allowing the recognition of new anatomical

structures such as dentinal pearls and interglobular dentine. It was this improved section quality that highlighted the need for a newer classification of equine dentine than that previously used (Kilic 1995; Muylle et al. 2000a).

The reclassification of dentine types (namely into primary; regular and irregular secondary; and tertiary dentine) has simplified the manner in which dentine was evaluated in both control and diseased CT (Sections 2.7.1.1, 4.3 and 4.7.3). Identification of the presence of tertiary dentine in transverse sections from four (8%) of the 50 CT with apical infections (in pre-mineralised and fully mineralised states) is clear evidence of recruitment of undifferentiated ecto-mesenchymal cells from the pulp that were transformed into odontoblast-like cells, capable of tertiary dentine production. It is surprising that tertiary dentine was found in only 8% of CT examined histologically with apical infections, however it must be remembered that a maximum of four transverse sections were examined from each tooth, and tertiary dentine may have been present elsewhere within the pulp chambers of some additional apically infected CT.

In the sections of equine tertiary dentine that were examined, a linear break in dentine formation was observed, between tertiary and adjacent dentine. This is unlike the transitions between primary and regular secondary dentine, and between regular and irregular secondary dentine, where there is usually a varying degree of transition, i.e. from the presence of an obvious resting line, through to a gradual change with no exact transition point being identifiable, where dentine type changed (Figures 4.4 to 4.10). This agrees with findings in human dentine (Shellis 1981; Fawcett 1987; Foreman & Soames 1989; Jones 1990; Ten Cate 1992; Ten Cate 1998a; Ten Cate 1998d; Ten Cate 1998f; Torneck 1998; Trowbridge 2003).

Zones of demineralisation have been identified in undecalcified histological sections from apically infected equine CT in this study, indicating that equine dental caries is a progressive condition, as it also is in humans (Leach 1968; Silverstone & Poole 1969; Takuma et al. 1969; Brannstrom et al. 1980; Kidd et al. 1981; Shafer et al. 1983b; Johansen et al. 1987; Soames & Southam 1993a; Ashley et al. 1998; Robinson et al. 2000)

It was originally hoped that statistical comparisons, (in particular of dentinal measurements) would be possible between every diseased CT and a control CT of comparable Triadan position and dental age on an individual basis, as was performed for Case 23 (Appendix 2). However, results from such attempted individual statistical analyses did not yield statistically significant results.

By ensuring that at least one control CT of comparable age and Triadan position was available for direct (albeit non-statistical) comparison with each diseased CT, direct comparisons could be made, and later statistical analyses between groups of control and diseased CT were possible and gave valid results.

The deposition of secondary dentine was, as expected, found to increase with increasing dental age in control and diseased CT, in both maxillary and mandibular CT. However, the amount and rate of this secondary dentine deposition was less in diseased, as compared to control CT. This pattern of reduced secondary dentine formation in diseased CT was expected, and occurred because odontoblasts are compromised or later destroyed following infection of pulp (Ten Cate 1998d; Ten Cate 1998f).

Primary dentine thickness did not increase with increasing age in either control or diseased, maxillary or mandibular CT. Interestingly, less primary dentine was present in diseased, than control CT (both maxillary and mandibular teeth). Equine apical infection of CT is generally believed to be an acquired disorder, affecting teeth after they have erupted into the oral cavity (Crabill & Schumacher 1998; Mueller & Lowder 1998; Dixon et al. 2000a). The fact that decreased primary dentine was present in the diseased maxillary and mandibular CT as compared to their control CT groups ( $p < 0.001$  and  $p = 0.001$  respectively), indicates that changes occurred in at least some of these apically infected CT, prior to secondary dentine formation (*i.e.* before the CT came into occlusal contact).

Thicker secondary dentine was present in occlusal transverse sections than in mid-transverse sections, in both control and diseased maxillary and mandibular CT. This confirms that secondary dentine formation in equine CT is progressive - in an occlusal

to apical direction, a feature particularly necessary in hypsodont teeth that are undergoing a relatively high rate of occlusal attrition (Bennett 1992; Dixon 1999). Similar adaptive changes have been recognised in human (brachydont) teeth, but this occurs at a greatly reduced rate (Berry & Poole 1976).

Greater amounts of primary and secondary dentine were present on the palatal than the buccal aspects, in both control and diseased maxillary CT. This contrasts with the findings in control and diseased mandibular CT where there was no difference in dentinal thickness between the lingual and buccal aspects. This difference may be explained by normal anatomical differences, for example the maxillary CT are approximately 30% wider than their mandibular counterparts (Taylor 2001).

The phasic nature of calcified dental tissue formation results in incremental lines being present in both ground and decalcified dental sections. The presence of resting lines in decalcified dentine may indicate a temporary halt or decrease in dentine formation (Klevezal & Kleinenberg 1967), with such a line commonly occurring in teeth at time of the individual's birth – the so-called *neonatal line* (Ten Cate 1998d).

The increased incidence of resting lines in diseased maxillary and mandibular CT dentine, as compared to control CT, indicates that dentine formation has been disturbed more frequently in diseased CT. This may have been caused by insults to individual teeth, or by a disturbance to the growth of the whole individual. Most of the dentinal resting lines recorded occurred in transitional dentine, between primary and secondary dentine, and this may indicate that stresses occurred to these particular CT when they first came into occlusal wear. There were many CT however, where multiple resting lines were present within both primary and secondary dentine. These may represent intermittent growth disturbances in these individuals, potentially caused by factors such as nutritional disturbance or systemic disease.

The reason for a reduced presence of larger areas of intertubular dentine in diseased CT, as compared with control CT in this study is less clear. Large areas of intertubular dentine are believed to represent areas that have undergone rapid dentine deposition (Ten Cate 1998a). The reduction of this pattern of dentine deposition in diseased (as

compared to control CT) may indicate that sub-optimal conditions for dentine formation were present in the diseased teeth, similar to those conditions that may have resulted in formation of resting lines.

The presence of predentine surrounding pulp canals indicates that odontoblasts are still actively secreting predentine matrix around the pulp chamber. It is not surprising therefore, that predentine was present less frequently in apically infected maxillary and mandibular CT than in control CT as pulp tissue, and more specifically the odontoblasts they support, had frequently been destroyed in apically infected CT.

### **5.5.5 Electron Microscopy**

Scanning and transmission electron microscopy was performed in a limited number of apically infected maxillary CT. High quality images were gained from both the Phillips EM505 and XL30/CP SEM units, with only a small pilot study being carried out using the Phillips EM400 TEM, due to time constraints. The electron microscopy images gained have been useful to help further identify features seen under light microscopy. This rather limited investigation has identified electron microscopy to be a worthwhile tool for future studies on equine CT (Chapter 7) and in particular the use of semi-quantitative line scans to assess proportions of key elements (e.g. calcium, phosphate) present in both control and diseased calcified dental tissues (Section 5.3.4).

### **5.5.6 General Conclusions on the Aetiology of CT Apical Infection**

In the study by Dixon *et al.* (2000a), CT with apical infections present of an unknown aetiology were termed *primary* apical infections. CT where pathology was present that was likely to have caused the apical infection were termed *secondary* apical infections. Many of the CT with 'primary idiopathic apical infections' from Dixon *et al's* study were included in this present work (Section 3.3.2). Detailed examination of these CT has revealed the aetiological factors responsible for the apical infection development in most cases.

While it may be argued that once the aetiology has been established for a primary idiopathic apical infection, it is by definition no longer a *primary* apical infection, but a secondary apical infection. This distinction between primary and secondary apical infections is still useful at a clinical (i.e. gross pathological) level. Four aetiologies were proposed for these CT suffering from supposed idiopathic primary CT apical infection, namely:

- **Maxillary infundibular caries**

Infundibular caries has been reported as one of the principle causes of apical infection in maxillary CT (Baker 1970; Baker 1974; Wafa 1988; Mueller & Lowder 1998; Dixon et al. 2000a). As reported in Section 2.9.3.4, infundibular caries is present more frequently in older maxillary CT ( Honma et al. 1962; Baker 1979a; Wafa 1988), unlike CT apical infection, which most frequently occurs in younger CT (Dixon et al. 2000a).

In a study of 355 horse skulls collected from an abattoir, Wafa (1988) did not find a single instance of infundibular cemental caries extending beyond infundibular enamel, concluding that “a connection could not be demonstrated between dental caries and periapical infections.” In contrast, the current study strongly indicated infundibular caries as the primary aetiological factor in 11/50 maxillary CT with apical infection. However, most (eight) of these 11 cases had an incomplete or absent dental history, and in three of these cases the tooth had fractured in the midline plane following infundibular coalescence, with an apical infection having assumed to have arisen thereafter. In two of the three CT with full histories examined histologically, a direct communication was histologically confirmed to be present between carious infundibula and infected pulp chambers. In conclusion, infundibular caries were found to cause apical infection in maxillary CT either by direct pulp infection from carious infundibula (in younger CT), or following maxillary CT fracture following coalescence of carious infundibula (in older CT), however in contrast to much of the literature, it was not the major cause of maxillary apical infection in this study.

Interestingly only two CT in the 355 skulls examined by Wafa (1988) had caries present at sites other than in maxillary infundibular cementum. This differs from the present study where caries of the peripheral cementum was often present, in both maxillary and mandibular CT.

- **Periodontal disease**

Advanced periodontal disease can cause apical infection in brachydont teeth (Harvey & Emily 1993) and equine (hypsodont) CT (Mueller & Lowder 1998; Dixon et al. 2000a). Dixon *et al.* (2000a) recorded periodontal disease to be present in seven (10%) of 70 cases of mandibular CT and 12 (13%) of 92 cases of maxillary CT apical infection. However, it was not established whether this periodontal disease had resulted from drainage of the apical infection into the oral cavity via the periodontium, or alternatively, if descending periodontal disease (i.e. progression of periodontal disease from a gingival to apical region) had actually caused the apical infection.

Wafa (1988) found that 130/355 skulls (36.6%) in his abattoir survey were affected with periodontal disease. He suggested that gross periodontal pocketing and alveolar sepsis in these cases might permanently compromise the health of the affected tooth and its surrounding structures, but in no case was periodontal disease found to be associated with occlusal pulp exposure or apical changes.

In the present study, periodontal disease was determined to be the primary aetiological factor in five (18%) of the maxillary CT and two (9%) of the mandibular CT with apical infection that were examined in detail. In some cases, the CT were dysplastic (Cases 31 and 33, Appendix 2) or malpositioned (Case 9, Appendix 1), with teeth not fitting tightly into their alveoli and thus allowing deep food impaction and secondary periodontal disease, to eventually infect the apex. In only three cases had a *primary* descending periodontal tract been present (i.e. where no other pathology such as enamel dysplasia or tooth displacement was found) that was thought to have resulted in the apical infection (e.g. Case 2, Appendix 1). In conclusion, *primary* periodontal disease was found to be an uncommon cause of

apical infection, especially in young CT (with long reserve crowns). However, it may be slightly more important in the aetio-pathogenesis of apical infection in older CT with shorter reserve crowns.

- **Occlusal pulp exposure**

Wafa (1988) found occlusal pulp exposure in 14 maxillary and 11 mandibular CT in the 355 skulls he examined, with maxillary CT 09 being the most frequently affected CT. Nine of these CT had radiographic changes associated with apical infection. In 14 other CT that he described as having “occlusal crevices,” the occlusal defects extended for only a few millimeters below the occlusal surface, with no communication with the pulp chamber beneath and the periapical areas appeared normal.

In the present study 13/59 (20%) maxillary CT and 8/41 (20%) mandibular CT with apical infections had occlusal pulp exposure. In contrast to Wafa’s findings, the occlusal defects in all cases were found to extend down into the pulp chambers. This questions whether the occlusal defects (“crevices”) observed by Wafa were all defects within occlusal dentine (i.e. were cases of pulp chamber exposure) or in fact were defects in the occlusal cementum or enamel.

It is interesting to speculate if pulps can become exposed following normal occlusal attrition. A simple answer is that under *normal* conditions a pulp chamber should never become exposed at the occlusal surface, as with correct stimulation and sufficient supply of nutrients to the underlying odontoblasts, adequate formation of secondary dentine should prevent occlusal exposure (Kilic 1995).

Conditions may become *abnormal* either because occlusal attrition has increased, or because dentine formation has decreased. An increase in occlusal attrition may result from grazing pasture or eating hay made from pasture with unusually high amounts of phytoliths or adhered silicates; or by increased grazing time (which is unlikely in modern domesticated horses c.f. evolutionary forebears of the horse).

Reasons for decreased dentine formation may be hereditary, insufficient availability of dentine precursors (e.g. calcium and phosphate) for either dietary or non-dietary reasons, or more probably due to some insult to the odontoblasts themselves (e.g. an anachoretic pulpitis) (Siar 1986; Soames & Southam 1993c; Soames & Southam 1993d; Ten Cate 1998a; Ten Cate 1998d; Torneck 1998; Appleton et al. 2000). In the present study measurements of dentine were taken to establish if there was in fact, a relationship between the deposition of dentine and apical infection.

In the present study, where dentine thickness (with respect to its dental age and Triadan position) was reduced in any particular extracted apically infected CT, this was taken as an indication that an anachoretic pulpitis or even sepsis and pulp death had been present. It is always possible that some of these CT thought to have suffered from pulpar disorders may in fact have had other factors adversely affecting their rate of dentine formation, such as systemic disorders or nutritional deficiency. However in view of the fact that just single, individual CT were affected in these horses, rather than multiple teeth (as might be expected with systemic disorders), this would support a local dysfunction, such as anachoresis, as the cause of reduced dentinal thickness in apically infected CT. Dental fractures may also result in pulp exposure and this type of pulp exposure is discussed in more detail in Chapter 6.

In the future, clinicians should specifically examine the integrity of the secondary dentine overlying pulp horns to detect pulpar exposure as part of the routine evaluation of equine teeth, and should pay particular attention to this area in teeth with apical infection.

- **Anachoretic pulpitis**

No previous studies have established if anachoresis played a part in the aetiology of equine CT apical infection. This study identified anachoretic pulpitis as the most likely cause of apical cheek tooth infection in both maxillary and mandibular cheek teeth, being identified as the most likely aetiological factor in 17/31 (55%) maxillary and 11/22 (50%) mandibular cheek teeth with apical infections examined in detail. This finding has implications concerning the diagnostic procedures used to detect

apical tooth infection and in the potential treatment options following diagnosis. The finding of food impacted down the pulp canals of a high proportion of apically infected CT and the previous poor knowledge of endodontic anatomy, may well explain the poor results reported with endodontic treatment of equine CT apical infections to date (Schramme et al. 2000).

## Chapter Six: Idiopathic Cheek Teeth Fractures

### 6.1 Introduction

Eleven maxillary and 9 mandibular idiopathically fractured CT with known clinical histories were examined in detail following either: complete extraction of the CT (if concurrent apical infection was present) (17 CT); or extraction of a fractured dental fragment (three CT). All teeth were examined grossly, radiographically, histologically (decalcified and undecalcified) and in the scanning electron microscope (SEM). Details of these CT and the results of the above examinations are presented in Table 6.3.

Using the enhanced imaging techniques previously described (Chapter 3) it was hypothesised that the nature of pathological features present in fractured CT, as well as changes (both qualitatively and quantitatively) present in dentine, could be examined in detail not previously possible. All fractured CT will have their fracture plane classified to determine possible patterns of such fractures. The Triadan position of fractured CT will be examined to determine if any CT are more prone to such fractures. In contrast to the literature findings it is proposed that all such fractures will involve the pulp chambers of affected CT and that in some cases, prior pulpar changes may be the cause of some such fractures. Quantative dentinal thickness data will be compared with the clinical history of each case (on an individual or grouped basis) to test the hypothesis that differences observed between both diseased and control CT, and between comparable diseased CT would be reflected in the duration of clinical signs. Individual cases are reported in greater detail in Appendix 3.

### 6.2 Cheek Teeth Categorisation and Fracture Plane Classification

The median dental age of all (20) fractured CT was seven years, with the fractured maxillary CT (median dental age 12 years) being significantly older (Mann-Whitney 95% CI  $p < 0.005$ ) than the mandibular CT (median dental age three years) as shown in Table 6.1 and Figure 6.1.

Category	Median dental age (years)
Maxillary CT (n=11)	12
Mandibular CT (n=9)	3
Total CT (n=20)	7

**Table 6.1:** Median dental age of the 20 fractured CT examined in detail.

The Triadan position of affected maxillary and mandibular CT also varied significantly (Table 6.2) with an over-representation of maxillary CT Triadan 09s ( $\text{Chi}^2= 43.9$ ;  $p<0.005$ ) and of mandibular CT Triadan 08s ( $\text{Chi}^2= 72.2$ ;  $p<0.005$ ).

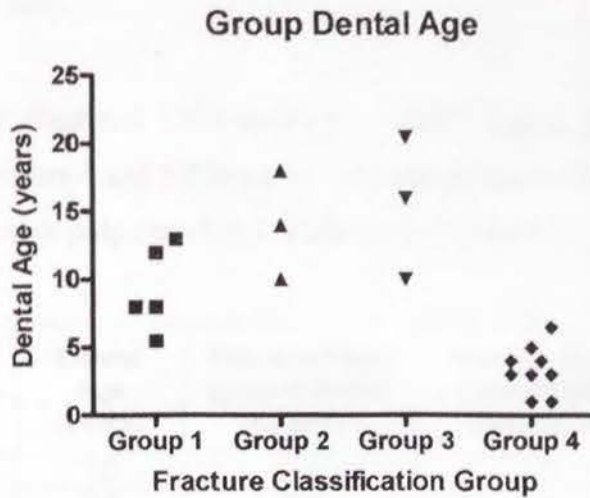
Triadan position	06	07	08	09	10	11
Maxillary CT (n=11)	0/11 (0%)	2/11 (18%)	2/11 (18%)	7/11 (64%)	0/11 (0%)	0/11 (0%)
Mandibular CT (n=9)	0/9 (0%)	1/9 (11%)	7/9 (78%)	0/9 (0%)	1/9 (11%)	0/9 (0%)
Total CT (n=20)	0/20 (0%)	3/20 (15%)	9/20 (45%)	7/20 (35%)	1/20 (5%)	0/20 (0%)

**Table 6.2:** Triadan position of the 20 idiopathically fractured cheek teeth examined in detail.

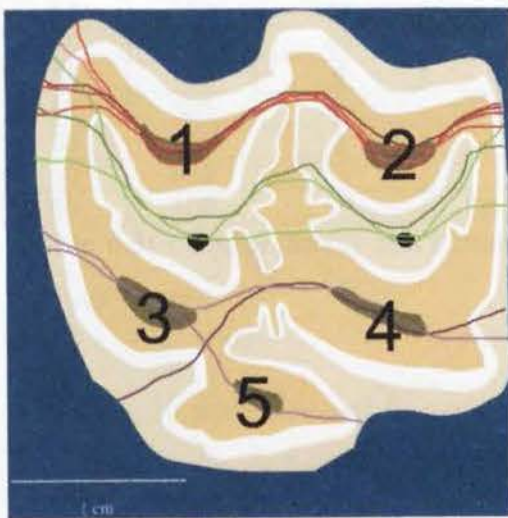
On gross examination, the CT fractures were classified as:

- **Group 1 Maxillary buccal ‘slab’ fractures:** Maxillary CT with a vertical fracture plane through pulp chambers 1 and 2
- **Group 2 Infundibular sagittal fractures:** Maxillary CT with a single vertical fracture plane running through the rostral and caudal infundibula
- **Group 3 Miscellaneous maxillary fracture patterns:** Maxillary CT with fracture planes different from the above classifications (Groups 1 and 2), and usually running through palatal pulp chambers
- **Group 4: Mandibular buccal ‘slab’ fractures:** Mandibular CT with a vertical fracture plane running through pulp chambers 4 and 5
- **Group 5: Miscellaneous mandibular fracture patterns:** Mandibular CT with fracture planes other than as for Group 4.

The fracture patterns of the 20 CT examined in detail are shown diagrammatically in Figures 6.2 and 6.3. Five of the **maxillary** CT had fractured through both buccal pulp chambers (chambers 1 and 2) (Group 1), three through both infundibula (Group 2) and three through varied palatal planes (pulp chambers 3-5).

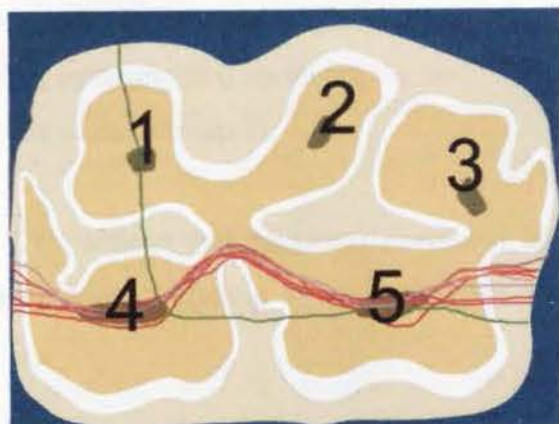


**Figure 6.1:** Dental age of 20 cheek teeth examined in detail with dental fractures grouped by fracture type (Group 1= maxillary buccal slab fracture; Group 2= (maxillary) infundibular sagittal fracture; Group 3= miscellaneous maxillary fracture; Group 4= mandibular buccal slab fracture).



**Figure 6.2:** Diagrammatic representation of fracture planes observed from the occlusal surface in maxillary CT. The red lines represent a vertical fracture plane through pulp chambers 1 and 2 (Group 1), green lines a single vertical fracture plane running through the rostral and caudal infundibula (Group 2), and purple lines the remaining fracture planes (Group 3).

**Figure 6.3:** Diagrammatic representation of gross fracture planes present in 9 mandibular CT examined in detail, when viewed from the occlusal surface. All 9 CT fracture planes run through pulp



chambers 4 and 5, with one of these fracture planes additionally entering pulp chamber 1 (green line).

All 9 mandibular fractured CT examined in detail had a fracture plane running through pulp chambers 4 and 5 (Group 4), with one of these CT also having a fracture plane running through pulp chamber 1 as shown in Figure 6.3.

Case	Triadan	Dental Age (years)	Fracture Plane (pulp chamber numbers)	Fracture Group Classification (Section 7.2)	Decreased Dentine (Yes/No)
41	109	10	3-4	3	N
42	407	6.5	4-5	4	N
43	107	5.5	1-2	1	Y
44	408	4	4-5	4	N
45	210	8	1-2	1	-
46	408	5	4-5	4	N
47	207	20.5	3-5	3	N
48	109	18	Infundibula	2	-
49	109	10	Infundibula	2	N
50	308	1	4-5	4	-
51	109	12	1-2	1	N
52	408	4	4-5	4	Y
53	408	1	4-5	4	Y
54	109	16	4	3	N
55	209	13	1-2	1	Y
56	108	8	1-2	1	N
57	308	3	4-5	4	N
58	308	3	4-5	4	-
59	408	3	4-5	4	N
60	109	14	Infundibulum	2	N

**Table 6.3:** Clinical details and classification of 20 fractured CT examined in detail. (Y=yes; N=no)

A further 10 maxillary and five mandibular CT with fractures that did not have full clinical histories or histology performed were also examined. Of the additional 10 maxillary CT with idiopathic fractures examined, four teeth were fractured through both buccal pulp chambers (Group 1), two were fractured through both infundibula (Group 2) and four had mixed fracture types, including two involving the body of the tooth (below clinical crown, not involving the roots) (Group 3).

Four of the five additional mandibular CT (without full histories) examined had buccal slab fractures through pulp chambers 4 and 5 (Group 4), and one tooth was

fractured through pulp chamber 5. Classification of all 35 fractured CT based on their fracture group are summarised in Table 6.4.

	Group 1 Maxillary buccal slab fractures	Group 2 Maxillary infundibular sagittal fractures	Group 3 Miscellaneous maxillary fractures	Group 4 Mandibular buccal slab fractures	Group 5 Miscellaneous mandibular fractures
Fractured CT examined in detail	5/11 46%	3/11 27%	3/11 27%	9/9 100%	0/9 0%
Fractured CT examined grossly	4/10 40%	2/10 20%	4/10 40%	4/5 80%	1/5 20%
<b>Total</b>	9/21 (43%)	5/21 (24%)	7/21 (33%)	13/14 (93%)	1/14 (7%)

**Table 6.4:** Prevalence of fracture type in 35 cheek teeth suffering from idiopathic fracture.

### 6.3 History, Gross Examination and Dissecting Microscopy

Nine of the 20 (45%) cases with idiopathic CT fracture examined in detail in this study were reported to be quidding at time of referral, with six having associated facial or mandibular swellings (30%). Halitosis was present in six cases (30%).

The five cases examined in detail from Group 1 had a median dental age of eight years, with the fractures arising in maxillary Triadan positions 07, 08, 09 (twice) and 10. Group 2 had a median dental age of 14 years, with all three cases involving maxillary Triadan 109 CT. Group 3 had a median dental age of 16 years with two maxillary Triadan 09 CT and one 07 CT affected. Group 4 had a median dental age of three years with 7/9 fractured mandibular CT being in Triadan 08 position. No CT with dental histories were present with Group 5 type fractures.

The thickness of dentine was not reduced in either of the two maxillary CT with infundibular sagittal fractures (Group 2), or in any (3/3) of the palatal fractures in Group 3 (miscellaneous maxillary CT fractures), with these two groups having the greatest median dental ages. The thickness of dentine was reduced in two of the four CT in Group 1 (buccal maxillary CT slab fractures) and in two of the seven CT in Group 4 (buccal mandibular CT slab fractures).

## 6.4 Histology

The majority of sections processed for decalcified histology totally disintegrated during decalcification (Section 3.8.1). With sections from only four cases remaining, it was not possible to analyse dentinal thickness measurements meaningfully on a grouped basis from decalcified histological sections, as performed for apically infected CT in Chapters 4 and 5. Undecalcified slide sections were not analysed statistically on a grouped basis, as it was difficult to consistently distinguish the type of dentine present.

## 6.5 Discussion

In human brachydont teeth, dental fracture most commonly arises from sudden and severe external trauma, with children (8-12 years) being most frequently affected (Trope et al. 2002). It is estimated that approximately 5% of children suffer traumatic dental fracture (Shafer et al. 1983f), although a study in 18 year-old school-children found 13% to have had dental injuries during adolescence, with not surprisingly, boys being more frequently involved than girls (Schutzmannsky 1963).

The frequency of equine dental fractures has been reported from 0.7% in 30,000 cavalry horses (Becker 1962) to 3.5% observed radiographically in skulls collected post-mortem (where the incidence may have been over-estimated due to post-mortem fracture of teeth) (Geres 1962).

Dental trauma is common in horses, as a result of kicks, biting inanimate objects, crib biting, and high-speed encounters with immobile objects (Hague & Honnas 1998). It has been proposed that dental fracture in cheek teeth may also result from animals unexpectedly chewing or biting a hard substance such as a piece of flint (O'Connor 1930).

A more recent study has clinically categorised the incidence and causes of equine dental fractures in horses. Dixon *et al.* (2000b) described 11 cases of incisor fracture from 400 cases of dental disorders referred to this institution. These accounted for 25% of incisor disorders presented. Three of the 11 cases of fractured incisors (6.8%

of all incisor cases) were not believed to be due to trauma, i.e. were classified as idiopathic fractures.

In the same study, 26 cases were presented with traumatic fractures to CT (7.5% of CT cases), with 71% being mandibular CT fractures, in contrast with the incisor fractures where 73% involved upper (premaxillary) incisors. There is also a definite maxillary predilection for tooth fracture in humans, with 75-90% of traumatic fractures occurring in maxillary teeth (Shafer et al. 1983f).

Fractures to mandibular CT in the above study by Dixon *et al.* (2000b) were most commonly associated with kicks from other horses (11/26), although gross misuse of the bit, leading to mandibular damage and osteomyelitis was recorded as the causal factor in three cases. Iatrogenic traumatic damage was associated with half (5/10) of maxillary CT examined. Iatrogenic dental fractures are often associated with use of dental shears to reduce large dental overgrowths, particularly in animals aged eight years or less where there is still relatively little secondary dentine laid down within the tooth (Scrutchfield et al. 1997).

Dixon *et al.* (2000b) also identified 24 cases that had a total of 27 idiopathic CT fractures (7% of CT cases) – including 22 maxillary and 5 mandibular CT. The most common clinical signs associated with the idiopathic CT fractures in the study by Dixon *et al.* were quidding (50% of cases) and external swelling to the cheek (33%) compared with 45% and 30% respectively, of these findings in the present study.

Nearly one third (29%) of idiopathic CT fracture cases reported by Dixon *et al.* (2000b) had a nasal discharge (indicative of maxillary CT apical infection) present. Seventeen of the 20 CT examined in detail in this study also had concurrent apical infection, though not all causing clinical signs of apical infection. Apart from the three Group 2 (infundibular sagittal fractures) CT examined in detail, all fractured CT in this study had gross pulp exposure of the pulp cavities involved in the fracture present at the time the dental fracture occurred. As discussed in Chapter 5 (Section 5.5), when pulp is exposed in human teeth, the pulp becomes infected almost immediately, making the success of a vital pulp capping unlikely. Following

development of pulpitis, with or without subsequent apical tooth infection, most human teeth require a pulpectomy and root canal filling (Shafer et al. 1983e). It is highly probable that pulpitis was present in CT with idiopathic fractures examined in this study, however criteria for determining presence of pulpitis ante-mortem have yet to be established for the horse.

Selection of the 20 fractured CT for examination in this study was based on the availability of case material. However, there were significantly more Triadan maxillary 09 and mandibular 08 CT, than other dental positions (Section 6.2).

Maxillary 09 CT have been identified as being more susceptible to caries of infundibulum, possibly because it is the oldest maxillary CT in the skull (Dixon et al. 2000b). O'Connor (1930) proposed that CT may fracture following carious attack, "in consequence of its weakened condition by the force of mastication. The disease most commonly occurs at nine or ten years of age." These suggestions about 09s being the oldest CT and also possibly subjected to most occlusal force as a result of its central position in the CT row may be reasons for the over-representation of maxillary Triadan 09 in this group (Table 6.2).

It is significant that 7/9 mandibular CT examined were from position Triadan 08. One possible explanation is that this centrally positioned mandibular CT receives maximal occlusal force. Humans select the part of the occlusal surface to bear maximal masticatory pressures, and these may range from 10-20N pressure while soft foods are chewed, up to 500N for more resistant objects (Proffit 1986). Occlusal bite force has not been measured in horses.

Having observed that buccal slab fractures usually involved less than 20% of the occlusal surface of CT, Dixon et al. (2000b) erroneously reported that pulp was seldom involved in these fractures, and this explained why clinical signs of apical infection was usually absent in such cases. Dixon et al. proposed that these fractures occurred in equine Type-1 enamel, with this type of enamel having parallel lines of brittle enamel prisms with limited decussation (inter-weaving) (Kilic et al. 1997b) that made them more susceptible to idiopathic fractures.

In this current study in contrast, the pulp chambers and respective dental pulps were found to be involved in *all* maxillary and mandibular buccal slab fractures (22/22). This new information changes the clinical implications when such fractures are identified, with the very likely exposure of pulp making pulpitis and apical tooth infection likely sequelae. However, follow-up information in cases of lateral 'slab' fracture showed total resolution of signs and no progression to apical infection in these cases (Dixon et al. 2000b), indicating that the inevitable pulpar infection in these CT was contained or was of a level that did not cause changes in the adjacent bones or paranasal sinuses.

Defective enamel, dentine and cementum have been reported as causal factors in equine dental fracture (Becker 1962) however no such predispositions were identified in fractured CT examined in this study.

The proportion of CT with different fracture types identified between CT groups examined in detail and those examined at a gross level are comparable (Table 6.4). It is felt by the author that with knowledge of the above findings, examination of CT at a gross level, and even *in situ* in clinical cases, can correctly identify structures involved in fracture to the clinical crown of equine CT.

With the continued improvement of endodontic and restorative techniques in horses, it may become possible to correct infundibular caries from the occlusal aspect and also to restore clinical crowns following fracture. Although endodontic restoration of fractured equine CT is still in its infancy, it should be remembered that endodontic procedures have been linked to dental fracture in humans. These can occur following removal of caries within the centre of the occlusal table of molars or premolars, leaving unsupported cusps which give way under the stress of mastication (Shafer et al. 1983b).

It was noted in some fractured CT in this study (Appendix 3) that the apical third of the fractured CT surface had not become darkly stained, as the infundibula had. This may have been due to lack of time for caries and plant pigments to stain this particular

surface, however clinical signs indicative of dental fracture had been present for five months in one of these cases. Muylle *et al.* (2002) have shown equine secondary dentine to stain darkly within six days of being immersed in extracts of crushed grass. Therefore it is likely any secondary dentine present at the fractured surface would have become stained if this fracture had been present for more than six days. It appears therefore in this particular CT, that despite signs of dental disease having been present for approximately five months, the actual displaced sagittal fracture of the CT occurred much more recently. This reiterates Uhlinger's findings that horses are poor at indicating the true state of their dental health, thus necessitating regular dental examinations (Uhlinger 1987).

The use of a dental probe and mirror, along with a good light source and full mouth gag are obligatory to determine such pathology, with sedation of the patient also being a great benefit. All these tools are currently routinely employed in the oral examination of dental cases at this institution. With early detection of dental fracture (before the onset of advanced signs of apical infection) clinicians have greater treatment options.

## Chapter 7: Summary and Future Work

The principle aims of this thesis were to examine maxillary and mandibular equine cheek teeth extracted from clinical cases suffering from apical infections or idiopathic fractures. Various examination traditional and novel techniques were employed to determine the pathological features and likely aetiopathogenesis of these lesions, including radiography, computer assisted tomography, light microscopy, scanning and transmission electron microscopy.

Dissecting microscopy was very well suited for establishing normal equine CT endodontic anatomy and establishing a nomenclature to describe it. These findings are now widely accepted in many countries and are currently used by clinicians to assess and record clinical crown pathology in greater detail. This has had direct implications on the diagnosis and prognosis of dental cases, with implied benefits to the welfare of patients.

With the increased awareness of the need to complete dental charts following oral examination, future analysis of such detailed records will give an in depth view of the progression of even subtle dental pathology, such as occlusal pulp exposure, which currently remains largely unknown. One area of future work should be to accurately note the incidence of occlusal pulp exposure in clinical cases and to monitor the progression of these lesions to assess what proportion of such cheek teeth develop apical infections requiring tooth extraction, and what percentage can be managed conservatively by either use of antibiotics or endodontic procedures.

The major part of this work has been to try and establish the role of the various proposed aetiologies for apical tooth infection, namely apical infection through: infundibular caries; occlusal pulp exposure; fracture; descending periodontal disease; and anachoretic pulpitis in the 100 apically infected cheek teeth that were examined in this work.

When considering apical cheek tooth infection, it must be remembered that much of the clinical signs are due to the involvement of structures (especially the supporting

bones) that are outside the tooth proper. One potential weakness of this study has been that by only examining extracted CT, no extra-dental structures other than the attached periodontal ligaments have been pathologically evaluated, although clinical (pre-extraction) radiographs were taken for all cases. A limited amount of information on the changes in extra-dental tissues has also been gained from the clinical histories of horses whose extracted CT were examined in detail, such as the concurrent presence of sinus tracts or periodontal disease.

The production of high quality equine dental histological slides can be a technically challenging task. The histological examination of extracted CT in this study necessitated improvement of previously used techniques for both decalcified and undecalcified slide production and eventually allowed the production of equine dental histological slides of equivalent quality to current human dental histology slides.

Evaluation of dentinal thickness measurements from both control and diseased decalcified histological sections has not only given information on changes that occur to apically infected teeth, but also on the dentinogenesis of normal teeth. Questions currently being asked in human dentistry such as 'what is the stimulus to change from production of primary to secondary, or from secondary to tertiary dentine' may now also be asked in horses. The fact that equine teeth are considerably larger, and have a much faster rate of dentine formation than human teeth may lend them to being a better dental model for dental research than the rat and mice teeth, which are currently used (Edmunds et al. 1988).

Having further demonstrated normal and pathological equine dental histological features in unstained tissues and following basic (haematoxylin and eosin) staining, future work could involve the use of additional staining techniques, including the use of silver-based stains to identify nerve fibre types in dental pulp, and their possible association with dentinal tubules. Similar work has already been carried out on the nerves present in elephant tusks (another dentinal structure) (Weissengruber et al. 2005).

The present study focused on the examination of calcified dental tissues, especially dentine, as the degree of soft tissue preservation in the pathological specimens used in this study was unknown at the outset. Indeed, it was clear that the pulp had been fully destroyed by the apical infection in some diseased teeth. An in-depth evaluation of normal and diseased equine dental pulp has yet to be undertaken. For example, the claim that equine pulp seems to be in a “chronically inflamed state” (Baker 1970) needs to be re-visited. We have yet to quantitatively classify the histology of equine pulp in its normal state; when pulp is possibly compromised during eruption (especially in teeth with dental impaction); and pulp in the presence of pulpar exposure and apical infections.

Another deserving area of work would be the use of immuno-histochemical techniques in both pulp and calcified dental tissues, as have been used in dental studies in other species and in other equine tissues. These techniques would help identify the types and levels of proteins present during various stages of dentogenesis and disease. In particular, the presence and levels of inflammatory markers in unerupted teeth may provide some further clues to our understanding of the aetiopathogenesis of apical infection.

The present study almost exclusively examined teeth that had erupted into the oral cavity and as such were expected to have completed their primary dentine formation. However, the results from this work showed primary dentine was reduced in some apically infected teeth, which suggested that these teeth had been subjected to some factors that later influenced the development of apical tooth infection even whilst in their early development and still laying down primary dentine.

In spite of so many unanswered questions remaining on CT apical infection, this study has answered some of the basic questions on this clinically important equine disease. Despite its common acceptance in the literature as a major cause of apical tooth infection in maxillary cheek teeth, this study has shown infundibular caries to be one of the least likely causes of apical tooth infection, being suspected as the primary aetiological factor in only 11/50 maxillary CT examined, with most (8/11) of these

cases having no dental history, and in three of these cases the tooth having fractured in the midline plane following infundibular coalescence.

In contrast, this study identified anachoretic pulpitis as the most likely cause of apical cheek tooth infection in both maxillary and mandibular teeth, it being suspected as an aetiological factor in 17/31 maxillary and 11/22 mandibular cheek teeth. This finding has implications concerning the diagnostic procedures used to detect apical tooth infection and the potential treatment options following diagnosis. The finding of food impacted down the pulp canals of a high proportion of apically infected CT and the previous poor knowledge of endodontic anatomy, may well explain the poor results reported with endodontic treatment of equine apical infections to date (Schramme et al. 2000).

The continued development of endodontic procedures for preservation of equine cheek teeth, to avoid extraction of such infected teeth is a high priority for equine dental clinicians when considering post-extraction sequelae. Prichard et al. (1992) recorded serious post-operative complications following 47% of equine maxillary and 32% of mandibular CT repulsions. Lane (Lane 1994) reported that 35% of all horses having CT repulsion required a second surgery, in addition to other cases requiring additional, non-surgical treatments. Following CT repulsion, Dixon *et al.* (2000a) found that 33% of 15 cases with rostral maxillary CT infection, 39% of 28 cases with mandibular CT infection and 68% of 28 dental sinusitis cases required further treatment (overall - 49% of 71 cases). Tremaine and Dixon (2001b) similarly found that 41% of 54 dental sinusitis cases required a second sinusotomy following dental repulsion and another 29% of cases required further sinus lavage or antibiotic therapy.

Post-operative complications are much less likely following CT oral extraction (11% than CT repulsion (30-77%, for mandibular and maxillary CT, respectively) (Dixon et al. 2005). With more clinicians orally extracting apically infected CT, we should expect a decrease in post-extraction complications. However, extraction of a cheek tooth from its row will also initiate supra-eruption of the opposing tooth, creating a step-mouth; and cause tooth drifting, that may exacerbate or create diastemata within the row.

The second main focus of this work has been on idiopathic cheek teeth fractures. In this work, the fracture plane and calcified tissue status at the fracture plane were assessed using dissecting microscopy and scanning electron microscopy, respectively. Having clarified the endodontic morphology of equine cheek teeth, it is apparent that most idiopathic cheek teeth fractures involve one or (usually) more of the cheek teeth pulp chambers. Considering the latero-medial movement of the mandible against the maxilla during mastication, it was not surprising to find most (13/18) mandibular cheek teeth with fractures to the clinical crown were fractured through both pulp chambers on the buccal aspect of the tooth.

In maxillary cheek teeth, where a greater incidence of idiopathic cheek tooth fracture occurs than in mandibular teeth, 6/15 teeth with idiopathic fractures involved the pulp chambers on the buccal aspect of the tooth. This may be because it is this area of the occlusal surface that receives greatest force during mastication. Such hypotheses however need further investigation and this work might involve expertise from biological stress engineers who could test bite force and direction, as an extension of the work performed by Leue in the last century (Leue 1941).

Although a relatively low numbers (35) of fractured CT were examined in this study and categorised by fracture type, by having defined these common sites of fracture planes, the current study has enabled a large clinical survey of over 150 horses to be performed subsequently (Lucy Smith personal communication, 2004).

It is this author's opinion that Mayhew (1893) was correct in his opinion regarding the phrase "No legs, no horse", that "*the horseman, also, say "No teeth, no horse."*

## References:

- Appleton,J., Chesters,J., Kierdorf,U., & Kierdorf,H. (2000) Changes in the structure of dentine from cheek teeth of deer chronically exposed to high levels of environmental fluoride. *Cells Tissues Organs* **167**, 266-272
- Ashley,P.F., Blinkhorn,A.S., & Davies,R.M. (1998) Occlusal caries diagnosis: an in vitro histological validation of the Electronic Caries Monitor (ECM) and other methods. *Journal of Dentistry* **26**, 83-88
- Baden,E. (1971) Odontogenic tumours. *Pathology Annual* **6**, 475-568
- Baker,G.J. (1970) Some aspects of equine dental disease. *Equine Veterinary Journal* **2**, 105-110
- Baker,G.J. (1971) Some aspects of equine dental radiology. *Equine Veterinary Journal* **3**, 46-51
- Baker,G.J. (1972) The radiology of equine dental diseases. *Acta Radiologica Supplementum* **319**, 67-69
- Baker,G.J. (1974) Some aspects of equine dental decay. *Equine Veterinary Journal* **6**, 127-130
- Baker,G.J. (1979a) A study of dental disease in the horse. PhD thesis, Glasgow University 1-96
- Baker,G.J. (1979b) Dental disease in horses. *In Practice* 19-26
- Baker,G.J. (1982) Dental disorders in the horse. *The Compendium of Continuing Education* **4**, S507-S514
- Baker,G.J. (1985) Oral anatomy of the horse in: *Veterinary Dentistry*. Edited by Harvey C.E., W.B.Saunders, Philadelphia 203-216

Baker,G.J. (1991a) Dental morphology, function, and pathology. *Proceedings of the 37th American Association of Equine Practitioners Annual Convention* 83-93

Baker,G.J. (1991b) Diseases of teeth in: *Equine Medicine and Surgery* 3<sup>rd</sup> edition. Edited by Colahan,P.T., Merritt,A.M., Moore,J.N. and Mayhew,I.G. CV Mosby, St Louis 550-570

Baker,G.J. (1998) Dental physical examination. *Veterinary Clinics of North America - Equine Practice* **14**, 247-57

Baker,G.J. (1999a) Abnormalities of Development and Eruption in: *Equine Dentistry*. Edited by Baker,G.J. and Easley,J. WB Saunders, London 49-59

Baker,G.J. (1999b) Dental physiology in: *Equine Dentistry*. Edited by Baker,G.J. and Easley,J. WB Saunders, London 29-34

Baker,G.J. & Allen, M.L. (2002) The use of power equipment in equine dentistry. *48th American Association of Equine Practitioners Conference Proceedings* 438-441

Barakzai,S.Z. (2004) Equine dental radiography. Part 1: Radiographic techniques. *UK Vet* **9**, 11-16

Barakzai,S.Z. & Dixon,P.M. (2003) A study of open-mouthed oblique radiographic projections for evaluating lesions of the erupted (clinical) crown. *Equine Veterinary Education* **15**, 143-148

Barbee,D.D., Allen,J.R., & Gavin,P.R. (1987) Computed tomography in the horse - technique. *Veterinary Radiology* **28**, 144-151

Barone,R. (1997) Dents in: *Anatomie Comparee des Mammiferes Domestiques*, 3<sup>rd</sup> edition. Edited by Barone,R. Vigot , Paris 91

Becker,E. (1962) Zahne in : Handbuch der speziellen pathologischen anatomie der haustiere 3<sup>rd</sup> edition. Edited by Dobberstein,J., Pallaske,G. and Stunzi,H. Verlag Paul Parey, Berlin 249-260

Bennett,D. (1992) The evolution of the horse in: Horse Breeding and Management. Edited by Evans, J.W. Elsevier, Amsterdam 1-37

Berkovitz,B.K.B. & Moxham,B. (1981) Early stages of tooth development in : Dental Anatomy and Embryology. Edited by Osborne,J.W. Blackwell Scientific Publications, Oxford 166-174

Berry,D.C. & Poole,D.F. (1976) Attrition: possible mechanisms of compensation. *Journal of Oral Rehabilitation* **3**, 201-206

BEVA (1965) British Equine Veterinary Association survey of equine disease, 1962-63. *The Veterinary Record* **77**, 528-538

Bishop,M.A. & Boyde,A. (1986) Distribution of capillaries in relation to the life cycle of odontoblasts in the rat incisor. The fate of the pulp at the incisal end. *Anatomy and Embryology (Berlin)* **175**, 189-198

Bonte,B., Linden,R.W., Scott,B.J., & van Steenberghe,D. (1993) Role of periodontal mechanoreceptors in evoking reflexes in the jaw- closing muscles of the cat. *Journal of Physiology* **465**, 581-594

Boyde,A., Fortelius,M., Lester,K.S., & Martin,L.B. (1988) Basis of the structure and development of mammalian enamel as seen by scanning electron microscopy. *Scanning Microscopy* **2**, 1479-1490

Brannstrom,M., Johnson,G., & Friskopp,J. (1980) Microscopic observations of the dentin under caries lesions excavated with the GK-101 technique. *ASDC Journal of Dentistry for Children* **47**, 46-49

Brescia,N.J. (1966) Development and growth of the teeth in: Orban's Oral Histology and Embryology, 6<sup>th</sup> edition. Edited by Sicker,H. Mosby, London 18-37

Brigham,E.J. & Duncanson, G. (2000) An equine postmortem study: 50 cases. *Equine Veterinary Education*. **12**, 59-62

Budiansky,S. (1997) The Nature of Horses: Their Evolution, Intelligence and Behaviour. Weidenfield & Nicolson, London 50-55

Budtz-Jorgensen,E., Theilade,E., Theilade,J., & Zander,H.A. (1981) Method for studying the development, structure and microflora of denture plaque. *Scandinavian Journal of Dental Research* **89**, 149-156

Burke,A. & Castanet,J. (1995) Histological observations of cementum growth in horse teeth and their application to archaeology. *Journal of Archeological Science* **22**, 479-493

Burns,R.C. & Herbranson, E. J. (2002) Tooth morphology and cavity preparation in: Pathways of the Pulp, 8<sup>th</sup> edition. Edited by Cohen,S. and Burns,R.C. Mosby, St. Louis 173-229

Byers,M.R. & Holland, G. R. (1977) Trigeminal nerve endings in gingiva, junctional epithelium and periodontal ligament of rat molars as demonstrated by autoradiography. *Anatomical Record* **188**, 509-523

Camus,A.C., Burba, D. J., Valdes, M. A., & Taylor, H. W. (1996) Intraosseous epidermoid cyst in a horse. *Journal of the American Veterinary Medical Association* **209**, 632-633

Capper,S.R. (1992) The effects of feed types on ingestive behaviour in different horse types. MSc thesis, University of Edinburgh 1-160

Carmalt,J.L. (2003) Understanding the equine diastema. *Equine Veterinary Education* **15**, 34-35

- Castanet, J. (1980) Quelques remarques sur la méthode squelettochronologique chez les vertèbres supérieurs (oiseaux et mammifères). *Bulletin Société Zoologique de France*. **105**, 371-376
- Castelnuovo, J. & Tjan, A.H. (1997) Temperature rise in pulpal chamber during fabrication of provisional resinous crowns. *Journal of Prosthetic Dentistry* **78**, 441-446
- Churcher, C.S. & Richardson, M.L. (1978) Equidae in: Evolution of African mammals. Edited by Maglio, V.J. and Cooke, H.B.S. Harvard University Press, Cambridge 379-442
- Coy, J.P., Jones, R.T., & Turner, K.A. (1982) Absolute ageing of cattle from tooth sections and its relevance to archaeology in: Ageing and Sexing Animal Bones from Archaeological Sites. Edited by Wilson, B., Grigson, H. and Payne, S. British Series 109, 127-140
- Crabill, M.R. & Schumacher, J. (1998) Pathophysiology of acquired dental diseases of the horse. *Veterinary Clinics of North America - Equine Practice* **14**, 291-307
- Critchley, P., Wood, J.M., Saxton, C.A., & Leach, S.A. (1967) The polymerisation of dietary sugars by dental plaque. *Caries Research* **1**, 112-129
- Culling, C.F.A. (1974) Handbook of Histopathological and Histochemical Techniques, 3<sup>rd</sup> edition. Edited by Culling, C.F.A. Butterworth, London 66
- Dacre, I.T., Dacre, K.J., Uttley, L., & Dixon, P.M. (2005) Thermal changes in equine dental pulp associated with mechanical grinding. Submitted to *Journal of Veterinary Dentistry*.
- Dacre, I.T. & Dixon, P.M. (2002) Aetiology and pathogenesis of apical abscesses in equine cheek teeth. *16<sup>th</sup> Annual Veterinary Dental Forum Proceedings* 227-231

Dacre,K.J., Dacre,I.T., & Dixon,P.M. (2002) Motorised equine dental equipment. *Equine Veterinary Education* **14**, 263-266

DEFRA (2004) Horse passports [www.defra.gov.uk/animal/int-trde/default.htm](http://www.defra.gov.uk/animal/int-trde/default.htm)

DeLahunta,A. & Habel,R.E. (1986) Applied Veterinary Anatomy. WB Saunders, Philadelphia 4-16

Dick,W. (1862) Manual of Veterinary Science. Adam & Charles Black, Edinburgh 76

Dixon,P.M. (1992) Equine cheek tooth disease - is periodontal disease still a problem? *Proceedings of the 4th British Veterinary Dentistry Association Annual Scientific Meeting* 1-8

Dixon,P.M. (1993) Equine dental disease: a neglected field of study. *Equine Veterinary Education* **5**, 285-286

Dixon,P.M. (1999) Dental anatomy in: Equine Dentistry. Edited by Baker,G.J. and Easley,J. WB Saunders, London 3-28

Dixon,P.M. (2002) The gross, histological, and ultrastructural anatomy of equine teeth and their relationship to disease. *Proceedings of the 48th American Association of Equine Practitioners Annual Convention* 421-437

Dixon,P.M. & Copeland, A. N. (1993) The radiological appearance of mandibular cheek teeth in ponies of different ages. *Equine Veterinary Education* **5**, 317-323

Dixon,P.M., Dacre,I., Dacre,K., Tremaine,W.H., McCann,J., & Barakzai,S. (2005) Standing oral extraction of cheek teeth in 100 horses (1998-2003). *Equine Veterinary Journal* **37**, 105-112

Dixon,P.M., Tremaine,W.H., Pickles,K., Kuhns,L., Hawe,C., McCann,J., McGorum,B., Railton,D.I., & Brammer,S. (1999a) Equine dental disease part 1: a

long-term study of 400 cases: disorders of incisor, canine and first premolar teeth.

*Equine Veterinary Journal* **31**, 369-377

Dixon,P.M., Tremaine, W. H., Pickles, K., Kuhns, L., Hawe, C., McCann, J., McGorum, B. C., Railton, D. I., & Brammer, S. (1999b) Equine dental disease part 2: a long-term study of 400 cases: disorders of development and eruption and variations in position of the cheek teeth. *Equine Veterinary Journal* **31**, 519-528

Dixon,P.M., Tremaine, W. H., Pickles, K., Kuhns, L., Hawe, C., McCann, J., McGorum, B. C., Railton, D. I., & Brammer, S. (2000a) Equine dental disease part 4: a long-term study of 400 cases: apical infections of cheek teeth. *Equine Veterinary Journal* **32**, 182-194

Dixon,P.M., Tremaine, W. H., Pickles, K., Kuhns, L., Hawe, C., McCann, J., McGorum, B. C., Railton, D. I., & Brammer, S. (2000b) Equine dental disease part 3: a long-term study of 400 cases: disorders of wear, traumatic damage and idiopathic fractures, tumours and miscellaneous disorders of the cheek teeth. *Equine Veterinary Journal* **32**, 9-18

Dubielzig,R.R., Wilson, J. W., Beck, K. A., & Robbins, T. (1986) Dental dysplasia and epitheliogenesis imperfecta in a foal. *Veterinary Pathology* **23**, 325-327

Easley,J. (1998) Dental corrective procedures. *Veterinary Clinics of North America - Equine Practice* **14**, 411-32

Easley,J. (1999) Dental and oral examination in: Equine Dentistry. Edited by Baker,G.J. and Easley,J. WB Saunders, London 107-126

Edmunds,D.H., Whittaker, D. K., & Green, R. M. (1988) Suitability of human, bovine, equine, and ovine tooth enamel for studies of artificial bacterial carious lesions. *Caries Research* **22**, 327-336

Edwards,G.B. (1993) Retention of permanent cheek teeth in three horses. *Equine Veterinary Education* **5**, 299-302

- Eisenmann,D.R. (1998) Amelogenesis in: Oral Histology, 5<sup>th</sup> edition. Edited by Ten Cate,A.R. Mosby, St. Louis 197-217
- Ellis,R.G. & Davey, K. W. (1970) The Classification and Treatment of Injuries to the Teeth of Children, 5<sup>th</sup> edition. Edited by Ellis,R.G. Year Book Publishers, Chicago
- Fawcett,D.W. (1987) A textbook of histology. W.B.Saunders, Philadelphia 603-618
- Ferguson,M. (1990) The dentition throughout life in: The dentition and dental care, 3<sup>rd</sup> edition. Edited by Elderton,R.J. Oxford Heinemann Medical Books, Oxford 1-18
- Floyd,M.R. (1991) The modified Triadan system: nomenclature for veterinary dentistry. *Journal of Veterinary Dentistry* **8**, 18-19
- Foreman,P.C. & Soames, J. V. (1989) Comparative study of the composition of primary and secondary dentine. *Caries Research* **23**, 1-4
- Fortelius,M. (1985) Ungulate cheek teeth: developmental, functional and evolutionary interrelations. *Acta Zoologica Fennica* **180**, 1-76
- Foster,D.L. (1996) Nomenclature for Equine Dental Anatomy Based on the Modified Triadan System. *Proceedings of the 42<sup>nd</sup> American Association of Equine Practitioners Annual Convention* 318-319
- Frank,R.M. (1970) Quantitative radioautography of amelogenesis in electron microscopy using tritiated proline in the cat. *Archives of Oral Biology* **15**, 569-581
- Freeman,E. (1998) Periodontium in: Oral Histology, 5<sup>th</sup> edition. Edited by Ten Cate,A.R. Mosby, St. Louis 253-288
- Freeman,E. & Ten Cate,A.R. (1971) Development of the periodontium: an electron microscopic study. *Journal of Periodontology* **42**, 387-395

- Galvayne,S. (1912) *The XXth Century Book on the Horse*, 3<sup>rd</sup> edition. Balliere, Tindall & Cox, London 212
- Geres,V. (1962) Pathology and diagnosis of diseases of the teeth in horses. *Veterinary Archives* **32** 258-261
- Getty,R. (1975) Sisson and Grossman's *The Anatomy of Domestic Animals*, Volume 1, 5<sup>th</sup> edition. W.B.Saunders, Philadelphia.
- Gibbs,C. (1978) Uses of diagnostic radiology in veterinary practice. *The Veterinary Record* **103**, 93-96
- Gibbs,C. (1999) Dental Imaging in: *Equine Dentistry*. Edited by Baker,G.J. and Easley,J. WB Saunders, London 139-172
- Gibbs,C. & Lane, J. G. (1987) Radiographic examination of the facial, nasal and paranasal sinus regions of the horse. II. Radiological findings. *Equine Veterinary Journal* **19**, 474-482
- Gorrel,C. (1998) Radiographic evaluation. *Veterinary Clinics of North America - Small Animal Practice* **28**, 1089-1110
- Gutman,J.L. & Harrison, J. W. (1991) *Surgical Endodontics*. Blackwell Scientific Publications, Boston 449-461
- Hague,B.A. & Honnas, C. M. (1998) Traumatic dental disease and soft tissue injuries of the oral cavity. *Veterinary Clinics of North America - Equine Practice* **14**, 333-347
- Harcourt-Brown,F.M. (1996) Calcium deficiency, diet and dental disease in pet rabbits. *The Veterinary Record* **139**, 567-571
- Hartles,R.L. & Leach, S. A. (1975) Effect of diet on dental caries. *British Medical Bulletin* **31**, 137-141

- Harvey,C.E. & Emily, P. P. (1993) *Small Animal Dentistry*. Mosby, St. Louis 157-213
- Hayward,A.F. (1981) *Human Tissue: Pulp in: Dental Anatomy and Embryology*. Edited by Osborn,J.W. Blackwell Scientific Publications , Oxford 187-190
- Head,K.W. & Dixon, P. M. (1999) Equine nasal and paranasal sinus tumours. Part 1: review of the literature and tumour classification. *The Veterinary Journal* **157**, 261-278
- Hillson,S. (1986) Archaeology and the study of teeth. *Endeavour*. **10**, 145-149
- Hofmeyer,C.F.B. (1960) Comparative dental pathology. *Journal of the South African Veterinary Medical Association* **29**, 471-480
- Hollands,T. (2004) Masticatory rates. Personal communication
- Honma,K., Yamakawa, M., Yamauchi, S., & Hosoya, S. (1962) Statistical study on the occurrence of dental caries of domestic animals. *Japanese Journal of Veterinary Research* **10**, 31-37
- Hoppe,K.A., Stover, S. M., Pascoe, J. R., & Amundson, R. (2004) Tooth enamel biomineralization in extant horses: implications for isotopic microsampling. *Palaeo* **206**, 355-365
- Hunt,R.J., Allen, D., & Mueller, P. O. (1991) Intracranial trauma associated with extraction of a temporal ear tooth (dentigerous cyst) in a horse. *Cornell Veterinary Journal* **81**, 103-108
- Ingham,K.E., Gorrel, C., Blackburn, J., & Farnsworth, W. (2001) Prevalence of odontoclastic resorptive lesions in a population of clinically healthy cats. *Journal of Small Animal Practice* **42**, 439-443

- Johansen,E., Papas, A., Fong, W., & Olsen, T. O. (1987) Remineralisation of carious lesions in elderly patients. *Gerodontics* **3**, 47-50
- Johnson,G. & Brannstrom, M. (1974) The sensitivity of dentin. Changes in relation to conditions at exposed tubule apertures. *Acta Odontologica Scandanavia* **32**, 29-38
- Jones,S.J. (1981) Human tissue: cement in: Dental Anatomy and Embryology. Edited by Osborn,J.W. Blackwell Scientific Publications, Oxford 193-209
- Jones,S.J. (1990) The pulp-dentine complex in: The Dentition and Dental Care. Edited by Elderton,R.J. Oxford Heinemann Medical Books, Oxford 193-209
- Jones,S.J. & Boyde,A. (1987) Scanning microscopic observations on dental caries. *Scanning Microscopy* **1**, 1991-2002
- Kempson,S.A., Davidson, M., & Dacre, I. T. (2003) The effect of three types of rasps on the occlusal surface of equine cheek teeth: a scanning electron microscopic study. *Journal of Veterinary Dentistry* **20**, 19-27
- Kertesz,P. (1993) In search of Mr Bishop. *The Veterinary Record* **133**, 608-610
- Kidd,E.A., Thylstrup,A., & Fejerskov,O. (1981) The histopathology of enamel caries in fluorosed deciduous teeth. *Caries Research* **15**, 346-352
- Kierdorf,H. & Kierdorf,U. (1992) A scanning electron microscopic study on the distribution of peritubular dentine in cheek teeth of Cervidae and Suidae. *Anatomy And Embryology (Berlin)* **186**, 319-326
- Kilic,S. (1995) A light and electron microscopic study of calcified dental tissues in normal horses. PhD thesis, University of Edinburgh 1-193
- Kilic,S., Dixon,P.M., & Kempson,S.A. (1997a) A light microscopic and ultrastructural examination of calcified dental tissues of horses: 1. The occlusal surface and enamel thickness. *Equine Veterinary Journal* **29**, 190-197

- Kilic,S., Dixon,P.M., & Kempson,S.A. (1997b) A light microscopic and ultrastructural examination of calcified dental tissues of horses: 2. Ultrastructural enamel findings. *Equine Veterinary Journal* **29**, 198-205
- Kilic,S., Dixon, P. M., & Kempson, S. A. (1997c) A light microscopic and ultrastructural examination of calcified dental tissues of horses: 3. Dentine. *Equine Veterinary Journal* **29**, 206-212
- Kilic,S., Dixon, P. M., & Kempson, S. A. (1997d) A light microscopic and ultrastructural examination of calcified dental tissues on horses: 4. Cement and the amelocemental junction. *Equine Veterinary Journal* **29**, 213-219
- Kim,S., Dorscher-Kim,J.E., & Liu,M. (1989) Microcirculation of the dental pulp and its autonomic control. *Proceedings of the Finnish Dental Society* **85**, 279-287
- Kirkland,K.D. (1994) The morphology of the endodontic system reserve crown and roots of equine mandibular cheek teeth. MSc thesis, University of Illinois 24-102
- Kirkland,K.D., Baker, G. J., Marretta, S., Eurell, J. A., & Losonsky, J. M. (1996) Effects of aging on the endodontic system, reserve crown, and roots of equine mandibular cheek teeth. *American Journal of Veterinary Research* **57**, 31-38
- Kirkland,K.D., Mareta, S. M., Inoue, O. J., & Baker, G. J. (1994) Survey of equine dental disease and associated oral pathology. *Proceedings of the 40th American Association of Equine Practitioners Annual Convention* 119-120
- Klevezal,G.A. & Kleinenberg,S.E. (1967) Age determination of mammals from annual layers in teeth and bone. *Academy of Sciences, USSR*. Translation by the Department of the Interior and National Science Foundation, U.S. Department of Commerce
- Klugh,D.O. (2003) Equine incisor pulp canals: a closer look. *17<sup>th</sup> Annual Veterinary Dental Forum Proceedings* 200-202

- Knottenbelt,D.C. (1999) Oral and dental tumours in: *Equine Dentistry*. Edited by Baker,G.J. and Easley,J. WB Saunders, London 85-103
- Kovacs,I. (1971) A systematic description of dental roots in: *Dental morphology and evolution*. Edited by Dahlberg,A.A. University of Chicago Press, Chicago 211-256
- Kozawa,Y., Mishima, H., & Sakae, T. (1988) Evolution of tooth structure in the Equoidea. *Journal of Nihon University School of Dentistry* **30**, 287-296
- Kvaal,S., Koppang, H., & Solheim, T. (1994) Relationship between age and deposit of peritubular dentine. *Gerodontology*. **11**, 93-98
- Lane,J.G. (1994) A review of dental disorders of the horse, their treatment and possible fresh approaches to management. *Equine Veterinary Education* **6**, 13-21
- Lane,J.G., Gibbs,C., Meynink,S.E., & Steele,F.C. (1987a) Radiographic examination of the facial, nasal and paranasal sinus regions of the horse: I. Indications and procedures in 235 cases. *Equine Veterinary Journal* **19**, 466-473
- Lane,J.G., Longstaffe,J.A., & Gibbs,C. (1987b) Equine paranasal sinus cysts: a report of 15 cases. *Equine Veterinary Journal* **19**, 537-544
- Lane,J.G. & Mair,T.S. (1987) Observations on headshaking in the horse. *Equine Veterinary Journal* **19**, 331-336
- Latshaw,W.K. (1987) Face, mouth and pharynx in: *Veterinary Developmental Anatomy - A Clinically Oriented Approach*. BC Decker, Toronto 95-100
- Leach,S.A. (1968) Plaque chemistry and caries. *Alabama Journal of Medical Sciences* **5**, 247-255
- Leach,S.A., Lee, G. T., & Edgar, W. M. (1989) Remineralization of artificial caries-like lesions in human enamel in situ by chewing sorbitol gum. *Journal of Dental Research* **68**, 1064-1068

- Leue,G. (1941) Beziehungen zwischen Zahnanomalien und Verdauungsstörungen beim Pferde unter Heranziehung von Kaubildern. Veterinary Medicine Dissertation, Hannover 170-174
- Levine,M. (1982) The use of crown height measurements and eruption-wear sequences to age horse teeth in: Ageing and sexing animal bones from archaeological sites. Edited by Wilson,B., Grigson,H. and Payne,S. British Series 109, 223-250
- Linden,R.W. (1990) An update on the innervation of the periodontal ligament. *European Journal of Orthodontics* **12**, 91-100
- Linden,R.W. & Millar, B. J. (1988) The response characteristics of mechanoreceptors related to their position in the cat canine periodontal ligament. *Archives of Oral Biology* **33**, 51-56
- Little,W.L. (1913) Periodontal disease in the horse. *Journal of Comparative Pathology and Therapeutics* **24**, 240-249
- Lowder,M.Q. (1997) Who is teaching equine dentistry? *The Compendium on Continuing Education for the Practising Veterinarian* **19**, 624-627
- Lowder,M.Q. & Mueller,P.O. (1998) Dental embryology, anatomy, development, and aging. *Veterinary Clinics of North America - Equine Practice* **14**, 227-45
- Mair,T.S. (1999) Assessment of bilateral infra-orbital nerve blockade and bilateral infra-orbital neurectomy in the investigation and treatment of idiopathic headshaking. *Equine Veterinary Journal* **31**, 262-264
- May,S.A. & Wyn-Jones, G. (1987) Contrast radiography in the investigation of sinus tracts and abscess cavities in the horse. *Equine Veterinary Journal* **19**, 218-222
- Mayhew,E. (1873) The teeth - their natural growth, and the abuses to which they are liable in: *The Illustrated Horse Management*. W.H. Allen, London 135-175

- Miles, A.E.W. & Grigson, C. (1990) Colyer's Variations and diseases of the teeth of animals, 2<sup>nd</sup> edition. Cambridge University Press, Cambridge
- Miller, W.D. (1891) The human mouth as a focus of infection. *The Dental Cosmos* **33** 689-706
- Mitchell, S. (2004) Peripheral cementum of normal equine cheek teeth: a qualitative and quantitative study. MSc thesis, University of Edinburgh 1-146
- Mueller, P.O. (1991) Equine dental disorders. *The Compendium*. **13**, 1451-1461
- Mueller, P.O. & Lowder, M.Q. (1998) Dental sepsis. *Veterinary Clinics of North America - Equine Practice* **14**, 349-63
- Muyllé, S., Simoens, P., & Lauwers, H. (1996) Ageing horses by an examination of their incisor teeth: an (im)possible task? *The Veterinary Record* **138**, 295-301
- Muyllé, S., Simoens, P., & Lauwers, H. (1999a) Age-related morphometry of equine incisors. *Zentralblatt für Veterinärmedizin Reihe A* **46**, 633-643
- Muyllé, S., Simoens, P., & Lauwers, H. (2000a) The dentinal structure of equine incisors: a light and scanning electron-microscopic study. *Cells Tissues Organs* **167**, 273-284
- Muyllé, S., Simoens, P., & Lauwers, H. (2000b) Tubular contents of equine dentin: a scanning electron microscopic study. *Journal of Veterinary Medicine. A, Physiology, Pathology, Clinical Medicine* **47**, 321-330
- Muyllé, S., Simoens, P., & Lauwers, H. (2001) The distribution of intratubular dentine in equine incisors: a scanning electron microscopic study. *Equine Veterinary Journal* **33**, 65-69

- Muyllle,S., Simoens, P., & Lauwers, H. (2002) A study of the ultrastructure and staining characteristics of the 'dental star' of equine incisors. *Equine Veterinary Journal* **34**, 230-234
- Muyllle,S., Simoens, P., Verbeeck, R., Ysebaert, M. T., & Lauwers, H. (1999b) Dental wear in horses in relation to the microhardness of enamel and dentine. *The Veterinary Record* **144**, 558-561
- Myres,J.S. (1994) The effects of body size, grass height and time of day on the foraging behaviour of horses. MSc thesis, Aberystwyth University 56
- National Institute of Dental and Craniofacial Research (2003) Internet communication on: Periodontal diseases: microbial and host genomics / proteomics.  
[www.nidr.nih.gov](http://www.nidr.nih.gov)
- Noden,D.M. & DeLahunta, A. (1985) Causes of congenital malformations in: The Embryology of Domestic Animals; Developmental Mechanisms and Malformations. Edited by Stamathis and Vaughn,V.M. Williams and Wilkins, Baltimore 81-91
- O'Connor,J.J. (1930) Regional surgery: Affections of the teeth in: Dollar's Veterinary Surgery, 2<sup>nd</sup> edition. Bailliere, Tindall and Cox, London 522-537
- Obry-Musset,A.M., Cahen, P. M., Turlot, J. C., & Frank, R. M. (1988) Approximal caries diagnosis in epidemiological studies: transillumination or bitewing radiographs? *Journal de Biologie Buccale* **16**, 13-17
- Owall,B. & Moller, E. (1974) Oral tactile sensibility during biting and chewing. *Odontologisk Revy* **25**, 327-346
- Paphangkorakit,J. & Osborn, J. W. (2000) The effect of normal occlusal forces on fluid movement through human dentine in vitro. *Archives of Oral Biology* **45**, 1033-1041

- Peabody,F.E. (1961) Annual growth zones in living and fossil vertebrates. *Journal of Morphology* **108**, 11-62
- Perkins,J. (2001) Qualitative and quantitative anatomy of the equine maxillary and conchal sinuses, with particular reference to the nasomaxillary aperture. MSc thesis, University of Edinburgh 1-117
- Pfretzschner,H.U. (1992) Enamel microstructure and hypsodonty in large mammals in: *Structure, Function and Evolution of Teeth*. Edited by Smith,P. and Tcherov,E. Freund Publishing House, London 147-162
- Pirie,R.S. & Dixon, P. M. (1993) Mandibular tumours in the horse: a review of the literature and 7 case reports. *Equine Veterinary Education*. **5**, 287-294
- Prichard,M.A., Hackett, R. P., & Erb, H. N. (1992) Long-term outcome of tooth repulsion in horses. A retrospective study of 61 cases. *Veterinary Surgery* **21**, 145-149
- Proffit,W.R. (1986) The biologic basis of orthodontic therapy in: *Contemporary Othodontics*, 2<sup>nd</sup> edition. Edited by Proffit,W.R. and Fields,H.W. Mosby, St. Louis 266-288
- Raab,W.H. (1992) Temperature related changes in pulpal microcirculation. *Proceedings of the Finnish Dental Society* **88**, 469-479
- Ralston,S.L., Foster, D. L., Divers, T., & Hintz, H. F. (2001) Effect of dental correction on feed digestibility in horses. *Equine Veterinary Journal* **33**, 390-393
- Ramzan,P.H. (2002) The need for chemical restraint while performing routine dental procedures using a full mouth speculum: a retrospective study of 581 examinations. *Equine Veterinary Education* **14**, 30-32
- Ramzan,P.H., Dixon, P. M., Kempson, S. A., & Rosedale, P. D. (2001) Dental dysplasia and oligodontia in a thoroughbred colt. *Equine Veterinay Journal* **33**, 99-104

- Rashmir-Raven, A., Cash, W. C., DeBowes, R. M., Gatewood, D. M., & Clem, M. F. (1990) Dentigerous cysts. *The Compendium* **12**, 1120-1125
- Rensberger, J.M. (1992) Relationship of chewing stress and enamel microstructure in rhinocerotoid cheek teeth in: *Structure, Function and Evolution of Teeth*. Edited by Smith, P. and Tcherov, E. Freund Publishing House, London 163-183
- Richardson, J.D., Cripps, P. J., Hillyer, M. H., O'Brien, J. K., Pinsent, P. J., & Lane, J. G. (1995a) An evaluation of the accuracy of ageing horses by their dentition: a matter of experience? *The Veterinary Record* **137**, 88-90
- Richardson, J.D., Cripps, P. J., & Lane, J. G. (1995b) An evaluation of the accuracy of ageing horses by their dentition: can a computer model be accurate? *The Veterinary Record* **137**, 139-140
- Richardson, J.D., Cripps, P. J., & Lane, J. G. (1995c) An evaluation of the accuracy of ageing horses by their dentition: changes of dental morphology with age. *The Veterinary Record* **137**, 117-121
- Richardson, J.D., Lane, J. G., & Waldron, K. R. (1994) Is dentition an accurate indication of the age of a horse? *The Veterinary Record* **135**, 31-34
- Robinson, C., Kirkham, J., & Hallsworth, A. S. (1988) Volume distribution and concentration of protein, mineral and water in developing bovine enamel. *Archives of Oral Biology* **33**, 159-162
- Robinson, C., Shore, R. C., Brookes, S. J., Strafford, S., Wood, S. R., & Kirkham, J. (2000) The chemistry of enamel caries. *Critical Reviews in Oral Biology and Medicine* **11**, 481-495
- Rooney, J.R. & Robertson, J. L. (1996) *Equine Pathology*. Iowa State University Press, Ames 60-64

- Schramme,M., Boswell,J., Robinson,J., May,S.A., Smith,R.K., Platt,D. & Schumacher,J. (2000) Endodontic Therapy for Periapical Infection of the Cheek Teeth: A Study of 19 Horses. *Proceedings of the 46th American Association of Equine Practitioners Annual Convention* 113-116
- Schumacher,J. (2001) The present state of equine dentistry. *Equine Veterinary Journal*. **33**, 2-3
- Schumacher,J. & Honnas, C. M. (1993) Dental surgery. *Veterinary Clinics of North America - Equine Practice* ,**9** 133-152
- Schutzmannsky,G. (1963) Unfallverletzungen an jungenlichen zahnen. *Deutsch Stomatologie* **13**, 919
- Scrutchfield,W.L. (1999a) Dental Prophylaxis in: Equine Dentistry. Edited by Baker,G.J. and Easley,J. WB Saunders, London 185-205
- Scrutchfield,W.L. (1999b) Equine dental instrumentation in: Equine Dentistry. Edited by Baker,G.J. and Easley,J. WB Saunders, London 173-184
- Scrutchfield,W.L. & Schumacher, J. (1993) Examination of the oral cavity and routine dental care. *Veterinary Clinics of North America - Equine Practice* **9**, 123-131
- Scrutchfield,W.L., Schumacher, J., & Martin, M. T. (1996) Correction of abnormalities of the cheek teeth. *Proceedings of the 42<sup>nd</sup> American Association of Equine Practitioners Annual Convention* 11-21
- Scrutchfield,W.L., Schumacher, J., & Martin, M. T. (1997) Equine dentistry - cheek teeth procedures. *Proceedings of the Fifth World Veterinary Dental Congress* 107-112

- Shafer,W.G., Hine, M. K., & Levy, B. M. (1983a) Cysts and tumours of odontogenic origin in: A Textbook of Oral Pathology, 4<sup>th</sup> edition. W.B.Saunders, Philadelphia 258-317
- Shafer,W.G., Hine, M. K., & Levy, B. M. (1983b) Dental caries in: A Textbook of Oral Pathology, 4<sup>th</sup> edition. W.B.Saunders, Philadelphia 406-478
- Shafer,W.G., Hine, M. K., & Levy, B. M. (1983c) Developmental disturbances of oral and paraoral structures in: A Textbook of Oral Pathology, 4<sup>th</sup> edition. W.B.Saunders, Philadelphia 2-85
- Shafer,W.G., Hine, M. K., & Levy, B. M. (1983d) Diseases of the periodontium in: A Textbook of Oral Pathology, 4<sup>th</sup> edition. W.B.Saunders, Philadelphia 760-805
- Shafer,W.G., Hine, M. K., & Levy, B. M. (1983e) Diseases of the pulp and periapical tissues in: A Textbook of Oral Pathology, 4<sup>th</sup> edition. W.B.Saunders, Philadelphia 479-510
- Shafer,W.G., Hine, M. K., & Levy, B. M. (1983f) Physical and chemical injuries to the oral cavity in: A Textbook of Oral Pathology, 4<sup>th</sup> edition. W.B.Saunders, Philadelphia 528-593
- Shellis,P. (1981) Human tissue: dentine in: Dental anatomy and embryology. Edited by Osborne,J.W. Blackwell Scientific Publications, Oxford 193-209
- Shuttleworth,A.C. (1948) Dental disease of horses. *Veterinary Record* **60**, 563-567
- Siar,C.H. (1986) Quantitative histological analysis of the human coronal dentine in dentinogenesis imperfecta types I and II. *Archives of Oral Biology* **31**, 387-390
- Silverstone,L.M. & Poole,D.F. (1969) Histologic and ultrastructural features of remineralized carious enamel. *Journal of Dental Research* **48**, 766-770

- Simhofer, H., Griss, R., & Zetner, K. (2003) Pathological findings in cheek teeth in 300 horses employing a standardised endoscopy technique. *Personal communications*.
- Slavkin, H.C., Mino, W., & Bringas, P., Jr. (1976) The biosynthesis and secretion of precursor enamel protein by ameloblasts as visualized by autoradiography after tryptophan administration. *Anatomical Record* **185**, 289-312
- Smith, J.M. & Savage, R. J. G (1959) The mechanics of mammalian jaws. *The School Science Review* **141**, 289-301
- Soames, J.V. & Southam, J. C. (1993a) Dental caries in: *Oral Pathology*, 2<sup>nd</sup> edition. Oxford University Press, Oxford 19-33
- Soames, J.V. & Southam, J. C. (1993b) Diseases of the periodontium in: *Oral Pathology*, 2<sup>nd</sup> edition. Oxford University Press, Oxford 91-111
- Soames, J.V. & Southam, J. C. (1993c) Disorders of development of teeth in: *Oral Pathology*, 2<sup>nd</sup> edition. Oxford University Press, Oxford 1-18
- Soames, J.V. & Southam, J. C. (1993d) Disorders of the dental pulp in: *Oral Pathology*, 2<sup>nd</sup> edition. Oxford University Press, Oxford 49-55
- Soana, S., Gnudi, G., & Bertoni, G. (1999) The teeth of the horse: evolution and anatomo-morphological and radiographic study of their development in the foetus. *Anatomica Histologia Embryologia* **28**, 273-280
- Stanley, H.R., Pereira, J. C., Spiegel, E., Broom, C., & Schultz, M. (1983) The detection and prevalence of reactive and physiologic sclerotic dentin, reparative dentin and dead tracts beneath various types of dental lesions according to tooth surface and age. *Journal of Oral Pathology* **12**, 257-289
- Stewart, K.A. & Genetzky, R. M. (1984) Odontodysplasia in a horse. *Modern Veterinary Practice* **65**, 87-89

- Stokstad,E. (2001) Tooth theory revises history of mammals. *Science* **291**, 26-26
- Suga,S. (1979) Comparative histology of progressive mineralisation pattern of developing incisor enamel of rodents. *Journal of Dental Research* **58**, 1025-1026
- Takuma,S., Sunohara, H., Watanabe, H., & Yama, K. (1969) Some structural aspects of carious lesions in human dentin. *Bulletin of Tokyo Dental College*. **10**, 173-181
- Tape,M.W. & Tye,E. (1995) Ectodermal dysplasia: literature review and a case report. *Compendium of Continuing Education in General Dentistry*. **16**, 524-528
- Taylor,A.C. (2001) An investigation of mandibular width and related dental disorders in the equine oral cavity. MSc thesis, Coventry University 1-51
- Ten Cate,A.R. (1992) Dentin/pulp complex reactions: a reaction. *Proceedings of the Finnish Dental Society* **88**, 275-278
- Ten Cate,A.R. (1998a) Dentinogenesis in: Oral Histology, 5<sup>th</sup> edition. Edited by Ten Cate,A.R. Mosby, St. Louis 128-149
- Ten Cate,A.R. (1998b) Development of the periodontium in: Oral Histology, 5<sup>th</sup> edition. Edited by Ten Cate,A.R. Mosby, St. Louis 236-288
- Ten Cate,A.R. (1998c) Development of the tooth and its supporting tissues in: Oral Histology, 5<sup>th</sup> edition. Edited by Ten Cate,A.R. Mosby, St. Louis 78-103
- Ten Cate,A.R. (1998d) Hard tissue formation and destruction in: Oral Histology, 5<sup>th</sup> edition. Edited by Ten Cate,A.R. Mosby, St. Louis 69-77
- Ten Cate,A.R. (1998e) Physiologic tooth movement: eruption and shedding in: Oral Histology, 5<sup>th</sup> edition. Edited by Ten Cate,A.R. Mosby, St. Louis 289-314

- Ten Cate,A.R. (1998f) Repair and regeneration of dental tissue in: Oral Histology, 5<sup>th</sup> edition. Edited by Ten Cate,A.R. Mosby, St. Louis 408-423
- Ten Cate,A.R. (1998g) Structure of the oral tissues in: Oral Histology, 5<sup>th</sup> edition. Edited by Ten Cate,A.R. Mosby, St. Louis 1-9
- Ten Cate,A.R., Deporter,D.A., & Freeman,E. (1976) The role of fibroblasts in the remodeling of periodontal ligament during physiologic tooth movement. *American Journal of Orthodontics* **69**, 155-168
- Thoma,K.H. & Goldman,H.M. (1960) Oral Pathology, 5<sup>th</sup> edition. Mosby, St. Louis 1168-1233
- Tietje,S., Becker,M., & Bockenhoff,G. (1996) Computed tomographic evaluation of head diseases in the horse: 15 cases. *Equine Veterinary Journal* **28**, 98-105
- Tohda,H., Takuma, S., & Tanaka, N. (1987) Intracrystalline structure of enamel crystals affected by caries. *Journal of Dental Research* **66**, 1647-1653
- Torneck,C.D. (1998) Dentin-pulp complex in: Oral Histology, 5<sup>th</sup> edition. Edited by Ten Cate,A.R. Mosby, St. Louis 150-196
- Traub-Dargatz,J.L., Salman,M.D., & Voss,J.L. (1991) Medical problems of adult horses, as ranked by equine practitioners. *Journal of the American Veterinary Medical Association* **198**, 1745-1747
- Tremaine,W.H. (1997) Dental care in horses. *In Practice*. **19**, 186-199
- Tremaine,W.H. & Dixon,P.M. (2001) A long-term study of 277 cases of equine sinonasal disease. Part 1: details of horses, historical, clinical and ancillary diagnostic findings. *Equine Veterinary Journal* **33**, 274-282

Trope,M., Chivian, N., Sigurdsson, A., & Vann, W. F. (2002) Traumatic injuries in: Pathways of the pulp, 8<sup>th</sup> edition. Edited by Cohen,S. and Burns,R.C. Mosby, St. Louis 603-650

Trowbridge,H.O. (2003) Pulp biology: progress during the past 25 years. *Australian Endodontic Journal* **29**, 5-12

Tucker,R.L. & Farrell, E. (2001) Computed tomography and magnetic resonance imaging of the equine head. *Veterinary Clinics of North America - Equine Practice* **17**, 131-44

Uhlinger,C. (1987) Survey of selected dental abnormalities in 233 horses. *Proceedings of the 33rd American Association of Equine Practitioners Annual Convention* 577-583

Uhlinger,K.A. (1990) Disorders of the oral cavity in: Large Animal Internal Medicine. Edited by Smith,B.P. Mosby, St. Louis 624-631

van Foreest,A.W. (1995) An update in dentistry. *Veterinary Quarterly* **17**, S8-S9

Voss,H.J. (1937) Periodontal disease in the horse. Enke, Stuttgart

Wafa,N.S. (1988) A study of dental disease in the horse. MVM thesis, University College Dublin 1-205

Walmsley,J.P. (1993) Some observations of ageing 5-7 year old horses by examination of their incisor teeth. *Equine Veterinary Education* **5**, 295-298

Walsh,K.M., Denholm,L.J., & Cooper,B.J. (1987) Epithelial odontogenic tumours in domestic animals. *Journal of Comparative Pathology* **97**, 503-521

Warshawsky,H. (1983) The teeth in: Histology, 5<sup>th</sup> edition. Edited by Weiss,L. The Macmillan Press, New York 609-655

Weissengruber,G.E., Egerbacher,M., & Forstenpointner,G. (2005) Structure and innervation of the tusk pulp in the African elephant (*Loxodonta africana*). *Journal of Anatomy* **206**, 387-393

Weller,R., Livesey,L., Maierl,J., Nuss,K., Bowen,I.M., Cauvin,E.R., Weaver,M., Schumacher,J., & May,S.A. (2001) Comparison of radiography and scintigraphy in the diagnosis of dental disorders in the horse. *Equine Veterinary Journal* **33**, 49-58

Wintzer,H.J. & Jaksch, W. (1986) Digestive diseases in: *Equine Diseases*. Edited by Wintzer,H.J. Verlag Paul Parey, Berlin 90-98

Wyn-Jones,G. (1985) Interpreting radiographs 6: Radiology of the equine head (Part 2). *Equine Veterinary Journal* **17**, 417-425

Zaluski,P. & Davis, M. (2003) How to obtain diagnostic radiographs of the equine molars. *17<sup>th</sup> Annual Veterinary Dental Forum Proceedings* 189-190

## Appendix 1: Case Reports on Maxillary Cheek Teeth with Apical Infections

### Case 1: 99/998

7 year-old Welsh pony, mare

#### History and clinical examination:

Upon referral with a swelling of the right rostral maxillary area of approximately two months duration, radiographic examination confirmed the presence of an apical infection of Triadan tooth 106 (dental age 5.5 years). The CT was orally extracted under standing sedation. A large amount of calcified granulomatous material was present around the apical region of the tooth.

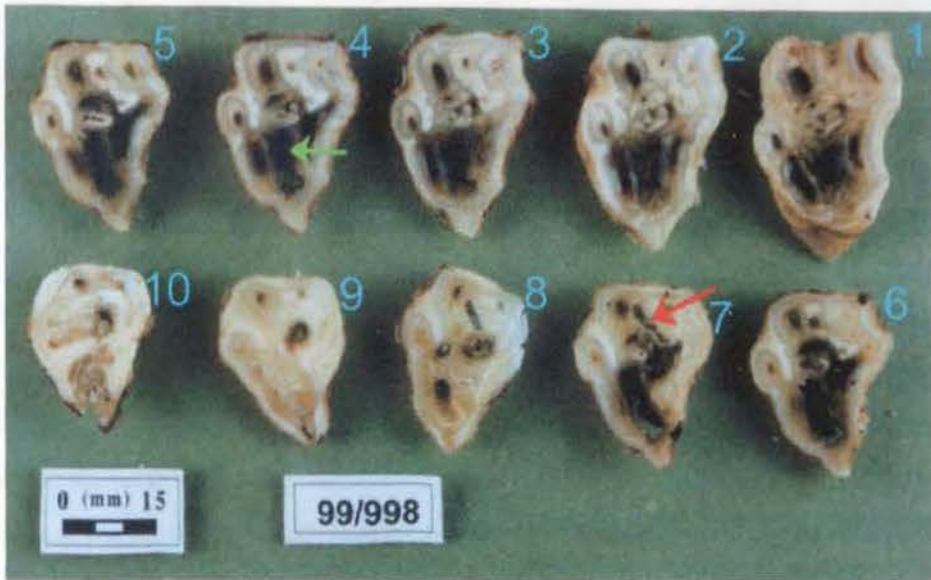
#### Radiology of the Extracted CT:

**Figure 1. 1:** Exposure factors of 66kVp and 5.0 mA (d=65cm) were used for optimal imaging of the extracted tooth. In this rostro-caudally oriented radiograph, a large radiolucent area is present near the apical limit of the rostral infundibulum (red arrow). A separate radiolucent line runs from the occlusal surface to the apical region, at the site of pulp horn 4 (green arrows).

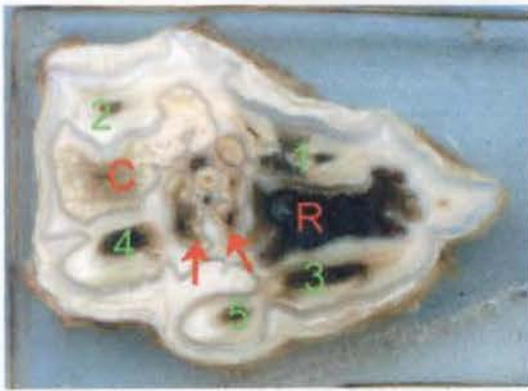


#### Dissecting Microscopy:

A 4mm high focal, rostral overgrowth ('hook') was present on the occlusal surface. Pulp chambers 1-5 were all exposed on the occlusal surface, however the 6<sup>th</sup> pulp chamber was not. The rostral infundibulum had severe (stage 3 –involving cementum, enamel and dentine) caries of the complete length of the infundibulum and the infundibular enamel was discoloured. The caudal infundibulum had cemental hypoplasia of its apical third, but was completely occluded by cementum more occlusally (Figure 1.2). At the caudal aspect of the tooth, interdental attrition (presumably caused by micro-movements of this tooth during mastication) had worn through the peripheral cementum, peripheral enamel, and the dentine to the level of the caudal infundibular enamel.



**Figure 1.2:** Transverse sections of CT 106 from Case 1 examined under dissecting microscopy. This triangular-shaped CT contains six pulp horns. Sections are from the occlusal surface (1) to apex (10). The rostral infundibulum is carious over its full length (identified in section 4 by a green arrow). Note the cemental hypoplasia of the more apical aspect of the caudal infundibulum in section 7 (red arrow). No caries were present within this caudal infundibulum.



**Figure 1.3:** Transverse sub-occlusal section 2 of CT 106 from Case 1 prior to processing for decalcified histology. Note the carious rostral infundibulum (R), and the slightly darker than normal appearance of the central region of the caudal infundibulum (C). Between these infundibula a third ‘central’ infundibulum

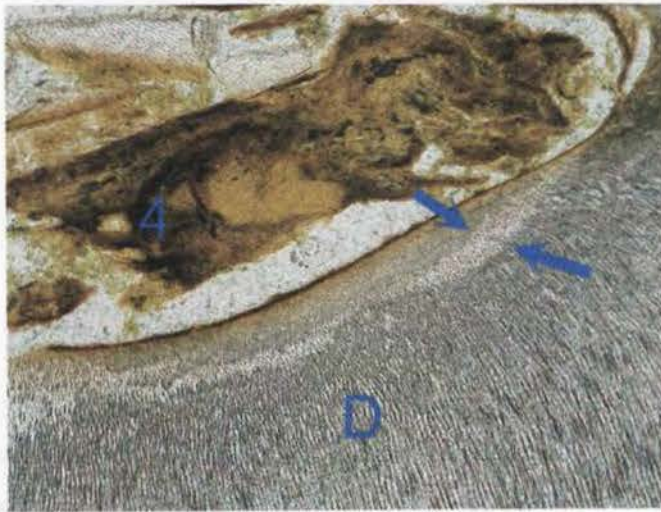
is occasionally present in maxillary 06 CT, as is the case here (arrows). Note the darkened appearance of all five exposed pulp chambers (1-5).

**Histology:**

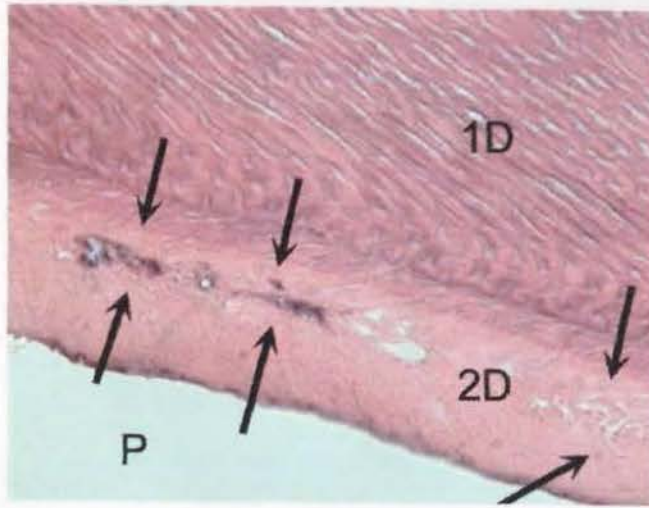
Decalcified histology of sub-occlusal section 2 showed pulp to be absent from all six pulp chambers. Tertiary dentine was present in pulp chambers 1 and 6, however neither of these two chambers were fully occluded by intraluminal deposition of

dentine. Cementum was absent from the rostral infundibulum at this level, but was present as normal, in the caudal infundibulum. The median thickness of buccal and palatal secondary dentine in all six pulp chambers in Control CT 38 (Triadan 106), with a dental age of 5.5 years, was 500 $\mu$ m in the sub-occlusal section (n = 12; see Section 3.8.1). In this affected tooth (CT 106, Case 1) the median secondary dentine thickness of all pulp chambers at this level was 285 $\mu$ m.

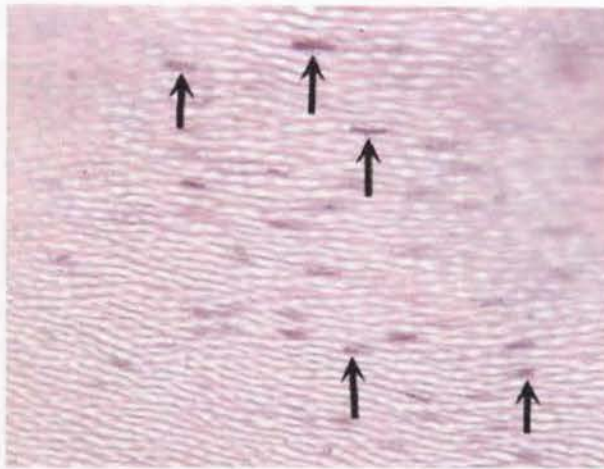
Examination of decalcified and undecalcified sections showed evidence of carious destruction of secondary dentine surrounding the pulp chambers that were exposed on the occlusal surface – with vegetable matter packed deep within the pulp chambers and evidence of demineralisation of the surrounding dentine (Figures 1.4 and 1.5). Additionally, bacteria were present in primary dentinal tubules surrounding the exposed pulp chambers, as seen in decalcified sections (Figure 1.6).



**Figure 1.4:** Undecalcified transverse section of CT 106 from Case 1. Pulp chamber 4 (numbered) is filled with food material. A surrounding zone of demineralised dentine (D) is present (between arrows). (Unstained x100)

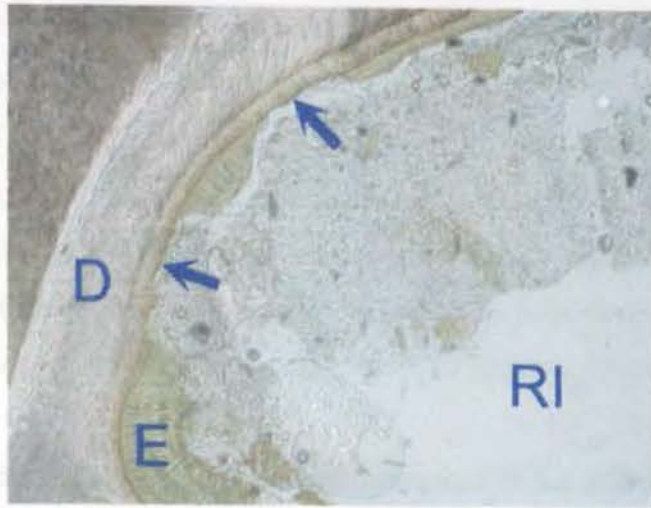


**Figure 1.5:** Decalcified transverse section from Case 1. Carious secondary dentine (2D) is present (between arrows) between pulp chamber 1 (P) and primary dentine (1D). (H&E x400)

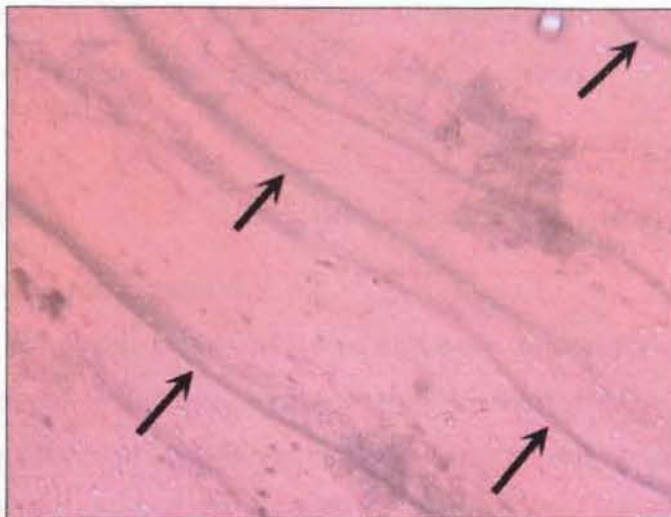


**Figure 1.6:** Decalcified transverse sub-occlusal section of CT 106 from Case 1 showing pioneer microorganisms (bacteria) present in primary dentine tubules (arrows). The dentinal tubules have been cut obliquely in this section. (H&E x400)

Histological examination of the rostral infundibulum of this tooth showed caries extending from the infundibular cementum, through the infundibular enamel into dentine (Figure 1.7).



**Figure 1.7:** Undecalcified (ground) transverse section from CT 106 from Case 1. Carious enamel (E) is still present on some margins of the rostral infundibulum (RI), but has fully disintegrated in other areas (arrows) where the carious attack now contacts dentine (D). (Unstained x40)



**Figure 1.8:** Decalcified transverse section of CT 106 from Case 1 showing incremental lines in the peripheral cementum (dark lines indicated by arrows). These incremental lines may indicate periods when deposition of peripheral cementum has slowed or stopped and are considered to be seasonal by some authors (Section 2.7) (H&E x100)

### **Conclusions:**

Caries within the rostral infundibulum of this CT was seen to progress beyond the infundibular cementum to involve the infundibular enamel and then to progress

through the enamel to affect the adjacent dentine. This carious advance may have allowed pathogenic bacteria from the oral cavity to infect the pulp, resulting in a bacterial pulpitis of the adjacent pulp horn(s) initially, with subsequent development of an apical abscess. Pulp horns 1 and 3 are situated buccally and palatally to the rostral infundibulum. However, there was no evidence to confirm that these pulps were the first to be infected, i.e. the caries of these two pulp chambers was not more advanced than the caries present in the other infected pulp chambers.

The degree of decreased secondary dentine formation in the affected pulp chambers supports the clinical history that this infection had been longstanding, as odontoblasts had not been active within this tooth for some months. The pulpar exposure present in five of the six pulp chambers in this tooth is thought to have arisen through continued dental attrition of the remaining occlusal dentine (primary and secondary dentine) overlying the occlusal limit of the pulp chambers. This would have followed decreased dentine production from initially compromised odontoblasts, and then complete cessation of dentine production following their death.

## **Case 2: 99/558**

## **10 year-old Warmblood, mare**

### **History and clinical examination:**

Swelling of the left rostral maxillary region had been present for two weeks in this mare prior to referral to this institute. Radiography revealed infection of the caudo-lateral root of Triadan tooth 207 (dental age 6.5 years). A large, open apical foramen was radiographically present, with minimal destructive changes present in the surrounding periapical region, suggesting that the pulp might still be viable. The horse was given a two-week course of antibiotics, but five weeks later, an external sinus tract developed rostro-dorsal to the left facial crest.

Following attempted oral extraction (resulting in fracture of the clinical crown), the tooth was repulsed under general anaesthesia. Due to disruption to the periodontal membrane during the attempted oral extraction, repulsion was readily performed without the usual extensive percussive damage to the apex of the tooth.

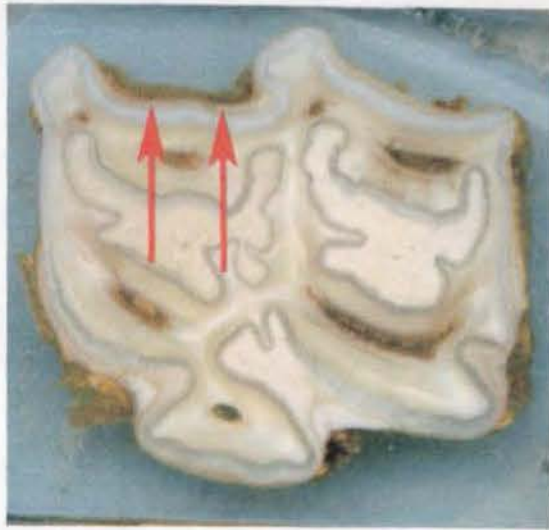
**Radiology of the Extracted CT:**

Exposure factors of 66kVp and 5.0 mA (d=65cm) were used for optimal imaging of the extracted tooth. The only distinguishing radiological features identified were the iatrogenically fractured caudo-lateral root caused by repulsion, and the iatrogenically fractured clinical crown.

**Dissecting microscopy:**

A darkened band (6-8mm wide) of periodontal ligament was present, running from the gingival margin along the buccal face of the tooth, to the apex, between the rostral and central buccal cingulae (Figure 1.9). This band may possibly have resulted from haemorrhage that occurred during oral extraction, but this area of periodontal ligament was much thicker and cellular than normally would occur from oral extraction trauma. It was not possible to examine the entire clinical crown, as much had been lost during the attempted oral extraction.

In the transverse sections examined, all five pulp chambers were patent, and contained either viable, partially autolysed (Figure 1.10) or necrotic pulp. No pulp chambers contained food material, suggesting that occlusal pulp exposure had not occurred in this tooth, prior to attempted extraction. In Figure 1.9 the pulp regions appear dark due to the presence of semi-autolysed pulp and haemorrhage within the pulp chambers, the latter possibly occurring during the attempted oral extraction the day before. Neither infundibulum showed any evidence of cemental hypoplasia or caries, with their cementum appearing normal under dissecting microscopy (Figure 1.9).



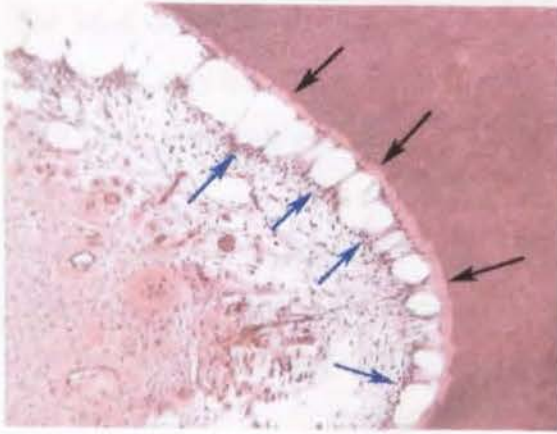
**Figure 1.9:** Transverse sub-occlusal section of CT 207 from Case 2. A dark band of buccal periodontal ligament (red arrows) is present. Both infundibula are normal in appearance (non-carious and not hypoplastic) however all five pulp horns appear darker than usual, possibly from haemorrhage during the attempted oral extraction.

**Histology:**

No cemental hypoplasia was identified at any level in either infundibulum, and no caries were present in either infundibulum. Predentine was present within all pulp chambers. Dentinal thickness in all pulp chambers was similar to the dentinal thickness of two control 107 CT of similar dental ages, as presented in Table 1.1.

Median Dentinal Measurements (microns)	<b>Control 50</b> Dental age 4.5 years	<b>Control 70</b> Dental age 7.5 years	<b>Case 3</b> Dental age 6.5 years
Primary buccal dentine	850	1000	950
Secondary buccal dentine	350	350	350
Primary palatal dentine	1850	1850	1750
Secondary palatal dentine	700	700	550

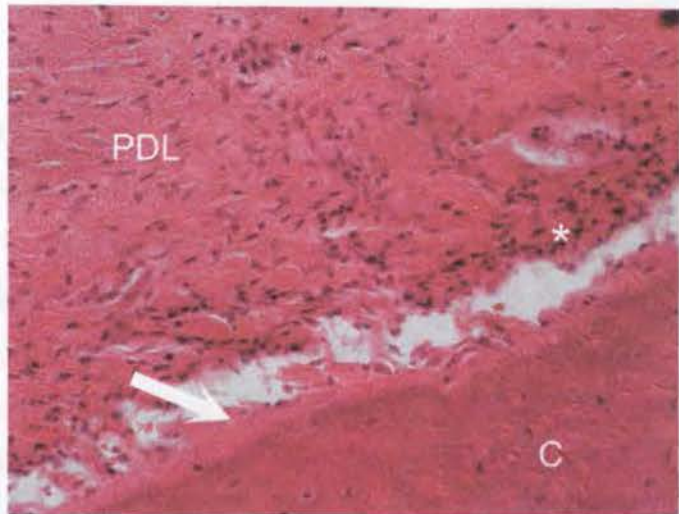
**Table 1.1:** Median dentinal thickness within pulp chambers of two control 107 CT and of abscessed CT 207 from Case 2.



**Figure 1.10:** Decalcified apical transverse section of CT 207 from Case 2, showing partially autolysed pulp. Black arrows highlight the pale band of predentine adjacent to the shrunken, semi-autolysed odontoblasts (blue arrows). There was artefactual pulpar shrinkage due to fixation procedures that

meant the odontoblasts were drawn closer towards the centre of the pulp horn. This has resulted in 'wheat-sheafing' (i.e. the contracted appearance of the odontoblasts) at the pulp periphery (blue arrows). (H&E x400)

**Figure 1.11:** Decalcified apical transverse section of CT 207 from Case 2 showing the periodontal ligament (PDL) adjacent to peripheral cementum (C). This area of PDL was thickened and darkly coloured (Figure 1.9) unlike other areas of PDL attachment. This area also had a marked increase in inflammatory cells (\*) near a partially mineralised band of precementum (arrow). (H&E x400)



### Conclusions:

All pulp chambers contained remnants of pulp, some of which were still viable and all had recently been supporting odontoblasts that were laying down predentine. Therefore from a histological point of view this was likely to have been a very acute apical infection, as the clinical history suggests. The absence of food material within the pulp chambers eliminates occlusal pulpar exposure as an aetiological factor for apical infection in this tooth. Neither infundibulum was carious, thereby also eliminating infundibular caries as a possible cause of the apical infection.

The band of darkened periodontal ligament present from the gingival margin to the apical area may have been a (descending) route of infection to the apex, and this is the *most likely* source of infection, given the marked neutrophilia present in this specific area (Figure 1.11). If the periodontal disease were to have arisen *following* apical infection (i.e. ascending periodontal infection following from an initial anachoretic pulpitis), more changes are likely to have occurred to pulpar tissue during this time. Alternatively, it is possible that the thickened periodontium was iatrogenic due to the oral extraction procedure, as other cases identified as having apical infection caused by descending periodontal infection (e.g. related to abnormal folding of the peripheral enamel) have had localised areas of more severely damaged or even absent periodontium (Dixon et al. 1999b).

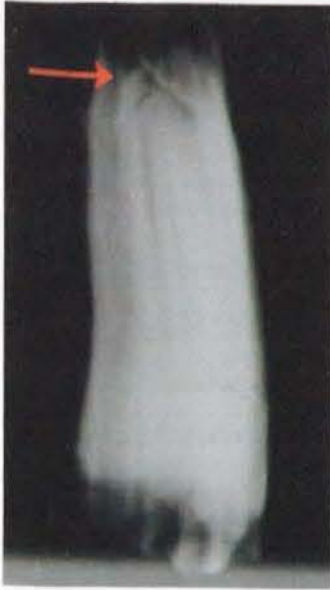### **Case 3: 99/457**

### **3 year-old Welsh cross Arab, mare**

#### **History and clinical examination:**

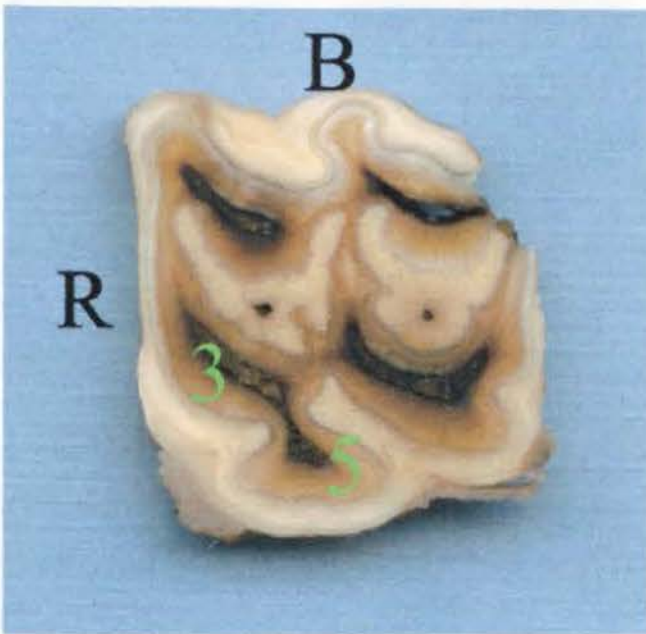
Clinical examination of this case showed marked swelling of the left maxillary area overlying the rostral CT that was associated with a malodorous purulent left-sided nasal discharge. Triadan teeth 206 and 207 (dental ages 0.5 and -0.5 years) were orally extracted following radiographic confirmation of gross destruction of the entire apex of 207 and of the caudal apical region of 206. Additionally, there was widespread destruction of the nasal conchae with focal mineralisation (dystrophic calcification) of some of the remaining conchae. No gross abnormalities of the clinical crowns were detected on oral examination. Due to extensive periodontal disease, both teeth were orally extracted easily. Only 207 has been included in the study as this was considered the primary source of infection, with 206 later becoming infected by local transalveolar spread from 207.

### Radiology of the Extracted CT:



**Figure 1.12:** AP radiograph of Triadan 207 from Case 3. Exposure factors of 66kVp and 5.0 mA (d=65cm) were used for optimal imaging of the extracted tooth. Apical changes associated with infection (arrow), and fracture to the clinical crown (which occurred during extraction), are radiologically evident. There is no radiographic evidence (such as decreased radiopacity or lost definition) that the pulp chambers have been exposed at the occlusal surface.

### Dissecting Microscopy:



**Figure 1.13:** Transverse sub-occlusal section of CT 207 from Case 3, prepared for dissection microscopy examination. Pulp chambers 3 and 5 are numbered. (B = buccal; R = rostral)

All five pulp chambers were exposed at the occlusal surface with food impacted down their entire length and into the common pulp chamber. There were connections between pulp chambers 3 and 5 in the sub-occlusal transverse section, undecalcified (3<sup>rd</sup>) transverse section and mid transverse section of this young CT (Section 3.6). Both infundibula had small, darkened central areas of hypoplastic cementum where the central vascular supply had been present during dentogenesis that were not pathologically significant (Figure 1.13).

At this level of magnification, areas of peripheral cementum remodelling were visible in the apical third of the tooth, possibly in reaction to infection of the adjacent periodontium. No such remodelling, or indeed changes of any kind, was present in peripheral cementum in the occlusal two-thirds of the tooth.

**Histology:**

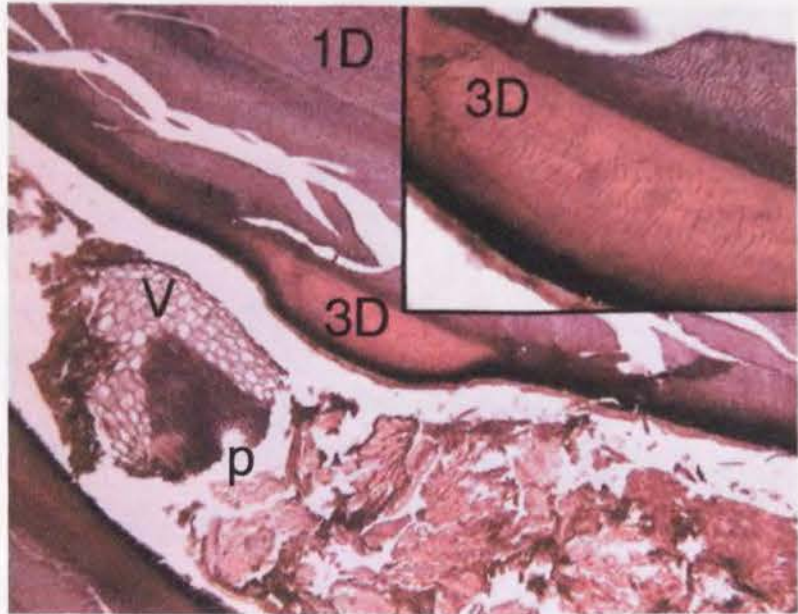
In a non-diseased control CT of similar dental age and the same Triadan position as that of CT 207 from Case 3, all five pulp chambers were fully occluded by irregular secondary dentine on the occlusal surface and the sub-occlusal transverse section. In the diseased tooth, no irregular secondary dentine was present in pulp chambers 1 and 4 at sub-occlusal level, and as mentioned previously, all five pulp chambers were exposed on the occlusal surface i.e. had not become occluded by irregular secondary dentine. There was also less secondary dentine present in pulp chamber 1, and less buccal primary dentine in pulp chambers 1 and 4 in the infected CT as compared to the control CT.

<b>Pulp chamber and dentinal measurements (microns)</b>	<b>Control 19 Pulp chamber 1</b>	<b>Case 3 Pulp chamber 1</b>	<b>Control 19 Pulp chamber 4</b>	<b>Case 3 Pulp chamber 4</b>
Pulp chamber diameter	0	750	0	550
Irregular secondary dentine	100	0	650	0
Primary buccal dentine	1450	800	1300	1000
Regular secondary buccal dentine	350	50	0	0
Primary palatal dentine	1100	1000	1600	1500
Secondary palatal dentine	400	150	0	0

**Table 1.2:** Pulp chamber diameter and thickness of primary and secondary dentine at transverse section 2 in Control 19 (Triadan 107, dental age 1.5 years) and Case 3 (Triadan 107, dental age -0.5 years). Pulp chambers 2, 3 and 5 are not included as their measurements were incomplete due to slide artefact.

**Figure 1.14:**

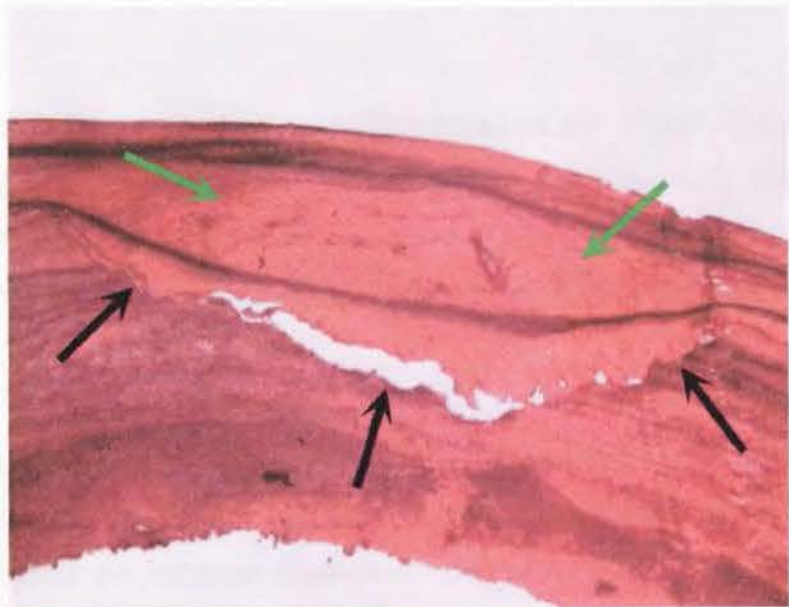
Decalcified, transverse apical section of CT 207 from Case 3 showing tertiary dentine (3D) laid down within pulp chamber 1 (magnified insert top-right). Primary dentine (1D) has broken apart



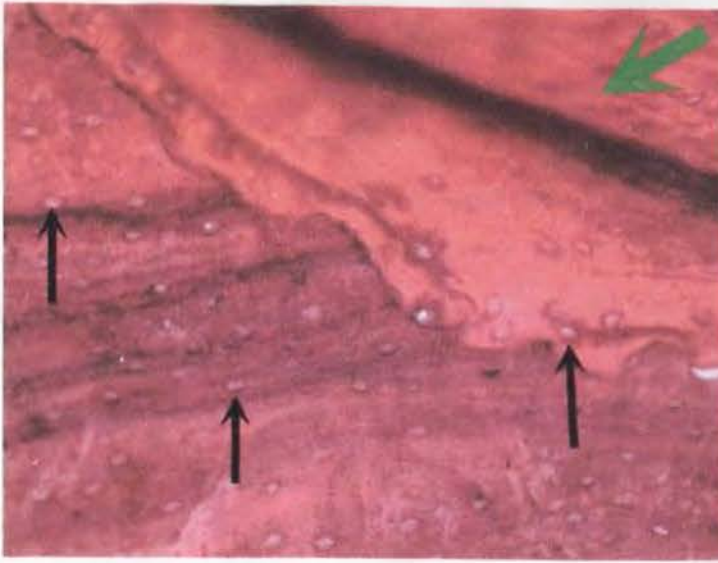
during processing. Vegetable matter (V) is present within the pulp chamber next to necrotic pulp tissue (p). (H&E x100 [insert top right x400])

**Figure 1.15:**

Decalcified transverse section 2 of CT 207 of Case 3 showing new (reparative) cementum deposition (green arrows) over a previous defect (black arrows) in the peripheral cementum. This may have been a developmental defect,



or alternatively, may have arisen through carious attack. (H&E x40)



**Figure 1.16:** Decalcified transverse sub-occlusal section of CT 207 from Case 3 showing the previously illustrated defect in peripheral cementum and reparative cementum (green arrow) of this area under higher magnification. Lacunae of cementocytes are now visible (arrows). (H&E x200)

#### **Conclusions:**

The case history states that there were no abnormalities found on the clinical crown (despite subsequent identification of exposed pulp chambers) but that the tooth was easily removed due to extensive periodontal disease present. This tooth was extracted in 1999, at which time pulpar exposure was not systematically identified at this clinic, or indeed anywhere.

Periodontal disease, when present at the gingival margin, is usually very obvious clinically. In this case, its absence at the gingival margin is likely to indicate that the apical infection in this tooth did not arise from descending periodontal disease, it being most unlikely that a descending tract of periodontal disease would have been able to completely heal over whilst infection was still present further apically.

Previously damaged peripheral cementum observed in the sub-occlusal transverse section had been repaired. This confirms the highly reactive nature of cementum, probably having responded to periodontal infection by laying down additional cementum. This may explain the comment of “extensive periodontal disease” of this

CT recorded in the dental extraction records. There were no signs of infundibular caries.

As noted, all five pulps had been exposed occlusally and all pulp chambers were impacted with food. Histologically, in particular the paucity of secondary dentine deposition, suggests that this infection was chronic, although it was unclear from the referral history when the clinical signs were first noted.

It is interesting to note that *secondary* dentine had already been laid down in this extracted CT with a recorded dental age of  $-0.5$  years, when by definition, secondary dentine should only be present in teeth that have erupted and are in occlusion. This finding draws attention to two factors.

Firstly, many cases in this study have had their age recorded as per the equine custom of having their date of birth as January 1<sup>st</sup> of the year in which they are born, and so are termed one year old at the end of that year, potentially making their dental age appear *older* than they are. (This traditional ageing system does not explain our findings in this tooth).

Secondly, there is much normal variation in CT eruption times. The 207 tooth from Case 3 had actually erupted at the time of extraction and was just in occlusal wear. As such we would expect it to have begun laying down secondary dentine (which it was) despite having a dental age of  $-0.5$  years. Because of this individual variation between CT eruption, all statistical analyses of histological measurements were carried out on either case controlled sets of CT or by grouping CT, in order to limit and balance these variations.

In conclusion the most probable aetiology for apical infection of this CT is from either pulpar exposure or anachoretic pulpitis (with subsequent dental attrition exposing pulp chambers).

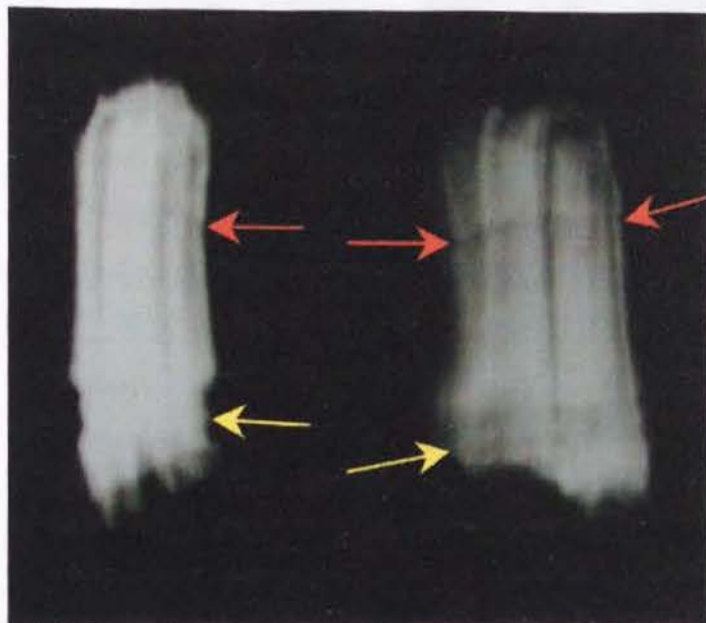
## Case 4: 98/019

## 2 year-old Cob, gelding

### History and clinical examination:

This case had intermittent swelling to the right maxillary area for three months that partially and temporarily responded to antibiotic therapy. After referral and radiographic confirmation of apical infection, Triadan 106 (dental age -0.5 years) was orally extracted under standing sedation.

### Radiology of the Extracted CT:

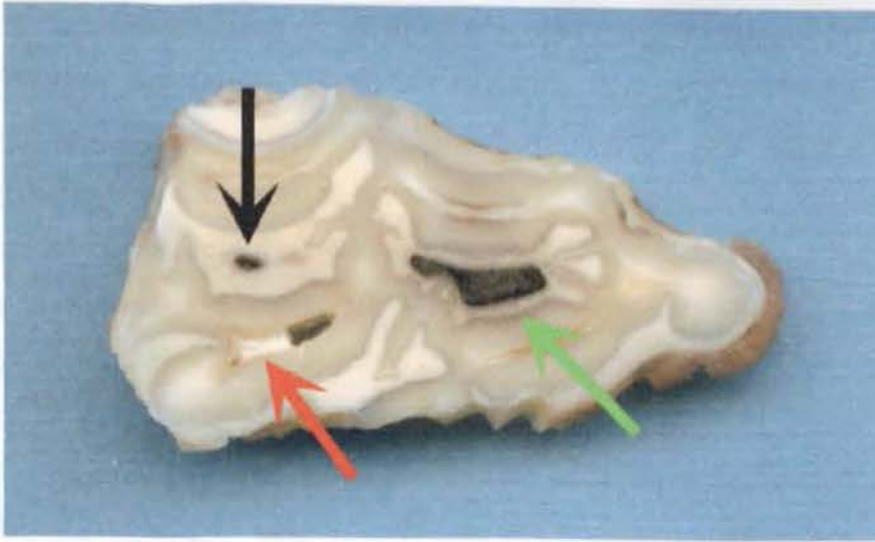


**Figure 1.17:** Radiograph of CT 106 from Case 4 using exposure factors of 66kVp and 5.0 mA (d=65cm) for optimal imaging of the extracted tooth. Radiological features identified were a transverse, radiolucent line in the apical third of the tooth (red arrows); crush marks on the tooth where extractors had been placed during extraction

(yellow arrows); and some loss of apical definition, which could be due to the apical infection, although as it is a very young CT, it would be expected to still have a poorly radiographically defined apex.

### Dissecting Microscopy:

The occlusal surface was intact with no pulps exposed. After transversely sectioning the tooth into 16 segments (Section 3.6), it was observed that pulp chamber 4 was filled with pus throughout its length. An apparently healed fracture was present in the peripheral cementum and dentine, adjacent to pulp chamber 4 in the apical third of the reserve crown, which corresponds with the radiolucent line identified radiographically.



**Figure 1.18:** Transverse sub-occlusal section of CT 106 from Case 4 prior to decalcification. Pulp chamber 4 (red arrow) contains pus, whereas all other pulp chambers have been occluded with secondary dentine at this level. The rostral infundibulum (green arrow) has more severe cemental hypoplasia (and secondary cemental caries) than the caudal infundibulum (black arrow).

### Histology:

As presented in Table 1.3, secondary dentine was present in all pulp chambers except pulp chamber 4.

Pulp Chamber and Dentinal Measurements (microns)	Case 4 Pulp chamber 1	Case 4 Pulp chamber 3	Case 4 Pulp chamber 4	Case 4 Pulp chamber 5	Case 4 Pulp chamber 6
Pulp chamber diameter	1350	1300	2000	1400	1600
Primary buccal dentine	600	800	650	600	700
Secondary buccal dentine	450	700	0	200	500
Primary palatal dentine	850	650	800	350	450
Secondary palatal dentine	600	400	0	150	450

**Table 1.3:** Pulp and dentinal measurements from the mid-section of CT 106 from Case 4. Pulp chamber 2 was not measured due to a preparation artefact. Secondary dentine was only absent in pulp chamber 4.

### Conclusions:

In Table 1.3 it can be seen that no secondary dentine was laid down within pulp chamber 4, yet secondary dentine was present within all other pulp chambers (including in pulp chamber 2 whose dentinal thickness could not be measured). Pulp

chamber 4 had a healed fracture in the apical region that may have been the initial predisposition to this apical abscess, possibly from external trauma (such as facial trauma) to the apical area whilst this tooth was developing. The apical areas of the equine upper 06s are very close to the maxillary bone at this young age and in some horses, the apices temporarily protrude through the thinned overlying bone, i.e. the maxillary equivalent of 3-4 year old mandibular eruption cysts ('eruption bumps') (Miles & Grigson 1990).

There was no pulpar exposure at the occlusal surface in this tooth, however as dentine production had ceased in pulp chamber 4, with further occlusal wear this pulp chamber would have become occlusally exposed within the following few months, had it not been extracted.

There were no records of any scarring on the skin covering the maxillary area over CT 106 from possible external penetrating trauma (and potential source of infection) although it is unlikely that this was looked for specifically during the clinical examination. In conclusion it is most likely that this apical infection resulted from anachoretic pulpitis of pulp horn 4, possibly being initiated by blunt trauma to the region.

### **Case 5: 97/777**

### **6 year-old Welsh pony, gelding**

#### **History and clinical examination:**

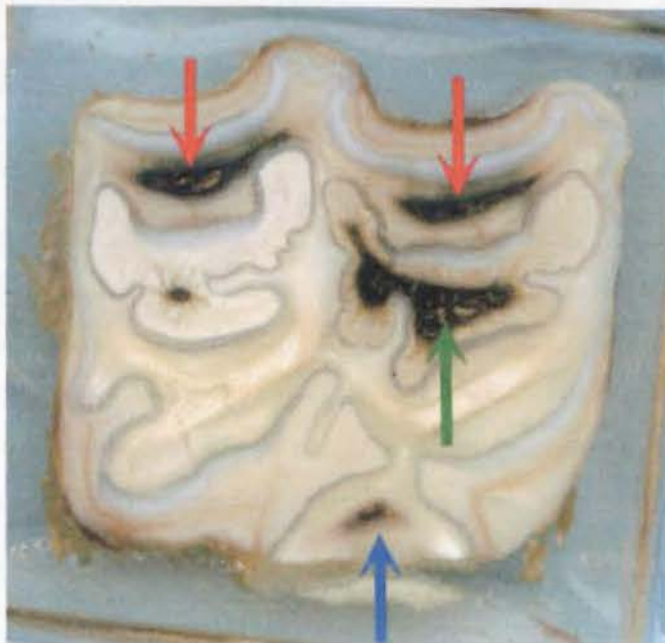
A unilateral right maxillary swelling (with no associated nasal discharge or facial tract) was present for six months prior to referral of this case. Radiography revealed extensive sclerosis surrounding the apex of CT 108, with blunting of the 108 apical structures and loss of the adjacent lamina dentis dura. The CT was orally extracted.

#### **Radiology of the Extracted CT:**

Exposure factors of 70kVp and 8.0 mA (d=65cm) were used for optimal imaging of the extracted tooth. Even allowing for the young age and immature apex of this tooth, there was some loss of apical definition as a result of the apical infection.

### Dissecting Microscopy:

There was no evidence of any occlusal pulpar exposure or dental fracture in this CT. Infundibular caries of the rostral infundibular cementum (Figure 1.19 - green arrow) did not involve the infundibular enamel (i.e. did not progress beyond stage 1). Clinically non-significant cemental hypoplasia was present in the caudal infundibulum. No periodontal disease was evident.

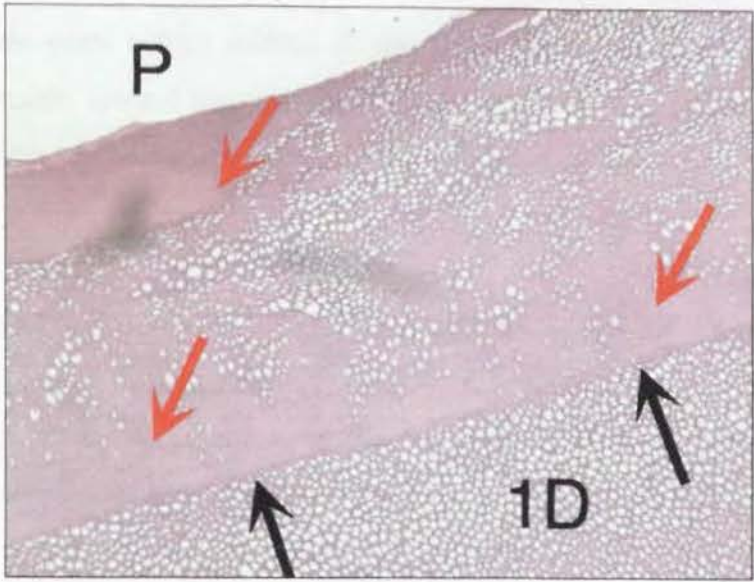


**Figure 1.19:** Transverse undecalcified (3<sup>rd</sup>) section of CT 108 from Case 5 prior to histology. Pulp chambers 1 and 2 are darkly discoloured by the presence of necrotic pulp (red arrows). Pulp chamber 5 is filled with haemorrhagic pulp (blue arrow). Caries localised to the cementum (stage 1) of the rostral infundibulum (green arrow) is present. Localised central cemental hypoplasia of the caudal infundibulum is also present.

### Histology:

Pulp chambers 1 and 2 in the sub-occlusal and mid sections of this tooth (CT 108 of Case 5) contained infected necrotic pulp, with however, viable pulp present in the more apical sections of these pulp chambers. Secondary dentine was not present in pulp chambers 1 and 2, but tertiary dentine had been laid down within pulp chamber 1 in the sub-occlusal section. Secondary dentine was present in pulp chambers 3, 4 and 5, and the pulp was still viable in all sections of these three pulps. Large amounts of

intertubular dentine was present in primary dentine, close to all (five) pulp chambers in the mid transverse section (Fig. 1.20).



**Figure 1.20:** Decalcified transverse mid section of CT 108 from Case 5 showing primary dentine (1D) in two distinctive regions, with greater amounts of intertubular dentine (homogenous pink areas – red arrows) present on the pulpar side (P) of a resting line (black arrows) (H&E x100).

**Conclusions:**

Examination showed that pulpar exposure, infundibular caries, dental fracture or descending periodontal disease were not aetiological factors in the apical infection of this CT. Therefore, the most likely aetiology for this apical infection is therefore anachoretic pulpitis leading on to apical abscess formation. The histological structure of the dentine in this tooth is thought to be a response to apical pulp infection (i.e. the increased deposition of intertubular dentine and the presence of tertiary dentine). This may indicate that a low-grade initial insult occurred to this pulp, i.e. that the infection was not virulent and was contained locally for a prolonged period. This agrees with the clinical history of infection having been present for over six months, yet no pulpar exposure had occurred, as secondary dentine deposition had continued by the infected, but still vital pulp.

## Case 6: 96/801

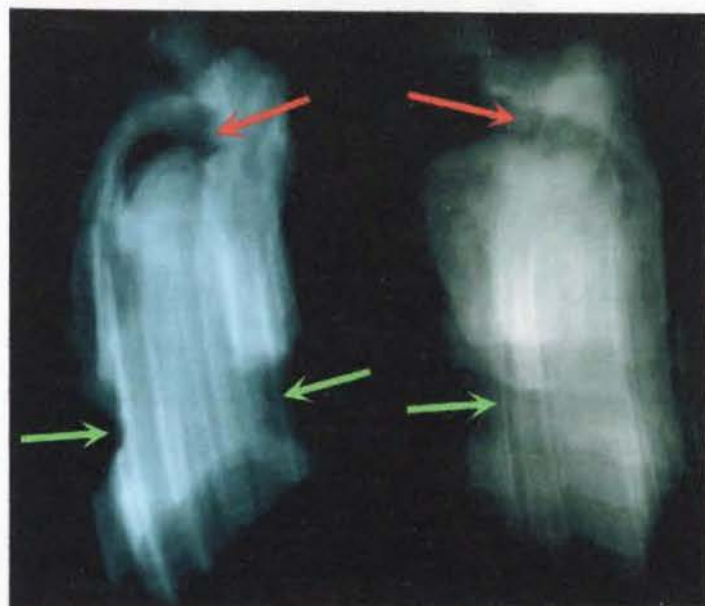## 6 year-old Cleveland bay, mare

### History and clinical examination:

A left sided maxillary swelling (with no other significant clinical findings) was present for two years before referral of this case. Radiography showed a calcified periapical reaction around the grossly abnormal apex of CT 206 (dental age 3.5 years). The tooth was orally extracted under standing sedation.

### Radiology of the Extracted CT:

Exposure factors of 66kVp and 5.0 mA (d=65cm) were used for optimal imaging of the extracted tooth. Radiological features identified included marked destructive apical changes, a large radiolucency in the region of the common pulp chamber, and deep crush marks where extractors had been placed.

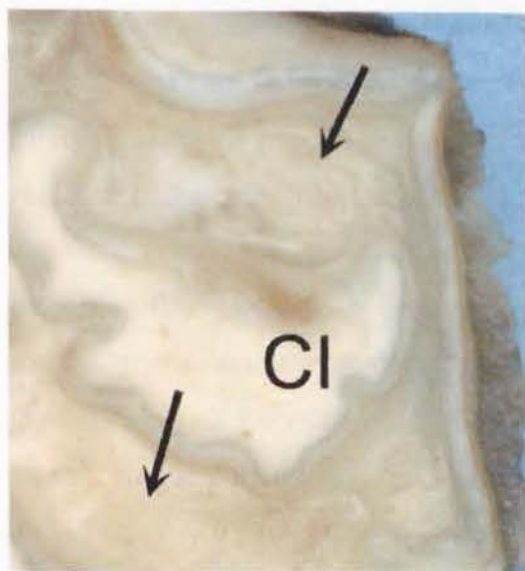


**Figure 1.21:** Rostro-caudal (left) and latero-medial (right) radiographs of CT 108 from Case 6 following oral extraction. The radiolucent common apical pulp chamber (red arrows), blunted apex and extractor forceps crush mark (green arrows) are readily visible.

### Dissecting Microscopy:

A portion of the clinical crown was lost during extraction, however examination of the first complete transverse section present occlusally showed that no pulps had been exposed at the occlusal surface, as all pulp chambers were still occluded with dentine even at this more apical level. However dentine did appear abnormal even under dissecting microscopy, as shown in Figure 1.22. This dentine was not stained darker on the occlusal surface, as secondary dentine normally does (e.g. when seen as 'dental

stars' on incisor teeth). This tooth also had extensive deposition of peripheral cementum around its apex. Neither infundibulum was carious nor did the periodontium show any changes, other than destructive changes adjacent to the apical infection.



**Figure 1.22:** Abnormal mottled appearance of dentine (arrows) in the regions of pulp chambers 2 and 4 either side of the normal caudal infundibulum (CI) in the transverse sub-occlusal section of CT 108 from Case 6. (x8)

#### **Histology:**

Tertiary dentine had been laid down throughout all six pulp chambers in the sub-occlusal, undecalcified (3<sup>rd</sup>), mid and apical sections of this tooth, completely occluding all six pulp chambers in the sub-occlusal and undecalcified sections. The abnormal appearance of the dentine noted in Figure 1.22 was due to the presence of this tertiary as opposed to secondary dentine at these sites and in fact secondary dentine was not present in any pulp chamber at any level of this tooth. Tertiary dentine, unlike secondary dentine, does not become stained by plant pigments in the horse's food and thus retains its pale colour.

#### **Conclusions:**

In a control 106 and 206 CT of 1.5 years dental age (Control CT 1 and 6), secondary dentine was present in all six pulp chambers in the sub-occlusal, undecalcified (3<sup>rd</sup>) and mid sections. In contrast, CT 106 from Case 6 had a dental age of 3.5 years, yet had no secondary dentine, but large amounts of tertiary dentine were present in all pulp chambers. The absence of secondary dentine at any site in this tooth supports the view that this infection was of more than two years duration. This long duration of

infection indicates the presence of a less virulent, chronic infection that did not kill the pulp and thus allowed sufficient time for large amounts of tertiary dentine to be laid down.

Changes in peripheral cementum were only present in the apical region and there was no evidence of descending periodontal disease. There was also no evidence of dental fracture and the infundibula were not carious. The long-standing nature of the infection makes it difficult to assess if occlusal pulpar exposure had initiated, or was a response to the pathological changes seen in this tooth. However, it is likely that such exposure would have caused infection and death of the underlying pulp, at least in the pulp horn that was initially occlusally exposed and so would not have allowed time for the large amounts of tertiary dentine present in this tooth to have been laid down. On balance, it is therefore most likely the apical infection in this tooth resulted from an anachoretic pulpitis.

### **Case 7: 96/148**

### **10 year-old Hanoverian, gelding**

#### **History and clinical examination:**

The case presented with a right rostral maxillary swelling of five weeks duration. Oral examination showed food packing in an occlusal defect in the rostral infundibulum of CT 107. Radiography revealed sclerosis of the rostral root of 107 (dental age 6.5 years). The tooth was extracted one month later, following unsuccessful antibiotic therapy in the interim.

#### **Radiology of the Extracted CT:**

Exposure factors of 66kVp and 5.0 mA (d=65cm) were used for optimal imaging of the extracted tooth. Radiological features identified were destructive apical changes and crush marks where extractors had been placed.

#### **Dissecting Microscopy:**

There was no pulpar exposure, although the occlusal border of pulp chamber 1 was within 1mm of the occlusal surface. This pulp horn was separated from other pulps by dentine for its entire length, where as pulp horns 2, 3, 4 and 5 communicated in the

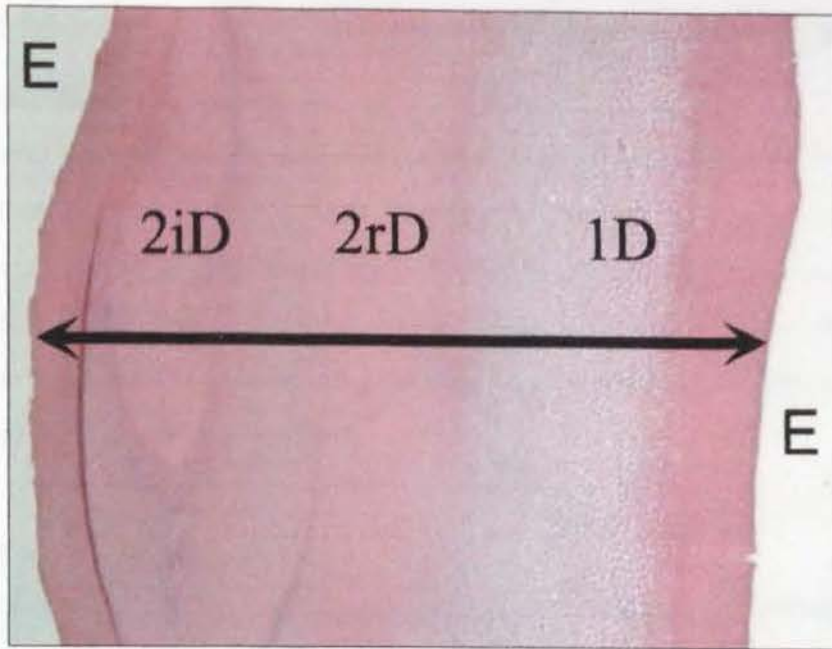
apical section. There was no evidence of dental fracture. Neither infundibulum was carious, despite food being impacted into an area of central cemental hypoplasia in the rostral infundibulum. Interproximal wear had worn completely through the peripheral cementum and peripheral enamel to the dentine margin, on both the rostral and caudal aspects of the clinical crown. No periodontal disease was associated with the tooth, other than periapically near the site of infection.

**Histology:**

Pulp Chamber and Dentinal Measurements (microns)	Control 50 Dental age 4.5yrs Pulp chamber 1	Control 70 Dental age 7.5yrs Pulp chamber 1	Case 7 Dental age 6.5yrs Pulp chamber 1
Pulp chamber diameter	200	0	350
Irregular secondary dentine	0	250	0
Primary buccal dentine	700	950	900
Secondary buccal dentine	350	350	250
Primary palatal dentine	1150	1200	1200
Secondary palatal dentine	500	450	550

**Table 1.4:** Pulp and dentinal measurements from buccal and palatal directions of the sub-occlusal transverse section of CT 107 from Case 7, and equivalent sections from two control CT with dental ages of 4.5 and 7.5 years. Note that pulp chamber 1 of Case 7 has similar amounts of primary and secondary dentine laid down as the two control 107 CT of comparable dental age. However in CT 107 of Case 7, no irregular secondary dentine had been laid down and consequently, the pulp chamber diameter was still relatively large in this section.

Pulp chamber 1 was filled with necrotic pulp and pus throughout its length. This pulp chamber exited individually through its own separate apical foramen, which was narrow - as would be expected for a tooth of this dental age. Viable pulp was present in the other four pulp chambers that had a separate, common apical foramen from that of pulp chamber 1. Dentinal measurements of this tooth and of two control CT are presented in Table 1.4.



**Figure 1.23:** Decalcified transverse sub-occlusal section of CT 107 from Case 7 showing complete occlusion of pulp chamber 2 (black arrow) by primary dentine (1D), regular secondary dentine (2rD) and irregular secondary dentine (2iD). Enamel surrounding this single pulp chamber (white areas identified by 'E') has been removed during decalcification. (H&E x40)

**Conclusions:**

There is no evidence that pulpar exposure, fracture, descending periodontal disease or infundibular caries caused the apical abscess in this CT. Only pulp chamber 1 was infected (as determined from histological examination) at the time of dental extraction. With clinical signs of apical infection being present for two months and antibiotics given in this period, this CT infection is likely to have arisen around 2-3 months prior to dental extraction due to an anachoretic pulpitis of pulp chamber 1. The infection is not likely to have been present much longer than this, as both primary and secondary dentine thickness present at time of extraction were within the normal range for a CT 107 of this dental age (i.e. odontoblasts were still depositing dentine until very recently). The very high degree of interdental wear to this CT's rostral and caudal faces indicates it was tightly compressed between CT 106 and 108, possibly suggesting that a vertical dental impaction may have predisposed to an anachoretic pulpitis.

**Case 8: 95/935****5 year-old Thoroughbred, mare****History and clinical examination:**

After referral with unilateral nasal discharge of four months duration that was non-responsive to antibiotics, along with swelling of the left maxillary region of one months duration, radiography confirmed destructive changes to the apical area of CT 109 (dental age four years). On visually examining the periapical area under general anaesthesia via a maxillary sinus surgical flap, much periapical alveolar necrosis was present and so the tooth was repulsed.

**Radiology of the Extracted CT:**

Exposure factors of 66kVp and 5.0 mA (d=65cm) were used for optimal imaging of the extracted tooth. Apart from apical changes due to the chronic infection and repulsion, no other abnormalities were detected radiographically.

**Dissecting Microscopy:**

Examination of the occlusal surface showed that pulp chambers 3, 4 and 5 were exposed at the occlusal surface and each contained impacted food. Neither infundibulum had cemental hypoplasia or was carious, nor were there any signs of descending periodontal disease.

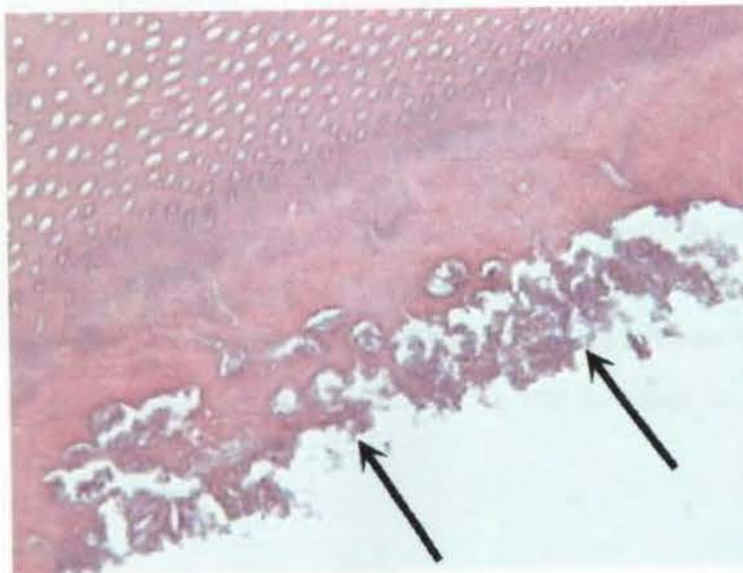
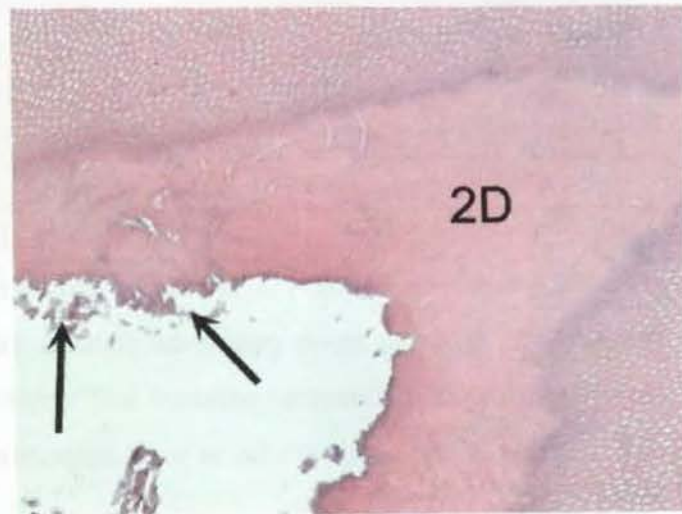
**Histology:**

Necrotic pulp and carious secondary dentine were present in all five pulp chambers (Figures 1.24 and 1.25). Carious dentine was present surrounding pulp chambers 3, 4 and 5, however no food material was present in any of the sections examined (Figures 1.24 and 1.25), despite food having been observed in exposed pulp chambers on the occlusal surface under dissecting microscopy. Bacteria were present in dentinal tubules adjacent to carious dentine (Figure 1.26).

Pulp Chamber and Dentinal Measurements (microns)	Control 21 Dental age 4y Pulp chamber 4	Case 8 Dental age 4y Pulp chamber 4
Pulp chamber diameter	0	1400
Irregular secondary dentine	1650	0
Primary buccal dentine	1600	500
Secondary buccal dentine	0	200
Primary palatal dentine	2700	1350
Secondary palatal dentine	150	400

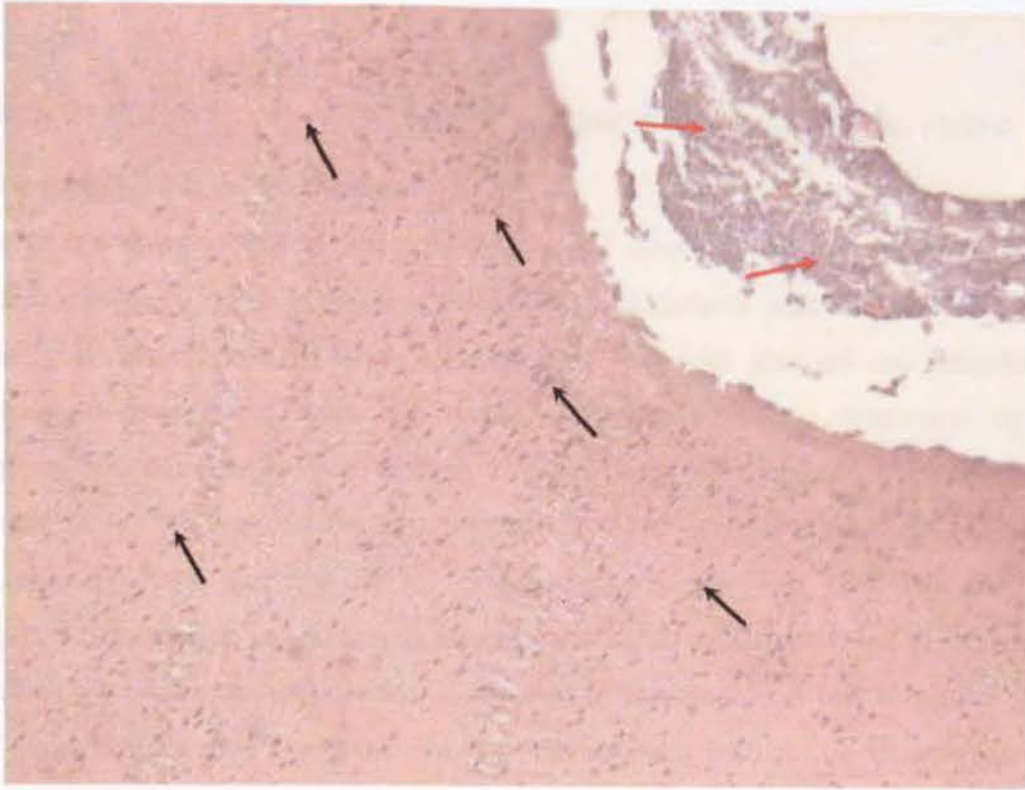
**Table 1.5:** Pulp chamber diameter and dentinal measurements of pulp chamber 4 from transverse section 2 of Control 21 and Triadan 109 of Case 8. The pulp chambers were still patent in the sub-occlusal transverse section of Case 8 but were occluded at this level in the control CT. Primary dentine was much thicker in pulp chamber 4 of the control CT as compared to the exposed pulp chamber (pulp chamber 4) in Triadan 109 of Case 8.

**Figure 1.24:** Decalcified, transverse mid-section of CT 209 from Case 8 showing carious attack to the secondary dentine (2D) surrounding pulp chamber 4 (arrows). (H&E x40)



**Figure 1.25:** Decalcified transverse mid-section of CT 209 from Case 8 showing carious attack to the dentine at the margin of the pulp chamber (arrows) at higher magnification. Instead of viewing odontoblasts

directly adjacent to the dentinal border depositing predentine matrix, only bundles of necrotic organic remnants of dentine were present. (H&E x400)



**Figure 1.26:** Decalcified transverse mid-section of CT 209 from Case 8 showing pioneer organisms (bacteria) (black arrows) advancing down dentinal tubules away from the grossly infected pulp chamber that contains remnants of necrotic pulp (red arrows). Note the absence of the predentine layer or odontoblasts. (H&E x100)

### **Conclusions:**

There is no evidence that periodontal disease, dental fracture or infundibular caries caused the apical abscess in this CT from Case 8. This infection may have arisen either from anachoretic pulpitis or pulpar exposure. Because the apical abscess was clinically present for only four months prior to tooth extraction, it would have been necessary for the occlusal limit of pulp chambers 3-5 to be very close (<2mm) to the occlusal surface, if normal dental attrition is to account for their subsequent exposure during a period of four months or so, and this may be why pulp chambers 1 and 2 were not exposed.

In apically infected CT such as this, where caries of the pulpar canals has destroyed dentine (thus decreasing the thickness of the various dentinal layers) their dentinal thickness values have been omitted from further statistical analysis.

## **Case 9: 95/301**

## **5 year-old Clydesdale, mare**

### **History and clinical examination:**

The case was referred due to a right-sided nasal discharge of three years duration. Oral examination revealed the remnants of 508 (deciduous precursor of permanent 108) to be rotated and overlying a malerupted 108, with gingival and periodontal disease present around these two teeth. Radiography showed destructive apical changes and demineralisation of both 107 and 108, with an extensive, periapical sclerotic bony reaction present above both CT. Under general anaesthesia, 508 was found to be loose and was readily extracted *per os*, however both 107 and 108 required repulsion. Being so chronically diseased, with preferential loss of the softer, but flexible cementum and dentine as opposed to the harder but brittle enamel, both CT fragmented during repulsion, however the occlusal half of 108 (dental age one year) remained intact and underwent histological examination.

### **Radiology of the Extracted CT:**

Exposure factors of 66kVp and 5.0 mA (d=65cm) were used for optimal imaging of the extracted CT 108 from Case 9. As noted, there was much destruction to its apical region.

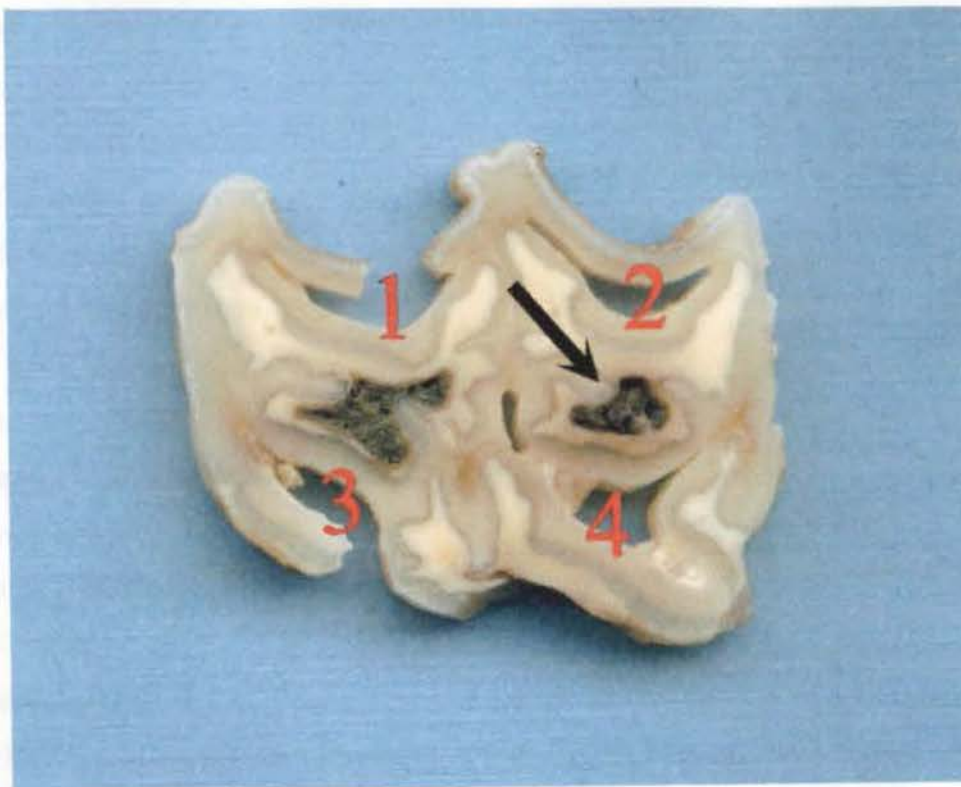
### **Dissecting Microscopy:**

As its deciduous CT was still in place, and having not been in wear, CT 108 was still covered in occlusal cementum and enamel (the primary hypsodont occlusal surface) and so no pulps were exposed. Both infundibula showed cemental hypoplasia and were impacted with food that had entered beneath the loose, overlying deciduous 508 CT. Caries of the caudal infundibulum had progressed to stage 3 caries, i.e. involving the cementum, enamel and the adjacent dentine (Figure 1.27). There was minimal peripheral cementum present on this part of 108 and no evidence of periodontal

disease at this level, although periodontal disease had been clinically noted on the gingiva.


**Histology:**

Secondary dentine was present in this tooth (e.g. 100µm buccal wall thickness in pulp chamber 2 in section 2 of CT 108 from Case 9), a thickness that would be expected in a CT with a dental age of one year, despite this tooth having not yet erupted into the oral cavity. The pulp chambers were either empty (pulp lost) or occluded with secondary dentine in the transverse sub-occlusal section. Primary dentine appeared normal and no tertiary dentine was present.

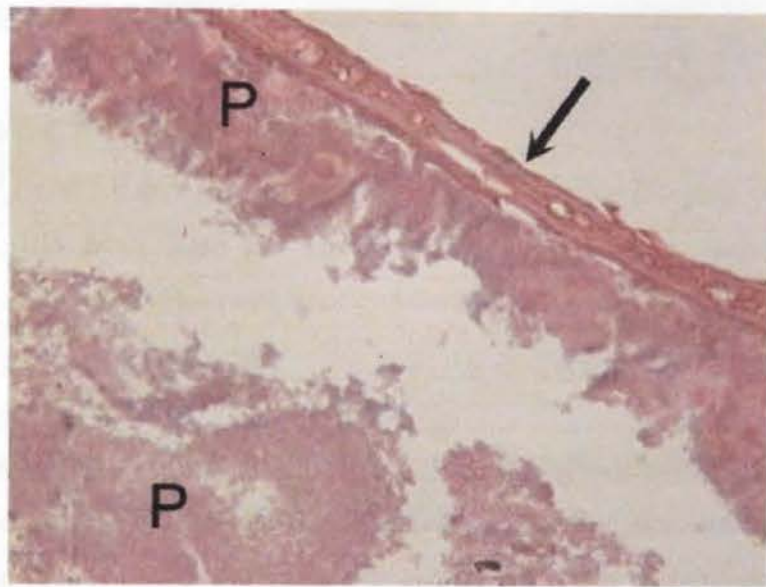


**Figure 1.27:** Transverse mid-section of CT 108 from Case 9. Pulp chambers 1-4 are numbered. Peripheral cementum is absent or very thin except where infolded. Food is present within the rostral and caudal infundibula and caries has breached the integrity of the caudal infundibular cementum and enamel, and involves the adjacent dentine (stage 3 infundibular caries) (black arrow).

**Figure 1.28:** Transverse decalcified sub-occlusal section of CT 108 from Case 9 showing pulp chamber 2 fully occluded with secondary dentine (2iD). Primary dentine (1D) is present on the other sides of very obvious resting lines (arrows). (H&E x40)



**Figure 1.29:** Dental plaque (P) is present on the unerupted crown of CT 108 from Case 9 due to its exposure caused by periodontal disease at this level. An interface where the plaque had adhered to the peripheral cementum is highlighted (arrow). (H&E x400)



### Conclusions:

The history and clinical findings indicate that CT 508 was physically trapping CT 108 (vertical impaction), and so preventing its normal eruption. With 108 having a dental age of one year and having secondary dentine present, yet no occlusal wear, supports this impaction theory.

The route of infection of this apical abscess is not clear and may have been caused by descending periodontal disease (as CT 108 fitted poorly into its alveolus); advanced infundibular caries (as seen in Figure 5.27); or anachoretic pulpitis predisposed to by dental maleruption. For all these three potential causes of apical infection, the

developmental malpositioning of CT 508 and 108 is likely to be a significant aetiological factor.

## **Case 10: 94/282                      6 year-old Thoroughbred, stallion**

### **History and clinical examination:**

The horse was referred with a right-sided maxillary swelling of three months duration and a more recent, ipsilateral purulent nasal discharge. Radiography revealed periapical radiopacity around the rostro-lateral root of CT 108 (dental age two years). Under general anaesthesia, using a maxillary bone flap, the apex was directly examined - revealing a necrotic area of alveolus with exposure of necrotic pulp in the underlying root. The tooth was surgically repulsed.

### **Radiology of the Extracted CT:**

Exposure factors of 66kVp and 5.0 mA (d=65cm) were used for optimal imaging of the extracted tooth (CT 108 from Case 9). The only abnormal features noted radiographically were the apical areas that were fractured during repulsion.

### **Dissecting Microscopy:**

No pulp chambers were exposed on the occlusal surface. Neither infundibulum was carious nor was there evidence of pre-existing fracture or having descending periodontal disease. Pulp chamber 1 was filled with pus and necrotic pulp throughout its length and communicated directly with pulp chamber 2 in the apical half of the tooth. In the apical quarter of the CT, the pulp in the common pulp chamber appeared viable.

### **Histology:**

Pulp chambers 1, 2 and 3 all contained necrotic pulp in the transverse sub-occlusal section. Pulp chamber 4 was empty (contents artefactually lost during processing) and pulp chamber 5 contained healthy pulp tissue. In the apical quarter of the tooth, the pulp chambers merged to form the common pulp chamber and the pulp at this site was still vital. Table 1.6 shows that secondary dentine deposition had been greatly reduced in the diseased CT (108 from Case 10), as compared to both younger and older

control 108 CT. Additionally, it shows that no irregular secondary dentine was present, and that the pulp chamber diameters were larger in the diseased tooth.

### Conclusions:

The presence of secondary dentine in this infected two-year-old CT from Case 10 supports the history of this apical infection having been present for only a few months. Having no infundibular caries, fracture, occlusal pulpar exposure or descending periodontal disease present, it is most likely that this apical abscess has resulted from anachoretic pulpitis. This may have begun in pulp chamber 1 which histologically contained the most degenerated pulp.

Pulp Chamber and Dentinal Measurement (microns)	Control 20 Dental age 1yr Pulp chamber 3	Control 39 Dental age 3yrs Pulp chamber 3	Case 10 Dental age 2yrs Pulp chamber 3
Pulp chamber diameter	0	0	650
Irregular secondary dentine	100	300	0
Secondary buccal dentine	500	450	150
Secondary palatal dentine	500	450	150
	Control 20 Dental age 1yr Pulp chamber 4	Control 39 Dental age 3yrs Pulp chamber 4	Case 10 Dental age 2yrs Pulp chamber 4
Pulp chamber diameter	0	0	550
Irregular secondary dentine	150	200	0
Secondary buccal dentine	650	250	200
Secondary palatal dentine	800	500	150
	Control 20 Dental age 1yr Pulp chamber 5	Control 39 Dental age 3yrs Pulp chamber 5	Case 10 Dental age 2yrs Pulp chamber 5
Pulp chamber diameter	0	0	500
Irregular secondary dentine	100	200	0
Secondary buccal dentine	400	650	200
Secondary palatal dentine	400	700	200

**Table 1.6:** Pulp chamber diameter and secondary dentine measurements of pulp chambers 3, 4 and 5 from the transverse sub-occlusal section from two control CT 108s and from CT 108 from Case 10.

## Grouped Examination

The 28 maxillary CT with apical infection examined in detail were also compared with control CT after categorising all CT into 16 groups on the basis of their tooth (Triadan) position and dental age, as shown in Table 1.7. Groups seven and eight are reported in detail to illustrate the benefits and limitations of this type of comparison.

Set Number	Triadan Position	Dental Age (years)	Control CT No:	Case No:
1	06	4.5 to 5.5	38	1, 13 & 19
2	06	-0.5 to 1.5	1 & 6	4 & 18
3	06	2.5 & 3.5	25	6
4	06	6.5 & 8.5	69	12
5	07	6.5 to 7.5	70	2 & 7
6	07	-0.5 & 1.5	26	3
7	07	3.5 to 4.5	50	20, 101, 103 & 107
8	07	0.5 to 1.5	19	17, 102, 104 & 106
9	07	8.5 to 10.5	81 & 87	105
10	08	1.0	20 & 27	5, 9 & 11
11	08	2 & 3	39	10
12	08	8 & 20	82	14
13	08	-1	2	16
14	09	4	21 & 28	8
15	09	11 & 17	83	108
16	11	7.5 & 11.5	74	15

**Table 1.7:** Apically infected maxillary CT and control CT in 16 groups based on their Triadan position and dental age.

### Group Seven: Cases 20, 101, 103, 107 and Control 50

Four apically infected Triadan 107 or 207 CT with a dental age of 3.5-4.5 years were examined together for comparison with Control CT 50 (Triadan 107, dental age 4.5 years).

#### History and clinical examination:

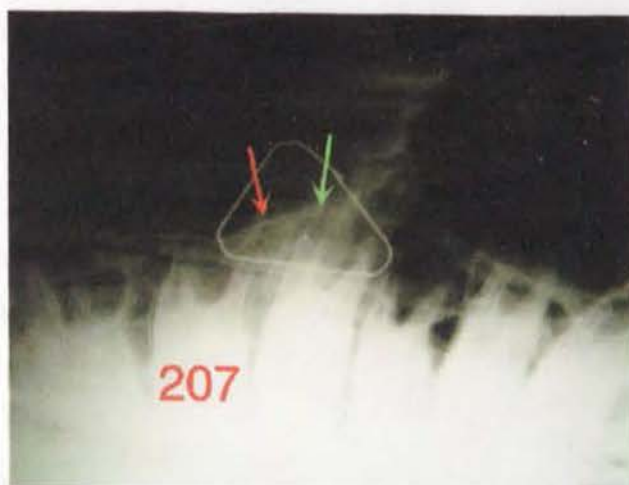**Case 20:** A seven-year-old pony mare, presented with a discharging sinus tract over the apex of CT 107 of three months duration that had responded temporarily to antibiotic therapy. Radiography revealed periapical infection surrounding the caudo-buccal root of CT 107, and this tooth was subsequently orally extracted under standing sedation.

**Case 101:** A seven-year-old cob stallion presented with a left-sided rostral maxillary swelling that had been present for one week. Radiography revealed a radiolucent halo surrounding the apex of CT 207, surrounded in turn by a periapical zone of sclerosis. Triadan 207 was orally extracted under standing sedation.

**Case 103:** An eight-year-old  $\frac{3}{4}$  bred Thoroughbred mare was referred with a left sided rostral maxillary swelling of three months duration (Figure 1.30). Clinical examination and radiography confirmed apical infection of CT 207 (Figure 1.31). The tooth was orally extracted intact after two separate attempts under standing sedation 24 hours apart.



**Figure 1.30:** Case 103 showing the area of rostral maxillary swelling (arrow) associated with an apical infection to CT 207.



**Figure 5.31:** Lateral radiograph, with a paperclip taped to the site of maximal facial swelling, highlighting the left maxillary area of Case 103. CT 207 has a radiolucent area overlying its caudal root (red arrow) indicating presence of apical infection. The rostral root of CT 208 also has a smaller radiolucent periapical area (green arrow), however this was not thought to have been caused by apical infection.

**Case 107:** An eight-year-old Warmblood mare presented with a right maxillary facial swelling that had been present for one month. Clinical examination confirmed the swelling with no intra-oral abnormalities detected. Radiography revealed lucency around the apex of CT 107 with surrounding periapical sclerosis. CT 107 was subsequently extracted orally.

#### **Radiography of the Extracted CT:**

**Case 20:** Exposure factors of 66kVp and 5.0 mA (d=65cm) were used for optimal imaging of the extracted tooth. A fracture was present in the caudal aspect of the clinical crown extending into the reserve crown of the tooth. It was suspected that pulpar exposure was present because a linear, vertical radiolucency was present corresponding to pulp chamber 3.

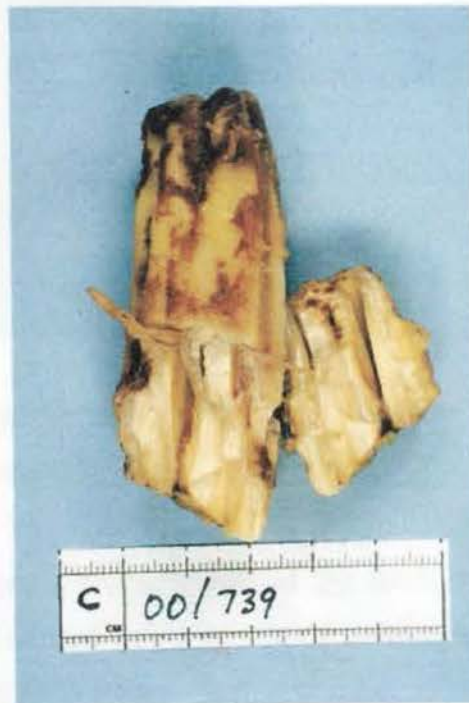**Case 101:** Exposure factors of 66kVp and 5.0 mA (d=65cm) were used for optimal imaging of the extracted tooth. Crush marks from placement of the extraction forceps were evident.

**Case 103:** Exposure factors of 66kVp and 5.0 mA (d=65cm) were used for optimal imaging of the extracted tooth. The clinical crown had been fractured during extraction.

**Case 107:** Exposure factors of 63kVp and 6.3 mA (d=65cm) were used for optimal imaging of the extracted tooth. Crush marks from placement of the extraction forceps were evident.

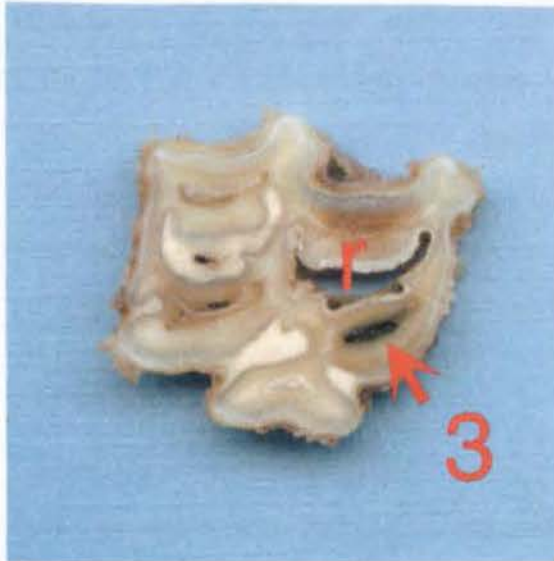
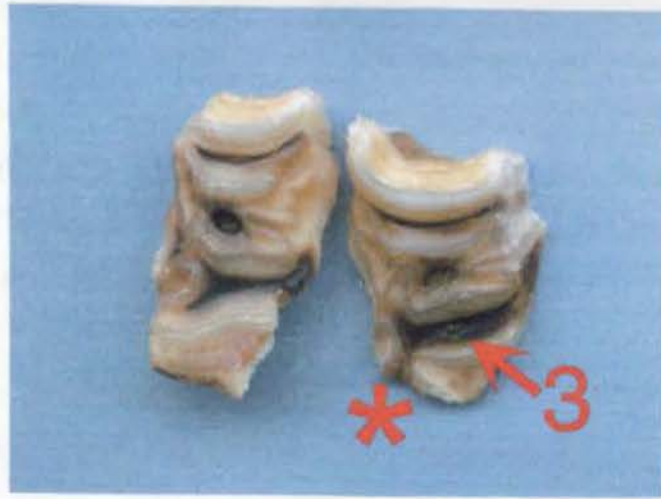#### **Dissecting Microscopy:**

**Case 20:** The caudal aspect of the clinical crown had iatrogenically fractured (Figure 1.32) at time of extraction, but the fracture did not involve pulp chamber 3, that was exposed occlusally (Figure 1.33). The rostral infundibulum cement was hypoplastic, but not carious (Figure 1.34).



**Figure 1.32:** Caudal view of CT 107 from Case 20. A portion of the caudal aspect of the clinical crown has fractured during extraction, exposing pulp horns 2 and 4.

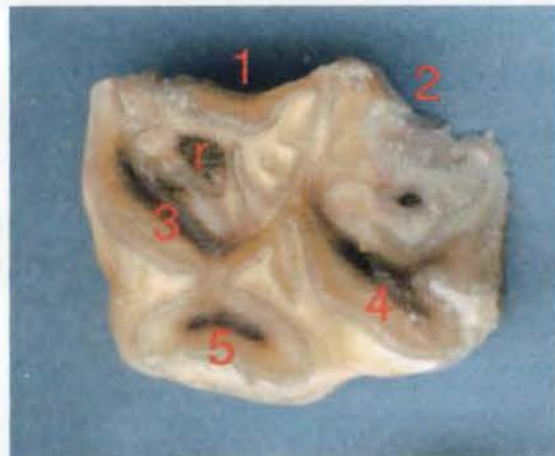
**Figure 1.33:** The occlusal surface of CT 107 from Case 20. Pulp chamber 3 ( $\leftarrow$ 3) had been exposed occlusally, prior to tooth fracture during extraction. The fracture resulted in loss of clinical crown in the region of pulp chamber 5 (\*).



**Figure 1.34:** The mid transverse section of CT 107 from Case 20. Note the impacted food present in pulp chamber 3 ( $\leftarrow$ 3) and the hypoplastic rostral infundibulum (r).

**Case 101:** Under dissecting microscopy CT 207 from Case 101 had the appearance of a normal 207 CT of similar dental age.

**Case 103:** At extraction, gross inspection of the tooth confirmed infection of the rostro-buccal root. The clinical crown had iatrogenically fractured during extraction, with the fracture line running through pulp chambers 1 and 2 (Figure 1.35).



**Figure 1.35:** Occlusal transverse section from Case 103. The clinical crown had iatrogenically fractured through pulp chambers 1 and 2 at time of extraction. Pulp horns 3 and 4 were exposed occlusally. The rostral infundibulum (r) had food impacted in its central vascular channel in this occlusal section, however this food impaction did not progress further apically.

**Case 107:** Under dissecting microscopy there were no features of note in CT 207 from this case other than crush marks where extractor forceps had been placed.

### **Histology:**

**Case 20:** Pulp chamber 5 was completely occluded by secondary dentine in occlusal and mid transverse sections. Pulp chambers 1, 2 and 4 contained necrotic pulp, and pulp chamber 3 contained food, as would be expected -it being the only pulp chamber exposed on the occlusal surface in this CT. Secondary dentine was greatly under-developed (<50% transverse linear thickness compared with a similar control CT) in all pulp chambers (Table 1.8).

**Case 101:** All five pulp chambers were filled with necrotic pulp in both occlusal and mid transverse sections. Again secondary dentine was greatly under-developed (<50%) when compared to the control CT (Table 1.8).

**Case 103:** All pulp chambers were occluded with irregular secondary dentine in the occlusal transverse section of this CT. All pulps appeared shrunken (artefactual) but were viable in pulp chambers 2, 3, 4 and 5 in the mid transverse section. Necrotic pulp was present in pulp chamber 1. Secondary dentine was present in similar proportions to the control CT in both occlusal and mid transverse sections, even in pulp chamber 1 (Tables 1.8 and 1.9).

**Case 107:** The pulp present in pulp chamber 1 was necrotic, with all others pulps appearing to be viable. Once more, secondary dentine was present in similar proportions to that of matched control CT, in both occlusal and mid transverse sections (Tables 1.8 and 1.9).

Pulp chamber	Control CT 50 2D (buc)	Case 20 2D (buc)	Case 101 2D (buc)	Case 103 2D (buc)	Case 107 2D (buc)	Control CT 50 2D (pal)	Case 20 2D (pal)	Case 101 2D (pal)	Case 103 2D (pal)	Case 107 2D (pal)
1	<b>400</b>	100	100	-	200	<b>500</b>	100	200	500	400
2	-	50	-	-	200	-	50	-	600	500
3	<b>650</b>	-	350	700	850	<b>700</b>	-	450	750	650
4	<b>800</b>	100	-	400	650	<b>850</b>	150	-	1000	700
5	<b>650</b>	300	500	700	400	<b>800</b>	100	-	500	600

**Table 1.8:** Transverse measurements of regular secondary dentine (2D) taken from *occlusal* sections of both control (in bold) and apically infected maxillary CT. (buc=buccal direction, pal=palatal direction, empty cell= data not available either due to slide artefact preventing an accurate measurement, or pathological changes of the area to be measured e.g. fracture of clinical crown as in Case 103).

Pulp chamber	Control CT 50 2D (buc)	Case 103 2D (buc)	Case 107 2D (buc)	Control CT 50 2D (pal)	Case 103 2D (pal)	Case 107 2D (pal)
1	<b>200</b>	150	200	<b>700</b>	300	300
2	<b>250</b>	300	200	<b>750</b>	250	300
3	-	300	200	-	300	300
4	<b>250</b>	300	200	<b>500</b>	350	300
5	<b>300</b>	300	-	<b>200</b>	350	-

**Table 1.9:** Transverse measurements of regular secondary dentine (2D) taken from *mid sections* of both control (in bold) and apically infected maxillary CT. (buc=buccal direction, pal=palatal direction, empty cell= data not available either due to slide artefact preventing an accurate measurement, or CT pathology having damaged the area to be measured).

### Conclusions:

As would be expected of teeth extracted because of apical infection, necrotic pulp was present in individual pulp chambers from all four teeth. Being 3.5-4.5 years old in dental age, all diseased teeth were moderately mature at time of extraction, and all had laid down secondary dentine prior to the development of apical infection.

The varying degree of secondary dentine present, however, suggests that dental infection had been present in Cases 20 and 101 for longer than in Cases 103 and 107. However, this finding is not supported by their clinical histories, with all infected CT

having relatively recent clinical signs of apical infection, i.e. first detected within the last three months prior to extraction.

The CT of Cases 101 and 107 appeared normal when examined externally under dissecting microscopy, with neither having occlusal pulp exposure. The degree of secondary dentine present however indicates that the odontoblasts in the tooth of Case 101 had stopped laying down dentine much earlier than those in Case 107.

As noted, Cases 20 and 103 both had clinical signs of apical infection for around three months, and both extracted CT had occlusal pulpar exposure. However, in the CT of Case 103, this pulpar exposure most likely occurred at the time of extraction, as no feed was present down any pulp chamber, and all measurements of secondary dentine were within normal limits. Food was only seen in pulp chamber 3 of CT 207 from Case 20; unfortunately this pulp chamber had a slide artefact that prevented measurement of secondary dentine.

Measurements shown in Table 1.9 show that dentine production in the mid transverse sections in Cases 103 and 107 had not decreased as would be expected with recent pulp infection.

None of these diseased CT showed signs of progressive infundibular caries, although the CT of Case 20 had a hypoplastic rostral infundibulum and the CT of Case 103 had an enlarged central vascular channel of its rostral infundibulum in the occlusal section. There were pre-existing fractures and no periodontal tracts on the external surfaces of the diseased CT, the only periodontal changes recorded were those seen in apical regions where infection had been present.

Having ruled out the possibility of apical infection having arisen through infundibular caries, fracture or periodontal disease, the most likely cause of apical infection in these four cases is via anachoretic pulpitis. Occlusal pulp exposure cannot be ruled out in Case 20 as the cause of the apical infection, however, it is more likely that occlusal pulp exposure arose through continued occlusal attrition following pulpar death. The greatly reduced amount of secondary dentine present for a CT of this

dental age (3.5 years) indicates that odontoblasts had been compromised or necrotic for a long period prior to the tooth's extraction – a factor not indicated in its clinical history.

Because of the large standard deviations present in both control and diseased primary and secondary dentine measurements it has not been possible to perform meaningful statistical calculations between *individual* control and diseased CT. Statistical analyses have therefore been limited to sub-group levels (Section 5.3).

### **Group Eight: Cases 17, 102, 106 and control 19**

Four cases involving either Triadan 107 or 207 CT with a dental age of 0.5-1.5 years were examined together for comparison with Control CT 19 (Triadan 107, dental age 1.5 years).

#### **History and clinical examination:**

**Case 17:** A four-year-old pony was referred with history of swelling over the left rostral maxillary area of one month's duration. Radiography revealed changes in the apical region of CT 207. At oral examination, a 21-gauge needle could be inserted more than 2cm into the caudal infundibulum. The tooth was subsequently repulsed under general anaesthesia.

**Case 102:** A five-year-old Shetland mare was referred with a right rostral maxillary swelling of 2-3 years duration and an ipsilateral nasal discharge of 2-3 weeks duration. Radiography confirmed the presence of a chronic periapical infection of CT 107. Oral examination did not detect any defects to the clinical crown of this tooth, which was then extracted *per os*.

**Case 104:** A five-year-old Thoroughbred mare had a left rostral maxillary swelling of one month's duration. Radiography confirmed periapical infection of CT 207. Oral examination did not reveal any changes and the tooth was then extracted orally under standing sedation.

**Case 106:** A five-year-old Quarter horse mare had right-sided maxillary and left sided mandibular swellings of three weeks and three months duration, respectively. Oral examination showed CT 307 to be laterally displaced with a diastema present between it and CT 306. Radiography revealed periapical lucency around the rostral root of CT 107 and cementoma formation periapically to CT 307. These radiological features were consistent with apical infection and both CT were subsequently orally extracted.

#### **Radiography of the Extracted CT:**

**Case 17:** Exposure factors of 66kVp and 5.0 mA (d=65cm) were used for optimal imaging of the extracted tooth. There was some loss of apical dental tissue following repulsion of this CT.

**Case 102:** Exposure factors of 66kVp and 5.0 mA (d=65cm) were used for optimal imaging of the extracted tooth. Radiographic features identified were loss of apical definition and a generalised decreased radiodensity of the tooth, indicating demineralisation.

When scanned in a Somatom Esprit CAT scanner, a loss of radiodensity of both the rostral and caudal infundibula was evident throughout the entire length of the tooth. The presence of occlusal pulp exposure could also be detected (Video 1.1 in enclosed CD).

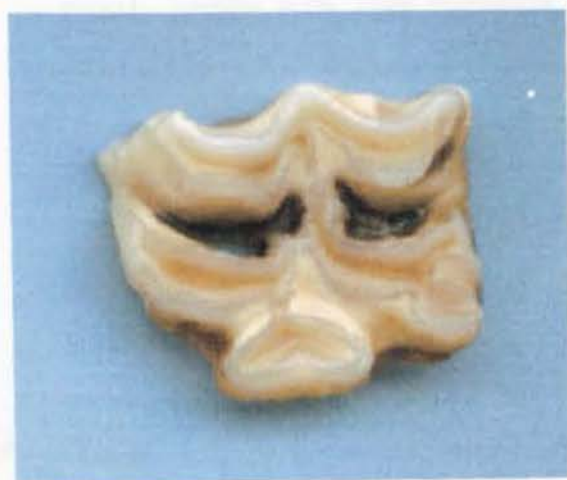**Case 104:** Exposure factors of 66kVp and 5.0 mA (d=65cm) were used for optimal imaging of the extracted tooth. No significant radiographic features were identified. However, when scanned with a Somatom Esprit, loss of structure of the apical region surrounding pulp chamber 1 was clearly visible, as was the hypoplastic nature of the rostral infundibulum (Video 1.2 in enclosed CD).

**Case 106:** Exposure factors of 63kVp and 6.3 mA (d=65cm) were used for optimal imaging of the extracted tooth. Crush marks were noted radiographically on the tooth where extractors had been placed. A CAT scan of the CT showed the cement in both infundibula to be hypoplastic, with this hypoplasia becoming more severe apically.

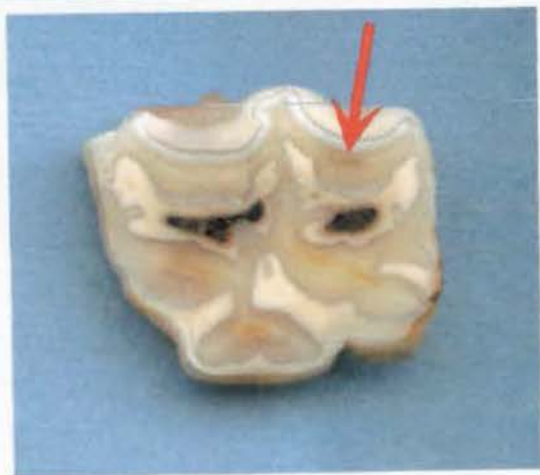There was no communication through infundibular enamel into dentine (Video 1.3 in enclosed CD).

### Dissecting Microscopy:

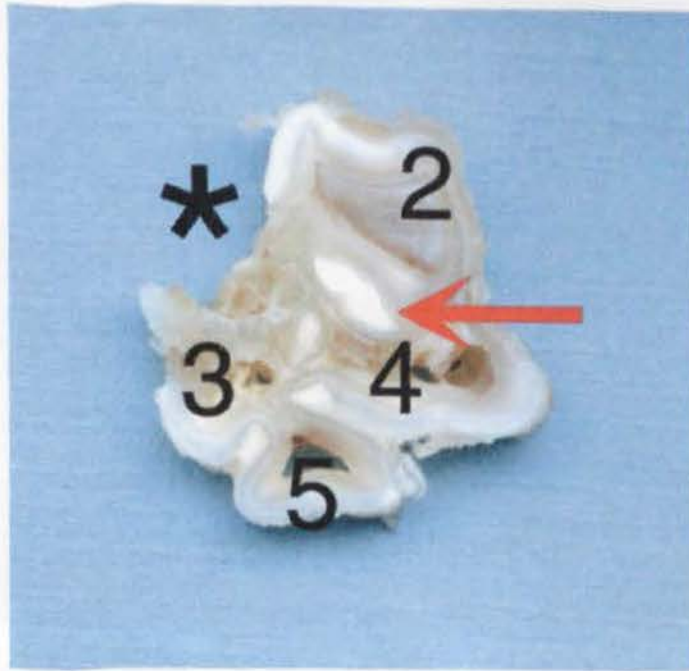
**Case 17:** Having recently erupted, the occlusal surface of this CT was mainly its 'primary' occlusal surface, i.e. cementum covered enamel folds (c.f. secondary occlusal surface that is present when a tooth has become worn on the occlusal surface exposing layers of enamel, dentine and cementum that will be present for the majority of the tooth's dental life). There was no occlusal pulp exposure present in this case. Both rostral and caudal infundibula had cement hypoplasia at the occlusal surface (Figures 1.36 and 1.37) with food material packed into their occlusal aspects (see conclusions). There were signs of early (grade 1- involving cementum only) cemental caries in the more occlusal infundibular regions, but cemental hypoplasia, caries or feed impaction did not progress into the apical portions of either infundibulum (Figure 1.38).



**Figure 1.36:** The occlusal section from Triadan 107 of Case 17 showing both rostral and caudal infundibula to be dark stained and hollow ("open"), as is frequently the case in young maxillary CT that have recently erupted and have yet to wear their 'primary' occlusal surface into their 'secondary' or 'mature' occlusal surface.



**Figure 1.37:** Sub-occlusal section of CT 107 from Case 17 showing food packed in both rostral and caudal infundibula. Four pulp chambers are occluded with dentine (primary and secondary) but pulp chamber 2 (red arrow) has a small amount of pulp still present at this level.



**Figure 1.38:** Apical transverse section from Case 17 showing the apical tip of (normal) infundibular cementum lying within the caudal infundibulum (red arrow). Pulp chamber 1 has been destroyed during repulsion (\*). Pulp chamber 2 contains grossly healthy pulp. Pulp chambers 3, 4 and 5 are empty with grossly abnormal dentine adjacent to pulp chambers 3 and 4.

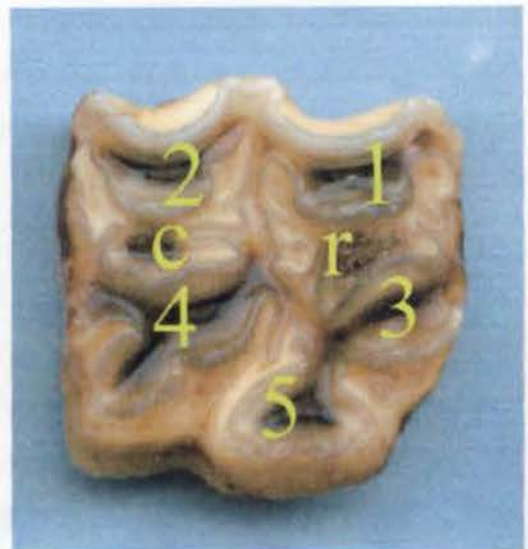
The most striking feature of this tooth observed under dissecting microscopy was the developmental changes present within pulp chamber 1 (Figure 1.39) below. The lumen of this pulp chamber was seen to expand greatly in all directions, at approximately 1/3<sup>rd</sup> of the tooth's length from its apical limit. This expansion had caused a deviation to the usual pattern of adjacent infundibular enamel (laid down during early dentogenesis), and had allowed direct communication between pulp chamber 1 and the adjacent rostral aspect of tooth surface. Pulp chamber 1 was filled with pus.



**Figure 1.39:** A longitudinal section of Triadan 107 from Case 17 showing pulp chambers 1 and 3 (numbered) lying on either side of the rostral infundibulum (i). Pulp chamber 3 is empty, having lost its pulp during processing. Pulp chamber 1 and the surrounding dentine are dysplastic and carious. Note how infundibular enamel has deviated caudally towards pulp chamber 3, as pulp chamber 1 has expanded greatly in size, to the extent of having a direct communication with the periodontium on its rostral aspect (red arrow).

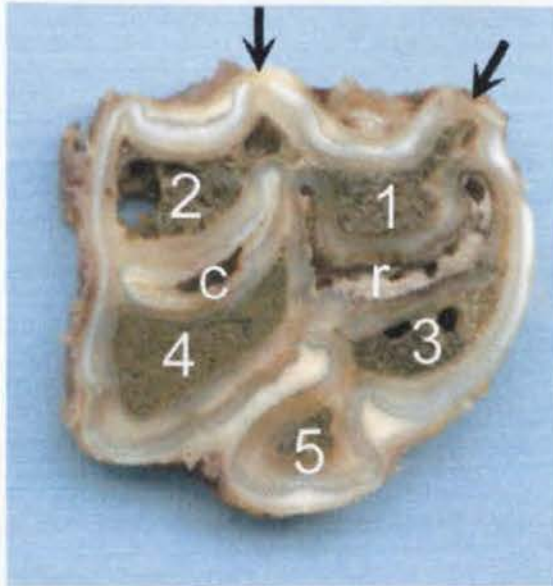
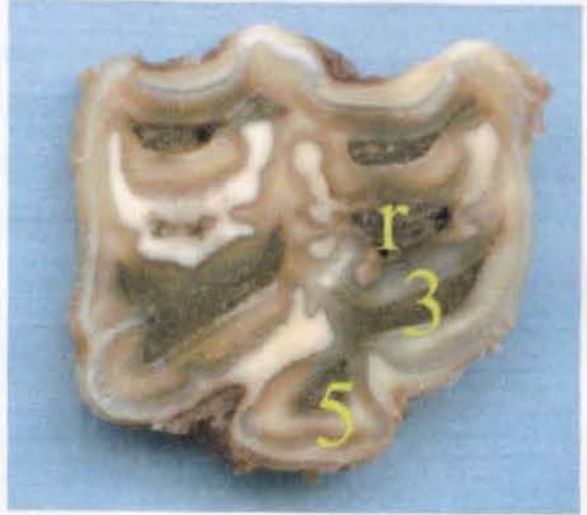
**Case 102:** All five pulp chambers were exposed at the occlusal surface (Figure 1.40) with feed packing all chambers right down to their apical limit (Figures 1.41 and 1.42).

**Figure 1.40:** All five pulp chambers (numbered) have been exposed on the occlusal surface of CT 107 from Case 102. There is also some food packed into the central areas of both rostral (r) and caudal (c) infundibula.



The rostral infundibulum was carious (stage 2) i.e. involving the infundibular cement and the surrounding enamel in the mid-tooth region (Figure 1.41).

**Figure 1.41:** Mid-section from CT 107 of Case 102 showing all five pulp chambers to be impacted with food at this level. Pulp chambers 3 and 5 still communicate through a very narrow opening at this level. The rostral infundibulum (r) is carious (stage 2) and the caudal infundibulum has cemental hypoplasia centrally with some discoloration localised from caries of the surrounding cementum.

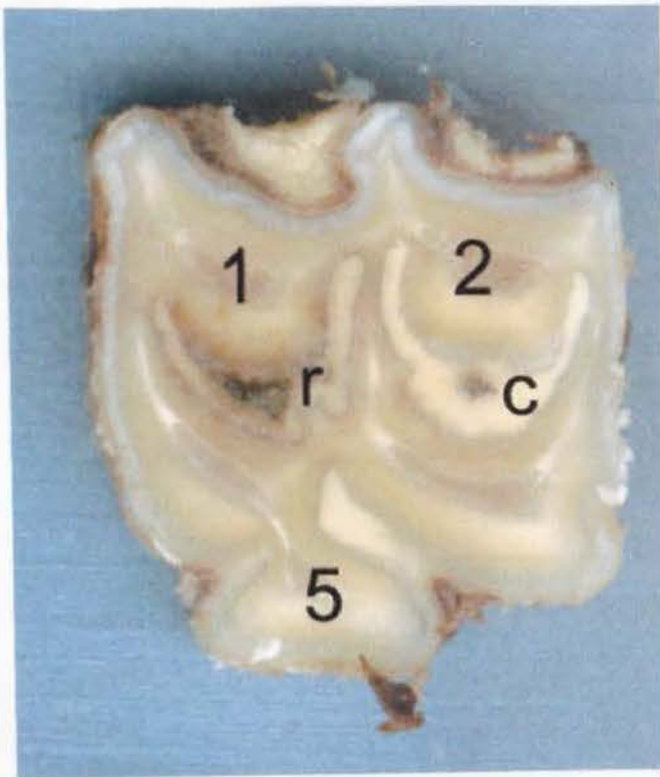


**Figure 1.42:** Apical section from CT 107 of Case 102 showing all five pulp chambers to have feed impacted within them, even at this deep apical level. The rostral infundibulum has extensive cemental and enamel caries (r) and the caudal infundibulum has cemental hypoplasia (c). Pulp chambers 3 and 5 are fully separated by dentine at this level. There are two areas (on the buccal aspect of tooth) where peripheral enamel is absent (arrows), as is common in apical sections of CT with apical infections.

The apical transverse section from CT 107 of Case 102 shows the rostral infundibular cementum to be carious, yet this caries had not penetrated the infundibular enamel layer at a gross level, indicating that it did not cause the apical infection. Pulp chambers 3 and 5 were separate, indicating that dentine had continued to be deposited

at this level, even after deposition had been halted in more occlusal regions of this tooth. This finding is contrary to the normal dentogenesis pattern, where pulp horns become separated by dentine deposition more occlusally, as odontoblasts retreat in an occlusal to apical direction.

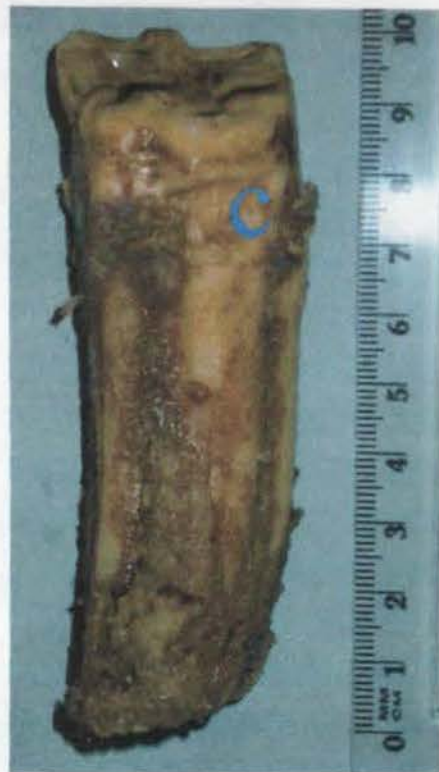**Case 104:** No pulp was exposed on the occlusal surface and the pulp appeared viable within all endodontic regions (Figure 1.44). The rostral infundibulum had a small degree of infundibular hypoplasia, with the surrounding cementum being discoloured by mild (stage 1) caries present adjacent to the central vascular canal.



**Figure 1.44:** A mid-transverse section from CT 207 of Case 104. All five pulp chambers contain viable pulp (1, 2, 5 are numbered). The caudal infundibulum (c) appears normal while the rostral (r) is hypoplastic with stage-1 caries.

**Case 106:** Peripheral enamel had been worn away on both the rostral and caudal interproximal surfaces. Crush marks were present on the clinical crown from extractor forceps placement (Figure 1.45). No pulps were exposed on the occlusal surface. No other abnormalities were detected.

**Figure 1.45:** Palatal view from Case 106 of extracted CT 107. Note the crush marks (c) caused by placement of extractor forceps. This photo was taken prior to placement into buffered formalin, which bleaches the colour from the teeth.



**Histology:**

**Case 17:** The occlusal transverse section of pulp chamber 2 contained pus, while all other chambers were occluded by irregular secondary dentine at this level. The thickness of primary dentine in this CT was similar to that in the control CT, however there was less secondary dentine (<50% in occlusal sections) than in the control CT (Tables 1.10 and 1.11).

**Case 102:** As previously found under dissecting microscopy, all five pulp chambers were impacted with feed. The amount of primary dentine present in occlusal and mid transverse sections was similar to that of the control CT, however secondary dentine was completely absent from this tooth (Tables 1.10 and 1.11).

**Case 104:** In both occlusal and mid transverse sections, viable pulp was still present in all pulp chambers. Both primary and secondary dentine were present in quantities similar to the control CT (Tables 1.10 and 1.11).

**Case 106:** Irregular secondary dentine had occluded all pulp chambers, except pulp chamber 2 in the occlusal transverse section. In the mid transverse section, shrunken,

viable pulp was present in all pulp chambers. Both primary and secondary dentine were present in quantities similar to the control CT (Tables 1.10 and 1.11).

Pulp chamber	Control CT 19 1D (buc)	Case 17 1D (buc)	Case 102 1D (buc)	Case 104 1D (buc)	Case 106 1D (buc)	Control CT 19 1D (pal)	Case 17 1D (pal)	Case 102 1D (pal)	Case 104 1D (pal)	Case 106 1D (pal)
1	-	900	-	1000	1400	-	-	-	2100	1200
2	<b>850</b>	600	800	900	1000	<b>1300</b>	1400	1800	1850	1550
3	-	1300	-	1200	1800	-	2200	-	-	2150
4	<b>1000</b>	1150	1200	1200	1350	<b>1500</b>	2200	2450	1800	2300
5	<b>1050</b>	950	-	750	1200	<b>1300</b>	1050	-	2400	2000

**Table 1.10:** Transverse measurements of regular primary dentine (1D) taken from occlusal sections of control (in **bold**) and apically infected maxillary CT. (buc=buccal direction, pal=palatal direction, empty cell= measurement not available).

Pulp chamber	Control CT 19 2D (buc)	Case 17 2D (buc)	Case 102 2D (buc)	Case 104 2D (buc)	Case 106 2D (buc)	Control CT 19 2D (pal)	Case 17 2D (pal)	Case 102 2D (pal)	Case 104 2D (pal)	Case 106 2D (pal)
1	-	150	-	100	150	-	250	-	700	500
2	<b>200</b>	100	0	150	200	<b>800</b>	200	0	650	550
3	-	250	-	250	450	-	300	-	600	500
4	<b>750</b>	300	0	200	600	<b>850</b>	250	0	800	750
5	<b>500</b>	250	-	450	350	<b>500</b>	200	-	300	500

**Table 1.11:** Transverse measurements of regular secondary dentine (2D) taken from occlusal sections of control (in **bold**) and apically infected maxillary CT. (buc=buccal direction, pal=palatal direction, empty cell= measurement not available).

### Conclusions:

Unlike group seven, the CT of two cases in this group (Cases 104 and 106) did not have grossly diseased dental pulp, nor was there any reduction in thickness of dentine present in these teeth. Both teeth were extracted on the basis of clinical history, general clinical examination (with neither showing intra-oral pathology) and radiographic findings.

A CAT scan of CT 207 from Case 104 clearly showed severe destruction of the apical region (not caused by repulsion, as the tooth was extracted orally). The scan also identifies the hypoplastic nature of the rostral infundibulum, with its apical region having infundibular enamel hypoplasia - resulting in direct communication between

the infundibular cementum and adjacent dentine. If this were the route for apical infection of the pulp, it had happened very recently as pulp still appeared viable histologically.

CT 107 from Case 106 showed no gross or histological evidence of apical infection, despite the clinical findings of such a problem and subsequent radiographic confirmation of this diagnosis. Pulpar tissue has not been examined within this study specifically to address if pulpitis was present in cases such as this, on the basis that most of the pathological specimens examined had no or grossly destroyed pulp present, with the remaining pulps having fixation artefacts present. The localised maxillary swelling in this case had only been noticed three weeks before referral and it is possible that the infection in this case was fully contained in the periapical (extra-dental) region, i.e. a true peri-apical infection. This area needs further investigation.

The CT of Case 17 and 102 in this group had greatly reduced amounts of secondary dentine present, with Case 102 having none present. These findings agree with the clinical history from Case 102 of a swelling being present over the apical region of this tooth for 2-3 years. If this swelling indicated an apical infection was present in this CT for this period in such a young tooth (dental age 1.5 years) odontoblasts would certainly have been destroyed before any secondary dentine had been laid down. Pulpar exposure with feed impacted in all pulp chambers is an almost inevitable finding in apically infected CT that have been present for several years, as dental attrition of the occlusal surface following destruction of the pulp would result in such exposure of the endodontic system. With such advanced pathology present in cases such as Case 17 and 102, it was not possible to identify a cause of the apical infections.

The dysplastic enamel in the apical region of pulp chamber 1 in Case 17 CT would have occurred during amelogenesis early in the dentogenesis of the CT. The direct communication between this pulp chamber and the periodontium (Figure 1.39) may have been a source of further pulp compromise or infection. In the absence of periodontal disease, or communication through a carious infundibulum, or the presence of occlusal pulp exposure, it is therefore most likely apical infection of this

case arose following an anachoretic pulpitis. This is most likely to initially have occurred in pulp chamber 1 where secondary dentine was greatly reduced.

## Appendix 2: Case Reports on Mandibular Cheek Teeth with Apical Infections

### Case 23: 98/412

### 4 year-old Welsh Pony, Gelding

#### History and Clinical Examination:

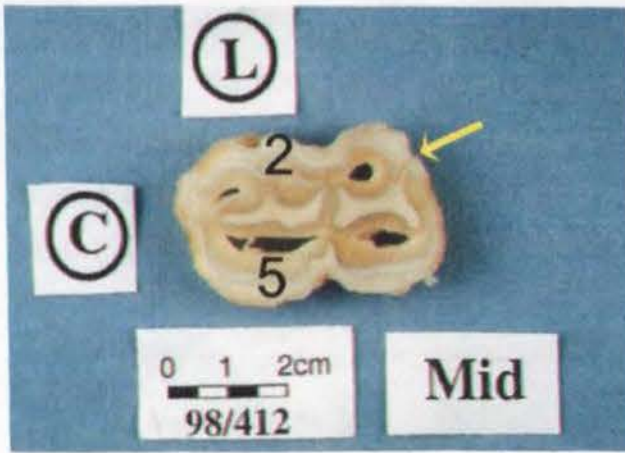
This case was referred because of a right ventral mandibular swelling with intermittent sinus tracts of five months duration. Radiography revealed periapical sclerosis surrounding CT 407 (with a dental age of six months), with destructive changes to the apex. A sinus tract was identified from the apical region of the tooth, exiting on the ventral aspect of the mandible. The tooth was subsequently extracted intact under standing sedation. This tooth was sectioned for tissue fixation prior to radiographing the tooth. Consequently neither standard radiography nor a CAT scan was performed on this tooth.

#### Dissecting Microscopy:

No occlusal pulp exposure or dental fracture was present. Cementum in the rostral enamel infolding of this tooth had been laid down in an irregular fashion throughout its length (Figures 2.1-4). An increased amount of cementum had been irregularly laid down over the lingual aspect of the tooth indicating possible localised periodontal inflammation in this region. Closer examination of transverse sections showed peripheral cementum within the rostral enamel infolding to be hypoplastic at multiple sites (Figures 2.2-3).

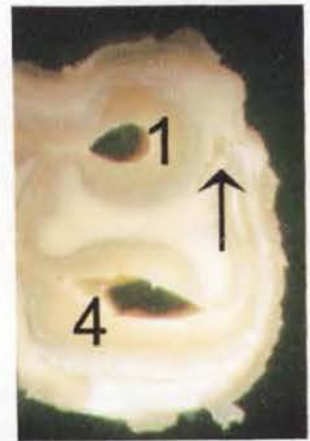**Figure 2.1:** Rostro-lingual view of CT 407 extracted from Case 23. Hypercementosis is present on the lingual aspect, especially in the apical area. A fold of soft tissue still adheres to the tooth apex. (L=lingual; R=rostral)



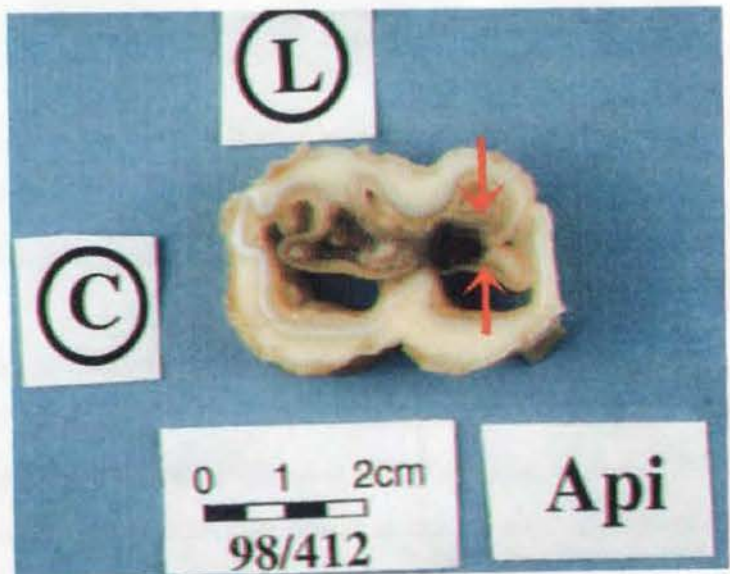

**Figure 2.2:** Transverse mid-section of Triadan 407 from Case 23. An area of hypoplastic cementum is present within the rostral enamel infolding (arrow). Pulp chambers 1, 3, 4 and 5 are almost empty; however viable pulp is still present within pulp chamber 2. Pulp chambers 2 and 5 are numbered. (C=caudal, L=lingual)

**Figure 2.3:** Close-up view of the transverse, mid-section of CT 407 from Case 23. An area of hypoplastic cementum can be seen within the rostral enamel infolding (arrow). Pulp chamber 1 is empty and some necrotic pulp is present peripherally in pulp chamber 4.



**Figure 2.4:** Transverse apical section of CT 407 from Case 23. All (five) pulp chambers communicate at this level and they contain necrotic material. The surrounding dentine and enamel are carious. Caries of dentine, enamel and cementum is also present within the rostral enamel



infolding (between arrows) to the extent that there was direct communication between the apical endodontic and periodontal regions. (C=caudal, L=lingual).

### Histology:

All five pulp chambers were occluded with secondary dentine in the sub-occlusal transverse section. This was also the case in a comparable control CT (Control CT 12, Triadan 307, dental age six months). Measurements of primary dentine in buccal and lingual directions from each of the five pulp chambers, for both the control and diseased CT, found primary dentine thickness to be slightly thinner in the diseased as compared to the control CT (Table 6.1) ( $t_{35}=1.45$ ,  $p=0.157$ ). Secondary dentine thickness was reduced in the diseased CT in both occlusal and mid transverse sections, being totally absent in the mid transverse section ( $t_{20}=3.76$ ,  $p=0.001$ ).

Although statistical calculations (two-way Students t-test on transformed data – Sections 3.11 and 4.4.3) were made to directly compare the measurements from these two CT (Control CT 12 and CT 407 from Case 23), such calculations have not been made on other individual cases, as statistical differences were not obtained due to insufficient sample size when just comparing two teeth. Instead, statistical calculations have been made between comparable groups of CT (Section 5.4).

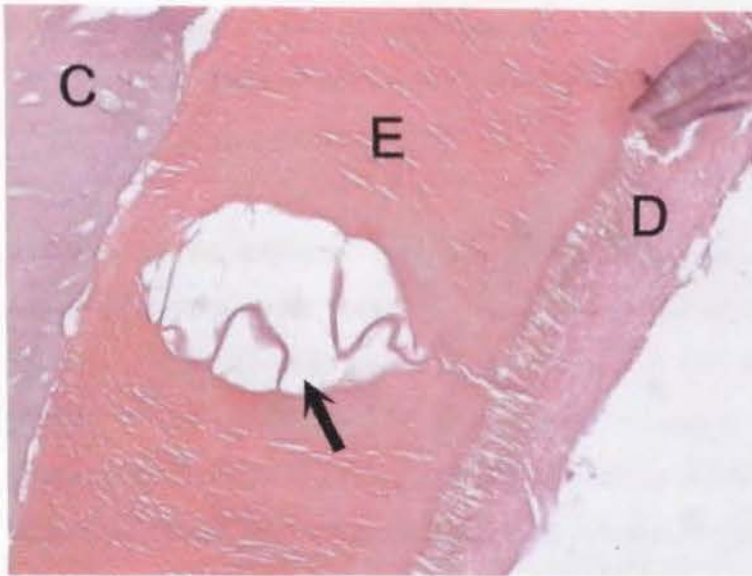
<b>Section</b>	<b>Primary Dentine Measurement</b> (range in $\mu\text{ms}$ )		<b>Secondary Dentine Measurement</b> (range in $\mu\text{ms}$ )	
	Control CT 12 (Dental age 6 months)	Case 23 (Dental age 6 months)	Control CT 12 (Dental age 6 months)	Case 23 (Dental age 6 months)
<b>Occlusal</b>	900-3050	700-2450	400-600	150-300
<b>Mid</b>	650-1900	350-1550	50-300	0 (Not present)

**Table 2.1:** Dentinal thickness in sub-occlusal and mid transverse sections (range in micrometers) from Control CT 12 and Case 23. Measurements are from all pulp chambers (1-5) in both buccal and lingual directions.

Enamel is usually lost in decalcified histological sections because of its highly mineralised nature. Tooth 407 from Case 23 is one of eight apically infected CT with a dental age of less than one year that was examined in detail. The presence of a higher organic component in enamel in these sections is likely because this recently formed enamel is incompletely mineralised (Figure 2.5).

Cementum was hypoplastic within the rostral enamel infolding of CT 407 when viewed under a dissecting and light microscope. Figure 2.6 shows an abnormal pattern

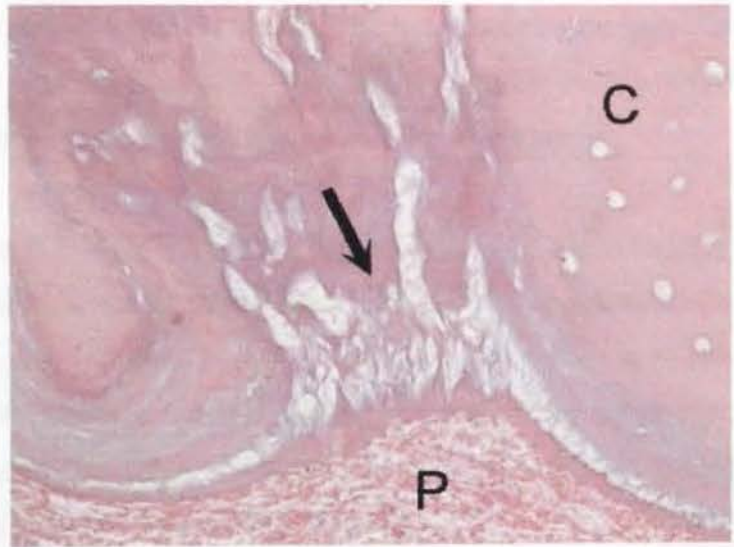
to be present in the cementum at the periphery of this rostral enamel infolding. No bacteria are present and the cementum did not appear to be carious in this mid transverse decalcified section.



**Figure 2.5:** Decalcified transverse apical section of CT 407 from Case 23 showing a defect within the partially mineralised enamel layer (E). Cementum (C) is present peripherally to the enamel and a thin layer of dentine (D) is present on the pulpal side of the infolded

enamel. As the apical enamel is still mineralising it still has a high amount of organic material present in this decalcified section. (H&E x400)

**Figure 2.6:** Decalcified transverse mid section of CT 407 from Case 23 showing abnormal cementum (arrow) near the rostral enamel infolding, adjacent to normal cementum (C). Necrotic periodontal ligament (P) is adjacent to this area. As this



is a decalcified section, we do not see mineralised carious changes in the enamel (such as demineralisation banding) however areas of disorganised collagen are present at the site of the enamel. (H&E x400)

**Conclusions:**

Most pulp tissue in this CT had been destroyed through infection and no secondary dentine was present in the apical half of the tooth, with reduced amounts of dentine (primary and secondary) present in the remaining parts. This reduced dentine production suggests that the infection to the pulp of this CT may have been present throughout the time clinical signs were reported to be present in this case (i.e. five months) or even longer.

There were no exposed pulp chambers on the occlusal surface. Interestingly, identifiable pulp tissue was still present in pulp chamber 2 of the mid transverse section, despite all pulp tissue being necrotic in the apical section. A defect was present in the cementum from the gingival margin to the apical region along the rostral aspect of the CT. However there were no signs of bacteria or caries of the adjacent cementum in the occlusal half of the tooth. Although this hypoplastic cemental defect within the rostral enamel infolding may have been a potential route for pathogenic oral organisms to reach the apical region of the tooth, there was no histological evidence to support this. For this apical infection to have arisen from descending periodontal disease, microbes would have needed to descend the entire length of reserve crown (over 80mm long) overcoming the local immune response, to invade pulp tissue and then destroy odontoblasts in order to cause the observed reduction in secondary dentine production, prior to the tooth's actual eruption.

The presence of occlusal wear in this CT shows that the stimulus for secondary dentine production was present (Kierdorf & Kierdorf 1992), but that odontoblasts were no longer capable of responding. This occurred sometime during the six-month clinical course of the infection - between initial secondary dentine production present in the occlusal transverse section, and when it should have been deposited in the mid transverse sections (where no secondary dentine was present).

The most likely cause for apical infection in this case is that an anachoretic pulpitis led to a generalised apical tooth infection. This is supported by the more advanced calcified tissue destruction present within the apical region. As seen in Figure 2.4, a direct communication is present between the necrotic (infected) apical endodontic

region and the periodontium. Additionally, reactive cemental hyperplasia was most advanced over the apical portion of the tooth. It is most likely that these cemental changes arose following periodontal spread of the infection towards the gingival margin, once the apical infection had become established from the anachoretic pulpitis.

## **Case 25 97/1121**

## **6 year-old Hunter, Mare**

### **History and clinical examination:**

This horse was referred with a left mandibular swelling and sinus tract of one-month duration. Radiography showed periapical changes that confirmed the presence of abscess formation of Triadan 309 (dental age five years). No periodontal disease was noted around this tooth at intra-oral examination. The infected tooth was fully extracted *per os* under standing sedation. As for Case 23, the extracted tooth was sectioned for tissue fixation prior to radiography.

### **Dissecting Microscopy:**

Deep tracts were present in the cementum on the buccal aspect of this tooth, running from the apical region to the gingival margin. There were also focal areas of cemental caries on its buccal face, well beneath the gingival margin (Figure 2.7).

A fissure was present on the occlusal surface within secondary dentine overlying pulp chamber 5. This connected with a vertical (longitudinal) hairline fracture extending from cementum, through enamel and into the dentine surrounding pulp chamber 5, that was identified in occlusal, sub-occlusal and mid transverse sections (Figure 2.8). A depression into the secondary dentine overlying pulp chamber 1 was present, however examination of the reverse (apical) face of this occlusal section showed that this depression did not progress any further apically.

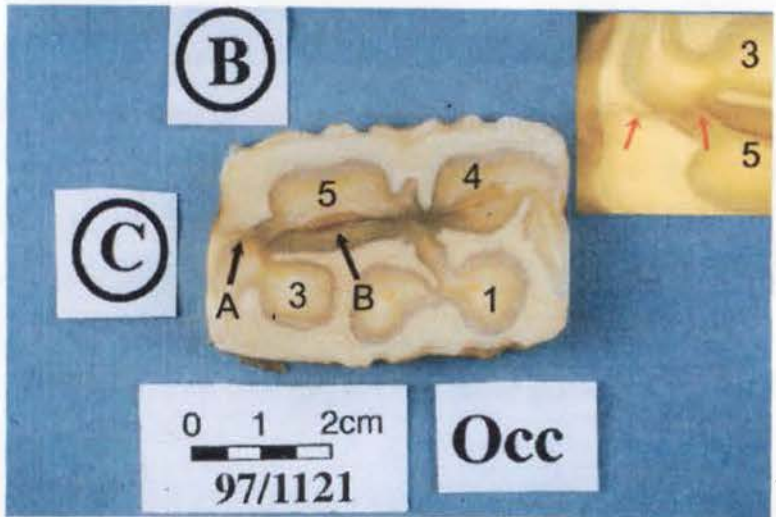
In the mid transverse section, all five pulp chambers were separate, with the remnants of necrotic pulp present within the lumen of these chambers. Necrotic remnants of pulp were also present in the apical transverse section, with the dentine at this level

more discoloured than in the mid section. Pulp chambers 1 and 2, and 3 and 5 communicated apically (Figure 2.9).

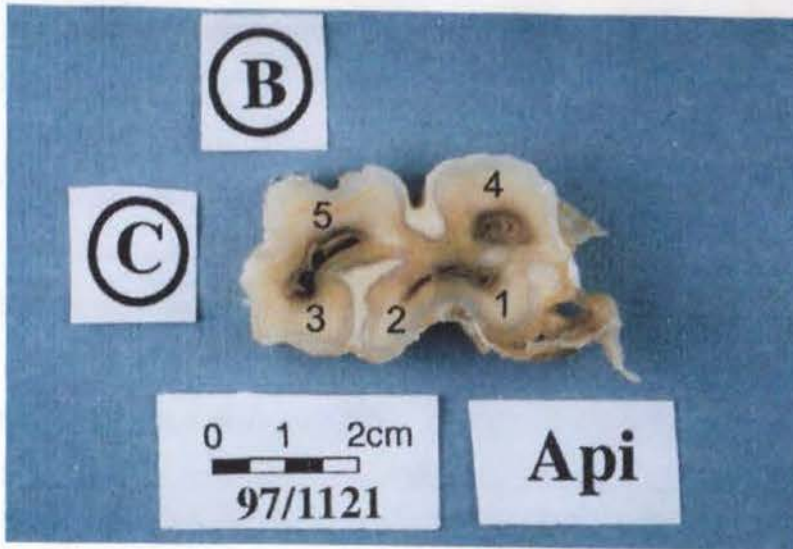


**Figure 2.7:** Buccal aspect of CT 309 from Case 25 showing linear tracts and focal erosions in the peripheral cementum (arrows). These cemental lesions have exposed the underlying enamel, which was unaffected macroscopically. (C=caudal, B=buccal)

**Figure 2.8:** The reverse (apical) face of the transverse occlusal section of CT 309 from Case 25. All five pulp chambers are occluded with secondary dentine, however pulp chamber 5 has dark staining around a central fissure (B). A



hairline fracture (A) extended through the cementum and enamel at the caudal aspect of the tooth, to join up with the fissure present in dentine at pulp chamber 5. A higher magnification of this area is shown in the insert (top right), with red arrows identifying the fracture line. Crush marks where extractor forceps had been placed are present on the lingual and buccal faces. Note how this iatrogenic damage has not damaged adjacent enamel and dentine. The (occluded) pulp chambers are numbered 1-5. (C=caudal, B=buccal)



**Figure 2.9:** Dark staining dentine surrounds the pulp chambers (numbered) in this apical transverse section from CT 309, Case 25. Pulp chambers 1 and 2, and 3 and 5 communicate. (C=caudal, B=buccal)

**Histology:**

All five pulp chambers were occluded with secondary dentine in the occlusal transverse section, and all five pulp chambers contained necrotic pulp and regular secondary dentine in the mid transverse section. When compared to Control CT 35 (Triadan 409, dental age four years), the amounts of primary and secondary dentine present were similar, and in some cases were greater in the diseased than in the control CT. The infected CT came from a large horse and was 103mm in length, however Control CT 35 was 98mm long and so both CT were comparable in this respect.

**Conclusions:**

Signs of periodontal disease and occlusal pulp exposure (via the fissure over pulp horn 4 and the fracture leading into it) were present in this CT. Having a dental age of five years, it is possible that oral microbes descended from the gingival margin, causing the tracts present in cementum before reaching and then infecting apical pulp tissue. However, reasons against this possible route of infection are that there were no signs of periodontal disease recorded on oral examination, and no clinical signs of oral discomfort were present until one month before referral – it being assumed that a

descending periodontal disease would have taken much longer than one month to reach the apical region.

In other CT examined in this study where apical infection resulted from an anachoretic pulpitis, secondary dentine formation was found to be reduced, but secondary dentine thickness was not reduced in this case.

The fracture leading into pulp chamber 4 occurred prior to tooth extraction, as evidenced by adjacent calcified tissue staining (either from plant or microbial pigments). There was no reduction in dentine present within this or any other pulp chamber, and predentine was still present in the mid transverse section to the periphery of pulp chamber 4, despite the pulp being necrotic. These findings all concur with the history of clinical signs having been present for only one month, suggesting recent and rapid pulp necrosis. On balance, the most likely source of infection to create such a rapid destruction of pulp would be from bacteria infecting pulp horn 4 from the fracture site on the clinical crown, possibly of traumatic origin, with resultant spread of infection throughout the tooth.

## **Case 28 95/889**

## **6 year-old Irish Draught, Mare**

### **History and clinical examination:**

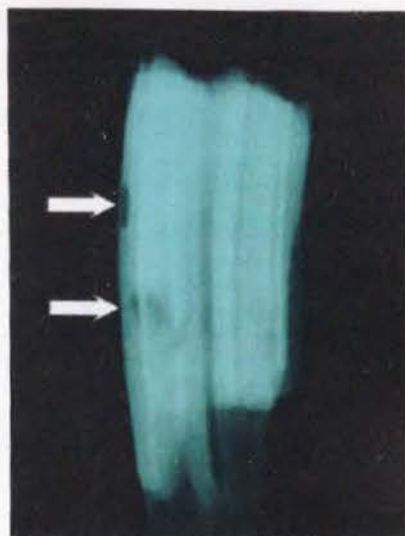
This six-year-old mare was referred with a history of a left-sided mandibular swelling and quidding of four months duration. The case temporarily responded to antibiotic therapy, however at re-examination one month later, radiographs showed changes to CT 308 and 309 suggestive of periapical tooth infection. To further investigate this area, the apical area was dissected under general anaesthesia revealing a periapical abscess adjacent to the rostral root of CT 309. This tooth was then repulsed into the oral cavity.

### **Radiology of the Extracted CT:**

Exposure factors of 66kVp / 6.3 mA and 55kVp / 5.0 mA (d=65cm) were used for optimal imaging of the extracted tooth in anterior-posterior and lateral planes, respectively. Iatrogenic fractures of the apical region associated with repulsion were

evident in both views. Radiolucencies were detected on the rostral border of the upper part of reserve crown and in the rostral body of the CT more apically in the lateral radiograph (Figure 2.10).

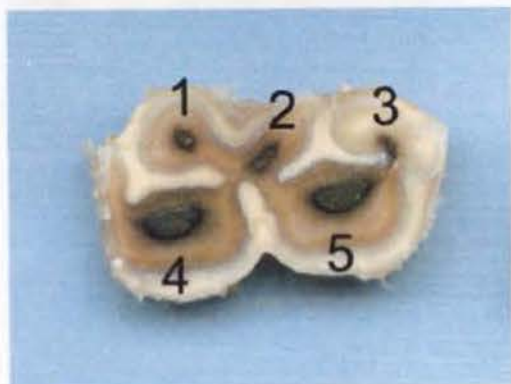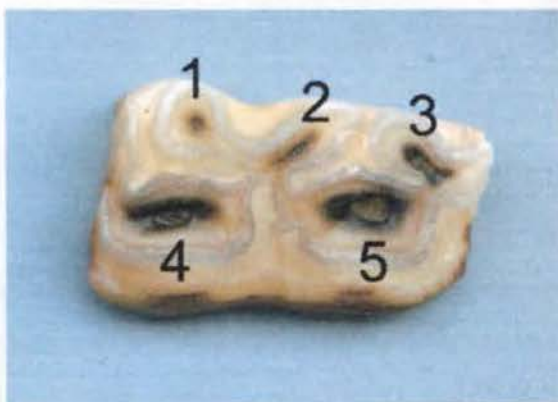**Figure 2.10:** Lateral radiograph of CT 309 from Case 28. Focal radiolucencies are present on the rostral margin and within the rostral body of this CT (arrows). The fractured apex has resulted from repulsion trauma.



#### Dissecting Microscopy:

All five pulp chambers were exposed occlusally (Figure 2.11) and food was present within all five pulp chambers in the mid section (Figure 2.12). Cemental caries were present beneath the gingival margin on the rostral aspect of the CT.

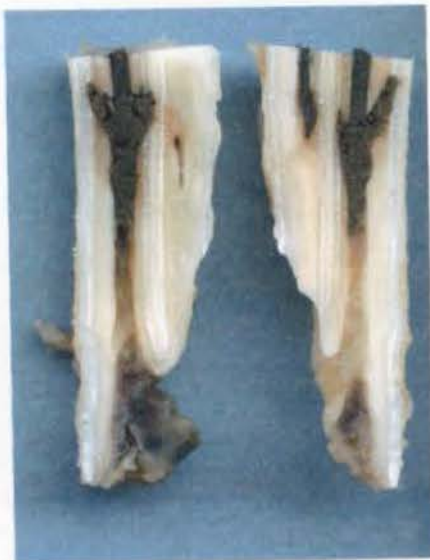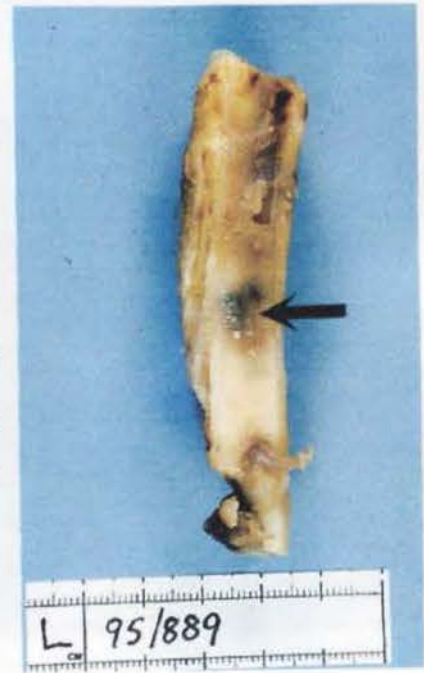**Figure 2.11:** The occlusal surface of CT 309 from Case 28 showing all five pulp chambers (1-5) to be exposed and have food impacted within the central portion of the pulp chambers. In this figure, the pulp chamber exposure is most obvious in the larger 4<sup>th</sup> and 5<sup>th</sup> pulp chambers.



**Figure 2.12:** Mid transverse section of CT 309 from Case 28. All five pulp chambers are completely impacted with food at this level and the adjacent dentine is discoloured from plant pigments and caries.

Having observed food present in pulp chambers from the occlusal to mid tooth level, pulp chambers 4 and 5 were sectioned longitudinally to assess the progression of impacted food more apically. An area approximately one third of the CT's length from the apex, in the rostral aspect of the tooth, appeared darker through the semi-translucent enamel and cementum (Figure 2.13) and when transected, revealed an irregular area within pulp chamber 4 that was impacted with food (Figure 2.14).

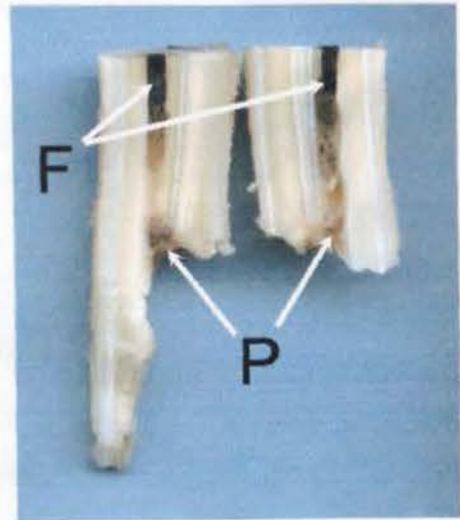
**Figure 2.13:** CT 309 from Case 28. A discoloured area (arrow) is present on the rostral aspect of the periphery of the tooth, caused by plant material packed into an enlarged area of pulp chamber 4 (as seen in figure 2.14). The semi-translucent nature of interposed cementum and enamel has resulted in this discolouration being present on the external tooth surface.



**Figure 2.14:** Longitudinal section of the apical half of pulp chamber 4 from CT 309, Case 28. Food has been packed into this pulp chamber for nearly its entire length and has also managed to advance in a retrograde manner, filling two expansions of pulp chamber 4.

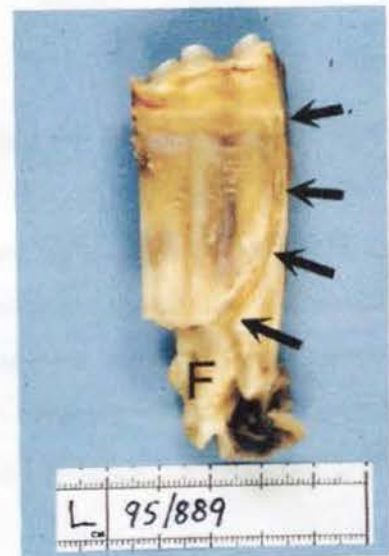In Figure 2.14 food is seen to pass beyond dentine of pulp chamber 4 and into defective adjacent enamel. This divergent area corresponds to both the rostral radiolucency of the crown noticed in the lateral radiograph (Figure 2.10), and the discoloured rostral region noted grossly (Figure 2.13). It is most likely these retrograde extensions from pulp chamber 4 were developmental in origin, with enamel and dentinal hypoplasia affecting this area initially, thus allowing food material to enter these chamber extensions. Caries of the adjacent dentine may have enlarged these extensions subsequently.

**Figure 2.15:** Longitudinal section of pulp chamber 5 from CT 309, Case 28, sectioned into two halves in a bucco-lingual plane. This apical portion of the tooth shows food material (F) in this pulp chamber, but food impaction has not yet progressed to the apical limit of the tooth. Necrotic pulp is still present in the most apical chamber region in both sections (P). Similar features are present in pulp chamber 4, as shown in Figure 2.14.



Periodontal changes have also occurred, as indicated by a tract present in the cementum on the lingual face of the CT, running from the apical region to the gingival margin (Figure 2.16). Note that this cemental tract does not progress beyond the gingival margin onto the clinical crown.

**Figure 2.16:** A tract (arrows) is present in the cementum on the lingual aspect (L) of CT 309 from Case 28. It extends occlusally and rostrally from the region of the iatrogenic apical fracture (F) to the gingival margin.



### Histology:

As observed under dissecting microscopy, all pulp chambers were packed with food material in the occlusal and mid transverse sections. When compared to Control CT 24 (Triadan 409, dental age four years), the amount of primary dentine present was similar in both sub-occlusal and mid transverse sections in both CT. There was no irregular secondary dentine present in CT 409 from Case 28, yet irregular secondary dentine had occluded all pulp chambers in the occlusal section of Control CT 24. Instead, the occlusal aspects of the pulp chamber openings were open, varying from 750-1750 $\mu$ m in width. There was also noticeably less regular secondary dentine present in the diseased CT, as shown in Table 2.2.

Pulp Horn	Buccal Secondary Dentine ( $\mu$ m)		Lingual Secondary Dentine ( $\mu$ m)	
	Control CT 24	Case 28	Control CT 24	Case 28
1	650	-	700	-
2	500	100	300	50
3	250	0	400	100
4	1150	150	500	100
5	1200	250	450	100

**Table 2.2:** Regular secondary dentine thickness in buccal and lingual directions in the sub-occlusal transverse sections from Control CT 24 and CT 409 from Case 28. Measurements are from pulp chambers 1-5 in both buccal and lingual directions.

### Conclusions:

A number of pathological changes were present in this CT. Some were likely to have been developmental such as the retrograde extensions from pulp chamber 4 into dentine and enamel, and some were acquired, such as the occlusal pulp exposure of all five chambers.

The large decrease of secondary dentine production within the pulp chambers of this diseased CT indicates that apical infection was present for some months – possibly longer than the reported five months duration of clinical signs. It is not possible to categorically determine whether the original infection that caused the decreased dentine formation arose from occlusal pulpar exposure or from an anachoretic pulpitis. It is unlikely however that all five pulp chambers became exposed simultaneously. It is more likely that they became exposed through continued occlusal

wear, with the pulps having already become compromised in their ability to produce dentine, most likely from an anachoretic pulpitis.

## Case 21: 01/181

## 9 year-old Pony, Gelding

### History and Clinical Examination:

This case was presented with a painful swelling on the medial aspect of the left mandible with intermittent sinus tracts, of approximately six months duration. Oral examination was unremarkable, however radiography revealed changes, including marked loss of definition of the periodontal membrane and lamina dura denta, around the caudal root of Triadan 310 (dental age seven years), indicative of an apical infection. The tooth fractured during the later stages of oral extraction, when a fulcrum was being used to help elevate this loosened tooth from the alveolus. The apical third of the CT (including the infected caudal root) remained in the alveolus, and was subsequently repulsed under general anaesthesia.

**Figure 2.17:** Buccal view of extracted CT 310 from Case 21. Indentations (crush marks) are visible on the clinical crown due to placement of extraction forceps. A clean, iatrogenic, diagonal fracture line is apparent. (C=caudal, B=buccal aspect facing camera)




The CT was one of six CT sectioned for tissue fixation prior to radiography of the tooth. Consequently neither standard radiography nor a CAT scan was performed on the tooth.

### Dissecting Microscopy:

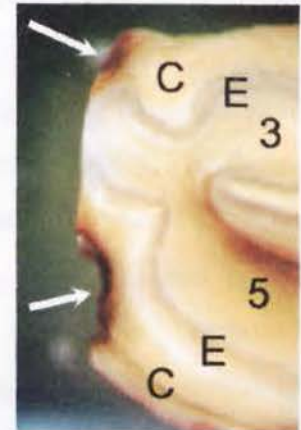
There was no evidence of occlusal pulp exposure or of descending tracts in the peripheral cementum that might be suggestive of descending periodontal disease. Cemental caries was present at two sites on the caudal aspect of the clinical crown

(Figures 2.18 and 2.19). There was no evidence of dental fracture other than that which occurred during oral extraction.



**Figure 2.18:** The apical aspect of the sub-occlusal transverse section from CT 310, Case 21. Note that all pulp chamber regions (1-5) are occluded by dentine (primary and secondary). Two focal areas of cemental caries are evident (arrows) on the caudal aspect of the tooth. (B=buccal; C=caudal)

**Figure 2.19:** Close-up view of two focal areas of caries (arrows) present in the cementum of CT 310 from Case 21. Pulp chambers 3 and 5 are occluded with dentine. (C=cementum; E=enamel layer between cementum and dentine)



### **Histology:**

Irregular secondary dentine had occluded all pulp chambers in the transverse sub-occlusal section. Even though necrotic pulp and pus was present in all pulp chambers in the mid transverse section, predentine was still present on the margins of all pulp chambers. Pulp chambers 1 and 2 still communicated in this section.

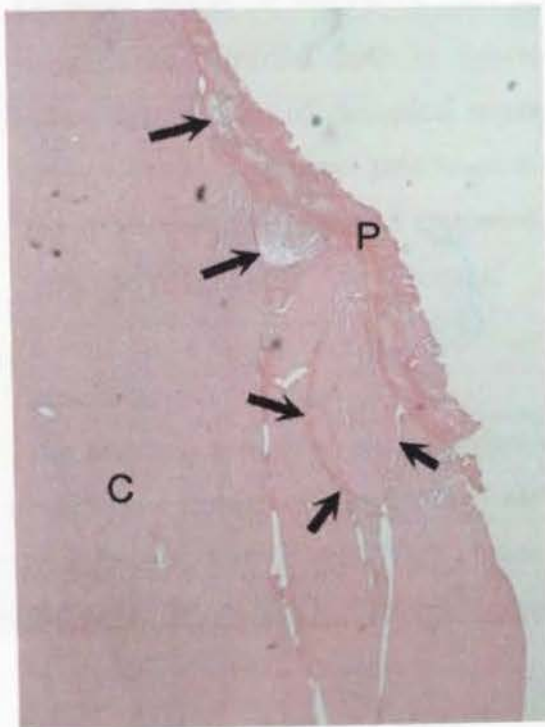
When compared to Control CT 64 and Control CT 67 (Triadan 310 and 410 respectively, each with a dental age of six years), the amount of primary dentine in

sub-occlusal transverse sections of the diseased CT and the two control CT was similar. However, there was a decreased amount of secondary dentine present in the diseased CT, particularly in pulp chambers 1 and 3, as shown in Table 2.3.

Pulp Horn	Buccal Secondary Dentine ( $\mu\text{m}$ )			Lingual Secondary Dentine ( $\mu\text{m}$ )		
	Control CT 64	Control 67	Case 21	Control CT 64	Control CT 67	Case 21
1	900	850	200	400	400	100
2	200	100	300	0	100	100
3	-	1250	600	-	150	50
4	1000	1200	800	650	800	500
5	650	950	600	-	750	350

**Table 2.3:** Regular secondary dentine thickness in buccal and lingual directions in the occlusal transverse sections from Control CT 64 and 67, and CT 310 from Case 21. Measurements are from pulp chambers 1-5 in both buccal and lingual directions.

Slides from the mid transverse sections of control CT could not be examined for comparison to the diseased CT section due to slide artefact. As illustrated in Figures 2.18 and 2.19, cemental caries were present in the clinical crown. When viewed at higher magnification remodelling of cementum is evident as seen in Figure 2.20.



**Figure 2.20:** Decalcified, longitudinal section of clinical crown of CT 310 from Case 21 showing normal cementum (C) and where reactive cementum has been deposited over previously carious cementum, resulting in an irregular junction between these two types of cementum formation (arrows). Plaque (P) is present amongst the redeposited cementum. (H&E x40)

**Conclusions:**

There were no signs of subgingival periodontal disease, deep caries, fracture or occlusal pulp exposure in this extracted CT. Pulp chambers 2, 4 and 5 all had normal amounts of dentine (primary and secondary) present, while pulp chambers 1 and 3 had decreased secondary dentine present. The absence of other identifiable causes of apical infection and the presence of evidence of longstanding infection of pulp horns 1 and 3 makes anachoretic pulpitis the most likely cause of this apical infection.

**Case 31 93/586****4 year-old Mare****History and Clinical Examination:**

This mare was referred with a history of a swollen left mandible with a ventral sinus tract of 12 months duration. Radiographic examination showed extensive destructive changes to the roots of Triadan 307 (dental age 0.5 years). The tooth was subsequently repulsed under general anaesthesia

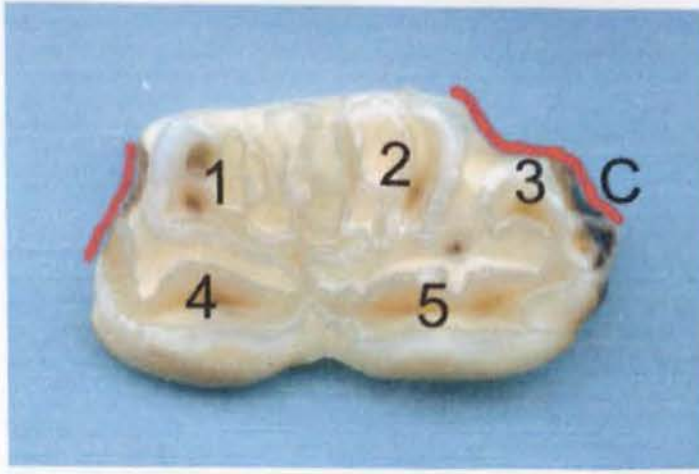
**Radiology of the Extracted CT:**

Exposure factors of 66kVp / 6.3mA and 55kVp / 5.0mA (d=65cm) were used for imaging the extracted tooth in anterior-posterior and lateral planes, respectively. Iatrogenic fractures of the apical region, caused by repulsion were evident in both views. Lytic changes were present on root areas that were not iatrogenically damaged and there was a generalised increased radiodensity of the tooth crown due to its increased (dysplastic) enamel content.

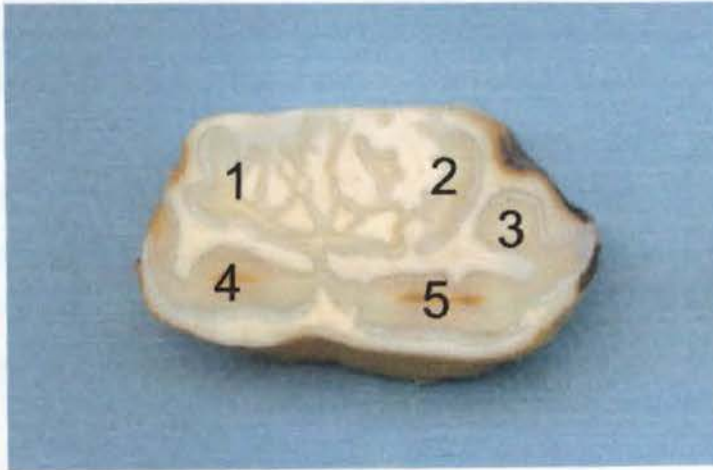
**Dissecting Microscopy:**

The standard pattern of pulp chamber anatomy, described earlier in this work, was clearly not present on the occlusal surface of this CT. Enamel in the area of pulp chambers 1 and 2 was finely branched, with adjacent cementum and dentine following this dysplastic pattern (Figure 2.21).

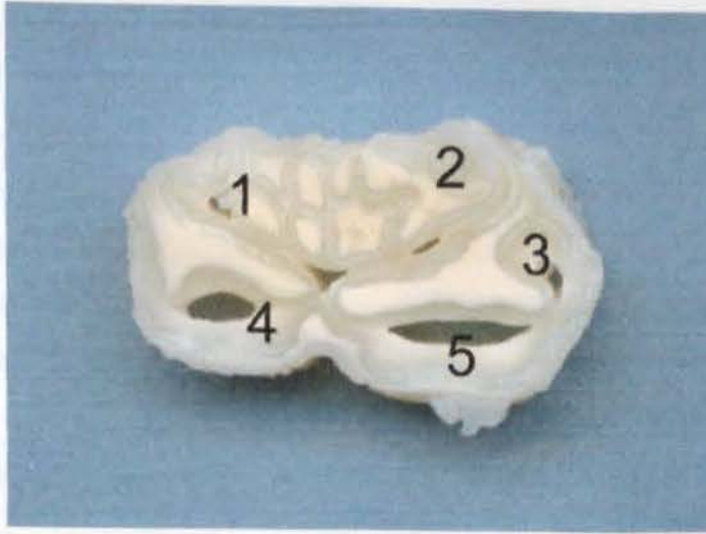
The dysplastic nature of enamel around pulp chambers 1 and 2 was present throughout the length of the tooth, as seen in Figures 2.22 and 2.23.



**Figure 2.21:** The occlusal surface of CT 307 from Case 31 showing pulp chambers 1 and 2 to be dysplastic as a result of dysplastic enamel (that acted as scaffolding for subsequent dentine and cementum formation). Caries of cementum (C) is present on the caudal aspect of this occlusal section. The dysplastic enamel surrounding pulp chambers 1 and 2 has altered the overall shape of the tooth. Consequently it fitted poorly into the dental alveolus, and areas of periodontal food pocketing and periodontitis including cemental loss resulted (indicated by superimposed red lines).



**Figure 2.22:** The apical face of the occlusal section of CT 307 from Case 31 showing pulp chambers 1 and 2 to be dysplastic as a result of dysplastic enamel. The abnormal nature of the enamel is clearer than when viewed from the occlusal surface (Fig 2.21).



**Figure 2.23:** The mid section of CT 307 from Case 31 showing empty pulp chambers 1-5. Because of the branched nature of enamel in pulp chambers 1 and 2, dentine thickness has been reduced and cementum has become 'pinched off' to become like maxillary infundibula i.e. completely surrounded by enamel.

#### **Histology:**

Despite no pulp chambers being exposed on the occlusal surface of this CT, irregular secondary dentine had not been deposited immediately beneath the surface, in the transverse occlusal section examined histologically (approximately 2-4mm beneath the occlusal surface). All pulp chambers were empty in both occlusal and mid transverse sections examined. When compared to Control CT 12 (Triadan 307, dental age of 0.5 years), the amount of primary dentine in occlusal and mid transverse sections was reduced (although measurements were not taken from dysplastic pulp chambers 1 and 2). There was decreased secondary dentine present in the diseased CT, with none being present in the mid transverse section.

#### **Conclusions:**

During the present study, two apically infected mandibular CT from different horses were found to have dysplastic enamel around pulp chambers 1 and 2. The other case (Case 37) was an eight-year-old Welsh Cob mare, and again Triadan 07 was affected. Neither CT had occlusal pulp exposure or fracture to the clinical crown.

In both cases there was associated periodontal food pocketing and periodontal disease and some local destruction to cementum of the clinical crown. It does not however appear that this periodontal disease descended to infect the apical tissues, as in both cases there was minimal change to cementum beneath the gingival margin i.e. no descending tracts were present in cementum as were observed in other CT. It is possible that the poor apposition of the CT within its alveolus caused only localized periodontal ligament destruction.

Additionally, the presence of a ventral sinus tract from the apical region in these two cases strongly indicates that there was not any low pressure route for inflammatory material from the infected apex to discharge directly into the oral cavity (as occurs in cases of apical infection caused by descending periodontal disease). On balance therefore, it is most likely an anachoretic pulpitis initiated the apical infection requiring the extraction of this CT.

### Grouped Examination

The 22 mandibular CT with apical infection examined in detail were also compared with control CT in 12 groups based on Triadan position and dental age as shown in Table 2.4. Details of group seven are presented below.

Group Number	Triadan Position	Dental Age (years)	Diseased CT Case No:	Control CT No:
1	06	0.5-1.5	304	6
2	06	2.5-3.5	34	31,32
3	07	-0.5-0.5	23,30,31,35,36	12
4	07	1.0-1.5	24,39,301	22,33
5	07	4.5	37	61
6	07	7.5	302	76
7	08	0	27,33	13
8	08	3	303	45
9	09	2-3	32,40	16
10	09	4-5	25,28,38	24,35
11	09	9-10	29	78
12	10	6-7	21	64,67

**Table 2.4:** Details of apically infected mandibular CT and Control CT groups based on Triadan position and dental age.

## **Group Seven: Cases 27 and 33, and Control CT 13**

Two cases involving mandibular Triadan position 08 were examined together for comparison with an age and Triadan position matched control CT (dental age 0 years). These three CT were selected to highlight how even when 'case matching' CT to eliminate inter-tooth variation, interpretation of results must be carefully performed. Despite this limitation, much useful information can be obtained from such comparisons.

### **History and Clinical Examination:**

**Case 27:** A four-year-old mare was referred with a discharging sinus tract from its swollen right hemimandible of five months duration. Oral examination showed no detectable abnormality of the tooth but radiography confirmed the presence of apical tooth infection of CT 408. This tooth was then extracted intact *per os* under standing sedation.

**Case 33:** A four-year-old Warmblood mare had a discharging sinus tract in the left ventral mandible of approximately three months duration. Two months previously a retained deciduous tooth remnant ('cap'- Triadan 708) had been extracted. Oral examination revealed that Triadan 308 and 309 had erupted but were not in wear. In addition, malodorous food material was packed around Triadan 308. Radiography confirmed apical changes around CT 308, which was then orally extracted under standing sedation.

### **Radiology of Extracted CT:**

**Case 27:** Exposure factors of 66kVp / 6.3mA and 55kVp / 5.0mA (d=65cm) were used for optimal imaging of the extracted tooth in anterior-posterior and lateral planes respectively. There was a marked loss of radiodensity to the apical area, in particular to the rostral aspect. The body and clinical crown appeared normal radiographically.

**Case 33:** Exposure factors of 66kVp / 6.3mA and 55kVp / 5.0mA (d=65cm) were used for optimal imaging of the extracted tooth in anterior-posterior and lateral planes respectively. In comparison to the CT of Case 27, this CT had a generalised decrease

in radiodensity. Sharp occlusal points indicated the unworn primary occlusal surface to still be present.

### **Dissecting Microscopy:**

**Case 27:** All five pulp chambers of this CT 408 had become exposed occlusally (Figure 2.24). This feature would have been difficult to detect on oral examination without using a dental explorer to aid diagnosis. Examination at an oblique angle to the light source showed small areas of subtle pitting in the darker secondary dentine overlying the pulps. Food was packed down all pulp chambers throughout the entire tooth (Figures 2.24-25).

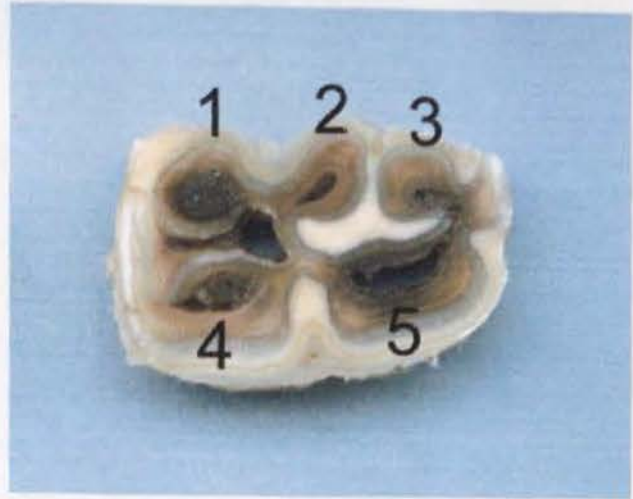The occlusal wear and pulp chamber exposure in this CT indicates that it may have erupted earlier than the standard eruption time (four years of age) of a Triadan 08 CT.

There was a marked presence of reactive cementum deposited around the roots of the tooth with the apex of the caudal root appearing to have partially resorbed, making it shorter than the rostral root. Cementum had become hyperplastic on the rostral face of the CT overlying the rostral enamel infolding.



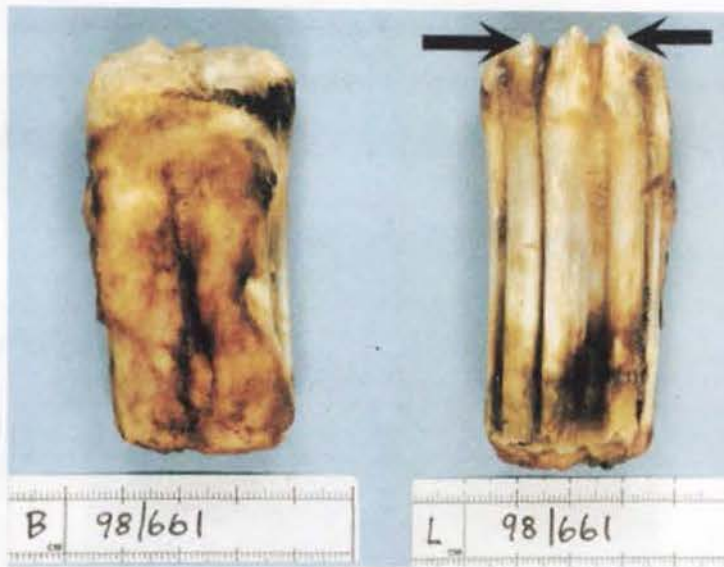**Figure 2.24:** Occlusal surface of CT 408 from Case 27 showing all five pulp chambers (1-5) to be exposed on the occlusal surface. The slight central pitting in pulp chambers 4 and 5 are the most convincing evidence of occlusal pulp exposure in this figure.

**Figure 2.25:** Transverse mid section of CT 408 from Case 27. Pulp chambers 1, 3, 4 and 5 contain food within their lumens. Pulp chamber 2 is empty. The dentine around all five pulp chambers is darkly stained due to a combination of plant pigments and caries.

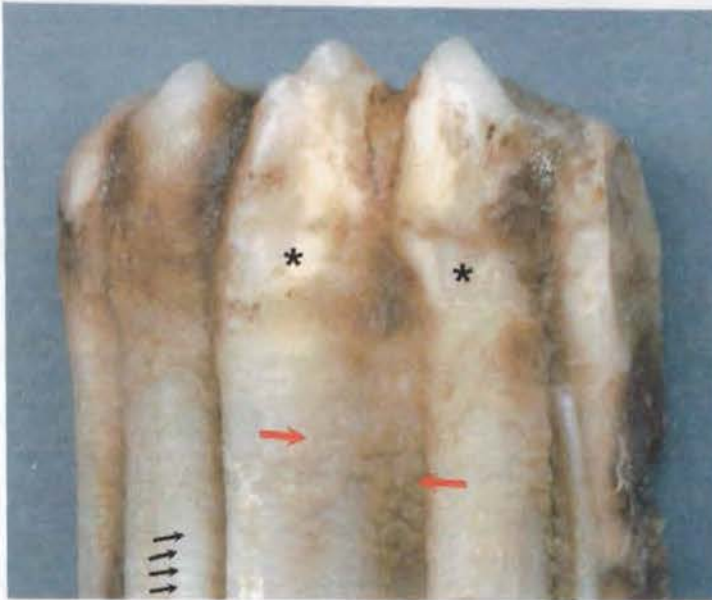

**Case 33:**

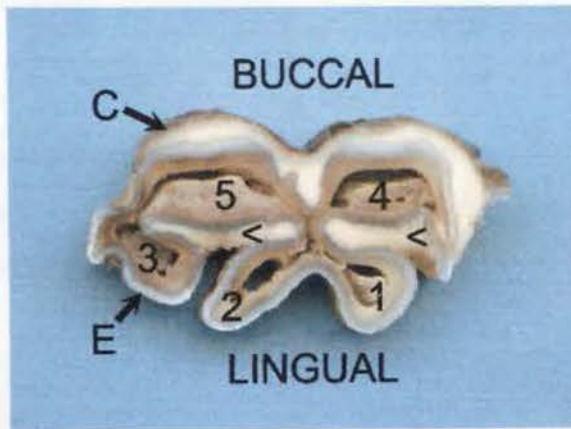
There was an almost total lack of cementum deposition on the lingual aspect of this Triadan 308 tooth (Figures 2.26-27). Following extraction, the alveolus was checked to ensure that no dental remnants remained, which was found to be the case.



**Figure 2.26:** Buccal (B) and lingual (L) views of CT 308 from Case 33. Periodontal ligament covers the majority of the buccal tooth face, while none is present on the lingual face. The lingual aspect of the apical region is discoloured. Smooth continuous enamel lophes (arrows) on the occlusal surface indicate the tooth has not yet come into occlusal wear.



**Figure 2.27:** A magnified view of the occlusal aspect of the lingual face of CT 308 from Case 33 highlighting the sparse cementum formation present on this lingual aspect. Small patchy areas of cementum (red arrows) are present, becoming more continuous at the level of the gingival margin. Further apically on the tooth, cementum is completely absent and lines illustrating the periodic nature of enamel formation are seen in the exposed enamel (black arrows). Crush marks (\*) are also present on cementum where the extractor forceps were placed during extraction.



**Figure 2.28:** The mid transverse section from CT 308, Case 33, shows cementum (C) to be present in normal quantities on the buccal aspect of the tooth, but only present deep within the two enamel (E) infoldings on the lingual face of the tooth (<). Necrotic pulp is present within all the discoloured pulp chambers (1-5).

### Histology:

Histological evaluation of dentinal measurements in these CT was potentially misleading as later discussed in the conclusions of this section.

**Case 27:** Pulp chambers 1-3 were impacted with food in the occlusal transverse section. Pulp chambers 4 and 5 contained pus, as did all pulp chambers in the mid transverse section. Despite the occlusal surface being in wear (to the point of pulp chambers becoming exposed) there was little or no secondary dentine present in either the occlusal or the mid transverse sections examined.

**Case 33:** Necrotic pulp was present in all endodontic chambers throughout the entire tooth. No secondary dentine was present in any area of the tooth.

**Control CT 13:** In contrast to the two infected CT, secondary dentine was present in all pulp chambers, as recorded in Table 2.4.

Pulp Horn	Buccal Secondary Dentine Measurement ( $\mu\text{m}$ )			Lingual Secondary Dentine Measurement ( $\mu\text{m}$ )		
	Control CT 13	Case 27	Case 33	Control CT 13	Case 27	Case 33
1	600	0	0	450	0	0
2	450	0	0	400	0	0
3	600	0	0	300	50	0
4	300	100	0	300	0	0
5	300	0	0	350	0	0

**Table 2.4:** Regular secondary dentine thickness in buccal and lingual directions in the occlusal transverse sections from Control CT 13, and apically infected CT from Cases 27 and 33. Measurements are from pulp chambers 1-5, in both buccal and lingual directions.

### Conclusions:

As all three CT had a *dental age* of 0 years, we would expect these teeth to have erupted into the oral cavity but not yet come into substantial wear. The occlusal surfaces of Control CT 13 and the infected CT of Case 27 were both worn to the degree that their secondary occlusal surface had been established. Secondary dentine was present in the control CT, yet was absent in the CT of Case 27 due to destruction

of pulp (specifically odontoblasts) before the CT came into occlusal wear. The infected CT from Case 33 did not have any secondary dentine either, however it is unknown if this was due to the destruction of pulp, or alternatively because this tooth did not come into occlusal wear – as both a viable pulp *and* occlusal contact stimulation are thought to be necessary for secondary dentine formation. Clinical signs associated with apical abscess formation were present in both cases for 3-5 months prior to their extraction. It is possible therefore that primary dentine formation could have also been affected, however primary dentine values between all three CT were comparable.

These two cases presented with similar clinical signs, and both had suffered from periodontal disease. The periodontal disease in Case 27 is likely to have arisen following apical abscess development, with infectious exudates tracking within the dental alveolus to potentially escape either into the oral cavity or through a mandibular sinus tract (or both). In Case 33, the apical infection is likely to have arisen while the deciduous tooth ('cap', CT 708) was still present, with food trapped beneath it (and overlying CT 308) prior to removal two months previously. The cemental hypoplasia present on the lingual aspect of CT 308 likely indicates that cementoblasts were destroyed by periodontal infection associated with the food trapped beneath CT 708. Staining of apical enamel on the lingual face of this CT may indicate this periodontal disease may have deeply invaded the dental alveolus. In view of these findings, this case (Case 33) is one of just two cases in this study where descending periodontal disease is likely to have caused apical tooth infection.

In conclusion, even when grouping cases to very defined and limited criteria (namely similar Triadan position and dental age), all cases must still be evaluated on an individual basis. In Case 27, anachoretic pulpitis or occlusal pulp exposure are the most likely causes of the apical infection, with anachoretic pulpitis being the most likely for similar reasons as given for Case 28.

## Appendix 3: Case Reports of Idiopathic Cheek Teeth Fracture in Different Fracture Groups

Case examples are given for each fracture group type, with comparisons of (transverse) histological measurements of dentinal thickness from fractured CT being made to control teeth of similar dental age and Triadan position.

### Group 1: Maxillary Buccal Slab Fractures

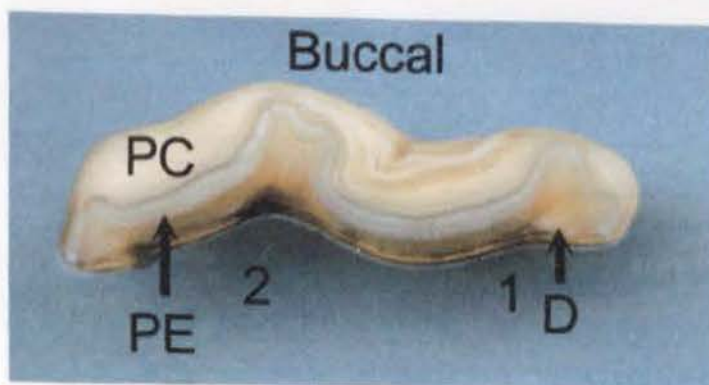
#### Case 56:

A 12-year-old Thoroughbred gelding presented with a history of sudden onset abnormal biting behaviour and food packing between the right upper CT row and the right cheek one week before referral. Examination revealed a buccal slab fracture of CT 108 through pulp chambers 1 and 2, with food packed into the fracture site causing the buccal slab fracture to be displaced laterally into the cheek, causing buccal ulceration.

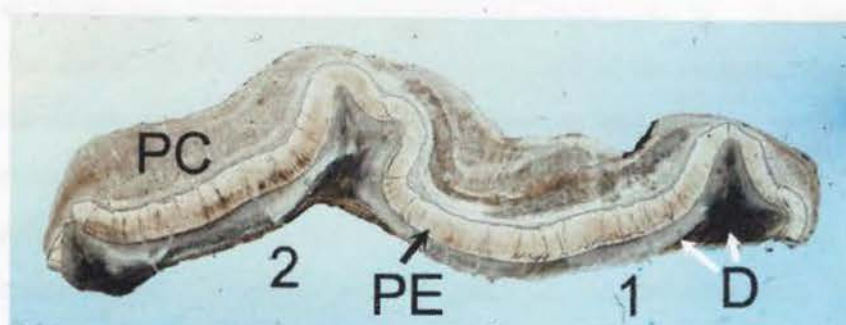
The loose buccal slab was removed under sedation with the larger, stable part of the tooth being left *in situ*, as there was no clinical evidence (maxillary swelling or nasal discharge) of apical abscess formation (Figure 3.1). The buccal tooth fragment was 40mm in length (occlusal – apical), with approximately  $\frac{3}{4}$  of this length being subgingival. This dental fragment was radiographed and processed for histology.



**Figure 3.1:** The internal (medial) face of the buccal slab fracture removed from CT 108 of Case 56. The internal dentinal faces of pulp chambers 1 and 2 (numbered) have been stained dark brown following their exposure when the CT fractured.




**Figure 3.2:** The occlusal view of the buccal slab fracture removed from CT 108 from Case 56. Peripheral cementum (PC) is present as the cream layer on the buccal face of the fractured piece of tooth, with peripheral enamel (PE) sandwiched between the peripheral cementum and the recently exposed dentine layer (D) that has become heavily stained in parts. The approximate positions of pulp chambers 1 and 2 are numbered.



**Figure 3.3:** Ground undecalcified section of the buccal slab fracture removed from CT 108 from Case 56. Peripheral enamel (PE) is present between dentine (D) and peripheral cement (PC) as for Figure 7.5, with the regions of pulp chambers 1 and 2 labelled. Adjacent dentine had become discoloured. The translucent nature of these three calcified tissues is evident, with enamel appearing as the most ordered of the three tissue types, and cementum the least ordered.

Histological measurements (as detailed in Chapter 3) showed that the dentinal thickness in this diseased tooth was similar to that of a control CT of similar dental age and Triadan position (Control 85), with both having 800 $\mu$ m total buccal dentine thickness in occlusal transverse sections adjacent to pulp chamber 1, and 1000 $\mu$ m total buccal dentine thickness adjacent to pulp chamber 2.

When examined under the SEM, the fracture site (involving enamel, dentine and cementum) appeared slightly abraded but non-carious (Figure 3.4). A magnification bar is present along the base of the image, as for all SEM figures.



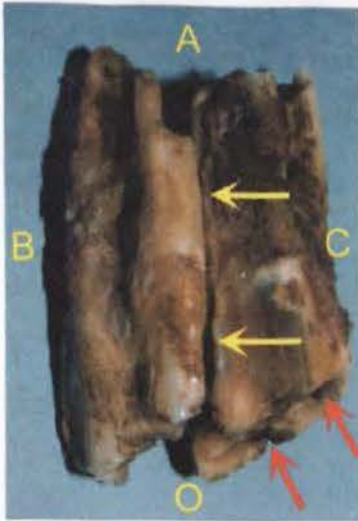
**Figure 3.4:** A scanning electron micrograph of the exposed pulpar face of dentine (D) and the perpendicular fracture plane in CT 108 from Case 56. The fracture plane makes up the left of half of this micrograph, to the left of the vertical crack identified by a yellow arrow. The fracture runs through dentine and enamel, to the left of the amelo-dental junction (the irregular vertical line identified by ←ADJ). The pulp's dentinal surface (which has an artefactual fracture line -red arrow) was smooth, in contrast to its irregular appearance on the surface of the fracture plane. (SEM 1bar = 0.1mm)

The similar dentinal thickness of the fractured dental fragment to that of control CT, and the absence of caries to the dental fragment when viewed under SEM concurred with the history that this fracture was of very recent origin. No other pathological abnormalities were detected in this dental fragment.

#### **Case 43:**

A 9-year-old Connemara mare presented with a fractured 107 CT of unknown duration, and an intercurrent apical abscess of this tooth that had discharged into the nasal cavity. The remaining diseased crown fractured further during attempted oral extraction and the CT was subsequently removed by repulsion.

Atypically, the fracture ran through the entire length of the repulsed tooth, as seen in Figure 3.5. Additionally, pulp chambers 3, 4 and 5 had all been exposed at the occlusal surface, and the dentine surrounding these three pulp chambers was carious.



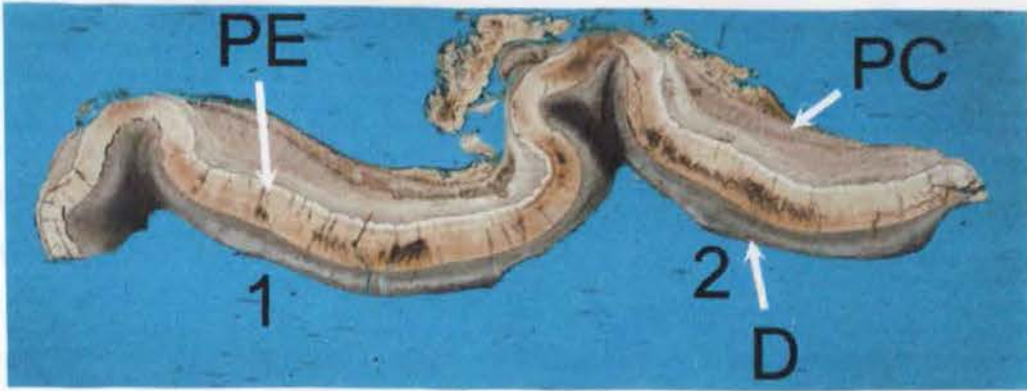**Figure 3.5:** Rostral view of fractured CT 107 from Case 43 with the fracture line (yellow arrows) running from the occlusal surface (O) to the apical region (A), that was further damaged during repulsion. Pulp chambers 3, 4 and 5 had been exposed at the occlusal surface (red arrows identify two exposed pulp chambers) in addition to pulp chambers 1 and 2 that were exposed by the dental fracture. (B=buccal; C=caudal)

In a control 107 CT of similar dental age (4.5 years), considerable secondary dentine had been laid down, however only primary dentine was present in the buccal slab of this slightly older (5.5 years dental age) fractured CT as shown in Table 3.1.

Pulp chamber	1° Dentine (buccal) Control CT 50 (4.5 years)	1° Dentine (buccal) Case 43 (5.5 years)	2° Dentine (buccal) Control CT 50 (4.5 years)	2° Dentine (buccal) Case 43 (5.5 years)
1	700	700	400	0
2	600	650	350	0

**Table 3.1:** Comparison of dentinal thickness in pulp chambers 1 and 2 of Control CT 50 and Case 43.

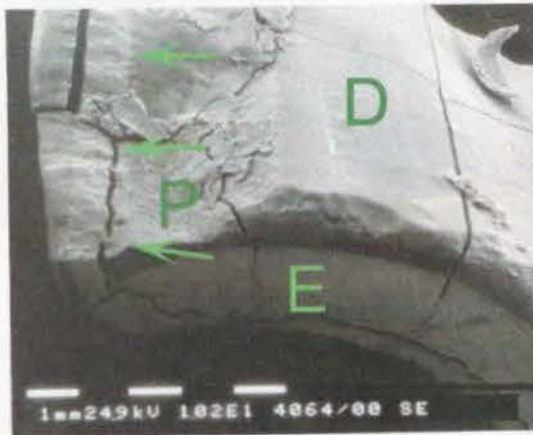
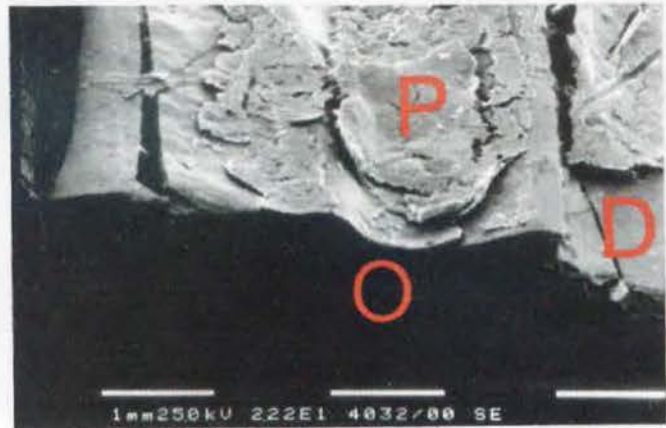
The lack of secondary dentine present in Case 43 may be one reason why there is no staining or discolouration of dentine immediately adjacent to pulp chambers 1 and 2 that were exposed following fracture, as seen in Figure 3.6 in contrast to the findings of fractured CT 56 (shown in Figure 3.3).



**Figure 3.6:** A ground, undecalcified transverse section of the buccal slab fracture from Case 43. Peripheral enamel (PE) and peripheral cementum (PC) lie buccally to primary dentine (D). The dentine was not discoloured by caries or food pigments.

When examined under SEM, an organic plaque layer was present on the fracture surface even after acid etching (as described in Chapter 3) as shown in Figure 3.7.

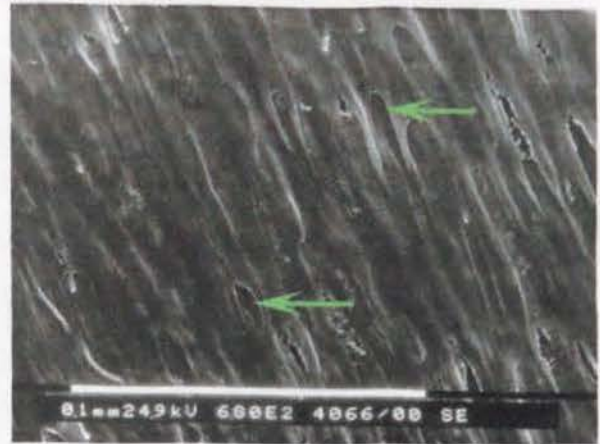**Figure 3.7:** Palatal aspect of the exposed dentinal surface (D) of the buccal slab fracture from CT 107, Case 43. An organic plaque layer (P) is present on the exposed dentinal surface. The occlusal surface (O) is in shadow at the bottom of the figure. (SEM 1bar =1mm)



**Figure 3.8:** Palatal aspect of the fractured surface of the buccal slab of CT 107, Case 43. A plaque layer (P) is present on some of the exposed dentinal surface (D). An enamel band (E) of lighter shading is apparent where the tooth has been transversely sectioned. The fracture plane lies to the left of the green arrows, with the

surface to the right being dentine previously adjacent to pulp chambers 1 and 2. (SEM 1bar =1mm)

**Figure 3.9:** A scanning electron micrograph of the exposed dentine surface of pulp chamber 1 of CT 107, Case 43 following fracture. Dentinal tubules (arrows) have been exposed obliquely and the surrounding dentine appears smooth. There is no evidence of carious attack. (SEM 1bar =0.1mm)



The absence of secondary dentine within pulp chambers 1 and 2 and the occlusal exposure (with subsequent food impaction) of pulp chambers 3, 4 and 5 would indicate that the apical infection in this fractured CT had been present for many months, as secondary dentine would normally be present in a tooth of this dental age. As there was no caries of the exposed dentine at the fracture site, the absence of secondary dentine in this fractured fragment is due to lack of its development, rather than to its destruction by caries. It is therefore most likely that this CT had been weakened prior to its fracture by a lack of development in secondary dentine. One possible reason for this could be the presence of an anachoretic pulpitis prior to fracture having decreased dentine formation and thus the structural strength of the tooth.

## **Group 2: Maxillary Infundibular Sagittal Fractures**

### **Case 49**

An 11-year-old Thoroughbred gelding presented with a history of right-sided nasal discharge of five months duration, and latterly of epiphora, quidding, and chewing with the left side of the mouth only.

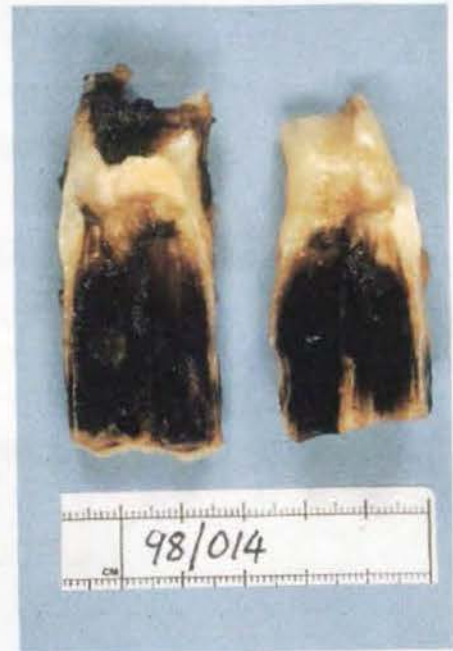Oral examination revealed CT 109 had been fractured sagittally, with the buccal fragment displaced laterally due to food impaction within the sagittal fracture site.

Nasal endoscopy showed pus draining from the maxillary sinus drainage area and radiography confirmed periapical infection of the fractured tooth. Both halves of the tooth were orally extracted under standing sedation.

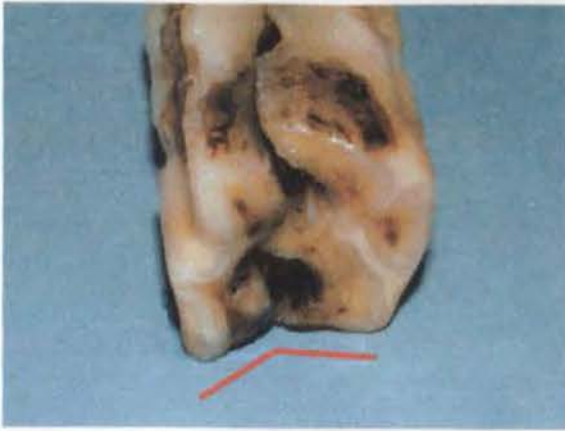Digital examination showed no gross communication of the affected alveolus with the overlying maxillary sinus, however subsequent endoscopic examination of the middle nasal meatus 10 days later showed food and inspissated pus present at this site, with an opening now apparent between the nasal cavity and the ventral concha. This food material was likely to have originated from the alveolus of the fractured tooth, forming an oro-maxillary fistula that later fistulated into the nasal cavity.

Dissecting microscopy of the extracted CT showed marked infundibular caries of both buccal and palatal tooth halves involving infundibular cementum and enamel, and with coalescence (involving the intervening dentine) between the two infundibula (Figure 3.10).

**Figure 3.10:** Buccal (left) and palatal (right) halves of CT 109 from Case 49 showing their sagittally fractured infundibula. The rostral and caudal infundibula had coalesced, with very dark staining across the majority of their exposed surfaces. The apical third of the CT had only recently been exposed to the oral environment and had not become noticeably stained.

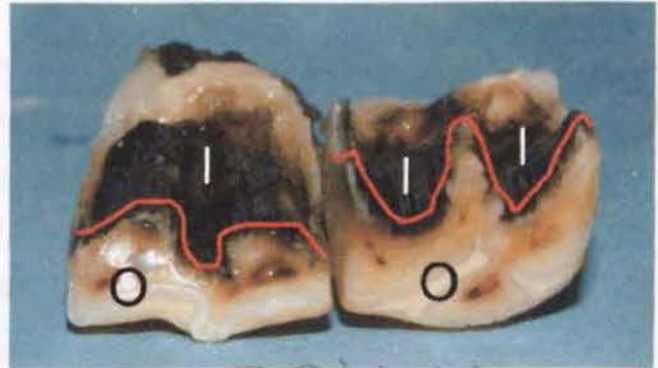


The occlusal surfaces of both halves of the tooth were worn at abnormal angles that occurred once both parts had displaced following fracture (Figure 3.11). None of the pulp chambers had been exposed occlusally.



**Figure 3.11:** Case 49 (CT 109) viewed from the occlusal surface, with the buccal (left) and palatal (right) halves of the fractured CT opposed, showing the abnormal occlusal wear angles (red line).

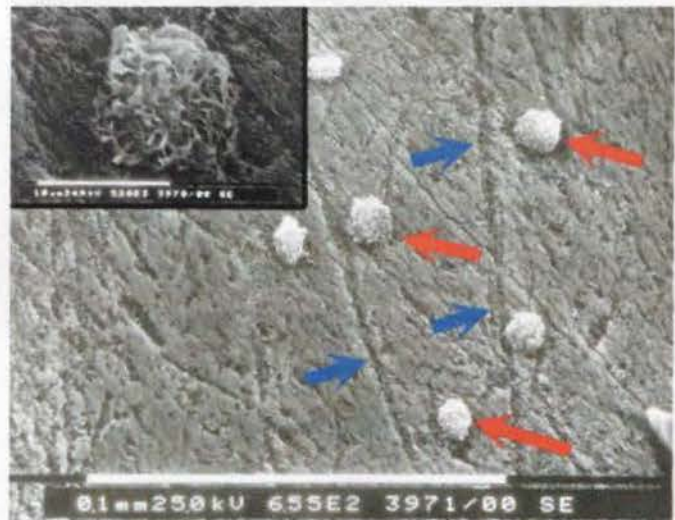
**Figure 3.12:** Occlusal (O) view, looking down on the remaining infundibular enamel surfaces of CT 109 from Case 49. All infundibular cementum has been removed by carious attack and the infundibular enamel (I) has

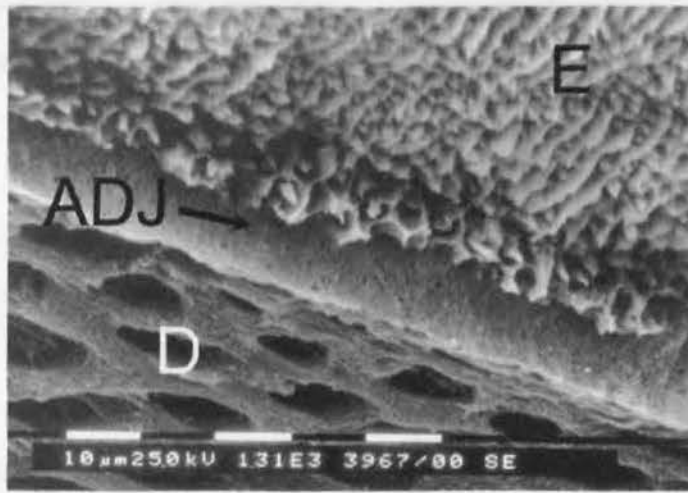


become darkly discoloured by plant pigments and caries. Red lines follow the infundibular margins of both buccal (left) and palatal (right) fragments.

On SEM examination, mild abrasion was present to most areas of infundibular enamel, and in some areas, spherical objects thought to be fungal hyphae or yeasts were identified (Figure 3.13).

**Figure 3.13:** A scanning electron micrograph of exposed infundibular enamel from CT 109 of Case 49. A layer of organic debris with score lines (blue arrows) running through it covers the enamel. Irregular spherical objects thought to be fungal hyphae or yeasts (red arrows and insert) are adhered to this layer. (SEM 1bar =0.1mm)

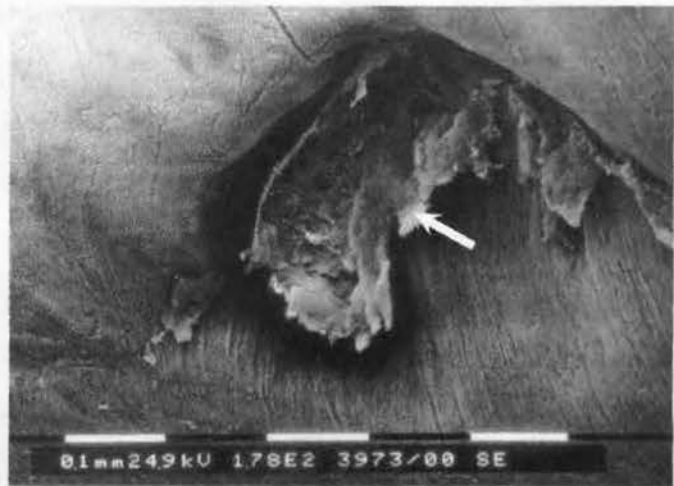



**Figure 3.14:** The amelo-dentinal junction (ADJ) has become exposed at the fracture surface of CT 109 of Case 49, as equine Type-1 enamel (E) and primary dentine (D) have separated during processing. Their etched surfaces reveal a normal (i.e. non-carious) appearance beneath the layer of organic debris. (SEM 1bar = 10μm)

When examined in the SEM, enamel and dentine present at the fracture sites was found to be non-carious (Figure 3.14). This agrees with the observation that the *fracture sites* were not stained or discoloured on dissecting microscopy examination (Figure 3.12).

**Figure 3.15:** Organic debris (arrow) is present within this enamel defect on the occlusal surface of CT 109 from Case 49. Note the regular arrangement of the surrounding equine Type-1 enamel. (SEM 1bar = 0.1mm)



Dentine was present in similar quantities in this fractured CT, to that of a comparable Control CT (CT 72, Triadan position 109, dental age 10) as shown in Table 3.2.

<b><i>Pulp chamber</i></b>	<b>Orientation</b>	<b>Total Dentine Present Case 49 (µm)</b>	<b>Total Dentine Present Control Tooth 72 (µm)</b>
1	Buccal	2050	1850
1	Palatal	3500	2850
2	Buccal	1900	1750
2	Palatal	3400	3450

**Table 3.2:** Dentinal measurements (primary and secondary combined) adjacent to pulp chambers 1 and 2 from CT 109 of Case 49 and control CT 72.

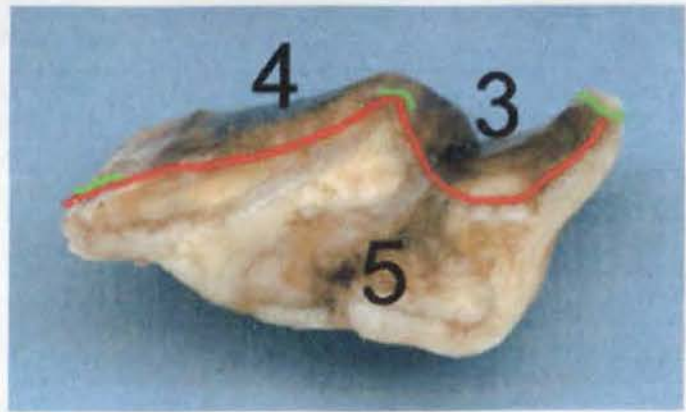
The similar thickness of dentine surrounding pulp chambers 1 and 2 from CT 109 Case 49 and Control CT 72 indicates that the disease present in the CT of Case 49 had not affected dentine production. With this CT having a dental age of 10 years, we would expect most dentine to have already been laid down within the endodontic system (Chapter 4). The sagittal infundibular fracture had resulted from caries and subsequent coalescence of both infundibula, weakening the tooth sufficiently for it to eventually completely fracture for its entire length.

### **Group 3: Miscellaneous Maxillary Fractures**

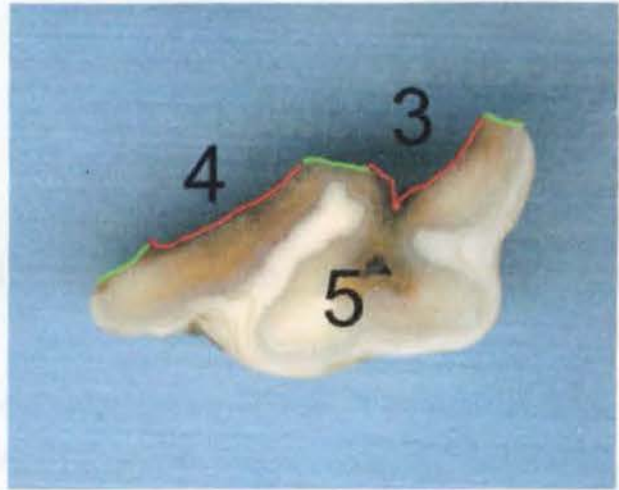
#### **Case 41:**

An 11-year-old Thoroughbred mare was presented with a history of abnormal head movements and placing the tongue over the bit when being ridden. Oral examination revealed CT 109 to be fractured, with medial displacement of a 3cm-long palatal tooth fragment towards the hard palate. Following irrigation of the fracture site to remove impacted food, the palatal fragment was removed with extraction forceps. The remainder of the tooth (i.e. the larger firmly attached buccal part) appeared healthy and was retained *in situ* along with the more apical part of the palatal fragment. At re-examination six months later, the owner reported resolution of the previous complaints and there was still no clinical evidence of apical abscess formation.

**Figure 3.16:** Palatal fragment of CT 109 from Case 41 showing the fractured occlusal aspect, with the fracture plane (red line) running through pulp chambers 3 and 4. The *calcified* areas of the tooth that were fractured are highlighted by green lines c.f. areas of pulp that were exposed and then destroyed.



**Figure 3.17:** Mid-transverse section of CT 109 from Case 41, showing the fracture plane running through pulp chambers 3 and 4 (sites outlined by numbers), and brown stained dentine within pulp chamber 5. The fracture plane consists of exposed endodontic pulp chamber walls (red lines) and sites of fractured calcified tissue (green lines).



Under dissecting microscopic examination, the fracture plane was seen to run through pulp chambers 3 and 4. The occlusal aspect of the tooth fragment had been fractured prior to extraction leaving an unworn, lightly stained, irregular occlusal surface (Figure 3.16).

Both primary and secondary dentine were present in pulp chambers 3, 4 and 5 from this CT 109 of Case 41, however total palatal dentinal thickness was reduced in pulp chambers 3 and 5, when compared to a control CT of similar Triadan position and dental age as recorded in Table 3.3.

<i>Pulp chamber</i>	<i>Orientation</i>	<i>Total Dentine Case 41 (µm)</i>	<i>Total Dentine Control CT 72 (µm)</i>
3	Palatal	2200	2700
4	Palatal	2600	2650
5	Palatal	2000	2900

**Table 3.3:** Dentinal measurements (primary and secondary dentine combined) of CT 109 from Case 41 and Control CT 72 adjacent to pulp chambers 3, 4 and 5.

The non-carious appearance of dental sections from Case 41 when viewed histologically or in the SEM, together with the similar quantities of dentine present in this diseased CT and the comparable control CT indicate that the fracture to the clinical crown of this tooth was recent, as is supported by the clinical history. It is not possible to determine from the sections examined, whether there had been a more recent decline in dentine production. The exact aetiology of this fracture therefore remains unclear.

#### **Group 4: Mandibular Buccal Slab Fractures**

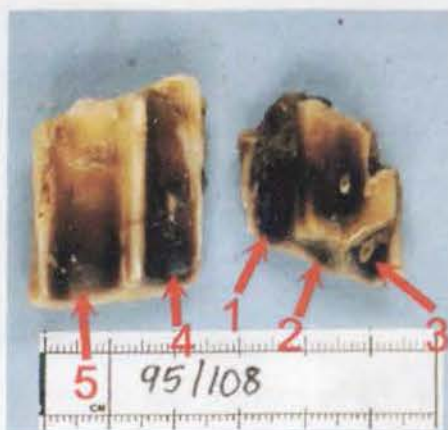##### **Case 42:**

A 10-year-old Eriskay pony gelding presented with a history of halitosis and food impaction to the left side of the mouth of unknown duration. An oral examination revealed fracture of the clinical crown of CT 407. Radiographic changes were present in the periapical region of this tooth.

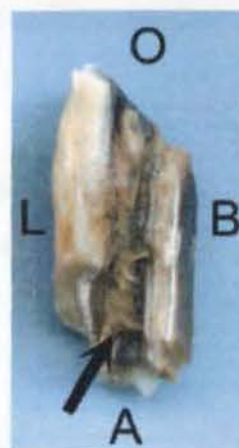The loose buccal fragment of CT 407 was readily extracted *per os* under standing sedation, however the non-displaced lingual fractured portion of the tooth was firmly attached (by generally healthy periodontal ligaments), and a small fragment of this lingual part remained sub-gingivally, following its oral extraction.

Examination of the lingual and buccal fragments of this CT showed the fracture plane to run through pulp chambers 4 and 5. In addition, pulp chambers 1, 2 and 3 had been exposed on the occlusal surface (through attrition) as seen in Figure 3.18. Food had become impacted down these exposed chambers and dentine around these pulp chambers was darkly stained (Figure 3.18).

**Figure 3.18:** Buccal (left) and lingual (right) fragments of CT 407 from Case 42, with the sites of the pulp chambers numbered. Pulp chambers 4 and 5 were most likely to have been exposed at the time of fracture, with pulp chambers 1, 2 and 3 becoming exposed subsequently through dental attrition.




**Figure 3.19:** This figure shows food (arrow) impacted down pulp chamber 3 in the lingual fragment of CT 407 from Case 42. Note how the occlusal table has worn to approximately 45° from the horizontal plane (i.e. ‘shearmouth’ in a non-displaced tooth). (O=occlusal, B=buccal, A=apical, L=lingual)



The total dentinal thickness present on the buccal aspect of the pulp chambers in the fractured CT was considerably less than that present in Control CT 76 (Triadan position 407, dental age 7.5 years) as recorded in Table 3.4.

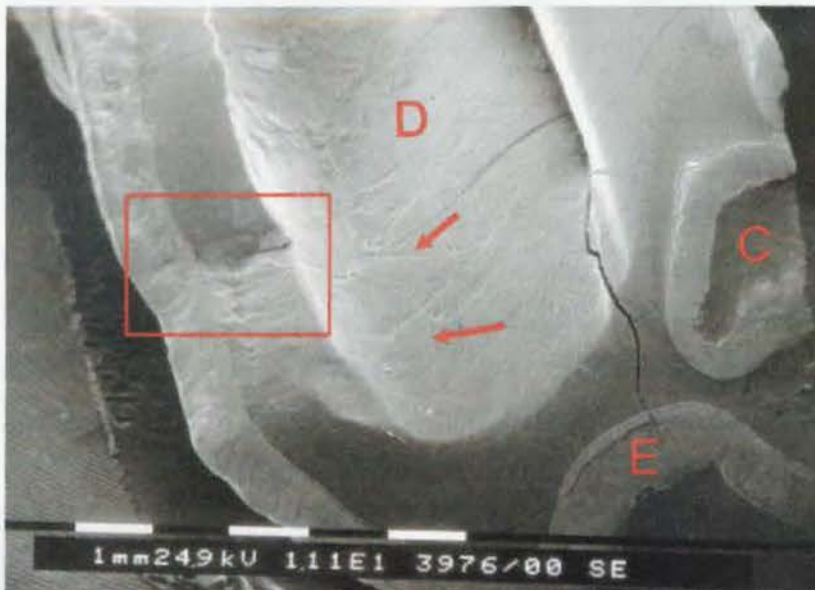
Pulp chamber	Total Buccal Dentine 407 of Case 42 (µm)	Total Buccal Dentine Control 76 (µm)
4	950	1550
5	1250	1950

**Table 3.4:** Dentinal measurements adjacent to pulp chambers 4 and 5 (primary and secondary dentine combined) from CT 407 of Case 42 and from a matched Control CT 76.




**Figure 3.20:** Transverse undecalcified section of the buccal slab fracture of CT 407 from Case 42. Enamel (E), dentine (D) and peripheral cementum (C) are identified, as are the areas previously occupied by pulp chambers 4 and 5. Resting lines are present within the unusually thick layer of buccal cementum.

The degree of dental damage (e.g. through wear or carious attack) cannot be assessed when viewing samples prepared for SEM at low magnification, and so areas of interest are first identified at low magnification (e.g. Figure 3.21) and then viewed at higher magnification, as shown in Figures 3.21-23.



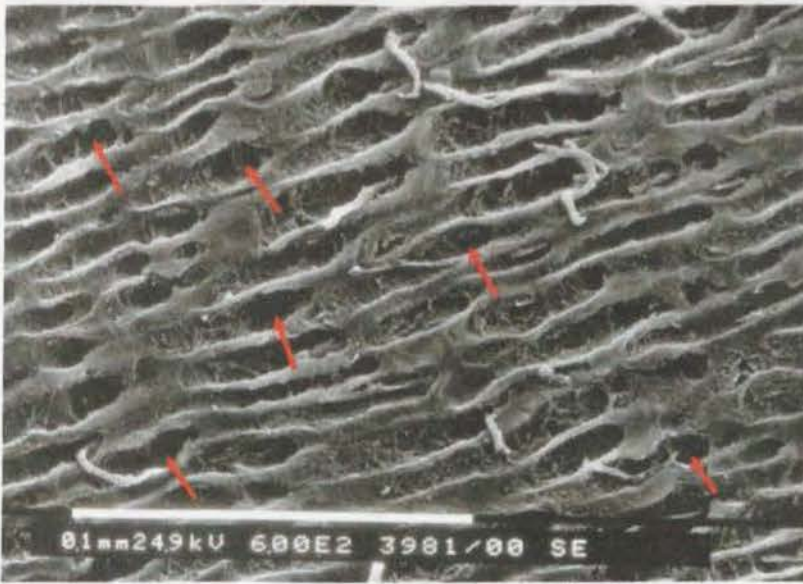
**Figure 3.21:** A scanning electron micrograph of the lingual fragment of CT 407 from Case 42. A band of enamel (E) is seen both from its occlusal surface (at bottom of figure) and the fracture site (at left of figure), with dentine (D) and cementum (C) on either side. Score marks (arrows) are seen on the now exposed dentine surface of pulp chamber 1. A magnified view of the fracture site (insert box) is shown in Figure 3.22.



**Figure 3.22:** A magnified view of the insert from Figure 3.21 (CT 407, Case 42) showing the general appearance of enamel (E) and dentine (D) at the fracture site. The dentinal face of the pulp chamber (PC) is also identifiable. Inserts A and B are presented in Figures 3.23 and 3.24. (SEM 1bar = 1mm)



**Figure 3.23:** Insert A from Figure 3.22 of CT 407 from Case 42. The swirling irregular nature of the enamel present at the fracture site identifies this to be equine Type-2 enamel. It is non-carious, as indicated by the sharp outline of the enamel prisms present. (SEM 1bar = 0.1mm)



**Figure 3.24:** Insert B from Figure 3.23 of CT 407 from case 42. Openings of dentinal tubules (arrows) are present at the fracture site. The tubules appear to be slightly disrupted, possibly from carious attack.

Having dental ages of 6.5 and 7.5 years respectively, both the diseased and control Triadan 407 CT would have been expected to have laid down significant amounts of secondary dentine by this stage of their dental life. However, the amount of secondary dentine, as compared to primary dentine, present in the undecalcified histological sections from the fractured CT could not be determined, as the distinction between primary and secondary dentine could not be clearly established on undecalcified histology alone.

Dentine exposed at the fracture site appeared to have undergone a limited degree of carious attack, which may have decreased the dentinal thickness measured in these transverse sections. However, this was believed to be minimal, on assessment of the degree of carious destruction present using SEM.

As pulp chambers 1-3 had all been exposed occlusally, and there was reduced dentine present within pulp chambers 4 and 5 when compared with a control CT, it appears that the pulp had ceased dentine production prior to fracture of the tooth. This would have structurally weakened the tooth.

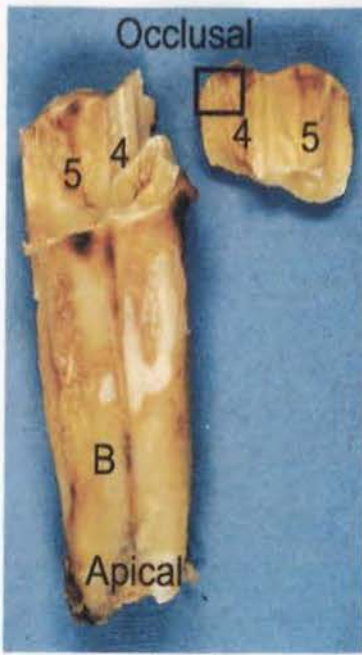
The radiographic periapical changes around this CT indicated the presence of periapical infection at time of tooth extraction, and this is likely to have been the reason for pulp ceasing to produce dentine prior to the buccal slab fracture of the clinical crown. The presence of endodontic infection may also have weakened adjacent dentine, further predisposing to fracture.

**Case 44:**

An eight-year-old Thoroughbred mare presented with a *circa* one-year history of intermittently being dull, febrile, and holding her head to one side when ridden. External palpation confirmed diffuse swelling of the right mandible. Oral examination revealed a fracture of CT 408. Radiography confirmed the presence of a periapical abscess of this tooth.

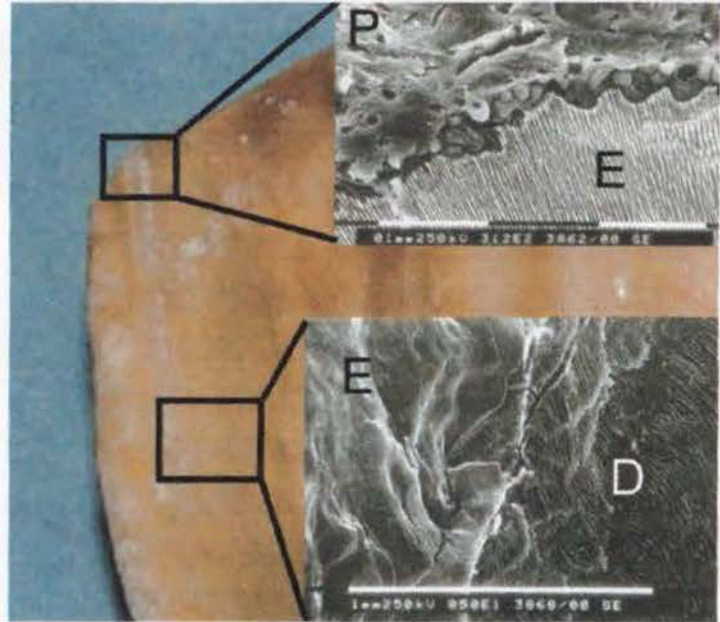
During attempted oral extraction of this tooth under standing sedation, the buccal fragment was easily removed, and was found to extend 15mm below the buccal gingiva. The remaining part of the clinical crown fractured transversely during attempted extraction, leaving no crown for further attachment of extractor forceps, and so the remaining portion of the tooth was (readily) repulsed into the oral cavity the following day. Whilst using molar separators during the attempted oral extraction, the adjacent CT 407 was unfortunately also iatrogenically fractured and so this tooth was repulsed the following day.

On examination of CT 408 under dissecting microscopy, the original vertical fracture plane was seen to run through pulp chambers 4 and 5, as shown in Figures 3.25-26.



**Figure 3.25:** The buccal aspect (B) and the lingual buccal slab fragment post-extraction of CT 408 from Case 44. Pulp chambers 4 and 5 (numbered) were exposed at the time of the dental fracture. Changes observed to the tooth are minimal at this gross level of examination. Magnified images of the insert (box) of the dental fragment are presented in Figure 3.26.

**Figure 3.26:** Two scanning electron micrographs have been inserted onto the enlarged area identified in Figure 3.25 of CT 408 from Case 44. The upper insert highlights the ordered appearance of equine Type-1 enamel present (E), with its irregular edge lying beneath an organic pellicle (P) covering the occlusal surface.



The lower insert identifies the irregular face of the fracture site, involving both enamel (E) and dentine (D).

The sections viewed in the scanning electron microscope had not suffered from carious attack. The amount of dentine present in buccal orientation adjacent to pulp chambers 4 and 5 exceeded that present in Control CT 62 (Triadan 408, dental age four years) as shown in Table 3.5.

Dentine type	Pulp chamber	Buccal Dentine Case 44 ( $\mu\text{m}$ )	Buccal Dentine Control CT 62 ( $\mu\text{m}$ )
Primary	4	1750	1550
	5	1300	1200
Secondary	4	900	800
	5	700	550

**Table 3.5:** Dentinal measurements (combined primary and secondary) adjacent to pulp chambers 4 and 5 of CT 408 from Case 44 and Control CT 62.

The clinical history of the horse having head carriage problems for one year prior to referral is not supported by any evidence of long-standing apical infection being present in this case (i.e. there was no decreased dentine production, or exposure of pulp chambers 1-3 occlusally). On both SEM appearance and histological measurements, the dentine of CT 408 from Case 44 appeared normal. There is no obvious underlying reason why this dental fracture occurred, beyond the assumption that in this relatively young CT (dental age four years), with minimal secondary dentine laid down, stress during mastication may have been sufficient to cause the buccal slab fracture.