

OBSERVATIONS  
ON THE  
DIAGNOSIS  
OF  
TUBERCULOUS BRONCHIAL  
ADENOPATHY  
IN  
CHILDREN.

---

A THESIS

SUBMITTED FOR THE DEGREE OF M.D.(EDIN.) 1923.

BY

B. GORDON EDELSTON, M.B. CH.B.(EDIN.)

---

1923.



## I N D E X

### SECTION I.

page

Incidence	1-6
Pathways of Infection	7-22
The Primary Focus	23-26

### SECTION II.

Development of Tuberculosis	27-30
-----------------------------	-------

### SECTION III.     DIAGNOSIS

General Considerations	31-34
Symptoms and Physical Signs	35-40

### SECTION IV.

Twenty-six Cases with their Histories and X-rays	41-76
---	-------

### SECTION V.

Personal Experience	77-92
Conclusions	93-95

<u>BIBLIOGRAPHY</u>	96-98
---------------------	-------

---

SECTION I.

SECTION I.

Chapter I.

I N C I D E N C E .

Medicine does not know a greater scourge than Tuberculosis. No disease is more widespread, more common, or more terrible in its consequences than is it. It stands first in the list of causes of death in this country. Pitiful though the sight of an adult in an advanced tuberculous state may be, a child in the grip of this pernicious disease presents one more pitiful still, and when death does not ensue, it frequently relegates to a life of misery its child victim.

A few statistics will prove how common, and how fatal, is this preventable disease :-

Still (1) in his work at the Children's Hospital, Great Ormond Street, found that out of a series of 769 autopsies on children under twelve years of age, 269 presented tuberculous lesions, and in 28.9% of these tuberculosis was the direct cause of death.

2. Hamburger & Sluka of Vienna	40.0%
3. Comby of Paris	38.5%

Several investigators, working independently, have arrived at figures which correspond closely and show how common is primary thoracic tuberculosis. Thus, Still (6) at Great Ormond Street, and King's College Hospitals, records 63.8% in 216 cases. Carr (7) at the Chelsea Hospital for Sick Children, 65.8% in 120 cases; Guthrie (8) at Paddington Green Hospital for Sick Children, 77 cases, 53%; Shennan (9) at the Royal Hospital for Sick Children, Edinburgh, 331 cases 67%, and Northrup (10) in New York, 70%. All these children were under the age of fourteen years. From these interesting figures, it is not too much to assert that tuberculosis is practically universal in children, be it latent or evident.

It is desirable, and necessary also, to make some mention of this infection in infancy, at which period of life the mortality is appalling. The

danger period here is during the second year, as a series of cases of Still's (11) shows :-

Still's series numbered 500 cases collected from the post-mortem records of Great Ormond Street Hospital for Sick Children, and on analysis he found that actually no less than 130 cases, i.e. over 25%, of these were tuberculous infants in the second year of life. This investigation also showed that the liability to infection gradually increases during the early months of infancy, and reaches its climax at the age period 1-2 years; after this age it gradually decreases as the child gets older.

Cobbett (12) in one of his papers, gives the following figures which represent the average number of deaths assigned to tuberculosis at different age periods of life, in England and Wales, during the years 1911-1915. These figures confirm Still's conclusions that the mortality rises as the child grows older and begins to decrease after the second year :-

---

<u>1st Month.</u>	<u>2-3 Months.</u>	<u>4-6 Months.</u>	<u>7-12 Months.</u>
475.	1,727.	3,045.	3,077.

---

---

<u>1st Year.</u>	<u>2nd Year.</u>	<u>3rd Year.</u>	<u>4th Year.</u>	<u>5th Year.</u>
2,668.	2,262.	1,267.	813.	643.

---

Thus, we see that tuberculosis in infancy is a condition of extreme danger, but, once the danger period is passed, it may well be that a process of immunisation is set up, which is of some protective value during the first two decades of life. It is a question of resistance, acquired as age advances, which the infant does not possess. In infancy the child's body is virgin soil to the bacillus of tuberculosis, and but feeble resistance is offered to the infection, which frequently proves rapidly fatal. The relation of the infant to tuberculosis may be compared with the relation of the savage races to unaccustomed disease, as, for example, measles. The infant, unable to protect itself against so virulent an organism, succumbs to its onslaught; the savage goes

under to a disease to which he has never before  
been exposed.

---

Chapter 2.

PATHWAYS OF INFECTION .

On the subject of the mode of entry of the pathogenic organism of tuberculosis, much work of a contradictory nature has been done. No definite conclusion has been reached as yet, and considering the extraordinary complexity of the subject, this does not cause surprise.

The number of pathways of infection is many, though only three are of any practical importance, namely :-

- (1) By Ingestion (alimentary tract).
- (2) By Inhalation (respiratory tract).
- (3) By Mouth Infection (partaking of (1) & (2) ).

Before discussing these modes of entry, we must first consider the organism.

There are three types of Tubercle Bacillus - the Human, the Bovine, and the Avian. This last

need not detain us, for immunity to this particular strain exists in the human being. As regards the other two types, children are susceptible to both human and bovine strains; the adult is practically immune to the bovine type.

These two types differ from each other both culturally and morphologically. Culturally, the bovine strain is more stable in character, grows less quickly and with greater difficulty than the human type. Morphologically, it is shorter, thicker, more irregular and stains less uniformly than the human type. As regards pathogenicity, the bovine type is more virulent than its human relative.

It has been asserted, though not proved, that the bacillus of the human strain can be converted by "passage" experiments into that of the bovine strain.

Both types of organism are relatively easily killed by sunlight and by boiling. It has a liking for darkness, and this medium safeguards the bacillus from destruction. Dried tuberculous sputum, if not

exposed to light, is said to keep its virulence for several months.

THE IMPORTANCE OF THE VARIOUS PATHWAYS  
OF INFECTION.

INGESTION. The English Royal Commission, in its second Report of 1907, came to the conclusion, after experiments, that a certain number of cases of tuberculosis in the human subject, especially in children, were brought about by the introduction of the bovine bacillus into the body, and that such infection was conveyed by cow's milk.

Again, they say :- "of the sixty cases of human tuberculosis investigated by us, fourteen of the viruses belonged to Group I - that is to say - contained the bovine bacillus. If, instead of taking all these sixty cases, we confine ourselves to cases of tuberculosis in which the bacilli were apparently introduced into the body by way of the alimentary canal, the proportion of Group I becomes very much larger. Of the

total sixty cases investigated by us, twenty-eight possessed clinical histories indicating that in them the bacillus was introduced through the alimentary canal. Of these, thirteen belonged to Group I. Of the nine cases in which cervical glands were studied by us, three, and of the nineteen cases in which the lesions of abdominal tuberculosis were studied by us, ten, belonged to Group I.

These facts indicate that a very large proportion of tuberculosis contracted by ingestion is due to tubercle bacilli of bovine origin!"

Calmette (13) introduced tuberculous material of bovine nature into the fourth stomach of goats and kids. They were infected by means of the stomach-tube in order to prevent the bacilli being drawn into the trachea. He then found that the bovine organism produced tuberculous disease in the mediastinal and mesenteric glands and lungs of the kids. The adult animals showed pulmonary and but little mesenteric trouble. Further, Calmette and two of

his co-workers, - namely, Vansteenberghe and Grysez - performed certain experiments on anthracosis which tended to support the results gained by Calmette's feeding experiments. Calmette then arrived at the following conclusions :-

1. That animals readily contract tuberculosis by way of the intestine, not only in youth, but also during adult life, without the passage of the bacilli through the walls of the digestive tube being marked by any visible lesions.

2. That in the case of young animals, bacilli are ordinarily retained by the mesenteric glands. Sometimes the infection remains localised there for a longer or shorter period, and is, in the end, cured; sometimes it ends in the formation of caseous tubercles, and is then propagated by the efferent lymphatics to the major lymphatic circulation.

3. That in the case of adult animals whose defensive glandular reaction is much less marked, the bacilli are more generally carried, with the leucocytes

containing them, into the major lymphatic circulation, and by way of the pulmonary artery towards the lung.

4. That the so-called primary pulmonary tuberculosis is generally intestinal in origin.

5. Finally, that of all the methods of infection, that by way of the digestive canal is at once the most efficacious, and that which best agrees with the normal conditions of natural infection.

It is interesting to note , in this connection, that MacFadyen and MacConkey (14) in 1903 examined the glands of 20 non-tuberculous and 8 tuberculous children, 26 being under the age of two years. The mesenteric glands showed virulent organisms in 5 tuberculous and 5 non-tuberculous children, though in 7 out of the 10, microscopic examination of the glands was negative.

Rabinovitch (15) in 1908 inserted bovine bacilli into sucking pigs through a gastric fistula, the oesophagus being closed. In twenty-two hours he found them in the blood, lungs and glands. His experiment

lends support to the theories advanced by Calmette.

Latham (16) considers that infection takes place by alimentation, and says that the primary infection is by the lymphatics. Further, he believes that up to the age of  $3\frac{1}{2}$  years, infection occurs on account of an infected milk supply. Latham considers that the bronchial glands are those first affected, and points out that the mucous membrane of the upper respiratory and alimentary tracts is common to both. Bacilli from infected milk are deposited, but do not remain, there. They pass on by way of the lymphatics to the bronchial glands. In support of his argument, he points to the marked differences which exist between the tuberculous of the adult and that of the child, and affirms that if tuberculosis is caused by inhalation, then one ought to expect, and find, similar types of the disease in both types of patient.

INHALATION. Cobbett (17) denies that the alimentary tract is the commoner portal of entry, and

gives that distinction to the respiratory tract. In support of his view, he has performed some striking experiments.

Cobbett has investigated to what extent bacteria are present in the living tissues of the body, and he has never failed to find organisms in the lungs of the various animals he has examined, while the blood and solid organs have usually been sterile. He has discovered that the organisms commonly present are those which are ordinarily found in the air. That these organisms enter by the air-stream and not by some other channel, he has proved by an experiment in which an organism was used which is easily recognised and which is not, as a rule, found in the lung. *Bacillus Prodigiosus* suspended in water was sprayed into the air breathed by guinea-pigs. The finest possible form of spray was used, and in very small amount. The animals were killed so soon after the experiment that no time was allowed for absorption into the lymphatics. After this experiment, Cobbett was always able to de-

monstrate the organism in the lungs.

He next turned his attention to the possibility of direct aspiration of bacteria into the bronchi during feeding experiments, for he had a strong suspicion that this occurred. Working with Dr. Graham Smith, he investigated the matter. He used the following method :-

Rabbits and guinea-pigs were fed on lettuce leaves spread with a culture of *Bacillus Prodigiosus*. Others were fed with a thick suspension of the same organism, the mixture being put into their mouths, drop by drop, with a platinum loop. Within ten minutes they were killed, and the organism was always found in small quantities in the lungs. Every precaution was taken to avoid anything unnatural which might have caused the entry of the organism into the bronchi. In this way, Cobbett and his fellow-worker proved that even the eating of infected material could directly infect the respiratory organs. Cobbett is careful to state that he does not suppose that small quantities of tubercle

bacilli which gain an entrance to the lungs in this way would set up tuberculous, otherwise everyone would become tuberculous. In a very susceptible person this might happen.

Cobbett was strongly impressed during his work with the difficulty of infecting by way of the alimentary tract even so susceptible an animal as the guinea-pig. He regards Calmette's experiments as very poor, and states that the easiest way of infecting animals is by way of the respiratory tract. He himself had never any difficulty in infecting animals in this way, and he mentions experiments by other workers which bear out his contentions.

Thus, Gebhardt, working with dilute tuberculous sputum, found that 800 bacilli if inhaled caused infection, whereas 10-20 millions were swallowed with impunity.

Weber and Titze, who made their experiments on calves, discovered that 1/100 m.g. of tubercle bacilli may cause infection by inhalation, but that 10 m.g. of

bacilli were necessary to cause infection by ingestion. Findel, experimenting with dogs, found that .14 m.g. of tubercle bacilli was sufficient to cause infection by inhalation, while 63 m.g. produced no effect when swallowed. Lastly, he used guinea-pigs, and discovered that if 62 bacilli were inhaled, infection always followed; 20,000 as food caused no effect.

Cobbett argues that the reason why it is difficult to infect by way of the alimentary tract is that the intestine, which is the point of attack, is guarded by the efficiency of its lymphoid tissue and by the powers of resistance of the abdominal glands. It is otherwise with the respiratory system, which has not developed so powerful a defence. In conclusion, he states that he has no doubt that tuberculosis is frequently due to intestinal infection, yet inhalation is the common mode of infection, not only in phthisis, but also in tuberculosis of other types, especially in those cases where the bronchial glands are the parts first affected.

MOUTH INFECTION. This last mode of infection partakes of factors belonging to both ingestion and inhalation. Supporters of this pathway of infection contend that the tubercle bacilli, taken into the mouth with food or in some other way, are deposited upon the buccal mucous membrane and upon the tonsils; thence they find their way to the cervical lymphatics, setting up a cervical adenitis. But the supporters of this theory do not stop here, for they believe that the bacilli find their way down the cervical lymphatics to the intrathoracic lymph glands.

CONCLUSIONS. One has no doubt that infection is often caused by ingestion, but it is difficult to believe that infection is most commonly caused in this way. The evidence of the post-mortem room is overwhelmingly against it. Shennan (18) investigated the channel of infection in 355 cases of tuberculosis in which autopsies had been performed. In 331 of these cases he was able to make out the pathway. In 67.07%

it was respiratory; in 28.1% it was alimentary.

Still (19) examined in a similar manner 269 tuberculous children under the age of 12 years. In 216 he established the mode of entry; in 138 - 63.8% - infection had occurred through the respiratory system; in 63 - 29.1% - primary infection was through the intestine; in 15 it had entered through the ear.

Again, Still examined by autopsy infants up to 2 years of age. In 100 of these, the mode of entry was respiratory in 65; only 22 were primarily intestinal. He also examined 50 infants up to 1 year old. In 39 of these the mode of entry was as follows : 27 were primarily infected through the respiratory tract; 5 through the intestinal tract; and 7 through the ear.

Carr (20) similarly examined 120 cases. He found primary thoracic infection in 65.8%; 16.7% only shewed signs of primary abdominal infection.

Guthrie (21) examined a series of 77 cases; evidence of primary thoracic infection was found in 42 of these; 19 showed infection by the bowel.

These figures , by entirely independent observers, give strong support to the view that inhalation is the common mode of entry.

Sociologically also this view is born out. In Japan, infants are breast fed for two or three years, and cow's milk is little used as a food for them. Nevertheless, tuberculous disease is common amongst children in that country. In China, artificial feeding of infants is unknown, yet tuberculosis is extremely common.

Again, tuberculosis is more prevalent amongst the poor than amongst the wealthy, yet less milk is used by them.

As regards the theory of mouth infection, little need be said. It does not appear to be tenable from the point of view that the intrathoracic glands may be infected through the tonsils by way of the cervical chain. No one has ever proved that there is a connecting path between the cervical glands and the mediastinal glands. If we look at the theory of mouth infection

from the other point of view, namely that this mode of entry of infection partakes of the respiratory tract as well as of the alimentary tract, and if also we remember that Cobbett in his feeding experiments could always demonstrate the Bacillus Prodigiosus in the lungs, although he took special precautions to keep them out, then we must admit that aspiration of mouth bacilli into the lungs in this manner is at least possible.

It seems to the writer that, taking everything into consideration, the premier place must be given to inhalation as a means of introducing infection. The observations of Cobbett, Weber and Titze, Findel and others on the small doses of tubercle bacilli necessary to cause tuberculosis by inhalation, and the enormous doses required to cause the disease by ingestion are significant. It has been estimated that a patient with open tuberculosis of the lungs may expectorate 4,000 million bacilli daily. The position of a child who occasionally ingests a few tubercle bacilli in

milk is immeasurably safer than that of a child who daily comes into contact with such a patient. A history in which such a state of things exists is unfortunately only too commonly obtained.

---

Chapter 3.

THE PRIMARY FOCUS IN CHILDREN -  
IS IT GLANDULAR OR PULMONARY ?

Involvement of the bronchial glands in childhood is the most frequent form of tubercular glandular disease. In many cases it represents the chief tubercular lesion.

The question arises, however, since we accept the respiratory tract as the commonest portal of entry of infection, where is the primary focus? Is it glandular or pulmonary.

In 1916 there appeared a translation by D. Barty King of a monograph on this subject by Dr. Anthon Ghon (22) of Prague. In the preface to his book, Ghon states that in 1876 Parrot formulated a law which said that there is, in a child, no affection of the lungs which will not be present in the adjoining lymphatic glands, and vice versa. In other words, that the glands are a mirror of the lungs. Parrot further

stated that this focus might be difficult to find but nevertheless, it was always there.

Ghon's work is a monument of minute and painstaking research. His conclusions are entirely based upon anatomical-pathological grounds. He is convinced that the lung focus, however small, almost invariably precedes the glandular focus.

In 184 autopsies of tuberculous children at St. Anne's Hospital, Vienna, Ghon found a primary lung lesion in 92.4% of cases and only 7.6% of involvement of the glands without such definite pulmonary focus. Of these primary lung foci, the right lung showed a greater number than the left, and the right upper lobe was the most often affected. The apices are seldom involved, and it was owing to the distribution of the pulmonary lesions in children (usually the lower part of the upper lobes, in the middle lobe on the right, and the upper parts of both lower lobes,) that the idea of the bronchial glands being the seat of primary infection arose, for it was argued that from here the

disease spread to the lungs. Ghon's laborious investigation, it would seem, entirely disproves this, for he points out that the lymph stream flows towards the bronchial glands. However closely one may cling to the retrograde infection theory, it must be admitted that anatomically such a theory is untenable, on account of the valvular arrangements in the lymphatics.

Ghon's series of cases showed much evidence of healing; thus 55% of the lung lesions were progressing; but 15% showed evidence of anatomical healing, and 30% were anatomically healed.

Many other eminent pathologists support Ghon's view, for instance, Küss, E. Albrecht, Birch-Hirschfeld, and Nagele.

While, therefore, we may admit the existence of the primary lung focus, our admission does not detract from the importance of tuberculous bronchial glands. The primary focus in the lung may tend to heal rapidly, and sometimes no primary lesion is discovered at all,

the bacillus having passed through without leaving any tracks behind it. While the small lung lesions heal, the infection may lie latent in the bronchial glands as MacFadyen and MacConkey showed in 1903.

It, therefore, behoves us to do our utmost to discover the enlargement and tuberculous nature of these glands, for though the lung lesion may ultimately heal, they may, and frequently do, caseate, and tuberculous disease may spread by contiguity to the bronchi, pleurae and lungs.

Tuberculosis of the intrathoracic glands is difficult of diagnosis, and the object of this dissertation is to set forth what has been the writer's experience in the diagnosis of this condition in children.

---

SECTION II.

SECTION II.

DEVELOPMENT OF TUBERCULOSIS IN CHILDREN.

It has been pointed out that TUBERCULOUS INFECTION is practically universal in children. TUBERCULOUS DISEASE, however, does not always occur, though the danger is omnipresent. What are the factors then governing the non-development or development of tuberculosis in children ?

Every pathogenic organism provides the means for its own destruction, or the destruction of its toxins. The tubercle bacillus is no exception, and it stimulates the production of its specific antibodies. These specific antibodies are present in greater or less degree.

Now, if the antibodies are abundantly present, the child is protected from the development of tuberculous disease. But they are not always present in large amount, and their deficiency depends on many factors, including especially the state of the child's

health, surroundings, nourishment, and the consideration of its progenitors' family history. The production of immunity largely depends upon the physical well-being of the child. The development of the TUBERCULOUS INFECTION into TUBERCULOUS DISEASE, therefore, in the writer's opinion, depends upon two factors :-

- (1) That the immunity has never been sufficient.
- (2) That the immunity was sufficient, but was destroyed by circumstances following its production.

Let us now discuss these two new propositions.

(1) If immunity has never been sufficient, this must depend upon one, or both, of the following factors :-

- (a) Sudden, crushing infection by the organism.
- (b) Sluggish production of antibodies.

(a) This needs no explanation, the child, overwhelmed by a sudden attack of the organism, has no time to develop his protective forces.

(b) The strongest argument the writer can think of in support of the contention of sluggish production of antibodies, is provided by the children that one sees at Tuberculosis Dispensaries. At a glance one realises the struggle that is going on in the child's organism. Poor, thin, pale, undersized, underfed children, with flat chests and winged scapulae, no appetites and constantly ailing, they present to the writer, at least, a picture of chronic tuberculous toxæmia. They are an example of insufficient production of antibodies - they antagonise a certain amount of toxin, but no more. They live, generally, in sunless, airless houses and streets, brought up by parents, as a rule, who are hopelessly ignorant and often desperately poor.

(2) Should immunity have been sufficient, what may occur to weaken it ?

There are three diseases which stand out pre-eminently as enemies of the tuberculously disposed child, and these are measles, whooping cough and influenza. Now if a child who has complete immunity

suddenly develops one or more of these diseases, the only explanation of the lessening of immunity must be :-

(a) That the antibodies either diminish in amount or disappear entirely. The infection, until then inactive, may become active through the removal of its efficient control, and the child develops tuberculosis.

(b) That, though immunity may have been sufficient, some long continued strain, such as overwork in a school child, insufficient or unsuitable food, unhealthy surroundings, and a generally unhygienic life, ultimately break down, or destroy the immunity, giving the infection opportunity for developing into disease.

---

SECTION III.

SECTION III.            DIAGNOSIS.

Chapter 1.

GENERAL CONSIDERATIONS .

The diagnosis of tuberculosis in children requires the most careful attention. It is, therefore, very desirable that certain investigations should be carried out before turning to the clinical examination of the child patient. These investigations should be applied assiduously to the following matters, namely :-

- (a) The question of exposure to infection, and the family and personal histories of the relatives and the patient.
- (b) The surroundings in which the patient lives.
- (c) The presence or absence of the symptoms of tuberculous disease.

(a) The Family History.

This should be inquired into as thoroughly as possible, though it frequently happens that the parents

can tell little or nothing concerning their various relatives. Parents will often unintentionally mislead the doctor regarding these histories, and a clean record in the family health should not be too readily believed. Parents do not like to admit the presence of "consumption" in their families, but careful inquiry will often reveal significant facts, for instance, chronic bronchitis in a grandparent, or actual phthisis, a "weak chest" in father or mother, or a history of chronic cough in a brother or sister of either parent.

The child's personal history is of the utmost importance, and should likewise be most carefully investigated. A history of frequent bronchitis, asthma or pleurisy is significant. Most especially should be noted the occurrence of measles, whooping cough or influenza. They are, indeed, a child's worst enemies.

(b) The Patient's Surroundings.

The surroundings of a child in its home life have a direct bearing on the case. Light and air and hygiene are the mortal enemies of the tubercle bacillus.

Filthy, dark homes, lack of fresh air, absence of sunlight, and overcrowding are its very good friends.

(c) The Presence or Absence of the Symptoms of Tuberculous Disease. ( Constitutional Symptoms )

The constitutional symptoms of tuberculous disease depend on the toxaemia produced by the specific organism, and its effects are numerous. They vary according to the amount of infection, and the ability of the child to keep it under. Many cases of vague, indefinite illness are undoubtedly due to such trouble, and anaemia, dyspepsia, mal-assimilation of food, and poor nutrition are often a child's heritage from an obscure tuberculous infection.

The history one may obtain from a mother bringing her child to a Dispensary is often striking. One is told that the child is "not getting on". Something is hindering him. Perhaps he has never been a strong child; on the other hand, he may always have appeared to be well and robust. An attack of measles, whooping cough, or influenza has not improved matters. In the case of the

robust child any one of these diseases may have been a turning point in the child's health. There is frequently a history of bronchitis, asthma, and sometimes pleurisy.

The child is listless and languid. He has become indifferent to strenuous games. He has lost his appetite, and digestive disturbances may be frequent. Night sweats are occasionally observed. He is losing weight; at least he is not gaining any. The mother may have noticed an inclination to feverishness at night.

More striking than any of these is the change sometimes observed by a parent in the child's nature, that is, mentally. The happy, good-tempered child, obedient to his parents, becomes naughty, peevish, ill-tempered and disobedient. The child getting on well at school begins to fall off in his work. Strange fancies and curious habits occasionally occur.

---

Chapter 2.

SYMPTOMS AND PHYSICAL SIGNS.

The bronchial glands comprise three main groups - the tracheo-bronchial group, at the bifurcation of the trachea; the bronchial group, surrounding the main bronchi; and the pulmonary or hilus group, accompanying the smaller bronchi into the lung tissue.

Tuberculosis of the bronchial glands gives rise to toxic constitutional symptoms such as one finds to be present in tuberculosis of other parts of the body, and which we have already considered in the previous chapter. This condition is also said to give rise to another set of symptoms, the value of which we are about to investigate - THE PRESSURE SYMPTOMS.

PRESSURE SYMPTOMS : The symptoms which are said to be most common are two :-

(a) Cough : (b) Dyspnoea.

(a) Cough : Two types of cough have been distinguished :-

(1) A hard "brassy" cough.

(2) A cough occurring in paroxysms, resembling that of pertussis.

(b) Dyspnoea : This may be of -

(1) Expiratory type or

(2) Inspiratory Type.

PHYSICAL SIGNS : The physical signs which have been advanced as diagnostic of bronchial adenopathy are :-

(1) Engorgement of the veins of the upper chest in front, usually in the second interspace and passing from just below the coracoid process to the inner end of the space; (2) Cyanosis of the face and lips in the absence of cardiac or renal disease; (3) the Hilus Dimple of Stoll and Heublein; (4) increased resistance on pressure over the manubrium sterni, normal resilience

being lost; (5) palpation of an enlarged gland in the hollow behind the manubrium sterni; (6) rigidity of the intercostal muscles over the hilus region (Pottinger); (7) Petruschsky's spinalgia; (8) impairment of the percussion note in the 2nd and 3rd intercostal spaces close to the sternum; (9) dulness about the root of the lung in the interscapular region; (10) dulness on percussion over the 5th and 6th thoracic vertebrae; (11) change in breath sounds in the region of the 2nd and 3rd intercostal spaces, right or left; (12) Eustace Smith's retraction murmur sign; (13) a bronchial blowing sound in the interscapular region; (14) D'Espine's whisper sign.

Of these, (3), (6), (7), (10), (12) and (14) require a word of explanation.

(3) Stoll and Heublein (23) drew attention to a sign which they called the Hilus Dimple. This is a depression occurring at the end of inspiration in the 2nd right or left intercostal space; it is said to be

an indication of enlarged bronchial glands. The dimple is best seen in an oblique light.

(6) Pottinger (24) believes that the condition of bronchial adenopathy may give rise to a rigidity of the intercostal muscles over the hilus region, comparable to the rigidity found in the abdominal muscles in cases of appendicitis.

(7) Petruschsky's spinalgia is a tenderness over the spinous processes of the 2nd to the 7th dorsal vertebrae. It has been said to be a sign of great utility in the diagnosis of the condition of bronchial adenopathy.

(10) A dull note is normally obtained on percussion over the upper four thoracic vertebrae. Over the remaining dorsal spines the note is said to be a combination of osteal and pulmonary resonance. Dulness over the 5th and 6th thoracic spines is said to be pathological, and is indicative of mediastinal glandular

enlargement.

(12) Eustace Smith (25) in 1875 described the sign which bears his name. This is said to be a loud blowing murmur heard with the stethoscope over the manubrium sterni. An essential condition for its production is that the patient must have his head extended as far as possible. Extension of the head throws forward the lower end of the trachea, carrying with it the glands in its bifurcation, and the left innominate vein, as it passes transversely behind the first bone of the sternum, is compressed between this and the enlarged glands, resulting in the production of the murmur.

(14) D'Espine's whisper sign (26) consists in the persistence of the tracheal whisper beyond its normal limits. This whisper normally ceases in infancy at the 7th cervical vertebra, and in childhood at the 2nd thoracic vertebra. The presence of the sign beyond

these limits is said to be pathological, and to be indicative of bronchial adenopathy.

The cause of the whisper is said to be the enlarged glands surrounding the trachea and bronchi, which conduct the sound of the whispered voice to the vertebral column.

---

SECTION IV. TWENTY SIX CASES WITH THEIR HISTORIES  
AND X - RAYS.

The 26 cases included in this section were all seen at the Dispensary of the Manchester Consumption Hospital. A far greater number was examined, but as it was only possible to have 26 x-rayed, it was thought undesirable to include more.

The cases are here divided into two Groups, I and II. In Group I are included those cases which presented symptoms of vague illness and the signs which have been reputed to be of value in the diagnosis of bronchial adenopathy. In Group II are placed those patients who presented none of the major signs, but in two of whom Stoll's Hilus Dimple, and in another a network of veins over the upper chest, occurred.

Whilst symptoms of vague illness were present in all the cases in Group I, they were not complained of in every case in Group II, and in those which did not show such symptoms, the usual complaint was that of loss of weight. Complaint of chest trouble was common in Group I.

The family histories of every case of the 26 were carefully enquired into. Of the 16 cases in Group I, 12 had

been exposed to human infection, either familial or otherwise; and of the 10 cases in Group II, 5 had been so exposed.

It is here to be noted that in the following histories references to tuberculous persons are typed in red, and that, except when otherwise stated, tubercle of the lungs is to be understood.

The environs of these 26 patients were, as a rule, bad, and, in many instances, had become worse consequent on the War.

After histories as detailed as possible had been obtained, a clinical examination was carefully made and the signs noted. Every case was then submitted to the x-rays, and the radiologist was unaware of the clinical signs at the time of making his reports.

VALUE OF THE X-RAYS. Sir James Kingston Fowler has sarcastically referred to hilus tuberculosis as "a shadow first seen in a darkened room, and not yet clearly recognised in the daylight of the post mortem room". No one, however, has any doubt now that such a condition does actually exist, and all will agree that there is no more elusive disease in the whole of medicine. Sir James' reference is intended for the radiologist who relies upon his art alone

for the diagnosis of this condition.

Dr A. Brinchmann (27) of Christiania, considers that the positive and negative evidence of the x-rays is unreliable. He selected 180 skiagrams taken of the chests of 154 children, and while he was examining these he was unaware of the clinical reports. The skiagrams showed signs of enlarged bronchial glands in 41 cases, and infiltration of the lungs in 12. The evidence was doubtful in 51 cases, and in 50 he found no definite sign of bronchial adenopathy. Of the 41 children with x-ray evidence of enlarged bronchial glands, 10 showed no clinical sign of this condition. On the other hand, amongst the 50 children whose skiagrams were negative, there were as many as 28 with clinical evidence very suggestive of hilus tuberculosis.

Compared with Brinchmann's, my experience of this condition may, perhaps, be said to be minute, nevertheless, the results of my investigations do not bear out his conclusions. Of the 16 cases in Group I, all had clinical signs of bronchial adenopathy, and the x-rays showed the condition to be present in 15 of these. Of the 10 cases in Group II, which presented none of the usual signs of enlarged bronchial glands, 5 were shown by the skiagram to have such glands. The presence of the clinical sign indicative of glandular enlargement

found in Case 8 of Group I, but not confirmed by the radiogram, is possible of other explanation.

---

SECTION IV.

G R O U P I.

(16 CASES).

---

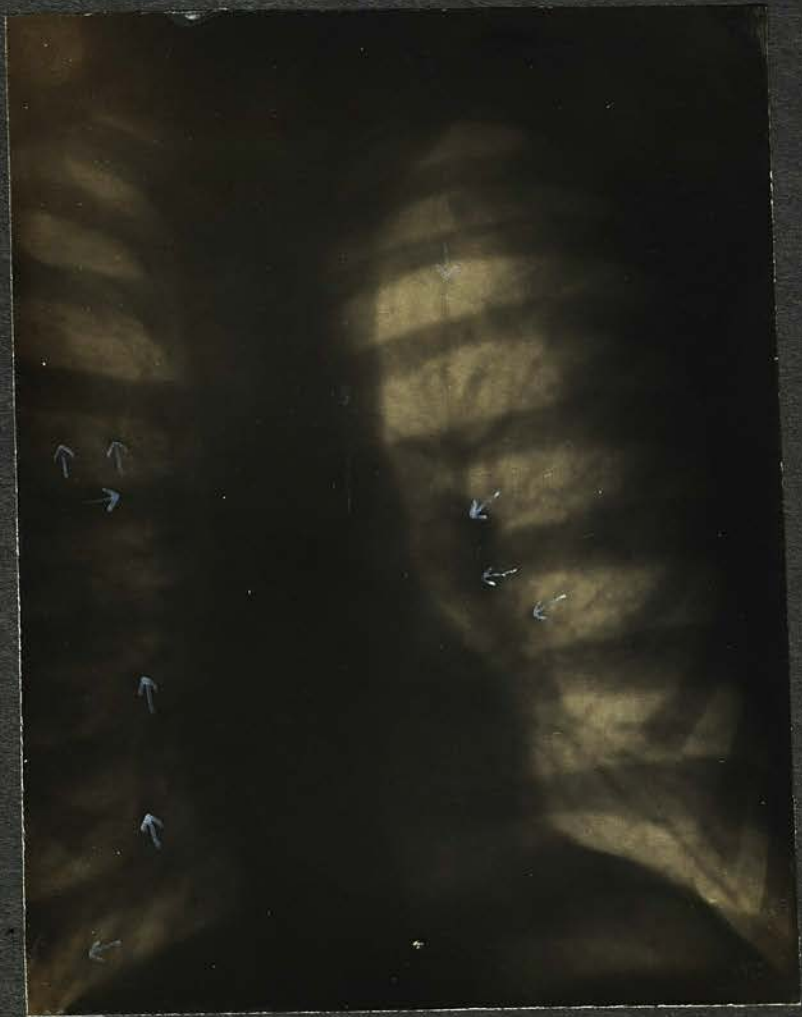

Plate 1

CASE I. F.L. (MALE) PLATE I.

Height 57". Weight 80 lbs. Aet.13.

FAMILY HISTORY. Mother : aet. 39, is chesty. M's M. d. aet. 57 (11). M's F. d. aet. 33 (asylum). M's B.s 2 aet. 44 & 42, healthy. 1 B. aet.35, killed. 1 S. d. aet. 37 (8).

Father : aet. 39 healthy (?) F's M. aet. 57, healthy. F's F. d. aet. 62 (9). F's B.s 1 aet. 22 healthy. 1 aet. 20 d. influenza & pneumonia (4). F's S.s, 6, healthy.

Patient's brothers & sisters: 2 B.s aet. 11 & 3, healthy. 2 S.s aet. 11 & 4, both have bad coughs.

ENVIRONS : Good; healthy district; no overcrowding in house; adequate good food.

PERSONAL HISTORY: Measles & whooping cough (4). Long convalescence. Influenza (5). Long convalescence. Has never been a healthy boy; a constant sufferer from bronchitis & asthma, with hard dry cough. T.s & A.s removed (1). Before attending Tuberculosis Dispensary was losing weight rapidly, was listless and apathetic, with fever nocte. Easily catches cold. Has improved under treatment considerably, but still has a hard, barking cough with bouts of asthma. Is always dyspnoeic.

EXAMINATION. Inspection : Slightly cyanotic about the lips, slightly bloated facies. Is not unduly thin. Has a poorly formed chest with some winging of the scapulae. Chest movements appear fair. Bilateral Hilus Dimple. No enlarged veins over the upper chest. Palpation : Cervical glands enlarged. No glands felt elsewhere. Chest movements equal and fair. Normal resilience of manubrium on pressure. No rigidity of intercostal muscles over the hilus region. No spinalgia. Percussion: Slight dulness anteriorly in the second right and left intercostal spaces. Double paravertebral dulness. Dulness over the 5th & 6th thoracic spines. Auscultation: Breath sounds harsh all over the chest with scattered rhonchi. Bronchitis both bases. No interscapular blowing sound. No D'Espine's sign. No Eustace Smith's sign.

TUBERCULIN TESTS. Von Pirquet's Test triple positive.

CLINICAL DIAGNOSIS. Bronchitis & asthma. Tuberculous

Cervical glands. Tuberculous bronchial adenopathy, right and left.

X RAY REPORT. Air entry reported fair. Marked thickening of root shadows both lungs due to enlargement of the bronchial glands. No involvement of the lung tissue. Peribronchial thickening.

---

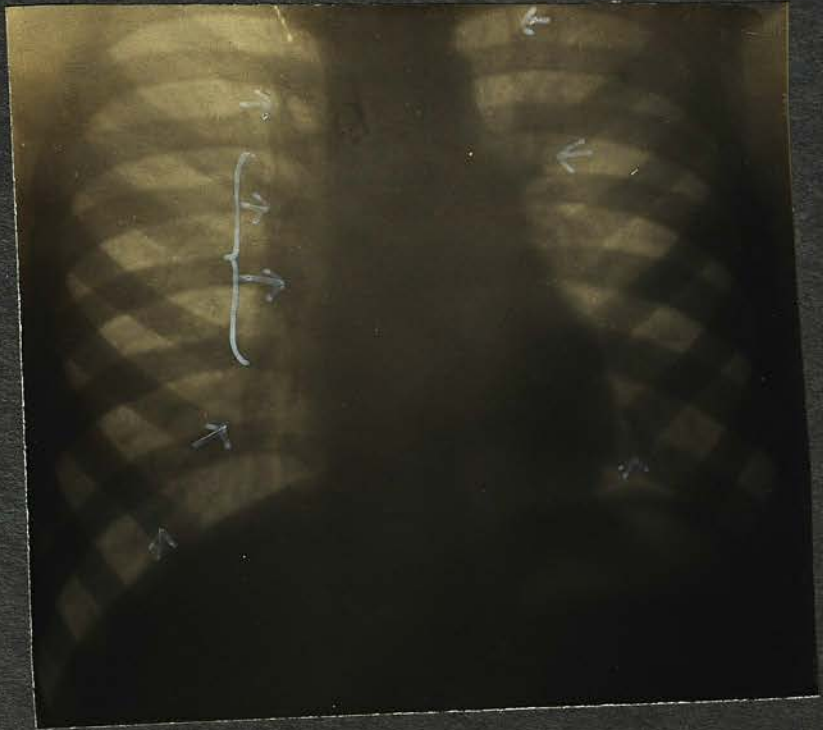


Plate 2.

CASE 2. J.H. (MALE) PLATE 2.

Height 40". Weight 42 lbs. Aet.8.

FAMILY HISTORY. Mother, d. aet. 22, in confinement (8) M's M. nothing known. M's F. nothing known. No brothers or sisters. Step-mother of patient is healthy, aet.30. Her brother d.aet.37 (3).

Father: aet. 31, healthy. F's M. aet. 54, healthy. F's F. aet.54, healthy. F's S.s, aet. 21 & 26, healthy. F's B. aet. 14, healthy.

Patient has 1 step-brother, aet. 4, healthy.

ENVIRONS. Poor and damp. Unhealthy district. Sleeps in room with father and step-mother, but in separate bed.

PERSONAL HISTORY. Measles & whooping cough (3). Bronchitis every winter. After whooping cough developed a hard, dry cough which has never left him. Complains of slight dyspnoea. Before attending Dispensary was losing weight and was languid, irritable and frequently feverish nocte. Anorexia and other symptoms of illness occurred. Has improved under treatment.

EXAMINATION. Inspection: Pale child, small for his age, though not unduly thin. No flatness of the chest; movements good. Scapulae slightly winged. Right Hilus Dimple. No enlarged veins over the upper chest. Palpation: Cervical glands enlarged. No glands felt elsewhere. Chest movements equal and good. Normal resilience of manubrium on pressure. No rigidity of intercostal muscles over the hilus region. No spinalgia. Percussion: Slight dullness anteriorly in the right intercostal space. Right paravertebral dullness. Dullness over the 5th & 6th thoracic spines. Auscultation: Breath sounds harsh all over the chest. No adventitious sounds. No interscapular blowing sound. D'Espine's sign exquisitely heard. No Eustace Smith's sign.

TUBERCULIN TESTS. Von Pirquet's Test moderately positive.

CLINICAL DIAGNOSIS. Tuberculous cervical glands. Tuberculous bronchialadenopathy, right.

X RAY REPORT. Air entry good. Thickening of root shadows, especially on right, due to bronchial adenopathy.

---

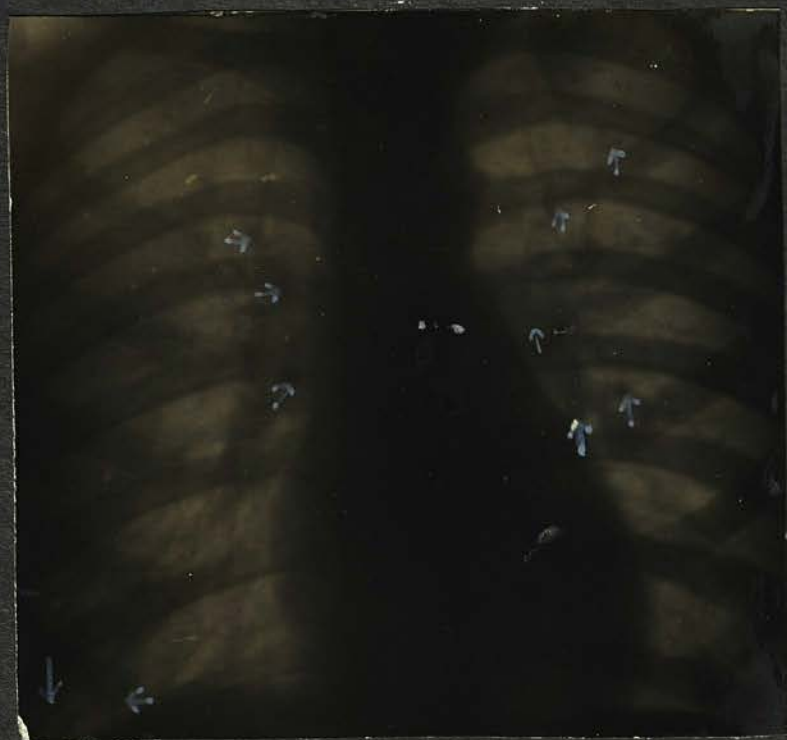

Plate 3

CASE 3. F.H. (MALE) PLATE 3.

Height 53". Weight 73 lbs. Aet.12.

FAMILY HISTORY. Mother. aet.45, weak chest. Pneumonia and pleurisy (5). M's M. d.aet. 78 (4) bronchitis. M's F. d. aet. 76 (6), heart disease. M's B. aet. 50, healthy. M's S. aet. 48, healthy. S's husband d.aet. 42 (7).

Father: aet. 45, chronic cough. Had pneumonia in May 1922. M's M. aet. 79 healthy. F's F. d.aet. 80, senile decay. F's B.s, 2 healthy. F's S.s 4, healthy.

Patient's B.s, 2, aet. 14 & 7, both healthy. No Sisters.

ENVIRONS. Comparatively good, no overcrowding at home. Patient sleeps by himself; receives sufficient good food. Previously been in contact with his Uncle (see above).

PERSONAL HISTORY. Measles (9), whooping cough (6), scarlet fever (3), German measles (1), influenza (5), bronchitis every winter. Taken to Dispensary for Tuberculosis 12 months ago for losing weight. Was languid, irritable and disobedient, whereas before influenza his nature has been equable. Anorexia and vague symptoms of illness. Temperature rose nocte. Slight night sweats. After treatment, cod liver oil, etc, and open air regime, he improved considerably.

EXAMINATION. Inspection : Pale and thin, flat, narrow chest; winging of scapulae. Slight lagging, upper chest on right. Bilateral Hilus Dimple. No veins over upper chest. Palpation : Cervical glands enlarged. No glands felt elsewhere. Chest movements good on left, slight lagging over right upper chest. Normal resilience of manubrium on pressure. No rigidity of intercostal muscles over the hilus region. No spinalgia. Percussion : Slight impairment of resonance in the second intercostal spaces, right and left. Double paravertebral dullness. Dullness absent over the 5th & 6th thoracic spines. Auscultation : Harsh cog-wheel respiration over the hilus region in front, right and left, and interscapularly on both sides. No adventitious sounds. D'Espine's sign present. No interscapular blowing sound. No Eustace Smith's sign.

TUBERCULIN TESTS. Von Pirquet's test triple positive.

CLINICAL DIAGNOSIS . Tuberculous cervical glands. Tuberculous bronchial adenopathy, right and left.

X RAY REPORT. Air entry reported good. Marked thickening of root shadows due to obvious glandular enlargement, in which some tubercles can be seen. Abundant peribronchial thickening, which extends towards the apex on the left.

---

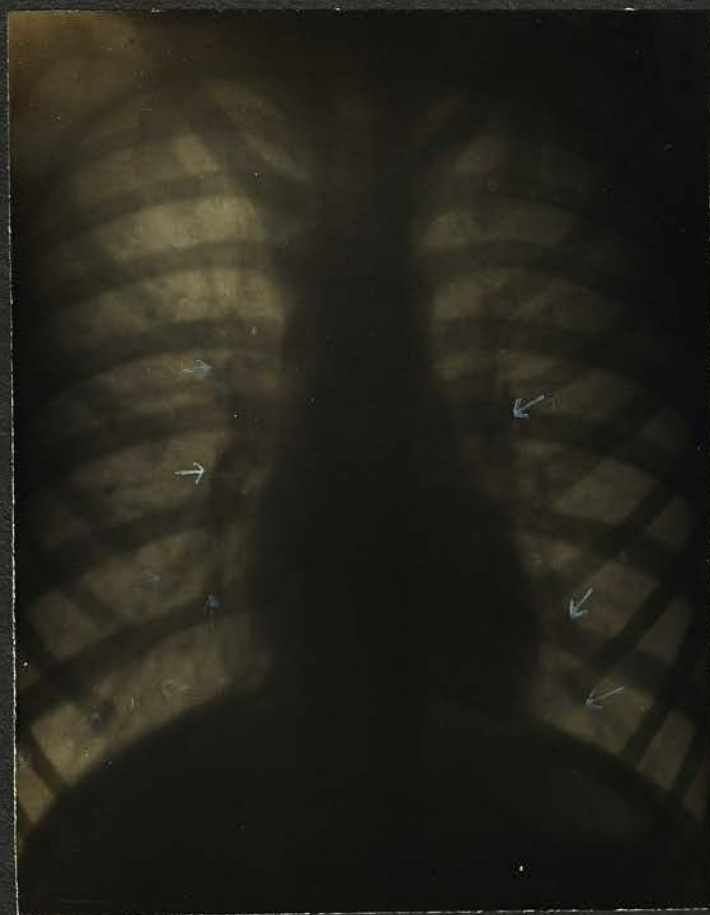

Plate 4

CASE 4. M.P. (FEMALE). PLATE 4.

Height 48". Weight 53 lbs. Aet.11.

FAMILY HISTORY. Mother, aet. 34, anaemic, M's M. aet.55, d. perforated gastric ulcer. She was also very chesty. M's F. aet. 55 healthy. M's B.s 2 living, aet.31 & 28, 3 d. aet. 2 (13), 16 (3), 18 (5).

Father: aet. 36 healthy. F's M. d.aet.66, cancer. F's F. d. aet. (?), cause (?). F's B. killed in the War. No S.s.

Patient's S.s, 2, aet. 14 & 4, both under treatment at Tuberculosis Dispensary.

ENVIRONS. Poor district, old houses, unsatisfactory food.

PERSONAL HISTORY. Has had no infectious disease of any kind, but has frequently had bronchitis. When brought to Dispensary she was of quiet, languid disposition and did not play games, was losing weight. Anorexia, constipation, anaemia, nervous and easily upset. Feverish nocte. Night sweats slight. Occasional nocturnal enuresis. Has a hard, dry, barking cough and dyspnoea.

EXAMINATION. Inspection: Pale, thin child, flat chest, winging of scapulae. Chest movements good. Bilateral Hilus Dimple. No enlarged veins over chest. Palpation: Cervical glands enlarged. No glands felt elsewhere. Chest movements good. No rigidity of intercostal muscles over the hilus region. Slight spinalgia. Slight myoidema and myotatic irritability. Percussion: No noticeable dullness anteriorly. Double paravertebral dullness. Dullness over the 5th & 6th thoracic spines. Auscultation: Breath sounds harsh over front of chest, of bronchial character interscapularly. No adventitious sounds. D'Espine's sign present. Eustace Smith's sign present.

TUBERCULIN TESTS. Von Pirquet's Test triple positive.

CLINICAL DIAGNOSIS. Tuberculous cervical glands. Tuberculous bronchial adenopathy, right and left.

X RAY REPORT. Air entry reported good. Very marked thickening of root shadows particularly on right side, due to glandular enlargement. Peribronchial thickening; more marked on right side. Extension into upper lobe left lung.



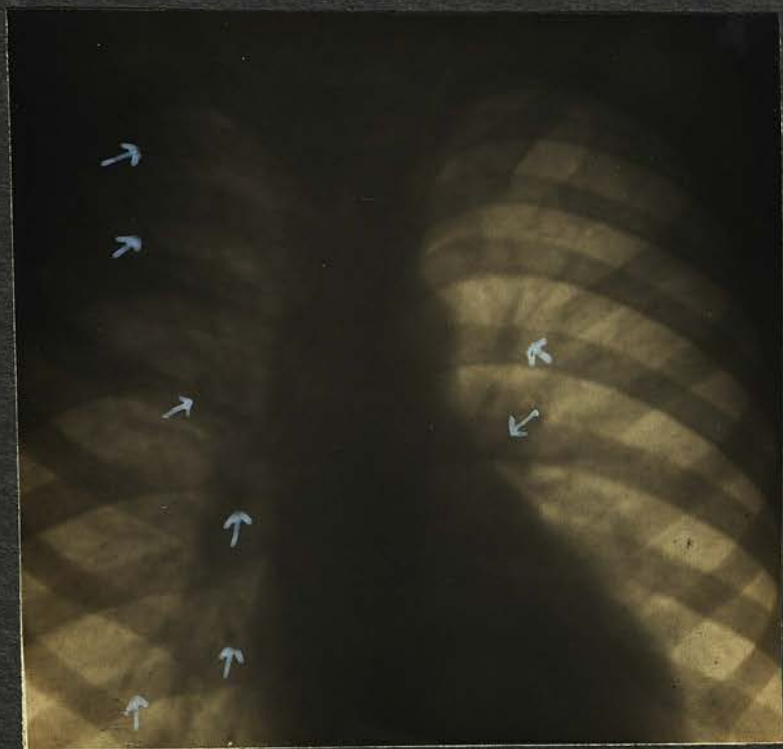


Plate 5

CASE 5. A. H. (MALE) PLATE 5.

Height 51". Weight 65 lbs. Aet.13.

FAMILY HISTORY. Mother: aet.48. M's M. d. aet.54 (35) heart disease. M's. F. was drowned, aet.47 (40) M's B.s. 4, nothing known. No S.s.

Father: aet. 46 healthy. F's M. & F. nothing known. F's S. aet. 50 healthy. F's B.s 2, nothing known.

Patient's B. aet. 9 healthy (?). No Sisters.

ENVIRONS. Lives under poor conditions with overcrowding. Sleeps with brother in same bed. Father & Mother occupy bed in same room in which the patient sleeps. Insufficient food.

PERSONAL HISTORY. Can get no definite history of the patient's previous health. He "went off" suddenly about 12 months ago (?) Lost weight quickly and had vague signs of illness. He then formed a cold abscess in right axilla which broke down and left a sinus. Is moderately dyspnoeic and has a loose cough.

EXAMINATION. Inspection: Adenoid facies, pale. Slight flatness of chest and winging of scapulae. Deficient movement over right apex. Bilateral Hilus Dimple.No enlarged veins over the chest. Palpation: Cervical glands enlarged. No glands palpable elsewhere. Deficient movement right apex. Manubrium resilience normal.No rigidity of intercostal muscles over the hilus region. No spinalgia. Percussion: Impaired resonance over right apex. Paravertebral dulness on right. Dulness over 5th & 6th thoracic spines. Auscultation : Breath sounds bronchial in type over right apex. Harsh breath sounds interscapularly. No blowing sound. No adventitious sounds. D'Espine's sign present. Eustace Smith's sign present.

TUBERCULIN TESTS. Von Pirquet's Test triple positive.

CLINICAL DIAGNOSIS. Tuberculous cervical glands.Tuberculous bronchial adenopathy. Infection of right apex.

X RAY REPORT. Air entry reported deficient at right apex. Marked thickening of root shadows, especially on right, due to enlarged bronchial glands. Generalised peribronchial thickening. Haziness at right apex.

---



CASE 6. V.R. (FEMALE) PLATE 6.

Height 48". Weight 59 lbs. Aet. 10.

FAMILY HISTORY. Mother, aet.32, bronchitis. M's M. aet.60 bronchitis. M's F.d.aet.40, lead poisoning. Nothing else known of M's relatives.

Father: aet. 33, chronic bronchitis. F's M. nothing known. F's F. nothing known. No B.s or S.s.

Patient's B.d.aet. 3, broncho-pneumonia.

ENVIRONS. Poor, very unhealthy district, thickly populated. Does not get satisfactory food.

PERSONAL HISTORY. Measles (3), broncho-pneumonia 3 times. No definite history is obtainable as it has been impossible to see the parents. As far as can be ascertained, the patient has been falling off for some considerable time. She has frequent attacks of bronchitis and typical asthma. Has always a cough which is sometimes of a "loose" variety and sometimes hard and barking. Takes cold easily. Appetite poor

EXAMINATION.. Inspection: Pale child with chest slightly inclined to pigeon shape. Winging of scapulae. Chest movements fair. Hilus Dimple on right. No veins apparent over chest. Palpation: Cervical glands enlarged. No glands palpable elsewhere. Chest movements equal and fair. No rigidity of intercostal muscles over the hilus region. No spinalgia. Normal manubrium resilience. Percussion: Impaired resonance, right and left 2nd intercostal space. Paravertebral dulness on right. Dulness over 5th & 6th thoracic spines. Auscultation: Harsh breath sounds all over the chest. Bronchial breathing interscapularly, right. Coarse rales over both bases extensively, and also over chest in front with a variety of rhonchi. D'Espine's sign present. Eustace Smith's sign present.

TUBERCULIN TESTS. Von Pirquet's Test triple positive.

CLINICAL DIAGNOSIS. Tuberculous cervical glands. Chronic bronchitis and asthma. Tuberculous bronchial adenopathy, right.

X RAY REPORT. Air entry reported good. Well marked thickening of root shadows with glandular enlargement on right. Peribronchial thickening.

---

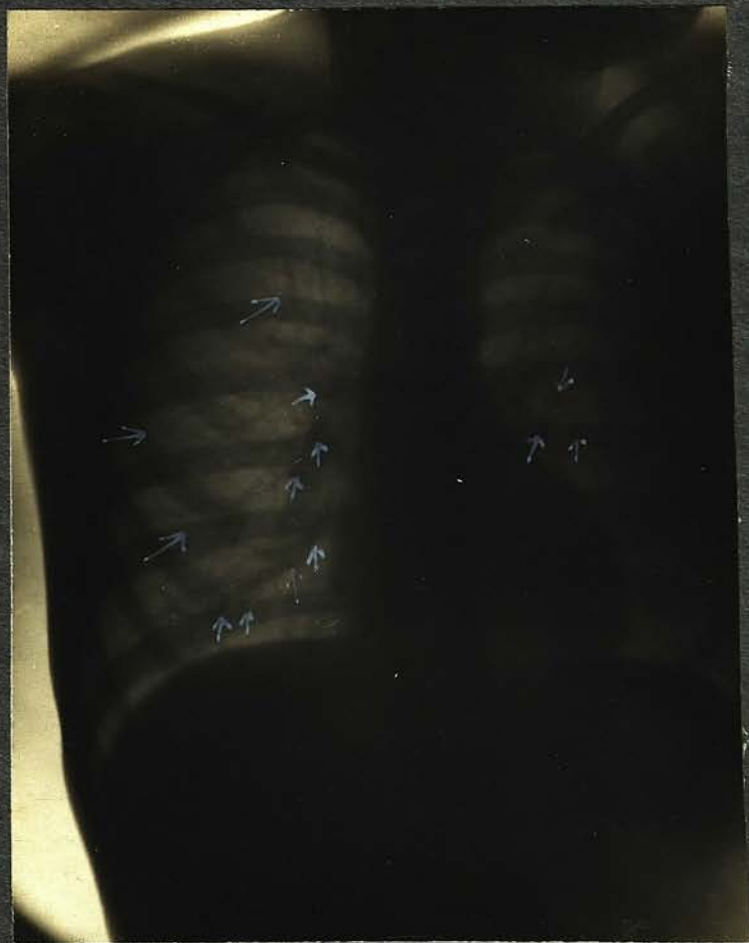

Plate 7

CASE 7. T. R. (MALE). PLATE 7.

Height 49½". Weight 54½ lbs. Aet.9.

FAMILY HISTORY. Mother, aet.44, chesty. M's M. d.aet.60, chronic bronchitis (21). M's F.d.aet. 40, chronic bronchitis (?). M's B.s, 2 d.aet.60 & 46, chronic bronchitis (5) & (9) respectively. There is more than a suspicion that these deaths were due to phthisis. 1 B. d.aet.50 in Sanatorium (6 months). M's S.s aet.60 & 49. The elder has chronic bronchitis. 1 S.d.aet 9 "congestion of the lungs".

Father: aet.55. F's M. d.aet.47, cancer of liver (18). F's F. d.aet. (?) bronchitis. No B.s. F's S. d.aet.46, of "some stomach trouble".

Patient's B.s & S.s ; 1 B. still-born (12) 1 B.d.aet.3 T.B. enteritis (4). 1 S.d.aet. 2, T.B. enteritis (2). 1 S.d.aet. 14 (13). 3 S.s aet.19, 13, 3. The first two have anaemia, dyspepsia, and "chest trouble".

ENVIRONS. Bad; sleeps with father, separate beds. Poor house; damp. Unsatisfactory food.

PERSONAL HISTORY. Has never been strong. Measles (3), whooping cough (2), influenza (3), pneumonia (8 months), bronchitis many times; long convalescence from measles and whooping cough. Is listless and languid; easily tired, irritable, nervous and disobedient. Has been losing weight. Fever nocte. Anaemia, anorexia, and has a hard, dry cough of a barking type. Is very dyspnoeic.

EXAMINATION. Inspection : Delicate looking boy, very thin; bright eyes; unhealthy pink colour in cheeks. Chest narrow and flat, winging of scapulae. Chest movements good. Bilateral Hilus Dimple. No enlarged veins over the upper chest. Palpation: Cervical glands enlarged. No glands felt elsewhere. Chest movements equal and good. Normal resilience of manubrium. Myoedema and myotatic irritability. Slight rigidity of intercostal muscles over the hilus region. Slight spinalgia over the thoracic spines. Percussion: Slight dulness anteriorly in 2nd & 3rd intercostal spaces R & L. Paravertebral dulness\*. Dulness over 5th & 6th thoracic spines. Auscultation: Harsh breath sounds all over the chest, except in right interscapular region where there is bronchial breathing. Slight bronchitis both bases. D'Espine's sign present, and can be heard both sides vertebral column. Eustace Smith's sign present.

\* Double.

TUBERCULIN TESTS . VonPirquet's Test triple positive.

CLINICAL DIAGNOSIS. Tuberculous cervical glands.  
Tuberculous bronchial Adenopathy, especially right.

X RAY REPORT. Air entry reported good. Thickened roots, with glandular enlargement. Peribronchial thickening, extending to the apices and bases, and throughout the substance of the right lung.

---

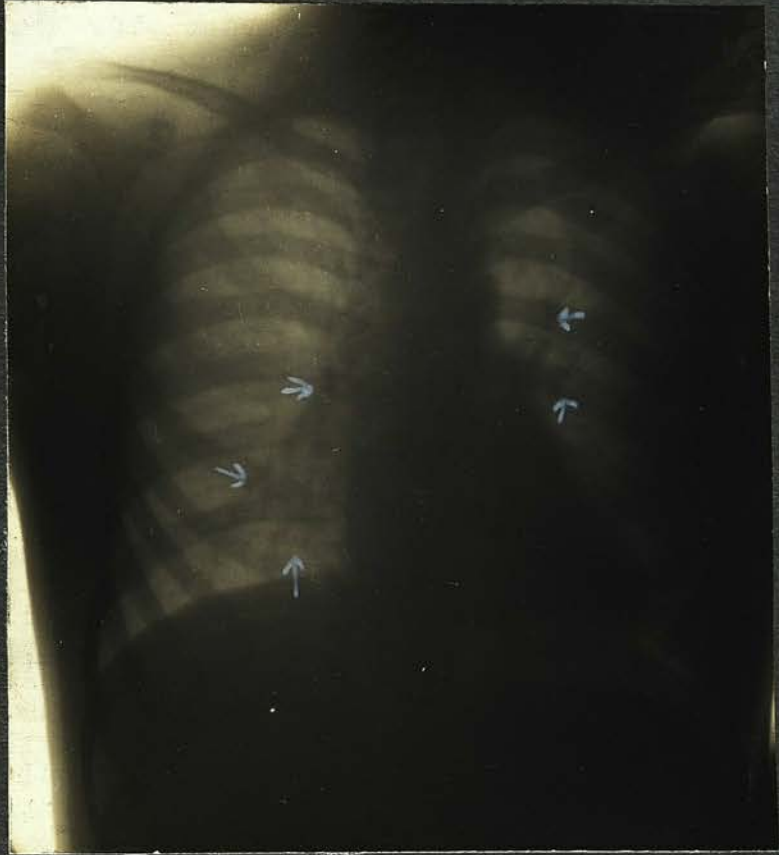

Plate 8

CASE 8. A.M. (FEMALE). PLATE 8.

Height 48". Weight 50 lbs. Aet.10.

FAMILY HISTORY. Mother, aet.35 healthy. M's M. aet (?) healthy. M's F. aet.70 bronchitis. M's B. nothing known. M's S.s 6 healthy.

Father, aet. 46 healthy. F's M. d.aet.70 cause (?). F's F. d.aet.(?), cause (?). F's B.s,2, 1 aet.(?) d. cause (?).

Patient's. B's 2, aet. 14 & 6, healthy. No sisters.

ENVIRONS. Poor, overcrowding .

PERSONAL HISTORY. Never a strong child. Measles (5), chicken pox (6). Can get no definite history from the mother concerning the patient. Is listless and languid. Gets cold easily and sweats slightly nocte. She is dull, stupid and apathetic. Has a hard, dry cough, but is not dyspnoeic.

EXAMINATION. Inspection: Hypothyreoid appearance, expressionless pale face. Chest is flat, slight winging of scapulae, chest movements appear good. Bilateral Hilus Dimple. No veins apparent over the chest. Palpation: Cervical glands enlarged. No glands palpable elsewhere. Chest movements equal and good. Normal manubrium resilience. No rigidity of the intercostal muscles over the hilus region. No spinalgia. Percussion: No anterior dulness. No paravertebral dulness. No dulness over 5th & 6th thoracic spines. Auscultation: Harsh breath sounds. No adventitious sounds. No blowing interscapular sound. Exquisite D'Espine's sign heard from the 2nd thoracic vertebra - 8th thoracic vertebra. No Eustace Smith's sign.

TUBERCULIN TESTS. Von Pirquet's Test well marked.reaction.

CLINICAL DIAGNOSIS. Tuberculous cervical glands. Tuberculous bronchial adenopathy.

X RAY REPORT. Air entry reported good. Slight thickening of both roots. No signs of glandular enlargement.

---

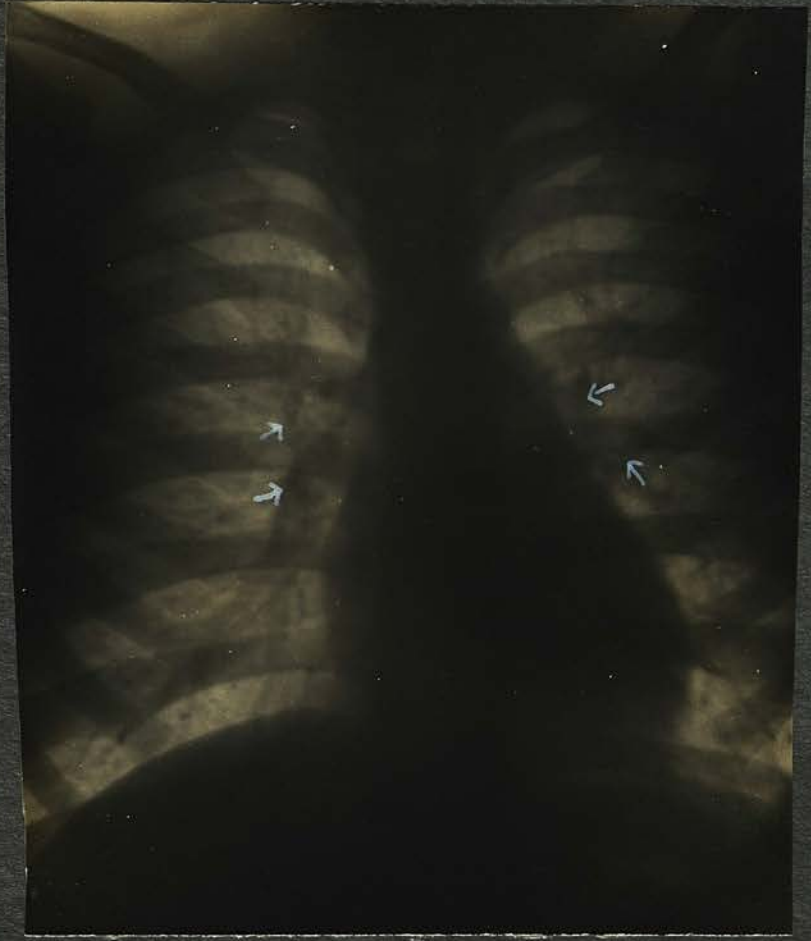

Plate 9

CASE 9. J.B. (MALE). Plate 9.

Height 56". Weight 74 lbs. Aet.13.

FAMILY HISTORY. Mother, d.aet.37 (1). M's M. aet. 72 healthy. M's F. d. aet.(?), "stroke". No brothers or sisters.

Father, aet.41 healthy. F's M. aet. 65 healthy. F's F. d. aet. (?), cause (?). No brothers or sisters.

Patient's B.s & S.s. 1 B. aet. 10 healthy. 2 S.s aet. 15 & 16 healthy.

ENVIRONS. Poor district, thickly populated; insufficient food.

PERSONAL HISTORY. Cannot get satisfactory history from the patient as he cannot remember his illnesses, and have not been able to see the father. He was ailing some time before attending the Dispensary. Says he does not feel ill though he does not put on weight. He does not present any symptoms of indisposition, other than a slight dry cough with a little dyspnoea.

EXAMINATION. Inspection: Does not look ill. has fairly good colour. Chest fairly well formed. Slight winging of scapulae. Chest movements appear good. Bilateral Hilus Dimple. No enlarged veins over the upper chest. Palpation. Cervical glands enlarged. No glands felt elsewhere. Chest movements equal and good. Normal manubrium resilience. No rigidity of intercostal muscles over the hilus region. No spinalgia. Percussion: Slight dulness anteriorly, in the 3rd right intercostal space. Paravertebral dulness on right. No dulness over the 5th & 6th thoracic spines Auscultation: Harsh breath sounds all over the chest; a few fine crepitations over the 3rd right intercostal space. No blowing sound interscapularly. D'Espine's sign present. No Eustace Smith's sign.

TUBERCULIN TESTS. Von Pirquet's Test triple positive.

CLINICAL DIAGNOSIS. Tuberculous cervical glands. Tuberculous bronchial adenopathy, right.

X RAY REPORT. Air entry reported good. Thickening of both roots due to bronchial adenopathy. Peribronchial thickening throughout.

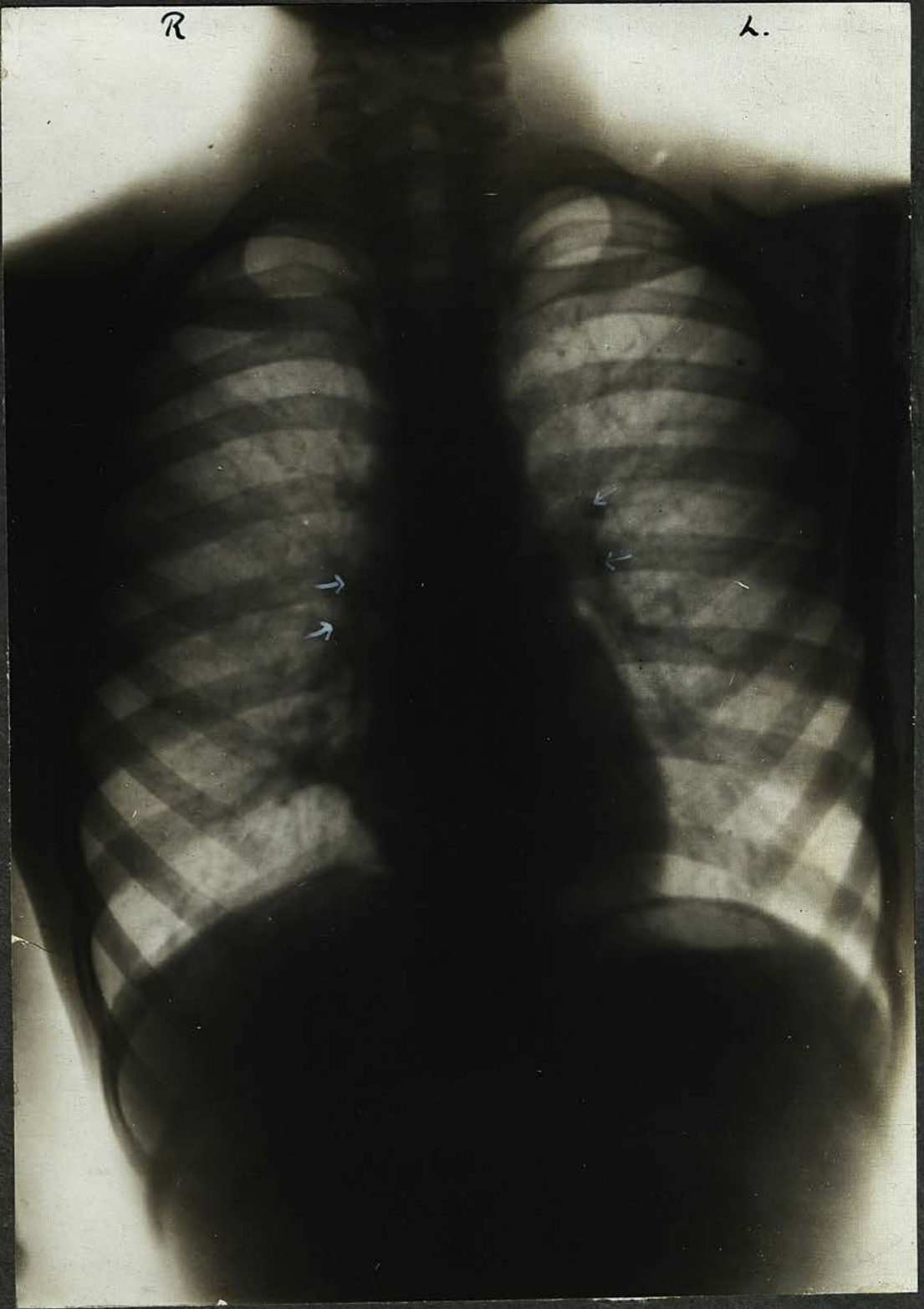

Plate 10

CASE 10. H. W. (FEMALE). PLATE 10.

Height 53". Weight 63 lbs. Aet. 10.

FAMILY HISTORY. Mother, aet. 39, healthy. M's M. d. aet. 50, cancer of stomach (5). M's F. d. aet. 45 (20) cause(?) M's B. aet. 36, chesty (T.B.?). M's S.s 3 aet. 34, 32, 29, healthy.

Father, aet. 49, with T.B. larynx. F's M. d. aet. (?) cause (?). F's F. d. aet. (?) cause (?). F's S.s. 4, aet. 55, 50, 45, 43, healthy. No brothers.

Patient's B.s & S.s. 1 B. d. aet. 3, pneumonia (4), 1 step-B. aet. 16, chesty, 1 step-S. aet. 21, chesty.

ENVIRONS. Poor, very closed in. The child is in constant contact with her father. She sleeps alone. Gets good and sufficient food.

PERSONAL HISTORY. Measles (8½), influenza (4), pneumonia (7), tonsillitis (3). Has not been well since influenza from which she made a long convalescence. She is irritable and nervous. Plays games but easily tires. Was losing weight. Languid and feverish nocte. Her mother says she has a "hot head". Slight night sweats. Fair appetite. No cough; moderate dyspnoea.

EXAMINATION. Inspection: Good colour, and fairly well nourished. Markedly flat chested. Slight winging of scapulae. Chest movements appear good. Bilateral Hilus Dimple. No enlarged veins over the upper chest. Palpation: Cervical glands enlarged. No glands felt elsewhere. Chest movements equal and good. Normal manubrium resilience. No rigidity of intercostal muscles over hilus region. No spinalgia. Percussion: No appreciable dulness anteriorly. Marked double paravertebral dulness, especially on the right. Dulness over 5th & 6th thoracic spines. Auscultation: Breath sounds harsh over the upper chest. No interscapular blowing sound. D'Espine's sign present. No Eustace Smith's sign.

TUBERCULIN TESTS. Von Pirquet's Test triple positive.

CLINICAL DIAGNOSIS. Tuberculous cervical glands. Tuberculous bronchial adenopathy, right and left, especially right.

X RAY REPORT. Heavy root shadows with enlarged glands, and slight patches of infiltrated lung tissue close to roots. Diaphragm movements fair. Air entry at apices good.

---

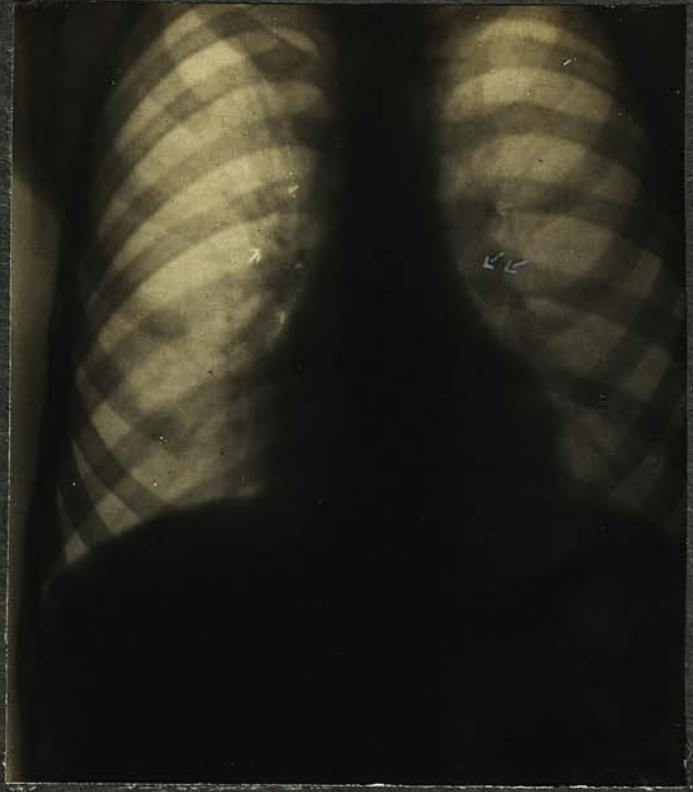

Plate 11

CASE 11. G. S. (MALE). PLATE 11.

Height 41". Weight 49 lbs. Aet. 8.

FAMILY HISTORY. Mother, aet. 29, slight bronchitis occasionally, otherwise healthy. M's M. aet. 47, healthy. M's F. d. aet. 47, cause (?) (17). M's B. d. aet. 19 (1).

Father, aet. 34, healthy. F's M. aet. 70, healthy. F's F. aet. 70 healthy. No B.s or S.s.

Patient has no B.s or S.s.

ENVIRONS. Poor. He was in constant contact with his Uncle (see above). There is no overcrowding at home, and the patient sleeps under as good conditions as are possible. He receives good and sufficient food.

PERSONAL HISTORY. Measles (3), pleurisy & bronchitis (3 months). He plays games vigorously, but cannot continue long as he is rather dyspnoeic. He is not languid or listless and there is no history of his having been so. He was losing weight slightly when brought for treatment, and had anorexia. No history of fever nocte. Has a hard, hollow cough.

EXAMINATION. Inspection : Small child, pinkish colour, unhealthy appearance. Chest poorly formed, flat and narrow. Slight winging of scapulae. Chest movements appear good. Bilateral Hilus Dimple. No enlarged veins over chest. Palpation: Cervical glands enlarged. No glands felt elsewhere. Chest movements equal and good. Normal manubrium resilience. No rigidity of intercostal muscles over the hilus region. Slight spinalgia. Pleuritic friction can be felt at the left base. Percussion : Impairment of resonance 2nd & 3rd intercostal spaces right and left. Double paravertebral dullness, more marked on left. Dulness over the 5th & 6th thoracic spines. Slight dullness over the left base in the region of pleuritic friction. Auscultation : Harsh breath sounds over chest in front and in the right interscapular region. The breath sounds in the left interscapular region are of bronchial quality. Weakened respiration over left base. Few coarse rales heard here. No D'Espine's sign. Eustace Smith's sign markedly present.

TUBERCULIN TESTS. In this case Von Pirquet's Test was not made.

CLINICAL DIAGNOSIS. Tuberculous cervical glands. Tuberculous bronchial adenopathy, especially left.

X RAY REPORT. Air entry reported fair. Roots - shadows much thickened on both sides, especially the left, due to enlargement of the bronchial glands. There are some calcified nodules and areas towards the right apex which give the appearance of caseous patches.

---

CASE 12. A.D. (MALE). SCREEN.

Height 41". Weight 42 lbs. Aet. 5 $\frac{1}{2}$ .

FAMILY HISTORY. Mother, aet.32. M's M. aet.73 healthy.  
M's F. d. aet.50 pneumonia (2). M's B. d.aet.45 (6).  
M's S. aet.52 healthy.

Father, aet.33 healthy. F's M. aet.70 healthy. F's F. aet.  
71 healthy. F's B.s 4 aet.44, 42, 38, 36 healthy. F's S.s  
aet. 50, 38, 31 healthy.

Patient's B.s & S.s. 3 B's aet. 10, 7, 3 healthy. 2 S.s aet.  
8, 2 $\frac{1}{2}$  healthy.

ENVIRONS. Poor, is in constant contact with his Mother (see  
above). Does not get sufficient food.

PERSONAL HISTORY. Measles (2), whooping cough (2), pneu-  
monia (1), bronchitis every winter. Long convalescence  
from measles and whooping cough and did not progress satis-  
factorily. Was losing weight when brought for treatment.  
Was apt to take cold easily. Inclined to "lie about".  
Loss of appetite and somewhat feverish nocte. Has slight  
hard cough and slight dyspnoea.

EXAMINATION. Inspection: Fairly good colour, not thin. Has  
an excoriating nasal discharge which is constantly present.  
Chest is inclined to flatness with some winging of scapulae.  
Movements appear to be good. Bilateral Hilus Dimple. No  
enlarged veins over the upper chest. Palpation. Cervical  
glands enlarged. No glands palpable elsewhere. Chest move-  
ments equal and good. Normal manubrium resilience. Slight  
myoidema and myotatic irritability. Slight rigidity of  
intercostal muscles over the hilus region. No spinalgia.  
Percussion: No appreciable dulness anteriorly. Paravertebral  
dulness on right. Dulness over the 5th & 6th thoracic spines.  
Auscultation: Harsh breath sounds. Slight bronchitis both  
bases. No interscapular blowing sound. D'Espine's sign pre-  
sent. Eustace Smith's sign present.

TUBERCULIN TESTS. Von Pirquet's Test triple positive.

CLINICAL DIAGNOSIS. Tuberculous cervical glands. Tuberculous  
bronchial adenopathy on the right side.

X RAY REPORT. Air entry reported good. Thickening of root  
shadows especially on the right, due to glandular enlargement.

---

CASE 13. D.R. (FEMALE) SCREEN.

Height 56". Weight 57 lbs. Aet.10.

FAMILY HISTORY. Mother, aet.33 healthy. M's M. aet.65 healthy. M's F. d.aet.(?), cause (?). M's B. aet. 27 healthy. M's S.s 1 aet 37 healthy. 1 S.d.aet.29 (6).

Father, aet.33, advanced and active. F's M. d.aet. (?), rheumatic fever (9). F's F. d. aet.47 (13). F's B.s 2 aet. 29 and 35. 3 B.s aet.23, 37, 29 healthy. F's S.s aet.27, 29. The former has gastritis.

Patient's S.aet.10 healthy. No brothers.

ENVIRONS. Poor, bad district. In constant contact with father (see above). Sleeps with mother and sister in same bed. Insufficient food.

PERSONAL HISTORY. Measles (5), whooping cough (5), influenza (5). Pneumonia with pleurisy (left) (7) & (1). Said to have made a good recovery from measles and whooping, but not well since last attack of pneumonia and pleurisy. She became very nervous with habit spasms. Peevish, naughty and cries on the least provocation. What little appetite she has is capricious. Is frequently listless and languid and is easily tired. Fever nocte. The mother complains that the child's whole nature has changed. She has a paroxysmal cough of a (clanging) hard character. She is moderately dyspnoeic. Before treatment was losing weight.

EXAMINATION. Inspection: Pale, thin child too tall for her age. Chest flat, slight winging of scapulae; inclined to stoop. Chest movements appear good. Hilus Dimple on right. No enlarged veins over upper chest. Palpation: Cervical glands enlarged. No glands palpable elsewhere. Chest movements equal and good. Normal manubrium resilience. No rigidity of intercostal muscles over the hilus region. Slight myoidema and myotatic irritability. Slight spinalgia over the thoracic vertebrae. Percussion: Slight dulness 2nd & 3rd intercostal spaces, right. Paravertebral dulness on right. No dulness over 5th & 6th thoracic spines. Auscultation: Harsh breath sounds. No adventitious sounds. No inter-scapular blowing sound. D'Espine's sign present. No Eustace Smith's sign.

TUBERCLIN TESTS. Von Pirquet's Test triple positive.

CLINICAL DIAGNOSIS. Tuberculous cervical glands. Tuberculous bronchial adenopathy, right.

X RAY REPORT. Air entry reported good. Thickening of root shadows, especially on right, due to bronchial enlargement.

CASE 14. G.C. (FEMALE). SCREEN.

Height 38". Weight 36 lbs. Aet.7.

FAMILY HISTORY. Mother, aet.37 healthy. M's M. d.aet.53 accident. M's F. d.aet.62, pneumonia. M's S.d. aet.1½ cause (?) (34). No B.s.

Father, aet.53, healthy. F's M. d.aet.70, cause (?). F's F. d.aet.74, cause (?). F's B.s,6, healthy. F's S.s,6, healthy.

Patient's B.s & S.s. 2 B.s, aet. 9 & 5, healthy. 1 step-S. aet.16, healthy.

ENVIRONS. Poor and closed in. Poor food.

PERSONAL HISTORY. Measles (4), whooping cough (4), chicken pox (3), pneumonia (2), influenza (1). Long convalescences. Does not play. Has "bad turns" when she "lies about". Listless and apathetic. Slight fever nocte sometimes. Slight sweats nocte. Was losing weight. Appetite capricious. Easily catches cold. Has a hard, dry cough. Dyspnoea (?).

EXAMINATION. Inspection: Pale and wan, very small, very thin. flat chest, winging of scapulae. Chest movements good. Bilateral Hilus Dimple. No enlarged veins over the upper chest. Palpation: Cervical glands enlarged. No glands felt elsewhere. Chest movements equal and good. Normal manubrium resilience. No rigidity of intercostal muscles over the hilus region. No spinalgia. Percussion: No anterior dullness. Right paravertebral dullness. No dullness over 5th & 6th thoracic spines. Auscultation: Harsh breath sounds. No interscapular blowing sound. No adventitious sounds. D'Espine's sign present. No Eustace Smith's sign.

TUBERCULIN TESTS. Von Pirquet's Test positive.

CLINICAL DIAGNOSIS. Tuberculous cervical glands. Tuberculous bronchial adenopathy.

X RAY REPORT. Air entry reported good. Thickening of root shadows, especially right, with glandular enlargement.

---

CASE 15. E.L. (FEMALE) SCREEN.

Height 47½". Weight 65 lbs. Aet.11.

FAMILY HISTORY. Mother, aet. 35 healthy. M's M. d.aet.(?) cancer of uterus. M's F. aet. 64 healthy. M's B.aet.43 healthy. M's S.s 3 aet. 46, 39, 37 healthy.

Father, aet.33 chronic cough. F's M. d.aet.(?) cause (?) F's F. aet. 65 healthy. F's B. aet.23 healthy. F's S.s 2 aet. 40 & 36 healthy.

Patient's B.s & S.s 1 B.aet.3 healthy. 2 S.s aet.7 & 11 months healthy.

ENVIRONS . Poor. The patient was in contact with a child friend who died (2) of miliary tuberculosis. The patient does not receive sufficient good food.

PERSONAL HISTORY. Measles (4), scarlet fever (5), whooping cough (10), pneumonia (4), bronchitis frequently, chicken pox (3) and appendicitis (3). She is languid and listless, and "lies about" a good deal. Her appetite is poor and she is slightly feverish nocte. She was losing weight slightly when brought to Dispensary. She has a very hard, dry cough and is somewhat dyspnoeic.

EXAMINATION. Inspection: Small child with unhealthy colour. Chest inclined to flatness, winging of scapulae. Chest movements appear good. Bilateral Hilus Dimple. No enlarged veins over upper chest. Palpation: Cervical glands enlarged.No glands felt elsewhere. Chest movements equal and good. Normal manubrium resilience. No rigidity of intercostal muscles over hilus region. No spinalgia. Percussion: No appreciable dulness anteriorly. Paravertebral dulness on right. No dulness over 5th & 6th thoracic spines. Auscultation: Harsh breath sounds. No adventitious sounds. No interscapular blowing sound. D'Espine's sign present. No Eustace Smith's sign.

TUBERCLIN TESTS. Von Pirquet's Test moderately positive.

CLINICAL DIAGNOSIS. Tuberculous cervical glands. Tuberculous bronchial adenopathy right.

X RAY REPORT. Air entry reported good. Thickening of root shadows, due to glandular enlargement, more marked on right.

---

CASE 16. J. G. (MALE). SCREEN.

Height 47". Weight 48½ lbs. Aet. 7.

FAMILY HISTORY. Mother, aet.30, healthy. M's M. aet.55, healthy. M's F.aet.60, healthy. M's B. aet.(?) healthy. M's S.aet.(?), healthy.

Father, aet.32, healthy. F's M.aet.56 healthy. F's F.d. aet.(?), cause(?). F's B.s & S.s, nothing known.

Patient's B.aet.4, bronchitis.

ENVIRONS. Poor; crowded district. Insufficient and poor food.

PERSONAL HISTORY. Measles (1), diphtheria (3), scarlet fever (4), pneumonia (4½), bronchitis (4½). Has never been strong, but after measles, diphtheria and scarlet fever his health was very bad. Improved under private treatment at home, until recently when he was brought to Dispensary for losing weight and because he had a bad cough and would not take his food. Languid, listless, fever nocte. Easily takes cold. Has a hard, dry cough, and is very dyspnoeic.

EXAMINATION. Inspection: Pale child. Chest flat and there is winging of the scapulae. Chest movements deficient on right. Double Hilus Dimple. No enlarged veins over chest. Palpation: \* Cervical glands enlarged. No glands felt elsewhere. Chest movements deficient on right. Normal manubrium resilience. No rigidity of intercostal muscles over hilus region. No spinalgia. Percussion: Dulness in the 2nd & 3rd intercostal spaces, right and left. Double paravertebral dulness. No dulness over the 5th & 6th thoracic spines. Auscultation: Breath sounds harsh all over the chest. Fine crepitations in the 2nd 3rd & 4th intercostal spaces on both sides. Bronchitis at both bases. No interscapular blowing sound. D'Espine's sign present. No Eustace Smith's sign.

TUBERCULIN TESTS. Von Pirquet's Test triple positive.

CLINICAL DIAGNOSIS. Tuberculous cervical glands. Tuberculous bronchial adenopathy.

X RAY REPORT. Air entry reported poor at right apex. Thickening of root shadows with enlargement of bronchial glands. Thickening of peribronchial shadows.

---

\* The patient had marked myoidema and myotatic irritability.

G R O U P II.

(10 CASES).

—

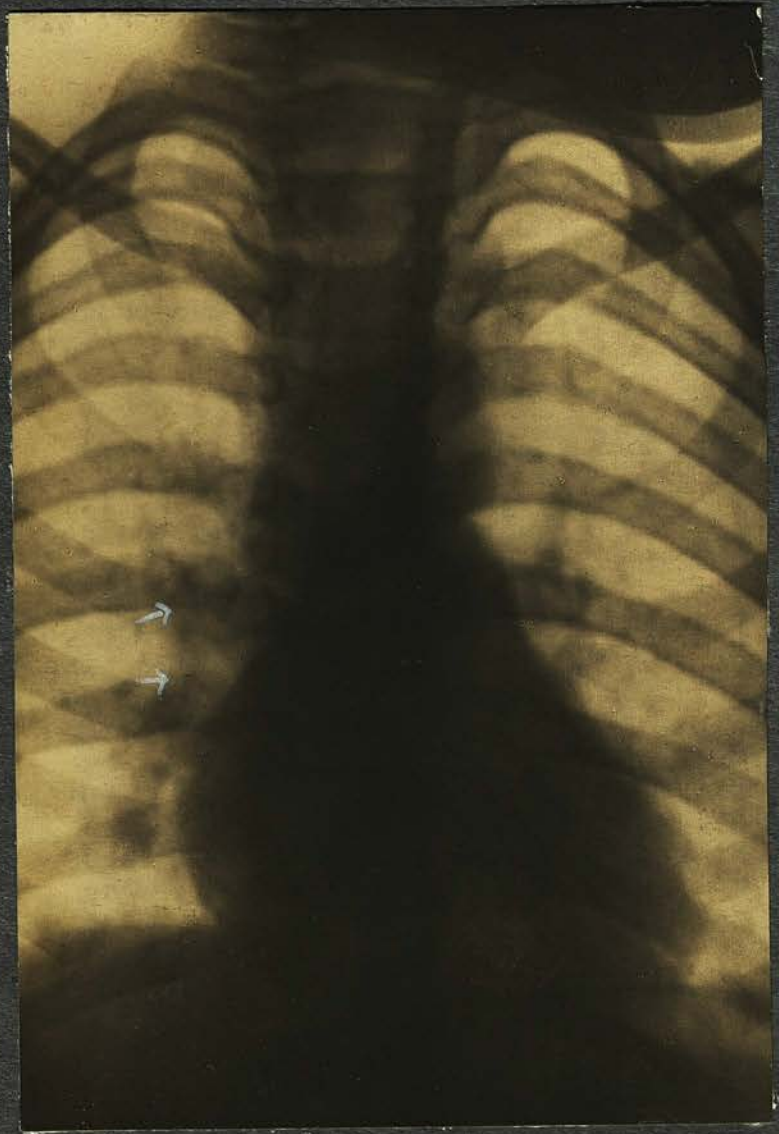


Plate 1

CASE I. G. B. (MALE) PLATE I.

Height 45". Weight 47½ lbd. Aet.7.

FAMILY HISTORY. Mother, aet.43 healthy. Her family history is free from any tuberculous trouble.

Father, aet. 44 healthy. His father d.aet. 42 (33). The rest of the family is healthy.

Patient's B.s & S.s. B.aet 20 suffers from a "weak chest". 2 S.s aet. 14 & 18, d. (4), the elder from T.B. kidneys.

ENVIRONS. Poor and dirty. A woman who lodges in the same house has "chest trouble". The patient slept in the same room as the 2 sisters mentioned above. He does not get good or sufficient food.

PERSONAL HISTORY . Measles and influenza (4). Good convalescence. Has not had any severe chest trouble. Was brought to Dispensary for slight bronchitis. Plays games vigorously, and shows no signs of illness. He does not cough, and does not complain of dyspnoea.

EXAMINATION.Inspection: Has a good colour and is not thin. Chest is inclined to be flat. No winging of scapulae. Chest movements good. No Hilus Dimple. Network of veins over upper chest. Palpation: Cervical glands enlarged. No glands felt elsewhere. Chest movements equal and good. Normal manubrium resilience. No rigidity of intercostal muscles over hilus region. No spinalgia. Percussion: No anterior dullness. No paravertebral dullness. No dullness over 5th & 6th thoracic spines. Auscultation: Harsh breath sounds. No adventitious sounds. No interscapular blowing sound. No D'Espine's sign. No Eustace Smith's sign.

TUBERCULIN TEST. Von Pirquet's Test : moderately positive.

CLINICAL DIAGNOSIS. Tuberculous cervical glands.

X RAY REPORT. Air entry reported good. Heavy root shadows. Enlarged bronchial glands on right.

---

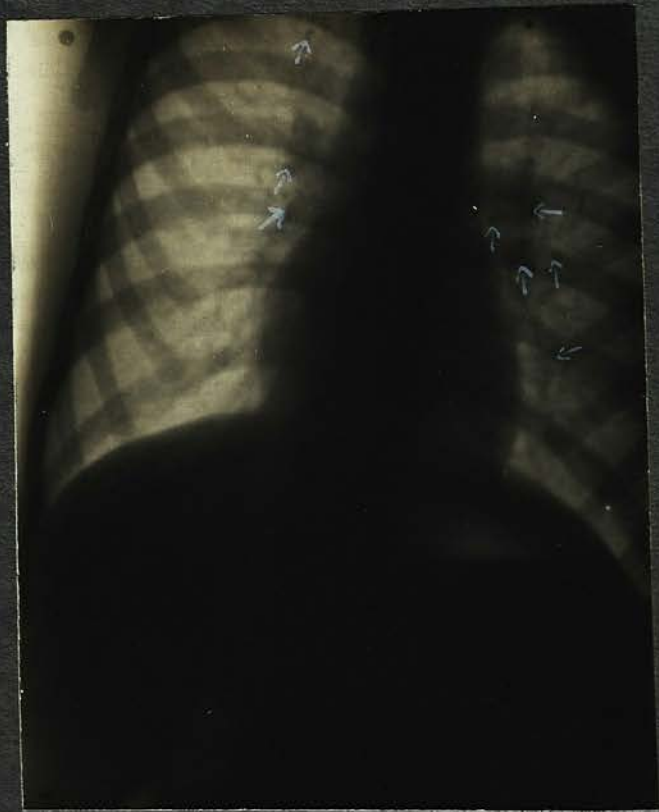

Plate 2

CASE 2. L. R. (FEMALE) PLATE 2.

Height 49". Weight 53 lbs. Aet. 8.

FAMILY HISTORY. Mother : aet 37, healthy. M's M. d. aet. 47 heart disease. M's F. d. aet. 45 Bright's disease. M's B.s aet. 40 & 41 healthy. M's S.s aet. 43 & 45 healthy.

Father: aet. 41. F's M. aet. 76 healthy. F's F. d. aet. 40 pneumonia. No B.s or S.s.

Patient's B.s & S.s. 2 B.s aet. 10 & 6 healthy. 2 S.s aet. 14 & 4 healthy.

ENVIRONS. Bad. Overcrowding in house. Slept in separate bed in small room occupied by four other persons. Constant contact with father. Poor food.

PERSONAL HISTORY. Measles and whooping cough (3). Jaundice (3). Has never been a strong child, and did not recover well after measles and whooping cough. The only thing the mother noticed wrong was that she was "not getting on". Losing weight, languid and indifferent to games. Anorexia; no history of fever. No cough or dyspnoea.

EXAMINATION. Inspection: Pale, with unhealthy pallor. Not thin. The chest is slightly asymmetrical, being noticeably flattened on right. No winging of scapulae. Chest movements appear good. No Hilus Dimple. No enlarged veins over upper chest. Palpation: No cervical glands. No glands palpable elsewhere. Chest movements good. Normal manubrium resilience. No rigidity of intercostal muscles over hilus region. No spinalgia. Percussion: No anterior dulness. No paravertebral dulness. No dulness over 5th & 6th thoracic spines. Auscultation: Harsh breath sounds. No adventitious sounds. No inter-scapular blowing sound. No D'Espine's sign. No Eustace Smith's sign.

TUBERCULIN TESTS. Von Pirquet's Test markedly positive.

CLINICAL DIAGNOSIS. Anaemia and Tuberculous cervical glands.

X RAY REPORT. Air entry reported good. Well marked thickening of both roots, especially on left, due to enlargement of bronchial glands.

---

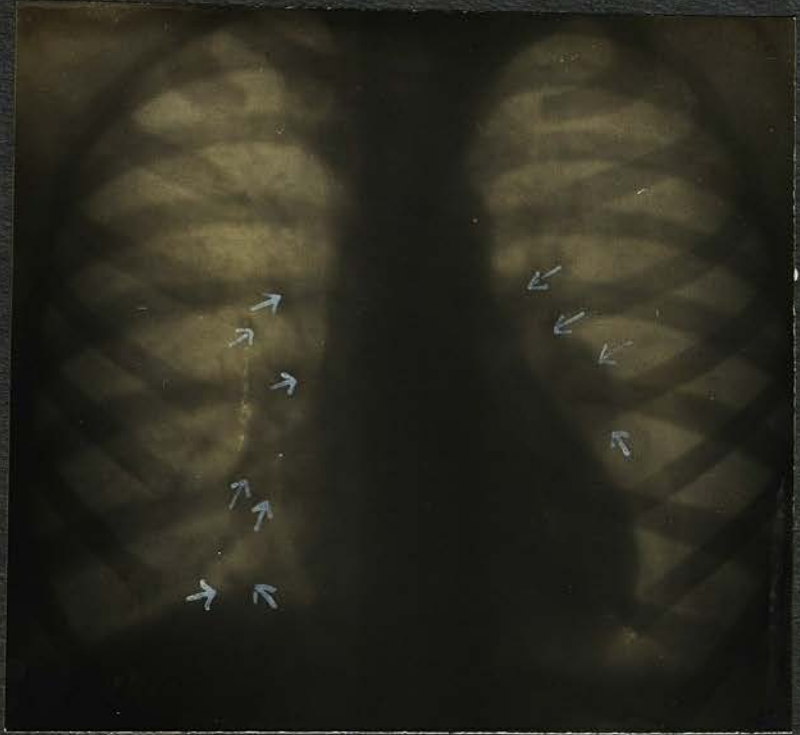


Plate 3

CASE 3. G.P. (FEMALE) PLATE 3.

Height 48". Weight 52 lbs. Aet.9.

FAMILY HISTORY. Mother, aet.48 advanced. M's M. aet.70 has neuritis, otherwise healthy. M's F. aet.70 healthy. M's B.s aet. 30 & 44 healthy. M's S.s aet.45 & 47 healthy

Father: aet.41, advanced with T.B. larynx. F's M. d.aet. (?) cause (?). F's F. aet.70 chesty. F's B.s aet.47 & 48 and step-brother aet.33, healthy. F's S.aet.40 healthy.

Patient has no B.s or S.s.

ENVIRONS. Good as regards district, housing and cleanliness. Has constantly been in contact with her parents. They have been removed to Sanatorium, and the child now sleeps alone. Receives good and sufficient food.

PERSONAL HISTORY. Measles (4), whooping cough (4), scarlet fever (3) and diphtheria (1). She made good recoveries from these and has never complained of anything. Has never had any chest trouble, and was only brought to the Dispensary because her parents were tuberculous. There is no history of malaise, or symptoms of vague illness. Her appetite is good, and she has no cough, or dyspnoea.

EXAMINATION. Inspection: Pale, flabby child. Not thin. Chest is well formed. No winging of scapulae. Chest movements appear good. No Hilus Dimple. No enlarged veins over chest. Palpation: Cervical glands enlarged. No glands felt elsewhere. Chest movements good. Normal manubrium resilience. No rigidity of intercostal muscles over the hilus region. No spinalgia. Percussion: No anterior dulness. No paravertebral dulness. No dulness over the 5th & 6th thoracic spines. Auscultation: Breath sounds harsh. No adventitious sounds. No interscapular blowing sound. No D'Espine's sign. No Eustace Smith's sign.

TUBERCULIN TESTS. Von Pirquet's Test triple positive.

CLINICAL DIAGNOSIS. Anaemia. Tuberculous cervical glands.

X RAY REPORT. Marked thickening of root shadows on both sides, but especially on left, where marked glandular enlargement is seen. The diaphragm on the right is held up.

---

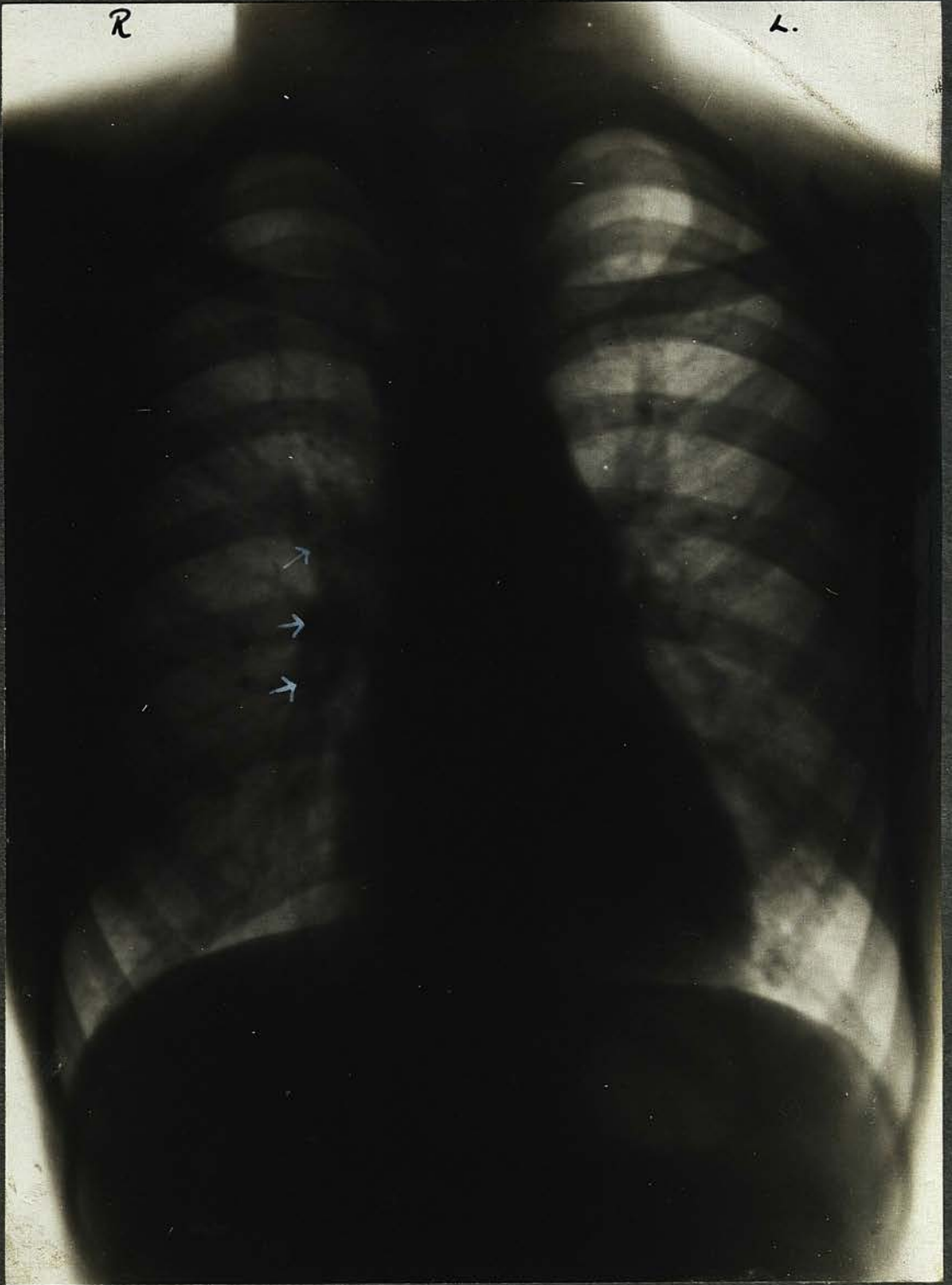

Plate 4

CASE 4. M.D. (FEMALE) PLATE 4.

Height 58". Weight 77 lbs. Aet.12.

FAMILY HISTORY. Mother, aet.38, suffers from "catarrh". Frequently has quinsy; neuritis and influenza (1); otherwise healthy. M's M. d.aet.80, cause (?); M's F. d.aet. 82 cause (?). M's B.s 6, all healthy. M's S. healthy.

Father ; aet.40, healthy. F's M. aet.68, healthy. F's F.d.aet. 46, pneumonia (?). F's S. healthy.

Patient's B.s. 3, aet.15, 13 and 5½. The second is under treatment at the Dispensary, The others are said to be healthy.

ENVIRONS. Good, and the patient frequently has the opportunity of going away to the country. She receives good food in sufficient quantity.

PERSONAL HISTORY . Pneumonia (11), chicken pox (10), diphtheria (11), measles (11), whooping cough (10), mumps (10). Diphtheria (9) and pneumonia (9). Influenza (5). Was brought to the Dispensary because she was pale and had slight bronchitis. Growing rapidly. Easily gets cold. Appetite good. No languor. No cough or dyspnoea.

EXAMINATION. Inspection: A tall, pale child. The chest is inclined to flatness. Slight winging of scapulae. Chest movements appear good. Hilus Dimple on right. No enlarged veins over upper chest. Palpation: Cervical glands enlarged. No glands felt elsewhere. Chest movements good. No rigidity of intercostal muscles over hilus region. Normal manubrium resilience. No spinalgia. Percussion: No anterior dulness. No paravertebral dulness. No dulness over 5th & 6th thoracic spines. Auscultation: Harsh breath sounds. No adventitious sounds. No interscapular blowing sound. No D'Espine's sign. No Eustace Smith's sign.

TUBERCULIN TESTS. Von Pirquet's Test triple positive.

CLINICAL DIAGNOSIS. Anaemia;tuberculous cervical glands.

X RAY REPORT. Air entry reported fair. Heavy root shadows with numerous enlarged glands. Increase in peribronchial shadows and one or two patches of infiltrated lung tissue.

---

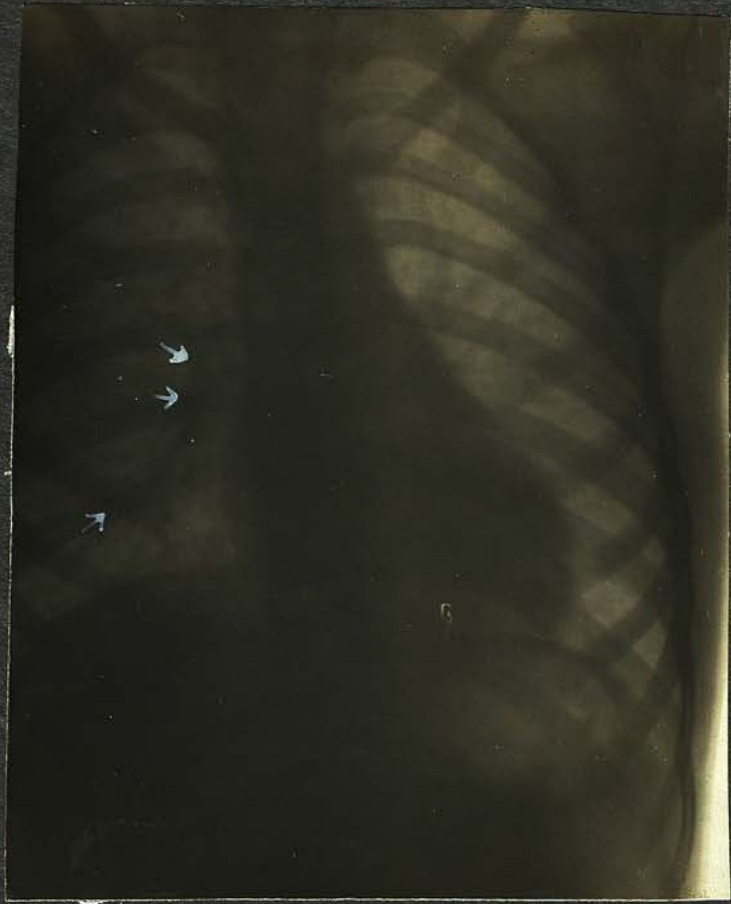


Plate 5

CASE 5. K.H. (FEMALE). PLATE 5.

Height 43". Weight 40 lbs. Aet. 7.

FAMILY HISTORY. Mother : aet. 40, healthy(?). M's M. aet. 67, paralysed. M's F. d. aet. (?) of chronic nephritis. M's S aet. 35, healthy.

Father : d. aet. 38 (2). F's M. d. aet. (?) of pneumonia. F's F. d. aet. (?) cause (?). F's Bs 1 d. aet 17 (12) of pneumonia.

Patient's B s and S s. B. d. aet. 2(7) of bronchitis and whooping cough. S d. aet. 4½ (6) of bronchitis and whooping cough. 2 other sisters are anaemic and have enlarged glands in the neck.

ENVIRONS. Very poor ; patient shares bed with mother. In the same room are two sisters sharing a bed. She does not get good or sufficient food.

PERSONAL HISTORY. Has never been strong. Always weak and ailing. Has not had any of the infectious diseases. The mother says that the child has never "got on". She was losing weight up to the time of bringing her for treatment. Her appetite is good. She is easily tired. She is slightly dyspnoeic. No cough.

EXAMINATION. Pale, and of very poor physique. The chest is very flat. Winged scapulae. The chest movements appear good. No Hilus Dimple. No enlarged veins over the upper chest. Palpation. Cervical glands enlarged. No glands felt elsewhere. Chest movements equal and good. Normal manubrium resilience. No rigidity of the intercostal muscles over the hilus region. No spinalgia. Percussion. No anterior dulness. No paravertebral dulness. No dulness over the 5th and 6th thoracic spines. Auscultation. Harsh breath sounds. No adventitious sounds. No interscapular blowing sound. No D'Espine's sign. No Eustace Smith's sign.

TUBERCULIN TESTS. Von Pirquet's Test : moderately positive.

CLINICAL DIAGNOSIS. Anaemia ; tuberculous cervical adenitis.

X RAY REPORT. Air entry reported good. Thickening of root shadows slight, right, but no glandular enlargement. Slight peribronchial thickening.

---

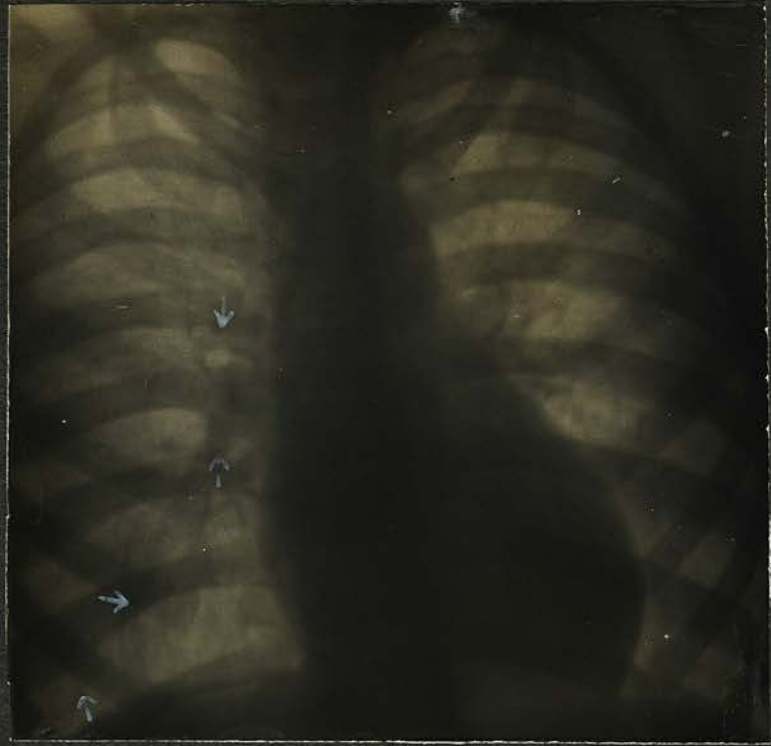

Plate 6

CASE 6. L.F. (FEMALE). PLATE 6.

Height 52". Weight 52 lbs. Aet.12.

FAMILY HISTORY. Mother, aet.36 healthy. M's M. aet.65 healthy. M's F. d. aet. 36, pneumonia (32). M's B. 2 aet. 42 & 33, healthy, 2 B.s killed in the War. No sisters.

Father, aet.37 healthy. F's M. d.aet. 50, "dropsy" (10) F's F. aet. 72 healthy. F's B. aet. 32 healthy. F's S.s aet. 42 & 40 healthy.

Patient's B.s & S.s. 2 B.s aet.10 & 8 coughs. 2 S.s aet. 16 & 2 healthy.

ENVIRONS. Poor district, closed in and unhealthy. The home is next door to a badly kept stable. Patient sleeps with her sister aet.16. She does not get sufficient food.

PERSONAL HISTORY. Whooping cough and broncho-pneumonia (11), influenza (5). Is subject to sore throats and "growing pains", these she has had since 1918. Twelve months ago began to be languid and easily tired, peevish and fretful. The mother says that until twelve months ago the child was sweet tempered, but is now so irritable as to be almost unbearable at times. She has some anorexia and gets frequent headaches. She still suffers from sore throat occasionally. She is not dyspnoeic and has no cough.

EXAMINATION. Inspection: Unhealthy pinkish complexion. Very intelligent. Thin, markedly flat chest; winging of scapulae. Chest movements appear good. Bilateral Hilus Dimple. No veins over upper chest. Palpation: Slight enlargement of cervical glands. No glands palpable elsewhere. Chest movements equal and good. Normal manubrium resilience. No rigidity of intercostal muscles over hilus region. No spinalgia. No rheumatic nodules to be felt in any of the usual positions. Percussion: No anterior dullness. No paravertebral dullness. No dullness over 5th & 6th thoracic spines. Auscultation: Harsh breath sounds over chest. No adventitious sounds. No blowing sound interscapularly. D'Espine's sign: not present. Eustace Smith's sign : not present.

TUBERCULIN TESTS. Von Pirquet's Test slightly positive.

CLINICAL DIAGNOSIS. Tuberculous cervical glands. Anaemia. Rheumatic diathesis.

X RAY REPORT. Air entry reported good. Slight peribronchial thickening. No thickening of root shadows or glandular enlargement reported.

---



CASE 7. A.D. (FEMALE). PLATE 7.

Height 56½". Weight 74 lbs. Aet.12.

FAMILY HISTORY. Mother, aet.39 healthy. M's M. d. aet.69 cause (?) (11). M's F. d. aet.(?), cause (?) M's B. aet.42 healthy. M's S.s 2, aet. 42 & 36 healthy. 1 S.d. aet.8 diphtheria (38).

Father, aet. 40, chronic cough. F's M. d.aet.75, cause(?) F's F. d.aet.78, cause (?). F's B. nothing known. F's S.s 3, healthy.

Patient's B.s & S.s. 1 B. aet.9 healthy. 3 S.s aet.15,13 & 2 healthy.

ENVIRONS. Surroundings poor. Shared bed with 2 sisters, the brother having separate bed in same room. Poor food.

PERSONAL HISTORY. Measles (2). No further particulars as to previous illnesses and present state of health were obtainable. The child has no cough and is not dyspnoeic. Her appetite is good.

EXAMINATION.Inspection: Fairly good colour, not thin. The chest is fairly well formed. No winging of scapulae. Chest movements slightly deficient on right. No Hilus Dimple. No enlarged veins over the upper chest. Palpation:Cervical glands enlarged. No glands palpable elsewhere. Chest movements deficient on right. Normal manubrium resilience. No rigidity of intercostal muscles over hilus region. No spin-algia. Percussion: No anterior dulness. No paravertebral dulness. No dulness over the 5th & 6th thoracic spines. Auscultation: Harsh breath sounds. No adventitious sounds. No interscapular blowing sound. No D'Espine's sign. No Eustace Smith's sign.

TUBERCULIN TESTS. Von Pirquet's Test moderately positive.

CLINICAL DIAGNOSIS. Tuberculous cervical glands.

X RAY REPORT. Air entry reported good. Both lungæ are interspersed throughout with numerous fine markings and small indefinite shadows of varying density. These small shadows appear to be connected by fine lines to the roots and are probably tuberculous foci. No enlargement of bronchial glands reported.

---

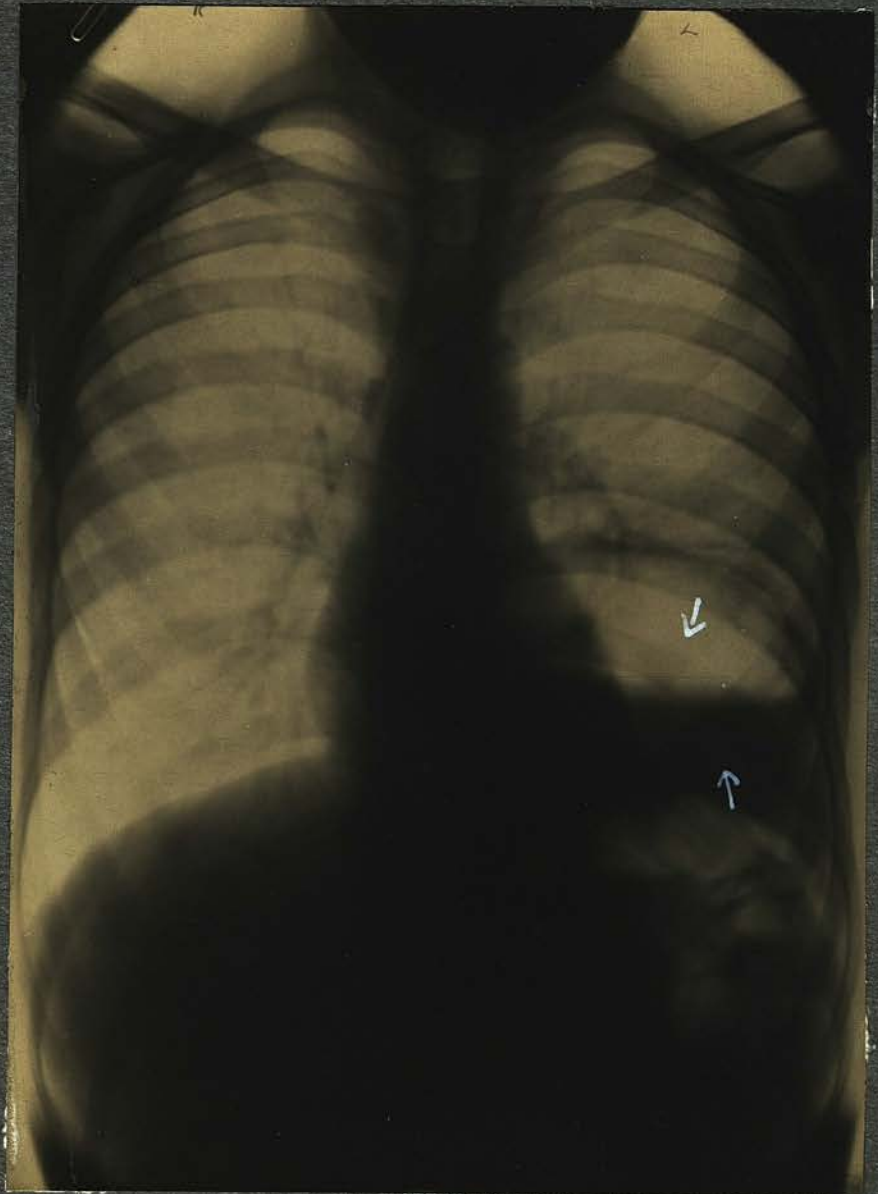

Plate 8

CASE 8. F.N. (MALE). PLATE 8.

Height 52". Weight 75 $\frac{3}{4}$  lbs. Aet.12.

FAMILY HISTORY. Parents separated, therefore, no coherent history could be obtained. The mother can tell nothing about her family, or that of her husband.

Patient has no B.s or S.s.

ENVIRONS. Poor. Patient has lived in very straightened circumstances.

PERSONAL HISTORY. Patient has spent much of his time in hospital, but for what illnesses the mother could not state definitely. He has had scarlet fever (7), bronchitis (3) These particulars are all that could be obtained.

EXAMINATION. Inspection: Pale, thin child with dull, vacant face, suggestive of thyroid deficiency. Marked pigeon chest; winged scapulae. Chest movements fair. No Hilus Dimple. No veins over upper chest. He has marked hypertrophic osteo-arthritis in the fingers of both hands and both wrists are swollen. The knees are baggy, and the internal condyles of both the femora are enlarged. The feet and ankles present similar characteristics. There is some degree of knock-knee. Palpation: Cervical glands enlarged, No glands palpable elsewhere. Chest movements appear equal. Normal manubrium resilience. No rigidity of intercostal muscles over hilus region. No spinalgia. Fluid can be distinctly felt in wrists, knees & ankles. Percussion: In the region of 4th intercostal space, on left, is a localised high pitched tympanic resonance. Immediately below this is the absolute dullness of fluid, and this extends posteriorly to the angle of the scapulae. No anterior dullness. No paravertebral dullness on left. Auscultation: Over area of high pitched tympanic resonance there is absence of breath sounds and vocal resonance. This applies also to area over which fluid occurs. Over the rest of the lungs, on both sides, is harsh inspiration. No inter-scapular blowing sound. There are a few coarse crepitations at base of left lung. No D'Espine's sign. No Eustace Smith's sign.

TUBERCULIN TESTS. Von Pirquet's Test mildly positive.

CLINICAL DIAGNOSIS. Localised hydropneumothorax on left.

X RAY REPORT. Air entry reported good, except at left base. There is a layer of fluid lying above the left diaphragm, above this is a clear air space, there being a localised hydropneumothorax. Root shadows are heavy. There is a patch of mottling of lung tissue close to the left root.

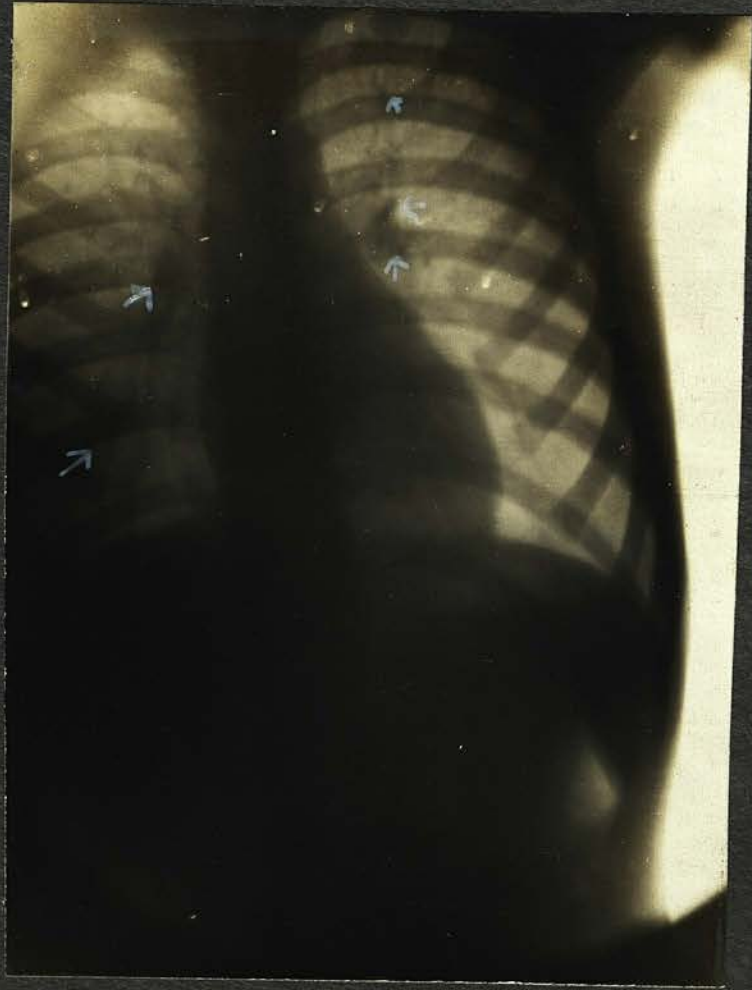


Plate 9

CASE 9. T.T. (MALE). PLATE 9.

Height 56". Weight 61 lbs. Aet, 13.

FAMILY HISTORY. Mother, aet.43, anaemic. M's M. aet.84 healthy. M's F. d.aet.70, rheumatic fever (14) M's S.s 4 aet.45, 47, 49, 51, healthy. 1 S.d.aet.21 pneumonia (35) No B.s.

Father, aet.50 healthy. F's M. d.aet.62, cause (?). F's F. d.aet.(?), cause (?). No B.s or S.s.

Patient's B.s & S.s. 1 B.aet.11 healthy. 1 S. aet.13 in Sanatorium. 1 S.aet 7 chesty.

ENVIRONS . Poor. Sleeps with B. in same bed. Receives good food.

PERSONAL HISTORY. Measles (12), (4), scarlet fever (2), whooping cough (1½), diphtheria (1½). Made good recoveries from these illnesses. There is no history of any vague symptoms of illness, all the mother says is that "his weight is not what it should be". He has a good appetite and plays games vigorously. Has no cough and no dyspnoea.

EXAMINATION. Inspection: Thin, but good colour. Not very bright mentally. No flatness of chest. No winging of scapulae. No Hilus Dimple. Chest movements good. No enlarged veins over upper chest. Palpation: Cervical glands enlarged. No glands palpable elsewhere. Chest movements equal and good. Normal manubrium resilience. No rigidity of intercostal muscles over hilus region. No spinalgia. Percussion: No anterior dullness. No paravertebral dullness. No dullness over 5th & 6th thoracic spines. Auscultation: Breath sounds harsh. No blowing interscapular sound. No adventitious sounds. No D'Espine's sign. No Eustace Smith's sign.

TUBERCULIN TESTS. Von Pirquet's Test moderately positive.

CLINICAL DIAGNOSIS. Tuberculous cervical glands.

X RAY REPORT. Air entry reported good. Slight thickening at both roots. Peribronchial thickening..

---

CASE 10. R.R. (MALE). SCREEN.

Height 53". Weight 72 lbs. Aet.11.

FAMILY HISTORY. Mother, aet. 35 healthy. M's M. d.aet.51 Bright's disease (16). M's F. d.aet.41, cause (?) (20) M's B.d.aet.13, pneumonia (22). No sisters.

Father, aet.52 healthy. F's M. aet.(?) healthy. F's F.d.aet.70, cause (?). F's B.s 3, healthy. F's S.s.4, healthy.

Patient's B.s & S.s. 1. B. aet.3 healthy. 1 S.aet.7  
1 S. aet. 9 months, both healthy.

ENVIRONS. Poor, over crowding. Patient sleeps with 2 others in same bed. Poor and insufficient food.

PERSONAL HISTORY. Measles (4), whooping cough (4). pleurisy (2). "He has never been the same since pleurisy". Before treatment at Dispensary was languid and listless and did not play games. His appetite was poor, and he was inclined to be feverish nocte. No cough and does not complain of dyspnoea. Was inclined to lose weight before treatment. Has since improved considerably.

EXAMINATION. Inspection: Somewhat pale; dull face. Chest normal in shape and well covered. No winging of scapulae. Chest movements fair. No Hilus Dimple. No enlarged veins over upper chest. Palpation: Cervical glands enlarged. No glands felt elsewhere. Chest movements equal. Normal resilience of manubrium. No rigidity of intercostal muscles over hilus region. No spinalgia. Percussion: No anterior dulness. No paravertebral dulness. No dulness over 5th & 6th thoracic spines. Auscultation: Breath sounds harsh; diminished at base, left. No blowing interscapular sound. No adventitious sounds. No D'Espine's sign. No Eustace Smith's sign.

TUBERCULIN TESTS. Von Pirquet's Test slightly positive.

CLINICAL DIAGNOSIS. Anaemia; Tuberculous cervical glands.

X RAY REPORT. Air entry reported good; diminished entry at left base. Marked thickening of roots, especially on right, with enlargement of bronchial glands. Some peribronchial thickening.

---

SECTION V.

SECTION V.

Chapter 1.

PERSONAL EXPERIENCE .

SYMPTOMS. As far as symptoms are concerned, I do not suppose that my experience has been any different from that of others working in the same field. The onset of the disease is insidious to a degree, and we do not know how long after infection takes place that the clinical signs and symptoms develop. These symptoms are, to say the least of it, vague, and suggestive, rather than conclusive, of the condition. It has been my experience that of all the conditions which give rise to symptoms simulating those of early tuberculosis, hypertrophied tonsils and adenoid vegetations in the nasopharynx are the worst offenders. The removal of these, as I have more than once demonstrated to myself, frequently acts like a charm. The symptoms disappear, appetite returns, and the child thereafter never looks back. It must, also, always be kept in mind, that of other vague conditions, hereditary lues produces indefinite symptoms of illness, and that it especially simulates tuberculous disease in the production of evening temperature. It is essential, also, in

the differential diagnosis to remember that Hodgkin's disease may commence in the mediastinal glands, and that lympho sarcoma, though rare, may originate in the same position. Therefore, it is necessary to exclude these diseases before we arrive at a diagnosis of early tuberculosis.

Of all the foes of childhood, there are three which may be termed arch-enemies. These are measles, whooping cough and influenza. Illness dating from one or more of these diseases should always make us suspicious. It is, however, surprising how little most parents of the class which attends Tuberculosis Dispensaries remember of the consequences of their children's illnesses. They can generally recollect what infectious diseases the patients have had, but that is all. It is, therefore, well to bear in mind the great part these maladies do play in the production of the tuberculosis of children, and to take them into account when examining the patient.

The most common complaint in my experience, is that the child is not gaining weight, and that he does not seem to derive benefit from his food. Enquiry will elicit the facts that the child is frequently languid and listless, that he does not take his food well, and that instead of playing strenuous games like other children, he tends to "lie about".

Towards the evening he gets irritable, in some cases to an almost unbearable degree, and often becomes flushed. The mother may complain that the child sweats at night. This, however, is not a symptom upon which I am inclined to lay too much stress, as many healthy children have night sweats. Moreover, the conditions under which many of these children sleep, often in an overcrowded room with the windows tightly closed, are certainly conducive to sweating. In my opinion, even true night sweats are, and should be, preventable.

PRESSURE SYMPTOMS. A hard "brassy" cough and dyspnoea of expiratory type are frequently, but not always present in tuberculous bronchial adenopathy. The cough is extremely characteristic, and when present is a most valuable sign. Of the cases in Group I, 14 had this type of cough, 13 had dyspnoea, of which number 2 had it severely, and the remaining 11 in varying degree. The 2 cases mentioned above suffered from chronic bronchitis and from occasional distressing asthma of suffocating type. Of the cases in Group II, 5 had bronchial adenopathy, but these pressure symptoms were absent from them. Of the remaining 5, 1 case was slightly dyspnoeic.

The cause of the cough and of the dyspnoea has long

been in doubt, but the most probable explanation is that both are due to mechanical causes, namely pressure.

The cough is almost certainly due to irritation of the vagus ganglion, and is doubtless produced in exactly the same way as is the "gander" cough of aortic aneurism.

INSPECTION. . The child victim of tuberculous disease in any form, latent or active, is frequently of a frail constitution, but this is not always the case. The mask of health often hides disease beneath. It is difficult to know where to draw the line for many circumstances join issue to disturb the age: weight: height ratio. The period of growth is a period of great activity, and avoirdupois often lags behind, while growth goes on. In such cases a pathological process is not necessarily present. I think that the definition of a healthy child and an unhealthy one may be this: a healthy child, though he may be under weight for his age and height, will show a steady, though maybe slow, increase in his weight; the unhealthy child will either lose weight, or at least will not put any on over a long period of time.

It is necessary to say a word about contours. In Group I, 10 had flat chests; 10 had winging of the scapulae; 1 was pigeon-chested; 2 had deficient chest movements; 3 were

undersized and under weight for their ages; 4 were of normal height but under weight; 4 were undersized but of normal weight for their height; 2 were under height and over weight for their height; 1 was over height and under weight; and 2 were normal in height and weight.

In Group II, 2 cases had flat chests; 4 slightly flat chests; 1 had winging of the scapulae; 1 had deficient movement of the right apex; and 1 deficient movement of the left base. 1 was under height and under weight; 3 were of normal height but under weight; 2 were over height and under weight for their age; and 4 were of normal height and weight for their age.

Conspicuous and dilated veins. It is common to find in text books the statement that enlarged superficial veins over the anterior wall of the chest is a valuable sign in the diagnosis of bronchial adenopathy. This does not correspond with my experience. In one case only of my 26 was a network of veins seen in this position, and this was a case in Group II presenting no other signs of enlarged bronchial glands. These veins were uniformly distributed over the chest, and could hardly be said to be dilated. As it happened, the case in question had enlarged glands, but in the other cases, both in Groups I and II, where the glands were

relatively enormous, and sufficiently large to exert pressure on the superior vena cava, this "sign" was absent. When the superficial veins are conspicuous, I regard them more as a sign of deficient panniculus than of anything else.

Cyanosis. I have only seen this in one case (Case 1, Group I). Here there was cyanosis of the lips with slight swelling of the face. The patient was very dyspnoeic, and suffered from asthmatic attacks. He had marked bronchial adenopathy, and while the cyanosis could have been caused by the dyspnoea, I think that pressure on the superior vena cava, with some venous stasis, could easily have been present in this case.

Stoll's Hilus Dimple. I observed this sign in 18 cases in all, 15 in Group I and 2 in Group II. Stoll regards it as suggestive, but although it was so constantly present in my cases, I cannot feel a great deal of confidence in it. It seems to be present in most children that one examines, most often in those with flat chests thinly covered, and one cannot help thinking that it is an optical illusion, and of no practical significance.

PALPATION. I have never palpated enlarged glands behind the manubrium sterni in any case, nor have I ever noted an increased resistance to pressure over the manubrium.

Pottinger's rigidity sign. I have demonstrated this

sign to my own satisfaction in 2 cases of the 26. It was found in those cases where one would most expect to find it, namely, those which were very definitely toxic, (see Cases 7 and 12, Group I.) In both these there was myoidema and myotatic irritability. In three other cases, however, also toxic, this sign was absent (Cases 4, 13 and 16, Group I). It was also absent in the remaining cases. At best, therefore, I regard this sign also as uncertain, and not to be relied upon. When it is present, I think it is suggestive.

Petruschsky's spinalgia. It has been stated that the presence of this spinalgia is the most reliable means we have of differentiating between active and inactive bronchial glandular disease.

Petruschsky (28) reported 79 cases of spinalgia, 77 of which reacted to tuberculin. Stoll (29) reported 23 cases of spinalgia in 58 of his series; 83% reacted to tuberculin. Of my own cases, in Group I, 4 cases presented this sign - Cases 4, 7, 11, 12. On the other hand, in 2 other cases which were indubitably active, spinalgia was absent - Cases 13 and 16, Group I. In all other cases the sign was absent, though symptoms of languor, anorexia, etc, pointed

to their undoubted toxaemia.

PERCUSSION. No method of diagnosis has been more adversely criticized than that of percussion, and especially anterior percussion. For this scepticism as regards percussion in the interspaces, I think there is some justification, as the position of the bronchial glands is such that probably none but marked degrees of enlargement will materially affect anterior resonance. Moreover, there is always the possibility of the existence of a persistent thymus gland, and the presence of this will effectually vitiate the percussion note. Paravertebral percussion, however, has, I think, a very distinct value.

It is true that between the bronchial glands and the interscapular region there is a considerable thickness of tissue. But in spite of this, the normal interscapular space has a distinct normal resonance, which bronchial adenopathy will disturb. I believe that by careful light percussion this impairment can be recognised. Repeated examination should be made and both sides of the interscapular region carefully compared. The touch must be light in order that too large an area of lung tissue may not be set in vibration. The finger must be well pressed against

the chest wall. Ewart (30) has called this light percussion the "percussion of the deaf".

By means of this light percussion, I found anterior impairment of resonance in 10 cases of the 16 in Group I. In 6 it was bilateral (Cases 1, 3, 6, 7, 11, 16). In 4 it was unilateral (Cases 2, 5, 9, 13). Paravertebral dulness was found in 15 cases. In 7 it was double (Cases 1, 3, 4, 7, 10, 11, 16). In 8 it was single (Cases 2, 5, 6, 9, 12, 13, 14, 15).

Ewart (31) and Da Costa (32) have both advocated spinal percussion. I found this dulness over the 5th and 6th thoracic spines in 7 cases in Group I (Cases 1, 2, 4, 5, 7, 10, 12).

The dulness is, as a rule, more marked on the right side than on the left, owing to the greater number of bronchial glands there present.

The cause of dulness in bronchial adenopathy has been much debated. Anterior dulness in the intercostal spaces may be due to a persistent thymus gland, and for this reason is probably not to be relied upon per se. Bing (33) considers that dulness at the right apex, existing without disease in the lung, is due to enlarged bronchial glands,

which are more grouped on the right than on the left. Such dulness was present in one of my cases (see Case 5 Group I), but this was shown by the x-rays to be caused by apical disease. Various suggestions have been made as to the cause of posterior dulness. Thus, lessening of the pulmonary resonance from the pressure exerted by the enlarged glands upon the lungs; and engorgement of the blood and lymph vessels in this region, due to glandular pressure. In all probability the cause partakes of both these factors.

AUSCULTATION. The character of the breath sounds in children is so uncertain a quality, even in health, that per se it is unreliable in diagnosis. In children the breathing is normally harsh, and quite often it is actually bronchial in type, without any disease being present. The sounds were generally harsh in my series of cases. In one case (Case 3, Group I) the breath sounds were harsh "cog-wheel" in type over the hilus region in front. Marked glandular enlargement was found in this region on x-raying the case. 5 cases had breath sounds of bronchial type, in one (Case 5, Group I) over the right apex anteriorly, and in the other 4 over the interscapular region.

Although I do not think that harsh respiration in children has any significance, Stoll (34) is inclined to believe that it may be an indication of hilus involvement. Whether or not the cog-wheel type of breathing is of any value in the diagnosis of this condition, I cannot, on the strength of one case only, express an opinion. I believe, however, that bronchial breathing heard interscapularly and associated with other signs, may be a sign of some considerable importance.

Adventitious sounds. In two of the cases (Cases 9 and 16, Group I) crepitant rales were detected in the 3rd right intercostal space, and in the 2nd, 3rd and 4th intercostal spaces on both sides respectively. Pleuritic friction was heard in one case (Case 11, Group I) at the left base.

Miller and Woodruff (35) called attention to crepitant rales present in the 4th, 5th and 6th interspaces in the mid-clavicular line in many children suspected of having tuberculosis. A positive diagnosis was made of tuberculosis in 82 of their cases which had fine rales near the nipple. These workers consider that such rales are very suggestive of tuberculosis. In the two cases in which they occur in

my series, bronchial adenopathy was present.

Stoll (36) has observed these fine rales in 46 of his 137 cases, generally in the 4th space. He expresses the opinion that they may indicate a tuberculous focus there; but the fact that it does not tend to spread and does not leave post mortem evidence is against this hypothesis. In my own cases there was also no tendency to extension of these fine rales. Lowman (37) considers that these rales are due to the congestion of lymph vessels from the presence of enlarged bronchial glands. This seems an eminently reasonable suggestion. I myself have not found these moist sounds sufficiently often to express an opinion upon them.

D'Espine's Whisper Sign. For many years past, D'Espine has diagnosed tuberculous bronchial adenopathy on the strength of his whisper sign alone. As an example, he mentions the case of a girl (38) of 11 years seized with unaccountable fever and who had tuberculous adenopathy in the glands of her neck. She presented his whisper sign, and he diagnosed bronchial glands from this one fact. In the seventh month of her illness she developed pericarditis and ascites. Later she died of tuberculous meningitis. Autopsy showed tuberculous glands, no pulmonary tuberculosis, tuberculous

pericarditis, nut-meg liver. There were also tuberculous mesenteric glands; there was no tuberculous peritonitis.

Stoll (39) has also demonstrated by autopsy the value of whispered bronchophony in the diagnosis of enlarged bronchial glands. .

Sewall (40) believes the cause of whispered bronchophony to be congestion of the lung parenchyma, and considers it the earliest sign of tuberculous infiltration.

I found D'Espine's Whisper Sign in 14 cases of the 26 examined, these all being in Group I. Thirteen were shown by the x-rays to have bronchial adenopathy; the remaining case is somewhat of an anomaly. This patient (see Case 8) had, perhaps, the most exquisitely heard whisper sign in the whole series in which it was present. No other signs were noted. The x-rays revealed slight thickening of the root shadows on the right, and no evidence of glandular involvement. I am unable to explain this, unless the cause be that the tracheal glands, which lie behind the heart and are not shown by the x-rays, were the means of conduction of the whispered voice, as Stoll suggests. It may be, however, that Sewall's view pertains in this case, and that congestion of the lung parenchyma was here

the cause of D'Espine's sign.

Interscapular Bronchial Blowing. Mention of bronchial interscapular breathing has already been made. Such breathing was present in 4 cases. (Cases 4, 6, 7 and 11)

Eustace Smith's Sign. This occurred in 6 instances in Group I, namely, Cases 4, 5, 6, 7, 11 and 12).

The value of this sign has been much discussed. I myself do not think it is a sign on which much reliance can be placed. Anaemia is so constantly present in these cases that it is difficult not to believe that it may have a part in the production of this sign.

TUBERCULIN TESTS. Every case in Groups I and II was subjected to Von Pirquet's cutaneous tuberculin reaction. I graded my results in the following manner : slightly positive, positive, moderately positive, markedly positive and triple positive.

In Group I, 12 cases had been exposed to infection, familial, or otherwise, and 9 of these gave a triple positive reaction within 24 hours. Of the 3 remaining cases, the test was not made in one case, and the other two reacted moderately within 48 hours.

Of the cases in Group I which had not been exposed to infection, two reacted violently within 24 hours; one

was marked, and one was moderate.

In Group II, 5 cases had been directly exposed to infection, and 5 not so exposed. Of these, 2 exposed cases gave a triple positive reaction; one was marked and two were moderate. Of the 5 unexposed cases, one gave a triple positive reaction; one reacted moderately, and three were slightly positive.

I do not know whether or not any attempt has been made to estimate the value of Von Pirquet's test as an indicator of tuberculous activity, judging of this activity by the rapidity and the type of the reaction noted; but the possibility that Von Pirquet's test might be a trustworthy indicator of activity occurred to me while watching the results of the test in my cases. I was especially struck by this fact, that in practically every case in which a triple positive reaction was obtained, the family history revealed a source of infection with which the patient had frequently been in contact. This seemed to me to be peculiarly significant, and it was especially interesting in certain cases. Thus, for instance, in Group II is a case (Case 3) where the patient had been in the most intimate contact with her parents, both of them far advanced in

phthisis; yet she, herself, had no sign of any type beyond anaemia. The x-rays showed marked bronchial adenopathy, and her Von Pirquet reaction was triple positive in 24 hours. Similarly, in Case 4, Group II, though there is no history of exposure and no physical signs, save the Hilus Dimple on the right, a triple positive reaction was obtained. The x-rays showed marked bronchial adenopathy. This case also had no symptoms.

In Group I, where physical signs and symptoms were present, a similar phenomenon was observed.

The fact that these cases presented such marked reaction is an earnest of the fact that the patients so reacting must have a large amount of immune bodies in their blood plasma, and it is, therefore, reasonable to believe that this indicates an active process, either evident, or occult. I should not like, on such a few cases, to express a definite opinion, but it seems to me that von Pirquet's test may be a very real help in the estimation of tuberculous activity.

---

SECTION V.

Chapter 2.

CONCLUSIONS.

Dr A. Brinchmann of Christiania (see 27) has made a comparative study of the value of the various classical signs of bronchial adenopathy. His conclusions do not flatter them. The results of the investigations in the present series of cases have led me to believe that some of these symptoms and signs, when present, are of the greatest value. Tuberculous bronchial adenopathy is a condition of the vaguest character, and vague conditions in general are not to be relied upon always to present their signs.

Of the 20 cases in my series in which the x-rays showed bronchial adenopathy to be present, 15 showed symptoms and physical signs.

After a careful survey of my 26 cases, I have come to the following conclusions :-

(1) That the earliest symptoms are generally indefinite and toxic in origin.

(2) That the pressure symptoms - cough of a hard "brassy" type and expiratory dyspnoea are generally present, and that, of the two, cough is the more characteristic and is a symptom of great value.

(3) That the significant signs, collected from all the methods of examination, are: paravertebral dulness, spinous dulness, and D'Espine's whisper sign. Parasternal dulness may be significant when associated with other signs.

(4) That cyanosis due to bronchial adenopathy is not of frequent occurrence.

(5) That superficial dilated veins over the upper chest are the exception rather than the rule.

(6) That Stoll's Hilus Dimple is suggestive when allied with other signs.

(7) That the manubrium resilience sign and palpation of glands behind the manubrium, are of no value.

(8) That Pottinger's rigidity sign is uncertain, but is suggestive when present.

(9) That the same may be said of Petruschsky's spinalgia.

(10) That bronchial blowing respiration, interscapularly, is infrequent in its occurrence, but useful when co-existent

with other signs.

(11) That the value of Eustace Smith's sign can be seriously questioned.

(12) That in all cases, whether they present physical signs or not, if bronchial adenopathy is present the x-rays will demonstrate it.

(13) That Von Pirquet's Tuberculin Test should be performed in all cases, and ~~that~~ it is most suggestive where a triple positive reaction is obtained within 24 hours, especially in those cases where the child has constantly been in contact with tuberculous persons.

(14) That the recognition of the disease, while it is still limited to the bronchial glands, is of the utmost possible importance.

---

BIBLIOGRAPHY.

BIBLIOGRAPHY.

- (1) Still : Diseases of Children, p.352 et seq.
- (2) Colman : B.M.J. 1893, Vol. 2, p.740.
- (3) Carr : Internat. Med. Mag. 1893, p.498.
- (4) P.R. Soc. Med. for the Study of Diseases of Children, Vol. 2, note p.103.
- (5) Kelynack : Tuberculosis in Infancy and Childhood, 1908 p.350.
- (6) Still : Diseases of Children, p. 352.
- (7) Trans.Med. Soc. London, 1894, p. 292.
- (8) Lancet, 1899, Vol.1, p. 286.
- (9) Edin. Hosp. Reports 1900.
- (10) New York Med. Journal, February, 1891.
- (11) Still : Diseases of Children, p.352.
- (12) Cobbett : Practitioner, Vol.100, 1918, p. 406
- (13) Ann. de l'Inst. Pasteur. Par.1905, 19, p.601. See also the same, p.787; and (5) above, p.38.
- (14) Cautley, Diseases of Children, 1910 p.849.
- (15) P.R. Soc.Med.1910-11, Vol.4 Part I, p.221.
- (16) Lancet : 1900, Vol.I, p.1785.
- (17) P.R.Soc.Med. 1910-11, Vol.4. Part I p.205 et seq.
- (18) Edin. Hosp. Reports 1900.
- (19) Still : Diseases of Children, p.352.
- (20) Carr : Trans. Med. Soc. London, 1894, p.292.

- (21) Guthrie : Lancet, 1899, Vol.I, p.286.
- (22) Ghon : Primary Lung Focus of Tuberculosis in Children  
translated by D. Barty-King, J. & A.Churchill, 1916.
- (23) Amer. Journ. of the Med. Sciences, 1914, Vol.148, p.373.
- (24) Journ.Amer.Med. Assoc. 1909, Vol.52, p.771, and Amer.  
Journ. Med. Sciences, 1909, Vol.137, p.669.
- (25) Lancet : August 14th 1875, p.240.
- (26) Bull. Acad. de Med. 1907, Vol.57, p.167, and Brit.Journ.  
of Children's Diseases, abstract 1907, p.306.
- (27) Brinchmann : Lancet, 1923, Vol.I, No.10, p.499.
- (28) Petruschsky : quoted by Stoll, Amer. Journ. Med.  
Sciences, 1911, vol.141, p.87.
- (29) Stoll : the same as (28)
- (30) Progressive Medicine, 1913, Vol.3, p.67.
- (31) Lancet : 1899, vol.2, p. 261.
- (32) Amer.Journ. Med. Sciences, 1909, Vol.128, p.815.
- (33) Bing : quoted by Stoll Amer.Journ.Med.Sciences, 1911,  
Vol.141, p.89.
- (34) Stoll, Amer. Journ. Med. Sciences, 1914, Vol.148, p.378
- (35) Journ.Amer.Med. Assoc. 1909, Vol.52, p.1016.
- (36) Stoll : Amer. Journ. Med.Sciences, 1911. Vol.141, p.91.
- (37) Lowman : Quoted by Stoll, Amer. Journ.Med. Sciences,  
1911, Vol.141, p.92.
- (38) Abstract, Brit.Journ.Children's Diseases, 1907, p.306.

(39) Stoll : Boston Med. & Surg. Journ. 1912, Vol. 167, p. 291.

(40) Sewall : Archiv. Int. Med. 1912, Vol. 10, p. 45.

---