

FUNGOID CONDITIONS OF THE LUNGS.

PART II.

by

RICHARD FAWCITT, M.B., Ch.B. Edin.



April 1936.

Fountain Street House,
Ulverston.

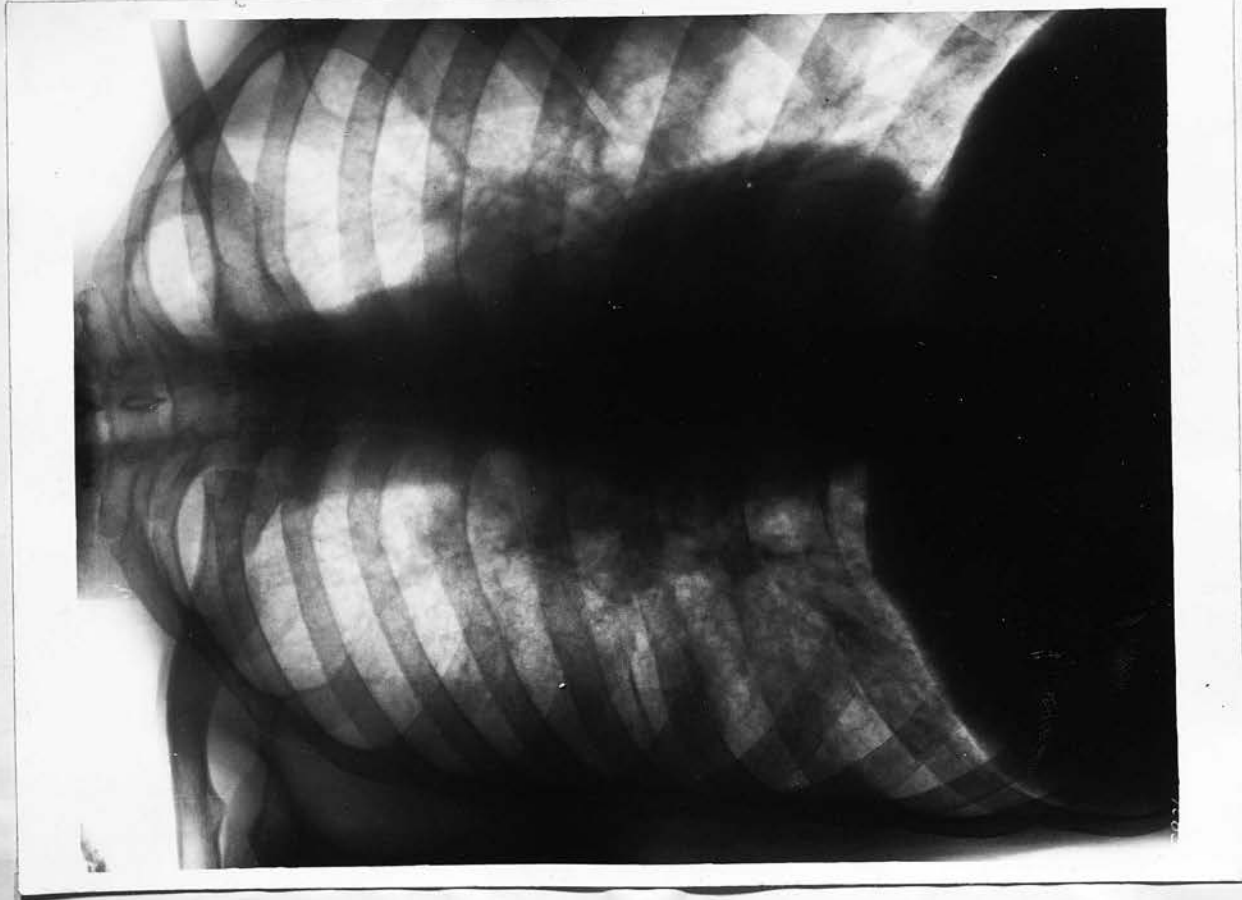


Fig. 20.
January 5, 1931.

Blastomycosis

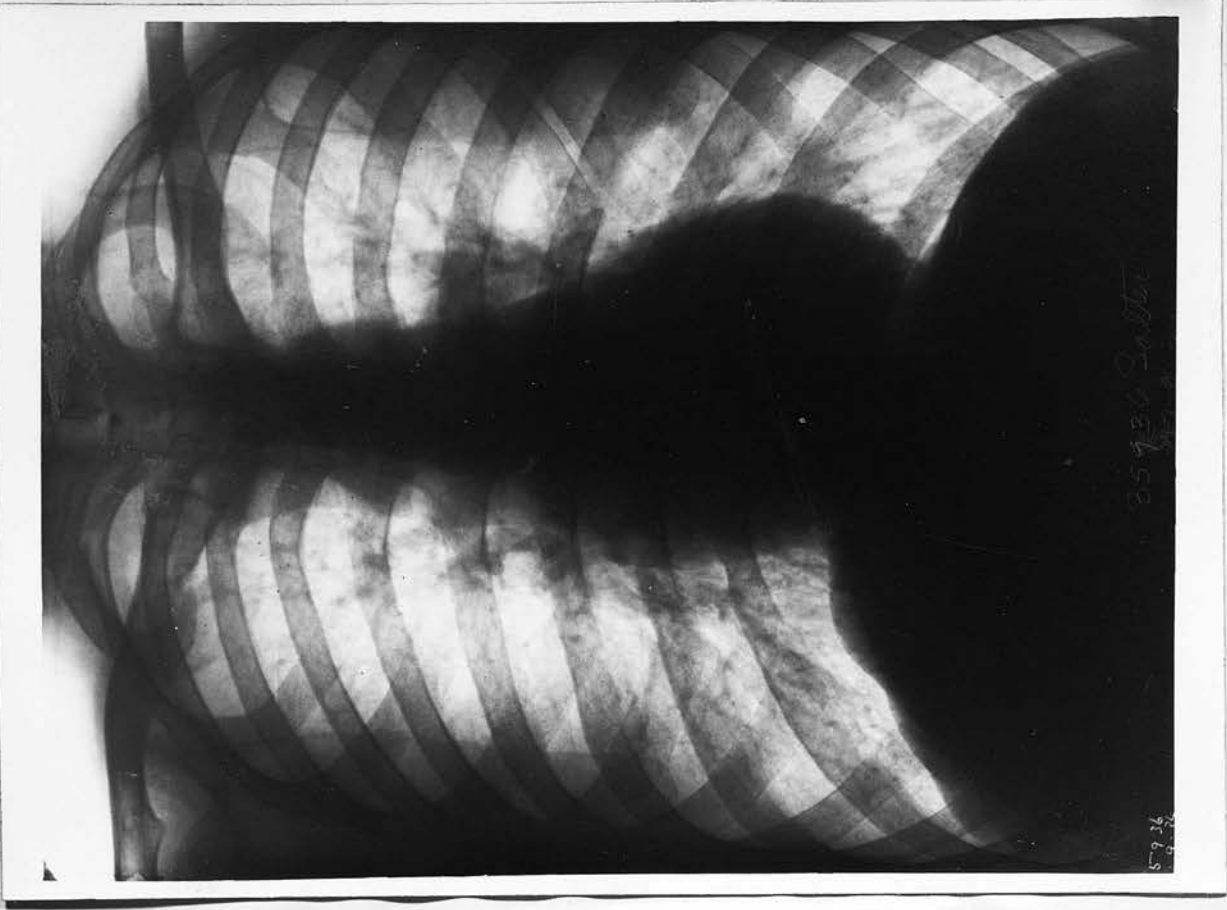


Fig. 21.
September 27, 1934.

35936 S. S. S. S.

5936
4

(10) First described in 1894 by D.C. Gilchrist. Large round bodies with exceedingly well-marked double contour and markedly granular protoplasm, larger than monilia cells, saccharomyces and usual cryptococci.

Pathology: Lesions resemble tubercle, lungs studded with numerous white nodules. Cut surfaces show purulent fluid and cheesy material - cavities may exist.

Symptoms: chronic cough, purulent sputum, at times haemorrhagic, general condition poor, loss of weight; signs of bronchitis. In advanced stages, signs of consolidation. Course is chronic, death due to systemic infection, skin lesions being common.

Diagnosis based on the finding of the fungi.

Treatment, Potassium Iodide administered internally in large doses. (11) Rypins describes two cases of granulated blastomycosis affecting lung tissue.

(12) Mackerby described a case affecting the larynx and trachea, and the skin over the tracheotomy incision. The case cleared up under large doses of potassium iodide and X-ray therapy.

(13) Medlar and (14) Miller describe Blastomycosis in lung. The most exhaustive work so far on the subject of this fungus is that of Ricketts (15).

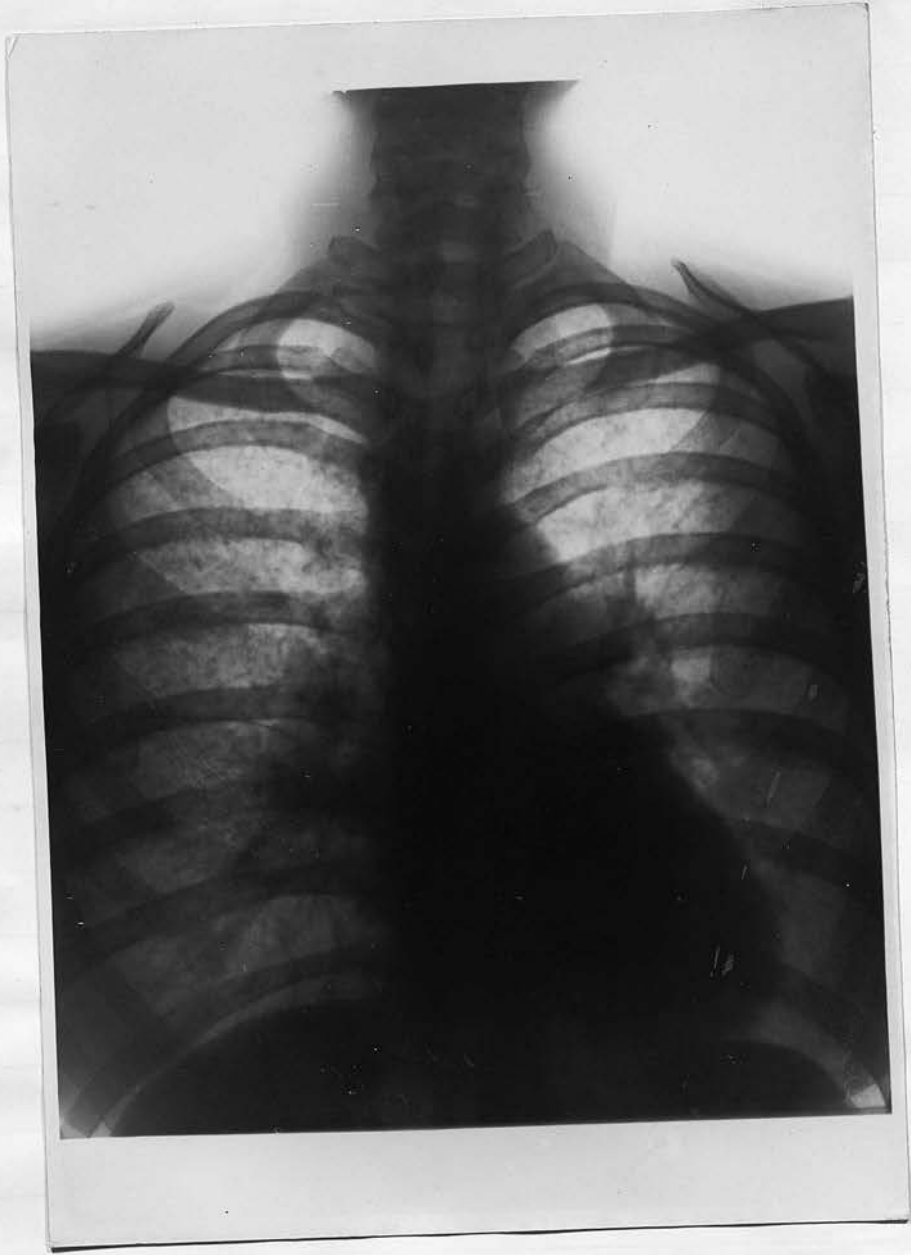


Fig. 22.
Miliary Tuberculosis - R.I. - March 12. 1935.

Dr. R. L. Rawlinson describes a case of broncho-blastomycosis in a male now aet. 29 years. This patient had pneumonia as a child, bronchitis since. Aet. 19 years he went to Guy's Hospital suffering from bronchitis and loss weight. He attended Brompton Hospital 1931, and was suffering from dyspnoea and cough accompanied by moderate expectoration. He had clubbing of the fingers and the physical signs of bronchitis. He has improved but blastomyces still found in the sputum.

Radiograph taken in 1931 shows the generalised small patches of mottling and fibrosis almost identical with Hay Dust cases.

A second film taken more than three years later shows marked improvement in the lung condition.

I am indebted to Dr. Rawlinson for the description of the case and the use of his films.

A comparative radiograph of the chest of a girl, aet. 22 years suffering from military tuberculosis shows the difficulty with which the radiologist is faced. The lung mottling in military tuberculosis is very similar to broncho-blastomycosis, but slightly coarser.

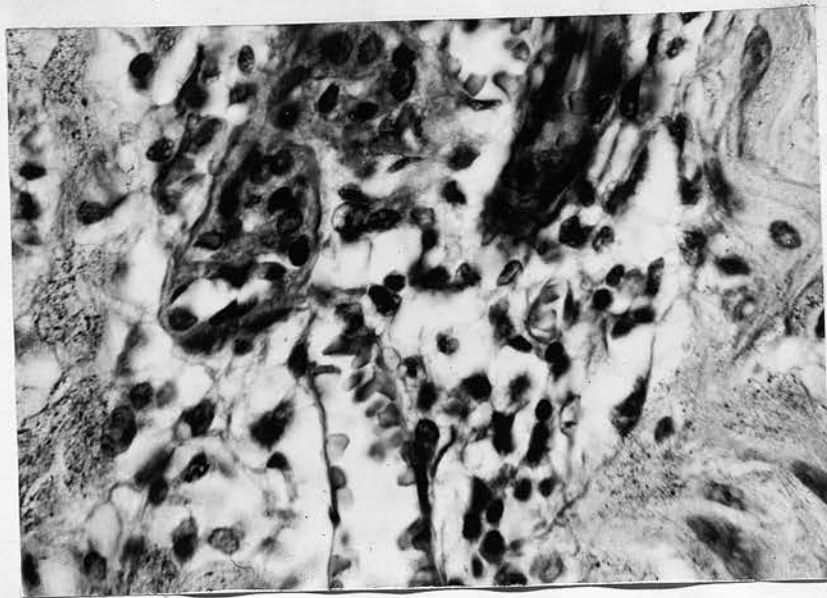

Fig. 23.
Section of Tonsil - 1 x 700
see Text.

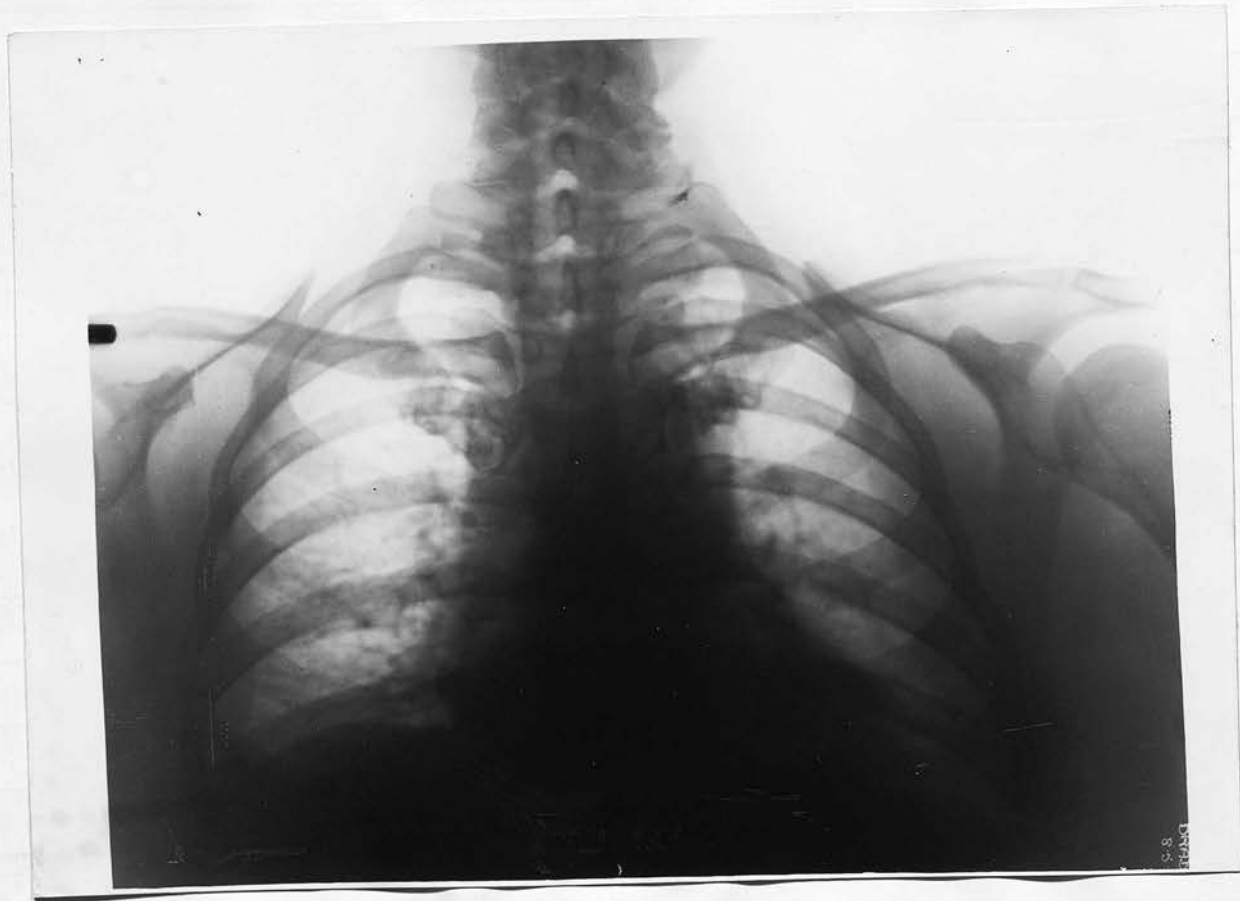


Fig. 24.
Case 1.- Mrs B.- May 8, 1935. - Broncho-Actinomycosis (Bronchitic Type)

Actinomycosis. Broncho-actinomycosis, Broncho-nocardiasis. *Nocardia bovis* (Harz 1877). *Nocardia Israeli* (1896).

These groups of fungi have been the subject of extensive investigations by Miss Dagny Erikson; her findings were published in 1935 (16) and reference is made to the previous work of others. This monograph provides an excellent insight into their mycology. Miss Erikson follows the classification of Ørskov (17) but has added fifteen new species.

The microphotograph, made from a slide kindly lent by Mr. Herbert Tilley, illustrates the condition in tonsillar tissue and shows the club shaped fungi. It has long been supposed that actinomycosis was due to infection by a fungus existing on grain, barley in particular. This parasite was first discovered in the ox by Bollinger in 1877. The name *Actinomyces*, or Ray fungus, was given to it by Harz owing to the radiate, club shaped structures observed in colonies of the parasite seen in the tissues. The reason that this organism is supposed to be associated with barley as a saprophyte is that the parasite has been discovered around fragments of grain embedded in the mucous membrane of ox and pig. It has, however, been shown that the type of streptothrix isolated from the majority of cases of infection in the human is a

strict parasite and incapable of growth at a temperature much below body temperature, and therefore unlikely to be a saprophyte. Lord has shown mycelial organisms similar to actinomycetes around carious teeth, and in the crypts of the tonsils. There is a certain amount of evidence that this organism may inhabit the alimentary canal.

It does occur in granulomatous conditions in the tissues and has been described as occurring in the lung.

In 1878 (18) Israel described a mycotic disease in lung in which the associated fungus was identical with that discovered by Bollinger the year previously in ox. The commonest site of primary infection is the jaw, and the incidence of the condition is much more common in men than women. It is a chronic disease, more common in Germany than in Great Britain or America. In the lungs the lesion is usually unilateral, occasionally bilateral, the symptoms being cough, fever, wasting and muco-purulent sputum, frequently associated with haemoptysis. Pleurisy with effusion, empyema, bronchiectasis, or pericarditis with effusion may occur. It is frequently a generalised disease involving muscles, bones, etc. (19) Osler, and (20) Price give full descriptions of this condition. (21) Ponfick and (22) Sanford have done much work on the subject.

Christison and Warwick describe four types⁽²³⁾,
(24) Bell, (25) Gittings and Thorpe, (26) Turner,
(27) Miller and Merkel have recorded cases. Cases
have been seen by a number of British radiologists,
but few recorded. There is no record of any case of
broncho-actinomycosis in the British Journal of
Radiology during the last ten years, though
actinomycosis of other tissues has been described,
and (28) Stewart Harrison has described Radiation
treatment of Actinomycosis.
(29) Ellis describes a case of broncho-actinomycosis
in a boy of 5 years and 3 months, and showed
radiograms showing a homogeneous opacity at the base
of the right lung resembling consolidation, with
marked thickening of the pleura. (30) Rodgers showed
the same case at a meeting of the Royal Society of
Medicine two years later. The boy now showed marked
improvement clinically and radiologically, after
intensive iodine therapy.
(31) Morrison Davies has described the condition as
compared with syphilis and tuberculosis.
(32) Chevalier Jackson describes a case in which he
made a bronchoscopic examination and aspiration,
withdrawing pus from a lung which yielded clubbed
ray fungi. (26) Turner describes the X-ray picture
and differentiates between it and that of syphilis
and tuberculosis.

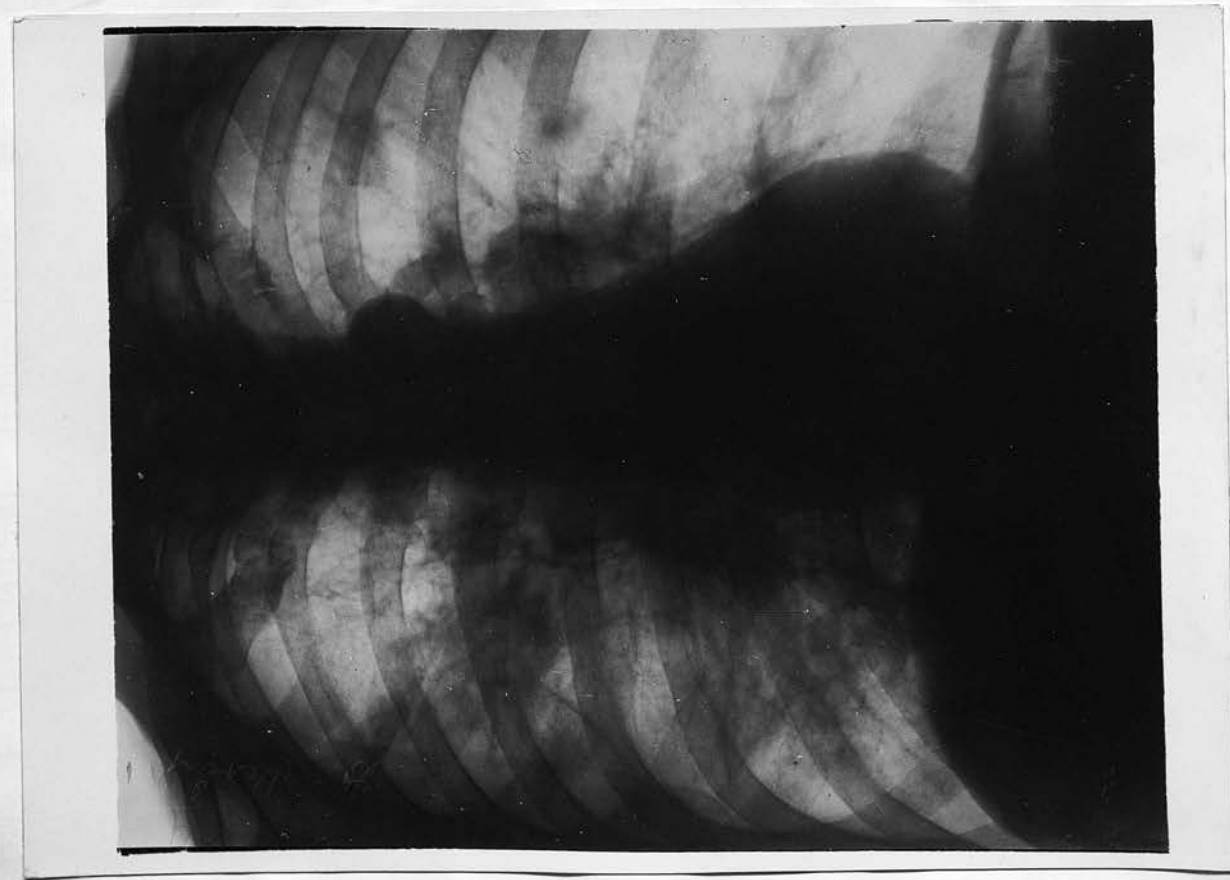


Fig. 25.
 Broncho-Actinomycosis - (Pneumonic Type) Case 2.
 Secondary to infection of Jaw.

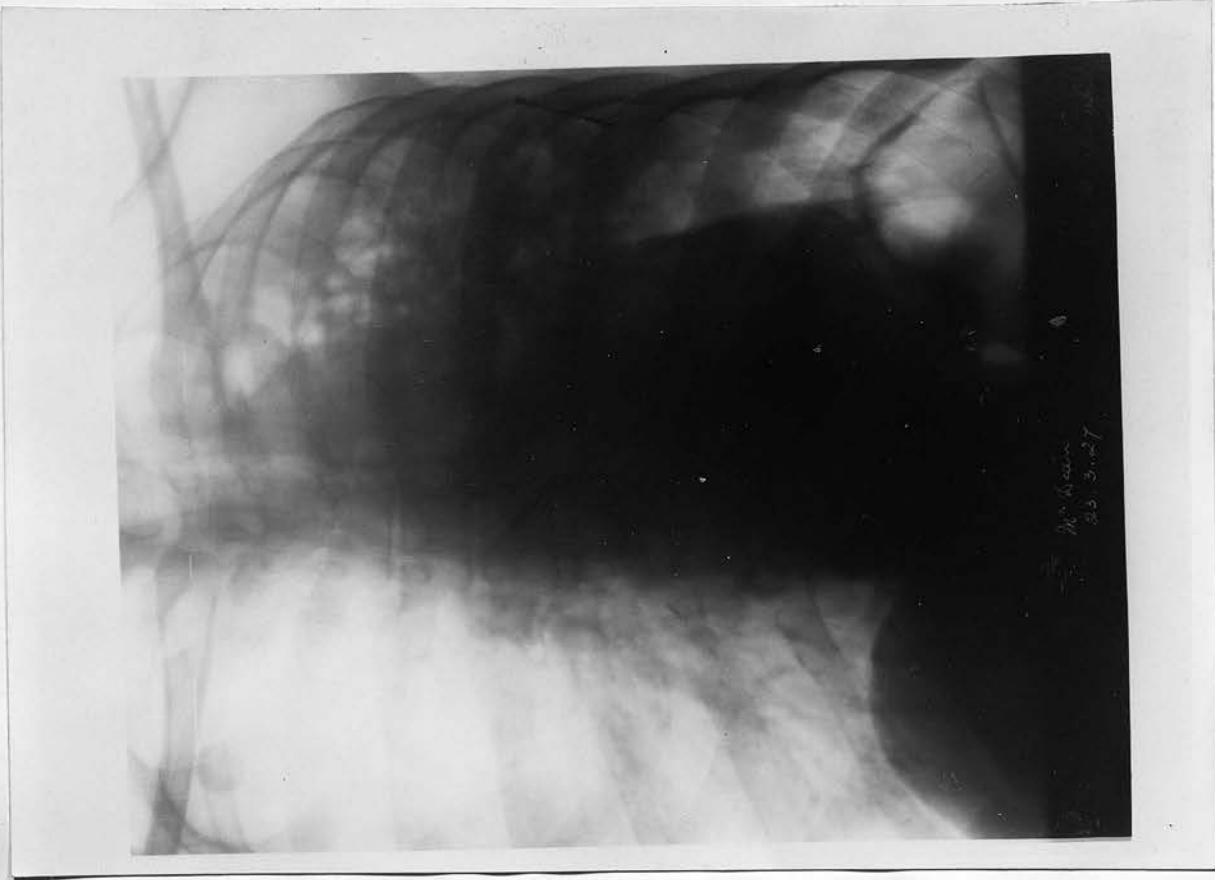


Fig. 26.
 Case 3. Actinomycosis - Perforation through Pleura;
 Sinus communicating with Chest wall.
 (Pleuro-pneumonic Type.)

The four types of Christison and Warwick are described as follows by Jacobson⁽³³⁾.

(1) The bronchitic type. In this form of actinomycosis the infection is confined to the bronchi; and is characterised by the presence of pus and fungi.

(2) The pneumonic type. In this type the process spreads from the bronchi to the surrounding alveoli, which are filled with pus but rarely with fibrin and which resembles an ordinary bronchopneumonia in its first appearance and progress. At various points in the alveoli earlier affected there is an attempt at healing by the replacement of the exudate by connective tissue, which grows in from the side and obliterates the lumen, thus producing hard, fibrous nodules which alternate with the typical softer lesions or abscesses. In some areas there is no attempt at organisation, but instead the alveolar walls are lost, and replaced by pus and fungi. The picture varies greatly.

(3) The pleuropneumonic type. In this type of the disorder the abscesses have grown larger and the pus burrowed to the pleural cavity, where it may accumulate, or where granulation tissue may appear. Here the pus frequently burrows, and invades the chest wall. The three types represent different stages of the same process.

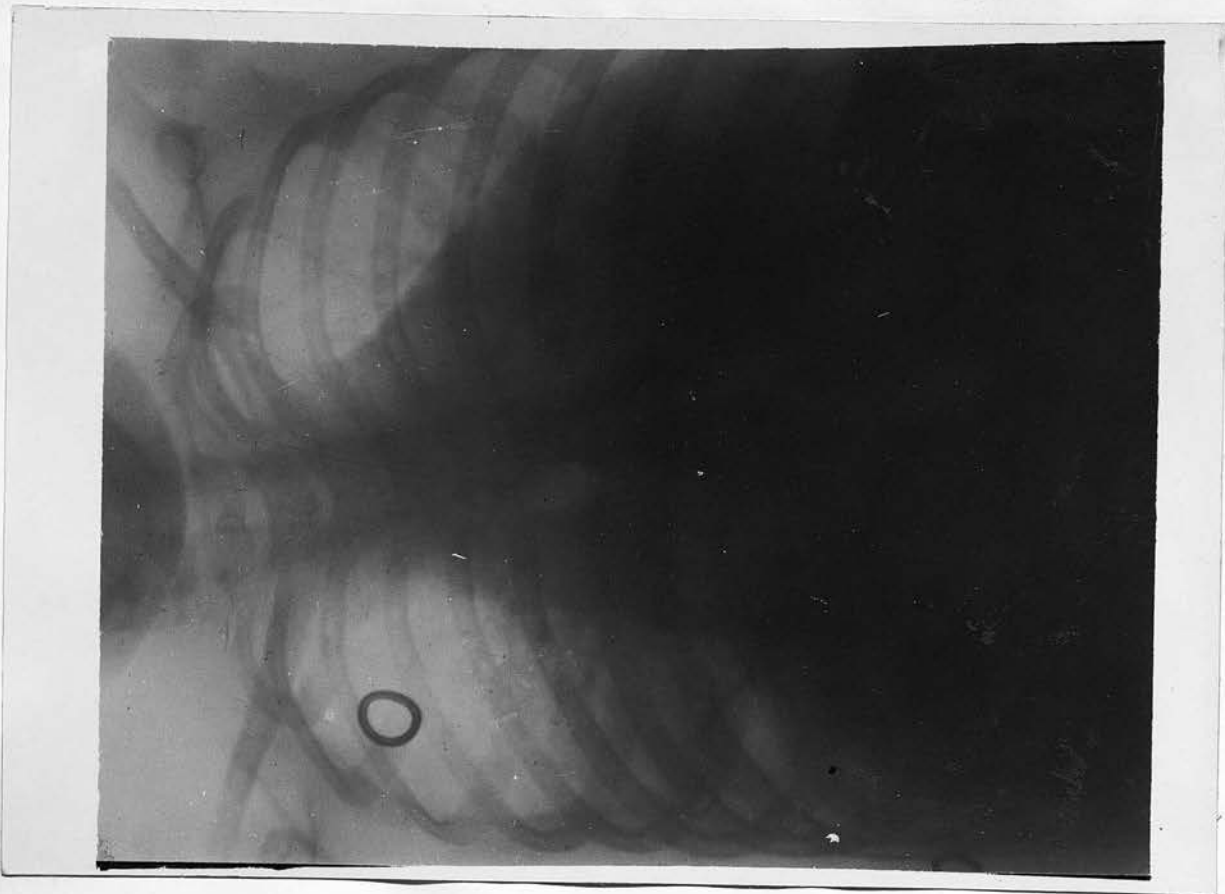


Fig. 28.

Case 4. Later stage; showing Pericarditis with Effusion.

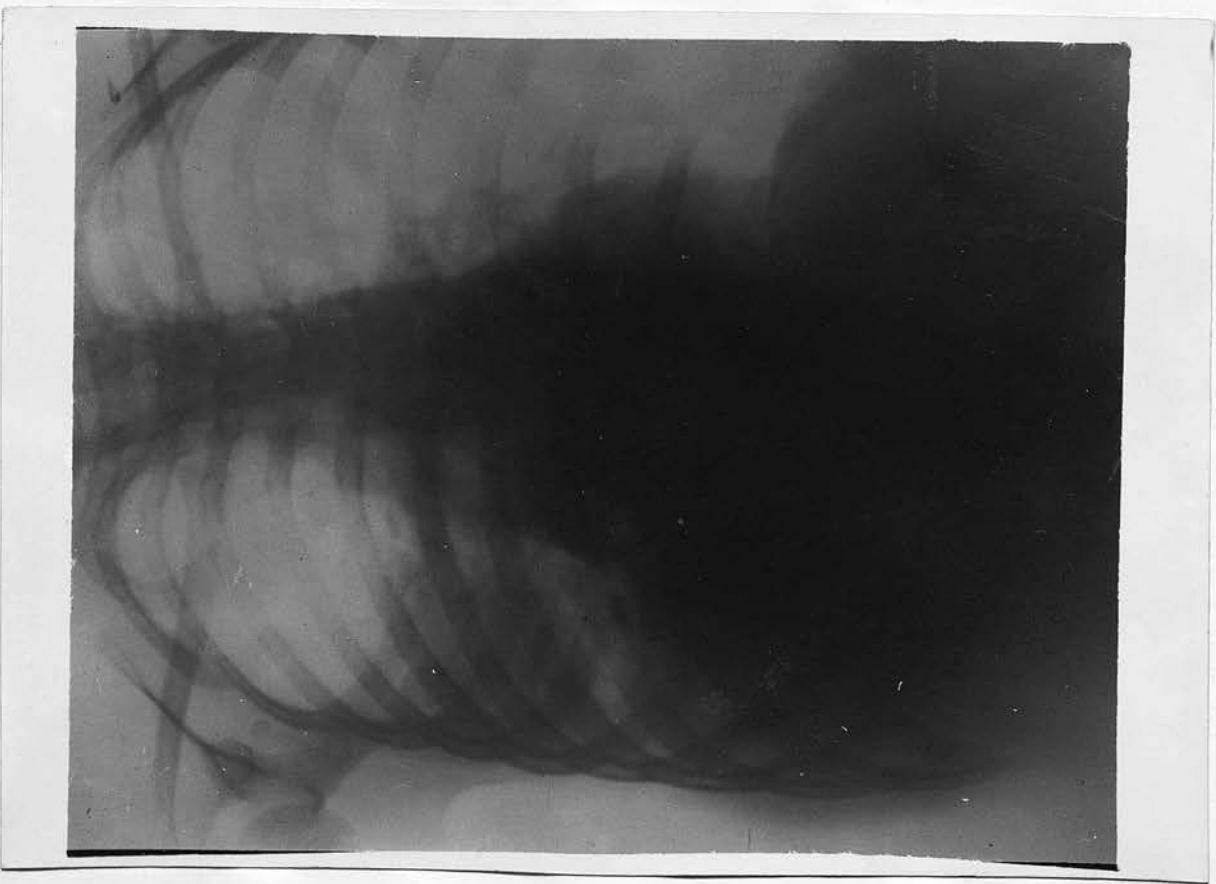


Fig. 27.

Case 4. Pneumonic Type.

(4) The fourth type. This form of the infection is characterised by the formation of metastatic nodules, in various parts of the lungs, which are supposed to represent sites of location of the organisms, transported by the blood stream.

The X-ray appearances will vary then according to the type and progress of the disease, and the differential diagnosis lies between actinomycosis, tuberculosis, syphilis, pneumonia and malignant disease. In actinomycosis there is a tendency for the fibrosis to extend downwards rather than upwards along the bronchial trunks, and the progress to the other types of the condition is gradual. This can be checked by repeated X-ray examination. The presence of the fungus in the sputum is the deciding factor.

In tuberculosis the fibrosis has a tendency to spread upwards rather than downwards in the adult. The presence of tubercle bacilli in the sputum is the deciding factor.

In syphilis the development of the fibrosis is slower and the fibrosis tends to spread out in a fan shape from the hilum in all directions - the gumma casts a denser shadow than the fibrosis around an actinomycotic or tubercular abscess. A Wassermann reaction is essential.

A pneumonic patch may only be differentiated by the clinical history and course of the case.

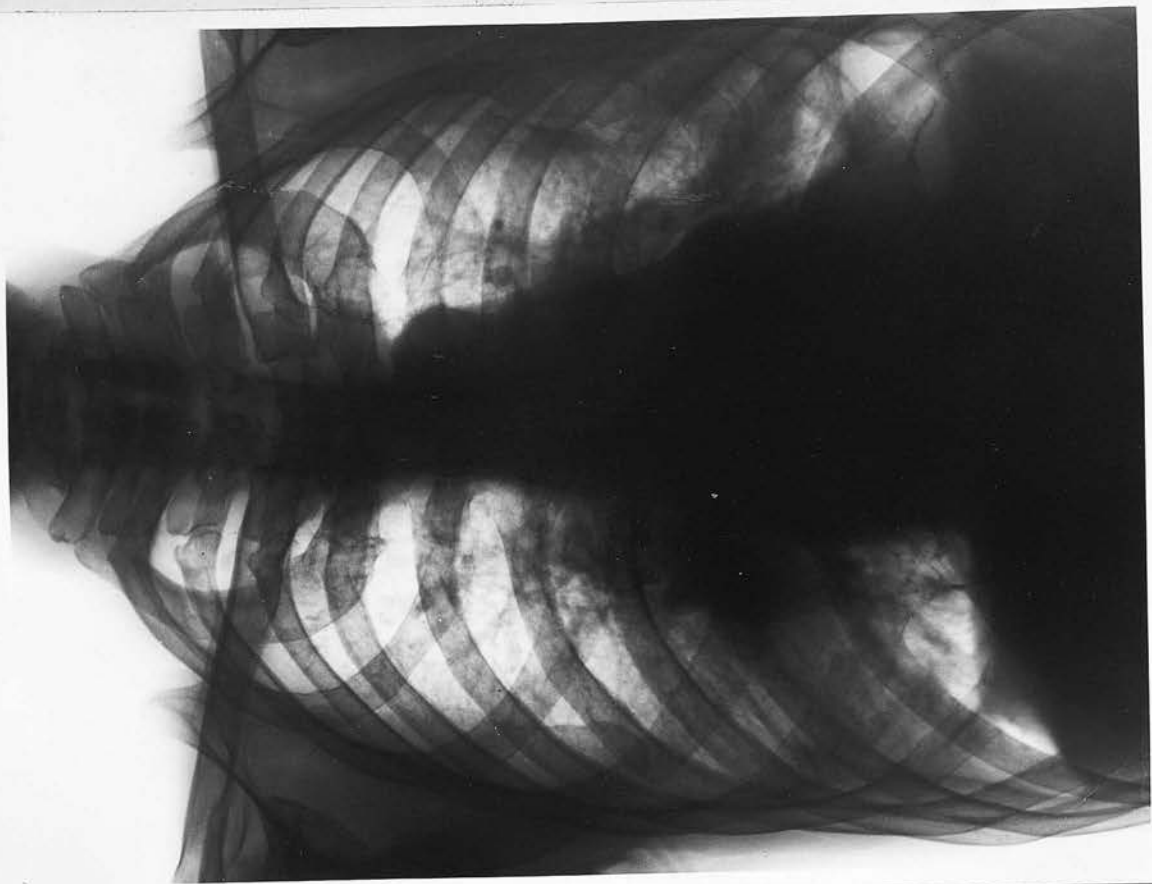


Fig. 30.

Case 6. Atypical Broncho-pneumonia.
J. H. 29 Nov. 1955.

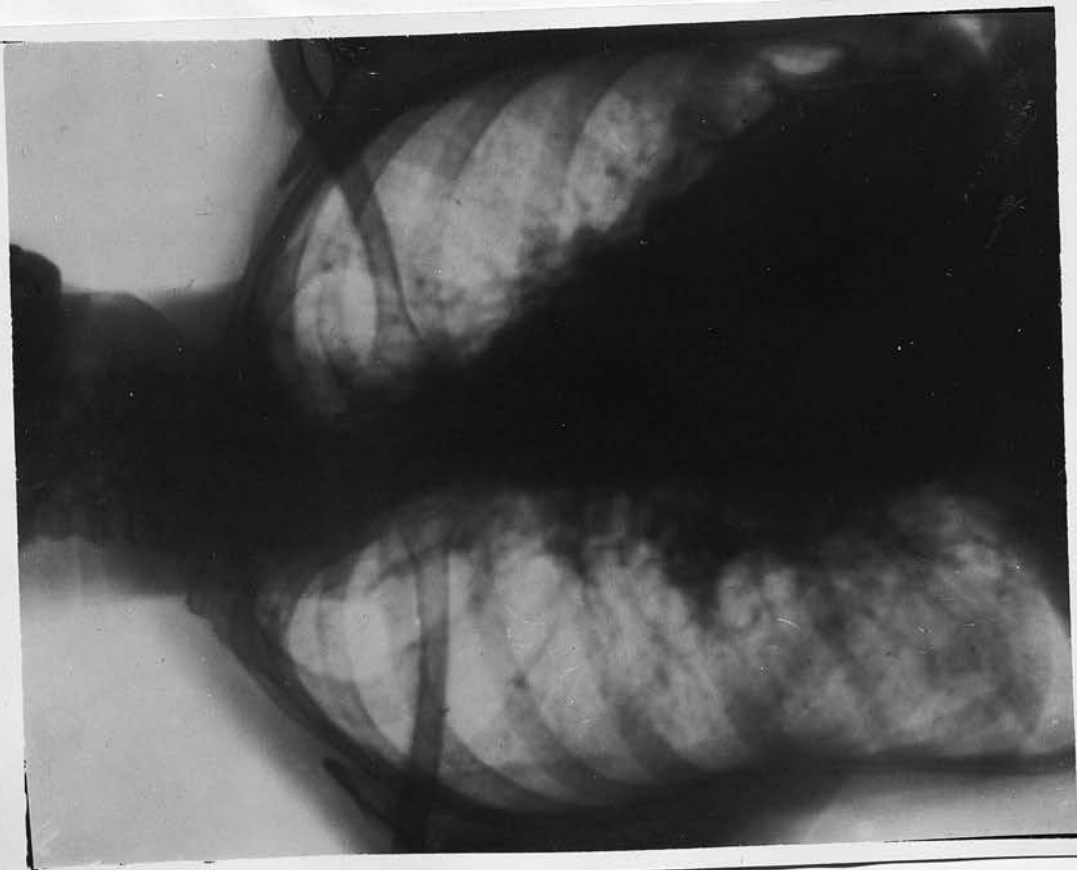


Fig. 29.

Case 5. Syphilis.

Whilst these points of differentiation have been described they are by no means constant, and a correct diagnosis can only be arrived at through the co-operation of the Clinician, Radiologist and Pathologist.

Case I. 8/5/35. Mrs. B. aged 46 yrs., referred to me in Barrow-in-Furness as case of suspected pulmonary tuberculosis because of periodic attacks of dyspnoea, purulent sputum associated with haemoptysis. No hyperpyrexia. Patient was very obese.

X-ray shows the bronchitic type. No other primary focus. Streptothrix actinomyces isolated from sputum. Patient improving on potassium iodide.

Case II. Secondary to infection from jaw. Shows the pneumonic type, peribronchial involvement with dense radiating masses in right and left upper lobes; rather suggestive of type four.

Case III. Case of type 3, the pleuropneumonic type. The pus has burrowed through the pleura, and a sinus is communicating with the chest wall.

I am indebted to Dr. R.L. Rawlinson for this case.

Case IV. In a child showing actinomycosis of pneumonic type, later associated with pericarditis with effusion.

Case V. A case of Syphilis of the lung. In this case the fibrosis is most marked in the hilus area and the heart is drawn over to the left side. Note the clear area at the apices and bases.

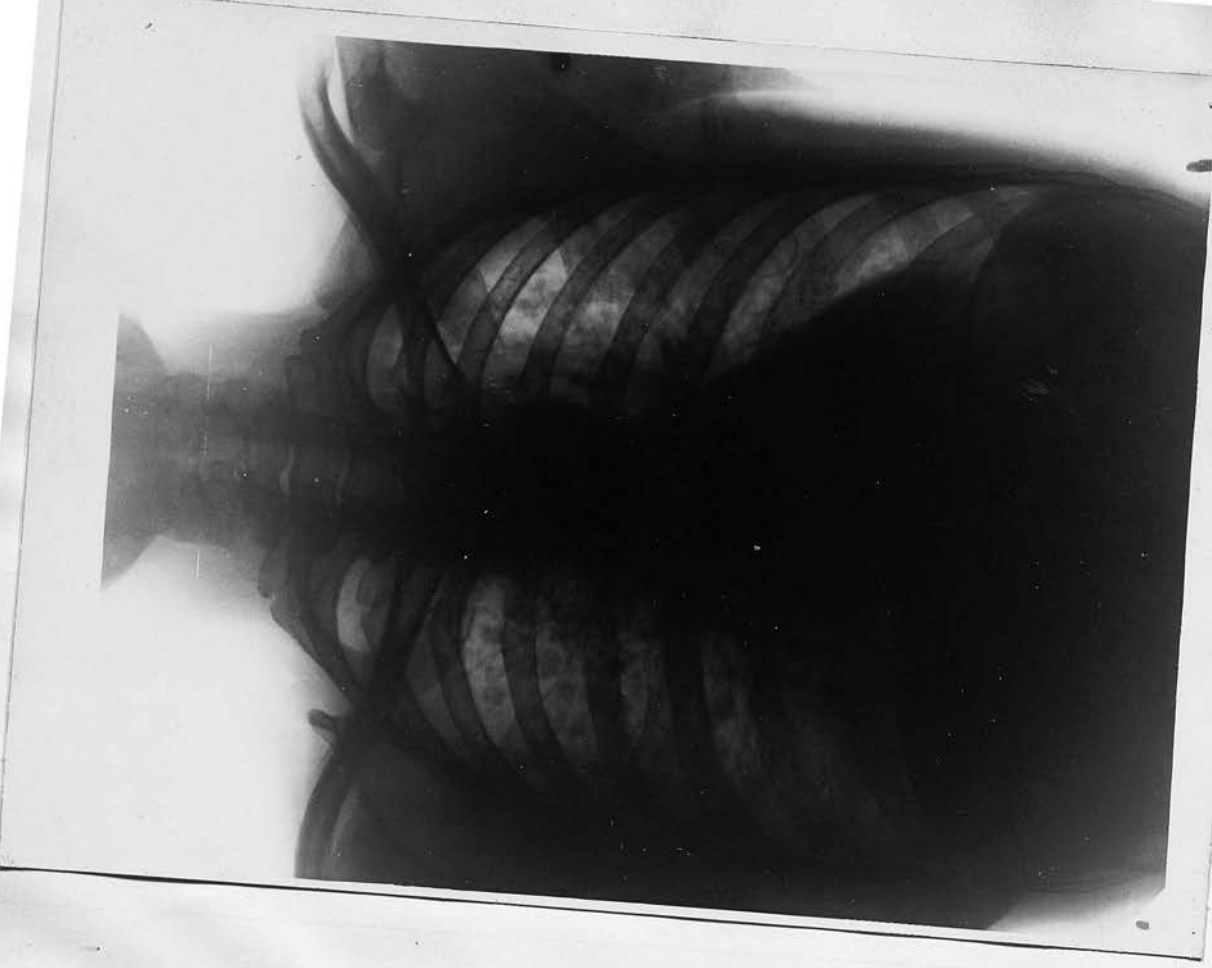

Fig. 32.

Case 8. Mrs. M. W. - Malignant Deposits in Lungs, secondary to Carcinoma of Stomach.

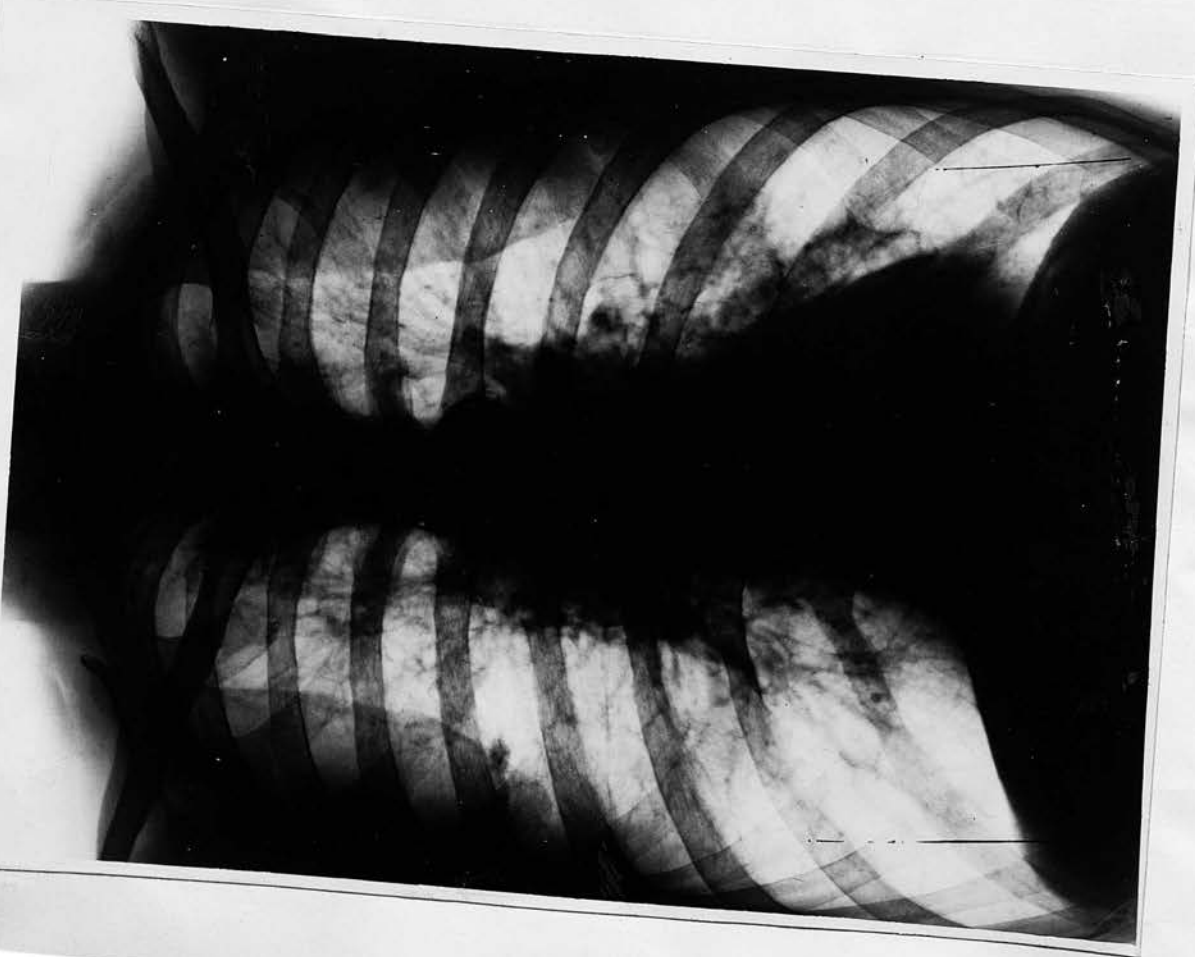


Fig. 31.

Case 7. Tuberculosis of Lungs.

Case VI. An atypical broncho-pneumonia (radiologically)
J.H. (Nov. 29th 1935) in-patient North Lonsdale
Hospital, clinically a typical broncho-pneumonia.

Case VII. Feb. 1936. Pulmonary tuberculosis of
fibroid type demonstrating the apical fibrosis.
Tubercle bacilli present in sputum.

Case VIII. Mrs. M.W. aet. 49 yrs., (April 1936).
Malignant deposits in lungs, secondary to carcinoma
mammae. Left breast removed in November 1935.

These cases serve to illustrate the comparative
conditions referred to in the text.

I am indebted to Dr. Peter Kerley for the use of
the notes and illustrations of cases II, IV and V.

Broncho-monilliasis. Genus *Monilia* (Persoon) 1797.

Discovered by Langenbeck in 1839 and later investigated by Charles Robin.

In 1905 Castellani described Tea Taster's Cough in Ceylon. Tea dust contains monilia of genus *aspergillus* and *penicillium* frequently, and *oidium* occasionally. To quote Castellani⁽³⁴⁾ the work was carried on by Chalmers, O'Connell, Farah, Macfie, Iacono, Tarekath Sur, Johns, Pollacci, Redaelli, Perin, etc. Pinoy has described cases in France, Pijper in South Africa, Macfie in West Africa, Chalmers and Macdonald and Farah in the Sudan and Egypt, Tarekath Sur in India, Iacono in South Italy, Castellani, Douglas and Thompson in England, Johns, Boggs, Pineoff and Simon in America, and others.

The condition appears to be caused by several species of the genus *Monilia* Persoon, usually *M. Tropicalis* Castellani, *M. Pinoy* Castellani, *N. Krusei* Castellani and *M. metalondinensis* Castellani.

Castellani⁽³⁵⁾ is responsible for numerous records of this condition.

⁽³⁶⁾ Stokes, Kiser and Smith describe two cases of chronic interstitial fibrosis of the lungs (broncho-monilliasis) in which inoculation of the sputum in white rats produced fungi of the yeast form resembling *monilia albicans* (Castellani).

Classification of fungi:

Class	Sub-class	Family
Fungi.	Fungi Imperfecti.	Oosporaceae.

Genus and Species.

Genus *Monilia* Persoon.Genus *Oidium* Link.

(37) Steinfield, (38) De Potter, (39) Shaw, (40) Kotkis, Wachowiak and Fleisher, (41) Stovall and Greeley, (42) McKinney, (43) Gilbert and Boresbeck, (44) Galbreath and Weiss, (45) Grossi and Balog, (46) Hoffstadt and Lingenfelter, (47) Jockes, (48) Mendleson, (49) Wheeler and Hoffstadt and others have all described cases. (50) Craik has written a monograph on the subject.

Castellani later decided the term *Monilia* should include all the organisms of the family Oosporaceae Saccardo 1886.

The vegetative body of these organisms forms a mass of mycelial threads of free budding forms. On culture media the old yeastlike forms are more numerous, while the mycelial threads, or hyphae, are very scarce or absent. When present they are short and narrow. This family produces gas in various sugars, and Castellani's article contains a table showing the gas formation and reaction in milk of the genus *monilia*. *Monilia metalondiensis* when injected into the lungs of rabbits in quantities of 1 cc. of a slant agar growth produced numerous white nodules in from 15 to 20 days. Centre composed of masses of small cells and polymorphonuclear

leukocytes surrounded by a ring of phagocytes and endothelial cells, and a few giant cells and eosinophiles. At times the centres of the nodules were caseous. Weigert's bacterial stain showed a small number of monilia. Creamy growth with circular creamy smooth colonies elevated in the centre grown on Sabouraud's agar.

Monilia candida, grouped with fungi imperfecti (J.D.G. Shrewsbury's monograph (51)), yeastlike organisms, but differ from yeasts in the optimum growth temperature, frequently found in milk, according to Marett, and associated with "thrush", has been the subject of extensive investigations in Jersey during the last ten years or more by Marett, (52) Stewart, Young, Wood and others, some of whom have published articles on their work.

Marett has described in a personal letter to me the routine method of growth:

"Specimen of early morning sputum is taken after the mouth has been washed out with normal saline. A purulent portion of sputum is 'fished' and washed in normal saline and transferred to a tube of 'beer wort'. The culture is incubated for 48 hours. Monilia are recognised as a surface growth of three types:

(1) collar formation, (2) surface formation, (3) islet. This latter in time becomes surface formation.

Isolation is carried out on Sabouraud's medium. Optimum temperature 37°C. Sputa which have been through the post, i.e. stale, do not grow monilia in transit. Pathogenicity varies. Two signs of pathogenicity are: (1) staining with Ziehl-Neelsen - the greater the acid fast content the greater the pathogenicity. (2) Presence of pseudo-mycelium in direct sputum or in culture is, I believe, a sign of chronicity, and the greater the chronicity the harder to eradicate.

Nocardia. The morphological description is that of thin wavy mycelium varying considerably in length, the mycelium containing acid fast granules when broken up, the size may be that of an ordinary bacillus (circ. 5 μ) with an acid fast granule at each end. Unbroken mycelium may vary in length up to about 40 μ . Very occasionally a granule is seen with typical ray fungus morphology. The vast majority of cases show no granules but only the thin mycelium with acid fast granules.

I regret that I haven't figures by me to show the proportional distribution, but the incidence of these two organisms taking Monilia as 100, Nocardia would be between 15 - 20%. Cases of lung infection due to T.B. monilia and nocardia occur. I have not known the triple infection to recover."

Marett says it may be the precursor of T.B. infection. When found alone the clinical picture is that of a bronchiectasis. X-ray picture is that which is seen in bronchitis or asthma, plus "fluffing" of the lung alveoli up to abscess formation.

(52)

Marett has published a number of articles in the British Medical Journal and Lancet. Interesting statistics were published in the Lancet, March 5th, 1932:

	1927.	1928.	1929.	1930.
Total number of patients examined	295	304	376	381
Number due to T.B. & Blastomycetes	80	72	92	79
" " " Blastomycetes only	120	160	189	247
" " " other organisms	95	62	94	55

Preventive treatment (to quote Marett) against infection with monilia consists in the pasteurisation of milk. Cows suffering from mastitis excrete monilias in their milk. Warts on the teats are an indication of the infection.

My commentary on Marett's investigation is as follows: I have been in touch with numerous veterinary surgeons and they are all definite in their opinion that *oidium lactis* is not responsible for sore udder, the recognised causes of which are tubercle bacilli and streptococcus, although they admit the presence of *oidium lactis* as a common contaminant of milk and cream. Other common contaminants are the mucors, and torulae, *allenaria*, *cladosporium* and *oospora lactis*.

Mr. S. J. Edwards B.Sc., M.F.C.V.S., and Miss Nichols of the Hannah Dairy Research Institute at Ayr, although not wishing to be dogmatic on the point, think it is extremely doubtful that the human is infected from moulds on the udder, which in this country are extremely rare. The obvious source of infection is from spores in the forage, manure, litter, etc., and the milk, if it stands, may be contaminated.

The most dangerous source of infection to the human is from cows infected with actinomyces which are occasionally found on the udders.

Marett's opinion is quite contrary to this as far as Jersey is concerned. He informed me that he procured monilia from milk collected into sterile vessels and obtained under perfect conditions, and lays **stress** on the fact that broncho-moniliasis attacks persons irrespective of class, but not irrespective of milk supply.

Oliver has described the condition as a definite clinical entity. It has been attributed to a sequela of whooping-cough, or measles, adenoids, rickets and unresolved pneumonia. In 1934 he⁽⁵³⁾ published a record of 50 cases treated with success by means of autogenous vaccine and a prolonged course of potassium iodide. There is no record of any death or post mortem findings in his book. He publishes

the following figures:

During the years 1929, 1930, 1931 (P.J. Marett)
the sputa of 1,335 cases were examined.

Number containing T.B. & blastomycetes	...	261.
" " blastomycetes in absence of T.B.	762 .
" " other organisms only	312.

(54) Young has described the condition as a chronic bronchial catarrh commencing in early childhood and persisting through adolescence into adult life.

Marett has described to me a recent case of mixed infection of nocardia and monilia. The specimen was sent in as a liver abscess. It had been vomited up and the abscess was supposed to have burst into the oesophagus. It was, however, suggested that the specimen came from an inter-lobar abscess and microscopically showed no liver cells, and had not the colour usually associated with liver abscess.

The presence of monilia gives rise to pus formation in chronic lung infection. There is a mechanical action due to local growth of the fungi on the mucous membrane, (similar to thrush in the mouth). Two types are described, (1) affecting the bronchial tree

and resulting in bronchiectasis: (2) occurring as the result of occlusion of the bronchioles and collapse of the lung alveoli.

The clinical signs and symptoms are similar to those described in other types of broncho-mycosis, also allergic manifestations are seen in skin reactions, hay fever, asthma, etc. Untreated cases are liable to super-added infection by tubercle bacilli.

All the writers lay stress on the extreme dyspnoea out of all proportion to the physical signs or X-ray appearances in the lungs.

Wood describes the X-ray picture as follows:

The condition is best seen in children; right hilum much longer and denser than normal with a "fan" or "smudgy" lines running downwards and outwards towards the base. These are inflamed bronchial vessels accompanying the bronchi.

A second "fan" runs from the upper end of the "hilum" into the subclavian region, sometimes the lower half of the upper zone right side is "honeycombed", i.e. outlining the alveoli. On the left side the hilar shadow is more extensive than usual, "scattered" with denser small area in it, the subclavian fan more marked than the right, while traces of the basal fan can be seen behind and outside the cardiac shadow. In adults the picture tends to be more confined as if mixed up with a scattered bronchitis.

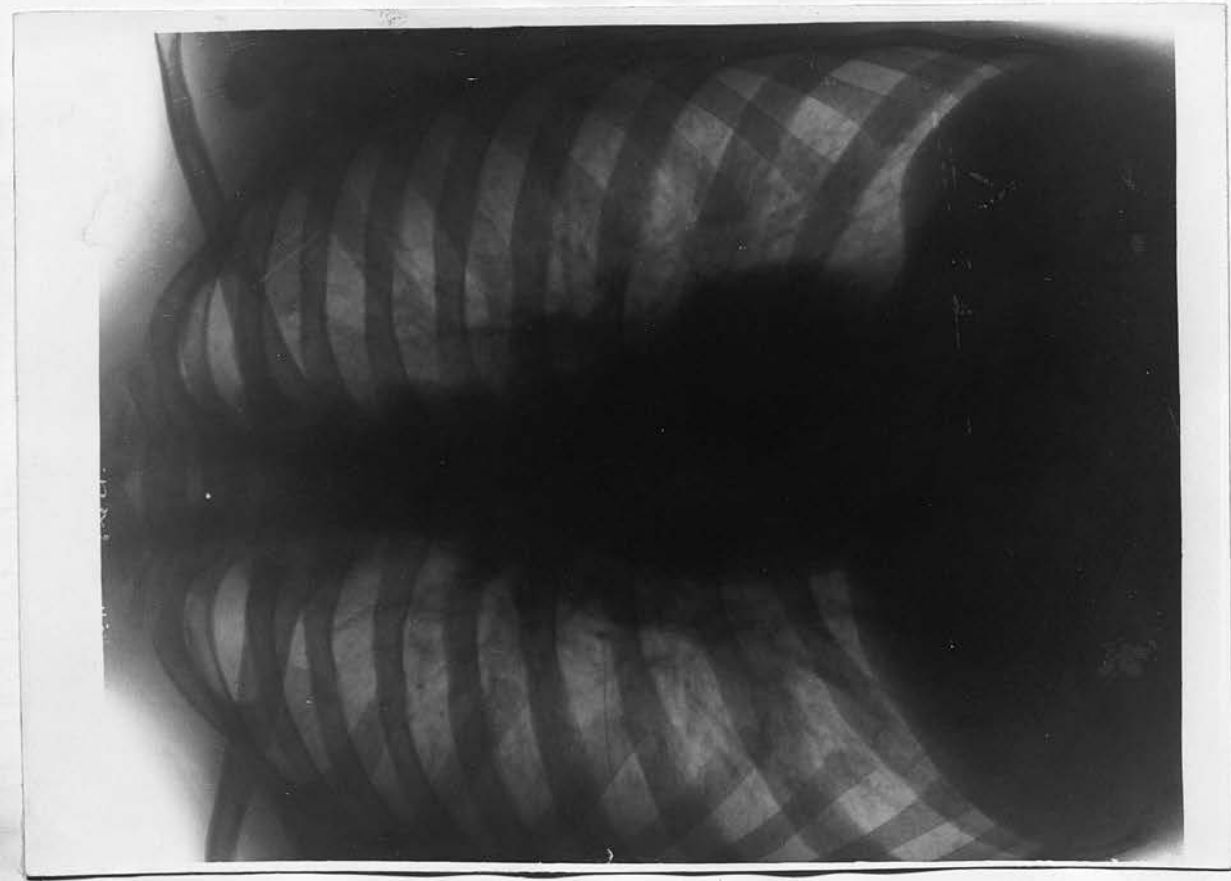


Fig. 33.

Case 1. - P.N. - November 11, 1933.

Broncho-Moniliae

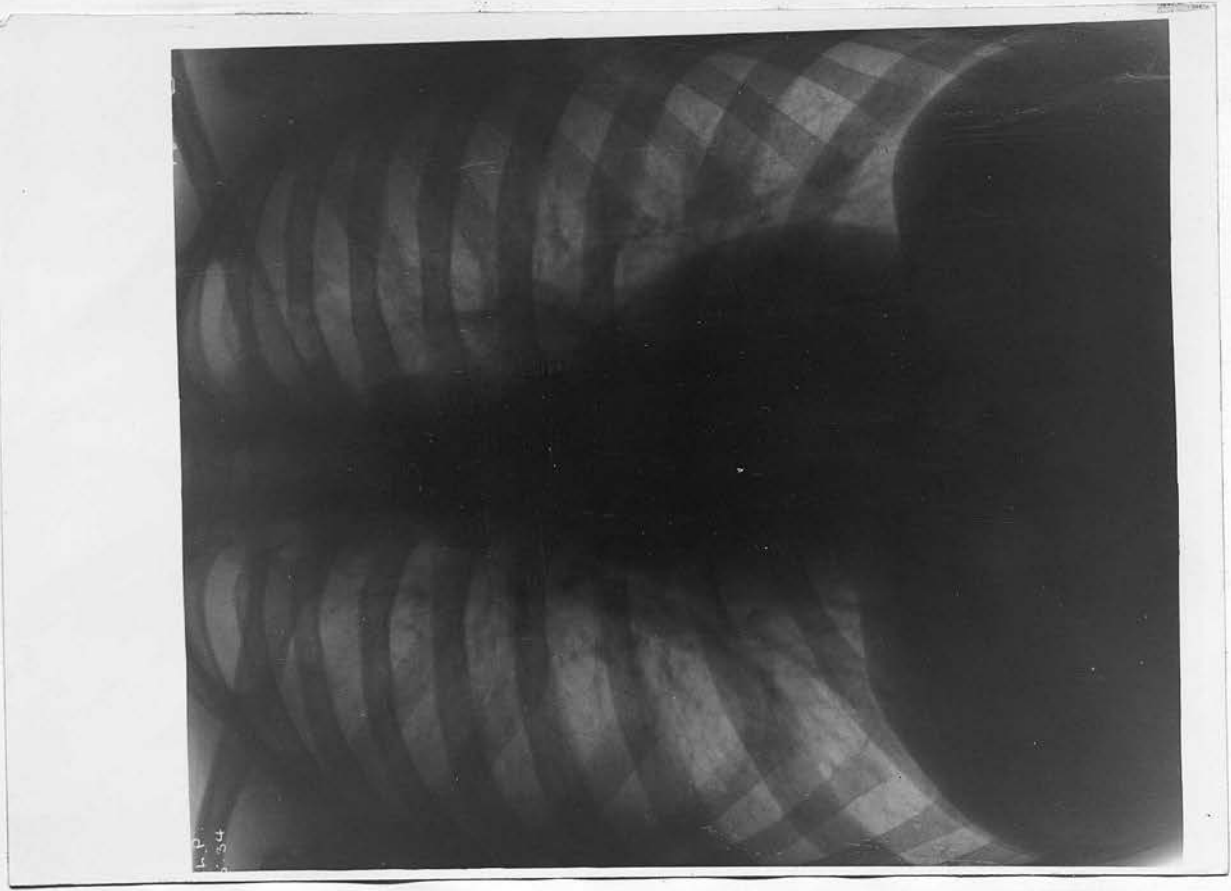


Fig. 34.

Case 1. - P.N. - May 24, 1934

The condition yields readily to a prolonged course of potassium iodide combined with an autogenous vaccine. The action of the potassium iodide is threefold. (1) It is the natural solvent of mucous and accordingly loosens the sputum. (2) It increased the flow of sputum from within outwards, thereby aiding the excretion of organisms. (3) It has a selective action on fungi.

Vaccines increase the immunity against monilia.

Two forms of vaccine are used - (1) the yeast form of monilia grown on agar; (2) monilia grown on Sabouraud, containing all elements of monilia including mycelium. This latter is only used if the condition does not yield to the first vaccine. Stewart considers an autogenous vaccine is most advantageous.

Case I. P.N. aet. 13 years. Male. 1/7/33.

History of two or three attacks of asthma per month, each lasting two or three days. No hay fever, no skin lesions. Any gastric disturbance brings on attack.

Family history: nil of note.

Physical signs: rhonchi present both lungs, and expiratory wheeziness.

Sputum: monilia, ac. fast cocci +.

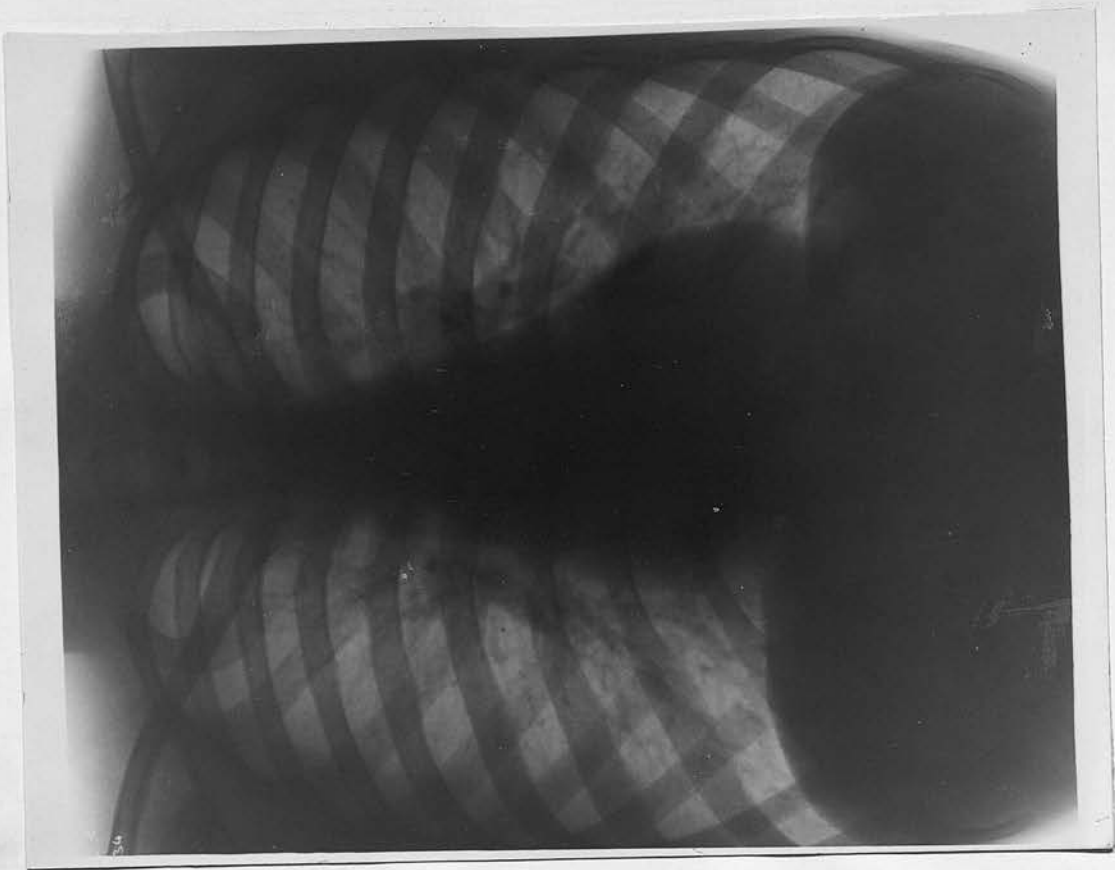


Fig. 36.

Case 2. - C.G. - May 24, 1934.

Broncho-Moniliaiasis.

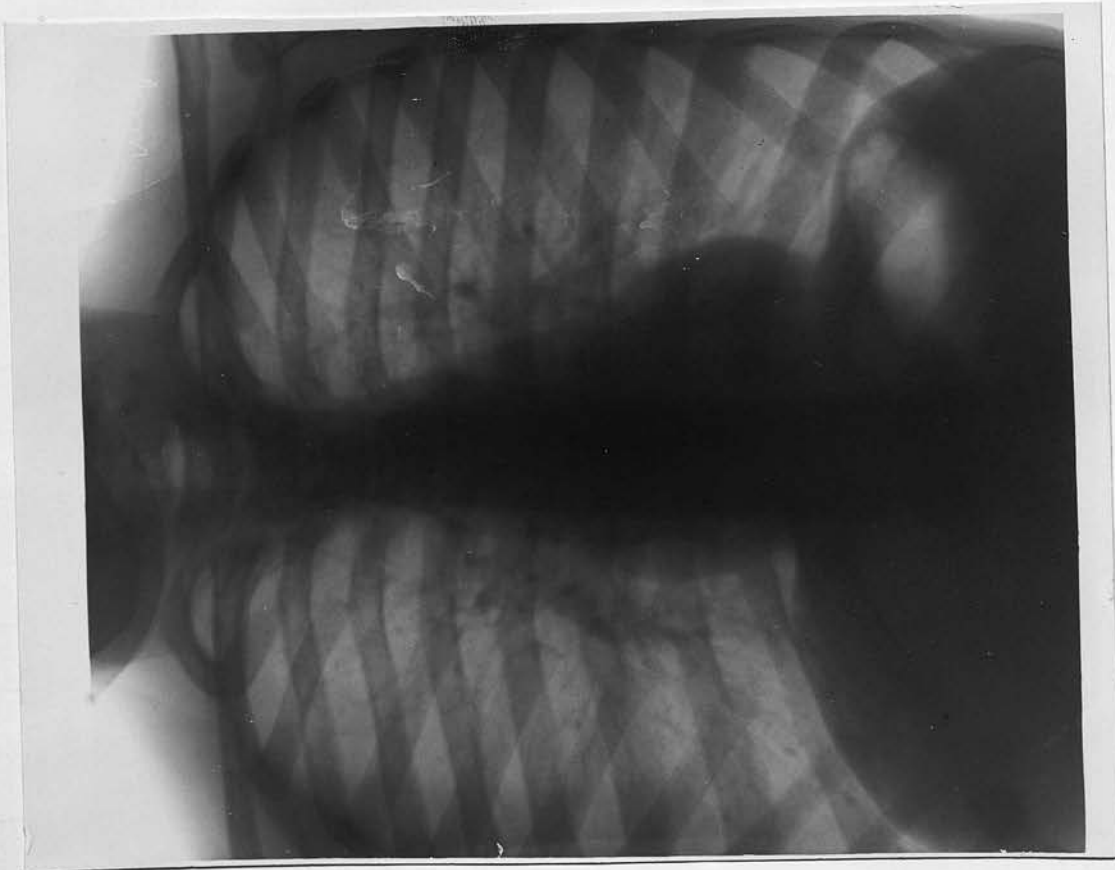


Fig. 35.

Case 2. - C.G. - February 16, 1933.

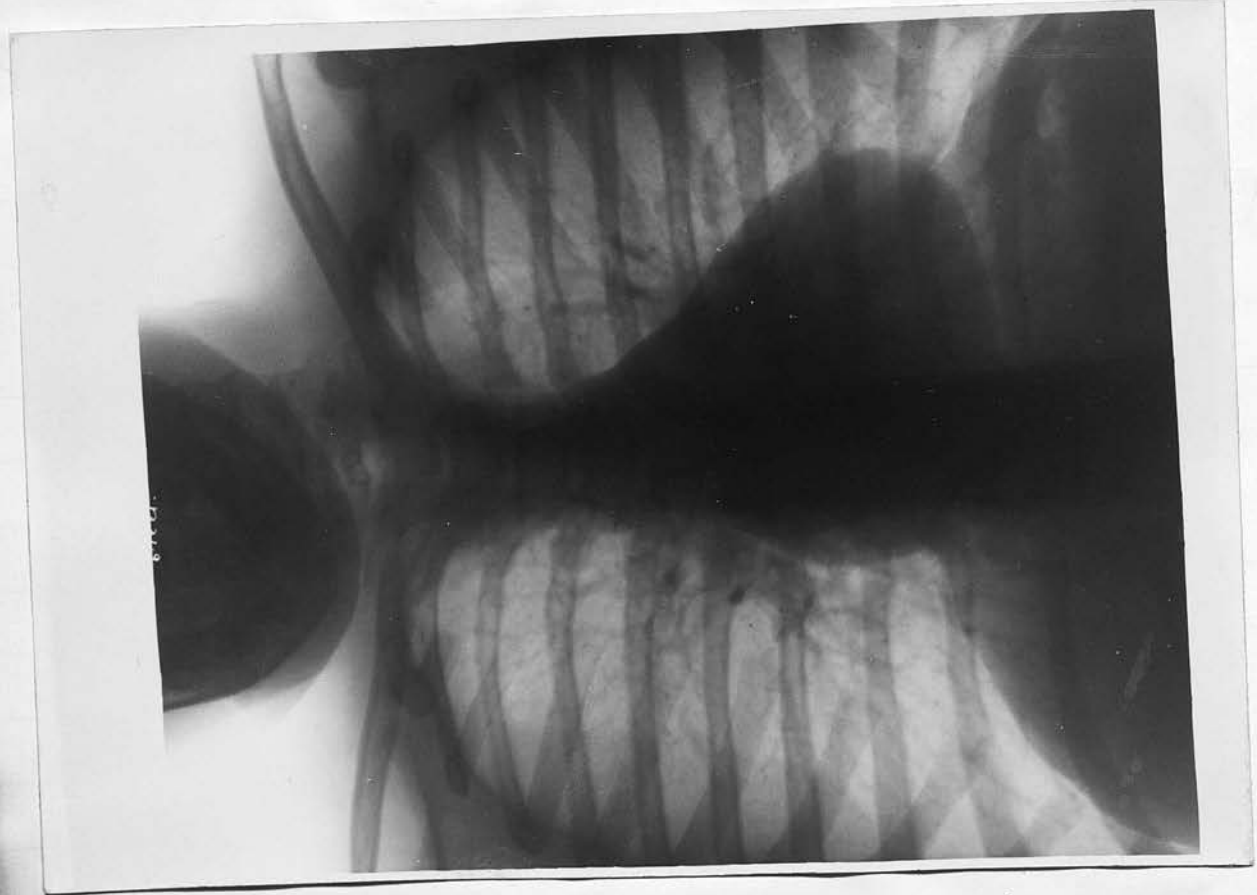


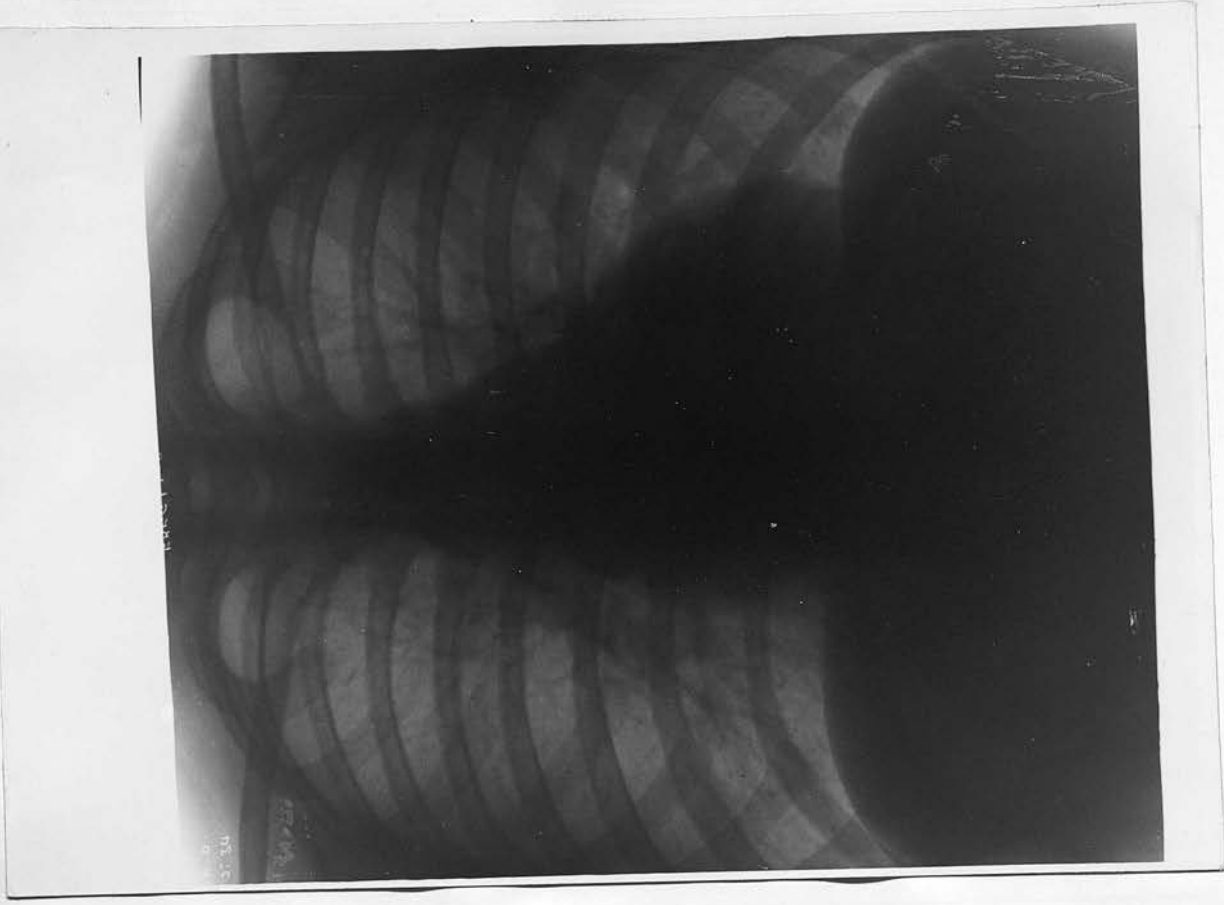
Fig. 37.

Case 3.- D.B.- February 6, 1933.

Broncho-Momiliasis.

Fig. 38

Case 3.- D.B.- March 30, 1934.



Potassium iodide started.

18/7/33. Monilia++ in sputum. Vaccine started.

Attacks of asthma gradually diminished.

31/10/34. Now quite well. No asthma since summer.

X-ray films 11/11/33 and 24/5/34 show typical picture already described.

Case II. C.G. aet. 9 years. Female. January 1933.

Previous history of whooping cough and subject to colds, cough and bronchitis. Mother treated for Moniliasis 1929, brother also had moniliasis.

Rhonchi at upper lobes and right base.

Sputum: monilia++. Rapid recovery under treatment.

21/3/33 No sputum available for examination.

X-ray films 13/4/33 and 24/5/34 show typical picture and improvement.

Case III. D.B. aet. 9 years. Male.

Chronic cough, subject to colds, had measles at age of 6 years and whooping cough followed by bronchitis.

Sputum: monilia++. A few rhonchi in both upper lobes.

Father has chronic bronchitis with nocardia and monilia in sputum.

X-ray examination 16/2/33 shows typical picture plus some widening of the intercostal spaces and emphysema.

Rapid recovery on routine treatment.

20/5/34 X-ray examination shows a normal lung picture apart from the resultant fibrosis of the usual fan-shaped type.

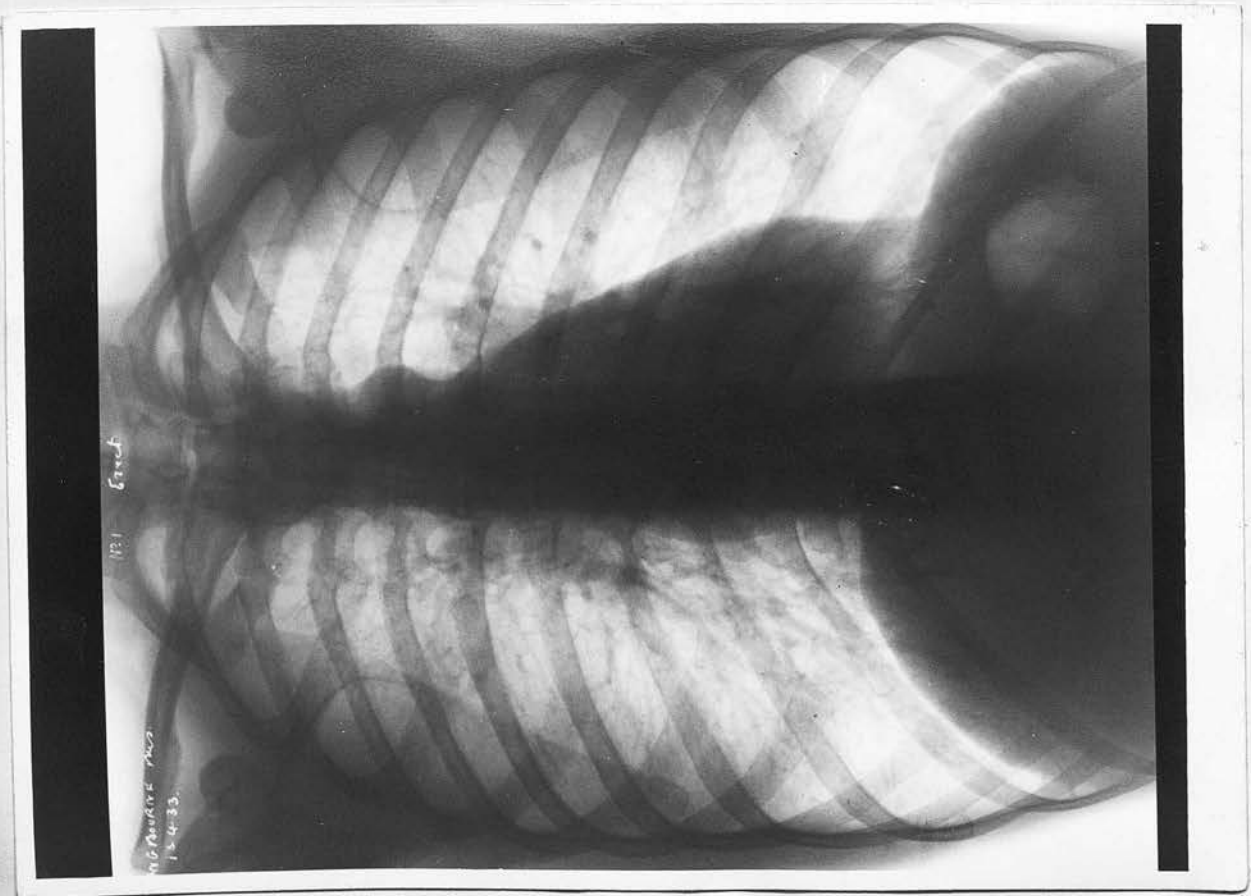


Fig. 39.

Case 4 - Mrs R. - April 13, 1933.

Broncho-Moniliae

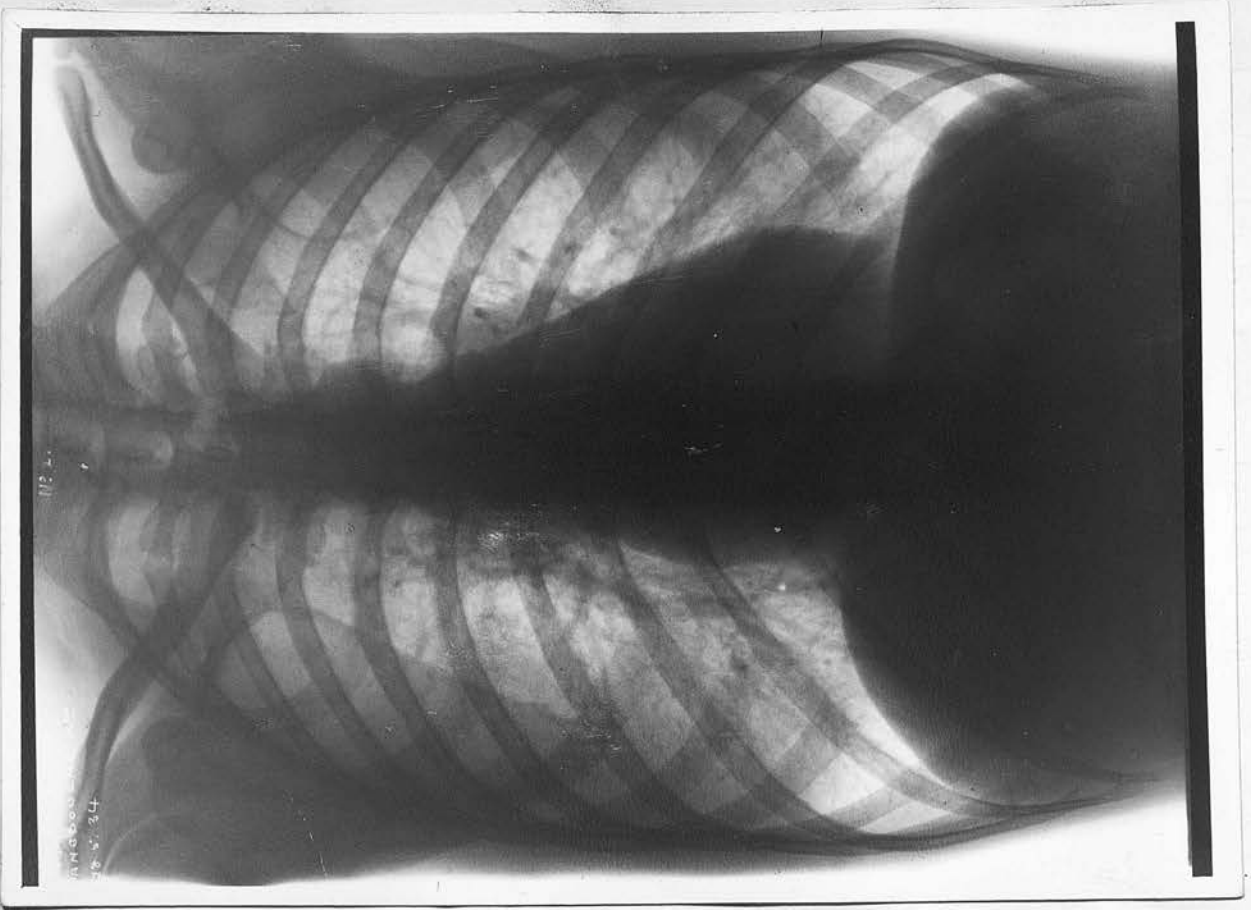


Fig. 40.

Case 4 - Mrs R. - May 8, 1934.

Case IV. Mrs. P. aet. 37 years. Female. 13/4/33.

Old-standing bronchitis. Dyspnoea of six years duration. Patient emaciated, severe cough, copious purulent sputum. Generalised rhonchi both lungs, tachycardia. Sputum: monilia++.

X-ray examination shows typical picture plus some calcified glands and increased translucency of the outer lung fields.

Routine treatment adopted, and by 2/8/33 patient quite well.

X-ray film 28/5/34 shows normal lungs apart from the resultant fibrosis.

Healed Psittacosis (Case V) and Bronchitis (Case VI) closely resemble this condition.

The pathogenicity of monilia has given rise to much diversity of opinion. To those who doubt it I would say that the work in Jersey has been carried out most carefully and conscientiously, and this condition may be a local one and most radiologists do not meet it.

Furthermore it has the support of many other distinguished workers.

I have on several occasions seen films of patients referred as suspected tuberculosis where the X-ray

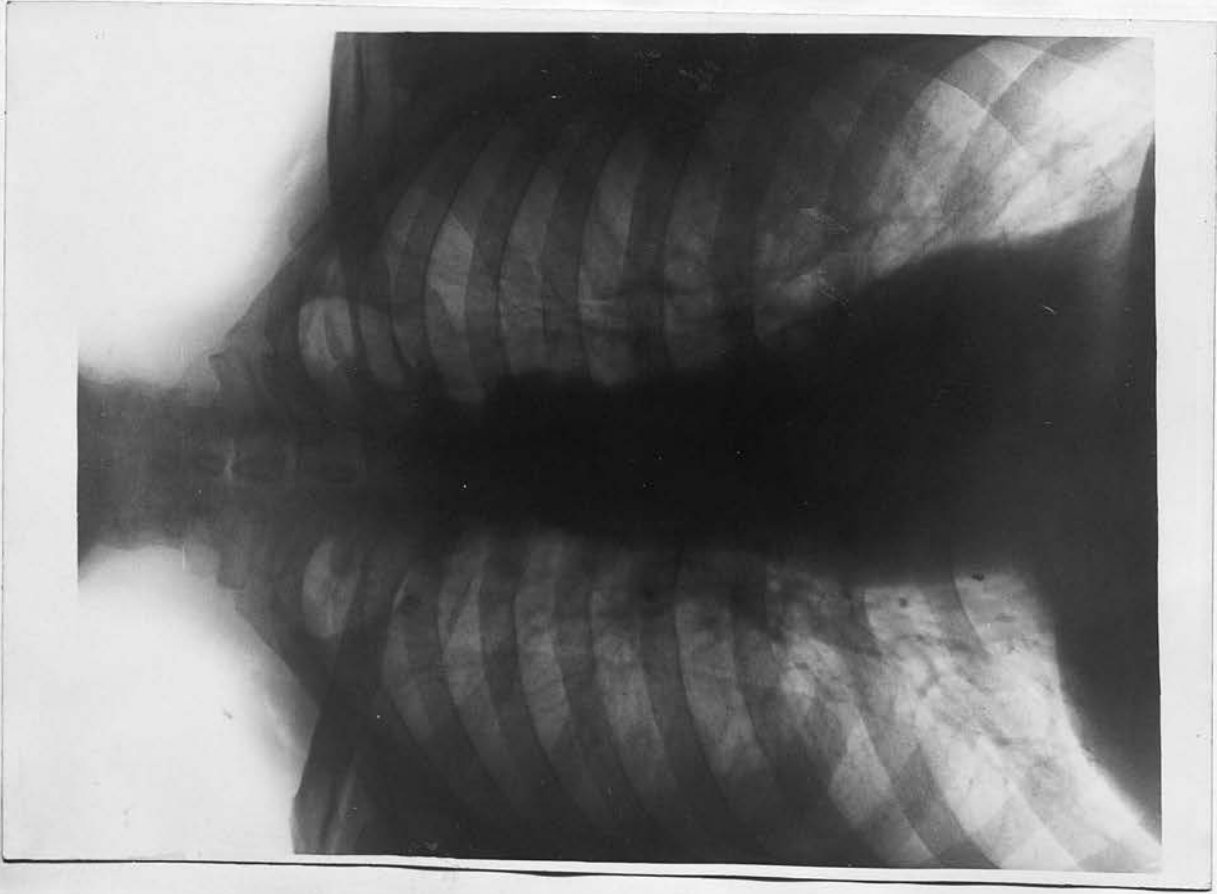


Fig. 41.

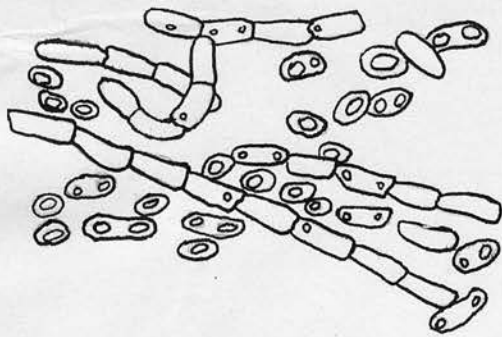
Case 5. G. Healed Psittacosis. - Dec. 1935.

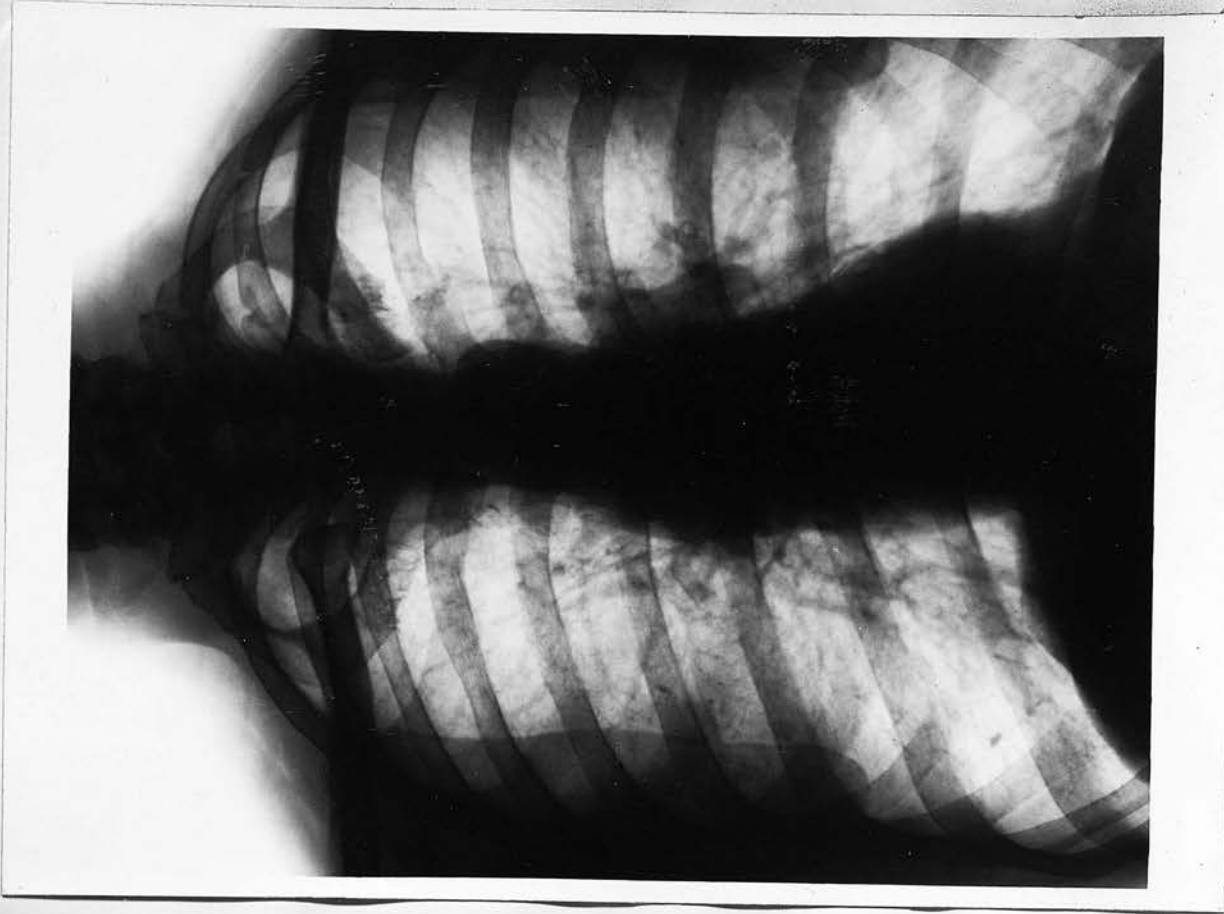

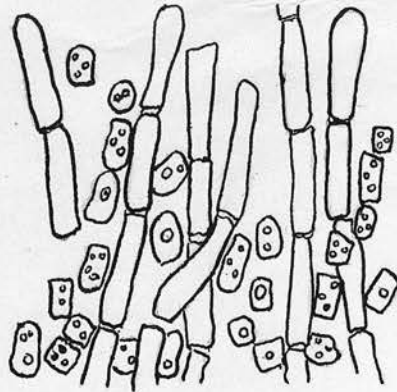
Fig. 42.

Case 6. M.L. - Chronic Bronchitis - Dec. 1935.

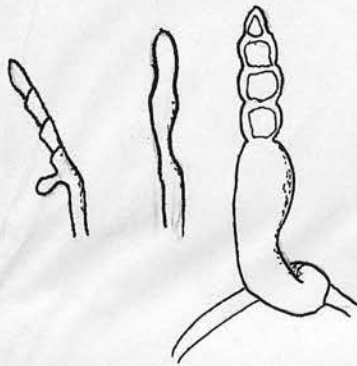
appearances and clinical symptoms suggested a broncho-moniliasis. In no case has the pathologist discovered monilia in the sputum, but it must be borne in mind that mycology is so very definitely a law unto itself, that few pathologists have the facilities for dealing with cases of this type. Whereas many sputa will produce fungi, these fungi are frequently contaminants and the tendency is to regard them as such. It is infinitely more difficult to prove fungi in sputa to be pathogenic than to accept their non-pathogenicity.




oidium Rotundatum



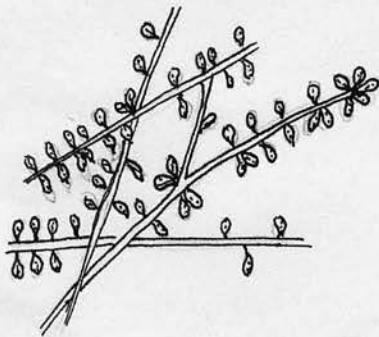
Oidium Asteroides.



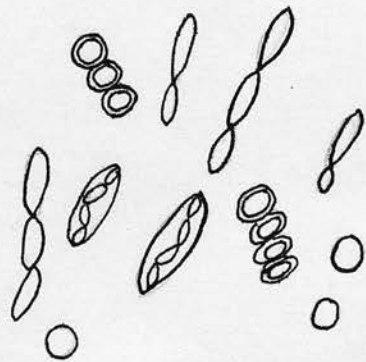
Hemispora.



Willia.



Sporotrichum



Saccaromyces

Fig. 43.

Some types of Fungi mentioned in the text.

(55) Castellani has mentioned the following types of broncho-mycosis which may simulate pulmonary tuberculosis.

Broncho-anaeromycosis. (Castellani, Douglas and Thompson).

Two types: (1) the haemorrhagic resembling tuberculosis, (2) the muco purulent, resembling sub-acute or chronic bronchitis.

Broncho-vibriothricosis. Fungi of type vibriothrix have been found in some cases of bronchitis. The pathogenicity is doubtful.

Broncho-oidiosis.

Oidium lactis - Link 1809.

"	<i>rotundatum</i> ,	Castellani	1911.
"	<i>asteroides</i>	"	1914.
"	<i>matalense</i>	"	1915.

Clinically identical with broncho-moniliasis.

Broncho-hemisporosis. Genus *hemispora* vullenium.

(1) *Hemispora rugosa*, Castellani, 1910.

(2) *Hemispora pararugosa*, Castellani, Douglas and Thompson, 1921.

Mild and severe types.

Broncho-endomycosis. Rare. Similar to moniliasis.

Broncho-cryptococcosis. Rare. Fungi consist of numerous yeastlike budding cells with no mycelium. Cultures never produce asci, thus distinguishing

this condition from

Broncho-saccharomycetosis. The symptomology and treatment are as for broncho-moniliasis.

Broncho-williasis. Very rare. Bowler-hat like ascospores. Castellani has had one case. Symptomology and treatment as in broncho-moniliasis.

Broncho-nocardiasis. The term used to include all bronchial conditions due to nocardia (Toni and Trevisan), and the genus Cohnistreptothrix (Pinoy), more commonly known as streptothrix, actinomyces, discomyces, oospora. Two types, one characterised by presence of fungal granules (sclerotia) in the sputum - Granular broncho-nocardiasis.

The other type, no such granules present - Agrenular broncho-nocardiasis. The first type is known as actinomycosis bronchialis, or pulmonalis. The second, pseudo-actinomycosis.

Symptoms severe, mistaken for tuberculosis. Symptoms as in broncho-moniliasis, only more severe.

Broncho-cremoniellosis (Perin and Pollacci).

Clinically identical with broncho-aspergillosis.

Broncho-cladosporiosis (Castellani.) One case.

Broncho-acladiosis (Castellani). Two cases.

All three cases recovered on treatment by means of potassium iodide.

Broncho-sporothricosis, usually secondary to skin lesions, but has been described as a primary invader of lung.

The extensive work of Dodge has been referred to at the beginning of the paper.

In conclusion it is quite obvious to me from my very limited experience of the subject, that there is ample scope for investigation in this country, where, apart from the work of a few enthusiasts, we are sadly behind America and many countries on the Continent. Accordingly, few pathologists have the necessary experience in dealing with this type of case, and, through no fault of their own, their findings are not altogether reliable.

As previously mentioned the establishment of the pathogenicity of any fungus found in a sputum may take months of infinite care and patience; first the group, then the particular member of that group, and possibly the stage of development at which the fungus is pathogenic. These particulars have to be worked out. The isolation of groups and members of groups is undoubtedly work for a whole-time mycologist. Mycology is, in itself, a life-time study.

Apart from the fact that no one in this country has made any attempt to tabulate, or compare radiologically, the broncho-mycoses I do not claim anything new, but rather an effort to revive an important, but sorely neglected subject.

SUMMARY:

-:-:-

The subject matter of this paper deals with fungous and fungoid infections of the lungs, or broncho-mycosis, from a radiological point of view.

The occurrence in agricultural workers of acute pulmonary symptoms, the most severe of which is extreme dyspnoea, and showing a distinctive type of X-ray picture, led to my starting some investigations on the subject. The cases were similar to the five recorded by Munro Campbell, three of which are described in conjunction with six or more cases which came under my observation. These patients we believe to be suffering from primary Broncho-mycosis, and in the sputa of cases referred to me fungi of the aspergillus group have been isolated. Further investigations are in progress.

This condition has (in my experience) been confined so far to the farming class when working amongst mouldy hay or cereals, and may be termed a temporary occupational disease. An interesting and important point is that all these cases referred to us were suspected to be suffering from pulmonary tuberculosis. Other similar milder cases have undoubtedly occurred in Westmorland, South Cumberland and the Lake District, but have not reached the Radiological department.

The isolation of the fungi is not easy and entails time and expense, which as yet few County Health Authorities are in a position to undertake; the presence, or absence, of tubercle bacilli in the sputum being all that is sought. This is unfortunate, as the administration of potassium iodide alleviates the symptoms and, in some cases, brings about a cure.

A brief résumé of other types of broncho-mycosis follows (special reference being made to broncho-moniliasis and broncho-actinomycosis) and are compared with other types of lung lesions from a radiological standpoint.

As a result of these investigations I have been particularly impressed by the fact that the incidence of broncho-mycosis is, in all probability a great deal higher than is supposed. The sputa of patients demonstrating certain symptoms and radiological appearances call for systematic and thorough investigation, the mere report "No tubercle bacilli found" may be fraught with great danger.

Medical mycology has not received the attention in this country which it has on the Continent and in the United States of America.

It is impossible to arrive at a correct interpretation of the films of any of these patients suffering from bronchomycosis without the co-operation of the clinician and a pathologist who is an efficient mycologist.

The failure to recognise these types of cases may lead to the patient being suspected of pulmonary tuberculosis and referred to a sanatorium with disastrous results, as bronchomycotics are very prone to secondary infections.

On the other hand they might be considered inevitable cases of chronic bronchitis and emphysema of accepted and doubtful etiology without any thought of fungus infection, and therefore no treatment by potassium iodide given.

In conclusion I wish to express my thanks to those who have kindly supplied me with radiographs and notes, all of which I have acknowledged in the text. To Dr. Faulds a special word of thanks for his co-operation; to my radiographers, Miss Mason and Miss Hodgson at the North Lonsdale Hospital, and Nurse Hankinson at the Whitehaven & West Cumberland Hospital, for their interest and help. Lastly to Miss Hoggarth, my radiographer at Ulverston who has spent many hours in the preparation of the prints and the typing of the text, my grateful thanks. Without her willing help this work would be impossible.

ZUSAMMENFASSUNG

-:-:-:-

Fungus und Fungus aehnliche Infectionen in der Lunge oder Bronchomycosen sind in dieser Arbeit vom roentgenologischen Standpunkt besprochen.

In Landarbeitern kommen acute Lungensymptome vor, unter denen aeusserste Kurzatmigkeit das schwerste ist und in denen ein auffallendes Roentgenbild beobachtet wird. Diese Punkte veranlassten mich, Untersuchungen an diesem Gegenstand zu beginnen. Die Faelle waren den fuenf von Munro Campbell mitgeteilten Faellen aehnlich; von diesen sind drei Faelle in Verbindung mit sechs oder mehr Faellen beschrieben, die unter meine Beobachtung kamen. Wir glaubten, dass diese Patienten an primaerer Bronchomycosis litten, und in den Sputen von Faellen, die von mir mitgeteilt waren, waren Fungi der Aspergillus Gruppe isoliert. Weitere Untersuchungen sind ⁱⁿ Bearbeitung.

Diese Krankheit ist in meiner Erfahrung auf Landarbeiter beschraenkt, so weit sie mit schimmeligem Heu oder schimmeligem Kornfruechten arbeiten, und kann als eine zeitliche Berufskrankheit angesehen werden. Ein interessanter und wichtiger Punkt ist, dass alle uns ueberwiesenen Faelle unter dem Verdacht standen, an Lungentuberkulose zu leiden.

Andere aehnliche leichtere Faelle sind zweifellos in Westmorland, Sued Cumberland und im Lake Distrikt vorgekommen, sind aber noch nicht bis zum Roentgeninstitut vorgedrungen.

Die Isolierung der Pilze ist nicht leicht und verlangt Zeit und Unkosten, die bis jetzt nur wenige Gesundheitsbehoerden in der Lage sind, zu uebernehmen. Das Vorkommen oder das Fehlen von Tuberkelbazillen im Sputum ist alles, was gesucht wird. Das ist zu bedauern, da die Anwendung von Jodkali die Symptome mildert und sogar in einigen Faellen die Patienten heilt.

Es folgt eine kurze Zusammenfassung anderer Typen von Bronchomycosen - mit besonderem Hinweis auf Bronchomoniliasis und Bronchoaktinomykose - die vom roentgenologischen Standpunkt mit andersartigen Lungenerkrankungen verglichen werden.

Als Ergebnis dieser Untersuchungen hat die Tatsache einen besonderen Eindruck auf mich gemacht, dass Bronchomycosen wahrscheinlich viel haeufiger vorkommen als man vermutet. Sputen von Patienten, die bestimmte Symptome und Roentgenbilder zeigen, erfordern systematische und gruendliche Untersuchung; die einfache Mitteilung "Keine Tb. Bazillen gefunden" kann mit grosser Gefahr verbunden sein. Aerztliche Mykologie hat in England noch nicht die Beachtung gefunden, die sie auf dem Continent und in America hat.

Unmoeglich kann man zu einer richtigen Deutung der Filme von vielen dieser Patienten, die an Bronchomycosen leiden, ohne die Mitarbeit des Kliniker und Pathologen gelangen, der ein ausgebildeter Mykologe ist. Der Misserfolg, diese Typen zu erkennen, kann dazu fuehren, einen Patienten einer Lungentuberkulose zu verdaechtigen und ihn in eine Lungenheilanstalt mit verheerendem Ergebnis zu verschicken, da Bronchomykotiker zu secundaeren Infectionen neigen. Andererseits koennte man annehmen, dass dies Patienten unvermeidliche Faelle von chronischer Bronchitis und Emphysem zweifelhafter Aetiologie sind, ohne an eine Fungusinfection zu denken, und aus diesem Grunde nicht mit Jodkali behandelt werden

Cette affection, d'après l'expérience de l'auteur, paraît se rencontrer plus spécialement parmi les travailleurs des champs et des mines exposés à inhaler des spores de ces microbes. On a vu, en effet, que dans les mines de charbon, ainsi que dans les mines de fer, on trouve une véritable maladie professionnelle.

On peut inférer, en fait, que les microbes observés ont été transportés par les courants d'air, et, certainement, plusieurs autres ont été apportés par le vent dans le territoire, le North District et le Lake District.

RÉSUMÉ.

Dans son ouvrage, l'auteur envisage du point de vue radiologique, les infections "fongoides" du poumon ou broncho-mycoses - en effet, l'apparition chez des gens de la campagne de symptômes pulmonaires aigus, dont le plus sévère est une dyspnée extrême, et dont l'examen radiologique montre une image d'un type tout à fait spécial, l'a amené à faire une série d'investigations à ce sujet.

Les cas étaient semblables aux cinq rapportés par Munro Campbell dont trois avaient été personnellement observés par l'auteur - ces malades sont diagnostiqués comme atteints de broncho-mycoses primitives et l'examen des crachats révèle la présence de champignons du groupe "aspergillus" que l'on a pu isoler - de nouveaux examens sont en cours.

Cette affection, d'après l'expérience de l'auteur, paraît se rencontrer presque exclusivement parmi les travailleurs des champs et des fermes exposés à inhaler des foin ou des céréales moisies, aussi, peut-on la classer comme une véritable maladie professionnelle.

Un point intéressant, est que tous les cas observés ont été suspects de tuberculose pulmonaire, et, certainement, plusieurs autres plus bénins ont dû se produire dans le Westmorland, le South Cumberland et le Lake District,

mais, ils n'ont pas atteint le service radiologique. L'isolement du champignon n'est pas aisé, prend du temps, et entraîne des dépenses qu'actuellement peu de Services d'Hygiène départementaux pourraient supporter, la présence ou l'absence de Bacille de Koch étant la seule recherche faite, ce qui est dommage, car l'administration d'iodure de potassium diminue les symptômes et dans quelques cas amène la guérison

L'auteur fait un bref résumé des autres types de bronchomycoses, s'arrêtant particulièrement aux bronchomoniliases et aux broncho-actinomycoses, et discute du point de vue radiologique le diagnostic différentiel avec les autres lésions pulmonaires.

Comme résultat de ses investigations, l'auteur a été frappé de la plus grande fréquence de cette affection qu'on ne le croyait, et il conclue que tout malade, présentant certains symptômes ou certains aspects radiologiques suspects et mal définis doit être l'objet d'investigations très serrées et systématique, le simple rapport "T.B. négatif" étant plein de danger. La mycologie dans la médecine n'a pas retenu en Angleterre toute l'attention qu'on lui a déjà porté sur le Continent ou aux Etats-Unis.

Il est impossible d'interpréter correctement les clichés de beaucoup de ces malades atteints de

bronchomycose, sans la collaboration du clinicien et du pathologiste connaissant bien la mycologie. Manquer de reconnaître ces cas, peut amener la malade à être suspecté du tuberculose pulmonaire, et envoyé dans un sanatorium avec les résultats désastreux que l'on devine car, d'une part les broncho-mycoses prédisposent singulièrement aux infections secondaires, d'autre part elles se transformeront inévitablement en affections pulmonaires chroniques, bronchite chronique ou emphysème dont l'étiologie restant obscure écartera le possibilité d'un traitement à l'iodure de potassium qui seul pourrait agir utilement.

References.

-:-:-:-:-

- (1) Dodge, C.W.: Medical Mycology - Fungous diseases of man and other mammals. 1936.
- (2) Myers, J. Arthur: Diseases of the Chest, 1935. p. 312 et. seq.
- (3) Henrici, Arthur T.: The Biology of Bacteria, D.C. Heath & Co., 1934.
- (4) Lemon, Willis S.: Clinical Manifestations of Coccidioides Granuloma. Proc. of Staff Meetings of Mayo Clinic. 4: 305, 1929.
- (5) Novak, Milan V., and Henrici, A.T.: Pleomorphic Organism showing relationships between Staphylococci and Actinomycetes. Jour. of Infect. Dis. 52: 253, 1933.
- (6) Norris, Geo.W., and Landis, Henry R.M.: Diseases of the Chest and the Principles of Physical Diagnosis, 5th ed., W.B. Saunders Co., Philadelphia, 1933.
- (7) Pents, Arthur Q.: Fungous diseases of the Lungs. Lancet. 55: 131, 1935.
- (8) Stovall, W.D. & Bubolz, Anne A: Yeastlike fungi. Jour. of Lab. & Clin. Med. 18: 890, 1933.
Stovall, W.D. & Pessin, S.B.: Classification and Pathogenicity of certain Monillias. Am. Jour. of Clin. Path. 2: 347, 1933.
Stovall & Pessin: Pathogenicity of certain species of Monilia. Am. J. Pub. Health. 24: 594, 1934.
Stovall, W.D.: A study of forty strains of yeastlike Fungi isolated from Sputa. J. of Infect. Dis. Dec. 1929.
Cultural and biochemical characteristics of Monilia isolated from Human Sources. J. of Infect. Dis. Vol. 50. Jan. 1932.
Identification of certain funguses Pathogenic for Man. Am. J. Pub. Health, 22. No. 5. May 1932.
- (9) Wangensteen, Owen H.: Actinomycosis of the Thorax with report of a case successfully operated upon. J. of Thoracic Surgery, 1: 612, 1932.

References - continued.

References to Blastomycosis.

-:-:-:-:-:-:-:-:-:-

- (10) Gilchrist, D.C.: A case of Blastomycotic Dermatitis in man. Johns Hopkins Hosp. Reports. 1: 269, 1896.
- (11) Rypins, E.L.: Amer. Year Book of Radiology, 1934. p. 26.
- (12) Mackerby, J.E.: Archives of Otolaryngology. Sept. 1934. Vol. 20 p.p. 297 - 328.
- (13) Medlar, E.M.: Pulmonary Blastomycosis. Am.J. Path. 3: 305. July 1927.
- (14) Miller, W.S.: The Reticulum of the Lung; its similarity in blastomycosis to that in Tuberculosis. Am.J. Path. 3: July 1927.
- (15) Ricketts: Contributions to Medical Science. University of Chicago Press. 1911.

References to Bronch^o-actinomycosis.

-:-:-:-:-:-:-:-:-:-

- (16) Erikson, Dagny.: The Pathogenic Aerobic Organisms of the Actinomyces Group. 1935.
- (17) Ørskov, J.: Investigations into the Morphology of the Ray-fungi. Copenhagen, 1923.
- (18) Israel: Neue Beobachtungen auf dem Gebiete der Mykosen des Menschen; Virchow's Arch. f. path. Anat. 74: 15. 1878.
- (19) Osler: Principles and Practice of Medicine. p. 223.
- (20) Price: Textbook of the Practice of Medicine. p. 1079.
- (21) Ponfick: Die Aktinomykose des Menschen, Eine Neue Infectious Krankheit auf Vergleichend-Pathologischer und Experimenteller Grundlage Geschildert, Berlin, A. Hirschwald, 1882, 138: Über aktinomykose, Berl. klin. Wchnschr., 17: 660, 1880; Breslau aerztl. Ztschr., 1: 116, 1879.

References - continued.

Broncho-actinomycosis.

- (22) Sanford, A.H.: Distribution of Actinomycosis in the United States, J.A.M.A., 81 655 - 659. August 1923.
- (23) Christison, Jas.T., & Warwick Margaret: Actinomycosis of lungs and Suprarenals, J.A.M.A., 89: 1043. Sept. 24. 1927.
- (24) Bell, Howard, H.: Infection of Meninges and Lungs by a species of Actinomyces. J. Infect. Dis. 30: 99. Jan. 1922.
- (25) Gittings, J.C., & Thorpe, E.S.: Pulmonary Actinomycosis. Am. J. Dis. Child. 32: 501, Oct. 1926.
- (26) Turner, G.: Actinomycosis of the Lungs. Radiology 7: 39 - 43. July 1926.
- (27) Miller, S.R. & Merkel, W.C.: Pulmonary Actinomycosis. Am. Yr. Book of Radiology, 1935. p. 138.
- (28) Stewart Harrison, R.: Radiation treatment of Actinomycosis. Brit. Jr. of Radiology 1934, p.98.
- (29) Ellis, R.W.B. Actinomycosis of Lung. Proc. Royl. Soc. Med. Vol. XXVI. Pt. I. p. 513.
- (30) Rodgers, T.S.: Actinomycosis of Lung. Proc. Royl. Soc. Med. Vol. XXVIII. Pt. I. p. 813.
- (31) Morrision Davies, H.: Recent advances in the Surgery of the Lungs and Pleura. British Jour. of Surgery. Vol. I. 1913. p. 252.
- (32) Jackson, Chevalier.: Suppurative Diseases of the Lung; report on a series of Bronchoscopic Observations. Proc. Roy. Soc. Med. Nov. 1930. Vol. XXIV, Pt. I. p. 14.
- (33) Jacobson, H.P.: Fungous diseases, 1932.

References - continued.

Broncho-moniliasis.

- (45) Grossi, G. & Balog, P.: Clinical and Experimental Studies on Castellani's Pulmonary Moniliasis. J. of Trop. Med. 32:243. Sept. 16. 1929.
- (46) Hoffstadt, R.E., & Lingenfelter, John S.: A Pulmonary Infection caused by *Monilia Balconica*. Am. J. Trop. Med., 9: 461. November 1929.
- (47) Jockes, Th.: Bronchomoniliasis, Lancet, 1: 108. June 21. 1923.
- (48) Mendleson, R.W.: Tropical Bronchopulmonary Mycosis. J. Am. Med. Assoc. 77, 110. July 9. 1921.
- (49) Wheeler, H. & Hoffstadt, R.A.: Bronchomoniliasis caused by *Monilia Metalondinensis*. J. Lab. & Clin. Med. 15: 122. Nov. 1929.
- (50) Craik, Robt.: Observations on the Pathogenic Yeasts and *Monilia* and *Microsporon*. The Med. Press & Circular. Mar. 20. 1923. April 11. 1928.
- (51) Shrewsbury, J.F.D.: The Genus *Monilia*. Jour. Path. & Bact. Vol. XXXVIII, 1934.
- (52) Marett, P.J.: British Med. Jour. 4th. May 1929.
British Med. Jour. 27th, May 1933.
Lancet. 5th March 1932. p. 511.
- (53) Oliver, H.G.: British Med. Jour. 7th May 1932.
Etiology of treatment of Spasmodic Bronchial Asthma. 1934.
- (54) Young, F.H. British. Med. Jour. 2nd April 1932.

References to other Broncho-mycoses.

-:-:-:-:-:-:-:-

- (55) Castellani, A.: Fungi and Fungous Diseases. 1928. p.p. 118 - 134.

APPENDIX.

-:-:-:-

References in Dodge's Medical Mycology relevant to Fungoid infections of the lungs.

Bronchitis.Eremascaceae.

Zymonema Cruzei (Froilano de Mello & Paes) Dodge,
n. comb.
Endomyces Cruzei " " " " , Arq. Hig. Pat.
Exot. 6: 51-60, 1918.

Isolated from sputum of patient suffering from bronchitis and asthma. (p. 176.)

E. Imperfectae.

Geotrichum rugosum (Castellani) Dodge, n. comb.
Originally isolated from cases of bronchitis and tonsillitis in Ceylon. ? Isolated from cases of thrush by Pijper (1917) in South Africa. (p. 219.)

Geotrichum Muisa (Mattlet) Dodge, n. comb.

Torula Muisa Mattlet, Ann. Soc. Belge Méd. Trop.
6: 25 - 26, 1926.

Patient a chief in the Belgian Congo who had a Bronchitis of long standing. Mucous sputum containing well-defined, greenish purulent islets which on examination showed cells of above organism. Medication with potassium iodide and sodium cacodylate caused amelioration of symptoms. Patient disappeared. (p. 220.)

Mycoderma pseudalbicans (Neveu-Lemaire) Dodge, n. comb.

Monilia pseudoalbicans Neveu-Lemaire, Précis Parasitol.
Hum. 77, 1921.

Isolated from sputum of bronchitis patient. No trace of stomatitis or other symptoms of M. albicans infection. (p. 229.)

Candida bethaliensis (Pijper) Dodge, n. comb.

Monilia sp. Pijper, Med. Jour. S. Africa, 12:129-130
1917.

Isolated from sputum of patient suffering from cough,
periods of feverishness, bronchitis, hyperleucocytosis.

Sputum whitish yellow. No T.B. bacilli found.

Inoculation to rabbit proved fatal in 48 hours.

Hæmorrhages in lungs. (p. 231.)

Parendomyces zeylanoides (Castellani, Douglas &
Thompson) Dodge n. comb.

Monilia zeylanoides Castellani, Douglas & Thompson,
Jour. Trp. Med. Hyg. 28: 257-258, 1925.

Isolated from a case of bronchial infection, but case
history not given. (p.240.)

Castellania tropicalis (Castellani) Dodge n. comb.

Isolated from sputum in 4 cases of coughing, 2 of
the patients having been exposed to tea dust. Three
cured by medication with potassium iodide. Tuber-
culosis absent. Later same organism isolated in
cases of tonsillomyces and thrush. (p. 258.)

Pseudomonilia matalensis (Castellani) Dodge, n. comb.

Isolated from ulcers and from sputum of cases of
bronchitis in the tropics. (p. 296.)

Pseudomonilia alessandrina (Panayotatou) Dodge, n. comb.

Isolated from mucopurulent sputum in a case of bron-
chitis. Medicated with potassium iodide. Intravenous
injection into rabbit caused generalised infection
and finally death. Organism reisolated. (p.297.)

Saccharomyces Lemmonieri Sartory & Lasseur, C.R. Soc.
 Biol. 73: 48-49, 1915: Bull. Sci. Pharma.
 23: 151-157, 1916.

Isolated from a case of bronchitis and pulmonary
 congestion. Pathogenic to guinea-pigs, white mice
 and rabbits. (p. 321.)

Var. Mekundu (Mattlet) Dodge, n. comb.

Cryptococcus Mekundu Mattlet. Ann. Soc. Belge. Trop.
 Med. 6: 14, 15, 1926.

(p.350.)

Actinomyces Thjoettae Dodge, n. sp.

Cohnistreptothrix sp. Thjøtta & Gundersen, Jour.
 Bact. 10: 1-12, 9 figs., 1925.

Found in a case of generalised infection with acute
 rheumatism, pleuritis, pericarditis, and bronchitis.

Thought by authors to be a saprophyte close to that of
 Löhlein. Nonpathogenic to laboratory animals. (p.713.)

Actinomyces buccalis (Roger, Bury & Sartory) A. Sartory
 & A. Bailly, Mycoses Pulmonaires 256, 1923.

Actinomyces sp. A. Sartory & R. Sartory, Bull. Acad.
 Med. 111, 94: 893, 894. 1925.

Isolated from patient with bronchitis. Pathogenic
 to rabbit and guinea-pig. (p.755.)

Chronic bronchitis.

-:-:-:-

Endomycetales.

Hansenula.

Saccharomyces Beauveriei Froilano de Mello, Arq.
 Hig. Pat. Exot. 6: 246, 1918 (based on
 case of Beauverie & Lesieur, 1912).

Reported occasionally from sputum but in none of the cases has pathogenicity been clearly shown. Beauverie & Lesieur (1912) reported a case of phthisis with the organism in the mucopurulent sputum. Grigorakis and Péju (1922) also report a case. Shrewsbury (1930) in a monograph on the genus reports his strain 209 isolated from sputum from a case of chronic bronchitis along with Monilia, and an unidentified yeast. Shrewsbury was unable to find any pathogenicity for his strain in experimental animals. (p. 143.)

Geotrichum asteroides (Castellani) Basgal, Contr.
 Estudo Blastomycoses Pulmonares, 48, 1931.

Reported from cases of chronic bronchitis. (p.218.)

Mycoderma Nyabisi Mattlet, Ann. Soc. Belge Méd. Trop.
 6: 30, 31, 1926.

Geotrichum Nyabisi Basgal, Contr. Estudo Blastomycoses
 Pulmonares 49, 1931.

Isolated in Belgian Congo from a case of chronic bronchitis, showing regular presence of cylindric cells, 3-5x6-8 . (224.)

Mycoderma Caoi Jannin, Les Mycoderma 186-187, 1913.

Isolated from a case of chronic bronchitis in an old man. Pathogenic to rabbits. (p. 225.)

Castellani Mannitofermentans (Castellani) Dodge, n. comb.

Monilia mannitofermentans Castellani, Proc. Soc. Exp.
Biol. Med. 26: 544-545. 1929.

Isolated from sputum in a case of chronic bronchitis.

(p.255.)

Torulopsis.

Var. *pararosea* (Lodder) Dodge, n. comb.

Cryptococcus pararoseus Castellani, Arch. Derm. Syphilol.
16: 402, 1927. Amer. Jour. Trop. Med. 8: 393,
1928.

Rhodotorula mucilaginosa var. *pararosea* Lodder,
Anskosporogenen Hafen 1: 102-104, 1934.

Isolated from sputum in a case of chronic bronchitis.

(p.353.)

Aspergillus cyaneus (Mattlet) Dodge, n. comb.

Sterigmatocystis cyaneus Mattlet, Ann. Soc. Belge.
Méd. Trop. 6: 32, 1926.

Isolated from a case of chronic bronchitis with a
little emphysema. Author unable to follow up case

(Tamshunga).

(p.636.)

Actinomyces carneus (Rossi-Doria) Gasperini, Centralbl
Bakt. 15: 684, 1894.

Streptothrix carnea Rossi-Doria, Ann. Inst. Ig. Sperim.
Univ. Roma 1: 399-438, Pl. 8, 1891.

Nocardia carnea Castellani & Chalmers, Man. Trop. Med.
ed. 2. 818, 1913.

Discomyces carneus Neveu-Lemaire, Précis Parasitol.
Hum. 42, 1921.

Oospora carnea Sartory, Champ. Paras. Homme Anim.
810. 1923.

Originally isolated from the air. Reported by
Boldoni from a case of chronic bronchitis. Pathogenic
to rabbit and guinea-pig, producing pseudo-tuberculosis.

Gram-positive.

(p. 741.)

Actinomyces Pijperi (Castellani & Chalmers) A. Sartory
& A. Bailly, *Mycoses Pulmonaires* 256, 1923.

Nocardia sp. Pijper, *Folio Microdiol.* 5: 50-53, 1 pl.,
1917.
Med. Jour. S.Africa 12: 141-142, 1917.

Nocardia Pijperi Castellani & Chalmers, *Man. Trop.*
Med. ed. 3, 1060, 1919.

Discomyces Pijperi Neveu-Lemaire, *Précis Parasitol.*
Hum. 44, 1921.

Oospora sp. Sartory, *Champ. Paras. Homme Anim.* 811,
1923.

Found in the mucopurulent sputum of a patient with
chronic bronchitis that had lasted eleven years.

Pathogenic to guinea pigs on intraperitoneal
injection. (p.756.)

Bronchomycosis.

-:-:-

Mucorales.

Absidia corymbifera (Cohn) Saccardo & Trotter in
Saccardo Sylloge Fungorum 23: 825, 1912.

Mucor corymbifer Cohn in Lichtheim, Zeitschr. Klin.
Med. 7: 147, Pl. 6-8, 1884.
Barthelst, Ann. Parasitol. 7: 25-30, 1904.

Lichtheimia corymbifera Vuillemin, C.R. Acad. Sci.
Paris 136: 516, 1903.

Mucor corymbifera var *typica Lichtheimi* Lucet &
Constantin, Arch. de Parasit. 4: 380, 1901.

Absidia Lichtheimi Lendner, Mat. Fl. Cryptog. Suisse 3:
143 - 144, 1908.

Many cases in the literature dealing with broncho-
mycosis (Paltauf 1885, etc.). Lang & Grubauer (1923)
discuss the clinical and pathological aspects fully
and summarise earlier cases. (p. 112.)

Eremasceae.

Zymonema album, Dodge n. sp.

Monilia sp. Bianchi & Niño, Bol. Inst. Clín. Quirúrg.
Univ. Buenos Aires 4: 531-538, 6 figs., 1927.

Producing bronchomycosis. Pathogenic for guinea-pig.

(p. 175.)

E. Imperfectae.Mycocandida.

In the respiratory tract, many of the symptoms closely
simulate pulmonary tuberculosis, from which they may be
differentiated by the absence of *Mycobacterium tuber-*
culosis in the sputum and the presence of large numbers
of blastospores. A specialised form from the Orient,
variously known as "tea factory cough" or "tea taster's
cough", is a bronchomycosis supposed to be spread by the

dry tea leaves which are sniffed in determining
odour while grading tea. (p. 204.)

Castellania macedonensoides (Castellani & Taylor)
Dodge, n. comb.

Monilia macedonensoides Castellani & Taylor, Jour.
Trop. Med. Hyg. 28: 244, 1925.
Castellani, Douglas & Thompson, Jour. Trop.
Med. Hyg. 28: 258, 1925.

Found in vagina? Or bronchomycosis fide Zepponi, 1931.
(p. 253.)

Castellania nivea (Castellani) Dodge, n. comb.

Endomyces niveus Castellani, Lancet 1: 15, 1912.
Brit. Med. J. 2: 1208-1212, 1912.

Candida nivea Basgal, Contr. Estudio Blastomycoses
Pulmonares, 49, 1931.

Reported to cause bronchomycosis, but isolated from
sputum not collected in a sterile vessel, and there-
fore of doubtful pathogenicity. (p. 256.)

Castellania Guilliermondi (Castellani) Dodge, n. comb.

Endomyces " Castellani, Brit. Med. J. 2:
1208 - 1212, 1912.

Monilia Guilliermondi Castellani & Chalmers, Man.
Trop. Med. ed. 2, 826. 1913.

Myceloblastanion Guilliermondi Ota, Jap. Jour. Derm.
Urol. 28: (4) 1928.

Isolated from sputum in case of bronchomycosis.
(p. 257.)

Castellania nitiada (Castellani) Dodge, n. comb.
Candida nitiada Basgal, Contr. Estudio Blastomycoses
Pulmonares, 50, 1931.

Isolated from sputum in a case of bronchomycosis.
(p. 261.)

Castellania accraensis (Macfie & Ingram) Dodge, n. comb.

Candida accraensis Basgal. Contr. Estudo Blastomycoses Pulmonares 49, 1931.

A complicating organism in fatal cases of tuberculosis of the lungs. (p. 264.)

Castellania paratropicalis (Castellani) Dodge, n. comb.

Candida paratropicalis Basgal, Contr. Estudo Blastomycoses Pulmonares, 49, 1931.

Isolated from case of bronchomycosis, also from two cases of blastomycetic dermatitis in Ceylon. (p.264.)

Parasaccharomyces parachalmersi (Castellani & Chalmers) Dodge, n. comb.

Isolated from sputum.

Parasaccharomyces Colardi. Dodge n. sp.

Monilia sp. Jaumain & Colard, C.R. Soc. Biol. 93: 858-860, 1925.
Colard & Jaumain, Bruxelles Med. 5: 1503-1506, 1925.

Isolated from sputum in case of bronchomycosis in the Belgian Congo which was under observation in 1924-1925. (Fetel). (p. 267.)

Blastodendron Pinoyi (Castellani) Langeron & Talice, Ann. Parasit. Hum. Comp. 62, 1932.

Monilia Pinoyi Castellani & Chalmers, Man. Trop. Med. ed. 2. 826 - 827, 1913.

Originally isolated from sputum in case of bronchomycosis. (p. 285.)

Aspergillaceae.

Aspergillus giganteus (Mattlet) Dodge, n. comb.

Sterigmatocystis giganteus Mattlet, Ann. Soc. Belge. Méd. Trop. 6: 31-32, 1926.

Sterigmatocystis cas V Mattlet, Ann. S. B. Méd. Trop. 4: 167 - 176, 3 figs., 1924.

Along with this species a *Parasaccharomyces irritans* was isolated from a case of severe bronchomycosis in the Belgian Congo. Animal inoculations not reported. (p. 629.)

Aspergillus fumigatus Frensenius, Beitr.z.Myk. 81, Pl.10, figs.1-11, 1850.

This is the commonest species isolated from cases clinically resembling tuberculosis of the lungs in which *Mycobacterium tuberculosis* has not been found. (p. 634.)

Aspergillus Brodeni (Mattlet) Dodge, n. comb.

Sterigmatocystis Brodeni Mattlet, Ann. Soc. Belge. Méd. Trop. 6: 31, 1926.

" Cas I, II, IV Mattlet, Ann. Soc. Belge. Méd. Trop. 4: 3: 167-176, 3 figs. 1924.

Isolated from bronchomycoses with abundant sputum containing spores and later some filaments of *aspergillus*, no trace of *Mycobacterium tuberculosis* either in smears or guinea pig inoculation. (p. 635.)

Var. *Vancampenhouti* (Mattlet) Dodge, n. comb.

Sterigmatocystis Vancampenhouti Mattlet, Ann. Soc. Bel. Méd. Trop. 6: 31, 1926.

" Cas III, Mattlet, Ann. Soc. Bel. Méd. Trop. 4: 167 - 176, 3 figs, 1924.

Isolated from bronchomycosis, cases similar to those reported in *A. Brodeni*. Recovery following potassium iodide emetine treatment. (p. 636.)

Sporotrichese

Sporotrichum bronchiale Montagne, Plant. Cell. Nouv. 92 (cited by Saccardo, Syll. Fung. 4: 100, 1886.

Isolated from bronchomycosis, case of Gubler. (p. 810.)

Bronchopneumonia.

-:-:-:-:-

Endomycetales.

Actonia tropicalis (Acton) Dodge, n. comb.

Endomyces tropicalis Acton, Indian Jour. Med. Res.
6: 591 - 600, 1919.

Monilia Actoni Vuillemin, Champ Paras. Homme.
Anim.84, 1931 nom. nud.

Producing small creamy patches on the tonsils and
uvula in throats of soldiers in Mesopotamia.

---In debilitated persons it may extend to the
bronchi and bronchioles causing fatal broncho-
pneumonia. (p. 146.)

Eremascaceae

Octomyces Etiennei (Potron) Dodge, n. comb.

Saccharomyces Etiennei Potron Rev. Méd. de l'Est.
45: 814 - 826, 841 - 855, 3 figs.,
1913.

Isolated from severe pleuropulmonary infection and
bronchopneumonia with abundant yeasts appearing in
the sputum. Producing local pyogenesis in rabbit
and guinea-pig. (p. 181.)

Saccharomycetaceae Imperfectae.

Torulopsis bronchialis Ciferri & Redaelli, Atti Ist.
Bot. R. Univ. Pavia, III,2: 245 - 248,
283, 1925.

Rhodotorula bronchialis Lodder, Anaskosporogenen
Hefen 1: 91 - 93, 1934.

Isolated from sputum of a patient with bronchopneumonia,
not pathogenic for laboratory animals. (p.349.)

Actinomyceteae.

Actinomyces cruoris (Macfie & Ingram) Brumpt, Précis
Parasitol. ed.4, 1195, 1927.

Notardis cruoris Macfie & Ingram, Ann. Trop Med.
Parasitol. 15: 283 - 285, 1921.

Oospora cruoris Sartory, Champ. Paras. Homme Anim.
809, 1923.

Isolated from the heart blood of a patient, both
of whose lungs were affected with bronchopneumonia
and whose case had otherwise presented the clinical
picture of encephalitis lethargica. Pathogenicity
not proved. (p. 753.)

Other Lung conditions.

-:-:-:-:-:-:-:-

Mucorales.

Absidia itzaliana (Costantin & Perin) Dodge, n. comb. nov.

Lichtheimia italiana Costantin & Perin. Bull. Soc.
Med. Chir. di Pavia, 35: 1922.

Lichtheimia italica Pollacci & Nannizzi I miceti patogeni
dell'uomo e degli animali 3: No.26, 1924.
Perin, Arch. di Clin. e Patol. Med. 2: 5,
Oct. 1923.
Trattato Micopatol. Umana 1: 55-73, 1925.

I have been unable to locate any of the original
descriptions of this organism. Some have reduced it
to synonymy with A. corymbifera. The following notes
are based on Perin (1925). Isolated from sputum and
from tissue fragments from the lungs. Pathogenic
for laboratory animals. (p. 113.)

Rhizopus.

Rhizopus equinus Costantin & Lucet, Bull. Soc. Myc. France 19: 200, 1903.

Var. annamensis, P. N. Bernard, Bull. Soc. Myc. France 30: 230 - 232, Pl. 14, 1914.
Bull. Soc. Path. Exot. 7: 430, 1914.

Isolated from sputum of an Annamite, aged 32 in 1911; sputum blackish, as if mixed with carbon grains. Cough with a little dyspnoea. Whole left lung infected. No previous history except bronchitis with complete recovery. Hospitalized for cough in fall, 1910, worse July, 1911, but alive in December, disease seemingly arrested and localized. Intravenous inoculations in pigeons, no effect; nor intraperitoneal in guinea-pig; rabbit succumbed to both methods, but not to subcutaneous inoculation. Organism recovered. (p. 116.)

Rhizopus parasiticus (Lucet & Costantin) Lendner, Mat. Fl. Cryptog. Suisse 3: 115, 1908.

Rhizopus parasiticus Lucet & Costantin, Rev. Gén. Bot. 12: 81, Pl. 3, 1900.
Arch. de Parasitol. 4: 384-408, 1901.

Mycosis of lung of country woman, final recovery after several months treatment with arsenic. See Arch. de Parasitol. 4: 386-389, 1901, for case history and results of inoculations. Nonpathogenic in subcutaneous inoculations. (p. 117.)

Endomycetales.Coccidioides.

Eight types of lesions have been reported. Primary cutaneous or primary pulmonary lesions both with later

generalisation, primary pulmonary lesions with secondary subcutaneous lesions. ...It is supposed the organism enters through the lungs or through skin injuries. (p. 149.)

Histoplasma Darling, Jour. Amer. Med. Assn. 46: 1283-1285, 1906.
Arch. Int. Med. 11: 107-123, 1908.
Jour. Exp. Med. 11: 515-531, 1909.

The lungs and both small and large intestines are studded with pseudotubercles, giving the appearance of miliary tuberculosis. (p. 153.)

Paracoccidioides brasiliensis (Splendore) Almeida, Annaes Fac. Med. São Paulo 5: 1-19. 19 pls. 1930.

Apparently this species gains entrance into the host usually through the digestive tract, while Coccidioides immitis enters through the lungs.....

(p. 156.)

Neogeotrichum pulmoneum (O. Magalhães) O. Magalhães Mem. Inst. Oswaldo Cruz. 26: 151-167, Pls. 36-40, 1932.

Oidium pulmoneum O. Magalhães, Brasil Med. 28: 313, 1914.

Candida brasiliensis Basgal, Contr. Estudo Blastomycoses Pulmonares 50, 1931.

Case with usual symptoms of pulmonary tuberculosis. Mycobacterium tuberculosis not found by any method. Neogeotrichum inoculated into monkeys, reproduced human disease very closely, and the organism was reisolated. (p. 157.)

Ereмассeae.Zymonema Harteri (Verdun) Dodge, n. comb.

Isolated from a case of generalised blastomycosis presumably contracted in Cochin China. Organism has evidently invaded the intestinal tract, liver, lungs and finally produced subcutaneous nodules.

(Case of Harter, C.R. Soc. Biol. 64: 241 - 242,
1908.)
(p. 178.)

E. Imperfectae.Geotrichum versiforme Moore, Ann. Missouri Bot. Gard. 21: 349-366, 1 pl. 1934.

Isolated from thick, greenish, mucopurulent, at times bloody tenacious sputum from a patient with bronchiectasis and pulmonary infiltration of several years duration.
(p. 221.)

G. Membranogenes (Martins) Dodge, n. comb.Zymonema pulmonalis n. Mertins, C.R. Soc. Biol. 98: 1162 - 1164, 1928.

Isolated from a case of ill-defined pneumonopathy, frequent and abundant hemoptyses, temperature oscillating between 37° and 39° C. Portugal. Not markedly pathogenic for laboratory animals. (p.222.)

Candida Krusei (Castellani) Basgal, Contr. Estudo Blastomycoses Pulmonares, 50, 1931.

Found in sputum of convict suffering from a severe cough, other symptoms obscure. Case under observation for two months. Monilia tropicalis also present.

(p. 231.)

Pseudomycoderma Rabesalama (Fontoynt & Boucher)
Dodge, n. comb.

Mycoderma Rabesalama Fontoynt & Boucher. Ann. Derm.
Syphiligr. VI, 4: 330 - 338, 1922.

Geotrichum Rabesalama Basgal, Contr. Estudio Blastomicrocoses pulmonares 50, 1931.

Isolated from abscess of lung with hemoptysis.

Abscesses on rabbit heal spontaneously. Reculture
negative. (p. 236.)

Syringospora inexorabilis (Mazza & Palamedi) Dodge,
n. comb.

Monilia inexorabilis Mazza & Palamedi, Reunión Soc.
Argentina Patol. Reg. del Norte en Tucumán
7: 424 -467, 1 pl., 50 figs., 1932.

Mycotorula candida Talice & Mackinnon, Reunión Soc.
Argentina Patol. Reg. del Norte en Santiago
del Estero 8: 165-166, 1933.

Lesion began in the commissural surface of the lips,
edematous, spreading to the gingival mucosa, tongue,
and interior of the mouth generally, producing ulcers.
Thence it spread to the lungs (x-ray) the organism
being isolated from sputum. Ulcers then appeared on
the arms and foot. The disease proved fatal, autopsy
showing the lungs to be the principal internal focus
of infection. (p. 242.)

Castellania balcanica (Castellani & Chalmers) Dodge, n. comb.

Monilia balcanica Castellani & Chalmers, Man. Trop. Med.
ed. 3. 1090, 1919.

Found in sputum. Hoffstadt & Lingenfelter (1929)
describe in detail a case of pulmonary infection due to
this organism. They found it pathogenic for rabbits.

(p. 249.)

Castellania bronchialis (Castellani) Dodge, n. comb.

Endomyces bronchialis Castellani, Brit. Med. Jour.
2: 1208-1212, 1912.

Candida bronchialis Basgal Contr. Estudo Blastomycoses
Pulmonares, 49, 1931.

Isolated from sputum. Probably the organism of Smith
& Sano (1933) from a case showing meningeal involvement
should be referred here. (p. 254.)

Castellania aegyptiaca (Khouri) Dodge, n. comb.

Monilia aegyptiaca Khouri, Bull. Soc. Path. Exot.
26: 7-9, 1933.

Isolated from sputum mixed with blood from a case of
pulmonary blastomycosis. No trace of Mycobacterium
tuberculosis, no blood parasites. Wassermann reaction
negative. Organism slightly pathogenic for guinea-
pig. (p. 254.)

Castellania platensis (Peruchena) Dodge, n. comb.

Monilia platensis Peruchena, Semens Méd. 36: 1-31,
10 figs. 1929.

Isolated from a patient who suffered from cough,
expectoration, loss of strength and weight. Lung
involved. Pathogenic for rabbits. (p. 262.)

Mycotoruloides triadis Langeron & Talice, Ann.
Parasitol. Hum. Comp. 10: 48, 1932.

Monilia sp. Brocq-Rousseu, Guilliermond & Cilleuls.
Ann. Parasitol. Hum. Comp. 5: 4862, 1927.

Isolated from an infection of the lung, Clinically
suggestive of tuberculosis. After the diagnosis was
established, patient cured in a short time by potassium
iodide. Pathogenic to guinea-pig and rabbit. (p. 292.)

Mycocandida mortifera (Redaelli) Langeron & Talice, Ann. Parasitol. Hum. Comp. 10: 58, 1932.

Candida mortifera Redaelli.

Isolated from the lungs. (p. 295.)

Saccharomycetaceae, imperfectae.

Cryptococcus rotundatus (Redaelli) Dodge, n. comb.

Torulopsis rotundata Redaelli, I Miceti come Associazione Microbica nella Tuberculosis Polmonare Cavitaria 46, 1925, (fide Lodder Anaskosporogenen Hefen 1: 170 - 172, 1934).

Isolated from a case simulating tuberculosis of the lung. (p. 333.)

C. hondurianus (Castellani) Dodge, n. comb.

Torulopsis hominis var. honduriana Castellani, Med. Press Circular 136: 438-443, 1933. Jour. Trop. Med. Hyg. 36: 311, fig. 36, 1933.

r. Neoformans Lodder, Anaskosporogenen Hefen 1: 176 - 178, 1934.

Isolated from blastomycosis of the skin with pulmonary complications in Honduras. (p. 334.)

C. conglobatus (Redaelli) Pollacci & Nannizzi, Miceti Pat. dell 'uomo e degli Anim. 7: No. 63, 1928.

T. conglobata Redaelli, I Miceti come Associazione Microbica nella Tuberculosis Polmonare Cavitaria, 1925.

Isolated from lungs with much destruction of tissue, in Italy. Later isolated by Carnevale-Ricci from tonsillar crypts. Subsequently found in several other cases in lesions of the lung. (p. 334.)

C. Guilliermondi Beauverie & Lesieur (name with reference to previous description) Jour. Physiol. Path. Gén. 14: 998, Pl. 11, 1912.

Levure Guilliermond & Lesieur, C.R. Soc. Biol. 70: 952-954, 1911.

Isolated from the lungs of a man dying of cancer of the kidney. Lung symptoms resembled tuberculosis without accompanying fever. Inoculations into guinea-pig negative. (p. 335.)

Torulopsis Sanniei Ciferri & Redaelli, Atti Ist. Bot. R. Univ. Pavia 111, 2: 245-248, 283, 1925.

Rhodotorula Sanniei Lodder, Anaskosporogenen Hefen 1: 99 - 101, 1934.

Isolated from lungs. Not pathogenic to laboratory animals. (p. 352.)

Aspergillaceae

Scopulariopsis Bertacini Redaelli in Bertacini, Giorn. Italy. Derm. Sifilol. 75: 783-828, Pls. 1-9, 1934.

Isolated from a fatal case of blastomycosis originating in Brazil, showing cutaneous ulcers mostly about mouth and neck with lesions in the lung, etc. Pathogenic to laboratory animals. (p. 646.)

Phaeoscopulariopsis Bestae (Pollacci) Ota, Jap. Jour. Derm. Urol. 28: 4. 7. 1928.

Torula Bestae Pollacci, Riv. Biol. 4: 313-318, 1 fig. 1922.

Isolated from subcutaneous abscesses in a patient suffering also from high fever, gastrointestinal disturbances, and bronchopulmonary trouble. (p. 651.)

Actinomycetaceae.

Actinomyces americanus (Chalmers & Christopherson)
Dodge, n. comb.

Streptothrix sp. Bloomfield & Bayne Jones, John Hopkins
Hosp. Bull. 26: 230 - 233, 1915.

Cohnistreptothrix americana Chalmers & Christopherson,
Ann. Trop. Med. Parasit. 10: 273, 1916.

Isolated from a liver abscess, also from a chronic,
low grade pulmonary infection. (p. 716.)

A. anaerobius Flaut.

A. sp. Butterfield, Jour. Infect. Dis. 2: 421-430,
pl. 1, 1905.

Cospora Anaerobius Sartory, Champ. Paras. Homme
Anim. 830 - 832, 1923.

Isolated from the lung of an American male, 19
years old, primarily suffering from diabetes mellitus.

(p. 717.)

A. Rivierei (Verdun) Brumpt, Précis Parasitol. ed. 4.
1201, 1927.

Streptothrix sp. Rivière Cong. Fracs. Méd. Bordeaux
1895, 2: 1003 - 1011, 1896.

Cospora Rivierei Sartory, Champ. Paras. Homme. Anim.
792, 1923.

Isolated from sputum and pus of a bronchopleuropulmonary
infection followed by multiple military subcutaneous
abscesses. Early symptoms those of tuberculosis, but
Mycobacterium tuberculosis absent. Found pathogenic
for laboratory animals by the use of specialised
technique. (p. 722.)

Actinomyces Leishmani (Chalmers & Christopherson)
Sartory & Bailly, *Mycoses pulmonaires*
253, 1923.

Isolated from empyema of the lungs. Pathogenic to
guinea-pigs, rat and rabbit. (p. 740.)

A. Donnae Dodge, n. sp.

Streptothrix sp. Donna, *Ann. Ig. Sperim.* 14:
449 - 459, Pl.3. 1904.

Isolated from sputum in a pulmonary infection.
Pathogenic to rabbits. (745.)

A. Japonicus Caminiti, *Centralbl. Bakt.* I 44: 198,
1907.

Streptothrix sp. Aoyama & Miyamoto, *Mitteil, Med.*
Fak. K.Jap. Univ. Tokio 4: 231 - 276,
pls. 16 - 18, 1901.

Cultivated from the pus in a fatal infection of the
lungs. Sputum too contaminated with bacteria to
permit easy isolation of the fungus. Pathogenic to
guinea-pigs. Mixed tuberculosis and actinomycosis.
(p. 747.)

A. bronchialis Sartory, *Bull. Sci. Pharm.* 23: 12-19
1916.

Discomyces bronchialis Neveu-Lemaire, *Précis Parasitol.*
Hum. 43, 1921.

Found in the sputum of a patient suffering with cough,
loss of weight, putrid breath. Pathogenic to guinea-
pigs and rabbits. (p. 757.)

A. Fijperi (Castellani & Chalmers) A. Sartory & A.
Bailly, *Mycoses pulmonaires* 256, 1923.

See chronic bronchitis. (p. 756.)

A. pulmonalis (Roger, Sartory & Bory) A. Sartory & A. Bailly, Mycoses pulmonaires 256, 1923.

Oospora pulmonalis Roger, Sartory & Bory, C.R. Soc. Biol. 66: 150 - 152, 1909.

Discomyces pulmonalis Brumpt, Précis Parasitol. 1910. Froilano de Mello & Pais, Arq. Hig. Pat. Exot. 6: 186, 1918.

Nocardia pulmonalis Castellani & Chalmers, Man. Trop. Med. ed. 2. 817, 1913.

Found in the whitish grains in the expectoration of a patient with pulmonary mycosis. (p. 758.)

Streptothrix hominis IV Foulerton, 1906, 1910.

Isolated in a case of renal infection secondary to pulmonary infection. (p. 763.)

A. Pelletieri (Laveran) Brumpt, Précis Parasitol. ed. 4. 1204, 1927.

Oospora Pelletieri Thiroux & Pelletier, Bull. Soc. Path. Exot. 5: 588, 1912.

Thiroux & Pelletier report a case of mycetoma in the thorax with evidently some of the lung near the lesion infected and an area in the side of the thorax. (p. 764.)

A. Bolognesii-Chiurcoi (Vuillemin) Dodge, n. comb.

Malbranchea Bolognesii-Chiurcoi Vuillemin apud Bolognesi & Chiurco, Arch. di Biol. 1: 13 figs., 1925.

Isolated from ulcers in the thorax; grayish sero-purulent discharge. Finally metastasis to the lungs. Pathogenic to white rats and guinea-pigs. (p. 766.)

Sporotrichese.

Trichosporium Gammeli (Pollacci & Nannizzi) Dodge,
n. comb.

Glenospora G. Pollacci & Nannizzi in Blankenhorn &
Gammel, Jour. Clin. Invest. 4:
471 - 484, 9 figs., 1927.

Case history by Blankenhorn & Gammel, Trans. Assoc.
Amer. Physicians 41: 268 - 282,
9 figs., 1926.

Isolated from a case of generalised mycosis in-
volving lungs, digestive tract (?), and the epidermis.

Organism not pathogenic to monkeys, guinea-pigs
or rabbits. (p. 792.)

Acremoniella Perinii Pollacci, Rev. Biol. 5:
358 - 367, 3 figs., 1923.

Found in sputum from a patient with pulmonary lesion.

Pathogenic to guinea-pig. (p. 798.)

Rhinocladium parvulum Redaelli, 1923; Grandinetti,
Contr. Estudo Esportricose São Paulo
43, 1934.

Sporotrichum parvulum Brunaud.

Isolated from lungs in cases clinically resembling
tuberculosis. (p. 811.)