

FUNGOID CONDITIONS OF THE LUNGS.

PART I.

by

RICHARD FAWCITT, M.B., Ch.B., Edin.

M. D. 1936



April 1936.

Fountain Street House,
Ulverston.

Briefly, the science of mycology dates back to the year 1677 when Hooke discovered that the yellow spots found on the leaves of roses consisted of filamentous fungi; but it was not until 1839 when Langenbeck discovered the *oidium albicans* - the fungus of thrush - and found it to be parasitic to man that the medical profession recognised the incidence of fungous diseases.

Largely owing to the discoveries of Pasteur and Koch in the realms of bacteriology the science of mycology fell somewhat into abeyance. This was only a temporary matter, as by the end of 1906 (10) Saccardo and his co-workers in Italy published a *Sylloge Fungorum* containing 57,660 fungi. Ramsbottom, the Keeper of Botany at the British Museum, admits over 100,000 known and named species of fungi. Without the occurrence of fungi it would be impossible for this world we live in to carry out its daily balance of growth and decay. Fungi exist as parasites, or saprophytes, or both, on almost every growing and decaying thing. If a Petri dish is exposed to the air for a few minutes it will proceed to grow fungi of various kinds under appropriate conditions according to the medium and conditions of culture employed.

Fungi, and bacteria also, belong to the group of plants known as thallophyta. This group includes a great variety of plants - the sea-weeds may be mentioned in passing - the common characteristic being that the plant body, devoid of definite root or shoot, consists of many cells forming a more or less branched tissue known as a thallus. Whilst the algae (Roth 1797), other members of the thallophyta, contain chlorophyll - the green colouring matter which enables ordinary plants to build up their food from simple inorganic substances - the fungaceae (Linnaeus 1737) do not. Their existence is therefore, as previously mentioned, parasitic, saprophytic, or both.

The Botanical classification of fungi is based on the mode of formation of the sexual spore, and the main divisions of filamentous fungi, or eumycetes - as distinguished from the myxomycetes, which have a multinucleate, naked plasmodium as a vegetative body, are - (1) Phycomycetes, (2) Ascomycetes, (3) Basidiomycetes, (4) Fungi imperfecti or Hyphomycetes. A true fungus consists of tubular branched filaments - "hyphae" - the protoplasm is contained within thin limiting continuous walls (divided into compartments by "septa"). The whole vegetative body of the fungus consisting of numerous hyphae is termed the "mycelium". In addition a true fungus is

characterised by a special spore-bearing apparatus. The mycelium may be loose and web-like in structure as in common moulds, or may take the form of a compact mass produced by the branching and interweaving of the hyphae - as in toad-stools.

The hyphae of the Phycomycetes - a lowly organised group of fungi - are typically continuous tubes devoid of septa, apart from where the reproductive organs occur - in contrast to the more highly organised fungi where the hyphae show definite cross septa. The lowermost fungi betray alga-like habits in their life history, i.e. an aquatic mode of existence. In a number of phycomycetes the ends of the hyphae tend to be shut off by a transverse wall, the terminal chamber becomes swollen and divided into a number of cells, the outer wall ruptures and the cells escape as ciliated swarm-spores.

This terminal organ in which the asexual spores develop is a zoosporangium. The swarm-spores (swimming about in ponds, in rain drops, etc.) eventually develop a thin cell-wall emitting hyphae - and so a new plant develops.

Mucor Mucedo (in the class Zygomycetes) occurs on damp bread, horse dung and other organic matter. In appearance it is a white, or smoky, mould composed of fine filamentous, usually non-septate, hyphae

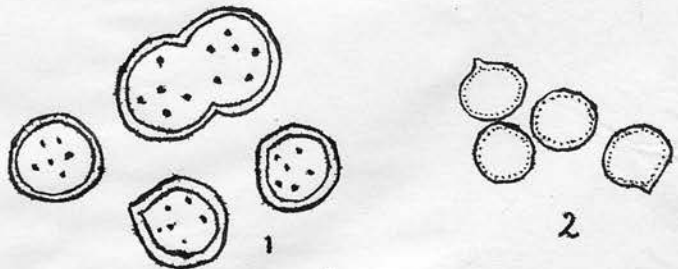
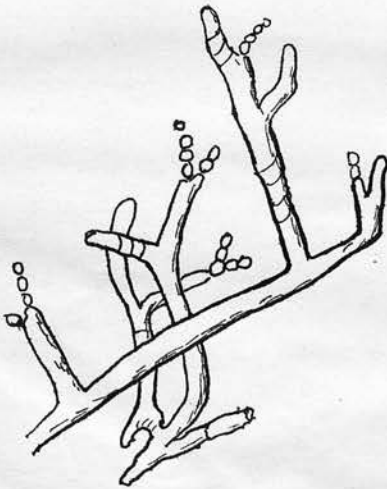
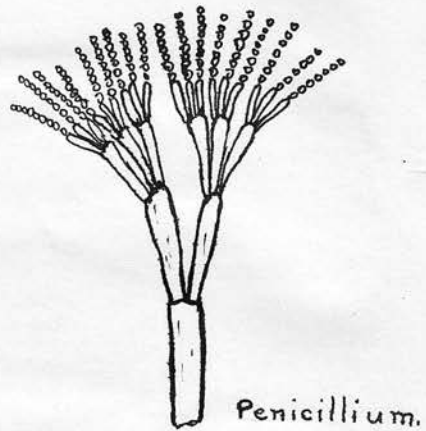
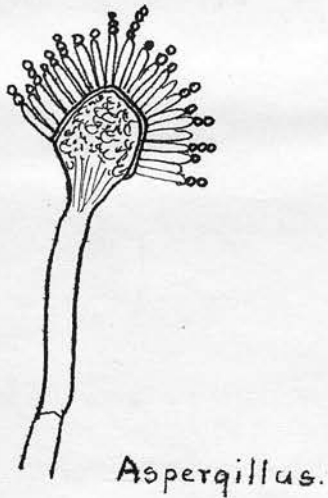
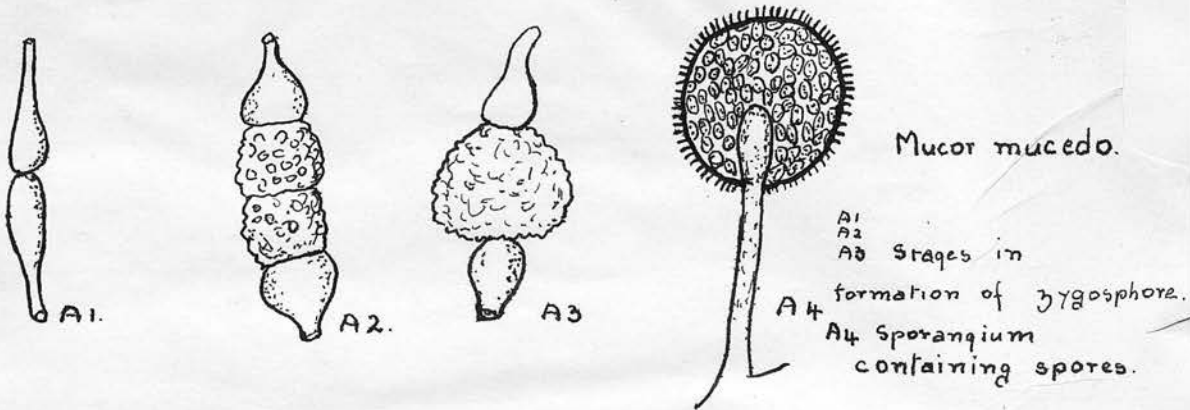
spreading over the substratum. Here and there erect hyphae may be seen ending in spherical sporangia. In *mucor mucedo* the spores acquire a cell wall before the rupture of the sporangium and are thus capable of being air born.

In the more highly organised fungi the hyphae show numerous septa, and the sexual organs and asexual process are more or less difficult to recognise. They never as an immediate result of sexual fusion produce a well-defined zygospore, or oospore, capable of developing into an independent vegetating fungus. There are two main series. One in which the number of spores, usually eight in number, or other multiples of two, are formed within a structure termed an ascus, the spores ascospores and the group Ascomycetes. In most the asci are grouped together forming an ascocarp - to this group belong *aspergillus* and *penicillium*. In a few the asci are separate, as in yeasts.

The other series are the Basidiomycetes to which the common mushrooms, toadstools, smuts and rusts belong. Here the spores are formed, usually in fours, on the outside of a structure known as a basidium, or club-like hypha, mycelium septate.

The majority of fungi pathogenic to man are found in the large class of fungi imperfecti, or Hyphomycetes (40% of all fungi). Reproduction is by free-born

PLATE I.



1. Blastomycoides type.

Cryptococcoid type.

spores, and the spore-forms do not include the sexual or perfect stage.

Plate I illustrative of some of the fungi mentioned in this paper:

- (1) *Mucor mucedo* - the common fungus which occurs on damp bread, horse dung, and other organic matter.
- (2) *Penicillium* - the mould commonly found on cheese, etc.
- (3) *Aspergillus* - found on dead vegetable matter.
- (4) Filamentous *oidium lactis* associated with milk and cheese.
- (5) *Cryptococcus* and *blastomycoides* of *blastomycosis* - a yeastlike fungus.

Fortunately the vast majority of micro-fungi as far as is known, are non-pathogenic to man; but some are pathogenic, and in years to come no doubt their numbers will be added to. (3) Castellani states that over 20 per cent of tropical diseases are caused by fungi.

In this country we more generally associate fungous infections with skin diseases and affections of the mucous membranes. This paper deals exclusively with infection of lung tissue by fungi - mainly from a

radiological standpoint.

The published works on the subject run into three figures. The most extensive work in modern times is probably that of Castellani, and his classification of broncho-mycoses, and the principles which he has laid down in the investigation of broncho-mycoses are followed. He classifies them as follows:

- (1) Due to fungi of the "Nocardia" - Toni and Trevisan 1899; Cohnistrepthrix Pinoy, 1911, and Anaeromyces Castellani, Douglas and Thompson, 1921.
- (2) Due to fungi of the genus Monilia Persoon, 1797. Oidium link, 1890; Cryptococcus Gilchrist and Stoker, 1896; Coccidioides Rixford and Gilchrist, 1898.
- (3) Due to fungi of the genus Hemispora Vuillemin, 1906.
- (4) Due to fungi of the genus Aspergillus, 1729; Sterigmatocystis Cramer, 1869; Penicillium link, 1908; Mucor Micheli, 1729; Rhizomucor Lucet et Constantin, 1900; Lichtheimia Vuillemin, 1904.
- (5) Due to the fungi of the genus Acremoniella Saccardo (broncho-acremonielliasis).
- (6) Due to fungi of the genus Sporotrichum link, 1809.

- (7) Due to fungi of the genus Acladium link.
- (8) Due to fungi which has not yet been classified.

In more simple language they are classified thus:

- (1) Due to yeastlike fungi, viz: fungi of the types monilia, cryptococcus, saccharomyces, blastomycoides and endomyces.
- (2) Due to filamentous fungi: (a) of the slender type, viz: fungi of the types nocardia, anaeromyces and vibriothrix; (b) of the largertype, viz., fungi of the types oidium and hemispora; (c) with characteristic fruitifications - aspergillus, penicillium, mucor, rhizomucor, acremoniella, sporotrichum, acladium, etc.

* Castellani has laid down the following principles in investigating the cases of suspected bronchomycosis, and if the subject is to be understood they must be recorded. It is essential to remember that the mere presence of fungi in the sputum is not sufficient to establish a diagnosis of bronchomycosis. When the sputum has been collected with due care to avoid outside contaminations and examined at once, there are three possibilities, that

* Note. This is not a strictly accurate quotation. Castellani is referring to Monilia in particular. In my opinion the principles probably apply to all types of Broncho-mycoses.
 See - Castellani, A. Fungi and Fungous Diseases. 1928. page 124.
 R.F. Author.

(1) The fungus, though present in the expectoration is not virulent and not pathogenic, and lives saprophytically in the bronchi. Such fungi when injected intravenously or directly into the lung of a rabbit will produce no general or localised lesions.

(2) The fungus, though present, may represent only a secondary invader - a secondary infection. In this case intravenous inoculation of the fungus will kill the rabbit - the cause of death being a generalised fungus septicaemia; but intrapulmonary inoculation will not cause any localised nodular lesions in the lungs.

(3) The fungus is the real primary cause of the broncho-alveolar condition. In such cases the intrapulmonary inoculation into a rabbit will produce a characteristic nodular appearance of the lung, the animal dying spontaneously in from 15 to 21 days, both lungs being infected (the one in which the inoculation was made and the other). The nodules are usually about $\frac{1}{8}$ " in diameter; they may coalesce and become caseous. There is no intervening pneumonia, but some congestion, and the fungi and spores may be recovered from these nodules.

Bearing in mind then (1) that many fungi are abundant in air especially in tropical countries and that samples of sputum exposed to the air may readily get

contaminated; (2) that fungi are fairly common in the saliva, and that accordingly a patient should be made to gargle and rinse out his mouth with sterile salt solution before being asked to cough and expectorate and produce his specimen of sputum;

(3) that even if the fungus is present, it may be non-pathogenic, and merely a saprophytic micro-organism.

Therefore if all these things have been taken into consideration and tubercle bacilli are absent, and the sputum yields fungi which produces in rabbit or guinea-pig the intra-pulmonary lesions described, then it is safe to make a diagnosis of broncho-mycosis of the primary type.

Symptoms and clinical picture are more or less uniform in most cases of broncho-mycosis. The cases simulate pulmonary tuberculosis, but no tubercle bacilli are found in the sputum. The patient complains of cough, muco-purulent sputum (often scanty), cyanosis and frequently extreme shortness of breath on slight exertion with very evident distress; in some of the more severe cases, haemoptysis, emaciation and fever. In some cases too, the sputum has a definite odour resembling brewer's yeast. On physical examination, patches of dulness and crepitations, rales, rhonchi, and areas of increased vocal resonance may be found.

In the case of Monilia infection of the lungs Marett believes that the fungi give rise to pus formation within the alveoli of the lung.

This is a mechanical action due to the local growth of fungi on the mucous membrane (similar to Thrush in the mouth). There are two types (1) affecting the bronchial tree and resulting in bronchiectasis, (2) occurring as the result of occlusion of the bronchioles and collapse of the lung alveoli.

This view is shared by Munro Campbell, who considers that the fine mottling seen in the X-ray picture is due to the collapsed alveoli of the lung, which as the condition improves, is replaced by the coarser mottling of fibrous tissue, as seen later in some of the films to be shown.

Some workers believe that the presence of fungi in the sputum as a result of repeated examinations is sufficient evidence of broncho-mycosis.

Marett believes that sputa which have travelled through the post will yield fungi on incubation at blood heat if those fungi are pathogenic, but not if non-pathogenic.

Castellani remarks the X-ray picture may resemble that of tuberculosis. This opinion is only partially shared by myself.

Speaking generally the radiographic appearances are those of a fine mottling throughout both lung fields, the apices being clear, together with a considerable amount of emphysema, superseded by a generalised fibrosis as the condition improves, or associated with fibrous rings walling off small cavities or surrounding calcified nodules. This picture is common to a number of types of broncho-mycosis; there are, however, finer points which help to differentiate between mine and others. The X-ray appearances in the early stages more resemble a Bronchitis than a Pulmonary Tuberculosis, but, as stated, they may resemble tuberculosis and in that lies the difficulty and the chance of error in diagnosis, disastrous to the patient; as primary broncho-mycotics are extremely liable to acquire secondary infection such as tuberculosis.

No case of broncho-mycosis has been described in the British Journal of Radiology during the last ten years.

Broncho-aspergillosis. Genus *A. Micheli* (1729) and *Sterigmatocystis* (Cramer) 1859. Genus *Aspergillus*. The species usually associated with pathological conditions of the lungs are *A. fumigatus* and *A. niger*. These are common fungi found in dead vegetable matter. They grow readily on gelatin, and consist of a mass of filaments which, under the microscope, are seen to form a septate branching mycelium. There are two stages depending on the conditions of growth - the less common showing ascocarps, the more common type showing conidia. These fungi (or moulds) are greenish and later brown.

Various types have been described: *A. herbariorum* (Wiggiers); *A. repens* and *A. flavus* (De Barry); *A. fumigatus* (Fresenius - 1775) and others. This condition has been called "Bird fancier's disease" and is particularly prevalent amongst pigeon and canary fanciers, owing possibly to the habit some of them have of allowing their birds to feed from their lips.

Broncho-aspergillosis was first recognised by Bennett in 1842. (1) Virchow in 1856 described the post-mortem appearances. (2) Dieulafoy, Chantemasse, and Widal in 1890 published their observations on pigeon feeders and hair sorters in Paris. (3) Renon in 1897 published similar observations. (4) Macaigne and Nicaud in 1926 established the fact of primary broncho-aspergillosis by means of experiments on animals.

Mixed infections. *A. herbariorum* with tuberculosis have been described by (5) Castellani, (6) Lapenta, and others, (7) Wheaton in 1890 recorded *A. niger* associated with pulmonary tuberculosis. (8) Sayers reports the finding of *A. fumigatus* and *niger* from the sputum of 31 out of 125 cases where the X-ray appearances show typical healed military disease of lung. (9) Kampmeier and Black describe a case secondary to bronchial carcinoma. (10) Schneider has outlined the symptoms present in fungus infections of the lungs. (11) Hansen found 15% of his asthmatic patients reacting to moulds.

The published records of pulmonary aspergillosis alone reach three figures - a large number of these have been referred to in (12) Bethune and Moffat's paper on Aspergillosis in which they express their doubts as to the pathogenicity of *A. niger* (the common *A.* in dust and foods); their opinion being supported by experiments on animals. They record a case of pulmonary tuberculosis, admitted to the Royal Victoria Hospital, Montreal in 1928 for thoracoplasty, in a farmer and chicken raiser in which a fungus was grown from the sputum which was identified by Charles Thom as *aspergillus niger*. The pathogenicity of the fungus was investigated in rats (18) rabbits (14), guinea-pigs (28) using intratracheal injections in some cases, in others intranasal, and in

others intraoral injections of the spores. These animals were killed in from one week up to 540 days. Whilst during the course of their investigations a multiplicity of conditions occurred there was little or no evidence of fibrosis up to the 540 day period. By inhalation experiments a chronic pulmonary granulomatous lesion, regressive in nature, was found. No evidence of mycelial invasion of tissue, and the spores inhaled were rapidly engulfed by phagocytes in a week. No positive cultures obtained from trachea or bronchi.

The general consensus of opinion is that *A. fumigatus* is the *A.* responsible for severe primary and secondary changes in the lungs, and *A. niger* does not produce the extensive fibrosis and nodular calcification seen in X-ray films. This, however, is not the opinion of (8) Sayers and Meriwether who suspect the pathogenicity of both.

Symptomatology are as of a muco-purulent bronchitis, and the generalised symptoms as already described under the general heading.

In severe cases, haemoptysis, other organs frequently invaded. Secondary type frequently develops into tuberculosis and gangrene of lungs. In 1856 Virchow described the post-mortem appearances as those of small grey nodules composed of necrotic material and leucocytes, which break down to form cavities,

associated with broncho-pneumonia, and frequently with fairly wide-spread, odourless necrosis of the lung. Masses of fruitifying mycelia are present in the cavities and extend into the surrounding tissues.

Broncho-penicilliosis. Fungi belonging to the Genus *Penicillium* (Link) P. Glaucum is the inclusive name given to this, the most common group of fungi. There are about 80 green penicillium species. It is found largely in cheese. Its spores are extraordinarily resistant, the mycelium is like that of Aspergillus. The commonest form of reproduction is by conidia, and the filament grows out and its ends fray out like a paint brush in finger-like branches. *Penicillium Crustaceum* (Linnaeus) described by Castellani (13) in a Serbian soldier during the Great War. Symptomatology, etc., as in *Aspergillosis*.

Broncho-mucormycosis. Fungi belonging to genus *Mucor Micheli* (1729). Rarely pathogenic. Lucet, Constantin and Lambry have described a case of Bronchitis associated with *Rizo-mucor parasiticus*. (14) Castellani describes the case of a Serbian soldier in 1917 who was supposedly infected with horse dung.

Similar X-ray appearances have been described in these three types of Broncho-mycosis, namely, an absence of calcified glands with clear apices and

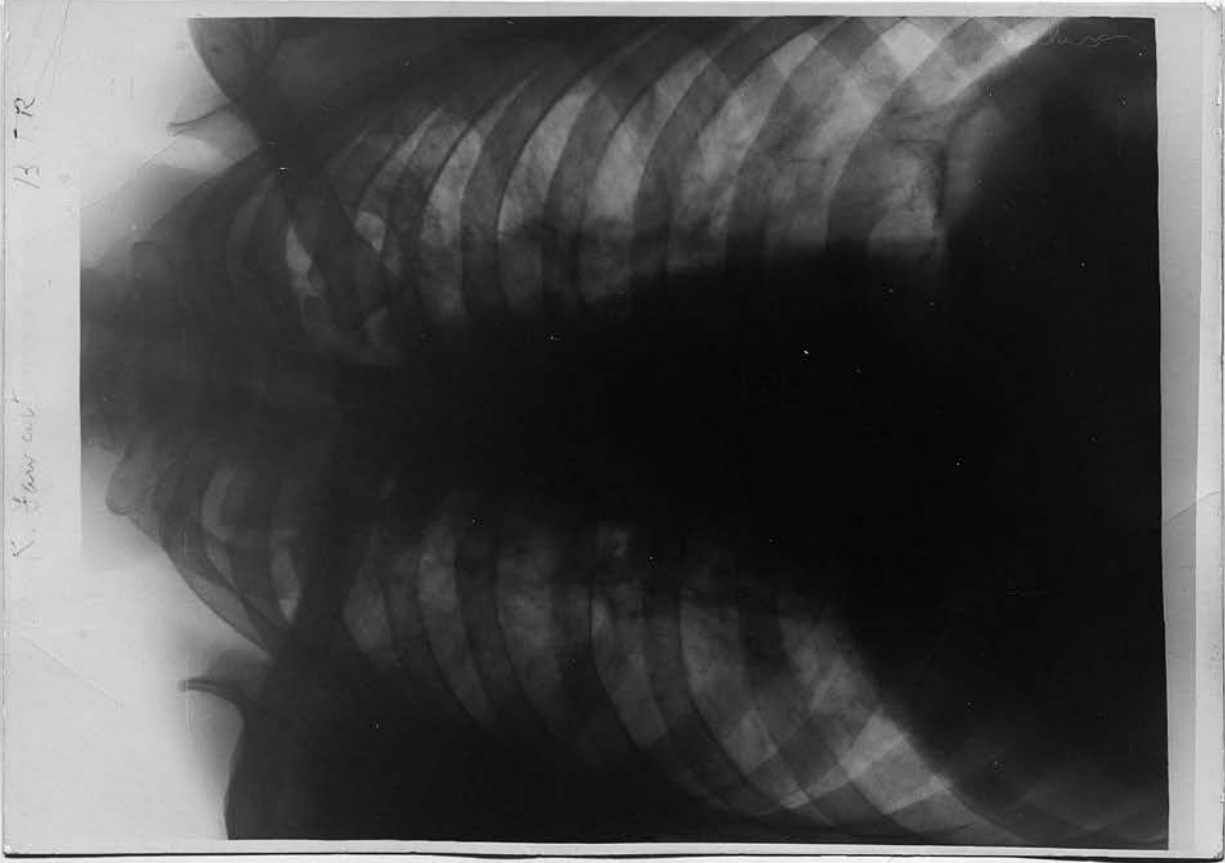


Fig. 2.

Case 1. - J.J. Broncho-mycosis fenestriorum. Nov. 1934.

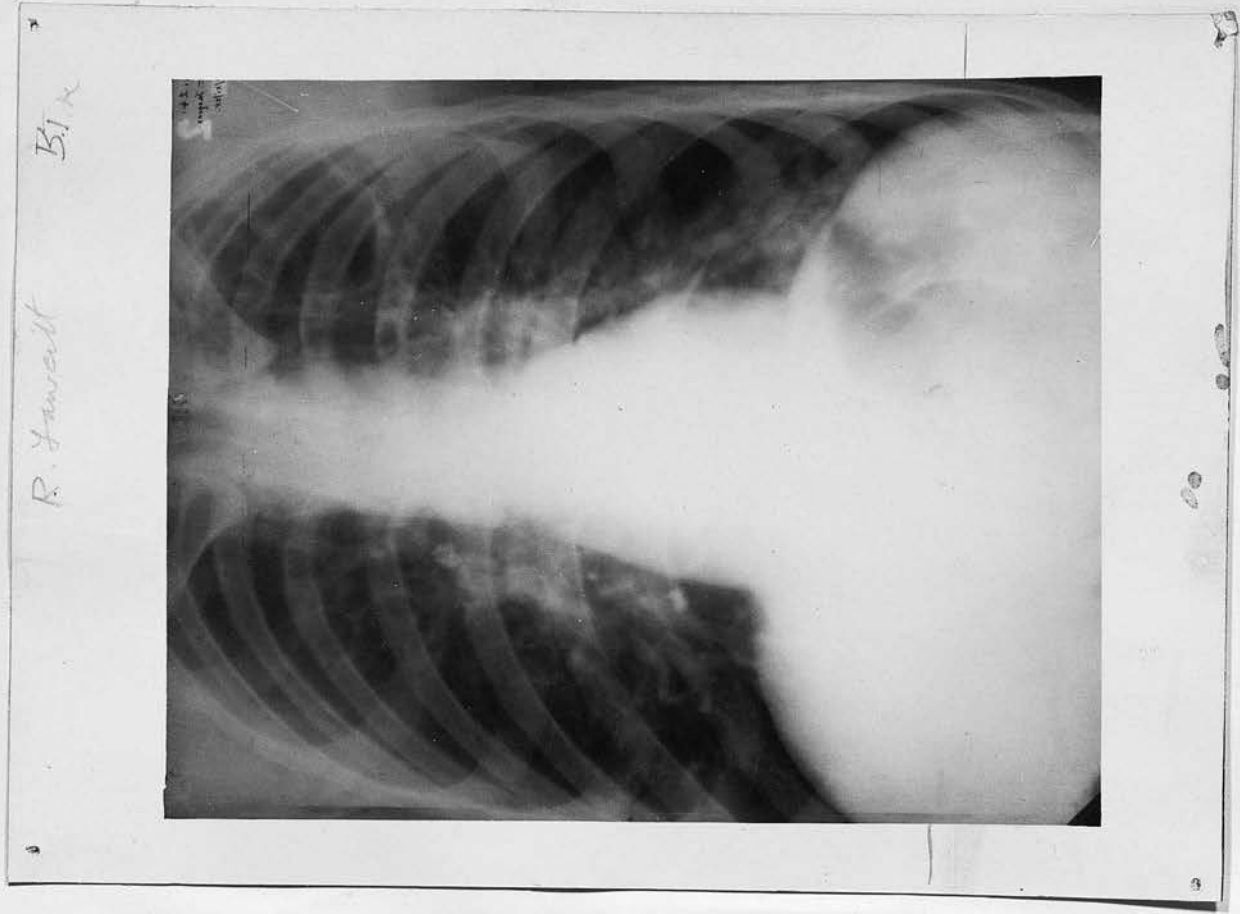


Fig. 3.

Cf. Case 1. - J.J. Glanders 1925.

dense shadows radiating in coarse lines from the hilum to one lobe. (Osler.)

Broncho-mycosis associated with Hay-dust - or
Broncho-mycosis feniseclorum.

Case 1. On November 20th 1934 J.J. - a farmer, aged 41 years, was referred to me for X-ray examination at the Whitehaven and West Cumberland Hospital, by Dr. Mitchell of Egremont as a case of pulmonary tuberculosis. His film presented to me an X-ray appearance with which I was not familiar. Screen examination showed very limited expansion of the lungs; the heart shadow was considerably pulled over to the right and there was marked tachycardia. The lungs as a whole did not light up well - the right apex did not light up as well as the left. There was extensive coarse mottling and fibrosis throughout both lungs, but more especially below the right clavicle where there was a honeycombed appearance, - I compare them to bunches of grapes. There was a marked increase in the hilar shadows. The appearance suggests fibrous rings round the alveoli rather than inflamed peribronchial vessels. The man was much emaciated, was extremely dyspnoeic and looked very ill. Bearing in mind a case of Glanders⁽¹⁵⁾ which I saw in 1925, in which I demonstrated an unusual

radiographic appearance - showing the woolly appearance which I described, and from which case we were able to establish the diagnosis by means of inoculating a guinea-pig with the patient's sputum, I got in touch with Dr. Mitchell and asked him to collect the sputum which was in due course investigated by Faulds - the County Pathologist of the County of Cumberland. This sputum yielded fungi, not all identified, but aspergillus was present - and, alas, the specimen was removed by an enthusiastic laboratory attendant!

Dr. Mitchell sent me the following letter which I think speaks for itself:

J.J. a farmer, aged 39, called me to see him in November 1932 and at the first glance he gave me the impression that he was suffering from galloping consumption, and would be dead in a few weeks. He said that he felt perfectly well and hadn't a pain or ache, but got short of breath on the least exertion and had lost all his strength.

On examination I found his heart slightly enlarged, but otherwise perfectly normal.

His chest puzzled me very much. He had only about $\frac{3}{4}$ " expansion and it was hyper-resonant as in emphysema.

He had crepitations all over his chest similar to those in acute military tuberculosis on breathing

easily, but in deep breathing I heard sounds that I had never heard in a chest before.

At the end of a deep breath the sounds were like the separation of two surfaces glued together. The sounds appeared moist to me and were like pulling your foot out of wet clay - a sort of sucking sound. He never had a raised temperature and had practically no cough except on going to bed and getting up in a morning, or on exertion. Expectoration was slight and mostly confined to the morning.

I asked him if he knew anything to account for his illness and he said that it had been coming on gradually after he had been working amongst hay for a month. The hay had been housed damp after lying a long time after being cut. The season had been very damp and warm. Every time he fed his cattle he felt worse till he felt cold shivers down his back and got short of breath on the least exertion.

I put him to bed for a month and apart from his heart becoming normal in size there was little change, and as he said he felt perfectly well, I let him up and out. He said that the dust rose from the hay like white smoke every time he worked in it.

Two other men helped him on the farm and I found them suffering in the same way only to a far milder extent. One was 45 and the other 49, and they are

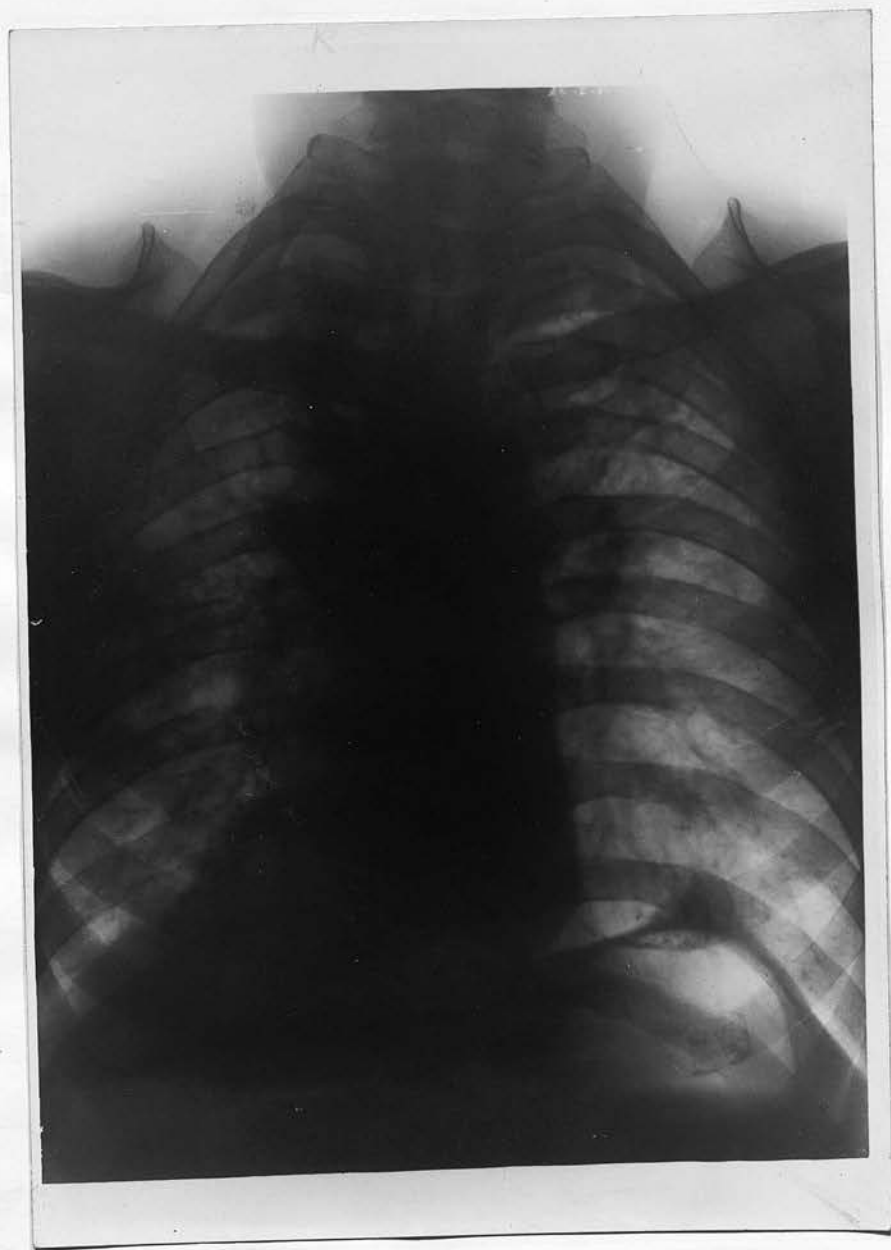


Fig. 4.

Case 1. - J.J. February, 1935.

both now perfectly normal.

I was attending a neighbouring farmer who had the same sort of hay and he developed the same condition. He, however, was handicapped by a very badly deformed chest due to rickets as a child, and subject to bronchitis, and the handicap was too much for him and he died.

J. J. was again referred for X-ray examination in February 1935 when a marked change was seen in the X-ray appearance of his right lung which now showed a considerable increase in the fibrosis. This illustrates an advanced state of the condition. He has not attended since, but I hear that he is taking Potassium iodide and that he is very much in status quo physically. A further specimen of sputum was taken with the necessary precautions.

In July 1935 Professor Ramsbottom investigated Petri dish cultures from the sputum of this case, and produced:

- (1) Aspergillus,
- (2) Mucor - the species common to soil.
- (3) A common non-pathogenic penicillium.

He was of opinion that these were contaminants; but against this is the fact that this patient had been living in retirement for 6 months and was in no way associated with the usual contaminants. Furthermore

the sputum was collected according to the technique of Castellani.

The cultures, however, eventually developed:

Aspergillus (*Eurotium*) *herbariorum*.

Aspergillus *versicolor*.

Mucor *mucedo*.

Mucor *racemosus*.

Penicillium species which would formally be classified as *P. glaucum*.

It will be seen that *aspergillus niger* and *fumigatus* were not identified in this specimen.

I am much indebted to Professor Ramsbottom for the valuable help he has given me on the mycology of this paper throughout.

Now arising out of Mitchell's letter is a point of extreme importance, namely that three men on the one farm, and one on a neighbouring farm were troubled with this condition at, or about, the same time. It would appear from this that there must have been some particular property in the hay in that locality which was a causative factor. Still more important the radiological appearances do not resemble either tuberculosis or silicosis, (common to that locality).

This investigation was carried on by us in ignorance of the work of Munro Campbell⁽¹⁶⁾. To him must be given the credit for first publishing notes on this condition. Rather earlier in 1932 there was a similar outbreak in Westmorland, and cases were referred by Drs'. Sprott and Cowan of Appleby, Dr. King of Temple Sowerby, and Dr. Caldwell of Milnthorpe to Dr. Munro Campbell, the Medical Superintendent of the Westmorland Sanatorium, as cases of suspected pulmonary tuberculosis. These cases were investigated by him and his assistant, Dr. Fraser, in conjunction with Dr. Faulds, and by his kind permission I am able to describe the following three cases and notes thereon.

To quote a portion of his monograph:

"The summer of 1931 proved a very bad season for hay-making in Westmorland owing to rain, and much of the hay was eventually taken in in an unsatisfactory damp condition. The inevitable result was the development of a great deal of mould, especially in the lower strata, so that working with it later produced dense clouds of 'white' or 'hay' dust, stated by those afflicted to be the worst they had ever experienced. In the ordinary course of farm-work transient cough and wheeziness are recognised effects of contact with 'white' dust, but in five of the cases which

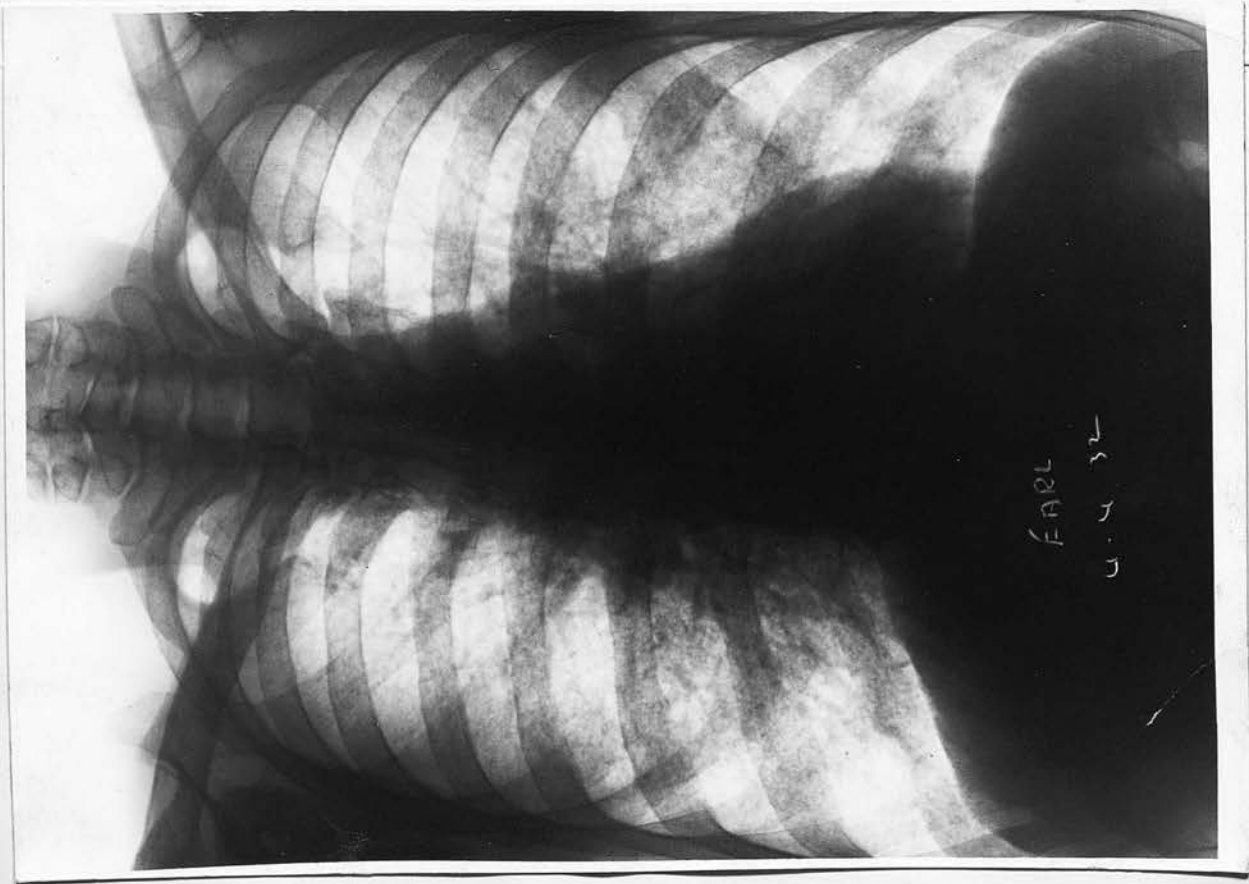

Fig. 5.

Case 2. - Broncho-pneumonia feriseciorum (E.) Apr. 4. 1932.

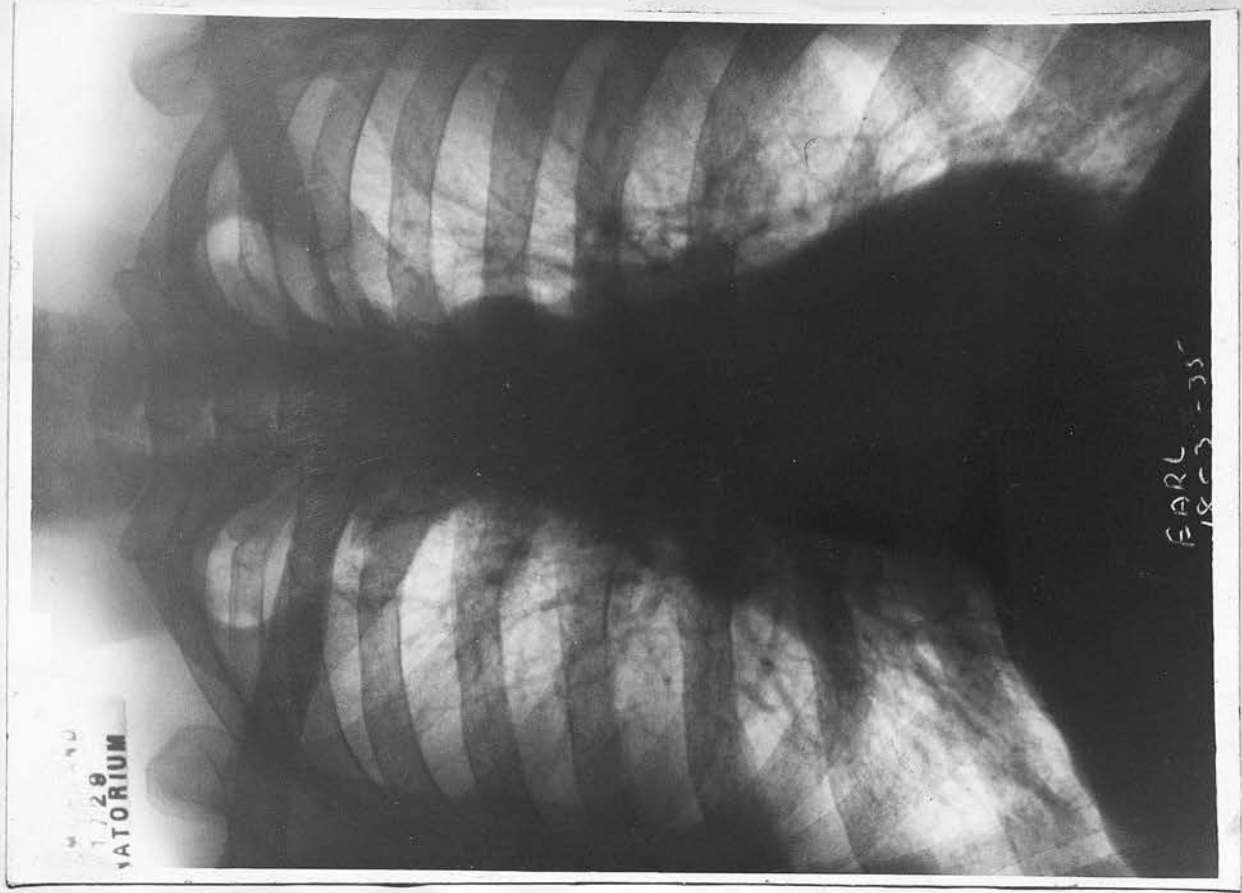


Fig. 6.

Case 2. - Broncho-pneumonia feriseciorum (E.) Mar. 18. 1935.

I had the opportunity of examining the symptoms were so severe that they seem worth recording. These cases were seen during the period April to June 1932, which in itself is significant as being the period when the supply of last year's hay was nearing the end. As the onset and course of the disease were almost identical, they may be grouped....."

Now all these cases are of the farmer class.

Case 2. 7/5/32, I.E. aged 40 years. Farmer.

March 1932 - increasing dyspnoea till very acute, following the moving of dusty hay.

Slight cough, frothy spit. Temperature; slightly febrile. Dyspnoea+++ . Sputum, all examinations: no T.B. No fungi. Blood sedimentation rate rather more than normal: 24%

Clinical signs: No dulness. A fine bronchial catarrh. Myoidema present.

Blood:	Hb.	85%
R.B.C.	5,780,000	
W.B.C.	8,600	
	N.	58%
Diff.	Poly.	B. 1
		E. 7
Lymph L.		18
	S.	9
Large monos		7

He showed a very gradual improvement in dyspnoea, but is now fit again (April 1935).

4/4/32. X-ray shows a fine mottling extending throughout both lung fields, except for the apices which are clear. The mottling is most dense towards

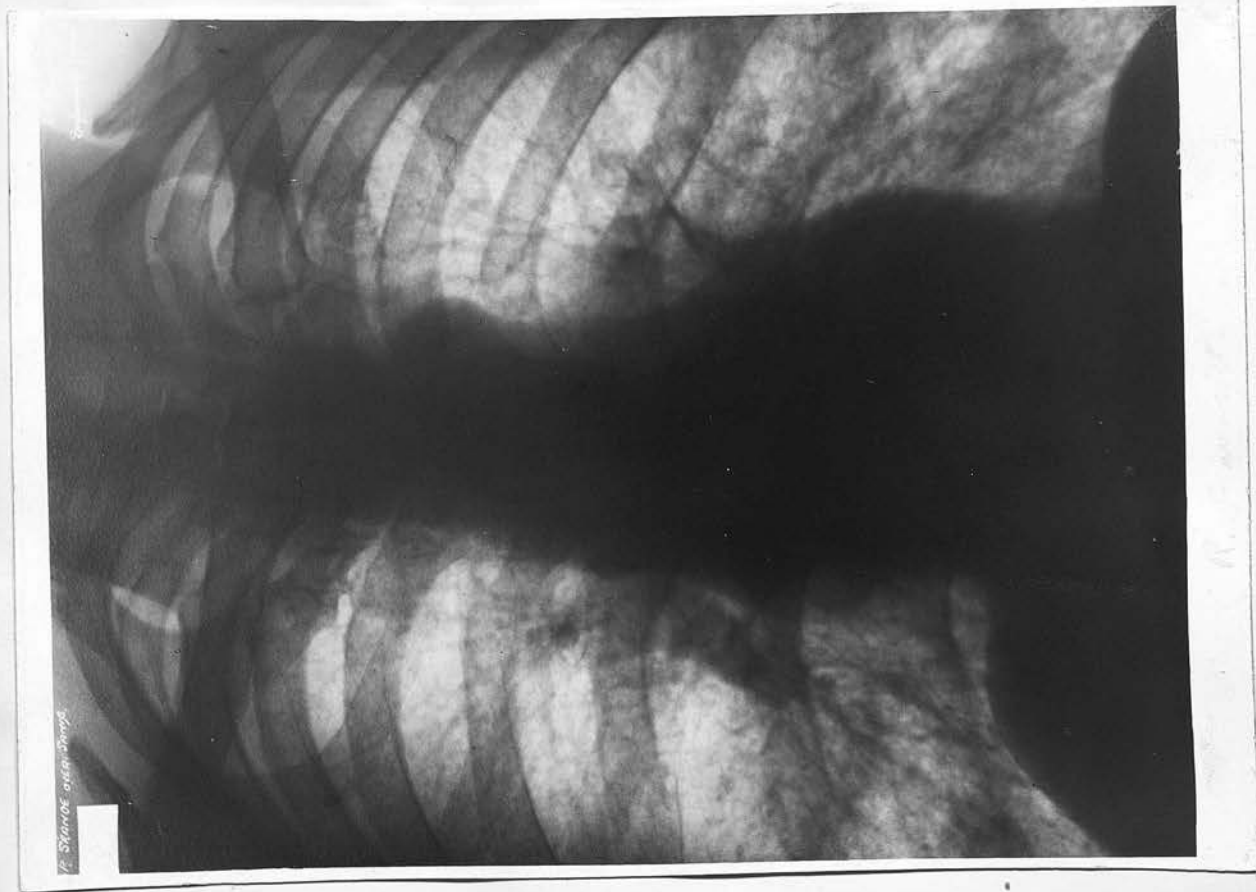


Fig. 7.

Case 3 — R.M. April 22. 1932.

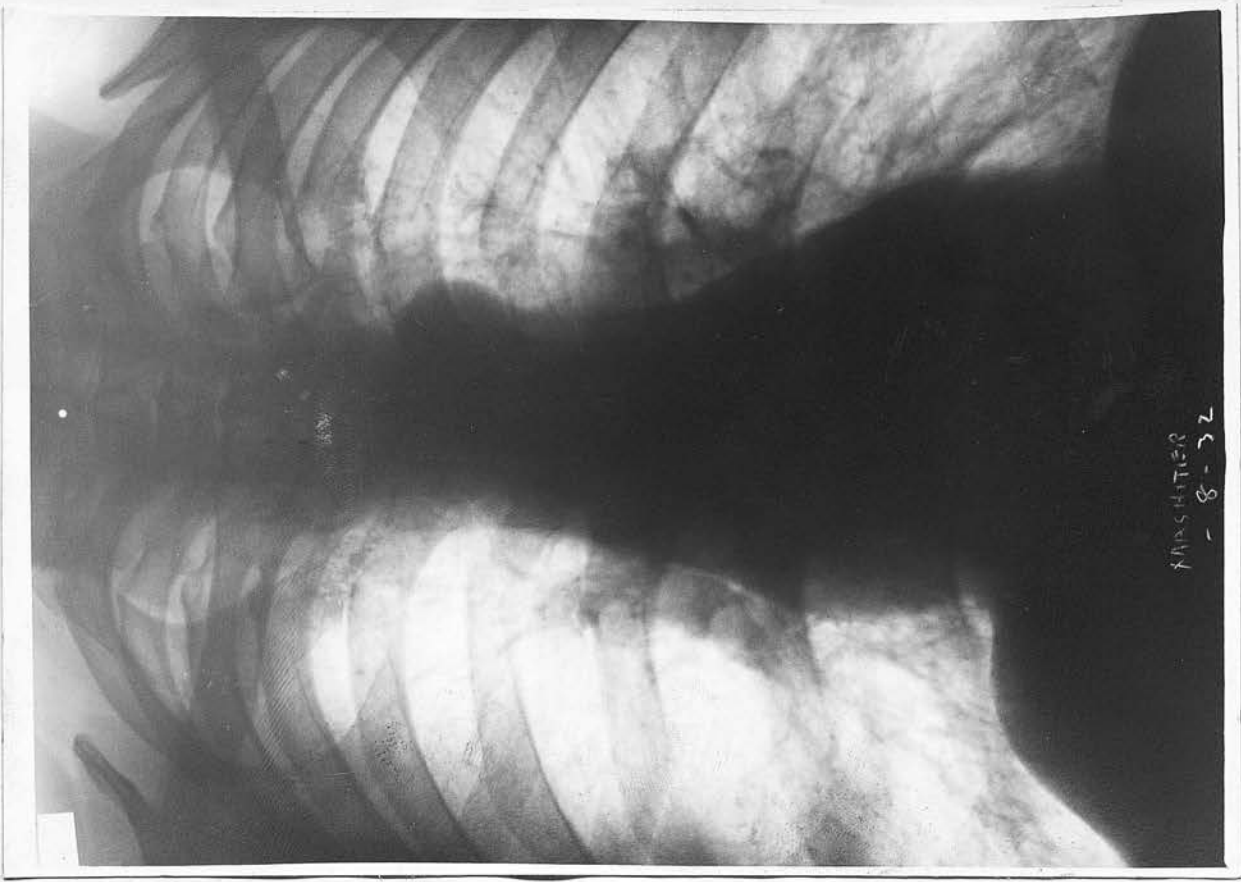

Fig. 8.

Case 3. — R.M. August 1932.

the root shadows. Bases light up well suggestive of some emphysematous condition.

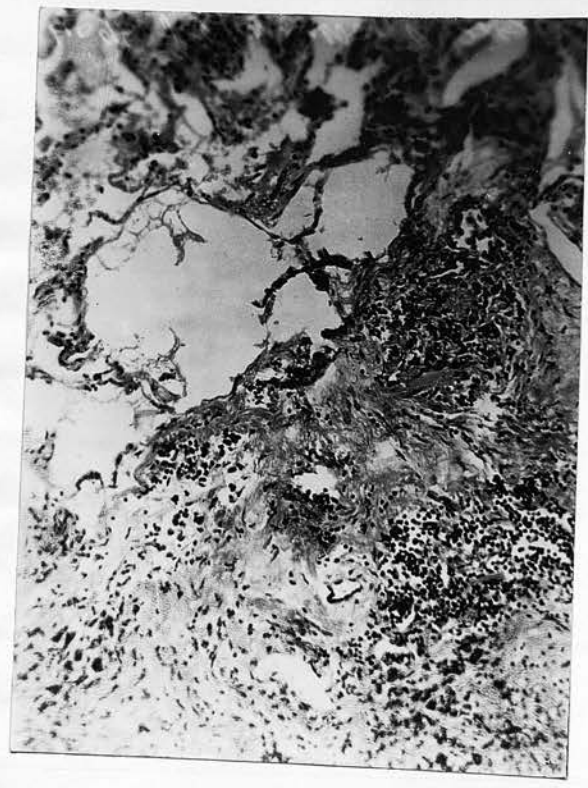
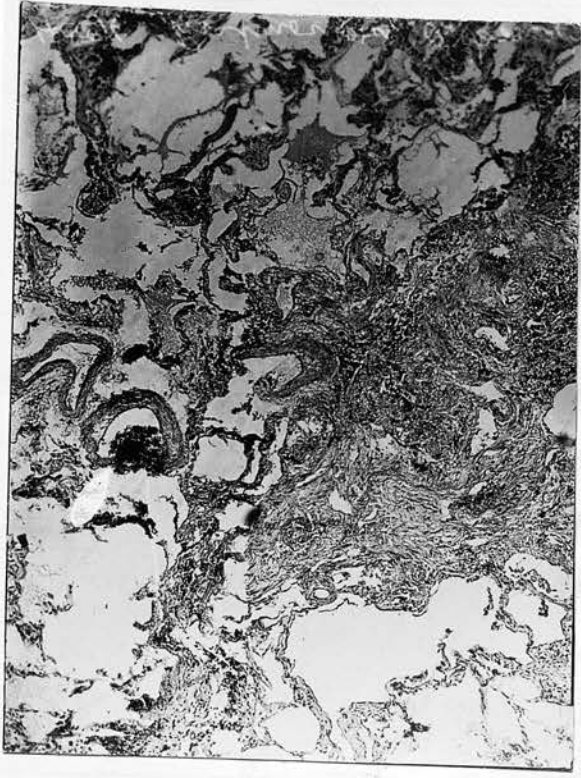
Films taken May 1932, August 1932, March 1933, show an increasing fibrosis with gradual disappearance of the discrete fine mottling.

18/3/35. The lungs have assumed a much more normal appearance, a few calcified areas are seen. The root shadows and vessels in relation to bronchi are more pronounced, and there is considerable fibrosis spreading out in a fan shape; but the X-ray appearances do not suggest an active pathological condition.

Case 3. R.M, 44 years, farmer. Similar symptoms to E. Very severe, after work in a dusty barn. Mucor + in sputum.

22/4/32. X-ray appearances similar, a mixture of fine and coarse mottling is seen throughout both lung fields, the apices again being clear. Some definite rings of fibrosis are seen and both bases show the coarsest mottling and fibrosis. The root shadows are definitely heavy. A fine pleural band is seen in the right interstitial space. Some calcified glands seen in hilar region. These were only seen in the later stages of E.

Aug. 1932. The mottling is finer, and the lungs are clearing particularly at the bases, but arboration and calcification more marked. Quite well by 1935.



Figs. 10 and 11.
Sections of lung of H. (1) Low power, (2) High
power. See text.

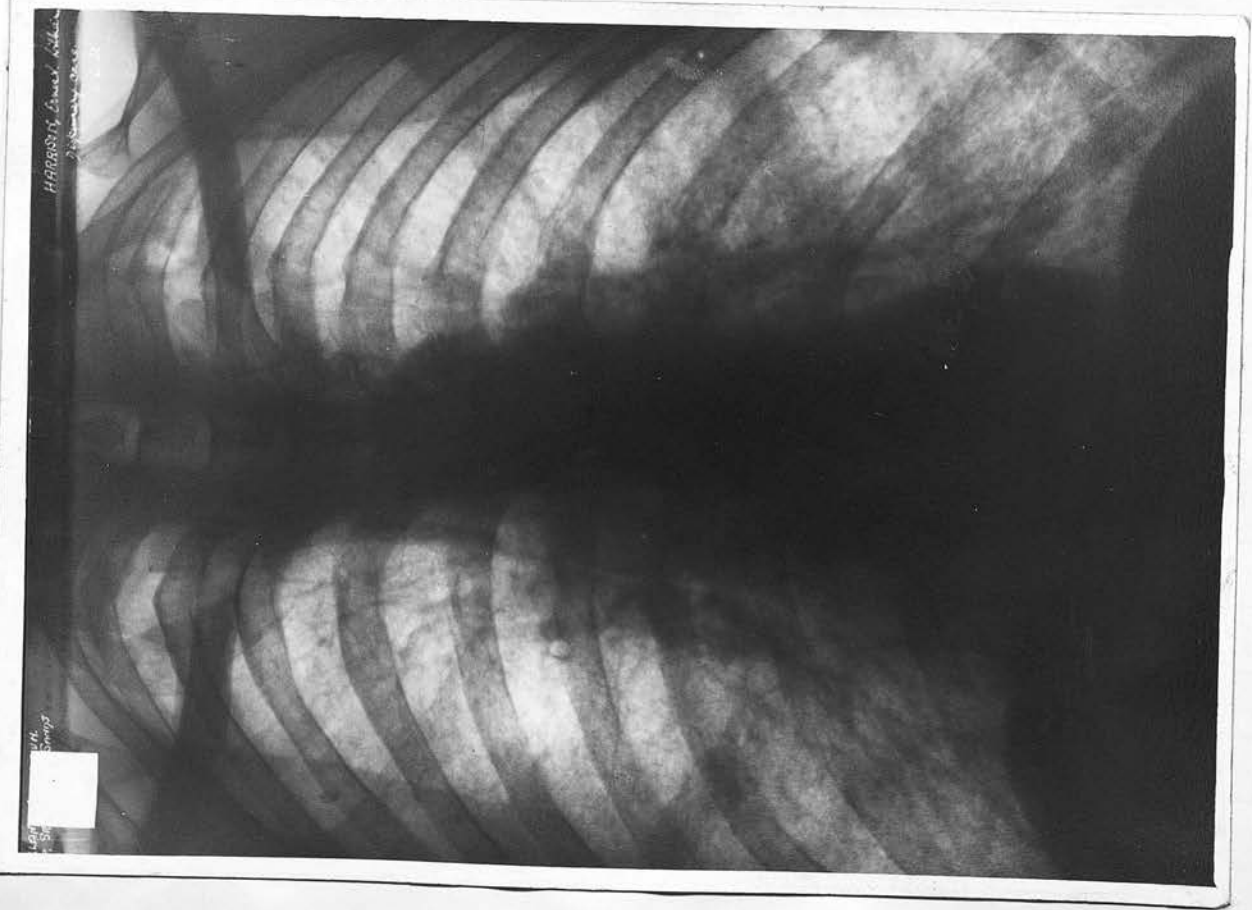


Fig. 9.
Case 4. - E.W.K. June 1. 1932.

Case 4. E.W.H. 45 years (in 1932) farmer.

April 1932. Onset - dyspnoea, after work work with dusty hay. This patient was always more ill than M. and E. and for some time doubts of the presence of a superimposed T.B. infection were considered.

Blood Sed. rate was 50%. Did not make a good recovery. Dyspnoea was very persistent and the patient eventually died in 1934.

X-ray appearances; 1/6/32, show an extensive fine mottling throughout both lungs, the apices being involved in this case, the mottling and fibrosis tending to be most marked towards the bases. The heart shadow is narrow and the hilar shadows pronounced. An emphysematous area is seen in each central lung field and a band of thickened pleura below the base of the right upper lobe. A narrow heart is a bad sign in dust infections.

1/11/32. There is now a definite increase in fibrosis and the mottling is coarser, and both diaphragms are irregular. The annular areas of fibrosis are seen,

appearing like bunches of grapes, or small cavities, (a bad sign) tending to resemble the first case - J.J.

P.M. report on left lung from H. 8th Oct. 1935 (Faulds).

The lung is voluminous and pleura is considerably thickened and shows numerous bullae. One specially large bulla overlies a broken-down friable area of lower part of upper lobe. On section of all areas

the lung substance shows acute congestion and oedema, squeezing producing a blood-stained, frothy, exudate. the main bronchus and branches show the presence of acute bronchitis.

Histological characters. Section of lung stained with Haematoxylin and Eosin. The alveoli are dilated through emphysema and the walls flattened. Many show rupture into neighbouring alveoli. The alveolar capillaries and vessels show acute congestion. Many alveoli are filled with inflammatory exudate. There is evidence of much fibrosis - bands of fibrous tissue traversing the lung substance.

Bacteriological characters: Exudate examined by stained films from various areas show the presence of long-chained streptococci, micrococcus catarrhalis, a post-mortem anaerobic bacilli, etc. What is particularly interesting, however, is the presence of yeastlike cells, or spores. No actual mycelium hyphae, sporangia, or coccidia were observed.

Pathological report: Microscopic examination shows emphysema, collapse of the lung and very marked patchy fibrosis, particularly around the vessels. There are patches of lymphocytic infiltration but no evidence of tubercle is present. Under polarised light small refractile granules are visible, but not silica.

Chemical analysis: Silica content .15% Fe .58% of dried lung.

Specimen consists of the left lung weighing 500 grams in which is included the weight of the great vessels. The lung has a thickened pleura which has been torn off in removing the specimen. It is a greyish colour and a few enlarged hilar glands are anthracotic.

On section the lung shows marked emphysema with several cavities the size of a green-pea. There is no gross evidence of tubercle to the feel. The lung is markedly fibrotic.

Faulds sums up: The hay dust obtained from various farms, including that on which the deceased worked, contained the following types of fungi: (1) *Mucor mucedo*; (2) *aspergillus niger*; (3) *penicillium glaucum*. It seems feasible that these led to chronic irritation in the lungs of those in contact, leading to emphysema and fibrosis, and, in the case of deceased, preparing the way for the terminal and fatal streptococcal infection.

Stewart and Faulds⁽¹⁷⁾ point out that the Silica content in various occupational diseases varies from 0.75% to 2.96% - averaging 1.72%. The Silica content of normal lung is 0.16%.

The Silica content of the lung of H. was .15%. Now the grasses contain a certain silica content according to the species, and yet this lung did not contain

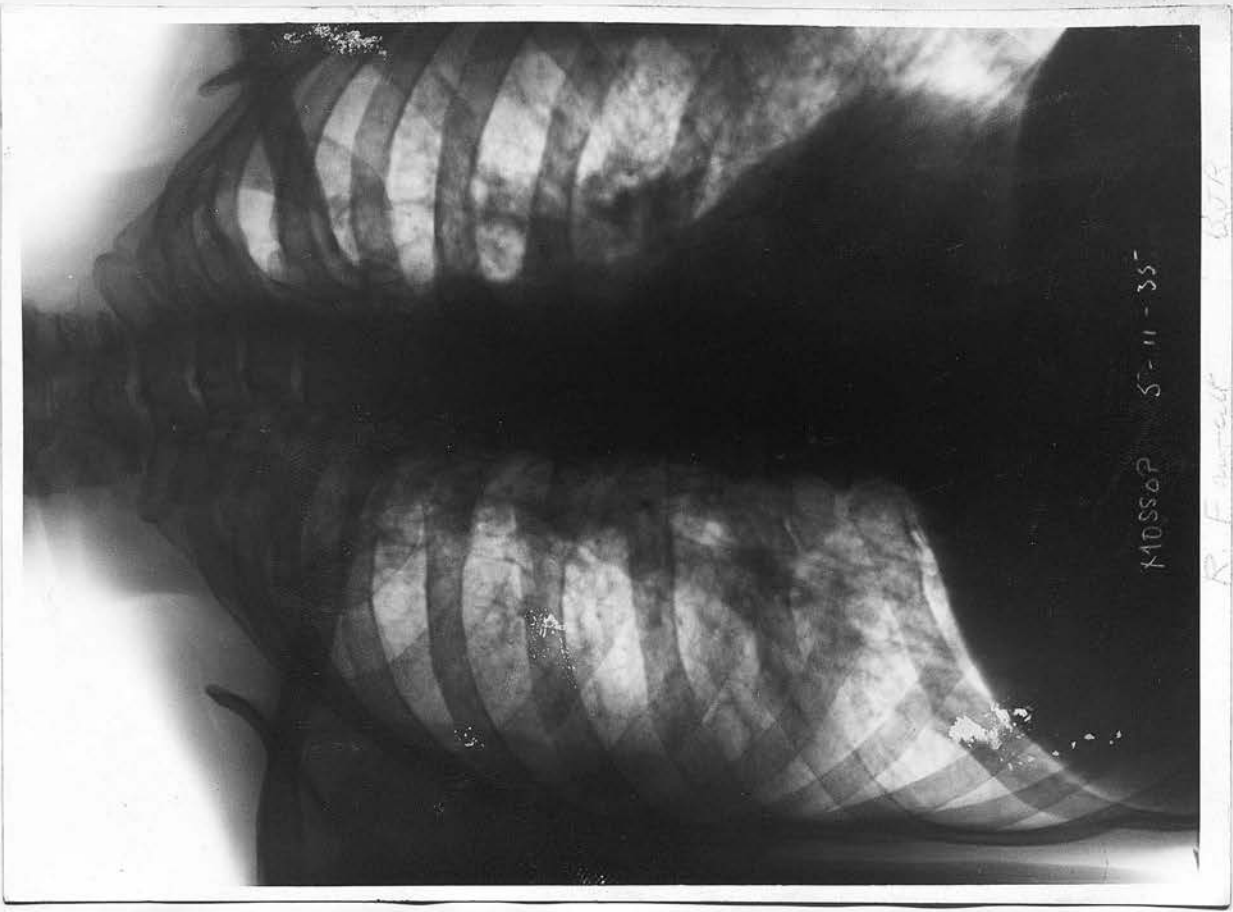


Fig. 13.

Case 6. — M. November 5, 1935.

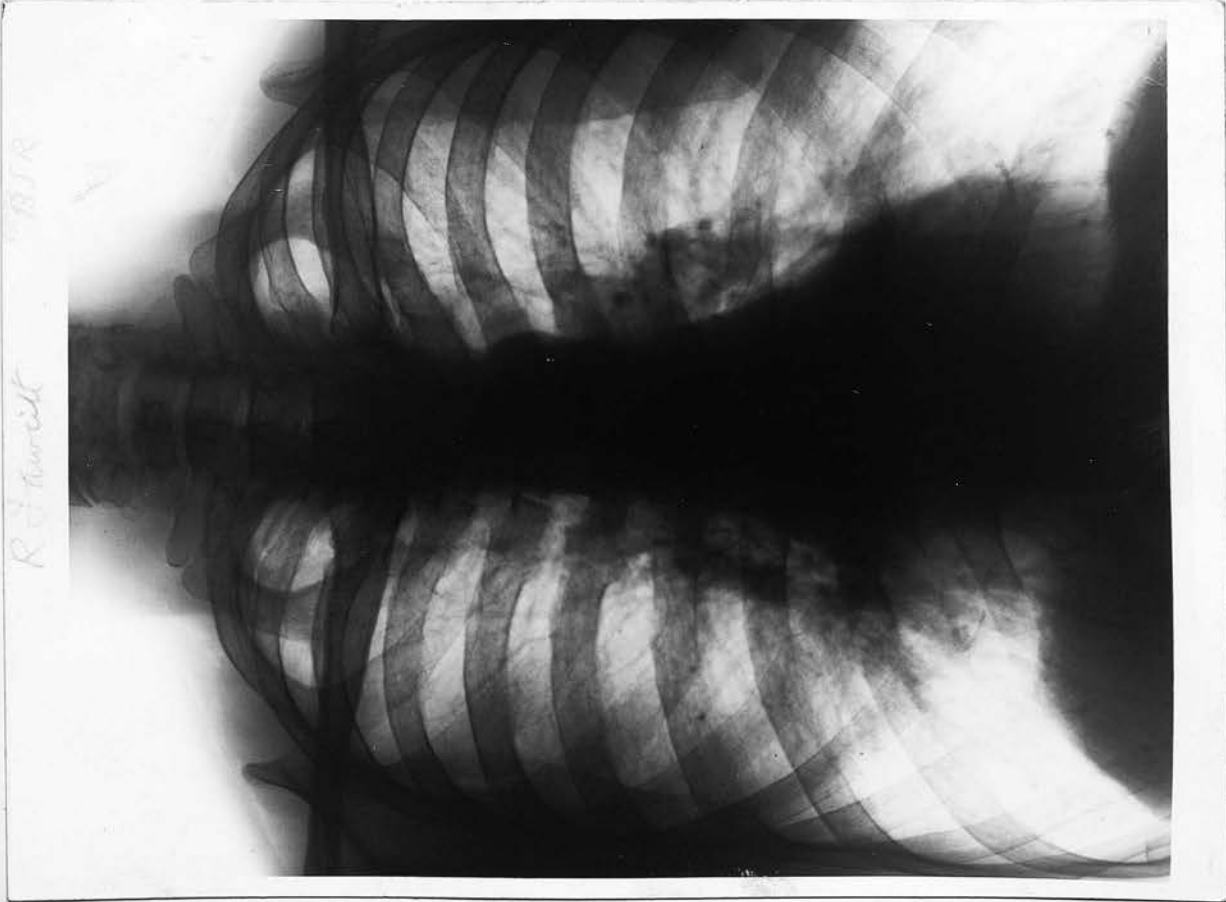


Fig. 12.

Case 5. — J.B. August 27, 1935.

more than normal silica content. From this we might reasonably assume that, if the actual "dust" of the grass was the cause of the condition of the lungs, the silica content should have been higher - as in other dust diseases. It therefore seems reasonable to me that there must be some other agent to account for the changes in the lungs.

A considerable number of milder cases occurred in Westmorland about the same time as the cases described.

Now the years 1934 - 1935 have not been good years for producing fungi, or shall we say mouldy hay. The summers have been dry and the hay well got. Nevertheless I have been on the constant lookout for X-ray films showing similar radiographic appearances to those seen in the cases already described.

Case 5. On 27/8/35 J.B. - aged 34 years, farm labourer, was referred to me by Dr. Ablett for X-ray examination at Whitehaven because of definite lung symptoms, query pulmonary tuberculosis. After seeing the film I was so struck by the similarity to Dr. Campbell's hay dust cases that I went into his symptoms and history most carefully, and I found his symptoms dated back to haytime, three months earlier, and were similar to the hay dust cases. I made a tentative suggestion that this

might be a case of broncho-mycosis and that his sputum should be examined for fungi. Feulds found aspergillus. This man was immediately put on potassium iodide and further examination of his sputum on 8th November failed to show the presence of fungi. He failed to report for further X-ray examination.

Case 6. M. aged 58 years. Referred to Whitehaven for X-ray examination by Dr. Dewhurst-Thomas, (Gosforth, Cumberland) on 5th November 1935. Farm-labourer of the peripetatic type, has had no fixed abode - sleeping frequently in barns and doing odd jobs on local farms. Symptoms: loss of weight, indifferent health, no haemoptysis, sputum present, extreme dyspnoea. No tubercle bacilli found in sputum on frequent examinations. This case resembles J.J. - the first case of this condition shown. Note the collapsed right upper lobe. Sputum showed growth of fungi of aspergillus group. A further examination of sputum in March 1936 failed to reveal any fungi. The patient was treated by means of potassium iodide and is now quite well.

Case 7. T. , chauffeur, referred by Dr. Morris of Ravenglass. Seen June 1935. Extreme dyspnoea. This man had indefinite chest symptoms and was suspected of pulmonary tuberculosis. The X-ray picture suggested more a bronchiectatic condition or a chronic bronchitis.

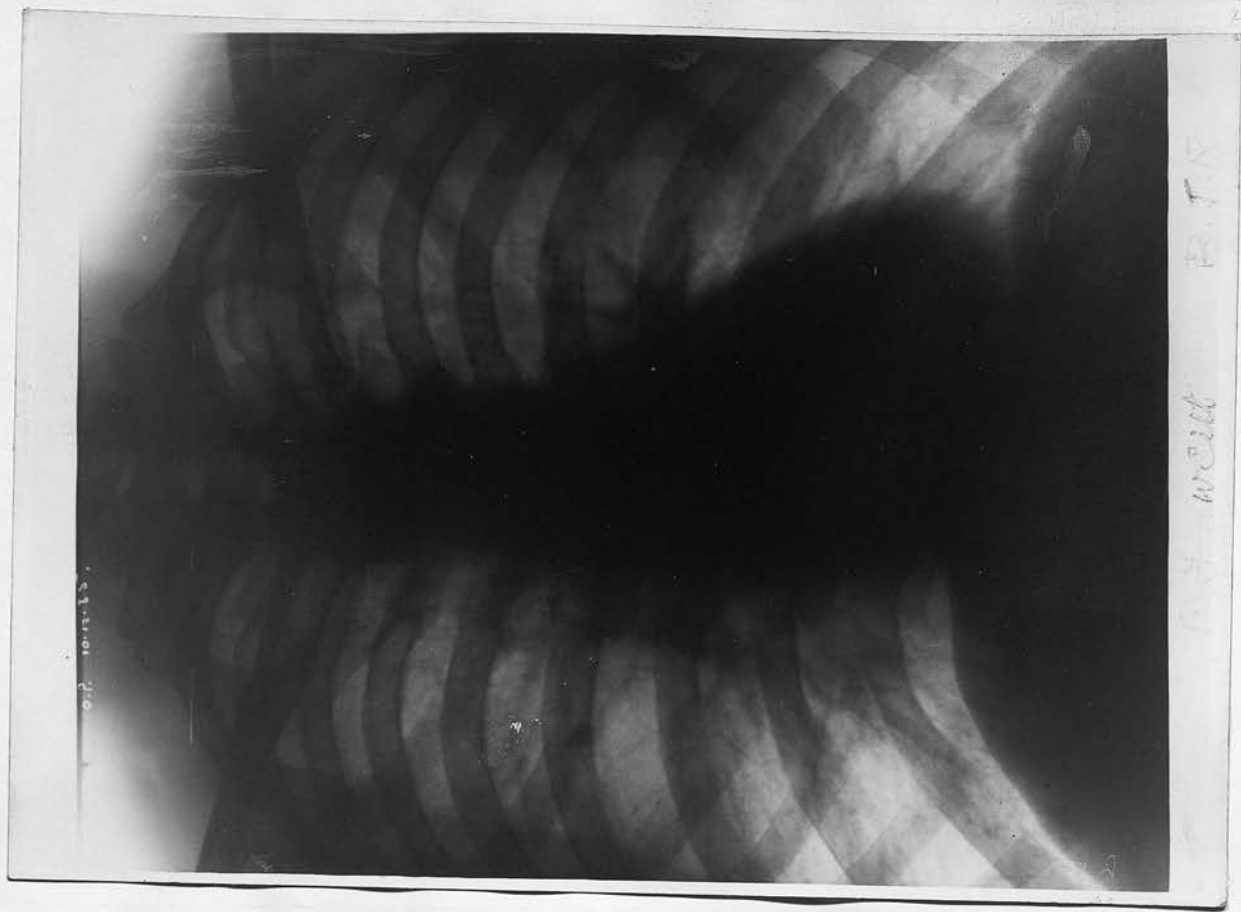
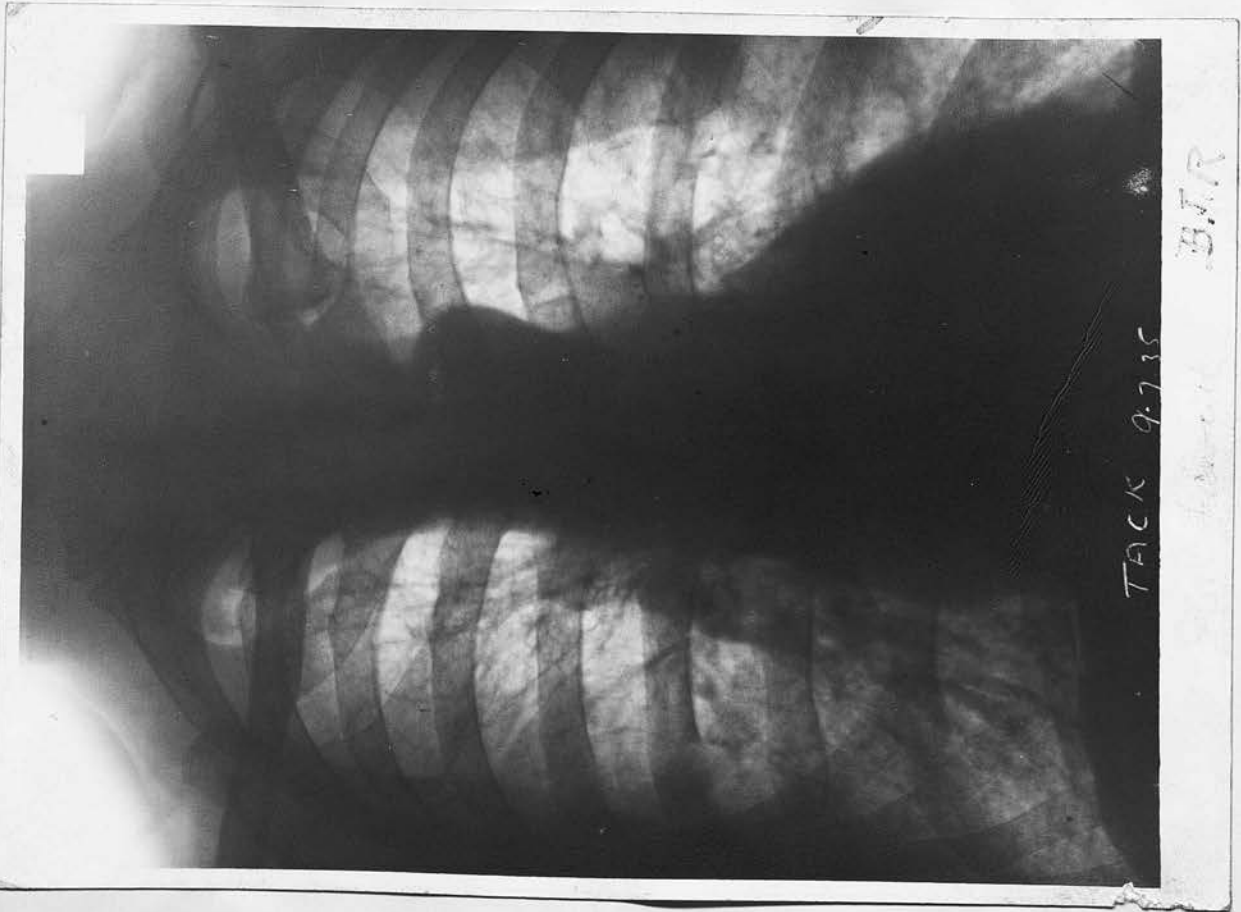

Fig. 15.

F. F. W. B. T. N.

Fig. 15.

Case 8. - F. Corn-Thresher. Dec. 10, 1935.
See page 43.



TACK 9-7-35

B. J. R.

Fig. 14.

Case 7. - T. July 9, 1935.

It was only when I was reviewing all my chest films from 1932 up to date in order to try and trace more films of the type which I have described that I realised that he too might be a case of bronchomycosis. Note the similarity to the later stages of E. (Case 2). He has, however, failed to produce any fungi in his sputum.

It will be noted that in all Campbell's cases the hay from the farms on which the infected men worked yielded fungi, aspergillus, penicillium and mucor. One patient only yielded mucor. The examination of these sputa was incomplete.

In my cases all the sputa yielded fungi, the sputum being collected under the supervision of the man's doctor under the statutory rules. The pathological difficulties have been considerable owing to the fact that Faulds lives in Carlisle, and accordingly the sputa from Grange may have been of little value when they reached him; furthermore at that time he was not equipped with suitable media.

During the last twelve months I have investigated radiologically the chests of at least five or six hundred men who follow dusty occupations, including at least 250 Haematite minders, a number of coal miners, blast-furnace men, workers in Blue mills, gunpowder factory, limestone quarries, asbestos workers, etc., and in each type there is a distinguishing

feature, frequently clinical or occupational. The same applies to pulmonary tuberculosis, or an acute or sub-acute bronchitis, or broncho-pneumonia. The occupational dusts have been the subject of investigations by (18)Collis, Kettle (19), and others.

I have made the following observations; namely, that in the lung affections due to the inhalation of inorganic dusts the onset of clinical symptoms is more gradual, as indeed is the spread of fibrosis seen in the X-ray picture, and the X-ray picture never improves, it gets progressively worse.

In the case of organic dusts, and probably fungus infection, the onset is more sudden, associated with a much more marked dyspnoea. The X-ray picture frequently shows emphysematous bullae and patches, and under treatment recovery may take place with a considerable amount of fibrosis.

This may even apply to Actinomycosis.

The Dust conditions seldom give rise to hyperpyrexia. The changes are bilateral and eventually extend to the whole of both lung fields. This does not always apply to moniliasis.

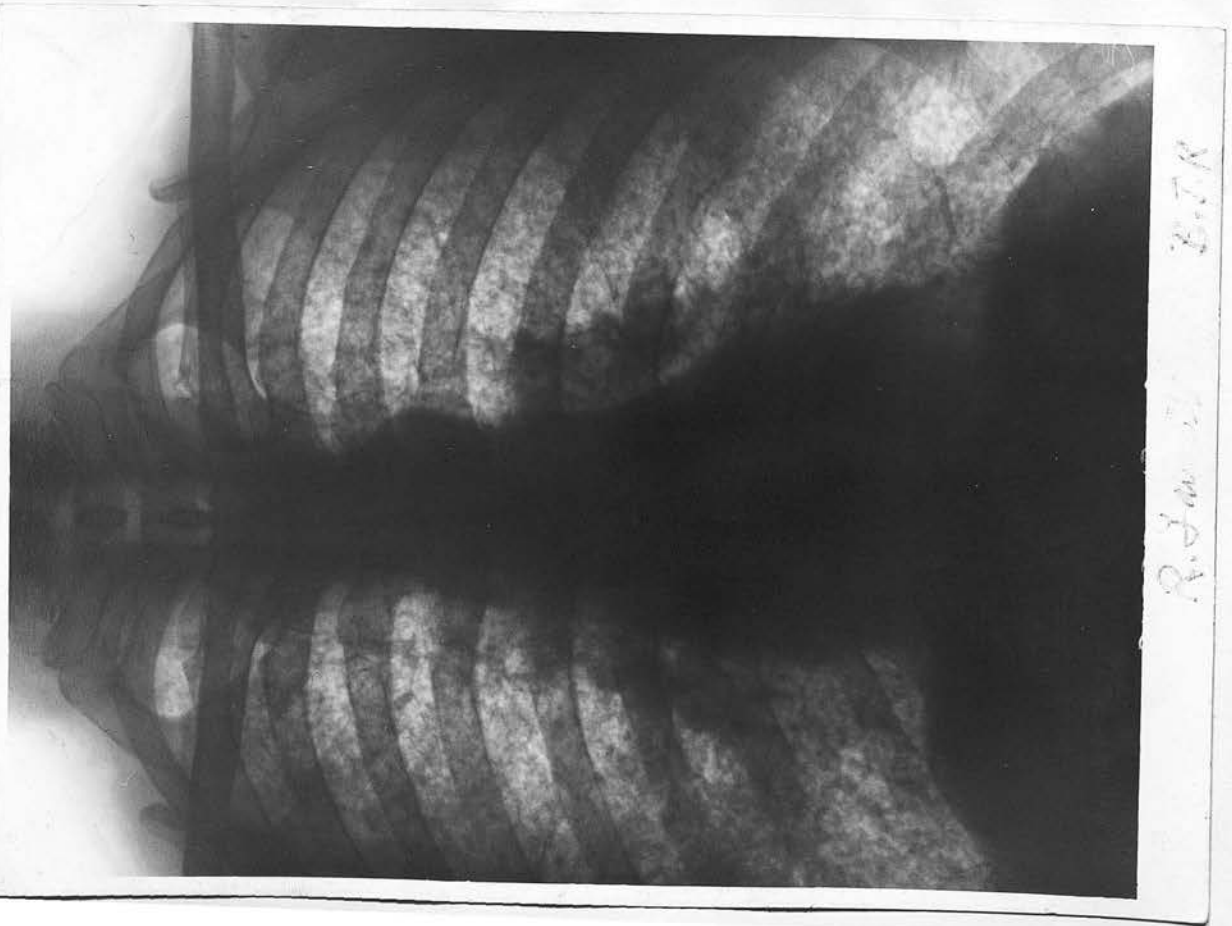


Fig. 18.
Haematite iron-ore worker.

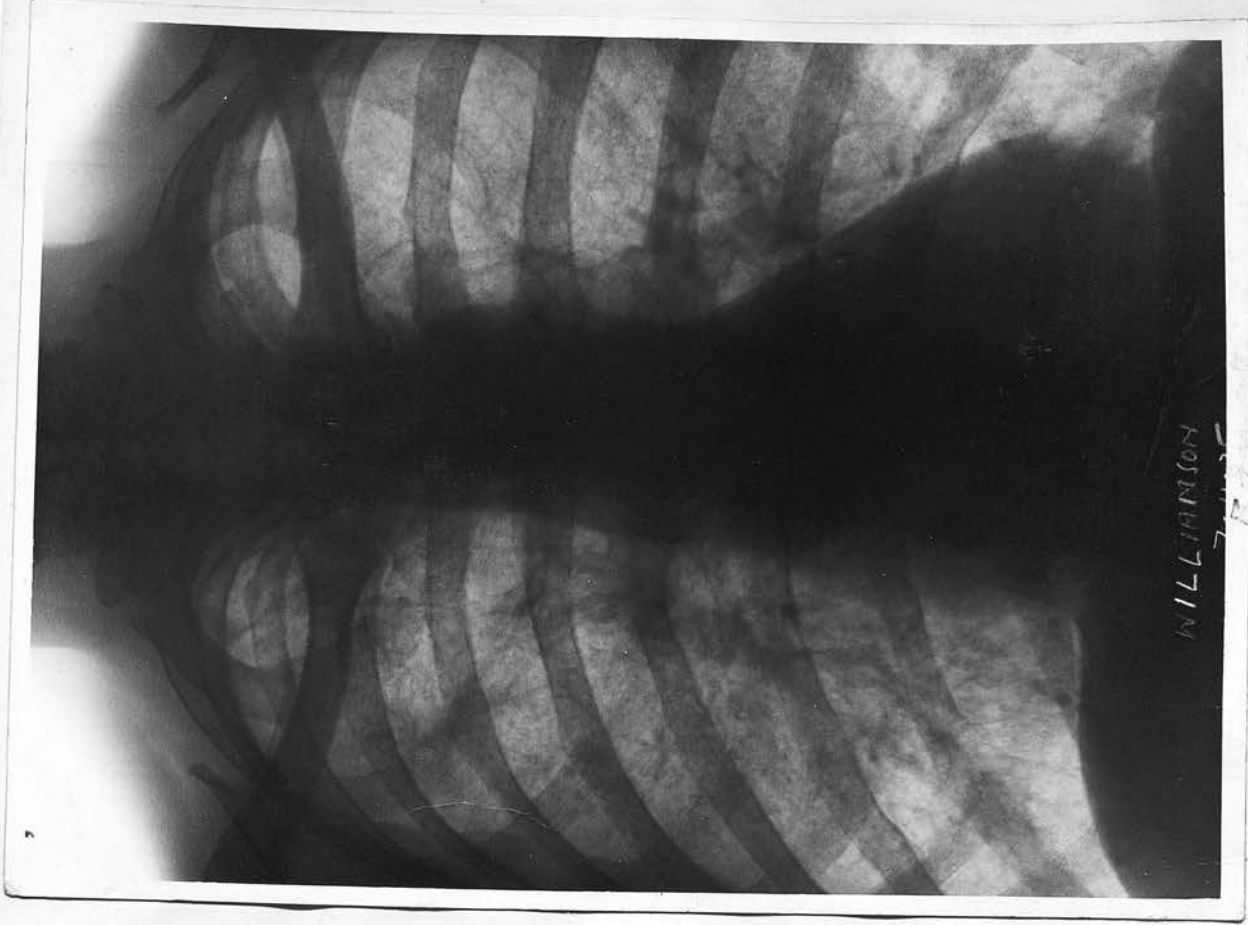


Fig. 19.
Gunpowder worker.

Illustrative of the inorganic dusts and showing somewhat similar X-ray appearances:

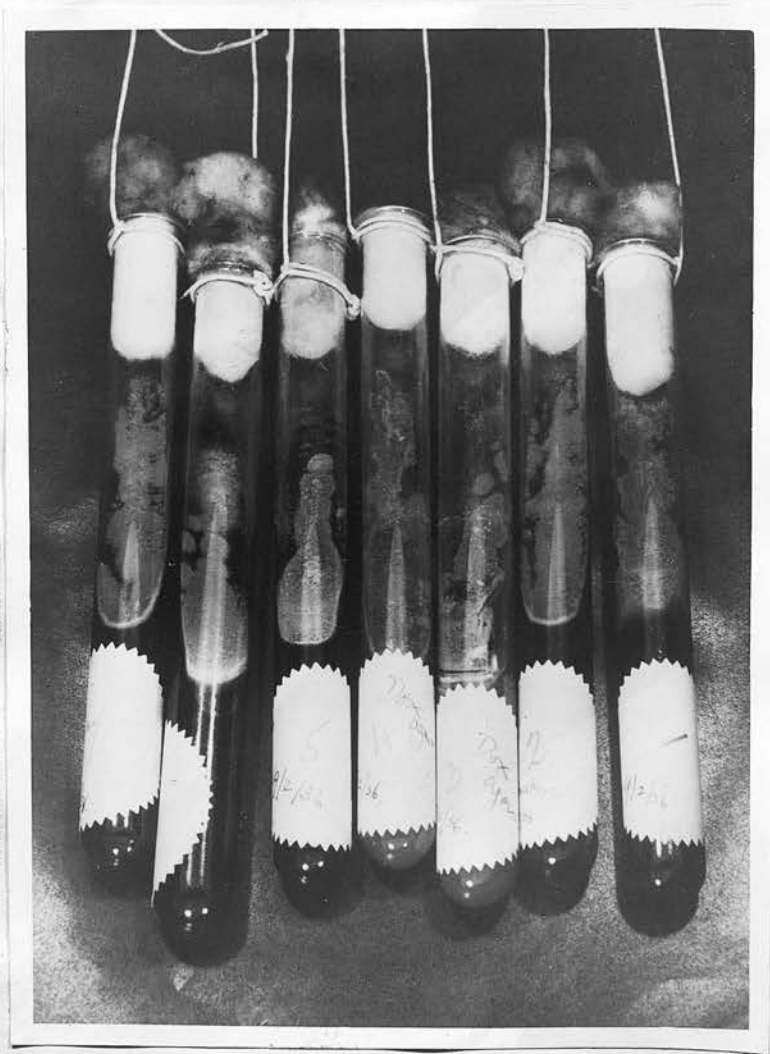
- (1) The chest of the Gunpowder worker (aet 60 years), unemployed for six months, but with 40 years employment to his credit. His symptoms are practically nil - yet the X-ray picture shows a very fine mottling throughout the whole of the lung fields, supposed by some to be a very mild form of silicosis.
- (2) The chest of the Haematite Iron-ore worker (aet 37 years), employed 8 years on machine drills. This man has a definite dyspnoea on slight exertion, and cough with very scanty sputum. Radiologically the lungs show a coarse mottling and fibrosis - a silicosis of the second degree.

In the case of the organic dusts (fungus infection) the X-ray appearance is very similar in Blastomycosis and in some cases of Moniliasis. These will be described and illustrated in the second half of the paper.

At this juncture the Asthma and Bronchitis associated with men threshing "moulded" grain is worthy of mention. The Smut and Rust fungi (Basidiomycetes), Ustilaginaceae and Uredinaceae are found in cereals.

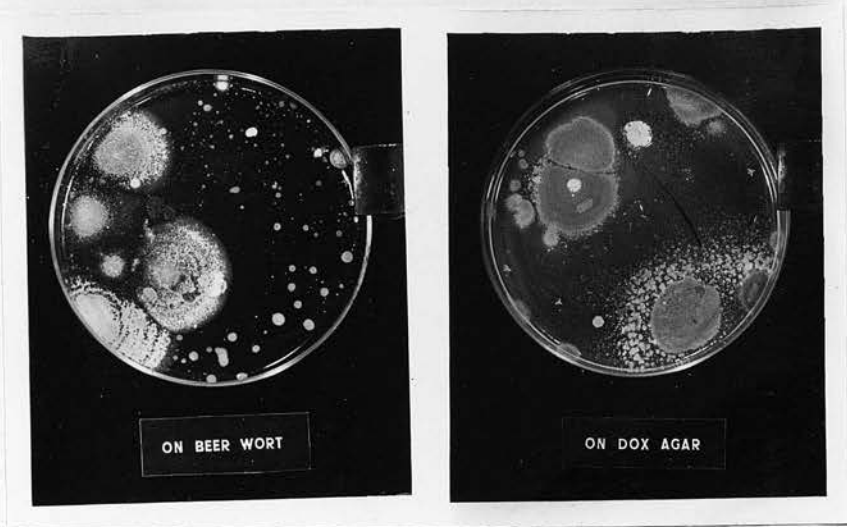

Fig. 16.
Petri Dishes - Case 8.



Sub-cultures.

As yet we have no reliable evidence that these fungi are pathogenic, but it is a well-known fact amongst farmworkers that there is a high incidence of asthma and bronchitis amongst threshers and corn millers; that this only occurs when the grain is "moulded" (to use the local term). I have examined radiologically the chest of several such men and in two cases the X-ray appearances were similar to the Hay dust cases. These cases only occurred in December. The sputa were collected and the men put on to Pot. Iodid. with rapid and marked benefit. The mycological investigations are as yet incomplete. In one case penicillium has been isolated, but its type and pathogenicity is not yet established. (Case 8.) Petri dishes inoculated with sputum from these cases show the typical appearances associated with this condition. (See plate.) *fig. 16.*

Still more recently I have seen three other cases with similar clinical symptoms and radiographic appearances which I do not, as yet, feel justified in including in my published series. One of these cases is the wife of a general "hawker" - the others are corn-threshers. (This is the season - Spring - when many local farmers are threshing their grain.) The sputa of these cases are under investigation and fungi have developed in the media in the petri dishes. These would appear to be pathogenic.

pathogenicity of the fungi found.

The co-operation of Clinician, Pathologist, Mycologist and Radiologist is absolutely imperative.

All these films show evidence of an atypical Bronchitis, but it would seem that this Bronchomycosis feniseclorum is a definite entity. In support of it being a Broncho-mycosis:

- (1) Fungi were isolated from the sputa in several cases, (all mine and one of Campbell's).
- (2) Fungi - aspergillus, penicillium, and mucor - were isolated from the hay in all Campbell's cases. (The hay has not yet been investigated in my cases.)
- (3) In all the cases mouldy hay was the supposed causative factor, and the condition only occurs when the hay is mouldy.
- (4) The cases so far recorded have been confined to the farming class, in other words the type of person whose daily life brings him particularly in contact with fungi.
- (5) The silica content of the lung of the only case which died and on which a post mortem was held was within normal limits. The grasses and presumably, their dust, contain silica, and

one would expect a higher silica content if the hay dust itself were the cause.

- (6) The post mortem appearances in the lung are very similar to those described by Virchow (1) except that no nodules are reported, and still more similar to those described in rats (5) and (8) by Bethune and Moffat (12) in their experiments on animals.
- (7) The curative effect of potassium iodide in most of these cases - potassium iodide being the recognised fungicide.
- (8) The aspergillus group is known to be pathogenic.

Now according to Castellani these cases would not be considered proved, in that the lesions have not been produced in the lungs of guinea-pig or rabbit. This I hope to do personally in the near future - or rather investigate the X-ray appearances in animals which I have inoculated intrapulmonary with the sputa of the cases I have seen, and Cousins and Faulds have promised to work out the mycology and pathology.

Meanwhile it is of interest that every single country doctor in this area with whom I have discussed the subject, or who has read the portion of the paper which has so far been published, ⁽²⁰⁾ makes a remark something like this - "I can recall a

number of cases corresponding to those you describe, and I can recollect epidemics of such cases; and, when I come to think of it they nearly always occurred after a bad haytime."

On looking back on the twelve years which I spent in country practice I too recollect many such cases. I called them broncho-pneumonia, and following my father's principle I gave them potassium iodide and creosote and they all got well, some cases, however, running a very protracted course. I feel convinced that in this area there occurs periodically a pathological condition of the lungs in which the causative factor is fungus infection. I am equally convinced that it will take many months, if not years, before the proof of this is definitely established. Meanwhile the work is in progress. The progress is bound to be slow, largely owing to the scattered nature of the cases.

ADDENDUM.

On April 8th I received the following letter from Dr. R. St. John Brooks in relation to subcultures which we obtained from the Petri dishes of Case 8, (corn thresher) and which we had sent to the Lister Institute for identification:

"The culture dishes to which you refer appear to us to be strains of Penicillium sp., belonging, I imagine, to the Glaucus group. The identification of Penicillia has now become the work of the specialist, and if you want an accurate diagnosis I would suggest you get into touch with Dr. Chas. Thom, U.S. Dept., of Agriculture, Bureau of Plant Industry, Washington, D.C., U.S.A."

Cousins and I were of opinion that we had mixed cultures of Aspergillus and Penicillium.

This letter serves to illustrate the magnitude and difficulties of the work that is before us. It also to some extent excuses me for publishing a work which I realize is incomplete, and for my remarks - which were not meant to be unkind - about Pathological departments.

Referring to my first case (1), aspergillus, penicillium and mucor were identified in the cultures of the sputum. In case 3 Campbell isolated mucor. It

appears to me that it is just possible that we may be dealing with a number of cases of broncho-mycosis of different origin. It may, however, be that penicillium and not aspergillus is the pathogenic fungus (if any) in this type of case.

A Summary will be found commencing on page 89 of Part II.

References to Introductory.

-:-:-:-:-:-:-:-:-:-:-:-

- (1) Bodin E.: Les Champignons Parasites de l'Homme, 1902.
- (2) Brumpt -: Precis de Parasitologie.
- (3) Castellani, A.: Fungi & Fungous Diseases, 1928.
- (4) Castellani, A., & Chalmers -: Manual of Tropical Medicine, 1919.
- (5) Gedoelst, L.: Les Champignons Parasites, 1902.
- (6) Gueguen, F.: Les Champignons parasites de l'Homme et des animaux, 1904.
- (7) Jacobson, H.P.: Fungous Diseases, 1932.
- (8) Muir, R., & Ritchie, J.: Manual of Bacteriology.
- (9) Remsbottom, J.: (1) Fungi, an Introduction to Mycology.
(2) Fungi pathogenic to Man - Vol. VIII of a system of bacteriology in relation to medicine.
- (10) Saccardo.: Sylloge Fungorum 1906, in 18 vols.
- (11) Sartory, A.: Champignons parasites de l'Homme et des Animaux. 1920 - 1923.
- (12) Thom : The Aspergilli.
- (13) Thom & Church.: The Penicillia.
- (14) Erikson, Dagny.: The Pathogenic aerobic organisms of the Actinomyces Group. 1935.
- (15) Dodge, C.W.: Medical Mycology, fungous diseases of Man and other mammals. 1936.

References to Broncho-aspergillosis.

-:-:-:-:-:-:-:-:-:-:-:-

- (1) Virchow, R.: Arch. f. Path. Anat. u. Physiol. 2: 557. 1856.
- (2) Jacobson, H.P.: Fungous Diseases. Dieulafoy, Chantemesse & Widal. p. 276.

