

PATTISON PRIZE 1943.

SIX CASES ILLUSTRATING LITHIASIS OF THE
URINARY TRACT

from the

Western General Hospital, Edinburgh,

by

G.V.R. BORN

handed in on the 6th June 1943.

INTRODUCTION.

The six cases here described illustrate the clinical features, diagnosis and treatment of urinary calculi. The problems of aetiology, pathology and treatment, both operative and conservative, are discussed. The commentaries at the end of each case merely contain a summary and discussion of the clinical findings and treatment of that particular case. A general discussion in these matters, together with a review of aetiology, pathology and diagnosis of calculous disease, is put at the end of the paper. It is evident that in such a short series of cases as this no conclusive treatment of the very large topic is possible. The only inherent value of an assembly of a few cases under a common heading lies in the fact that it helps to marshal and clarify one's ideas on the subject under review.



C A S E I.

SINGLE LARGE CALCULUS IN RENAL PELVIS

TREATED BY NEPHRECTOMY.

Mrs Jean Boyce, aged 34.
9 Crewe Place, Pilton, Edinburgh.

Occupation: Housewife.

Date of Admission: 11. 5.43.

Date of Operation: 18. 5.43.

COMPLAINT:

Abdominal pain and numbness of right leg for seven years.

HISTORY:

Nearly eight years ago the patient was in hospital in Newcastle with "acute appendicitis". The appendix was removed at that time. Six months later she had an attack of acute agonising pain in the right side. This pain shot across from the right iliac bone to the symphysis pubis in agonising spasm. The pain only lasted one day. She felt very sick and did actually vomit. The whole right hip region was hyperaesthetic and she was unable to move her right leg freely. She was examined radiologically then and was told that she had a kidney stone.

She had never had a recurrence of that acute pain but she had had a dull ache in the right side and had had a feeling of nausea on waking in the morning, off and on. Recently the dull ache had been present more or less continuously and on sudden movement she had experienced acute shooting pains lasting a few seconds.

Four months ago the patient also experienced severe pain in the left hypochondrium. This pain was gripping in character and lasted several hours, leaving the patient very fatigued afterwards.

Micturition was sometimes painful, scalding in character, but there was no frequency except when the patient had a cold. The urine was often cloudy, more so recently, but the patient had never noticed it to be blood-stained. The bowels were very regular and the menstrual periods were normal. Generally the patient had not felt up to the mark for the last four or five months. She got depressed for no reason and did not sleep well and had frequent headaches. There was no loss of weight.

Only previous illnesses she had had were acute tonsillitis and influenza. A possibly inflamed appendix was removed seven years ago. There was no evidence of renal lithiasis in the family, all relations being exceptionally healthy.

CLINICAL/

CLINICAL EXAMINATION:

The patient was a bright young woman, intelligent and pleasant.

Abdominal Examination:

The abdomen moved freely on respiration and looked normal; the old appendectomy scar was seen. Palpation revealed tenderness in the left hypochondrium more marked when the kidney was pressed anteriorly. There was also tenderness in the right iliac fossa. This tenderness was nowhere marked or severe and could only be elicited on deep palpation. The liver and spleen were not enlarged. Kidneys were not palpable.

CARDIOVASCULAR SYSTEM:

Pulse rate 80. Rhythm regular in time and force. Vessel wall not palpable.

Heart: apex beat in 5th interspace inside mid-clavicular line. Heart sounds pure, no murmurs heard.

RESPIRATORY SYSTEM:

Chest expansion good. No dulness on percussion. Breath sounds vascular in all areas. No accompaniments heard.

URINE EXAMINATION:

Albumin +

No sugar.

Microscopically - pus cells and epithelial cells of the ureteral type.

Blood urea nitrogen: 14 mgs. %

Blood calcium: 10.3 "

Blood phosphates: 0.18 units (Kay).

HAEMOPOIETIC EXAMINATION:

Hb. 92%. W.B.Cs. 5,800.

X-RAY REPORTS:12.5.43 RENAL TRACT:

Large calculus occupying right kidney pelvis. Some dilatation of right ureter. Left pyelogram normal.

12.5.43 RETROGRADE PYELOGRAMS:

Catheters in situ. There is a large calculus occupying right renal pelvis. The ureter is dilated and the calices indefinitely outlined.

14.5.43 INTRAVENOUS PYELOGRAMS:

Normal function left side. Large calculus in right renal pelvis with poor function right side.

TREATMENT/

TREATMENT:

Operation: 18.5.43 Nephrectomy.

With the patient on her left side and with the left leg bent and the right leg straight and a large air-cushion underneath her waist, the kidney was approached through an oblique incision running from the angle between the 12th rib and the sacrospinalis muscle to just about the anterior superior iliac spine. Skin fascia, latissimus dorsi and serratus posterior were divided to expose the external oblique and the lumbar fascia, which were divided in the line of their fibres. The peritoneum was retracted anteriorly and the quadratus lumborum posteriorly together with the subcostal nerve and vessels. The kidney was freely mobile. The renal pedicle was cleared, artery and vein ligated, ureter ligated and these structures divided. Two rubber tube drains were inserted through the posterior margin of the wound, stay sutures were inserted and the muscles closed with catgut and the skin closed with continuous catgut.

Since operation the patient's progress was very good. She had some considerable pain in the wound area but was otherwise comfortable, and eats and sleeps well. The urine was beginning to clear and there was less albumin.

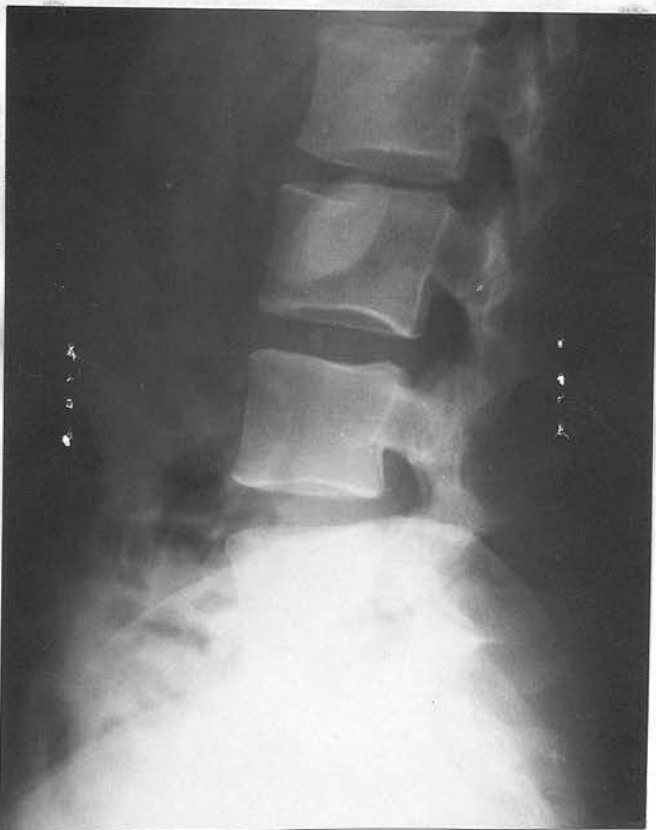

FIG. I Mrs Boyce 12.5.43. Left lateral view. showing large calculus in renal pelvis.

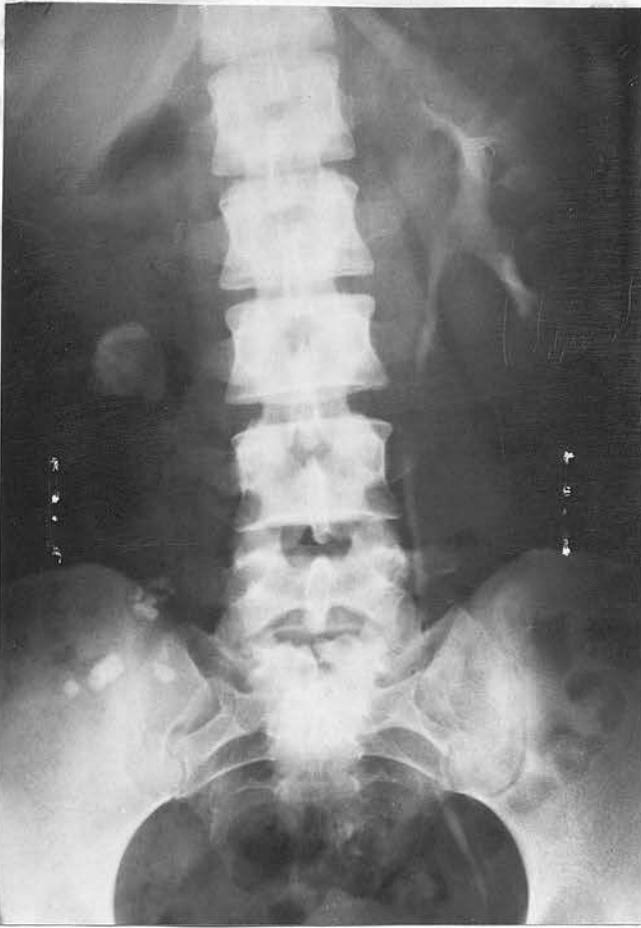

FIG. II. Mrs Boyce. 14.5.43.

Intravenous pyelograms; normal function left side. Large calculus in right renal pelvis and poor function right side.

Five mins. after uroselectan.

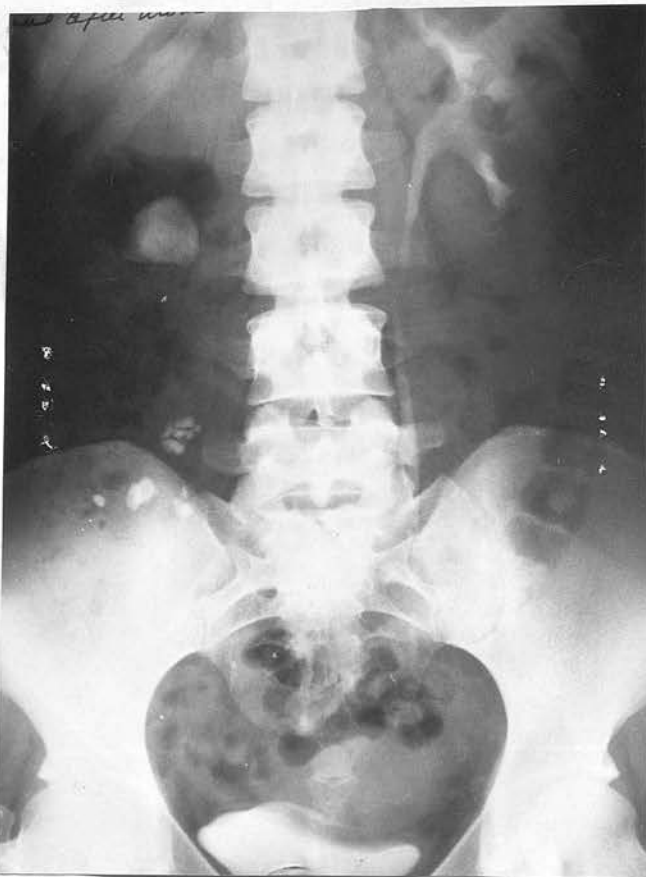

FIG. III. Mrs Boyce. 14.5.43.

Fifteen mins. after uroselectan.

COMMENTARY ON CASE I.

The interesting feature of this case was the long time during which symptoms were present but no treatment was undertaken.

It would be interesting to know whether the patient really had acute appendicitis nearly eight years ago. Unfortunately, no accurate clinical or pathological data are available. It is quite possible, however, that the "appendicitis" was really the first attack of right-sided renal colic. This illustrates a common problem in differential diagnosis. But, on the other hand, if the patient did suffer from acute appendicitis at that time, then the long rest in bed following operation may have been the final factor in precipitating calculous disease in the kidney.

Early on in the history the stone was small and tried to pass down the ureter, and so the clinical features were those of renal colic. Later, as the stone grew, the ureter gave up trying to squeeze it down, and in the succeeding years the ^{enlarging} calculus stuck in the renal pelvis, giving rise to the continuous ache in the loin and the nausea which she complained of. Any sudden jerks would throw the plain muscle surrounding the stone into spasm and thus produce her sudden short severe pains. By the time it was removed the stone was about 5 cms. in diameter and nearly filled the renal pelvis. It had done considerable damage to the kidney, and blood cells were found in the urine. The pus cells were probably due to traumatic inflammation, for there was no bacteriological evidence of urinary infection. This/

This is unusual in such a long-standing case.

The affected kidney was examined after operation. It was moderately hydronephrotic but the secreting tissues had degenerated badly. In spite of this severely damaged and functionless kidney, there were no signs of renal failure, showing that the healthy kidney had taken over all renal functions to the full. Pyelograms and dye-excretion tests also showed a normal left kidney. The tenderness in the left hypochondrium was suggested to be due to a temporarily overstrained kidney undergoing work hypertrophy.

Treatment. had obviously to be concerned with removal of the stone, for it was far too large ever to pass down the urinary tract. The choice lay between nephrolithotomy and nephrectomy. Since the history was so old and since pyelograms showed the loss of function of the damaged organ to be so complete, removal of the whole kidney was decided upon. This was done in the usual way.

Prognosis. This depends upon the capacity of the other kidney to take over the function of both, and also on the possible occurrence of lithiasis in the remaining kidney. As the aetiology of the disease here is in doubt, the latter question cannot be answered. It is possible, however, to estimate renal function, and this will have to be done repeatedly in the future, by blood urea nitrogen estimations and by urea clearance tests.

Given adequate renal function, the outlook is good, and the patient may live to as ripe an age as if she still had both kidneys.

C A S E II.

URETERAL AND RENAL CALCULI
IN BIFID URETER ON LEFT SIDE

TREATED BY HEMI-URETERO-NEPHRECTOMY.

Dr Frederick Bath, aged 42.
6 Forrest Road.

Occupation: Lecturer in mathematics.

Date of Admission: 28.4.43.

Date of Operation: 18.5.43.

COMPLAINT:

Pain in the left side for ten days.

HISTORY:

This patient felt a general discomfort in the upper abdomen 14 days ago. Four days later this settled to a pain in the left loin which radiated to the small of the back and the left groin. The pain was a continuous ache and not colicky; it was never very severe. He could relieve it by Aspirin or Veganin. After four or five days it disappeared and there was no pain or discomfort since. He had had frequency of micturition for the same length of time. There had been no dysuria or haematuria and the urine had remained a clear yellow. He had no sickness during the last fortnight, although he had occasional nausea during the first few days of the pain. Some diarrhoea was present for two nights, a fortnight ago, when the patient had the abdominal discomfort first mentioned. The right side was not affected this time but 15 years ago he had a severe attack of pain in the right side and was told that it was renal colic.

His general health was quite good but for the past two months or so he had been feeling very tired and rundown. He believed this to be associated with the sedentary office life he had been forced to lead during the war years. He had no exercise at all for a good time past. There was no loss of weight and he ate well. He had no headaches and there was no other complaint.

CLINICAL EXAMINATION:

The patient was a well-built man with rather flabby muscles. On abdominal examination there was distinct tenderness in the left renal angle and over the upper part of the ureter. In these areas the muscles went into spasm on deep palpation. There was no tenderness on the right side and neither kidney could be felt. The rest of the abdomen was normal. The other systems were normal.

Blood pressure was 130/80 and the blood urea nitrogen was 12 mgs.%. Blood calcium was 9.8 mgs.% and blood phosphatase was normal.

URINE/

URINE EXAMINATION:

Urine contained some epithelial squames, a few pus cells and a fair number of red blood cells. There were a good many oxalate and uric acid crystals. The reaction of the urine was acid. It contained no albumin or sugar.

HAEMOPOIETIC EXAMINATION:

Hb. 74%. W.B.Cs. 7,600.

UROLOGICAL EXAMINATION:

The bladder was normal. Left ureteral orifice was catheterised with a little difficulty to 15 cms. where arrest occurred.

X-RAY REPORTS:Preliminary X-Ray:

The catheter has been arrested opposite a small calculus close to the 4th lumbar vertebra. A larger round calculus is present opposite the transverse process of the 3rd lumbar vertebra and two or three little calculi are in the renal region.

Pyelogram left: 20 ccs. Iodide injected.

On injecting the Iodide it was seen that the bifurcation of the ureter occurred just below the point of arrest of the catheter, and that a pyelogram has been obtained of a lower segment of the kidney. On withdrawing the catheter the presence of two ureteral calculi, one large and one small, and two or three renal calculi in the upper ureter and upper segment of a bifid ureter and double kidney of the left side, was confirmed.

Uroselectan Examination:

There are two calculi in the upper segment of a bifid ureter on the left side, and there are several smaller stones in the left kidney in its upper segment.

TREATMENT:

With these findings, the operation of hemi-uretero-nephrectomy was decided upon and this was carried out on the 18th May 1943 by Mr David Band, under gas, oxygen and ether anaesthesia, as follows:—

The usual lumbar incision was made on the left side for access to the kidney. After opening into the kidney fossa, the kidney was freed from its fascia and brought to the surface. The two ureters were seen descended from the hilum and joining about four inches lower down. The upper ureter was seen to bulge in two places and stones were felt in these bulges. Another stone was found in the common ureter lower down.

An/

An incision was made into the kidney and the upper third of the kidney was removed. The cuts were deepened towards the centre of the kidney from either side so that the upper end of the kidney presented a groove, 'V'-shaped on cross-section. The correct amount to be removed was judged by looking out for bleeding from the blood vessels to the lower renal unit. The upper part of the kidney was now laid aside and the groove was closed with two layers of strong catgut mattress sutures; all bleeding was controlled in this way.

Next, the stone in the common duct was milked backwards into the upper ureter, that ureter was then ligated just before its junction with the other ureter and it was divided. The excised portion of the kidney and its ureter were then removed in one piece with the stones in situ. In the pelvis of the removed part of the kidney another small round stone was found. After attending to careful haemostasis, the kidney was brought back into place and some of the perirenal fat was sutured over the incision into the kidney to cover it in.

The wound in the abdominal wall was then closed in layers, a tube drain being left in down to the upper pole of the kidney and another to its lower pole.

After operation the patient's progress was satisfactory. He found some difficulty in passing urine for the first day or two but after being catheterised twice there was no more difficulty with this.

On 28th May 1943 that is, ten days after operation there was a leakage of clear straw coloured fluid from the posterior end of the wound. This was thought to be urine and a urinary fistula established itself for the next six days. During that time there was a good deal of leakage, so that he had to have his wet dressings changed four or five times a day. But his urinary output through the normal channels remained high, and the soakage became gradually less. At the time of writing it has practically ceased and the wound is healing finally. He is to get up in a few days, and urological examination is to be carried out in the future with the hope that the lower kidney unit on the left side will be found to be functioning perfectly.

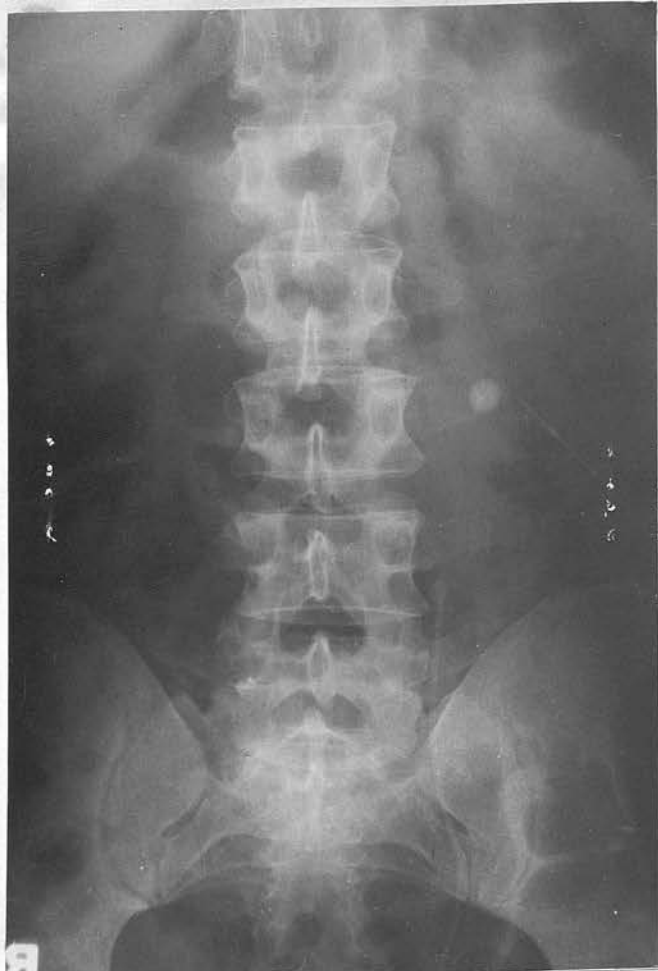

FIG. IV. Dr Bath. 5. 5.43.

Preliminary film with ureteral catheter in position on left side. Shadow in region of left renal pelvis suggestive of renal calculus. Renal outlines normal.

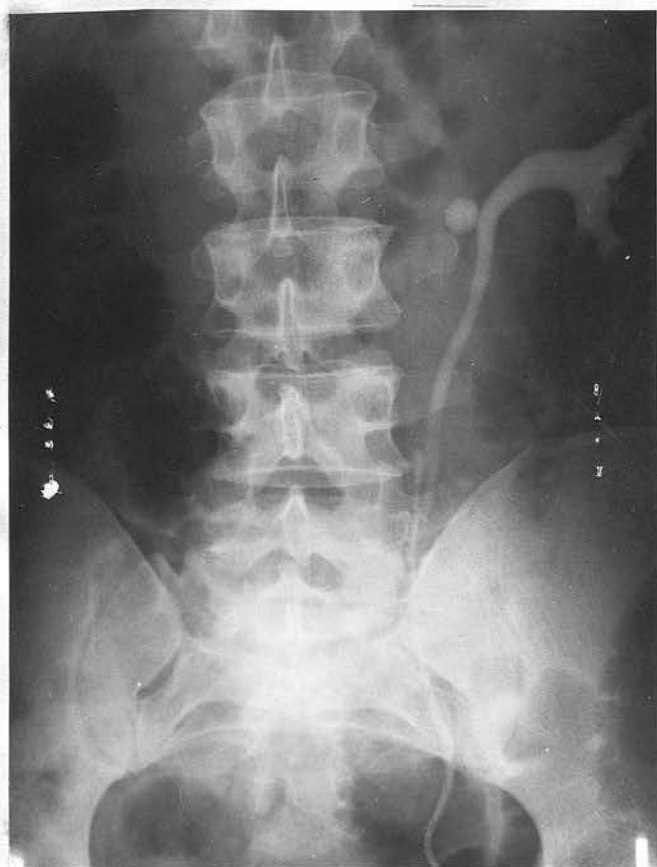

FIG. V. Dr Bath. 5. 5.43.

Retrograde pyelograms: Bifid left ureter. Large calculus at upper left pelvi-ureteric junction, and several smaller ones in upper calices.

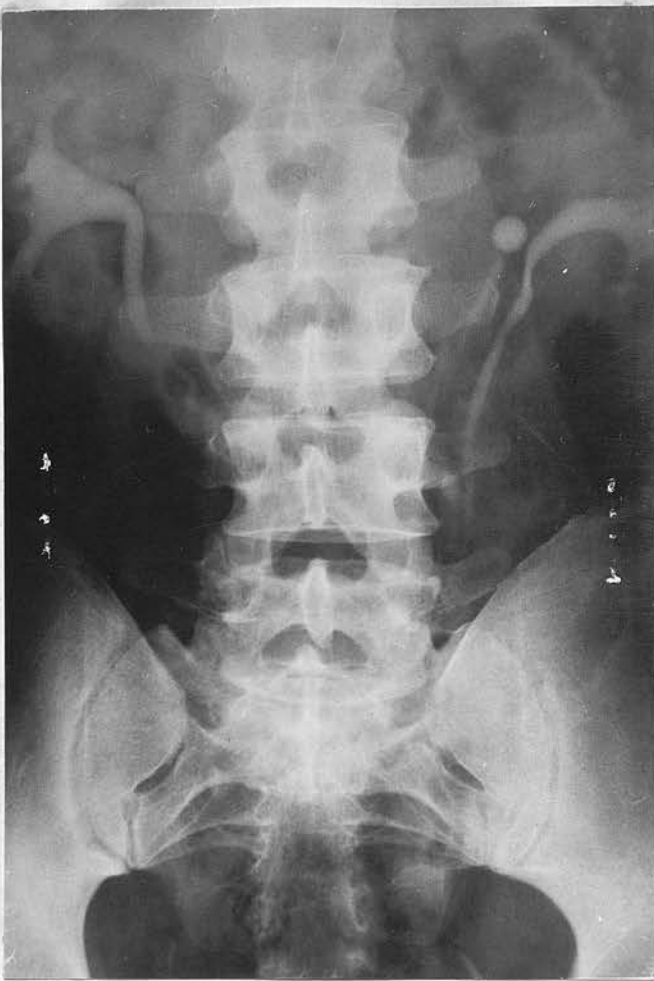

FIG. VI. Dr Bath. 1. 5.43.

Intravenous pyelograms: Normal function right side. Bifid kidney and ureter left side with calculus at pelvi-ureteric junction of upper branch.

Five mins. after uroselectan.

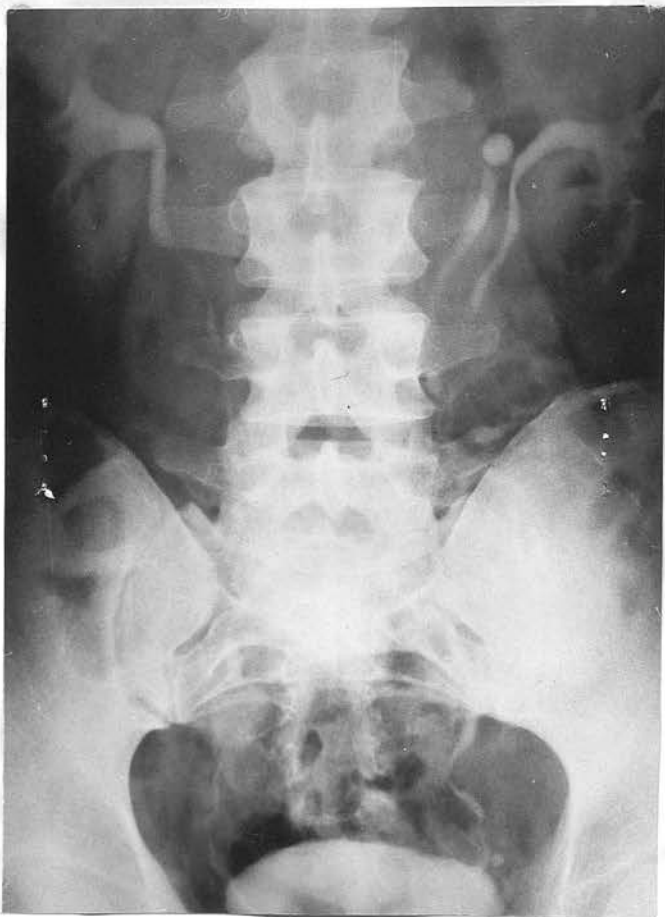

FIG. VII. Dr Bath. 1. 5.43.

Forty mins. after uroselectan.

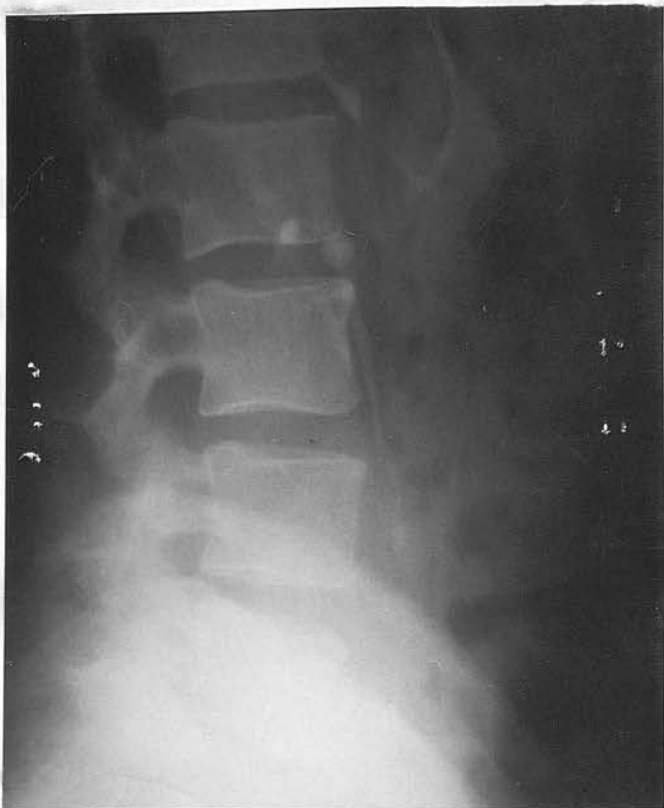

FIG. VIII. Dr Bath. 1. 5.43.

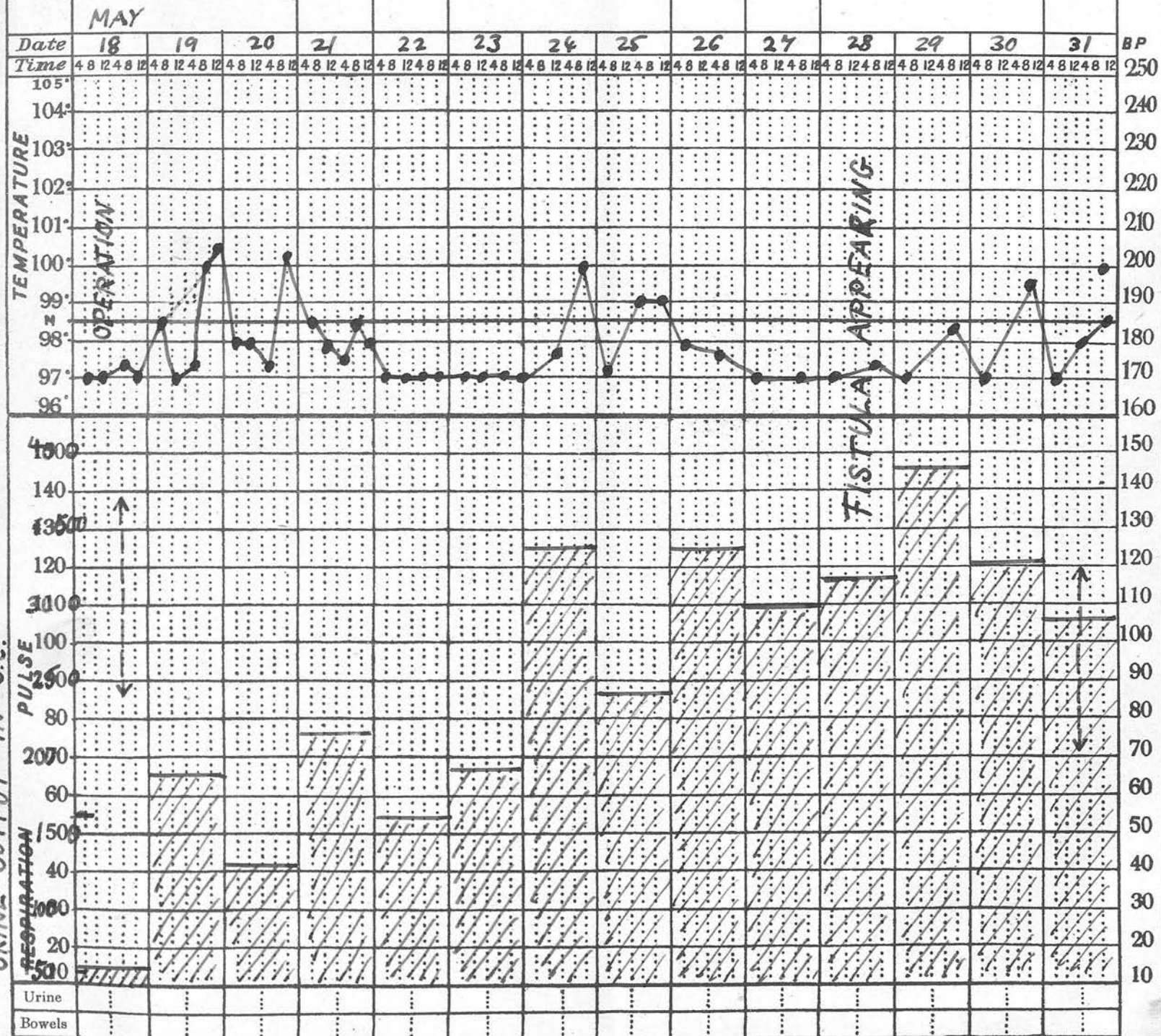
Intravenous pyelogram: Right lateral view:
Calculus remains in line of upper ureter.

City of Edinburgh - Public Health Department - General Hospitals.

Hospital	Ward	Name and age of Patient.	Doctor
		DR. FREDERICK BATH - CASE II	Clinical Clerk

Start	Diet	Stop	Start	Medicines	Stop	Start	Medicines	Stop
-------	------	------	-------	-----------	------	-------	-----------	------

CHART SHOWING TEMPERATURE AND URINARY OUTPUT
BOTH BEFORE AND AFTER THE APPEARANCE OF THE
URINARY FISTULA.



that it was COMMENTARY ON CASE II.

The case of Dr Bath is instructive for these reasons:-

(1) There were two evident predisposing factors to stone formation: The presence of the double ureter on the affected side, and the patient's sedentary mode of life, but it may be noted that there was a history of renal colic fifteen years ago, on the right side, where the anatomy is normal. This fact questions the validity of the double ureter as a predisposing factor. Rather would it point to a more general nature of the calculous diathesis. These matters are discussed later in the general section on aetiology. (2) Exceedingly accurate diagnosis of the state of affairs could be made by radiography, and the radiological findings here determined treatment. (3) The treatment was by the uncommon operation of hemi-uretero-nephrectomy, which preserves the healthy part of the kidney intact.

The clinical features began with diarrhoea and abdominal discomfort, the relation of which to the renal disease is not clear. They may have been due to a coincident gastro-enteritis, for, in contrast to nausea and vomiting, diarrhoea is not commonly associated with renal pain.

There was no renal colic proper, but instead there was the typical aching pain in the loin which is caused by the presence of stationary stones in the renal pelvis and the upper ureter and which Osler described so well from personal experience. (Christian). Frequency of micturition is due to a reflex excitability of the bladder, but the patient quite rightly said that/

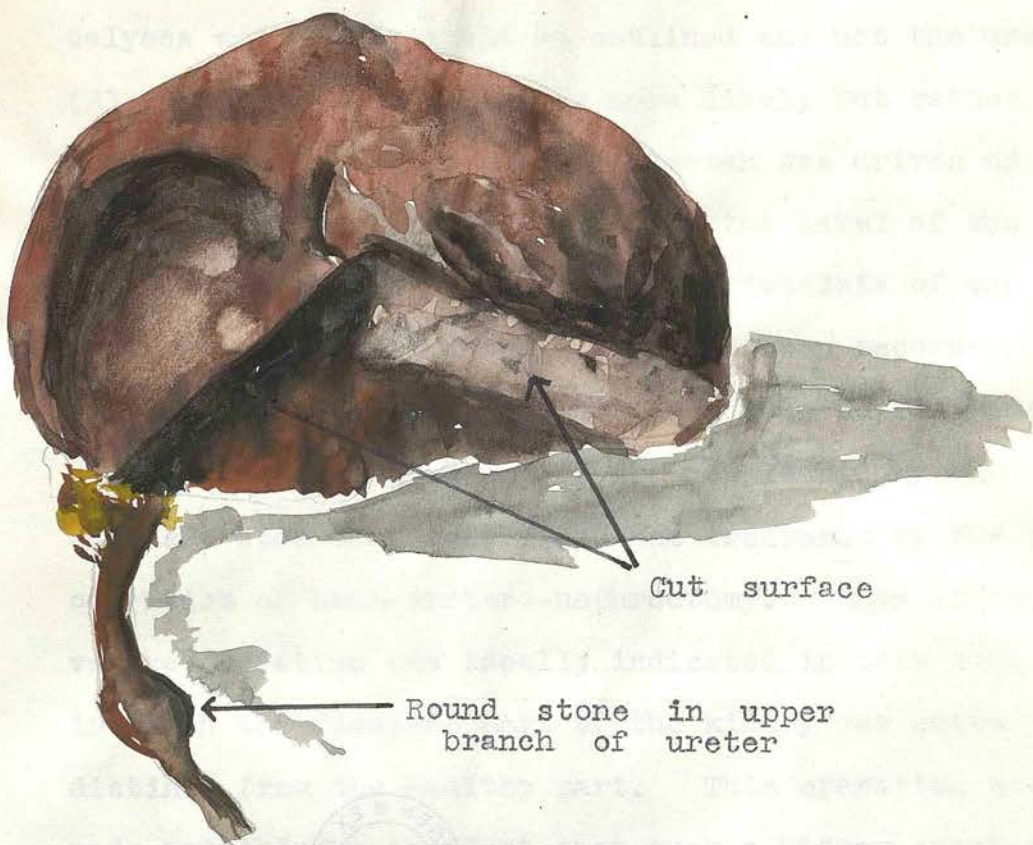
that it was also due to his augmented fluid intake, for his doctor had told him to drink as much as possible.

The epithelial and red blood cells in the urine indicated trauma to the walls of the urinary passages. Pus cells were found also as in the other cases in which there had been no infection. (Case I and Case VI). They probably appear, as already stated, as a result of traumatic inflammation of the walls of pelvis and ureter. The oxalate and uric acid crystals were in keeping with the small round hard mulberry stones found in the specimen after operation. These stones were made of urates and oxalates laid down in concentric lamellae.

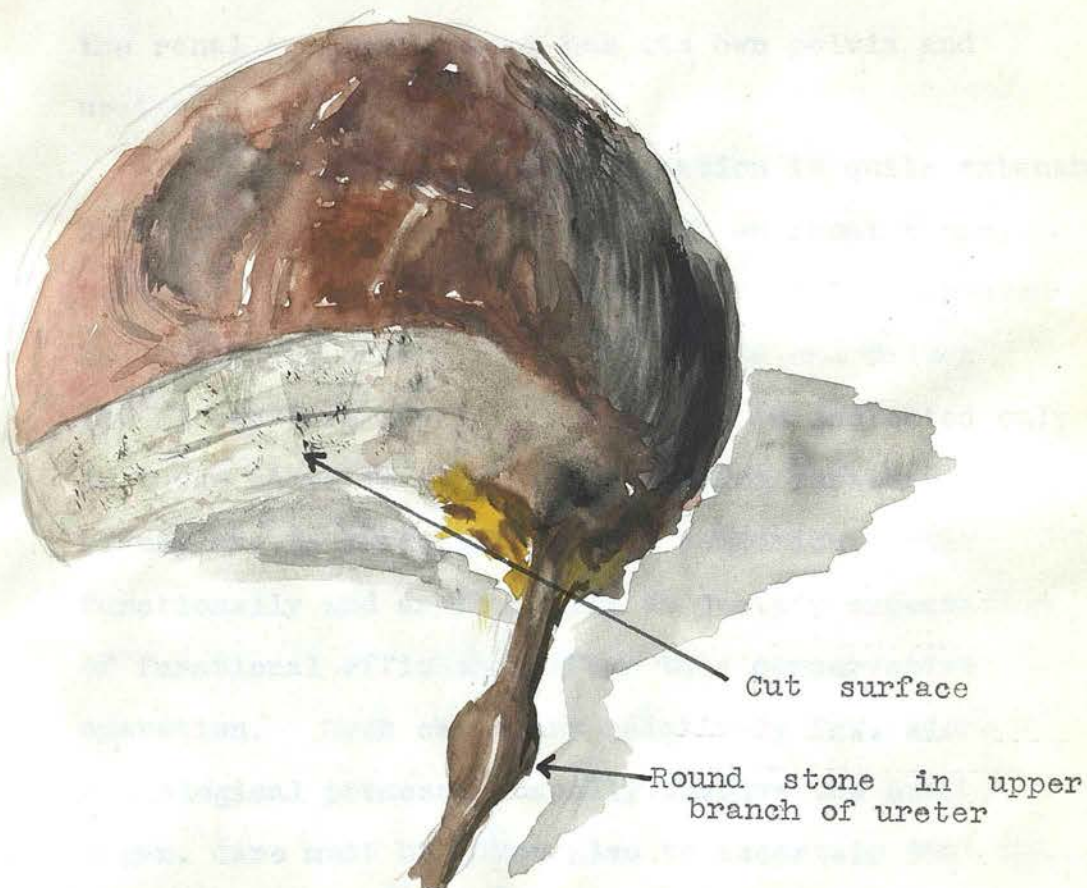Radiological examination was the all-important factor here in coming to definite conclusions about diagnosis and treatment. Preliminary X-rays only showed the presence of several shadows on the left side which might be renal calculi. A ureteral catheter was introduced which entered the lower branch of the bifid ureter. Retrograde pyelograms thus showed up only the lower system, although a little sodium iodide solution leaked into the lower end of the upper branch, so that the point of junction of the branches were seen. (Fig. V).

Intravenous pyelograms curiously enough failed to show up the upper calyceal system, but showed the course of the upper ureter below the big stone in it. (Figs. VI, VII and VIII). This means one of two things: (1) Either the upper kidney unit was functioning and excreted the uroselectan normally. Then the films were taken when the uroselectan had already left the pelvis, and, being able to trickle past the big stone/

PAINTING OF UPPER PART OF LEFT KIDNEY
REMOVED FROM DR. BATH AT OPERATION OF
HEMI-URETERO-NEPHRECTOMY.



I. ANTERIOR VIEW



II. POSTERIOR VIEW

(Enlargement times 2)

stone, showed up the ureter below it. This explanation is most unlikely, for actually the stone would be a block to the passage of the uroselectan, so that if the upper part of the kidney was excreting it, the calyces and pelvis would be outlined and not the ureter.

(2) The other explanation is more likely but rather curious. It is that the uroselectan was driven up the upper ureter from below, up to the level of the stone. This must be due to antiperistalsis of the ureteric muscles. Whether this has been recorded in ureteric pathology, I have not been able to find out.

It was the finding of the double kidney on the left side that determined the treatment by the rare operation of hemi-uretero-nephrectomy. This conservative operation was ideally indicated in this case, in which the diseased part of the kidney was quite distinct from the healthy part. This operation was made possible by the fact that such a kidney consists of two separate and entirely distinct units. Each unit has its own blood supply from the common stem of the renal artery and each has its own pelvis and ureter.

The literature on this operation is quite extensive. Swift Joly mentions it in his book on renal stone, published in 1929, and more recently it is discussed by Scholl and others (1942). Garcia and Galvez (1941) say that partial nephrectomy is indicated only in those cases in which the remaining portions of the kidney are in sufficiently good condition, both functionally and anatomically to justify expectation of functional efficiency after this conservative operation. Such cases are relatively few, since pathological processes usually involve the entire organ. Care must be taken also to ascertain that the blood supply is adequate and that the evacuation of urine /

urine is normal of the part that is to be left. If these conditions are fulfilled, then perfect repair and cicatrisation of the operative wound is possible, and function of the remainder of the kidney will be good.

Until recently, partial nephrectomy was considered appropriate only in cases of solitary cyst of the kidney, small localised benign tumour, in certain cases of renal trauma and cases of double kidney in which the pathological process affect only one of the excretory systems. Now, however, a new field of usefulness for the procedure has been found, namely in cases of renal lithiasis, such as the case under review.

On the problem of technique, the paper by Scholl and others (1942) should be consulted. They state the two fundamental problems to be (1) the assurance of circulation to the organ, together with complete haemostasis of the sectioned surfaces of the parenchyma; and (2) the reparation of the excretory tract where this has been interfered with. But whereas these authors advise the cutting of the remaining parenchyma as a wedge, as was done also in the present case, and the coaptation of the flaps for haemostasis, Joly (1929) maintains in his book that this is unnecessary and that a straight section gives the best results. Instead, he ties the vessels crossing the gap individually, a difficult procedure, as I gathered at this operation.

The development of the urinary fistula on the tenth day after operation was unfortunate but not serious as spontaneous closure is the rule. The cause of the fistula here was neither infection nor gross damage to the lower excretory unit. It was probably due to the catgut used to suture the renal flaps tearing or dissolving too early. Thus the wound in the kidney would gape again and a little urine would leak out. This is a likely explanation in view of the fact that some of the latest catgut has been definitely bad.

In our case, urine continued to leak through the fistula until the twentieth day. By that time it had practically closed and the patient was getting up slowly. Garcia and Galvez (1941) report a similar case of multiple calyceal lithiasis in a kidney with double pelves and ureters. A urinary fistula which appeared on the eighth day after operation and which discharged only when the patient was recumbent, closed spontaneously on the fiftieth postoperative day.

The other possible complication is haemorrhage, of which there was fortunately no sign.

Prognosis: The whole point about this conservative operation is the preservation of maximal renal function. That total renal function was good was shown by the latest blood urea nitrogen level of 14 Mgm.%. But function-tests will have to be carried out for each kidney individually for proper assessment. On the whole one would say that the outlook regarding his renal capacity was very good. The only point of doubt is whether stones will form again, due to some hidden underlying cause. The patient will be advised on the usual general points regarding diet, plenty fluid and regular exercise which are thought to reduce the chance of recurrence of stones. These are discussed of the/ later. Here, two predisposing factors found, one, the congenital abnormality, has been removed. The other, the lack of exercise, can also be overcome. All this should certainly better the prognosis.

C A S E III.

IMPACTED URETERIC CALCULUS

TREATED BY URETERO-LITHOTOMY.

Mrs Eugenia Brown, aged 24.
19 Albion Place, Edinburgh.

Occupation: Housewife.

Date of Admission: 18. 1.43.

Date of Discharge: 23. 3.43.

COMPLAINT:

Pain in the left iliac fossa for five months.

HISTORY:

In September of last year the patient first experienced pain coming down from the left loin into the left iliac fossa. This pain recurred several times and the week before admission she had a severe attack in which she was sick several times and sweated profusely. The pain was sharp and colicky and doubled her up. She found that she had a strong desire to pass water and the act of micturition relieved the pain. The urine was not discoloured. Since then she had a dull ache in the left iliac fossa but no serious colic.

The patient gave birth to a child in March 1942. During the pregnancy she had left-sided pyelitis but this settled down and there was no trouble until six months later.

In every other respect she was a healthy young woman. She ate, worked and slept well and had no headaches. Her bowels were regular and there was no loss of weight.

Outstanding amongst her previous illnesses was a thyrotoxicosis, for which thyroidectomy was done in September 1942. Since then her general condition stabilised.

The family history was negative.

CLINICAL EXAMINATION:

The patient proved to be an introspective and nervous person, which might have been a remnant of her previous hyperthyroid state.

Abdominal Examination:

Tenderness on deep pressure in the left iliac fossa at the level of the anterior superior iliac spine; otherwise abdomen was normal.

Rectal Examination:

Rectal Examination:

Some tenderness on deep pressure to the left side. The uterus and cervix were normal in position.

CARDIOVASCULAR SYSTEM:

Normal, apart from a fast pulse rate.

Other systems were normal.

URINE EXAMINATION:

Acid reaction.

No albumin and no surgar.

Microscopically: epithelial cells and a few coliform bacilli. Some pus cells. Cultures yielded a moderate growth of b.coli.

Blood urea nitrogen: 16 mgs. %.

Blood calcium and blood phosphatase normal.

UROLOGICAL REPORT:

Bladder normal. Both ureters catheterised - the right to 30 cm. and the left to 5 cm. where arrest occurred.

X-RAY REPORTS:Preliminary X-Ray:

Calculus present opposite left ischial spine.

Right pyelogram normal in every respect.

Left pyelogram: double ureter present and calculus seen to lie within one branch of the left double ureter just at its bifurcation of the ureteral orifice.

TREATMENT:

The treatment was by uretero-lithotomy carried out on the 19th January 1943 by Mr David Band, under spinal anaesthesia, as follows:-

An oblique incision was made in the left iliac fossa about one inch above the inguinal ligament. Having incised the abdominal walls, the ureter was approached retroperitoneally and it was identified by means of first noting the position of the common iliac artery and its external and internal iliac branches. The left ureter was bifid at this point and it was dissected free from surrounding fascia, and just about an inch or two below the bifurcation a stone was felt in its lumen. The ureter was then held up by two stay sutures and its lumen opened into between those sutures. A Desjardin's duct forceps was then passed down, and by milking up the ureter the stone was withdrawn. The incision in the ureteral wall was then closed up by three Lembert sutures, after having passed a catheter down the ureter and into the bladder to make sure that all stones had been removed. A rubber dam drain was left in and the abdominal wall was closed up in layers.

Pathological report showed that the calculus was moderately hard and contained albuminous material and leukocytes, as well as crystalline material. The latter appeared to be mainly a deposit of urates with a little phosphatic deposit as well.

After operation her general condition was good but the wound failed to heal and a persistent urinary fistula developed in the middle of the wound in the left iliac fossa.

Urological report at that time stated that there was stenosis at the lower end of the upper branch of the double ureter with a persistent urinary fistula. There was no urinary infection at that time.

After this fistula had been given every chance to heal but had refused to do so, and as the opposite renal tract was functioning perfectly, nephrectomy was decided upon and carried out on 23rd February 1943 under gas, oxygen and ether anaesthesia, by Mr David Band, as follows:-

A skin incision was made parallel to and two inches above the left iliac crest, very near the 12th rib, towards the midline of the abdomen. The external oblique, internal oblique and transversalis muscles were divided and the kidney exposed extra-peritoneally. The kidney was mobilised out of its fascia and both ureters caught in strong forceps and divided between ligatures. The renal pedicle was then divided between ligatures. The kidney was removed. A tube drain was inserted into the renal fossa and the abdominal wall sutured in layers.

After this both wounds healed perfectly.

The pathological report showed that the kidney presented considerable patchy loss of secreting tissue, indicating a low grade pyelonephritis.

The patient was discharged from hospital on the 23rd March 1943. The blood urea nitrogen was 13 mgs% when she went out of hospital.

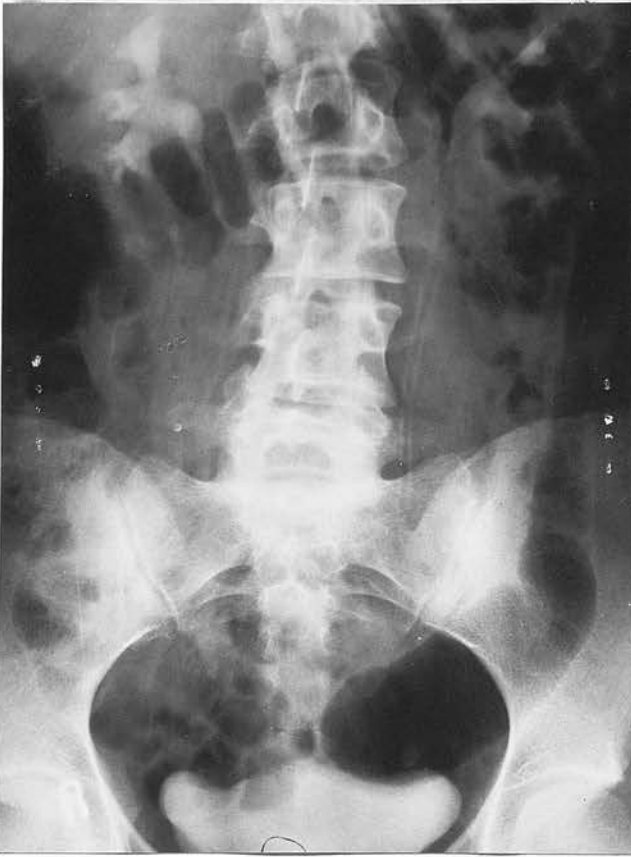

FIG. IX. Mrs Brown. 28. 8.42.

Intravenous pyelograms: Normal function right side; double ureter left side; normal left renal function; shadow opposite left ischial spine, possibly due to calculus.

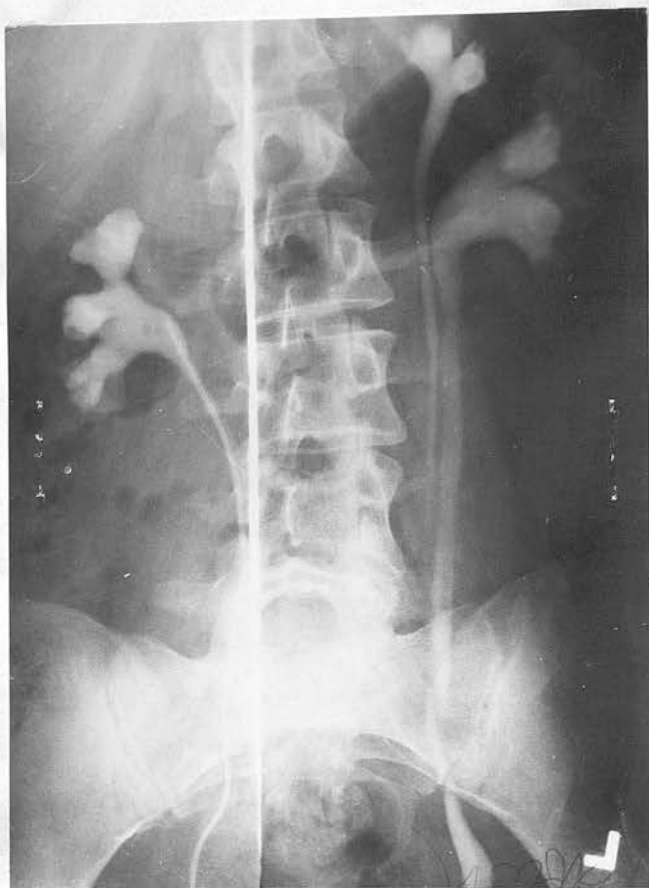

FIG. X. Mrs Brown. 25.11.42.

Retrograde Pyelograms: Shadow previous noted now seen to be almost certainly calculus in ureter, as there is poorly defined filling defect opposite ischial spine at junction of ureters. Moderate dilatation affecting lower calices and ureters supplying them.

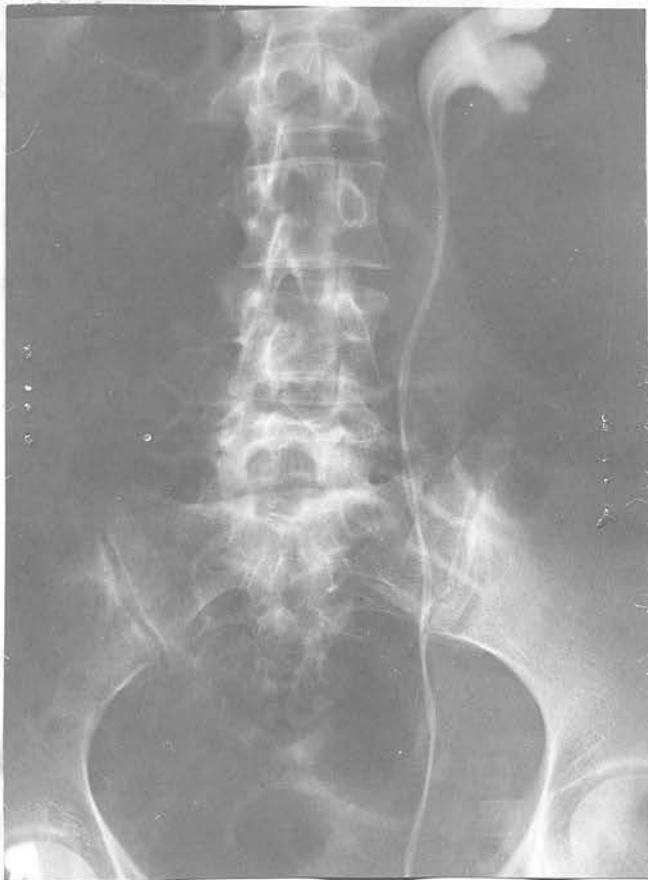

FIG. XI. Mrs Brown. 17. 2.43.

Retrograde Pyelograms: Now no opaque calculus seen. The lower ureter and renal pelvis only have been filmed and show less distension than previously.

COMMENTARY ON CASE III.

The interesting features in this case were

- (1) the possible aetiological factors of the previous pyelitis (July 1929), of the thyrotoxicosis (Egickson and Morrison 1942), and of the double ureter;
- (2) the fistula following uretero-lithotomy and
- (3) the low grade pyelonephritis found histologically in the kidney after operation.

The clinical features were classically those of recurring renal colic, and require no special explanation. Even after removal of the thyroid gland, she was a high-strung anxious woman, and her continual anxiety about her present disease and future health greatly increased the problems of nursing and treatment.

The low grade urinary infection was a remainder of the former pyelitis of pregnancy. The acid urine indicated that the stone consisted of urates or oxalates, which was later confirmed pathologically.

The diagnosis was never really in doubt, and was clinched by radiography. The only other likely condition to consider on the left side was an acute exacerbation of ~~old~~ pyelitis, and this was excluded by the lack of much pus in the urine and the absence of fever.

The treatment in such a young woman with the nervous instability described was at first as conservative as possible. The stone alone was therefore removed at operation.

But unfortunately a persistent urinary fistula developed from the wound in the ureter. This had two causes - (1) a stenosis just below the site from which the stone had been removed, forcing the urine to find another way out, and (2) the slight infection/

UROGENITAL SYSTEM CASE IV.

RENAL AND VESICAL CALCULI, OSTEITIS
 DEFORMANS AND SIMPLE HYPERTROPHY OF PROSTATE

TREATED BY REMOVAL OF VESICAL CALCULUS
 AND TWO STAGE PROSTATECTOMY.

William James Chalk, aged 67.
 8 Forbes Road.

Occupation: Retired Schoolmaster.

Date of Admission: 4. 4.43.

COMPLAINT:

Urgency of micturition for two months.

HISTORY:

The patient first had an attack of urgency of micturition and straining when he passed water seven years ago. He was examined at that time and told that he had cystitis. The trouble passed away.

For two months before admission he had urgency and great frequency of micturition. He passed water every hour or so and had to rise two to four times at night. He had no dysuria and no incontinence. Occasionally there were dragging sensations in the lower abdomen and in the penis, especially after waking. He described the urine as being very hazy and having chocolate-coloured bits of matter in it. He had never noticed any blood in the urine. About three months ago he had pain in the left leg which was worse at the knee. It was a continuous ache, sometimes round the back in the calf, sometimes in the front. It was not due to walking or overstrain of the muscles. The thigh felt weak, as if the leg could not bear the weight of the body. He had no numbness or paresthesiae in the leg. These symptoms disappeared one month ago. His general deformity was present for a good number of years. He first noticed his legs becoming bent and later he developed a hunchback. His head also grew in size. His health generally was quite good. He ate well and had no digestive troubles but the bowels were loose for many years. The colour of the stool was blackish or dark brown. He had no loss of weight. There was some cough and spit but no breathlessness. He had very little exercise of late. Previously he had "cystitis and an infection of the right testicle" 22 years ago. He often had bronchitis.

The family history was negative.

CLINICAL EXAMINATION:

The patient was an intelligent man with a large bossy skull and sharp features. He had a marked kyphosis at the lower thoracic region and stooped forward. His legs were bowed outward and forward. He found great difficulty in walking.

UROGENITAL/

UROGENITAL SYSTEM:

The abdomen was soft and well-covered. The kidneys were not palpable. There was no tenderness in the renal regions or over the bladder.

Rectal Examination:

A greatly enlarged and firm but not hard prostate was revealed.

URINE EXAMINATION:

Reaction acid.
 Albumin + .
 Sugar - .
 Very many pus cells and epithelial debris.
 Many oxalate crystals.
 Blood calcium 9.5 mgs.%.
 Blood phosphatase 0.86 units (Kay).
 Blood urea nitrogen 18 mgs.%.
 Plasma chlorides 600 mgs.%.

CARDIOVASCULAR SYSTEM:

Blood pressure 170/110.
 Pulse 86, regular in time and force. Poor volume. Vessel wall tortuous and hard.

Heart: apex beat in 5th space outside mid-clavicular line. Systolic murmur in mitral area. Second aortic sound accentuated.

RESPIRATORY SYSTEM:

Chest barrel shaped. Ribs stood out. Percussion note was resonant. Breath sounds harsh, vesicular in all areas.

HAEMOPOIETIC SYSTEM:

Hb. 76%. W.B.Cs. 8,000.

UROLOGICAL EXAMINATION: 7. 4.43.

Bladder capacity reduced. Bladder walls very inflamed, with a large stone present. Bladder neck was oedematous and contracted. Prostate was enlarged and firm and tender from prostatitis.

Urine:

Many gram-negative bacilli.
 Culture: A profuse growth of b.coli.

X-Ray Report:

Calculi in right kidney and bladder. Advanced Paget's disease of bone. Osteitis deformans.

Treatment/

TREATMENT: *pathological report on the prostate*

As soon as he came in a tidal lavage of the bladder was put up and 1/1,000 Silver Nitrate used to irrigate the bladder. Sulphathiazole and Pot. Citrate were given in full doses. All this helped to clear up the cystitis.

On 13.4.43 under spinal anaesthesia, Mr David Band performed a suprapubic cystostomy, as follows:-

A midline incision was made from below the umbilicus to two inches above the pubis. The anterior rectus sheath was divided, the recti muscles were separated and the space of Retzius was opened up. The peritoneal reflection was dissected upwards from the bladder and the bladder wall caught in two peritoneal forceps.

A stab incision was made into the bladder and its contents allowed to escape. A finger was then inserted into the bladder and the vesical calculus removed. This stone was gray and yellow in colour, oval in shape and about 2 cms. long and 1 cm. broad. The prostate was felt to be greatly enlarged. A de Pezzer catheter was then inserted into the bladder and the bladder wall closed round it. The abdominal wall was then closed in layers. A piece of rubber dam was left extruding from the space of Retzius, as a drain. The catheter was connected to a drainage system.

The pathological report on the stone was as follows:-

Weight 3.65 gms.

Mainly calcium oxalate with Magnesium and Calcium phosphates. Also albuminous material.

Murexide Test:

Negative.

After the suprapubic cystostomy the urinary tract was quite free, and with the clearer urine the symptoms begun to abate.

On 3. 5.43 under gas, oxygen and ether anaesthesia, Mr David Band performed a suprapubic prostatectomy, as follows:-

The bladder was filled with weak Silver Nitrate through the indwelling de Pezzer catheter, which was then removed. The suprapubic wound was excised and the recti muscles were separated. The bladder was identified, the peritoneal reflection was dissected upwards and the bladder was opened again. A self-retaining retractor was inserted and the bladder was inspected. The retractor was then removed and with one finger of the left hand in the rectum the hypertrophied part of the prostate was enucleated from its bed with the right hand. Bleeding was not excessive. The prostatic bed was packed firmly, any little tags of prostatic tissue being removed by fringectomy forceps. A Freyer's tube was inserted into the bladder and the bladder and abdominal wall were closed in the usual way. A rubber dam drain was left in the space of Retzius. The catheter which was held in the Freyer's tube by a spiral wire, was connected to a little suction pump for continuous bladder suction.

The pathological report on the prostate was as follows:-

Glandular hyperplasia of prostate.
No evidence found of malignancy.

Since that operation his progress was very good. The suprapubic wound healed in and the de Pezzer catheter was taken out on the 28th May, after some urine had passed in the normal way.

Bougies were passed on him and he is now nearing the end of the wet stage. His general condition is very satisfactory.

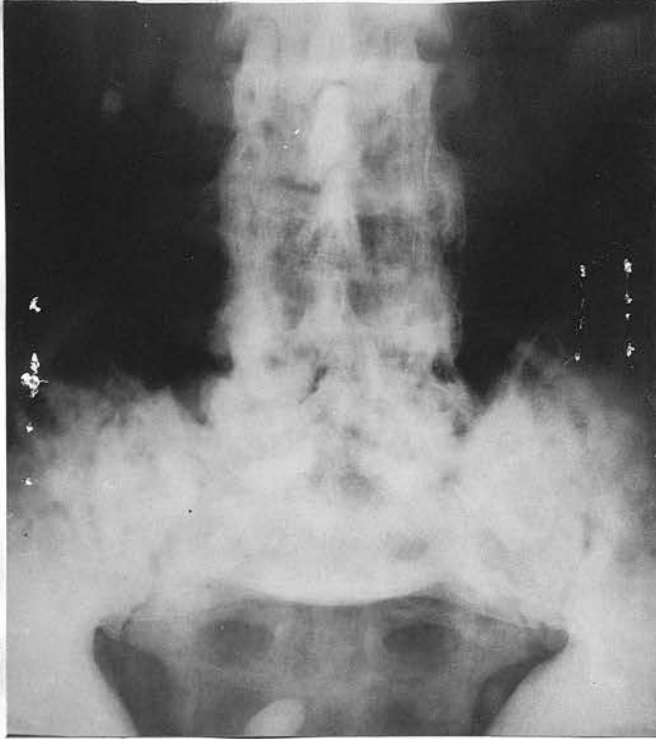


FIG. XII. Mr Chalk. 6. 4.43.

Straight X-Ray of Abdomen: shows very advanced irregular sclerosis and osteoporosis of lumbar spine, indicative of osteitis deformans. Also shadow in right renal region, probably calculus.

FIG. XIII. Mr Chalk.

Straight X-Ray of skull: shows irregular sclerosis of the skull bones indicative of osteitis deformans.

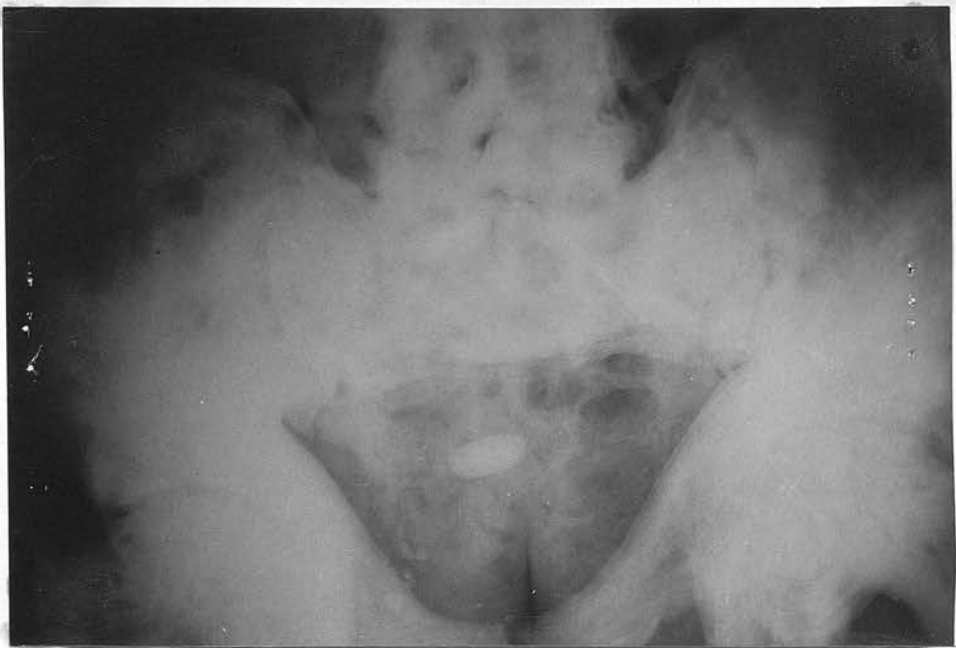

FIG. XIII. Mr Chalk. 6. 4.43.

Straight X-Ray of Pelvis: Advanced osteitis deformans affecting pelvic bones. Large bladder calculus.

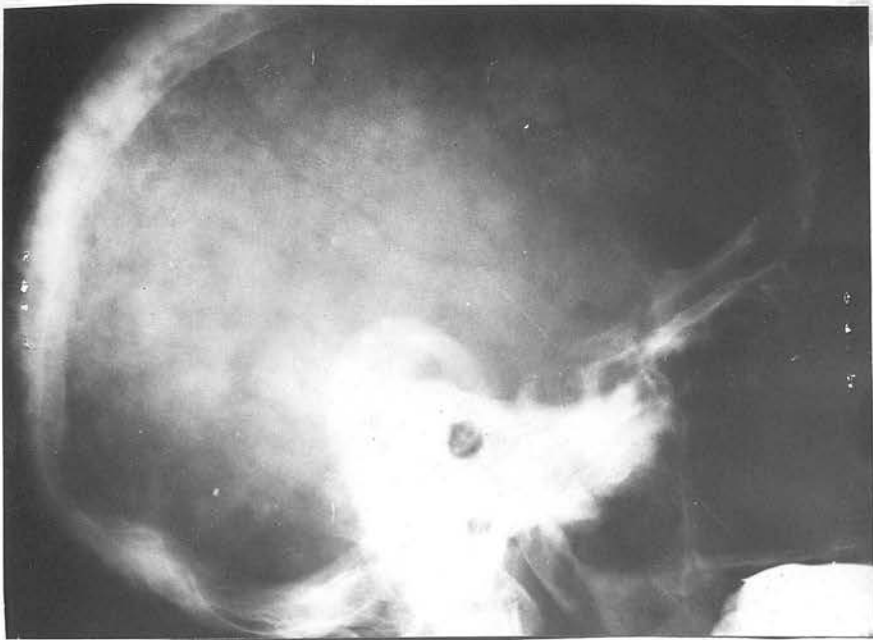


FIG. XIV. Mr Chalk. 6. 4.43.

Straight X-Ray of Skull: shows great thickening of the skull bones indicative of osteitis deformans.

COMMENTARY ON CASE IV.

The feature of particular interest in this case was the presence of Osteitis Deformans, which may well have a causative connection with the calculous disease. The aetiology is more fully discussed later.

Clinically, the long history of recurrent cystitis seems to show that infection existed long before the prostate enlarged and gave rise to urinary stasis. There was no evidence of gonococcal infection formerly.

The stones in the right kidney formed quietly without attempting to pass down to the bladder, for there was no renal colic. The vesical stone, therefore, must have originated in the bladder, and that was only to be expected in such an inflamed organ in which cellular debris and stale urine together made a deposition of crystalloids inevitably. The roaring cystitis masked any symptoms that the bladder stone might have given rise to by itself. There was no evidence of renal failure.

The enlarged prostate blocked the way out, and thus if a stone once formed, it could never leave the bladder but went on growing in it. The prostate was at first thought to be malignant because of its very firm consistence, and the pains in the left leg were explained as being due to metastatic deposits. But the pathological report indicated simple prostatic hypertrophy, and the leg pains were probably those often found in osteitis deformans. (Donald Hunter).

The diagnosis of the cystitis was easily made, and the enlarged prostate was discovered on routine examination of the rectum. The man was so typically

a case of Paget's disease when I looked at him that radiography and the raised blood phosphatase were only necessary for strict confirmation. The bowing of the legs was so bad that they could not be sufficiently separated for cystoscopic examination to be carried out.

Treatment. The principle that it is useless to treat urinary infection without first removing obstruction to the outflow was well illustrated in this case. It was obvious that to clear up such a frightful inflammation, one would have to remove the obstructing prostate. But conversely, before prostatectomy could be safely attempted, the bladder infection must settle. Therefore, suprapubic drainage was instituted and the irritating calculus removed, as a first stage. This free drainage could then be helped by continuous antiseptic bladder lavage, and by Sulphonamide drugs and much drink.

The technique of tidal lavage used here is to connect the indwelling catheter by a three-way junction to a reservoir of silver nitrate solution raised up on a stand, and to a collecting bottle on the floor. The tube to the collecting bottle is first led upwards to a level of about 72 to 84 inches above that of the pubic symphysis, before descending to the floor. A drip connection below the reservoir allows the bladder to fill at any desired speed. When the bladder walls have reached a certain distension and the intravesical pressure has reached a certain height, reflex contractions of the bladder wall occur, raising the pressure further and forcing some of the fluid in the bladder up and over the elevated part of the outflow. The rest of the bladder/

bladder contents then drain away in a rush by syphonage. The cycle repeats itself automatically.

Three weeks later, the infection had abated and the prostate was removed by the suprapubic route. After that, healing proceeded uninterruptedly.

No treatment has yet been discovered for Paget's disease. Paget himself treated his patients with large doses of potassium iodide, but he was never very enthusiastic about this method. Orthopaedic measures to straighten the limbs were not indicated in as old a man as Mr Chalk.

Prognosis. With the healing of the prostatic wound and the arrest of the cystitis, all his urinary symptoms should vanish, and soon control of micturition should return to normal. The immediate prognosis is therefore good.

There is now no evidence of decline in renal efficiency, but the right kidney still contains a stone and it is possible that the obstruction has caused moderate hydronephrosis. Hence renal failure is a late possibility.

This, together with the arterio-sclerotic hypertension of Paget's disease, may lead to premature death. The present deformities by themselves are not dangerous to life. Considering everything, the outlook for an active future is poor.

C A S E V.

RIGHT RENAL COLIC

TREATED CONSERVATIVELY DURING A PREGNANCY.

Mrs Vera Connolly, aged 24,
1 Albany Street, Leith.

Occupation: Housewife.

Date of Admission: 17. 5.43.

COMPLAINT:

Pain in the left side for five years.

HISTORY:

In 1938 at Walton Hospital the patient had an attack of what she was told was acute renal colic on the ~~left~~ side. Since then she had attacks of this ~~left~~-sided pain every now and then. These were particularly severe during April 1943.

On the day of admission she felt a sudden sharp colicky pain on the ~~left~~ side. She fell on the floor and rose in agony, feeling very cold and faint at the same time. The pain continued until after admission to hospital, when it was relieved by anti-spasmodic drugs. She also complained of sickness and of frequency of micturition, for some time past.

The history of the pregnancy was that the last menstrual period was in October 1942, but she had felt herself getting stouter before that and thought herself pregnant. Quickening was first felt at the new year. She was well up till April, when the attacks of pain began. She already had two children, one born in February 1938 and the other in July 1940. Her health otherwise was very good. Previous illnesses and family history were irrelevant.

CLINICAL EXAMINATION:Abdominal Examination:

Patient was seven months pregnant. The fundus was three fingers breadth below the xiphisternum. The foetus was breech presentation but the breech The position was R.S.L. The foetal heart was easily heard above the umbilicus.

There was definite tenderness in the left loin but no tenderness anywhere else in the abdomen.

Cardiovascular and Respiratory Systems were normal.

Blood urea nitrogen: 10 mgs. %.

Blood calcium and phosphatase normal.

URINE EXAMINATION:

Acid reaction.

Albumin + +

Heavy deposit of pus cells.

Calcium oxalate crystals.

X-RAY REPORTS:Renal Tract:

A large collection of opaque calculi was present in the left kidney. There was a single foetus of about 8 months, breech presentation, R.S.L.

TREATMENT:

On admission Pethidine, 25 mgs., was given by mouth, but this failed to relieve the severe renal colic. The pain was abolished by Morphia grs.1/6. In view of the advanced state of the pregnancy, conservative treatment was decided upon until the baby was born.

The frequent attacks of pain were controlled by Pethidine in 25 or 50 mg.doses and later, when Pethidine began to lose its action, by Morphia grs.1/6. By the 24th May 1943 the patient generally required at least two injections of Morphia grs.1/6 in each 24 hour period. On the 26th May 1943 the patient had an attack of haematuria but this soon passed off.

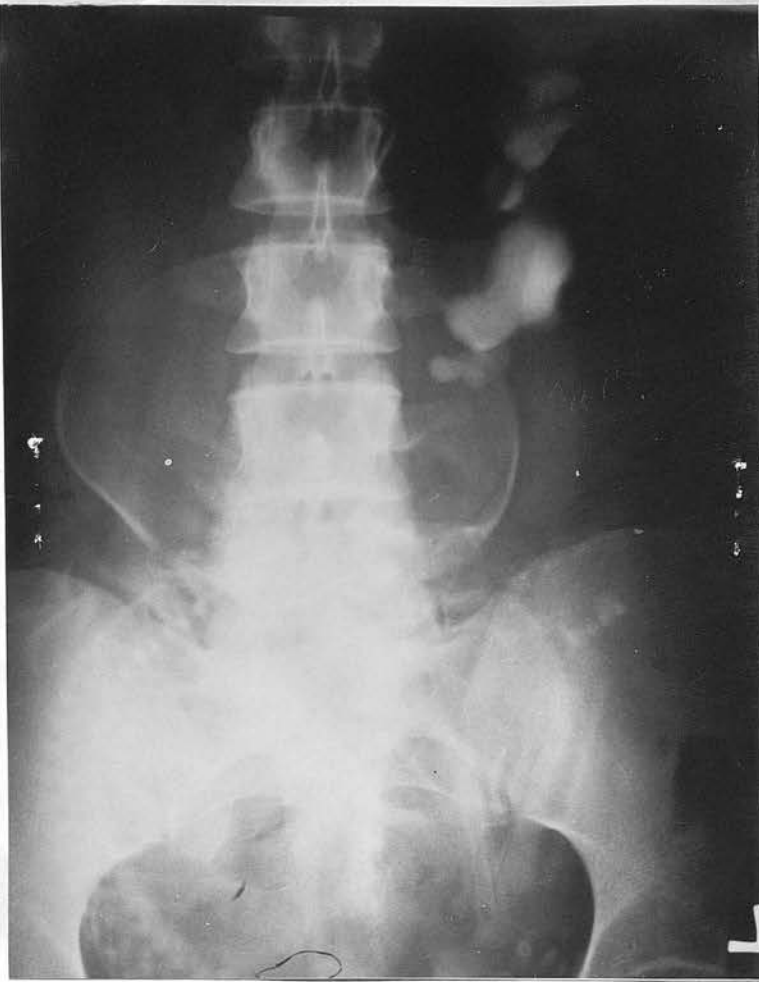

FIG. XV. Mrs Connolly. 18. 5.43.

Straight X-Ray of Abdomen: Large collection of opaque calculi present in the left kidney. There is a single foetus of about eight months, breech presentation R.S.L.

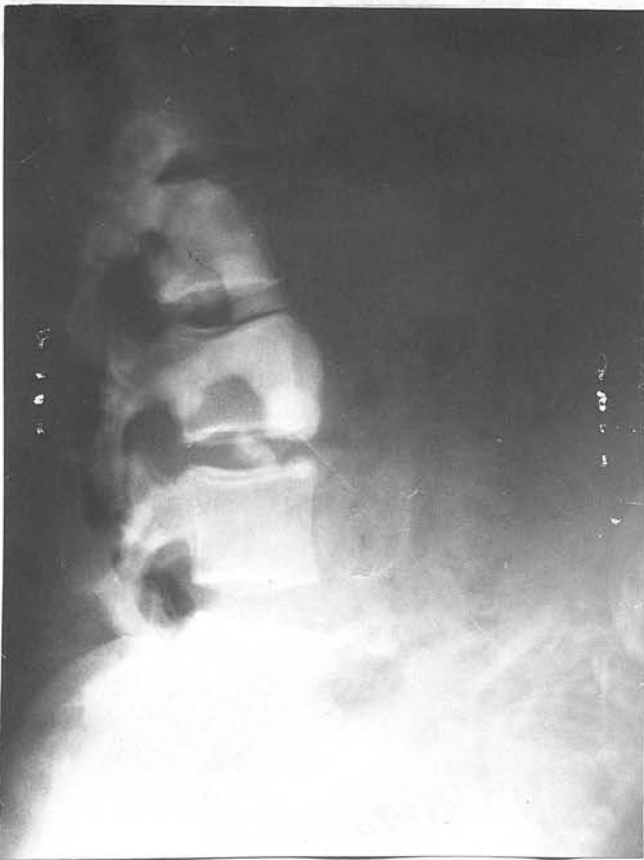

FIG. XVI. Mrs Connolly. 18. 5.43.

Right lateral view of Abdomen showing calculi in position of renal pelvis.

COMMENTARY ON CASE V.

The features of interest in this case were:

(1) The pregnancy as a complicating factor in the clinical examination, diagnosis and treatment of the calculous disease. (2) The presenting symptom of renal colic, in spite of the fact that the stones as seen radiologically were far too big to pass down the ureter. One would have expected the pain to be more of the nature of a constant ache in the loin, analogous to that felt by Mrs. Boyce (Case I), who had the splitary renal calculus which was too large to pass. It is, of course, possible that some smaller concretions which were not shown up by X-rays were constantly passing down the ureter and irritating its walls. The questions of the different types of renal pain are most interestingly discussed by Osler, who spoke from personal experience. (3) The youth and general good health of the patient. In this, she compares with Mary Shepherd (Case VI). It is a curious fact, commented on by several writers, that renal calculus frequently occurs in young and otherwise healthy people. This is of concern in aetiological considerations.

The pregnancy made it imperative to look at all the symptoms ^{at} a new angle. The differential diagnosis was from those conditions commonly occurring in pregnancy. The sudden pain made one think of acute pyelitis, and this would explain the heavy deposit of pus cells in the urine. But the long history of right-sided pain, as well as its colicky nature, pointed the way to the correct diagnosis. There were also neither rigor nor fever. Sickness is not only a common accompaniment of renal colic, but is often found in pregnant women. It occurs, however, usually in the earlier months. Frequency of micturition is common both in normal pregnancies and in pyelitis.

Radiography put the diagnosis beyond doubt, and at the same time of course showed the position, presentation and approximate age of the foetus. The kidney was so full of stones that its functional value could only be negligible. The opposite renal tract appeared to be normal. In this case, the use of contrast media to show up further detail radiologically was not necessary and, during the course of the pregnancy, certainly undesirable.

The urine was acid and contained oxalate crystals. So the calculi probably contain a good proportion of oxalates, but other things as well, for it is rare for pure oxalate stones to reach a large size (July 1929). The numerous pus cells in the urine are almost certainly an indication of infection. There were too many of them to be due to trauma and bleeding, as in many of the other cases. It may be that she did have an acute urinary infection in her first pregnancy, for details about her first attack of pain could not be obtained.

Treatment: As the patient was ^{nearly} in the eighth month of pregnancy, treatment was of as much concern to the obstetricians as it was to the surgeons. Both parties agreed that medical measures only were, of course, to be used till well after the termination of the pregnancy. The renal pains were not severe enough to indicate premature induction of labour, but this step could always be taken later if necessary, for the foetus had reached a viable age. In any case, it was likely that severe long-continued colic would induce labour by itself.

In this case, antispasmodic drugs like Atropine and Pethidine were indicated in full doses. For, unlike Case VI, the pains of renal colic here were not "useful" pains - that is, they did not mean that a stone was being expelled. The pains of Mrs. Connolly got her nowhere /

nowhere, and therefore it was right to stop them. the difficulty came, when tolerance began to be established to Pethidine so that it lost its action. Recourse had then to be made to the opiates, and the question was whether doses large enough to control the pain would not at the same time harm the foetus. It was found that Morphine gr.1/6 had no ill effect apart from a temporary slowing of the foetal heart-rate. Whether the repetition of such doses at frequent intervals leads to foetal injury, it is too early to say here. At the time of writing, this particular foetus is very much alive, as his mother testifies, and its heart is heard strongly and regularly. (See Balch, 1942).

Apart from antispasmodic and analgesic drugs, the usual method was adopted of giving much fluid by mouth and of reducing the acidity of the urine by alkaline mixtures with potassium citrate.

After this pregnancy is over, surgical treatment will have to be considered. If renal function tests then corroborate that the left kidney is useless and that the right kidney is working well, with adequate reserve, the diseased kidney will probably be removed. After that she will be advised regarding the diet, from which all much oxalic acid-containing foods will be cut out. She will also have to continue much drinking and if possible, to alkalinise her urine: All this to prevent oxalate stones- and others- from forming again.

Prognosis: It is possible that during pregnancy one useless kidney throws too great a strain on the other one. A lookout must therefore be kept for pre-eclamptic toxæmia, which may become more likely. If renal failure should develop, Caesarian section may have to be done. In that case the ultimate outlook is bad. Pregnancy is the great testing time of the kidneys, and if she gets normally over this pregnancy without symptoms of renal strain /

strain, then the outlook is good. The pains of renal colic will be stopped by nephrectomy, after which remains only the problem of the recurrence of the stones, as in all the other cases. If the stones were associated with left-sided infection, then there is less danger of lithiasis on the sterile right side. To make recurrence still more unlikely, the oxalate intake is reduced to a minimum.

Date of Admission: 5. 3. 45.
Date of Discharge: 20. 3. 45.

COMPLAINT:

Severe pain in the left side for four days.

HISTORY:

Four days ago in the late afternoon while at rest the patient was seized with a sudden and acute pain in the left side of the abdomen. The pain radiated round to the loin and down to the left thigh. It was severe and colicky in nature. It doubled the patient up and made her cry. Within a few minutes of the onset of the pain the patient vomited but this did not relieve the pain.

Between that time and admission to hospital the pain went away occasionally, but always came back and was associated with vomiting. She also noticed some frequency of micturition but the urine was never bloody stained. She was constipated and the bowels did not move from the onset of the pain till three days later. At the time of admission the patient was still in severe pain. Since the symptoms began she had lost her appetite completely and only took cups of tea and a little light food. She had never had a pain like this before.

Her general condition was good. She had not been losing weight and had been quite fit for her work. She lived a quiet indoor and sedentary life, she slept well and was not troubled with headache. Her appetite was normally good and her bowels were regular. She had had no serious illnesses previously and had no history of urinary disease in the 15 years before she was seized with the present attack. There was a fracture of both leg-bones

CLINICAL EXAMINATION:

The patient was a well-built young girl. She did not look notably ill but her tongue was moist and her pulse was fast. Her temperature was normal on admission but soon settled to normal.

C A S E VI.

RENAL COLIC DUE TO A SMALL CALCULUS

TREATED CONSERVATIVELY,

WITH NATURAL PASSAGE OF STONE.

Miss Mary Shepherd, aged 17.
c/o Mrs Bain, 19 Grange Road.

Occupation: Art Student.

Date of Admission: 3. 2.43.

Date of Discharge: 20. 2.43.

COMPLAINT:

Severe pain in the left side for four days.

HISTORY:

Four days ago in the late afternoon while at rest the patient was seized with a sudden and acute pain in the left side of the abdomen. The pain radiated round to the loin and down to the left iliac fossa. It was severe and colicky in nature. It doubled the patient up and made her cry. Within a few minutes of the onset of the pain the patient vomited but this did not relieve the pain.

Between that time and admission to hospital the pain went away occasionally, but always came back and was associated with vomiting. She also noticed some frequency of micturition but the urine was never blood-stained. She was constipated and the bowels did not move from the onset of the pain till three days later. At the time of admission the patient was free from pain. Since the symptoms began she had lost her appetite completely and only took cups of tea and a little light food. She had never had a pain like this before.

Her general condition was good. She had not been losing weight and had been quite fit for her work. She lived a quiet indoor and sedentary life. She slept well and was not troubled with headaches. Her appetite was normally good and her bowels regular. She had had no serious illnesses previously and there was no history of calculous disease in the family, but 5 years ago she was in bed for many months with a fracture of both leg-bones.

CLINICAL EXAMINATION:

The patient was a well-built young girl. She did not look acutely ill but her tongue was heavily furred and her pulse was fast. Her temperature was 99°F. on admission but soon settled to normal.

ABDOMINAL/

ABDOMINAL EXAMINATION:

There was no rigidity anywhere but definite tenderness in the left loin and renal angle. This tenderness was also present in the line of the left ureter.

URINE EXAMINATION:

Acid reaction.

No albumin and no sugar.

Microscopically:

A few pus cells and some red blood cells were seen in a catheter specimen.

Blood urea nitrogen was 12 mgs. %.

Blood calcium and phosphatase were unfortunately not estimated.

UROLOGICAL EXAMINATION: 5. 2.43.

The bladder was normal and right ureteral orifice normal. The left ureteral orifice showed surrounding mild congestion. Right and left ureters were catheterised with ease and clear urine obtained from each.

X-Ray Report:

Pyelogram right:

Normal.

Pyelogram left:

Pyelogram showed failure of filling owing to low position of ureteral catheter. There was, however, a shadow seen in the line of the ureter which was thought to be a ureteral calculus. On refilling the pelvis and taking an oblique film the above-mentioned shadow was found to remain in the line of the left ureter.

Bacteriological report of urine was negative.

The conclusion was left ureteral calculus with some renal dilatation involving especially the calices.

TREATMENT:

On admission she was given plenty of fluid to drink and the first attack of pain was arrested by giving Morphia grs. $\frac{1}{4}$ and Atropine Sulphate grs. 1/100 given subcutaneously. Medical treatment was decided upon and thereupon all urine passed by the patient was carefully strained to observe any stone that might be passed.

4. 2.43. In the early hours of this morning she was seized with severe colic. This was relieved by Morphia grs. $\frac{1}{4}$ and Atropine grs. 1/100. After a cup of tea she vomited. She was comfortable till 6.2.43 when there were three attacks of pain, which were controlled by Pethidine tablets in doses of 50 mgs. given by mouth. The pain stopped about half-an-hour later. On 8.2.43 the patient had great pain during the night which was not relieved by Pethidine tablets orally but dispersed by Pethidine/

Pethidine 1 c.c. intramuscularly. The pain stopped then after ten minutes. After this date she had no more pain at all and was discharged home on 20.2.43.

Radiography then showed the stone to be passing down the ureter and to have almost reached the bladder.

A letter was sent to her own doctor telling him that Pethidine was found to have been effective and should be used if there was any further pain in the final passage.

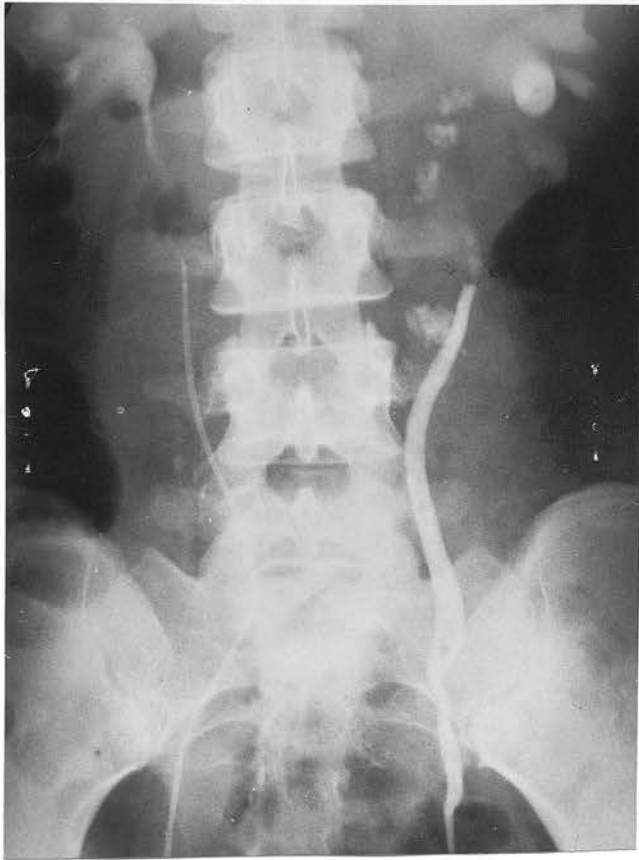

FIG. XVII. Miss Shepherd. 5. 2.43.

Retrograde Pyelograms: Right side normal. Left pyelogram showed failure of filling owing to low position of ureteral catheter. There was, however, a shadow seen in the line of the ureter thought to be a ureteral calculus.

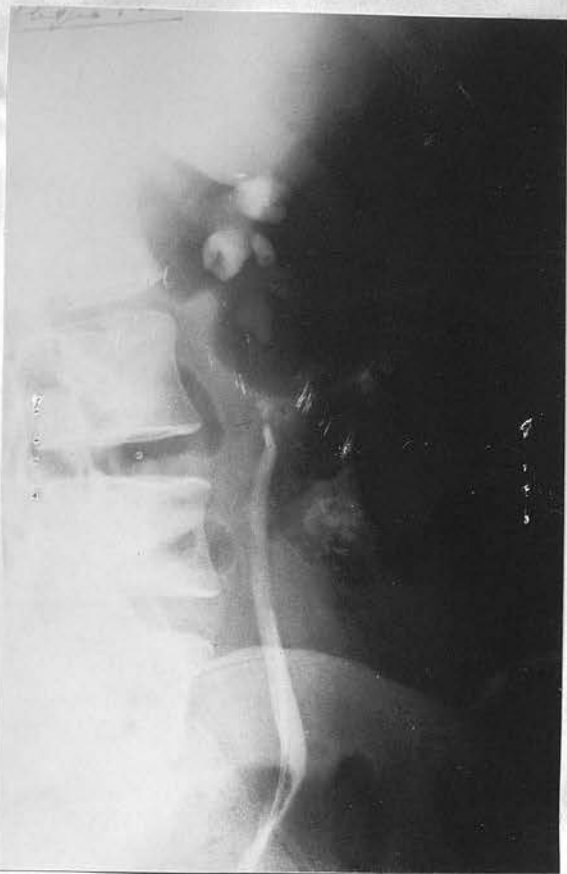

FIG. XVIII. Miss Shepherd. 5. 2.43.

Pyelogram: On refilling the pelvis and taking an oblique film the above-mentioned shadow was found to remain in the line of the left ureter.

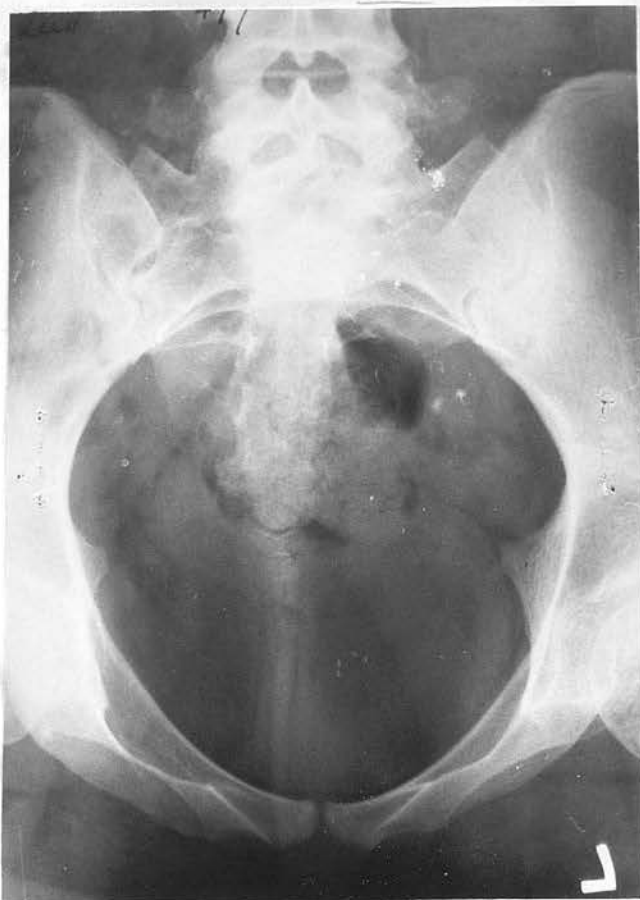

FIG. XIX. Miss Shepherd. 13. 2.43.

An opacity below sacroiliac joint, probably the calculus which has moved down the ureter, as it was not seen there previously.

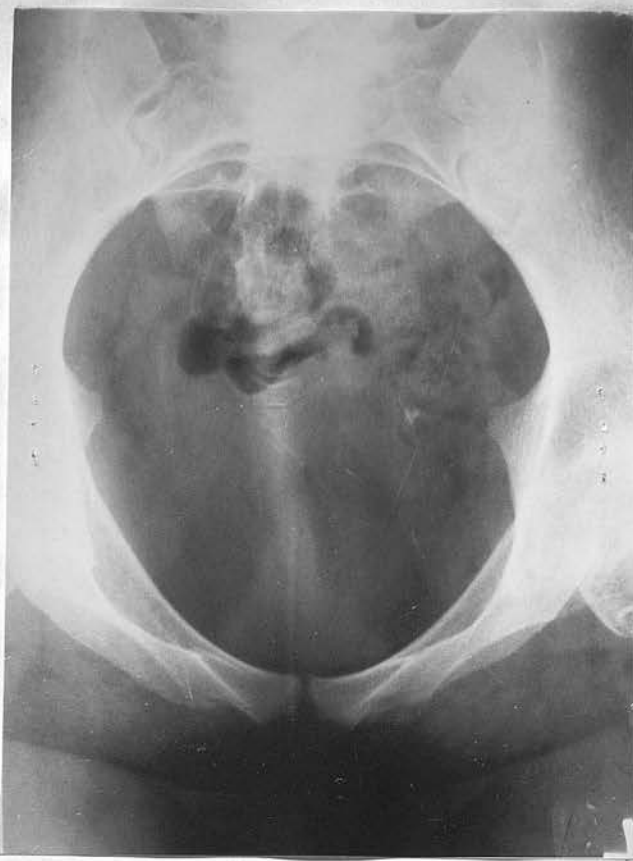

FIG. XX. Miss Shepherd. 18. 2.43.

The calculus has moved further down and is now opposite the ischial spine.

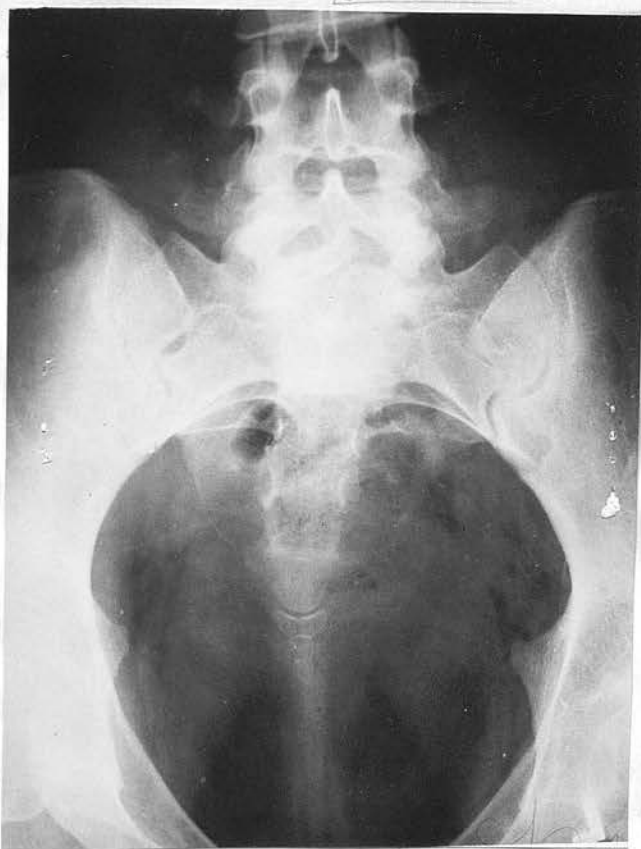

FIG. XXI. Miss Shepherd. 8. 3.43.

Now no calculus can be seen anywhere in the pelvis.

COMMENTARY ON CASE VI.

The interesting features of this case were (1) the youth and otherwise good health of the girl, so that the only obvious predisposing factor was her sedentary occupation; and the fracture; (2) the pursuit of the stone throughout the whole length of its journey by radiography and (3) the conservative treatment adopted, especially the use of pethidine.

The clinical features were those of renal colic. The spasms of pain lasted altogether for nine days, so that the stone took nine days to pass from the renal pelvis to the bladder. This is quite a short time in comparison to the other cases we have seen here, which often went on for weeks with only brief remissions. The total duration of colic depends upon many factors, in which the size of the stone and the activity of the ureter are the two most important ones. In this case the stone was small and the ureteric action was rigorous for the attacks of colic were frequent. Hence the rapidity of passage. The few pus cells in the urine are due to traumatic inflammation.

The diagnosis again was easy, and x-ray photographs showed one small opaque calculus in the upper ureter, which was followed by repeated x-rays all the way down to the bladder, and had probably been passed without giving rise to further symptoms.

The treatment here was conservative. Operation was contraindicated (1) because the youth of the patient made it undesirable on account of the loss of time and general upset involved; (2) because it was hoped that such a little stone would soon be passed/

passed naturally, as indeed it was and (3) because there was the chance that in future stones might form repeatedly, since no cause amenable to treatment was discovered.

Fluids were forced to increase the secretion of urine and to dilute it, so that crystallisation might be reduced. The urine was made amphoteric by the alkaline potassium citrate in order to change the acid environment which had probably favoured formation of the stone. (W.Langdon Brown and Geoffrey Evans).

The attacks of colic were treated first by Morphine and Atropine. Morphine "relieves pain more efficiently than any other drug" (Clark) and hence it is most useful in the severe pain of renal colic, especially if combined with Atropine which inhibits smooth muscle and so damps down ureteric spasm. Later, the comparatively new drug pethidine was used. This compound is analgesic (1) by relaxing spasm of smooth muscle and (2) by raising the pain threshold. (Eisleb and Schaumann 1939 and Duguid and Heathcote 1940). It is reputed to be a valuable substitute of Morphine in relieving pain without impairing the consciousness or the co-ordination of the patient (Branwood 1943) but may be habit forming (Himmelsbach 1942). In the present case it acted well in relieving pain. There was little danger of addiction in such a short time, but some degree of solevance did appear to be established. Pethidine will be more fully discussed later.

The prognosis is governed by the question whether more stones are going to form in the future. At the moment the general prognosis is excellent, for no renal damage is likely, but if calculous disease were/

were to recur, the usual pathological sequelae might commence. Even if this was avoided, life would be made a misery by the dreaded pains. All possible steps should therefore be taken to find and, if possible, eliminate any known cause, such as Vitamin A deficiency and the lack of exercise. If this is done, the outlook is as good as one can make it.

DISCUSSION.

AETIOLOGY. It is difficult to discuss causation in relation to so few cases. The findings of those who had material of statistical value available to them must be applied to these cases. Statistical considerations are very important in renal lithiasis. It is not possible to point out THE case of the disease. Note one but many factors enter into its aetiology.

These factors can be grouped into those which MUST be fulfilled before a stone can form, and those which predispose to stone.

A. FACTORS ESSENTIAL FOR THE FORMATION OF STONE. Here a brief note on urinary Biochemistry is necessary. For a detailed account, Swift Joly's treatise should be consulted.

The urine is a complex fluid which contains many substances in molecular, ionic or colloidal solution. The stone-forming substances can be divided into crystalloids and colloids.

The principle CRYSTALLOIDS are uric acid and urates, calcium oxalate and carbonate and various phosphates. The Uric compounds come from 1) the food, in which it occurs as various nucleo-proteins in meat, and ii) the endogenous metabolism of the body, as the result of the breakdown of cellular tissues. Oxalates are derived from food as the calcium salt, particularly from such vegetables as spinach and rhubarb. An endogenous source must also exist, for oxalates are excreted even in extreme starvation. Phosphates are derived from food; in the blood they circulate partly as inorganic sodium phosphate, but mostly as organic nucleo-proteins. The nucleic acid contains four molecules of phosphoric acid. The kidney contains a ferment, phosphatase, which splits off the inorganic salt from the organic substance

This /

This is probably of great importance in relation to the aetiology of stone in the case of Mr. CHALK, the patient with osteitis deformans, as explained later.

The stone-forming salts in the urine are all only sparingly soluble. Normal urine is always a strongly supersaturated solution of these substances, which do not obey the ordinary laws of chemical solution. This abnormal solubility was found to be due to the presence of certain colloids in the urine (Lichtwitz, 1919). The chief colloids are mucin, nucleic acid and chondroitin; their origin is still obscure. These colloids exert a protective action tending to prevent precipitation of the salts. Several theories have been advanced to explain this action (Schade, 1923). The theory most in accordance with observed facts is that adsorption of the crystalloids onto the colloid takes place, so that the solubility of the stone-forming salts in the urine depends upon the state of subdivision of the urinary colloid. If the colloid coalesces, these salts will be thrown out of solution. If the colloid ages so that its surface area is reduced, some of the salts adsorbed crystallise out, though they do not precipitate completely.

When the colloidal protection is reduced, a deposit forms. When this deposit occurs in the urinary passage, a stone may form around it. The stones that may form are classified into primary or pure stones and secondary or mixed stones.

A PRIMARY CALCULUS is one which forms in an apparently healthy urinary tract, of substances that are normally present in the urine. It has no preformed nucleus. None of the stones analysed in this series of cases were of this nature, although it is likely that MARY SHEPHERD suffered from this kind. The mode of

of formation was probably somewhat as follows: Some predisposing factors were present, say physical inactivity, causing slight urinary stasis. The colloid aged and some crystals were formed, usually in the lower calyces which are the worse drained part of the tract. Being in a supersaturated solution, the largest crystal grew at the expense of the smaller ones (Bayliss, 1924). This went on until ultimately a visible calculus was formed. MARY SHEPHERD's small stone was visible on the X-ray films and must have contained calcium salts.

SECONDARY CALCULI are far commoner than primary ones. The stones of Dr. BATH, Mrs. BROWN and Mr. CHALK were all of this kind. They were called the ordinary type by Ebstein (1884). They are formed 1) around primary calculi when these irritate the walls of the passages and produce an exudate of serum or blood, as happened in Dr. BATH's case; or ii) around other foreign matter, such as pus and debris from infection, as in Mrs. BROWN and Mr. CHALK. Their lamellation is due to the alternating precipitation of colloid and crystalloid (Schade, 1911; Joly, 1929; and Kleinschmidt, 1911).

The urinary colloid acts as the binding material which glues the stone-forming salts together. Absolutely pure stones are very rare and did not occur in my series.

B. FACTORS PREDISPOSING TO THE FORMATION OF URINARY CALCULI.

These factors are very numerous and can be divided into general and personal.

GENERAL FACTORS. It has long been known that stone has certain geographical distribution. Most of these patients came from Edinburgh which belongs to the British East Coast area of stone mentioned by Joly. Socially, stone is now known to occur more in poorer than in richer people. This does not fit into our

picture, for all except one of the patients were business or professional people. Only Mrs. CONNOLLY came from a working class home.

Diet is undoubtedly closely linked with both the geographical and the sociological factors. Deficiencies in the quality and variation of the food has been shown to increase the incidence of stone (Pousson and Carles). In particular, lack of vitamin A leads to a keratinisin hyperplasia of the renal pelvis³ epithelium (Wolbach and others, 1937), which causes the shedding of dead cells into the pelvis around which stones may form. Our patients were all well enough off to afford an adequate diet in normal times,; but like everybody else they had less fat and protein and more carbohydrate foodstuffs to eat since the outbreak of war. Bad though this is, in no case was there any evidence of gross dietary faults. But none of the patients had been in the habit of taking extra Vitamin A as cod liver oil or Adexolin. It would be interesting to know in this connection if the incidence of stone has increased amongst the warring populations.

In none of these patients was there any family-history of stone. The evidence for a hereditary factor is in any case inconclusive.

PERSONAL FACTORS. Stone affects all ages. This is borne out by these patients, who were respectively 17, 24, 24, 34, 42, and 67 years old. AS to sex, the only thing that can be said here is that vesical calculus is practically confined to men. This is probably connected with the greater frequency of urinary stasis in the male bladder due to prostatic obstruction as in the case of Mr. CHALK, or due to urethral stricture.

Occupation is certainly important. Sedentary workers like Dr. BATH, Mr. CHALK and Miss SHEPHERD, are /

are much more commonly affected than those who get enough exercise. The other three cases were housewives and had to run about on their legs all day. But each of them had been severely immobilised about the time of onset of the disease: Mrs. BOYCE was lying up after appendicectomy; Mrs. BROWN had been in bed during the pyelitis/^{of} pregnancy, the puerperium, and later the thyrotoxicosis; Mrs. CONNOLLY's story began shortly after the delivery of her first child. Finally MARY SHEPHERD was in bed for many months with a fracture. Immobilisation is regarded as a definite factor in etiology.

Congenital abnormalities were present in two of the cases. Both Dr. BATH and Mrs. BROWN had a double ureter on the side afflicted with stones. It is well known that such abnormalities predispose to stone. The reason is that urinary drainage is not as free as in the normally developed organs, and that stones are more likely to form in sluggish urine. It is perhaps noteworthy that these two cases developed urinary fistulae.

Urinary obstruction was certainly present in Mr. CHALK, who had prostatic hypertrophy, and in the congenitally deformed ureter of Mrs. BROWN. Obstruction causes stasis of urine, so that dissolved substances have more time to settle out, apart from the degenerative changes of the colloid which make for crystallisation. Obstruction also predisposes to urinary infection, which in turn predisposes to lithiasis.

Urinary infection used to be regarded as the most important predisposing factor, but it is now known that it is as often a result of lithiasis as a cause.

It /

It was definitely present in the cases of Mrs. BROWN and Mr. CHALK, in both of which infection preceded stone. Mrs. CONNOLLY had much pus in her urine and in her case stone seems to have preceded infection. Infection causes co-agulation of colloid, and much foreign material, round which secondary stones can form. Rosenow and Meisser claim to have shown that focal sepsis elsewhere in the body may give rise to stone. This is still under investigation. There was no evidence of any gross focal sepsis in these patients.

Increase in urinary crystalloids supersaturates the urine still more and so furthers the tendency to crystallisation. In this connection Mr. CHALK's case is most instructive. This man suffered from osteopititis deformans, in which there is an upset in osseus calcification. One of the features is a rise in the serum phosphatase concentration. Normally this is 0.15 Kay units. In Mr. CHALK it was first 0.80 units, later 0.51 units. Phosphatase is an enzyme which hydrolyses monophosphoric esters. There are two classes of phosphatases, 'acid' and 'alkaline' phosphatases, which vary in their optimum pH ranges of activity. Next to growing bones and interstitial mucosa, the renal cortex contains the most acid phosphates per unit of wet weight. Following the hypothesis advanced by Robison and Soames (1924), it is suggested that in Mr. CHALK an excess of phosphatase is present in the kidneys. This enzyme hydrolyses phosphoric esters brought in the blood, with consequent local increase in the concentration of phosphate ions. The solubility product for calcium phosphate is exceeded locally and deposition of calcium phosphate occurs in or near the cells which secretes /

secrete or contain the active enzyme. The blood calcium concentration is unaffected. There is merely an increased turnover of calcium. This idea may in part account for Mr. CHALK's calculi, but obstruction and infection were also present.

Finally a recent paper by Ezickson and Morrison (1941) suggests that an abnormally high basal metabolic rate predisposes to lithiasis. This is relevant in the case of Mrs. BROWN, who was very thyrotoxic shortly before the onset of calculus disease.

PATHOLOGY. The kidney of Mrs. BOYCE was hydro-nephrotic. The part of the kidney removed from Dr. BATH also showed dilated calyces. These were mechanical back pressure effects due to hindrance of outflow. The kidney of Mrs. BROWN showed evidence of chronic infection which concurred with her history.

All the stones analysed were mixed or secondary calculi. Infection had always been present. The typical laminations were well seen in the stones of Mr. CHALK and Dr. BATH. The layers were alternatively spongy and compact. The spongy layers contained the organic material (MacCallum).



CLINICAL FEATURES. A general comment is that the symptoms and signs were few but definite. The duration of the histories was very variable. Once begun, the symptoms are usually so severe that the doctors called in for treatment at once. The delay in treatment of Mrs. BOYCE and Mrs. CONNOLLY was therefore unusual. Mrs. BOYCE might have kept her kidney if the stone had been taken out in time. Clinical diagnosis is usually made easy by the characteristic pains. Osler describes three sorts of pains: i) a constant localised dull pain in the renal region like that in Dr. BATH; ii) paroxysms of pain radiating in the course of the ureter like that of Mrs. BROWN; iii) flushes or rushes of hot pain at intervals, often momentary, which none of these patients specially described.

DIFFERENTIAL DIAGNOSIS includes nearly all other conditions causing abdominal pain and vomiting.

Radiology is, of course, invaluable. Stones which do not show up as positive shadows are estimated at 10% of the total. They are mainly pure uric acid stones. Blood-clot and infectious debris may also cause renal colic without being visible on X-ray plates. In all these patients the stones were visible on the straight films.

TREATMENT (Sanford and Barnhart, 1941). The series contains four cases treated surgically and two treated medically. Unless there are definite indications to the contrary, surgical removal of stone is done. The contra-indications are: i) large bilateral stones; ii) very small stones, or disease of opposite kidney as in MARY SHEPHERD, where pain was not severe and little danger of renal damage; iii) cases in which /

which small stones repeatedly form and pass; iv) general contra-indications, such as pregnancy as in Mrs. CONNOLLY, intercurrent disease, and extremes of age.

Before operation, the patient must be built up to his best health. Dr. BATH, who was anaemic, was transfused with two pints of red blood cells in saline to this end. Fluid should be forced. The active infections are cleared up by sulphonamide.

After operation still much fluid was given. All the patients were put on Sulphathiazole, one 0.5 gm. tablet three times a day, and potassium citrate gr. 30 three times a day, merely as a prophylactic measure.

Medical management consisted in forcing fluids and given anti-spasmodic drugs. Pethidine was tried in both Mrs. CONNOLLY and MARY SHEPHERD, but both soon established tolerance to it. The usual story was that renal colic was controlled first by Pethidine Mgm.25 by mouth, then Mgm.50 by mouth, then Mgm.50 intramuscularly, and finally only by Morphia gr. 1/6 and Atropine gr.1/100. Like Branwood (1943) I found that when Pethidine did act, pain was relieved in about 10 minutes, and produced drowsiness and sleep in about half-an-hour. No toxic effects were noted, nor any changes in the blood picture or the urine. (Pethidine is the name given by the Pharmacopoeia Commission to the hydrochloride of the ethyl ester of 1-methyl-4-phenyl-piperidine-4-carboxylic acid.) Because of its loss of action, I have found Pethidine not very effective.

Dietary instructions were given to the patients on leaving Hospital to decrease their intake of oxalates and urates. They were told to avoid eating spinach, rhubarb /

rhubarb and asparagus, on the one hand, and red meat on the other. Joly think these measures are effective in preventing recurrence of stone. None of these patients will be able to benefit from drink-cures at Spas, like Harrogate, at the present time.

.....

This series of cases illustrates a wide variety of problems connected with urinary lithiasis. The successful treatment of a patient afflicted with this disease is one of the most satisfying deeds in surgery.

I wish to thank Professor Learmonth and Mr. David Band for having given permission to describe cases under their charge. I am also very grateful to Miss Parbury for the beautiful A-ray illustrations and to Miss Macfarlane for her help with the type-script.

REFERENCES.

- Blach, J. F.: Renal Calculi assoc. with pregnancy: Consideration of management with report of 3 cases 47:705-710, May 1942.
- Bayliss, Sir W. M.: 'Principles of General Physiology', 4th ed., pp. 146-168. 1942.
- Branwood, A. W.: Abstract of Clinical trials of pethidine, Ed. Med. Journal, p. 177, March 1943.
- Cantarow, A.: Internat. Clin., 1:230, 1936.
- Christian, H. A.: 'The Principles and Practice of Medicine', 14th ed., p. 931, 1942.
- Clark, A. J.: 'Applied Pharmacology', 7th ed., 1940.
- Duguid, A. H. E., and Heathcote, R. St. A.: Quarterly Journal and Yearbook of Pharmacology, 13:318, 1940.
- Ebstein, W.: 'Natur und Behandlung der Harnsteine', Wiesbaden, 1884.
- Eisleb, O., and Schaemann, O.: Deutsch. Med. Wschr., 65:957, 1939.
- Ezickson, W. I., and Morrison, L. M.: The Role of the Liver and Thyroid as Metabolic Factors in the production of Renal Calculi, J. Urol, 46:359-375, September 1941.
- Garcia, A. E., and Galvez, I.: La nefrectomia parcial, Rev. argent. de urol., 10:209-234, (March-April) 1941.
- Himmelsbach, C. K.: J. pharmacol, 75:64, 1942.
- Hunter, D.: In 'A Textbook of Medicine', ed. by F. W. Price, 6th ed., 1377-1379, 1941.
- Joly, J. Swift: 'Stone and Calculous Disease of the Urinary Organs,' 1929.
- Kay, H. D.: Physiol. Rev. 12:384, 1932.
- Kleinschmidt, D.: 'Die Harnsteine', Berling, 1911.
- Langdon-Brown, W., and Evans, Geoffrey: In 'A Textbook of Medicine', ed. by F. W. Price, 6th ed. pp. 1338-1341, 1941.
- Lichtwitz, L.: 'Über die Bildung von Niederschlagen und Konkrementen im Harn und in den Harnwegen'. Spezielle Pathologie und Therapie innerer Krankheiten, Kraus and Brugsch, 1:270, 1919.
- MacCallum, W. G.: In 'A Textbook of Pathology', 6th ed., p. 429, 1938.
- Pousson and Carlos: 'Affection Calculeuse', Encyclopédie française d'Urologie, 2:475.

- Robison, R.: Herter Lectures, New York University Press, New York, 1932.
- Robison, R.: and Soames, K. M., Biochem. J., 18:740, 1924.
- Rosenow and Meisser: 'Nephritis and Urinary Calculi following the Experimental Production of Chronic foci of Infection', Collected papers of the Mayo Clinic, 13:253.
- Sanford, J. H., and Barnhart, W. T., Surg. and non-surgical management of renal calculi, J. Urol., 46:1061-1069, Dec. 1941.
- Scholl, A. J., and others: Review of Urologic Surgery, Arch. Surg. 44:383-397, 1942.
- Schade, H.: 'Die physikalische Chronik in der inneren Medizin', 3rd ed., p. 352, 1923.
- Schade, H.: 'Beiträge zur Konkrementbildung', Munich Med. Wochenschrift, p. 723, 1911.
- Wolbach, S. B.: The Pathologic Changes Resulting from Vitamin Deficiency, J.A.M.A., 108: 7-13, Jan. 1937.