

CONGENITAL HAEMOLYTIC DISEASE.

( Haemolytic Disease of the Newborn).

A study of 157 cases, with special reference  
to the morbid anatomy and morbid histology of  
the disease process and to the pathogenesis  
of kernicterus.

- by -

ALBERT EDWARD CLAIREAUX M.B., Ch.B. (Edin).

—  
A Thesis presented for the Degree of Doctor  
of Medicine of the University of Edinburgh.

—  
Dept. of Child Life and Health,  
University of Edinburgh.

March, 1949.



VOLUME 1.

Table of Contents.

Chapter 1	Introduction.....	Page	1
Chapter 2	Case Reports :		
	Series 1 : Simpson		
	Maternity Pavilion.....	Page	15
Chapter 3	Case Reports : Series 2 :		
	Royal Edinburgh Hospital		
	for Sick Children.....	Page	111
Chapter 4	Case Reports : Series 3:		
	Elsie Inglis Memorial		
	Maternity Hospital.....	Page	172
Chapter 5	Analysis of Cases.....	Page	190

## Chapter 1.

### INTRODUCTION.

The term " congenital haemolytic disease " has been chosen as it represents more closely the conditions which are under review, than does its earlier counterparts.

Rautmann (1912) favoured the term erythroblastosis foetalis. This name has been in common use in this country and Parsons (1933) used it to distinguish certain types of what he called " erythronoclastic anaemias. " Hawksley and Lightwood (1934) also made use of it as an inclusive term. More recently Levine (1946) and Wiener (1946) have brought the name " congenital haemolytic disease " into general use. It is felt that erythroblastosis is a term which lays too much stress on one of the features of the disease ; a feature, moreover, which will be shown to be by no means constantly present.

The term " haemolytic disease of the newborn " has found favour among workers in this country (Parsons 1947). Unfortunately it tends to be confused with " haemorrhagic disease of the newborn. "

It is fully realised that " congenital haemolytic/

haemolytic anaemia " is a synonym of acholuric jaundice. On the other hand " anaemia haemolytica neonatorum " is rather ponderous although technically more correct. Since this work is concerned only with haemolytic disease resulting from maternal isoimmunisation, any reference to " haemolytic anaemia " or " congenital haemolytic anaemia " is to be regarded as signifying the form of haemolytic disease in which anaemia is the predominant clinical feature. It has no connection with acholuric jaundice in this context.

Congenital haemolytic disease is a disease complex which may easily be separated into three more or less distinct clinical entities. These are

1. Hydrops foetalis.
2. Icterus gravis neonatorum.
3. Congenital haemolytic anaemia.

Hydrops foetalis develops in utero and usually results in a still-birth or in the birth of an extremely oedematous infant whose survival is only a matter of hours. The longest recorded survival is six days without specific treatment. It is thus the most severe/

severe type of this disease. Congenital haemolytic anaemia of the newborn, on the other hand is at the opposite end of the scale and has a low mortality. Indeed it may well be that numerous instances of it occur in such a mild form as not to be detectable on routine clinical examination. This type develops soon after birth and varies greatly in severity. The great majority recover and there are no unfortunate sequelae.

Icterus gravis neonatorum occupies an intermediate position between the above types. Severe jaundice in the newborn is frequently fatal and among those who recover there is the danger of a considerable proportion developing lesions in the central nervous system known as kernicterus.

The connection between these three forms of congenital haemolytic disease has not always been apparent. Extramedullary erythropoiesis is a prominent though not an invariable feature of the syndrome. It became a connecting factor quite early. Schridde (1910) first described it in hydrops foetalis and Buchan and Comrie (1909) showed it occurred in icterus gravis. Severe haemolytic anaemia was first described in full by Ecklin (1919). It was not till 1933, however, that Diamond, Blackfan and Baty in America and Parsons, Hawksley and Gittins in this country brought the three types under the one name of erythroblastosis foetalis.

Another striking, but likewise inconstant feature/

feature was the familial incidence of the disease. This was first noted in connection with icterus gravis, by Ashby (1884) who found a severe and fatal jaundice in the last three children of a family of five. Although various authors since then have reported cases showing this familial tendency it was not until very recently that the reason became apparent.

Although many of the more striking features were described the etiology remained obscure. After Buchan and Comrie (1909) had described the characteristics of extramedullary erythropoiesis, the attention of most workers became riveted on this aspect of the condition.

Hydrops foetalis had, of course, been confused with congenital syphilis for a very long time and continued to be so until serological tests and careful histological examination of post-mortem material made an accurate diagnosis possible.

Congenital haemolytic anaemia was not such a severe or fatal disease and moreover was inclined to be overlooked when occurring in its milder forms. It was therefore on icterus gravis that the main weight of clinical and pathological investigation fell during the first three decades of the present century. Many and varied were the theories propounded as to the nature and origin of this condition. Originally it had been classified along with other types of neonatal jaundice such as physiological/

physiological jaundice of the newborn, congenital obliteration of the bile ducts, syphilis with jaundice etc. Gradually it emerged from this group to occupy a place, at first on its own and later in company with hydrops foetalis and congenital haemolytic anaemia.

At first it was regarded as a result of toxic damage to the liver or to obstruction of the bile outflow. Cruse (1880) one of the earliest workers thought it was due to obstruction caused by desquamation of biliary epithelium. Bloomfield (1901) described it under congenital hepatic cirrhosis; Pfannenstiel (1908) took the view that it was merely a severe form of physiological jaundice ; Knoepfelmacher (1910) was in favour of septicaemia. Pfaltzer (1915) was also inclined to believe in the theory of sepsis, while Wooley (1916) interpreted the erythroblastosis as being a neoplastic manifestation. Abt (1917) ascribed the condition to liver failure and Rolleston (1920) postulated a hepatitis secondary to an ascending cholangitis.

Many authors favoured the view that the mother was directly or indirectly responsible for the condition. Hampson (1929) believed the foetus failed to produce an antihaemolytic hormone previously supplied by the mother and de Lange (1932) thought maternal toxæmia was primarily to blame.

It was at this period that the interrelationship between the three main types became recognised as is shown/

shown in the articles of de Lange (1932), Diamond Blackfan and Baty (1932) and Parsons, Hawkesley and Gittens (1933), Von Gierke (1930) and Salomonsen (1931).

There was, however, still no agreement on the underlying cause. Diamond, Blackfan and Baty believed the cause was a primary defect in the erythron, while Parsons, Hawksley and Gittins thought the erythroblastosis was secondary to the haemolysis.

Meanwhile, attention had again been drawn to the familial aspect of the disease group by Rolleston (1920). Hawksley and Lightwood (1934) noted the possibility of a Mendelian recessive character as an agent in the disease process. Hoffmann and Hausmann (1926) had also recorded cases in families. Clifford and Hertig (1932) were among the first to draw attention to the fact that the first child is very often spared while subsequent children of the same parents manifest the disease in one of its forms. Abbott and Abbott (1935) reported a series of cases occurring in one family. Pasachoff and Wilson (1935) also found cases of congenital haemolytic anaemia of the newborn and hydrops foetalis occurring in the one family. Macklin (1937) undertook a statistical study of the disease group and concluded that a character was inherited as a dominant mutation. She also suggested that congenital haemolytic disease is the result of multiple allelomorphs adjoined to the normal genes responsible for the formation of foetal blood.

Her/

Her statistics were strongly challenged by Darrow (1938) who did not believe the conditions were inherited either as a dominant mutation or recessive characteristic.

Darrow propounded a new theory.

With regard to congenital haemolytic anaemia, she believed that the red cells of the infant were destroyed by an immune reaction. The mother was thought to be actively immunised by foetal red cells passing through the placenta. Antibodies then formed in the mother and were returned to the foetus via the placenta and also, in the case of an infant, via the colostrum and breast milk. This was a surprisingly accurate forecast of the actual process. It also explained the escape of first born children by postulating a delay in the onset of acquired immunity by the mother. She further postulated a state of anaphylaxis in the foetus to account for other manifestations of the disease, namely increased capillary permeability, oedema and respiratory distress. She cited Hampson's (1929) therapeutic success with daily intramuscular injections into the infant of its own mother's serum and Rolleston's (1930) withholding of mothers milk in support of this hypothesis. As the Rhesus blood groups had not yet been discovered, she advocated an immunological difference between foetal and adult haemoglobin as the responsible agent for the antigen-antibody reaction. It is worthy of note/

note, at this point, that while Darrow (1947) has modified this latter part of her hypothesis to conform with recent discoveries, she still maintains that anaphylaxis plays a part in the etiology of congenital haemolytic disease.

While this considerable research into the nature of congenital haemolytic disease was being prosecuted, a vast amount of work was being done in another field of medical research, namely the human and animal blood groups. As Levine (1946) remarks this really began with the discovery by Landsteiner (1900) of the four main human blood groups - A, B, AB and O. The next step was taken by Ehrlich and Morgenroth (1900) who discovered iso immunisation by injecting haemolyzed goat blood into other goats and demonstrated the presence of immune bodies in the latter. Landsteiner and Levine (1928) discovered the additional factors M, N and P but these lacked the capacity to produce isoimmunisation. Levine and Stetson (1939) reported a case of serious transfusion reaction in a pregnant woman. They attributed the reaction to some hereditary property in foetal blood not present in the blood of the mother. This was the first occasion that such a property had been demonstrated. This research into the human blood groups culminated in the epoch-making discovery of Landsteiner and Wiener (1940) that there was an agglutinable factor in human blood which could be recognised /

recognised by immune sera for blood from Rhesus monkeys. This was the discovery of the Rhesus factor, or more accurately, the Rhesus blood groups.

Landsteiner and Wiener had no means of knowing at this time how important their discovery was from the clinical point of view. As Cappell (1948) has stated this is an excellent example of the reason why research should be carried out for its own sake and not be directed solely according to a preconceived plan. Landsteiner and Wiener were merely prosecuting a line of research which they hoped would clear up some biological and hereditary anomalies. In so doing they made a discovery of first-rate importance to clinical medicine. Bloods reacting to their immune sera were classified as Rhesus (Rh +) positive and those which failed to react as Rhesus (Rh-) negative.

Shortly after this discovery Wiener and Peters (1940) showed that patients whose blood failed to react with Rhesus-positive serum later developed intolerance to repeated transfusions with Rhesus-positive blood. It was then proved that the patient of Levine and Stetson (1939) was, indeed, Rh-negative. Levine, Katzin and Burnham (1940) studied further cases of intra-group transfusion reactions. They found that not only were the women Rh-negative but that they showed a high foetal and neonatal death rate. These authors therefore correlated the incidence of Rh-negativity with the foetal mortality. The fatal cases were shown to suffer from congenital haemolytic disease/

disease and the writers suggested that maternal anti-Rh agglutinins passed through the placental barrier and reacted with the foetal Rh-positive blood, causing haemolysis of the latter.

Thus the etiological importance of the Rhesus blood groups in the causation of congenital haemolytic disease became established. Since 1940 many hundreds of papers on this subject have been contributed to the literature. A full discussion of the various factors involved will be dealt with later (Chapter 7).

Certain facts may, however, be stated here. Landsteiner and Wiener (1941) and others have shown that 85% of white races are Rh-positive and 15% negative. Negro races have fewer Rh-negative elements (10%) and Polynesians none. Thus iso-immunisation by one of the Rhesus blood groups is commoner amongst the white than amongst the coloured peoples.

Levine and his co-workers (1941) were able to demonstrate that 92 % of the mothers of children suffering from congenital haemolytic disease were Rh-negative. The remaining 7-8 % showed iso-immunisation with A or B groups or were later shown to belong to less common Rhesus sub-types.

Nevertheless it soon became apparent that no hard and fast rule could be applied to the development of isoimmunisation and it was by no means every case which revealed the development of antibodies. Some mothers/

mothers gave birth to children with severe haemolytic disease while they themselves showed no antibodies in their serum. The converse was also often true. This apparent anomaly was partially cleared up by the discovery of the so-called " blocking " antibodies by Race (1944), Wiener (1944) and Diamond (1944). The development of a special test by Coombs et al (1945) and Diamond and Denton (1945) to detect these previously unrecognised antibodies was a further advance.

On the basis of these and other findings, Wiener (1946) and Wiener and Sonn (1946) evolved an attractive hypothesis to cover the etiology of all types of congenital haemolytic disease i.e. hydrops foetalis, icterus gravis and congenital haemolytic anaemia. Their theory was based on the reaction of the foetal organism to different types and different doses of maternal immune bodies. Unfortunately their theory will not bear close examination, as Levine (1946) has observed. Wiener (1946) has also postulated a constitutional factor K in mothers with children showing haemolytic disease to account for the disparity between the actual incidence of such disease and the theoretical incidence based on the number of incompatible matings.

It thus became increasingly obvious that, although the discovery of the Rhesus blood groups had been a most important and fundamental step forward in the study of congenital haemolytic disease, the whole problem/

problem of the etiology had not been solved. It has yet to be discovered why some children of incompatible marriages exhibit the disease while others do not ; why some are still-born and exhibit hydrops foetalis, while others are born alive to die later from severe jaundice ; or why others again eventually recover from a severe haemolytic anaemia. Furthermore, the etiology of kernicterus, that dread complication of icterus gravis, is still most obscure. Indeed as has already been stated, Darrow (1947) while accepting the etiological relationship of the Rhesus blood groups, maintains that anaphylaxis plays its part in the causation of haemolytic disease. This is in accord with a theory she had evolved ten years previously.

In the field of treatment also, there are many diverse theories as to the correct form to be undertaken. Some advocate transfusion of the affected child by Rh-negative blood ( Wiener (1943), Levine 1943), Brandes (1944), etc. ); others prefer to use Rh-positive blood ( Davis (1946), Sandford (1946), and Darrow (1947).

Not only does the use of blood of different types have its advocates but there is a difference of opinion as to how it should be given. Some like Wiener (1946) have used repeated intravenous infusions of Rh-negative blood with some success. Others like Diamond (1947) and Wallerstein (1947) prefer/

prefer the withdrawal-replacement technique by which the blood of the affected infant is changed, temporarily, from Rh-positive to Rh-negative in its serological reaction.

It is at this stage in the controversy that the present work has been undertaken. It was carried out in order to achieve the following :-

1. To study the cases of Congenital Haemolytic Disease which have occurred in certain hospitals in Edinburgh during the period 1937 to 1947.
2. To compare the incidence of the various types of this disease in Edinburgh with that reported by authors elsewhere.
3. To determine the importance of the Rhesus blood groups as a major factor in the etiology of the present series of cases.
4. To describe in detail the pathological changes found in the blood and organs of patients who have suffered from this disease. It was felt that, although an enormous spate of literature concerning the serological implications of the Rhesus blood groups had followed the discovery of Landsteiner and Wiener (1940), insufficient attention had been paid to the morbid anatomy and morbid histology of the condition. The present series is quite a large one and all available autopsy material from cases in which a post-mortem examination was carried out has been carefully studied personally.
5. To investigate all cases in which Kernicterus has complicated icterus gravis neonatorum in an attempt/

attempt to define the histological changes which occur therein and to clarify the etiology of this peculiar condition.

The present series of 157 cases is divided into three groups. Series I comprises cases admitted to the Simpson Maternity Pavilion of the Royal Infirmary Edinburgh between 1937 and 1947 ; Series II comprises cases admitted to the Royal Edinburgh Hospital for Sick Children during the same period ; Series III comprises cases admitted to the Elsie Inglis Memorial Maternity Hospital also during that period. The investigations on the Rhesus blood groups of these patients were carried out in the Clinical Laboratories of the Royal Infirmary Edinburgh under the direction of Dr. Cummings and of the late Dr. Macrae.

This work has been carried out from the Departments of Pathology and of Child Life and Health of the University of Edinburgh during the years 1947 to 1949.

Chapter 2.Series 1 - Case Reports from the Simpson  
Maternity Pavilion.

These case reports have been greatly curtailed and all non-essential details have been excluded.

Case 1 : Baby D. Born 11.6.39. Died 22.7.39.  
Female infant aged 6 weeks.

Maternal History :

The mother was aged 30 and this was her 5th. pregnancy. Her first four children were normal at birth and are alive and well. She had suffered from severe nutritional anaemia during the present pregnancy.

Clinical Findings in the Child :

The child was delivered spontaneously (vertex L.O.A ) and weighed 7 lbs. 6 ozs. at birth. It became jaundiced a few hours after birth and the jaundice gradually deepened. On the 6th day it was very lethargic. 10cc. blood were injected intramuscularly. On the 17th day it was still very jaundiced. The blood showed Hb 36 % R.B.C. 1.7 million/cu.mm. C.I. 1.09. Reticulocytes 11 %. On the 28th day Hb 33 %. Reticulocytes 14 %. On the 41st day Hb 47 % child seemed to be improving but late the same day it suddenly collapsed and died.  
Postmortem/

Postmortem report : (168/39)

The body was that of a rather emaciated, jaundiced, female infant weighing 5 lbs. 12 ozs.

Thorax : No abnormality present.

Abdomen : The spleen was twice the normal size, pink in colour, and firm in consistence. The liver was of normal size and rather yellow in colour. The other organs had a normal appearance.

Head : The falx and the tentorium were intact. The brain showed some icteric tinting. No true kernicterus was present.

Microscopic Findings :

Liver : There was a moderate degree of extra-medullary haemopoiesis and increased portal fibrosis. The bile-ducts were rather tortuous and some deposits of bile pigment were found.

Spleen : There was no unusual haemopoiesis. The Malpighian bodies had a normal appearance. There was some reticulosis.

Lungs : A moderate degree of pulmonary oedema was present.

Other organs : No abnormality present.

Summary : Icterus gravis neonatorum.

Case 2 a /

Case 2 a : Baby B (1) Born 5.1.40. Still-birth.

Maternal History : The mother had had five previous pregnancies and three of these ended at six months. In this pregnancy she was delivered of still-born twins, a few weeks before term.

Post-mortem Report : (4/40)

The body was that of a grossly oedematous female infant weighing 3 lbs.

Thorax : No abnormality present.

Abdomen : The liver and spleen were of normal size and the other organs showed no abnormality.

Microscopic Report :

Liver, spleen and kidney showed extensive extra-medullary erythropoiesis. The lung was unexpanded and showed no haemopoietic foci.

Summary : Hydrops foetalis.

Case 2 b : Baby B. Born 5.1.40. Still-birth.

Post-mortem Report : (5/40)

The body was that of a grossly oedematous female infant weighing 3 lbs.

Thorax : No abnormality present.

Abdomen : The liver and spleen were of normal size and had a normal appearance. The other viscera showed no abnormality.

Microscopic Report :

The/

The liver, spleen and suprarenal glands show extensive extramedullary erythropoiesis. The kidney is normal.

Summary : Hydrops foetalis.

Case 3. Baby C. Born 31.1.40. Died 3.2.40., aged 4 days.

Clinical Features : The baby became jaundiced shortly after birth, and the jaundice gradually deepened. In spite of this the baby remained quite well until 3 hours before death. It then began to vomit, respiratory distress became very marked and the baby died at the age of four days.

Postmortem Report :

The body was that of a full-time infant weighing 9 lbs. The umbilicus had healed. There was marked jaundice.

Thorax : No abnormality present.

Abdomen : The liver and spleen were greatly enlarged and the Prussian Blue reaction was positive. The other organs showed no change.

Head : The brain was yellow in colour but no nuclear staining was found.

Microscopic Report :

The liver showed marked erythropoiesis. The spleen was very congested but there was no excessive erythropoiesis. The lung was well expanded and slightly oedematous. The pancreas was normal.

Summary : Icterus gravis neonatorum.

Case 4. Baby F. (2) Born 29.8.40., died 5.9.40. aged/

aged 7 days.

Maternal History : The mother was aged 32 years and this was the fifth pregnancy. The other four children were alive and well. There is no evidence of illness during this pregnancy.

Clinical History of Child :

29.8.40 The child was born spontaneously (vertex L.O.A.), as one of twins.

30.8.40 The child was jaundiced and very pale.

5.9.40 Child died.

Post-mortem Report : (199/40)

The body was that of a male twin weighing 4 lbs. 4 ozs. It was pale and jaundiced.

Thorax : There was some yellow fluid in the serous sacs. The lungs were poorly expanded.

Abdomen : The liver was pale but normal in size. The spleen and kidneys showed no abnormality.

Head : Sections of the brain revealed a marked yellow staining of the large nuclei.

Summary : Icterus gravis and Kernicterus.

Case 5. Baby H. Born 28.10.40. Still-birth.

Clinical Features : The infant was six weeks premature. The mother had had five previous miscarriages. In the present instance the placenta was found to be unduly large.

Post-mortem Report :

The body was that of a small female infant weighing 6 lbs. 8 ozs. There was severe generalised subcutaneous oedema.

Thorax/

Thorax : There was clear fluid in the serous sacs. The heart was slightly enlarged.

Abdomen : There was some yellow fluid in the peritoneal cavity. The alimentary tract showed no abnormality. The liver was enlarged but of normal consistence. The spleen was very enlarged and measured  $2\frac{1}{2}$ " in length. It was soft and dark red in colour. The kidneys were rather pale.

Microscopic Report :

The liver showed marked extramedullary erythropoiesis. There were many nests of primitive erythroblasts and some central necrosis of the liver lobules. The spleen showed active haemopoiesis. The lungs were rather oedematous.

Summary : Hydrops Foetalis.

Case 6. Baby G. Born 28.11.40.

Maternal History : This was the mother's third pregnancy. The first child is alive and well. The second pregnancy terminated in an abortion. She had no illness during the present pregnancy.

Case History of Child :

28.11.40 : Born spontaneously (vertex R.O.A.). Child was full-term and weighed 7 lbs. 14 ozs.

29.11.40 Jaundiced.

30.11.40 Very jaundiced.

2.12.40 Jaundice less.

6.12.40 Jaundice disappeared. Now very pale.

10.12.40 Liver and spleen palpable. Haemoglobin

27% (Sahli) Red blood count 1.07 million/cu. mm.

Reticulocytes/

Reticulocytes 20%. Prothrombin index 70%.

11.12.40 Laevulose tolerance test was normal.

12.12.40 Haemoglobin 28%

14.12.40 Haemoglobin 36%

23.12.40 Haemoglobin 30%. Child was fairly well, and was discharged.

Summary : Icterus gravis (recovered).

Case 7. Baby K. Born 12.2.41. Still-birth.

Maternal history : The mother had suffered from eclampsia during the present pregnancy.

Post-mortem Report :

The body was that of a small male infant weighing 5 lbs. 8 ozs. There was extreme and universal oedema.

Head : Slight sub-arachnoid haemorrhage present.

Thorax : There was some blood-stained fluid in the serous sacs. The lungs were airless and the heart was slightly enlarged.

Abdomen : There was some clear fluid in the peritoneal cavity. The alimentary tract was normal. The liver and spleen were of normal size and shape. The kidneys were rather pale.

Microscopic Report :

Liver : There is active haemopoiesis and numerous nests of erythroblasts were found.

Spleen : There is active haemopoiesis and numerous primitive red cells were present in the pulp.

Kidney : The organ is oedematous and there are haemopoietic foci in the cortex, boundary zone and the peripelvic connective tissue.

Lung/

Lung : The organ is unexpanded. There is no haemopoiesis.

Blood : Large numbers of primitive red cells present.

Summary : Hydrops Foetalis.

Case 8. Baby F. Born 25.2.41. Still-birth.

Maternal History : The mother suffered from severe toxæmia during the present pregnancy.

Post-mortem Report : (41/41).

The body was that of a small female infant weighing 5 lbs. There was moderate, universal oedema. The abdomen was very distended.

Thorax : There was some clear fluid in the pleural sacs. The lungs were pale and airless. The heart was slightly enlarged, the enlargement being due to hypertrophy of the ventricular walls.

Abdomen : The peritoneal cavity contained some clear fluid. The alimentary tract was normal. The liver was enlarged and brown-red in colour. The spleen was enlarged and 2½" in length. The kidneys were pale.

Microscopic Report :

Blood Film : There was an excess of primitive nucleated red cells.

Liver : There were numerous nests of erythroblasts seen.

Spleen : There was active haemopoiesis and numerous nests of erythroblasts.

Kidney : Numerous foci of erythropoiesis.

Lung /

Lung : Immature and oedematous.

Summary : Hydrops Foetalis.

Case 9. Baby O'M. Born 28.2.41. Died 2.3.41.,  
aged 2 days.

Maternal History : This is the third pregnancy. The child of the first is alive and well. The second pregnancy ended with the delivery of a still-born macerated hydropic foetus.

Post-mortem Report : (45/41)

The body was that of a small male infant weighing  $5\frac{3}{4}$  lbs. It was deeply jaundiced.

Head : The olivary nuclei and the nuclei in the floor of the 4th. ventricle were bile stained.

Thorax : The serous sacs were normal. The lungs were healthy. The heart was quite normal.

Abdomen : There was little bile-stained fluid in the peritoneal cavity. The alimentary tract was normal. The liver was enlarged, deep green in colour and of normal consistence. The spleen was enlarged, fully 3" long and quite firm. The kidneys were of average size and rather green.

Microscopic Report :

Liver : The bile canaliculi are full of inspissated bile. Large foci of haemopoiesis are present and erythroblasts are conspicuous. The total amount of haemopoiesis is not excessive for this age but the primitive character of the cells is abnormal. There is some intercellular fibrosis.

Spleen : Shows increased cellularity of the pulp,  
in/

in which are found numerous blood-forming cells, among them primitive erythroblasts.

Kidney : No haemopoietic foci present.

Blood Film : There is a great excess of nucleated red cells.

Summary : Icterus Gravis and Kernicterus.

Case 10. Baby M. Born 21.8.41. Died 31.8.41. Aged 10 days.

Clinical History of Child : The baby had been jaundiced since the second day of life. In addition to the jaundice it became very pale. It was then given 10 cc. of maternal blood by intra-muscular injection. It died suddenly on the tenth day.

Post-mortem Report : (150/41)

The body was that of a male infant weighing 6 lbs. The skin was pale and there was slight jaundice.

Head : The leptomeninges were slightly bile-stained. There was no nuclear staining.

Thorax : The serous sacs contained a little bile-stained fluid. The lungs were pale and slightly oedematous. The heart was slightly enlarged. The ventricles were dilated and the myocardium was very pale.

Abdomen : The alimentary tract was normal. The liver was enlarged and of normal consistence. The spleen was very enlarged and measured 3" in length. It was deep red in colour and very soft.

Microscopic Report :

Liver : Haemopoietic activity is well in excess of/

of normal. Many nests of primitive erythroblasts are present. The liver cells in the central zones of the lobules show degenerative changes. The liver cells contain an excess of haemosiderin.

Spleen : Shows excessive cellularity of the pulp and numerous groups of primitive erythroblasts.

Suprarenal gland : Large numbers of primitive erythroblasts are present in the medulla.

Summary : Icterus gravis neonatorum.

Case 11. Baby S. Born 16.9.41. Still-birth.

Maternal History : The child of the previous pregnancy died on the 2nd. day of life from icterus gravis.

Post-mortem Report :

The body was that of a small male foetus weighing 5 lbs. The abdomen was distended and there was oedema of the face and head. There was advanced maceration.

Thorax : The serous sacs contained a quantity of blood-stained fluid. The heart was slightly enlarged.

Abdomen : The peritoneal sac contained a large quantity of blood-stained fluid. The alimentary tract was normal. The liver was moderately enlarged, yellowish-brown in colour and rather tough to cut. The spleen was greatly enlarged, being 3" long.

Microscopic Report :

Liver : Maceration is severe and no cellular detail remains. There is a fine intercellular fibrosis. Spleen is very macerated.

Summary : Hydrops Foetalis.

Case 12 /

Case 12. Baby T. Born 17.9.41. Still-birth.

Maternal History : Mother's first and second child are alive and well. The third died aged 3 weeks and the fourth aged 2 days. The fifth and sixth were still-born. This is the seventh child and was also still-born.

Post-mortem Report :

The body was that of a small, macerated, male foetus weighing 5 lbs. 4 ozs.

Head and thorax : No abnormality present.

Abdomen : There was a large quantity of blood-stained fluid in the peritoneal cavity. The alimentary tract was normal. The liver was moderately enlarged, tough and greenish-yellow in colour. The spleen was enlarged, soft and measured 2" in length.

Microscopic Report :

Liver : Severe maceration has occurred. There is a diffuse intercellular fibrosis.

Spleen : Severe maceration.

Kidney : Numerous nucleated red cells in the vessels.

Suprarenal Gland : Numerous foci of erythropoiesis.

Placenta : The villi are large and oedematous. There are no foci of haemopoiesis.

Summary : Hydrops Foetalis.

Case 13. Baby C. Born 5.10.41. Still-birth.

Maternal History : This is the 4th. pregnancy. The first child had hydrocephalus and was still-born. The second child was also still-born. The third died in 5 minutes. /

Series 1.

Table 1.

HAEMOTOLOGICAL DATA

BABY McK.

Case 14.

<u>Age</u> <u>in</u> <u>days</u>	<u>Hb%</u> <u>Sahli</u>	<u>R. B. C. /</u> <u>cu. mm.</u>	<u>C. I.</u>	<u>W. B. C /</u> <u>cu. mm.</u>	<u>Nucleated</u> <u>R. B. C. /</u> <u>100 W. B. C.</u>	<u>Reticulo-</u> <u>cytes.</u>	<u>Icteric</u> <u>index.</u>	<u>Vanden</u> <u>Berg</u> <u>re-</u> <u>action</u>	<u>Miscellan-</u> <u>eous.</u>
1	112	4.54 m	1.1	-	-	11%	-	-	
2	110	4.50 m	1.2	-	-	9%	-	-	
3	110	4.4 m	1.2	-	-	8%	53	Indirect Positive	
4	110	4.14 m	1.2	-	-	8%	-	-	
5	100	3.94 m	1.25	-	-	5%	-	-	
6	85	3.9 m	1.1	-	-	4%	-	-	
7	86	3.5 m	1.1	-	-	-	-	-	
14	70	2.8 m	1.2	-	-	-	-	-	
21	60	-	-	-	-	-	31	Indirect faint positive.	

5 minutes.

Post-mortem Report :

The body was that of a very small premature male foetus weighing 1 lb . 4 ozs. It was very macerated. The liver and spleen were very macerated and little detail could be made out. The spleen appeared to be slightly enlarged.

Microscopic Report :

Severe maceration of all organs. No spirochaetes found.

Summary : Hydrops Foetalis.

Case 14. Baby McK. Born 26.9.41.

Maternal History : The mother was aged 38 years and this was her sixth pregnancy. The fifth pregnancy had terminated in the birth of an infant suffering from severe icterus. The child subsequently died.

Clinical Appearance of the Child : (See Table 1 )

The child was spontaneously delivered at term (vertex L.O.A) and weighed 10 lbs. It was born at 5 a.m. on 26.9.41 and by 10 a.m. it was slightly jaundiced. By 4.30 p.m. the jaundice was very marked.

Progress : 26.9.41. Liver and spleen impalpable. Haemoglobin 112% (Sahli). R.B.C. 4.54 million/cu.mm. Reticulocytes 11%.

27.9.41 Jaundice worse. Hb. 110%. R.B.C. 4.5 Million/cu.mm. Retics. 9%.

30.9.41 Jaundice less. Hb. 100 %. R.B.C. 3.94 Million/cu.mm. Retics. 6%

9.10.41 Jaundice slight. Hb. 70 %. R.B.C. 2.8 million/cum.mm.

17.10.41/

17.10.41 Very slightly jaundiced. Hb. 60 %.

21.10.41 Condition satisfactory. Discharged.

Summary : Icterus gravis (recovered)

Case 15. Baby McF. Born 11.2.42. Died 14.2.42, aged four days.

Maternal History : This is the 3rd. pregnancy. The previous children are alive and well. She had no illness during the present pregnancy. The mother is 29.

Clinical Appearance of the Child : The child was delivered spontaneously at the 39th. week and weighed 5½ lbs. (breech R.S.A.) It was not jaundiced at birth.

Progress :

12.2.42 Jaundiced. Spleen and liver enlarged.

Haemoglobin (Sahli) 78%. Icteric index 200. Slight stitching of limbs.

14.2.42 Died.

Post-mortem Report : (24 /42 )

The body was that of a female infant weighing 5¼ lbs. There was very deep jaundice.

Head : There was a slight subdural haemorrhage on the right side due to a tentorial tear. The meninges were deeply bile-stained. The brain showed bile staining of the nuclei in the basal ganglia and in the brain stem. The tonsils of the cerebellum were yellow. The grey matter of the spinal cord was also bile-stained.

Thorax : The lungs were slightly congested and there were a few patches of haemorrhage present. The heart was normal.

Abdomen /

Abdomen : The alimentary tract was slightly congested. The liver was enlarged, reddish-brown in colour and of normal consistence. The spleen was rather friable and  $2\frac{1}{2}$ " in length. The kidneys were somewhat bile-stained and showed deposits of uric acid crystals.

Microscopic Report :

Liver : Haemopoiesis is active and many primitive erythroblasts are present. There is no fibrosis and the liver cells are normal.

Spleen : The pulp is less cellular than usual and the sinuses are congested. Haemopoietic foci, containing erythroblasts of the same type as in the liver are numerous.

Kidney : No haemopoietic foci present.

Lung : Some oedema present.

Brain : Sections of parietal cortex, basal ganglia, cornu ammonis, lower mid-brain, lower medulla and cord were examined but no areas of pathological change were found.

Summary : Icterus gravis and Kernicterus.

Case 16 : Baby C. Born 16.3.42. Still-birth.

Post-mortem Report : The body was that of a small, premature, female infant weighing 2 lbs. 10 ozs. There was widespread subcutaneous oedema.

Head : Very slight subarachnoid haemorrhage.

Thorax : No abnormality present.

Abdomen : The alimentary tract was slightly congested. The liver was very enlarged and weighed 110 gms./

110 gms. There was considerable fatty degeneration and the cut surface showed nutmeg mottling. The spleen was enlarged to 2" in length. The kidneys were congested.

Microscopic Report :

Liver : There was very active haemopoiesis. The nucleated red cells were mainly normoblasts, but some erythroblasts were also present. The portal tracts were invaded by blood-forming cells. There was severe passive venous congestion.

Spleen : The organ was very congested and there was conspicuous haemopoiesis.

Summary : Hydrops Foetalis.

Case 17 : Baby G. Born 16.5.42. Still-birth. Mother had had hydramnios.

Post-mortem Report :

The body was that of a small female infant weighing 3 lbs. 10 ozs.

Head : There was a slight subdural haemorrhage on the right side as a result of a tentorial tear.

Thorax : The pleural and pericardial sacs contained a moderate amount of clear straw-coloured fluid. The lungs were compressed, congested and quite airless.

Abdomen : The peritoneal sac contained an excess of clear fluid. The liver was slightly enlarged but was of normal colour and consistence. The spleen was enlarged and measured  $2\frac{1}{2}$ " in length. It was rather thick and broad. The kidneys were healthy. /

healthy.

Microscopic Report :

Liver : Haemopoiesis was active and many groups of primitive erythroblasts were present.

Spleen : Considerable haemopoietic activity.

Numerous groups of erythroblasts were seen.

Blood Film : Nucleated red cells were in excess of normal.

Summary : Hydrops foetalis.

Case 18 : Baby L. Born 13.8.42 Died 14.8.42.  
aged 1 day.

Maternal History : This was the first pregnancy in a woman aged 23. She had not suffered from any illness during the present pregnancy.

Clinical Findings in the Child : The child was delivered spontaneously (vertex L.O.A.) at the 38th. week and weighed 4 lbs. Numerous purpuric spots were present over the trunk and limbs. It died the following day.

Post-mortem Report : (144/42)

The body was that of a premature female infant weighing 4 lbs. Numerous petechial haemorrhages were present over the face, head and trunk. Several ecchymoses were present over the back.

Head : There was an excess of cerebro-spinal fluid in the subarachnoid space and the meningeal vessels were very congested. The brain was very congested and there were a few petechial haemorrhages under the ependyma of the lateral ventricles.

Thorax /

Thorax : The serous sacs were healthy and there was a slight excess of free fluid in the pericardial sac. A few subpleural and subepicardial petechial haemorrhages were found. The lungs were completely atelectatic.

Abdomen : The alimentary tract had a normal appearance. The liver was moderately enlarged, yellowish-brown in colour and firm in consistence. The spleen was very large and measured  $2\frac{1}{2}$ " by  $1\frac{1}{2}$ ". It was very congested but quite firm in consistence. The kidneys were rather congested.

Microscopic Report :

Liver : Numerous haemopoietic foci present. These are mainly normoblastic in character but numerous erythroblasts are also present. The portal tracts are heavily infiltrated with nucleated red cells. The portal tracts also show a slight increase in the connective tissue. The liver cells are healthy.

Spleen : The organ is very congested and the Malpighian bodies are mainly absent. They have become fibrosed. Numerous haemopoietic cells are found in this new fibrous tissue and in the pulp.

Kidney : There are many foci of haemopoiesis, and these foci are mainly perivascular in character. The peripelvic connective tissue is heavily infiltrated with haemopoietic cells. A considerable degree of perivascular haemorrhage is also present.

Summary : Hydrops foetalis.

Case 19 : Baby B. Born 29.9.42. Still-birth.

Maternal/

Maternal History : The mother was aged 42 and this was her 6th. pregnancy. Her first and second child are alive and well. The next three pregnancies ended in miscarriages at the 5th month. During the present pregnancy she suffered from pre-eclamptic toxæmia.

Post-mortem Report :

The body was that of a small, premature, female foetus weighing 4 lbs. 13 ozs. There was very severe generalised oedema.

Thorax : The serous sacs contained an excess of clear fluid. The heart was moderately enlarged.

Abdomen : The peritoneal cavity contained a large quantity of clear fluid. The alimentary tract was normal. The liver was moderately enlarged and rusty-brown in colour. The consistence was normal. The spleen was enlarged and measured 2" in length. The other organs were normal. The bone-marrow was highly reactive.

Microscopic Report :

Blood film : A large number of primitive nucleated red cells were present.

Bone Marrow : Numerous primitive erythroblasts present.

Liver : Haemopoiesis was active and primitive in type. The liver cells contained a large amount of haemosiderin. The portal tracts were heavily infiltrated with erythroblasts. There was no fibrosis.

Spleen : Primitive erythroblasts were very conspicuous and the pulp showed haemosiderin-containing histiocytes.

Kidney/

Kidney : Very few foci of haemopoiesis. The convoluted tubules showed haemosiderin in their lining cells.

Placenta : The villi were much larger than normal and the stroma was extremely oedematous. The stromal cells were not conspicuous and the Langhans cells were not recognisable.

Summary : Hydrops foetalis.

Case 20. Baby C. Born 28.9.42. Died 17.10.42. aged 19 days.

Maternal History : The first child was jaundiced at birth but is now alive and well. The second child was normal at birth and is now alive and well. This is her third child. She is 33 years of age and was quite well during the present pregnancy.

Clinical Findings in the Child : The child was delivered spontaneously (vertex L.O.A.) during the 39th week of the pregnancy, and weighed 8 lbs. at birth. Two or three days after birth it was very jaundiced, and haemoglobin was 46%. A week later the jaundice was less pronounced but the spleen was still enlarged and the haemoglobin was only 28%. On the 19th. day the haemoglobin was still 28% and the baby died while being transfused.

Post-mortem Report : (173/42)

The body was that of a female infant weighing  $7\frac{1}{2}$  lbs. There was marked jaundice and the skin was very pale.

Head : There was a large amount of blood in the subdural/

subdural space. This had recently been extravasated. The brain was pale and the meninges were slightly bile-stained. There was no kernicterus.

Thorax : The serous sacs were healthy. The lungs were well-expanded but slightly oedematous. The heart was normal.

Abdomen : The alimentary tract was normal. The liver was considerably enlarged, reddish-brown in colour and firm in consistence. The spleen was very large and measured 4" in length. It was light red and very soft. The kidneys were pale and bile-stained.

Microscopic Report :

Bone Marrow : There was active haemopoiesis and numerous nucleated red cells and erythroblasts were present.

Liver : There was great haemopoietic activity and numerous foci of primitive cells were present. There was a fair amount of haemosiderin deposited in the liver cells. Most of the bile-ducts contained a purulent exudate and the periductal connective tissue was infiltrated with polymorphs. This was due to a superadded cholangitis.

Spleen : Active haemopoiesis with numerous primitive cells throughout the pulp.

Summary : Icterus Gravis with superadded acute cholangitis.

Case 21: Baby B. Born 27.11.42. Still-birth.

Maternal History : Few clinical details are available, but more than one of the mother's previous children had/

had suffered from icterus gravis.

Post-mortem Report : (194/42)

The body was that of a small male foetus weighing 5 lbs. 10 ozs. There was generalised subcutaneous oedema and considerable maceration had occurred.

Head : No abnormality present.

Thorax : The serous sacs contained some blood-stained fluid. The heart was enlarged as a result of ventricular hypertrophy. The myocardium was pale and yellowish in colour.

Abdomen : There was some blood-stained fluid in the peritoneal sac. The liver was moderately enlarged and brown-green in colour. It was soft but not diffluent. The spleen was enlarged to  $2\frac{1}{2}$ " in length.

Microscopic Report :

Blood film : Nucleated red cells were present.

Liver : Severe maceration had occurred, and cellular detail had been lost. There was some interlobular fibrosis and a fair amount of haemosiderosis.

Spleen : There was active haemopoiesis.

Kidney : A few foci of haemopoiesis were present.

Placenta : The villi were large and the stroma was oedematous. There were very large numbers of nucleated red cells in the vessels.

Summary : Hydrops foetalis.

Case 22 : Baby B. Born 1.12.42. Still-birth.

No clinical details were obtained.

Post-mortem Report : (198/42)

The body was that of a female foetus weighing 6 lbs/

6 lbs. 9 ozs. It showed advanced maceration.

Thorax : The serous sacs contained some blood-stained fluid. The organs were severely macerated.

Abdomen : The peritoneal cavity contained a large amount of blood-stained fluid. The spleen was greatly enlarged and measured  $2\frac{3}{4}$ " in length and  $1\frac{1}{2}$ " in breadth. It was soft but not completely diffluent. The liver was slightly enlarged, green-brown in colour and rather rubbery in consistence. There was no fibrosis.

Microscopic Report :

Blood Film : The blood was too haemolysed for useful examination.

Liver : There is a fine diffuse fibrosis, with a uniform distribution. The nuclear staining has been lost as a result of maceration, and no erythropoiesis could be seen. The liver cells contain a considerable quantity of haemosiderin granules.

Summary : Hydrops foetalis.

Case 23 : Baby C. Born 7.1.43. Still-birth.

Maternal History : The mother had had three previous pregnancies, all of which have ended in abortions. In the present pregnancy she had had no illness. The placenta at the birth was large and pale.

Post-mortem Report : (4/43)

The body was that of a very small male foetus weighing 1 lb.. It was in a state of very advanced maceration.

Thorax : There was no free fluid in the serous sacs/

sacs and all the tissues were bleached. The pericardial sac was very dilated.

Abdomen : The spleen was very enlarged for this stage of development. The liver was not enlarged and showed no fibrosis.

Microscopic Report :

Liver : Maceration was advanced and all nuclear staining had been lost. A few nests of erythropoiesis, mainly erythroblastic in character were found. Most of the liver cells contained granules of haemosiderin in excess of normal. There was no excessive fibrous tissue.

Summary : Hydrops foetalis.

Case 24 : Baby U. Born 21.1.43. Died 21.1.43., lived for 2 hours.

Maternal History : The mother was suffering from secondary syphilis during the present pregnancy, and her Wassermann reaction was strongly positive. The birth occurred at the 38th. week of pregnancy. It was her first pregnancy.

Post-mortem Report : ( 8/43)

The body was that of a small female infant with generalised subcutaneous oedema. The abdomen was distended.

Head : No abnormality present.

Thorax : The heart was slightly enlarged.

Abdomen : There was some clear yellow fluid in the peritoneal sac. The alimentary tract was normal. The liver was enlarged, brown in colour and firm in consistence/

consistence. The spleen was very enlarged and measured  $3\frac{1}{2}$ " in length.

Bones : The epiphysis at the knee-joint showed a bright yellow line suggestive of syphilitic infiltration.

Microscopic Report :

Liver : There was marked haemopoiesis, and numerous nucleated red cells were found. There was central necrosis of the liver lobules. Some pericellular fibrosis had occurred. Haemosiderin was found in the Kupffer cells. No spirochaetes were present.

Bones : No syphilitic lesions were present.

Spleen : There was active haemopoiesis with numerous erythroblasts. No spirochaetes were present.

Blood : Numerous nucleated red cells were found.

Summary : Hydrops foetalis. No evidence of congenital syphilis.

Case 25 : Baby W. Born 23.4.43. Still-birth.

Maternal History : This was the mother's seventh pregnancy. The first child was born at term and is alive and well. The second was also born at term but died after 19 hours. The next four were born prematurely and were still-births. The present pregnancy also ended prematurely. The placenta was large and very oedematous.

Post-mortem Report : (58/43)

The body was that of a small male foetus weighing 5 lbs. /

5 lbs. It showed very severe generalised sub-cutaneous oedema. The abdomen was greatly distended.

Head : There was a large amount of haemorrhage into the scalp and the latter was very oedematous. The brain was pale and the gyral pattern primitive.

Thorax : The pleural sacs contained a small quantity of clear fluid. The lungs were unexpanded and rather oedematous. The myocardium was pale.

Abdomen : The peritoneal sac contained a large quantity of clear fluid. The alimentary tract was rather compressed. The liver was enlarged, brownish-red in colour and of normal consistence. It showed a moderately marked Prussian Blue reaction. The spleen was enlarged to three times the normal size and was dark red and soft. The kidneys were rather pale.

#### Microscopic Report :

Placenta : The villi are enlarged, chiefly due to oedema. The stroma cells are conspicuous but are not increased in number. The syncytium is a little hyperplastic. No persistent Langhan's cells were seen. The foetal capillaries contain an excess of nucleated red cells.

Liver : The organ is packed with erythroblasts. Primitive forms are exceedingly numerous but some normoblasts are also present. The haemopoietic cells occupy every available space throughout the section and the liver cells are compressed. In a few areas the liver cells are degenerate and there is a suspicion of fibrosis. There is no widespread necrosis.

The/

The liver cells contain granules of haemosiderin.

Spleen : Great erythroblastic activity is present.

Kidney : Numerous nests of erythroblasts are present in the boundary zone.

Blood : Nucleated red cells are exceedingly numerous and are very primitive in type.

Summary : Hydrops foetalis.

Case 26 a : Baby S (1). Born 25.4.43. Died 28.4.43. Aged 3 days.

Maternal History : The mother was aged 32 and this was her 10th. pregnancy. No details were available for the previous pregnancies.

Post-mortem Report : (60/43)

The body was that of a small male infant weighing 4 lbs. 7 ozs. The cord was attached and beginning to dry. The skin was bright yellow. There was slight oedema of the lower limbs.

Head : There was no intracranial haemorrhage. The meninges were bile-stained. The nuclei in the pons, basal ganglia and medulla were bright yellow. The nuclei in the floor of the 4th. ventricle were also stained.

Thorax : Both pleural sacs contained a slight excess of yellow fluid. The lungs were well expanded and bile-stained. The heart was normal.

Abdomen : The peritoneal sac contained a slight excess of bile-stained fluid. The liver was enlarged, brownish/

40.

brownish-red in colour and of normal consistence. The spleen was slightly enlarged and rather soft. The kidneys were of average size and bile-stained.

Microscopic Report :

Blood Film : There were fairly numerous nucleated red cells.

Liver : Moderate haemopoietic activity was present. Numerous foci of erythroblasts were seen. The liver cells contain a large amount of haemosiderin. There was no fibrosis.

Spleen : Slight erythroblastic activity. There was a great deal of haemosiderin in the histiocytes of the pulp.

Lung, kidney and suprarenal are normal.

Summary : Icterus gravis neonatorum with severe kernicterus.

Case 26 b : Baby S (2) Born 25.4.43. Died 28.4.43. Aged 3 days. Twin of the above. It developed shallow breathing, had an epistaxis and died.

Post-mortem Report :

The body was that of a very small female infant weighing 2 lbs. 11 ozs. The skin was bright yellow in colour.

Head : The meninges were bile-stained, as were the nuclei in the basal ganglia, pons and medulla. The olivary nuclei were not affected, but the nuclei in the floor of the 4th. ventricle and the flocculus of the cerebellum were intensely bile-stained.

Thorax /

Thorax : The pleural and pericardial sacs contained an excess of clear fluid. The lungs were poorly expanded, congested and oedematous. The heart was normal.

Abdomen : The peritoneal sac contained a small quantity of clear yellow fluid. The alimentary tract was normal. The liver was slightly enlarged and deeply congested. The spleen was enlarged to 2" in length. It was dark red, firm and tense. The kidneys were of average size, pale and bile-stained.

Microscopic Report :

Blood Film : numerous normoblasts and erythroblasts present.

Liver : Considerable erythropoiesis present. The liver cells contained haemosiderin and the inter-cellular canaliculi are plugged with bile, there was no necrosis of the liver cells and no fibrosis.

Spleen : Considerable haemopoiesis but less haemosiderosis than in Twin 1.

Lung, kidney and suprarenal show little of note.

Summary : Icterus gravis neonatorum with severe kernicterus.

Case 27 : Baby A. Born 26.4.43. Died 26.4.43. Lived for six hours.

Maternal History : The mother was aged 29 and this was her first pregnancy. She had suffered from pre-eclamptic toxæmia and hypertension during the pregnancy.

Post-mortem Report :

The body was that of a very small male infant weighing/

weighing 3 lbs.

Head : There was a subarachnoid haemorrhage present and the cerebro-spinal fluid was blood-stained. A few subependymal haemorrhages were found in the walls of the lateral ventricles.

Thorax : The serous sacs were healthy. The lungs were unexpanded and deeply congested.

Abdomen : The peritoneal sac was healthy. The organs showed no pathological change.

Microscopic Report :

Liver : Considerable haemopoiesis was present and much of it was primitive in type. The liver cells contained a small amount of haemosiderin.

Spleen : Slight haemopoietic activity was found.

Blood Film : Numerous nucleated red cells were present.

Summary : Hydrops foetalis.

Case 28 : Baby M. Born 31.5.43. Died 31.5.43.

Lived for one hour.

Maternal History : The mother was aged 30 and this was her second pregnancy. The first child was normal. She had had no illness during the present pregnancy. The mother was Rh-positive and had antibodies in her serum.

Post-mortem Report :

The body was that of a well developed male infant weighing 6 lbs. 5 ozs. There was moderately deep jaundice of the skin and conjunctivae. Numerous petechial haemorrhages were present over the face and posterior/

posterior trunk.

Head : There was a slight subdural haemorrhage on the right side from a small tear in the falx at its base. There was no kernicterus.

Thorax : The serous sacs were healthy. The lungs were poorly expanded and slightly bile stained. The heart was enlarged as a result of dilatation of both ventricles.

Abdomen : The peritoneal cavity was healthy. The alimentary tract was normal. The liver was enlarged, greenish-brown in colour and of normal consistence. The spleen was greatly enlarged, soft and deep red in colour. The kidneys were of normal size and slightly bile-stained.

#### Microscopic Report.

Liver : Very excessive haemopoiesis was present. Erythroblasts were predominant though normoblasts were also numerous. The liver cells and the Kupffer cells contained large amounts of haemosiderin.

Spleen : Very active haemopoiesis present. The pulp was crammed with erythropoietic cells and erythroblasts were very numerous. Only a small amount of haemosiderin was found.

Kidney : A few foci of erythropoiesis were seen.

Suprarenal : A few foci of haemopoiesis were present in the cortex.

Lung : The lungs were very oedematous and some amniotic debris was found in the alveoli.

Blood Film : Nucleated red cells were very numerous.

Summary : Icterus gravis neonatorum.

Case 29 a/

Case 29 a : Baby G. (1) Born 26.6.43. Died 29.6.43.  
Aged three days. No clinical records were available.

Post-mortem Report :

The body was that of a male infant weighing 5 lbs. The skin and mucous membranes were deeply jaundiced.

Head : The leptomeninges showed yellow discoloration. Intense bile-staining of all the nuclei in the brain stem and basal ganglia had occurred. The olives and the dentate nuclei of the cerebellum were particularly affected.

Thorax : The serous sacs were healthy. The lungs were well expanded and bright yellow in colour. The heart was of normal size. The myocardium was pale and bile-stained.

Abdomen : The peritoneal sac was healthy. The alimentary tract was healthy. The liver was slightly enlarged and rusty-brown in colour. The spleen was enlarged to  $2\frac{1}{2}$ " in length, was red in colour and firm in consistence. The kidneys were of normal size and were bile-stained. The suprarenal glands showed a yellow discoloration of the cortex.

Microscopic Report :

Blood Film : Nucleated red cells were not very numerous.

Liver : There was some excess of haemopoiesis. Some of the erythropoietic foci only showed erythroblasts. The liver cells contained a large amount of haemosiderin and show some fatty degeneration. The intercellular canaliculi are plugged with bile.

Spleen : Considerable erythropoietic activity was/

was present.

Summary : Icterus gravis neonatorum with severe kernicterus.

Case 29 b : Baby G (2) The twin of the above. Also lived for three days.

Post-mortem Report :

The body was that of a female infant weighing 4 lbs. 14 ozs. The skin and mucous membranes showed severe jaundice.

Head : The leptomeninges showed slight yellowish discoloration. Kernicterus was well developed and was conspicuous in the flocculus of the cerebellum on both sides.

Thorax : The serous sacs were healthy. The lungs were normal. The myocardium was pale and bile-stained.

Abdomen : The peritoneal sac was healthy. The alimentary tract was normal. The liver was not enlarged and was rusty-brown in colour. The spleen was enlarged to  $2\frac{1}{2}$ " in length. It was soft and diffluent. The kidneys showed intense bile-staining of the apices of the pyramids.

Microscopic Report :

Brain : Many of the large nerve cells were either shrunken with hyperchromatic cytoplasm or had pale swollen cytoplasm. Several cells in the cornu ammonis showed bright orange pigmentation.

Liver : Little excessive haemopoiesis. Many of the nucleated cells are normoblasts. The liver cells contain/

contain an excess of haemosiderin and there are a few bile plugs in the intercellular canaliculi.

Spleen : Erythropoiesis is not conspicuous.

There are some macrophages containing haemosiderin.

Summary : Icterus gravis with severe kernicterus.

Case 30 : Baby S. Born 4.7.43. Died 12.7.43. Aged 9 days.

Maternal History : The mother was aged 36 and this was her second pregnancy. The first had ended in a miscarriage.

Clinical Findings in the Child : The child was delivered with forceps (breech L.S.A.) some weeks before term. It became jaundiced soon after birth and did not respond to treatment. It died on the 9th day.

Post-mortem Report : (117/43)

The body was that of a very small male infant weighing 3 lbs. There was a fairly deep jaundice of the skin.

Head : There was a small subdural haemorrhage on the right side as a result of a tentorial tear. Both lateral ventricles contained blood and there was a ruptured subependymal haemorrhage on the right side. A certain amount of subarachnoid haemorrhage was also present. The brain showed diffuse yellowish discoloration and the leptomeninges were bile-stained. Nuclei in the basal ganglia, mid-brain, pons and the floor of the 4th. ventricle were bright yellow in colour.

Thorax : The serous sacs were healthy. The lungs were well expanded and bile-stained.

Abdomen/

Abdomen : The peritoneal sac was healthy, and the alimentary tract was normal. The liver was enlarged, dark in colour and rather soft. The spleen was twice the normal size and firm in consistence.

Microscopic Report :

Liver : A few haemopoietic foci were present. The liver cells were healthy. There were no deposits of haemosiderin.

Spleen : No abnormality present.

Blood Film : A few normoblasts were present.

Summary : Icterus Gravis neonatorum with kernicterus and intra-ventricular haemorrhage.

Case 31 : Baby P. Born 19.7.43. Died 26.7.43. Aged 7 days. Female.

Maternal History : The mother was aged 27 and this was her first pregnancy. She was Rh.-ve (The father was Rh. positive).

Clinical Findings in the Child : The child was delivered spontaneously (vertex R.O.C.) during the 36th. week of the pregnancy. She weighed 5 lbs. at birth. She became jaundiced soon after birth and this jaundice increased. Six days after birth there were clinical signs of kernicterus, and the child died on the 7th. day.

Post-mortem Report : (134/43.)

The body was that of a small female infant weighing 4 lbs. 5 ozs. There was moderate jaundice of the skin and mucous membranes.

Head : The surface of the brain was lightly bile-stained. The nuclei in the basal ganglia, hypothalamus/

hypothalamus, mid-brain, pons and medulla were bright yellow in colour. The spinal cord showed bile-staining of the grey matter.

Thorax : The serous sacs were healthy and there was a small amount of yellow fluid in the pericardial sac. The lungs and heart were lightly bile-stained.

Abdomen : The peritoneal sac contained a small amount of yellow fluid. The liver was slightly enlarged, of normal consistence and brow-red in colour. The spleen was enlarged, firm and dark in colour. The kidneys were lightly bile-stained.

Microscopic Report :

Brain : In the regions affected by kernicterus there was loosening up of the cerebral tissue with necrosis and the formation of globules of lipid material. Most of the latter was present within the cells or in the bodies of phagocytes. There was a slight astrocytic reaction but no evidence of vascular occlusion.

Blood Film : A few nucleated red cells were present.

Liver : Haemopoiesis was not marked and only a few groups of normoblasts were seen. The inter-cellular canaliculi contain bile plugs, and a few of the liver cells contain fat globules.

Spleen, kidney and suprarenal glands showed no abnormality.

Summary : Icterus gravis neonatorum with kernicterus.

Case 32. : Baby M. Born 21.7.43. Still-birth.

Maternal/

Maternal History : The mother's previous pregnancy also ended in a still-birth.

Post-mortem Report : (128/43)

The body was that of a well developed female infant weighing 7 lbs 14 ozs. The skin was covered with a bright orange-yellow vernix. There was jaundice of the skin and mucous membranes. There was some subcutaneous oedema over the face.

Head : No abnormality present.

Thorax : There was considerable quantity of dark yellow fluid in the pleural sacs and also in the pericardial sac. The lungs were congested, oedematous and airless. The heart was considerably enlarged due to dilatation of both ventricles. The myocardium was soft and pale.

Abdomen : The peritoneal sac contained a large quantity of dark yellow fluid. The alimentary tract was normal. The liver was enlarged, firm in consistence and greenish-brown in colour. The spleen was enlarged to four times the normal size. It was soft and dark red in colour. The kidneys were of average size and slightly bile-stained.

Placenta : Weighed 2 lbs. It was larger and paler than normal.

Microscopic Report :

Liver : Haemopoiesis was excessive and very primitive in type. Many foci were composed entirely of primitive erythroblasts. There was considerable haemosiderosis and the Prussian Blue reaction was positive. The liver cells were normal and there was no/



no fibrosis.

Spleen : The sinusoids were dilated and the lining cells were prominent. Numerous nucleated red cells were present throughout the pulp.

Kidney and Suprarenal : A few haemopoietic foci were present.

Blood Film : Numerous primitive red cells present.

Summary : Hydrops foetalis ( with jaundice).

Case 33 : Baby T. Born 19.9.43. Still-birth.

Maternal History : This was the mother's eighth pregnancy. The first two children are alive and well. The remaining pregnancies have all ended in still-births.

Post-mortem Report :

The body was that of a female foetus weighing 6½lbs. There was slight oedema of the face and limbs. Maceration was moderately well advanced and the epidermis was peeling. The abdomen was rather distended.

Head : No abnormality present.

Thorax : The serous sacs contained some blood-stained fluid. The heart was slightly enlarged and the myocardium was hypertrophied.

Abdomen : The peritoneal sac contained some blood-stained fluid. The liver was enlarged and rusty-brown in colour. The spleen was considerably enlarged and measured 3" in length. It was very soft and/

and diffluent.

Microscopic Report :

Blood Film : There was great excess of nucleated red cells. Many of these were normoblasts but some more primitive types were present.

Liver : The liver cells had suffered severely from maceration and the cell detail had been lost. They contained an excess of haemosiderin and the Prussian Blue reaction was positive. A fine diffuse fibrosis was present.

Spleen : Maceration was severe. A few normoblasts were seen.

Kidney and Suprarenal : A few foci of haemopoiesis were present in the connective tissue surrounding the arteries and veins.

Placenta : The villi were large swollen and oedematous. The syncytial layer was prominent but no Langhan's cells were identified. There were large numbers of nucleated red cells in the foetal capillaries.

Summary : Hydrops foetalis.

Case 34 : Baby W. Born 9.10.43. Died 18.10.43.  
Aged 9 days.

Maternal History : The mother was aged 26 and this was her third pregnancy. The first two children are alive and well. She had no illness during the present pregnancy. Her blood is Rh. negative and that of the child was Rh. positive.

Clinical Findings in the Child :

The child was delivered spontaneously (vertex  
L.C.A. /

L.O.A.) at term. Forty-eight hours after birth it became jaundiced. On the 4th. day it was very jaundiced and lethargic. It was transfused with 90 cc. Rh. negative blood. It then developed spasticity and head retraction and died on the 9th day.

Post-mortem Report : (166/43)

The body was that of a small male infant weighing 5 lbs. 2 ozs. There was fairly severe jaundice.

Head : The meninges and the brain showed diffuse bile-staining. The nuclei in the basal ganglia, floor of the 4th. ventricle and the olivary nuclei of the medulla were heavily bile-stained. There was a slight subarachnoid haemorrhage over the left cerebral hemisphere.

Thorax : The serous sacs were healthy. The lungs were well expanded and rather pale. The myocardium was also rather pale.

Abdomen : The peritoneal sac was healthy. The alimentary tract was healthy. The liver was enlarged, slightly soft and greenish-brown in colour. The spleen was enlarged and measured 3" in length. It was deep red and rather soft. The Malpighian bodies were not visible. The kidneys were of normal size and bile-stained.

Microscopic Report:

Blood Film : There was no excess of nucleated red cells, only a few normoblasts were seen.

Liver : Haemopoiesis was slight. There was no haemosiderin/

haemosiderin present.

Spleen : Haemopoiesis was slight. A few eosinophils were present in the pulp.

Summary : Icterus Gravis neonatorum with Kernicterus.

Case 35 : Baby G. Born 18.8.43. Still-birth.

Clinical Findings : The foetal heart failed 4 days before delivery. The mother had suffered from hydramnios during the pregnancy. The placenta was very large and weighed 3 lbs. 14 ozs. It was pale and hydropic.

Post-mortem Report : (146/43)

The body was that of a macerated male foetus. There was generalised subcutaneous oedema.

Head : No abnormality present.

Thorax : The serous sacs contained some blood-stained fluid. The organs were macerated.

Abdomen : There was some blood-stained fluid in the peritoneal sac. The liver and spleen were enlarged but were macerated.

Microscopic Report :

Liver : Maceration was severe but some foci of haemopoiesis could be made out.

Summary : Hydrops foetalis.

Case 36 : Baby B. Born 26.2.44. Died 29.2.44. Aged 3 days.

Maternal History : The mother was aged 34 and this was her 5th. pregnancy. Her first pregnancy ended in a miscarriage. Her second, third and fourth terminated normally and the children are alive and well. Her blood/

blood is Rh. negative and antibodies were present during the pregnancy. She had suffered from an ante-partum haemorrhage as a result of a placenta praevia, and the child was born prematurely.

Clinical Findings in the Child : The child was delivered spontaneously (vertex L.O.A.) a few weeks before term and weighed 5 lbs. 13 ozs. at birth. It was jaundiced at birth and the jaundice rapidly increased. The child died on the 3rd. day.

Post-mortem Report : (30/44)

The body was that of a small male infant weighing 4 lbs. 13 ozs. It was very deeply jaundiced.

Head : Some haemorrhage had occurred between the layers of the falx and the tentorium but there was no free haemorrhage into the subdural space. The meninges and the brain substance were diffusely stained with bile. The nuclei in the basal ganglia, brain stem and medulla were heavily bile-stained. The grey matter of the spinal cord was also deep yellow.

Thorax : The serous sacs were healthy. The lungs were well expanded and showed no abnormality. The myocardium was pale and bile-stained.

Abdomen : The peritoneal sac contained some yellow fluid. The alimentary tract was normal. The liver was slightly enlarged, light red on the outer surface and greenish-brown on the cut surface. The spleen was enlarged to  $2\frac{1}{2}$ " in length. It was firm and dark red in colour. The kidneys were pale and bile/

bile-stained.

Microscopic Report :

Brain : The nerve cells were shrunken and hyperchromatic. The cells in the cornu ammonis had a bright yellow cytoplasm.

Blood Film : There was a great increase of nucleated red cells and many of them were primitive in type.

Liver : There was excessive haemopoiesis and the foci contained both normoblasts and primitive erythroblasts. The portal tracts were infiltrated with haemopoietic cells. The liver cells contained haemosiderin.

Spleen : The pulp was crowded with erythroblasts and with histiocytes laden with haemosiderin.

Suprarenal : Numerous foci of haemopoiesis were present in the medulla.

Kidney : There were some small haemopoietic foci in the peripelvic tissue. A piece of pelvic wall was ulcerated and infiltrated with polymorphs. The adjacent part of the medulla showed a dense polymorphonuclear cell infiltration. This had the appearance of an acute pyelonephritis.

Summary : Icterus gravis neonatorum with kernicterus.

Case 37 : Baby S. Born 21.5.44.

Maternal History : The mother was aged 39 and this was her 7th. pregnancy. Her first five children are alive and well. She was admitted to hospital in December 1943 after a miscarriage. She became very anaemic/

SERIES 1.

TABLE 2.  
BABY McL.

HAEMATOLOGICAL DATA

Case 38.

Age in days	Hb% Sahli	R.B.C./cu. mm.	C. I.	W. B. C./cu. mm.	Nucleated R. B. C. / 100 W. B. C.	Reticulo-cytes.	Icteric Index.	Vaden Bergh reaction	Miscellaneous.
1	-	-	-	-	-	-	-	-	Jaundice
5	72	-	-	-	-	-	-	-	Kernicterus
9	-	-	-	-	-	-	133	Strong Bi-phasic	<u>Cerebro-spinal fluid</u> : Sugar 71 mgr chlorides 656 mgr Colloidal gold 000000000 Fluid yellow in colour. Van den Berg reaction weak biphasic.

anaemic and was given four transfusions of whole blood (Rh. group not specified). She had a severe reaction after the second pint of blood. During the present pregnancy antibodies to Rh. positive blood were found. Her blood is Rh. negative.

Clinical Findings in the Child :

The child was delivered spontaneously (vertex L.O.A.) at term and weighed  $7\frac{1}{4}$  lbs. at birth. 48 hours after birth it became jaundiced and rather pale. The spleen and liver were not enlarged. The haemoglobin fell to 48% (Sahli) but the child thrived quite well and the jaundice gradually faded.

Summary : Icterus gravis neonatorum (recovered).

Case 38 : Baby McL. Born 25.6.44. Died 6.7.44.  
Aged 12 days.

Maternal History : The mother was aged 36 and this was her 5th. pregnancy. Her first and second children were normal at birth and are alive and well. The third child was jaundiced on third day after birth. The mother was quite well during the present pregnancy.

Clinical Findings in the Child ( See Table 2)

The child was delivered spontaneously (vertex R.O.A.) at the 38th week and weighed  $7\frac{1}{2}$  lbs. at birth. The following day it became very jaundiced and on the 5th. day there were signs of cerebral involvement. The child did not thrive and died on the 12th. day.

Post-mortem Report : (97/44)

The body was that of a well developed male infant/

infant. It was severely jaundiced.

Head : The brain and meninges were diffusely bile-stained. There was a small amount of blood in the subdural space over the lateral aspect of the temporal lobes. This was due to small tears in the tentorium. There was a diffuse leptomeningitis, more marked on the left side and on section there was pus in the ventricles. The cornu ammonis was bright yellow.

Thorax : The serous sacs were healthy. The alimentary tract was normal. The liver was slightly enlarged and greenish-brown in colour. The spleen was slightly enlarged and dark red in colour. The kidneys were pale and bile-stained.

Microscopic Report :

Blood Film : Nucleated red cells were very scanty.

Liver : There was active haemopoiesis but this was not very excessive. The liver cells contained some haemosiderin. The cells in the central zone of the lobules showed some loss of nuclear staining but there was no actual necrosis.

Spleen : There were some haemosiderin-laden histiocytes.

Brain : An acute purulent leptomeningitis and ventriculitis was present, and this masked the lesions associated with kernicterus.

Summary : Icterus gravis neonatorum with kernicterus and meningitis.

Case 39 : Baby B. (2) Born 7.7.44. Died 13.7.44.  
Aged 6 days.

Maternal History : The mother was aged 32 and this was/

was her second pregnancy. Her first child is alive and well. She had no illness during the present pregnancy, which ended in the delivery of twins. The mother is Rh. positive.

Clinical Findings in the Child : The child was the second of twins. It became jaundiced 48 hours after birth. The jaundice increased and on the fifth day there was evidence of cerebral involvement. The child died on the 6th. day.

Post-mortem Report : (101/44)

The body was that of a small male infant weighing 4 lbs. 5 ozs. There was deep jaundice of the skin and mucous membranes.

Head : The meninges and the brain were diffusely bile-stained. The nuclei in the basal ganglia were deep yellow in colour. Other cerebral nuclei were not affected.

Thorax : The serous sacs were healthy. The lungs were moderately well-expanded but the lower lobes were rather collapsed and oedematous. The heart was normal.

Abdomen : The peritoneal sac was healthy and the alimentary tract was normal. The liver and spleen had a normal appearance. The kidneys were healthy.

Summary : Icterus gravis with kernicterus.

Case 40 : Baby A. Born 25.7.44 and lived for one hour.

Maternal History : Mother was 23 and this was her first pregnancy. She had not suffered any illness. Her blood was Rh. negative : there were no antibodies.

Clinical Findings in the Child : The child was delivered/

delivered spontaneously and was jaundiced at birth. The vernix was golden yellow in colour. It lived for one hour.

Post-mortem Report : (107/44)

The body was that of a male infant weighing  $5\frac{3}{4}$  lbs. Jaundice was not pronounced.

Head : The meninges and brain were rather congested.

Thorax : The serous sacs were healthy. The lungs were well expanded and the heart had a normal appearance.

Abdomen : The peritoneal sac contained a few drops of clear yellow fluid. The liver was of normal size and shape. The spleen was enlarged and measured  $2\frac{1}{2}$ " in length. The kidneys were healthy. The alimentary tract was normal.

Microscopic Report :

Blood Film : There was some excess of nucleated red cells present. These were mainly normoblastic in character.

Liver : Haemopoiesis was greatly in excess of normal. Many foci of primitive erythroblasts and normoblasts were found. The liver cells contained a small amount of haemosiderin. Some early fatty change had occurred in the parenchymal cells.

Spleen : There were numerous nucleated red cells in the pulp.

Summary : Icterus gravis neonatorum.

Case 41 : Baby. B. Born 9.8.44 and lived for 1 hr.

40 mins.

Maternal/

Maternal History : The mother was aged 36 and this was her 10th. pregnancy. Her first child is alive and well. The second pregnancy ended in a miscarriage. The third and fourth children were still-born. The fifth child died at birth. The seventh, eighth and ninth, were still-born. She was grossly over-weight and weighed 22 stone. She had suffered from pre-eclamptic toxæmia during the present pregnancy.

Clinical Findings in the Child : The child was delivered spontaneously during the 37th. week of the pregnancy, and weighed 3 lbs. 3 ozs. at birth. It lived for one hour and forty minutes.

Post-mortem Report : (117/44)

The body was that of a very small female infant weighing 3 lbs. 3 ozs. There was slight jaundice of the skin and mucous membranes, and there was generalised subcutaneous oedema.

Head : The brain was slightly oedematous. There was no kernicterus.

Thorax : The serous sacs were healthy. The lungs were fairly well expanded but were pale and soft. The heart was enlarged and the myocardium was very pale.

Abdomen : The peritoneal sac contained a small amount of clear yellow fluid. The alimentary tract was normal. The liver was enlarged and reddish-brown in colour. The spleen was enlarged and dark red in colour. The kidneys were of normal size and rather pale. The placenta was thick and bulky and pale.

Microscopic Report :

Liver /

Liver : The organ was crowded with haemopoietic cells. The liver cells contained haemosiderin.

Spleen : The pulp contained many primitive erythroblasts. The histiocytes contained haemosiderin.

Placenta : The villi were enlarged and the stroma was oedematous. The syncytium was normal and Langhan's cells were not seen. There was a great excess of nucleated red cells in the foetal vessels.

Summary : Hydrops foetalis.

Case 42 : Baby R. Born 30.9.44. Died 4.10.44.

Aged 5 days.

Maternal History : The mother was aged 42 and this was her 8th. pregnancy. Her first two children were still-born. The third child is alive and well. The 4th. 5th. and 6th. children were still-born. The seventh is alive but has kernicterus. Her blood is Rh. negative and antibodies were present at a dilution of 1/2. She had suffered from hypertension during the present pregnancy.

Clinical Findings in the Child : The child was delivered spontaneously (vertex L.O.A.) a few weeks before term and weighed 6 lbs. 4 ozs. at birth. It was jaundiced from birth. On the third day it was transfused with 90 cc. of Rh. negative blood but did not respond and died on the 5th. day.

Post-mortem Report : (144/44)

The body was that of a male infant weighing 6 lbs. There was deep jaundice of the skin and mucous membranes.

Head/

Head : The leptomeninges and the brain were deeply bile-stained. The nuclei in the basal ganglia, mid-brain, pons, olive, cerebellum and in the floor of the 4th. ventricle were bright yellow in colour. The grey matter of the spinal cord was also affected.

Thorax : The serous sacs were healthy. The lungs were fully expanded, deeply congested and bile-stained. The heart was slightly dilated.

Abdomen : The peritoneal sac contained a little clear fluid. The alimentary tract was normal. The liver was enlarged and reddish-brown in colour. The Prussian blue reaction was positive. The spleen was greatly enlarged and measured  $3\frac{3}{4}$ " in length. It was quite firm and was dark red in colour. The kidneys were bile stained.

#### Microscopic Report :

Blood Film : There were numerous nucleated red cells and many were primitive erythroblasts.

Liver : Many erythropoietic foci were found. These were mainly normoblastic in type. Some of the liver cells were vacuolated.

Spleen : The pulp contained a large number of erythroblasts.

Summary : Icterus gravis neonatorum with kernicterus.

Case 43 : Baby R. Born 13.1.45 Died 19.1.45. Aged 6 days.

Maternal History : The mother was aged 29 and this was her second pregnancy. Her first child is alive and well. Her blood pressure was slightly raised and she/

she had some peripheral oedema during the present pregnancy. Her blood is Rh. negative.

Clinical Findings in the Child : The child was delivered spontaneously at term (vertex L.O.A) and weighed 6 lbs. 5 ozs. at birth. It was jaundiced the following day and the jaundice progressively increased. The child also became pale and the haemoglobin was 40% (Sahli). It did not thrive and died on the 6th. day.

Post-mortem Report : ( 6/45)

The body was that of a male infant and was deeply jaundiced.

Head : The brain and meninges were diffusely bile-stained. There was no kernicterus.

Thorax : The serous sacs were healthy. The lungs were well expanded and were bile-stained. They were congested and oedematous. The heart was moderately dilated and the myocardium was pale.

Abdomen : The peritoneum was healthy and the peritoneal sac contained a little yellow fluid. The alimentary tract was normal. The liver was enlarged and brownish-green in colour. The spleen was greatly enlarged and measured 3" in length. The kidneys were of normal size and were bile-stained.

Microscopic Report :

Liver : There was excessive erythropoiesis and numerous foci of normoblasts and primitive erythroblasts were found. The intercellular canaliculi contained bile plugs. The liver cells contained haemosiderin and the Prussian Blue reaction was positive.

Spleen : There was excessive haemopoiesis and the/

the pulp was unduly cellular. Normoblasts and erythroblasts were very numerous.

Kidney : The blood vessels in the boundary zone were surrounded by foci of erythropoietic cells. Most of these were primitive erythroblasts. The epithelial cells of the convoluted tubules were filled with haemosiderin and the Prussian blue reaction was positive.

Suprarenal glands : There were a few haemopoietic foci.

Blood Film : There was a great excess of nucleated cells, both normoblasts and erythroblasts.

Summary : Icterus gravis neonatorum.

Case 44 : Baby McG. Born 11.3.45. Still-birth.

Post-mortem Report : (34/45)

The body was that of a female foetus weighing 7 lbs. There was severe generalised subcutaneous oedema. The abdomen was rather distended.

Head : No abnormality present.

Thorax : The serous sacs contained a quantity of clear fluid. Numerous subpleural petechiae were present over the surface of the lungs. The lungs were collapsed and rather congested. The heart was dilated.

Abdomen : The peritoneal sac contained a large quantity of blood-stained fluid. The liver was slightly enlarged and rather soft. The spleen was of normal size. The kidneys were normal.

Microscopic Report :

Liver : The cells were affected by maceration.  
Numerous/

Numerous haemopoietic foci were found. Some were composed of primitive erythroblasts. There was no haemosiderin in the liver cells.

Spleen : Some primitive red cells were present throughout the pulp.

Placenta : The villi were enlarged and the stroma were very oedematous.

Blood Film : There was an excess of nucleated red cells.

Summary : Hydrops foetalis.

Case 45 : Baby S. Born 30.4.45. Still-birth.

Maternal History : Two years previous to this pregnancy the mother was delivered of twins who suffered from icterus gravis. The year previous to this pregnancy she had a macerated foetus.

Post-mortem Report :

The body was that of a very small foetus weighing  $2\frac{1}{2}$  lbs. There was generalised subcutaneous oedema. The scalp, face and trunk were most severely affected. The abdomen was distended and there was pronounced yellow discoloration of the umbilical cord.

Head : There was an excess of cerebro-spinal fluid. The brain was rather immature and there was no kernicterus.

Thorax : The serous sacs contained some clear fluid. The lungs were collapsed and airless. The heart was dilated and the myocardium was pale.

Abdomen : The peritoneal sac contained a large quantity of clear yellow fluid. The alimentary tract was/

was normal. The liver was enlarged and reddish brown in colour. It was quite firm. The spleen was greatly enlarged and was dark red in colour. The kidneys were pale.

Microscopic Report :

Blood Film : Nucleated red cells were very numerous. Normoblasts and erythroblasts were both found in large numbers.

Liver : There was great erythropoietic activity and many foci of primitive erythroblasts were seen. Many of the liver cells contained haemosiderin. There was no fibrosis.

Spleen : The pulp was crowded with erythroblasts and normoblasts.

Summary : Hydrops foetalis.

Case 46 : Baby P. Born 16.5.45. Died 16.5.45.

Aged 9 hours.

Maternal History : The mother was aged 32 and this was her third pregnancy. Her first child was normal at birth, and is alive and well. Her second child is alive and well but required three transfusions after birth. The mother's blood is Rh. negative and antibodies are present.

Clinical Findings in the child

The Child was born spontaneously some weeks before term and weighed 4 lbs. 10 ozs. at birth. It was severely jaundiced and was transfused with 100 cc. Rh. negative blood through the umbilical vein. The child failed to thrive and died after 9 hours.

Post-mortem Report : (63/45)

The/

The body was that of a small male infant weighing 4 lbs. 10 ozs. There was jaundice of the skin and mucous membranes. There was slight generalised subcutaneous oedema.

Head : No abnormality present.

Thorax : The serous sacs were healthy. The lungs were unexpanded and oedematous. The heart was normal.

Abdomen : The peritoneal sac contained some yellow fluid. The alimentary tract was normal. The liver was of normal size, and slightly congested. The spleen was enlarged. The kidneys were pale.

Microscopic Report :

Blood Film : There were a few normoblasts present.

Liver : There was an excess of haemopoietic activity. This was mainly normoblastic in type but many primitive erythroblasts were present. The liver cells contained some haemosiderin.

Spleen : There were many small collections of normoblasts throughout the pulp.

Summary : Icterus gravis neonatorum.

Case 47 : Baby M. Born 29.7.45. Died 4.8.45. Aged 6 days.

Maternal History : The mother was aged 19 and this was her first pregnancy. Her blood is Rh. positive. She had no illness during the present pregnancy.

Clinical Findings in the Child :

The child was born spontaneously (vertex L.O.A.) a few weeks before term and weighed 4 lbs. 12 ozs. at birth. On the following day it developed jaundice. It/

It did not thrive and died on the 7th day.

Post-mortem Report : (92/45)

The body was that of a small premature male infant. It was moderately jaundiced.

Head : The nuclei of the basal ganglia, brain stem and floor of the 4th. ventricle were deeply bile-stained.

Thorax : The serous sacs were healthy. The lungs were collapsed and deeply congested. Numerous subpleural petechiae were present. The heart was normal.

Abdomen : There was a fibrinous exudate over the spleen and the alimentary tract was very congested.

Microscopic Report :

Blood Film : There was some increase of nucleated red cells.

Brain : No abnormality was found.

Lung : The organ was deeply congested and poorly expanded.

Liver : There were some foci of normoblasts, and the portal tracts were invaded by haemopoietic cells. The liver cells showed slight fatty change but they did not contain haemosiderin.

Spleen : The pulp was very congested but there was no haemosiderosis.

Summary : Icterus gravis with kernicterus.

Case 48 : Baby C. Born 17.10.45.

Maternal History : The mother was aged 23 and this was her 3rd. pregnancy. Her first child is alive and well/

SERIES 1.

BABY C.

HAEMATOLOGICAL DATA.

TABLE 3.

Case 48.

Age in days	Hb% Sahli	Miscellaneous
1	76	Jaundiced. Transfused with 100 cc. Rh. negative blood.          Transfused with 90 cc. Rh. negative blood.
3	90	
10	82	
15	72	
19	67	
29	50	
33	40	
34	72	
37	74	

well. The second was still-born. She was quite well during the present pregnancy. Her blood was Rh. negative and there were antibodies present.

Clinical Findings in the Child : (see Table 3)

The child was delivered spontaneously (vertex L.O.A.) during the 38th. week of the pregnancy and weighed 5 lbs. 10 ozs. at birth. On the following day it was jaundiced. It was transfused with 100 cc. of Rh. negative blood. On the 33rd. day it was again transfused with 90 cc. of Rh. negative blood. The child's general condition improved steadily and he was discharged from hospital on the 37th. day.

Summary : Icterus gravis neonatorum (recovered).

Case 49 : Baby Mc.C. Born 27.10.45.

Maternal History : The mother was aged 39 and this was her 6th. pregnancy. The first two children are alive and well. The third had suffered from icterus gravis and had died from pneumonia. The fourth is alive and well. The 5th. child had icterus gravis and died of kernicterus. The mother's blood is Rh. positive, but no antibodies were present. She was quite well during the present pregnancy.

Clinical Findings in the Child ( for sibling see case 38 ) The child was delivered spontaneously (vertex R.O.A.) at term and weighed 7 lbs. 13 ozs. at birth. After 48 hours it was very jaundiced. On the 6th. day the haemoglobin had dropped from 90% to 57% and the child was rather pale. It steadily improved during the next 48 hours and the jaundice gradually faded/

faded.

Summary : Icterus gravis neonatorum ( recovered).

Case 50 : Baby C. Born 4.11. 45. Died 7.11.45.  
Aged 3 days.

Maternal History : The mother was aged 36 and this was her 3rd. pregnancy. The first child was still-born. The second child died after 6 hours. It had been delivered by Caesarian section. The mother had suffered slightly from pre-eclamptic toxæmia during the present pregnancy. Her blood-pressure was 185/90 and there was a trace of albumin in the urine. Her blood was Rh. negative and there were antibodies present. That of the child was Rh. positive.

Clinical Findings in the Child : The child was delivered at term by lower segment Caesarian section and weighed 9 lbs. 4 ozs. at birth. After 24 hours it became very jaundiced. On the 3rd. day there were clinical signs of kernicterus and the child died.

Post-mortem Report : (114/45)

The body was that of a large female infant weighing 9 lbs. It was severely jaundiced.

Head : There was diffuse bile-staining of the meninges and brain. The nuclei of the basal ganglia and brain stem were bright yellow. The grey matter of the spinal cord was also yellow.

Thorax : The serous sacs were healthy. The lungs were very congested and there was a patch of pneumonic consolidation near the right apex and another in the upper posterior part of the right lower lobe. The heart/

heart was slightly dilated.

Abdomen : The peritoneal sac contained a little bile-stained fluid. The alimentary tract was normal. The liver was enlarged and was yellow-brown in colour. The spleen was enlarged and measured  $2\frac{1}{2}$ " in length. It was dark in colour and rather friable. The kidneys were pale and bile-stained.

Microscopic Report :

Liver : There was a slight excess of haemopoiesis and this was mainly normoblastic in character. Erythroblasts were scanty. The liver cells and the Kupffer cells contained some haemosiderin and the Prussian blue reaction was positive. Some of the bile ducts and the intercellular canaliculi contained bile plugs.

Spleen : The pulp showed erythropoiesis of the normoblastic type. Histiocytes throughout the pulp were full of haemosiderin and the Prussian blue reaction was positive.

Lung : Patches of pneumonic consolidation were found.

Blood Film : Normoblasts were present.

Summary : Icterus gravis neonatorum with kernicterus and pneumonia.

Case 51 : Baby H. Born 10.12.45. Died 10.12.45. Lived for 15 minutes.

Maternal History : The mother was aged 23 and this was her second pregnancy. The first pregnancy ended with the birth of twins both of whom died. She suffered/

suffered from ante-partum haemorrhage during this pregnancy which ended prematurely.

Clinical Findings in the Child : The child was delivered spontaneously ( breech) some weeks before term and weighed 3 lbs. 6 ozs. at birth. It was very oedematous and only lived for 15 minutes.

Post-mortem Report : (132/45)

The body was that of a small female infant. There was generalised subcutaneous oedema, and numerous small cutaneous petechiae in the skin. These were most noticeable over the abdomen, lower limbs and face.

Head : There was a subarachnoid haemorrhage over the base of the brain and there was a clot of blood in the 4th. ventricle. The centre of both cerebral hemispheres had undergone softening and the cerebrum was represented by a thin shell of brain tissue covered by meninges and enclosing on each side a cavity filled with partially liquefied brain tissue and gelatinous yellow fluid. The brain stem was not affected.

Thorax : Both pleural sacs contained a considerable quantity of clear deep yellow fluid. The pericardial sac contained a similar excess of clear fluid. The lungs were pale, airless and oedematous. There were a few subpleural petechiae. The heart was of normal size and the myocardium was pale. A few subepicardial haemorrhages were found.

Abdomen : The peritoneal sac contained a quantity of clear fluid. The alimentary tract was normal/

normal. The liver was considerably enlarged. It was bright brown in colour and firm in consistence. The Prussian blue reaction was positive. The spleen was greatly enlarged and measured 3" in length. It was dark red in colour and firm in consistence. The Prussian blue reaction was positive. The kidneys were rather pale.

Microscopic Report :

Blood Film : Nucleated red cells were more numerous than usual, and many normoblasts and erythroblasts were found.

Bone Marrow : There was a great excess of haemopoiesis which was partly normoblastic and partly erythroblastic in type. Primitive cells were found throughout the lobules and also in the portal tracts. The liver cells contained an excess of haemosiderin. The liver cells showed a severe degree of degeneration amounting to necrosis and chiefly found in the cells of the central zone of the lobule.

Spleen : The pulp was very cellular and many primitive erythropoietic cells were seen.

Kidney : There was a great deal of erythropoietic activity. These were found chiefly in the boundary zone of the cortex. It was extremely dense in some places. Some of the cells lining the convoluted tubules contained haemosiderin.

Suprarenal : There was active haemopoiesis especially in the medulla. Some areas of the cortex had undergone coagulative necrosis.

Pancreas/

Pancreas : The whole of the stroma was densely infiltrated with cells among which were not only nucleated red cells but also eosinophils in very large numbers. There was also a patchy necrosis of the pancreatic tissue and a large proportion of the acinar tissue had been destroyed.

Brain : The brain is necrotic from the meninges inwards and has undergone softening with haemorrhage. The meninges were infiltrated with many cells - eosinophils, lymphocytes, histiocytes, polymorphs and nucleated red cells. Many compound granular corpuscles were found. The necrosis would seem to have been caused by arterial occlusion.

Summary : Hydrops foetalis (with cerebral necrosis).

Case 52 : Baby A. Born 16.12.45 (male).

Maternal History : The mother was aged 29 and this was her second pregnancy. The first had ended with the birth of a very jaundiced infant who died after 11 days. She had no illness during the present pregnancy. The mother's blood was Rh. negative and there were antibodies in her serum.

Clinical Findings in the Child : The child was delivered during the 37th. week of the pregnancy (breech R.S.A. assisted) and weighed 6 lbs. 13 ozs. at birth. After 24 hours it became jaundiced and also rather pale. The jaundice deepened but the child continued to thrive without treatment and by the 10th. day the jaundice began to lessen. The child's condition was now very good and it was discharged from hospital.

Summary/

Summary : Icterus gravis neonatorum (recovered)

Case 53 : Baby R. Born 12.3.46. Died 14.3.46.  
Aged 48 hours.

Maternal History : The mother was aged 30 and this was her third pregnancy. No family history was available.

Clinical Findings in the Child : The baby was delivered spontaneously during the 33rd. week of the pregnancy and weighed 4 lbs. 6½ ozs. at birth. It was jaundiced at birth and failed to thrive. It died after 48 hours.

Post-mortem Report : ( 66/46)

The body was that of a small male infant and was deeply jaundiced. Considerable post-mortem change had occurred.

Head : Some haemorrhage had occurred between the layers of the tentorium and the falx. The brain and the meninges were diffusely bile-stained. The nuclei in the basal ganglia, brain stem, medulla and the floor of the 4th. ventricle were bright yellow in colour.

Thorax : The serous sacs contained a small quantity of yellow fluid. The lungs were well expanded and there were areas of intrapulmonary haemorrhage. The heart was of normal size and the myocardium was pale and bile-stained.

Abdomen : The peritoneal sac contained some yellow fluid. The alimentary tract was normal. The liver was enlarged and firm. The Prussian blue reaction/

reaction was strongly positive. The kidneys were pale and bile-stained, the Prussian blue reaction was faintly positive.

Microscopic Report :

Blood Film : Nucleated red cells were very numerous and both normoblasts and erythroblasts were found.

Bone Marrow : An excessive number of primitive cells of the erythropoietic series were present.

Liver : Haemopoiesis was active and numerous foci were found. The predominant cell was the normoblast. Erythroblasts were scanty. The liver cells contained an excess of haemosiderin.

Kidney : Some haemopoietic cells were found in the boundary zone.

Spleen : The pulp contained many nucleated cells and histiocytes filled with haemosiderin.

Summary : Icterus gravis neonatorum with kernicterus.

Case 54 : Baby S. Born 10.4.46. Died after a few hours.

Maternal History : The mother was aged 31 and this was her 6th. pregnancy. Her first two children were normal at birth and are alive and well. The 3rd. child died after birth from cerebral haemorrhage. The 4th. child was still-born. The 5th. child died soon after birth from congenital haemolytic disease. The mother had no illness during the present pregnancy. Her blood is Rh. negative.

Clinical Findings in the Child : The child was delivered/

79.  
delivered spontaneously at term and weighed 7 lbs.  
9 ozs. at birth. It was jaundiced at birth and died  
a few hours later.

Post-mortem Report : (82/46)

The body was that of a well developed female  
infant. The skin was covered with deep golden-yellow  
vernix. There was jaundice of the skin and there  
were a few subcutaneous haemorrhages over the cheeks.

Head : There was a subarachnoid haemorrhage over  
the left cerebral hemisphere. There was no  
kernicterus.

Thorax : The serous sacs contained some deep  
yellow fluid. There were no petechiae. The lungs were  
poorly aerated and very oedematous. The heart was  
slightly dilated but the myocardium was healthy.

Abdomen : The peritoneal sac contained some  
clear yellow fluid. The alimentary tract was normal.  
The liver was enlarged and reddish-brown in colour.  
The Prussian blue reaction was positive. The spleen  
was enlarged and measured  $2\frac{1}{2}$ " in length. The Prussian  
blue reaction was strongly positive. The kidneys were  
of normal size and rather pale.

Microscopic Report :

Blood Film : Nucleated red cells were very  
numerous. Normoblasts were predominant but erythro-  
blasts were also present.

Bone Marrow : Erythropoiesis was active and an  
excess of erythroblasts was found.

Liver/

Liver : There was excessive erythropoiesis of a primitive type. Numerous foci of normoblasts and erythroblasts were present. Many liver cells were vacuolated but there was no necrosis. The liver cells contained some haemosiderin. A few of the inter-cellular canaliculi contained bile plugs.

Spleen : The pulp was not unduly cellular although there was some active haemopoiesis and primitive erythroblasts were not numerous. The walls of the sinusoids were thicker than usual. Some histiocytes filled with haemosiderin were present.

Summary : Icterus gravis neonatorum.

Case 55 : Baby W. Born 19.6.46 Still-birth.

Maternal History : This was the mother's 4th. pregnancy. The first child was normal at birth and is alive and well. The next two pregnancies ended with still-births. The present pregnancy ended at the 34th. week.

Post-mortem Report : (120/46)

The body was that of a premature female foetus weighing 3 lbs. 2 ozs. There was generalised sub-cutaneous oedema.

Head : There was no abnormality present.

Thorax : The pleural and pericardial sacs contained some yellow fluid. The lungs were completely airless and rather pale. The heart was normal.

Abdomen : The peritoneal sac contained a large quantity of yellow fluid. The alimentary tract was normal. The spleen was very enlarged. The liver was slightly/

slightly enlarged and firm in consistence. The Prussian blue reaction was strongly positive. The kidneys were normal.

Microscopic Report :

Blood Film : Nucleated red cells were very numerous and although normoblasts predominated there were very many erythroblasts also.

Bone Marrow : Erythropoiesis was active and normoblasts and erythroblasts were numerous.

Lungs : These organs were very immature and a few cells derived from the liquor amnii were found.

Liver : Erythropoiesis was very active and numerous foci of erythropoietic cells were found. Both normoblasts and erythroblasts were numerous. The liver cells contained considerable quantities of haemosiderin.

Spleen : Numerous nucleated red cells were present throughout the pulp. The splenic histiocytes contained haemosiderin.

Summary : Hydrops foetalis.

Case 56 : Baby W. Born 23.6.46. Died after 2 hrs. The child was delivered spontaneously and rather precipitately. It did not respond to treatment and died after two hours. There was no family history available.

Post-mortem Report : 123/46)

The body was that of a male infant weighing 6 lbs. 6 ozs. The skin was jaundiced.

Head : No abnormality present.

Thorax/

Thorax : The pleural and pericardial sacs were healthy. The lungs were pale and oedematous. The heart was normal.

Abdomen : The peritoneal sac contained a considerable quantity of bile-stained fluid. The alimentary tract was normal. The spleen was enlarged and congested. The liver was enlarged and deep brown in colour. It was firm in consistence. Both the liver and the spleen gave a strongly positive Prussian blue reaction. The kidneys were normal.

Microscopic Report :

Blood Film : Large numbers of nucleated red cells were present and erythroblasts and normoblasts were numerous.

Bone Marrow : There was very active haemopoiesis and erythroblasts were numerous.

Lungs : There was evidence of inhalation of liquor amnii. There was congestion and oedema but no pneumonia.

Liver : Foci of erythropoiesis were numerous and many consisted of erythroblasts and primitive nucleated red cells. Numerous normoblasts were also found. The liver cells contained haemosiderin and a few of the intercellular canaliculi contained bile plugs.

Spleen : The splenic pulp was very cellular owing to the presence of numerous normoblasts. Many histiocytes in the pulp contained haemosiderin. There was no fibrosis.

Kidney : Foci of erythropoiesis were not numerous/

SERIES 1.

BABY R.  
TABLE 4.

HAEMATOLOGICAL DATA

Case 59.

Age in days	Hb% Sahli	R. B. C. / cu. mm.	C. I.	W. B. C. / cu. mm.	Nucleated R. B. C. / 100 W. B. C.	Reticulocytes %	Miscellaneous.
6	50	-	-	-	-	-	
7	40	-	-	-	-	2	
9	55	-	-	-	-	-	Spleen just palpable. 90 cc. Rh. negative blood transfused.
14	45	-	-	-	-	15	
15	36	-	-	-	-	-	
16	70	-	-	-	-	4.8	
17	63	-	-	-	-	-	
26	45	-	-	-	-	1	
30	46	-	-	-	-	-	
31	50	-	-	-	-	-	90 cc. Gp.O. Rh. negative blood.

numerous and were situated in the peripelvic tissue and in the boundary zone.

Summary : Icterus gravis neonatorum.

Case 57 : Baby S. Born 5.9.46. Died 10.9.46.

Aged 5 days.

Maternal History : The mother was aged 22 and this was her third pregnancy. The first two pregnancies had ended in miscarriages. She had no illness during the present pregnancy. She had suffered from severe menorrhagia at the age of 16 and had then received repeated blood transfusions which were not of Rh. negative blood. Her blood is Rh. negative and that of the husband and child was Rh. positive.

Clinical Findings in the Child : The child was delivered by mid-cavity forceps during the 37th. week. of the pregnancy and weighed 5 lbs. 7 ozs. at birth. After 24 hours it became jaundiced and vomited a good deal. On the second day there were signs of cerebral involvement. The baby did not thrive and died on the 5th. day.

Post-mortem Report : (193/46).

The body was that of a small female infant weighing 4 lbs. 15 ozs. There was jaundice of the skin and mucous membrane.

Head : There was a bilateral subdural haemorrhage present, and a large haemorrhage between the layers of the falx and the tentorium. The tentorium was torn on the left side. The brain and the meninges showed diffuse bile staining. The nuclei of/  
of/

of the basal ganglia, mid-brain medulla and the floor of the 4th. ventricle showed marked kernicterus. The flocculus of the cerebellum and the grey matter of the spinal cord were also affected.

Thorax : The pleural sacs contained a little clear fluid. The lungs were poorly expanded and rather oedematous. The heart was normal.

Abdomen : The peritoneal sac was healthy. The alimentary tract was normal. The liver was enlarged and reddish brown in colour. The Prussian blue reaction was negative. The spleen was enlarged and measured 2" in length. It was dark red in colour and the Prussian blue reaction was positive. The kidneys were pale and bile-stained.

Microscopic Report :

Blood Film : There were numerous nucleated red cells and there was a large proportion of primitive cells. Normoblasts were also found.

Bone Marrow : There was active haemopoiesis and many erythroblasts were seen.

Spleen : A large number of normoblasts were present throughout the pulp. The histiocytes in the pulp contained haemosiderin.

Blood Tests : The blood of the mother was Rh. negative Group O., and that of the husband and the child was Rh. positive Group O. No antibodies were found in the mother's blood.

Summary : Icterus gravis neonatorum with kernicterus and subdural haemorrhage.

Case 58 : Baby F. Born 8.7.46.

Maternal History : The mother was aged 30 and this was her 3rd. pregnancy. Her first two children were normal at birth and are alive and well. The mother had no illness during the present pregnancy. Her blood is Rh. negative and that of her husband and child is Rh. positive.

Clinical Findings in the Child : The child was delivered spontaneously ( vertex L.O.A. ) at term and weighed 7 lbs.3 ozs. at birth. After 24 hours it became jaundiced and there were numerous small petechial haemorrhages over the face and limbs. On the 2nd. day the jaundice was deeper and the blood showed Hb. 70% Sahli, R.B.C. 2.1 million/cu.mm. On the 3rd. day the spleen was palpable and the Hb 68%. By the end of the first week both the liver and the spleen were enlarged and the Hb. 60%. By the end of the second week the general condition of the child had improved. The spleen and liver were no longer palpable and the jaundice was gradually fading. There was no evidence of cerebral involvement. The child was discharged from hospital.

Summary : Icterus gravis neonatorum (recovered)

Case 59 : Baby R. Born 1.12.46

Maternal History : The mother was aged 31 and this was her 3rd. pregnancy. The previous two pregnancies had ended with the delivery of still-born infants. The mother had no illness during the present pregnancy.

Clinical Findings in the Child : (see Table 4).

The child was delivered spontaneously (vertex L.O.A.) at/

at term and weighed 7 lbs. 13 ozs. at birth. It was the first of twins. The other twin was quite healthy. After 6 days the child was very pale but the liver and spleen were not palpable. At the end of the first week the spleen was just palpable. There was some scrotal oedema and the infant was transfused with 90 cc. of Rh. negative blood. This was repeated at the end of the second week. The child's condition gradually improved and at the end of the first month it was sufficiently recovered to be discharged from hospital.

Summary : Congenital haemolytic anaemia (recovered).

Case 60 : Baby McL. Born 9.12.46. Still-birth.

Maternal History : The mother was aged 35 and this was her 7th pregnancy. The first four children were normal at birth and are alive and well. The 5th. was still-born. The 6th. pregnancy ended with the delivery of still-born twins who showed the typical features of hydrops foetalis. The mother had suffered from severe pre-eclamptic toxæmia during the present pregnancy. Her ankles, face and abdomen had been oedematous and she had had albuminuria. Her blood was Rh. negative and antibodies were present in the serum.

Clinical Findings in the Foetus : The foetus was delivered spontaneously a few weeks before term and weighed 5 lbs. 12 ozs. at birth. It was very hydropic.

Post-mortem Report : (282/46).

The body was that of an hydropic female foetus. There was marked generalised subcutaneous oedema and the/

the abdomen was distended.

Head : No abnormality was found.

Thorax : The pleural and pericardial sacs contained an excess of clear fluid. The lungs were pale, soft and unexpanded. The heart was enlarged, hypertrophied and dilated. The myocardium was rather pale.

Abdomen : The peritoneal sac contained a large quantity of bile-stained fluid. The alimentary tract was normal. The spleen was enlarged and dark red in colour. The Prussian blue reaction was slightly positive. The liver was considerably enlarged and reddish-brown in colour. The Prussian blue reaction was strongly positive. The kidneys were pale and the Prussian blue reaction was weakly positive.

Microscopic Report :

Lungs : The organs were oedematous and airless.

Liver : There was greatly increased haemopoiesis and numerous foci of very primitive nucleated red cells were found. The liver cells showed hydropic degeneration and many contained haemosiderin. The Prussian blue reaction was positive. The sinusoids were very congested.

Spleen : There were numerous nucleated red cells in the pulp. The majority were normoblasts but more primitive forms were also seen. The histiocytes in the subcapsular region contained haemosiderin and the Prussian blue reaction was positive.

Suprarenal Gland : There were a few foci of haemopoiesis, mainly normoblastic in character.

Pancreas/

Pancreas : There were a few clusters of normoblasts in the interstitial tissue.

Kidney : Haemopoietic foci were fairly numerous in the cortex. Both normoblasts and erythroblasts were present. Many of the cells lining the convoluted tubules contained haemosiderin and the cells gave a positive Prussian blue reaction.

Heart : The myocardial fibres were widely separated by oedema fluid, thus accounting for the hypertrophy observed post-mortem.

Summary : Hydrops foetalis.

Case 61 : Baby S. Born 12.2.47. Still-birth.

Maternal History : The mother was aged 36 and this was her 5th. pregnancy. The first pregnancy ended in a miscarriage at 3 months. The second ended with the birth of a normal child who is now alive and well. The next child was normal at birth but subsequently died of meningitis. The fourth child was normal at birth and is alive and well. The mother had no illness during the pregnancy and her blood is Rh. negative.

Post-mortem Report : (55/47)

The body was that of a very small male foetus weighing 2 lbs. 2 ozs. There was severe generalised subcutaneous oedema. The skin had a slight yellow tint.

Head : The scalp was extremely oedematous and there were a few blood clots in the subdural space on the right side. There was large tear in the tentorium extending into the posterior part of the falx. There was no cerebral lesion.

Thorax : There was an excess of clear fluid in/

in the serous sacs. The lungs were airless and very pale. The heart was slightly dilated and the myocardium was very pale.

Abdomen : The peritoneal sac contained a large quantity of clear yellow fluid. The alimentary tract was normal. The liver was enlarged and rusty brown in colour. The spleen was considerably enlarged for this stage of development and measured  $1\frac{1}{2}$ " in length. It was quite firm and dark red in colour. The Prussian blue reaction was slightly positive. The kidneys were pale.

Microscopic Report :

Blood Film : Nucleated red cells were extremely numerous. The majority were normoblasts but a number of erythroblasts were also found. The foetal cells were Rh. positive.

Bone Marrow : There was active haemopoiesis and both erythroblasts and normoblasts were extremely numerous.

Summary : Hydrops foetalis.

Case 62 : Baby A. Born 18.3.47. Male.

Maternal History : The mother was aged 26 and this was her second pregnancy. The first child was delivered by Caesarian section since the mother has a severe contraction of the pelvis. It was normal at birth and is alive and well. The mother had no illness during this pregnancy. Her blood is Rh. negative, and antibodies were present in her serum.

Clinical/

SERIES 1.

BABY A.

HAEMATOLOGICAL DATA.

TABLE 5.

Case 62.

Age in days	Hb% Sahli	R. B. C. / cu. mm.	C. I.	W. B. C. / cu. mm.	Nucleated R. B. C. / 100 W. B. C.	Reticulocytes %	Miscellaneous
5	70	-	-	-	145	5	
6	56	-	-	-	-	-	
7	48	-	-	-	-	-	15 cc. Gp.O. Rh. negative blood via anterior fontanelle.
11	52	-	-	-	10	14	
17	50	-	-	-	-	-	
20	48	-	-	-	-	-	100 cc. Gp.O. Rh. negative blood by intravenous drip.
22	64	-	-	-	-	-	
25	-	-	-	-	-	-	150 cc. Gp.O. Rh. negative blood by intravenous drip.

Clinical Findings in the Child : (see Table 5)

The child was delivered at term by lower segment Caesarian section. It weighed 8 lbs. 15 $\frac{1}{4}$  ozs. at birth. The child's blood was Rh. positive. After 48 hours it became jaundiced and the jaundice steadily increased. It also became very pale and received a total of three blood transfusions with Gp. O Rh. negative blood amounting in all to 265 cc. The first transfusion was via the anterior fontanelle. The child's condition improved rapidly and the jaundice and pallor resolved. Unfortunately it developed athetosis of the left arm. This may have been due to damage resulting from a subdural leak at the first transfusion or to the onset of kernicterus. The latter explanation is the more probable.

Summary : Icterus gravis neonatorum with slight kernicterus ( improved).

Case 63 : Baby McK. Born 5.4.47. Male.

Maternal History : The mother was aged 26 and this was her fifth pregnancy. The first two children were normal at birth and are alive and well. The third and fourth children were very jaundiced at birth but are now alive and well. The mother had no illness during this pregnancy.

Clinical Findings in the Child : (see Table 6).

The child was delivered spontaneously at term and weighed 6 lbs. 14 ozs. at birth. After 24 hours it became very jaundiced and was given a transfusion of 95 cc. Rh. negative blood over a period of 24 hours.

On /

SERIES 1.

BABY MCK.  
TABLE 6.

HAEMATOLOGICAL DATA.  
Case 63.

Age in days	Hb% Sahli	R B.C. / cu. mm.	C. I.	W. B.C. / cu. mm.	Nucleated R. B.C. / 100 W. B.C.	Reticulo-cytes.	Miscellaneous
1	85	-	-	-	53	-	95 cc. Gp. O. Rh. negative blood by intravenous drip over a period of 24 hours.
2	95	-	-	-	-	-	
6	85	-	-	-	-	-	
9	72	-	-	-	-	-	150 cc. Gp. O. Rh. negative blood in 2½ hours, by intravenous drip.
11	98	-	-	-	-	-	
13	78	-	-	-	-	-	
16	69	-	-	-	-	-	
24	60	-	-	-	-	-	
31	50	-	-	-	-	-	90 cc. Gp. O. Rh negative blood by intravenous drip.
37	75	-	-	-	-	-	

On the second day it was still very jaundiced and the spleen became palpable. On the 9th. day it was again transfused with Rh. negative blood and received 150 cc. On the 13th. day it was still very jaundiced and rather pale. By the 24th. day the jaundice was beginning to fade. On the 31st. day it received a transfusion of 90 cc. Rh. negative blood. Thereafter the child's condition steadily improved. The jaundice disappeared and the pallor decreased. It was discharged from hospital on the 37th. day. There were no signs of cerebral involvement.

Summary : Icterus gravis neonatorum ( recovered).

Case 64 : Baby S. Born 24.5.47. Died 26.5.47.  
Aged 2 days. Female.

Maternal History : The mother was aged 23 and this was her second pregnancy. The first child was normal at birth, and is alive and well. The mother was suffering from heart disease (Grade I cardiac failure) and had an antepartum haemorrhage during this pregnancy. Her blood is Rh. negative. The direct Coomb's test on the child's cells was positive.

Clinical Findings in the Child : The child was delivered spontaneously (vertex L.O.A.) at the 30th. week of the pregnancy and weighed 2 lbs. 13 ozs. at birth. It was very jaundiced at birth and the spleen was enlarged. The blood showed Hb. 120 %. There were no erythroblasts in the peripheral blood film. The child was given 0.5 cc. Kapilon but did not rally and died on the second day.

Postmortem /

Post-mortem Report : (156 /47)

The body was that of a small premature female infant weighing 2 lbs. 11 ozs. There was marked jaundice of the skin and mucous membranes.

Head : The brain and meninges were diffusely bile-stained. The brain showed a rather immature gyral pattern. There was no kernicterus.

Thorax : The serous sacs were healthy. The lungs showed patches of pneumonic consolidation along the posterior border of the lower lobes and at both apices. Some intrapulmonary haemorrhage was also present. The heart was normal.

Abdomen : The peritoneal sac was healthy. The alimentary tract was normal. The spleen was considerably enlarged and measured 2" in length. It was firm in consistence and dark red in colour. The liver was of normal size and reddish-brown in colour. The kidneys were healthy.

Microscopic Report :

Blood Film : There was a considerable increase of nucleated red cells. The majority were normoblasts and erythroblasts were scanty. The red cells were Rh. positive.

Bone Marrow : There was active haemopoiesis at the normoblast level.

Liver : There was no excessive haemopoiesis and the liver and von Kupffer cells contained only small amounts of haemosiderin.

Spleen : There were numerous normoblasts in the splenic/

splenic pulp. The splenic histiocytes contained large quantities of haemosiderin.

Lung : The areas of consolidation found at post-mortem were found to be entirely due to severe intrapulmonary haemorrhage. There was no pneumonia.

Summary : Icterus gravis neonatorum ( with severe intrapulmonary haemorrhage).

Case 65 : Baby B. Born 6.8.47. Died after 12 hours. Female.

Maternal History : The mother was aged 31 and this was her second pregnancy. The first child was normal at birth and is alive and well. The mother had no illness during this pregnancy.

Clinical Findings in the Child : The child was born spontaneously at term and weighed 8 lbs. 10 ozs. at birth. It was very jaundiced at birth and the liver was enlarged. The spleen was also enlarged and the blood showed Hb. 70% with 80,000 nucleated red cells per cubic millimetre. The child received 1 cc. of Kapilon and two transfusions of Gp. O Rh. negative blood, totalling 200 cc. in all. It failed to rally and died after 12 hours.

Post-mortem Report : (208/47)

The body was that of a female infant weighing 8 lbs. 12 ozs. There was severe jaundice.

Head : There was a severe subarachnoid haemorrhage over the left parietal region.

Thorax : The serous sacs were healthy. There were numerous subpleural petechial haemorrhages. The

lungs/

lungs were congested and oedematous and there were numerous intrapulmonary haemorrhages. The heart was dilated.

Abdomen : The peritoneum contained a quantity of viscid blood. This had originated from a tear in the capsule of the spleen. The spleen was greatly enlarged and measured fully 3" in length. It was tense and dark red in colour. The liver was enlarged and firm in consistence. The left suprarenal gland was enlarged and there was a haemorrhage into the subcapsular cortex. The kidneys were very congested. The alimentary tract was normal.

Microscopic Report :

Blood Film : There was increase in the number of normoblasts. Erythroblasts were scanty.

Bone Marrow : There was active haemopoiesis at the normoblast level. Erythroblasts were scanty.

Lungs : The organs were incompletely expanded. There was evidence of inhalation of meconium and there were signs of a developing pneumonia. Large areas of intrapulmonary haemorrhage were present.

Liver : There was excessive haemopoiesis and throughout the parenchyma were large foci of nucleated red cells. These foci were composed chiefly of normoblasts but erythroblasts were also found. The liver cells were slightly hydropic.

Spleen : The sinusoids were congested and there were numerous normoblasts and erythroblasts throughout the pulp. Numerous splenic histiocytes contained haemosiderin/

haemosiderin.

Summary : Icterus gravis neonatorum ( Ruptured spleen and intrapulmonary haemorrhages).

Case 66 : Baby N. Born 14.9.47. Male.

Maternal History : The mother was aged 33 and this was her third pregnancy. The first child was normal at birth and is alive and well. The second pregnancy ended in a miscarriage. She had no illness during this pregnancy. Her blood is Rh. negative and that of her husband and child is Rh. positive. The direct Coomb's test on the child's cells was positive.

Clinical Findings in the Child : The child was born spontaneously (vertex R.O.A.) at term and weighed 7 lbs. 4 ozs. at birth. After 48 hours it became jaundiced and the jaundice steadily increased. The child became slightly pale but continued to thrive without any specific treatment. The jaundice gradually faded and the child was able to leave hospital at the end of the second week.

Summary : Icterus gravis neonatorum (recovered).

Case 67 : Baby L. Born 1.10.47. Male.

Maternal History : The mother was aged 34 and this was her seventh pregnancy. The first five children were normal at birth and are alive and well. The sixth child was very jaundiced at birth. The mother had no illness during this pregnancy. Her blood was Rh. negative and that of the husband and child was Rh. positive. The direct Coomb's test on the child's cells was positive.

Clinical/

HAEMATOLOGICAL DATA.

Case 67.

BABY L.

TABLE 7.

SERIES 1.

Age in days.	Hb. % Sahli	R. B. C. / cu. mm.	C. I.	W. B. C. / cu. mm.	Nucleated R. B. C. / 100 W. B. C.	Reticulo-cytes.	Miscellaneous.
8	40	-	-	-	-	15	
11	22	1.08 m	-	-	-	17	120 cc. Gp. O. Rh. negative blood by intravenous drip.
12	58	-	-	-	-	-	
15	55	-	-	-	-	-	
19	53	-	-	-	-	-	

Clinical Findings in the Child : (see Table 7 )

The child was delivered spontaneously at term and weighed 8 lbs. 12 ozs. at birth. After 12 hours it became jaundiced and the jaundice gradually deepened. At the same time the child became very pale and on the 11th. day it was transfused with 120 cc. Rh. negative blood. The jaundice gradually lessened and the child began to thrive. It was able to be discharged from hospital at the end of the 3rd. week.

Summary : Icterus gravis neonatorum (recovered).

Case 68 : Baby H. Born 13.10.47. female.

Maternal History : The mother was aged 26 and this was her first pregnancy. She gave no history of previous blood transfusions. She had no illness during her pregnancy. Her blood is Rh. negative and that of her husband and child is Rh. positive. The direct Coomb's test on the child's cells was positive.

Clinical Findings in the Child : The child was born spontaneously (vertex R.O.A.) during the 33rd. week of pregnancy and weighed 4 lbs. 6½ ozs. at birth. After 24 hours it became jaundiced and the liver and spleen were enlarged. The jaundice gradually deepened and persisted for ten days after which it gradually lessened. By the end of the first month the jaundice had faded and the child was discharged from hospital.

Summary : Icterus gravis neonatorum (recovered).

Case 69 : Baby P. Born 14.11.47 male.

Maternal History : The mother was aged 25 and this was/

was her second pregnancy. The first child was normal at birth and is alive and well. The mother had no illness during this pregnancy. Her blood is Rh. negative and there were antibodies present in the serum. The blood of the husband and child was Rh. positive. The direct Coomb's test on the child's cells was positive.

Clinical Findings in the Child : The child was delivered spontaneously at term and weighed 6 lbs. 15 ozs. at birth. After 24 hours it became jaundiced and the spleen was enlarged. The jaundice persisted for a week but the child's general condition remained good. The blood showed Hb. 111%. The child was discharged from hospital at the end of the second week.

Summary : Icterus gravis neonatorum (recovered).

Case 70. Baby E. Born 17.12.47. Died 30.12.47.  
Aged two weeks, male.

Maternal History : The mother was aged 28 and this was her fourth pregnancy. The first child was normal at birth and is alive and well. The second pregnancy ended in a miscarriage. The third child was normal at birth and is alive and well. The mother had no illness during the present pregnancy. Her blood is Rh. negative and that of the child is Rh. positive. The direct Coomb's test on the child's cells was positive.

Clinical Findings in the Child : The child was delivered spontaneously (vertex L.O.A.) during the 33rd. week of the pregnancy. It weighed 3 lbs. 11 ozs. at birth and was jaundiced. After 24 hours the jaundice/

jaundice had deepened and the spleen was enlarged. The blood showed Hb 140 % and numerous nucleated red cells were found in the peripheral blood. The child failed to thrive and died after two weeks.

Post-mortem Report : (294/47)

The body was that of a rather small male infant weighing 3 lbs. 6 ozs. There was marked jaundice of the skin and mucous membranes.

Head : Meninges and brain were diffusely bile-stained. There was very marked icteric tinting of the brain in the hippocampel region and the nuclei of the basal ganglia, brain stem, medulla were bright yellow in colour. The dentate nucleus of the cerebellum was also affected.

Thorax : The lungs were well expanded but the lower lobes of both lungs were congested and rather bulky. The heart was normal.

Abdomen : The peritoneum was healthy and the alimentary tract was normal. The liver was of normal size and shape. The spleen was twice the normal size and the pulp was dark red in colour.

Microscopic Report :

Lungs : numerous areas of early bronchopneumonic consolidation were present throughout the lungs. A few cornified cells derived from the liquor amnii were seen.

Brain : The affected areas still/show bile-staining in the sections. The cells show no histological/

histological change.

Spleen : The pulp was congested and numerous foci were mainly normoblastic in character, but numerous erythroblasts were also found.

Kidney : A few foci of haemopoiesis were found in the boundary zone.

Summary : Icterus gravis neonatorum ( with kernicterus) Terminal bronchopneumonia.

Case 71 : Baby M. Born 15.4.37. Died 17.4. 37.  
Aged 2 days.

Maternal History : This was the mothers third pregnancy. She was aged 28. The first two children were normal.

Clinical Findings in the Child : The child was born spontaneously (vertex R.O.A.) at term, and weighed 6 lbs. 5 ozs. at birth. It became jaundiced 24 hours after birth and the jaundice steadily increased. It was given 15 cc. whole blood intravenously but did not rally and died on the 2nd. day after birth.

Post-mortem Report : (60 /37)

The body was that of a small male child showing deep jaundice.

Head : The basal ganglia and nuclear masses in the brain stem were deeply bile stained.

Thorax : Lungs were well expanded and moderately oedematous. The other organs were normal.

Abdomen : The peritoneal sac was healthy. The stomach showed ulceration of the mucous membrane. The intestines were normal. The liver was of normal size/

Table 8a.

Case 72.

Baby T.

HAEMATOLOGICAL DATA.

Age in days	R. B. C. Millions per Cu: Mm.	H. B. % (Sahli)	C. I.	Rets.	Nuc: R. B. C. %	W. B. C.
16	2.17	45	1.04	12	.0	14,000
17	2.13	44	1.03	19.5		
18	1.93	45	1.17	21		
19	1.94	48	1.24	23.5		
20				28		
21	2.12	48	1.13			
22				36.5		
23				26		
24	2.46	51	1.04	25		13.600
25				20		
26				11.5		
28	2.51	51	1.02	9.5		
30				8.5	.0	
32	2.77	54	.98	9.5		
34				6		
37	2.95	56	.95	6		
40	3.15	58	.92	5.5		
43	3.01	56	.93	5.5		
47	3.10	57	1.92	2		
50	2.85	59	1.04	3.5		
53	2.88	61	1.06	8		
76	3.85	64	.83	2.5		
90	4.24	69	.81			
112	4.99	74	.74	3		
144	4.80	75	.78	1.5		

size and brown in colour. The spleen was twice the normal size. The kidneys were bile-stained.

Microscopic Report :

Lung, liver, spleen and kidney showed little of interest.

Brain : No histological change.

Summary : Icterus gravis neonatorum with kernicterus.

Case 72 : Baby T. Female. Born 21.1.37.

Maternal History : The mother was aged 27 and this was her second pregnancy. The first child is alive and well. She had no illness during this pregnancy.

Clinical Findings in the child : (see Table 8 a)

On the 8th. day the child was slightly jaundiced and rather pale. By the 12th. day the jaundice had disappeared but the pallor had increased. The 16th. day the anaemia was very marked. The anaemia persisted for some time and it was not till the 32nd. day that any noticeable improvement occurred. The child was treated with liver extract ( 1 cc. intramuscularly on three occasions) and Ferrous sulphate gr.  $1\frac{1}{2}$  t.d.s. By the 53rd. day the child had improved and given z 1 Ovoid ferrin b.i.d. instead of Ferrous sulphate. On the 78th. day the child was looking very well. On the 112th day. it was very fit and by the 144th. day had completely recovered.

Summary : Congenital haemolytic anaemia (recovered).

Case 73 : Baby S. (Female) Born 10.5.38. Died 11.5.38. Aged 38 hours.

Maternal/

Maternal History : The mother was aged 32 and this was her second pregnancy. Her first child is alive and well. Placenta weighed 1 lb. 10 ozs.

Clinical Findings in the Child : The child was born spontaneously (vertex L.O.A.) and weighed 8 lbs. 3 ozs. at birth. The vernix was golden yellow in colour. The child was jaundiced at birth. It seemed quite well at first but then collapsed and died after 38 hours. Before death the blood showed Hb. 84%. R.B.C. 2.9m/cu.m. C.I. = 1.48. Nucleated red cells 162,00/cu.mm. Reticulocytes 35%. It was transfused with 75 cc., father's blood. The Van den Bergh reaction was delayed direct positive. The W.R. was negative.

Post-Mortem Report : (66/38)

The body was that of a well-developed female infant weighing  $8\frac{1}{4}$  lbs.

Head : There was a slight subarachnoid haemorrhage over the right cerebral hemisphere. The olivary nuclei, nuclei in the floor of the 4th. ventricle, pons and midbrain and the dentate nucleus and tonsils of the cerebellum were deeply bile-stained. The cornu ammonis, corpus Luysii, thalamus, putamen and globus pallidus were less severely affected.

Thorax : Some bile-stained fluid was present in both pleural sacs, and in the pericardial sac. The lungs were oedematous and some haemorrhages were found.

Abdomen : The peritoneal sac contained some bile-stained fluid. The alimentary tract was normal.

The/

The liver was enlarged and brown in colour. The spleen was enlarged, measuring  $2\frac{1}{2}$ " in length and proportionately increased in other dimensions. The pulp was diffluent and dark red in colour. The kidneys were bile-stained.

Microscopic Report :

Liver : There was excessive haemopoiesis and the parenchyma was crowded with blood-forming cells. Many were of primitive type but some normoblasts were also present. There was no fibrosis.

Spleen : Excessive haemopoiesis are also present but not to the same extent as in the liver. There was considerable infiltration of the pulp with polymorphonuclear leucocytes.

Kidney : No haemopoiesis. The capillaries contained numerous nucleated red cells.

Lung : The organ was very oedematous and small intra-alveolar haemorrhages were present.

Brain : No histological change present.

Summary : Icterus gravis neonatorum with kernicterus.

Case 74. Baby D.F. (male) Born 12.10.41.

Maternal History : The mother was aged 31 and this was her second pregnancy. The first child was normal at birth and is alive and well. She had no illness during the pregnancy.

Clinical Findings in the child : The child was born spontaneously (vertex L.O.A.) and weighed 8 lbs. 3 ozs. at birth. It was jaundiced at birth and on the 3rd. day it was bright yellow in colour. The spleen was palpable/

HAEMATOLOGICAL DATA.

BABY E.

TABLE 8 b.

SERIES 1.

Case 75.

Age in days	Hb% Sahli	R. B. C. / cu. mm.	Nucleated R. B. C. / 100 W. B. C.	Reticulo-cytes.	Icteric index	Van den Bergh reaction	Miscellaneous.
2	105	3.85 m.	150	30%	200	-	Prothrombin index 58.5 %
3	90	3.69 m.	-	26%	-	-	" 50 %
4	97	3.70 m.	-	27%	-	-	Colour index 1.2
5	90	-	-	28%	-	-	Total fat 51.4 mgm. %
6	88	-	-	28%	-	-	Split fat 75 % total.
7	84	-	-	19%	-	-	Unsplit fat 25 % "
8	75	-	-	12%	-	-	Albumin 3.6 mgm. %
9	55	1.86 m.	-	4%	-	-	Globulin 1.9 Gm. %
10	50	1.8 m.	-	6%	-	-	Laevulose Tolerance sub-normal.
11	80	3.24 m.	-	1.2%	142	Direct	Colour index 1-4 fusion
13	64	-	-	4%	-	-	75cc. packed cells trans-
16	42	2.09 m.	-	6%	-	-	75cc. packed cells trans-
18	58	3.09 m.	-	6%	-	-	Laevulose Tolerance sub-normal.
20	54	-	-	11%	-	-	Albumin 3.1 Gm. %
24	48	-	-	11%	66	-	Globulin 1.4 Gm. % normal.
25	47	-	-	21%	-	-	Laevulose Tolerance sub-
30	52	2.4 m.	-	34%	63	-	Alb. 4.3 Gm. % Glob. 2.3 Gm. %
33	62	-	-	39%	-	-	-
35	60	-	-	30%	-	-	-
37	60	-	-	31%	55	-	Jaundice lessening.
51	71	3.34 m.	-	13%	-	-	" gone.
57	65	3.34 m.	-	8%	-	-	Looks well.

palpable 1 finger breadth below the costal margin. The blood showed Hb 105 %, Reticulocytes 3%, Icteric index 111, Van den Bergh indirect positive. By the 9th. day the jaundice was commencing to fade. The child was discharged from hospital on the 10th day.

Summary : Icterus Gravis neonatorum (recovered).

Case 75 : Baby E. (male) Born 28.4.41.

Maternal History : This was the mother's 4th. pregnancy. The first two children were normal at birth and are alive and well. The third child died at the age of 10 days from icterus gravis. The mother suffered from hypertension during the present pregnancy.

Clinical Findings in the Child : ( see Table 8 b.)

The child was delivered spontaneously (vertex R.O.A.) at the 37th. week and weighed 5 lbs. 9 ozs. at birth. It was jaundiced at birth and the jaundice gradually deepened. On the 2nd. day the spleen was palpable, 1 finger breadth below the costal margin. On the 3rd. day there was slight head retraction and clenching of hands ; the baby was slow at feeding but this slowly improved. On the 10th day it received a transfusion of 75 cc. packed red cells. On the 11th day its colour had improved but on the 12th. day it became paler. On the 16th. day it was again transfused with 75 cc. packed cells. By the 17th day it was very lethargic and head retraction was still present. On the 18th day the jaundice was even more pronounced. On the 19th day it had improved slightly and was taking/

taking its feeds better. On the 21st day the improvement was continuing. On the 31st day it began to regurgitate some of its feeds and 2 large vomits occurred. By the 36th day the vomiting had ceased and the child was improving. This improvement steadily continued and the jaundice gradually lessened. By the 57th. day the jaundice had almost disappeared and the spleen was no longer palpable.

The liver function was poor as shown by the laevulose tolerance test and low prothrombin index.

The child has been under the care of Dr. J.L. Henderson and is still alive. There is marked clinical evidence of kernicterus but slow improvement is taking place. The child is not mentally deficient and is able to walk.

Summary : Icterus gravis neonatorum with kernicterus (recovered).

Case 76 : Baby McC (Female) Born 4.2.38. Died 7.2.38. Aged  $2\frac{1}{2}$  days.

Maternal History : This is the mother's 8th. pregnancy. The first child was normal at birth and is alive and well. The second died aged two hours. The third died at  $4\frac{1}{2}$  months. The fourth child is alive and well. The 5th. child is alive and well. The sixth pregnancy ended in a miscarriage. The seventh child is alive and well.

Clinical Findings in the Child : The child was born spontaneously and weighed 7 lbs. at birth. It was jaundiced at birth and the jaundice rapidly deepened. The child failed to thrive and died aged  $2\frac{1}{2}$  days.

Post-/

Post-mortem Report :

The body was that of a well developed female infant. There was intense jaundice of skin and mucous membranes.

Head : Brain was normal. There was no kernicterus.

Thorax : No abnormality present.

Abdomen : The liver was enlarged and bile-stained. The spleen was enlarged to twice the normal size. It was dark red in colour and soft.

Microscopic Report :

Liver : Active haemopoiesis was present. Foci of normoblasts and erythroblasts were present throughout the liver parenchyma and in the portal tracts.

Spleen : Active haemopoiesis present.

Blood : A few normoblasts were present.

Polychromasia and anisocytosis were marked.

Summary : Icterus gravis neonatorum.

Case 77. Baby McK. (Female) Born 31.1.37. Died 8.2.37. Aged 8 days.

Maternal History : The mother had four other children all of whom are alive and well. She had no miscarriage and no child was jaundiced in the neonatal period. She had no illness during this pregnancy.

Clinical Findings in the Child : The child was born spontaneously and weighed 9 lbs. at birth. It became jaundiced after 72 hours and the jaundice rapidly deepened. The stools were pale and the urine was

bile-stained. On the 8th. day the icteric index was 40/

40 and the Van den Bergh reaction direct positive. The child had become very pale and on the 8th. day the blood showed Hb. 15 %. The liver and spleen were not palpable. The child suddenly collapsed and died on the 8th. day.

Post-mortem Report.

The body was that of a severely jaundiced female infant.

Head : The tentorium was torn on both sides and a slight bilateral subdural haemorrhage had resulted. There was no kernicterus.

Thorax : No abnormality present.

Abdomen : The liver was enlarged and bile-stained. The spleen was enlarged and measured 3" in length. It was very soft. The kidneys showed congestion and a few small haemorrhages into the pyramids.

Microscopic Report :

Liver : Active haemopoiesis was present. Numerous foci of normoblasts and primitive erythroblasts were found. Numerous parenchymal cells contained bile pigment.

Spleen : The pulp was densely packed with erythropoietic foci. An increase of eosinophil myelocytes was also noted.

Summary : Icterus gravis neonatorum.

Case 78. Baby P. Born 7.6.38. (Male).

Maternal History : This was the mother's second pregnancy. The first child was normal at birth.

Clinical/

Clinical Findings in the Child : The child was born spontaneously and weighed 6 lbs. 9 ozs. at birth. There was no jaundice. The child was waxy pale at the end of the 1st. week and blood showed Hb. 20 %. R.B.C. 770,000/cu.mm. It was transfused (group and amount unspecified) and on the 9th. day Hb. 34 %. R.B.C. 1.25 m/cum. On the 16th. day there was a relapse Hb. 28 %. R.B.C. 1.0 m/cu.m. and a second transfusion (group and amount unspecified) was carried out. Steady improvement occurred thereafter. 21st. day Hb. 31 %. R.B.C. 1.2 m/cum. 28th day. R.B.C. 1.82 m/cu.m. Hb. 44%. 67th day R.B.C. 3.35 m/cum. Hb. 66 %. Liver extract and iron were also given for a period of two weeks but did not seem to help unduly.

Summary : Congenital haemolytic anaemia (recovered).

Case 79. Born 12.5.38. Died 12.5.38. After 15 minutes. Female.

Maternal History : This was the mother's fourth pregnancy. The first child was normal at birth and is alive and well. The second child died at 2 days from icterus gravis. The third pregnancy ended with a still-born macerated foetus.

Clinical Findings in the Child : The child was delivered spontaneously at term and weighed 6½ lbs. at birth. It never breathed properly and died after 15 minutes.

Post-mortem Report :

The body was that of a female infant showing slight/

slight abdominal distension and oedema of the legs.

Head : no abnormality present.

Thorax : Both pleural sacs contained a small quantity of clear fluid. The heart was moderately enlarged. The lungs were oedematous. Severe oedema glottidis was present.

Abdomen : The peritoneal sac contained some clear, yellow fluid. The liver was enlarged and brown in colour. The spleen was enlarged and measured 3" in length. It was firm and dark red in colour.

Microscopic Report.

Liver : Active haemopoiesis present. Numerous erythroblasts were seen. The parenchymal cells contained some bile pigment.

Spleen : Numerous haemopoietic foci were found.

Kidney : A few haemopoietic foci in the boundary zone of the cortex.

Blood : 70 % of all nucleated cells were erythroblasts. Polychromasia of the red cells was present.

Summary : Hydrops foetalis.

Case 80. Baby L. Born 21.9.38.

Maternal History : The mother was aged 31 years and this was her 4th. pregnancy. The first three children were normal at birth. One has since died.

Clinical Findings in the Child : The child was delivered spontaneously at term (vertex L.O.A.) and weighed 9 lbs. at birth. The vernix was golden yellow in/

in colour and the child was jaundiced at birth. The liver and spleen were greatly enlarged. The blood showed Hb 55 % R.B.C. 2 m/cum. C.I. 1.3. Nucleated red cells 120,000/cu.m. Reticulocytes 36 %. The icteric index was 77 and the Van den Bergh reaction biphasic. It was transfused with 100 cc. father's blood via the anterior fontanelle. On the 2nd. day the blood showed Hb. 70 % R.B.C. 2.7 m./cu.m. C.I. 1.3. Nucleated red cells 75,000/cu.m. Reticulocytes 11%. The anaemia was less marked. On the 3rd. day Hb. 86%. R.B.C. 3.5 m/cu.m. C.I. 1.2. Nucleated red cells 59,000/cu.m. Reticulocytes 23 %. The icteric index was 80. It was taking feeds moderately well but was rather lethargic. Liver and spleen were still very enlarged. On the 4th. day Hb. 78%. R.B.C. 3.6 m/cu.m. C.I. 1.0. Nucleated red cells 47,000. Reticulocytes 28 %. On the 5th. day Hb. 76 %. R.B.C. 3.29 m/cu.m. C.I. 1.1. Nucleated red cells 15,000. Reticulocytes 29 %. On the 6th. day Hb. 78% R.B.C. 3.4 m/cu.m. C.I. 1.1. Nucleated red cells 5,000 /cu.m. Reticulocytes 48 %. The icteric index was 50 and the Van den Bergh reaction weak biphasic. On the 9th. day Hb 76 %. R.B.C. 3.45 m/cu.m. C.i. 1.1. Nucleated red cells 1,000 /cu.m. The jaundice was fading and the spleen was no longer palpable. The liver was less enlarged. The child was allowed home. Nucleated red cells. Reticulocytes 7 %. On the 21st. day Hb 73 %. R.B.C. 3.18 m/cu.m. C.I. 1.1. Reticulocytes 4 %. The child steadily gained in weight and by the end of the second month. Hb. 83 %.

R.B.C./

R.B.C. 4.4 m/cu.m. C.I. 0.9.

Summary : Icterus gravis neonatorum (recovered).

CHAPTER 3.Series 11. Cases from Royal Hospital for Sick Children.

Case 1. Baby R. Born 24.6.37. Died 2.7.37. Aged 10 days. Male.

Maternal History : This was the mother's second pregnancy. The first child was normal at birth and is alive and well.

Clinical Findings in the Child : The child was born spontaneously at term and was of average weight at birth. It became jaundiced after 48 hours and the jaundice quickly became intense. It was also very pale and at the 10th day the blood showed Hb. 18 %. The spleen was palpable. The child died on the 10th. day shortly after admission to hospital.

Post-mortem Report :

The body was that of a well-nourished male baby of average size and was deeply jaundiced.

Head : The cerebro-spinal fluid was bile-stained but the cerebral nuclei had a normal appearance.

Thorax : Lungs were well-expanded, pale and soft, The myocardium was also pale.

Abdomen : Alimentary tract was normal. The liver was enlarged, smooth, and of normal consistence. The spleen was greatly enlarged and measured 4" in length. The kidneys were pale and bile-stained.

Microscopic Report :

Liver : active haemopoiesis was present.

Spleen : Active haemopoiesis was present and numerous/

numerous nests of primitive erythroblasts were found.

Kidneys : No abnormality present.

Summary : Icterus gravis neonatorum.

Case 2. Baby H. Born 4.4.38. Died 30.9.38.

Maternal History : The mother was 36 years old and this was her second pregnancy. She had suffered severely from pre-eclamptic toxæmia during the first pregnancy was the child was still-born.

Clinical Findings in the Child : The child was delivered by Caesarian section and weighed  $7\frac{1}{2}$  lbs. The following day he became jaundiced. At the end of the first week he was still jaundiced. Haemoglobin was 70 % (Sahli). On 19th April the jaundice was lessening. R.B.C. 4.37 m/cu.mm. Hb. 77%. W.B.C. 11,000/cu.mm. On the 23rd. the jaundice was almost gone and the child was discharged as well on 8th May (he died on 30th. September from cerebro-spinal meningitis).

Summary : Icterus gravis neonatorum, ( recovered but died later from meningitis).

Case 3. Born 14.11.39. Died 8.12.39. Aged 12 days. Male.

Maternal History : The mother was aged 36 years and this was her third child. The first child was observed in hospital for congenital heart disease. The second child is alive and well.

Clinical Findings in the Child : The child was born spontaneously and weighed 6 lbs. 12 ozs. at birth. It became jaundiced 12 hours after birth and the jaundice gradually deepened. On the 6th. day the blood/

blood showed Hb. 32 %. R.B.C. 1.12 m/cu.mm. C.I. 1.43. Reticulocytes 13 %. On the 7th. day Hb. 22 %. R.B.C. 1 m/cu.mm. C.I. 1.15. Reticulocytes 13 %. W.B.C. 25,400 /cu.mm. Transfused with father's blood. On the 10th. day Hb. 35 %. R.B.C. 1.2 m/cu.mm. C.I. 1.4. Reticulocytes 60 %. Icteric index 300. Van den Bergh reaction positive biphasic. The liver was enlarged and palpable two fingers breadth below the costal margin. On the 11th day Hb. 36 %. R.B.C. 1.52 m/cu.mm. C.I. 1.18. Reticulocytes 65 %. W.B.C. 24,400 /cu.mm. The child collapsed and died on the 12th day after birth.

Post-mortem Report:

The body was that of a small male infant. There was very intense jaundice of a deep greenish-yellow colour.

Head : The brain showed a slight yellow tint but no nuclear staining was present.

Thorax : Serous sacs were healthy, and contained a small amount of bile-stained fluid. The lungs were congested and oedematous. The heart was enlarged and the myocardium was soft and pale.

Abdomen : The stomach was dilated. The small and large bowel were healthy. The liver was considerably enlarged, greenish-brown in colour and quite firm. The spleen was enlarged and measured 3" in length. It was dark red and soft. The kidneys were bile-stained and the pyramids were loaded with uric acid crystals.

Microscopic/

Microscopic Report :

Liver : Considerable erythroblastic activity was present. Bile plugs were present in the smaller ducts and in the intercellular canaliculi. The parenchymal and Kupffer cells contain haemosiderin. The outer zones of the lobules show degeneration of the liver cells. There is some fibrosis.

Kidney : A few perivascular foci of haemopoiesis are present. The tubules show degenerative changes.

Spleen : Some foci of haemopoiesis are present.

Myocardium : The fibres show early fatty change.

Summary : Icterus gravis neonatorum.

Case 4. Baby C.T. Born 18.11.39. Died 5.1.40. Aged 8 weeks. (Female).

Maternal History : The mother was aged 32 and this was her second pregnancy. The first child was normal at birth and is alive and well. She had no illness during this pregnancy.

Clinical Findings in the Child : The child was born spontaneously and weighed  $6\frac{3}{4}$  lbs. at birth. The following day it became jaundiced. The jaundice gradually deepened. The liver was enlarged and palpable two finger breaths below the costal margin. The spleen was not palpable. On the 28th day the blood showed Hb. 75 % R.B.C. 3.0 m/cu.mm. On the 34th day R.B.C. 2.7 m/cu.mm. Hb 58 %. Reticulocytes 11 % and W.B.C. 18,000 /cu.mm. The child gradually went downhill and died on 5.1.40.

Post-mortem Report :

The/

The body was that of a small, emaciated deeply jaundiced female infant.

Head : no abnormality present.

Thorax : The right lower lobe contained patches of bronchopneumonic consolidation. The heart was dilated and the myocardium was soft.

Abdomen : The alimentary tract was normal. The liver was slightly enlarged and dark green in colour. The spleen was moderately enlarged. The kidneys were bile stained.

Microscopic Report :

Liver : There was considerable periportal fibrosis. The small canaliculi were plugged with inspissated bile. The fibrosis was monolobular in distribution and the fibrous bands contained numerous small bile-ducts. No haemopoietic foci were present.

Spleen : was very congested. There was a large amount of bile pigment in the endothelial cells of the pulp.

Kidney : The cells of the convoluted tubules contain bile pigment.

Summary : Icterus gravis neonatorum.

Case 5. Baby H.L. Born 13.12.40. Died 4.1.41.

Aged 3 weeks. (Male).

Maternal History : The mother was aged 45 and this was her 5th. pregnancy. The previous four children were normal at birth and are alive and well. She had headaches and complained of slight swelling of the ankles in this pregnancy.

Clinical/

Clinical Findings in the Child : The child was born spontaneously and weighed 7 lbs. at birth. It developed jaundice after 72 hours and was still present on admission to hospital at the age of 3 weeks. On examination the anterior fontanelle was bulging, there was some neck rigidity, the limbs were spastic and Kernig's sign was positive. The liver and spleen were palpable. On lumbar puncture, heavily blood stained fluid was obtained. 3 cc. of whole blood were injected into the superior sagittal sinus. The baby died shortly afterwards.

Post-mortem Report : (2/41)

The body was that of a small male infant. There was deep jaundice of skin and conjunctivae.

Head : A large subdural haemorrhage was present. The brain was healthy and no nuclear staining had occurred.

Thorax : No abnormality present.

Abdomen : Peritoneum was healthy and the alimentary tract were normal. The liver was enlarged and bile-stained. The spleen was enlarged to  $2\frac{1}{2}$ " in length. It was soft and deep red in colour. Kidneys were bile-stained.

Microscopic Report :

Blood Film : Very numerous nucleated red cells present.

Liver : Many small clumps of haemopoietic cells were present and in these erythroblasts predominated.

A large amount of bile pigment was present in the

Kupffer/

Kupffer cells and in histiocytes in the portal tracts.

A slight portal fibrosis was present.

Spleen : The pulp was full of nucleated red cells. Some haemosiderin was present in the macrophages.

Summary : Icterus gravis neonatorum : Subdural haemorrhage.

Case 6. Baby McL. Born 13.1.41. Died 14.1.41. Aged 1 day.

Post-mortem Report :

The body was that of a well developed male infant. There was very intense jaundice. A few petechial haemorrhages were present over the face.

Head : The cerebro-spinal fluid and meninges were deeply bile-stained. There was intense staining of the cerebral nuclei, the nuclei of midbrain, pons and medulla and of the grey matter of the cord.

Thorax : The serous sacs were healthy. The lungs were congested, oedematous and bile-stained. The heart was of normal size, and a few subepicardial haemorrhages were present.

Abdomen : The liver was enlarged and light brown in colour. It was firm in consistence. The spleen was enlarged to  $2\frac{1}{2}$ " in length, soft and deep red in colour.

Microscopic Report :

Blood film : Large numbers of nucleated red cells were present.

Liver : Greatly excessive haemopoiesis had occurred. Many nests of erythroblasts were present and/

Series 2.

TABLE 8.

BABY J.D. Case 7.

## HAEMATOLOGICAL DATA.

Age in days.	Hb. % Sahli	R. B. C. / cu. mm.	C. I.	Miscellaneous.
10	26	1.0 m.	1.3	70 cc. of father's blood intravenously
11	46	1.8 m.	1.3	-
13	35	-	-	15 cc. of blood (unspecified) intravenously
14	46	-	-	30 cc. father's blood into anterior fontanelle
15	48	-	-	-
16	43	-	-	65 cc. father's blood.
18	63	-	-	-
19	58	3.4 m.	0.9	-
22	50	-	-	-
23	42	-	-	50 cc. father's blood intravenously
26	35	-	-	45 cc. father's blood intravenously.
28	42	-	-	Gluteal abscess present
37	50	2.3 m.	1.1	-
50	56	-	-	-
59	61	3.1 m.	1.0	-
69	71	3.8 m.	0.9	Well. Discharged.

and a certain degree of leucopoiesis has also occurred. The liver cells contained haemosiderin and the Prussian Blue reaction was positive.

Spleen : The pulp was cellular and many haemopoietic cells were present. The veins show subendothelial infiltration with haemopoietic cells.

Pancreas : Some perivascular haemopoietic foci were seen.

Kidney : A few haemopoietic foci were present in the peripelvic tissue.

Summary : Icterus gravis neonatorum with kernicterus.

Case 7. Baby J.D. Born 12.4.41. Male.

Maternal History : The mother was aged 32 and this was her 5th. pregnancy. Her previous children are all alive and well. She had had no illness during the present pregnancy.

Clinical Findings in the Child : The child was delivered spontaneously at term and weighed 7 lbs. at birth. The following day he was jaundiced. On the 8th. day he was still very jaundiced and rather pale (see Table 8). On the 10th. day he was transfused with 40 cc. of the father's blood and again on the 13th. and 14th. days, when he received 15 cc. and 30 cc. of father's blood. On the 15th. day he was transfused with 65 cc. and on the 22nd. day with 45 cc. of father's blood. He developed a gluteal abscess on the 26th day, but gradually recovered and was discharged on the 69th day.

Summary : Icterus gravis neonatorum (recovered).

Case 8 /

Case 8. Baby L.G. Born 11. 4. 41. Died 25.4.41.  
Aged 2 weeks. No clinical details were available.  
Post-mortem Report ( 86/41)

The body was that of a well developed and well nourished male infant.

Head : No abnormality present.

Thorax : Serous sacs were healthy. The lungs were very oedematous. The heart was dilated and the myocardium was pale and soft.

Abdomen : Peritoneal sac was healthy. The alimentary tract was normal. The liver was enlarged, smooth and reddish-brown in colour. The Prussian Blue reaction was strongly positive. Spleen was enlarged to 3" in length. It was rather friable and dark red in colour. The Prussian Blue reaction was positive. Kidneys were pale and the prussian Blue reaction was positive.

Microscopic Report :

Liver : A few foci of haemopoiesis were present, and a few nests of erythroblasts were found therein. Some leucocytic infiltration of the portal tracts had occurred. The parenchymal and Kupffer cells were loaded with haemosiderin.

Spleen : The pulp was highly cellular and numerous erythropoietic cells were seen. Haemosiderin was present in numerous histiocytes.

Kidney : Some haemosiderin was deposited in the cells of the convoluted tubules.

Suprarenal : Numerous erythropoietic foci were present/

present in the cortex.

Summary: Congenital haemolytic anaemia.

Case 9. Baby J.B. Born 9.6.41. Died 4.7.41. Aged 4 weeks. No clinical details were available.

Post-mortem Report : (129/41)

The body was that of a thin, deeply jaundiced male infant.

Head : There was some bile-staining of the leptomeninges but no kernicterus.

Thorax : A thrush oesophagitis was present. The lungs were congested.

Abdomen : The peritoneal sac was healthy and the alimentary tract showed no abnormality. The liver was moderately enlarged, firm and greenish in colour. The spleen was enlarged to 3" in length. The Malpighian bodies were not visible.

Microscopic Report :

Liver : The intercellular canaliculi were plugged with bile and there was fibrosis of the central zones of the lobules. There was no portal fibrosis but some bile duct proliferation had occurred.

Spleen : The histiocytes in the pulp contained bile pigment. There was no excessive haemopoiesis.

Summary : Icterus gravis neonatorum ( late case)

Case 10. Baby J.J. (male) Born 25.7.41. Died 29.8.41. Aged 5 weeks.

Maternal History : The mother was aged 19 and this was her first pregnancy. She had slight oedema of the ankles during the pregnancy.

Clinical/

Clinical Findings in the Child : The child was delivered by forceps after a difficult labour. It weighed  $7\frac{1}{2}$  lbs. at birth. It became jaundiced after 24 hours and a purpuric rash appeared on the 2nd. day. The spleen and liver were enlarged and the abdomen swollen and tense. The blood showed Hb 80%. W.B.C. 13,600/cu.mm. No nucleated red cells in film. The child went rapidly downhill, with increasing jaundice and died on the 3rd. day after admission.

Post-mortem Report :

The body was that of an extremely jaundiced male infant. Numerous petechial haemorrhages were present over the body.

Head : No abnormality was present.

Thorax : Pleural sacs were normal. The lungs were congested and oedematous. Numerous subpleural petechiae were present. The heart was dilated and some haemorrhages into the myocardium had occurred.

Abdomen : Peritoneal cavity contained a large quantity of clear orange-coloured fluid. The alimentary tract was rather distended. The spleen was firmly bound down to the posterior abdominal wall. The liver was greatly enlarged, dark green-orange in colour and rather fibrous. The left kidney was cystic.

Microscopic Report :

Liver : There was a generalised fibrosis associated with necrosis of liver tissue. In the surviving parenchyma there was an excess of haemopoiesis. The fibrosis was diffuse, intercellular and most/



most severe in the central zones of the lobules where the liver cells had disappeared. Numerous nests of erythroblasts were present.

Spleen : Numerous groups of erythropoietic foci in the sinuses.

Kidney : Excess numbers of nucleated cells in the capillaries. No foci of haemopoiesis were present.

Summary : Icterus gravis neonatorum.

Case 11. Baby A.B. (female) Born 6.5.42.

Maternal History : The mother was aged 33 years and this was her 5th. pregnancy. The third child was jaundiced after birth and her 4th. was still-born. She had suffered no illness during the present pregnancy.

Clinical Findings in the Child : (see Table 9).

The child was born spontaneously shortly before term and weighed  $4\frac{1}{2}$  lbs. at birth. It was jaundiced at birth and this became progressively deeper. Her spleen and liver were enlarged and she became markedly pale. On the 10th. day after birth she was transfused with 60 cc. whole blood. Her colour improved and she steadily gained in weight. She was discharged on the 64th. day after birth.

Summary : Icterus gravis neonatorum.

Case 12. Baby J.W. Born 7.1.43 Died 24.1.43.  
Aged 17 days. (Male).

Maternal History : This was the mother's 5th. pregnancy. The previous four children are alive and well/

well. She had had no illness during the present pregnancy.

Clinical Findings in the Child : The child was born spontaneously at term. The following day he was rather pale. After one week the abdomen became rather distended, the child failed to thrive and died on the 17th day.

Post-mortem Report : (9/43)

The body was that of a well nourished male infant. The skin was pale and the abdomen was greatly distended.

Head : No abnormality present.

Thorax : Serous sacs healthy. The lungs were pale and oedematous. The heart was of average size but the myocardium was rather pale.

Abdomen : The peritoneal sac contained a large amount of yellow fluid and some blood lay in the posterior part of the sac. A small blood clot was adherent to the anterior border of the spleen where there was a small rupture of the capsule. The alimentary tract was normal. The spleen was greatly enlarged and measured  $4\frac{1}{2}$ " in length. The surface was bright red in colour. The liver was only slightly enlarged and red-brown in colour. The Prussian Blue reaction was positive.

Microscopic Report :

Blood Film : Nucleated red cells were numerous and were mainly normoblasts.

Liver : Small collections of erythropoietic cells, mainly normoblasts, were found. The liver cells contained/

contained haemosiderin and the Prussian blue reaction was positive.

**Spleen :** The sinusoids were greatly dilated and formed large spaces crammed with cells, most of which are erythroblasts. The endothelial cells are swollen and laden with haemosiderin. The remaining pulp is congested and compressed. The Malpighian bodies are small and poorly developed.

Summary : Congenital haemolytic anaemia.

Case 13. Baby H. 18.6.43. Died 8.9.43. Aged 3 months. Female.

Maternal History : The mother was aged 24 years and this was her third pregnancy. The first two children are alive and well. She was Rh. negative and she had no illness during the present pregnancy. The baby was Rh. positive.

Clinical Findings in the Child : The child was delivered spontaneously a few weeks before term and weighed 6 lbs. 4 ozs. at birth. She became jaundiced 24 hours after birth and the jaundice reached its maximum at the 5th. day gradually fading thereafter. On the 6th. day the jaundice had faded but some head retraction was present. Liver and spleen were not palpable. On the 39th day the head retraction was more marked. Lumbar puncture yielded a yellow slightly turbid fluid not under pressure. Numerous polymorphs were found but no organisms and the culture was sterile. The baby gradually went downhill and died on the 85th day.

Post-mortem/

Post-mortem Report : (149/43)

Head : Acute leptomeningitis was present. There was no kernicterus.

Abdomen : the liver was of normal size. The spleen was slightly enlarged.

Microscopic Report :

Brain : A purulent leptomeningitis and ventriculitis were present. The brain was healthy.

Liver : The cells contained an excess of haemosiderin. A few intercellular canaliculi were plugged with bile. There was no fibrosis.

Summary : Icterus gravis neonatorum with terminal meningitis.

Case 14. Baby I.B Born 10.7.43. (Female).

Maternal History : The mother was 27 years of age and this was her second pregnancy. The first child is alive and well. She had no illness during the present pregnancy.

Clinical Findings in the Child : The child was born spontaneously and weighed 7 lbs. 8 ozs. The following day it was very pale and slightly jaundiced. It was transfused with 50 cc. Rh. negative blood. On the third day the jaundice was severe and the pallor less marked. On the fourth day the haemoglobin was 20 % (Sahli) and the child was transfused with 90 cc. Rh. negative blood. On the fifth day the haemoglobin was 54 %. On the seventh day the jaundice was less. Haemoglobin 45 %. One month after birth the haemoglobin was 52 % and the child was very well.

Summary/

Summary : Icterus gravis neonatorum (recovered).

Case 15. Baby B. Born 15.8.43. Died 18.8.43.

Aged 3 days.

Maternal History : This was the mother's second pregnancy. Her first child is alive and well. She had no illness during the present pregnancy.

Clinical Findings in the Child : The child was delivered spontaneously and was jaundiced at birth. The jaundice steadily deepened and the child died after 3 days.

Post-mortem Report (126/43)

The body was that of a well nourished male infant. Deep jaundice was present.

Head : Icteric tinting of the brain had occurred. There was no kernicterus.

Thorax : the pleural sacs were healthy. There was haemorrhagic oedema of both lungs.

Abdomen : Liver was not enlarged but very congested. The spleen was twice the normal size, firm in consistence and dark in colour. The kidneys were congested.

Microscopic Report :

Blood Film : Numerous normoblasts and some erythroblasts present.

Liver : Some haemopoietic foci are present but are mainly normoblastic in character. Liver cells in the central zone of the lobules show degenerative changes.

Spleen : congested.

Lung/

Lung : Severe oedema.

Summary : Icterus gravis neonatorum.

Case 16. Baby J. McK. Born 6.3.44. Died 7.3.44.

Aged 1 day.

Maternal History : The mother was aged 41 and this was her 4th. pregnancy. She had had one previous miscarriage. She had no illness during the present pregnancy.

Clinical Findings in the Child : The child was delivered spontaneously at term and weighed 7 lbs. at birth. It was jaundiced at birth. The following day it was very jaundiced and had marked respiratory distress. Haemoglobin was 25% (Sahli) and the R.B.C. 2.0 mm/cu.m.m. The blood film shows the presence of numerous nucleated red cells. The child did not rally and died on the 2nd. day.

Post-mortem Report : (43/44)

The body was that of a well developed male infant. It was very jaundiced.

Head : A small amount of blood was present in the subdural space over the hemispheres. The leptomeninges and brain substance were deeply bile-stained. The nuclei in the basal ganglia, midbrain, pons and medulla were bright yellow in colour. The olivary nuclei were especially vivid. The grey matter of the spinal cord was also stained.

Thorax : Serous sacs were healthy. There were a few subepicardial petechiae. Lungs were well expanded, oedematous and bile-stained. Several patches of haemorrhage/

haemorrhage were present. The myocardium was pale and bile-stained.

Abdomen : Peritoneal sac contained a small quantity of bright yellow fluid. Alimentary tract was normal. Liver was enlarged, firm and reddish-brown in colour. The spleen was enlarged to 3" in length, dark red and rather friable. Kidneys were bile-stained and pale.

Microscopic Report :

Liver : Haemopoiesis was very marked. A large number of foci of erythroblasts were present. There was considerable eosinophilic infiltration of the portal tracts. The liver cells were loaded with haemosiderin. There was no fibrosis.

Spleen : The pulp was crowded with nucleated red cells. These were mainly normoblasts ; erythroblasts were less numerous. Histiocytes were loaded with haemosiderin.

Kidney : A few foci of haemopoiesis were present in the boundary zone.

Summary : Icterus gravis and kernicterus.

Case 17. Baby L.H. (Female) Born 19.6.44. Died 4.11.44. Aged 4 months.

Maternal History : The mother was aged 32 and this was her 4th. pregnancy. Her first three children are alive and well. She had no illness during the present pregnancy. She is Rh. negative and husband and child are Rh. positive.

Clinical Findings in the child : (See Table 10).

The/

TABLE 10.

Series 2.    Case 17.    Baby L. H.

HAEMATOLOGICAL DATA.

Age in days.	Hb % Sahli	Icteric Index.	Van den Bergh Reaction	Miscellaneous.
1	82	-	-	Severe jaundice. Spleen enlarged.
4	-	300	-	Athetosis and opisthotonus.
5	34	-	Biphasic	-
16	-	71	Biphasic	-
19	-	91	-	Serum bilirubin 7 mgm%.
34	-	-	-	Jaundice gone.
60	-	-	-	Head retraction still present.
90	-	-	-	Opisthotonus. Kernig positive.
95	-	-	-	Died.

The baby was delivered spontaneously (vertex L.O.<sup>A</sup>,) a few weeks before term and weighed 6 lbs. at birth. The following day the child was jaundiced and spleen enlarged. On the 4th. day head retraction and athetosis were noted. The jaundice gradually disappeared after six weeks but signs of cerebral involvement persisted. She had severe spasms of the limbs and the arms and legs were spastic. The reflexes were sluggish and the Kernig sign was present. She developed an acute bronchitis and died.

Post-mortem Report : ( 156/44)

The body was that of a small, poorly nourished female infant.

Head : The meninges and brain showed no abnormality on naked eye examination.

Thorax : The serous sacs were healthy. The lungs were overexpanded and very congested. The bronchi contained muco-pus and their mucous membrane was inflamed.

Abdomen : The peritoneal sac was healthy. The alimentary tract was normal. Liver was not enlarged, light brown in colour and firm in consistence. The spleen was of normal size and appearance.

Microscopic Report :

Liver : A slight excess of haemosiderin was found in the liver cells. Slight portal fibrosis was present.

Spleen : Slight haemosiderosis.

Lungs : The bronchi contained an acute inflammatory/



inflammatory exudate.

Brain : The cornu ammonis was small and severe cell loss with astrocytic replacement had occurred. Neuronal loss with astrocytic replacement had also occurred in the globus pallidus and dentate nuclei. In the putamen, inferior olives, thalamus and mid-brain a few foci of polymorphs, lymphocytes and microglial cells were seen.

Summary : Icterus gravis neonatorum with kernicterus (death was a result of acute bronchitis).

Case 18. Baby J.R. (Female) Born 24.7.44. Died 18.8.44. Aged one month.

Maternal History : The mother was aged 34 and this was her eighth pregnancy. Her first five children are alive and well. The sixth child died of meningitis and the seventh of icterus gravis. She had no illness during the present pregnancy.

Clinical Findings in the Child : ( See Table 11)

The child was delivered spontaneously at term and weighed 9 lbs. It was jaundiced at birth and the spleen was enlarged. She became gradually paler and was transfused on the 16th day. She improved slightly but developed gastroenteritis and died on the 20th. day. No postmortem examination was performed.

Summary : Icterus gravis neonatorum ( death as a result of gastroenteritis).

Case 19. Baby A.M. Born 19.8.44. Died 1.10.44.

Aged 6 weeks ( female).

Clinical Findings in the Child : ( see Table 12)

The/

TABLE 12.

Series 2.

Case 19.

Baby A.M.

HAEMATOLOGICAL DATA.

Age in days	Hb% Sahli	R. B. C. / cu. mm.	C. I.	Nucleated R. B. C. / 100 W. B. C.	Reticulo-cytes.	Miscellaneous.
5	75	-	1.1	130	1%	Marked jaundice. Spleen enlarged. 70 c.c. Rh. -ve. blood given.
7	90	-	-	-	-	-
26	46	2.1	1.1	-	8%	Still jaundiced.
28	-	-	-	-	-	30 cc. Rh-ve. blood
34	58	-	-	-	-	Severe diarrhoea
43	-	-	-	-	-	Died.

The child was delivered spontaneously a few weeks before term and weighed 6 lbs. 10 ozs. at birth. She became jaundiced soon after birth and this increased steadily. She was transfused with 70 c.c. Rh. negative blood on the 5th. day and improved. On the 26th. day she was still jaundiced and rather pale. She was given 30 c.c. of Rh. negative blood. On the 34th. day she developed gastro-enteritis and in spite of treatment with sulphaguanadine she died. There was no postmortem examination.

Summary : Icterus gravis neonatorum ( death from gastro-enteritis).

Case 20. Baby G.O. (female) Born 17.2.45. Died 23.2.45. Aged 1 week.

Maternal History : The mother was aged 27 and this was her second pregnancy. The first child is alive and well. She had no illness during the present pregnancy.

Clinical Findings in the Child : The child was born spontaneously at term and weighed 7 lbs. 6 ozs. It became jaundiced the following day. The jaundice deepened and signs of cerebral involvement appeared. There was twitching of the limbs and Kernig's sign was present. The liver and spleen were enlarged. On the 6th. day the child had repeated convulsions and died.

Post-mortem Report : ( 27/45)

The body was that of a female infant weighing 6 lbs./

6 lbs. 4 ozs. There was deep orange yellow jaundice of the skin.

Head : The leptomeninges and brain were lightly bile-stained. The nuclei in the basal ganglia, hippocampus, medulla and floor of the 4th. ventricle were bright yellow in colour. The grey matter of the spinal cord was not affected.

Thorax : Serous sacs were healthy. The lungs were well-expanded and deeply bile-stained.

Abdomen : The peritoneal sac was healthy. The alimentary tract was normal. The liver was enlarged, rusty brown in colour and firm in consistence. The spleen was enlarged to 3" in length. It was firm and dark. The kidneys were pale and bile-stained. Uric acid deposits were present on the pyramids.

Microscopic Report :

Blood Film : Numerous normoblasts were seen. The primitive nucleated cells were not present in large numbers.

Liver : A few foci of haemopoiesis were present. These were mainly normoblastic in character. The liver cells contained a large amount of haemosiderin and the Prussian Blue reaction was positive. Some plugs of bile were present in the intercellular canaliculi. There was no fibrosis.

Spleen : was extremely congested. The Malpighian bodies were small and no foci of haemopoiesis were found. There was much haemosiderin in the histiocytes and in the endothelial cells lining the sinusoids.

Brain/

TABLE 13.

Case 21. Baby D.

Series 2.

HAEMATOLOGICAL DATA

Age in days	Hb% Sahli	R. B. C. / cu. mm.	C. I.	W. B. C. / cu. mm.	Nucleated R. B. C. / 100 W. B. C.	Reticulo-cytes.	Miscellaneous.
2	50	2.3 m.	1.1	30,000	30	4	Jaundiced, spleen enlarged.
3	-	-	-	-	-	-	100 cc. Rh. negative blood via fontanelle.
5	-	-	-	-	-	-	Improved.
24	-	-	-	-	-	-	Jaundiced and pale. Died.

Brain : Some nuclear degeneration had occurred, especially in the hippocampal region.

Summary : Icterus gravis neonatorum with kernicterus.

Case 21. Baby E.D. (female) Born 21.4.45. Died 14.5.45. Aged 3½ weeks.

Maternal History : The mother was aged 29 and this was her 5th. pregnancy. Her first two children were alive and well and were normal at birth. Her third and fourth are alive and well but they were jaundiced at birth. She had no illness during the present pregnancy.

Clinical Findings in the Child : ( see Table 13)

The child was delivered spontaneously at term and weighed 7 lbs. It was weak and pale at birth and shortly afterwards was jaundiced. On the 3rd. day it was very jaundiced and the spleen was enlarged. She was transfused with 100 cc. of Rh. negative blood via anterior fontanelle. She improved slightly until the 23rd. day when she became drowsy. She was still jaundiced and pale. The reflexes were exaggerated and the child died on the 24th day.

Post-mortem Report : (73/45)

The body was that of a thin female infant weighing 6 lbs. 2 ozs. There was severe jaundice and several small haemorrhages in the skin of the thighs.

Head : There was a severe subdural haemorrhage on the right side where a large recent blood clot lined the inner aspect of the skull vault and floor of the anterior/

anterior and middle fossa. This clot was 1 cm. thick and was exerting pressure on the underlying brain. There was also a subarachnoid haemorrhage over the left lobe of the cerebellum. The source of the haemorrhage was not found. The leptomeninges were bile-stained but there was no kernicterus.

Thorax : Serous sacs were healthy. The lungs were well-expanded, pale and rather oedematous. The heart showed slight dilatation of the right ventricle and the myocardium was pale and soft.

Abdomen : the peritoneal sac was healthy. The alimentary tract was normal. The liver was enlarged, firm and dark-green in colour. The spleen was slightly enlarged, pale red and rather soft. The kidneys were of normal size and were bile-stained.

Microscopic Report :

Blood Film : Numerous nucleated red cells were found. Normoblasts predominated but more primitive types were also seen.

Bone Marrow : Few mature red cells were seen ; normoblasts were very numerous ; haemocytoblasts and erythroblasts were also found.

Liver : A few foci of haemopoiesis were present. These were mainly normoblastic but erythroblasts were also seen. The portal tracts were infiltrated with nucleated red cells, eosinophils and histiocytes. The liver cells were loaded with haemosiderin and the intercellular canaliculi were plugged with bile-pigment /

pigment. Liver cells in the central zones of the lobules showed early fatty change. There was no fibrosis.

Spleen : The pulp was highly cellular and numerous nucleated red cells were present. Numerous histiocytes packed with haemosiderin were present.

Kidney : The cells of the convoluted tubules contained haemosiderin.

Summary : Icterus gravis neonatorum ( death as a result of subdural haemorrhage).

Case 22. Baby M.D. (female) Born 2.7.45 Died 3.9.45. Aged 2 months.

Maternal History : This was the mother's seventh pregnancy. Her first six children are alive and well. She had no illness during the present pregnancy. Her blood is Rh. negative and that of her child is Rh. positive.

Clinical Findings in the Child : The child was born spontaneously at term and weighed 9 lbs. 4 ozs at birth. She became jaundiced a few days after birth. The jaundice deepened and the child became pale. Forty-seven days after birth she was still jaundiced. Her R.B.C. was 3.0 m/cu.mm. W.B.C. 22,000/cm. and Haemoglobin 65 % (Sahli). On the 49th day she was transfused with 20 cc. Rh. negative blood via the fontanelle and again on the 51st day. By the 54th day the haemoglobin was 80% and the jaundice was decreasing. On the 59th day the haemoglobin was 70%. She then developed diarrhoea and vomiting and died on the/

the 61st day.

Post-mortem Report : (105/45)

The body was that of a very small, poorly nourished female infant weighing 6 lbs. 3 ozs. Jaundice of skin and mucous membrane was present.

Head : The meninges were not bile-stained and there was no kernicterus. Both middle ears contained thin muco-pus.

Thorax : Serous sacs were healthy. Lungs were fairly well expanded. The heart was normal.

Abdomen : Peritoneal sac was healthy. The alimentary tract was normal. The liver was of normal size and consistence and dark green-brown in colour. Spleen was of normal size and consistence and dark red in colour. The kidney showed a subacute pyelonephritis.

Microscopic Report :

Liver : The cells in the outer zone of the lobules showed fatty degeneration. The Kupffer cells and inter-cellular canaliculi contained bile-pigment.

Spleen : The pulp was very congested and some histiocytes contained bile-pigment.

Kidney : The interstitial tissue was infiltrated with polymorphonuclear leucocytes. Some tubular atrophy had occurred but the glomeruli were not affected. The appearance was that of a subacute pyelonephritis.

Summary : Icterus gravis neonatorum ( death as a result of pyelonephritis and otitis).

Case 23. Baby W.B. (Female) Born 2.10.45. Died

13.10.45. Aged 11 days.

Maternal/

TABLE 14.

Series 2.

Case 23.

Baby W.B.

HAEMATOLOGICAL DATA

Age in days	Hb% Sahli	R. B. C. / cu. mm.	C. I.	W. B. C. / cu. mm.	Nucleated R. B. C. / 100 W. B. C.	Miscellaneous.
3	80	3.6 m.	1.2	24,000	Numerous	Very jaundiced, liver and spleen enlarged.
7	58	2.6 m.	1.1	-	-	-
8	45	2.1 m.	1.1	-	7	50 cc. Gp. 0 Rh. negative blood given.
9	56	-	-	-	-	-
10	42	1.7 m.	1.2	-	-	40 cc. Gp. 0 Rh. negative blood.
11	40	2.0 m.	1.0	-	-	Died.

Maternal History : The mother was aged 31 and this was her fourth pregnancy. The first 3 children are alive and well. She had no illness during the present pregnancy.

Clinical Findings in the Child : ( see Table 14)

The child was delivered spontaneously (breech) at term and weighed 7 lbs. On the following day it became jaundiced and some head retraction was noticed. It became rather pale and on the 8th day it was transfused with 50 cc. Rh. negative blood and again on the 10th day with 40 cc. Group O Rh. negative blood. It failed to rally, however, and died on the 11th. day.

Post-mortem Report : ( 125/45).

The body was that of a well-developed female infant. There was severe jaundice and some generalised subcutaneous oedema.

Head : The meninges and brain showed slight diffuse bile-staining. There was no kernicterus. Some blood clot was found in the subdural space, over the right cerebral hemisphere and over the tentorium on the left side, and bilaterally beneath the tentorium. A small clot was adherent to the wall of the superior sagittal sinus near the site of a transfusion. The subdural haematoma may have been the result of the transfusion.

Thorax : Serous sacs were healthy. The lungs were oedematous and congested. The heart was of normal size but the myocardium was pale and bile-stained.

Abdomen : The peritoneal sac contained a little yellow/

yellow fluid. The alimentary tract was normal. The liver was enlarged, firm and green-brown in colour. The spleen was twice the normal size, dark red and soft. The kidneys were swollen, pale and bile-stained.

Microscopic Report : Liver : A few foci of haemopoiesis, mainly normoblastic in character, were found. The liver cells and Kupffer cells were packed with haemosiderin and the Prussian Blue reaction was positive. The intercellular canaliculi contained bile-plugs.

Spleen : The pulp was congested and normoblasts were fairly numerous. Haemosiderin had occurred.

Lung : An early patch of bronchopneumonic consolidation was developing in one lung.

Summary : Icterus gravis neonatorum.

Case 24. Baby E.B. (Female) Born 29.12.45. Died 4.1.46. Aged 6 days.

Maternal History : The mother was aged 33 and this was her fourth pregnancy. The first child is alive and well. The second died of cerebral haemorrhage. The third was still born.

Clinical Findings in the Child : The child was delivered spontaneously and weighed 7 lbs. at birth. It became jaundiced after 48 hours. The jaundice deepened and 5 cc. of the father's blood was injected into each buttock on the 4th. day. The child became very pale and both liver and spleen were enlarged. On the 6th. day the Haemoglobin was 15% (Sahli) and the R.B.C./

R.B.C. 0.5m/cu.mm. The child died on the 6th. day in spite of a transfusion.

Post-mortem Report ( 1/46)

The body was that of a jaundiced female infant weighing 6 lbs.

Head : There was a considerable haemorrhage into the subdural space, especially on the right side. The source of the haemorrhage was a transfusion via the anterior fontanelle. The brain showed slight diffuse bile-staining. There was no kernicterus.

Thorax : The serous sacs were healthy. The lungs were pale and a few subpleural petechiae were present. The heart was of normal size. The myocardium was pale and soft.

Abdomen : The peritoneum was healthy. The alimentary tract was normal. The liver was enlarged, firm and smooth. It was rusty brown in colour. The Prussian Blue reaction was strongly positive. The spleen was enlarged to  $2\frac{1}{4}$  " in length and was firm, tense and dark-red in colour. The Prussian Blue reaction was strongly positive. The kidneys were pale.

Microscopic Report :

Blood Film : Nucleated red cells were very numerous. Normoblasts predominated but numerous primitive types were also found.

Bone Marrow : Erythroblastic elements were conspicuous. Normoblasts and megaloblasts were present in large numbers.

Liver : Excessive haemopoiesis was present. A large/

large proportion of the foci were composed almost entirely of primitive erythroblasts though normoblasts were abundant in blood vessels. The liver cells contained large amounts of haemosiderin especially in the peripheral zones of the lobules. Slight fatty degeneration of cells in the central zone had occurred.

Spleen : The pulp was very congested and normoblasts were numerous.

Kidney : No extramedullary erythropoiesis present.

Summary : Icterus gravis neonatorum.

Case 25. Baby M.E. Born 19.2.46 Died 23.2.46.

Aged 4 days.

Maternal History : This was the mother's third pregnancy and her first two children are alive and well.

Clinical Findings in the Child: The child was born spontaneously 3 weeks before term and weighed 6 lbs. 8 ozs. at birth. It became jaundiced 24 hours after birth. The jaundice increased and the child's condition steadily deteriorated till it died on the 4th day.

Post-mortem Report : (34/46)

The body was that of a male infant weighing 6 lbs. It was deeply jaundiced and the abdomen was rather distended. A few subcutaneous petechiae were present over face, trunk and limbs.

Head : The meninges and brain were diffusely bile/

bile-stained. There was no kernicterus.

Thorax : The serous sacs were healthy. The lungs were well expanded. A large subpleural haemorrhage was present over the left upper lobe. Slight pulmonary oedema was present. The heart was dilated and the myocardium was pale.

Abdomen : The peritoneum contained a large quantity of fluid blood and some clots were found, the largest being attached to a rupture  $\frac{1}{2}$ " deep over the anterior border of the spleen. The alimentary tract was normal. The liver was enlarged, firm and greenish-brown in colour. The Prussian Blue reaction was positive. The spleen was enlarged and measured 3" in length. It was soft and friable. The Prussian Blue reaction was positive in the subcapsular region. The kidneys were pale.

Microscopic Report :

Liver : There was excessive haemopoiesis and many foci of primitive erythroblasts were present. The liver cells were loaded with haemosiderin and the intercellular canaliculi contained bile plugs.

Kidney : A few haemopoietic foci lay in the peripelvic connective tissue.

Summary : Icterus gravis neonatorum (rupture of spleen leading to intraperitoneal haemorrhage).

Case 26. Baby A.R. Born 9.5.46. Died 24.5.46.

Aged 2 weeks.

Maternal History : This was the first child in a mother aged 23 years. She had no illness during her present/

TABLE 15.

Series 2.

Case 26.

Baby A. R.

HAEMATOLOGICAL DATA.

Age in days.	Hb% Sahli	R. B. C. / cu. mm.	C. I.	W. B. C. / cu. mm.	Miscellaneous.
4	70	3.2 m	1.1	29,000	Jaundiced, Liver and spleen enlarged.
7	85	3.3 m	1.2	24,000	-
9	80	3.3 m	1.2	-	-
11	75	3.3 m	1.1	19,800	-
12	-	-	-	-	100 c. c. Gp. O. Rh negative blood.
13	100	4.6 m	1.1	21,000	-
14	-	-	-	-	Collapsed and died.

present pregnancy.

Clinical Findings in the Child : ( see Table 15).

The child was delivered spontaneously 2 weeks before term and weighed 7 lbs. 6 ozs. It became jaundiced after twenty-four hours and the jaundice gradually deepened. The spleen and liver became enlarged. On the 12th. day it was transfused with 100 cc. Rh. negative blood. It did not rally and collapsed and died on the 14th day.

Post-mortem Report : (84/46)

The body was that of a poorly nourished deeply jaundiced male infant.

Head : the meninges and brain showed diffuse bile-staining. There was no kernicterus.

Thorax : Serous sacs were healthy. The lungs and heart were normal.

Abdomen : There was a sticky fibrinous exudate over the spleen and the omentum was adherent. The alimentary tract was normal. The liver was enlarged firm and greenish-brown in colour. The spleen was enlarged to 3" in length and was firm and dark red in colour. The kidneys were pale and bile-stained.

Microscopic Report :

Liver : There was no extramedullary erythropoiesis. The liver cells contained haemosiderin and the inter-cellular canaliculi were plugged with bile.

Spleen : The pulp was very congested and numerous histiocytes containing haemosiderin were present. Haemopoiesis was not conspicuous.

Bone/

Bone Marrow : No excessive erythropoiesis was found.

Pancreas : Changes suggestive of early fibro-cystic disease were found.

Summary : Icterus gravis neonatorum.

Case 27. Baby K.H. Born 24.6.46. Died 1.8.46  
Aged 5½ weeks.

Maternal History : This was the mother's second pregnancy. Her first child is alive and well. The mother is aged 32.

Clinical Findings in the Child : The child was born spontaneously and weighed 6 lbs. 12 ozs. at birth. It became jaundiced after 24 hours and the jaundice steadily increased. There was no anaemia. The haemoglobin was 105 % (Sahli) and the R.B.C. 5.2m/cu.mm. The W.B.C. were 10,000/cu.mm. The spleen was slightly enlarged. The child began to vomit on the 35th day and gradually went downhill and died on the 38th day.

Post-mortem Report : (132/46)

The body was that of a thin jaundiced female infant with Mongol facies.

Head : Brain and meninges were healthy. There was no kernicterus.

Thorax : Serous sacs were healthy. The lungs showed patches of collapse at both bases. The bronchi contained aspirated gastric contents. The heart was normal.

Abdomen : Peritoneal sac was healthy. The alimentary/

TABLE 16.

Series 2.

Case 28.

Baby G.

## HAEMATOLOGICAL DATA

Age in days.	Hb% Sahli.	R. B. C. / cu. mm.	G. I.	W. B. C. / cu. mm.	Nucleated R. B. C. / 100 W. B. C.	Miscellaneous.
1	60	2.1 m.	1.3	-	Numerous	Jaundiced. Spleen enlarged.
2	-	4.0 m	-	-	-	60 cc. Gp.O. Rh. negative blood given intravenously.
6	-	-	-	-	-	60 cc. Gp.O. Rh. negative blood.
7	-	3.7 m.	-	-	-	Jaundice slight.
15	-	-	-	-	-	60 cc. Rh. <u>positive blood</u> (in error)
16	-	-	-	-	-	Deep jaundice. Spleen enlarged.
18	-	2.2 m.	-	-	-	80 cc. Gp.O. Rh. negative blood.
19	-	2.95 m	-	-	-	-
22	75	4.19 m	0.9	-	-	-
29	65	3.5 m.	0.9	-	-	Well

alimentary tract was normal. The spleen was enlarged, firm and dark red in colour. The Prussian Blue reaction was faintly positive. The liver was enlarged and greenish-brown in colour. The Prussian Blue reactive was negative. The kidneys were normal.

Microscopic Report :

**Liver** : The Kupffer cells and parenchymal cells contained haemosiderin. The intercellular canaliculi were distended with bile. A few foci of haemopoiesis were found.

**Spleen** : Histiocytes in the pulp were distended with haemosiderin. There was no excessive haemopoiesis.

**Kidney** : Some haemosiderin had been deposited on the cells of the convoluted tubules.

**Lung** : Diffuse bronchopneumonic consolidation was present. It was undergoing organisation.

**Pancreas** : Changes suggestive of cystic fibrosis were found.

Summary : Icterus gravis neonatorum ( bronchopneumonia and fibrosis of pancreas. )

Case 28. Baby G. Born 29.7.46

Maternal History : The mother was aged 36 and this was her third pregnancy. The first two children were jaundiced at birth and the second required a transfusion. They are both alive and well. The mother had had no illness during the present pregnancy.

Clinical Findings in the Child : (see Table 16)

The/

The child was born spontaneously at term and weighed 6 lbs. 13 ozs. at birth. It was jaundiced at birth, and the spleen was enlarged. It was given two transfusions and improved considerably. A third transfusion of Rh. positive blood (given in error) caused a sharp increase in the jaundice, but a 4th. transfusion of Rh. negative blood restored the balance. By the end of the 4th. week the child was free from jaundice and was discharged from hospital.

Summary : Icterus gravis neonatorum (recovered).

Case 29. Baby L. Born 3.8.46. Died 6.8.46. Aged 3 days.

Maternal History : The mother was aged 23 and this was her second pregnancy. The first child was alive and well and was normal at birth. The mother had no illness during the present pregnancy.

Clinical Findings in the Child : The child was delivered spontaneously at term and weighed 7 lbs. 2½ ozs. at birth. It became jaundiced shortly after birth and the jaundice gradually deepened. The child became pale - Haemoglobin 45% (Sahli) R.B.C. 2.3m/cu.mm. numerous nucleated red cells were found in the film. The child became very distressed on the 3rd. day and died.

Post-mortem Report (136/46)

The body was that of a well developed male infant weighing 7 lbs. 4 ozs. The skin was deep golden yellow in colour.

Head : The brain was diffusely bile-stained and the/

the nuclei in the basal ganglia and brain stem were bright yellow in colour.

Thorax : Serous sacs were healthy. The lungs were bile-stained and congested.

Abdomen : The peritoneum was healthy and the alimentary tract was normal. The spleen was enlarged and measured  $2\frac{1}{2}$ " in length. It was dark red in colour and firm in consistence. The Prussian Blue reaction was strongly positive. The liver was greatly enlarged and deep red-brown in colour. The kidneys were of normal size and consistence.

Microscopic Report :

Blood Film : Numerous normoblasts and erythroblasts were present. The blood was Rh. positive.

Summary : Icterus gravis neonatorum with kernicterus.

Case 30. Baby Ma. Born 19.9.46.

Maternal History : The mother was aged 22 and this was her 4th. pregnancy. The first three pregnancies ended in miscarriages at the 6th, 4th, and 3rd. months respectively. Her blood is Rh. negative and that of her husband and child is Rh. positive. She had no illness during the present pregnancy.

Clinical Findings in the Child : (see Table 17)

The child was delivered spontaneously (vertex L.O.A.) at term and weighed 7 lbs. 1 oz. at birth. On the following day it became jaundiced. On the 5th. day it received 60 cc. Group O Rh. negative blood. This was repeated on the 11th and 15th days. The child steadily/

TABLE 17.

Baby M.

Case 30.

Series 2.

## HAEMATOLOGICAL DATA.

Age in days	Hb% Sahli	R. B. C. / cu. mm.	C. I.	W. B. C. / cu. mm.	Nucleated R. B. C. / 100 W. B. C.	Miscellaneous.
1	78	-	-	-	-	Jaundiced.
3	65	-	-	-	-	-
4	64	3.2 m	1.0	13000	5	60 cc. Gp. O. Rh. negative blood intravenously.
5	53	-	-	-	-	-
6	74	3.2 m	0.9	-	-	-
7	74	-	-	-	-	Jaundice less.
8	63	3 m	1.0	-	-	Jaundice increased.
10	62	3 m	-	-	-	-
11	59	2.9 m	-	-	-	60 cc. Gp. O. Rh. negative blood
13	70	3 m	0.9	-	-	Improving.
15	55	2.2 m	0.9	-	-	60 cc. Gp. O. Rh. negative blood.
16	70	3 m	1.1	-	-	-
28	60	3.3 m	0.9	-	-	Well

the nuclei in the basal ganglia and brain stem were bright yellow in colour.

Thorax : Serous sacs were healthy. The lungs were bile-stained and congested.

Abdomen : The peritoneum was healthy and the alimentary tract was normal. The spleen was enlarged and measured  $2\frac{1}{2}$ " in length. It was dark red in colour and firm in consistence. The Prussian Blue reaction was strongly positive. The liver was greatly enlarged and deep red-brown in colour. The kidneys were of normal size and consistence.

Microscopic Report :

Blood Film : Numerous normoblasts and erythroblasts were present. The blood was Rh. positive.

Summary : Icterus gravis neonatorum with kernicterus.

Case 30. Baby Ma. Born 19.9.46.

Maternal History : The mother was aged 22 and this was her 4th. pregnancy. The first three pregnancies ended in miscarriages at the 6th, 4th, and 3rd. months respectively. Her blood is Rh. negative and that of her husband and child is Rh. positive. She had no illness during the present pregnancy.

Clinical Findings in the Child : (see Table 17)

The child was delivered spontaneously (vertex L.O.A.) at term and weighed 7 lbs. 1 oz. at birth. On the following day it became jaundiced. On the 5th. day it received 60 cc. Group O Rh. negative blood. This was repeated on the 11th and 15th days. The child steadily/

steadily improved, the jaundice faded and the child was discharged at the end of a month.

Summary : Icterus gravis neonatorum (recovered).

Case 31. Baby Mu. Born 3.10.46 Died 10.10.46.

Aged 1 week.

Maternal History : This was the mother's second pregnancy. Her blood is Rh. negative and antibodies were present in the serum during this pregnancy.

Clinical Findings in the Child : The child was born spontaneously at term and was jaundiced at birth. The liver and spleen were not enlarged. A blood film showed 62 normoblasts per 100 W.B.C. and the haemoglobin was 76% (Sahli). The child did not thrive, and died at the end of one week.

Post-mortem Report : 176/46)

The body was that of a deeply jaundiced male infant.

Head : The leptomeninges and brain substance were diffusely bilestained. There was no kernicterus. There was a small haemorrhage into the subarachnoid space over the left cerebral hemisphere. This was the result of needle puncture through the anterior fontanelle.

Thorax : The serous sacs were healthy. The lungs were well-expanded and very oedematous. The heart was dilated.

Abdomen : The peritoneum was healthy and the alimentary tract was normal. The liver was enlarged, firm and greenish-brown in colour. The Prussian Blue reaction was positive. The spleen was enlarged to  $3\frac{1}{2}$ " in length, firm and dark red in colour. The Prussian/

Prussian Blue reaction was strongly positive. The kidneys were pale and bile-stained. The Prussian Blue reaction was positive.

Microscopic Report:

Blood Film : Nucleated red cells were numerous and were chiefly normoblasts. Some erythroblasts were also seen.

Bone Marrow : Active erythro- and leucopoiesis. Numerous primitive nucleated red cells were present.

Liver : Excessive haemopoiesis was present. Numerous foci of erythroblasts were seen. Many liver cells contained haemosiderin and the intercellular canaliculi were dilated with bile pigment. Some of the liver cells showed degenerative changes.

Spleen : The pulp was abnormally cellular due to excessive haemopoiesis which was both normoblastic and erythroblastic in character.

Kidney : No extramedullary haemopoiesis.

Summary : Icterus gravis neonatorum.

Case 32. Female. Baby G.H. Born 18.11.46. Died 13 days.

Maternal History : (see also case 17).

The mother was aged 34 and this was her 5th. pregnancy. The first three children were normal at birth and are alive and well. The fourth child died from icterus gravis (case 17). The mother's blood was Rh. negative and that of husband and child was Rh. positive.

Clinical Findings in the Child : (see Table 18)

The/

TABLE 18.

Baby C. H.

Case 32.

Series 2.

HAEMATOLOGICAL DATA.

Age in days.	Hb% Sahli	R. B. C. / cu. mm.	C. I.	W. B. C. / cu. mm.	Nucleated R. B. C. / 100 W. B. C.	Miscellaneous.
1	108	4.76 m	1.1	51,000	18	Jaundiced. 60 cc. Gp.O. Rh. negative blood.
2	100	4.2 m	1.2	-	-	-
3	85	4.0 m	1.1	-	-	90 cc. Gp.O. Rh. negative blood.
4	115	4.8 m	1.1	-	-	Very jaundiced.
6	80	3.0 m	1.2	-	-	90 cc. Gp.O. Rh. negative blood.
7	90	3.6 m	1.2	-	-	-
9	77	3.0 m	1.2	-	-	90 cc. Gp.O. Rh. negative blood
10	65	2.5 m	1.2	-	-	Very jaundiced.
12	50	2.0 m	1.2	-	-	Condition poor.
13	50	1.9 m	1.2	-	-	Died.

The child was born spontaneously and weighed 6 lbs. 9 ozs. at birth. After 24 hours it became jaundiced and was transfused with 60 cc. Rh. negative blood. It was again transfused with 90 cc. Rh. negative blood on the 3rd. day and on the 6th. day. The haemoglobin then fell from 90% (Sahli) to 77% and a further 90 cc. Rh. negative blood were given on the 9th day. The child's condition rapidly deteriorated. It became very pale and the spleen was enlarged. It died on the 13th day.

Post-mortem Report : (215/46)

The body was that of a poorly nourished, deeply jaundiced, female infant.

Head : The meninges and brain were diffusely bile-stained but there was no kernicterus.

Thorax : Some bile-stained fluid was present in the serous sacs, the lungs were congested and oedematous. The right lower lobe was partially collapsed and several small patches of consolidation were present. The heart was slightly dilated and the myocardium was pale and soft.

Abdomen : The peritoneal sac contained some yellow fluid. The liver was enlarged, firm in consistence and green in colour. The Prussian Blue reaction was positive. The spleen was enlarged and measured  $2\frac{1}{2}$ " in length. It was firm in consistence and dark red in colour. The Prussian Blue reaction was positive. The kidneys were swollen and the cortex was bile-stained.

Microscopic/

Series 2.

TABLE 19.  
BABY A.C.

Case 33.

## HAEMATOLOGICAL DATA.

Age in days	Hb% Sahli	R.B.C. / cu. mm.	C.I.	W.B.C. / cu. mm.	Nucleated R.B.C. / 100 W.B.C.	Reticulo-cytes.	Icteric Index.	Miscellaneous
2	98	3.5 m	1.2	20,000	24	-	-	Jaundice. 80 cc. Gp.O. Rh. negative blood transfusion.
3	120	4.0 m	1.2	-	-	-	-	-
5	99	3.9 m	1.2	-	-	-	-	-
6	-	3.9 m	1.0	-	-	-	-	80 cc. Gp.O. Rh. negative blood transfusion.
7	105	5.1 m	1.0	-	-	-	-	-
9	105	4.6 m	1.1	-	-	-	-	-
11	105	4.5 m	1.1	-	-	-	-	80 cc. Gp.O. Rh. neg. blood transfusion. Spleen impalpable.
13	95	5.0 m	0.9	-	-	-	-	-
14	90	4.5 m	1.0	-	-	-	-	150 cc. Gp.O. Rh. neg. blood transfusion.
15	120	6.0 m	1.0	-	-	-	-	-
19	100	5.0 m	1.0	-	-	-	-	-
26	84	4.7 m	0.9	-	-	-	-	Well.

Microscopic Report.

Blood Film : White cells were numerous and included many myelocytes. No nucleated red cells were found.

Summary ; Icterus gravis neonatorum.

Case 33. Baby A.C. Born 29.1.47,

Maternal History : The mother was aged 26 and this was her 4th pregnancy. Her first 3 children are alive and well and were normal at birth. Her blood is Rh. negative but did not have antibodies. The baby's blood is Rh. positive. The mother has valvular disease of the heart.

Clinical Findings in the Child : ( see Table 19)

The child was delivered spontaneously and weighed  $7\frac{1}{2}$  lbs. at birth. After 48 hours it developed jaundice and the liver and spleen were enlarged. It was transfused with Rh. negative blood on the 2nd, 6th, 11th and 14th days after birth. His condition was steadily improved by this treatment and he was discharged from hospital after 4 weeks.

Summary : Icterus gravis neonatorum (recovered).

Case 34. Baby D.H. Born 2.3.47. Died 29.3.47.

Aged 23 days.

Maternal History : The mother was aged 32 and this was her second pregnancy. The first child was normal at birth and is alive and well. Her blood is Rh. negative and that of husband and child is Rh. positive.

Clinical Findings in the Child ( see Table 20)

The/

Microscopic Report.

Blood Film : White cells were numerous and included many myelocytes. No nucleated red cells were found.

Summary ; Icterus gravis neonatorum.

Case 33. Baby A.C. Born 29.1.47,

Maternal History : The mother was aged 26 and this was her 4th pregnancy. Her first 3 children are alive and well and were normal at birth. Her blood is Rh. negative but did not have antibodies. The baby's blood is Rh. positive. The mother has valvular disease of the heart.

Clinical Findings in the Child : ( see Table 19)

The child was delivered spontaneously and weighed  $7\frac{1}{2}$  lbs. at birth. After 48 hours it developed jaundice and the liver and spleen were enlarged. It was transfused with Rh. negative blood on the 2nd, 6th, 11th and 14th days after birth. His condition was steadily improved by this treatment and he was discharged from hospital after 4 weeks.

Summary : Icterus gravis neonatorum (recovered).

Case 34. Baby D.H. Born 2.3.47. Died 29.3.47.

Aged 23 days.

Maternal History : The mother was aged 32 and this was her second pregnancy. The first child was normal at birth and is alive and well. Her blood is Rh. negative and that of husband and child is Rh. positive.

Clinical Findings in the Child ( see Table 20)

The/

HAEMATOLOGICAL DATA.  
Case 34.

TABLE 20.  
BABY D.H.

Series 2.

Age in days	Hb Sahli	R. B. C. / cu. mm.	C. I.	W. B. C. / cu. mm.	Nucleated R. B. C. / 100 W. B. C.	Reticulo-cytes	Icteric Index	Miscellaneous.
1	85	3.8 m	1.1	-	52	-	-	110 cc. Gp. O. Rh. negative blood transfusion.
2	-	-	-	-	-	-	-	120 cc. Rh. negative blood transfusion.
3	100	4.5 m	1.1	-	-	-	-	-
4	100	-	-	-	-	-	-	140 cc. Rh. negative G. p. O. blood transfusion.
5	90	-	-	-	-	-	-	-
6	60	-	-	-	-	-	-	-
7	-	-	-	-	-	-	-	-
8	90	4.7 m	-	-	-	-	-	120 cc. Gp. O. Rh. negative blood transfusion. Gaining weight.
11	-	-	-	-	-	-	-	40 cc. Gp. O. Rh. negative blood transfusion.
13	95	4.6 m	1.0	17,600	-	-	-	120 cc. Gp. O. Rh. negative blood transfusion.
14	95	4.6 m	1.0	17,800	-	-	-	Abscess on buttock.
16	-	-	-	20,000	-	-	-	Very ill.
17	100	5.0 m	1.0	24,000	-	-	-	Abscess drained.
23	-	-	-	-	-	-	-	Collapsed and died.

The child was jaundiced at birth and was transfused with 110 cc. Rh. negative blood. On the 2nd. day it received 120 cc. Rh. negative blood, and on the 4th. day 140 cc. It was again transfused on the 7th day with 120 cc., on the 11th day with 40 cc. and on the 13th day with 120 cc. This is a total of 650 cc. Rh. negative blood. Meanwhile it developed an abscess over the buttock. The child's condition deteriorated and it collapsed and died on the 23rd. day.

Post-mortem Report: (84/47)

The body was that of an emaciated, deeply jaundiced male infant. There were abscesses over the left thigh, left buttock, both ankles, both cubital fossae and both popliteal fossae.

Head : No abnormality.

Thorax : Serous sacs were healthy. The lungs were slightly oedematous and bile-stained. The heart was dilated and the myocardium was pale and bile-stained.

Abdomen : The peritoneal sac contained some yellow fluid and a fibrinous exudate was present over the coils of intestine. The stomach contained altered blood, but no bleeding point was found. The intestine showed two areas of haemorrhage and necrosis caused by kinking of the bowel as a result of peritoneal adhesions. The liver was enlarged, firm and green-brown in colour. The Prussian Blue reaction was positive. The spleen was enlarged to 3" in length and was rather soft. The Prussian Blue reaction was strongly positive. The kidneys were pale and bile-stained/

Series 2.

TABLE 21.  
BABY C.G.

HAEMATOLOGICAL DATA.

Case 35.

Age in days	Hb% Sahli	R. B. C. / cu. mm.	C. I.	W. B. C. cu. mm.	Nucleated R. B. C. / 100 W. B. C.	Reticulo-cytes.	Miscellaneous.
3	-	-	-	-	-	-	Very jaundiced.
8	25	1.0 m	1.25	-	Scanty	-	-
9	-	-	-	-	-	-	150 cc. Gp.O. Rh. negative blood transfusion.
10	85	-	-	-	-	-	-
15	55	-	-	-	-	-	-
16	60	2.7 m	1.2	8,000	-	-	-
24	65	3.4 m	0.9	-	-	-	-
47	62	3.0 m	1.0	-	-	-	Well.

stained.

Microscopic Report :

Blood Film : No nucleated red cells present.

Bone Marrow : Erythropoiesis was moderate in amount and normoblastic in type.

Liver : The liver cells contained much haemosiderin. There was little haemopoiesis.

Spleen : The histiocytes in the pulp were packed with haemosiderin. There was no haemopoiesis.

Summary : Icterus gravis neonatorum (terminal peritonitis and multiple abscess formation).

Case 35 Baby C.G. Born 1.4.47.

Maternal History : The mother was aged 34 and this was her 4th. pregnancy. The first 3 children are alive and well. She suffered from no illness during the present pregnancy. Her blood is Rh. negative and that of the child is Rh. positive.

Clinical Findings in the child : ( see Table 21)

The child was delivered spontaneously and weighed 9 lbs. at birth. It became jaundiced after 48 hours and the jaundice gradually increased. At the end of one week it was very pale and on the 9th. day was transfused with 150 c.c. Group O Rh. negative blood. The condition of the child steadily improved and on the 26th day was discharged from hospital. Three weeks later the progress had been maintained.

Summary : Icterus gravis neonatorum (recovered).

Case 36 Baby W.S. Born 4.4.47.

Maternal History : The mother was aged 24 and this was/

was her first pregnancy. She had no illness during the pregnancy. Her blood was Rh negative.

Clinical Findings in the Child : The child was delivered spontaneously and weighed  $7\frac{1}{2}$  lbs. at birth. It was mildly jaundiced shortly after birth. On the 17th day it was still rather jaundiced and very pale. On the 28th day it was very pale and its general condition was poor. The liver was enlarged but the spleen was not palpable. R.B.C. 1.9 million/cu.mm. Reticulocytes 2.8% W.B.C. 13,400/cu.mm. It was transfused with 120 cc. Group O Rh. negative blood. On the 30th day the Haemoglobin was 100% and the child was improving rapidly. On the 42nd. day the haemoglobin was 85 % (Sahli) and the child was discharged from hospital.

Summary : Congenital Haemolytic Anaemia (recovered).

Case 37. Baby C. Born 14.5.47. Died 16.5.47. Aged 2 days.

Maternal History : The mother was aged 31 and this was her 4th. pregnancy. The first and second children are alive and well. The third died after 5 days ; cause not ascertained. Her blood is Rh. negative and antibodies were present at a titre of 1/1. The direct Coomb's test on the child's cells was positive.

Clinical Findings in the Child : The child was jaundiced at birth and was immediately transfused with Rh. negative blood via the umbilical vein. The following day the baby was very jaundiced and both the spleen and liver were enlarged. R.B.C. 4.9 m/cu.mm.

W. B. C. /

W.B.C. 40,000 cu/mm. Reticulocytes 8%. There were 12 normoblasts/100 W.B.C. On the second day the baby suddenly collapsed and died.

Post-mortem Report : (128/47).

The body was that of a very jaundiced male infant.

Head : The nuclei in the basal ganglia, medulla and cerebellum were intensely bile-stained. The meninges were healthy.

Thorax : The serous sacs were healthy. The lungs were very congested and bile-stained. The heart was normal.

Abdomen : The peritoneal sac contained a small quantity of bile-stained fluid. The alimentary tract was normal. The spleen was greatly enlarged and measured 3" in length. It was dark red in colour and the Prussian Blue reaction was positive. The liver was enlarged and brown in colour. The Prussian Blue reaction was positive. The kidneys were congested and bile-stained.

Microscopic Report :

Blood Film : Many normoblasts were present. Erythroblasts were scanty.

Spleen : The pulp was congested and very cellular and numerous groups of erythropoietic cells were found. The majority of these were normoblasts, but more primitive types were also seen. There was a considerable quantity of haemosiderin both lying free and contained by histiocytes in the subcapsular region.

Liver/

Liver : The liver cells were healthy but contained some haemosiderin. There was very active haemopoiesis. The liver cells tended to be obscured by large foci of normoblasts and primitive erythroblasts. The portal tracts were also infiltrated with these primitive cells.

Kidney : A few haemopoietic cells were present in the peri-vascular connective tissue in the boundary zone.

Brain : The nuclei of cells in the basal ganglia show chromatolysis. The appearance did not differ greatly from ordinary postmortem change.

Summary : Icterus gravis neonatorum with kernicterus.

Case 38. Baby C. Born 5.6.47. Died 1.7.47. Aged 26 days.

Maternal History : This was the mother's second pregnancy. Her blood is Rh. positive Group O and that of the child Group A Rh. positive. There were no antibodies in the mother's blood.

Clinical Findings in the Child : The child was delivered spontaneously at term. It became jaundiced after 48 hours and the jaundice steadily increased. On the 23rd. day it became feverish and vomited. The child was pale and haemoglobin was 50% (Sahli) It died on the 26th day.

Post-mortem Report : (154/47)

The body was that of a poorly nourished, deeply jaundiced male infant.

Head/

Head : No abnormality present.

Thorax : The serous sacs were healthy. A few subserous petechiae were present. The lungs were congested and the heart was normal.

Abdomen : The peritoneum was healthy. The lower ileum was deeply congested and there was some blood in the lumen. The colon was normal. The spleen was greatly enlarged and dark red in colour. The Prussian Blue reaction was positive. The liver was of normal size and consistence. The Prussian blue reaction was negative. The kidneys contained uric acid deposits over the pyramids.

Microscopic Report :

Lung : The pleura was healthy. The lung was congested and oedematous. There was no pneumonia.

Liver : The liver cells were healthy and the normal lobular pattern was present. No extramedullary haemopoiesis was found. The Prussian Blue reaction was negative.

Spleen : The pulp was congested but was less cellular than usual and there was an increase in the fibrous tissue framework. The Malpighian bodies were small, poorly developed and scanty. There was a diffuse haemosiderosis of the pulp and the Prussian blue reaction was strongly positive.

Small intestine : The mucous membrane was quite healthy. There were a few patches of congestion but no inflammatory reaction had occurred.

Summary : Icterus gravis neonatorum.

Case 39/

Case 39. Baby McK. Born 24.7.47. Died 5.8.47.

Aged 12 days.

Maternal History : The mother was aged 25 and this was pregnancy. The first child was alive and well. She had no illness during the present pregnancy. Her blood is Group O Rh. negative (rr) and that of the child Group O Rh. positive (heterozygous Rh<sub>2</sub>r). The direct Coomb's test on the child's cells was positive.

Clinical Findings in the Child : The child was born spontaneously and weighed 7 lbs. 12 ozs. at birth. It became jaundiced 6 hours after birth. The following day the liver and spleen were enlarged. Hb 80% (Sahli) R.B.C. 3.3m/cu.mm. C.I. 1.2 The child was transfused with 70 cc. Rh negative blood. On the third day Hb 95% R.B.C. 3.7m/cu.mm. On the 6th. day it was again transfused with 100 cc. Rh. negative blood. On the 8th day the blood showed Hb 75%. R.B.C. 3.0 m/cu.mm. W.B.C. 30,000/cu.mm. On the 11th day 150 cc. Rh. negative blood were given. The child became very drowsy and died on the 12th day.

Post-mortem Report :

The body was that of a severely jaundiced infant.

Head : There was a small area of subarachnoid haemorrhage over the left temporal pole. The basal ganglia and the medullary nuclei were bright yellow in colour.

Thorax : The pleural and pericardial sacs contained a small quantity of bile-stained fluid. The lungs were/



were congested and there were areas in the lower lobes suggestive of consolidation. The heart was normal.

Abdomen : The peritoneal sac contained a small quantity of bile-stained fluid. The alimentary tract was normal. The spleen was enlarged and firm in consistence. The Prussian Blue reaction was strongly positive. The liver was enlarged and rusty brown in colour. The Prussian blue reaction was strongly positive. There was a haemorrhage into the left suprarenal gland. The kidneys were normal.

Summary : Icterus gravis neonatorum with kernicterus.

Case 40. Baby R.H. Born 26.9.47 (male)

Maternal History : The mother was aged 30 and this was her 4th. pregnancy. The first and third children were normal at birth and are alive and well. The second child was jaundiced at birth but is now well. The mother had no illness during the present pregnancy. Her blood is Group A Rh negative and that of the child Group B Rh positive. The direct Coomb's test on the child's cells was positive.

Clinical Findings in the Child : (see Table 22)

The child was born spontaneously and became jaundiced 24 hours after birth. On the 6th day it became very pale. It became gradually paler and on the 13th day it was transfused with 180 cc. Group O Rh negative blood. The liver was enlarged at this stage. The baby's condition improved for 2 days, but then it became pale again. It received 30 cc. Group O Rh negative blood on the 18th day, and thereafter steadily improved/

improved until discharge on the 23rd day.

Summary : Icterus gravis neonatorum (recovered).

Case 41. Baby K. Born 7.10.47. Died 12.10.47. Aged 5 days.

Maternal History : The mother was aged 26. Her blood was Rh negative and there were antibodies present at a titre of 1/16. The father was heterozygous Rh rh and the child was Rh positive. The direct Coomb's test on the Child's cells was positive.

Clinical Findings in the Child : The child was delivered spontaneously and weighed 9 lbs. 4 ozs. at birth. After 24 hours it became jaundiced and the jaundice steadily increased. Liver and spleen were not enlarged. The blood showed Hb 85% and numerous nucleated red cells, were present in the film. The child died on the 5th. day.

Post-mortem Report : (192/47)

The body was that of a well nourished baby with marked jaundice of skin and mucous membranes.

Head : The hippocampus, thalamus, olivary nuclei and the dentate nuclei of the cerebellum were bright yellow in colour.

Thorax : The pleural sacs contained a small quantity of clear straw-coloured fluid. The lungs were congested and a few areas of pneumonic consolidation were present in both lower lobes.

Abdomen : The peritoneum was normal. The alimentary tract was healthy. The liver was of normal size and rather rusty-brown in colour. The Prussian Blue reaction was negative. The spleen was twice the normal size and dark in colour. The kidneys showed bilateral congenital hydronephrosis.

Microscopic/

Microscopic Report :

Blood Film : Numerous early and late normoblasts were present.

Bone Marrow : Active erythropoiesis was found. Normoblasts were most numerous.

Brain : The nuclei from the affected zones show degeneration and faint bile-staining.

Lung : Early bronchopneumonia is present.

Liver : The liver cells showed degenerative changes. Very few foci of erythropoiesis were present and these were normoblastic in character.

Summary : Icterus gravis neonatorum with kernicterus (terminal bronchopneumonia).

Case 42. Baby A. Born 7.11.47. Died 14.11.47.

Aged 1 week.

Maternal History : This was the mother's second pregnancy. The first child is alive and well. The mother had no illness during the present pregnancy.

Clinical Findings in the Child : The child was delivered spontaneously and was rather pale at birth. It became jaundiced after 48 hours and the jaundice gradually lessened. On the 5th day the child was very pale and collapsed. There was some oedema of the feet and ankles, but little jaundice. The spleen was enlarged and the blood showed Hb 20% (Sahli) W.B.C. 50,000/cu.mm. There were 60 nucleated red cells per 100 W.B.C. The child was transfused with 100 cc. Group O Rh negative blood by slow intravenous drip. It did not rally and died on the 7th day.

Post-mortem/

Postmortem Report : (207/47)

The body was that of a very pale, slightly jaundiced, female infant weighing 6 lbs. 3 ozs.

Head : There was no kernicterus. The brain and meninges showed slight diffuse bile-staining.

Thorax : The serous sacs contained some clear yellow fluid. The lungs were congested and oedematous. The heart was dilated but the myocardium was healthy.

Abdomen : The peritoneal sac contained some yellow fluid. The small intestine was slightly congested. The liver was enlarged, firm in consistence and rusty-brown in colour. The Prussian Blue reaction was strongly positive. The spleen was enlarged and measured 3" in length. It was firm in consistence and dark red in colour. The prussian blue reaction was strongly positive. The kidneys were normal.

Microscopic Report :

Lung : The organ was oedematous and small intra-alveolar haemorrhages were present. An inflammatory reaction was commencing but there was no consolidation.

Liver : There was excessive haemopoiesis and a large proportion of erythroblasts were found. The liver cells showed early fatty change in the central zones.

Spleen : There was active haemopoiesis of primitive type. Haemopoietic cells were present in the pulp and the walls of the larger vessels. Histocytes contained haemosiderin.

Summary/



Summary : Congenital Haemolytic Anaemia.

Case 43. Baby W. McB. Born 26.11.47 (male)

Maternal History : The mother was aged 36 and this was her 5th. pregnancy. The other four children are alive and well and were normal at birth. The mother had no illness during the present pregnancy. Her blood is Group O Rh negative and that of the child is Group O Rh positive. The direct Coomb's test on the Child's cells was positive.

Clinical Findings in the Child : (see Table 23)

The child was delivered spontaneously at term. It became jaundiced after 48 hours and was transfused with 90 cc. Group O Rh negative blood. It gradually improved but was transfused again on the 24th day with 100 cc. Group O Rh negative blood. Improvement was rapid and the child was discharged from hospital at the end of the 4th week. At the end of the 6th. week progress had been maintained.

Summary : Icterus gravis neonatorum (recovered).

Case 44 : Baby K. Born 23.11.47 Died 25.11.47.

Aged 2 days.

Maternal History : The mother was aged 26 and this was her 3rd. pregnancy. The first child was normal at birth and is alive and well. The second child died soon after birth from icterus gravis. The mother had no illness during the present pregnancy. Her blood is Rh negative and that of her husband Rh positive. The direct Coomb's test on the child's cells was positive/

positive.

Clinical Findings in the Child : The child was delivered spontaneously at term and weighed  $6\frac{1}{2}$  lbs. at birth. The child's blood was Rh positive and the Coomb's test was positive. It was jaundiced at birth. On the second day the spleen and liver were enlarged. The blood showed Hb 70% R.B.C. 2.5m/cu.mm. W.B.C. 8,000/cu.mm. There were 50 nucleated red cells per 100 W.B.C. in the blood film. The child was transfused with 100 cc. Rh negative blood but did not rally.

Post-mortem Report : (216/47)

The body was that of a severely jaundiced male infant weighing 6 lbs.

Head : The brain and meninges were diffusely bile-stained and the nuclei in the basal ganglia, medulla and floor of the 4th. ventricle were bright yellow in colour. The dentate nucleus of the cerebellum, hippocampus and the grey matter of the spinal cord were also affected.

Thorax : Serous sacs were healthy. The lungs were congested and oedematous. The heart was dilated and the myocardium was pale.

Abdomen : The peritoneal sac contained some clear yellow fluid. The alimentary tract was normal. The liver was enlarged and brown in colour. The Prussian Blue reaction was positive. The spleen was enlarged to  $3\frac{1}{2}$ " in length and was firm and dark-red in colour. The Prussian Blue reaction was positive.  
The/

The kidneys were pale and bile-stained.

Microscopic Report :

**Blood Film** : Numerous nucleated red cells were present. These were mainly normoblasts but more primitive forms were also found.

**Bone Marrow** : Greatly excessive erythropoiesis had occurred and numerous erythroblasts were also present.

**Liver** : Active haemopoiesis was present and many foci of normoblasts and erythroblasts were seen. The liver cells were healthy and some contained haemosiderin. Many intercellular canaliculi contained bile-plugs.

**Spleen** : There were many normoblasts and erythroblasts in the pulp.

**Kidney** : There were small collections of erythropoietic cells in the stroma surrounding blood vessels in the boundary zone.

**Thyroid gland** : **Suprarenal gland** : **Psoas muscle** : **Tongue** : & **Heart** were normal.

**Brain** : In the affected grey matter the cells were shrunken and their nuclei were pyknotic. Some faint yellow staining remained.

Summary : Icterus gravis with kernicterus.

Case 45. Baby E. A. Born 18.12.47,

Maternal History : The mother was aged 33 and this was her 3rd. pregnancy. Her other two children were normal at birth and are alive and well. She had no illness during the present pregnancy. Her blood is Group A Rh/

## Series 2.

TABLE 24.

Baby E. A.

## HAEMATOLOGICAL DATA.

Case 45.

Age in days	Hb% Sahli	R. B. C. / cu. mm.	C. I.	W. B. C. / cu. mm.	Nucleated R. B. C. 100 W. B. C.	Reticulo-cytes	Icteric Index	Miscellaneous
1	-	-	-	-	-	-	-	Jaundiced.
2	-	-	-	-	-	-	-	Jaundice fading.
21	36	1.8 m	1.0	15,000	-	-	-	Pale spleen enlarged. 180 cc. Gp.O. Rh. negative blood transfusion.
22	58	-	-	-	-	-	36	-
23	60	3.7 m	0.9	-	-	-	-	-
27	60	3.6	0.9	-	-	-	-	Well.

Group A Rh negative and that of her husband Group A Rh Positive. The direct Coomb's test on the Child's cells was positive.

Clinical Findings in the child : ( see Table 24)

The child was delivered spontaneously at term. Its blood was Rh positive. It became jaundiced after 24 hours but the jaundice quickly disappeared. After 3 weeks the baby became very pale and was transfused with 180 c.c. Group O Rh negative blood. A slight recurrence of jaundice was noted but the baby improved rapidly and was discharged at the end of the 4th week.

Summary : Congenital Haemolytic anaemia (recovered).

Case 46. Baby G. Born 3.12.47. Died 5.12.47. Aged 2 days.

The child was dead on admission to hospital and no family history was available.

Post-mortem Report : (223/47)

The body was that of a well-developed female infant and was intensely jaundiced.

Thorax : Serous sacs were healthy. The lungs were well-expanded, moderately congested and very bile-stained. The heart was normal.

Abdomen : The peritoneum was healthy. The alimentary tract was normal. The liver was of normal size and firm in consistence. The Prussian Blue reaction was normal. The spleen was four times normal size and dark red in colour. The Prussian Blue reaction was positive. The kidneys were normal.

Head/



Head : The brain showed intense yellow staining of the basal ganglia, medullary nuclei and the dentate nucleus of the cerebellum.

Microscopic Report :

Liver : Numerous islands of erythropoiesis were present and normoblasts and erythroblasts were numerous. The liver cells showed postmortem change.

Spleen : The pulp was congested and erythropoiesis was excessive.

Kidney : A few perivascular collections of erythropoiesis were present in the boundary zone.

Pancreas : A few foci of erythropoiesis were present.

Lung : There was no evidence of inhalation of liquor amnii.

Summary : Icterus gravis neonatorum with kernicterus.

Case 47 Baby A.S. Born 6.12.47. Died 22.12.47.

Aged 16 days.

Maternal History : The mother was aged 34 and this was her 3rd. pregnancy. Her first child was normal at birth and is alive and well. The second child was jaundiced at birth but recovered and is now alive and well. The mother's blood was Rh negative and the father's Rh positive. The direct Coomb's test on the child's cells was positive.

Clinical Findings in the child : ( see Table 25)

The child was delivered spontaneously at term and weighed 8 lbs at birth. It became jaundiced after 48 hours and on the 4th day the spleen was enlarged.  
The/

The following day the liver was enlarged. The jaundice increased and the child became rather pale. It was transfused with 100 cc. Group O Rh negative blood on the 10th day. On the 15th day an operation was carried out to see if the bile-ducts were obstructed. No such obstruction was found and the ducts were washed out with saline. The child did not rally and died on the 16th day. The child's blood was Rh positive.

Post-mortem Report : (231/47)

The body was that of a well nourished, severely jaundiced, female infant. There was a recent right paramedian incision in the abdominal wall.

Head : Brain and meninges showed diffuse bile-staining. There was no kernicterus.

Thorax : Serous sacs were healthy. The lungs were well expanded but bile-stained. The heart was of normal size but the myocardium was pale.

Abdomen : The peritoneum was healthy. The alimentary tract was normal. The liver was enlarged and greenish brown in colour. The gall bladder contained a little blood - the bile ducts were healthy. The liver gave a doubtful Prussian Blue reaction. The spleen was enlarged and measured 3" in length. The Prussian blue reaction was strongly positive. The kidneys were pale and bile-stained.

Microscopic Report :

Blood Film : There was a great increase in nucleated red cells and many normoblasts were found.

Liver/

**Liver :** The parenchymal cells showed postmortem change. The liver cells and Kupffer cells contained haemosiderin and many intercellular canaliculi contained bile plugs. Excessive haemopoiesis was present and the predominant cell was the normoblast.

**Spleen :** The histiocytes of the pulp were filled with haemosiderin. Excessive haemopoiesis was present.

Pancreas, kidneys, suprarenal gland, psoas and pectoralis muscles showed no haemopoiesis.

Summary : Icterus gravis neonatorum ( simulating congenital obliteration of the bile-ducts).

Case 48. Baby R.C. Died 14.3.44.

Previous History : The patient had suffered from severe neonatal jaundice and thereafter had presented the clinical features of kernicterus. The child was in good physical health till it died at the age of seventeen months.

Post-mortem Report : (56/44)

The body was that of a well nourished male child.

**Organs :** There was slight pulmonary congestion. No other change was present. The brain showed no abnormality on external examination. On section there was some decrease in the size of the cornu ammonis.

Microscopic Report :

The liver, spleen, kidney and suprarenals were perfectly normal. There was no residual fibrosis in the portal tracts of the liver.

The spinal cord, brain stem and cerebral cortex was/

was normal. The globus pallidus showed loss of large nerve cells associated with marked reparative gliosis. In the cornu ammonis there was complete disappearance of nerve cells in the fascia dentata, and an astrocytic response in the surrounding region.

Summary : Icterus gravis neonatorum (recovered), died later from kernicterus.

Case 49. Baby J. (male). Born 11.2.38.

Maternal History : This was the mother's 4th. pregnancy. The first child was normal at birth and is alive and well. The second child died of icterus gravis at age of 4 days. The third child had jaundice in the neonatal period.

Clinical Findings in the Child : The child was born spontaneously and weighed 9 lbs. at birth. It was jaundiced after 24 hours. On the 5th day the Icteric index was 153 and the Van den Bergh reaction was positive biphasic. By the 10th day the jaundice had lessened and the icteric index was 40. On the 12th day Hb 44% R.B.C. 1.54 mill./cu.mm. and the child was transfused with 50 cc. whole blood (group unspecified) On the 13th day Hb 47 % R.B.C. 1.85 m/cu.mm. On the 20th day Hb 28 % R.B.C. 1.04 m/cu.mm. Transfused with 50 cc. whole blood. 22nd. day Hb 35 %. R.B.C. 1.66 m/cu.mm. Transfused with 50 cc. whole blood. 29th day Hb 48 % R.B.C. 2.5 m/cu.mm. On the 35th day Hb 44% R.B.C. 2.1 m/cu.mm. Transfused with 50 cc. 64th day Hb 59 % R.B.C. 3.75 m/cu.mm. 83rd day Hb 72 %. R.B.C. 4.9 m/cu.mm. With the help/

help of blood transfusions the child gradually recovered.

Summary : Icterus gravis neonatorum (recovered).

Case 50. Baby S. (female). Born 18.2.38.

Maternal History : This is the mother's 4th pregnancy. The 1st child was normal at birth and is alive and well. The second pregnancy ended in a miscarriage. The third pregnancy ended with a still-born hydropic foetus.

Clinical Findings in the Child : The child was born spontaneously and weighed 7 lbs. at birth. It was jaundice after 48 hours and the jaundice persisted for one month. As the jaundice faded it was found that a severe anaemia was developing. On the 24th day the blood showed Hb 29 % R.B.C. 1.2 m/cu.mm. C.I. 1.17., reticulocytes 48 %. The spleen was enlarged 2 fingers breadth below the costal margin and the liver was also enlarged. The child's condition steadily improved without treatment. By the 31st day Hb 33%. R.B.C. 1.5 m/cu.mm. By the 45th day Hb 49 % and R.B.C. 2.3 m/cu. mm. and by the end of the 4 months Hb 64%. R.B.C. 4 m/cu.mm.

Summary : Icterus gravis neonatorum (recovered).

Case 51 : Baby M. Born 21.4.38. Male.

Maternal History : This was the mother's second pregnancy. The first child was normal at birth and is alive and well.

Clinical Findings in the Child : The child was delivered/

delivered spontaneously and was of average weight at birth. After 24 hours it became jaundiced and the jaundice steadily deepened. The urine was dark in colour. The Van den Bergh reaction was positive biphasic. The jaundice gradually disappeared over a period of six weeks. There was a moderate degree of anaemia Hb 53% R.B.C. 2.5 m/cu.mm. This steadily improved and at six weeks Hb 60 % R.B.C. 3 m/cu.mm. Neither spleen nor liver were enlarged.

Summary : Icterus gravis neonatorum (recovered).

CHAPTER 4.Series 111. Cases from the Elsie Inglis  
Memorial Maternity Hospital.

Case 1. Baby R. Born 11.2.37. Still-birth.

Maternal History : The mother was aged 38 and this was her 9th pregnancy. The first and second children were normal at birth and are now alive and well. The 3rd. child died 7 hours after birth. The 4th, 5th, 6th, 7th and 8th were still-born.

Clinical Findings in the foetus : The foetus was born spontaneously (vertex R.O.A.) several weeks before term. It was still-born and showed generalised subcutaneous oedema. A post-mortem examination was not carried out. (see Case 3)

Summary : Hydrops foetalis.

Case 2. Baby P. Born 23.9.38. Died 25.9.38. Aged 2 days.

Maternal History : The mother was aged 33 and this was her 3rd. pregnancy. The first child was normal at birth and is alive and well. The second child died 2 hours after birth as a result of asphyxia. The mother was well during the present pregnancy.

Clinical findings in the child : The child was born spontaneously (vertex L.O.A) and weighed 6 lbs. 14 ozs at birth. It became jaundiced and the jaundice steadily deepened until the child died on the 2nd. day.

Summary : Icterus gravis neonatorum.

Case 3. /

Case 3. Baby R. Born 10.9.39. Still-birth.

Maternal History : (see Case 1)

This was now the mother's 10th pregnancy.

Clinical findings in the child : the foetus was born spontaneously (vertex R.O.A.) at term. It was still-born but not macerated. It showed generalised subcutaneous oedema.

Summary : Hydrops foetalis.

Case 4. Baby S. Born 19.7.41.

Maternal History : The mother was aged 30 and this was her 6th pregnancy. The 1st, 2nd, 3rd and 5th children were normal at birth and are now alive and well. The fourth child was still-born. She had no illness during the pregnancy.

Clinical findings in the child : The child was delivered spontaneously (vertex L.O.A.) at term and weighed 7 lbs. at birth. It was very pale. On the 14th day it was given 10 cc. of the mother's blood intravenously. On the 17th day it was still very pale and numerous nucleated red cells were found in the film. The child gradually recovered and was quite well at the end of the first month. No further treatment was required.

Summary : Congenital haemolytic anaemia (recovered).

Case 5. Baby E. Born 22.8.41. Still-birth.

Maternal History : The mother was aged 28 and this was her 3rd. pregnancy. The first two children were normal at birth and are alive and well. The mother had suffered from hydramnios during the present pregnancy/

pregnancy.

Clinical findings in the foetus : The foetus was delivered by forceps (brow presentation). It was a full term foetus and there was generalised sub-cutaneous oedema. Blood examination revealed the presence of large numbers of nucleated red cells. These were mainly normoblasts but erythroblasts were also present.

Summary : Hydrops foetalis.

Case 6. Baby B. Born 20.4.42. Died 21.4.42. Aged 1 day.

Maternal History : The mother was aged 27 and this was her 3rd. pregnancy. The first two children were normal at birth and are alive and well. She had no illness during the present pregnancy.

Clinical findings in the child: (compare with Case 12)  
The child was delivered spontaneously (vertex R.O.A) at term and weighed 7 lbs. 9 ozs. at birth. It became jaundiced a few hours after birth and the liver and spleen were enlarged. The Van Den Bergh reaction was direct positive. The following day it was transfused with 60 cc. blood (group unspecified) via the anterior fontanelle. The child failed to rally and died shortly afterwards.

Post-mortem Report :

The appearances were those of icterus gravis with kernicterus. A full report was not available.

Summary : Icterus gravis neonatorum with kernicterus.

Case 7./

Case 7. Baby C. Born 11.8.42.

Maternal History : The mother was aged 40 and this was her 3rd. pregnancy. The first child was normal at birth and is alive and well. The second pregnancy ended in a miscarriage. The mother had no illness during the present pregnancy.

Clinical findings in the child : The child was born spontaneously (vertex L.O.A.) at term and weighed 7 lbs. 12 ozs. at birth. The child was jaundiced at birth. The jaundice steadily increased for ten days and then slowly began to fade. The child received no treatment and after 4 weeks was no longer jaundiced and seemed well.

Summary : Icterus gravis neonatorum (recovered)

Case 8 (a) Baby B 1. Born 10.7.43. Died 15.7.43.

Aged 5 days.

Maternal History : The mother was aged 30 and this was her 4th pregnancy. Her first 3 children were normal at birth and are alive and well. She had no illness during the present pregnancy.

Clinical findings in the child : The child was delivered spontaneously (vertex R.O.P.) at term as the first of twins. It weighed  $5\frac{3}{4}$  lbs. at birth. It was very pale and very jaundiced at birth. The jaundice persisted and the child was pale, feeble and failed to thrive. It died on the 5th. day.

Post-mortem Report : (21/43).

The body was that of a pale, jaundiced, male infant.

Head/

Head : The meninges and brain were diffusely bile-stained. There was a diffuse yellow discoloration of the basal ganglia.

Thorax : The serous sacs were healthy. The lungs were oedematous and bile-stained. The heart was moderately dilated and the myocardium was pale.

Abdomen : The peritoneal sac contained a quantity of bright yellow fluid. The alimentary tract was normal. The liver was enlarged and rusty-brown in colour. The spleen was greatly enlarged and measured 3" in length. It was rusty-brown in colour. The kidneys were pale and bile-stained.

Microscopic Report :

Blood Film : Nucleated red cells were excessively numerous. These were mainly normoblasts but more primitive types were also present.

Liver : There was increased haemopoietic activity. A high proportion of the cells were primitive erythroblasts. The liver cells contained haemosiderin.

Spleen : Erythroblasts were present throughout a congested pulp.

Summary : Icterus gravis neonatorum.

Case 8 b. Baby B 2.

Clinical findings in the foetus : The foetus was delivered spontaneously as the second of twins. It was a macerated female foetus and very hydropic. No post-mortem examination was performed.

Summary : Hydrops foetalis.

Case 9. Baby I. Born 28.7.43. Still-birth.

Maternal/

TABLE 26.

Series 3.

Case 10.

Baby S.

HAEMATOLOGICAL DATA.

Age in days	Hb% Sahli	R. B. C. / cu. mm.	C. I.	Miscellaneous.
8	50	2.3 m	1.1	-
10	-	-	-	40 cc. blood (group unspecified) via fontanelle.
11	-	-	-	20 c.c. blood into tibia.
13	25	1.0 m	1.2	70 c.c. blood by transfusion intravenously.
15	-	-	-	20 c.c. blood transfusion.
16	48	-	-	-
25	30	-	-	Given "Ferolac "
43	60	-	-	-
54	-	-	-	Discharged well.

Maternal History : This was the mother's second pregnancy. The first pregnancy had also ended with a still-birth.

Clinical findings in the foetus : The foetus was delivered spontaneously (breech) some weeks before term. It was macerated and very oedematous. An examination of a blood film revealed the presence of very numerous nucleated red cells, mainly normoblasts.

Summary : Hydrops foetalis.

Case 10. Baby S. Born 5.11.42.

Maternal History : The mother was aged 24 and this was her second pregnancy. The first child was normal at birth and is alive and well. The mother had no illness during this pregnancy.

Clinical findings in the child : ( see Table 26)  
The child was born spontaneously (vertex R.O.P.) at term and weighed 8 lbs. 13 ozs. at birth. It was very pale and the pallor was most marked at the end of the first week. It received four transfusions of whole blood. (group unspecified) and gradually recovered. By the end of the 8th week it was able to be discharged from hospital.

Summary : Congenital haemolytic anaemia (recovered).

Case 11. Baby McC. Born 18.2.44.

Maternal History : This was the mother's second pregnancy and the first child was still-born. She had no illness during this pregnancy.

Clinical findings in the child : The child was delivered/

delivered by mid-cavity forceps (vertex R.O.A.) at term and weighed 8 lbs. 10 ozs. at birth. The vernix caseosa was golden-yellow in colour. It was jaundiced at birth and the jaundice increased. Many nucleated red cells were present in the peripheral blood. These were mainly normoblasts but more primitive types were also found. On the 5th day the child was transfused with 160 cc. Group O Rh negative blood. Its condition thereafter steadily improved and the jaundice gradually faded. The child was discharged from hospital during the 3rd. week.

Summary : Icterus gravis neonatorum (recovered).

Case 12. Baby B. Born 9.12.44 Still-birth.

Maternal History : (see also case 6)

The mother was aged 30 and this was her 4th. pregnancy. The 3rd. child died of icterus gravis and kernicterus (Case 6). Her blood was Rh negative and antibodies were present in the serum.

Clinical findings in the foetus : The foetus was delivered spontaneously (vertex L.O.A.) a few weeks before term. It weighed 4 lbs. at birth. The appearances were typical of Hydrops foetalis and no post-mortem examination was performed.

Summary : Hydrops foetalis.

Case 13. Baby J. Born 18.5.45. Died 20.5.45.

Aged 2 days.

Maternal History : The mother was aged 37 and this was her/

her 3rd. pregnancy. The first two children were normal at birth and are alive and well. Her blood is Rh negative and antibodies were present in the serum. The father's blood and that of the child was Rh positive.

Clinical findings in the child : The child was born spontaneously (vertex R.O.A.) and weighed 5 lbs. 14 ozs. at birth. It was jaundiced at birth and both the liver and spleen were enlarged. The blood film showed numerous nucleated red cells and erythroblasts were prominent. The child did not thrive and died on the 2nd day.

Post-mortem Report : (18/45)

The body was that of a male infant weighing 5 lbs. 6 ozs. There was moderately severe jaundice.

Head : There was slight subarachnoid haemorrhage over the cerebral hemispheres and cerebellum. There were large clots of blood in both lateral ventricles and blood was present throughout the ventricular system. The meninges were diffusely bile-stained. Nuclei in the basal ganglia, floor of the 4th ventricle and olivary nuclei in the medulla were bright yellow in colour. The dentate nucleus of the cerebellum was also affected.

Thorax : The serous sacs were healthy and there were no subserous petechiae. The lungs were well-expanded, congested and oedematous. The heart was dilated.

Abdomen : There was some bright yellow fluid in the/

the peritoneal sac. The alimentary tract was normal. The liver was enlarged, fairly firm and bright brown in colour. The spleen was very enlarged and measured  $2\frac{1}{2}$ " in length. It was firm and dark-red in colour.

Microscopic Report :

Blood Film : Normoblasts and primitive erythroblasts were numerous.

Liver : Very active haemopoiesis was found. The erythropoietic cells were distributed uniformly throughout the liver substance and not arranged focally. Normoblasts and erythroblasts were prominent. The liver cells showed marked degenerative changes and in some parts actual necrosis. The central zone of the lobule was most severely affected. The other liver cells contained haemosiderin.

Spleen : The pulp was congested and highly cellular. The blood forming cells were found near trabeculae and even in the subendothelial connective tissue of veins in the trabeculae. Primitive erythroblasts were especially numerous.

Lung : Some areas of collapse were present and in these areas there was an inflammatory exudate. Some patches of haemorrhage were also present.

Summary : Icterus gravis neonatorum with kernicterus (severe intraventricular haemorrhage and early pneumonia).

Case 14. Baby K. Born 28.11.45. Died 29.11.45.

Aged 18 hours.

Maternal History : This was the mother's 9th pregnancy/

pregnancy. Her first 3 children were normal at birth and are alive and well. The 4th child was still-born and had hydrocephalus. The 5th child, 6th child and 7th child were normal at birth and are alive and well. The 8th pregnancy ended with a miscarriage. After this miscarriage the mother was transfused with whole blood (group unspecified). Her own blood is Rh negative and that of husband and child is Rh positive.

Clinical findings in the child : The child was born spontaneously at term and weighed  $6\frac{1}{2}$  lbs. at birth. It was very pale and the legs were oedematous. After a few hours it became jaundiced and died.

Post-mortem Report : (34/45)

The body was that of a male infant weighing 6 lbs. There was slight jaundice and generalised oedema. The oedema was greater in the lower limbs.

Head : The meninges were diffusely bile-stained. Nuclei in the basal ganglia were yellow in colour. Those in the brain-stem were unaffected. There were numerous subependymal haemorrhages and the ventricular system was filled with blood clot.

Thorax : Some yellow fluid was present in the serous sacs. The lungs were well-expanded but oedematous. The heart was enlarged and ventricles hypertrophied.

Abdomen : The peritoneal sac contained yellow fluid. The alimentary tract was normal. The liver was enlarged and brown in colour. The spleen was enlarged/

enlarged and measured 3" in length. The kidneys were normal.

Microscopic Report :

Liver : Extramedullary haemopoiesis was excessive. The liver was packed with nucleated red cells and foci of erythroblasts were numerous. The liver cells contained haemosiderin.

Kidney : The cells lining the convoluted tubules contained haemosiderin.

Blood Film : A great excess of nucleated red cells was found. Normoblasts and erythroblasts were numerous.

Summary : Early icterus gravis neonatorum with kernicterus (severe intraventricular haemorrhage).

Case 15. Baby W. Born 19.1.46 Died after 5 hours.

Maternal History : The mother was aged 34 and this was her 3rd. pregnancy. Her other two children were normal at birth and are alive and well. She had no illness during this pregnancy. Her blood is Rh negative and that of her husband and child is Rh positive.

Clinical findings in the child : the child was born spontaneously (vertex R.O.<sup>A</sup>) during the 37th week of pregnancy and weighed 5 lbs. 14 ozs. It was jaundiced at birth and died after 5 hours.

Post-mortem Report : (2/46)

The body was that of a female infant. There was jaundice and numerous small subcutaneous haemorrhages over the face and scalp.

Head/

Head : The meninges were slightly bile-stained but there was no kernicterus.

Thorax : The serous sacs were healthy. The lungs were incompletely expanded, oedematous and bile-stained. The heart was dilated and the myocardium was pale and soft.

Abdomen : The peritoneal sac contained clear deeply bile-stained fluid. The alimentary tract was normal. The liver was considerably enlarged, firm and rusty brown in colour. The Prussian blue reaction was strongly positive. The spleen was enlarged to  $2\frac{1}{2}$ " in length. It was firm in consistence and dark-red in colour. The Prussian blue reaction was strongly positive. The kidneys were pale, bile-stained and the Prussian Blue reaction was faintly positive.

Microscopic Report :

Liver : Erythropoiesis was excessive and primitive in type. Foci of haemopoiesis were large and some were composed of normoblasts, some of more primitive forms and some were mixed. The portal tracts were also infiltrated with haemopoietic cells. The liver cells in the central zone showed fatty change and some intercellular canaliculi contained bile-plugs. The liver cells and some von Kupffer cells contained haemosiderin.

Kidney : A few foci of erythropoiesis were present in the peripelvic connective tissue. The cells lining the convoluted tubules contained haemosiderin and many were vacuolated as a result of fatty change.

Heart/

Heart : The muscle bundles were separated by oedematous stroma and some fibres showed vacuolation indicating hydropic change.

Summary : Icterus gravis neonatorum.

Case 16. Baby W. Born 25.1.46. Died 2.2.46. Aged 8 days. Male.

Maternal History : The mother was aged 31 and this was her second pregnancy. The first child was normal at birth and is alive and well. The mother's blood was Group O Rh negative and that of the child Group A Rh negative.

Clinical findings in the child : The child was born spontaneously (vertex R.O.A.) at term and weighed 7 lbs. at birth. There was jaundice and the blood showed Hb 120 %. Numerous nucleated red cells, normoblasts and erythroblasts were present in the peripheral blood. The child did not thrive and died after 8 days. No post-mortem<sup>examination</sup>/was performed.

Summary : Icterus gravis neonatorum (intragroup incompatibility).

Case 17. Baby B. Born 1.5.46. Female.

Maternal History : The mother was aged 21 and this was her second pregnancy. The first child was normal at birth and is alive and well. The mother had no illness during this pregnancy. Her blood is Group B Rh negative. The blood of the child is Rh positive.

Clinical findings in the child : ( see Table 27)  
The child was delivered spontaneously (vertex L.O.A.) at term and weighed 8 lbs. 12 ozs. at birth. It was jaundiced/

TABLE 27.

Series 3. Case 17. Baby B.

HAEMATOLOGICAL DATA

Age in days	Hb% Sahli	R. B. C. / cu. mm.	C. I.	Miscellaneous.
1	96	-	-	Jaundiced. 150 cc. Gp. 0. Rh negative blood.
2	125	-	-	-
3	120	-	-	-
5	60	-	-	Pale. 150 cc. Gp. 0. Rh. negative blood.
7	85	-	-	Very jaundiced. 90 cc. Rh. negative blood.
10	82	-	-	-
11	92	-	-	-
22	65	-	-	Jaundice fading.
23	-	-	-	200 cc. Gp. 0 Rh-ve. blood.
30	65	-	-	-
31	-	-	-	150 cc. Gp. 0 Rh-ve blood.
37	70	3.5	1.0	160 cc. Gp 0 Rh-ve blood.
38	104	-	-	-
48	90	-	-	-
60	75	3.1	0.9	180 cc. Gp 0 Rh-ve blood.
68	97	-	-	Very jaundiced. Liver enlarged.
76	90	-	-	Very jaundiced.
85	75	-	-	Less yellow.
94	72	-	-	Liver less enlarged.
103	80	-	-	-
117	95	-	-	Discharged well.

jaundice at birth. It was transfused with 150 cc. Group O Rh negative blood. By the 5th day the infant was becoming rather pale and received a further transfusion of 150 cc. Rh negative blood. At the end of the first week it was still very jaundiced and received 90 cc Rh negative blood. By the end of the 2nd week the jaundice began to fade. At the end of the third week the jaundice had gone but the infant was again pale and received 200 cc. Rh negative blood and a further 160 cc. at the end of the 4th week. At the end of the 5th week it received 160 cc. Group o Rh negative blood and 180 cc. at the end of the 7th week. The infant became jaundiced, the liver enlarged and the stools clay coloured. By the 10th week it was still jaundiced and the liver was three fingers below the costal margin. At the end of the 13th week the jaundice began to fade and by the 17th week had almost disappeared. The child was then well and was discharged from hospital. Three months later it was still very well and the blood showed haemoglobin 100%. R.B.C. 5.0 million/cu.mm. It had received altogether 1080 cc. Group O Rh negative blood.

Summary : Icterus gravis neonatorum (recovered).

Case 18. Baby P. Born 22.7.46. Male.

Maternal History : The mother was aged 30 and this was her 4th pregnancy. The first two children were normal at birth and are alive and well. The third pregnancy ended with a miscarriage. She gave a history of being treated for menorrhagia by blood transfusion in 1937.

She/

TABLE 28.

Series 3.      Case 19.      Baby B.

HAEMATOLOGICAL DATA.

Age in days	Hb% Sahli	Miscellaneous.
4	67	Very jaundiced.
7	58	140 c.c. Gp. 0 Rh. negative blood transfusion.
8	74	-
13	60	110 c.c. Gp. 0 Rh negative blood transfusion.
18	88	-
21	80	-
31	74	-
39	82	Jaundice fading.
43	92	Discharged well.

She had no illness during the present pregnancy. Her blood was Rh negative and that of the child Rh positive.

Clinical Findings in the child : The child was delivered spontaneously (vertex R.O.Ā.) at term and weighed 8 lbs. 8 ozs. at birth. After 48 hours the infant became jaundiced and the jaundice steadily increased in intensity. At the same time the infant became rather pale. The jaundice persisted for 14 days and then gradually faded. At the end of the 4th week the child was well and the jaundice had almost disappeared.

Summary : Icterus gravis neonatorum (recovered)

Case 19. Baby B. Born 9.3.47 Female.

Maternal History : The mother was aged 32 and this was her 4th pregnancy. The first two children were very jaundiced at birth but are now alive and well. The third pregnancy ended with a miscarriage. The mother had no illness during this pregnancy. Her blood was Rh negative and antibodies were present in the serum. The blood of husband and child was Rh positive.

Clinical findings in the child : (see Table 28)

The child was delivered spontaneously (vertex L.O.A.) at term and weighed 7 lbs. 12 ozs. at birth. It was jaundiced at birth and the jaundice deepened during the first twenty-four hours. The infant became paler during the first week and on the 7th day received 140 c.c. of Group O Rh negative blood. There was a temporary improvement in the child's condition but  
by/

by the end of the second week it was again rather pale and received 110 c.c. Group O Rh negative blood. The jaundice persisted but the child's general condition steadily improved. By the end of the 4th. week the jaundice began to fade. After 6 weeks the child was very well and was discharged from hospital.

Summary : Icterus gravis neonatorum (recovered).

Case 20. Baby W. Born 23.3.47. Male.

Maternal History : The mother was aged 36 and this was her 10th pregnancy. The first two children were normal at birth and are alive and well. The 3rd. and 4th pregnancies ended in miscarriages. The 5th and 6th pregnancies produced children who were normal at birth and are alive and well. The 7th and 8th pregnancies ended in miscarriages. The 9th pregnancy resulted in the birth of a normal child who is alive and well. The mother had no illness during this pregnancy. Her blood was Rh negative Group O. The blood of the child was Rh positive.

Clinical findings in the child : The child was delivered spontaneously at term and weighed 9 lbs. at birth. It was jaundiced at birth and the jaundice increased during the first 24 hours. The jaundice persisted for one week and then gradually commenced to fade. It was still jaundiced at the end of four weeks but the icterus disappeared after the 6th week and the child was very well.

Summary : Icterus gravis neonatorum (recovered).

Case 21/

Case 21. Baby S. Born 18.6.47. Still-birth.

Maternal History : The mother was aged 28 and this was her 4th pregnancy. The first child was normal at birth and is alive and well. The second child suffered from congenital haemolytic anaemia (case 10 in this series). The third child had also suffered from congenital haemolytic anaemia and was treated by transfusion with Rh negative blood. The mother was well during this pregnancy. Her blood was Group O Rh negative and antibodies were present in the serum.

Clinical findings in the foetus : The foetus was delivered spontaneously (breech L.S.A.) a week or two before term and weighed 6 lbs. 9 ozs. It was hydropic and macerated.

Post-mortem Report : ( 17/47)

The body was that of a macerated, male foetus. There was severe oedema of the face and anterior abdominal wall.

Thorax : The serous sacs contained an amount of blood-stained fluid. The lungs were collapsed.

Abdomen : The spleen was enlarged and measured 3" in length. It was very soft. The Prussian blue reaction was positive. The liver was of normal size, rusty brown in colour and rather soft. The Prussian blue reaction was strongly positive. The other organs showed no pathological change. The blood showed lysis of the red cells and although some nucleated red cells were found, identification was not possible.

Summary/

Summary : Hydrops foetalis (macerated).

Case 22. Baby D. Born 9.11.37. Male.

Maternal History : This was the mother's second pregnancy. The first child was normal at birth.

Clinical findings in the child : The child was spontaneously delivered at term and was of average weight. It was slightly jaundiced at birth and this faded in a day or so. It was then very pale Hb 40 % R.B.C. 2.06 m/cu.mm. There was a gradual reticulocytes response during the second week - Reticulocytes 34 - 44%. By the 21st day Hb 50 % and R.B.C. 2.8 m/cu.mm. and by the end of the 6th week Hb 60 % R.B.C. 3 m/cu.mm. Neither the spleen nor liver were enlarged. It was treated with 10 cc. father's blood intra-muscularly at birth and liver  $\frac{1}{2}$  c.c. daily for 1st week with Ferri et Ammon @ Cit gr XV.

Summary : Congenital haemolytic anaemia (recovered).

## Chapter 5.

### Analysis of Cases from the Combined Series.

The total number of cases of haemolytic disease in the series is 157. These were the offspring of 149 women.

(1) Sex : Eighty were male and sixty-seven were female. In 10 cases the sex was not noted. The slight preponderance of males over females has probably no statistical significance. Litchfield (1945), in a review of cases of erythroblastosis, found a preponderance of males but Potter (1948) in a review of a large number of cases came to the conclusion that no valid statistical difference was present.

(11) Maturity: The index of maturity taken was a birth weight over  $5\frac{1}{2}$  lbs, except in the case of hydropic foetuses, where crown-heel length was taken as the index. In this series 111 were mature and 39 were premature. In 7 cases data were not available. Thirty-four of the 39 premature births were among cases reported in Series I. These included a large number of cases of Hydrops foetalis and three pairs of twins. Even so, 72% of the cases were mature at birth and thus prematurity does not play a conspicuous part in the etiology of the disease, although it adds to the hazards of affected infants.

(111) Twin Pregnancies : Congenital haemolytic disease occurred in 6 sets of twins ; in 4 of these sets both twins were affected. The first pair (Cases

2a & 2b, Series I ) were both examples of Hydrops foetalis ; the second pair and third pair were cases of icterus gravis neonatorum with kernicterus (Cases 26a & b and 29a & b Series I ). The fourth pair were cases of icterus gravis neonatorum and hydrops foetalis respectively (Cases 8a & 8b Series III).

In the remaining 2 sets, the first twin was spared while the second twins both suffered from icterus gravis with kernicterus (Case 4 & Case 9 Series I).

The first pair (Cases 2a & 2b Series I) were identical twins the 2nd., 3rd. and 4th pairs (Cases 26 a & b and 29 a & b Series I and 8a & 8b Series III) were not identical twins.

Two interesting facts emerge from these considerations a) That twins may not necessarily suffer each to the same extent although exposed to the same concentration of maternal antibody ( Cases 8a & 8b Series III).

b) That one twin may escape altogether while its fellow is severely affected (Case 4 and Case 39 Series I).

This latter fact is explained by Potter (1948). She has shown that when one twin escapes the father is heterozygous  $\left\{ \begin{array}{l} D \\ Rh \end{array} \begin{array}{l} d \\ rh \end{array} \right\}$  (see Chapter 7) and one twin is Rhesus positive and affected while the other is Rhesus negative and escapes.

This question of a heterozygous parent could not be demonstrated in the above cases as they occurred/

occurred before Rhesus testing was generally available.

(IV) Rhesus blood Groups :

Serological investigations were carried out in 56 cases. In 50 cases (90%) the usual pattern of Rhesus negative mother and Rhesus positive father and child was present. In 5 out of the remaining 6 cases mother and child were both Rhesus positive. In the last case the mother was Group O Rh. negative and the child was Group B Rh negative. There could therefore theoretically have been an isoimmunisation of the mother to Group B of the foetus blood but unfortunately no anti-B was present in the mother's serum.

Thirteen of the 50 Rhesus negative women had antibodies present in their serum in dilutions from 1/1 to 1/16.

In three cases Rhesus negative women had been treated by transfusion of group-unspecified blood after a miscarriage. The following pregnancy the women were delivered of infants suffering from icterus gravis. Two of the infants recovered but the third died and kernicterus was found post-mortem. (Case 37 Series I; Cases 18 & 14 Series III). This well illustrates the dangers of giving other than the appropriate blood to women during the child-bearing period.

The proportion of 90% Rhesus negative women is exactly comparable with that found by Wiener (1946) and other workers. The remaining 10% of cases may be/

be due to intragroup incompatibility, to A and B factors or to the rarer Rh subtypes. The technical facilities for diagnosis of the latter were not available at the time the cases in this series were under observation.

A fuller discussion of the significance of the Rhesus blood groups will be held in a later chapter (Chapter 7).

(V) Type of Congenital Haemolytic Disease :

Congenital haemolytic disease may take the form of Hydrops foetalis, Icterus gravis neonatorum or Congenital haemolytic anaemia. These are not rigid classifications and cases of Hydrops may be jaundiced and cases of icterus gravis may show oedema. For the purpose of this survey the cases have been classified according to the type of disease they most closely resemble. Bearing this in mind, the 157 cases may be divided up as follows :

	Live born	Still- born	Macerated. Total.	Total.
Hydrops foetalis	5	21	10	36
	without kernicterus.		with kernicterus.	
Icterus gravis neonatorum	73		37	
			Total	110.
Congenital Haemolytic anaemia				11

The figure for congenital haemolytic anaemia (11 Cases) is almost certainly too low. This is the result of some cases of slight anaemia being clinically normal.

Nowadays many workers include all children who have a positive Coombs test among their cases of haemolytic disease and their series will show a much higher proportion of cases of congenital haemolytic anaemia/

anaemia which are examples of the milder manifestation of the disease. A few mild cases of icterus gravis may also have escaped diagnosis in the earlier years.

(VI) Mortality.

a) Mortality of entire series : The mortality figures in the whole series are unduly high for the following reasons :

1) A number of cases of the milder forms of the disease will have escaped diagnosis.

2) Cases in Series II admitted to the Royal Edinburgh Hospital for Sick Children were all examples of the severer type of the disease, otherwise they would not have required hospitalisation.

For these reasons no emphasis will be placed on the results. Of the 157 cases, 31 were still-births (20%) Eighty-five (67%) of the remaining 126 live born children died. The overall mortality, including both intra-uterine and extra-uterine deaths was 116 of 157 cases (74%). Even taking into consideration the fact that 88 of the 126 live-born cases were untreated, the mortality figure is unduly high and cannot be regarded as accurate.

The figures from Series III, although a much smaller group (23 cases) are more representative. The overall mortality including still-births was 13 out of 23 cases (56.6%). The number of deaths in the 16 live-born cases was 7 (43%). These included both cases treated by transfusion with Rhesus negative blood and those untreated.

Most/

Most modern workers report a much lower mortality rate among their cases.

A recent review by Mollison and Cutbush (1949) of 74 cases of haemolytic disease showed that the total number of deaths was 24 (33%). Their series was most accurately controlled and their figure was an indication of what results may be expected under modern conditions. The majority of their live-born cases were treated by exchange-replacement transfusion of Rh-negative blood.

The mortality rates of the three main types of the disease in live born cases of the present series may be of some interest :

Table 29.  
Live - born cases.

Type of disease.	Died.	Recov.	Total	Mortality %.
Hydrops Foetalis	5	0	5	100
Icterus gravis	77	33	110	70
Haemolytic anaemia	3	8	11	27
	85	41	126	67

The table shows clearly the order of severity but the general outlook is not so black in reality as these figures would suggest.

(VII) Cases occurring in the First Pregnancy :

It is well known that congenital haemolytic disease occurs less commonly in a first pregnancy than in later pregnancies. It is believed that some time has/

has to be allowed for the development of antibodies in the mother and thus the first child may well escape. In this series 10 of the 149 women (7%) were pregnant for the first time. The result of the pregnancy is shown below.

Table 30.

Issue of 1st. Pregnancy.	No.
Hydrops foetalis	3
Icterus gravis with kernicterus (died)	2
Icterus gravis neonatorum (died)	3
" " " (recovered)	1
Congenital Haemolytic Anaemia (recovered)	1
Total	10

A history of previous blood transfusion was not obtained from these 10 women.

A further 5 women (3.5%) had had previous pregnancies which had ended in miscarriages and they had no viable children before the first child with congenital haemolytic disease was born. One of them (Case 57 Series I) had been treated with blood which was not Rhesus negative following one of her miscarriages. The result of their pregnancies is shown below (Table 31).

Thus 15 women (10%) had no viable children when their first affected child was born. Potter (1948) in her/

her series found that 7% were childless at the time first affected child was born.

Of the 15 children suffering from congenital haemolytic disease all but three died. Thus 12 of the 149 women (8%) were still childless at the time of writing. This is in agreement with the findings of Potter (1948).

Table 31.

Issue of 1st. pregnancy following miscarriages only.	No.
Hydrops Foetalis	2
Icterus gravis with kernicterus (died)	2
Icterus gravis (recovered)	1
Total	5

It will be seen that the type of the disease in these first pregnancies is generally severe. Potter (1948) did not find such severe cases in early pregnancies.

(VIII) Abnormalities in Pregnancy :

The majority of the women had uneventful pregnancies. Sixteen women (11%), however, had some disturbance of pregnancy. Their offspring show 100% mortality. Six were still born and the remainder died after birth.

This probably means that any extra hazard in cases of congenital haemolytic disease greatly increases the/

the danger to the foetus. The detailed results of the pregnancies are shown below.

Table 32.

Complication of Pregnancy.	Result on Foetus.		
	Still born.	Died	Total
Hydramnios	3	-	3
Eclampsia	1	-	1
Pre-eclamptic Toxaemia	2	4	6
Secondary Syphilis	1	-	1
Antepartum Haemorrhage	-	3	3
Hypertension	-	1	1
Cardiac Disease	-	1	1
Total	7	9	16

The case of secondary syphilis in the mother is interesting (Case 24, series I) as it shows how both diseases may co-exist. Javert (1942) believes that toxaemia is more common in pregnancies ending with the delivery of an hydropic foetus.

(IX) Abnormalities in Delivery.

In 9 cases the delivery was not spontaneous. Three were delivered by forceps ; 2 died, 1 recovered. Two were delivered by Caesarian section ; 1 died and 1 recovered. Three were breech deliveries and all died. One was an assisted breech delivery and recovered.

(X) Incidence of Congenital Haemolytic Disease :

Accurate/

Accurate figures were available for cases in Series I (Cases from the Simpson Memorial Maternity Pavillion). In a total of 25,200 deliveries (including still-births) there were 73 cases of congenital haemolytic disease, or an incidence of 1 in 330. This approximates to the figure of 1/300 of Wiener (1946). It is almost half the figure of 1/180 of Potter (1948). As was stated previously, the cases in this series are mostly severe ones and many cases showing slight manifestations of the disease have probably been missed. Even so Potter's figures seem to be rather on the high side.

(XI) Congenital Abnormalities in the Foetus :

Congenital abnormalities were rare in the cases in this series. Only three cases showed congenital abnormalities at post-mortem examination. In two cases (Cases 26 & 27 Series 2) there was early congenital fibrocystic change in the pancreas. In the third (Case 42, Series 2) there was bilateral congenital hydronephrosis.

Ellis (1948) thought that congenital abnormalities might be unduly common in cases of Hydrops foetalis. This was not the case, but it is interesting to note that Potter (1946) found congenital abnormalities quite frequently in cases of idiopathic hydrops which were not the result of congenital haemolytic disease.

(XII) Post-Mortem Examinations :

Post-/

Post-mortem examinations were carried out in 104 of the 116 cases of intrauterine or extrauterine death occurring in this series. A summary of the chief necropsy findings is included in a table at the end of Chapter Six.

(XIII) Obstetrical Histories of the Mothers :

A full history of previous pregnancies, miscarriages and abortions was obtained from 128 of the 149 women.

These 128 women gave birth to 478 infants and foetuses. They had delivered a total of 278 infants and foetuses before a case of haemolytic disease was diagnosed among their offspring.

Of these 278 early pregnancies 37 ended in miscarriages, 23 in still-births and of the remainder 14 died during the neonatal period. Only 204 pregnancies resulted in the birth of normal children.

The number of unsuccessful pregnancies, 60 out of 278 (21.5%) is rather high. Potter (1948), in a review of a similar series, found that 25% of pregnancies occurring before the diagnosis of haemolytic disease were unsuccessful. She found that only 11% of pregnancies in an unselected series were unsuccessful and she believes that deaths, still-births and abortions contribute to the subsequent birth of an infant suffering from congenital haemolytic disease. Her figures are very comparable with those obtained in this series and there is little doubt that previous miscarriages and abortions all assist in the development/

development of isoimmunisation in the mother.

In only one respect do the figures differ from those of Potter (1948) and that is in the number of first pregnancies. In addition to the 10 cases mentioned previously, three other mothers had been delivered of infants suffering from haemolytic disease prior to the siblings dealt with in this series. These were first pregnancies. One of the 3 offspring suffered from icterus gravis and died, the other 2 infants suffered from icterus gravis also, but recovered. The mortality among these offspring of first pregnancies was 9 out of 13 (70%) which is also much higher than the results of Potter (1948). She, like most other writers, believes that the disease is rare in first pregnancies and when it does occur it is not likely to take a severe form. This last feature, the occurrence of the disease in a mild form, does not hold if there is a history of incompatible blood transfusion prior to the pregnancy. Blood transfusion is a better method of producing a state of sensitisation in the mother than pregnancy and the disease is liable to take a severe form in a pregnancy following such a transfusion. No history of previous transfusions was given in the 13 cases of this series.

Twelve women had one or more miscarriages interpolated between the birth of the last normal child and the first suffering from haemolytic disease. In three instances these miscarriages had led to severe haemorrhage/

Table 53. (after Potter, 1948)

Pregnancy in which the Diagnosis of Haemolytic Disease was first made.

Outcome of 1st. Pregnancy with Haemolytic Disease.	Pregnancy.										Total.
	1	2	3	4	5	6	7	8	9	10	
Infant survived	4	13	11	5	2	2	1	0	0	1	39
Infant died	6	24	16	6	9	0	3	1	1 (B.T.)	0	66
Still Birth	3	3	7	4	2	5	0	0	0	0	24
Total	13	40	34	15	13	7	4	1	1	1	129 <sup>x</sup>

x 1 pair of twins is included in this table.

B.T. Case following transfusion of blood not tested for Rh compatibility.

haemorrhage which had been treated by blood transfusion. The blood they had received had not been tested for Rhesus compatibility.

The pregnancy in which haemolytic disease first occurred is shown in Table 33 and Graph 1. It will be seen that 66% of the women gave birth to their first affected child before their fourth pregnancy. (72% according to Potter, 1948). Of the 129 children, 90 died or were still-born, a mortality of 70% (65% in Potter's series).

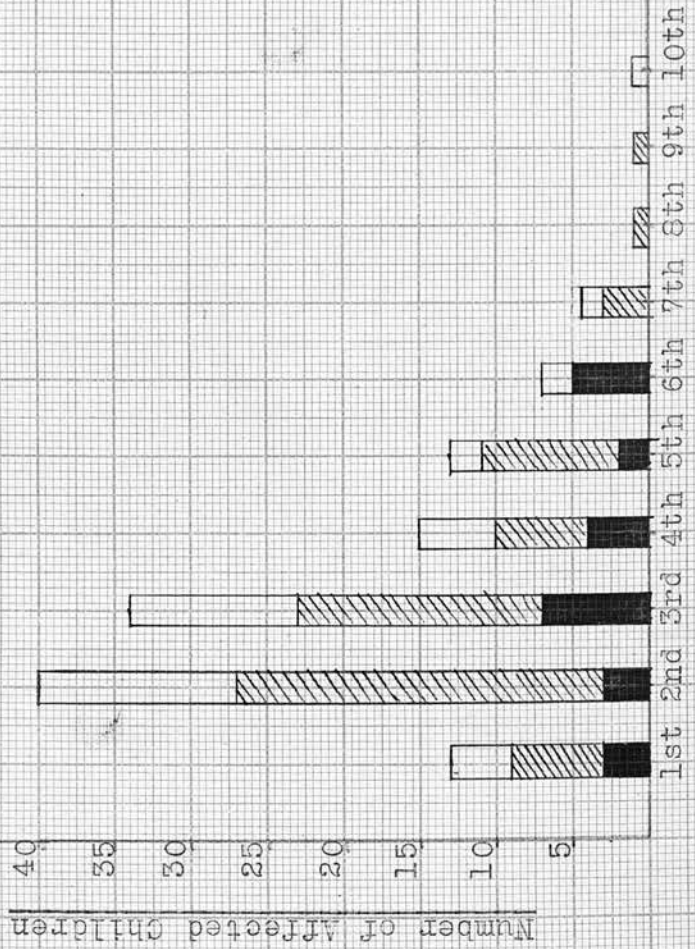
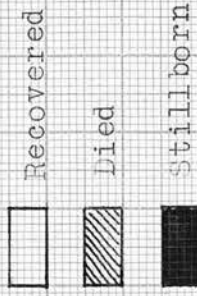Potter (1948) is of the opinion that the disease tends to be more severe in later pregnancies. A study of Table 33 will show that the majority of the cases which survive are those occurring before the 4th. pregnancy. As the majority of cases occur in this period the result is only to be expected. Hydrops foetalis, however, does seem to occur more often in the later pregnancies than congenital haemolytic anaemia.

(XIV) Pregnancies following the Birth of Child with Haemolytic Disease.

In this series 33 women had one or more pregnancies subsequent to the birth of a child suffering from haemolytic disease. Two of these pregnancies ended in a miscarriage. These 33 women had a total of 70 children. Sixty-eight of these children were affected with haemolytic disease. Of these 68 children, 35 were still-born, 13 died and 20 were affected but survived. The mortality rate of 70% /

GRAPH I

Pregnancy in which the Diagnosis of Haemolytic Disease  
was first made.



Pregnancy

70% is the same as for those in which haemolytic disease is first diagnosed. Potter (1948) on the other hand found a survival rate of only 10% in the subsequent pregnancies.

The 128 women thus gave birth to 198 children affected with haemolytic disease. Of these 59 survived, 79 died and 59 were still-born. (Mortality 70%)

(XV) Yearly Incidence of Haemolytic Disease.

Potter (1948) found that there was some increase of recent years (1943-48) in the incidence of haemolytic disease. She pointed out that this was not entirely the result of an increase in the frequency of clinical diagnosis as she had an increase in fatal cases and the criteria for post-mortem diagnosis of the disease have not greatly changed since 1933. The figures for the present series fail to show any such increase and the reasons for Potter's findings remains obscure.

(XVI) Clinical Features of Haemolytic Disease.

A study of the principal clinical features of the cases of haemolytic disease in this series will be deferred till Chapter 9. A summary of the more important findings will be found at the end of that chapter.