

AN ESSAY ON INTUSSUSCEPTION
with an account
And Analysis of 103 Cases.
In two Volumes.

Presented to the Faculty of Medicine
of the University of Edinburgh
for the degree of Master in Surgery.

-By-

DUNCAN C. L. FITZWILLIAMS,
M.D., Ch.B., F.R.C.S.S. Edin. & Eng.

1907.

Vol. 11.



No. 1. Ernest Grant. Aged 3 years. Admitted Nov. 4. 1867.

History. This is told at length in a letter from Dr. Hart of Hitchin, here given.

On Aug. 12th. I was requested to ~~go~~ see a child a little over 3 years of age, the son of a painter and glazier residing in the town. On reaching the house I was informed that since the preceeding evening the child had been suffering from pain in the belly and that two desertspoonfuls of castor oil had been sucessively administered without obtaining any relief from the bowels.

The little patient presented the symptoms of an ordinary attack of colic, and deeming it such I prescribed a grain of calomel combined with Dover's powder - an aperient draught to be taken in the morning should the bowels not be previously opened - fomentation of poppy lotion to be applied to the abdomen.

The next morning much to my surprise, found the child considerably worse, the parents had passed a sleepless night in constant attendance upon the child whose screams disturbed the whole neighbourhood. The pains came on by paroxysms about every 10 minutes, the child writhing with agony and throwing himself down on the floor against which he pressed his belly. The bowels had not been relieved, the tongue was furred. There was no perceptible increase in the temperature of the body or in the frequency of the pulse. The pain was referred to the navel but notwithstanding the most careful exploration, I could not detect signs of rupture, tenderness, or tumefaction.

The nature of the symptoms together with the occupation of the father, naturally led me to enquire whether the child had not swallowed some of the preparations of lead used in the trade, or been exposed to any noxious exhalations arising from the trituration and other manipulations to which that metal is subjected.

At the back of the ~~shop~~ house, the father had built a workshop, here were several open jars of prepared white lead, a substance which, from its creamy aspect, would naturally present a most inviting appearance to a child - here too the little patient was wont, whilst his father was at work, to play with putty a substance which, though harmless in itself, not infrequently contains a considerable amount of lead. On examining the teeth, I could not ~~find~~ perceive the pathognomonic bluish tinge, but this sign, so characteristic of the

disease in adults, is in very young children, owing to the almost total absence of tartar, of comparatively little value.

Next day (Aug. 14th.) constant and distressing vomiting was superadded to the existing symptoms, rendering the exhibition of medicine as well as food impossible. An emollient enema was administered but only a small ~~quantity of fluid (which was immediately returned)~~ quantity of fluid (which was immediately returned) could be thrown up. A warm bath was tried without however obtaining any alleviation of the symptoms. At night a draught containing a full dose of laudanum was administered but immediately rejected. After the lapse of a few hours the dose was repeated in a teaspoonful of water at the time retained. Very little abatement if any of the symptoms followed the narcotic until the next morning when the bowels were twice copiously opened, and almost immediate relief experienced.

During the next three days the little patient seemed so much better that he was able to be taken out in a ~~perambulator~~ perambulator. The sickness had stopped and an occasional twinge whilst at play, which made him stoop and grasp his belly, was all that remained of the disease. His bowels however had not been relieved.

Suddenly on the 19th. the symptoms manifested themselves with increased violence. The little sufferer breaking ~~away~~ loose from those who attempted to hold him would run upon all fours under the table, the bed, or anywhere out of reach and yell most piteously.

Knowing how necessary yet how difficult it is in similar cases to obtain a ~~thorough~~ thorough evacuation of the bowels I at once administered a dose of oil of turpentine. This had the desired effect, the bowels were copiously relieved and the little patient though not entirely ~~free~~ free from an occasional gripe was so much improved as to lead me to hope the poison had been fairly expelled from the system. One eighth of a grain of morphia hydrochlorate administered at night ensured a good nights rest; and I may ~~say~~ as well remark that during the whole course of the disease, opiates seemed to have no perceptible action on the size of the pupils.

The benefit derived from the cathartic was only due to a temporary remission of the symptoms for after the lapse of a few days they returned with unabated severity, and then they continued alternating with sometimes, only a few hours, at other times even days of comparative freedom from pain. The bowels previously

confined, now became so relaxed that the child had as may as 8 evacuations in the day. These, small in quantity fluid, and horribly offensive, besides containing shreds of mucus, were not infrequently tinged with blood. The appetite was normal and when the pains were " on " the child to make sure would bolt his food during the intervals of the paroxysms.

Emaciation however made rapid strides and the outline of the bones became daily more defined.

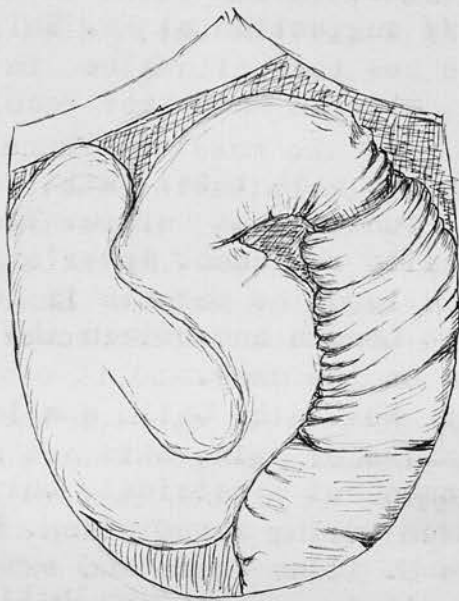
With regard to remedies none with the exception of the temporary relief obtained from opiates seemed to be of any avail. Having remarked that the pains were usually preceded by borborygmi, antispasmodics were exhibited and at the ~~suggestion~~ suggestion of Mr. Shillitoe whom I requested to see the child Alum in 5 gr. doses in mucilage was tried but with no better results than the preceding.

Oct. 6th. The symptoms with their usual remissions and exacerbations still continue as before. The bowel prolapses but is easily replaced. Dover's powder at night.

Oct. 9th. I have advised the parents if possible to take the child up to London and obtain the opinion of some eminent man on the case.

On Admission. ~~Aug~~ Nov. 4th. Child emaciated and flabby, face expressive of pain, skin not hot, pulse 120. tongue furred. Abdomen not symmetrical, bulging in the L. iliac fossa, moves during respiration. Palpation, a tumour occupies the L. iliac fossa and extends upwards as far as the ribs. It is ill defined and gives the idea of a distended large intestine, it is not tender, but is dull on percussion. The rest of the abdomen is flaccid and natural. Per rectum. The anus and bowel are large and lax, a large mass occupies the rectum, the finger can pass up on each side - evidently invaginated intestine. The finger can be passed up the invaginated gut. The gut can be pushed up with the finger, when the child cries the bowel is prolapsed. As much as 5 to 6 ins. were seen hanging from the anus at one time as a reddish brown mucous surface. A little to one side was a nipple like projection of a grayish red colour.

Every hour the child suffers from attacks of pain and cries out for some minutes, 3 to 4 watery faeculent stools passed, no scybala. There is a continuous mucus discharge from the anus. The intestine prolapses 3 to 4 times a day.



Distended small intestine seen
entering the colon.

14

Treatment. Tinct. camph. Co. min. 10 with Mist ol. ricini given. Warm water enemata which were immediately returned, 8 ounces used at a time, this had no effect on reducing the gut.

Nov. 6. Last night vomited 4 times and bowels moved 4 times, prolapsing each time, easily returned. Vomited twice this morning. The tumour has in great measure disappeared, merely fulness in the L. iliac fossa, abdomen quite flaccid not distended. Child vomited all afternoon and night. Attempts were made at reduction by inflation ~~with~~ but owing to the patulous state of the anus this failed. Child died at 8 a.m. on Nov. 7th.

Post Mortem Notes.

On opening the abdomen the mass was found to be the descending colon which occupies the whole left side, the R. side is occupied by the small intestine. No free lymph in the peritoneal cavity. The intussuscepted mass was removed from the small intestine. Small intestine dilated seen entering the upper end of the intussusception, there is no constriction as it enters and it can be drawn slightly out of the sheath. On opening the intussusception the lower part was coloured deeper than the upper, probably being inverted at a much earlier date. At the lower end of the returning layer of the large intestine the nipple like projection, previously described is found, it is the appendix within the inverted gut. A little to one side of this is the ileo-caecal valve through which the finger was inserted during life.

No. 2 Leonard Maclean. Aged 5 years. Admitted April 25. 1876.

History. Quite well till April 23rd. when early in the morning he complained of pain in the abdomen, and went back to bed, hot fomentations were applied. Bowels have not opened since the 21st, no straining, no slime, no blood. Great thirst. 5 other children well.

On Admission. Expression anxious, abdomen soft, tender in epigastrium, no tumour felt, liver and spleen not enlarged, glands in neck slightly large. Pulse 120. Per rectum, a few hard masses adherent to wall. About 3 ins. from anus a tumour was felt, round which the finger can sweep more freely behind than in front - like an intussusception. 36 ounces of warm water injected and retained for half an hour and then passed with a small amount of faeces.

Calomel grs. 2; Ol. Crotonis min. ½, given at once, this was followed by a dose of castor oil and the warm water injection repeated.

26th. Vomited at 9 a.m., at 3 p.m. vomited castor oil, given mag. sulph Grss. 60 to the ounce of water every 4 hrs.

27th. No motion of bowels, pulse 136 very feeble. A min. of croton oil given. Abdomen very tender, distension increased, coils of intestine felt. Injection of castor oil.

28th. Abdomen more distended, ~~not~~ pulse 156 very feeble. A consultation was held by Drs. Cheadle and Dickinson with Messers Smith and Marsh. The boy was nearly pulseless, Mr. Marsh could feel no tumour per rectum. Diagnosis of acute obstruction not intussusception. Died at 10.15 p.m.

(There was never any straining, passage of blood, nor any tumour felt, though distended coils of intestine could be felt. The abdomen was tympanic)

Post Mortem Notes.

Abdomen. A small amount of blood stained serum in the peritoneal sac, no effusion of faeces, no free lymph. The surface of the gut was purple and congested. The large gut was empty, contracted and pale. At the caecum there a dark knot of intestine which looked at first like a volvulus. This was found to be an intussusception commencing about 4 ins. above the ileo-caecal valve.

On slitting this up the lower end was found gangrenous, but the sheath was not tight and could easily be moved over the invaginated part to which it was not adherent.

Above this the whole alimentary tract was distended and full of fluid, The mucous membrane of the duodenum was emphysematous. No other morbid appearances.

No. 3 Henry Wooff. Aged 5 mos. Admitted Aug. 8. 1877.

History. Was quite well till Aug. 4th.. On that day at 10 a.m. he began to scream, draw up his legs and vomit. At 3 p.m. passed about an ounce of blood by the bowel, straining a lot. Bowels open again on the 6th. motion almost black, has passed streaks of blood. Vomiting has been present since the onset.

Previous History. Parents well, one other child well, one died with measles. Has been fed on the breast alone.

On Admission. A well nourished fat child, does not look very ill, strains and cries so that palpation is useless, abdomen seems distended. Chloroform given and an intussusception felt 2 inches from the anus. Child was sick all the afternoon. Pulse 148 poor quality.

Operation. Abdomen opened in middle line below the umbilicus, distended gut prolapsed and could not be reduced. The intussusception was easily reduced till the last part was reached, this was hard and quite irreducible $\frac{7}{8}$ (this was apparently left unreduced).

The small intestines had to be punctured before they could be replaced. The wound was sutured/secured with 3 hare-lip pins and covered with cotton wool and a bandage. The peritoneum was torn in the reduction and stripped from the bowel. Child died 11.30 p.m.

Post Mortem Notes.

The abdomen contained 2 drams of faeculent fluid, a piece of small intestine was included in the deeper layers of the wound. The intussuscepted part is in the angle made by the transverse and descending colons, and is collected into a mass about 4 inches long, of an angular shape, part being in the transverse and part in the descending colon. Just below the angle, the sheath is ruptured longitudinally for $2\frac{1}{2}$ inches and the mucous membrane of the bowel is exposed. Drawn in with the intussusceptum, is a piece of mesentery of the small gut close to the duodenum and pancreas, both of which are drawn up close to the sheath. On slitting up the rectum and colon the advanced head is found to be a conical mass 1 inch thick and presenting just below the apex, a small aperture - probably that of the appendix.

1 inch below the tip is the ileocaecal valve very swollen. The whole is very firm and swollen, the rest of the invaginated portion does not appear excessively thickened or adherent. The other organs normal.

No 4 Fras. Skelley. Aged 6 mos. Admitted Jan 4. 1883.

History. Bowels moved naturally at 7.30 p.m. on the 2nd. at noon vomiting began. Blood and slime passed on the 3rd. "Stretches himself a great deal" belly said to be tender.

Previous History. Youngest of 4, no miscarriage, 1 still born, 1 died at 18 mos. with "something in the brain", 1 died diarrhoea at 6 weeks.

On Admission. 6 p.m. Child very ill and collapsed, The abdomen distended, pulse 160, temp. 101.8. No tumour felt in abdomen or per rectum. Child restless and vomiting. Died at 10 p.m.

Post Mortem Notes.

An intussusception in R. iliac fossa, a cylindrical tumour about 2½ inches long, the appendix lay free in the abdominal cavity. Bowel easily reduced, peritoneum not split, no adhesions, no peritonitis. All Peyer's patches swollen, especially the last which is included in the intussusception. 2 inches of gut on each side of the ileo-caecal valve affected, the valve formed the head of the intussusception and was deeply congested, but not gangrenous. Small intestine contained fluid and gas, large gut empty. No polypus found, other organs found healthy.

No. 5 Adelaide Oakley Aged 2years. Admitted Sept.18.1885.

History. Seven weeks ago began to have diarrhoea, this commenced suddenly one morning with great pain. This was at first thought to be due to a chill. At first the motions were large and yellow. For the last fortnight blood has occasionally been passed. For a week there has been occasional prolapse.

Previous History. Parents healthy, 1 other living child, 1 child died in infancy. No previous illness.

On Admission. Greatly wasted, with hollow orbits, extremities cold, oedema of the feet. Abdomen is rather distended and peristalsis can be seen with great distinctness. There is a projection at the junction of the L.hypochondrium and epigastrium. On palpation a distinct sausage shaped tumour, about 1½ inches in diameter, is felt in the region of the descending colon. Its upper end reaches just to the middle line in the epigastrium, the lower end is lost in the pelvis.

It is dull on percussion, firm and resistant, and slightly tender. The rest of the abdomen is clear. Sept.19. Bowels have acted very often, motions small, fluid and slimy, no blood, much pain and straining during defaecation. In the afternoon a large amount of prolapse came down. The bowel was very dark red and projected for more than 2 inches. In the middle was a piece of intussuscepted gut of a dark greenish grey colour.

Operation.11 p.m. The abdomen was opened and the intussusception was reduced in the usual way.

Sept.22. Has progressed satisfactorily but is more collapsed to day. Died at 3.30 p.m.

Post Mortem Notes

Weight 15¼ lbs. On opening the wire sutures of the abdominal wound and continuing the incision upwards, fibro plastic adhesions were found binding the large and small intestines together, these were of recent date. The caecum and sigmoid occupied the L. hypogastric area and were bathed in pus which had also travelled up to the spleen. There was no pus on the R. side. The stomach and omentum were pushed up out of sight. Immediately below the stomach was the colon which had formed a loop, the caecum being adherent to the sigmoid. The walls of the caecum had sloughed especially the mucous membrane, which was black and bloodstained and at one point nearly perforated, adhesions prevented extravasation. The ileo-caecal valve was discoloured. There was a small area of sloughing about 4 inches above the valve, above this the mucous membrane was normal. No other organs appeared diseased.

No. 6 Elsie Lockwood. Aged 11 mos. Admitted Aug 18.1887.

History. During the last 3 weeks the child has had three attacks of vomiting, between these the motions have been quite healthy. On the 16th. inst. vomiting began, this was accompanied with the passage of clots of blood with slime. The previous health of the child has been good.

On Admission. Well nourished child apparently in good health. In the L. iliac region an ill defined, rounded swelling can be felt, the abdomen is rather tense. The finger in the rectum can feel the opening at the extremity of the intussuscepted part.

Operation. Manipulations having failed, abdominal section was performed and the intussusception reduced.

The child did not recover from the effects of shock and died at 11.15 p.m.

Post Mortem Notes.

A portion of intestine removed through the wound, no other examination allowed. The ileo-caecal valve can not be made out but the lower end of the ileum projects into the colon for about a third of an inch, and can not be reduced. The mucous membrane of the inverted portion is extremely ulcerated all round where it joins that of the caecum.

No. 7 Chas. J. Ellis. Aged 5 mos. Admitted Mar 23. 1888.

History. On Mar. 17 the child was taken ill, screamed and drew its knees up to its chest, in 2 hours time some blood appeared in the motions. On the 18th. vomiting began. On the 20th. the bowel was seen protruding from the anus and a quantity of blood and slime was passed.

On Admission. General condition good, no collapse, no apparent peritonitis. The gut was seen protruding from the anus dark in colour, dry and gangrenous. On ~~the~~ introducing the finger no reflection of mucus membrane could be felt on either side, a polypus presented.

Operation. A median incision made above pubes. The condition could not be satisfactorily made out, there was some ~~lymph~~ lymph on the intestines. A portion of the presenting gut was opened and stitched to the wound, bloody mucus, but no flatus, escaped. The finger was introduced into the gut but ~~it~~ did not detect anything abnormal.

The child rallied after the operation but died next day.

Post Mortem notes.

There was no fluid in the peritoneal cavity, but general peritonitis had matted the coils together with lymph which was especially present at the upper part of the intussusception. The descending colon was in its natural position, but at the splenic flexure the gut took a sudden turn down ~~to the~~ towards the pubes. The caecum and adjacent portion of the small intestine were involuted into the large intestine. At the abdominal wound there was much lymph found matting the coils together, the opening in the gut, made at the time of the operation, was below the point of involution.

All the gut implicated in the intussusception was very soft and tore readily.

No. 8 Wilfred Champion. Aged 6 mos. Admitted June 14. 1888.

History. On June 9th. Child woke screaming with pain. The mother gave him some castor oil, an hour or two afterwards he passed a very dark motion which was soon followed by some blood and slime. The child has vomited continuously since the commencement of the illness, the vomit has been very offensive. Previous to this the child has been very strong and healthy.

On Admission. The child was placed under chloroform, but even when the abdomen was non resting no sausage shaped tumour was made out. On introducing finger into the rectum, the involuted gut could easily be felt about an inch from the ~~the~~ sphincter. The child was very collapsed and the anaesthetic was discontinued, brandy and ether were given and the pulse improved. Inflation of the bowel was then resorted to, and the intussusception receded out of reach of the finger, but returned after a short time to its former position. This occurred as often as the operation was performed. The child vomited dark feculent matter. Later in the day attempts were made by the House Physician to return the bowel by inflation, but with no success, and the child died the same night.

Post Mortem Notes.

Well nourished child of 14½ lbs. On opening the abdomen a small amount of fluid was found in the peritoneal cavity. There were signs of commencing peritonitis, viz red lines and lymph were the coils came in contact with each other. The intussusception occupied the left lumbar region. On opening the gut, the invaginated part was found to consist of the lower portion of the ileum, with the caecum and portion of the large intestine. The intussuscepted portion was gangrenous and terminated at a point quite 10 inches from the anus.

The other organs were not examined.

No. 9 Arthur Newbold. Aged 9½ years. Admitted Oct. 12. 1886.

History. Complains of pain in the abdomen, especially after passing urine, has had to force himself to pass urine for 1½ years. Has been wasting for 1 year. Has been liable to vomit, this has been more marked during the last few months. Pain during and after micturition, none on defaecation, Occasional haedache.

Previous History. Granfather died of cancer of the bowel, phthisis on mother's side. Is an only child, has had the usual childrens diseases, no fits or rickets.

On Admission. General weakness, skin darkly coloured. Complains of pain across the lower part of the abdomen. The abdomen is tender all over and held so rigid that palpations reveals nothing, dulness in the R. iliac and hypogastric regions. Abdominal veins dilated.

Temp. normal. Urine, acid, sp.gr. 1020, contains mucus but no albumin or blood. Pain ~~is~~ starts in the groins and passes down to knees at the end of micturition.

Aug. 22. Some enlargement of cervical glands. Liver edge felt 3 fingers breadth below costal margin, very hard, resistance felt below the base of the R. lung.

Ag. 27th. Growing weaker. Early this morning sudden collapse, some fluid aspirated from the base of the R. lung. Child died soon afterwards. The bowels and urine have been normal throughout.

Post Mortem Notes.

Abdomen. On opening about a pint of turbid yellow fluid escaped- no peritonitis. On displacing the small intestine, many glands found, some of which were enormously enlarged, in the angle between the ileum and the large gut. In the lower part of the R. lumbar and iliac regions was a large tumour, consisting of an intussusception of the ileum into the ascending colon. The appendix was much thickened and lay with the caecum entirely outside the intussusception. On opening the large gut a mass of ileum was seen protruding through the ileo-caecal valve. The whole forms a firm hard mass, in the centre of which is the lumen of the gut. This admits the little finger. The ileo-caecal valve is not connected with the intussusception. The mucous membrane of that part of the ileum which protrudes into the colon is reddened and ulcerated. Externally there was no lymph in the neighbourhood of the valve and the peritoneal surface is not affected. No perforation above or below the intussusception, as proved by the tap.. In the region both above and below, the mesentery is infiltrated with new growth, being much thickened and very firm, containing many large glands which form a lig. extending up to the spinal column.

and very firm, containing many large glands which form a big bunch extending up to the spinal column.

The rest of the growth in the peritoneum consists first of large white masses, many of which are glands, and secondly of a general infiltration of the omentum ~~with~~ and mesentery with areas of growth which could always be distinguished with the naked eye from the fat. The infiltration was especially well marked in the region of the liver and the spleen, There were many adhesions between the omentum and both these organs. These adhesions were firm and white.

Peyer's patches were normal. The liver was much enlarged and studded throughout with white masses which stood out from its surface. The spleen had no deposits but the growth was attached to its capsule. The supra renals were normal. The kidneys were congested but the growth was confined to the cortex; the pelves, ureters, and bladder were normal.

Fluid was found in both pleura. The heart was normal. The mediastinal glands were affected.

The growth consisted of small round cells -
round celled sarcoma.

No. 10 Emily Deller. Aged 8 mos. Admitted Mar. 22. 1890.

History. Quite well till the 13th. when she was drowsy and languid and the bowels did not act. She ~~was~~ was sick after each feed, screaming and restless on the 17th. Strained a lot on the 19th. Passed blood on the 20th. The vomiting became green and faeculent on the 19th. when medicine was given but the bowels did not act.

Previous History. Parents well, youngest of 6 all well, full time, breast fed no other food, measles at 5 mos.

On Admission. A sausage shaped tumour felt in the right loin. A milk enema 14 ounces given, after which the tumour became indistinct, enema all returned unstained. The child was very drowsy, anterior fontanelle depressed, given brandy and small doses of opium..

23rd. Tinct opii continued, mucus passed 3 times.

24th. Treatment continued, mucus passed 4 times, once with a little blood, sick several times, semi solid motion without mucus or blood passed. Very restless.

25th. Condition the same, tinct. opii. a little blood and mucus passed.

26th. Nothing felt in abdomen or per rectum, a semi-solid green motion passed.

28th. Examined under an anaesthetic and a definite tumour felt in L. hypochondrium, the R. iliac fossa empty. Air injected per rectum and the tumour returned several times to the middle line but went back again immediately. Water was tried and tumour became indistinct, R. iliac fossa did not fill up. Vomited after the chloroform and died collapsed after passing blood at 10 p.m.

Post Mortem Notes.

On opening abdomen small intestine distended, a little bile stained fluid in cavity, no peritonitis. The colon runs transversely across the abdomen to the middle line and then loops sharply downwards and returning upwards is tethered to the spine by the mesentery. The small intestine is seen entering the large at the middle line, it is pale, the mesentery being congested. The head of the intussusception was 9 ins. from the anus, purple in colour with gray patches covered with lymph, the appendix was near the head.

Other organs normal.

Specimen in museum

No. 11

Albert Harding Aged 8 months. - Admitted April 8. 1890.

History. On the afternoon of the 4th. inst. he was restless and fretful, vomited in the evening and has been sick at short intervals ever since. Last natural motion was passed on the 4th. Blood was passed at midday on the 5th. on the 7th. and again this morning. No slime, no straining.

Previous History. Mother dyspeptic, father healthy, only child, fulltime, breast fed, has been quite well till now, no diarrhoea, has 4 teeth.

On Admission. An elongated sausage shaped tumour felt extending from the L. iliac crest nearly to the costal margin. R. iliac fossa empty.

At 11.15 a.m. chloroform given and tumour was then found to have gone back, being only a little to the left of the middle line. The patient became collapsed and the pulse was very poor, brandy enemata given and warmth applied. Later he was again anaesthetised and injections of warm water given. The injections, 10 ounces each, were returned almost direct, each was returned before the next was given, a Higginson's syringe used.

After these the tumour seemed to disappear but a sense of resistance in the epigastrium remained and a good deal of bleeding took place from the rectum.

Tinct. opii was given in one minim doses every hour with 30 mins. of brandy and 2 drams of milk.

April 9th. Not sick since midday yesterday, bowels not moved, no tumour felt, abdomen distended, Tinct Opii every second hour.

10th. Last night passed 3 loose motions dark brown no blood, tinct. opii continued.

11th. Temp. 104.6 Abdomen very tense nothing to be felt, semisolid motion passed during night.

Chloroform given and the tumour again felt passing from Poupart's ligament to the costal margin on the L. side, the end of the tumour could be felt through the wall of rectum. Warm water enemata given, a pint each time, from a funnel held 3 to 4 feet above the patient.

The tumour became indistinct but in 5 minutes was easily palpable again. After the third injection it was not felt, there was fulness about the umbilical regions as before. The child had been constantly sick for the last 12 hours.

12th. No sickness after midnight, head retracted, no tumour felt per rectum or definitely palpable. At 5 p.m.

11. 216
infections repeated, nearly 20 ounces passed in from funnel raised 2 feet.

13th. Sickness continues, bowels moved once during night semisolid motion. At midday warm water infected 20 ounces, child bore it badly. At 3.30 p.m. child died after vomiting.

Post Mortem Notes.

The abdomen contained some turbid flakey fluid, lymph found between liver and diaphragm and among coils of intestines. In the left flank and in cavity of the pelvis there is semipurulent fluid. There is an intussusception of the small into the large intestine.

The tumour thus formed reaches nearly to the splenic flexure of the colon. No signs of thrombosis of the mesentery, the intussusception was dark purple but not gangrenous. Three ruptures of the peritoneal coat of the descending colon were found; one involved the peritoneal coat only, the second had the mucous and the submucous coats herniated through the the peritoneal, the third was a rupture the size of a pea situated about one ~~and~~ inch from the end of the intussusception.

(It is not stated that there was leakage in any)

The variety of intussusception was ileo-caecal.

No cause for the intussusception was found.

↳ but the peritonitis showed that such must have occurred.

17

No. 12 Gladys Gale. Aged 3 mos. Admitted Sept. 25. 1890.

History. Child was always inclined to strain. On the morning before admission she was sick and passed some blood, there was a protrusion at the anus.

On Admission. Temp 100, 3 p.m. A round moveable tumour easily felt in the L. Iliac region, blood stained mucus about anus. The finger could just reach a smooth globular mass, which gradually came down on straining and presented at the anus. This was dark, congested, and tense, no pedicle or apical dimple. The child was not collapsed.

4 p.m. Under an anaesthetic inflation by a Higginson's syringe. To make any impression rapid forcible pressure had to be used as there was leakage at anus. The tumour gradually disappeared but the abdomen did not distend. No return of symptoms till 8 p.m. when a little blood was passed, vomiting began at midnight and lasted through the night. A minim of tinct. opii given hourly.

26th. 10 a.m. Vomiting brown fluid frequently, no milk retained, abdomen distended and hard, no abdominal respiration. Pulse 156 small and weak. Looks very collapsed. Blood and mucus passed 4 to 5 times, Temp. 102.6 Death at 3.10 p.m.

Post Mortem Notes.

Abdomen. No actual peritonitis, no excess of fluid, a few flakes of lymph. Small intestines distended. An intussusception found, the head of which is at the splenic flexure. The descending colon is empty and contracted. The intussusception is purple and the entering mesentery is congested, no perforation. No other abnormality except a small cyst of the left ovary.

No. 13.

William Seymour Aged 4 months. Admitted Feb. 5. 1890.

History. In the morning of the 2nd. the child was as bright as usual, vomited in the afternoon. In the evening passed a large motion, yellow in colour and very offensive. On the 3rd. he passed some blood and was brought to the Out Patient Department and given some medicine. On ~~the~~ the 4th. continued the same, ~~passing~~ passing blood and vomiting. The child previously has always been constipated.

On Admission. Child much collapsed, lips blue, chest and abdomen pulsate, especially the left side of the abdomen. No thrill over the chest, but heart sounds are replaced by a loud systolic murmur. Vomited once after taking the breast. An indistinct mass is felt in the L. half of the abdomen. Nil per rectum, no obvious hollow in the R. iliac fossa. It was thought that the child has an intussusception together with congenital morbus cordis. The pulse could not be ~~heard~~ felt at the wrist.

The child died within an hour of admission, it was too bad to consider operation.

Post Mortem Notes.

Weight 14lbs. Abdomen - no excess of fluid found, the intestines are injected and full. There were a few flakes of lymph in the peritoneal cavity. The descending colon was occupied by a dark mass, an intussusception, which is situated in the middle line. The appendix projects about one inch from the entrance of the intussusception.

The intussusception could not be reduced by fair traction. On opening the gut, the mucous membrane of the intussusceptum is covered on its last inch with grey flakes of lymph, no gangrene. On making a hole in the small intestine above and passing a catheter down the point emerges to one side about one inch from the tip of the intussusceptum. The intussusceptum is firmly wedged at its base and can not be undone by traction.

Its is formed by small intestine entering the large at the ileo-caecal valve. There is no rupture of the ~~coats~~ coats. Nothing abnormal was found in the heart and the other viscera were normal.

Henry Hales. Aged 10 months. Admitted April. 7. 1891.

History. For seven weeks the child has been getting thin. 6 weeks ago diarrhoea started and has continued ever since, some 15 motions a day being passed, green, slimy and tinged with blood. For the last 3 weeks prolapse of the bowels has been frequent, is easily replaced by mother. About 3 ins. protrude. About a week ago a small hole was noticed in the side of the main mass, this has gradually increased in size, and 4 days before admission the mother saw a small piece of bowel by the side of the main mass. This had come through the opening spoken of. The child has been getting rapidly worse so was brought to hospital.

On admission. Child collapsed. An intussusception protrudes $3\frac{1}{2}$ ins. from the anus, about half an inch of the appendix was protruding from the side but the base of the appendix could not be found. It looked like a polypus. No abdominal distension or pain.

The bowel was returned, 8 ounces of boracic lotion injected. The solution entered and returned freely and the tumour could be felt on the left side of the abdomen. The tumour then disappeared but a quarter of an hour later was protruded from the anus, increased in size so that the opening through which the appendix protruded could easily be made out. The child was considered too bad for operation The bowel was returned gently into the rectum and kept up by cotton wool pad.

The child was quite apathetic, the bowels moved about 6 times, the motions being greenish liquid, no blood. The temp. 102'2

April 9th. The child died at 1.15 am. very restless, there was a constant discharge of mucus from the anus.

Post Mortem Notes.

Weight 10½ lbs. There was not much distension. On opening the abdominal cavity. The small intestines occupied the R. iliac fossa while occupying the whole hypogastric and L. iliac spaces was an enormously distended large gut. There was lymph along the lines of contact of the coils and thick pus found in the dependent parts especially about the pelvis. The whole pelvis was filled with an intussusception, the bladder being empty. The small intestine generally was empty and collapsed. The intestines were removed en masse together with the peritoneum from the posterior abdominal wall. Within ~~the~~ the sigmoid and rectum was the

intussusception, the apex of which was formed by the ileo-caecal valve, the orifice of which was swollen, the margins lying transversely. The valve was not tilted to the side. Beneath this orifice is a smaller one admitting a No 5 catheter, its edges are deeply congested and swollen. Between these two orifices there is superficial ulceration. Behind the orifice is a clean cut ulceration of the returning layer through which the appendix has prolapsed. A probe passed into the smaller of the two orifices enters the appendix with some difficulty on account of the acute bend of the appendix on itself. The serous surface of the appendix is covered with lymph. A similar appearance is seen on the entering layer. There is not a adhesion between the peritoneal surfaces of the entering and returning layers. A probe and infected fluid readily passes through the intussusceptum into the lumen of the gut above. The intussusceptum which is curved on itself measures about 5 1/4 inches along the convexity. The neck is thrown into deep transverse folds and is thickened.

Into the neck are crowded, the ileum with its mesentery, and in front of this the omentum which has dragged the pylorus and duodenum close to the neck of the invagination. The intestines and mesentery are congested for one inch above the neck, but no adhesions have formed. There is a congenital nodulated diverticulum about an inch in length about 1 foot above the neck of the intussusception, no cord from its apex. Other organs healthy.

No. 15.

Albert Pope. Aged 7 months. Admitted July 6.1891.

History. Child was quite well till 10.30 p.m. on July 4th. when he woke up and took the breast but vomited almost at once. The mother gave him a powder which was at once returned. The child had screaming bouts all through the night and was repeatedly sick.

A green motion was passed during the night. Next morning his napkin was found full of blood. Blood and slime has been repeatedly passed till 4 p.m. on the 5th. none has been passed since then. The child was twice seen by a Dr. who gave it medicine.

Previous History. Breast fed with an occasional crust or biscuit, never had diarrhoea nor was ill previously.

On Admission. Child looks very ill. The abdomen was examined and a distinct swelling made out in the R. iliac fossa. Chloroform was given and water injected under low pressure and the swelling was thought to disappear. Child was afterwards sick. 5 or 6 hours later chloroform again given and water injected as a tumour was felt in the region of the transverse colon.

July 7. At 2 a.m. under chloroform given first air and then water injected. Sick again at 4 a.m. Has been fed alternately by mouth and rectum, enema not retained, child looks better, abdomen not examined.

July 8. Awake all night and died at 4.30 a.m.

Post Mortem Notes.

" Before opening abdomen a rounded mass was felt in left half of epigastrium, certainly half an hour before death no mass was felt."

On opening abdomen an ileo-caecal intussusception was discovered in the epigastric region extending more to the L. than to the R. of the middle line. No peritonitis, no rupture. Injection of water with manipulation and squeezing reduced the intussusception without any manifest injury to the gut, but the last inch required considerable force and was the most intensely congested.

The peritoneum of this part was shiney but black in colour. The most advanced part of the intussusception was the ileum an inch above the ileo-caecal valve.

About 30 ins. above the valve was a small Meckel's diverticulum unattached, but shewing a dimpled facet as though it had once been attached to the abdominal wall.

No. 16

Chas Green. Age not stated. Date of Admission and date of Death not stated.

Post Mortem Notes Only - Between July 18 and 20.1891.

Body well nourished weight 15½ lbs (the age therefore was under 1 year) On opening the abdomen no excess of fluid was found and no faecal extravasation.

The coils of intestine are distended and have lost their gloss. There is a little early peritonitis.

A mass is felt lying in the transverse colon and having its head at the splenic flexure.

The descending colon is contracted and there is no evidence of rupture of the peritoneal coat. The neck of the intussusception is just to the R. of the middle line, and from the neck the appendix protrudes.

It is very long and much congested. (appendix or intussusception ?) no rupture. By cutting windows in the tumour the mucous membrane is seen intensely congested and covered with yellowish grey exudation, but there is no actual gangrene. A soft catheter can be passed down the gut. There is no tumour, the intussusception is very firmly gripped at the neck. It is seen to have commenced about 2 ins. above the ileo-caecal valve and then to have passed through the valve, and to have dragged the colon and appendix in with it, the last named structure protruded at the entering ring.. Other portions of intestine were examined and found natural. Mesenteric glands a little swollen, no tubercle, no Meckel's diverticulum. Other organs normal.

(From the solicitous care with which rupture of the coats of the gut is looked for here, one would think that probably injections had been used to try and reduce the intussusception.)

No. 17

Archibald Arundell. Aged 11mos. Admitted July 24. 1891.

History. Quite well till the evening of July 23, when sudden pain came on just after taking the breast, this stopped in 3 hours. He was given a small dose of castor oil and vomited 10 minutes later, he has vomited since then each time after food. On the 23rd. he passed a natural motion, but on the 24th. the motion consisted almost entirely of blood "with dark red pieces of skin floating in it."

On Admission. No collapse, nothing definite made out in abdomen, nothing felt in rectum but the finger came away covered with blood.

At 8 p.m. inflation with air tried, followed by injection of boracic solution. The intussusception was not reduced and another blood stained motion was passed, vomiting continued.

11 p.m. Laparotomy performed. An intussusception found and reduced without much difficulty. The lower 1½ ins. of ileum had passed through the ileo-caecal valve. The operation lasted 1 hour and 10 mins.

July 25. Passed a restless night, bowels moved at 8.30 a.m. Died at 9.45 a.m.

Post Mortem Notes.

Body well nourished, early peritonitis in the neighbourhood of the wound. The intussusception has not returned but its position is indicated by a patch beginning 1½ ins. above the ileo-caecal valve. No rupture and no polypus found. W Peyer's patches were swollen but not ulcerated, they were more marked in the lower ileum than elsewhere. Glands very enlarged not caesating.

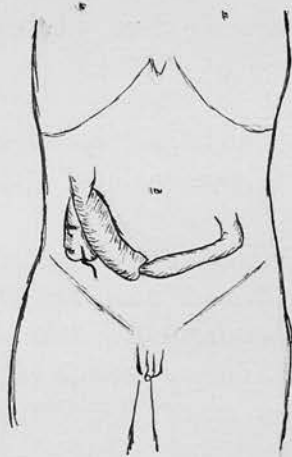
Other organs normal.

No. 18

Bobt. Brown. Aged 12 years. July 11. 1892.

Post Mortem Notes Only -

Well made muscular boy. On opening the abdomen a little fluid was found in the cavity, there was recent peritonitis over the lower half of the abdomen glueing the distended coils together. When these were unravelled, an intussusception was found lying over the caecum as in this diagram. It was found to have started in the ileum about a foot from the ileo-caecal valve. It was the size of a Cambridge sausage, purplish grey in colour. It could not be reduced. The intestine both above and below it was inflamed, and the mucous membrane purple with numerous effusions into the submucous coat. There were no tuberculous ulcers found in the intestine but the mesenteric glands were all enlarged and most of them contained cretacious masses. The internal organs were natural, there was no sign of tubercle anywhere. The brain and spinal cord were not examined.



No. 19.

Feb

Gertrude Eady. Aged 5 months. Admitted 16.1893.

History. Child quite well on the morning of the 16th. but the mother did not think the bowels had acted so gave the child some manna. After this the child seemed to be in pain, two motions were passed and then some blood was seen, bright blood was again passed so she brought the child to hospital.

Previous Health. Has been good, a strong well nourished child.

On Admission. An intussusception was discovered reaching almost down to the anus. 12 ounces of warm water were injected into the bowel and the lump disappeared. It however came down again 4 hours later and was again reduced and this time could not be felt per rectum.

Feb. 17. About 9 a.m. passed some blood and slime, at 11 a.m. a tumour felt extending up from the R. iliac fossa. The abdomen was not distended, tense, or tender. Small doses of opium given.

Feb 18. The intussusception was reduced by manipulations under chloroform, inflation having been previously tried. A normal motion was passed in the evening.

Feb. 20. Nothing to be felt in the abdomen, child well.

" 23. Discharged.

(What the nature of the manipulations were is not stated, nor if the abdomen was opened.)

April 7th. 1893. Gertrude Eadie. Aged 1 year.

The child, an old patient who had been in for intussusception and sent out as cured, was brought into the waiting room in a collapsed condition and died in an hour. The child which had been under observation in the Out Patient Department, had been quite well till early morning on the 7th.

Post Mortem Notes.

Nothing to account for death found, no signs of intussusception. Some patches of emphysema and collapse in both lungs.

No. 20

Walter Holmes. Aged 2½ years. Admitted Feb. 23. 1893.

History. The child had been attending the Out Patient Department with rickets and bronchitis.

He had been constipated for some days and on the 23rd. while straining at stool, he was siezed with abdominal pains and began to vomit.

On Admission. At 7 p.m. Rather collapsed, there was the usual sausage shaped tumour on the left side, , nothing felt per rectum, but there was a discharge of mucus and blood.

At 7.30 p.m. He was anaesthetised and a pint of water injected, the tumour altered its position and lay obliquely from the R. iliac fossa to the umbilicus, but was not reduced. Distinct lumps could be felt outside the intussusception and forming part of the lump. No further attempts were made.

11 p.m. Abdominal section was performed and the intussusception was gradually reduced, but enlarged glands rendered this difficult. The last structure to be reduced was an enlarged gland. The small gut was extremely oedematous and deeply indented by the pressure of the enlarged glands. The child was restless and passed no urine.

Feb. 24. Catheter passed no urine, no action of the bowels. Died at noon.

Post Mortem Notes.

Body well nourished, no peritonitis or effusion found. The caecum was greatly congested but resilient. The last foot of ileum was a deep claret colour, it contained some faecal material but there was none in the bowel below. The mucous membrane was very congested, the Peyer's patches and solitary glands were nearly black, there was a slough commencing at one place. The enlargement of the Peyer's patches and solitary glands was present but marked to a less extent higher up the ileum.

The mesenteric glands, especially those in connection with the lower part of the ileum were enlarged and varied from the size of a cherry to that of a walnut.

On section they were caeseous, and where part of the gland remained it was deeply congested. The condition of the glands seemed much older than that of the Peyer's patches. There were no tubercular lesions discovered anywhere else on the peritoneum.

Tubercles found in both lungs and bronchial glands. The other organs normal, the brain not examined.

No. 21

Lydia Bouser Aged 12 months. Admitted Mar. 1. 1893.

History. For three weeks frequent movements of the R. side of the face, neck and right arm have been noticed, but there has been no convulsion. There was diarrhoea alternating with constipation, no vomiting, no abdominal pain. No blood passed per anum. The child has been very apathetic for 24 hours before admission.

On Admission. Movements had ceased. There was a protrusion of mucous membrane from the anus, easily reduced, the anus being extremely patulous. Even after reduction a mass could be felt per rectum. Nothing was felt through the abdominal wall. Next day there were no symptoms of obstruction, but the mass being still felt, the rectum was injected with warm water. During the injection the child began to vomit for the first time and continued to do so. The vomit became faecal and the child died five hours later.

Post Mortem Notes.

Well nourished child weighed 14½ lbs.

On opening the abdomen a large amount of watery fluid escaped, with flakes of lymph and mucous.

There were some adhesions between the coils of intestines especially on the left side. There was a large intussusception in the bowel reaching nearly to the anus. It formed a tumour of the usual shape lying almost vertically to the left of the middle line.

Anteriorly there was a rent in the wall of the sigmoid flexure, through which very oedematous mucous membrane of the anterior layer of the intussusceptum protruded.

The intussusceptum itself was hard to reduce because of adhesions. The caecum was found at its lowest part. There was nothing to shew the cause of the invagination, the mesenteric glands generally were slightly enlarged, no tubercle found in them. One gland near the caecum was swollen and intensely congested, the rest of the intestine was healthy.

sketch

No. 22.

Male. Aged $2\frac{1}{4}$ years. Admitted Mar. 11. 1893

History. The child was breast fed till 13 months old. When 9 months old he had a sudden attack of pain in the belly, vomiting and the passage of blood in his motions. A similar attack occurred when he was 12 months old and at that time a lump was noticed in the abdomen.

Four or five other attacks of a like nature had taken place since then. At first the child was quite well between the attacks but lately he had suffered from constipation and diarrhoea. A few days ago he was again taken with pain in the belly and 24 hours later passed blood with his motions. Two days later he began to vomit.

He was then taken to hospital as no improvement was seen.


On Admission. A fairly well nourished child with a small moveabl lump in $\frac{1}{2}$ the right side of his abdomen.

The abdomen was not distended and the walls were lax, slight tenderness over the lump. For the next 14 days he suffered from frequent pains and passed blood, the lump varied in size and position. Under an anaesthetic it was found to take up the position of the ascending colon. As he had lost 3 lbs in weight since admission, it was decided to operated.

Operation. Mar. 27. Laparotomy through the right linea semilunaris and the tumour readily brought out. It was found to be an intussusception of about 2 ins. of ileum into the caecum, of the ileo-colic variety with the appendix not engaged. A vertical incision was made in the wall of the ascending colon, for 2 ins. The intussusceptum was thickened and solid like an on uteri. It was ulcerated and the lumen reduced to the size of a goose-quill.

Reduction was out of the question and it was necessary to remove it. The ileum above the neck was stitched with Lembert sutures to the large bowel, and $1\frac{1}{2}$ ins. of intussusception were then cut away with scissors. The mucuos coats were united within the colon with interrupted silk sutures. The lumen with a little stretching admitted the forefinger.

Convalescence was steady and no more blood was passed. During the following year the child had to be treated in hospital for constipation, He was seen quite well on Feb. 7 1897.



a Sutures
c Apex of Intussusception
B line of removal

No. 23.

John Evans. Aged 7½ years. Admitted May.17.1893.

History. On April 25rd child had pains in the elbows and knees spots on the elbows, elbows were swollen (rheumatism ?) He had pains also in the stomach which lasted 10 days, he passed some blood 4 or 5 times, had diarrhoea and was sick. He got better but May 14th, was siezed with the same pains. He was rather better next ~~morning~~ evening. On the 16th. pain in the stomach and sickness came on and he is able to keep nothing down. The bowels have lately been costive and the motions hard, an enema was given and a little blood come away.

On Admission Pulse 120, Resp. 24, Temp. 99'2.

A healthy looking boy lies with legs drawn up. The abdomen moves very little with respiration, not distended, a tumour can be seen 2 ins. below and to the R. of the umbilicus. The tumour is 3 by 2½ ins. and quite dull. Per rectum bowel feels large, a great quantity of mucus.

A half pint enema given and the tumour moved but not reduced.

May 18. Choloroform given, pulse was 180, tumour less distinct than yesterday. The abdomen was opened and a quantity of ascitic fluid escaped. The tumour was brought out of the wound, it was an intussusception of the small intestine, 9 ins. long, very congested and almost sloughing in parts. Resection of gut was performed.

The two ends were sewn loosely together and the lower end invaginated into the upper and a suture applied all round the exterior. A drain was put in and the abdomen closed. The patient was considerably collapsed.

5 p.m. Not recovered from the operation, very collapsed. Temp. 102'8, pulse not felt at wrist.

Transfused but died at 9 p.m.

No Post Mortem Notes to be found, an examination is stated to have taken place.

(It seems very probable that the injection on the 17th. caused a rupture of the gut and that this was the cause of the rapid change for the worse, and accounted for the escape of ascitic fluid at the operation.)

No. 24

Flo. McCormack. Aged 7 months. Admitted July 4. 1893.

History. Taken ill with diarrhoea and vomiting on the 2nd. and this has continued till admission. The bowels have moved 14 times but no vomiting since admission. Temp. at time of death 105'8. Diagnosis - gastro-enteritis.
Post Mortem Notes.

Body well nourished weight 9½ lbs. At the middle of the small intestine was an intussusception which was easily reduced. The peritoneum being quite smooth, this portion of gut was however intensely congested and had the appearance of having been strangulated. On opening the gut the mucous membrane was injected at the above mentioned part, otherwise the intestines were normal. The mesenteric glands were rather large but not tubercular. Other organs normal.

No. 25.

John Simmonds Aged 5 months. Admitted July 6. 1894.

History. On the 4th. vomiting began and has continued till the present time, the vomit is greenish and offensive.

The bowels acted last on the 4th. at 7 a.m. There has been a good deal of pain in the stomach today.

Previous History. Has been a healthy child, no other illness. 2 other children well, no miscarriages, was suckled till a week ago, has had milk and Mellins food since.

On Admission. Seems in great pain, cries and tosses about, passed some mucus and blood after admission. Nothing at first felt in abdomen. Per rectum a conical mass like a multiparus os uteri felt. At 3 p.m. the bowel was injected with warm water under chloroform, and the mass disappeared from the rectum. Under the anaesthetic a tumour was felt in abdomen.

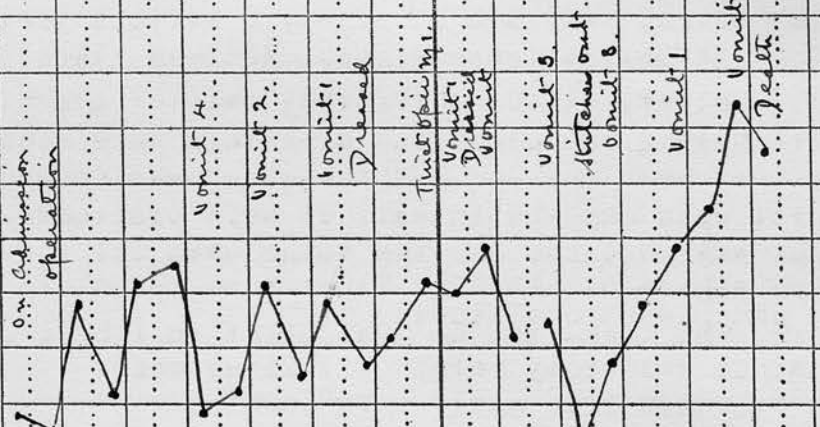
At 6.45 p.m. the swelling again found in the rectum.

Laparotomy was performed while hot water was injected per rectum. The intussusception was reduced in the abdomen. The intussusception was large reaching from the ileo-caecal valve to the rectum. The child seemed relieved after the operation but suddenly sank and died at 11.30 p.m.

No Post Mortem was allowed.

No.	NAME	AGE	WARD	UNDER CARE OF															
	W ^m . Simmons	7 Mos	alice	W. Lees.															
DISEASE	Intussusception				RESULT	Death													
DATE,	1	2	3	4	5	6	7	8	9	10	11	12	13						
Sept.																			
C°	F°	M:	EM:	EM:	EM:	EM:	EM:	EM:	EM:	EM:	EM:	EM:	EM:	EM:	EM:	EM:	EM:	EM:	EM:
107°	106																		
41°	105																		
	104																		
	103																		
	102																		
	101																		
	100																		
	99																		
	98																		
	97																		
	96																		
	95																		
	PULSE			140	140	144	140	84	124			114							
	RESP.							50	48										
	BOWELS	1	3	4	3	8	5	8	10	7	4	0	3						
	WEIGHT																		

N TO BE LEFT FOR BINDING.



No. 26

William Simmons Aged 7 mos. Admitted Sept. 1. 1894.

History. Taken ill last night at 7 p.m. with pain in the stomach, vomited very often during the night. Bowels moved last night, motion brown, no diarrhoea. Blood and slime passed at 4 a.m. this morning.

Previous History. One other child well aged 8. No previous illness, breast fed till now, was given a small piece of steak two days ago.

On Admission. A sausage shaped swelling felt running transversely across the abdomen. Vomiting frequently. After a rectal examination some blood and slime passed. At 2.30 p.m. the tumour was reduced by injection and then some blood and slime was passed.

8 p.m. the tumour returned. Laparotomy was performed and the greater part of the intussusception returned without difficulty but the part just above the ileo-caecale valve was tightly grasped and took a little force to reduce it. Natural motions passed after the operation.

Sept. 2. Better, two motions passed, no more vomiting.

" 3. Not looking well, eyes sunken, pulse rapid, temp. raised.

Sept. 5. Temp. still raised pulse 144, bowels open 3 times.

" 7. Wound healing, pulse and temp. high.

" 8. Worse, very sick at night, 8 motions yesterday bright yellow loose stools. Abdomen flaccid.

" 10. Better, stitches removed, calomel given,

" 11. During the night the dressings were seen to be wet, they were changed and the wound was found to have burst open and the intestines were protruded.

The gut was replaced and the wound sewn up, the edges shewed no signs of healing. Since then the child has vomited and passed one stool.

Sept. 12. The temp. ran up last night to 105'4, bowels not opened since yesterday morning, vomited once.

Sept. 13. Child died early this morning.

Post Mortem Notes.

No regular examination of the body allowed but the wound was opened and 2 ins. of the ileum and 3 of the caecum and large intestine were seen congested and echymosed, no peritonitis.

No.	NAME	AGE	WARD	UNDER CARE OF																						
	Wm. Yellow	9 Mos.	Alice	D. Penrose																						
DISEASE	Intussusception															RESULT Cured										
DATE	Mar.	11	12	13	14	15	16	17	18	19	20	21	22	23	24	25										
C°	F°	M.	EM.	EM.	EM.	EM.	EM.	EM.	EM.	EM.	EM.	EM.	EM.	EM.	EM.	EM.	EM.	EM.	EM.	EM.	EM.					
107°																										
41°	106																									
	105																									
40	104																									
	103																									
39	102																									
	101																									
38	100																									
	99																									
37	98																									
	97																									
36	96																									
	95																									
	PULSE		124	132	120	160	132		128	132	140	114	128	100												
	RESP.		26	16																						
	BOWELS		4	5	4	5	6	4	2	4	4	1	2	1	0											
	Urine.	Contained uric acid but no albumen																								
	Wettest																									
	DATE	DIET					TREATMENT					DATE					DIET					TREATMENT				

ARGIN TO BE LEFT FOR BINDING.

Urine. 1
Operative

Diarrhea

Diarrhea

Diarrhea

Diarrhea

Diarrhea

Diarrhea (2)

Diarrhea

D

D

D

D

D

D

D

No. 27

Thos. Dellow. Aged 9 months. Admitted Mar. 11. 1895.

History. Took food well till yesterday when he suddenly began vomiting and has continued to do so since. There has been no diarrhoea but last night at 11 p.m. blood and mucus was passed, this has been repeated in small quantities twice since then.

Previous History. Full time, breast fed, had some potato and gravy shortly before he vomited, easy labour, 3 other children, 1 died at birth, 1 at 8 months he had been passing blood and when the Dr. saw him it was too late to operate (intestinal obstruction), the third child is not strong. This child has had bronchitis but no other illness and has till now been healthy..

On Admission. Fat child good colour, abdomen not tense, an indefinite mass felt on the L. side. At 1 p.m. examined under chloroform and a pint of water injected into rectum.

3.30 p.m. A tumour found in the splenic region when under chloroform again.

4.15 p.m. Abdomen opened in middle line, an intussusception found, the lower end of the ileum being invaginated into the large intestine. The invaginated part was congested and oedematous. Reduction was effected and the wound closed. Before reduction a small elongated depression was noticed just outside the intussusception.

Mar. 14. Temp. rose to 104'2 at midnight, very restless all night, dressing changed.

Mar. 15. Wound rather red, pus in a stitch hole, two stitches removed, seems only superficial.

Mar. 19. Another stitch removed yesterday and one again today, the lower part of the wound strapped. Child takes food well, motions contain some mucus..

Mar. 20 Two more stitches removed, slight discharge.

" 26. Lower part of wound has closed.

" 29. Upper part of wound not quite healed still strapped.

April. 10 Wound healed.

" 24. Child left hospital Strapping off, there is slight bulging.

No. 28

John Wynn. Aged 8 months. Admitted Oct. 10. 1895.

History. In the afternoon of the 26th Sept. was suddenly taken with pains in the belly, vomited then, and off and on for the next 7 days passed a little slime

but no blood. Brought to the Out Patient Department on the 3rd inst. but the child seemed well and nothing was discovered in the abdomen, a little blood was passed on this day. It appears to have been brought up again sometime, being sick and passing slime, the mother was told to come on the 7th but did not come till the 10th. as the vomiting stopped on the 6th. and did not start again till the 10th. The bowels have moved every day till today.

Previous History. Full time, breast fed, no previous illness. Three other healthy children, no miscarriage.

On Admission. Child does not look ill, pulse 80.

Seems in pain and draws up its legs. Abdomen resistant and distended, no lump felt, resistance more marked over the descending colon. Peristalsis seen passing from the R. to L. above the umbilicus. Under an anaesthetic a typical sausage like swelling felt. Per rectum at first the apex of the intussusception could be felt against the internal sphincter, an hour later it could only be felt through the wall of the rectum lying in the recto-vesical pouch. The finger came away blood stained.

Operation. Median incision below umbilicus, intussusception found up by splenic flexure which was occupied by the caecum. The bowel congested, no adhesions, some petechiae on caecum. Some saline left in belly.

Oct. 16. Making an uninterrupted recovery.

" 22. Discharged.

No. 29.

A Male. Aged 1 year and 8 months. Admitted Dec. 17. 1895.

History. Quite well till Nov. 30th. when, while being nursed he stretched himself backwards over the arm of his nurse and tried to break free. Shortly afterwards he vomited, and again next morning, but did not seem in pain. Pain began Dec. 1st. and blood appeared in the motions first on that day. Sickness and pain have been intermittent till admitted.

On Admission. The abdomen was not distended, but in the region of the transverse colon, a sausage-like tumour was to be felt, it was felt to harden and was visible to the eye. The general condition was good considering the length of the history.

Operation. An incision was made in the right linea semilunaris. An ileo-caecal intussusception was found and easily reduced, the chief obstacle being the presence of enlarged glands.

Recovery ^{after} operation was satisfactory, but on the 31st. Dec. when about to leave the hospital, he took varicella and was not discharge till Feb. 1st.

On April 10th. He was readmitted with Diphtheria. He has a slight bulging of the lower part of the wound.

No. 30

Margaret Clarke. Aged 5 mos. Admitted Feb. 11. 1896.

History. Quite well till 7 p.m. on the 10th. inst. when violent vomiting occurred, at first of curdled milk, afterwards the vomit smelt like faeces. Blood and slime passed at 11 p.m. and twice subsequently.

On Admission. Fat child not looking particularly ill, does not seem in great pain. The abdomen is supple and not distended. There is a sausage shaped tumour passing upwards from the caecal region across the umbilicus. Nothing felt per rectum.

Operation. 5 p.m. R. ilea semilunaris opened and an intussusception 3 ins. in length found, very congested, easily reduced. The caecum and lower part of ileum were much thickened.

Feb. 12. Child gradually got worse, bowels moved thrice.

" 13. Died at 1 a.m. about 30 hours after operation.

Post Mortem Notes.

Examination only took place through the wound.

No general peritonitis. The caecum and lower 2 ins. of the ileum and the appendix were purple and thickened and on the caecum were many subserous haemorrhages.

On taking the caecum between the fingers a mass like a polypus could be felt inside, this proved to be the swollen lips of the ileo-caecal valve. There had been no retraction of the intussusception. The mucous membrane was intensely congested and haemorrhagic for 5 ins. below and 2 above the valve. There was no ulceration. The mesenteric glands were a good deal congested. The other abdominal viscera appeared to be normal.

No. 31.

A Male. Aged 9 months. Admitted March 11.1895.

History. During the 24 hours preceeding admission, he had suffered from abdominal pain, had vomited, and passed three motions containing blood.

On Admission. A well nourished child, he had been languid and out of sorts for the last 4 days. The abdomen was not distended, but an indefinite tumour was to be felt on the left side. At 1 p.m. under an anaesthetic a warm water enema was given and the tu^mour seemed to disappear. At 3 p.m. as the condition was not considered satisfactory, an anaesthetic was given and the tumour felt in the splenic region.

Operation. Median laparotomy and the intussusception found and reduced after some minutes of traction and compression. It was of the ileo-caecal variety, a portion of the ileum, with the caecum and appendix, being engaged in the colon. The bowel was very oedematous and the chief obstacle to reduction was formed by the mesentery which contained some enlarged glands. The thickened ileum was greatly indented by these glands and shewed no signs of resilience.

The recovery was uninterrupted, and the child discharged well on April 24th. and was kept under supervision for the next 6 months.

No. 32.

William Richards. Aged 10 mos. Admitted Feb. 27. 1897.

History. On Feb. 19 at 6.30 p.m. had bloaters for tea. At 9 p.m. on the 20th. awoke ~~for~~ screaming and passed blood, has been vomiting ever since directly after food and has had paroxysmal screaming fits. No proper motion passed since the 19th.

On Admission. A thin pale child, apathetic. The abdomen is distended and a well marked sausage shaped tumour is felt in the L. hypochondriac, lumbar, and iliac regions. Occasionally the child becomes rigid and screams. Per rectum ^{no} nothing felt but the finger is covered with mucus and blood.

At 2.30 p.m. Chloroform given and warm water injection tried and tumour disappeared from the L. lumbar region and was only vaguely felt in the epigastrium. A $\frac{1}{2}$ head of 2 feet of water was used.

At 8.30 p.m. under Chloroform injection was again tried and it was thought that the tumour receded to the R. lumbar region. During the night the child vomited altered blood and seemed to be in pain.

Feb. 28. The surgeon did not think it advisable to operate as the child was moribund. The child died an hour later.

Post Mortem Notes.

Abdomen. The small intestines were moderately distended throughout with gas and fluid faeces. Just below the stomach was the intussusception. This was primarily an ileo colic one, the small intestine had passed through the valve which later had ~~inself~~ ^{been} dragged in. About $2\frac{1}{4}$ ins. of small gut and $2\frac{1}{2}$ ins. of colon was invaginated. The appendix was completely invaginated (from the diagram it was turned inside out) The head of the intussusception was in a sloughy condition, but matting had prevented the escape of intestinal contents. The layers were matted sufficiently to render it impossible to reduce the intussusception without rupture of the wall. The mesentery and glands behind the caecum had become considerably enlarged.

No. 33

Thos. Rose. Aged 3 years 1 month. Admitted Ap. 26. 1897.

History. Bleeding from the rectum for one day when 9 mosd Old, accompanied by vomiting. 2 mos. ago bleeding for 1 day again occurred. Since last Feb. has frequently been doubled up with abdominal pain. Yesterday passed half a tea cupfull of bright red blood with no straining, has vomited and this morning passed more blood.

Previous History. Brother was operated on by Mr. Pitts for intussusception 4 years ago and is now quite well. Father is epileptic.

On Admission. Fine looking healthy child, no distress. On Ap. 28 a transverse mass noticed running across the epigastrium, this seems to alter in hardness at times.

The abdomen is quite supple and not tender.

Ap. 29. Under chloroform the abdomen was opened and the intussusception reduced. The caecum was opened and the valve was examined together with the intussuscepted portion of the ileum. The wound in the caecum was closed and the appendix removed.

Ap. 30. Child gradually got worse and died today.

Post Mortem Notes.

Abdomen. Wound healthy, no peritonitis. The lower end of the ileum had been stitched to the anterior abdominal wall. One of the stitches in the caecum had cut out and a little pus had formed about the stitch, but no water escaped on filling the gut. The lips of the ileo-caecal valve were very swollen and congested and projected nearly $\frac{1}{2}$ and inch into the caecum. The mucous membrane was injected for 2 ins. above the valve.

The glands about the back of the caecum had enlarged to the size of a small walnut and were intensely congested. The other organs were normal.

No. 34

Beatrice Philip. Aged 5 mos. Admitted June 17. 1897.

History. Quite well till June 14 when suddenly taken with pain at 3 p.m. and vomited. Bowels were opened once that afternoon and once the following morning but not since then. On the 15th. the vomit became bright yellow in colour .

Previous History. Only child, full time, instrumental labour, fed entirely on the breast.

On Admission. A well nourished child, much collapsed, vomited some yellow material without faecal odour.

Abdomen. Seemed full but supple, peristalsis seen.

A sausage shaped tumour was easily felt above the umbilicus, not apparently tender. Per rectum the tip could not be felt, but the mass was palpable through the rectal wall.

Operation. Under chloroform injection was tried with warm saline which seemed to reduce the mass a little. A 3 in. incision was made in the R. linea semilunaris. Some 6 ounces of clear fluid escaped from the abdomen. So great was the distension of the small intestine that it was necessary to puncture it before going further. Some fluid and gas was let out and the wound in the intestine closed. The intussusception was then brought out. It was of the enteric variety which had passed some 3 ins. through the ileo-caecal valve. The intussusception was reduced with some difficulty and especially the last inch where the peritoneal coat gave way. The last part was much congested and a deep purple colour but owing to the state of the child it was decided to return it.

The small intestines needed a second puncture before they could be replaced. The wound was closed.

The child died about 4 hours later with a temp. of 105.

Post Mortem Notes.

The caecum was normally placed and not particularly mobile. The intussusception had been completely reduced. The small intestine for about 8½ ins. above the valve was deeply congested, while 2 ins. situated about 6 to 8 ins. above the valve were greenish purple and smelt very offensive, evidently gangrenous.

The peritoneum had split in two places over the gangrenous area. The Peyer's patches below the gangrenous portion were enormously distended and also throughout the ileum. The glands were not markedly enlarged.

No. 35

May Lamb. Aged 5 mos. Admitted June 17.1897.

History. Quite well till noon today, when as she being dressed, the mother thought she was going to have a fit, as she turned blue and began to scream and draw her legs up. At 2.30 she passed some blood and slime. At 3.30 she began to vomit.

Previous History. Family history good, full time, natural labour, bowels move 2 to 3 times a day.

On Admission. 8 p.m. well nourished child rather collapsed, the legs are not drawn up. The abdomen is flat and supple, a very distinct sausage shaped tumour is felt in the L. lumbar region and L. iliac fossa. It was not observed to harden. Per rectum the tip of the intussusception could be felt.

Operation. At 9.30 p.m. Chloroform was given and the intussusception reduced by manipulation through the abdominal wall. As a small vague tumour could still be felt through the abdominal wall in the hypogastrium, it was thought right to open the abdomen.

To everyones surprise it was found that the intussusception had merely been reduced from the lower into the upper part of the sigmoid. With the fingers in the abdominal cavity the intussusception was easily reduced, except at the last part where a little difficulty was encountered.

It was of the ileo-caecal variety. The operation lasted 25 minutes.

June 18. The child had been doing well when suddenly the temp. went up and the child collapsed and died about 3 p.m. → to 108.2.

Post Mortem Notes.

There was congestion of about 3 ins. of the large and the same amount of the small gut in the neighbourhood of the ileo-caecal valve. There was superficial ulceration round the valve. The solitary follicles were conspicuous and the glands rather enlarged. The mesenteries were very long. Nothing else of note.

No. 36

Philip Cegan. Aged 10mos. Admitted Oct.5.1897.

History. For six weeks has been fretful with occasional vomiting, bowels irregular, sometimes passing blood and mucus.

On Admission. Looks extremely ill, facies Hypocratica. Abdomen tumid, coils of intestine seen and an intussusception tumour easily felt and seen extending from the L.iliac fossa across the lower part of the epigastrium to the R.flank. Per rectum the tip of the intussusception could be felt just within the sphincter ani.

Operation, 2.30 p.m. Water led into rectum, 3 feet pressure allowed, median laparotomy. The intussusception could not even be reduced from the rectum.

An opening was made in the small intestine after fixing the bowel to the abdominal wall.

Oct.6. Child died about noon.

Post Mortem Notes.

Examination only allowed through the wound. The L flank, L.iliac fossa, and pelvis were filled with the intussusception, which had its highest point in the middle line of the epigastrium and its apex at the anus. An attempt to reduced it in situ completely failed. After removal it was found impossible to reduced it until the greater part of the receiving layer had been cut through, even when force ~~was~~ sufficient to rupture the gut had been used. The difficulty was not due to adhesions, but to the great swelling and congestion of the advanced portion in the rectum, which was gripped tightly.

The apex was formed by ileum, about 4 ins. of which had passed through the valve before the latter was dragged in. The tumour measured 14 ins. before reduction.

On opening the gut the wall of the large intestine was found much thickened and the mucous membrane for 6 ins. below the valve was a deep maroon colour and shewed two or three linear ulcerations running an the long axis of the gut. The appendix was normal, not even congested although in the intussusception. The glands at the back of the gut were enlarged and slightly congested. The samall intestine was congested for about a foot above the valve. No cause for the intussusception could be found. The solitary and Peyer's glands were not obviously enlarged.

No. 37

William Tester. Aged 1 year 4 mos. Admitted Feb. 9. 1898.

History. Pains in abdomen for 3 weeks off and on.

The pain comes on suddenly and causes him to roll about doubled up, it lasts some hours and comes on about once a day. He vomited 5 times since yesterday, and only 3 times previously in the 3 weeks. This attack is much worse than the previous ones. Bowels regular but are sometimes slimy and offensive.

On Admission. A well nourished child - apathetic - facies not suggestive of abdominal condition, lies doubled up. Abdomen: not distended, moves with respiration. In L. iliac fossa a sausage shaped tumour in the direction of the descending colon, the lower end was just below the anterior superior spine, the upper end could be traced up and across the abdomen just above the umbilicus to the R. lumbar region. The R. iliac fossa seemed empty. The tumour was felt to harden on palpation. Rectal examination revealed nothing, semisolid faeces in rectum, finger came away blood stained.

8.30 p.m. A 20 ounce oil enema was given with no effect, later a glycerine enema was tried with the same ill success.

11 p.m. Chloroform given and the abdomen opened in the middle line, an intussusception found and was easily reduced with the exception of the last 3 ins. which had to be brought out of the wound and were then only reduced with difficulty. The caecum and adjoining part of the small intestine were much swollen, as were also the glands in the mesentery, no signs of gangrene. There was no adhesion between the layers.

The caecum at the base of the appendix seemed to have formed the apex of the intussusception. The appendix had no mesentery, the caecum had a long one. (meaning probably that the caecum was very mobile.) Morphia given.

Feb. 11. Urine ammoniacal, green - carbouluria, temp. 104. Bowels have moved 3 times.

Feb. 17. Some thickening still felt in R. iliac fossa.

" 23. Stitches removed.

Mar. 3. Quite well.

No. 38.

Robt. Pavett. Aged 5 months. Admitted June 8. 1898.

History. On May 26th. looked ill in the afternoon and at 7 p.m. passed a few streaks of blood in a motion.

For the next three days he passed pure blood three times each day. He seemed in great pain, crying, straining, and drawing up his legs. No blood passed since May 29, but for two days the stools have been dark and slimy. He began to vomit on May.28 and this lasted till June 4th.

Previous Health. Good.

On Admission. Looks ill and apathetic. Abdomen: is distended, visible coils of peristalsis seen, a mass - spleen ? - felt in L.hypochondrium, not well defined, not felt to harden with peristalsis. Nothing felt per rectum.

Operation. 7.p.m. Abdomen opened in the middle line. The caecum was absent from its normal position and the colon was not found. After the operation had lasted 1½ hours, during which time no intussusception was found and no cause for the trouble made out except distended small intestine, the abdomen was closed.

The child died at 8.50 a.m. June 8th.

Post Mortem Notes.

About half an ounce of serum in the peritoneal cavity, the small intestines were distended. The caecum had passed into an intussusception about 6 ins. long which extended from about the middle line of the epigastrium around the splenic flexure and terminated at the brim of the pelvis. The meso-colon was thus tightly stretched across the duodenum. At the operation a coil was thought to have passed into a retroperitoneal sac, this was the duodenum passing behind the meso-colon. The caecum and appendix seemed to have passed completely into the intussusception.

No. 39.

William Moore. Aged 6 months. Admitted July 16. 1898.

History. Perfectly well till last night at 8.30 p.m. when he began to scream at intervals of about 10 mins.

This continued all through the night. The bowels were opened at 8 p.m. yesterday and were quite normal but at 10 a.m. today only blood was passed. This has occurred twice since then. He has been vomiting frequently.

Previous History. Full time, breast fed but for the last two months has had occasionally Robb's biscuits, always healthy, an only child.

On Admission. A fat child, good colour, does not look ill, cries when disturbed. At 11.30 p.m. abdomen flaccid, no distension, no mass felt, liver and spleen normal, tongue clean. Rectal examination revealed nothing, the finger came away blood stained.

Child screamed several times and then went to sleep with no further symptoms.

July 19. Seems quite well again.

21. No further symptoms.

No. 40

Alfred West. Aged 9 months. Admitted Oct.31.1898.

History. Has been quite well till yesterday, when he suddenly began screaming and drawing up his legs. Two hours later he passed some blood stained mucus. A Dr.saw him. Next morning the abdomen became distended and the screaming continued. He was becoming exhausted when the Dr.saw him again and diagnosed an intussusception.

He is the 7th. child, 4 have died (causes unstated) no tubercle in the family.

On Admission. Child was fairly well nourished, was collapsed and apathetic, pulse weak. An elongated sausage like tumour felt in the upper part of the abdomen. The R.ilic fossa was very empty. A body could be felt per rectum.

Operation. The abdomen was opened in the middle line. The intestines were removed temporarily from the abdominal cavity. The intussusception was found, its apex was at the ilæo-caecal valve. The intussusception was reduced. The peritoneum was roughened and sodden.

Nov. 2. No return of any of the symptoms but the temp.rose and the child died at 5 a.m.

Post Mortem Notes.

Examination only through the wound. Very little found except congestion of the intestine round the site of intussusception. The wall of the caecum was sodden, and congested, and ulcerated on the side opposite the valve which was swollen but not perforated. No general peritonitis.

No. 41

John Sawyer. Aged 1 year 9 mos. Admitted Dec. 2. 1898.

History. Quite well till 1 a.m. today when he screamed out suddenly and then tried to defaecate but nothing passed. Pain continued all day with exacerbations, no motion was passed though straining was frequent. He vomited many times.

Previous History. Full time, natural labour, youngest of 6 healthy children, no other illness, is still breast fed, no previous constipation.

There is a family history of consumption.

On Admission. Well nourished, good colour but does not look well. Abdomen rather flat, quite supple. R. iliac fossa is empty. In the R. hypochondrium there was a tumour about 2¼ ins. long lying transversely below the costal margin, it seems harder at one time than at another. Child is vomiting. Per rectum no tumour is felt but blood stained faecal matter comes from the anus.

Chloroform given and air pumped into the rectum with a Higginson's syringe. With a stethoscope the air was heard in the bowel more distinctly in the R. iliac fossa than elsewhere. Abdomen became distended and the tumour disappeared, but was subsequently felt about the size of a large walnut in the R. lumbar region.

Operation. The abdomen was opened through the R. linea semilunaris on to the tumour: an intussusception was found and reduced with ease, the caecum containing the intussusceptum was raised to the wound and reduced. The lower end of the ileum had passed into the caecum. The lower end of the ileum was considerably swollen. Small doses of morphia given.

Dec. 5. Child doing well, bowels not open yet, no more sickness.

" 6. A glycerine suppository brought away a well formed motion.

" 15. Stitches removed, child made an uninterrupted recovery.

No. 42

1900

Laura Tomey. Aged 6 months. Admitted April.9.1900

History. Duration of abdominal pain and the passage of blood, is 4 days.

On Admission. Fat child, abdomen quite soft a large tumour easily felt following the course of the colon from the \varnothing R. to the L. iliac fossa. Child in a bad condition.

Operation. Under an anaesthetic, irrigation was practised with a pressure of two feet of water, with this and a finger passed through a small hole in the abdominal wall nearly the whole of the intussusception was reduced. The last three inches were however found to be gangrenous and were removed, the ends being then sewn together. The child collapsed and died about 12 hours after the operation.

Post Mortem Notes.

In the R. iliac fossa was a good deal of plastic peritonitis, and a small amount of purulent fluid at the site of operation. The whole gut was discoloured, the various coils adhering to one another. About 2 ins. above the ileo-caecal valve, the gut had been divided and sutured. Immediately below the suture line was a hole with ragged edges admitting the tip of the little finger. The gut for about 2 ins. below this was gangrenous and the caecum and appendix almost black and quite rotten. The other viscera were normal.

No. 43

Eric Croner. Aged 2 years. Admitted April 4. 1901.
History and ~~of~~ state On Admission not noted.

Brandy a dram given, rather collapsed, temp. 98'6,
pulse 144

Operation. Very little anaesthetic. Abdomen opened
and an intussusception found about 8 ins. long, of
small intestine. The bowel was brought out and the
intussusception reduced and gut returned. Portion of
gut very oedematous at commencement of the operation.

Fed hourly with milk and water.

April 5. Doing well.

" 8. Catheter had to be passed to draw off
water, circumcision done, and glycerine enema given.

Ap. 9. Temp. slightly raised.

" 10. A 1000 units of antitoxine diptheritic given

" 14 Fomentations to penis continued.

" 15. Stitches removed, wound healed.

" 25. Went out of hospital.

No. 44

William Franklin Aged 11 years. Admitted May 11. 1901.
History. On April 28 he had severe abdominal pain which was paroxysmal and accompanied by vomiting. Bowels opened by enemata on the 6th inst.

Previous History. Grandfather on mother's side died of phthisis, has had measles, whooping cough, and chicken pox.

On admission. Thin boy looks ill, temp. 99, pulse 72, Resp. quiet. Abdomen distended, soft and flaccid, no peristalsis, no resistance or tumour felt. Nothing felt per rectum. Bowels opened by enemata much mucus came away.

May 14. Enema rash.

" 16. Visible peristalsis and paroxysmal pain.

" 17. Vomiting, no evacuation of bowels in spite of enemata.

May 18. Operation. Abdomen opened and a chronic ileo-caecal intussusception found and removed, the gut being sutured together.

There was a good deal of diarrhoea after the operation but otherwise the child did well till June 6, when vomiting began again with fresh pain and more visible peristalsis. A well defined tumour felt in the R. iliac fossa.

June 8. Operation. Abdomen again opened and the suture line at the junction of the gut was found to have contracted and swollen so as to form an almost complete obstruction. An enterectomy with subsequent end to end suture done.

June 12. Faecal fistula, sepsis.

" 26. Small drainage tube opening made to the left of the middle line. Child was now extremely exhausted by his suppuration.

July 1. Child died.

Post Mortem Notes.

On opening the abdomen, the coils of intestine were firmly united to each other and to the abdominal wall. Four separate collections of pus found. 1 the largest reaching from the R. iliac fossa to the upper limit of the R. kidney, destroying the psoas muscle and laying bare the nerves; 2 a small collection in the L iliac fossa behind the sigmoid; 3 a small faecal abscess in direct connection with the sutured bowel; 4 a small collection of pus among the coils of small intestine. The bone bobin inserted at the second operation was not found. A portion of the suture line was black with dense adhesions round about. The mesenteric glands were enlarged.

No. 45.

Daniel Frue Aged 11 months. Admitted May 12. 1901.
History. Child suddenly taken ill on the 8th. with pain, sickness, and restlessness. On the 9th. passed a motion like "raw meat", the vomiting has continued in spite of medicine.

Previous History. Full time, instrumental, labour, first child, breast fed with biscuits, oranges, apples etc. since the 7th month.

On Admission. Child well nourished, collapsed, cold extremities, fontanelle depressed. Abdomen rather distended, R. iliac fossa empty, rest of abdomen rather rigid, pulse 144. temp. 99.

May 13. Median laparotomy and an intussusception 2½ ins. long brought out of the wound. It was of the ileac variety and could not be reduced. The coils of small intestine were tapped and then enterectomy performed. The ends of the gut were stitched to the abdominal wall which was then closed round. Child died at 6.15 p.m.

In the excised portion, the swollen apex of the intussusception was found to prevent reduction.

No. 46

Edith Moore Aged 6 months. Admitted May 24. 1901.

History. Quite well till May 23 when at noon she became cross and drew up her legs as though in pain. Bowels moved ~~not~~ at 7 p.m. when she passed a quarter of a pint of pure blood, no slime. A Dr. sent here to hospital.

Previous History. Full time, natural labour, breast fed with Robbs biscuits in addition for the last 3 mos. Is the last of 4 children, no other illness, not costive.

On Admission. Well developed child, crying too much to be examined without chloroform. A sausage shaped tumour felt running across the upper part of the abdomen in R. hypogastrium and epigastrium. R. iliac fossa empty.

Operation. A pint of saline with an ounce of brandy was injected into the bowel and the lump driven up into the R. iliac fossa. A small incision now made and the finger introduced and reduction effected. A large gland was felt in connection with the lower part of the caecum which was thought to have caused the intussusception. The abdominal wound was closed.

May 25. Not sick after operation, slept well, no pain, stools dark in colour, mother comes to feed child.

Dec. 28. Patient sent out in garden yesterday.

" 29. Sent home.

No. 47

Henry Buchanan Aged 7 months. Admitted May 26.1901. History. On May 25, ~~he~~ was suddenly taken with pain in the belly and screamed all night with the pain, vomited, and passed blood several times. He vomited this morning and was brought to hospital at 2.15 p.m.

On Admission. Well nourished infant, breast fed supplemented by Allenbury's feed. Temp.98, pulse140. Paroxysmal abdominal pains, passing small quantities of dark blood.

Abdomen: large lump felt in the L.iliac fossa, impaired note on percussion, the lump gurgles on pressure.

Per Rectum an intussusception felt 2 ins. from anus.

Operation.4 p.m. The rectum was injected with 14 ounces of boracic solution. An incision made in the L. linea semilunaris, some blood stained fluid in the peritoneal cavity. The reduction was accomplished by manipulations only with great difficulty, many splits being made in the peritoneal coat, a few of which needed suturing. All the prolapsed gut was small intestine, there were many inches of dark purple ileum. The operation lasted an hour. The child became steadily worse and died at 7.50 p.m.

Post Mortem Notes.

A little blood stained fluid in the pelvis. The omentum had been stitched to the wound at several points. Many coils of small intestine had lost their polish and were found sticking to the wall of the ascending colon. The caecum and ascending colon were in their normal position but freely moveable, the peritoneum being dragged forwards into a long meso-colon. The lower 4 ins. of the ileum, the caecum, and the lower few inches of the ascending colon, were a deep purple colour. The peritoneum being dull throughout this area. There were patches where the peritoneal coat had been ruptured allowing the muscular or mucous coats to be seen through. Some of the ruptures had been stitched up. Some haemorrhages were scattered about.

On opening the gut, many submucous haemorrhages were found.

The solitary glands stood out prominently. The mesenteric glands were enlarged and acutely inflamed.



No. 48

Alfred Milton. Aged 5 months. Admitted July 16.1901.

History. Mother noticed child was very cross on ~~Saturday~~ ⁷ the 14th. in the afternoon, vomited when ever it was put to the breast. Diarrhoea had preceeded the ~~region of the~~ ^{blood was noticed on the evening of the} 14th, but no vomiting. Blood was no-ticed on the evening of the 14th and also on the two following days, no motion came with it. The vomiting continued and the child lay with its legs drawn up and appeared in great pain.

On Admission. 9 p.m. Temp.100, vomiting, a lump could be felt in the middle line below the margin of the liver.

At 10.15 p.m. Operation. Reduction was attempted by water pressure - briny 4 ounces to saline a pint. a small incision was made in the R.ilicac region. Manipulation through the incision made out a large intussusception.

This was four fifths reduced by water pressure at a height of 2 feet, when reduction was almost complete the bowel burst and the injection spurted through the wound. The incision was enlarged and bowel taken out of the abdomen. Reduction by manipulation found impossible.

The large intestine had given way and allowed the escape of fluid. Clamps were applied above and below the intussusception which was excised. An end to end anastomosis with a Murphy's button performed. The wound in the abdominal wall was left open at the lower part. Ether minims 15 was needed as the pulse failed when the colon ruptured. The button was rather large for the size of the gut. The mesenteric glands in the region of the intussusception were greatly enlarged.

The intussusception was gangrenous. Child died at 2 a.m. July 17th.

No. 49

Emmie Haynes. Aged 8 months. Admitted Nov. 26. 1901.

History. Quite well yesterday, the bowels acted twice naturally and once at 7 a.m. today. At 10.30 a.m. today the child was sitting in bed when she suddenly began to scream. A quarter of an hour later she passed some slime and blood. There was a history of an attack of pain and the passage of slime and blood some 6 months previously.

On Admission. A lump was detected about the region of the splenic flexure.

Operation. 12.30 p.m. The mass was reduced to the right side by a warm water enema. The abdomen opened on the right side and the intussusception felt. The last portion was easily reduced. The caecum was withdrawn and examined, the intussusception had started at the ileo-caecal valve. The intestine was congested above the intussusception. The child was fed in the evening and the bowels moved the same night, some blood and slime passed.

Nov. 29. No bad symptoms, bowels act, no distension

" 31. Temp. 102, has bronchitis.

Dec. 4. Wound healed, no bulging, the bronchitis is better.

No. 50

Frank Reed. Aged 6 months. Admitted Dec. 23. 1901.

History. The bowels have been moving 4 times a day for 3 weeks; yesterday morning they acted as usual, a little later the child began to vomit and has continued to do so since. There is constant retching and the vomit has become faecal in smell. The diarrhoea was more marked yesterday and in the evening some blood and slime were passed. Since then the motions have been constantly stained with blood.

On Admission. Fat ~~Healthy~~ looking child, the abdomen not distended, moves slightly, R. iliac fossa feels empty. A mass is felt in the L. iliac fossa and also per rectum. After examination a motion of blood and slime passed.

Operation. Salt water irrigation largely reduced the mass to the right of the middle line. An incision made in the R. linea semilunaris and reduction of the last part of the bowel effected by the finger. The ileo-caecal valve was very oedematous as was also the neighbouring gut. The abdomen was closed, the child standing the operation well.

Jan. 1. No bad symptoms after the operation, stitches removed.

" 2. Discharged.

No. 51

William Pullen Aged 8 mos. Admitted Jan.11.1902.

History. Well till Jan.9 when at 5 a.m. he began to cry as if in pain, two hours later he vomited, the vomiting recurred frequently till the evening of the 10th. On the 9th he passed half a tea cup full of bright blood, he did this four times later. He had been given powders for constipation for 2 days previously.

On Admission. A well nourished baby, very ill, with an abdominal look, legs drawn up. Abdomen distended and tender, a mass felt in L. iliac fossa. The apex of the intussusception felt 2 ins. from the anus, blood passed after examination. Pulse 170, tmp. 98.

Operation. 1 p.m. Median incision below the umbilicus, afterwards prolonged upwards. Part of the intussusception was reduced with ease, but the rest could neither be reduced nor brought out of the wound on account of the tightness of the mesentery. The lower part of the abdominal wound was closed and a piece of gut above the intussusception fixed in the upper part of the wound and there opened, only gas escaped. The child was very collapsed and never rallied, dying about 2 hours after the operation.

Post Mortem Notes.

Slight Adhesive peritonitis causing adhesions of coils of gut. The apex of the intussusception was at the junction of the middle and lower thirds of the descending colon and could only be reduced as far as the splenic flexure. It was fixed by the entering mesentery which was afterwards found normal. The small intestine was seen entering the large about the middle line. The ileum above for 4 ins. or more was empty, blue, and congested, especially so in the case of the loop fixed to the wound. The returning layer of the intussusception was very swollen and the site of many submucous haemorrhages, the serous coat looked sodden. The entering layer was not much swollen but had submucous haemorrhages in it. No definite adhesions between the two layers. The meso-colon had one or two deeply congested enlarged glands. Other abdominal viscera normal.

No. 52

Fred. Mitchener. Aged 7 mos. Admitted Feb. 14. 1902.

History. Vomiting and melaena for 48 hours, fretful, screams and draws up its legs.

On Admission. Child is very fretful and has an abdominal facies, was very collapsed soon after admission. Faint feeling of something in the R. hypochondrium, temp. normal, pulse 160. No dulness, a large stool passed after a rectal examination, nothing felt.

Operation. A 3 inch incision made in the R. linea semilunaris and about 5 inches of an ileo-caecal intussusception drawn out of the wound and easily reduced, only very slightly congested.

Feb. 15. Child worse, great abdominal distension, bowels opened and flatus passed as a result of a magnesium sulphate enema early this morning, no blood.

Feb. 16. Child died early this morning.

Post Mortem Notes.

On opening the abdomen, the great omentum was found knotted together by fresh adhesions just beneath the wound and deeply congested. The gut below the last inch of ileum was contracted that above much distended. The intestines on each side of the ileo-caecal valve was much swollen and oedematous, but no ulceration was present. Both the lower part of the ileum and the ascending colon were purple.

No other abnormalities.

No. 53

Henry Pyatt. Aged 6 months. Admitted Ap.25.1902.

History. Child was quite well till yesterday morning at 3 a.m. when he suddenly screamed. A quarter of an hour later he passed one and a half wine glasses full of bright blood. He did not scream again till 4 p.m., when he passed about half a wine glass full of blood bright red in colour, he vomited at this time but not since. The screaming is frequent. He takes the breast quite well.

Previous History. Breast fed, instrumental labour, no previous illnesses.

On Admission. Fat well nourished child with abdominal facies. A large tumour felt in the middle of the abdomen.

Operation. 11 p.m. A 6 inch incision made in the L. linea semilunaris and the intestines turned out. An intussusception found about 8 inches long, of the ileo-caecal variety. Reduced with great difficulty especially at the end. A dimple of the caecum retarding the reduction.

Ap.25. A little blood passed after the operations
Died the same day. with no particular symptoms.

No Post Mortem Notes..

No. 54.

David Veglio Aged 8 months. Admitted Mar. 13. 1902.

History. The child was quite well until 3 p.m. on the 10th, he then began to scream and kick, and within a few moments he passed a motion which seemed to give him relief. Shortly afterwards however he began again to scream violently, at 4 p.m. he was sick; at 10 p.m. and again at 10.15 p.m. he passed bright red blood, the latter occasion it was accompanied by slime. The Dr. give a large enema of warm water but the baby continued to scream off and on till 7 a.m. next morning, having passed blood several times during the night. The vomiting and and the passage of blood has gone on ever since.

The child has become dull and heavy. He has been put to the breast at 2 hourly intervals.

Previous Health. Good, breast fed till 5 mos. old, since then has had bread potato and gravy in addition.

On Admission. The abdomen is too tense to feel anything by palpation. Per rectum a feeling of resistance is experienced in the middle line..

Operation. An incision was made in the middle line below the umbilicus and greatly distended small intestine at once escaped. As it was impossible to return this, it was punctured in two places and the flatus and faeces evacuated, the holes being sewn up with Lembert sutures. An intussusception reaching into the transverse colon was exposed. The Terminal portion was irreducible and very dusky. This portion was left outside the wound and the child sent back to bed

The child died at 9 p.m.

No. 55.

Ellen Wilkinson. Aged 6 months. Admitted May 5, 1902.

History. Vomiting since May 1, passage of blood by the rectum since May 2nd. Before this she was quite well, she was suddenly siezed with the vomiting which has continued ever since. The screaming has been frequent and blood and slime have passed two or three times a day.

Previous History. Full time, breast fed, the child was very constipated for the first month and used to have soap and water enemata, since that time the bowels have been quite regular. There are three other children quite healthy.

On Admission. A well nourished child looking extremely ill, temp. 101, pulse feeble, she does not cry. Passed blood twice since mid day. no vomiting since admission.

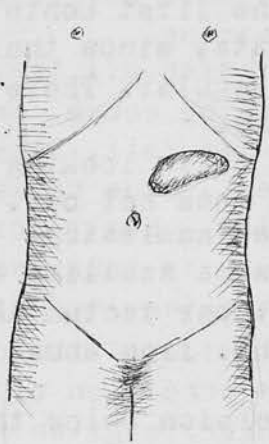
Abdomen slightly distended, a large swelling can be felt low in the L. iliac fossa; per rectum the intussusception can be felt 1½ ins. from anus, hard tense and bleeding.

Operation. A 3 inch median incision below the umbilicus made, and an extensive intussusception found. The small intestines were very distended. There was a double intussusception found, the first one, 2½ inches long was intussuscepted bodily. Reduction could not be completed so a portion of the ascending colone was brought to the anterior abdominal wall and fixed in position, an incision was made into the intussusceptum and a glass tube tied in. The child was very collapsed at the end of the operation, 4 ounces of saline was injected into the cellular tissue of the left thigh. The child only lived for 4 hours after the operation.

Post Mortem Notes.

The intestines uniformly distended as far as the end of the ileum, no signs of peritonitis, the ascending colon had been stitched to the abdominal wall and an incision made into it. The caecum and appendix had been reduced, but the lower 4 ins. of the ileum together with the commencement of the colon were still invaginated into the colon. The intussusception was fairly easily reduced except the last part.

About 2½ ins. of ileum were invaginated into the main intussusception so that for some distance the invagination was double. The bowel was very congested and filled with blood stained fluid. At no point was there any actual sloughing. The other organs were normal.



No. 57

Emma King. Aged 6 years 10 mos. Admitted July 31. 1902.

History. Complains of pain in the abdomen and wasting.

She was quite well till 9 weeks ago when she had an attack of vomiting accompanied with abdominal pain, she was rather constipated at the time. This has continued with intermissions ever since. During this last week it has been rather more severe as regards both the pain and the vomiting.

Previous History. One of 5 children all the others well, has had scarlet fever, whooping cough, measles.

On Admission. Addomen: Spleen not felt, liver at costal margin, a lump felt on the L. side corresponding in position to the descending colon.. Heart normal, the note at the base of the R. lung is impaired.

In the evening a mass was felt extending across the abdomen from the R. to the L. side of the umbilicus, attention was paid chiefly to the condition of the R. lung, a full account of which is given. (The child was in a Medical ward.)

Aug. 6. General doughiness in the upper part of the left side of the abdomen. Chest condition unchanged.

Aug. 11. Abdominal lump not felt. Full notes on chest - harsh breathing with prolongation of expiration all over.

Aug. 17. Sent to a convalescent home at Epsom.

" 29. Readmitted from Epsom as lumps were felt in the abdomen and the child was in pain. The child was a better colour than when in the ward last.

In the abdomen, a lump is felt above the umbilicus running from the middleline to the left hypochondrium. It appears to be solid, not tender, is smooth, regular, and rounded, no other lumps felt in the abdomen.

Aug 30. Chronic intussusception diagnosed.

At 9.45 p.m. Chloroform given and laparotomy performed, a 4 inch incision made in the L. linea semilunaris over the upper part of the swelling. The intussusception found and reduction attempted. After some manipulation there was slight apparent reduction but the apex was found to have ruptured through the wall of the descending colon. The intussusceptum was drawn through the rupture and excised. The colon and ileum were anastomosed by Maunsell's method and the abdominal wound closed.

The intussusception was of the ileo-caecal variety.

Aug 31. The child died at 1.10 p.m.

No Post Mortem Notes. No sectio allowed.

100

Fred. Philips. Aged 20 months. Admitted Nov. 21. 1902.

History. Quite well till yesterday at midday when he was thought to have twisted himself, but was playing about till 6.30 p.m. when he suddenly screamed and drew up his legs, no sickness, no action of the bowels.

Has had no constipation or diarrhoea lately.

On Admission. Plump child with abdominal facies. Examination impossible till chloroform given when a lump could be felt in the position of the hepatic flexure. Per rectum nothing felt. He was slightly sick afterwards.

Operation 10.30 p.m. A 2½ inch incision made in the R. linea semilunaris and an intussusception found about 1½ ins. long and situated up under the liver. It was easily reduced by the fingers in situ, the caecum was then drawn out and examined, the lower end of the ileum was reddened. The wound was closed in 3 layers.

Nov. 22. Bowels moved no blood, no sickness since the operation, till he was sick this morning after food. he is breast fed 2 hrly. He was restless and distended in the afternoon but was easier after having a good result from an enema.

Nov. 26. Progressing well, slight rise of temp., slight bronchitis.

" 28. Wound dressed found bulging, no pus, sometime during the day the wound burst open. This was only discovered at 11.30 p.m, the child had been playing all day and had had no symptoms. The intestines were washed with hot saline and returned, the wound closed.

Nov. 30. Pulse bad 140-160, distension relieved yesterday by a turpentine enema, bowels moved naturally today. Vomiting continuous since yesterday, looks sunken.

Dec. 1. Vomiting and worse, Tinct. iodi mins ½ tried every ½ hour for 4 times, vomiting stopped.

Dec. 3. Better yesterday. Today the temp. ran up to 105. at 10 a.m., pulse 120, resp. 60. Child gradually sank with signs of mischief at the base of the R. Lung, at

5 a.m. Dec. 4.

Post Mortem Notes. The R. pleural cavity contained 10 ounces of turbid red brown fluid, the pleura was coated with recent lymph all over. At the base of the R. lung was an infarct the size of a tangerine orange. L. lung and pleura normal. The peritoneum over the coils of ileum was dull and coated with recent flakey lymph. There was no trace of change referable to the intussusception. The localized peritonitis suggested lesions caused by the subsequent escape of the gut and its handling.

The wound was healthy a tag of omentum loosely adherent to it, only a trace of clear fluid in peritoneum. The intestines were on the whole, distended. The other organs were normal.

No. 59. John Stowers Age 3 mos. Admitted Dec. 31. 1902.

History. Illness had lasted 4 days, vomiting and passing blood per rectum.

On Admission. Child very ill, great distension of the abdomen. Under an anaesthetic a tumour was felt under the umbilicus.

Operation. A large intussusception was discovered, on attempting to reduce which the colon ruptured and a large resection became necessary. The child died an hour or two later.

Post Mortem Notes.

Fat well nourished child weighing 8½ lbs. The ileo-caecal valve, the ascending colon and two thirds of the transverse colon were missing, the ileum having been joined to the transverse colon by a Murphy's button. No loose flakes of lymph found. Child seemed otherwise normal.

No. 56 A.E.Griffiths. Aged 6 mos. Admitted May. 13. 1902.

History. At 11 p.m. on the 11th. inst. suddenly took sick and vomited, has screamed more or less continually ever since then. On the 12th. he was brought to the Out Patient department and given some medicine, the bowels moved in the morning and the motion was yellow, about an hour after reaching home he began to strain and passed some blood and slimy mucus. This condition of things went on till next day when he was brought up again, an intussusception diagnosed, and the child admitted.

Previous History. Father and mother healthy, is the youngest of 3. One died at 10 mos. from meningitis.

On Admission. Does not look ill and allows the abdomen to be examined. The belly is rather distended, and a swelling can be felt in the ½ L. Iliac fossa and umbilical region, moveable and slips about under the fingers. Per rectum the intussusception can be felt just within the internal sphincter.

Operation. An incision made in the R. linea semilunaris, while saline was injected per rectum. The last two or three inches had to be reduced by the fingers. The intussusception was of the ileo-caecal variety. The child stood the operation well, fed at once, no more vomiting.

May. 14. Doing well, no distension or vomiting

" 26th. Discharged wound healed.

sq. on same page as No. 56

No. 60 Lilian Jones. Aged 4 mos. Admitted Jan 4. 1903.

History. Jan 1st. Child seemed ill and was given a teething powder. Jan 2nd. Child vomited a great deal and passed some bloody mucus. Jan 3rd. More blood and mucus passed and the vomiting continues. Jan 4th. The condition of the child remains the same.

On Admission Child hollow eyed and rather collapsed. A lump felt in R. side of abdomen at the level of the umbilicus. There is some difficulty in feeling the lump as the R. rectus is held stiffly. Nil per rectum but an escape of mucus and blood..

Operation. Laparotomy performed and the intussusception reduced, rectal irrigation at the same time.

Jan 5. The child died about 3 a.m.

Post Mortem Notes.

Fat well developed child, weight 13¼ lbs.

The greater portion of the small intestine from the middle of the duodenum to the ileo-caecal valve, was collapsed. On opening the gut the mucous membrane throughout was a little injected and the Peyer's patches and solitary glands were swollen and congested. The tip of the appendix was swollen and congested. The other organs were normal.

No. 61 + 62. on page 64 (next page).

No. 63. Vi. Henderson. Aged 5 mos. Admitted April 20. 1903.

History. Vomiting and constipation from the morning of the 18th. Passage of blood stained mucus per rectum.


On Admission. Pale and collapsed with a bad pulse. Abdomen rather rigid, but an elongated swelling felt running across the abdomen above the umbilicus and down to the left iliac fossa, rounded and elastic. Its extremity could be felt 2 to 3 inches from the anus per rectum.

Operation. Injection of saline and massage under the anaesthetic reduced the swelling to the L. hypochondrium. An incision was then made and the swelling completely reduced after pulling out the gut.

April 21. Died at 11 p.m.

Post Mortem Notes.

Weight 11 lbs, Intestines dilated generally, in contraction in one or two places in the small intestine and in the descending colon, caecum, and ascending colon, no hepatic flexure. Intestine covered with lymph and in a state of recovery after intussusception. A small haemorrhage at the extremity of the caecum where intussusception started. Other organs normal.



3 or 4 inches from
the valve.

~~no 59 on same page as no 56~~

No. 61

Helen Stoble. Aged 10 months. Admitted Feb. 29. 1903.

History. On the morning of the 21st she was taken with pain in the abdomen and twice during the afternoon she passed some blood and mucus.

Previous History. An only child, breast fed.

On Admission. Did not seem acutely ill, the abdomen was not distended, an elongated tumour was felt lying transversely above the umbilicus, it was felt better under the anaesthetic.

Operation. The rectum was injected with fluid under a pressure of 18 ins.. The abdomen opened and the condition was found to have righted itself, being quite reduced. The abdomen was closed.

Feb. 29. Child has progressed favourably.

No. 62

Geo. Livy. Aged 1 year 2 mos. Admitted Mar. 30. 1903.

History. Quite well till 4 a.m. on the 28th, when he seemed to have pain in the stomach and rolled about screaming and passed a large motion. At 8 p.m. passed some blood but no motion and a little later began to vomit. This has continued ever since. Passed blood and slime to day, seems much weaker, eyes more sunken, than yesterday.

Previous history. Healthy since birth always a little constipated, parents healthy.

On Admission. Well nourished child, very quiet, no cry, eyes sunken, temp. 96. Abdomen moderately distended, rigid so that nothing could be felt. Per rectum a tense elastic swelling could just be felt. Admitted 2 p.m.

At 6 p.m. chloroform given and an elongated swelling felt running up to the spleen from the R. iliac fossa. Faecal vomiting since admission, pulse poor.

Operation. Abdomen opened in the middle line from pubis almost to ensiform, about an ounce of clear fluid escaped.

An intussusception found extending to the L. iliac fossa, it was easily reduced by manipulation. It looked like an ileo-caecal form, but when the caecum was replaced, 3 or 4 inches of ileum were found invaginated before entering the valve. The ileum was dark and oedematous and encircled with a band of lymph. The wound closed.

The child continued vomiting faecal matter after the operation and gradually became comatose and died during an attack of vomiting at 10.30 p.m. Nothing was retained and saline infusion was unsuccessful.

No Post Mortem Allowed.

stitch

No. 63. on same Page as No 60. on p. 63.

65.

No. 64. FRED PERRY Aged 9 years and 5 mos.

Admitted 5th. Aug. 1903.

History. Quite well till Aug 1st. when after a cup of tea in the early morning, he complained of pain in the back and stomach. Vomited soon afterwards and bowels moved. Vomiting continued all day, pain went off in 24 hours. Since then bowels have only moved once after an enema, motion quite black. Vomit is green and has a faecal odour. The boy overate himself the day before.

Previous History. The elder of two, the other well, no miscarriages, always been delicate. Within the last year has had similar severe attacks.

On Admission. Pale thin boy with sunken eyes and cheeks and with the general appearance of a wasting illness. Free from pain, respirations not hurried.

Abdomen slightly retracted, movements good, no limitation, no rigidity or general tenderness. At junction of R. hypochondriac, epigastric and umbilical regions a rounded mass could be seen bulging out the belly wall, about the size of a tangerine orange, moveable in all directions, does not move with respirations, is slightly tender, feels solid, dull on percussion. Below this peristalsis was visible evidently small intestine, no other mass felt in abdomen. Nil felt per rectum.

In the evening an enema was given which brought away some dark red blood, no mucus. Vomited in the evening not feculent.

Operation. The abdomen was opened, the rectus being pulled inwards. The mass proved to be an intussusception. There was no blood stained fluid in the peritoneum. The mass was brought out, the intussusception was fully a foot in length and curved on itself, it was very congested, had some lymph on its surface and there were some dull grey patches near the mesenteric attachment. The mass was resected and an end to end suture performed, abdomen irrigated and the wound closed with the exception of a small drain. Saline enema per rectum.

Aug. 7. Had a good night, no pain, pulse 128.

Aug. 8. Small amount of faeces passed, saline enemata.

Aug. 10. Passed a good motion containing well formed masses.

Aug. 11. Takes food and has now lost the abdominal fascies.

Sept. 9. Made an ~~ix~~ uninterrupted recovery and leaves today.

No. 65.

Elint (sex ?) Aged 6 months. Admitted Aug. 12. 1903.

History. Had sudden pain in the abdomen this morning, drawing up its legs and crying, vomited once and later in the day passed some blood and slime in stools.

On Admission. A healthy looking baby, fat and flabby. Abdomen fairly mobile, walls rather relaxed. In the left part of the umbilical and lumbar regions there is a definite resistance to be felt. The lower pole of the swelling is rounded and points to the L. iliac fossa. Palpation gives pain. Per rectum a firm mass is felt high up in the rectum bulging the posterior wall forwards, the finger withdrawn covered with blood stained mucus.

Operation. Mesial incision below the umbilicus, a large intussusception of the colic variety found. This was easily reduced, the apex was in the descending colon, there was slight difficulty in reducing the last part at the caecum. The abdomen was flushed with warm saline and the wound closed.

The child stood the operation well, was given tinct. camph. co. Mins. 3 and had nothing to drink during the night.

Aug. 13. Passed a quiet night free from pain feeding begun.

Aug 14. Tinct. camph. co continued, rather restless.

" 26. Stitches removed, wound quite healed, no stretching of wound. scar.

No. 66 A.J. Clarke. Aged 5 mos. Admitted Dec. 21, 1903.

History. Dec. 18. Cried all the evening, slept at night.
Dec. 19. Would not take the breast, vomited continually.

bowels moved motions very hard, saw a Dr.
and was given some medicine.

" 20. Vomiting continued, passed some blood and
slime by the bowel.

" 21. Brought to hospital as there was no relief.
Family History. Youngest of six, 2 died of
whooping cough, the others all well.

On Admission. A tumour can be felt in the left
subcostal region. The abdomen not rigid or tender.

Operation. An injection of saline given per rectum.
Abdomen opened in the middle line. Attempts to reduce
the intussusception failed. A perforation was found
below the intussusception which was then excised
and sutured up. The gut above the perforation was
swollen tense and irreducible, it was incised
and the contents (the intussusceptum) was cut off
and sutured to the lower end of the gut, the incision
in the outer layer was then closed. The abdominal
wound was sewn up.

Saline enemata were given during night but the
child died 31 hours after the operation.

No post mortem notes found.

No. 68 Winifred Williams Aged 6 mos. Admitted 25th. Dec. 1903.

History. The illness had lasted 30 hours before admission. When admitted the child was passing blood and slime from the rectum, the legs were drawn up, the vomiting was continuous. Laparotomy was performed, an intussusception was reduced and the wound sewn up.

During the night the child was collapsed, saline was given subcutaneouslv every four hours. Next day she was much better and took milk by the mouth. The temperature became normal on the 4th day.

Jan. 2. Has a cough, temp. up, signs of slight bronchitis

" 6. Vomiting begun again, temp. still high.

" 9th. Very collapsed, takes food badly, saline subcutaneouslv again, feeding by mouth stopped for 12 hours.

Jan 10 no vomiting. Jan 11. Slight vomiting.

" 12. Vomiting worse, crepitations all over lungs.

" 13. Child died.

Post Mortem Notes. Extremely emaciated, weighed 8 pounds.

Heart and lungs normal. On opening the oesophagus, the tube was found lined from pharnx to cardia with a thick yellowish white membrane which could be stripped off only with difficulty, and left a raw and inflamed surface exposed. Films from the membrane showed

" diphtheroid " bacilli and cocci present. No traces of membrane found elsewhere in throat. The abdominal organs presented nothing abnormal. Cranium natural.

No. 67 Daisy Bashbott. Aged 2 years and 2 mos.

Admitted Dec. 22. 1903.

History. Brought to the out patient department on Dec 21. on account of a cough, nothing was discovered on examination.

Soon after returning home she became violently sick, vomited frequently all the afternoon and evening and passed some blood by the rectum. Came up early the next day to hospital. Abdominal and rectal examination revealed nothing. The child died a few minutes after admission.

Post Mortem Notes.

Weight 23 lbs. Deep down in the abdomen there was found an intussusception of the ileum into the colon, the ileo-caecal valve was partly involved but could easily be drawn out. Higher up the condition was apparently of older standing for the parts were more firmly fixed and could not be reduced by traction. On section the mucous membrane was found greatly congested and the Peyer's patches enlarged and friable. Elsewhere the intestines were healthy. Nothing else abnormal.

No. 69 Alfred Sims Aged 1 year and 6 mos.

Admitted Jan. 23. 1904. ↓

History. Was quite well till Jan 23 when he was suddenly taken with pains in the abdomen and vomited about 2 hours afterwards and at the same time passed a motion in which the faeces were mixed with blood and mucus. On the following day was apparently quite well, but the day afterwards was sick several times and again passed blood. The child was brought to the hospital and admitted.

On Admission. No tumour felt, more resistance on the right than on the left side of abdomen. Child was evidently under morphia so had no pain or tenderness. Per rectum nothing felt. Had a bloody motion since admission.

Operation. The abdomen was opened through the right rectus muscle. No lump was found in the belly but on drawing out the ileum, the lower 8 inches were found collapsed and of a red-brown colour. At the upper end of the collapsed portion was a raised and oedematous area with a central depression laterally placed. There were two or three small haemorrhages into the wall of this portion of the gut, while the mesentery here contained some enlarged glands.

There had evidently been an intussusception of the enteric variety which had reduced itself spontaneously. The wound was closed.

Feb. 8. The stitches removed.

" 10. Child sent home.

No. 72 Irene Gay Aged 5 mos. Admitted June 24. 1904.

History. About 2 a.m. on the 23rd. she began to scream and then passed some blood by the bowel. the bowels had moved the previous morning naturally.

During the day the bowels moved several times. and last night a good motion was passed. to day only slime has been passed. The child strains a great deal.

Previous History. Breast fed for 2 mos. since then has had cows milk and various artificial foods. With the exception of great constipation during the first month, the child has been quite well

On Admission. Well nourished child rather collapsed, vomiting. A tumour felt on the left side extending down into the pelvis from under the costal margin.

Nothing felt per rectum.

Operation. Laparotomy performed. most of the tumour was reduced by water pressure, the last part being finished by manipulation. There was a well marked dimple with a surrounding ring of thickening in the anterior caecal wall. Intussusception was thought to be primarily caecal.

July 13. Recovery uneventful. Discharged.

No. 70 Flo. Nast. Aged 8 mos. Admitted Mar 31. 1904.

History. Child was quite well till 5 p.m. of the 30th. when it had pain. cried. and drew up its legs. Soon after this it began to vomit which it has done ever since. occasionally taking the breast. At 8 a.m. to day she passed a quantity of pure blood from the rectum. this was repeated at 3.30 p.m.. no mucus or faeces were mixed with the blood. The bowels were opened before the child was taken ill. some days ago she had been given a powder which had caused a lot of griping.

On Admission. 8 p.m. A fine baby. looks ill with sunken eyes. No tumour felt. no resistance in the R. iliac fossa. Per rectum nothing found.

Operation. Under chloroform a tumour felt in the middle line. Abdomen opened vertically. saline given per rectum and most of the tumour was reduced. the remainder was pulled out and the last 6 inches of ileum were reduced. The gut was then returned and the wound closed.

April 8. The stitches were removed. recovery uneventful

No. 71

Edna Cole. Aged 5 months. Admitted May.4.1904.

History. Child had the first symptoms on the 2nd, vomiting, pain in the abdomen, but passed no blood or slime. The vomiting has continued with only short intermissions, the bowels were open yesterday.

On Admissions Child looks fairly well, but under an anaesthetic, a typical tumour felt in the epigastric region.

Operation. The rectum was injected with warm water to reduced a part of the intussusception, and then an incision was made through the R. rectus, and the last part reduced with the fingers through the ileo caecal valve.

May. 20. No symptoms since the operation, discharged.

no 72 on same page as no 70

NO. 73

Mabel Seymour. Aged 7 mos. Aug.22.1904.

History. None noted.

On Admission. About 8 inches of bowel prolapsed through anus containing an intussusception.

Operation. Laparotomy performed and the intussusception reduced. It was found to be of the colic variety.

Child died about 3 hours later.

No Post Mortem notes.

No.78 *Maud Collett. aged 9 mos. admitted April 25.1905.*

Name, Age, Sex, and date of admission all unstated.

Duration of the condition 48 hours.

Operation. The abdomen opened and a very long intussusception found which was reduced with great difficulty. It was evil smelling, ulcerated, and bad coloured intestine. The case considered hopeless, the abdominal wound was sewn up with silkworm gut through all the layers.

April.28. Child still alive, getting more feeble, breathing more sighing in character.

Died.

No Post Mortem Notes.

Nov. 74

Leonard Lasher. Aged 3 months. Admitted Oct. 5. 1904.

History. Diarrhoea and vomiting for one week, blood and slime in the motions for 4 days. The vomit had a faecal odour for 2 days and was like black mud.

Child had previously always been rather constipated.

On Admission. Patient is in an extremely collapsed condition, earthy looking, almost pulseless.

Abdomen very distended with signs of fluid in the flanks. Owing to the tense condition, nothing was made out by palpation, wall moved with respiration.

Operation. Peritoneal cavity found full of dark greenish, fluid, no odour, no signs of peritonitis.

An intussusception was found of the ileo-caecal variety, situated in the transverse colon. A large rent in the colon allowed the intussusceptum to protrude into the peritoneal cavity. Owing to the condition of the child further proceedurn was considered hopeless.

Child died in about 2 hours.

no 75. next page.

No. 76

Chas. Taylor. Aged 1 year 3 mos. Admitted Nov. 30. 1904.

History. Quite well 2 days ago, yesterday morning was sick many times and retched continually, seemed in pain Was given a dose of castor oil but this only made him worse. The sickness has continued, the bowels have been loose and yesterday blood passed, but no more has been passed although bowels are loose.

On Admission. There is a large moveable mass to be felt in the umbilical region.

Operathon. A median incision made into abdomen and the intussusception found and reduced. It was of the ileo-caecal variety, caecum very oedematous.

Dec. 6. Child has progressed well, but for the last 36 hours has been vomiting. There is a hernia of the gut beneath the skin of the wound. The wound was opened and the distension relieved. When the hole was closed the intestine was returned to the abdomen and the wound sewn up. There was some shock after the operation. The wound suppurated superficially but afterwards healed perfectly.

No. 75.

Violet Pugh. Aged 6 months. Admitted Oct.29.1904.

History. None noted.

On Admission. Fairly good general condition, a mass made out in the R.lumbar region.

Operation. Laparotomy and the intussusception reduced with ease except for the last 2 or 3 ins. where the tissues on each side of the ileo-caecal valve were much thickened, and felt as if a foreign body was in the lumen of the gut.

Oct.30. Vomiting returned and a slight motion of mucus passed, an anaesthetic given but nothing felt, magnesium sulphate given.

Oct.31 Vomiting stopped and bowels moved.

Nov.4. Patient was taken home, appears well the wound satisfactory.

Nov.9. Patient readmitted with an omental hernia protruding through the upper part of the wound. Operation at once performed and a portion of omentum removed and the wound closed. The tissues round were considerably swollen.

No 77

April 8.1905. Readmitted.

History none.

Operation. The abdomen opened and an ileo-caecal intussusception found. There was a fibrous band half round the gut attached to the outer wall of the intestine. This looked like a fibrous and adherent appendix epiploica, it was removed, the intussusception reduced and the wound close. The child stood the operation well.

April 16. The wound opened slightly and a small amount of pus discharged

no 78 same page at 71.

On. 79

Thomas Eells. Aged 8 months. Admitted May 13. 1905.
History. At 11 p.m. on the 11th, the child was taken pain in the belly, screamed and drew its legs up, the bowels had acted that day. The vomiting began soon after the pain. On the 12th. A Dr. gave some castor oil, child vomited all day. On the 13th, more castor oil given, an enema only brought some bloody mucus away.

On Admission. Child ill, crying and straining, and drawing its legs up, pulse 130. Abdomen very hard tense and swollen, moves slightly on respiration, too rigid to feel anything. after chloroform was given a tumour was felt rather indefinitely, in the R. lumbar region. Nothing felt per rectum. After examination some bloody mucus passed.

Operation. 9 p.m. Under chloroform tumour again felt stretching across the abdomen in the position of the transverse colon. Abdomen opened in middle line and a large intussusception was found reaching to the splenic flexure, it had ^{ar}st~~ated~~ some 18 ins. above the ileo-caecal valve. The caecum and appendix were not involved in the mass. It was all reduced except the last 6 ins. which were so firmly bound together that the coats of the bowel were burst in two places in attempting to reduce it. A portion was resected and an end to end anastomosis performed.

The child stood the operation very badly and continued to vomit for some time, became weaker and died at 7 a.m. May 14th.

757
NO. 80

Sidney Long. Aged 11 mos. Admitted May 15. 1905.

History. In the morning of the 13th, the child began to shriek and draw up its legs and was sick. A Dr. who had seen him though it was the first time he had been given a short time before, hot fomentations were applied, and castor oil given. The bowels moved on the 13th, another dose of castor oil was given on the 14th. At 10 a.m. on this day he passed some blood and slime. On the 15th. the vomiting continued and the child was worse.

Previous History. Breast fed still, never been ill, 4 other children living, 1 dead of tubercle, parents well.

On Admission. At 11 a.m. Child has an abdominal look, cries and draws up its legs. Abdomen moves with respiration but not freely, walls so rigid that palpation is useless. Under chloroform a tumour felt near the under surface of the liver, passing across some way in the direction of the transverse colon. Nothing made out per rectum. Saline and brandy enema given some bile stained faeces came away but no blood. Such a lot of faecal material came away that it was thought that no intussusception was present but as the child did not improve during the course of the day operation was decided on. The child looked worse, vomiting continued pulse 120, no blood passed, screams periodically.

Operation 8.30 p.m. A small incision made in the middle line below the umbilicus and the finger introduced, warm water allowed to run into the rectum and by manipulation with the finger the intussusception was reduced. It was of the ileo-caecal variety.

The vomiting stopped after the operation.

May. 16. Slept well, pulse 108, temp. 101,

May. 24. Some stitches taken out, as the child strains so hard the other stitches left in and a large collodion dressing applied

May. 27. Went home

June 1st. Seen in Out patient department the wound has quite healed.

No. 81.

William Alberici. Aged 4 mos. Admitted May 29. 1905.

History. Quite well till 11 p.m. yesterday when he began to scream and draw up his legs. This morning was found to have passed a lot of blood and slime after screaming the whole night, vomited this morning.

Previous History. Parents healthy, 2 other living children, 1 killed in an accident, no miscarriages, health has been good, breast fed.

On Admission. 9.30 a.m. Under an anaesthetic a tumour 2½ to 3 ins. long felt on the right side, none felt passing across the abdomen, none felt per rectum.

Operation. 10.30 a.m. A 3 insh incision was made over the tumour which was pulled out and the intussusception easily reduced. It was of the ileo-caecal variety, the appendix was about 3 ins. long and the end much congested.

The wound was closed and the operation over in about 8 minutes. No sickness followed, pulse 188, Chloral given.

May.30. Mother comes up every 4 hrs to feed child.

June.7. Wound dressed for first time, nearly healed, some stitches removed but as child strains a lot, the rest were left in, the wound bulges when the child cries.

June 9. Wound dressed, the skin margins have separated for a quarter of an inch and gut appantent. The wound was opened up and the intestine cleaned and the walls stitched up in 4 layers.

June 11. Sick continuously bowels have not acted, enemata and grey powder have been tried. Chloroform given for the dressing which looks septic. Resistance is felt over a dull area towards the middle line - thought to be an abscess.

June 12. No better vomits everything, looks very bad. Abdomen again opened up, the old wound being sealed off, a new wound being made towards the middle line. It was found that a swab had been left in the peritoneal cavity at a previous operation. The child died soon after the operation.

Post Mortem Notes.

Local peritonitis and a few adhesions found round the site of the old wound, no general peritonitis. Nothing found to account for the formation of an intussusception.

See also p. 82

No. 82 Geo. Walters. Aged 6 mos. Admitted July 6, 1905.

History. Quite well till midday yesterday when he became very sick and pale. He was taken to the North West London Hospital where nothing was found the matter. he was then brought here and treated for diarrhoea and vomiting. he was brought again in the evening but all that was discovered was some moist sounds in the chest. The child at this time appeared to be under the influence of opium. did not cry. small pupils. Brought to the hospital again next morning and thought to be developing pneumonia. As the mother was going home about 1 p.m. the child passed some bright red blood. she at once returned and a lump was discovered in the abdomen.

Operation at once. The abdomen was opened and a four inch intussusception was reduced. of the ileo-caecal variety. the wound was closed.

July 7. The mother comes up to feed the child every 4 hours in addition to this he takes cow's milk and barley water. Bowels moved 3 times today. dark mucus no blood. Still very wheezy in chest.

July 9. Improving. chest condition remains the same.

July 13. wound looked well stitches removed.

" 15. Wound burst open and the intestines prolapsed. they were washed and replaced and the wound sewn up.

July 28 The child had some diarrhoea but recovered quite well

Previous History. Father and mother well. no miscarriages. an only child. full time. breast fed. has had good health.

No. 83

Bertie Bandoock. Aged 7 mos. Admitted July 27.1905.

History. On the 23rd the child was taken ill with sickness and crying, and drew up its legs; the vomiting has persisted ever since, laterly it has become more frequent. The bowels have moved 4 times since the 23rd, much blood and slime at first none lately.

Previous History. Breast fed, 2 other children both dead, one at 5 weeks from bronchitis, the other at 15 mos. from diarrhoea and vomiting, parents healthy.

On Admission. Well developed child looks ill. Abdomen flaccid slightly distended and rather tender. A tumour felt in the L. lumbar region, very apparent under chloroform. Per rectum no descending bowel to be felt but the lump was palpable through the rectal wells.

Operation 6 p.m. Saline injection per rectum. A small incision made in the middle line. The intussusception was reduced inside the abdominal cavity with the exception of the last 2 ins. which had to be drawn out before reduction could be effected. The mesentery was blotched and congested but not gangrenous. The intussusception ~~was~~ appeared to be starting from the caecum which shewed a dimple at its lower end. The child was very collapsed and died about 8.30 p.m. after a series of convulsions.

Faecal matter was washed from the stomach on admission, but faecal vomiting continued during and after the operation.

Post Mortem Notes.

Margins of the ileo-caecal valve very swollen and rather necrotic at the edges. The valve patent to the little finger. Small intestine not ecchymosed, caecum and the first 4 ins. of ascending colon were ecchymosed as was also the mesentery in the region.

At the position of the dimple on the caecum was a swollen necrotic patch the size of a shilling.

No. 84

James Jacobs. Aged 3 years and 2 mos. Admitted Aug. 4. 1905.

History. Diarrhoea on the 1st, this stopped on the 2nd, and a hard motion was passed on the 3rd. early in the morning. Since that time pain has come on at short intervals lasting a few minutes. Vomiting began last night, no blood has been passed.

Previous History. Parents well, 1 other child well, no miscarriages, has had slight rickets.

On Admission. Looks pale and ill. Rigidity of lower part of abdomen, no distension. A swelling felt in the R. lumbar region, slightly moveable, painful when manipulated, not felt to harden when the pains are on.

Pulse 128, temp. 100'4. Per rectum nothing felt.

Operation. A small incision made and finger introduced but the lump which had been previously felt as a small round moveable ball had dissappeared. The caecum and lower end of the ileum were brought out of the wound. The lower 2 ins. of ileum were thickened and ruddy, small haemorrhages had taken place in its walls and mesentery. Evidently had been a small intussusception which had been reduced by the manipulations done when the child was under the anaesthetic to make sure of the position of the tumour. ~~##~~ The wound was then closed and a brandy and saline enema was given.

Aug. 14. The stit ones were removed yesterday and the child made an uneventful recovery.

No. 85.

Harry Floode. Aged 10 mos. Admitted Sept. 4. 1905.
History. Ill for 9 days, Dr. thought it was colic but there was no diarrhoea or sickness. Had 2 fits first day of illness. There has been very little the matter with the child except the colic for which he has seen the Dr. every other day. At 1 p.m. today passed blood and slime, he did this again at 6 p.m.. He is not always in pain but suddenly screams and draws up his legs.

Previous History. No other illness, breast fed and has milk puddings, 2 other children well.

On Admission. Well developed healthy looking baby, cries incessantly. Abdomen not particularly tender, no tumour felt by palpation or per rectum. When under chloroform a lump felt in the position of the descending colon.

Operation. Sept. 5. 11 p.m. Median incision while the rectum was inflated. The intestines brought out, no intussusception found but the last few feet of small gut had many petichae in its wall and in mesentery, one haemorrhage the size of a half penny very prominent. abdomen closed. Child vomited at short intervals through the night and next morning. At 11 a.m. Sept 12 it was decided to again explore as the child was becoming rapidly worse. The last few feet of ileum were found paralysed and a small pin hole perforation was found in the middle of the haemorrhagic patch already noted.

The perforation closed and the gut cleaned and returned
Child died at 3 p.m.

Post Mortem Notes.

Gut had a small ulceration at the point of perforation, the cause of the ulceration was uncertain.

The echymosis and congestion of the lower part of ileum looked very much as if there had been an intussusception which had recently spontaneously reduced itself.

Glands in the mesentery were large, there were haemorrhagic spots in the mesentery. Possibly the ulceration and the paralysis were both due to the recent intussusception of the gut.

No. 86

Eva Park. Aged 1 year 11 mos. Admitted sept. 5. 1905.

History. Patient had been admitted the same day to a medical ward, as soon as intussusception was diagnosed she was taken to the theatre.

On Examination. a small hard tumour was found to the right of the epigastrium. Per rectum nothing felt.

Operation. A 2½ inch incision was made in the right iliac region. The intestines were much distended and partial evisceration had to be performed.

Several feet of dark and partly paralytic ileum were found or were reduced from an intussusception, the last part to be reduced was a part of the caecum which had a deep dimple projecting well into the interior.

The walls of the caecum were dark and oedematous, the mesentery was haemorrhagic. The wound was closed, the operation having lasted an hour.

Sept. 6. The child rallied after the operation and seemed better this morning. At midday signs of a general toxæmia shewed themselves. The child became cold and almost pulseless, vomited several times and died at 4 p.m., 17 hours after the operation.

Post Mortem Examination.

The last 24 inches of small intestine were distended with blood which was effused into its lumen and into its walls. The caecum, but for a few haemorrhages, was nearly normal.

No. 87

Arthur Gurney. Aged 13 months. Admitted Oct. 5. 1906
 History. Brought to Out Patient Department 11 days ago with pains in the stomach and wind, diarrhoea and vomiting and fits. 7 weeks ago had diarrhoea for 5 weeks. this attack began a weeks ago. Motions like slime, greyish curds, no blood ever past, child is wasting.

Previous History. Parents healthy, a history of spina bifida on the mothers side, Ed This is an 8 mos. child breast fed for 3 weeks then bread pulp added, one other child born dead, one with spina bifida lived for 22 days.

On Admission. Abdomen nothing abnormal, motions loose 4 a day, no vomiting, not very ill.

Oct. 8. Looks ill, eyes sunken, sleeps badly, 11 motions in last 24 hours, no blood passed, vomited for 2 days, cutting teeth.

Oct. 9. Seems better slept well, passed a little blood.

" 10. No vomiting, 2 loose motions today with no blood. In the evening an intussusception protruded from the anus, not very congested like a prolapse.

Operation. A small incision made in the middle line above the umbilicus, while the prolapsed bowel was pushed back up the rectum and an enema given. Most of the reduction was done in the abdominal cavity, the wound was then enlarged and the last part brought out and reduced easily. The type was ileo caecal, the region of the valve was not at all congested - rather pale and looked as if it had been in a state of intussusception for a short distance for some time. A haemorrhage had occurred in the wall of the transverse colon. The child was under the anaesthetic for nearly 40 minutes and looked very bad. A saline injection was given subcutaneously.

For the next 2 days there was diarrhoea (see chart)

Made an uninterrupted recovery.

No. 88

Ernest Rich. Aged 1 year 9 mos. Admitted Oct. 27, 1905.

History. In Nov. last child was taken ill with sudden pain in the abdomen and was very sick, passed blood and slime. This lasted 4 days and the child seemed going to die. A Dr. saw it and admitted it to hospital where by injecting air the condition was relieved and the child seemed well the same evening. At the end of April or the beginning of May, he had a similar attack, was sick and passed blood but not to the same extent as in Nov. In the evening a Dr. saw him and cured the condition with an injection of warm water under an anaesthetic. The child which had been screaming and drawing its legs up seemed at once to get well.

This morning between 7 and 8 a.m. pain came on and he was sick at 11.30; crying and drawing his legs up, the bowels moved yesterday and again ~~at~~ this morning, no blood.

On Admission. Healthy looking child, lies quiet when not touched, temp. 99, pulse 132, thighs drawn up on abdomen. The abdomen moves with respiration but is very much more resistant on the R. side over the iliac fossa. An elongated swelling felt extending up towards the liver, dull on percussion. Per rectum the lower end of the tumour can be felt through the bowel wall in the R. iliac fossa, blood and slime on the finger, passed some blood after examination.

Previous History. Parents healthy, younger of 2 children, 2 miscarriages, full time, breast fed for 10 mos.

Operation. 10 p.m. Abdomen opened through R. linea semilunaris. The caecum and colon were normal. The lower end of the ileum was full, being occupied for the last 8 ins. with an intussusception of small gut, which did not pass through the ileo caecal valve. This was easily reduced, the bowel though purple and thick had no adhesions. The glands in the mesentery of the part were much enlarged. The abdomen closed and small doses of morphia given, child stood the operation very well.

Oct. 31. bowels moved.

Nov. 7. Child seems quite well, wound healed.

In the beginning of Feb. the child was brought to the waiting room by the mother who stated that there had just been another attack of pain in the belly with vomiting and passage of blood. The pain had passed off and the child seemed quite well, so after a negative examination he was not admitted.

See over.- hoi.

No 89. Ada Marchani Aged 3 months. Admitted Nov.13.1905.

History. Taken ill on the 7th. with screaming and vomiting but no diarrhoea; on the 8th passed blood; since then there have been frequent streaks of blood passed. On the 11th. the abdomen began to swell.

Previous History. 1 of 4 children others well, parents healthy, breast fed, no diarrhoea, quite healthy.

On Admission. Taken at once to theatre an enema of saline and brandy given but not retained, a well formed motion passed.

Operation. Abdomen opened in the middle line and distended intestines allowed to escape. An intussusception found and an attempt made to reduce it, this was easily done, but the descending colon gave way and also the small intestine where it entered the intussusception.

The walls at these two places were quite rotten and purple. The gangrenous parts were cut away and Paul's tubes tied into the end of the bowel. The child died in about 2 hours.

No Post Mortem examination was held.

No. 90 Constance Colombo. Aged 12 mos. Admitted DEC.18.1905.

History. Child was admitted for diarrhoea and vomiting. 6 days ago the vomiting began and this has gone on ever since. The bowels have not been open for 2 days. Child screams but passes no blood or mucus.

Previous History. One other child well, parents healthy, no previous illness, full time, breast fed up till time of illness.

On Admission. Seems very ill, abdomen rigid, no distension, per rectum a tumour felt and finger blood stained. No tumour felt in the abdomen till an anaesthetic was given, it was then found above the umbilicus.

Operation. Abdomen opened in mid line, the intussusception occupied the ascending and a portion of the transverse colon. It was reduced easily. The appendix was outside, the caecum was inside the mass and congested. The small intestine was invaginated but the ileo caecal did not form the apex of the intussusceptum. The wound was closed and peptonised milk and brandy given 2 hrly.

Dec.20. There has been a slight motion, no blood

" 30. Stitches out, wound healed.

28.

No. 91 (Continued)

Readmitted April.17.1906.

History. At 7 a.m. today taken with pain in the abdomen, was sick at 9 a.m. and four or five times afterwards, latterly vomited a little blood.

Bowels not open yesterday, blood and slime passed at 2.30 p.m. today.

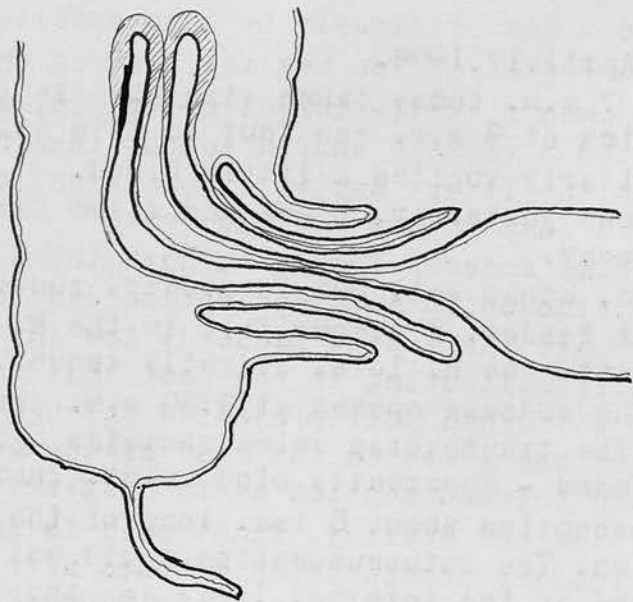
On Admission. Looks well but is drowsy, abdomen flaccid and not tender. A tumour felt in the R. iliac fossa passing into the R. loin, slightly tender.

Operation. The abdomen opened at 9.30 p.m. through the old scar. The transeverse colon contains a large dark moveable mass - apparently blood clot. There was an intussusception about 5 ins. long of the lower end of the colon. The intussusception could not at first be reduced as the internal layer was shorter than the returning layer which was thrown into ridges and furrows which prevented reduction. The end was pushed through the ileo-caecal valve and the rest was easily reduced. There were no adhesions, the mesentery was congested and the gut swollen especially at the apex of the intussusception. Many enlarged glands, some 1½ ins. long, were found in the mesentery of this part of the gut. Three silk sutures were put into the mesentery opposite the point of entrance of the intussusception shortening and plicating the mesentery. The wound was closed in layers. Small doses of opium given.

alt.

April 19. The bowels were open and a little blood passed.

May.8. Quite well.



No. 92.

William Coomber. Aged 8 months. Admitted May 29.1906.

History. The day before the child was taken ill with pain in the abdomen, vomiting and at 2 p.m. today it passed some blood. Has previously been in excellent health.

On Admission. 7 p.m. A fine healthy looking child, not in pain, abdomen slightly tumid, not rigid, abdominal palpation detected a sausage shaped tumour running upwards towards the liver. Rectal examination confirmed the presence of a lump in the R.iliac fossa.

Operation. 8p.m. Abdomen opened through the R. linea semilunaris. An ileo-colic intussusception was found and the greater part was easily reduced, the last part was more difficult owing to the fact that a collar of ileum which had just projected through the ileo-caecal valve had grasped the rest of the gut. There was thus a double intussusception as in diagram. The bowel was congested but healthy. Tinct opii in small doses was given, and feeding commenced in 6 hours after.

June 2. Wound has been bulging for 2 to 3 days. It was opened and a coil of gut found under the ~~skin~~ dressing at 7 a.m. the child looked quite well in spite of this.

The gut was washed and returned into the abdomen and the wound closed in layers.

June 25. Uninterrupted recovery, wound soundly healed.

No. 93 next page.
No. 94.

Eliz. Graham. Aged 3mos. Admitted July 2.1906.

History. At 9 a.m. on July 1st pain began, bowels moved at 11 p.m. but not since, no blood, no slime. The child cried all night and vomited at 8 a.m. today and twice since then, Blood passed twice since 2 p.m.

Previous History. Breast fed, rather constipated; 3 weeks ago had a similar attack of pain in the belly.

On Admission. 4 p.m. looks very ill, face earthy, eyes sunken, temp.98. Abdomen rather tumid, moves with respiration. Under chloroform a firm mass felt in R. iliac fossa. Recto-abdominal examination confirms this blood on finger.

Operation. 6 p.m. Abdomen opened, a little fluid in the peritoneal cavity, the ascending colon occupied by the intussuscepted intestine, caecum and ileum, which extended up to liver. Intussusception easily reduced, the last part to be reduced was the caecum, bowel congested but healthy. Was fed by mother and made an uninterrupted recovery. Stitches out on 10th day and went home July 14th. Wound quite sound

No. 43.

Eva Keen. Aged 11 mos. Admitted June 4.1906.

History. 5 hours before admission while being carried in the Zoo, the child suddenly screamed and became ill. She was taken home but cried incessantly as if in great pain, 3 hours later passed some blood and stime.

Previous History. Breast fed, healthy.

On Admission. A fine healthy looking child, does not seem in pain. Abdomen soft and moves with respiration.

In the R. iliac fossa a rounded mass is felt extending up towards the liver. It is easily defined by recto-abdominal palpation, blood and mucus passed after examination.

Operation. The abdomen was opened in the middle line through the R. Rectus. An ileo-colic intussusception was easily reduced and abdomen closed. Small doses of liquor morphinae were given. The child was breast fed some 5 hours after the operation.

June 5. Temp. 100, bowels moved.

" 20. Made an uninterrupted recovery, wound healed and firm.

No. 95

Arthur Martin. Aged 5 months. Admitted Aug. 29. 1906.

History. At 6 p.m. on the 28th was seized with abdominal pain, screamed and doubled himself up. At 9 p.m. vomited and bowels moved. At 7.30 a.m. on the 29th passed blood passed and a Dr. diagnosed intussusception.

Previous History. Breast fed, second child, always healthy.

On Admission. Fine well developed child, looks ill, eyes sunken. Abdomen not distended, moves freely, flaccid, a firm irregular moveable mass felt in umbilical, L. lumbar and L. iliac regions. Per rectum mass felt bimanually.

Operation. A small incision made in the R. rectus and finger inserted, saline injected per rectum.

The wound had to be enlarged and the last part reduced outside the abdominal cavity, the bowel purple and congested, one of the ileo-colic variety. Tube drain left in. Bowels open next day, recovery uninterrupted.

No. 96

Gladys Dennison. Aged 4 mos. Admitted Oct. 30. 1906.

History. Began to scream with pain 30 hours before admission, vomited and the bowels have moved several times, but only blood and mucus has come away.

On Admission. A big well nourished child, temp. normal, abdomen not distended, a large moveable mass felt in the L. iliac and lumbar regions.

Operation. Abdomen opened through the R. rectus, some free fluid found in the peritoneal cavity. An intussusception of the ileo-colic type had passed into the ascending colon. It was reduced with some difficulty and some superficial abrasions of the ascending colon were made in the process, they were covered with peritoneum. The bowel was a little distended so a coil of ileum was opened, emptied and then sewn up. The wound was closed in layers and small doses of opium given.

Oct. 31. Temp. 105, pulse uncountable, castor oil and opium given and bowels acted well and temp. came down

Nov. 1. Temp. normal, bowels acted 4 times, seems well.

Nov. 4. Dressed wound bulging, the wound was opened and gut found under the skin, the catgut used had given way, silkworm gut and silk sutures used and wound closed.

Nov. 5. Vomiting frequently, nothing made out on examination. Abdomen reopened, intestines found distended, a coil sharply kinked the limbs of the kink adherent to each other, adhesions between coils, as these were being separated the bowels was torn. In closing it the lumen was unduly narrowed and a lateral anastomosis had to be done.

Child died about 2½ hrs after.

No Post Mortem Notes.

No. 97

E. S. Female Aged 5 mos. Admitted May. 21.1906.

History. Breast fed, healthy child, Last night about 11.30 p.m., the bowels acted normally. About mid night child began to cry and vomit and shortly afterwards passed a motion of blood and slime. This has occurred three times since.

Admitted 9 p.m. Abdomen slightly distended, a large sausage-like tumour felt in the left flank, nothing per rectum.

Operation. 10.30 p.m. The abdomen was opened through the right rectus and a large intussusception of the ileum reduced. The intussusception did not pass through the valve. There was very slight congestion for the amount of haemorrhage. The child stood the operation well and was in good condition. Chloral and potassium bromide given.

May.22nd. Cried a lot and looked ill, temp.101. Bowels have not acted. 2 p.m. vomited, an enema only produced bright red blood, the child was crying and straining so that nothing could be felt.

6 p.m. Vomited again and does so now continuously, calomel had been given but produced no effect.

7.p.m. Screams with pain and passes blood and slime, pulse 144, Resp. 44.

9.30 p.m. Under an anaesthetic a sausage-like tumour felt in the R. flank. The abdomen was reopened and an intussusception found. This was primarily in the ileum but had just passed through the valve, it was very congested.

May 23rd. The bowels acted after a saline enema, no more blood was passed, no more vomiting.

June 4th. The wound has healed, the sutures removed and a pad and strapping applied, no bulging.

M.E. Female. Aged 6 mos. Admitted Oct. 30. 1906.
History. On Oct. 27th. Suddenly cried out as if in pain and passed a motion containing blood, since then has had much pain and frequently passed blood but no slime. Castor oil and enemata have been tried, but without any satisfactory result. Vomiting has been constant since the onset.

Previous History. Always been healthy, breast fed, was a little out of sorts with diarrhoea before the onset. Is the 5th child others all healthy.

On Admission. A fine well nourished child, Temp. 102, eyes sunken, condition bad, rather restless. Abdomen is distended and kept rigid, recto-abdominal palpation reveals a firm rounded mass in the splenic flexure. Blood on the finger on withdrawal.

Operation. Had convulsions and twitching of the left face and arm. The abdomen opened through the right rectus. A lot of free fluid present, the intussusception was of the ileo-caecal variety, it reduced with difficulty. There was vomiting throughout the operation and the child died before the wound was closed.

Post Mortem Notes.

The abdominal cavity contained blood stained fluid not purulent. The caecum was situated in the right iliac fossa about the level of the anterior superior iliac spine.

The appendix ran inwards parallel to the ileum. The caecum and appendix were both very dark in colour but the intussusception was entirely reduced. The caecum contained some fairly hard substance presumably blood clot.

The peritoneal surface of the colon was much injected near the caecal end. In the caecum ~~was~~ near the base of the appendix was a depression shewing where the invagination had started (I think I have shewn conclusively that the dimple is not where the intussusception starts) In this depression was a little lymph, no perforation.

Above in the angle between the ileum and the caecum was an enlarged gland.

The other organs were normal.

No. 99

Male. Aged 5 months, Admitted

History. Twenty hours previous to admission, he was taken with pain in the abdomen and vomiting. The bowels had previously been troublesome. Eight hours after the commencement blood was passed with a very little solid motion. The pain was spasmodic.

On Admission. Condition good, only under Chloroform was a small elongated mass felt, quite moveable, high up under the liver. Nothing per rectum.

Operation. The abdomen was opened through the right rectus. The condition had reduced itself evidently to within 3 ins. of the ileo-caecal valve. The reduction was easy. The appendix was long, oedematous, and the end was haemorrhagic. It was removed in the usual way.

There was one large gland in the angle between the colon and the ileum.

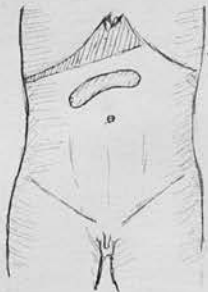
The stomach had to be washed out before vomiting stopped. The child was fed by the mother.

7th. Day superficial stitches removed as wound was reddening. Tension sutures left.

The wound burst and the intestines began to come out. The old wound was excised and sewn up with mattress sutures through at the whole thickness of the wall. Continuous vomiting ensued and death took place 3 days later.

Post Mortem Notes.

The omentum was adherent to the wound shutting off some pus, there was no general peritonitis. The appendix region was healthy and sound.



gland

Oedematous
Appendix

No. 100

Female. Aged 2½ years. Admitted

History. A sudden onset of pain, vomiting and the passage of blood six days ago. On the second day she was worse and in great pain. The 3rd. day there was slight improvement. Since this time she has steadily become worse. The Dr. described a tumour to the right of the umbilicus. The bowels have not been open from the onset except for blood and mucus.

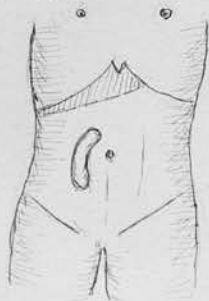
On Admission The child's general condition very bad. The abdomen greatly distended, veins prominent. The sausage-shaped tumour described by the Dr. was not now felt, but there was evidently acute obstruction.

operation. The abdomen was opened through the right rectus and an intussusception entirely of the enteric variety was found reaching down to within about 3 inches of the ileo-caecal valve. Only a portion of the tumour was reducible, and a part 5 to 6 ins. long containing 1½ feet of gut was irreducible. Over 2 feet of gut were resected, the ends being brought out of the wound, Paul's tubes were tied in.

Death took place some two hours after the operation.

Post Mortem Notes.

There was no evident peritonitis and no free fluid in the abdominal cavity. The portion of gut resected was the lower part of the ileum, reduction was effected outside the body. The gut wall was friable and tore in two places. A large gland projected into the lumen of the gut opposite one of the tears. This might have been the cause of the invagination. The mesentery contained many large glands.



Position of tumour
felt by Dr.

No. 101

Alfred Sharp. Aged 7 months, Admitted Mar. 11. 1907.

History. Child was taken ill suddenly on the previous evening with screaming and this has continued at intervals ever since. Vomiting has been frequent.

Blood and slime were passed this morning.

The intestine appeared at the anus at 4 p.m. today and has gradually come out.

Previous History. Up till now the child has always been healthy, fed on cow's milk and water, the night before the onset the mother had given the child a grey powder.

On Admission. A fine child not in much pain. Pulse 160, temperature 98.8.

The abdomen is flaccid, a sausage-shaped mass is felt in the left flank, this mass is felt to harden and relax. A congested portion of gut presents at the anus when he cries and strains, it returns in the intervals.

Operation. The abdomen was opened to the right of the middle line and an ileo-caecal intussusception was reduced. Some difficulty was met with in reducing the last part. The gut was healthy.

Mar. 12th. The child has been fed and has only vomited once, the bowels have been opened but no blood passed.

Mar. 13th. The child has improved and takes its food well

Mar. 25th. The scar is quite healthy and the child is soon going home.

No. 102

Alfred Sheridan. Aged 6 mos. Admitted Ap.2.1907.

History. The child was taken ill suddenly 4 days ago, screaming began between 11 and 12 p.m. Vomiting began 6 hours later and has continued ever since. Blood was passed after 6 hours, no blood has passed since the 2nd. day, but slime has appeared at intervals, no proper motion.

Previous History. The child has, up till now, been healthy, fed on boiled milk and bread, two other children, 1 miscarriage.

On Admission. 12.30 p.m. The child is very collapsed, the eyes sunken and surrounded by dark rings.

The abdomen is distended and tympanitic, but moves freely on respiration, no free fluid and nothing felt per rectum.

18 ounces of saline were injected into a vein.

Operation. 4.30 p.m. The abdomen was opened and an ileo-caecal intussusception found and reduced. The gut was punctured and fluid and faeces were drawn off. The wound was closed. Vomiting continued and the stomach was washed out at 7 p.m.

Ap.3rd. Saline 15 ounces were injected into a vein, the child was very collapsed. At 11 p.m. the abdomen was again opened and the bowel punctured. Fluid and gas were drawn off and a tube was tied in, the distension was only partially relieved.

Death took place at 4 p.m.

Post Mortem Examination.

A fat well nourished child, weight 12¼ lbs.

Abdomen. Soft adhesions were found gluing together the coils of small intestine and the descending colon which was adherent to the abdominal wall. In one area of the mesentery there was a small amount of purulent exudate. The intestines were distended with a thin brown fluid. The caecum, situated to the right of the middle line, was a dark red colour, the walls thick and oedematous. The appendix, which was long, was of a dark colour almost black. The extreme end was kinked and there was peritonitis on the tip but no perforation.

The glands in the neighbourhood were enlarged.

No. 103.

S.B. Male. Aged 5 mos. Admitted. Mar. 24th. 1907.

History. For 48 hours there has been a history of acute obstruction, pain, vomiting and the discharge of blood and mucus.

On Admission. A sausage-shaped tumour is felt in the left flank, it can be made out to harden and relax. It can be felt per rectum.

Operation. The abdomen was opened, and an *ileo-caecal* intussusception was found. The caeum was gangrenous, and 6 inches of gut were excised and the ends brought up and sutured to the wound. Saline infusions were given but the child died in six hours.

Post Mortem Notes.

The Body was fat and weighed 15 lbs. No free fluid was found in the abdomen. The colon was small and empty and the intestine above the resection contained only thin watery fluid. The caecum had been removed together with the adjacent portion of gut. The gut above the artificial anus was dark in colour and extremely friable so that it readily tore.