

The  
Third Inguinal Ring

being the

THESIS FOR THE DEGREE OF MASTER OF SURGERY 1927.

submitted by

ALEXANDER LEE MC GREGOR, M.B.(ED), F.R.C.S.(ENG).

Late head of the department of Anatomy,  
Late lecturer in clinical Anatomy,  
University of the Witwatersrand.

Surgical clinical assistant,  
Johannesburg General Hospital.



JOHANNESBURG, JULY, 1927.



(d)	Varicocele.	58
(e)	Relative height of testis.	59
(3)	Ilio-inguinal neuralgia.	59
(4)	The imperfectly descended testis.	60
(a)	Review of literature.	60
(i)	normal descent.	60
(ii)	imperfect descent.	63
(b)	The gubernacular tails of Lockwood.	66
(c)	Discussion.	68
(d)	The anatomical explanation of imperfect descent.	69
(e)	Ectopia testis.	70
(i)	Definition.	70
(ii)	Frequency.	71
(iii)	Types of ectopia.	71
(5)	Conclusions.	83
(6)	Summary.	86
(7)	Bibliography.	90

.....

1. INTRODUCTION

Fasciae present problems of such profound interest that no excuse is necessary in submitting a thesis on so absorbing a subject. Bland Sutton (4) and others have shown that the higher the evolutionary plane of the animal, the more complex become the fibrous structures such as fascial planes and ligaments. Moreover reptiles and amphibia show little in the way of fasciae or inter-muscular septa. In man these structures reach a high development and much has been learnt of human morphology by their study. Elliot Smith, Zuckerkandl, Proust, Schwalbe, Denonvilliers, Kirmisson and others have, by their investigations, solved many of the riddles presented by the pelvic fascial layers. It remains for others to elucidate with equal clearness the fasciae elsewhere. This work is an attempt to enable the superficial fasciae of the lower abdomen and perineum to be better understood and to show that important surgical conditions such as ectopia testis may be explained on purely anatomical grounds.

The investigation embodied in this paper was instigated by a purely fortuitous circumstance. Reading one of the surgical periodicals, the writer met with an anatomical statement which seemed quite incorrect. On examining certain cadavers, it was found that the remark in question was partially true. In pursuing the subject further it was found to be of such surpassing interest and



inserting them behind the posterior layer they enter a space of loose tissue which at first may give one the impression of being in the upper part of the scrotum, while actually the fingers are in the loose areolar tissue of the upper and inner thigh." It was this last sentence which was referred to as instigating this inquiry. It will be noticed that the writers consider Scarpa's fascia passes behind the spermatic cord or maldescent occurs.

It will also be seen that this description differs entirely from the usual account of the fasciae as given in anatomy text books. So striking is the passage that the opinion of surgeons in this City was solicited about it. They agreed with the present author that Burdick and Coley were mistaken. The first specimen examined in the dissecting room showed a large fascial process behind the cord, which process was found to be a part of Scarpa's fascia.

The anatomy of the fascial planes of the scrotum and lower abdominal wall was therefore investigated. The writer has taught anatomy for ten years, and must candidly state that the fasciae in question have never been thoroughly understood by him. He has considered them as unpleasant to teach about and avoided the matter as much as possible. The impression he has received from other teachers leads him to conclude that they dislike the subject just as much. It would seem that these connective tissue sheets are ill understood generally, so much so that a congress of learned and famous

anatomists, whilst relegating Morgagni, Schwalbe, Zuckerkañdl, Wrisberg, and others to the realms of history, had sufficient respect for this fasciae to leave them as they were, dignified by the names of Camper, Scarpa and Colles. The subject of ectopia testis is obscure and not well understood, and it is also of great surgical and economic importance. Anything which renders its etiology less obscure is necessarily important. It is hoped to show in the following pages that anatomical facts may go far to explain the situation if not the cause of the ectopic testicle. Twenty cadavers were examined. Fifteen were adult. These were all natives (kafirs), five were new born or foetuses of five months and over. These were European. Dissections and injections of red lead were the methods used. As the author is anxious to submit this thesis in time for the November graduation ceremony, the work was confined to males. Entirely different factors obtain here to those in the female, in whom the fasciae are of scant practical importance.

It is hoped to pursue this aspect of the research at a later date.

The relations of 40 normal testes have therefore been examined together with the fasciae and perinea. Subjects of all ages were used, from young foetuses to old men of 80.

Age in no way effects the findings which are common to all males. In fact the fascial layers and pouches are better marked in new born infants. It has been considered proper to deal seriatim with the various anatomical structures investigated. Subsequently the clinical and surgical

bearings of the anatomical findings will be discussed.

## 2. ANATOMY

### 1. DEVELOPMENT

- (a). The scrotum is formed during the 4th month by the external genital folds which form the labia majora in the female.

(Keith 27).

- (b). Nature of fasciae

About the end of the third week of development, when the limb buds have appeared, the mesoblastic cells of the limbs and body wall become grouped to form the bones (paraxial mesoblast), muscle plates, walls of vessels and sheaths of nerves. The cells having become differentiated, numerous cells are left over which form the basis in which the specialized cells and groups of cells are packed and ensheathed. This undifferentiated mesoblast forms the fascial system of the body. From the nature of its development, obviously the connective tissue system of the body, which forms fasciae and septa, must form a continuous sponge work of sheaths, each being in continuity with that of every surrounding structure. In view of the nature of the development of fasciae, it is entirely arbitrary to speak of the fasciae of Camper, Scarpa and Colles as separate entities. They form one continuous sheet with some little difference here and there which has led to this profusion of names.

### 2. The fascia of Camper

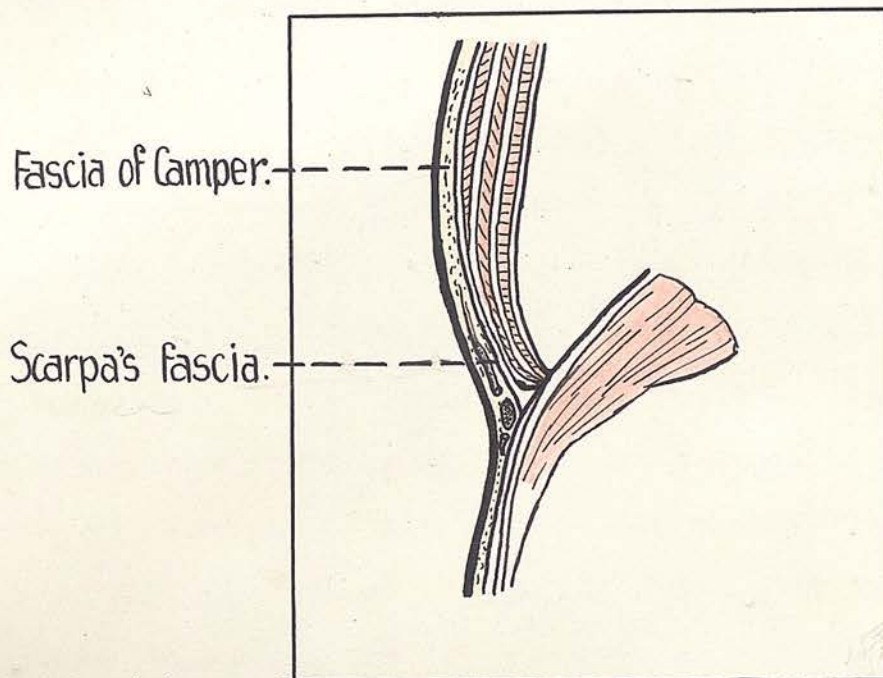


FIG.1(a). From Cunningham (*modified*) to show the layers of the region of the groin. Note the lymph-vascular layer which lies between the fasciae of Camper and Scarpa at the groin.

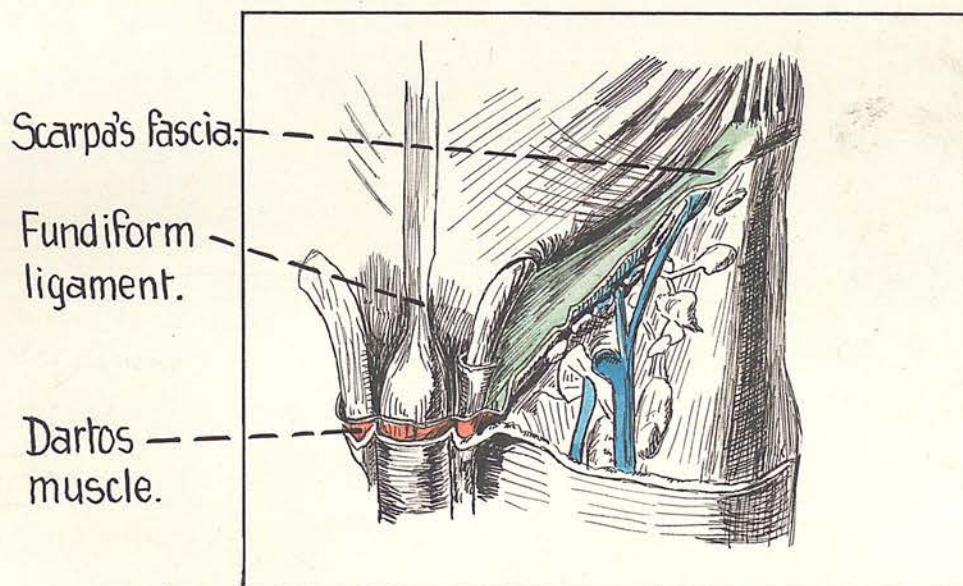


FIG.1(b). From Cunningham, to show the attachment of Scarpa's fascia to the inguinal ligament and anterior superior iliac spine. Note that Scarpa's fascia sends a process behind the cord.

2. The fascia of Camper:-

The description of this layer of superficial fascia as given in text books of anatomy admits of little addition.

Camper's fascia is that portion of the subcutaneous fat in relation to a variable part of the lower abdominal wall, which is bounded on its deep surface by a well marked membranous condensation. It is continuous above and below with the general subcutaneous fat, but over penis and scrotum is replaced by unstriated muscle. Between Camper and Scarpa lie the superficial arteries and veins such as the superficial circumflex iliac, the superficial inferior epigastric and the superficial external pudendal vessels, also the lymph glands of the groin, which latter structures never transgress the inguinal ligament.

The best account of the relation of this layer to that of Scarpa is that which the writer heard Professor Wright of the London Hospital give in 1919. He stated that these fasciae were inseparable over the lower abdomen except with the edge of a knife. He aptly compared them to a layer of surgeon's lint, that is to say one layer in reality, the rough surface being Camper and the smooth surface being the membranous layer of Scarpa. This description exactly fits the fasciae over the lower abdomen, but over the base of the thigh they are easily separable because of the lymph-vascular interposition. That a cleavage plane exists here is of moment surgically in relation to the upward path frequently

/taken

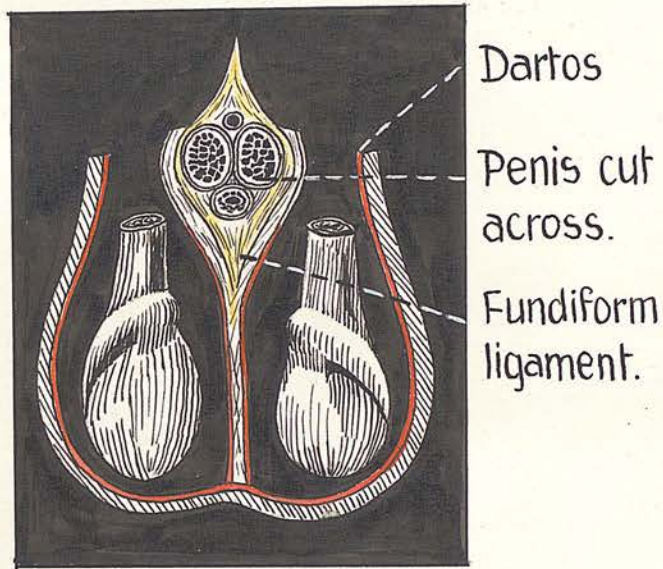


FIG.2(a). From Testut, showing on section, the scrotal dartos and relation of fundiform ligament to the penile root and septum of the scrotum.

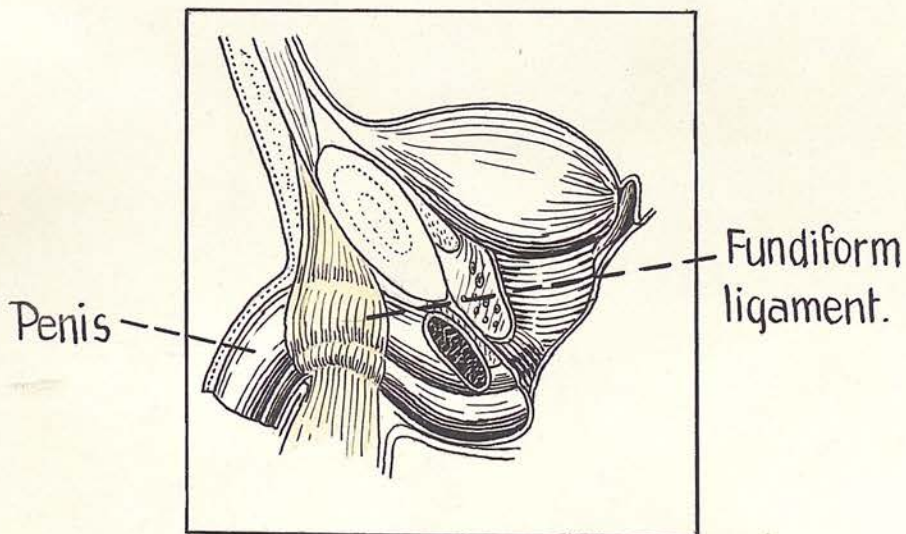


FIG.2(b). The root of the penis, from the side, showing how half the fundiform ligament courses over the side of the penis towards the scrotal septum. (After Testut).

taken by a femoral hernia. (Figure. 1A ).

THE Professor then went on to say that such a condensation occurred elsewhere in the body:-

- (a) the fascia transversalis being merely an external condensation of the extra peritoneal fat.
- (b) the capsule of Gerota; this being an internal condensation of the perirenal fat and ascribable to the effect of the pulsation of the kidney.

3. The dartos "tunic"

This is described by Gray (22) as follows:-

" In the male Camper's fascia is continued over the penis and outer surface of the spermatic cord to the scrotum, where it helps to form the dartos; as it passes to the scrotum it changes its characteristics becoming thin, destitute of adipose tissue and of a pale reddish colour; in the scrotum it acquires some involuntary muscular fibres and forms the dartos tunic. From the scrotum it may be traced backwards into continuity with the superficial fascia of the perineum." This account agrees with that of other British text books. The French anatomists seemed to have realised more thoroughly that this muscle is in reality very large and extensive and not the vestigial structure it is usually considered to be in English speaking countries. ( Fig. 2A ).

The present research has shown that the muscle sometimes forms a complete investment for penis and scrotum.

Displayed in a new born male child one is astounded by the extent of this muscle. ( Fig. 3 ).

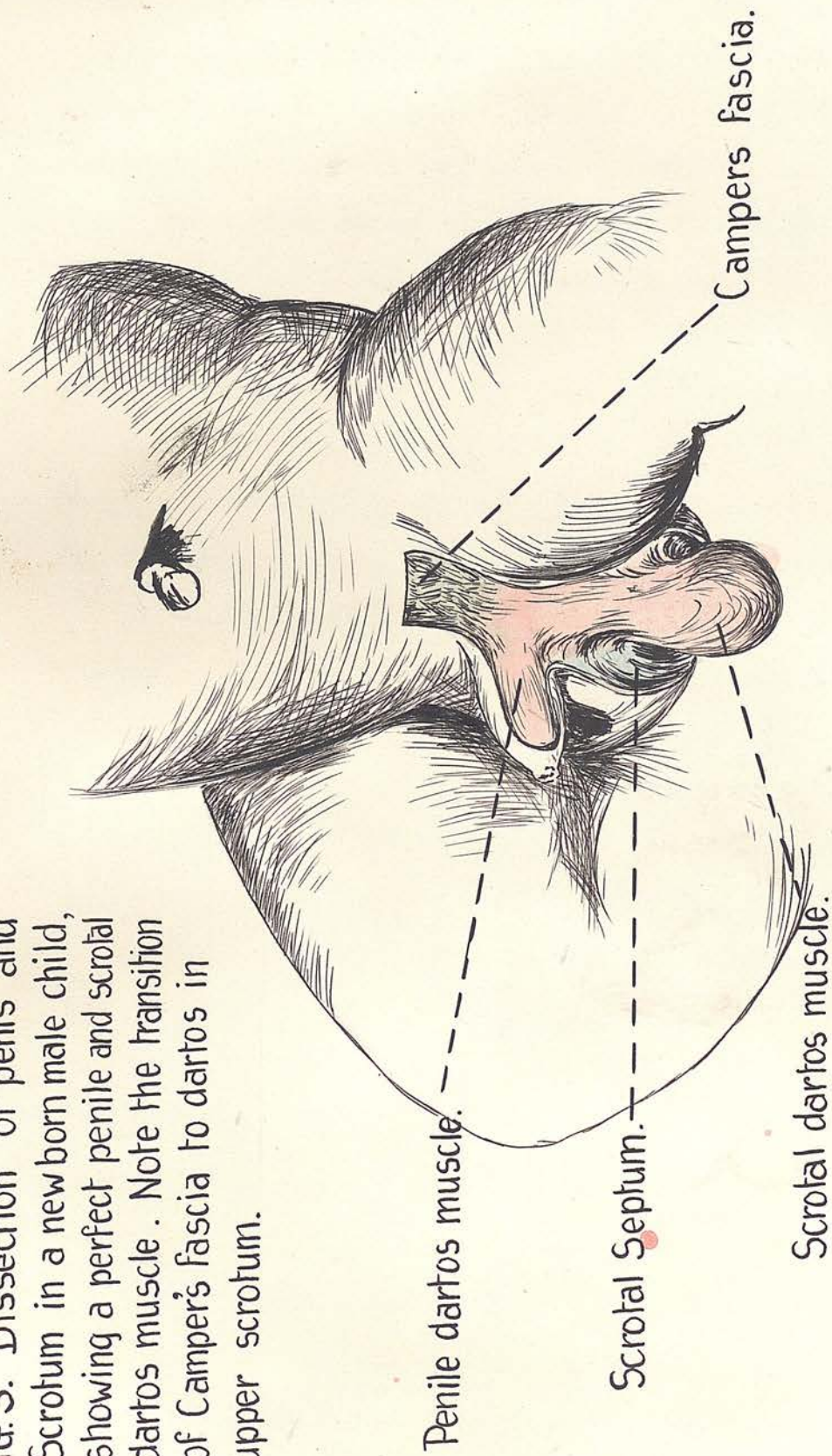
Penile dartos muscle :-

It commences at the pubic aspect of the root of the penis as a definite layer of reddish muscle which blends here with Camper and fundiform ligament. It extends in longitudinally arranged muscle fibres to the very tip of the prepuce and invests the entire projecting portion of the penis.

The scrotal dartos muscle

At the region of the third inguinal ring (vide infra) the yellow fascia of Camper suddenly changes to the red dartos. The transition is sudden and remarkable and well shown in figure 3 taken from an actual dissection. The muscle completely invests the testis and its coverings except where the cord enters. It is big and powerful, its fibres are generally directed vertically in the long axis of the testis. The fibres arise from the skin on one side and are inserted into the septum of the scrotum or the layer of the fascia of Colles which covers the testis. Many of the fibres extend right round the longest circumference of the testis. The observer was profoundly amazed on first displaying the structure shown in figure 3. That it possesses an important supporting function cannot be questioned. There are two layers of dartos in the scrotal septum, one from each testicular compartment. In the adult one usually

FIG. 3. Dissection of penis and Scrotum in a newborn male child, showing a perfect penile and scrotal dartos muscle. Note the transition of Camper's fascia to dartos in upper scrotum.



sees an incomplete layer of pinkish fibres irregularly scattered over the testis. The dartos muscle can often be displayed over the adult penis. It is not usually looked for here. The muscle supports the testis and scrotum as a hammock and wrinkles the skin over the scrotum. This account applies to the dartos muscle and not to the subjacent membranous layer of superficial fascia. The dartos is in series with Camper's fascia and the subcutaneous fat on the perineum and bears the same relation to the subjacent fascia which Camper does to Scarpa. The simile of surgeon's lint is still applicable to the two layers of superficial fascia over penis and scrotum

The dartos has as its deep relation a thick strong membranous sheet of fascia continuous with the fascia of Colles below and that of Scarpa above. It will be shown later that this fascia is in all respects similar to the fascia of Colles rather than to that of Scarpa and should be included as a part of the former, although all three are continuous with each other. It should be emphasized that this is an entirely different structure to the dartos muscle despite their intimate relation and blending, and the term "dartos tunic" should be understood to represent two important penile and testicular coverings, the outer muscular, the inner membranous.

#### 4. The fascia of Scarpa

This layer will be considered in great detail as it is one of the most important structures investigated in the research.

The account given of it in different standard text books

of anatomy and surgical anatomy are so similar that comparing or contrasting is unnecessary. The main points about the fascia as classically described are as follows:-

Towards the lower part of the abdomen the panniculus adiposus develops a deep membranous stratum containing much elastic tissue. It is a relic of the elastic tunic of the lower animals such as the horse. In the region of the pubis it is carried continuously downwards over the spermatic cords, the penis and scrotum, into the perineum where it becomes continuous with the fascia of Colles, which is attached on each side to the corresponding body and ramus of the pubis. On the lateral side of the spermatic cord in the region of the groin, Scarpa's fascia ends immediately distal to the inguinal ligament by blending with the fascia lata of the thigh. ( Fig.1b ).

According to Burdick and Coley (7) the testis and cord pass down into the scrotum in front of the fascia of Scarpa and behind that of Camper i.e. between the two layers of superficial fascia. This is entirely contrary to all accepted anatomical teaching. The following description is based on the writer's researches:-

Sir William Turner on being asked by a student where the sympathetic began, frightened him out of his wits by roaring in his deep voice, " the sympathetic begins nowhere. ".

Something of the same sort may be said of the fascia of Scarpa. The upper limit shades so gradually into the

and left halves of the fascia. /subcutaneous

subcutaneous fat, that one cannot say exactly where it starts. It is certainly most variable in its extent upwards and the degree of its development. Sometimes it may be traced well above the umbilicus. Laterally it disappears in a similar fashion in the region of the loins.

In colour it is bluish or grey and in well covered specimens and babies its fibres may be seen separated by much fat and fibrous tissue. In these characters it differs from the fascia of Colles which is whiter, thicker and has no fat. The fascia over the penis and scrotum in series with these fasciae conforms to the description of Colles fascia and should be so called.

Scarpa's fascia may be said to extend:-

- (1). medially, to fuse with the fundiform ligament of the penis.
- (2). a). Distally, to the neighbourhood of the root of the penis, where it fuses with the fascia of Colles.
- b). to the third inguinal ring, where it fuses with Colles.
- c). to the fascia lata and pubic bone as will be described.

The fascia has no relation to penis and scrotum other than above described unless Colles' fascia be considered merely as a name for a part of Scarpa's.

Over the lower linea alba it blends with a mass of tissue, the fundiform ligament, which binds Scarpa to the linea alba, so that there is a septum here between right and left halves of the fascia.

It has no attachment to the suspensory ligament of the penis.

Relations and attachments of Scarpa's fascia at the root of the thigh.

The research discloses surprising facts of much practical importance in connection with ectopia testis.

The attachments here are :-

1. Lateral attachments.
2. Medial attachments. (a) direct  
(b) reflected

Lateral attachments.

The arrangement is simple in the outer half. Here the fascia blends with the fascia lata a little below the outer half of the inguinal ligament. Quite as often it blends with the fascia lata actually where the latter meets the inguinal ligament. Fig. 1B. Frequently the most lateral attachment is to fascia lata at anterior superior iliac spine. This point is of some importance in connection with the position of the superficial inguinal ectopic testis.

In the inner half of its attachment at the root of the thigh, the fascia has :-

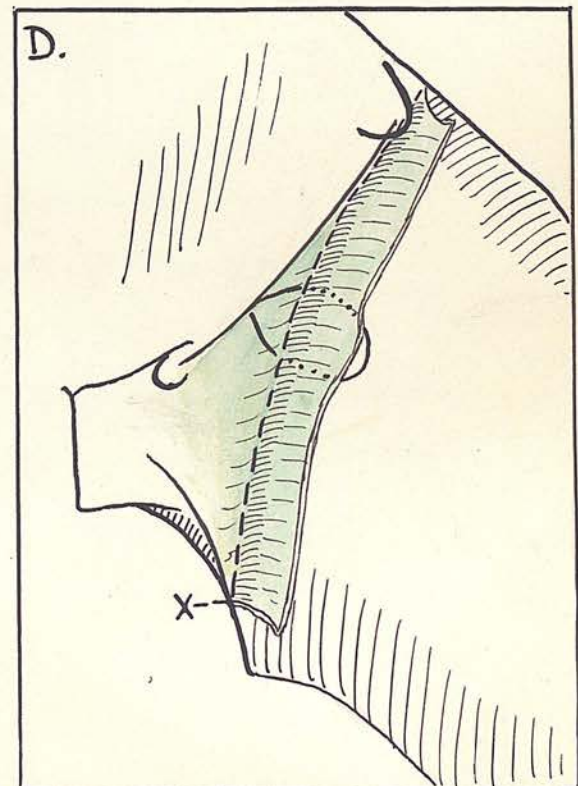
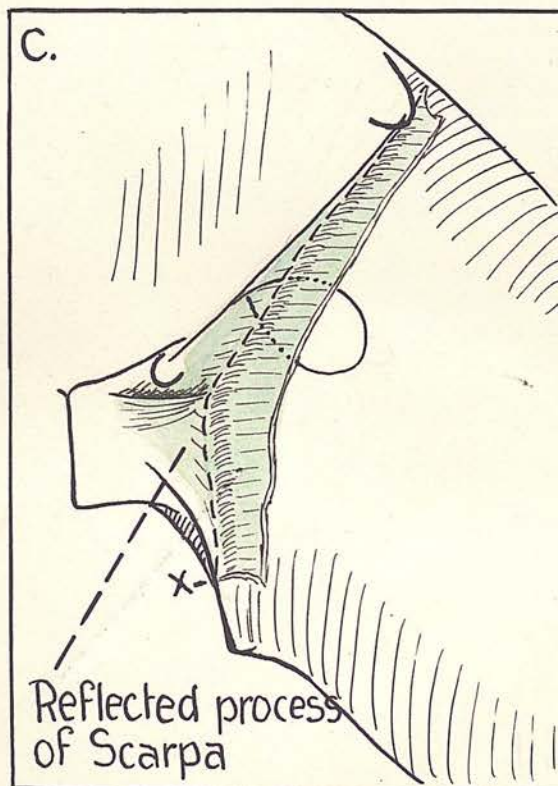
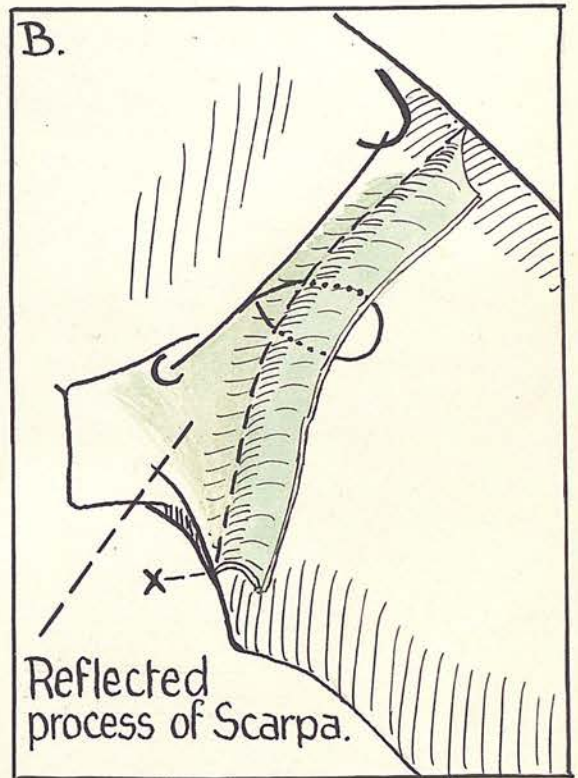
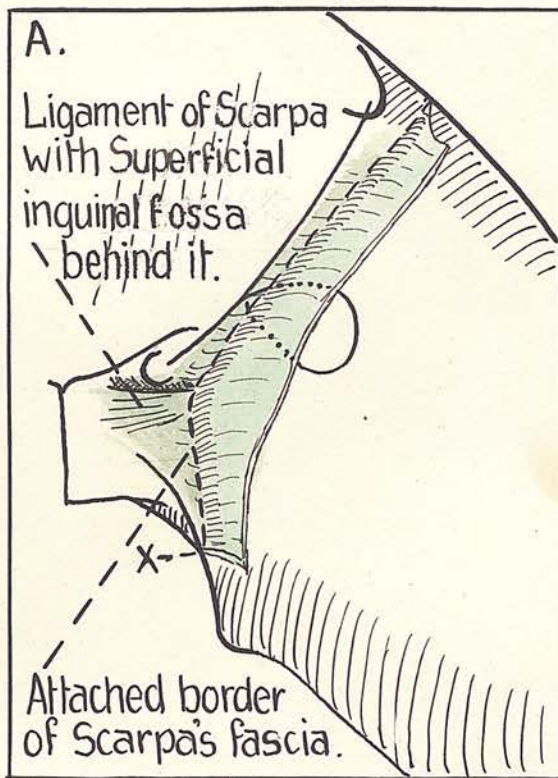
Medial attachments:-

1. direct
2. reflected.

Direct:-

The fascia is attached just below the inguinal ligament in the region of the femoral vessels; its attachment then descends

FIG. 4. A diagram to show the relation of the attached and reflected portions of Scarpa's fascia to the fossa ovalis. In A and B the fascia is attached lower laterally than in C and D. Note how in A and C the ligament of Scarpa holds the attached border



nearer the pubic tubercle than in B and D. In these latter no ligament of Scarpa exists and the attachment of Scarpa to the Fascia lata is therefore lower, and it crosses the fossa ovalis at a lower level than in A and C. X is the spot where attached border of Scarpa meets the bony attachment of Colles.

descends obliquely from the fascia lata to a point on the ischio-pubic ramus about  $2\frac{1}{2}$ " to 3" below the pubic spine. Along this line it blends with the fascia lata. Its attachment therefore crosses the femoral vessels the adductor longus, and ends at the ramus on the gracilis expansion. The line of attachment crosses the fossa ovalis. The manner of crossing is variable. It may cross the upper or lower part of the fossa and obviously influences the relations of a femoral hernia. This point will be elaborated later. ( Fig. 4 ).

It will be seen that the line of fusion of the inner portions of the direct attachment of the fascia of Scarpa with the fascia <sup>lata</sup> is much below that given in the text books.

The inner half of the fascia is stated to be attached to the inner half of the inguinal ligament (25), whereas its line of fusion is often a variable distance below this point. The fascial attachment descends about 1" to  $1\frac{1}{2}$ " below and lateral to the pubic spine. The great importance of this will be pointed out later. There is therefore frequently an area above this fascial attachment where 2" of the adductor longus tendon may be palpated.

Injections under Colles' fascia in the perineum show this as defined above to be correct. (Fig. 5 ).

#### Reflected attachments

What Burdick and Coley call the deep layer of the superficial fascia (Scarpa) of the lower abdomen, the

/writer

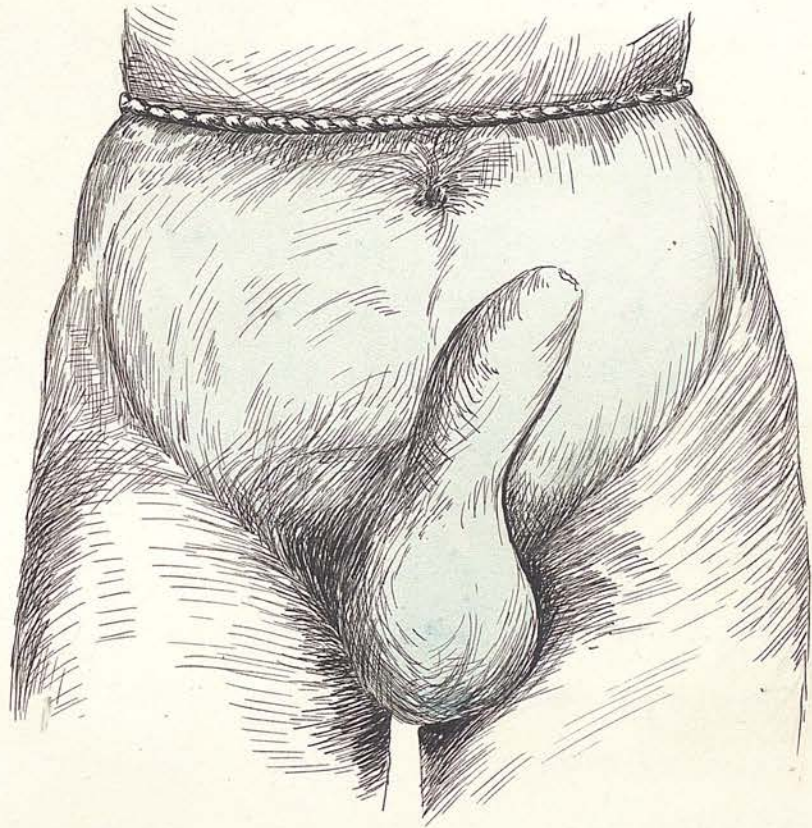


FIG.5.

Drawing taken from a recently dead body in which an injection under pressure has been made under the fascia of Colles in the scrotum. Note delimitation of injection material at roots of thighs. A ligature limits the upward spread.

writer ventures to call the reflected attachment of the fascia of Scarpa. Just as some fibres of the parietal layer of pelvic fascia end at the ischio pubic ramus, while others cross the pubic arch to form the superior layer of the urogenital diaphragm, so while some of the fibres gain a direct attachment to the fascia lata as indicated above, many of its fibres take a reflected course across the fascia lata, and while some are lost in the fascia, others blend with Poupart's ligament, others sweep across to fuse with the ligaments on the front of the body of the pubis, and still others pass in over the adductors and are attached to the pubic ramus. It will be seen that these fibres of Scarpa pass down on the anterior abdominal wall to the line of the direct attachment and then bend sharply inwards towards the pubis. If this part of the fascia is to be called the posterior layer, it must be distinctly understood that by the anterior layer is meant the fascia of Scarpa passing down from the anterior abdominal wall and not the fascia of Camper as Burdick and Coley intend.

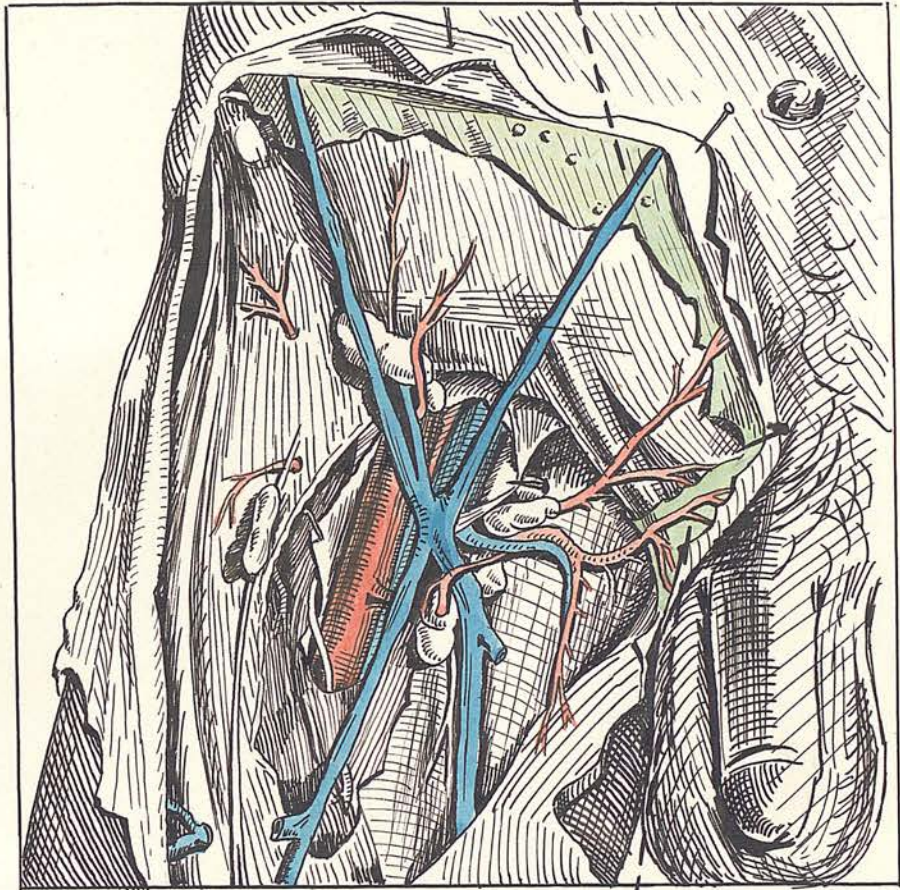
It is of great importance to observe that the fasciculi of the reflected attachments are directed horizontally for the most part. This reflected process while always presenting the same attachments differs in the appearance of its anterior surface. This difference is probably of profound importance in the etiology of ectopia testis.

#### TYPE 1.

The reflected fibres sweep across to the pubis in a smooth unbroken line and the anterior surface of the process is flat and even.

/Type

Fascia of Scarpa.



Fascia of Scarpa  
winding round to  
back of cord.

FIG. 6. A dissection from Quain showing fascia of Scarpa. Note the fascia winding to the back of the cord.

TYPE 2

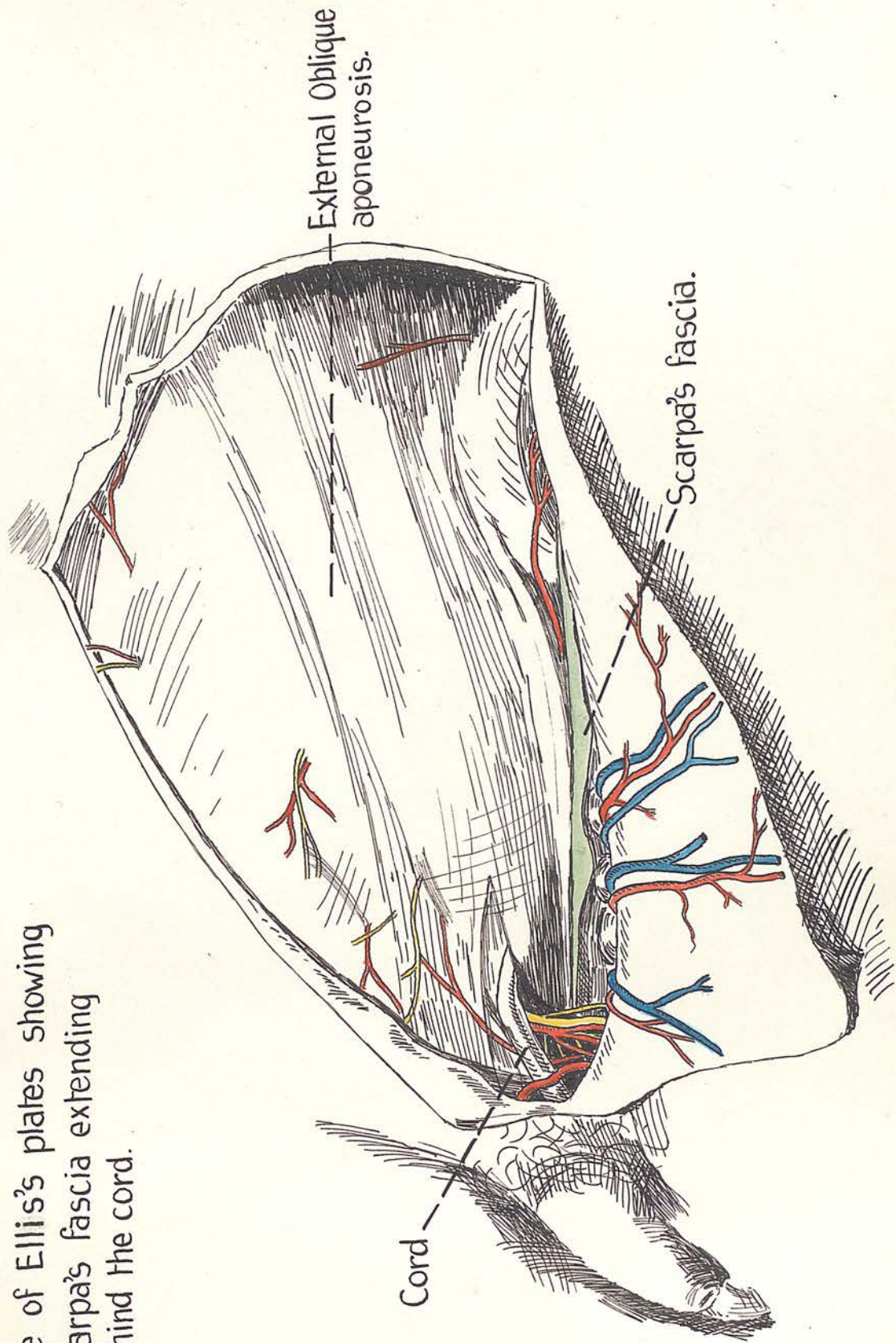
In this variety a fasciculus of the reflected attachment forms a definite ligament with an upper border which is usually horizontal but sometimes curved with its concavity upwards and outwards. Behind this border there is a depression which sometimes forms a definite fossa, which fossa is immediately below the outer part of the external abdominal ring.

Where this ligament ( for simplicity called Scarpa's ligament ), meets the direct attachment, there is formed an acute angle the sharpness of which is rounded off by certain arcuate fibres. Immediately above this angle the ilioinguinal nerve pierces the fascia of Scarpa usually as one sometimes as two trunks. The very greatest interest attaches to this arrangement of the reflected process of Scarpa. The ligament extends horizontally to fuse with the ligaments on the symphysis.

Out of twenty subjects this ligament was found strong and well marked and forming a definite ridge in twenty six cases. In eight cases the arrangement of the reflected attachment was smooth and even. In the remaining six the ligament was rather membranous and formed a well marked edge about 1/2" below the upper border of the body of the pubis. In three bodies type 1. was seen on one side and type 2. on the other. This is an important observation.

/It

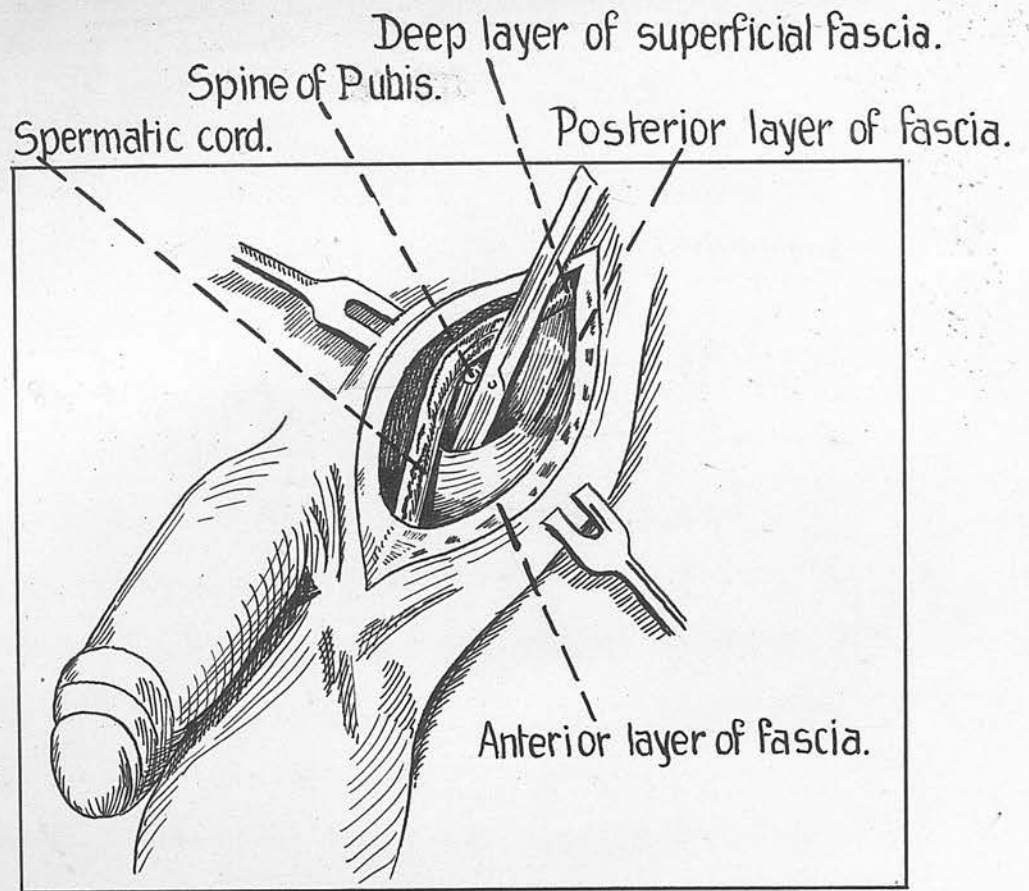
FIG. 7. One of Ellis's plates showing Scarpa's fascia extending behind the cord.



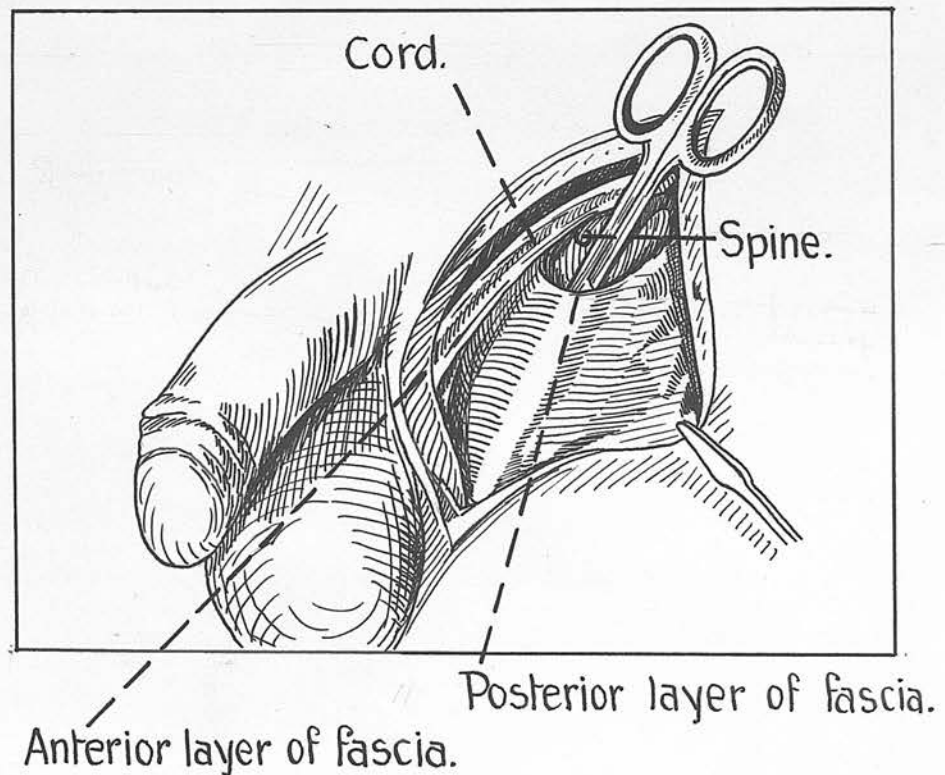
It was further observed that a strong ligament on one side was sometimes associated with a membranous one on the other side ( 20 bodies enable the region to be examined in 40 cases ). Great importance is attached to the fact that in the case of new born babies and foetuses examined in this investigation, the reflected process of Scarpa was type 2. in conformation. This shows that the ligament is present in the foetus and does not develop in later life as the result of such factors as strain or weight ~~lifting~~<sup>BEARING</sup> or the pull of the testicle.

It is further to be noted that there was a definite dimple behind the ligament in such young subjects. In a five months foetus, this ligament was big, very strong, and bilateral, with a definite recess behind it. All this indicates that it is not a development of post uterine life.

It is of vast and far reaching importance to notice that the reflected attachment of the fascia of Scarpa is behind the spermatic cord. Though faint and poorly marked at times, in most cases there is a strong process of Scarpa behind the cord. This is contrary to all accepted anatomical doctrines. Though nowhere referred to in anatomical books, reference to Figures 6 & 7 will show that the artists ( who faithfully depicted dissections ) represent portions of this reflected process of Scarpa passing behind the cord. Credit for this observation must go to Burdick and Coley, who however are wrong in



FIGS. 8,9. From Burdick and Coley. Note that what they call the "posterior layer of fascia" meaning Scarpa's fascia, is in reality the ligament of Scarpa, and what they call the anterior layer of fascia meaning Camper is Scarpa's fascia proper. The scissors have been pushed down through the floor of the superficial inguinal fossa and are in the cellular tissue at the root of the thigh.



the interpretation they place on it. Figure 8 borrowed from Burdick and Coley's article, shows the ligament formed by the reflected attachment of Scarpa with the cord passing anterior to it. This is correct. The author has never found the precise arrangement of the ligament which they figure, also they do not show the angle of fusion of the ligament with the direct attachment of Scarpa.

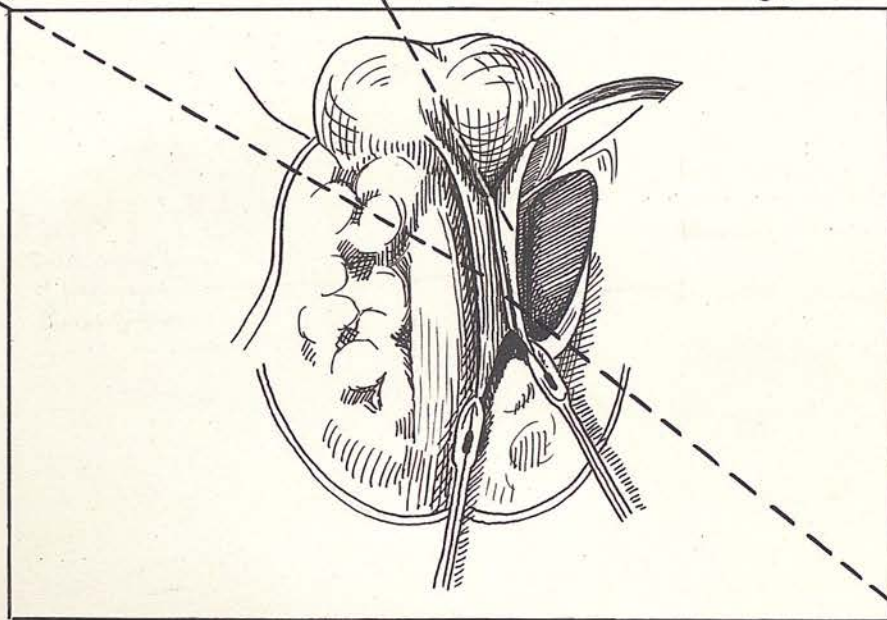
The scissors are in the pouch behind the ligament and in Figure 9 are shown in the areolar tissue over the adductors. They point out that anything pushed down behind the ligament would seem to enter the upper part of the scrotum, but in reality enters the root of the thigh between the ligament and the fascia lata over the adductors.

They also point out that it is impossible for anything entering here to enter the perineum. Entire agreement is expressed with this. It must be pointed out however, that only by the use of considerable force or a sharp instrument can a passage be made behind the ligament. In all the cases examined where this pouch or ligament existed there was found to be a strong fascial floor to the recess.

This floor is formed by the reflected attachment of the fascia of Scarpa. It is in view of these facts that the assumption made by Burdick and Coley that in crural ectopia the testis passes down behind this fascia, must be considered untenable. In Figure 10a they show the attachment of the fasciae of Colles and Scarpa to the pubic ramus stating that

Fig. 10(b). A transverse section of the penis at its middle to show its coverings. Note the deep fascia of penis.

Superficial fascia of perineum. Colles fascia. Posterior layer of fascia attached to descending ramus.



Descending ramus.

FIG.10(a). From Burdick and Coley. For description see text.

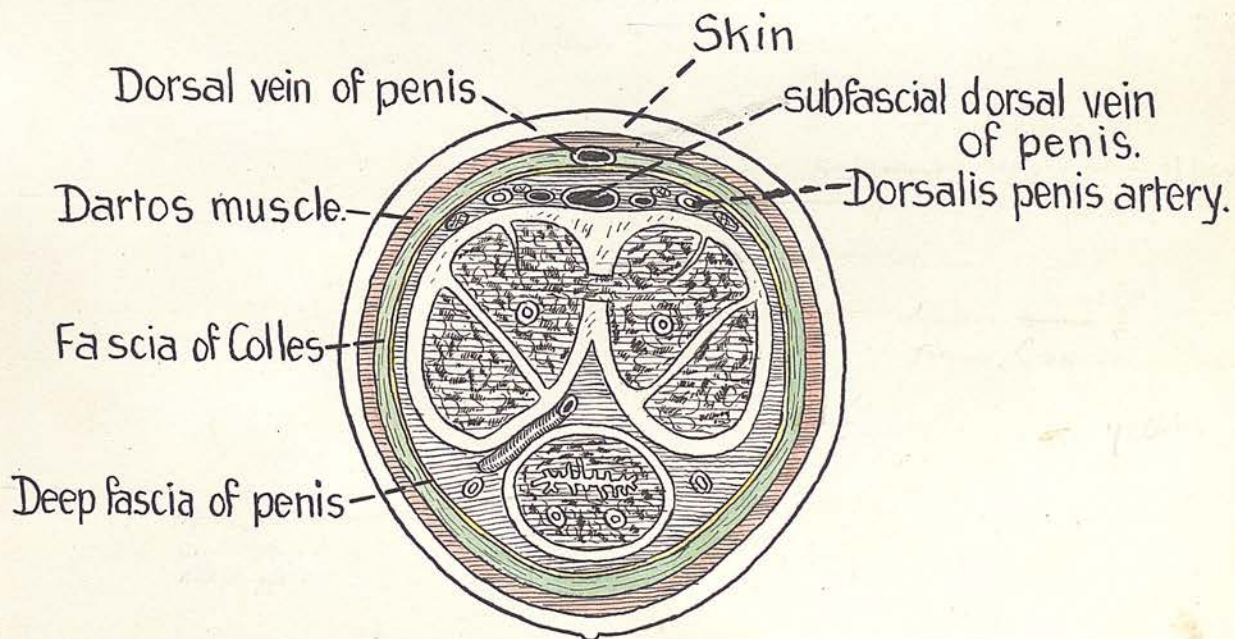


FIG.10(b). A transverse section of the penis at its middle to show its coverings. Note the deep fascia of penis.

a testis under the layer of fascia joining the ramus on the reader's right cannot possibly enter the perineum. This is agreed. They do not show the direct attachment of the fascia of Scarpa, and from the drawing it would seem that the layer they call "the posterior layer of fascia" is the fascia lata of the thigh. The reflected layer in this situation has a similar attachment to the pubis which the fascia lata has and is superficial to it.

Figure 4 shows type 1. and type 2. arrangements of the reflected fascia as found in this research.

Before leaving the fascia of Scarpa it should be pointed out that in type 2. of the reflected process, the ligament going behind the cord holds the direct attachment forward, angulating it, so that the line of attachment is sharply convex towards the pubic spine.

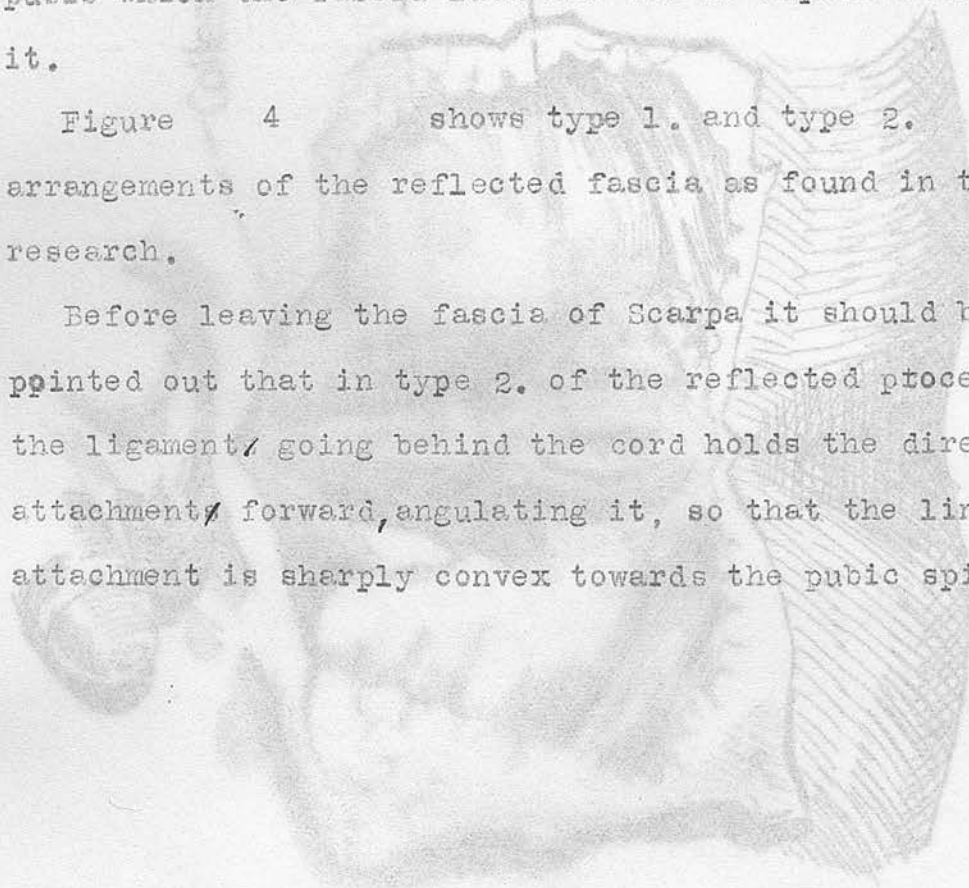


FIG. 11. Quain's plate of the perineal region. No trace of a deep fascia is seen.

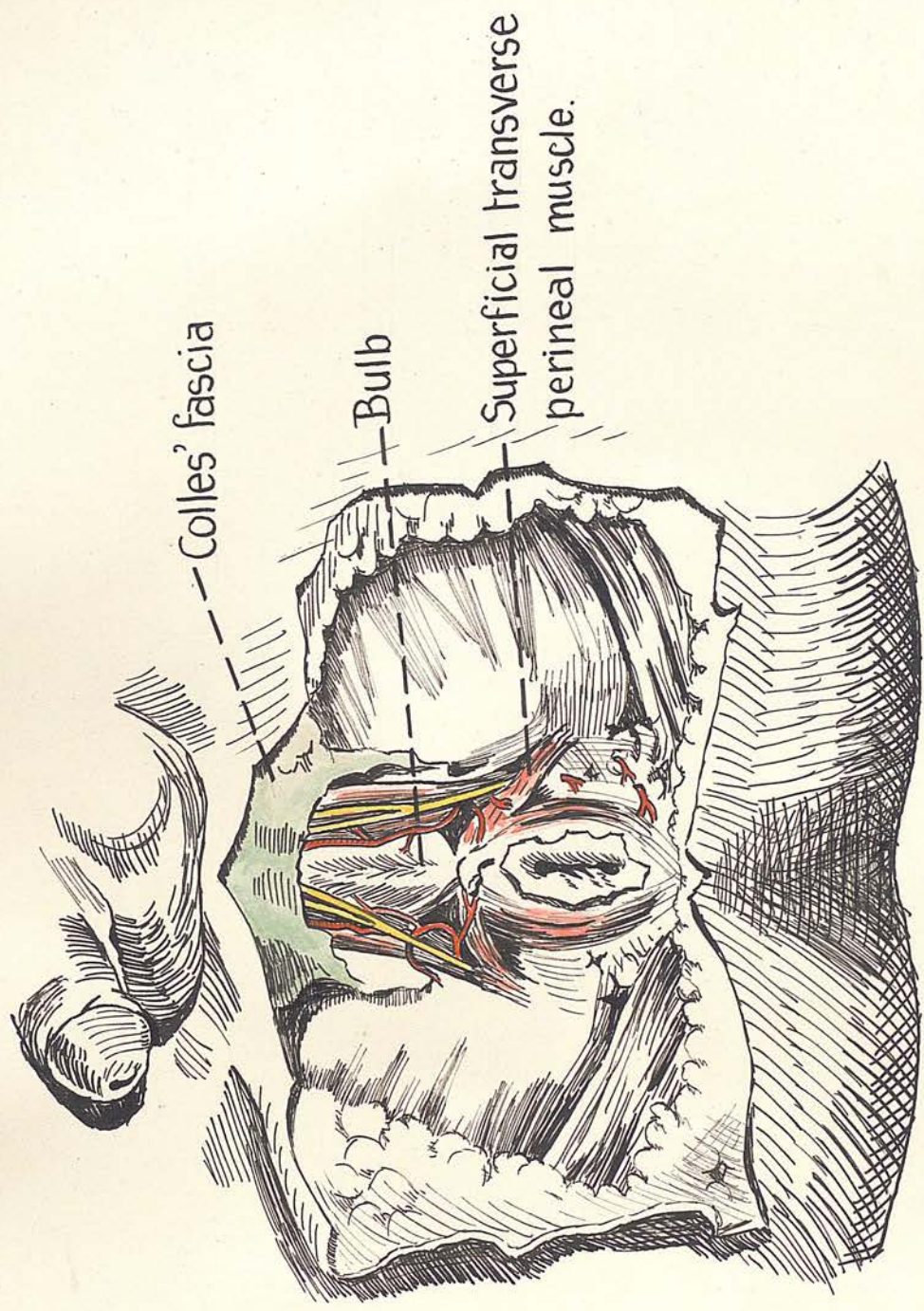


FIG.11. Quain's plate of the perineal region. No trace of a deep fascia is seen.

5. The fascia of Colles

This layer, as usually described, is confined to the perineum, where it is attached to the ischio-pubic rami and the base of the urogenital diaphragm. Fig. 11

Cunningham (10) states ( conforming to all other descriptions) that towards the front of the perineum, the fascia of Colles is continuous with the Dartos tissue of the scrotum and that in its turn is continuous more anteriorly with the fascia of Scarpa. He states further that the bony attachment of Colles is prolonged upwards as it becomes continuous with the fascia of Scarpa along the front of the symphysis on each side. For reasons given above the writer considers the fascia of Colles to extend over the scrotum and penis deep to the dartos muscle.

Continuing, Cunningham states that the superficial pouch of the perineum is open above across the front of the symphysis pubis where its cavity is continuous with the areolar tissue filled interval between the superficial and deep fascia of the anterior wall of the abdomen.

Anteriorly the fascia of Colles passes over the scrotum, penis and spermatic cords to the anterior aspect of the abdomen where it becomes continuous with the fascia of Scarpa. Note that Cunningham here definitely states that the fascia of Colles covers the genitals. The posterior scrotal vessels and nerves are immediately deep to this fascia. A more or less well developed septum dips down from the fascia of Colles to the inferior

aspect of the bulb of the urethra.

The researches have shown some very important differences in the attachments of the fascia as described above and by other anatomists. The fascia will be described as consisting of two portions;

- (1). the general investing layer.
- (2). the falciform process.

though this division is to some extent arbitrary, it is of great significance and valuable for descriptive purposes.

(1). The general investing layer:

From its nether attachment to the base of the urogenital diaphragm the fascia extends up immediately under the subcutaneous tissue forming the lower wall of the superficial perineal pouch.

Along a horizontal line a short distance above the head of the epididymis, the fascia is folded back on itself forming a well marked even ridge when the testis is dependent. (The perineo-scrotal reduplication). This ridge bounds the entrance to the cavity for the testis in front and the superficial pouch of the perineum behind. Fig. 12

The spermatic cord with its three coverings from the anterior abdominal wall lies anterior to this ridge to which the external <sup>SPERMATIC</sup> fascia is attached. In the 5 months foetus the scrotum is the size of a pea and not dependent, yet there is a definite cavity in it for the testis to occupy

/when

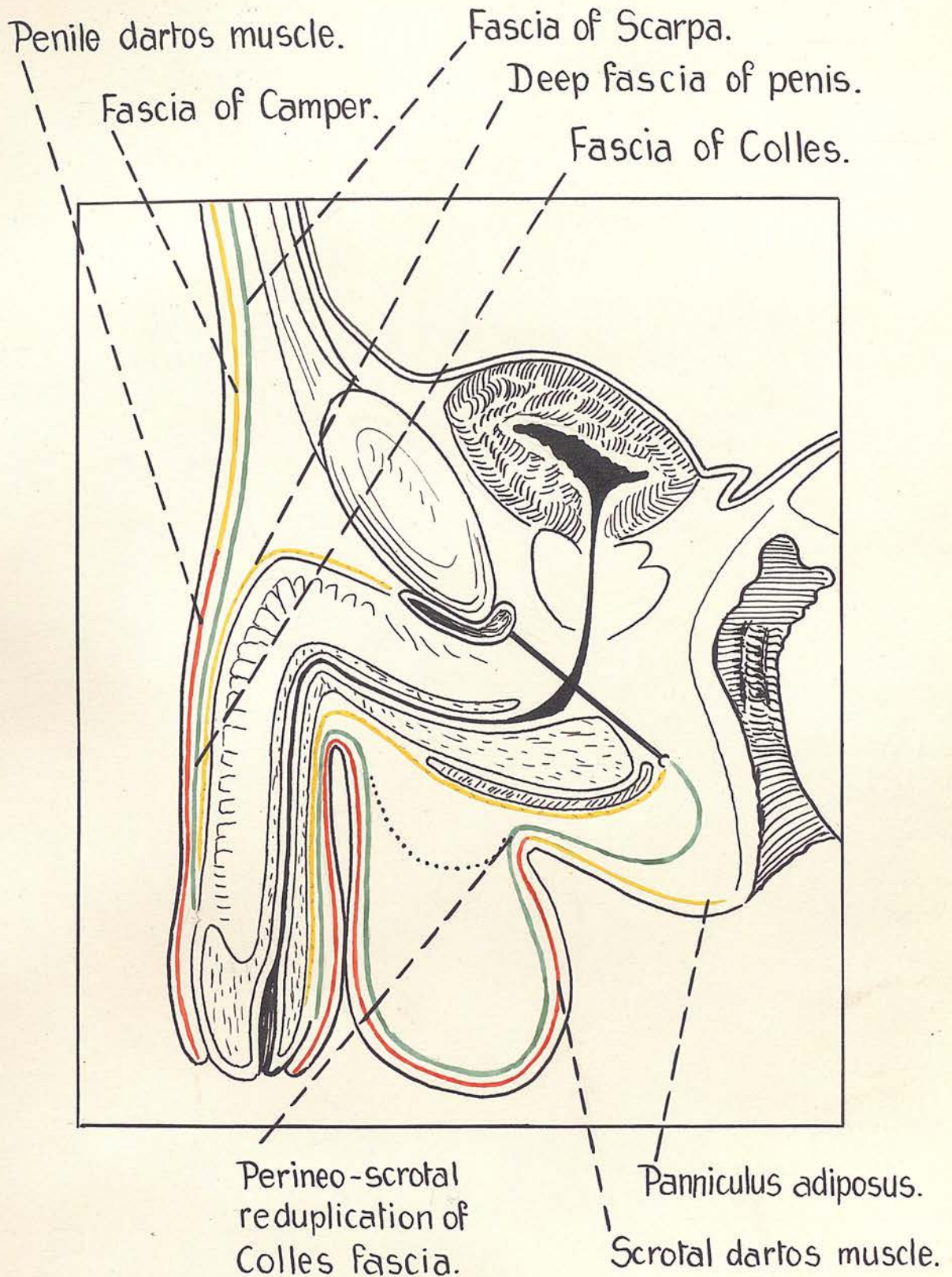


FIG.12. Longitudinal section (diagrammatic) to show fascial coverings and relations of penis and scrotum. The dotted black line shows the form of the scrotal pouch in the foetus before the testis has entered it. Note that in the adult the perineo-scrotal reduplication forms an acute angle whereas

when it descends, and the reduplication of Colles' fascia though <sup>not</sup> an even ridge as in the adult yet forms a definite shelf which the testis must cross (Fig 12). Next the fascia of Colles' is reflected over the testicle and up on to the anterior aspect of the cord, becoming continuous with the fascia of Scarpa at the third inguinal ring and joining laterally with the fascia of Scarpa where it passes down to its direct attachment to the fascia lata. The projectile portion of the penis is invested with a complete sheath of Colles' fascia as far as the base of the glans. On or in this sheath lies the superficial dorsal vein of the penis and underneath the fascia a fibrous stratum separates it from the dorsal vessels and nerves. Figure 10b. On the ventral aspect of the penis, there is a septum binding the fascia of Colles to the fibrous investment of the corpus cavernosum urethrae. The fascia of Colles covers the projectile portion of the penis exactly as a finger stall open at both ends covers a finger. Figure 12.

Where the suspensory ligament joins the penis the fascia of Colles presents a different relations in the adult and the young child. In the adult the fascia is fused with the fibrous penile coat beneath it in the form of a ring round the organ. In the child the fascia of Colles is not bound down on its deep surface, but fuses with the fundiform ligament of the penis, the two meeting at a right angle, and there is a passage for fluid to

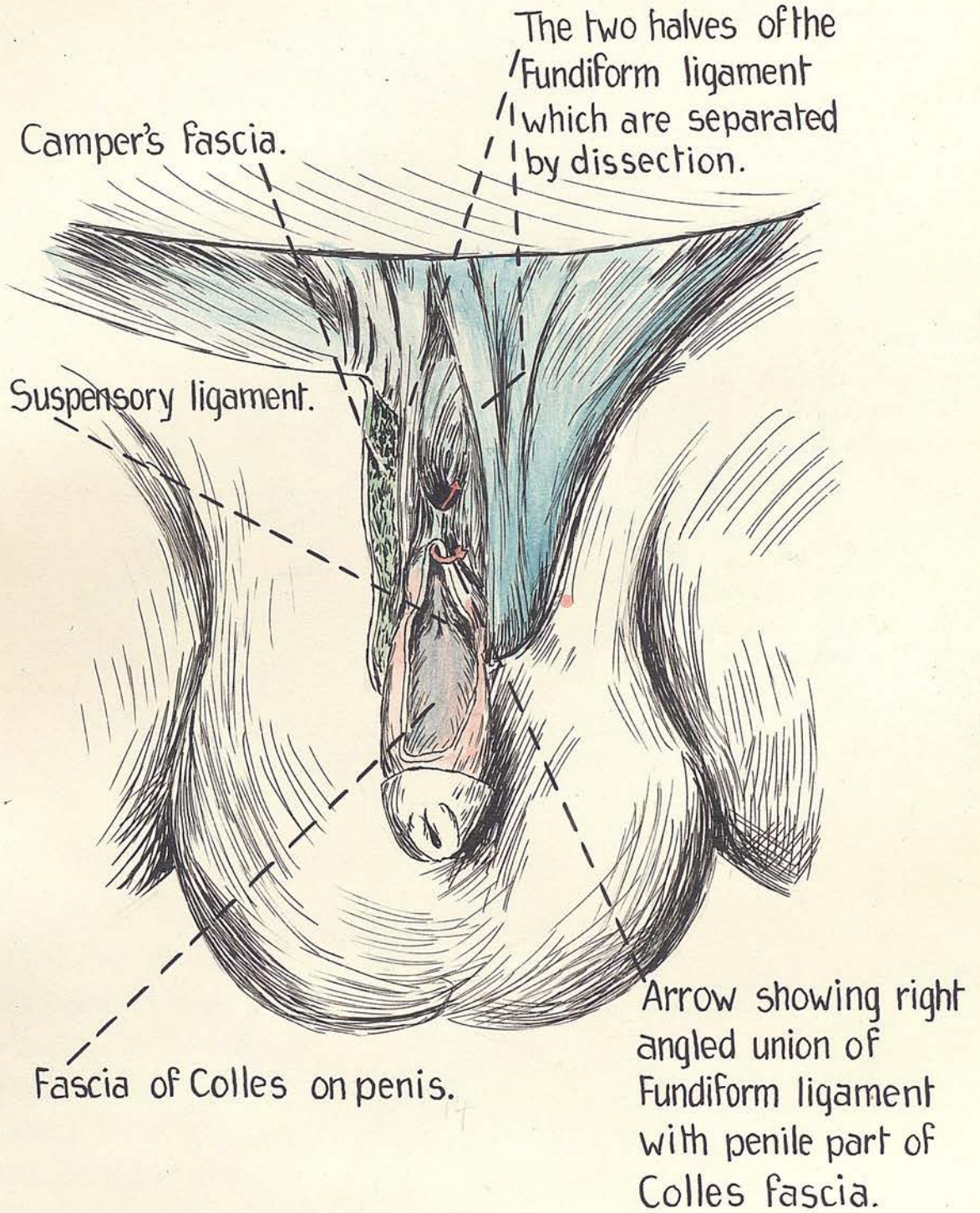


FIG.13. Dissection in a new born child to show right angled fusion of penile Colles fascia with fundiform ligament — see arrow passing under the union. A route for fluid on penis (under Colles) to anterior abdominal wall. (*much enlarged*).

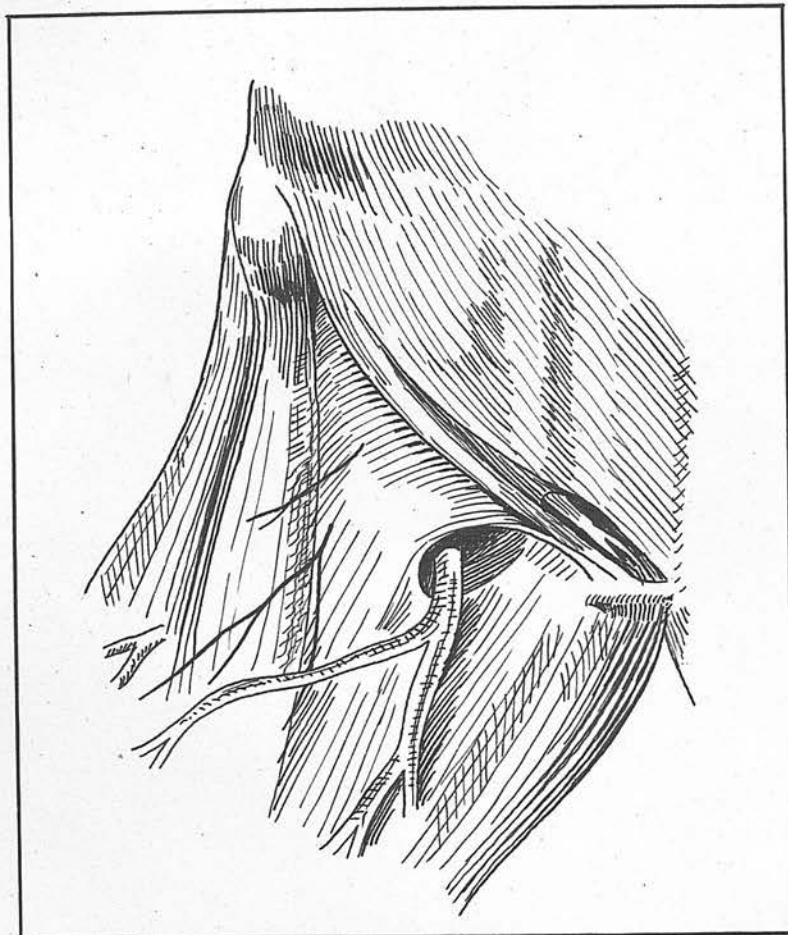
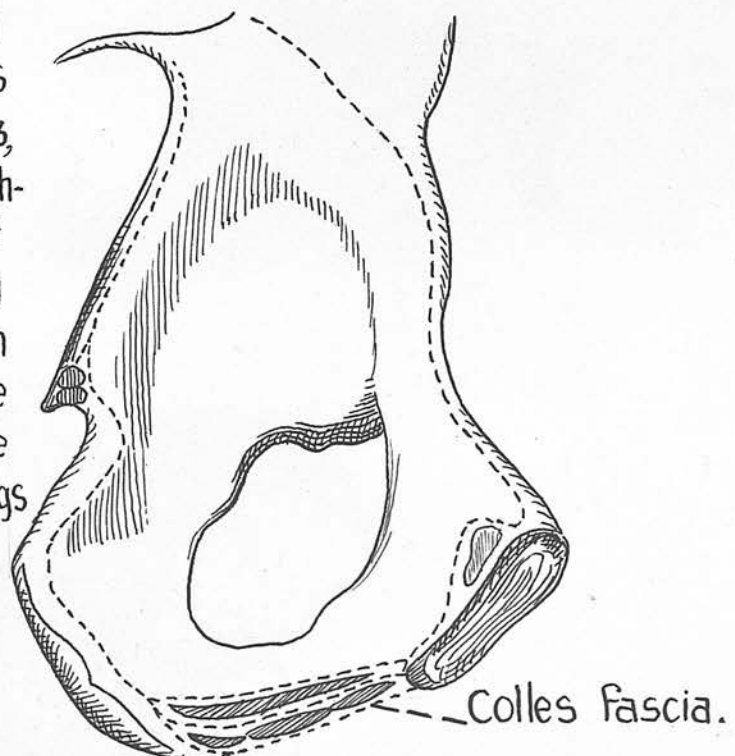


FIG.14(a).The fossa ovalis (from *Grays' Anatomy*.)

FIG.14(b). From an old edition of Morris's Anatomy, London 1893, showing the bony attachment of the fascia of Colles to the conjoined ramus. Compare with Frazer's figure. The condition in this picture agrees with the findings in this research.



to reach the anterior abdominal wall when it passes upwards from under the penile portion of the fascia of Colles. ~~Fig. 13~~. In the adult it is questionable whether this can happen unless the fluid be under sufficient tension to break through the layer of connective tissue which binds Colles to the underlying fibrous stratum just in front of the suspensory ligament. If in the child the fusion of Colles with the fundiform ligament ~~XXXX~~ be lifted or divided, the suspensory ligament will be seen unattached to either of the former layers. Fig. 14

Passing from penis and cord to anterior abdominal wall the fascia of Colles fuses with the fascia of Scarpa.

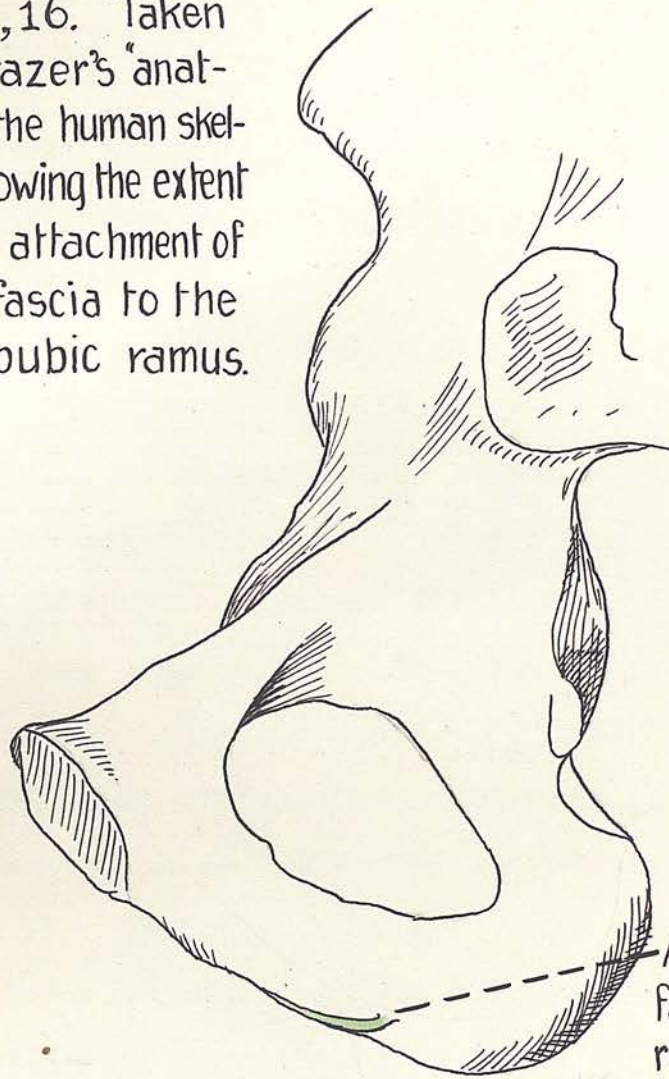
Stress must be laid on the fact that the fascia of Colles which is superficial to the scrotal vessels and nerves and penile vessels and nerves is perforated in numerous places by small cutaneous branches of these.

The falciform process:

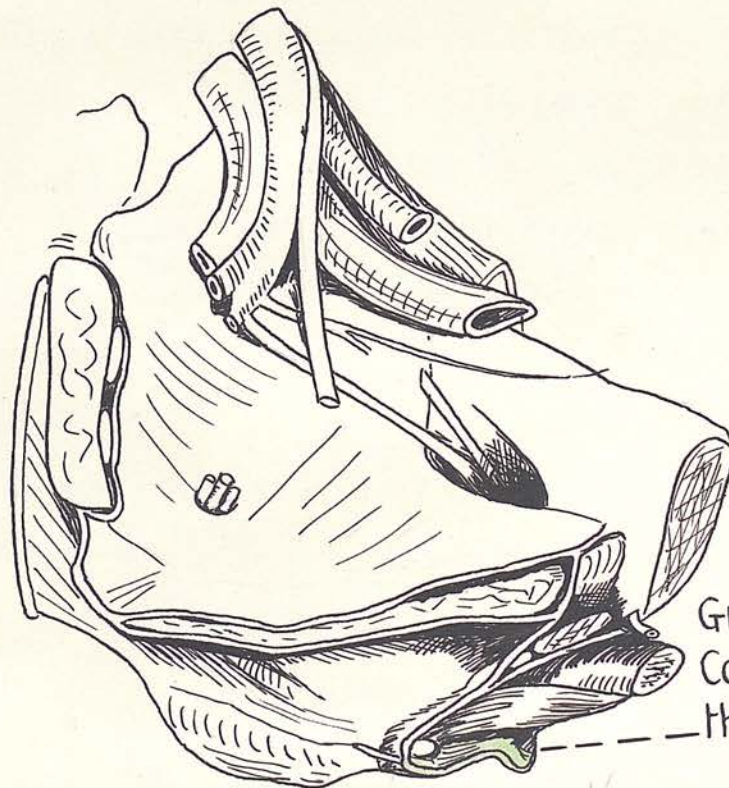
The attachment of Colles' fascia to the conjoined ramus is not confined to the lower part of this bone, but extends upwards nearly to the inferior aspect of the symphysis. This is represented accurately in Figure. 14b which is reproduced from an old edition of Morris' Anatomy (1893). Figures. 15 & 16 from Fraser's "Human Skeleton" (1914), show but a small bony attachment for the fascia. This attachment forms a complete septum between perineum and thigh for half the

/distance

FIGS. 15, 16. Taken from Frazer's "anatomy of the human skeleton" showing the extent of bony attachment of Colles fascia to the ischio-pubic ramus.



Attachment of Colles fascia to ischio-pubic ramus.



Green layer is Colles' fascia in the perineum.

distance from the base of the uro-genital diaphragm to the pubic tubercle. Above the mid point the fascia of Colles sends a peculiar falciform process upwards to the region of the symphysis and this falciform process is the only structure ( when the testis with its coverings have been removed ) intervening between the upper part of the superficial perineal pouch and the area at the root of the thigh above the direct attachment of Scarpa's fascia. This process forms therefore not a partition between the two areas but merely a ridge. This falciform process continues the line of attachment of Colles to the pubic ramus, which it leaves, before reaching the angle of the pubic arch, to cross the body of the pubis and to blend with the ligaments of the front of the pubis, and particularly with the external oblique aponeurosis with the fibres of which it is often directly continuous.

Figure. 17 This fasciculus of Colles is often composed of strong ligamentous fibres which seem by their size to have a supporting function as a sling for the scrotum. This falciform process is firmly bound by its anterior edge to the external spermatic fascia covering the cord. When this is removed by careful dissection it becomes a free edge. The writer has been much impressed by the constancy of this fascial process and by its apparently important function in regard to both the support of the scrotum and ectopia testis. It is this fascial process

/which

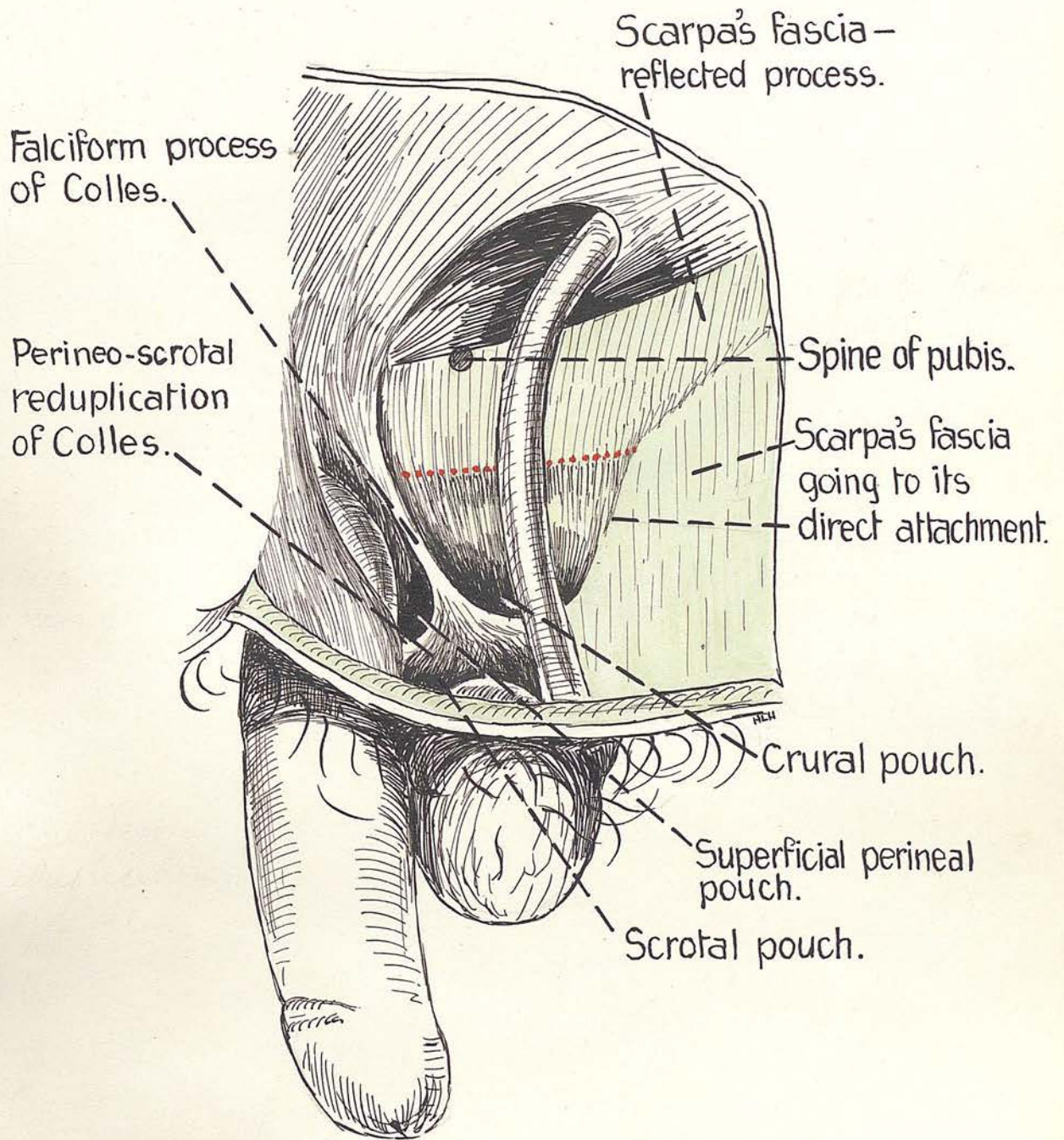


FIG.17. Dissection in an adult. Note the absence of a ligament of Scarpa. Note the falciform process of Colles, and the Crural, superficial perineal and Scrotal pouches. The dotted red line shows the third inguinal ring of the funnel shape with anterior wall removed.

which bounds the tunnel from the superficial perineal pouch to the anterior abdominal wall on the outer side.

If the testis and cord with external spermatic fascia be removed it will at once be seen that the falciform process forms a raised ridge between the superficial perineal pouch and the compartment at the root of the thigh between the fascia of Scarpa and the fascia lata (covered of course by the reflected process of the fascia of Scarpa ). The direct attachment of Scarpa reaches and fuses with the fascia of Colles at the pubic ramus just below the point where the attached margin of Colles gives off the falciform process. It will be apparent on referring to the illustrations of dissections shown here, that there is a well marked pouch between the fascia of Colles and the direct attachment of the fascia of Scarpa where they fuse at the pubic ramus. This is the crural or femoral pouch. Figure. 17 It is remarkable how frequently the falciform process can be traced into the external oblique. Tendinous fibres of this muscle may be seen passing down into this process of Colles. Is it possible that the testis receives one of its main slings by <sup>an</sup> insertion of external oblique into the fascia of Colles ?

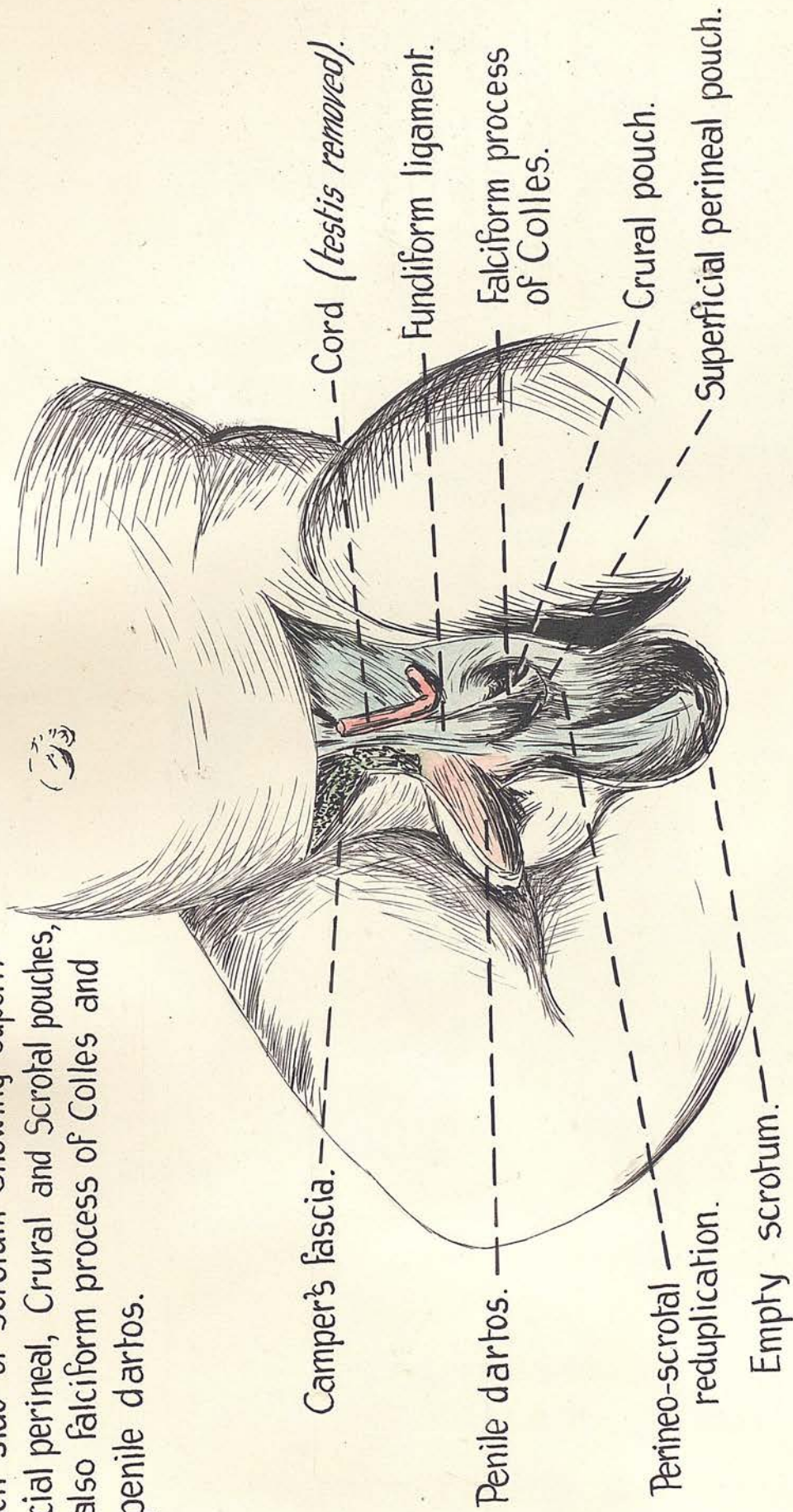
The falciform process was found particularly strong, well developed, and forming a definite ridge on both sides in a new born child. Notice that the thin sickle shaped edge forms but a very faint ridge above and a high

pro

/prominent

Fig. 18. Full time child. Dissection of left side of scrotum showing superficial perineal, Crural and Scrotal pouches.

FIG.18. Full time child. Dissection of left side of scrotum showing superficial perineal, Crural and Scrotal pouches, also falciform process of Colles and penile dartos.



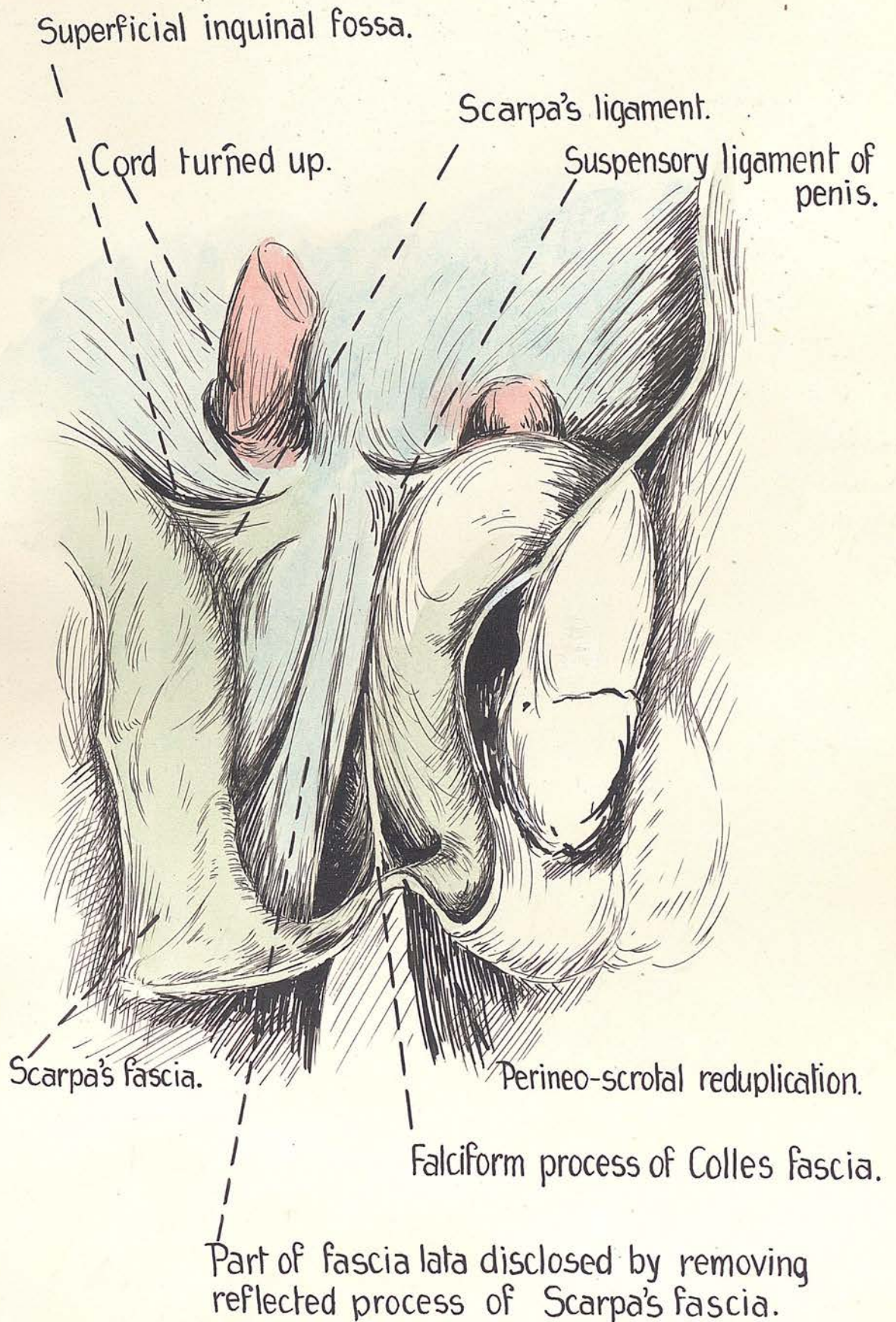


FIG.19. Dissection of an adult. Note how a process of fascia lata may be mistaken for falciform process of Colles when the reflected process of Scarpa is removed.

prominent one in its lower part. Figure 18

It would therefore be negotiated with ease above, but with great difficulty below. Notice also that this process is not apparent until the attachments of the external spermatic fascia have been separated from it, though arching fibres may be seen on exposing the envelopes of the testis and cord from their lateral aspect. The arching fibres will be seen close to the pubic ramus gaining an attachment to this bone. The dissection to expose the process requires meticulous care in its performance or else the reflected process of the fascia of Scarpa and the fascia lata over the adductor longus may be torn through, in which case the sheath of the adductor longus will be exposed, and the fibres of the fascia lata going to the body of the pubis which have a longitudinal direction, may be mistaken for the falciform edge. However on tracing these fibres down they will be seen to continue down the thigh and not to fuse with the fascia of Colles. Figure 19

In one exceptional case certain fibres of the fascia of Scarpa were seen to cross the lower part of the falciform edge, passing down to gain an attachment to the testicular aspect of the fascia of Colles enveloping the scrotum. This was not found in any other case. So greatly did this falciform process intrigue the author that it was thought of the first importance to examine for it in

Fig 20 Dissection in a five months foetus of the left side of the scrotum and deeper parts. Note falciform process of Colles, gubernaculum, ligament of Scarpa, and superficial inguinal fossa. The perineo-scrotal pouches are shown. (Muller)

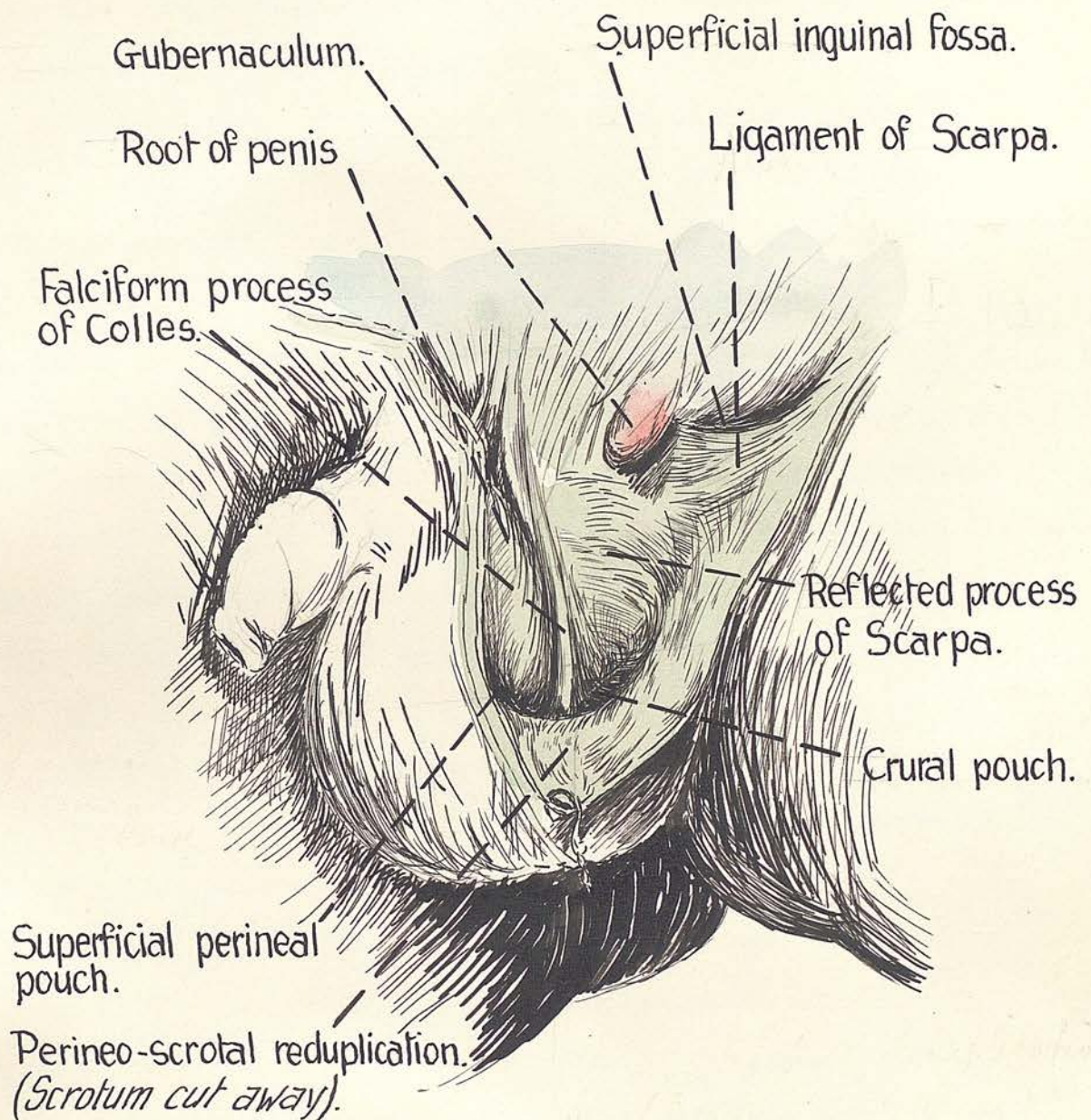


FIG.20. Dissection, in a five months foetus, of the left side of the scrotum and deeper parts. Note falciform process of Colles, gubernaculum, ligament of Scarpa, and superficial inguinal fossa. The perineo-scrotal reduplication and Crural and superficial perineal pouches are shown. *(Much enlarged).*

at an age preceding the descent of the testis. The result of these dissections was further proof of the existence and function of the ledge. In the five months foetus shown, Figure 20 the falciform process was seen to form a definite vertical ridge separating perineum from crural region. It conformed exactly in miniature to the state in the adult and was better seen because the testis with its coverings had not descended to obscure the process. This part of Colles' fascia appears to be relatively stronger in the late foetus or early new born child. Once again the strength and definition of the structure at so early an age would seem to bespeak for it some important function.

(6). The deep fascia of the perineum:

Reference to any text book of human anatomy discloses the fact both in the text and in the illustrations of the perineal region, that on the removal of the fascia of Colles the muscles of the superficial pouch are exposed, some areolar tissue intervening, Figure. 11

The author has repeatedly found that it is necessary to remove another layer of fascia before coming on to the muscles. In this research this fascia has been found present in all cases, differing considerably in its development. At times the muscles are seen shining through it, but frequently it is very dense, strong and aponeurotic.

ATTACHMENTS:

It blends behind the superficial transverse perineal

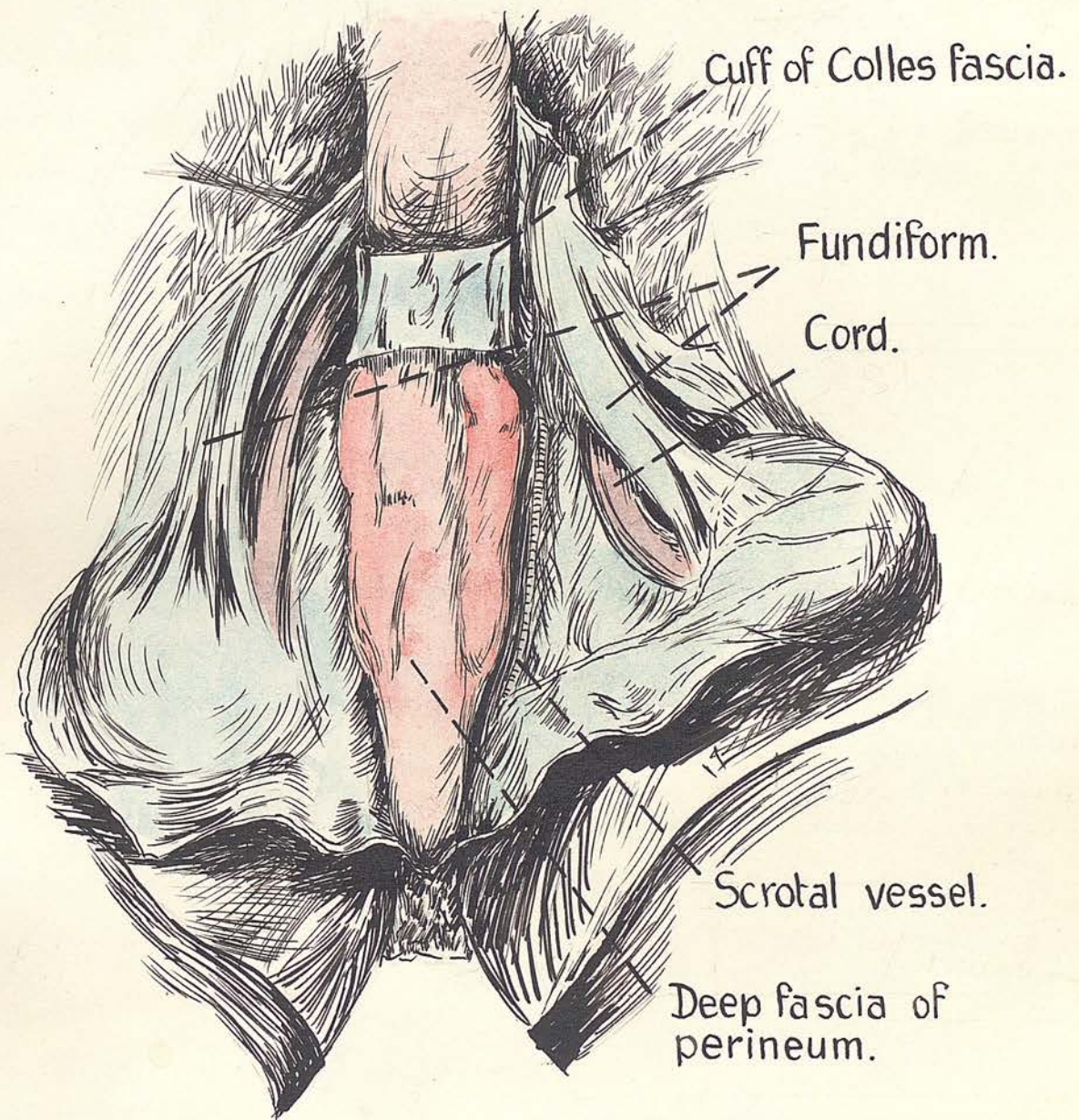


FIG.21. Dissection showing deep fascia of penis and perineum from below with red lead injection beneath it.

muscle with the fascia of Colles and the uro-genital diaphragm. It is attached at the sides to the ischio-pubic ramus and extends on to the penis where it is continuous with the fibrous tunic of that organ, sometimes called the deep fascia of the penis. It therefore forms the first line of resistance which will be met by any extravasation of fluid deep to it. Near its base posteriorly it is sometimes perforated by the medial and lateral posterior scrotal nerves. Like the fascia of Colles it is perforated by small vessels in numerous places. Injections of a red lead solution made under the fascia extend on to the sides of the penis. The fascia confines the injection except where it is perforated by vessels and nerves, in which case it oozes out along these structures into the area just deep to Colles' fascia.

It is bound down in the middle line on its muscular aspect to form a median septum. The author has called this layer the deep fascia of the perineum. It is shown in Figures. 21 & 22

(7). The fundiform ligament of the penis:

**Morriss** (29) describes this structure as arising from the linea alba and Scarpa's fascia just above the pubic symphysis. It forms a broad elastic band (superficial suspensory ligament of the penis) which sends a fasciculus on each side of the organ. Below the penis these fasciculi re-unite. Testut and others state that

/after

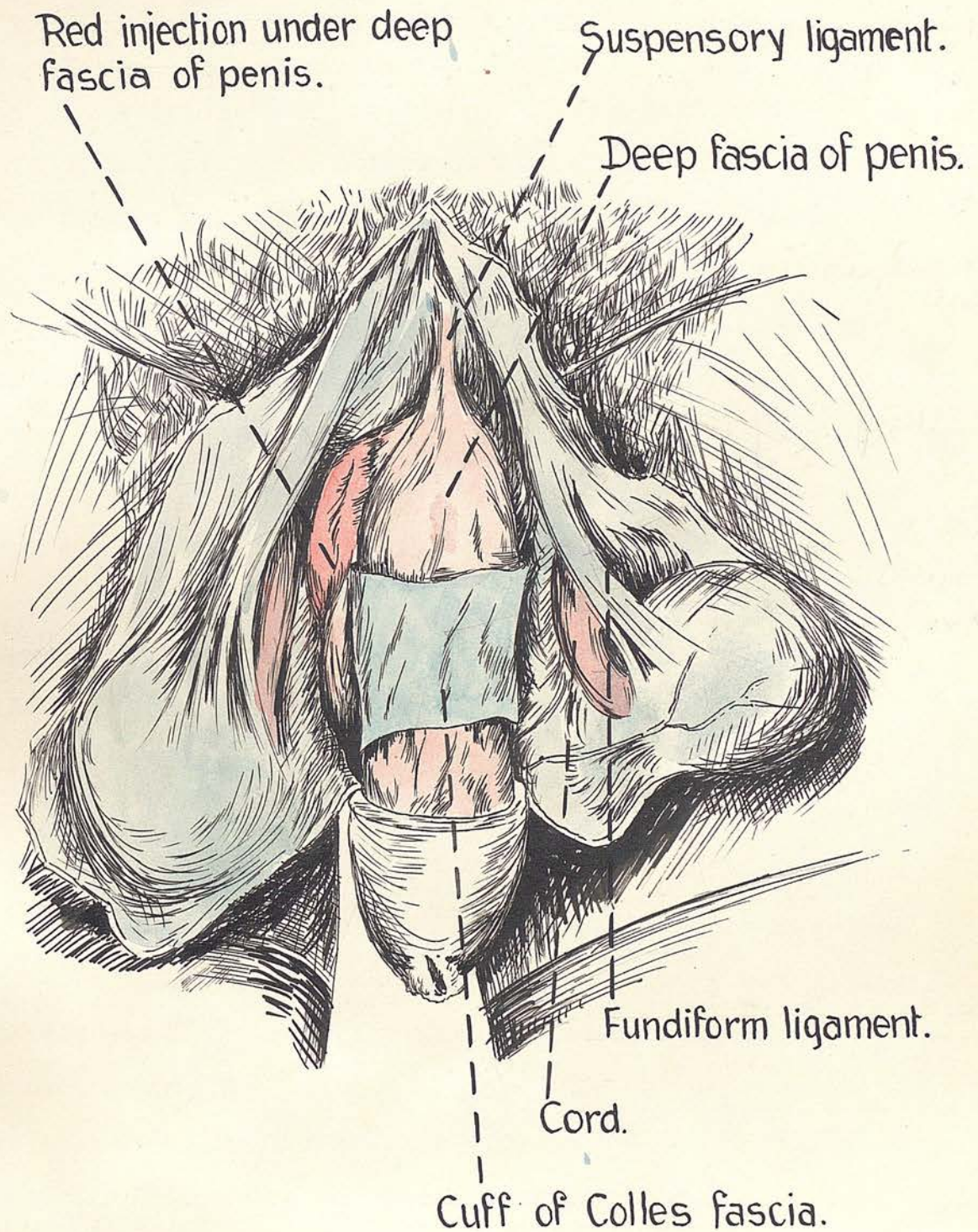
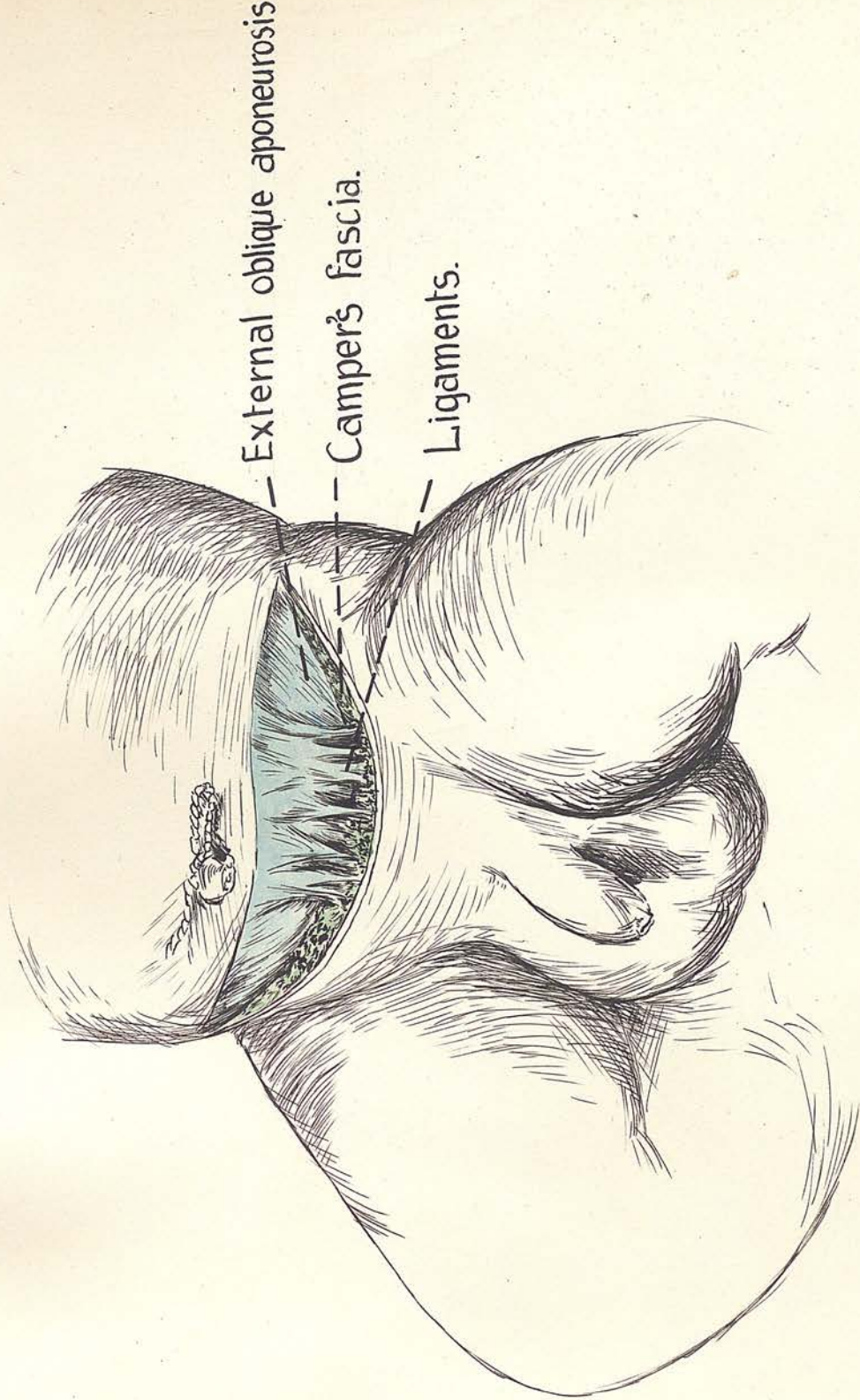


FIG.22. A dissection showing how fundiform ligament divides and reaches scrotal septum. Note deep fascia of penis seen from above with red lead underneath it.

down to the anterior abdominal wall and pubis. Laterally after this reunion the ligament continues down into the the fossa and space. This the writer has labelled the septum of the scrotum. Figure. 2a & b The fundiform ligament pubic fossa. Figure 21a Its importance will be referred has no attachment to the suspensory ligament of the penis. to later.

(2) They are entirely separate structures. It is a large suspensory ligament of the penis; band of fibrous and elastic tissue firmly attached to the lower two or three inches of the linea alba and the triangular in shape which is attached to the symphysis external oblique aponeurosis. Some fibres of the external pubis on the one side and to the deep fascia of the penis oblique end in it. The fascia of Colles, the Fascia of Scarpa, and some fibres of the penile dartos fuse with it. In the young child it is of considerable extent and thickness. There is no difficulty in tracing it round the sides of the penis as a broad band or in showing how it enters the scrotal septum below. Figure. 21<sup>22</sup>. The relatively great size of this structure in very young babies is so striking that the relations of the ligament were examined with particular care. A discovery of great importance was made. In a five months foetus the ligament was exceptionally broad and strong considering the diminutive size of the specimen. The ligament was as thick and as long as the through external spermatic fascia. When the reflected process penis, but the point of greatest interest was the finding of a well marked fossa in relation to the ligament. This existed only on the right side and was bounded below by fusion of the ligament with the direct attachment of the dorsum of the penis, anteriorly by the fundiform Scarpa. The pouch or recess above this ligament is bounded medially and above by the nerve with its sheath for 1/8", posteriorly by the ligaments on the front of the It is noteworthy that the ilio-inguinal nerve with its pubis, and medially by the fundiform ligament extending

/sheath  
/down



External oblique aponeurosis

Camper's fascia.

Ligaments.

FIG.23. New born child. Note strong ligaments passing from External Oblique into superficial fascia.

The superficial fascia close to the external ring and sheath forms a strong ligament immediately below and of directing the structures passing down from the testis to the outer side of the subcutaneous inguinal ring, and also bounds the third inguinal ring just above its lateral margin. Figure 29

(10) The coverings of testis and cord:

Only those derived from the abdominal wall will be referred to here. These are:-

- (i) The external spermatic fascia.
- (ii) The cremaster and fascia.
- (iii) The internal spermatic or infundibuliform fascia.

The external spermatic fascia:

This layer is a prolongation of the external oblique aponeurosis which is evaginated by the tunica vaginalis in its prolapse from the peritoneum. Usually described as a thin fascial layer subserving the function of ensheathing testis and cord, these researches amply demonstrate a much more active and important function for this aponeurosis. Figures 23 & 28 show what would seem to be a constant finding.

Strong ligamentous fibres pass from the external oblique in the neighbourhood of the external ring which gain a strong attachment to the fascia of Scarpa near the external ring. Strongly marked in the adult they are disproportionately larger and more powerful in the foetus and the new born. These ligaments may be looked on as separate fibres of the external spermatic fascia, and they serve the important office of holding

and perineum. Anyone who has tried to deliver the testis at operation without first dividing its coverings of directing the structures passing down from abdomen to will realize how firmly the external spermatic fascia testis. This is made clear by the next figure (figure 31b is attached throughout its course. This layer may which shows in a young foetus these fibres binding the be considered an important sling holding up the scrotum superficial fascia to the external oblique at a stage through the external oblique above as the one hand and preceding the descent of the gubernaculum. This is the superficial fascia below on the other, a surprising finding and indicates an important function its inner surface is free and it is in this plane that for these ligaments.

the testis cover so freely up and down. It is this As the third inguinal ring is immediately below the fascia which is the main difficulty in defining the exact external inguinal ring it will be understood that the relations of the fascia of Colles, ligaments which are attached to the anterior margin of the third ring (which margin is movable ) served to hold the orifice up towards the opening in the external oblique, and also hold the third ring open, so that the descending structures, having negotiated the abdominal wall, prolapse forming loops which descend over testis and cord, directly into the gaping hole.

Hunter (23), so justly honored for his great contributions to science, pointed out that this muscle would seem to serve an important function in animals with testes of the external oblique as shown by Figure 31b .

The external spermatic fascia proper is firmly attached normally abdominal, as in those whose testes become scrotal, in the whole of its extent to the surrounding coverings He could not define this function, though he pointed out on its circumference. Therefore it attaches to the fasciae of Scarpa and Colles and also to the falciform process of peritoneum to attach to the testis. In animals with Colles and the reduplication of this layer at the junction scrotal testes its supports these organs and by the degree of scrotum of its

/and  
/its

and perineum. Anyone who has tried to deliver the testis at operation without first dividing its coverings will realise how firmly the external spermatic fascia is attached throughout its course. This layer may be considered an important sling holding up the scrotum through the external oblique above on the one hand and the superficial fasciae below on the other.

Its inner surface is free and it is in this plane that the testis moves so freely up and down. It is this fascia which is the main difficulty in defining the exact relations of the fascia of Colles.

The cremaster:

This interesting muscle which arises in the angle between the lower border of the internal oblique and Poupart's ligament, is inserted into the pubic tubercle, its fibres forming loops which descend over testis and cord. John Hunter (23), so justly honoured for his great contributions to science, pointed out that this muscle would seem to serve as important a function in animals with testes normally abdominal, as in those whose testes become scrotal.

He could not define this function, though he pointed out that in the former cases the muscle ascends behind the peritoneum to attach to the testis. In animals with scrotal testes it supports these organs and by the degree of its

/its

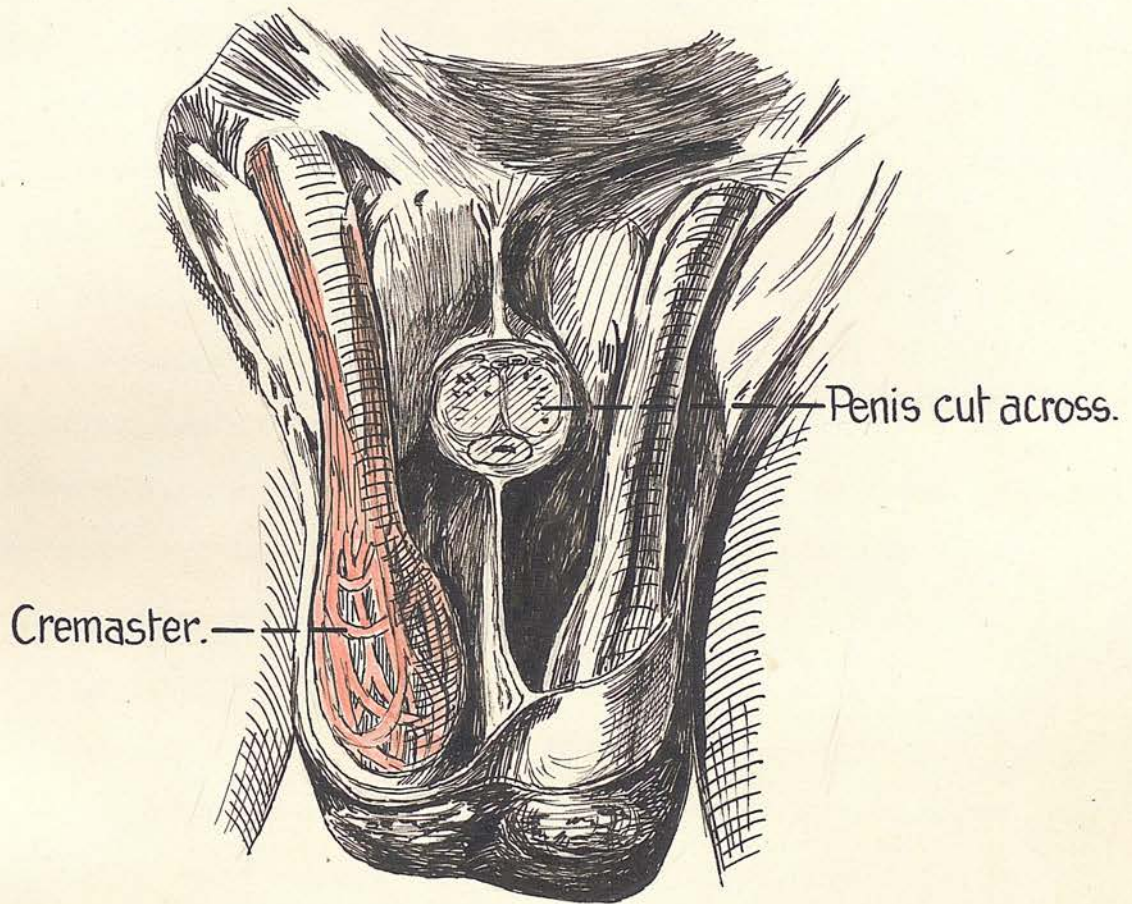


FIG.24. Spalteholtz's figure showing the cremaster muscle exposed on the right side.

This reaction arises often enough whether the cause be a  
its contraction determines whether the testes rest in  
the scrotum or higher. In children its excitability  
frequently causes mistakes in diagnosis, as the testis  
may be pulled temporarily into the inguinal canal.

Hunter also pointed out that this muscle is much  
hypertrophied in people with a hydrocele of the tunica  
vaginalis testis.

A wrong impression of the size of the muscle is  
often obtained at operation where only a small part of t  
it is exposed. It then appears to be represented by  
a few discrete muscle fibres. When fully exposed in  
the post mortem or dissecting room it is seen to be  
a large muscle, Figure. 24

Internal spermatic fascia:

Little will be said about this layer, except to  
point out that it is laminated and two or more layers  
may be divided before the structures it encloses are  
exposed.

This was first pointed out to the writer by Professor  
D.P.D. Wilkie.

(11) The slings of the scrotum:

By the liberality with which nature has supplied the  
scrotum with supporting bands and ligaments, it would  
almost seem as if a far seeing Providence were providing  
so profuse a system of supports to prevent undue sagging  
should the scrotum have more to sustain than the testis.

This occasion arises often enough whether the cause be a rupture, a collection of fluid, a granuloma, or a tumour.

These slings are derived entirely from the superficial fascia assisted by the external oblique:

(i). The scrotal dartos by its continuity with Camper's fascia and the manner in which this muscle surrounds the scrotal part of Colles' fascia, acts as a muscular hammock.

(ii). Scarpa's fascia holds up the scrotum by means of:-

- (a). Its fusion with Colles in the region of the third ring.
- (b) The direct attachment of Scarpa to Colles where they meet at the pubic ramus.
- (c) The occasional fasciculus of the reflected attachment of Scarpa ~~shown in Figure~~ ~~as~~ described above.
- (d) The fundiform ligament which is an important support for the septum of the scrotum.

(iii) Colles fascia: "the upper and inner thigh." These

remarks are applicable to the falciform process acts as a strong ligament suspending the fascia of Colles from the pubis and anterior abdominal wall. Its descent. It has been

(iv) The external oblique: sometimes, in fact in

(a) The ligaments binding this muscle to the fascia of Scarpa at the third ring.

(b) The ligamentous fibres of the external

/oblique

oblique which pass down into the falciform process of the fascia of Colles.

- (c) The very strong support supplied to the scrotum by the diffuse manner in which the external spermatic fascia fuses with the fascia of Scarpa, the fascia of Colles, and its falciform process.

(12) Anatomical pouches normally found in the genital region:

One of the foremost results of this investigation has been the discovery of certain pouches, detailed hereunder, which the author thinks to be of profound interest and practical significance.

The superficial perineal pouch is known to everyone.

Burdick and Colley say that "by inserting the fingers behind the posterior layer of the superficial fascia (the fingers actually passing behind the ligament of Scarpa, as has been indicated above) they enter a space of loose tissue which gives the impression of being in the scrotum, while actually the fingers are in the loose areolar tissue of the upper and inner thigh." These remarks are applied to the normal cadaver. This is the only reference made in the literature to a recess which might misdirect the testis in its descent. It has been pointed out above, that there is sometimes, in fact in about 50% of cases, a more or less well defined pouch

Superficial Inguinal Pouch  
Reflected process of Scarpa  
Scrotal pouch.  
Perineal pouch.  
Fascia of Colles.  
Superficial perineal pouches, also  
and superficial inguinal pouches, also  
and the falciform process of Colles.

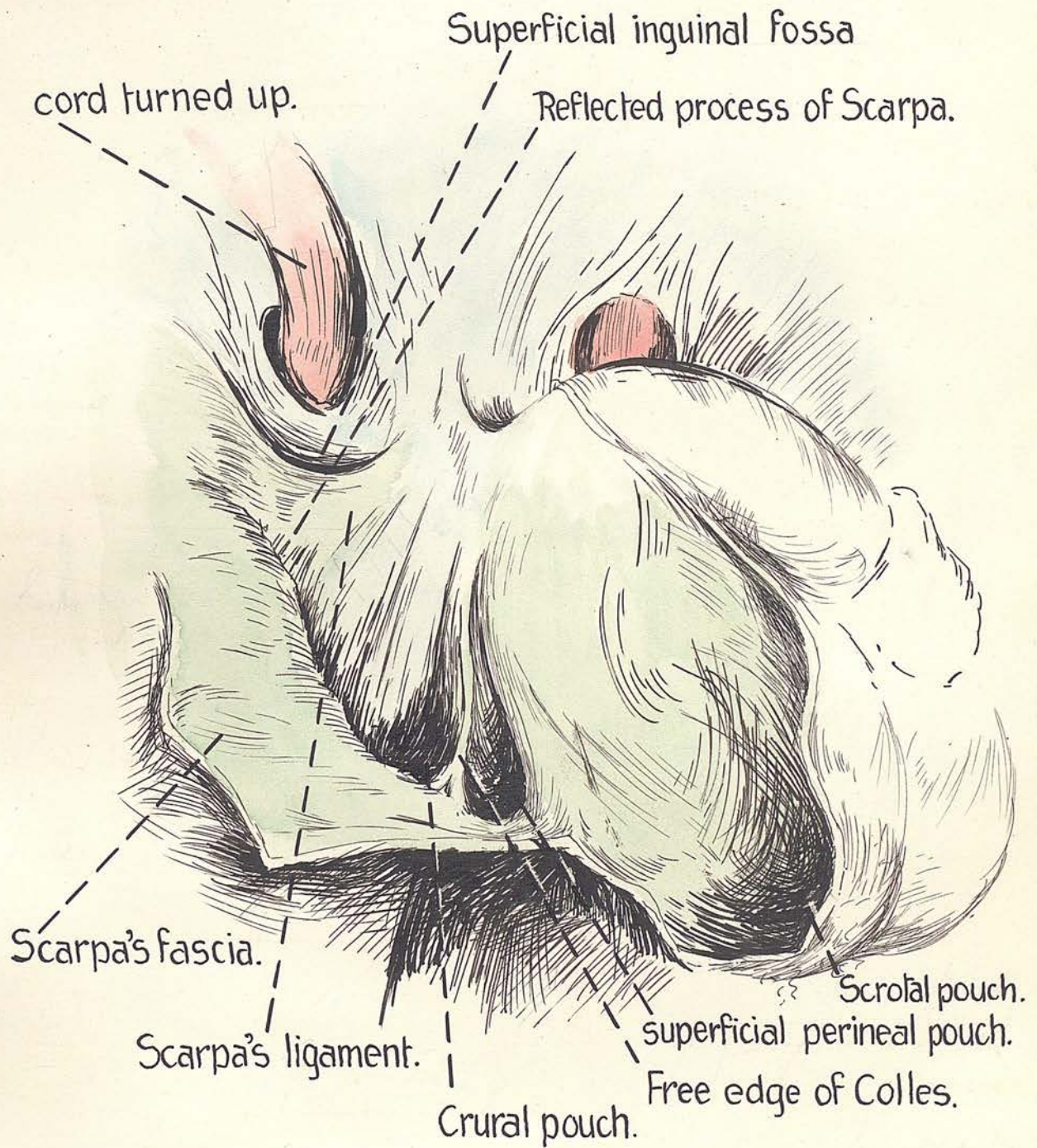


FIG.25. Dissection in an adult showing superficial perineal, crural, scrotal and superficial inguinal pouches, also Scarpa's ligament and the Falciform process of Colles.

in this situation.

There are in and about the genital region five pouches. Three of these are always present, one is frequently present, and the remaining one has only been found in a five months foetus.

- (i) The pubic pouch.
- (ii) The superficial inguinal pouch.
- (iii) The crural or femoral pouch.
- (iv) The perineal pouch.
- (v) The scrotal.

The pubic pouch:

This was found on one side in a dissection of a five months foetus. It is shallow and lies just to one side of the mid line over the pubic bone. Figure 31a.

Boundaries:

Anteriorly: A projecting shelf of the fundiform ligament and lateral to that Scarpa's fascia. This shelf caused a projection much like that formed by the peritoneum which forms the anterior wall of the para-duodenal fossa, and which contains the inferior mesenteric vein in its free edge.

Posteriorly:

The ligaments on the front of the pubis and the external oblique.

Medially: The fundiform ligament.

Laterally:

The fossa was open, and the external abdominal ring lies close to the open wall of the fossa

in Figure P. 31, 32, 33, 34, 35, 36, 37, 38, 39, 40, 41, 42, 43, 44, 45, 46, 47, 48, 49, 50, 51, 52, 53, 54, 55, 56, 57, 58, 59, 60, 61, 62, 63, 64, 65, 66, 67, 68, 69, 70, 71, 72, 73, 74, 75, 76, 77, 78, 79, 80, 81, 82, 83, 84, 85, 86, 87, 88, 89, 90, 91, 92, 93, 94, 95, 96, 97, 98, 99, 100.

lateral to the pubis

spine, fossa, external inguinal ring, and the inner portion  
 Superiorly: ligament.

Boundary: the fossa tapers to a point where the fundiform  
 anterior ligament meets the linea alba. by certain of the  
 Inferiorly: reflected fibres of Scarpa's fascia.

Posteriorly: The dorsal surface of the root of the penis. It  
 is in this situation that the fundiform ligament  
 blends with the fascia of Colles.

The Superficial inguinal pouch: a very acute angle, where

This recess was found in twenty-six out of forty cases.  
 It may exist on one side and not on the other. It may be  
 well marked on one side and slightly on the opposite side.  
 It may be well developed or absent on both sides. It can  
 only exist when a fasciculus of the reflected attachment to  
 of Scarpa's fascia forms a definite ligament (Scarpa's  
 ligament). It has been shown above that this ligament  
 usually has a horizontal upper border, though it is sometimes  
 curved with its concavity upwards and outwards. The fibres  
 of this ligament blend with the tissue on the front of the  
 pubis, the border fading away about half an inch from the  
 mid line. The length of the ridge is about an inch if  
 well marked, but is often less. It may be membranous or strong  
 strong and ligamentous. Reflected attachment of Scarpa going to

It was well marked in the subjects examined before or  
 just after birth, giving the impression that the foetal  
 development exceeded that in the adult. The fossa is shown  
 in Figures F.19, 20, 31a, 31c. It is situated below and also  
 lateral to the pubic

in this situation.

There are in and about the genital region five pouches. Three of these are always present, one is frequently present, and the remaining one has only been found in a five months foetus.

- (i) The pubic pouch.
- (ii) The superficial inguinal pouch.
- (iii) The crural or femoral pouch.
- (iv) The perineal pouch.
- (v) The scrotal.

The pubic pouch:

This was found on one side in a dissection of a five months foetus. It is shallow and lies just to one side of the mid line over the pubic bone. Figure 31a.

Boundaries:

Anteriorly: A projecting shelf of the fundiform ligament and lateral to that Scarpa's fascia. This shelf caused a projection much like that formed by the peritoneum which forms the anterior wall of the para-duodenal fossa, and which contains the inferior mesenteric vein in its free edge.

Posteriorly:

The ligaments on the front of the pubis and the external oblique.

Medially: The fundiform ligament.

Laterally:

The fossa was open, and the external abdominal ring lies close to the open wall of the fossa

in Figures P.32, 33, 34, 35. It is situated just after

lateral to the pubis

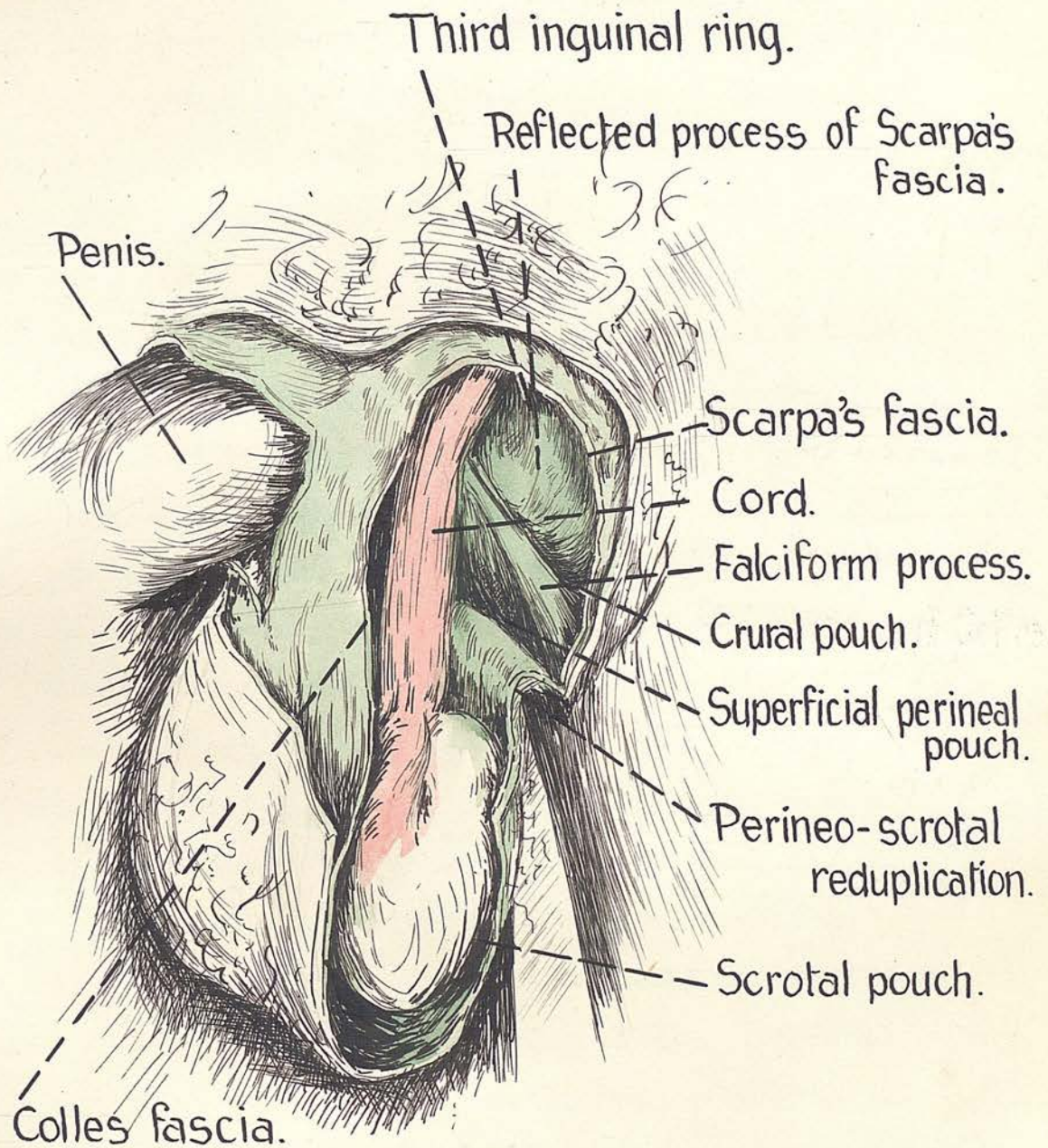


FIG.26. A dissection from the side showing the third inguinal ring as seen from below. Note falciform process of Colles and perineo-scrotal reduplication. Also pouches. (see text).

This floor forms a strong fibrous area through which nothing can pass without cutting or violence. The fact is again stressed that no case has yet been seen by the writer where the finger could be passed behind the ligament through the floor of the fossa unless great violence was used. An easy way behind the ligament, which Burdick and Coley found, has never been found during this research.

Although an instrument pushed through the floor of the fossa passes to the root of the thigh and not to the perineum, as pointed out by Burdick and Coley, the writer cannot conceive that a mis-directed testicle could pass through the floor of the fossa. Superiorly: The pouch is open upwards as well as outwards.

It may present the appearance of a small slit or of quite a wide orifice. The important point is that just above the fossa is found the pubic tubercle, the external inguinal ring, and the medial end of the inguinal ligament. This fossa like the pubic one is situated immediately behind the deep layer of the superficial fascia of the lateral anterior abdominal wall. the direct and reflected

The crural or femoral pouch:

The position of this is difficult to describe in words but immediately apparent in the drawings taken from the actual specimens. Figures 25 & 26

It is remarkably constant in relation, structure and situation. It was noted above that the direct attachment of Scarpa's fascia in the thigh passed down with an oblique trend inwards to meet the ischio-pubic ramus and the fascia of Colles' at a point just below the origin of the falciform process from the fascia of Colles'. This point being about three inches or less from the pubic tubercle. It is exactly here that the pouch lies.

Boundaries:

- Anteriorly:** The fascia of Scarpa coming down as the deep layer of superficial fascia to the inner end of its direct attachment.
- Posteriorly:** The lower most reflected fibres of Scarpa going to the ramus and courding over the fascia lata where it covers the expansion of origin of the gracilis.
- Medially:** The fascia of Colles' where it forms the anterior wall of the outer part of the superficial perineal pouch. Note particularly that only this fascia separates the fossa from this perineal compartment.
- Laterally:** The angle between the direct and reflected attachments of Scarpa.  $\sphericalangle$
- Superiorly:** The fossa is open above into the wide area bounded medially by the falciform edge of Colles' and laterally by the direct attachment

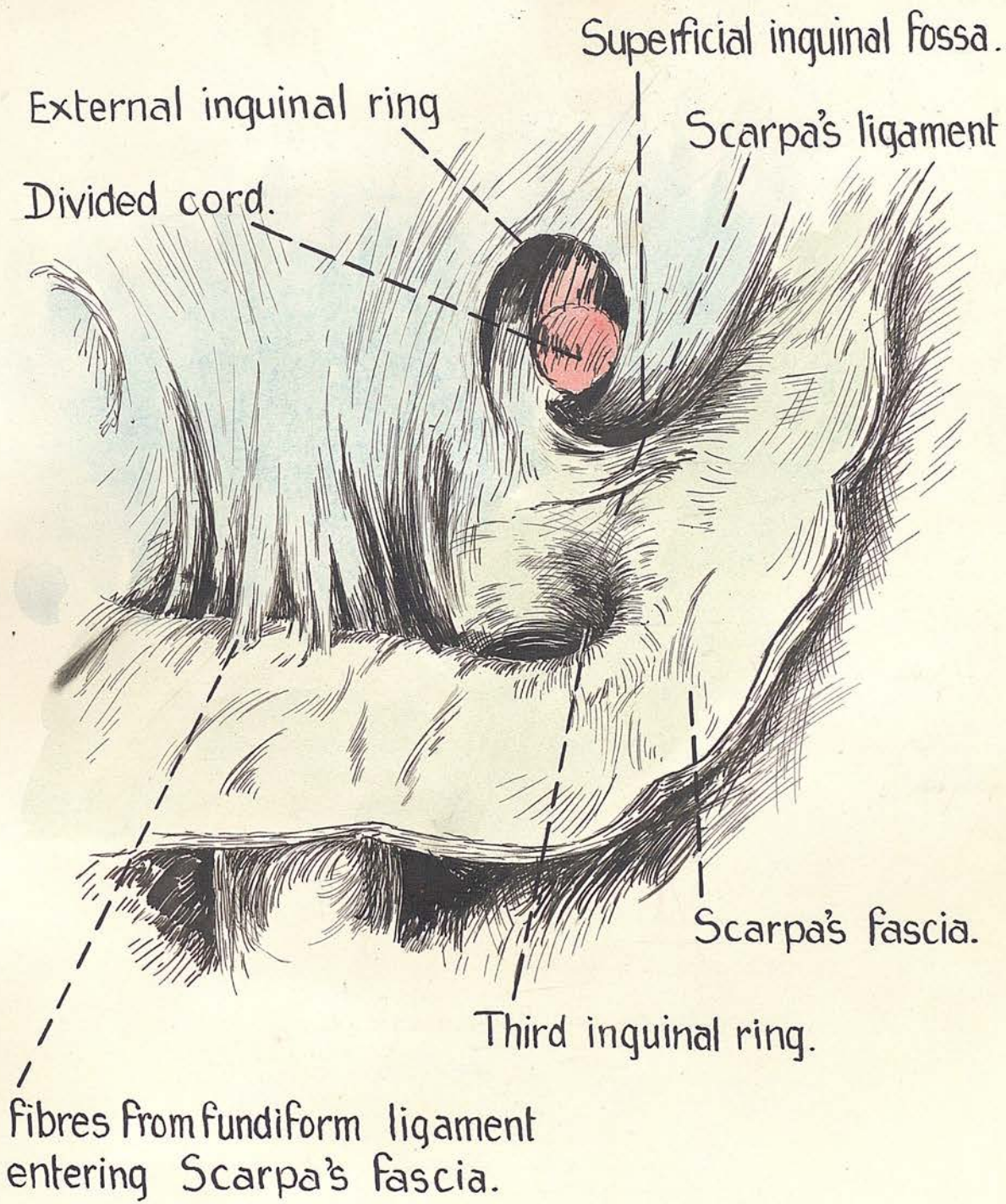


FIG.27. Dissection in an adult. Note the third inguinal ring, the superficial inguinal fossa with post ligament of Scarpa.

of Scarpa in its inner oblique part. The pouch may be likened to the apex of a V, Scarpa's and Colles' attachments just described forming the limbs of the V. The open limbs of the V would direct into the apex anything descending from above.

The perineal pouch:

It is unnecessary to go into detail about this space by which <sup>is</sup> intended the un<sup>^</sup>iversally recognised superficial perineal pouch.

Boundaries:

Anteriorly: the fascia of Colles, which in the upper part of the pouch is reduplicated to form the shelf which leads into the scrotal pouch.

Posteriorly: the deep fascia of the perineum covering the superficial perineal muscles and perforated by certain scrotal vessels or nerves.

Medially: the septum dividing the pouch into two so that any solid structure entering this pouch from above, necessarily lies to one side of the mid line.

Laterally: The fascia of Colles below, and its falciform edge above, which latter separates this pouch from the crural one.

Inferiorly: the pouch ends by the fusion of Colles' fascia with the deep fascia of the perineum and the uro-genital diaphragm.

/Superiorly

Superiorly: the pouch is open towards the anterior abdominal wall, by a canal which traverses the third inguinal ring.

Contents: posterior scrotal vessels and nerves, perineal branch of the posterior cutaneous nerve of the thigh, and fat.

The scrotal pouch:

This is the actual cavity containing the testis. Dissections of fetuses before the gubernaculum has descended show the pouch to exist at this early date. Figure 31a It is unnecessary to go into detail about the scrotal pouch, except to point out that its posterior wall just above the head of the epididymis turns sharply back on itself to form the inferior boundary of the superficial perineal pouch, i.e. the fascia of Colles, and that here is situated an even ridge dividing scrotal and perineal pouches. In front of the ridge is scrotal pouch, behind it is superficial perineal pouch. In the adult with the body erect, the angle formed by the meetings of perineal and scrotal portion of Colles' fascia is acute, in the foetus where the scrotum is not dependent, they form a right angle. Figure 12

An observation of the first importance may be made in concluding this paragraph. Notice that the crural, scrotal, and perineal pouches are all constant, lie

/very

very close together, and that two ridges namely, the falciform process of Colles, and the perineo-scrotal reduplication of Colles are responsible for the formation of the fossae.

This is well shown in dissections at all ages. See figures. 20, 25, 26

(13) The third inguinal ring:

The testis in the course of its hazardous journey, from the posterior abdominal wall to its scrotal destination, must first negotiate the narrow defile formed by the inguinal canal; this stage safely completed, it must cross a small strip of no man's land and then pass through a gateway which gives admittance to the scrotum. This gateway the author has ventured to call the third inguinal ring.

Passing reference has been made to this orifice in the foregoing. It is situated immediately to one side of the mid line and half to one inch below the horizontal level of the upper border of the body of the pubis and the external inguinal ring in the adult. In the foetus it is immediately below these structures.

A definite ring exists only in those cases where the reflected process of Scarpa's fascia forms a well marked ligament. When this is absent the outer boundary of the ring is necessarily missing, giving the opening a funnel shape. The entrance of the scrotum presents

therefore

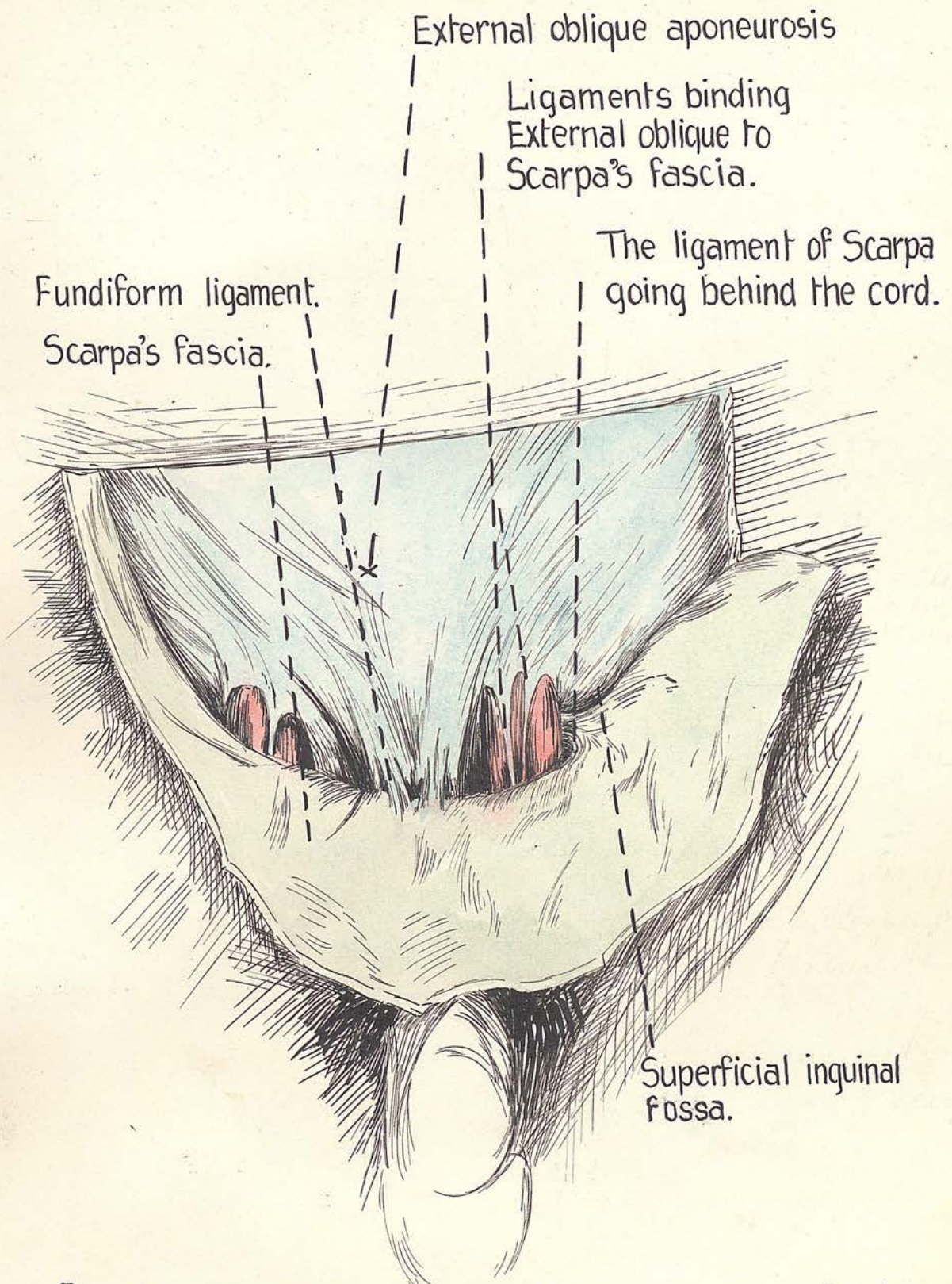


FIG.28. Dissection of a new-born child, enlarged. Note the left cord disappearing into the third inguinal ring. A well marked ligment of Scarpa and superficial inguinal fossa are seen on the left side. Observe the ligaments binding external oblique to Scarpa in the region of the third ring.

very close together, and that two ridges namely, the falciform process of Colles, and the perineo-scrotal reduplication of Colles are responsible for the formation of the fossae.

This is well shown in dissections ~~at~~ all ages. See figures. 20, 25, 26

(13) The third inguinal ring:

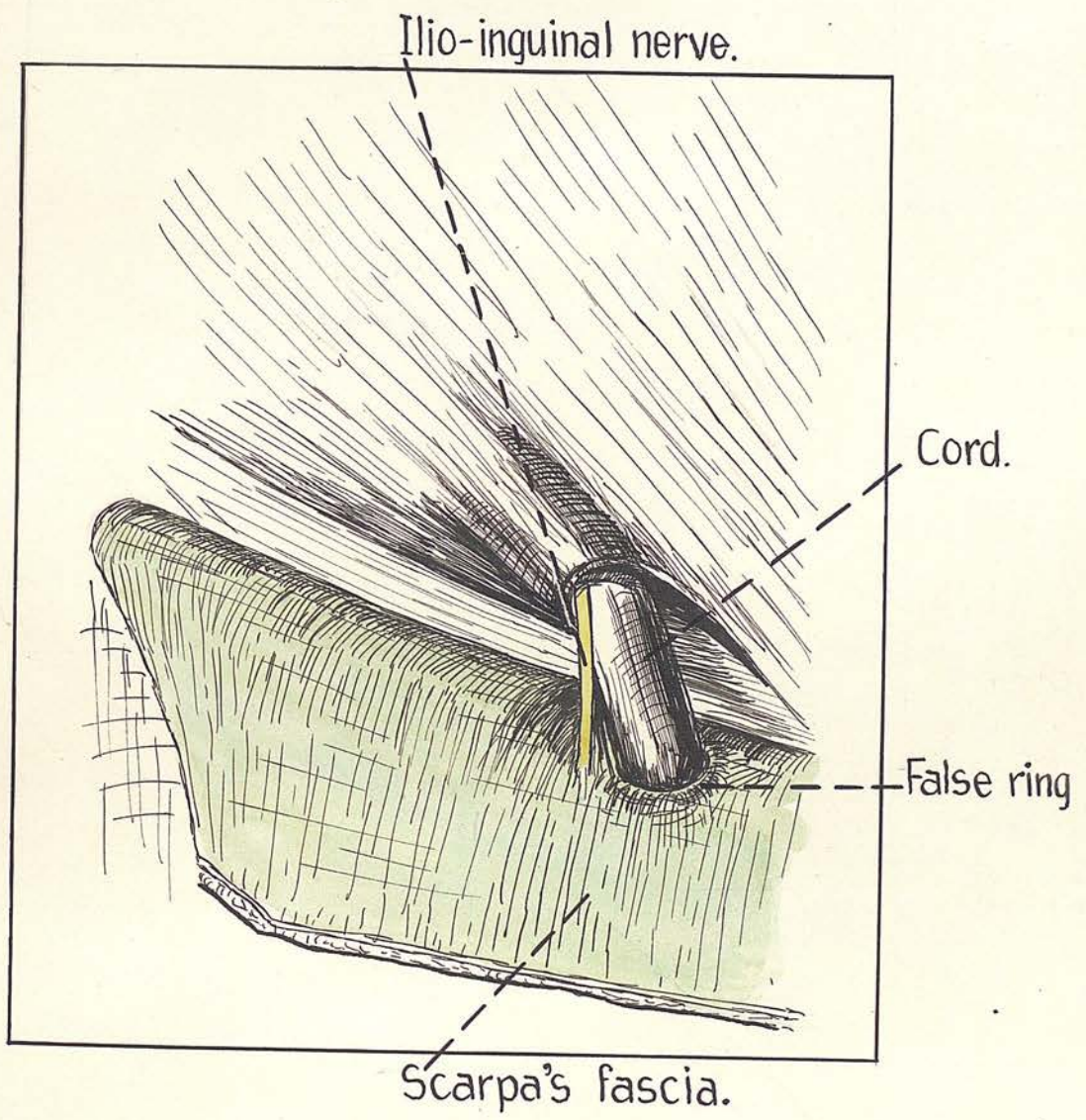
The testis in the course of its hazardous journey, from the posterior abdominal wall to its scrotal destination, must first negotiate the narrow defile formed by the inguinal canal; this stage safely completed, it must cross a small strip of no man's land and then pass through a gateway which gives admittance to the scrotum. This gateway the author has ventured to call the third inguinal ring.

Passing reference has been made to this orifice in the foregoing. It is situated immediately to one side of the mid line and half to one inch below the horizontal level of the upper border of the body of the pubis and the external inguinal ring in the adult. In the foetus it is immediately below these structures.

A definite ring exists only in those cases where the reflected process of Scarpa's fascia forms a well marked ligament. When this is absent the outer boundary of the ring is necessarily missing, giving the opening a funnel shape. The entrance of the scrotum presents

therefore

FIG.29. Student's dissection showing a false ring which is not the third inguinal ring.



off by arcuate fibres. Immediately above this angle is the ilio-inguinal nerve, which heightens the lateral boundary of the opening, a small gap intervening between nerve and orifice.

Particular attention is directed to the fact that this opening is not seen immediately superficial fascia is raised from anterior abdominal wall, as is done in hernia operations. Like the external inguinal ring, this one is only apparent when the external spermatic fascia is removed. Now this fascia is attached fairly generally to the circumference of the ring particularly in front, though but slightly behind.

The ligaments which <sup>the</sup> external oblique gives to Scarpa's fascia (described above) are attached to the anterior margin of the ring, holding it up towards the opening in external oblique. Figures 25, 28, 31b This is especially noticeable in babies and fetuses. Obviously these bands serve to hold open the orifice as well as to hold it up towards the external ring. Figure 29 is an actual drawing from a dissecting room subject in which the superficial fascia had been thrown down by the dissectors working in that region. Though a strong ligament is seen behind the cord and a well marked third ring exists, it is not the ring shown in the picture. The external spermatic fascia has been torn from the external ring, but is attached to the third ring below, and it is

this attachment which shows as a ring in the drawing.

This of course is an artefact and is reproduced here to point out how an error may arise in defining the ring.

If now the external spermatic fascia be separated the third ring will come into view.

#### Surface marking

This opening is represented in the adult by a horizontal line drawn outwards from the middle line for 1" - 1½" at a level ¾" below the pubic tubercle.

#### Clinically:

A finger invaginating the scrotum to feel the external ring, passes through the third ring, the boundaries of which may be defined thus:-

Medially is root of the penis and suspensory ligament, and laterally the ligament of Scarpa or the "gutter" alluded to. The cord is often lying in this gutter.

On palpating the neck of the scrotum clinically, the soft silky skin of this structure will be found to change abruptly at the upper part of the scrotal neck to the thick elastic skin of the lower most part of the abdomen.

This difference is still more apparent on invaginating the scrotum through the third ring. The site where this abrupt transformation occurs is the third inguinal ring, and here Camper gives place to dartos and Scarpa gives place to Colles.

this body. It is alluded to mainly because it has been  
Contents: most universally to play a major part in the

In the adult these are the structures passing to and from  
the testis together with the coverings they derive from the  
abdominal wall.

In the foetus before the descent of the gubernaculum  
the ring is well formed, patent, held widely open by  
ligaments from external oblique, and is empty. Figure. 31c

Observe that this orifice leads not only to the scrotum  
but also to the perineal and crural pouches.

Type 2. Funnel shaped

In this variety the entrance to the scrotum is wider as  
the lateral crus of the ring (Scarpa's ligament) is  
absent. The other boundaries are the same. Laterally  
there is a gutter formed where the fascia of Scarpa gains  
its direct attachment to the fascia lata of the thigh.

Therefore, instead of there being a prominent sharp  
margin here, there is a gently sloping gutter. There is  
here no ledge to deflect outwards anything solid which  
is trying to enter the scrotal gateway from above. On  
the contrary, the lateral gutter would tend to direct  
any such body into the scrotum. This type of opening  
is shown in Figure 17

(14) THE gubernaculum testis or chorde gubernaculi:

This structure has received an amount of attention out  
of all proportion to its size and possibly to its importance.

It is not a part of this research to deal at length with

this body. It is alluded to mainly because it has been held almost universally to play a major part in the normal or ectopic descent of the testis.

John Hunter in 1762 gave this title to the tissue under consideration, and gave the first account of it, being stimulated thereto by a case which his brother encountered of a seven <sup>months</sup> foetus with abdominal testes. Neither of these two could explain the fact, and thus his research was incepted. He was further stimulated by the publication in 1755 of Baron Haller's "Opuscula Pathologica" (2). Not the least monument to the colossal genius and scientific acumen of John Hunter is the fact that his account of the gubernaculum testis is still the best extant. Much work has centred round the subject and Keith, Berry Hart, McAdam Eccles, Coley, Mixter, Bevan, Cowers, Godard, Curling Lockwood and others, have made valuable contributions to the subject. All that ~~was~~ known of fact was elucidated by John Hunter. Though many theories about and yet about have come and gone, Hunter's theory of the cause of non-descent is today once again the most popular one.

At the end of the second month of intra-uterine life the gubernaculum appears. At that stage it is an actively growing cellular mesenchymal condensation.

Though no muscle is apparent at this stage, this tissue is regarded as being pre-muscular (36). Striped and unstriped muscle fibres replace this tissue. The gubernaculum is then triangular, base above, apex below

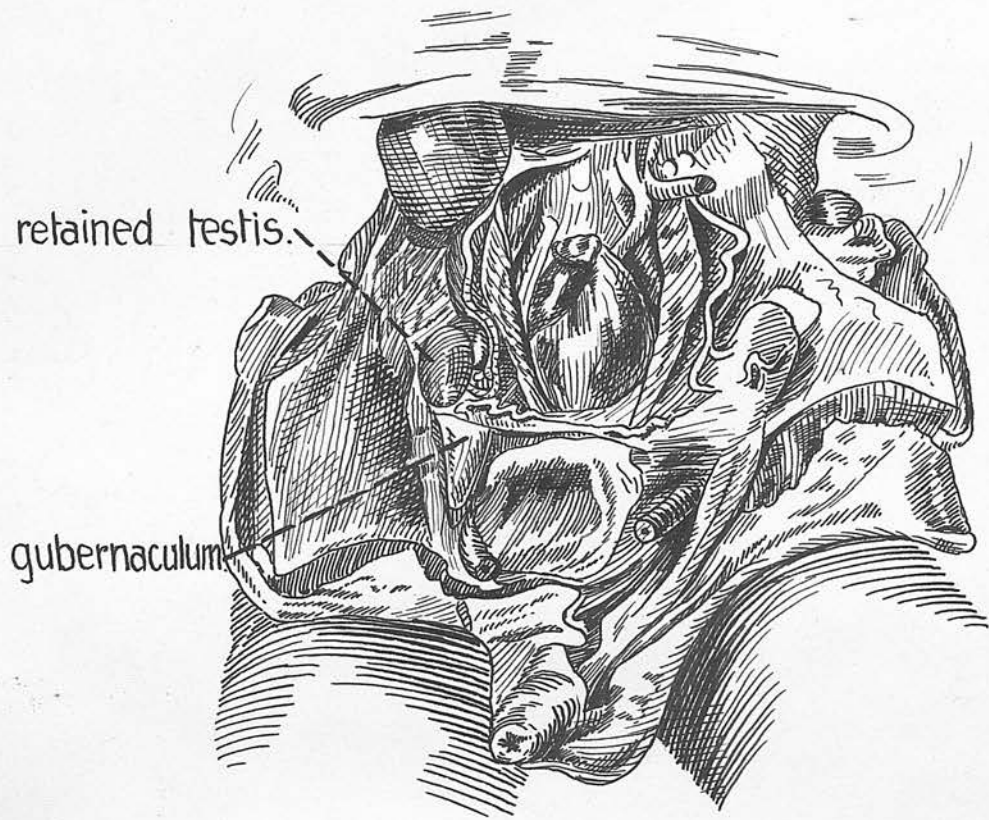


FIG.30. Taken from John Hunter's original figure showing the gubernaculum in a case of retention of the testis.

## Fig.31. Dissection of a five months foetus.

The fibres being directed in its long axis. The apex is credited with the ability to excavate a path for the testis. Figure 30 is reproduced from Hunter's original one. According to some it grows rapidly through the inguinal region, according to others the inguinal canal is formed round the gubernaculum. It was Lockwood (28) in 1887, who postulated a sub-division of the structure into six tails after its emergence at the external ring. One of these went to the scrotum, the others going to each of the commoner sites of the ectopic testis. Though most ingenious there is no corroborative evidence embryological or anatomical to support this contention (31). Others say definitely that these tails exist normally at one stage of development (16,36).

As the theory serves to explain the otherwise inexplicable it is generally used for teaching. Lockwood (28) in support of his theory says "it is irrational to deny this element its function, namely that of contraction."

In searching for this structure or its remains in the adult one may find a nodule of tissue incorporated with the lower pole of the testis and its tunica. Just as often nothing is found. In cases of ectopia there is frequently tissue attached to the testis which is taken to be the gubernaculum. Such a structure unquestionably exists, but it is seriously open to question if it performs

FIG.31. Dissection of a five months foetus.

A.

The right side — a well marked superficial inguinal fossa in which the delicate gubernaculum is caught. Note the pubic fossa.

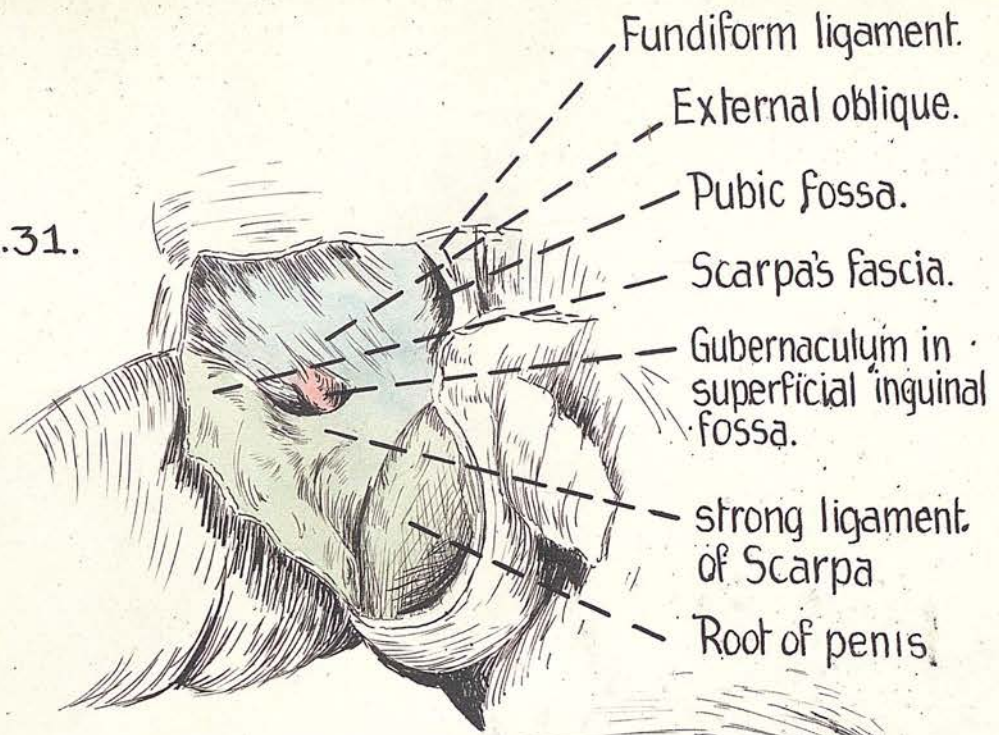
B.

Showing the fascia of Scarpa thrown down to show the strong ligaments passing down in front of the gubernaculum and attached to margins of third ring, thus holding it patent and up towards the External abdominal ring.

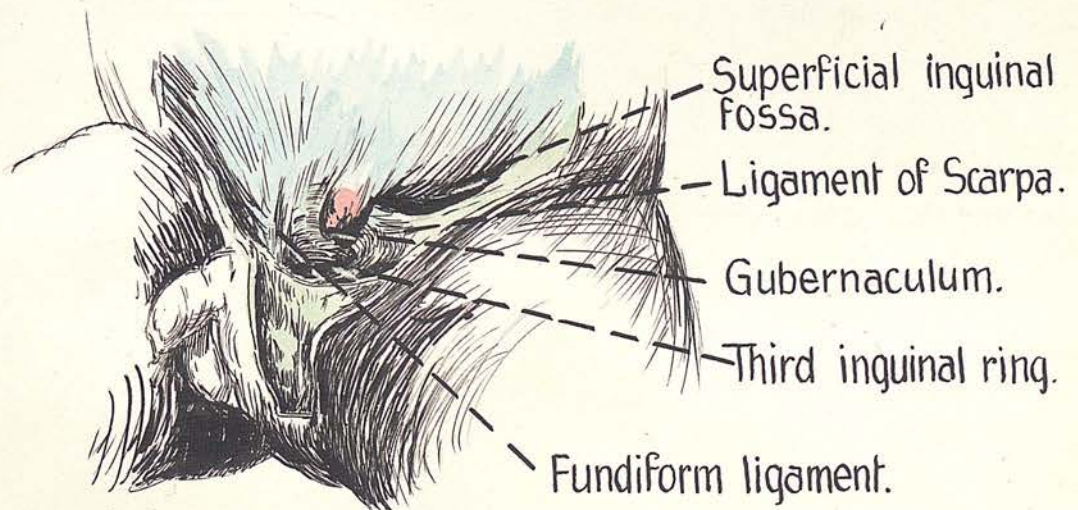
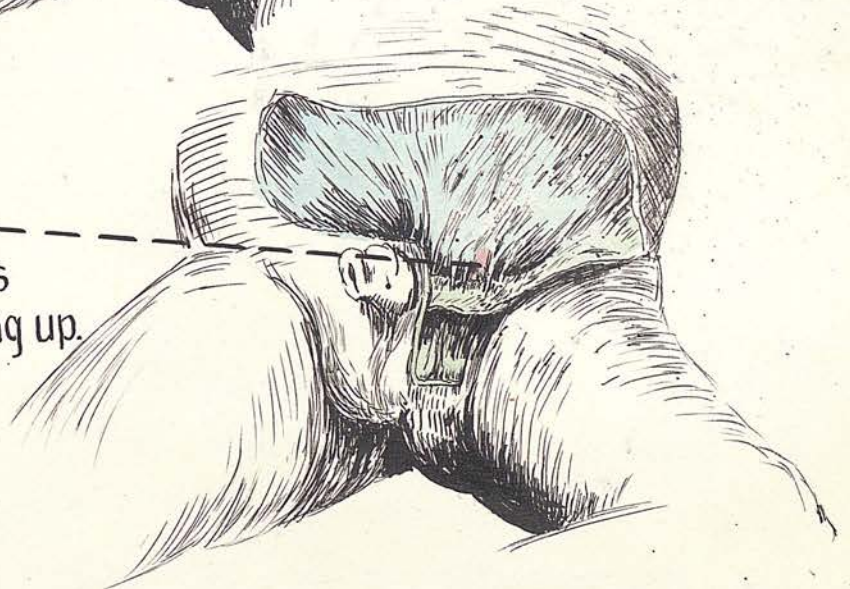C.

The left side dissected further. Note the superficial inguinal fossa and third ring. The gubernaculum has avoided the fossa and is well situated to enter the third ring.

FIG. 31.



Gubernaculum behind ligaments holding third ring up.



the functions so long accredited to it. In a five months foetus an extremely interesting condition of the apices of the gubernacula was found. On the left the structure has emerged from the external ring and its apex had surmounted the hither wall of a well marked superficial inguinal pouch. On the right it was not quite so far advanced and the delicate apex was arrested in the right superficial inguinal pouch. These conditions are shown in Figures 20, 31a, 31c. and will be referred to later.

(15) The spermatic cord:

This structure is usually described as passing over the pubis on its way to the scrotum (3). In surgical text books the relation of inguinal and femoral herniae to the pubic spine is one of the chief points in the differential diagnosis between these two types of rupture (34). "The most reliable method of differentiation (between femoral and inguinal hernia) is to recognise that the neck of an inguinal hernia lies above and medial to the spine of the pubis, while that of a femoral hernia lies below and lateral to the spine."

Discussing this classical statement Souttar (33) says "this statement does not, however, rest on a very secure basis of anatomical fact, for an examination of any normal male will show that the spermatic cord either crosses the pubic spine or lies lateral to it, crossing the inner extremity of Poupart's ligament, and this remains the

PART II

PATHOLOGICAL AND CLINICAL OBSERVATIONS.

natural position of an ordinary oblique hernia. It is however true that the pubic spine is most readily palpated from the outer side of an inguinal hernia, by displacing the latter inwards and upwards, and from the inner side of a femoral hernia." The present writer, since reading Souttar's article, has been at pains to investigate this point. He can amply corroborate the truth of the statement.

In every one of the cases examined during this research, the cord was situated lateral to the pubic spine. In no case was it medial. In babies it lay immediately outside the tubercle, in adults usually 1/2" lateral to this prominence. Figure 17

If it be remembered that the inferior crus of the external ring is formed by the inguinal ligament and is horizontal, it will be easily understood that the testis on emerging from this orifice will tend to pass down over the inferior crus. On the living subject, clinical observation bears out these facts.



of interest in connection with the extraordinary...  
in a vertical rupture at the usual site...  
specimens of a red lead...  
at the perineum were made. A hard...  
the abdomen at the umbilicus in...  
(24 hours). The spread of the material...  
the distal and lateral

PART 11PATHOLOGICAL AND SURGICAL OBSERVATIONS.

In many cases the outer half of the attachment of the anatomical findings stated in the foregoing gain their chief interest because of their practical applications.

Certain surgical conditions affected by these findings will be discussed here briefly or at length according to their importance and relationship to the research.

(1) Extravasation of urine:

Thomson and Miles (35) state that in rupture of the urethra at the common site - in front of or through the anterior layer of the triangular ligament - the urine infiltrates the cellular tissue of the anterior part of the perineum, the scrotum, penis, groins, and abdominal wall. It is prevented from passing backwards by the attachment of the perineal fascia to the base of the triangular ligament; and from passing down the thigh by the attachment of the deep layer of the superficial fascia of the abdominal wall to the fascia lata, along a line a little below Poupart's ligament. This investigation has brought out a few points of interest in connection with the extravasation of urine due to urethral rupture at the usual site.

- (a) Injections of a red lead solution under Colles' fascia in the perineum were made. A band was tied tightly round the abdomen at the umbilicus in males recently dead. (24 hours). The spread of the material defined the distal and lateral

/attachment

sloughing of superficial tissues occurs in these

/cases

attachments of Scarpa's and Colles' fasciae. In many cases the outer half of the attachment of Scarpa in the thigh did not extend below the inguinal ligament and the anterior superior iliac spine. In other cases the attachment was a little below this line. The inner half of its attachment

(a)

in the thigh stood out in relief and corresponded to the oblique downward and inward attachment described for the direct attachment of Scarpa. Figure 5

(b)

It is usually understood from anatomical descriptions that perineal extravasations extend underneath Colles' fascia. Experimentally it is found that though this occurs to some extent, it is overshadowed by the amount of infiltration of the cellular tissue which occurs. This is plainly indicated by the Edinburgh surgeons quoted above.

When dissecting a part injected in this way, it is found that the superficial tissues have a myxomatous jelly like appearance, due to the amount of fluid in the tissue spaces. This agrees exactly with the state of affairs found when making incisions for extravasation of urine. The knife cuts through 1/2" or more of sodden, boggy tissues before reaching the collection under the deep layer of the superficial fascia. This fact accounts also for the frequency with which sloughing of superficial tissues occurs in these

cases. The scrotum and penis are infiltrated in precisely the same way. The fluid is enabled to reach this superficial cellular tissue along the branches of cutaneous vessels and nerves, which have to pierce Scarpa and Colles to reach their destinations.

- (c) Injections under the deep fascia of the perineum (when this is well developed) are fairly well localized by this layer. Extending back to the base of the triangular ligament, laterally to the conjoined ramus, and forwards on to the dorsum of the penis at the sides of the suspensory ligament (Figures 21 & 22 . When a fair amount of tension exists under the fascia, the fluid may be seen squirting alongside the vessels and nerves which pierce the deep fascia of the perineum. (Posterior, scrotal and small unnamed branches of perineal artery).

When the fascia is strong, if the urethra is ruptured proximal to it, and it itself is intact, it will be the first line of resistance to the fluid.

As this increases it will reach superficial perineal pouch along vessel and nerve sheaths. In a similar fashion these structures will guide it to the subcutaneous cellular tissue i.e. Colles, Scarpa, dartos, and Camper.

(2). Herniae and Hydrocele:

- (a) Inguinal Hernia

i

in front of the hernial sac is anchored to the third  
indirect:- this is the commonest type of hernia  
 inguinal ring having no direct adherent there for some  
 It may reach the scrotum on the first occasion  
 without reason. It is known that the anchoring  
 of its descent, or only after existing for some  
 of the vaginal process occurs just beyond the  
 time as a bubonocoele. Every surgeon must have been  
 external ring and this is also the situation of the  
 impressed by the fact that these herniae frequently  
 third ring.  
 exist for many years without any great increase  
 in size. Occasionally, particularly in the days  
 and remains a bubonocoele almost invariably. It  
 before surgery became so aggressive as it now is,  
 the rather rare cases where such a hernia resists  
 inguinal herniae sometimes increased to enormous  
 to the scrotum, it is of the type which leaves  
 dimensions. These had "lost the right of  
 domicile". (12). Such herniae are not common and  
 are interesting. If now the slow rate of growth  
 of an ordinary indirect inguinal hernia, be compared  
 with the rate of growth of umbilical (adult type)  
 and scar herniae it will be found that the rate of  
 growth of the latter is very rapid by comparison.  
 This is easily understood when it is remembered  
 that the inguinal hernia is supported in the  
 scrotum by two muscle systems and by the numerous  
 slings which hold up this structure. It is likely  
 that herniae which have forfeited the right of  
 domicile result from a developmental weakness  
 in the scrotal supports. In cases of infantile  
 and encysted herniae the writer ventures to  
 suggest that the peritoneal process which lies  
 the superficial inferior epigastric vessels

/in

in front of the hernial sac is anchored to the third inguinal ring having become adherent there for some unknown reason. It is known that the anchoring of the vaginal process occurs just beyond the external ring and this is also the situation of the third ring.

- ii. direct:- this variety of rupture is not common and remains a bubonocoele almost invariably. In the rather rare event where such a hernia reaches to the scrotum, it is of the type which leaves the abdomen lateral to the obliterated hypogastric artery, and it must, to get into the scrotum, prolapse into the large sac of a pre-existent extensive indirect hernia. This combination of events must be excessively rare. If the rupture does not manage to enter such a sac the reason why it remains outside the scrotum is probably that it cannot negotiate the third inguinal ring, being prevented from so doing by the size of this orifice and its normal contents.

(b) Femoral hernia:

A rupture leaving the abdomen through the femoral canal, tends, when it attains a fair size, to extend in an upward direction along the line of the superficial inferior epigastric vessels

over the inguinal ligament. This is the classical description given, the reason adduced being that this is the line of least resistance.

This ascent is between the fascia of Camper and that of Scarpa. Now it is a well known fact that these herniae though they may attain the size of an orange, usually remain small, which is one of the difficulties in their diagnosis.

(11)

Reference to Figure 4,14a will show that the line of the direct attachment of Scarpa's fascia usually crosses the fossa ovalis obliquely from above downwards and inwards. There would seem on anatomical grounds to be two possible routes which might be taken by a femoral hernia which has reached the saphenous opening;

(a)

- (i) The hernia may pass above this oblique line and would then push the fibres of Scarpa, which are reflected towards the pubis, before it. it would then be compelled to pass upwards and outwards in the gutter between the direct and reflected attachments of Scarpa's fascia. Such a hernia would ascend gently upwards and outwards supporting function of the muscles and slings of the scrotum and also of the efficiency with which they carry out their functions.
- of Scarpa, the more superficial layer being the deep layer of superficial fascia (Scarpa). This hernia

(12)

The aetiology of this condition like that of varicose veins is unknown. It is thought that

/would

/some

would have a tendency to remain small because of the resistance offered to its growth by these strata. Once however it reaches the gutter it will be prevented from extending downwards by the same reason which prevents fluid extravasated under Colles from extending down the thigh.

- (ii) The hernia may appear below the oblique attachment of Scarpa crossing the saphenous opening. It is probably this type of case in which the swelling follows the superficial inferior epigastric. Here there is no fascia of Scarpa in front of it, and there should therefore be less resistance to its increase in size.

(a) Hydrocele, haematocele, tumours of the testis:

In all these conditions the scrotum has frequently to support a considerable weight. In spite of this it does not hang very low, and also, even in large hydroceles, the apex of the swelling passes as a rule through the third ring. It was in cases like these that Hunter found the cremaster hypertrophied. This is further evidence of the supporting function of the muscles and slings of the scrotum and also of the efficiency with which they carry out their functions.

(d) Varicocele:

The etiology of this condition like that of varicose veins is unknown. It is thought that

mediates in the distribution of the nerve i.e. upper  
some congenital weakness of the veins exists. The  
One of the characteristic features of the condition  
is that the testis hangs very low on the affected side,  
another is the frequency with which it affects young  
adults soon after puberty, the third is the, apart  
occasional presence of severe neuralgic pains. It  
is found that the dartos muscle is lacking in tone.

(3) The inner The writer would suggest that either the testicular  
(a) Review supports are developmentally inefficient or that the  
(1) Normal scrotum is slung too low, either conditions resulting

The in a constant drag on the cord and on the pampinniform  
(2) in plexus. This would result in stagnation of blood  
into and dilation of veins, it would also cause dragging  
on the ilio-inguinal nerve which runs inside the cord  
a great for a short distance below the external ring. In  
explain this way pain in the distribution of the anterior  
subject scrotal nerves may be accounted for, year which does

(e) Relative height of testes: one fresh theoretical  
explanation: **Nothing has been found in this research to account**

it was for the usual lower situation of the left testisaculum  
or to explain the great preponderance of varicocele  
on the left side. At the same time we suggested

that Ilio-inguinal neuralgia: better called the "musculus  
testis". This is a rare condition. It does sometimes  
never occur as a complication of varicocele. The pain

The gubernacular theory has been simplified/radiates  
necessarily /altered

x  
59

radiates in the distribution of the nerve i.e. upper part of the scrotum and upper and inner thigh. The explanation is that the relatively unsupported testis in varicocele is more dependent and pulls on the nerve which runs inside the external spermatic fascia for  $\frac{1}{2}$ ". In cases of ilio-inguinal neuralgia, apart from varicocele, it is possible that a small degree of traction may be responsible.

(3) The imperfectly descended testis:

(a) Review of literature:

(i) Normal descent:

The publication of Baron Haller's "Opuscula Pathologica" (2) in 1755 led John Hunter to undertake his classic research into the descent of the testis. Since then an enormous mass of literature has grown up round this subject, and a great many ingenious theories have been mooted in explanation of it or its aberrations. One writer on the subject remarks that it is indeed a barren year which does not see the addition of at least one fresh theoretical explanation of these phenomena. It will be remembered, that it was Hunter (23) himself who gave the name of gubernaculum to the structure he invested with the function of causing the testicular descent. At the same time he suggested that the ~~to~~ cremaster would be better called the "musculus testis". It seems strange that so wise a suggestion has never been carried into effect.

The gubernacular theory has been amplified and occasionally /altered

devoted to this matter about 15 years ago, but has not altered somewhat, but still remains vastly the most popular one in explanation of the migration of the testis. Curling (11) was of opinion that the chief and only cause of descent is the gubernaculum.

Lockwood (28) in his classical account, originated multiple gubernacular tails. By his careful anatomical researches in 1887 he was able to show several inferior insertions of portions of this structure. This has been very widely accepted and is very generally taught. Sonneland (31) questions this and finds no corroborative evidence embryological or anatomical for the existence of these tails. R.H. Hunter (24) points out that in the newborn the testis with its coverings and the tunica vaginalis can be lifted out of the scrotum without tearing anything; and argues that if the gubernaculum is not attached to the scrotal tissues, obviously it can have no action in pulling the testis down. Coley (9) was not altogether convinced by Lockwood's article. Championnière (8) emphatically opposed the gubernacular theory and remarked that such a physiological explanation was antiquated and childish, but ended up somewhat lamely by stating that nothing was known regarding the descent of the testis. Gowers, Godard, McAdam Eccles, Coley, Mixter, Eisendrath, Bevan, Sebileau, Büdinger, and many others have made contributions to the subject. The writer understands that a Ch.M. thesis was having no inferior attachment, the migration /devoted

devoted to this matter about 18 years ago, but has not been able to gain access to it.

Whether the testis has any intra-abdominal descent is questioned by Sonneland and others. These consider that actual descent only begins at the internal abdominal ring, stating that degeneration of ten or eleven body segments causes the testis to attain this position. John Hunter pointed out that all the pelvic viscera are higher in the foetus than in the adult. According to Sonneland (31) the inguinal canal is formed by the abdominal musculature developing around the gubernaculum and a process of peritoneum which becomes the processus vaginalis.

The existence of the gubernaculum is too firmly established to admit of any doubt, What is questionable is whether it does function as Hunter suggested, and it is just as doubtful whether Lockwood's tails effect ectopia as intimately as he supposed.

According to Sonneland (31) the testis reaches the external ring through the agency of three forces acting together. These are intra-abdominal pressure, inter-muscular pressure, and active contraction of smooth muscle of the gubernaculum. Once beyond the external ring the only one of these three agencies which can be effective is the last. According to Hunter (24) it is the enlargement of the gut which is the main cause of the increase of intra-abdominal pressure. He argues that the gubernaculum having no inferior attachment, the migration of the testis

is entirely due to this pressure. Bland Sutton inclines to the opinion that migration is due to increase of intra-abdominal pressure in late foetal life.

John Hunter must have considered increase of pressure in the etiology of descent as he makes the important negative statement that as descent is complete before birth, respiration cannot effect it.

Fraser(19) states that normal descent depends on the plica vascularis and the gubernaculum. While discountenancing the former as a cause of imperfect descent he remarks that beyond doubt the abnormality lies in the gubernaculum. Recent work tends to favour some hitherto unsuspected reason for descent. Experiments with animals indicate that the extra-abdominal position of the testes may be necessary to ensure proper temperature conditions.

This work being concerned with mal-descent rather than with normal migration, the physiological side of the question will not be further discussed.

#### 11. Imperfect descent:

This is a general term which was first used by McAdam Eccles to include any departure from the normal descent of the testis. According to Eccles (14), imperfect descent includes:-

- (1) Arrest of the testis at some situation in the normal route of its migration.
  - (1) In the abdomen.
  - (2) In the inguinal canal.

scrotum, (3) Just below the external ring, (4) In the upper part of the scrotum. (Non-descent, Partial descent, retention.)

(15) ascribes it to faulty development of the muscles of (2). Having emerged at the external ring, the testis may deviate from the line of its normal route and hence of the gubernaculum, shortness of the spermatic vessels (1) The perineum, shortness of the vas, faulty act (2) Scarpa's triangle, (3) The root of the penis, (4) between Scarpa's fascia and external oblique.

Numerous explanations have been put forward to explain these abnormalities. It is not within the province of this paper to discuss imperfect descent proximal to the external inguinal ring. Distal to that the testis may be: (a) in the scrotum, (b) partially descended, (c) ectopic.

Partial descent:

Some abnormality of the gubernaculum is most generally held responsible for errors affecting migration from the external ring to the scrotal bed. Arrest of the testis between these two points is partial or incomplete descent. This has been ascribed to fracture or loss of function of the gubernaculum, under development of the gravity theory. Briefly this implies a funicular gubernaculum, following the escape of the testis



at the external ring, a long cord, the constancy of the fascial planes of the lower abdomen and perineum, and the operation of physical laws which govern a moving body. Some authors states that the site of ectopia is often determined by a fascial pocket, but beyond the bare statement, adduce no evidence in support of it.

The testis is said to roll in a fascial plane until it comes to a pocket which stops it. According to Burdick and Coley ectopia is often due to the testis passing posterior to Scarpa's fascia. These authors affirming that the normal path to the scrotum is between Camper and Scarpa. According to others the gubernaculum is normally attracted by the lymphatic tissue of the groin and they assume that a congenital absence or abnormality of the distribution of this lymphatic tissue is the original cause of the ectopia ( Quoted by Fraser 20). It seems a strained explanation, as lymphatic tissue is more plentiful in the lumbar region where the testis develops than in the groin.

(B) The gubernacular tails of Lockwood:(22):

Because of the important function attributed to these structures, it may be well to consider the present position of knowledge in regard to them.

Lockwood described the lower end of the gubernaculum as dividing into six processes. One of these passes to the normal terminus of the testis in the scrotum; a

second goes to the perineum, a third to the pubis, a fourth to the root of the penis, a fifth to the external oblique aponeurosis near the anterior superior iliac spine, and the sixth to Scarpa's triangle. He assumed the scrotal fasciculus to be the best developed; it would therefore overcome the other processes and thus the testis would reach its normal scrotal situation. Should it happen that one of the other processes was the largest and strongest the testis would be pulled in that direction and become ectopic. In support of this a well developed gubernaculum is often ascribed in connection with the ectopic testis and Coley and others have figured this. It has already been noted that some surgeons have thought that this represents a secondary attachment of a gubernaculum which has become fractured. Though one gubernaculum is often referred to, multiple processes are neither described or figured at operation. If this structure has no integumentary insertion as R.H. Hunter claims, it is quite justifiable to assume the ectopia to be due to some other factor in which case the gubernaculum would follow the testis into its aberrant site. Opinions on the matter are therefore divided. The Kangaroo has testes which are normally pubo-penile in situation, the pig has perineal testes. Those who favour Lockwood's theory say that this

/is

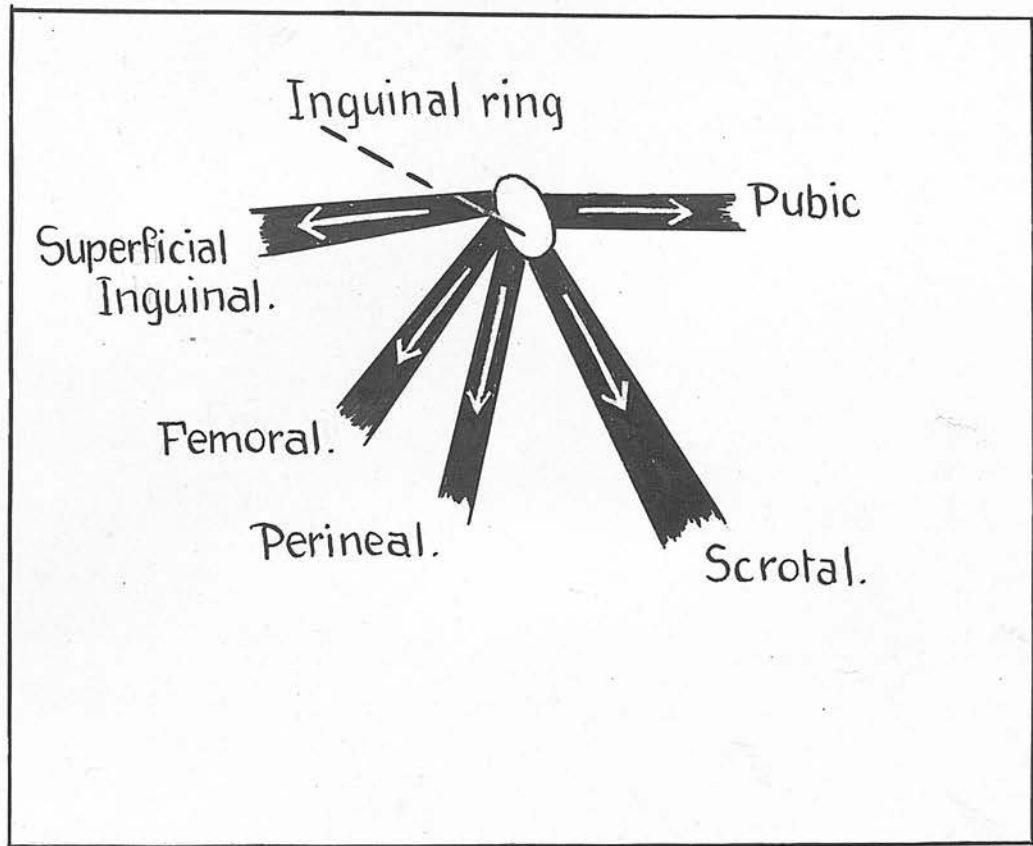


FIG.32.

A diagram, modified from Eisendrath, showing the gubernacular tails of Lockwood. The scrotal tail is represented as being the largest.

is due to the penile tail in marsupials, and the perineal tail in swine being the strongest. Figure 32 modified from Eisendrath, is a diagrammatic representation of these tails in the human being. The writer's own researches have failed to demonstrate any subdivision of the gubernaculum. When some writers deny the existence of any evidence embryological or anatomical (Sonneland) for the existence of these tails, and others speak of the evidence being unconvincing (Coley), and others again deride the whole gubernacular theory as being childish and archaic (Championiere), it must be concluded that Lockwood's view is unproven.

(C) Discussion:

Many of the opinions given in explanation of imperfect descent after the testis has left the external ring, are difficult or impossible to disprove. Were this not so the suggestions in question would have been ruled out. Lately John Hunter's original view has been revived, namely that imperfect descent is dependent on imperfect development of the organ. It is obviously impossible to disprove this, the more so that there is in all probability much truth in it. It is stated by many that whereas the retained or partially descended testis is deficient in development of the elements subserving its external secretion, the ectopic testis is usually fully developed. This is in favour of Hunter's view. Eisendrath's opinion

that the primary fault lies in the development of the posterior wall of the inguinal canal is equally difficult to dispose of. At operations for partial descent the commonest reason why the testis cannot be replaced in the scrotum is the lack of development resulting in the shortening of the mesoblastic elements of the cord. There would seem to be some ground for the idea that this incomplete descent is due to abnormal persistence of the plica vascularis. On the other hand it might be argued that this was secondary and not primary. The same remark applies to the theory that adhesions are the cause of the trouble. Atresia of the acrotal neck has been observed and this would be an absolute bar to further descent.

It is uncommon so it cannot account for all cases. It may exist more commonly than is supposed for the reason that it is probably not looked for. Occasionally imperfect descent is associated with an absence of development of the homo-lateral half of the scrotum. This is much the same as atresia of the scrotal neck in regard to the obstruction to descent. Sonneland(32) makes allusion to fascial pockets as the cause of ectopia, but produces no evidence in support of this.

(D) The anatomical explanation of imperfect descent of the testis after it has left the external ring:

Although it must be conceded in the present imperfect state of knowledge that such factors as congenital

characterized by /shortness

only with

shortness of the mesoblastic elements of the cord, shortness of the vas, or adhesions may conceivably interfere with normal and complete descent, the author is of opinion, because of the results forthcoming in this investigation, that incomplete descent affecting the testis in its extra-abdominal course, and ectopia are explainable on purely anatomical grounds. When structural conditions occur uniformly or very commonly which offer an explanation for these abnormalities, it is only rational to accept the natural explanation rather than some theoretical assumption which does not admit of proof.

Therefore the writer ventures to bring forward the following explanation to account for incomplete descent below the external ring and for ectopic testis:-

Imperfect descent is due to one or more of the following factors:-

- (1) Congenital anomalies or absence of the third inguinal ring.
- (2) Congenital fascial pockets.
- (3) Congenital fascial ridges.

To render this statement lucid it has been thought wise to deal somewhat fully with the subject of ectopia testis.

(e) Ectopia testis:

(1) Definition:

A congenital or traumatic anatomical anomaly which is characterised by the position of a testis which lies not only without /the

the scrotum, but outside of the normal path of its descent (Sonneland) 31).

(ii) Frequency:

Among 59,235 cases of inguinal hernia in males at the hospital for Ruptured and Cripples, from 1890-1907 there were 737 cases of imperfectly descended testis.

The American War Department, in the examination of Army recruits found 8,538 cases of monorchism or synorchism. This gave a frequency rate of 3.1 per 1000 males examined. It was noted that the distribution in certain big areas was unequal which led to the suggestion that some racial peculiarity might be causative.

Rennes and Marshall reported 17 cases of ectopia in 14,400 recruits examined for the army (9). Da Costa states that in one person out of one hundred there is either undescended or ectopic testis. (13).

Wrisberg (37) says that 30% of new born male children have undescended testes. In most of these descent is completed in the first few weeks after birth.

(iii). Types of Ectopia:

There are four varieties of ectopia testis:-

- (1) Superficial inguinal or interstitial.
- (2) Pubo-penile.
- (3) Perineal.
- (4) Crural or femoral.

These are the usual types. Banks (1) reported a case of

/transverse

transverse ectopia of the testis. The condition is extremely rare and of an entirely different nature to the variety under discussion. The right testis had made its way through the left inguinal canal having crossed the space of Retzius. Cases occur with extreme rarity where a crossing of the testes has occurred. Dichotomy of the testis is known to have occurred. In all these cases entirely different factors come into play which do not affect ectopia in the ordinary sense.

The superficial inguinal testis:

This variety was described as being extremely rare. Colley (7) who has operated on a big series of cases of ectopia states that it is the commonest type. It occurred 73 times in a series of 537 reported cases by Burdick and Colley.

The testis lies lateral to the external ring, somewhere between the opening and the anterior superior iliac spine. Frequently it is just above and external to this ring. Like other forms of ectopia it is invariably associated with a hernia behind it. The common belief is that it is pulled here by abnormal development of a gubernacular strand.

When the gubernaculum has emerged at the external ring it finds the third ring immediately below it. This ring is held open and towards the external ring by ligamentous

/fibres

and becomes a part of the gubernaculum. It is then repeated in the same manner as the first and the second fibres of the external oblique. It is the easiest route for the gubernaculum to take and the line of least resistance formed before the testis is descended.

In the event of the third ring being closed, the force exerted on the testis, which is still in the canal, is transmitted to the gubernaculum which may be deflected in some other direction. There are four possibilities:

Should it go medially it will come in contact with the fundiform ligament. If the pubic fossa exists the gubernaculum and testis may be ensnared in the fossa.

If no fossa exists it may continue to pass up and out and may come to lie just above the external ring. If however the gubernaculum is deflected out from the site where the third ring ought to be it will pass up in the gutter between the direct and reflected attachments of Scarpa. Along this gutter it may reach the anterior superior spine or fall short of this point. It has been shown that Scarpa in its outer half is often attached to the inguinal ligament and the spine. The attachments of Scarpa therefore direct the line of movement of the testis travelling in this way.

The fourth possibility is that the emerging gubernaculum, finding its way to the scrotum barred, may remain in contact with the site where the third ring ought to be, most probably by contracting adhesions. In this case the testis has not been deflected from its normal path

/and

and becomes a case of incomplete descent. It is here repeated to emphasise an important point, that the third ring and the testicular scrotal bed are normally well formed before the gubernaculum reaches these areas.

These have been the consistent findings in this research. The gubernaculum has therefore no tunnelling to do in this region but finds its way prepared. If the gubernaculum possessed the excavating property so generally attributed to it, there is no reason why it should not bore its way through any obstruction below the external ring. It fails to do this and becomes partially descended or ectopic.

An obstructed third ring is one possible cause of interstitial ectopia. A second possibility exists. Figures 3la & c show the gubernacula in different relations to the superficial inguinal fossae on the two sides of a foetus. On the left side the apex of the structure has emerged from the fossa and has surmounted the ligament of Scarpa which forms the anterior boundary of the fossa, and the postero-lateral boundary of the third ring. On the right side the gubernaculum has not advanced so far and its apex lies in the fossa. It has been shown that in a large percentage of cases a well defined fossa lies just below the external ring, which fossa is formed by a prominent ridge - the gubernacular tail is described as going to the ligament of Scarpa. The advancing gubernacular apex falls into however hard to see how with its pubic attachment, it could

/the

/bring

this fossa. No doubt it usually surmounts the ridge. Should it however fail to do so, it will pass in the line of least resistance which is towards the lateral <sup>OPEN</sup> side of the fossa and so gain the gutter between the two attachments of Scarpa, and in this way lie on the external oblique aponeurosis, somewhere in the situation occupied by the superficial inguinal testis. Once the testis has reached this fossa the ilio-inguinal nerve is an additional bar to its return to its normal path.

The pubo-penile type:

This variety is rare. A case was reported by Sir Berkeley Moynihan (30), who describes it as one of the rarest forms of ectopia. The left testis lay on the dorsum of the penis  $1\frac{1}{2}$ " below the pubis. It is significant that the left half of the scrotum was imperfectly developed. Cairns Forsythe (18) records and notes a second case, also from Leeds, which was operated on by Mr. Edward Ward in 1902. The testis was tubercular.

The condition of the scrotum is not referred to. Other cases of ectopia pubo-penilis are on record.

The testis rests in front of the pubis at the root of the penis, or on the dorsum anterior to the pubis.

One of the gubernacular tails is described as going to the pubis. This is held the responsible agent. It is however hard to see how with its pubic attachment, it could

/bring

bring a pubic testis to a position  $1\frac{1}{2}$ " anterior to the bone. Anatomically the explanation is simple. The third ring being closed, and the gubernaculum directed medially, it slides up alongside the fundiform ligament unless it meets the rare pubic fossa (Figure 31a).

In the latter case it remains in the fossa where the testis follows. It may stay here forming an ectopia testis in contact with the pubis. The testis then rests on the dorsum of the penile root which is the inferior boundary of the fossa. Now it has been shown in the foregoing that the layer of the fascia of Colles ensheathing the penis, continues proximally with the fundiform ligament at a right angle. (Figure 13.)

The testis therefore in the pubic fossa may slip down and pass under this fascial junction and the only bar to its progress along the penis is the length of the cord. Anatomically there is no reason why the testis should not sag to the lateral aspect of the penis or even to its ventral surface where it would be barred by the median raphe. Similarly with a sufficiently long cord it might advance to the reflection of the inner layer of preputial skin at the base of the glans. The writer would like to point out that a scrutiny of the delicately pointed gubernaculum on its emergence from the abdominal wall, strongly supports the assumption that this "feeler" would be very easily deflected.

The perineal type:

John Hunter (23) described two cases in 1786.

Curling (12) gave the first detailed account of the condition in 1841 and collected nine cases. He was the first to operate. The patient was four weeks old and succumbed.

In 1879 Annadale performed the first successful operative cure. Godard (21) noticed three cases of perineal ectopia in 53 cases of imperfect descent. He mentions a case where both father and son ~~both~~ possessed a perineal testis. Klein (26) reviewed the subject of extopia. Among the 17 cases of ectopia in 14,400 recruits reported by Rennes and Marshall not one was perineal. There were only five cases of perineal ectopia in 936 cases of imperfect descent associated with hernia reported by Eccles. Coley had nine cases of perineal ectopia among 126 cases of hernia associated with imperfect descent. This variety of ectopia occurred fifteen times in 737 cases of imperfectly descended testicle observed at the Hospital for the Ruptured and Crippled from 1890 to 1907. The vast majority ~~are~~ are unilateral.

Hutchinson reported one case of bilateral perineal testis and Ammon reported another. Sonneland (32) states that of 92 cases of perineal testis many were traumatic rather than congenital in origin. This statement is rather surprising. Godard (21) reported the cases of a man age 56 in whom an interstitial variety of ectopia became perineal as a result

result of a bandage having been worn for a long period.

This case will be referred to again

The gubernaculum is said to send a strand into the perineum, which is held to be responsible for the testis occasionally reaching this situation. In these cases there is a lump in front of the anus to one side of the middle line. It has a restricted range of movements and rests in the superficial perineal pouch. The testis is usually of normal size and development.

It has been shown in the foregoing that in the perineal region there exists on each side two ridges of fascia which separate three pouches. The perineo-scrotal reduplication of Colles' fascia separates the scrotal from the superficial perineal pouch. This reduplication forms a smooth ridge. The fascia Colles here doubles back on itself at an acute angle in the adult dependent scrotum, and at a right angle in the foetal scrotum.

Figure 12 The testis or gubernaculum having traversed the third ring, passes down the scrotal neck and arrives at this ridge. At the sixth month there is a well marked scrotal pouch in the vast majority of cases. Should the fascial reduplication narrow or occlude the orifice, the testis cannot enter and may pass posterior to it into the perineum. It is not atresia of the scrotal neck as supposed by Sonneland which causes this type of ectopia, but atresia or lack

through this canal. This mode of descent is a result of development of the actual testicular pouch. Atresia of the scrotal neck causes, as seen above, incomplete descent or interstitial or pubo-penile ectopia.

In those few cases where perineal ectopia is due to trauma applied to a partially descended or interstitial testis, the same mechanism occurs. The testis is forced down, and as the empty scrotum will be contracted, it may easily pass behind the ridge into the perineum.

Where the corresponding half of the scrotum is entirely undeveloped the descending testis must necessarily be ectopic, whether this be perineal or crural.

In these cases of ectopia the cord is long and there is no difficulty in retaining the testis in the scrotum by operation.

#### Crural or femoral ectopia:

This is agreed to be one of the rarest forms. There are two views in regard to its development. The testis is somewhere in the neighbourhood of the saphenous opening at the root of the thigh. According to Wakeley (36) and others the condition is due to a very long mesorchium.

As the testis approaches the internal ring, the long mesorchium cannot exercise its customary control, so that instead of the testis being held close to the internal ring, it slips down to and prolapses through the femoral canal. It is in other words a hernia of the testis

/through

through this canal. This mode of descent is doubted by many writers. Eccles states that it is extremely doubtful if the testis has ever reached the upper part of the thigh by a spontaneous passage through the femoral canal. He further states that the classical instances of this are not very convincing. That this mechanism may extremely rarely be operative is shown by the case of Fauntleroy (17). This case is introduced as being the only one in surgical literature where the testis has descended through the femoral canal and into the scrotum. So that it was not a case of ectopia finally, though it must have been so at one stage of its descent, a simple view is that the crural testis is deflected once it gets beyond the external ring. Eccles says that the gubernacular fibres going to Scarpa's triangle are fairly constant, but are only found at a comparatively early stage of intra-uterine life, disappearing usually two months before birth. He goes on to say that it is not clear that the gubernaculum can cause crural ectopia, seeing that the testis may go to Scarpa's triangle as late as commencing adult life. In this variety of displacement the cord can usually be traced through the external ring by palpation. and against the general belief, this fold crosses the It has been shown earlier in this paper that the line of the direct attachment of Scarpa's fascia to the fascia lata is variable. It may, as shown (Figure 4) cross the

cross the saphenous opening at a higher or lower level, depending usually on the degree of development of Scarpa's ligament. In those cases where the ligament is absent, Scarpa's fascia crosses the adductors and the opening rather more obliquely on its way to the ischio-pubic ramus, than it does in those instances where the ligament of Scarpa holds the fascial attachment forward towards the pubic tubercle. It has also been seen that where no ligament of Scarpa exists, the outer boundary of the third ring is the gutter between the direct and reflected attachment of Scarpa, and that this gutter passes across the adductors to the fusion of Scarpa, and Colles at the pubic ramus just below the situation where the falciform process of Colles is given off. The crural pouch is situated at the site of this fusion. It is of great interest to observe that the crural pouch is situated behind or internal to the inguino-scrotal fold. The most cursory examination of any male subject will show that this fold does not directly overlie and correspond to the ischio-pubic ramus, which intervenes between perineum and thigh. On the contrary, and against the general belief, this fold crosses the root of the thigh. Now as the femoral pouch is behind or medial to this fold, a testis in the pouch bears the same relation to the fold. Such a testis may bulge medial to it, or lateral to it, or push the fold

forwards. Thus it may easily be mistaken for a perineal testis when in reality it is crural. Only a thin fascia, namely that of Colles at its attachment to the scrotal ramus, separates it from the perineum. Operative in the methods through the usual inguinal incision, would fail to distinguish the situation of the testis. It may be stated that unless the inner border of the organ impinges on the mid line, it is probably a crural and not a perineal testis. It would seem therefore that this abnormality may arise in one or two or possibly three ways.

(1). The testis having passed the third ring lies in the neck of the scrotum suspended above three pouches, the scrotal, the perineal and the crural. Just as the perineo-scrotal reduplication separates scrotal from perineal pouches, so the falciform process of Colles intervenes between the perineal and crural fossae. Only the razor edge of this process separates the descending gubernaculum from the crural pouch. Now this edge is level with the bone above, and rises gently to a ridge as it is followed down. The gubernacular apex is easily deflected, should it pass lateral to the edge, the testis is crural.

(2) When the third ring is of a wide funnel variety as happens when the ligament of Scarpa is undeveloped, the testis may be hung up somewhere along the gutter bounding the ring laterally. Atresia of the lower part of the scrotal

in reaching its normal destination through such a mass neck or a short cord may be at fault. In this way the of deviant paths.

testis may come to lie over the saphenous opening or any where along the gutter, right down to the crural pouch.

As often as not the first barrier encountered by the ascending gubernaculum is the dog-bark formed by Scarpa's ligament. Here it lies in a deep valley which may cause upper part of this gutter, whether it be superficial, inguinal or upper crural in type, may through trauma negotiating this depression and, if successfully, it be pushed down to enter one of the three perineal pouches, arriving at the entrance to the scrotal tunnel i.e. the depending on the direction it is forced to take by the third inguinal ring. Should this be absent or under two fascial ridges. It will be remembered in Godard's developed case this may be the case with an apparent normal case an interstitial ectopia became perineal through the scrotal development as viewed from without the gubernaculum wearing of a bandage. It is more than likely that even which is incapable of excavating any adhesion to the site though the testis occupied the crural pouch it would be where the orifice should be, and remained permanently called perineal because of its relation to the inguino-partially descended. On the other hand it may trend scrotal fold.

medially and then will either travel up or about along (3) The writer has wondered whether a testis lying in a the fundiform ligament to a high superficial inguinal deep superficial inguinal fossa may not be called a crural resting place. Should it however encounter a cave at testis as this fossa is just above and medial to the the side of the fundiform ligament, it may adhere there, uppermost part of the saphenous opening.

or slip down by its own weight; nothing obstructing its (5).

progress along the gents but the length of its own central Conclusions: attachments.

It is therefore apparent that once the migrating testis emerges at the external inguinal ring it enters upon the it has not yet passed the dangers. It may come to rest most perilous and hazardous stage of its journey. When somewhere in the gutter formed by Scarpa's fascia, or it the obstacles to the successful performance of this may be pushed off the road by either of two additional transit are reviewed, the marvel is not that the organ ridges, namely the fundiform process of Collins, or the becomes ectopic at times, but that it should<sup>so</sup> often succeed

in reaching its normal destination through such a maze of devious paths. As often as not the first barrier encountered by the scouting gubernaculum is the hog-back formed by Scarpa's ligament. Here it lies in a deep valley which may cause it to travel out at right angles to its intended path. Negotiating this depression and ridge successfully, it arrives at the entrance to the scrotal tunnel i.e. the third inguinal ring. Should this be absent or under developed ( and this may be the case with an apparent normal scrotal development as viewed from without ) the gubernaculum which is incapable of excavating may adhere to the site where the orifice should be, and remain permanently partially descended. On the other hand it may trend medially and then will either travel up and out along the fundiform ligament to a high superficial inguinal resting place. Should it however encounter a cave at the side of the fundiform ligament, it may adhere there, or slip down by its own weight; nothing obstructing its progress along the penis but the length of its own central attachments:

If the third ring transmitting to the scrotum is open it has not yet passed the dangers. it may come to rest somewhere in the gutter formed by Scarpa's fascia, or it may be pushed off the road by either of two additional ridges, namely the falciform process of Colles, or the

## SUMMARY

- perineo-scrotal reduplication. Failure to negotiate
- (1) one of these obstructions will permanently prevent the testis arriving at its scrotal bed.
  - The author wishes to suggest that these anatomical
  - (2) ridges, fossae, and orifices, some of which are present in all subjects, others of which exist in a large proportion of cases, are the most natural and likely explanation of cases of partial descent or of ectopia affecting the testis
  - (3) during the extra-abdominal portion of its transition from abdomen to scrotum.
  - (4) The complicated method whereby the scrotum is always is analysed in detail and serves to throw some light on the cause of the inequality in rate of growth of hernia.
  - (5) Certain fascial pockets exist in the perineum and groin in a large percentage of cases. These pockets are proportionately better marked in the foetus than in the adult.
  - (6) A third orifice is described in the inguinal region which has been named the third inguinal ring. This presents the form of a ring in 50% of cases, and the shape of a funnel in the remaining cases. It is of vast importance in connection with imperfect descent of the testis. It is easily felt clinically.
  - (7) No evidence has been forthcoming in this research which lends the least support to:-
    - (a) the supposed "excavating" function of the gubernaculum.

S U M M A R Y

6.

- (1) The superficial fasciae of the groin and perineal regions have been investigated in great detail in the male subject from foetal life to old age.
- (2) Certain hitherto unsuspected anatomical features of great practical importance have been disclosed by the research, particularly in regard to the fasciae of Scarpa and of Colles.
- (3) An undescribed layer of fascia in the perineum has been named the deep fascia of the perineum.
- (4) The complicated method whereby the scrotum is slung is analysed in detail and serves to throw some light on the cause of the inequality in rate of growth of hernia.
- (5) Certain fascial pockets exist in the perineum and groin in a large percentage of cases. These pockets are proportionately better marked in the foetus than in the adult.
- (6) A third orifice is described in the inguinal region which has been named the third inguinal ring. This presents the form of a ring in 50% of cases, and the shape of a funnel in the remaining cases. It is of vast importance in connection with imperfect descent of the testis. It is easily felt clinically.
- (7) No evidence has been forthcoming in this research which lends the least support to:-
- (a) the supposed "excavating" function of the gubernaculum.

elements (b) the "traction" function of this band.

points (c) the existence of the gubernacular tails and not primary. of Lockwood.

- (8) It is shown that the spermatic cord lies as a rule 1/2" lateral to the pubic tubercle and not medial to the it. as is explained.
- (9) Extravasation of urine is shown to extend largely as an infiltration of the superficial fasciae rather than as an extravasation deep to them.
- (10) Femoral hernia may emerge above or below the attachment of Scarpa's fascia in the groin. The size of the hernia and the direction it takes may be dependent on its relationship to this fascia.
- (11) The literature of imperfect extra-abdominal testicular descent is reviewed.
- (12) A new explanation of this imperfection is put forward. It is based on anatomical findings and may fittingly be called the "anatomical explanation". Partial descent and ectopia are due to one or more of the following factors:-
- (a) congenital anomalies or absence of the third ring.
  - (b) congenital fascial pockets.
  - (c) congenital fascial ridges.

It is impossible to exclude as further possible causes such factors as shortness of the mesoblastic

elements of the cord, or adhesions. It is however pointed out that such occurrences may be secondary and not primary.

(13)

The anatomical explanation of the various types of ectopia is entered into in considerable detail, and the genesis is explained.

The author wishes to record his gratitude to the University of the Witwatersrand for permission to conduct this research in the department of anatomy to Professor Raymond A. Part of this department for such helpful advice and encouragement; to Drs. Strachan and Simpson of the South African Institute for Medical Research for access to post mortem material; and to Messrs La Halle and Thomas for the great trouble they have taken in the preparation of the drawings.

The author wishes to record his gratitude to the University of the Witwatersrand for permission to conduct this research in the department of Anatomy, to Professor Raymond A. Dart of this department for much helpful advice and encouragement; to Drs. Strachan and Simpson of the South African Institute for Medical Research for access to post mortem material; and to Messrs Le Hellpco and Thomas for the great trouble they have taken in the preparation of the drawings.

7. Burdick and ...  
December, 1928.
8. Championniere .....  
Clinique
9. Coley; Vol. 1.
10. Cunningham; ...  
Vol. 2, P. 1
11. Curling; Treatise ...  
1827, 1845.
12. De Meis; ...
13. De Meis; ...
14. Hooper, W. Hooper; ...
15. Hooper, W. Hooper; ...
16. ...

7.

B I B L I O G R A P H Y

1. Banks, A.G.; B.M.J. Vol.2 P. 589. Oct. 2,1926.
2. Baron Holler; "Opuscula Pathologica", Lausan, 1755.
3. Beesley & Johnston; Surgical Anatomy P. 259.London 1923
4. Bland Sutton; Sir John. Selected Lectures & Essays  
P.1 London 1920.
5. Bland Sutton; Sir John, Introduction to general  
pathology. 1886.
6. Budinger; Etiology of the undescended testis.  
Zeitschr f. chir. Oct, 1907
7. Burdick and Coley; Annals of Surgery,P.867.  
December, 1926.
8. Championniere; Les Anomalies du Testis, Lecon de  
Clinique chirurgical faite a l'Hotel Dieu.
9. Coley; Wm.B; Annals of Surgery,Vol 48.P.321.
10. Cunningham; Manual of Practical Anatomy. 7th Edition  
Vol.2.P.152.1920.
11. Curling; Traite pratique des Maladies de Testicle  
1857, 1878.
12. Da Costa; Modern Surgery P.1276 (illustration) 1920
13. Da Costa; Modern Surgery P. 1539. 1920
14. Eccles, W. McAdam: Lancet P.569.March 1st,1902
15. Eccles, W. McAdam: Lancet P.842 (illustration) August  
1926
16. Eisendrath, Daniel N. Surgical Clinics of Northern  
America. Vol.6. No.4 8/1926

17. Fauntleroy, A.M.: Annals of Surgery. Vol. 62. P. 675. 1920
18. Forsythe, Cairns: B.M.J. Vol. 1, P. 626. March 1924.
19. Fraser, John: Surgery of Childhood, Vol. ii. P. 784. 1926
20. Fraser, John: Surgery of Childhood Vol. ii. P. 785 1926
21. Godard: Compte Rendus des Seance et Memoires de la  
Soc. de Biologie, iii P. 315. 1856.
22. Gray: Anatomy. P. 457. London 1918
23. Hunter, John; Observations on Certain parts of the Animal  
Oeconomy, 1786.
24. Hunter, R.H.: British Journal of Surgery, Vol. 14,  
P. 125, July 1926
25. Jamieson, E.B.: Companion to Manuals of Practical  
Anatomy, P. 240, Edinburgh. 1914.
26. Klein: L'Ectopie Perineale. These de Paris. 1905-06
27. Keith, Arthur: Human Embryology & Morphology, P. 379, 398  
3rd Edition, London 1913.
28. Lockwood: Hunterian Lecture, B.M.J. Vol. 1 P. 444, 610, 1887
29. Morris, Treatise on Anatomy. P. 427. London 1915.
30. Moynihan, Sir Berkeley: B.M.J. Vol 1. P. 467. 15/3/1924
31. Sonneland, S. Gaylord: Surhery, Gynaecology & Obstetrics  
Vol. 40. P. 535, April 1925.
32. Sonneland. S. Gaylord, Annals of Surgery, P. 7716,  
November, 1924.
33. Souttar, H.S.; The Surgical Anatomy of Femoral Hernia  
B.M.J. P. 367, 1/4/24.

34. Thom~~p~~son & Miles; Manual of Surgery, vol.3. P.142.  
6th Edition, London 1921.
35. Thom~~p~~son & Miles, Manual of Surgery. Vol.3. P. 456.
36. Wakeley, C.P.G. Lancet Vol.ii P. 245, July 31st,1926
37. Wrisberg: Quoted by C.G. Mixter, Surgery, Gynaecology,  
& Obstetrics, Vol 39.P.275.Sept. 1924.

.....