



THE UNIVERSITY *of* EDINBURGH

This thesis has been submitted in fulfilment of the requirements for a postgraduate degree (e.g. PhD, MPhil, DClinPsychol) at the University of Edinburgh. Please note the following terms and conditions of use:

- This work is protected by copyright and other intellectual property rights, which are retained by the thesis author, unless otherwise stated.
- A copy can be downloaded for personal non-commercial research or study, without prior permission or charge.
- This thesis cannot be reproduced or quoted extensively from without first obtaining permission in writing from the author.
- The content must not be changed in any way or sold commercially in any format or medium without the formal permission of the author.
- When referring to this work, full bibliographic details including the author, title, awarding institution and date of the thesis must be given.

Immunopathogenesis of bovine neosporosis throughout gestation

Germán José Cantón

Thesis submitted for the degree of Doctor of Philosophy to

The College of Medicine and Veterinary Medicine

University of Edinburgh

Research was carried out at Moredun Research Institute

2013

Abstract

Despite *Neospora caninum* being recognised as a major cause of bovine abortion, its pathogenesis is only partially understood. Evidence of immune mediated placental pathology has been reported as being responsible for compromising pregnancy probably due to an exacerbated Th1 immune response at the maternal-foetal interface. Different clinical outcomes are known to follow experimental infections at different stages of gestation, with foetal death being the most common finding during early gestation infections, and the birth of live congenitally infected calves following infection in mid or late gestation. The aim of the current study was to characterise the placental cellular immune responses and cytokine expression following experimental *Neospora* infection during pregnancy. Placentomes were collected from cattle experimentally inoculated with the tachyzoites of the Nc-1 strain during early, mid and late gestation.

Inflammation in early gestation was generally moderate to severe. Differently in mid gestation, inflammation was mild to moderate and minimal to mild in late gestation. Generally cellular infiltrates were mainly characterised by the presence of CD3⁺, CD4⁺ and $\gamma\delta$ T-cells; whereas CD8⁺ and NK cells were less numerous. Macrophages were detected in larger numbers during later time-points after infection. A moderate to severe infiltration of IL-12, IFN- γ and TNF- α expressing cells was observed in the placentas collected in early gestation. This infiltration was more pronounced in the samples of placentome collected from dams carrying a dead foetus or in those that had aborted, compared with mothers carrying live foetuses at the time of sampling.

The distribution of the cellular subsets observed in the three studies was similar. However, cellular infiltrates were more severe following infection during the first trimester in comparison to the second and third trimester. Similarly, the infiltration of Th1 cytokine expressing-cells was more severe in early gestation compared with the milder and more minimal infiltrations observed following *N. caninum* infection in mid and late gestation, respectively. These results may explain the milder clinical outcome observed when animals are infected in later stages of pregnancy.

Table of contents

Abstract	1
Table of contents	3
Author declaration	9
Acknowledgements	11
List of figures	13
List of tables	17
List of abbreviations	19
Chapter 1 - General introduction	23
Different stages and life cycle	28
Natural cases of <i>Neospora</i> abortion	34
Bovine neosporosis pathogenesis	35
Factors influencing <i>N. caninum</i> infection	39
Factors influencing the clinical outcome of infection	43
Economic impact of bovine neosporosis.....	47
Control of bovine neosporosis.....	47
Treatment and Vaccination.....	52
Experimental Neosporosis throughout gestation.....	53
Aims of studies and Thesis outline.....	60
Chapter 2 - Characterisation of placental cellular immune infiltrates following inoculation with <i>Neospora caninum</i> in late gestation	63
Introduction	65
Materials and methods.....	67
Animals and experimental design.....	67
Experimental inocula	68

Phenotypic analysis of inflammatory cells in placental tissue	69
Scoring of the immunolabelling of the tissues.....	70
Statistical analysis.....	72
Results	73
Phenotypic analysis of inflammatory cells in placental tissue	73
CD68 ⁺ cells	75
CD3 ⁺ cells	77
CD4 ⁺ cells	80
CD8 ⁺ cells	83
$\gamma\delta$ TCR ⁺ cells	85
NKp46 ⁺ cells	88
CD79 _{acy} ⁺ cells and cytokeratin.....	90
Discussion	95
Chapter 3 - Characterisation of bovine placental immune cell infiltrate after experimental inoculation with <i>N. caninum</i> throughout gestation	103
Introduction	105
Materials and methods.....	105
Collection of samples at the three time points.....	105
Placental tissues and immunohistochemistry	106
Early gestation.....	106
Mid gestation.....	106
Late gestation	107
Scoring methodology.....	107
Statistical analysis.....	107
Results	108

CD68 ⁺ cells during early gestation	108
CD68 ⁺ cells during mid gestation	111
CD68 ⁺ score comparison at the three stages of gestation	112
CD3 ⁺ cells during early gestation	115
CD3 ⁺ cells during mid gestation	117
CD3 ⁺ score comparison at the three stages of gestation	118
CD4 ⁺ cells during early gestation	121
CD4 ⁺ cells during mid gestation	123
CD4 ⁺ score comparison at the three stages of gestation	124
CD8 ⁺ cells during early gestation	127
CD8 ⁺ cells during mid gestation	129
CD8 ⁺ score comparison at the three stages of gestation	130
$\gamma\delta$ TCR ⁺ cells during early gestation	132
$\gamma\delta$ TCR ⁺ cells during mid gestation	134
$\gamma\delta$ TCR ⁺ score comparison at the three stages of gestation	135
NKp46 ⁺ cells during early gestation	137
NKp46 ⁺ cells during mid gestation	138
NKp46 ⁺ score comparison at the three stages of gestation	139
CD79 _{acy} ⁺ cells during early gestation	142
CD79 _{acy} ⁺ cells during mid gestation	142
CD79 _{acy} ⁺ score comparison at the three stages of gestation	143
Discussion	148
Chapter 4 - Cytokine expression in the bovine placenta after inoculation with <i>Neospora caninum</i> throughout gestation.....	157
Introduction	159

Materials and methods.....	163
Placental sampling for ISH.....	163
Cytokine mRNA probes.....	163
Production of positive controls.....	167
<i>In situ</i> hybridisation.....	168
Scoring the positive infiltration.....	170
Statistical analysis.....	170
Results.....	171
Clinical findings.....	171
Standardisation of the BoIL-12p40 probe.....	171
Standardisation of the BoIFN- γ probe.....	174
IL-12 mRNA expression in the placentas.....	175
Early gestation.....	175
Mid-gestation.....	176
Late gestation.....	176
Comparison over gestation stages.....	177
IFN- γ mRNA expression.....	179
Early gestation.....	179
Mid gestation.....	180
Late gestation.....	180
Comparison over gestation stages.....	180
TNF- α mRNA expression.....	183
Early gestation.....	183
Mid gestation.....	184
Late gestation.....	184

Comparison over gestation stages.....	185
Discussion	189
Chapter 5 - General discussion	197
Discussion	197
Concluding remarks	203
References	205
Appendix I - Buffers and solutions.....	259
Appendix II - Tables and figure of statistical results.....	269
Appendix III - Alignment of the cytokine probes	273
Appendix IV - Presentations and publications.....	279

Author declaration

I hereby declare that this thesis is of my own work and all results presented therein have been conducted by the author between September 2009 and May 2013 and under supervision of Dr. Francesca Chianini, Dr. Frank Katzer (Moredun Research Institute) and Dr. Sionagh Smith (University of Edinburgh). The work has not been previously submitted for any other degree or professional qualification. When relevant, acknowledgement has been made of collaboration with other colleagues.

.....
Germán José Cantón

Acknowledgements

My most sincere gratitude to my supervisors Dr. Francesca Chianini and Dr. Frank Katzer from Moredun Research Institute (MRI) and Dr. Sionagh Smith from the University of Edinburgh, for their continuous support and guidance during this process.

I am also grateful to Instituto Nacional de Tecnología Agropecuaria (INTA) in Argentina for awarding the Scholarship to carry out this project during these years, and to Scottish Government's Rural and Environment Science and Analytical Services Division (RESAS) for funding the experimental work.

I am also particularly obliged to Dr. Carlos Campero from INTA for endorsing this project from the beginning, and for his constant personal and professional advice. I am likewise thankful to professionals and friends at Animal Health Group of INTA in Balcarce for their support.

Many thanks also to Moredun Research Institute for being my home during this time and especially to Julio Benavides Silván, Stephen Maley, Paul Bartley, Alison Burrells, Lee Innes and the rest of the Protozoology Group (MRI). I would particularly like to acknowledge to Dr. David Buxton for his initial help when this project was indeed just a draft. Also, I am thankful to Clare Underwood, Jeanie Finlayson, Val Forbes and Yvonne Pang for their technical assistance at the Pathology lab (MRI); to Helen Todd, Kathryn Bartley, George Russell (MRI) for their “molecular” help; to Sean Wattedegera and Gary Entrican (MRI) for their “immunological” support; to Alex Schock from Animal Health and Veterinary Laboratories Agency and Javier Palarea Albaladejo from Biomathematics and Statistics Scotland (BioSS) for their help; to Scott Hamilton (MRI) for kindly providing Figure 1 in Chapter 1. To all of them I am very thankful for their technical support and generous discussion.

Finally, this entire project would not be accomplished without the company and help of Patricia; also to my family for always supporting my decisions on my personal and professional life.

List of figures

Figure 1: Transmission of bovine neosporosis	34
Figure 2: Schematic representation of the experimental design	56
Figures 3a-d: Examples of different infiltrate scores in placentomes.....	72
Figures 4a-h: Positive control tissues.....	74
Figures 5 a-f: Examples of CD68 ⁺ cell infiltrates in placentomes in late gestation. .	76
Figure 6: Mean CD68 ⁺ cell scores in placentomes in late gestation.....	77
Figures 7 a-f: Examples of CD3 ⁺ cell infiltrates in placentomes in late gestation	79
Figure 8: Mean CD3 ⁺ cell scores in placentomes in late gestation.....	80
Figures 9 a-f: Examples of CD4 ⁺ cell infiltrates in placentomes in late gestation	82
Figure 10: Mean CD4 ⁺ cell scores in placentomes in late gestation.....	83
Figures 11 a-f: Examples of CD8 ⁺ cell infiltrates in placentomes in late gestation ..	84
Figure 12: Mean CD8 ⁺ cell scores in placentomes in late gestation.....	85
Figures 13 a-f: Examples of $\gamma\delta$ -T cell infiltrates in placentomes in late gestation	87
Figure 14: Mean $\gamma\delta$ TCR ⁺ cell scores in placentomes in late gestation	88
Figures 15 a-b: Examples of NK cell infiltrates in placentomes in late gestation	89
Figure 16: Mean NK cell scores in placentomes in late gestation	89
Figures 17 a-f: Examples of CD79 ⁺ cell infiltrates in placentomes in late gestation	91
Figure 18: Mean CD79 ⁺ scores in placentomes in late gestation.....	92
Figures 19 a-d: Examples of CD79 ⁺ cell infiltrates in the ovine and buffalo placenta, and cytokeratin labelling in the bovine placenta.....	93
Figure 20: Summary of the mean infiltrates scores in placentomes in late gestation	94
Figures 21 a-f: Examples of CD68 ⁺ cell infiltrates in placentomes in early gestation	110

Figures 22 a-d: Examples of macrophage infiltrates in placentomes in mid gestation	112
Figure 23: Mean CD68 ⁺ cell scores in the placentomes in early, mid and late gestation	114
Figures 24 a-f: Examples of CD3 ⁺ infiltrates in placentomes in early gestation	116
Figures 25 a-d: Examples of CD3 ⁺ infiltrates in placentomes in mid gestation	118
Figure 26: Mean CD3 ⁺ cell infiltrate scores in the placentas in early, mid and late gestation	120
Figures 27 a-f: Examples of CD4 ⁺ infiltrates in placentomes in early gestation	122
Figures 28 a-d: Examples of CD4 ⁺ infiltrates in placentomes in mid gestation	124
Figure 29: Mean CD4 ⁺ cell infiltrate scores in the placentas in early, mid and late gestation	126
Figures 30 a-f: Examples of CD8 ⁺ cell infiltrates in placentomes in early gestation	128
Figures 31 a-b: Examples of CD8 ⁺ infiltrates in placentomes in mid gestation	129
Figure 32: Mean CD8 ⁺ cell infiltrate scores in the placentas in early, mid and late gestation	131
Figures 33 a-f: Examples of $\gamma\delta$ TCR ⁺ infiltrates in placentomes in early gestation .	133
Figures 34 a-b: Examples of $\gamma\delta$ TCR ⁺ infiltrates in placentomes in mid gestation ..	134
Figure 35: Mean $\gamma\delta$ TCR ⁺ cell infiltrate scores in the placentas in early, mid and late gestation.	136
Figures 36 a-d: Examples of NKp46 ⁺ infiltrates in placentomes in early gestation	138
Figures 37 a-b: Examples of NKp46 ⁺ infiltrates in placentomes in mid gestation ..	139
Figure 38: Mean NKp46 ⁺ cell infiltrate scores in the placentas in early, mid and late gestation	141
Figures 39 a-d: Examples of CD79 _{acy} ⁺ cells in placentomes in early and mid gestation.	143

Figure 40: Mean CD79 _{acy} ⁺ cell infiltrate scores in the placentas in early, mid and late gestation.	145
Figure 41: Schematic representation of the BoIL-12p40 probe production	165
Figure 42: Schematic representation of <i>in situ</i> hybridisation.....	169
Figures 43 a-b: Labelling of bovine placentas using BoIL-12p40 probes by ISH... ..	172
Figures 44 a-b: OvIL-12p40 CHO transfected cells used as positive controls	173
Figures 45 a-b: Examples of IL-12p40 expressing cell infiltrates in ovine and caprine tissues.	174
Figures 46 a-b: OvIFN- γ CHO transfected cells used as positive controls.....	175
Figures 47 a-f: Examples of IL-12p40 mRNA expressing cellular infiltrates in the placentomes in early, mid and late gestation	178
Figure 48: Mean IL-12p40 expressing cell infiltrate scores in the placentas in early, mid and late gestation.....	179
Figures 49 a-f: Examples of IFN- γ mRNA expressing cells detected in the placentomes in early, mid and late gestation	182
Figure 50: Mean scores for cells expressing IFN- γ mRNA in placentas in early, mid and late gestation.....	183
Figures 51 a-f: Examples of TNF- α mRNA expressing cells detected in the placentomes in early, mid and late gestation	186
Figure 52: Mean scores for TNF- α mRNA positive cells in placentas in early, mid and late gestation.....	187
Figure 53: Mean infiltration score for placentomes in early, mid and late gestation	272

List of tables

Table 1: mAb used to label different immune cell type.....	71
Table 2: Mean of immune cell infiltrate scores on placentomes in early, mid and late gestation.	146
Table 3: Mean of immune cell scores in placentomes in early gestation.....	147
Table 4: Mean of immune cell scores on placentomes in early gestation.....	147
Table 5: Mean scores for cytokine expressing cells in placentomes in early gestation	187
Table 6: Mean scores for cytokine expressing cells in placentomes in early, mid and late gestation.....	188
Table 7: <i>p</i> -values for differences in cell scores between negative control and <i>N. caninum</i> -inoculated animals at each gestation stage.....	269
Table 8: Adjusted <i>p</i> -values for differences in cell scores between <i>N. caninum</i> -inoculated and negative control animals in early gestation.	269
Table 9: <i>p</i> -values for differences in cell scores between dams inoculated with <i>N. caninum</i> carrying non-viable and viable foetuses in early gestation.	270
Table 10: <i>p</i> -values for cell scores following overall and pair-wise comparisons of <i>N. caninum</i> inoculated animals at each gestation stage	270
Table 11: <i>p</i> -values for cell scores following overall and pair-wise comparisons of negative control animals at each gestation stage.....	271

List of abbreviations

DAB	3,3'-diaminobenzidine
BCIP	5-bromo-4-chloro-3-indolyl phosphate
AI	artificial insemination
bp	base pair
BioSS	Biomathematics and Statistics Scotland
<i>B. indicus</i>	<i>Bos indicus</i>
<i>B. taurus</i>	<i>Bos taurus</i>
BHV	bovine herpesvirus
BoIFN- γ	bovine interferon gamma
BovIL-12	bovine interleukin 12
BVDV	bovine viral diarrhea virus
<i>B. abortus</i>	<i>Brucella abortus</i>
Ca(C ₂ H ₃ O ₂) ₂	calcium acetate
CaCl ₂	calcium chloride
°C	Celsius grade
CNS	central nervous system
CHO	Chinese hamster ovary
<i>C. abortus</i>	<i>Chlamydia abortus</i>
C ₂ H ₃ Cl ₃ O ₂	chloral hydrate
C ₆ H ₈ O ₇	citric acid
CD	cluster of differentiation
CSF	colony stimulating factor
cDNA	complementary deoxyribonucleic acid
dpi	day(s) post inoculation
DNase	deoxyribonuclease
DNA	deoxyribonucleic acid
DIG	digoxigenin
ELISA	enzyme-linked immunosorbent assay
EDTA	ethylenediamine tetraacetic acid

e.g.	<i>exempli gratia</i>
FDR	false discovery rate
fv	foetal villi
Fab	fragment, antigen binding
GJC	Germán José Cantón
GM-CSF	granulocyte-macrophage colony-stimulating factor
HCl	hydrogen chloride
i.e.	<i>id est</i>
IHC	immunohistochemistry
ISH	<i>in situ</i> hybridization
INTA	Instituto Nacional de Tecnología Agropecuaria
IFN- γ	interferon gamma
IL	interleukin
IV	intravenous(ly)
MgCl ₂	magnesium chloride
MgSO ₄	magnesium sulphate
MCH	major histocompatibility complex
mRNA	messenger ribonucleic acid
μ g	microgram(s)
μ l	microlitre(s)
mg	milligram(s)
ml	millilitre(s)
mM	millimolar
min	minute(s)
M	molar
mAb	monoclonal antibody
KH ₂ PO ₄	monopotassium phosphate
MRI	Moredun Research Institute
NK	natural killer cell
n	necrotic/necrosis
<i>N. caninum</i>	<i>Neospora caninum</i>
<i>N. hughesi</i>	<i>Neospora hughesi</i>

NBT	nitroblue tetrazolium
ng	nanogram(s)
NGS	normal goat serum
ND	not determined
OvIFN- γ	ovine interferon gamma
OvIL-12	ovine interleukin 12
OvTNF- α	ovine tumor necrosis factor alpha
PBMC	peripheral blood mononuclear cells
PBS	phosphate-buffered saline
PCR	polymerase chain reaction
KAl(SO ₄) ₂	potassium aluminium sulphate
KCl	potassium chloride
RNase	ribonuclease
RNA	ribonucleic acid
RT	room temperature
SSC	saline-sodium citrate buffer
STWS	Scott's tap water substitute
RESAS	Scottish Government's Rural and Environment Science and Analytical Services Division
NaHCO ₃	sodium bicarbonate
NaCl	sodium chloride
NaOH	sodium hydroxide
NaIO ₃	sodium iodate
Na ₂ HPO ₄ 2H ₂ O	sodium phosphate dibasic dihydrate
SEM	standard error of the mean
SC	subcutaneous(ly)
TCR	T cell receptor
Th1	T helper type 1
Th2	T helper type 2
<i>T. circumcincta</i>	<i>Teladorsagia circumcincta</i>
<i>T. gondii</i>	<i>Toxoplasma gondii</i>
tRNA	transfer ribonucleic acid

Tris	trisaminomethane
$(\text{HOCH}_2)_3\text{CNH}_2$	Tris base
TBS	tris-buffered saline
<i>T. pyogenes</i>	<i>Trueperella pyogenes</i>
TNF- α	tumor necrosis factor alpha
U	unit
UK	United Kingdom of Great Britain
USA	United States of America
UTP	uridine-5'-triphosphate
$\text{Zn}(\text{O}_2\text{CCH}_3)_2$	zinc acetate
ZnCl_2	zinc chloride
ZSF	zinc salt fixative

Chapter 1:

General introduction

“Currently, we face a growing population, finite fossil energy and water, and competition for land needed to produce human food (...). In spite of recent growth in consumption, many people are still deficient in the nutrients that can be provided by animal source foods, which are complete, nutrient-dense and important for the high quality protein and bio-available micronutrients they contain (...). During the past 40 years (1967–2007), global production of meat (...) has grown steadily (...). While the global supply of livestock products has more than kept up with the human population expansion, the situation has not been the same in all regions (...). Livestock make their most important contribution to total food availability when they are produced in places where crops cannot be grown easily, such as marginal areas, or when they (...) use feed sources that cannot directly be eaten by humans...”

(FAO, 2011)

In the coming decades the real challenge is to expand agricultural output massively without significantly increasing the amount of land used (Nature, 2010). In dairy and beef systems, herd efficiency is mainly determined by factors such as reproduction rate of the cowherd, the survival rate of the calves and calf weaning weight (du Plessis *et al.*, 2006). Furthermore, in dairy production systems, the increase in milk yield observed over the past 40 years has been accompanied by a decline in cow fertility and reproductive losses (Diskin *et al.*, 2006). Similarly, losses during pregnancy due to reproductive diseases have impacted significantly in the economics of beef systems. Most of these losses are due to reproductive infectious diseases which are an important cause of low weaning rates in cattle (Campero *et al.*, 2003b). A realistic target for weaning rates depending of the intensity and geographical

conditions of each production system is a minimum of 80 calves weaned for each 100 cows mated. This may be as high as 90% in extremely good seasons with excellent management; however, these parameters could be significantly diminished when unfavourable conditions are present, reducing these numbers up to 65-70%, or further in more extreme cases (Meat and Livestock Commission, 1994; Fordyce and Cooper, 1999). Bovine abortion is an important problem in the dairy and beef industry causing a negative economic input, due to direct and indirect costs (Anderson *et al.*, 1990; Campero *et al.*, 2003b; Anderson, 2007; Reichel *et al.*, 2013).

Although abortion is a major problem for livestock operations and welfare worldwide, the identification of a specific cause is particularly difficult and achievable in less than 50% of cases, even in well-established diagnostic laboratories. Of this percentage, most of the losses are due to reproductive infectious diseases (Anderson *et al.*, 1990; Murray, 1990; Kirkbride, 1993; Agerholm *et al.*, 1997; Campero *et al.*, 2003b; Anderson, 2007).

Herd management and intensity of different livestock production systems vary greatly in different regions of the world; therefore the most commonly diagnosed pathogens associated with abortion in cattle in different areas are also significantly different. Management practice in Argentina and the UK serves as a good comparison. Argentinean production systems tend to be more extensive with the use of large grassland areas and exposure to different external factors, while the UK system is more intensive with periods of indoor management. Accordingly, differences have been reported in the causes of spontaneous bovine abortion. In a study carried out in Argentina in beef and dairy herds, a definitive diagnosis was accomplished in 45.5% of the cases, and in 34.4% an infectious agent was identified. Between them, *Brucella abortus* (23.5%), *Campylobacter* spp. (21.9%), *Neospora caninum* (21.1%), bovine viral diarrhoea virus (BVDV) (7.3%), *Escherichia coli* (7.3%), bovine herpesvirus (BHV) (4.8%), *Trueperella pyogenes* (formerly *Arcanobacterium pyogenes*) (4.0%) and others (9.7%) were diagnosed (Campero *et al.*, 2003b). Results from a study in the UK were a little different. The most common causes of bovine abortion here were *Bacillus licheniformis* (15.8%), *N. caninum* (15.5%), *T. pyogenes* (13.1%), *Salmonella dublin* (9.8%), *Campylobacter*

spp. (4.6%) and BVDV (3.3%), with others not specified accounting for 37.8% (VIDA, 2011). After observing the list of different pathogens, some differences can be established. For instance, *B. abortus* is still an important pathogen in Argentina; however, it is eradicated from the UK. On the other hand, *N. caninum* is one of the leading causes of infectious abortion in both countries and around the world.

Bovine neosporosis is a recently diagnosed disease which is nowadays recognised as a major cause of abortion and neonatal loss in cattle worldwide, resulting in significant economic losses to the dairy and beef industries (Thilsted and Dubey, 1989; Barr *et al.*, 1991a; Dubey and Lindsay, 1996; Trees *et al.*, 1999; Dubey, 2003a; Goodswen *et al.*, 2013). The causative agent, *N. caninum* is an intracellular, heterogeneous cyst-forming, coccidian protozoal parasite (Ellis *et al.* 1994; Holmdahl *et al.* 1994) which was first isolated from Norwegian dogs prior to 1960 and, at the time, was thought to be *Toxoplasma gondii*. These dogs were ataxic and paretic and after *post mortem* examination encephalomyelitis and myositis were observed (Bjerkås *et al.*, 1984). Later, some ultrastructural differences between the identified parasite and *T. gondii* were described (Bjerkås and Presthus, 1988) allowing classification of this new protozoal parasite as *N. caninum* (Dubey *et al.*, 1988a; Bjerkås and Dubey, 1991; Dubey *et al.*, 2002).

N. caninum is currently placed into the family *Sarcocystidae* and is established as a sister group to *Toxoplasma* and *Sarcocystis* in the phylum Apicomplexa (Apicomplexa : Eimeriina : Sarcocystidae) (Dubey, 1992; Ellis *et al.*, 1994). *Neospora* and *Toxoplasma* are very closely related sharing several biological characteristics (Marsh *et al.*, 1995). Due to their relatively recent evolutionary divergence, several proteins are well conserved in these two Apicomplexan species. At the same time, some unique antigens (i.e. surface antigens, secretory proteins) have been identified in these parasites probably allowing them to occupy their respective evolutionary niche (host). These unique antigenic determinants can be utilised in the differentiation of both species using differential diagnostic tools. These have been proven useful in the application as of experimental immunogens [reviewed by Howe and Sibley (1999) and Innes *et al.* (2011)].

Apicomplexan parasites share an apical organelle complex consisting of a polar ring, micronemes, rhoptries and a conoid (Levine, 1970; Goodswen *et al.*, 2013), which in conjunction with surface antigens, are involved in host-cell adhesion and active invasion (Hu *et al.*, 2006). After initial attachment and reorientation, the conoid is extruded and final attachment is mediated by adhesin proteins secreted from micronemes leading to the entire introduction of the parasite into the parasitophorous vacuole which will initially encase the parasite within the host cell [reviewed by Buxton *et al.* (2002b)]. These key mechanisms are essential for the survival of intracellular parasites such as *N. caninum* and *T. gondii* (Hemphill *et al.*, 1999, 2004).

Until recently, *N. caninum* was the only member of the genus *Neospora*. However, an apicomplexan parasite identified in the central nervous system of an adult equine is ultrastructurally very similar to *Neospora*, although there are distinct differences to the bovine and canine isolates, justifying its classification as a new species, named *N. hughesi* (Marsh *et al.*, 1998).

N. caninum has a facultative heteroxenous life cycle (involving more than one obligatory host), including a definitive canid host and a range of intermediate hosts, in which cattle are one of the most relevant (McAllister, 1999; Williams *et al.*, 2009). To date, domestic dogs (*Canis lupus familiaris*) (McAllister *et al.*, 1998a; Lindsay *et al.*, 1999), coyotes (*Canis latrans*) (Gondim *et al.*, 2004d), grey wolves (*Canis lupus*) (Dubey *et al.*, 2011) and dingoes (*Canis lupus dingo*) (King *et al.*, 2010) are the only identified definitive hosts; furthermore *Neospora*-like oocysts were also identified in a low number of faeces of juvenile and adult foxes (*Vulpes vulpes*) (Wapenaar *et al.*, 2013). However, the evidence provided in the latter species is not sufficient to confirm its role as definitive host involved in the introduction of new infections in a herd.

A wide range of warm-blooded animals can act as intermediate hosts for *N. caninum* and so far it has been identified in other livestock species: horses (*Equus ferus caballus*) (Dubey and Porterfield, 1990), goats (*Capra aegagrus hircus*) (Barr *et al.*, 1992), deer [*Cervus eldi siamensis* (Dubey *et al.*, 1996b), *Dama dama* (Soldati *et al.*,

2004), *Odocoileus hemionus columbianus* (Woods *et al.*, 1994; Dubey *et al.*, 1996b) and *Odocoileus virginianus* (Dubey *et al.*, 2013)], water buffaloes (*Bubalus bubalis*) (Guarino *et al.*, 2000), llama (*Lama glama*), alpacas (*Vicugna pacos*) (Serrano-Martínez *et al.*, 2004) and sheep (*Ovis aries*) (Dubey *et al.*, 1990b; Hässig *et al.*, 2003; Asadpour *et al.*, 2013).

N. caninum infection in wildlife has also been reported and epidemiologic evidence supports a sylvatic transmission cycle between wild species and domestic livestock (Barling *et al.*, 2000; Rosypal and Lindsay, 2005; Gondim, 2006; King *et al.*, 2011; Bartley *et al.*, 2013b; Stuart *et al.*, 2013; Dubey *et al.*, 2013). Clinical cases of neosporosis have been diagnosed in different deer species (Woods *et al.*, 1994; Dubey *et al.*, 1996b; Soldati *et al.*, 2004; Vianna *et al.*, 2005; Bartley *et al.*, 2013b) and there is serological evidence of *N. caninum* in wild carnivores (foxes and wolves), indicating exposure to the parasite, although it remains to be determined if these animals can be a definitive host (Simpson *et al.*, 1997; Buxton *et al.*, 1997a; Lindsay *et al.*, 2001; Wolfe *et al.*, 2001; Vitaliano *et al.*, 2004; Cañón-Franco *et al.*, 2004; Hamilton *et al.*, 2005; Bartley *et al.*, 2013b; Stuart *et al.*, 2013). *N. caninum* infection has also been confirmed in rodents (Huang *et al.*, 2004; Jenkins *et al.*, 2007; Truppel *et al.*, 2010; Meerburg *et al.*, 2012; Medina-Esparza *et al.*, 2013), having considerable epidemiological importance, because some of these species can reside in urban and/or rural areas and their infected tissues can potentially be consumed by wild and domestic animals, and therefore be involved in sylvatic transmission (Gondim, 2006). Although antibodies to *N. caninum* have been reported in humans, the parasite has not been demonstrated in clinical cases, therefore it has not been confirmed as a zoonotic pathogen (Tranas *et al.*, 1999; Graham *et al.*, 1999; Petersen *et al.*, 1999; Lobato *et al.*, 2006; McCann *et al.*, 2008).

The first report of bovine neosporosis described the presence of organisms in brain tissue of aborted foetuses from a dairy herd in 1987 in USA (Thilsted and Dubey, 1989; Lindsay and Dubey, 1989b). Since then, *N. caninum* was identified as a leading cause of abortion worldwide and it has been reported in Europe (Wouda *et al.*, 1992; Agerholm and Barr, 1994; McNamee and Jeffrey, 1994; Otter *et al.*, 1995; Holmdahl *et al.*, 1995; Ferrari *et al.*, 1995; Buxton *et al.*, 1997b; Fondevila *et al.*,

1998; Gottstein *et al.*, 1998; Thompson *et al.*, 2001; Pitel *et al.*, 2001; Edelhofer *et al.*, 2003; Armengol *et al.*, 2006), Africa (Wells, 1996; Ghalmi *et al.*, 2011; Ibrahim *et al.*, 2011; Njiro *et al.*, 2011; Adu-Addai *et al.*, 2012), Asia (Ogino *et al.*, 1992; Harmelin *et al.*, 1995; Kim *et al.*, 2000; Cheah *et al.*, 2004; Sadrebazzaz *et al.*, 2007; Zhang *et al.*, 2007; Konnai *et al.*, 2008; Kul *et al.*, 2009), Latin America (Campero *et al.*, 1998; Pérez *et al.*, 1998; Morales *et al.*, 1998; Corbellini *et al.*, 2002) and North America (Thilsted and Dubey, 1989; Barr *et al.*, 1990; Anderson *et al.*, 1991b; Bildfell *et al.*, 1994; Bryan *et al.*, 1994; McIntosh and Haines, 1994) and Oceania (Thornton *et al.*, 1991; Boulton *et al.*, 1995; Obendorf *et al.*, 1995).

Different stages and life cycle

Neospora undergoes a life cycle involving three principal infectious stages: oocysts, tachyzoites and bradyzoites (Dubey *et al.*, 2002) (see Figure 1). Morphological features of these infectious stages have been reviewed by Speer *et al.* (1999). Oocysts are generated through sexual reproduction in the intestinal epithelial cells of definitive hosts (McAllister *et al.*, 1998a; Lindsay *et al.*, 1999; Williams *et al.*, 2009) and are excreted in their faeces after they ingest bradyzoites or tissue cysts (McAllister *et al.*, 1998a; Lindsay *et al.*, 1999; Gondim *et al.*, 2004d). Oocysts are shed unsporulated but they can sporulate outside the host in 24 hours (Lindsay *et al.*, 1999). They then contain two sporocysts, each of which contains four sporozoites (McAllister *et al.*, 1998a; Williams *et al.*, 2009). The prepatent period (period of time between the ingestion of tissue cysts of experimentally or naturally infected animals, and the excretion of oocysts) in the definitive host may vary from 5 to 17 days (McAllister *et al.*, 1998a; Lindsay *et al.*, 1999; Gondim *et al.*, 2004d; Dubey *et al.*, 2007; King *et al.*, 2010) and the total duration of oocyst shedding after primary infection may vary from 1 to 30 days (Dubey *et al.*, 2007; King *et al.*, 2010).

The maximum number of oocysts an infected dog may excrete has been estimated to be around 500,000 after feeding on tissues from an infected intermediate host. This number of oocysts is potentially capable of infecting hundreds or thousands of cattle (Gondim *et al.*, 2002; Gondim *et al.*, 2005; Schares *et al.*, 2005). Nevertheless, only

young animals are able to excrete higher number of oocysts (Gondim *et al.*, 2005) and adult canids tend to be low level shedders (McAllister *et al.*, 1998a; Lindsay *et al.*, 1999; Dijkstra *et al.*, 2001b; Schares *et al.*, 2005; King *et al.*, 2010).

N. caninum only forms asexual stages (tachyzoites and encysted bradyzoites) in all its intermediate hosts, including cattle (Dijkstra *et al.*, 2001a; Williams *et al.*, 2009). Acute and chronic *N. caninum* infections in cattle are represented by tachyzoite and bradyzoite stages respectively, and the clinical consequences of these two stages differ significantly (Aguado-Martínez *et al.*, 2009). Tachyzoites are the rapidly replicating stage, disseminating throughout host tissues and triggering lesion development by multiplying in and rupturing cells. In the absence of an appropriate host immune response, tachyzoites continue to multiply, causing progressively more cell death until the host dies (Buxton *et al.*, 2002b). In infected animals, tachyzoites are mainly found in neurons and macrophages, but also in fibroblasts, vascular endothelial cells, hepatocytes and other cells (Dubey and Lindsay, 1996). In pregnant cattle, tachyzoites can also be identified in the placenta (Shivaprasad *et al.*, 1989). However, with the onset of the host immune response and the presence of other physiological factors, tachyzoites differentiate into bradyzoites and a persistent tissue cyst infection is established, generally in neural tissue, where most of the cysts are found, with a similar mechanism as described for *T. gondii* infections (Lyons *et al.*, 2002).

Bradyzoites are the slowly dividing stage of *N. caninum* and they allow the parasite to persist in the tissues of the intermediate host. Bradyzoites form tissue cysts around themselves to protect them from the host's immune system. They remain latent commonly in the brain, spinal cord and retina or extraneural tissues (skeletal muscles, heart and liver) until the immune system of the host is suppressed, allowing them to recrudesce (Barr *et al.*, 1991b; Lindsay *et al.*, 1993; Wouda *et al.*, 1997; McAllister *et al.*, 1998a; Sawada *et al.*, 2000; Innes *et al.*, 2002; Buxton *et al.*, 2002b; Dubey *et al.*, 2004; Williams *et al.*, 2009). Tissue cysts can persist within an infected host for several years without causing any significant clinical manifestations, thus acting as a reservoir for infection either for the foetus during

pregnancy or for another intermediate host via the consumption of infected tissue (Dubey and Lindsay, 1996).

Transmission from the definitive to the intermediate host has been confirmed experimentally. *N. caninum* oocysts shed by dogs fed infected mouse tissues have been shown to be infectious for cattle after oral ingestion (de Marez *et al.*, 1999; Trees *et al.*, 2002; Gondim *et al.*, 2004b; McCann *et al.*, 2007). Infected bovine placenta or other tissues containing infective stages of *N. caninum* also constitute a source of infection for dogs, which in turn may spread the parasite, with subsequent oocysts being shed into the environment (Fioretti *et al.*, 2000; Dijkstra *et al.*, 2001b; Dubey *et al.*, 2007).

When oocysts are ingested by the intermediate host, they excyst in the intestinal tract and liberate infective sporozoites which penetrate cells to become tachyzoites (Dubey and Lindsay, 1996). They then cross the epithelium, reach blood and lymphatic vessels, and infect other nucleated cells, including macrophages and lymphocytes. In the initial phases of the infection, parasites disseminate throughout the body, and transform to the rapidly proliferating tachyzoite stage. Subsequently, the stress caused by the host immune response is believed to be one of the factors that trigger stage conversion to the slowly proliferating bradyzoites (Buxton *et al.*, 2002b). Intermediate hosts may also become infected following consumption of tachyzoites and bradyzoites (Lindsay and Dubey, 1990b; Hemphill *et al.*, 2006; Dubey *et al.*, 2006).

Neospora transmission can be vertical or horizontal. Vertical transmission has been experimentally and naturally reported in canids (Bjerkås *et al.*, 1984; Dubey and Lindsay, 1989; Dubey *et al.*, 1990c; Cole *et al.*, 1995) and in ruminants (Dubey and Lindsay, 1990; Dubey *et al.*, 1992b; Barr *et al.*, 1994b; McAllister *et al.*, 1996b; Buxton *et al.*, 1997c; Chryssafidis *et al.*, 2011; Altbuch *et al.*, 2012; Konrad *et al.*, 2012; Dubey *et al.*, 2013; Mesquita *et al.*, 2013) after inoculation with tachyzoites and oocysts (Trees and Williams, 2005; Dubey *et al.*, 2007) and it can occur repeatedly in cattle (Barr *et al.*, 1993; Fioretti *et al.*, 2003; Landmann *et al.*, 2011). In fact, one remarkable characteristic of *N. caninum* infection in cattle is the high

efficiency of vertical transmission of the parasite from a persistently-infected dam to her offspring (up to 95%) during pregnancy, which can contribute significantly to the persistence of the infection in a herd by propagating the infection to successive generations (Björkman *et al.*, 1996; Anderson *et al.*, 1997; Schares *et al.*, 1998; Davison *et al.*, 1999b; Bergeron *et al.*, 2000; Dijkstra *et al.*, 2008; Moré *et al.*, 2009; Barbosa de Macedo *et al.*, 2013).

Later, the terms “exogenous” and “endogenous” transplacental transmission were introduced in order to differentiate two clearly different transmission scenarios and to describe more precisely the origin of transplacental infection. If naïve cattle are infected during pregnancy by ingesting oocysts, the sporozoites differentiate to tachyzoites which spread, probably via the circulation in cells of the mononuclear phagocytic system, as “exogenous transplacental transmission” to the uterus and finally across the placenta to the foetus. “Endogenous transplacental transmission” occurs as the result of reactivation of an existing persistent infection of a cow during pregnancy. In this case, bradyzoites differentiate into tachyzoites which spread across the placenta and into the foetus (Trees and Williams, 2005). The mechanisms of the reactivation of this chronic infection are not fully explained. Some experiments have shown that if this trigger occurs in early pregnancy the foetus can die, while if it occurs in late gestation it is possible that asymptomatic calves are born alive but congenitally infected (Williams *et al.*, 2000). Reactivation could possibly be triggered by the “down regulation” of cell-mediated immunity that occurs around mid-gestation in ruminants (Innes *et al.*, 2001; Innes *et al.*, 2002; Innes *et al.*, 2005).

Whether the foetus is infected by endogenous or exogenous transplacental transmission the potential outcomes are the same: the foetus may die or it may survive but be born persistently infected (Paré *et al.*, 1996; Anderson *et al.*, 1997; Moen *et al.*, 1998; Guy *et al.*, 2001; Williams *et al.*, 2009). The majority of *Neospora* congenitally infected calves will be born clinically normal but some may be underweight or have signs of neurological disease (O'Toole and Jeffrey, 1987; Parish *et al.*, 1987; Dubey *et al.*, 1990a; Dubey *et al.*, 1992a; Barr *et al.*, 1993; Dubey and de Lahunta, 1993; Illanes *et al.*, 1994; Bryan *et al.*, 1994; Graham *et al.*, 1996; De Meerschman *et al.*, 2005). If they survive they will remain infected for life

with female progeny transmitting the parasite to their offspring during gestation in several consecutive pregnancies (Anderson *et al.*, 1995; Dubey and Lindsay, 1996; Wouda *et al.*, 1998; Fioretti *et al.*, 2003) or intermittently (Boulton *et al.*, 1995; Wouda *et al.*, 1998; Guy *et al.*, 2001; Innes *et al.*, 2001).

Although vertical transmission contributes significantly to the persistence and perpetuation of *Neospora* infection in cattle herds, horizontal post-natal infections in cattle have been documented, although at low levels. This mode of transmission is necessary to introduce new infections into the herd (McAllister *et al.*, 1996a; Hietala and Thurmond, 1999; Davison *et al.*, 1999b; Bergeron *et al.*, 2000; Dijkstra *et al.*, 2001a). Postnatal transmission rates have been estimated at between 1 to 8.5 infections per 100 cow-years at risk (Davison *et al.*, 1999b; Bartels *et al.*, 2007a). However, other serological studies indicate higher rates of horizontal transmission (Björkman *et al.*, 2003; Romero and Frankena, 2003; Hall *et al.*, 2005; Moré *et al.*, 2009). Even low levels of horizontal transmission may be important in the maintenance of the infection within herds, because transmission by endogenous transplacental infection is below 100% and thus would lead to a continuous decrease in infection prevalence in infected herds (French *et al.*, 1999).

Horizontal transmission has been corroborated after ingestion of tissues infected with tachyzoites or tissue cysts or by ingestion of food or drinking water contaminated by sporulated oocysts (McAllister *et al.*, 1998a; McAllister *et al.*, 2000; Dubey *et al.*, 2007). Theoretically, *N. caninum* may be excreted in milk or uterine discharges of infected cattle and therefore, galactogenic transmission of *N. caninum* tachyzoites, or ingestion of foetal membranes or uterine fluids containing tachyzoites, may contribute to such infection. However, these routes are believed to be of little importance (Uggla *et al.*, 1998; Davison *et al.*, 2001; Moskwa *et al.*, 2003; Moskwa *et al.*, 2007). If colostrum and/or milk from naturally infected cows were infective, they would also be an important source of horizontal transmission within herds due to the common practice of feeding pooled colostrum and milk to neonatal calves (Antony and Williamson, 2001; Corbellini *et al.*, 2006b).

Neospora infected placentas can also be a source of infection for definitive hosts since successful transmission of *N. caninum* to dogs by feeding them naturally infected bovine placenta (placentophagia) was confirmed (Dijkstra *et al.*, 2001b; Dijkstra *et al.*, 2008). Therefore, placentophagia might represent another route of horizontal transmission of neosporosis among cattle and could explain the high prevalence of *N. caninum* in herds which are kept out of direct contact with potentially infected dogs (Modrý *et al.*, 2001).

Venereal transmission of *N. caninum* through contaminated semen has not been proven (Serrano-Martínez *et al.*, 2007b; Osoro *et al.*, 2009), although it has been possible to detect very low copy numbers of parasite DNA in semen samples from the seropositive bulls (Ortega-Mora *et al.*, 2003; Caetano-da-Silva *et al.*, 2004; Ferre *et al.*, 2005; Serrano-Martínez *et al.*, 2007a; Jozani *et al.*, 2012).

After either horizontal or vertical transmission, *N. caninum* infection usually occurs as a symptomless persistent infection but, in some cases, a common outcome of infection is foetal death and abortion from 3 months of gestation to term (Barr *et al.*, 1990; Yaeger *et al.*, 1994; Anderson *et al.*, 1995; Thurmond and Hietala, 1997a; Moen *et al.*, 1998; González *et al.*, 1999; Guy *et al.*, 2001; Buxton *et al.*, 2002b; López-Gatius *et al.*, 2004a; Corbellini *et al.*, 2006a; Goodswen *et al.*, 2013).

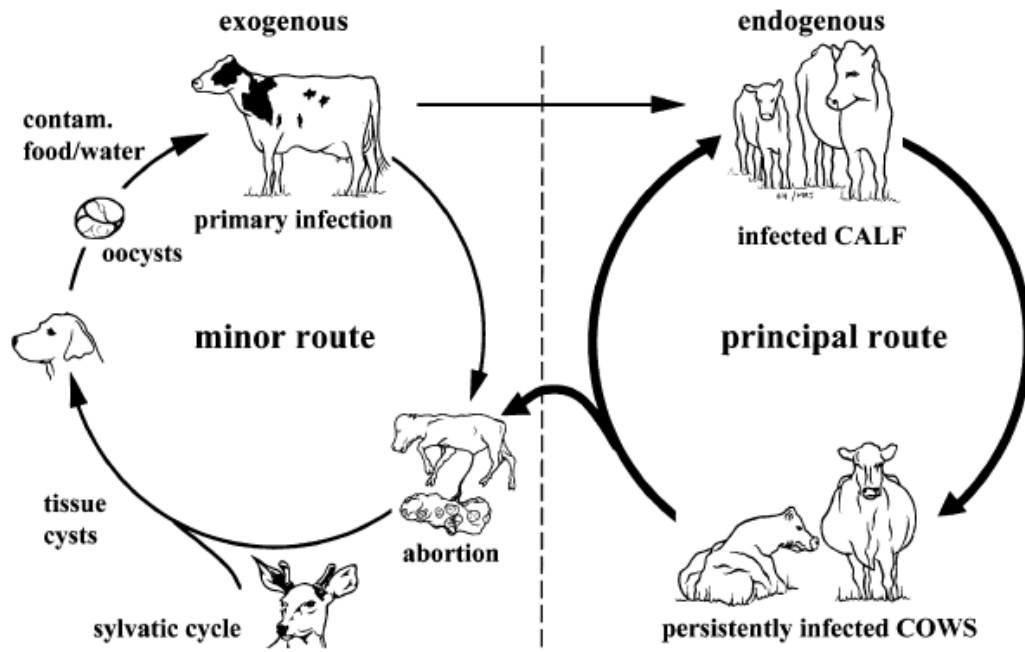


Figure 1: Transmission of bovine neosporosis. Image taken from Journal of Comparative Pathology (Dubey *et al.*, 2006) and reproduced with the permission of D. Buxton and S. Hamilton.

Natural cases of *Neospora* abortion

N. caninum-associated abortions can occur as sporadic, endemic or epidemic abortions (Davison *et al.*, 1999a; Dubey, 2003a; Goodswen *et al.*, 2013). There are reports that in the years after a *Neospora* epidemic abortion outbreak, the affected herd may experience endemic abortions (Moen *et al.*, 1998; Pfeiffer *et al.*, 2002; Björkman *et al.*, 2003). In contrast, some herds that have experienced a prolonged history of sporadic *Neospora* abortions, epidemic abortion outbreaks could be observed occasionally (Anderson *et al.*, 2000). Abortion storms can occur either in herds with recently infected cows (horizontal transmission) (Thilsted and Dubey, 1989; Waldner *et al.*, 1999) or in herds with moderate or high seroprevalence due to previous *N. caninum* infection (Thornton *et al.*, 1991; McAllister *et al.*, 1996a; Moen *et al.*, 1998; Wouda *et al.*, 1999a; Dijkstra *et al.*, 2002a). Point-source epidemics often producing abortion storms are caused by sufficient exposure of a large number of susceptible animals to a causative agent during a brief period, usually through ingestion of oocyst-contaminated feed or water (Yaeger *et al.*, 1994; McAllister *et*

al., 1996a; Wouda *et al.*, 1997; Thurmond *et al.*, 1997; Moen *et al.*, 1998; McAllister *et al.*, 2000; Dijkstra *et al.*, 2001a; Schares *et al.*, 2002; Dijkstra *et al.*, 2002b; Crawshaw and Brocklehurst, 2003; Bartels *et al.*, 2007a; Basso *et al.*, 2010).

In contrast, an abortion problem is regarded as endemic if it persists in the herd for several months or years and when more than 3% of at-risk cattle abort in one year (Davison *et al.*, 1999a; Trees and Williams, 2005). It is considered sporadic when a single abortion or a number of abortions occur at irregular intervals (Thurmond *et al.*, 1997; Moen *et al.*, 1998; Davison *et al.*, 1999a). There is evidence that the major route of transmission in herds experiencing endemic abortions is vertical, usually associated with chronic *Neospora* infections (Thurmond *et al.*, 1997; Davison *et al.*, 1999b; Pereira-Bueno *et al.*, 2000; Dijkstra *et al.*, 2001a; Schares *et al.*, 2002).

Bovine neosporosis pathogenesis

The pathogenesis of bovine neosporosis is complex and only partially understood, and the reasons why some animals abort and others do not remain unclear [reviewed by Buxton *et al.* (2002b), Dubey *et al.* (2006) and Goodswen *et al.* (2013)]. Macroscopic changes are not pathognomonic and are usually similar to those observed in other causes of abortion (Illanes *et al.*, 1994; Barr *et al.*, 1994b; De Meerschman *et al.*, 2005; Pescador *et al.*, 2007). Hydrocephalus, scoliosis, hypoplasia of the cerebellum and medulla, narrowing of the spinal cord and foetal mummification have all been associated with neosporosis (Parish *et al.*, 1987; O'Toole and Jeffrey, 1987; Dubey *et al.*, 1990a; Barr *et al.*, 1991b; Barr *et al.*, 1993; Dubey and de Lahunta, 1993; Bryan *et al.*, 1994; Dubey *et al.*, 1998a; Guy *et al.*, 2001; Campero *et al.*, 2003b; Ghanem *et al.*, 2009).

Published studies indicate that *N. caninum* is a primary abortifacient in cattle as it is capable of producing necrotic lesions after a few days in infected fetuses, and causes cell death by the active multiplication of tachyzoites, especially in neural cells (Barr *et al.*, 1990; Anderson *et al.*, 1991b; Dubey, 2003a; Dubey *et al.*, 2006). The most common findings in aborted fetuses are non-suppurative encephalitis and

myocarditis, and they are considered sufficient to cause foetal death (Ogino *et al.*, 1992; Conrad *et al.*, 1993a; Peters *et al.*, 2001; Buxton *et al.*, 2002b; Macaldowie *et al.*, 2004; Collantes-Fernández *et al.*, 2006a). The most significant changes are lymphocytic encephalomyelitis with multifocal microgliosis; lymphocytic cuffing; meningitis; and necrosis in the brain and spinal cord. Occasionally, there is also calcification of the necrotic foci in the central nervous system (CNS) (Boulton *et al.*, 1995; González *et al.*, 1999). While any part of the CNS may be affected, lesions tend to occur more frequently in the cerebral grey matter than in the medulla and cerebellum (Ogino *et al.*, 1992; Helman *et al.*, 1998; Nishimura *et al.*, 2013). In addition, lymphocytic myocarditis and myositis may be found, as well as lymphocytic periportal hepatitis, with or without foci of hepatocellular necrosis. Cysts are usually confined to the CNS, with clusters of tachyzoites in muscular tissue, liver and the CNS (Barr *et al.*, 1990; Anderson *et al.*, 1990; Anderson *et al.*, 1991a; Barr *et al.*, 1991b; Dubey and Lindsay, 1993; Lindsay *et al.*, 1993; De Meerschman *et al.*, 2002). The number of *N. caninum* tachyzoites may be too few to be seen in some histologic sections although the use of immunohistochemical techniques allows easier detection of parasitic structures (tachyzoites, or tissue cysts containing bradyzoites) (Thilsted and Dubey, 1989; Anderson *et al.*, 1990; Dubey *et al.*, 1990d; Barr *et al.*, 1991b; Dubey and de Lahunta, 1993; Wouda *et al.*, 1997; Morales *et al.*, 2001).

In pregnant animals *N. caninum* tachyzoites reach the placenta via the bloodstream and invade the caruncular septa in the placentome before infecting the trophoblast cells in the chorionic villi and then spreading to the foetus (Barr *et al.*, 1994b; Otter *et al.*, 1995; Maley *et al.*, 2003; Bartley *et al.*, 2004; Dubey *et al.*, 2006). Placentitis is one of the most common pathological findings in aborted livestock, and it has been suggested that abortion could also occur as a direct result of parasite-induced placental damage, as it was previously described in ovine toxoplasmosis (Buxton *et al.*, 1982) and in bovine neosporosis (Barr *et al.*, 1991b; Barr *et al.*, 1994b; Buxton *et al.*, 2002b; Maley *et al.*, 2003; Macaldowie *et al.*, 2004; Benavides *et al.*, 2012). Multifocal necrosis of either maternal (caruncles) or foetal (cotyledons) tissues in the placentome has been reported, accompanied by non suppurative (eosinophils, lymphocytes, monocytes and macrophages) inflammation (and sometimes

mineralisation) of the chorioallantois (Shivaprasad *et al.*, 1989; Thilsted and Dubey, 1989; Thornton *et al.*, 1991; Barr *et al.*, 1991a; Dubey *et al.*, 1992b; Schock *et al.*, 2000; Macaldowie *et al.*, 2004; Maley *et al.*, 2006; Gibney *et al.*, 2008; Rosbottom *et al.*, 2011; Benavides *et al.*, 2012; Caspe *et al.*, 2012). The severity of placental lesions is a crucial factor in the occurrence of *N. caninum*-associated abortion since its ability to sustain the foetus is likely to be impaired (Maley *et al.*, 2003; Dubey *et al.*, 2006; López-Gatius *et al.*, 2007b; Gibney *et al.*, 2008; Almería *et al.*, 2010). Therefore, foetal damage may occur due to insufficient oxygen/nutrition supply following placental insufficiency. Alternatively, placental injury during late gestation may trigger foetal adrenocorticotrophic hormone release and subsequent premature foetal adrenal stimulation (Dubey *et al.*, 2006).

Finally, it has been proposed that the maternal immune response recruited to control *Neospora*-mediated cell damage in the placenta may be detrimental to foetal survival, since the effect of an exacerbated pro-inflammatory response could be incompatible with successful pregnancy (Khan *et al.*, 1997; Lundén *et al.*, 1998; Marks *et al.*, 1998; Innes *et al.*, 2002; Quinn *et al.*, 2002a; Innes *et al.*, 2005; Innes, 2007).

Pregnancy in mammals presents an interesting situation for the immune system because the mother carries what is essentially a foreign graft (the foetus) without allorejection taking place. Pregnancy-associated hormones modify the cytokine production pattern towards a Th2 phenotype, favouring a micro-environment dominated by “beneficial” cytokines, allowing the dam to accept the foetus (Wegmann *et al.*, 1993; Lin *et al.*, 1993; Robertson *et al.*, 1994; Athanassakis and Iconomidou, 1995; Piccinni *et al.*, 1995; Szekeres-Bartho *et al.*, 1996; Raghupathy, 1997; Kruse *et al.*, 2000; Innes *et al.*, 2002; Entrican, 2002; Sammin *et al.*, 2009). The regulatory Th2-type cytokines characteristic of this process include colony stimulating factor-1 (CSF-1) (Arceci *et al.*, 1989), granulocyte-macrophage CSF (Gallo *et al.*, 1991), transforming growth factor beta (Nagaeva *et al.*, 2002), and interleukin-3 (IL-3), IL-4, IL-5, and IL-10 (Wegmann *et al.*, 1993; Lin *et al.*, 1993; Robertson *et al.*, 1994; Athanassakis and Iconomidou, 1995; Piccinni *et al.*, 1995; Chaouat *et al.*, 1996; Szekeres-Bartho *et al.*, 1996; Krishnan *et al.*, 1996a; Kalinski *et*

al., 1997; Bennet *et al.*, 1998; Kruse *et al.*, 2000; Entrican, 2002). Significantly, this shift to a Th2 response may favour the reactivation of the protozoan and the recrudescence of infection often observed at mid gestation in chronically infected dams (Khan *et al.*, 1997; Eperon *et al.*, 1999; Long and Baszler, 2000; Innes *et al.*, 2001).

Intracellular pathogens, such as *N. caninum*, stimulate cell-mediated immune mechanisms where parasite-specific CD4⁺ T lymphocyte host responses are likely to have a significant protective role (Marks *et al.*, 1998; Innes *et al.*, 2000; Staska *et al.*, 2003; Bartley *et al.*, 2004; Maley *et al.*, 2006; Cantón *et al.*, 2013b). However, this immune response can also invoke cytokines that may be harmful to pregnancy (classified as proinflammatory or Th1) such as interferon- γ (IFN- γ), IL-2, IL-12 and tumor necrosis factor- α (TNF- α) (Chaouat *et al.*, 1990; King and Loke, 1990; Raghupathy, 1997; Clark *et al.*, 1998; Entrican, 2002; Buxton *et al.*, 2002a). These cytokines are likely to play a role in reducing the replication of *N. caninum*, hence reducing parasitaemia (Khan *et al.*, 1997; Lundén *et al.*, 1998; de Marez *et al.*, 1999; Baszler *et al.*, 1999; Williams *et al.*, 2000; Innes *et al.*, 2000; Andrianarivo *et al.*, 2001; Trees *et al.*, 2002; Innes *et al.*, 2002; Quinn *et al.*, 2002a; Almería *et al.*, 2003; Boysen *et al.*, 2006; López-Gatius *et al.*, 2007a; Rosbottom *et al.*, 2008; Bartley *et al.*, 2012). If the stimulus from *N. caninum* infection is sufficient, a shift from the beneficial Th2-type response to an excessive Th1-type response could be triggered during gestation, potentially endangering pregnancy (Innes *et al.*, 2002; Quinn *et al.*, 2002a; Innes *et al.*, 2005). In some instances, therefore, relatively small numbers of parasites causing relatively little local damage may cause a considerable effect by eliciting cytokines that jeopardise pregnancy. This mechanism will be fatal for the foetus, but it will allow the mother to survive and breed again (Innes *et al.*, 2005).

This immune-mediated cause of abortion has been previously suggested during infections with other pathogens in different species. Severe infections lead to increased risk of pregnancy loss, but this can be a programmed event that is useful because the mother can devote all her energies to fighting the infection, and then re-establish pregnancy after eliminating the pathogen (Brabin and Brabin, 1992; Krishnan *et al.*, 1996b). For instance, malaria infections due to *Leishmania major* in

pregnant humans stimulate a bias towards Th1 cytokines with production of IFN- γ , IL-2 and TNF- α , generating foetal death and resorption (Krishnan *et al.*, 1996a; Krishnan *et al.*, 1996b; Fried *et al.*, 1998; Moormann *et al.*, 1999).

Factors influencing *N. caninum* infection

A wide range of putative risk and protective factors for bovine neosporosis have been identified by various retrospective studies. Increasing our knowledge and understanding of these factors is important in the development and implementation of measures to control the disease (Dubey *et al.*, 2007). However, caution should be used when applying the results of a risk factor analysis obtained in a particular region or management system to another (Bartels *et al.*, 1999; Bartels *et al.*, 2006a; Dubey *et al.*, 2007).

One of the factors associated with the risk of *N. caninum* infection is the age of the cow. Most of the studies have demonstrated that the highest *N. caninum* seroprevalence is registered in older females (Paré *et al.*, 1996; Paré *et al.*, 1997; Thurmond and Hietala, 1997a; Thurmond and Hietala, 1997b; Jensen *et al.*, 1999; Wouda *et al.*, 1999a; Sanderson *et al.*, 2000; Dyer *et al.*, 2000; Dijkstra *et al.*, 2001a; Rinaldi *et al.*, 2005; Bartels *et al.*, 2006c; Armengol *et al.*, 2007; Woodbine *et al.*, 2008; Razmi *et al.*, 2010; Yániz *et al.*, 2010; Ghalmi *et al.*, 2012), probably influenced either by variations in the probability of horizontal transmission (increased chances of acquiring infection), regional differences regarding replacement rates or management practices (Hernández *et al.*, 2002; Bartels *et al.*, 2006a; Yániz *et al.*, 2010).

The presence and number of *N. caninum*-positive domestic and feral dogs on a farm (Paré *et al.*, 1998; Bartels *et al.*, 1999; Mainar-Jaime *et al.*, 1999; Wouda *et al.*, 1999b; Romero *et al.*, 2002; Dijkstra *et al.*, 2002a; Dijkstra *et al.*, 2002b; Schares *et al.*, 2004; Rinaldi *et al.*, 2005; Corbellini *et al.*, 2006b; Nasir *et al.*, 2010; Imre *et al.*, 2012; Ghalmi *et al.*, 2012; Asmare *et al.*, 2013), or the presence of wild canids in the area where farms are located (Boulton *et al.*, 1995; Barling *et al.*, 2000; Stoessel *et*

al., 2003; Gondim *et al.*, 2004d; Hobson *et al.*, 2005; Frössling *et al.*, 2008; Asmare *et al.*, 2013), have been associated with an increased risk of *Neospora* seropositivity and abortion. Oocyst-contaminated pastures, fodder and drinking water are regarded as potential sources for postnatal infection and similarly, farmers of herds with evidence of postnatal infection were more likely to have observed dogs feeding on bovine placenta, uterine discharge, and colostrum or milk than farmers of control herds (McAllister *et al.*, 2000; Dijkstra *et al.*, 2002a; Dubey *et al.*, 2007).

The presence of other intermediate hosts (other than cattle) could also influence the presence of *N. caninum* infection in a herd, since non bovine intermediate hosts can be a source of infection for definitive hosts. *Neospora* infection has been found in rodents, suggesting that these animals may be important sources of infection for carnivore hosts (Dubey *et al.*, 2007; Arunvipas *et al.*, 2012). Along similar lines, Hoar *et al.* (1996) described an increased number of mice on pastures the season immediately prior to an episode of *Neospora* abortions. Finally, Hobson *et al.* (2005) identified the presence of stray cats on premises as a putative protective factor, which could presumably reduced the number of other intermediate hosts.

Several farm characteristics or management practices have been suggested as risk factors for bovine neosporosis. For instance, larger farms with higher livestock density have been associated with elevated *N. caninum* seroprevalences (Hattel *et al.*, 1998; Quintanilla-Gozaño *et al.*, 1999; Bergeron *et al.*, 2000; Otranto *et al.*, 2003; Schares *et al.*, 2004; Corbellini *et al.*, 2006b; Almería *et al.*, 2009; Arunvipas *et al.*, 2012). Different explanations have been proposed. For instance, farms with larger herd sizes could have an increased chance of acquiring *N. caninum* infection via the purchase of larger number of external replacement heifers (Mainar-Jaime *et al.*, 1999; Bartels *et al.*, 1999; Schares *et al.*, 2004; Corbellini *et al.*, 2006b; Ghalmi *et al.*, 2011; Asmare *et al.*, 2013).

Farm hygiene status seems to play a role as a risk factor for *Neospora* infection (Yaeger *et al.*, 1994; Bartels *et al.*, 1999; Barling *et al.*, 2001; Dubey *et al.*, 2007; Ghalmi *et al.*, 2012). For example, measures to prevent dogs from feeding on infected placentas or foetuses have been associated with lower seroprevalences

(Schares *et al.*, 2004; Corbellini *et al.*, 2006b; Ghalmi *et al.*, 2011). Use of supplemental feeding may increase the risk of horizontal transmission through faecal contamination of feed and water sources by a definitive host in regions with an abundance of wild canids (Ould-Amrouche *et al.*, 1999; Barling *et al.*, 2000; Sanderson *et al.*, 2000; Barling *et al.*, 2001; Dijkstra *et al.*, 2002b; Frössling *et al.*, 2005; Klevar *et al.*, 2010).

N. caninum DNA has been found in bovine milk (Moskwa *et al.*, 2003; Moskwa *et al.*, 2007) so that neonatal calves may become infected by the ingestion of milk or pooled colostrum containing tachyzoites (Uggla *et al.*, 1998; Davison *et al.*, 2001). In fact, some studies suggest that feeding of pooled colostrum is a putative risk factor for seropositivity (Corbellini *et al.*, 2006b).

N. caninum affects both dairy (Dubey and Lindsay, 1996) and beef cattle (Barr *et al.*, 1994b; Hoar *et al.*, 1996; Waldner *et al.*, 1998; Waldner *et al.*, 1999; McAllister *et al.*, 2000; Campero *et al.*, 2003b). However, significantly higher *Neospora* seroprevalences and abortion rates have been described in dairy herds worldwide (Boulton *et al.*, 1995; Quintanilla-Gozalo *et al.*, 1999; Venturini *et al.*, 1999; Koiwai *et al.*, 2005; Moore *et al.*, 2009). These differences could mainly be attributable to management differences, since beef cattle are commonly managed more extensively on grasslands (Forar *et al.*, 1996; Sanderson *et al.*, 2000; Otranto *et al.*, 2003).

Differences in susceptibility to *N. caninum* infection have been observed among livestock breeds in some surveys. *Bos taurus* animals have a higher chance of becoming infected than *B. indicus* or crossbreeds (*B. taurus* x *B. indicus*) (Guimarães *et al.*, 2004; Escalona *et al.*, 2010). Similarly, Bartels *et al.* (2006a) showed that some cattle breeds were more likely to be *N. caninum* seropositive, while other studies revealed different *N. caninum* seroprevalences in pure and cross-breed cattle (Romero-Salas *et al.*, 2010; Santolaria *et al.*, 2011; Asmare *et al.*, 2013). Other reports also describe differences in the likelihood of abortion in cows chronically infected with *N. caninum*, depending on the breed of bull used for semen (López-Gatius *et al.*, 2005a; López-Gatius *et al.*, 2005b; Almería *et al.*, 2009; Yániz *et al.*, 2010). Therefore, the use of semen of particular breeds which have a lower

association with seroprevalence and abortion due to *N. caninum* has been recommended for artificial insemination (AI) on *N. caninum* seropositive cows (Almería *et al.*, 2009).

Several case control and cross-sectional studies have observed a high *N. caninum* seroprevalence in herds or individuals associated with an increased risk of early pregnancy losses. This is probably explained by the increased abortion risk in chronically infected as well as in recently infected individual dams (Anderson *et al.*, 1995; Paré *et al.*, 1997; Thurmond and Hietala, 1997a; Schares *et al.*, 1998; Moen *et al.*, 1998; Bartels *et al.*, 1999; Jensen *et al.*, 1999; Mainar-Jaime *et al.*, 1999; Wouda *et al.*, 1999a; Davison *et al.*, 1999c; Sager *et al.*, 2001; Hernández *et al.*, 2002; Hässig and Gottstein, 2002; Schares *et al.*, 2004; García-Vázquez *et al.*, 2005; Hobson *et al.*, 2005; Moore *et al.*, 2009). Furthermore, cohort studies into the risk of abortion in cows congenitally infected with *Neospora* have demonstrated that dams that had previously aborted had higher abortion risk than those that had not previously aborted, indicating that *N. caninum*-infected cows that aborted could not develop adequate protective immunity (Thurmond and Hietala, 1997a; Corbellini *et al.*, 2006a).

Although *Neospora*-induced abortions may occur throughout the year in cattle (Anderson *et al.*, 1991b; Thurmond *et al.*, 1995; Hemphill and Gottstein, 2000; Schares *et al.*, 2003; Rinaldi *et al.*, 2005; Bartels *et al.*, 2006a; O'Doherty *et al.*, 2013), some reports have recorded more abortions during a particular season, probably associated with differences in livestock management during different seasons in different locations (Anderson *et al.*, 1991b; Thurmond *et al.*, 1995; Wouda *et al.*, 1999a; Bergeron *et al.*, 2000; Barling *et al.*, 2000; Sanderson *et al.*, 2000; Barling *et al.*, 2001; Dijkstra *et al.*, 2002b; Nematollahi *et al.*, 2011). These observations could also be due to climatic conditions that are probably favourable for the sporulation and survival of *N. caninum* oocysts (Lindsay *et al.*, 1982; Bartels *et al.*, 1999; Schares *et al.*, 2004; Rinaldi *et al.*, 2005; López-Gatius *et al.*, 2005a; Ibrahim *et al.*, 2011), or high levels of rainfall that could increase the probability of contamination of water sources by oocysts (Romero *et al.*, 2002) and could also pose stress to cattle which could trigger *N. caninum*-associated abortion in latently

infected cattle (López-Gatius *et al.*, 2005a; Yániz *et al.*, 2010). Furthermore, this seasonality could be related to the presence of whelping season in wild canids in the area (Andreotti *et al.*, 2004; Dubey *et al.*, 2007).

Geographical clustering of *Neospora* infection was previously reported by different authors, probably also associated with climatic factors, and/or the resident domestic and wild canine population (Quintanilla-Gozaló *et al.*, 1999; Sanderson *et al.*, 2000; Romero *et al.*, 2005; Balkaya *et al.*, 2012; da Silva Andrade *et al.*, 2012; Ghalimi *et al.*, 2012).

Other causes of stress in livestock systems which could influence the outcome of *N. caninum* infections are concurrent infections with other pathogens, supporting the theory that these pathogens may lead to immunosuppression and recrudescence of chronic infections or postnatal transmission (Thurmond and Hietala, 1995; Björkman *et al.*, 2000; Hobson *et al.*, 2005). Evidence for this includes seropositivity to BVDV, *Coxiella burnetii*, *Chlamydia psittaci* and *Leptospira* species in herds with *N. caninum* infection and associated abortions (Alves *et al.*, 1996; Björkman *et al.*, 2000; Hässig and Gottstein, 2002; Romero *et al.*, 2002; Rinaldi *et al.*, 2007).

Factors influencing the clinical outcome of infection

Although *Neospora* infection is common and transplacental transmission is highly efficient, only a proportion of infected cattle actually abort. The pathological processes leading to abortion in these animals are still not completely explained (Dubey *et al.*, 2006). After experimental inoculation of *N. caninum* during gestation, several factors could affect the clinical and infection outcome, including infections with different *N. caninum* strains, magnitude of parasitaemia after different inoculation doses, stage of gestation when inoculated, hereditary factors, and immune status of the dam, amongst others. Some of these factors are discussed further below.

Determining the existence of genetic variation among different isolates of *N. caninum* is important to understand its contribution to the heterogeneity of disease manifestation as well as transmission patterns (Innes *et al.*, 2000; Blackston *et al.*, 2001; Al-Qassab *et al.*, 2009). Some studies show extensive genetic diversity and polymorphism between isolated *Neospora* strains from different regions (Atkinson *et al.*, 1999; Schock *et al.*, 2001; Miller *et al.*, 2002; Okeoma *et al.*, 2004; Gondim *et al.*, 2004a; Regidor-Cerrillo *et al.*, 2006; Hemphill *et al.*, 2006; Al-Qassab *et al.*, 2009) and these could have an impact on the pathogenesis of neosporosis (Lindsay and Dubey, 1990b; Lindsay *et al.*, 1995; Atkinson *et al.*, 1999; Schock *et al.*, 2001; Quinn *et al.*, 2002b; Regidor-Cerrillo *et al.*, 2006; McInnes *et al.*, 2006; Al-Qassab *et al.*, 2009). Studies carried out with different strains of *N. caninum* have had different outcomes in murine and ruminant models (Quinn *et al.*, 2002b; Dubey *et al.*, 2006). For instance, experimental infections with Nc-1 (the first isolated *N. caninum* strain), Nc-2, Nc-Nowra, Nc-SweB1 and Nc-Liv using murine models showed different clinical outcome, pathogenicity and mortality rates (McGuire *et al.*, 1999; Atkinson *et al.*, 1999; Miller *et al.*, 2002; Quinn *et al.*, 2002b; Collantes-Fernández *et al.*, 2006b; Aguado-Martínez *et al.*, 2009). Different Spanish *N. caninum* strains induce different clinical signs after inoculation in mice, with Nc-Spain 7 being the most pathogenic (Pereira García-Melo *et al.*, 2010). The same Nc-Spain 7 strain was experimentally inoculated in pregnant cattle during early gestation, and abortion was registered although showing clinical and pathological differences in comparison with experimental inoculation with Nc-1 at the same gestation stage (Caspé *et al.*, 2012). Similarly, *N. caninum* isolated from aborted bovine foetuses (Conrad *et al.*, 1993a) were used to experimentally inoculate pregnant cattle, resulting in foetal infection and death (Barr *et al.*, 1994b). All these studies demonstrate the crucial influence that the pathogenicity of different *Neospora* strains has on the variation seen in clinical outcome.

N. caninum infective dose is an important factor which can determine the clinical outcome of infection after exogenous transplacental transmission. This has been experimentally proven after inoculation with different doses of parasites (Long *et al.*, 1998; Gondim *et al.*, 2004b; McCann *et al.*, 2007; Serrano-Martínez *et al.*, 2007b). Different doses also ultimately influence the level of parasitaemia in inoculated

animals (Innes *et al.*, 2002). In a murine model, similar results were observed when mice were inoculated with varying doses of *N. caninum*. The higher the dose, the more severe were the lesions produced (Collantes-Fernández *et al.*, 2004). Likewise, a higher parasite burden was detected in the brain of mice with more severe lesions (Gottstein *et al.*, 2001).

Several studies have established that the timing of placental/foetal *Neospora* infection is crucial to the clinical outcome of *N. caninum* infection, regardless of whether infection is *de novo* or recrudescence in chronically infected cattle (Dubey *et al.*, 1996a; Buxton *et al.*, 1998; González *et al.*, 1999). Despite the fact that foetal death usually occurs throughout the whole gestation period in chronically infected dams, (Thornton *et al.*, 1991; Barr *et al.*, 1991a; Boulton *et al.*, 1995; Dubey and Lindsay, 1996; Guy *et al.*, 2001), the mean gestation age when abortion occurs has been established at mid- and late gestation (discussed below).

In natural *N. caninum* infections pregnancy losses during the first trimester are rare but, since early abortions are not usually delivered to diagnostic laboratories, it is difficult to know whether or not this apparently low early abortion rate is a real phenomenon (López-Gatius *et al.*, 2004b; Collantes-Fernández *et al.*, 2006c). Foetal infections occurring early in the gestation of naïve pregnant cattle are likely to be fatal for the foetus, due to its relative immunological immaturity, resulting in foetal resorption or abortion (Dubey *et al.*, 1992b; Barr *et al.*, 1993; Barr *et al.*, 1994b; Buxton *et al.*, 1997c; Buxton *et al.*, 1998; Williams *et al.*, 2000; Guy *et al.*, 2001; Andrianarivo *et al.*, 2001; Trees *et al.*, 2002; Almería *et al.*, 2003; Bartley *et al.*, 2004; Macaldowie *et al.*, 2004; Gondim *et al.*, 2004b; McCann *et al.*, 2007; Gibney *et al.*, 2008; Rosbottom *et al.*, 2008). The immunological maturity of the foetus develops progressively throughout gestation and only after the middle trimester is the foetus able to recognise and respond to microorganisms (Osburn *et al.*, 1982; Nettleton and Entrican, 1995; Tierney and Simpson-Morgan, 1997a; Tierney and Simpson-Morgan, 1997b; Hein *et al.*, 1998; Almería *et al.*, 2003; Bartley *et al.*, 2004). Thus, in the first trimester, the foetus is exceptionally vulnerable to *N. caninum* infection and is unlikely to survive (Barr *et al.*, 1994b; González *et al.*, 1999; Andrianarivo *et al.*, 2001; Innes *et al.*, 2002; Almería *et al.*, 2003; Bartley *et*

al., 2004; Innes *et al.*, 2005). Further support for this hypothesis comes from various studies collectively describing more protozoa in foetuses less than 5 months old and a higher number of PCR-positive tissue samples in foetuses aborted due to *N. caninum* in the first half of pregnancy (Barr *et al.*, 1991a; Barr *et al.*, 1994a; Otter *et al.*, 1995; Collantes-Fernández *et al.*, 2006c; Gibney *et al.*, 2008). An alternative explanation is based on the finding that, in early gestation, the mother is able to mount a strong IFN- γ response to parasite antigen (Williams *et al.*, 2000; Innes *et al.*, 2001). Therefore, it is possible that the clinical outcome is partially aggravated by the presence of pro-inflammatory type 1 cytokines at the maternal-foetal interface as the maternal immune system fights the infection (Innes *et al.*, 2001; Innes *et al.*, 2002).

Later in bovine gestation, *N. caninum* infections may result in abortion or the birth of persistently infected calves (Hemphill and Gottstein, 2000; Williams *et al.*, 2000; Innes *et al.*, 2001; Guy *et al.*, 2001; Maley *et al.*, 2003). During the second trimester, down regulation of the cellular immune response (Innes *et al.*, 2001), rather than the already functional foetal immune response, appears to be critical for foetal survival (Osburn *et al.*, 1982; Paré *et al.*). Furthermore, in contrast to the stimulated maternal immune response in early gestation, significant immunomodulation of the IFN- γ response occurs in mid gestation, which could imply dampening of inflammation, less severe immunopathology and a later clinical outcome (Innes *et al.*, 2001).

In late pregnancy, when the foetus is immunocompetent, the most likely outcome of *Neospora* infection is the birth of a *N. caninum* congenitally infected calf which is otherwise healthy and clinically normal, perpetuating infection within the herd (Dubey and Lindsay, 1996; Wouda *et al.*, 1997; Schares *et al.*, 1999; Williams *et al.*, 2000; Hemphill and Gottstein, 2000; Innes *et al.*, 2001; Andrianarivo *et al.*, 2001; Guy *et al.*, 2001; Innes *et al.*, 2002; Almería *et al.*, 2003; Williams *et al.*, 2003; Maley *et al.*, 2003; Gibney *et al.*, 2008; Rosbottom *et al.*, 2008; Benavides *et al.*, 2012).

Economic impact of bovine neosporosis

Neospora abortion has negative economic impacts in the livestock industry, imposing large direct and indirect productivity losses on affected farms (Trees *et al.*, 1999; Chi *et al.*, 2002; Larson *et al.*, 2004; Reichel and Ellis, 2006; Häsler *et al.*, 2006a; Bartels *et al.*, 2006b; Häsler *et al.*, 2006b; Reichel *et al.*, 2013). Direct losses are due to premature culling and mortality, abortions or reduced reproductive performance (Trees *et al.*, 1999; Davison *et al.*, 1999c; Antony and Williamson, 2001; Chi *et al.*, 2002; Bartels *et al.*, 2006b) and the result is major economic losses in many countries (Dubey and Schares, 2006; Ortega-Mora *et al.*, 2006).

In addition to the direct costs, there are also substantial indirect losses, arising from the need for professional advice, the expense of establishing a diagnosis and rebreeding (Dubey and Schares, 2006; Ortega-Mora *et al.*, 2006), reduced milk yield (Thurmond and Hietala, 1996; Thurmond and Hietala, 1997b; Trees *et al.*, 1999; Romero *et al.*, 2005) and replacement costs if aborted cows are culled (Thurmond and Hietala, 1996; Pfeiffer *et al.*, 2002; Cramer *et al.*, 2002; Dubey *et al.*, 2007).

Control of bovine neosporosis

Due to the influence of several risk factors that can influence *N. caninum* infection and abortion in cattle in different regions and under different management conditions, there is currently no effective method for controlling this disease (Barr *et al.*, 1994b; Innes *et al.*, 2002; Goodswen *et al.*, 2013; Almería and López-Gatius, 2013). Diverse control strategies need to be adopted on the basis of an initial cost-benefit calculation at farm level, comparing the expense of testing and control measures with the benefit of reduced economic losses due to *N. caninum* (Larson *et al.*, 2004; Reichel and Ellis, 2006; Häsler *et al.*, 2006a; Häsler *et al.*, 2006b; Bartels *et al.*, 2006c). Other aspects to consider are herd type, management system, herd seroprevalence, predominant route of transmission (if known), existing biosecurity measures, and the calculated effects of infection on reproductive and productive performance in each particular region (Antony and Williamson, 2001; Haddad *et al.*,

2005; Hall *et al.*, 2005; Ortega-Mora *et al.*, 2006; Bartels *et al.*, 2006a; Dubey *et al.*, 2007). For instance, modelling based on dairy herds with a low *N. caninum* prevalence (<21%) indicated that ‘doing nothing’ is the optimal economic option; however, this depends on other input parameters (Reichel and Ellis, 2006).

Initially, an accurate monitoring program to confirm that *N. caninum* is not present in the target herd is recommended and estimation of the level of infection should be carried out in order to develop strategies to control the disease (Thurmond and Hietala, 1995; Haddad *et al.*, 2005). This program should initially include the serological testing of all aborting cows and their foetuses for antibodies against *N. caninum*. A cow with a negative test in a herd with no history of *N. caninum* is likely to be a true negative. On the contrary, a positive antibody test from a cow that aborts should only implicate *N. caninum* as the cause of the abortion in the absence of negative tests for other abortifacients, and/or when a positive IHC or PCR test on foetal or placental tissue is confirmed (Haddad *et al.*, 2005). In order to further estimate the level of *Neospora* prevalence in the herd serological screening from a randomly selected sample of the herd, using a well characterised test with high specificity and sensibility, is recommended (Thurmond and Hietala, 1995).

In a confirmed *N. caninum*-free herd all measures should be directed at preventing the introduction of infection through standard biosecurity measures (Haddad *et al.*, 2005). In contrast, control programs in *N. caninum*-infected herds should depend on whether endogenous or exogenous transplacental transmission is predominant (McAllister, 2001). Where endogenous transmission predominates, the target is to reduce *Neospora* abortion rates and decrease vertical transmission by reducing the number of seropositive (infected) cattle. If exogenous transplacental transmission is predominant, the main objective is to decrease the risk of horizontal transmission by controlling the definitive host population and thus the environmental oocyst burden (Reichel and Ellis, 2002; Larson *et al.*, 2004; Trees and Williams, 2005; Haddad *et al.*, 2005; Hall *et al.*, 2005). It might also be preferable to retain infected animals that will resist challenge, and a vaccine could prove beneficial (Trees and Williams, 2005).

On farms where *Neospora* infection is confirmed, initial efforts might be concentrated on identifying infected animals for culling or to allow more selective breeding (Dubey, 1999; Trees and Williams, 2005; Hall *et al.*, 2005; Dubey *et al.*, 2007; Yániz *et al.*, 2010; Almería and López-Gatius, 2013). In order to justify this measure, farmers and practitioners need to consider a *Neospora* infected cow as a reservoir for *N. caninum* that could be spread to the rest of the herd, either slowly and insidiously through vertical transmission or rapidly and explosively through horizontal transmission (Haddad *et al.*, 2005). For these reasons, it is necessary to standardise diagnostic tools in particular serological testing of bovine neosporosis among official and private institutions (Ortega-Mora *et al.*, 2007).

The use of regular bulk-milk testing in order to monitor within-herd *N. caninum* prevalence has been proposed as a possible alternative in dairy herds (Dijkstra *et al.*, 2001a; Bartels *et al.*, 2005; Bartels *et al.*, 2006c). However, in order to determine the extent of *N. caninum* infection in a herd, systematic serological testing of old and young stock (precolostrally or after 6 months of age to avoid maternal antibody false positives) should be applied (Dijkstra *et al.*, 2003; Larson *et al.*, 2004; López-Gatius *et al.*, 2004a; Haddad *et al.*, 2005; Pabón *et al.*, 2007). Based on these serological test results, selective rearing of seronegative young stock and culling of *N. caninum* seropositive animals is the most straightforward approach for long-term prevalence reduction and therefore transplacental transmission of the parasite (Thurmond and Hietala, 1995; French *et al.*, 1999; Innes *et al.*, 2001; Sager *et al.*, 2001; López-Gatius *et al.*, 2004a; Haddad *et al.*, 2005; Frössling *et al.*, 2005; Reichel and Ellis, 2006; Häslér *et al.*, 2006b; Bartels *et al.*, 2007b; Altbuch *et al.*, 2012).

Although it is one of the most effective options, it might not necessarily be the most economically feasible (Reichel and Ellis, 2006) since in high prevalence herds, a program of culling all seropositive animals may be economically impractical due to the loss of animals with superior genetic merit and high commercial value (Thurmond and Hietala, 1995; Dubey, 1999; Antony and Williamson, 2001; Baillargeon *et al.*, 2001).

Another approach is to cull the offspring of seropositive dams to reduce a continued cycle of transplacental parasite transmission (Frössling *et al.*, 2005; Dubey *et al.*, 2007; Bartels *et al.*, 2007b). However, in herds with a high seroprevalence, this strategy could be similarly impractical (Antony and Williamson, 2001; Baillargeon *et al.*, 2001).

One of the most effective ways to maintain *N. caninum*-free status in a herd is to purchase replacement cattle from *Neospora*-free herds or herds with records of excellent reproductive performance and to test all potential replacements (Dubey *et al.*, 2007; Woodbine *et al.*, 2008).

On farms with predominantly *N. caninum* exogenous transplacental transmission, control efforts should be concentrated on reducing the risk of oral infection by *Neospora* oocysts shed from a putative definitive host and by preventing the contamination of feed or water (Ould-Amrouche *et al.*, 1999; Dubey, 1999; Trees and Williams, 2005; Haddad *et al.*, 2005). It is essential to minimise the number of dogs cohabiting with the herd and to deny wild dogs and domestic carnivores' access to calving areas and cattle accommodation. Preventing canine faecal contamination of all feed and drinking water is necessary, in order to break the life cycle of the parasite (Thurmond and Hietala, 1995; Bartels *et al.*, 1999; Ould-Amrouche *et al.*, 1999; McAllister *et al.*, 2000; Antony and Williamson, 2001; Gondim *et al.*, 2004c; Frössling *et al.*, 2005; Dubey *et al.*, 2007; Bartels *et al.*, 2007a; Regidor-Cerrillo *et al.*, 2010; Almería and López-Gatius, 2013).

A specific strategy to control or reduce horizontal transmission is the prompt removal of aborted bovine foetuses, foetal membranes, placentas or dead calves that could serve as a source of infection for definitive hosts and rodents (Thurmond and Hietala, 1995; Dubey, 1999; McAllister *et al.*, 2000; Antony and Williamson, 2001; Gondim *et al.*, 2004c; Hall *et al.*, 2005; Dubey *et al.*, 2007). Cattle could also theoretically become infected after licking or ingesting tissues infected with *N. caninum*. Such transmission could take place when a non-infected cow or calf ingests infected tissues or fluids expelled from an infected cow during calving or abortion. It is conceivable that some abortion storms attributable to *N. caninum*

could result from exposure to a foetus or placenta aborted from an infected dam. Therefore, strategies to prevent this type of transmission would also include the use of individual calving pens, and segregation of positive and negative cows before calving when possible (Thurmond and Hietala, 1995; Paré *et al.*, 1998; McAllister *et al.*, 1998a; Sager *et al.*, 2001; Hall *et al.*, 2005; Dubey *et al.*, 2007).

Appropriate hygiene regarding dog faeces on pastures is also recommended. However, in extensively managed farms, the presence of dogs could be of help in reducing the number of other wild canids (Gondim *et al.*, 2004c; Rosypal and Lindsay, 2005). Since young dogs shed more oocysts after infection than older dogs (Gondim *et al.*, 2005), the presence of pregnant bitches or bitches carrying litters should also be prevented (Dubey *et al.*, 2007).

Calves should not be fed pooled milk unless it comes from known *N. caninum*-negative cows (Hall *et al.*, 2005). This policy was established in a *Neospora* infected goat herd; new born kids were immediately removed from their dams and reared with heat-treated colostrum and milk to reduce horizontal transmission (Altbuch *et al.*, 2012).

Herds applying embryo transfer technology should use only *Neospora* seronegative recipients in order to prevent endogenous transplacental transmission of *N. caninum* (Thurmond and Hietala, 1995; Bergeron *et al.*, 2000; Baillargeon *et al.*, 2001; Landmann *et al.*, 2002; Campero *et al.*, 2003a; de Oliveira *et al.*, 2010). However, prior serological testing of recipient cows is of crucial importance, because embryo transfer into seropositive recipients has resulted in vertical transmission of *N. caninum* (Baillargeon *et al.*, 2001; de Oliveira *et al.*, 2010). This technique may be used to recover uninfected calves from genetically valuable but *N. caninum*-infected dams (Bielanski *et al.*, 2002; Dubey *et al.*, 2007).

Some studies in dairy farms with high *Neospora* seroprevalence have demonstrated that artificial insemination with beef bull semen reduces *N. caninum* prevalence and the risk of abortion, probably due to the favourable effect of crossbreed pregnancies on placental function. Furthermore, cross-breed calves are not usually retained as

replacements, so the ongoing cycle of transplacental transmission is also reduced (López-Gatius *et al.*, 2005a; López-Gatius *et al.*, 2005b; Pabón *et al.*, 2007; Almería *et al.*, 2009; Yániz *et al.*, 2010; Almería and López-Gatius, 2013). This approach may be an alternative to breeding only from seronegative cattle since it reduces the prevalence of *N. caninum*, results in lower abortion rates, increases the number of complete lactations in seropositive cows and provides an economic return from selling crossbred offspring (French *et al.*, 1999).

Treatment and Vaccination

Canine neosporosis has been treated successfully with some chemotherapeutics, such as trimethoprim-sulfadiazine, pyrimethamine and clindamycin hydrochloride (Dubey *et al.*, 1995; Lyon, 2010). Although several drugs have been tested *in vitro* (Lindsay and Dubey, 1989a; Lindsay *et al.*, 1994; Lindsay *et al.*, 1996; Dubey and Lindsay, 1996; Lindsay *et al.*, 1997; Kim *et al.*, 2002; Darius *et al.*, 2004) or *in vivo* (Lindsay and Dubey, 1990a; Gottstein *et al.*, 2001; Kritzner *et al.*, 2002; Gottstein *et al.*, 2005; Haerdi *et al.*, 2006), currently there is no known drug that can be used to clear the infection in ruminants (Hoar *et al.*, 1996; Anderson *et al.*, 2000; Dalton and Mulcahy, 2001; Dubey, 2003b; Haddad *et al.*, 2005; Williams *et al.*, 2009; Goodswen *et al.*, 2013).

There is accumulating evidence that some *N. caninum*-infected cows can develop a degree of protective immunity against abortion and/or congenital transmission, indicating that immunoprophylaxis, at least to prevent abortion or congenital transmission, is a feasible goal (Innes *et al.*, 2001; Innes *et al.*, 2002; Innes *et al.*, 2011; Weber *et al.*, 2013). However, the situation seems to be different in naturally, chronically infected cattle since these animals were protected against abortion following exogenous exposure (McAllister *et al.*, 2000; Williams *et al.*, 2003; Dubey *et al.*, 2007), but not against vertical transmission of the parasite (Anderson *et al.*, 1995; McAllister *et al.*, 2000; Innes *et al.*, 2002). Therefore, development of an effective *N. caninum* vaccine for prevention of congenital infection might be difficult to achieve (Atkinson *et al.*, 1999).

Ideally, any vaccine developed against bovine neosporosis should protect against foetal loss and avoid transplacental transmission. Additionally, this vaccine should allow discrimination between infected and vaccinated animals with serological tools in an integrated control approach (Dubey *et al.*, 2007).

The advantages and drawbacks of live and dead vaccines have been reviewed extensively (Innes *et al.*, 2002; Williams and Trees, 2006; Innes *et al.*, 2011). Different approaches have been followed in vaccine development for bovine neosporosis, and several groups have shown that it is possible to induce at least partial protection in cattle (Innes *et al.*, 2001; Innes and Vermeulen, 2006; Innes *et al.*, 2007; Williams *et al.*, 2007; Innes *et al.*, 2011; Weber *et al.*, 2013).

A *Neospora* killed vaccine, licensed for cattle and based on crude parasite extract, is available on the market in several countries. Some evaluations have suggested that it is able to induce protection against abortion, although this protection may only be measurable on farms with on-going risks of abortion (Choromanski and Block, 2000; Williams *et al.*, 2003; Romero *et al.*, 2004). However, there are still concerns about the use of this vaccine due to its interference with serological diagnosis (Innes *et al.*, 2002) and the possibility of early embryonic death induced by the immune response to the vaccine and its subsequent effects on placental attachment in early gestation (Purtle, 2001; Heuer *et al.*, 2003). There is still no scientific evidence to indicate that the vaccine can prevent foetal infection in commercial herds, therefore the use of this vaccine as it is currently recommended according to license is controversial and requires further evaluation (Haddad *et al.*, 2005).

Experimental Neosporosis throughout gestation

As stated before, one of the key factors affecting the clinical outcome of *Neospora* infection during bovine gestation is the stage of gestation when infection occurs. The effects of experimental inoculation with the Nc-1 strain of *N. caninum* in pregnant cattle in early, mid and late gestation have been reported by several authors at Moredun Research Institute (Maley *et al.*, 2003; Bartley *et al.*, 2004; Macaldowie

et al., 2004; Maley *et al.*, 2006; Bartley *et al.*, 2012; Benavides *et al.*, 2012). The samples used in this thesis were generated from these studies and a summary of their experimental designs is outlined in Figure 2.

In **early gestation**, an inoculum of 5×10^8 live tachyzoites of the Nc-1 strain was intravenously (IV) (n=8) or subcutaneously (SC) (n=8) injected in pregnant Holstein-Friesian cows at day 70 of gestation (*N. caninum*-inoculated group). Simultaneously, negative control animals (n=8) were inoculated with the same number of Vero cells without *N. caninum* (negative control group). Pairs of animals from IV, SC *N. caninum*-inoculated and negative control groups were culled at 14, 28, 42 and 56 dpi, and samples were subjected to *post-mortem* examination (Macaldowie *et al.*, 2004).

Data concerning the animals, inocula and experimental design of the inoculation at **mid gestation** have been described by Maley *et al.* (2003). Two different inocula doses were used (1×10^7 and 5×10^8 tachyzoites) and therefore, for the purposes of the current analysis, only the animals experimentally inoculated with the same *N. caninum* dose used at early and late gestation were included for the future comparison. Briefly, an inoculum of 5×10^8 live tachyzoites of the Nc-1 strain was SC injected at day 140 of gestation in 6 Holstein-Friesian dams (*N. caninum*-inoculated group). A suspension of 5×10^8 Vero cells was SC injected in 3 negative control dams (negative control group). Two *N. caninum* inoculated and 1 negative control dam were then culled and further analysed at 14, 28 and 42 dpi (Maley *et al.*, 2003).

Similarly to the previous trials, 11 pregnant Aberdeen Angus cross or Belgian Blue cross cattle were SC inoculated with 5×10^8 live tachyzoites of the Nc-1 strain of *N. caninum* at **late gestation** (day 210 of gestation) (*N. caninum*-inoculated group). Four dams were inoculated with Vero cells at the same time, acting as negative control. As previously, animals from both groups were culled at 14, 28, 42 and 56 dpi, as described by Benavides *et al.* (2012) and Cantón *et al.* (2013b).

During the experiments at early, mid and late gestation, experimentally inoculated dams were subjected to clinical monitoring, and blood and tissue samples were

collected during *post-mortem* examination. Immediately after euthanasia, the uterus was removed from each dam and foetus checked for viability. Maternal, placental and foetal tissue samples were taken for routine histopathology and IHC and PCR (Maley *et al.*, 2003; Macaldowie *et al.*, 2004; Benavides *et al.*, 2012).

Clinical outcome after the experiments at early (Macaldowie *et al.*, 2004), mid (Maley *et al.*, 2003) and late gestation (Benavides *et al.*, 2012) were previously published. Briefly after inoculation at **early gestation**, the 4 foetuses recovered from the cows culled at 14 dpi were alive (from IV and SC *Neospora* inoculated cows). Nevertheless, foetuses were found to be dead when the pair of IV inoculated animals was culled at 28 dpi. From the pair of SC-*N. caninum*-inoculated dams culled at the same time-point, one foetus was alive and the other was dead. When the pair of IV-*N. caninum*-inoculated animals was culled at 42 and 56 dpi their uteri were empty. In the meantime, 1 live and 1 dead foetus were recovered from the SC-*N. caninum*-inoculated cows at 42 and 56 dpi (Macaldowie *et al.*, 2004).

Following *Neospora* inoculation at **mid gestation** (day 140) no abortion or foetal death was observed in all the *N. caninum*-inoculated animals although congenital transmission was confirmed by IHC and PCR in half of the recovered foetuses (Maley *et al.*, 2003).

No abortions were registered in *N. caninum*-inoculated dams at **late gestation** since on the day of euthanasia, all dams carried a viable foetus (Benavides *et al.*, 2012).

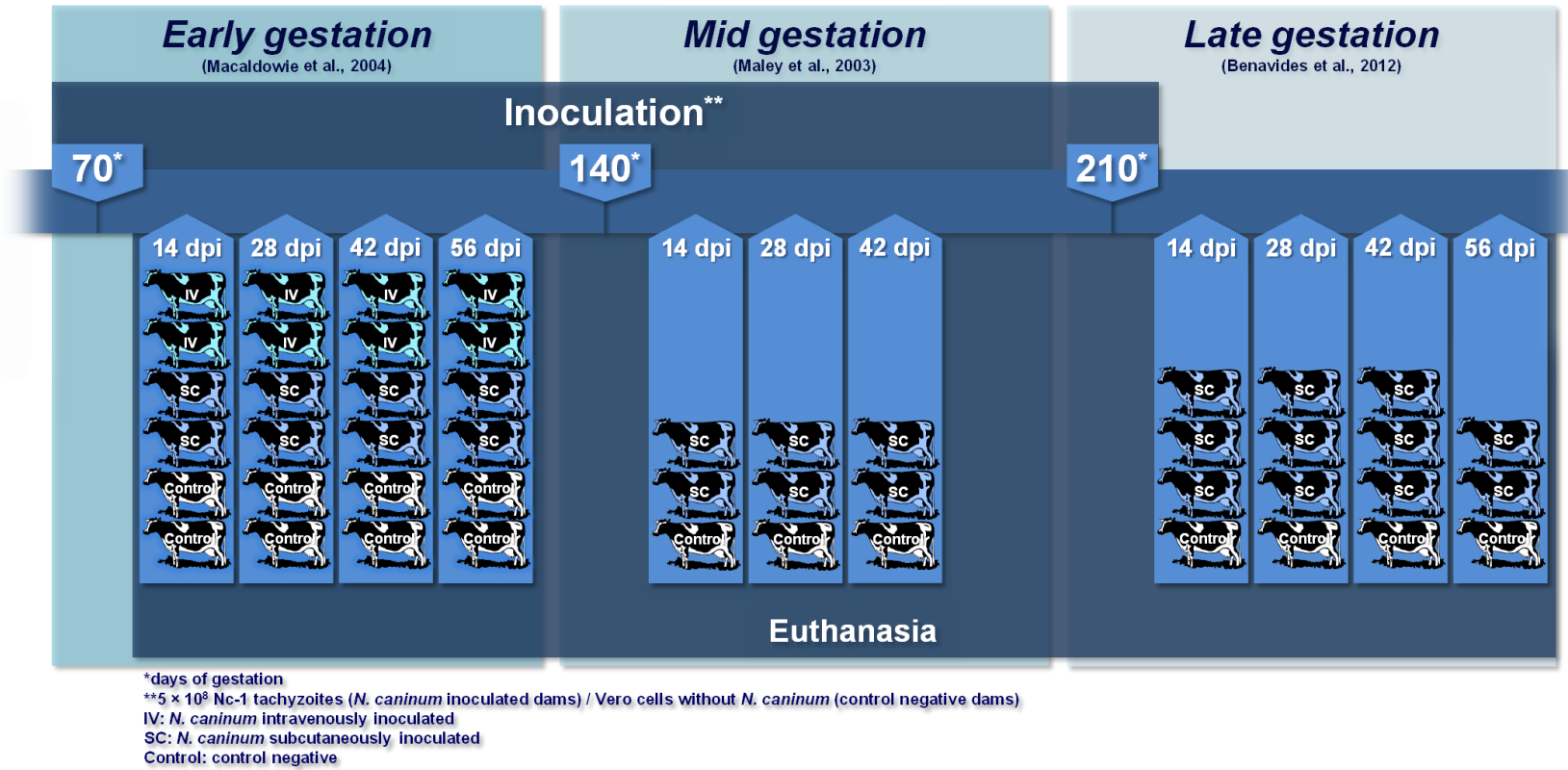


Figure 2: Schematic representation of the experimental design (Maley et al., 2003; Macaldowie et al., 2004; Benavides et al., 2012). Figure produced by GJC.

Following experimental IV inoculation with *N. caninum* at **early gestation**, placental lesions were described in both dams culled at 14 dpi. At 28 dpi and onwards, pregnancy had ended in all the IV inoculated dams and extensive autolysis and necrosis were registered. In the same experiment, placental tissues collected from the SC *N. caninum* inoculated dams also showed lesions at 14 dpi although changes were less severe than those identified in IV inoculated dams. At 28 dpi, no significant lesions could be identified in placentomes from the animal carrying a live foetus. By contrast, severe lesions were identified in all placentomes from the animal containing the foetus that had died. Each animal carrying dead foetuses at 42 and 56 dpi presented also placentome lesions and signs of regeneration. *N. caninum* antigen was detected by IHC in placental samples collected from all the IV and SC inoculated animals culled at 14 and 28 dpi. Labelled antigen was associated with lesions and resembled the morphological appearance of *N. caninum* tachyzoites or of particulate antigen in the form of fine to coarse granular deposits. *N. caninum* appeared to be restricted to the interstitium, necrotic fetal trophoblast and mesenchyme cells. No antigen was observed in the caruncular remains collected from IV inoculated animals culled at 42 and 56 dpi. However, placentomes collected from the SC inoculated animals carrying dead foetuses were *N. caninum* positive at 42 and 56 dpi. *Neospora* antigen was not detected in placentome samples from animals carrying live foetuses at 28, 42 and 56 dpi. Nc-1 immunolabelling was invariably absent in the placentomes collected from negative control animals (Macaldowie *et al.*, 2004).

During the **mid gestation** infection experiment, placentomes collected from the 2 dams experimentally *N. caninum* inoculated culled at 14 dpi, focal lesions were observed only in a small percentage of cows (2 out of 20 placentomes). At 28 dpi, focal lesions were present in both examined animals (9 out of 20 placentomes). At 42 dpi, focal lesions were only observed in one of the two dams (5 out of 10 placentomes) but none in the other. *N. caninum* was detected either with PCR or IHC in placentomes collected from *N. caninum* inoculated dams culled at 14, 28 and 42 dpi which also presented pathological findings (Maley *et al.*, 2003).

During the histopathological analysis of the placentas collected from the inoculated dams during **late gestation**, lesions were present in the samples collected from the *N. caninum*-inoculated dams since 28 dpi. Placental lesions were characterised by focal to coalescence coagulative necrosis areas of foetal villi, accompanied by necrotic debris and serum leakage between foetal villi and caruncular septa. Accumulation of mononuclear inflammatory cells were infiltrating the surrounded necrotic areas in the placentome. *Neospora*-antigen was labelled by IHC resembling tachyzoite-like structures located in the necrotic areas at the caruncular septa (Benavides *et al.*, 2012).

Since some of the uteri of the dams experimentally inoculated during **early gestation** with *N. caninum* were empty at the moment of the *post mortem* examination, not many foetal tissues could be analysed histologically. Focal lesions with clusters of protozoal organisms were identified in the CNS from foetuses collected at 14 dpi from the IV inoculated dam. Foetuses collected from the IV inoculated dams at 28 dpi were in an advanced state of autolysis and at 42 and 56 dpi no foetal tissues were present. In dead foetuses collected from the SC inoculated dams at early gestation after 28, 42 and 56 dpi, advanced autolysis did not allowed a correct histopathological evaluation, but in the corresponding live foetuses no significant histopathological changes were seen. *N. caninum* antigen was detected in the foetuses recovered from the IV inoculated dams culled at 14 dpi. However, antigen could not be detected in the foetuses recovered from the IV-inoculated animals culled at 28 dpi due to the autolytic process that was previously described during the histopathology. Nevertheless, *Neospora* antigen was observed in the foetus recovered from the SC-inoculated dam at 28 dpi, but not in the live foetus recovered simultaneously. At 42 dpi, *Neospora* IHC was positive in the autolysed foetus recovered from the SC inoculated dam. All other foetal samples collected in the rest of the foetuses (*Neospora* inoculated or negative control) were IHC negative. Positive samples were characterised by an intense labelling observed within the neuropil in the same area of the mesencephalon where lesions and protozoal structures were seen during the histopathological analysis, but also in prosencephalon, thoracic and cervical spinal cord and in myocardial cells (Macaldowie *et al.*, 2004).

During the **mid gestation** experiment, the main pathological changes were observed in the foetal CNS from 14, 28 and 42 dpi. Liver and skeletal muscular (semitendinosus) lesions were also observed in foetuses collected after 28 dpi. Neither *Neospora* DNA nor antigen were detected using PCR or IHC in the foetal samples collected at 14 dpi. However, foetal tissues sampled at 28 dpi tested *N. caninum* positive by PCR and IHC. At 42 dpi, parasite DNA was detected in the spinal cord, lung and skeletal muscle from one foetus. All other foetal samples collected from *N. caninum* inoculated and negative control animals were negative (Maley *et al.*, 2003).

Similarly to previous descriptions in the placental samples, lesions were described in foetal tissues recovered from *N. caninum*-inoculated animals during **late gestation**, and then culled at 28 and 42 dpi only. Lesions consisted of focal coagulative necrosis surrounded by a mild mononuclear infiltration of the neuropil of the frontal cortex, midbrain and lumbar spinal cord. Liver, lung, kidney and muscular lesions were also described in some foetuses. *N. caninum* positive labelling was found using IHC in the placental samples collected from some dams at 28, 42 and 56 dpi and in the CNS of foetuses collected at 28 dpi. Similarly, no *Neospora* DNA was detected in any of the foetuses from 14 dpi, while at 28, 42 and 56 dpi parasite DNA was detected in tissue samples collected in lumbar spinal cord, heart, lung or lymph nodes. No lesions, *Neospora* antigen or DNA were described in the foetuses collected from the negative control dams (Benavides *et al.*, 2012).

Comparing the results of the experiments following experimental inoculation with *N. caninum* at early, mid and late gestation, one of the most remarkable findings is that although a high rate of *Neospora* congenital infection was registered in the foetuses recovered in the 3 trials, foetal death and abortion was only observed at early gestation. Different pathological findings were also described for each time-point making further analysis of samples generated during these studies an interesting and necessary step forward.

Aims of studies and Thesis outline

After reviewing the available literature on bovine neosporosis, it is apparent that, so far, there is no treatment available to control *Neospora* infection in cattle, and the proposed control measures are unable to eradicate the disease. Furthermore, there are several knowledge gaps and some aspects of the host-pathogen interaction that are not fully understood. One of these interesting aspects is the reported differences in clinical outcome after transplacental transmission of the parasite at different periods of gestation in cattle. An interesting hypothesis in the pathogenesis of bovine neosporosis is the suggestion that an exacerbated response of the maternal immune system triggered by *N. caninum*, could be detrimental to placental wellbeing, and therefore could lead to a reduced foetal vascular supply and contribute ultimately to foetal pathology.

Therefore, one of the initial objectives for this PhD work was to evaluate and characterise the cellular immune population in the placenta of dams experimentally inoculated with *N. caninum* during late gestation (day 210 of gestation) (Benavides *et al.*, 2012). To achieve this objective a previously described methodology was used to characterise the phenotype of immune cells in fixed placental tissues following *Neospora* inoculation in early gestation (day 70 of gestation) (Maley *et al.*, 2006). The results of this first analysis were recently published (Cantón *et al.*, 2013b) and are presented in Chapter 2.

Afterwards the immune cell populations observed in the placentas following experimental *N. caninum* infection in early (day 70) (Macaldowie *et al.*, 2004; Maley *et al.*, 2006) and mid-gestation (day 140) (Maley *et al.*, 2003) were also analyzed and compared using the same scoring system applied in the characterisation of the placental samples in late gestation (Cantón *et al.*, 2013b). These results are presented in Chapter 3.

Another objective of this Thesis was to further characterise the immune response against *N. caninum* infection, not only by describing the phenotypes of immune cells infiltrating the placenta, but also by evaluating the cytokine expression of these cells in placental samples from the same three experiments (experimental inoculation at

days 70, 140 and 210 of gestation). For this purpose characteristic cytokines usually expressed during a Th1-biased response were evaluated. TNF- α probe was already available in the immunological toolbox at Moredun Research Institute, and therefore was applied to the placental tissues. Completely new IL-12 (Cantón *et al.*, 2013a) and IFN- γ probes were designed, produced and tested in different ruminant tissues. Cytokine expression in the placentas from *Neospora*-inoculated dams is presented in Chapter 4.

Hopefully, the information provided in this Thesis will increase knowledge of bovine Neosporosis, and will help in future research into the development of control strategies, and ultimately in the inception of successful vaccines aimed at attenuating the disastrous effects of *N. caninum*.

Chapter 2:

Characterisation of placental cellular immune infiltrates following inoculation with *Neospora caninum* in late gestation

Adapted from:

Benavides, J., Katzer, F., Maley, S.W., Bartley, P.M., Cantón, G., Palarea, J., Pang, Y., Rocchi, M., Chianini, F., Innes, E.A. (2012) High rate of transplacental transmission and infection following experimental inoculation of *Neospora caninum* at late gestation. *Veterinary Research* 43:83.

Cantón, G., Katzer, F., Benavides-Silván, J., Maley, S., Palarea-Albaladejo, J., Pang, Y., Bartley, P., Rocchi, M., Innes, E., Chianini, F. 2013b. Phenotypic characterisation of the cellular immune infiltrate in placentas of cattle following experimental challenge with *Neospora caninum* on day 210 of gestation. *Veterinary Research* 44, 60.

In this chapter I was responsible for reviewing the literature, performing the IHC on tissue from the late gestation experiment, scoring the infiltrates, photographing the slides, analysing the results and writing the manuscript.

Introduction

As stated in Chapter 1, *Neospora* infection may occur postnatally following ingestion of oocysts shed in the faeces of infected canids (horizontal transmission), potentially leading to exogenous transplacental transmission (vertical transmission) (McAllister *et al.*, 1998b; de Marez *et al.*, 1999) or through recrudescence of a previous infection leading to endogenous transplacental transmission of the parasite from mother to foetus via the placenta (Paré *et al.*, 1996; Davison *et al.*, 1999b; Williams *et al.*, 2009). Regardless of transmission route, the consequences of infection may include foetal death *in utero*, the birth of live but clinically affected calves, or the birth of clinically normal but persistently infected calves (Dubey and Lindsay, 1996; Dubey, 1999).

The pathogenesis of bovine neosporosis is complex and not completely understood. *Neospora* is a primary abortifacient in cattle since the brain and heart lesions usually observed in infected foetuses may be severe enough to cause mortality (Barr *et al.*, 1990; Dubey *et al.*, 1990d; Dubey *et al.*, 2006) and the infection-associated placental damage can disrupt the vascular supply of nutrients leading to foetal death (Maley *et al.*, 2003; Macaldowie *et al.*, 2004). Additionally, there is evidence that *N. caninum*, like other intracellular pathogens, stimulates a cell-mediated immune response, characterised by a Th1 type response (Innes *et al.*, 2005), with cytokines, such as IFN- γ playing a critical role in limiting multiplication of the organism (Innes *et al.*, 1995a). Th1 responses may inhibit parasite multiplication; however, pro-inflammatory immune responses may also cause placental damage and lead to abortion (Innes *et al.*, 2002). Thus, in some instances, relatively small numbers of parasites, whilst producing mild lesions, may cause a shift from a beneficial Th2 response towards a more harmful Th1 response during pregnancy, thereby inducing abortion (Entrican, 2002; Innes *et al.*, 2005). Although infection with *N. caninum* is common and transplacental transmission of tachyzoites is highly efficient, only a relatively small proportion of infected cattle abort. Some of the pathological processes that transform an apparently harmless infection into a fatal disease are still unclear (Dubey *et al.*, 2006).

The clinical outcome of bovine neosporosis during pregnancy is influenced by several factors further described in the Chapter 1. In summary, these include the timing and duration of parasitaemia after a primary infection or the recrudescence of a persistent infection. In persistently infected cows, *N. caninum* does not appear to affect the embryonic and early foetal period (López-Gatius *et al.*, 2004b), whereas *de novo* infections in naïve pregnant cattle during early gestation are likely to be fatal, partially due to the immature foetal immune response (Björkman *et al.*, 1996; Williams *et al.*, 2000; Macaldowie *et al.*, 2004; Bartley *et al.*, 2012). During the second trimester of pregnancy *Neospora* infections can result in abortions or the birth of congenitally infected calves, depending in the severity of lesions (Dubey *et al.*, 1992b; Barr *et al.*, 1994b; Williams *et al.*, 2000; Guy *et al.*, 2001; Maley *et al.*, 2003; Rosbottom *et al.*, 2011). Finally, after experimental inoculation in the final trimester of pregnancy, when foetuses are more immunologically mature and able to control the infection, congenitally infected live foetuses are recovered (Williams *et al.*, 2000; Gibney *et al.*, 2008; Benavides *et al.*, 2012).

It is known that, early in gestation, the mother is able to mount a strong Th1 response to parasite antigens (Andrianarivo *et al.*, 2001; Almería *et al.*, 2003; Innes *et al.*, 2005; Bartley *et al.*, 2012). Therefore, it is possible that the abortion may be caused by this response at the maternal-foetal interface while the immune system fights the infection. Significant immunomodulation of this maternal Th1 response occurs in mid gestation (Williams *et al.*, 2000; Innes *et al.*, 2001), which might be a trigger for recrudescence of persistent *N. caninum* infections due to immune modulation leading to excystation of parasites contained within tissue cysts. At this stage of gestation, the consequences of infection might be the death of the foetus, or the calf may be born congenitally infected, with some clinical signs at birth (Innes *et al.*, 2001).

The severity of placental damage is a determining factor in the occurrence of abortion and also important in permitting invasion of the foetus (Maley *et al.*, 2003; Dubey *et al.*, 2006). Improving our understanding of the host-pathogen interaction in pregnant cattle infected with *N. caninum* will help to determine the critical factors involved in disease pathogenesis and host protective immune responses. This in turn will help in the development of effective control strategies, especially for vaccines.

Investigating the host immune response at the materno–foetal interface may improve our understanding as to why some infected cattle abort and some do not (Innes *et al.*, 2005). The aim of the present study was to characterise the phenotype of the cellular immune infiltrate in the placenta of cattle experimentally inoculated with live *N. caninum* (Nc-1 strain) tachyzoites on day 210 of gestation.

Materials and methods

Animals and experimental design

A full description of the animals and experimental design has been published by Benavides *et al.* (2012). Briefly, 15 pregnant Aberdeen Angus cross or Belgian Blue cross cattle aged 20 to 23 months, seronegative for *N. caninum*, *T. gondii*, BVDV, BHV and *Leptospira hardjo* were oestrus synchronised and artificially inseminated with a mixture of semen from different bulls as previously described (Maley *et al.*, 2003). Pregnancy and foetal viability were confirmed by ultrasound scanning on day 35 after AI and again before challenge. Animals were observed twice daily throughout the experiment and rectal temperatures were recorded 2 days before inoculation and then daily until 14 dpi. Animals were considered to be febrile when the temperature was over 39.5°C. All animals were housed together until the end of the study (Benavides *et al.*, 2012).

Before the beginning of the experiment, the animals were divided into 2 groups: *N. caninum*-inoculated (n = 11) and negative control (n = 4), but were housed together until the end of the study. At day 210 of gestation animals (at 27 to 30 month of age) were either subcutaneously inoculated with *N. caninum* tachyzoites (*N. caninum*-inoculated group) or with uninfected Vero cells (negative control group), over the left pre-femoral lymph node (see comments in Chapter 1). Three *N. caninum*-inoculated cows and 1 negative control cow were culled at 14, 28 and at 42 dpi by intravenous barbiturate overdose, following which dams and foetuses were examined *post mortem*. At 56 dpi, the remaining animals were culled and examined (Benavides *et al.*, 2012).

All animal procedures complied with the Animals (Scientific Procedures) Act 1986 and were approved by the MRI ethics committee.

Experimental inocula

Animals from the *N. caninum*-inoculated group were subcutaneously inoculated over the left prefemoral lymph node with 2ml of PBS containing 5×10^8 live tachyzoites of the Nc-1 strain (Dubey *et al.*, 1988b) of *N. caninum* at day 210 of gestation. Tachyzoites were cultured in Vero cells and the inoculum was prepared from the same low-passage (p-36) stabilate, which had been cryopreserved at -180°C in vapour phase liquid nitrogen storage since the early and mid gestation experiments in pregnant cattle (Maley *et al.*, 2003; Macaldowie *et al.*, 2004). Four dams from the negative control group were inoculated with Vero cells (5×10^7 Vero cells), equivalent to that in the parasite inocula, in 2ml PBS (see in Chapter 1) (Benavides *et al.*, 2012).

Collection of tissue samples

Immediately after euthanasia and *post mortem* examination of the dams and foetuses, 10 randomly selected placentomes were sampled from each dam and fixed in non aldehyde fixative containing zinc salts (zinc salt fixative; ZSF) (see Appendix 1) (Beckstead, 1994; González *et al.*, 2001; Maley *et al.*, 2006) for IHC examination. After 3 days of fixation, tissues were processed in an automated processor (Shandon Pathcentre[®] Tissue Processor) then embedded in paraffin wax. One section was trimmed from each placentome and then IHC analysed with each of the monoclonal antibodies (mAb).

Phenotypic analysis of inflammatory cells in placental tissue

To investigate the immunopathology following inoculation with *N. caninum*, the phenotypes of the cells present in the inflammatory infiltrate were characterised using a technique similar to that described by Maley *et al.* (2006). For each placentome sample, 5µm sections were cut and were mounted on glass microscope slides (Superfrost® Plus, Thermo Scientific, Braunschweig, Germany), dewaxed in xylene and hydrated through graded ethanol solutions using an automated slide stainer (Shandon Varistain® 24-4). Endogenous peroxidase was blocked by incubating with 3% hydrogen peroxide in methanol for 30 minutes at room temperature (RT). Non-specific labelling was reduced by incubating the slides in 25% normal goat serum (NGS) in Tris-buffered saline (TBS) (see Appendix 1) at RT. Immunohistochemistry was performed using an EnVision + kit (Dako North America Inc, Carpinteria, USA). Briefly, previously reported mAbs that specifically recognise different markers in immune cells [macrophages, total T cells, T helper cells, cytotoxic T cells, $\gamma\delta$ -T cells, natural killer (NK) cells and B cells] were used at different dilutions in TBS (described in Table 1). Sections were then incubated overnight at 4°C with each mAb. The following day, slides were incubated with a peroxidase labelled polymer conjugated to goat anti-mouse immunoglobulins (secondary antibody provided in the commercial kit) for 30 min at RT. After this incubation, the staining process was completed by 8 minute incubation with 3, 3'-diaminobenzidine (DAB) and substrate-chromogen (provided in the EnVision + kit) at RT. Slides were counterstained with Mayer's haematoxylin for 2 minutes followed by immersion in Scott's tap water substitute (STWS) (see Appendix 1). Slides were washed in tap water and then dehydrated through graded alcohols, cleared in xylene and mounted with coverslides. Sections of bovine lymph nodes fixed in ZSF were used as positive control tissues.

Selected placentome sections were also labelled using a mAb raised against human cytokeratin (clone AE1/AE3, Dako Cytomation, Glostrup, Denmark) (as a primary antibody) using the same technique as described above, in order to identify the population of trophoblastic cells, as previously described by Zeiler *et al.* (2005) and Koshi *et al.* (2012).

Scoring of the immunolabelling of the tissues

Similarly to the technique described by Tekin and Hansen (2004), slides were blind-coded and examined for each inflammatory cell marker (listed above). To eliminate inter-operator error all slides were read by a single investigator (GJC). The whole tissue section was examined and scored for the presence and distribution of immunolabelled cells by optical microscopy using various magnifications (10x, 20x and 40x). The scores were defined according to the extent of cellular infiltration of the placentomes and whether there were associated pathological changes. The following scoring system was established (see Figures 3a-d). **Score 0**: no infiltration of labelled cells or diffuse/minimal infiltration of labelled cells that are not associated with pathological changes (see Figure 3a); **Score 1**: minimal/diffuse infiltration of labelled cells (in some cases forming small foci) associated with small necrotic areas (see Figure 3b); **Score 2**: mild infiltration and focal aggregation of labelled cells surrounding necrotic foci (see Figure 3c); **Score 3**: moderate infiltration and focal aggregation of labelled cells surrounding areas of necrosis (see Figure 3d); and **Score 4**: severe and large aggregations of positive cells surrounding areas of necrosis and/or mineralization. The individual scores from 10 sampled placentomes were used to calculate a single mean score for each animal, similar to previous descriptions (Buxton *et al.*, 2001; Oliveira and Hansen, 2008) and then were statistically analysed (see below).

Table 1: Specific mAb used to label different immune cell type in the bovine placentas from animals experimentally inoculated with *N. caninum* at early, mid- and late gestation

Cluster of differentiation	mAb clone	Targeted immune cell	Dilution	References
CD68	EBM11 ⁽¹⁾ (a, b, c)	Monocytes/macrophages	1:100	(Kelly <i>et al.</i> , 1988; Ackermann <i>et al.</i> , 1994; Gutierrez <i>et al.</i> , 1999; Schlafer <i>et al.</i> , 2000; Tekin and Hansen, 2004; Oliveira and Hansen, 2008; Orozco <i>et al.</i> , 2013)
CD3	MM1A ⁽²⁾ (a, b, c)	Total T cells	1:2000	(Naessens <i>et al.</i> , 1997; Van Kampen and Mallard, 1997; Kimura <i>et al.</i> , 1999; Davis <i>et al.</i> , 2001; Maley <i>et al.</i> , 2006; Cantón <i>et al.</i> , 2013c)
CD4	CC30 ⁽³⁾ (c)	T helper cells	1:50	(Bensaid and Hadam, 1991; Naessens, 1991; Anonymous, 1991; Gutierrez <i>et al.</i> , 1999; Sopp and Howard, 2001; Summers <i>et al.</i> , 2012; Cantón <i>et al.</i> , 2013c)
	ILA-12 ⁽⁴⁾ (a, b)		1:1000	(Baldwin <i>et al.</i> , 1986; Teale <i>et al.</i> , 1987; Morrison <i>et al.</i> , 1987; Baldwin <i>et al.</i> , 1987; Bensaid and Hadam, 1991; Anonymous, 1991; Maley <i>et al.</i> , 2006)
CD8	CC58 ⁽³⁾ (c)	Cytotoxic T cells	1:200	(Keech and Brandon, 1991; MacHugh and Sopp, 1991; Anonymous, 1991; Naessens, 1991; Davis <i>et al.</i> , 2001; Cantón <i>et al.</i> , 2013c)
	ILA-105 ⁽⁴⁾ (a, b)		1:200	(Van Kampen and Mallard, 1997; Naessens <i>et al.</i> , 1997; Maley <i>et al.</i> , 2006; Kessy and Matovelo, 2011)
$\gamma\delta$ TCR	IL-A29 ⁽²⁾ (a, b, c)	$\gamma\delta$ -T cells	1:4000	(Morrison and Davis, 1991; Anonymous, 1991; Naessens, 1991; Naessens <i>et al.</i> , 1997; Van Kampen and Mallard, 1997; Maley <i>et al.</i> , 2006; Cantón <i>et al.</i> , 2013c)
CD335	NKp46 ⁽³⁾ (a, b, c)	Natural killer cells	1:250	(Storset <i>et al.</i> , 2004; Maley <i>et al.</i> , 2006; Boysen <i>et al.</i> , 2006; Entrican and Wheelhouse, 2006; Connelley <i>et al.</i> , 2011; Cantón <i>et al.</i> , 2013c)
CD79 _{acy}	HM57 ⁽¹⁾ (a, b, c)	Total B cells	1:100	(Pillozzi <i>et al.</i> , 1998; Maley <i>et al.</i> , 2006; Polledo <i>et al.</i> , 2011; Cantón <i>et al.</i> , 2013c)

(1) Dako Cytomation, Glostrup, Denmark

(2) VMRD Inc, Washington, USA

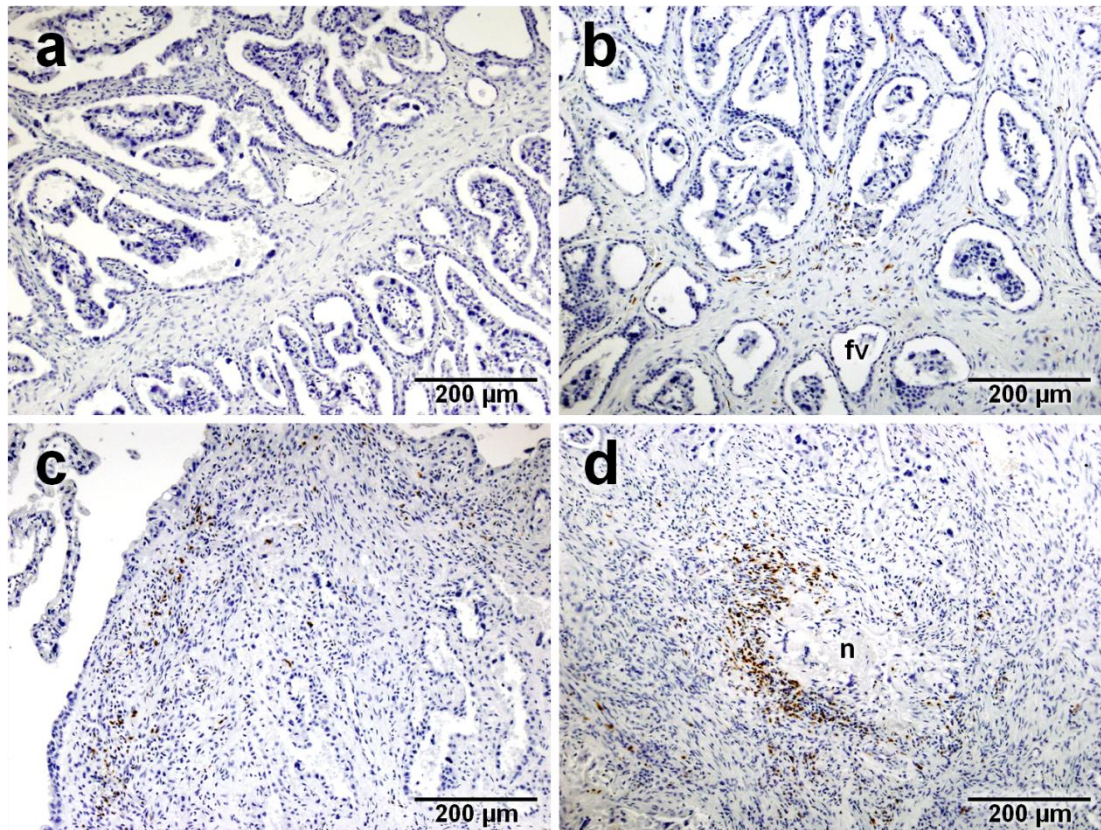
(3) AbD Serotec, Oxford, UK

(4) ILRI, International Livestock Research Institute, Nairobi, Kenya

(a) Early gestation

(b) Mid gestation

(c) Late gestation



Figures 3a-d: Examples of different scores of CD3⁺ cell infiltrates in placentomes from *N. caninum*-inoculated animals. (a) Score 0: no infiltration of CD3⁺ cells in a placentome of a negative control cow. (b) Score 1: rare CD3⁺ cells in the caruncles surrounding some necrotic foetal villi (fv) in the placentome of a *N. caninum*-inoculated cow culled 14 dpi. (c) Score 2: mild infiltrate of CD3⁺ cells surrounding area of detachment of foetal trophoblast and mesenchyme of the caruncle of the placentome of an inoculated cow culled 14 dpi. (d) Score 3: focal aggregation of CD3⁺ cells surrounding focal necrotic area in the caruncle of the placentome of an inoculated cow culled 14 dpi. All of them counterstained with haematoxylin. IHC slides produced and photographed by GJC.

Statistical analysis

Given the limited sample sizes and the lack of replication in the negative control group at each time point, the time factor was omitted and it was assumed that the data originated from the same population in order to gain statistical power. This was supported by results from robust Fligner and Kruskal-Wallis tests on homogeneity, variability and location parameters among *N. caninum*-inoculated animals over time. Then, non-parametric two-tailed Mann-Whitney tests allowing for ties were conducted on the pooled data to investigate statistically significant differences in the

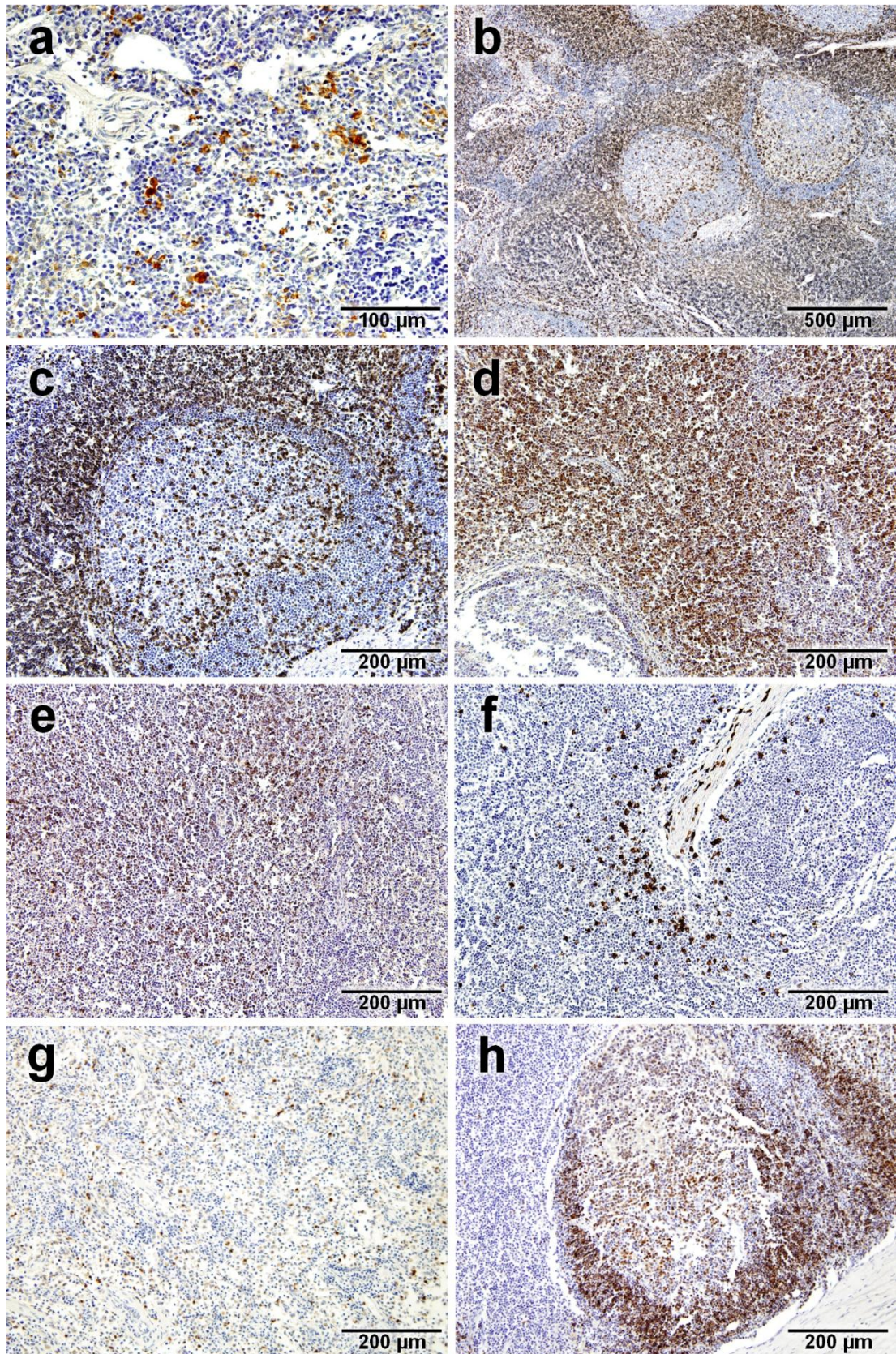
distribution of scores between *N. caninum*-inoculated and negative control animals for each cell type. Statistical significance was assessed at the 95% confidence interval.

Results

Clinical and *post mortem* examination findings from dams and foetuses were outlined in Chapter 1 and published by Benavides *et al.* (2012). Briefly, no abortions were recorded in *N. caninum*-inoculated or negative control animals since, on the day of euthanasia, all dams carried a viable foetus. Although the negative control dam culled at 14 dpi was later found to be *Neospora* PCR positive in different tissues, microsatellite markers indicated that the genotype of the parasite was different from the Nc-1 genotype used in the experimental inocula (Benavides *et al.*, 2012).

Phenotypic analysis of inflammatory cells in placental tissue

Examples of positive control tissues stained with each mAb are illustrated below, Figures 4a-h).

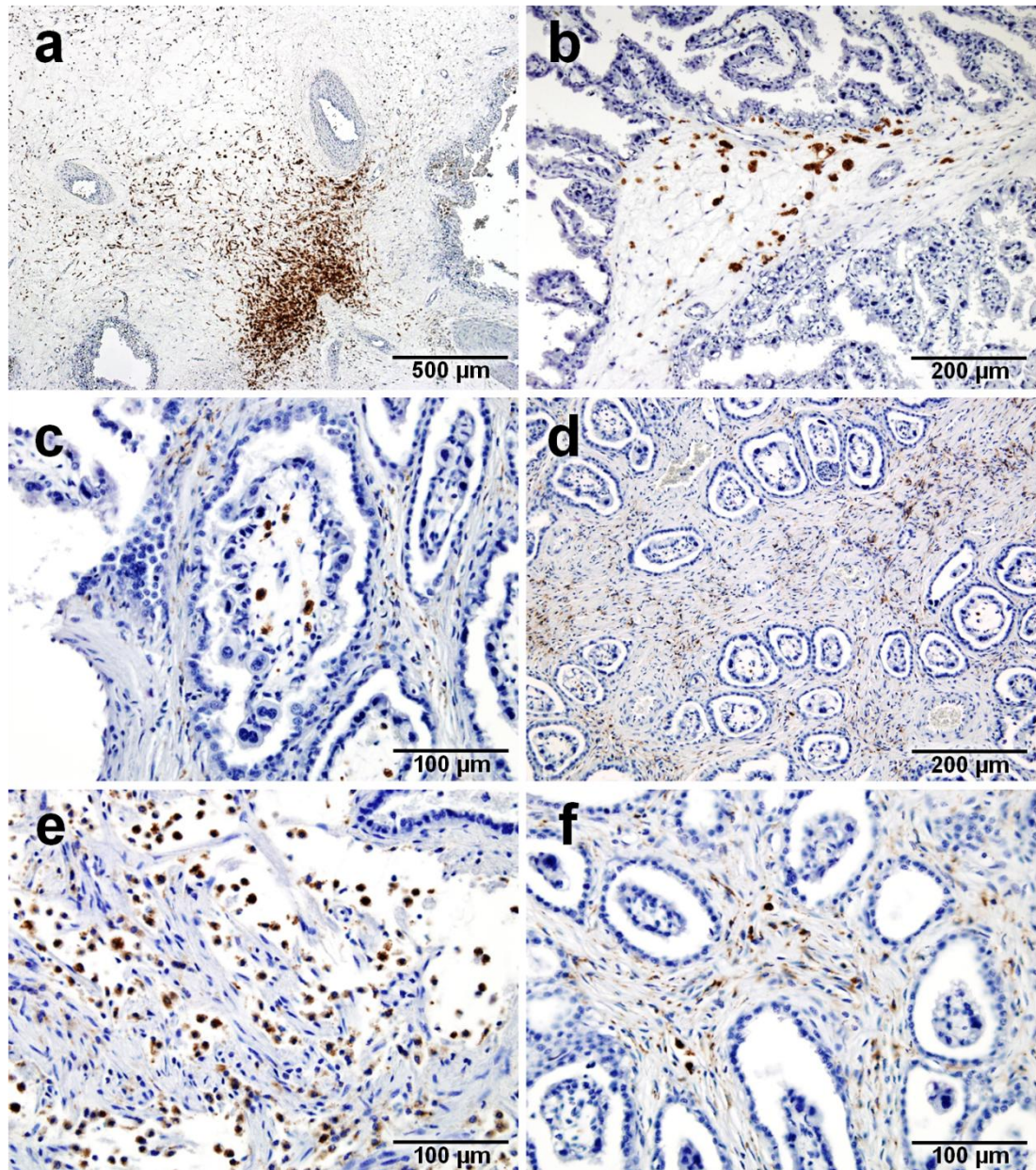


Figures 4a-h: Positive control tissues (retropharyngeal lymph node of a negative control dam) stained with the different mAbs used to phenotypically characterise the placental tissues. (a) CD68⁺ (macrophages); (b and c) CD3⁺ (T cells); (d) CD4⁺ (T

helper cells); (e) CD8⁺ (cytotoxic T cells); (f) $\gamma\delta$ TCR⁺ ($\gamma\delta$ -T cells); (g) CD335⁺ (NK cells) and (h) CD79_{acy}⁺ cells. All of them counterstained with haematoxylin. IHC slides produced and photographed by GJC.

CD68⁺ cells

Macrophages were observed in the placentas of all the *N. caninum*-inoculated animals throughout the period of study. The infiltrate of macrophages was more evident in the *N. caninum*-inoculated animals culled at 14 dpi. It ranged from mild to severe and was concentrated at the base of the caruncles and between the endometrial glands (see Figure 5a). Large labelled cells in the connective tissue of the caruncle (not always associated with pathological changes) (see Figure 5b) were also observed. In some cases, macrophages infiltrating necrotic foetal villi were seen. The placentas of *N. caninum*-inoculated animals culled at 28 dpi contained a milder infiltrate of macrophages compared to those sampled at 14 dpi. This was characterised by a minimal diffuse infiltrate at the caruncle base, with some large labelled cells in the caruncle stalk connective tissue or in some foetal villi (see Figure 5c). These were generally not associated with any other lesions. At 42 and 56 dpi the infiltrate of macrophages was heavier than at 28 dpi, but still not as pronounced as in the placentas sampled at 14 dpi. At 42 and 56 dpi, the macrophages mainly surrounded small areas of necrosis in the caruncle and in necrotic foetal villi. They also infiltrated the base of caruncles but were not associated with any lesions there (see Figures 5d and 5e, respectively). Rare non-aggregated CD68⁺ cells were observed in placentas of negative control animals (see Figure 5f). The observed differences in the scores of macrophage infiltration between *N. caninum*-inoculated and negative control groups (see Figure 6) were not statistically significant ($p = 0.099$).



Figures 5 a-f: Examples of macrophage infiltrates in placentomes from *N. caninum*-inoculated (a-e) and negative control (f) animals. (a) Severe infiltration (score 4) of macrophages in the base of a caruncle of a *N. caninum* inoculated dam culled at 14 dpi. (b) Infiltrates of large macrophages in the connective tissue of the caruncle stalk (score 2) of a *N. caninum* inoculated dam culled at 14 dpi. (c) Minimal infiltrate (score 1) of macrophages in some foetal villi of the placentome from a *N. caninum* inoculated dam culled at 28 dpi. (d) Mild infiltration (score 2) of macrophages in the connective tissue in a caruncular stalk of a placentome from a *N. caninum* inoculated dam culled at 42 dpi. (e) Moderate infiltrate (score 3) of large macrophages in the connective tissue in the caruncle of a placentome from a *N. caninum* inoculated dam culled at 56 dpi. (f) Minimal infiltrate (score 1) of macrophages in the caruncle in a placentome from the negative control dam culled at 14 dpi. All of them counterstained with haematoxylin. IHC slides produced and photographed by GJC.

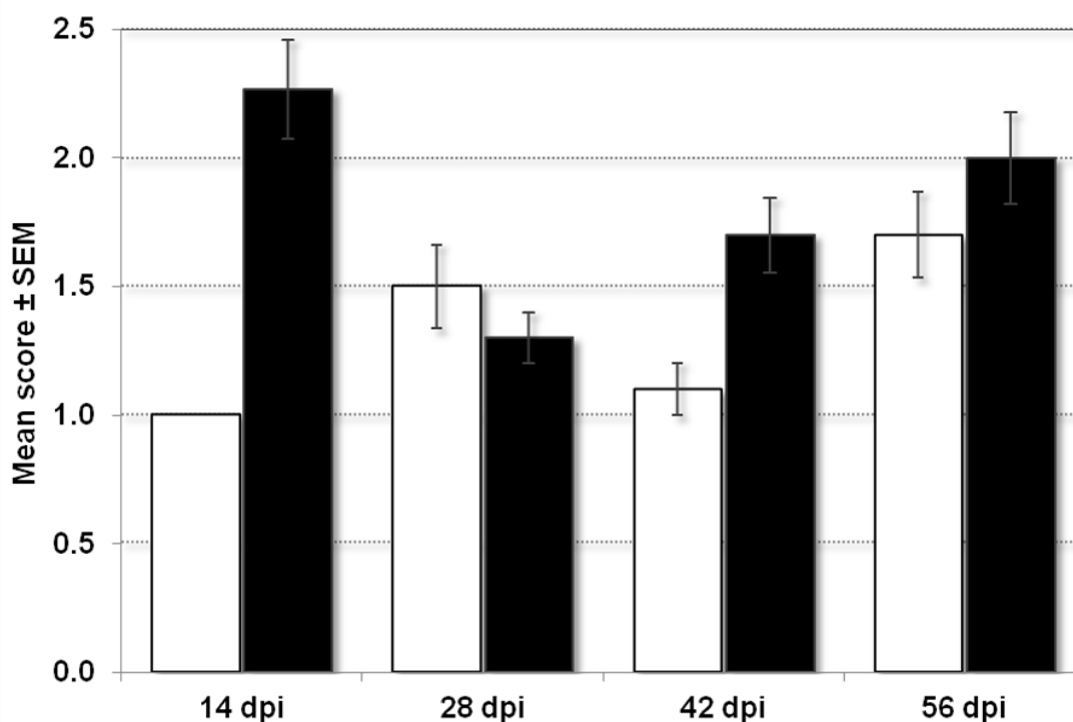
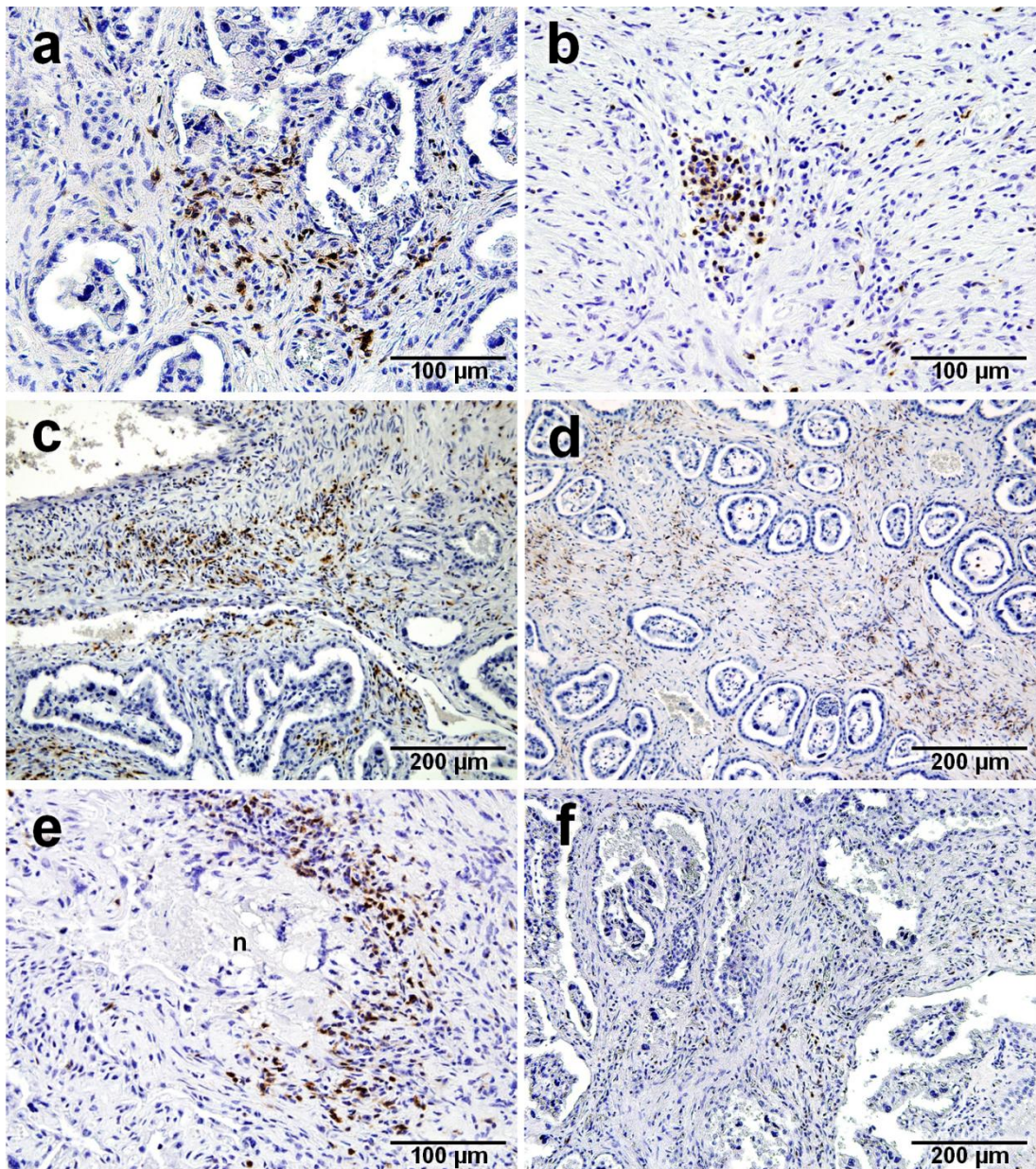


Figure 6: Mean CD68⁺ cell scores in placentomes collected from *N. caninum* inoculated (black bars) and negative control (white bars) dams. Error bars indicate standard error of the means (SEM). Modified from Cantón *et al.* (2013b)

CD3⁺ cells

In 10 to 70% of the sampled placentomes of the *N. caninum*-inoculated dams culled at 14 dpi there was a minimal to mild infiltrate of CD3⁺ cells in areas of necrosis in the caruncle and sporadically surrounding necrotic foetal villi, occasionally forming little aggregates (see Figure 7a). Scattered perivascular CD3⁺ cells were observed in the caruncle, though not associated with pathological changes. Minimal diffuse infiltrates of CD3⁺ cells were also observed in the base of the caruncles of the *N. caninum*-inoculated animals. In 40 to 90% of the placentomes of the *N. caninum*-inoculated animals culled at 28 dpi there was a minimal to mild infiltrate of CD3⁺ cells forming multifocal aggregates (see Figures 7b and 7c) in areas surrounding necrotic foetal villi, necrotic foci and in connective tissue in caruncle. Some of these aggregates were also located in perivascular areas. Rare CD3⁺ cells were also

observed in areas of the caruncle where no pathological lesions were present. In 90 to 100% of the collected placentomes from the *N. caninum*-inoculated dams culled at 42 dpi, mild multifocal infiltrates of CD3⁺ cells were located in large areas of necrosis in caruncles (see Figure 7d), in the caruncular stalk surrounding cryptal epithelium, and in necrotic foetal villi. Some of these infiltrates were also in the perivascular regions of the caruncle. Finally, in 10 and 60% of the placentomes of the *N. caninum*-inoculated dams culled at 56 dpi, mild aggregates of CD3⁺ cells were surrounded necrotic foci (see Figure 7e) in perivascular areas of the caruncles and in necrotic foetal villi. Single rare CD3⁺ cells were observed in the caruncle of negative control animals, not associated with any pathological changes in the negative control animals (see Figure 7f). The mean scores of total T cells in negative control and *N. caninum*-inoculated animals over time are shown in Figure 8. Statistically significant differences in cellular infiltrate scores between *N. caninum*-inoculated and negative control animals were found overall for CD3⁺ cells ($p < 0.05$).



Figures 7 a-f: Examples of T cell (CD3⁺) infiltrates of placentomes from *N. caninum*-inoculated (a-e) and negative control (f) animals. (a) Mild aggregate of CD3⁺ cells in the caruncle of a *N. caninum* inoculated dam culled at 14 dpi. (b) Small foci of CD3⁺ cell infiltration in the base of the placentome from a *N. caninum* inoculated dam culled at 28 dpi. (c) Moderate infiltration of CD3⁺ cell infiltration in caruncle stalk of the placentome from a *N. caninum* inoculated dam culled at 28 dpi. (d) Mild infiltration of CD3⁺ cells surrounding in the caruncle of a placentome from a *N. caninum* inoculated dam culled at 42 dpi. (e) Moderate infiltration of CD3⁺ cells surrounding a necrotic focus (n) in the caruncle of a placentome from a *N. caninum* inoculated dam culled at 56 dpi. (f) Minimal infiltration of CD3⁺ cells in the caruncle of a placentome from the negative control dam culled at 28 dpi. All of them counterstained with haematoxylin. IHC slides produced and photographed by GJC.

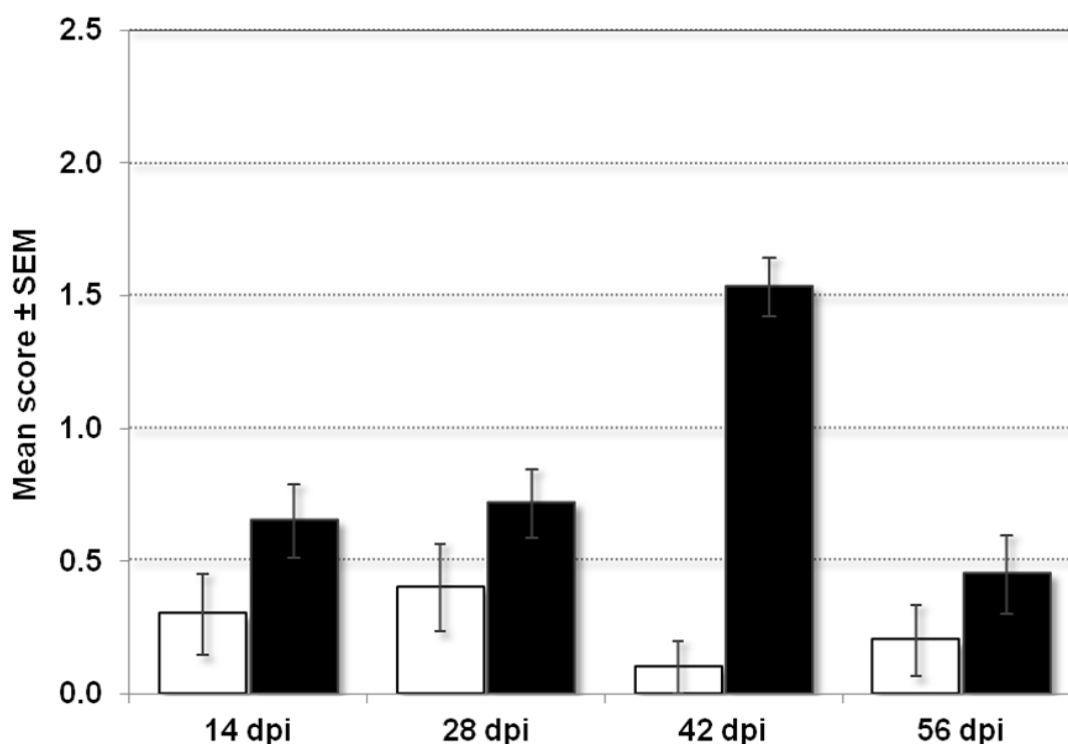
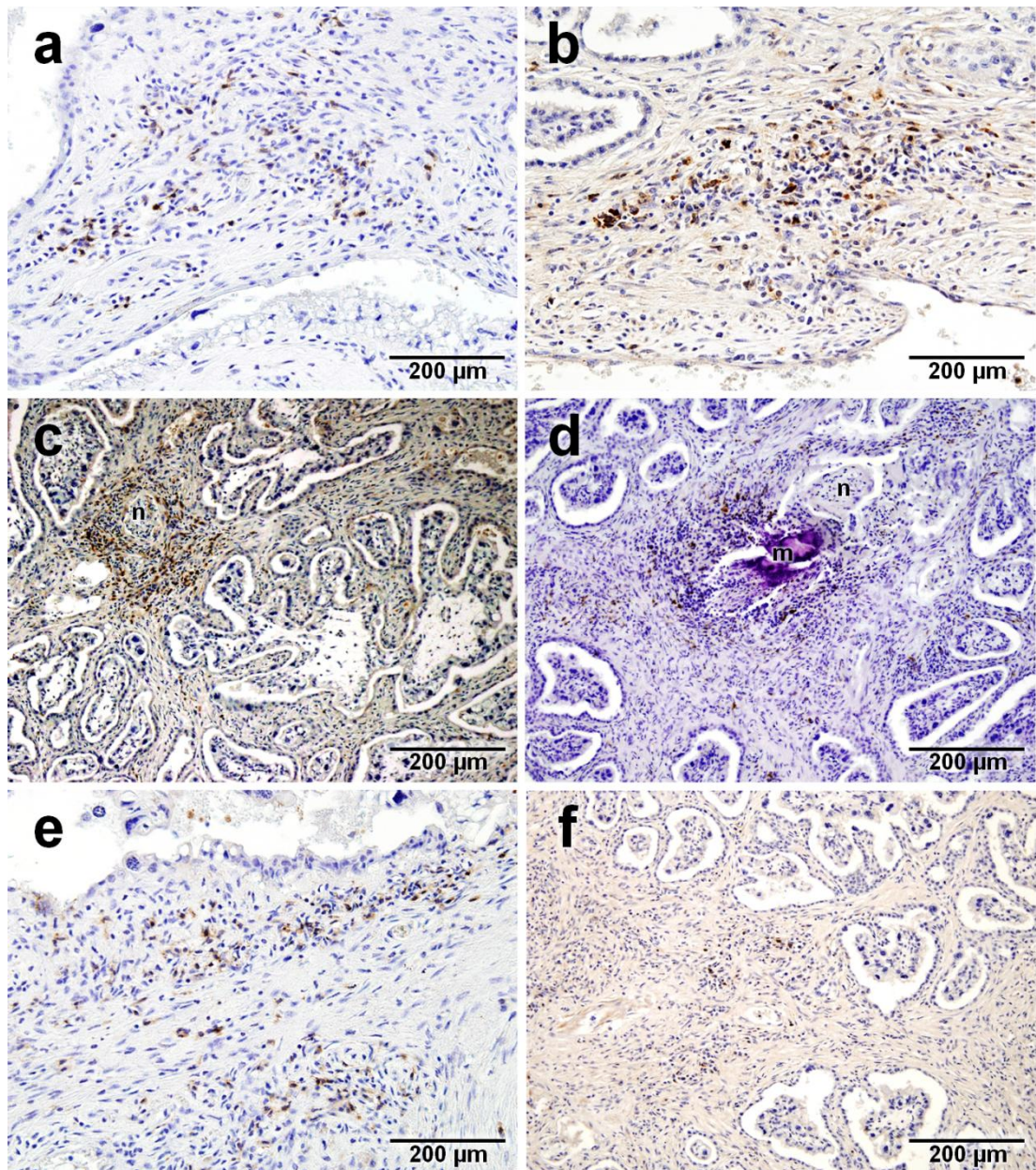


Figure 8: Mean CD3⁺ cell scores in placentomes collected from *N. caninum* inoculated (black bars) and negative control (white bars) dams. Error bars indicate SEM. Modified from Cantón *et al.* (2013b).

CD4⁺ cells

CD4⁺ cells were only observed in 10% of the placentomes of one out of three *N. caninum*-inoculated dams culled at 14 dpi, forming small aggregates in necrotic foci in the caruncles and surrounding necrotic foetal villi. Some CD4⁺ cells were also observed in areas of the caruncle not associated with any pathological features (see Figure 9a). In the samples taken at 28 dpi, between 10 to 70% of the placentomes from *N. caninum*-inoculated dams had scattered single or small aggregates of CD4⁺ T cells associated with necrotic foci in the caruncles (see Figure 9c) and, in some cases, in the periphery of blood vessels. They were also present focally in caruncles, though not associated with pathological changes (see Figure 9b). In the *N. caninum*-inoculated cows culled at 42 dpi, 40 to 80% of the placentomes had small aggregates of CD4⁺ cells in the caruncle, surrounding necrotic and mineralised foci and in necrotic foetal villi (see Figure 9d). Minimal infiltrates of CD4⁺ cells were also observed at the base of caruncles not associated with any pathological changes. In

the placentomes of the two *N. caninum*-inoculated animals culled at 56 dpi, a similar pattern of CD4⁺ cell infiltration was observed, but only in 10 to 40% of the sampled tissues, surrounding necrotic areas in caruncles in a perivascular location not associated with lesions (see Figure 9e). Single CD4⁺ cells were observed in caruncle of negative control animals, with no associated pathological changes (see Figure 9f). The mean scores of CD4⁺ T cells in negative control and *N. caninum*-inoculated dams over time are shown in Figure 10. No statistically significant differences in the distribution of CD4⁺ infiltration scores between the *N. caninum*-inoculated and control animals were detected ($p = 0.168$).



Figures 9 a-f: Examples of T helper cell (CD4⁺) infiltrates in placentomes from *N. caninum*-inoculated (a-e) and negative control (f) animals. (a) Mild infiltration of CD4⁺ cells in the base of the placentome caruncle of a *N. caninum* inoculated dam culled at 14 dpi. (b) Moderate aggregate of CD4⁺ cells in the caruncle of a placentome collected from a *N. caninum* inoculated dam culled at 28 dpi. (c) Moderate aggregate of CD4⁺ cells surrounding a necrotic foetal villus (n) in the placentome from a *N. caninum* inoculated dam culled at 28 dpi. (d) Mild infiltration of CD4⁺ cells surrounding a necrotic foetal villus (n) and mineralisation (m) from a placentome from a *N. caninum* inoculated dam culled at 42 dpi. (e) Mild aggregates of CD4⁺ cells in the base of a placentome from a *N. caninum* inoculated dam culled at 56 dpi. (f) Rare CD4⁺ cells in the caruncle of a placentome from a negative control dam culled at 14 dpi. All of them counterstained with haematoxylin. IHC slides produced and photographed by GJC.

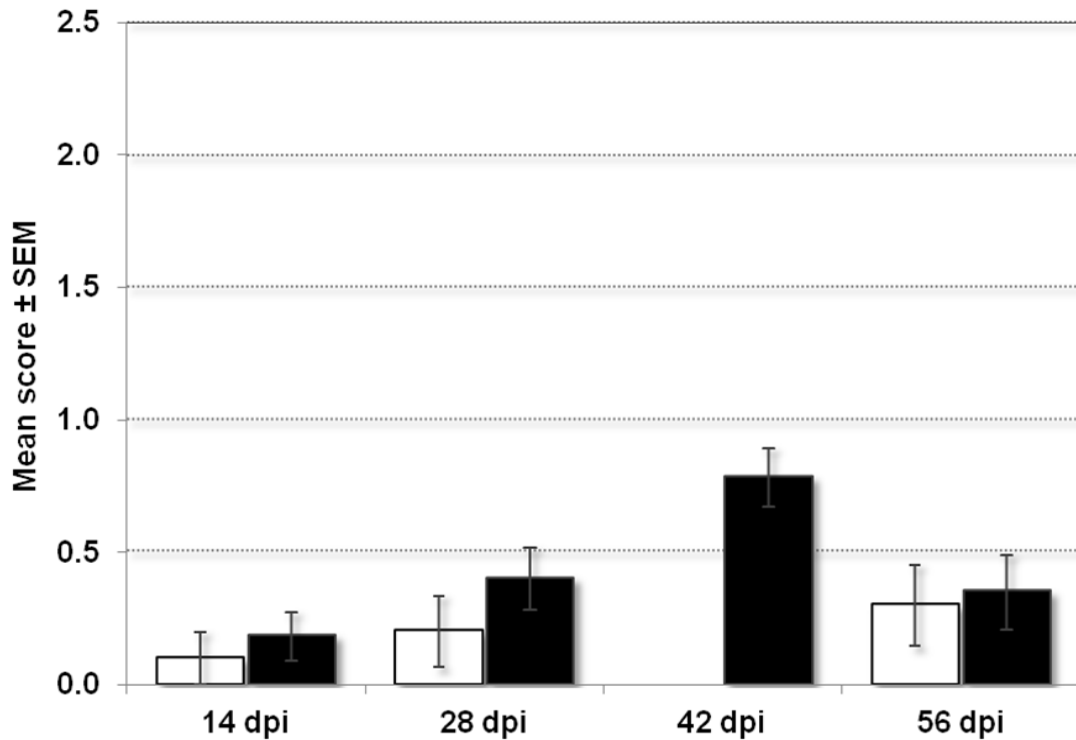
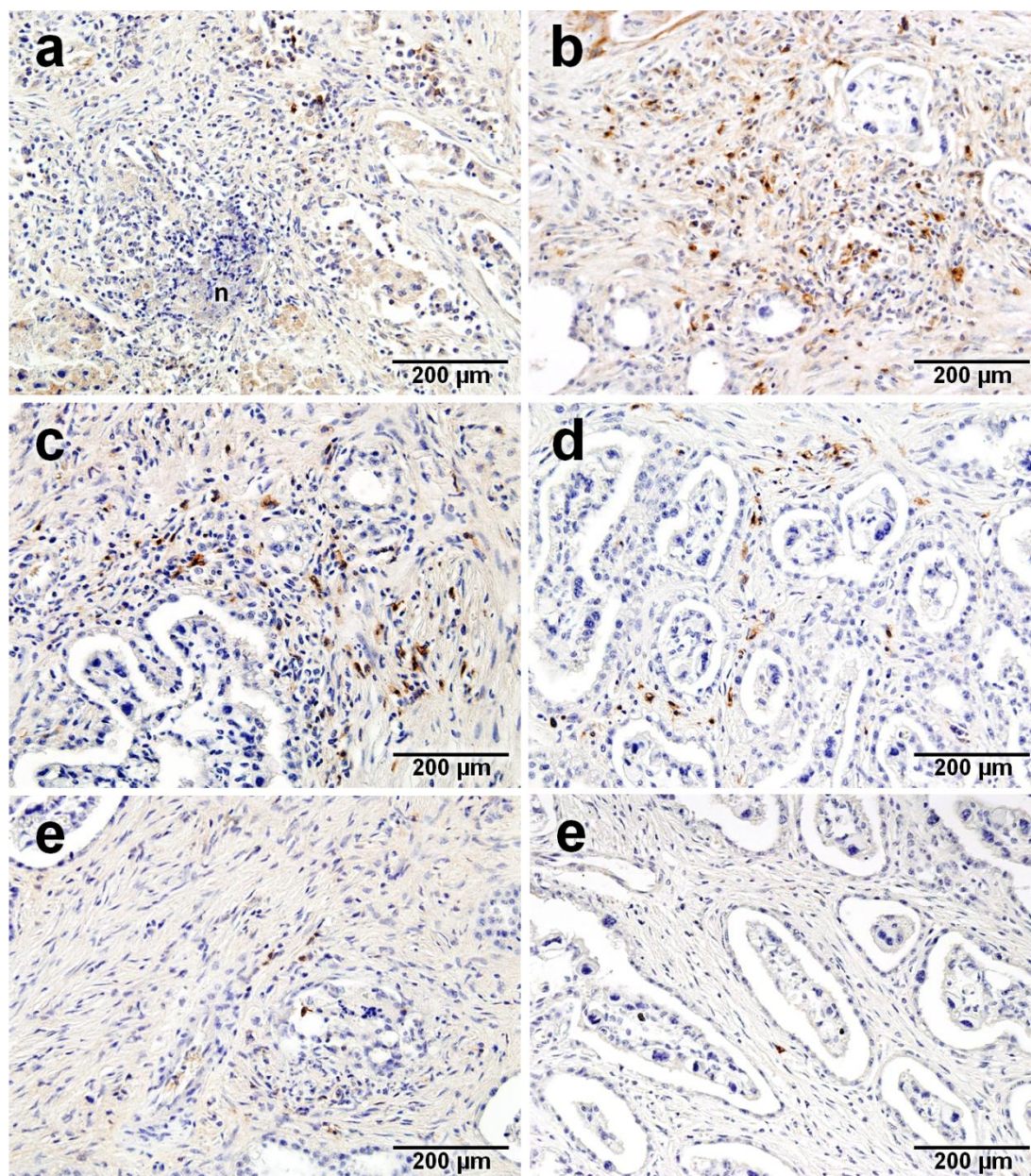


Figure 10: Mean CD4⁺ cell scores in placentomes collected from *N. caninum* inoculated (black bars) and negative control (white bars) dams. Error bars indicate SEM. Modified from Cantón *et al.* (2013b).

CD8⁺ cells

In the three *N. caninum*-inoculated dams culled at 14 dpi, there were rare CD8⁺ T cells surrounding small necrotic foci in the caruncles of 10% of placentomes (see Figure 11a). In all *N. caninum*-inoculated dams culled at 28 dpi, there were rare to moderate numbers of CD8⁺ T cells around necrotic foci in the caruncles of between 10 and 30% of placentomes (see Figure 11b). In the *N. caninum*-inoculated animals culled on 42 dpi, rare CD8⁺ cells were observed near foci of necrosis in the caruncle in 10 to 50% of the placentomes (see Figures 11c and 11d). Rare CD8⁺ cells were associated with small necrotic foci in the caruncle in 10% of the placentomes in one of the two *N. caninum*-inoculated animals culled at 56 dpi (see Figure 11e). Rare and diffusely distributed CD8⁺ cells were also observed in caruncles of some placentomes of *N. caninum*-inoculated and negative control animals, though not associated with pathological changes (see Figure 11f). In Figure 12, the mean CD8⁺ T cell scores are summarised. Similarly to the CD4⁺ cells, the differences in the

distribution of CD8⁺ scores between *N. caninum*-inoculated and negative control groups were not statistically significant ($p = 0.255$).



Figures 11 a-f: Examples of cytotoxic T cell (CD8⁺) infiltrates in placentomes from *N. caninum*-inoculated (a-e) and negative control (f) animals. (a) Mild infiltration of CD8⁺ cells in the caruncle surrounding some areas of necrosis (n) in a placentome from a *N. caninum* inoculated dam culled at 14 dpi. (b) Mild infiltration of CD8⁺ cells in the caruncle in a placentome from a *N. caninum* inoculated dam culled at 28 dpi. (c) Mild infiltration of CD8⁺ cells in the caruncle of a placentome from a *N. caninum* inoculated dam culled at 42 dpi. (d) Minimal infiltration of CD8⁺ cells in the caruncle of a placentome from a *N. caninum* inoculated dam culled at 42 dpi. (e) Minimal infiltration of CD8⁺ cells in the placentome from a *N. caninum* inoculated dam culled at 56 dpi. (f) Single CD8⁺ cells in the caruncle of a placentome of the negative control dam culled at

28 dpi. All of them counterstained with haematoxylin. IHC slides produced and photographed by GJC.

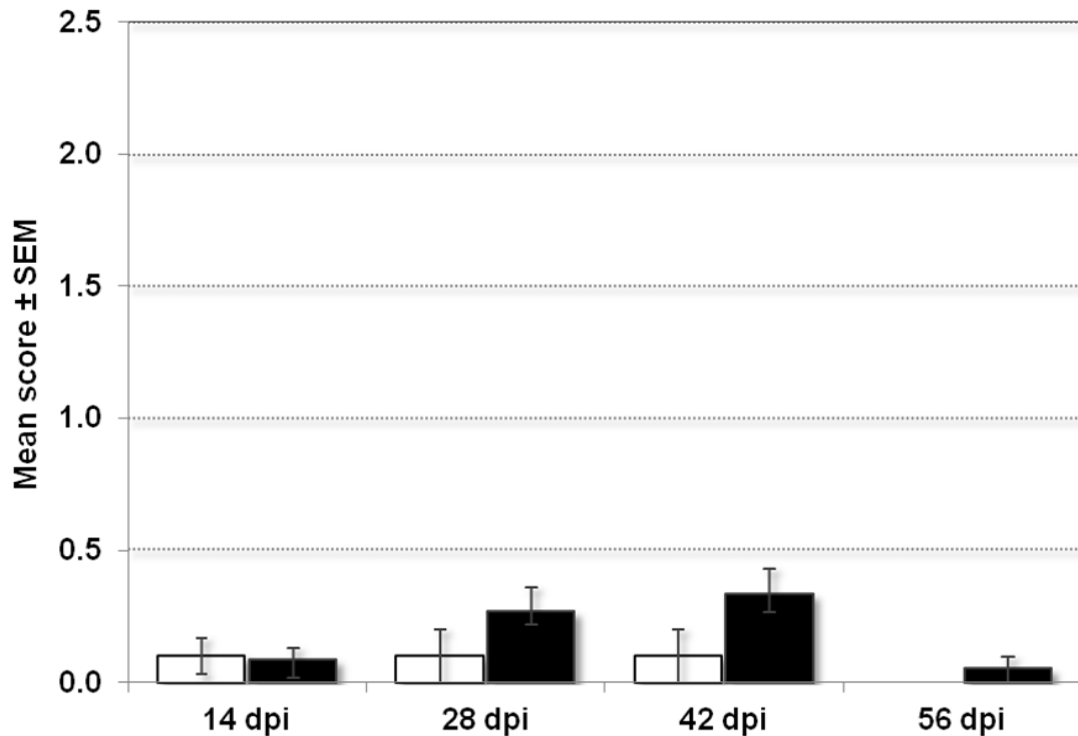
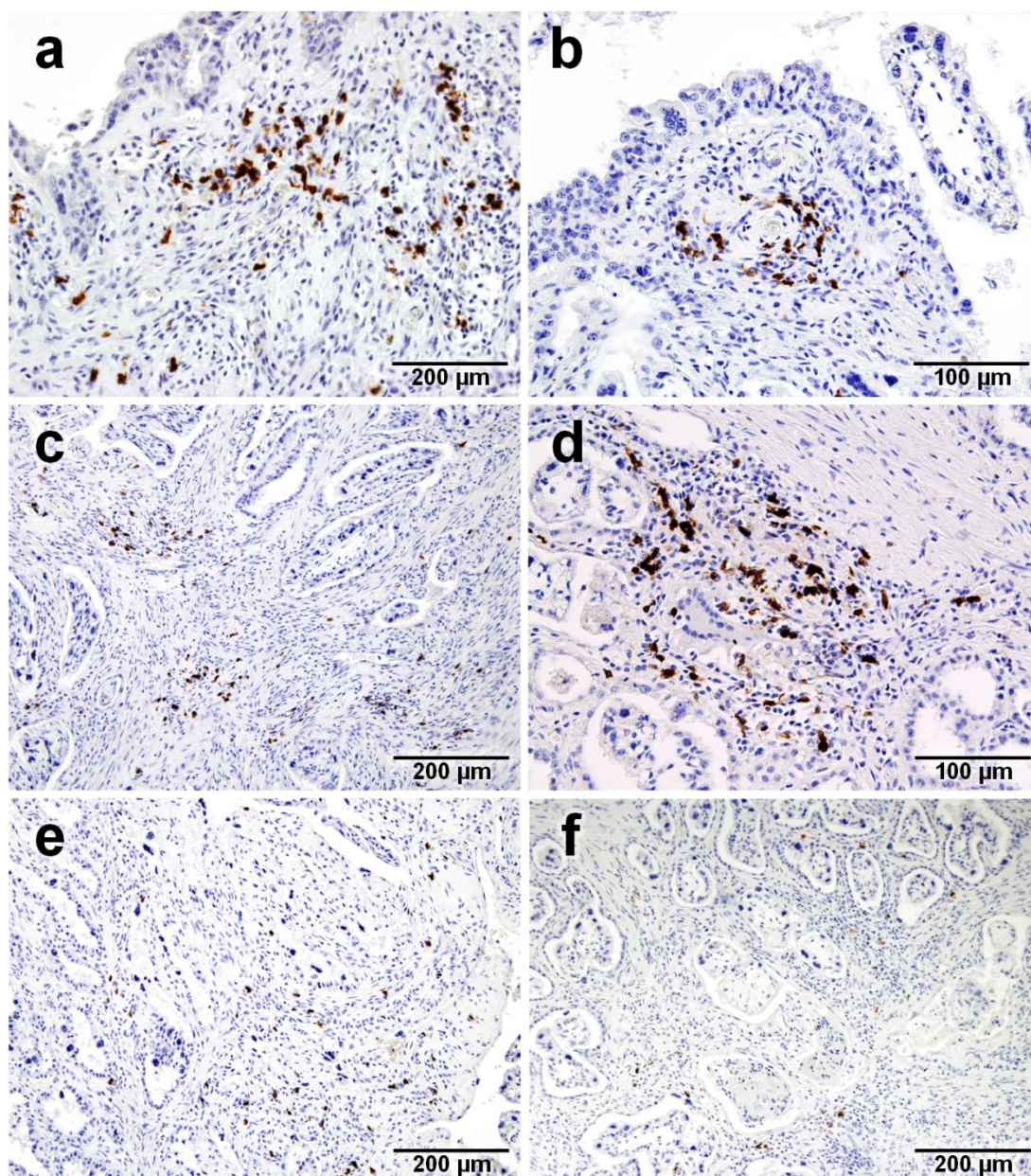


Figure 12: Mean CD8⁺ cell scores in placentomes collected from *N. caninum* inoculated (black bars) and negative control (white bars) dams. Error bars indicate SEM. Modified from Cantón *et al.* (2013b).

$\gamma\delta$ TCR⁺ cells

In 10 to 70% of the selected placentomes from the *N. caninum*-inoculated animals culled at 14 dpi, there was a minimal to mild $\gamma\delta$ -T cell infiltrate in necrotic foci in the caruncles or in necrotic and mineralised foetal villi. Gamma delta T cells also surrounded blood vessels and infiltrated areas with no pathological changes (see Figures 13a and 13b). In 80 to 90% of the placentomes from three of the *N. caninum*-inoculated animals culled at 28 dpi there was a minimal to mild infiltrate of $\gamma\delta$ -T cells in necrotic and mineralised areas of the caruncle, in necrotic and mineralised foci at the base of the caruncles (see Figure 13c) and in necrotic foetal villi. In 60 to 100% of the placentomes from the *N. caninum*-inoculated animals

culled at 42 dpi, there was a minimal to mild focal infiltrate of $\gamma\delta\text{TCR}^+$ cells surrounding necrotic and mineralised foci at the base of the caruncles (see Figure 13d). In the two *N. caninum*-inoculated animals culled at 56 dpi, 70 and 90% of the placentomes, respectively, contained a minimal to mild focal infiltrate of $\gamma\delta$ -T cells in necrotic foetal villi, in the connective tissue of the foetal-maternal junction and at the base of the caruncles, associated with necrosis (see Figure 13e). Gamma delta T cells were also diffusely observed at the base of the caruncles, generally not associated with pathological changes in negative control and *N. caninum*-inoculated animals at 14, 28, 42 and 56 dpi (see Figure 13f). The $\gamma\delta$ -T cell score for negative control and *N. caninum*-inoculated animals are plotted against time and illustrated in Figure 14. Statistically significant differences were found overall in the distribution of $\gamma\delta$ -T cell scores between *N. caninum*-inoculated and negative control animals ($p < 0.05$).



Figures 13 a-f: Examples of $\gamma\delta$ -T cell infiltrates in placentomes from *N. caninum*-inoculated and negative control animals. (a) Moderate infiltrate of $\gamma\delta$ TCR⁺ cells in the caruncle of a placentome from a *N. caninum* inoculated dam culled at 14 dpi. (b) Mild perivascular infiltrate of $\gamma\delta$ TCR⁺ cells in the caruncle of a placentome from a *N. caninum* inoculated dam culled at 14 dpi. (c) Mild aggregates of $\gamma\delta$ TCR⁺ cells in the caruncle of a placentome collected from a *N. caninum* inoculated dam culled at 28 dpi. (d) Moderate aggregate of $\gamma\delta$ TCR⁺ cells in the caruncle surrounding some necrotic foetal villi, observed in a placentome from a *N. caninum* inoculated dam culled at 42 dpi. (e) Rare $\gamma\delta$ TCR⁺ cell infiltration in the caruncle of a placentome of a *N. caninum* inoculated dam culled at 56 dpi. (f) Rare individualised $\gamma\delta$ TCR⁺ cells in the caruncle of a placentome collected from a negative control dam culled at 14 dpi. All of them counterstained with haematoxylin. IHC slides produced and photographed by GJC.

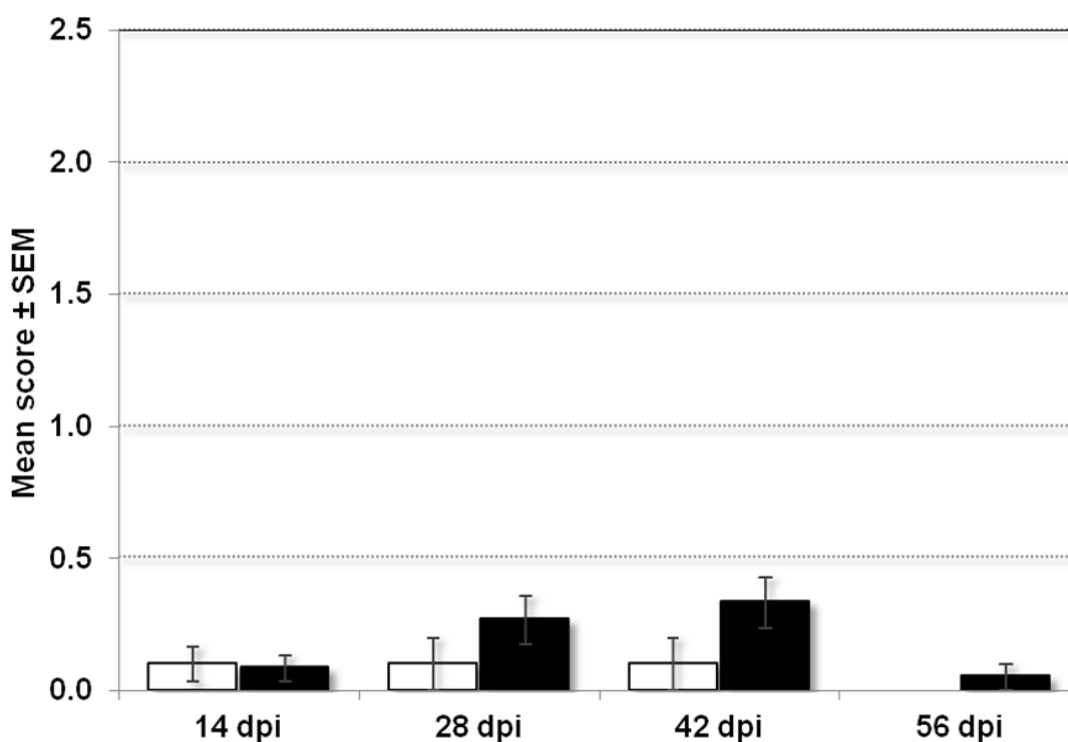
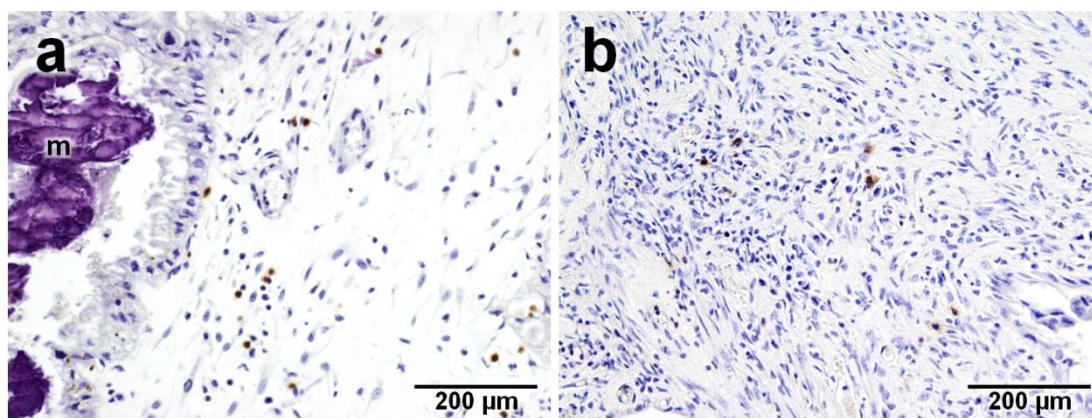


Figure 14: Mean $\gamma\delta\text{TCR}^+$ cell scores in placentomes collected from *N. caninum* inoculated (black bars) and negative control (white bars) dams. Error bars indicate SEM. Modified from Cantón *et al.* (2013b).

***NKp46*⁺ cells**

Single *NKp46*⁺ cells were observed throughout the caruncle in the placentomes of all the *N. caninum*-inoculated animals culled at 14, 28, 42 and 56 dpi. In two out of three and in one out of three *N. caninum*-inoculated animals culled at 28 and 42 dpi, respectively, aggregates of *NKp46*⁺ cells were detected in caruncles surrounding foci of necrosis and mineralisation (see Figure 15a). Minimal infiltrates of *NKp46*⁺ cells were also observed in the base of the caruncle of all the *N. caninum*-inoculated and negative control animals, though not associated with pathological changes (see Figure 15b). The *NKp46* scores are plotted against time and highlighted in Figure 16. Statistically significant differences in the distribution of *NKp46*⁺ infiltration scores were observed between *N. caninum*-inoculated and negative control groups ($p < 0.01$).



Figures 15 a-b: Examples of NK cell infiltrates in placentomes from *N. caninum*-inoculated and negative control animals. (a) Mild infiltrates of NK cells in the base of a placentome surrounding an area of mineralisation from a *N. caninum* inoculated dam culled at 14 dpi. (b) Rare NK cells in the caruncle of a negative control dam culled at 28 dpi. Both counterstained with haematoxylin. IHC slides produced and photographed by GJC.

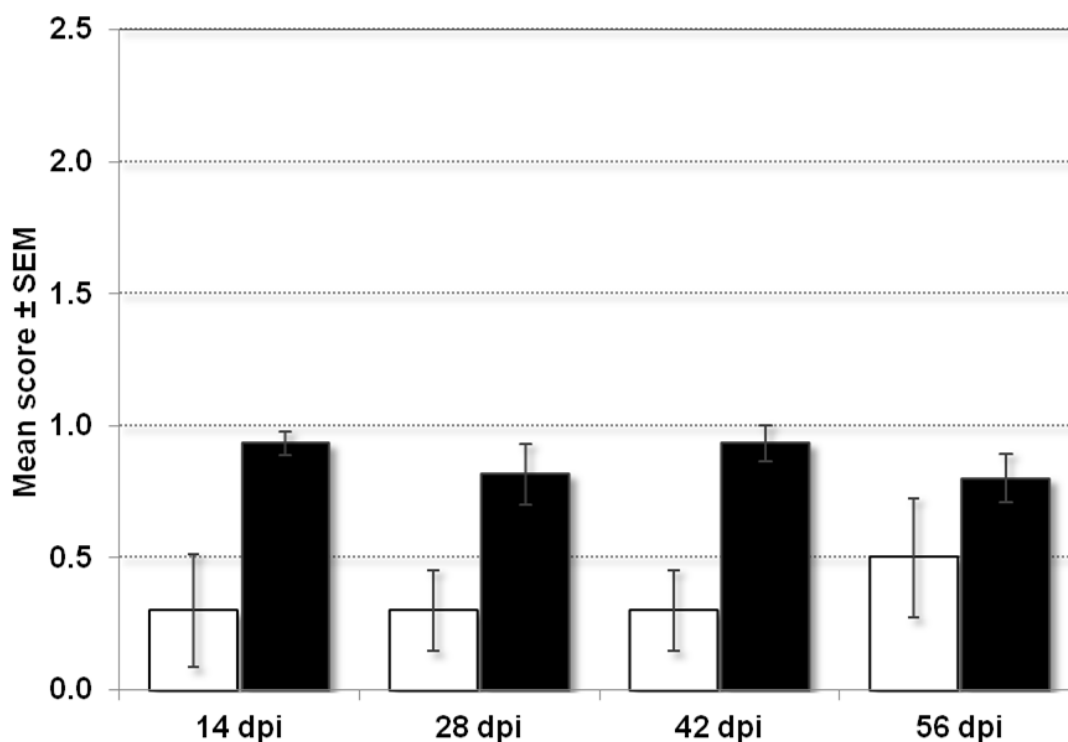
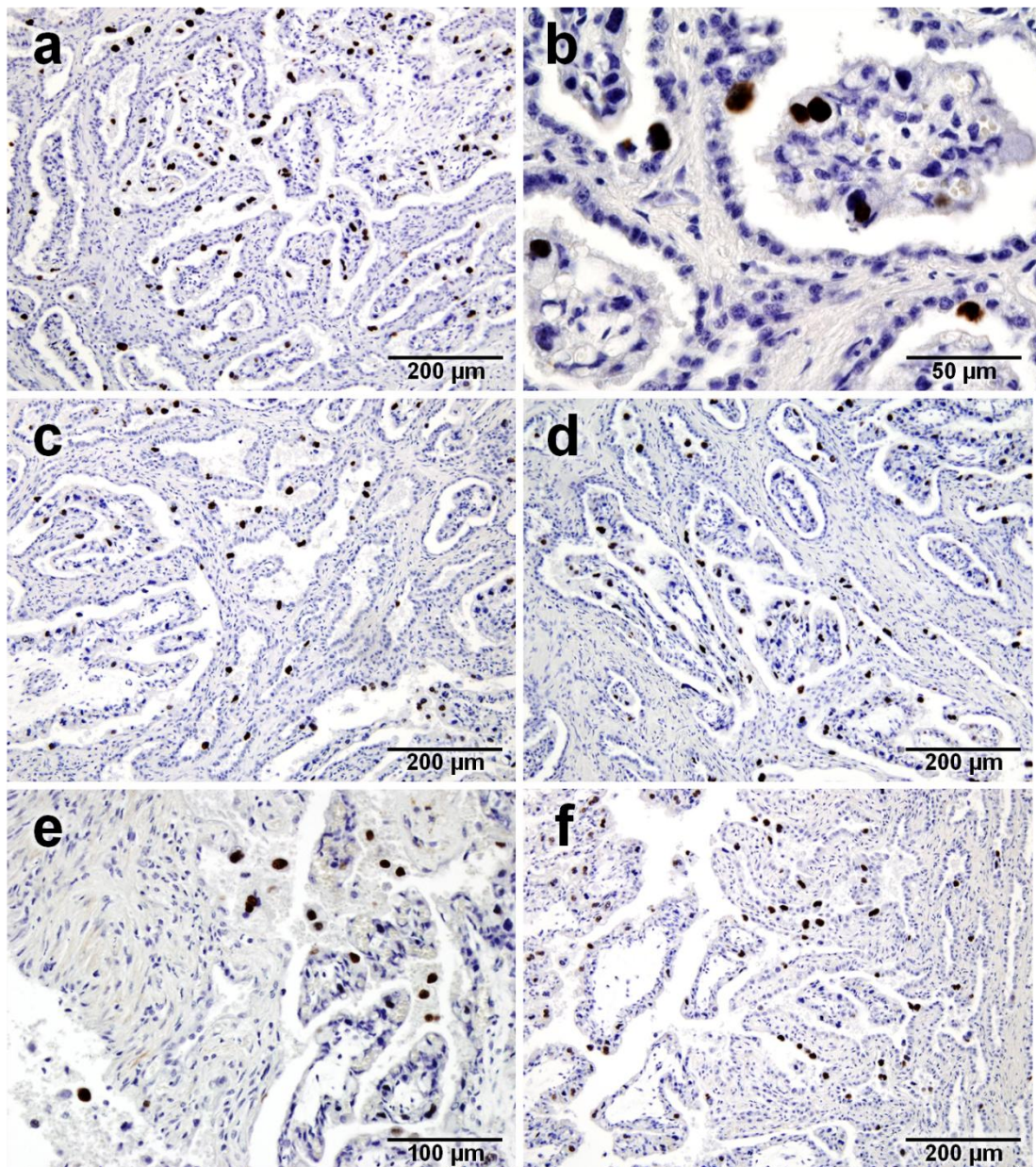


Figure 16: Mean NKp46⁺ cell scores in placentomes collected from *N. caninum* inoculated (black bars) and negative control (white bars) dams. Error bars indicate SEM. Modified from Cantón *et al.* (2013b).

CD79_{acy}⁺ cells and cytokeratin

Rare individualised CD79_{acy} positive cells were observed in all animals from both the *N. caninum*-inoculated and negative control groups on 14, 28, 42 and 56 dpi (see Figures 17a-f, respectively). These cells were diffusely distributed, mainly aligned with the endometrial epithelium in the caruncles and in some foetal villi, but not associated with pathological changes. The time pattern of this infiltration is shown in Figure 18. No statistically significant differences in scores were found for CD79_{acy}⁺ cells between the *N. caninum*-inoculated and negative control groups ($p = 0.890$). When HM57 (anti CD79_{acy} antibody) was incubated overnight with non bovine ruminant placental tissues (ovine and water buffalo) it stained cells which were morphologically and histologically similar to those that reacted positively in the bovine tissues (see Figures 19a, 19b and 19c, respectively).

When selected placental tissues from *N. caninum*-inoculated and negative control dams were incubated with the mAb against cytokeratin, the trophoblast layer of mononuclear cuboidal cells and occasional binucleated cells were labelled (see Figures 19d), with the same localisation of the CD79_{acy}⁺ cells, confirming that HM57 mAb is indeed identifying trophoblast cells instead of B cells in the placentas.



Figures 17 a-f: Examples of CD79_{acy}⁺ cell infiltrates in placentomes from *N. caninum*-inoculated (a-e) and negative control (f) animals. (a) Diffuse distribution of CD79_{acy}⁺ cells in the caruncles of a *N. caninum* inoculated dam culled at 14 dpi. (b) Diffuse distribution of CD79_{acy}⁺ cells in the caruncles of a *N. caninum* inoculated dam culled at 14 dpi. (c, d and e) Diffuse distribution of CD79_{acy}⁺ cells in the caruncles of a *N. caninum* inoculated dam culled at 28, 42 and 56 dpi, respectively. (f) Diffuse distribution of CD79_{acy}⁺ cells in the caruncles of a negative control dam culled at 14 dpi. All of them counterstained with haematoxylin. IHC slides produced and photographed by GJC.

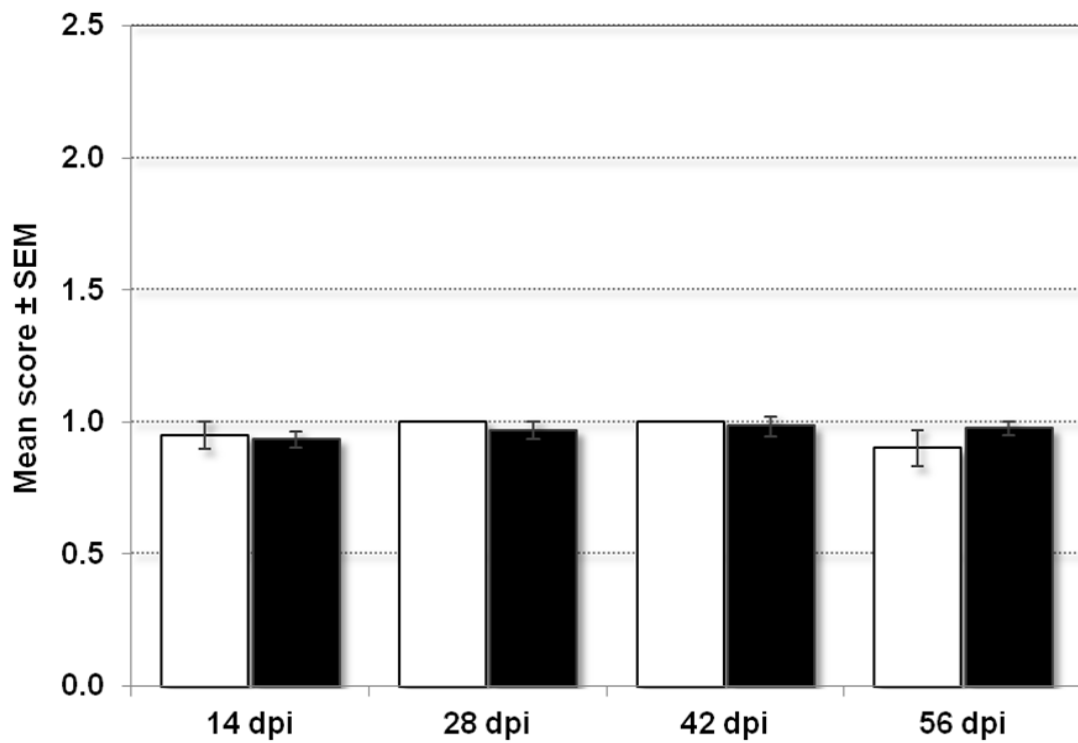
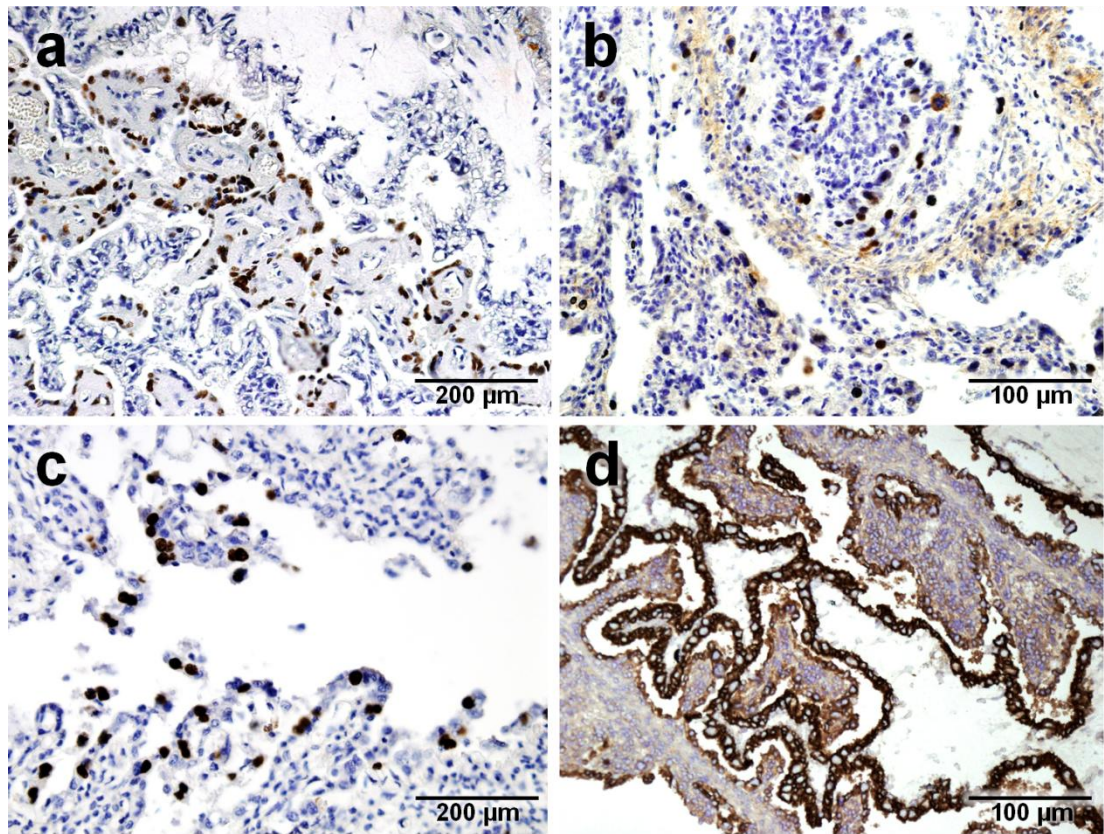


Figure 18: Mean CD79_{acy}⁺ scores in placentomes collected from *N. caninum* inoculated (black bars) and negative control (white bars) dams. Error bars indicate SEM. Modified from Cantón *et al.* (2013b).



Figures 19 a-d: Examples of CD79_{acy}⁺ cell infiltrates in the ovine (a) and buffalo (b and c) placenta, and cyokeratin labelling in the bovine placenta (d). All of them counterstained with haematoxylin. IHC slides produced and photographed by GJC.

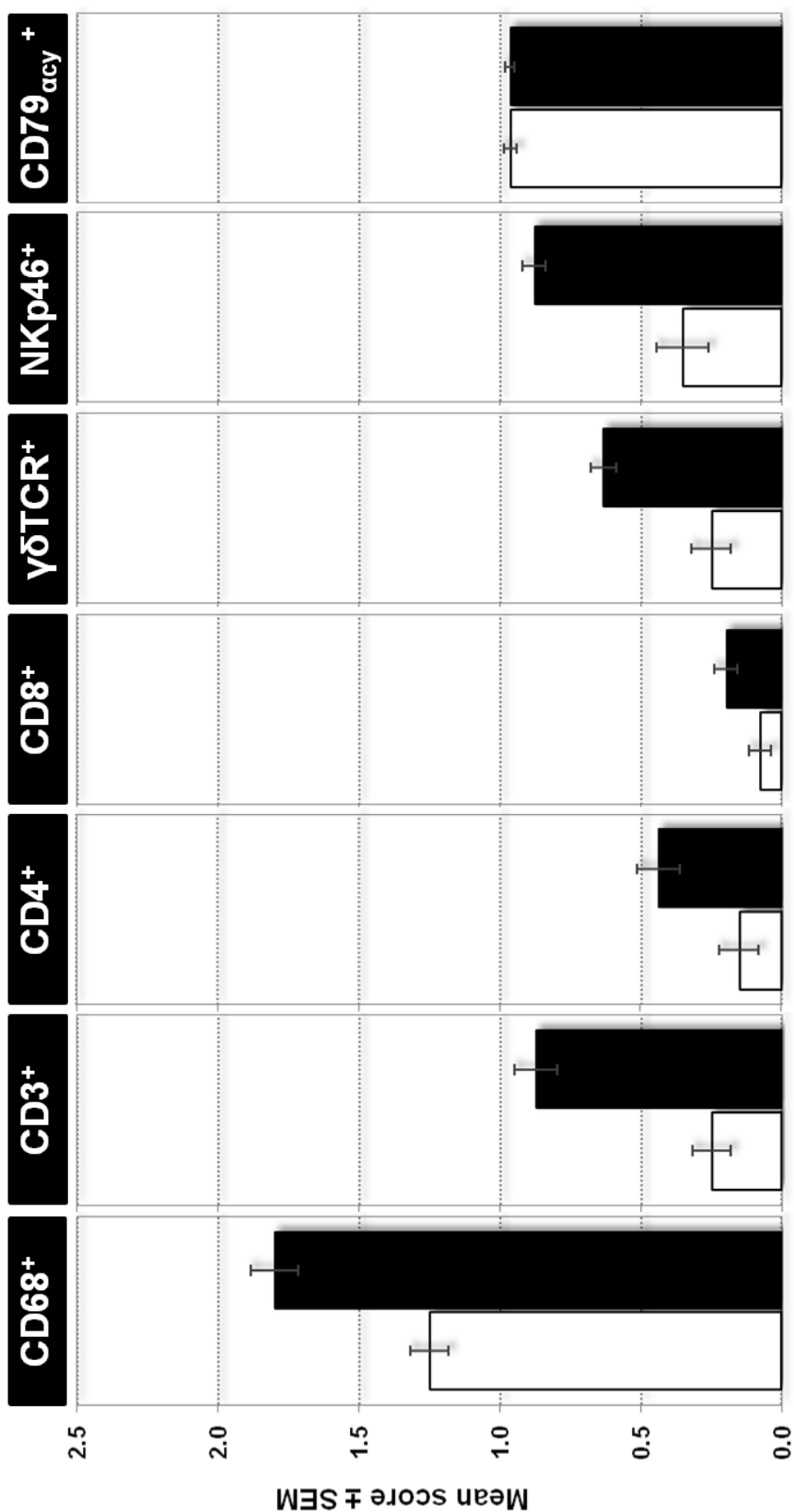


Figure 20: Summary of the mean infiltrates scores of the different phenotypes of inflammatory cells in placentomes collected from *M. caninum* inoculated (black bars) and negative control (white bars) dams. CD68⁺ (macrophages), CD3⁺ (total T cells), CD4⁺ (T helper), CD8⁺ (cytotoxic T cells), γδTCR⁺ (γδ T cells), NKp46⁺ (NK cells) and CD79_{acy}⁺ labelled cells in the placentas. Error bars indicate SEM. Modified from Cantón et al. (, 2013b).

Discussion

After inoculation with live tachyzoites of Nc-1 isolate at day 210 of gestation, all dams showed evidence of infection although no abortions occurred and only minimal to mild necrotic and inflammatory lesions were observed in placental and foetal tissues (Benavides *et al.*, 2012). These findings are similar to previous studies where dams intravenously inoculated with Nc-Liv at the same gestational age gave birth to asymptomatic congenitally infected calves (Williams *et al.*, 2000; Gibney *et al.*, 2008). In comparison, the outcome of infection in early gestation is often fatal with extensive lesions (Barr *et al.*, 1994b; Williams *et al.*, 2000; Macaldowie *et al.*, 2004; Gibney *et al.*, 2008) while infection in mid-gestation may result in abortion or the birth of persistently infected calves with mild lesions (Dubey *et al.*, 1992b; Barr *et al.*, 1994b; Williams *et al.*, 2000; Maley *et al.*, 2003; Williams *et al.*, 2003; Rosbottom *et al.*, 2008; Rosbottom *et al.*, 2011).

During the analysis of these placental samples a novel scoring methodology was developed, similar to that described by Tekin and Hansen (2004). Although comparable approaches have been used in different pathological studies, this methodology has allowed a clear characterisation of the infiltrating immune cells in fixed tissues, particularly with regard to their location and organisation, and culminating in the generation of objective data that can be statistically analysed. This methodology could be standardised because the same IHC protocols were used in all the samples and the scoring was undertaken by the same observer (GJC). Furthermore, this technique could be modified and applied to other studies with the aim of characterising and comparing cellular immune responses in fixed tissue samples. In fact, later the same methodology was applied to the placental samples collected during the previous studies following experimental inoculation with Nc-1 in early (Macaldowie *et al.*, 2004) and mid gestation (Maley *et al.*, 2003), allowing a better comparison and proving to be effective (see Chapter 3). Whereas with a single assessor the investigation error was negligible, more than one evaluator may have reduced the subjectivity and tested the repeatability of the system. For this reason, to give strength to the method and reduce error to a minimum, a randomised system was put in place by blind-coding the slides.

The results of the phenotypic analysis of the immune cell infiltrate in the placentas of the present study have shown that, although differential infiltration was observed between *N. caninum*-inoculated and negative control animals at each time point (14, 28, 42 and 56 dpi), no statistically significant differences were found for macrophages. Initially, macrophages were observed in large numbers in the placentas of *N. caninum*-inoculated dams culled at 14 dpi. Although *Neospora* was not detected by PCR or IHC in the placentas of these animals (Benavides *et al.*, 2012) the macrophage infiltration could have been involved in the initiation of an immune response to the parasite challenge in these *N. caninum*-inoculated animals. Monocytes/macrophages are one of the principal cellular components of innate immunity, acting as antigen presenting cells and consequently influencing the functional direction of the subsequent adaptive immune response (Raghupathy, 1997; Nishikawa *et al.*, 2001c). Indeed Rosbottom *et al.* (2008) demonstrated that endometrial macrophage populations were increased in pregnant cows after experimental infection with *N. caninum*. Macrophages have a crucial role in protective immunity, inhibiting intracellular multiplication of tachyzoites and exhibiting cytotoxic activity against the intracellular parasite in murine models of neosporosis (Tanaka *et al.*, 2000a).

At 28 dpi, macrophage infiltration was minimal to mild and an increased number of positive cells was observed at 42 and 56 dpi, associated with the presence of more severe pathological changes in the placenta (Benavides *et al.*, 2012). Macrophages are not only involved in anti-parasitic activity but also play a key role in the tissue repair process, since they are the principal cell type responsible for wound debridement (Leibovich and Ross, 1975). This may help to explain their presence after the appearance of tissue damage.

Statistical differences between the *N. caninum*-inoculated and the negative control animals were observed for the infiltration of CD3⁺ T cells over time and a similar phenomenon was observed for $\gamma\delta$ -T cells. A positive correlation was observed between these cellular infiltrates and the presence of pathological changes. The mild inflammatory infiltrates observed in the analysed placentomes of *N. caninum*-inoculated dams primarily expressed CD4⁺ and $\gamma\delta$ -T cell markers, indicating a

predominant Th1 response. Mean CD8⁺ T cell scores were lower than those for $\gamma\delta$ T cells and T helper cells (see Figure 20). The time pattern for the appearance of inflammatory cells in the placenta was related to the presence of *Neospora* (PCR and IHC) in the placental samples (Benavides *et al.*, 2012). Orozco *et al.* (2013) found scattered and fewer CD4⁺ and CD8⁺ T cells in the uteri and placentas of pregnant cows naturally infected with *N. caninum* and found no differences when compared with seronegative cattle. However, it has been established that *Neospora* is largely controlled by cell-mediated immune mechanisms and, specifically, CD4⁺ T lymphocytes have a significant protective role, demonstrable by the direct lysis of *N. caninum*-infected cells and production of IFN- γ which can significantly inhibit multiplication of the parasite (Marks *et al.*, 1998; Innes *et al.*, 2000; Staska *et al.*, 2003; Bartley *et al.*, 2004; Tuo *et al.*, 2004). Following infection with *N. caninum* in cattle, CD4⁺ T lymphocytes are principal components of the Th1 response and produce pro-inflammatory Th1 type cytokines including IFN- γ , TNF- α and IL-12, which have an essential role in protective immunity against the parasite (Innes *et al.*, 1995a; Khan *et al.*, 1997; Marks *et al.*, 1998; Baszler *et al.*, 1999; Williams *et al.*, 2000; Tuo *et al.*, 2004; López-Gatius *et al.*, 2007a). Mice depleted of IL-12 or IFN- γ , as well as IFN- γ -knockout mice, are unable to survive infection with *N. caninum* (Khan *et al.*, 1997; Baszler *et al.*, 1999). On the other hand, this Th1 response can be detrimental to pregnancy and can compromise foetal survival (Raghupathy, 1997; Quinn *et al.*, 2002a; Innes *et al.*, 2005). *In vitro* studies have shown that treatment of ruminant cells with IFN- γ significantly inhibited intracellular multiplication of *N. caninum* (Innes *et al.*, 1995a). The lower levels of Th1 cellular responses observed in this current study [when compared with studies conducted on placental tissue in early (Maley *et al.*, 2006) and mid-gestation (Rosbottom *et al.*, 2011) (see Chapter 3)], may help to explain the milder clinical outcome observed in this study.

In humans and ruminants, $\gamma\delta$ -T cells are one of the immune cells associated with mucosal surfaces and in the placenta they may be part of the first line of defence against pathogens (Haas *et al.*, 1993; Entrican, 2002; Maley *et al.*, 2006). In the peripheral blood and lymphoid organs of young ruminants, they represent up to 50% of all T cells (Hein and Mackay, 1991), but their role in combating *N. caninum* infections is not yet known (Maley *et al.*, 2006). In murine models, $\gamma\delta$ -T cells may

also have the capacity to trigger foetal losses by reacting against the foetal trophoblast (Arck *et al.*, 1999). After *N. caninum* infection in early gestation, placentas contain moderate numbers of $\gamma\delta$ -T cells which can increase to large numbers if dams are carrying dead foetuses (Maley *et al.*, 2006). The mild $\gamma\delta$ -T cell infiltration that was detected in the present trial supports the hypothesis that, during pregnancy, an anti-*Neospora* maternal immune response at a later stage is less harmful than one that occurs in early gestation.

Natural killer (NK) cells play an important role in the early response to a wide variety of pathogens, including *N. caninum*, and also direct the adaptive immune response towards a Th1 response. Natural killer cells act as an important source of IFN- γ during early infection in the placenta and there is evidence of direct interactions between protozoa, or protozoan-infected cells, with NK cell receptors (Korbel *et al.*, 2004; Boysen *et al.*, 2006; Klevar *et al.*, 2007; Rosbottom *et al.*, 2008). Furthermore, after *N. caninum* infection during early gestation, dams carrying live foetuses show a lower number of NK cells in their placentas when compared with dams with dead foetuses, suggesting a role for these cells in the immunopathogenesis of neosporosis (Maley *et al.*, 2006) (see Chapter 3). During the present trial, mean scores of NK infiltration were relatively constant throughout the period of study (see Figure 16), unlike that observed with T cells (CD3⁺, CD4⁺, CD8⁺ and $\gamma\delta$ -T cells). The degree of infiltration of NK cells was similar when compared with the observations in the early gestational studies in dams carrying live foetuses (Maley *et al.*, 2006).

In previously reported work, B-cell-deficient mice were shown to be increasingly susceptible to *N. caninum* cerebral infection or acute disease model, suggesting an important role for B cells in host immunity against *N. caninum* (Eperon *et al.*, 1999). In the present study, rare and single CD79_{acy}⁺ cells were observed with no differences between negative control and *N. caninum*-inoculated dams, similarly to infection in early gestation (Maley *et al.*, 2006) and after recrudescence of infection in mid and late-gestation (Rosbottom *et al.*, 2011) suggesting that these cell types are probably not involved in protection against this protozoan or in the immunopathogenesis of neosporosis. However, further analysis will be required in

order to elucidate the true identity of the CD79_{acy}⁺ cells, because labelled cells morphologically and histologically resembled trophoblast cells instead of B cells. In fact the CD79_{acy}⁺ cells were also cytokeratin positive which supports epithelial origin since cytokeratin has been established as a very sensitive and reliable marker for all types of trophoblastic tissues (Daya and Sabet, 1991). CD79_{acy}⁺ cells were located in the trophoblast layer and, even though the majority were mononuclear cuboidal cells, occasional binucleated cells were also labelled. When the HM57 mAb (against CD79_{acy}) was applied to other ruminant species placentas (sheep and water buffalo) similar results were observed (see Figures 19a-c). More studies using other mAbs are required to establish the presence or absence of B cells in these placentas, and to clarify the genuine identity of these placental CD79_{acy}⁺ cells.

The observed differences in the pattern of cellular responses at different stages of gestation may be attributable to differences in the immunological environment which allow or hamper the multiplication of the parasite within the placenta. This is further reflected in the clinical outcome of infection at different stages of pregnancy. Previous studies have reported *N. caninum* specific cellular proliferation responses and a corresponding production of IFN- γ early in gestation while, in mid-gestation, these immune responses are not as powerful, allowing *Neospora* transmission. This suggests that biological changes associated with pregnancy may allow reactivation of tissue cysts of *N. caninum* leading to the release of bradyzoites (Innes *et al.*, 2001; Rosbottom *et al.*, 2011). The host immune response may also be influenced by hormones produced during pregnancy. Progesterone and prostaglandin E2 are known to bias a T-cell response towards a Th2 phenotype during human pregnancy (Piccinni *et al.*, 1995; Kalinski *et al.*, 1997). Steadily increasing levels of progesterone in the plasma of pregnant cattle have been documented from early to mid-gestation then these values significantly declined in the last few weeks of gestation (Pope *et al.*, 1969). Collectively, these observations tend to favour a bias towards a more regulatory Th2-type cytokine *milieu* during normal pregnancy, especially in mid-gestation (Innes *et al.*, 2002). In accordance with previous work (Innes *et al.*, 2005; Rosbottom *et al.*, 2011), a stronger Th1 response was expected in this study. However, a milder Th1-type cellular balance was observed when compared with responses to infection during early and mid stages of pregnancy

(Maley *et al.*, 2006) (see Chapter 3), possibly resulting in the minor clinical consequences of the disease in late gestation. However, it is important to consider that the immunological maturity of the foetus may also play an important role in influencing the pathogenesis of *Neospora* infection.

No differences were observed for each of the immune cell markers between the negative control animals culled at 28, 42 and 56 dpi when compared with the one negative control animal culled at 14 dpi, which tested *N. caninum* positive by PCR (Benavides *et al.*, 2012). This was an unexpected observation, especially in light of the other immunological findings, since this animal was serologically negative (Benavides *et al.*, 2012) and no response to *Neospora* tachyzoites in the lymphoproliferation assays was confirmed (Bartley *et al.*, 2013a). Microsatellite markers showed that the *Neospora* genotype identified was different from the Nc-1 strain used in the inoculum, ruling out any accidental infection or laboratory contamination (Benavides *et al.*, 2012). This technique allows the identification of genetic diversity among isolates of *N. caninum* (Atkinson *et al.*, 1999; Schock *et al.*, 2001; Gondim *et al.* 2004a; Regidor-Cerrillo *et al.*, 2006). Therefore, it was concluded that this negative control dam culled at 14 dpi was infected before the experimental Nc-1 inoculation and that the serological analysis was not able to detect the infection. Further serological analysis confirmed the presence of antibodies against NcSAG4, a bradyzoite stage-specific protein associated with chronic infections. Antibodies against NcGRA7, a marker of acute primary infection, recrudescence or reinfection were not detected. In addition, there was no vertical transmission of the parasite to this dam's foetus (Benavides *et al.*, 2012). Fluctuations in the serological responses of infected cattle against *N. caninum* tachyzoite antigens have been previously reported (Conrad *et al.*, 1993b; Waldner *et al.*, 1998) in association with the age of the animal and the gestational stage [reviewed by Dubey and Schares (2006)]. All these findings raise concerns over the effectiveness of the currently available serological techniques that are widely used to identify infected dams. Further research is indicated to improve the available serological tests.

In conclusion, following infection of pregnant cattle at day 210 of gestation, the immune cell infiltrate in placental tissues was milder than that observed in similar studies that investigated infection at earlier gestational stages and can partially explain the milder clinical outcome, i.e. congenital transmission but no abortions.

Previous reports on neosporosis show an association between production of inflammatory cytokines, such as IFN- γ , TNF- α and IL-12 and disease pathogenesis (Innes *et al.*, 1995a; Khan *et al.*, 1997; Marks *et al.*, 1998; Baszler *et al.*, 1999; Innes *et al.*, 2000; Innes *et al.*, 2001; Staska *et al.*, 2003; Bartley *et al.*, 2004; Rosbottom *et al.*, 2011). However, it remains unclear which cells are responsible for the production of these cytokines and how the cells and cytokines relate to pathogenesis, particularly at different stages of gestation. In order to investigate this aspect of bovine neosporosis immunopathogenesis, cytokine expression by placental tissues following experimental inoculation during early, mid and late gestation was evaluated and this work is described in Chapter 4 of this Thesis.

Chapter 3:

Characterisation of bovine placental immune cell infiltrate after experimental inoculation with *N. caninum* throughout gestation

Adapted from:

Cantón, G.J., Katzer, F., Maley, S.W., Bartley, P., Benavides-Silván, J., Palarea-Albaladejo, J., Burrells, A., Pang, Y., Rocchi, M., Smith, S., Innes, E.A., Chianini, F. Degree of immune cell infiltration into placentas of *Neospora caninum* challenged cattle correlates with clinical outcome of pregnancy. Article submitted for publication in Veterinary Research.

In this chapter I was responsible for reviewing the literature, performing IHC on tissue from early and mid gestational experiments using mAb against macrophages, scoring the inflammatory infiltrate in samples from early, mid and late gestational experiments, photographing the IHC slides including the ones previously immunolabelled by Stephen Maley and Yvonne Pang (MRI), analysing the generated scores and writing the manuscript.

Introduction

As explained in previous chapters, the pathogenesis of bovine neosporosis is only partially understood, and the reasons for the diverse clinical outcomes observed at different times of gestation remain unclear. There is some evidence that infection with *N. caninum* triggers a Th1-type immune-response at the maternal–foetal interface (Khan *et al.*, 1997; Long *et al.*, 1998; Lundén *et al.*, 1998; Marks *et al.*, 1998; Baszler *et al.*, 1999; Eperon *et al.*, 1999; Tanaka *et al.*, 2000a; Tanaka *et al.*, 2000b; Quinn *et al.*, 2002a) and this type of immune response could be detrimental for pregnancy since it can damage the maternal placenta, disrupting the foetal vascular supply of nutrients (Maley *et al.*, 2003; Macaldowie *et al.*, 2004; Innes *et al.*, 2005).

The main aim of this study was to characterise and compare the cellular immune responses in pregnant cattle experimentally inoculated with *N. caninum* in early, mid and late gestation, in order to explain the different clinical outcomes observed in different periods of pregnancy.

Materials and methods

Collection of samples at the three time points

The placental samples from the present study were generated from previous *Neospora* experimental inoculations carried out at MRI. Samples were collected as follows: uterus was removed during *post-mortem* examination immediately after euthanasia and 5, 3 or 10 randomly selected placentomes were sampled from each placenta in early (Macaldowie *et al.*, 2004), mid (Maley *et al.*, 2003) and late gestation (Benavides *et al.*, 2012), respectively. They were placed in ZSF for 3 days, and then embedded in paraffin-wax as previously published (Maley *et al.*, 2006; Cantón *et al.*, 2013b) and described in Chapter 2.

Placental tissues and immunohistochemistry

The samples of placentas reported in this study were generated during three different experiments partially published and also reported in previous chapters. A full list of mAbs used in this study can be found in Table 1 in Chapter 2.

Early gestation

Macaldowie *et al.* (2004) reported the study carried out in early gestation wherein pregnant cows were inoculated IV and SC with *N. caninum* (Figure 2 in Chapter 1). Later, Maley *et al.* (2006) published the IHC results on immune cell infiltrates in placentas from this experiment. However, to ensure consistency, the slides from this earlier experiment were re-assessed using the recently published scoring system already described in Chapter 2 (Cantón *et al.*, 2013b). Furthermore, IHC using EBM11 (mAb raised against CD68 antigen present in monocytes / macrophages) had to be carried out on placental samples from early gestation in order to compare the infiltrates at that later stage with the other stages of gestation.

The inflammatory cell infiltrate following infection with *Neospora* in early gestation has already been well described and published by Maley *et al.* (2006), so it will be limited to a brief summary in the Results section here.

Mid gestation

Experimental *Neospora* inoculation in mid gestation (140 days of gestation) was carried out at MRI (Figure 2 in Chapter 1) and part of this study, including experimental design, histopathology, serology and molecular results, was published by Maley *et al.* (2003). Immunohistochemistry had been performed on the placentas collected in ZSF using the same mAbs as those used by Macaldowie *et al.* (2004) but the results were never assessed. To complete this study, all the IHC slides were assessed using the same recently published scoring system already described in Chapter 2 (Cantón *et al.*, 2013b). IHC using EBM11 (monocytes / macrophages)

was also performed on the placental samples collected from the mid gestation experiment, in order to complete the immune cell characterisation and maintain consistency across all three experiments.

Late gestation

Placental material for late gestation has already been published (Cantón *et al.*, 2013b) and is described in Chapter 2.

Scoring methodology

As described in Chapter 2 and as recently published by Cantón *et al.* (2013b), the slides were blind-coded and examined for each inflammatory cell marker as outlined before (Table 1 in Chapter 2); for each slide, the entire section was examined by optical microscopy at various magnifications and categorised, similar to previous descriptions (Buxton *et al.*, 2001; Oliveira and Hansen, 2008).

Statistical analysis

Given the limited sample sizes, the time factor for each experiment (early, mid and late gestation) was omitted and the average scores originated from the same distribution was assumed in order to gain statistical power. This was supported by results from Fligner and Kruskal-Wallis tests on homogeneity of variances and medians among inoculated animals over time. Non-parametric Mann-Whitney tests were then conducted to determine any significant differences in scores among *N. caninum*-inoculated and negative control animals for each cell type in each experiment. Statistical significance was set at $p < 0.05$.

In the early gestation experiment, non-parametric Mann-Whitney tests were applied to pair-wise comparison of scores from IV-, SC-*N. caninum*-inoculated and negative

control groups for each cell type. The resulting *p*-values were adjusted for multiplicity by the false discovery rate (FDR) method.

Among all the *N. caninum*-inoculated animals in the early gestation experiment (regardless of the time point), a distinction was made between samples from dams carrying a dead foetus or empty uterus at the *post mortem* examination (from now on termed “non-viable”) and those carrying a live foetus (from now on termed “viable”). The scores for each cell type were compared between these two groups (7 animals each) using non-parametric Mann-Whitney tests.

In order to compare *N. caninum*-inoculated, and separately, negative control animals over the various gestation stages (early, mid and late gestation), Kruskal-Wallis tests were applied, and then pair-wise Mann-Whitney tests (with FDR adjusted *p*-values) were performed.

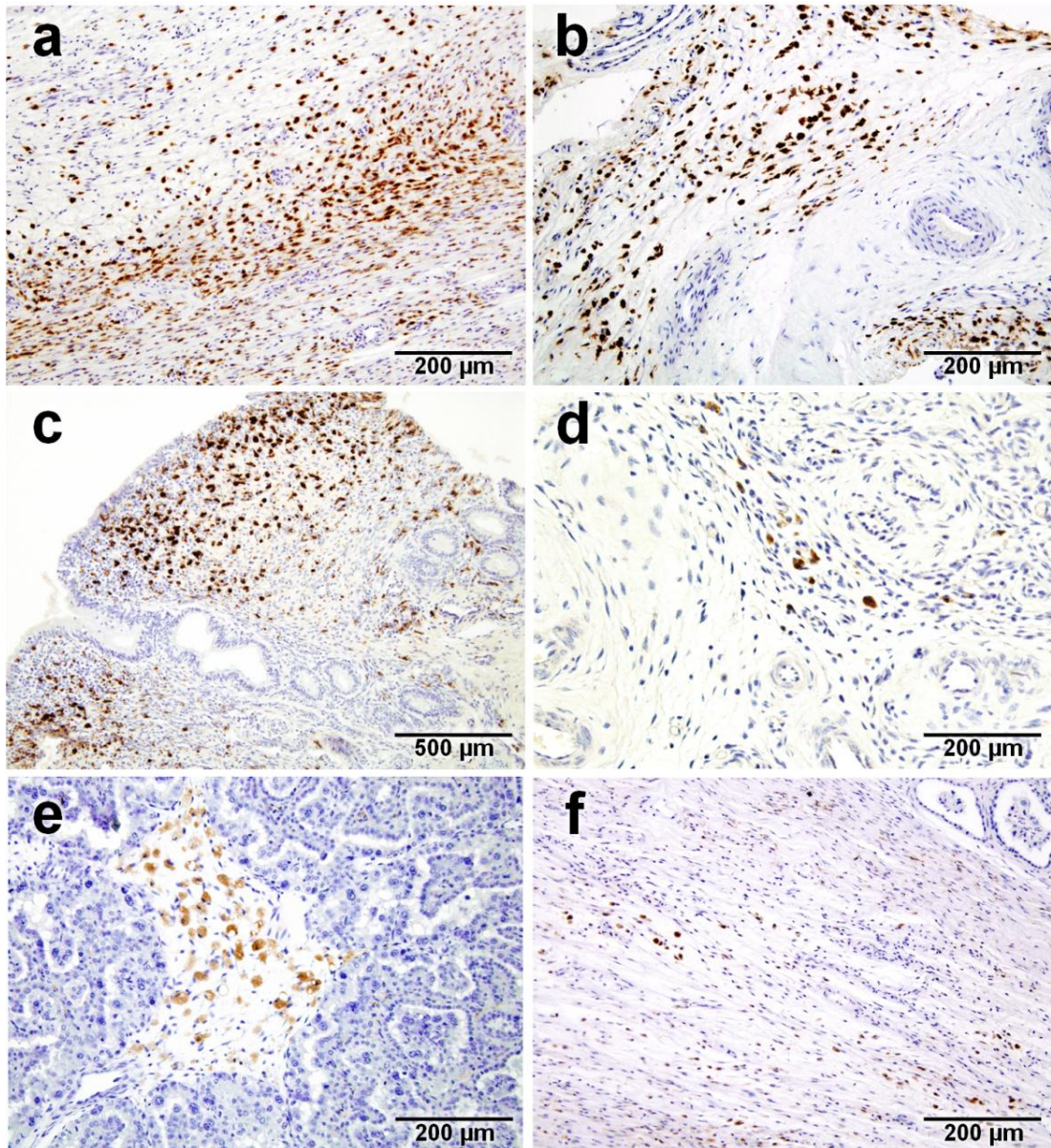
Results

CD68⁺ cells during early gestation

All placental samples collected from the IV and SC *N. caninum* inoculated dams culled at 14 dpi were mildly to heavily infiltrated by CD68⁺ cells in the base of the caruncle (see Figure 21a), and positive cells formed large aggregates surrounding some endometrial glands and blood vessels. Furthermore, moderate to severe infiltrates of macrophages were observed in the caruncle stalk, though generally not associated with any other pathological findings. Most of the placentomes collected from animals inoculated IV and culled at 28 dpi were mildly to moderately infiltrated by CD68⁺ cells, while only a few of the placentomes collected from the SC inoculated animals were moderately infiltrated with macrophages (see Figure 21b). This infiltrate was also observed in the base of the caruncle or the caruncle stalks (though was not associated with any other pathological findings in the latter). In dams experimentally inoculated IV with *N. caninum* and culled at 42 dpi, there was a severe infiltrate of macrophages in the caruncle base of all the placentomes (see

Figure 21c). In those samples, a severe infiltrate was observed in areas of the caruncle associated with large areas of necrosis. However, macrophage infiltrate was only mild to moderate in the samples collected from the dams inoculated SC (see see Figure 21d), mainly in the base of the placentome and/or in areas of necrosis in some caruncle stalks. All the placental samples collected from the animals inoculated IV and culled at 56 dpi contained a mild to moderate infiltrate of macrophages, which formed large aggregates in the base of the caruncle or around areas of necrosis (see Figure 21e). Some of the placental samples collected from the negative control animals also contained a mild to moderate infiltrate of macrophages in the base of the caruncle (see Figure 21f).

Mean scores for CD68⁺ cell infiltrates in animals inoculated with *N. caninum* (IV and SC) during early gestation (culled at 14, 28, 42 and 56 dpi) and in negative control animals are shown in Figure 23. A higher CD68⁺ score was observed overall in *N. caninum*-inoculated animals compared with negative controls ($p < 0.05$). However, no significant differences were apparent with pair-wise analysis: inoculated IV vs. negative control ($p = 0.068$), inoculated SC vs. negative control ($p = 0.096$) and inoculated IV vs. inoculated SC ($p = 0.431$). There were no significant differences in macrophage scores between placentas from *N. caninum*-inoculated (IV or SC) dams carrying viable foetuses and those carrying non-viable foetuses ($p = 0.193$).

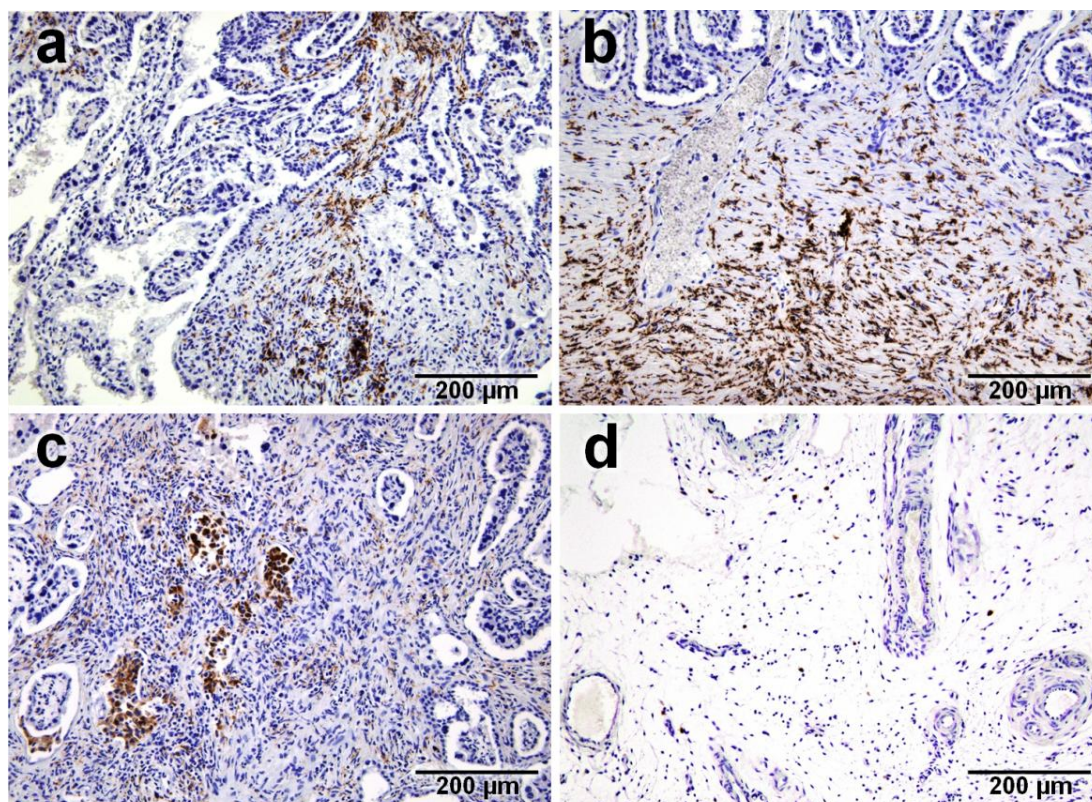


Figures 21 a-f: Examples of macrophage infiltrates in placentomes from dams inoculated with *N. caninum* (a-e) and negative control (f) during early gestation. (a) Severe macrophage infiltrates in the base of a caruncle from a dam *N. caninum*-inoculated SC and culled at 14 dpi. (b) Moderate macrophage infiltrates in the base of a placentome from a dam *N. caninum*-inoculated SC and culled at 28 dpi. (c) Moderate macrophage infiltrates in a caruncle from a dam *N. caninum*-inoculated IV and culled at 42 dpi. (d) Low number of macrophages in a caruncle surrounding blood vessel in the placentome from a dam *N. caninum*-inoculated SC and culled at 42 dpi. (e) Moderate infiltrate of macrophages in connective tissue of a caruncle stalk from a dam *N. caninum*-inoculated SC and culled at 56 dpi. (f) Mild macrophage infiltrate in the base of a caruncle from a negative control dam culled at 42 dpi. Counterstained with haematoxylin. IHC slides produced and photographed by GJC.

CD68⁺ cells during mid gestation

A low number of diffusely distributed CD68⁺ cells infiltrated the placentomes of *N. caninum*-inoculated animals, with the number of macrophages increasing with the time interval between infection and culling. At 14 dpi a minimal to mild infiltrate of macrophages was observed in the base of the caruncle in some cases, though not associated with any other pathological changes. Occasionally, small aggregates surrounded small necrotic areas in the caruncle (see Figure 22a). The placentomes of one of the animals culled at 28 dpi were more severely infiltrated with macrophages, in some cases forming large aggregates around necrotic foci and areas of serum leakage. A moderate diffuse infiltrate was observed in the base of the caruncles, though generally not associated with any other lesions (see Figure 22b). At 42 dpi macrophage infiltrates in the placentomes of the two *N. caninum*-inoculated animals were more severe than at 28 dpi, forming large aggregates of cells around necrotic foci and foetal villi (see Figure 22c), as well as areas of serum leakage and detachment of the foetal cotyledons from the caruncles. Furthermore, macrophages infiltrated the base of the caruncles, though were not associated with any other pathological findings. Rare labelled cells also infiltrated the caruncle stalks and the base of the caruncles (see Figure 22d) in negative control animals.

Mean scores for CD68⁺ cell infiltration in the *N. caninum* inoculated animals during mid gestation (culled at 14, 28 and 42 dpi) are plotted in Figure 23 below. Although there was some evidence for higher CD68⁺ scores in *N. caninum*-inoculated animals for the mid gestational experiment, these scores were not statistically significant ($p = 0.091$).



Figures 22 a-d: Examples of macrophage infiltrates in placentomes from *N. caninum*-inoculated (a-c) and negative control (d) dams during mid gestation. (a) Aggregates of macrophages in a caruncle of a *N. caninum* inoculated dam culled at 14 dpi. (b) Severe macrophage infiltrate in the base of a placentome collected from a *N. caninum* inoculated dam culled at 28 dpi. (c) Aggregates of macrophages in necrotic foetal villi of a placentome from a *N. caninum* inoculated dam culled at 42 dpi. (d) Low number of macrophages in the base of a placentome from a negative control dam culled at 14 dpi. Counterstained with haematoxylin. IHC slides produced and photographed by GJC.

CD68⁺ score comparison at the three stages of gestation

Overall inter-experiment placental scores were compared for the animals inoculated with *N. caninum* and significant differences were established for macrophage infiltrates between early, mid- and late pregnancy ($p < 0.05$). When pair-wise comparisons were made, significant differences were only detected between early and late gestation samples ($p < 0.05$) but not between early and mid-gestation, or mid- and late gestation ($p = 0.203$ and 0.647 , respectively).

Likewise, no significant overall differences were observed for the macrophage infiltrates in the placentomes collected from the negative control dams in early, mid and late gestation ($p = 0.104$). When pair-wise comparison was carried out in the same negative control animals, no significant differences were observed between early vs. mid, early vs. late, and mid vs. late gestation ($p = 0.493$; 0.121 and 0.236 , respectively).

Tables summarising mean infiltration scores for CD68⁺ cells in early, mid and late gestation are shown below in Tables 2, 3 and 4. Tables summarising p -values of the different statistical analyses and a comparison figure of the different immune cell scores are shown in Appendix II.

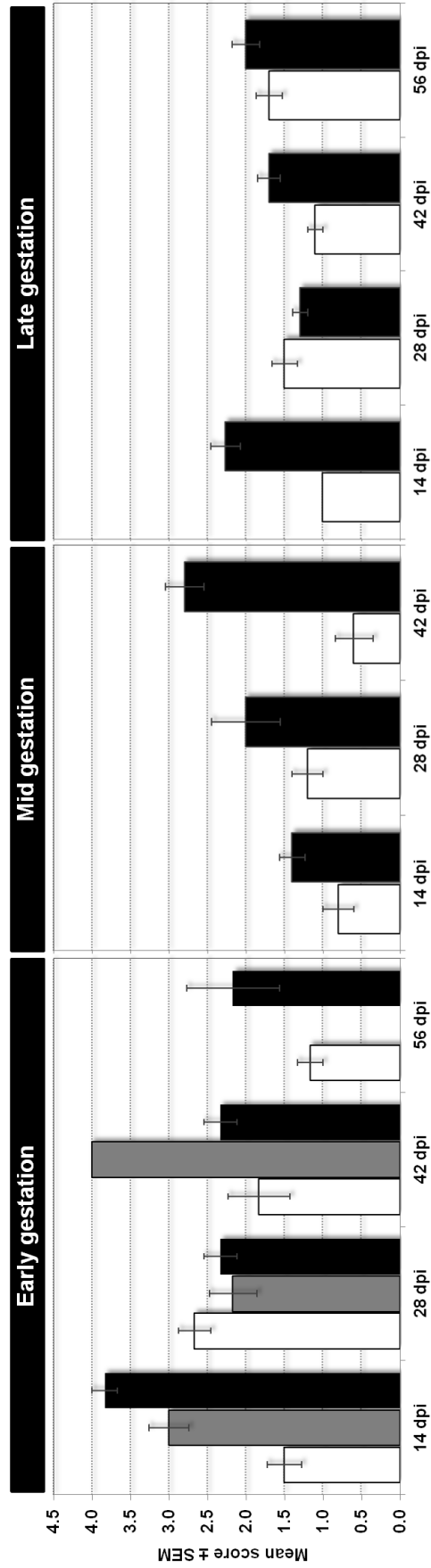
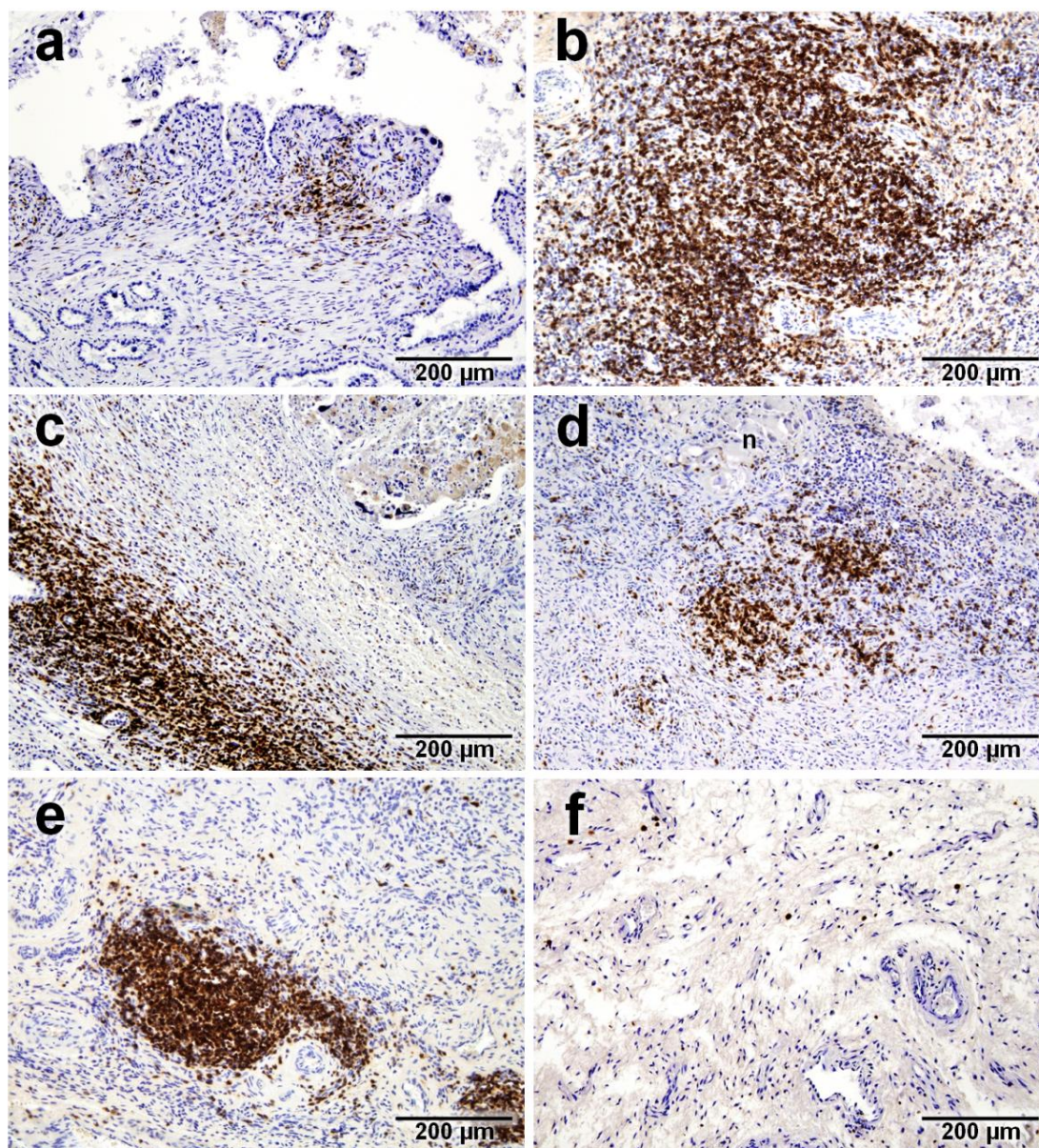


Figure 23: Mean CD68+ cell (macrophages) scores in the placentas collected from negative control (white bars), SC (black bars) and IV *N. caninum*-inoculated dams (gray bars) at early, mid and late gestation. Error bars indicate SEM

CD3⁺ cells during early gestation

Moderate number of CD3⁺ cells infiltrated the caruncular septa from animals inoculated with *N. caninum* IV and culled at 14 dpi (see Figure 24a). Small aggregates of CD3⁺ cells infiltrated the base of the caruncles from culled animals inoculated with *N. caninum* SC and culled at 14 dpi. At 28 dpi, there were large numbers of CD3⁺ cells in placental samples from the SC inoculated dam carrying the dead foetus and in placental samples from the IV inoculated dams. These CD3⁺ cells infiltrated the stalk (Figure 24b) and the base (Figure 24c) of the caruncle, and surrounded necrotic foetal villi. A heavy infiltrate of CD3⁺ cells was also present in the placentomes from both IV inoculated dams culled at 42 dpi (see Figure 24d), and in the SC inoculated dams carrying a dead foetus at the time of *post mortem* examination at 42 and 56 dpi (see Figure 24e). In contrast, a lower number of CD3⁺ cells was observed in the placentomes collected from the SC inoculated dams carrying live foetuses at 28, 42 and 56 dpi. These were characterised by a minimal and single cell infiltrate in the base of the caruncle and caruncle stalks (see Figure 24f).

Mean CD3⁺ infiltrate scores in *N. caninum* (IV and SC) inoculated and negative control animals during early gestation (culled at 14, 28, 42 and 56 dpi) are plotted in Figure 26 below. CD3⁺ scores in early gestation were higher in *Neospora*-inoculated dams when compared with negative control animals ($p < 0.05$). When the scores from *N. caninum*-inoculated animals were pair-wise analysed, significantly higher scores were observed in the *Neospora*-inoculated dams (IV and SC) compared to the negative controls ($p < 0.05$), but there were no differences between dams inoculated IV and SC ($p = 0.299$). T lymphocyte scores were also higher in the placentas from dams carrying non-viable foetuses, when compared to those carrying viable foetuses ($p < 0.05$).

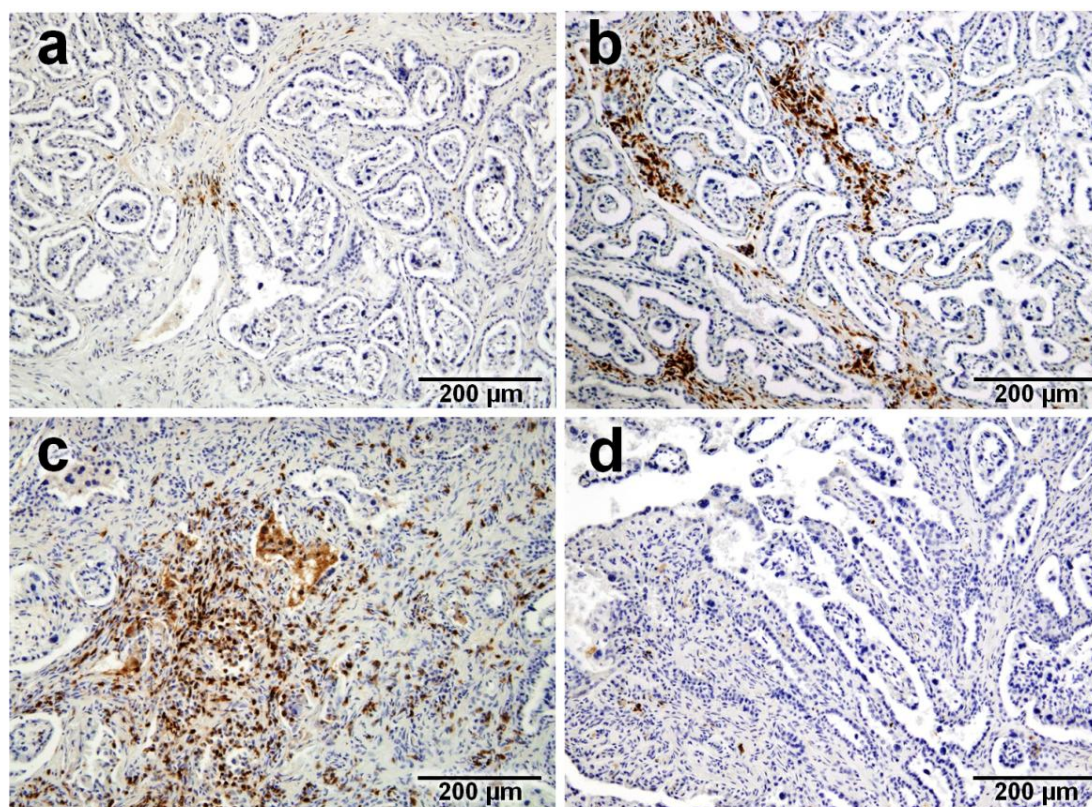


Figures 24 a-f: Examples of CD3⁺ infiltrates in placentomes from *N. caninum*-inoculated (a-e) and control negative (f) dams during early gestation. (a) Small aggregate of CD3⁺ cells in a caruncle of a *N. caninum* inoculated dam (IV) culled at 14 dpi. (b) Severe CD3⁺ cell infiltrate in a caruncle of a *N. caninum* inoculated dam (IV) culled at 28 dpi. (c) Severe infiltrate of CD3⁺ cells in the base of a placentome from a *N. caninum* inoculated dam (SC) culled at 28 dpi. (d) Moderate CD3⁺ cell infiltrate surrounding a necrotic focus (n) in the base of a placentome of a *N. caninum* inoculated dam (SC) culled at 42 dpi. (e) Large CD3⁺ cell aggregate in a caruncle of a *N. caninum* inoculated dam (SC) culled at 56 dpi. (f) Rare single CD3⁺ cells sparsely distributed in the connective tissue of a caruncle base from a negative control dam culled at 14 dpi. Counterstained with haematoxylin. IHC slides produced by Stephen Maley (Maley *et al.*, 2006), scored and photographed by GJC.

CD3⁺ cells during mid gestation

A minimal to mild diffuse infiltrate of CD3⁺ cells was observed in the placentomes of *N. caninum*-inoculated dams culled at 14 dpi, in some cases forming small aggregates (see Figure 25a) surrounding small necrotic areas in caruncle stalks. The cells were also sporadically observed in the caruncle, though not associated with any other pathological changes. In some samples CD3⁺ cells also infiltrated the base of the caruncle. In the two animals culled at 28 dpi, there was an increased number of CD3⁺ cells in the placentomes, sometimes forming large aggregates around necrotic foetal villi and necrotic areas of the caruncle (see Figure 25b). Particularly in one of the animals culled at 42 dpi, the placentomes were multifocally infiltrated by a heavy (severe) CD3⁺ infiltrate which formed large aggregates (see Figure 25c) around large necrotic foci in the caruncle. Single and rare CD3⁺ cells were also observed in the caruncles of negative control dams, not associated with any other pathological changes (see Figure 25d).

Mean CD3⁺ cell scores in the *Neospora*-inoculated animals during mid gestation (culled at 14, 28 and 42 dpi) are plotted in Figure 26 below. CD3⁺ scores in mid gestation were higher in *N. caninum*-inoculated dams compared with the negative control animals ($p < 0.05$).



Figures 25 a-d: Examples of CD3⁺ infiltrates in placentomes from *N. caninum*-inoculated (a-c) and negative control (d) animals during mid gestation. (a) Small CD3⁺ cell aggregate in a caruncle stalk of a *N. caninum* inoculated dam culled at 14 dpi. (b) Moderate CD3⁺ cell infiltrate in a caruncle stalks of a *N. caninum* inoculated dam culled at 28 dpi. (c) Large CD3⁺ cell infiltrate in an area of a caruncle of a *N. caninum* inoculated dam culled at 42 dpi. (d) Single CD3⁺ cells in a caruncle of a negative control dam culled at 28 dpi. Counterstained with haematoxylin. IHC slides produced by Stephen Maley and Yvonne Pang (MRI, data not published), scored and photographed by GJC.

CD3⁺ score comparison at the three stages of gestation

Overall inter-experiment scores were compared for the animals inoculated with *N. caninum* and significant differences were established for total T cell infiltrates between early, mid- and late gestation ($p < 0.001$). When they were pair-wise compared, CD3⁺ scores were significantly higher in early ($p < 0.001$) and mid-gestation ($p < 0.05$) compared with the late gestation scores. However, no significant differences were found between the early and mid-gestation scores ($p = 0.090$).

Immunopathogenesis of bovine neosporosis throughout gestation

Significant overall differences were found for the CD3⁺ scores in the placentomes from negative control dams in early, mid and late gestation ($p < 0.05$). When pairwise compared, significant differences were established between early and mid and between early and late gestation ($p < 0.05$), but not between mid and late gestation scores ($p = 0.105$).

Tables summarising mean infiltration scores for CD3⁺ cells in early, mid and late gestation are shown below in Tables 2, 3 and 4. Tables summarising p -values of the different statistical analyses and a comparison figure of the different immune cell scores are shown in Appendix II.

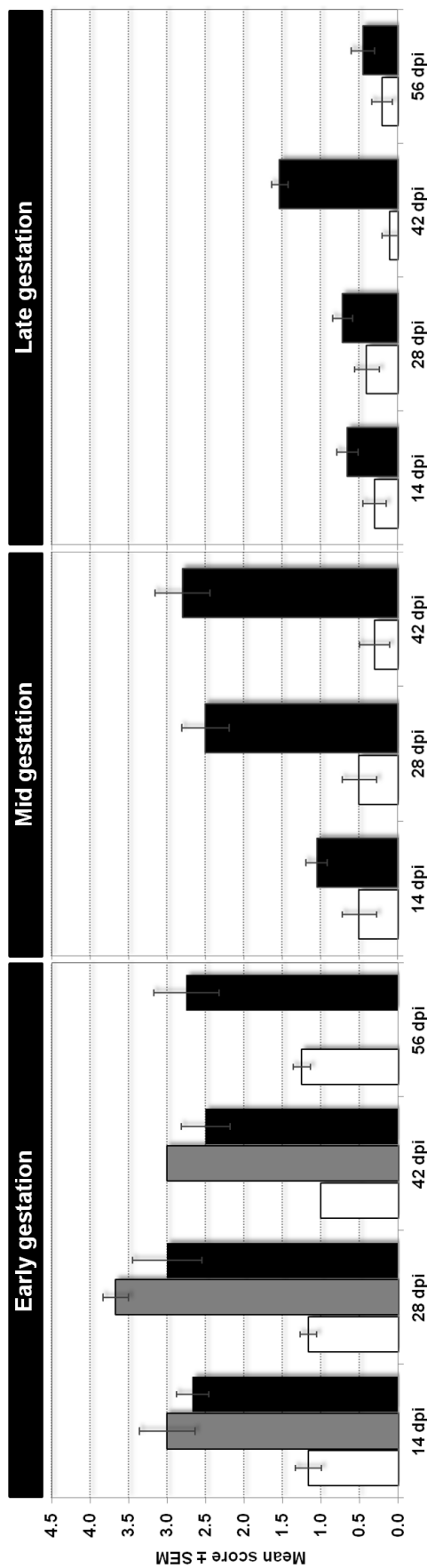
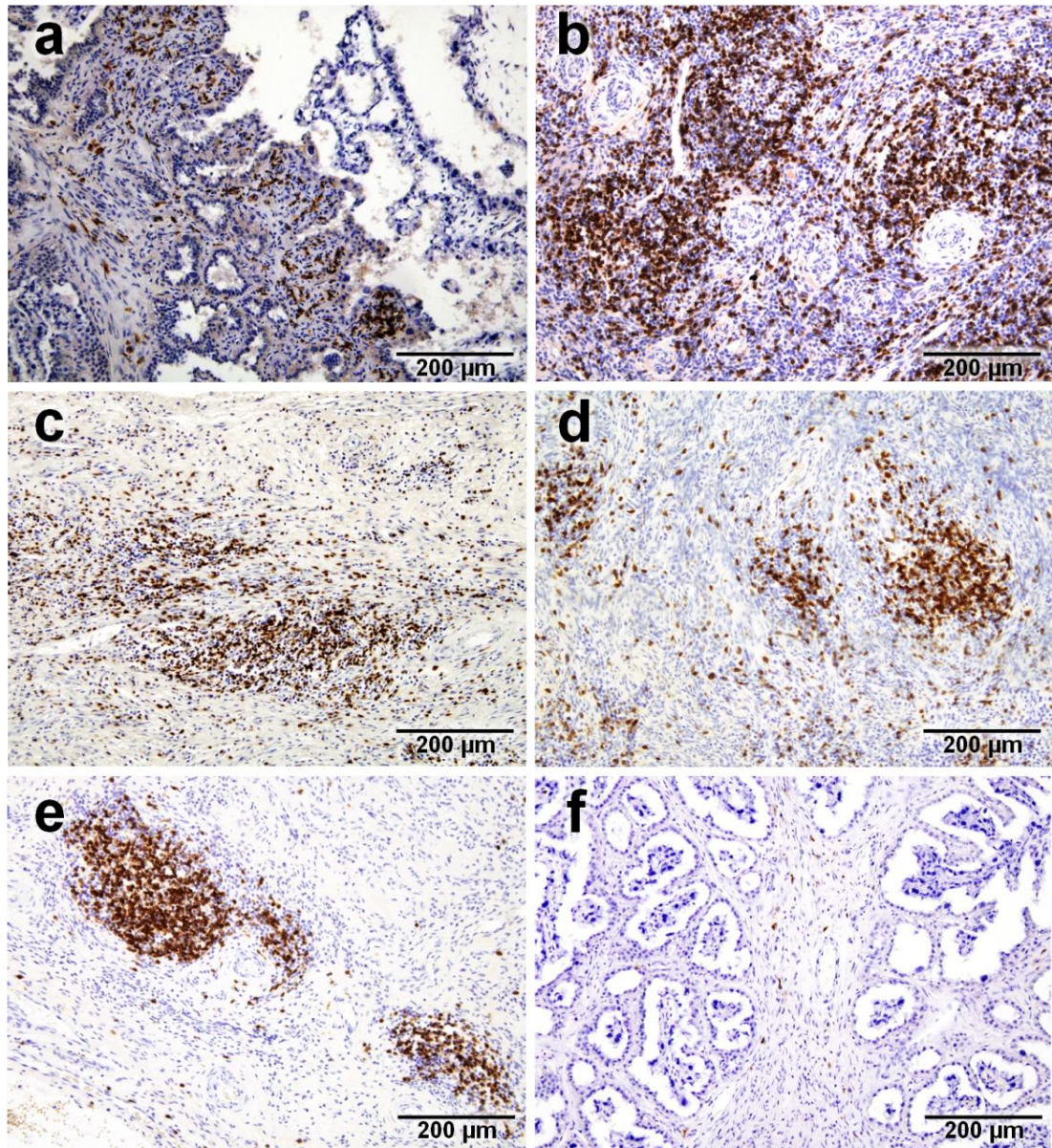


Figure 26: Mean CD3⁺ cell (total T cells) infiltrate scores in the placentas collected from negative control (white bars), SC (black bars) and IV *N. caninum*-inoculated dams (gray bars) at early, mid and late gestation. Error bars indicate SEM.

CD4⁺ cells during early gestation

Placental samples collected from most of the IV and SC inoculated dams presented a similar pattern of CD4⁺ infiltration when compared with the CD3⁺ infiltrates in the same samples. Similarly to the previously described pattern for CD3⁺ cells, more severe T helper infiltrates were observed in the SC inoculated dams carrying a dead foetus at 28, 42 and 56 dpi compared with the CD4⁺ infiltrate in those carrying live foetuses (see Figures 27a-d). Negative control placentomes were also infiltrated with rare CD4⁺ cells in the base of the caruncle (see Figure 27f).

Mean scores for CD4⁺ cell infiltrates in the *N. caninum* (IV and SC) inoculated animals during early gestation (culled at 14, 28, 42 and 56 dpi) were plotted in Figure 29 below. CD4⁺ scores were significantly higher in the placentas of *N. caninum*-inoculated animals of this experiment when compared with the negative control dams ($p < 0.001$). Like the CD3⁺ T cell scores, the T helper scores were higher in dams inoculated with *Neospora* IV and SC when compared with negative control placentas using pair-wise analysis ($p < 0.05$). However, no differences were established when both *N. caninum*-inoculated groups were compared with each other (i.e. IV vs. SC) ($p = 0.261$). When CD4⁺ scores in the dams carrying non-viable and viable foetuses in the *N. caninum*-inoculated (IV and SC) group were compared, they were higher in the former ($p < 0.05$).

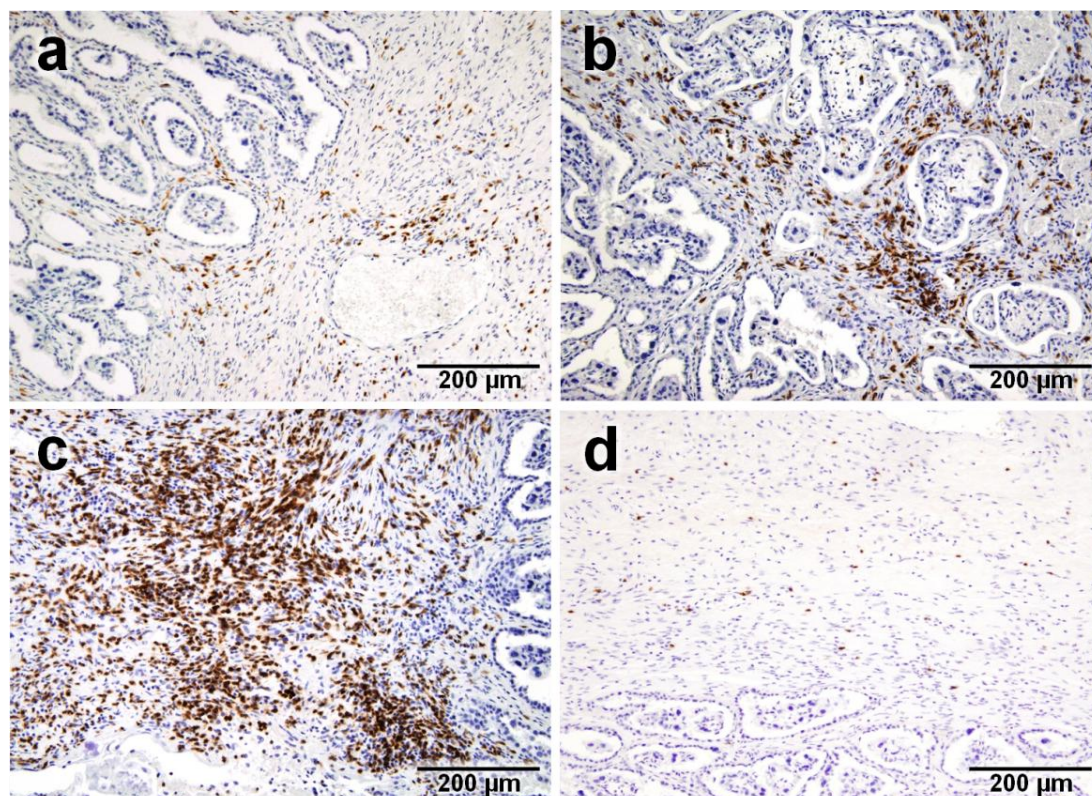


Figures 27 a-f: Examples of CD4⁺ infiltrates in placentomes from *N. caninum*-inoculated (a-e) and negative control dams (f) during early gestation. (a) Mild CD4⁺ cell infiltrate in a caruncle of a dam inoculated with *N. caninum* IV and culled at 14 dpi. (b) Severe CD4⁺ cell infiltrate in a caruncle of a dam inoculated with *N. caninum* IV and culled at 28 dpi. (c) Moderate CD4⁺ cell infiltrate in the base of a caruncle of a dam inoculated with *N. caninum* SC and culled at 28 dpi. (d) Moderate CD4⁺ cell aggregate in a caruncle of a dam inoculated with *N. caninum* IV and culled at 42 dpi. (e) CD4⁺ cell aggregates in a caruncle of a dam inoculated with *N. caninum* SC and culled at 56 dpi. (f) Rare single CD4⁺ cells diffusely distributed in a caruncle stalk from a negative control dam culled at 14 dpi. Counterstained with haematoxylin. IHC slides produced by Stephen Maley (Maley *et al.*, 2006), scored and photographed by GJC.

CD4⁺ cells during mid gestation

During the mid gestation experiment, a similar finding previously reported for CD3⁺ cells was recorded: The CD4⁺ cell infiltrate increased with the length of time since inoculation. Only a minimal diffuse infiltrate was observed in some of the placentomes from the *N. caninum*-inoculated animals culled at 14 dpi (see Figure 28a). In all the placental samples from *N. caninum*-inoculated dams collected at 28 dpi, scattered single or moderate CD4⁺ infiltrates forming aggregates of labelled cells (see Figure 28b) were associated with necrotic foci in caruncles and necrotic foetal villi. In the group of *N. caninum*-inoculated cows culled at 42 dpi, all the collected placentomes had a mild to severe infiltrate of CD4⁺ cells which formed large aggregates in the caruncles (see Figure 28c), around necrotic foci and in necrotic foetal villi. A moderate CD4⁺ infiltrate was also observed in the base of the caruncles not associated with any pathological changes. Single CD4⁺ cells were also observed in the caruncles of negative control animals, not associated with any other pathological changes (see Figure 28d).

Mean CD4⁺ scores in the *N. caninum* inoculated animals during mid gestation (culled at 14, 28 and 42 dpi) are plotted in Figure 29 below. No statistical differences were established between the placental scores for the negative control animals and those for the *N. caninum*-inoculated animals in mid gestation ($p=0.434$).



Figures 28 a-d: Examples of CD4⁺ infiltrates in placentomes from *N. caninum*-inoculated dams (a-c) and negative controls (d) during mid gestation. (a) Mild CD4⁺ cell infiltrate in a caruncle stalk of a dam inoculated with *N. caninum* and culled at 14 dpi. (b) Moderate CD4⁺ cell infiltrate in a caruncle stalk of a dam inoculated with *N. caninum* and culled at 28 dpi. (c) Severe CD4⁺ cell infiltrate in an area of a caruncle of a dam inoculated with *N. caninum* and culled at 42 dpi. (d) Single rare CD4⁺ cells in the base of a caruncle of a negative control dam culled at 14 dpi. Counterstained with haematoxylin. IHC slides produced by Stephen Maley and Yvonne Pang (MRI, data not published), scored and photographed by GJC.

CD4⁺ score comparison at the three stages of gestation

Overall inter-experiment scores were compared for the animals inoculated with *N. caninum* and significant differences were established for T helper cell infiltrates between early, mid- and late gestation ($p < 0.001$). When pair-wise analysed, higher CD4⁺ scores were found in early gestation compared with the experiment in late gestation ($p < 0.001$), but no clear differences were established when comparing placentas from *N. caninum*-inoculated animals in early vs. mid-gestation, or mid- vs. late gestation ($p = 0.145$ and 0.065 , respectively).

Immunopathogenesis of bovine neosporosis throughout gestation

In the negative control animals, CD4⁺ scores were significantly different in early, mid and late gestation ($p < 0.01$). When pair-wise compared (early vs. mid, early vs. late, and mid vs. late gestation), significant differences were observed in the three analyses ($p < 0.05$).

Tables summarising mean infiltration score values for CD4⁺ cells at early, mid and late gestation are showed below in Tables 2, 3 and 4. Also, tables summarising p -values of the different statistical analyses carried out and a comparison figure of the different immune cell scores are showed in Appendix II.

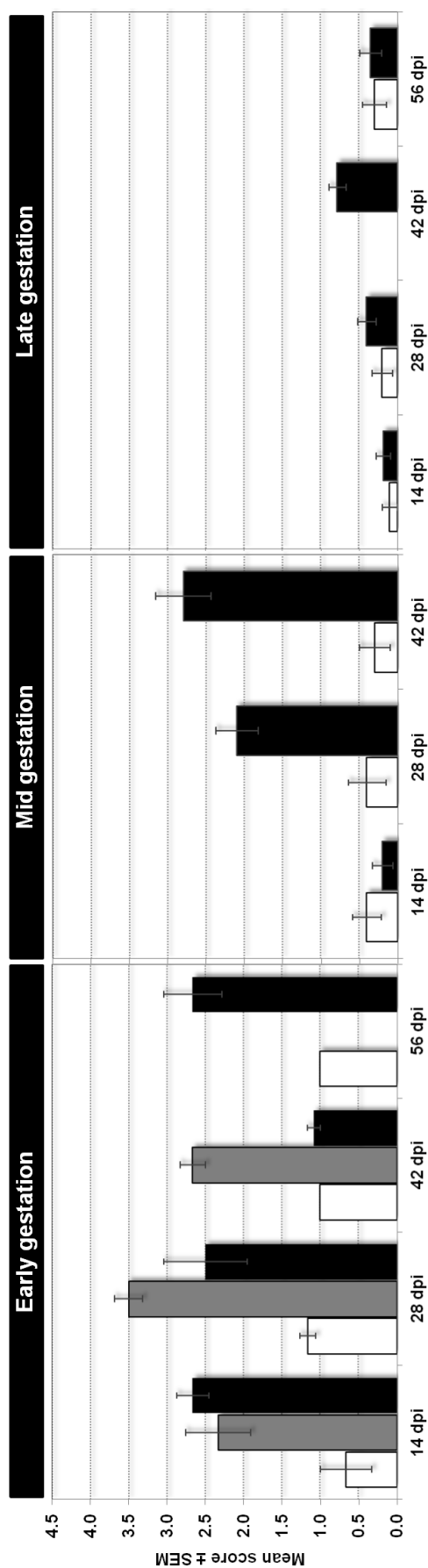
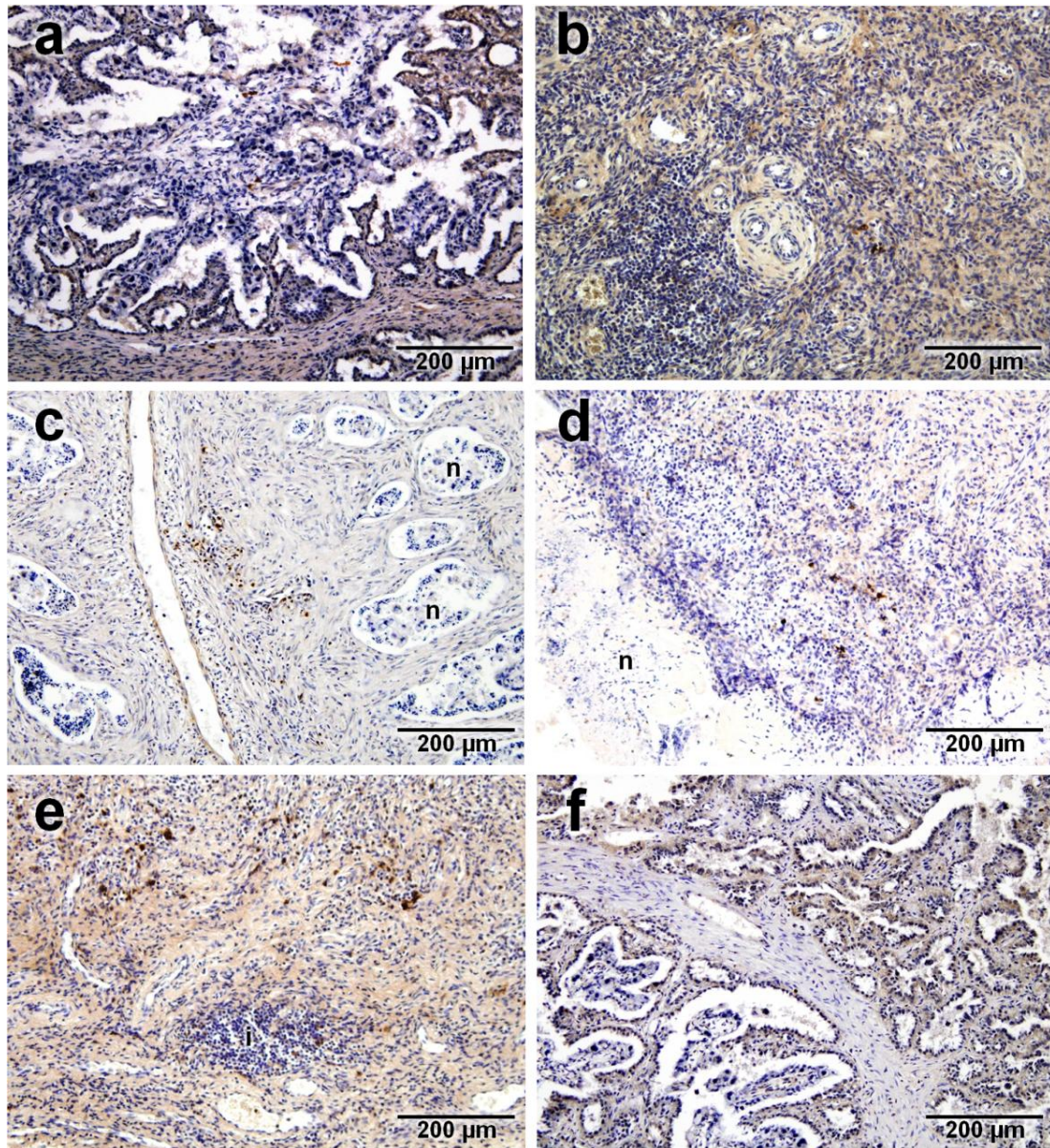


Figure 29: Mean CD4⁺ cell (T helper cells) infiltrate scores in the placentas collected from negative control (white bars), SC (black bars) and IV *N. caninum*-inoculated dams (gray bars) at early, mid and late gestation. Error bars indicate SEM.

CD8⁺ cells during early gestation

Low numbers of CD8⁺ cells infiltrated placentomes collected during the early gestation experiment. These were located in the caruncular septa surrounding necrotic foetal villi. CD8⁺ cells were found in greater numbers in dams inoculated with *N. caninum* SC, culled at 28 dpi and carrying a dead foetus compared to the same group at 14 dpi (see Figures 30a-c). In the dams inoculated IV and culled at 28 dpi, CD8⁺ cells formed small aggregates. Low numbers of CD8⁺ cells infiltrated placentomes collected from dams inoculated IV and culled at 42 dpi and from dams inoculated SC, culled at 56 dpi and carrying a dead foetus (see Figures 30d-e). Rare CD8⁺ cells infiltrated placental tissues of dams inoculated SC, culled at 28, 42 and 56 dpi and carrying live foetuses at the time of euthanasia. They were also seen in the negative control dams (see Figure 30f).

Mean CD8⁺ scores in the animals inoculated with *Neospora* (IV and SC) during early gestation (culled at 14, 28, 42 and 56 dpi) are plotted in Figure 32. Significantly higher CD8⁺ scores were found in the placentas from animals inoculated with *N. caninum* in early gestation compared to the negative controls ($p < 0.01$). When pairwise compared, significantly higher cytotoxic T cell scores were observed when dams inoculated with *Neospora* IV and SC were compared with negative control animals ($p < 0.05$); however, no differences were seen when IV and SC scores were compared to each other ($p = 0.686$). Placentas from animals inoculated with *N. caninum* and carrying non-viable foetuses had higher CD8⁺ scores when compared with those carrying viable foetuses ($p < 0.01$).

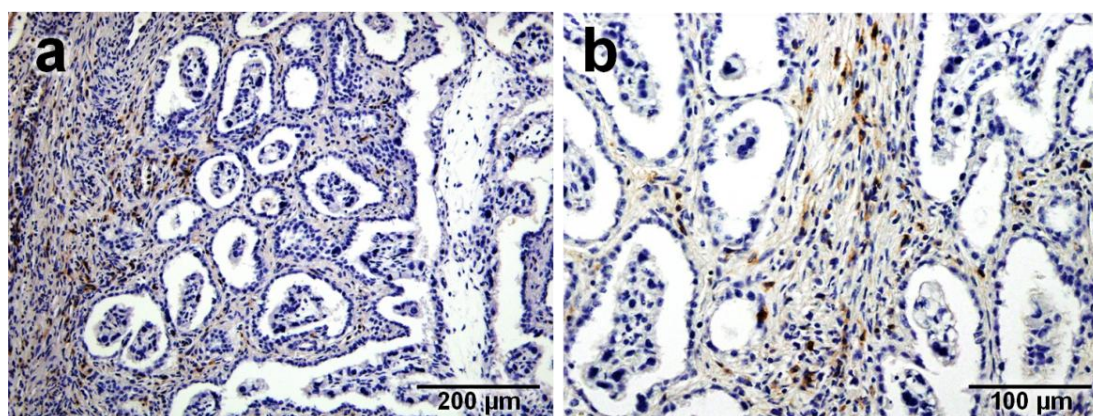


Figures 30 a-f: Examples of CD8⁺ cellular infiltrates in placentomes from dams inoculated with *N. caninum* (a-e) and negative controls (f) during early gestation. (a) Rare CD8⁺ cells in a caruncle of a dam inoculated with *N. caninum* SC and culled at 14 dpi. (b) Rare CD8⁺ cells in a caruncle of a dam inoculated with *N. caninum* IV and culled at 28 dpi. (c) Mild CD8⁺ cell infiltrate in a caruncle stalk of a dam inoculated with *N. caninum* SC and culled at 28 dpi, surrounding necrotic foetal villi (n). (d) CD8⁺ cells infiltrating a caruncle of a dam inoculated with *N. caninum* IV and culled at 42 dpi, surrounding a large area of coagulative necrosis (n). (e) CD8⁺ cells surround a lymphocytic aggregate (i) in a caruncle of a dam inoculated with *N. caninum* SC and culled at 56 dpi. (f) Rare single CD8⁺ cells diffusely distributed in a caruncle stalk from a negative control dam culled at 14 dpi. Counterstained with haematoxylin. IHC slides produced by Stephen Maley (Maley *et al.*, 2006), scored and photographed by GJC.

CD8⁺ cells during mid gestation

In the two dams inoculated with *Neospora* and culled at 14 dpi, the caruncles of only a few placentomes were infiltrated with a few CD8⁺ cells, similarly to the negative control animals (see Figure 31a). Minimal to mild CD8⁺ infiltrates were observed in some placentomes of the *N. caninum*-inoculated dams of the 28 dpi group (see Figure 31b), mainly surrounding necrotic foci in the caruncles. In the animals inoculated with *N. caninum* and culled at 42 dpi, only rare CD8⁺ cells were observed diffusely distributed in the caruncles. Rare CD8⁺ cells also surrounded small necrotic foci in the caruncles. Minimally and diffusely distributed CD8⁺ cells were noted in some placentomes of negative control animals, not associated with any other pathological changes.

Mean CD8⁺ scores in the animals inoculated with *N. caninum* during mid gestation (culled at 14, 28 and 42 dpi) are plotted in Figure 32. No significant differences were observed in the CD8⁺ scores between dams inoculated with *N. caninum* and negative controls in the mid gestation experiment ($p = 0.113$).



Figures 31 a-b: Examples of CD8⁺ infiltrates in placentomes from dams inoculated with *N. caninum* during mid gestation. (a) Mild CD8⁺ cell infiltrate in a caruncle stalk of a dam inoculated with *N. caninum* and culled at 14 dpi. (b) CD8⁺ cells infiltrating a caruncle of a dam inoculated with *N. caninum* and culled at 28 dpi. Counterstained with haematoxylin. IHC slides produced by Stephen Maley and Yvonne Pang (MRI, data not published), scored and photographed by GJC.

CD8⁺ score comparison at the three stages of gestation

Overall inter-experiment scores were compared for the animals inoculated with *N. caninum* and significant differences were established for cytotoxic T cell infiltrates between early, mid- and late gestation ($p < 0.001$). When this difference was pair-wise analysed, scores were significantly different in the animals inoculated with *N. caninum* in early gestation, compared with late gestation ($p < 0.001$), and also between mid and late gestation ($p < 0.05$). No differences could be determined between placentas recovered from animals inoculated with *N. caninum* in early and mid-gestation ($p = 0.147$).

No significant overall differences were observed in the CD8⁺ T cell scores in the placentomes from negative control dams in early, mid and late gestation ($p = 0.267$). Furthermore, pair-wise comparisons between early vs. mid, early vs. late, and mid vs. late gestation were also analysed and no significant differences were observed (early vs. mid and early vs. late: $p = 0.357$; 0.534 and 0.531 , respectively).

Tables summarising mean infiltration score values for CD8⁺ cells in early, mid and late gestation are shown below in Tables 2, 3 and 4. Also, tables summarising p -values of the different statistical analyses carried out and a comparison figure of the different immune cell scores are shown in Appendix II.

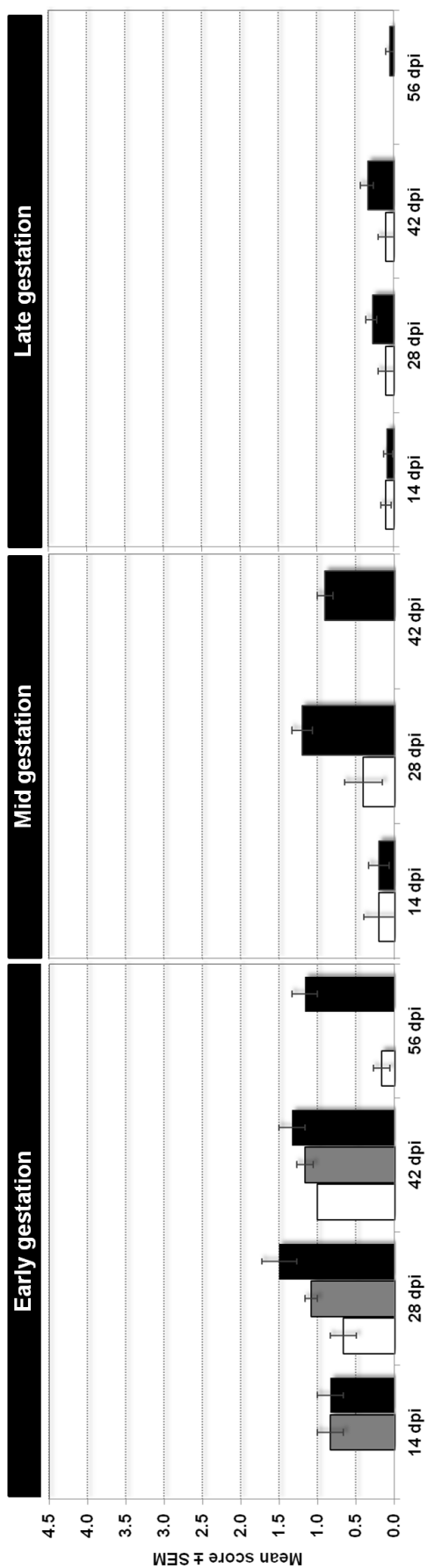
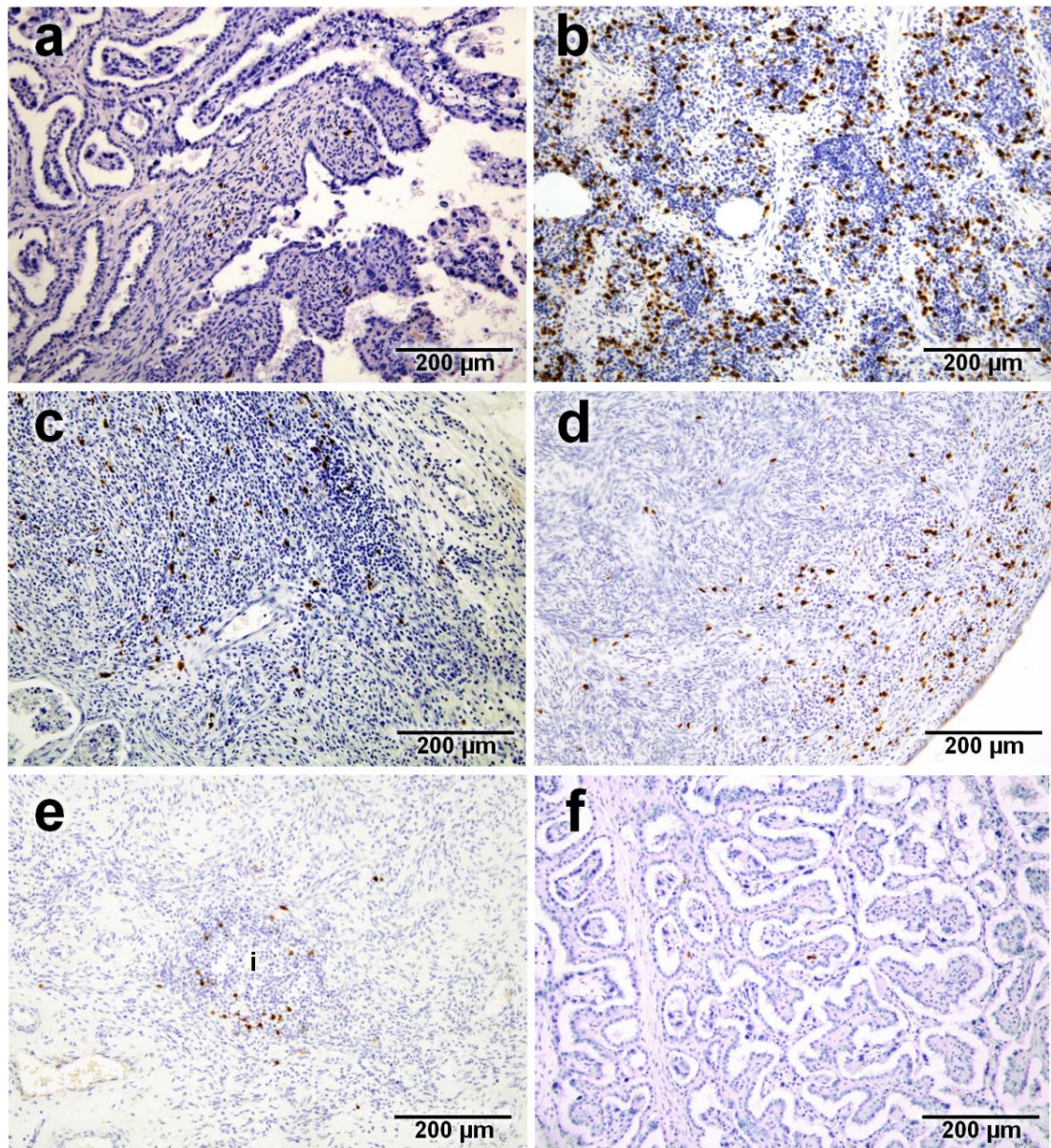


Figure 32: Mean CD8⁺ cell (cytotoxic T cells) infiltrate scores in the placentas collected from negative control (white bars), SC (black bars) and IV *N. caninum*-inoculated dams (gray bars) at early, mid and late gestation. Error bars indicate SEM.

$\gamma\delta$ TCR⁺ cells during early gestation

Although $\gamma\delta$ TCR⁺ infiltration was considered minor in the dams inoculated with *Neospora* IV and SC and culled at 14 dpi (see Figure 33a), in the only dam inoculated SC, culled at 28 dpi and carrying a dead foetus this infiltration was moderate in the base of the caruncle, forming lymphoid aggregations (see Figure 33c). In the dams inoculated IV and culled at 28 and 42 dpi (see Figures 33b and d), and in the SC inoculated dams culled at 42 and 56 dpi (only in the animals carrying non-viable foetuses) $\gamma\delta$ TCR⁺ infiltration was moderate within lymphoid aggregations in the base of the caruncles (see Figure 33e). In negative control dams at all time points (see Figure 33f), and in the SC inoculated dams culled at 28, 42 and 56 dpi (only in the ones carrying viable foetuses), low numbers of $\gamma\delta$ TCR⁺ cells were observed scattered in the caruncular base and septa.

Mean scores for $\gamma\delta$ TCR⁺ cells in the animals inoculated with *N. caninum* (IV and SC) and negative controls during early gestation (culled at 14, 28, 42 and 56 dpi) are plotted in Figure 35. During this experiment, higher $\gamma\delta$ TCR⁺ scores were found in the placentas of cows inoculated with *N. caninum* when compared with the negative control animals ($p < 0.05$). When intra-trial pair-wise analysis was carried out, significantly higher $\gamma\delta$ -T cell placental scores were detected in dams inoculated with *N. caninum* IV and SC, compared with negative control dams ($p < 0.05$); however, no differences were observed when dams inoculated with *N. caninum* IV and SC were compared with each other ($p = 0.348$). Furthermore, after inoculation at day 70 of gestation, higher $\gamma\delta$ T-cell scores were observed in the placentas from animals inoculated with *N. caninum* and carrying non-viable foetuses at the time of euthanasia, compared with those carrying viable foetuses ($p < 0.01$).

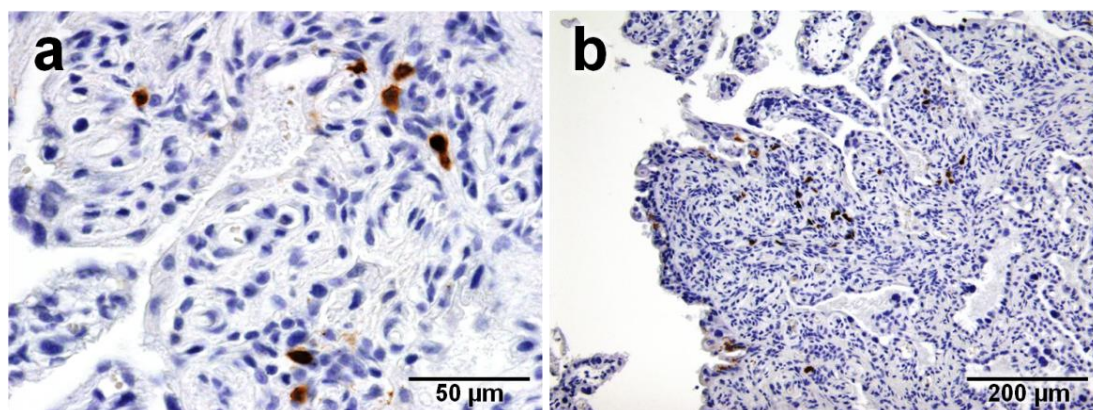


Figures 33 a-f: Examples of $\gamma\delta$ TCR⁺ infiltrates in placentomes from dams inoculated with *N. caninum* (a-e) and negative controls (f) during early gestation. (a) Rare $\gamma\delta$ TCR⁺ cells in a caruncle of a dam inoculated with *N. caninum* SC and culled at 14 dpi. (b) Large numbers of $\gamma\delta$ TCR⁺ cells in a caruncle of a dam inoculated with *N. caninum* IV and culled at 28 dpi. (c) Mild $\gamma\delta$ TCR⁺ cell infiltrates in a caruncle of a dam inoculated with *N. caninum* SC and culled at 28 dpi. (d) Mild $\gamma\delta$ TCR⁺ cell infiltrates in a caruncle of a dam inoculated with *N. caninum* IV and culled at 42 dpi. (e) $\gamma\delta$ TCR⁺ cell infiltrates surrounding a small necrotic focus and inflammation (i) in a caruncle of a dam inoculated with *N. caninum* SC and culled at 56 dpi. (f) Rare single $\gamma\delta$ TCR⁺ cells diffusely distributed in a caruncle from a negative control dam culled at 42 dpi. Counterstained with haematoxylin. IHC slides produced by Stephen Maley (Maley et al., 2006), scored and photographed by GJC.

$\gamma\delta$ TCR⁺ cells during mid gestation

The analysed samples collected at 14 dpi from the animals inoculated with *N. caninum* were minimally infiltrated with $\gamma\delta$ TCR⁺ cells in necrotic areas of the caruncles. At 28 dpi, a similar infiltrate was observed, characterised by single labelled cells (see Figure 34a) or minimal aggregations in necrotic foci of the caruncles, or in the base of the caruncles. Lastly, at 42 dpi, minimal to mild infiltrates of $\gamma\delta$ TCR⁺ cells were noted in the base of the caruncles (see Figure 34b) surrounding necrotic foci. Labelled cells were also diffusely distributed in the base of the caruncles, generally not associated with any other pathological changes in negative control animals.

Mean scores for $\gamma\delta$ TCR⁺ cell infiltration in animals inoculated with *N. caninum* and in negative controls during mid gestation (culled at 14, 28 and 56 dpi) are plotted in Figure 35. After inoculation of *N. caninum* in mid gestation, higher $\gamma\delta$ TCR⁺ scores were found in the placentas from cows inoculated with *N. caninum* when compared with the negative control animals ($p < 0.05$).



Figures 34 a-b: Examples of $\gamma\delta$ TCR⁺ infiltrates in placentomes from *N. caninum*-inoculated animals during mid gestation. (a) $\gamma\delta$ TCR⁺ cells in a caruncle stalk of a dam inoculated with *N. caninum* and culled at 28 dpi. (b) $\gamma\delta$ TCR⁺ cells in a caruncle of a dam inoculated with *N. caninum* and culled at 42 dpi. Counterstained with haematoxylin. IHC slides produced by Stephen Maley and Yvonne Pang (MRI, data not published), scored and photographed by GJC.

$\gamma\delta$ TCR⁺ score comparison at the three stages of gestation

Overall inter-experiment scores were compared for the animals inoculated with *N. caninum* and significant differences were established for $\gamma\delta$ TCR⁺ cell infiltrates between early, mid- and late gestation ($p < 0.001$). Moreover, pair wise analysis indicated significantly higher scores during *Neospora* infection at early gestation compared with late stages ($p < 0.001$) and also higher during mid gestation compared with the scores at late gestation ($p < 0.01$) from animals inoculated with *N. caninum*. No differences were found between early and mid-gestation placentas ($p = 0.184$).

Overall, inter-experiment $\gamma\delta$ TCR⁺ scores were significantly different in the placentomes from the negative control dams in early, mid and late gestation ($p < 0.01$). When pair-wise compared, significant higher $\gamma\delta$ TCR⁺ scores were observed at early gestation compared with the ones at mid and late stages ($p < 0.05$) but no differences were observed between mid and late gestation ($p = 0.354$).

Tables summarising mean infiltration score values for $\gamma\delta$ TCR⁺ cells in early, mid and late gestation are shown below in Tables 2, 3 and 4. Also, tables summarising p -values of the different statistical analyses and a comparison figure of the different immune cell scores are shown in Appendix II.

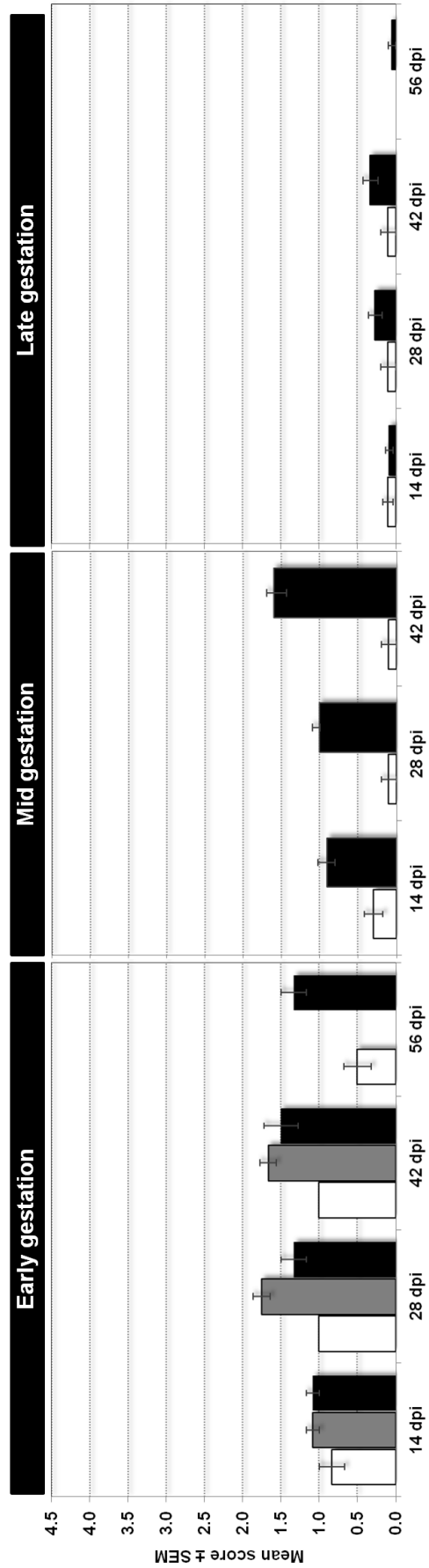
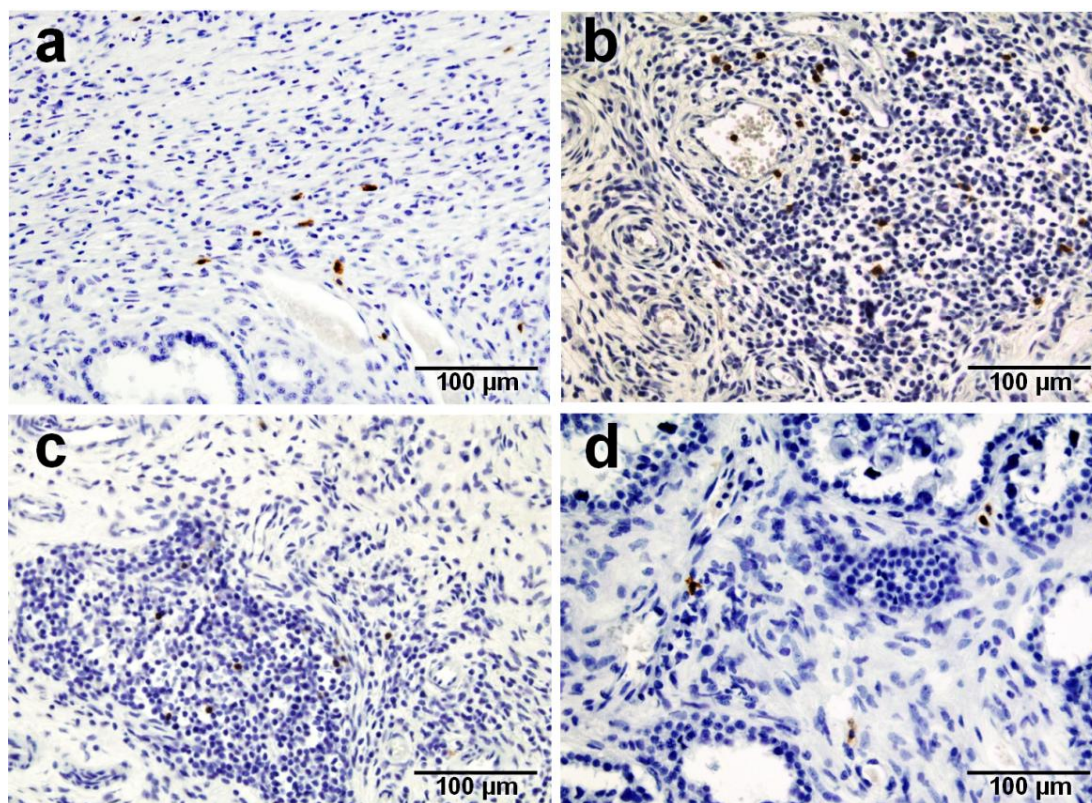


Figure 35: Mean $\gamma\delta$ TCR⁺ cell ($\gamma\delta$ -T cells) infiltrate scores in the placentas collected from negative control (white bars), SC (black bars) and IV *N. caninum*-inoculated dams (gray bars) at early, mid and late gestation. Error bars indicate SEM.

NKp46⁺ cells during early gestation

At 14 dpi in both dams inoculated with *N. caninum* SC, and in one animal inoculated IV, infiltrates of low numbers of NKp46⁺ cells were observed throughout the caruncle (see Figure 36a). In the dam inoculated SC, culled at 28 dpi and carrying a dead foetus at the moment of the *post mortem* examination, moderate numbers of NKp46⁺ cells were noted within areas of lymphoid infiltration in the caruncle septa (see Figure 36b). In both dams inoculated with *Neospora* IV and culled at 28 dpi, moderate NKp46⁺ cell infiltrates were observed in the base of the caruncles. In dams inoculated with *N. caninum* SC and culled at 28, 42, and 56 dpi (carrying live foetuses) (see Figure 36c) and in negative control dams (see Figure 36d) low numbers of NKp46⁺ cells were observed.

Mean NKp46⁺ scores in the animals inoculated with *N. caninum* IV and SC during early gestation (culled at 14, 28, 42 and 56 dpi) are plotted in Figure 38. NKp46⁺ scores were significantly higher in the placentas of dams inoculated with *N. caninum* at day 70 of gestation, when compared with the negative controls ($p < 0.01$). However, when the placental NK cell scores were analysed separately in a pair-wise fashion, no significant differences were found between dams inoculated with *Neospora* IV and negative controls ($p = 0.051$), between dams inoculated SC and controls ($p = 0.095$) and between dams inoculated IV and those inoculated SC ($p = 0.141$). At the same period, higher NK scores were found in the animals inoculated with *N. caninum* and carrying non-viable foetuses compared with those carrying viable foetuses ($p < 0.01$).



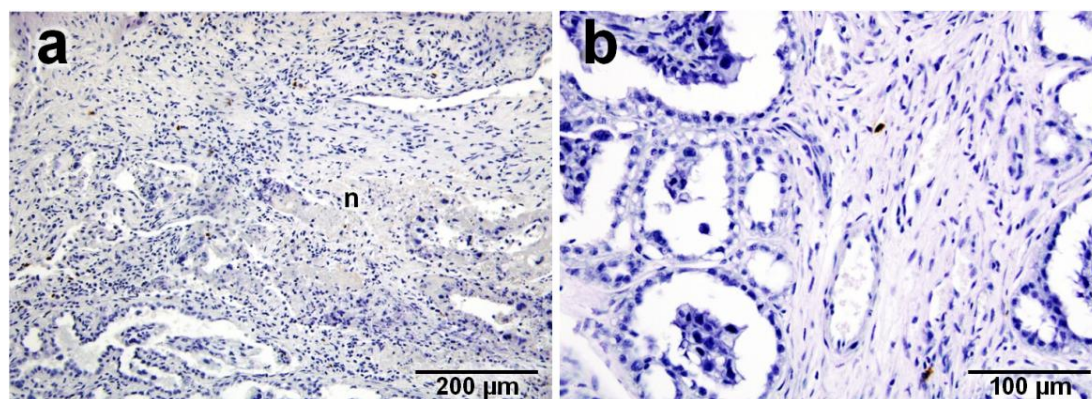
Figures 36 a-d: Examples of NKp46⁺ infiltrates in placentomes from dams inoculated with *N. caninum* (a-c) and negative controls (d) during early gestation. (a) Single rare NKp46⁺ cells in a caruncle of a dam inoculated with *N. caninum* IV and culled at 14 dpi. (b) Mild NKp46⁺ cell infiltrates in a caruncle of a dam inoculated with *N. caninum* IV and culled at 28 dpi. (c) Rare NKp46⁺ cells in an inflammatory focus in a caruncle of a dam inoculated with *N. caninum* SC and culled at 56 dpi. (d) Single NKp46⁺ cells in the placentome of a negative control dam culled at 28 dpi. Counterstained with haematoxylin. IHC slides produced by Stephen Maley (Maley *et al.*, 2006), scored and photographed by GJC.

NKp46⁺ cells during mid gestation

Rare single labelled NK cells infiltrated the caruncles of most of the animals culled at 14, 28 and 42 dpi, these infiltrates were easier to see in animals inoculated with *N. caninum* when compared to negative controls, in most cases associated with necrotic areas (see Figures 37a and b).

Mean scores for NKp46⁺ cell infiltration in dams inoculated with *N. caninum* and negative controls during mid gestation (culled at 14, 28 and 42 dpi) are plotted in

Figure 38. NKp46⁺ scores were significantly higher in the placentas of dams inoculated with *N. caninum* when compared with negative controls ($p < 0.05$).



Figures 37 a-b: Examples of NKp46⁺ infiltrates in placentomes from dams inoculated with *N. caninum* (a) and negative controls (b) during mid gestation. (a) Single rare NKp46⁺ cells in the caruncle surrounding a necrotic area (n) of a dam inoculated with *N. caninum* and culled at 28 dpi. (b) Single rare NKp46⁺ cells in a caruncle stalk of a negative control dam culled at 14 dpi. Counterstained with haematoxylin. IHC slides produced by Stephen Maley and Yvonne Pang (MRI, data not published), scored and photographed by GJC.

NKp46⁺ score comparison at the three stages of gestation

When overall NK scores contrasted in dams inoculated with *N. caninum* in early, mid and late gestation, significant differences were found ($p < 0.05$). Nevertheless, when they were pair-wise compared, higher NK scores were only established between early and late gestation ($p < 0.05$) and not between early and mid gestation ($p = 0.054$) or between mid- and late gestation samples ($p = 0.917$).

Significant overall differences were also observed in the NK scores found in placentomes from negative control dams in early, mid and late gestation ($p < 0.01$). When pair-wise compared, significant differences were observed only between early and mid and between early and late gestation ($p < 0.05$). No differences were observed in these scores between mid and late gestation ($p = 0.079$).

Tables summarising mean infiltration score values for NKp46⁺ cells in early, mid and late gestation are shown below in Tables 2, 3 and 4. Also, tables summarising p -

values of the different statistical analyses and a comparison figure of the different immune cell scores are shown in Appendix II.

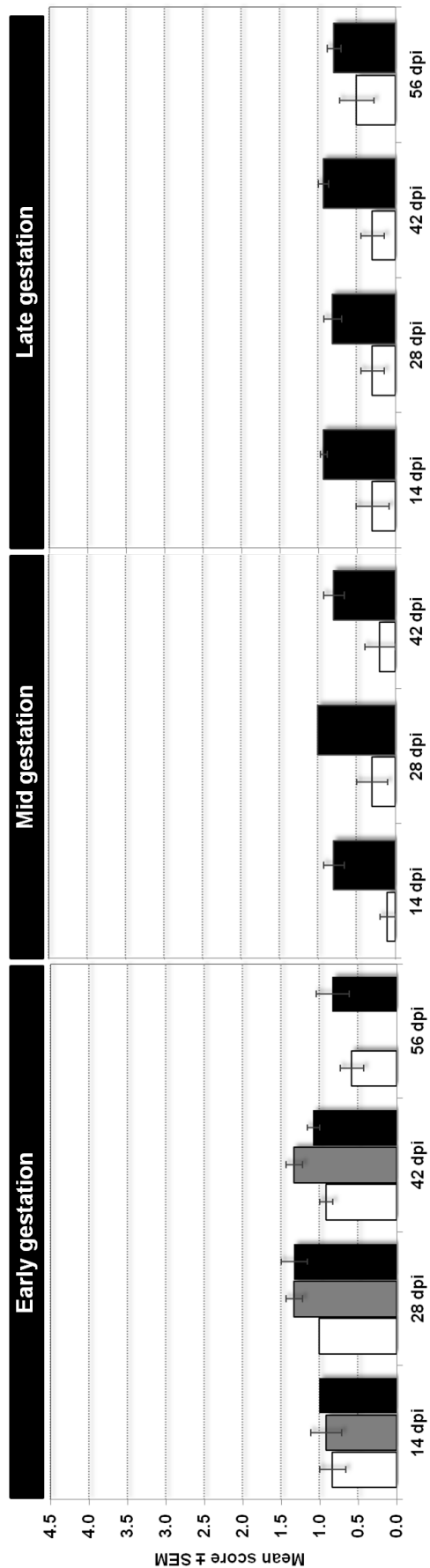


Figure 38: Mean NKp46⁺ cell (NK cells) infiltrate scores in the placentas collected from negative control (white bars), SC (black bars) and IV *N. caninum*-inoculated dams (gray bars) at early, mid and late gestation. Error bars indicate SEM.

CD79_{acy}⁺ cells during early gestation

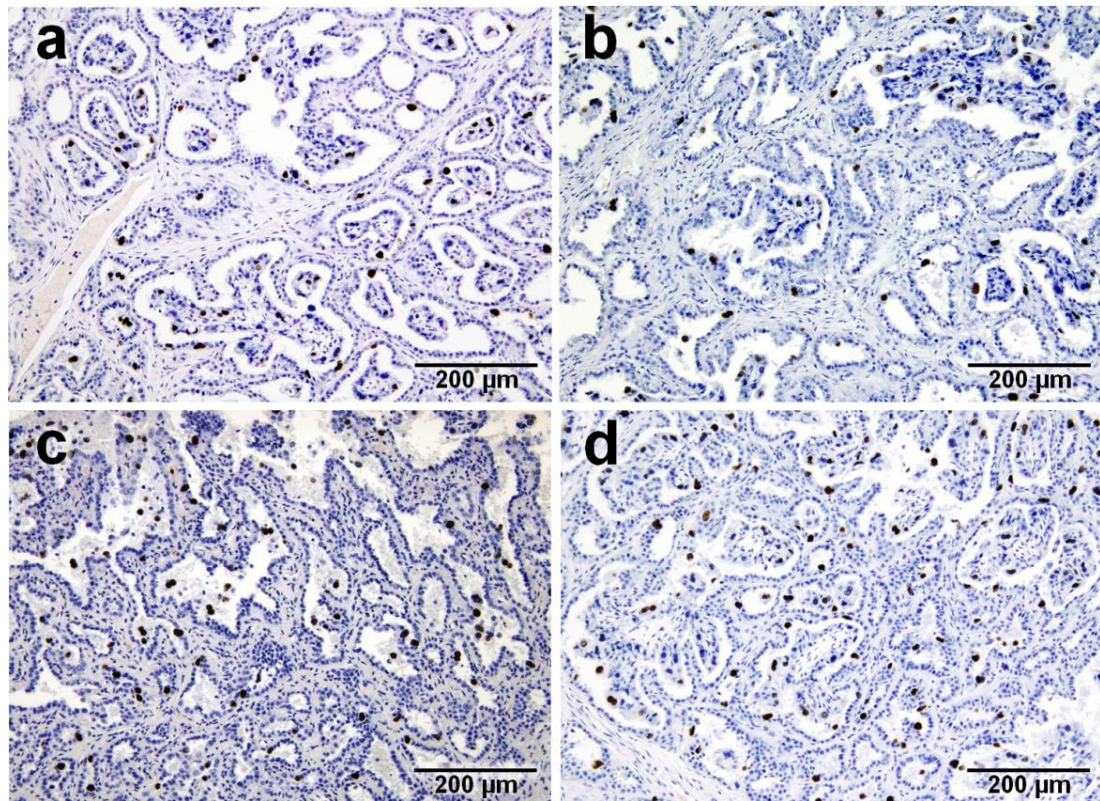
The number of CD79_{acy}⁺ cells in the placentomes collected from dams inoculated with *N. caninum* IV and SC at day 70 of gestation was low (see Figure 39a), although there was an apparent increase in the dams inoculated IV and culled at 28 dpi, with no differences between animals carrying live or dead fetuses. Single CD79_{acy}⁺ cells were also present in the negative control dams (see Figure 39b). The location of these CD79_{acy}⁺ cells was similar to that described in the late gestation experiment, the cells morphologically and histologically resembling trophoblast cells.

Mean CD79_{acy}⁺ scores in the dams inoculated with *N. caninum* IV and SC during early gestation (culled at 14, 28, 42 and 56 dpi) are plotted in Figure 40. No significant differences were observed in the CD79_{acy}⁺ scores between dams inoculated with *N. caninum* and the negative controls ($p = 0.432$). Likewise, no significant differences were observed for pair-wise analysis between those inoculated IV and negative controls ($p = 0.199$), between those inoculated SC and negative controls ($p = 0.945$) and between those inoculated IV and SC ($p = 0.199$). CD79⁺ scores were lower in the dams inoculated with *N. caninum* and carrying non-viable fetuses, compared with those carrying viable fetuses ($p < 0.01$).

CD79_{acy}⁺ cells during mid gestation

Rare single CD79_{acy}⁺ cells were particularly observed in dams inoculated with *N. caninum* and culled at 14 and 28 dpi. These were diffusely distributed in the caruncles but there were not associated pathological changes in the placentomes, similar to the negative controls (see Figures 39c and d). In the animals inoculated with *N. caninum* and culled at 42 dpi, the infiltration was more evident.

Mean CD79_{acy}⁺ scores in the animals inoculated with *N. caninum* and negative controls during mid gestation (culled at 14, 28 and 42 dpi) are plotted in Figure 40. At mid gestation no significant differences were observed in the CD79_{acy}⁺ scores between dams inoculated with *N. caninum* and negative controls ($p = 0.386$).



Figures 39 a-d: Examples of CD79_{acy}⁺ cells in placentomes from dams inoculated with *N. caninum* (a and c) and negative controls (b and d) during early and mid gestation. (a) CD79_{acy}⁺ cells in a caruncle of a dam inoculated with *N. caninum* SC at day 70 of gestation, and then culled at 28 dpi. (b) CD79_{acy}⁺ cells in a caruncle of a negative control dam inoculated with *N. caninum* at day 70 of gestation, and then culled at 42 dpi. (c) CD79_{acy}⁺ cells in a caruncle of a dam inoculated with *N. caninum* at day 140 of gestation, and then culled at 14 dpi. (d) CD79_{acy}⁺ cells in a caruncle of a negative control dam at day 140 of gestation, culled at 42 dpi. Counterstained with haematoxylin. IHC slides from the early gestation experiment were produced by Stephen Maley (Maley *et al.*, 2006), scored and photographed by GJC. IHC slides from the mid gestation experiment were produced by Stephen Maley and Yvonne Pang (MRI, data not published), scored and photographed by GJC.

CD79_{acy}⁺ score comparison at the three stages of gestation

Overall there were significant differences in the CD79_{acy}⁺ score comparison between animals inoculated with *N. caninum* in early, mid and late gestation ($p < 0.05$). However, when they were pair-wise contrasted, significant differences in the CD79_{acy}⁺ scores were only detected between dams inoculated with *Neospora* in early and mid-gestation, and between mid- and late gestation ($p < 0.05$) but not between early and late gestation ($p = 0.908$).

Immunopathogenesis of bovine neosporosis throughout gestation

No significant overall differences were observed in the CD79_{acy}⁺ scores in the placentomes collected from negative control dams in early, mid and late gestation ($p = 0.143$). When pair-wise compared, no significant differences were observed between early vs. mid ($p = 0.265$), early vs. late ($p = 0.195$), and mid vs. late gestation ($p = 0.195$) in negative control animals.

Tables summarising mean infiltration score values for CD79_{acy}⁺ cells in early, mid and late gestation are shown below in Tables 2, 3 and 4. Also, tables summarising p -values of the different statistical analyses carried out and a comparison figure of the different immune cell scores are shown in Appendix II.

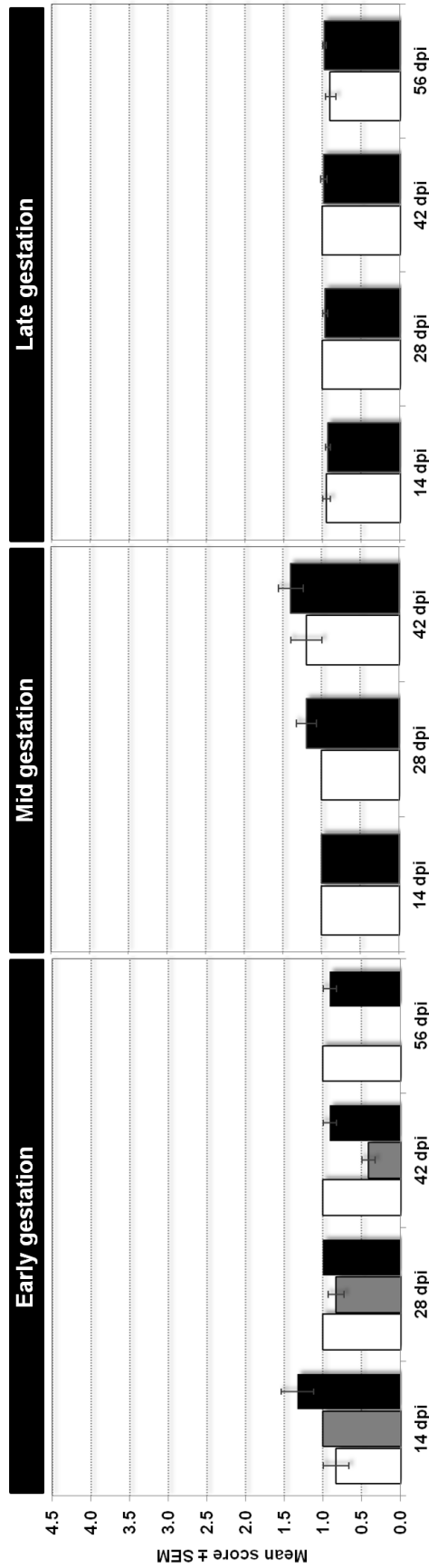


Figure 40: Mean CD79_{acy}⁺ cell infiltrate scores in the placentas collected from negative control (white bars), SC (black bars) and IV *N. caninum*-inoculated dams (gray bars) at early, mid and late gestation. Error bars indicate SEM.

Table 2: Mean (\pm SEM) of different immune cell infiltrate scores on placentomes collected from dams inoculated with *N. caninum* and negative control dams during early, mid and late gestation.

Cell type	Early gestation		Mid gestation		Late gestation	
	Control	Inoculated (SC+IV)	Control	Inoculated	Control	Inoculated
CD68	1.79 (\pm 0.17) ^b	2.83 (\pm 0.16) ^{aA}	0.87 (\pm 0.13) ^a	2.07 (\pm 0.20) ^{aAB}	1.25 (\pm 0.07) ^a	1.80 (\pm 0.08) ^{aB}
CD3	1.15 (\pm 0.06) ^b	2.94 (\pm 0.12) ^{aA}	0.43 (\pm 0.12) ^b	2.12 (\pm 0.21) ^{aAB}	0.25 (\pm 0.07) ^b	0.87 (\pm 0.08) ^{aB}
CD4	0.96 (\pm 0.09) ^b	2.49 (\pm 0.15) ^{aA}	0.37 (\pm 0.11) ^a	1.70 (\pm 0.25) ^{aAB}	0.15 (\pm 0.06) ^a	0.44 (\pm 0.06) ^{aB}
CD8	0.46 (\pm 0.09) ^b	1.13 (\pm 0.07) ^{aA}	0.20 (\pm 0.11) ^a	0.77 (\pm 0.10) ^{aAB}	0.08 (\pm 0.04) ^a	0.20 (\pm 0.04) ^{aB}
$\gamma\delta$ TCR	0.83 (\pm 0.07) ^b	1.39 (\pm 0.06) ^{aA}	0.17 (\pm 0.06) ^b	1.17 (\pm 0.08) ^{aA}	0.25 (\pm 0.07) ^b	0.63 (\pm 0.05) ^{aB}
NKp46	0.83 (\pm 0.07) ^b	1.12 (\pm 0.06) ^{aA}	0.20 (\pm 0.10) ^b	0.87 (\pm 0.06) ^{aAB}	0.35 (\pm 0.09) ^b	0.88 (\pm 0.04) ^{aB}
CD79 _{acy}	0.96 (\pm 0.04) ^a	0.92 (\pm 0.05) ^{aB}	1.07 (\pm 0.07) ^a	1.20 (\pm 0.07) ^{aA}	0.96 (\pm 0.02) ^a	0.96 (\pm 0.02) ^{aB}

^{a, b} Different lower case superscript letters indicate significant different scores between negative control and *N. caninum* inoculated dams in each experiment (early, mid and late gestation)

^{A, B} Different uppercase superscript letters indicate significant different overall scores for each cell marker between *N. caninum* inoculated dams in early, mid and late gestation (Kruskal-Wallis test)

Table 3: Mean (\pm SEM) of different immune cell scores in placentomes collected from dams inoculated with *N. caninum* IV and SC and negative controls during early gestation.

Cell type	Control	IV inoculated	SC inoculated
CD68	1.79 (\pm 0.17) ^a	3.06 (\pm 0.17) ^a	2.67 (\pm 0.21) ^a
CD3	1.15 (\pm 0.06) ^b	3.22 (\pm 0.15) ^a	2.73 (\pm 0.17) ^a
CD4	0.96 (\pm 0.09) ^b	2.83 (\pm 0.19) ^a	2.23 (\pm 0.21) ^a
CD8	0.46 (\pm 0.09) ^b	1.03 (\pm 0.08) ^a	1.21 (\pm 0.10) ^a
$\gamma\delta$ TCR	0.83 (\pm 0.07) ^b	1.50 (\pm 0.09) ^a	1.31 (\pm 0.08) ^a
NKp46	0.83 (\pm 0.07) ^a	1.19 (\pm 0.09) ^a	1.06 (\pm 0.08) ^a
CD79 _{acy}	0.96 (\pm 0.04) ^a	0.75 (\pm 0.07) ^a	1.04 (\pm 0.07) ^a

^{a, b} Different letters indicate significantly different scores between negative controls, and dams inoculated with *N. caninum* SC and IV in early gestation

Table 4: Mean (\pm SEM) of different immune cell scores on placentomes collected from dams inoculated with *N. caninum* carrying non-viable and viable foetuses during early gestation.

Cell type	Non-viable	Viable
CD68 ⁺	2.55 (\pm 0.25) ^a	3.09 (\pm 0.19) ^a
CD3 ⁺	3.43 (\pm 0.10) ^a	2.50 (\pm 0.17) ^b
CD4 ⁺	2.90 (\pm 0.21) ^a	2.11 (\pm 0.20) ^b
CD8 ⁺	1.40 (\pm 0.09) ^a	0.89 (\pm 0.07) ^b
$\gamma\delta$ TCR ⁺	1.73 (\pm 0.06) ^a	1.09 (\pm 0.05) ^b
NKp46 ⁺	1.30 (\pm 0.08) ^a	0.95 (\pm 0.07) ^b
CD79 _{acy} ⁺	0.75 (\pm 0.07) ^a	1.07 (\pm 0.07) ^b

^{a, b} Different letters indicate significant different scores between placentas from dams carrying non-viable and viable foetuses in the dams inoculated with *N. caninum* in early gestation

Discussion

This chapter describes for the first time the characterisation of the cellular immune response in pregnant cows after inoculation with *N. caninum* at day 140 of gestation. The data generated in this chapter allowed a comparison with similar data in early (Maley *et al.* 2006) and late gestational experiments (Chapter 2 and Cantón *et al.*, 2013b) using the same dose and strain of *N. caninum*.

Previous studies have hypothesised about the influence of a differential cellular immune response in the pathogenesis of bovine neosporosis (Rosbottom *et al.*, 2008; Rosbottom *et al.*, 2011). Maley *et al.* (2006) described a severe infiltrate of immune cells in the placentas of cattle experimentally inoculated with Nc-1 in early gestation. After comparing the infiltrate of immune cells in the placentomes of *Neospora* inoculated animals at different stages of gestation, the existence of such changes was confirmed.

Studies clarifying the cellular immune response in placental tissues were previously published after experimental inoculation of pregnant cattle in early (Maley *et al.*, 2006) and late gestation (Cantón *et al.*, 2013b). The main aim of this chapter was to characterise the cellular immune response in pregnant cows after inoculation with the same dose and strain of *N. caninum* at day 140 of gestation. The infiltration pattern of T-cells (CD3⁺, CD4⁺, CD8⁺ and $\gamma\delta$ TCR⁺), CD79_{acy}⁺ cells and NK cells in the placentomes was similar for the three time points (Maley *et al.*, 2006; Cantón *et al.*, 2013b). However, macrophage scores in mid-gestation were different, with scores increasing from 14 to 28 and 42 dpi, when they were more severe.

Using the same scoring methodology allows a more objective comparison between placental samples collected in each trimester of gestation. After infection at days 70 and 210 of gestation, similar macrophage infiltrates were initially observed at 14 dpi. At this stage of the early gestation experiment, *N. caninum* was already identified in placental and foetal samples (Macaldowie *et al.*, 2004). Although later in gestation no significant differences were established in the macrophage scores between *Neospora* inoculated and control animals, some slight differences were observed.

Interestingly, while the parasite was present in the blood stream, it was not present in either the placental or the foetal samples collected at 14 dpi (Benavides *et al.*, 2012). It may be that the macrophages in early and late gestation are involved in initiating an immune response. Monocytes / macrophages are one of the principal cellular components of innate immunity, acting as antigen presenting cells; consequently, they can influence the functional deviation of the subsequent adaptive immune response (Raghupathy, 1997; Nishikawa *et al.*, 2001c). Similar results were previously described for endometrial macrophages which increased after *Neospora* infection in pregnant cattle (Rosbottom *et al.*, 2008), seemingly playing a crucial role in the inhibition of intracellular tachyzoite multiplication (Tanaka *et al.*, 2000a). However, after inoculation in mid-gestation, the macrophage score was lower at 14 dpi. This could be related to the significant immunomodulation which occurs during this stage of pregnancy (Williams *et al.*, 2000; Innes *et al.*, 2001), which is influenced by hormones (Piccinni *et al.*, 1995; Kalinski *et al.*, 1997). Later on, after 28 dpi in each experiment (inoculation at days 70, 140 and 210 of gestation) there were reduced macrophage scores, but after 42 (mid gestation) and 42 and 56 dpi (early and late gestation) CD68⁺ cells were increased. This may be due to the presence of more severe pathological changes in the placenta (Maley *et al.*, 2003; Macaldowie *et al.*, 2004; Benavides *et al.*, 2012) because these cells also play a key role in the tissue repair process, being the principal cell type responsible for wound debridement (Leibovich and Ross, 1975). The increase in the placental macrophage population in late gestation could also be related with the role of this cell population near parturition (Oliveira and Hansen, 2009). The involvement of macrophages in the immunopathogenesis of *Neospora* abortion in early gestation could not be established because no differences were observed between the CD68⁺ score in animals carrying non-viable and viable foetuses. However, significantly higher macrophage scores were observed in the *Neospora* inoculated animals in early gestation, when compared with placental samples in late gestation, when no abortions were produced. This last finding is interesting, since the important macrophage infiltration in the placenta in early gestation could be responsible for appropriate initial presentation of the parasite to the immune system, although it

could also be the initial trigger for an intense adaptive immune response that could injure the maternal-placental junction and later endanger the foetus.

In the current study higher T lymphocyte (CD3⁺) scores were found in the placentas from *N. caninum*-inoculated animals in early, mid- and late gestation when compared to the negative controls. In early gestation, higher T lymphocyte scores were observed in animals inoculated with *N. caninum* IV and SV compared to negative controls; no significant differences were observed between IV- and SC-*N. caninum*-inoculated animals, although more non-viable foetuses were found in the IV-inoculated animals, in accordance with Maley *et al.* (2006) who used a different scoring method in the same placental samples. As previously stated, higher T lymphocyte scores were found in placentas from dams that carried non-viable foetuses or were empty at culling. When the statistical analysis was carried out on the scores at early, mid and late gestation, significantly higher scores were observed in early gestation. Similarly, previous work reported significantly higher lymphocyte infiltrates in uterine and placental tissues collected from pregnant *N. caninum*-seropositive dams compared with seronegative ones (Orozco *et al.*, 2013). Collectively, these results support a positive association between the infiltration of T lymphocytes and *Neospora* abortion.

Most of the lymphocytes infiltrating the placentas of experimentally inoculated animals during gestation were T helper cells (CD4⁺) although only in early gestation were significant differences observed between *Neospora* inoculated dams and control animals. Similar to the differences between total T lymphocyte infiltrates, higher T helper cell scores were recorded in placentas from cows inoculated with *Neospora* in early gestation compared with those inoculated in mid- and late gestation, and also compared with dams inoculated with *N. caninum* and carrying dead foetuses or empty. Similar results were reported previously after experimental inoculation with *N. caninum* in early, mid- and late gestation (Rosbottom *et al.*, 2007; Rosbottom *et al.*, 2008; Rosbottom *et al.*, 2011). CD4⁺ T-cell infiltration is a characteristic of a Th1 response (Khan *et al.*, 1997; Baszler *et al.*, 1999; Williams *et al.*, 2000; López-Gatius *et al.*, 2007a) and was commonly reported after experimental infection of

cattle with *N. caninum* tachyzoites, with corresponding production of IFN- γ (Innes *et al.*, 1995a; Innes *et al.*, 1995b; Innes *et al.*, 1997; Marks *et al.*, 1998; Tanaka *et al.*, 2000a; Staska *et al.*, 2003; Bartley *et al.*, 2004; Staska *et al.*, 2005). Besides that, it has already been established that this Th1 response can be harmful to pregnancy and could affect foetal survival (Innes *et al.*, 1995a; Raghupathy, 1997; Quinn *et al.*, 2002a).

In contrast, a minimal infiltrate of cytotoxic T cells (CD8⁺) was observed in the Nc-1 inoculated animals during the three experiments compared with the T helper cell infiltrates. Nevertheless, similarly to the T helper cell infiltrate, significantly higher cytotoxic T cell scores were observed in animals inoculated with *N. caninum* in early gestation compared with negative controls. Also in early gestation, higher cytotoxic T cell scores were observed in the placentas from dams carrying a dead foetus compared with those from *Neospora* inoculated animals carrying live foetuses. However, no differences were observed between control and *Neospora*-inoculated animals in the mid- and late gestation experiment. When the three time-point experiments were compared, higher cytotoxic T cell scores were observed in the placentas from animals inoculated with Nc-1 in early and mid-gestation compared with the placentas of animals inoculated at day 210 of gestation. Similar results were reported by another research group, when minimal infiltrate of cytotoxic T cells were found in placentas after recrudescence of *Neospora* infection at mid and late gestation (Rosbottom *et al.*, 2011) and after experimental inoculation at late gestation (Rosbottom *et al.*, 2007; Rosbottom *et al.*, 2008). The role of cytotoxic T cells in immunity against *N. caninum* is still unclear (Rosbottom *et al.*, 2007) but it has been shown that cytotoxic lymphocytes from cattle could kill *N. caninum*-infected autologous target cells *in vitro* (Staska *et al.*, 2003). However, studies in mice have demonstrated that cytotoxic T cells have a minimal role in the protection against this parasite (Tanaka *et al.*, 2000a).

The role of $\gamma\delta$ T-cells in combating *N. caninum* infection is not known, but some studies have demonstrated that their presence in the placenta may be the first line of defence against pathogens (Entrican, 2002; Maley *et al.*, 2006). In the three

experiments (after experimental inoculation with *N. caninum* at days 70, 140 and 210 of gestation), significantly higher $\gamma\delta$ T-cell scores were observed in *Neospora*-inoculated animals compared with non-inoculated controls. In the early gestation experiment, higher $\gamma\delta$ T-cell infiltrates were also recognised in the placentas collected from dams carrying dead foetuses compared with those carrying viable foetuses. Similarly to T lymphocytes and cytotoxic T cells, higher numbers of $\gamma\delta$ T-cells were observed in the placentas of Nc-1-inoculated animals in early and mid-gestation, compared with late gestation placentas. Gamma delta T-cells are described as producers of Th1 cytokines, such as IFN- γ (Raghupathy, 1997; Sopp and Howard, 2001; Amills *et al.*, 2002), which may help provide protective immunity against the early stage of *N. caninum* infection (Tanaka *et al.*, 2000a). Nevertheless, as cited previously, $\gamma\delta$ T cells may also have the capacity to trigger foetal losses in murine models (Arck *et al.*, 1999). These results support the hypothesis that an anti-*Neospora* immune response during late gestation is less harmful than during early pregnancy.

Like $\gamma\delta$ T-cells, NK cells act as a first line of defence against infections, especially against protozoa (Trinchieri, 1989; Korbel *et al.*, 2004). It is well established that NK cell cytotoxicity and IL-12 and IFN- γ production play a crucial role in the resolution of viral and protozoan infections (Korbel *et al.*, 2004). In the three experiments described here, higher NK cell placental infiltrates were observed in *Neospora*-inoculated animals compared with non-inoculated control animals; in the early gestation experiment, higher NK scores were also observed in placentas from dams carrying non-viable foetuses compared with those carrying life foetuses. Similarly to T lymphocytes (CD3⁺, CD4⁺, CD8⁺ and $\gamma\delta$ T-cell), significant differences were observed between the Nc-1-inoculated animals in early and mid-gestation compared with late gestation. Interaction of *N. caninum* tachyzoites with bovine NK cells has been demonstrated, whereby NK cells were able to kill *N. caninum* infected cells (Boysen *et al.*, 2006). Klevar *et al.* (2007; 2009) also described an initial induction of NK cells during early experimental infection of calves with *N. caninum*. These previous reports, in conjunction with the findings in this Thesis, enforce the hypothesis of the key role that this immune cell may play in

influencing the cytokine microenvironment during induction of the adaptive immune response.

In previous studies, B-cells were thought to play an important role in host immunity against *N. caninum* (Eperon *et al.*, 1999). Nevertheless, other researchers suggested that this cell type is not involved in protection against *N. caninum* and the immunopathogenesis of neosporosis (Rosbottom *et al.*, 2011). Further analysis needs to be carried out in order to elucidate the true identity of the CD79_{acy}⁺ cells [as previously stated by Cantón *et al.* (2013b) and described in Chapter 2]. Morphologically and histologically these labelled cells resemble trophoblasts, which could explain the results of the current study where no differences were observed in the CD79_{acy}⁺ cell infiltrates between animals inoculated with *N. caninum* and negative controls. Furthermore, CD79_{acy}⁺ cell infiltrates were lower in inoculated dams carrying non-viable foetuses than in those carrying viable foetuses. These differences could be attributed to the large areas of necrosis in the placentomes which could have destroyed the trophoblasts.

Significant differences were also observed in the overall T lymphocyte (CD3⁺, CD4⁺, $\gamma\delta$ TCR⁺ and NKp46⁺) scores between negative control animals in early, mid and late gestation. After pair-wise analysis was concluded that the differences are mainly due to the scores in early gestation being significantly different to those in the later stages. It has been shown before that ruminant pregnancy is characterised by an increase in the macrophage, $\gamma\delta$ -T and NK cells populations within the uterus (Entrican and Wheelhouse, 2006; Oliveira and Hansen, 2008). Pregnancy-associated changes in immune cell populations are likely to be important for protection of the conceptus from maternal immune attack or for removal of cellular debris and microorganisms from the uterus following parturition (Oliveira and Hansen, 2008). The periparturient dairy cow is immunosuppressed, with a decline in the number of T helper, cytotoxic T and $\gamma\delta$ -T cells in peripheral blood (Van Kampen and Mallard, 1997; Kimura *et al.*, 1999; Kimura *et al.*, 2002); however, other authors have not observed immunosuppression at this stage (Oliveira and Hansen, 2008). Unfortunately, characterisation of the resident immune cell population in a transient

tissue like the placenta is rare, especially in ruminants. This study found significant differences in some of the immune cells analysed; however, further studies with a larger number of animals would be necessary to clarify this.

Summarising the placental infiltrates of all the immune cell types analysed during these experiments, decreased cell infiltrate scores were observed as pregnancy advanced. The infiltrate was basically composed of total T lymphocytes, and most of these T lymphocytes were T-helper cells. As stated above, significantly higher scores were observed for most of these cells when comparison was made between Nc-1-inoculated animals in early and mid- gestation (versus late gestation). Additionally, significantly higher scores of T lymphocytes, T helper cells, cytotoxic T cells, $\gamma\delta$ -T cells, NK cells and CD79_{acy}⁺ cells were observed in the placentomes collected from dams carrying dead foetuses compared with those carrying live foetuses before culling. These results could partially explain the clinical finding of abortion and the severity of lesions in the placentomes during the experiment in early gestation, and could also support the hypothesis that immune-mediated abortion is more likely when an exacerbated Th1 response is present, producing damage of the maternal placenta and interruption of the nutrient supply of the foetus (Maley *et al.*, 2003; Macaldowie *et al.*, 2004; Innes *et al.*, 2005).

Another important hypothesis which could explain the different clinical outcomes of *Neospora* infection during gestation is the immunological maturity of the foetus. Such a contributory role has been previously described for the foetus (Ogino *et al.*, 1992; Dubey *et al.*, 1996a; Buxton *et al.*, 2002b). The foetal calf is capable of mitogenic blastogenesis at around day 80 of gestation (Osburn *et al.*, 1982; Entrican, 2002) and it has been shown that, around day 100 to 150 of gestation, the foetus is able to mount an immune response (Osburn, 1986; Nettleton and Entrican, 1995; Bartley *et al.*, 2012). This could explain why *N. caninum* was less widely disseminated in late gestation compared with the trials carried out in early and mid-gestation (Maley *et al.*, 2003; Macaldowie *et al.*, 2004; Benavides *et al.*, 2012).

Some studies provide evidence that some routes of experimental infection of cattle do not entirely mimic natural infection (Innes *et al.*, 2002). Intravenous inoculation tries to mimic the natural occurrence of haematogenous spread of the parasite after either exogenous or endogenous infection (Williams *et al.*, 2000; Gibney *et al.*, 2008). However, in the study carried out by Macaldowie *et al.* (2004), comparison of cattle inoculated IV or SC found differences in clinical, serological and pathological responses, indicating that the number of parasites reaching the placenta in early gestation may be critical in determining whether foetal death occurs or not (Macaldowie *et al.*, 2004). While the intravenous route immediately creates a parasitaemia, subcutaneous inoculation arguably more closely models a natural primary infection, as the parasite is “processed” through a draining lymph node before circulating in the blood (Macaldowie *et al.*, 2004). Nevertheless, after re-analysing the samples collected from all three experiments, using a different scoring method to that used by Maley *et al.* (2006), no significant differences were observed in the immune cell subtypes when the two routes of inoculation were compared.

In conclusion, a distinctive immune cell infiltrate in placentomes collected from pregnant cows inoculated with *N. caninum* in early, mid- and late gestation can partially explain the less severe clinical outcome later in gestation. These results may help to improve the understanding of the immune pathogenesis of bovine neosporosis and the contribution of the maternal immune response to disease progression. More studies aimed at the further characterisation of this immune response and the evaluation of the production of pro-inflammatory (Th1) cytokines were carried out and are presented in the next Chapter.

Chapter 4:

Cytokine expression in the bovine placenta after inoculation with *Neospora caninum* throughout gestation

Adapted from:

Cantón, G., Bartley, P., Bartley, K., Todd, H., Chianini, F., Katzer, F. 2013a. Production of a bovine IL-12p40 probe and application using *in situ* hybridization on ruminant fixed tissues. *Veterinary Immunology and Immunopathology* 151 (3-4), 342-347.

Cantón, G.J., Katzer, F., Maley, S.W., Bartley, P., Benavides-Silvan, J., Palarea-Albaladejo, J., Burrells, A., Pang, Y., Rocchi, M., Smith, S., Innes, E.A., Chianini, F. Cytokine expression in the placenta of pregnant cattle after inoculation with *Neospora caninum* throughout gestation. Article submitted for publication in *Veterinary Immunology and Immunopathology*.

In this chapter I was responsible for reviewing the literature, producing new RNA probes, applying ISH on the placental tissues, scoring and photographing the slides, analysing these results and writing the manuscript.

Introduction

Cytokines are soluble mediators of the immune system, acting as a communication network between cells of both lymphoid and non-lymphoid origin (Kelso, 1998; Entrican, 2002). Virtually every nucleated cell type is able to produce cytokines, although the cells of the immune system are the main producers (Lim *et al.*, 1998; Kelso, 1998). Most of the cytokines are produced by, and act on, antigen presenting cells (such as monocytes / macrophages), lymphocytes and local inflammatory cells within sites of infection and associated lymphoid tissues (Kelso, 1998), creating particular microenvironments (Druckmann and Druckmann, 2005).

Cytokines play the most critical role in T helper cell polarization, with IL-12 and IL-4 being vital controls of Th1 and Th2 differentiation, respectively (Glimcher and Murphy, 2000). Distinct sets of cytokines are optimally protective against different types of pathogens (Seder and Paul, 1994; Anderson *et al.*, 2001), and there is sufficient evidence that an infection with *N. caninum* is able to trigger the release of Th1 cytokines at the materno-foetal interface to control the parasite (Khan *et al.*, 1997; Long *et al.*, 1998; Lundén *et al.*, 1998; Marks *et al.*, 1998; Baszler *et al.*, 1999; Eperon *et al.*, 1999; Tanaka *et al.*, 2000a; Tanaka *et al.*, 2000b; Quinn *et al.*, 2002a).

However, depending on cytokine concentration and the stage of pregnancy, some cytokines may also have detrimental effects (Entrican, 2002). The cytokine microenvironment during pregnancy is generally physiologically characterised as favouring a Th2 immune response, therefore a shift towards a Th1-type immune response during *Neospora* infections in gestating cows could be harmful to placental wellbeing and stability of the pregnancy (Raghupathy, 1997; Innes *et al.*, 2002; Innes *et al.*, 2005; Dubey *et al.*, 2006; Innes and Vermeulen, 2006). Furthermore, in humans, IL-12 significantly augments the cytolytic activity of lymphocytes *in vitro* against trophoblast cells (Hayakawa *et al.*, 1999) and elevated serological IL-12 levels have been detected in pregnant women with recurrent abortion (Wilson *et al.*, 1997). IL-12p40 has been implicated as a potential abortifacient in a murine model

(Zenclussen *et al.*, 2002) and administration of IL-12 (along with IL-18) to pregnant mice has also been shown to result in pregnancy loss (Muranaka *et al.*, 1998).

Interferon- γ is produced by several immune cells (CD4⁺, CD8⁺, $\gamma\delta$ T cells and NK cells) (Lederer *et al.*, 1996; Scharton-Kersten and Sher, 1997; Marks *et al.*, 1998) and has been described as the hallmark cytokine of the Th1 response in different species (Glimcher and Murphy, 2000; Robertson, 2000). IFN- γ plays a major role in activating other cells, such as macrophages, to kill both intracellular and extracellular microorganisms (Scharton-Kersten and Sher, 1997; Entrican, 2002). It has been previously shown that, although IFN- γ is expressed in the placenta in normal pregnancy (Yui *et al.*, 1994), it can also be cytotoxic for trophoblasts if it is overproduced and may result in reproductive failure in humans (Meegdes *et al.*, 1988; Yui *et al.*, 1994; Raghupathy, 1997; Raghupathy *et al.*, 1999; Kwak-Kim *et al.*, 2010) or murine models (Hill *et al.*, 1987; Kinsky *et al.*, 1990; Haimovici *et al.*, 1991; Tangri and Raghupathy, 1993; Krishnan *et al.*, 1996b; Kim *et al.*, 2005). Furthermore, it has been hypothesised that IFN- γ may up-regulate expression of MHC class I and class II molecules on trophoblast cells, promoting T-cell recognition of foetal alloantigens and generating a harmful response (Athanasakis *et al.*, 2000; Entrican, 2002). Finally, it has been suggested that IFN- γ may activate NK cells that can damage the trophoblast (Drake and Head, 1989) or down-regulate the production of trophoblast growth-promoting CSF and granulocyte-macrophage colony-stimulating factor (GM-CSF) by the uterine epithelium (Robertson *et al.*, 1992; Robertson *et al.*, 1994), all mechanisms that are associated with a negative impact on human pregnancy.

Interferon- γ is one of the Th1 cytokines that has been most frequently associated with *N. caninum* infections, and it has been hypothesised that its presence may be beneficial or harmful to the host depending on the concentration and tissue location. This may have important implications in the design of vaccines to control bovine neosporosis (Innes *et al.*, 2011). IFN- γ is known to inhibit intracellular multiplication of *Neospora* tachyzoites *in vitro* (Innes *et al.*, 1995a; Yamane *et al.*, 2000; Nishikawa *et al.*, 2001a) and *in vivo* (Khan *et al.*, 1997; Baszler *et al.*, 1999).

Also, IFN- γ knock-out mice or mice treated with mAb against IFN- γ (Dubey and Lindsay, 1996; Khan *et al.*, 1997; Dubey *et al.*, 1998b; Baszler *et al.*, 1999; Tanaka *et al.*, 2000a; Nishikawa *et al.*, 2001c; Ritter *et al.*, 2002) are extremely susceptible to neosporosis, suggesting that IFN- γ may have a crucial role during the parasite infection (Nishikawa *et al.*, 2001b). Further support for this lies in studies that found significant quantities of IFN- γ mRNA following *Neospora* experimental infection in mice (Khan *et al.*, 1997; Eperon *et al.*, 1999; Quinn *et al.*, 2004; López-Pérez *et al.*, 2011) and cattle (Lundén *et al.*, 1998; Guy *et al.*, 2001; Ferre *et al.*, 2005; Serrano-Martínez *et al.*, 2007a; Rosbottom *et al.*, 2008; Caspe *et al.*, 2012). In addition, IFN- γ expression was shown to be increased in the placenta after recrudescence of *N. caninum* infection at mid and late gestation (Rosbottom *et al.*, 2011).

Tumour necrosis factor- α is another Th1 cytokine known to be produced by different phenotypes of immune cells, especially macrophages, lymphocytes and NK cells during inflammatory or reparative responses (Carswell *et al.*, 1975; Chaouat *et al.*, 1990; Hunt *et al.*, 1992; Scharton-Kersten and Sher, 1997; Kwak-Kim *et al.*, 2010). Depending on the stimulus and the cellular target, TNF- α has cytotoxic, cytostatic, immunomodulatory, growth promoting, and many other activities (Sidhu and Bollon, 1993). TNF- α is also released by endometrial cells and endothelium paracrinally to control hormonal synthesis by the endometrium in cattle (Miyamoto *et al.*, 2000; Okuda *et al.*, 2010).

All of these Th1 cytokines usually act in a synergistic fashion and such “cytokine collaboration” has been previously suggested in neosporosis. For instance, TNF- α enhances antimicrobial activity by triggering IFN- γ -primed macrophages to inhibit intracellular multiplication (Chao *et al.*, 1994) and also stimulates the production of IFN- γ by different cells (Langermans *et al.*, 1992; Hunter *et al.*, 1994). Moreover, TNF- α is able to stimulate apoptosis of human trophoblast cells while IFN- γ augments TNF- α -mediated killing of trophoblasts (Yui *et al.*, 1994).

Consequently, it has been hypothesised that the foetus is not only directly affected by *Neospora*-associated lesions observed in foetal and placental tissues, but also by

enhanced Th1 cytokine expression (such as IL-12, IFN- γ and TNF- α) in the placenta during gestation (Raghupathy, 1997; Innes *et al.*, 2002; Innes *et al.*, 2005; Dubey *et al.*, 2006; Innes and Vermeulen, 2006).

In situ hybridization (ISH) is a technique that aims to localise specific nucleic acid sequences within individual cells in tissue sections based on the complementary binding of a single-stranded nucleotide probe to a specific target sequence (McNicol and Farquharson, 1997; Hougaard *et al.*, 1997; Brown, 1998). Therefore, ISH can be used for the detection of gene expression by the detection of mRNA (McNicol and Farquharson, 1997), representing a perfect synergy between fundamental molecular biology techniques (e.g. Southern/Northern blotting, PCR), and traditional histopathologic interpretation and thus, ideally suited to veterinary pathologists (Brown, 1998). This technique has the further advantage of allowing the assessment of nucleic acid localization in association with histological changes, which is completely lost with other traditional procedures (Brown, 1998). *In situ* hybridisation offers an improvement over IHC as it can detect the very early stages of an infection or disease process, since mRNA production precedes that of the corresponding protein (Brown, 1998). However, a drawback of the technique is that mRNA expression does not necessarily equate with the downstream production of the biologically active protein (Hougaard *et al.*, 1997; Entrican, 2002).

With regards to the immune-mediated theory of abortion due to neosporosis, data previously published and detailed in Chapters 2 and 3 describes the phenotype and extent of infiltration of the immune cell population in the placenta after experimental infection with *N. caninum* in early, mid and late gestation (Maley *et al.*, 2006; Cantón *et al.*, 2013b).

The main aim of the work described in this chapter was to characterise and compare the expression of different cytokines in pregnant cattle experimentally inoculated with *N. caninum* in early, mid and late gestation, in order to explain the different clinical outcomes observed in the different stages of pregnancy.

Materials and methods

Placental sampling for ISH

In order to characterise the expression of cytokines in placentas, samples were collected from cattle experimentally inoculated with *N. caninum* in early (Macaldowie *et al.*, 2004), mid (Maley *et al.*, 2003) and late gestation (Benavides *et al.*, 2012). A summary of the experimental designs is shown in Chapter 1, Figure 2.

Immediately following euthanasia, randomly selected placentomes were sampled from the animals inoculated at days 70, 140 and 210 of gestation and fixed in 4% paraformaldehyde solution (Sigma-Aldrich, Dorset, England) (see Appendix I) overnight at 4°C, as previously described by (Maley *et al.*, 2003). After trimming, tissue samples were processed through graded alcohols and xylene, before paraffin wax embedding. Paraffin blocks were maintained at 4°C. Placentomes with severe inflammatory infiltrates in the previous studies (Maley *et al.*, 2006; Cantón *et al.*, 2013b), as reported in Chapter 2 and 3, were selected and 4 µm thick sections were cut and mounted on Superfrost Plus slides (Merck, Leicester, England).

Cytokine mRNA probes

Digoxigenin-labelled riboprobes (both sense and antisense) to detect IL-12p40, IFN- γ and TNF- α mRNA-expressing cells were prepared.

A brand new BoIL-12p40 probe was designed for these purposes; a description of this process is already published (Cantón *et al.*, 2013a). In order to select which portion of the BoIL-12p40 gene sequence to use as a specific probe, the complete coding regions of the IL-12p40 subunit were aligned from different ruminant species *Bos taurus* - U11815, *Ovis aries* - AF209435, *Capra hircus* - AF007576, *Cervus elaphus* - U57752 and *Bubalus bubalis* - EF424254. This sequence alignment revealed a large central region with high homology for the selected ruminant species.

One forward and two reverse primers were designed to flank the region of sequence homology, as follows:

Forward 1 (F1): TTCCCTGGTTTTGCTGGCATC

Reverse 1 (R1): GCAGCAGGAGGAGTGAACGACTCAG

Reverse 2 (R2): ACGCTGCTCCGCACGTCACCCCTCG

This allowed the amplification of two fragments of the BoIL-12p40 gene, measuring 280bp (probe #1 - F1-R1) and 447bp (probe #2 – F1-R2), respectively. RNA was extracted from bovine lymphoid tissues previously shown to express BoIL-12p40 using an IL-12 specific antigen capture ELISA (Bartley *et al.*, 2012). RNA was reverse transcribed using a high capacity cDNA reverse transcription kit (Applied Biosystems, Foster City, USA) following the manufacturer's instructions. The resulting cDNA was amplified in a PCR using primer combinations F1-R1 and F1-R2 under the following PCR reaction conditions (95°C for 5 minutes followed by 40 cycles of 95°C for 1 minute, 56°C for 1 minute and 72°C for 1 minute and a final extension of at 72°C for 5 minutes). PCR products were purified using the isolate PCR and gel kit (Bioline, London, UK) and cloned into the pGEM-T easy Vector system (Promega, Madison, USA) as per the manufacturer's instructions. The validity and orientation of the cloned products within the plasmids were confirmed by sequencing, performed by Eurofins MWG Operon (Ebersberg, Germany). Both plasmids contained inserts in the same orientation in frame from the T7 promoter and complementary from the SP6 promoter.

The QIAprep Spin Maxiprep Kit (Qiagen, Manchester, UK) was used according to the manufacturer's instructions to generate plasmid DNA for probe production. Both sense and antisense RNA probes were prepared by *in vitro* transcription from the T7 and SP6 promoter incorporating digoxigenin UTP, as previously described (Anderson *et al.*, 2001), linearising the plasmid with restriction enzymes SalI (New England BioLabs, Inc., Hertz, UK) and NcoI (New England BioLabs) in conjunction with the T7 and SP6 promoters, respectively. The concentration of each labelled

probe was determined by dot blot analysis, as described in the DIG RNA Labelling Kit (SP6/T7) (Roche Applied Science, Penzberg, Germany).

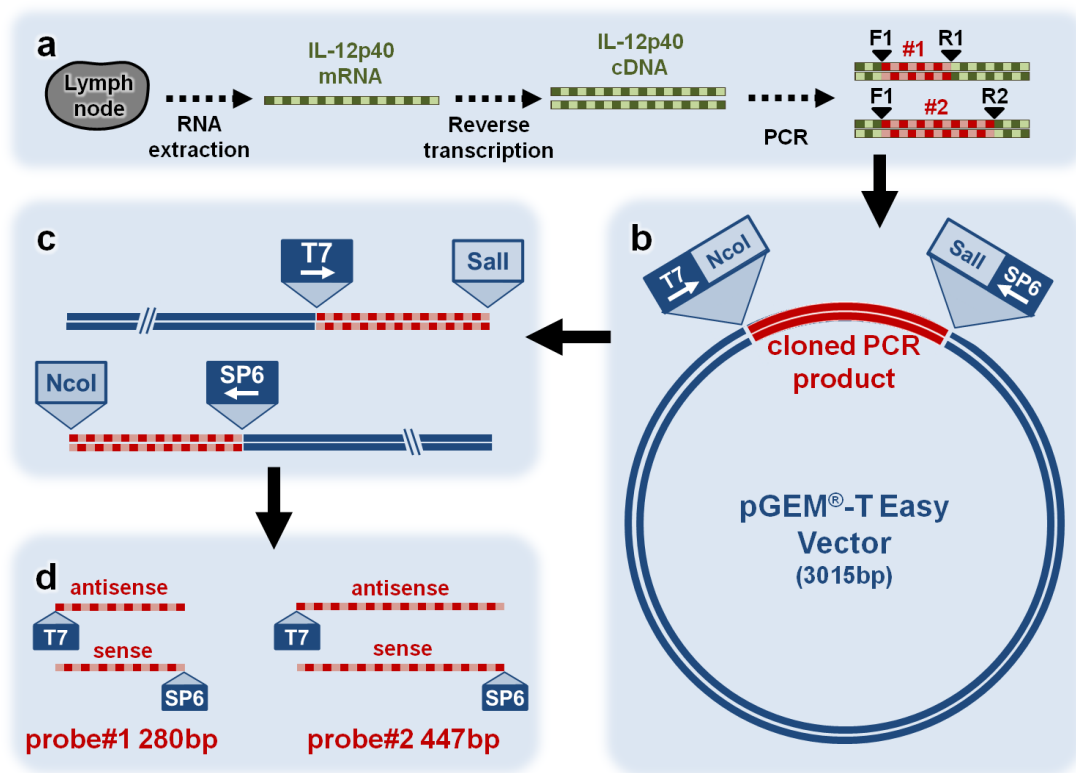


Figure 41: Schematic representation of the BoIL-12p40 probe production. (a) RNA was extracted from lymph nodes, and then reverse transcribed. Resulting cDNA was amplified using PCR and primer combinations F1-R1 and F1-R2. (b) PCR products were cloned into pGEM-T easy Vector. (c) Plasmid was linearised using SalI and NcoI in conjunction with T7 and SP6 promoters, respectively. (d) Both sense and antisense RNA probes were obtained. Figure produced by GJC.

Similarly, a bovine sequence (accession number EU276066) homologous to a previous OvIFN- γ probe already produced and tested in MRI (Anderson *et al.*, 2001), was selected to produce a new BoIFN- γ probe (96.2% homology between bovine and ovine sequence). PCR was carried out on cDNA from bovine tissues that had been previously confirmed to produce BoIFN- γ by ELISA (Bartley *et al.*, 2012). Based on the BoIFN- γ sequence, one forward and one reverse primer were designed:

Forward: CCTAACTCTCTCCTAAACAATG

Reverse: CATCCACCGGAATTTGAATCAG

PCR was applied using the same protocol described for the production of the BoIL-12p40 probe, and a product of 392bp was obtained and cloned into the transcription pGEM[®]-T Easy Vector system (Promega). The BoIFN- γ probe was later produced as described previously for the BoIL-12p40 probe.

An OvTNF- α riboprobe was already available in the immune toolkit at MRI, as previously described (Anderson *et al.*, 2001). Briefly, restriction enzyme fragments of OvTNF- α cDNA were cloned into the transcription vector pSPT 18/19 (Roche Diagnostics, Lewes, England). This probe (504bp) shares 95.8% homology with bovine TNF- α (accession number NM_173966) at the nucleic acid level.

BoIFN- γ plasmid DNA was linearised using NcoI and Sall to generate single stranded probes using the T7 and SP6 promoters, respectively, as described for the BoIL-12p40. Similarly, OvTNF- α plasmid DNA was linearised using BamHI (Promega) and HindIII (Promega) to generate single stranded probes using T7 and SP6 promoters. Both sense and antisense RNA probes for BoIL-12p40 (probe #1), BoIFN- γ and OvTNF- α were prepared by *in vitro* transcription from the T7 and SP6 promoter incorporating digoxigenin UTP (Roche). The concentration of each labelled probe was determined by dot blot. The whole sequence of each probe is detailed below. The alignments of these probes with the RNA sequences of their respective cytokines in different ruminant species are shown in Appendix III.

BoIL-12p40 probe:

```

TTCCCTGGTTTTGCTGGCATCTCCCATCGTGGCCATGTGGGAACTGG
AGAAAAATGTTTATGTTGTAGAATTGGATTGGTATCCTGATGCTCCT
GGAGAAACAGTGGTCCTCACATGTGACACTCCTGAAGAAGATGGCA
TCACCTGGACCTCAGACCAGAGCAGTGAGGTCTTGGGCTCTGGCAA
AACCTTGACCATCCAAGTCAAAGAGTTTGGAGATGCTGGGCAGTAC
ACCTGTCACAAAGGAGGCGAGGCTCTGAGTCGTTCACTCCTCCTGCT
GCACAAAAGGAAGATGGAATTTGGTCCACTGATATTTAAAGGAT
CAGAAAGAACCCAAAGCTAAGAGTTTTTTAAATGTGAGGCAAAGG
ATTATTCTGGAC
    
```

BoIFN- γ probe:

CCTAACTCTCTCCTAAACAATGAAATATACAAGCTATTTCTTAGCTT
 TACTGCTCTGTGGGCTTTTGGGTTTTTCTGGTTCTTATGGCCAGGGCC
 AATTTTTTAGAGAAATAGAAAACCTTAAAGGAGTATTTAATGCAAG
 TAGCCCAGATGTAGCTAAGGGTGGGCCTCTCTTCTCAGAAATTTTGA
 AGAATTGGAAAGATGAAAGTGACAAAAAATCATTGAGCCAAA
 TTGTCTCCTTCTACTTCAAACCTTTGAAAACCTCAAAGATAACCAG
 GTCATTCAAAGGAGCATGGATATCATCAAGCAAGACATGTTTCAGA
 AGTTCTTGAATGGCAGCTCTGAGAACTGGAGGACTTCAAAAAGCT
 GATTCAAATTCCGGTGGATG

OvTNF- α probe:

ATGAGCACCAAAGCATGATCCGGGATGTGGAGCTGGCCGGAGGAG
 GTGCTCTCCAACAAAGCAGGGGGCCCCAGGGCTCCAGAAGTTGCT
 GGTGCCTCAGCCTCTTCTCCTTCCTCCTGGTTGCAGGAGCCACCACG
 CTCTTCTGCCTGCTGCACTTCGGGGTAATCGGCCCCAGAGGGGAAG
 AGCAGTCCCCAGCTGGCCCCCTCCTTCAACAGGCCTCTGGTTCAGACA
 CTCAGGTCATCTTCTCAAGCCTCAAATAACAAGCCGGTAGCCCACG
 TTGTAGCCAACATCAGCGCTCCGGGGCAGCTCCGATGGGGGGACTC
 GTATGCCAATGCCCTCATGGCCAACGGCGTGGAGCTGAAAGACAAC
 CAGCTGGTGGTGCCCACTGACGGGCTTTACCTCATCTACTCGCAGGT
 CCTCTTCAGGGGCCACGGCTGCCCTTCCACCCCCTTGTTCTCACC
 ACACCATCAGCCGCATTGCAGTCTCCTACCAGACCAAGGTC

Production of positive controls

Ovine IL-12p40 (OvIL-12p40) cDNA-transfected Chinese hamster ovary cells (CHO cells) that were expressing OvIL-12 (Hope *et al.*, 2002) (kindly provided by G. Entrican, MRI) were pelleted and fixed using paraformaldehyde. The obtained “pseudotissue” was used to test the new BoIL-12p40 probe. Similarly, archived ruminant tissue paraffin-blocks, from previous experiments carried out at MRI, were used to test the newly manufactured bovine IL-12p40 (BoIL-12p40) probe. Placentomes and lymph nodes collected from pregnant cows (Macaldowie *et al.*, 2004; Hecker *et al.*, 2013) and water buffaloes (Konrad *et al.*, 2012) experimentally inoculated with *N. caninum* and from pregnant sheep experimentally inoculated with *Chlamydia abortus* (*C. abortus*) (Maley *et al.*, 2009), as well as jejunal samples

collected from goats experimentally challenged with *Teladorsagia circumcincta* (*T. circumcincta*) (Macaldowie *et al.*, 2003) were used for this purpose. Some of the placental samples collected from *N. caninum* inoculated cows and all the bubaline tissue samples were fixed in buffer formalin solution (Cantón *et al.*, 2013a).

A “pseudotissue” produced with ovine OvIFN- γ cDNA-transfected Chinese hamster ovary cells (CHO cells) expressing ovine IFN- γ (kindly provided by G. Entrican, MRI) and fixed with paraformaldehyde was used to test the new BovIFN- γ probe.

***In situ* hybridisation**

In situ hybridisation was performed using an Omnislide thermal cycler and wash module (Hybaid, Ashford, UK) as previously described (Anderson *et al.*, 2001; Maley *et al.*, 2006). Tissue sections on slides were de-waxed and rehydrated using xylene, graded absolute ethanol, autoclaved distilled water and PBS. Then slides were treated with 200 mM HCl for 20 min and with 15–25 μ g/ml proteinase K (Roche, Mannheim, Germany) for 15 min at 37°C in order to permeabilise cell membranes (see Appendix I). After post-fixation with 4% paraformaldehyde in PBS for 4 min, sections were treated with an acetylation solution (to decrease background staining and to inactivate RNAses) for 10 min (see Appendix I). Slides were then pre-hybridised for 1 hour at 52°C in pre-hybridisation solution. The pre-hybridisation solution was replaced with a hybridisation solution (see Appendix I) containing digoxigenin labelled probes (sense and antisense) at concentrations ranging from 0.1 to 0.5 ng/ μ l.

Hybridization reactions were performed overnight at 52°C. Evaporation during hybridization was prevented using Hybaid EasiSeal frames (Thermo Scientific, Reading, UK). Unbound probe was removed by washing with 6x Saline-sodium citrate (SSC) buffer containing 45% formamide (Fisher Scientific) and by RNase treatment (see Appendix I). Sections were washed twice for 5 min with 2x SSC at RT and twice with 0.2x SSC for 15 min at 50°C.

Bound probe was detected using anti-digoxigenin antibody Fab fragments conjugated to alkaline phosphatase (Roche) (see Conjugate solution in Appendix I). Colour reaction was performed overnight in the dark at 4°C with a colour solution, and then washed with DIG Buffer 4 (see Appendix I). Sections were counterstained with Mayer’s haematoxylin and mounted under coverslips with water-based mounting medium.

Cytokine cDNA-transfected CHO cells expressing ovine IL-12 (Hope *et al.*, 2002), IFN- γ and TNF- α (Wheelhouse *et al.*, 2009) mRNA that had been pelleted, paraformaldehyde fixed and processed to paraffin wax were used as positive controls for the ISH. Sections treated with the sense RNA probe were used as specificity controls.

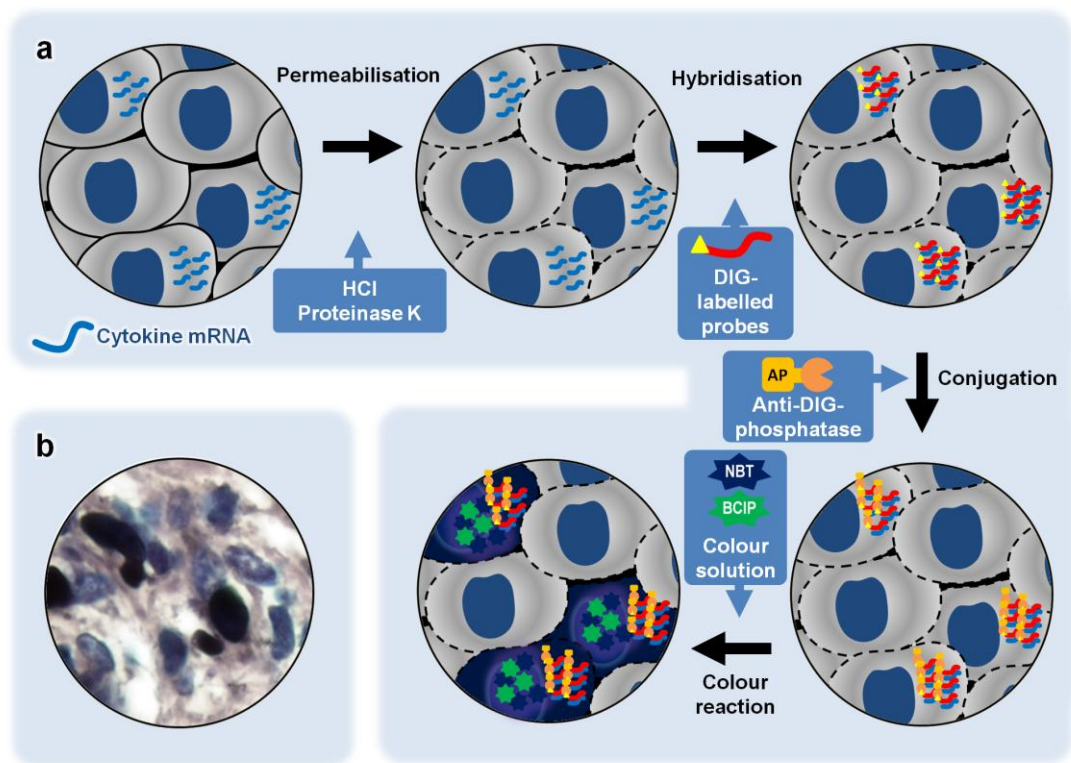


Figure 42: *In situ* hybridisation. (a) Schematic representation of the technique, including permeabilisation, hybridisation, conjugation and colour reaction steps. (b) Example of positive reaction (in black) of cells expressing BoIL-12p40 in the placenta of a dam experimentally infected with *N. caninum* in early gestation. Figure produced by GJC.

Scoring the positive infiltration

A scoring system was applied similar to that used to characterise the cellular immune response after experimental inoculation with *N. caninum* during gestation (Cantón *et al.*, 2013b). Slides were blind-coded and the entire section was examined by optical microscope at various magnifications. To eliminate inter-operator error all slides were read by a single investigator. Each section was then categorised as: 0: no infiltration of labelled cells or diffuse/minimal infiltration of labelled cells not associated with pathological changes; 1: minimal/diffuse infiltration of labelled cells associated with pathological changes; 2: mild infiltration and focal aggregation of labelled cells surrounding necrotic foci; 3: moderate infiltration and focal aggregation of labelled cells surrounding areas of necrosis, and 4: severe infiltration of positive cells surrounding areas with other pathological changes. The individual scores from randomly sampled placentomes were averaged into a single score value for each animal, similarly to previous descriptions (Buxton *et al.*, 2001; Oliveira and Hansen, 2008; Cantón *et al.*, 2013b).

Statistical analysis

As for the statistical analysis in Chapter 3, and due to the limited sample number, the time factor was omitted for each experiment (i.e. early, mid and late gestation) and it was assumed that the averaged scores originated from the same distribution in order to gain statistical power. This was supported by results from Fligner and Kruskal-Wallis tests on homogeneity of variances and medians among *Neospora*-inoculated animals over time. Then, non-parametric Mann-Whitney tests were conducted to determine any significant differences in scores among inoculated and control animals for each cell type in each experiment. Statistical significance was set at $p < 0.05$.

Furthermore, for the early gestation experiment results, non-parametric Mann-Whitney tests (with ties) were applied to pair-wise comparison of scores from IV-,

SC-inoculated and control groups for each cell type. The resulting *p*-values were adjusted for multiplicity by the FDR method.

Among all the *Neospora* inoculated animals in this experiment (regardless of the time point), a distinction was made between placentas collected from dams carrying a dead foetus or an empty uterus (from now on both referred to as “carrying a non-viable foetus”) and placentas from dams carrying a live foetus (referred to as “carrying viable foetuses”) at the time of culling. Then the scores were compared for each cell type using non-parametric Mann-Whitney tests.

In order to compare placentas from animals inoculated at different stages of gestation (early, mid and late gestation), Kruskal-Wallis tests were applied followed by pairwise Mann-Whitney tests (with FDR adjusted *p*-values).

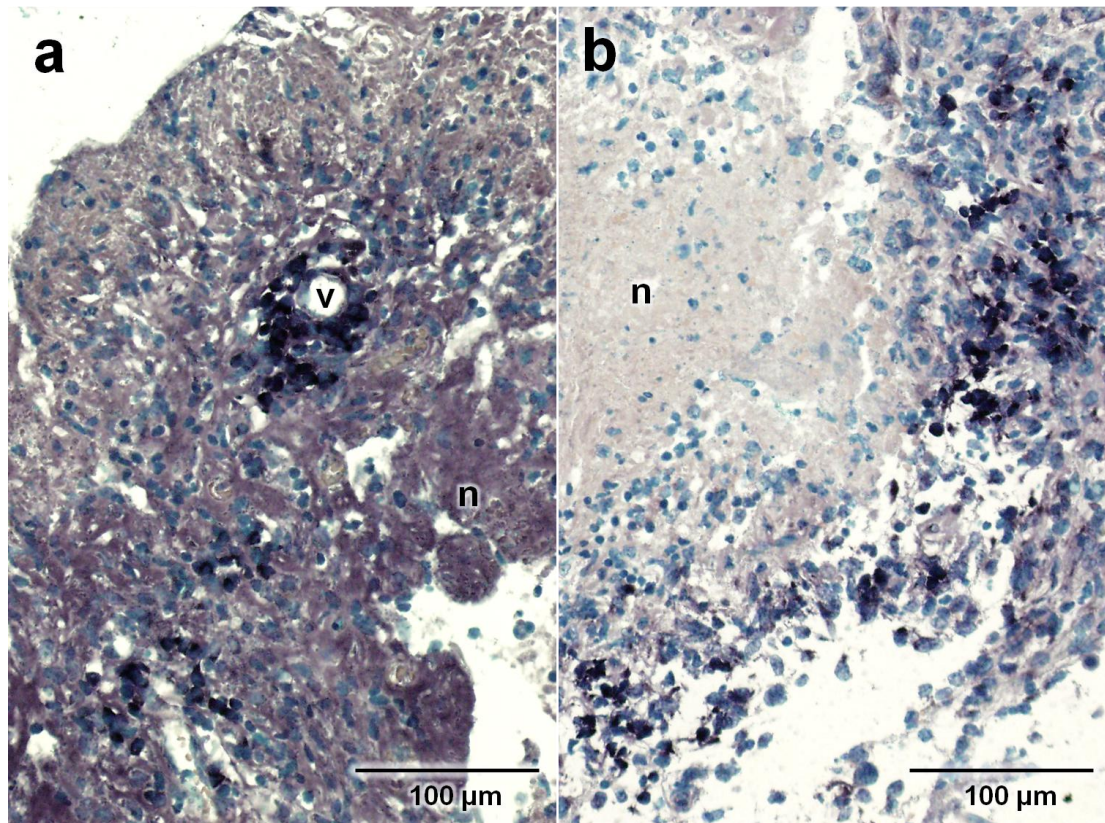
Results

Clinical findings

Clinical findings observed after experimental inoculation with *N. caninum* in early, mid and late gestation have been previously published (Maley *et al.*, 2003; Macaldowie *et al.*, 2004; Benavides *et al.*, 2012) and are described in Chapters 1, 2 and 3.

Standardisation of the BoIL-12p40 probe

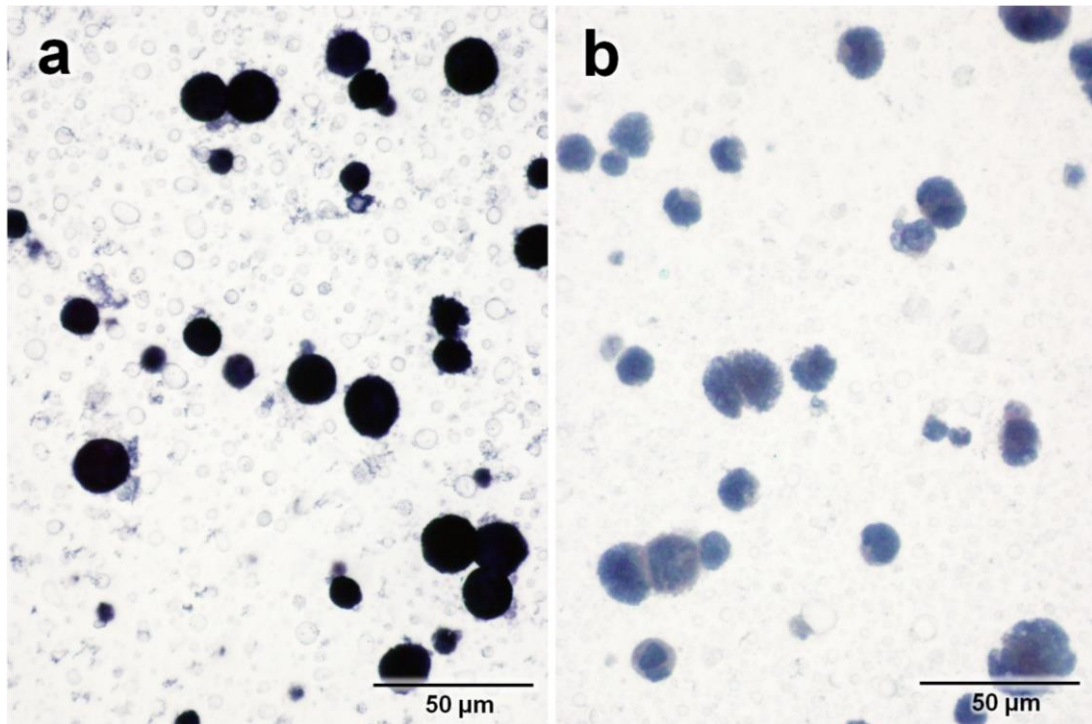
Both BoIL-12p40 probes (#1 and #2) were shown to be efficient in identifying IL-12p40 expressing cells in fixed tissues from several different ruminant species (bovine, ovine, caprine and bubaline tissues). Both probes achieved distinctive and specific labelling; however, probe #2 allowed a better distinction of positive cells when compared to probe #1, due to very weak background staining (see Figures 43a and b).



Figures 43 a-b: Labelling of bovine placentas using BoIL-12p40 probes by ISH. (a) Labelled cells (black) for IL-12p40 mRNA were present in the caruncle in the placenta of *N. caninum* infected cows, surrounding some areas of necrosis (n) and blood vessels (v). ISH using probe #1, showing intense background staining. (b) Labelled cells for IL-12p40 mRNA in the placentome of another cow experimentally inoculated with *N. caninum*, surrounding some areas of necrosis (n). ISH using probe #2, showing very weak background staining. Both counterstained with haematoxylin. ISH slides produced and photographed by GJC.

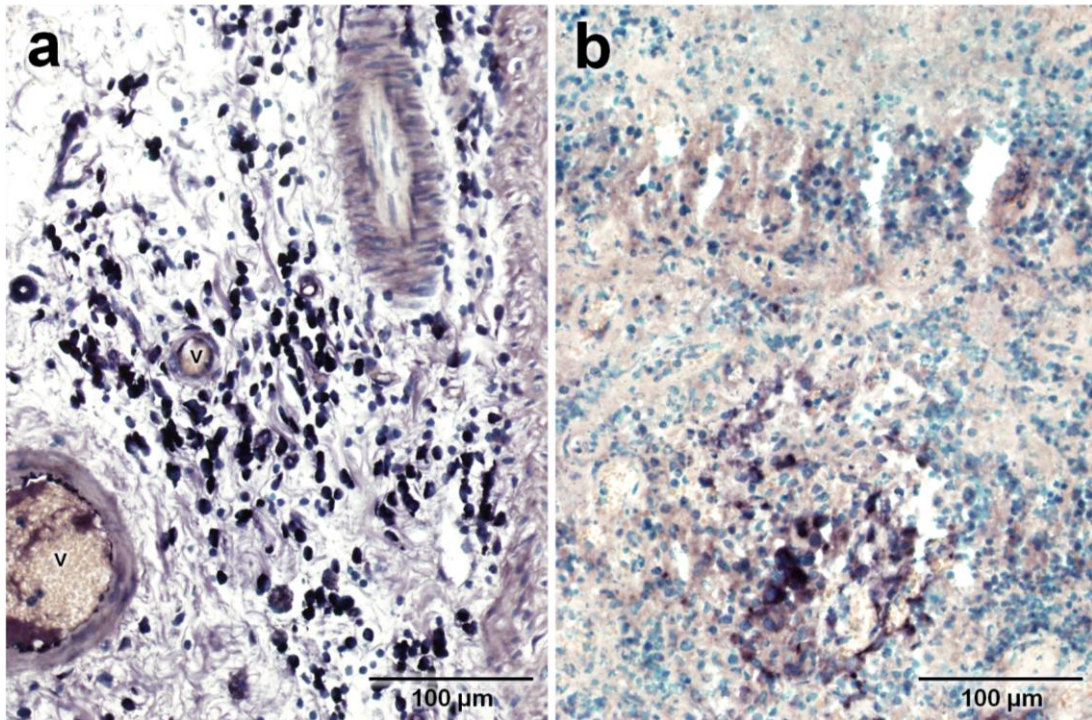
Performing ISH on paraformaldehyde fixed tissues produced better labelling and less non specific background staining than ISH on formalin fixed tissues.

With *in situ* hybridisation performed on the “pseudotissue” produced with transfected CHO cells expressing OvIL-12p40, there was specific labelling with both antisense probes, while the sense probes did not bind (see Figures 44a and b, respectively).



Figures 44 a-b: OvIL-12p40 CHO transfected cells used as positive controls. (a) Labelled transfected CHO cells (black) expressing OvIL-12p40 using the antisense (SP6) probe in the “pseudotissue”. ISH using probe #2. (b) Negative-labelled OvIL-12p40 transfected CHO cells (counterstained in blue) using the sense (T7) probe. ISH using probe #2. Both counterstained with haematoxylin. ISH slides produced and photographed by GJC.

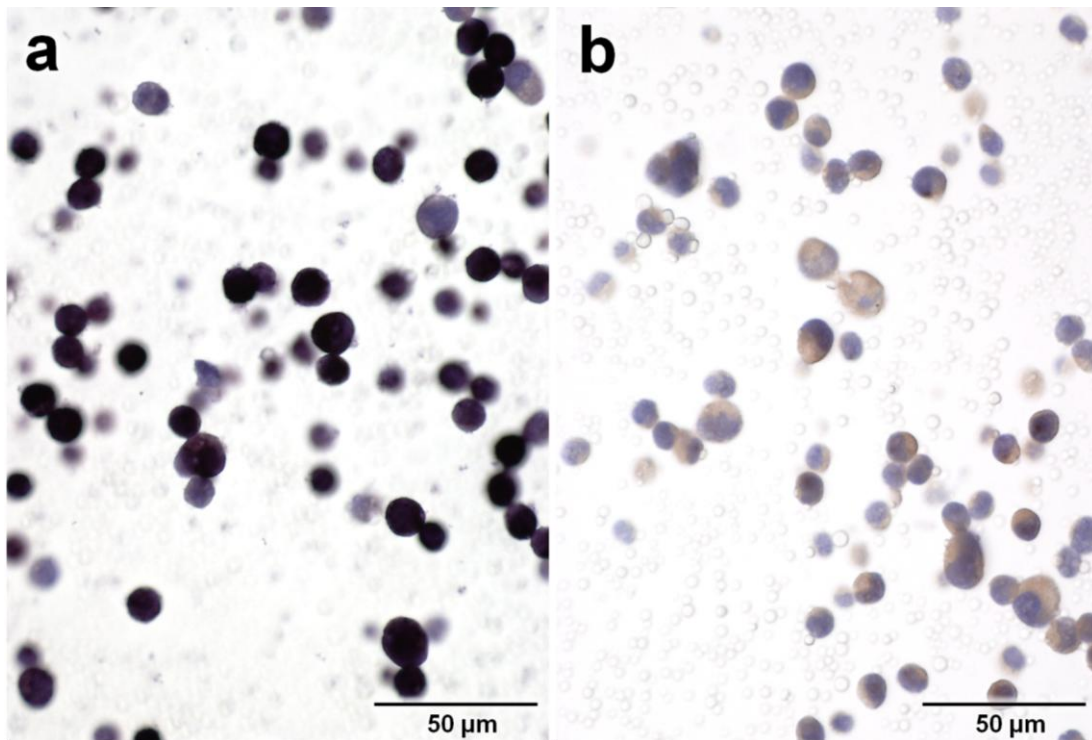
There was a moderate and minimal infiltration of IL-12p40 labelled cells observed in the jejunal submucosa of goat kids experimentally inoculated with *T. circumcincta* (see Figure 45a) and in lymph node and placentome samples collected from pregnant sheep after experimental *C. abortus* infection (see Figure 45b), respectively (Cantón *et al.*, 2013a).



Figures 45 a-b: Examples of IL-12p40 expressing cell infiltrates in ovine and caprine tissues. (a) Labelled cells (black) in the jejunal submucosa of a goat kid experimentally challenged with *T. circumcincta*. Blood vessels (V). ISH using probe #2. (b) Rare labelled cells (black) in the medulla of a uterine lymph node from a *C. abortus*-infected sheep. ISH using probe #2. Both counterstained with haematoxylin. ISH slides produced and photographed by GJC.

Standardisation of the BoIFN- γ probe

Similarly to the standardisation of the BoIL-12p40 probes, the new BoIFN- γ probe was tested on OvIFN- γ transfected CHO cells. There was a positive reaction using ISH with the antisense probe (see Figure 46a) and a negative result with the sense probe (see Figure 46b).



Figures 46 a-b: OvIFN- γ CHO transfected cells used as positive controls. (a) Labelled transfected CHO cells (black) expressing OvIFN- γ using the antisense (T7) probe in the “pseudotissue”. ISH using BoIFN- γ probe. (b) Negative-labelled OvIFN- γ transfected CHO cells (counterstained in blue) using the sense (SP6) probe. ISH using BoIFN- γ probe. Both counterstained with haematoxylin. ISH slides produced and photographed by GJC.

IL-12 mRNA expression in the placentas

Early gestation. In the placental samples collected from the dams inoculated with *N. caninum* at day 70 of pregnancy and culled at 14 dpi, IL-12p40 mRNA positive cytoplasmic labelling was observed with minimal to mild infiltrate of mononuclear cells at the base of the caruncles and surrounding some blood vessels. Minimal to mild infiltrates of large mononuclear cells, morphologically resembling macrophages, surrounded small areas of necrosis of the caruncle and it extended into some necrotic foetal villi. Rare trophoblast cells were also positive for IL-12p40 mRNA. There were similar labelling scores in the placental samples collected from dams inoculated with *Neospora* IV and SC. In the samples collected from dams inoculated with *N. caninum* at day 70 of pregnancy and culled at 28 and 42 dpi, a moderate to severe infiltrate of IL-12 expressing cells was detected around blood

vessels and around large areas of necrosis in the placentomes, as well as in areas of serum leakage (see Figures 47a and b). Tissues collected from the negative control dams in early gestation contained only a few IL-12 mRNA positive cells in the base of the placentome, not associated with any other pathological lesions.

Independent Mann-Whitney tests (allowing for ties) were conducted for the overall results obtained from the placental samples collected during the early gestation experiment (as previously described, discarding the time post-infection factor and assuming the averaged scores). Significantly higher IL-12 mRNA expressing cell infiltration scores were detected in the *N. caninum* inoculated dams compared with the infiltration score in the negative control placentas ($p < 0.01$) (see Table 6).

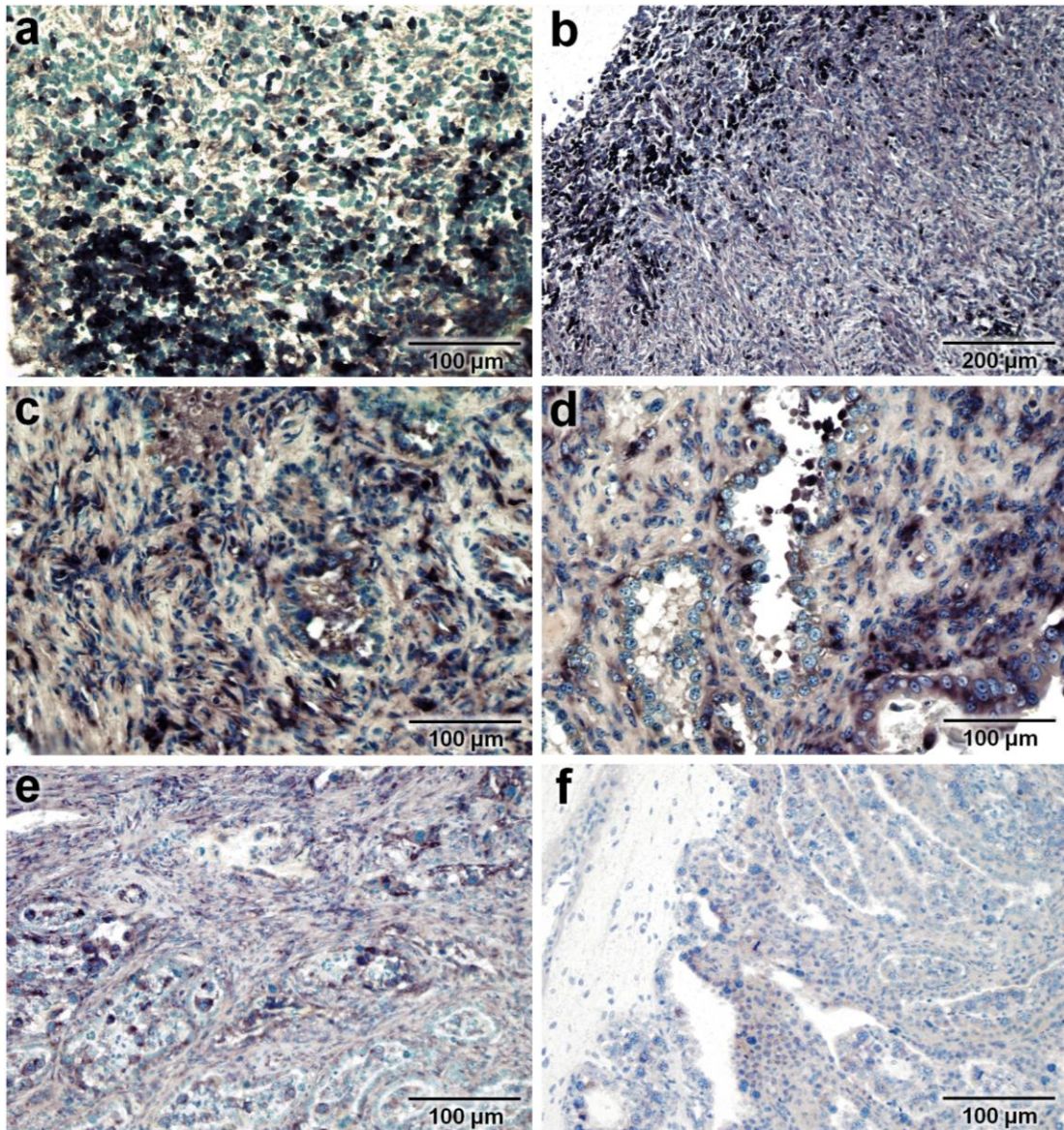
IL-12 mRNA expression scores on placental samples collected from dams carrying non-viable foetuses were higher when compared with those assessed in the placentas from dams carrying viable foetuses ($p < 0.001$) (see Table 5).

Mid-gestation. In the placental samples collected from the dams inoculated with Nc-1 at day 140 of gestation and then culled 14 dpi, there was a minimal to mild infiltrate of large positive macrophage-like cells surrounding small necrotic foci in the caruncles and in the base of the placentomes (see Figure 47c). A similar infiltrate was observed in the samples collected from the *N. caninum*-inoculated animals culled at 28 dpi and 42 dpi, characterised by a minimal to moderate infiltrate of cells in the base of the caruncle, as well as around some blood vessels and small areas of necrosis (see Figure 47d). There were also rare positive cells, including some trophoblast cells surrounding large areas of necrosis. A minimal infiltrate of IL-12 mRNA positive cells was observed in the base of the placentomes from the negative control animals. Higher IL-12 mRNA scores were found in the *N. caninum* inoculated dams in mid gestation compared with the negative control dams ($p < 0.05$).

Late gestation. Minimal infiltrates of IL-12p40 mRNA expressing cells surrounded small necrotic foci in the caruncles, some necrotic foetal villi and perivascular areas at the base of placentomes from dams inoculated with *N. caninum*

at 210 days of gestation and culled at 14, 28, 42 and 56 dpi (see Figures 47e and f). There were no or only rare IL-12 mRNA positive cells in the base of the placentomes and in the caruncles from the negative control dams culled at 14, 28, 42 and 56 dpi. No significant differences were found between the IL-12p40 mRNA infiltration scores for the dams inoculated with *N. caninum* and the negative control dams during the late gestation study ($p = 0.176$).

Comparison over gestation stages. Overall inter-experiment IL-12p40 mRNA scores were compared for the animals inoculated with *N. caninum* and significant differences were established between early, mid- and late pregnancy ($p < 0.001$). Pair-wise analysis also revealed significant differences between the IL-12p40 mRNA scores in the placentas from dams inoculated with *Neospora*. Early gestation scores were higher than those observed in mid gestation ($p < 0.05$) and higher scores were detected in early gestation compared with those in late gestation, and also in the mid gestation study compared with the late gestation study ($p < 0.01$). No significant differences were found amongst the controls at different stages of gestation ($p = 0.291$). Mean scores and SEM of the infiltration scores observed in *N. caninum* inoculated and negative control dams for each experiment are outlined in Figure 48. Summarising data with mean IL-12p40 scores in early, mid and late gestation are shown below in Tables 5 and 6. Tables summarising p -values of the different statistical analyses are shown in Appendix II.



Figures 47 a-f: Examples of IL-12p40 mRNA expressing cellular infiltrates (in black) detected in the placentomes from *N. caninum*-inoculated animals. (a) Severe aggregates of positive cells in a caruncle of a *N. caninum* inoculated dam (IV) at day 70 of gestation, culled 28 dpi and carrying a non-viable foetus at the time of culling. (b) Severe infiltration of positive cells in a caruncle of a *N. caninum* inoculated dam (IV) at day 70 of gestation, culled at 42 dpi and in which the uterus was empty at the time of culling. (c) Mild infiltrate of positive cells in the caruncle surrounding some foetal villi collected from a *N. caninum* inoculated dam at day 140 of gestation and culled 14 dpi. (d) Mild infiltrate of positive cells in a caruncle and foetal villi from a *N. caninum* inoculated dam at day 140 of gestation, culled 28 dpi. (e) Rare cells in some foetal villi in a placentome collected from a *N. caninum* inoculated dam at day 210 of gestation and culled 14 dpi. (f) Placentome collected from a *N. caninum* inoculated dam at day 210 of gestation and culled 28 dpi with no IL-12p40 expressing cells apparent. All counterstained with haematoxylin. ISH slides produced and photographed by GJC.

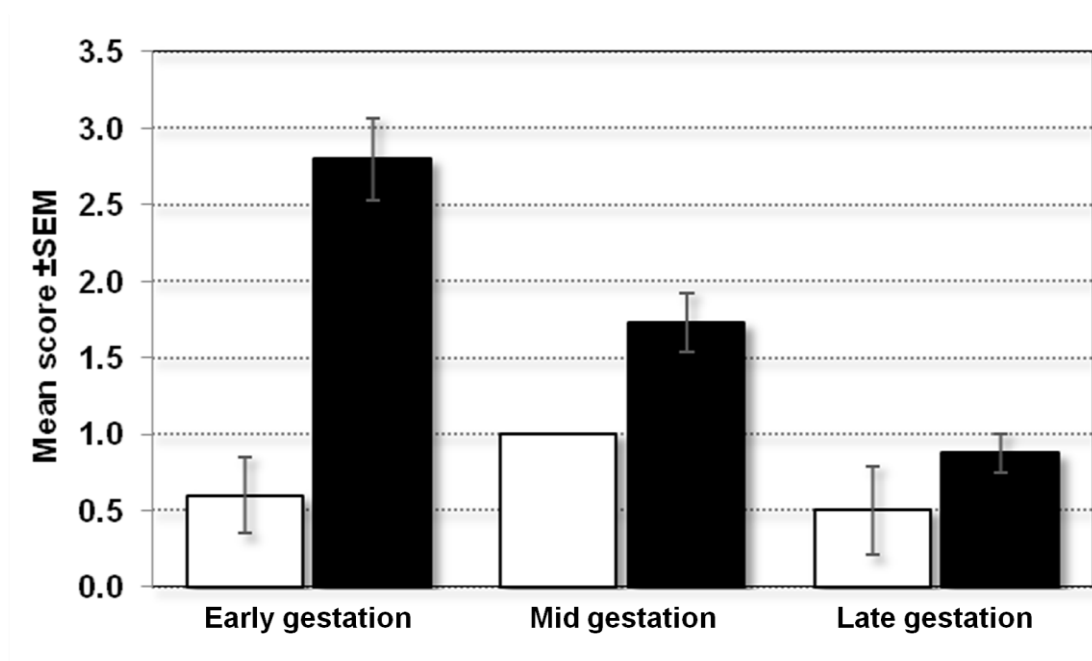


Figure 48: Mean IL-12p40 expressing cell infiltrate scores in the placentas collected from negative control (white bars) and *N. caninum*-inoculated (black bars) dams in early, mid and late gestation. Error bars indicate SEM.

IFN- γ mRNA expression

Early gestation. Placental samples collected from animals inoculated with *N. caninum* at 140 days of gestation and later culled at 14 dpi were infiltrated by a minimal to mild infiltrate of IFN- γ mRNA expressing cells which surrounded small areas of necrosis. There was also IFN- γ mRNA expressing lymphocytic infiltrate in the caruncles and in some necrotic foetal villi. No clear differences were observed between the IV and SC inoculated animals culled at this time point. At 28 dpi, the infiltration of positive cells was moderate to severe in most of the placental samples collected from dams inoculated with *N. caninum*. This infiltrate surrounded large areas of necrosis in the caruncle and some necrotic foetal villi (Figure 49a). Severe infiltrates of IFN- γ mRNA expressing cells were also observed in the samples from inoculated dams culled at 42 dpi (Figure 49b), surrounding large areas of necrosis and serum leakage in the caruncle and some endometrial glands in the base of the placentomes. Negative control placentas were infiltrated by rare positive cells,

which mainly infiltrated the caruncles. A few individual trophoblast cells in the caruncle and foetal villi were also positive for IFN- γ mRNA.

Significantly higher IFN- γ mRNA expression scores were found in the placental samples collected from *N. caninum*-inoculated dams compared with the negative controls ($p < 0.001$). When the IFN- γ scores of dams inoculated IV and SC were compared during the early gestation experiment, no significant differences were detected ($p = 0.525$). IFN- γ mRNA expression scores from dams carrying non-viable and viable foetuses were compared and higher scores were found in the “non-viable” group ($p < 0.01$).

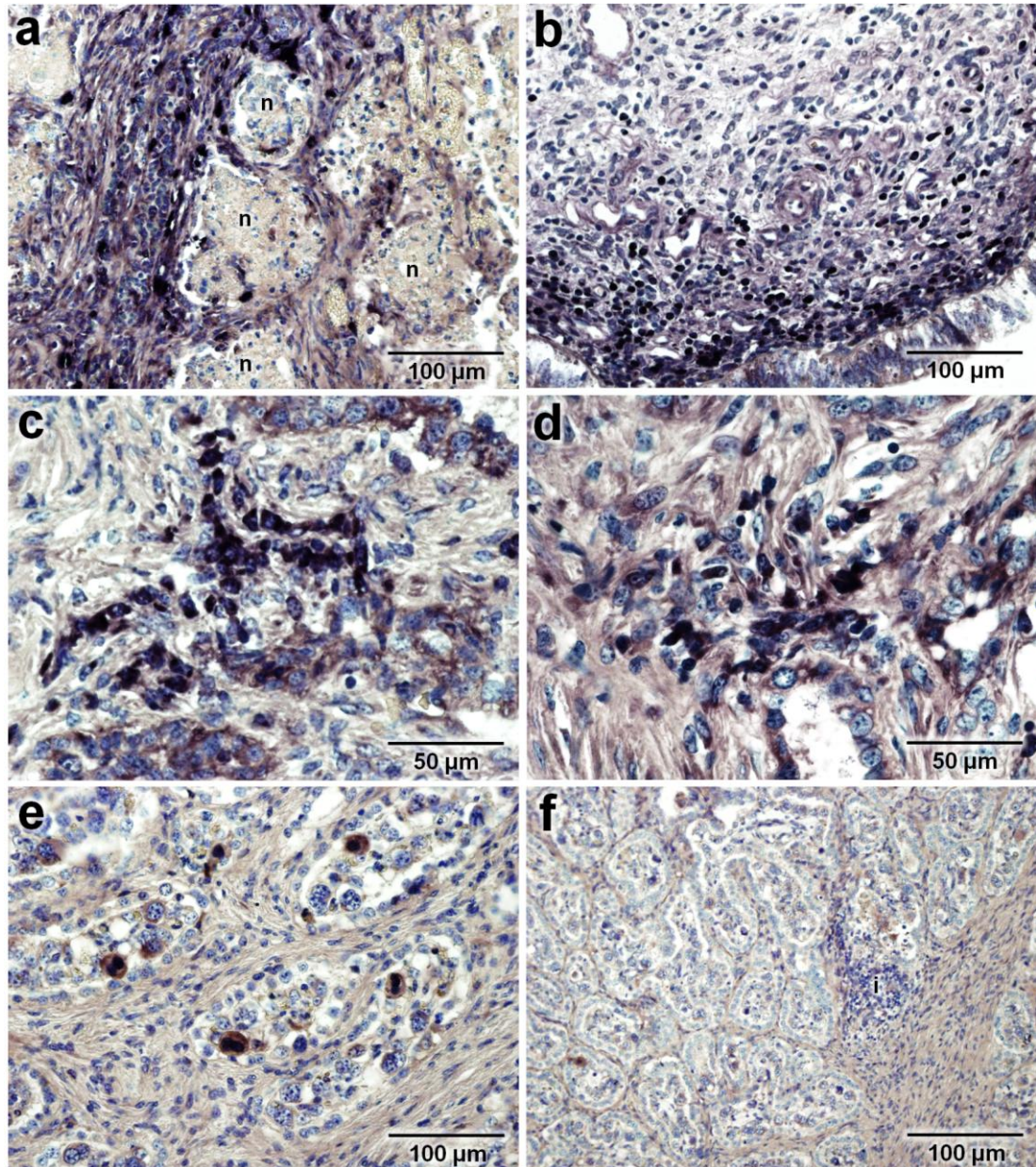
Mid gestation. When placental samples collected from the *N. caninum* inoculated animals at day 140 of gestation and culled at 14 and 28 dpi were analysed, a minimal to mild infiltrate of IFN- γ mRNA expressing cells were detected in the caruncle, generally surrounding small necrotic foci or not associated with any pathological changes (Figure 49c). At 42 dpi, this infiltrate was mild in all the samples analysed (Figure 49d). The placentas collected from negative control dams at 14, 28 and 42 dpi contained very few or no cells expressing IFN- γ mRNA.

Overall IFN- γ mRNA scores were analysed and a significantly higher number of positive cells was detected in the samples collected from animals inoculated with *N. caninum* compared with the negative control dams ($p < 0.01$).

Late gestation. A few placental samples collected from dams inoculated with *N. caninum* at day 210 of gestation and culled at 14, 28, 42 and 56 dpi were minimally infiltrated with IFN- γ mRNA expressing cells in the caruncle and in some foetal villi (some morphologically resembling trophoblast cells, see Figures 49e and f). The placental samples from the correlating negative control dams were similarly infiltrated and there were no significant differences between their scores ($p = 0.736$).

Comparison over gestation stages. Overall inter-experiment IFN- γ mRNA scores were compared for the animals inoculated with *N. caninum* and significant differences were established between early, mid- and late pregnancy ($p = 0.001$).

Pair-wise analysis carried out using Mann-Whitney tests revealed significant differences between the IFN- γ mRNA scores of early and mid gestation ($p < 0.01$) and also between mid and late gestation ($p < 0.01$), but no differences were established between early and mid gestation ($p = 0.314$). No significant differences were found in the inter-experiment scores for the controls ($p=0.513$). Mean scores and SEM of the infiltration scores observed in *N. caninum* inoculated and negative control dams for each experiment are summarised in Figure 50. Tables summarising mean IFN- γ mRNA scores in early, mid and late gestation are shown below in Tables 5 and 6. Summary tables with p -values of the different statistical analyses are shown in Appendix II.



Figures 49 a-f: Examples of IFN- γ mRNA expressing cells (staining black) detected in the placentomes from *N. caninum*-inoculated animals. (a) Aggregate of positive cells in a caruncle stalk surrounding some necrotic foetal villi (n) of a dam inoculated with *N. caninum* SC at day 70 of gestation, culled 28 dpi and carrying a dead foetus at the time of culling. (b) Severe infiltration of positive cells in a caruncle of a dam inoculated with IV at day 70 of gestation and culled at 42 dpi, in which the uterus was empty at the time of culling. (c) Mild infiltration of positive cells in a caruncle from a dam inoculated with *N. caninum* at day 140 of gestation and culled 28 dpi. (d) Mild infiltration of positive cells in a caruncle collected from a dam inoculated with *N. caninum* at day 140 of gestation and culled 42 dpi. (e) IFN- γ mRNA expressing cells (morphologically compatible with trophoblast cells) in some foetal villi from a placentome collected from a dam inoculated with *N. caninum* at day 210 of gestation and culled 56 dpi. (f) Placentome with a small lymphoid aggregate (i) but containing no IFN- γ mRNA expressing cells collected from a dam inoculated with *N. caninum* at day 210 of gestation and culled 28 dpi. All counterstained with haematoxylin. ISH slides produced and photographed by GJC.

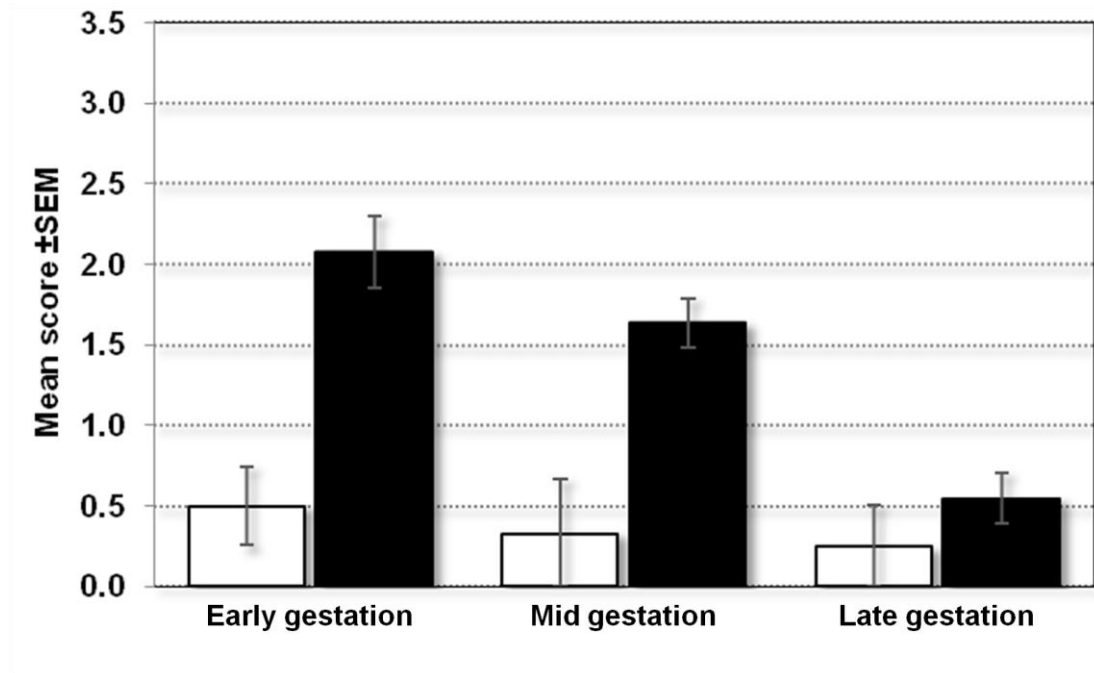


Figure 50: Mean scores for cells expressing IFN- γ mRNA in placentas collected from negative control (white bars) and *N. caninum*-infected (black bars) dams at early, mid and late gestation. Error bars indicate SEM.

TNF- α mRNA expression

Early gestation. Cells expressing TNF- α mRNA were observed in placentomes collected from dams experimentally inoculated with *N. caninum* at day 70 of gestation and culled at 14 dpi. A mild to moderate infiltrate of TNF- α mRNA positive cells (small round cells, morphologically resembling lymphocytes) were mainly observed in the caruncle surrounding some areas of necrosis. Similar positive cells also infiltrated the base of the placentome, surrounding some blood vessels. Placentomes collected from dams infected at day 70 of gestation and culled at 28 and 42 dpi were similarly infiltrated with TNF- α mRNA expressing cells. These were mainly in the caruncles surrounding areas of necrosis and serum leakage and also in the base of the placentomes surrounding blood vessels (see Figures 51a and b). A minimal infiltrate of positive cells was observed in the placentomes collected from the negative control animals, though generally not associated with any pathological changes. No infiltration, or the presence of single rare TNF- α mRNA expressing cells were observed in the base of some of the placentomes collected from the

negative control animals culled at 14, 28 and 42 dpi. Some trophoblast cells were also positive in a few placentomes from negative control animals.

Overall TNF- α mRNA expression scores were significantly higher in the samples collected from animals infected with *N. caninum* when compared with the negative control dams during early gestation ($p < 0.01$). In contrast to what was observed using the IL-12 and IFN- γ probe, no significant differences were detected in TNF- α mRNA expression when a comparison was made between placentomes from dams carrying non-viable and those carrying viable foetuses ($p = 0.386$).

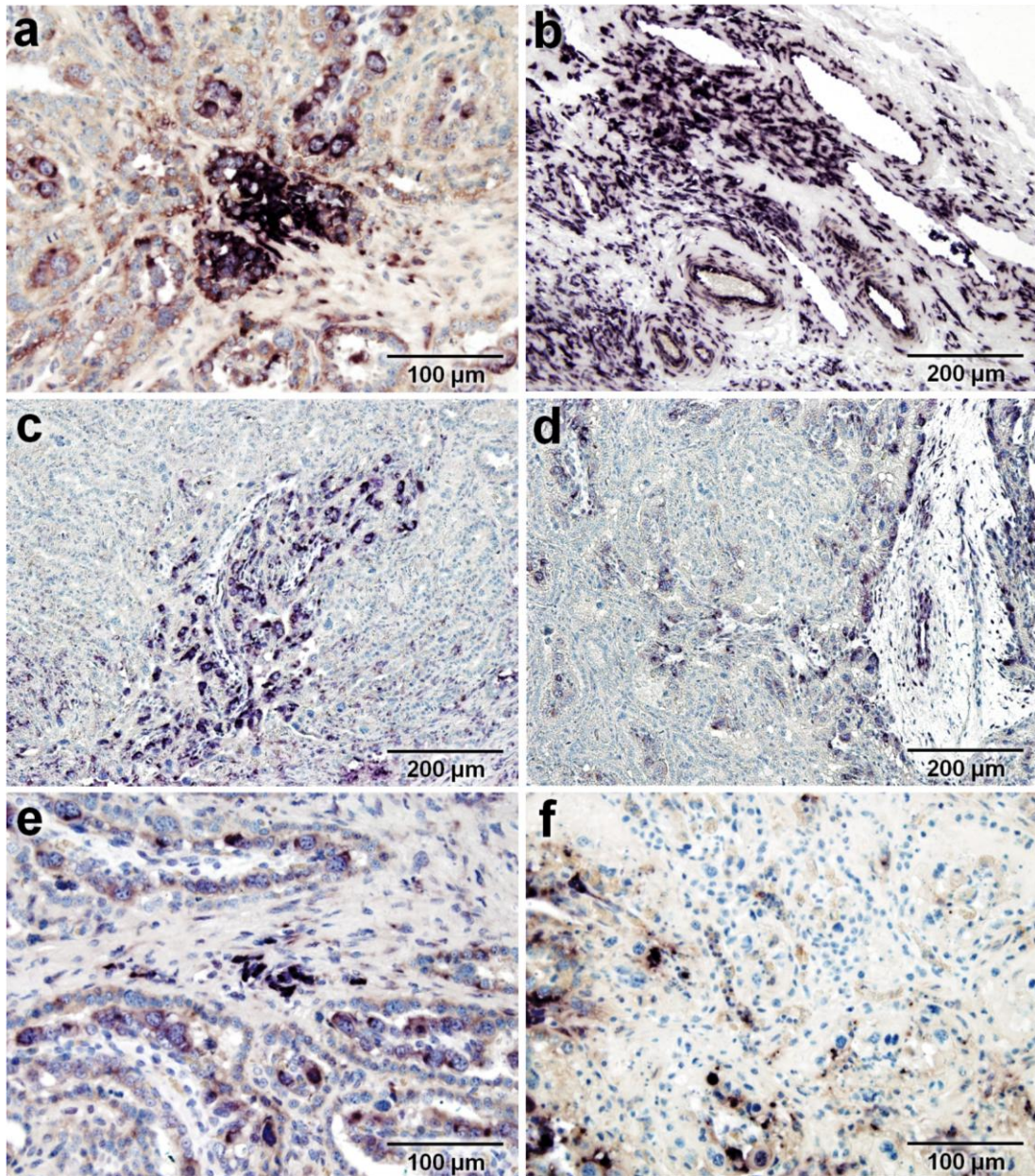
Mid gestation. After experimental inoculation at day 140 of gestation with *N. caninum*, placentomes collected from dams culled 14 dpi were infiltrated by a mild to moderate number of TNF- α mRNA expressing cells. These were around small areas of necrosis and in the base of the placentomes. Similar to the observations during the early gestation experiment, some TNF- α mRNA positive trophoblast cells (some binucleated) were also observed. Similar infiltrates were observed in the placental samples collected after 28 dpi, consisting of rare to moderate numbers of TNF- α mRNA positive cells in the caruncle surrounding small areas of necrosis and serum leakage, as well as infiltrating the base of the placentomes (see Figures 51c and d). A few positive round cells (morphologically resembling lymphocytes) were also observed in some foetal villi, but with no associated lesions.

Overall averaged results of the TNF- α mRNA scores showed a significantly higher number of positive cells in the samples collected from animals infected with *N. caninum* compared to the negative control dams at mid gestation ($p < 0.01$).

Late gestation. Placentomes collected from dams inoculated with *N. caninum* at day 210 of gestation and culled at 14, 28, 42 and 56 dpi were infiltrated with rare to moderate numbers of TNF- α mRNA expressing cells, most of which formed small aggregates in the caruncle or around some blood vessels (see Figures 51e and f), though not associated with any other pathological changes. Placentomes collected from negative control dams were either infiltrated with rare positive cells or contained no positive cells at all; when present, these cells were diffusely distributed

in the caruncle. Overall averaged results of the TNF- α mRNA scores were significantly higher in the samples collected from dams infected with *N. caninum* compared with the negative control dams ($p < 0.01$).

Comparison over gestation stages. When overall TNF- α mRNA scores were compared in dams inoculated with *N. caninum* in early, mid and late gestation, significant differences were found ($p < 0.01$). From these results those differences were mainly due to differences between scores at early gestation and all other stages. Pair-wise Mann-Whitney tests support this, since significant differences were only detected between early vs. mid ($p < 0.05$) and early vs. late gestation ($p < 0.01$) but not between mid and late gestation ($p = 0.205$). Using Kruskal-Wallis tests, no significant differences were found between different gestational stages in the negative control animals ($p = 0.277$). Mean scores and SEM of the infiltration scores observed in *N. caninum* infected and negative control dams for each experiment can be observed in Figure 52. Tables summarising mean TNF- α mRNA scores in early, mid and late gestation are shown below in Tables 5 and 6. Summary tables with p -values of the different statistical analyses are shown in Appendix II.



Figures 51 a-f: Examples of TNF- α mRNA expressing cells (staining black) detected in the placentomes from *N. caninum*-inoculated animals. (a) Aggregate of positive cells, some resembling trophoblasts, in a caruncle stalk of a dam inoculated with *N. caninum* IV at day 70 of gestation, culled 28 dpi and carrying a non-viable foetus at the time of culling. (b) Severe infiltration of positive cells in the base of a placentome of a dam inoculated with *N. caninum* IV at day 70 of gestation and culled at 42 dpi, in which the uterus was empty at the time of culling. (c) Infiltration of positive cells in a caruncle and foetal villi in a placentome from a dam inoculated with *N. caninum* at day 140 of gestation and culled 42 dpi. (d) Positive cells, some of them consistent with trophoblast cells in foetal villi and in the connective tissue of the caruncle stalk in a placentome collected from a dam inoculated with *N. caninum* at day 140 of gestation and culled 42 dpi. (e) Infiltration of positive cells in a caruncle stalk from a placentome collected from a dam inoculated with *N. caninum* at day 210 of gestation and culled 14 dpi. (f) TNF- α mRNA expressing cells in the caruncle of a placentome collected from a dam inoculated with *N. caninum* at day 210 of gestation and culled 42

dpi. All counterstained with haematoxylin. ISH slides produced and photographed by GJC.

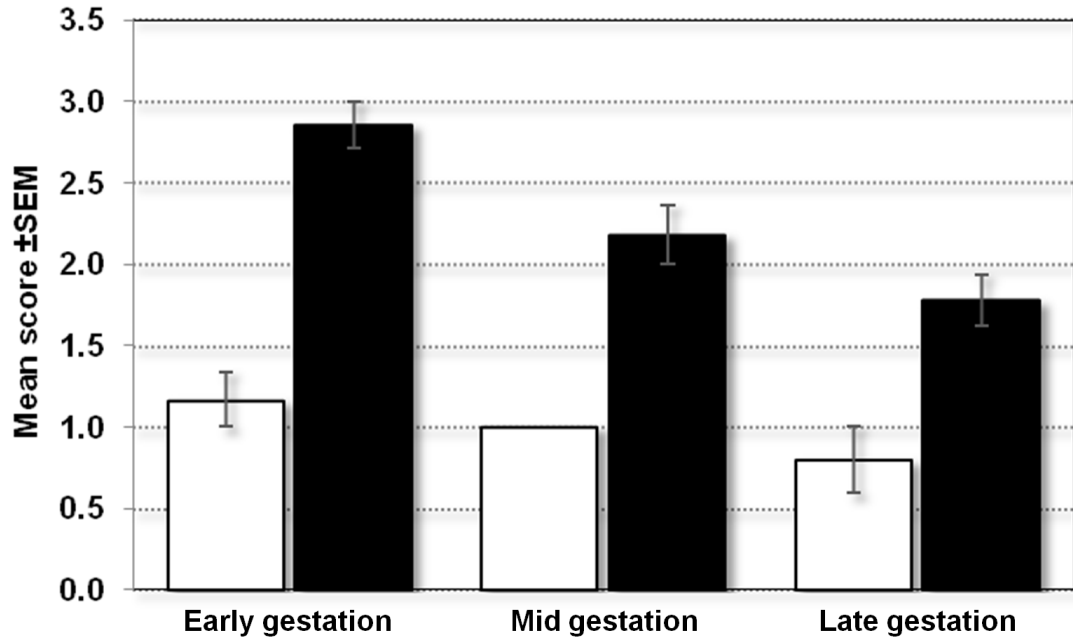


Figure 52: Mean scores for TNF- α mRNA positive cells in placentas collected from negative control (white bars) and *N. caninum*-infected (black bars) dams at early, mid and late gestation. Error bars indicate SEM.

Table 5: Mean scores (\pm SEM) for different cytokine mRNA expressing cells in placentomes collected from dams inoculated with *N. caninum* carrying non-viable or viable fetuses during early gestation.

Cell type	Non-viable	Viable
IL-12p40	3.67 (\pm 0.14) ^a	1.50 (\pm 0.19) ^b
IFN- γ	2.60 (\pm 0.29) ^a	1.36 (\pm 0.20) ^b
TNF- α	3.00 (\pm 0.00) ^a	2.80 (\pm 0.25) ^a

^{a, b} Different letters indicate significantly different scores

Table 6: Mean scores (\pm SEM) for different cytokine mRNA expressing cells in placentomes collected from *N. caninum* inoculated dams and negative controls during early, mid and late gestation.

Cell type	Early gestation		Mid gestation		Late gestation	
	Control	Inoculated	Control	Inoculated	Control	Inoculated
IL-12p40	0.60 (\pm 0.24) ^b	2.80 (\pm 0.29) ^{aA}	1.00 (\pm 0.00) ^b	1.73 (\pm 0.19) ^{aB}	0.50 (\pm 0.29) ^a	0.87 (\pm 0.12) ^{aC}
IFN- γ	1.00 (\pm 0.24) ^b	2.08 (\pm 0.22) ^{aA}	0.33 (\pm 0.33) ^b	1.64 (\pm 0.15) ^{aA}	0.25 (\pm 0.25) ^a	0.54 (\pm 0.16) ^{aB}
TNF- α	1.17 (\pm 0.17) ^b	2.86 (\pm 0.14) ^{aA}	1.00 (\pm 0.00) ^b	2.18 (\pm 0.18) ^{aB}	0.80 (\pm 0.20) ^b	1.78 (\pm 0.15) ^{asB}

^{a, b} Different lower case superscript letters indicate significantly different scores between negative control and *N. caninum* inoculated dams in each experiment (early, mid and late gestation)

^{A, B} Different uppercase superscript letters indicate significantly different overall scores for each cell marker between *N. caninum* inoculated dams in early, mid and late gestation (Kruskal-Wallis test)

Discussion

Previous studies have shown that in most cases there is a direct correlation between detectable levels of mRNA by ISH and the recognition of the corresponding protein by IHC (Gibbs *et al.*, 1989; Larsson and Hougaard, 1991; Larsson and Hougaard, 1992; Hougaard *et al.*, 1997). However, mRNA expression does not necessarily equate with production of biologically active protein (Entrican, 2002), and overinterpretation of results should be avoided (Cantón *et al.* 2013).

Interleukin-12 is a heterodimeric cytokine and a potent inducer of the Th1 response (Kobayashi *et al.*, 1989; Stern *et al.*, 1990; Trinchieri, 1995). It is recognised to play a major role in cell-mediated immunity directed against a broad class of infectious agents and tumours (Zarlenga *et al.*, 1995). IL-12 is comprised of two subunits; transcription of 40 kDa subunit (IL-12p40) mRNA is limited to lymphoid cells, whereas mRNA from the 35 kDa subunit (IL-12p35) has been found in both lymphoid and non haematopoietic tissues. Nevertheless, co-expression of both subunits is required for the generation of a bioactive molecule (Trinchieri, 1995; Zarlenga *et al.*, 1995). For this reason, the IL-12p40 gene was selected for detection, since this mRNA encoding p40 seems to be restricted to cells that produce the biologically active heterodimer (Trinchieri, 2003). Nevertheless, the p40 subunit is also a constituent of interleukin-23 (Gillessen *et al.*, 1995; Brombacher *et al.*, 2003) so care should be taken when interpreting the results generated by these probes.

Both of the newly designed IL-12p40 probes (#1 and #2) tested in fixed tissues from cattle, sheep, goat (Cantón *et al.*, 2013a) and water buffalos (Cantón *et al.*, in preparation) produced positive results. However, probe #2 (447bp), with its low background, allowed better distinction of positive cells when compared to probe #1 and, for this reason, it was selected to test the tissues collected from the *Neospora* inoculated dams. Since this was a shorter probe, which is thought to penetrate tissues more efficiently (Hougaard *et al.*, 1997; Mathey *et al.*, 2003), it may have increased the chances of detecting undamaged target sequence. Nevertheless, longer probes can carry higher numbers of labelled molecules, allowing better visibility and

the formation of stable hybrids even if only parts of the target sequence are available (Hougaard *et al.*, 1997).

Numerous IL-12p40 expressing cells were detected for the first time, using ISH, in placentas collected from pregnant cows experimentally infected with *N. caninum*. This concurs with previous studies that reported up-regulation in the expression of the IL-12 protein and increased transcription of the IL-12p40 gene in *N. caninum*-infected animals (Baszler *et al.*, 1999; Rosbottom *et al.*, 2008; Almería *et al.*, 2012; Bartley *et al.*, 2012).

Although the probes were designed using the bovine sequence of IL-12p40 they also worked in ovine, caprine and bubaline tissues. This is not surprising as the gene sequence used to generate the probes for this cytokine is highly conserved in these species of ruminant (de Rose *et al.*, 2000; Premraj *et al.*, 2006).

The modified scoring system previously used to score the different immune cells, as described in Chapters 2 and 3 (Cantón *et al.*, 2013b), was used to measure expression of mRNA for several cytokines, allowing more objective analysis and statistical comparison of the average expression scores following *Neospora* infection at different stages of pregnancy in cattle.

Overall, higher numbers of cells expressing IL-12 mRNA infiltrated the bovine placentas from *N. caninum* infected dams when compared with their respective negative control group. This infiltrate was more severe in placentomes collected from *Neospora* infected dams during early gestation, compared with those infected in mid and late gestation and, interestingly, higher infiltrates were identified in the dams carrying non-viable foetuses when compared with those carrying a viable foetus at the time of culling, supporting an association between the Th1 response and the occurrence of abortion. Cells expressing this cytokine in some placentomes resembled macrophages, and in fact it has already been proven that antigen presenting cells (macrophages and dendritic cells) are able to produce IL-12 after *N. caninum* infections (Dion *et al.*, 2011). Previous studies reported that IL-12p40 mRNA expression was significantly up-regulated in the caruncles from dams

infected with a different *N. caninum* strain (Nc-Liv) at early stages of pregnancy when compared with those infected at late stages (detected by PCR) (Rosbottom *et al.*, 2008). These experiments were carried out using a different strain; however, infiltrates of cells specifically expressing IL-12p40 mRNA were identified for the first time, mainly around areas of necrosis in the placentomes, not only supporting previous studies but also the hypothesis of immune-mediated abortion.

Peripheral blood mononuclear cells (PBMC) and lymphoid tissues collected during the current work in early gestation were also analysed using ELISA by Bartley *et al.* (2012), and IL-12 levels were increased in the dams inoculated with *Neospora*. Nevertheless, in this work, higher IL-12 ELISA results were detected in the PBMC samples of dams carrying viable foetuses, compared with those carrying non-viable foetuses or those with an empty uterus at the time of culling (Bartley *et al.*, 2012), indicating a general immune response, not specifically localised at placental level. Similarly, Almería *et al.* (2012) demonstrated up-regulation of IL-12p40 expression in PBMC of *Neospora* seropositive non-aborting animals compared with seropositive aborting animals. Its expression was also increased in placentas after *Neospora* infection recrudescence in pregnant cattle (Rosbottom *et al.*, 2011) and has been involved in the protection against *Neospora* infection (Khan *et al.*, 1997; Eperon *et al.*, 1999; Baszler *et al.*, 1999; Ritter *et al.*, 2002; Hemphill *et al.*, 2006). These results differ from the current study but it may be that there is a compartmentalisation of the immune response, with a particular increased Th1 response at the placental level that could influence the final clinical outcome of *Neospora* infection. More studies would be required to investigate this hypothesis.

While some authors suggest that IFN- γ expression during natural infection decreases the risk of abortion, others clearly question the abortifacient effects of IFN- γ in cows chronically infected with *Neospora* (Williams *et al.*, 2007; López-Gatius *et al.*, 2007a). In our experiments, cells expressing IFN- γ mRNA were significantly more numerous in the placentomes collected from infected animals compared to negative control dams. Moreover, there were clear differences in IFN- γ mRNA expression between animals inoculated with *Neospora* in early, mid and late gestation. Cells

expressing IFN- γ mRNA in early gestation were previously reported in the same samples used in this study, but using a different probe (Maley *et al.*, 2006). When the samples were re-analysed using a BoIFN- γ probe, similar results were obtained. There was infiltration following infection in early gestation, with labelled cells observed at 14, 28 and 42 dpi. There was also a distinct difference in the number of labelled cells in placentomes collected from dams carrying a non-viable foetus, or already aborted, compared to placentomes from non-aborting dams. These cells tended to surround large areas of necrosis and serum leakage, similar to previous descriptions (Rosbottom *et al.*, 2008). During the previous experiment in which cows were infected with *N. caninum* in early gestation, a rise in serological IFN- γ and antigen specific-IFN- γ following the stimulation of splenic and lymph node cells was also confirmed when compared with control animals (Bartley *et al.*, 2012). Similarly, Rosbottom *et al.* (2008) identified increasing expression of IFN- γ in the placentomes of pregnant cattle experimentally inoculated with Nc-Liv at day 70 of gestation (up to 785-fold up-regulation when compared with uninfected animals).

Following experimental *Neospora* infection in mid gestation, a milder infiltrate of IFN- γ mRNA expressing cells were observed in the placentomes compared with those observed after inoculation at day 70 of gestation, but differences were still observed between control and inoculated dams. Analysing samples collected simultaneously, Bartley *et al.* (2004) found an increased activity of IFN- γ in lymphocytes from uterine lymph nodes from experimentally inoculated dams. These results could be explained by the transitory immunosuppression usually observed around mid gestation in cattle (Stenlund *et al.*, 1999; Innes *et al.*, 2001). Also, the foetal immunological maturity reached at mid gestation (Osburn *et al.*, 1982; Osburn, 1986) could be enough to control parasite growth in foetal tissues, therefore diminishing placental re-invasion and any further immune response (Gibney *et al.*, 2008).

In late gestation, IFN- γ expression following experimental inoculation with Nc-1 was rare compared with the findings after inoculation at day 70 of gestation. Similar results have been previously described after infection in late gestation where, despite

up-regulation of IFN- γ mRNA in infected dams compared to negative controls, it was much lower than in early gestation (Rosbottom *et al.*, 2007; Rosbottom *et al.*, 2008). However, other studies have previously shown that an IFN- γ response in supernatants from *N. caninum* stimulated PBMC was similar following inoculation of cattle with Nc-Liv in early and late gestation (Williams *et al.*, 2000). In humans, a reduction in the generation of IFN- γ was observed in the third trimester of gestation compared with the first two trimesters (Marzi *et al.*, 1996) similar to what was observed in cattle during these three experiments.

During the experiments following Nc-1 infection in cattle throughout gestation, TNF- α was expressed by cells in the placentas, with a higher expression in the animals infected with *Neospora* compared to negative control dams overall. It has been previously shown that TNF- α is able to inhibit *N. caninum* tachyzoite growth in bovine cell cultures (Innes *et al.*, 1995a; Yamane *et al.*, 2000). TNF- α mRNA expression was increased in the placenta following *N. caninum* recrudescence in chronically infected cattle (Rosbottom *et al.*, 2011) and in seropositive (aborting and non-aborting) cattle during gestation (Almería *et al.*, 2012). TNF- α mRNA was also significantly higher in the placentas of mice experimentally inoculated with *N. caninum* in mid gestation (López-Pérez *et al.*, 2010). However, Ritter *et al.* (2002) reported that TNF- α does not appear to be an important factor in protecting the host against *N. caninum* using a murine model.

During the current experiments, some of the cells expressing TNF- α mRNA morphologically resembled lymphocytes and macrophages, although several trophoblast cells (even in the negative control groups) were also labelled. It is likely that bovine trophoblast cells can produce TNF- α , as happens in humans (King *et al.*, 1995).

Higher expression of TNF- α and other Th1 cytokines has been recorded in placentas from mice prone to foetal losses (Hill *et al.*, 1987; Chaouat *et al.*, 1990; Kinsky *et al.*, 1990; Gendron *et al.*, 1990; Haimovici *et al.*, 1991; Tangri and Raghupathy, 1993; Gazzinelli *et al.*, 1996; Haddad *et al.*, 1997; Clark *et al.*, 1998). It is also

incompatible with successful human pregnancy in a dose-dependent manner (Meegdes *et al.*, 1988; Hill, 1991; Yui *et al.*, 1994; Raghupathy *et al.*, 2000). Other intracellular pathogens have been reported to stimulate the production of TNF- α by different host immune cells. For instance, high levels of TNF- α have been observed after infection with *T. gondii* and have been suggested to be harmful to the maintenance of gestation in mice (Gazzinelli *et al.*, 1993; Gazzinelli *et al.*, 1996). A number of foetal resorptions have been associated with IFN- γ and TNF- α production following infection with *Leishmania* in mice (Krishnan *et al.*, 1996a). Furthermore, after *C. abortus* abortions in sheep, TNF- α was expressed in the placentas by macrophages (Buxton *et al.*, 2002a) and trophoblast cells (Wheelhouse *et al.*, 2009). However, no significant difference was identified in placental TNF- α mRNA expression in placental TNF- α mRNA expression in *Neospora* infected dams that were empty or carrying a non-viable foetus compared with those carrying a live foetus at time of culling in the early gestation experiment. Similar findings have been described in women suffering recurrent spontaneous abortion, where the TNF- α levels were not significantly different compared with normal women (Raghupathy *et al.*, 1999).

However, significant differences were observed when the infiltrate of cells expressing TNF- α mRNA following Nc-1 infection was compared in different stages of pregnancy, with the higher scores detected during early gestation. Similar results were reported after experimental infection with Nc-Liverpool tachyzoites in cattle in early and late gestation (Rosbottom *et al.*, 2008). In contrast, Williams *et al.* (2000) found no differences in systemic TNF- α levels (plasma or culture of PBMC) from cattle infected experimentally with Nc-Liverpool prior to gestation, or at 70 and 210 days after gestation. Differences in TNF- α mRNA expression throughout gestation could be associated with variations in the hormonal environment during pregnancy. It has been proven that increasing levels of oestrogen and/or progesterone can modulate or decrease the synthesis of TNF- α in the murine model (Miller and Hunt, 1998) and it has been proposed that such changes could influence the outcome of pregnancy during protozoal infections (Roberts *et al.*, 2001).

The results obtained during these three experiments clearly identified significant differences in the pro-inflammatory Th1 cytokine expression in the placental samples collected following *N. caninum* infection throughout gestation. This expression was higher in the placentas at day 70 of gestation and, in particular, in the placentomes from cattle carrying non-viable foetuses.

It is very difficult to confirm that the higher infiltration in early gestation is totally responsible to the occurrence of abortion, since it was shown that foetuses were not immunological mature until 28 dpi (Bartley *et al.*, 2012). It is well known that the foetal immune system is continuously developing and that the foetuses are able to mount a measurable cell-mediated and humoral immune response against different pathogens from day 100 of gestation (Swift and Kennedy, 1972; Rossi *et al.*, 1978; Osburn *et al.*, 1982; Osburn, 1986; Nettleton and Entrican, 1995; Tierney *et al.*, 1997; Tierney and Simpson-Morgan, 1997a; Hein *et al.*, 1998). Specifically, after *N. caninum* experimental infection, foetal thymus and spleen cells were able to respond to T-cell mitogens from three months of gestation (Innes *et al.*, 2005), whereas by four to seven months of gestation, *N. caninum* specific cell-mediated and antibody responses were detected in foetal blood and lymph nodes (Andrianarivo *et al.*, 2001; Almería *et al.*, 2003; Bartley *et al.*, 2004), probably indicating that as pregnancy progresses the foetus is better able to protect itself against invading pathogens, leading to decreased disease severity (Innes *et al.*, 2011).

Based on the current results on the placental cellular immune response against experimental *Neospora* infection during gestation, it can be hypothesised that the high pro-inflammatory response observed in early gestation in the animals carrying non-viable foetuses could be pertinent to the pathogenesis of this disease and may collaborate in placental deterioration, reduced foetal blood supply of nutrients, and subsequent abortion.

Chapter 5:

General discussion

Discussion

Neospora is one of the most frequently identified abortifacient infectious agents in cattle, and it is responsible for substantial economic losses in the livestock production industry as explained in Chapter 1 (Dubey, 2003a; Reichel *et al.*, 2013). However, despite being reported worldwide for over 20 years, its pathogenesis is still not completely understood.

Several factors, discussed in the literature review, could influence the occurrence of abortion following *N. caninum* infection in a cow either following *de novo* infection or recrudescence of a chronic parasitosis. The stage of gestation when the infection takes place is a key factor. The clinical outcome after infection during early pregnancy is usually abortion attributed to the immunological immaturity of the foetal immune system (Williams *et al.*, 2000; Macaldowie *et al.*, 2004; Caspe *et al.*, 2012). In contrast, foetal infections during mid and late gestation are generally asymptomatic, with production of congenitally infected but otherwise healthy calves (Williams *et al.*, 2000; Maley *et al.*, 2003; Benavides *et al.*, 2012).

Although the lesions produced by the protozoan in foetal and placental tissues are usually severe enough to cause foetal death (Barr *et al.*, 1991a; Barr *et al.*, 1994b; Maley *et al.*, 2003; Macaldowie *et al.*, 2004), immune-mediated placental pathology has also been hypothesised as a potential cause of abortion in bovine *Neospora* infections (Raghupathy, 1997; Innes *et al.*, 2002; Innes *et al.*, 2005; Dubey *et al.*, 2006; Innes and Vermeulen, 2006).

The main objective of this Thesis was to investigate this last hypothesis. Initially, the phenotypic characterisation of the inflammatory cells in the placentas of cattle experimentally inoculated in late gestation (day 210) was performed (Benavides *et al.*, 2012). The scoring methodology standardised during this first study allowed a measurable comparison of the different immune cell infiltrates.

After obtaining these first results, the new scoring methodology was applied to placental samples collected from Nc-1 inoculated dams during early and mid gestation (day 70 and 140 of gestation, respectively). These results have been previously reported (Maley *et al.*, 2006) but only from a descriptive standpoint without any objective scoring or statistical assessment. A new scoring system addressed this and the results are presented in detail in Chapter 3.

Along similar lines, IHC slides produced after incubation with the same mAbs were available after *Neospora* inoculation using the same experimental design on cattle during mid pregnancy (day 140 of gestation) (Maley *et al.*, 2003). Since these IHC results had never been previously reported, the inflammatory cells in these placentas were immunophenotypically characterised and the results are presented in conjunction with those produced for the other stages of pregnancy in Chapter 3.

The results of these three studies indicated that a similar immune cell population infiltrated the placentas of *Neospora* inoculated dams, regardless of stage of pregnancy and time of inoculation. In particular, there was an increased number of T lymphocytes (CD3⁺), most of which were T helper (CD4⁺) and $\gamma\delta$ TCR⁺. These cells mainly surrounded areas of necrosis in the placentomes. The phenotypes of the placental immune cell population were similar to those previously reported by other authors working with experimental and natural *Neospora* infections (Maley *et al.*, 2006; Rosbottom *et al.*, 2011; Orozco *et al.*, 2013).

These findings have also been previously corroborated in work quantifying immune cells in peripheral blood from experimentally inoculated cattle (Staska *et al.*, 2003; Bartley *et al.*, 2004; Rosbottom *et al.*, 2007).

One of the innovative aspects of this Thesis was the creation of a more objective method of immune cell quantification which was then applied to samples from experiments using comparable study designs and inocula (Maley *et al.*, 2003; Macaldowie *et al.*, 2004; Benavides *et al.*, 2012). As discussed in Chapter 3, these immune cell infiltrates were more severe in the placental samples collected from dams inoculated with *N. caninum* in early gestation and, in particular, in dams carrying dead foetuses at the time of culling. Together with the pattern of infiltration around areas of necrosis, this difference in infiltrate severity suggests an association with abortion.

A second novel approach, aimed at further characterisation of the immune cell infiltrates, was to compare cytokine expression in the same series of placental samples. Since Th1 cytokines were previously reported to be involved in the immunopathogenesis of bovine neosporosis (Khan *et al.*, 1997; Long *et al.*, 1998; Lundén *et al.*, 1998; Marks *et al.*, 1998; Baszler *et al.*, 1999; Williams *et al.*, 2000; Tanaka *et al.*, 2000a; Tanaka *et al.*, 2000b; Quinn *et al.*, 2002a; Bartley *et al.*, 2004; Rosbottom *et al.*, 2007; Rosbottom *et al.*, 2008; López-Pérez *et al.*, 2010; Innes *et al.*, 2011; Rosbottom *et al.*, 2011; Almería *et al.*, 2012; Bartley *et al.*, 2012), the characterisation of the expression of IL-12, IFN- γ and TNF- α was performed. For this purpose, new probes were designed and produced. This work is described in Chapter 4 (Cantón *et al.*, 2013a). These cytokines were expressed by a large number of cells in the placentas from cattle experimentally inoculated with *Neospora* during gestation. Cells expressing Th1 cytokines were more frequently observed in the placentas from cattle experimentally inoculated in early gestation, compared with mid- and late-gestation. In cattle inoculated in early gestation, cells expressing Th1 cytokines were more frequent in the placentas from dams carrying non-viable foetuses or from dams with an empty uterus. Similar results have been described before, indicating that *N. caninum* is able to trigger the release of Th1 cytokines that control parasite infection. Nevertheless, this expression may be harmful to the foetus (Raghupathy, 1997; Hayakawa *et al.*, 1999; Innes *et al.*, 2002; Innes *et al.*, 2005; Dubey *et al.*, 2006; Innes and Vermeulen, 2006) and this is in accordance with the clinical outcome of these three experiments.

The results presented in this Thesis show clear differences in the immune cell response and cytokine expression in cattle experimentally inoculated with *N. caninum* at different stages of gestation. The Th1 response was more severe in cattle infected with *Neospora* in early gestation and a distinct association was observed between the severity of this response in the placenta and the presence of a non-viable foetus or empty uterus (presumably aborted or reabsorbed) at the time of *post mortem* examination. Although it is not possible to confirm that this association is completely responsible for the foetal pathogenicity of *Neospora* (as the Th2 response was not evaluated), the immune response may at least partially contribute to the placental damage, which could diminish the nutrient and oxygen supply to the foetus, compromising pregnancy.

Further studies, including the expression of cytokines, are necessary in order to further progress our understanding of the immune response against *Neospora* infection during pregnancy in cattle, and to determine its involvement in the pathogenesis of bovine neosporosis.

Interestingly, this immune mediated hypothesis of abortion has not been identified in *Toxoplasma* infections, a closely related intracellular protozoan parasite (Ellis *et al.*, 1998; Ellis *et al.*, 1999; Howe and Sibley, 1999) that produces large economic losses, mainly in sheep, but also in other ruminant species (Dubey and Beattie, 1988; Dubey, 1990; Innes, 1997; Buxton, 1998). Several aspects of both diseases, bovine neosporosis and ovine toxoplasmosis, are almost identical: Both belong to the phylum Apicomplexa; both share a similar heteroxenous life cycle; and both compromise pregnancy in ruminants (Quinn *et al.*, 2002a; Innes and Mattsson, 2007). However, morphological, ultrastructural, metabolic and antigenic differences have been described between these parasites (Dubey, 1992; Dubey *et al.*, 1988a; Ellis *et al.*, 1998; Speer *et al.*, 1999; Shanmugasundram *et al.*, 2013). These differences could be responsible for the different clinical outcomes of infection with *N. caninum* and *T. gondii* in cattle and sheep. Unlike toxoplasmosis, which stimulates protective immunity following primary infection, in most instances cows that abort a *Neospora*-infected foetus will either abort again in the future (Obendorf *et al.*, 1995; Wouda *et*

al., 1995; Anderson *et al.*, 1995; Dannatt *et al.*, 1995; Moen *et al.*, 1995; Dubey and Lindsay, 1996) or will produce infected fetuses in subsequent pregnancies (Barr *et al.*, 1993; Dubey and Lindsay, 1996; Guy *et al.*, 2001).

Resistance to toxoplasmosis has been associated with a Th1 immune response, with an important role performed by CD4⁺ (Vollmer *et al.*, 1987) and the production of pro-inflammatory cytokines, such as IFN- γ , IL-12 and IL-2 (Hauser, Jr. *et al.*, 1983; Sharma *et al.*, 1984; Sharma *et al.*, 1985; Suzuki *et al.*, 1988; Gazzinelli *et al.*, 1991; Gazzinelli *et al.*, 1994; Pfaff *et al.*, 2007), which is very similar to the findings observed in the *Neospora*-infected cattle described in this Thesis. However, after analysing the immune cells infiltrating the placentas of *Neospora*-infected cattle, the cytotoxic T cell population was scant, with CD8⁺ cells occurring only rarely in association with placental lesions. This is one of the main apparent differences between *Neospora* and *Toxoplasma* infections, since CD8⁺ T cells have been shown to play a crucial role in resistance against acute *T. gondii* infections (Suzuki and Remington, 1988; Parker *et al.*, 1991; Hakim *et al.*, 1991; Subauste *et al.*, 1991). Differences in the pathogenicity between very similar protozoan parasites, or differences in the immune response mounted by closely related ruminant species (cattle and sheep), may underpin different immunopathogenic mechanisms of both protozoa.

Another important intracellular pathogen causing abortion in sheep is *C. abortus* (Buxton *et al.*, 1990; Buxton *et al.*, 1996; Aitken, 2000). Characterisation of the placental immune infiltration was carried out in pregnant ewes following experimental *Chlamydia* infections (Buxton *et al.*, 2002a). During this characterisation, most of the inflammatory cells were identified as monocytes/macrophages, with rare CD4⁺, CD8⁺ and $\gamma\delta$ TCR⁺ lymphocytes. However, TNF- α mRNA was largely expressed by mononuclear cells in affected placentas, and low numbers of cells expressing IFN- γ mRNA were observed. The authors, therefore, postulated that this production of TNF- α , aside from the placental damage produced by the bacteria during chlamydial infection, could partially contribute to the placental damage and later contribute to abortion (Buxton *et al.*,

2002a; Kerr *et al.*, 2005; Entrican *et al.*, 2010). These results are in alignment with the hypothesis of immune mediated abortion during *Neospora* infections in cattle.

There were also intriguing differences in the T lymphocyte infiltrate as gestation progressed in the negative control animals, with a more severe infiltrate in early gestation compared to the later stages. Previous reports have demonstrated that ruminant pregnancy is characterised by an increase in some types of immune cell within the uterus (Entrican and Wheelhouse, 2006; Oliveira and Hansen, 2008). Immunological changes have also been reported during pregnancy, where they seemingly play a critical function in the protection of the foetus and are involved in “housekeeping” of the placenta, which is a temporary tissue in constant flux (Van Kampen and Mallard, 1997; Kimura *et al.*, 1999; Oliveira and Hansen, 2008). Further studies should be undertaken in order to expand our knowledge of physiological changes occurring during gestation, which could help in the understanding of other reproductive diseases.

These studies should also take into account that the whole genome of the domestic cow (*Bos taurus*) has now been assembled and published (Zimin *et al.*, 2009), allowing the application of new approaches such as microarray and transcriptomic techniques, to identify new molecules involved in the host response to the parasite.

Another interesting finding was the presence of trophoblast cells that were recognised by the HM57 mAb that is generally used to label B cells (Pillozzi *et al.*, 1998; Maley *et al.*, 2006; Polledo *et al.*, 2011). Furthermore, some trophoblast cells in the placentomes expressed IL-12, IFN- γ and TNF- α mRNA in both *N. caninum* and negative control dams during all stages of gestation. In ruminant ungulates, trophoblasts are morphologically and functionally distinct cell types of the placental trophoctoderm. These cells can either be mononuclear or binucleated (Wimsatt, 1951; Greenstein *et al.*, 1958) and they assume specialised functions. Mononuclear trophoblast cells form the majority of the maternal-foetal interface and are primarily involved in nutrient exchange. In contrast, binucleated cells are endocrinologically active, producing different hormones (Duello *et al.*, 1986; Myers and Reimers, 1988;

Matamoros *et al.*, 1994; Schlafer *et al.*, 2000; Igwebuike, 2006; Paulesu *et al.*, 2012). Moreover, trophoblast cells are considered innate immune cells, able to undergo phagocytic activity (Schlafer *et al.*, 2000; Igwebuike, 2006) and acting as ‘sensors’ of the surrounding environment, recognising various pathogens and secreting cytokines that, in turn, act upon the immune cells within the decidua in humans (King *et al.*, 1995; Roth *et al.*, 1996; Wilczynski, 2005; Koga *et al.*, 2009).

The immunological role of trophoblast cells has not been extensively studied in livestock species, therefore, caution should be taken when extrapolating results observed in human or murine models. In order to clarify their role in these species, further studies are necessary. Currently, a new line of research has begun in order to further characterise trophoblast cells which may shed some light on this aspect in the future and could further impact our understanding of the dam’s immune response during the delicate physiological time of pregnancy.

Concluding remarks

Currently there are no tools to effectively control neosporosis in affected herds. The vaccine available in some countries has been shown to be inefficient in preventing transplacental transmission of the parasite although, in some instances, it has generated an immune response sufficient to prevent abortion (Choromanski and Block, 2000; Williams *et al.*, 2003; Romero *et al.*, 2004).

The data collected for this Thesis clarified some aspects of the immune response to *Neospora* infection during bovine pregnancy and has allowed a more robust comparison of this response at different stages of pregnancy, as well as in dams carrying viable and non-viable fetuses. This data may be useful for future development of appropriate tools, such as vaccines, to control parasite growth. These tools should aim to mimic some aspects of the immune response, but at a lower level, in order to avoid the undesirable effects of an exacerbated Th1 response.

Vaccinology have provided many adjuvants that have already been studied in the inception of experimental *Neospora* vaccines (Andrianarivo *et al.*, 1999; Andrianarivo *et al.*, 2000; Choromanski and Block, 2000; Moore *et al.*, 2005; Williams *et al.*, 2007; Innes *et al.*, 2011). New approaches have been developed in the last decade such as the use of immune stimulating complexes (i.e. ISCOMs) that have already been experimentally tested in protozoal infections in livestock with partial success (Garcia *et al.*, 2005; Moore *et al.*, 2011). Such approaches or the use of more advanced technology like nanoparticules should be further investigated in order to facilitate a correct antigen presentation and the generation of an appropriate immune response (Elamanchili *et al.*, 2007; Leleux and Roy, 2013).

In the future, developers of *Neospora* vaccines and therapeutic compounds should take this information into account, in order to design more relevant tools, probably including immune modulators or adjuvants, which can generate the appropriate immune response able to control the parasite without injuring the placenta of an infected dam.

References

- Ackermann, M.R., DeBey, B.M., Stabel, T.J., Gold, J.H., Register, K.B., Meehan, J.T., 1994. Distribution of anti-CD68 (EBM11) immunoreactivity in formalin-fixed, paraffin-embedded bovine tissues. *Veterinary Pathology Online* 31, 340-348.
- Adu-Addai, B., Koney, E.B., Addo, P., Kaneene, J., Mackenzie, C., Agnew, D.W., 2012. Importance of infectious bovine reproductive diseases: an example from Ghana. *Veterinary Record* 171, 47.
- Agerholm, J.S., Barr, B.C., 1994. Bovine abortions associated with *Neospora* in Denmark. *Acta Veterinaria Scandinavica* 35, 461-464.
- Agerholm, J.S., Willadsen, C., Nielsen, T.K., Giese, S.B., Holm, E., Jensen, L., Agger, J.F., 1997. Diagnostic studies of abortion in Danish dairy herds. *Journal of Veterinary Medicine Series A* 44, 551-558.
- Aguado-Martínez, A., Ortega-Mora, L.M., Álvarez-García, G., Rodríguez-Marco, S., Risco-Castillo, V., Marugán-Hernández, V., Fernández-García, A., 2009. Stage-specific expression of *NcSAG4* as a marker of chronic *Neospora caninum* infection in a mouse model. *Parasitology* 136, 757-764.
- Aitken, I.D., 2000. Enzootic (chlamydial) abortion. In: Martin, W.B., Aitken, I.D. (Eds.), *Diseases of sheep*. Blackwell Scientific Publications, London, pp. 81-86.
- Al-Qassab, S.E., Reichel, M.P., Ivens, A., Ellis, J.T., 2009. Genetic diversity amongst isolates of *Neospora caninum*, and the development of a multiplex assay for the detection of distinct strains. *Molecular and Cellular Probes* 23, 132-139.
- Almería, S., Araujo, R., Tuo, W., López-Gatius, F., Dubey, J.P., Gasbarre, L.C., 2010. Fetal death in cows experimentally infected with *Neospora caninum* at 110 days of gestation. *Veterinary Parasitology* 169, 304-311.
- Almería, S., de Marez, T., Dawson, H., Araujo, R., Dubey, J.P., Gasbarre, L.C., 2003. Cytokine gene expression in dams and foetuses after experimental *Neospora caninum* infection of heifers at 110 days of gestation. *Parasite Immunology* 25, 383-392.
- Almería, S., López-Gatius, F., 2013. Bovine neosporosis: Clinical and practical aspects. *Research in Veterinary Science* 95, 303-309.
- Almería, S., López-Gatius, F., García-Ispuerto, I., Nogareda, C., Bech-Sàbat, G., Serrano, B., Santolaria, P., Yániz, J.L., 2009. Effects of crossbreed pregnancies on the abortion risk of *Neospora caninum*-infected dairy cows. *Veterinary Parasitology* 163, 323-329.

- Almería, S., Serrano, B., Yániz, J.L., Darwich, L., López-Gatius, F., 2012. Cytokine gene expression profiles in peripheral blood mononuclear cells from *Neospora caninum* naturally infected dams throughout gestation. *Veterinary Parasitology* 183, 237-243.
- Altbuch, J.A., Schofield, M.J., Porter, C.A., Gavin, W.G., 2012. *Neospora caninum*: a successful testing and eradication program in a dairy goat herd. *Small Ruminant Research* 105, 341-344.
- Alves, D., McEwen, B., Hazlett, M., Maxie, G., Anderson, N., 1996. Trends in bovine abortions submitted to the Ontario Ministry of Agriculture, Food and Rural Affairs, 1993-1995. *Canadian Veterinary Journal* 37, 288.
- Amills, M., Ramiya, V., Norimine, J., Olmstead, C.A., Lewin, H.A., 2002. Reduced IL-2 and IL-4 mRNA expression in CD4⁺ T cells from Bovine Leukemia Virus-infected cows with persistent lymphocytosis. *Virology* 304, 1-9.
- Anderson, I.E., Reid, H.W., Nettleton, P.F., McInnes, C.J., Haig, D.M., 2001. Detection of cellular cytokine mRNA expression during orf virus infection in sheep: differential interferon-[gamma] mRNA expression by cells in primary versus reinfection skin lesions. *Veterinary Immunology and Immunopathology* 83, 161-176.
- Anderson, M.L., 2007. Infectious causes of bovine abortion during mid- to late-gestation. *Theriogenology* 68, 474-486.
- Anderson, M.L., Andrianarivo, A.G., Conrad, P.A., 2000. Neosporosis in cattle. *Animal Reproduction Science* 60-61, 417-431.
- Anderson, M.L., Barr, B.C., Conrad, P.A., Thurmond, M.C., Picanso, J.P., Dubey, J.P., 1991a. Bovine protozoal abortions in California. *Bovine Practitioner* 26, 102-104.
- Anderson, M.L., Blanchard, P.C., Barr, B.C., Dubey, J.P., Hoffman, R.L., Conrad, P.A., 1991b. *Neospora*-like protozoan infection as a major cause of abortion in California dairy cattle. *Journal of the American Veterinary Medical Association* 198, 241-244.
- Anderson, M.L., Blanchard, P.C., Barr, B.C., Hoffman, R.L., 1990. A survey of causes of bovine abortion occurring in the San Joaquin Valley, California. *Journal of Veterinary Diagnostic Investigation* 2, 283-287.
- Anderson, M.L., Palmer, C.W., Thurmond, M.C., Picanso, J.P., Blanchard, P.C., Breitmeyer, R.E., Layton, A.W., McAllister, M.M., Daft, B.M., Kinde, H., Read, D.H., Dubey, J.P., Conrad, P.A., Barr, B.C., 1995. Evaluation of abortions in cattle attributable to neosporosis in selected dairy herds in California. *Journal of the American Veterinary Medical Association* 207, 1206-1210.

- Anderson, M.L., Reynolds, J.P., Rowe, J.D., Sverlow, K.W., Packham, A.E., Barr, B.C., Conrad, P.A., 1997. Evidence of vertical transmission of *Neospora* sp. infection in dairy cattle. *Journal of the American Veterinary Association* 210, 1169-1172.
- Andreotti, R., Pinckney, R.D., Pires, P.P., Silva, E.A.E., 2004. Evidence of *Neospora caninum* in beef cattle and dogs in the state of Mato Grosso do Sul, Center-Western Region, Brazil. *Revista Brasileira de Parasitologia Veterinária* 13, 129-131.
- Andrianarivo, A.G., Barr, B.C., Anderson, M.L., Rowe, J.D., Packham, A.E., Sverlow, K.W., Conrad, P.A., 2001. Immune responses in pregnant cattle and bovine fetuses following experimental infection with *Neospora caninum*. *Parasitology Research* 87, 817-825.
- Andrianarivo, A.G., Choromanski, L.J., McDonough, S.P., Packham, A.E., Conrad, P.A., 1999. Immunogenicity of a killed whole *Neospora caninum* tachyzoite preparation formulated with different adjuvants. *International Journal for Parasitology* 29, 1613-1625.
- Andrianarivo, A.G., Rowe, J.D., Barr, B.C., Anderson, M.L., Packham, A.E., Sverlow, K.W., Choromanski, L.J., Loui, C., Grace, A., Conrad, P.A., 2000. A POLYGEN-adjuvanted killed *Neospora caninum* tachyzoite preparation failed to prevent foetal infection in pregnant cattle following i.v./i.m. experimental tachyzoite challenge. *International Journal for Parasitology* 30, 985-990.
- Anonymous, 1991. Comparison of reactivity of monoclonal antibodies on bovine, ovine and caprine tissues and on cells from other animal species. *Veterinary Immunology and Immunopathology* 27, 32-34.
- Antony, A., Williamson, N.B., 2001. Recent advances in understanding the epidemiology of *Neospora caninum* in cattle. *New Zealand Veterinary Journal* 49, 42-47.
- Arceci, R.J., Shanahan, F., Stanley, E.R., Pollard, J.W., 1989. Temporal expression and location of colony-stimulating factor 1 (CSF-1) and its receptor in the female reproductive tract are consistent with CSF-1-regulated placental development. *Proceedings of the National Academy of Sciences of the United States of America* 86, 8818-8822.
- Arck, P.C., Dietl, J., Clark, D.A., 1999. From the decidual cell internet: trophoblast-recognizing T cells. *Biology of Reproduction* 60, 227-233.
- Armengol, R., Pabón, M., Adelantado, C., López-Gatius, F., Almería, S., 2006. First report of *Neospora caninum* abortion in a beef cow-calf herd from Andorra, Europe. *The Journal of Parasitology* 92, 1361-1362.
- Armengol, R., Pabón, M., Santolaria, P., Cabezón, O., Adelantado, C., Yániz, J.L., López-Gatius, F., Almería, S., 2007. Low seroprevalence of *Neospora caninum*

infection associated with the Limousin breed in cow-calf herds in Andorra, Europe. *The Journal of Parasitology* 93, 1029-1032.

Arunvipas, P., Inpankaew, T., Jittapalapong, S., 2012. Seroprevalence and risk factors of *Neospora caninum* infection among dairy cows in the Western Provinces of Nakhon Pathom, Ratchaburi and Kanchanaburi, Thailand. *Kasetsart Journal (Natural Science)* 46, 64-70.

Asadpour, R., Jafari-Joozani, R., Salehi, N., 2013. Detection of *Neospora caninum* in ovine abortion in Iran. *Journal of Parasitic Diseases* 37, 105-109.

Asmare, K., Regassa, F., Robertson, L.J., Skjerve, E., 2013. Seroprevalence of *Neospora caninum* and associated risk factors in intensive or semi-intensively managed dairy and breeding cattle of Ethiopia. *Veterinary Parasitology* 193, 85-94.

Athanassakis, I., Iconomidou, B., 1995. Cytokine production in the serum and spleen of mice from day 6 to 14 of gestation: cytokines/placenta/spleen/serum. *Developmental Immunology* 4, 247-255.

Athanassakis, I., Ranella, A., Vassiliadis, S., 2000. IFN-gamma facilitates release of class II-loaded intracellular pools in trophoblast cells: a novel property independent of protein synthesis. *Journal of Interferon & Cytokine Research* 20, 823-830.

Atkinson, R.A., Harper, P.A.W., Ryce, C., Morrison, D.A., Ellis, J.T., 1999. Comparison of the biological characteristics of two isolates of *Neospora caninum*. *Parasitology* 118, 363-370.

Baillargeon, P., Fecteau, G., Paré, J., Lamothe, P., Sauvé, R., 2001. Evaluation of the embryo transfer procedure proposed by the International Embryo Transfer Society as a method of controlling vertical transmission of *Neospora caninum* in cattle. *Journal of the American Veterinary Medical Association* 218, 1803-1806.

Baldwin, C.L., Morrison, W.I., Naessens, J., 1987. Differentiation antigens and functional characteristics of bovine leukocytes. In: Trnka, Z., Miyasaka, M. (Eds.), *Comparative aspects of differentiation antigens in lympho-haemopoietic tissues*. Marcel Dekker Inc., New York, USA.

Baldwin, C.L., Teale, A.J., Naessens, J.G., Goddeeris, B.M., MacHugh, N.D., Morrison, W.I., 1986. Characterization of a subset of bovine T lymphocytes that express BoT4 by monoclonal antibodies and function: similarity to lymphocytes defined by human T4 and murine L3T4. *Journal of Immunology* 136, 4385-4391.

Balkaya, I., Bastem, Z., Avcioglu, H., Onalan, S.K., 2012. Seroprevalence of *Neospora caninum* antibodies in cattle in Eastern Turkey. *Israel Journal of Veterinary Medicine* 67, 109-112.

Barbosa de Macedo, C.A., Barbosa de Macedo, M.F.S., Cardim, S.T., Custódio Paiva, M.C.D., Taroda, A., Barros, L.D., Leme da Cunha, I.A., Zulpo, D.L., Garcia,

- J.L., 2013. *Neospora caninum*: evaluation of vertical transmission in slaughtered dairy cows (*Bos taurus*). *Revista Brasileira de Parasitologia Veterinária* 22, 13-17.
- Barling, K.S., McNeill, J.W., Paschal, J.C., McCollum, F.T., Craig, T.M., Adams, L.G., Thompson, J.A., 2001. Ranch-management factors associated with antibody seropositivity for *Neospora caninum* in consignments of beef calves in Texas, USA. *Preventive Veterinary Medicine* 52, 53-61.
- Barling, K.S., Sherman, M., Peterson, M.J., Thompson, J.A., McNeill, J.W., Craig, T.M., Adams, L.G., 2000. Spatial associations among density of cattle, abundance of wild canids, and seroprevalence to *Neospora caninum* in a population of beef calves. *Journal of the American Veterinary Medical Association* 217, 1361-1365.
- Barr, B.C., Anderson, M.L., Blanchard, P.C., Daft, B.M., Kinde, H., Conrad, P.A., 1990. Bovine fetal encephalitis and myocarditis associated with protozoal infections: a two year retrospective study of cases in California. *Veterinary Pathology* 27, 354-361.
- Barr, B.C., Anderson, M.L., Dubey, J.P., Conrad, P.A., 1991a. *Neospora*-like protozoal infections associated with bovine abortions. *Veterinary Pathology Online* 28, 110-116.
- Barr, B.C., Anderson, M.L., Woods, L.W., Dubey, J.P., Conrad, P.A., 1992. *Neospora*-like protozoal infections associated with abortion in goats. *Journal of Veterinary Diagnostic Investigation* 4, 365-367.
- Barr, B.C., Conrad, P.A., Breitmeyer, R.E., Sverlow, K.W., Anderson, M.L., Reynolds, J.P., Chauvet, A.E., Dubey, J.P., Ardans, A.A., 1993. Congenital *Neospora* infection in calves born from cows that had previously aborted *Neospora*-infected fetuses: four cases (1990-1992). *Journal of the American Veterinary Association* 202, 113-117.
- Barr, B.C., Conrad, P.A., Dubey, J.P., Anderson, M.L., 1991b. *Neospora*-like encephalomyelitis in a calf: pathology, ultrastructure, and immunoreactivity. *Journal of Veterinary Diagnostic Investigation* 3, 39-46.
- Barr, B.C., Conrad, P.A., Sverlow, K.W., Tarantal, A.F., Hendrickx, A.G., 1994a. Experimental fetal and transplacental *Neospora* infection in the nonhuman primate. *Laboratory Investigation* 71, 236-242.
- Barr, B.C., Rowe, J.D., Sverlow, K.W., BonDurant, R.H., Ardans, A.A., Oliver, M.N., Conrad, P.A., 1994b. Experimental reproduction of bovine fetal *Neospora* infection and death with a bovine *Neospora* isolate. *Journal of Veterinary Diagnostic Investigation* 6, 207-215.
- Bartels, C.J.M., Arnáiz-Seco, I., Ruiz-Santa-Quitera, A., Björkman, C., Frössling, J., von Blumröder, D., Conraths, F.J., Schares, G., van Maanen, C., Wouda, W., Ortega-Mora, L.M., 2006a. Supranational comparison of *Neospora caninum*

seroprevalences in cattle in Germany, The Netherlands, Spain and Sweden. *Veterinary Parasitology* 137, 17-27.

Bartels, C.J.M., Hogeveen, H., van Schaik, G., Wouda, W., Dijkstra, T., 2006b. Estimated economic losses due to *Neospora caninum* infection in dairy herds with and without a history of *Neospora caninum* associated abortion epidemics. In: Annual Meeting of the Society for Veterinary Epidemiology and Preventive Medicine, pp. 191-201.

Bartels, C.J.M., Huinink, I., Beiboer, M.L., van Schaik, G., Wouda, W., Dijkstra, T., Stegeman, A., 2007a. Quantification of vertical and horizontal transmission of *Neospora caninum* infection in Dutch dairy herds. *Veterinary Parasitology* 148, 83-92.

Bartels, C.J.M., van Maanen, C., van der Meulen, A.M., Dijkstra, T., Wouda, W., 2005. Evaluation of three enzyme-linked immunosorbent assays for detection of antibodies to *Neospora caninum* in bulk milk. *Veterinary Parasitology* 131, 235-246.

Bartels, C.J.M., van Schaik, G., van Maanen, K., Wouda, W., Dijkstra, T., 2007b. Factors associated with variation in *Neospora caninum* bulk-milk S/P ratios in initially bulk-milk negative testing Dutch dairy herds. *Preventive Veterinary Medicine* 81, 265-273.

Bartels, C.J.M., van Schaik, G., Veldhuisen, J.P., van den Borne, B.H.P., Wouda, W., Dijkstra, T., 2006c. Effect of *Neospora caninum*-serostatus on culling, reproductive performance and milk production in Dutch dairy herds with and without a history of *Neospora caninum*-associated abortion epidemics. *Preventive Veterinary Medicine* 77, 186-198.

Bartels, C.J.M., Wouda, W., Schukken, Y.H., 1999. Risk factors for *Neospora caninum*-associated abortion storms in dairy herds in The Netherlands (1995 to 1997). *Theriogenology* 52, 247-257.

Bartley, P.M., Katzer, F., Rocchi, M.S., Maley, S.W., Benavides Silván, J., Nath, M., Pang, Y., Cantón, G.J., Chianini, F., Innes, E.A., 2013a. Development of maternal and foetal immune responses in cattle following experimental challenge with *Neospora caninum* at day 210 of gestation. *Veterinary Research* 44, 91.

Bartley, P.M., Kirvar, E., Wright, S.E., Swales, C., Esteban-Redondo, I., Buxton, D., Maley, S.W., Schock, A., Rae, A.G., Hamilton, C.M., Innes, E.A., 2004. Maternal and fetal immune responses of cattle inoculated with *Neospora caninum* at mid-gestation. *Journal of Comparative Pathology* 130, 81-91.

Bartley, P.M., Wright, S.E., Maley, S.W., Macaldowie, C.N., Nath, M., Hamilton, C.M., Katzer, F., Buxton, D., Innes, E.A., 2012. Maternal and foetal immune responses of cattle following an experimental challenge with *Neospora caninum* at day 70 of gestation. *Veterinary Research* 43, 38.

- Bartley, P.M., Wright, S.E., Zimmer, I.A., Roy, S., Kitchener, A.C., Meredith, A., Innes, E.A., Katzer, F., 2013b. Detection of *Neospora caninum* in wild carnivorans in Great Britain. *Veterinary Parasitology* 192, 279-283.
- Basso, W., Schares, S., Minke, L., Bärwald, A., Maksimov, A., Peters, M., Schulze, C., Müller, M., Conraths, F.J., Schares, G., 2010. Microsatellite typing and avidity analysis suggest a common source of infection in herds with epidemic *Neospora caninum*-associated bovine abortion. *Veterinary Parasitology* 173, 24-31.
- Baszler, T.V., Long, M.T., McElwain, T.F., Mathison, B.A., 1999. Interferon-[gamma] and interleukin-12 mediate protection to acute *Neospora caninum* infection in BALB/c mice. *International Journal for Parasitology* 29, 1635-1646.
- Beckstead, J.H., 1994. A simple technique for preservation of fixation-sensitive antigens in paraffin-embedded tissues. *Journal of Histochemistry & Cytochemistry* 42, 1127-1134.
- Benavides, J., Katzer, F., Maley, S.W., Bartley, P.M., Cantón, G.J., Palarea, J., Pang, Y., Burrells, A., Rocchi, M., Chianini, F., Innes, E.A., 2012. High rate of transplacental transmission of *Neospora caninum* following experimental challenge at late gestation. *Veterinary Research* 43, 83.
- Bennet, W.A., Lagoo-Deenadayalan, S., Stopple, J.A., Barber, W.H., Hale, E., Brackin, M.N., Cowan, B.D., 1998. Cytokine expression by first-trimester human chorionic villi. *American Journal of Reproductive Immunology* 40, 309-318.
- Bensaid, A., Hadam, M., 1991. Bovine CD4 (BoCD4). *Veterinary Immunology and Immunopathology* 27, 51-54.
- Bergeron, N., Fecteau, G., Paré, J., Martineau, R., Villeneuve, A., 2000. Vertical and horizontal transmission of *Neospora caninum*. *Canadian Veterinary Journal* 41, 464-467.
- Bielanski, A., Phipps-Todd, B., Robinson, J., 2002. Effect of *Neospora caninum* on *in vitro* development of preimplantation stage bovine embryos and adherence to the zona pellucida. *Veterinary Record* 150, 316-318.
- Bildfell, R., Davidson, J., Dubey, J.P., 1994. *Neospora*-induced protozoal bovine abortion in Prince Edward Island. *Canadian Veterinary Journal* 35, 122.
- Bjerkås, I., Dubey, J.P., 1991. Evidence that *Neospora caninum* is identical to the *Toxoplasma*-like parasite of Norwegian dogs. *Acta Veterinaria Scandinavica* 32, 407-410.
- Bjerkås, I., Mohn, S.F., Presthus, J., 1984. Unidentified cyst-forming Sporozoon causing encephalomyelitis and myositis in dogs. *Parasitology Research* 70, 271-274.
- Bjerkås, I., Presthus, J., 1988. Immuno-histochemical and ultrastructural characteristics of a cyst-forming sporozoon associated with encephalomyelitis and

- myositis in dogs. *Acta Pathologica, Microbiologica et Immunologica Scandinavica* 96, 445-454.
- Björkman, C., Alenius, S., Manuelsson, U.L.F.E., Uggla, A., 2000. *Neospora caninum* and Bovine Virus Diarrhoea Virus infections in Swedish dairy cows in relation to abortion. *The Veterinary Journal* 159, 201-206.
- Björkman, C., Johansson, O., Stenlund, S., Holmdahl, O.J.M., Uggla, A., 1996. *Neospora* species infection in a herd of dairy cattle. *Journal of the American Veterinary Medical Association* 208, 1441-1444.
- Björkman, C., McAllister, M.M., Frössling, J., Näslund, K., Leung, F., Uggla, A., 2003. Application of the *Neospora caninum* IgG avidity ELISA in assessment of chronic reproductive losses after an outbreak of neosporosis in a herd of beef cattle. *Journal of Veterinary Diagnostic Investigation* 15, 3-7.
- Blackston, C.R., Dubey, J.P., Dotson, E., Su, C., Thulliez, P., Sibley, D., Lehmann, T., 2001. High-resolution typing of *Toxoplasma gondii* using microsatellite loci. *The Journal of Parasitology* 87, 1472-1475.
- Boulton, J.G., Gill, P.A., Cook, R.W., Fraser, G.C., Harper, P.A.W., Dubey, J.P., 1995. Bovine *Neospora* abortion in north-eastern New South Wales. *Australian Veterinary Journal* 72, 119-120.
- Boysen, P., Klevar, S., Olsen, I., Storset, K., 2006. The protozoan *Neospora caninum* directly triggers bovine NK cells to produce gamma interferon and to kill infected fibroblasts. *Infection and Immunity* 74, 953-960.
- Brabin, L., Brabin, B.J., 1992. Parasitic infections in women and their consequences. *Advances in Parasitology* 31, 1-81.
- Brombacher, F., Kastelein, R.A., Alber, G., 2003. Novel IL-12 family members shed light on the orchestration of Th1 responses. *Trends in Immunology* 24, 207-212.
- Brown, C., 1998. *In situ* hybridization with riboprobes: an overview for veterinary pathologists. *Veterinary Pathology Online* 35, 159-167.
- Bryan, L.A., Gajadhar, A.A., Dubey, J.P., Haines, D.M., 1994. Bovine neonatal encephalomyelitis associated with a *Neospora* sp. protozoan. *Canadian Veterinary Journal* 35, 111-113.
- Buxton, D., 1998. Protozoan infections (*Toxoplasma gondii*, *Neospora caninum* and *Sarcocystis* spp.) in sheep and goats: recent advances. *Veterinary Research* 29, 289-310.
- Buxton, D., Anderson, I.E., Longbottom, D., Livingstone, M., Wattedgedera, S., Entrican, G., 2002a. Ovine chlamydial abortion: characterization of the inflammatory immune response in placental tissues. *Journal of Comparative Pathology* 127, 133-141.

- Buxton, D., Barlow, R.M., Finlayson, J., Anderson, I.E., Mackellar, A., 1990. Observations on the pathogenesis of *Chlamydia psittaci* infection of pregnant sheep. *Journal of Comparative Pathology* 102, 221-237.
- Buxton, D., Gilmour, J.S., Angus, K.W., Blewett, D.A., Miller, J.K., 1982. Perinatal changes in lambs infected with *Toxoplasma gondii*. *Research in Veterinary Science* 32, 170-176.
- Buxton, D., Maley, S.W., Innes, E.A., Pastoret, P.P., Brochier, B., 1997a. Examination of red foxes (*Vulpes vulpes*) from Belgium for antibody to *Neospora caninum* and *Toxoplasma gondii*. *Veterinary Record* 141, 308-309.
- Buxton, D., Maley, S.W., Marks, J., Innes, E.A., Caldow, G.L., 1997b. Neosporosis and bovine abortion in Scotland. *Veterinary Record* 141, 649-651.
- Buxton, D., Maley, S.W., Thomson, K.M., Trees, A.J., Innes, E.A., 1997c. Experimental infection of non-pregnant and pregnant sheep with *Neospora caninum*. *Journal of Comparative Pathology* 117, 1-16.
- Buxton, D., Maley, S.W., Wright, S.E., Thomson, K.M., Rae, A.G., Innes, E.A., 1998. The pathogenesis of experimental neosporosis in pregnant sheep. *Journal of Comparative Pathology* 118, 267-279.
- Buxton, D., McAllister, M.M., Dubey, J.P., 2002b. The comparative pathogenesis of neosporosis. *Trends in Parasitology* 18, 546-552.
- Buxton, D., Rae, A.G., Maley, S.W., Thomson, K.M., Livingstone, M., Jones, G.E., Herring, A.J., 1996. Pathogenesis of *Chlamydia psittaci* infection in sheep: detection of the organism in a serial study of the lymph node. *Journal of Comparative Pathology* 114, 221-230.
- Buxton, D., Wright, S.E., Maley, S.W., Rae, A.G., Lundén, A., Innes, E.A., 2001. Immunity to experimental neosporosis in pregnant sheep. *Parasite Immunology* 23, 85-91.
- Caetano-da-Silva, A., Ferre, I., Collantes-Fernández, E., Navarro, V., Aduriz, G., Ugarte-Garagalza, C., Ortega-Mora, L.M., 2004. Occasional detection of *Neospora caninum* DNA in frozen extended semen from naturally infected bulls. *Theriogenology* 62, 1329-1336.
- Campero, C.M., Anderson, M.L., Conosciuto, G., Odriozola, H., Bretschneider, G., Poso, M.A., 1998. *Neospora caninum*-associated abortion in a dairy herd in Argentina. *Veterinary Record* 143, 228-229.
- Campero, C.M., Moore, D.P., Lagomarsino, H., Odeón, A.C., Castro, M.D., Visca, H., 2003a. Serological status and abortion rate in progeny obtained by natural service or embryo transfer from *Neospora caninum*-seropositive cows. *Journal of Veterinary Medicine B* 50, 458-460.

- Campero, C.M., Moore, D.P., Odeón, A.C., Cipolla, A.L., Odriozola, E., 2003b. Aetiology of bovine abortion in Argentina. *Veterinary Research Communications* 27, 359-369.
- Cañón-Franco, W.A., Yai, L.E.O., Souza, S.L.P., Santos, L.C., Farias, N.A.R., Ruas, J., Rossi, F.W., Gomes, A.A.B., Dubey, J.P., Gennari, S.M., 2004. Detection of antibodies to *Neospora caninum* in two species of wild canids, *Lycalopex gymnocercus* and *Cerdocyon thous* from Brazil. *Veterinary Parasitology* 123, 275-277.
- Cantón, G.J., Bartley, P.M., Bartley, K., Todd, H., Chianini, F., Katzer, F., 2013a. Production of bovine IL-12p40 probe and application using *in situ* hybridization on ruminant fixed tissues. *Veterinary Immunology and Immunopathology* 151, 342-347.
- Cantón, G.J., Katzer, F., Benavides-Silván, J., Maley, S.W., Palarea-Albaladejo, J., Bartley, P.M., Rocchi, M., Innes, E.A., Chianini, F., 2013b. Phenotypic characterization of the cellular immune infiltrate in placentas of cattle following experimental inoculation with *Neospora caninum* at late gestation. *Veterinary Research* 44, 60.
- Cantón, G.J., Konrad, J.L., Moore, D.P., Caspe, S.G., Palarea-Albaladejo, J., Campero, C.M., Chianini, F., 2013c. Characterization of the immune cell infiltration in the placentas from water buffaloes (*Bubalus bubalis*) inoculated with *Neospora caninum* during pregnancy. *Journal of Comparative Pathology*, submitted.
- Carswell, E.A., Old, L.J., Kassel, R.L., Green, S., Fiore, N., Williamson, B., 1975. An endotoxin-induced serum factor that causes necrosis of tumors. *Proceedings of the National Academy of Sciences of the United States of America* 72, 3666-3670.
- Caspe, S.G., Moore, D.P., Leunda, M.R., Cano, D.B., Lischinsky, L., Regidor-Cerrillo, J., Álvarez-García, G., Echaide, I.G., Bacigalupe, D., Ortega Mora, L.M., Odeón, A.C., Campero, C.M., 2012. The *Neospora caninum*-Spain 7 isolate induces placental damage, fetal death and abortion in cattle when inoculated in early gestation. *Veterinary Parasitology* 189, 171-181.
- Chao, C.C., Gekker, G., Hu, S., Peterson, P.K., 1994. Human microglial cell defense against *Toxoplasma gondii*. The role of cytokines. *Journal of Immunology* 152, 1246-1252.
- Chaouat, G., Menu, E., Clark, D.A., Dy, M., Minkowski, M., Wegmann, T.G., 1990. Control of fetal survival in CBA x DBA/2 mice by lymphokine therapy. *Journal of Reproduction and Fertility* 89, 447-458.
- Chaouat, G., Menu, E., de Smedt, D., Khrihnan, L., Hui, L., Assal Meliani, A., Martal, J., Raghupathy, R., Wegmann, T.G., 1996. The emerging role of IL-10 in pregnancy. *American Journal of Reproductive Immunology* 35, 325-329.

- Cheah, T.S., Mattsson, J.G., Zaini, M., Sani, R.A., Jakubek, E.B., Uggla, A., Chandrawathani, P., 2004. Isolation of *Neospora caninum* from a calf in Malaysia. *Veterinary Parasitology* 126, 263-269.
- Chi, J., Van Leeuwen, J.A., Weersink, A., Keefe, G.P., 2002. Direct production losses and treatment costs from bovine viral diarrhoea virus, bovine leukosis virus, *Mycobacterium avium* subspecies *paratuberculosis*, and *Neospora caninum*. *Preventive Veterinary Medicine* 55, 137-153.
- Choromanski, L.J., Block, W., 2000. Humoral immune responses and safety of experimental formulations of inactivated *Neospora* vaccines. *Parasitology Research* 86, 851-853.
- Chryssafidis, A., Soares, R., Rodrigues, A., Carvalho, N., Gennari, S., 2011. Evidence of congenital transmission of *Neospora caninum* in naturally infected water buffalo (*Bubalus bubalis*) fetus from Brazil. *Parasitology Research* 108, 741-743.
- Clark, D.A., Chaouat, G., Arck, P.C., Mittrucker, H.W., Levy, G.A., 1998. Cutting edge: Cytokine-dependent abortion in CBA DBA/2 mice is mediated by the procoagulant fgl2. *Journal of Immunology* 160, 545-549.
- Cole, R.A., Lindsay, D.S., Blagburn, B.L., Sorjonen, D.C., Dubey, J.P., 1995. Vertical transmission of *Neospora caninum* in dogs. *The Journal of Parasitology* 81, 208-211.
- Collantes-Fernández, E., Álvarez-García, G., Pérez-Pérez, V., Pereira-Bueno, J., Ortega-Mora, L.M., 2004. Characterization of pathology and parasite load in outbred and inbred mouse models of chronic *Neospora caninum* infection. *The Journal of Parasitology* 90, 579-583.
- Collantes-Fernández, E., Arnáiz-Seco, I., Moreno Burgos, B., Rodríguez-Bertos, A., Aduriz, G., Fernández-García, A., Ortega-Mora, L.M., 2006a. Comparison of *Neospora caninum* distribution, parasite loads and lesions between epidemic and endemic bovine abortion cases. *Veterinary Parasitology* 142, 187-191.
- Collantes-Fernández, E., López-Pérez, I., Álvarez-García, G., Ortega-Mora, L.M., 2006b. Temporal distribution and parasite load kinetics in blood and tissues during *Neospora caninum* infection in mice. *Infection and Immunity* 74, 2491-2494.
- Collantes-Fernández, E., Rodríguez-Bertos, A., Arnáiz-Seco, I., Moreno, B., Aduriz, G., Ortega-Mora, L.M., 2006c. Influence of the stage of pregnancy on *Neospora caninum* distribution, parasite loads and lesions in aborted bovine fetuses. *Theriogenology* 65, 629-641.
- Connelley, T., Storset, A., Pemberton, A., MacHugh, N., Brown, J., Lund, H., Morrison, I., 2011. NKp46 defines ovine cells that have characteristics corresponding to NK cells. *Veterinary Research* 42, 37.

- Conrad, P.A., Barr, B.C., Sverlow, K.W., Anderson, M.L., Daft, B., Kinde, H., Dubey, J.P., Munson, L., Ardans, A.A., 1993a. *In vitro* isolation and characterization of a *Neospora* sp. from aborted bovine fetuses. *Parasitology* 106, 239-249.
- Conrad, P.A., Sverlow, K., Anderson, M., Rowe, J., BonDurant, R., Tuter, G., Breitmeyer, R., Palmer, C., Thurmond, M., Ardans, A., Dubey, J.P., Duhamel, G., Barr, B. 1993b. Detection of serum antibody responses in cattle with natural or experimental *Neospora* infections. *Journal of Veterinary Diagnostic Investigations* 5, 572-578.
- Corbellini, L.G., Driemeier, D., Cruz, C.F.E., Gondim, L.F.P., Wald, V., 2002. Neosporosis as a cause of abortion in dairy cattle in Rio Grande do Sul, southern Brazil. *Veterinary Parasitology* 103, 195-202.
- Corbellini, L.G., Pescador, C.A., Frantz, F., Wunder, E., Steffen, D.J., Smith, D.R., Driemeier, D., 2006a. Diagnostic survey of bovine abortion with special reference to *Neospora caninum* infection: Importance, repeated abortion and concurrent infection in aborted fetuses in Southern Brazil. *The Veterinary Journal* 172, 114-120.
- Corbellini, L.G., Smith, D.R., Pescador, C.A., Schmitz, M., Correa, A., Steffen, D.J., Driemeier, D., 2006b. Herd-level risk factors for *Neospora caninum* seroprevalence in dairy farms in southern Brazil. *Preventive Veterinary Medicine* 74, 130-141.
- Cramer, G., Kelton, D., Duffield, T.F., Hobson, J.C., Lissemore, K., Hietala, S.K., Peregrine, A.S., 2002. *Neospora caninum* serostatus and culling of Holstein cattle. *Journal of the American Veterinary Medical Association* 221, 1165-1168.
- Crawshaw, W.M., Brocklehurst, S., 2003. Abortion epidemic in a dairy herd associated with horizontally transmitted *Neospora caninum* infection. *Veterinary Record* 152, 201-206.
- da Silva Andrade, G., Bruhn, F.R.P., Rocha, C.M.B.M., de Sá Guimarães, A., Gouveia, A.M.G., Guimarães, A.M., 2012. Seroprevalence and risk factors for *Neospora caninum* in sheep in the state Minas Gerais, southeastern Brazil. *Veterinary Parasitology* 188, 168-171.
- Dalton, J.P., Mulcahy, G., 2001. Parasite vaccines - a reality? *Veterinary Parasitology* 98, 149-167.
- Dannatt, L., Guy, F., Trees, A.J., 1995. Abortion due to *Neospora* species in a dairy herd. *Veterinary Record* 137, 566-567.
- Darius, A.K., Mehlhorn, H., Heydorn, A.O., 2004. Effects of toltrazuril and ponazuril on *Hammondia heydorni* (syn. *Neospora caninum*) infections in mice. *Parasitology Research* 92, 520-522.
- Davis, W.C., Khalid, A.M., Hamilton, M.J., Ahn, J.S., Park, Y.H., Cantor, G.H., 2001. The use of crossreactive monoclonal antibodies to characterize the immune

- system of the water buffalo (*Bubalus bubalis*). *Journal of Veterinary Science* 2, 103-109.
- Davison, H.C., French, N.P., Trees, A.J., 1999a. Herd-specific and age-specific seroprevalence of *Neospora caninum* in 14 British dairy herds. *Veterinary Record* 144, 547-550.
- Davison, H.C., Guy, C.S., McGarry, J.W., Guy, F., Williams, D.J.L., Kelly, D.F., Trees, A.J., 2001. Experimental studies on the transmission of *Neospora caninum* between cattle. *Research in Veterinary Science* 70, 163-168.
- Davison, H.C., Otter, A., Trees, A.J., 1999b. Estimation of vertical and horizontal transmission parameters of *Neospora caninum* infections in dairy cattle. *International Journal for Parasitology* 29, 1683-1689.
- Davison, H.C., Otter, A., Trees, A.J., 1999c. Significance of *Neospora caninum* in British dairy cattle determined by estimation of seroprevalence in normally calving cattle and aborting cattle. *International Journal for Parasitology* 29, 1189-1194.
- Daya, D., Sabet, L., 1991. The use of cytokeratin as a sensitive and reliable marker for trophoblastic tissue. *American Journal of Clinical Pathology* 95, 137-141.
- de Marez, T., Liddell, S., Dubey, J.P., Jenkins, M.C., Gasbarre, L.C., 1999. Oral infection of calves with *Neospora caninum* oocysts from dogs: humoral and cellular immune responses. *International Journal for Parasitology* 29, 1647-1657.
- De Meerschman, F., Focant, C., Detry, J., Rettigner, C., Cassart, D., Losson, B., 2005. Clinical, pathological and diagnostic aspects of congenital neosporosis in a series of naturally infected calves. *Veterinary Record* 157, 115.
- De Meerschman, F., Speybroeck, N., Berkvens, D., Rettigner, C., Focant, C., Leclipteux, T., Cassart, D., Losson, B., 2002. Fetal infection with *Neospora caninum* in dairy and beef cattle in Belgium. *Theriogenology* 58, 933-945.
- de Oliveira, V.S.F., Álvarez-García, G., Ortega-Mora, L.M., Borges, L.M.F., da Silva, A.C., 2010. Abortions in bovines and *Neospora caninum* transmission in an embryo transfer center. *Veterinary Parasitology* 173, 206-210.
- de Rose, R., Scheerlinck, J.-P.Y., Casey, G., Wood, P.R., Tennent, J.M., Chaplin, P.J., 2000. Ovine Interleukin-12: analysis of biologic function and species comparison. *Journal of Interferon & Cytokine Research* 20, 557-564.
- Dijkstra, T., Barkema, H.W., Eysker, M., Beiboer, M.L., Wouda, W., 2003. Evaluation of a single serological screening of dairy herds for *Neospora caninum* antibodies. *Veterinary Parasitology* 110, 161-169.
- Dijkstra, T., Barkema, H.W., Eysker, M., Hesselink, J.W., Wouda, W., 2002a. Natural transmission routes of *Neospora caninum* between farm dogs and cattle. *Veterinary Parasitology* 105, 99-104.

- Dijkstra, T., Barkema, H.W., Eysker, M., Wouda, W., 2001a. Evidence of post-natal transmission of *Neospora caninum* in Dutch dairy herds. *International Journal for Parasitology* 31, 209-215.
- Dijkstra, T., Barkema, H.W., Hesselink, J.W., Wouda, W., 2002b. Point source exposure of cattle to *Neospora caninum* consistent with periods of common housing and feeding and related to the introduction of a dog. *Veterinary Parasitology* 105, 89-98.
- Dijkstra, T., Eysker, M., Schares, G., Conraths, F.J., Wouda, W., Barkema, H.W., 2001b. Dogs shed *Neospora caninum* oocysts after ingestion of naturally infected bovine placenta but not after ingestion of colostrum spiked with *Neospora caninum* tachyzoites. *International Journal for Parasitology* 31, 747-752.
- Dijkstra, T., Lam, T.J.G.M., Bartels, C.J.M., Eysker, M., Wouda, W., 2008. Natural postnatal *Neospora caninum* infection in cattle can persist and lead to endogenous transplacental infection. *Veterinary Parasitology* 152, 220-225.
- Dion, S., Germon, S., Guiton, R., Ducournau, C., Dimier-Poisson, I., 2011. Functional activation of T cells by dendritic cells and macrophages exposed to the intracellular parasite *Neospora caninum*. *International Journal for Parasitology* 41, 685-695.
- Diskin, M.G., Murphy, J.J., Sreenan, J.M., 2006. Embryo survival in dairy cows managed under pastoral conditions. *Animal Reproduction Science* 96, 297-311.
- Drake, B.L., Head, J.R., 1989. Murine trophoblast can be killed by lymphokine-activated killer cells. *Journal of Immunology* 143, 9-14.
- Druckmann, R., Druckmann, M.A., 2005. Progesterone and the immunology of pregnancy. *The Journal of Steroid Biochemistry and Molecular Biology* 97, 389-396.
- du Plessis, I., Hoffman, L.C., Calitz, F.J., 2006. Influence of reproduction traits and pre-weaning growth rate on herd efficiency of different beef breed types in an arid sub-tropical environment. *South African Journal of Animal Science* 36, 89-98.
- Dubey, J.P., 1990. Status of toxoplasmosis in sheep and goats in the United States. *Journal of the American Veterinary Medical Association* 196, 259-262.
- Dubey, J.P., 1992. A review of *Neospora caninum* and *Neospora*-like infections in animals. *Journal of Protozoology Research* 2, 40-52.
- Dubey, J.P., 1999. Recent advances in *Neospora* and neosporosis. *Veterinary Parasitology* 84, 349-367.
- Dubey, J.P., 2003a. Neosporosis in cattle. *The Journal of Parasitology* 89, S42-S56.

- Dubey, J.P., 2003b. Review of *Neospora caninum* and neosporosis in animals. Korean Journal of Parasitology 41, 1-16.
- Dubey, J.P., Abbitt, B., Topper, M.J., Edwards, J.F., 1998a. Hydrocephalus associated with *Neospora caninum* infection in an aborted bovine fetus. Journal of Comparative Pathology 118, 167-173.
- Dubey, J.P., Barr, B.C., Barta, J.R., Bjerkås, I., Björkman, C., Blagburn, B.L., Bowman, D.D., Buxton, D., Ellis, J.T., Gottstein, B., Hemphill, A., Hill, D.E., Howe, D.K., Jenkins, M.C., Kobayashi, Y., Koudela, B., Marsh, A.E., Mattsson, J.G., McAllister, M.M., Modrý, D., Omata, Y., Sibley, L.D., Speer, C.A., Trees, A.J., Uggla, A., Upton, S.J., Williams, D.J.L., Lindsay, D.S., 2002. Redescription of *Neospora caninum* and its differentiation from related coccidia. International Journal for Parasitology 32, 929-946.
- Dubey, J.P., Beattie, C.P., 1988. Toxoplasmosis of animals and man. CRC Press, Boca Raton, Fla, USA.
- Dubey, J.P., Buxton, D., Wouda, W., 2006. Pathogenesis of Bovine Neosporosis. Journal of Comparative Pathology 134, 267-289.
- Dubey, J.P., Carpenter, J.L., Speer, C.A., Topper, M.J., Uggla, A., 1988a. Newly recognized fatal protozoan disease of dogs. Journal of the American Veterinary Association 192, 1269-1285.
- Dubey, J.P., de Lahunta, A., 1993. Neosporosis associated congenital limb deformities in a calf. Applied Parasitology 34, 229-233.
- Dubey, J.P., Dorrough, K.R., Jenkins, M.C., Liddell, S., Speer, C.A., Kwok, O.C.H., Shen, S.K., 1998b. Canine neosporosis: clinical signs, diagnosis, treatment and isolation of *Neospora caninum* in mice and cell culture. International Journal for Parasitology 28, 1293-1304.
- Dubey, J.P., Hartley, W.J., Lindsay, D.S., 1990a. Congenital *Neospora caninum* infection in a calf with spinal cord anomaly. Journal of the American Veterinary Association 197, 1043-1044.
- Dubey, J.P., Hartley, W.J., Lindsay, D.S., Topper, M.J., 1990b. Fatal congenital *Neospora caninum* infection in a lamb. The Journal of Parasitology 76, 127-130.
- Dubey, J.P., Hattel, A.L., Lindsay, D.S., Topper, M.J., 1988b. Neonatal *Neospora caninum* infection in dogs: isolation of the causative agent and experimental transmission. Journal of the American Veterinary Medical Association 193, 1259-1263.
- Dubey, J.P., Janovitz, E.B., Skowronek, A.J., 1992a. Clinical neosporosis in a 4-week-old Hereford calf. Veterinary Parasitology 43, 137-141.

- Dubey, J.P., Jenkins, M.C., Kwok, O.C.H., Ferreira, L.R., Choudhary, S., Verma, S.K., Villena, I., Butler, E., Carstensen, M., 2013. Congenital transmission of *Neospora caninum* in white-tailed deer (*Odocoileus virginianus*). *Veterinary Parasitology* In press.
- Dubey, J.P., Jenkins, M.C., Rajendran, C., Miska, K., Ferreira, L.R., Martins, J., Kwok, O.C.H., Choudhary, S., 2011. Gray wolf (*Canis lupus*) is a natural definitive host for *Neospora caninum*. *Veterinary Parasitology* 181, 382-387.
- Dubey, J.P., Koestner, A., Piper, R.C., 1990c. Repeated transplacental transmission of *Neospora caninum* in dogs. *Journal of the American Veterinary Association* 197, 857-860.
- Dubey, J.P., Lindsay, D.S., 1989. Transplacental *Neospora caninum* infection in dogs. *American Journal of Veterinary Research* 50, 1578-1579.
- Dubey, J.P., Lindsay, D.S., 1990. *Neospora caninum* induced abortion in sheep. *Journal of Veterinary Diagnostic Investigation* 2, 230-233.
- Dubey, J.P., Lindsay, D.S., 1993. Neosporosis. *Parasitology Today* 9, 452-458.
- Dubey, J.P., Lindsay, D.S., 1996. A review of *Neospora caninum* and neosporosis. *Veterinary Parasitology* 67, 1-59.
- Dubey, J.P., Lindsay, D.S., Adams, D.S., Gay, J.M., Baszler, T.V., Blagburn, B.L., Thulliez, P., 1996a. Serologic responses of cattle and other animals infected with *Neospora caninum*. *American Journal of Veterinary Research* 57, 329-336.
- Dubey, J.P., Lindsay, D.S., Anderson, M.L., Davis, S.W., Shenk, S.K., 1992b. Induced transplacental transmission of *Neospora caninum* in cattle. *Journal of the American Veterinary Medical Association* 201, 709-713.
- Dubey, J.P., Metzger, F.L., Hattel, A.L., Lindsay, D.S., Fritz, D.L., 1995. Canine cutaneous Neosporosis: Clinical improvement with clindamycin. *Veterinary Dermatology* 6, 37-43.
- Dubey, J.P., Miller, S., Lindsay, D.S., Topper, M.J., 1990d. *Neospora caninum*-associated myocarditis and encephalitis in an aborted calf. *Journal of Veterinary Diagnostic Investigation* 2, 66-69.
- Dubey, J.P., Porterfield, M.L., 1990. *Neospora caninum* (Apicomplexa) in an aborted equine fetus. *The Journal of Parasitology* 76, 732-734.
- Dubey, J.P., Rigoulet, J., Lagourette, P., George, C., Longeart, L., LeNet, J.L., 1996b. Fatal transplacental neosporosis in a deer (*Cervus eldi siamensis*). *The Journal of Parasitology* 82, 338-339.
- Dubey, J.P., Schares, G., 2006. Diagnosis of bovine neosporosis. *Veterinary Parasitology* 140, 1-34.

- Dubey, J.P., Schares, G., Ortega-Mora, L.M., 2007. Epidemiology and control of Neosporosis and *Neospora caninum*. *Clinical Microbiology Reviews* 20, 323-367.
- Dubey, J.P., Sreekumar, C., Knickman, E., Miska, K.B., Vianna, M.C.B., Kwok, O.C.H., Hill, D.E., Jenkins, M.C., Lindsay, D.S., Greene, C.E., 2004. Biologic, morphologic, and molecular characterisation of *Neospora caninum* isolates from littermate dogs. *International Journal for Parasitology* 34, 1157-1167.
- Duello, T.M., Byatt, J.C., Bremetl, R.D., 1986. Immunohistochemical localization of placental lactogen in binucleate cells of bovine placentomes. *Endocrinology* 119, 1351-1355.
- Dyer, R.M., Jenkins, M.C., Kwok, O.C.H., Douglas, L.W., Dubey, J.P., 2000. Serologic survey of *Neospora caninum* infection in a closed dairy cattle herd in Maryland: risk of serologic reactivity by production groups. *Veterinary Parasitology* 90, 171-181.
- Edelhofer, R., Loeschenberger, K., Peschke, R., Sager, H., Nowotny, N., Kilodziejek, J., Tews, A., Doneus, G., Prosl, H., 2003. First PcR-confirmed report of a *Neospora caninum*-associated bovine abortion in Austria. *Veterinary Record* 152, 471-473.
- Elamanchili, P., Lutsiak, C.M., Hamdy, S., Diwan, M., Samuel, J., 2007. "Pathogen-mimicking" nanoparticles for vaccine delivery to dendritic cells. *Journal of Immunotherapy* 30, 378-395.
- Ellis, J.T., Amoyal, G., Ryce, C., Harper, P.A.W., Clough, K.A., Homan, W.L., Brindley, P.J., 1998. Comparison of the large subunit ribosomal DNA of *Neospora* and *Toxoplasma* and development of a new genetic marker for their differentiation based on the D2 domain. *Molecular and Cellular Probes* 12, 1-13.
- Ellis, J.T., Luton, K., Baverstock, P.R., Brindley, P.J., Nimmo, K.A., Johnson, A.M., 1994. The phylogeny of *Neospora caninum*. *Molecular and Biochemical Parasitology* 64, 303-311.
- Ellis, J.T., Morrison, D.A., Liddell, S., Jenkins, M.C., Mohammed, O.B., Ryce, C., Dubey, J.P., 1999. The genus *Hammondia* is paraphyletic. *Parasitology* 118, 357-362.
- Entrican, G., 2002. Immune regulation during pregnancy and host-pathogen interactions in infectious abortion. *Journal of Comparative Pathology* 126, 79-94.
- Entrican, G., Wattedegera, S., Wheelhouse, N., Allan, A., Rocchi, M., 2010. Immunological paradigms and the pathogenesis of Ovine Chlamydial Abortion. *American Journal of Reproductive Immunology* 64, 287-294.
- Entrican, G., Wheelhouse, N.M., 2006. Immunity in the female sheep reproductive tract. *Veterinary Research* 37, 295-309.

- Eperon, S., Brönnimann, K., Hemphill, A., Gottstein, B., 1999. Susceptibility of B-cell deficient C57BL/6 (μ MT) mice to *Neospora caninum* infection. *Parasite Immunology* 21, 225-236.
- Escalona, J., García, F., Mosquera, O., Vargas, F., Corro, A., 2010. Factores de riesgo asociados a la prevalencia de Neosporosis Bovina en el municipio Bolívar del estado Yaracuy, Venezuela. *Zootecnia Tropical* 28, 201-212.
- FAO, 2011. World livestock 2011. Livestock in food security. Rome, Italy.
- Ferrari, A., Dellepiane, M., Carbonaro, M., 1995. Segnalazione di episodi abortigeni da protozoi in un allevamento bovino. *Atti SIS Vet* 49, 745-746.
- Ferre, I., Aduriz, G., del-Pozo, I., Regidor-Cerrillo, J., Atxaerandio, R., Collantes-Fernández, E., Hurtado, A., Ugarte-Garagalza, C., Ortega-Mora, L.M., 2005. Detection of *Neospora caninum* in the semen and blood of naturally infected bulls. *Theriogenology* 63, 1504-1518.
- Fioretti, D.P., Pasquali, P., Diaferia, M., Mangili, V., Rosignoli, L., 2003. *Neospora caninum* infection and congenital transmission: serological and parasitological study of cows up to the fourth gestation. *Journal of Veterinary Medicine Series B* 50, 399-404.
- Fioretti, D.P., Rosignoli, L., Ricci, G., Moretti, A., Pasquali, P., Polidori, G.A., 2000. *Neospora caninum* infection in a clinically healthy calf: parasitological study and serological follow-up. *Journal of Veterinary Medicine Series B* 47, 47-53.
- Fondevila, D., Añor, S., Pumarola, M., Dubey, J.P., 1998. *Neospora caninum* identification in an aborted bovine fetus in Spain. *Veterinary Parasitology* 77, 187-189.
- Forar, A.L., Gay, J.M., Hancock, D.D., Gay, C.C., 1996. Fetal loss frequency in ten Holstein dairy herds. *Theriogenology* 45, 1505-1513.
- Fordyce, G., Cooper, N., 1999. Breeder herd management and production. In: Swan's Lagoon Beef Cattle Research Station, Research Station 1998/1999. Queensland Department of Primary Industries, Swan's Lagoon, Millaroo, Queensland, Australia, pp. 7-24.
- French, N.P., Clancy, D., Davison, H.C., Trees, A.J., 1999. Mathematical models of *Neospora caninum* infection in dairy cattle: transmission and options for control. *International Journal for Parasitology* 29, 1691-1704.
- Fried, M., Muga, R.O., Misore, A.O., Duffy, P.E., 1998. Malaria elicits Type 1 cytokines in the human placenta: IFN- γ and TNF- α associated with pregnancy outcomes. *Journal of Immunology* 160, 2523-2530.

- Frössling, J., Nødtvedt, A., Lindberg, A., Björkman, C., 2008. Spatial analysis of *Neospora caninum* distribution in dairy cattle from Sweden. *Geospatial Health* 3, 39-45.
- Frössling, J., Uggla, A., Björkman, C., 2005. Prevalence and transmission of *Neospora caninum* within infected Swedish dairy herds. *Veterinary Parasitology* 128, 209-218.
- Gallo, R.L., Staszewski, R., Sauder, D.N., Knisely, T.L., Granstein, R.D., 1991. Regulation of GM-CSF and IL-3 production from the murine keratinocyte cell line PAM 212 following exposure to ultraviolet radiation. *Journal of Investigative Dermatology* 97, 203-209.
- Garcia, J.L., Gennari, S.M., Navarro, I.T., Machado, R.Z., Sinhorini, I.L., Freire, R.L., Marana, E.R.M., Tsutsui, V., Contente, A.P.A., Begale, L.P., 2005. Partial protection against tissue cysts formation in pigs vaccinated with crude rhoptry proteins of *Toxoplasma gondii*. *Veterinary Parasitology* 129, 209-217.
- García-Vázquez, Z., Rosario-Cruz, R., Ramos-Aragón, A., Cruz-Vázquez, C., Mapes-Sánchez, G., 2005. *Neospora caninum* seropositivity and association with abortions in dairy cows in Mexico. *Veterinary Parasitology* 134, 61-65.
- Gazzinelli, R.T., Eltoun, I., Wynn, T.A., Sher, A., 1993. Acute cerebral toxoplasmosis is induced by in vivo neutralization of TNF-alpha and correlates with the down-regulated expression of inducible nitric oxide synthase and other markers of macrophage activation. *Journal of Immunology* 151, 3672-3681.
- Gazzinelli, R.T., Hakim, F.T., Hieny, S., Shearer, G.M., Sher, A., 1991. Synergistic role of CD4⁺ and CD8⁺ T lymphocytes in IFN-gamma production and protective immunity induced by an attenuated *Toxoplasma gondii* vaccine. *Journal of Immunology* 146, 286-292.
- Gazzinelli, R.T., Wysocka, M., Hayashi, S., Denkers, E.Y., Hieny, S., Caspar, P., Trinchieri, G., Sher, A., 1994. Parasite-induced IL-12 stimulates early IFN-gamma synthesis and resistance during acute infection with *Toxoplasma gondii*. *Journal of Immunology* 153, 2533-2543.
- Gazzinelli, R.T., Wysocka, M., Hieny, S., Scharon-Kersten, T.M., Cheever, A., Kuhn, R., Muller, W., Trinchieri, G., Sher, A., 1996. In the absence of endogenous IL-10, mice acutely infected with *Toxoplasma gondii* succumb to a lethal immune response dependent on CD4⁺ T cells and accompanied by overproduction of IL-12, IFN-gamma and TNF-alpha. *Journal of Immunology* 157, 798-805.
- Gendron, R.L., Nestel, F.P., Lapp, W.S., Baines, M.G., 1990. Lipopolysaccharide-induced fetal resorption in mice is associated with the intrauterine production of tumour necrosis factor-alpha. *Journal of Reproduction and Fertility* 90, 395.

- Ghalmi, F., China, B., Ghalmi, A., Hammitouche, D., Losson, B., 2012. Study of the risk factors associated with *Neospora caninum* seroprevalence in Algerian cattle populations. *Research in Veterinary Science* 93, 655-661.
- Ghalmi, F., China, B., Kaidi, R., Losson, B., 2011. *Neospora caninum* is associated with abortion in Algerian cattle. *Journal of Parasitology* 97, 1121-1124.
- Ghanem, M.E., Suzuki, T., Akita, M., Nishibori, M., 2009. *Neospora caninum* and complex vertebral malformation as possible causes of bovine fetal mummification. *Canadian Veterinary Journal* 50, 389-392.
- Gibbs, R.B., McCabe, J.T., Buck, C.R., Chao, M.V., Pfaff, D.W., 1989. Expression of NGF receptor in the rat forebrain detected with *in situ* hybridization and immunohistochemistry. *Molecular Brain Research* 6, 275-287.
- Gibney, E.H., Kipar, A., Rosbottom, A., Guy, C.S., Smith, R.F., Hetzel, U., Trees, A.J., Williams, D.J.L., 2008. The extent of parasite-associated necrosis in the placenta and foetal tissues of cattle following *Neospora caninum* infection in early and late gestation correlates with foetal death. *International Journal for Parasitology* 38, 579-588.
- Gillessen, S., Carvajal, D., Ling, P., Podlaski, F.J., Stremlo, D.L., Familletti, P.C., Gubler, U., Presky, D.H., Stern, A.S., Gately, M.K., 1995. Mouse interleukin-12 (IL-12) p40 homodimer: a potent IL-12 antagonist. *European Journal of Immunology* 25, 200-206.
- Glimcher, L.H., Murphy, K.M., 2000. Lineage commitment in the immune system: the T helper lymphocyte grows up. *Genes & Development* 14, 1693-1711.
- Gondim, L.F.P., 2006. *Neospora caninum* in wildlife. *Trends in Parasitology* 22, 247-252.
- Gondim, L.F.P., Gao, L., McAllister, M.M., 2002. Improved production of *Neospora caninum* oocysts, cyclical oral transmission between dogs and cattle, and *in vitro* isolation from oocysts. *The Journal of Parasitology* 88, 1159-1163.
- Gondim, L.F.P., Laski, P., Gao, L., McAllister, M.M., 2004a. Variation of the internal transcribed spacer 1 sequence within individual strains and among different strains of *Neospora caninum*. *The Journal of Parasitology* 90, 119-122.
- Gondim, L.F.P., McAllister, M.M., Anderson-Sprecher, R.C., Björkman, C., Lock, T.F., Firkins, L.D., Gao, L., Fischer, W.R., 2004b. Transplacental transmission and abortion in cows administered *Neospora caninum* oocysts. *The Journal of Parasitology* 90, 1394-1400.
- Gondim, L.F.P., McAllister, M.M., Gao, L., 2005. Effects of host maturity and prior exposure history on the production of *Neospora caninum* oocysts by dogs. *Veterinary Parasitology* 134, 33-39.

- Gondim, L.F.P., McAllister, M.M., Mateus-Pinilla, N.E., Pitt, W.C., Mech, L.D., Nelson, M.E., 2004c. Transmission of *Neospora caninum* between wild and domestic animals. *The Journal of Parasitology* 90, 1361-1365.
- Gondim, L.F.P., McAllister, M.M., Pitt, W.C., Zemlicka, D.E., 2004d. Coyotes (*Canis latrans*) are definitive hosts of *Neospora caninum*. *International Journal for Parasitology* 34, 159-161.
- González, L., Anderson, I.E., Deane, D., Summers, C., Buxton, D., 2001. Detection of immune system cells in paraffin wax-embedded ovine tissues. *Journal of Comparative Pathology* 125, 41-47.
- González, L., Buxton, D., Atxaerandio, R., Aduriz, G., Maley, S., Marco, J.C., Cuervo, L.A., 1999. Bovine abortion associated with *Neospora caninum* in northern Spain. *Veterinary Record* 144, 145-150.
- Goodswen, S.J., Kennedy, P.J., Ellis, J.T., 2013. A review of the infection, genetics, and evolution of *Neospora caninum*: From the past to the present. *Infection, Genetics and Evolution* 13, 133-150.
- Gottstein, B., Eperon, S., Dai, W.J., Cannas, A., Hemphill, A., Greif, G., 2001. Efficacy of toltrazuril and ponazuril against experimental *Neospora caninum* infection in mice. *Parasitology Research* 87, 43-48.
- Gottstein, B., Hentrich, B., Wyss, R., Thür, B., Busato, A., Stärk, K.D.C., Müller, N., 1998. Molecular and immunodiagnostic investigations on bovine neosporosis in Switzerland. *International Journal for Parasitology* 28, 679-691.
- Gottstein, B., Razmi, G.R., Ammann, P., Sager, H., Llern, N., 2005. Toltrazuril treatment to control diaplacental *Neospora caninum* transmission in experimentally infected pregnant mice. *Parasitology* 130, 41-48.
- Graham, D.A., Calvert, V., Whyte, M., Marks, J., 1999. Absence of serological evidence for human *Neospora caninum* infection. *Veterinary Record* 144, 672-673.
- Graham, D.A., Smyth, J.A., McLaren, I.E., Ellis, W.A., 1996. Stillbirth/perinatal weak calf syndrome: serological examination for evidence of *Neospora caninum* infection. *Veterinary Record* 139, 523-524.
- Greenstein, J.S., Murray, R.W., Foley, R.C., 1958. Observations on the morphogenesis and histochemistry of the bovine pre-attachment placenta between 16 and 33 days of gestation. *Anat. Rec.* 132, 321-341.
- Guarino, A., Fusco, G., Savini, G., Di Francesco, G., Cringoli, G., 2000. Neosporosis in water buffalo (*Bubalus bubalis*) in southern Italy. *Veterinary Parasitology* 91, 15-21.

- Guimarães, J., Souza, S.L.P., Bergamaschi, D.P., Gennari, S.M., 2004. Prevalence of *Neospora caninum* antibodies and factors associated with their presence in dairy cattle of the north of Paraná state, Brazil. *Veterinary Parasitology* 124, 1-8.
- Gutierrez, M., Forster, F.I., McConnell, S.A., Cassidy, J.P., Pollock, J.M., Bryson, D.G., 1999. The detection of CD2+, CD4+, CD8+, and WC1+ T lymphocytes, B cells and macrophages in fixed and paraffin embedded bovine tissue using a range of antigen recovery and signal amplification techniques. *Veterinary Immunology and Immunopathology* 71, 321-334.
- Guy, C.S., Williams, D.L.S., McGarry, J.W., Guy, F., Trees, A.J., Kelly, D.F., Smith, R.F., Björkman, C., 2001. *Neospora caninum* in persistently infected, pregnant cows: spontaneous transplacental infection is associated with an acute increase in maternal antibody. *Veterinary Record* 149, 443-449.
- Haas, W., Pereira, P., Tonegawa, S., 1993. Gamma/delta cells. *Annual Review of Immunology* 11, 637-685.
- Haddad, E.K., Duclos, A.J., Lapp, W.S., Baines, M.G., 1997. Early embryo loss is associated with the prior expression of macrophage activation markers in the decidua. *Journal of Immunology* 158, 4886-4892.
- Haddad, J.P.A., Dohoo, I.R., Van Leeuwen, J.A., 2005. A review of *Neospora caninum* in dairy and beef cattle - a Canadian perspective. *Canadian Veterinary Journal* 46, 230-243.
- Haerdi, C., Haessig, M., Sager, H., Greif, G., Staubli, D., Gottstein, B., 2006. Humoral immune reaction of newborn calves congenitally infected with *Neospora caninum* and experimentally treated with toltrazuril. *Parasitology Research* 99, 534-540.
- Haimovici, F., Hill, J.A., Anderson, D.J., 1991. The effects of soluble products of activated lymphocytes and macrophages on blastocyst implantation events *in vitro*. *Biology of Reproduction* 44, 69-75.
- Hakim, F.T., Gazzinelli, R.T., Denkers, E.Y., Hieny, S., Shearer, G.M., Sher, A., 1991. CD8+ T cells from mice vaccinated against *Toxoplasma gondii* are cytotoxic for parasite-infected or antigen-pulsed host cells. *Journal of Immunology* 147, 2310-2316.
- Hall, C.A., Reichel, M.P., Ellis, J.T., 2005. *Neospora* abortions in dairy cattle: diagnosis, mode of transmission and control. *Veterinary Parasitology* 128, 231-241.
- Hamilton, C.M., Gray, R., Wright, S.E., Gangadharan, B., Laurenson, K., Innes, E.A., 2005. Prevalence of antibodies to *Toxoplasma gondii* and *Neospora caninum* in red foxes (*Vulpes vulpes*) from around the UK. *Veterinary Parasitology* 130, 169-173.

- Harmelin, A., Perl, S., Nyska, A., Yakobson, B., Shpigel, N., Orgad, U., Dubey, J.P., 1995. Neosporosis-associated bovine abortion in Israel. *Veterinary Record* 136, 80.
- Häsler, B., Regula, G., Stärk, K.D.C., Sager, H., Gottstein, B., Reist, M., 2006a. Financial analysis of various strategies for the control of *Neospora caninum* in dairy cattle in Switzerland. *Preventive Veterinary Medicine* 77, 230-253.
- Häsler, B., Stärk, K.D.C., Sager, H., Gottstein, B., Reist, M., 2006b. Simulating the impact of four control strategies on the population dynamics of *Neospora caninum* infection in Swiss dairy cattle. *Preventive Veterinary Medicine* 77, 254-283.
- Hässig, M., Gottstein, B., 2002. Epidemiological investigations of abortions due to *Neospora caninum* on Swiss dairy farms. *Veterinary Record* 150, 538-542.
- Hässig, M., Sager, H., Reitt, K., Ziegler, D., Strabel, D., Gottstein, B., 2003. *Neospora caninum* in sheep: a herd case report. *Veterinary Parasitology* 117, 213-220.
- Hattel, A.L., Castro, M.D., Gummo, J.D., Weinstock, D., Reed, J.A., Dubey, J.P., 1998. Neosporosis-associated bovine abortion in Pennsylvania. *Veterinary Parasitology* 74, 307-313.
- Hauser, W.E., Jr., Sharma, S.D., Remington, J.S., 1983. Augmentation of NK cell activity by soluble and particulate fractions of *Toxoplasma gondii*. *Journal of Immunology* 131, 458-463.
- Hayakawa, S., Nagai, N., Kanaeda, T., Karasaki-Suzuki, M., Ishi, M., Chishima, F., Satoh, F., 1999. Interleukin-12 augments cytolytic activity of peripheral and decidual lymphocytes against choriocarcinoma cell lines and primary culture human placental trophoblasts. *American Journal of Reproductive Immunology* 41, 320-329.
- Hecker, Y.P., Cantón, G.J., Regidor-Cerrillo, J., Chianini, F., Ortega-Mora, L.M., Campero, C.M., Innes, E.A., Moore, D.P., 2013. Characterization of leucocytes in placenta of heifers inoculated with the NC-6 strain of *Neospora caninum* and challenged with NC-1 strain. In preparation.
- Hein, W.R., Mackay, C.R., 1991. Prominence of gamma delta T cells in the ruminant immune system. *Immunology Today* 12, 30-34.
- Hein, W.R., Shelton, J.N., Simpson-Morgan, M.W., Morris, B., 1998. Traffic and proliferative responses of recirculating lymphocytes in fetal calves. *Immunology* 64, 621-626.
- Helman, R.G., Stair, E.L., Lehenbauer, T.W., Rodgers, S., Saliki, J.T., 1998. Neosporal abortion in Oklahoma cattle with emphasis on the distribution of brain lesions in aborted fetuses. *Journal of Veterinary Diagnostic Investigation* 10, 292-295.

- Hemphill, A., Fuchs, N., Sonda, S., Hehl, A., 1999. The antigenic composition of *Neospora caninum*. International Journal for Parasitology 29, 1175-1188.
- Hemphill, A., Gottstein, B., 2000. A European perspective on *Neospora caninum*. International Journal for Parasitology 30, 877-924.
- Hemphill, A., VonLaufen, N., Naguleswaran, A., 2006. Cellular and immunological basis of the host-parasite relationship during infection with *Neospora caninum*. Parasitology 133, 261-278.
- Hemphill, A., Vonlaufen, N., Naguleswaran, A., Keller, N., Riesen, M., Guetg, N., Srinivasan, S., Alaeddine, F., 2004. Tissue culture and explant approaches to studying and visualizing *Neospora caninum* and its interactions with the host cell. Microscopy and Microanalysis 10, 602-620.
- Hernández, J.A., Risco, C., Donovan, A., 2002. Risk of abortion associated with *Neospora caninum* during different lactations and evidence of congenital transmission in dairy cows. Journal of the American Veterinary Medical Association 221, 1742-1746.
- Heuer, C., Nicholson, C., Muñoz-Bielsa, J., Weston, J.F., 2003. Efficacy of a vaccine against *Neospora caninum* related abortions in New Zealand dairy herds. In: International Symposia on Veterinary Epidemiology and Economics (ISVEE), p. 331.
- Hietala, S.K., Thurmond, M.C., 1999. Postnatal *Neospora caninum* transmission and transient serologic responses in two dairies. International Journal for Parasitology 29, 1669-1676.
- Hill, J.A., 1991. The rationale for leukocyte immunization in women with recurrent spontaneous abortion: Fact or fiction? In: Chaouat, G., Mowbry, G. (Eds.), Cellular and Molecular Biology of the Materno-Fetal Relationship. Colloque INSERM John Libbey Eurotext Ltd., Paris, London, pp. 263-269.
- Hill, J.A., Haimovici, F., Anderson, D.J., 1987. Products of activated lymphocytes and macrophages inhibit mouse embryo development in vitro. Journal of Immunology 139, 2250-2254.
- Hoar, B.R., Ribble, C.S., Spitzer, C.C., Spitzer, P.G., Janzen, E.D., 1996. Investigation of pregnancy losses in beef cattle herds associated with *Neospora* sp. infection. Canadian Veterinary Journal 37, 364-366.
- Hobson, J.C., Duffield, T.F., Kelton, D., Lissemore, K., Hietala, S.K., Leslie, K.E., McEwen, B., Peregrine, A.S., 2005. Risk factors associated with *Neospora caninum* abortion in Ontario Holstein dairy herds. Veterinary Parasitology 127, 177-188.
- Holmdahl, O.J.M., Björkman, C., Ugglå, A., 1995. A case of *Neospora* associated bovine abortion in Sweden. Acta Veterinaria Scandinavica 36, 279-281.

- Hope, J.C., Kwong, L.S., Entrican, G., Wattedegera, S., Vordermeier, H.M., Sopp, P., Howard, C.J., 2002. Development of detection methods for ruminant interleukin (IL)-12. *Journal of Immunological Methods* 266, 117-126.
- Hougaard, D.M., Hansen, H., Larsson, L.I., 1997. Non-radioactive *in situ* hybridization for mRNA with emphasis on the use of oligodeoxynucleotide probes. *Histochemistry and Cell Biology* 108, 335-344.
- Howe, D.K., Sibley, L.D., 1999. Comparison of the major antigens of *Neospora caninum* and *Toxoplasma gondii*. *International Journal for Parasitology* 29, 1489-1496.
- Hu, K., Roos, D.S., Murray, J.M., 2002. A novel polymer of tubulin forms the conoid of *Toxoplasma gondii*. *The Journal of Cell Biology* 156, 1039-1050.
- Huang, C.-C., Yang, C.-H., Watanabe, Y., Liao, Y.-K., Ooi, H.-K., 2004. Finding of *Neospora caninum* in the wild brown rat (*Rattus norvegicus*). *Veterinary Research* 35, 283-290.
- Hunt, J.S., Chen, H.L., Hu, X.L., Tabibzadeh, S., 1992. Tumor necrosis factor-alpha messenger ribonucleic acid and protein in human endometrium. *Biology of Reproduction* 47, 141-147.
- Hunter, C.A., Subauste, C.S., Van Cleave, V.H., Remington, J.S., 1994. Production of gamma interferon by natural killer cells from *Toxoplasma gondii*-infected SCID mice: regulation by interleukin-10, interleukin-12, and tumor necrosis factor alpha. *Infection and Immunity* 62, 2818-2824.
- Ibrahim, A., Elfahal, A., El Hussein, A., 2011. First report of *Neospora caninum* infection in cattle in Sudan. *Tropical Animal Health and Production*, 1-4.
- Igwebuike, U.M., 2006. Trophoblast cells of ruminant placentas - A minireview. *Animal Reproduction Science* 93, 185-198.
- Illanes, O., Moore, A., Pringle, J., Saindon, A., 1994. *Neospora*-induced congenital myelitis and polyradiculoneuritis in a one-month-old Holstein calf. *Canadian Veterinary Journal* 35, 653-654.
- Imre, K., Morariu, S., Ilie, M., Imre, M., Ferrari, N., Genchi, C., Darabus, G., 2012. Serological survey of *Neospora caninum* infection in cattle herds from Western Romania. *The Journal of Parasitology* 98, 683-685.
- Innes, E.A., 1997. Toxoplasmosis: comparative species susceptibility and host immune response. *Comparative Immunology, Microbiology and Infectious Diseases* 20, 131-138.
- Innes, E.A., 2007. The host-parasite relationship in pregnant cattle infected with *Neospora caninum*. *Parasitology* 134, 1903-1910.

- Innes, E.A., Andrianarivo, A.G., Björkman, C., Williams, D.J.L., Conrad, P.A., 2002. Immune responses to *Neospora caninum* and prospects for vaccination. *Trends in Parasitology* 18, 497-504.
- Innes, E.A., Bartley, P.M., Maley, S.W., Wright, S.E., Buxton, D., 2007. Comparative host-parasite relationships in ovine toxoplasmosis and bovine neosporosis and strategies for vaccination. *Vaccine* 25, 5495-5503.
- Innes, E.A., Bartley, P.M., Rocchi, M., Benavides-Silvan, J., Burrells, A., Hotchkiss, E., Chianini, F., Canton, G.J., Katzer, F., 2011. Developing vaccines to control protozoan parasites in ruminants: Dead or alive? *Veterinary Parasitology* 180, 155-163.
- Innes, E.A., Buxton, D., Maley, S., Wright, S., Marks, J., Esteban-Redondo, I., Rae, A.G., Schock, A., Wastling, J.M., 2000. Neosporosis. Aspects of epidemiology and host immune response. *Annals of the New York Academy of Science* 916, 93-101.
- Innes, E.A., Marks, J., McLean-Tooke, A., 1997. Cell-mediated immune response to *Neospora caninum*. In: VIIth International Coccidiosis Conference, p. 85.
- Innes, E.A., Mattsson, J.G., 2007. *Neospora caninum* emerges from the shadow of *Toxoplasma gondii*. *Trends in Parasitology* 23, 43-44.
- Innes, E.A., Panton, W.R.M., Marks, J., Trees, A.J., Holmdahl, O.J.M., Buxton, D., 1995a. Interferon gamma inhibits the intracellular multiplication of *Neospora caninum*, as shown by incorporation of 3H uracil. *Journal of Comparative Pathology* 113, 95-100.
- Innes, E.A., Panton, W.R.M., Sanderson, A., Thomson, K.M., Wastling, J.M., Maley, S.W., Buxton, D., 1995b. Induction of CD4⁺ and CD8⁺ T cell responses in efferent lymph responding to *Toxoplasma gondii* infection: analysis of phenotype and function. *Parasite Immunology* 17, 151-160.
- Innes, E.A., Vermeulen, A.N., 2006. Vaccination as a control strategy against the coccidial parasites *Eimeria*, *Toxoplasma* and *Neospora*. *Parasitology* 133, S145-S168.
- Innes, E.A., Wright, S.E., Bartley, P.M., Maley, S.W., Macaldowie, C.N., Esteban-Redondo, I., Buxton, D., 2005. The host-parasite relationship in bovine neosporosis. *Veterinary Immunology and Immunopathology* 108, 29-36.
- Innes, E.A., Wright, S.E., Maley, S.W., Rae, A.G., Schock, A., Kirvar, E., Bartley, P.M., Hamilton, C.M., Carey, I.M., Buxton, D., 2001. Protection against vertical transmission in bovine neosporosis. *International Journal for Parasitology* 31, 1523-1534.
- Jenkins, M.C., Parker, C., Hill, D.E., Pinckney, R.D., Dyer, R., Dubey, J.P., 2007. *Neospora caninum* detected in feral rodents. *Veterinary Parasitology* 143, 161-165.

- Jensen, A.M., Björkman, C., Kjeldsen, A.M., Wedderkopp, A., Willadsen, C., Ugglå, A., Lind, P., 1999. Associations of *Neospora caninum* seropositivity with gestation number and pregnancy outcome in Danish dairy herds. Preventive Veterinary Medicine 40, 151-163.
- Jozani, R.J., Asadpour, R., Nematollahi, A., Hosseininejad, M., 2012. Detection of non-spermatozoal cells of *Neospora caninum* in fresh semen of naturally infected bulls. Acta Scientiae Veterinariae 40, 1034.
- Kalinski, P., Hilkens, C.M., Snijders, A., Snijdewint, F.G., Kapsenberg, M.L., 1997. IL-12-deficient dendritic cells, generated in the presence of prostaglandin E₂, promote type 2 cytokine production in maturing human naive T helper cells. Journal of Immunology 159, 28-35.
- Keech, C.L., Brandon, M.R., 1991. Workshop findings on the ovine homologue of CD8. Veterinary Immunology and Immunopathology 27, 109-113.
- Kelly, P.M.A., Bliss, E., Morton, J.A., Burns, J., McGee, J.O'D., 1988. Monoclonal antibody EBM/1 1: high cellular specificity for human macrophages. Journal of Clinical Pathology 41, 510-515.
- Kelso, A., 1998. Cytokines: principles and prospects. Immunology and Cell Biology 76, 300-317.
- Kerr, K., Entrican, G., McKeever, D., Longbottom, D., 2005. Immunopathology of *Chlamydophila abortus* infection in sheep and mice. Research in Veterinary Science 78, 1-7.
- Kessy, V.M.J., Matovelo, J.A., 2011. Immunohistochemical characterization and quantification of lymphocytes infiltrating bovine lungs in East Coast Fever. The International Journal of Applied Research in Veterinary Medicine 9, 87-99.
- Khan, I.A., Schwartzman, J.D., Fonseca, S., Kasper, L.H., 1997. *Neospora caninum*: role for immune cytokines in host immunity. Experimental Parasitology 85, 24-34.
- Kim, J.H., Sohn, H.J., Hwang, W.S., Hwang, E.K., Jean, Y.H., Yamane, I., Kim, D.Y., 2000. *In vitro* isolation and characterization of bovine *Neospora caninum* in Korea. Veterinary Parasitology 90, 147-154.
- Kim, J.T., Park, J.Y., Seo, H.S., Oh, H.G., Noh, J.W., Kim, J.H., Kim, D.Y., Youn, H.J., 2002. *In vitro* antiprotozoal effects of artemisinin on *Neospora caninum*. Veterinary Parasitology 103, 53-63.
- Kim, S., Lee, D.S., Watanabe, K., Furuoka, H., Suzuki, H., Watarai, M., 2005. Interferon-gamma promotes abortion due to *Brucella* infection in pregnant mice. BMC Microbiology 5.

- Kimura, K., Goff, J.P., Kehrli, M.E., Harp, J.A., 1999. Phenotype analysis of peripheral blood mononuclear cells in periparturient dairy cows. *Journal of Dairy Science* 82, 315-319.
- Kimura, K., Goff, J.P., Kehrli, M.E., Harp, J.A., Nonnecke, B.J., 2002. Effects of mastectomy on composition of peripheral blood mononuclear cell populations in periparturient dairy cows. In: pp. 1437-1444.
- King, A., Jokhi, P.P., Smith, S.K., Sharkey, A.M., Loke, Y.W., 1995. Screening for cytokine mRNA in human villous and extravillous trophoblasts using the reverse-transcriptase polymerase chain reaction (RT-PCR). *Cytokine* 7, 364-371.
- King, A., Loke, Y.W., 1990. Human trophoblast and JEG choriocarcinoma cells are sensitive to lysis by IL-2-stimulated decidual NK cells. *Cellular Immunology* 129, 435-448.
- King, J.S., Jenkins, D.J., Ellis, J.T., Fleming, P., Windsor, P.A., Šlapeta, J.R., 2011. Implications of wild dog ecology on the sylvatic and domestic life cycle of *Neospora caninum* in Australia. *The Veterinary Journal* 188, 24-33.
- King, J.S., Šlapeta, J.R., Jenkins, D.J., Al-Qassab, S.E., Ellis, J.T., Windsor, P.A., 2010. Australian dingoes are definitive hosts of *Neospora caninum*. *International Journal for Parasitology* 40, 945-950.
- Kinsky, R., Delage, G., Rosin, N., Thang, M.N., Hoffmann, M., Chaouat, G., 1990. A murine model of NK cell mediated resorption. *American Journal of Reproductive Immunology* 23, 73-77.
- Kirkbride, C.A., 1993. Diagnoses in 1,784 ovine abortions and stillbirths. *Journal of Veterinary Diagnostic Investigation* 5, 398-402.
- Klevar, S., Kulberg, S., Boysen, P., Storset, A.K., Moldal, T., Björkman, C., Olsen, I., 2007. Natural killer cells act as early responders in an experimental infection with *Neospora caninum* in calves. *International Journal for Parasitology* 37, 329-339.
- Klevar, S., Kulberg, S., Boysen, P., Storset, A.K., Moldal, T., Björkman, C., Olsen, I., 2009. Bovine natural killer cells act as primary responders in the early stages of *Neospora caninum* infected cattle. *Veterinary Immunology and Immunopathology* 128, 292-293.
- Klevar, S., Norström, M., Tharaldsen, J., Clausen, T., Björkman, C., 2010. The prevalence and spatial clustering of *Neospora caninum* in dairy herds in Norway. *Veterinary Parasitology* 170, 153-157.
- Kobayashi, M., Fitz, L., Ryan, M., Hewick, R.M., Clark, S.C., Chan, S., Loudon, R., Sherman, F., Perussia, B., Trinchieri, G., 1989. Identification and purification of natural killer cell stimulatory factor (NKSF), a cytokine with multiple biologic effects on human lymphocytes. *The Journal of Experimental Medicine* 170, 827-845.

- Koga, K., Aldo, P.B., Mor, G., 2009. Toll-like receptors and pregnancy: trophoblast as modulators of the immune response. *Journal of Obstetrics and Gynaecology Research* 35, 191-202.
- Koiwai, M., Hamaoka, T., Haritani, M., Shimizu, S., Tsutsui, T., Eto, M., Yamane, I., 2005. Seroprevalence of *Neospora caninum* in dairy and beef cattle with reproductive disorders in Japan. *Veterinary Parasitology* 130, 15-18.
- Konnai, S., Mingala, C.N., Sato, M., Abes, N.S., Venturina, F.A., Gutierrez, C.A., Sano, T., Omata, Y., Cruz, L.C., Onuma, M., Ohashi, K., 2008. A survey of abortifacient infectious agents in livestock in Luzon, the Philippines, with emphasis on the situation in a cattle herd with abortion problems. *Acta Tropica* 105, 269-273.
- Konrad, J.L., Moore, D.P., Crudeli, G., Caspe, S.G., Cano, D.B., Leunda, M.R., Lischinsky, L., Regidor-Cerrillo, J., Odeón, A.C., Ortega-Mora, L.M., Echaide, I., Campero, C.M., 2012. Experimental inoculation of *Neospora caninum* in pregnant water buffalo. *Veterinary Parasitology* 187, 72-78.
- Korbel, D.S., Finney, O.C., Riley, E.M., 2004. Natural killer cells and innate immunity to protozoan pathogens. *International Journal for Parasitology* 34, 1517-1528.
- Koshi, K., Suzuki, Y., Nakaya, Y., Imai, K., Hosoe, M., Takahashi, T., Kizaki, K., Miyazawa, T., Hashizume, K., 2012. Bovine trophoblastic cell differentiation and binucleation involves enhanced endogenous retrovirus element expression. *Reproductive Biology and Endocrinology* 10, 41.
- Krishnan, L., Guilbert, L.J., Russell, A.S., Wegmann, T.G., Mosmann, T.R., Belosevic, M., 1996a. Pregnancy impairs resistance of C57BL/6 mice to *Leishmania major* infection and causes decreased antigen-specific IFN-gamma response and increased production of T helper 2 cytokines. *Journal of Immunology* 156, 644-652.
- Krishnan, L., Guilbert, L.J., Wegmann, T.G., Belosevic, M., Mosmann, T.R., 1996b. T helper 1 response against *Leishmania major* in pregnant C57BL/6 mice increases implantation failure and fetal resorptions. Correlation with increased IFN-gamma and TNF and reduced IL-10 production by placental cells. *Journal of Immunology* 156, 653-662.
- Kritzner, S., Sager, H., Blum, J., Krebber, R., Greif, G., Gottstein, B., 2002. An explorative study to assess the efficacy of Toltrazuril-sulfone (Ponazuril) in calves experimentally infected with *Neospora caninum*. *Annals of Clinical and Microbiology Antimicrobials* 1, 1-10.
- Kruse, N., Greif, M., Moriabadi, N.F., Marx, L., Toyka, K.V., Rieckmann, P., 2000. Variations in cytokine mRNA expression during normal human pregnancy. *Clinical and Experimental Immunology* 119, 317-322.

- Kul, O., Kabakci, N., Yildiz, K., İcal, N., Kalender, H., İlkme, N.A., 2009. *Neospora caninum* associated with epidemic abortions in dairy cattle: The first clinical neosporosis report in Turkey. *Veterinary Parasitology* 159, 69-72.
- Kwak-Kim, J., Park, J.C., Ahn, H.K., Kim, J.W., Gilman-Sachs, A., 2010. Immunological modes of pregnancy loss. *American Journal of Reproductive Immunology* 63, 611-623.
- Landmann, J.K., Gunn, A.A., O'Donoghue, P.J., Tranter, W.P., McGowan, M.R., 2011. Epidemiology and impact of *Neospora caninum* infection in three Queensland tropical dairy herds. *Reproduction in Domestic Animals* 46, 734-737.
- Landmann, J.K., Jillella, D., O'Donoghue, P.J., McGowan, M.R., 2002. Confirmation of the prevention of vertical transmission of *Neospora caninum* in cattle by the use of embryo transfer. *Australian Veterinary Journal* 80, 502-503.
- Langermans, J.A., van der Hulst, M.E., Nibbering, P.H., van Furth, R., 1992. Endogenous tumor necrosis factor alpha is required for enhanced antimicrobial activity against *Toxoplasma gondii* and *Listeria monocytogenes* in recombinant gamma interferon-treated mice. *Infection and Immunity* 60, 5107-5112.
- Larson, R.L., Hardin, D.K., Pierce, V.L., 2004. Economic considerations for diagnostic and control options for *Neospora caninum*-induced abortions in endemically infected herds of beef cattle. *Journal of the American Veterinary Medical Association* 224, 1597-1604.
- Larsson, L.I., Hougaard, D., 1992. Detection of gastrin and its messenger RNA in Zollinger-Ellison tumors by non-radioactive *in situ* hybridization and immunocytochemistry. *Histochemistry and Cell Biology* 97, 105-110.
- Larsson, L.I., Hougaard, D.M., 1991. Combined non-radioactive detection of peptide hormones and their mRNA's in endocrine cells. *Histochemistry* 96, 375-380.
- Lederer, J.A., Perez, V.L., DesRoches, L., Kim, S.M., Abbas, A.K., Lichtman, A.H., 1996. Cytokine transcriptional events during helper T cell subset differentiation. *The Journal of Experimental Medicine* 184, 397-406.
- Leibovich, S.J., Ross, R., 1975. The role of the macrophage in wound repair. A study with hydrocortisone and antimacrophage serum. *American Journal of Pathology* 78, 71-100.
- Leleux, J., Roy, K., 2013. Micro and nanoparticle-based delivery systems for vaccine immunotherapy: an immunological and materials perspective. *Advanced Healthcare Materials* 2, 72-94.
- Levine, N.D., 1970. Taxonomy of Sporozoa. *The Journal of Parasitology* 56, 208-209.

- Lim, K.J., Odukoya, O.A., Ajjan, R.A., Li, T.C., Weetman, A.P., Cooke, I.D., 1998. Profile of cytokine mRNA expression in peri-implantation human endometrium. *Molecular Human Reproduction* 4, 77-81.
- Lin, H., Mosmann, T.R., Guilbert, L., Tuntipopipat, S., Wegmann, T.G., 1993. Synthesis of T helper 2-type cytokines at the maternal-fetal interface. *Journal of Immunology* 151, 4562-4573.
- Lindsay, D.S., Butler, J.M., Blagburn, B.L., 1997. Efficacy of decoquinate against *Neospora caninum* tachyzoites in cell cultures. *Veterinary Parasitology* 68, 35-40.
- Lindsay, D.S., Butler, J.M., Rippey, N.S., Blagburn, B.L., 1996. Demonstration of synergistic effects of sulfonamides and dihydrofolate reductase/thymidylate synthase inhibitors against *Neospora caninum* tachyzoites in cultured cells, and characterization of mutants resistant to pyrimethamine. *American Journal of Veterinary Research* 57, 68-72.
- Lindsay, D.S., Current, W.L., Ernst, J.V., 1982. Sporogony of *Isospora suis* Biester, 1934 of swine. *The Journal of Parasitology* 68, 861-865.
- Lindsay, D.S., Dubey, J.P., 1989a. Evaluation of anti-coccidial drugs' inhibition of *Neospora caninum* development in cell cultures. *The Journal of Parasitology* 75, 990-992.
- Lindsay, D.S., Dubey, J.P., 1989b. Immunohistochemical diagnosis of *Neospora caninum* in tissue sections. *American Journal of Veterinary Research* 50, 1981-1983.
- Lindsay, D.S., Dubey, J.P., 1990a. Effects of sulfadiazine and amprolium on *Neospora caninum* (Protozoa: Apicomplexa) infections in mice. *The Journal of Parasitology* 76, 177-179.
- Lindsay, D.S., Dubey, J.P., 1990b. Infections in mice with tachyzoites and bradyzoites of *Neospora caninum* (Protozoa: Apicomplexa). *The Journal of Parasitology* 76, 410-413.
- Lindsay, D.S., Dubey, J.P., Cole, R.A., Nuehring, L.P., Blagburn, B.L., 1993. *Neospora*-induced protozoal abortions in cattle. *The Compendium on Continuing Education for the Practising Veterinarian, Food Animal* 15, 892-895.
- Lindsay, D.S., Dubey, J.P., Duncan, R.B., 1999. Confirmation that the dog is a definitive host for *Neospora caninum*. *Veterinary Parasitology* 82, 327-333.
- Lindsay, D.S., Lenz, S.D., Cole, R.A., Dubey, J.P., Blagburn, B.L., 1995. Mouse model for central nervous system *Neospora caninum* infections. *The Journal of Parasitology* 81, 313-315.
- Lindsay, D.S., Rippey, N.S., Cole, R.A., Parsons, L.C., Dubey, J.P., Tidwell, R.R., Blagburn, B.L., 1994. Examination of the activities of 43 chemotherapeutic agents

against *Neospora caninum* tachyzoites in cultured cells. *American Journal of Veterinary Research* 55, 976-981.

Lindsay, D.S., Weston, J.L., Little, S.E., 2001. Prevalence of antibodies to *Neospora caninum* and *Toxoplasma gondii* in gray foxes (*Urocyon cinereoargenteus*) from South Carolina. *Veterinary Parasitology* 97, 159-164.

Lobato, J., Silva, D.A.O., Mineo, T.W.P., Amaral, J.D.H.F., Segundo, G.R.S., Costa-Cruz, J.M., Ferreira, M.S., Borges, A.S., Mineo, J.R., 2006. Detection of immunoglobulin G antibodies to *Neospora caninum* in humans: high seropositivity rates in patients who are infected by human immunodeficiency virus or have neurological disorders. *Clinical and Vaccine Immunology* 13, 84-89.

Long, M.T., Baszler, T.V., 2000. Neutralization of maternal IL-4 modulates congenital protozoal transmission: comparison of innate versus acquired immune responses. *Journal of Immunology* 164, 4768-4774.

Long, M.T., Baszler, T.V., Mathison, B.A., 1998. Comparison of intracerebral parasite load, lesion development, and systemic cytokines in mouse strains infected with *Neospora caninum*. *The Journal of Parasitology* 84, 316-320.

López-Gatius, F., Almería, S., Donofrio, G., Nogareda, C., García-Ispierto, I., Bech-Sàbat, G., Santolaria, P., Yániz, J.L., Pabón, M., Melo de Sousa, N., Beckers, J.F., 2007a. Protection against abortion linked to gamma interferon production in pregnant dairy cows naturally infected with *Neospora caninum*. *Theriogenology* 68, 1067-1073.

López-Gatius, F., Garbayo, J.M., Santolaria, P., Yániz, J.L., Almería, S., Ayad, A., de Sousa, N.M., Beckers, J.F., 2007b. Plasma pregnancy-associated glycoprotein-1 (PAG-1) concentrations during gestation in *Neospora*-infected dairy cows. *Theriogenology* 67, 502-508.

López-Gatius, F., García-Ispierto, I., Santolaria, P., Yániz, J.L., López-Béjar, M., Nogareda, C., Almería, S., 2005a. Relationship between rainfall and *Neospora caninum*-associated abortion in two dairy herds in a dry environment. *Journal of Veterinary Medicine Series B* 52, 147-152.

López-Gatius, F., López-Béjar, M., Murugavel, K., Pabón, M., Ferrer, D., Almería, S., 2004a. *Neospora*-associated abortion episode over a 1-year period in a dairy herd in Northeast Spain. *Journal of Veterinary Medicine B* 51, 348-352.

López-Gatius, F., Pabón, M., Almería, S., 2004b. *Neospora caninum* infection does not affect early pregnancy in dairy cattle. *Theriogenology* 62, 606-613.

López-Gatius, F., Santolaria, P., Yániz, J.L., Garbayo, J.M., Almería, S., 2005b. The use of beef bull semen reduced the risk of abortion in *Neospora*-seropositive dairy cows. *Journal of Veterinary Medicine Series B* 52, 88-92.

- López-Pérez, I., Collantes-Fernández, E., Rojo-Montejo, S., Navarro-Lozano, V., Risco-Castillo, V., Pérez-Pérez, V., Pereira-Bueno, J., Ortega-Mora, L.M., 2010. Effects of *Neospora caninum* infection at mid-gestation on placenta in a pregnant mouse model. *The Journal of Parasitology* 96, 1017-1020.
- López-Pérez, I., Collantes-Fernández, E., Rojo-Montejo, S., Navarro-Lozano, V., Risco-Castillo, V., Pérez-Pérez, V., Pereira-Bueno, J., Ortega-Mora, L.M., 2011. Pathological and immunological findings in placentas from pregnant BALB/c mice infected with *Neospora caninum* at early and late stages of gestation. *Acta Parasitologica* 56, 245-254.
- Lundén, A., Marks, J., Maley, S.W., Innes, E.A., 1998. Cellular immune responses in cattle experimentally infected with *Neospora caninum*. *Parasite Immunology* 20, 519-526.
- Lyon, C., 2010. Update on the diagnosis and management of *Neospora caninum* infections in dogs. *Topics in Companion Animal Medicine* 25, 170-175.
- Lyons, R.E., McLeod, R., Roberts, C.W., 2002. *Toxoplasma gondii* tachyzoite-bradyzoite interconversion. *Trends in Parasitology* 18, 198-201.
- Macaldowie, C., Jackson, F., Huntley, J., Mackellar, A., Jackson, E., 2003. A comparison of larval development and mucosal mast cell responses in worm-naïve goat yearlings, kids and lambs undergoing primary and secondary challenge with *Teladorsagia circumcincta*. *Veterinary Parasitology* 114, 1-13.
- Macaldowie, C.N., Maley, S.W., Wright, S.E., Bartley, P.M., Esteban-Redondo, I., Buxton, D., Innes, E.A., 2004. Placental pathology associated with fetal death in cattle inoculated with *Neospora caninum* by two different routes in early pregnancy. *Journal of Comparative Pathology* 131, 142-156.
- MacHugh, N.D., Sopp, P., 1991. Bovine CD8 (BoCD8). *Veterinary Immunology and Immunopathology* 27, 65-69.
- Mainar-Jaime, R.C., Thurmond, M.C., Berzal-Herranz, B., Hietala, S.K., 1999. Seroprevalence of *Neospora caninum* and abortion in dairy cows in northern Spain. *Veterinary Record* 145, 72-75.
- Maley, S.W., Buxton, D., Macaldowie, C.N., Anderson, I.E., Wright, S.E., Bartley, P.M., Esteban-Redondo, I., Hamilton, C.M., Storset, A.K., Innes, E.A., 2006. Characterization of the immune response in the placenta of cattle experimentally infected with *Neospora caninum* in early gestation. *Journal of Comparative Pathology* 135, 130-141.
- Maley, S.W., Buxton, D., Rae, A.G., Wright, S.E., Schock, A., Bartley, P.M., Esteban-Redondo, I., Swales, C., Hamilton, C.M., Sales, J., Innes, E.A., 2003. The pathogenesis of Neosporosis in pregnant cattle: inoculation at mid-gestation. *Journal of Comparative Pathology* 129, 186-195.

- Maley, S.W., Livingstone, M., Rodger, S.M., Longbottom, D., Buxton, D., 2009. Identification of *Chlamydophila abortus* and the development of lesions in placental tissues of experimentally infected sheep. *Veterinary Microbiology* 135, 122-127.
- Marks, J., Lundén, A., Harkins, D., Innes, E.A., 1998. Identification of *Neospora* antigens recognized by CD4⁺ T cells and immune sera from experimentally infected cattle. *Parasite Immunology* 20, 303-309.
- Marsh, A.E., Barr, B.C., Packham, A.E., Conrad, P.A., 1998. Description of a new *Neospora* species (Protozoa: Apicomplexa: Sarcocystidae). *The Journal of Parasitology* 84, 983-991.
- Marsh, A.E., Barr, B.C., Sverlow, K., Ho, M., Dubey, J.P., Conrad, P.A., 1995. Sequence analysis and comparison of ribosomal DNA from bovine *Neospora* to similar coccidial parasites. *Journal of Parasitology* 81, 530-535.
- Marzi, M., Vigano, A., Trabattoni, D., Villa, M.L., Salvaggio, A., Clerici, E., Clerici, M., 1996. Characterization of type 1 and type 2 cytokine production profile in physiologic and pathologic human pregnancy. *Clinical and Experimental Immunology* 106, 127-133.
- Matamoros, R.A., Caamano, L., Lamb, S.V., Reimers, T.J., 1994. Estrogen production by bovine binucleate and mononucleate trophoblastic cells *in vitro*. *Biology of Reproduction* 51, 486-492.
- Mathey, E., Pollard, J., Armati, P., 2003. *In situ* hybridization for cytokines in human tissue biopsies. In: *Cytokine Protocols*, pp. 41-46.
- McAllister, M.M., 1999. Uncovering the biology and epidemiology of *Neospora caninum*. *Parasitology Today* 15, 216-217.
- McAllister, M.M., 2001. Do cows protect fetuses from *Neospora caninum* transmission? *Trends in Parasitology* 17, 6.
- McAllister, M.M., Björkman, C., Anderson-Sprecher, R.C., Rogers, D.G., 2000. Evidence of point-source exposure to *Neospora caninum* and protective immunity in a herd of beef cows. *Journal of the American Veterinary Association* 217, 881-887.
- McAllister, M.M., Dubey, J.P., Lindsay, D.S., Jolley, W.R., Wills, R.A., McGuire, A.M., 1998a. Dogs are definitive hosts of *Neospora caninum*. *International Journal for Parasitology* 28, 1473-1479.
- McAllister, M.M., Huffman, E.M., Hietala, S.K., Conrad, P.A., Anderson, M.L., Salman, M.D., 1996a. Evidence suggesting a point source exposure in an outbreak of bovine abortion due to neosporosis. *Journal of Veterinary Diagnostic Investigation* 8, 355-357.

- McAllister, M.M., Jolley, W.R., Wills, R.A., Lindsay, D.S., McGuire, A.M., Tranas, J.D., 1998b. Oral inoculation of cats with tissue cysts of *Neospora caninum*. *American Journal of Veterinary Research* 59, 441-444.
- McAllister, M.M., McGuire, A.M., Jolley, W.R., Lindsay, D.S., Trees, A.J., Stobart, R.H., 1996b. Experimental Neosporosis in pregnant ewes and their offspring. *Veterinary Pathology Online* 33, 647-655.
- McCann, C.M., McAllister, M.M., Gondim, L.F.P., Smith, R.F., Cripps, P.J., Kipar, A., Williams, D.J.L., Trees, A.J., 2007. *Neospora caninum* in cattle: Experimental infection with oocysts can result in exogenous transplacental infection, but not endogenous transplacental infection in the subsequent pregnancy. *International Journal for Parasitology* 37, 1631-1639.
- McCann, C.M., Vyse, A.J., Salmon, R.L., Thomas, D., Williams, D.J.L., McGarry, J.W., Pebody, R., Trees, A.J., 2008. Lack of serologic evidence of *Neospora caninum* in humans, England. *Emerging Infectious Diseases* 14, 978-980.
- McGuire, A.M., McAllister, M.M., Wills, R.A., Tranas, J.D., 1999. Experimental inoculation of domestic pigeons (*Columbia livia*) and zebra finches (*Poephila guttata*) with *Neospora caninum* tachyzoites. *International Journal for Parasitology* 29, 1525-1529.
- McInnes, L.M., Irwin, P., Palmer, D.G., Ryan, U.M., 2006. *In vitro* isolation and characterisation of the first canine *Neospora caninum* isolate in Australia. *Veterinary Parasitology* 137, 355-363.
- McIntosh, D.W., Haines, D.M., 1994. Neospora infection in an aborted fetus in British Columbia. *Canadian Veterinary Journal* 35, 114-115.
- McNamee, P.T., Jeffrey, M., 1994. *Neospora*-associated bovine abortion in Northern Ireland. *Veterinary Record* 134, 48-4a.
- McNicol, A.M., Farquharson, M.A., 1997. *In situ* hybridization and its diagnostic applications in pathology. *Journal of Pathology* 182, 250-261.
- Meat and Livestock Commission, 1994. Meat and Livestock Commission, 1994. Beef Yearbook 1994. Milton Keynes, UK.
- Medina-Esparza, L., Macías, L., Ramos-Parra, M., Morales-Salinas, E., Quezada, T., Cruz-Vázquez, C., 2013. Frequency of infection by *Neospora caninum* in wild rodents associated with dairy farms in Aguascalientes, Mexico. *Veterinary Parasitology* 191, 11-14.
- Meegdes, B.H.L.M., Ingenhoues, R.U.U.D., Peeters, L.L.H., Exalto, N.I.E.K., 1988. Early pregnancy wastage: relationship between chorionic vascularization and embryonic development. *Obstetrical & Gynecological Survey* 43.

- Meerburg, B.G., De Craeye, S., Dierick, K., Kijlstra, A., 2012. *Neospora caninum* and *Toxoplasma gondii* in brain tissue of feral rodents and insectivores caught on farms in the Netherlands. *Veterinary Parasitology* 184, 317-320.
- Mesquita, L.P., Nogueira, C.I., Costa, R.C., Orlando, D.R., Bruhn, F.R.P., Lopes, P.F.R., Nakagaki, K.Y.R., Peconick, A.P., Seixas, J.N., Júnior, P.S.B., Raymundo, D.L., Varaschin, M.S., 2013. Antibody kinetics in goats and conceptuses naturally infected with *Neospora caninum*. *Veterinary Parasitology* 196, 327-333.
- Miller, C.M.D., Quinn, H.E., Windsor, P.A., Ellis, J.T., 2002. Characterisation of the first Australian isolate of *Neospora caninum* from cattle. *Australian Veterinary Journal* 80, 620-625.
- Miller, L., Hunt, J.S., 1998. Regulation of TNF-alpha production in activated mouse macrophages by progesterone. *Journal of Immunology* 160, 5098-5104.
- Miyamoto, Y., Skarzynski, D.J., Okuda, K., 2000. Is tumor necrosis factor α a trigger for the initiation of endometrial prostaglandin $F_{2\alpha}$ release at luteolysis in cattle? *Biology of Reproduction* 62, 1109-1115.
- Modrý, D., Václavek, P., Koudela, B., Šlapeta, J.R., 2001. Placentophagia - an alternative way for horizontal transmission of *Neospora caninum* in cattle? *Trends in Parasitology* 17, 573.
- Moen, A.R., Wouda, W., Mul, M.F., Graat, E.A.M., van Werven, T., 1998. Increased risk of abortion following *Neospora caninum* abortion outbreaks: a retrospective and prospective cohort study in four dairy herds. *Theriogenology* 49, 1301-1309.
- Moen, A.R., Wouda, W., van Werven, T., 1995. Clinical and sero-epidemiological follow-up study in four dairy herds with an outbreak of *Neospora* abortion. In: *Dutch Society for Veterinary Epidemiology and Economics*, pp. 93-103.
- Moore, D.P., Echaide, I., Verna, A.E., Leunda, M.R., Cano, A., Pereyra, S., Zamorano, P.I., Odeón, A.C., Campero, C.M., 2011. Immune response to *Neospora caninum* native antigens formulated with immune stimulating complexes in calves. *Veterinary Parasitology* 175, 245-251.
- Moore, D.P., Leunda, M.R., Zamorano, P.I., Odeón, A.C., Romera, S.A., Cano, A., de Yaniz, M.G., Venturini, M.C., Campero, C.M., 2005. Immune response to *Neospora caninum* in naturally infected heifers and heifers vaccinated with inactivated antigen during the second trimester of gestation. *Veterinary Parasitology* 130, 29-39.
- Moore, D.P., Pérez, A., Agliano, S., Brace, M., Cantón, G.J., Cano, D.B., Leunda, M.R., Odeón, A.C., Odriozola, E., Campero, C.M., 2009. Risk factors associated with *Neospora caninum* infections in cattle in Argentina. *Veterinary Parasitology* 161, 122-125.

- Moormann, A.M., Sullivan, A.D., Rochford, R.A., Chensue, S.W., Bock, P.J., Nyirenda, T., Meshnick, S.R., 1999. Malaria and pregnancy: placental cytokine expression and its relationship to intrauterine growth retardation. *The Journal of Infectious Diseases* 180, 1987-1993.
- Morales, E., Trigo, F.J., Ibarra, F., Puente, E., Santacruz, M., 2001. Neosporosis in Mexican dairy herds: Lesions and immunohistochemical detection of *Neospora caninum* in fetuses. *Journal of Comparative Pathology* 125, 58-63.
- Morales, S.E., Ramírez, L.J., Trigo, T.F., Ibarra, V.F., Puente, C.E., Santacruz, M., 1998. Descripción de un caso de aborto bovino asociado a infección con *Neospora* sp. en México. *Veterinaria México* 28, 353-357.
- Moré, G., Bacigalupe, D., Basso, W., Rambeaud, M., Beltrame, F., Ramirez, B., Venturini, M.C., Venturini, L., 2009. Frequency of horizontal and vertical transmission for *Sarcocystis cruzi* and *Neospora caninum* in dairy cattle. *Veterinary Parasitology* 160, 51-54.
- Morrison, W.I., Baldwin, C.L., MacHugh, N.D., Teale, A.J., Goddeeris, B.M., Ellis, J., 1987. Phenotypic and functional characterization of bovine lymphocytes. In: Pandey, R. (Ed.), *Progress in Veterinary Microbiology and Immunology*. S. Karger AG, Basel.
- Morrison, W.I., Davis, W.C., 1991. Differentiation antigens expressed predominantly on CD4- CD8- T lymphocytes (WC1, WC2). *Veterinary Immunology and Immunopathology* 27, 71-76.
- Moskwa, B., Cabaj, W., Pastusiak, K., Bien, J., 2003. The suitability of milk in detection of *Neospora caninum* infection in cows. *Acta Parasitologica* 48, 138-141.
- Moskwa, B., Pastusiak, K., Bien, J., Cabaj, W., 2007. The first detection of *Neospora caninum* DNA in the colostrum of infected cows. *Parasitology Research* 100, 633-636.
- Muranaka, J., Tsuji, Y., Hasegawa, M., Ida, A., Nakata, Y., Kanazawa, R., Koyama, K., 1998. Interleukin-18 as an important new cytokine in pregnancy. *American Journal of Reproductive Immunology* 40, 278.
- Murray, R.D., 1990. A field investigation of causes of abortion in dairy cattle. *Veterinary Record* 127, 543-547.
- Myers, D., Reimers, T., 1988. Purification and endocrine evaluation of bovine binucleate trophoblastic cells. *Journal of Tissue Culture Methods* 11, 83-88.
- Naessens, J., 1991. Characterisation of lymphocyte populations in African buffalo (*Syncerus caffer*) and waterbuck (*Kobus defassa*) with workshop monoclonal antibodies. *Veterinary Immunology and Immunopathology* 27, 153-162.

- Naessens, J., Howard, C.J., Hopkins, J., 1997. Nomenclature and characterization of leukocyte differentiation antigens in ruminants. *Immunology Today* 18, 365-368.
- Nagaeva, O., Jonsson, L., Mincheva-Nilsson, L., 2002. Dominant IL-10 and TGF- β mRNA expression in $\gamma\delta$ -T cells of human early pregnancy decidua suggests immunoregulatory potential. *American Journal of Reproductive Immunology* 48, 9-17.
- Nasir, A., Ashraf, M., Khan, M.S., Yaqub, T., Javeed, A., Avais, M., Akhtar, F., 2010. Seroprevalence of *Neospora caninum* in dairy buffaloes in Lahore District, Pakistan. *Journal of Parasitology* 97, 541-543.
- Nature, 2010. How to feed a hungry world. *Nature* 466, 531-532.
- Nematollahi, A., Jaafari, R., Moghaddam, G., 2011. Seroprevalence of *Neospora caninum* infection in dairy cattle in Tabriz, Northwest Iran. *Iranian Journal of Parasitology* 6, 95-98.
- Nettleton, P.F., Entrican, G., 1995. Ruminant pestiviruses. *British Veterinary Journal* 151, 615-642.
- Nishikawa, Y., Iwata, A., Nagasawa, H., Fujisaki, K., Otsuka, H., Mikami, T., 2001a. Comparison of the growth inhibitory effects of canine IFN- α , - β and - γ on canine cells infected with *Neospora caninum* tachyzoites. *The Journal of Veterinary Medical Science* 63, 445-448.
- Nishikawa, Y., Mishima, M., Nagasawa, H., Igarashi, I., Fujisaki, K., Otsuka, H., Mikami, T., 2001b. Interferon-gamma-induced apoptosis in host cells infected with *Neospora caninum*. *Parasitology* 123, 25-31.
- Nishikawa, Y., Tragoolpua, K., Inoue, N., Makala, L., Nagasawa, H., Otsuka, H., Mikami, T., 2001c. In the absence of endogenous gamma interferon, mice acutely infected with *Neospora caninum* succumb to a lethal immune response characterized by inactivation of peritoneal macrophages. *Clinical and Vaccine Immunology* 8, 811-817.
- Nishimura, M., Kohara, J., Hiasa, J., Muroi, Y., Yokoyama, N., Kida, K., Xuan, X., Furuoka, H., Nishikawa, Y., 2013. Tissue distribution of *Neospora caninum* in experimentally infected cattle. *Clinical and Vaccine Immunology* 20, 309-312.
- Njiro, S.M., Kidanemariam, A.G., Tsotetsi, A.M., Katsande, T.C., Mnisi, M., Lubisi, B.A., Potts, A.D., Baloyi, F., Moyo, G., Mpofo, J., Kalake, A., Williams, R., 2011. A study of some infectious causes of reproductive disorders in cattle owned by resource-poor farmers in Gauteng Province, South Africa. *Journal of the South African Veterinary Association* 82, 213-218.
- O'Doherty, E., Sayers, R., O'Grady, L., 2013. Temporal trends in bulk milk antibodies to *Salmonella*, *Neospora caninum*, and *Leptospira interrogans* serovar hardjo in Irish dairy herds. *Preventive Veterinary Medicine* 109, 343-348.

- O'Toole, D., Jeffrey, M., 1987. Congenital sporozoan encephalomyelitis in a calf. *Veterinary Record* 121, 563-566.
- Obendorf, D.L., Murray, N., Veldhuis, G., Munday, B.L., Dubey, J.P., 1995. Abortion caused by neosporosis in cattle. *Australian Veterinary Journal* 72, 117-118.
- Ogino, H., Watanabe, E., Watanabe, S., Agawa, H., Narita, M., Haritani, M., Kawashima, K., 1992. Neosporosis in the aborted fetus and newborn calf. *Journal of Comparative Pathology* 107, 231-237.
- Okeoma, C.M., Williamson, N.B., Pomroy, W.E., Stowell, K.M., Gillespie, L.M., 2004. Isolation and molecular characterisation of *Neospora caninum* in cattle in New Zealand. *New Zealand Veterinary Journal* 52, 364-370.
- Okuda, K., Sakumoto, R., Okamoto, N., Acosta, T.J., Abe, H., Okada, H., Sinowatz, F., Skarzynski, D.J., 2010. Cellular localization of genes and proteins for tumor necrosis factor- α (TNF), TNF receptor types I and II in bovine endometrium. *Molecular and Cellular Endocrinology* 330, 41-48.
- Oliveira, L.J., Hansen, P.J., 2008. Deviations in populations of peripheral blood mononuclear cells and endometrial macrophages in the cow during pregnancy. *Journal of Reproduction and Fertility* 136, 481-490.
- Oliveira, L.J., Hansen, P.J., 2009. Phenotypic characterization of macrophages in the endometrium of the pregnant cow. *American Journal of Reproductive Immunology* 62, 418-426.
- Orozco, M.A., Morales, E., Salmerón, F., 2013. Characterization of the inflammatory response in the uteri of cows infected naturally by *Neospora caninum*. *Journal of Comparative Pathology* 148, 148-156.
- Ortega-Mora, L.M., Fernández-García, A., Gómez-Bautista, M., 2006. Diagnosis of bovine neosporosis: recent advances and perspectives. *Acta Parasitologica* 51, 1-14.
- Ortega-Mora, L.M., Ferre, I., del-Pozo, I., Caetano-da-Silva, A., Collantes-Fernández, E., Regidor-Cerrillo, J., Ugarte-Garagalza, C., Aduriz, G., 2003. Detection of *Neospora caninum* in semen of bulls. *Veterinary Parasitology* 117, 301-308.
- Ortega-Mora, L.M., Gottstein, B., Conraths, F.J., Buxton, D., 2007. Protozoal abortion in farm ruminants. Guidelines for diagnosis and control. CAB International, Oxford, United Kingdom.
- Osburn, B.I., 1986. Ontogeny of immune responses in cattle. In: Morrison, W.I. (Ed.), *The ruminant immune system in health and disease*. Cambridge University Press, Cambridge, UK, pp. 252-260.
- Osburn, B.I., MacLachlan, N.J., Terrell, T.G., 1982. Ontogeny of the immune system. *Journal of the American Veterinary Medical Association* 181, 1049-1052.

- Osoro, K., Ortega-Mora, L.M., Martínez, A., Serrano-Martínez, E., Ferre, I., 2009. Natural breeding with bulls experimentally infected with *Neospora caninum* failed to induce seroconversion in dams. *Theriogenology* 71, 639-642.
- Otranto, D., Llazari, A., Testini, G., Traversa, D., di Regalbono, A.F., Badan, M., Capelli, G., 2003. Seroprevalence and associated risk factors of neosporosis in beef and dairy cattle in Italy. *Veterinary Parasitology* 118, 7-18.
- Otter, A., Jeffrey, M., Griffiths, I.B., Dubey, J.P., 1995. A survey to determine the incidence of *Neospora caninum* infection in aborted and stillborn bovine foetuses in England and Wales. *Veterinary Record* 136, 602-605.
- Ould-Amrouche, A., Klein, F., Osdoit, C., Mohammed, H.O., Touratier, A., Sanaa, M., Mialot, J.P., 1999. Estimation of *Neospora caninum* seroprevalence in dairy cattle from Normandy, France. *Veterinary Research* 30, 531-538.
- Pabón, M., López-Gatius, F., García-Ispuerto, I., Bech-Sàbat, G., Nogareda, C., Almería, S., 2007. Chronic *Neospora caninum* infection and repeat abortion in dairy cows: A 3-year study. *Veterinary Parasitology* 147, 40-46.
- Paré, J., Fecteau, G., Fortin, M., Marsolais, G., 1998. Seroepidemiologic study of *Neospora caninum* in dairy herds. *Journal of the American Veterinary Association* 213, 1595-1598.
- Paré, J., Thurmond, M.C., Hietala, S.K., 1996. Congenital *Neospora caninum* infection in dairy cattle and associated calfhood mortality. *Canadian Journal of Veterinary Research* 60, 133-139.
- Paré, J., Thurmond, M.C., Hietala, S.K., 1997. *Neospora caninum* antibodies in cows during pregnancy as a predictor of congenital infection and abortion. *The Journal of Parasitology* 83, 82-87.
- Parish, S.M., Maag-Miller, L., Besser, T.E., Weidner, J.P., McElwain, T.F., Knowles, D.P., Leathers, C.W., 1987. Myelitis associated with protozoal infection in newborn calves. *Journal of the American Veterinary Association* 191, 1599-1600.
- Parker, S.J., Roberts, C.W., Alexander, J., 1991. CD8+ T cells are the major lymphocyte subpopulation involved in the protective immune response to *Toxoplasma gondii* in mice. *Clinical and Experimental Immunology* 84, 207-212.
- Paulesu, L., Pfarrer, C., Romagnoli, R., Ietta, F., Callesen, H., Hambruch, N., Dantzer, V., 2012. Variation in macrophage migration inhibitory factor (MIF) immunoreactivity during bovine gestation. *Placenta* 33, 157-163.
- Pereira García-Melo, D., Regidor-Cerrillo, J., Collantes-Fernández, E., Aguado-Martínez, A., del-Pozo, I., Minguijón, E., Gómez-Bautista, M., Aduriz, G., Ortega-Mora, L.M., 2010. Pathogenic characterization in mice of *Neospora caninum* isolates obtained from asymptomatic calves. *Parasitology* 137, 1057-1068.

- Pereira-Bueno, J., Quintanilla-Gozaolo, A., Seijas-Carballedo, A., Costas, E., Ortega-Mora, L.M., 2000. Observational studies in *Neospora caninum* infected dairy cattle: pattern of transmission and age-related antibody fluctuations. *International Journal for Parasitology* 30, 906-909.
- Pérez, E., González, O., Dolz, G., Morales, J., Barr, B.C., Conrad, P.A., 1998. First report of bovine neosporosis in dairy cattle in Costa Rica. *Veterinary Record* 142, 520-521.
- Pescador, C.A., Corbellini, L.G., Oliveira, E.C., Raymundo, D.L., Driemeier, D., 2007. Histopathological and immunohistochemical aspects of *Neospora caninum* diagnosis in bovine aborted fetuses. *Veterinary Parasitology* 150, 159-163.
- Peters, M., Lütkefels, E., Heckerroth, A.R., Schares, G., 2001. Immunohistochemical and ultrastructural evidence for *Neospora caninum* tissue cysts in skeletal muscles of naturally infected dogs and cattle. *International Journal for Parasitology* 31, 1144-1148.
- Petersen, E., Lebech, M., Jensen, L., Lind, P., Rask, M., Bagger, P., Björkman, C., Uggla, A., 1999. *Neospora caninum* infection and repeated abortions in humans. *Emerging Infectious Diseases* 5, 278-280.
- Pfaff, A.W., Abou-Bacar, A., Letscher-Bru, O., Villard, O., Senegas, A., Mousli, M., Candolfi, E., 2007. Cellular and molecular physiopathology of congenital toxoplasmosis: the dual role of IFN- γ . *Parasitology* 134, 1895-1902.
- Pfeiffer, D.U., Williamson, N.B., Reichel, M.P., Wichtel, J.J., Teague, W.R., 2002. A longitudinal study of *Neospora caninum* infection on a dairy farm in New Zealand. *Preventive Veterinary Medicine* 54, 11-24.
- Piccinni, M.P., Giudizi, M.G., Biagiotti, R., Beloni, L., Giannarini, L., Sampognaro, S., Parronchi, P., Manetti, R., Annunziato, F., Livi, C., 1995. Progesterone favors the development of human T helper cells producing Th2-type cytokines and promotes both IL-4 production and membrane CD30 expression in established Th1 cell clones. *Journal of Immunology* 155, 128-133.
- Pilozzi, E., Pulford, K., Jones, M., Müller-Hermelink, H.K., Falini, B., Ralfkiaer, E., Pileri, S., Pezzella, F., de Wolf-Peeters, C., Arber, D., Stein, H., Mason, D., Gatter, K., 1998. Co-expression of CD79a (JCB117) and CD3 by lymphoblastic lymphoma. *Journal of Pathology* 186, 140-143.
- Pitel, P.-H., Pronost, S., Chatagnon, G., Tainturier, D., Fortier, G., Ballet, J.-J., 2001. Neosporosis in bovine dairy herds from the west of France: detection of *Neospora caninum* DNA in aborted fetuses, seroepidemiology of *N. caninum* in cattle and dogs. *Veterinary Parasitology* 102, 269-277.
- Polledo, L., González, J., Benavides, J., Morales, S., Martínez-Fernández, B., Delgado, L., Reina, R., Glaria, I., Pérez, V., Ferreras, M.C., García Marín, J.F., 2011.

- Patterns of lesion and local host cellular immune response in natural cases of ovine Maedi-Visna. *Journal of Comparative Pathology* 147, 1-10.
- Pope, G.S., Gupta, S.K., Munro, I.B., 1969. Progesterone levels in the systemic plasma of pregnant, cycling and ovariectomized cows. *Journal of Reproduction and Fertility* 20, 369-381.
- Premraj, A., Sreekumar, E., Jain, M., Rasool, T.J., 2006. Buffalo (*Bubalus bubalis*) interleukin-12: Analysis of expression profiles and functional cross-reactivity with bovine system. *Molecular Immunology* 43, 822-829.
- Purtle, L., 2001. Reduced abortions after challenge in beef cattle administered inactivated *Neospora caninum* vaccine. In: *Neospora 2001*, Moredun Research Institute, Edinburgh, UK, p. 35.
- Quinn, H.E., Ellis, J.T., Smith, N.C., 2002a. *Neospora caninum*: a cause of immune-mediated failure of pregnancy? *Trends in Parasitology* 18, 391-394.
- Quinn, H.E., Miller, C.M.D., Ellis, J.T., 2004. The cell-mediated immune response to *Neospora caninum* during pregnancy in the mouse is associated with a bias towards production of interleukin-4. *International Journal for Parasitology* 34, 723-732.
- Quinn, H.E., Miller, C.M.D., Ryce, C., Windsor, P.A., Ellis, J.T., 2002b. Characterization of an outbred pregnant mouse model of *Neospora caninum* infection. *The Journal of Parasitology* 88, 691-696.
- Quintanilla-Gozalo, A., Pereira-Bueno, J., Tabarés, E., Innes, E.A., González-Paniello, R., Ortega-Mora, L.M., 1999. Seroprevalence of *Neospora caninum* infection in dairy and beef cattle in Spain. *International Journal for Parasitology* 29, 1201-1208.
- Raghupathy, R., 1997. Th 1-type immunity is incompatible with successful pregnancy. *Immunology Today* 18, 478-482.
- Raghupathy, R., Makhseed, M., Azizieh, F., Hassan, N.A., Al-Azemi, M.M., Al-Shamali, E., 1999. Maternal Th1- and Th2-Type reactivity to placental antigens in normal human pregnancy and unexplained recurrent spontaneous abortions. *Cellular Immunology* 196, 122-130.
- Raghupathy, R., Makhseed, M., Azizieh, F., Omu, A., Gupta, M., Farhat, R., 2000. Cytokine production by maternal lymphocytes during normal human pregnancy and in unexplained recurrent spontaneous abortion. *Hum. Reprod.* 15, 713-718.
- Razmi, G.R., Zarea, H., Naseri, Z., 2010. A survey of *Neospora caninum*-associated bovine abortion in large dairy farms of Mashhad, Iran. *Parasitology Research* 106, 1419-1423.

- Regidor-Cerrillo, J., Pedraza-Díaz, S., Gómez-Bautista, M., Ortega-Mora, L.M., 2006. Multilocus microsatellite analysis reveals extensive genetic diversity in *Neospora caninum*. *The Journal of Parasitology* 92, 517-524.
- Regidor-Cerrillo, J., Pedraza-Díaz, S., Rojo-Montejo, S., Vázquez-Moreno, E., Arnaiz, I., Gomez-Bautista, M., Jimenez-Palacios, S., Ortega-Mora, L.M., Collantes-Fernández, E., 2010. *Neospora caninum* infection in stray and farm dogs: seroepidemiological study and oocyst shedding. *Veterinary Parasitology* 174, 332-335.
- Reichel, M.P., Ayanegui-Alcérreca, M.A., Gondim, L.F.P., Ellis, J.T., 2013. What is the global economic impact of *Neospora caninum* in cattle – The billion dollar question. *International Journal for Parasitology* 43, 133-142.
- Reichel, M.P., Ellis, J.T., 2002. Control options for *Neospora caninum* infections in cattle - current state of knowledge. *New Zealand Veterinary Journal* 50, 86-92.
- Reichel, M.P., Ellis, J.T., 2006. If control of *Neospora caninum* infection is technically feasible does it make economic sense? *Veterinary Parasitology* 142, 23-34.
- Rinaldi, L., Fusco, G., Musella, V., Veneziano, V., Guarino, A., Taddei, R., Cringoli, G., 2005. *Neospora caninum* in pastured cattle: determination of climatic, environmental, farm management and individual animal risk factors using remote sensing and geographical information systems. *Veterinary Parasitology* 128, 219-230.
- Rinaldi, L., Pacelli, F., Iovane, G., Pagnini, U., Veneziano, V., Fusco, G., Cringoli, G., 2007. Survey of *Neospora caninum* and bovine herpes virus 1 coinfection in cattle. *Parasitology Research* 100, 359-364.
- Ritter, D.M., Kerlin, R., Sibert, G., Brake, D.A., 2002. Immune factors influencing the course of infection with *Neospora caninum* in the murine host. *The Journal of Parasitology* 88, 271-280.
- Roberts, C.W., Walker, W., Alexander, J., 2001. Sex-associated hormones and immunity to protozoan parasites. *Clinical Microbiology Reviews* 14, 476-488.
- Robertson, S.A., 2000. Control of the immunological environment of the uterus. *Rev Reprod* 5, 164-174.
- Robertson, S.A., Mayrhofer, G., Seamark, R.F., 1992. Uterine epithelial cells synthesize granulocyte-macrophage colony-stimulating factor and interleukin-6 in pregnant and nonpregnant mice. *Biology of Reproduction* 46, 1069-1079.
- Robertson, S.A., Seamark, R.F., Guilbert, L.J., Wegmann, T.G., 1994. The role of cytokines in gestation. *Critical Reviews in Immunology* 14, 239-292.

- Romero, J.J., Frankena, K., 2003. The effect of the dam-calf relationship on serostatus to *Neospora caninum* on 20 Costa Rican dairy farms. *Veterinary Parasitology* 114, 159-171.
- Romero, J.J., Pérez, E., Dolz, G., Frankena, K., 2002. Factors associated with *Neospora caninum* serostatus in cattle of 20 specialised Costa Rican dairy herds. *Preventive Veterinary Medicine* 53, 263-273.
- Romero, J.J., Pérez, E., Frankena, K., 2004. Effect of a killed whole *Neospora caninum* tachyzoite vaccine on the crude abortion rate of Costa Rican dairy cows under field conditions. *Veterinary Parasitology* 123, 149-159.
- Romero, J.J., Van Breda, S., Vargas, B., Dolz, G., Frankena, K., 2005. Effect of neosporosis on productive and reproductive performance of dairy cattle in Costa Rica. *Theriogenology* 64, 1928-1939.
- Romero-Salas, D., García-Vázquez, Z., Montiel-Palacios, F., Montiel-Peña, T., Aguilar-Domínguez, M., Medina-Esparza, L., Cruz-Vázquez, C., 2010. Seroprevalence of *Neospora caninum* antibodies in cattle in Veracruz, Mexico. *Journal of Animal and Veterinary Advances* 9, 1445-1451.
- Rosbottom, A., Gibney, E.H., Guy, C.S., Kipar, A., Smith, R.F., Kaiser, P., Trees, A.J., Williams, D.J.L., 2008. Upregulation of cytokines is detected in the placentas of cattle infected with *Neospora caninum* and is more marked early in gestation when fetal death is observed. *Infection and Immunity* 76, 2352-2361.
- Rosbottom, A., Gibney, H., Kaiser, P., Hartley, C., Smith, R.F., Robinson, R., Kipar, A., Williams, D.J.L., 2011. Up regulation of the maternal immune response in the placenta of cattle naturally infected with *Neospora caninum*. *PLoS ONE* 6, e15799.
- Rosbottom, A., Guy, C.S., Gibney, E.H., Smith, R.F., Valarcher, J.F., Taylor, G., Williams, D.J.L., 2007. Peripheral immune response in pregnant cattle following *Neospora caninum* infection. *Parasite Immunology* 29, 219-228.
- Rossi, C.R., Kiesel, G.K., Kramer, T.T., Hudson, R.S., 1978. Cell-mediated and humoral immune responses of cattle to *Brucella abortus*, *Mycobacterium bovis*, and tetanus toxoid: evaluation of immunization and assay techniques. *American Journal of Veterinary Research* 39, 1738-1741.
- Rosypal, A.C., Lindsay, D.S., 2005. The sylvatic cycle of *Neospora caninum*: where do we go from here? *Trends in Parasitology* 21, 439-440.
- Roth, I., Corry, D., Locksley, R., Abrams, J.S., Litton, M., Fisher, S., 1996. Human placental cytotrophoblasts produce the immunosuppressive cytokine interleukin 10. *The Journal of Experimental Medicine* 184, 539-548.
- Sadrebazzaz, A., Habibi, G., Haddadzadeh, H., Ashrafi, J., 2007. Evaluation of bovine abortion associated with *Neospora caninum* by different diagnostic techniques in Mashhad, Iran. *Parasitology Research* 100, 1257-1260.

- Sager, H., Fischer, I., Furrer, K., Strasser, M., Waldvogel, A., Boerlin, P., Audigé, L., Gottstein, B., 2001. A Swiss case-control study to assess *Neospora caninum*-associated bovine abortions by PCR, histopathology and serology. *Veterinary Parasitology* 102, 1-15.
- Sammin, D., Markey, B., Bassett, H., Buxton, D., 2009. The ovine placenta and placentitis - A review. *Veterinary Microbiology* 135, 90-97.
- Sanderson, M.W., Gay, J.M., Baszler, T.V., 2000. *Neospora caninum* seroprevalence and associated risk factors in beef cattle in the northwestern United States. *Veterinary Parasitology* 90, 15-24.
- Santolaria, P., Almería, S., Martínez-Bello, D., Nogareda, C., Mezo, M., González-Warleta, M., Castro-Hermida, J.A., Pabón, M., Yániz, J.L., López-Gatius, F., 2011. Different humoral mechanisms against *Neospora caninum* infection in purebred and crossbreed beef/dairy cattle pregnancies. *Veterinary Parasitology* 178, 70-76.
- Sawada, M., Kondo, H., Tomioka, Y., Park, C.H., Morita, T., Shimada, A., Umemura, T., 2000. Isolation of *Neospora caninum* from the brain of a naturally infected adult dairy cow. *Veterinary Parasitology* 90, 247-252.
- Schares, G., Bärwald, A., Staubach, C., Söndgen, P., Rauser, M., Schröder, R., Peters, M., Wurm, R., Selhorst, T., Conraths, F.J., 2002. p38-avidity-ELISA: examination of herds experiencing epidemic or endemic *Neospora caninum*-associated bovine abortion. *Veterinary Parasitology* 106, 293-305.
- Schares, G., Bärwald, A., Staubach, C., Ziller, M., Klöss, D., Schröder, R., Labohm, R., Dräger, K., Fasen, W., Hess, R.G., Conraths, F.J., 2004. Potential risk factors for bovine *Neospora caninum* infection in Germany are not under the control of the farmers. *Parasitology* 129, 301-309.
- Schares, G., Bärwald, A., Staubach, C., Ziller, M., Klöss, D., Wurm, R., Rauser, M., Labohm, R., Dräger, K., Fasen, W., Hess, R.G., Conraths, F.J., 2003. Regional distribution of bovine *Neospora caninum* infection in the German state of Rhineland-Palatinate modelled by Logistic regression. *International Journal for Parasitology* 33, 1631-1640.
- Schares, G., Conraths, F.J., Reichel, M.P., 1999. Bovine neosporosis: comparison of serological methods using outbreak sera from a dairy herd in New Zealand. *International Journal for Parasitology* 29, 1659-1667.
- Schares, G., Pantchev, N., Barutzki, D., Heydorn, A.O., Bauer, C., Conraths, F.J., 2005. Oocysts of *Neospora caninum*, *Hammondia heydorni*, *Toxoplasma gondii* and *Hammondia hammondi* in faeces collected from dogs in Germany. *International Journal for Parasitology* 35, 1525-1537.
- Schares, G., Peters, M., Wurm, R., Bärwald, A., Conraths, F.J., 1998. The efficiency of vertical transmission of *Neospora caninum* in dairy cattle analysed by serological techniques. *Veterinary Parasitology* 80, 87-98.

- Scharton-Kersten, T.M., Sher, A., 1997. Role of natural killer cells in innate resistance to protozoan infections. *Current Opinion in Immunology* 9, 44-51.
- Schlafer, D.H., Fisher, P.J., Davies, C.J., 2000. The bovine placenta before and after birth: placental development and function in health and disease. *Animal Reproduction Science* 60-61, 145-160.
- Schock, A., Buxton, D., Spence, J.A., Baird, A., Low, J.C., 2000. Histopathological survey of aborted bovine fetuses in Scotland with special reference to *Neospora caninum*. *Veterinary Record* 147, 687-688.
- Schock, A., Innes, E.A., Yamane, I., Latham, S.M., Wastling, J.M., 2001. Genetic and biological diversity among isolates of *Neospora caninum*. *Parasitology* 123, 13-23.
- Seder, R.A., Paul, W.E., 1994. Acquisition of lymphokine-producing phenotype by CD4⁺ T Cells. *Annual Review of Immunology* 12, 635-673.
- Serrano-Martínez, E., Casas-Astos, E., Chávez-Velásquez, A., Collantes-Fernández, E., Álvarez-García, G., Ortega-Mora, L.M., Rodríguez-Bertos, A., 2004. *Neospora* species-associated abortion in alpacas (*Vicugna pacos*) and llamas (*Llama glama*). *Veterinary Record* 155, 748-749.
- Serrano-Martínez, E., Ferre, I., Martínez, A., Osoro, K., Mateos-Sanz, A., del-Pozo, I., Aduriz, G., Tamargo, C., Hidalgo, C.O., Ortega-Mora, L.M., 2007a. Experimental neosporosis in bulls: parasite detection in semen and blood and specific antibody and interferon-gamma responses. *Theriogenology* 67, 1175-1184.
- Serrano-Martínez, E., Ferre, I., Osoro, K., Aduriz, G., Mota, R.A., Martínez, A., del-Pozo, I., Hidalgo, C.O., Ortega-Mora, L.M., 2007b. Intrauterine *Neospora caninum* inoculation of heifers and cows using contaminated semen with different numbers of tachyzoites. *Theriogenology* 67, 729-737.
- Shanmugasundram, A., Gonzalez-Galarza, F.F., Wastling, J.M., Vasieva, O., Jones, A.R. 2013. Library of Apicomplexan metabolic pathways: a manually curated database for metabolic pathways of apicomplexan parasites. *Nucleic Acids Research* 41.
- Sharma, S.D., Hofflin, J.M., Remington, J.S., 1985. *In vivo* recombinant interleukin 2 administration enhances survival against a lethal challenge with *Toxoplasma gondii*. *Journal of Immunology* 135, 4160-4163.
- Sharma, S.D., Verhoef, J., Remington, J.S., 1984. Enhancement of human natural killer cell activity by subcellular components of *Toxoplasma gondii*. *Cellular Immunology* 86, 317-326.
- Shivaprasad, H.L., Ely, R., Dubey, J.P., 1989. A *Neospora*-like protozoon found in an aborted bovine placenta. *Veterinary Parasitology* 34, 145-148.

- Sidhu, R.S., Bollon, A.P., 1993. Tumor necrosis factor activities and cancer therapy - A perspective. *Pharmacology & Therapeutics* 57, 79-128.
- Simpson, V.R., Monies, R.J., Riley, P., Cromey, D.S., 1997. Foxes and neosporosis. *Veterinary Record* 141, 503.
- Soldati, S., Kiupel, M., Wise, A., Maes, R., Botteron, C., Robert, N., 2004. Meningoencephalomyelitis caused by *Neospora caninum* in a juvenile fallow deer (*Dama dama*). *Journal of Veterinary Medicine Series A* 51, 280-283.
- Sopp, P., Howard, C.J., 2001. IFN γ and IL-4 production by CD4, CD8 and WC1 $\gamma\delta$ TCR⁺ T cells from cattle lymph nodes and blood. *Veterinary Immunology and Immunopathology* 81, 85-96.
- Speer, C.A., Dubey, J.P., McAllister, M.M., Blixt, J.A., 1999. Comparative ultrastructure of tachyzoites, bradyzoites, and tissue cysts of *Neospora caninum* and *Toxoplasma gondii*. *International Journal for Parasitology* 29, 1509-1519.
- Staska, L.M., Davies, C.J., Brown, W.C., McGuire, T.C., Suárez, C.E., Park, J.Y., Mathison, B.A., Abbott, J.R., Baszler, T.V., 2005. Identification of vaccine candidate peptides in the NcSRS2 surface protein of *Neospora caninum* by using CD4 cytotoxic T lymphocytes and gamma interferon-secreting T lymphocytes of infected Holstein cattle. *Infection and Immunity* 73, 1321-1329.
- Staska, L.M., McGuire, T.C., Davies, C.J., Lewin, H.A., Baszler, T.V., 2003. *Neospora caninum*-infected cattle develop parasite-specific CD4⁺ cytotoxic T lymphocytes. *Infection and Immunity* 71, 3272-3279.
- Stenlund, S., Kindahl, H., Magnusson, U., Ugglå, A., Björkman, C., 1999. Serum antibody profile and reproductive performance during two consecutive pregnancies of cows naturally infected with *Neospora caninum*. *Veterinary Parasitology* 85, 227-234.
- Stern, A.S., Podlaski, F.J., Hulmes, J.D., Pan, Y.C., Quinn, P.M., Wolitzky, A.G., Familletti, P.C., Stremlo, D.L., Truitt, T., Chizzonite, R., 1990. Purification to homogeneity and partial characterization of cytotoxic lymphocyte maturation factor from human B-lymphoblastoid cells. *Proceedings of the National Academy of Sciences* 87, 6808-6812.
- Stoessel, Z., Taylor, L.F., McGowan, M.R., Coleman, G.T., Landmann, J.K., 2003. Prevalence of antibodies to *Neospora caninum* within central Queensland beef cattle. *Australian Veterinary Journal* 81, 165-166.
- Storset, A., Kulberg, S., Berg, I., Boysen, P., Hope, J., Dissen, E., 2004. NKp46 defines a subset of bovine leukocytes with natural killer cell characteristics. *European Journal of Immunology* 34, 669-676.

- Stuart, P., Zintl, A., de Waal, T., Mucahy, G., Hawkins, C., Lawton, C., 2013. Investigating the role of wild carnivores in the epidemiology of bovine neosporosis. *Parasitology* 140, 296-302.
- Subauste, C.S., Koniaris, A.H., Remington, J.S., 1991. Murine CD8+ cytotoxic T lymphocytes lyse *Toxoplasma gondii*-infected cells. *Journal of Immunology* 147, 3955-3959.
- Summers, C., Benito, A., Ortin, A., de Jalon, J.A.G., González, L., Norval, M., Sharp, J.M., De las Heras, M., 2012. The distribution of immune cells in the lungs of classical and atypical ovine pulmonary adenocarcinoma. *Veterinary Immunology and Immunopathology* 146, 1-7.
- Suzuki, Y., Orellana, M.A., Schreiber, R.D., Remington, J.S., 1988. Interferon-gamma: the major mediator of resistance against *Toxoplasma gondii*. *Science* 240, 516-518.
- Suzuki, Y., Remington, J.S., 1988. Dual regulation of resistance against *Toxoplasma gondii* infection by Lyt2⁺, Lyt1⁺ and L3T4⁺ T-cells in mice. *Journal of Immunology* 140, 3943.
- Swift, B.L., Kennedy, P.C., 1972. Experimentally induced infection *in utero* of bovine foetuses with bovine parainfluenza-3 virus. *American Journal of Veterinary Research* 33, 57-63.
- Szekeres-Bartho, J., Faust, Z., Varga, P., Szereday, L., Kelemen, K., 1996. The immunological pregnancy protective effect of progesterone is manifested via controlling cytokine production. *American Journal of Reproductive Immunology* 35, 348-351.
- Tanaka, T., Hamada, T., Inoue, N., Nagasawa, H., Fujisaki, K., Suzuki, N., Mikami, T., 2000a. The role of CD4+ or CD8+ T cells in the protective immune response of BALB/c mice to *Neospora caninum* infection. *Veterinary Parasitology* 90, 183-191.
- Tanaka, T., Nagasawa, H., Fujisaki, K., Suzuki, N., Mikami, T., 2000b. Growth-inhibitory effects of interferon- γ on *Neospora caninum* in murine macrophages by a nitric oxide mechanism. *Parasitology Research* 86, 768-771.
- Tangri, S., Raghupathy, R., 1993. Expression of cytokines in placentas of mice undergoing immunologically mediated spontaneous fetal resorptions. *Biology of Reproduction* 49, 850-856.
- Teale, A.J., Baldwin, C.L., Morrison, W.I., Ellis, J., MacHugh, N.D., 1987. Phenotypic and functional characteristics of bovine T lymphocytes. *Veterinary Immunology and Immunopathology* 17, 113-123.
- Tekin, P., Hansen, P.J., 2004. Regulation of numbers of macrophages in the endometrium of the sheep by systemic effects of pregnancy, local presence of the

conceptus, and progesterone. *American Journal of Reproductive Immunology* 51, 56-62.

Thilsted, J.P., Dubey, J.P., 1989. Neosporosis-like abortions in a herd of dairy cattle. *Journal of Veterinary Diagnostic Investigation* 1, 205-209.

Thompson, G., Canada, N., Topa, M.d.C., Silva, E., Vaz, F., Rocha, A., 2001. First confirmed case of *Neospora caninum*-associated abortion outbreak in Portugal. *Reproduction in Domestic Animals* 36, 309-312.

Thornton, R.N., Thompson, E.J., Dubey, J.P., 1991. *Neospora* abortion in New Zealand cattle. *New Zealand Veterinary Journal* 39, 129-133.

Thurmond, M.C., Anderson, M.L., Blanchard, P.C., 1995. Secular and seasonal trends of *Neospora abortion* in California dairy cows. *The Journal of Parasitology* 81, 364-367.

Thurmond, M.C., Hietala, S.K., 1995. Strategies to control *Neospora* infection in cattle. *Bovine Practitioner* 29, 60-63.

Thurmond, M.C., Hietala, S.K., 1996. Culling associated with *Neospora caninum* infection in dairy cows. *American Journal of Veterinary Research* 57, 1559-1562.

Thurmond, M.C., Hietala, S.K., 1997a. Effect of congenitally acquired *Neospora caninum* infection on risk of abortion and subsequent abortions in dairy cattle. *American Journal of Veterinary Research* 58, 1381-1385.

Thurmond, M.C., Hietala, S.K., 1997b. Effect of *Neospora caninum* infection on milk production in first-lactation dairy cows. *Journal of the American Veterinary Medical Association* 210, 672-674.

Thurmond, M.C., Hietala, S.K., Blanchard, P.C., 1997. Herd-based diagnosis of *Neospora caninum*-induced endemic and epidemic abortion in cows and evidence for congenital and postnatal transmission. *Journal of Veterinary Diagnostic Investigation* 9, 44-49.

Tierney, T.J., Simpson-Morgan, M.W., 1997a. The immune response of foetal calves. *Veterinary Immunology and Immunopathology* 57, 229-238.

Tierney, T.J., Simpson-Morgan, M.W., 1997b. The proliferative responses of lymphocytes from foetal calves and adult cattle. *Veterinary Immunology and Immunopathology* 59, 49-64.

Tierney, T.J., Trevella, W., Simpson-Morgan, M.W., 1997. The cellular response of lambs to *Brucella ovis* before and after birth. *Veterinary Immunology and Immunopathology* 59, 369-373.

- Tranas, J., Heinzen, R.A., Weiss, L.M., McAllister, M.M., 1999. Serological evidence of human infection with the protozoan *Neospora caninum*. *Clinical and Vaccine Immunology* 6, 765-767.
- Trees, A.J., Davison, H.C., Innes, E.A., Wastling, J.M., 1999. Towards evaluating the economic impact of bovine neosporosis. *International Journal for Parasitology* 29, 1195-1200.
- Trees, A.J., McAllister, M.M., Guy, C.S., McGarry, J.W., Smith, R.F., Williams, D.J.L., 2002. *Neospora caninum*: oocyst challenge of pregnant cows. *Veterinary Parasitology* 109, 147-154.
- Trees, A.J., Williams, D.J.L., 2005. Endogenous and exogenous transplacental infection in *Neospora caninum* and *Toxoplasma gondii*. *Trends in Parasitology* 21, 558-561.
- Trinchieri, G., 1989. Biology of natural killer cells. *Advances in Immunology* 47, 187-376.
- Trinchieri, G., 1995. Interleukin-12: a proinflammatory cytokine with immunoregulatory functions that bridge innate resistance and antigen-specific adaptive immunity. *Annual Review of Immunology* 13, 251-276.
- Trinchieri, G., 2003. Interleukin-12 and the regulation of innate resistance and adaptive immunity. *Nat Rev Immunol* 3, 133-146.
- Truppel, J.H., Montiani-Ferreira, F., Lange, R.R., Vilani, R.G.D.C., Reifur, La., Boerger, W., da Costa-Ribeiro, M.C.V., Thomaz-Soccol, V., 2010. Detection of *Neospora caninum* DNA in capybaras and phylogenetic analysis. *Parasitology International* 59, 376-379.
- Tuo, W., Davis, W.C., Fetterer, R., Jenkins, M.C., Boyd, P.C., Gasbarre, L.C., Dubey, J.P., 2004. Establishment of *Neospora caninum* antigen-specific T cell lines of primarily CD4⁺ T cells. *Parasite Immunology* 26, 243-246.
- Uggla, A., Stenlund, S., Holmdahl, O.J.M., Jakubek, E.B., Thebo, P., Kindahl, H., Björkman, C., 1998. Oral *Neospora caninum* inoculation of neonatal calves. *International Journal for Parasitology* 28, 1467-1472.
- Van Kampen, C., Mallard, B.A., 1997. Effects of peripartum stress and health on circulating bovine lymphocyte subsets. *Veterinary Immunology and Immunopathology* 59, 79-91.
- Venturini, M.C., Venturini, L., Bacigalupe, D., Machuca, M., Echaide, I., Basso, W., Unzaga, J.M., Di Lorenzo, C., Guglielmono, A., Jenkins, M.C., Dubey, J.P., 1999. *Neospora caninum* infections in bovine fetuses and dairy cows with abortions in Argentina. *International Journal for Parasitology* 29, 1705-1708.

- Vianna, M.C.B., Sreekumar, C., Miska, K.B., Hill, D.E., Dubey, J.P., 2005. Isolation of *Neospora caninum* from naturally infected white-tailed deer (*Odocoileus virginianus*). *Veterinary Parasitology* 129, 253-257.
- VIDA, 2011. *Veterinary Investigation Diagnosis Analysis*. Veterinary Laboratories Agency.
- Vitaliano, S.N., Silva, D.A.O., Mineo, T.W.P., Ferreira, R.A., Bevilacqua, E., Mineo, J.R., 2004. Seroprevalence of *Toxoplasma gondii* and *Neospora caninum* in captive maned wolves (*Chrysocyon brachyurus*) from southeastern and midwestern regions of Brazil. *Veterinary Parasitology* 122, 253-260.
- Vollmer, T.L., Waldour, M.K., Steinman, L., Conley, F.K., 1987. Depletion of T-4+ lymphocytes with monoclonal antibody reactivates toxoplasmosis in the central nervous system: a model of superinfection in AIDS. *Journal of Immunology* 138, 3737.
- Waldner, C.L., Janzen, E.D., Henderson, J., Haines, D.M., 1999. Outbreak of abortion associated with *Neospora caninum* infection in a beef herd. *Journal of the American Veterinary Association* 215, 1485, 1448-1490, 1449.
- Waldner, C.L., Janzen, E.D., Ribble, C.S., 1998. Determination of the association between *Neospora caninum* infection and reproductive performance in beef herds. *Journal of the American Veterinary Medical Association* 213, 685-690.
- Wapenaar, W., Barkema, H.W., O'Handley, R., 2013. Fecal shedding of *Toxocara canis* and other parasites in foxes and coyotes on Prince Edward Island, Canada. *Journal of Wildlife Disease* 49, 394-397.
- Weber, F.H., Jackson, J.A., Sobecki, B., Choromanski, L., Olsen, M., Meinert, T., Frank, R., Reichel, M.P., Ellis, J.T., 2013. On the efficacy and safety of vaccination with live tachyzoites of *Neospora caninum* for prevention of *Neospora*-associated fetal loss in cattle. *Clinical and Vaccine Immunology* 20, 99-105.
- Wegmann, T.G., Lin, H., Guilbert, L.J., Mosmann, T.R., 1993. Bidirectional cytokine interactions in the maternal-fetal relationship: is successful pregnancy a Th2 phenomenon? *Immunology Today* 14, 353-356.
- Wells, B.H., 1996. *Neospora*-induced abortion in a dairy herd in Zimbabwe. *Zimbabwe Veterinary Journal* 27, 9-12.
- Wheelhouse, N., Wattedgedera, S., Stanton, J., Maley, S., Watson, D., Jepson, C., Deane, D., Buxton, D., Longbottom, D., Baszler, T., Entrican, G., 2009. Ovine trophoblast is a primary source of TNF- α during *Chlamydophila abortus* infection. *Journal of Reproductive Immunology* 80, 49-56.
- Wilczynski, J.R., 2005. Th1/Th2 cytokines balance--yin and yang of reproductive immunology. *European Journal of Obstetrics & Gynecology and Reproductive Biology* 122, 136-143.

- Williams, D.J.L., Guy, C.S., McGarry, J.W., Guy, F., Tasker, L., Smith, R.F., MacEachern, K., Cripps, P.J., Kelly, D.F., Trees, A.J., 2000. *Neospora caninum*-associated abortion in cattle: the time of experimentally-induced parasitaemia during gestation determines foetal survival. *Parasitology* 121, 347-358.
- Williams, D.J.L., Guy, C.S., Smith, R.F., Ellis, J.T., Björkman, C., Reichel, M.P., Trees, A.J., 2007. Immunization of cattle with live tachyzoites of *Neospora caninum* confers protection against fetal death. *Infection and Immunity* 75, 1343-1348.
- Williams, D.J.L., Guy, C.S., Smith, R.F., Guy, F., McGarry, J.W., McKay, J.S., Trees, A.J., 2003. First demonstration of protective immunity against foetopathy in cattle with latent *Neospora caninum* infection. *International Journal for Parasitology* 33, 1059-1065.
- Williams, D.J.L., Hartley, C.S., Björkman, C., Trees, A.J., 2009. Endogenous and exogenous transplacental transmission of *Neospora caninum* - how the route of transmission impacts on epidemiology and control of disease. *Parasitology* 136, 1895-1900.
- Williams, D.J.L., Trees, A.J., 2006. Protecting babies: vaccine strategies to prevent foetopathy in *Neospora caninum*-infected cattle. *Parasite Immunology* 28, 61-67.
- Wilson, R., McInnes, I., Leung, B., McKillop, J.H., Walker, J.J., 1997. Altered interleukin 12 and nitric oxide levels in recurrent miscarriage. *European Journal of Obstetrics & Gynecology and Reproductive Biology* 75, 211-214.
- Wimsatt, W.A., 1951. Observations on the morphogenesis, cytochemistry, and significance of the binucleate giant cells of the placenta of ruminants. *Am. J. Anat.* 89, 233-281.
- Wolfe, A., Hogan, S., Maguire, D., Fitzpatrick, C., Mulcahy, G., Vaughan, L., Wall, D., Hayden, T.J., 2001. Red foxes (*Vulpes vulpes*) in Ireland as hosts for parasites of potential zoonotic and veterinary significance. *Veterinary Record* 149, 759-763.
- Woodbine, K.A., Medley, G., Moore, S.J., Ramírez Villaescusa, A., Mason, S., Green, L.E., 2008. A four year longitudinal sero-epidemiology study of *Neospora caninum* in adult cattle from 114 cattle herds in south west England: associations with age, herd and dam-offspring pairs. *BMC Veterinary Research* 4.
- Woods, L.W., Anderson, M.L., Swift, P.K., Sverlow, K.W., 1994. Systemic neosporosis in a California black-tailed deer (*Odocoileus hemionus columbianus*). *Journal of Veterinary Diagnostic Investigation* 6, 508-510.
- Wouda, W., Bartels, C.J.M., Moen, A.R., 1999a. Characteristics of *Neospora caninum*-associated abortion storms in dairy herds in The Netherlands (1995 to 1997). *Theriogenology* 52, 233-245.

- Wouda, W., de Gee, A.L., Moen, A.R., van Knapen, F., 1995. Laboratory experiences with bovine *Neospora* abortion in Dutch dairy herds. In: Symposium *Neospora Abortus Bij Het Rund*, pp. 3-9.
- Wouda, W., Dijkstra, T., Kramer, A.M.H., van Maanen, C., Brinkhof, J.M.A., 1999b. Seroepidemiological evidence for a relationship between *Neospora caninum* infections in dogs and cattle. *International Journal for Parasitology* 29, 1677-1682.
- Wouda, W., Moen, A.R., Schukken, Y.H., 1998. Abortion risk in progeny of cows after a *Neospora caninum* epidemic. *Theriogenology* 49, 1311-1316.
- Wouda, W., Moen, A.R., Visser, I.J., van Knapen, F., 1997. Bovine fetal neosporosis: a comparison of epizootic and sporadic abortion cases and different age classes with regard to lesion severity and immunohistochemical identification of organisms in brain, heart, and liver. *Journal of Veterinary Diagnostic Investigation* 9, 180-185.
- Wouda, W., van den Ingh, T.S.G.A.M., van Knapen, F., Sluyter, F.J.H., Koeman, J.P., Dubey, J.P., 1992. *Neospora abortus* bij het rund in Nederland. *Tijdschr Diergeneeskd* 117, 599-602.
- Yaeger, M.J., Shawd-Wessels, S., Leslie-Steen, P., 1994. *Neospora* abortion storm in a midwestern dairy. *Journal of Veterinary Diagnostic Investigation* 6, 506-508.
- Yamane, I., Kitani, H., Kokuho, T., Shibahara, T., Haritani, M., Hamaoka, T., Shimizu, S., Koiwai, M., Shimura, K., Yokomizo, Y., 2000. The inhibitory effect of interferon gamma and tumor necrosis factor alpha on intracellular multiplication of *Neospora caninum* in primary bovine brain cells. *The Journal of Veterinary Medical Science* 62, 341-351.
- Yániz, J.L., López-Gatius, F., García-Ispierto, I., Bech-Sàbat, G., Serrano, B., Nogareda, C., Sánchez-Nadal, J.A., Almería, S., Santolaria, P., 2010. Some factors affecting the abortion rate in dairy herds with high incidence of *Neospora*-associated abortions are different in cows and heifers. *Reproduction in Domestic Animals* 45, 699-705.
- Yui, J., García-Lloret, M., Wegmann, T.G., Guilbert, L.J., 1994. Cytotoxicity of tumour necrosis factor-alpha and gamma-interferon against primary human placental trophoblasts. *Placenta* 15, 819-835.
- Zarlenga, D.S., Canals, A., Aschenbrenner, R.A., Gasbarre, L.C., 1995. Enzymatic amplification and molecular cloning of cDNA encoding the small and large subunits of bovine interleukin 12. *Biochimica et Biophysica Acta (BBA) - Molecular Basis of Disease* 1270, 215-217.
- Zeiler, M., Leiser, R., Pfarrer, C., 2005. Bovine trophoblast cells: establishment of cell culture system and comparison to *in vivo* qualities. *Anatomia, Histologia, Embryologia* 34, 59.

Zenclussen, A.C., Joachim, R., Hagen, E., Peiser, C., Klapp, B.F., Arck, P.C., 2002. Heme oxygenase is downregulated in stress-triggered and interleukin-12-mediated murine abortion. *Scandinavian Journal of Immunology* 55, 560-569.

Zhang, W., Deng, C., Liu, Q., Liu, J., Wang, M., Tian, K.G., Yu, X.L., Hu, D.M., 2007. First identification of *Neospora caninum* infection in aborted bovine foetuses in China. *Veterinary Parasitology* 149, 72-76.

Zimin, A.V., Delcher, A.L., Florea, L., Kelley, D.R., Schatz, M.C., Puiu, D., Hanrahan, F., Pertea, G., Van Tassell, C.P., Sonstegard, T.S., Marçais, G., Roberts, M., Subramanian, P., Yorke, J.A., Salzberg, S.L. 2009. A whole-genome assembly of the domestic cow, *Bos taurus*. *Genome Biology* 10, R42.

Appendix I

Buffers and solutions

Acetylation solution

Purified water	600.0 ml
Acetic anhydride [(CH ₃ CO) ₂ O] (Sigma-Aldrich [®])	1.5 ml
Triethanolamine (Fisher Scientific [®])	9.0 ml

Blocking tRNA solution

Ribonucleic acid from baker's yeast (Sigma-Aldrich [®])	100 mg
RNAse free water (Sigma-Aldrich [®])	10 ml

Blocking solution

10x DIG blocking buffer (see below)	250 µl
10% Triton X-100 (Sigma-Aldrich [®])	75 µl
DIG buffer 1	2175 µl

Colour solution

Nitroblue tetrazolium (NBT) (Sigma-Aldrich [®])	12.0 µl
5-bromo-4-chloro-3-indolyl phosphate (BCIP) (Sigma-Aldrich [®])	9.6 µl
Levamisole solution (see below)	30.0 µl
DIG buffer 3 (see below)	2948.4 µl

Conjugate solution

10x DIG blocking buffer (see below)	250 µl
10% Triton X-100 (Sigma-Aldrich®)	75 µl
DIG buffer 1 (see below)	2170 µl
Anti-Digoxigenin-AP, Fab fragments from sheep (Roche®)	5 µl

Dextran sulphate solution (50%)

Dextran sulphate (Sigma-Aldrich®)	5 g
RNAse free water (Sigma-Aldrich®) (pre-heated)	5 ml

Mix well, allow standing until dissolved and adjust volume to 10 ml with RNAse free water.

DIG blocking buffer (10x)

DIG buffer 1 (1x) (see below)	450 ml
DIG blocking reagent (Roche®)	50 g

Heat very gently to dissolve and make up to 500 ml with DIG buffer 1. Autoclave at 121°C for 15 min.

DIG buffer 1 (5x)

Maleic acid (Fisher Scientific [®])	145.1 g
NaCl (Fisher Scientific [®])	110.0 g
Purified water	2000.0 ml

Dissolve and adjust pH to 7.5 with approximately 90-100g of sodium hydroxide (NaOH) (Fisher Scientific[®]). Make up to 2500 ml with purified water. Autoclave at 121°C for 15 min and store at RT.

DIG buffer 3 (1x)

1M Tri HCl (pH 9.5)	60 ml
5M NaCl (Fisher Scientific [®])	12 ml
1M MgCl ₂ (Fisher Scientific [®])	30 ml
Purified water	498 ml

Mix and use immediately.

DIG buffer 4 (1x)

1M Tri HCl (pH 8.0)	25 ml
0.5M EDTA (pH 8.0)	5 ml
Purified water	2470 ml

Mix and autoclave at 121°C for 15 min.

EDTA solution (0.5M)

EDTA (Sigma-Aldrich [®])	93.06 g
Purified water	400 ml

Mix and adjust pH to 8.0 with NaOH and make up to 500 ml with purified water.
Autoclave at 121°C for 15 min.

Heparin solution

50,000U of heparin (Sigma-Aldrich [®])	50 ml
Distilled water	2450 ml

Autoclave at 121°C for 15 min.

Hybridisation salts

5M NaCl	30 ml
0.5M EDTA pH 8.0 (see above)	10 ml
0.5M Pipes solution pH 7.0 (see below)	10 ml

Hybridisation stock solution

Deionised formamide (Sigma-Aldrich [®])	16.0 ml
Hybridisation salts (see above)	8.0 ml
50x Denhardt's solution (Sigma-Aldrich [®])	3.2 ml
5,000U/ml heparin (Sigma-Aldrich [®])	320 µl
10% Triton X-100 (Sigma-Aldrich [®])	320 µl

Hybridisation solution

Hybridisation stock solution (see above)	805 µl
50% Dextran sulphate solution (see above)	144 µl
Blocking tRNA solution (see above)	51 µl

Hydrogen chloride solution (0.2M)

Concentrated HCl (approximately 10M) (Fisher Scientific [®])	20.4 ml
Purified water	1,000.0 ml

Autoclave at 121°C for 15 min.

Levamisole solution

Levamisole (Sigma-Aldrich [®])	150 mg
RNAse free water (Sigma-Aldrich [®])	5 ml

Magnesium chloride solution (1M)

Magnesium chloride (MgCl ₂ 6H ₂ O) (Fisher Scientific [®])	10.1 g
RNAse free water	40 ml

Dissolve and make up to 50 ml with RNAse free water.

Mayer's haematoxylin

Mayer's haematoxylin (CellPath Ltd., Powis, UK)	1.0 g
Sodium iodate (NaIO ₃) (Fisher Scientific [®])	0.2 g
Potassium aluminium sulphate [KAl(SO ₄) ₂] (Fisher Scientific [®])	50.0 g
Chloral hydrate (C ₂ H ₃ Cl ₃ O ₂) (Fisher Scientific [®])	50.0 g
Citric acid (C ₆ H ₈ O ₇) (Fisher Scientific [®])	1.0 g
Purified water	1,000 ml

Dissolve the first three ingredients in purified water, mix and leave overnight at room temperature. Add the remaining ingredients, boil for 5 min, cool and filter.

Paraformaldehyde fixative solution (4%)

PBS	1,000 ml
Paraformaldehyde (Sigma-Aldrich [®])	40 g

In a fume cupboard add the paraformaldehyde to pre-heated PBS. With continual stirring, heat until dissolved. Filter solution through Whatman N°1 filter paper and adjust volume to 1,000 ml with purified water.

Pipes solution (0.5M)

Pipes (Piperazine-1,4-Bis(2-ethanesulfonic acid) sesquisodium salt) (Fisher Scientific [®])	15.12 g
RNAse free water	100 ml

Mix to dissolve and adjust pH to 7.5 and make up to 100 ml with RNAse free water. Autoclave at 121°C for 15 min.

Phosphate-buffered saline (PBS)

NaCl	8.0 g
Potassium chloride (KCl) (Fisher Scientific [®])	0.2 g
Sodium phosphate dibasic dihydrate (Na ₂ HPO ₄ 2H ₂ O) (Fisher Scientific [®])	1.8 g
Monopotassium phosphate (KH ₂ PO ₄) (Fisher Scientific [®])	0.3 g
Purified water	1,000 ml

Autoclave at 121°C for 15 min.

Prehybridisation stock solution

20x Saline-sodium citrate (SSC) buffer (see below)	4.5 ml
Deionised formamide (Sigma-Aldrich [®])	6.75 ml
50x Denharts solution (Sigma-Aldrich [®])	1.5 ml
RNAse free water	2.1 ml

Prehybridisation solution

Prehybridisation stock solution (see above)	974 µl
Blocking tRNA solution (see above)	26 µl

Proteinase K solution

1M Tris HCl (pH 8.0) (Sigma-Aldrich [®])	146.0 µl
1M Calcium chloride (CaCl ₂) (Fisher Scientific [®])	14.6 µl
Proteinase K (Roche [®])(*)	8.3-13.9 µl
RNAse free water (Sigma-Aldrich [®])	8.5 ml

(*) Proteinase K concentration of different batches may vary, therefore amount needs to be adjusted accordingly. Likewise, different tissues may need different concentration. Final solution is prepared immediately before use.

RNAse solution

3M NaCl	166.4 µl
1M Tris HCl pH 8.0 (Sigma-Aldrich [®])	10.0 µl
0.5M EDTA pH 8.0	2.0 µl
RNAse, DNase-free (Roche [®])	0.2 µl
RNAse T1 from <i>Aspergillus oryzae</i> (Roche [®])	0.2 µl
RNAse free water (Sigma-Aldrich [®])	821.2 µl

Saline-sodium citrate (SSC) buffer (20x)

NaCl	175.3 mg
Tri-Sodium citrate (Na ₃ C ₆ H ₅ O ₇) (Fisher Scientific [®])	88.2 mg
Purified water	1,000 ml

Scott's tap water substitute (STWS)

Sodium bicarbonate (NaHCO ₃) (Fisher Scientific [®])	3.5 g
Magnesium sulphate (MgSO ₄) (Fisher Scientific [®])	20.0 g
Tap water	1,000 ml

Sodium chloride (5M)

Sodium chloride (NaCl) (Fisher Scientific [®])	292.2 g
Purified water	800 ml

Mix and make up to 1 litre with purified water. Autoclave at 121°C for 15 min.

Tris-buffered saline wash buffer (TBS)

Purified water	1500 ml
1M Tris HCl solution (Sigma-Aldrich [®])	100 ml
5M NaCl	60 ml

Mix and adjust pH to 7.6. Add purified water to give a final volume of 1 litre.

Zinc salt fixative buffer (ZSF)

Purified water	800 ml
Tris base [(HOCH ₂) ₃ CNH ₂] (0.1M) (Fisher Scientific®)	12.1 g
Calcium acetate [Ca(C ₂ H ₃ O ₂) ₂] (0.05%)	0.5 g

Mix and adjust pH to 7.0-7.4 with 1M hydrogen chloride (HCl). After pH is adjusted add:

Zinc chloride (ZnCl ₂) (Fisher Scientific®)	5.0 g
Zinc acetate [Zn(O ₂ CCH ₃) ₂] (Fisher Scientific®)	5.0 g

Make up to 1 litre with purified water and store at RT. This solution has to be used within 2 months of preparation.

Appendix II

Tables and figure of statistical results

Table 7: *p*-values for differences in cell scores between negative control and *N. caninum*-inoculated animals at each gestation stage.

Cell type	Early gestation	Mid gestation	Late gestation
CD68 ⁺	0.0151	0.0906	0.0987
CD3 ⁺	0.0001	0.0196	0.0424
CD4 ⁺	0.0005	0.4347	0.1677
CD8 ⁺	0.0032	0.1135	0.2548
γδTCR ⁺	0.0156	0.0176	0.0216
NKp46 ⁺	0.0017	0.0176	0.0036
CD79 _{acy} ⁺	0.4326	0.3865	0.8905
IL-12p40 ⁺	0.0020	0.0394	0.1757
IFN-γ ⁺	0.0010	0.0040	0.7360
TNF-α ⁺	0.0015	0.0048	0.0051

Table 8: Adjusted *p*-values for differences in cell scores between *N. caninum*-inoculated (SC and IV) and negative control animals in early gestation.

Cell type	IV vs. control	SC vs. control	IV vs. SC
CD68 ⁺	0.0679	0.0958	0.4309
CD3 ⁺	0.0026	0.0021	0.2990
CD4 ⁺	0.0043	0.0062	0.2612
CD8 ⁺	0.0251	0.0251	0.6865
γδTCR ⁺	0.0113	0.0161	0.3486
NKp46 ⁺	0.0509	0.0947	0.1408
CD79 _{acy} ⁺	0.1992	0.9449	0.1992
IL-12p40 ⁺	ND	ND	ND
IFN-γ ⁺	ND	ND	0.5251
TNF-α ⁺	ND	ND	ND

ND: not determined

Table 9: *p*-values for differences in cell scores between dams inoculated with *N. caninum* carrying non-viable and viable fetuses in early gestation.

Cell type	Mann-Whitney test (ties)
CD68 ⁺	0.1938
CD3 ⁺	0.0084
CD4 ⁺	0.0426
CD8 ⁺	0.0063
γδTCR ⁺	0.0054
NKp46 ⁺	0.0012
CD79 _{acy} ⁺	0.0088
IL-12p40 ⁺	0.0001
IFN-γ ⁺	0.0070
TNF-α ⁺	0.3865

Table 10: *p*-values for cell scores following overall and pair-wise comparisons of *N. caninum* inoculated animals at each gestation stage.

Cell type	Overall	Early vs. Mid	Early vs. Late	Mid vs. Late
CD68 ⁺	0.0190	0.2029	0.0151	0.6466
CD3 ⁺	0.0001	0.0901	0.0001	0.0236
CD4 ⁺	0.0001	0.1454	0.0001	0.0653
CD8 ⁺	0.0001	0.1471	0.0001	0.0160
γδTCR ⁺	<0.0001	0.1844	0.0001	0.0051
NKp46 ⁺	0.0194	0.0538	0.0402	0.9166
CD79 _{acy} ⁺	0.0190	0.0448	0.9085	0.0234
IL-12p40 ⁺	0.0003	0.0164	0.0013	0.0074
IFN-γ ⁺	0.0010	0.3136	0.0013	0.0038
TNF-α ⁺	0.0050	0.0286	0.0064	0.2055

Table 11: *p*-values for cell scores following overall and pair-wise comparisons of negative control animals at each gestation stage.

Cell type	Overall	Early vs. Mid	Early vs. Late	Mid vs. Late
CD68 ⁺	0.1037	0.4931	0.1209	0.2359
CD3 ⁺	0.0035	0.0173	0.0183	0.1052
CD4 ⁺	0.0046	0.0143	0.0471	0.0477
CD8 ⁺	0.2675	0.3571	0.5337	0.5315
γδTCR ⁺	0.0037	0.0143	0.0147	0.3543
NKp46 ⁺	0.0037	0.0180	0.0180	0.0792
CD79 _{acy} ⁺	0.1429	0.2650	0.1951	0.1951
IL-12p40 ⁺	0.2913	ND	ND	ND
IFN-γ ⁺	0.5130	ND	ND	ND
TNF-α ⁺	0.2771	ND	ND	ND

ND: not determined

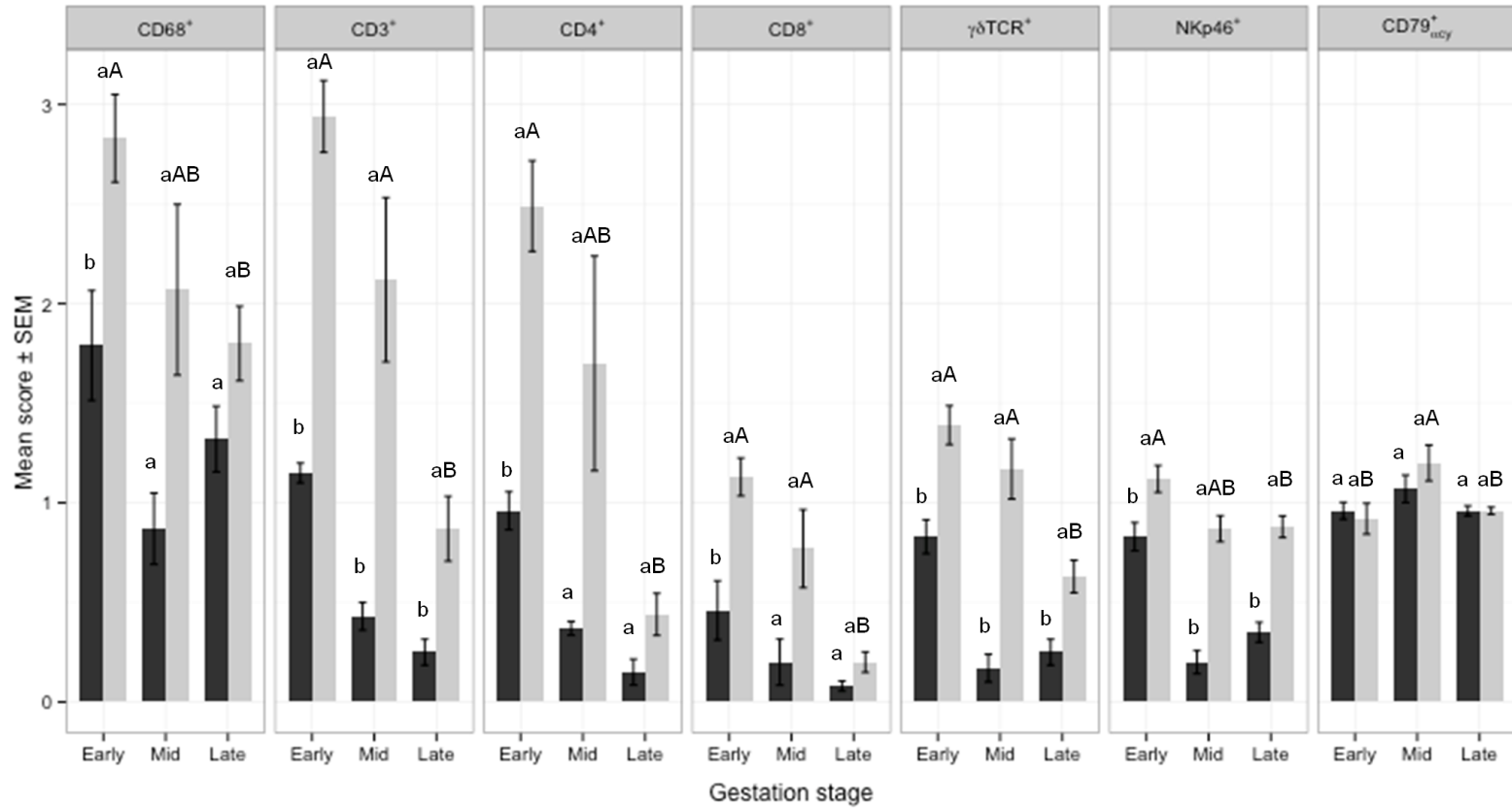


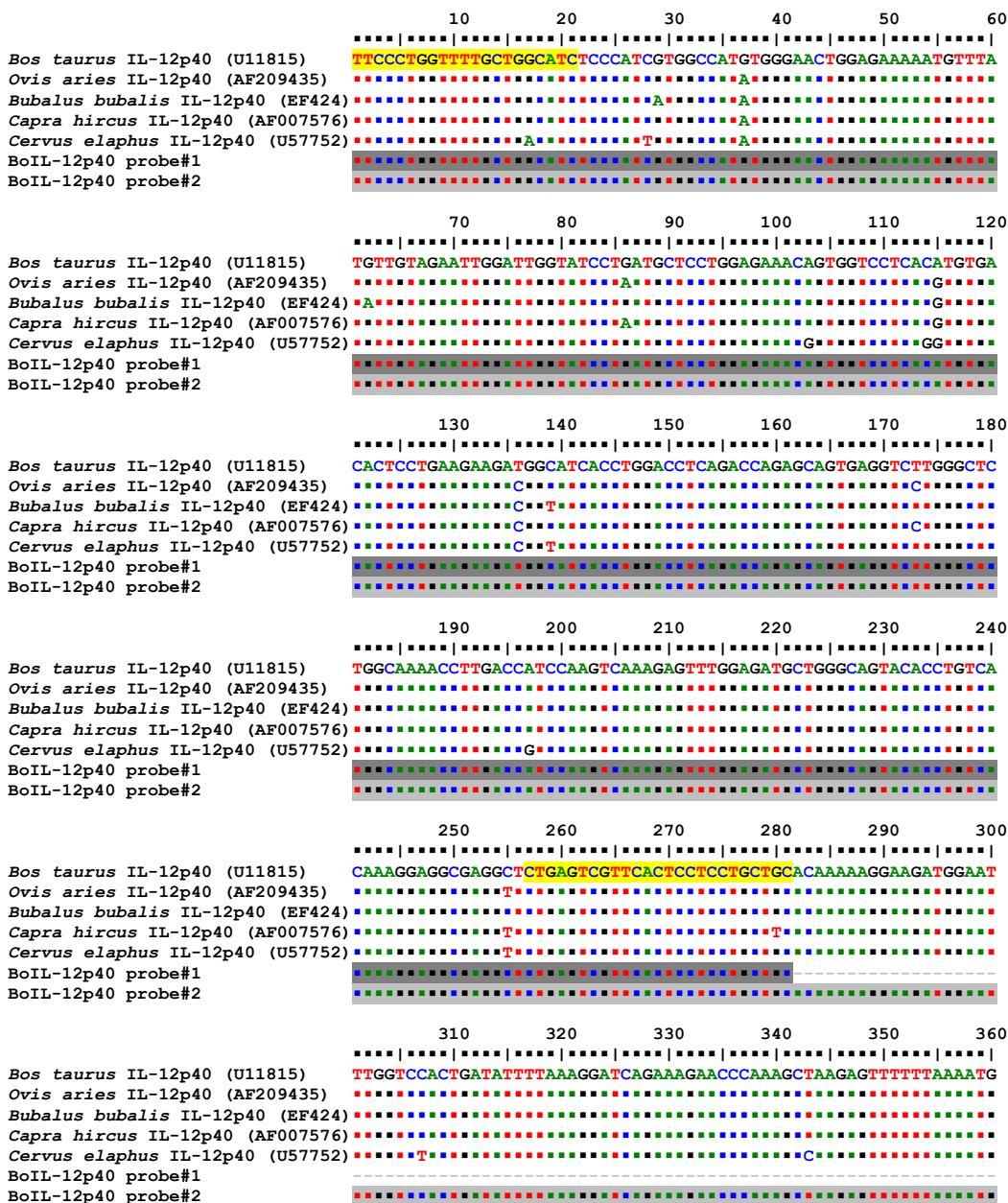
Figure 53: Mean infiltration score for placentomes collected from negative control (black bars) and *N. caninum* inoculated (grey bars) cows during the early, mid and late gestation experiments. Error bars indicate standard error of the means. Different lowercase letters indicate statistically significantly different infiltration scores between control negative and *N. caninum*-inoculated dams in each experiment (early, mid and late gestation). Different uppercase letters indicate statistically significantly different overall infiltration scores for each cell marker between *N. caninum*-inoculated dams at early, mid and late gestation. Adapted from Cantón *et al.* (submitted).

Appendix III

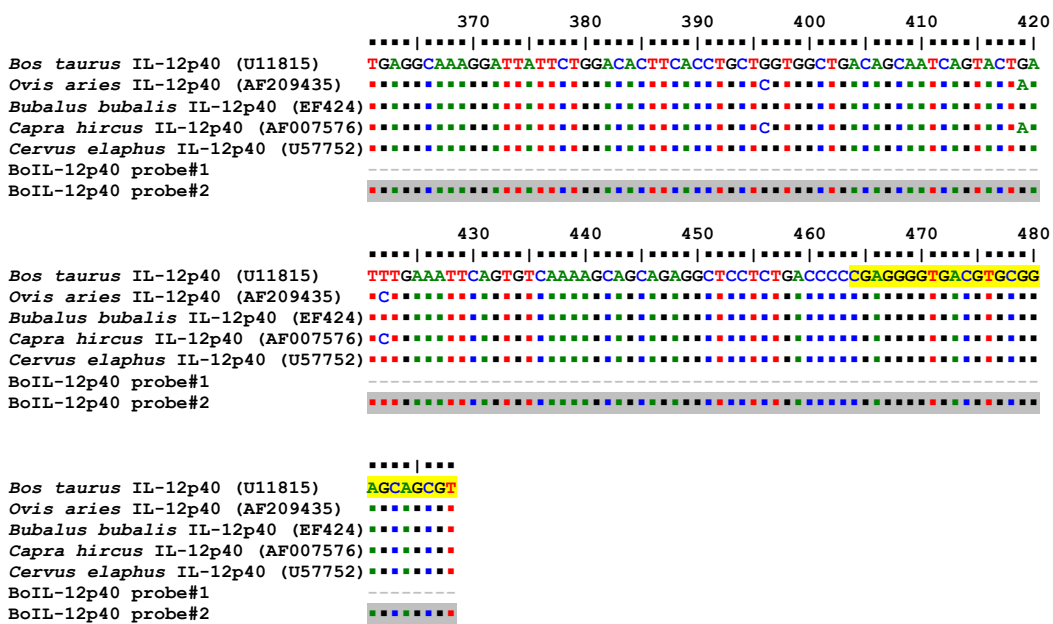
Alignment of the cytokine probes

IL-12p40 alignment:

Key: **Forward and reverse primer pairs**; BoIL-12 probe#1; BoIL-12 probe#2

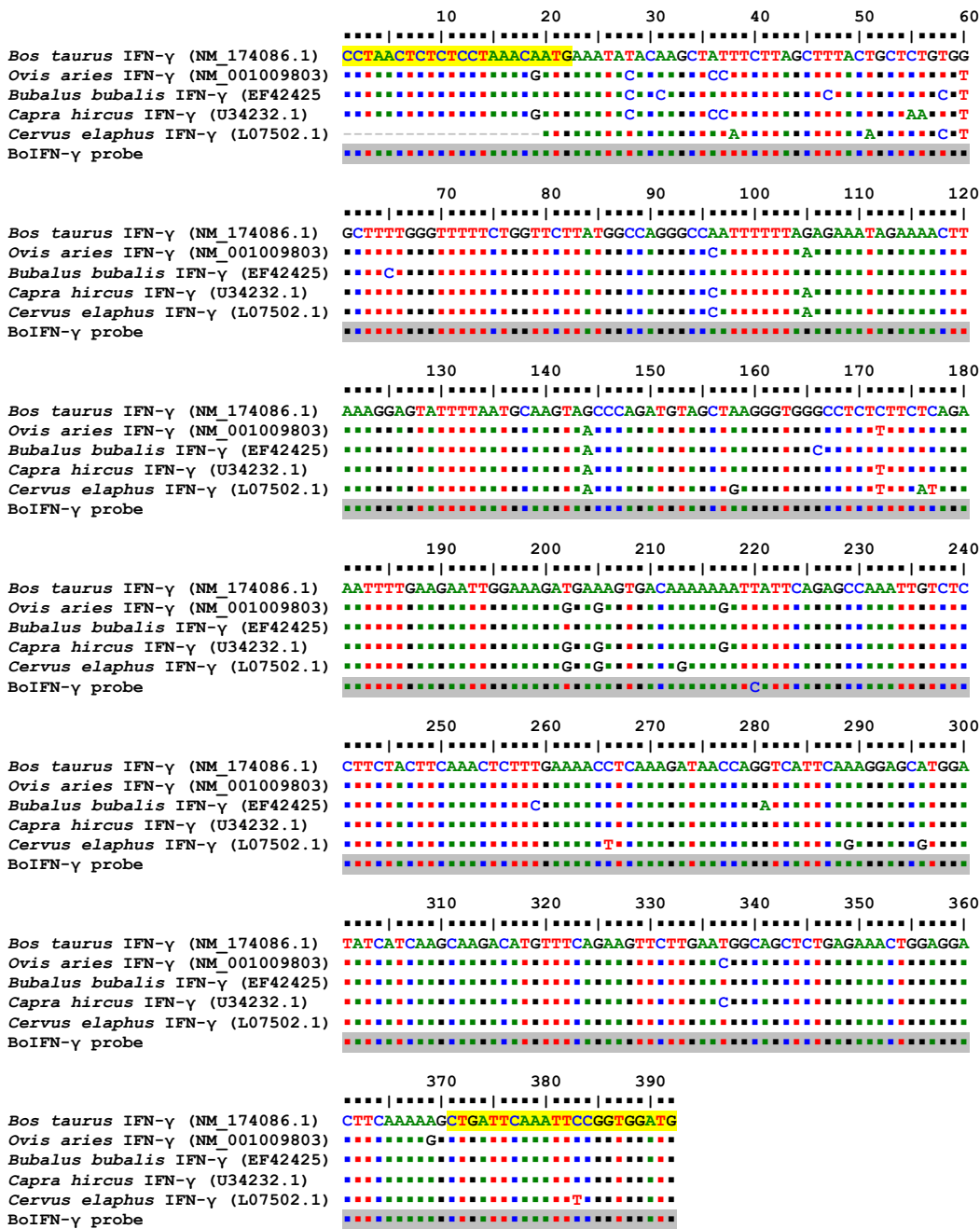


IL-12p40 alignment (continued):



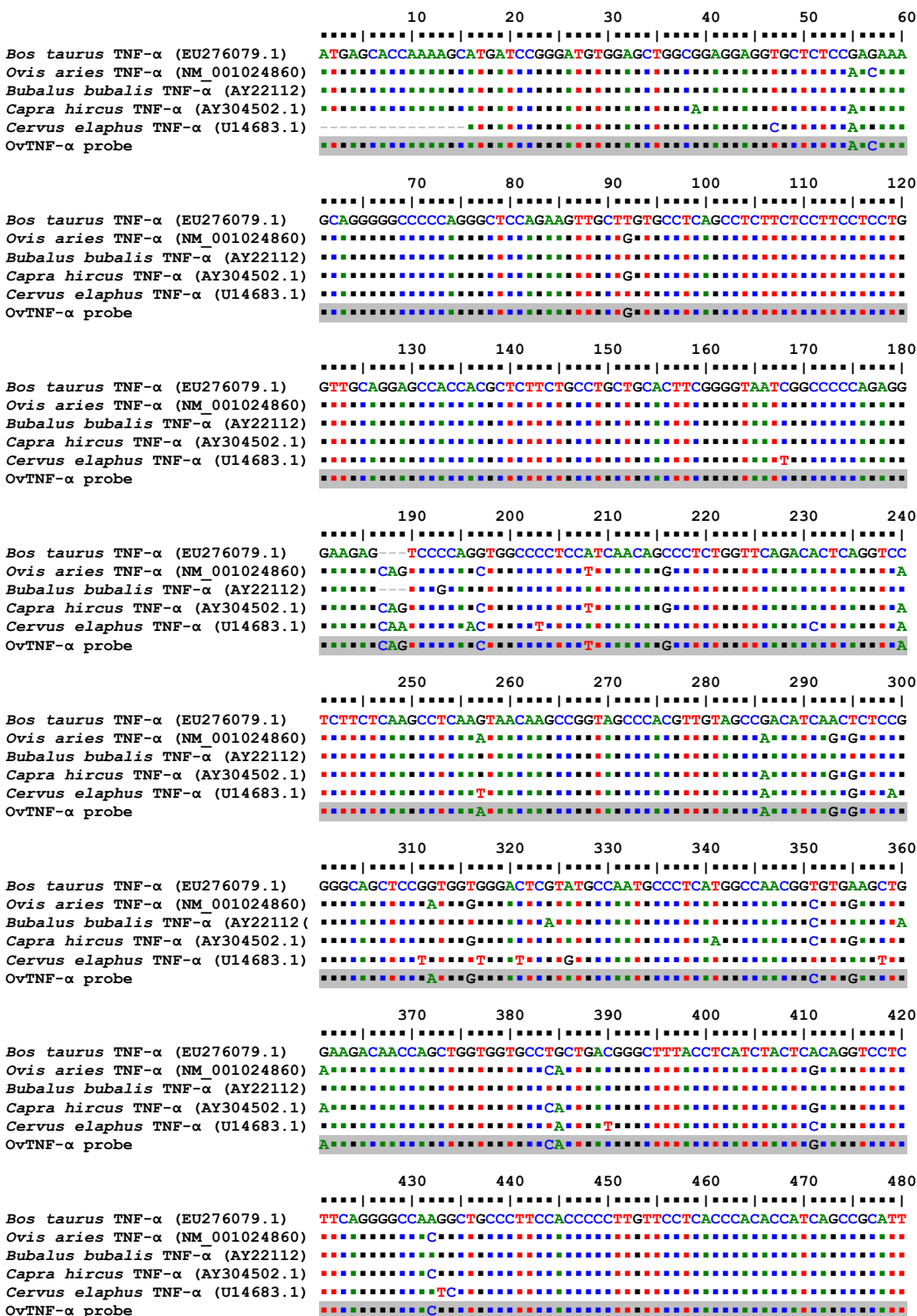
IFN- γ alignment:

Key: **Forward and reverse primer pairs**; **BoIFN- γ probe**



TNF-α alignment:

Key: OvTNF-α probe



Appendix IV

Presentations and publications

Peer reviewed publications – Published (5):

[Permission for reproduction of these publications was granted from all the co-authors (see below)]

Innes, E.A., Bartley, P.M., Rocchi, M., Benavides-Silvan, J., Burrells, A., Hotchkiss, E., Chianini, F., **Canton, G.**, Katzer, F. (2011) Developing vaccines to control protozoan parasites in ruminants: dead or alive? *Veterinary Parasitology* 180 (1-2), 155-163.

<http://www.sciencedirect.com/science/article/pii/S030440171100389X>

Benavides, J., Katzer, F., Maley, S.W., Bartley, P.M., **Canton, G.**, Palarea, J., Pang, Y., Rocchi, M., Chianini, F., Innes, E.A. (2012) High rate of transplacental transmission and infection following experimental inoculation of *Neospora caninum* at late gestation. *Veterinary Research* 43:83.

<http://www.veterinaryresearch.org/content/43/1/83>

Canton, G., Bartley, P., Bartley, K., Todd, H., Chianini, F., Katzer, F. (2013) Production of a bovine IL-12p40 probe and application using *in situ* hybridization on ruminant fixed tissues. *Veterinary Immunology and Immunopathology* 151 (3-4), 342-347.

<http://www.sciencedirect.com/science/article/pii/S0165242712004242>

Canton, G., Katzer, F., Benavides-Silvan, J., Maley, S., Palarea-Albaladejo, J., Pang, Y., Bartley, P., Rocchi, M., Innes, E., Chianini, F. Phenotypic characterisation of the cellular immune infiltrate in placentas of cattle

following experimental challenge with *Neospora caninum* on day 210 of gestation. *Veterinary Research* 44, 60.

www.veterinaryresearch.org/content/44/1/60

Bartley, P.M., Katzer, F., Rocchi, M.S., Maley, S.W., Benavides-Silvan, J., Nath, M., Pang, Y., **Canton, G.**, Chianini, F., Innes, E.A. Development of maternal and foetal immune responses in cattle following experimental challenge with *Neospora caninum* at day 210 of gestation. *Veterinary Research* 44, 91.

www.veterinaryresearch.org/content/44/1/91

Peer reviewed publications – Submitted (4):

Canton, G.J., Konrad, J.L., Moore, D.P., Caspe, S.G., Palarea-Albaladejo, J., Campero, C., Chianini, F. Characterization of the immune cell infiltration in the placentas from water buffaloes (*Bubalus bubalis*) inoculated with *Neospora caninum* during pregnancy. *Journal of Comparative Pathology*.

Chryssafidis, A.L., **Canton, G.**, Chianini, F., Innes, E., Hoffmann Madureira, E., Gennari, S.M. Nc-Bahia strain of *Neospora caninum* is less pathogenic than Nc-1 after experimental infection during early pregnancy in cattle. *Veterinary Parasitology*.

Canton, G.J., Katzer, F., Maley, S.W., Bartley, P., Benavides-Silvan, J., Palarea-Albaladejo, J., Burrells, A., Pang, Y., Rocchi, M., Smith, S., Innes, E.A., Chianini, F. Degree of immune cell infiltration into placentas of *Neospora caninum* challenged cattle correlates with clinical outcome of pregnancy. *Veterinary Research*.

Canton, G.J., Katzer, F., Maley, S.W., Bartley, P., Benavides-Silvan, J., Palarea-Albaladejo, J., Burrells, A., Pang, Y., Rocchi, M., Smith, S., Innes, E.A., Chianini, F. Cytokine expression in the placenta of pregnant cattle after

inoculation with *Neospora caninum* throughout gestation. Veterinary Immunology and Immunopathology

Peer reviewed publications – In preparation (4):

Katzer, F., **Cantón, G.**, Burrells, A., Palarea-Albaladejo, J., Horton, B., Bartley, P.M., Pang, Y., Chianini, F., Innes, E.A., Benavides, J. Immunization of lambs with the S48 strain of *Toxoplasma gondii* reduces parasite colonization of tissues after oral inoculation with the M4 strain; safer meat for human consumption.

Burrells, A., **Cantón, G.**, Benavides, J., Thomson, J., Bartley, P., Pang, Y., Harvey, C., Chianini, F., Innes, E., Katzer, F. Vaccination of pigs against *Toxoplasma gondii* reduces tissue cyst formation; safer meat for human consumption.

Hecker, Y.P., **Cantón, G.**, Regidor-Cerrillo, J., Chianini, F., Ortega-Mora, L.M., Campero, C.M., Innes, E., Moore, D.P. Characterization of leucocytes in placenta of heifers inoculated with the NC-6 strain of *Neospora caninum* and challenged with NC-1 strain.

Ricci, E., Benavides-Silván, J., **Cantón, G.**, Eaton, S., Maley, S., Cantile, C., Chianini, F. iNOS is not detectable in ovine brain infected with *Toxoplasma gondii*.

Conference proceedings – Oral presentations (19):

Cantón, G.J., Katzer, F., Maley, S.W., Bartley, P.M., Benavides-Silván, J., Palarea-Albaladejo, J., Pang, Y., Rocchi, M.S., Buxton, D., Innes, E.A., Chianini, F. Characterization of the immune cell response in the placentas from cattle following experimental inoculation with *Neospora caninum* throughout pregnancy. Apicowplexa 2013: International Meeting on Apicomplexan

Parasites in Farm Animals. Pine Bay Hotel, Kuşadası, Turkey. October 31 – November 2, 2013.

Katzer, F., Burrells, A., **Cantón, G.**, Benavides, J., Thomson, J., Bartley, P., Horton, B., Pang, Y., Harvey, C., Chianini, F., Innes, E. Vaccination of pigs and lambs against *Toxoplasma gondii* reduces tissue cyst formation; safer meat for human consumption. Apicowplexa 2013: International Meeting on Apicomplexan Parasites in Farm Animals. Pine Bay Hotel, Kuşadası, Turkey. October 31 – November 2, 2013.

Burrells, A., **Cantón, G.**, Benavides, J., Thomson, J., Bartley, P., Pang, Y., Harvey, C., Chianini, F., Innes, E., Katzer, F. Vaccination of pigs and lambs against *Toxoplasma gondii* reduces tissue cyst formation; safer meat for human consumption. 24th International Conference of the World Association for the Advancement of Veterinary Parasitology. A. Burrells – Speaker. Perth Convention and Exhibition Centre, Perth, Australia. August 25-29, 2013.

Cantón, G., Katzer, F., Maley, S., Bartley, P., Benavides-Silvan, J., Palarea-Albaladejo, J., Pang, Y., Rocchi, M., Buxton, D., Innes, E., Chianini, F. Cytokine expression in the placenta of cattle following inoculation with *Neospora caninum* throughout gestation. 24th International Conference of the World Association for the Advancement of Veterinary Parasitology. Perth Convention and Exhibition Centre, Perth, Australia. August 25-29, 2013.

Cantón, G. Neosporosis: understanding a major cause of abortion in cattle. Internal seminar at Moredun Research Institute, Edinburgh, UK. June 20, 2013.

Bartley, P., Katzer, F., **Cantón, G.**, Pang, Y., Benavides, J., Chianini, F., Innes, E. Comparison of the maternal and foetal immune responses of cattle, following an experimental inoculation with *Neospora caninum* at early, mid and late gestation. Apicowplexa 2012: International Meeting on Apicomplexan Parasites in Farm Animals. Paul Bartley (Speaker). Proceedings page 47.

Escola Superior de Tecnologia da Saúde de Lisboa, Portugal. October 25-28, 2012.

Innes, E., Bartley, P., Rocchi, M., Benavides-Silvan, J., Burrells, A., Opsteegh, M., Chianini, F., **Canton, G.**, Katzer, F. Control of *Neospora caninum* and *Toxoplasma gondii* in farm livestock. Apicowplexa 2012: International Meeting on Apicomplexan Parasites in Farm Animals. Lee Innes (Invited speaker). Proceedings page 56. Escola Superior de Tecnologia da Saude de Lisboa, Portugal. October 25-28, 2012.

Canton, G., Benavides, J., Maley, S., Katzer, F., Palarea-Albaladejo, J., Bartley, P., Rocchi, M., Innes, E., Chianini, F. Immune phenotyping of placentas following experimental inoculation with *Neospora caninum* during gestation. 30th Meeting of the European Society of Veterinary Pathology. Proceeding page 77. Universidad de Leon, Spain. September 5-8, 2012.

Canton, G. Neosporosis: understanding a major cause of abortion in cattle. Seminar offered to a group of Brazilian farmers. Royal Highland Show, Edinburgh, UK. June 23, 2012.

Canton, G., Katzer, F., Benavides, J., Maley, S., Bartley, P., Rocchi, M., Palarea-Albaladejo, J., Smith, S., Innes, E., Chianini, F. Neosporosis: understanding a major cause of abortion in cattle. Science for Life 2012 - Inter-Institute Postgraduate Student Competition 2012. Scottish Agricultural College – Roslin Institute Building, Midlothian, UK. May 31 – June 1, 2012.

Canton, G., Katzer, F., Benavides, J., Maley, S., Bartley, P., Rocchi, M., Smith, S., Innes, E., Chianini, F. Characterisation of immune cells within bovine placental tissue following experimental inoculation with *Neospora caninum* at different stages of gestation. PhD Student Day at Moredun Research Institute, Edinburgh, UK. April 27, 2012.

Canton, G., Katzer, F., Benavides, J., Maley, S., Bartley, P., Rocchi, M., Smith, S., Innes, E., Chianini, F. Characterisation of immune cells within bovine

placental tissue following experimental inoculation with *Neospora caninum* at different stages of gestation. Royal (Dick) School of Veterinary Studies – Roslin Institute. Postgraduate Presentations. Edinburgh, UK. April 18, 2012.

Cantón, G. Bovine neosporosis: Characterization of immune system cell subsets in placentas. Seminar of the British Society of Veterinary Pathology. Invited speaker. Veterinary Pathology Unit, Royal (Dick) School of Veterinary Studies and the Roslin Institute, University of Edinburgh, UK. February 2, 2012.

Cantón, G., Benavides, J., Maley, S., Katzer, F., Bartley, P., Rocchi, M., Smith, S., Innes, E., Chianini, F. Immune phenotyping of bovine placentas following experimental inoculation with *Neospora caninum* at late gestation. 29th Meeting of the European Society of Veterinary Pathology. Proceeding page 24. Swedish University of Agricultural Sciences, Uppsala, Sweden. September 7-10, 2011.

Innes, E.A., Bartley, P.M., Rocchi, M., Benavides-Silvan, J., Burrells, A., Hotchkiss, E., Chianini, F., **Cantón, G.,** Katzer, F. Developing vaccines to control protozoan parasites in ruminants. 23rd International Conference of the World Association for the Advancement of Veterinary Parasitology. Lee Innes (invited speaker). Buenos Aires, Argentina. August 21-25, 2011.

Cantón, G., Benavides, J., Maley, S., Katzer, F., Bartley, P., Rocchi, M., Smith, S., Innes, E., Chianini, F. Immune cell characterisation of placental lesions following experimental infection with *Neospora caninum* at 210 days of gestation in cattle. Royal (Dick) School of Veterinary Studies – The Roslin Institute. Postgraduate Presentations. Edinburgh, UK. May 12, 2011.

Cantón, G. Immune cell characterisation of placental lesions following experimental infection with *Neospora caninum* at 210 days of gestation in

cattle. PhD Student Day at Moredun Research Institute, Edinburgh, UK. April 8, 2011.

Cantón, G.J., Benavides, J., Maley, S., Katzer, F., Bartley, P., Rocchi, M., Smith, S., Innes, E., Chianini, F. Immunohistochemistry findings in foetal, placental and maternal tissues from cattle experimentally inoculated with *Neospora caninum* in late gestation. Annual Conference of the Association for Veterinary Teaching and Research Work. Proceeding page 19. Royal York Hotel, York, UK. March 29-30, 2010.

Cantón, G.J. Immunohistochemistry findings in foetal, placental and maternal tissues from cattle experimentally inoculated with *Neospora caninum* in late gestation. PhD Student Day at Moredun Research Institute, Edinburgh, UK. March 5, 2010.

Conference proceedings – Poster presentations (12):

Cantón, G.J., Schock, A., Chianini, F. Characterization of CD79_{acy}⁺ cells in placentas from ruminants. The 4th Improving Immunohistochemistry Discussion Forum. Cineworld: The O2, London, UK. October 11, 2013.

Cahalan, S., **Cantón, G.**, Bartley, P., Katzer, F., Chianini, F. Protozoan encephalitis with *Neospora caninum* and *Sarcocystis tenella* co-infection in an adult dog from the UK. 24th International Conference of the World Association for the Advancement of Veterinary Parasitology. Perth Convention and Exhibition Centre, Perth, Australia. August 25-29, 2013.

Cantón, G., Burrells, A., Bartley, P., Pang, Y., Chianini, F., Innes, E., Benavides-Silvan, J., Katzer, F. *Toxoplasma gondii* vaccination in lambs reduces tissue cysts formation in muscles of commercial value after experimental inoculation. 24th International Conference of the World Association for the

Advancement of Veterinary Parasitology. Perth Convention and Exhibition Centre, Perth, Australia. August 25-29, 2013.

Cantón, G., Maley, S., Katzer, F., Bartley, P., Konrad, J.L., Caspe, G., Moore, P., Campero, C., Innes, E., Chianini, F. Characterization of the immune cell infiltration of cattle and buffalo placentas following experimental inoculation with *Neospora caninum* during early pregnancy. Apicowplexa 2012: International Meeting on Apicomplexan Parasites in Farm Animals. Proceedings page 107. Escola Superior de Tecnologia da Saúde de Lisboa, Lisbon, Portugal. October 25-28, 2012.

Cantón, G., Konrad, J., Caspe, G., Moore, P., Campero, C., Chianini, F. Cellular immune response in water buffalo placentas after inoculation with *Neospora caninum* during early gestation. 30th Meeting of the European Society of Veterinary Pathology. Proceeding page 202. Universidad de León, Spain. September 5-8, 2012.

Cantón, G., Bartley, K., Bartley, P., Todd, H., Chianini, F., Katzer, F. Production of bovine IL-12p40 probe for *in situ* hybridization on ruminant fixed tissues. 4th European Veterinary Immunology Workshop. Proceeding page 42. Royal College of Physicians of Edinburgh, UK. September 2-4, 2012.

Cantón, G., Konrad, J., Campero, C., Chianini, F. Cellular immune response in water buffalos placentas after inoculation with *Neospora caninum* at early gestation. British Society of Parasitology - Spring Meeting 2012. Proceeding P243, Addendum. University of Strathclyde, Glasgow, UK. April 2-5, 2012.

Cantón, G., Maley, S., Katzer, F., Bartley, P., Rocchi, M., Smith, S., Palarea-Albaladejo, J., Innes, E., Chianini, F. Immune phenotyping of placentas following experimental inoculation with *Neospora caninum* in cows at mid gestation. British Society of Parasitology - Spring Meeting 2012. Proceeding P220, page 221. University of Strathclyde, Glasgow, UK. April 2-5, 2012.

Cantón, G., Konrad, J., Campero, C., Chianini, F. Immunohistochemical characterisation of immune cell subsets on lymph nodes from water buffaloes. 29th Meeting of the European Society of Veterinary Pathology. Proceeding P23, page 87. Swedish University of Agricultural Sciences, Uppsala, Sweden. September 7-10, 2011.

Rodríguez, A., Weber, N., **Cantón, G.**, Moore, D., Moreira, A., Morrell, E., Odeón, A., Odriozola, E., Campero, C. Causes of bovine abortion in Argentina. 29th Meeting of the European Society of Veterinary Pathology. Proceeding P60, page 123. Swedish University of Agricultural Sciences, Uppsala, Sweden. September 7-10, 2011.

Cantón, G., Benavides, J., Maley, S., Katzer, F., Bartley, P., Rocchi, M., Smith, S., Innes, E., Chianini, F. Immune cell characterisation of placental lesions following experimental infection with *Neospora caninum* at 210 days of gestation in cattle. British Society for Immunology – Annual Congress. Proceeding page 81. Liverpool, UK. December 6-10, 2010.

Cantón, G.J., Benavides, J., Maley, S., Katzer, F., Bartley, P., Rocchi, M., Smith, S., Innes, E., Chianini, F. Immunohistochemistry findings in foetal, placental and maternal tissues from cattle experimentally inoculated with *Neospora caninum* in late gestation. Research Student Day of the University of Edinburgh. Royal (Dick) School of Veterinary Science, The University of Edinburgh, UK. April 21, 2010.