

Australasian Club,
Edinburgh

To the Dean of the Faculty of Medicine
University of Edinburgh
4th March 1903

Dear Sir,

I beg to submit my Thesis for the
Degree of Doctor of Medicine.

This thesis is an ~~of~~ account of
some medical and surgical cases
treated by me while a Civil Surgeon
in the South African Field Force
during the late Boer War.

During the war I was on medical
duty in Base Hospitals in Natal
and Transvaal, in Detention Hospitals
on Blockhouse lines and on Column
with troops in the Field.

Many of the observations on the cases
were made under conditions of great
disadvantage and inconvenience,
— Conditions necessarily present in
a state of active warfare.

I am, Sir,

Your obedient servant

Arthur A. Martin M.B.

address.

A. A. Martin M.B.

Lumsden

Southland

New Zealand

Title:—

"Medical and Surgical Experiences while a
Civil Surgeon, South African Field Force.

late Boer War"

by

Arthur Anderson Martin, M.B., Ch.B.,

late Civil Surgeon, attached

Royal Army Medical Corps,

South African Field Force.



BH 254. Dalmantina



usual type of Blockhouse in Eastern Transvaal.
(late Boer War)

Medical Duty on a Blockhouse Line in the Eastern

Transvaal.

Lord Kitchener during the second phase of the late war, in order to control districts, towns and railways, constructed those little forts or blockhouses, which eventually honeycombed the country. Each blockhouse was a fort, well nigh impregnable to rifle fire, but quite at the mercy of any big gun or shell fire.

The Blockhouse lines were divided into districts. Each district was placed under a Commanding Officer, who garrisoned the posts with his regiment. To each district a medical officer was appointed in order to preserve the health of the garrisoning troops, attend the wounded in attacks on the Blockhouses, and maintain a watchful eye on the sanitation and water supply. I was posted to a remote hamlet or "dorp" called Belfast away in the Eastern Transvaal. My orders were to ride round the Blockhouses of the Belfast command at least once a week, see that the water supply was as good as could be obtained, that latrines were properly constructed and attended to, and to withdraw any soldier seriously ill, from his blockhouse to my detention hospital/

hospital and then send him by hospital train to the Stationary Hospital. At Belfast the headquarters was situated. Both the hospital and fort were protected by turf walls and loop-holed blockhouses. On the highest point of the turf wall round the hospital, the red cross flag was planted in order to show the enemy during an attack, what was neutral ground. Attacks, however, generally took place at night when no distinguishing emblem designated the hospital. My hospital consisted of three large marquees, two E.P.I.P tents (European Private Indian Pattern type), and two bell tents. An abundance of blankets, mattresses, bedsteads and the ordinary hospital accessories were provided. An army operating case, dozens of boxes of drugs of all kinds, anti-septic dressings, ligatures, etc., etc. were also kept in stock. For rationing the patients there were several boxes of tinned milk (Ideal Brand), Bovril, Valentine's Beef Extract, preserved chicken, tongue, soup powders, arrowroot, etc, etc. and port wine, brandy, and champagne were at hand for emergencies. My staff consisted of two hospital orderlies, (one a clever St. John Ambulance volunteer), the other was a raw recruit from the regiment), a cook, and a personal servant to look after my horse and tent. We had a big stove fitted up in a shelter/

shelter made of corrugated iron, and an abundant water supply from an iron tank at the railway siding close by. All the water was passed through our Berkefeld filter before using. The latrines were on the "dry earth" system and chloride of lime and Condy's fluid were lavishly employed to keep all clean. We were quite close to the railway and twice a week a hospital carriage stopped at the hospital for two purposes. One was that I could put my sick on it for transfer to the Stationary Hospital at Middelburg, and the other was that I could board the carriage and see if any of the sick already in it required any medical attention. These sick came from as far as Komati Poort and were on the way to Base Hospitals. No doctor travelled by the train, but two R.A.M.C. orderlies attended to the wants of the invalids. If one of the sick were dying or in a dangerous state he was taken out of the train and carried into the Detention Hospital. This same procedure took place all along the line where a Detention Hospital was situated. When the Hospital carriage (which was attached to an ordinary goods train) left the siding, I wired to the next Detention Hospital apprising the medical officer there of the fact. The name Detention Hospital indicates its purpose. Patients were detained there under medical treatment till they could be safely transferred/

ferred to a Stationary Hospital. Cases which were of a mild medical or surgical nature were not transferred, but were treated at the Detention Hospital. For instance, all cases of serious gunshot wounds, serious accidents, enteric fever, dysentery or pneumonia were transferred. A Mild bronchitis diarrhoea, slight gunshot wound, etc., were treated till they were cured and were then sent back to duty.

The Blockhouse lines I had the medical charge of extended for about 20 miles along a railway line. Each blockhouse had a garrison of 6 or 8 men. The houses were very warm and comfortable inside. The ventilation was efficiently carried out by the loop, holes pierced in the side. There were about 16 of these loopholes in each house. The door was either on a level with the floor, or close up to the roof. When situated on the floor level one got in and out by half stooping or on "all-fours". When near the roof one got in and out by going up steps of stones or wood. Round the blockhouse was a deep trench in which a sentry patrolled at night. At one part of this trench an excavation was made to hold the 60 gallon corrugated iron tank in which the water was stored. Each tank had a tap attached and a movable wooden cover. A barbed wire fence and barbed wire entanglements surrounded all, leaving a space of about/

about 15 yards where the kitchen and water jars stood. At a distance of 500 yards more or less, the latrine was made. This was simply a hole in the ground. Every week this hole was filled in with soil, and a new one made. Each blockhouse had a box of chloride of lime for disinfecting and permanganate of potash for swilling out the tank at intervals. The water for drinking was obtained from wells sunk near small streams or sometimes from a clear stream near by. As a rule a well of about 3 ft. deep was sunk and a pile of stones laid on the bottom. The water was then carried to the blockhouse tank where it was stored. Before using it for drinking purposes, the men were compelled, by medical orders, to boil the water. A big kettle was specially reserved for boiling the water. When boiled the water was put into empty rum casks. Each blockhouse, all along the line, was provided with four of these empty rum casks and excellent receptacles for water they were. Every week the tank had to be lifted out and cleaned with Condly's fluid. The men as a rule when thirsty drank cold tea or coffee. Very few of them cared for the boiled water. The water obtained from the wells and streams was brackish and earthy. Most of the old soldiers were fully alive to the dangers of enteric and Bilharzia Haematobia from drinking unboiled Transvaal water.

The/

The food supplied to the men was as a rule wholesome and good.

The daily ration issued to each soldier was:-

1 lb. biscuits or $1\frac{1}{4}$ lbs. bread, or 1 pound flour, or $1\frac{1}{2}$ lbs. mealie meal.

Fresh meat - $1\frac{1}{4}$ lbs, or 2 ounces cheese, or 1 quarter bacon.

Sugar, 3 oz.
Salt $\frac{1}{2}$ "
Coffee 1 "

Jam, $\frac{1}{4}$ lb.
Tea, $\frac{1}{4}$ oz.

Compressed vegetables
1 oz. or $\frac{1}{4}$ lb. potatoes,
or $\frac{1}{4}$ lb. onions.

Small issue of Rum twice a week.

By judicious arrangement the six men at a Blockhouse got a varied dietary. Fresh meat and potatoes, however, often were not obtainable. In many cases where the blockhouse was near a ruined farmhouse, fresh vegetable marrows and sometimes fruit could be got from the old garden. Turnip, carrot, parsnip seeds, young plants and seed potatoes were supplied to blockhouses in certain districts on application to the proper authorities. The men were allowed to cultivate the ground round the blockhouse if they felt inclined so to do.

The health of the troops in the Houses, as a rule, was excellent. They had all to do hard physical work for three hours daily. Deep trenches had to be cut along the line from one blockhouse to another, and every man had to dig one cubic yard of trench every six days. The wire entanglements and wire fences continually required strengthening and repairing/

repairing, so that this work, while not excessive, gave just the necessary amount of physical exercise to keep the men in good condition. The average soldier is proverbially idle and when not on duty sleeps or smokes, so that I consider the digging and wiring were very necessary correctives in an otherwise monotonous and dreary life in a lonely blockhouse.

Troops recently arrived in South Africa were very prone to contract enteric fever, dysentery, and diarrhoea. A volunteer section of Fusiliers recently arrived in the country, ^{was} were posted to this line and almost all of them suffered at first from diarrhoea. Several also developed enteric fever, but these I consider contracted the disease on the way up from Cape Town. The only cases of enteric fever or dysentery I had on this line occurred amongst these newly arrived troops. They were invalided within ten days after their arrival, so I do not blame the water supply or sanitation of my blockhouses in this particular.

Veldt sores were the greatest scourge to the troops on the blockhouses. Handling so much barbed wire, they could hardly escape lacerating their hands and arms. The laceration if neglected, developed into a chronic indurated and septic sore. If the laceration/

laceration were at once treated antiseptically it, as a rule, healed rapidly. Many of the officers lacerated their hands in this way and I provided them with tabloids of corrosive sublimate, directing them to wash their hands several times a day for the first day with this lotion and keep the part covered with a piece of lint. This usually sufficed. On the third day the hand would be well. The soldiers, however, were careless about these cuts and very frequently only came for treatment when their hands were in an extremely inflamed and septic condition. Most of the sores were on the knuckles and the backs of the hands. Every blockhouse on this line was provided with some tabloids of corrosive, a pot of zinc and mercury ointment, lint and a couple of gauze bandages. These were given to the sergeant in charge with directions for use. The frequency of the sores soon became markedly less when this measure had been carried out in all the houses on the line.

Another point of some medical interest in the blockhouse life presented itself during the war. That was the number of self-inflicted injuries. A man would injure himself in order to be admitted to hospital and so removed from the loneliness and the undoubted monotony of a life in a blockhouse on the high veldt. I saw three such cases in South Africa. In one a bullet had been discharged through the/

the left foot, and in another through the fleshy part of the leg. In the third case the little finger of the left hand had been blown off. Courts of Enquiry were held on these cases, and two of the men were sent to England as "Prisoners".

The following case was that of a man, Private Jones, 2nd Lancashire Fusiliers (Volunteers) who had been five months in South Africa. All this time he had been on duty in a blockhouse on this line. He had never left the place and the monotony of the life, as he said, "was getting on his nerves". On riding round to this blockhouse on 20th May, 1902, this man reported himself to me as unfit for duty. He said he was "losing his memory", and the "slightest work tired him out". He said he frequently forgot the countersign at night. The sergeant in charge told me that the previous night, this man while on sentry had fired off his rifle three times into the darkness, thinking he saw Boers creeping up. Of course he may have seen these Boers, but the sergeant and the other men said it was all imagination. I took the man into hospital for observation and gave him five grains of Calomel at once. He was quite lively and active in Hospital. He told me that he was tired of the life in a blockhouse and got nervous at night. I told him that if he came to/
to/

to me with a similar tale again he would be brought before his commanding officer. He was then sent back to his blockhouse, and during the remaining three months caused no further trouble. The man of course may only have been malingering, but the case appeared to me to be Hysteria.

The following cases will typify the class of diseases one met with as Medical Officer on a Blockhouse line in the Transvaal.

Rheumatic Tonsillitis and Pericarditis.

Pte. J. Beard. 2nd Lancashire Fusiliers.
Admitted to Detention Hospital on 30th April, 1902 with "sore throat". His tonsils were markedly congested and the right one projected well towards the middle line. Submaxillary gland enlarged and tender. Temperature 102°. Pulse 91. He was put to bed and placed on milk diet. Given grs. v. calomel at once and Sodii Salicylatis, grs. xv. six hourly. An alum gargle given for throat.

Next day, temperature 102.3° pulse 92. Throat still very painful. The right tonsil was very prominent. I therefore incised it under cocaine with a curved bistoury and at once a quantity of pus gushed out. This gave the patient almost instant relief. That evening temperature fell to 99°. He was much better next morning and wished to/

to get up. He was sent by Hospital train to Middelburg Stationary Hospital this day. I was much surprised to hear that he developed Pericarditis a fortnight later in Middelburg, and died.

Diarrhoea.

Pte. Pullin, 2nd Lancashire Fusiliers admitted 12th ~~April~~^{MAY}, 1902 with a history of "diarrhoea having come on the night previously". Went to stool 7 times during the night. Had severe colicky pains. Temperature 102°. Did not notice any blood in the motions. Given at once Castor Oil 1½ ounces, and then Bismuth Subnitrate grs. XX. every 4 hours. At night given Tinct. Opii minims XX. Next day bowels moved once. Motion formed. This diarrhoea never again occurred. Discharged for duty on 15th ~~April~~^{MAY}, 1902. The Bismuth was given on the second day three times and on the 3rd day night and morning. This case of Diarrhoea is typical of a large number of such cases. Most of the soldiers arriving in South Africa, and young soldiers especially, develop diarrhoea of a mild or severe description. Sometimes the attack lasted a day, sometimes several days. Sometimes, a chronic diarrhoea, with intervals of comparative freedom developed. Various theories/

theories have been advanced as to its causations. Many attribute it to the cold nights, following days of almost intolerable heat. Others attribute it to the water, the dietary, fruits, etc. Certainly at sundown, one can at once appreciate the sudden fall in the thermometer. The wise man then puts on a heavy coat or a cholera belt. He especially shows his wisdom in this particular if he is a new arrival in the country. Pine apples so common and so appetising in Natal, have been accused of causing the diarrhoeas which attacks the newcomer in that Colony. In these cases of diarrhoea the abdominal pain is generally very severe. Often the patient is "doubled up" with it, resembling a man in the throes of Renal Colic.

I generally prescribed for the condition, a dose of Castor Oil to be taken at once and followed by Subnitrate of Bismuth in large doses, or by Salol for 2 days. This was generally effective. Opium is often necessary to relieve the intestinal colic. Milk diet or "slops" only should be taken for at least 24 hours. One of the favourite remedies in Natal, is a strong dose of whisky containing thirty drops of Laudanum.

The only other cases of interest that occurred on this line were two cases of paraplegia from Lightning Stroke. I, however, lost my notes of these cases.

The Medical Officer in Charge on a Blockhouse line was responsible to the Principal Medical Officer (P.M.O.) of the district for his orders and duties, and this official at intervals inspected the various Detention Hospitals of his command. Returns had to be weekly posted to the P.M.O. reporting on the health of the troops, sanitation, or any matter of medical concern. The following copies of memos will well illustrate some of the administrative procedures. As the Blockhouse system of warfare is comparatively novel, the documents are of a certain historical medical value.

COPY:

From

Medical Officer in Charge,
Detention Hospital, Belfast, Transvaal,

To

P.M.O., Pretoria and L. of C.E.

Sir,

Attached is my list of cases admitted into Hospital during the week. Forty men were admitted from Colonel Park's column in the last drive in the Dulstroom District. Of these, four were seriously wounded. Six had developed Dysentery and two Enteric Fever. Of the remainder, several were invalidated/

valided for Debility, Disordered action of the Heart, Diarrhoea, Bronchitis, etc. Several of the cases are undiagnosed - pyrexia being the only symptom. Eight cases were sent from the column as being unable to march owing to blistered feet. The majority of the cases I have sent on by ambulance coach to the Stationary Hospital at Middelburg.

During the week, I visited the Blockhouses round the village of Belfast and the Boer Concentration Camp, and the houses on the line from Nos. 255 to 264. In all of these houses, the latrines were properly attended to, and the water tanks regularly cleansed. In the majority of the houses, the men drink cold tea in preference to boiled water.

Veldt sores are still extremely common on the line. This is due to the lacerations caused by the barbed wire fencing and entanglements. I have supplied ointment and dressings to all the houses (as per my suggestion in last weekly report).

Diarrhoea is very prevalent with the volunteer troops on the Dalmanutha blockhouses. These troops have recently arrived in South Africa.

The Camp of 300 National Scouts still remains here. These men, so far, have not required much medical/

medical attendance. Several, however, are under treatment for Scabies, two for Syphilis and one for Dyspepsia (Alcoholic).

During the week, I destroyed 144 tins of milk and a box of biscuits - all unfit for consumption. Circular 125 is being complied with.

I am, Sir,

Your obedient Servant,

(Sd.) A. A. MARTIN, M.B.,

Civil Surgeon,
M.O.¹/c Troops
Belfast.

CIRCULAR:

To M.O.¹/c. Belfast,

NO. 125.

CIRCULAR MEMO No. I.

As the Enteric and Dysentery season is now at hand, will you please inquire into the Sanitary arrangements of every Camp and blockhouse under your charge. You should make yourself acquainted with water supply and recommend boiling in every case. I am aware that some blockhouses are supplied from one central water supply; other blockhouses are depending on some local source. In the first/

first instance, the water might be boiled before distribution; in the second, the boiling should be done by one of the men in the blockhouse; small Kaffir pots or kettles ought to be supplied to the blockhouses depending on a local supply, and one of the men in the blockhouse be told off to perform this duty.

It is advisable to advise the troops to use only boiled water and to point out the danger of using it where unboiled or unfiltered. The coming hot season will very likely be an unhealthy one on account of the number of unburied carcasses all over the country. I must therefore ask you to make immediate recommendations to Commanding Officers as to the steps they should take in order to preserve the health of the men. I need hardly add that all carcasses near Camps or blockhouses, or near water supply should be at once buried or burned.

(Sd.) W. D. WILSON,

Pretoria,
28th Aug. 1901.

Surgeon General, A.M.S.,
P.M.O., Army,
So. Africa.

Please bring this to the Notice of your O.C.

Please forward report to me on water supply of every blockhouse at your station and section of line./

line. State the source of supply in each case and whether the water is boiled or filtered, or both, whether a camp kettle for boiling is provided at every blockhouse requiring one - what means of storing the boiled or filtered water is provided.

In each weekly report state if this circular 125 is being complied with.

(Sd.) M. DORMAN,

Colonel, R.A.M.C.,
P.M.O., L. of C.E.

M^hburg,
29th Aug. 1901.

CIRCULAR MEMO NO. 1.

From

P.M.O., Pretoria, and N. & E., L. of C.

To

M.O.ⁱ/c, Troops, Belfast.

With reference to P.M.O. Army's Circular No. 125, it is not necessary to boil water drawn directly from the town supply, or the water pumped to the Forts from covered deep wells - when taken direct - but all water from whatever source, when carried to Block-houses in barrels or canvas bags, should be boiled before being used for drinking purposes. The bags/

bags should be placed in boiling water once a week,
and all barrels cleaned out with a solution of
Permanganate of Potassium.

(sd.) M. DORMAN,

Colonel, R.A.M.C.,
P.M.O., Pretoria,
N. & E., L. of C.
Pretoria,
8th Oct. 1901.



Ration train. Belfast East Terminal
Troops conveying deep rations to
Blackhouse



BA 254



part of No: 7 General Hospital Pretoria



Belfast.
E. Traversel

Detention Hospital
Blackhouse Linn.




part of Detention Hospital Belfast
Blockhouse line.



Conveying wounded into Detention
Hospital. Belfast. E. Transvaal.



Mc Cormack Brooke Stretcher at work.
Conveying wounded men from Hospital train



Mc Cormack Brooke wheeled stretcher

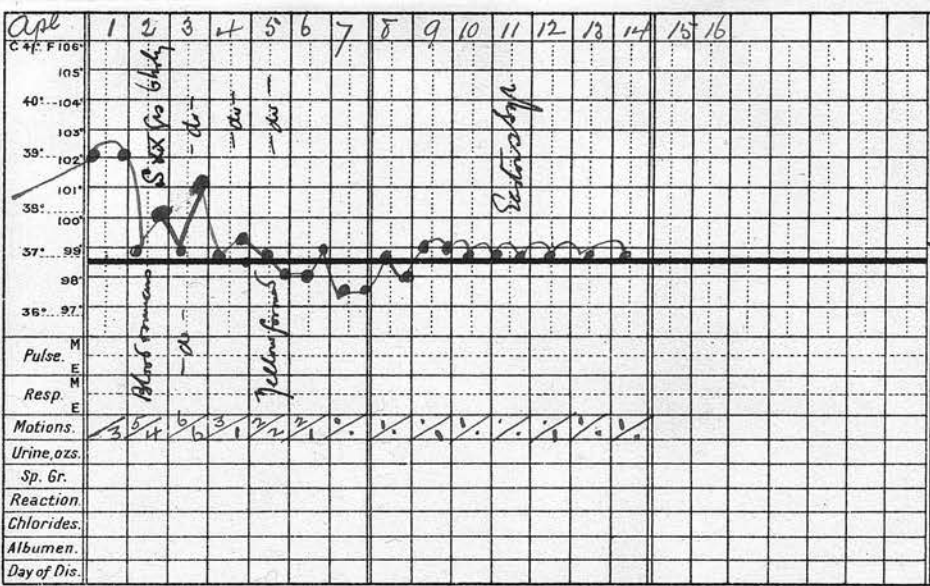
The Sulphur Treatment of Dysentery.

My attention was drawn by an article in the Lancet (November 23rd, 1901) to the admirable ~~and~~ therapeutical value of sulphur in the treatment of dysentery. I had tried magnesia sulphate and for a time pinned my faith on its therapeutic orthodoxy. It however failed in certain cases and in combination with ipecacuanha it had also often failed. After reading Dr Richmond's article I tried sulphur. Altogether I tried its effects in 19 cases of dysentery. Of this number I have been able to keep notes of only five or six, but these will illustrate the nineteen. The sulphur in these cases rapidly exerts its action, it stops - almost after the first dose - the tenesmus and colicky pains of which the patients complain so grievously. Flatulence soon disappears and a cure is established. Dr Richmond, after using the sulphur on his dysentery cases at the Imperial Yeomanry Hospital of Deelfontein and Pretoria during the war, sums up his experiences as follows: "In every case treated with sulphur a cure has resulted and there seemed little or no tendency for relapses or chronic conditions of alternating diarrhoea and constipation to occur."

In my limited number of cases, however, I had one which resisted the action of sulphur entirely.

An/

Name *Wm Murphy D. Sick* Age *21*
 Disease *Dysentery*
 Result



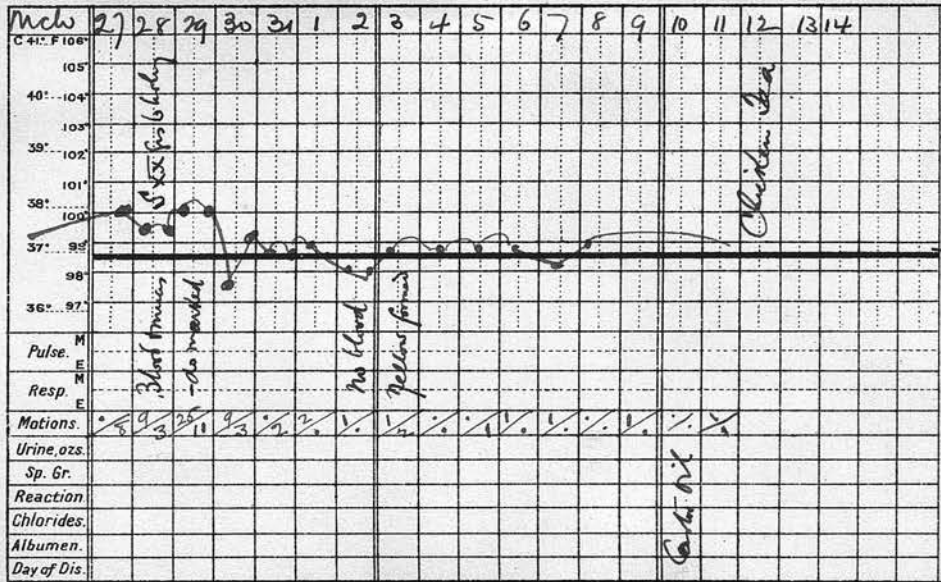
An interesting point presents itself in this connection. Is the liability to hepatic abscess lessened in cases of dysentery treated by sulphur, as compared with those cases of dysentery treated by magnesia and ipecacuanha?

Pte. Murphy, age 21. 2nd Royal Irish.

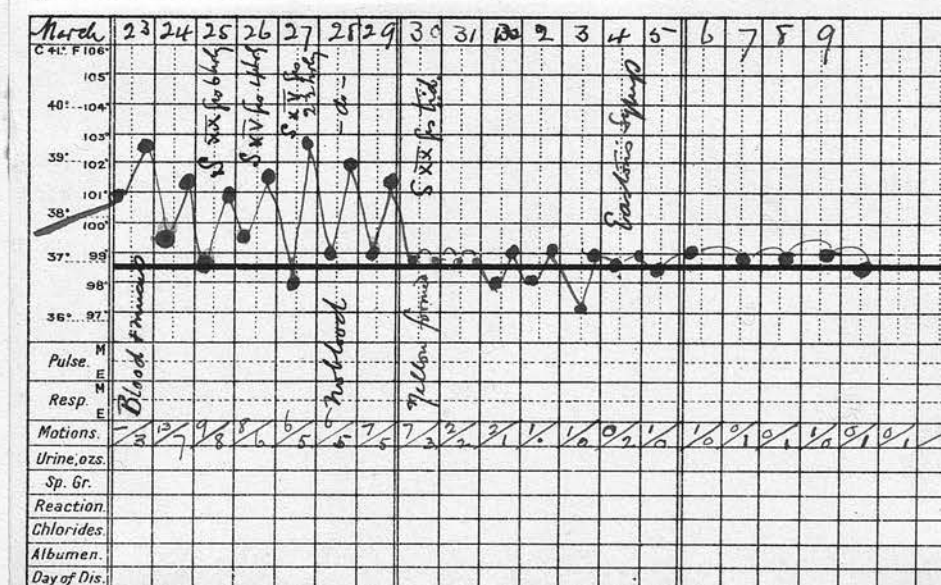
Admitted to No. 19 General Hospital, Pretoria, on 1st April, 1902, with a temperature of 102° and severe diarrhoea, tenesmus, and griping abdominal pains. While on sentry-go the previous night he had diarrhoea. Stated that he was at the latrine "almost all the night". At first had no pain. Towards morning had pain in abdomen and constant desire to defaecate. Passed little. What was passed was watery and blood stained.

This man on the next day was put on xx. grs. sulphur, six hourly, and morning and evening was given x gr. Dover Powder.

The griping pain and tenesmus disappeared after the second dose of sulphur. The motions from being fluid, blood-stained and of foul odour, became light yellow and formed on the 3rd day of treatment. Temperature continued normal till his discharge from hospital. The diarrhoea ceased on the 8th. He was kept on milk and Benger's food till 13th, when a little chicken-tea was given. Gradually went on to normal diet.



Name **Bond T. G. Willey**
 Disease **Dysentery**
 R.F.A.
 Age **27**
 Result



Name **De Wilson I. X**
 Disease **Dysentery**
 Age **28**
 Result

Bombadier Willey. R.Field Artillery. age 27.
Admitted on 27th March, 1902, with abdominal pain, tenesmus, severe diarrhoea and passage of bloody mucus. He had had the diarrhoea for two days previously and was weak, haggard and exhausted when admitted. Says that he fainted twice on the way up to Hospital and feels "pins and needles" in his legs. On the second day of the diarrhoea he noticed blood in the watery motions. His motions were of the usual type, bloody and mucoid, with a scum or froth on the surface.

He was put on milk diet alone and given no medicine for 24 hours. Next day he was put on xx. grs. sulphur six hourly, and x grs. Dover's powders night and morning. Next day the diarrhoea was less. Still watery and particles of sulphur could be seen suspended in it. Tenesmus and griping pains had absolutely disappeared. He felt very much better.

On 3rd April the stools were yellow and formed.

On 12th April he was given chicken-tea and gradually ascended the usual dietary ladder to "full diet." The response to sulphur in this case was marked.

Private Wilson, age 28. Imperial Yeomanry.
This man was admitted with a temperature of 101°F. and a slight diarrhoea. Was then not complaining of any pain or tenesmus. He was put on plain milk and/

and soda water and was given no medicine. At this time diagnosis was not made.

During the afternoon he had diarrhoea three times and temperature rose to 102.6°. Sweated profusely and complained of violent headache and pain in the eyes. Abdomen slightly distended and tympanitic. Lungs normal. One thought that it was probably going to turn out to be Enteric Fever.

Next morning his temperature was normal and before midday he had diarrhoea thirteen times and during the rest of the day seven times. Liquid, frothy, foul-smelling stools were passed. Abdominal pain became marked and tenesmus became extreme. By 9 o'clock next morning he had diarrhoea nine times and the stools were now frothy, mucoid, and bloody. The case was obviously dysentery. He was put on xx. grs. sulphur six hourly, and x. grs. Dover's powder twice a day. Diarrhoea did not cease, but the tenesmus and griping pain almost disappeared after the third dose of sulphur. Temperature kept up, however.

Next day he was given xx. grs. sulphur four hourly and x. grs. Dover night and morning.

Next day given xv. grs sulphur two hourly and x. grs. Dover three times during the day. This was continued next day. The temperature now began to/

to fall, and although diarrhoea was present there was no blood present and the feculence had disappeared.

On 30th March he was put on xx. grs. sulphur three times daily.

On 31st March the stools were yellow and showed a tendency to be formed. No blood or mucus. Benger's added to food. The future course was uninterrupted. He made a good recovery.

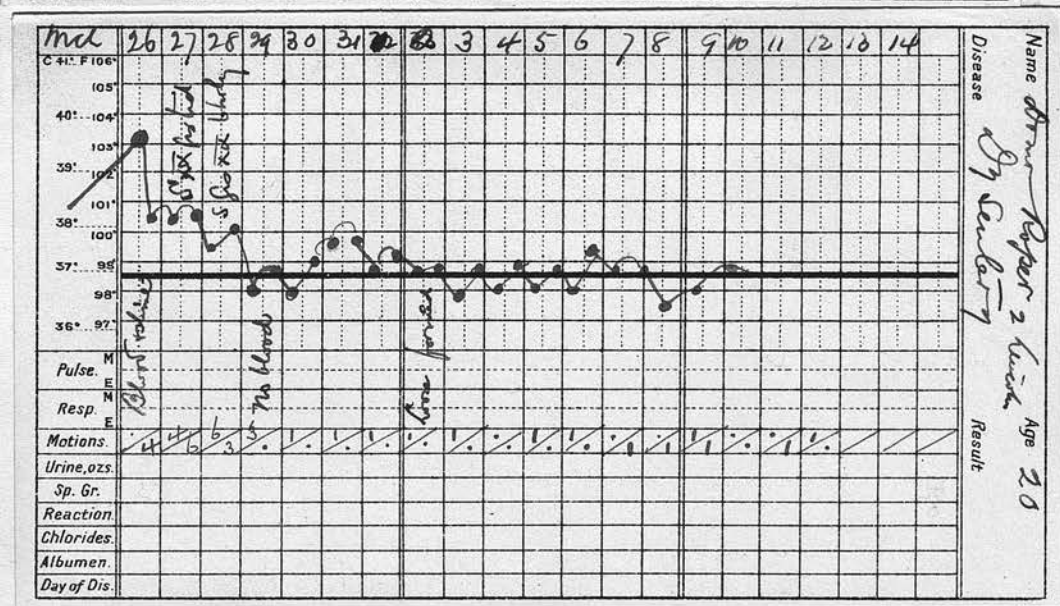
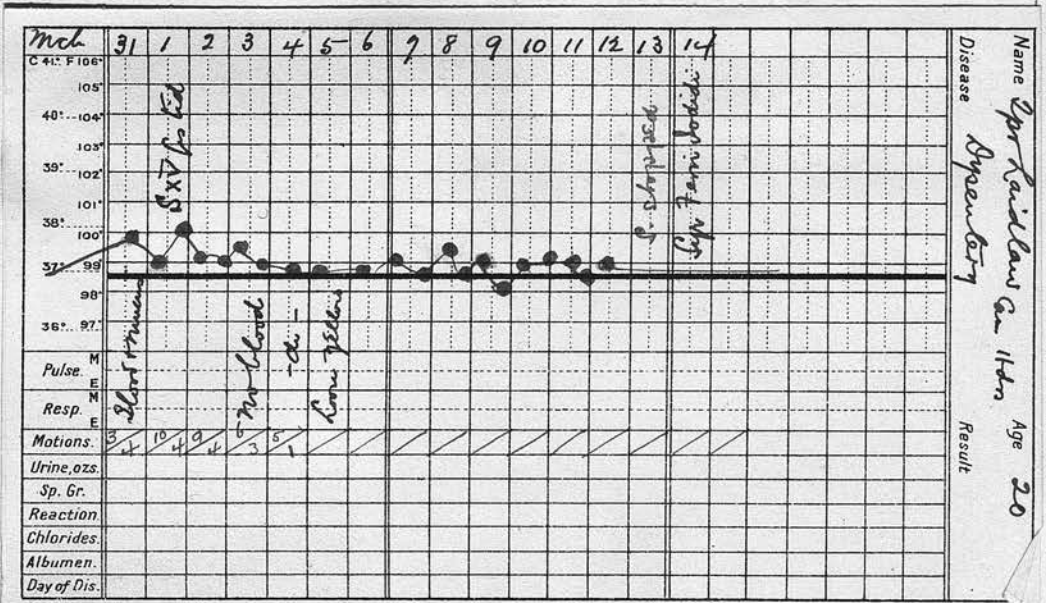
This was one of the most obstinate of the cases I have had under treatment with sulphur, but even in this case the tenesmus, griping pains and blood rapidly disappeared.

Pte. Laidlaw, age 21. Cameron Highlanders.

On 29th March, 1902 had diarrhoea during the day five times and twice during night. On 30th March 1902 went to stool six times and had tenesmus and flatulence. Noticed blood in the stools on this day.

Admitted 31st March, 1902. He had diarrhoea seven times during the day and night. The stools were of the usual dysenteric type and contained blood.

On 1st April he was put on xx. grs. sulphur three times daily and x. grs. Dover night and morning. Flatulence and tenesmus rapidly disappeared. Blood was absent on the 3rd day and the after course was/



was uneventful. Given chicken broth on the 14th April. Previous to this he was on a diet of milk and Benger's food. The temperature chart will illustrate the case.

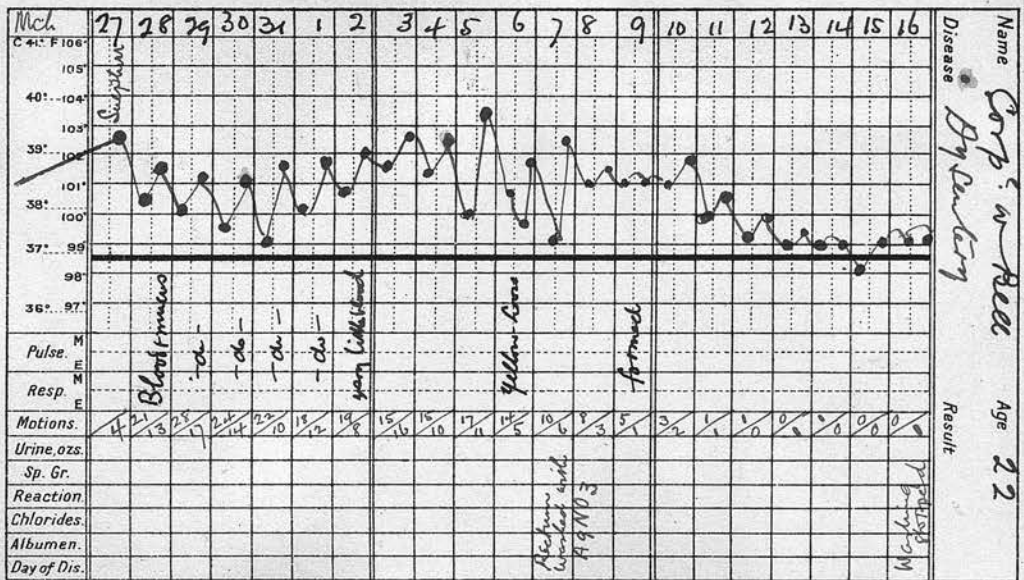
Dr^r. Roper: 2nd Lincoln's. age 20. Dysentery. Diarrhoea developed on 25th March, 1903. States that "he was up all night with it". Pain in abdomen developed towards the morning of the 26th. Tenesmus severe.

He was put on sulphur xx. grs. three times daily on the 27th and x. grs. Dover night and morning. Stools bloody and slimy. Next day the dose was increased to xx. grs. sulphur six hourly. On the 29th the blood had disappeared. The pain in abdomen and tenesmus never troubled him after the second dose of sulphur.

On the 31st the stools were loose and yellow. On 12th April he was given chicken tea and then gradually went on to full diet.

During the convalescence of all these patients they were given iron and arsenic or Easton's syrup. They were all given thick woollen cholera belts to wear round their abdomen and back, and were cautioned about drinking water from streams, etc., etc.

One disadvantage about using sulphur so plentifully is that the air of the wards becomes saturated with sulphuretted hydrogen.



Chronic Dysentery:

Corpl. W. Bell, 2nd Dragoons. Admitted on 27th March, 1902, with diarrhoea and tenesmus. He had been two years in South Africa and had had two previous attacks of dysentery. For a fortnight previous to admission he had irregularity of the bowels, with sometimes the passage of blood and mucus. The chart will show his state on admission.

The sulphur did not act in this case, and this is the only case in which I have seen it fail. On 7th April I began to wash out the rectum daily with a solution of silver.

A cocaine suppository was first inserted into the rectum. Three to four pints of a solution of silver nitrate (20 grs. to the pint) at a temperature of 98° was injected every morning.

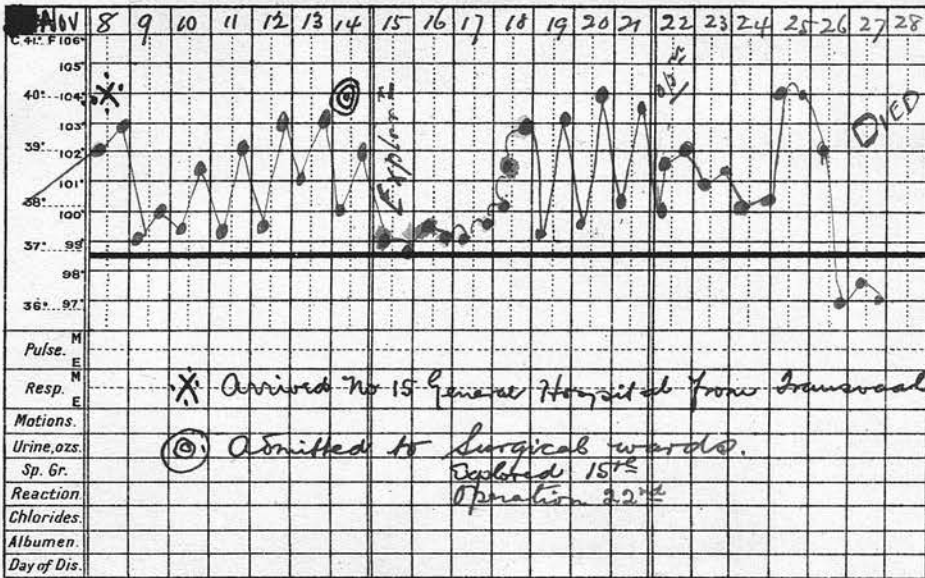
During the injection the patient was kept lying on his back, with his hips elevated on two pillows. This treatment eventually effected a cure.

Two Cases of Hepatic Abscess (multiple).

The following two cases are representative of the course and termination of a vast number of abscesses of the Liver, met with in South Africa. The patient has one, two, or three attacks of Dysentery followed by an Hepatic abscess. If operated upon in the very early stages, he will probably recover. If operation is delayed, he dies. Hepatic abscesses following South African dysentery are, as far as one can gather, generally multiple. The Liver abscess met with in India is generally single.

In the early stage of Hepatic abscess, one has very little to form a diagnosis upon. The patient looks ill, - he may have the "liver abscess look", - he has had dysentery and his temperature ranges between 101° and 99°. He may have no pain over the liver, - he may not be jaundiced - his liver may not even be enlarged. Yet as the liver abscess is not an infrequent sequela of dysentery in South Africa, in any case of doubt, one should plunge an aspirating needle into the liver and explore that organ thoroughly. The exploration must be thorough, because it is so easy to miss a small abscess with the needle.

Case I./



Name **Mr. K. Cameron.**
 Disease **Obstructive**
 Age **35**
 Result **Death**

* Arrived No 15 General Hospital from Invervaal
 @ Admitted to surgical wards.
 Exploded 15th
 Operation 22nd

Case I. Private K. Cameron, Cameron Highlanders, aet. 35.

Was sent to No. 15 General Hospital from the Transvaal, "convalescent from Malaria and Dysentery". His temperature remained persistently high, and he had occasional rigors and sweatings. He was fully dosed with Quinine on the assumption that the temperature was Malarial. At this time he was complaining of occasional pains over his liver and between his shoulders. He was very emaciated and anaemic, took his nourishment badly and his pulse was of small volume and very rapid. His liver dullness extended from the 4th space in the right mammary line to 2 finger breadths below the costal margin. Posteriorly, it reached up to the angle of the scapula. He had moist mucous rales at his right base, but no expectoration. Above all, he had the "liver abscess facies", which requires to be seen to be appreciated. It is a sort of muddy-grey-yellow cadaverous expression. The facies somewhat resembles that of a woman in the last stage of cancer of the uterus. The patient was transferred to the surgical wards under my care, and with strict antiseptic precautions, a Potain's aspirating needle was used to fully explore the Liver. The needle was pushed freely about in all directions/

directions and slowly withdrawn, but no pus could be found. For the next 3 or 4 days he improved. His temperature fell to 99° . He took his food better, and stated that the pain had almost disappeared. These signs were deceptive however, for on the 4th day after the exploration, pain again returned; temperature crept up again to 103 and his condition was very much worse. Eight days after the exploration, he was accordingly put under a general anaesthetic and a needle with a very large calibre was again driven in various directions through his liver. This time, an abscess cavity was struck in the posterior part of the right lobe just under the diaphragm. The needle was left in as a guide and 2 inches of the 8th rib was resected in the posterior axillary line. With a sharp knife, the liver tissue intervening between the abscess cavity and the chest wall was then divided and a plentiful flow of fetid pus resulted. Two large rubber drainage tubes were then fixed into the cavity and the patient was carried to bed in a very collapsed state. He rallied well during the next 2 days, his pulse improved, and his temperature fell. Then he gradually sank into a general toxæmic state and died 5 days after the operation.

Post/

Post Mortem:- Liver found in a state of fatty degeneration. A large abscess cavity found in the upper lobe with irregular sloughy walls. (It had drained freely through the tubes). The rest of the liver was studded with hundreds of small abscesses. One was about the size of a small marble. The remainder were about the size of wheat seeds. In the region of the caecum and rectum, old dysenteric ulcers were found. The other organs were negative, except for a slight pleuritic effusion at the base of right lung.

Case II. Private S., 2nd Devons, aet. 30.
Had a severe attack of Dysentery while in Ladysmith during the siege three years ago. Had a second attack about 2 years ago, while on "trek" in the Transvaal. Had a third attack in January 1902 and was in a military hospital up north till the middle of February. On admission into No. 15 General Hospital on 16th February 1902, he was jaundiced, anaemic and emaciated. His diarrhoea had ceased. He complained of pain over the Right Hypochondrium, Epigastrium and over the Spleen. His pulse was feeble and "rocky". Had a septic temperature ranging between 102° at night and 99° in the morning. He had the "liver abscess facies" well/
well/

well marked. The Liver dulness extended in the Right Mammary Line from the fourth rib to a full handsbreadth below the costal margin. The edge was distinctly palpable. Posteriorly, the upper border extended to the middle of the scapula. The liver was painful on superficial and deep palpation. Spleen was enlarged. Abdomen rigid and protuberant. This pain over the liver came on in the initial stage of his last attack of Dysentery, and had been present for about 4 weeks previous to his admission to this hospital.

On 17th February, the day after his admission, he was put under a general anaesthetic and the liver was needled in the usual way. Directly the needle entered the middle of the right lobe, a rush of blood took place into the aspirating bottle, and this was immediately followed by pus. The needle was left in in the usual way, as a guide, and the 8th rib was resected in the mid axillary line. When the abscess was opened, about a pint and a half of pus welled out. Two large drainage tubes were inserted into the cavity and the patient was then carried to bed.

18th February, 1902: Pulse 168. Volume and tension poor. General condition very unpromising.

Heart's/

Heart's action weak and rapid. Given Tinct. Digitalis MX. and Liq. Strychninae Mv every 4 hours. Stimulants by mouth. Nutrient enemata and rectal salines.

19th February, 1902: Pulse 170. "Runs" at times. Tubes draining well. Dressings require changing twice daily. Is slightly better, but still critical.

23rd February, 1902: Pulse 100. Volume better. Patient's general condition improving. Tubes still draining well.

24th February, 1902: Takes food better. Pus is bile stained and more "mucoid" in its consistence. Patient feels better.

26th February, 1902: During last night the dressings were soaked with blood. On removing the dressings and the tube, and on inserting the finger into the abscess cavity, a large blood clot was felt. I plugged the cavity with cyanide gauze and gave Rectal Saline, etc., as the patient was very weak.

27th February, 1902: No recurrence of the haemorrhage, but patient is obviously sinking. Lies in/

in a semi-comatose condition and rambles at intervals in his speech.

28th February, 1902: Died.

Post Mortem:- Liver markedly enlarged and fatty. One large abscess cavity in right lobe with ragged walls and containing a blood clot, which in places was breaking down. This haemorrhage appeared to have come from an Hepatic venous tributary which lay in the midst of a mass of sloughing tissue at one side of the abscess cavity. The remainder of the liver tissue contained about six or seven small abscesses, some situated near the surface and some situated much deeper.

Spleen large, friable and deeply congested.

Intestines - the lower end of the small intestine and coecum showed several large dysenteric ulcers - some were healed and cicatrized, some partially so. Healed ulcers present in rectum.

Appendix - healthy. Other organs negative.

Remarks:- In both of the above cases, the operation was performed too late in the course of the disease to do a lasting good. In both, the abscesses were multiple. Both were very bad subjects to operate upon as they were weak and debilitated/

itated by the prolonged septic poisoning. Officers of the R.A.M.C., who have had considerable experience in Tropical diseases in India and South Africa, agree that a liver abscess following on South African dysentery is one of the gravest of sequelae and is a condition in which, even under the most favourable circumstances, the prognosis should be very guarded.

— Bilharzia Haematobia. —

The following three cases are illustrative of the usual type of Endemic Haematuria which occurred amongst our soldiers while on service in the Transvaal and Natal during the late war.

Pte. Parker 2nd Duke of Cornwall's Light Infantry, aged 28. Went to Komati Port in the Eastern Transvaal in August 1900 and remained there for 9 months. He then "reported sick" complaining of "blood in his water, pains in the lower part of the belly on making water, and weakness." The first indication he had of trouble was that one morning he "noticed his water to be very red." This "redness" continued every day.

Three days later he says that he passed a long thin clot of blood at the end of the act of micturition. Clots were frequently passed after this. The passage of these clots caused him at first marked pain in the Hypogastrium. This pain became less later on in the course of the disease. He very soon developed frequency of micturition, had to get up 3 or 4 times at night to micturate, and had a general sense of uneasiness in the Hypogastric Zone. He became/

became very weak, and very pale and disinclined for any exertion. At the end of 4 weeks he had several shivering fits and was then sent into Hospital.

Previous illness:- Malaria 8 months previously. Short attacks. Occasionally now has a mild rigor and sweating usually followed by headache. This responds readily to Quinine.

On admission he was very pale and emaciated. Conjunctiva tinged with yellow. Had haemic murmurs over his pulmonary and aortic areas and the "bruit de diable" in the neck. Was constipated. Temperature normal except for a slight rise at night.

Urine alkaline in reaction contained blood clots. The colour of the urine was of a dark red "portwine." appearance, and gave the Guaiac and Ozonic Ether reaction readily. No urinometer was in stock so the specific gravity could not be ascertained. Had frequency of micturition both during day and night and complained of the ever present uneasiness, often actual pain, in the Hypogastric region. Bladder not distended.

Microscopically pus cells, red blood corpuscles and lymphocytes were abundant. Bilharzia ova were extremely/

extremely abundant in the nests of mucus which lay at the bottom of the glass containing the urine. They lay moored "stern on" to the little clumps of mucus and epithelial cells as seen through the microscope. The spike at the end appeared to be the "mooring agent" or the "anchor" On putting salt solution on to the slide the ova became active and moved rapidly about the slide. Some of the ova appeared to be undergoing disintegration. These ones lay still and did not move about with the rest. These (?) disintegrating ova were deeply stained with a yellowish pigment..

Ptv. McGargle, 1st Welsh Regt. age 26.

In March 1902 reported himself as unfit for duty. He was then at Norval's Pont. He then was complaining of frequency of micturition. Had to get up several times during the night to micturate. Had smarting pain along the whole length of the urethra when micturating. Passing blood, and blood clots per urethram. Clots always appear at the end of the act of micturition. Has been getting weaker and paler during the period from the onset of Haematuria. Has a constant uncomfortable uneasy sensation over the Hypogastrium. No actual pain in this region. The urine in this case contained blood, blood clots and abundant mucus. Microscopically the ova of Bilharzia were as abundant as in the previous case and found in great numbers in the clumps of mucus and epithelium. The urine was alkaline in reaction. No pus cells were present as in the former case.

The man was very anaemic and had the usual haemic bruits at the base of heart. He had palpitation and cardiac dyspnoea on the slightest exertion.

Ptv. Harold, 1st Welsh.

In July 1901 he was sent to No 15, General Hospital, Natal from Komati Poort as a "Convalescent Malaria." Here he noticed that his urine was blood stained. Shortly afterwards he developed frequency of micturition by day and night. Pain at the root of the penis at the end of the act of micturition and occasional passage of long shreddy blood clots at the end of the act. This man likewise complained of Hypogastric pain and pain in the loins. These pains he described as being constantly present when he was up or sitting on a chair but disappeared on lying down in bed. The frequency of micturition was a very marked feature in this case. He stated that he often had to micturate about nine or ten times during the night.

He had the usual signs of Anaemia - marked pallor of face, lips, and gums, glistening conjunctiva. Haemic bruit at the base of heart, palpitation, dyspnoea on exertion. The urine was alkaline in reaction. Contained a few pus cells, blood, blood clots and ova of Bilharzia.

I have taken these 3 cases as examples of Endemic Haematuria. The symptoms in these 3 cases were well marked. In many of the cases I have examined, no blood clots were passed and the urine was only faintly stained with blood. In some the bleeding was profuse. In others it consisted only of a slight trickle at the end of the act of micturition. The majority of the cases suffered from cystitis. In some the cystitis was marked as in the 3rd case above mentioned, whilst in others it caused little inconvenience. In almost all of the cases there was uneasiness, discomfort or actual pain over the Hypogastric region. This pain or uneasiness was most marked immediately after the act of micturition. I have not met with a case in which the Rectum has been involved (causing diarrhoea, passage of bloody mucus, and tenesmus). In all my cases a rectal examination was made but the examination in every one was negative. The three cases described suffered from marked anaemia. Many of the cases presented no signs of anaemia or ill health. Undoubtedly many soldiers have had the disease in so mild a form that practically no symptoms/

symptoms at all were in evidence.

I have never heard of a death amongst the troops in South Africa being directly attributed to Bilharzia although I made many inquiries on this point from medical officers at various base hospitals. On one occasion while performing a post-mortem on a South African Colonial trooper who had died of Enteric Fever, I found some small hard somewhat gritty areas on the trigone of his bladder. The trigone of the bladder was excised and sent to Major Beveridge, D.S.O., R.A.M.C. who examined the tissue. He reported that the gritty elevations were inflammatory thickenings due to the presence of Bilharzia Haematobia in the submucous layer immediately subjacent.

The origin of the infection is still doubtful. In case 1 the man developed the disease at Komati Poort which is one of the hot-beds of Malaria and Bilharzia. Komati Poort lies in a marshy country watered by the Komati River. There are many pools of stagnant water surrounded by tall reeds and the soldiers quartered about the district used to bathe in and fill their water bottles from the water in these/

these pools. In case 1 the man avers that he always drank boiled water while at Komati except on one occasion. While out fishing one day in the Komati River he felt very thirsty and drank some water from a small clear pool near the bank. Five days afterwards the initial symptoms occurred.

Case 11 had been careless about the water he drank. He stated that he had partaken of the water from the Modder River, Crocodile River, &c. &c. and from small streams round Harrismith, Kroonstadt, Barberton. In 1900 he was in the Rustenburg district, which is a stronghold of Bilharzia in the Transvaal.

Case 111 evidently developed the disease like Case 1 while in the Komati Poort district. He took no precautions about boiling water. He had also been in the Nelspruit district for several months. This district is also infected with Bilharzia.

Treatment:- All cases were sent down to the Base Hospitals and most of them were sent to England for change. The symptoms soon ceased on leaving the infected district. For medicinal treatment I prescribed/

prescribed Iron and Quinine or Easton's Syrup as a tonic or 'recuperant.' The patients certainly required some medicine of this description. A combination of Tincture of Hyoscyamus, Boracic Acid and Infusion of BUCHU was given night and morning for the Cystitis. Light diet, no alcoholic stimulant, and rest in bed soon encouraged a very rapid improvement. In three cases where the urine was markedly ammoniacal and contained pus and where Cystitis was a prominent and painful symptom, I washed out the bladder daily with weak Boracic lotion. This measure soon effected improvement in the state of the urine. In such a case as this it is quite possible that the patient may develop a surgical kidney.

In all of the cases, the Cystitis, Haemorrhage, and subsequent Anaemia, soon disappeared and the patients rapidly gained strength. None of them however could be written down as cures. The treatment at the best is not scientific. It will remain unscientific as long as we treat the symptoms and not the cause. Until an agent is found to act specifically on the worms or ova through the blood, our treatment is imperfect.

Sonsino (in the British Medical Journal June 1885/

1885) maintained that "we have no means of curing the infection of Bilharzia better than is done by nature" - and that the "true prophylaxis.....is..... that only well filtered water should be drunk."

Dr. Harley, one of the earliest writers on this subject, pointed out that the "Ova may be present in the urine when all other signs of Existence of the parasite have disappeared." This observation has been frequently confirmed.

The ova remain as such in the urine. They soon die. In pure or salt water the embryos break through their shells and the ciliated bodies then lash themselves along at furious speed from place to place. [When making microscopical examinations of the ova, the easiest way to break the shell and let out the embryos is to firmly press the cover slip on to the slide until the embryo begins to wriggle out.]

An interesting point in connection with the ova is that they perish in impure water. I have frequently proved this to be so, and so has Major Beveridge, D.S.O. R.A.M.C. the Bacteriologist to the Army at Pretoria.

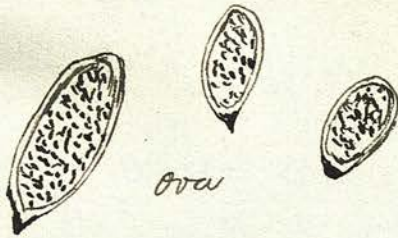
Water taken from swampy reedy pools round Pretoria/

Pretoria was inimical to the life of the ova. Yet it appears that it is by drinking the water of such pools that the disease is contracted.

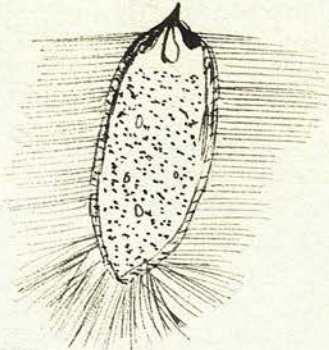
Prophylaxis is of vital importance in this affection. To both officers and men of the army during the late war the importance of drinking nothing but filtered or boiled water was being continually pointed out by the army surgeons. Yet a most lamentable ignorance and heedlessness prevailed.

The average soldier when thirsty filled his water bottle from the nearest pool of water. In many cases his officer did the same. Enteric Fever and Bilharzia were often the consequence. Nearly all of the columns at the later stage of the war possessed Berkefield Filters, but as a rule neither officers nor men were particular about seeing that the water they drank had been passed through these filters.

Rough outlines of Balantzia Haematobium in recently passed urine

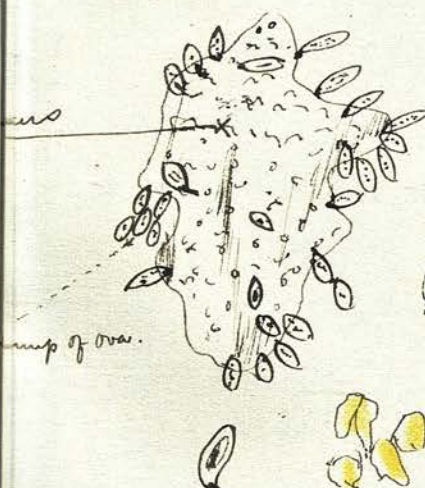
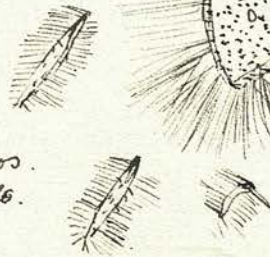


ova

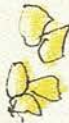

Ciliated Embryo
(much magnified)


Ciliated embryos
actively mobile.



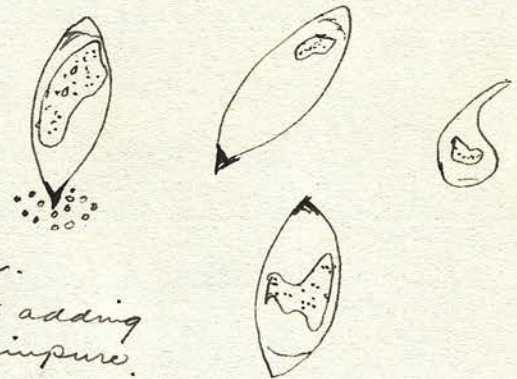
Rough indication of the manner in which the ova lie anchored to a mass of mucus. They lie rounded end on with the hooklet or spine



Deeply yellow or fold stained cells found almost invariably round clumps of mucus + ova.
- not uric acid. -



Empty shells after escape of embryo. The cells assume various shapes.



Degenerating ova.

Seen often after adding decomposing or impure water to a slide containing ova in recently passed urine. The embryos seem to shrivel up.

Myelitis (?Syphilitic)

Private Parfitt, Army Pay Department, was admitted to No.19 General Hospital, Pretoria, on 30th May, 1902, suffering from 'Retention of Urine!'. The urine was drawn off with a catheter. The man gave the following history and was detained in this hospital for treatment.

For the previous eighteen months he had been a clerk in the District Pay Office in Pretoria. During this time he felt quite well and could perform his duties well. On 30th May however, he found that he was unable to pass water. About 11 o'clock in the morning he went to the urinal to micturate, but found when there, that although the desire to pass water was quite strong, he was totally unable to void any urine. Several times during the day he tried to pass water, but always with the same result. He reported himself to Hospital about 6 o'clock in the evening, and, as above stated, he was detained and the bladder emptied with a catheter. During the ensuing two weeks he was quite paralysed in his lower extremities - limbs lay flaccid on the bed, knee jerks absent, anaesthesia present over both lower limbs. Sensation to heat and cold absent. Sensation to pain quite gone. Faeces passed involuntarily. Urine drawn off three times daily with a catheter/

catheter. Urine then ammoniacal. Specific gravity 1023. Pus abundant. (The bladder had probably become infected from the catheter, which was passed by the ward orderly.) At the end of a week he complained of a severe "girdle pain" round the iliac bones just above the trochanters. This pain was so severe that he required hypnotics in order to obtain sleep at night. At the end of a fortnight sensation gradually returned in his lower limbs, but rigidity slowly developed. Knee jerks returned. He shortly afterwards was able to move his legs a little. When he did attempt movement spasms and twitchings in the muscles occurred. This was most marked in the left lower limb. Incontinence of faeces still persisted. Instead of retention, incontinence of urine now developed.

On 1st October this patient was handed over to me for examination and for invaliding to England as "unfit for further service as a soldier".

I saw him then for the first time and his condition was as follows. He was a poorly developed man, muscularity poor, anaemic. Lay comfortably on a water bed and could move himself about. Conjunctivae markedly injected.

Nervous System:- Knee jerks extremely active. A mere touch to the ligamentum patellae sent the legs into a clonus. Quadriceps jerk active and exaggerated/

exaggerated. Ankle clonus present. Flexor response on tickling soles of feet. When he voluntarily attempts to move his limbs, violent clonic spasms occur. When he flexes the leg on thigh, and lays the limb on the outer side the spasms stop. On attempting extension they are again violently produced. They are so severe that the whole bed quivers when they occur. No girdle pain now present. Has frequent shooting pains of a severe lancinating character down both lower limbs. Has complete loss of control over sphincters of rectum and bladder,=urine dribbles away continuously. On making a rectal examination the finger is not grasped by the sphincter ani. He states that he can feel the urine passing, but has no control over it. Same with faeces. Sensation to touch present but delayed. Sensation to heat and cold is delayed, but present, as tested by hot and cold tubes. Superficial reflexes present.- Spermatic reflex exaggerated. No bed sores present - this is due to careful nursing and a water bed. A history of syphilis was elicited. He had a hard sore, rash and throat symptoms five years ago and was in hospital for a month under treatment for it. Took no medicine after this. No history of rheumatism, pneumonia, severe chills, wetting or fatigue. Heart, lungs and other viscera normal. Urine alkaline/

ine, specific gravity 1022. Pus cells abundant.

Temperature normal.

No temperature chart came with this case. At this date the temperature was 98.8°F. and the pulse 81 per minute.

Treatment: Up to the date when he came under my care he had been taking strychnine and quinine internally; massage had been applied to the muscles. The condition had not been diagnosed and a history of syphilis had not been inquired into. He was handed over to my care for examination and report and for invaliding.

It appeared to me that the case was one of myelitis, probably of a specific nature, and situated in the upper part of lumbar enlargement or just above this. The sudden onset (very much like a haemorrhage) the retention of urine, and incontinence of faeces, and then almost immediately a girdle sensation of pain and complete paralysis below this girdle, closely resembled an acute diffuse myelitis. Then later on the return of heat and cold sensation, spasticity instead of flaccidity, exaggerated knee jerks and ankle clonus in place of the abolition of deep reflexes - all these pointed to involvement of the upper or central neuron.

The rectal and bladder centres had probably been destroyed by softening.

None/

None of the usual causes of an acute myelitis were ascertainable, except syphilis, viz., no history of injury to spine, fevers, rheumatism, pneumonia, fatigue, exposure to wet or cold.

For treatment I at once stopped the strychnine and quinine which he had been having and gave the following mixture.

| | |
|------------------------------|-------------------|
| R. Liquor Hydrarg. Perchlor. | 1 drachm. |
| Potass Iodi. | grs. xv. |
| Glycerini | M. x. |
| Aq. Anesi. ad | $\frac{1}{2}$ oz. |

$\frac{1}{2}$ oz. six-hourly at first, for four days, and then three times daily after meals.

The spine was dry cupped at different places on alternate days. The dry cupping was performed with urine test tubes. Water was boiled in these. Then the water was poured out and the open end of the tube pressed against the skin. Massage was stopped as there seemed no indication for it in such a spastic condition. Bladder washed out daily with boric lotion.

The man was sent down to Cape Town by hospital train en route for Netley six days after he came under my care, and so I was unable to follow the after history of the case. I was very anxious to keep the case in order to observe the effect of the mercury/

mercury and the iodide of potash.

This case differed from Erb's Syphilitic Spinal Paralysis in that the onset was sudden: in Erb's it is gradual. In Erb's paralysis the tendon reflexes are exaggerated out of all proportion to the muscular rigidity. In this case the two went on pari passu. In Erb's, however, the girdle sensation is present as a rule, and the bladder and rectum are early involved.

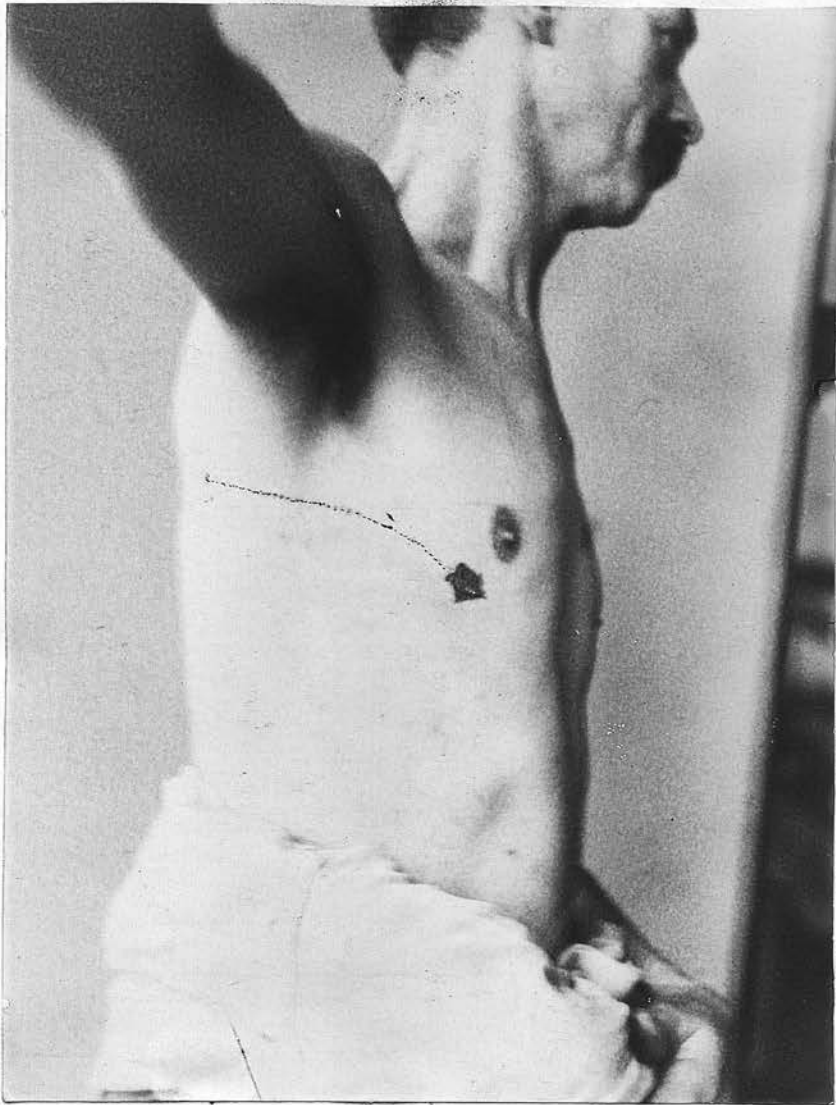
Case 1.

Bullet in Ulna.

I. Y. Private struck by a spent bullet at Tweefontein. A distinct lump could be felt over the posterior border of the right ulna in its upper part. Five inches lower down there was the outlet of a tortuous sinus which evidently reached up to the hard lump already mentioned. This opening was the wound of entrance of a bullet and the lump felt, obviously was the bullet. Under chloroform an incision was made over this lump and a flattened out Martini bullet was found to be lying partly embedded in the ulna.

It was easily extracted. The sinus was then scraped. A small piece of metal cartridge casing was found lying in the wall of the sinus. Iodoform was dusted on the wounds and a gauze dressing applied. Healed without further trouble.

I take it that the bullet struck a stone or some other obstacle in its course and then, glancing off, struck this man. When struck he was retiring with his rifle at the trail. He says he only felt a sharp burning pain at the time and did not drop his rifle.



To illustrate course and
direction of Bullet in Case II

Dotted line indicates track of
bullet. White mark on Pectoris
indicates site of metal casing

Case 11.

Bullet Wound in Chest Wall. Metal Casing in Humerus.

1:1:02. This man an Imperial Yeoman states that while retiring at Tweefontein he was struck on the right side of the chest. Very little bleeding occurred and a first field dressing was soon afterwards applied.

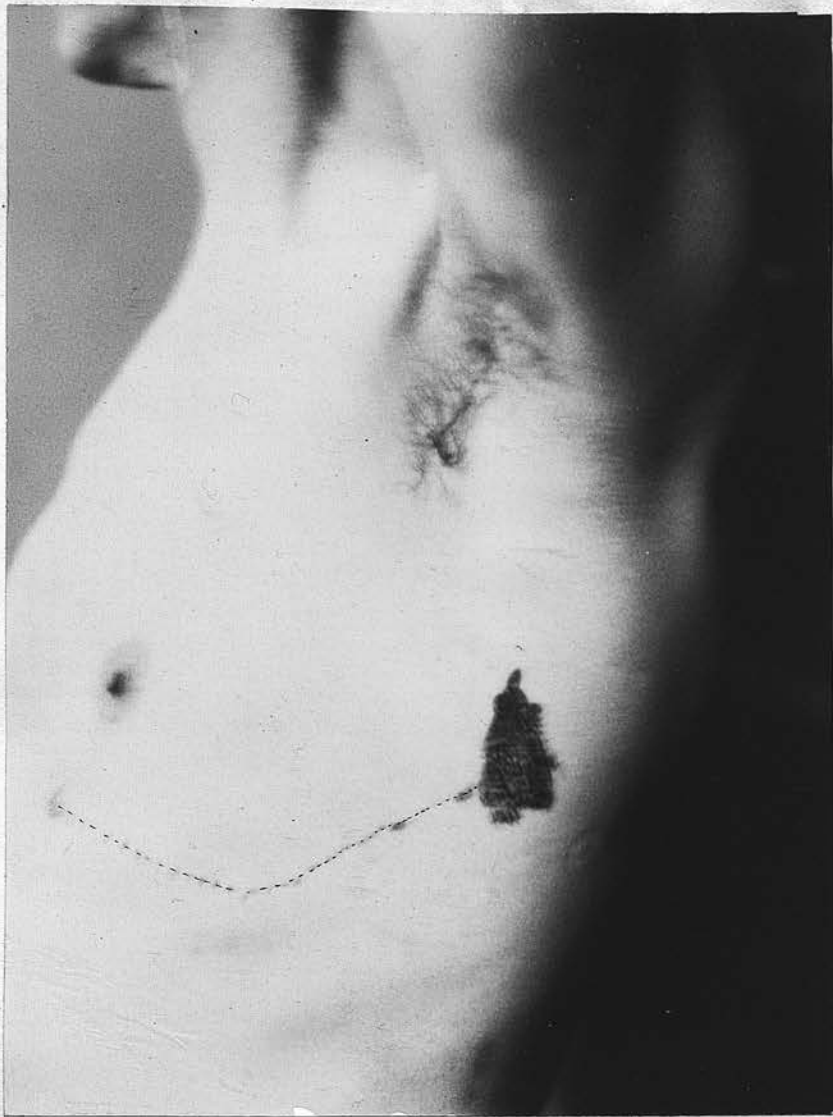
When he came under my care seven days afterwards he had a small wound of entrance of a bullet in the posterior axillary line on the right side and a lacerated exit wound in front external to the nipple. He complained of pain over the Right Biceps muscle in the upper part of the arm. This pain had only come on during the last 3 days. On examination a very small healed scar could be both seen and felt in the skin on the inner side of the Biceps muscle in the upper part of the arm. One could feel some resistant structure on palpating over this scar. Pressing on this caused pain to the patient. It was doubtful whether this was cicatricial tissue or a foreign body. The patient did not remember having been struck in the arm. Under Cocaine locally injected I removed a piece of cartridge metal casing. This casing, which had sharp edges and was about the size of a threepenny/

threepenny piece, was stuck half under the periosteum of the bone and half outside it.

This man's arm must have been closely applied to his side when he was struck. The bullet did not fracture any ribs but ploughed its way through the Serratus and pectoral muscles and emerged anteriorly. The piece of metal casing probably was carried along with the bullet, but left it at the wound of exit and entered the arm.

Case 1V.

This case somewhat resembles case 11. This man a Yeoman, was struck on the left side of the chest while endeavouring to take cover at Tweefontein. He fainted at once. The entrance wound of the bullet was situated over the 5th rib in the left nipple line, ploughed its way towards the axilla anterior to the rib and emerged through the skin at the posterior axillary line high up. The exit wound was ragged and lacerated, and fibres of the Latissimus Dorsi muscle protruded through it. The course of the bullet could be easily^{made} out on holding up the patient's arm, by a long ridge of darkened and thickened skin. Two weeks afterwards this track felt like a thickened cord under the skin owing to the cicatricial induration.



I illustrate Case IV.

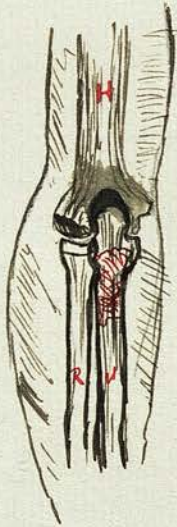Shattering of shaft of Ulna in its upper third, from
a Bullet Wound.

Trooper J., Imperial Yeomanry struck by a bullet at Tweefontein. Bullet entered through the muscles on the anterior aspect of upper third of left forearm and emerged posteriorly through the upper third of the ulna. The ulna was shattered into dozens of splinters of bone and the haemorrhage at the time was stated to have been severe.

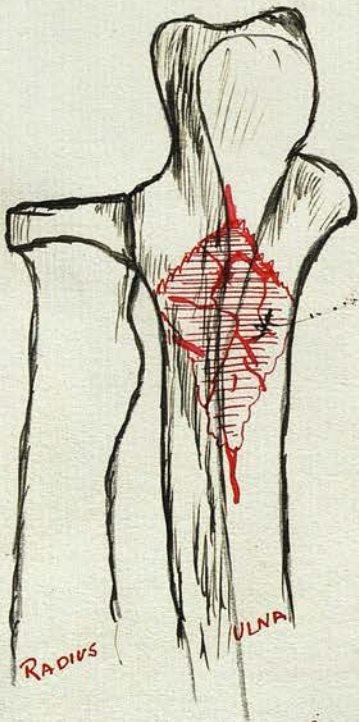
On 1:1:02 the man came under my care. He had then a very large lacerated wound posteriorly over the upper third of the Ulna. The wound of entrance had almost healed. No nerves were injured. Under Chloroform all the splinters of bone were removed. A gap into which one could put three fingers remained between the Olecranon and the rest of the shaft of the Ulna. Cavity was drained with a tube inserted into the bottom part of the wound. The skin edges at the upper part were trimmed and held together with 2 interrupted silk-worm gut stitches. Limb then put up on a rectangular splint. Movement of fingers and wrist carried out gently, daily. At the end of 4 weeks* the man was invalid to England, a sinus still existed, and occasionally discharged minute gritty particles of bone.

7. Imp. Germany. Wounded at Swerforden 25.12.01.

Shattering of upper part of Ulna.



Red area represent shattered portion of Ulna.



Shattered area.

In this case a suspicion arose that the bullet which caused the injury must have been an "explosive bullet" on account of the marked comminution of the bone. It may however have been caused by a ricochet bullet. The bullet may have struck some other object on the way and had its mantle torn, thus exposing the leaden core, and transforming it into an expanding bullet. If so one would have expected a larger or a more irregular wound of entrance than in this case. Also in an "explosive" bullet wound one would expect to find a greater destruction of skin than occurred in this case. I incline to the opinion that this wound must have been inflicted at a close range and that the bullet was travelling at a high velocity. A very large number of the wounded at Tweefontein were shot at close range. Many of the Yeomanry were shot at close quarters as they rushed and scrambled out of their tents. The Boers under De Wet surprised the camp and for a time all was chaos and confusion on our side.

Case V.

Bullet wound of Thigh. Injury to Sciatic Nerve.

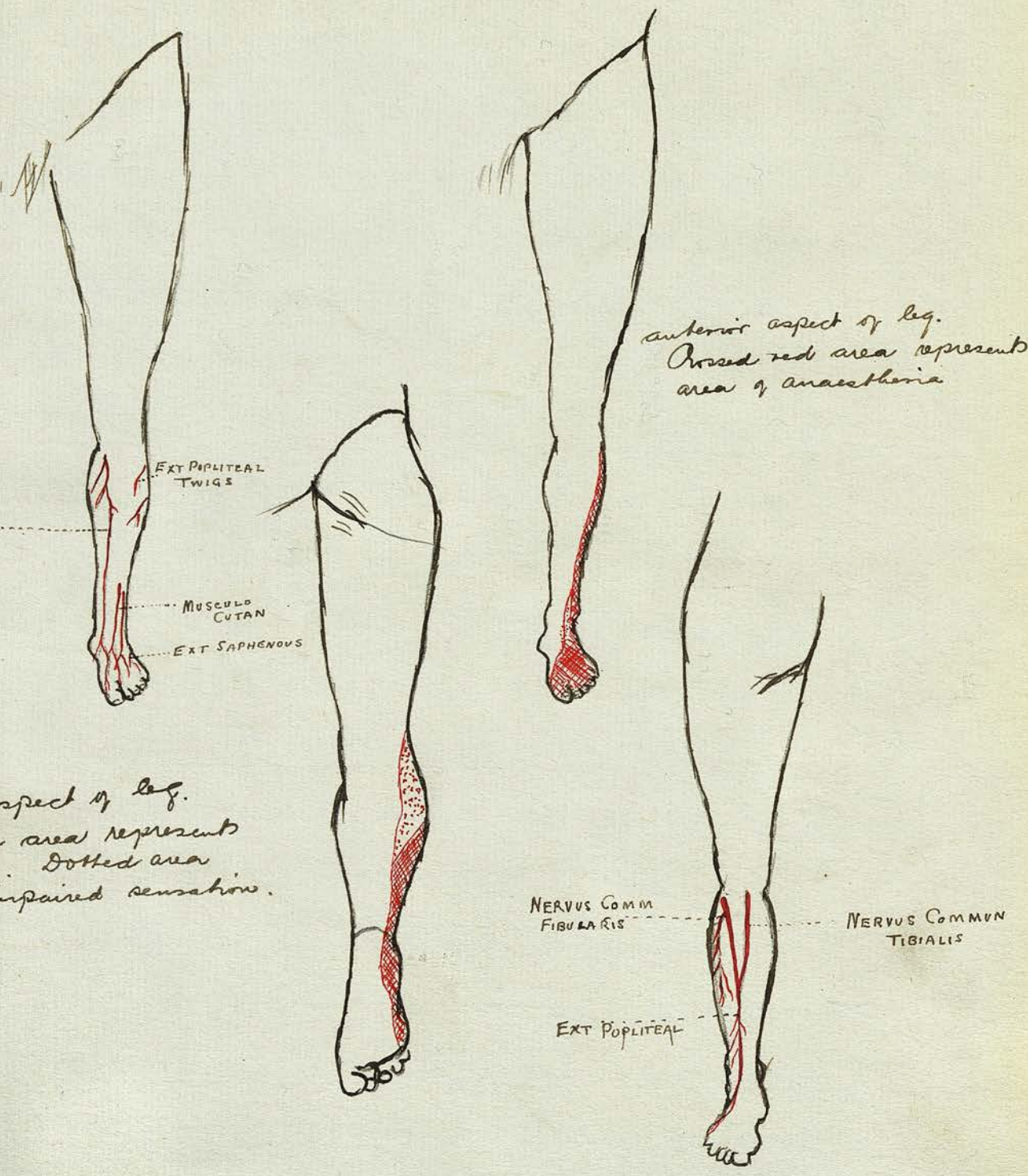
Drop Foot.

This/

Trooper H. Supt. [unclear]
Wound of Sciatic nerve

Wounded at Lucefontain 25.12.

Hos.
[unclear]



SAPHENOUS

EXT POPLITEAL TWIGS

MUSCULO CUTAN

EXT SAPHENOUS

anterior aspect of leg.
Crossed red area represents
area of anaesthesia

Posterior aspect of leg.
Crossed red area represents
anaesthesia. Dotted area
represents impaired sensation.

NERVUS COMM. FIBULARIS

NERVUS COMM. TIBIALIS

EXT POPLITEAL

the External Saphenous is formed from cutaneous branches of both the Internal and External Popliteal. In this case the injury to the nerve must have been directly caused by the bullet, because the paralysis developed at once. In many of the nerve lesions following bullet wounds the paralysis does not develop till weeks afterwards. It is then due to the cicatricial tissue pulling upon the nerve and involving it in the contracting area. The next case will illustrate this.

Case VI.

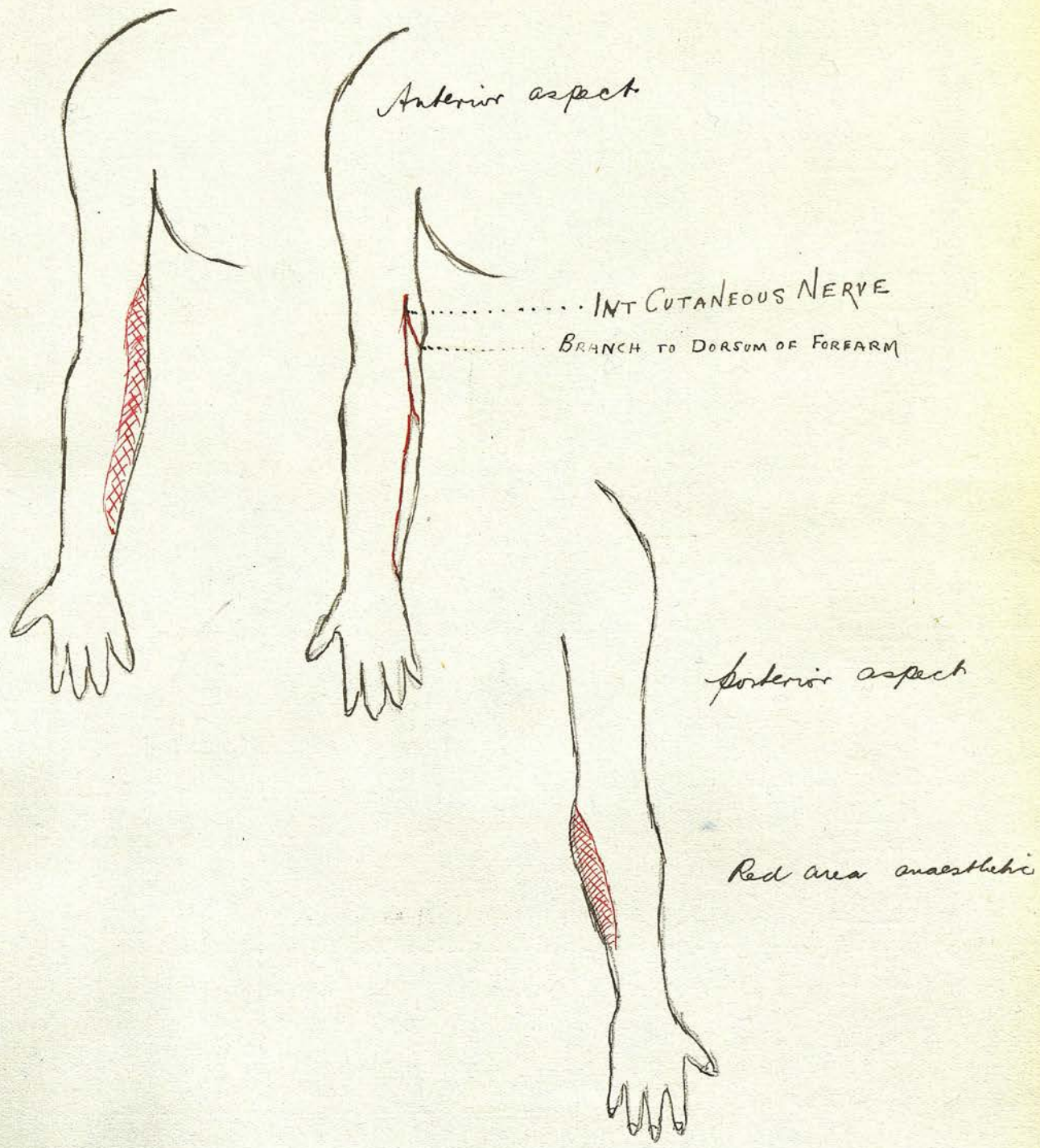
Trooper Stevens, I.Y. was struck by a bullet in the upper part of the Right arm at Tweefontein. A small circular drilled wound of entrance was found situated immediately below the pectoralis major muscle at its attachment to the Humerus. The exit wound which was also small was situated about the same level posteriorly. The bullet had evidently torn its way through skin subcutaneous* and deep fascia only. The man suffered no inconvenience from the wound till the 5th day when he stated that he felt tingling and occasional prickling sensations down the inner side of the upper arm and forearm. On testing this area with a pin and by touch

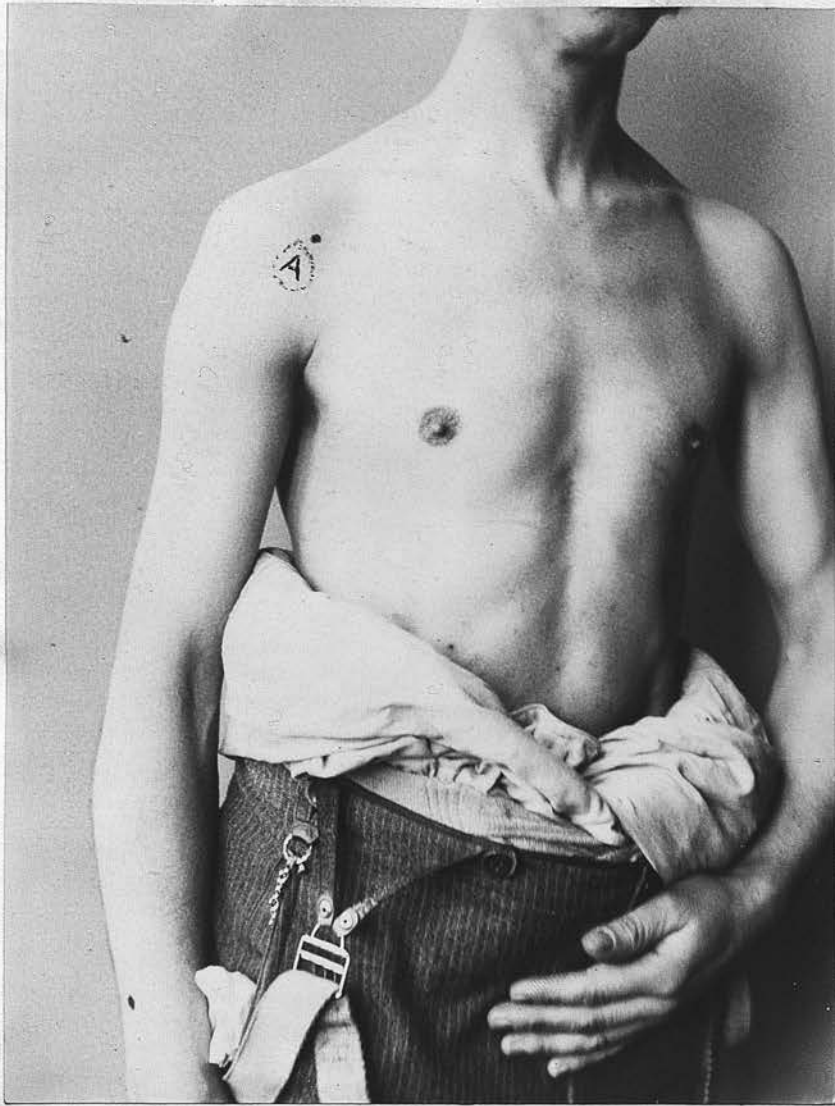'impaired/

Trooper Stevens Impt. Jeomanry. Wounded at Swefortkins
28:12:01

Paralysis of Sensation over area
of distribution of Int. Cutaneous Nerve.

160
2/





To illustrate Case VII
A indicates site of Aneurism.
Entrance wound indicated above this

'impaired sensation' was elicited. For instance on touching lightly below the elbow joint with the finger, the man although he felt the touch could not say definitely where he was touched. Fourteen days after the injury the area supplied by the Internal cutaneous was quite anaesthetic. This area is indicated in the sketch. Here it appeared therefore that the Internal cutaneous nerve had been caught up by the cicatricial adhesions in the track of the bullet. The ulnar nerve at its origin, entirely escaped.

Case VII.

Trooper Mills, I.Y. Wounded at Tweefontein.

The bullet entered below the Coracoid Process on the Right side and emerged at the same level posteriorly. Both wounds were clean drilled holes. On its course the bullet crossed the Axillary artery (and as will be seen, injured it) and the Brachial nerve trunks.

This man says that he saw the Boer fire at him from a distance of about ten yards. There was a great deal of bleeding from the front wound, but this was easily arrested by the pressure of a Pad and bandage. He was admitted to Hospital with paralysis of the extensor muscles of the Forearm. He was

totally unable to extend his fingers, but he could flex them easily. Flexion and extension at the elbow joint could be carried out perfectly. He extended his forearm in a slow and laboured manner. I was very doubtful whether the Supinator Longus was active. He certainly could supinate his forearm but it appeared to me that the Biceps was principally concerned in the movement.

Sensation was present over the front and back of the hand and fingers but was impaired over the ulnar and radial sides of the Thumb. Sensation was abolished over the outer side of the upper arm and forearm as far as the wrist.

Evidently then it was the Musculo Spiral nerve which was injured. It could not have been completely cut across because then the Triceps would have been paralysed and sensation would have been abolished over the area supplied by the Radial nerve. The posterior Interosseous nerve was paralysed and the cutaneous branches of the Musculo Spiral supplying the outer part of the arm and forearm as far as the wrist were also put out of action. But why did some fibres escape while others were injured?

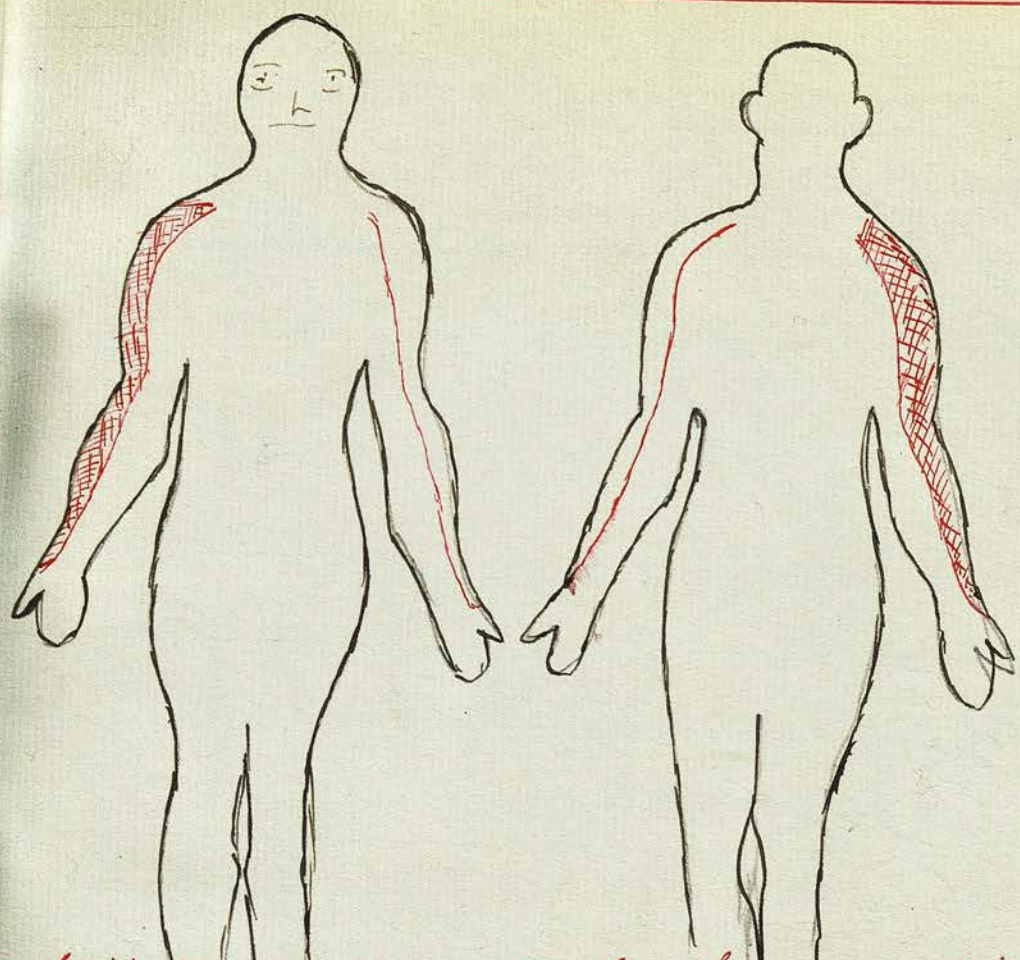
The musculo spiral nerve arises from the posterior/

posterior cord of the Brachial Plexus by a common trunk with the Circumflex nerve and is afterwards joined by the posterior division of the trunk formed by the junction of the 8th cervical and first dorsal nerves. (Gray's Anatomy) Is it not possible that the bullet caught up the trunk before it was joined by the posterior division of the 8th cervical and first dorsal, or again perhaps it is this posterior division which was injured.

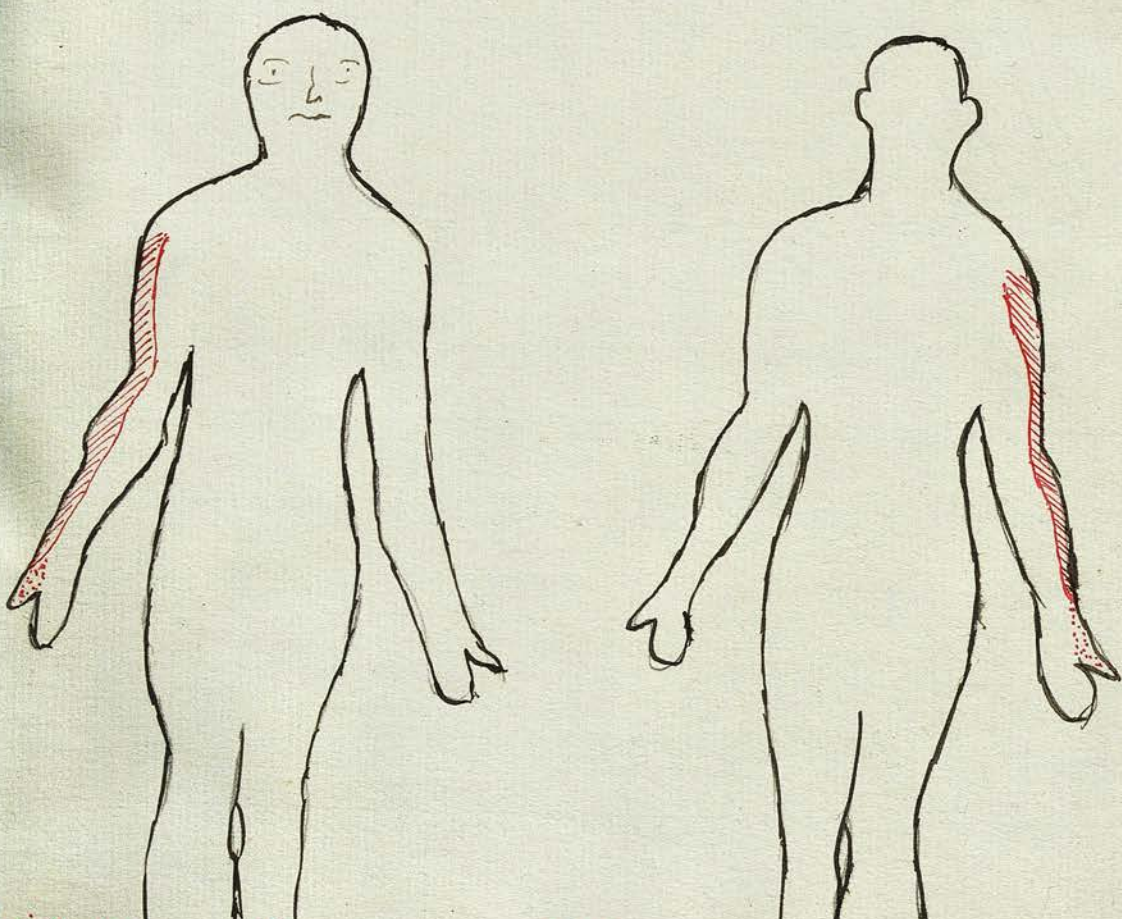
The area of anaesthesia on the outer aspect of the arm and forearm closely corresponds to the sensory distribution of the 5th spinal nerve root. (see diagram taken from Judson Bury's Clinical Medicine.)

One other point remains in this interesting case and that is, a small aneurism developed under the site of the anterior cicatrix. The heaving pulsation synchronous with the cardiac systole was quite marked. On compressing the subclavian artery the aneurism disappeared. The bullet had evidently torn the artery wall or injured it, in its passage and the traumatic aneurism developed.

Owing to the great demand for beds at this time in the Hospital, this man was sent to England by Hospital ship.



cross lined red area represents the sensory distribution of 5th Cervical root



cross lined area right arm anaesthetic
Dotted area on thumb unpaired sensation

Gunshot Wound. Left Trochanter and Thigh.

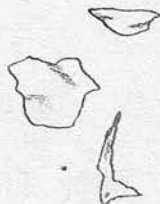
This man, a trooper in the I.Y. was wounded at Tweefontein while lying on the ground behind a small ant heap. Over the left Trochanter was a very large ragged wound which bled smartly for about three or 4 minutes.

On probing this wound in Hospital at Howick, I was surprised to find three sinuses leading away from it into the deeper tissues. One ran anteriorly and inwards. At the bottom of this sinus was a large piece of metal casing from a cartridge. Another sinus led backwards toward the gluteal region, a smaller piece of metal casing lay at the bottom of this. A third sinus not so long as the others, pointed directly downwards, a piece of Khaki cloth lay at the bottom of this. The whole wound was carefully cleansed ~~out~~ and an Iodoform dressing applied.

Four days after the man directed my attention to a small lump which he had felt with his hand, lying lower down on the outer part of the thigh and six inches away from the previously described wound. On cutting on to this little hard body I found a piece of lead about the size of the nose of a Mauser bullet/



A To illustrate the tearing
of thin of Cartilage casing



B Various sizes
of casing found

bullet. It was easily extracted as it lay just under the deep fascia.

This man was evidently struck by a ricochet bullet travelling at a low velocity.

This was the 6th case from which I had extracted pieces of metal casing. It certainly seems odd that the bullet should carry metal casing with it in its flight. Yet it cannot be a rare thing. The six cases, in which I found the casing, were all wounded during the fight at Tweefontein on 25th December, 1902.

Being interested in this connection I went through all the trenches occupied by the Boers and by our own men at the battles of Geluk and Bergendal in the Eastern Transvaal. There were hundreds of empty Mauser, Lee Metford, Martini, and Mannlicher Cartridges lying in these trenches. I collected 25 of these empty cartridge cases showing bits torn off at the rim where the bullet had been grasped. Some of the bits torn off were very small, some were as large as a sixpenny piece. These bits evidently had accompanied the bullets in their flight. Being sharp and jagged, if they caught a nerve/

nerve or an artery they could easily inflict serious damage to these structures.

Case 1X.

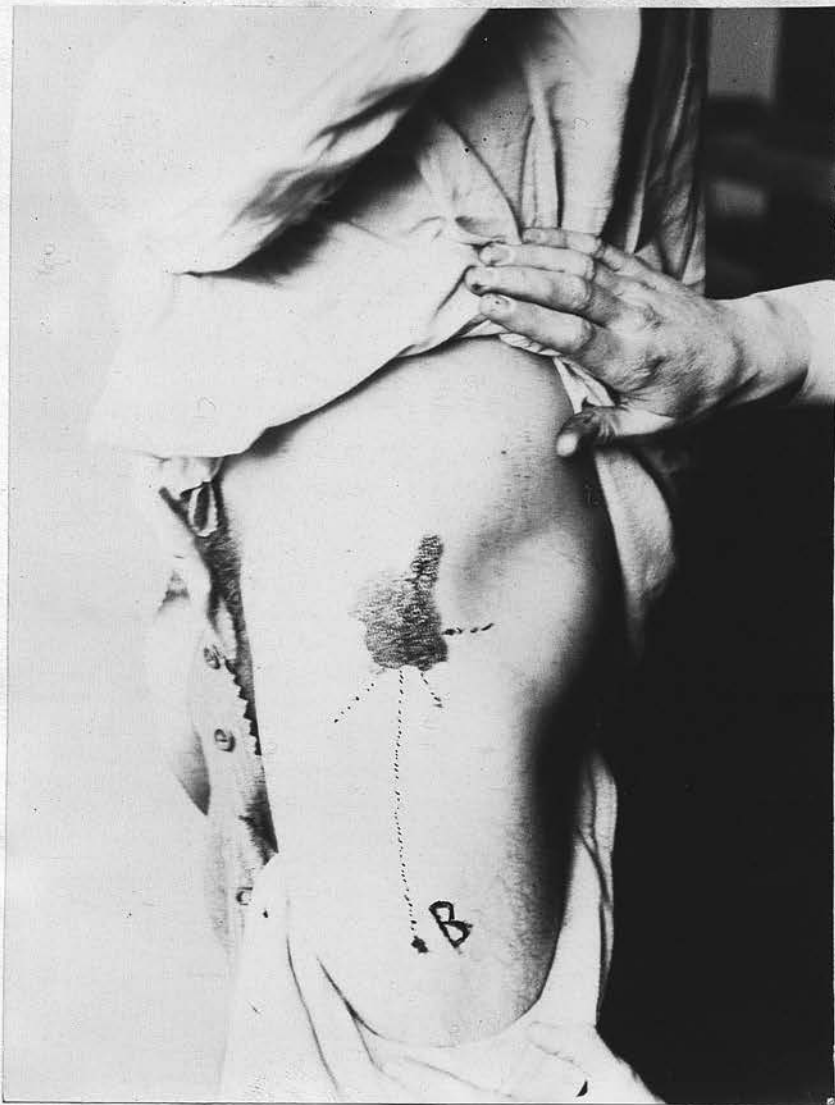Gunshot Wound. Face and Eye.

This man, a trooper in the I.Y. was wounded at Tweefontein. One bullet, travelling transversely, cut his upper lip. Another travelling in the same direction struck the external angular process of the left frontal bone, and after piercing the left eyeball, smashed the nasal bones and so emerged.

Four days afterwards his left eye was removed in Harrismith Stationary Hospital. A fortnight after this he came under my care. He said that during the fortnight after the extraction of the left eye he could see figures and distinguish men in the ward. Then his vision became cloudy and obscure.

At this time, 18 days after the fight, he was unable to distinguish light from darkness. His Iris was firmly adherent all round the lens.

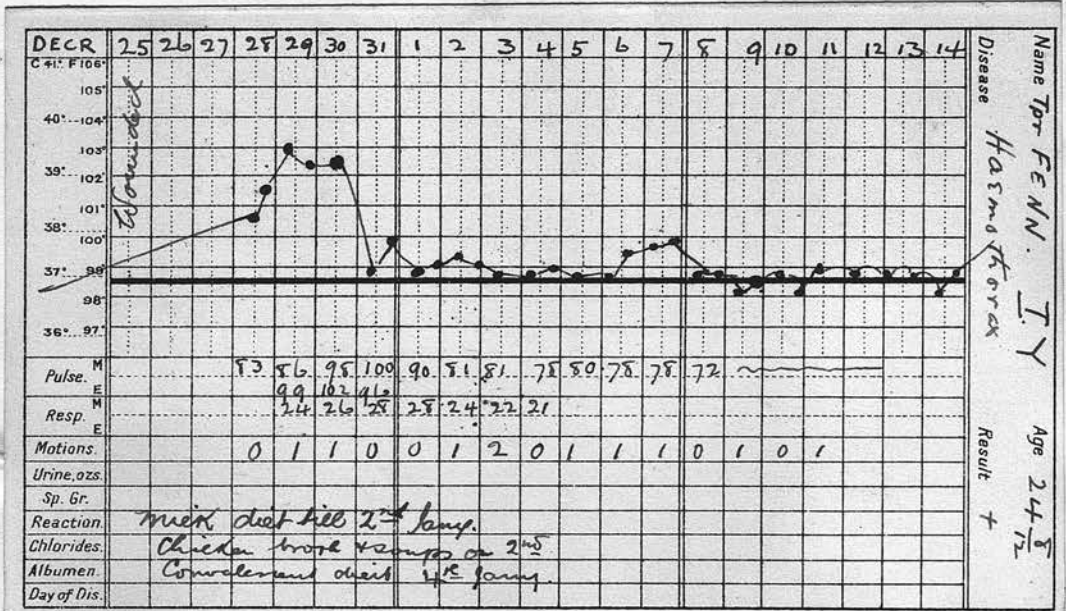
(Atropine had evidently not been used) Marked conjunctivitis was present. The optic disc looked cloudy. This was probably a case of Sympathetic Ophthalmia and the Prognosis was not encouraging.



To illustrate Case VIII

B when piece of lead lodged
in deep fascia.

dotted lines indicate direction
of sinuses as explained in context



Haemothorax.

This man, a trooper in the Yeomanry was wounded at Tweefontein on 25:12:01. The bullet struck him over the middle of the Right Scapula, pierced the bone and lung and emerged below the nipple on the right side. He had Haemoptysis directly after having been struck. He was admitted to the Stationary Hospital at Harrismith and while there felt quite well. On 27th Decr. he was sent by Hospital train to 15 General Hospital, Natal. He walked from the train to the Hospital, a distance of about 500 yards and then told the nursing sister in the ward that he was "feeling very ill."

On examination one saw the entrance and exit wounds in chest as above described. The man was flushed and sweating. Temperature 100.5. Pulse 83 and Respirations 24 per minute. The right side of the chest did not expand on respiration and on taking a deep breath the patient complained of pain in the right side. On Percussion, absolute dulness was present over the whole of the base of the Right Lung as high up as the 3rd intercostal space. Aegophony heard at the upper margin while over the dull/

dull area the breath sounds were inaudible. Vocal
Fremitus and Resonance quite absent over the dull
area. Skodaic resonance present at upper margin of
dull area. The diagnosis of fluid in the Pleural
Cavity, probably Haemothorax, was at once clear. He
passed a restless night and next morning, 29th, his
condition was much worse. He was now slightly
cyanosed and in great respiratory distress. Spoke
in a whisper. Temperature 103° F. Respirations
between 24 and 26 per minute. The Respiratory excur-
sion was very shallow. Pulse volume good. As his
distress was so marked I tapped his chest in the Right
Mid Scapular line at the 7th interspace and drew off
nineteen ounces of sero-sanguineous fluid which close-
ly resembled port wine in appearance. Fomentations,
which had been applied from the first, were still
continued.

In the evening he was much better. Slept three
hours during the day and woke up feeling hungry.
The great distress had in a large measure disappeared
but his breathing was still short and 'gasping' in
character. Temperature 102. Pulse good. The
course of the case after this was quite uneventful.
In four weeks the fluid had quite disappeared except
for/

for an area of slight comparative dulness at the right base. In six weeks he was allowed up and was eventually sent home to England for a change.

At this time the man though to all intents cured got breathless on doing any physical exertion such as a smart walk. This probably was due to some adhesions between the lung and the pleura.

Remarks:- In this case I take it that the Haemothorax did not develop immediately after the wound. The man felt very well until after the train journey and the walk from the station to Hospital. It was this exertion that must have caused the bleeding into the pleural cavity.

In this regard the conclusions of Makins in his "Surgical Experiences in South Africa 1899-1900." are noteworthy. He says "During the early part of the campaign on the Western side I saw a large number of chest wounds, and had I been asked my opinion as to the relative frequency of occurrence of Haemothorax I should have placed it at about 30 per cent. The patients in these early battles needed little wagon transport and when sent down to the Base travelled in comfortable ambulance trains." At a later stage in the campaign when the patients had/

had to undergo a three days and nights' journey to Stationary Hospitals, Mr. Makins calculated that at least 90 per cent. of the chest cases developed Haemothorax.

A point of interest in this case is the comparatively sudden fall of temperature to normal, on aspirating some of the fluid. All of the fluid was not aspirated. The common practice in treating cases of Haemothorax was if possible (1) leave the fluid alone and let nature absorb it or (2) if necessary by reason of Dyspnoea and distress to tap, do not remove all the fluid. If all the fluid is aspirated there is a tendency to a secondary Haemorrhage and a return of the symptoms, perhaps due to the sudden relief of pressure on the Intercostal vessels which are the usual sources of Haemorrhage in cases of Haemothorax from Gunshot wounds.—

Case XI.

This case is interesting on account of the multiplicity of Wounds. The man was in the thick of the fight at Tweefontein. One bullet struck him on the right cheek and emerged through the hard palate into the mouth. What became of this bullet no one knows/

knows. The man does not remember it going out of his mouth and the Rontgen Rays have failed to localise it.

Another bullet entered at the lower angle of the left scapula and emerged to the left of the apex of the heart. No Haemothorax developed. Had a slight Haemoptysis at the time.

A third bullet tore through the skin and muscles in front of the chest and did no further damage.

A fourth bullet, spent, struck him over the Right Tibia and embedded itself in the bone. The only complaint he made after all these injuries was that "he had lost the sense of feeling in the right side of his palate and that he could not chew biscuits so well as he used to."

Case XII.

Multiple Keloids.

This case was that of a trooper in the Queensland Imperial Bushman. He also had been several times wounded during the "drives" in the Transvaal and Orange River Colony. All the scars left from the bullet wounds took on a Keloid formation.

He had one big Keloid scar behind the right upper arm/

arm. One on the right forearm. One very large one on the right thigh. This one was growing fairly rapidly. He had another one on the left leg. The man states that any cuts and injuries he received when a child healed up rapidly.

The large Keloid on the thigh was the only one that was at all tender. The surface of the Keloids was smooth, glistening and raised. Small venules were present at the periphery. Projecting "claws" or processes of fibrous tissue radiated irregularly from the periphery outwards.

Case Xlll.

Gunshot Wound of Upper and Lower Jaw.

This man was shot at night by a sentry at Tigerskloof. The sentry mistook him for a Boer and fired without challenging. The bullet entered the right cheek, perforating the maxillary antrum and smashing off a triangular piece of bone from the right upper jaw. The bullet then travelled across the mouth, and shattered the ramus of the lower jaw on the left side. Then emerging through the skin it buried itself in the upper part of the left Deltoid, ploughed its way through the fibres of this muscle and/

and emerged through the skin about the insertion of the Deltoid, leaving a large irregular wound of exit. The bullet must have been travelling at a high rate of velocity.

Four days after the accident the man was admitted to Hospital under my care. All the wounds were then reeking with foul smelling pus, the face was enormously swollen and the man was in very considerable pain.

The mouth was douched hourly with weak antiseptic lotions. Liquid diet ordered and X ounces Port Wine daily. On 23:2:02 (5 days after the infliction of the wound) under chloroform the exit wound at the angle of the jaw was enlarged, and seven loose fragments of bone were removed from just anterior to the masseter muscle. A horizontal fracture extended from the shattered area for about 2 inches towards the Symphysis menti. The area was thoroughly cleaned, and a rubber drainage tube inserted.

On examining the wound of the right upper jaw a triangular wedge of bone was found to have been broken off. This, at the time of the accident, must have opened the maxillary antrum. The mucous membrane of the antrum however, had afterwards become swollen and oedematous and now blocked up this opening, for on plunging/

plunging a closed Kocher's artery forceps into the antrum through this opening a great gush of exceedingly fetid pus occurred. Cavity was then syringed out with Euthymol lotion and the opening made patent. A plug of Cyanide gauze was then inserted firmly into the antrum.

The wound in the deltoid was then cleaned, and the usual dressings applied.

Douching and gargling were carried out 2 hourly during the next day. On the 2nd day the gauze plug was removed from the antrum, and a lightly packed one inserted in its place. The man meanwhile took his milk, Bovril, Chicken Tea and Port Wine. He rapidly improved. The mouth became clean and the offensive odour of his breath disappeared. The tube at the angle of the jaw was removed on the 7th day and the gauze plug on the 8th day.

I had the man under observation for three weeks after this. He then daily syringed out the maxillary antrum and the mouth, with a lotion containing Euthymol (one drachm to the ounce of water) The external wound at the angle of the jaw had closed. He could eat minced meat, potatoes and vegetables and masticate thin bread and butter with comfort. The/

The lower jaw was still freely movable at the seat of fracture but fibrous tissue^{union}* was taking place.

A cork was fashioned to plug the opening in the antrum at meal times, and this acted efficiently, the patient being able to insert it with ease and comfort.

This case followed the usual course of injuries to the mouth and jaws. The wounds became septic as a rule but by frequent douching and syringing with weak antiseptic lotions the injured areas became clean. Healing as a rule was rapid owing to the great vascularity of the parts.

Case XIV.

Tpr. J.R.S., Imperial Yeomanry, struck by bullet at Tweefontein at the left border of the Erector Spinae just above the sacrum.

Bullet emerged about three inches higher up over the Right Erector Spinae. The interest in the case is the exit wound which is of the "expanding" or "explosive" type. The skin was very much torn, lacerated, and everted at the exit wound. The entrance wound was small and circular.

A somewhat similar wound is described by Mr. Makins in his "Surgical Experiences in South Africa" page/

62
page 100. In his case the exit wound was very much larger than in this case.

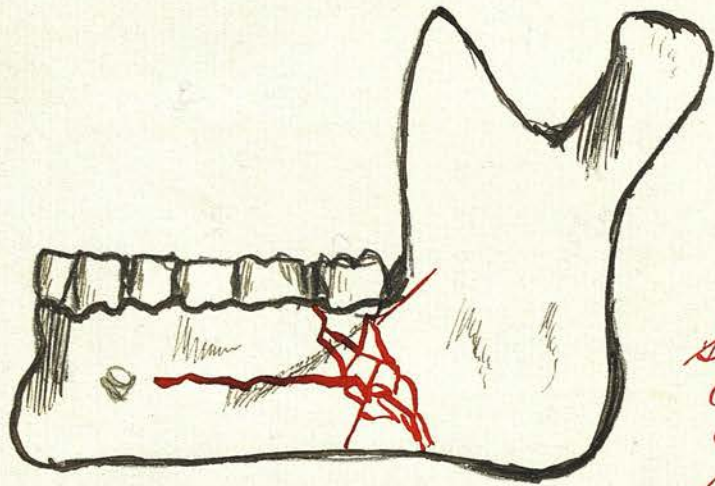
Wounds of the back in this situation were fairly frequent during the war.

Gunshot wound face.

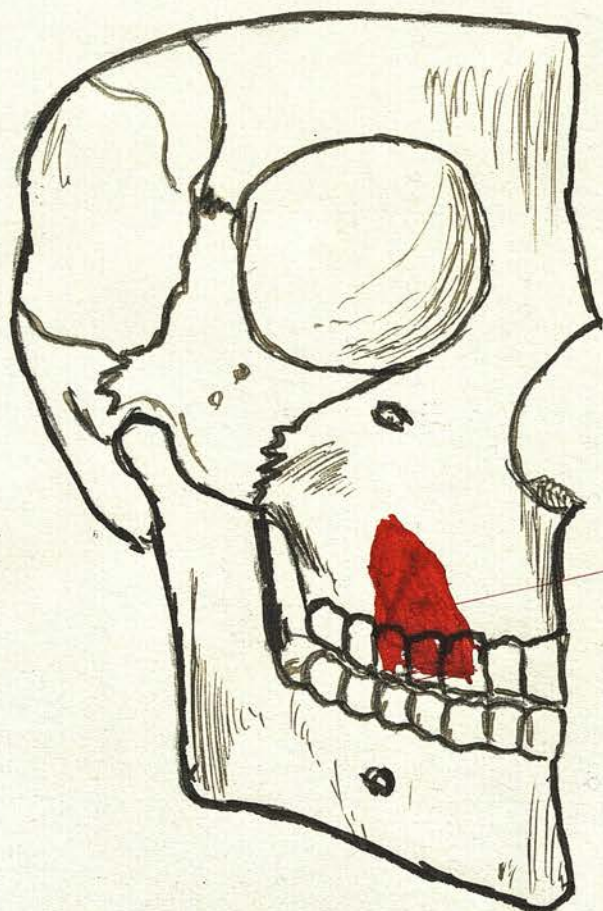
Fracture into Maxillary Antrum

" lower jaw.

To illustrate Case XIII



Shattering of Horizontal Ramus.
Crossed red lines indicate the
Comminution. Note the fracture
running forwards towards symphysis



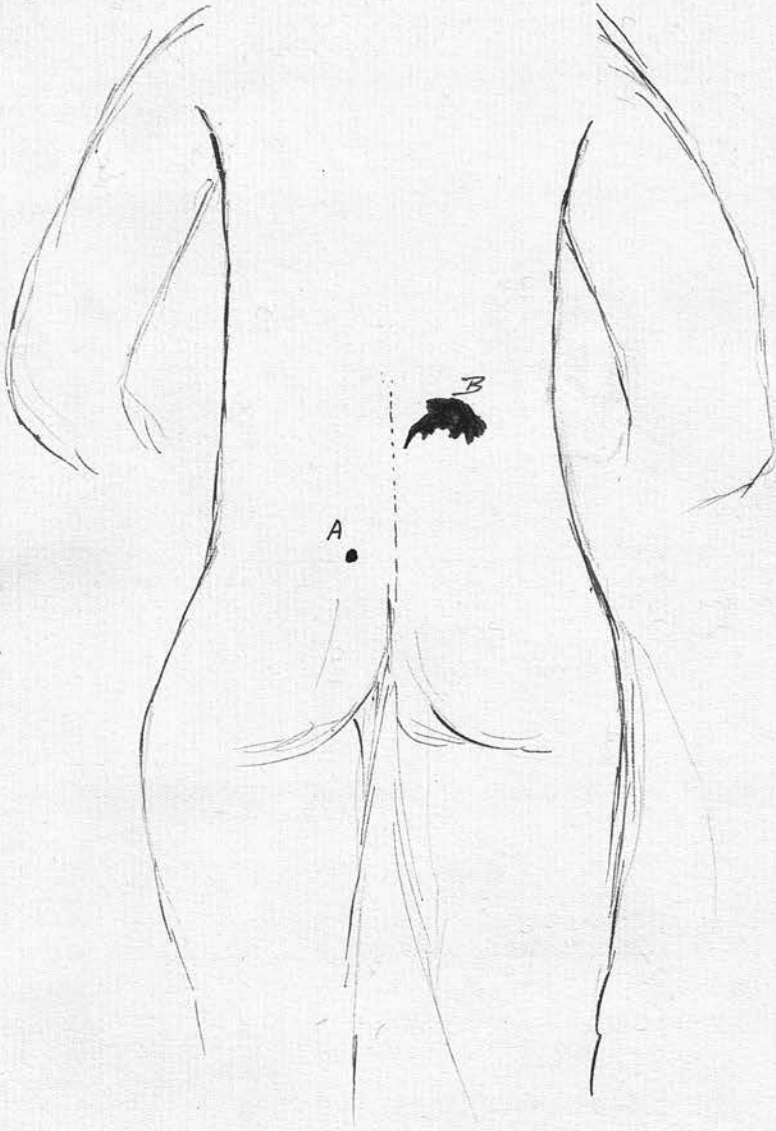
Wedge of Bone
Chipped off by bullet
on its way across mouth.
This exposed the Maxillary
antrum

Sto J.R.S. - Inpl Yomanoy

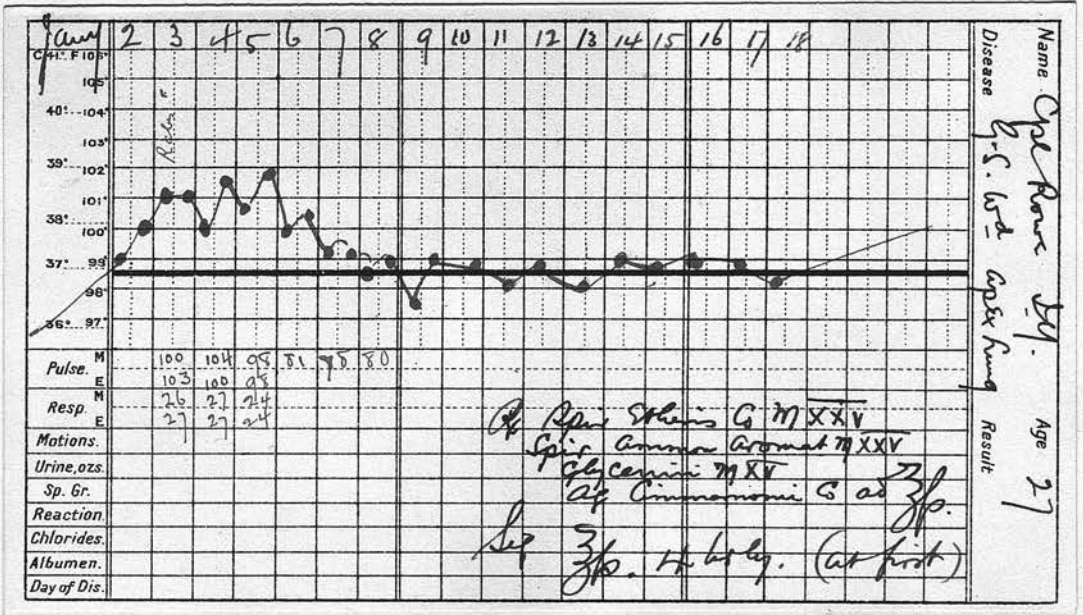
wounded Sweetfontein
25/12/01

Transverse Wound Back.

A = entrance wound
B = exit wound. of "expanding" type.



To illustrate Case XIV



Abscess of Apex of Lung Due to Lodgement of a Bullet:

Extraction of Bullet: Recovery.

History.- Corporal R., aged 27, of the Imperial Yeomanry, was struck by a bullet in the back while in action at Tweefontein on Christmas Day, 1901. This yeoman was in a trench when he was ordered by his officer to retire to another position. While retiring he was struck by the bullet in the back, ran forward a few more paces then fell, and, as he states, "coughed up a mouthful of blood." He was shortly afterwards conveyed in an ambulance to Harrismith Hospital, where he remained till January 31st, 1902. He was then transferred to No. 15 General Hospital, Howick, where he came under my care.

State on Admission.- He was very anaemic and weak, had an irritative cough, and a temperature of 99.7° F. Situated above the spine of the right scapula on a level with the second rib was a large irregular wound with gaping edges and dirty granulations. This was the wound of entrance of the bullet; there was no wound of exit. On probing this wound one came on the second rib, which was here denuded of periosteum and partially fractured. The expansion of the right apex of the lung was impaired, and a/

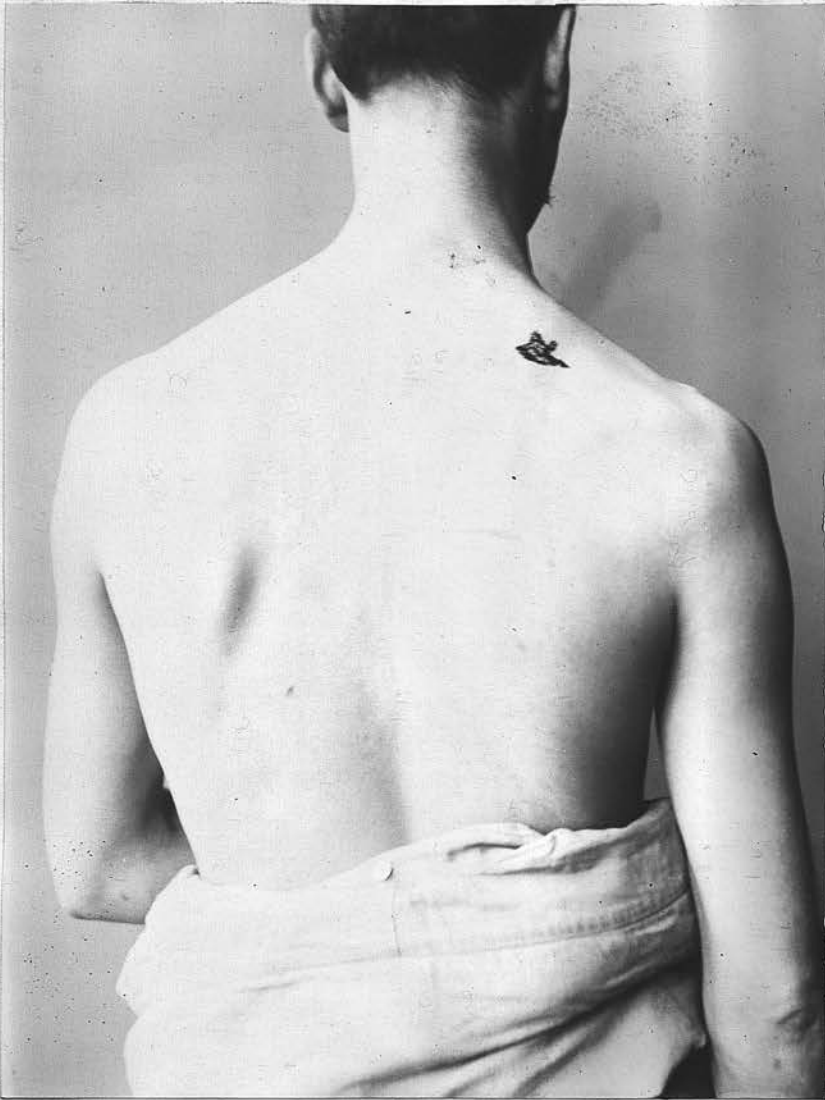a dull note was obtained on percussing above and slightly below the clavicle. The respiratory sounds were very distant and feeble on listening over the apex with a stethoscope.

Operation.- On January 22nd, 1902, under an anaesthetic this wound was enlarged. A piece of lead about the size of a pea was found embedded in the rib. This was removed, and about 1 in. of the rib was then cut away with bone forceps in order to give free room for exploring the apex. The lung was firmly adherent to the rib and felt hard and resistant. On plunging a closed Kocher's artery forceps into this resistant area a quantity of pus gushed forth. The forceps were then withdrawn with the blades widely open, and the finger inserted into the abscess cavity. At once some hard foreign bodies were felt, and on extraction these proved to be a piece of lead, twisted and indented, and about the size of a small marble, three small pieces of the metal casing of a cartridge, a piece of cloth, and two small chips of bone. The walls of the cavity felt very firm. A large rubber drainage tube was then inserted, and the wound was left open. On recovering from the anaesthetic he coughed violently and expectorated some blood-stained mucus.

After-History/

After-History.- On January 3rd his condition was not promising. His temperature ran up to 101° , he had frequent coughing and brought up pus and mucus by the mouth. All over his right lung coarse bubbling rales were heard. By January 8th all these bad signs had cleared up; no expectoration of pus, no rales, and normal temperature. The drainage tube was taken out on the seventh day after the operation and the wound then closed rapidly. He left the Hospital for England on March 9th perfectly well.

Remarks:- I take it that the bullet had entered the apex of the lung, and set up the haemoptysis which he had immediately after having been struck: that it had then become surrounded by dense fibroid tissue, and that the abscess had, so to speak, become encysted. During the operation the walls of the abscess cavity had been broken and loosened at places, and some of the pus had evidently got into the air spaces and bronchi, and so set up the septic bronchitis which followed immediately after the operation.



To illustrate case of abscess
of apex of lung. Rapped opening
of sinus indicated

Traumatic Aneurysm in Left Groin: Ligature of
Left Common Iliac: Recovery.

The following case is of marked interest, adding as it does, one more to the very meagre list of recoveries from the formidable operation of ligature of the common iliac artery.

History.- Private J.S., of the Victorian Mounted Rifles, aged 31, while in action against the Boers near Vryheid, Transvaal, received a bullet wound in the left groin. He states that he fell off his horse a few minutes afterwards owing to faintness. He was at once conveyed to Hospital, and remained in bed for three or four weeks. Was then sent down to the hospitals at Dundee, Mooi River, and finally to the Convalescent Depot at Howick, Natal. / All this time he says he felt very weak, and walked with a decided limp. Had frequent pains in the left groin, and felt a hard lump there. While at the depot he met with an accident. A soldier fell on him, driving the knee with great violence into the left groin of the already injured man. This was followed by acute pain, increased swelling in the groin, faintness, and inability to use the limb. He was admitted into the surgical wards/

wards of No. 15 General Hospital, Howick, on November 18th, 1901.

State on Admission.- He looked thin and wasted, and very pale. He lay on his back, and moved with difficulty owing to the pain in his left groin. On examining the groin the healed wound of entrance of a bullet was found, situate about three fingerbreadths above Poupart's ligament, and internal to the course of the external iliac artery. The wound of exit was situated below the crest of the ilium on the same side. The bullet had on its way directly crossed the line of the external iliac artery (and as the case will show, wounded that artery high up), pierced the iliac bone, and emerged externally. The skin of the left inguinal region was erythematous, and tender to touch. The oblique inguinal glands were enlarged and painful. A marked bulging was easily observed, situated above Poupart's ligament, and below and external to the umbilicus. By laying the hand over this area a heaving pulsation, synchronous with the cardiac systole, could be felt. The whole area felt boggy to the touch. By compressing the aorta slightly (this caused the patient excruciating pain) the pulsations in the mass were distinctly lessened. There were/

were no bruits in the heart to account for the marked systolic bruit heard on placing the stethoscope over the swollen area. The diagnosis of aneurysm of the external iliac artery was therefore arrived at with comparative certainty. From the history one could deduce that an aneurysm must have formed after the bullet wound, that this aneurysm had been probably increasing slowly or had begun to coagulate, and that the injury he received shortly before his admission to Howick Hospital had probably ruptured the sac and occasioned a fresh outpouring of blood from the torn artery.

Progress and Treatment.- The patient was put to bed, with the limb elevated and bandaged from toes to hip, lead and opium fomentations were applied to the groin to reduce the inflammation of the inguinal glands already referred to; given a smart purge, and put on milk diet. November 19th.-Patient very restless; complains of agonizing pains in the left groin and hip; cannot sleep; given morphine subcutaneously. Temperature 100.5° , and rising. The aneurysmal mass is distinctly larger: the outer part of the aneurysm feels more resistant than the inner: systolic bruit over mass is very loud. A large pad was placed over the/

the aorta, and a firm bandage applied to hold it in place. This pad gives the patient a great deal of pain. November 22nd.-Temperature 101.2° . Inflammation of inguinal glands has disappeared: aneurysmal mass larger; patient extremely weak and restless; still has the acute pain in the left groin and hip. November 23rd.-Temperature 101.6° . The aneurysm is now about one fingerbreadth below the umbilicus, and has extended well into the middle line, heaving pulsations very marked. A consultation was held to-day, and it was agreed that without operation the patient's chance was hopeless, on account of the extreme rapidity with which the aneurysm was growing. Prolonged compression of the abdominal aorta under an anaesthetic was out of the question owing to the patient's enfeebled state, and owing to the danger of rupturing the thin sac of the aneurysm. The patient was accordingly prepared for operation.

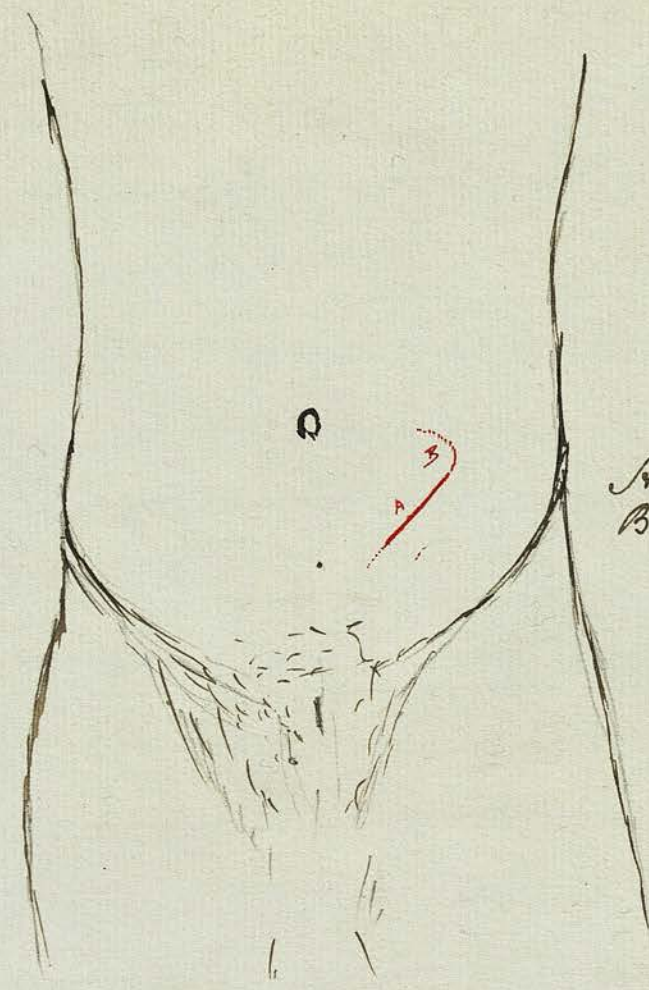
Operation.-An incision was made from a point $1\frac{1}{2}$ inch above and external to the centre of Poupart's ligament to 1 in. above and internal to the left anterior superior spine, cutting through the skin and various muscle and fascial layers. This incision exposed the aneurysm sac, which looked extremely thin and/

and felt very soft. One could not get above the sac by this incision, so it was prolonged upwards in a slight curve, with the convexity downwards and outwards. The peritoneum was exposed and incised, and the intestines held back by warm sterile cloths. The sac could now be clearly defined. It was found to extend over to the brim of the pelvis and well outwards into the iliac fossa. The external iliac artery could not be defined. The common iliac entered directly into the aneurysmal mass, and the internal iliac emerged from the upper part of the mass. All hope of tying the external iliac was therefore abandoned: the iliac vein, therefore, having been defined and separated, a double silk ligature was then tied round the common iliac artery in two places close to the aneurysm, and the artery divided between the ligatures. Pulsation immediately ceased in the internal iliac and over the aneurysm. The incision was then closed in the ordinary way, the peritoneum and muscles and skin being brought together separately, and a sealed dressing applied. The limb was surrounded evenly with thick layers of cotton wool, and a flannel bandage firmly applied from the toes to the hip. He was put to bed and surrounded by hot water/

Traumatic Aneurysm

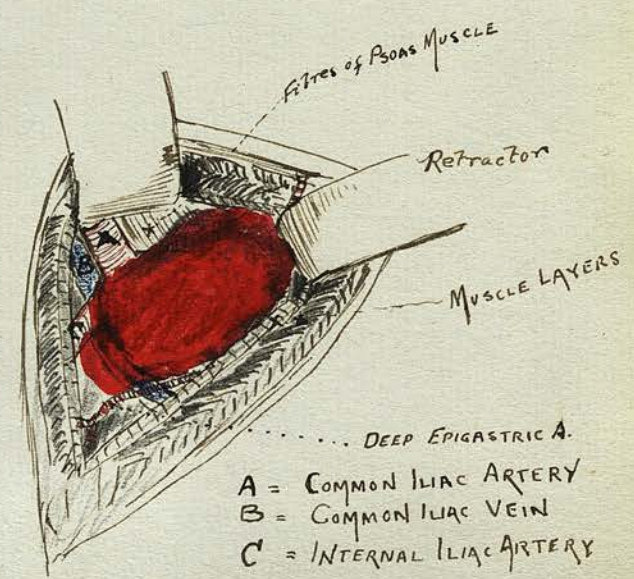
Left External Iliac Artery
Ligature of Left Common Iliac Artery

Supple
V.M. Rifles
15. G. H. Hornick
Notab



A = original incision
B (dotted) prolongation
of incision to
give more room

rough outline of parts exposed during
operation
Common Iliac will be observed to
be its continuity in the aneurysmal mass
(indicated by red smear). The Internal Iliac
artery appears to arise out of the
aneurysmal mass. The aneurysm projects
all out toward iliac fossa & well in to
of pelvis



water bottles. He took the anaesthetic badly, and had to be frequently stimulated with strychnine, ether, etc., during the operation.

November 24th. Had a restless night. Given morphine subcutaneously. Pulse volume and tension good. Temperature 100° F.

November 25th. Bandage round limb not disturbed. Patient weak, but takes milk and chicken-tea well. Says that he "cannot feel his left leg." Temperature 98.4° .

November 26th. Vomited several times during the night. No abdominal distension. Pulse good. Kept on nutrient enemata for eight hours with sips of warm water by mouth. Bandage round limb removed. The left lower limb is much colder than the right. Roots of the toes very oedematous. Limb looks very blanched. Below the knee the skin is quite anaesthetic. No pulsation present in tibial or popliteal. Again bandaged as before.

November 27th. Several large watery blebs have formed on the leg and foot. Still anaesthetic below knee. Toes still oedematous. Limb colder than right, but has a certain degree of warmth of its own. General condition fair. Has not had any pain/

pain in the groin since the operation, and sleeps well during the day and night.

November 30th. Temperature of left limb is now almost equal to that of right. The anaesthetic area below the knee has now disappeared, and patient complains of pain in his calf. Can now "feel" his leg, but says it is "as heavy as lead." The blisters and oedema of toes have gone.

December 22nd. Circulation in limb freely established. Temperature of two limbs equal. On grasping limb firmly, the skin becomes pale, and when pressure is relaxed a rosy blush follows. No pulsation is present. The patient can extend and flex his limb quite freely. Massage is being carried out daily to the left limb.

January 20th, 1902. Moves leg freely. Can extend, flex, and rotate easily, but is unable to lift the whole leg up vertically while lying on his back.

January 22nd. Up on a wheeled chair. Is putting on flesh daily.

January 23rd. Up on crutches. Gets along well. Puts left foot to the ground at intervals.

February 3rd. Can walk about slowly without the/

the aid of crutches or stick. A hard firm mass about the size of a goose egg can be felt in the left iliac fossa.

Remarks:- The question arises in this case whether, having cut down on the sac, one should not have carried out Syme's operation - namely incising the sac, turning out the blood clot, and catching all the bleeding points. This is a much more formidable and prolonged operation than simple ligation and statistics show that secondary Haemorrhage is not an uncommon sequel. Again, should one have tried prolonged compression of the abdominal aorta under an anaesthetic? Against this method one must place the extremely weak state of the patient. The anaesthetic would have had to be carried out for several hours, and the patient could not have undergone this. During the short time he was under the anaesthetic, while the operation was being performed, he was weak and collapsed and constantly required stimulation. The fact that this patient was cured and able to walk about ten weeks after the operation is sufficient justification for the procedure adopted. One other point of interest is the/

the collateral circulation which in this case must have been largely carried out by the anastomosing lumbar, circumflex and lower intercostals, with assistance from the pudics, inferior haemorrhoidals, and sacral arteries. The deep epigastric and deep circumflex iliac arteries fortunately came off below the aneurism.

The literature on the subject of ligature of the Common Iliac artery is interesting. The mortality from the operation, immediate and remote, is undoubtedly high. The Medical Times of July 19th 1884 quotes from the Philadelphia Medical News of April 5th 1884 a summary of this operation in 79 recorded cases. viz:—

The vessel has been tied for:—

- (1) Haemorrhage. - 28 cases with 24 deaths.
- (2) Cure for Aneurism - 43 cases with 28 deaths.
- (3) For Pulsating Tumours indicating aneurism.
5 cases with 4 deaths.
- (4) Preliminary, to stop Haemorrhage as in a removal of a tumour or amputating at the Hip Joint. 3 cases, all died.

Kümmell is quoted in this article as an advocate of the view that it (i.e. ligature of Common Iliac) is "preferable to ligature of the External Iliac for/

for aneurism of that vessel situated high up" because of less liability to gangrene. The Compiler of the above statistics however does not consider this sound surgery.

Smith (American Journal of Medical Science. vol. xl. pp. 7-46, year 1860) collected Statistics showing that ligature of the External iliac gives a mortality of 28% and ligature of the Common iliac a mortality of 77%. Up to this date there had been 15 cases of ligature of the Common iliac for aneurism (14 males 1 female) with 5 recoveries. Secondary Haemorrhage seems to have been the cause of death in most of the cases.

The methods adopted for ligaturing this important vessel have been various. In almost all recorded cases the Extra peritoneal method has been carried out.

In a case reported by Jamieson (Lancet March 6th. 1836) a novel operation was performed. A woman aged 28 had a large pulsating aneurism above Poupart's ligament on the right side. Its size was stated to be ^{as big} as a foetal head. In the words of this operator "from the extent of the tumour it seemed impossible to expose the common iliac artery by operating on the right/

right side." His incision was therefore made, down to the peritoneum, in the left groin, and the peritoneum pushed aside till the Right common iliac artery was reached. This was then tied with silk.

The Intraperitoneal method, has, so far, had few successful exponents. Treves "Operative Surgery" text book, 1891, states in reference to the Intraperitoneal method. "I am not aware that the operation has been carried out upon the living subject." In the British Medical Journal, October 29th, 1892, a very interesting question was propounded by Mr. Marmaduke Shield in "A Query in Operative Surgery" viz. "Now that it is acknowledged on all sides that aseptic wounds of the peritoneum are safe and heal rapidly it is worth putting the question to our leading authorities on operative surgery, whether the old operations for ligature of the Iliac arteries are altogether advisable. Their principal merit was avoidance of wounds of the peritoneum. The great drawback the difficulty of the operation and the extensive wound in the abdominal walls."

In reply to the above (British Medical Journal, Novr. 5th, 1892) Mr. Lucas stated that in 1889 he "acted/

"acted on the belief in favour of Intraperitoneal operating and ligatured the common iliac artery through a median laparotomy incision for a rapidly increasing aneurism of the External iliac." The patient recovered.

Stevenson (B.M.J. 25th Jan, 1896) reports a case of "Transperitoneal ligature of Common iliac artery for diffuse traumatic aneurism of the External iliac and common Femoral arteries." In this case first an incision was made in the middle line, the peritoneal cavity opened and a silk ligature tied round the left common iliac artery. The wound was then closed in the usual way. When the man had fully recovered from this operation, a second one was performed by cutting directly into the old aneurismal sac, and turning out 2½ pounds of blood clot.

This second operation was evidently done to prevent the clot suppurating. In my own case such a measure would have been quite unnecessary and I certainly should not adopt this procedure unless signs of suppuration manifested.

In the Medical and Surgical History of the war of the Rebellion (American Civil War) Pt. 11 p.333,
four/

36.
four cases of ligature of the Common Iliac artery are recorded by Dr. Otis. The 1st case died 3 months after the operation from exhaustion and debility. The 2nd case died 2 days after the operation from secondary Haemorrhage.

The 3rd case died four days after the operation from suppuration in Sac and Gangrene. The 4th case died four days after the operation. In the 4th case the peritoneal cavity was opened during the operation and the immediate cause of death was peritonitis. The first two of these cases were gunshot wounds on the groin and buttock. The third was a bayonet wound of the buttock and groin. The fourth case was an aneurismal varix of the Femoral artery and vein from a punctured wound below Poupart's ligament.

In the American Journal of Medical Science (vol xl pp.7-46, 1860) it is stated that Gibson of Philadelphia first performed the operation in 1812, but Mott's case performed in 1827 was the 1st successful case on record.

I have looked through the tables of operations compiled by the late Sir Wm. MacCormac in his "Notes and Recollections of an Ambulance Surgeon" but can find/

57
find no mention of the common iliac having been ligatured for gunshot wounds. The records here referred to the cases treated at various base hospitals and ambulance stations during the Franco-Prussian Campaign of 1870.

It will not be out of place here to refer briefly to Syme's brilliant operation in a case of Iliac Aneurism. Professor Syme before the Royal Medical and Chirurgical Society on May 27th 1862, related a case of "Iliac Aneurism remedied by opening the Sac and tying the common iliac and the internal iliac arteries." (Medical Times and Gazette, 14th June, 1862) The case was that of a seaman aged 31, who had a large aneurism in the left groin. "The aneurism extended from below Poupart's ligament considerably higher up than the umbilicus and from two inches beyond the middle line of the abdomen towards the right side completely across the left iliac region so as to overlap the crest of the Ilium."

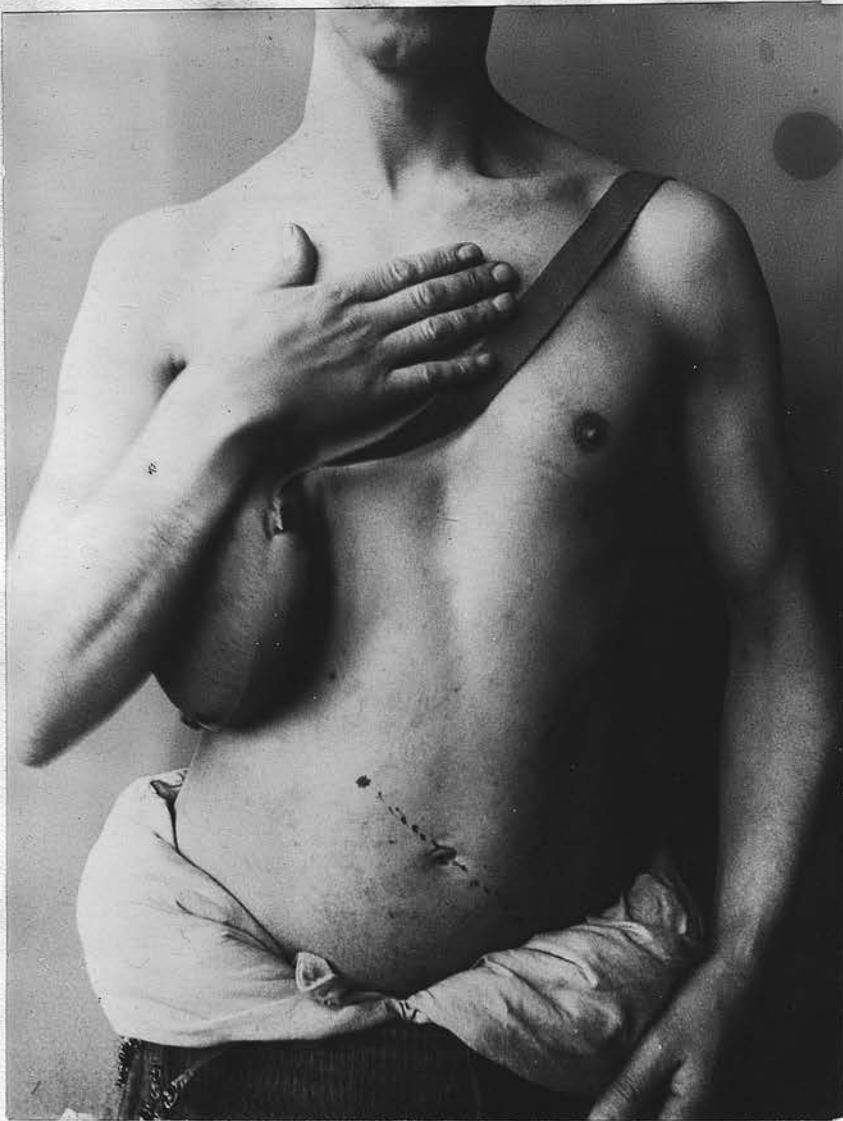An incision was made into the sac. Six pounds of blood and blood clot was scooped out. The openings of the external iliac and internal iliac were then tied .

It/

It is interesting to note, in this classic operation, that Lister's screw clamp was used to compress the abdominal aorta.

Ligature of the common Iliac artery is assuredly a grave operation.- grave in results, but not in mere surgical technique. - The operation of tying the vessel intraperitoneally is a simple anatomical dissection. In my own case the soft fluctuating sac alone gave me cause for anxiety. One can avoid rupturing the sac by exercising patience and gentleness in manipulating the tissues.

The gravity of the operation of course is much diminished in cases of traumatic aneurism where the artery is healthy and where the patient is robust. I attribute a great deal of the success in my case to the fact that the collateral circulation had, in a measure, been started before I operated. Where a large pulsating aneurism of a main artery exists, it follows that the smaller vessels above and below gradually take on a little more work. Especially is this the case if clotting in the sac commences. In this case clotting must have been going on well until the man met with his accident.



To illustrate Case of Dramatic
Aneurysm of Femoral Artery
Water bottle fixed in order to
give an idea of course of bullet
(1) through forearm
(2) " water bottle
(3) into peritoneal cavity
Dotted line indicates course
of Bullet

Gunshot Wound of Abdomen: Traumatic Aneurysm of
Femoral Artery: Amputation through Thigh.

The following case is of interest, not only from the grave sequelae following on a gunshot wound of the abdomen, but also for the splendid "power of resistance" of the man who was struck.

History (for which I am indebted to the medical officers of Vryheid Hospital).—Sergeant P., of the 7th New Zealand Mounted Rifles, during a skirmish with the Boers at Orangedale on October 17th, 1901, was struck by a Mauser bullet at a range of about 400 yards. The bullet passed between the radius and ulna of the right arm, then through his water-bottle and then entered the peritoneal cavity about 2 in. above and to the right of the umbilicus, travelling towards the left iliac fossa. He was admitted into Vryheid Hospital (October 22nd, 1901), and was then suffering from localized peritonitis in the neighbourhood of the abdominal wound—namely, tenderness, slight abdominal distension, rigidity of right rectus muscle, and a "rocky" pulse. ~~Had~~ Sweating cold extremities at this time also, ~~the~~ he was very weak and collapsed. In about three days' time this peritonitis disappeared, and the pain shifted to the region of the left iliac fossa./

fossa. On October 27th the pain in the left iliac fossa became very severe, and a fluctuating swelling was now made out, situated at the site of the pain, slightly external to the left common femoral artery. The temperature now took on a septic character, and the patient was getting very weak.

Operation.- On October 28th, under an anaesthetic, an incision was made into this swelling, external to the femoral. When the fluctuating area was reached a large quantity of stinking pus gushed out. This was followed by an alarming rush of arterial blood. A large suppurating aneurysmal sac was disclosed, and the common femoral was at once tied. After the operation the patient was very collapsed, and his life was despaired of for some time. He made a good rally, however, but gangrene of the foot shortly afterwards set in.

Second Operation.- This gangrene slowly advanced up the leg, and on November 29th, 1901, he was again put under an anaesthetic, and his leg was disarticulated at the knee-joint. The patella was retained. After this operation his condition was again critical for some time, and again he called on his reserve energy, and made a good rally. The flaps of this amputation/

117

amputation now sloughed, and left the lower end of the femur quite bare. Several weeks after this he was transferred to No. 15 General Hospital, Howick (owing to the Vryheid Hospital having been closed), and he was admitted under my care in the surgical ward. He was then very anaemic and emaciated. He had slight emphysema of the lungs and had frequent attacks of asthmatic bronchitis, the asthma at times being very severe. His heart and kidneys were healthy. The healed scars of the bullet wounds were present as described above, and also the linear cicatrix over the femoral artery. The left thigh muscles were flabby and wasted. The lower end of the left femur was projecting for about $1\frac{1}{2}$ in. beyond a ring of skin and cicatricial tissue. The cartilage was eroded in places, and covered with fungoid granulation tissue at others. Obviously the limb required amputating higher up in order to give him a good stump. As the patient was in such an enfeebled condition, we determined to delay the operation till he was stronger. He was accordingly put on a liberal diet of roast chicken, and vegetables, fish, eggs, rice, port wine, etc., was given respiratory stimulants, and carried out in his bed for /

*

112
for two or three hours on fine afternoons into the sunshine in order that the bracing air of Howick should have an opportunity to work good. Under this treatment his strength rapidly increased, his anaemia disappeared, and the crepitant rales in his chest became a thing of the past.

Third Operation.- On February 24th, 1902, four weeks after admission to Howick, under an anaesthetic (chloroform), I amputated his thigh in the lower fourth, making anterior and posterior flaps, with circular division of the muscles at the base. There was scarcely any haemorrhage during the operation. The popliteal artery was very much smaller than normal - it was about as large as the temporal artery - but was quite full of blood. Only two vessels required ligature; torsion stopped the bleeding from the others. The flaps had a very good vascular supply. The after result was perfectly satisfactory. Everything healed by primary union, and the stitches were removed on the ninth day. The cicatrix is now well posterior, and the bone is covered with firm healthy tissues. I should have mentioned that the bullet has never yet been discovered. The patient is now in good condition, but still has occasional attacks/

attacks of asthma. The artificial limb can be affixed with comfort later on.

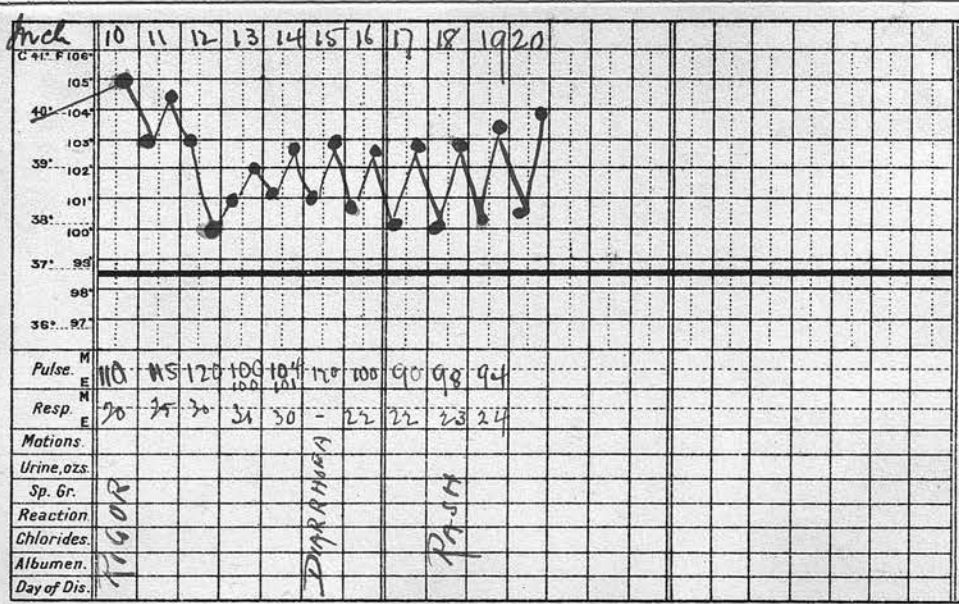
This case affords a good contrast to the former case. In the former the left common iliac artery was tied and the patient recovered with a sound limb. In this case, a smaller artery, the Common Femoral - was tied and the result was gangrene of the foot, spreading upwards and necessitating an amputation at the knee and later on an amputation above this. On admission to Vryheid Hospital he was suffering (vide notes) from "localized peritonitis in the neighbourhood of the abdominal wound,"

The bullet therefore evidently travelled for part of its course in the peritoneal cavity. It may have injured the small intestine or it may not. At all events, the injury could not have been a severe one. Had the coats of the small intestine been completely ruptured, the man almost certainly would have developed generalised peritonitis and would have probably died. A great deal has been written about the wonderful recoveries from perforating wounds of the small intestine without a laparotomy having been performed. If such cases were recoveries from perforating wounds then indeed they are/

are wonderful. But has the diagnosis always been reliable? Has not a localized peritonitis resulting from an injury to the parietal peritoneum, or an injury, short of complete rupture of the coats of the small intestine, been often diagnosed as a localized peritonitis resulting from a perforation of the small bowel. Differential diagnosis of abdominal wounds was an extremely difficult and doubtful matter.

In this regard the words of Mr. Makins in "Surgical Experiences in South Africa" chapter XI are striking. He says, "Although therefore I am not prepared to deny the possibility of spontaneous recovery from an injury to the small intestine.....
..... I believe that in the immense majority of cases in which a bullet crossed the small intestine area without the supervention of serious symptoms, the small intestine escaped perforating injury." Again later on he says, "in all the 5 cases (of perforation of small intestine) in which the injury was certainly diagnosed in hospital, death occurred."

In the case under discussion therefore I think it safe to assume that a perforation of the small intestine did not occur as the bullet travelled towards the left Iliac Fossa.



Name *Dr. R. A. S. Apr.* Age *22*
 Disease *Subacute Fever* Result

Enteric Fever simulating, in its Onset, Acute

Appendicitis.

Pte. R. Army Service Corps, was admitted to No. 15 General Hospital, Natal, on 26th Feby. '02 as a "Convalescent from Malaria" contracted while on "trek" on the Zululand border. He was placed in the usual Convalescent Malarial Ward, given a liberal diet, port wine and tonics. His attack of Malaria had evidently been a very sharp one, for, on admission he was very weak and anaemic and markedly jaundiced. Up to 10th March he improved greatly. His temperature while in Hospital up to this date was normal. On the night of 10th March he woke up from sleep complaining of intense pain in his right Iliac fossa. Vomited several times. Had a Rigor. Temperature was then 105° . Shortly afterwards he became extremely collapsed, and extremities were quite cold. Hot bottles were placed round him. Strychnine given hypodermically and sips of warm water and brandy given by mouth. His general condition shortly after this improved, but he had frequent retching and still complained of the severe pain over Right Iliac Region. The orderly Medical Officer who was called to see him during the night, in/

in his notes, stated that the pain was referred to McBurney's Point. A hot fomentation was applied over the painful area and this gave relief.

Next morning I was called to see the case in consultation with 2 other medical officers. The patient's temperature was then 103° F. Pulse 100 volume and tension good. Respirations 22 per minute. He lay on his back with his right leg drawn up. Still complained of pain in Right Iliac Fossa. On gently palpating this area the man cried out with pain. Tenderness over McBurney's Point, was extreme. Skin was oedematous over this area. One felt disinclined to palpate the area thoroughly. Rectal examination was negative. He had been constipated for 2 days. Tongue furred. Breath foul. Urine normal. Liver area not tender. We all felt perfectly agreed on the point that the case was one of Acute Appendicitis, and in view of the possibility of an operation being required, the man was handed over to me.

Progress of the Case:- He was given an oil enema with a good result. An icebag was placed over the Right Iliac Fossa and milk and barley water given by the mouth. Temperature rose this night to 104/

104. Tepid sponging reduced this to 102°. Pulse volume and tension good.

12th March. Temperature 103°. Pulse 120. Marked fulness present over right fossa and rigidity of abdominal wall over this area. Still tender over McBurney's Point. Tongue furred. Patient looks very ill, and lies curled up in bed.

13th March. Still fulness in right side and oedema of skin between Umbilicus and Anterior Superior Iliac Spine of Right side. Boggy fluctuating area present. Textures still resistant. Temperature down. Patient does not complain so much of pain in this region.

The history after this briefly was as follows. On 15th March diarrhoea developed. The motions were foul smelling and of the pea soup variety. The pain in the Right Iliac Fossa had practically disappeared but a marked resistant area could be palpated, and the skin was still oedematous over the area. On the 18th a typical Typhoid Fever rash developed.

Two days afterwards I left Natal and so was unable to follow the progress of the case. The doctor who had charge of the case after this wrote me/

me in May saying that the case had run an ordinary Enteric Fever course, with the exception of a slight relapse, and ^{that} the man had been invalided to England for a change.

From a surgical point of view this case is very interesting. All who saw the case on the 11th March felt quite positive about the accuracy of the diagnosis, viz. Acute Appendicitis. The sudden onset with vomiting and a temperature of 105° . (with no renal or hepatic mischief indicated) the rigidity of the abdominal wall, oedema of skin and the localized pain and tenderness over McBurney's Point, did not at all lead one to suspect Enteric Fever. Most probably the Mesenteric Glands round the Coecum and appendix were acutely inflamed, and the mucous membrane here itself may have been early implicated.

The danger of a case such as this is that one might be tempted to operate on the appendix.

Osler in his article on Typhoid Fever in his "Principles and Practice of Medicine" says, "Operation for Appendicitis has been performed in the early stage of Typhoid Fever owing to the combination of pain in the Right Iliac Fossa, fever and constipation. This has/

has happened twice at the Johns Hopkins Hospital."

Appendicitis. Removal of Appendix.

Private R., Post Office Corps, admitted to No. 15 General Hospital, Howick early in January with a Fistula in Ano which has been operated upon three weeks previously. On admission his temperature was normal, and his general condition good. He however complained of pain over the site of the operation on defaecation, and after walking for any length of time. On examination, the cicatrix of the operation on the Right side of anus was seen. At one part the cicatrix looked gelatinous and unhealthy, and on making a rectal examination, fluctuation above this was elicited. Evidently, some pus had collected behind the cicatrix. Under Cocaine locally applied the gelatinous looking area was slit freely open with a curved bistoury. At once about a drachm of pus welled out. The cavity, which was small, was scraped with a small Valkmann's spoon, the walls were swabbed with pure carbolic and an antiseptic dressing applied. The cavity healed rapidly from the bottom, and the man was then put on "light Hospital duty" in the wards. The Fistula never gave him any more trouble.

Previous/

Previous Illnesses:- Enteric Fever 9 months previously in South Africa.

On Feby. 15th after having had dinner he was siezed with a violent pain in the Right Iliac Fossa. Vomited three times and was slightly collapsed. He was at once put to bed, and the region of pain examined. He had intense pain below and to the right of the Umbilicus, and a hard resistant lump could be easily felt here. The lump felt very much like a stercoral mass. Skin over area not oedematous. The slightest touch made the patient wince. Rectal examination negative. Urine negative. No tenderness or enlargement of liver. Other viscera healthy. Temperature 102. Pulse 90. Volume and tension good. An icebag was put over the Right Iliac Fossa, and an oil enema administered. During the night he was restless but said that the icebag was very soothing. Temperature still 102°. Towards early morning he vomited twice. The vomited matter was bile stained. No blood in it. During the next few days the pain persisted as an ache or "uneasy sensation" in the right Iliac region, the temperature ranged between 101° and 102° - slight evening rise - and the hard resistant mass still persisted in the same situation. This/

This mass was about the size of a small orange. It was slightly tender on palpation. The fingers could be dipped between it and the umbilicus but not between it and the iliac crest. During this time he was kept on milk; and enemas were occasionally given, with very poor results.

On the 4th day after the acute attack the temperature fell to normal. The pain and uneasiness had quite disappeared and the patient asked for more solid food. This was not allowed. The fulness in the right iliac fossa was still present, and if anything a little larger than before. Palpation did not now cause any pain.

Two days afterwards a teaspoonful of Castor oil was given. This was repeated two hourly till four teaspoonfuls had been given. The patient passed a normal motion as a result. Next morning the lump could scarcely be felt. The tissues here however felt thickened and resistant. Beef tea and thin soup were then added to the dietary. Belladonna Extract was given internally.

On Feby. 23rd the lump was again present in the right iliac fossa, but was not so large as before, no pain or tenderness and temperature normal.

A consultation was now held on the case, and an operation was recommended.

The diagnosis seemed to point to some cicatricial band partially occluding the gut at this place. It was also suggested that the lump felt might be a localised abscess round the appendix which had discharged its contents into the lumen of the bowel, and then had again reaccumulated. Against this was the absence of pus in the stools, which had all through been carefully examined.

On Feby. 25th the swelling was still present, but not so large as before, between the umbilicus and the left anterior superior iliac spine. The patient was accordingly prepared for operation.

Under Chloroform next day, I cut down over the appendix by a curved incision between the umbilicus and the spine of the ilium, dividing the various muscular layers and the peritoneum. No adhesions were found between the parietal peritoneum and bowel. The coecum and appendix were ^{then} shut off from the general peritoneal cavity by sterile gauze. The appendix was found lying behind the ascending colon, and curved and twisted upon itself in a very marked manner. The tip of the appendix was firmly adherent to/

to the base and strong dense adhesions bound all to the large bowel. One strong band ran transversely across, behind the large bowel. This was divided between two ligatures. After considerable trouble and separating with a blunt dissector the appendix was freed from its dense adhesions. These adhesions bled freely during the operation. A cuff of peritoneum and muscular tissue was then turned down from the appendix to its base, and the appendix ligatured and removed. The stump was then touched with a point of pure carbolic and the cuff then stitched over it. The free oozing from the torn adhesions was stopped by gauze pressure applied for a little time. The peritoneum, muscle and fascial layers and skin were then united separately and a collodion dressing applied.

The patient made an uninterrupted recovery, the incisions healing by ~~primary~~^{primary} union.

The lumen of the appendix which was removed was occluded about the middle of the organ. A small ulcer was present near the base, the tissue over this ulcer was very thin.

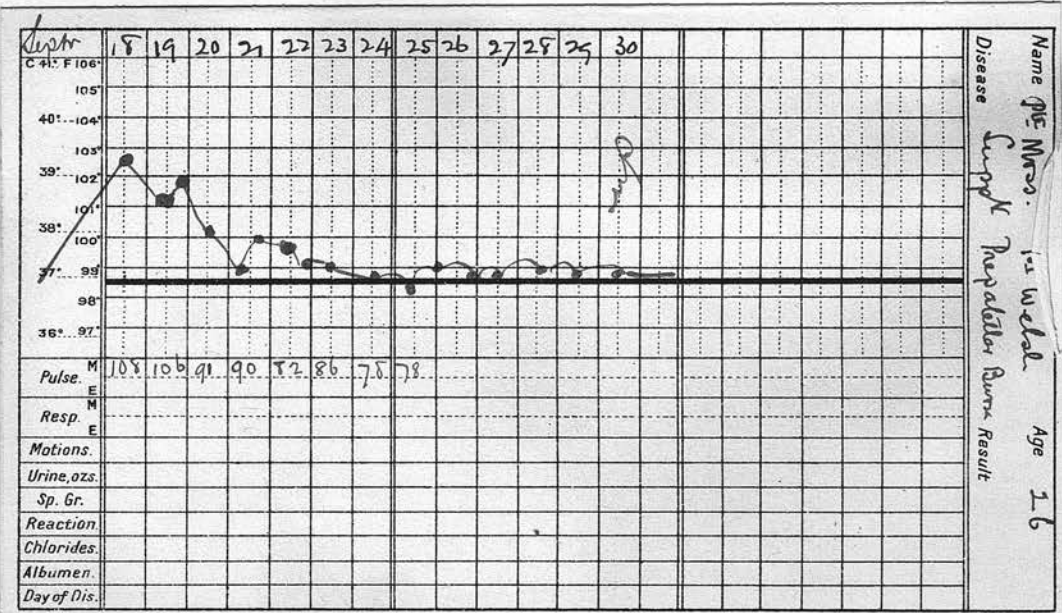
The adhesions did not appear to offer any marked obstruction to the lumen of the bowel. Perhaps the adhesions/

adhesions and dense matting of parts had caused a local stasis or atony of the bowel walls at this place, and in consequence the intestinal contents were delayed and retarded in their passage. The ulcer present in the appendix may have been a stercoral ulcer or it may have been a tuberculous ulcer.

The man had no signs of tubercular disease anywhere else, unless one should look upon the Fistula in ^{Ano} ~~and~~ as tubercular.

At one period during the case the possibility of a connection between the appendicular swelling and the fistula was considered, but nothing was found to establish a connection between the two. Rectal examinations always proved negative, and the operation dispelled the idea.

The curious point about the case is that the man never remembers having at any time previously had appendicitis, or trouble in the Right Iliac Fossa. The attack of Enteric Fever which he had 9 months previously may however have caused the matting and adhesions in the Right Iliac Fossa.



Suppurative Prepatellar Bursitis.

Pte. Moss. 1st Welsh.

This man was admitted to Hospital on 18th Sepr. '02 complaining of "swollen right knee"

On admission his temperature was 102.4° F.

Pulse 108. He was flushed in the face and complained of severe pain in the Right Knee joint on making the slightest movement. Four days previously he stated that he fell on his right knee and "tore the skin."

The Right Knee joint was markedly swollen.

On the most careful palpation the patient winced.

Over the lower end of the Patella was a dirty looking scar covered with a bloody crust. The effusion

into the knee joint ~~seemed~~ extended up into the

bursa under the lower part of the Quadriceps

Extensor and the Patella itself was surrounded by

erythematous looking tissue. The direct Inguinal

Glands were tender on palpation but not enlarged.

I cleaned the whole area of the knee with turpentine and Carbolic lotion (1-20) and then removed the dirty crust previously mentioned. At once a rush of pus and serum took place. I was not at the time sure whether this came from the knee/

knee joint itself or from the Patellar Bursa and I did not wish then, while the parts were so evidently septic, to probe the area. I therefore only pared the edges of the wound where they looked sloughy and ordered fomentations of Liq. Hydrarg Perchler (1-1000) 2 hourly and fixed the knee on a back splint and laid it elevated on a pillow. Calomel grs.vgiven//19:10. Temperature 101⁰ Pulse 106. Feels feverish. Kept on milk and chicken tea. The Joint is as swollen as before and the pus is flowing freely.

Fomentations still applied as before. In the evening I probed the area, because if the pus were coming from the joint cavity I determined to freely drain this by lateral incisions into it. The probe however did not enter the joint and was evidently in a large bursal cavity only. The bursa in this case was exceptionally large and its walls felt rough and irregular to the point of the probe. It bled a little on withdrawing the probe. I then put one blade of a scissors into the opening and passed it up for an inch and then cut the intervening tissue. This established a free drain to the bursa.

Fomentations 4 hourly.

20th/

20th. Temperature 100. Pulse 91. Effusion in knee joint still same. Still painful on slightest movement. Bursa draining freely but not so much pus as before, more serum now. Inguinal Glands no longer tender.

23rd. Temperature 98.6. Pulse 80. Effusion in knee joint going down. Has very little pain. Discharge from bursa now only clear serum. On convalescent diet.

25th. Temperature 98.3. Pulse 81. Effusion in knee almost gone. No discharge from bursa, wound granulating. Backsplint removed.

28th. Flexing and extending ^{at} the joint to prevent stiffness. Wound practically closed. No joint effusion.

30th. Up and walking about with aid of a stick.

This case was clearly a Suppurative Prepatellar Bursitis.— Infected probably from the fall which he had.— The chief interest lies in the fact of the large amount of pus which collected. This bursa was much larger than normal probably owing to the pus pushing aside the walls after being dammed back by the crust forming over the wound. The great effusion in/
in/

in the Knee joint is also interesting. It did not develop until the 3rd or 4th day after the fall, therefore it apparently was not caused by any twist given to the knee when the man fell. I should have mentioned that when the man was admitted the knee had assumed the usual position of greatest ease in effusion.- viz. flexion of the leg on thigh and limb lying on its outer aspect.

Three Cases of Fibromata:

Case I.:

Private Moore, admitted to No.7 General Hospital, Pretoria on 15th October 1902, with "two lumps on his thigh" according to his own statement.

These lumps complained of were situated, one over either great trochanter of the femur. They were about the size of a large Brazil nut. The skin was fairly movable over the tumours and they could be moved laterally on the subjacent textures. Edges faded away imperceptibly with the subcutaneous fatty tissue. Were not painful on manipulation. Skin over them a little indurated and erythematous. The man complained of them troubling him when he lay on one or other side for any length of time. These lumps were first noticed by the patient eight months previously while on trek.

He also had a very small nodule over the spine of the third piece of the sacrum. It had the same characteristics as the other two.

Under chloroform nodules were dissected out. They proved to be fibromata - simply hard masses of dense fibrous tissue.

Case II.:

This man was admitted with several small hard lumps over the left great trochanter, both olecranons, and/

and spines of the sacrum. Had stated that he noticed them 18 months before admission.

Under chloroform two small fibromata about the size of "flattened" marbles were removed from over the great trochanter. Four very small ones were removed from the olecranon processes, and one from the sacrum.

Case III.:

A fibroma was dissected from over the right trochanter and the head of the right fibula. These partook of the same characteristics as the two former.

For notes on these two last cases, I am indebted to Major Holt, R.A.M.C., under whose care they were. The first case was my own.

The only surgical interest in these cases is their causation. Why did they develop over prominent bony surfaces? Major Holt told me that he personally had seen three other such cases in South Africa and had heard of more from other medical officers. I myself saw one other in a patient who was in hospital for another condition. This man had fibromata on both trochanters and over the right malleolus, but they were very small. In fact they felt very much like rheumatic nodules. He told me that other men in his regiment also had them.

The/

The most generally accepted theory as to their causation is that they occur on body surfaces exposed to pressure when a man is lying on hard ground. When a soldier, wrapped in his blanket, lies asleep on his side on the hard sun-baked ground his trochanter is pressed upon. If he lies on his back his sacrum is exposed to pressure. By pursuing this theory a little further one can imagine that the olecranon or malleoli will in certain positions be also exposed to pressure. This "intermittent irritation", following a general axiom in surgery, will bring about "hypertrophy". The fibrous tissue hypertrophies in order to form a pad of protection to the prominent bony process. All the cases described occurred in soldiers who had done a lot of trekking and sleeping out on the veldt.

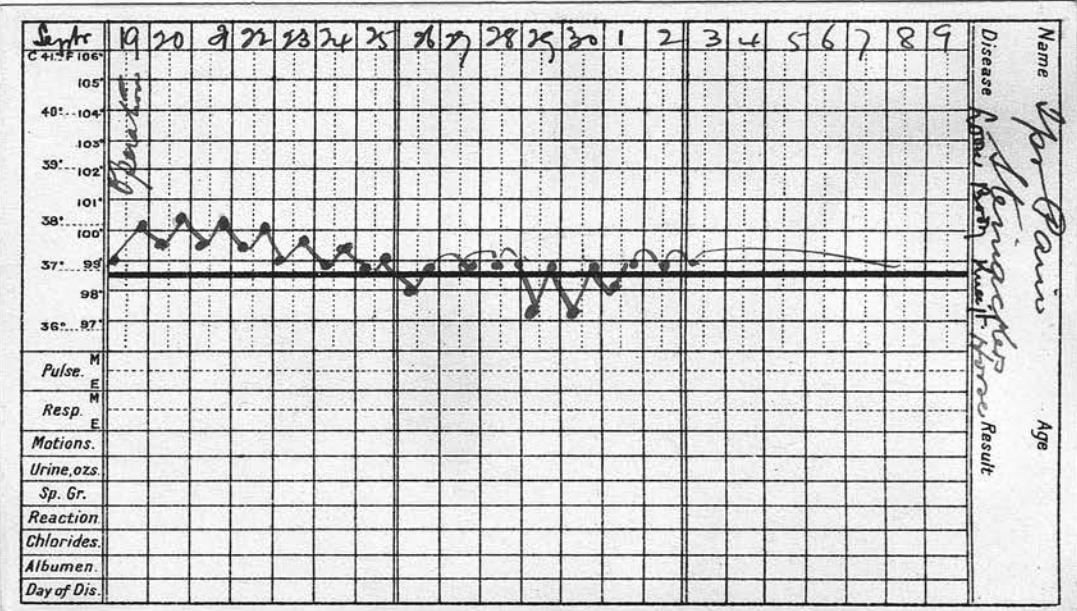
Loose body in Left Knee Joint. Removal.

Tpr. Pain, of Steinacker's Horse, age 43. On 28th May 1902, while riding on the veldt in the Eastern Transvaal, on scouting duty his horse put his fore-leg into the hole of an ant bear, stumbled and fell, bringing him to the ground. His left foot got caught between the horse and the ground and his left knee was twisted. He managed to mount again and ride back to camp. That evening his knee was very swollen and painful. He was put at rest in bed for ten days. The swelling had then disappeared and he attempted to walk about. After walking about a little he felt his left knee "give way suddenly" and he fell to the ground. That evening synovitis of the knee again occurred. The Synovitis disappeared in a day or two and the patient again got up and walked about. Three days afterwards "his knee again gave way" and effusion again took place into the joint. This train of events went on for about two months, - periods of apparent stability in the limb and then a sudden "give way". - The patient at this time himself felt a small loose nodule on the outer side of his left knee cap. He could move this body about to a limited extent.

In/

In September the man came under my care in Pretoria, bringing with him the above history. He was an intelligent man and at once directed me to the site of the loose body in the joint. This body could be easily felt. It could be moved up and down on the outer side of the patella and generally lay, when the patient was in bed, to the upper and outer quadrant of the patella. By flexing and extending the leg and pressing on the body it could be made to disappear from its usual site.

On 19th September therefore, under an anaesthetic, the knee having been previously prepared for operation in the usual way, a curved incision was made from the inner margin of the ligamentum patellae to the posterior part of the internal condyle of the femur, concavity of the incision being upwards. The flap of skin and subcutaneous tissue was then dissected upwards. The inner part of the capsule of the joint was then opened with a sharp knife and the finger inserted and worked up into the pouch on the outer side of the patella. The body could just be felt. Aided by external manipulation with the other hand, it was brought well within reach, caught with a Vulsellum forceps and extracted. A search was then made for any other foreign body. None other was found. The capsule was then closely stitched with/



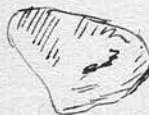with fine catgut and the skin incisions brought together with silkworm gut. Limb was fixed on to a back splint.

The case made an uninterrupted recovery. Silk worm gut stitches were removed on the 8th day, and back splint removed on the 9th day.

On the 11th day the patient was up on crutches and told to gently swing the leg at intervals. Passive movements were regularly carried out after this.

Twenty six days after the operation he was discharged for duty. He could then use his limb freely in every way, and had no more attacks of "giving way" of the joint or of effusion.

Remarks: In this case I might have simplified the operation considerably by cutting down directly over the loose body. I wished to make sure, however, that the joint did not contain any more loose bodies and to make a full exploration of the joint the inner incision seems to give greater room. The body removed was about the size of a halved bean, and felt fibro-elastic in texture.



Shape and size
of loose body.

Dislocated Semilunar Cartilage. Right Knee Joint.

Private Scott, R.A.M.C., age 23.

This man was an orderly doing duty in a Hospital marquee containing two patients who were prisoners for breach of Hospital discipline. During the night one of the prisoners attempted to rush out of the marquee. Scott put out his right foot to trip the runaway and the man fell heavily upon the outer side of Scott's leg. Scott fell and states that he "felt something give" in his knee joint. He shortly afterwards was brought to me complaining of pain and swelling in the knee joint and inability to walk. He had then very marked effusion into the joint and was evidently in great pain.

He was put to bed. Back splint applied to the knee joint and lead and opium fomentations applied.

Next day, 17th September, 1902, the effusion was as marked as before, but the pain was less.

On 24th September the effusion had disappeared and the limb could be flexed and extended easily while the patient lay in bed.

He was allowed up on the 25th and on the 26th walked about with a stick. In the afternoon he was walking about the ward without the aid of a stick when he suddenly felt his right knee give way. He got/

got into bed and examined the knee himself and was positive that he felt a small hard body on the inner side of his knee-cap. On careful examination of the knee next morning I could feel nothing, so ordered him to walk about the ward and bend his knee freely. This he did, and in a quarter of an hour told me that he could again feel the body. I examined the knee this time while the man stood up and could distinctly feel a hard, resistant pea-like body to the inner side of the patella and lying at the articular junction of the femur and tibia.

Major Holt, R.A.M.C., coming into the ward at this juncture, also felt this body and suggested either a dislocated semilunar cartilage or a loose body. The site was marked with a pencil of silver nitrate and the patient put to bed. He again had effusion into the joint.

The knee was prepared for operation and on 3rd October under chloroform a curved incision was made as in the previous case (Tpr.Pain's). On incising the capsule of the joint a considerable flow of synovial fluid took place. The internal semilunar cartilage was found to be broken right across close to its anterior horn and the coronary ligament at this place was ruptured. The whole internal semilunar cartilage was then removed with a fine curved blunt scissors. Considerable difficulty was met with in freely/

freely separating the posterior part of the cartilage through the small incision made in the capsule. The knee joint, in view of the great handling of the parts during the operation, was then douched out with weak antiseptic lotion (see note at end of case) The capsule was stitched with fine catgut and the skin surfaces with silkworm gut. No drainage employed. Cyanide dressings were then applied and large pads of wool with bandage over all to keep up elastic pressure. Limb laid on a short back splint and elevated on a pillow.

The attached temperature chart shows that the temperature was suspicious for some days after the operation and the possibility of septic infection suggested itself, especially as the patient complained of pain and "fulness" in the joint. The case was dressed on the third day after the operation in order to ascertain the cause. Beyond a great deal of effusion into the joint, everything looked perfectly healthy.

Three silkworm gut stitches were removed and a grooved probe worked into the joint. A little clear serum escaped.

On the 9th day all the silkworm gut stitches were removed. No sign of pus anywhere except the high temperature. The patient otherwise felt very well and stated that his knee gave him no trouble.

On/

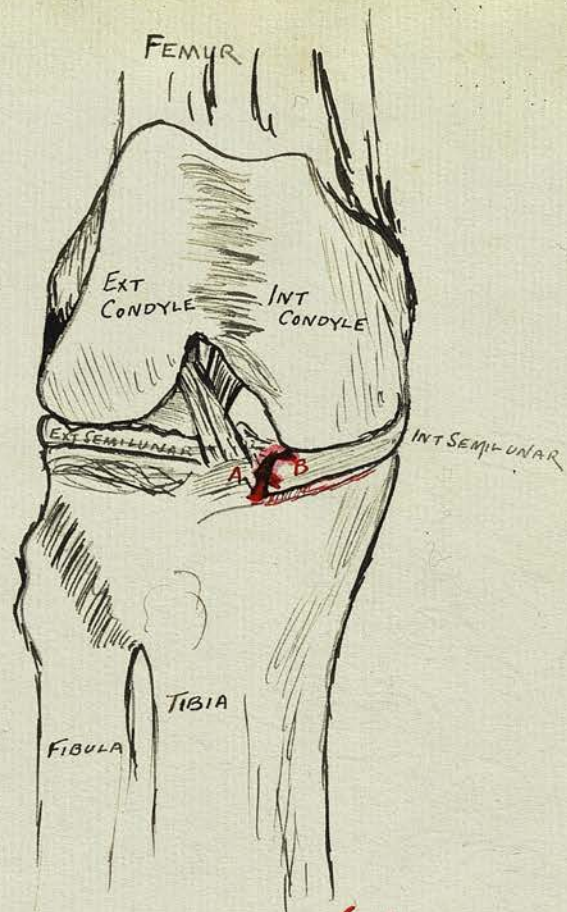
On the 21st he was allowed up on a wheeled chair and next day passive movements of the joint were carried out. This was continued till the 26th when I left Pretoria.

I cannot satisfactorily account for this temperature. At the time of operation when douching the joint I thought that I was using warm sterile lotion, but the orderly had given me warm 1-40 carbolic lotion instead. Perhaps this may have set up irritation and consequent effusion into the joint. The patient also suffered often from mild attacks of malaria. Perhaps this may have had something to do with the temperature. He was given gr.v. tabloids of Quinine three times daily for a few days.

I do not anticipate any stiffness in this joint, as the movements were very free on the 26th, when I last saw the case.

Private Secth. R. A. M. C.
No 7 General Hospital
Pretoria

Removal of Internal Semilunar Cartilage



Red marks the site of rupture of Internal Semilunar and tearing of ligaments.
A = part attached anteriorly and to transverse ligament.

Skajam I

Orlovation Kure point
(Back view)

Skrapaw II

Dislocation Kull #
[The binder unfortunately has this
print in upside down.]

Lateral Dislocation Right Knee joint and Sciatic
Dislocation of Hip of same side.

Lieut. Lindley, 7th Hussars: Admitted 23rd September 1902, into No. 7 General Hospital, Pretoria. This case is interesting on account of the unusual injury. A dislocation of the Hip is a comparatively rare event in surgery. A lateral dislocation of the knee is also rare. A combination of the two injuries in the same limb is extremely uncommon.

This officer, while riding in a steeplechase at Pretoria, came to grief over a stone wall. Horse and rider fell, the horse rolling over the rider. The rider managed to disengage himself from the stirrups, but was unable to get up.

On admission there was tremendous effusion into the Right Knee joint. The right leg did not lie in its normal axis with the thigh. The thigh was inverted and rotated inwards, and the leg was directed towards the middle line. The inner side of thigh and leg formed a marked concavity towards the middle line of body. The Officer was in great pain, so a careful examination was delayed for two hours. He was then put under an anaesthetic and a Sciatic dislocation of the Hip was discovered. The trochanter was well above Nelaton's/

Nelaton's line. The fingers could be "dipped in" above the Trochanter. Tensor Fascia Femoris was relaxed. Shortening $1\frac{1}{2}$ inches. The Head of Femur could be felt lying over Sciatic notch. A skiagram was taken of the Hip and Knee joint before the Officer was anaesthetised and by the time he was fully under, the negative was developed. The picture of the Hip was a poor one and no landmarks could be made out. The Knee showed a lateral dislocation (See Skiagram attached). The swelling and effusion in the Knee joint was so extreme that one could barely make anything out with certainty, by touch and manipulation.

Reduction of the Head of the Femur was attempted in the ordinary way. On the first attempt, the head was reduced into the Thyroid Foramen. On the second attempt, this again occurred. A loop of strong flannel was then passed round the upper part of the thigh and an assistant directed to pull outwards. On flexion, extension and rotation outwards being now attempted, the head of the bone went into the Acetabulum with an obvious click. The limb was now put on M'Ewen's long thigh splint with back rest and external supports. Extension of 14 lbs. was applied and the limb and bed elevated. An ice bag was applied over the Knee Joint.

The/

The Internal Condyle of the Femur in the first Skiagram looks unusually prominent and the external looks unusually small. This appearance is due, I think, to the fact that the outer condyle is not only displaced outwards, but that it is also rotated forwards on the Tibia, while the Internal Condyle is rotated backwards. This rotation was probably due to the dislocation of the Hip. In the second Skiagram, taken after the hip was reduced and before any manipulations had been applied to the Knee joint, the unusual disparity and distortion of the condyles is not seen.

Suppurative Necrosis left ankle Joint. Operation -
Death.

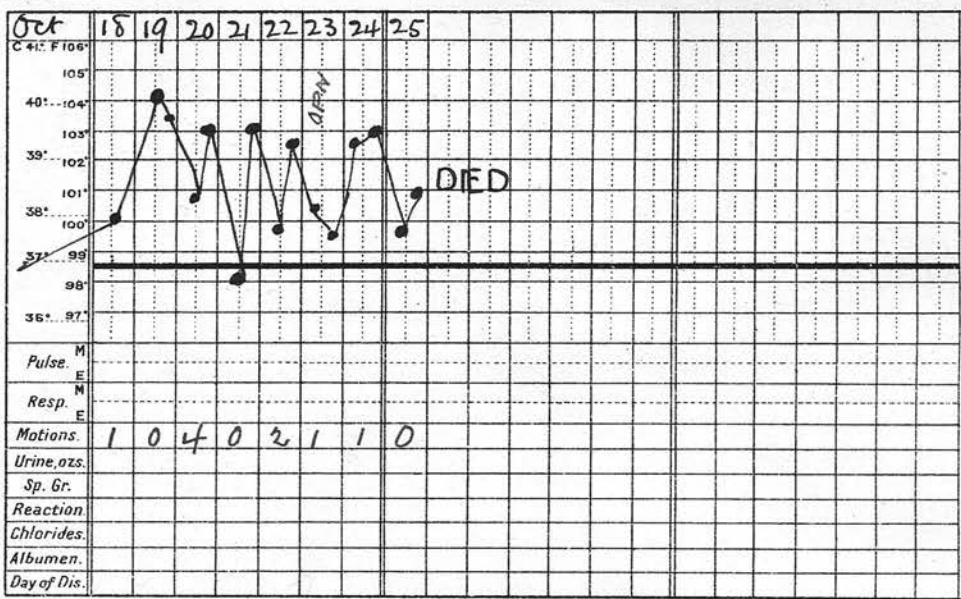
Quarter-master Sgt. Clarke, Royal Garrison Artillery admitted to No. 7 General Hospital, Pretoria on 18th October 1902, with the following History. Seven weeks previous to admission he jumped from a Cape cart in motion and sustained a Compound fracture of the lower end of his left Tibia and Fibula. He was treated in the South African Constabulary Hospital during these seven weeks. No temperature chart was kept. The medical officer in charge of the case stated that when the man came under his care "the lower end of the left Tibia/

Tibia was protruding through the skin on the inner side of the ankle and that the tip of the malleolus was broken off and lying external, i.e., on the Fibular side of the projecting lower end of the Tibia. The wound was dressed and the leg put on a back splint and foot piece. This was all the history obtainable. The case, up to this time, had obviously not been skilfully treated.

On admission, the left ankle joint was tremendously swollen and acutely painful on making the slightest examination. The foot was swollen and oedematous. There was a sinus on the inner side of the ankle joint covered with pus and unhealthy granulations and discharging pus and gritty particles of bony debris.

This sinus was dilated with dressing forceps and a drainage tube inserted. The joint cavity was then syringed out with 1-1000 Corrosive Sublimate lotion followed by Peroxide of Hydrogen. Foot bandaged and leg put on a Macintire's splint. Bare bone could be felt by probing this sinus. One could move the foot on the leg laterally and so elicit a distinct bony grating sensation.

The temperature (See Chart) for the next few days indicated the presence of pus. The drainage certainly/



Name *Ann Sgt Clarke* Age *44*
 Disease *Colic 2d & 3d I.* Result *Death*

certainly at this stage was not efficient. The ankle joint was boggy and intensely oedematous.

Operation on 23rd under Chloroform. The sinus was enlarged by cutting upwards and downwards and the granulations vigorously scraped away with a Volkmann's spoon. At the bottom of the sinus, the Tibia was seen bared of periosteum in front and back. Parts of this bone were breaking down and these parts were curetted. The ankle joint cavity was full of dirty debris and pus and the astragalus was lying with its upper articular cartilage quite eroded. The greater part of the upper surface of the astragalus was yellow and unhealthy. In fact, it looked like, and was of the consistence of hard yellow soap and was quite non-vascular. A vertical incision was then made over the lower end of the Fibula down past the joint. The Fibula was found to have been the seat of a fracture - the malleolus was united at a very bad angle to the rest of the shaft. The bone was therefore divided with a mallet at the line of junction and the fragments separated. At once a strong rush of pus took place through this part. This was evidently an abscess which had formed between the two bones from a suppurative localised periostitis. The whole was then flushed out with 1-1000 Corrosive lotion.

Two/

Two drainage tubes were inserted on the inner side, one reaching up between the lower ends of the fibula and tibia and the other draining the ankle joint.

The incision on the outer side was closed up except at the bottom, where a gauze drain was inserted. The lower fragment of the fibula was brought into good apposition with the shaft. The wound was surrounded with gauze and wool, bandaged and put on a Macintire's splint.

24th October: Wound dressed: draining well: passed a good night. Pulse regular, 81.

25th October:

10 a.m., Dressed. Condition as above.

2 p.m., Patient says he feels "queer". Looks very jaundiced. Pulse 99, slightly intermittent. Volume and tension low. Complains of cold hands and feet although the day is extremely hot.

10 p.m. Showing signs of collapse. Given strychnine and ether hypodermically. Brandy by mouth. Rectal injection of warm saline. Hot fomentations over precordia. Pulse intermittent, volume very poor, tends to become "thready". Eyes look oedematous and heavy.

3 a.m., Died.

Post Mortem: Rigidity marked. Hypostasis slight.

Heart: Extreme fatty infiltration of walls. Cardiac muscle feels soft and diffluent. Along the sulci great masses of fat are present. The muscle is extremely pale. In auricles and ventricles ante- and post-mortem clots present. Valves healthy.

Pericardium/

Brandy - 1 oz.

Spr. Ammon.

Aromat. - $\frac{1}{2}$ oz.

Pericardium: Covered on the outer side with flakes of yellow fat.

Endocardium: Pale yellow in appearance. Liver:- enlarged. Fatty degeneration.

Kidneys: Large, fatty.

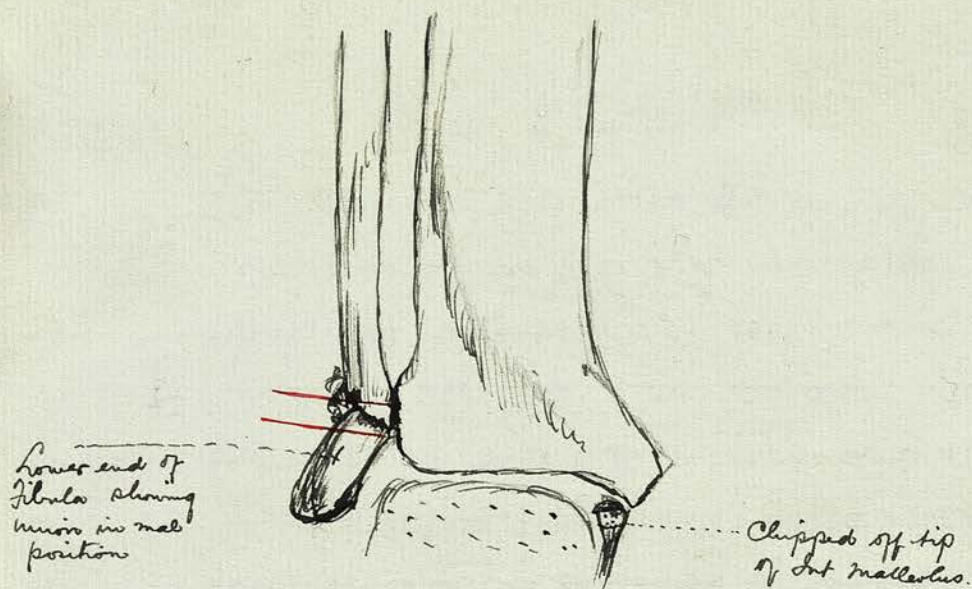
Brain: Normal. No signs of calcareous degeneration of arteries present anywhere.

Remarks: The man therefore died from fatty degeneration of the heart. Cardiac failure may have been due to the shock of the operation aggravated by the unusually hot and stifling weather which prevailed at the time. He, however, stood the operation very well and gave no trouble to the anaesthetist while under chloroform. The operation lasted an hour and a half.

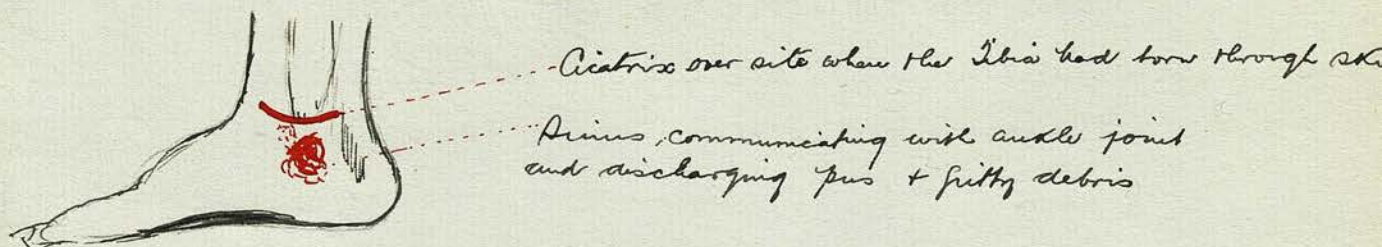
There is no doubt that the operation was necessary with such a marked swinging temperature and foul condition of his ankle joint. His death was a surprise and was not even remotely anticipated.

Quartermaster Sergt. Clarke. A. G. A.

Necrosis and suppuration ankle joint



Between the red lines the fibula, united in bad position, was divided with chisel, and then pus burst out (vide case) The lower fragment after this could be easily brought into good position



Inner side of foot. Cicatrix + sinus present on admission to No 7 General Hospital Pretoria

OPHTHALMIC NOTES.

Errors of Refraction and various pathological conditions of the eyes were responsible for the invaliding to England of a large number of soldiers during the late war. The eye cases were sent to Netley to be treated by experienced oculists.

The majority of the eye cases admitted to Hospital were for Errors of Refraction. During the war, a large number of men were hurriedly enlisted, and sent out to the front without having had their sight carefully tested. This was especially the case with some of the contingents of Imperial Yeomanry. Conjunctivitis was very common in some districts. Syphilitic Choroiditis, Keratitis, Iritis and Dacryo-cystitis, etc., were all represented.

The following few histories taken from my case book while in charge of the Eye ward in No. 7 General Hospital, Pretoria, are fairly representative of the class of Eye practice furnished by soldiers in the field.

Pterygium - Left Eye.

Pte. W., at Pretoria, No. 7 General Hospital.

Admitted with a Pterygium growing over left eye.

It/

It occupied the usual site, viz., inner canthus, and was of the usual outline, base to nose, apex on the cornea and with its neck on the corneal margin. This Pterygium was very large and very vascular, and the patient says that it had been rapidly growing during the last 3 weeks, while in Pretoria.

As it was so prominent an object on his eye and as it was increasing in size, I determined to remove it. Accordingly, on 30th September 1902, under 5% Solution of Cocaine Hydrochlorate dropped on to the conjunctiva 15 minutes before operation, the growth was dissected off. The apex was removed clearly and then by pulling forward the remainder of the growth with a fine pair of forceps, one quite easily slipped a fine Graefe's Knife under it towards the base, completing this stage by removing the knife and making two convergent incisions to the base. The conjunctiva was then freed from the sclerotic above and below, to a slight extent, and the 2 raw edges brought together as far as the Corneo-Scleral margin by 3 fine horse hair stitches. The area left bare over the cornea itself was not interfered with. The eye was then douched with Boric Lotion and a light/

light wool compress applied. It was douched at the end of 24 hours, and on the second day the pad was removed and dark glass substituted, the patient being kept in the tent and not allowed outside. Stitches removed on third day.

On 29th October, 1902, the patient was discharged for duty with his regiment. At this time, there was a linear pucker in the conjunctiva extending along the line of the stitches. The area over the Cornea originally occupied by the apex of the Pterygium looked somewhat steamy and granular, but showed no tendency to increased growth. Movements of eye normal. Refraction normal.

The cause of this condition, I consider to be, the irritation from the dust and grit of the Transvaal Veldt. I have seen cases of Pterygium while on active service in South Africa and in all cases, could trace a history of irritation from dust. The case in point illustrates a very definite history. This man had been trekking with an infantry regiment in the Middelburg District in the Eastern Transvaal. Middelburg and the surrounding country is very dusty and the dust is very fine and very hard. Added to this, it is one of the windiest places in the Transvaal.

This/

This man says that towards the latter part of the day his eyes gave him a lot of trouble. He felt them to be hot and full of dust, and frequently rubbed them with his dusty hands. At night, he often had to lie down on the sandy soil with nothing between his head and the ground save a waterproof oil sheet and a half turn of an army blanket. He says that in the morning his eyes were often full of sand grit. Add to all this, the scarcity of water for washing purposes. I give this case of Pterygium to illustrate the fact that it, as far as my observation went, was the result of direct irritation from dust. It occurs in healthy individuals. In none of the cases I saw could the origin be traced to corneal ulcers or Phlyctenular Conjunctivitis. Also this case was the only one which was considered to require operative interference. The other cases were left alone, merely putting them in better surroundings and for the time, making them wear dark glasses and bathe their eyes thrice daily with a weak Boracic lotion. The above case was progressive, vascular and very large, hence the necessity for removal.

Bandmaster Sgt. B., 1st Welsh - Hypermetropia.

Admitted with "Conjunctivitis and pain at the back of/

of both eyes." Dimness on reading print. Print quite blurred. Cannot see a target at 1,000 yds., and bull's-eye only at 200 yards. Small fissures present at outer angle of Right Eye. He is a Bandmaster and states that his chief difficulty is that after conducting the Regimental band for a few minutes, the music gets blurred and indistinct.

By Retinoscopy - Right Eye

$$\begin{array}{c} +1.5D \\ + \\ +1.75D \end{array}$$

Left Eye.

$$\begin{array}{c} +1.75D \\ + \\ +1.75D \end{array}$$

Vision - Left Eye $\frac{6}{6}$. (+1.0D = improvement)

Right Eye $\frac{6}{8}$ (+2.0D = $\frac{6}{6}$)

This man was aged 41. The near point had receded, and he had presbyopia. As this man was a most important non-commissioned officer and as his error was not marked, he was ordered glasses in order to enable him to return to his duties with the regiment. He also had a Fistula in Ano, which was operated upon while he was in Hospital.

Pte. G., 1st Welsh, age 24. Hypermetropic Astigmatism.

Sight getting slightly worse during last few months. Has frequent headaches; marked photophobia. Dimness of vision on reading printed matter. Internal Strabismus left eye.

Retinoscopy - Left Eye

$$\begin{array}{c} +5.5D \\ + \\ +4.0D \end{array}$$

Right Eye.

$$\begin{array}{c} +2.25D \\ + \\ +2.0D \end{array}$$

Discs healthy.

I might remark in passing here that with soldiers, it is often quite useless to test their vision with Snellen's types. They, if so inclined, give most conflicting answers. For instance, this man was extremely anxious to be invalided home to England, as he was tired of active service. On testing him with Snellen's types, I could see that the man was lying to me, so depended entirely in all my reports on the result of my examination by Retinoscopy.

This man was invalided home to Netley to be examined by a Medical Board.

NYSTAGMUS:

Pte. G. T., 2nd Northhamptons, age 23. Admitted with marked lateral and oblique nystagmus. Vertical nystagmus present but of slight degree. Under atropine, by shadow test, the following was found.

Right eye
+1.75D
-3.0D

Left Eye
+2.0D
+2.0D

His Knee jerks were present and equal. No exaggeration. Flexor response on tickling plantar surfaces of feet. Superficial reflexes present and unimpaired. No tremors of any sort. No history of/

of Syphilis obtainable. In fact, with the exception of the Nystagmus and Refractive error, he was apparently quite a healthy man. He had no coloboma of the choroid or microphthalmos, etc. to account for the nystagmus, and no sign of disseminated Sclerosis could be discovered. The patient himself complained of the oscillations - unlike the early congenital cases. He said that 12 months previous to admission into Hospital, he felt the condition coming on and that he is fully conscious of the oscillations of his eyeballs. After looking fixedly at an object for any length of time, he has to shut his eyes for fear of falling. At a distance of 200 yards, he said that he could not distinguish a man from a woman - only a blurred figure presented itself. He often failed to salute his officers when passing - not being able to distinguish the difference in uniform. When he attempts to do any reading now, his eyes begin to water and he has to close them and relinquish the attempt. During the three months immediately previous to admission, his sight has got rapidly worse, and he was afraid to go on duty as a sentry. I think that the refractive error may have a great deal to do with the nystagmus if his history given is at all accurate. The refractive error, however, is/

is not very marked. The nystagmus again may be a first symptom of disseminated sclerosis, disseminated Sclerosis being one of the most difficult of diseases to diagnose in its initial stages. A Medical board was held on this case, and as it was considered that he would be of little further use as a soldier, he was recommended for discharge from the service.

SIMPLE HYPERMETROPIA:

Lieutenant S., Royal Horse Artillery, aet. 28. This officer consulted me regarding his sight on 6th September, 1902. He said that he never was troubled with any difficulty in vision till a fortnight previously. He had worked his guns through the greater part of the war, and on the conclusion of peace, was camped with his battery in Pretoria. He now began to read for an examination in Mathematics connected with promotion to a higher rank. He worked at night mostly, beside a small paraffin lamp and a couple of lighted candles. After reading for about a quarter of an hour, he suffered most intolerable pain at the back of his eyes. The printed matter got blurred and his eyes watered considerably (Accommodative Asthenopia). Then a "splitting/

"splitting headache" came on and he had to go to bed. As this happened for three successive nights, he determined to rest for a fortnight. At the end of a fortnight, on again essaying to do his mathematical work, the same train of symptoms developed. He became alarmed and consulted me. I found the following condition present.

Right Eye (with Snellen's Types) Vision $\frac{6}{6}$
(+2.0 D = Improvement
Left Eye $V = \frac{6}{6}$ (+1.75 D = Improvement.

The fundus was quite healthy and Retinoscopy showed no astigmatism. I certainly expected to meet with Astigmatism in this case, as the headaches and other symptoms were so marked.

He was extremely anxious to go on with his examination, so he was ordered the necessary lenses. He procured them in Johannesburg and reported to me 3 weeks later that he could now read without any trouble whatever, and can sit for hours over his work without any untoward symptom developing. I should state that I examined this officer's urine for albumen, but found none.

MUSCAE VOLITANTES:

Pte. Davey, Royal Artillery.

Complains of "spots flickering in front of his eyes during strong daylight".

While on "trek" in very hot and dusty parts, he/

he stated that his eyes gave him considerable uneasiness owing to these specks always floating in front of him. He stated that he was quite free from them in the early morning after a night's sleep, but when the sun got up and he started trekking, the condition came on. There was no error of refraction or opacities of the Vitreous to account for the Muscae Volitantes. The discs were quite healthy. No albumen in urine. The man was very anaemic and debilitated and very nervous about himself.

He was kept in the Hospital for a month, during three weeks of which time he had to wear "London Smoke" glasses during the day. Strychnine and Iron were given internally, a liberal diet and a bottle of Stout daily. When discharged from Hospital, the muscae had quite disappeared and he was strong, robust and free from nervousness.

I heard from him a month after this, and he was then quite well and had had no return of the Muscae Volitantes.

The condition probably owed its origin to the debility of the patient and the heat and fatigue of serving day after day in a hot and dusty country under a scorching sun.

DEEP ULCER OF THE CORNEA:

Private T., age 28, Gordon Highlanders, admitted to No. 7 General Hospital, Pretoria, with pain in frontal and temporal regions, photophobia and purulent discharge from both eyes. This man states that 5 days before admission he was on duty in a very heavy dust storm and that the gritty particles of sand so irritated his eyes that he constantly had to rub them with his hands. Next day, his "eyes were inflamed" and he could not open them in strong sunlight. He was treated in Camp for 3 days and then sent to Hospital. Over the centre of the right Cornea was a deep purulent ulcer. Cornea surrounding looked steamy and milky. Towards the outer part of the cornea of left eye, was a smaller ulcer, purulent, but not very deep. Both ulcers were circular in outline. The Conjunctiva of both eyes was markedly injected and pus was everywhere abundant.

Progress and Treatment: Blisters applied to both temples. Eyes douched gently every 2 hours with warm weak corrosive sublimate lotion. Atropine and Cocaine solution instilled twice daily. The eyes were covered with warm Boracic fomentations. Under this treatment, the purulent condition and the/

the conjunctivitis rapidly cleared. The deep ulcer on the right eye did not perforate. (It looked at first, as if paracentesis of the anterior chamber through the floor of the ulcer would be necessary). On the 3rd day, a little Iodoform ointment was applied to the lid margins. In two weeks, the man was allowed up, wearing a pair of dark glasses. The ulcers were then rapidly healing. Photophobia was still slightly present. A week after this, he was unvalided to England in a Hospital ship.

Fracture. Base of Skull.

Brevet Maj. V. On 22nd Sept. was playing polo. His horse was sixteen hands high. During the game the horse shied and reared and the rider was thrown violently to the ground, striking the hard sun-baked ground with his occiput. He was at once carried to an ambulance and brought to Hospital. On the way up to Hospital in the ambulance he was "vomiting blood, was restless and struggling purposelessly with his arms and legs. Did not speak." These were the notes that the doctor who brought him up gave me.

On admission: There was a slight scalp wound of left side which did not go down to the bone. Still vomiting blood. Bleeding freely from both right and left ears. No cerebro-spinal fluid detected. No paralysis of limbs or face. Does not talk or articulate at all. Bladder distended. (Urine drawn off with a catheter.) No sub-conjunctival haemorrhage or proptosis. Pupils equal, no contraction or dilatation. React to light. Temperature 100°F. Pulse 78. Respirations 20 per minute. The ears were syringed out and any lacerations of the walls of the canal or meatus or membrane searched for. A view of the membrane could not be obtained on account of the free/

free oozing of blood. Corrosive wool was therefore plugged in meatus. Patient kept lying on his back with an icebag to his shaved head. Given vii. grs. calomel 12 p.m. Temperature 101.4° Pulse 52. Respirations 17. No sickness since 9 p.m. No more bleeding from left ear. Restless. Changes position from side to side about every quarter of an hour. Once or twice lay on his back and drew his legs up. Frequently opens and closes eyes in a rapid winking manner. Pulse at times irregular, but the tension is getting better. Volume small. Respiratory excursion good. The right ear still oozes blood.

3.15 a.m.: Urine passed in bed. Temperature 101.2°. Pulse 54. Respirations 18.

6.45 a.m.: Vomited oz. vi. coffee coloured fluid (which contained disintegrating blood). Lies now more quietly. Has not spoken or groaned.

9 a.m.: Pulse 64. Respirations 20. Milk oz. i.

11 a.m.: Pulse 72. Respirations 23. Temperature 102.4°.

11.30 a.m.: Bowels acted freely. Passed urine unconsciously. No oozing from right ear since 10 a.m. He was given oz. iii. of milk at this hour and seemed to swallow this fairly well.

3 p.m.: Restless from 2 p.m. Pulse 73. Respirations 23. Temperature 103°. Coughed at intervals. Quiet.

6 p.m.: Milk, oz. ij. Brand's Essence dr. i. Lifted both upper eyelids several times in a curious manner. (Sister's note).

8.30 p.m./

8.30 p.m.: Urine passed in bed. Lies quietly.
No paralysis anywhere, but a certain measure
of rigidity of the legs is present. No
abdominal distension.

10 p.m.: Pulse 58. Respirations 22. Temperature
101.4°.

11 p.m.: Right pupil larger than left. Does not
respond to light. Twitching of both upper
eyelids occasionally.

21st September:

1 a.m.: Temperature 106.6°. Pulse 76. Respiration
34.

3 a.m.: Temperature 106.6°. Pulse 80. Respiration
36.

12 a.m.: Same. Breathing tends to Cheyne-Stokes
type. Mucus collects in throat. Pulse
tension low and volume moderate. Is regular
in time. Bladder not distended. Is passing
urine involuntarily in bed. Pupils same
as last note. Do not react to light.

2.30 p.m.: Temperature 107.4 Pulse 118. Respiration
28.

3 p.m.: Temperature 108.2 Pulse barely felt at
at wrist. Both thumbs strongly adducted
into palms.

3.30 p.m.: Died. Cheyne-Stokes breathing during
last few hours of life.

The post mortem in this case is interesting. Rigidity marked. Hypostasis slight. Scalp wound on left side near parietal eminence does not reach bone. Blood was here extravasated under the scalp in a thin flake. On reflecting the scalp the line of fracture was evident. The fracture followed the lambdoidal suture along its whole length. The occiput and parietal bones looking as if prised apart at the sutural line. On the right side the fracture extended into the Sigmoid bend of the lateral sinus and into the petrous bone. The petrous bone was split in a tri-radiate manner, starting from the petro-squamosal suture as a base. One fracture ran horizontally inwards on the upper surface of the petrous towards the apex. Another ran down and inwards to join the fracture into the lateral sinus. The third fracture was on the anterior surface of the bone, and ended in the foramen lacerum medium. On the left side the lateral sinus escaped and the petrous was fractured for only a short distance on its anterior surface. There was a large haemorrhage over the site of the sigmoid curve of the right lateral sinus. Over the Dura Mater on the right side just under the parietal eminence there was a thin flake of blood clot, somewhat flame-shaped in outline. The pia mater looked unusually "milky" and opaque on either side of/

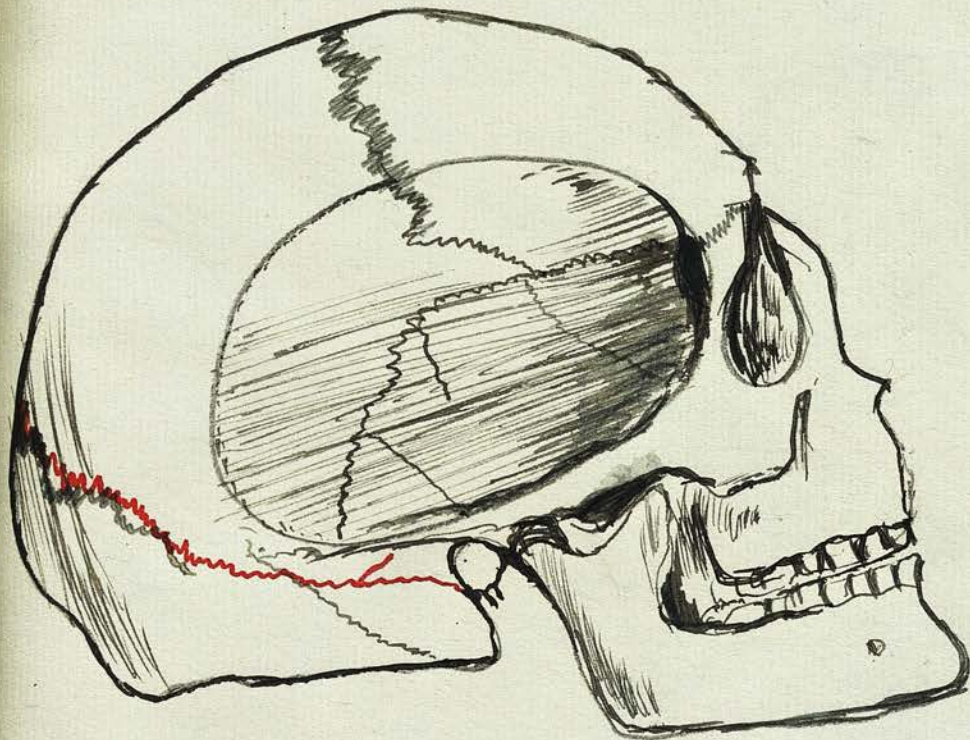
of the vertex. Under dura mater on right side was a large haemorrhage over the upper part of parietal lobe, but entirely escaping Rolandic area. The right frontal lobe was ploughed up by a huge blood clot as far as the lenticular nucleus, but the internal capsule had escaped injury. There was a smaller haemorrhage in the left frontal lobe. Both lateral ventricles were free from blood. The puncta cruenta were gaping and engorged. Brain tissue generally was very soft and diffluent.

The anterior and middle cranial fossae were filled with large blood clots. One large one was lying on the cribriform plate of the ethmoid. On the right side the clot was compressing the 3rd nerve on its way to the orbit (vide notes of case). The left ear was full of blood. On removing the tegmen tympani it oozed out. Spinal canal and other areas not affected.

Remarks: Of course this case was unsuitable for operation. The point of interest in the case is that the Rolandic areas and the motor tracts were unaffected by the blood clots. The 3rd nerve was compressed later on by blood clots, and this was probably the cause of the dilatation of the pupil on the right side observed about 8 hours after the accident.

The bleeding from the ears was due to the fractured petrous bones. The Eustachian tubes no doubt permitted/

permitted of the escape of blood from the ear into the pharynx and thence into the stomach. This bleeding must have been profuse at first, for almost immediately after the accident the deceased vomited blood.

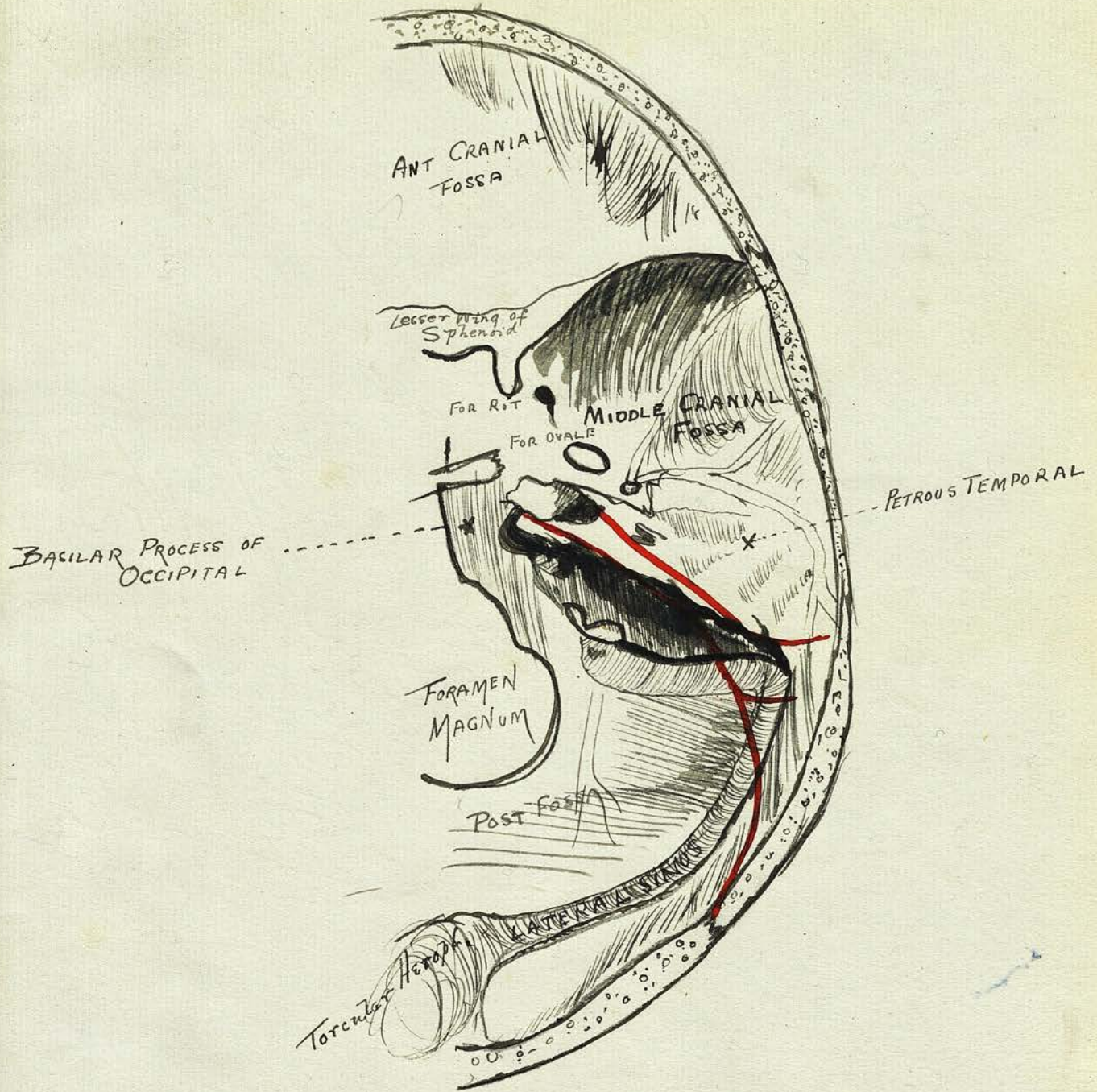


Dr. Raji Verma.

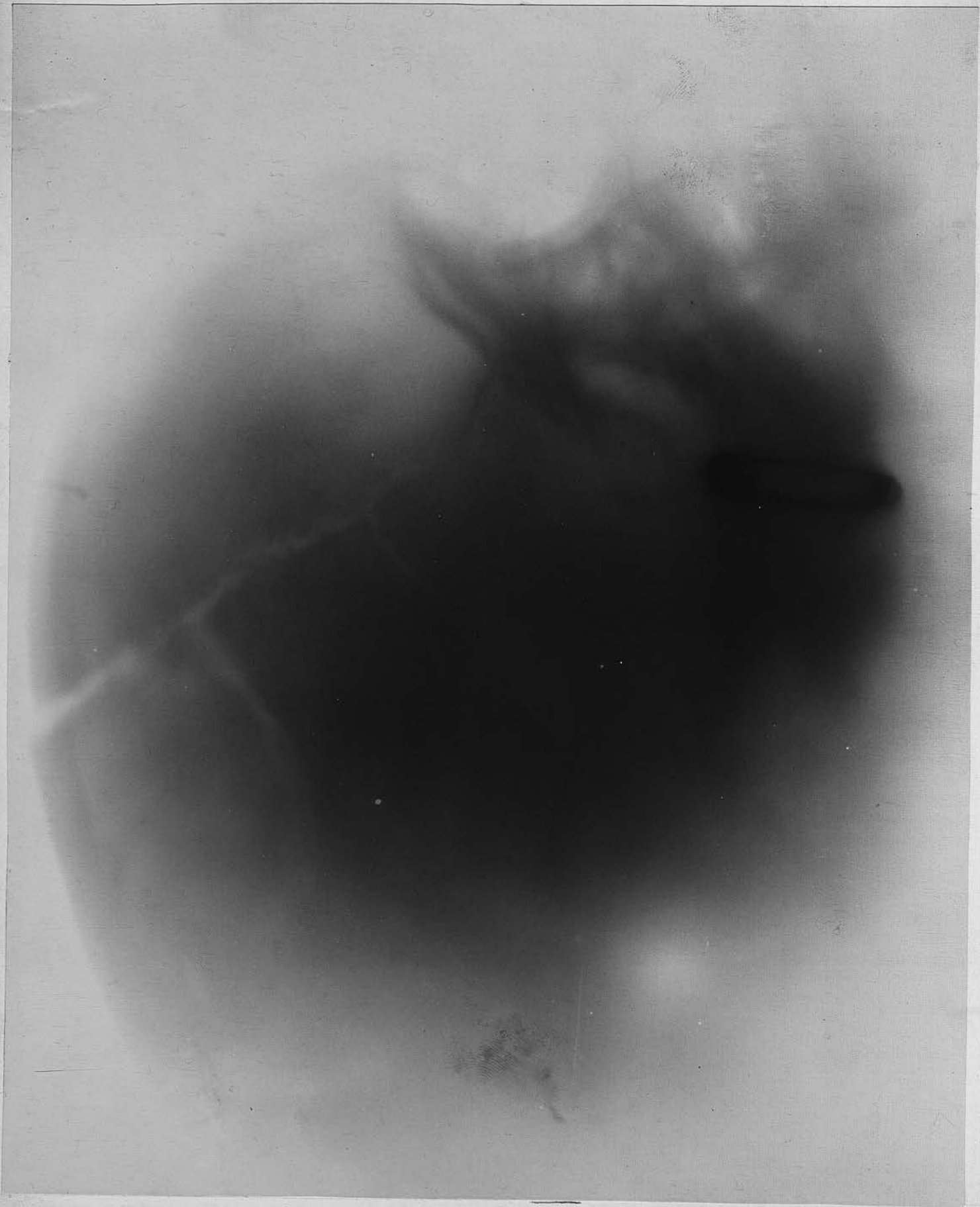
Fracture Skull.

Red line indicates line of fracture.

Rough Sketch of Base of Skull. Red lines
indicate fracture through Petrous bone.



Dr. Brewster Major Kemmer D.D.O.
No. 7 General Hospital
Pretoria



Fracture of skull. P^{te} Ricketts

Fracture of Skull. Basal Haemorrhage. Encephalitis.

Pte. Ricketts, 7th Hussars.

Admitted to General Hospital, Pretoria, on 2nd September with the following history and symptoms: He was riding his horse down the steep stony side of a kopje near Pretoria. The horse stumbled and plunged, pitching the rider off. The man evidently fell on his head. He was picked up unconscious shortly afterwards by another trooper who had seen the accident, and was conveyed to hospital in an ambulance.

On admission he was quite unconscious, pupils equal and not dilated or contracted. Reacted (doubtfully) to light. Bladder distended. Twelve ounces urine drawn off with a catheter. Over left parietal eminence was a puffy tumour (?Potts) which felt boggy to the touch. One finger breadth anterior to right parietal eminence was a marked depression in the skull.

3rd September: Restless. No paralysis. Passed urine and faeces involuntarily in bed. (This continued till death). Can be roused fairly easily. When asked a question he mutters an unintelligible reply.

9th September: Has taken his food fairly well during/

during last few days. Temperature 99. Pulse 81. Can be roused, but is very lethargic and sleeps all day. To-day he had two epileptiform convulsions. The orderly states that his "face was twitching" the previous evening, but can give no more definite information. On compressing the depressed area of skull twitching on the right side of face and pectorals and trapezium on the left side occurred.

11th September: Fits more frequent. Nine yesterday, four to-day. Is now quite conscious and able to answer all questions intelligently. His replies however, are very slow and his speech is measured and staccato in type. On protruding tongue it deviates to the left side. Left arm paretic. Can raise it with difficulty. Grip of left hand very feeble. Legs not affected.

13th September: Generalised fits more violent. Twitching of left platysma and trapezius then occurs. Had ten fits to-day, nine yesterday.

15th September: Temperature subnormal during last ~~three~~ three days. Pulse 72 per minute. Sixteen fits to-day. These fits are not localising at all. He simply lies with his eyes wide open and twitches occur over left trapezius and right side of face. Left arm lies paretic, but not absolutely paralysed. Left leg not affected.

On/

On 15th September I saw the case for the first time, and the history given above was shown me. The medical officer in charge of the case recommended trephining. An X-ray photograph was taken to-day and the condition of the skull shewn (vide attached copy). I found the left arm paresed. No signs of any paralysis elsewhere. Pupils normal. Incontinence of urine and faeces. Patient dull and lethargic; when roused protests in a guttural slurring voice. The depression in the skull previously noted could not now be felt. As the doctor in charge of the case was quite sure that the twitching was practically always present in the left trapezius and platysma he supported the advisability of trephining over the right Rolandic area.

A consultation of four medical officers was now held and it was deemed advisable to leave the case alone as the frequently recurring fits and the deep lethargy - almost coma - of the patient pointed to an encephalitis. Next morning early the patient had another fit and died shortly after.

Post Mortem: The skull was fractured as shown in the skiagram. The fracture followed the coronal suture along its full length on the right side and half its length on the left side. From this fracture on the right side two other small fractures extended backwards on the parietal and temporal bones. At the extreme end of the right suture the fracture/

bifurcated, one division ending close to the orbit, the other running down and back into the temporal fossa. There was nothing found post mortem to indicate the depression felt over the right parietal bone on admission. The parietal bone, however, was on a higher plane than the frontal, i.e. slightly overlapping, but both bones were firmly locked together. On removing calvarium the meningeal vessels were found to be uninjured.

The brain was felt to be tense and tightly filling the cranial cavity. On incising the dura mater disintegrating brain tissue protruded. This tissue felt soft and diffluent. The cerebral tissue lying over the right petrous bone had a greenish appearance. Brain tissue apparently healthy over left side. The lower part of right ascending parietal convolution looked grey in colour, and felt soft, friable and disintegrating. Remainder of Rolandic area appeared healthy.

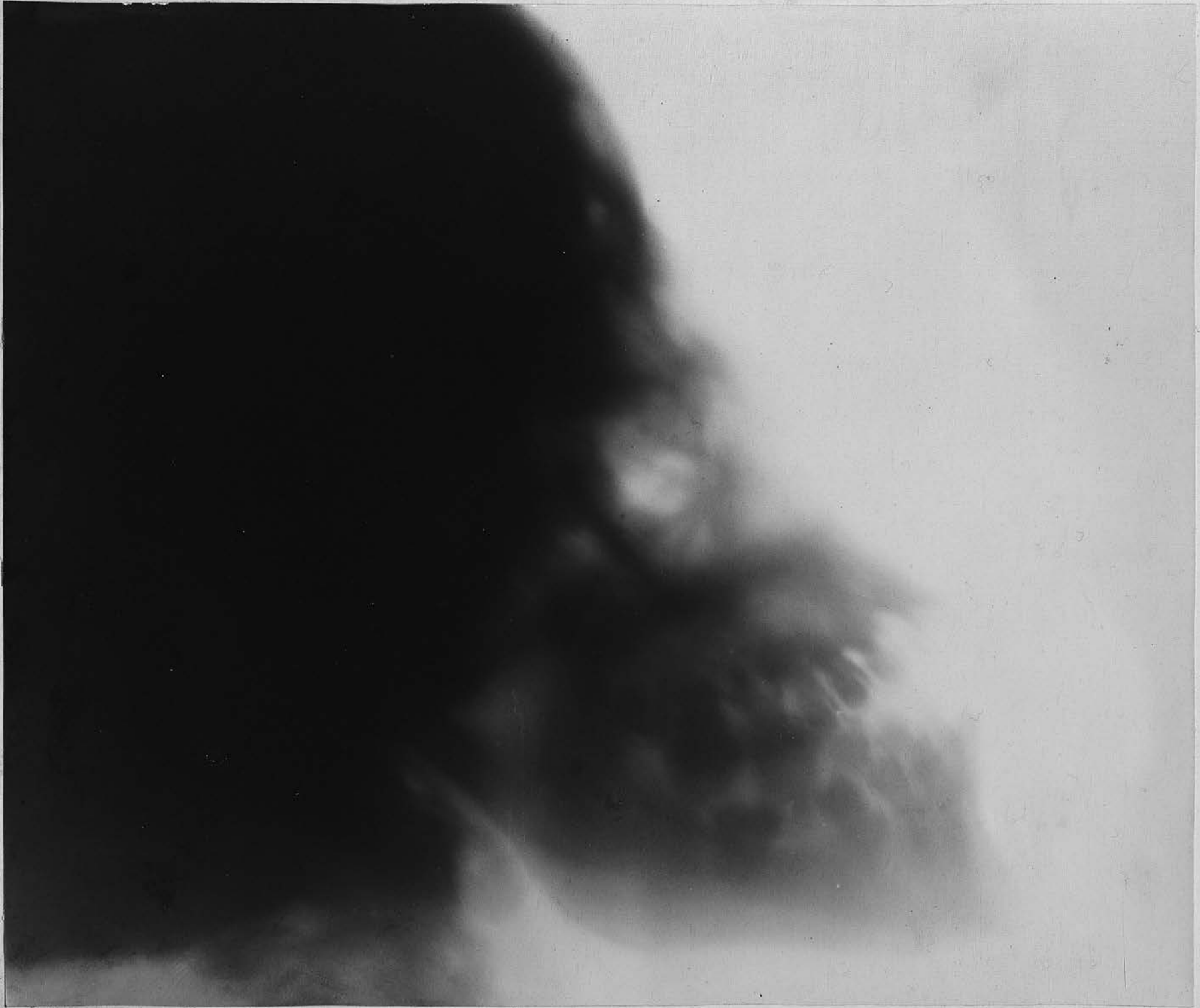
The 1st right temporo-sphenoidal convolution was broken up and disintegrated to a very marked extent. The 2nd broken up also, but not so markedly as the 1st. This area was really nothing more than a haemorrhagic debris.

On slicing the brain horizontally a large blood clot was found lying in the right corpus striatum and right lateral ventricle. The optic thalamus was/

was also partly broken up anteriorly. Right internal capsule compressed anteriorly, but free posteriorly.

Remarks: I take it that the fracture of the skull had caused severe bruising and contusion of the brain, and that a subsequent encephalitis developed. The haemorrhage at the lower part of the ascending parietal convolution on the right side may have been the cause of the twitching of the left trapezius and the paresis of the left arm. Had the first and second temporo-sphenoidal convolutions on the left side been as extensively injured as those on the right, the man would have had aphasia owing to the involvement of his centres for the reception of written and spoken speech. As it was he had no aphasia.

I report this case, as it was under my care during the last 24 hours of life. I did not see it in its earliest stage. The "X-ray" photograph is interesting from the way in which it shows the line of sutural fracture. It also shows the anterior end of the parietal bone lying on a higher plane than the frontal.



Cpl Bradley. Fr. lower jaw

Compound Multiple fracture of Lower Jaw:

Cpl. Broadley, Army Pay Dept., aet 22.

This man states that while passing along a lonely lane in Pretoria on the way to barracks late at night he was suddenly struck from behind with a "sand-bag". (Inter alia, sandbagging was rife in Pretoria at the conclusion of peace. The "Sand-bagger" held a small pillow-shaped bag full of sand in his hand and, striking his victim on the head with it, generally succeeded in felling him to the ground. This was evidently done in this case.)

This corporal then states that he was kicked on the face and head. The sergeant of the Ambulance who brought him to hospital told me that the man was found unconscious in a lane and was carried to barracks, where he quickly recovered consciousness.

On the day after the accident (September 16th, 1902) he was admitted to hospital. He was then conducting himself somewhat erratically, crying one moment and walking restlessly about the next. He was not drunk, but was certainly in a state of great excitement. On talking he grasped his lower jaw with both hands, unconsciously forming a splint.

The lower jaw was completely fractured through both condyles. These fractures were not compound as far as one could ascertain. To the right of the symphysis/

symphysis menti a vertical fracture extended from the alveolar margin to the lower border of the bone. This was between the 2nd lateral incisor and the 1st premolar tooth. A triangular fragment was caused by another fracture running from the centre of this last crack backwards and upwards to the alveolar margin between the 2nd premolar and the 1st molar tooth. This triangular fragment therefore carried two teeth on its base.

There was a great deal of swelling round the jaw, and severe bruising of the tissues. The injuries certainly appeared to have been caused by a kick. He had a scalp wound on the right side of head, but this was only of a trivial nature. Careful examination was made for any sign or symptoms of fracture of the skull, but none were found.

A poroplastic bandage was applied, forming it into a gutter for the jaw with the two tail pieces passing up vertically at the angles of the jaw. The mouth was cleansed at frequent intervals by passing in the nozzle of a Higginson's syringe between the cheek and the jaw and so pumping in Condy's fluid and lotion containing bicarbonate of soda.

18th September: Passed a very restless night, great swelling present under the tongue. Has great difficulty in speaking and can only swallow fluids/

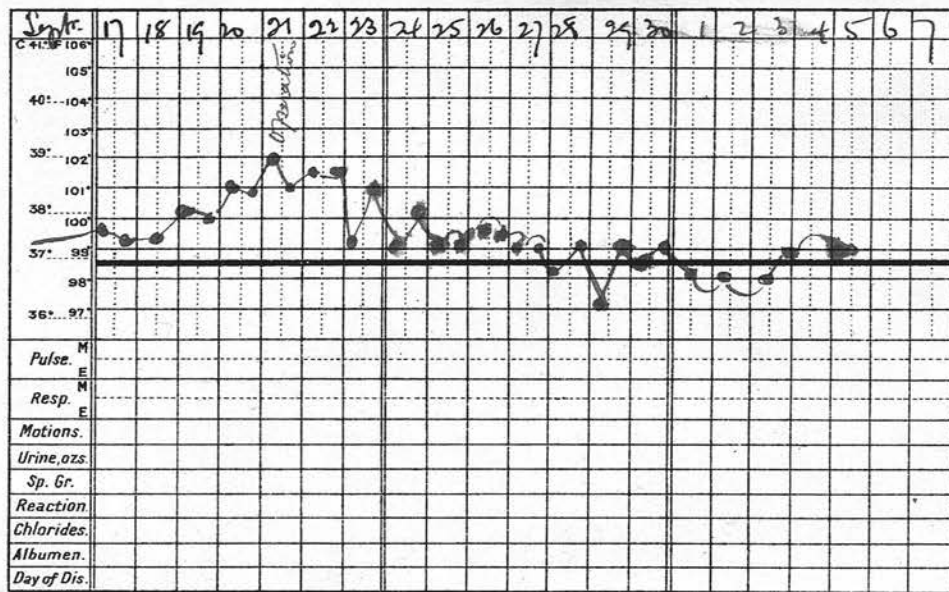
fluids. The fragments are in fairly good position, but the triangular fragment gives the patient a great deal of pain.

19th September: Still considerable oedema and swelling, parts obscured by the great oedema of the gingival mucous membrane. Still gargling as above.

20th September: Cannot speak at all now. The swelling has abated considerably from the 18th, but is still marked. He indicated that the right side of the jaw is giving him a great deal of pain. He is restless day and night and constantly requires sleeping draughts. Saliva dribbles out of the corners of his mouth and the splint does not seem to give a great deal of support, although it is well held up by the usual jaw bandage which is applied over it. He takes food with increasing difficulty. Temperature (see chart) creeping up. Pulse 102 per minute. A fluctuating area can be felt under the tongue at the root. Evidently a collection of pus from the site of fracture. I decided therefore to put the patient under an anaesthetic and explore the jaw thoroughly, and if necessary wire the fragments.

21st September: Under chloroform. I fully explored the jaw and found that the fractures were as indicated above (The skiagram taken when he was first admitted to hospital unfortunately is not a clear one.)

The/



Name: *Opel Braxley*
 Disease: *Tr. typhoid*
 Age: _____
 Result: _____

The fluctuating area under the tongue contained a collection of foul smelling pus. I incised the mucous membrane over it and swabbed it clean. This pus came from the fractured edge of the triangular fragment. The periosteum here was denuded. This fragment felt very loose, but the periosteum on its outer surface seemed to be intact. The main body of the right lower jaw also moved very freely between the two fractures, one in front and one at the condyle.

I therefore wired with stout silver wire the following fragments, and in the following order. A. to B., A. to C., and B. to C. There was a great deal of difficulty in passing the wire through the holes. The drill used was a bootmaker's bradawl filed down to the necessary size and shape and it answered excellently. The fractures at the condyles were left alone, as with such a septic mouth it would only have increased the risk of the operation to open up the tissue over these simple fractures. For the purpose of free drainage I made a counter opening behind the symphysis menti through the skin and passed a large rubber tube from this opening just into the mouth cavity. A jaw bandage was then applied. During the operation, which lasted an hour, the blood and mucus were a constant source of trouble. I should have stated that preparatory/

paratory to commencing the operation I passed a stout silk ligature through the tip of the tongue and by this an orderly was able to keep that organ well out of the way.

22nd September: Kept on nutrient enemata.

Mouth constantly douched freely out with bicarbonate of soda lotion and weak boracic through a Higginson's syringe. Temperature down (see chart). Patient looks very distressed. Given trional to keep him free from pain. He wrote on his book that he was feeling much better.

12 p.m.: Given grs. xv. chloral and grs. xxv. potass. bromidi by mouth through a long tube. For thirst given a saline injection per rectum. Sips of brandy and water by mouth. Pulse 99.

23rd September: Given by mouth through a tube Bovril, milk, brandy and beat up egg. Syringing mouth as before, the tube passing from the floor of mouth to the chin acts very efficiently. All the saliva comes out this way on to the dressing over the lower end of the tube. The swelling has abated considerably. Patient looks brighter.

28th September: Patient can now take by mouth "slop" food, such as puddings, soups, scrambled eggs, tea and coffee. Allowed outside in the sunshine. Can now douch his own mouth out efficiently. Still some/

some swelling and oedema, but it is rapidly going down. Not allowed to talk yet. Writes that he has no pain and sleeps well all night without being constantly troubled with saliva and mucus. Tube removed.

1st October: A loose tooth on the triangular fragment was removed with the fingers today. It was so loose that it was considered advisable to take it away or the patient might accidentally aspirate it into his trachea. Swelling down. Patient feels well, and is allowed to talk a little. He can articulate fairly well but has trouble with certain letters, such as "n", "e", &c.

12th October: Fragments united firmly. Wires all removed.

The after result was uneventful. A very large callus formed over the site of union of the triangular fragment with the body of the jaw. This callus has caused a quite noticeable prominence on the right side of the lower jaw, but no doubt the greater part of this will be absorbed later on. This man's articulation is now quite good. The position of the jaw is good, and except for the prominence caused by the callus no bad result has followed from what was undoubtedly a very severe injury and a very severe operation.

In reviewing this case I think I made a mistake in not operating earlier. The triangular fragment evidently/

evidently required mooring into a firm position from the first, and the right side of the jaw most certainly required wiring in order to get a good result. The apparent good position was deceptive, for every movement of the jaws must have caused a grating of the fragments and so delayed final union and occasioned a larger callus at the site of union.

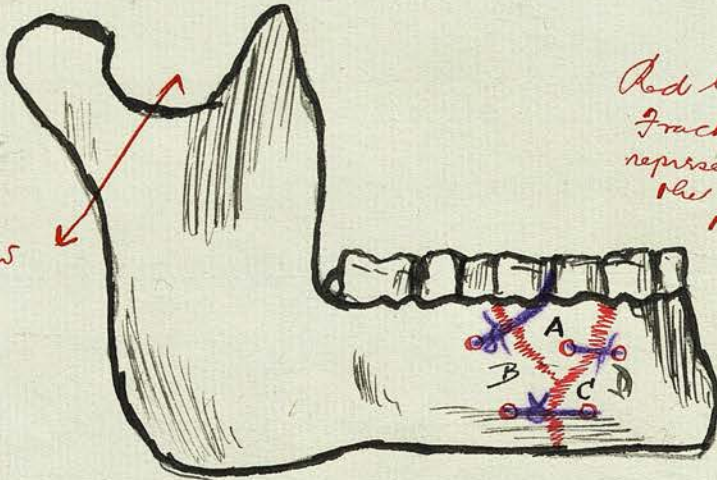
Rigidity is what one strives for in these fractures, and undoubtedly wiring with silver wire ensures an absolutely rigid structure.

Corporal Broadley. Army Pay Department.

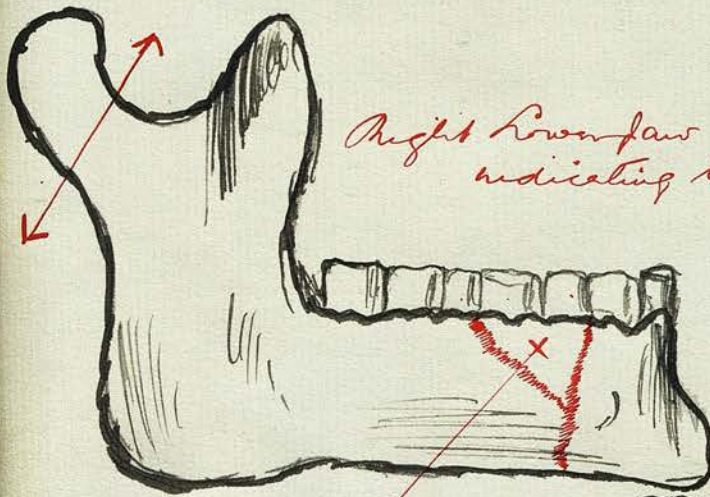
General Hospital
Pretoria.

Multiple Fractures. Lower Jaw.

Inside view
Right Lower Jaw

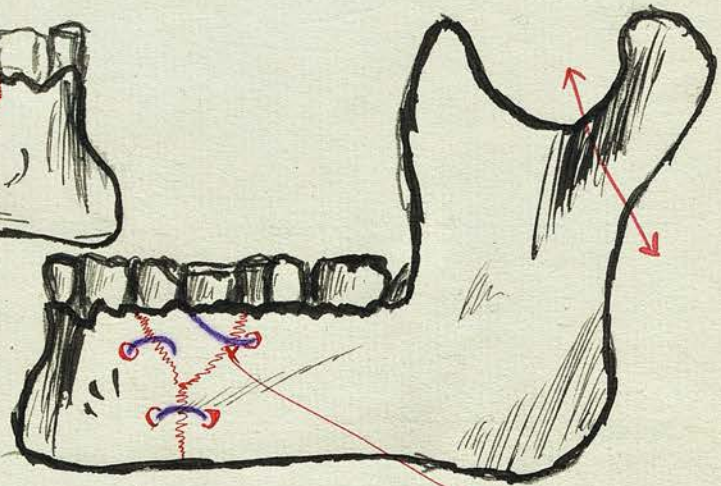


Red lines and zigzags indicate
fracture lines. The circular red
represent holes drilled for the wires
The colored pencil lines indicate
the wire inserted as shown and
twisted on the outside

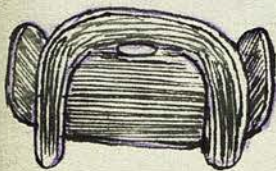


Right Lower Jaw
indicating lines of fracture

Loose fragment
C two teeth on
base.



Shows how the wire
was passed thro'
a hole in the body of
the jaw and round a
premolar tooth on the
loose fragment



Moulded poroplast
employed in this case as
a jaw splint. Over all a
tailed bandage was applied

Fracture Right Side. Lower Jaw. (No displacement)

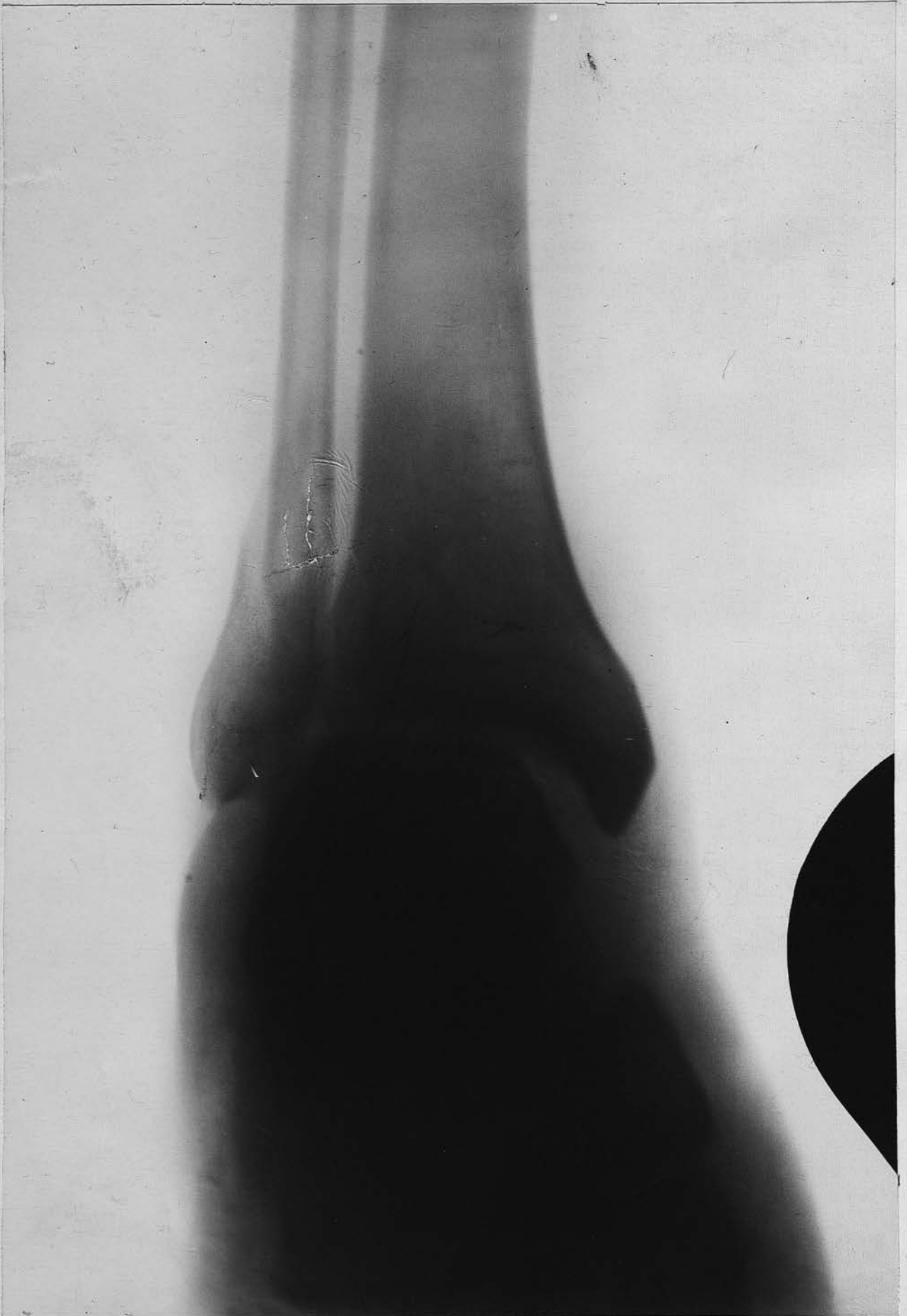Sapr. Toole, Royal Engineers, while boxing with a friend in barracks was struck smartly on the right side of chin and stated that he felt "something give" He reported to his medical officer who at once sent him to Hospital.

On admittance one could feel a distinct fracture on the right side of symphysis menti and passing almost vertically down between 1st premolar tooth and lateral incisor. By pressing on either side of the fracture crepitus was elicited. There was no displacement whatever. The line of the lower margin of the jaw and the level of the crowns of the teeth were practically perfect.

I simply treated the case by the ordinary tailed bandage for the jaw. Gave him "slop" food for a week and a mouth wash of Condy's fluid four or 5 times a day.

In 3 weeks he was put on ordinary hospital dietary and the bandage was removed. The after course was uneventful.

The point of interest in the case is the fact that though the fracture was complete there was no displacement.



St. Bartley. On admission

Simple Fracture of lower end left Fibula.

(Pott's fracture)

Driver J. Barsley. Royal Horse Artillery.

Act 24. This accident unlike the usual Pott's Fracture was caused by direct violence. This driver fell off an ammunition waggon while he was galloping it over a spruit near Pretoria. The wheel of the waggon passed over his left ankle on the outer side producing the fracture seen in the skiagram.

Crepitus could be elicited and the fingers could be deeply embedded below the internal malleolus of the Tibia. The foot was everted and displaced outward to a very slight degree.

A big pad of wool was placed over the ankle and an elastic bandage applied over this to reduce the swelling which was present. The limb was then fixed on to a back splint with a vertical foot piece and left untouched for 48 hours. The elastic bandage was then removed and the other foot kept on the splint for two weeks.

A "figure of eight" flannel bandage was then applied round the ankle and the splint dispensed with. Passive movements were carried out night and morning at the ankle joint and the calf muscles were/

4
were massaged after which the bandage was again applied. In 4 weeks the patient was allowed up on crutches with his foot in a sling. In six weeks he was allowed to put his foot to the ground.

Two months after the accident he was discharged for light duty, to his Battery. The result in this case was most gratifying. All the movements were free and easy and when he left Hospital he could jump with this leg without feeling any pain or weakness.

Certainly even if one had wired or pegged this fracture (as Mr. Arbuthnot Lane has so successfully done in many of his simple fractures) a better result could not have been attained.

2

Fracture left leg. Comminuted.

Sgt. White, 13th Hussars. Act 45. (See Skiagram) on attempting to alight from the front of a mule waggon in motion, the spur of his left foot was caught on a rope tracing in front of the wheel. He fell violently forward on his face and the moving waggon twisted his leg and dragged him some distance along the ground. He was a very heavy fat man and distinctly alcoholic.

About an hour after the accident he was admitted to Hospital under my care. There was then considerable swelling. The foot was displaced backwards and a projecting point of bone could be felt under the skin over the lower third of the Tibia. Another projecting point could with difficulty be felt on the peroneal side of the leg in the upper third. This will be understood from the skiagram attached. I put the limb on a back splint - without attempting to remedy the fracture - and then took an "X" ray photograph. From this the marked comminution will be seen.

The Fibula is completely fractured in its upper third and the upper fragment has been driven down on to it. The upper fragment has been also somewhat spirally/

spirally split. The Tibia has evidently been fractured by a severe twisting force for although there is very little displacement yet the bone is fragmented.

One point the skiagram does not show and that is that there was a piece of bone which projected anteriorly under the skin.

Treatment:- Fourteen lbs. extension applied and after gently cleaning the limb with 1 - 80 Carbolic lotion it was placed in a box splint with Scotch sheeting. Over the places where the projecting points of bone were felt Cyanide gauze and Iodoform powder were applied. The lower end of the bed was elevated and the box splint laid on a pillow.

Next morning on examining the limb the whole anterior and lateral aspects were found covered with huge watery blebs. The man was complaining of excessive pain. This pain he located to the back of the leg, in the calf muscles. It was not over the seats of fracture. After cleansing with weak Corrosive lotion the blebs were punctured and the serum pressed out. The whole limb was then dusted freely with equal parts of Iodoform and Boric Powder. The weight extension was increased by 7 lbs (making 21 lbs) as the projecting piece of bone anteriorly

4

felt suspiciously close to the skin and appeared as if it might at any time get through and so making the case a compound fracture. For the next week the case went on extremely unsatisfactorily. The patient loudly complained of the pain in his left leg and also complained of severe pains at the back of his right leg. On grasping the muscles of the right calf he winced and loudly protested. He woke the other patients at night by his groans and frequent calls for morphia. The man was undoubtedly an alcoholic and had for years been a heavy drinker. This accident and the enforced rest has brought on a condition very closely akin to Delirium tremens and the pains he complained of were, I feel sure, of the nature of an alcoholic neuritis. He was restless, refused to take his food, said that we (the doctor and the orderlies) had a spite against him.

On the 3rd day after the accident therefore, after a consultation with Major Holt R.A.M.C. the man was put on the following mixture.

R. Chloral grs. xv
Potass Bromidi grs. xxv
Glycerine 15 minims.
Aq. Anesi ad. half an ounce.
Sig. half ounce t.i.d. p.c.

The condition of the leg at this time gave one no cause/

5
cause for anxiety as the position was excellent, the blebs had disappeared rapidly and the projecting point of bone anteriorly could now scarcely be felt. On the 6th day after the accident the extra 7 lbs. extension was removed thus leaving 14 lbs. on.

At the same time I spent about half an hour every evening in attempting gentle massage to the calf muscles of his leg. (not removing the extension) This massage was really only of the nature of a gentle friction to the skin as it would have been inadvisable to attempt more forcible methods.

On the 12th day after the accident the patient no longer complained. His restlessness had ceased, and he was quiet at night. The Bromide was evidently exerting its therapeutic action. The dose was therefore diminished and he was given Grs.xx Potassium Bromide at night and had a mixture containing Iron and Arsenic in the morning.

Extension weight removed in 3 weeks but limb still kept on back splint.

The patient now developed a cough of an irritative hacking nature and expectorated a fair amount of/
of/

6

of mucus. He was therefore propped up in bed and given Ether and Ammonia as an expectorant and stimulant. The fear now of course, was that this heavy fat alcoholic man might develop Hypostatic Pneumonia. His temperature had an evening rise of one degree, ranging between 99° and 99.9° F. Fortunately all this cleared up in two or 3 days.

On the 4th week the ward sister began to massage the limb more forcibly. At this time as the position was so good I carried out gentle flexion and extension, inversion, and eversion at the ankle and slight flexion at the knee joint.

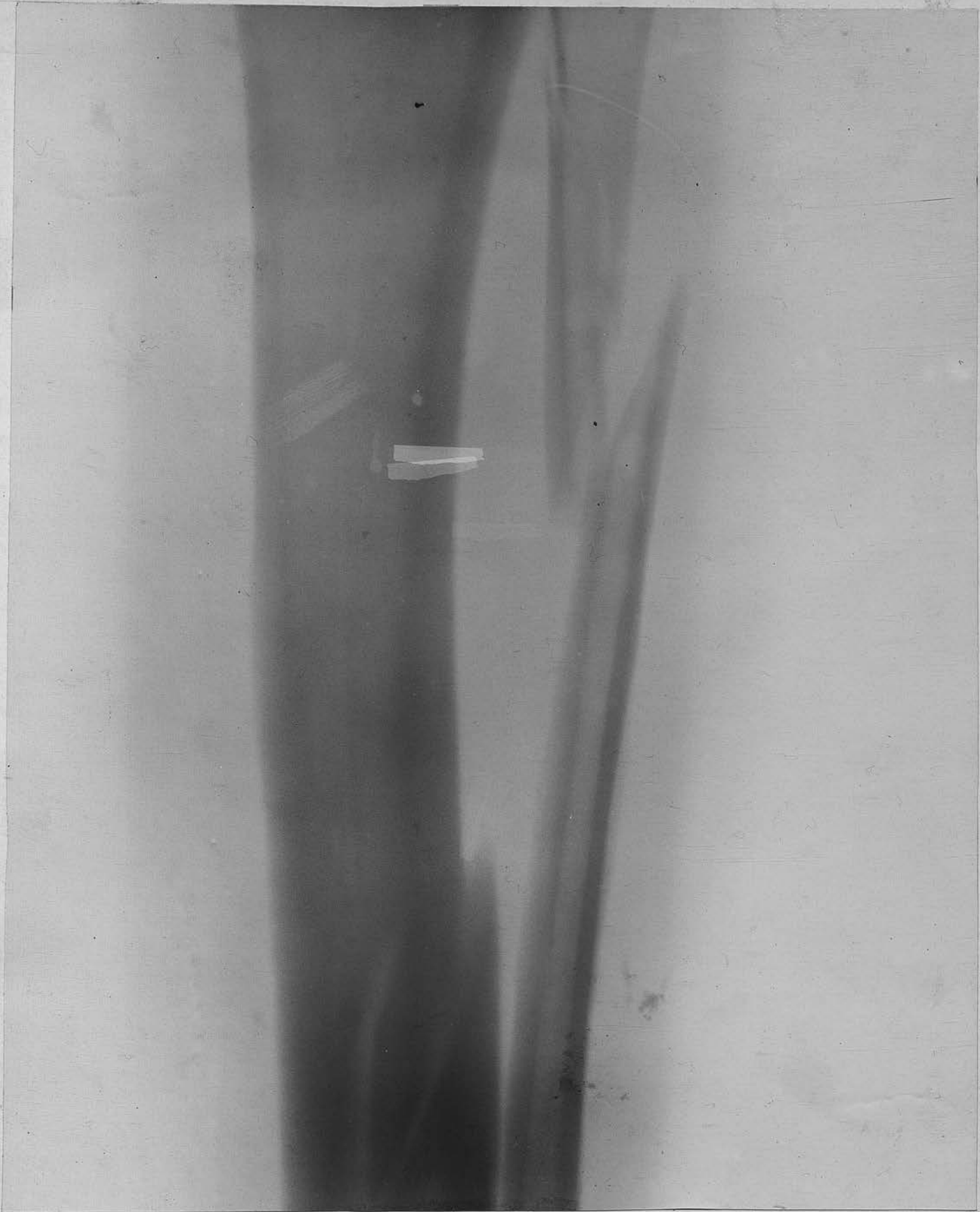This was still being carried out on the 6th week when the limb was put up in a Crofts Plaster Splint and the man got about on crutches.

Ten weeks after the accident the Croft was removed and the limb bandaged with flannel bandages. The patient was then made to walk about with a single stick and to put his foot to the ground. Night and morning passive movements and massage were carried out and the bandage reapplied.

The rest of the case was uneventful. Owing to the physical condition of the man and the great comminution/

7
comminution of the bones one was disinclined to start early movements as one would in a Pott's Fracture. The alcoholic taint made one maintain rigid fixation to the limb longer than usual as in such cases the union of the bones is delayed.

(I regret that owing to a break down in the "X" ray apparatus I was unable to get a 2nd radiogram of this case when the limb was in good position.)



Sgt. White. On admission (before extension
applied.)



Shells & missiles of sorts.
Picked up from the field of Geluk