

4794

**Virological and Immunological Aspects of Infection
with the Human Papova (Wart) Virus.**

by

Marie M. Ogilvie, M.B., Ch.B.

Thesis submitted for the Degree of Doctor of Medicine

University of Edinburgh

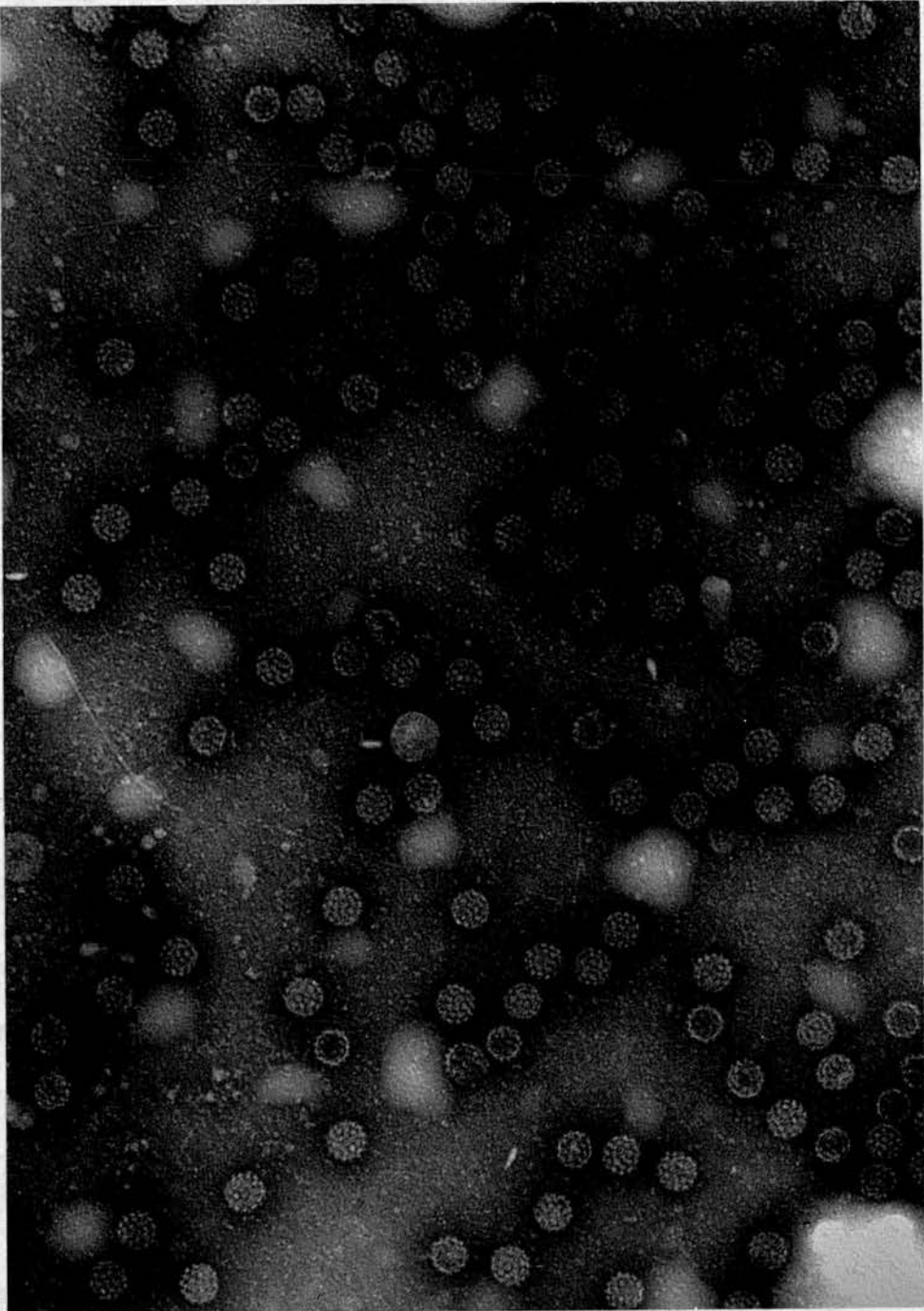
1970





THE UNIVERSITY *of* EDINBURGH

PAGE ORDER INACCURATE IN ORIGINAL



FRONTISPIECE

Electron micrograph of Human Papovirus (Wart) Virus particles eluted from the virus-specific protein zone located after electrophoresis of wart extracts.

PTA stain

× 120 000

SUMMARY.

This investigation included the examination of tissues for evidence of infection with the human wart virus, and the development and application of serological techniques for demonstrating response to the infection.

The majority of specimens were examined by negative staining methods, and the presence of virus particles and other structures in various types of wart at different stages is reported. Two cases of molluscum contagiosum of the sole of the foot, previously considered a site rarely if ever infected, were diagnosed.

A series of twelve genital wart specimens was studied by thin sectioning and negative staining techniques. Intranuclear virus particles with the morphology of wart virus were found in cells of the stratum granulosum, and the paucity of virus particles in such tissues noted for the first time. Examination of three specimens of bladder papillomata by such methods revealed no evidence of a virus infection.

Serological studies included the application of an established precipitin test for antibody to wart virus, and development of complement fixation and passive haemagglutination tests for this purpose. The specific nature of the antigen involved in these reactions was demonstrated, and the immunoglobulin class of the antibodies concerned determined.

These tests were applied to sera from 265 patients with different types of wart, and to sera from 110 people not currently infected with warts. The development of a full immune response with rising titres of antibody and appearance of immunoglobulin G was demonstrated/

(ii)

demonstrated in rabbits immunised with the virus, and in some patients, particularly those with the simple type of plantar wart. The relationship of the appearance of antiviral antibodies to regression of warts, spontaneous or following therapy, was observed and considered to be a result of increased exposure to the virus antigen at that time.

Earliest antibody was detected by the passive haemagglutination test, particularly sensitive in the detection of immunoglobulin M, but also useful in demonstrating low levels of later antibody not revealed by the less sensitive methods. The complement-fixing antibodies were found to appear late in infection and disappear within a few months of cure. Precipitating antibody remained longer, and was detectable up to seven years later, and antibody demonstrated by the passive haemagglutination test up to ten years later. Some antibody was also noted in sera from nine out of thirty four people who thought that they had never had warts.

Virus antigens from hand warts, and both simple and mosaic types of plantar wart, were compared and found to be identical. Some evidence for the same antigen in face warts and genital warts was established by demonstration of antibody to virus from plantar warts in sera from patients with these wart types and from a rabbit immunised with genital wart tissue.

Other experiments were limited by the difficulty of obtaining sufficient materials. Attempts to demonstrate virus and other antigens in wart tissues by immuno-electrophoresis were only partially successful, but the potential value of the methods is discussed. Similarly limited experiments to induce transformation or other changes in/
in/

in tissue cultures were unsuccessful under the conditions applied, but means of increasing the chances of success are considered in the light of recent knowledge concerning related systems. The question of the relation of wart virus to carcinogenesis is reviewed.

ACKNOWLEDGEMENTS.

Following much helpful initial discussion with Dr. Valerie Inglis, this study was carried out during the tenure of a Graduate Research Scholarship from the Faculty of Medicine, in the Bacteriology Department, Edinburgh University. For the facilities provided, the opportunity for instruction in methods and for helpful discussion, I am particularly grateful to Dr. Isabel Smith, Dr. J.F. Peutherer, Dr. R.H.A. Swain and Professor B.P. Marmion. Dr. Swain's particular interest in the project was at all times a great support and encouragement. Instruction in the use of the electron microscope and much help in this connection was provided by Mr. George Wilson and Mr. A.E.G. Dunn, and Mr. Dunn and Mrs. O. Gray are to be thanked for preparing the thin sections.

Facilities for obtaining materials from patients were made available at the Royal Infirmary, Edinburgh, and I am very grateful for the interest and support of all the staff in the departments of Dermatology and Venereology, particularly Dr. Mary Bunney, Dr. J. Hunter, Dr. S. Khan and Dr. D.H.H. Robertson. Dr. E. Skirving and students at the Dunfermline College of Education, and Mr. Selby Tulloch of the Western General Hospital have also to be thanked for supplying material.

My thanks are also due to Miss Jean Thomson for typing the thesis, /

thesis, and finally but most of all to my husband for his patience and encouragement throughout this work.

Some of the material in the thesis has already been published. The relevant references are:-

Bunney, M.H., Hunter, J.A.A. and Ogilvie, M.M. (1969). Brit. J. Derm., 81, 623.

Dunn, A.E.G. and Ogilvie, M.M. (1968). J. Ultrastruct. Res., 22, 282.

Ogilvie, M.M. (1970). Brit. med. J., i, 113.

Some of the early studies were incorporated in the Lewis Cameron Postgraduate Prize Essay, 1968, Edinburgh University.

A paper incorporating the serological studies has been submitted to the Journal of Hygiene.

Table of Contents.

	<u>Page</u>
List of illustrations	(viii)
<u>INTRODUCTION</u>	1
<u>Clinical aspects of infectious warts</u>	
1. Clinical types of wart	2
2. Natural history and epidemiology	4
3. Therapeutic measures	6
4. Spontaneous regression	9
5. Differential diagnosis	10
<u>Histological studies</u>	
1. Pathology	11
2. Inclusion bodies	12
3. Localisation of virus antigen	13
<u>Electron microscopy</u>	
1. Early studies	14
2. Development of virus in warts	14
3. Structure of wart virus	15
4. Size of papovaviruses	17
5. Abnormal variants	18
<u>Presence of wart virus in lesions</u>	
1. Common warts	19
2. Epidermodysplasia verruciformis	20
3. Oral papillomata	21
4. Condylomata acuminata	21
5. Laryngeal papillomata and others	22
<u>Further physico-chemical properties</u>	22
<u>Nucleic acid</u>	23
<u>Biological properties</u>	
1. Papovavirus infections in animals	25
2. Cytopathic effects	27
3. Proliferative changes	28
4. Neoplastic transformation	29
<u>New antigens</u>	
1. Tumour-specific transplantation antigen	31
2. Tumour antigen	31
<u>Other virus-induced functions</u>	
1. Arginase	32
2. DNA synthesis	33
3. Viral messenger RNA	34

	<u>Page</u>
<u>Induction of viral synthesis</u>	
1. Cell fusion	35
2. Temperature-related phenomena	35
<u>Antibodies to papovaviruses</u>	
1. Neutralising antibody	36
2. Precipitins	37
3. Character of antibodies	38
4. Immuno-electron microscopy	39
<u>Immunological aspects of viral tumours</u>	
1. Antiviral antibody	40
2. "Spontaneous" regression	40
3. Cell-mediated and humoral immune reactions	41
4. Antibody to T (tumour) antigen	42
<u>Wart virus and carcinogenesis</u>	43
 <u>MATERIALS AND METHODS</u>	 45
<u>Collection of specimens</u>	
1. Wart tissues	45
2. Human sera	46
<u>Preparation of antigens, vaccines and antisera</u>	
1. Wart virus antigens	46
2. Vaccines	47
3. Production of antisera	47
<u>Electron microscopy</u>	
1. Negative staining techniques	48
2. Counting of virus particles	50
3. Thin sectioning	51
<u>Serological techniques</u>	
1. Precipitin test	52
2. Agglutination test	53
3. Complement fixation test	53
4. Passive haemagglutination test	54
5. Reversed passive haemagglutination	57
6. Determination of immunoglobulin class	58
<u>Tissue culture methods</u>	
1. Inoculation of HEp-2 cells	59
2. Transformation studies	61
<u>Experiments to detect virus-induced antigens</u>	
1. Soluble "T type" antigen	63
2. Electrophoresis of wart extracts	63

	<u>Page</u>
<u>RESULTS</u>	66
<u>Electron microscopy</u>	
1. Negative staining of specimens	66
(a) Virus in plantar, hand and face warts	66
(b) "Empty" particles and filaments	68
(c) Genital warts and bladder papillomata	69
(d) Molluscum contagiosum of the sole	69
2. Thin sections	
(a) Simple plantar wart	70
(b) Genital warts	70
(c) Bladder papillomata	72
3. Concentration of virus	
(a) Plantar and hand warts	73
(b) Face warts and genital warts	73
<u>Serology</u>	
1. Demonstration of precipitins in sera	74
(a) Concentration of reagents	74
(b) Specificity of precipitin lines	74
(c) Examination of precipitate by EM	75
(d) Precipitins in patients with warts	76
(e) Immunoglobulin class	76
(f) Comparison of results	77
2. The agglutination test	78
3. Complement-fixing antibodies	78
(a) Complement-fixing antigen	78
(b) Development of CF antibody	79
(c) Class of CF antibody	80
4. Response in immunised rabbits	81
5. Passive haemagglutination	82
(a) Sensitisation of cells	82
(b) Demonstration of antibody	84
(c) Inhibition	85
(d) Reversed PHA test	86
6. Serology and epidemiology	86
(a) Antibodies and spontaneous regression	86
(b) Antibodies in people with a past history	87
(c) Antibodies in people who never had warts	88

	<u>Page</u>
<u>Virus and other antigen studies</u>	88
1. Antigenic identity of virus from different types of wart	
(a) Hand and plantar warts	88
(b) Genital warts	89
(c) Filaments	89
2. Electrophoresis of wart extracts	90
3. Extract from HEp-2 cells	92
<u>Tissue culture results</u>	
1. Cytology of HEp-2 cells inoculated with virus	92
2. Electron microscopic studies	93
3. Experiments to transform cells	94
<u>DISCUSSION</u>	95
Diagnosis of wart virus infection by EM	95
Serological diagnosis of wart virus infection	101
Antigenic identity of viruses from warts	104
Antigenic relationships among papova-like viruses from human tissues other than warts	106
Development of immune response in wart virus infection	108
Wart virus, new antigens, transformation and carcinogenesis	110
<u>REFERENCES</u>	113
<u>APPENDIX</u>	

<u>List of Illustrations</u>	<u>Page</u>
Frontispiece - Human papova virus particles	
Plate 1. Verrucae vulgares	2A
Plate 2. Simple plantar wart	3A
Plate 3. Mosaic plantar wart	3A
Plate 4. Cured plantar wart	11A
Plate 5. Passive haemagglutination test	56A
Plate 6. Wart specimen, negative stain	67A
Plate 7. Wart virus and filaments	68A
Plate 8. Molluscum contagiosum virus	69A
Plate 9. Thin section, plantar wart	70A
Plate 10. Thin section, genital wart	71A
Plate 11. " " " "	71A
Plate 12. " " " "	72A
Plate 13. Genital wart virus, negative stain	73A
Plate 14. Precipitin test, identity of antibodies	74A
Plate 15. Precipitin line, virus aggregate	75A
Plate 16. Precipitin line, antibody loops	75A
Plate 17. Sensitised red cell surface	83A
Plate 18. " " " "	83A
Plate 19. Precipitin test, identity of antigens	89A

Plates 1 - 4 by courtesy of Dr. M. Bunney.

I N T R O D U C T I O N

General Introduction.

The common wart (*verruca*) or papilloma has long been recognised even by laymen as a benign skin tumour of a trivial nature, not to be disguised on the faces of eminent men from Oliver Cromwell* (1658) to those appearing on television in our own day. The infective nature of the lesions was early suspected, and transmission from one person to another observed (Cooper, 1835) before clinicians were familiar with the causative agents of infectious diseases. Ciuffo (1907) was the first to report the experimental transmission of warts by inoculation of a bacteriologically sterile cell-free filtrate of wart extract, thus indicating the probable viral nature of the agent involved.

Virus particles were seen in aqueous extracts of warts prepared by shadow-casting and examined in the electron microscope in 1949. (Strauss, Shaw, Bunting and Melnick). The particles were roughly spherical, with an average diameter of 52 nanometres (nm.). Electron microscopic studies have yielded considerable information about the virus of human warts since then, and this virus has been classified as a member of the PAPOVA group (Melnick, 1962). The other original members of the group, all small deoxyribonucleic acid (DNA) - containing oncogenic viruses, are the papilloma virus of rabbits, mouse polyoma virus, and vacuolating virus of monkeys, simian virus 40 (SV40).

Although much has been learnt, particularly about the role of viruses in neoplasia, from study of two animal papovaviruses (SV40 and polyoma), in research concerned with the activity of the human papova (wart) virus progress has been slow. It is limited mainly by the continuing lack of any means of propagating the virus outside its natural host. Yet here is a virus that undoubtedly does cause/

* "... paint my picture truly remark these warts .."

cause tumours in man and is therefore worthy of study as a model for viral oncogenicity.

In this introductory review no attempt is made to cover comprehensively all that is known regarding papovaviruses. The features of human wart virus and infections associated with it are presented as they are known, and where relevant comparisons made with the generally better characterised members of the papova group.

CLINICAL ASPECTS OF INFECTIOUS WARTS.

1. Clinical types of wart.

Clinically, several morphologically different forms of wart or papilloma are recognised as being of likely viral origin. The Latin name verruca (= wart) is often mistakenly reserved by the public for a wart on the sole of the foot, but of course it applies to any wart. The descriptive terms used for the various forms of wart relate fairly well to features of the particular types, such as age of incidence or predilection for certain body sites, and those in current use are given here.

The most frequent is the common wart (verruca vulgaris), a circumscribed projecting tumour with a rough horny surface, seen most often on the dorsal aspect of the hand and fingers. (Plate 1.) Very flat, smooth warts, hardly raised at all, occur on the hands, face and knees, especially in children. (verrucae planae). Warts situated around the face, scalp and neck in adults usually have a projecting threadlike appearance and are termed filiform or digitate warts. Plantar warts in areas of the sole subjected to pressure do not project but lie deep in the epidermis, often sharply defined by a collar of thick horny keratin. This is the simple form of plantar wart. (Plate 2.) Similar appearances may be found in warts on parts of the hand where pressure/

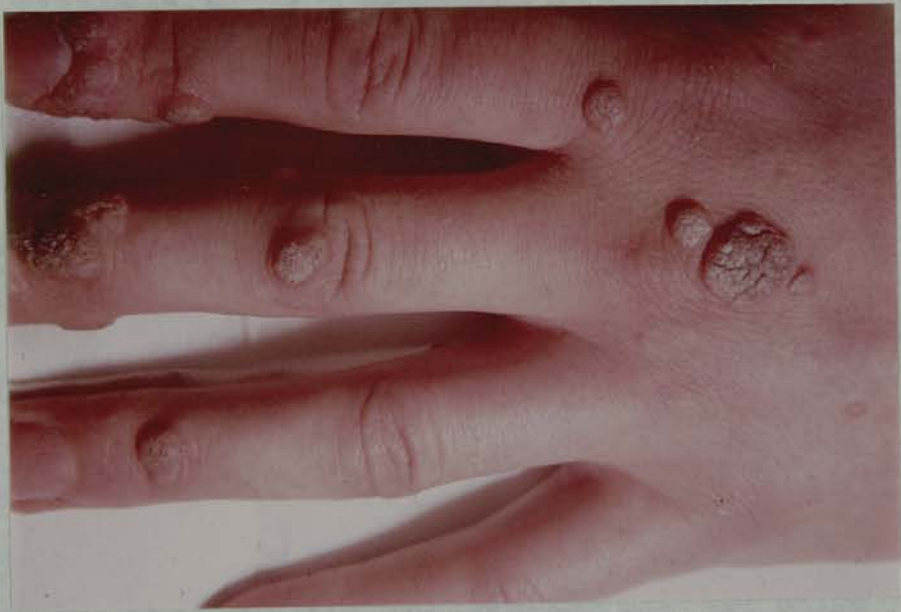

Plate 1.

Verrucae vulgares - common warts.

pressure is common, palm, finger pulp or sub-ungually. Lyell and Miles (1951) have advocated use of the name *myrmecia* for this type of wart, but it is not widely used.

In some plantar warts an appearance as of a multi-cellular lesion, resembling a mosaic is seen. (Plate 3.) The name mosaic was given to this type of wart by Montgomery and Montgomery (1937) who first described it and its features. Characteristically these mosaic warts are quite superficial, comparatively painless, (unlike the simple plantar type) and often remarkably persistent in spite of prolonged treatment. The Montgomerys (1948) found the average duration of mosaic plantar warts in 109 patients to be 3 years 7 months; 90% were cured within 5 years. Mosaic warts are found mainly in adults, and may cover large areas of skin such as the heel. They are also seen on the hands sometimes, limited to areas devoid of hair - knuckles, palms, peri-ungual. (Montgomery, 1963). Here again they resist treatment, and it is usually necessary to pare down the horny surface in order to reveal the mosaic nature of such warts.

Where the skin is soft, with a thin, non-horny surface layer, and subjected to friction and to moisture, warts often grow more exuberantly. The name condylomata acuminata is applied to such warts, or the term genital warts, for the majority are on the external genitalia and around the anus and are transmitted sexually (Teokharov, 1962). There is a form of giant condyloma, called a Buschké-Lowenstein tumour after those who described it, (Buschké and Lowenstein, 1925), which seems to arise most often from the penis. Excessive growth gives a clinical appearance of malignancy, but the pathological findings do not confirm this. (Davies, 1964).

Wart-like/

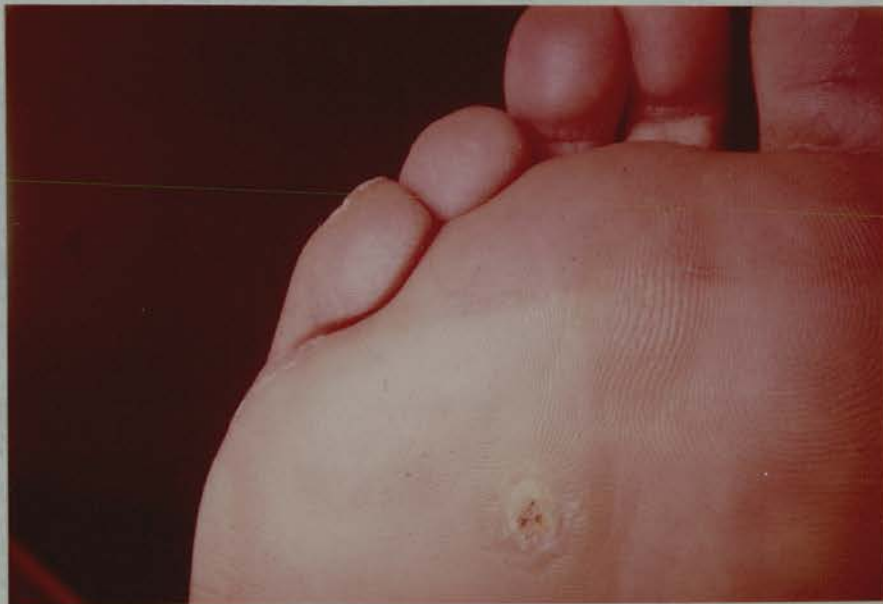

Plate 2.

A single simple plantar wart, the pared surface showing bleeding points.

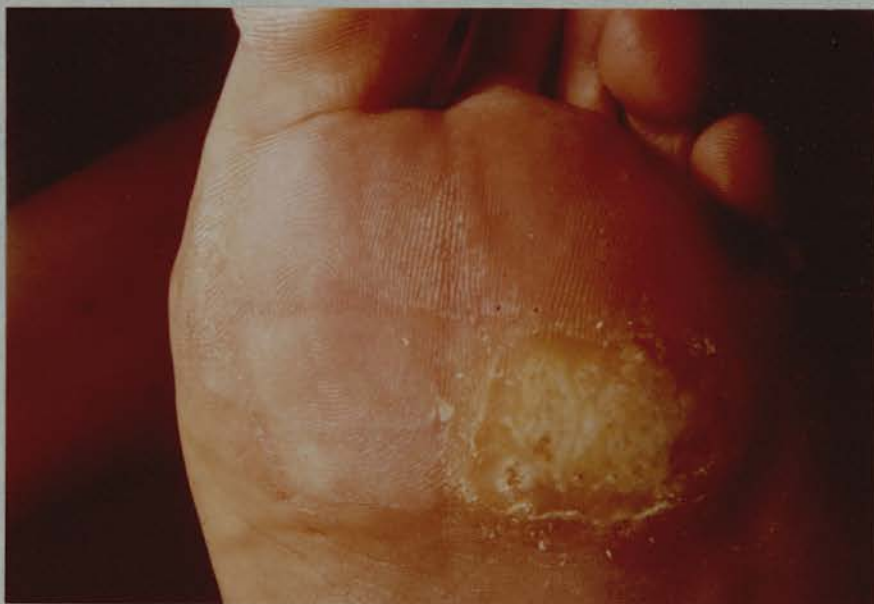

Plate 3.

The mosaic type of plantar wart.

Wart-like growths are not limited to the skin but can be recognised on other stratified epithelial surfaces such as the vagina, ano-rectum and oral cavity. Similar papillomata are found in the larynx, arising from the vocal cords. They tend to be multiple in children, recur frequently after surgical removal and eventually undergo spontaneous regression. A single type of laryngeal papilloma occurs in older people, and may be the site of subsequent carcinoma. Bladder papillomata, arising on transitional epithelium, are often particularly fragile filiform tumours. They also recur frequently after surgical treatment and have a tendency to become carcinomata.

2. Natural history and epidemiology of warts.

The peak incidence of warts is in children and young adults, (Rulison, 1942), and the lesions occur mainly on areas of skin exposed to minor trauma. The incubation period cannot be accurately determined for the natural infection, but has been found to vary from one month to twenty after experimental inoculation. (Rowson and Mahy, 1967). The natural history of untreated warts was observed by Massing and Epstein (1963) during a 2 year survey in a school for mentally defective children. Those with warts developed new lesions 3 times as often as uninfected individuals. 67% of the warts initially present had disappeared by the end of the 2 year period, though in some patients fresh warts appeared in other sites. The person's age (they were 4 to 20 years old) or the number of warts they had did not appear to influence the rate of disappearance of warts, but involution was nearly twice as common in boys and in those with large lesions. This spontaneous regression is a marked feature of warts, especially in young people. In adults the rate is generally thought to be slower, though/

though some workers quote that it is of the order of 30% over 3 to 6 months (Clarke, 1965).

Because of the long interval between exposure and subsequent development of the disease, and the lack of generally applicable means of detecting the virus, the epidemiology of warts has not been fully studied. Direct transmission of infection is supported by observations of genital warts in sexual partners, and the appearance of "Kissing" warts on apposing skin surfaces. Auto-infection is assumed to be responsible for the co-existence of warts on different body sites, as in the case of patients with genital warts frequently having hand warts also (Frey, 1924). Indirect contact through virus-contaminated media is probably the most common mode of infection. McLaughlin and Edington (1937) described an outbreak of warts in workers using glue from a container that had obviously become contaminated with infective material. Risk of infection is particularly recognised in connection with the use of communal bathing facilities, where the feet especially are exposed to trauma and contact with infected tissue from other people. (Rasmussen, 1958). Children and young adults are most frequently exposed in such environments, and this probably accounts for the high incidence of infection in this age group.

Many clinicians have commented on the apparent rise in the incidence of warts. Such opinions are confirmed by increasing numbers of people with warts treated at a London hospital where the incidence of other skin diseases is seen to have fallen slightly. (Neves, 1966). See Tables I and II.

Table I /

Table I

<u>Disease</u>	<u>Incidence (%)</u>	
	<u>over 14 years</u>	<u>in 1965</u>
eczema	28	15
acne	9	8
warts	9	13
seborrhoea	7	5
psoriasis	6	6
bacterial infections	4	2

Addendum : Table I - the "Incidence (%)" referred to is the percentage of patients attending St. John's Hospital between 1952 and 1965. The majority suffered from one of the eight diseases listed, the remainder making up the 100% had a variety of conditions not clearly defined.

No. of patients with warts

Year	1952	1953	1954	1955	1956	1957	1958
No.	1251	1243	1192	1283	1276	1343	1231
Year	1959	1960	1961	1962	1963	1964	1965
No.	1364	1416	1503	1453	1715	1624	1828

(from Neves, 1966)

The increased incidence of infection naturally creates a vicious circle by providing increasing numbers of people with warts to contaminate the environment. This is becoming a major problem in the many swimming baths available to the public.

3. Therapeutic measures.

At present there is no specific therapy for warts. No anti-viral/

anti-viral agents have been tried in vivo to my knowledge, and none can yet be tested experimentally for activity against wart virus because of the lack of any suitable culture system. The latest proprietary preparation to come on the market, "Callusolve" (Dermal Laboratories Ltd.) purports to be selective. It contains 25% alkyl-dimethyl-benzyl-ammonium-halide-dibromide in a volatile organic solvent. In their report of a clinical trial of this product, Yarrow and Hitchcock (1969) quote:- "In the presence of moisture this adduct liberates bromine on the wart tissue ... and quickly kills any virus." The trial results were apparently encouraging even though one must doubt the validity of the foregoing statement. The percentage of patients cured in the two-month treatment period was significantly greater than the 10% who would be expected to have spontaneous regression in that time, judging by Massing and Epstein's findings (1963).

Numerous more established methods of treatment are available, pointing to the fact that none are particularly effective in all cases. Freezing is favoured for common warts and small warts on the face and knees. The wart is frozen, may blister and separate with the roof of the blister, or may shrivel up and fall off within 2 or 3 weeks. In early cases one application is often sufficient, and usually dermatologists make use of liquid nitrogen for the purpose while general practitioners rely on the more easily obtainable carbon dioxide snow. Edinburgh experience with liquid nitrogen applied to hand warts shows that 80% of single lesions were cured by 2 applications, at 6 week intervals, and 61% of all cases were cured with two treatments. (Bunney, 1969).

Plantar warts are not often frozen, because of the risk of painful/

painful blistering, but are usually treated with a cytotoxic agent podophyllin. Podophyllin is a complex resinous mixture containing podophyllotoxin which can inhibit cell mitosis and produce necrosis. (Sullivan, 1949). It has been the first choice treatment for plantar warts in the Dermatology department of Edinburgh Royal Infirmary since 1950. (Duthie and McCallum, 1951). Used at 60% strength in liquid paraffin, it is applied to the exposed wart and kept dry under a plaster for 3 weeks. Podophyllin in lower concentration (25%) is also used to treat genital warts, applications being kept in place for 4 to 8 hours only. Commercially it is available as "Posalfilin" (Camden Chemical Co. Ltd.), containing podophyllin and salicylic acid in an ointment. Salicylic acid is a keratolytic agent, especially valuable in the management of large horny warts, to which it is applied as a plaster containing 20% salicylic acid.

Various solvents or caustics are used in attempts to remove warts. Formalin and chloroacetic acids are examples of some employed, especially in prolonged infection not responding to other forms of treatment. Curettage may be used, and is the only surgical procedure recommended. However, removal of all the infected cells cannot be guaranteed, and recurrences are seen. Surgical excision is not often justified, particularly for plantar warts, for again cure cannot be promised and the resultant scarring may well be more troublesome and painful than the original wart. The same may be said of radiotherapy for warts. (Lyell, 1966).

Recently there has been a vogue in the U.S.A. for inoculating smallpox vaccine into warts as a therapeutic measure. McGee (1967) reported his experience with this method in 166 warts in 60 patients. He found that 164 of the warts showed a local inflammatory/

inflammatory response and then disappeared. Other workers have had much lower success rates with this treatment, 30 to 60% cure rates, and scarring has been troublesome, as well as some severe local and systemic reactions. (Anglin and Franklin, 1968). As a result the U.S. Committee on Cutaneous Health and Cosmetics (1968) has announced its disapproval of this procedure, which it considers an "old and discredited technique".

More specific vaccine therapy has been employed by some workers, notably Biberstein (1944) who treated several hundred patients with a vaccine prepared from filtered wart extracts. This treatment had some effect, but quite non-specific injections of milk or saline have yielded similar results, according to Rowson and Mahy (1967). This raises the question of whether psychotherapy is an effective means of treating warts, as believed by some (Ullman, 1959) but not others. (Allington, 1952; Clarke, 1965). If it were so, perhaps through some mechanism whereby increased circulation leads to more efficient immunological response, any method of treatment might be expected to have some effect. Stankler (1967) carried out a well-controlled trial of suggestion therapy, applying tap water or "special rays" to warts of one hand in people who had them on both. One third of the patients were cured within 3 months, but in all cases the warts on both hands disappeared. It was concluded that this result was compatible with the rate of expected spontaneous remission.

4. Spontaneous regression.

Any assessment of the therapeutic value of various applications is necessarily confused by the common occurrence of spontaneous/

spontaneous cure in the total absence of treatment or in spite of it. The rate of regression is very difficult to measure for in many cases people apply something to their warts in attempts to cure them. The figures obtained from observation of untreated warts favour the order of 30% over 6 months quoted by Clarke (1965). Allington gives a rate of 29% over 6 months in 70 patients (1942). Massing and Epstein found rates of 11% over 2 months and 24% over 7 months. (1963). Any treatment must show a significantly greater rate of cure than can be expected to occur spontaneously before it can be accepted as useful and truly therapeutic. It is now realised that cure of a tumour such as a wart depends on either (i) complete removal or destruction by external means of all cells capable of maintaining this growth, although this may leave the patient open to re-infection by the virus at any subsequent exposure; or (ii) the patient's own immunological responses leading to rejection of the tumour cells and conferring some immunity to re-infection. The mechanisms responsible for rejection of tumours are cell-mediated and not dependent on humoral antibody. They are discussed in some detail later.

5. Differential diagnosis.

There is generally little difficulty in the clinical diagnosis of viral warts, certainly to dermatologists. Similar lesions that do occasionally confuse the issue are the "water warts" or lesions of molluscum contagiosum caused by the pox virus of that name. These are usually small pearly tumours with a smooth surface and characteristic central umbilication from which a cheesy mass of infected cell debris can be expressed. Seborrheic warts are also soft smooth lesions, with/

with a rather greasy surface and usually pigmented, occurring mainly around the neck and on the trunk and hands in the over-40 age group. Their aetiology is not known. Keratoacanthoma or squamous cell papilloma is also seen mainly in older people, on exposed areas of skin, and has a tendency to develop into carcinoma. Clinically the diagnosis rests on features such as the dry, scaly hyperkeratosis, reddish-brown pigmentation, and minimal hyperplasia in non-malignant lesions.

Perhaps the conditions most often confused with warts are the simple callous and corns, particularly on the sole of the foot. The correct diagnosis can be made if care is taken to pare down the thick covering of horny cells in each case. In a wart, the central infected area has an irregular dull white surface in which the heads of capillary loops may be seen as bleeding points (Plate 2), or as thrombosed black spots if the wart is regressing. Callosities, by contrast, have a uniformly smooth and rather transparent surface across which the ridges of normal epidermis under the horny top layer can be seen to continue. People do occasionally get wart virus infection in pre-existing callosities. Cure of a wart is clinically ascertained by observation of the restoration of the normal continuity of epidermal ridges across the previously infected area (Plate 4).

HISTOLOGICAL STUDIES.

1. Pathology.

Although there is variation among warts, certain basic features are characteristic histologically. The wart consists of a localised hyperplasia of epithelial cells. The basement membrane remains intact and cells of the stratum basale appear normal. Acanthosis, hyperplasia of the stratum spinosum is present, and mitotic figures may/

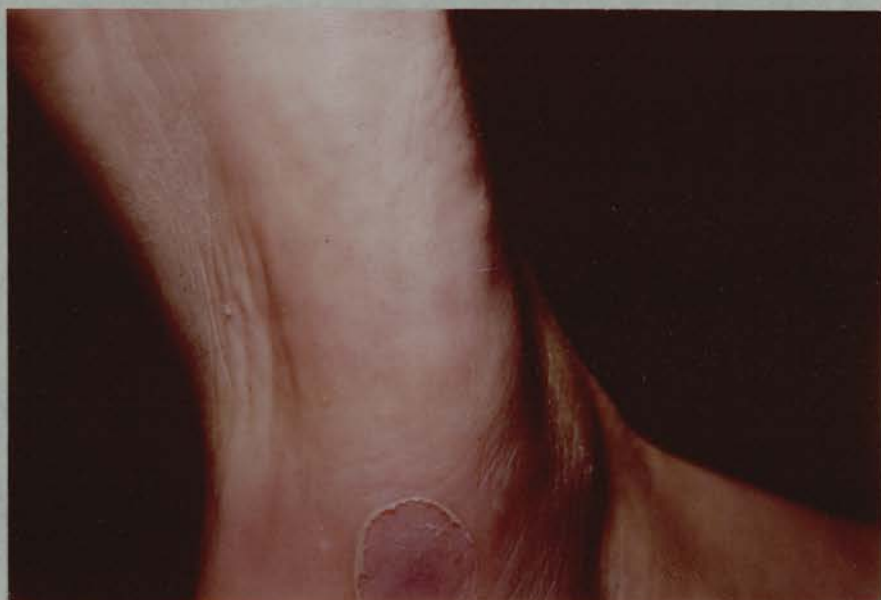

Plate 4.

Site of a cured plantar wart - note the continuity of the epidermal ridges from normal skin across the previously infected area.

may be observed in the cells of this layer. There is alteration in the keratinisation pattern, with retention of nuclei in stratum corneum cells (parakeratosis) and thickening of the stratum corneum and the underlying stratum granulosum (hyperkeratosis). The epithelial overgrowth and resultant folding of the epidermal layers with the underlying connective tissue stroma leads to elongation of dermal papillae, and loops of dermal capillaries are thus brought near the surface. Some features are predominant in warts on particular sites, for instance hyperkeratosis is marked in plantar and common warts. Plane warts show acanthosis but little papillomatosis or hyperkeratosis. Acanthosis and papillomatosis without hyperkeratosis are seen in warts on areas of thin skin, as on the face and genitalia.

2. Inclusion bodies.

Three kinds of inclusion have been described in cells of warts, and their significance was a matter of dispute until electron microscopic studies clarified the picture. Eosinophilic intranuclear inclusions are seen as round bodies in nuclei of cells of the stratum spinosum, increasing in size in the cells above this layer. They are usually accompanied by eosinophilic masses in the cytoplasm, (Strauss, Bunting and Melnick, 1951) and are present in 43% of simple plantar warts ("myrmecia") but only in 4% of common warts. (Lyell and Miles, 1951). These two groups of workers concluded that these eosinophilic inclusions were histological evidence of the presence of virus in the wart and were in fact associated with the developing viral particles. (Strauss et al. 1950). Indeed Melnick et al. (1952) reported finding virus particles only in warts with eosinophilic inclusions.

Basophilic/

Basophilic intranuclear inclusions are also seen in some warts, in the nuclei of stratum spinosum cells. They were shown to be Feulgen positive and closely associated with nucleoli. (Blank, Buerk and Weidman, 1951). These inclusions also enlarge in nuclei of stratum granulosum cells and persist as Feulgen positive masses in the stratum corneum. Hyden (1947) and Blank et al. (1951) thought that these basophilic inclusions represented developing aggregates of virus particles in the cells.

Comparative study of sections of wart tissue by histology and electron microscopy has now confirmed that the basophilic intranuclear inclusions are closely related to the virus particles, whereas eosinophilic inclusions appear to be unrelated to virus development and are thought to be a result of the keratinisation abnormality. (Almeida, Howatson and Williams, 1962). These authors noted virus particles in the sites occupied by the basophilic inclusions, and also found wart virus in cells lacking eosinophilic inclusions and absence of virus from other cells containing eosinophilic inclusions.

3. Localisation of virus antigen in warts.

Fluorescent antibody studies, involving the application of labelled antibody specific for wart virus to sections of wart tissue were carried out by Noyes (1965). Specific fluorescence corresponding to the viral antigen was seen only in nuclei of cells of the stratum granulosum and in areas of the corneum. There was none in the lower epidermal layers or the dermis. In a similar examination of sections of rabbit skin papillomata, Noyes and Mellors (1957) had earlier reported the distribution of rabbit papilloma virus antigen to be limited to these keratohyaline and keratinised layers. Bovine warts, similar/

similar to human and rabbit papillomata but with more connective tissue content, are caused by a virus which is probably also a papovavirus (Boiron, Levy et al. 1964). Studies with fluorescein-labelled antisera to the virus have detected viral antigen in the superficial keratinising layers of this wart also. (Smithies and Olson, 1961).

ELECTRON MICROSCOPY.

1. Early studies.

Particles thought to be the human wart virus were first seen by Strauss et al. (1949), who examined an aqueous extract of warts prepared for electron microscopy by shadow-casting. Regular spherical particles with an average diameter of 52 nm. were seen, sometimes in crystalline masses. Wart tissue was examined by ultra-thin sectioning techniques by Bunting (1953) and Charles (1960), who both described virus-like particles seen intranuclearly in some cells. Williams, Howatson and Almeida (1961) then compared the morphology of the particles seen in thin sections and shadowed preparations with negatively-stained virus from extracts, applying the method of Brenner and Horne (1959) that has become invaluable in revealing details of virus structure. Projecting "knobs" were seen on the surface of the virus when negatively stained. The size of the particles in sections was smaller (average diameter 46 nm.) than in extracts (average diameter 52 - 55 nm.). This was attributed to the shrinkage of tissue during the fixation and dehydration procedures preceding section cutting.

2. Development of virus in warts.

Light/

Light microscopy had indicated the sequence of viral production in wart tissue as represented by the development of the basophilic intranuclear inclusions. The electron microscopic study done by Almeida et al. (1962) confirmed the opinions of Hyden (1947). Wart virus particles were not found in cells of the basal epidermal layer: they appeared first in association with nucleoli in cells of the upper stratum spinosum. *S. granulosum* cells contained increasing amounts of particles scattered throughout their nuclei, and nuclei of cells in the upper part of this layer were often full of virus particles, with no nucleoli to be seen and margination of chromatin apparent at the nuclear membrane. In the stratum corneum, large aggregates of virus and masses of keratin were seen. Chapman, Drusin and Todd (1963) confirmed these observations.

The development of Shope's rabbit papilloma virus had been shown to follow this pattern also, (Stone, Shope and Moore, 1959), as has that of the bovine papilloma virus. (Tajima, Gordon and Olson, 1967). A very recent study of the cutaneous papilloma of the dog has for the first time shown the presence of a virus in this skin wart also. (Watrach, 1969). Intranuclear basophilic inclusions seen by light microscopy were shown to be masses of viral particles in nuclei of cells of the *S. granulosum* which also had margination of chromatin. The virus particles had the appearance of a papovavirus in section.

3. Structure of wart virus.

Although the structure of wart virus has been studied in considerable detail, there is still controversy regarding certain features. The technique of negative staining has enabled fine structural/

structural detail of virus particles to be examined. Essentially an electron-dense material is mixed with the particles, does not react chemically with them but is deposited around them and attracted into any surface crevices, showing up fine structure clearly. Use of such methods revealed that, like viruses of the adenovirus group, papovaviruses had an approximately spherical virion, the outer protein coat (capsid) being composed of morphological units (capsomeres) projecting from the surface like knobs and arranged with a cubical symmetry. (Caspar and Klug, 1962). These workers suggested that a virion with cubical symmetry is an icosahedron whose 20 equilateral triangular faces are sub-divided into equilateral triangles, the number of which is determined by a certain formula giving this triangulation number, T . (Caspar, 1965). The structural units (protein sub-units) of which the capsid is built each represent a third of a triangular face, so there are $3 \times 20 \times T$ such units. They combine in groups to form the visible morphological units, capsomeres, and in papovaviruses they are in groups of fives and sixes - the corresponding capsomeres being termed pentameres and hexameres. Geometrically this results in there being 12 groups of five and the remaining units form hexameres.

Klug and Finch (1965a) established the design of wart virus as having a $T = 7$ surface lattice composed of 420 structural units, 72 capsomeres. $T = 7$ is a skew class of icosahedral symmetry, with a right or a left-handed form. The hand is determined from study of the relation between pentameres, and has been found to be right-handed (*d*, *dextro*) in human wart virus (Klug and Finch, 1965a) and left-handed (*l*, *laevo*) in rabbit papilloma virus (Finch and Klug, 1965). Howatson (1965) disputes their arguments for the 72 capsomere structure, and adopted/

adopted the 42 capsomere model proposed for polyoma by Wildy, Stoker, Macpherson and Horne, (1960) on consideration of the negatively-stained appearance of wart virus (Williams et al. 1961) and from mean counts of capsomeres from disintegrated particles (Howatson and Crawford, 1963). The interpretation of these data is questioned convincingly by Klug and Finch (1965b), and though the solution of this argument must rest with the experts in this complex analysis, the 72 capsomere model is more acceptable.

4. Size of papovaviruses.

Papovaviruses are sub-divided into two groups on the basis of a clear separation according to particle size. The papilloma viruses constitute one sub-group, having a larger size - the average diameter when negatively stained is 52 - 55 nm. for human and rabbit papilloma viruses. (Klug and Finch, 1965a; Finch and Klug, 1965). Two other "candidates" also seem to belong in this group. Boiron et al. (1964) found average diameter for bovine papilloma virus (negatively stained) to be 47.5 nm. or 54 nm. (Tajima et al. 1967); and the virus seen in thin-sections of canine papillomata by Watrach (1969) measured on average 45 - 49 nm. in the sections.

The other sub-group contains polyoma virus and SV40, with average diameters 40 - 45 nm. (Wildy et al. 1960), and also K virus of mice, another papovavirus (Mattern, Allison and Rowe, 1963). An unidentified virus with typical papova morphology has been found in brain cells in the condition of progressive multifocal leuco-encephalopathy (Zu Rhein and Chou, 1965). This is a demyelinating condition in humans. The virus particle size determined after negative staining places it in the polyoma sub-group, not the papilloma one. (Waterson/

(Waterson and Almeida, 1969).

5. Abnormal variants.

Abnormal forms have been reported for several members of the papova group of viruses. "Empty" particles, penetrated by negative stain, are seen regularly in many preparations and can be separated from the normal "full" ones by their lighter weight on density gradients, as demonstrated with wart virus by Noyes (1964). These lighter, empty particles are associated with loss of infectivity due to absence of DNA (Winocour, 1963).

Filamentous forms are found occasionally among all the papovaviruses, and this was one of the characteristic features listed in the original description of the group. (Melnick, 1962). These "filaments" are tube-like variants, with cross-section diameter close to that of normal virus particles and a similar surface structure with capsomeres. In the density gradient study (Noyes, 1964) such forms occupied a layer below the normal particles of wart virus. Howatson and Almeida described them in polyoma (1960) and Williams, Kass and Knight found them in rabbit papilloma (1960). In the course of a quantitative study of 40 human warts, Barrera-Oro, Smith and Melnick (1962) saw the filamentous forms rarely.

Smith, Dougherty, Melnick and Rapp (1965) have described a patient with multiple common warts of 6 to 11 years' duration, on examination of whose warts large amounts of filamentous material resembling unassembled virus sub-units were seen. Normal wart virus particles were found associated with long cords of these filaments, which were much narrower in diameter and when negatively stained appeared to have a regular periodicity of about 30 Å. Some double cords/

cords were seen where the arrangement of these "sub-units" gave an approximate diameter (80 Å) and appearance like that of the virus capsomeres.

PRESENCE OF WART VIRUS IN LESIONS.

The evidence for regarding certain lesions as being caused by the human wart virus was initially based on the transmission of warts to another person by inoculation of extracts from lesions under study. Details of these early experiments are well summarised by Rowson and Mahy (1967). Recipients developed warts at inoculation sites within 6 months when injected with material from common warts (Jadassohn, 1896), condylomata (Gold-schmidt and Kligman, 1958) and laryngeal warts (Ullman, 1923). Further proof of wart virus being the aetiologic agent in these conditions has depended almost entirely on electron microscopic studies whereby the virus can be identified by its morphology in sections or extracts from the lesions. One other approach that has been used has been the application of an antiserum to purified wart virus, prepared in rabbits and conjugated with fluorescein, to sections of tissue. Noyes (1965) used this fluorescent antibody test to demonstrate wart virus antigen in the nuclei of *S. granulosum* cells of warts. Walter, Walker and Cooper (1965) also used it to identify wart virus antigen in various clinical types of wart. The current evidence regarding the rôle of human papova (wart) virus in the various tumours with which it has been associated will be presented.

1. Common warts, plane warts and plantar warts.

The majority of electron microscopic studies have been on thin/

thin sections of common warts. Almeida et al. (1962) clearly demonstrated intranuclear particles with the characteristic size and morphology of wart virus in cells from common warts, a plane wart and palmar and plantar warts. Negative staining applied to "68 unselected warts from various parts of the body" revealed the typical wart virus particles in all but one very small specimen. (Kingsley-Smith, Marks and Elek, 1967). The study by Barrera-Oro et al. (1962) involved counting the number of virus particles in homogenised suspensions of 35 common warts and 5 plantar ones. Maximum numbers of 7.3×10^9 particles per mg. of wart were found in few specimens. The lowest amount that could be counted was 10^7 particles per mg., and 45% of the warts had less than this.

2. Epidermodysplasia verruciformis.

This condition, sometimes called generalised verrucosis, was described by Lewandowsky and Lutz (1922). It takes the form of a multitude of plane warts covering the face, trunk and limbs. Successful transmission of the lesions was shown by Lutz (1946). Thin sections of the lesions have been examined in the electron microscope, and revealed the presence of particles morphologically similar to wart virus in nuclei of *S. granulosum* cells and in the *S. corneum*. (Ruiter and van Mullen, 1966). The more detailed morphology of these particles has been confirmed by observation of their papova-like structure in negatively stained preparations. (Baker, 1968). Other aspects of this condition will be considered in relation to the association of wart virus with malignant changes in tumour.

3. Oral papillomata.

Verrucous/

Verrucous papilloma of the oral cavity has not been transmitted experimentally. Fasske, Morgenroth and Themann (1964) examined sections of a single specimen in the electron microscope and concluded that large particles they had observed in the cytoplasm of cells might be a pox virus. However, Frithiof and Wersall (1967) examined three lingual and one palatal papilloma, and found certain abnormalities in the most superficial cells in two of them. These parakeratinised cells showed margination of chromatin in certain nuclei which also contained round particles with a dense core of approximately 35 nm. and a granulated halo of about 12 nm. In addition, in other nuclei slightly smaller particles were seen, with associated bundles of fibrils which had a suggestion of a sub-structure. No such changes could be found in biopsy specimens from the oral mucosa of 30 control subjects, and they are characteristic of papilloma virus infection.

4. Condylomata acuminata.

Transmission experiments with material from genital warts were successful in producing common warts in several instances. (Waelsh, 1918; Serra, 1924; Goldschmidt and Kligman, 1958). Electron microscopic studies have also been published, but in none have wart virus particles been satisfactorily demonstrated. Nasemann is quoted by Zimmer, Bahnsch and Grimm (1964) as being the first to report virus particles in genital warts, finding them in nuclei and cytoplasm of cells. These same authors describe the cytoplasmic structures, diameters ranging from 20 to 80 nm. and with an outer membrane, which they observed in sections of condylomata as virus particles. Melczer (1965) examined seven genital warts in section, and/

and in five found large numbers of intranuclear particles, 40 - 50 nm. diameter, that he considered to have the characteristic morphology of the papova group. He also inoculated extracts from these warts into HeLa cells, with production of a cytopathic effect in two cases and was able to see the intranuclear particles in the affected cells also. The published electron micrographs, however, do not reveal the morphology of the particles in the warts or cultured cells.

5. Laryngeal papillomata, ano-rectal warts and others.

Transmission studies were successful in the case of laryngeal warts (Ullman, 1923): they have not been carried out with ano-rectal warts as far as is known. The latter are associated with wart virus on the basis of their histological appearance, including a report of the demonstration of basophilic, intra-nuclear inclusions in some of the cells. (Young, 1964). There is no electron microscopic evidence for the presence of wart virus in laryngeal warts as yet. Such studies have not been applied to ano-rectal warts or apparently to bladder papillomata, for which Swain and Dodds (1967) suggest a viral aetiology might be sought on the grounds of the histological features and tendency to recurrence in these tumours.

FURTHER PHYSICO-CHEMICAL PROPERTIES OF WART VIRUS.

The ability of wart virus to pass through a filter capable of restraining bacteria was originally demonstrated by Ciuffo (1907). There are no known reports of experiments to determine the size of the virus particles by filtration. Resistance to ether is a characteristic of members of the papova group but has not been tested with wart virus. Resistance/

Resistance to heat at 50°C. for 30 minutes but not 55°C. for this period is recorded in transmission experiments by Biberstein (1944) and Templeton (1935). Particle density has been determined and found to be similar to values obtained for rabbit papilloma virus, but higher than those for polyoma. (Crawford and Crawford, 1963). Sedimentation coefficients in 0.15 M sodium chloride were 296 S (full) and 168 S (empty).

Capsid proteins have been examined in the case of some other papovaviruses. Polyoma virus appears to possess a single polypeptide component in its capsid on electrophoretic analysis (Horne and Warden, 1967), while SV40 probably has two in its capsid and one internal structural protein. (Dulbecco, 1969). Using a different technique, amino acid end group analysis, Kass and Knight (1965) investigated rabbit papilloma virus and concluded that only one polypeptide was present in the capsid.

NUCLEIC ACID.

Wart virus and other papovaviruses contain a double-stranded DNA with three forms, linear, circular and super-coiled. (Crawford, 1965). In that study molecular weight determinations gave a result for wart virus DNA of 5.3×10^6 , compared with 5×10^6 for rabbit papilloma virus (Kleinschmidt et al. 1965) and 3×10^6 for polyoma (Weil and Vinograd, 1963). The guanine plus cytosine base composition was found to be 41%, compared with 48% in polyoma virus. (Crawford and Crawford, 1963).

Polyoma and SV40 are able to transform tissue culture cells and these transformed cells produce malignant tumours on inoculation into some neonatal animals, as do the viruses themselves. This property will/

will be discussed later, but because of the lack of infectious virus production by the tumour cells there has been much interest in the question of persistence of viral DNA in such cells and the form that this takes. Recent work is beginning to produce evidence that the virus DNA is integrated with cell DNA in these cells. A mouse cell line transformed by SV40 has been studied extensively by Sambrook, Westphal, Srinivasan and Dulbecco (1968). They found by hybridisation techniques, using ribonucleic acid (RNA) prepared in vitro from an SV40 DNA template, that these transformed cells contained no free viral DNA of a size similar to that present in virions but there was SV40 RNA-hybridisable material in stable association with the isolated cellular chromosomes. The viral DNA appears integrated, bound by alkali-stable linkages, with the cell DNA in this case.

Another very interesting field in which information regarding papovavirus DNA has been obtained is in the base analysis work being applied in Glasgow and elsewhere to study of the origin of DNA in micro-organisms. Analysis of the nearest-neighbour sequence of nucleotide bases in DNA by the method originally described by Josse, Kaiser and Kornberg (1961), gives reproducible patterns for DNA from any organism, the sequence being highly characteristic and significantly non-random. Subak-Sharpe et al. (1966) have applied this technique to mammalian cell DNA and mammalian DNA viruses. The important feature noted was the close relationship between the mammalian cell DNA and DNA from small oncogenic viruses (polyoma and rabbit papilloma) whereas DNA from two larger more complex viruses (herpes simplex and vaccinia) had quite different base sequences, though not random.

This observation has been extended to include DNA from SV40
and/

and human wart virus (Morrison et al. 1967). The significance of these relationships lies in their possible indication of the evolution of such viruses from a stretch of host cell DNA.

Whether this has any bearing on oncogenic potential is not yet certain. The only obvious feature of the similarities in sequence is that these small viruses require to use the existing host cell translation apparatus, they contain insufficient DNA to direct production of their own system.

BIOLOGICAL PROPERTIES.

1. Papovavirus infections and tumours in animals.

Human wart virus infection in man has already been considered, in so far as its extent is known. Transmission of this virus to a variety of animals has been attempted many times in the past. Those experiments that were reported successful have not been reproducible and were never confirmed satisfactorily. The same host specificity appears to be generally true of the other papovaviruses also; there is no real evidence of transmission of infection by any of these agents to man, although one epidemiological survey did reveal a significantly high incidence of warts in vets and butchers. (Bosse and Christophers, 1964).

Polyoma virus produces no clinical disease in the mice which are its natural host, persisting in the tissues and being excreted in urine without any obvious effect. But on inoculation into the newborn of the species it causes the development of a wide range of tumours, carcinomata and sarcomata, from which it takes its name. It also produces sarcomata in other neonatal rodents, especially hamsters, with ensuing rapid death. SV40 infection is similarly sub-clinical in/

in its natural host, the rhesus monkey, but can produce sarcomata in neonatal hamsters. The carriage of latent SV40 by rhesus monkey tissues has been a source of trouble where monkey kidney tissue culture is used. The classic example was in the preparation of poliomyelitis vaccines in these cells before SV40 was recognised. Vaccinees were inadvertently given doses of SV40 as well as poliovirus in some contaminated batches of vaccine. The only known result of this so far has been the appearance of antibody to SV40 in such people, (Gerber, 1967), although a watch is being maintained for the development of any disease or tumour in this group. Current polio vaccines are not produced in SV40 contaminated cells.

The rabbit papilloma, a tumour of wild cottontail rabbits, was first described by Shope (1933). Rous and Beard (1935) then showed that the infection could be transmitted to the domestic rabbit, and that in these animals the papillomata progressed to become carcinomata, with metastases. Syverton (1952) gives the likelihood of this malignant change as 75% within 9 months of first developing a tumour. Noyes and Mellors (1957) in their fluorescent antibody study found very much less viral antigen in cells of the papillomata of the domestic rabbit than those of the wild one. Multiple papillomata of the buccal mucosa are found in rabbits (oral florid papillomatosis) and a papilloma-like virus can be extracted from these tumours, but whether it is the same as that causing the cutaneous papilloma is uncertain. Dogs also have cutaneous warts and oral papillomata, both conditions associated with a papova-like virus. (Watrach, 1969).

Cattle develop cutaneous fibro-papillomata, like human warts but with more of a connective tissue core, and these have been shown to be/

be due to a papova-like virus. (Boiron et al. 1964). This bovine papilloma virus can also produce non-metastasizing fibromatous tumours when inoculated into the bladder mucosa in cattle. (Brobst and Olson, 1965). On inoculation into neonatal rodents (rats, mice, hamsters) this virus produces fibrous nodules in the hamsters. Histologically the lesions showed proliferative changes, but no definite evidence of malignancy. (Boiron et al. 1964).

2. Cytopathic effects in tissue cultures.

Polyoma and SV40 are both able to produce cytopathic effects in some cells - mouse embryo (polyoma) or green monkey kidney (SV40) with lysis of the cells and production of much new infectious virus. (Winocour and Sachs, 1960). The growth cycle is slower than for viruses such as polio, and infectious virus does not begin to appear until about 20 hours after inoculation of cells. Tissue cultures supporting such productive virus infection are termed permissive systems.

Human wart virus has been reported as causing cytopathic effect in some tissues. Mendelson and Kligman (1961) passed wart extract blindly through three fortnightly passages in rhesus monkey kidney cells and observed a cytopathic effect (CPE) at the end of this time. Intradermal inoculation of fluid from the 6th passage into 20 volunteers was followed by the appearance of warts in 10 within one year. African green monkey kidney cells, free from SV40, were used by Macpherson (1962) in similar work. A CPE, consisting of rounding up and loss of cells from monolayers, was seen within 14 days of inoculating wart extracts. Rabbit antiserum to wart extract neutralised the CPE in some cases.

Human/

Human cell cultures have been used by Oroszlan and Rich (1964), who inoculated wart virus into foetal human and mouse skin cultures. Cytotoxicity was observed within 24 hours, but cells recovered and a CPE (rounding and detachment) was seen after 5 days. Using fluorescent antibody, they detected viral antigen in nuclei by 8 days and throughout the cells by 12 days, and also found virus particles by electron microscopy of fluid from the cultures. However, they themselves and other workers have not been able to reproduce these results, (quoted by Rowson and Mahy, 1967; Noyes, 1968).

Morgan and Balduzzi (1964) cultured fragments of genital warts, noted the development of sheets of epithelial and fibroblastic cells and then after two months found some focal clumps of rounded cells in one culture. In sub-cultures of these affected cells large basophilic intranuclear inclusions, Feulgen positive, were seen. However further investigation has now revealed that the agent responsible for these changes is a cytomegalovirus, (Morgan and Balduzzi, 1967) presumably originally infecting the same tissue as the wart virus.

3. Proliferative changes in cell cultures.

Rabbit papilloma virus had shown no CPE in regular tissue cultures, so De Maeyer (1962) tried to infect organ cultures of newborn rabbit skin with extracts from papilloma tissue. He found on a histological study that after 10 days control uninoculated cultures declined into a single layer of epidermal cells, but the inoculated cultures began to proliferate. In organ cultures of adult rabbit skin this proliferative change was much less frequently observed.

In 1963 Black, Hartley, Rowe and Huebner reported their findings/

findings after inoculating a semi-continuous line of foetal bovine conjunctival cells with extracts containing bovine papilloma virus. The epithelial cells in inoculated cultures became elongated and spindle-shaped after 3 - 10 days, then proceeded to grow over each other in a random fashion, producing thick plaques of piled-up cells. This characteristic was maintained in cells sub-cultured after trypsinisation. It could be induced by papilloma extracts diluted by a factor of 1,000, and the effect was neutralised by a specific antiserum to the virus.

Noyes (1965) inoculated human wart virus into human embryonic skin-muscle cultures. After 2 - 3 weeks control cultures were composed of an even monolayer of fibroblasts, whereas inoculated cultures showed areas of dense growth containing epitheloid cells piled up randomly over each other. These changes occurred in cultures inoculated with at least 10^8 virus particles, he estimated, and the effect was neutralised by antiserum to the virus. Viral antigen was not found in any of the cells by fluorescent antibody tests.

4. Neoplastic transformation.

Transformation of tissue culture cells into neoplastic cells was first described in an oncogenic RNA virus system. It was noted that chick embryo tissue cultures exposed to Rous sarcoma virus developed areas of cell proliferation and loss of contact inhibition. (Temin and Rubin, 1958). Vogt and Dulbecco (1960) showed that hamster fibroblast cultures were similarly transformed by the polyoma virus. Only a small proportion of cells in a culture is affected in this way, but the progeny of such transformed cells can be recognised by their rapid piling-up in a random fashion while normal fibroblasts grow more slowly in a single layer of parallel bundles. The other main feature/

feature that characterises truly transformed cells is their transplantability, whereby small numbers of such cells will quickly form tumours if inoculated into susceptible animals, while normal cells do not.

The changes seen by Noyes (1965) in human skin cultures affected by wart virus are quite possibly evidence of transformation, but this would have to be confirmed by animal inoculation. Similarly with the cells induced to proliferate by rabbit papilloma virus. (De Maeyer, 1962). It has recently been shown that bovine papilloma virus is capable of neoplastic transformation (Gerald, 1969). Secondary cultures of embryonic hamster cells were inoculated with the virus, and within 4 - 8 days these normally epithelioid cells had become spindle-shaped and produced plaques typical of transformed colonies. No viral particles were seen in these cells by electron microscopy. Sub-cutaneous inoculation of the cells into hamsters resulted in the appearance of rapidly growing tumours in the animals.

SV40 has been found to transform several kinds of cell, most significantly various human cells, embryonic and adult mucosal and skin cultures. (Koprowski et al. 1962). The efficiency of transformation by papovaviruses is generally low; it is estimated that the presence of 10^4 to 10^5 particles is required for every single cell transformed. (Stoker, 1962). A striking feature of cells transformed by DNA viruses is the lack of production of infectious virus by such cells, unlike the RNA virus transformed systems. It soon became evident that polyoma and SV40 transformed and tumour cells contained new antigens specifically induced by the virus concerned though not part of that virus structurally. These new antigens were evidence/

evidence of the persistence of the viral genome in these cells.

NEW ANTIGENS IN VIRUS-TRANSFORMED AND TUMOUR CELLS.

1. Tumour-specific transplantation antigen (TSTA).

These were demonstrated on the surface of cells transformed by polyoma virus by the rejection of transplants of such cells in animals previously immunised with the virus. (Habel, 1961). Such cell surface antigens have been detected in vitro by immuno-fluorescent tests using sera from animals immune to the virus (Hellstrom, 1965) and also by methods demonstrating specific cytotoxicity, colony inhibition and mixed haemadsorption. (Habel, 1969). There is suggestion of a relationship between the polyoma virus-induced transplantation antigen and a normal antigen in embryonic hamster cells (Pearson and Freeman, 1968) but this requires further investigation. Tumour-specific transplantation antigens, specific for the virus inducing the neoplasia whatever the cells involved, are now recognised in SV40 and other tumour virus systems such as the oncogenic adenoviruses.

2. Tumour antigen (T or neo-antigen.).

These are also new virus-specific but non-virion antigens, produced in the nuclei of cells containing tumour virus DNA. Originally they were detected in polyoma tumour and transformed cells by complement fixation with sera from animals bearing polyoma tumours (Habel, 1965) so were termed tumour antigens. However they are now known to appear early in infection of any cells by the virus, whether producing lysis or transformation. (Takemoto, Malmgren and Habel, 1966). These workers' immuno-fluorescent studies indicated that tumour antigen had a linear appearance in the nuclei of cells. Studies on adenovirus-12-induced/

adenovirus-12-induced tumour cells using a ferritin-labelled antiserum to adeno-12 tumour antigen revealed bundles of fibres in the cell nuclei and the fibres reacted with the labelled antiserum. (Kalnins et al. 1967). Similar results were found in cells productively infected with adeno 12, where the fibres were found in association with mature virus particles in the nuclei. In this context it is of interest that Mattern, Takemoto and Daniel (1966), studying the replication of polyoma virus in mouse embryo cells by electron microscopy, noted that small bundles of filaments appeared early in nuclei, increasing to some extent with time and becoming surrounded by viral particles. They wondered whether these filaments bore any close relationship to tumour antigen as the appearance of both followed the same time course.

Tumour antigens have not been identified yet in any of the papilloma virus systems. Those tumour antigens known have been found to be synthesised early after infection of cells, (before viral capsid proteins if it is a permissive system). Extracted T antigens are soluble, heat labile (inactivated by exposure to 60°C. for 10 minutes) and estimated molecular weights are in the region 160 000 to 200 000. (Kit et al. 1967).

OTHER VIRUS-INDUCED FUNCTIONS IN TUMOUR CELLS.

1. Arginase.

Human wart tissue was found to contain the enzyme arginase in amounts much greater than those found in comparable normal skin samples. (Van Scott, 1951). Similarly increased levels of arginase were noted in rabbit papilloma tissue, and the enzyme was thought to differ antigenically as well as in other properties from normal arginase of/

of rabbits. (Rogers and Moore, 1963). Beaty and Hodes (1967) were able to demonstrate that rabbit papilloma virus does code for a virus-specific arginase, by inducing its production in spheroplasts of Esch. coli, an organism devoid of arginase, by infection with the virus. Another enzyme of the urea cycle, ornithine transcarbamylase, has been found in quantity in rabbit papillomata though it is not present in normal rabbit skin. (Sato and Ito, 1968). Whether either of these enzymes is a form of T antigen is not certain.

Arginine has been shown to play an important role in the synthesis of several DNA viruses. It is essential for the final stages leading to infectious virus production in the case of herpes simplex (Becker, Olshevsky and Levitt, 1967) and adenovirus (Russell and Becker, 1968). Goldblum, Ravid and Becker (1969) have shown that the withdrawal of arginine from cultures of SV40 leads to a tenfold decrease in the number of cells containing virus capsid protein, but the synthesis of T antigen is unaffected. The question is raised whether control of arginine production is a pre-requisite for oncogenesis.

2. DNA synthesis.

Evidence for synthesis of DNA occurring in the absence of mitosis in cells of the *S. granulosum* of warts, when it is restricted to the basal layer of cells in normal epidermis, is presented by Rashad (1969). Tissue slices of warts and normal skin were exposed briefly to tritiated thymidine in vitro and processed for autoradiography. The label revealing DNA synthesis appeared in nuclei of cells of the granular, spinous and basal layer in the tumours, but only in basal cells in the normal skin. Whether this newly-synthesised/

synthesised DNA is viral or cellular is not yet determined, but it is presumed to be virus-induced; such findings are not seen in the chemically-produced papillomata, but were described in rabbit viral papillomata. (Rashad and Evans, 1967). Mention is also made of a similarly abnormal pattern of DNA synthesis in granular cells of laryngeal papillomata of children (Rashad, 1969).

3. Viral messenger RNA and other functions.

Other viral-induced functions are sought particularly in cells transformed by polyoma and SV40. These two smaller papovaviruses contain only sufficient DNA (3×10^6 molecular weight) to enable them to code for up to at most 10 functions, many of which have been elucidated and it is hoped to account for all soon. (Dulbecco, 1969). Those already covered here are the viral capsid protein(s), tumour antigen and transplantation antigen. Other functions that are recognised are presumably enzymic ones, and direct replication of viral DNA, induce host cell DNA synthesis, and synthesis of a virus-specific thymidine kinase. Virus messenger RNA has been demonstrated in polyoma transformed cells (Benjamin, 1966) and for SV40 in cells transformed by that virus (Aloni, Winocour and Sachs, 1968). The rationale of one major approach to finding the cause of human cancers is an attempt to show a viral origin for tumours along the lines of the established DNA virus models. Thus a search for the tumour antigens and virus messenger RNA of adenoviruses are being particularly pursued because of the common occurrence of acute infection with these agents in man. (McCormick 1968). So far the results have been unrewarding.

INDUCTION OF VIRAL SYNTHESIS IN TUMOUR CELLS./

INDUCTION OF VIRAL SYNTHESIS IN TUMOUR CELLS.

1. Cell fusion.

In addition to attempts to detect viral DNA in tumour cells by some of the methods just mentioned, induction of virion synthesis in the cells has been pursued. By analogy with the bacteriophage systems, whereby infectious virus production can be induced in lysogenic bacteria following certain stimuli such as ultra-violet light, many attempts were made to induce the release of virus from polyoma-transformed cells but were unsuccessful. (Dulbecco and Vogt, 1960). However techniques of cell fusion are now developed, and SV40 transformed cells can be lead to produce infectious virus by fusion with suitable permissive cells. (Koprowski, Jensen and Steplewski, 1967).

2. Temperature-related phenomena.

Another approach has been used with rabbit papilloma virus. A cell line was established from a papilloma in a domestic rabbit; viral antigen detectable in the cell nuclei with fluorescent antibody tests decreased in amount and had quite disappeared by the fourth sub-culture. (Shiratori et al. 1968). When the cells reached 80 generations they were divided into two lots, the one maintained at 37°C. as before but the other transferred to 30°C. In the cells kept at 30°C., specific viral antigen fluorescence re-appeared and was observed in the cytoplasm 7 days after transfer, reaching maximum incidence in 20 - 80% of cells by 13 days. The cultures at 37°C. remained quite negative. (Shiratori, Osala and Ito, 1969).

It is not clear whether cultivation at the lower temperature favoured induction of virus antigen synthesis or whether the decrease in/
in/

in cell metabolism simply allowed accumulation of previously undetectable small quantities of the antigen. The latter might be suspected as none of the fluorescence was in the nuclei where one might expect synthesis of the new antigen. Recently cells from such a papilloma line, when incubated with serum from a tumour-bearing rabbit and then exposed to fluorescent anti-rabbit gamma globulin, revealed an annular fluorescence at the surface membrane in 5% of the cells. Controls from a normal rabbit cell culture showed no such fluorescence. (Ishimoto and Ito, 1969). A virus-specific cell surface antigen may have been demonstrated.

The relation of temperature to virus production in tumours has also been demonstrated in the Lucke tumour, a renal adenocarcinoma of frogs. Tumours excised in the winter, or maintained at 5°C. in the laboratory, show very little mitotic activity and contain inclusion bodies in their cells with herpes-like virus particles in the inclusions. The higher temperature tumours show active mitoses, no inclusions and no virus particles. (Mizell, Stackpole and Halperen, 1968).

ANTIBODIES TO PAPOVAVIRUSES.

1. Neutralising antibody.

Antibody specific for the capsid protein antigen of a virus can neutralise the infectivity of that virus. Such antibody has been demonstrated to some extent for all the papova group.

Polyoma and SV40 both produce cytopathic effects in appropriate tissue cultures, so that antibodies to them can be demonstrated by the conventional neutralisation techniques. In some strains of newborn mice polyoma infection leads to the appearance of high levels of anti-viral antibody in serum while the tumours are developing./

developing. We have mentioned that neutralising antibodies to SV40 were found in children given polio vaccine contaminated with live SV40 (Gerber, 1967). The important features of antibody response to these viruses will be discussed later.

Virus-neutralising antibodies in sera of rabbits with papillomata were demonstrated by Kidd, Beard and Rous, (1936) by neutralisation of the infectivity of inocula in rabbit skin. The titres of antibody were much higher in sera from the wild rabbits than in those from domestic rabbits with comparable tumours, as would be expected in view of the greater amount of viral antigenic stimulus in the one as later revealed by fluorescent antibody studies (Noyes and Mellors, 1957). Growth of the tumours continues in the presence of neutralising antibody to the virus.

Neutralising antibody to bovine papilloma virus can be detected in sera from wart-bearing cattle by neutralisation of the proliferative change induced in foetal bovine conjunctival cells by the virus. (Black et al. 1963). Neutralisation of infectivity of inocula has also been used to detect such antibody (Segre, Olson and Hoerlein, 1955), and the fluorescein-conjugate used to detect virus in sections of the papillomata (Smithies and Olson, 1961).

Noyes (1965) describes neutralisation of proliferative changes in skin cultures produced by human wart virus with a rabbit antiserum to the virus, as well as use of this antibody in detection of viral antigen.

2. Precipitins.

The Ouchterlony double diffusion technique leading to formation of antigen antibody precipitates in agar has been applied to/

to detection of antibody to papovaviruses. The method is not commonly employed in viral serology but it is useful here as the viruses can usually be extracted in considerable quantities from the various warts and purified by ultracentrifugation. These small viruses are able to diffuse through agar gels and form precipitates with specific antibody. Almeida and Goffe (1965) described the method first for demonstrating antibody to wart virus in sera from patients with warts. In a series of sera from 42 patients they found precipitating antibody in 19.

The method was then applied to an examination of the antigenic relationships between various papovaviruses. Concentrated virus preparations from the different tumours were used as antigens, and the antisera had been obtained from rabbits immunised with the separate antigens. Precipitating antibodies were demonstrated in this way to human, rabbit, bovine and canine papilloma viruses (Le Bouvier, Sussman and Crawford, 1966). Each virus reacted only with its specific antiserum, there were no cross-reactions between viruses from different species, and no cross-reactions with a polyoma virus preparation that was included in the test. The antigens are quite distinct.

3. Character of antibodies.

Goffe, Almeida and Brown (1966) used the precipitin test to investigate the immunoglobulin nature of the antibodies present in the wart patients. After treatment with 2-mercaptoethanol, a disulphide reducing agent that destroys the heavy molecular weight (19 S) immunoglobulin M (IgM), 13 out of 18 sera containing antibody were negative in the test. This failure of 72% of these people to develop mercaptoethanol/

mercaptoethanol-resistant immunoglobulin G (IgG) while infected with warts was felt to be a possible explanation of the common recurrence of the tumours. IgM is the antibody formed first in a primary infection or where there is minimal antigenic stimulus, and it does not confer immunity, unlike the later-developing but longer-lasting IgG.

Recently the precipitin test has been applied in investigation of bovine papilloma virus infection. (Lee and Olson, 1969a). Specific precipitating antibody was detected in sera from experimentally and naturally infected cattle, including two sera taken from calves 18 months after regression of their tumours. Further analysis of the response to experimental infection in calves (Lee and Olson, 1969b), revealed the sequential appearance of IgM and IgG in the sera. The relation of precipitin to immunity was seen after attempts to produce further warts by re-inoculations of virus. Precipitins appeared in sera before the animals became resistant to re-infection, but this resistance increased progressively during the time IgG was produced. However, some calves were still susceptible to re-infection after they had developed IgG. Warts produced from the initial inoculations continued to grow after the development of IgG anti-viral antibody and development of resistance to re-infection.

4. Immuno-electron microscopy.

Almeida, Cinader and Howatson (1963) have described a procedure for demonstrating viral antibodies by observation of immune complexes in the electron microscope. Aggregates of virus are seen with their outlines faintly obscured by a "haze" of antibody molecules. Antibodies can be characterised by their appearances in these negatively/

negatively stained preparations. Though not easily applicable routinely, this method is being used considerably now in research, as in the demonstration of immune complexes in sera from certain cases of hepatitis. (Almeida and Waterson, 1969). The procedure was first used with wart virus and specific antisera from immunised animals, then sera from patients with warts. Sera containing antibody to the virus demonstrated by electron microscopy also contained precipitating antibody. (Almeida and Goffe, 1965).

IMMUNOLOGICAL ASPECTS OF VIRAL TUMOURS

1. Antiviral antibody, regression and immunity.

That the presence of humoral anti-viral antibody does not correlate with regression of papovavirus tumours is evident from the observations just made. Even IgG has no effect on the growths, but it does bear some relation to the development of immunity to re-infection as shown by the bovine papillomastudies. The immunity to transplantation of polyoma-transformed cells that develops in animals immunised with polyoma virus is dependent on live virus, killed virus will not induce it and this transplant immunity is not related to anti-viral antibody.

2. "Spontaneous" regression and rejection of tumours.

The polyoma transplant immunity just mentioned is thought to be due to the ability to recognise and respond to the virus-specific surface antigen (TSTA) on such transformed cells, with subsequent rejection and death of such cells. Polyoma virus-free tumour cells can also be used to induce this response in immunologically competent animals, although if over-whelming numbers of cells are used growth of/

of the tumour may occur before sufficient immunity develops.
(Stoker, 1962).

Newborn animals are immunologically immature and tumour cells grow without hindrance in them.

Similar situations are presumed to exist with regard to other virus tumours. Trials with vaccines in papilloma virus infections support this, though as yet TSTAs have not been demonstrated in the papillomata. Evans et al (1962) used a cellular tumour tissue suspension from rabbit papillomata and studied the effects of inoculating this "vaccine" into tumour-bearing rabbits. The rate of spontaneous regression of the tumours was 25% over the period observed: in vaccinated animals regression rates increased from 50 - 90%. This effect was noticed whether vaccine was given at the same time as the virus inoculum inducing the tumour or up to 28 days later, and vaccine could be prepared from tumours in the same rabbit (autologous) or others (homologous). Bovine papilloma tissue vaccines have been used with variable results. (Steele-Boder and Wright, 1959).

3. Cell-mediated and humoral immune reactions.

The role of cell-mediated immune responses in virus infections and oncogenesis has now been recognised as of prime importance. Some features are discussed by Allison (1967) illustrated by examples from polyoma, and a different rabbit tumour - the Shope fibroma, caused by the pox virus of that name. If an adult rabbit is inoculated with this virus, a tumour appears, grows rapidly for about 9 days then regresses. By the 5th day the animals show evidence of a cell-mediated immune response in the form of delayed hypersensitivity but circulating antibody is not detected until the 7th day. When methotrexate was given to/

to suppress all immune response, cellular and humoral, the rabbits developed multiple tumours at a distance from the inoculation site and regression was very noticeably inhibited. The administration of hyperimmune antiserum to the virus prevented development of the distant lesions but did not facilitate regression.

The newborn mice inoculated with polyoma virus develop humoral antibody to the virus but not cellular immunity, and their tumours grow and kill them. Thymectomy can produce a similar situation in older animals. Much is now being learnt about the basis of immunological response; the mechanisms are too complex for discussion here. Current views are well summarised by Roitt, 1969.

4. Antibody to T (tumour) antigen.

Infection with tumour viruses such as polyoma is accompanied by the appearance of humoral antibody to the T antigen of the virus. This was shown by Habel (1965) using sera from animals bearing polyoma tumours and finding that they contained complement-fixing antibody to the T antigen extracted from polyoma transformed and tumour cells. Similar antibodies are found in sera from animals bearing tumours induced by SV40 or adenovirus, they disappear rapidly after removal of the tumour. (Huebner, 1966). Immunofluorescent and precipitin tests may also be used to detect these antibodies. Significance of antibody to T antigen is purely a diagnostic one, presence of such antibody in serum must indicate a current infection with the specific virus. The value of such a diagnostic index is obvious in the search for DNA virus aetiology of tumours, where the likelihood of finding the virus itself is low.

The/

The children who developed anti-viral antibody to SV40 after receiving contaminated polio vaccine were also examined for anti-T antibody, but none was found. (Gerber, 1967). Of course, as T antigens are produced in all infections, whether lytic or tumour-forming, anyone undergoing even an inapparent, non-oncogenic infection with such viruses may produce some anti-T antibody.

WART VIRUS AND CARCINOGENESIS.

Is the human wart virus ever responsible for malignancy or are infections with it always of a benign, trivial nature? Certainly the usual and very common infection in the obvious form of a skin papilloma has not been shown to be malignant. There are some associations, however, which make one suspect that in certain circumstances the outcome may be more sinister. All the other viruses of the papova group are capable of inducing malignant changes, albeit usually in experimental systems, and the common form of infection with these agents is a benign or inapparent one in their natural hosts. The normal immunological responses make it unlikely that neoplastic cells of virus origin would proliferate extensively in most people but neonates or those with any of the varieties of immunological deficiencies would be susceptible.

Malignant change has been observed, after considerable periods of time, in some situations where the lesions were initially simple papillomata of presumed wart-virus origin. Genital warts have on several occasions been shown to be the site of subsequent carcinoma (Siegel, 1962; Harmel-Tourneur and Kalis, 1964) on clinical and pathological evidence. The condition of epidermodysplasia verruciformis, whose lesions contain a wart-like virus, is accompanied by/

by a genetic abnormality affecting the patient. There is a recognised tendency to development of carcinoma in the lesions at an early age, (27% by the age of 20, according to Touraine, 1961). Ruiter (1969) reports on examination of such a lesion: histologically carcinoma was diagnosed; electron microscopy of sections of the carcinoma revealed no virus particles.

The association of laryngeal papilloma and bladder papilloma with malignant change has already been mentioned. Viral aetiology for the original simple tumours has yet to be proved. Similarly with the rare condition of oral florid papillomatosis in man (Welsher and Fisher, 1962) in which squamous cell verrucous carcinoma has been found to develop. (Samitz, Ackerman and Lantis, 1967; Kanee, 1969).

Papova-like virus particles were recently found by Smith, Pinkel and Dabrowski (1969) in certain apparently-transformed cells obtained on prolonged culture of a Wilms' tumour (nephroblastoma). Small amounts of the particle (diameter 45 - 50 nm. and morphologically like wart virus in negative stained preparations) were seen in 1 - 10% of these abnormal cells. This virus, and its source, has yet to be identified.

The whole question of the role of viruses in human cancers is a fascinating one but very confusing, and many other factors have to be considered, genetic and environmental. With the development of the procedures described for the investigation of tumours in animals and at the cellular level the answer to some of the problems is nearer. It is hoped that study of wart virus infections may contribute usefully in this field.

MATERIALS AND METHODS

MATERIALS AND METHODS

COLLECTION OF SPECIMENS AND SERA.

1. Wart Tissues.

It was possible to obtain material from warts of patients attending the Dermatology Department and Venereal Diseases Clinics at the Royal Infirmary, Edinburgh, through the kindly co-operation of the members of staff treating these patients. The specimens available were of three types:- (1) parings of the superficial keratinised layers removed from the horny surface of warts before the application of treatment to the base of the wart. These parings constituted the bulk of material obtainable and were generally from plantar warts, but small quantities were obtained from some hand warts also. (2) whole warts removed with a curette. As this method of treatment is not regularly employed, such curetted warts were only occasionally received. They included some filiform facial warts, a few hand warts and simple plantar warts, and some genital warts. (3) punch biopsy specimens were taken from some genital warts that were being treated in situ. In addition, three specimens of bladder papillomata were made available from patients undergoing cystotomy.

Each specimen was collected individually in a few ml. of saline containing antibiotics (penicillin 200 units and streptomycin 200ug per ml.) and stored at -70° . When material from plantar warts was required in bulk, parings were collected together in 10 ml. of the saline. Care was taken to keep mosaic warts separate from simple ones, and "fresh" material from active, untreated warts apart from the older, treated warts. Where specimens were taken individually, a record was kept with details of the patient concerned and the wart infection, as/

as seen on the form used for this purpose. (see Appendix, Form A.).

2. Human sera.

Blood samples were taken from adult patients at the Wart Clinics. When possible samples were obtained at their first attendance and also later after treatment, but in some cases this could not be done, if patients defaulted, or required only one treatment, or if it was not possible for me to attend a clinic. In a few instances blood samples were obtained from people who returned by special request a year or more after they had been cured. Records were kept as for the wart specimens.

A survey into wart infection among the girls at a local residential college was carried out. The students were aged 17 to 23, and 350 of them completed the questionnaire displayed in the Appendix. (Form B.) With the assistance of the Blood Transfusion Service, blood samples were obtained from 135 of these girls.

Sera were separated from the clotted blood samples and stored at -30° .

PREPARATION OF ANTIGEN, VACCINES AND ANTISERA.

1. Wart virus antigens.

Material from several specimens of any one type of wart was pooled, and the tissues minced with scissors then ground as fine as possible in a mortar to release virus particles into the saline. Cell debris was removed by slow centrifugation and the clarified supernate then subjected to 100,000 g for 90 minutes in a Spinco model L ultracentrifuge. The pellets deposited by this procedure were resuspended in a very small volume of distilled water (up to 0.5 ml.) and evenly dispersed by mild sonication in an ultra-sonic bath/

bath (Kerry's). These concentrated suspensions of wart virus were used as antigen and stored at -70° .

2. Preparation of vaccines.

(a) Wart virus vaccine was obtained from an antigen prepared as described, from pooled simple plantar warts, and diluted, after counting in the electron microscope, to contain 10^{11} virus particles per ml. in phosphate-buffered saline (PBS) pH 7.2 (Cruickshank, 1965a).

(b) When it was found that genital wart tissue did not yield extracts containing many virus particles, a cellular suspension of pooled genital warts was prepared for use as a vaccine. The method used was one described by Evans et al. (1962) for obtaining rabbit papilloma tissue vaccines. An approximately 10% suspension was achieved by passing the minced tissue through a fine mesh stainless steel sieve.

3. Production of antisera in rabbits.

(a) Two Californian white rabbits were immunised with the concentrated virus vaccine from simple plantar warts.

Rabbit number I was given one subcutaneous injection of vaccine plus adjuvant:- 1 ml. of the vaccine had been emulsified in 1 ml. of oil-Arlacel adjuvant according to the method of Herbert (1967a).

Rabbit number II was given three intravenous injections, at weekly intervals, of 1 ml. vaccine. Both animals were given a booster dose of 1 ml. intravenously ten weeks after their first dose. The amount of virus injected on each occasion was 10^{11} particles.

Neither animal showed any local or systemic reaction to the/

the inoculations given intravenously, though the rabbit No. I developed a nodule around the site of injection of the adjuvant preparation. In each case blood samples were collected before the first inoculation, weekly thereafter for three or four weeks, and one week, and three months following the booster dose.

(b) A New Zealand white rabbit was inoculated with the cellular genital wart vaccine. Because so little of this tissue was available there was considerable lapse of time between the inoculations.

A total of 2 ml. of vaccine was given on the first occasion, divided between four sites intradermally. A second dose of 0.7 ml. was given subcutaneously four months later, and finally 1 ml. given intravenously after a further seven months. Blood was again collected pre-inoculation and following each injection.

The sera were separated and stored at -30° .

ELECTRON MICROSCOPY.

1. Negative staining techniques.

The electron-dense stain used was phosphotungstic acid (Analar), normally made up as a 2% solution (w/v) in sterile distilled water and the pH adjusted to 7.2 by addition of N sodium hydroxide. (PTA). Bovine serum albumin was routinely added to a final concentration of 0.01% to ensure even spreading of the stain. Specimens were prepared on copper grids with a fine mesh (400 or 483, Athene) and carrying a carbon-collodion film, and viewed in an AEI EM6 microscope at 50 KV.

(a) /

(a) For the routine examination of tissues for virus the method of Chambers, Ito and Evans, (1966) was used with minor modifications. Their original technique involved teasing out a small portion of tissue in a drop of negative stain. It was found that there was less crystallite formation to interfere with the stain if the piece of tissue (2 - 3mm.) was teased out in a drop of distilled water first. A specimen grid was then applied to the surface of the drop, film side down, and withdrawn with adherent fluid. Any small particles were allowed to remain on the film if the grid was held upright for 30 seconds and excess fluid then removed by touching the edge with filter paper. A drop of negative stain (PTA) was then applied in the same way. Any fluid specimen to be examined was prepared in this manner.

(b) While the macerated cells of wart parings were easily examined by method (a), more cellular, softer tissues like facial and genital warts tended to obscure the grids with cell material. The cell-spreading technique of Parsons (1963) was found to be a useful way of obtaining better preparations in these cases. A fine needle inserted into the wart surface and carefully withdrawn carried some cells with it. These were then floated off by rolling the tip of the needle across the surface of a drop of PTA, the manoeuvre being followed with the aid of a low power binocular microscope. The surface tension of the drop of stain spread the cells, and a specimen grid inverted on the surface picked up the released material.

(c) Parsons' method was used for staining tissue culture cells when they were harvested in numbers sufficient to produce a small pellet on centrifugation. Otherwise the method used was that/

that of Clarke and Attridge (1968). Tubes containing cell monolayers were drained of medium. Then 0.1 ml. of a 4% solution of PTA pH 7.0 was added to each and the tubes shaken briefly until cell lysis occurred. A further 0.4 ml. of stain was added to counteract the increased viscosity and specimen grids then prepared directly from the lysate.

2. Counting of virus particles.

The loop drop method of Watson, Russell and Wildy (1963) was employed as the technique is straightforward, enables accurate identification of small particles, and in their hands had given good results. Latex particles (diameter 188 nm.) in a suspension of known concentration were supplied by Dr. Pollett of the M.R.C. Institute of Virology, Glasgow.

The latex suspension for the counts contained 1.2×10^9 particles per ml. Virus suspensions had to be adjusted to contain approximately the same number of particles for accurate counting. Latex and virus preparations were evenly dispersed by mild sonication immediately before use. Equal volumes (0.05 ml.) of latex, virus and PTA were mixed thoroughly and a drop transferred by means of a bacteriological loop to the surface of a grid mounted on a cylindrical holder. The grid was allowed to dry naturally without blotting before examination.

Areas of film showing an even distribution of particles were viewed at an instrumental magnification of 40,000 x. The numbers of virus and latex particles were counted in at least three areas containing 20 to 25 latex particles. The virus count was obtained/

obtained from the ratio:-

$$\text{virus count} = 1.2 \times 10^9 \times \frac{\text{no. virus}}{\text{no. latex}} \text{ per ml.}$$

and any further correction for dilution made as required.

3. Thin sectioning.

(a) Thin sections from twelve genital warts and one simple plantar wart were prepared by Mr. A.E.G. Dunn. In each case a small portion (1mm.³) of the wart was placed in veronal-buffered 1% osmium tetroxide (Palade, 1952) at 4°C. for one hour immediately after collection. After this fixation the specimen was rinsed in distilled water, dehydrated in ethanol and embedded in Epon (Luft, 1961). Sections were cut on a Cambridge (Huxley) ultramicrotome and collected on uncoated copper grids. Staining was in uranyl acetate (Gibbons and Grimstone, 1960) and also occasionally lead citrate (Reynolds, 1963). The sections were examined in the electron microscope by both Mr. Dunn and myself, and the electron micrographs of these sections were taken by him.

(b) Later thin sectioning work was carried out by Mrs. Oonagh Gray using different procedures.

Portions of the three bladder papillomata were fixed in glutaraldehyde (5% in 0.1 M phosphate buffer pH 7.2) for four hours at room temperature. Subsequently they were washed thoroughly three times, for 15 minutes each, in a sucrose washing buffer (Key, 1965) and stored in this at 4°C. Three months later they were post-fixed in 1% osmium tetroxide, dehydrated in ethanol and embedded in Araldite. (Mercer and Birbeck, 1966). Sections were cut on a Porter-Blum ultramicrotome, and stained with uranyl acetate and lead citrate/



citrate as before.

Some tissue culture material was also sectioned in this way, except that gluteraldehyde prefixation was avoided and the cells fixed as a loose pellet directly in Palade's fixative.

Apart from the conjoint work on genital wart sections, all other electron microscope examinations and photography were carried out personally.

SEROLOGICAL TECHNIQUES.

1. Precipitin test.

This was initially carried out using 0.8% agar in Petri dishes according to the method of Almeida and Goffe (1965). However it was later decided to adopt a micro-test to conserve materials, and to use 0.7% agar, allowing better diffusion and more positive results. (Almeida, personal communication). All sera were retested in 0.7% agar. Mrs. Almeida kindly supplied a control positive human serum known to contain antibody to wart virus.

Microscope slides (3 x 1") were washed by boiling in detergent, dried in air then coated with 2ml. of 1% ionagar No. 2 (Oxoid) in distilled water at 100°C. This pre-coating layer was dried in an oven at 65°C. A 2 ml. top layer of 0.7% agar in phosphate-buffered saline pH 7.2 was added and when set, punched to give a pattern of wells 2 mm. in diameter arranged at a distance of 3 mm. around a central well. Reagents were added to the wells and the tests incubated in a humidified atmosphere at 37°C. They were examined at 24 and 48 hours for the appearance of any precipitin lines, viewing against a dark background with a bright light.

Precipitation/

Precipitation was recorded as strong (++) , weaker (+) , faint (1) or absent (-). Known positive controls were included in each test.

When it was required to study precipitin lines in more detail, 5 ml. amounts of the 0.7% agar in PBS were poured in Petri dishes, and larger wells cut. (5 mm. diameter and 7 mm. apart). The base of the wells was sealed with molten agar to prevent seepage of fluid underneath. These tests were incubated for 3 days. Precipitin lines were recorded using a photographic enlarger and dark ground illumination.

For examination of the nature of the precipitate, thin wedges of agar were carefully cut out, teased apart in a drop of distilled water and negatively stained as already described.

2. Agglutination test.

This method, reported by Almeida et al (1963) was not used at all routinely as it requires considerable quantities of concentrated virus and antibody. Serum containing precipitating antibody to wart virus was mixed with virus antigen containing 2×10^8 particles. (0.34 ml. serum and 0.66 ml. antigen) The mixture was incubated at 37°C . for one hour then left at 4°C . overnight. After centrifugation at 2000 rpm for 5 minutes, the visible pellet was washed twice in PBS then resuspended in 0.1 ml. of distilled water. A drop of this fluid was transferred to a coated specimen grid, allowed to dry in air and then negatively stained.

3. Complement fixation test.

It was hoped that the wart virus antigen would fix complement in the presence of antibody. The standard form of complement fixation test used in virology (Bradstreet and Taylor, 1962) was employed/

employed, incorporating the use of overnight fixation at 4°C., 0.1 ml. volumes in WHO Perspex plates and 3HD₅₀ of complement.

Chessboard titration of dilutions of antigen and antiserum was carried out to determine the optimal dilution of antigen for use and the complement-fixing titre of the antiserum that was to be used as a reference. Controls for anti-complementary activity of antigen or serum were included, and also controls for non-specific reactivity by testing the serum dilutions against an uninfected control antigen. This was prepared in the same way as the virus antigen but from parings of simple callouses, and the clarified suspension was used as no pellet was obtained on ultracentrifugation of this extract.

Complement was titrated in the presence of antigen at the dilution used in the tests. Sera were screened initially at a 1/8 dilution preferably using a sample obtained late in the wart infection. Those showing complement fixation at this dilution were then titrated to dilutions of 1/512, along with any other sera from the same patient. All sera were inactivated at 56°C. for 30 minutes before testing. The complement-fixing titre of a serum was taken as the highest dilution giving 50% fixation.

4. Passive haemagglutination test.

It was hoped to use tanned red cells as a passive carrier for wart virus antigen so that antibody might be detected by the very sensitive passive haemagglutination method of Boyden (1951). The procedure followed was that given by Herbert (1967b).

Fresh sheep red cells, defibrinated, were used within two days of collection. Cells were washed three times in saline and once in PBS pH 7.2. A cell pack was obtained by centrifugation at/

at 750g for 15 minutes and the supernate discarded. A 5% suspension of the cells in PBS was incubated with an equal volume of a tannic acid (BDH) solution in PBS (5mg. in 50 ml.) at 37°C. for 15 minutes. The tanned cells were washed once in PBS and a 5% suspension made. Some tanned cells were kept aside - unsensitised. Others were sensitised, coated with wart virus antigen, by incubating three volumes of 5% tanned cells in PBS pH 6.4 with one volume of virus antigen and a further two volumes of PBS pH 6.4, at 37°C. for 30 minutes. The cells were washed, as were the unsensitised ones, three times in PBS pH 7.2 containing 1% normal rabbit serum as stabiliser. This NRS diluent was used to make the final 1% cell suspensions.

Sera to be tested, and the normal rabbit serum for the diluent, were adsorbed with sheep red cells to remove any heterophile agglutinins. Generally a 1/10 dilution of serum was made in a 1% suspension of fresh sheep red cells and left at room temperature for 30 minutes. With the rabbit serum, or any sera retaining agglutinins after this procedure, a 1/4 volume of packed red cells was added to the undiluted serum. Cells were removed by centrifugation after the adsorption period, and the sera inactivated at 56°C. for 30 minutes before use in the tests.

Tests were performed in disposable plastic plates with conical-bottomed wells, (Linbro Chemical Co.) using pipette-droppers delivering constant-volume 0.025 ml. drops. Doubling dilutions of sera in NRS diluent were prepared with micro-diluter loops (Cooke Engineering Co.). One volume of sensitised cells was added to each serum dilution, and one of unsensitised tanned cells to each serum control (1/10 dilution). Controls containing sensitised cells in diluent/

diluent and unsensitised cells in diluent were included. Plates were left at 4°C. overnight before reading the tests. Haemagglutination was observed as an even carpet of cells (+++), less even (++) or with clumping of some cells (+) compared with the smooth compact "button" of sedimented non-agglutinated (-) cells. The serum titre was taken as the highest dilution showing (+) haemagglutination. (Plate 5).

The optimal amount of antigen for sensitising the cells was determined by chessboard titration of sera against cells coated with different antigen concentrations, and finding the lowest sensitising concentration giving the highest titres in the sera. The amount of virus absorbed by the cells was calculated from obtaining particle counts of the virus antigen used, virus remaining in fluid after sensitisation and the number of red cells sensitised. (The calculations are detailed in the results.) In addition, sensitised cells were examined in the electron microscope, and compared with unsensitised cells. One ml. volumes of the cells were lysed with 2 drops of 10% saponin, removed by centrifugation, washed in PBS and resuspended in 0.1 ml. distilled water. A drop of the fluid was then negatively stained. The procedures mentioned in this paragraph were performed under my supervision by a student investigating the use of this test. (Hopkins, 1969).

Inhibition of passive haemagglutination was tested as follows. Serum dilutions were prepared as for the passive haemagglutination test, but before adding cells, one volume of virus antigen was added to each dilution and the plates incubated at 37°C. for 30 minutes. Cells were then added and the test completed in the usual way.

5. Reversed passive haemagglutination. /




Plate 5.

Passive haemagglutination test.

Serum dilutions from 1/40 → 1/5120 top row
← 1/10240 second row

SC serum control
TC tanned cell control
SCC sensitised cell control

5. Reversed passive haemagglutination.

An attempt was made to coat tanned red cells with antibody to wart virus and use a "reversed" form of the passive haemagglutination test to determine antigen titres. •

A rabbit antiserum to wart virus was chosen because of its high antibody content. The gamma globulin fraction was isolated as follows.

Saturated ammonium sulphate (SAS) - 10 ml. was added to 0.5 ml. of the serum diluted to 10 ml. with distilled water and shaken. The precipitate was removed by centrifugation after 15 minutes, resuspended in a further 10 ml. of distilled water and the process repeated. The second precipitate was dissolved in 3 ml. of saline and dialysed against two changes of saline over a period of four hours, then finally made up to 5 ml. with saline. This was the antibody preparation.

Fresh sheep red cells were tanned as before with tannic acid and washed in PBS. A 3% suspension of the tanned cells was then incubated with antibody at room temperature for 20 minutes, using one volume of cells, one volume of antibody and four volumes of PBS pH 5.8. Aliquots of cells were incubated with different dilutions of antibody. After the sensitisation procedure, the cells were washed in NRS diluent and resuspended in it as a 3% suspension.

Tests were performed in approximately the same way as with antigen-coated cells, except that doubling dilutions of antigen had to be made in tubes and transferred to the plates. Cells were added and controls as before. Tests were examined after incubation at room temperature for four hours and overnight at 4°C.

6. Determination of immunoglobulin class./

6. Determination of immunoglobulin class.

Three methods were used in experiments to demonstrate the type of immunoglobulin present in antibody to wart virus at various stages of infection. Initially heat treatment was employed to inactivate immunoglobulin M, IgM, according to the method recommended by Pike (1967). Undiluted serum was heated at 65°C. for one hour and then examined in the precipitin test. Difficulty arose as some sera became congealed with this treatment, so the mercaptoethanol treatment was substituted.

The 2-mercaptoethanol was a 0.2 M concentration in phosphate-buffered saline pH 7.2. An aliquot of serum was treated by incubation with a 1/10 volume of the 2-mercaptoethanol (2ME) at 37°C. for one hour, and a corresponding amount of PBS was added to an untreated aliquot of the serum as a control. (Banatvala et al. 1967). Such sera were then examined directly in precipitin and passive haemagglutination tests, without dialysis, as the presence of 2ME did not interfere with either reaction.

Some sera were fractionated on sucrose density gradients and the distribution of antibody in the fractions determined. Gradients were prepared in nitro-cellulose tubes by layering successively 1.22 ml. of 40% sucrose in PBS pH 7.2, then 1.12 ml. each of 30%, 20% and finally 10% sucrose solutions. The gradients were left overnight at 4°C. to allow equilibration. Sera to be examined were diluted 1/2 in PBS and any gross debris removed by centrifugation. In each case 0.5 ml. of the serum dilution was layered on top of a gradient and the meniscus at the interface with the sucrose broken. The tubes were then centrifuged at 35,000 rpm. in the SW 39 rotor of the Spinco model L for 16 hours. Fractions of 0.48 ml. volume were collected from the top/

top of the tubes by means of a tuberculin syringe and right-angled hypodermic needle.

With each set of gradients a control serum containing the Paul Bunnell heterophile antibody was included, and a check of the distribution of this antibody made by carrying out Paul Bunnell tests on the fractions obtained from it. (Cruickshank, 1965b.). The fractions of wart sera were examined directly in complement fixation tests and passive haemagglutination tests, without dialysis as sucrose in the concentrations present did not interfere with either reaction.

TISSUE CULTURE METHODS.

1. Inoculation of wart virus into HEp-2 cells.

Human epithelial cells were an obvious choice for attempts to establish infection with the human wart virus. A continuous line of such cells (HEp-2 cells) was readily available in the laboratory. Carteaud (1958) had reported the appearance of cytological changes and Melczer (1965) noted the apparent development of papovavirus-like particles in cultures of HeLa cells, a similar continuous epithelial cell line of human origin, after inoculation of wart extracts. Cultures of HEp-2 cells were grown in Wellcome brand Eagle's medium (Eagle, 1959) containing 10% heat-inactivated calf serum, and for maintenance of cultures the serum content was reduced to 2%. Monolayers were prepared in tubes by inoculating 50,000 cells in 1 ml. of growth medium, and in Roux bottles by inoculation of six million cells in 100 ml. medium. Coverslip cultures were obtained by inoculating 1 ml. containing 100,000 cells into tubes with a glass coverslip (22 x 6 mm.) in each and incubating continuously in a stationary/

stationary position.

The wart virus extract used as inoculum in all the tissue culture experiments was prepared from active, untreated simple plantar warts. The parings were collected in very small amounts of fluid, minced, ground and clarified as in the preparation of antigen, then filtered through a membrane filter of pore size 220 nm. (Millipore). Only extracts containing 10^9 or more virus particles per ml. were used. An extract of parings from corns was similarly prepared and filtered for use as a control.

(a) Tubes containing 3 day old cultures were drained of medium and inoculated with 0.2 ml. of wart extract or corn extract or medium. After allowing for adsorption to the monolayers by incubation at 37°C . for 2 hours in a stationary position, inocula were decanted, 1 ml. of maintenance medium added and the tubes incubated at 37°C . in a roller drum. The cultures were observed daily and the medium renewed on the third and seventh days after inoculation. On the 12th day fluids from virus-inoculated cells were pooled and 0.2 ml. amounts passed into fresh cultures. The remaining cells from the tubes were disrupted by rapid freezing and thawing three times and 0.2 ml. of material from these also passed. In one experiment the pH in half of the tubes was maintained at pH 6.8.

(b) Tubes inoculated as in (a) were used for electron microscopic studies. Fluids harvested on the 3rd, 7th and 12th days were examined by negative staining. Pooled cells from several tubes were examined by the cell-spreading technique of Parsons (1963). The method of Clarke and Attridge (1968) was applied for negative staining of individual monolayers. For thin sectioning, cells were removed from glass/

glass by scraping with a silicone-tipped rod and centrifuged to form a loose pellet which was then fixed in 1% osmium tetroxide. In one experiment the inoculated tubes were incubated at 30°C. for 14 days and the cells then fixed and thin sections prepared.

(c) Tubes containing coverslip cultures of HEp-2 cells were inoculated on the third day with 0.2ml. virus or medium and maintained for 30 days at 37°C., medium being renewed twice weekly. Sufficient tubes were used to allow withdrawal of two inoculated and two control cultures at frequent intervals for microscopic examination. In each case, one coverslip was studied by phase-contrast microscopy and the other by light microscopy after fixation and staining by the rapid Giemsa method. (Cruickshank, 1965c.).

(d) Some Roux bottle monolayers of HEp-2 cells were inoculated and used in an attempt to detect virus-induced antigens, to be described in the next section. Some were inoculated and maintained at 30°C. for 14 days before examination of the cells by negative staining, using the method of Clarke and Attridge with 1 ml. PTA. In each case cultures were inoculated on the third day. Medium was decanted and an inoculum of 20 ml. containing 10^9 virus particles per ml. adsorbed at 37°C. for 3 hours. The inoculum was then removed and the monolayers washed twice with phosphate-buffered saline pH 7.2 before addition of 100 ml. medium.

2. Transformation studies.

(a) Insufficient amounts of cells were cultured from primary human embryonic skin to allow repetition of Noyes' experiments. In view of the susceptibility of baby hamster kidney cells to transformation by polyoma virus and the availability of some such cells,/

cells, they were used in experiments to determine whether wart virus might transform them. The semi-continuous line of baby hamster kidney (BHK21) cells (Stoker and Macpherson, 1962) were used. Growth medium was Eagle's (Gibco) containing 10% tryptose phosphate broth (Oxoid) and 10% unheated calf serum. The method used to detect transformed cells was the agar suspension assay of Macpherson and Montagnier (1964), who found that hamster cells exposed to polyoma virus **and held in** suspension in soft agar produced spherical colonies from transformed cells, whereas untransformed cells did not form colonies.

Glass Petri dishes (60 mm.) were prepared with a base layer of 6 ml. of 0.5% agar in growth medium. A suspension of BHK21 cells was obtained containing 3×10^5 cells per ml. and a fresh wart virus extract containing approximately 3×10^{10} virus particles per ml. The cells in suspension were exposed to virus in a shaking water bath at 37°C . for one hour, using 0.1 ml. of virus extract to 1 ml. of cell suspension (i.e. 10^4 virus particles per cell). After adsorption the cells were added to medium containing 0.5% agar at 44°C ., giving a final agar concentration of 0.34%, and 1.5 ml. of the suspension then added immediately to the preformed agar base in a Petri dish. Cultures were incubated at 37°C . in a humidified atmosphere of 5% carbon dioxide, for periods up to 30 days and examined at intervals under a low power microscope for colonies.

(b) Human skin fibroblast cultures supplied by the Pathology Department, Royal Hospital for Sick Children, Edinburgh, were used in similar transformation studies. These cells had been established from explant cultures of a skin biopsy from a normal child. As they had been grown in Eagle's medium containing 20% pooled human serum, they were /

were sub-cultured twice in Eagle's medium containing 10% unheated calf serum and 10% tryptose phosphate broth before use in these experiments. They were used in agar suspension assays, at their 19th passage, with the same procedure as adopted for the BHK21 cells. In addition, monolayer cultures in Petri dishes were exposed to 0.2 ml. virus (approx. 10^9 particles) for 1 hour at 37°C ., then covered with 10 ml. growth medium and incubated in humidified 5% CO_2 . After 14 days the cultures were fixed and stained (Giemsa) and examined for colonies.

EXPERIMENTS TO DETECT VIRUS-INDUCED ANTIGEN.

1. Experiment to detect soluble "T type" antigen.

Monolayer cultures of HEp-2 cells in a Roux bottle were inoculated with 20 ml. of wart extract as described in the previous section (d). The cultures were incubated at 37°C . for 24 hours, then the medium was decanted and the cells harvested by shaking with glass beads in 5 ml. of distilled water. The suspension obtained was treated at full power in an MSE ultrasonicator for 5 minutes and the clarified fluid used as antigen. This "T type" antigen preparation was examined in precipitin tests against a wide range of sera from people with warts. Unfortunately it remained anti-complementary even after dilution or heating at 56°C . for 30 minutes, so could not be tested for complement-fixing activity with these sera.

2. Electrophoresis and examination of proteins from wart tissues.

Steward, Mack and Foy (1968) demonstrated that extracts of wart tissue produced one or more bands of protein on electrophoresis in agarose. They had been concerned to identify the/

the band representing wart virus and had succeeded in this by negative staining of eluates from the bands. The concern here was rather to identify any other proteins in warts which might be virus-induced antigens like the "T" antigens of other papovaviruses.

Warts obtained by curettage and specimens of normal skin available from surgical procedures were used. Extracts were produced by grinding 200 mg. amounts of tissue in 1 ml. of 0.7 M urea in a borate buffer as used by Steward et al. (1968). (Boric acid 0.77 gm., ethylenediaminetetra acetic acid 1 gm., and tris (hydroxymethyl) aminomethane 10.1 gm. diluted to 1 litre with distilled water). The grinding was done in a Teflon-lined homogeniser with a motor driven pestle, using four 5-minute periods of grinding. Electrophoresis of the extracts was performed on cellulose acetate strips (Oxoid) in a Shandon electrophoresis cell, using a borate buffer pH 8.2. (Boric acid 18.5 gm. and sodium hydroxide 2.5 gm. diluted to 1 litre with distilled water.) Application of the extracts to the strips was made with a fine platinum loop, giving a narrow linear application approximately 1.5 cms. long. Migration was for 70 minutes at 145 volts. The strips were then placed in Ponceau-S dye fixative for 10 minutes and rinsed in three changes of 5% acetic acid before drying at 37°C. (Ponceau-S (Gurr) 0.36 gm., trichloroacetic acid 5.36 gm., and sulpho-salicylic acid 5.36 gm., diluted to 400 ml. in distilled water).

Some extracts were electrophoresed in triplicate and one strip stained as above while the others were used in immuno-diffusion or electron microscopy studies. For immuno-diffusion a large glass Petri dish was prepared with a thin layer of 0.7% agar in phosphate-buffered saline. The unstained electrophoresis strip was laid across the/

the central area and filter paper strips soaked in serum from people with warts laid parallel on either side to the long edge of the cellulose acetate strip and 5 mm. from it. These plates were incubated in a humidified atmosphere at 37°C. for 3 days and examined for the development of precipitin lines. For electron microscopy, portions of an unstained strip were cut out, their position noted by comparison with the corresponding stained strip, and placed in 0.5 ml. of distilled water for one hour. The eluates were examined after negative staining.

RESULTS

RESULTS

ELECTRON MICROSCOPIC EXAMINATION OF TISSUES.

1. Negative staining of specimens.

(a) Virus in plantar, hand and facial warts.

Two series of warts were examined individually by negative staining techniques. Series A comprised the early specimens collected at the beginning of this project, while the use of negative staining methods was being explored. The majority of specimens were parings from plantar warts; a few parings were from hand warts. All the facial warts were of the filiform type, removed by curettage, and some hand warts had been obtained in this way. The specimens in series B were all from plantar warts of patients involved in a clinical trial of different treatment methods. By this time considerable experience had been gained in the use of the negative staining technique adopted, the simple teasing-out method. Results showing the percentage detection of virus particles in different types of wart by this method are given in Table 1.

Table 1

Detection of virus in warts by negative staining

	Wart type*	SP	MP	HW	FW	Total
Series A.	No. examined	98	18	15	13	144
	Virus found in	81	9	9	3	102
	% with virus	83%	50%	60%	23%	71%
Series B.	No. examined	34	25	-	-	59
	Virus found in	34	23			57
	%with virus	100%	92%			97%
Overall % with virus		85%	79%	60%	23%	78%

* SP = simple plantar, MP = mosaic plantar,
H = hand, F = facial.

The specimens varied a great deal, and a very rough estimation
of /

of the amount of virus particles seen on the grids, as illustrated in Plate 6, revealed that large aggregates of virus were regularly found in simple plantar warts (41%) and hand wart parings (33%), but not in mosaic plantar or facial specimens.

Just comparing the results with the plantar warts, it is clear that the diagnostic value of the negative staining procedure was increased with experience. The only two specimens in series B in which virus particles were not detected were from patients with mosaic plantar warts that in both cases had been the site of considerable cellular necrosis following application of podophyllin. An additional factor probably contributing to the higher success rate in the second series was the greater proportion of warts of relatively short duration. In series B only 25% were of more than one year's duration, and 66% were less than eight months old, compared with 41% over one year in series A and 54% less than eight months. In their quantitative study, Barrera-Oro et al. (1962) had found that warts about six months old had the greatest amount of virus.

The limitation of the negative staining method lies in its threshold of sensitivity. Particles require to be present in considerable numbers before they can be revealed in this way, of the order of 10^7 particles per ml. of fluid. In the study by Barrera-Oro et al. (1962) the lower limit was found to be 10^7 particles per mg. of tissue, and 45% of their specimens contained less than this and were reported negative. Kingsley-Smith et al. (1967), using the technique of Chambers et al. (1966) similar to the one used here, found virus in 67 out of 68 specimens from various types of wart, a very high rate of detection.

(b) /

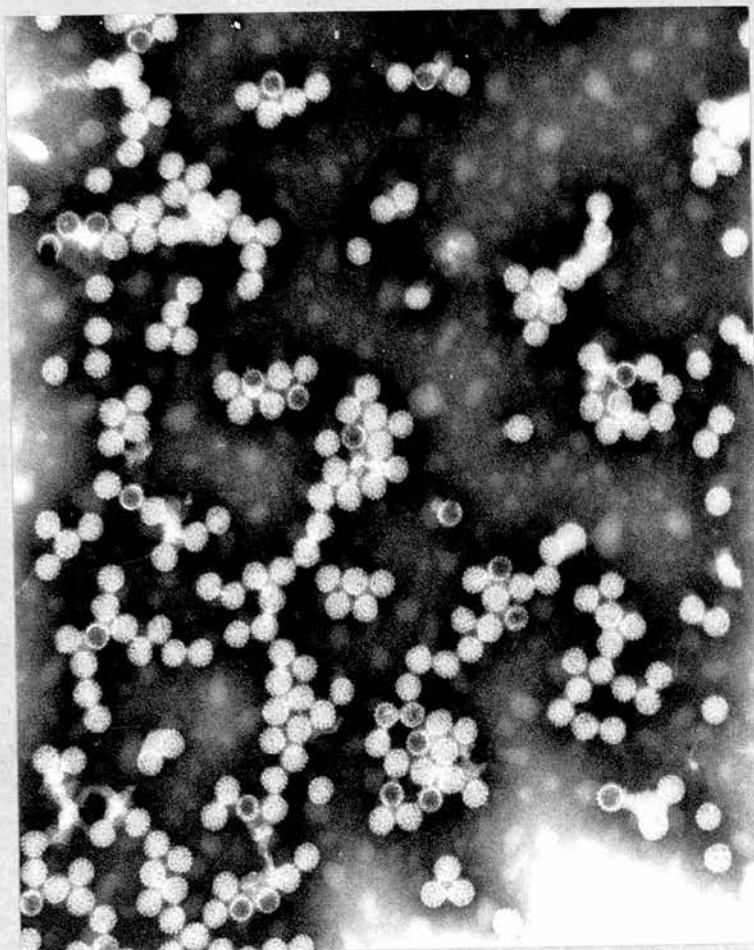


Plate 6.

Wart virus particles in a specimen from a
simple plantar wart prepared by the
negative staining technique. Note some "empty" particles.

PTA stain

x 80 000

(b) "Empty" particles and filaments.

Particles penetrated by negative stain were seen occasionally in preparations from all types of specimen. In particular large quantities, comprising at least half of all the virus particles seen in any one case, were noticeable in specimens taken at a time when the wart was clinically considered to be nearly cured. Thus in seven such specimens from series B, a preponderance of "empty" particles was noted in four cases. This finding did not always apply in regressing warts: in several instances cells from the surface of clinically cured lesions were found to contain a considerable number of normal "full" particles and no "empty" ones. The potential infectivity of such material should be borne in mind and sufficient time for the complete removal of such cells allowed before a patient is permitted to attend public baths, for instance.

Filaments, strands of varying length with a regular sub-structure of 45 Å periodicity, were seen in some negative stained warts. They appeared to be similar to those reported by Smith et al. (1965) and considered to be strands of unassembled viral subunits. In this investigation, these filaments have been seen in specimens from both types of plantar wart and facial warts, always with wart virus particles in close association. (Plate 7). None of the lesions were of unusually long duration, but the specimens most often found to contain these filaments were of the mosaic plantar type. Such filaments were never seen in any material from callouses, or other epidermal viral lesions such as molluscum contagiosum or orf examined by negative staining. In a few instances wart virus particles were found in material from lesions that were clinically provisionally diagnosed as corns.

(c) /

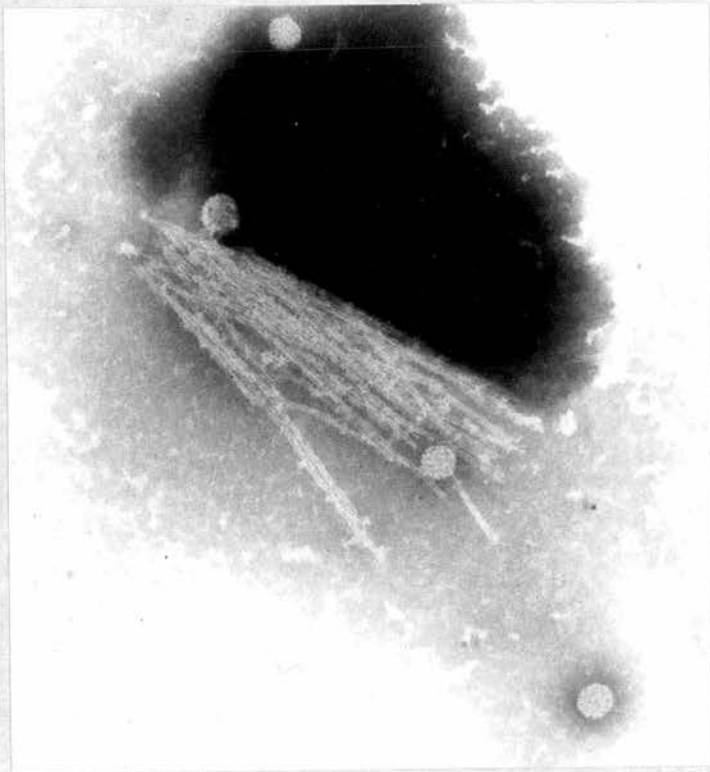


Plate 7.

Wart virus particles and filaments from a
mosaic plantar wart, negatively stained.

PTA stain

× 80 000

(c) Examination of genital warts and bladder papillomata.

Any wart specimen producing cell debris on grids was always examined by Parsons' cell-spreading method in addition to the regular negative staining procedure. This never resulted in virus particles being located in a previously negative specimen but did make it a great deal easier to screen the grids carefully.

The 21 specimens of genital warts were all examined in these ways. In none were wart virus particles detected. In two preparations clumps of small particles (35 - 45 nm. diameter) were seen, but no structural features could be discerned. In one of the specimens these particles were associated with filaments of the type seen in other wart preparations.

No virus-like particles or filaments were seen on examination of negative stained material from the three specimens of bladder papillomata.

(d) Molluscum contagiosum of the sole.

This pox virus infection was regarded by many as occurring very rarely, if ever, on the sole of the foot. (Blank and Rake, 1955; Warren, 1965.) The first documented case was reported by Baxter and Carson (1964), diagnosis being made on histological grounds after excision of the lesion. Two cases were detected and diagnosed by electron microscopy in the course of this study. In the first, which has been reported (Bunney, Hunter and Ogilvie, 1969.), a patient presented with what was clinically diagnosed as a suppurating wart. Negative staining of parings revealed no wart virus particles but numerous large particles with the typical morphology of the molluscum contagiosum virus (Williams, Almeida and Howatson, 1962).

At/

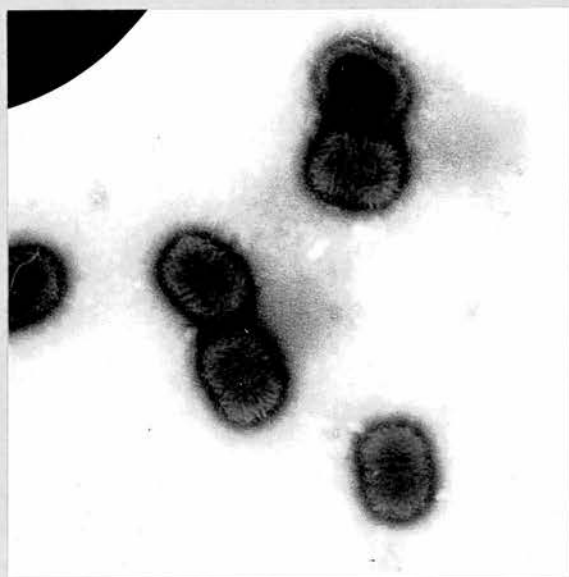


Plate 8.

Molluscum contagiosum virus particles,
negatively stained.

PTA stain

× 40 000

At the patient's second attendance new satellite lesions were found with the central umbilication characteristic of molluscum lesions, and the pox virus particles were again found. (Plate 8). A similar case occurred just shortly after. The presenting lesions were tiny blisters in appearance, such as those seen on the heel in hyperhidrosis, and molluscum virus particles were easily demonstrated. It would appear that the diagnosis is readily missed in these cases, particularly if suppuration is present (Henao and Freeman, 1964), but negative staining provides a simple and rapid diagnostic aid.

2. Examination of thin sections of tissues.

(a) Simple plantar wart sections.

Only one plantar wart specimen was examined after thin-sectioning, the features of such warts having been well documented by others. (Almeida et al., 1962). In the thin sections of this wart only the superficial stratum granulosum and stratum corneum layers were present. Numerous virus particles, diameter 40 nm., were seen in nuclei of S. granulosum cells and filling the cells of the surface layer. The crystalline formation of an aggregate of particles in a superficial degenerating cell may be seen in Plate 9.

(b) Genital wart sections.

Observations regarding the series of 12 genital warts examined in thin sections have been published (Dunn and Ogilvie, 1968).

In some of these specimens no stratum corneum was found, and the stratum granulosum lacked keratohyalin granules, having the appearance described by Brody (1962b) in other skin conditions associated with altered keratinisation and given the name stratum intermedium. The basal cells appeared normal.

Several/

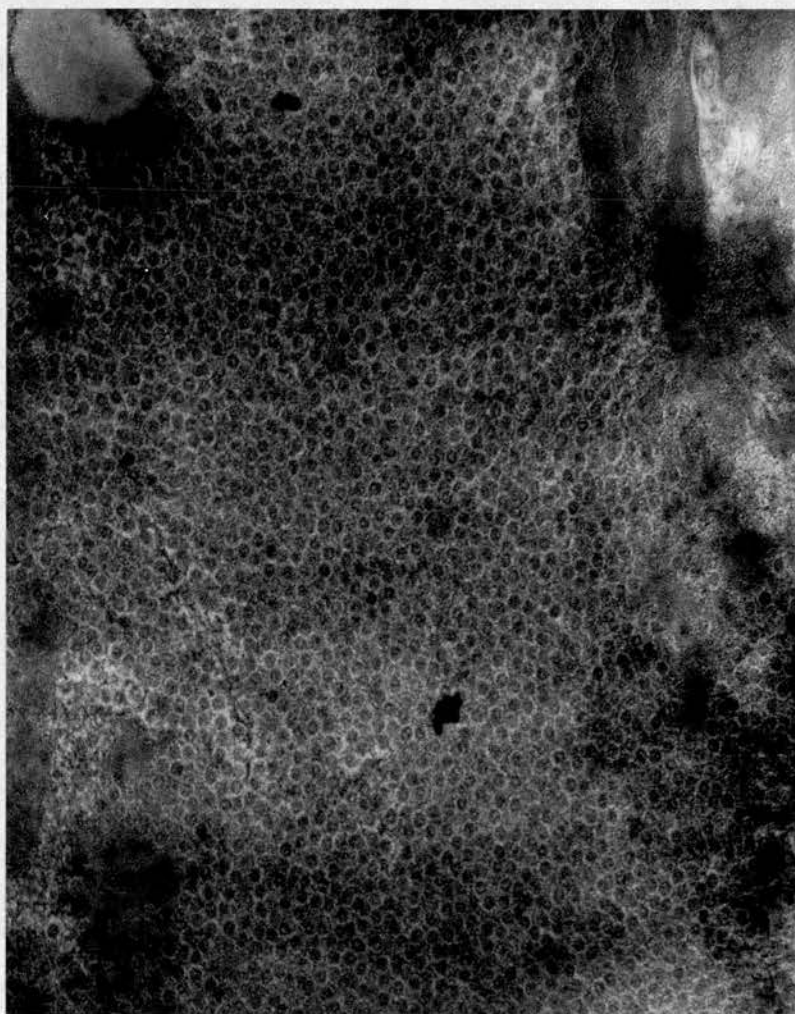


Plate 9.

Electron micrograph of a thin section from a simple plantar wart. Cell full of spherical virus particles.

Uranyl acetate

x 40 000

Several features were noted in cells of the stratum spinosum. In one specimen the nuclei contained unusual spiral inclusions, previously described in genital wart sections by Nasemann, 1965, but also in other conditions such as psoriasis and even in normal epidermis (Brody, 1962a). In another there were large numbers of vesicular structures in the cytoplasm. These appeared as light cores surrounded by dense outlines and varied in size from 34 to 85 nm., fitting the description of the particles identified as wart virus in genital wart tissues by Zimmer et al. (1964). However the irregularity in size, vesicular appearance and location around the nuclear poles lead us to conclude that these were normal cell constituents as described by Zelickson and Hartmann (1961).

In two of the warts the most superficial cells were of the stratum intermedium, flattened and interdigitating. Nearly all these cells contained numerous densely-stained particles 35 - 45 nm. in diameter, with no discernable surface structure, and in many cases close to short strands of granular material. These particles were in the few nuclei preserved in these cells and also throughout those cells where no nucleus was seen. These were the two wart specimens that yielded the small groups of particles and filaments when negatively stained, as described in 1.(c). While not identifiable as virus particles or associated structures, these particles might be precursors of mature viral particles.

In sections of only one of the genital warts were recognizable virus-like particles found, in nuclei of cells of the stratum granulosum of this specimen. All the nuclei had irregular outlines and some margination of chromatin that was not found in cells without intranuclear/

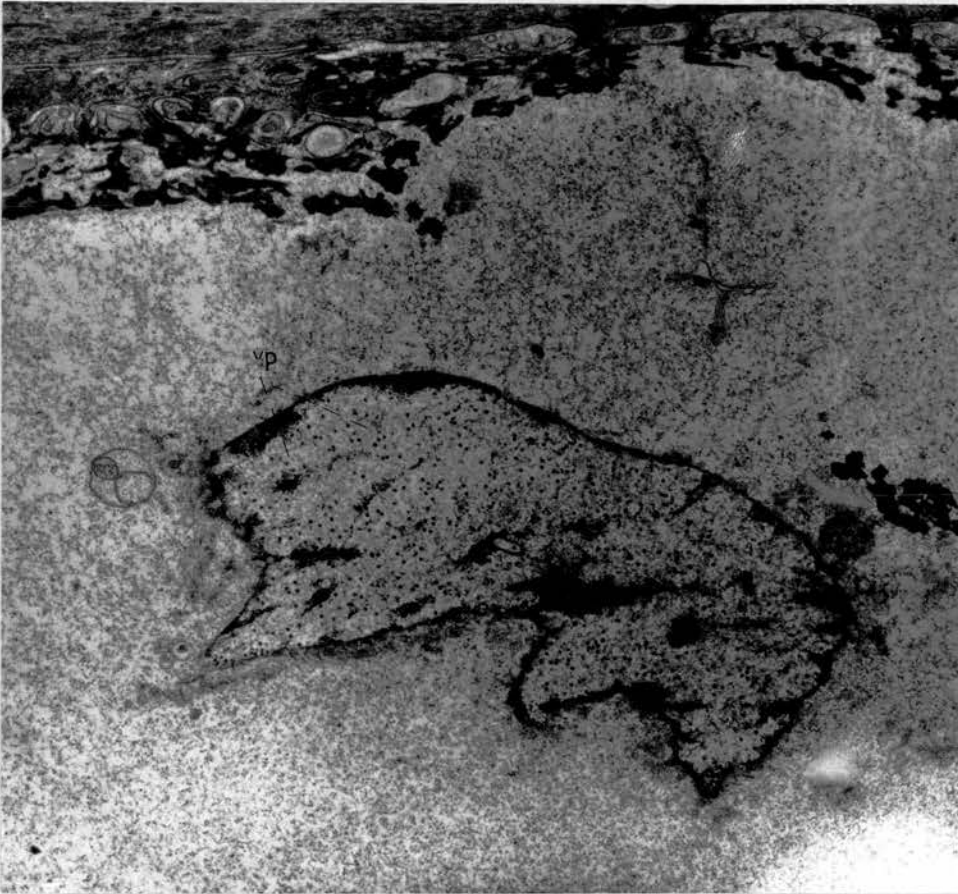


Plate 10.

Thin section of genital wart. Stratum intermedium cell with nucleus containing many virus-like particles (vp.)

Uranyl acetate and lead citrate

× 12 000

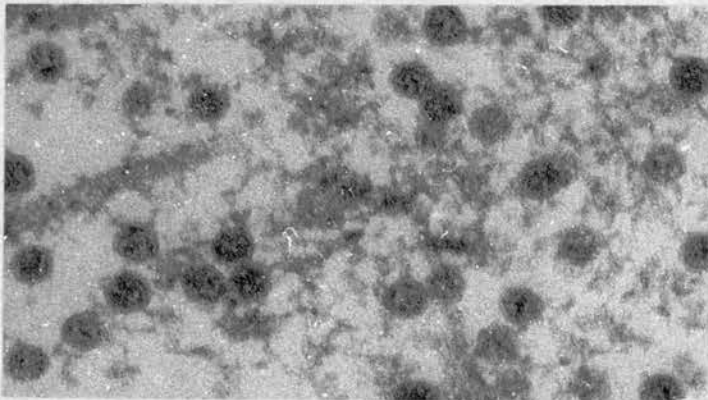


Plate 11.

Intranuclear virus particles (genital wart section).

Uranyl acetate and lead citrate

× 120 000

intranuclear virus particles. The particles were densely-staining regular spheres varying in size from 36 to 47 nm. in diameter, scattered throughout the nuclei. (Plate 10). They were not present in large numbers as is the case in common warts. Some detail of their surface structure, with their peripheral ring of "knobs", could be made out at high magnifications. (Plate 11). These features and the location of the particles are typical of papovavirus in tissue sections.

In most of the infected nuclei masses of granular material like that of the peripheral chromatin lay around the virus particles. Bundles of granular filaments were also noted in close association with the virus. These were very similar to the findings of Mattern et al. (1966) in early stages of polyoma virus infection of mouse embryo cells. (Plate 12).

(c) Bladder papillomata sections.

The three bladder papillomata had been embedded in Araldite and thin sections cut on a hand-operated Porter-Blum microtome, and the preparations were not as satisfactory as those of the genital warts. However some sections of all the specimens were suitable for viewing at high magnifications. The majority of cells seen were from the connective tissue core of the tumours, with much evidence of bundles of fibres sectioned transversely or longitudinally. Where the epithelial cells were found no margination of nuclear chromatin was seen or any virus-like particles or filamentous material. Some of the nuclei contained granules of varying size but the nature of these was uncertain.

3. Concentration and counting of wart virus./

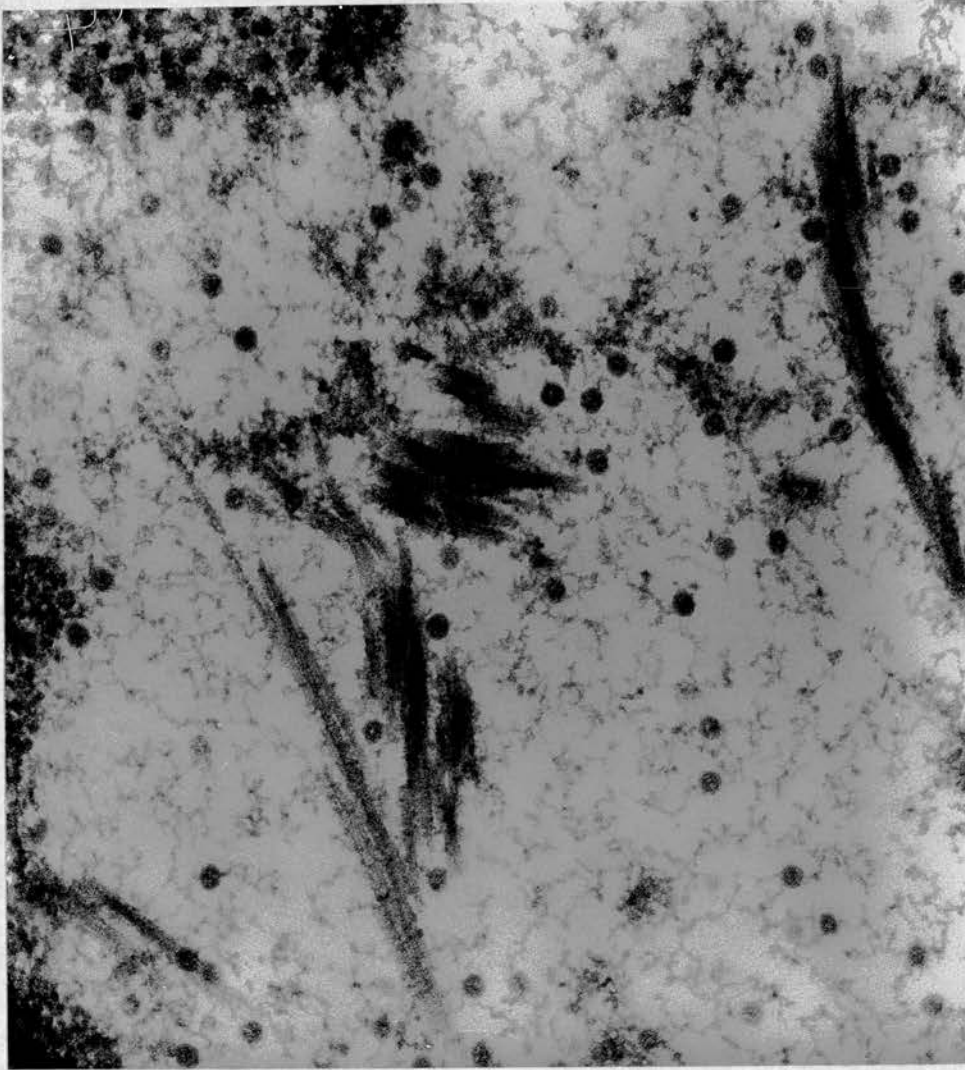


Plate 12.

Thin section of a genital wart. Infected nucleus in stratum intermedium containing virus particles and associated bundles of filaments.

Uranyl acetate and lead citrate

× 80 000

3. Concentration and counting of wart virus.

(a) Antigen extracts from planter and hand warts.

Examination of the extracts prepared from pooled planter wart parings revealed masses of wart virus particles, as seen in the Frontispiece. In the case of simple planter warts, particle counts of the concentrated antigens regularly revealed amounts of the order of 10^8 to 10^{14} virus particles per ml. Mosaic planter wart antigen counts were usually of a similar order. Only small amounts of hand wart parings were available by comparison, but a small volume of antigen containing 10^8 virus particles per ml. was obtained by pooling all the material. These antigen preparations were thus available for serological and other tests.

(b) Extracts of face warts, genital warts, and bladder Papillomata.

Few facial wart specimens were obtained and extracts of these revealed insufficient amounts of virus for counting accurately and for use in most of the tests. No studies on the virus antigen from these warts were done therefore.

In an extract from 12 pooled genital warts a very few virus particles were seen on negative staining. Their size was estimated at 46 nm. diameter and they had the typical structure of wart virus particles. (Plate 13). As this virus had not been identified previously, the cellular antigen was prepared for immunising a rabbit, as already described, in the hope that sufficient virus antigen might be introduced in this way to stimulate antibody production.

The ultracentrifugate from the pooled bladder papillomata extract did not reveal any virus particles on negative staining.

SEROLOGY. /

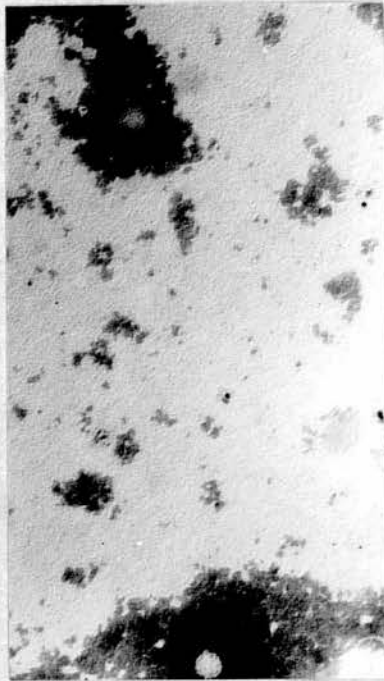


Plate 13.

Virus particles from extract of pooled genital
wart tissue, negatively stained.

PTA stain

x 80 000

SEROLOGY.

1. Demonstration of precipitins in sera during course of wart infection.

(a) Concentration of reagents required for the test.

Almeida and Goffe (1965) had already demonstrated antibody in sera from 19/42 patients with warts by the precipitin test, using an 0.8% agar gel. The 0.7% agar used in this investigation did allow detection of more positive results; of 150 sera tested ^{34 WERE POSITIVE IN THE 0.8% AND} in both concentrations, an extra 12 were found positive in the 0.7% (an increase of 35%). Sera were examined undiluted in these tests. Some of those producing very strongly positive precipitin lines could be diluted 1/2, or rarely 1/4 and still give a positive result, but the majority could not. The virus antigen concentration was also important in this test. A minimum of 10^{11} virus particles per ml. was required to produce a precipitin line, and a concentration of about 10^{12} per ml. regularly gave the clearest lines, about mid-way between the antigen and serum wells.

(b) Specificity of the precipitin lines.

The precipitin line usually formed was slightly curved towards the antigen well. Lines produced by human sera and sera from the rabbits immunised with the purified virus were seen to give a reaction of identity. (Plate 14). The preinoculation sera from these rabbits were negative, and in the case of 27 patients whose sera were examined on two occasions precipitin was absent in the early specimen and present in the later one. This precipitin line was not produced when the sera were tested against an extract of normal skin, unlike other precipitin lines seen in tests using the later rabbit sera. These lines were quite separate from the specific anti-viral one and are clearly due to antibodies to normal skin constituents. They are shown/

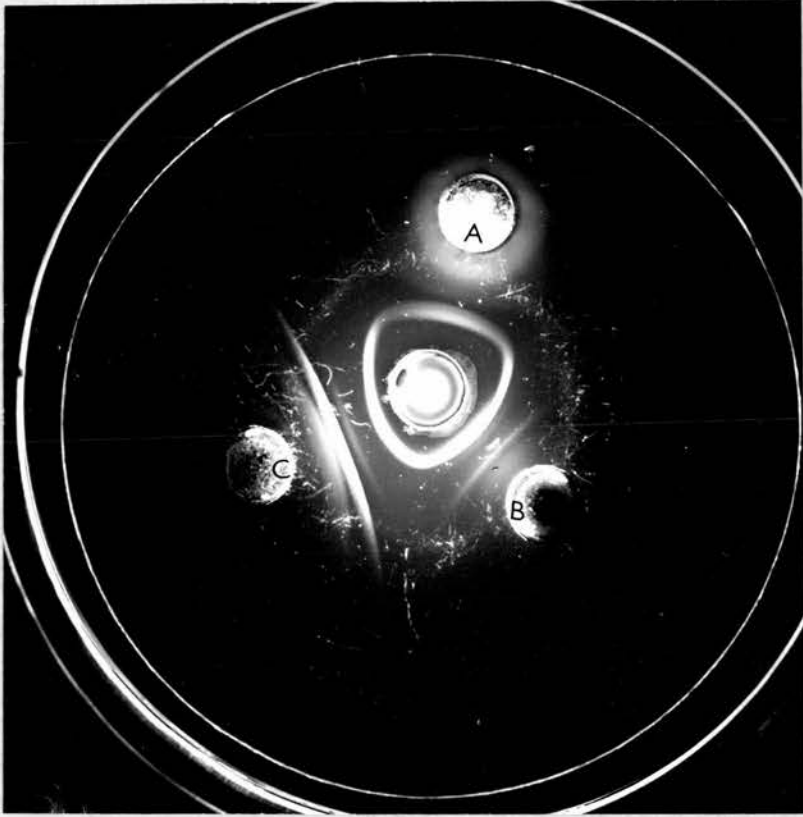


Plate 14.

Precipitin test record.

Central well - virus antigen from plantar warts

A - serum from patient with simple plantar wart

B - serum from rabbit immunised with simple
plantar wart virus antigen

C - serum from rabbit immunised with cellular
antigen from genital warts.

Note reaction of identity between antiviral precipitins
in the three sera (inner continuous precipitin line) and
presence of other precipitins against human tissue in the
rabbit sera.

shown in Plate 14 also. Proof of the nature of the specific precipitin line was revealed by electron microscopy.

(c) Examination of extracted precipitates by EM.

Agar blocks containing the precipitin line or separate areas were examined after negative staining. The precipitin line and no other areas revealed virus particles complexed with antibody, as described by Almeida et al. (1963) in agglutination tests. Some large clumps of virus particles were seen, obscured by a surrounding haze of links connecting particles together. In other fields single virions were found with an attached "loop" of antibody. (Plates 15 & 16).

In a few cases human sera produced two closely similar precipitin lines. When these were extracted and examined separately it was found that both contained virus-antibody complexes, and in both were "full" and "empty" particles found. This is in agreement with the findings of Le Bouvier et al. (1966) who used separate antigens containing only full or empty particles and found that they gave an identical line. They observed an occasional second line only with some old preparations of the empty particles. This contrasts with the situation in enteroviruses, where empty particles produce a separate line from full ones and each has a different antigenic specificity (Beale and Mason, 1968.) Conant and Barron (1967) had found that they got improved separation of the lines in this system by incorporating protamine sulphate in the agar. When this was applied to this wart virus system there was so much precipitate produced around the serum wells that the tests were very difficult to read.

(d) Demonstration of precipitins in patients with warts./

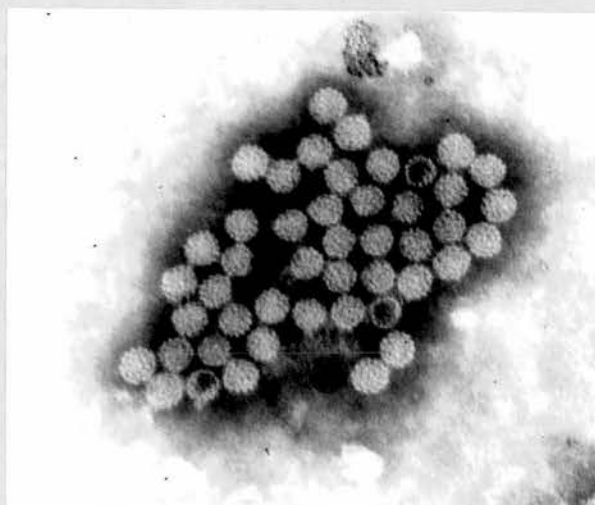


Plate 15.

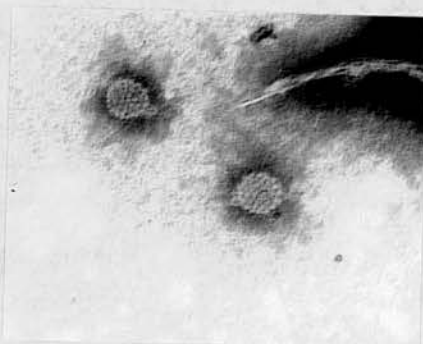

Plate 16.

Both plates are electron micrographs of the negatively stained precipitate from agar.

Plate 15 shows an aggregate of virus particles (including some empty ones) linked by antibody

× 80 000

Plate 16 shows single virions with attached antibody loops.

× 120 000

PTA stain

(d) Demonstration of precipitins in patients with warts.

Table 2

Incidence of precipitating antibody to wart virus in patients with different types of wart.

Precipitin in serum	<u>Condition of wart.</u>		<u>Type of wart.</u>					Total
	Active	Regressing	SP	MP	HW	FW	GW	
-	-	+	17	9	0	0	1*	27
+(IgM)	+(IgM)	+(IgG)	6	2	0	0	0	8
+	+	+	2	3	0	0	0	5
+	(ND)	(ND)	8	5	1	0	0	14
(ND)	(ND)	+	18	3	3	0	0	24
-	(ND)	(ND)	71	25	10	9	18	133
-	-	-	15	13	6	1	3	38
Total:			137	60	20	10	22	249
% with precipitin+			37%	37%	20%	0	5%	31%

Key: Precipitin - (absent), + (present), ND serum not available, IgM - mercaptoethanol sensitive, IgG not. SP = simple plantar, H = hand, F = facial, G = genital, MP = mosaic plantar. *history of hand warts 4 years before.

The results of the examination of all the sera collected from people with warts are given in Table 2. The presence or absence of precipitating antibody is recorded and the type of wart and its clinical condition at the time.

Addendum : Paragraph 2 - first sentence. The 116 patients mentioned comprise not only the 102 actually tested at the time of cure, but also the 14 who would have had antibody if tested at that time since they showed it in their early sera.

serum when there was none in their first. In eight others the replacement of mercaptoethanol sensitive antibody (immunoglobulin M) by resistant IgG was evidence of the developing antibody response.

(e) Immunoglobulin class of precipitins.

Sera containing precipitating antibody to wart virus were examined after treatment with 2-mercaptoethanol and any obvious decrease/

decrease in the precipitin line or failure to produce it after this treatment noted. Those sera that produced only faint lines before treatment could not be examined accurately in this way.

Out of 49 precipitin-containing sera, 20 (40%) contained only mercaptoethanol sensitive IgM, and 15 (30%) had reduced precipitin lines indicating the presence of some IgM and some IgG. Taking only sera from the late stage of wart infection the number with IgM only was reduced to 3%, and if people with simple or mosaic plantar warts were taken separately, 75% (21/28) of those with simple plantar warts had IgG by the time of cure whereas only 40% (4/10) of those with mosaic warts had. Sera from patients with other types of wart were so few and so many were only early specimens that there are no results worth considering.

(f) Comparison with the results of Almeida and Goffe (1965).

These workers found precipitating antibody in 19 out of 42 patients (45%) with unspecified warts, and also found that 72% with antibody had only IgM. The comparative overall results in this survey show 31% (78/249) with antibody and 40% with only IgM. The higher incidence of positive results in late sera, 68% with antibody, and lower number (33%) with only IgM by the time of cure in this investigation reflect the time taken for the antibody response to develop in this virus infection. Almeida and Goffe's patients were tested on their initial attendance and six weeks later. As many as possible in this project were tested at the time of clinical cure, and this was frequently three months, sometimes more after their early test.

2. The agglutination test./

2. The agglutination test.

To be precise it would probably be correct to use the term agglutination for the reaction between wart virus and antibody in the gel diffusion test, but as a visible precipitate is produced it is convenient to retain the term precipitin test to distinguish it from the direct agglutination reaction. This method was only employed on a few occasions as it used up so much antigen and antibody. Virus-antibody complexes were observed, similar to those seen in the negatively stained precipitin line. Only sera with precipitating antibody to wart virus could be shown to produce this agglutination. Recently Almeida, Oriel and Stannard (1969) have reported that using this method they were able to detect typical papovavirus particles complexed with antibody when they used a 10% suspension of genital wart homogenate as the antigen and sera from patients with genital warts. This enabled them to visualise more particles than in the wart homogenate alone.

3. Complement-fixing antibodies to wart virus.

(a) The complement-fixing antigen.

Wart virus antigen preparations were found capable of fixing complement in the presence of specific antibody. The complement-fixing activity in wart extracts sedimented with the virus particles on ultracentrifugation and no soluble complement-fixing antigen was found in the supernate, so the virus particle itself appears to be the antigen involved. This is not the case with complement-fixing antigen extracted from rabbit papillomata, where the rabbit sera react with a soluble antigen, according to work by Nartsissov, Avenirova, Stephanchenok and Solov'eva, 1955. It may be that these workers have/

have demonstrated an antigen similar to the "T" antigens of SV 40 and polyoma virus.

Chessboard titration of the wart virus antigens with antisera revealed that some antigen preparations gave a peak optimal titre and others a plateau; those showing a peak were used at the optimal peak dilution and those showing a plateau used at 4 units. (Grist, Ross, Bell and Stott, 1966). A particle count on one of the antigens revealed a virus concentration of 2×10^9 particles per ml. at the strength used, 4 units. Fortunately none of the antigens were anti-complementary at the dilutions required for the test.

(b) Development of complement-fixing antibodies.

Table 3

The development of complement-fixing and precipitating antibodies during wart virus infection.

<u>Patient</u>	<u>Clinical state of wart</u>			<u>Time since cure</u>	
	Active :	Regressing :	Cured		
A.D.	<8(-)*		32(+)		
J.P.	<8(-)		64(+)		
C.W.	8(-)	128(+)			
E.R.	<8(+)	32(+)	16(+)		
V.L.	<8(-)		64(+)	<8(+)	3 months
M.B.	<8(-)	16(+)		<8(+)	1 year
A.M.			64(+)	<8(+)	10 months
H.M.			32(+)	<8(+)	14 months
A.D.	<8(-)	16(+)		<8(+)	18 months
H.P.		32(+)		<8(+)	2 years
S.M.		16(+)		<8(+)	1 year

*Serum CF antibody titre given as reciprocal precipitating antibody in brackets.

Complement-fixing antibody to wart virus was shown to develop in the sera of some patients during the course of a wart infection. None of these sera reacted with the uninfected control antigen. The complement-fixing antibody developed late in the course of/

of infection; it was only found in patients whose warts were regressing. It was also seen to disappear from the circulation fairly quickly after cure of the wart, and none was found remaining in the sera of the seven people examined 3 months to 2 years after cure. Table 3 illustrates these results, and shows the situation regarding the precipitating antibody in comparison. Precipitating antibody was present in many cases where no complement-fixing antibody was detected, and it persisted longer after cure of the wart. This situation occurs in other virus infections, such as rubella (Sever et. al, 1965) where the presence of complement-fixing antibody in serum is taken as an index of comparatively recent infection. (Schmidt and Lennette, 1966).

The incidence of complement-fixing antibody was highest in patients with simple plantar warts, 74% (23/31) of those examined at the time when their warts were regressing had CF antibody. Of ten such with mosaic plantar warts, four (40%) had CF antibody. CF antibody was also found in two patients whose multiple hand warts were regressing, but in no other patients. These tests were all performed with antigens from plantar warts. Almeida et al. (1969) have very recently reported that sera from seven patients with genital warts showed complement-fixing activity with a genital wart virus antigen but only one reacted in the test with virus from common skin warts, indicating that the antigens involved were different. Sera from five people with skin warts reacted with both antigens.

(c) Class of complement-fixing antibodies.

Sera containing complement-fixing antibody to wart virus were fractionated on sucrose density gradients and the fractions then examined/

examined directly in the complement fixation test. The complement-fixing activity was seen in two quite distinct levels in the gradients:- (1) in the 7th and 8th fractions, near the bottom of the tube. These were the fractions found to contain the Paul Bunnell antibody in the controls, and this antibody is known to belong to the heavy class, immunoglobulin M (Carter, 1966). (2) in the 3rd and 4th fractions, that is above the centre of the tubes, where the lighter immunoglobulin G is expected. The majority of sera examined in this way were from the rabbits immunised with wart virus, and these results are seen in Table 4 in the following section. Two human sera were also fractionated, and both revealed complement-fixing activity in fractions 4 and 7 but not in any other fractions, indicating the presence of both IgM and IgG complement-fixing antibodies.

Not all systems have complement-fixing antibody of the IgM class, but this has been found in antisera to herpes simplex virus. (Smith and Peutherer, personal communication). It is usually found that use of more highly-concentrated antigen results in more frequent detection of this type of complement fixation (Pike, 1967), but with wart virus this could not be established as these higher antigen concentrations were anti-complementary.

4. The antibody response to wart virus in immunised rabbits.

These rabbits were immunised with concentrated wart virus from simple plantar warts. They developed a classical antibody response, with early antibody of the immunoglobulin M class being replaced later by immunoglobulin G. The rise and fall in titre of the complement-fixing antibody were also seen. The results are given in Table 4.

Table 4/

Table 4

Antibody response in rabbits immunised with wart virus.

Rabbit	*Virus inoculum	Serum taken at pre-inoc.	Prec. Ab. U / 2ME	CFT	Class of CF antibody
Rabbit I	SC		-	< 8	
		1 week	+ / -	< 8	
		2 "	++ / +	128	IgM
	IV at 10 weeks	3 "	++ / ++	512	
		11 weeks	++ / ++	512	IgM + IgG
		20 "	+ / +	16	
		24 "	+ / +	32	IgG
Rabbit II		pre-inoc.	-	< 8	
	IV				
	IV at	1 week	++ / +	16	
	IV at	2 "	++ / ++	64	IgM
		3 "	++ / ++	512	
		4 "	++ / ++	128	IgM + IgG
	IV at 10 weeks				
	11 weeks	++ / ++	512		
	24 "	+ / +	64	IgG	

*Key: 10" virus particles given on each occasion
 SC = subcutaneous plus adjuvant, IV = intravenous.
 Precipitating antibody in serum untreated (u) and
 after mercaptoethanol treatment (2ME)
 CFT = reciprocal of complement-fixing titre.

5. The passive haemagglutination test.

(a) Sensitisation of tanned red cells with wart virus.

It was found that the tanned sheep red cells could adsorb wart virus antigen and be agglutinated in the presence of specific antibody. The sensitisation process had to be carried out at pH 6.4 and not pH 7.2 as was used for the rest of the procedures involved. This has been the experience of workers using other virus antigens also; herpes simplex (Scott, Felton and Barney, 1957) and adenovirus (Lefkowitz, Williams, Howard and Sigel, 1966).

The optimal dilution of antigen for sensitising the cells was/

was found to be 1/64 for the particular antigen tested. As there was an ample amount of this simple plantar wart virus antigen available it was used for all the passive haemagglutination tests in this investigation. A particle count of the antigen revealed that the optimal dilution contained 13×10^{10} virus particles per ml. From the amount of virus present in the volume used to sensitise 2×10^9 red cells, and the virus count in the supernate removed after the coating process, an approximate estimation of the amount of virus adsorbed per cell was made.

Virus in sensitising antigen	=	107×10^9	particles
Virus removed after sensitisation	=	4×10^9	"
i.e. no. of particles adsorbed	=	103×10^9	"
no. of cells sensitised	=	2×10^9	"

∴ Approximate no. of particles adsorbed per cell = 52.

Electron microscopic examination of the negative stained, saponin-lysed sensitised cells was somewhat difficult in view of the corrugations in the collapsed cell membrane, but it was possible to identify virus-like particles on the cell surface (Plate 17) and at a higher magnification these were seen to have the size and structure of wart virus. (Plate 18). No such particles were seen in areas of the grid other than on red cell membrane, and none were seen on unsensitised red cells. The cells had been washed four times since the sensitisation process and any free virus particles should have been removed.

(b) Demonstration of antibody by passive haemagglutination.

Table 5/

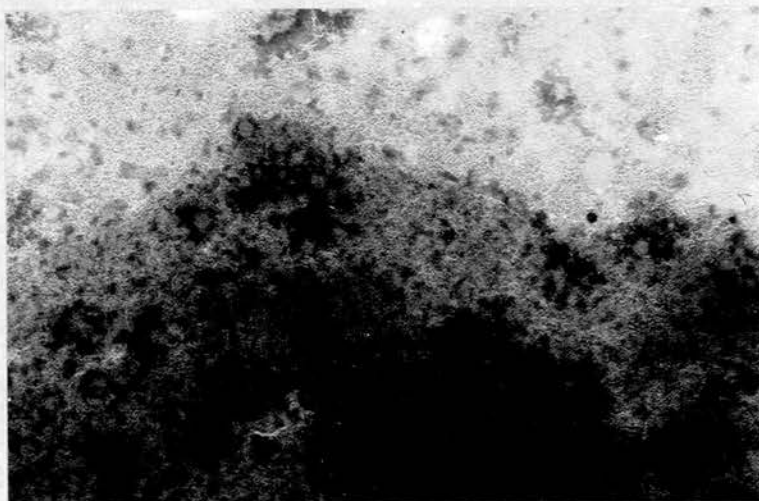


Plate 17.

Electron micrograph of negatively stained sensitised red cell showing some virus-like particles on the cell membrane.

PTA stain

x 40 000

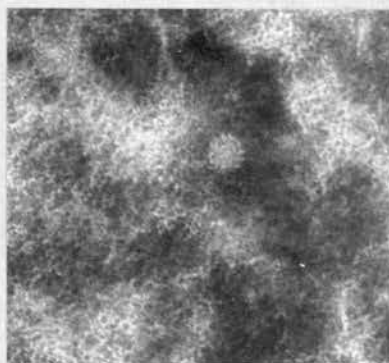


Plate 18.

Virus particle on surface of sensitised red cell.

PTA stain

x 120 000

Table 5

Comparison of antibody demonstration by passive haemagglutination with precipitin and complement fixation.

<u>Patient</u>	<u>Wart type</u>	<u>Wart Active</u>			<u>Wart Regressing</u>		
		<u>PHAU/2ME</u>	<u>PT</u>	<u>CFT</u>	<u>PHAU/2ME</u>	<u>PT</u>	<u>CFT</u>
R.L.	MP	320/10	-	< 8	640/320	+	8
L.B.	MP	160/40	-	< 8	320/160	+	< 8
C.M.	SP	20/NT	-	< 8	2560/640	+	32
M.G.	SP	10240/1280	-	< 8	2560/1280	+	AC
M.P.	SP	20/NT	-	< 8	320/320	+	< 8
B.B.	SP	640/10	-	< 8	160/20	-	32
S.S.	HW	NT			10240/NT	+	8
B.J.	HW	2560/NT	+	< 8	NT		
J.M.	HW	NT			160/NT	-	< 8
W.C.	HW	2560/NT	+	8	NT		
M.S.	FW	NT			320/NT	-	< 8
V2.	GW	640/NT	-	< 8	320/NT	-	< 8
V7.	GW	160/NT	-	< 8	NT		
V14.	GW	1280/NT	-	< 8	NT		

Key: MP = mosaic plantar, H = hand, F = facial, G = genital wart
 SP = simple plantar, NT = not tested.
 PHAU = passive haemagglutinin titre in untreated serum
 /2ME after treatment with 2-mercaptoethanol.
 PT = precipitin test result, CFT = reciprocal complement-fixing titre. AC = anti-complementary.

The sensitised tanned cells were agglutinated in the presence of specific antisera. This passive haemagglutination was particularly marked with some early sera which gave much higher titres than later sera from the same patients. The titres of these early sera were also considerably reduced (more than four-fold) after treatment with mercaptoethanol, indicating the presence of immunoglobulin M in the untreated serum. These observations accord with the findings of others that IgM is a much more efficient haemagglutinin than IgG. (Osler, Mulligan and Rodriguez, 1966). This particular sensitivity is of much value in the study of wart virus infection where so often it is the early sera that are obtainable. As can be seen from Table 5, antibody/

antibody to wart virus could be detected by the passive haemagglutination method in many sera that were negative in precipitin or complement fixation tests, including sera from people with hand warts, genital warts and a facial wart.

(c) Inhibition of passive haemagglutination and standardisation of the test.

The passive haemagglutination of wart virus-sensitised cells by specific antibody was completely inhibited if the serum was pre-incubated with wart virus antigen for 30 minutes at 37°C. Pre-incubation with other virus antigens prepared for neutralisation tests, herpes simplex and adenovirus, did not inhibit the haemagglutination. This test could be used to demonstrate the presence of wart virus antigens in extracts. The smallest amount of virus detectable in this way was not measured as most of the extracts tested produced non-specific haemagglutination of the tanned cells.

It may be that some sera contain non-specific inhibitors of haemagglutination in this test as a few sera gave titres of <20 in the test although they did contain some precipitating antibody, but it was mercaptoethanol resistant in the precipitin test.

The passive haemagglutination test was fairly satisfactory as regards reproducibility, at least when one person did all the readings. Forty sera tested with two separate batches of sensitised cells produced differences in titre of one or two wells only in four sera. The significance of agglutination in the lower titres is not certain, and the arbitrary level of 1/80 or over was chosen to indicate antibody to wart virus. Further standardisation of the test is required, and the use of purified antigen, prepared perhaps by density/

density gradient separation, would be advisable. A colleague pursuing the further use of this test reports some difficulty in sensitising the tanned cells with different batches of antigen, one of which was noted to contain an unusually large amount of filamentous material.

(d) Reversed passive haemagglutination test.

The method used in this test was one given by Abu Salih, Murant and Daft (1968) for coating tanned cells with antibody and using these to detect plant virus antigen. The results with wart virus antibody-sensitised cells were not so successful, but only the one method for sensitisation was used and only one serum used to provide the gamma globulin fraction used to coat the cells. Tanned cells sensitised with a 1/2 dilution of the globulin fraction did show haemagglutination with wart virus antigen, giving a titre of 1/1000 for the antigen which contained approximately 10^7 particles per ml. at that dilution.

It should be possible to develop a much more sensitive system, capable of detecting much smaller amounts of antigen. The serum used for sensitising the cells requires to be of a high titre and use of the optimal amount has been found to be of importance. (Abu Salih et al., 1968) Others have found that warming the reagents (at 56°C . for 50 minutes) before the sensitisation process greatly increases the sensitisation. (Nyerges, 1969.) All these variations in technique would have to be experimented with in order to produce a suitable test for wart virus.

6. Serology and epidemiology.

(a) Wart virus antibodies and spontaneous resolution.

Few sera were obtained from people whose warts were showing spontaneous/

spontaneous resolution as it is usually obvious to the patients if this is happening and they do not attend for treatment. However sera were obtained from seven patients who had received no form of treatment and were found to have spontaneous resolution. Two of these had simple plantar warts, one multiple filiform facial warts and four had multiple hand warts. Four had precipitating antibody to wart virus, and the four of these had complement-fixing antibody also. These were the two with plantar warts and two with hand warts. In addition the patient with facial warts had a passive haemagglutinin titre of 1/320 and one of the remainder with hand warts had a titre of 1/80: the last could not be tested. Thus it is quite clear that anti-viral antibodies do develop during a spontaneously-resolving wart infection.

(b) Antibodies in people with a past history of warts.

The survey carried out among the 348 college students revealed that 103 (29%) had never had warts, 56 (16%) were currently infected and 189 (55%) had had infection with warts in the past. Sera were obtained from 76 of those with a past history of warts and examined for antibody in the precipitin and passive haemagglutination test. The complement-fixation test was not used as it had already been found that complement-fixing antibody did not persist for long after cure of warts.

The results showed that six of the 76 had precipitating antibody to wart virus. Of these three had had plantar warts less than three years previously and one five years before, and the others had had hand warts three and seven years before.

Passive haemagglutinin titres greater than 1/80 were found in/

in seven sera from the 26 with a history of hand warts, and in 20 out of 50 with a planter wart history. The longest time since infection in any of these was 10 years. This time interval goes back to the age of 7 - 11 on average for these students, the age when many probably were first exposed to infection.

(c) Antibody in people who had never had warts.

Sera were obtained from 34 of the 103 girls who said they had never had warts. One of these did in fact have some precipitating antibody to the virus. Twenty five had passive haemagglutinin titres of 1/40 or less, three had titres of 1/80 and five of 1/160. As already mentioned, the significance of lower titres in the PHA test is not certain. However it is quite possible for people to have warts without being aware of it, and this was seen more than once in practice, so a childhood or teenage infection could easily be ignored or forgotten. The question arises as to whether some other antibody might be producing these results, and the obvious one to consider would be antibody to SV40 virus, which some of these students might just possibly have as a result of polio vaccination. It was not possible to test these sera for SV40 antibodies so the question remains unanswered as yet.

VIRUS AND OTHER ANTIGEN STUDIES.

1. Antigenic identity of virus from different wart types.

(a) Virus from hand warts and planter warts.

Morphologically the virus particles from all types of wart were identical. The only materials available in sufficient quantity for comparison of the virus antigens were from planter warts and hand warts./

warts. Mosaic plantar wart virus and simple plantar wart virus gave identical results in serological tests with a wide variety of sera. The complement-fixing antigen and precipitin antigen appeared identical. Similarly with virus from hand warts, though only a little of the antigen was available. The reaction of identity of these three antigens can be seen in Plate 19.

(b) Virus from genital warts.

There was insufficient genital wart material to provide antigen for direct testing, but by indirect methods the identity of this virus with that from the common skin warts is suggested. The rabbit inoculated with a cellular antigen from genital wart material produced, after two booster doses, a precipitin in its serum that gave a reaction of identity with precipitin to plantar wart virus, as seen in Plate 14. In addition sera from three patients with genital warts and no history of other warts had antibody to wart virus demonstrated by the passive haemagglutination test. (See Table 5) These reactions indicate a sharing of a major, if not the only, antigen by virus from the genital warts and other skin warts.

However, Almeida et al. (1969) have recently put forward evidence to the contrary. They found that sera from patients with genital warts did not react in complement-fixation tests or agglutination tests with virus from skin warts, but did react with virus from genital warts. Sera from people with skin warts reacted with both viruses.

(c) Filaments.

Only one antigen preparation was seen to contain much filamentous/

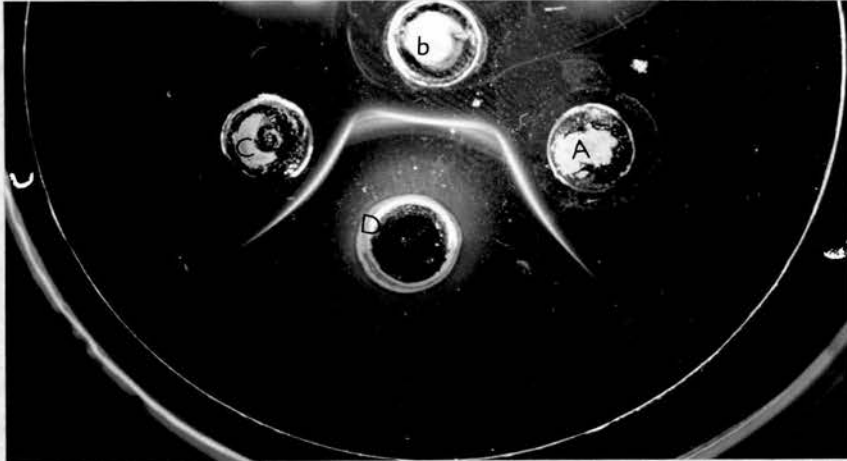


Plate 19.

Precipitin test record.

- Well A - virus antigen from simple planter warts
Well B - " " " mosaic " "
Well C - " " " hand warts
Well D - serum from patient with simple planter wart

Note reaction of identity between the precipitin lines formed by the three antigens.

filamentous material, and it was hoped to separate this from the virus particles and examine it antigenically. Separation was partly achieved on a sucrose density gradient. The gradient was prepared as described for fractionation of sera, 0.5 ml. antigen layered on top and ultracentrifuged at 20,000 rpm. for 2 hours in the SW50 rotor of the Spinco model L. One band was noted, a narrow one just above the centre of the tube. Fractions were collected dropwise from the bottom of the tube after piercing it with a fine needle; ten fractions in all. The content of each fraction was examined by negative staining. Much debris and virus particle content had deposited in a pellet at the bottom of the tube. In fraction 6 there was a considerable number of wart virus particles. In the fraction below this there were fewer virus particles and some filaments. Even after dialysis overnight against phosphate-buffered saline the fractions were found to be anti-complementary, and produced no lines in precipitin tests against antisera to the virus.

A greater concentration of filamentous material and experimentation with a range of density gradients is indicated if the identity of the filaments is to be determined in this way.

2. Electrophoresis of wart tissue extracts.

A limited number of experiments was performed owing to the small quantities of suitable material available. Extracts from simple planter hand and facial wart tissues were prepared and the pattern of protein bands detected after electrophoresis compared with those of normal skin extracts and of concentrated wart virus antigen after similar treatment.

The/

The concentrated virus antigens yielded two strongly staining protein bands, one migrating about 10 mm. from the origin (the site of application of the sample) and the other 25 mm. Eluates prepared from different areas of the strip and negatively stained showed that the eluate from the 10 mm. - migrating band contained numerous wart virus particles. (see Frontispiece). Virus particles were also noted in the eluate from the area of the origin, but not from any other areas, nor were any other structures recognised in the eluates. This finding is similar to that of Steward et al. (1968) except that their virus band migrated 20 mm. from the origin, they were using 0.6% agarose and not cellulose acetate as here.

Protein bands migrating 10 mm. were revealed in some of the extracts, simple plantar and hand warts, but not in extract of facial warts or normal skin. Other bands were also observed in these preparations, noticeably the one migrating about 25mm. which occurred in all the extracts including normal skin. One other band that migrated about 3 - 4 mm. was seen in the hand and facial wart extracts and in no others, not in normal skin. Other fainter bands between 10 and 25 mm. were found in some extracts but also in normal skin.

Steward et al. found that some wart extracts produced up to seven bands. The virus band was identified in 39% of 31 extracts. They had 24 normal skin extracts and only 13 produced a band at all, one migrating more than twice the distance of the virus band. It may be that their normal samples were insufficient to reveal all the normal bands, because other workers have detected the presence of several proteins in epidermal tissue by electrophoresis. (Fisher, 1966; Krebs, Sellei and Schaltegger, 1969).

The/

The results of the immunodiffusion tests on the electrophoresis strips indicate that greater amounts of material and more concentrated extracts require to be obtained to demonstrate the antigens in this way. In the case of one electrophoresed antigen preparation a precipitin line did develop between the strip and an antiserum to wart virus, curved around the origin. No other lines were seen between other areas of this strip and this serum or another serum from a patient with multiple warts. Nor were any precipitin lines detected around any of the other extracts tested against these sera.

3. Extract from HEp-2 cells inoculated with wart virus.

It had been hoped that the concentrated cell lysate obtained from the HEp-2 cells 24 hours after inoculation with wart virus might contain early virus-induced antigens similar to the "T" antigens of SV40 and polyoma virus. The preparation was tested in precipitin tests against a very wide range of sera, from the immunised rabbits and patients with all types of wart, particularly some with large or multiple tumours. In no case was a precipitin line seen, except with serum from the rabbit inoculated with the genital wart tissue and this reacted also with normal skin. The preparation was anti-complementary even on considerable dilution and after heating at 56°C. for 30 minutes so could not be examined for complement-fixing activity with the sera.

TISSUE CULTURE RESULTS.

1. Cytology of HEp-2 cells inoculated with wart virus.

The HEp-2 cell monolayers inoculated with wart extracts showed/

showed certain changes not found in the control cultures inoculated with medium or extract of normal skin (corn parings.) The changes were only observed in tubes inoculated with 10^8 virus particles or more; they were not passed to fresh cultures by inoculation of fluid or cells from these cultures, they developed equally in cultures maintained at pH 7.2 or pH 6.8; pre-incubation of the extract with antiserum to wart virus (at 37°C . for 1 hour) did not neutralise the effects.

The changes were most clearly observed in the stained coverslip cultures. By 24 hours after inoculation many of the cells were rounded up and stained very darkly. By 48 hours many cells had fallen off, leaving spaces, while controls showed an even monolayer. After one week the surviving cells had enlarged and small islands formed, gradually increasing as the cells proliferated, some becoming unusually large. The cells became rather granular after the third week and degenerated. Several multi-nucleate cells were seen. No inclusion bodies were observed. These changes were considered to be a result of the cytotoxicity of the extract rather than a specific viral cytopathic effect. Similar effects have been noted by other workers using wart extracts or molluscum extracts (Carteaud 1958), and even heated wart extracts (Oroszlan and Rich, 1964).

2. Electron microscopic study of tissue cultures.

Wart virus particles were not found in negative stained preparations from fluids or cells of any of the cultures inoculated, including those maintained at 30°C . Nor were wart virus particles, or filaments, or other virus-related abnormalities like nuclear margination/

margination of chromatin observed in any of the inoculated cultures examined after embedding and thin sectioning.

3. Experiments to transform cells with wart virus.

None of these experiments were successful. No transformed colonies were found in the agar suspension cultures of BHK21 cells or human skin fibroblasts, nor in the monolayer cultures of the latter. It must be considered that none of these cultures was maintained for longer than 30 days, and it was difficult to achieve the high levels of humidity desirable for such experiments. Another unknown quantity was the virus used in these attempts. A maximum of 10^4 particles per cell was used, and it is not known how many of these physical particles were infective or capable of inducing transformation. SV40 transformation of adult human skin fibroblasts requires about 10^4 infectious units per transformed cell, and the ratio of physical to infectious particles may be of the order of 200:1 (Aaronson and Todaro, 1968). The transformation of adult skin cultures by SV40 took 8 to 14 weeks in some cases. (Koprowski et al. 1962).

DISCUSSION

DISCUSSION

Diagnosis of wart virus infection by electron microscopy.

The simplest method of revealing virus particles in warts, negative staining and electron microscopic examination of material released from the tissues, is clearly of value in the diagnosis of the more common forms of wart occurring on the hands, feet and face. These warts, particularly those with hyperkeratosis, usually contain sufficiently large amounts of virus to be detected in this way. The results overall in this investigation show that in 78% of 207 specimens wart virus particles were demonstrated by the negative staining method, and in the examination of a series of specimens from 59 planter warts after experience had been gained in the use of the technique, wart virus was detected in 57 (97%). Others have reported equally good results with this technique, finding virus in 67 out of 68 specimens. (Kingsley-Smith et al. 1967). The use of a cell-spreading technique such as that of Parsons (1963) is recommended as an additional procedure in the examination of material from more cellular warts with minimal keratosis which usually result in cell debris obscuring films prepared by the other, teasing-out method.

Failure to reveal virus particles by negative staining of tissue does not necessarily mean that the cells do not contain virus. Particles require to be in a concentration of approximately 10^7 per ml. of fluid before they can be detected on a negative stained film. The nature of the specimen is thus of importance; collection of the degenerating infected cells of the most superficial layers, usually by paring with a scalpel, in a minimal volume of fluid to keep the material moist is the most satisfactory. It is more difficult to obtain/

obtain release of virus, much of which may be intranuclear, from cell layers below the stratum corneum, which may be very thin in warts of the face for instance. The importance of these reservations was demonstrated in the results of examination of material from genital warts by the negative staining techniques. In none of the twenty two specimens were wart virus particles demonstrated, only in a concentrated extract from pooled material and then very few particles were seen.

The incidental diagnosis of unsuspected lesions of molluscum contagiosum by the negative staining of tissue pared from the lesion was of some academic interest but also relevant from a therapeutic viewpoint. Such lesions on the sole have been confused with tumours in some cases and excised surgically. This could have led to painful scarring, whereas a simple examination could have given the diagnosis. As and when more specific anti-viral agents become available, their use in treating such virus infections will depend on a knowledge of the virus involved, for pox viruses will very likely be susceptible to agents different from those affecting papovaviruses.

Where there is no access to an electron microscope, specific diagnosis of the presence of wart virus in tissue might be achieved by one of the two other techniques currently applicable, in the continuing absence of any cultural methods for identifying the virus. One requires the preparation of extracts from large wart specimens and subsequent examination by electrophoresis for the presence of wart virus protein with a characteristic migration pattern, as demonstrated by Steward et al. (1968) and confirmed in this study. They were able to detect the specific protein in 39% of 31 specimens examined. An alternative/

alternative method would be the demonstration of specific virus antigen in wart tissues by a fluorescent labelled antiserum as used by Walter et al. 1965, who found antigen by this method in the superficial cells of each of 17 warts examined as thick sections. Rigorous controls would have to be applied to eliminate any non-specific fluorescence, but such problems are well-recognised nowadays with the widespread use of this as a diagnostic method in virology and other disciplines (Nairn, 1969). The technique was not used in this study since the majority of specimens were unsuitable for sectioning and no suitable antisera were available early in sufficient quantity. A brief experiment using smears of plantar wart parings, shown to contain virus by negative staining, and a rabbit serum containing high titre complement-fixing antibody to the virus, followed by application of fluorescein-labelled anti-rabbit gamma globulin (Winthrop Laboratories) gave negative results. The presence of antibody already complexed with the virus could produce negative results in this situation.

Examination of thin sections of warts had already been used by others and the appearance of wart virus and its development in the epidermal cells clearly demonstrated in common hand warts, plane warts and plantar warts. However there had been no satisfactory demonstration of papovavirus particles in genital warts, and indeed large intra-cytoplasmic particles resembling pox viruses have been claimed by some as the aetiological agent (Overbeck, 1967), while others had identified cytoplasmic structures of a size range 20 - 80 nm. as the virus particles. (Zimmer et al. 1964). Typical papovavirus particles, diameter 46 nm., were found in the nuclei of stratum granulosum cells in sections from one of the 12 genital warts examined here./

here. Their size, morphology and cellular location are all characteristic of the group, and the demonstration of their morphology by negative staining confirmed that these were papilloma virus particles. Their close association with filaments in cells, and possibly also in negative stained preparations, is a feature of the papovavirus-like structures seen in oral papillomata (Frithiof and Wersall, 1967) and in polyoma infected cells. (Mattern et al., 1966). The very small amount of virus present in these genital wart tissues was noticeable.

Almeida et al. (1969) report that they also have found virus particles indistinguishable from wart virus in thin sections of genital warts, and negative stained preparations, and that the particles were present in very small quantities. Their publication of this finding is to appear soon in the press. (Oriel and Almeida, 1970).

Other features that we identified in genital wart sections were normal cell constituents or characteristic of various conditions involving alterations of the keratinisation process. Some, particularly the small vesicles and perhaps the lacunae, large bodies of diameter 500 nm. in the superficial cells, might have been confused with viral particles by others.

The effects of treatment or duration of the wart did not exclude the possibility of demonstrating virus particles in the tissues. Some of the specimens in which virus was identified by negative staining were from warts up to three years old. One particular patient who attended clinics throughout the three years of this project continued to have detectable amounts of virus in parings/

parings from her mosaic plantar wart during this time. There did appear to be more virus in the "younger" lesions however, and no large aggregates of virus were ever found in those more than one year old. Treatment by means of applications such as podophyllin or the various paints in use did not prevent the demonstration of virus in lesions. Only 25% of all the warts had received no treatment at all before the virological examination. The observation of numbers of apparently normal virus particles in the "dead" tissue on the surface of some cured warts is a warning towards taking precautions against spread of infection from this source until all such tissue is removed.

No definite conclusion can be drawn from the observation of a large proportion of "empty" particles in some specimens, but it is interesting that in three of the four where this was particularly noticed regression of the warts was occurring at that time, and the lesions were cured within three weeks. The fourth lesion had not been noted clinically to be regressing, but the patient failed to attend for further examination or treatment so there may have been a speedy cure there also. Three of the four had received no treatment at all, one had used an unspecified ointment. The three with regressing lesions all had high levels of anti-viral antibody in their sera at that time. If spontaneous cure results in production of non-infectious virions and development of anti-viral antibody as this suggests it is clearly a most satisfactory outcome and one to be encouraged when possible.

Electron microscopic study of material is helpful in the selection of suitable sources of antigen, indicating the amount of virus/

virus present in extracts. However this could also be judged from consideration of the sites of virus production in the epithelium and the amount of stratum corneum present in the tissue, for it is here that the largest aggregates of particles were found. Parings of such cells from simple plantar warts were regularly the most productive and most readily available source of antigen in this study. Where the only wart tissue available is that removed by curettage it may be difficult to obtain good antigen preparations as most of the material will be from hand and facial warts, and though individual specimens contain on occasion large amounts of virus the yield from pooled material is small. (Elek 1968, personal communication). I am appreciative of my good fortune in that the choice of treatment for plantar warts in Edinburgh during this study involved paring off the superficial infected cells and that I was able to attend clinics to collect this material.

Demonstration of a virus in tissues does not provide a totally acceptable diagnosis of an infection by that agent. The virus may be a passenger in the cells or responsible for a contemporaneous infection in the same tissue, as illustrated by the isolation of a cytomegalovirus from a wart by Morgan and Balduzzi, 1967. Confirmatory evidence of the aetiologic significance of the particles must include the demonstration of their presence regularly in the particular lesions and absence from normal tissues, serological evidence of a host immunological response to the infecting agent, and production of the disease by inoculation of the agent. The last is not ethically readily possible with purified wart virus because of the potential dangers of carcinogenesis in/
in/

in man, and finding of an animal host must be awaited. However serological tests are now established.

Serological diagnosis of wart virus infection.

The four tests now established for demonstrating antibody to wart virus each have their advantages in different situations, and the choice of method must be considered in any investigation. The observation of agglutination by electron microscopy is not generally applicable and will be considered mainly in connection with the detection of antigens.

The precipitin test in gel, introduced by Almeida and Goffe in 1965 is the most generally applicable technique. It presents no difficulties in use and requires only small amounts of concentrated antigens. The specificity of the test has been clearly demonstrated by reactions of identity and electron microscopy, and the ease with which the presence of immunoglobulin M as the precipitating antibody can be shown is an advantage. Other workers have found that mercaptoethanol need not be removed by dialysis from sera so treated before they are examined in precipitin tests, for instance in the demonstration of IgG antibody to foot and mouth disease virus. (Cowan and Trautman, 1965). This present investigation has also shown that when sera are obtained from patients at a time when their warts are regressing, antibody can be demonstrated by the precipitin test in 68% of cases, compared with 9% of sera taken before any signs of regression are apparent. The incidence of antibody was highest (77%) in people with simple plantar warts, who formed the majority (55%) of those examined. In examination of single sera it would be necessary to determine whether any precipitin was IgM, for IgG could be present as/

as a result of a past infection, perhaps unrecognised.

Complement fixation by wart virus antigen and antibody was found in this study and has also been reported independently by Elek (1968, personal communication) and by Almeida et al. 1969. It has been shown here that complement-fixing antibody for wart virus can be IgM or IgG, although the use of concentrated antigens that are generally much more sensitive in detecting IgM CF antibodies could not be applied. In addition there was the finding that the CF antibody appeared later in infection than precipitating antibody and disappeared soon after cure of the lesion. This was not surprising in view of the knowledge of a similar situation in rubella infection, for instance, but it limits the use of this test to the investigation of current infection. Rising or falling titres of CF antibody were shown in 66% of 30 patients from whom paired sera were thus examined. In addition, 14 out of 25 single sera from people with regressing warts contained CF antibody. Once again patients with simple plantar warts most often had this antibody (85%), and again they were the majority examined (62%). In only one case was CF antibody demonstrated in the absence of precipitating antibody: the patient had only IgM antibody as seen in the passive haemagglutination results. (patient B.B., table 5) By using a micro-technique involving very small volumes, 0.025 ml., this test can be easily applied without requiring excessive amounts of antigen.

The technique of passive haemagglutination is not commonly applied in diagnostic virology as in most cases an alternative sensitive test is much more easily available, such as neutralisation or haemagglutination inhibition tests. The disadvantages of passive haemagglutination/

haemagglutination lie in the need to avoid any non-specific agglutination, of which there are several possible sources including virtually all the reagents used in the procedure, and the fact that it is a qualitative test rather than a quantitative one so that titres of paired sera are irrelevant unless the proportion of IgM present is determined. The ease with which this can be done, however, is a point in favour of the method, as is its very sensitivity in demonstrating IgM, and levels of IgG too low to produce precipitin lines. (As seen in the survey of past infections). By demonstrating antibody to wart virus in sera from people with facial and genital warts with this test it is now justifiable to continue using the only readily available antigen, virus from plantar warts, in these investigations.

There are several complicating factors to be considered with regard to the passive haemagglutination test. Technical details are important, such as use of conical-bottom wells for best observation of haemagglutination, and use of disposable plates as scratches interfere with the settling of the red cells. (Hopkins, 1969). The significance of low titres is not clearly established, as reading of the results by simple observation may vary between observers. Furthermore the question of the possibility of antibody to a closely related antigen causing some agglutination requires investigation. The antigen considered to be possible source of difficulty is the only other known papovavirus that patients might possibly have come in contact with, SV 40, through contaminated vaccines. No report of a direct comparison of the virus antigens of SV 40 and human wart virus is known to me.

Melnick/

Melnick and Rapp (1965) did demonstrate a possible relationship between the two viruses that was clearly dependent on similarities between the antigens of cells infected by them, presumably of the tumour-specific transplantation antigen type, but did not infer a virion antigen sharing necessarily. They used purified virus to immunise weanling hamsters and then challenged them with inoculations of SV 40-transformed cells that in control, unimmunised animals rapidly produced large tumours. Immunisation with SV 40 gave protection against these tumour cells so that overwhelming doses were required to produce even small tumours. But immunisation with human wart virus also gave protection, not to the same degree as SV 40, but sufficient to result in a 100-fold increase in the number of cells needed to produce even small tumours, and the development of these was greatly delayed. Khera, Ashkenazi, Rapp and Melnick (1963) had previously shown that immunisation with polyoma virus did not confer any protection against SV 40 tumour cells. It is known that anti-viral antibody is not responsible for such protection, so the wart virus must have been able to induce cell surface antigen changes in the hamster tissue that could be recognised immunologically and led to the development of some immunity. There is no record that the wart virus, given subcutaneously as three injections of approximately 10^9 particles, had any other effect on the animals. An alternative explanation would require the presence of sufficient of the wart virus-specific cell antigen in the immunising extract used, a total of 0.3 ml. was given.

The antigenic identity of viruses from warts.

That wart viruses possess more than one antigen is suggested
by/

by the observation of the occasional second precipitin line whose difference from the usual one has not yet been elucidated. As far as the major antigen goes, it is now clear that this is common to virus from hand warts, simple planter and mosaic planter warts, from the reactions of identity given by these three antigens. It would also appear to be present in genital wart virus as antibody to this antigen was produced by the rabbit immunised with genital wart tissue, and by patients with genital warts.

However, the results of Almeida et al. (1969) have recently indicated some antigenic difference between virus from skin warts and virus from genital warts. They found that sera from people with genital warts reacted only with the homologous virus in direct agglutination and complement fixation tests. The antigen they used was prepared from a genital wart homogenate centrifuged at 18,000 rpm. to give a pellet. It is just possible that this might have contained another antigen apart from virus particles to react in complement fixation tests, but the results of the agglutination test showed clumping of virus particles by antibody, so a virion antigen is involved. It may be that the antibody involved in these reactions was of an early, perhaps IgM class, with greater specificity than the antibody detected in the genital wart antisera in my investigation. It is recognised that early antibodies, sometimes IgM but not always, are in some systems more specific than later ones. For instance use is made of highly specific IgM in demonstrating antigenic differences between closely related Group B arboviruses. (Westaway, 1968).

The occurrence of antigenic differences in virus from skin lesions/

lesions and genital ones has been demonstrated with herpes simplex virus, and biological differences also found. (Dowdle, Nahmias, Harwell and Pauls, 1967). It may be that a similar situation exists with regard to wart virus, but the matter has not been fully resolved. The complete antigenic identity of the skin wart viruses have not been established, only the identity of the only antigen detected so far.

Antigenic relationships among papova-like viruses from human tissues other than warts.

The antigenic identity of the several papova-like viruses seen in human disease other than warts has not been demonstrated. The virus particles found in the brain cells in the condition of progressive multifocal leucoencephalopathy have been shown to be slightly smaller than wart virus and therefore less likely to be a variant of it. (Waterson and Almeida, 1969). The particles in the wart like lesions of epidermodysplasia verruciformis are much more likely candidates. Only one report is known of an attempt to demonstrate antibody to wart virus in serum from a patient with this disease, and it was unsuccessful. (Baker, 1969). The method used is not stated.

The papova-like virus particles in papillomata of the oral cavity are again possible variants of wart virus. (Frithiof and Wersall, 1967). The particles found by Smith et al. (1969) in the nephroblastoma cell cultures resemble wart virus and have been shown to lack the biological activities of the polyoma-SV 40 group. In attempting to establish the identity of these viruses some of the techniques developed in this project could be useful. Inhibition of passive haemagglutination, or agglutination of cells sensitised with antibody/

antibody to wart virus (the "reversed" PHA test) should be able to demonstrate the presence of small amounts of wart virus. Precipitin tests would require larger amounts of virus. Mrs. Almeida's agglutination technique would also be able to detect quite small numbers of particles. These techniques will become more useful if with the increasing examination of tissues by electron microscopy other wart-like viruses are found.

Another structure, related to wart virus, whose identity has still to be established, is the filamentous strand with apparent sub-structure found associated with the virus. Some features, the morphology particularly and also the theoretical possibility that excess virus sub-units might have this appearance (Rowson and Mahy, 1967) support the view put forward by Smith et al. (1965) that these are strands of unassembled protein sub-units. Similar structures have also been observed in cells infected with the herpes simplex virus. (Murphy, Harrison and Whitfield, 1967). DNA viruses such as herpes and adenovirus have been shown to produce viral protein in excess of the amount used for assembling virus capsids.. (Green, 1962).

The similar filaments observed by Mattern et al. (1966) early in polyoma infection of cells led them to suggest a possible relationship between the filaments and the intranuclear "T" antigen that develops at that time and has been shown in immunofluorescent studies to have a linear arrangement. (Takemoto et al. 1966). Likewise in adenovirus infected cells and tumour cells a fibrillar structure of this appearance, with periodicity of 75 \AA , was seen and found to react with ferritin-labelled antibody to the "T" antigen of the virus. (Kalnins et al. 1967). Such structures can be seen in the absence/

absence of recognisable viral particles and could be a diagnostic "pointer" to the presence of viral genome.

Development of immune response in wart virus infection.

The development of a full antibody response in the rabbits immunised with wart virus in concentrated amounts demonstrates the capacity of the virus to act as an immunogen. A complete response of this nature was also shown in patients with warts, whether after treatment or with spontaneously resolving lesions. This was most often so in people with the simple type of plantar wart, and it is thought that the reasons for this are most likely the large amounts of virus antigen present in these lesions and the apparent frequency with which they regress quite soon, unlike some mosaic warts. The correlation between appearance of antiviral antibody and regression of warts is marked, but the presence of anti-viral antibody is known not to effect the regression of the tumours: some patients had antibody present for up to 18 months before their warts were cured. It is possible though that the mechanism of regression, involving cell-mediated destruction of infected cells, leads to a much increased exposure of the virus antigen inside the cells to those cells capable of initiating a humoral antibody production. In some cases when simple plantar warts were observed at the time of regression the lesions could be clearly seen to have become separated from the surrounding tissues, and could be curetted out with ease, or if left fell out of their own accord. Such a result was never seen in any of the prolonged mosaic plantar warts. These were much more superficial lesions and cure seemed to depend more on the gradual destruction of all the infected cells by the treatments applied.

Similar/

Similar findings were reported by Barr and Coles (1966) after a statistical study of warts. They found that the simple type ("myrmecia") had a high incidence of natural resolution.

The role of IgG antiviral antibody must lie in preventing re-infection with the virus, and in limiting spread of the virus to other sites. It has not been possible yet to follow up patients in whom such antibody was found to determine whether immunity is indeed conferred. Lee and Olson's work with bovine papilloma virus infection (1969 b) showed that animals developing IgG antibody became resistant to re-infection with that virus.

In considering the treatment of warts some attention should be given to the desired result. The patient's benefit should come first, and clearly no method that results in any scarring, pain or other undesirable effects that are worse than the natural disease are acceptable. Removal of tumours also removes the stimulus to development of an immune response. If immunity is a desired aim then time for spontaneous regression, with or without application of treatments that may hasten this but do not prevent the immune response developing should be allowed. A clinical trial of four treatments for planter warts will be reported in the near future. (Bunney and Hunter, 1970).

The duration of specific antibody after a wart infection was shown to be as long as ten years in one case. As already mentioned the age of the girls surveyed did not exceed 23 years, and the occurrence of unrecognised infection was a definite possibility. The incidence of antibodies in the general population is unknown, but could approach that in the college students not currently infected, that is 5% with precipitating/

precipitating antibody or 24% with antibody demonstrated by passive haemagglutination.

Wart virus, new antigens, transformation and carcinogenesis.

None of the characteristic features of DNA tumour virus-transformed cells have as yet been identified in human papova (wart) virus infected tissues. The limited experiments that could be carried out with the material available in this investigation did not produce any useful results. However they merit some consideration as, in conjunction with new information emerging regarding other papovavirus systems, suggestions can be made as to the steps that might be taken to achieve some of the aims.

One primary aim is to identify any "T" type antigen specific for wart virus that would be an important diagnostic aid in the search for wart virus genome in tumour tissues, such as bladder papillomata and Wilms' tumour possibly, where virus particles are not seen. Identification of such antigens requires the application of sera from people with warts to suitable tissue extracts or preparations and demonstration of reactions between the antigen and specific antibody. Such antibody is most likely to be present in sera from people with large or multiple warts, by analogy with the polyoma tumours in hamsters.

Procedures are established for extracting "T" antigen from other virus-induced tumours, such as adenovirus ones (Jainchill, Candler and Anderson, 1969) as well as from tissue culture cells. Both the approaches used in this project could be useful, if tissue culture cells can be infected with wart virus or if sufficient amounts/

amounts of wart tissues can be obtained to use more concentrated extracts in the immuno-electrophoresis technique.

There is still no evidence for wart virus being an aetiologic factor in any malignant neoplasms. Attempts to induce transformation of tissue cultures should be extended, if adequate amounts of virus can be obtained. Some recent evidence regarding other systems might be of help in the selection of appropriate measures to increase the chances of success. Aaronson and Todaro (1968) have shown that SV 40 transformation of human fibroblast cell strains is much higher in cultures from people with genetic disorders, particularly Down's syndrome and Fanconi's anaemia, than in cultures from normal skin. The infectivity of SV 40 DNA was shown to be greatly increased in the presence of DEAE-dextran (McCutchan and Pagano, 1968). This was not incorporated in experiments in this study as intact virus was being used, and DEAE-dextran was found to reduce the infectivity of the intact SV 40. Stoker and Macpherson (1967) reported a personal communication from Le Bouvier and Thomas who found that bovine papilloma virus initiated growth of colonies from bovine embryo skin cells in agar suspension cultures. The proportion of colonies produced was low (0.06 - 0.17%) and conditions of very high humidity were required.

The whole question of viruses and carcinogenesis has produced much research, innumerable conferences and reports of a large variety of techniques for investigating the problem. There is still no evidence for any virus being the direct cause of cancer in man. Advances in understanding of the immunological responses involved/

involved confirm the opinion expressed by Stoker in 1962 that it is probably the tumours of infancy and childhood that should be considered most seriously in connection with viruses. In a review of current research in tumour virology, Dulbecco (1969) concludes that the mechanism of carcinogenesis by virus-specific proteins will be solved by study of the experimental models such as polyoma virus and SV 40.

REFERENCES

The abbreviations used in this list are those given in "World Medical Periodicals", 3rd edition, published in 1961 by the World Medical Association, New York.

REFERENCES.

- Aaronson, S.A. and Todaro, G.T. (1968) *Virology*, 36, 254.
- Abu Salih, H.S., Maurant, A.F. and Daft, M.J. (1968)
J. gen. Virol., 2, 155.
- Allington, H.V. (1952) *Arch. Derm. Syph. (Chic.)*, 66, 316
- Aloni, Y., Winocour, E. and Sachs, L. (1968) *J. Molec. Biol.*,
31, 415.
- Allison, A.C. (1967) *Brit. Med. Bull.*, 23, 60.
- Almeida, J.D., Cinader, B. and Howatson, A.F. (1963) *J. exp. Med.*,
118, 327.
- Almeida, J.D. and Goffe, A.P. (1965) *Lancet*, ii, 1205.
- Almeida, J.D., Howatson, A.F. and Williams, M.G. (1962)
J. invest. Derm., 38, 337.
- Almeida, J.D., Oriel, J.D. and Stannard, L.M. (1969) *Microbios*,
1, 225.
- Almeida, J.D. and Waterson, A.P. (1969) *Lancet*, ii, 983.
- Anglin, C.S. and Franklin, A.E. (1968) *Canad. med. Ass. J.*, 99, 122.
- Baker, H. (1968) *Proc. roy. Soc. Med.*, 61, 589.
- Banatvala, J.E., Best, J.M., Kennedy E.A., Smith E.E. and Spence, M.E.
(1967) *Brit. med. J.*, ii, 285.
- Barr, A. and Coles, R.B. (1966) *Trans. St. John's Hosp. derm. Soc.*
(Lond.) 52, 62.
- Barrera-Oro, J.G., Smith, K.O. and Melnick, J.L. (1962)
J. nat. Cancer Inst., 29, 583.
- Baxter, D.L. and Carson, W.E. (1964) *Arch. Derm.*, 89, 471.
- Beale, A.J. and Mason, P.J. (1968) *J. gen. Virol.*, 2, 203.
- Beaty, L.E. and Hodes, M.E. (1967) *J. cell. Biol.*, 35, 11A.
- Becker, Y., Olshevsky U. and Levitt, J. (1967) *J. gen. Virol.*,
1, 471.
- Benjamin, T.L. (1966) *J. molec. Biol.*, 16, 359.
- Biberstein, H. (1944) *Arch. Derm. Syph. (Chic.)*, 50, 12.
- Black, P.H., Hartley, J.W., Rowe, W.P. and Huebner, R.J.
(1963) *Nature (Lond.)*, 199, 1016.
- Blank, H., Buerk, M. and Weidman, F. (1951) *J. invest. Derm.*, 16, 19.
- Blank, H. and Rake, G. (1955) *Viral and Rickettsial Infections of the Skin, Eye and Mucous Membranes in Man.* p.182. London, Churchill.
- Boiron, M., Levy, J.P., Thomas, M., Friedmann, J.C. and Bernard, J.
(1964) *Nature (Lond.)*, 201, 423.

- Bosse, K. and Christophers, E. (1964) abstracted in *Excerpta med.* (Amst.) 1965. Sect. XIII, 19, abs. 101.
- Boyden, S.V. (1951) *J. exp. Med.*, 93, 107.
- Bradstreet, C.M.P. and Taylor, C.E.D. (1962) *Mth. Bull. Minist. Hlth. Lab. Serv.*, 21, 96.
- Brenner, S. and Horne, R.W. (1959) *Biochim. biophys. Acta*, 34, 103.
- Brobst, D.F. and Olson, C. (1965) *Cancer Res.*, 25, 12.
- Brody, I. (1962 a) *J. Ultrastruct. Res.*, 6, 304.
- Brody, I. (1962 b) *J. Ultrastruct. Res.*, 6, 341.
- Bunney, M.H. (1969) personal communication.
- Bunney, M.H., Hunter, J.A.A. and Ogilvie, M.M. (1969) *Brit. J. Derm.*, 81, 623.
- Bunting, H. (1953) *Proc. Soc. exp. Biol. (N.Y.)*, 84, 327.
- Buschké, A. and Lowenstein, L. (1925) *Klin. Wschr.*, 4, 1726.
- Carter, R.L. (1966) *Brit. J. Haemat.*, 12, 259.
- Carteaud, A.J.P. (1958) *Bull. Soc. Franc. Derm. Syph.*, 65, 260.
- Caspar, D.L.D. (1965) in *Viral and Rickettsial Infections of Man*, edited by Horsfall, F.L. and Tamm, I. 4th Ed., p. 51. London. Pitman.
- Caspar, D.L.D. and Klug, A. (1962) *Cold Spr. Harb. Symp. quant. Biol.*, 27, 1.
- Chambers, V.C., Ito, Y. and Evans, C.A. (1966), *J. Bact.*, 91, 2090.
- Chapman, G.B., Drusin, L.M. and Todd, J.E. (1963) *Amer. J. Path.*, 42, 619.
- Charles, A. (1960) *Dermatologica*, 121, 193.
- Ciuffo, G. (1907) *G. ital. Mal. vener.*, 48, 12.
- Clarke, G.H.V. (1965) *J. invest. Derm.*, 45, 15.
- Clarke, J.K. and Attridge, J.T. (1968) *J. gen. Virol.*, 3, 185.
- Conant, R.M. and Barron, A.L. (1967) *Virology*, 33, 549.
- Cooper, A. (1835) cited by Rowson and Mahy, 1967.
- Cowan, K.M. and Trautman, R. (1965) *J. Immunol.*, 94, 858.
- Crawford, L.V. (1965) *J. molec. Biol.*, 13, 362.
- Crawford, L.V. and Crawford, E.M. (1963) *Virology*, 21, 258.
- Cromwell, O. Remark, Walpole's *Anecdotes of Painting*. ch. 12.
- Cruickshank, R. (1965 a) *Medical Microbiology* 11th Ed. p. 852. Edinburgh, Livingstone.
- Cruickshank, R. (1965 b) *ibid.* p. 913.
- Cruickshank, R. (1965 c) *ibid.* p. 667.

- Davies, S.W. (1964) *Brit. J. Surg.*, 51, 338.
- De Maeyer, E. (1962) *Science*, 136, 985.
- Dowdle, W.R., Nahmias, A.J., Harwell, R.W. and Pauls, E.P. (1967) *J. Immunol.*, 99, 974.
- Dulbecco, R. (1969) *Ann. intern. Med.*, 70, 1019.
- Dulbecco, R. and Vogt, M. (1960) *Proc. nat. Acad. Sci. (Wash.)*, 46, 1617.
- Dunn, A.E.G. and Ogilvie, M.M. (1968) *J. Ultrastruct. Res.*, 22, 282.
- Duthie, D.A. and McCallum, D.I. (1951) *Brit. med. J.*, ii, 216.
- Eagle, H. (1959) *Science*, 130, 432.
- Epstein, W.L. (1967) personal communication cited by Rowson and Mahy, 1967.
- Evans, C.A., Gorman, L.R., Ito, Y. and Weiser, R.S. (1962) *J. nat. Cancer Inst.*, 29, 277.
- Fasske, E., Morgenroth, K. and Themann, H. (1964) *Klin. Wschr.*, 42, 546.
- Finch, J.T. and Klug, A. (1965) *J. molec. Biol.*, 13, 1.
- Fisher, J.P. (1966) *J. invest. Derm.*, 47, 336.
- Frey, E. (1924) cited by Rowson and Mahy, 1967.
- Frithiof, L. and Wersall, J. (1967) *Arch. ges. Virusforsch.*, 21, 31.
- Geraldes, A. (1969) *Nature (Lond.)*, 222, 1283.
- Gerber, P. (1967) *Proc. Soc. exp. Biol. (N.Y.)*, 125, 1284.
- Gibbons, I.R. and Grimstone, A.V. (1960) *J. biophys. biochem. Cytol.*, 7, 697.
- Goffe, A.P., Almeida, J.D. and Brown, F. (1966) *Lancet*, ii, 607.
- Goldblum, N., Ravid, Z. and Becker, Y. (1968) *J. gen. Virol.*, 3, 143.
- Goldschmidt, H. and Kligman, A.M. (1958) *J. invest. Derm.*, 31, 175.
- Green, M. (1962) *Cold Spr. Harb. Symp. quant. Biol.*, 27, 219.
- Grist, N.R., Ross, C.A.C., Bell, E.J. and Stott, E.J. (1966) Diagnostic Methods in Clinical Virology, p.59. Oxford. Blackwell Scientific Publications.
- Habel, K. (1961) *Proc. Soc. exp. Biol. (N.Y.)*, 106, 722.
- Habel, K. (1965) *Virology*, 25, 55.
- Habel, K. (1969) *Canad. Cancer Conf.*, 8, 390.

- Harmel-Tourneur, L. and Kalis, B. (1964) Bull. Soc. franc. Derm. Syph., 71, 665.
- Hellstrom, I. (1965) Nature (Lond.), 208, 652.
- Henao, M. and Freeman, R.G. (1964) Arch. Derm., 90, 479.
- Herbert, W.J. (1967a) in Handbook of Experimental Immunology, edited by D.M. Weir. p. 1207. Oxford. Blackwell Scientific Publications.
- Herbert, W.J. (1967b) ibid. p. 720.
- Hopkins, R. (1969) B.Sc. Thesis, Bacteriology Department, Edinburgh University.
- Howatson, A.F. (1965) J. molec. Biol., 13, 959.
- Howatson, A.F. and Almeida, J.D. (1960) J. biophys. biochem. Cytol., 8, 828.
- Howatson, A.F. and Crawford, L.V. (1963) Virology, 21, 1.
- Huebner, R.J. (1966) Canad. Cancer Conf., 6, 390.
- Hyden, H. (1947) Cold Spr. Harb. Symp. quant. Biol., 12, 104.
- Ishimoto, A. and Ito, Y. (1969) Virology, 39, 595.
- Jadassohn, J. (1896) cited by Rowson and Mahy, 1967.
- Jainchill, J.L., Candler, E.L. and Anderson, N.G. (1969) Proc. Soc. exp. Biol. (N.Y.), 130, 770.
- Josse, J., Kaiser, A.D. and Kornberg, A. (1961) J. biol. Chem., 236, 864.
- Kalnins, V.I., Stitch, H.F., Gregory, C. and Yohn, D.S. (1967) Cancer Res., 27, 1874.
- Kanee, B. (1969) Arch. Derm., 99, 196.
- Kass, S.J. and Knight, C.A. (1965) Virology, 27, 273.
- Kay, D. (1965) Techniques for Electron Microscopy, 2nd Ed. Oxford. Blackwell Scientific Publications.
- Khera, K.S., Ashkenazi, A., Rapp, F. and Melnick, J.L. (1963) J. Immunol., 91, 604.
- Kidd, J.G., Beard, J.W. and Rous, P. (1936) J. exp. Med., 64, 63.
- Kingsley-Smith, B.V., Marks, R. and Elek, S.D. (1967) Brit. med. J., 1, 301.
- Kit, S., Melnick, J.L., Dubbs, D.R., Piekarski, L.J. and de Torres, R.A. (1967) in Perspectives in Virology, V, ch. 3. Edited by Pollard, M. New York. Academic Press.
- Kleinschmidt, A.K., Kass, S.J., Williams, R.C. and Knight, C.A. (1965) J. molec. Biol., 13, 749.
- Klug, A. and Finch, J.T. (1965 a) J. molec. Biol., 11, 403.

- Klug, A. and Finch, J.T. (1965 b) *J. molec. Biol.*, 11, 424.
- Koprowski, H., Jensen, F.C. and Steplewski, Z. (1967) *Proc. nat. Acad. Sci. (Wash.)*, 58, 127.
- Koprowski, H., Ponten, J.A., Jensen, F.C., Ravdin, R.G., Moorhead, P. and Saksela, E. (1962) *J. cell. comp. Physiol.*, 59, 281.
- Krebs, A., Sellei, K. and Schaltegger, H. (1969) *Dermatologica*, 138, 129.
- Le Bouvier, G.L., Sussman, M. and Crawford, L.V. (1966) *J. gen. Microbiol.*, 45, 497.
- Lee, K.P. and Olson, C. (1969 a) *Amer. J. vet. Res.*, 30, 725.
- Lee, K.P. and Olson, C. (1969 b) *Cancer Res.*, 29, 1393.
- Lefkowitz, S.S., Williams, J.A., Howard, B.E. and Sigel, M.M. (1966) *J. Bact.*, 91, 205.
- Lewandowsky, F. and Lutz, W. (1922) *Arch. Derm. Syph. (Berl.)* 141, 193.
- Luft, J.H. (1961). *J. biophys. biochem. Cytol.*, 2, 409.
- Lutz, W. (1946) *Dermatologica*, 92, 30.
- Lyell, A. (1966) *Brit. med. J.*, ii, 1576.
- Lyell, A. and Miles, J.A.R. (1951) *Brit. med. J.*, i, 912.
- Macpherson, I.A. (1962) *Wistar Institute of Anatomy and Biology. Biennial Research Report, 1962-3.* p. 52.
- Macpherson, I.A. and Montagnier, L. (1964) *Virology*, 23, 291.
- Maderna, C. (1935) *Rif. Med.*, 51, 93.
- Massing, A.M. and Epstein, W.L. (1963) *Arch. Derm.*, 87, 306.
- Mattern, C.F.T., Allison, A.C. and Rowe, W.P. (1963) *Virology*, 20, 413.
- Mattern, C.F.T., Takemoto, K.K. and Daniel, W.A. (1966) *Virology* 30, 242.
- McCormick, K.J., Van Hoosier, Jr., G.L. and Trentin, J.J. (1968) *J. nat. Cancer Inst.*, 40, 255.
- McCutchan, J.H. and Pagano, J.S. (1968) *J. nat. Cancer Inst.*, 41, 351.
- McGee, A.R. (1967) *Cancer (Philad.)*, 20, 1647.
- McLaughlin, A.I.G. and Edington, J.W. (1937) *Lancet*, ii, 685.
- Melnick, J.L. (1962) *Science*, 135, 1128.
- Melnick, J.L., Bunting, H., Banfield, W.G., Strauss, M.J. and Gaylord, W.H. (1952) *Ann. N.Y. Acad. Sci.*, 54, 1214.
- Melnick, J.L. and Rapp, F. (1965) *J. nat. Cancer Inst.*, 34, 529.
- Melcozer, N. (1965) *Hautarzt*, 16, 150.
- Mendelson, C.G. and Kligman, A.M. (1961) *Arch. Derm.*, 83, 559.

- Mercer, E.H. and Birbeck, M.S.C. (1966) Electron Microscopy,
2nd Ed. Oxford. Blackwell Scientific Publications.
- Mizell, M., Stackpole, C.W. and Halperen, S. (1968) Proc. Soc. exp.
Biol. (N.Y.), 127, 808.
- Montgomery, A.H. and Montgomery, R.M. (1937) N.Y. St. J. Med.,
37, 1978.
- Montgomery, A.H. and Montgomery, R.M. (1948) Arch. Derm. Syph.
(Chic.), 57, 397.
- Montgomery, R.M. (1963) Arch. Derm., 87, 391.
- Morgan, H.R. and Balduzzi, P.C. (1964) Proc. nat. Acad. Sci. (Wash.),
52, 1561.
- Morgan, H.R. and Balduzzi, P.C. (1967) Amer. J. clin. Path., 47, 734.
- Morrison, J.M., Keir, H.M., Subak-Sharpe, H. and Crawford, L.V. (1967)
J. gen. Virol., 1, 101.
- Murphy, F.A., Harrison, A.K. and Whitfield, S.G. (1967) Arch. ges.
Virusforsch., 21, 463.
- Nairn, R.C. (1969) Fluorescent Protein Tracing, 3rd Ed., Edinburgh
Livingstone.
- Nartsissov, N.V., Avenirova, Z.A., Stephanchenok, G.I. and Solov'eva,
N.L. (1955) cited in The Virology and Immunology of Cancer,
by Zilber, L.A. and Abelev, G.I. (1968) Oxford.
Pergamon Press.
- Nasemann, T. (1965) Hautarzt, 16, 156.
- Neves, H. (1966) Trans. St. John's Hosp. dermat. Soc. (Lond.), 52, 255.
- Noyes, W.F. (1964) Virology, 23, 65.
- Noyes, W.F. (1965) Virology, 25, 358.
- Noyes, W.F. (1968) Cancer Res., 28, 1321.
- Noyes, W.F. and Mellors, C. (1957) J. exp. Med., 106, 555.
- Nyerges, G. (1969) Immunology, 17, 333.
- Oriel, J.D. and Almeida, J.D. (1970) in press Brit. J. vener. Dis.
- Oroszlan, S. and Rich, M.A. (1964) Science, 146, 531.
- Osler, A.G., Mulligan, J.J. and Rodriguez, E. (1966) J. Immunol.,
96, 334.
- Overbeck, L. (1967) Klin. Wschr., 45, 1153.
- Palade, G.E. (1952) J. exp. Med., 95, 285.
- Parsons, D.F. (1963) J. cell. Biol., 16, 620.
- Pearson, G. and Freeman, G. (1968) Cancer Res., 28, 1665.
- Pike, R.M. (1967) Bact. Rev., 31, 157.

- Rashad, A.L. (1969) *J. invest. Derm.*, 53, 356.
- Rashad, A.L. and Evans, C.A. (1967) *J. nat. Cancer Inst.*, 41, 845.
- Rasmussen, K.A. (1958) *Acta dermat.-venereol. (Stockn.)*, 38 (suppl. 39), 1.
- Reynolds, E.S. (1963) *J. cell. Biol.*, 17, 208.
- Rogers, S. and Moore, M. (1963) *J. exp. Med.*, 117, 521.
- Roitt, I.M., Greaves, M.F., Torrigani, G., Borstoff, J. and Playfair, J.H.L. (1969) *Lancet*, ii, 367.
- Rous, P. and Beard, J.W. (1935) *J. exp. Med.*, 62, 523.
- Rowson, K.E.K. and Mahy, B.W.J. (1967) *Bact. Rev.*, 31, 110.
- Ruiter, M. (1969) *Acta dermat.-venereol. (Stockh.)*, 49, 309.
- Ruiter, M. and van Mullem, P.J. (1966) *J. invest. Derm.* 47, 247.
- Rulison, R.H. (1942) *Arch. Derm. Syph. (Chic.)*, 46, 66.
- Russell, W.C. and Becker, Y. (1968) *Virology*, 35, 18.
- Sambrook, J., Westphal, H., Srinivasan, P.R. and Dulbecco, R. (1968) *Proc. nat. Acad. Sci. (Wash.)*, 60, 1288.
- Samitz, M.H., Ackerman, B.A. and Lentis, L.R. (1967) *Arch. Derm.*, 96, 286.
- Sato, P.S. and Ito, Y. (1968) *Virology*, 35, 335.
- Schmidt, N.J. and Lennette, E.H. (1966) *Proc. Soc. exp. Biol. (N.Y.)*, 121, 243.
- Scott, L.V., Felton, F.G. and Barney, J.A. (1957) *J. Immunol.*, 78, 211.
- Segre, D., Olson, C. and Hoerlein, A.B. (1955) *Amer. J. vet. Res.*, 16, 517.
- Serra, A. (1924) *G. ital. Mal. vener.*, 65, 1808.
- Sever, J.L., Huebner, R.J., Castellano, G.A., Sarma, P.S., Fabiyi, A., Schiff, G.M. and Cusumano, G.L. (1965) *Science*, 148, 385.
- Shiratori, O., Osata, T., Utsumi, K.R. and Ito, Y. (1968) *Proc. Soc. exp. Biol. (N.Y.)*, 128, 12.
- Shiratori, O., Osata, T. and Ito, Y. (1969) *Proc. Soc. exp. Biol. (N.Y.)*, 130, 115.
- Shope, R.E. (1933) *J. exp. Med.*, 58, 607.
- Siegel, A. (1962) *Amer. J. Surg.*, 103, 613.
- Smith, J.W., Pinkel, D. and Dabrowski, S. (1969) *Cancer (Philad.)*, 24, 527.
- Smith, K.O., Dougherty, E., Melnick, J.L. and Rapp, F. (1965) *J. Bact.*, 90, 278.
- Smithies, L.K. and Olson, C. (1961) *Cancer Res.*, 21, 1557.
- Stankler, L. (1967) *Practitioner*, 198, 690.
- Steele-Boder, A. and Wright, D. (1959) *Vet. Res.*, 71, 59.

- Steward, E.E., Mack, W.N. and Foy, R.B. (1968) *Lab. Invest.*, 19, 40.
- Stoker, M.G.P. (1962) Tumour Viruses: A Review of New Agents and New Concepts. Royal College of Physicians Edinburgh.
- Stoker, M.G.P. and Macpherson, I.A. (1962) *Virology*, 16, 147.
- Stoker, M.G.P. and Macpherson, I.A. (1967) in Methods in Virology, Vol. III, p.313. Edited by Maramorosch, K. and Koprowski, H. New York. Academic Press.
- Stone, R.S., Shope, R.E. and Moore, D.H. (1959) *J. exp. Med.*, 110, 543.
- Strauss, M.J., Bunting, H. and Melnick, J.L. (1950) *J. invest. Derm.*, 15, 433.
- Strauss, M.J., Bunting, H. and Melnick, J.L. (1951) *J. invest. Derm.*, 17, 209.
- Strauss, M.J., Shaw, E.W., Bunting, H. and Melnick, J.L. (1949) *Proc. Soc. exp. Biol. (N.Y.)*, 72, 46.
- Subak-Sharpe, H., Burk, R.R., Crawford, L.V., Morrison, J.M., Hay, J. and Keir, H.M. (1966) *Cold Spr. Harb. Symp. quant. Biol.*, 31, 737.
- Sullivan, M. (1949) *Arch. Derm. Syph. (Chic.)*, 60, 1.
- Swain, R.H.A. and Dodds, T.C. (1967) Clinical Virology, p. 239. Edinburgh, Livingstone.
- Syverton, J.T. (1952) *Ann. N.Y. Acad. Sci.*, 54, 1126.
- Tajima, M., Gordon, D.E. and Olson, C. (1968) *Amer. J. vet. Res.*, 29, 1185.
- Takemoto, K.K., Malmgren, R.A. and Habel, K. (1966) *Virology*, 28, 485.
- Temin, H.M. and Rubin, H. (1958) *Virology*, 6, 669.
- Templeton, H.J. (1935) *Arch. Derm. Syph. (Chic.)*, 32, 102.
- Teokharov, B.A. (1962) abstracted in *Excerpta med. (Amst.)* 1963 Sect. XIII, 17, abs. 1515.
- Thorne, H.V. and Warden, D. (1967) *J. gen. Virol.*, 1, 135.
- Touraine, A. (1961) cited by Ruiters, 1969.
- Ullman, E.V. (1923) *Acta oto-laryng. (Stockh.)*, 5, 317.
- Ullman, M. (1959) *Psychosom. Med.*, 21, 473.
- U.S. Committee on Cutaneous Health and Cosmetics (1968) *J. Amer. med. Ass.*, 206, 117.
- Van Scott, E.J. (1951) *Science*, 113, 601.
- Vogt, M. and Dulbecco, R. (1960) *Proc. nat. Acad. Sci. (Wash.)*, 46, 365.

- Waelsch, L. (1918) cited by Rowson and Mahy, 1967.
- Walter, E.L., Walker, D.L. and Cooper, G.A. (1965) Arch. Path., 79, 419.
- Warren, J. (1965) in Viral and Rickettsial Infections of Man, 4th Ed. p. 1170. Edited by Horsfall, F.L. and Tamm, I. London. Pitman.
- Waterson, A.P. and Almeida, J.D. (1969) in Virus Diseases and the Nervous System, p. 191. Edited by Whitty, C.W.M., Hughes, J.T. and MacCallum, F.O. Oxford. Blackwell Scientific Publications.
- Watrach, A.M. (1969) Cancer Res., 29, 2079.
- Watson, D.H., Russell, W.C. and Wildy, P. (1963) Virology, 19, 250.
- Weil, R. and Vinograd, J. (1963) Proc. nat. Acad. Sci. (Wash.), 50, 730.
- Welsher, H.R. and Fisher, E.R. (1962) Arch. Derm., 86, 480.
- Westaway, E.G. (1968) Nature (Lond.), 219, 78.
- Wildy, P., Stoker, M.G.P., Macpherson, I.A. and Horne, R.W. (1960) Virology, 11, 444.
- Williams, M.G., Howatson, A.F. and Almeida, J.D. (1961) Nature (Lond.), 189, 895.
- Williams, M.G., Howatson, A.F. and Almeida, J.D. (1962) Arch. Derm., 86, 290.
- Williams, R.C., Kass, S.J. and Knight, C.A. (1960) Virology, 12, 48.
- Winocour, E. (1963) Virology, 19, 158.
- Winocour, E. and Sachs, L. (1960) Virology, 11, 699.
- Yarrow, H. and Hitchcock, S. (1969) Brit. J. clin. Pract., 23, 395.
- Young, H.M. (1964) Surgery, 55, 367.
- Zelickson, A.S. and Hartmann, J.F. (1961) J. invest. Derm., 36, 65.
- Zimmer, S., Bahnsch, H. and Grimm, C. (1964) Derm. Wschr., 149, 490.
- Zu Rhein, G.M. and Chou, S. (1965) Science, 148, 1477.

Appendix

Form A

Project to study the Human Wart Virus
Virus Laboratory, Bacteriology Department,
University of Edinburgh Medical School

<p>Specimen</p> <p>* Delete inappropriate</p> <p>Patient's name</p> <p>Age</p> <p>Sex</p> <p>Your reference</p> <p>Site of wart</p> <p>Clinical appearance</p> <p>Duration of wart</p> <p>Treatment</p> <p>Past history of warts</p> <p>Collected by</p> <p>Date:</p>	<p>* Wart (paring)</p> <p>Blood</p>
---	-------------------------------------

Appendix
Form B
Survey of Warts

Student's name: _____

Age: _____

Year of Course: _____

Date: _____

Do you have any warts at present? YES/NO
(if unsure please ask Dr. Skirving)

If so, where are they and how long
have you had them?

sole of foot

hand for _____ weeks/months

face

elsewhere

What treatment has been given?

none brown ointment

paint freezing

Are they beginning to disappear? YES/NO

Have you ever had warts in the past?

on sole

hand at age _____ years

face

elsewhere

Intranuclear Virus Particles in Human Genital Wart Tissue: Observations on the Ultrastructure of the Epidermal Layer

A. E. G. DUNN¹ AND MARIE M. OGILVIE

*Department of Bacteriology, University of Edinburgh Medical School,
Edinburgh, Scotland*

Received November 27, 1967

Human genital warts (condylomata acuminata) were examined, and virus particles that had the morphology typical of papilloma virus were located in one specimen. Particles of the same size, but lacking a substructure, that could be viral in nature, were found in two specimens. These particles and the recognizable viruses were closely associated with strands of material possessing regular subunits similar to those described by other authors (23) and which they suggest may be unassembled viral subunits. Certain variations from normal epidermal ultrastructure were noted, but these do not appear to be specific for this condition.

The ultrastructure of normal human epidermis has been investigated (21), and it has been suggested that keratinization involves changes in the tonofilaments (3). In some pathological conditions both the stratum corneum and the deeper layers of the epidermis have been shown to be affected particularly in the distribution of the tonofilaments and in the appearance of the stratum granulosum (6). An electron microscope study of wart tissue showed that although the epidermis was thickened and thrown into folds by projecting papillae of the dermis the cell layers remained easy to recognize (1).

It has been suggested that human genital warts may have the same viral etiology as common warts. These suspicions were based on clinical findings, particularly the frequent association of both types of wart in the same patient. Waelsch (24) obtained a common wart in a patient at the site of inoculation of material from a genital wart, and Serra (22) confirmed this experiment using a Chamberland filtrate of genital warts. Electron microscope studies of genital warts have been published: Nasemann (14) was the first to report suspected viruses in the cytoplasm and nuclei of genital

¹ Present address: Pathology Department, University of the West Indies, Mona, St. Andrew, Jamaica.

wart cells and noticed that they are difficult to find; Zimmer, Bähnsch, and Grimm (28) examined six genital warts and found particles (200–800 Å) in the cytoplasm of epidermal cells which possessed an outer membrane and a dense core and are not seen in cell nuclei; Melczer (13) on the same material found intranuclear and cytoplasmic clumps of particles resembling human papilloma virus.

The present investigation was undertaken to confirm the presence of virus in genital warts, to compare its morphology, distribution, and incidence with that of common wart virus and to discover whether the cells comprising the epidermis of genital wart tissue differ from those of normal skin epidermis.

MATERIALS AND METHODS

Twelve specimens of genital warts, condylomata acuminata, were obtained by punch biopsy or surgical excision from male and female patients. The lesions had been present for from 10 days to 8 months. The clinical diagnosis in each case remained unchanged; in four cases it was confirmed by light microscopic examination and in all cases the warts disappeared after treatment with podophyllin or by cauterization. Consorts of four of the patients also had genital warts.

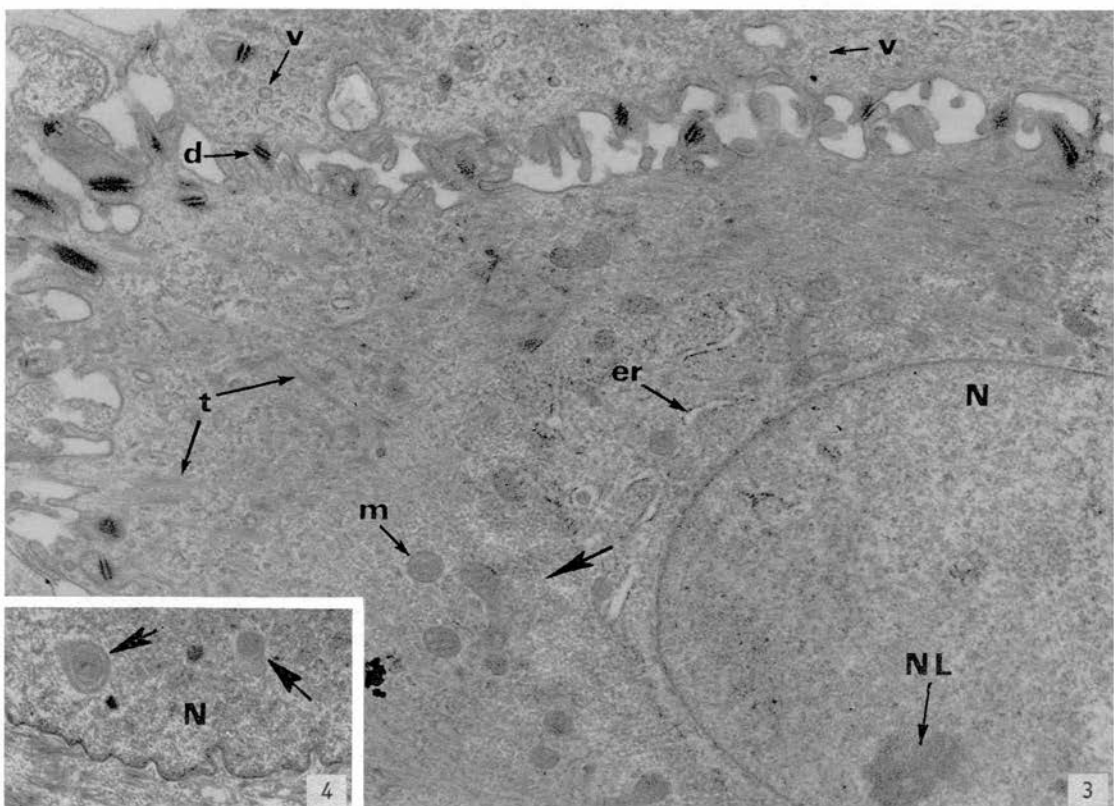
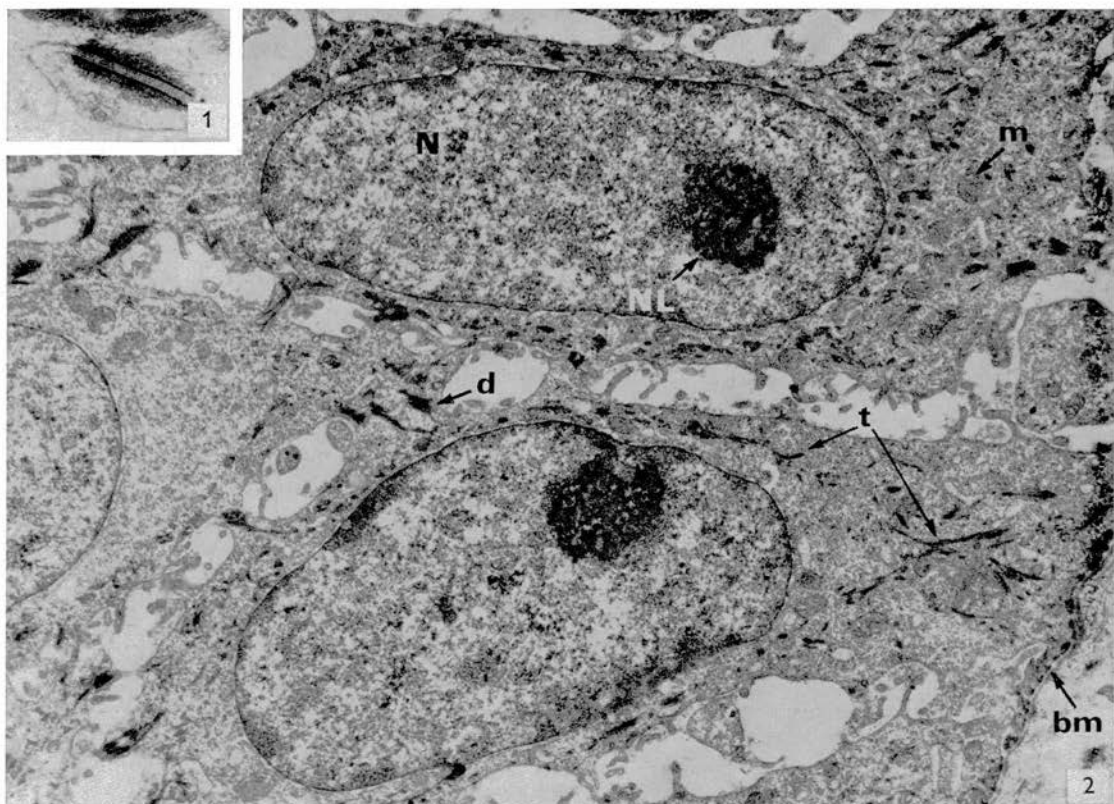
The main bulk of each specimen was collected in Veronal-buffered saline and stored at -70°C , but a small portion was fixed immediately in Veronal-buffered 1% osmium tetroxide (18), subsequently dehydrated in ethanol and embedded in Epon (12). Sections were cut on a Cambridge (Huxley) ultramicrotome, collected on uncoated specimen grids, stained in uranyl acetate (10) and occasionally lead citrate (20), and examined in an AEI, EM6 microscope.

Unfixed tissue was examined also by negative staining techniques. One method (8) was to tease out a piece of tissue in a drop of 2% phosphotungstic acid and apply a coated specimen grid to the surface. The viscous nature of genital wart tissue produced too much debris and so the surface spreading technique of Parsons (19) was used where a needle is inserted into the specimen and withdrawn with adhering tissue fragments which float off onto a drop of negative stain. The remainder of the wart tissue was pooled and homogenized in a glass homogenizer. After slow centrifugation the supernatant was ultracentrifuged at 30,000 rpm for 90 minutes. The resulting pellet was resuspended in distilled water and examined after staining.

RESULTS

The epidermal cells of genital wart tissue were in recognizable layers like those of normal skin, but some changes were obvious. In normal skin the stratum granulosum contains keratohyalin granules, but in certain pathological conditions these granules are absent and the layer has been called stratum intermedium (6). Similarly in genital wart tissue, the many cell types above the stratum spinosum can be included in the layer stratum intermedium whether or not keratohyalin granules are observed.

Stratum basale appeared normal. The elongated cells (Fig. 2) lay perpendicular to the basement membrane which separates the dermis and epidermis. The nuclei had



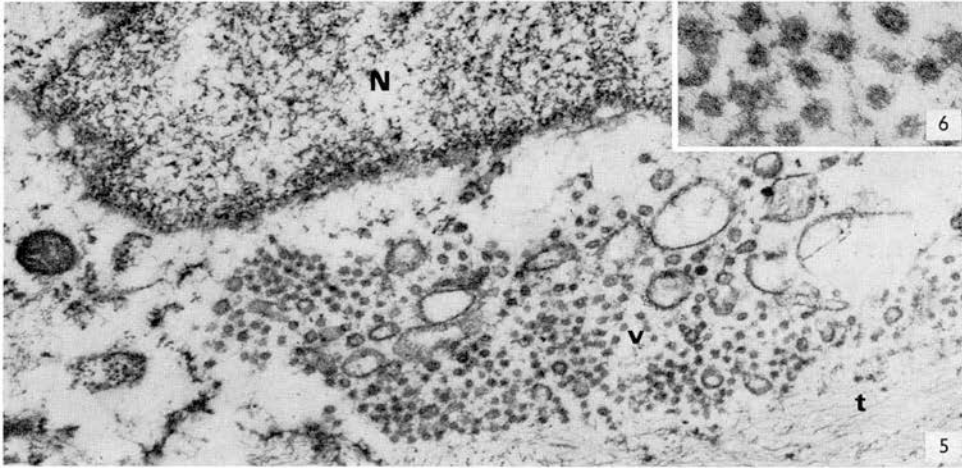


FIG. 5. An accumulation of vesicular structures (*v*) lying adjacent to a cell nucleus (*N*) in the stratum spinosum. *t*, tonofilaments. Uranyl acetate and lead citrate. $\times 25,500$.

FIG. 6. Higher magnification micrograph of vesicular structures. Uranyl acetate and lead citrate. $\times 102,000$.

a smooth outline and often contained a nucleolus with a distinctive mottled appearance. In the cytoplasm there were bundles of tonofilaments, usually loosely packed but sometimes fairly compact, and at the point of contact between opposing cell membranes desmosomes were frequently observed (Fig. 1).

The *stratum spinosum* cells were similar to those of the stratum basale but became more rounded and then flattened nearer to the stratum intermedium. Many of their nuclei had irregular outlines (Fig. 4). The tonofilaments were in loosely packed bundles in the lower stratum spinosum and packed into dense bundles forming tonofibrils in the upper region. However, even in the uppermost cells single tonofilaments were present (Fig. 5); this is said not to occur in normal epidermis (3).

In one specimen numerous cytoplasmic areas were observed composed of an aggregation of small dense particles within a definite cytoplasmic zone forming a reticular

Note: Unless otherwise indicated the micrographs are of sectioned genital wart tissue.

FIG. 1. Desmosome between two cells in the stratum basale. Uranyl acetate and lead citrate. $\times 48,000$.

FIG. 2. Stratum basale and dermis separated by a basement membrane (*bm*). Uranyl acetate. $\times 3150$.

FIG. 3. Typical stratum spinosum cell. The nucleus (*N*) has a smooth outline but can be irregular. A cytoplasmic area with a reticular pattern is indicated by an arrow. Uranyl acetate. $\times 12,350$.

FIG. 4. Part of a cell nucleus in the stratum spinosum containing two inclusion bodies (arrows). Uranyl acetate and lead citrate. $\times 9000$.

FIGS. 1-4. *bm*, basement membrane; *d*, desmosome; *er*, endoplasmic reticulum; *m*, mitochondrion; *N*, nucleus; *NL*, nucleolus; *t*, tonofilaments; *v*, vesicles.

pattern (Fig. 3, arrow). The areas also contained a few mitochondria and some small vesicles, and there was an apparent increase in the quantity of granular endoplasmic reticulum in the cells. Similar changes have been reported in psoriatic epidermal cells (5).

Some of the cell nuclei from one specimen possessed inclusion bodies (diameter 0.3–0.6 μ) composed of a finely granular compact substance sometimes disposed in concentric rings (Fig. 4). Such nuclear inclusions have been described in psoriatic epidermis (5), in keratoacanthomata (26), in genital wart tissue (15), and are thought to occur in normal epidermis (4).

Numerous small cytoplasmic vesicles were present (Fig. 3) and in one wart, which lacked a stratum corneum, these occurred in large numbers grouped at the nuclear poles (Figs. 5 and 6). Here they were quite uniform in size, diameter usually 500 Å (340–850 Å) and consisted of a light core surrounded by a denser area (Fig. 6), but they did not have a well-defined membrane. Zimmer *et al.* (28) and Nasemann (15) described similar structures in condyloma cells and identified them as viruses. These authors indicated that the structures possess a limiting membrane and a nucleoid, but their observations were not confirmed in the present study. Zelickson (27) described vesicles of varying size (500–900 Å) in normal human stratum spinosum cells; some vesicles had smooth membranes, others a rough surface and they often lay in groups at the nuclear poles forming a Golgi complex. We conclude that the vesicles found in the genital warts are not virus particles and suggest that they are normal cell constituents.

Stratum intermedium. This layer varied in the different specimens; some possessed typical granular cells containing keratohyalin granules (Figs. 14 and 19) while in others although a stratum corneum was present there were no keratohyalin granules and the cells in the upper stratum spinosum had a more necrotic appearance than was usual (Fig. 7). There the stratum intermedium cells resembled the transitional

FIG. 7. From left of micrograph—stratum spinosum, stratum intermedium, and stratum corneum. The stratum intermedium here does not possess keratohyalin granules. *L*, lacuna. Uranyl acetate. $\times 15,000$.

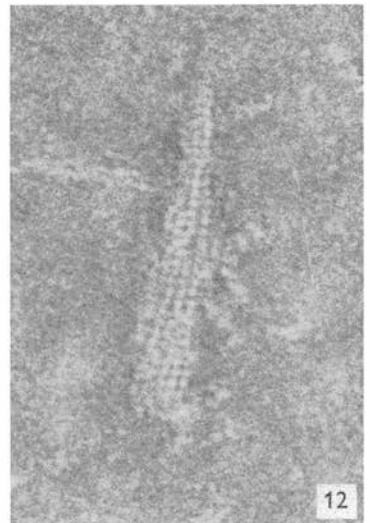
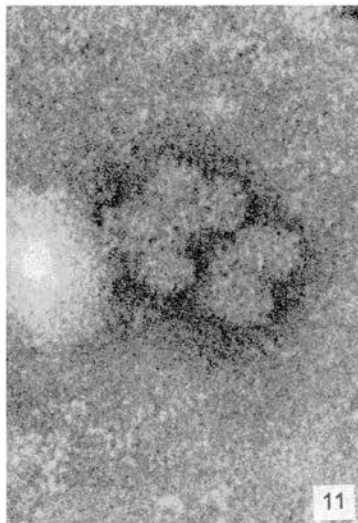
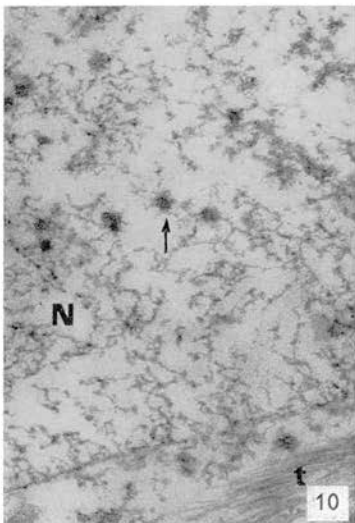
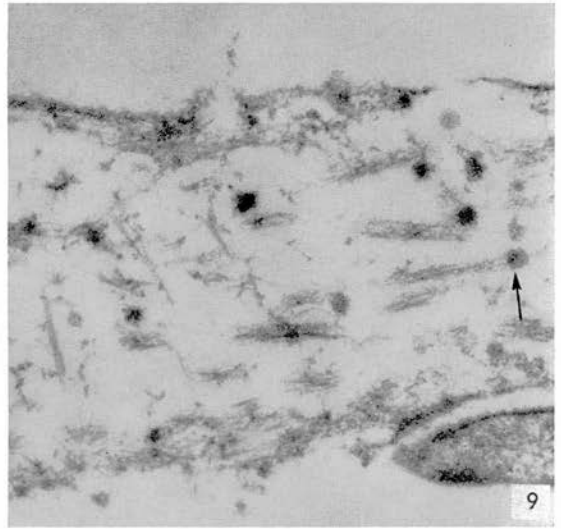
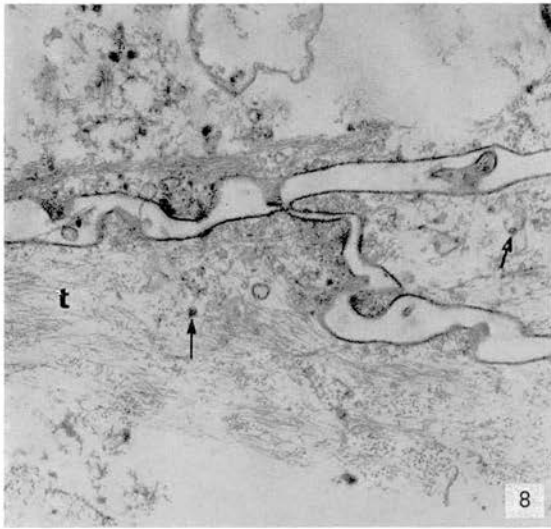
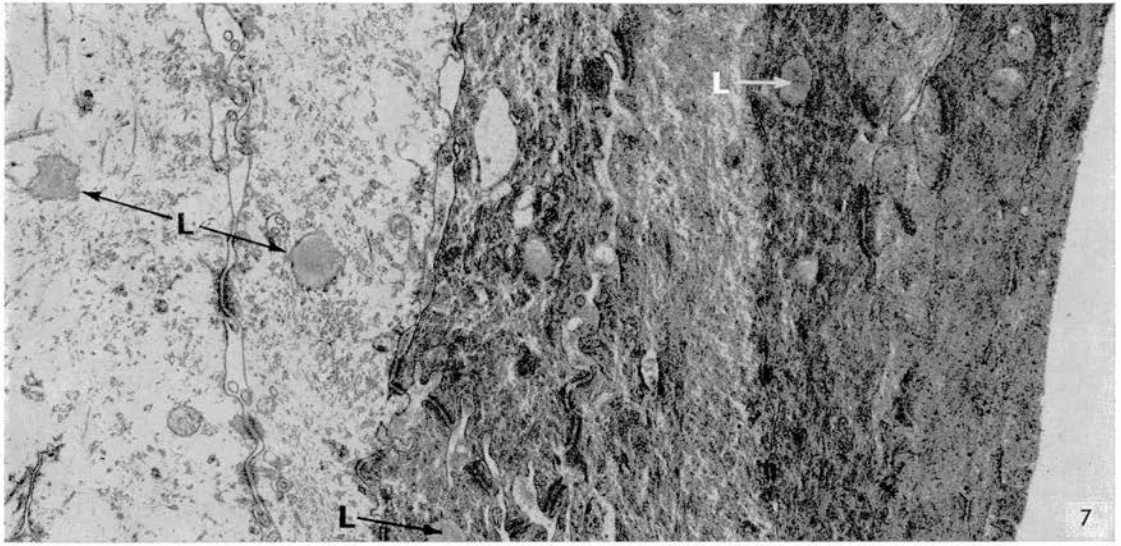
FIG. 8. Three interdigitating necrotic cells in the stratum intermedium from a specimen lacking a stratum corneum. Small opaque particles are distributed throughout the cytoplasm (arrows). Uranyl acetate. $\times 30,000$.

FIG. 9. Cell from an adjacent area to Fig. 8. A number of the opaque particles appear to be continuous with cytoplasmic strands (arrow). Uranyl acetate. $\times 60,000$.

FIG. 10. Opaque particles (arrow) in nucleus (*N*) of one of the cells from Fig. 8. *t*, tonofilaments. Uranyl acetate and lead citrate. $\times 60,000$.

FIG. 11. Negatively stained preparation of particles isolated from same specimen as in Fig. 8. PTA. $\times 230,000$.

FIG. 12. Negatively stained preparation showing stranded material with a definite subunit structure. PTA. $\times 230,000$.



cells of Brody (3) and their cytoplasm contained closely packed fibrils as in the lower stratum corneum (Fig. 7).

Amorphous lightly stained bodies, 0.5μ diameter, reminiscent of lipid droplets were observed in most of the warts. These were identical with the lacunae described in the stratum corneum of ultraviolet-irradiated human epidermis (16) and in psoriatic epidermal cells (6). They were present in typical granular cells including those containing nuclear virus (described later), in cells of the stratum intermedium which possessed no keratohyalin granules, and even in cells of the upper stratum spinosum (Fig. 7) where they had an irregular shape.

When the stratum corneum was absent the superficial stratum intermedium consisted of flattened cells held together by interdigitating processes (Fig. 8). Almost all these cells contained numerous densely stained particles, $350\text{--}450 \text{ \AA}$ in diameter, and an occasional nucleus. The outline of the particles was often irregular, and they had no internal structure. Some appeared to be associated with strands of granular material that also occurred in the cells (Fig. 9). Similar though smaller particles were present in the nuclei (Fig. 10). In negatively stained preparations from these specimens lacking a stratum corneum, adherent groups of particles of the same size range were located (Fig. 11), and in one such preparation (Fig. 12) there were also strands of material consisting of uniform closely packed 45 \AA spheres like those described by Smith, Dougherty, Melnick, and Rapp (23) as unassembled viral subunits in common wart tissue.

Virus particles, $360\text{--}470 \text{ \AA}$ in diameter, were found in sections of only one genital wart, and these were in the nuclei of stratum intermedium cells which contained keratohyalin granules (Fig. 14). An unusually wide perinuclear zone free from cytoplasmic organelles was evident in the infected cells. The nuclei all had irregular outlines with a peripheral rim of densely stained material (Fig. 14) resembling the margined chromatin described in other virus-infected nuclei (9). Nuclear chromatin was not evident in cells of genital wart tissue which were free from virus particles. The grain size of this nuclear peripheral material in the infected cells varied from $<100 \text{ \AA--} >200 \text{ \AA}$ and was similar to that of the granular substance (see below) found around virus particles in the nucleoplasm.

The concentration of virus was low compared with common warts (1) where the nuclei of the stratum intermedium cells had compact crystalline masses of virus particles. In the genital wart single viruses were scattered throughout the nucleoplasm and often lay close to the nuclear membrane (Fig. 14). The structure of the virus particles is shown in Figs. 13 and 17, and can be compared with the 400 \AA virus particles located in a plantar wart prepared in the same way (Fig. 18).

In some nuclei clumps of smaller and more diffuse particles occurred (Fig. 15), and in most of the infected nuclei compact granular material similar to that distributed

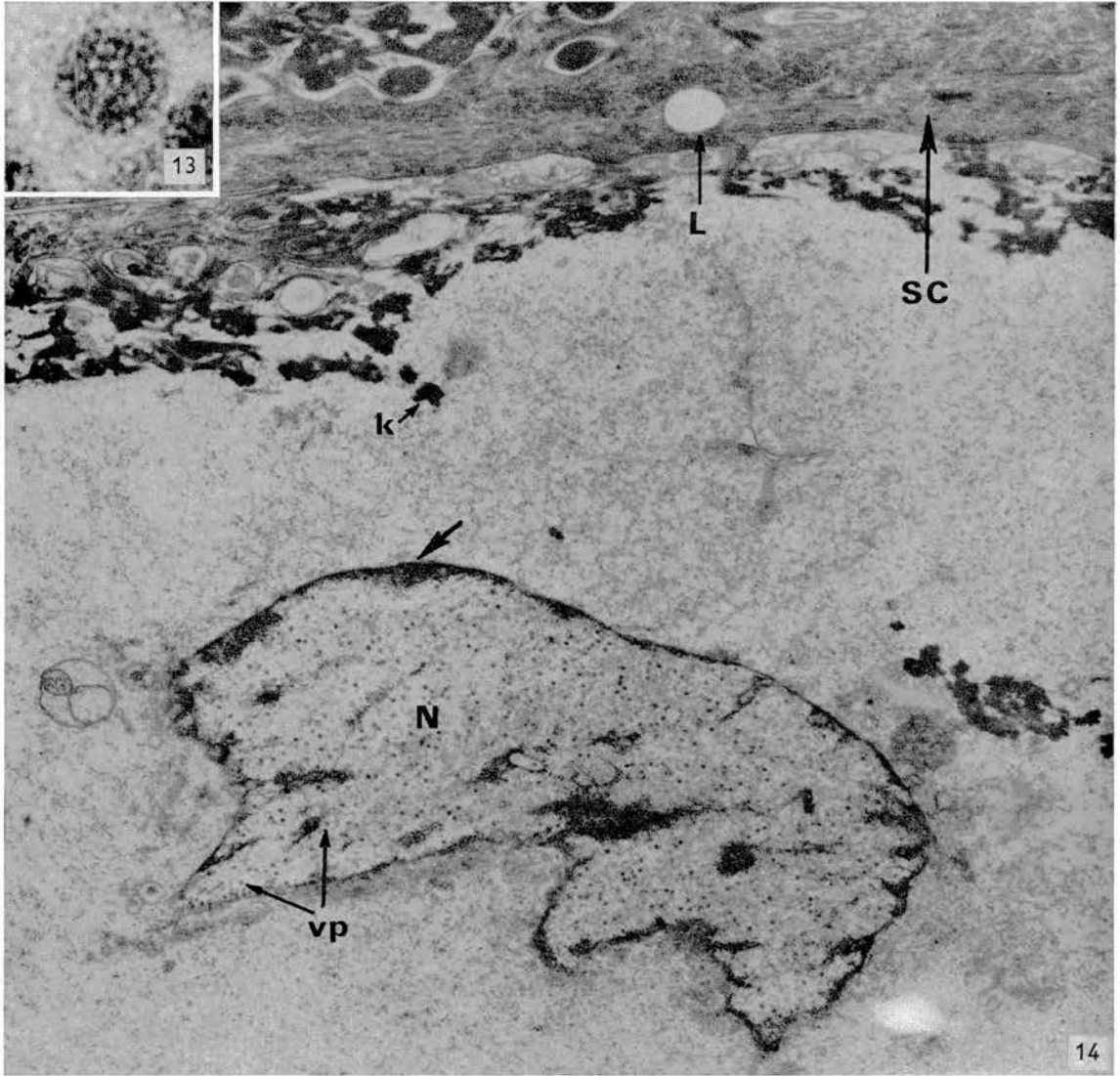


FIG. 13. Intranuclear virus particle in stratum intermedium. The virus substructure is evident. Uranyl acetate and lead citrate. $\times 400,000$.

FIG. 14. Nucleus (*N*) containing many virus particles (*vp*) in the stratum intermedium. Darkly stained material lies around the nuclear margin (arrow). *k*, keratohyalin granule; *L*, lacuna; *SC*, stratum corneum. Uranyl acetate and lead citrate. $\times 13,800$.

around the periphery lay among and was apparently continuous with the virus particles (Fig. 17). Association between virus particles and granular material has been reported with herpes-infected cells (25). Similar granular material also formed strands (Fig. 15) which sometimes appeared to be continuous with virus particles (Fig. 16) though this may be due to superimposition. These strands are similar to those already illustrated in Figs. 9 and 12.

No viruses were observed in the cytoplasm of the cells apart from near a ruptured nuclear membrane.

The *stratum corneum* was absent in some specimens and was as thick as $9\ \mu$ in others. Virus particles were not present. Bacteria were frequently embedded in the superficial tissue; most had a round profile and possessed a double limiting membrane $100\ \text{\AA}$ thick (Fig. 20). Large numbers of lacunae occurred throughout this layer (Figs. 7, 14, 19, and 20).

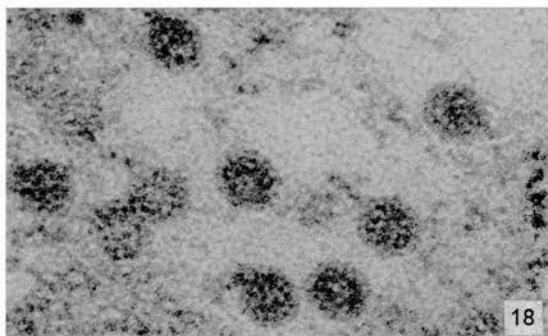
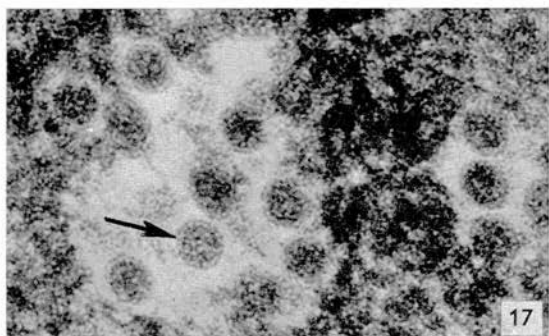
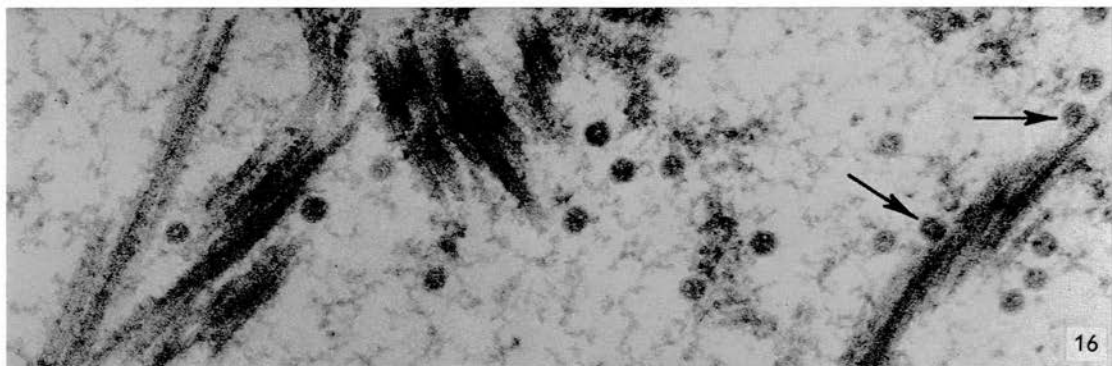
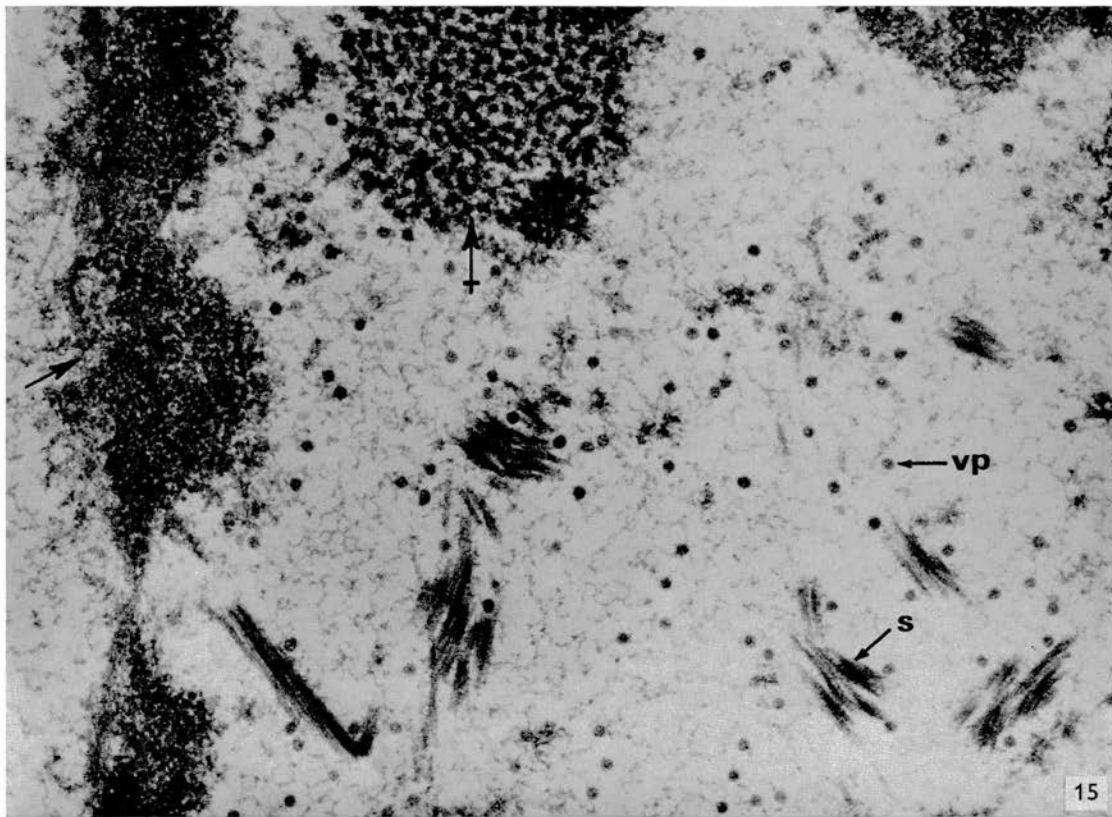
On the surface of the *stratum corneum* and immediately beneath it there were clumps of opaque particles (Fig. 20, arrow). Their significance is unknown, but they were not associated with the demonstration of virus in the deeper layer.

Virus in negatively stained preparations. In the negatively stained preparations from single genital warts no recognizable virus particle was located, but in a preparation from a semipurified fraction of 12 homogenized genital warts a few particles were found (Fig. 21). Their diameter of $460\ \text{\AA}$ and structure resembled virus particles located in plantar warts using the same technique (Fig. 22).

DISCUSSION

Less of the structure of virus particles in plantar warts can be seen in sections than in negatively stained preparations. However, the intranuclear particles in one of the genital warts possess several features of the human papilloma virus found in other warts. These are their size, which is uniformly around $400\ \text{\AA}$, their regular spherical outline without evidence of an outer membrane, their intranuclear location and their presence in the superficial degenerating epidermal cells. The differences from common wart virus are the scarcity of mature virus particles, and that in all but one specimen no viruses were seen. This quantitative difference between genital and common warts

-
- FIG. 15. Infected nucleus in the stratum intermedium. \rightarrow , peripheral granular material; \rightarrow , accumulation of virus-like particles smaller than the individual virus particles (*vp*). Numerous strands of granular material (*s*) occur throughout the nucleoplasm. Uranyl acetate and lead citrate. $\times 40,000$.
 FIG. 16. Area from same nucleus as in Fig. 15. Arrows indicate virus particles apparently associated with strands. Uranyl acetate and lead citrate. $\times 84,000$.
 FIG. 17. Intranuclear virus particles in the stratum intermedium. Substructure can be clearly observed (arrow). Uranyl acetate and lead citrate. $\times 180,000$.
 FIG. 18. Plantar wart section—virus particles in the stratum intermedium. Uranyl acetate. $\times 180,000$.



is similar to that found in Shope rabbit papillomas by Noyes and Mellors (17) using fluorescent antibody techniques. Only one-tenth of the sections from papillomas of domestic rabbits contained viral antigen and then it was present in small amounts confined to the most superficial epidermal layer, whereas papillomas of wild rabbits contained much greater amounts of virus in all the nonproliferative layers.

The reasons for these variations in the development of what may be the same human wart virus in different situations are as yet unknown. In the case of papillomas of domestic rabbits Noyes *et al.* postulated that viral nucleic acid ("masked virus") might be present in cells of the germinal (basal) layer, stimulating cell proliferation. In genital warts where the surface is frequently moist and the stratum corneum constantly being removed by friction, the rate of cell proliferation is higher than that of other warts. This might account for the absence of large numbers of mature virus particles.

The 350–450 Å densely stained particles which occurred in the cytoplasm and nuclei of superficial stratum intermedium cells and which were located in negatively stained preparations from some genital warts may be virus particles. Their close association with coarse strands of material is similar to that of obvious virus particles observed within the nuclei of some cells. In sectioned material these strands did not show any periodicity, but even if they possessed subunits they could be masked by the thickness of the section and the underlying tissue. In negatively stained preparations subunits were obvious, and we have since found similar strands in preparations from a facial wart and a mosaic plantar wart, both of which contained typical papilloma virus particles. The filaments described by Smith *et al.* (23) consisted of regular subunits measuring about 30 Å and frequently arranged in double rows and closely associated with typical papilloma virus particles. The same authors suggest that the structures are accumulations of protein subunits which had not been assembled into mature virus. Herpes and adenoviruses, two other DNA viruses which also replicate in the nucleus, have been shown to produce viral protein in excess of that needed for the assembling of virus particles (11).

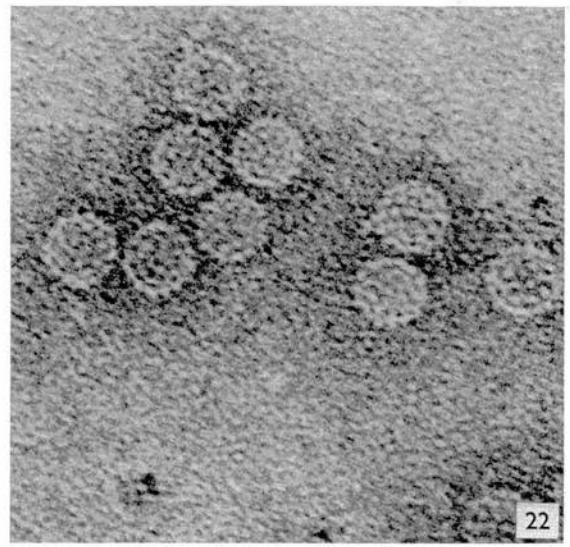
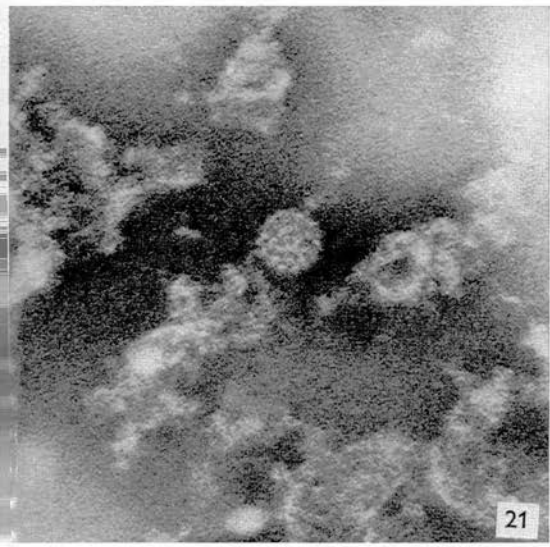
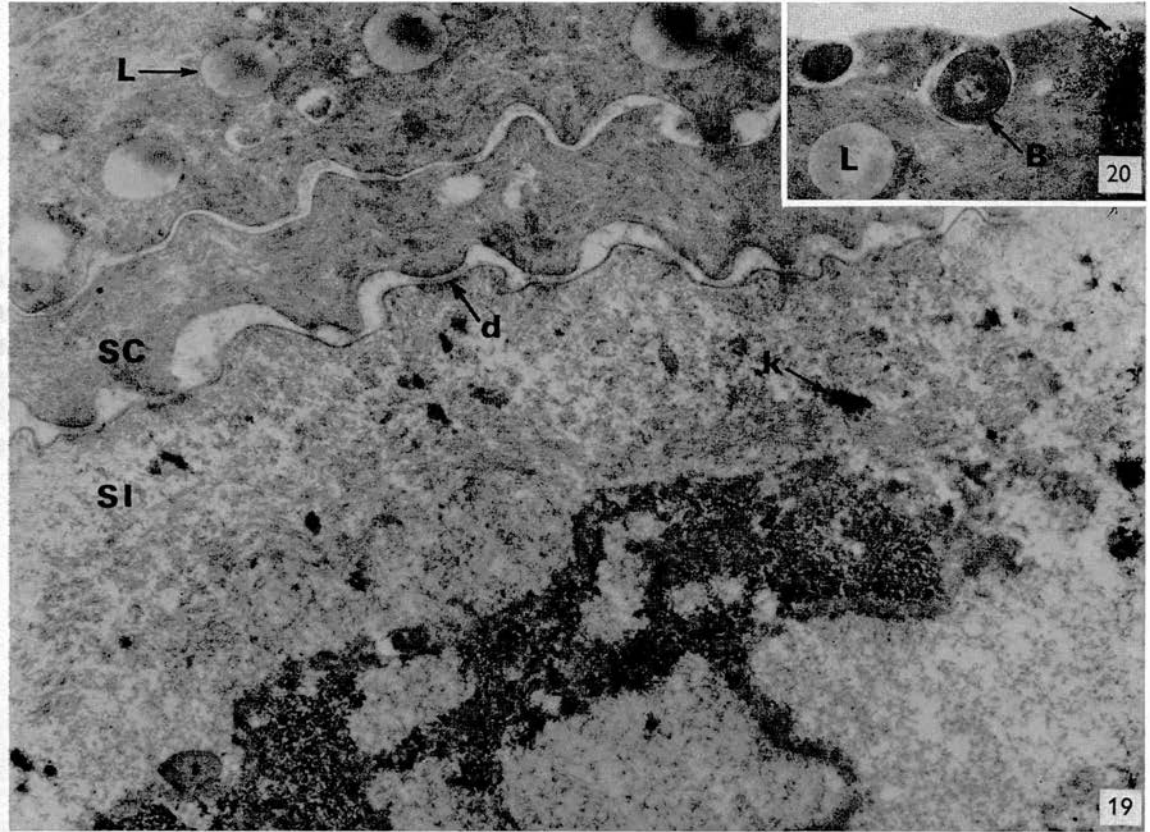
The nature of the granular material surrounding the intranuclear virus is unknown. Such material did not significantly occur in nuclei unless viruses were present. Herpes virus has been found to develop close to aggregates of granular material (25) with a grain size of 100 Å that could be distinguished from marginal chromatin, interchroma-

FIG. 19. Part of the stratum corneum (SC) and stratum intermedium (SI), showing typical features. *d*, desmosome; *k*, keratohyalin granule; *L*, lacuna. Uranyl acetate. $\times 21,600$.

FIG. 20. Outer edge of the stratum corneum with an embedded bacterium (*B*). Small particles (arrow) are breaking away from surface. *L*, lacuna. Uranyl acetate. $\times 24,700$.

FIG. 21. Negatively stained preparation of virus particle located in a pool of genital wart tissue. PTA. $\times 185,400$.

FIG. 22. Negatively stained preparation of virus particles located in a plantar wart. PTA. $\times 185,400$.



tin and nucleolar material all of which possessed a grain size of around 200 Å. The 100 Å grains were thought to be protein units. In the infected genital wart cell nuclei, the granular material which lies around the periphery or in patches in the nucleoplasm is often closely associated with virus particles. It consists of grains ranging from 100 Å to over 200 Å, and we feel that it is not possible to speculate from morphological evidence alone on its chemical nature.

Ben-Porat and Kaplan (2) have used radioactive labeling techniques to differentiate between cellular and viral DNA in the nuclei of tissue cultured cells after infection with the pseudorabies virus. They find that less than 21% of the nuclear pool of viral DNA is utilized to form virus particles. If this obtains with genital wart virus, much of the granular nuclear material may be viral DNA.

The lacunae and unusual nuclear inclusions that occur in genital wart tissue may not be specifically related to the presence of virus since a number of abnormal skin conditions are associated with similar cellular changes.

The apparent connection between the arrangement of the tonofilaments, the presence of keratohyalin granules, and the nature or presence of the stratum corneum are other observations common to a variety of skin conditions. Our observations support the view that tonofilaments and keratohyalin granules are associated with the production of keratin fibers (3). However, the epidermis of genital wart tissue can vary from area to area, and the absence of keratohyalin granules or a stratum corneum from one area need not represent a picture of the whole lesion.

Although positive identification of the virus concerned must depend on serological and other tests we conclude that genital warts are caused by a virus which is closely related to, or identical with, the human papilloma virus.

One of us (M. M. O.) is indebted to the Faculty of Medicine, Edinburgh University, for a Graduate Research Scholarship.

We wish to acknowledge our gratitude to Dr. D. H. H. Robertson of the Royal Infirmary, Edinburgh, for providing the specimens for this investigation. We are also indebted to Dr. R. H. A. Swain, Dr. Valerie Inglis, and Professor A. Muir for their interest and helpful criticism.

REFERENCES

1. ALMEIDA, J. D., HOWATSON, A. F. and WILLIAMS, M. G., *J. Invest Dermatol.* **38**, 337 (1962).
2. BEN-PORAT, T. and KAPLAN, A. S., *Virology* **20**, 310 (1963).
3. BRODY, I., *J. Ultrastruct. Res.* **4**, 264 (1960).
4. — *ibid.* **6**, 304 (1962).
5. — *ibid.* **6**, 324 (1962).
6. — *ibid.* **6**, 341 (1962).
7. — *ibid.* **6**, 354 (1962).

8. CHAMBERS, V. C., ITO, Y. and EVANS, C. A., *J. Bacteriol.* **91**, 2090 (1966).
9. CROUSE, H. V., CORIELL, L. L., BLANK, H. and MCNAIR SCOTT, T., *J. Immunol.* **65**, 119 (1950).
10. GIBBONS, I. R. and GRIMSTONE, A. V., *J. Biophys. Biochem. Cytol.* **7**, 697 (1960).
11. GREEN, M., *Cold Spring Harbor Symp. Quant. Biol.* **27**, 219 (1962).
12. LUFT, J. H., *J. Biophys. Biochem. Cytol.* **9**, 409 (1961).
13. MELCZER, N., *Der Hautarzt* **16**, 150 (1965).
14. NASEMANN, T., quoted by ZIMMER, S., BÄHNSCH, R. and GRIMM, C., *Dermatol. Wochschr.* **149**, 490 (1964).
15. NASEMANN, T., *Der Hautarzt* **16**, 156 (1965).
16. NIX, T. E., NORDQVIST, R. E., SCOTT, J. R. and EVERETT, M. A., *J. Invest. Dermatol.* **43**, 301 (1964).
17. NOYES, W. F., and MELLORS, C., *J. Exptl. Med.* **106**, 555 (1957).
18. PALADE, G. E., *J. Exptl. Med.* **95**, 285 (1952).
19. PARSONS, D. F., *J. Cell Biol.* **16**, 620 (1963).
20. REYNOLDS, E. S., *J. Cell Biol.* **17**, 208 (1963).
21. RHODIN, J., *J. Pediatrics* **66**, No. 1, Pt. 2, 171 (1965).
22. SERRA, A., *Giorn. Ital. Mal. Venereol.* **65**, 1808 (1924).
23. SMITH, K. O., DOUGHERTY, E., MELNICK, J. L. and RAPP, F., *J. Bacteriol.* **90**, 278 (1965).
24. WAELSCH, L., *Arch. Dermatol. Syphilis Wien.* **124**, 625 (1918).
25. WATSON, D. H., WILDY, P. and RUSSELL, W. C., *Virology* **24**, 523 (1964).
26. ZELICKSON, A. S., *Acta Dermato-Venereol.* **42**, 23 (1962).
27. ZELICKSON, A. S. and HARTMANN, J. F., *J. Invest. Dermatol.* **36**, 65 (1961).
28. ZIMMER, S., BÄHNSCH, R. and GRIMM, C., *Dermatol. Wochschr.* **149**, 490 (1964).

Case Report

Br. J. Derm. (1969) **81**, 623.

Department of Dermatology, Royal Infirmary, and Department of Virology, University of Edinburgh

MOLLUSCUM CONTAGIOSUM OF THE SOLE

A RARE DIAGNOSIS OR A RARE CONDITION?

MARY H. BUNNEY, JOHN A. A. HUNTER AND MARIE M. OGILVIE

SUMMARY.—A case is reported of molluscum contagiosum on the sole of the foot, which was diagnosed virologically. The difficulty of making the diagnosis on clinical grounds in this site is emphasized. The diagnosis may rather be missed than rare.

BAXTER AND CARSON (1964) reported a well substantiated case of molluscum contagiosum of the sole, which they considered to be the first to be documented. The lesion was excised and the diagnosis made histologically. Although in the illustration of molluscum contagiosum by Ingram and Brain (1957) the lesions are on the sole, no mention of this is made in the text and one suspects that the photograph may have been taken because of the unusual site, for authors in other standard text books had singled out the sole as an area never infected in their experience (Blank and Rake, 1955; Pillsbury *et al.*, 1956; Warren, 1965). The more recent text books refer to Baxter and Carson's paper but comment on the rarity of infection of the sole (Allen, 1967; Costello and Gibbs, 1967; Rook, 1968). We can find no other similar case reported in the literature and therefore details of a further case may be of interest.

CASE REPORT

The patient, a female computer operator aged 21, was referred to the Wart Clinic, Royal Infirmary, Edinburgh, in May 1968 with an infected "plantar wart" on the sole of the left foot; there had been no previous local treatment but systemic ampicillin had been prescribed. The patient at no time had lesions anywhere else on her body, and had not used public swimming baths or showers. She was examined by one of us and the small abscess beneath the "wart" was incised and drained. Some satellite lesions were present but in view of the infection no treatment was given to these. In August 1968, with no further treatment, the sole appeared free of any warts and the patient was discharged.

Three weeks later however she returned with a further infected lesion of the left sole on a different site. She was seen by two of us on this occasion and again the lesion was thought to be an infected wart with surrounding satellites. A swab was taken after the pustule had been incised but only *Staphylococcus albus* was cultured. Parings from the satellite lesions were taken for virological examination. A diagnosis of molluscum contagiosum was not suspected clinically.

Virological examination

The parings were collected in saline containing antibiotics. A small piece of tissue was teased out in a drop of distilled water to which a coated specimen grid was then

applied and subsequently stained with 2% phosphotungstic acid (pH 7.2). The grid was examined in an AEI EM6 electron microscope. No wart virus particles were seen in the specimen but several particles with the characteristic morphology of molluscum contagiosum virus were noted. The 2 common forms of the virus (Williams *et al.*, 1962) were found and are seen in the electron micrographs (Fig. 1).

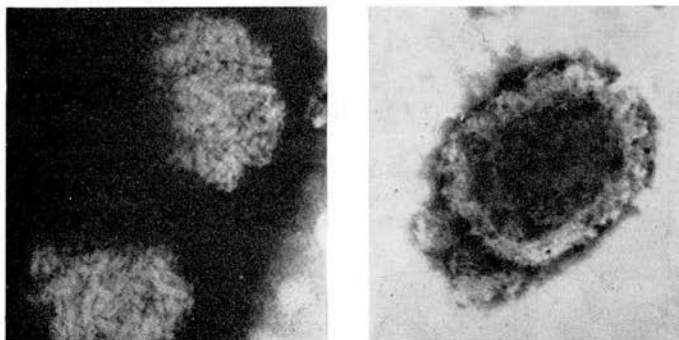


FIG. 1.

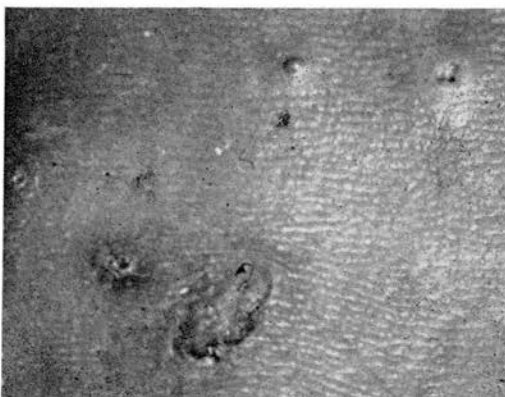

FIG. 2.

In the light of these findings careful examination of the foot 3 weeks later by two of us showed that several typical molluscum contagiosum lesions had now appeared (Fig. 2) and from them "seeds" were easily expressed. Molluscum virus particles were again seen on electron microscope examination of these. All lesions were treated by expression and the judicious application of phenol, and when examined three weeks later appeared to have healed.

DISCUSSION

We agree with Henao and Freeman (1964) that infected lesions of molluscum contagiosum may be difficult to diagnose in some sites. In Baxter and Carson's case the diagnosis was made histologically, and in our case virologically. We failed to make the diagnosis clinically, in spite of a fairly extensive acquaintance with the appearance of molluscum contagiosum. In retrospect we can recall other cases

with similar lesions on the feet, and we suspect therefore that molluscum contagiosum on the sole may often be unrecognized.

REFERENCES

- ALLEN, A. C. (1967) *The Skin*. 2nd. Ed. London: Heinemann, p. 783.
- BAXTER, D. L. and CARSON, W. E. (1964) Molluscum Contagiosum of the Sole. *Archs Derm.*, **89**, 471.
- BLANK, H. and RAKE, G. (1955) *Viral and Rickettsial Infections of the Skin, Eye and Mucous Membranes in Man*. London: Churchill, p. 182.
- COSTELLO, M. J. and GIBBS, R. C. (1967) *The Palms and Soles in Medicine*. Springfield: Thomas, p. 418.
- HENAO, M. and FREEMAN, R. G. (1964) Inflammatory Molluscum Contagiosum. *Archs Derm.*, **90**, 479.
- INGRAM, J. T. and BRAIN, R. T. (1957) In *Sequeira's Diseases of the Skin*. 6th Ed. Ed. J. T. Ingram & R. T. Brain. London: Churchill, p. 688.
- PILLSBURY, D. M., SHELLEY, W. B. and KLIGMAN, A. M. (1956) *Dermatology*. Philadelphia: Saunders. p. 702.
- ROOK, A. J. (1968) In *Textbook of Dermatology*. Vol. I. Ed. A. J. Rook, D. S. Wilkinson & F. G. Ebling. Oxford and Edinburgh: Blackwell, p. 789.
- WARREN, J. (1965) In *Viral and Rickettsial Infections of Man*. 4th Ed. Ed. F. L. Horsfall & T. Tamm. London: Pitman, p. 1170.
- WILLIAMS, M. G., ALMEIDA, J. D. and HOWATSON, A. F. (1962) Electron Microscope Studies on Viral Skin Disease. *Archs Derm.*, **86**, 290.
-
-

We should like to thank Professor A. S. Johnstone and Drs. N. L. Hurst and E. Vosloo for their help in the management of the patient.

—We are, etc.,

Karl Bremer Hospital,
Bellville, Cape,
S. Africa.

O. A. A. BOCK.
T. LE ROUX.

Virus in Genital Warts

SIR,—A recent report compares the serological characteristics of the viruses obtained from human genital warts and common skin warts using immune electron-microscopy and complement fixation techniques.¹ The authors suggest the existence of a one-way antigenic cross between the two viruses on the basis of their finding that sera from patients with skin warts reacted with the viruses from both skin and genital warts, whereas sera from those with genital warts reacted with genital wart virus only.

This interesting problem regarding the antigenic identity of the virus in genital warts has also been studied in this department since it was demonstrated that genital warts contained virus particles morphologically identical to those in skin warts but present in very small numbers.² As insufficient amounts of genital wart virus were available here for use in standard precipitation and complement fixation tests, other methods for identifying the virus had to be pursued.

A rabbit inoculated with a suspension of genital wart material was found after the third inoculation to have developed precipitating antibody to virus from skin warts—in fact simple plantar warts. The precipitin line formed by this rabbit's serum gave a reaction of identity with precipitin lines formed against the same virus by serum from a patient with a simple plantar wart and serum from another rabbit immunized with virus from simple plantar warts. These lines are illustrated in the accompanying drawing made from the photographic record of this test (see Fig.).

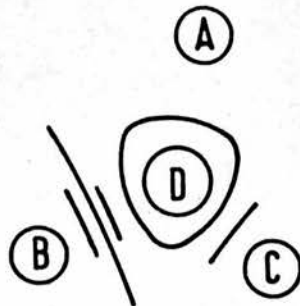


FIG.—(A) Serum from patient with plantar wart. (B) Serum from rabbit inoculated with genital wart suspension. (C) Serum from rabbit inoculated with plantar wart antigen. (D) Plantar wart virus antigen. The inner continuous line around well D shows the identity of the antibodies to wart virus in the three sera. The other lines represent antibody against other human antigens formed by the rabbits.

In addition sera from patients with genital warts were examined for antibody to the virus from plantar warts. Precipitation and complement fixation tests gave negative results with sera from 20 such patients. Recently, however, we have used a much more sensitive method for detecting antibody, particularly immunoglobulin M, to warts—a passive haemagglutination test. In this test tanned red cells sensitized with plantar wart virus are agglutinated by specific antibody in sera not only from people with plantar or other common warts but also from those with genital warts.³

These results show that human and rabbit antisera to genital warts do react in some circumstances with skin wart virus, though the genital wart sera of Mrs. Almeida and colleagues reacted only with genital wart virus in the test systems they employed. That wart viruses have more than one antigenic component has been suspected from the occasional observation of two parallel precipitin lines in some tests, but this position has not yet been clarified.

The genital wart material and sera for these investigations have been provided by Dr. D. H. H. Robertson, Royal Infirmary, Edinburgh.

The author holds a graduate research scholarship from the Medical Faculty of Edinburgh University.—I am, etc.,

MARIE M. OGILVIE.

Virus Laboratory,
Department of Bacteriology,
University of Edinburgh,
Edinburgh.

REFERENCES

- Almeida, J. D., Oriol, J. D., and Stannard M., *Microbios*, 1969, 1, 225.
- Dunn, A. E. G., and Ogilvie, M. M., *Journal of Ultrastructure Research*, 1968, 22, 232.
- Hopkins, R., *An investigation into the immune response of people infected with the human papilloma (wart) virus, using the technique of passive haemagglutination*. (Dissertation presented for B.Sc., Edinburgh). 1969.

Medical Education and the State

SIR,—I enjoyed Professor R. V. Christie's stimulating article (15 November, p. 385) on "Medical Education and the State," but his Table showing the number of whole-time clinical teachers was misleading.

The figures he quotes of 120 in London and 419 in Great Britain are taken from p. 275 of the report of the Royal Commission on Medical Education¹ and exclude all lecturers except senior lecturers, pathologists, and those academic staff engaged in research or administration. They may well not be directly comparable with North American and Scandinavian figures. The approximate total number in Great Britain can be calculated from *The Statistics of Education 1967*.²

The correct figures appear to be three to five times as high as Professor Christie's, depending on whether pathologists are included.—I am, etc.,

R. D. LOWE

Department of Medicine,
St. Thomas's Hospital Medical
School,
London S.E.1.