

THE SYMPATHETIC AND PARASYMPATHETIC
NERVOUS SYSTEMS OF THE FOWL.

Thesis for the Degree of Doctor of Philosophy

by

T.M. Hsieh, B.Sc., M.Sc.



May 1951.

Contents.

	<u>Page.</u>
Acknowledgement.	
Introduction.	1
Material and Method.	4
Description -	
The Sympathetic Trunk	5
The Sympathetic & Parasympathetic Nerves in the Cephalic Region.	16
The Ciliary Ganglion & the Ciliary Nerves.	17
The Internal Maxillary Nerve, the Lesser Superficial Petrosal Nerve and the Infra-temporal Plexus.	20
The Internal Carotid Nerve & the Cavernous Plexus.	27
The Vidian Nerve, the Ethmoidal Ganglion & the Spheno-palatine Ganglion.	29
The Maxillary Nerve.	35
The Nerve to the Angle of the Mouth.	36
The Chorda Tympani.	37
The Submandibular Ganglia.	42
The Glosso-pharyngeal Nerve.	42
The Vagus Nerve.	50
The Sympathetic & Parasympathetic Nerves in the Cervical Region.	63
The Descending Oesophageal Branch of the Glosso-pharyngeal Nerve.	63
The Common Carotid Plexus.	65
The Sympathetic & Parasympathetic Nerves in the Thoracic Region.	69
The Cardiac Nerve.	69
The Ground Plexus of the Vagus.	78
The Cardiac Plexus.	72
The Pulmonary Plexus.	80
The Oesophageal Plexus.	81
The Sympathetic & Parasympathetic Nerves in the Abdominal Region.	82
The splanchnic nerves.	90
The Pelvic Splanchnic & the Pudendal Nerves.	92
The Plexuses in the Abdominal Region.	94
The Coeliac plexus.	94
The Splenic " .	95
The Hepatic " .	95
The Pancreatico-duodenal plexus.	97
The Gastric plexus.	97
The Aortic " .	99
The Adrenal " .	100
The Testicular plexus.	101
The Ovarian " .	101
The Anterior Renal plexuses.	101
The Middle & Posterior Renal plexuses.	102
The Plexus in the Ligament of the Deferent Duct.	102

The Plexus in the Ligament of the Oviduct.	102
The Anterior Mesenteric Plexus.	102
The Intestinal Nerve of Remak.	103
The Hypogastric Plexus.	106
The Posterior Mesenteric Plexus.	107
The Pelvic Plexuses.	107
The Cloacal Plexuses.	108
Discussion.	110
Summary.	131
References.	134
Figures & Plates.	139

Acknowledgements.

My work has been carried out in the Department of Anatomy, Royal (Dick) Veterinary College, Edinburgh, under the supervision of Professor T. Grahame, with the aid of a Post-graduate Research Grant from Edinburgh University.

To Professor T. Grahame and the members of his staff I express my sincere thanks for their constant advice and criticisms.

My thanks are also due to Mr. R.S. Hood who was responsible for the excellent photographs and photomicrographs in this paper, and to his colleague Mr. E. Roberts for his technical advice and assistance in the preparation of the serial sections and the Bielschowsky Silver Method. I am also indebted to the latter for giving much time and thought to the preparation and eventual typing of the thesis.

Introduction.

A great many studies of the sympathetic nervous system of the fowl have been done.

Tiedmann^{e 57} in 1810 exhibited his work on the sympathetic system under the title "Systeme da la circulation du sang". He described in detail the anterior cervical ganglion, pointing out the existence of the cervical cord in the vertebral canal and indicating the carotid plexus.

Emmert^{17/3} (1810 & 1811) gave a similar description of the cervical sympathetic in some birds of prey. In addition he pointed out the cardiac nerve arising from the first thoracic ganglion.

Weber⁵⁴ (1817) studied the sympathetic system of mammals, birds, amphibia and fishes. He tried to establish the relations which exist between different groups of vertebrates as well as to confirm the vagal and sympathetic systems in vertebrates and invertebrates.

Then came Carus¹³ (1828), Sedillot⁴⁷ (1829), Bischoff⁷ (1832), Swan⁵³ (1835), Andrieu² (1837), Bazin^{3,4} (1839), Longet³¹ (1841), Bemberg⁵ (1842), Ritzel⁴² (1843), Sappey⁴⁹ (1847), Remak⁴¹ (1847), Bonsdorff⁴ (1852), Rouget⁴⁴ (1856), Budge¹² (1851/52), Samuel⁴⁵ (1860), Acconci¹ (1880), Vignal⁵⁸ (1881), Brenner¹⁰ (1883) and Onodi³⁷ (1884). Some of them studied the cerebro-spinal nerves in connection with the sympathetic, such as Carus, Bischoff, Swan, Bazin, Bonsdorff and Onodi. Some studied the innervation of certain organs, such as Sedillot (the action of the vagus on the digestive tube, larynx and the heart), Andrieu (the action of the vagus on the lung, voice, heart and digestive tube), Longet (the nerve of the voice), Bemberg & Ritzel (the nerves of the heart and/

and of the tongue), Remak (the intestinal nerve), Rouget (the action of the sympathetic nerve on the eye), Vignal (the innervation of the heart), Acconci & Brenner (inferior laryngeal nerve).

Rochas⁴³ (1885 - 1887) published five papers about the sympathetic nerves of the head, describing the "temporo-lacrimal" nerve, the "plexus of Weber", the "carotid nerve", the connections between certain ganglia and the segmental cranial nerves. He also indicated the existence of the ciliary plexus.

Magnien³² (1885) also did good work on the dissection of the head. He indicated the existence of the Vidian nerve and the chorda tympani and the absence of the lesser superficial petrosal nerve.

Laffont²⁹
Lafond (1885) did not agree with the demonstrations of the Vidian nerve and the chorda tympani given by Magnien.

Marage³³ (1887) studied the thoracic and abdominal sympathetic nerves in a great number of birds and showed the variations in different groups dissected by him.

Thebault⁵⁶ (1898) gave useful statements of the sympathetic and parasympathetic nerves in sparrows, crows and climbers.

Szantroch⁵⁴ (1927) called attention in studying the intestinal nerve of chick in both anatomy and development.

Ssinellnikow⁵⁰ (1928) studied the cardiac nerves with the staining method of Worobiew and published two papers. Both his descriptions and illustrations are useful.

It is from the above mentioned references that a general idea of the sympathetic and parasympathetic nervous systems of fowls and some detailed description of certain organs has been done. There is however no systematic study with a detailed description/

description of the entire sympathetic and parasympathetic systems of the domestic fowl. It has been the endeavour of this work to accomplish this task. Perhaps many of the problems which have been encountered could have been more easily solved and confirmed if some experimental work could have been carried out. Unhappily time is the controlling factor but it is hoped that some time in the future much of this work will be done.

Material and Method.

The material used was the domestic fowl (Gallus).

The head of an ostrich was dissected and served the very useful purpose of comparison. The nerves and vessels were so much larger and more readily followed.

The dissections were effected with the aid of a binocular dissecting microscope giving a magnification of approximately 14 diameters, a pair of sharpened forceps and a fine pointed dissecting needle.

The birds killed and bled from the sciatic artery and immediately injected with a 10% formalin solution.

It was difficult to recognise the small nerves from the small vessels and as a contrast the vessels were injected with gelatine coloured with Carmine.

Embryos of the following ages 24 hr, 36 hr, 48 hr, 60 hr, 72 hr, 78 hr, 84 hr, 90 hr, 96 hr, 100 hr, 108 hr, 116 hr, 120 hr, 126 hr, 131 hr, 144 hr, 155 hr, 170 hr, 200 hr, 228 hr, 264 hr and 300 hr were fixed for 24 hours in 5% formalin after the amnion was removed. Better results were obtained if the embryos were transferred to 8% formalin and kept for a week or longer.

All the embryos were prepared by the bulk method of Bielschowsky⁶ except one which was cut in series and the sections stained by Hollande's Chlorcarmine method.²⁴

Serial sections of 10 μ (microns) thick were made of the whole embryo and examined with the aid of a microscope.

Occasionally it was found expedient to examine fresh tissues, fowls were killed and the tissue examined at once.

Description.The Sympathetic Trunk.

There are two ganglionated trunks extending along the vertebral column, one on each side, from the base of the skull to the end of the tail. At the anterior end of the trunk is a big ganglion which represents the anterior cervical ganglion of mammals and is called by the same name, but at the posterior end there is no ganglion representing the ganglion impar of mammals, nevertheless the trunks of both sides meet with each other beneath the body of the sixth coccygeal vertebra. The number of ganglia on the sympathetic trunk including the anterior cervical ganglion is thirty-seven (Fourteen in the cervical part, seven in the thoracic, thirteen in the lumbo-sacral and three in the coccygeal). In two out of the six subjects dissected, only thirty-six ganglia (thirteen in the cervical part, seven in the thoracic, thirteen in the lumbo-sacral and three in the coccygeal) were found on one trunk and thirty-five (thirteen in the cervical part, seven in the thoracic, thirteen in the lumbo-sacral and two in the coccygeal) on the other trunk, and in still another subject there were thirty-eight ganglia (fourteen in the cervical part, seven in the thoracic, thirteen in the lumbo-sacral and four in the coccygeal) on one trunk while there were thirty-seven (fourteen in the cervical part, seven in the thoracic, thirteen in the lumbo-sacral and three in the coccygeal) on the other trunk.

The anterior cervical ganglion and the ganglia related to the nerves of the anterior and posterior limbs are much the largest; they are about 2mm in length: the thoracic segmental ganglia from which the splanchnic nerves to the abdominal

plexuses are derived, are a little smaller than the above-mentioned ganglia but bigger than the cervical segmental ganglia (from the third to the thirteenth cervical segment included) while the ganglia on the trunk in the posterior lumbo-sacral and coccygeal regions are the smallest.

The interganglionic cord is single between the adjacent ganglia of the trunk in the cervical region from the anterior cervical ganglion to the thirteenth cervical segmental ganglion and also in the lumbo-sacral region from the last thoracic segmental ganglion to the eleventh lumbo-sacral segmental ganglion, but it is double in the thoracic region from the thirteenth cervical to the last thoracic segmental ganglion, and also in the coccygeal region from the eleventh lumbo-sacral segmental ganglion to the last. In tracing the sympathetic trunk, no communicating branches came into sight until the ninth lumbo-sacral segmental ganglion was reached, except in the anterior cervical ganglion, and the segmental ganglia corresponding to the nerves of the thoracic and pelvic limbs, although in two cases the communicating branches appeared between the third lumbo-sacral and the succeeding segmental sympathetic ganglia and their corresponding spinal ganglia.

In the cervical region the segmental ganglia of the sympathetic trunk develop on the ventral rami of the cervical spinal nerves, while in the thoracic and the anterior part of the lumbo-sacral region they are attached to the spinal ganglia. Generally the third cervical segmental sympathetic ganglion is quite near the corresponding spinal ganglion, but the distances between the succeeding ganglia and the corresponding spinal ganglia become longer and longer, reaching the maximum, /

maximum, about 3mm in the thirteenth or fourteenth cervical segment. Thereafter they gradually come nearer the corresponding spinal ganglia and are finally attached to them in the segments from the second thoracic to the eighth lumbosacral. Afterwards the ninth lumbosacral and the succeeding segmental sympathetic ganglia leave the corresponding spinal ganglia again but remain connected with them by communicating branches.

To conform with the divisions of the vertebral column, the ganglionated trunk is also divided artificially into four parts, cervical, thoracic, lumbosacral and coccygeal in that order.

The Cervical Part of the Sympathetic Trunk.

The cervical part extends from the base of the skull to the root of the neck. It passes through the series of foramina intertransversaria of the cervical vertebrae, in company with the vertebral artery and vein in the segments from the first to the twelfth cervical vertebra and with the supreme intercostal artery and vein in the segments from the thirteenth to the fourteenth. In the anterior part of the neck it lies on the medial wall of the canalis intertransversarius of the cervical air sac, but when it passes backwards it is gradually enclosed in a fold which is invaginated from the medial wall of the canalis intertransversarius of the air-sac. There are thirteen or fourteen ganglia on the trunk of this part according to the number of the cervical vertebra, thirteen in the bird with thirteen cervical vertebrae and fourteen in the bird with fourteen cervical vertebrae. The first ganglion, the anterior or superior cervical ganglion is situated on the base of/

of the skull near the foramen lacerum posterius, while the rest are situated against the intervertebral foramina from which the cervical spinal nerves, from the third to the thirteen-th or fourteenth included, issue. With the exception of the anterior cervical ganglion and the last two cervical segmental ganglia, they are fusiform in shape and arranged segmentally in series with their tapering ends connected to the adjacent ganglia cranially and caudally by the interganglionic cords.

Generally between these segmental ganglia and their corresponding spinal nerves there are no communicating rami, although this is not the case with the anterior cervical ganglion and the last two cervical ganglia. They are attached to the ventral rami of the cervical spinal nerves in such a way that the branches of the ventral ramus of the spinal nerve pass through a notch on the dorso-lateral and lateral aspect of the sympathetic ganglion. Owing to the exchanges of nerve fibres in the notch, between the spinal nerve and the sympathetic ganglion, the branches of the spinal nerve can hardly be separated from the sympathetic ganglion. As shown in Figures 14A,Z1; 14B,U4b,Z1, the muscular branches of the spinal nerve to the *M. longus colli* and *M. profundus intertransversarius* are deeply placed in the notch; superficial to these branches is the ventral cutaneous nerve of the neck.

The last two cervical ganglia are more developed in size and more or less modified from the fusiform shape owing to the double interganglionic cords attached to each end of them.

The muscular branches of the ventral rami of the last two cervical spinal nerves supplying the *M. longus colli* pass through the mazes of their corresponding sympathetic ganglia, that/

that is, the segments of these muscular branches passing through the sympathetic ganglia are completely embedded in the mass of the ganglia while the branches which contribute^{to} the brachial plexus are developed so much that they are just attached to the posterior part of the dorso-lateral surface of the sympathetic ganglia instead of passing through the notches on them. In addition to the area of attachment between the sympathetic ganglia and the ventral ramus of the corresponding spinal nerve, there are some fine communicating branches, 6 - 10 in number, which are arranged around the attachment area. (Fig. 12B,Z2).

The anterior cervical ganglion (Fig. 5,Z1) is situated behind the posterior wall of the external acoustic meatus and lies on the common carotid artery just before the latter gives off the internal maxillary artery in the foramen lacerum posterius. It is rather a big sympathetic ganglion 2 - 2 $\frac{1}{2}$ mm in length. It is an irregular cone or spindle-shaped, having a rather bigger anterior end attached to the glosso-pharyngeal nerve and a tapering posterior end elongated into the retro-carotid trunk passing backward along the common carotid artery and contributing to the common carotid plexus. The inter-ganglionic cord is attached to this ganglion at the junction of the anterior and middle third on the medio-dorsal aspect of the ganglion. In front of the attachment point of the interganglionic cord, the communicating branches from the vagus join this ganglion. From the anterior end arise the internal carotid and the internal maxillary nerves. (Fig. 5,Z10,Z8; Fig. 6A,Z10,Z8; Fig. 6B,Z10).

The internal maxillary nerve has two heads, one arising together/

together with the internal carotid nerve from the medial part of the anterior end, the other from the lateral part of the anterior end. Between these two heads the glosso-pharyngeal nerve passes through. From the tapering posterior part of the ganglion numerous small strands take origin, most of them leading to the common carotid and occipital arteries, while one or two go to join the hypoglossal nerve.

The interganglionic cord between the anterior cervical ganglion and the ganglion on the sympathetic trunk corresponding to the third cervical spinal nerve is rather long and pursues a curved course. For convenience of description it may be divided into two parts, an anterior and a posterior. These two parts meet with each other at the point where this cord is attached to the ventral ramus of the first cervical spinal nerve. The anterior part lies between the M. rectus capitis dorsalis major and the M. trachelomastoideus in a ventro-lateral direction along the base of the skull. About mid-way between the anterior cervical ganglion and the first cervical spinal nerve it receives the communicating ramus from the ventral aspect of the medulla oblongata just in front of the origin of the hypoglossal nerve. It is, from the ventral aspect of the medulla oblongata ~~that~~ arises a series of fila radicularia of which the most anterior one or two arrange themselves in a small bundle piercing the dura mater and leaving the skull through the lesser condyloid canal to join the interganglionic cord while the rest converge to form the hypoglossal nerve piercing the dura mater and leading to the greater condyloid canal (hypoglossal canal). (Fig. 2A, 10, 9, T, Z2; Fig. 6A, T, Z2).

The/

The greater and lesser condyloid canals are two bony canals passing through the spongy lateral occipital bone in a direction backward and a little downward beside the basilar part of the occipital bone. The greater condyloid canal pursues a slightly curved course through which the hypoglossal nerve leaves the cranial cavity. The internal orifice opens in the posterior fossa of the cranial cavity between the occipital condyle and the recess for the superior ganglion of the glossopharyngeal and vagus nerves, just in front of the margin of the foramen magnum. The external orifice is situated on the posterior surface of the skull, ventro-lateral to and a little distance away from the occipital condyle. The lesser condyloid canal is smaller and rather more curved with the concavity toward the great condyloid canal. It conducts the communicating branch from the hind-brain to the sympathetic trunk. The internal orifice opens in the posterior fossa of the cranial cavity beside the basilar part of the occipital bone, in front of the internal orifice of the greater condyloid canal. The external orifice is on the posterior surface of the skull, situated ventro-lateral to the external orifice of the greater condyloid canal. The position of the greater and lesser condyloid canals and the external orifices is shown in Figure 2A, 9 & 10; and Figure 2B, 9a, & 10a, as occupied by the hypoglossal nerve and the communicating branch respectively.

Opposite the external orifice of the greater condyloid canal this interganglionic cord receives a communicating branch from the muscular branch of the hypoglossal nerve. This muscular branch gives off an anastomotic branch to the dorsal/

dorsal ramus of the first cervical nerve and supplies the M. rectus capitis ventralis lateralis. (Fig. 6A, Z2^h).

The posterior_{part} lies on the medial wall of the anterior part of the canalis intertransversarius of the cervical air-sac beside the atlas and the epistropheus. It passes round the antero-dorsal border of the M. trachelo-mastoideus to meet the anterior part which has been described above. It receives communicating branches from the ventral rami of the first and second cervical nerves. No ganglia develop on the trunk corresponding to these two spinal nerves. The fibres of the communicating branch from the first cervical nerve lead to the anterior cervical ganglion and the ganglion on the sympathetic trunk corresponding to the third cervical nerve, while those of the communicating branch from the second cervical nerve lead to the sympathetic ganglion corresponding to the third cervical spinal nerve only. (Fig. 2A, Z, Z1; Fig. 5, Z).

The Thoracic Part of the Sympathetic Trunk.

On the thoracic part of the sympathetic trunk there are seven ganglia corresponding to the seven thoracic spinal nerves. (Fig. 24). In fact, the thoracic part of the sympathetic trunk may be subdivided into three divisions, cervical, thoracic and abdominal. The cervical division containing the first two thoracic sympathetic ganglia is enclosed in a fold which is invaginated from the medial wall of the thoracic part of the canalis intertransversarius of the cervical air-sac in the same way as the cervical part of the sympathetic trunk is enclosed in the fold which is invaginated from the medial wall of the cervical part of the canalis intertransversarius. The fold/

fold is continuous with that in the cervical region. The thoracic division, containing the third, fourth and fifth thoracic sympathetic ganglia, lies on the lateral side of the third, fourth and fifth thoracic vertebrae and is covered by the costal pleura. The abdominal division, containing the last two thoracic sympathetic ganglia, lies on the lateral side of the last two thoracic vertebrae under cover of the peritoneum.

The first thoracic sympathetic ganglion is as well developed and has the same irregularly stellated shape as the last cervical sympathetic ganglion. It is attached to the ventral ramus of the first thoracic nerve, which contributes to the brachial plexus. Around the area of attachment there are 8 - 10 communicating branches connecting the sympathetic ganglion to the ventral ramus of the spinal nerve. The muscular branch of the spinal nerve which passes through this sympathetic ganglion to the *M. longus colli* is small. The cardiac nerve arises from this ganglion. (Fig. 12B, Z1, Z2, Z4, U4c; Fig. 15, Z1, Z4).

The second thoracic sympathetic ganglion is smaller than the first one and is spindle-shaped with its axis in a cranio-caudal direction. It is attached to the ventral ramus of the second thoracic spinal nerve near the spinal ganglion.

The last five thoracic sympathetic ganglia are cone-shaped with the base dorsal ~~and~~ attached to the corresponding spinal ganglia and with the apex ventral ~~and~~ elongated into the splanchnic nerves. In a well fixed specimen a distinct margin can be seen between the upper white spinal and the lower greyish sympathetic ganglia. (Fig. 2D, U1a, Z1). The interganglionic cord/

cord is double. That between the first and the second thoracic sympathetic ganglia is rather thick, one part passing above and the other below the costo-central joint. That between the adjacent ganglia of the last five ganglia is slender, one part passing above the costo-central joint and connecting the posterior part of the base of the sympathetic ganglion (or the posterior tapering end of the second thoracic sympathetic ganglion) to the anterior part of the base of the next sympathetic ganglion, while the other passes below the same joint, connecting the apex of the sympathetic ganglion (or the ventral aspect of the second thoracic sympathetic ganglion) to the anterior part of the base of the next. (Fig. 24,Z).

The Lumbo-sacral Part of the Sympathetic Trunk. (Figs. 1, 31 & 32).

Since the lumbar and sacral vertebrae are merged into one bony mass and no distinction can be made between them, the segment of the sympathetic trunk in this region is called the lumbo-sacral part. There are usually thirteen ganglia on the sympathetic trunk in this part when the number of the lumbo-sacral spinal nerves is fourteen, for the two sympathetic ganglia corresponding to the seventh and eighth lumbo-sacral spinal nerves are merged into one. In some cases a ganglion appears on the trunk between the ganglia which correspond to the adjacent lumbo-sacral spinal nerves and therefore fourteen or fifteen ganglia may be present. These ganglia are irregularly spindle-shaped with an anterior and a posterior end linking the adjacent ganglia by the interganglionic cords. Those connected to the spinal nerves which contribute to the lumbo-sacral/

sacral plexus are more developed than the rest, but nevertheless the splanchnic nerves derived from them are very small. The first lumbo-sacral sympathetic ganglion is attached to the corresponding spinal ganglion, the second lumbo-sacral sympathetic ganglion is also attached to the lower part of the spinal ganglion or to the ventral ramus of the spinal nerve near to the ventral part of the spinal ganglion. (Fig. 32, IS1). The third and fourth begin to leave the spinal ganglion and are either attached directly or connected by several very short communicating branches to the ventral rami of the corresponding spinal nerves. The fifth, sixth, seventh and eighth begin to leave the ventral rami of the corresponding spinal nerves but are still attached to them by one, two, three or more communicating branches. On the sympathetic trunk these ganglia are so closely placed that the fourth, fifth and sixth are attached to each other to form a swollen band with constrictions indicating the interganglionic cords and the ganglia corresponding to the seventh and the eighth lumbo-sacral spinal nerves are merged to form a single ganglion. The ninth, tenth, eleventh, twelfth, thirteenth and fourteenth are far from the corresponding spinal ganglia but are still connected to the ventral rami of the spinal nerves by long communicating branches. (Figs. 2E, 31, 32). The interganglionic cords are single but those between the last two, three or four are double. Between the two bundles of the double cord the sacral artery passes.

The Coccygeal Part of the Sympathetic Trunk. (Fig. 1B).

It pursues a course backward along the ventral aspect of the coccygeal vertebrae beside the middle coccygeal artery. There/

There are three or four ganglia on the sympathetic trunk connected by slender communicating branches with the ventral rami of the corresponding spinal nerves. Behind the last sympathetic ganglion the sympathetic trunk is usually connected by a communicating branch to the coccygeal nerve, arising from a position on the trunk similar to that of a sympathetic ganglion.

Finally the sympathetic trunk splits into a medial and a lateral branch on the ventral aspect of the fourth or fifth coccygeal vertebrae. The lateral branch leads to the lateral aspect of the tail. The medial branch which is destined to be distributed to the ventral aspect of the tail converges to meet its fellow from the opposite side on the median line on the ventral aspect of the fifth or sixth coccygeal vertebra. No ganglion representing the ganglion impar in mammals has been found. (Fig. 1B).

The Peripheral Nerves.

The peripheral branches of the sympathetic nervous system usually join the branches of the cerebro-spinal nerves to form common stems, or anastomose with each other and with the branches from the cerebro-spinal nerves to form plexuses with ganglia interposed within them, either outside or within the organs to which they are distributed. Therefore, the sympathetic nerves and cerebro-spinal nerves are described together. It is convenient to describe this nervous system topographically in the following regions.

The Sympathetic & Parasympathetic Nerves in the Cephalic Region.

Of the sympathetic ^{and para-sympathetic} nerves in the head, only the following nerves/

nerves and ganglia which are distributed to the intrinsic muscles of the eye-ball, to certain blood vessels and sinuses, to the salivary, nasal, Harderian and lacrymal glands, and to the mucous membrane of the oral and the nasal cavities, of the pharynx and larynx, are dealt with in this paper. They are the ciliary ganglion and the ciliary nerves, the internal maxillary nerve, the lesser superficial petrosal nerve and the infratemporal plexus, the internal carotid nerve and the cavernosus plexus, the Vidian nerve, the sphenopalatine ganglion and the ethmoidal ganglion, the chorda tympani of the facial nerve, the maxillary nerve, the lacrymal branches of the maxillary nerve, the nerve to the angle of the mouth of the mandibular nerve, and certain branches of the glossopharyngeal nerve.

The Ciliary Ganglion and the Ciliary Nerves.

The ciliary ganglion is a big ganglion, as big as the anterior cervical ganglion, about $2-2\frac{1}{2}$ mm in length. It lies in the posterior part of the orbital cavity on the optic surface of the M. rectus lateralis and the lateral border of the M. rectus ventralis, with the abducent nerve on its lateral side and the internal ophthalmic artery on its medial side. It is situated lateral and a little ventral to the optic nerve. It is pear-shaped with the base attached to the proximal part of the ventral branch of the oculomotor nerve and the apex elongated into the greater ciliary nerve. (Figs. 5 & 13, C6).

The sympathetic fibres joining the ciliary ganglion are derived from the Vidian nerve. They pass, as a delicate twig from the superior branch of the Vidian nerve, upward on the orbital surface of the M. rectus ventralis to join the ciliary ganglion/

ganglion directly or by way of the vantral ramus of the oculomotor nerve. In the latter case the bundle of the sympathetic fibres may be traced to the ciliary ganglion by separating it from the fibres of the oculomotor. (Fig. 13B, Z23).

The greater ciliary nerve (N. ciliary major^{14, 46}), including the apical part of the ciliary ganglion, shows an S-shaped double curve. On the level of the proximal curvature, really on the apical part of the ciliary ganglion, it receives a communicating branch from the muscular branch of the abducens which leads to the M. pyramidalis, while on the level of the distal curvature it receives a rather large communicating branch, the ^{N.} ciliary longus, from the ophthalmic division of the trigeminal nerve. (Figs. 5 & 13, E1). It pierces the sclera in company with the internal ophthalmic artery at a point lateral and a little ventral to the entrance of the optic nerve and then pursues a way forward between the sclera and the chorioid, within the ventro-lateral quarter of the eye-ball. In its course between the sclera and chorioid it ramifies again and again until there are 5 - 6 terminal branches in the circumference of the ciliary muscle. (Figs. 12C & D, C7).

The smaller ciliary nerves (Nn. ciliary breves^{14, 46}) (Fig. 13, C7). In addition to the greater ciliary nerve there are usually two smaller ciliary nerves arising from the ciliary ganglion proximal to the entrance of the communicating branch (N. ciliary longus) from the ophthalmic division of the trigeminal nerve. These smaller ciliary nerves penetrate the sclera in the triangular area between the optic nerve and the arcuate tendon of the M. pyramidalis. In the space between the sclera and the chorioid they are united with the branches of/

of the greater ciliary nerve.

In the circumference of the ciliary muscle, the terminal branches of the ciliary nerves, 5 or 6 in number, ramify and anastomose with each other in the ventro-lateral quarter of the eye-ball, arranging themselves into two bundles which extend in a clockwise and an anti-clockwise direction around the periphery of the cornea, and finally meet with each other on the medial side of the cornea. (Fig. 12C, C7 & C7a). The annular plexus (~~plexus ganglionsus-ciliaris~~) thus formed is flat and divides the ciliary muscle into two layers between which it lies. (Fig. 12E, C7a). As the muscle fibres arising from the corneo-sclerotic junction and the internal surface of the scleral ring pass meridionally to be inserted on the chorioid and the sclera, the nerve bundle of this annular plexus appear as crossing the muscle fibres at a right angle. (Fig. 12C & E, C7a). Under the low power dissecting microscope of 14 diameters, no ganglion has been found in this plexus.

In the ventro-lateral quarter of the eye-ball two branches are found arising from the annular plexus (~~plexus ganglionsus-ciliaris~~) within the ciliary muscle and leading to the iris. One is thicker and shorter than the other. The thick one divides in the periphery of the iris into two branches which enter the iris and pursue a course within the muscle in a clockwise and an anti-clockwise direction. The slender one passes, in company with the internal ophthalmic artery, to the space between the ciliary muscle and the chorioid where it too divides into two branches. These two branches are also separated from each other and run in a clockwise and an anti-clockwise direction, following the course of the two terminal branches/

branches of the internal ophthalmic artery, around the periphery of the iris. In this case they may be traced some distance into the dorso-lateral and medio-ventral quarters of the eye-ball respectively before they enter into the muscle of the iris. (Figs. 12D & E, C7b).

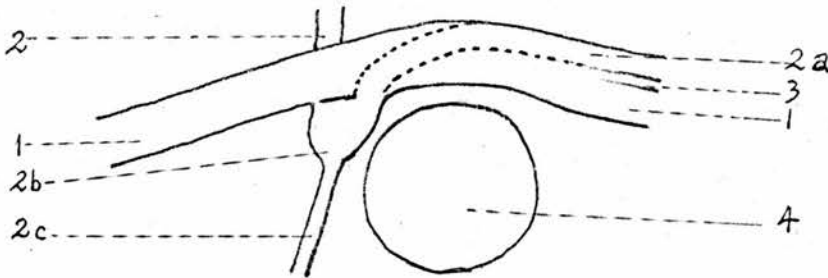
The Internal Maxillary Nerve, the lesser Superficial Petrosal Nerve and the Infratemporal Plexus.

Before describing the internal maxillary nerve, the lesser superficial petrosal nerve and the infratemporal plexus, I shall mention the internal maxillary artery and the internal maxillary plexus, to which the internal maxillary nerve, the lesser superficial petrosal nerve and the infratemporal plexus are closely related. As there is no artery in the fowl which corresponds to the external carotid artery in mammals, the internal maxillary artery (external ophthalmic,⁴³ carotico-¹⁴cephalic) is given off directly from the common carotid artery in the foramen lacerum posterior (jugular foramen). It passes forward through an arcuate bony canal to the infratemporal fossa where it gives off several branches which are corresponding to the external ophthalmic, deep temporal, middle meningeal, masseteric and inferior alveolar arteries. Concerning its origin and ramifications this artery doubtless^{ly} represents the internal maxillary artery in mammals. The arcuate bony canal which lodges this artery is then called the maxillary canal.

Diagram 'A' indicates the position of the maxillary canal. This arcuate canal is situated in the medial wall of the tympanic cavity just above the tympanic recess into which fenestra vestibuli and fenestra cochleae open. Its anterior orifice opens in the posterior/

posterior part of the infratemporal fossa under the temporo-quadratal joint, and its posterior orifice is situated in the foramen lacerum posterior just above the posterior orifice of the carotid canal. In Figure 2B, k indicates the position of the posterior orifice of this bony canal occupied by the internal maxillary artery.

Diagram 'A'.



- | | |
|--|---|
| 1. Maxillary canal. | 2. First part of the facial canal. |
| 2a. Second part of the facial canal. | 2b. Ampulla lodging the geniculate ganglion. |
| 2c. A bony canal for the greater superficial petrosal nerve. | 3. Bony canal for the internal maxillary nerve. |
| | 4. Tympanic recess. |

The internal maxillary plexus (rete temporale de Hahn,⁴³ rete mirabile ophthalmicum,¹⁴ plexus temporalis^{14,43}) is a comparatively large network of small blood vessels and is not in the form of a rete mirabile. It lies in the infratemporal fossa. On its lateral side is the superficial part of the masseteric muscle and the otic process of the quadrate bone; on its medial side is the deep part of the Masseteric muscle, the orbital process of the quadrate bone, the dorsal aspect of the sphenocranial muscle, the temporal bone and the temporal wing of the sphenoid bone.

Blood enters into this plexus from the internal maxillary artery and its collateral branches - external ophthalmic, deep/

deep temporal, middle meningeal, masseteric and the inferior alveolar etc. - by numerous twigs, of which two are considerable in size. One arises in a common stem with the deep temporal and the middle meningeal arteries from the internal maxillary artery in the posterior part of the infra-temporal fossa, while the other arises from the external ophthalmic artery just before it leaves the infra-temporal fossa to the orbita. (Fig. 7B,k2).

This vascular plexus is drained by several veins. They are the deep temporal, the superficial temporal, the veins in company with the ophthalmic and the naso-ciliary arteries and the veins connecting this plexus to the sinuses of the dura mater. The largest is the deep temporal vein which passes downwards between the deep part of the masseteric muscle, the mandibular division of the trigeminal nerve and the orbital process of the quadrate bone anteriorly and the sphenocranial muscle and the medial end of the pterygoid bone posteriorly, draining the plexus to the internal maxillary vein. (Fig. 5,1'; Fig. 7,1'). The tributaries of the superficial temporal vein draining this plexus are rather small in size and four or five in number. One of them passes upward in company with the deep temporal artery, piercing the masseteric muscle to the temporal region where it becomes the stem of the superficial temporal vein by union with other tributaries. Two of them pass backward across the otic process of the quadrate bone, one on each side, and join the superficial vein on the anterior rim of the tympanic cavity. One or two pass forward under cover of the superficial part of the masseteric muscle and then turn backwards round the anterior/

anterior border of the latter to join the superficial temporal vein under the auricular process. (Figs. 3, 4 & 7, g'1). The veins in company with the external ophthalmic and the naso-ciliary arteries are double, one on each side of the ^{Corresponding} artery. They drain the plexus into the internal maxillary vein in the orbital cavity. (Figs. 4 & 5, o, 9). Of the veins which connect this plexus to the sinus in the dura mater, one passes backward along the dorsal side of the maxillary-mandibular division of the trigeminal nerve, through the foramen ^{anterior} lacerum (preotic foramen³⁰) into the cranium and empties into the superior petrosal sinus of the dura mater at the level of the semilunar ganglion of the trigeminal. (Figs. 6B & 7A^w). The superior petrosal sinus is lodged in a semicircular groove on the cranial surface of the petrous temporal bone around the superior semicircular canal, (Figs. 4, 5, & 6A, w). and is, in turn, drained by a tributary of the occipital vein through the mastoid foramen. (Fig. 2B, b'1). One passes upward and, as the dorsal cerebral vein in mammals, penetrates the squamous temporal bone in the temporal fossa, in company with the middle meningeal artery, and joins the transverse sinus of the dura mater in the cranium. Still another one runs backward into the internal maxillary canal and pierces the temporal bone to join the transverse sinus of the dura mater in the cranium. (Fig. 6B, k^u).

In a specimen injected through the sciatic artery with red coloured gelatine, the gelatine is found in the form of small red globules in the deep temporal vein and the tributaries of the superficial temporal veins mentioned above, but this cannot be demonstrated in the veins which ^{drain} the capillaries elsewhere.

In/

In an Ostrich the infra-temporal plexus becomes a cavernous sinus in the temporal region under the skin.
internal maxillary

The Internal Maxillary Nerve. (Temporo-lacrymal⁴³) (Figs. 5 & 6A, Z8).

It is a sympathetic nerve reserving the name of internal maxillary for it pursues a course along the internal maxillary artery in the maxillary canal, just as the sympathetic nerve which runs in company with the internal carotid artery in the carotid canal is designated the internal carotid. It arises by two heads from the anterior cervical ganglion, as mentioned above in relation to the description of the latter, one from the lateral part of the anterior end of the ganglion while the other in a common stem with the internal carotid nerve from the medial part of the anterior end of the ganglion. These two heads pass forward, one on each side of the glossopharyngeal nerve and unite together to form a stem in the foramen lacerum posterior or in the small bony canal which is situated dorsal to the maxillary canal with its posterior orifice opening into the foramen lacerum posterior and its anterior orifice opening into the maxillary canal. In Figure 2B, the posterior orifice is shown as occupied by the internal maxillary nerve. (Z8). In the posterior part of this small canal it receives the superior branch of the tympanic nerve which passes forward into this canal through the posterior orifice. In the anterior part of this canal it is combined with two anastomotic branches of the anterior cervical ganglion, one from the facial nerve and the other from the glossopharyngeal. Then it advances through the anterior orifice into the maxillary canal. In the middle part of the maxillary canal, above the tympanic recess where the/

the maxillary canal is confluent with the facial canal, the internal maxillary nerve accompanies with or is rather attached to the facial nerve, (Fig. 6A,P,Z8), but it can be separated artificially from the latter. At the level of the anterior wall of the tympanic recess, where the facial nerve turns downward and medially to the geniculate ganglion, it leaves the facial nerve and continues its course forward, breaking-up into 3 - 5 terminal branches on the dorso-medial wall of the maxillary canal. (Fig. 6A,Z9). The lowest of these terminal branches is usually the largest which passes through a fissure in the medial wall of the maxillary canal and joins the anastomotic branch from the geniculate ganglion of the facial nerve to form the lesser superficial petrosal nerve. (Fig. 6,P2).

The superior branch of the tympanic nerve of the glossopharyngeal passes forward and upward crossing the lateral side of the terminal part of the common carotid artery to the posterior orifice of the small bony canal situated dorsal to the maxillary canal. In this canal it joins the internal maxillary nerve. (Figs. 5 & 6,R2).

The anastomotic branch of the facial nerve (Figs. 5 & 6,P2) which may be called the facial root of the lesser superficial petrosal nerve, arises from the geniculate ganglion and passes through a small canal in the ventral wall of the maxillary canal, dorsal and anterior to the geniculate ganglion, into a compact fibrous membrane which contributes to form the latero-ventral wall of the anterior part of the maxillary canal. The bony wall of the maxillary canal is thin and incomplete. The anterior part of the latero-ventral wall between the tympanic recess, which leads to the fenestra vestibuli and the fenestra cochleae/

cochleae, and the infra-temporal fossa, usually shows a notch which is filled up by a membrane of compact fibrous tissue. In this membrane it unites with the chorda tympani to form a common trunk leading forward until near the anterior end of the maxillary canal it leaves the ^{chorda} tympani and turns to the ventro-medial wall of the maxillary canal to join one of the terminal branches of the internal maxillary nerve, forming the lesser superficial petrosal nerve.

The Lesser Superficial Petrosal Nerve.

As mentioned above, this nerve does not quite represent the nerve of the same name in mammals. It is formed by the union of a branch of the internal maxillary nerve with a communicating branch from the facial nerve while the lesser superficial petrosal nerve in mammals is formed by the union of a stem derived from the tympanic plexus with a communicating branch from the facial. (Figs. 5 & 6, P2).

The Infra-temporal Plexus ⁴³ (External ophthalmic plexus, Plexus of Weber) ⁴³. (Fig. 7B).

In the anterior part of the maxillary canal and the posterior part of the infra-temporal fossa, the terminal branches of the internal maxillary nerve and the lesser superficial petrosal nerve ramify repeatedly on the medial aspect of the internal maxillary artery.

It is observed in the vascular plexus, the terminal branches of the internal maxillary nerve and the lesser superficial petrosal nerve join the maxillary and the mandibular nerves and their collateral branches. Most of them join the nerves of the trigeminal on the medial side of the internal maxillary artery and its collateral branches while some, as shown in Fig. 7B, /

Fig. 7B, cross over the external ophthalmic artery before they join the maxillary nerve and its collateral branches.

The branches which are destined to be distributed to the lacrymal glands are slender. They pass forward through the vascular plexus to the lacrymal gland individually or united with the lacrymal branches of the trigeminal nerve. In the gland they ramify and anastomose to form a plexus with ganglia interposed in it.

The finer collateral nerve filaments from the terminal rami of the internal maxillary nerve and similar filaments from the lesser superficial petrosal nerve with some fine fibres from the trigeminal nerve anastomose to contribute a rich plexus of nerve within the vascular plexus. Delicate fibres of the nervous plexus are mixed and tangled with the small vessels of the vascular plexus. Small ganglia are found here and there on the delicate fibres among the small vessels.

Two or three branches of the internal maxillary nerve run along the external ophthalmic artery and then along the naso-ciliary artery, around the dorsal border of the M. rectus lateralis, to the posterior aspect of the eye-ball. In their course they are connected together with anastomotic branches. In the space between the M. rectus lateralis and the eye-ball an anastomotic branch is given to the muscular branch of the abducence, which is destined to supply the M. quadratus. This anastomotic branch was found in one bird only but was not verified in other preparations.

The Internal Carotid Nerve and the Cavernous Plexus.

The internal carotid nerve (Carotid cephalic)⁴³ is greater in/

in size than the internal maxillary nerve. (Figs. 5 & 6, Z10). It arises from the medial part of the anterior end of the anterior cervical ganglion in a common stem with the medial head of the internal maxillary nerve. In the foramen lacerum posterior it passes forward and downward, crossing obliquely the glossopharyngeal nerve and the terminal part of the common carotid artery to the carotid canal. In the carotid canal near the posterior orifice it receives the inferior branch of the tympanic nerve of the glossopharyngeal on the dorsal aspect of the internal carotid artery. Following the curvature of the carotid canal, it pursues an S-shaped course on the dorso-lateral aspect of the internal carotid artery. The cavernous sinus which encloses the internal carotid artery in the cranium and in the carotid canal drains into the occipital vein through the posterior orifice of the carotid canal. (Fig. 6B, b''). The internal carotid nerve gives off collateral branches to form the cavernous plexus within the cavernous sinus, (Fig. 6B, Z21).

In the anterior part of the carotid canal, above the Eustachian tube, the internal carotid nerve unites with the greater superficial^{petrosal} nerve of the facial to form the Vidian nerve which divides into a superior and a inferior branch before it leaves the carotid canal. From the superior branch of the Vidian nerve, a considerable branch arises, which runs along the internal carotid artery into the cranium, it seems to be a continuation of the internal^{carotid} nerve. (Fig. 6B, P5, Z10, Z11, Z12, & Z14). In the cranial cavity after giving collateral branches to the cavernous sinus and the pituitary body it follows the internal carotid artery to the brain. The abducent nerve lies in/

in a bony canal beside the cavernous sinus and the oculomotor passes through the wall of the sinus, but no anastomotic branch from the internal carotid nerve was noted to either of these nerves. In one bird an anastomotic branch was found between the internal carotid nerve and the trigeminal nerve, which pursues a long course in a compact bony tube passing through the spongy bone of the basi-sphenoid, ~~This internal carotid nerve joins the semilunar ganglion of the trigeminal nerve.~~ The microscopic preparation of the anastomotic nerve fibre is nonmyelinated. This anastomotic branch is seldom found.

The Vidian Nerve, the Ethmoidal Ganglion and the Sphenopalatine Ganglion.

The Vidian nerve (Figs. 5 & 6B, Z11) is formed by union of the internal carotid nerve of sympathetic and the greater superficial petrosal nerve of the facial. It passes downward and forward in the lateral wall of the cavernous sinus following the internal carotid artery. Before it leaves the carotid canal, it divides into a superior and an inferior terminal branch. The inferior branch is mainly, if not all, composed of fibres derived from the greater superficial petrosal nerve. If fibres from the internal carotid nerve are present, they may be recognised by their darker colour.

The Superior Branch of the Vidian Nerve. (N. nasopalatinus,⁹ Ramus superior N. sympathetico-carotico-cephalici,^{6,2} N. orbitaire^{4,3}). (Figs. 5, 6B & 11B, Z12).

It passes through the pterygoid canal to the base of the skull under cover of the M. sphenopterygo-quadratus and posterior to the sphenopterygoid joint, in company with buccinator/

buccinator artery and the communicating vein between the buccinator vein and the cavernous sinus. (The buccinator artery is a branch from the internal maxillary artery in mammals, but in birds it arises from the internal carotid artery). It can now be traced over the spheno-pterygoid joint forward, at first in company with the buccinator artery and the vein mentioned above, and then along the medio-dorsal aspect of the internal maxillary vein to the orbita. In the orbital cavity it leaves the internal maxillary vein to the dorsal border of the Harder-ian gland along which it continues its course forward until it joins the ethmoidal ganglion on the anterior wall of the orbita.

The collateral branches are as follows:-

1. Branch to the cranium. In the carotid canal, the superior branch of the Vidian nerve gives off a branch ^{of} considerable ~~of~~ size, leading along the internal carotid artery to the cranium, which has been mentioned above and regarded as the continuation of the internal carotid nerve. (Fig. 5, Z10).

2. Branch to the ciliary ganglion. In the orbital cavity, on the medial aspect of the internal maxillary vein it ^{is} given off ^{as} a slender branch ^{and} which runs upward on the orbital surface of the M. rectus ventralis to join the ciliary ganglion directly ^{or} through the ventral branch of the oculomotor nerve. (Fig. 13B, Z23).

3. Anastomotic branch to the ventral branch of the oculomotor nerve. There is an anastomotic branch between the Vidian nerve and the oculomotor nerve. From the superior branch of the Vidian nerve on the medial surface of the internal maxillary vein a fibre arises to join the ventral branch of the oculomotor nerve just after the ventral branch of the oculomotor /

oculomotor nerve crosses the lateral face of this vein and immediately above the joining of the Vena Corticosa and the vein draining the Harderian gland to the internal maxillary vein. (Fig. 5).

4. Branches to the periorbita. When the Superior branch of the Vidian nerve runs along the dorsal border of the Harderian gland, it gives 2 - 3 collateral branches to the thin periorbita between the interorbital septum and the M. rectus medialis. In the periorbita they ramify and are connected with each other to form a network with great meshes. One of the branches, (Fig. 5,Z22) is considerable in size and is situated in front of and parallel to the segment of the internal maxillary vein when this vein runs on the orbital surface of the M. rectus medialis. This branch is destined to be distributed to the distal part of the naso-ciliary artery and its two terminal branches, after giving an anastomotic branch to join the trochlear nerve. The branches on the anterior meningeal artery may be traced to the dura mater.

5. Branches to the Harderian gland. Many branches are given off to the Harderian gland.

6. Anastomotic branch to the ophthalmic nerve. In the anterior part of the orbita a thick anastomotic branch is given off to the ophthalmic nerve just before it joins the ethmoidal ganglion.

The Inferior Branch of the Vidian Nerve. (Ramus pterygo-platinus, ⁹ inferior N. ^{Ramus} ^{sympath.} carotico-cephalic, ⁶² Branche interne.) ⁴³

(Figs. 5, 6B & 11B,Z14).

This branch leaves the carotid canal by the pterygoid canal in company with a branch of the internal carotid artery, which/

which supplies the pharynx, and a vein which connects the buccinator vein to the cavernous sinus in the carotid canal. After leaving the pterygoid canal, it follows these vessels, forward and downward on the ventral aspect of the sphenopterygoid joint to the posterior angle of the palatine bone. Then it runs forward and a little upward on the dorsal aspect of the palatine bone, near and parallel with the ventral border of the interorbital septum until it joins the sphenopalatine ganglion in front of the chonial notch of the palatine bone.

The collateral branches of the inferior branch of the Vidian nerve are as follows:-

1. Branches to the Eustachian tube and the sphenopterygoid glands. On the ventral aspect of the sphenop^{terygoid}palatine joint, small branches, 5 - 8 in number, arise going to the Eustachian tube and the sphenopterygoid glands which are aggregated into one or two groups in the roof of the pharynx beside the common opening of the Eustachian tubes. The branch to the sphenopterygoid glands is the most anterior and the largest of these branches. (Figs. 5 & 11B, Z15a, Z15b).

2. The posterior palatine nerve. (Figs. 5, 8 & 11B, Z16). On the anterior aspect of the sphenop^{terygoid}palatine joint, or on the medial side of the posterior angle of the palatine bone, the posterior palatine nerve is given off from the inferior branch of the Vidian nerve. It passes over the medial or the lateral aspect of the posterior angle of the palatine bone and then pursues an arcuate course leading forward, downward and laterally on the palatine glands from the posterior part of the medial group to the anterior part of the lateral group. It is distributed/

distributed to these glands. Anastomotic branches are given to the nerve to the angle of the mouth behind the gland at the angle of the mouth. (Fig. 5, Z16).

The Ethmoidal Ganglion. (Orbito-nasale)⁴³ (Figs. 4 & 5, 13a).

It lies in the antero-dorsal part of the orbita between the anterior part of the Harderian gland and the anterior cartilaginous wall of the orbital cavity and is situated ventral to the ophthalmic nerve, where the latter gives off the frontal nerves (Nn. palpebrales)¹⁴ and the lateral nasal nerve. It is a large irregular ganglion about 1 mm in length and stellate in shape. It is connected dorsally with the ophthalmic nerve by two or three thick and short communicating branches and ventrally with the sphenopalatine ganglion by a long communicating branch, which will be described later, while the superior branch of the Vidian nerve comes to join it at its posterior part. In addition to these anastomotic branches and the superior branch of the Vidian nerve, a lot of small nerves arise from this ganglion. Some of them are distributed to the periorbita in the anterior part of the orbita, some pass downward to the Harderian gland, some run upward and forward to the medial canthus and the nasal gland (Glandula frontalis)⁹ individually or united with branches from the lateral nasal or frontal nerves, and still some penetrate the anterior cartilaginous wall of the orbita or join the olfactory nerve leading to the nasal cavity and are distributed in the mucous membrane chiefly on the ethmoidal turbinate.

The Sphenopalatine Ganglion.

The sphenopalatine ganglion lies in a fold of mucous membrane which is invaginated into the maxillary sinus in front of/

of the chonial notch of the palatine bone. (Fig. 5, Z13b). In this fold it is situated medial to the maxillary nerve which passes through this fold from the periorbita to the lateral wall of the nasal cavity. It is a little smaller than the ethmoidal ganglion, about 1 mm in length, and is somewhat triangular in shape. At the posterior end it receives the inferior branch of the Vidian nerve. At the anterior end it gives off the medial naso-palatine nerve and an anastomotic branch leading to the ethmoidal ganglion, while in the ventral aspect it gives off a thick stem leading to the lateral wall of the nasal cavity to join the ^{Ventral} terminal branch of the maxillary nerve forming the lateral naso-palatine nerve.

The anastomotic branch (Fig. 5, Z17) pursues a long course from the sphenopalatine ganglion to the ethmoidal ganglion. It penetrates obliquely the antero-ventral part of the periorbita into the orbital cavity. It then crosses the anterior border of the *M. obliquus ventralis* and runs upward between the anterior cartilaginous wall of the orbita and the anterior part of the Harderian gland to join the ventral aspect of the ethmoidal ganglion. In its course, collateral branches are given off to the periorbita and Harderian glands.

The lateral naso-palatine nerve (Figs. 4 & 5, Z19, J4; Fig. 12A, J4) is formed by union of the stem derived from the sphenopalatine ganglion and the ventral terminal branch of the maxillary nerve. It passes downward and forward on the lateral wall of the nasal cavity, under cover of the mucous membrane of the maxillary sinus. On reaching the palate it divides into a medial and ² lateral branch. The medial branch, after giving off collateral branches to the anterior part of the medial group/

group of the palatine glands in its course, ramifies and is distributed to the maxillary gland. The lateral branch is distributed to the gland-free lateral part of the palate.

The medial naso-palatine nerve (Figs. 5 & 12A,Z20) passes obliquely downward and forward on the posterior part of the nasal septum and then forward along the ventral free border of the septum, which is against the long narrow median split between the nasal and oral cavities, to the maxillary glands in the palate in front of the median split. In its course in the nasal septum it is in company with the anastomotic branch between the pharyngeal artery and the medial nasal branch of the palatine artery, and its satellite vein which is useful as an indicator to show the position of this slender nerve. In the nasal septum numerous collateral branches are given to the mucous membrane of the septum and the posterior turbinate and to the vascular plexus in the septum. Ganglia are found on these collateral branches. In the space between the right and left maxillary glands it ramifies and anastomoses with its fellow of the opposite side to form a plexus. Connections take place between the medial and lateral naso-palatine nerves of the same side on the maxillary gland, nevertheless the medial naso-palatine nerve ramifies chiefly on the medial aspect of the gland and the lateral naso-palatine nerve ramifies on the lateral aspect. (Fig. 12A,J4,Z20).

The Maxillary Nerve. (Figs. 3,4,5 & 7,J) leaves the vascular plexus in the infra-temporal fossa and passes downward and forward around the postero-ventral aspect of the eye-ball, between the periorbita and the M. depressor palpebrae inferioris, in company with blood vessels. In the anterior part of the ventral/

ventral aspect of the eye-ball it is divided into a superficial and a deep branch.

The superficial branch (External nasal¹⁴) runs forward between the conjunctiva and the mucous membrane of the dorsal wall of the maxillary sinus, to the lateral wall of the maxillary sinus where it is distributed to the skin of the face and the upper jaw and to the mucous membrane of the maxillary sinus. Collateral branches are given off to the lower eye-lid, the lacrymal sac and the proximal part of the naso-lacrymal duct. (Fig. 3, J1)

The deep branch (Figs. 3,4 & 5,J2), owing to its size, may be regarded as the continuation of the trunk of the maxillary nerve. It runs medially in the periorbita under the eye-ball and then passes to the lateral wall of the nasal cavity through a fold of mucous membrane which is invaginated into the maxillary sinus in front of the chonial notch of the palatine bone. On the lateral wall, under cover of the mucous membrane of the maxillary sinus, it is divided into two terminal branches, a dorsal and a ventral. The dorsal branch (External maxillary¹⁴) (Figs. 3 & 4,J3) passes forward on the curved lateral wall of the nasal cavity to the ventral aspect of the nostril. The ventral branch (Superior alveolar¹⁴) (Figs. 3 & 4,J4) passes downward and forward and unites with a nerve stem from the sphenopalatine ganglion to form the lateral^{naso-}palatine nerve which has been described above.

The Nerve to the angle of the Mouth, and The Innervation of the Gland at the angle of the Mouth and the latero-dorsal Group of the Posterior Submandibular Glands.

The nerve to the angle of the mouth (Anguli oris¹⁴) (Figs. 4, 5 & 8,K) is/

is a branch from the mandibular nerve. It pursues a course similar to the buccinator nerve in mammals, downward and forward between the masseteric and pterygoid muscles to the angle of the mouth. Behind the gland at the angle of the mouth it is connected to the posterior palatine nerve by an anastomotic branch. It supplies the gland at the angle of the mouth, the latero-dorsal group of the posterior submandibular glands (posterior-lateral group of the posterior ^{sub}maxillary glands) and the adjacent mucous membrane.

The branches supplying the gland at the angle of the mouth enter this ~~group of~~ gland on the oral surface. Ganglia are found on these branches in the gland.

The dorso-lateral group of the posterior submandibular glands is supplied by a collateral branch from the nerve to the angle of the mouth. Occasionally a nerve bundle may be traced from the pharyngeal plexus along the palatine artery to this group of glands.

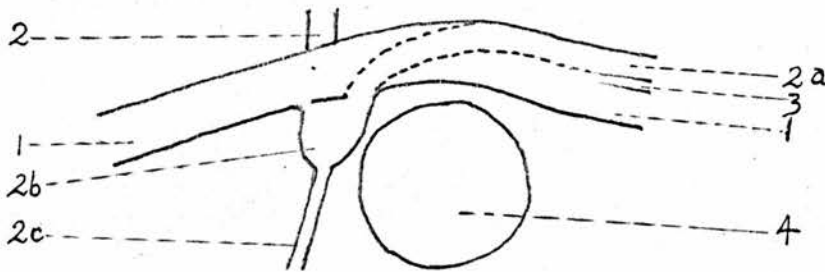
The Chorda Tympani.

Before dealing with the chorda tympani, it is necessary to mention the facial canal and the facial nerve.

The facial canal is within the petrous temporal bone, with its internal orifice opening in the antero-ventral corner of the fundus of the internal acoustic meatus and its external orifice opening in the foramen lacerum posterior, dorsal to the posterior orifice of the maxillary canal. As it is bent in an acute angle in front of the tympanic recess, it may be divided artificially into two parts. The first part lies in front of the proximal part of the cochlea and is placed in a transverse direction from the internal acoustic meatus to an ampulla/

ampulla which is situated in front of the tympanic recess and lodges the geniculate ganglion. The second part is slightly coiled spirally around the maxillary canal extending from the above mentioned ampulla to the posterior orifice. Owing to the absence of the partition wall between them, these two canals are confluent above the tympanic recess. Diagram 'A' shows the relation of the facial canal to the maxillary canal.

Diagram 'A'.



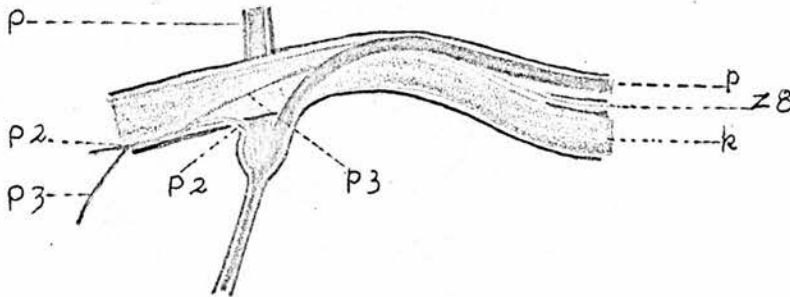
- | | |
|--|--|
| 1. Maxillary canal. | 2. First part of the facial canal. |
| 2a. Second part of the facial canal. | 2b. Ampulla lodging the geniculate ganglion. |
| 2c. A bony canal for the greater superficial petrosal nerve. | 3. Bony canal for the int. maxillary nerve. |
| | 4. Tympanic recess. |

Diagram 'B' shows the internal maxillary artery and the facial nerve in the maxillary canal and the facial canal respectively. Comparing these two diagrams with Figures 6A and 6B we may get an idea about the relation of the facial canal to the maxillary canal. In the anterio-dorsal and the ventral parts of the ampulla, two bony canals open, one leading to the facial root of the lesser superficial petrosal nerve to the maxillary canal, the other leading the greater superficial petrosal nerve to the carotid canal.

The facial nerve leaves the cranial cavity through the facial canal. In the ampulla of this canal, in front of the tympanic/

tympanic recess, is noted the geniculate ganglion from which the greater superficial petrosal nerve and the facial root of the lesser superficial petrosal nerve arise. In the second part of the facial canal it gives off the chorda tympani and a communicating branch to the anterior cervical ganglion of the sympathetic. (Fig. 6,P3).

Diagram 'B'.



- | | |
|---|---|
| k. Int. maxillary artery. | P. Facial nerve. |
| P1. Geniculate ganglion. | P3. Chorda tympani. |
| P2. Facial root of the lesser superficial petrosal nerve. | P5. Greater superficial petrosal nerve. |

The communicating branch to the anterior cervical ganglion has been mentioned in relation with the description of the internal maxillary nerve. It leaves the facial nerve in the facial canal and strays into the small bony canal between the facial canal above and the maxillary canal below. In this small bony canal it joins the internal maxillary nerve and a communicating branch from the glossopharyngeal nerve to the anterior cervical ganglion. Diagram 'C' shows the communicating branch joining the internal maxillary nerve in the small bony canal. Diagram 'D' shows that the communicating branch from the facial nerve joins the internal maxillary nerve and the communicating branch from the glosso-pharyngeal nerve before reaching the anterior cervical ganglion. This preparation is made by artificially separating the communicating branches/

branches, the internal maxillary nerve, and the superior branch of the tympanic nerve from each other.

Diagram 'C'.

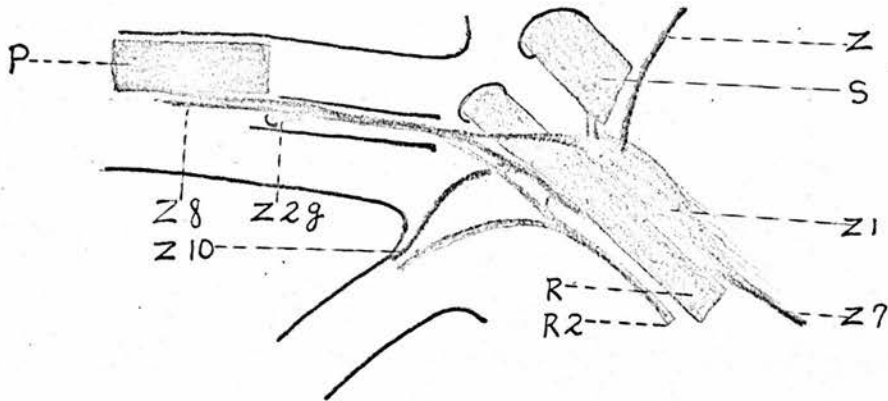
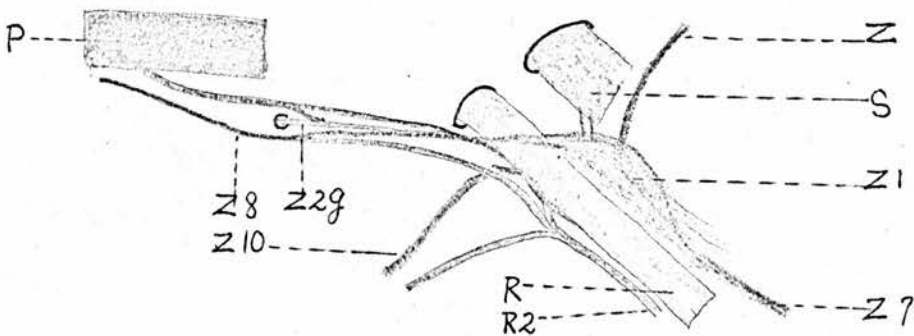


Diagram 'D'.



- | | |
|------------------------------------|--|
| P. Facial nerve. | R. Glossopharyngeal Nerve. |
| R2. Tympanic nerve. | S. Vagus. |
| Z. Sympathetic trunk. | Z1. Anterior cervical ganglion. |
| Z29. Communicating branch from Z7. | Sympathetic branch leading to the common carotid plexus. |
| Z8. Int. maxillary nerve. | |
| Z10. Int. carotid nerve. | |

The facial root of the lesser superficial petrosal nerve has been described in detail when we dealt with the internal maxillary nerve, the lesser superficial petrosal nerve and the *infra-temporal* internal maxillary plexus. The greater superficial petrosal nerve arises from the ventral part of the geniculate ganglion and passes downward and forward in a bony canal, to the anterior part of the carotid canal where it joins the internal carotid nerve/

nerve to form the Vidian nerve.

The chorda tympani arises from the trunk of the facial nerve in the second part of the facial canal or from the geniculate ganglion in a common stem with the facial root of the lesser superficial petrosal nerve. In the former case, it passes forward and downward, across the lateral aspect of the internal maxillary artery obliquely, to the latero-ventral fibrous wall of the maxillary canal, in which it joins the facial root of the lesser superficial petrosal nerve. The common stem, thus formed, runs forward until near the anterior end of the maxillary canal, it is again separated from the facial root of the lesser superficial petrosal nerve. It leaves the maxillary canal and runs through a small canal or a groove in the upper part of the anterior wall of the external acoustic meatus just below the notch accommodating the otic process of the quadrate bone.

Behind the M. sphenio-quadrate-pterygoideus it runs down the anterior wall of the external acoustic meatus in company with two branches of the superficial temporal vein which drains the internal maxillary plexus. When it reaches the quadrate-pterygoid joint, it crosses over the superficial temporal and the facial veins, and then pursues a long course forward within the M. pterygoideus lateralis near the medial surface of the mandible. In this muscle it gives off a considerable anastomotic branch leading upward to join the pterygoid nerve. Then it leaves the M. pterygoideus lateralis, pierces the M. mylohyoideus and gets into a groove on the medial surface of the mandible where it crosses the medial side of the mylohyoid nerve and unites with the sublingual branch from the inferior alveolar/

alveolar nerve. From this groove it continues its course forward along the dorsal aspect of the inferior alveolar nerve to the inferior alveolar canal. As the medial wall of the inferior alveolar canal becomes thinner and thinner and disappears it runs again in a groove on the medial surface of the mandible. Finally it penetrates the periosteum leading to the anterior part of the anterior submandibular glands and the adjacent part of the mucous membrane of the palate. (Figs. 4, 5, 6 & 8, P3).

The Submandibular Ganglia and The Innervation of the Submandibular Glands. (Figs. 4 & 8, P4, XL1).

In the inferior alveolar canal two or three or four ganglia develop on the trunk of the chorda tympani when it runs forward along the dorsal aspect of the inferior alveolar nerve. These ganglia are either directly attached to or connected by communicating branches with the inferior alveolar nerve. From these ganglia branches are given off, penetrating the medial wall of the alveolar canal, the M. mylo-hyoideus and the M. hyo-mandibularis, to the ^{anterior} submandibular glands which lie in the space between the mucous membrane of the floor of the mouth and the Mm. myo-hyoideus and hyo-mandibularis. On these branches ganglia may be found outside or within the glands. These ganglia doubtless^{ly} represent the submandibular ganglion in mammals since the ganglia develop on the chorda tympani and since the anterior submandibular glands are innervated by branches derived from these ganglia.

The Glosso-pharyngeal Nerve.

The glosso-pharyngeal nerve leaves the cranial cavity through a canal which penetrates the lateral occipital bone with its internal orifice opening in a recess which is situated/

situated behind the internal acoustic meatus and is occupied by the superior ganglion of the glosso-pharyngeal and vagus (jugular ganglion) and its external orifice opening in the foramen lacerum posterior as shown in Figure 2B,R. In the foramen lacerum posterior it passes downward and backward between the lateral and medial heads of the internal maxillary nerve and is attached to the anterior end of the anterior cervical ganglion. Then it continues its course downward and backward along the ventral aspect of the occipital vein, crossing the lateral aspect of the common carotid artery to the lateral aspect of the jugular vein. At the level of the origin of the external maxillary artery it is divided on the lateral aspect of the jugular vein, into the anterior laryngeal and the descending oesophageal nerves.

The spindle shaped petrous ganglion develops on the trunk of the glosso-pharyngeal nerve on the medial side of the lateral process of the tongue. (Fig. 5,R1).

There is a large anastomotic branch between the vagus and the glosso-pharyngeal nerve, which will be noted in relation with the description of the vagus.

Several branches are given off from the glosso-pharyngeal nerve and are distributed to the head and neck. The branches which belong to the cephalic region are described as follows.

1. The Communicating Branch to the Anterior Cervical Ganglion.

In the proximal part of the bony canal in the lateral occipital bone, the glosso-pharyngeal nerve gives off a communicating branch to the anterior cervical ganglion. This communicating branch passes laterally through a small curved canal in the posterior wall of the proximal part of the cochlea to/
to/

to the canal of the internal maxillary nerve, where it joins the internal maxillary nerve. (Fig. 6A, Z2^h; Diagrams C & D, Z2^h).

2. The Tympanic Nerve. (Figs. 5 & 6, R2).

The tympanic nerve arises from the petrous ganglion. Sometimes it arises in a common stem with the pharyngeal branch. It runs forward and upward along the ventral aspect of the common carotid artery to the foramen lacerum posterior. Here it breaks up into a superior and a inferior branch after giving off a small communicating branch to the anterior cervical ganglion.

The superior branch is the smaller. It passes upward and forward to the small canal of the internal maxillary nerve, which is situated dorsal to the posterior part of the maxillary canal. In this small canal it joins the internal maxillary nerve.

The inferior branch runs forward and a little upward to the carotid canal. In the posterior part of the carotid canal it crosses the lateral aspect of the internal carotid artery obliquely and joins the internal carotid nerve on the dorsal aspect of the same artery.

3. The Pharyngeal Branch. (Figs. 4, 5, 6 & 11B, R3).

The pharyngeal branch arises from the ventro-anterior aspect of the petrous ganglion. In the space between the M. rectus capitis ventralis medialis, medially, and the M. occipito-mandibularis and the lateral process of the tongue laterally, it pursues a curved course with the concave side forward and upward. At first it runs down the lateral surface of the M. rectus capitis ventralis medialis, then turns forward and downward, crossing the lateral aspect of the posterior auricular vein/

vein and finally passes forward and a little medially on the ventral surface of the *M. rectus capitis ventralis medialis*, across the medial aspect of the internal maxillary vein obliquely to the posterior border of the sphenopterygoid glands to which it is distributed.

On the lateral aspect of the *M. rectus capitis ventralis medialis* it gives off a branch which runs backward and is continuous, behind the external maxillary artery, with a branch from the trunk of the glosso-pharyngeal nerve. Thus a loop is formed around the external maxillary artery.

Just before it crosses the posterior auricular vein it gives off 2 or 3 branches which ramify repeatedly to form the pharyngeal plexus on the pharynx. Most of these branches are distributed to the wall of the pharynx while some can be traced to the sphenopterygoid glands and the intermediate group of the posterior submandibular glands (intermediate group of the posterior submaxillary glands²⁰) and still others lead to the external maxillary artery and its branches. (Fig. 11B,R3).

4. The Lingual Branch. (Figs. 3, 4, 5, 8, 9 & 10,R4).

The lingual branch pursues a long spiral course from the trunk of the glosso-pharyngeal in the anterior part of the neck to its distribution in the tongue. At first it passes backward and downward, across the lateral aspect of the proximal part of the external maxillary artery, and then turns forward and laterally around the common stem of the posterior auricular, the laryngeal and the lingual arteries to the lateral process of the tongue. (Fig. 4,R4). Then it crosses the concave aspect of the lateral process of the tongue obliquely, and passes forward and downward on the lateral aspect of the arcuate/

arcuate lateral process of the tongue to reach the floor of the mouth. (Figs. 3 & 4, R4). On the ventral border of the M. hyo-mandibularis it meets the lingual artery which passes forward and downward on the medial surface of this muscle while the nerve in question runs in the same direction on the lateral surface. In the floor of the mouth it runs upward, forward and medially, in company with the lingual artery around the lateral aspect of the anterior part of the lateral process of the tongue to the ventral surface of the lateral process of the posterior group of the lingual glands.

In addition to the muscular branches to the M. hyo-mandibularis, it gives off a branch to contribute to the pharyngeal plexus, when it crosses the concave aspect of the lateral process of the tongue. Most of the nerve fibres which supply the intermediate group of the posterior sub-mandibular glands are derived from this branch. (Figs. 5 & 11B, R3; XLIV).

In the floor of the mouth, when it comes to meet the lingual artery at the posterior end of the medio-ventral group of the posterior submandibular glands, (anterior-medial group of the submaxillary glands²⁰) it gives off branches to supply these glands. (Figs. 8, 9 & 10, R4 & XLII)

Now a brief description of the lingual glands should be interposed here before dealing with the innervation of these glands.

The lingual glands are gathered into three groups, two anterior and one posterior. The two anterior groups are enclosed in the free part of the tongue, one on each side of the entoglossal bone. There are three surfaces and two ends in/

in each group. The dorsal surface is crescent with a convex medial border and a slightly concave lateral border and is covered by a thick and horny epithelium. The latero-ventral surface is also crescent but it is covered by a thin and soft mucous membrane through which the ducts of the glands open into the oral cavity. The medio-ventral surface is convex anterior-posteriorly and concave dorso-ventrally in conformity with the shape of the lateral surface of the entoglossal bone. Both anterior and posterior ends are narrow and pointed. The anterior end reaches the middle part of the cartilage which is situated anterior to the entoglossal bone while the posterior end is a little beyond the posterior extremity of the lateral process of the entoglossal bone. (Figs. 9 & 10, LXIII).

The posterior group is extensive, nearly over the whole area between the larynx and the transverse row of the single, large and horny papillae on the dorsal ^{surface} of the tongue. The ducts of the glands open on the dorsal surface of the tongue. This group may be considered as consisting of a body, two lateral processes and two posterior processes. The body lies on the thyro-hyoid ligament and the right and left thyro-entoglossal muscles. The lateral process (Figs. 9 & 10, LXIV) extends from the anterior part of the body backward, lying on the articulo-hyoid muscle.

The posterior process (Fig. 10, LXV) extends from the posterior part of the body backward along the lateral border of the larynx to the crico-arytenoid glands. The anterior part lies on the ventral piece of the cricoid cartilage while the posterior part lies on the superior crico-arytenoid muscle.

Innervation of the Lingual Glands. (Figs. 9, 10, & 11A, R4).

On/

On the ventral surface of the lateral process of the posterior group of the lingual glands, the lingual branch of the glosso-pharyngeal nerve passes forward and medially in company with the lingual artery. It breaks up into terminal branches at the anterior end of the posterior group of the glands. These terminal branches on both sides, as well as the terminal branches of the lingual branches of the ^{anterior} laryngeal nerves anastomose with each other to form a primary plexus in the space between the posterior and the anterior groups of the glands. Numerous ganglia are interposed in this plexus. From the primary plexus fine branches lead to each group of the glands to form a secondary plexus. (Fig. 11A).

When it runs on the ventral surface of the posterior group of the lingual glands in company with the lingual artery, it gives off collateral branches to contribute the secondary plexus. (Fig. 11A).

5 The Anterior Laryngeal Nerve. (Figs. 3, 4, 5, 10 & 11, R7).

The anterior laryngeal nerve is not a collateral branch from the vagus, as it is in mammals, but a branch from the glosso-pharyngeal, although more than half of the fibres of this nerve may be traced to the vagus through the anastomotic branch between the vagus and the glosso-pharyngeal. (Fig. 5, S2). It pursues a wavy course on the lateral wall of the pharynx in company with blood vessels of the same name. Collateral branches are given off to the anterior part of the oesophagus. When it reaches the lateral piece of the cricoid cartilage, it breaks up into branches. Most of these branches are distributed to the intrinsic muscles of the larynx (superior crico-arytenoid, transverse cricoid, inferior crico-arytenoid, transverse/

transverse arytenoid) and the mucous membrane of the pharynx and the anterior part of the trachea. Some are destined to supply the crico-arytenoid and lingual glands.

One or two of the terminal branches of the anterior laryngeal nerve pass medially to the ventral surface of the crico-arytenoid glands and are distributed there. The crico-arytenoid glands are gathered into two groups one on each side of the opening between the pharynx and the larynx. They lie on the lateral piece of the cricoid cartilage and the posterior part of the arytenoid cartilage, and their ducts open individually on the covering mucous membrane.

The pharyngeal or lingual branch of the anterior laryngeal nerve (Figs. 10 & 11A,R7a) which is destined to supply the lingual glands, passes forward ~~in company with~~ with the blood vessels of the same name. At first it runs on the lateral surface of the ventral piece of the cricoid cartilage, then it crosses over the border and passes forward on the dorsal surface of the same cartilage. Finally it pursues a wavy course on the ventral surface of the posterior group of the lingual glands. About midway between the cricoid cartilage and the entoglossal bone it unites with its fellow of the opposite side to form a single stem which continues the course forward until breaking up into branches and joining the primary plexus in the space between the anterior and posterior groups of the lingual glands. Ganglia are found developed on this branch. Collateral branches are given off to the mucous membrane of the larynx and the tongue and to the posterior group of the lingual glands forming the secondary plexus.

It is necessary to deal with the vagus before describing the/

the innervation of the organs in the cervical, thoracic and abdominal regions.

The Vagus.

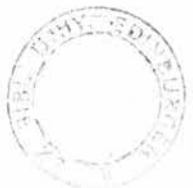The glosso-pharyngeal and vagus arise from the medulla oblongata and the anterior part of the spinal cord by a series of rootlets. The rootlets converge and are gathered together in a ganglion, the jugular ganglion or the superior ganglion of the glosso-pharyngeal and the vagus, from which the trunks of these two cranial nerves spring. The rootlets issuing from the spinal cord converge to form a stem before they join the ganglion, while those issuing from the medulla oblongata join the ganglion separately. Therefore we may divide the rootlets into a medullary group and a spinal group. The common stem of the spinal group may be traced back to the level of the second cervical spinal nerve. This stem becomes very small as the rootlets leave it one after another to enter the spinal cord. At the posterior end the stem usually bears a ganglionic swelling. This common stem runs forward along the spinal cord through the foramen magnum into the cranium to join the jugular ganglion at the posterior part; it is regarded as an independent nerve representing the accessory nerve (or the external branch of the accessory nerve) in mammals.¹⁴ If the adjacent rootlets are connected together at the points where they enter the medulla oblongata or the spinal cord by drawing a straight line, a curve will appear extending from the medulla oblongata just below the rim of the fourth ventricle to the dorso-lateral groove of the spinal cord. If this line is prolonged further backward it will be seen that this prolongation will pass through the points where the filaments of the dorsal/

dorsal roots of the spinal nerves enter the spinal cord in the dorso-lateral groove.

The common ganglion of the vagus and the glosso-pharyngeal nerves, the jugular or superior ganglion, is lodged in a recess on the cranial surface of the lateral occipital bone, just in front of the foramen magnum and postero-ventral to the internal acoustic meatus. From this ganglion the trunks of the glosso-pharyngeal and the vagus arise and leave the cranium through two bony canals. The glosso-pharyngeal nerve and its canal have been mentioned before. The canal of the vagus penetrates the lateral occipital bone in the same direction but dorsal to the glosso-pharyngeal canal, with its internal orifice opening in the recess of the jugular ganglion and its external orifice in the foramen lacerum posterior. (Fig. 2B,S).

After emerging from the cranium the vagus passing downward and backward along the dorsal aspect of the occipital vein and then backward along the dorsal aspect of the jugular vein (Figs. 3, 4, & 5,S) until it reaches the root of the neck where it moves gradually to the medial side of the jugular vein. (Figs. 20 & 21,S). When it passes over the thyroid gland it is slightly enlarged to form the thoracic ganglion (ganglion thoracic²⁷ or ganglion de Couvreur⁵⁶) (Figs 18 & 19,S). Sometimes the small plexiform ganglion²⁷ is found on the trunk about midway in its course in the neck.

In the anterior part of the thorax it passes backward between the cervical air-sac above, and the inter-clavicular air-sac below, on the medial side of the jugular^{vein} and anterior vena cava. It does not run back below the brachio-cephalic artery as in mammals, but at a level above this artery, the artery is contained/



in a fold within the inter-clavicular air-sac. Afterwards it continues its course backwards across the lateral side of the root of the lung and then turns medially around the concavity of the pulmonary vein to the ventral aspect of the oesophagus behind the heart. In front of the pulmonary artery it splits into a medial and lateral division both passing backward one on each side of the artery. These two divisions unite again behind the artery. The lateral division is larger and is regarded as the trunk. The medial division usually arises from the recurrent nerve of the vagus and is considered as an anastomotic branch. (Figs. 17, 18 & 21, S7).

At the level where the proventricular vein (vena proventricularis)⁵⁰ leaves the ventral wall of the oesophagus leading to the terminal part of the left anterior vena cava, it crosses this vein and unites its fellow of the opposite side behind the vein to form a trunk representing the ventral oesophageal trunk in mammals. This trunk soon divides again into two branches which are connected with each other by anastomotic branches and run backward and downward side by side, with the proventricular vein between them, along the curved ventral aspect of the glandular stomach to the muscular stomach. (Figs. 18, 19, & 28, S8).

In the lesser curvature of the stomach these two branches ramify repeatedly and anastomose with each other to form a thick gastric plexus which will be described later. (Figs. 28 & 29, S9).

The collateral branches are as follows.

1. Communicating branch to the anterior cervical ganglion. (Fig. 5, Z2^v).

In/

In the foramen lacerum posterior, one or two very short communicating branches leave the trunk of the vagus to the anterior cervical ganglion, joining this ganglion on the dorsal border in front of the inter-ganglionic cord.

2. The cutaneous branch.

It arises from the trunk of the vagus after the latter has left the foramen lacerum posterior. (Fig. 4,S1). It passes laterally and downward for a short distance under cover of M. rectus capitis ventralis lateralis, then turns upward, forward and laterally around the ventro-lateral border of the latter to the space between the M. occipito-mandibularis and the lateral process of the tongue, where it meets the posterior auricular blood vessels. Leaving the lateral process of the tongue it runs in company with the posterior auricular blood vessels upward, forward and medially on the M. occipito-mandibularis and is distributed to the M. cutaneous colli lateralis and the skin in the parietal and temporal region. This cutaneous branch is regarded as the accessory nerve¹⁴ (or the external branch of the accessory nerve). (Fig. 3,S1).

3. The anastomotic branch to the glosso-pharyngeal nerve. (Fig. 5,S2).

This anastomotic branch is larger than the cutaneous branch mentioned above. It arises from the vagus on the medial side of the lateral process of the tongue and passes backward and downward across the medial aspect of the occipital vein obliquely to join the glosso-pharyngeal nerve on the lateral side of the maxillary artery (external). Through this anastomotic branch, the anterior laryngeal nerve of the glosso-pharyngeal derives from the vagus a great many of its fibres.

In one specimen I found that this anastomotic branch is absent but in its place there is another anastomotic branch, much smaller than it, and leading backwards from the glosso-pharyngeal to the vagus.

4. Branches to the carotid plexus.

These branches are small and vary in number. They arise from the trunk or from the anastomotic branch between the vagus and the glosso-pharyngeal or from both. They join the plexus at the level of the origin of the external maxillary artery.

5. The anastomotic branch to the hypoglossal nerve.

There is an anastomotic branch leading to the hypoglossal nerve, when the hypoglossal crosses the lateral side of the vagus behind the lateral process of the tongue.

6. Branches to the thyroid, parathyroid glands and the ultimo-branchial bodies.

There are usually 4 or 5 branches from the distal part of the thoracic ganglion (ganglion de Couvreur) leading to the thyroid, parathyroid and the ultimo-branchial bodies. The most anterior branch passes to the posterior end of the thyroid gland. After giving branches to the thyroid, it joins the other behind to form a plexus on the cervical air-sac on the medial side of the parathyroid gland and the ultimo-branchial bodies. The most posterior one or two branches often arise from the trunk of the vagus behind the thoracic ganglion in a common stem with the anterior cardiac branch. (Figs. 18 & 19).

7. The anterior cardiac branch. (Figs. 18, 19 & 20, S6a, S'6a).

This branch arises from the vagus in the posterior part/

part of the neck by two, three or four heads, one behind the other. The most anterior head is from the distal end of the thoracic ganglion and usually in a ^{common} stem with the branches to the parathyroid gland and the ultimo-branchial bodies. It passes along the medial side of the jugular vein and then of the anterior vena cava in the dorsal wall of the lateral chamber of the inter-clavicular air-sac. The subsequent courses of the right and left anterior cardiac branches are different. The anterior cardiac branch of the right vagus turns medially and downward in front of the right atrium. Then it pursues a spiral course in the pericardium around the concavity of the aortic arch obliquely to the posterior and left aspect of the bulbus aortae where it breaks up into terminal branches anastomosing with each other to form the left coronary plexus behind the conus arteriosus following the blood vessels of the same name. (Fig. 22,S6g). When it leaves the right anterior vena cava in front of the right atrium it receives a sympathetic branch which comes from the ventro-medial or the latero-dorsal group of the sympathetic branches on the right anterior vena cava. (Fig. 20,Z7). In the pericardium, when it coils spirally on the concavity of the aortic arch, it gives off some collateral branches of which 3 - 5 run backwards to join the ground plexus of the vagus in the pericardium between the supracardiac diverticulum of the inter-clavicular air-sac above and the transverse sinus of the pericardial cavity below, (Fig. 20,S6a1) 2 or 3 lead backward and downward to contribute the superior cardiac plexus on the dorsal wall of the atria, (Fig. 20,S6a2; Fig. 22) and still another one passes down between the common pulmonary artery and the bulbus aortae to join/

join the right coronary plexus in front of the bulbus aortae. (Fig. 22).

The anterior cardiac branch of the left vagus, after receiving a sympathetic branch in front of the left atrium and on the medial side of the left anterior vena cava, turns downwards, medially and a little forward, making an acute angle on itself and leading to the left aspect of the left pulmonary artery. Then it winds round the anterior aspect of the common pulmonary artery obliquely to the right side of the conus arteriosus. Later it meets the right coronary artery in front of the bulbus aortae. (Figs. 18, 19 & 20, S6a).

On the anterior aspect of the pulmonary trunk, it gives off a lot of collateral branches, considerable in size, to form the anterior cardiac plexus on the anterior aspect of the conus arteriosus. (Figs. 20 & 22, S6e). In consequence the trunk decreases in size very much. In front of the bulbus aortae it breaks up into terminal branches to form the right coronary plexus following the blood vessels of the same name. (Figs. 18 & 20, S6h).

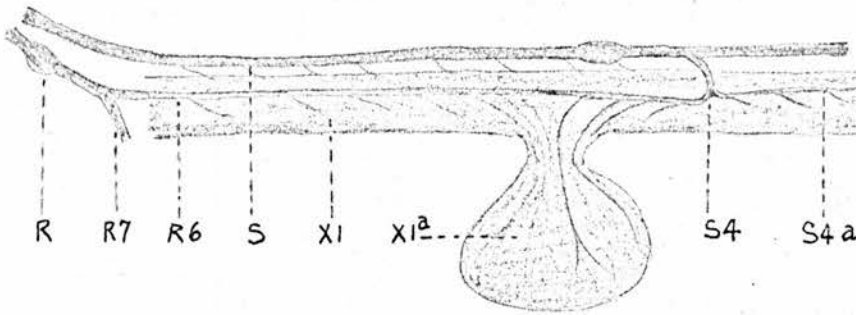
8. The recurrent nerve.

Both recurrent nerves are given off at or just behind the level of the ostium cervicale of the cervical air-sac in the anterior part of the thoracic cavity. They pass backward along side the trunks of the vagi on the dorsal wall of the lateral chambers of the inter-clavicular air-sac for a very short distance. The right nerve, before reaching the pulmonary artery, turns back making an acute bend around the concavity of the aortic arch and the left nerve, round the ligamentum arteriosum. Then they pursue a straight course forward/

forward on the dorsal wall of the medial chamber of the inter-clavicular air-sac to the root of the neck. (Figs. 18 & 20, S4; Figs. 19 & 20, S4). To be exact, in the thorax they run forward in the space between the dorsal wall of the inter-clavicular air-sac and the ventral wall of the cervical air-sac.

In the posterior part of the neck beyond the inter-clavicular air-sac they run on the ventral wall of the cervical air-sacs beside the oesophagus. Above the crop they are continuous with the trunk of the descending oesophageal branches of the glosso-pharyngeal nerves. (Diagram 'E').

Diagram 'E'.



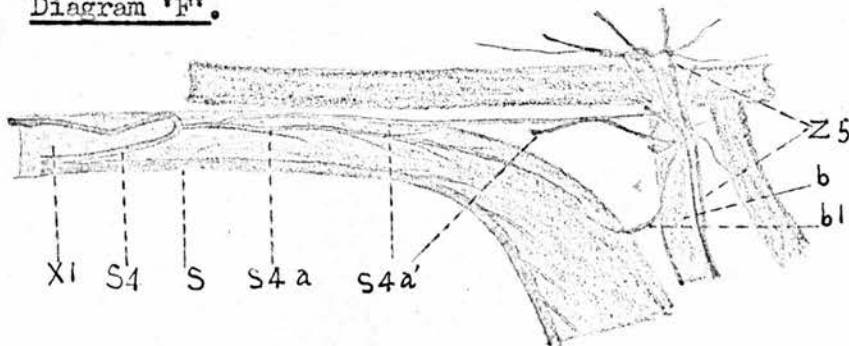
- | | |
|------------------------------------|-------------------------|
| R. Glosso-pharyngeal N. | S4. Recurrent N. |
| R6. Descending oesophageal branch. | S4a. Descending branch. |
| R7. Anterior laryngeal branch. | XI. Oesophagus. |
| S. Vagus. | XIa. Crop. |

The recurrent nerve is destined to supply the oesophagus, trachea and the muscles attached to the trachea. It gives off numerous collateral branches to the segment of the oesophagus between and including the crop and the glandular stomach, and gives off the posterior laryngeal nerve to the trachea. Of them the descending branch of the recurrent nerve and the posterior laryngeal ^{nerve} are described as follows.

The descending branch of the recurrent nerve is given off from the recurrent nerve in the concavity of the aortic arch or/

or at the ligamentum arteriosum. (Figs. 18, 20 & 23B, S4a; Figs. 19 & 20, S'4a). It passes backward on the dorso-lateral aspect of the oesophagus and is distributed there. The trunk may be traced to the posterior aspect of the glandular stomach before it sinks into the muscle of the wall. It gives one or two branches passing backwards in the mediastium between the aorta and the oesophagus. These branches unite with each other and with their fellows of the opposite side to form a very short trunk in front of the coeliac artery. This trunk can hardly be found in the adult bird but is always present in the young bird. It breaks up and joins the coeliac plexus on the left side of the coeliac artery. (Figs. 18 & 25, S4a'; Diagram 'F').

Diagram 'F'.

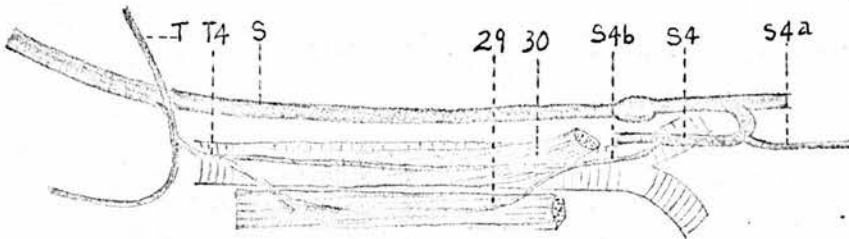


- | | |
|-------------------------|-----------------------------|
| b. Coeliac A. | S4a. Descending branch. |
| b1. Oesophageal branch. | S4a'. Anastomotic branches. |
| S. Vagus N. | Z5. Coeliac plexus. |
| S4. Recurrent N. | XI. Oesophagus. |

The posterior laryngeal nerve arises from the recurrent nerve. (Figs. 18 & 20, S4b; Figs. 19 & 20, S'4b). It passes forward, medially and upward, climbing the arched dorsal wall of the median chamber of the inter-clavicular air-sac to the dorsal border of the trachea. In some birds it runs in a fold/

fold of mucous membrane invaginated into the air-sac from the dorsal wall. Before reaching the trachea it gives off a branch to the syrinx and the adjacent part of the trachea and of the bronchus. On the trachea it runs forward within the M. ypsilo-trachealis and is finally continuous with the descending cervical branch of the hypo-glossal nerve at the anterior part of the trachea. This nerve is destined to supply the trachea, the M. ypsilo-trachealis, and the M. sterno-thyroideus. (Diagram 'G').

Diagram 'G'.



S. Vagus N.

S4. Recurrent N.

S4a. Descending branch.

S4b. Posterior laryngeal
branch.

T. Hypoglossal N.

T4. Descending cervical branch.

29. M. sterno-thyroideus.

30. M. ypsilo-trachealis.

In addition to the branches mentioned above, the recurrent gives off very fine branches to the thyroid gland and the inferior cervical artery, and following the artery to the thymus. Still more branches are given to the cervical and inter-clavicular air-sacs to contribute a nerve plexus on the wall of these air-sacs with branches derived from the vagus, from the second last cervical sympathetic ganglion and from the cardiac nerve. It is also found but can not be verified in/

in every bird, that the recurrent nerve receives, on the cervical air-sac, sympathetic branches derived from the second last cervical sympathetic ganglion.

9. The anterior pulmonary branch arises from the trunk of the vagus just behind, or in a common stem with the recurrent nerve. (Figs. 18 & 23^B, S5a; Fig. 19, S5a). It runs backward in the dorsal wall of the inter-clavicular air-sac, with the vagus on the lateral side and the recurrent nerve on the medial side. In front of the pulmonary artery it gives off 3 - 5 collateral branches which receive the sympathetic branches from the cardiac nerve and contribute the anterior part of the pulmonary plexus on the anterior aspect of the root of the lung. Some of these branches enter the lung at the hilus pulmonis, some are distributed to the ventral surface of the lung in front of the hilus. Meanwhile it gives off an anastomotic branch to the descending branch of the recurrent nerve. Then it passes backward under the visceral pleura, across the medial aspect of the root and the ventral surface of the lung to the ostium posterior, dividing the whole ventral surface into nearly two equal parts. On the ventral surface of the lung, posterior and medial to the ostium claviale it receives an anastomotic branch of considerable size from the posterior pulmonary branch of the vagus. Numerous collateral branches are given off and anastomose with each other as well as with the branches from the posterior pulmonary branch of the vagus, forming a network over the whole ventral surface of the lung, under the visceral pleura. (Fig. 23B).

10. The middle pulmonary branches. (Figs. 17 & 18, S5b; Fig. 19, S'5b).

These branches are 2 - 3 in number and arise from the

vagus on the lateral aspect of the root of the lung. They are connected with each other and with the posterior pulmonary branch, near their origin, by an anastomotic branch which is considerable in size and is placed parallel with and dorsal to the vagus. Beyond this anastomotic branch they ramify and unite with each other and with the sympathetic branches of the cardiac nerve to contribute the pulmonary plexus on the lateral aspect of the root of the lung. The strands of the pulmonary plexus, derived from the middle pulmonary branches, enter the lung at the hilus.

11. The oesophageal branch to the oesophageal plexus. (Figs. 18 & 21, S8a; Figs. 19 & 21, S'8a).

The course of the vagus in the neck and the thorax gives off numerous collateral branches to the oesophagus, but one of these oesophageal branches requires more attention. It arises on the lateral side of the root of the lung and runs medially and backward around the anterior and medial aspect of the pulmonary vein to the oesophageal plexus which lies on the ventral aspect of the oesophagus and is situated dorsal and posterior to the base of the heart. It gives 2 - 3 collateral branches to the ground plexus which is situated between the supracardial diverticulum of the inter-clavicular air-sac above and the transverse sinus of the pericardial cavity below, and 2 - 3 middle cardiac branches to the heart, forming the superior cardiac plexus. (Figs. 21 & 22, S6b, S'6b).

12. The branches to the ground plexus between the supracardiac diverticulum of the inter-clavicular air-sac and the transverse sinus of the pericardial cavity.

They are fine branches, 3 - 4 in number. The most anterior, /

anterior, which may disappear, is given from the trunk of the vagus on the lateral side of the root of the lung. The others arise, as mentioned above, from the oesophageal branch. (~~Figs. 21 & 22, S6b, S'6b~~).

13. The posterior pulmonary branch. (Figs. 17 & 18, S5c; Fig. 19, S'5c).

This branch arises from the vagus in front of, or on the lateral aspect of, the pulmonary vein. It is connected near its origin with the middle pulmonary branches of the vagus by an anastomotic branch. It gives off one or two branches to join the middle pulmonary branches of the vagus and the sympathetic branches from the cardiac nerve to form the pulmonary plexus on the lateral side of the root of the lung. Then it passes backward and upward around the lateral and posterior aspect of the pulmonary vein to the ventral or diaphragmatic surface of the lung, contributing a network under the visceral pleura. (Fig. 23, B, S5c). Behind the pulmonary vein it gives off a branch to the thoracic diaphragm.

14. The posterior cardiac branches. (Figs. 18 & 21, S6c; Figs. 19 & 21, S'6c).

There are usually three posterior cardiac branches from the right vagus and two from the left vagus. The most anterior branch arises on the lateral aspect of the pulmonary vein. It passes backward, downward and medially around the lateral and posterior aspect of the pulmonary vein to the posterior aspect of the common pulmonary vein. At this point, it joins the upper end of the big ganglion in the middle of the posterior cardiac plexus. It receives the ~~right~~ cardiac nerve within the pericardium at the lateral aspect of the pulmonary vein/.

vein. The other branches arise behind the pulmonary vein and pass downward, joining the anterior branch within the pericardium. In some birds the posterior cardiac branches are very small or disappear completely. Instead of them a rather large branch is given from the above mentioned oesophageal branch from which the middle cardiac branches arise. This branch runs backward and medially in the groove between the dorsal wall of the atrium and the lateral aspect of the common pulmonary vein, leading to the posterior aspect of the heart.

The Sympathetic & Parasympathetic Nerves in the Cervical Region.

In the cervical region only the common carotid plexus and the innervation of the oesophagus, trachea and certain glands are noted in this paper.

The glosso-pharyngeal nerve and its branches which are distributed to the cephalic region have been described before. The branches which belong to the cervical region are the descending oesophageal branch and certain branches leading to the oesophagus or to the common carotid plexus.

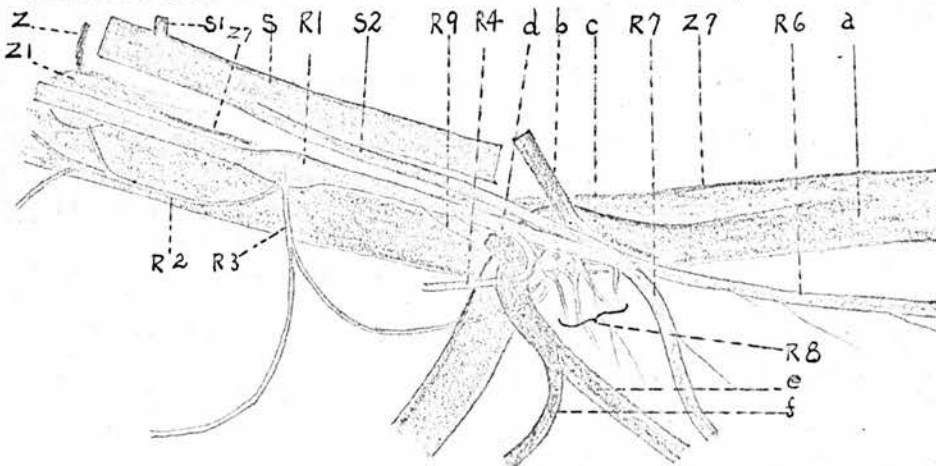
The Descending Oesophageal Branch of the Glosso-pharyngeal Nerve. (Figs. 3, 4 & 5, R6).

It is a terminal branch of the glosso-pharyngeal nerve and continues the course of the parent nerve backward along the ventral aspect of the jugular vein. The right and left descending oesophageal branches have different courses although both run back along the dorso-lateral aspects of the oesophagus. The right descending oesophageal branch follows the right jugular vein to the root of the neck. The left descending oesophageal branch accompanies the left jugular vein/

vein only in the anterior part of the neck. It then leaves the jugular vein and follows the oesophagus leading to the right side of the trachea. Both right and left descending oesophageal branches are continuous with the corresponding recurrent nerves above the crop. Most of the collateral branches are given to the oesophagus and the crop but a few slender branches can be traced to the trachea.

In addition to the collateral branches of the descending oesophageal branch of the glosso-pharyngeal nerve, there are several branches supplying the anterior part of the oesophagus and the pharynx. These oesophageal branches arise either from the trunk of the glosso-pharyngeal nerve or from the anterior laryngeal nerve. The branches from the glosso-pharyngeal trunk are connected, behind the external maxillary artery, with each other as well as with a branch from the pharyngeal branch of the glosso-pharyngeal nerve before they enter the wall of the pharynx and the oesophagus. (Diagram 'H', R8).

Diagram 'H'.



- | | |
|-------------------------------------|--|
| a. Common carotid artery. | b. Occipital artery. |
| c. Ext maxillary artery. | d. Post auricular artery. |
| e. Laryngeal artery. | f. Lingual artery. |
| R1. Petrous ganglion. | R2. Tympanic nerve. |
| R3. Pharyngeal branch. | R4. Lingual branch. |
| R6. Desc oesophageal branch. | R7. Ant laryngeal branch. |
| R8. Oesophageal branches. | R9. Branches to the common carotid plexus. |
| S. Vagus. | |
| S1. Cutaneous branch of the vagus./ | |

S2. Anastomotic branch between the glosso-pharyngeal and vagus.

Z7. Retro-carotid trunk.

Z. Sympathetic trunk.
Z1. Ant cervical ganglion.

Branches of the Glosso-pharyngeal Nerve to the Common Carotid Plexus.

Very fine branches arise from the trunk of the glosso-pharyngeal nerve and from the oesophageal branches mentioned in the last paragraph, leading to the bifurcation between the common carotid, the occipital and the external maxillary arteries to contribute to the common carotid plexus. These branches are homologous to the sinus nerve of the glosso-pharyngeal nerve in mammals. There is always a branch of considerable size from this plexus, in fact, derived from the glosso-pharyngeal nerve, to join the retro-carotid trunk of the sympathetic nerve.

The Oesophageal Branch^{es} of the Vagus.

The vagus gives off several slender collateral branches at various intervals when it runs backward along the jugular vein. Most of these thin branches lead to the oesophagus but very few can be found leading to the trachea. If the plexiform ganglion develops on the trunk of the vagus, 2 - 4 branches may be easily traced from this ganglion to the oesophagus owing to their considerable size.

The Common Carotid Plexus. (Fig. I).

It is a rich plexus on the common carotid artery. In the middle part of the neck from the fifth to the eleventh cervical vertebrae, since both right and left common carotid arteries are enclosed in a common sheath (the common carotid sheath), the right and left common carotid plexuses are fused together around both common carotid arteries. This plexus extends to the/

the occipital and external maxillary arteries at the anterior end of the neck and is continuous with the fine nerve branches distributed to the cervical air-sacs at the root of the neck.

The common carotid plexus is formed mainly by the retro-carotid trunk but receiving branches from the anterior cervical ganglion, the second last cervical sympathetic ganglion and from the glosso-pharyngeal and the vagus nerves.

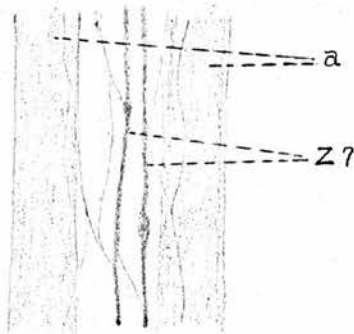
The Retro-carotid Trunk.⁵⁵ (Fig. 1; Diagram 'H', Z7).

It arises from the tapering posterior end of the anterior cervical ganglion of its own side. From this point it runs back along the common carotid artery, to the root of the neck. Ganglia of various size, shape and number are interposed on this trunk at various intervals. Numerous collateral branches are given off from this trunk, anastomosing with each other to form the common carotid plexus around the common carotid artery. In the common sheath of both right and left common carotid arteries, communicating branches appear between the two retro-carotid trunks, in fact, the arteries and the nerve trunks of both sides are entangled in a common plexus. When the common sheath is opened and the fibrous tissue between the arteries is stretched by separating the right and left common carotid arteries, the retro-carotid trunks may be found lying side by side between the two arteries, with the collateral branches beside or between them, as shown in Diagram 'I'. The retro-carotid trunk receives a considerable branch from the glosso-pharyngeal nerve of its own side. Owing to the reinforcement of the nerve fibres which arise from the ganglionic cells in the ganglia on the trunk itself, the retro-carotid trunk does not decrease its size and can be traced very easily from the anterior/

anterior cervical ganglion to the level of the eleventh or twelfth cervical vertebra. Further back it breaks up into very fine terminal branches distributing to the common carotid artery and the adjacent part of the cervical air-sac.

The anastomotic branches between the sympathetic trunk and the retro-carotid trunk illustrated by Terni⁵⁵ who finds these anastomotic branches in serial sections prepared with the silver impregnation method, cannot be demonstrated in gross anatomy using a dissecting microscope.

Diagram 'I'. - The Common Carotid Plexus.



- a. Right and left common carotid artery.
Z?. Right and left retro-carotid trunks.

The Filaments from the Anterior Cervical Ganglion to the Common Carotid Plexus.

The anterior cervical ganglion is of irregular cone- or spindle-shape with a tapering posterior end elongated to the retro-carotid trunk. From the whole surface of the posterior part of this ganglion numerous filaments arise. They run backwards beside the retro-carotid trunk to the common carotid and the occipital arteries where they join the common carotid plexus.

The Peripheral Nerve from the Second last Cervical Sympathetic Ganglion.

There are peripheral nerves from the cervical ganglia on the/

the sympathetic trunk leading to the adjacent vertebral artery. Except the nerve which arises from the second last cervical sympathetic ganglion, these nerves are very thin and can hardly be traced for any distance on the vertebral artery. The nerve derived from the second last cervical sympathetic ganglion is of considerable size and may be called the retro-vertebral nerve. It pursues a course on the vertebral artery, running downward and a little backward across the canalis intertransversarius of the cervical air-sac in the fold of mucous membrane which is invaginated from the medial wall of the canalis, and then passing through the space between the M. longus colli and the M. intertransversarius superficialis to the cervical air-sac proper. In its course, collateral branches are given off and twist around the vertebral artery. It breaks up into terminal branches on the cervical air-sac, near the thyroid gland. Most of the terminal branches are distributed to the cervical air-sac where they anastomose with the branches derived from the cardiac, retro-carotid, vagus and recurrent nerves. While some are found leading to the thyroid, along the inferior cervical artery to the thymus, or joining the recurrent nerve. (Figs. 1; 15, 23).

The Innervation of the Thyroid, Parathyroid, Thymus Glands, and the Ultimo-branchial Bodies.

The thyroid, parathyroid and the ultimo-branchial bodies are mainly supplied by the collateral branches of the vagus, which are connected with each other on the medial surface of these organs. These organs also receive nerve fibres from the branches of the recurrent, cardiac, retro-carotid and retro-vertebral nerves, since these branches are connected with/

with each other on the cervical air-sac. The thymus is supplied by the branches of the retro-vertebral and of the recurrent nerves, which run along the inferior cervical artery to this gland. The collateral branches of the vagus, which leads to the thymus as illustrated by Terni⁵⁵ who finds them in serial sections, can not be found in gross anatomy.

The Sympathetic and Parasympathetic Nerves in the Thoracic Region.

These are the cardiac nerve, the cardiac plexus, the ground plexus of the vagus, the pulmonary plexus and the oesophageal plexus.

The Cardiac Nerve.

The cardiac nerve is the only sympathetic nerve in the thoracic region supplying the heart and the lung. It arises from the first thoracic ganglion on the sympathetic trunk. (Figs. 15 & 16, Z4). It passes downward and backward on the lateral wall of the cervical air-sac, in company with the costo-cervical vein, to the dorsal aspect of the jugular vein. Then it runs backward along the dorso-lateral aspect of the jugular vein and the anterior vena cava. The right and left cardiac nerves from this point have different courses.

The right cardiac nerve penetrates the fibrous layer of the pericardium above the sinus venosus. Within the pericardium it either unites with the most anterior one of the posterior cardiac branches of the right vagus on the latero-posterior aspect of the pulmonary vein, or joins the posterior cardiac plexus on the posterior aspect of the left anterior vena cava. If it joins the posterior cardiac plexus directly, it usually gives off an anastomotic branch to the vagal branch. (Figs. 18 & 21, Z4)./

& 21, Z4).

The left cardiac nerve divides into two terminal branches on the dorso-lateral aspect of the left anterior vena cava beside the root of the lung. One continues its course backwards on the lateral aspect of the left anterior vena cava, joining the big ganglion in the middle of the posterior cardiac plexus. The other is larger and turns medially and downward across the dorso-medial aspect of the left anterior vena cava to the antero-lateral aspect of the common pulmonary vein, where it joins the posterior cardiac branch of the left vagus.

On the lateral wall of the cervical air-sac, the cardiac nerve is usually united with one or two branches from the ventral ramus of the first thoracic spinal nerve. The combined trunk thus formed varies in length, depending on the somatic nerves leaving this trunk. The somatic nerves leave the combined trunk to supply the internal and external intercostal muscles of the first intercostal space. (Figs. 15 & 16, U4e).

The collateral branches of the cardiac nerve.

1. Branches distribute to the lateral wall of the cervical air-sac. (Fig. 16, Z5; Fig. 19, Z'5).
2. A branch of considerable size arises on the lateral wall of the cervical air-sac and runs downward and backward across the lateral aspect of the jugular vein to the bifurcation of the anterior vena cava where the latter is divided into the jugular and subclavian veins. After giving twigs to the latero-dorsal aspect of the anterior vena cava, it receives, in some birds, a branch from the ventral ramus of the third last cervical spinal nerve. It runs backward and breaks/

breaks up into two or three branches which anastomose with each other on the ventro-medial aspect of the anterior vena cava. These branches are regarded as the ventro-medial group of the sympathetic branches on the anterior vena cava. The branches on the right anterior vena cava run back to the dorsal wall of the right atrium, forming a plexus partly embedded in the myocardium near the junction of the right anterior vena cava. (Figs. 15 & 16, Z'6; Fig. 19, Z'6).

A branch leaves the ventro-medial group of the sympathetic branches on the right anterior vena cava, in front of the right atrium, and ~~the~~ joins the anterior cardiac branch of the right vagus, which is destined to form the left pulmonary plexus. In the same manner, a branch leaves the ventro-medial group of the sympathetic branches on the left anterior vena cava in front of the left atrium and joins the anterior cardiac branch of the left vagus, which is destined to form the anterior cardiac and the right coronary plexuses. This sympathetic branch may arise from the trunk of the cardiac nerve on the dorso-lateral aspect of the anterior vena cava. (Figs. 19 & 20, Z'7).

3. The pulmonary branches, usually two in number, arise from the cardiac nerve on the dorso-lateral aspect of the anterior vena cava. They ramify repeatedly and join the pulmonary branch^{es} of the vagus to form the pulmonary plexus on the lateral and anterior aspect of the root of each lung. (Fig. 17, Z'9; Fig. 19, Z'9).

4. Numerous collateral branches are given off from the cardiac nerve on the dorso-lateral aspect of the anterior vena cava. They are regarded as the dorso-lateral group of the sympathetic/

sympathetic branches. The branches of both the dorso-lateral and the ventro-medial groups communicate freely, forming a network with large irregular meshes and twisting the anterior vena cava. Some of these branches can be traced to the posterior cardiac plexus. (Figs. 19 & 21, Z'8)

The Cardiac Plexus.

The cardiac nerve of the sympathetic combines with the cardiac branches of the vagus to form the cardiac plexus on the heart, which is artificially divided into five plexuses: the anterior cardiac, the right coronary, the left coronary, the posterior cardiac and the superior cardiac.

The anterior cardiac plexus (Figs. 18, 19, 20 & 22, S6e) lies mainly in the subepicardial fat on the anterior surface of the conus arteriosus. Numerous ganglia were found in the plexus. Ssinefnikow⁵⁰ regards it as the ganglionic field of the right anterior cardiac plexus. It is continuous with the right coronary plexus on the right side and connected with the left coronary plexus on the left side. From this plexus together with the right and left coronary plexuses 10 - 15 branches arise and run down the anterior and lateral surfaces of the right and left ventricles in a direction downward and laterally from left to right, in general parallel to the course of the superficial branches of the right and left coronary arteries. Those from the left coronary plexus are mainly on the left ventricle while ^{the} others are on the right ventricle. Anastomoses appear between the adjacent branches. When these branches run down the anterior surface of the ventricles, they give off branches to the myocardium and terminate/

terminate at various levels, some reaching as far as the apex or leading to the posterior surface of the right ventricle.

The right coronary plexus is situated in the sulcus atrio-ventricularis, on the right side of the conus arteriosus and in front of the bulbus aortae. (Figs. 18, 20 & 22, S6h).

On the left side, it is continued by the anterior cardiac plexus. Following the circumflex branch of the right coronary artery, it extends to the right side of the heart with 2 - 3 branches which, connected with each other by anastomotic branches, become gradually diminished after collateral branches are given off to the right atrium and ventricle and finally unite to form a small stem which joins the posterior cardiac plexus in the coronary groove. The branches to the right ventricle have been mentioned in connection with the description of the anterior cardiac plexus. Those to the right atrium supply the auricle and the part adjacent to the coronary groove. Following the course of the deep descending branch of the right coronary artery it extends and enters into the myocardium, throughout the middle and posterior parts of the interventricular septum. (Fig. 23A). Two or three branches run, in this manner, along both sides of the vessel and its branches and are connected with each other by anastomotic branches. Small ganglia appear in their courses, giving collateral branches to the myocardium and endocardium on both sides of the interventricular septum. The stems run, in general, along the deep descending branch of the right coronary artery in the upper part of the septum only. In the lower part of the septum they leave the blood vessels and pursue a course in the myocardium alone.

The/

The anterior cardiac and the right coronary plexuses are formed mainly by the anterior cardiac branch of the left vagus. The sympathetic branch which contributes these plexuses arise from the network of nerves on the medio-ventral aspect of the left anterior vena cava and joins the anterior cardiac ramus of the left ^{vagus} nerve before the left auricle of the heart. A branch from the anterior cardiac branch of the right vagus or from the left coronary plexus passing forward between the common pulmonary artery and the bulbus aortae take part in the formation of the right coronary plexus.

The left coronary plexus lies in the sulcus atrio-ventricularis behind the conus arteriosus and on the left side of the bulbus aortae. On the left side of the conus arteriosus it is connected with the anterior cardiac plexus. It extends, following the circumflex branch of the left coronary artery in the coronary groove, to the left side of the heart and follows the deep descending branch of the same artery to the anterior part of the interventricular septum in the same manner as the right coronary plexus follows the circumflex and deep descending branches to the right side of the heart in the coronary groove and the middle and posterior parts of the interventricular septum, (Figs. 19, 20 & 22, S6g). Nine to fourteen branches run to the right and left atria, innervating the portion of the right atrium around the bulbus aortae, the left auricle, and the portion of the left atrium adjacent to the coronary groove. By means of these branches it is connected with the superior cardiac plexus. As mentioned above in connection with the description of the anterior cardiac plexus, branches, 4 - 6 in number, are given off to the anterior and lateral surfaces/

surfaces of the left ventricle. An anastomotic branch is given to the right coronary plexus which, as mentioned above, passes forward between the common pulmonary artery and the bulbus aortae and ramifies on the right aspect of the conus arteriosus. In some cases this branch arises from the anterior cardiac branch of the right vagus.

This plexus is formed by the anterior cardiac branch of the right vagus, which receives a sympathetic branch from the network of nerves on the medio-ventral surface of the right anterior vena cava in front of the right auricle of the heart.

The posterior cardiac plexus lies on the posterior aspect of the common pulmonary vein, the left anterior vena cava and the right atrium, the left atrium and the upper part of the right and left ventricles. (Figs. 18 & 21, S6f). From the upper part it extends forward and upward and is connected with the superior cardiac plexus in the groove between the right pulmonary vein and the sinus venosus on the right side and in the groove between the left pulmonary vein and the left anterior vena cava on the left side. From the lower part it extends laterally in the coronary groove to the right and left sides of the heart where it is connected with the right and left coronary plexuses respectively. A big ganglion, about 1 cm in length and irregular in shape was found in the middle of the plexus, on the posterior surface of the left anterior vena cava, above and to the left of the junction of the middle cardiac vein. This ganglion is an aggregation of several ganglia.

This plexus is destined to innervate; (a) the posterior part of the common pulmonary vein and the posterior part of the left atrium, (b) the posterior part of the left anterior vena cava/
cava/

cava and the adjacent part of the right atrium including the sinus venosus and the posterior vena cava, (c) the posterior and lateral part of the right and left ventricles and the adjacent parts of the right and left atria, (d) the interatrial septum and (e) the posterior part of the interventricular septum. Branches, 10 - 14 in number, arise from the lower part of this plexus and run down the posterior and lateral surfaces of the ventricles in a direction more or less parallel to the course of the middle cardiac vein. The adjacent branches are connected with each other. The branches from the lower end of the big ganglion are much larger than those from the right and the left lower parts of this plexus in the coronary groove and most of them pass into the myocardium at various levels in the posterior interventricular groove. Some of these branches were traced to the interventricular septum.

The posterior cardiac plexus is formed by the posterior cardiac branches of both vagus nerves and the terminal branches of both cardiac nerves. There are usually 3 posterior cardiac branches from the right vagus and 2 from the left vagus. They all end in the upper part of the big ganglion in the middle of this plexus. The right cardiac nerve joins the most anterior one of the posterior cardiac branches of the right vagus. The left cardiac nerve contributes to this plexus by two terminal branches. One passes backward along the lateral aspect of the left anterior vena cava to join the big ganglion in the middle of this plexus; the other turns to the medial surface of the left anterior vena cava and after giving an anastomotic branch to the anterior one of the posterior cardiac branches of the left vagus, joins this plexus on the antero-lateral aspect of the/

the left pulmonary vein where this plexus is connected with the superior cardiac plexus. The sympathetic branches of the latero-dorsal group on both right and left anterior venae cavae have also taken part in the formation of this plexus.

The superior cardiac plexus lies on the dorsal aspect of the atria in front of the common pulmonary vein and extends nearly over the whole dorsal surface of the atria. It is partly embedded in the myocardium. Anteriorly it is connected with the left coronary plexus, posteriorly with the posterior cardiac plexus on both sides of the common pulmonary vein, dorsally with the ground plexus of the vagus on the pericardium above the sinus transversus of the pericardium and laterally with the plexus on the dorsal surface of the right atrium adjacent to the junction of the right anterior vena cava, which is formed by sympathetic branches from the medio-ventral group on the right anterior vena cava. However, the last mentioned plexus should be regarded as a part of the superior cardiac plexus. This plexus is destined to innervate the dorsal surface of the atria and the adjacent part of the interatrial septum.

The superior cardiac plexus is formed by the middle cardiac branches of the right and left vagus nerves, the collateral branches of the anterior cardiac branch of the right vagus, the left cardiac nerve, sympathetic branches from the medio-ventral group on the right anterior vena cava and the communicating branches from the ground plexus of the vagus which lies on the pericardium above the transverse sinus of the pericardium. The middle cardiac branches, 2 - 3 in number from each vagus, arise from the oesophageal branch of the vagus, which pursues a course around/

around the anterior and medial aspects of the pulmonary vein to the oesophageal plexus above the heart. These branches run down the anterior aspect of the pulmonary vein to join this plexus at its posterior part beside the junction of the common pulmonary vein. The collateral branches of the anterior cardiac branch of the right vagus contributing to this plexus at its anterior part are 2 - 3 in number. The left cardiac nerve joins this plexus on the antero-lateral aspect of the left pulmonary vein where this plexus is connected with the posterior cardiac plexus. The sympathetic branches from the medio-ventral group on the right anterior vena cava form, as mentioned above, a plexus on the dorsal wall adjacent to the junction of the right anterior vena cava, through which they join the superior cardiac plexus. The communicating branches from the ground plexus of the vagus lead to the superior cardiac plexus around and behind the transverse sinus of the pericardium.

The Ground Plexus of the Vagus.

This plexus lies in the space between the ventral wall of the supra-cardinal diverticulum (diverticulum supracardale) of the interclavicular air-sac and the dorsal wall of the transverse sinus of the pericardial cavity. It is continuous with the oesophageal plexus behind. Ganglia are found in this plexus. Behind the transverse sinus anastomotic branches lead to the superior cardiac plexus. (Diagram 'J').

The plexus is formed by the following branches:

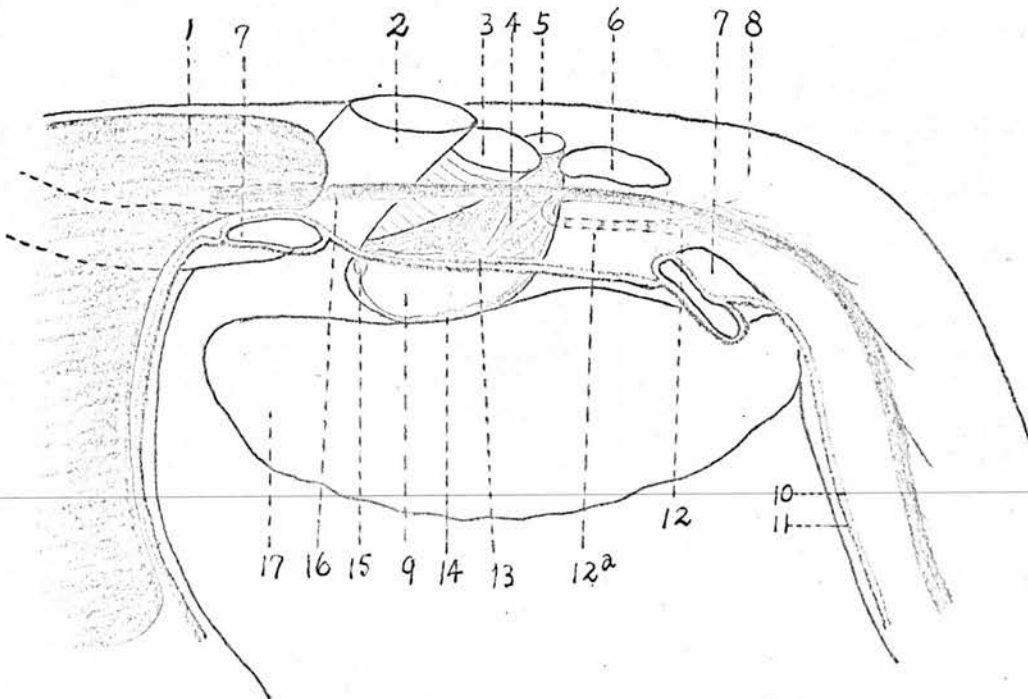
1. One or two branches from the trunk of the vagus, on the lateral side of the root of the lung, in front of the oesophageal branch which is mentioned in the next paragraph. They pass medially, in front of the pulmonary vein, to the pericardium. These/

These branches are very thin and frequently absent.

2. Two or three branches from the oesophageal branch of each vagus. They arise on the antero-medial aspect of the pulmonary vein and pass forward and medially to the pericardium above the transverse sinus. These branches and those derived from the trunk of the vagus mentioned above are regarded by Ssinelnikow⁵⁰ as the middle cardiac branches of the vagus. The oesophageal branch mentioned above arises from the vagus in front of the pulmonary vein and runs medially backward around the antero-medial aspect of the pulmonary vein to the oesophageal plexus situated dorsal and posterior to the heart.

3. Collateral branches, 3 - 5 in number, from the anterior cardiac branch of the right vagus. They run backward in the fold of the serous membrane of the pericardium, in which, the aorta and the pulmonary artery pass through. (Fig. 20, S6a1).

Diagram 'J' - Showing the Ground plexus of the Vagus, the Oesophageal Plexus and the Superior Cardiac Plexus.



- | | |
|---|---|
| 1. Interclavicular air-sac. | 2. Pulmonary artery. |
| 3. Mesobronchus. | 4. Supracardinal diverticulum of the interclavicular air-sac. |
| 5. Ostium claviale. | 8. Oesophagus. |
| 6. Pulmonary vein. | 11. Cut edge of serous layer of pericardium. |
| 7. Left Ant vena cava. | 12a. Oesophageal branch of the vagus. |
| 10. Cut edge of the fibrous layer of pericardium. | 15. Ant cardiac branch of the right vagus. |
| 12. Oesophageal plexus. | 9. <i>Transverse sinus.</i> |
| 13. Ground plexus of vagus. | |
| 14. Superior cardiac plexus. | |
| 16. Left vagus. | |
| 17. left atrium. | |

The ground plexus derives the sympathetic fibres from the anterior cardiac branch of the right vagus which receives a sympathetic branch in front of the right atrium on the medial side of the right anterior vena cava. Other sympathetic branches arise from the cardiac nerves on the anterior venae cavae. They are very thin and vary in position.

The Pulmonary Plexus.

The pulmonary plexus lies on the lateral and the anterior aspect of the root of the lung. It is formed by the pulmonary branches of the vagus and the pulmonary branches of the cardiac sympathetic nerve. The sympathetic branches in this plexus unite with the vagal branches to form common stems before they enter the substance of the lung. Most of these stems (derived from all the middle pulmonary branches of the vagus and partly from the anterior and posterior pulmonary branches of the vagus and the cardiac nerve) enter into the substance of the lung through the hilus pulmonis, while some cross the medial aspect (derived from the anterior pulmonary branch of the vagus and the cardiac nerve) or wind round the posterior aspect (derived from the posterior pulmonary branch of the vagus and the cardiac nerve) of the root of the lung to the ventral or diaphragmatic surface. (Figs. 16, 17, 19 & 23B).

Under/

Under the visceral pleura, a network is extended over the whole ventral surface of the lung. (Fig. 23B). It is formed by the anterior and posterior pulmonary branches of the vagus, reinforced by the pulmonary branches of the cardiac nerve. Nerve fibres from this network pass into the substance of the lung. Still a few very fine filaments pass from this network, through the folds of the serous membrane, across the pleural cavity, to the thoracic diaphragm.

Similar folds of serous membrane extend from the parietal pleura on the vertebral column to the visceral pleura on the medial surface of the lung, but no nerve filaments have been found passing through these folds from the splanchnic nerves to the lung.

Within the lung, an intrinsic plexus is formed by anastomosis of the nerve bundles derived from the pulmonary plexus on the anterior and lateral aspect of the root and the network under the visceral pleura on the ventral surface of the lung. Numerous ganglia are interposed in this plexus. Wherever the bundles unite or separate from each other a ganglion develops. From the ganglia, bundles stretch out in every direction between the tertiary bronchi and across them at various angles, in fact they do not follow the course of the tertiary bronchi. Unlike the blood vessels which decrease their calibre when they branch repeatedly, the nerve bundles are rather uniform in size throughout the organ, although the stems on the mesobronchus and pulmonary blood vessels in the hilus are much larger. The ganglia are also of the same size. (Fig. 17).

The Oesophageal Plexus. It lies on the ventral aspect of/

of the oesophagus, dorsal and posterior to the base of the heart. It is continuous with the ground plexus of the vagus in front and is connected with the pulmonary plexus on both sides and the superior and posterior cardiac plexuses below. (Figs. 18 & 19, S8b; Diagram 'J', 12).

This plexus is formed by several oesophageal branches from both vagus nerves. The most anterior branch arises on the lateral side of the root of the lung running medially and backward around the ^{anterior} lateral and medial aspect of the pulmonary vein.

Branches from the plexus enter the oesophagus on the ventral and lateral aspect while the descending branch of the recurrent nerve is distributed to the dorso-lateral aspect. In addition to the branches supplying the oesophagus, delicate branches run to the abdominal diaphragm and the tendinous part of the thoracic diaphragm which is attached to the oesophagus at the level of this plexus. Perhaps the nerve fibres to the diaphragm is sensory because the pulmonary muscles of Percault in the thoracic diaphragm are innervated by the collateral branches from the 3rd, 4th, 5th and 6th intercostal nerves, which enter the muscles in a line on the dorsal surface, more or less parallel to the diaphragmatic line of the pleural reflection.

The Sympathetic and Parasympathetic Nerves in the Abdominal Region.

The distribution of the sympathetic and parasympathetic nerves is extensive in the abdominal region. Great plexuses are formed, serving to distribute nerves to the viscera and vessels of the abdominal cavity. Since most of these plexuses lie/

lie in the mesentery and, in general, following the course of the vessels, the mesentery and the vessels should be noted briefly.

The Mesentery is extended between the aorta above and the stomach and the intestine below. Imagine a simplified mesentery^{fi} composed of two layers of serous membrane extending in the abdominal cavity, in the median plane, with the stomach and the intestine enclosed in the ventral free border and the aorta in the dorsal border where the serous membranes are reflected to the lateral wall of the abdomen. (Diagrams 'K' & 'L').

Diagram 'K'.

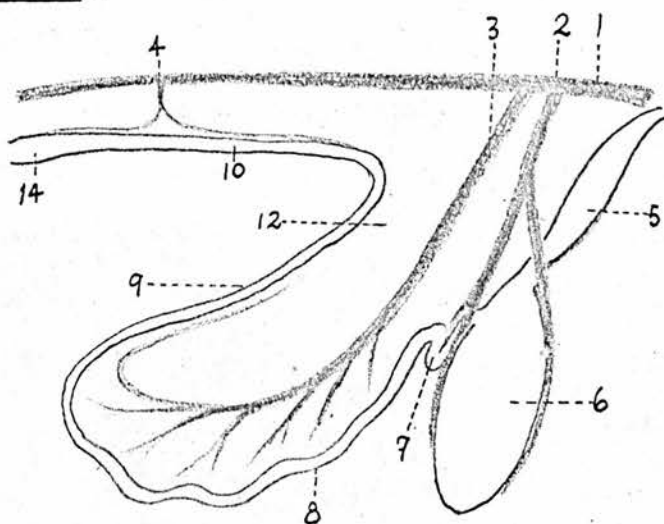
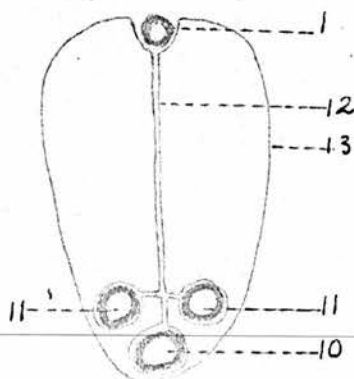


Diagram 'L'.



1. Aorta. 2. Coeliac A. 3. Ant mesenteric A.
4. Post mesenteric A. 5. Glandular stomach. 6. Gizzard.
7. Duodenum. 8. Jejunum. 9. Ileum. 10. Colon.
11. Caecum. 12. Serous membrane of mesentery.
13. Serous membrane lining the abdominal cavity. 14. Rectum.

This/

This simplified ^{fi}mesentery becomes complicated by the presence of the liver, the spleen, the elongated duodenal loop with the pancreas, and the right and left caeca. The liver, the duodenal loop with the pancreas, and the right caecum push the right serous layer of the mesentery from the median plane at three points. Thus, on the right side of the mesentery are three bags of serous membrane lodging the liver, the duodenal loop with the pancreas and the right caecum respectively. Two bags of serous membrane are produced on the left side of the mesentery, lodging the spleen and the left caecum.

Three arteries, which correspond to the coeliac, anterior mesenteric and posterior mesenteric arteries in mammals, ramify in the simplified mesentery as shown in Diagram 'K'. The coeliac artery divides into an anterior and a posterior branch of about the same calibre. The anterior branch is destined to be distributed to the left side of the gizzard and to the posterior part of the left lobe of the liver. The posterior branch which is destined to furnish blood to the right side of the gizzard, to the right lobe and the anterior part of the left lobe of the liver, to the spleen, to the duodenum, to the pancreas, to the proximal part of the jejunum, to the right and left caeca, is regarded as the continuation of the stem of the parent artery for some reason in designation. The anterior mesenteric artery pursues a course more or less corresponding to the loop of the jejunum and gives off, on the convex side, many collateral branches to the intestine. The posterior mesenteric artery is also divided into an anterior and a posterior branch corresponding to the ^{left colic} ~~right~~ coeliac and the anterior rectal arteries respectively.

Owing to the rotation of the gizzard on itself with the anterior surface turning towards the left and the posterior surface towards the right, the glandular stomach pulls the anterior end of the mesentery to the left and the gizzard pushes the proximal part of the duodenal loop with the pancreas and the adjacent part of the mesentery to the right. Thus the anterior part of the mesentery is placed in a more or less transverse direction with the liver ahead and the spleen behind. In other words the mesentery is bent from the sagittal plane to the left, at the place between the origin of the anterior mesenteric artery above and the proximal part of the jejunum below. In consequence, the relative situation of the anterior branch of the coeliac artery to the parent stem is changed. The anterior branch is now situated on the left side of the parent artery and will be called the left gastro-hepatic artery, reserving this name not only because it is situated left to the parent artery in the mesentery ~~artery~~, but also because it is destined to be distributed to the left side of the gizzard and to the posterior part of the left lobe of the liver.

The Coeliac, Anterior Mesenteric and the Posterior Mesenteric Arteries.

The anterior and the posterior mesenteric arteries arise from the ventral aspect of the aorta under the posterior part of the fifth thoracic vertebra and under the twelfth lumbosacral vertebra respectively. As mentioned above they are quite homologous with the arteries of the same name in mammals and they need no further description. On the other hand, the coeliac artery is, in some points, different from the corresponding artery in mammals. Proportionally it is much longer than/

than the corresponding artery in mammals. It does not divide into three main branches, the hepatic, splenic and left gastric arteries as in mammals, but splits into two main branches of about equal calibre, each giving off a hepatic artery to the liver. The splenic arteries are small as collateral branches.

The coeliac artery arises from the ventral aspect of the aorta under the fifth thoracic vertebra. It passes downward and backward in the anterior part of the mesentery, leading to the right aspect of the proximal end of the duodenum, where it divides into two terminal branches, the right gastric and the pancreatico-duodenal arteries. Compared with the corresponding arteries in mammals, the stem of this artery could be divided artificially into three parts. The first part is the segment between the aorta and the superior splenic artery and is called the coeliac artery. When it gives off the superior splenic artery, it enters the second part which is the segment lying beside the spleen, between the superior splenic and the right hepatic arteries and is called the ^{right} gastro-hepatic artery. The second part represents the hepatic artery in mammals. From the level of the right hepatic artery downwards until it divides into the two terminal branches on the right aspect of the proximal part of the duodenal loop, it becomes the third part and is called the gastro-duodenal artery.

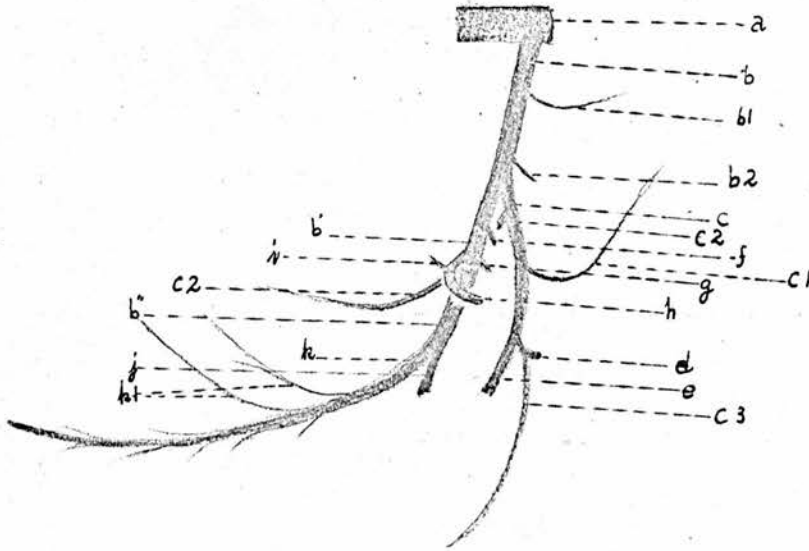
The Collateral Branches from the Coeliac Artery are as follows.

1. The Oesophageal Branch. It passes forward in the mesentery and is distributed to the posterior part of the oesophagus in the hilus oesophagus of the diaphragm. (Figs. 18 & 24, b1; Diagram 'M', b1).

2./

2. The Dorsal Proventricular Branch. Just before crossing the right aspect of the glandular stomach, the coeliac artery gives off this branch to the dorsal aspect of the glandular stomach. (Fig. 28,b2; Diagram 'M',b2).

Diagram 'M'.



- | | |
|--|---|
| a. Abdominal aorta. | b. Coeliac artery. |
| b'. Right gastro-hepatic artery. | b ¹ . Gastro-duodenal artery. |
| c. Left gastro-hepatic artery. | b ¹ b ² . Cesophageal & dorsal proventricular branches. |
| c ² c ³ . Dorsal & ventral gastro-epiploic arteries. | c ¹ . Ventral proventricular branch. |
| e. Left gastric artery. | d. Left hepatic artery. |
| g. Inf splenic artery. | f. Sup splenic artery. |
| i. Duodenal branch. | h. Right hepatic artery. |
| k. Pancreatico-duodenal artery. | j. Right gastric artery. |
| | k ¹ . Caecal branches. |

3. The Left Gastro-hepatic Artery. This artery is more corresponding to the left gastric artery than to any other branch of the coeliac artery in mammals. Yet it is different from the left gastric artery, in that, this artery is proportionately much larger than the left gastric artery and that this artery gives off a branch to the left lobe of the liver. This artery arises from the coeliac artery at the dorsal aspect of the glandular stomach. It passes downward and backward/

backward around the anterior and ventral aspects of the spleen on the right surface of the glandular stomach to the lesser curvature of the gizzard where it divides into the left gastric and the left hepatic arteries. The branches are as follows:-

(a) The dorsal gastro-epiploic artery arises near the origin of the parent artery. It passes backwards to the dorsal border of the gizzard. (Figs. 28 & 29, C2; Diagram 'M', C2).

(b) The ventral proventricular branch. It arises on the ^{right} left side of the glandular stomach and runs forward and upward in company with the ventral oesophageal trunk of the vagus nerves along the ventral aspect of this organ where it is distributed. (Fig. 28, C1).

(c) The left hepatic artery runs forward to the left end of the portal fissure of the liver. It is communicated with the right hepatic artery by an anastomotic branch lying in the portal fissure. This artery supplies the posterior part of the left lobe of the liver. (Figs. 28 & 29, d; Diagram 'M', d).

(d) The ventral gastro-epiploic artery. It usually rises in a common stem with the left hepatic artery. It passes backward and downwards and is distributed to the ventral border of the gizzard. (Figs. 28 & 29, C3; Diagram 'M', C3).

(e) Branches to the lesser curvature of the gizzard.

(f) The left gastric artery. It is much larger than the left hepatic artery. It passes backward and is distributed to the left surface of the gizzard as shown in Figure 29A, e.

4. The Superior Splenic Artery. It is a very short and small branch of the coeliac artery. It enters the substance of the spleen through the upper end of the hilus. (Figs. 28 & 30, f).

30,f).

The Branches from the Right Gastro-hepatic Artery are as follows.

1. The Inferior Splenic Arteries, one or two in number, are smaller than the superior splenic artery. They enter the substance of the spleen through the lower end of the hilus. (Figs. 28 & 30,g).

2. The Right Hepatic Artery. It is larger than the left hepatic artery and furnishes blood to both the right and left lobes of the liver and the gall-bladder. It arises from the gastro-hepatic artery beside the spleen. It runs forward and a little upward on the left side of the portal vein. At the right end of the portal fissure it breaks up into branches leading to the right lobe and the anterior part of the left lobe. It gives off a considerable cystic artery to the left aspect of the gall-bladder. There is an anastomotic branch between the right and left hepatic arteries, this anastomotic branch lies in the portal fissure along the right aspect of the portal vein and dorsal to a hepatic duct which carries the bile from the posterior part of the left lobe of the liver to the duodenum.

The Branches of the Gastro-duodenal Artery are as follows.

1. Right Gastric Artery. This artery is distributed to the right surface of the gizzard as shown in Figures 28 & 29B,j.

2. The Pancreatico-duodenal Artery. It is a little larger than the right gastric artery and furnishes blood to the pancreas, duodenum as well as the right and left caeca. It passes backward among the pancreatic lobes in the duodenal loop in company with the satellite vein and the longest pancreatic duct. In the/

the long course from the proximal end of the duodenal loop to the distal end, numerous collateral branches are given off to the pancreatic lobes and the descending and ascending limbs of the duodenal loop. Two considerable branches arise from this artery in the proximal part of the duodenal loop and, across the left aspect of the ascending limb of the duodenal loop leading to the right and left caeca, anastomoses with the anterior mesentery artery and with the caecal branch of the ilio-caeco-colic artery respectively. (Fig. 30,k & k1; Diagram 'M',k).

The Splanchnic Nerves.

There are nine or more splanchnic nerves. The first arises from the ventral aspect of the second thoracic sympathetic ganglion or from the interganglionic cord which lies below the costo-central articulation and links the second and third thoracic sympathetic ganglia. The next five arise from the tapering lower ends of the third, fourth, fifth, sixth and seventh thoracic sympathetic ganglia. The seventh and eighth splanchnic nerves arise from the ventral aspect of the first two lumbo-sacral sympathetic ganglia while the last splanchnic nerve arises from the inter-ganglionic cord, which runs across the ventral aspect of the femoral artery and links the second and third lumbo-sacral ganglia. Frequently from the tapering lower end of the thoracic sympathetic ganglion two splanchnic nerves arise and still more frequently splanchnic nerves are given off from the inter-ganglionic cords which are situated below the costo-central articulations, so that usually ten or more splanchnic nerves are found. The adjacent nerves are connected with each other by anastomotic branches./

branches. Thus a loose network with irregular meshes results on the ventral spines of the thoracic vertebral column.

The splanchnic nerves derived from the second, third, fourth and fifth thoracic sympathetic ganglia converge and unite above or on the lateral aspect of the abdominal aorta at the level of the origin of the coeliac artery. Ganglia develop at points where two or more nerves unite together. (Fig. 25, Z5b). These ganglia, which are proportionately much larger in the young birds than those in the adult, correspond to the splanchnic ganglion in mammals. From these ganglia nerves pass down and converge to join the coeliac ganglion on the posterior aspect of the proximal part of the coeliac artery just below the aorta. Therefore these splanchnic nerves are corresponding to the greater splanchnic nerves in mammals. (Fig 24, Z3^a)

The splanchnic nerves from the last two thoracic and the first three lumbo-sacral sympathetic ganglia join the adrenal, testical (os ovarian) and the anterior renal plexuses, therefore, they correspond to the lesser splanchnic nerve in mammals. (Fig. 24, Z3^b).

The splanchnic nerves from the first six lumbo-sacral sympathetic ganglia are rather small. The first three lumbo-sacral splanchnic nerves, as mentioned above, run to the adrenal, the testicle (os ovarian), anterior mesenteric and the anterior renal plexuses, the next three which are smaller and frequently one or two of them are absent, run to the adjacent aortic plexus, or the posterior part of the aortic plexus. The splanchnic nerve derived from the fused sympathetic ganglion, which corresponds to the seventh and eighth lumbo-sacral spinal nerves, and those derived from the ninth, tenth/

tenth and eleventh lumbo-sacral sympathetic ganglia are each much larger. They run downward, backward and medially alongside the body of the lumbo-sacral vertebral column and dorsal to the hypogastric vein to form the hypogastric plexus in the sublumbo-sacral region. The splanchnic nerves in the adult hen, which arise from the 6th, 7th, 8th, 9th, 10th, 11th, 12th and 13th lumbo-sacral ganglia and supply the active oviduct and the rectum are noticed to be much better developed. (Fig. 32,23).

The splanchnic nerves derived from the last two or three lumbo-sacral and the first two or three coccygeal sympathetic ganglia are small and contribute to a plexus on the middle lumbo-sacral and middle coccygeal arteries.

The Pelvic^{splanchnic} and the Pudendal Nerves.

The ventral rami of the 9th, 10th, 11th, 12th and 13th lumbo-sacral spinal nerves, as well as a branch from the ventral ramus of the 8th lumbo-sacral spinal nerve, unite with each other to form the pudendal plexus under the posterior part of the wing of the fused lumbo-sacral vertebral column, the posterior part of the ilium and the coccygeo-ischiatic ligament. From this plexus are derived the nerves which are homologous with the pelvic splanchnic nerve, the pudendal nerve, the perforating cutaneous nerves and the ventral coccygeal trunk in mammals. In some birds, the ventral rami of the last lumbo-sacral and the first one, two or three coccygeal spinal nerves join the ventral coccygeal trunk, therefore the pudendal plexus extends under the transverse processes of the coccygeal vertebrae.

In mammals the pudendal nerve contains both somatic and splanchnic (parasympathetic) nerve fibres. The somatic nerve fibres/

fibres are distributed to the external sphincter ani muscle and the skin around the anus by the posterior haemorrhoidal nerve and supply the muscles and skin in the perineal region by the perineal nerve. The splanchnic nerve fibres supply the erectile tissue of the bulb and corpus cavernosum urethrae by the perineal nerve, and supply the erectile tissue of the crus and the corpus cavernosum penis by the dorsal nerve of the penis (or clitoris). In birds the pudendal nerves serves to distribute somatic nerves fibres only. The nerve which corresponds to the dorsal nerve of the penis (or clitoris) does not arise from the pudendal nerve but from, as a terminal branch, the pelvic splanchnic nerve. (Figs. 31 & 32, Y1).

The Pudendal Nerve. (Figs. 31 & 32, U4g).

This nerve derives the nerve fibres from the 8th, 9th and 10th lumbo-sacral spinal nerves. It passes backward on the dorsal wall of the pelvic cavity. Behind the posterior border of the ilium it leaves the pelvic cavity by penetrating the coccygeo-ischiatic ligament in company with the parietal branch of the hyogastric artery. Between the coccygeo-ischiatic ligament and the M. semi-membranosus it breaks up into branches to supply the Mm. coccygeus, dilator, ani, sphincter ani externus, levator ani and the skin around the cloaca and in the posterior part of the pelvis below the cloaca. These branches no doubt represent the posterior haemorrhoidal and perineal nerves of the pudendal nerve in mammals.

The Pelvic Splanchnic Nerve. (Figs. 31 & 32, Y).

The pelvic nerve is composed of parasympathetic fibres. It derives the fibres from the 8th, 9th, 10th, 11th and 12th lumbo-sacral nerves. It passes backward, downward, and a little/

little laterally following the hypogastric artery and then the middle haemorrhoid artery (the visceral branch of the hypogastric artery) to the cloaca. After giving collateral branches to contribute to the plexus in the ligament of the deferent duct (or oviduct) and the cloaca plexus in the wall of the cloaca, it runs as a slender terminal branch, in company with a small artery, around the anus (and the terminal part of the active oviduct in the hen) towards the median point under the anus. This slender terminal branch of the pelvic nerve is homologous with the dorsal nerve of the penis (or clitoris) in mammals and the accompanied artery represents the dorsal artery of the penis (or clitoris).

The Plexuses in the Abdominal Region.

The plexuses which distribute nerves to the viscera and vessels in the abdominal and pelvic cavities are continuous with each other. They are constituted by splanchnic nerves from the sympathetic trunks of the thoracic and lumbo-sacral parts and by the vagus and pelvic ^{splanchnic} nerves. They include three chief plexuses, the coeliac, aortic, and the pelvic. From the coeliac and aortic plexuses nerves proceed to form subsidiary plexuses which are named according to the organs which they supply or the vessels whose courses they follow.

The Coeliac Plexus. (Figs. 24, 25, 28, & 30, 25).

This plexus is not quite homologous with the plexus of the same name in mammals. The coeliac plexus in mammals is a very extensive plexus from which nerves proceed to form the phrenic plexus, suprarenal plexus, renal plexus, ^{superior} superior mesenteric plexus and the aortic plexus. In birds the coeliac plexus is much smaller, it is limited to the plexiform nerves which unite with/

with each other above or on the lateral aspect of the aorta under the 5th thoracic vertebra and twist round the coeliac artery and its main branches. The aortic plexus with the anterior mesenteric, the testicular (or ovarian), and the renal plexuses is evidently independent of the coeliac plexus. (Figs. 24 & 25).

The coeliac ganglion is situated behind and a little to the left side of the proximal part of the coeliac artery just below the aorta. It receives the greater splanchnic nerves from the 2nd, 3rd, 4th, and 5th thoracic sympathetic ganglia and gives off nerves to form the coeliac plexus passing down and twisting the coeliac artery and its main branches. This ganglion is much developed in young birds. In adult birds it is small or disappears completely. (Figs. 25, 25a).

The coeliac plexus receives, on the left side of the coeliac artery, anastomotic branches from both vagi. (Fig. 25, S4a').

From the coeliac plexus the following subsidiary plexuses are continued on the branches of the coeliac artery and in the organs which it supplies.

1. The Splenic Plexus. It lies in the hilus of the spleen between the superior and the inferior splenic arteries. Nerves follow the superior and the inferior splenic arteries from the coeliac plexus to the hilus and hence to the substance of the spleen. (Figs. 28 & 30, 25a).

2. The Hepatic Plexuses. There are two hepatic plexuses on the right and left hepatic arteries respectively outside of the liver. The plexus on the right hepatic artery (Fig. 30, E6a) is much larger than the other and is constituted by nerves derived/

derived from different origins. Most of the nerve fibres are derived from a large ganglion lying in the anterior part of the right adrenal plexus by a plexiform nerve which is constant and will be called the hepatic nerve. (Figs. 24, 25, & 30, Z6). The other nerves come from the coeliac plexus proceeding to this plexus along the right hepatic artery.

The plexus on the right hepatic artery proceeds into the liver at the anterior ^(or right) end of the portal fissure. While some nerves of considerable size lead from this plexus to the gall-bladder and the pancreatico-duodenal plexus in the proximal part of the duodenal loop.

The plexus on the left hepatic artery is continued from the coeliac plexus on the left gastro-hepatic artery. Since the plexus (coeliac) on the left gastro-hepatic artery is connected by anastomotic branches with the gastric plexus of the vagus nerves in the lesser curvature of the gizzard, the plexus on the left hepatic artery may receive fibres derived from the vagus nerves.

In the portal fissure, a rich plexus is formed along the right aspect of the portal vein, against the caudal process of the liver. When the Capsule of Glisson is opened this plexus can be demonstrated proceeding from the plexus on the right hepatic artery along the right aspect of the portal vein to the posterior ^(or left) end of the portal fissure. On the posterior end it becomes thicker and receives the nerves on the left hepatic artery. The anastomotic branch between the right and left hepatic arteries lies within this plexus.

The Hepatic Nerve. (Fig. 24, Z6). It is a large plexiform nerve lying in the mesentery where the mesentery is bended to the/

the left as described before. It arises from a large ganglion situated in the anterior part of the right adrenal plexus. (Figs. 24, 25C & 26B, Z4a & Z6). It passes downwards and to the left in the mesentery between the coeliac and the anterior mesenteric arteries. In its course it receives branches from the ganglia in the left adrenal and the anterior mesenteric plexuses, (Fig. 24, Z4b & Z7a) and gives off branches to the coeliac plexus on the coeliac artery (Figs. 24 & 25) and to the pancreatico-duodenal plexuses in the proximal part of the duodenal loop. (Fig. 30). It is the main nerve to form the plexus on the right hepatic artery and yet, nerve fibres can be traced from this nerve passing through the hepatic plexus to the coeliac plexus which enlaces the gastro-hepatic artery.

3. The Pancreatico-duodenal Plexus. (Fig. 30, Z5b).

This plexus is continued from the coeliac plexus but receives branches from the hepatic nerve and the anterior mesenteric plexus. It extends along the pancreatico-duodenal artery among the pancreatic lobes from the proximal end of the duodenal loop to the distal end. Several ^{nerve} stems of considerable size can be demonstrated running in company with the pancreatico-duodenal vessels and the longest pancreatic duct. Intermingled between the lobes of the pancreas or near the attached borders of the pancreas numerous delicate nerve filaments enter the limbs of the duodenal loop and the lobes of the pancreas. In addition several sympathetic nerves run along with branches of the pancreatico-duodenal artery to each caecum. A few very small ganglia are found in this plexus.

4. The Gastric Plexus. (Fig. 28 & 29). This plexus is distributed along the lesser curvature, the dorsal and ventral borders/

borders of the gizzard. Another portion follows the course of the gastric vessels to the surfaces of the gizzard.

The very thick part of the plexus at the lesser curvature gradually thins out as the fibres ramify in the muscle.

The nerve fibres completely circumscribe the peripheral part of the gizzard.

The circumscribing plexus of nerves is derived mainly from the vagus nerves and inter-mingled with filaments from the sympathetic coeliac plexus following the course of the dorsal and ventral gastro-epiploic arteries and the branches of the left gastro-hepatic artery on the lesser curvature.

The plexuses on the right and left gastric arteries are continued from the coeliac plexus and consist of sympathetic nerves. They are distributed to the right and left surfaces of the gizzard following the gastric arteries. The gizzard is composed of a glistening tendon covering each surface and a powerful mass of red muscular tissue in the periphery. In the periphery of the central tendon, where a transition from tendon to muscle gradually takes place, the sympathetic nerves follow the branches of the gastric arteries and pierce the tendon obliquely into the muscular tissue. (Fig. 28). The distribution of the entrances of sympathetic nerves into the substance of the gizzard is shown in Figure 29. by the purple points.

In addition to the above mentioned subsidiary plexuses, the sympathetic nerves proceed from the coeliac plexus along the oesophageal branch and the dorsal and ventral proventricular branches of the coeliac artery to the oesophagus and the glandular stomach respectively.

The/

The Aortic Plexus. (Figs. 24, 25 & 26, 24).

This plexus lies on the abdominal aorta in the segment between the anterior mesenteric and the sciatic arteries. In front, it is connected with the coeliac plexus and behind it is continued by the hypogastric plexus. The anterior part of this plexus is powerfully developed under the last two thoracic vertebrae. The adrenal glands are interposed in this part. It is in the powerfully developed anterior part that the aortic plexus receives the splanchnic nerves derived from the last three thoracic and the first three lumbo-sacral sympathetic ganglia, and the anterior mesenteric plexus, the right and left testicular (or ovarian) plexuses and the right and left anterior renal plexuses are continued on the corresponding arteries. The anterior part of the aortic plexus is described under the title of the adrenal plexuses.

The posterior part of the aortic plexus, which is situated under the first seven lumbo-sacral vertebrae, is not so well developed. Usually a single stem which bears ganglia extends along the ventral aspect of the aorta between the adreno-reno-testicular artery (or the adreno-reno-ovarian artery) and the sciatic artery. This stem splits at the bifurcation of the aorta where the sciatic artery arises, into two terminal branches each proceeding along the sciatic artery to the middle and posterior renal plexuses and to the plexus in the ligament of the deferent duct or oviduct. (Figs. 31, 212; Fig. 32, 212'). Two or three ganglia of considerable size occur in the bifurcation of the aorta and the origin of the sciatic arteries.

The posterior part of the aortic plexus receives minute splanchnic nerves from the anterior seven lumbo-sacral ganglia on/

on both sympathetic trunks and gives off small branches to the adjacent intestinal nerve and the deferent ducts or oviducts.

1. The Adrenal Plexuses, one on each side of the aorta. (Figs. 24, 25 & 26). They are really the anterior part of the aortic plexus. In other words, the anterior part of the aortic plexus attached to the substance of the adrenal glands under the 7th thoracic vertebra is called adrenal plexuses. Therefore, this plexus is quite different from the plexus of the like name in mammals as described in some text-books of Anatomy.^{26,52} The right and left plexuses are connected with each other by anastomotic branches below the aorta. Each plexus is formed by the splanchnic nerves from the last three thoracic and the first two or three lumbo-sacral sympathetic ganglia. There are three large ganglia in each plexus partly embedded in the substance of the adrenal gland.

(a) One ganglion lies in the anterior and medial part of the gland. It receives the splanchnic nerves from the 5th and 6th thoracic sympathetic ganglia. The nerve arising from this ganglion of the right adrenal plexus leads to the hepatic plexus on the right hepatic artery, and is called the hepatic nerve. (Figs. 24, 25 & 26,26). While the nerve from the ganglion of the left adrenal plexus passes to the anterior mesenteric plexus below the aorta and behind the anterior mesenteric artery. (Figs. 24, 25 & 26,27).

(b) One ganglion lies on the tapering posterior end of the adrenal gland. It is a long ganglion with the anterior part embedded in the adrenal gland and the posterior part lying along the latero-ventral aspect of the aorta below the adreno-reno-testicular (or the adreno-reno-ovarian) artery. It receives/

receives the splanchnic nerves from the last thoracic and first three lumbo-sacral sympathetic ganglia. Nerves arising from this ganglion of each adrenal plexus proceed to the anterior mesenteric, testicular (or ovarian) and anterior renal plexuses. (Figs. 24, 25 & 26, 27, 28, & 29).

(c) The other ganglion is smaller, lying on the medial aspect of the adrenal gland between the above mentioned two ganglia. It receives the splanchnic nerves from the last two thoracic sympathetic ganglia.

2. The Testicular Plexuses, (Figs. 24B & 25A, 28), are paired plexuses. They are derived from the aortic plexus, and receive nerves from the ganglia in the adrenal glands. Each plexus leads to the testicle and the epididymis, following the course of the testicular arteries, which are usually two in number, one arising from the aorta in front of the adreno-reno-testicular artery, the other from the adreno-reno-testicular artery.

(a) The Ovarian Plexuses are the homologues of the testicular plexuses. They follow the ovarian arteries to the ovaries and the anterior part of the oviduct. The plexus supplying the active ovary and ^{oviduct is} ~~the~~ powerfully developed ~~oviduct~~. (Fig. 26, 28).

3. The Anterior Renal Plexuses are paired plexuses. (Figs. 24, 25A & 26, 29). Each plexus is continued from the aortic plexus and receives nerve fibres from the ganglion in the tapering posterior end of the adrenal gland. Minute ganglia occur in the course of this plexus on the anterior renal artery. This plexus gives off branches to the epididymis or the anterior part of the oviduct.

4. The Middle & Posterior Renal Plexuses. The middle and posterior renal arteries are two collateral branches from the proximal part of the sciatic artery and furnish blood to the middle and posterior lobes respectively. Upon these two arteries are the middle and posterior renal plexuses continued from the aortic plexus on the sciatic artery. Minute ganglia are interposed in both middle and posterior ^{/renal} plexuses.

5. The Plexus in the Ligament of the Deferent Duct. This plexus extends along the deferent duct from the testicular plexus in front to the pelvic plexus and the cloacal plexus behind. It is formed by the sympathetic fibres from the hypogastric plexus and parasympathetic nerve fibres from the pelvic splanchnic nerve. It also receives branches from the testicular, anterior renal and the aortic plexuses in the abdominal cavity.

(a) The plexus in the ligament of the oviduct. This plexus is the homologue of the preceding plexus. The plexus supplying the active oviduct is noticed to be powerfully developed. (Fig. 32A, Y2 & Z12').

The plexuses in the ligament of the deferent duct (or oviducts) are paired, one on each side.

6. The Anterior Mesenteric Plexus. (Figs. 24, 25 & 27, 27). This is an extensive plexus situated between the two layers of the mesentery. It is continued above from the right and left adrenal and the aortic plexuses. Large mesenteric ganglia occur in the triangular area below the aorta and behind the proximal part of the anterior mesenteric artery. (Figs. 24A & 25C, 27). Most of the nerves which arise from this ganglionated area twist around the anterior mesenteric artery. (Figs. 24B & 27, 27)./

& 27,27). While some pass down across the anterior mesenteric artery and anastomose with each other as well as with the plexiform hepatic nerve to form a network in the mesentery between the coeliac and the anterior mesenteric arteries. The last mentioned network extends into the duodenal loop, becoming the pancreatico-duodenal plexus.

One nerve of considerable size is noticed in this plexus. It passes down behind the hepatic nerve and gives rise to the intestinal nerve and a branch to the falciform ligament of the liver. This nerve seems to be the duodenal nerve of Mitchell.³⁶

From the rich plexus which twists around the anterior mesenteric artery, numerous branches arise leading to the intestinal nerve of Remak.

The Intestinal Nerve of Remak. (Figs. 24B, 27 & 31,210).

The intestinal nerve of Remak is a ganglionated trunk extending in the mesentery from the proximal part of the duodenal loop, in front, to the space between the bursa cloacae (Fabricius) and the rectum^{behind.} It arises as a slender trunk from the network of the anterior mesenteric plexus, between the coeliac and anterior mesenteric arteries, or from the pancreatico-duodenal plexus among the bile ducts and the pancreatic ducts outside of the pancreas, or from both. There is usually noticed a nerve of considerable size, passing down parallel with and behind the hepatic nerve, from the anterior mesenteric plexus to the pancreatico-duodenal plexus, from which the intestinal nerve of Remak arises by one, two or three roots at various levels. (Figs. 27 & 30,210). But the intestinal nerve does not always arise from such a nerve. In some birds no such nerve appears and the intestinal nerve starts from a network/

network of the anterior mesenteric plexus. The anterior end of the intestinal nerve is sometime obscure, buried in the substance of the pancreas. Szantroch⁵⁴ finds the anterior end of the intestinal nerve entering into the wall of the intestine at the level between the jejunum and duodenum. The posterior end of the intestinal nerve divides into two branches which lie side by side on the dorsal wall of the rectum.

Generally the intestinal nerve of Remak lies in the mesentery between the abdominal aorta and its visceral branches (the anterior mesenteric, posterior mesenteric and the middle rectal arteries) on one hand and the jejunum, ileum and the large intestine on the other hand. It receives branches from the anterior mesenteric, aortic, posterior mesenteric and the hypo-gastric plexuses and gives off branches to the jejunum, ileum and the large intestine. It is noticed that nearly all the nerves which arise from the above mentioned plexuses and are destined to supply the intestines, pass through the intestinal nerve of Remak. The ganglia on the intestinal nerve vary in size and number in different parts. The ganglia on the intestinal nerve along the anterior part of the jejunum are very small, some of them can only be distinguished from the white slender trunk by their slightly darker colour. The ganglia on the intestinal nerve along the posterior part of the jejunum are a little larger and appear as ganglionic swellings with sharp outlines. (Figs. 24B & 27, Z10). The ganglia in the posterior part of the intestinal nerve along the large intestine are well developed. (Figs. 30 & 31, Z10).

The posterior part of the intestinal nerve along the large intestine is well developed, bearing 12 - 15 large ganglia and is/

is designated by Remak⁴¹ as the recto-colic part. The anterior part which pursues a long course along the jejunum and the ileum appears as a uniform ganglionated trunk, bearing 16 - 35 ganglia and is designated by Remak⁴¹ as the ileo-jejunal part.

The distribution of the ganglia on the intestinal nerve suggests considering the ilio-jejunal part in two portions an ileal and a jejunal.

The jejunal part of the nerve has many small ganglia about 4/5th of the total ganglia on the entire length of the ileo-jejunal part of the intestinal nerve. It extends from the origin (anterior end) to where it crosses the anterior mesenteric artery. (Figs. 24B & 27).

The ileal part of the intestinal nerve is continued from the jejunal part and runs along the ileum to the level of the junction of the caeca. There are 4 - 8 small ganglia on the trunk. The branches that it gives off to the ilium are more than the branches that it receives from the anterior mesenteric and the aortic plexuses. (Fig. 27,Z10,01; Fig. 31,Z10,Z7).

The recto-colic part will be subdivided into a rectal and a colic part. The colic part is still a single trunk along the dorsal aspect of the colon. There are 6 - 8 ganglia on the trunk. The ganglia on the posterior part are well developed and are connected with each other by double interganglionic cords between which the branches of the posterior mesenteric artery pass. These ganglia receive the branches from the posterior mesenteric plexus and give off branches to the colon.

The anterior 2 or 3 ganglia are smaller. They may or may not receive branches from the posterior mesenteric plexus.

But/

But 2 or 3 branches are given off from each ganglion to the colon. (Figs. 30, & 31, Z10).

The rectal part of the intestinal nerve of Remak includes two ganglionated limbs which lie side by side on the dorsal wall of the rectum. (Fig. 31, Z10a & Z10b). There are three ganglia of considerable size on each limb. The two rectal limbs are connected with each other by anastomotic branches. The ganglia on the right limb receive sympathetic branches from the posterior mesenteric plexus and the plexus which follows the course of the right hypogastric artery, and parasympathetic branches from the right pelvic splanchnic nerve. (Fig. 31, Z10a, Z11 & Z13). The ganglia on the left limb receive sympathetic branches from the posterior mesenteric plexus and the plexus which enlaces the left hypogastric artery, and parasympathetic branches from the left pelvic nerve. (Fig. 31, Z10b, Z11, Z13'; Fig. 32, Z10b, Z13'). From both limbs numerous branches are given off to the rectum and the cloaca.

The two limbs of the intestinal nerve of Remak with the branches that they receive from the hypogastric plexus, posterior mesenteric plexus and the pelvic splanchnic nerves and the branches that they give off to the rectum and the cloaca form two rich plexuses respectively, corresponding to the right and left pelvic plexuses in mammals.

The Hypogastric Plexus.

This plexus lies in the sublumbo-sacral region under the 9th - 13th lumbo-sacral vertebrae and is situated alongside the aorta. This plexus extends along both right and left hypogastric arteries for some distance on the dorsal wall of the pelvic cavity. In front, it is continued from the much thinner aortic/

aortic plexus.

The hypogastric plexus is formed by the well developed splanchnic nerves derived from the 6th - 12th or the fused 7th & 8th - 12th lumbo-sacral ganglia on both sympathetic trunks. Nerves arising from the part of the hypogastric plexus, which is situated along-side the aorta lead to the posterior mesenteric plexus, while those which arise from the part along the hypogastric artery lead to the pelvic plexus.

The Posterior Mesenteric Plexus is continued above from the hypogastric plexus and is inseparable behind from the pelvic plexuses. In the upper part of the colic mesentery it follows the courses of the posterior mesenteric artery and the terminal branches (the left colic and the anterior rectal arteries). In the lower part of the colic mesentery the nerves of this plexus leave the arteries to the ganglia of the intestinal nerve of Remak. (Fig. 31, Z11).

The hypogastric and the posterior mesenteric plexuses are situated between the aortic plexus in front and the pelvic plexuses behind. It forms the continuation of the splanchnic nerves to the pelvic plexuses.

The Pelvic Plexuses.

The rectal part of the intestinal nerve of Remak receives branches from the posterior mesenteric plexus, hypogastric plexus, and the pelvic splanchnic nerve and forms the pelvic plexus. The pelvic plexuses are paired plexuses which lie side by side on the dorsal aspect of the rectum partly between the two layers of the meso-rectum, partly in the retro-peritoneal region behind the pelvic cavity. The right and left pelvic plexuses are connected by anastomotic branches between the two limbs of the intestinal nerve.

There/

There are two thin sheaths of smooth muscle, one on each side of the meso-rectum, lying behind the sacro-rectal pouches. They arise from the sphincter muscle of the cloaca above the bursa cloacae (Fabricius) passing downward and forward around the dorso-lateral aspect of the bursa cloacae to the dorso-lateral aspect of the rectum, where they are continuous with the longitudinal muscular layer of the intestine. Each of these muscular sheaths rotates on itself in such a way with the upper part placed in a longitudinal direction covering the bursa cloacae and the lower part in a more or less transverse direction to be continued by the longitudinal muscle of the intestine. This smooth muscle sheath will be called the suspensory muscle of the rectum. The lower part of the suspensory muscle is lined by the peritoneum which forms the bottom of the sacro-rectal pouch while the upper part is embedded in the connective tissue in the retro-peritoneal region. (Figs. 31 & 32, XXIV & XXV).

The retro-peritoneal parts of both pelvic plexuses are localised in the space between the right and left suspensory muscles of the rectum by which they are separated from the cloacal plexuses on both sides.

The Cloacal Plexuses. (pericloacalst). The cloacal plexus, one on each side, is a rich plexus with numerous ganglia of various sizes interposed in it. (Figs. 31 & 32^{ya}). It lies in the retro-peritoneal region around the anus and the terminal parts of the ureter and the deferent duct (or oviduct). It is constituted by the pelvic splanchnic nerve, and distributes nerve fibres to the anus, the distal part of the ureter, the vagina (or the distal part of the deferent duct), the bursa cloacae, /

cloacae, and the sphincter muscle of the cloaca. The cloacal plexus is connected with the pelvic plexus by communicating branches which pierce through or run behind the suspensory muscle of the rectum, and both right and left cloacal plexuses are connected with each other above and below the anus.

Discussion.

1. Rochas⁴³ reports there exists in all birds a series of sympathetic ganglia connected to the cranial nerves in the following order:-

- (a) The orbito-nasal ^(ethmoidal) ganglion which is connected with the olfactory nerve.
- (b) The ciliary ganglion connected to the oculomotor.
- (c) The sphenopalatine ganglion to the trigeminal.
- (d) The carotid ganglion to the facial and
- (e) The superior cervical ganglion (anterior cervical ganglion), representing two ganglia fused together of which one is connected to the glosso-pharyngeal and the other to the vagus. This statement is confirmed as the ethmoidal, ciliary, sphenopalatine, and the anterior cervical ganglia are connected by the Vidian nerve. He contends that the ethmoidal (orbito-nasal) ganglion is connected to the trigeminal and olfactory nerves, the ciliary ganglion to the oculomotor nerve, the sphenopalatine ganglion to the trigeminal nerve, the anterior cervical ganglion to the glosso-pharyngeal and vagus nerves. These communications are confirmed but further connections have been noted which are the communicating branches between the Vidian nerve and the trochlear nerve, between the Vidian nerve and abducent nerve, between the Vidian nerve and the ventral branch of the oculomotor, between the Vidian nerve and the ophthalmic nerve, of the trigeminal, between the submandibular ganglion and the chorda tympani, between the submandibular ganglion and the inferior alveolar nerve, between the internal maxillary nerve and the trigeminal, between the internal maxillary nerve and the abducent, between the internal maxillary nerve/

nerve and the facial nerve, between the internal maxillary nerve and the glosso-pharyngeal, between the interganglionic cord of the sympathetic trunk and the medulla oblongata, between the interganglionic cord and the hypoglossal nerve.

The carotid ganglion can not be found in our laboratory nor verified by Rochas himself,

Since the Vidian nerve and the internal maxillary nerve are composed of nerve fibres derived from the anterior cervical ganglion, doubtlessly the anterior cervical ganglion is connected with the 1st, 3rd, 4th, 5th, 6th, 7th, and the 9th cranial nerves by the internal maxillary and Vidian nerves, and receives communicating branches from the vagus directly and from the hind brain and the hypoglossal nerves by the interganglionic cord. In other words, the anterior cervical ganglion is connected, as a centre of communication with all the cranial nerves except the special sensory nerves, the optic and the acoustic.

2. Wolff⁶⁰ mentions in his 'Anatomy of the Eye and Orbit', "In birds there is only a motor and no sensory or sympathetic root of the ciliary ganglion. These join the ciliary nerves". Blount has a similar mention in his 'Diseases of Poultry'. Perhaps the works of Schwalbe⁴⁶ and Holtzmann²⁵ established these statements of Wolff and Blount. Schwalbe and Holtzmann have done some investigations on the ciliary ganglion and the ciliary nerves in birds and deny the existence of the sympathetic root of the ciliary ganglion.

Many of the dissections that have been done clearly demonstrate that the ciliary ganglion in the fowl receives a branch of the Vidian nerve which is composed of fibres from the/

the internal carotid nerve and the greater superficial petrosal nerve, but in several birds this communication was not found.

Rochas⁴³ has seen a sympathetic nerve fibre extending to the ciliary ganglion from the infra-temporal plexus on the external ophthalmic artery. He says "I call particular attention to the very thin fibre which comes out of the sympathetic system and then after a short course enters the ophthalmic ganglion at varying levels, and often very close to the point where the ciliary nerve comes out". Rochas statement is not confirmed. A Filament has been seen extending to the abducent nerve from the infra-temporal plexus on the external ophthalmic artery in the orbita but not to the ciliary ganglion.

3. Magnien³² in 1885 reported that the chorda strays from the facial nerve near the external opening of the canalis Fallopieae and joins a branch of the mandibular nerve, leading to the floor of the mouth. This statement is confirmed by Gaupp in the descriptions of the chorda tympani of the fowl in ~~spite of~~^{against} the opinion of Gadow⁶² who says "Entsprechend dem Fehlen eines N. lingualis des dritten Trigeminus-Astes, ist keine Verbindung mit dem ^{N. ~~fascialis~~ ^{vorhanden}}, welche etwa der Chorda tympani der Säugetiere vergleichbar wäre". Cords¹⁴ describes the course of the chorda tympani of birds in detail but she does not mention the submandibular ganglia and the distribution of the chorda tympani. She concludes that according to the origin and end, as well as to the characteristic course, there can be no doubt that this nerve branch is the chorda tympani. This conclusion is confirmed now by the existence of the submandibular ganglia and the innervation of the anterior submandibular glands.

4. The vascular plexus in the infra-temporal fossa (the internal maxillary plexus or rete temporale de Hahn⁴³) is not a rete mirabile but a network composed of minute blood vessels through which blood passes directly from the artery to the veins. Unfortunately it is sometimes called "rete mirabile ophthalmicum"⁴⁴. This vascular plexus is innervated by the nerve fibres that are derived from the internal maxillary nerve and form a plexus (the infra-temporal plexus or plexus of Weber⁴³) within the vascular plexus. This plexus serves as a "shortway" for the blood passing through from the internal maxillary artery and its main branches to the deep and superficial temporal veins. To say more than this would require some physiological experiments. Imagination however leads one to think that the blood vessels of the internal maxillary plexus are constricted by the vaso-motor fibres of the infra-temporal plexus.

5. The following facts are mentioned in the above description:

(a) The anterior cervical ganglion receives communicating branches from the facial, glosso-pharyngeal and vagus nerves.

(b) The interganglionic cord between the anterior cervical ganglion and the sympathetic ganglion which corresponds to the 3rd cervical spinal nerve, receives communicating branches from the hind brain in front of the hypoglossal nerve, from the hypoglossal and from the 1st two cervical nerves, but no ganglia appear on this interganglionic cord. In the same manner, the sympathetic trunk usually receives a communicating branch behind the last ganglion on the sympathetic trunk. The nerve fibres of the communicating branches derived from the hind brain/

brain, hypoglossal ^{nerve} and ^{a part derived from} the first cervical spinal nerve can be traced to the anterior cervical ganglion while those derived from the second cervical spinal nerve ^{and a part from the first cervical spinal nerve} lead to ~~both anterior cervical ganglion and~~ the ganglion on the sympathetic trunk corresponding to the third cervical spinal nerve.

(c). The 7th and 8th lumbo-sacral spinal nerves are always connected with one ganglion on the sympathetic trunk by communicating branches.

(d) Occasionally an additional ganglion appears on the sympathetic trunk between the two sympathetic ganglia which correspond to two adjacent spinal nerves. Such an additional ganglion is frequently seen on the interganglionic cord which lies below the transverse process of the 13th cervical vertebra and links the two sympathetic ganglia corresponding to the 13th and 14th cervical spinal nerves respectively. Pick and Sheehan⁴⁰ ✓ throw light upon these phenomena and suggest "There is a division of each primordial ganglionic mass into cranial and caudal portions, the ultimate fate of which will determine the number and type of ganglia". The anterior cervical ganglion is produced from the primordial ganglionic masses of the facial, glosso-pharyngeal, vagus, hypoglossal, ~~the 1st cervical spinal nerve~~ and the communicating branch from the hind brain and the cranial portion of the primordial ganglionic mass of the 1st cervical spinal nerve. The ganglion on the sympathetic trunk which is connected with both the 7th and 8th lumbo-sacral spinal nerves is produced from the primordial ganglionic masses of the 7th and 8th lumbo-sacral fused spinal nerves. The additional ganglion is produced by the persisting of the caudal part of the primordial ganglionic mass which corresponds to the spinal nerve/

nerve in front, or of the cranial part of the primordial ganglionic mass which corresponds to the spinal nerve behind, or of both fused together. The primordial ganglionic mass behind the last ganglion on the sympathetic trunk is missing, but the sympathetic trunk behind the last ganglion is still connected by a communicating branch with the coccygeal nerve from which the missing primordial ganglionic mass is derived.

6. Using Worobiew's Staining Method for nerve elements,⁶¹ Ssinelnikow⁵⁹ studies the cardiac nerve of the fowl, and describes it in detail with illustrations. There are some differences between his description and the specimens dissected.

(a) The cardiac plexus, according to the partition of the heart, is artificially divided by Ssinelnikow into six parts:-

I. The ~~right~~^{left} anterior cardiac plexus (Plexus anterior Cardis sinister), on the antero-lateral aspect of the left ventricle.

II. The right anterior cardiac plexus (Plexus Cardis dexter) on the anterior and lateral aspects of the right ventricle.

III. The right posterior cardiac plexus (Plexus Cardiacus posterior dexter) on the posterior aspect of the right atrium between the right anterior vena cava and the inferior vena cava on one hand and the right pulmonary vein^{on the other hand,} and on the posterior aspect of the upper part of the right ventricle.

IV. The left posterior cardiac plexus (Plexus cardiacus posterior sinister) on the posterior aspects of the left atrium and of the upper part of the left ventricle.

V. The anterior atrial plexus (Plexus atriorum anterior) on the superior surface of the atria.

VI./

VI. The posterior atrial plexus (Plexus atriorum posterior) on the posterior aspect of the common pulmonary vein. In fact, the above mentioned right and left anterior cardiac plexuses are inseparable and therefore called the anterior cardiac plexus in this paper. The right and left posterior cardiac plexuses and the posterior atrial plexus are also inseparable and therefore called the posterior cardiac plexus in this paper.

(b) Ssinellnikow mentions ganglionic chains which represent the right and left coronary plexus^s, named in this paper. Their courses follow the circumflex branches of the right and left coronary arteries in the coronary groove on the anterior and ~~of~~ the lateral sides of the heart. He does not mention the plexus which enlaces the left coronary artery behind the conus arteriosus. It has been called the left coronary plexus in this paper.

(c) The nerve ring around the bulbus aortae described and illustrated by Ssinellnikow can not be confirmed.

(d) Ssinellnikow notes that he finds no branches of the left sympathetic cardiac nerve, which runs directly from the cardiac nerve to the heart. It is found that the left sympathetic cardiac nerve divides into two terminal branches one of which passes backward along the lateral aspect of the left anterior vena cava to join directly the big ganglion in the posterior cardiac plexus.

(e) Ssinellnikow reports the anterior (superior) cardiac branch of the right vagus forms the right anterior cardiac plexus on the anterior and right aspect of the heart and the anterior (superior) cardiac branch of the left vagus forms the left/

left anterior cardiac plexus on the anterior and left aspects of the heart. In other words, the anterior cardiac branch of the vagus constitutes the cardiac plexus supplying the heart on the same side. On the other hand, the fowls dissected in our laboratory show that the anterior cardiac branch from the right vagus passes behind the bulbus aortae and the conus arteriosus to form the left coronary plexus supplying the anterior and left aspects of the heart while the anterior cardiac branch from the left vagus passes in front of the conus arteriosus to form the anterior cardiac and the right coronary plexuses supplying the anterior and right aspect of the heart; thus, the anterior cardiac branch of the vagus crosses the median line and forms the cardiac plexus on the opposite side of the heart. Thebault⁵⁶ has a similar statement. He says that from the ganglion de Couvreur a fibre detaches itself, crosses to the other side and goes towards the heart, that is, the right ganglion supplies the left ventricle while the left ganglion supplies the right ventricle. The forces which lead the anterior cardiac branches of the vagi across the median line to the opposite sides of the heart are unknown. The distribution of the nerve fibres of the cardiac plexus is complicated, as shown above. The anterior cardiac branch from the right vagus gives off a branch to the right coronary plexus. The left coronary plexus which is formed by the anterior cardiac branch of the right vagus, receives communicating branches from the anterior cardiac branch of the left vagus.

Thebault⁵⁶ dissects a great many birds including three groups: small sparrows, crows and climbers. He says, in conclusion, that the sympathetic nerves, less well developed than/

than those derived from the vagus, go mostly to the auricles, while those of the vagus innervate mostly the ventricles. The same happens in the domestic fowls. The sympathetic cardiac nerves ramify and twist around the right and left anterior venae cavae but giving branches to join the anterior and posterior cardiac branches of the vagus nerves. It is noticeable that the terminal branches or the stems of both right and left sympathetic cardiac nerves join the posterior cardiac plexus directly or by union with the posterior cardiac branches of the vagi.

7. The innervation of the lung is carefully studied. The sympathetic nerve fibres are derived from the first thoracic ganglion on the sympathetic trunk through the cardiac nerve, while the parasympathetic nerve fibres from the vagus. ²¹ Hirt mentions that the pulmonary nerve arises from the first thoracic ganglion and the succeeding ganglion on the sympathetic trunk. The pulmonary nerves or the roots of the pulmonary nerve which are derived from the second thoracic ganglion and the succeeding ganglia on the sympathetic trunk can not be found in the gallinaceous birds.

8. Thebault ⁵⁶ considers the cervical part of the sympathetic trunk corresponding to the vertebral nerve in mammals in spite of the explanation given by Weber, ⁵⁹ that it is the equivalent of the sympathetic trunk in mammals. He calls it the Apophyso-cervical cord. He believes the sympathetic trunk of the cervical part exists, but it is fused with the vagus. He states that the superior cervical ganglion is the homologus of the ganglion of the same name in mammals, and the ganglion of Couvreur is the homologus of the inferior cervical ganglion, or/

or represents the inferior cervical ganglion fused with other ganglion belonging to the vagus. In his diagram which illustrates the relation of the sympathetic trunk to the vagus, he labels the plexiform ganglion as the middle cervical ganglion and marks the ganglion of Couvereur with two names, ganglion of Couvereur and inferior cervical ganglion. One can hardly agree with his statement and illustration since Kinkel²⁷ demonstrates that the three ganglia on the vagus, (the jugular ganglion, plexiform ganglion and the ganglion of Couvereur) are sensory ganglion containing cells doubtlessly to be sensory cells according to the form of the cell of the primitive structure. Thebault⁵⁶ says "Due to the absence of the cervical chain I consider that a branch, seen only under the microscope, joins the 10th cranial nerve. To support this view, I stand by comparative anatomy". The branch in question can not be confirmed. One or two communicating branches are found from the vagus leading backward and downward to join the anterior part of the anterior cervical ganglion. In no way can these communicating branches be considered representing the sympathetic chain going to form the vago-sympathetic trunk in mammals.

9. There is no nerve in domestic birds which is ^{the} homologous of the spinal root of the accessory nerve in mammals, although in some text-books of anatomy it is mentioned that there are twelve pairs of cranial nerves⁴⁸ and that the accessory nerve is combined with the vagus.¹⁶ The accessory nerve of gallinaceous birds described in detail and illustrated by Cords¹⁴ is but the spinal root of the vagus which is quite different from the spinal root of the accessory nerve in mammals, although both are formed by union of filaments issuing from the spinal cord and/

and pass forward through the foramen magnum into the cranial cavity. The spinal root of the vagus in bird issues from the spinal cord in a line which is the prolongation of the line in which, the dorsal roots of the spinal nerves issue from the spinal cord, while the spinal root of the accessory nerve in mammals emerge in a line midway between the dorsal and ventral roots of the spinal nerves.

Diagram 'N' to show the accessory nerve in mammals.

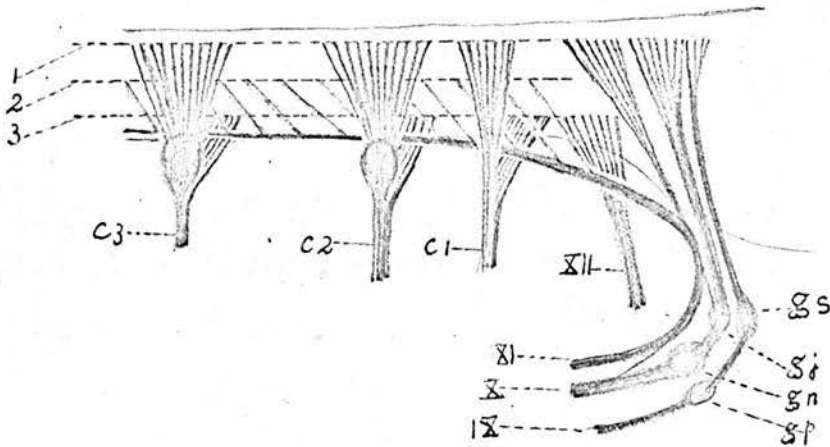
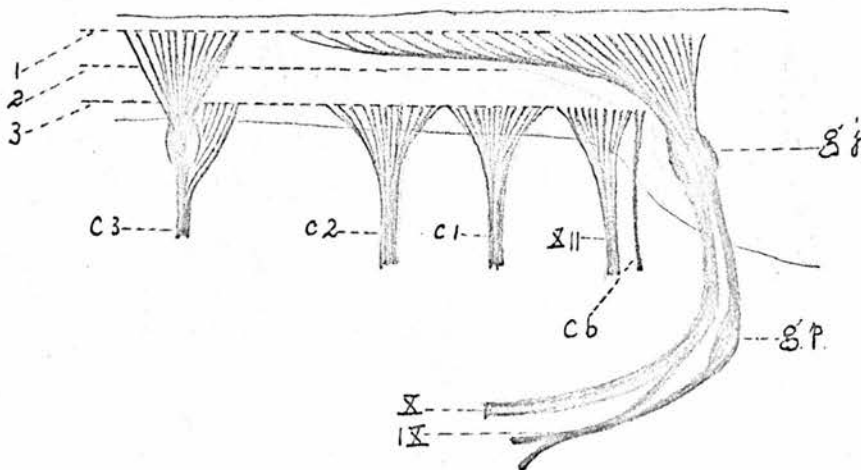


Diagram 'O' to show the spinal root of the vagus in birds.



- | | |
|---|--------------------------------------|
| 1. Line of dorsal nerve roots. | 2. Line of roots of accessory nerve. |
| 3. Line of ventral nerve roots. | C1. 1st cervical N. |
| | C2. 2nd cervical N. |
| Cb. Sympathetic communicating branch from hind-brain. | C3. 3rd cervical N. |

- | | |
|--------------------------|-----------------------|
| gn. Ganglion nodosum. | gj. Jugular ganglion. |
| gs. Superior ganglion. | gp. Petrous ganglion. |
| IX. Glosso-pharyngeal N. | X. Vagus N. |
| XI. Accessory N. | XII. Hypoglossal N. |

According to Holl,²³ the accessory nerve consists of two parts, a cranial part, which is really ^a part of the vagus, and a spinal part which is formed by union of a series of filaments from the spinal cord. Holl reports "There are no accessory nerves in the animals. In such animals the part innervated by the nerve which corresponds to the external branch of the accessory nerve in human being, fail to develop. The branch representing the inner branch in human being is quite present and is combined intimately with the vagus". This is the case in the domestic fowl. In mammals, the accessory nerve supplies the Mm sterno-mastoideus (sterno-cephalicus) and trapezius. In domestic birds there is no muscle which is the homologus of the M sterno-mastoideus or sterno-cephalicus in mammals. The M. trapezius is present, situated between the Mm. latissimus dorsi and rhomboideus, taking origin from the dorsal spines of the last two cervical and first five thoracic vertebrae, and innervation on the lateral surface ^{of the scapula} along the dorsal border, but ^{? innervated by the} it is innervated by the ventral ramus of the third last cervical spinal nerve. Cords¹⁴ calls the cutaneous branch of the vagus as the accessory nerve. One can hardly agree with this designation as there is no reason leading one to consider the M. cutaneous colli lateralis ^{which is innervated by the cutaneous branch of the vagus,} to be the homologus of either the M. sterno-mastoideus or M. trapezius in mammals. Lillie³⁰ reports in his "Development of the Chick", that no observations on the development of the spinal accessory nerve in the chick are known to him./

to him. Patten³⁸ shows the accessory nerve of a four day chick embryo, separated from the vagus, in an illustration. This nerve element can be identified in serial sections of the embryo of the same stage. It is continued from the spreading roots of the vagus and can be traced, as a thick cord, backward along the dorso-lateral aspect of the spinal cord, to the ganglion of the third cervical spinal nerve. It does not separate from the vagus. Plate 1 is a series of serial sections of 84 hour chick embryo showing the spinal part of the rootlets of the vagus, which Patten considers as the accessory nerve. In this Plate the spinal root of the vagus is seen to be continuous with the medullar root of the vagus in front and with the dorsal root of the third cervical spinal nerve ^{behind,} near the spinal ganglion. It is no surprise that the spinal root of the vagus is continuous with the dorsal root of the third cervical spinal nerve, since in the young embryo the dorsal roots of adjacent spinal nerves are continuous with each other. In 96 and 108 hour embryos, neuroblasts of Schaper are found in the spinal root of the vagus. These neuroblasts are characterized by a) the cytoplasm which is accumulated at one side of the nucleus and contains neurofibrils, and b) the big rounded or elongated eccentric nucleus. There are usually two large and round nucleoli in the nucleus. The neurofibrillae form a delicate network within the cytoplasm but converge together in the axon. In this stage the developing neuroblast is provided only ^{with} one process, the axon, leading to the spinal cord. The size of the neuroblasts and their nuclei in the 108 hour chick embryo are as follows.

	<u>Neuroblasts.</u>	<u>Nuclei.</u>
1.	11.84 X 8.88 microns.	8.88 X 7.40 microns.

	<u>Neuroblasts.</u>	<u>Nuclei.</u>
1.	11.84 X 8.88 microns.	8.88 X 7.40 microns.
2.	11.84 X 5.92 "	5.92 X 5.92 "
3.	10.36 X 5.92 "	5.92 X 5.92 "
4.	10.02 X 5.01 "	5.01 X 5.01 "
5.	11.69 X 5.01 "	5.01 X 5.01 "
6.	11.69 X 5.85 "	5.85 X 5.85 "
7.	11.84 X 2.90 "	5.92 X 2.90 "

Plate 2 shows these neuroblasts in three succeeding serial sections.

As described above the spinal root of the vagus which is labelled as the accessory nerve by Patten in his diagram is derived from the neural crest. The spinal root of the accessory in mammals is, as stated in Gray's Anatomy, composed of fibres arising from an elongated nucleus of motor cells which is situated in the lateral part of the anterior grey column of the spinal cord and extends downwards as low as the level of the 5th cervical nerve. Patten³⁹ mentions the accessory nerve of mammals. "Foriep's ganglion disappears in the adult so the accessory nerve is without ganglion and entirely motor". Therefore the spinal root of the vagus in birds is quite different from the spinal root of the accessory nerve. Patten³⁹ clearly shows in description and illustration a commissural ganglion of the embryo of pig. He says "The commissural ganglion which appears so closely associated with the accessory nerve is really a continuation of the jugular ganglion of the vagus". The spinal root of the vagus of the chick is homologous with this commissural ganglion but it extends farther back to the level of the 2nd cervical spinal nerve, while the nerve which represents the accessory nerve is absent.

In birds, the hypoglossal nerve and the 1st two cervical spinal nerves are composed of motor nerve fibres only. The spinal/

spinal root of the vagus extends as far back as the level of the 2nd cervical spinal nerve and is provided with a Forrier's type of ganglion at a position representing the rudimentary ganglion of the 2nd cervical spinal nerve. These facts lead one to consider that the dorsal roots of the hypoglossal and the 1st two cervical spinal nerves are present. They unite, forming the spinal root of the vagus, to join the jugular ganglion of the glosso-pharyngeal and vagus, but do not join the corresponding ventral roots of the hypoglossal and the 1st two cervical spinal nerves.

10. The glands in the cranial region are supplied by different nerves, the lacrimal gland by the internal maxillary nerve and the lacrimal branches of the trigeminal nerve; the Harderian gland by the Vidian nerve and by the nerve fibres derived from the ethmoidal ganglion; the nasal gland by the nerve fibres derived from the ethmoidal ganglion; the maxillary gland by the medial and lateral naso-palatine nerves derived from the sphenopalatine ganglion and the maxillary nerve; the palatine glands by the posterior palatine nerves and the lateral naso-palatine nerve; the sphenopterygoid glands by the pharyngeal branch of the glosso-pharyngeal nerve and ^{by} the Vidian nerve; the anterior submandibular glands by the chorda tympani and the sublingual branch of the inferior alveolar nerve; the dorso-lateral group ^{of the posterior submandibular glands} _^ by the nerve to the angle of the mouth of the trigeminal nerve; the intermediate group of the posterior submandibular glands by the lingual and pharyngeal branches of the glosso-pharyngeal nerve; the ventro-medial group of the posterior submandibular glands by the lingual branch of the glosso-pharyngeal nerve; the lingual glands by the lingual and the/

the anterior laryngeal branches of the glosso-pharyngeal nerve; the gland at the angle of the mouth by the nerve to the angle of the mouth; the crico-arytenoid glands by the anterior laryngeal nerve of the glosso-pharyngeal nerve. No sympathetic fibres have been seen leading to the anterior submandibular glands, to the posterior submandibular glands, to the lingual glands, to the crico-arytenoid glands and to the gland at the angle of the mouth, although there are two possibilities that the glands receive the sympathetic fibres from a) the invisible plexuses around the vessels and b) from the parasympathetic nerves which receive anastomotic branches from the sympathetic nerves. In every salivary gland supplied by both sympathetic and parasympathetic nerve fibres?. This question must be left open.

11. Staderini⁵¹ and Cords¹⁴ report that the vagus gives branches to the liver in the gallinaceous birds. Cords shows the hepatic branches of the vagus alongside the inferior vena cava in an illustration. These statements can not be confirmed. Vagal branches have been seen on the inferior vana cava under the microscope of 14 diameters, but can not be traced to the hepatic vein.

It is doubtful whether ^{or not} the liver is ~~or not~~ supplied by vagus nerve fibres. The coeliac plexus on the left gastro-hepatic artery, from which sympathetic nerves extend along the left hepatic artery to the liver, is connected with the ventral oesophageal trunk of the vagus nerves in the lesser curvature of the gizzard. This connection takes place usually after the hepatic branches of the sympathetic have been given off from the coeliac plexus. Marage³³ has a similar statement of the existence/

existence of the vago-sympathetic anastomoses in gallinaceous birds but Weber⁵⁹ and Thebault⁵⁶ denied the existence of this anastomosis in the other birds. Another possibility is that the liver may have vagus nerve fibres through the coeliac plexus on the coeliac artery, since the coeliac ganglion or the coeliac plexus has been demonstrated receiving vagus nerve fibres from the descending branch of one or both recurrent nerves. Couvreur¹⁵ has shown that, in gallinaceous birds the excitation of the vagus has considerable influence on the function of the liver.

The liver is innervated by sympathetic nerves derived from both the coeliac plexus and the hepatic nerve. The coeliac plexus is formed by the greater splanchnic nerves of both sides. The hepatic nerve arises from a ganglion in the right adrenal plexus but receiving branches from the anterior mesenteric plexus. In other words it is derived from the smaller splanchnic nerves of both sides but receiving more nerve fibres from the splanchnic nerves of the right side than from the left.

Thebault⁵⁶ reports that in crows and climbers only the great splanchnic nerves innervate the liver. It is not the case in the domestic fowl, in which the liver is innervated by all the greater and smaller splanchnic nerves of both sides, but receiving more nerve fibres from the smaller splanchnic nerves on the right side than from the left.

12. The intestinal nerve is first reported by Swan⁵³ as a special nerve in the mesentery. Remak⁴¹ and later Szantroch⁵⁴ published papers describing the intestinal nerve in detail. Marage³³ and Thebault⁵⁶ give special attention to the intestinal nerve/

nerve in convenience of the studies of the sympathetic nervous system in the other birds. Mitchell,³⁶ Maumus³⁴ and Kostanecki²⁸ also mention the intestinal nerve in the discussion of their papers on the digestive canal of the fowl.

Mitchell³⁶ states that the intestinal nerve arises from the ganglia in the plexuses on the edge of the stomach, on the ovary, on the suprarenal capsule and further back near the rectum. He says "The intestinal nerve starts in a common with the duodenal nerve as in the Palamedea and the Passeres". Similarly the intestinal nerve arises with its anterior end from a sympathetic nerve which arises from the ganglionic area of the anterior mesenteric plexus passing down parallel with and behind the hepatic nerve to the proximal part of the duodenal loop where it supplies the duodenum, the pancreas and usually gives off a branch of considerable size to the falciform ligament. This "origin" of the intestinal nerve has escaped the investigation of Szantrock⁵⁴ who describes the anterior end of the intestinal nerve entering the wall of the intestine at the level between the duodenum and the jejunum. Thebault⁵⁶ reports the intestinal nerve in sparrows, crows and climbers is continued from the vagus at the level of the duodenal loop. It is quite different in the gallinaceous birds. In the gallinaceous birds the ventral oesophageal trunk of the vagus nerves ends in the gastric plexus in the lesser curvature of the gizzard. No fibre can be traced to the duodenal loop either from the ventral oesophageal trunk or from the gastric plexus. The intestinal nerve is definitely observed arising from the anterior mesenteric plexus, receiving no branch from the vagus. Hirt²¹ mentions "Through the/

the connection of the vagus with the intestinal nerve the latter receives numerous vagus fibres". Marage³³ considers it as an essential part of the continuation of the vagus to the intestine. Perhaps variations exist between species or even in the same species. The intestinal nerve arises from the anterior mesenteric plexus receives branches from the anterior mesenteric plexus (twisting around the anterior mesenteric artery) aortic plexus, posterior mesenteric plexus, hypogastric plexus and the pelvic splanchnic nerves, and gives off branches to the intestine and the cloaca. It serves as a "station" for the sympathetic and parasympathetic nerve fibres passing through from the above mentioned plexuses and nerves to the intestine and the cloaca. Therefore it should be regarded as a communicating trunk between the sympathetic plexuses and the pelvic splanchnic nerves. It is not agreeable that Szantroch⁵⁴ regards it as a separated ganglionic system.

13. The anastomotic branches from the vagus nerves to the coeliac ganglion or the coeliac plexus are found. These have escaped the notice of previous investigators. They are branches derived from the descending branches of ^{one or} both the recurrent nerves. ²² His has seen the anastomotic branch from the right recurrent nerve to the coeliac ganglion in serial sections of chick embryo. Therefore the following organs, spleen, liver, pancreas, kidney, small intestine, testes or ovaries may receive vagal fibres from these anastomotic branches.

These anastomotic branches can only be demonstrated in young birds. A proportionally larger anastomotic branch has been expected to be found in the adult bird but in vain. Since the spleen, pancreas, liver, kidney, and the small intestine, except/

except the proximal part of the duodenum, are supplied by the branches derived from the sympathetic plexuses but receive no branches directly from the vagus or its derivatives, and since the anastomotic branches from the recurrent nerves to the coeliac ganglion or coeliac plexus are so small or absent in the adult bird that they can not be seen under the microscope of 14 diameters, it is doubtful whether ^{or not} the vagus nerve fibres are ~~or are not~~ active in these organs. However, there are two noticeable points: 1) Small ganglia are found in the substance of the pancreas, they are doubtless parasympathetic ganglia. 2) Thebault⁵⁶ says "It is surprising that the stimulation on the vagus has effect not only on the liver but also on the kidney", since he does not see the anastomotic branches from the recurrent nerves to the coeliac ganglion or coeliac plexus and denies the existence of anastomosis between the sympathetic and vagus nerves.

14. The aortic plexus on the aorta at the level of the 1st seven lumbo-sacral vertebrae is poorly developed. Mazarelli³⁵ and Thebault⁵⁶ consider it as a remnant of the embryonic stage whose development is arrested. Their statements are proved.

15. The kidney is supplied by the anterior, middle and posterior renal plexuses which enlase the corresponding renal arteries. Hirt²¹ states that the kidneys receive nerves directly from the abdominal sympathetic trunk but this could not be confirmed.

16. The cloacal plexus is formed mainly by the pelvic splanchnic nerves and supplies the sphincter muscle of the cloaca, the anus, the terminal part of the ureter, the vagina or the terminal part of the deferent duct. Although there are/

are anastomotic branches between the cloacal and the pelvic plexuses, These anastomotic branches are so few and small that even if the cloacal plexus receives sympathetic nerve fibres through these anastomotic branches from the pelvic plexus, it is doubtful whether ^{or not} the sympathetic nerve fibres are active in the cloacal plexus or on the sphincter muscles of the cloaca, anus, ureters and the deferent duct or vagina.

17. Different segments of the digestive canal are innervated by different nerves: the oesophagus mainly by the *descending* oesophageal branch^{es} of the glosso-pharyngeal and the recurrent nerve^s of the vagi, the glandular stomach and the gizzard by both vagi and sympathetic, the intestine with the liver and pancreas mainly by sympathetic, while the anus mainly by the pelvic splanchnic nerves. Nevertheless the oesophagus receives sympathetic nerve fibres from the retro-carotid, retro-vertebral and cardiac nerves, the anus receives sympathetic nerve fibres from the pelvic plexuses, the coeliac plexus and the intestinal nerve receives parasympathetic nerve fibres from the vagus and pelvic splanchnic nerves respectively.

Summary.

1. The sympathetic ganglia in the thoracic and anterior lumbo-sacral region fuse with spinal ganglia.
2. Sympathetic rami communicantes only appear in the post lumbo-sacral and coccygeal regions.
3. The interganglionic cord is single in the cervical and anterior lumbo-sacral regions, double elsewhere.
4. The anterior cervical ganglion serves as a centre of connections with the cerebro-spinal nerves.
5. There is no otic ganglion.
6. The nasal gland is innervated by branches from the ethmoidal ganglion, Harderian gland by the Vidian nerve, lacrimal gland by the internal maxillary and trigeminal nerves, maxillary gland by the medial and lateral naso-palatine nerves, palatine glands by the posterior palatine nerve, sphenopterygoid glands by the glosso-pharyngeal and the Vidian nerves, anterior submandibular glands by branches from the submandibular ganglia, the intermediate group and ventro-medial group of the posterior submandibular glands by the glosso-pharyngeal nerve also the lingual glands and the crico-arytenoid glands, the gland at the angle of the mouth and the dorso-lateral group of the posterior submandibular glands by ramus anguli oris of the trigeminal nerve.
7. The ciliary ganglion has connections with the oculomotor nerve, ophthalmic nerve and the Vidian nerve.
8. The glosso-pharyngeal nerve gives off the pharyngeal and the lingual as collateral branches and the anterior laryngeal and descending oesophageal as terminal branches. The anterior laryngeal is a branch of the glosso-pharyngeal nerve and not from/

from the vagus. The descending oesophageal branch is continuous with the recurrent nerve.

9. The posterior laryngeal^{st.} is a branch of the recurrent nerve and does not supply the larynx.

10. The anterior cardiac branch of the left vagus forms the anterior cardiac and right coronary plexuses. The anterior cardiac branch of the right vagus forms the left coronary plexus. The posterior cardiac branches of both vagi form the posterior cardiac plexus. The middle cardiac branches of both vagi, the right anterior cardiac branch and sympathetic cardiac branches form the superior cardiac plexus.

11. The sympathetic cardiac nerve gives branches to the anterior cardiac branch of the vagus, the pulmonary plexus, superior cardiac plexus and posterior cardiac plexus.

12. The pulmonary plexus is formed by anterior, middle, and posterior pulmonary branches of vagus and sympathetic branches from the cardiac nerve.

13. There is no accessory spinal nerve but the jugular ganglion extends backward alongside the spinal cord to the level of the second cervical spinal nerve. Neuroblasts appear in this spinal part of the jugular ganglion in 4 - 4 $\frac{1}{2}$ day embryos.

14. The greater splanchnic nerves arise from the 2nd, 3rd, 4th and 5th thoracic ganglia and form the coeliac plexus.

15. The lesser splanchnic nerves arise from the 5th, 6th, 7th thoracic, 1st & 2nd lumbo-sacral sympathetic ganglia and form the aortic plexus.

16. The nerves which arise from the 8th - 12th or 6th - 12th lumbo-sacral sympathetic ganglia form the hypo-gastric plexus, posterior mesenteric plexus and the pelvic plexus.

17./

17. No vagal branches can be traced to the hepatic, splenic, and pancreatico-duodenal plexuses.

18. The adrenal, anterior mesenteric, anterior renal, middle renal, posterior renal and testicular (or ovarian) plexuses are subsidiary to the aortic plexus and have no direct communication with the vagus nerve.

19. The gastric plexus supplies the gizzard and the glandular stomach.

20. The coeliac ganglion of young birds receives ~~recurrent~~ branches from the vagus.

21. The intestinal nerve of Remak is a ganglionated trunk and receives branches from the anterior mesenteric plexus, aortic plexus, posterior mesenteric plexus, hypogastric plexus and the pelvic splanchnic nerves.

22. The cloacal plexus is formed by the pelvic splanchnic nerves with many ganglia interposed amongst the fibres.

23. There is no ganglion impar.

References.

1. Acconci. (1880) Nervi laringei inferiori e glosso-faringei negli Ucelli (Atti Soc. Toscan. sc. nat. proc. verb., 1880-81, 162). ✓
2. Andrieu. A. (1837) Recherches sur les fonctions des nerfs pneumo-gastriques (These de medecine de Strasbourg). ✓
3. Bazin. A. (1839) These sur l' unite propre au systeme nerveux de la vie animale et a celui de la vie organique, et sur les rapports anatomiques et physiologiques qui existent entre eux, 53 pp., 4 pl. in-4. Paris, Moquet et Cie, 1839. ✓
4. Bazin. A. (1839) Sur le ganglion cephalique dit glande pituitaire et sur ses connexions avec le systeme nerveux de la vie organique (C.R. Ac. sc. Paris, IX, 507). ✓
5. Bemberg. C. (1842) De avium nervi rostri atque linguae (Dissertat. Halis typus). ✓
6. Bielschowsky. Silver Impregnation Method - Bolles Lee, Vade Mecum (1950). ✓
7. Bischoff. (1832) Commentatio de nervi accessorii Willisii anatomia et physiologia. Darmstadii. ✓
8. Blount. W.P. (1947) Diseases of Poultry. 1st Edition, 175. ✓
9. Bonsdorff. (1852) Symbolae ad anatomiam comparatam nervorum animalium vertebratorum;
 - I. Nervi cerebrales Corvi cornici (lin), 505.
 - II. Nervi cerebrales Gruis cinerea (lin) (Acta societatis scientium Fennicae, III).
10. Brenner. (1883) Ueber das Verhaltniss des Nervus laryngeus inferior vagi zu einigen Aortenvarietaten des Menschen und zu dem Aorten-system der durch Lungenathmenden Wirbelthiere uberhaupt (Arch. Anat. Phys. Anat. Abth., 373-396). ✓
11. Budge et Waller. (1851-1852) Recherches sur le systeme nerveux (C.R. Ac. sc. Paris, XXXIII, 370). ✓
12. Budge. (1858) - 1) Sur un second centre spinal du nerf grand sympathique (C.R. Ac. sc. Paris, XLVII, 586). ✓
 2) Ueber das Centrum genito-spinal des Nerven sympathicus (Arch. f. path. Anatom. u. Physiol. von Virchow, XV, 115). ✓
13. Carus. (1828) Tabulae anatomiam comparativam illustrantes quas exhibuit Carolus Gustavus Carus. Tabula sexta, fig. IX. ✓
14. Cords. E. (1904) Beitrage zur Lehre vom Kopfnervensystem der Vogel, (~~Beitrage und~~ Anatomische Hefte, 26, 50-97). ✓

15. Couvreur. (1892) Sur le pneumogastric^{gut} des Oiseaux, These de Paris, Faculte des Sciences. ✓

16. Ellenberger & Baum. (1932) Handbuch der Vergleichenden Anatomie der Haustiere. 1049.

17. Emmert. (1810) Abhandlung über den Einfluss der herumschweisenden Nerven auf das Athmen, (Reichert's Archiv, IX, 380-420). ✓

18. Emmert. (1811) Beobachtungen über einige anatomische Eigenheiten der Vogel, (Reil's Archiv, X, 377-392). ✓

19. Gaupp. E. (1888) Anatomische Untersuchungen über die Nervenversorgung der Mund und Nasenhohlräume der Wirbeltiere, (Morph. Jahrb. XIV). ✓
1436

20. Heidrich. K. (1907) Die Mund-schlundkopfhöhle der Vogel und ihre Drüsen, Gegenbaurs, (Morph. Jahrb. 37, 10-69). ✓

21. Hirt. A. (1934) Die vergleichende Anatomie des sympathischen Nervensystems, (Handbuch der vergleichenden Anatomie der Wirbeltiere, 2, 725-735).

22. His, jun. (1897) Über die Entwicklung des Bauch-Sympathicus beim Hühnchen und Menschen, (Arch. Anat. u Entw., Suppl.).

23. Holl. M. (1878) Über den Nervus accessorius Willisii, (Arch. für Anat. u Entw.).

24. Hollande. Chlorcarmine Staining Method - Bolles Lee, Vade Mecum (1950).

25. Holtzmann. (1896) Untersuchungen über Ciliarganglion und Ciliarnerven, (Morph. Arbeit. 6, Heft 1, 114-142).

26. Johnston, T.B. & Whillis, J. The suprarenal plexus. (Gray's Anatomy, 29th Edition). ✓
183

27. Kinkel. H. (1932) Der mikroskopische Aufbau der Vagus ganglien bei den Vögeln, (Zeitschrift für Anatomie und Entwicklungsgeschichte, 98, 375-379).

28. Kostanecki. K. (1926) Le caecum des vertebres, (Bulletin International de L'Academie Polonaise des Sciences et des Lettres).

29. Laffont. (1885) Recherches sur l'anatomie et la physiologie comparee des nerfs trijumeau, facial et sympathique cephalique des Oiseaux (C. R. Ac. sc. Paris, 1286). ✓

30. Lillie, F. R. (1908) The development of the chick, 269. ✓

31. Longet. (1841) Recherches experimentales sur les fonctions des nerfs et des muscles du larynx et sur l'influence du nerf accessoire de Willis dans la phonation (Gazette medicale de Paris, 465). ✓

32. Magnien. (1885) - 1) Sur le ganglion geniculaire des Oiseaux (C.R. Ac. sc. Paris, 1507). ✓

2) Recherches sur l'anatomie comparée de la corde du tympan des Oiseaux, (C.R. Ac. sc. Paris, 1013). ✓

(1887) 3) Etude sur les rapports des nerfs craniens et sympathiques cephaliques chez les Oiseaux, (C.R. Paris, CIV, 77). ✓

33. Marage. (1887) Contribution a L'etude anatomique et descriptive du sympathique thoracique et abdominal des Oiseaux, (These de medecine de Paris). ✓

34. Maumus. (1902) Les caecums des Oiseaux, (Ann. Science. Nat., XV,). ✓ 127

35. Mazarelli. (1894) Sull'origine del simpatico nei Vertebrati (Atti accad. Lincei Rend. (5), vol. III, sem. II, 269-273; et Monitore zool. Ital., anno 5, 82-83; et Arch. Ital. biol., XXI, VIII-IX). ✓

36. Mitchell. Ch. (1901) On the Intestinal Tract of Birds, (Transactions of Lincean Society of London, 2nd series, vol. VIII, 173-275). ✓

37. Onodi. A.D. (1884) Ueber die Verhaltniss der Cerebro-spinalen Faserbündel zum sympathischen Grenzstränge, (Arch. Anat. Phys. Anat. Abth., VII-VIII, 145-169). ✓

38. Patten. B.M. The Early Development of the Chick. (3rd Edition, Page 158). ✓ 122

39. Patten. B.M. The Embryology of the Pig. (2nd Edition, 166). ✓ 123

40. Pick. J. & Sheehan. D. (1946). Sympathetic rami in man, (Journal of Anatomy, 80). ✓ 114

41. Remak (1847) Ueber ein selbständiges Darmnervensystem. (Berlin 1847). ✓

42. Ritzel. (1843) Commentatio de nervi trigemini et glossopharengi avium. ✓

43. Rochas. (1885) 1) Sur quelques particularites relatives aux connexions des ganglions cervicaux du grand sympathique et la distribution de leurs rameaux afferents et efferents chez Anas Boschas, (C.R. Ac. sc. Paris, 649). ✓

2) Des nerfs qui ont ete appeles vidiens chez les Oiseaux, (C.R. Ac. sc. Paris, CI, 573). ✓

3) Du mode de distribution de quelques filets sympathiques intra-craniens et de l'existence d'une racine sympathique du ganglion ciliaire chez l'Oie, (C.R. Ac. sc. Paris, 829). ✓

(1886) 4) De L'existence, chez les Oiseaux, d'une espece de ganglion cephalique de nature sympathique correspondant aux nerfs craniens, (C.R. Ac. sc. Paris, 1028). ✓

(1887) 5) De la signification morphologique du ganglion cervical superieur et de la nature de quelques-uns des filets qui y aboutissent ou en emanent chez divers Vertebres, (C.R. Ac. sc. Paris, CIV, 865-868). ✓

44. Rouget. (1856) Recherches anatomiques et physiologiques sur les appareils erectiles, (C.R. Ac. sc. Paris, XLIII, 937-941). ✓

45. Samuel. (1860) Principes fondamentaux de l'histoire du systeme nerveux nutritif (in Journ. phys., III, 572). ✓

46. Schwalbe. G. (1879) Das ganglion oculomotorii Eine Beitrage zur Vergleichenden Anatomie der Kopfnerven, (Jena. Zeitschr. f. Naturwiss., 13, 173-268). ✓

47. Sedillot. C. (1829) Du nerf pneumogastrique et de ses fonctions, (these de medécine de Paris). ✓

48. Sisson. S. The Anatomy of the Domestic Animals, (3rd Edition), 947). ✓

49. Sappey. Recherches sur l'appareil respiratoire des oiseaux. (1847). ✓

50. Ssinellnikow. R. (1928) 1) Die Herznerven der Vogel, (Zeitschrift fur Anatomie und Entwicklungsgeschichte, 86, 540-562.) 1165

2) Das intramurale Nervensystem des Vogelherzens, (Zeitschr. f. Anat. und Entwicklungsgesch., 86, 563-578).

51. Staderini. R. (1889) Sopra la distribuzioni dei nervi glossofaringeo, vago e ipoglosso in alcuni Rettili ed Ucelli, (Atti. Accad. Fisiocritici Siena, I, 585-599).

52. Stopford. J.S.B. The suprarenal plexus, (Cunningham's Text-book of Anatomy, 6th Edition, 797-798). ✓

53. Swan. (1835) Illustrations of comparative anatomy of nervous Systems, (London). ✓

54. Szantoch. Z. (1927) Morphologie des Darmnerven beim Huhnchen, (Bulletin International de l'academie Polonaise des Sciences et des Lettres, No. 3B, Mars. 211-281).

55. Terni. T. (1931) Il Simpatico cervicale degli Amnioti, (Zeitschrift fur Anatomie und Entwicklungsgeschichte, 96, 289-426).

56. Thebault. V. (1898) Etude des rapports qui existent entre les systems Pneumogastrique and Sympathique chez les Oiseaux, (Annales des Science Naturelles (Zoologie), VI). ✓

57. Tiedemann. (1810) Zoologie, II, 44.

58. Vignal. W. (1881) Appareil ganglionnaire du coeur des vertebres, (Arch. de physiol. norm. et pathol., 6, 947). ✓

59. Weber. (1817) Beitrag zur vergleichenden Anatomie des sympathischen Nerven, (Meckel's deutsch. Arch. f. Phys., III, 396-417). ✓

60. Wolff. E. (1948) The Anatomy of the Eye and Orbit,
(3rd Edition, 424).

111 ✓

61. Worobiew. W.P. (1925) Methodik der Untersuchungen
von Nerven-elementen, (Berlin).

62. Gadow, H., u Selenka, E., Bronn's Klassen und
Ordnungen des Tierreichs. VI. Vogel. Leipzig 1891.

112 ✓


THE SYMPATHETIC AND PARASYMPATHETIC
NERVOUS SYSTEMS OF THE FOWL.

Thesis for the Degree of Doctor of Philosophy

by

T.M. Hsieh, B.Sc., M.Sc.

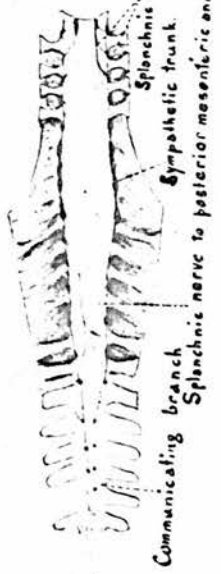FIGURES AND PLATES.



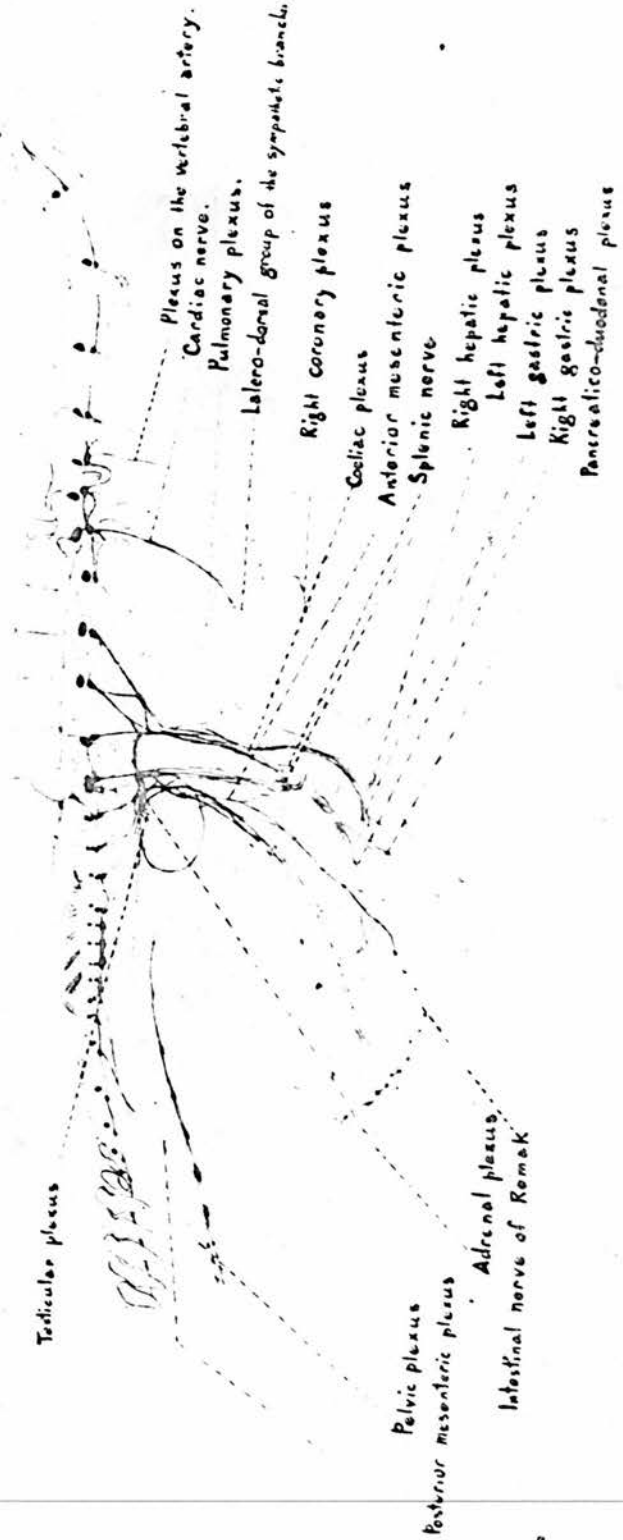
May 1951.

Figure 1

B. The sympathetic trunks and their connections in the sublumbar-sacral and coccygeal regions.



A. The right sympathetic trunk, its connections with the cephalic, cervical, thoracic, abdominal and pelvic plexuses.



Intra-temporal plexus
 Internal maxillary nerve
 Internal carotid nerve
 Anterior cervical ganglion
 Common carotid plexus
 Sympathetic trunk

KEY TO FIGURES 2 - 32.Figure 2.Connections between the Cerebro-spinal and SympatheticSystems.

- 'A' - A view from the left side. (c1, c2, c3, indicates the first, second and third cervical Nn.).
- 'B' - Nuchal surface of the skull.
- 'C', 'D' and 'E' - The 9th cervical, the 4th thoracic and the last lumbo-sacral spinal nerves and the corresponding ganglia. Viewed from the anterior and the lateral side.
- | | |
|---|--|
| a. Common carotid. | a'. Jugular V. |
| a'1. Ventral Cerebral V. | a'1'. Basilar sinus of dura mater. |
| b'. Occipital V. | b'1. Branch draining the superior petrosal sinus of dura mater thro the mastoid foramen. |
| d'. Post auricular V. | |
| k. Int maxillary A. | b'2. Branch draining cavernous sinus of dura mater, and the choroid plexus of 4th ventricle. |
| k'. Int maxillary V. | |
| s1. Post cerebellar A. | Q1. Vestibular N. |
| P. Facial N. | Q2. Cochlear N. |
| R. Glosso-pharyngeal. | |
| S. Vagus. | T1. Stem of the muscular branch to rectus capitis ventralis lateralis & the anastomotic branch to the 1st cervical N. |
| T. Hypoglossal N. | |
| U1. Dorsal root of the spinal N. | U1a. Spinal ganglion. |
| U2. Ventral root. | U3. Dorsal ramus. |
| U4. Ventral ramus. | Z. Sympathetic trunk. |
| Z2. Communicating branches. | Z1. Ant cervical ganglion & the ganglia corresponding to the 3rd cervical, 9th cervical, 4th thoracic & the last two lumbo-sacral spinal Nn. |
| Z3. Splanchnic branch from the last lumbo-sacral sympathetic ganglion to the plexus on the middle sacral A. | |
| 1. Cerebellum. | 2. Pons. |
| 3. Medulla oblongata. | 4. Spinal Cord. |
| 4a. Proximal end of segments of the spinal cord. | |

- 4b. Distal end of the segments of the spinal cord.
5. Dura mater.
6. Cut surface of the occipital bone.
7. Occipital condyle.
8. Foramen magnum.
9. Greater condylar canal.
- 9a. Ext orifice of the greater condylar canal (hypoglossal foramen).
10. Lesser condylar canal thro which the communicating branch passes from the hind brain to the sympathetic trunk.
- 10a. Ext orifice of the lesser condylar canal.
11. Foramen lacerum aboralis.
12. Mastoid foramen.
13. Tendon of tensor tympani M.

Fig. 2

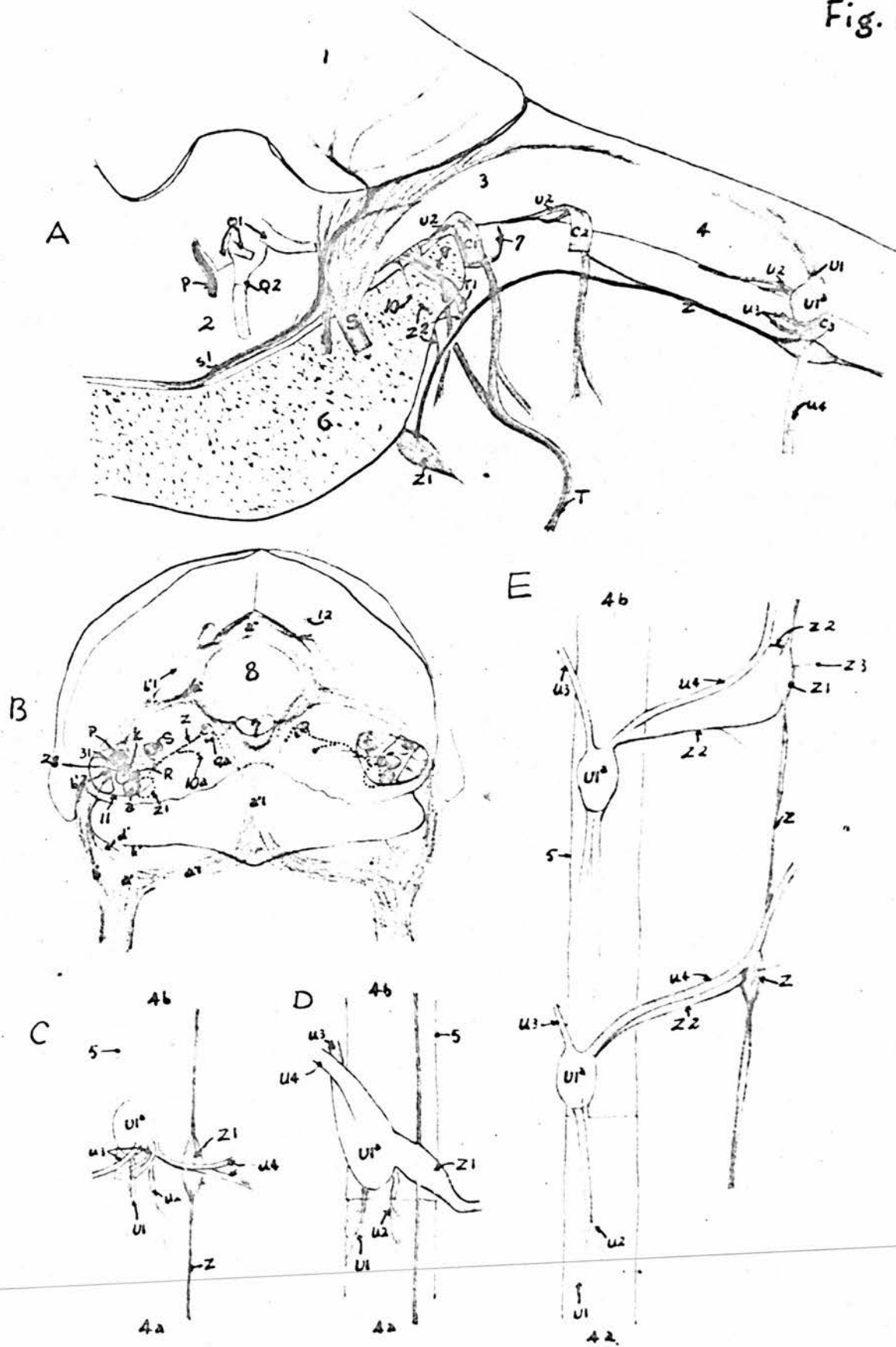


Figure 3.Superficial Dissection of the Head.

The Blood Vessels:

- | | |
|---|--|
| a'. Jugular V. | b1. Branches of the occipital A. |
| b'. Occipital V. | c. Ext. maxillary A. |
| d1. Branches of the post auricular A. & V. | e. Laryngeal A. |
| f'. Lingual V. | e'. Laryngeal V. |
| g. Superficial temporal A & V. | h. Sublingual A & V. |
| j. Facial A & V. | h1. Branches supplying & draining the wattle. |
| j3. Branches to the upper & lower eyelids. | j4. Branches to lat wall of the maxillary sinus. |
| j5. Terminal branches to the comb. | k. Int maxillary V. |
| n1. Mental branch of the inf alveolar A. | l. Deep temporal A. |
| o2. Frontal branches of the ext ophthalmic A & V. | o1. Lacrimal branches of the ext ophthalmic A & V. |
| r3. Anastomotic branch connecting the dorsal nasal & naso-labial A. | r1. Dorsal nasal A. |
| r'3. Anastomotic branch connecting the dorsal nasal & naso-palatine Vv. | r2. Branches supplying the comb. |
| | r4. Lateral nasal A & V. |
| | r'2. Branches draining the comb. |
| | t'1. Branch of the buccinator V. |

The Nerves:

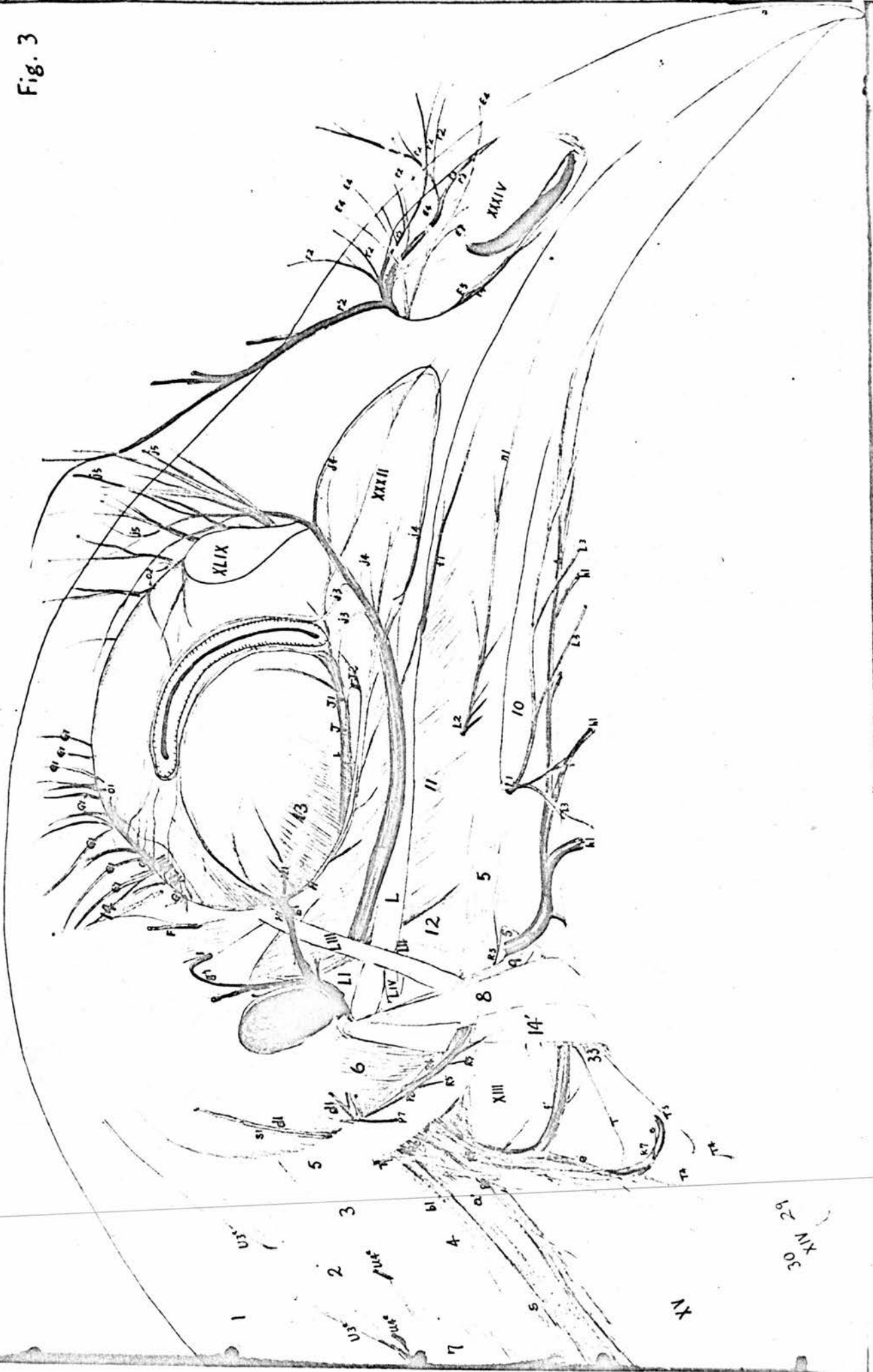- | | |
|--|--|
| E4. Branches of the lat nasal N to the comb. | E5. Branches of the lateral nasal N to the nostril & the upper beak. |
| F. Deep temporal N. | G1. Branches of the superficial temporal N. |
| H. Infraorbital N. | J. Maxillary N. |
| H1. Branches of the infra-orbital N. | J1. ^{superficial (or} Ext nasal) branch of maxillary N. |
| L1. Mylo-hyoid N. (Ram circumflexus). | J2. Deep branch of maxillary N. |
| L2. Ext mandibular N. | |

- | | |
|---|---|
| L3. Branches to wattle. | P7. Branch of Facial N. to cutaneous colli lateralis. |
| P8. Branch of facial N to cutaneous aucheniatria, articulo-glossum and articulo-hyoideus. | R4. Lingual branch of glosso-pharyngeal. |
| R5. Branches to M. hyo-mandibularis. | R6. Desc. Oesophageal branch. |
| R7. Ant laryngeal branch. | S. Vagus. |
| S1. Cutaneous branch of vagus. | T. Hypoglossal N. |
| T3. Branch to M. thyro-hyoideus. | T4. Branches to Mm sterno-thyroideus & ypsilo-trachealis. |
| U3a. Cutaneous branch of dorsal rami of 3rd & 4th cervical Nn. | U4a. Cutaneous branches of ventral rami of 3rd & 4th cervical Nn. |

The Muscles:

- | | |
|---|--|
| 1. M. complexus. | 2. M. trachelo-mastoideus. |
| 3. M. rectus capitis ventralis lateralis. | 4. M. rectus capitis ventralis medialis. |
| 5. M. Hyomandibularis. | 6. M. occipito-mandibularis. |
| 7. M. longus colli. | 8. M. articulo-glossum. |
| 9. M. articulo-hyoideus. | 10. M. mylo-hyoideus. |
| 11. M. masseter. | 12. M. quadrato-mandibularis. |
| 13. M. depressor palpebrarum ventralis. | 14. M. Cutaneous colli lateralis. |
| 14'. M. cutaneous aucheniatria. | 29. M. sterno-thyroideus. |
| 30. M. ypsilo-trachealis. | 33. M. thyro-hyoideus. |
| XIII. Pharynx. | XIV. Trachea. |
| XV. Oesophagus. | XXXII. Maxillary sinus. |
| XXXIV. Nostril. | XLVIII. Lacrimal gland. |
| XLIX. Lacrimal bone. | L. Quadrato-jugal bone. |
| LI. Quadrate bone. | LII. Condyle of quadrate bone. |
| LIII. Fronto-maxillary ligament. | LIV. Articulo-jugal ligament. |
| IV. Ext. acoustic meatus. | |

Fig. 3



30
XIV 29

XV

Figure 4.

Deep Dissection of the Head.

The Blood Vessels:

- | | |
|--|--|
| a. Common carotid A. | a'. Jugular V. |
| a'1. Ventral cerebral V. | b. Occipital A. |
| b1. Branch of occipital A. | b'. Occipital V. |
| c. Ext maxillary A. | b'1. Branch of occipital V. |
| d. Post auricular A. | d'. Post auricular V. |
| d'1. Anastomotic branch. | d'2. Anastomotic branch. |
| e. Laryngeal A. | e'. Laryngeal V. |
| f. Lingual A. | f'. Lingual V. |
| g. Superf temporal A. | g'. Superf temporal V. |
| g'1. Branches of Superf temporal V. | g'2. Dorsal cerebral V. |
| h. Sublingual A & V. | i. Palatine A & V. |
| i2. Anastomotic branch to lat nasal A. | i3. Branch to nasal septum. |
| i4. Right naso-labial branch. | i5. Left naso-labial branch. |
| i6. Sup alveolar branch. | j. Facial A & V. |
| j1. Branch to Mm pterygoideus. | j2. Anastomotic branch between facial & buccinator Aa. |
| k. Int maxillary A. | k'. Int maxillary V. |
| l. Deep temporal A. | m. Masseteric A & V. |
| n. Inf alveolar A & V. | n1. Mental branch. |
| o. Ext ophthalmic A. | o1. Lacrimal branches. |
| o2. Frontal branches. | q. Naso-ciliary A & V. |
| q1. Long ciliary A. | q3. Branches to Harder's gland. |
| q5. Nasal branch of the ethmoid A. | r. Infraorbital A & V. |
| r1. Dorsal nasal A. | r2. Branches to comb. |

- | | |
|------------------------------|--------------------------|
| r3. Anastomotic branch. | r4. Lateral nasal A. |
| r5. Anastomotic branch. | r'1. Dorsal nasal V. |
| r'2. Branches draining comb. | r'3. Anastomotic branch. |
| r'4. Lateral nasal V. | r'5. Anastomotic branch. |
| t. Buccinator A & V. | w. Sup petrosal sinus. |

The Nerves:

- | | |
|---|---|
| B. Optic N. | C5. Branch of oculomotor to M obliquus ventralis. |
| C6. Ciliary ganglion. | D. Trochlear N. |
| E. Maxillary N.
Ophthalmic | E2. Frontal Nn. |
| E3. Lat nasal N. | E4. Branches to comb. |
| E5. Branches to nostril and beak. | E6. Medial nasal N. |
| E7. Sup premaxillary branch. | E8. Inf premaxillary branch. |
| H. Infraorbital N. | G. Superf temporal N. |
| J3. Ext maxillary branch. | J. Maxillary N. |
| K. Ram anguli oris. | J2. Deep branch of maxillary N. |
| L1. Mylo-hyoid N. | J4. Medial nasal palatine N. |
| M. Pterygoid N. | L. Inf alveolar N. |
| O. Abducent N. | L2. Ext mandibular N. |
| P3. Chorda tympani. | N. Masseteric N. |
| P6. Branch to M tensor tympani. | P. Facial N. |
| R1. Petrous ganglion. | P4. Submandibular ganglia. |
| R3. Pharyngeal branches. | R. Glosso-pharyngeal N. |
| R5. Branch to M. Hyo-mandibularis. | R2. Tympanic N. |
| S. Vagus. | R4. Lingual branch. |
| T. Hypoglossal N. | R6. Desc oesophageal branch. |
| T1. Anastomotic branch between hypoglossal & 1st cervical Nn. | R7. Ant laryngeal N. |
| | S1. Cutaneous branch to the temporal region. |
| | T3. Branch to M. thyro-hyoides. |

- T4. Branches to Mm sterno-thyroideus & ypsilon-trachealis.
- T5. Branch to M rectus papitis ventralis lateralis.
- U3. Branch of 1st cervical N to Mm rectus papitis dorsalis major, semispinalis capitis, complexus, rectus capitis ventralis lateralis, trachelo-mastoideus.
- U3'. Branch of 2nd cervical N to Mm rectus capitis dorsalis major, complexus, trachelo-mastoideus & spinalis cervicis rectus.
- U3a. Dorsal cutaneous branches of 3rd & 4th cervical Nn.
- U4a. Ventral cutaneous branches of 3rd & 4th cervical Nn.
- Z. Sympathetic trunk.
- Z2b. Communicating branch from hind brain.
- Z2h. Communicating branch from hypoglossal N.
- Z5. Anastomotic branch to hypoglossal N.
- Z6. Communicating Branch from sup cervical ganglion to occipital A.
- Z12. Sup branch of Vidian N.
- Z13a. Ethmoidal ganglion.
- Z17. Anastomotic branch between sphenopalatine & ethmoidal ganglia.
- Z18. Branch from sphenopalatine ganglion to palatine glands.
- Z19. Branch from sphenopalatine ganglion to medial nasopalatine N.

The Muscles:

1. M. Complexus.
2. M. trachelo-mastoideus.
3. M. rectus capitis ventralis lateralis.
4. M. rectus capitis ventralis medialis.
5. M. hyo-mandibularis.
7. M. longus colli.
8. M. articulo-glossum.
9. M. articulo-hyoideus.
11. Deep of masseter M.
12. M. quadrato-mandibularis.
13. M. depressor palpebrarum ventralis.
- 13'. Periorbita.
16. M. pterygoideus lateralis.
15. M. Hyoideus transversus.
17. M. pterygoideus medialis.
18. M. spheno-quadrato-ptyerygoideus.
19. M. rectus capitis dorsalis major.
20. M. semispinalis capitis.
21. M. pyramidalis.
22. M. quadratus.
23. M. rectus dorsalis.
24. M. rectus lateralis.

- | | |
|---|---|
| 25. M. rectus ventralis. | 26. M. rectus medialis. |
| 27. M. obliquus dorsalis. | 28. M. obliquus ventralis. |
| 29. M. sterno-thyroideus. | 30. M. ypsilo-trachealis. |
| 31. M. tensor tympani. | 33. M. thyro-hyoideus. |
| III. Lat wall of nasal cavity. | IX. Sinus of ethmoid turbinate. |
| XI. Palatine bone. | X. Interorbital septum. |
| XII. Hard palate. | XIII. Pharynx. |
| XV. Oesophagus. | XIV. Trachea. |
| XVII. Spinal Cord. | XVI. Epistrôpheus. |
| XIX. Frontal bone. | XVIII. Temporal bone. |
| XXI. Incisive bone. | XX. Nasal bone. |
| XXIVa. Fenestra vestibuli. | XXII. Tympanic cavity. |
| XXVI. Lat semicircular canal. | XXV. Sup semicircular canal. |
| XXVIII. Otic process of quadrate bone. | XXVII. Post semicircular canal. |
| XXX. Pterygoid bone. | XXIX. Orbital process of quadrate bone. |
| XXXII. Maxillary sinus. | XXXI. Mandible bone. |
| XXXIV. Nostril. | XXXIII. Naso-lacrimal duct. |
| XXXVI. Right maxillary gland. | XXXV. Septum of incisive bone. |
| XXXIX. Lat group of palatine glands. | XXXVII. Left maxillary gland. |
| XLI. Ant submandibular glands. | XXXVIII. Medial group of palatine glands. |
| XLII. Ventro-medial group of post ^{sub} mandibular glands. | XL. Gland at the angle of the mouth. |
| | XLVI. Nasal gland. |
| | XLVII. Harderian gland. |

Fig. 4

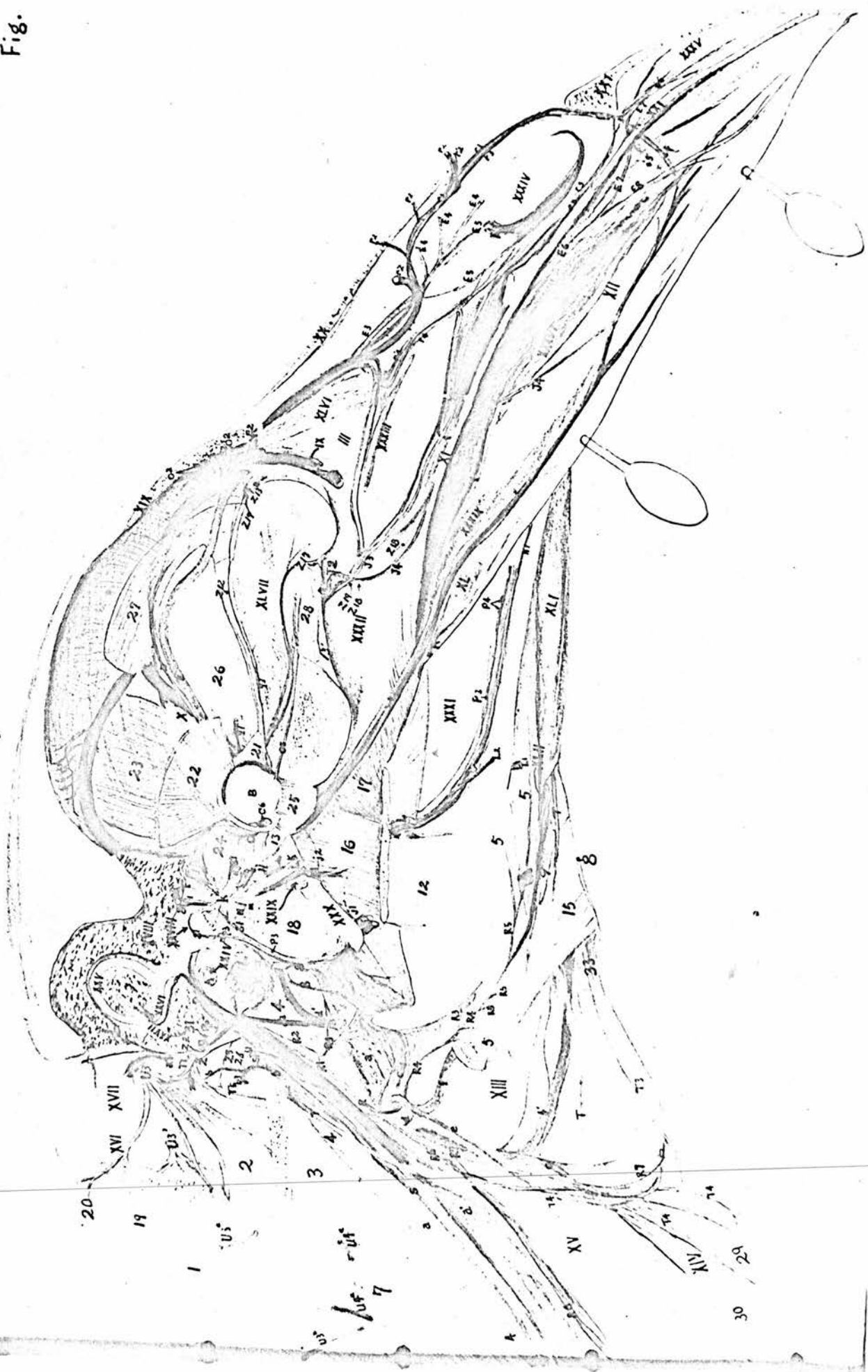

Figure 5.

Semi-diagrammatic scheme of the Blood Vessels and Nervesof the Head.

Blood Vessels:

a.	Common carotid A.	a'.	Jugular V.
b.	Occipital A.	b4.	Desc branch.
b5.	Spinal branch.	b'.	Occipital V.
c.	Ext maxillary A.	d.	Post auricular A.
d'.	Post auricular V.	e.	Laryngeal A & V.
f.	Lingual A.	f'.	Lingual V.
g.	Superf temporal A.	g'.	Superf temporal V.
h.	Sublingual A & V.	i.	Palatine A & V.
i1.	Anastomotic branch to pharyngeal A.	i2.	Anastomotic branch to lat nasal A.
i3.	Branch to nasal sept.	i4.	Naso-labial branch.
j.	Facial A & V.	k.	Int maxillary A.
k2.	Branch to int maxillary plexus.	k'.	Int maxillary V.
l'.	Deep temporal V.	k3.	Anastomotic branch to buccinator A.
m.	Masseteric A.	n.	Inf alveolar A.
o.	Ext ophthalmic A.	o1.	Lacrimal branches.
q.	Naso-ciliary A & V.	q1.	Long ciliary A.
q2.	Brevis ciliary A.	q3.	Branches to Harder's Gland.
q4.	Ethmoidal A.	q5.	Nasal branch of ethmoidal A.
q6.	Ant meningeal A.	q'1.	Lat venae vorticosae.
q'2.	Med venae vorticosae.	q'6.	Ant meningeal V.
r.	Infraorbital A & V.	r3.	Anastomotic branches between dorsal nasal & the incisive Aa.
s.	Int carotid A.		
t.	Buccinator A & V.	u.	Pharyngeal A & V.
u1.	Anastomotic branch to palatine A.	u2.	Anastomotic branch to lat nasal A.

v. Int ophthalmic A.

w. Sup petrosal sinus.

The Nerves:

- | | |
|---|--|
| A. Olfactory N. | B. Optic N. |
| C1. Dorsal branch of oculomotor N. | C2. Ventral branch of oculomotor N. |
| C3. Branch to M rectus ventralis. | C4. Branch to M rectus medialis. |
| C6. Ciliary ganglion. | C5. Branch to M obliquus ventralis. |
| C7. Ciliary N. | E. Trochlear N. |
| E. Ophthalmic N. | E1. Sensory root of ciliary ganglion. |
| E2. Frontal Nn. | E3. Lat nasal N. |
| E6. Med nasal N. | E7. Sup premaxillary branch. |
| E8. Inf premaxillary branch. | F. Deep temporal N. |
| G. Superf temporal N. | H. Infraorbital N. |
| J. Maxillary N. | J3. Ext maxillary N. |
| J2. Deep branch of Maxillary N. | K. Ram anguli oris. |
| J4. Med naso-palatine N. | L1. Mylo-hoid N. |
| L. Inf alveolar N. | N. Masseteric N. |
| M. Pterygoid N. | O1. Branch to M rectus lateralis. |
| O. Abducent N. | O2. Branch to M quadratus. |
| O2. Branch to M quadratus. | O3. Branch to M pyramidalis. |
| P. Facial N. | P1. Genuiculate ganglion. |
| P2. Facial root of ^{lesser} superf petrosal N. | P3. Chorda tympani. |
| R. Glosso-pharyngeal N. | P5. Greater superf petrosal N. |
| R2. Tympanic N. | R1. Petrous ganglion. |
| R4. Lingual branch. | R3. Pharyngeal branches. |
| R7. Ant laryngeal branch. | R6. Desc oesophageal branch. |
| S2. Anastomotic branch. | S. Vagus. |
| T1. Anastomotic branch to 1st cervical N. | T. Hypoglossal N. |
| T3. Branch to M. thyrohyoideus. | T2. Branch to M rectus capitis ventralis medialis. |

- T4. Branches to Mm sterno-thyroideus & ypsilo-trachealis.
- U4. Ventral branch of 1st cervical N.
- U3a. Dorsal cutaneous branches of 3rd & 4th cervical Nn.
- Z. Sympathetic trunk.
- Z2b. Communicating branch from hind brain.
- Z2b. Communicating branch from vagus.
- Z7. Retro-carotid trunk.
- Z10. Int carotid N
- Z12. Sup branch of Vidian N.
- Z13b. Spheno-palatine ganglion.
- Z15b. Branch to spheno-ptyergoid gland.
- Z17. Anastomotic branch between spheno-palatine & ethmoidal ganglia.
- Z20. Med naso-palatine N.
- U3. Dorsal branch of 1st cervical N.
- U3'. Dorsal branch of 2nd cervical N.
- U4'. Ventral branch of 2nd cervical N.
- U4a. Ventral cutaneous branches of 3rd & 4th cervical Nn.
- Z1. Sup cervical ganglion.
- Z2h. Communicating branch from hypoglossal N.
- Z5. Anastomotic branches to hypoglossal N.
- Z8. Int maxillary N.
- Z11. Vidian N.
- Z13a. Ethmoidal ganglion.
- Z14. Inf branch of Vidian N.
- Z15a. Branches to Eustachian tube.
- Z16. Post palatine N.
- Z18. Branch to medial group of palatine glands.
- Z19. Branch to lat naso-palatine N.
- Z22. Anastomotic branch between Vidian N & trachlear N.

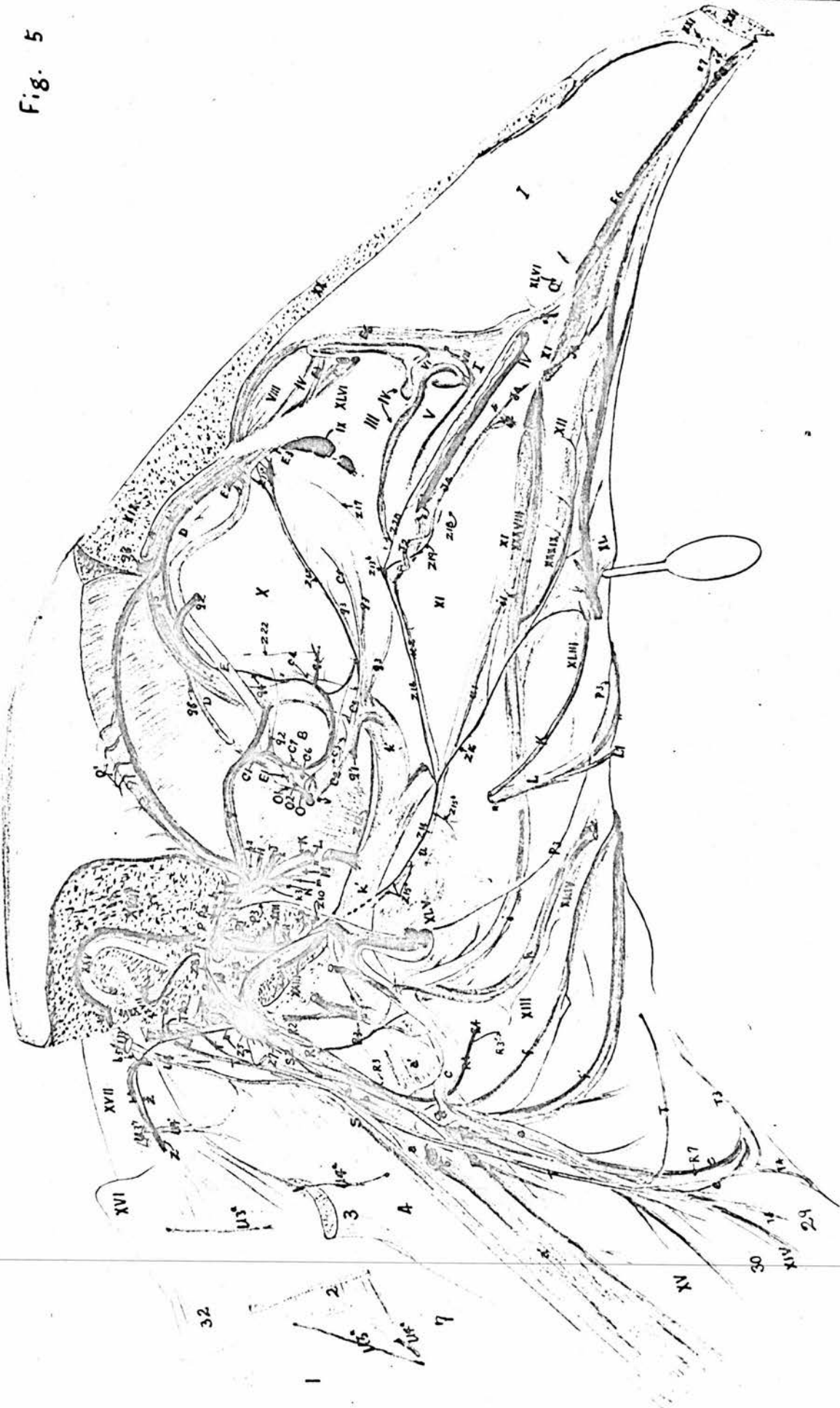The Muscles:

- | | |
|---|--|
| 1. M. complexus. | 2. M. trachelo-mastoideus. |
| 3. M. rectus capitis ventralis lateralis. | 4. M. rectus capitis ventralis medialis. |
| 7. M. longus colli. | 29. M. sterno-thyroideus. |
| 30. M. ypsilo-trachealis. | 32. M. spinalis cervicis rectus. |

- I. Nasal septum. II. Opening between the nasal & oral cavities.
- III. Lat wall of nasal cavity. IV. Cut edge of wall of nasal cavity.
- V. Posterior turbinate.

- | | |
|--|---|
| VI. Cut edge of turbinate. | VII. Cut edge of mucous membrane on the nasal septum. |
| VIII. Ethmoidal turbinate. | IX. Opening between maxillary sinus and nasal cavity. |
| X. Interorbital septum. | XII. Hard palate. |
| XI. Palatine bone. | XIII. Trachea. |
| XIII. Pharynx. | XIV. Epistropheus. |
| XV. Oesophagus. | XV. Temporal bone. |
| XVII. Spinal Cord. | XVI. Nasal bone. |
| XIX. Frontal bone. | XVII. Recess of tympanic bone. |
| XXI. Incisive bone. | XVIII. Fenestra vestibuli. |
| XXIII. Eustachian tube. | XXIX. Lat semicircular canal. |
| XXV. Sup semicircular canal. | XXXI. Maxillary gland. |
| XXVII. Post semicircular canal. | XXXII. Lat group of palatine glands. |
| XXXVIII. Medial group of palatine glands. | XXXIII. Dorso-lateral group of post submandibular glands. |
| XL. The gland at the angle of the mouth. | XXXIV. Spheno-pterygoid glands. |
| XLIV. Intermediate group of post submandibular glands. | XXXV. Nasal gland. |

Fig. 5



32

30

XV

31

32

Figure 6.Deep Dissection of the Temporal Bone showing the Internal Maxillary and the Internal Carotid Plexuses.

- A. Viewed from the posterior and lateral side with the head lying on its right side.
- B. Viewed from the lateral side.
- | | |
|---|---|
| a. Common carotid A. | b. Occipital V. |
| b ¹ . Cavernous sinus. | g ¹ . Branches of the superf temporal V. |
| k. Int maxillary A. | k ¹ . Int maxillary plexus. |
| k ¹ . Branch to transverse sinus. | l ¹ . Deep temporal V. |
| s. Int carotid A. | t. Buccinator A. |
| t ¹ . Anastomotic branch between buccinator V & cavernous sinus. | u. Pharyngeal A. |
| P. Facial N. | w. V to sup petrosal sinus. |
| P2. Lesser superf petrosal. | P1. Genuiculate ganglion. |
| P5. Greater superf petrosal N. | P3. Chorda tympani. |
| R1. Petrous ganglion. | P6. Branch to M tensor tympani. |
| R3. Pharyngeal Branch. | R. Glosso-pharyngeal N. |
| T. Hypoglossal N. | R2. Tympanic N. |
| Z. Sympathetic trunk. | S. Vagus. |
| Z1. Ant cervical ganglion. | T1. Anastomotic branch to 1st cervical N. |
| Z2g. Communicating branch from glosso-pharyngeal. | Z2b. Communicating branch from hind brain. |
| Z7. Retro-carotid trunk. | Z2h. Communicating branch from hypoglossal N. |
| Z9. Infra-temporal plexus. | Z8. Int maxillary N. |
| Z11. Vidian N. | Z10. Int carotid N. |
| Z14. Inf branch of Vidian N. | Z12. Sup branch of Vidian N. |
| | Z21. Branches to cavernous plexus. |

XVIII. Temporal bone.

XXIII. Eustachian tube.

XXIVb. Fenestra cochleae.

XXVI. Lat semicircular
canal.

XXII. Recess of tympanic cavity.

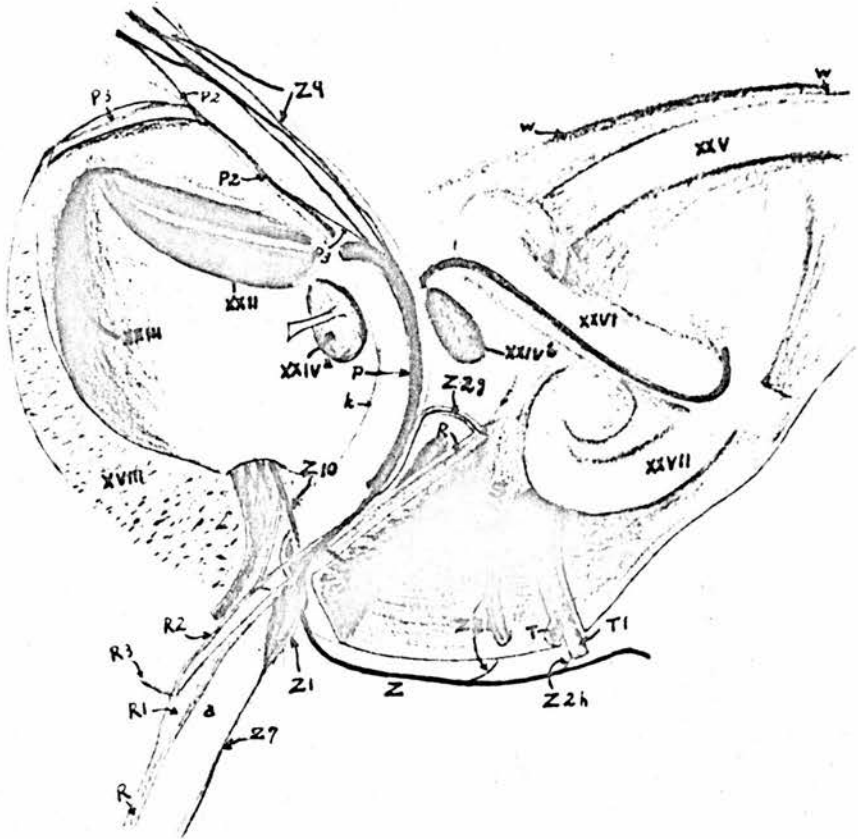
XXIVa. Fenestra vestibuli.

XXV. Sup semicircular canal.

XXVII. Post semicircular.

Fig. 6

A



B

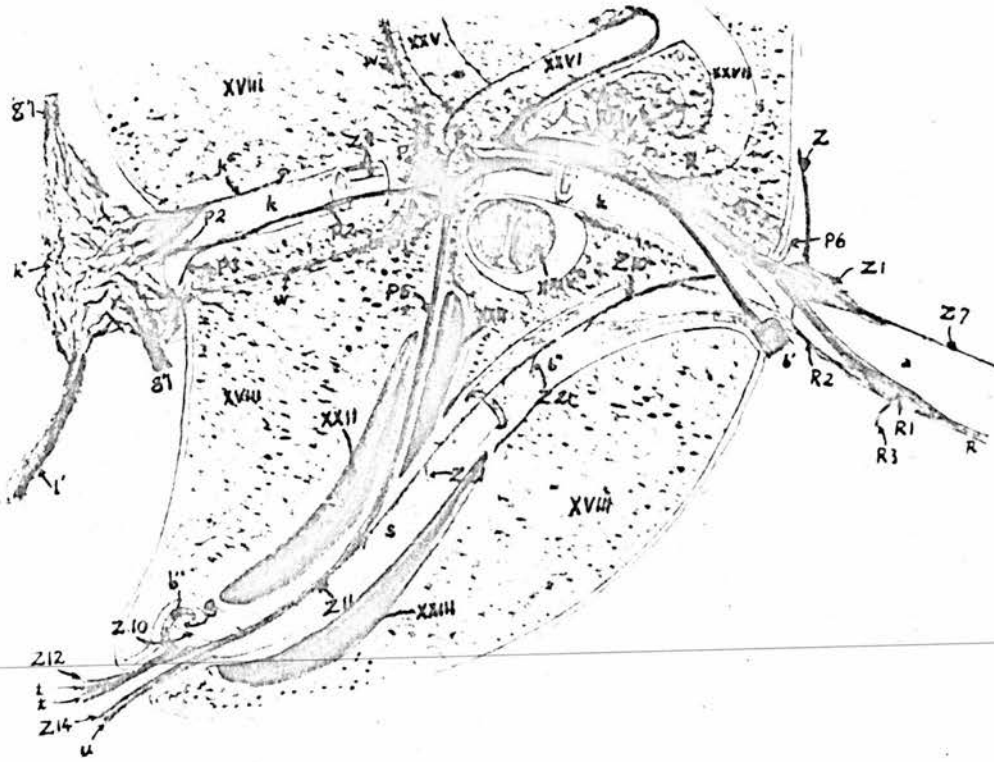


Figure 7.The Internal Maxillary Plexus and the Infra-temporal Plexus.

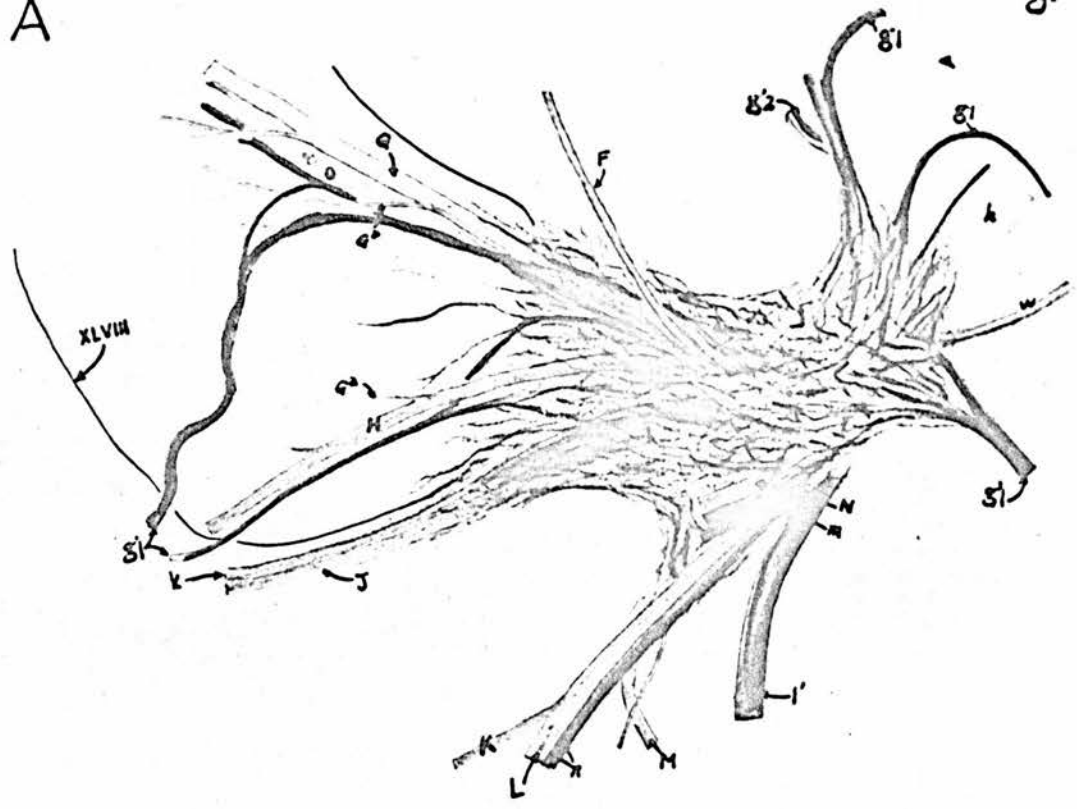
- A. Shows the Internal Maxillary Plexus.
 B. Shows the Infra-temporal Plexus with the Internal Plexus removed.

- | | |
|---|--|
| g'1. Branches of Superf temporal V. | g'2. Dorsal cerebral V. |
| k'1. Branch to M sphenopterygo-quadratus. | k. Int maxillary A. |
| k'3. Anastomotic branch to buccinator A. | k2. Branches to int maxillary plexus. |
| la. Middle meningeal A. | l. Deep temporal A. |
| m. Masseteric A & V. | l'. Deep temporal V. |
| o. Ext ophthalmic A & V. | n. Inf alveolar A & V. |
| q. Nasal ciliary A. | o1. Lacrimal branch. |
| F. Deep temporal N. | w. V to sup petrosal sinus. |
| Ga. Lacrimal branches. | G. Superf temporal N. |
| Ia. Branch to M. depressor palpebrarum ventralis. | H. Infraorbital N. |
| J. Maxillary N. | Ib. Branch to M sphenopterygo-quadratus. |
| L. Inf alveolar N. | K. Ram anguli oris. |
| N. Masseteric N. | M. Pterygoid N. |
| Z9. Int maxillary plexus. | P2. Lesser superf petrosal N. |

XLVIII. Lacrimal gland.

Fig. 7

A



B

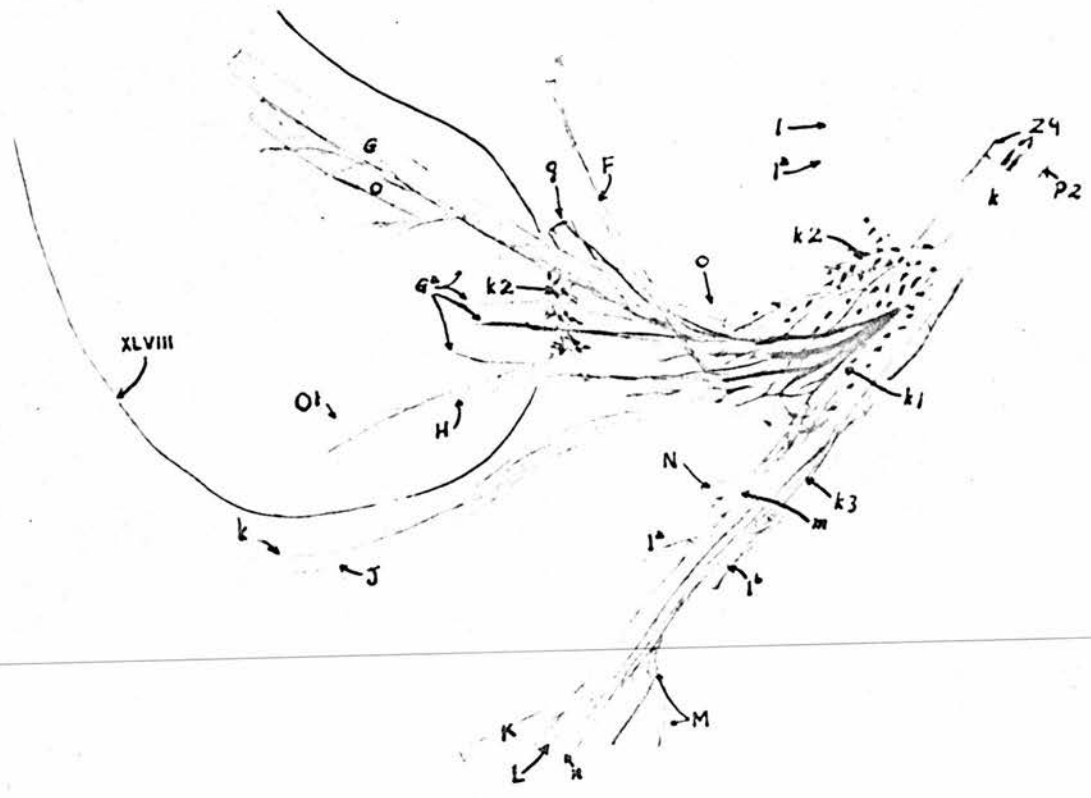


Figure 8.The Blood and Nerve Supplies of the Submandibular Glandsand the Gland at the Angle of the Mouth.

- | | |
|--|--|
| f. Lingual A. | f1. Branches of lingual A & V. |
| h. Sublingual A & V. | i. Palatine A & V. |
| t. Buccinator A & V. | |
| K. Ram anguli oris. | L. Inf alveolar N. |
| L1. Mylo-hyoid N. | P3. Chorda tympani. |
| P4. Submandibular ganglia. | R3. Pharyngeal branch of glosso-
-pharyngeal N. |
| R4. Lingual branch of glosso-
-pharyngeal N. | Z16. Anastomotic branch between
post palatine & buccinator
Na. |
| XL. The gland at the angle
of the mouth. | XLI. Ant submandibular glands |
| XLIII. Dorso-lateral group of
post submandibular
glands. | XLII. Ventro-medial group of
Post submandibular glands. |
| | XLIV. Intermediate group of post
submandibular glands. |

Fig. 8

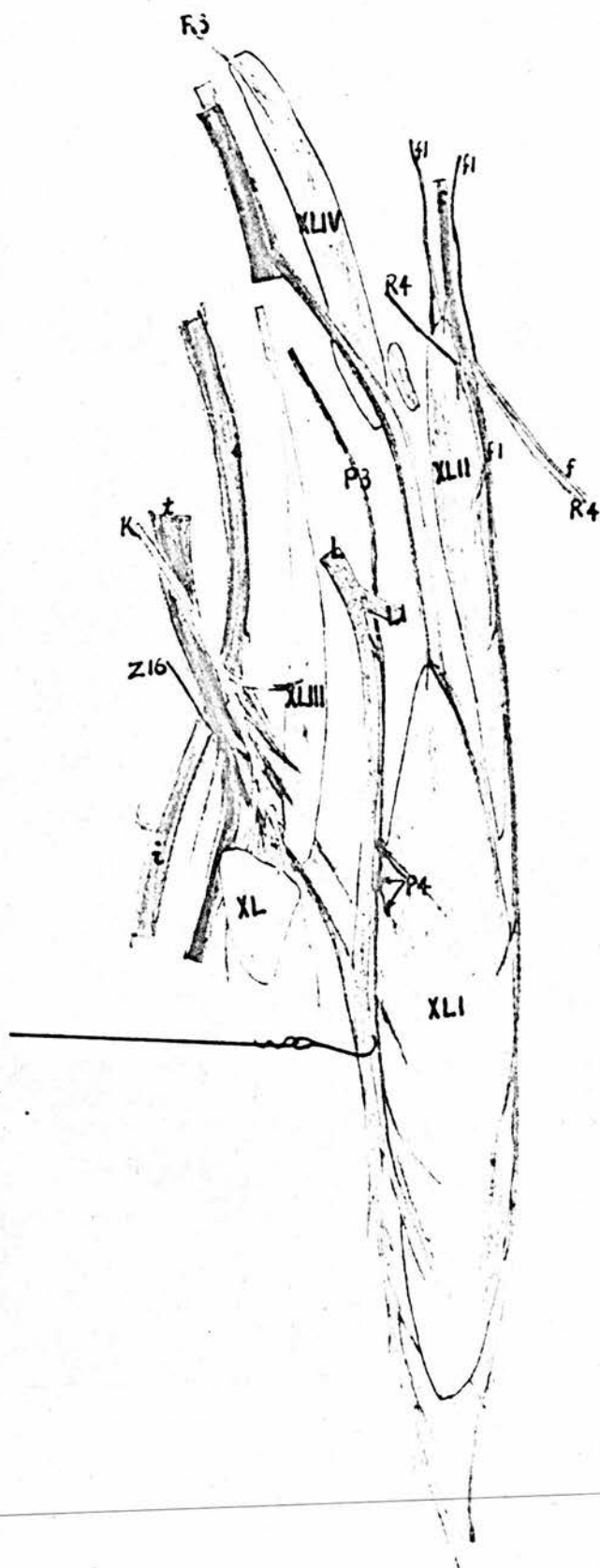


Figure 9.Dissection of the Tongue.

Viewed from the Ventral and Lateral Side.

- | | |
|---|---|
| f. Lingual A. | f'. Lingual V. |
| f1. Branches of lingual A & V. | |
| R4. Lingual branch of glosso-pharyngeal N. | T. Hypoglossal N. |
| T7. Branch to M obliquus copula entglossum. | T6. Branch to M hyoideus transversus. |
| | T8. Branch to Mm stylo-entglossum & rectus copula-entglossum. |
| 9. M. articulo-hyoideus. | 15. M. hyoideus transversus. |
| 33. M. thyro-hyoideus. | 34. M. Stylo-entglossum. |
| 35. M. obliquus copula entglossum. | 35'. Rectus copula entglossum. |
| XLII. Ventro-medial group of post submandibular glands. | LVI. Entoglossal bone. |
| LVIII. Uro-hyoid bone. | LVII. Basi-hyal bone. |
| LX. Lat process of entoglossal bone. | LIX. Basi-brachial bone. |
| LXIII. Ant group of lingual glands. | LXI. Cut edge of mucous membrane. |
| | LXII. Papillae of tongue. |
| | LXIV. Lat process of post group of lingual glands. |

Figure 10.Dissection of the Larynx and the Tongue.

Dorsal View.

- | | |
|---|--|
| e. Laryngeal A. | e1. Branches of laryngeal A. |
| f. Lingual A. | f'. Lingual V. |
| h. Sublingual A & V. | |
| R4. Lingual ^{branch} of glosso-pharyngeal N. | R7. Ant. Laryngeal Branch of glosso-pharyngeal N. |
| 5. Hyo-mandibularis. M. | 9. M. articulo-hyoideus. |
| 15. M. hyoideus transversus. | 33. M. thyro-hyoideus. |
| 34. M. stylo-entglossum. | 36. M. sup crico-arytenoideus. |
| XV. Oesophagus. | XLI. Ant submandibular glands |
| XLII. Ventro-medial group of post submandibular glands. | XLIV. Intermediate group of post submandibular glands. |
| LXIII. Ant group of lingual glands. | LX. Lat process of the entoglossal bone. |
| LXV. Post group of lingual glands. | LXIV. Lat process of post group of lingual glands |
| LXVI. Aditus laryngis. | LXVII. Crico-arytenoid glands. |
| LXIX. Arytenoid cartilage. | LXVIII. Cut edge of mucous membrane. |
| LXX. Cricoid cartilage. | |

Fig. 10

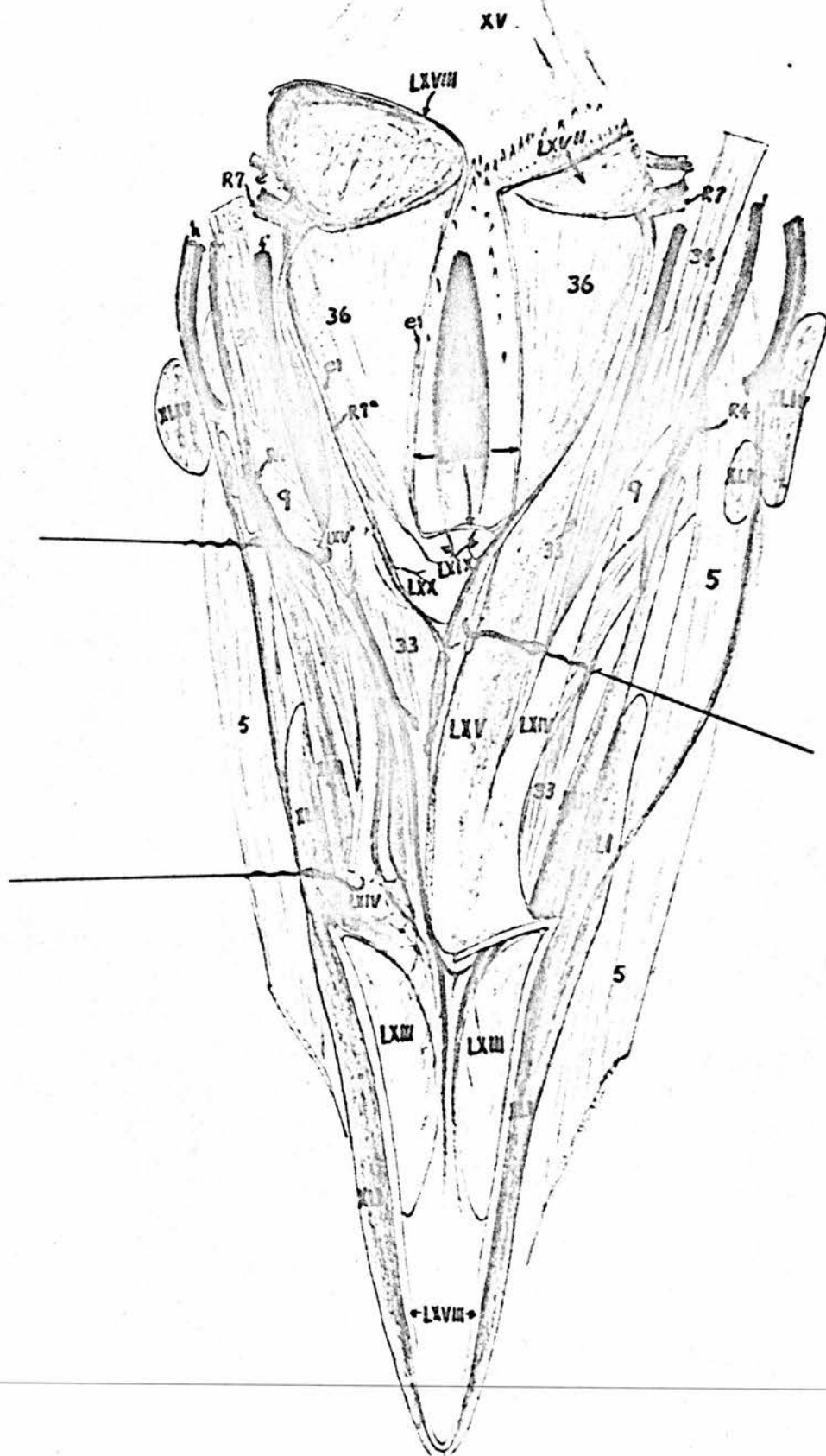


Figure 11.A. The Innervation of the Lingual Glands. - Dorsal View.

- | | |
|---|--|
| f. Lingual A. | f'. Lingual V. |
| R4. Lingual branch of the
glosso-pharyngeal N. | R7a. Pharyngeal branch of ant
laryngeal N. |
| LXIII. Ant group of lingual
glands. | LXIV. Lat process of posterior
group of lingual glands. |
| LXV. Posterior group of
lingual glands. | LXX. Cricoid cartilage. |

B. Pharyngeal Plexus - Lateral View.

- | | |
|--|--|
| a'. Jugular V. | a'1. Ventral cerebral V. |
| b. Occipital A. | b'. Occipital V. |
| c. Ext maxillary A. | d. Posterior auricular A. |
| d'. Posterior auricular V. | e. Laryngeal A. |
| e'. Laryngeal V. | f. Lingual A. |
| f'. Lingual V. | g. Superficial temporal A. |
| g'. Superf temporal V. | h. Sublingual A & V. |
| i. Palatine A & V. | j. Facial A & V. |
| k'. Int maxillary V. | l'. Deep temporal V. |
| t. Buccinator A & V. | t''. Anastomotic branch between
int maxillary V & cavernous
sinus. |
| u. Pharyngeal A. | |
| Z12. Sup branch of Vidian N. | Z14. Inf branch of Vidian N. |
| Z15a. Branches to Eustach-
ian tube. | Z15b. Branch to spheno-pterygoid
glands. |
| Z16. Posterior palatine N. | |
| XLIV. Intermediate group of
post submandibular
glands. | XLV. Spheno-pterygoid glands. |
| R. Glosso-pharyngeal N. | R1. Petrous ganglion. |
| R2. Tympanic N. | R3. Pharyngeal branches. |
| R4. Lingual branch. | R6. Desc. oesophageal branch. |
| R7. Ant. laryngeal branch. | S. Vagus N. |

Fig. 11

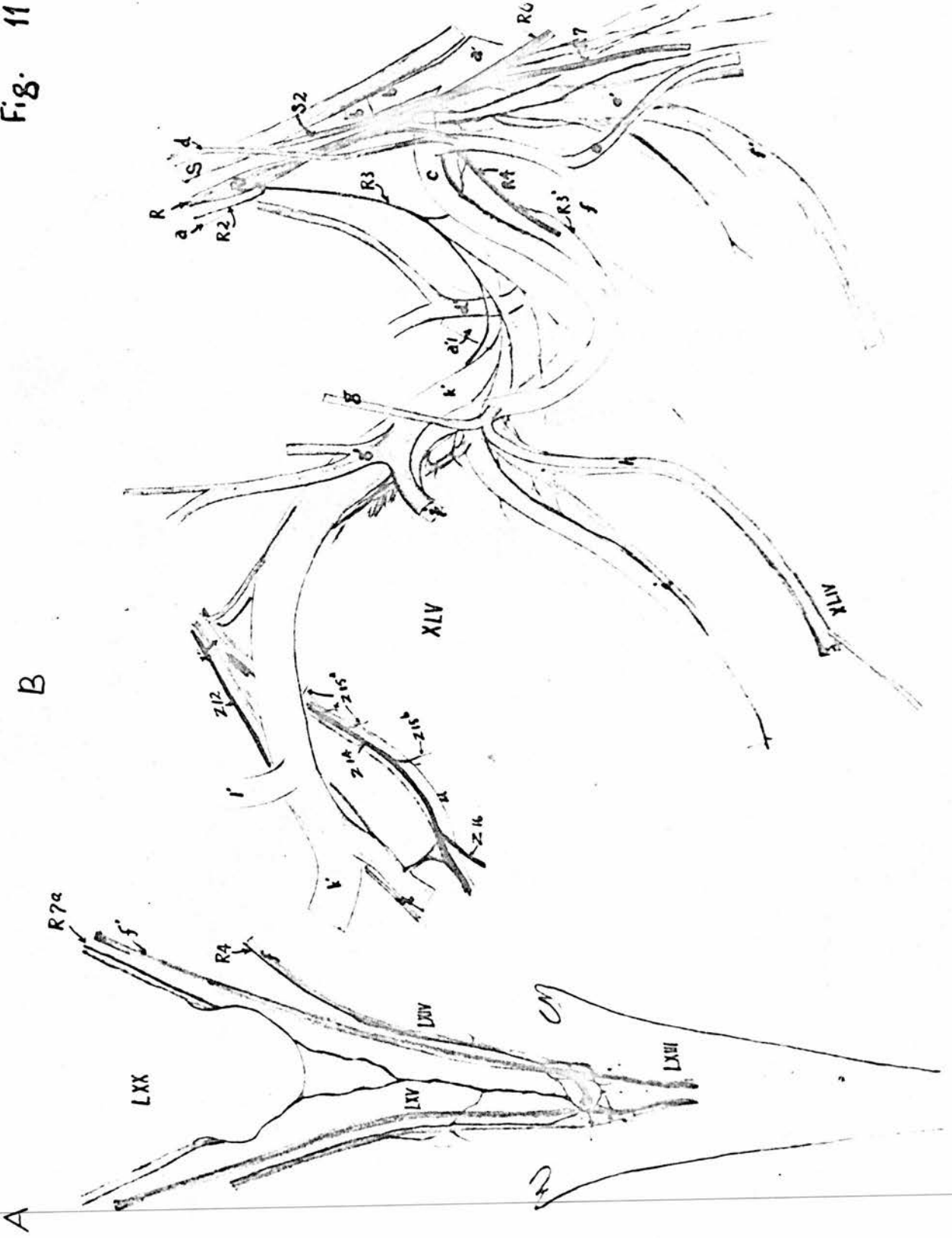


Figure 12.A. The Innervation of the Maxillary Glands - Dorsal View.

- | | |
|-------------------------------|-------------------------------|
| i. Palatine A. | i3. Branch to nasal septum. |
| ii. Naso-labial A. | ii4. Lateral naso-palatine N. |
| Z20. Medial naso-palatine N. | |
| XXXVI. Right maxillary gland. | XXXVII. Left maxillary gland. |

B. The Communicating Branches between the Last Cervical, First Thoracic Sympathetic Ganglia and their Corresponding Spinal Nerves. The ventral rami of the spinal nerves are reflected upward to show the sympathetic ganglia and the communicating branches on the medial surface.

- | | |
|--|---|
| c3. Vertebral A. | c4. Supreme intercostal A. |
| c4a. Spinal A. | |
| U1. Dorsal root of spinal N. | U1'. Spinal ganglion. |
| U2. Ventral root of spinal N. | U4. Ventral ramus. |
| U4c. Branch to M. longus colli. | Z. Interganglionic cord in transverse foramen. |
| Z'. Interganglionic cord below transverse process, or centro-costal joint. | Z1. Last cervical & 1st thoracic sympathetic ganglia. |
| Z4. Cardiac N. | |

C. The Nerve Supply of the Ciliary Muscle. - Anterior view.D. The Innervation of the Iris - Anterior View.

E. Diagram showing the position of the Annular Plexus in the Ciliary Muscle and the Nerves running in the Iris.

v. Int ophthalmic A.

- | | |
|--|--|
| C7. Branches of Ciliary Nn. | C7a. Annular plexus in ciliary muscle. |
| C7b. Branches from annular plexus in ciliary muscle to iris. | |

LXXI. Cornea.

LXXIa. Cut edge of cornea.

LXXIb. Scleral ring.

LXXII. Ciliary muscle.

LXXIIa. Cut edge of ciliary M. LXXIII. Choracoid.

LXXIV. Iris.

LXXV. Retina.

LXXVI. Lens.

Fig. 12

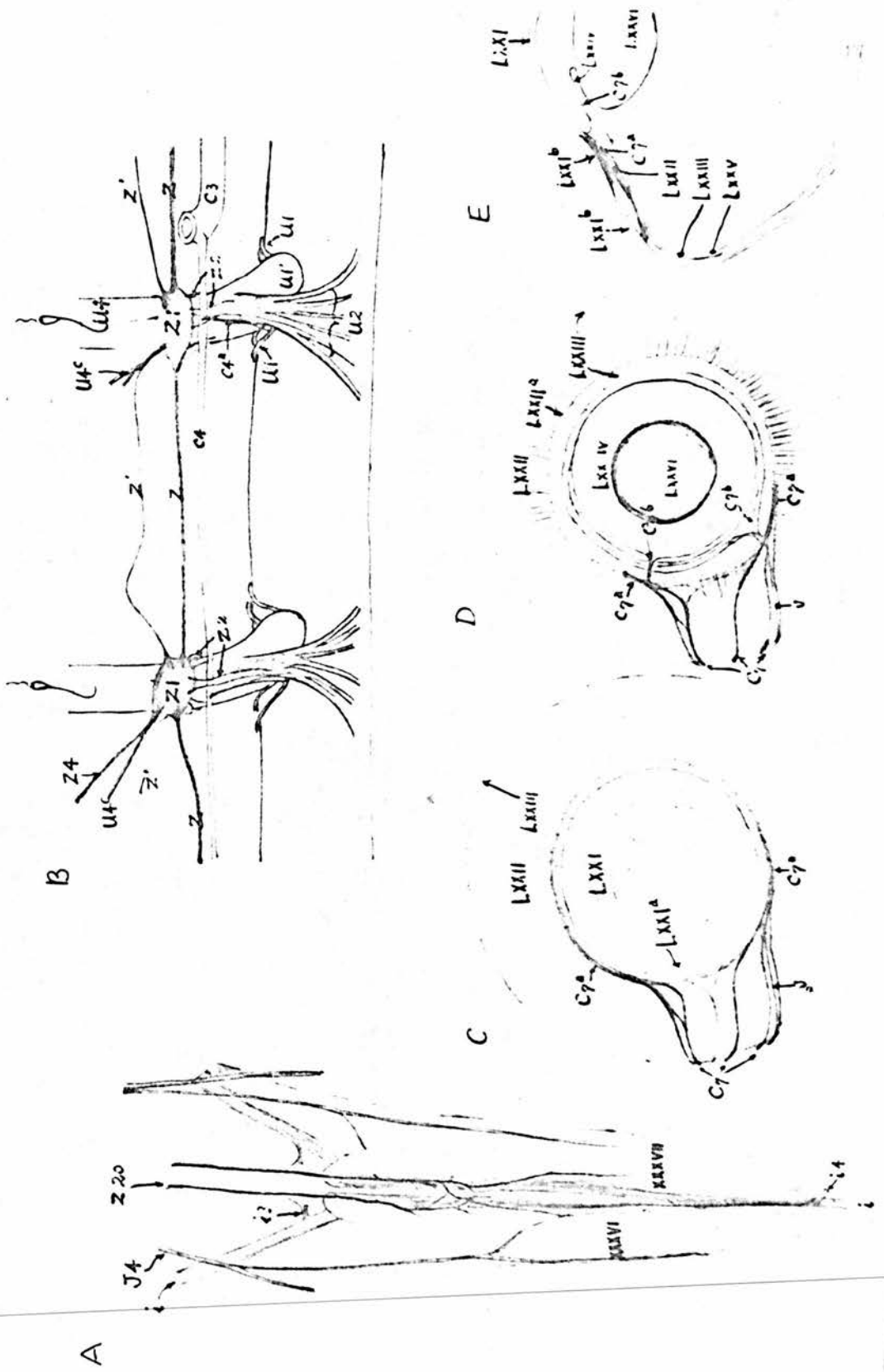


Figure 13.The Nerve Supply of the Eye-ball.

A. Medio-posterior View.

B. Medio-posterior and Ventral View.

B. Optic N.

C. Oculomotor N.

C1. Dorsal branch of oculomotor N.

C2. Ventral branch of oculomotor N.

C6. Ciliary ganglion.

C7. N. ciliary major.

C7'. Nn. ciliary brevis.

E. Ophthalmic N.

E1. Sensory root of ciliary ganglion.

O1. Branch of abducent N. to rectus lateralis.

O2. Branch of abducent N. to quadratus.

O3. Branch of abducent N. to pyramidalis.

Z12. Sup branch of Vidian N.

Z23. Sympathetic root of ciliary ganglion.

21. Tendon of pyramidalis.

22. M. quadratus.

23. M. rectus dorsalis.

24. M. rectus lateralis.

25. M. rectus ventralis.

Fig. 13

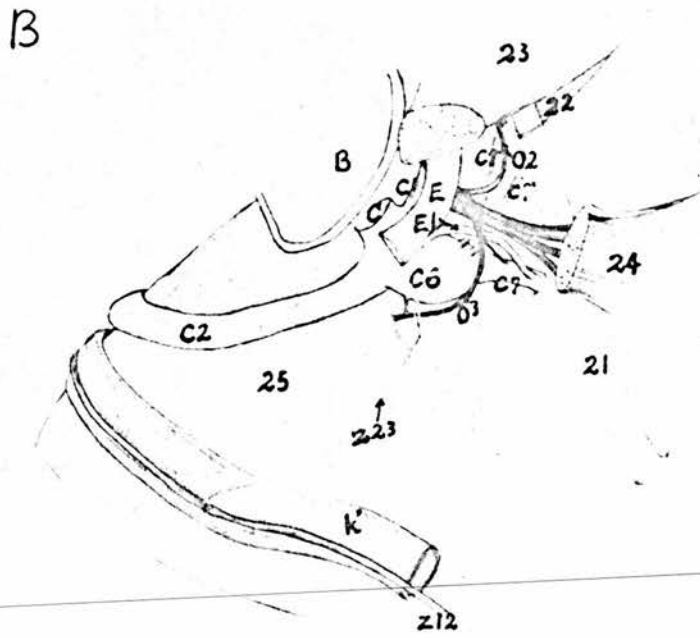
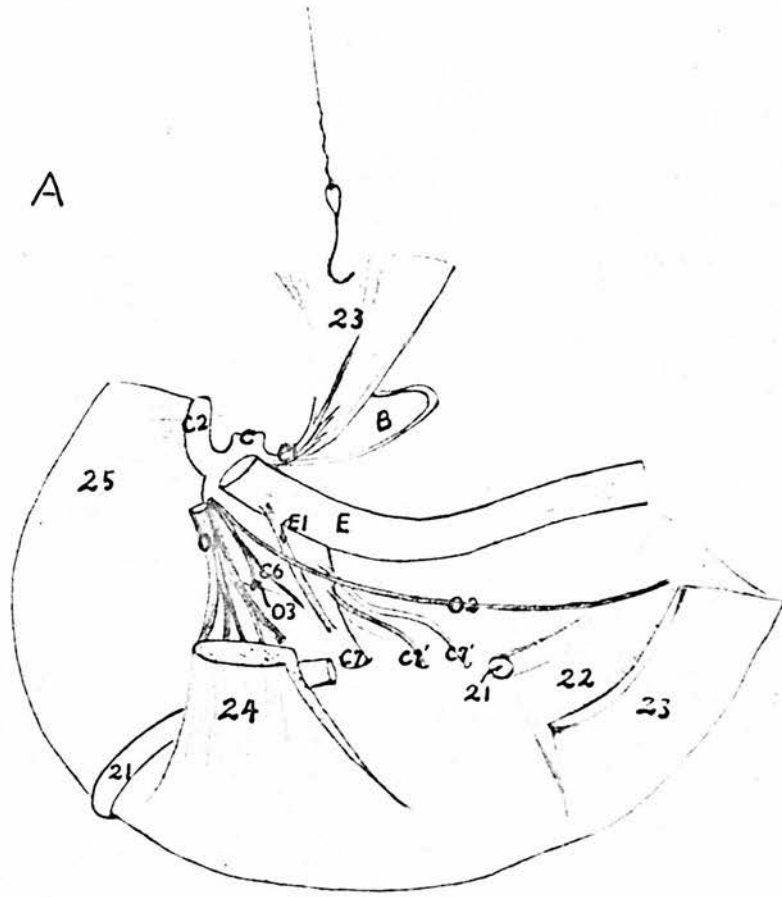


Figure 14.

A. Dissection of the neck on the left side of the joint between the 7th and 8th Cervical Vertebrae. (C6 = 6th cervical vertebra, C7 = 7th cervical vertebra, T1,2 = 1st & 2nd thoracic vertebrae, and so on).

B. Sagittal Section of the 8th Cervical Sympathetic Ganglion showing its relation to the Ventral Ramus of the Spinal Nerve.

b. Vertebral A & V.

U1. Spinal ganglion of 8th cervical N.

U3a. Dorsal cutaneous branch.

U3b. Branch of the dorsal ramus to Mm. spinalis capitis, semispinalis^ocervicis, multifidus cervicis superficialis, multifidus cervicis profundus, spinalis cervicis rectus & spinalis cervicis obliquus.

U3c. Branch of dorsal ramus to M. intertransversalis superficialis.

U3d. Branch of dorsal ramus to accessory part of M. transversalis superficialis.

U4a. Ventral cutaneous branch.

U4b. Branch of ventral ramus to Mm. intertransversalis profundus & longus colli.

Z. Sympathetic trunk.

Z1. Sympathetic ganglion.

1. Mm. semispinalis capitis & semispinalis cervicis.

2. M. multifidus cervicis superficialis (C9 - C6).

3'. M. multifidus cervicis superficialis (C8 - C5).

4. M. multifidus cervicis profundus (C9 - C7).

4'. M. multifidus cervicis profundus (C8 - C6).

7. M. longus colli.

7a. Tendon of M. longus colli.

8. Intertransversalis superficialis (C8 - C7).

8a. Accessory part of M. intertransversalis superficialis (C8 - C7).

8'. M. intertransversalis superficialis (C9 - C8).

9. M. intertransversalis profundus (C8 - C7).

9'. M. intertransversalis profundus (C9 - C8).

I. Articular process. (C7). II. Ant articular process (C8).

III. Transverse process (C8). IV. Transverse process (C7).

V. Canalis intertransversarius of cervical air-sac. VI. Diverticulum medullarium.

C. Cross Section of the Neck through the Joint between

the 8th and 9th Cervical Vertebrae. A part of the left side

is dissected out to show the relation of the sympathetic ganglion to the ventral ramus of the spinal nerve and the vertebral artery.

- | | |
|---|------------------------------------|
| a. Common carotid A. | a'1. Tributary of the jugular V. |
| b. Vertebral A. | b'. Vertebral V. |
| b1. Spinal branch of vertebral A. | b'1. Spinal branch of vertebral V. |
| c. Ventral spinal A. | c'. Supra-medullary sinus. |
| c'1. Longitudinal vertebral sinus. | |
| U1. Dorsal root of 9th cervical spinal N. | U1'. Spinal ganglion. |
| U4. Ventral ramus. | U3. Branches of the dorsal ramus |
| Z. Sympathetic trunk. | Z1. Sympathetic ganglion. |

1. M. Semispinalis capitis (C13,14; T1,2 to occipital bone).

2. M. Semispinalis cervicis (C13,14; T1,2 to C2).

2'. M. Semispinalis cervicis (C13,14; T1,2 to C6).

2'''. M. Semispinalis cervicis (C13,14; T1,2 to C7).

2'''''. M. Semispinalis cervicis (C13,14; T1,2 to C8).

3. M. multifidus cervicis superficialis (C11 to C8).

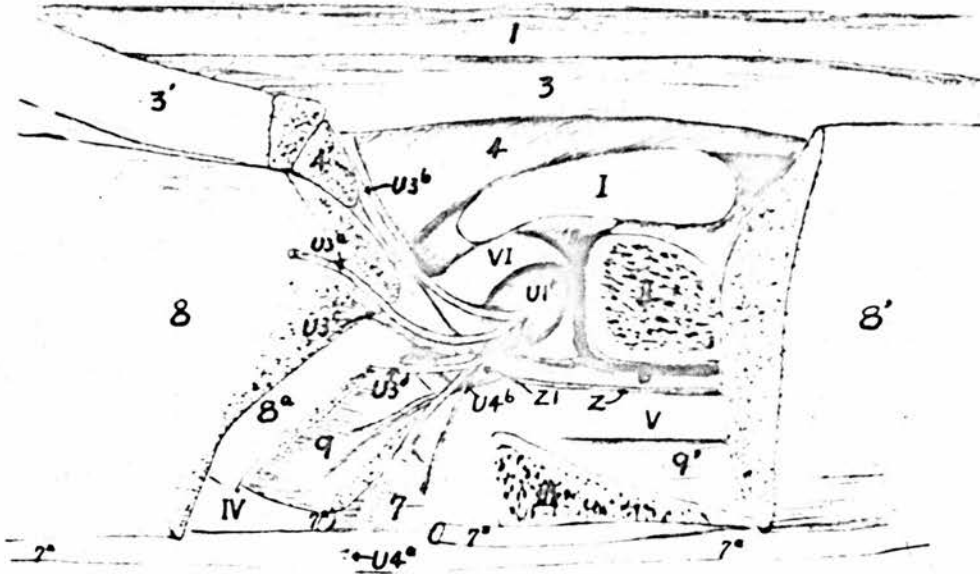
3'. M. multifidus cervicis superficialis (C10 to C7).

3'''. M. multifidus cervicis superficialis (C9 to C6).

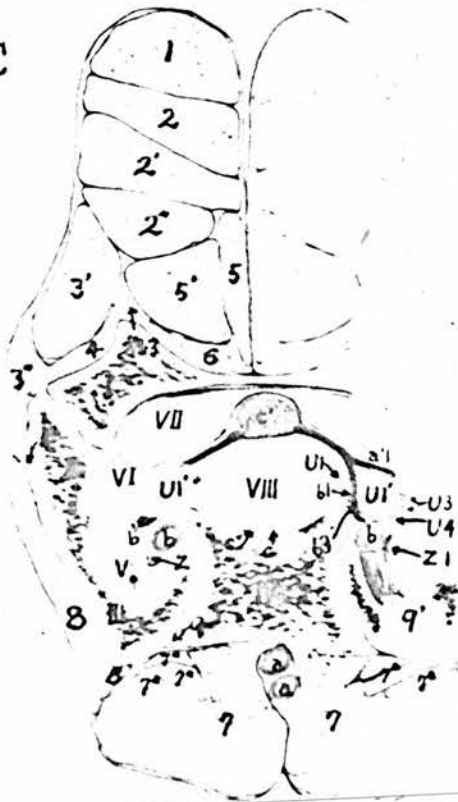
4. M. multifidus cervicis profundus (C9 to C8).
 - 4'. M. multifidus cervicis profundus (C9 to C7).
 5. M. spinalis cervicis obliquus (C9 to C7).
 - 5'. M. spinalis cervicis obliquus (C10 to C8).
 6. M. spinalis cervicis rectus (C9 to C8).
 7. M. longus colli.
 - 7a. M. tendon of longus colli.
 8. M. intertransversalis superficialis (C9 to C8).
 9. M. intertransversalis profundus (C9 to C8).
 - 9'. M. intertransversalis profundus (C10 to C9).
-
- I. Posterior articular process (C8).
 - II. Anterior articular process (C9).
 - III. Transverse process (C9).
 - IV. Vertebral body (C8).
 - V. Canalis intertransversarius.
 - VI. Diverticulum medullarium.
 - VII. Canalis supra-medullaris.
 - VIII. Spinal cord.

Fig. 14

A



C



B

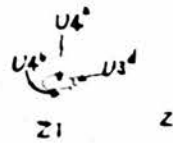


Figure 15.Dissection of the Lower Part of the Neck on the LeftSide.

- | | |
|---|---------------------------------------|
| b2. Right common carotid A. | c. Left brachio-cephalic A. |
| c'. Left ant vena cava. | c1. Left subclavian A. |
| c'1. Left subclavian V. | c2. Left common carotid A. |
| c'2. Left jugular V. | c3. Left vertebral A. |
| c4. Left supreme intercostal A. | c5. Left inf cervical A. |
| c6. Left thyroid Aa. | |
| S. Left vagus | S4. Left recurrent N. |
| U4. Ventral rami of last 3 cervical & 1st thoracic Nn. | U4a. Branch to M. trapezius and skin. |
| U4b. Branches to intertransversalis profundus, scalenus and muscles in the first intercostal space. | |
| U4c. Spinal nerve branches passing through the sympathetic ganglia to the M. longus colli. | |
| U4d. Communicating branch to the 2nd thoracic sympathetic ganglion. | |
| U4e. Spinal nerve branches crossing the cardiac nerve to the intercostal and subcostal muscles. | |
| U4f. Brachial plexus. | Z. Sympathetic trunk. |
| Z1. Sympathetic ganglia. | Z2. Communicating branch. |
| Z3. Retro-vertebral N. | Z4. Sympathetic cardiac N. |
| Z5. Branches to cervical air-sac. | Z6. Branch to ant vena cava. |
| 1. Left longus colli. | 1'. Right longus colli. |
| 2. M. intertransversalis profundus. | |
| 3. M. intertransversalis superficialis. | |
| 4. M. scalenus. | 5. M. levator costorum. |
| 6. M. ext intercostal. | 7. M. int intercostal. |
| I. Left lung./ | |

I. Left lung.

XI. Oesophagus.

XII. Left thyroid gland.

XXVIII. Transverse processes.

XXIX. 1st and 2nd ribs.

Figure 16.Superficial Dissection of the Pulmonary Plexuses. The

Lung and Subclavian Vein are slightly reflected.

- | | |
|--|---|
| a. Aorta. | b. Right brachio-cephalic A. |
| c. Left brachio-cephalic A. | b'. Right ant vena cava. |
| b'1. Subclavian V. | b'2. Jugular V. |
| b'3. Vertebral V. | b'4. Costo-cervical V. |
| d. Pulmonary A. | |
| S. Vagus. | S5a. Ant pulmonary branch. |
| S5b. Middle pulmonary branches. | S5c. Post pulmonary branch. |
| S6a. Ant cardiac branch of right vagus. | U4. Ventral rami of last 3 cervical & 1st thoracic Nn. |
| U4c. Branch to longus colli. | U4d. Communicating branch from 2nd thoracic Sympathetic ganglion. |
| U4e. Branch to muscles in the 1st intercostal space. | |
| Z. Sympathetic trunk. | Z1. Sympathetic ganglia. |
| Z4. Sympathetic cardiac N. | Z5. Branches to cervical air-sac. |
| Z6. Branch to ant vena cava. | Z6a. Branch from the 3rd last cervical gang spinal N. |
| Z9. Pulmonary branches of cardiac N. | |
| I. Right lung. | IV. Trachea. |
| XI. Oesophagus. | XIa. Crop. |
| XIII. Thyroid gland. | XIV. Right lobe of liver. |
| XV. Left lobe of liver. | XVI. Right atrium. |
| XXVI. Right ventricle. | XXVII. Left ventricle. |

Fig. 16

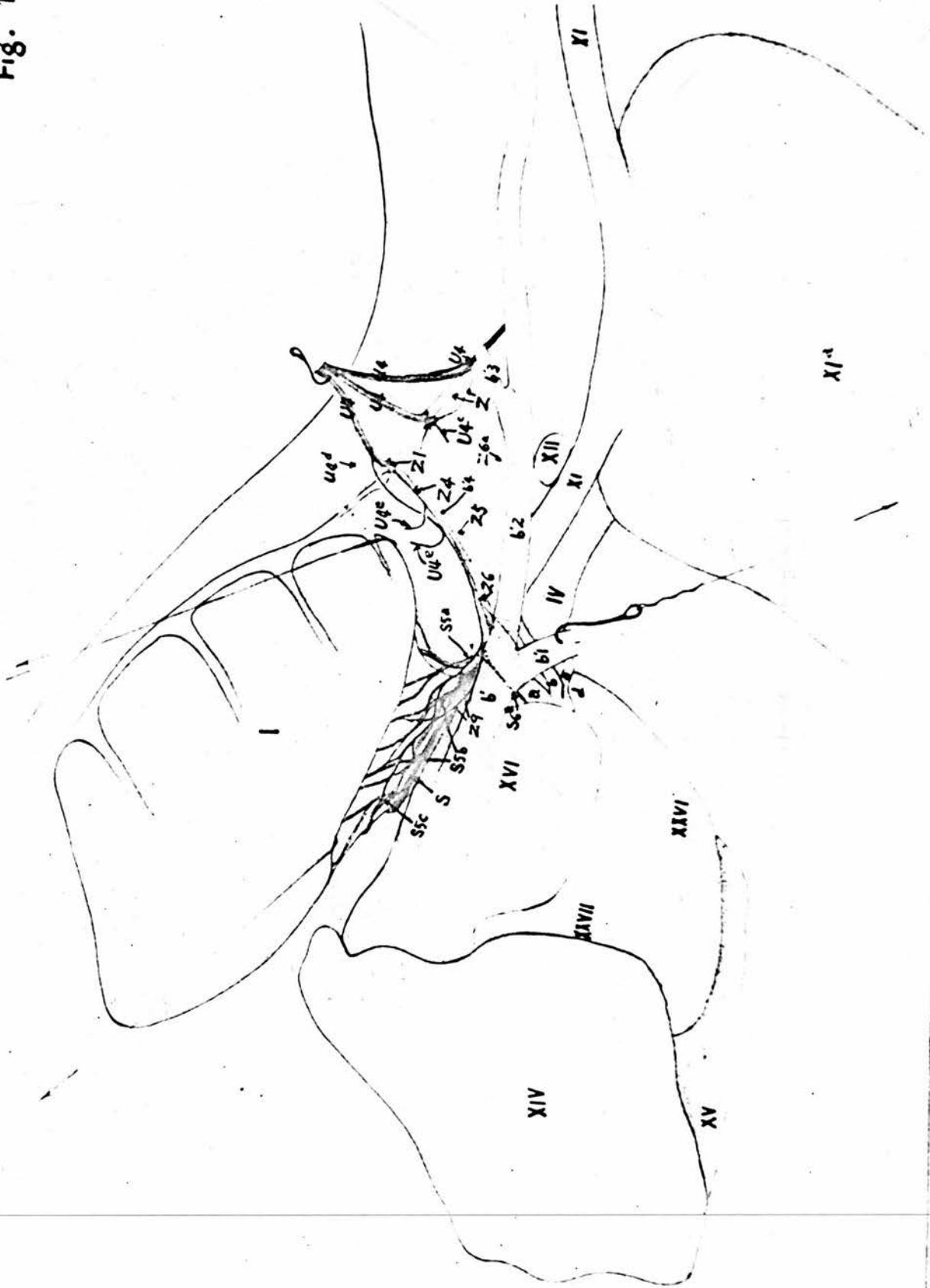


Figure 17.Deep Dissection of the Right Pulmonary Plexus. Viewed

from the lateral side.

- | | |
|---|-----------------------------------|
| a. Aorta. | d1. Pulmonary A. |
| d'1. Pulmonary V. | |
| S. Vagus. | S4. Recurrent N. |
| S5a. Ant pulmonary branch. | S5b. Middle pulmonary branches. |
| S5c. Post pulmonary branch. | S5d. Ganglia in pulmonary plexus. |
| S6a. Ant cardiac branch. | S6c. Post cardiac branch. |
| S7. Anastomotic branch between the vagus and recurrent Nn. | |
| S8a. Oesophageal branch. | Z4. Sympathetic cardiac N. |
| Z6. Sympathetic branch to anterior vena cava. | |
| Z7. Sympathetic branch to anterior cardiac branch of vagus. | |
| Z9. Sympathetic branches to pulmonary plexus. | |
- I. Dorsal border of lung.
- II. Costal impressions.
- III. Lateral border.
- IV. Trachea.
- V. Mesobronchus.
- VI. Dorsal bronchi.
- VII. Lateral bronchus.
- VIII. Ventral bronchus to cervical air-sac.
- X. Para-bronchi.

Figure 18.The Cardiac Plexus on the Right Side of the Heart. The

dotted lines indicate the right anterior vena cava and its branches.

- | | |
|---|--|
| a. Bulbus aortae. | a1. Descending aorta. |
| b. Right brachio-cephalic A. | b1. Subclavian A. |
| b2. Common carotid A. | b3. Vertebral A. |
| b5. Inf cervical A. | c. Left brachio-cephalic A. |
| d. Common pulmonary A. | d1. Right pulmonary A. |
| d'. Common pulmonary V. | d'1. Right pulmonary V. |
| d'2. Left pulmonary V. | e. Right coronary A. |
| S. Right vagus. | S'. Left vagus. |
| S4. Right recurrent N. | S4a. Descending branch. |
| S4a'. Anastomotic branch to
coeliac plexus. | S4b. Post laryngeal N. |
| S5b. Middle pulmonary branches. | S5a. Ant pulmonary branch. |
| S6a. Ant cardiac branch. | S5c. Post pulmonary branch. |
| S6b. Middle cardiac branches
of right vagus. | S'6a. Ant ^{cardiac} coronary branch of
left vagus. |
| S'6c. Post cardiac branch of
left vagus. | S6c. ^{Post} Inf cardiac branch of
right vagus. |
| S6e. Ant cardiac plexus. | S6d. Sup cardiac plexus. |
| S6h. Right coronary plexus. | S6f. Post cardiac plexus. |
| S8. Oesophageal trunk. | S7. Anastomotic branch between
vagus and recurrent Nn. |
| S8a. Oesophageal branches of
right vagus. | S'8a. Oesophageal branches of
left vagus. |
| S8b. Oesophageal plexus. | Z3. Retro-vertebral N. |
| Z4. Right cardiac N. | Z'4. Left cardiac N. |
| IV. Trachea. | V. Right mesobronchus. |
| XI. Oesophagus. | XII. Thyroid gland. |

- XIIIIa. Parathyroid gland.
- XIIIIb. Ultimo-branchial body.
- XVI. Cut surface of right atrium.
- XVII. Cut edge of endocardium.
- XVIII. Right auricle.
- XIX. Intervenous crest.
- XX. Orifice of left anterior vena cava.
- XXI. Fossa ovalis.
- XXII. Orifice of coronary sinus.
- XXIII. Right atrio-ventricular orifice.
- XXVI. Right ventricle.
- XXVII. Left ventricle.

Fig. 18

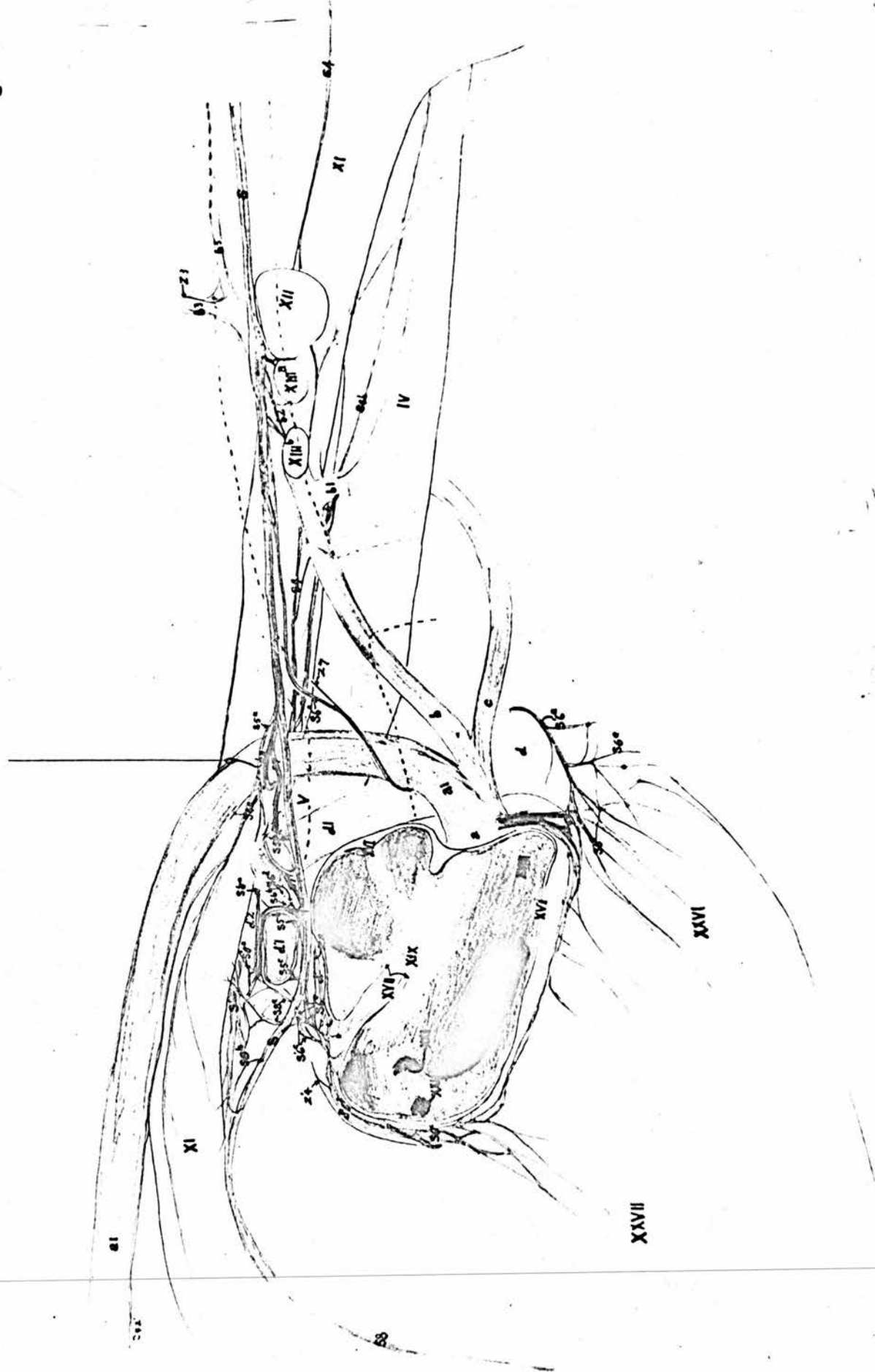


Figure 19.The Cardiac Plexus on the Left Side of the Heart.

- | | |
|--|--|
| a. Aorta. | c. Left brachio-cephalic A. |
| c'. Left ant vena cava. | c1. Left subclavian A. |
| d'1. Left subclavian V. | c2. Left common carotid A. |
| d'2. Left jugular V. | c3. Left vertebral A. |
| c5. Left inf cervical A. | c6. Left ant & post thyroid Aa. |
| d. Common pulmonary A. | d2. Left pulmonary A. |
| d'. Common pulmonary V. | d'2. Left pulmonary V. |
| f. Left coronary A. | g'. Middle cardiac V. |
| S. Right vagus. | S'. Left vagus. |
| S'4. Left recurrent N. | S'4a. Descending branch of left recurrent N. |
| S'4b. Left post laryngeal N. | S'5a. Ant pulmonary branch of left vagus. |
| S'5b. Middle pulmonary branches. | S6a. Ant cardiac branch of right vagus. |
| S'5c. Post pulmonary branch. | S'6b. Middle cardiac branches of left vagus. |
| S'6a. Ant cardiac branch of left vagus. | S6d. Superior cardiac plexus. |
| S'6c. Post cardiac branch of left vagus. | S6f. Post cardiac plexus. |
| S6e. Ant cardiac plexus. | S'7. Anastomotic branch between vagus and recurrent N. |
| S6g. Left coronary plexus. | |
| S8. Oesophageal trunk. | |
| S8a. Right oesophageal branches. | S'8a. Left oesophageal branches. |
| S8b. Oesophageal plexus. | Z'4. Left sympathetic cardiac N. |
| Z5. Sympathetic branches to cervical air-sac. | |
| Z'6. Sympathetic branch to the left anterior vena cava. | |
| Z'7. Branch to anterior cardiac branch of the left vagus. | |
| Z'8. The latero-dorsal group of the sympathetic branches on left anterior vena cava. | |
| Z'9. Branches of the cardiac nerve to the pulmonary plexus. | |

Z'10. Sympathetic branch to the oesophageal plexus.

IV. Trachea.

V. Left mesobronchus.

XI. Oesophagus.

XII. Left thyroid gland.

XIIIa. Parathyroid gland.

XIIIb. Ultimo-branchial bodies.

XVI. Cut surface of the left atrium.

XXIV. Left atrio-ventricular orifice.

XXV. Musculi pectinati.

XXVI. Right ventricle.

XXVII. Left ventricle.

30a. M. sterno-trachealis.

30b. M. ypsilo-trachealis.

Fig. 19

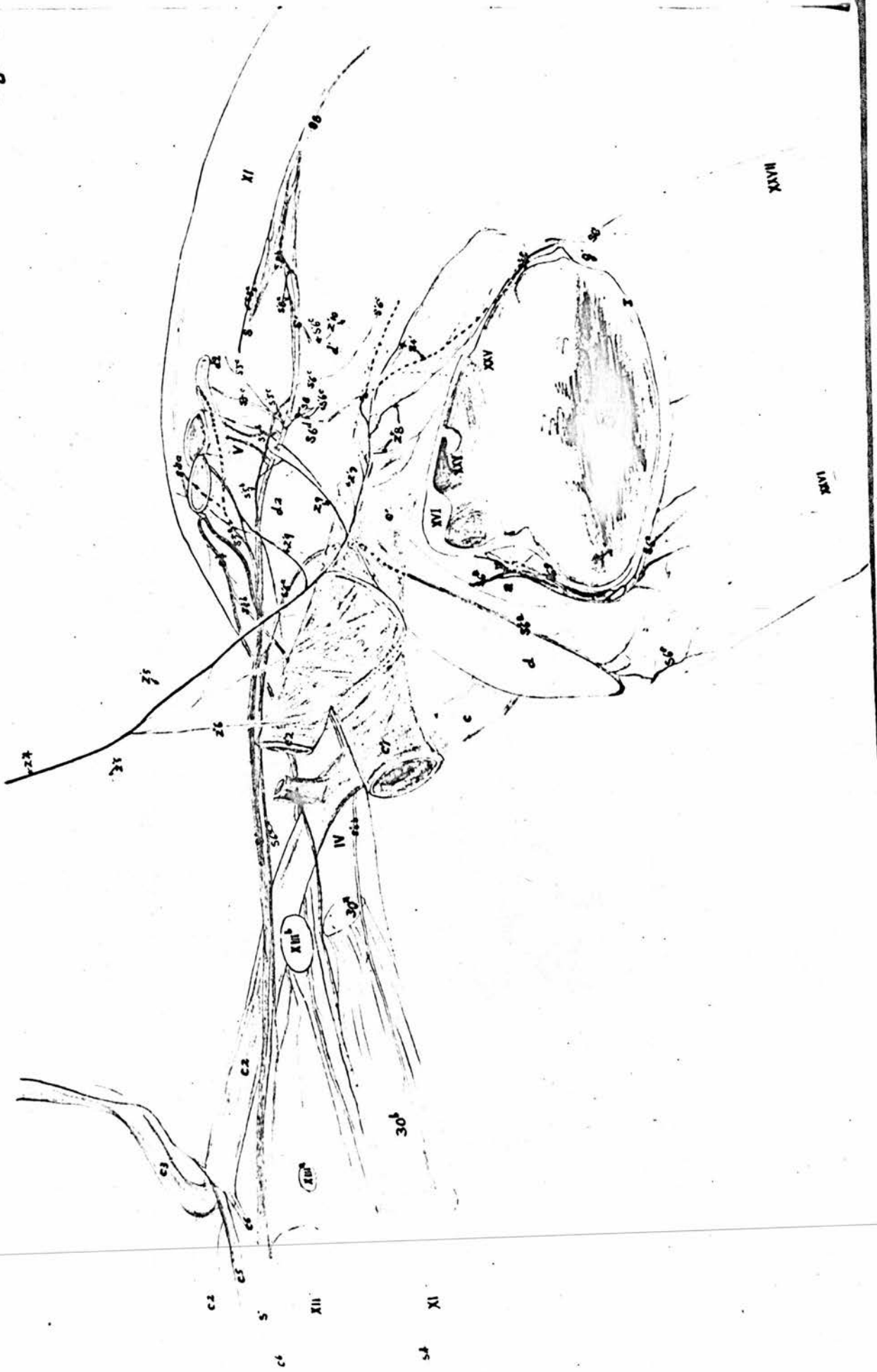


Figure 20.Cardiac Plexuses on the Anterior Surface of the Heart.

- | | |
|--|---|
| a. Aortic bulb. | a1. Aortic arch. |
| b'. Right ant vena cava. | b'1. Right subclavian V. |
| b'2. Right jugular V. | c'. Left ant vena cava. |
| c'1. Left subclavian V. | c'2. Left jugular V. |
| d1. Right pulmonary A. | d2. Left pulmonary A. |
| e. Right coronary A. | e'. Right ant cardiac V. |
| e1. Superficial descending branch of right coronary A. | |
| f. Left coronary A. | f'. Left ant cardiac V. |
| f1. Superficial descending branch of left coronary A. | |
| S. Right vagus. | S'. Left vagus. |
| S4. Right recurrent N. | S'4. Left recurrent N. |
| S4a. Descending branch of right recurrent nerve. | |
| S'4a. Descending branch of left recurrent nerve. | |
| S4b. Right post laryngeal N. | S'4'b. Left post laryngeal N. |
| S5a. Ant pulmonary branch of right vagus. | S'5a. Ant pulmonary branch of left vagus. |
| S6a. Ant cardiac branch of right vagus. | S6a1. Branches to ground plexus of vagus. |
| S6a2. Branches to the superior cardiac plexus. | |
| S'6a. Anterior cardiac branch of the left vagus. | |
| S6e. Ant cardiac plexus. | S6g. Left coronary plexus. |
| S6h. Right coronary plexus. | |
| S7. Anastomotic branch between vagus and the recurrent Nn. | |
| Z6. Medio-ventral group of sympathetic branches on the right anterior vena cava. | |
| Z'6. Medio-ventral group of sympathetic branches on the left anterior vena cava. | |
| Z6a. Branch from the third last cervical spinal nerve. | |

Z7. Sympathetic branch to anterior cardiac branch of right vagus.

Z'7. Sympathetic branch to anterior cardiac branch of left vagus.

IV. Trachea.

XI. Oesophagus.

XVI. Right atrium.

XVII. Left atrium.

XXVI. Right ventricle.

XXVII. Left ventricle.

Fig. 20

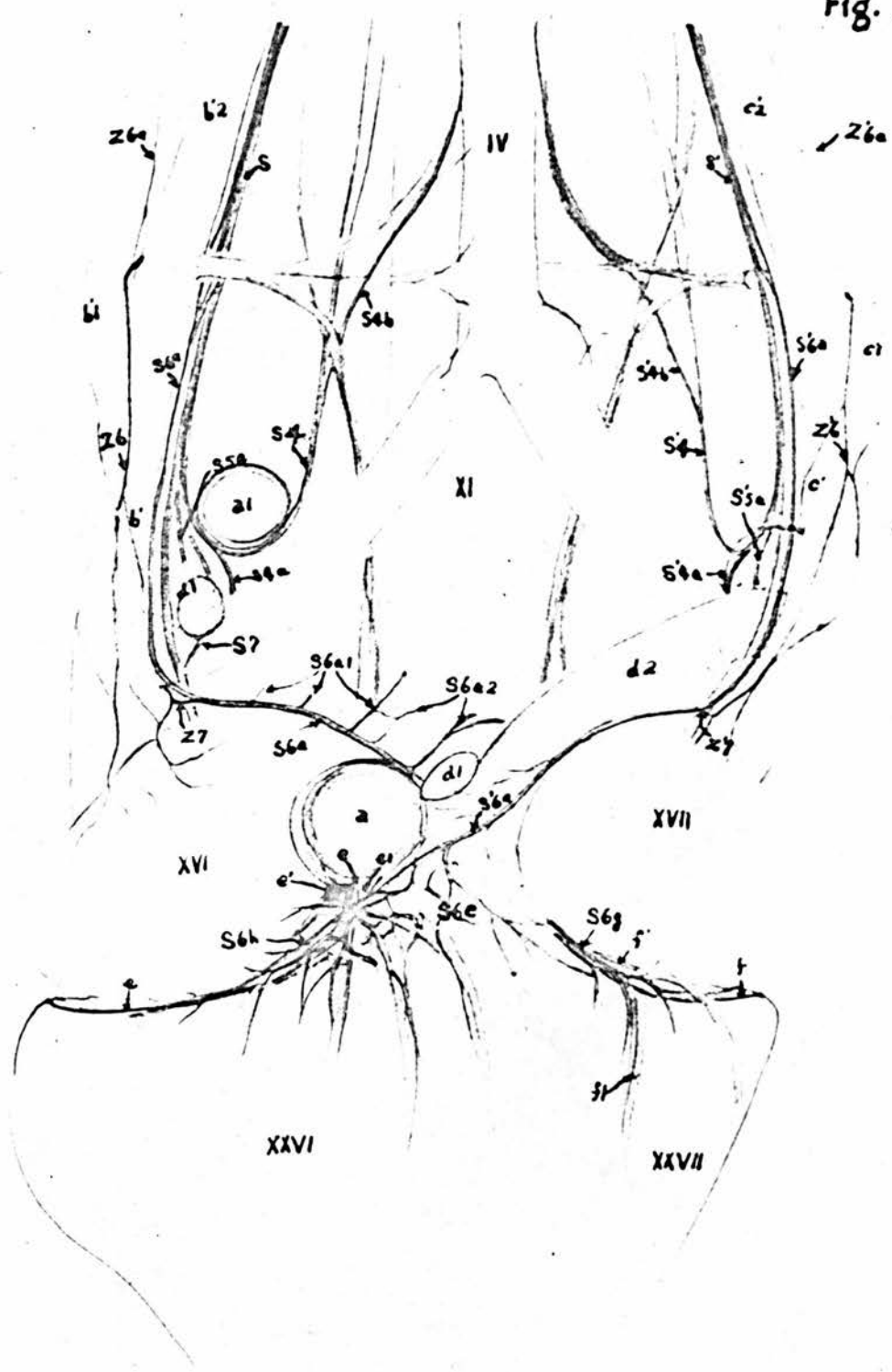


Figure 21.Cardiac Plexus on the Posterior Surface of the Heart.

- | | |
|---|------------------------------|
| a'. Posterior vena cava. | a'''. Vena proventricularis. |
| a1. Aortic arch. | b'. Right ant vena cava. |
| b'1. Right subclavian V. | b'2. Right jugular V. |
| c'. Left ant vena cava. | c'1. Left subclavian V. |
| c'2. Left jugular V. | d1. Right pulmonary A. |
| d'1. Right pulmonary V. | d2. Left pulmonary A. |
| d'2. Left pulmonary V. | e. Right pulmonary A. |
| f. Left coronary A. | g'. Middle cardiac V. |
| S. Right vagus. | S'. Left vagus. |
| S4. Right recurrent N. | S'4. Left recurrent N. |
| S4a. Descending branch of right recurrent N. | |
| S'4a. Descending branch of left recurrent N. | |
| S5a. Anterior pulmonary branch of right vagus. | |
| S'5a. Anterior pulmonary branch of left vagus. | |
| S6a. Anterior cardiac branch of right vagus. | |
| S'6a. Anterior cardiac branch of left vagus. | |
| S6b. Middle cardiac branches of right vagus. | |
| S'6b. Middle cardiac branches of left vagus. | |
| S6c. Posterior cardiac branches of the right vagus. | |
| S'6b. Posterior cardiac branches of the left vagus. | |
| S6f. Posterior cardiac plexus. | |
| S7. Anastomotic branch between the vagus and recurrent N. | |
| S8. Ventral oesophageal trunk. S8b. Oesophageal plexus. | |
| S8a. Oesophageal branch of the right vagus. | |
| S'8a. Oesophageal branch of the left vagus. | |
| Z4. Right sympathetic cardiac N. | |

Z'4. Left sympathetic cardiac N.

~~Z'4a. The latero-dorsal group of sympathetic branches on the right anterior vena cava.~~

Z'6. The medio-ventral group of sympathetic branches on the right anterior vena cava.

Z'6. The medio-ventral group of sympathetic branches on the left anterior vena cava.

Z'8. The latero-dorsal group of sympathetic branches on the right anterior vena cava.

Z'8. The latero-dorsal group of sympathetic branches on the left anterior vena cava.

Z'9. Pulmonary branches of the right sympathetic cardiac N.

Z'9. Pulmonary branches of the left sympathetic cardiac N.

IV. Trachea.

XVI. Right atrium.

XVII. Left atrium.

XXVI. Right ventricle.

XXVII. Left ventricle.

Fig. 21

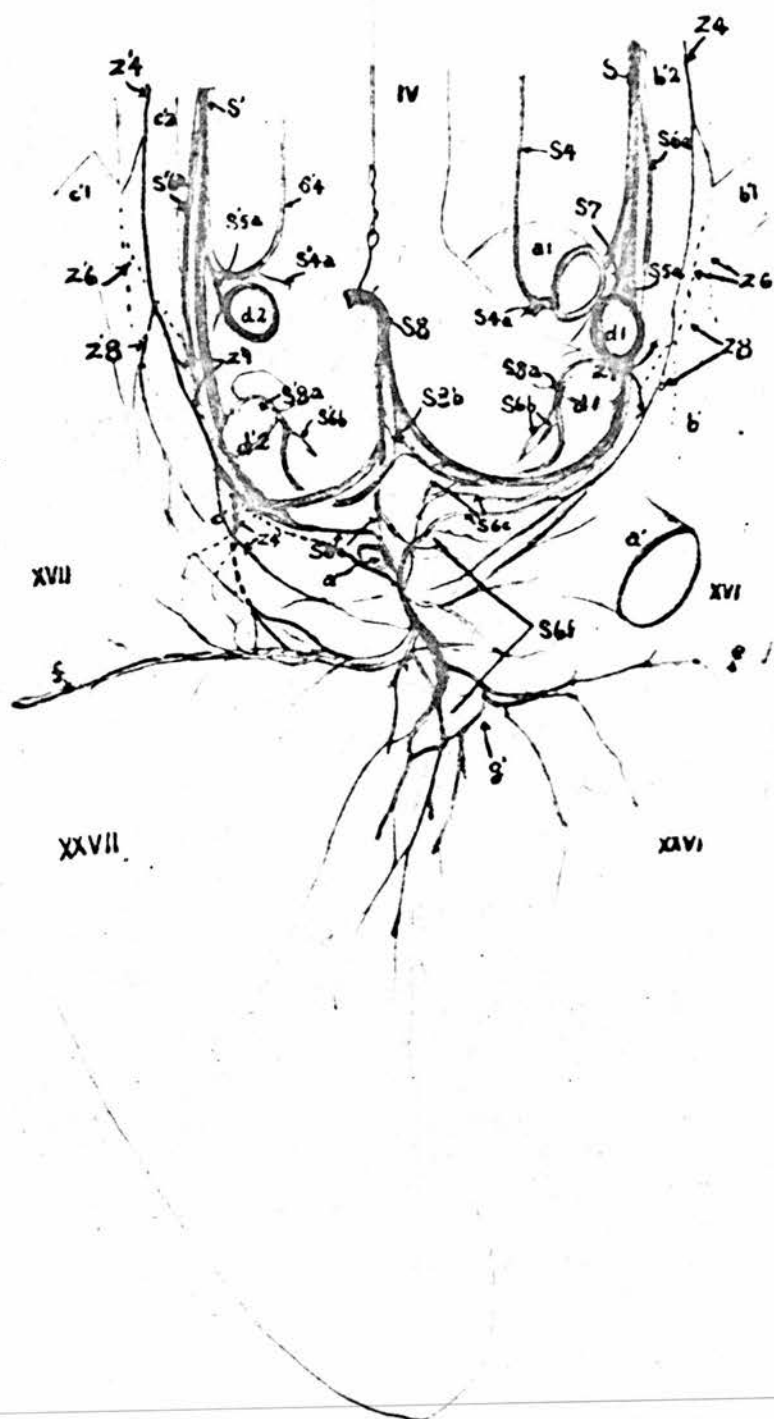


Figure 22.Cardiac Plexuses on the Base of the Heart.

- a. Bulbus aortae.
- a'. Posterior vena cava.
- b'. Right anterior vena cava.
- c'. Left anterior vena cava.
- d'. Common pulmonary V.
- d'1. Right pulmonary V.
- d'2. Left pulmonary V.
- e. Right coronary A.
- e'. Right anterior cardiac V.
- e1. Superficial descending branch of right coronary A.
- e2. Deep descending branch of right coronary A.
- f. Left coronary A.
- f'. Left anterior cardiac V.
- f1. Superficial descending branch of left coronary A.
- f2. Deep descending branch of left coronary A.
- S6a. Anterior cardiac branch of right vagus.
- S'6a. Anterior cardiac branch of left vagus.
- S6b. Middle cardiac branches of right vagus.
- S'6b. Middle cardiac branches of left vagus.
- S6d. Superior cardiac plexus.
- S6e. Anterior cardiac plexus.
- S6f. Posterior cardiac plexus.
- S6g. Left coronary plexus.
- S6h. Right coronary plexus.
- S8a. Oesophageal branch of right vagus.
- S8'a. Oesophageal branch of left vagus.

Z'4. Left cardiac N.

Z6. The medio-ventral group of sympathetic branches on the right anterior vena cava.

XVI. Right atrium.

XVII. Left atrium.

XXVI. Conus arteriosus.

Figure 23.A. The Right and Left Coronary Plexuses Following the DeepDescending Branches of the Right and Left Coronary Arteries.

The dotted line shows the attachment of the lateral wall of the right ventricle to the inter-ventricular septum.

a. Bulbus aortae.

e. Right coronary A.

e2. Deep descending branch of the right coronary A.

f. Left coronary A.

f1. Superficial descending branch of the left coronary A.

f2. Deep descending branch of the left coronary A.

B. The Pulmonary Plexus on the Ventral Surface of the Lung.

a1. Descending aorta.

b'. Right vena cava. (anterior)

b'1. Right subclavian V.

b'2. Right jugular V.

b'4. Right costo-cervical V.

d1. Right pulmonary A.

d'1. Right pulmonary V.

S. Right vagus.

S4. Right recurrent N.

S4a. Descending branch of right recurrent N.

S5a. Ant pulmonary branch of right vagus.

S5c. Post pulmonary branch of right vagus.

S6a. Ant cardiac branch of right vagus.

S7. Anastomotic branch between the vagus and the recurrent N.

Z4. Right cardiac N.

S6. Branch of cardiac N. to ant vena cava.

Z9. Sympathetic pulmonary branch.

Ib. Medial surface.

Ic. Ventral surface.

II. Costal impressions.

III. Lateral border.

V. Mesobronchus.

Va. Ostium posterius.

VIa. Ostium clavicle.

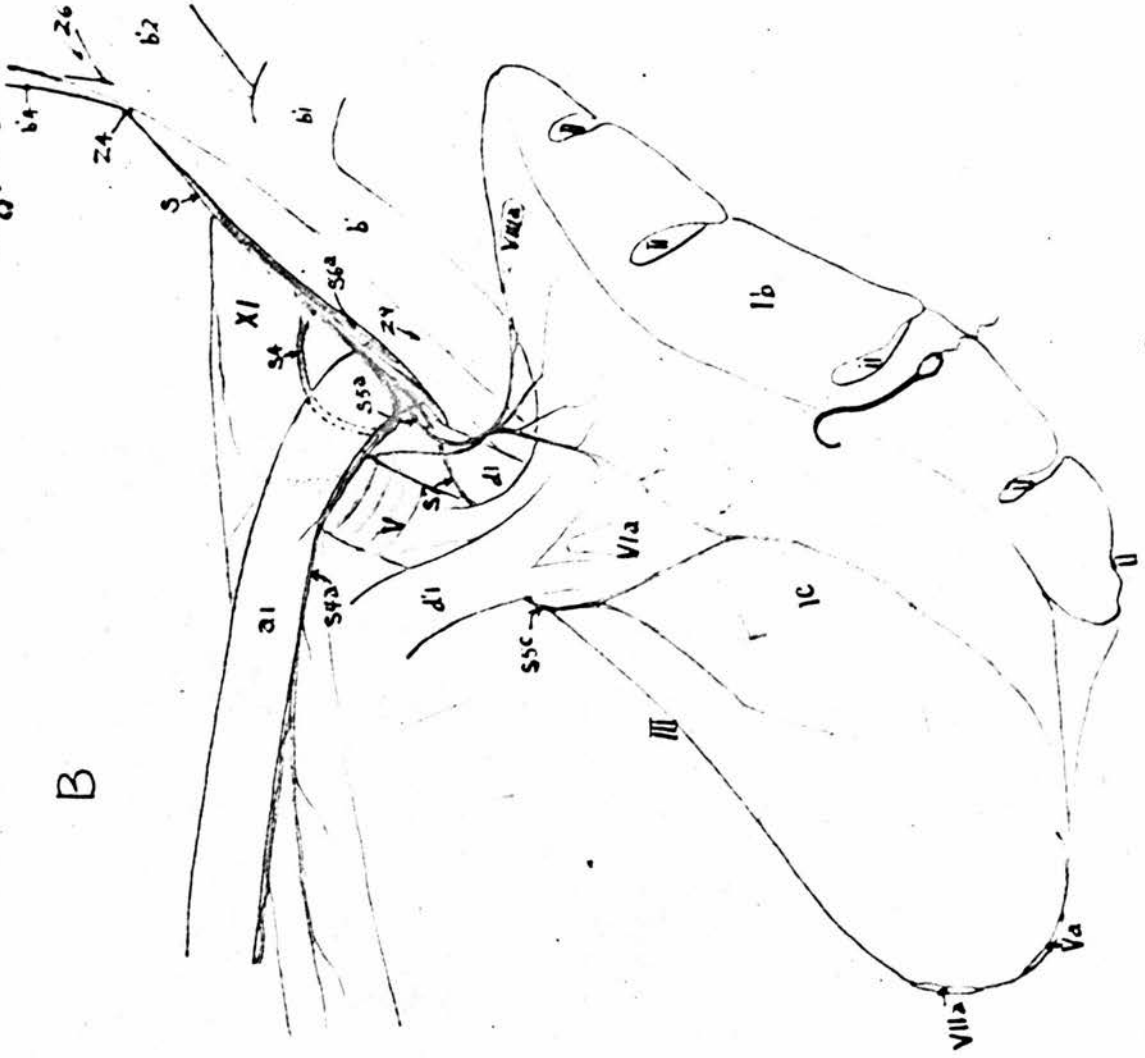
VIIa. Ostium intermedium posterius.

VIIIa. Ostium cervicale.

XI. Oesophagus.

Fig. 23

B



A




Figure 24.The Abdominal Plexuses.

A. Viewed from the left side.
 B. " " " right side.

- | | |
|--|--------------------------------------|
| a. Abdominal aorta. | a1. Supreme intercostal A. |
| a2. Thoracic & lumbo-sacral Aa. | b. Coeliac A. |
| b'''. Gastro-duodenal A. | b1. Oesophageal branch. |
| c. Left gastro-hepatic A. | f. Superior splenic A. |
| h. Right hepatic A. | j. Right gastric A. |
| k. Pancreatico-duodenal A. | k1. Caecal branches. |
| l. Ant mesenteric A. | m. Jejunal Aa. |
| n. Middle colic A. | p3. Ant renal A. |
| r. Femoral A. | s. Sciatic A. |
| t. Posterior mesenteric A. | u. Left colic A. |
| v. Ant rectal A. | a'. Posterior vena cava. |
| b'1. Right common iliac V. | b'2. Left common iliac V. |
| U4a. Ventral ramus of 1st thoracic N. | U4b. Intercostal & last thoracic Nn. |
| U4c. Common stem of femoral, obturator & ant gluteal Nn. | U4d. Sciatic N. |
| U4f. Pudendal plexus. | U4e. Post gluteal N. |
| Z1. Sympathetic ganglia. | Z. Sympathetic trunk. |
| Z3b. Lesser splanchnic Nn. | Z3a. Greater splanchnic Nn. |
| Z4a. Right adrenal ganglia. | Z4. Aortic plexus. |
| Z5. Coeliac plexus. | Z4b. Left adrenal ganglia. |
| Z7. Ant mesenteric plexus. | Z6. Hepatic N. |
| Z8. Testicular plexus. | Z7a. Ant mesenteric ganglia. |
| Z10. Intestinal N. of Remak. | Z9. Ant renal plexus. |
| I. Outline of adrenal gland. | II. Outline of testicle. |

IV. Spleen.

V. Gall Bladder.

VI. The first limb of the duodenal loop (descending).

VII. The ascending limb of the duodenal loop.

VIII. Jejunum.

IX. Ilium.

X. Right caecum.

XII. Colon.

XIII. Rectum.

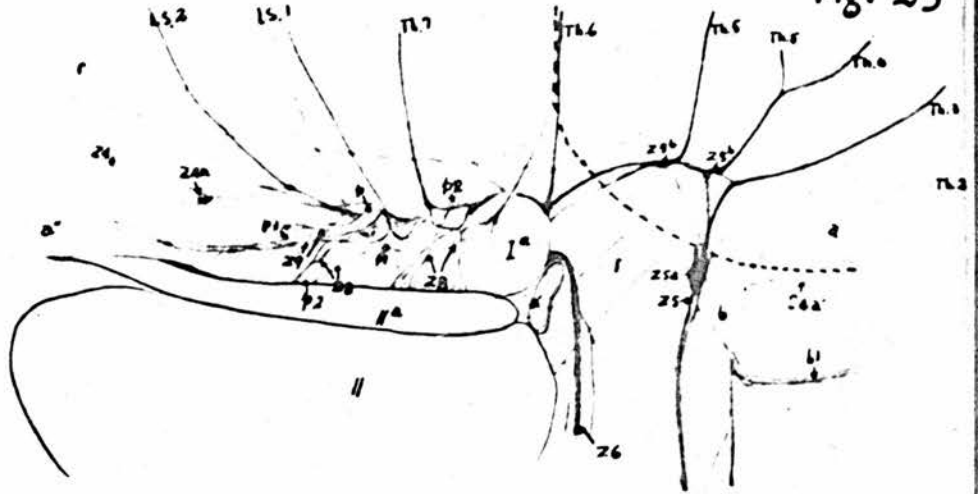
Figure 25.The Sympathetic Plexuses in the Dorsal Part of theAbdominal Cavity. The dotted line indicates the diaphragm.

- A. The testicular and anterior renal plexuses are present.
 B. The testicular and anterior renal plexuses are removed.
 C. The posterior vena cava is also removed and the right adrenal gland is reflected to show the anterior mesenteric plexus.

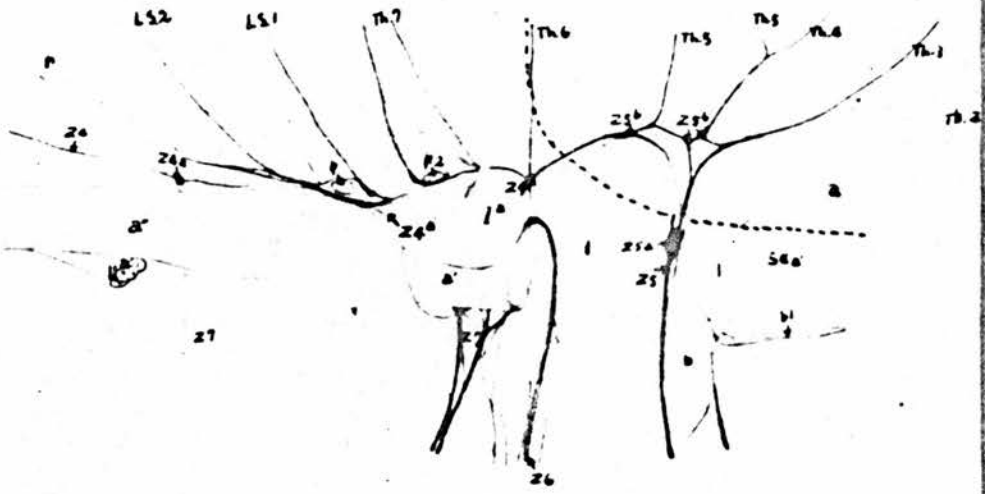
- | | |
|----------------------------|------------------------------------|
| a. Abdominal aorta. | a'. Post vena cava. |
| a''. Right common iliac V. | a'''. Left common iliac V. |
| b. Coeliac A. | b1. Oesophageal branch. |
| l. Ant mesenteric A. | p. Right adreno-reno-testicular A. |
| p1. Right adrenal A. | p2. Right testicular A. |
| p2'. Left testicular A. | p3. Right ant renal A. |
| p3'. Left ant renal A. | r. Right femoral A. |
- S4a. Anastomotic branch from the recurrent Nn.
 Z4. Aortic plexus.
 Z4a. Ganglia in aortic and right adrenal plexuses.
 Z4b. Ganglia in left adrenal plexus.
 Z5. Coeliac plexus. Z5a. Coeliac ganglion.
 Z5b. Splanchnic ganglia. Z6. Hepatic N.
 Z7. Ant mesenteric plexus. Z8. Testicular plexus.
 Z9. Ant renal plexus.
- Ia. Right adrenal gland.
 Ib. Left adrenal gland.
- II. Right testicle.
 IIa. Right epididymis.

Fig. 25

A



B



C

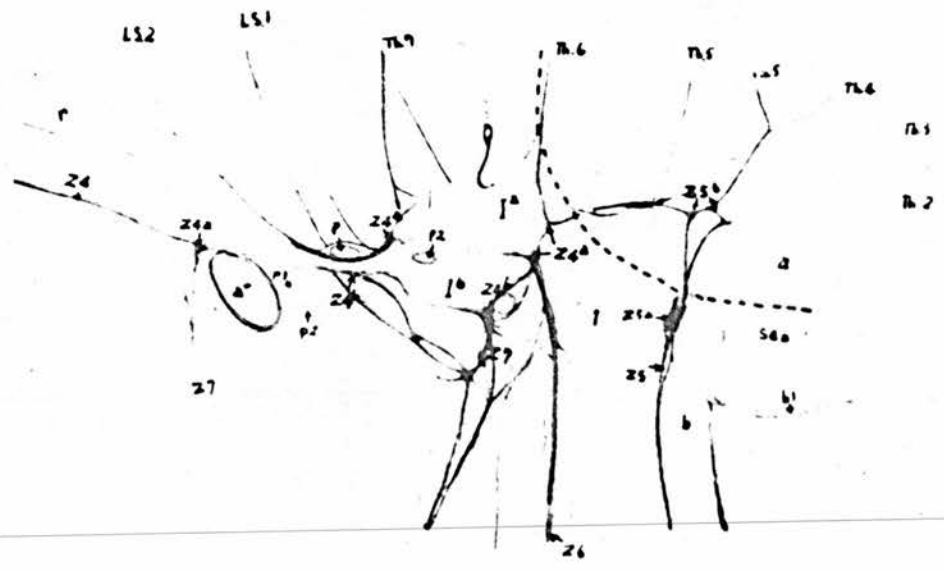


Figure 26.The Aortic and the Adrenal Plexuses.

- A. Viewed from the right side.
 B. " " " ventral side.
 C. " " " left side.

a. Aorta.

a2. Last two thoracic and the 1st two lumbo-sacral arteries of the right side.

a2'. Last two thoracic and the 1st two lumbo-sacral arteries of the left side.

p. Right adreno-reno-ovarian A.

p1. Right adrenal A.

p3. Right ant renal A.

p2. Right ovarian Aa.

p1'. Left adrenal A.

p'. Left adreno-reno-ovarian A.

p3'. Left ant renal A.

p2'. Left ovarian Aa.

Z3. Lesser splanchnic Nn. of right side.

q. Accessory ant renal A.

Z3'. Lesser splanchnic Nn. of left side.

Z4a. Right adrenal ganglia.

Z4b. Left adrenal ganglia.

Z5. Nerve to coeliac plexus.

Z5b. Splanchnic ganglion.

Z6. Hepatic N.

Z7. Nn to ant mesenteric plexus.

Z8. Right ovarian plexus.

Z8'. Left ovarian plexus.

Z9. Right ant renal plexus.

Z9'. Left ant renal plexus.

Ia. Right adrenal gland.

Ib. Left adrenal gland.

Fig. 26

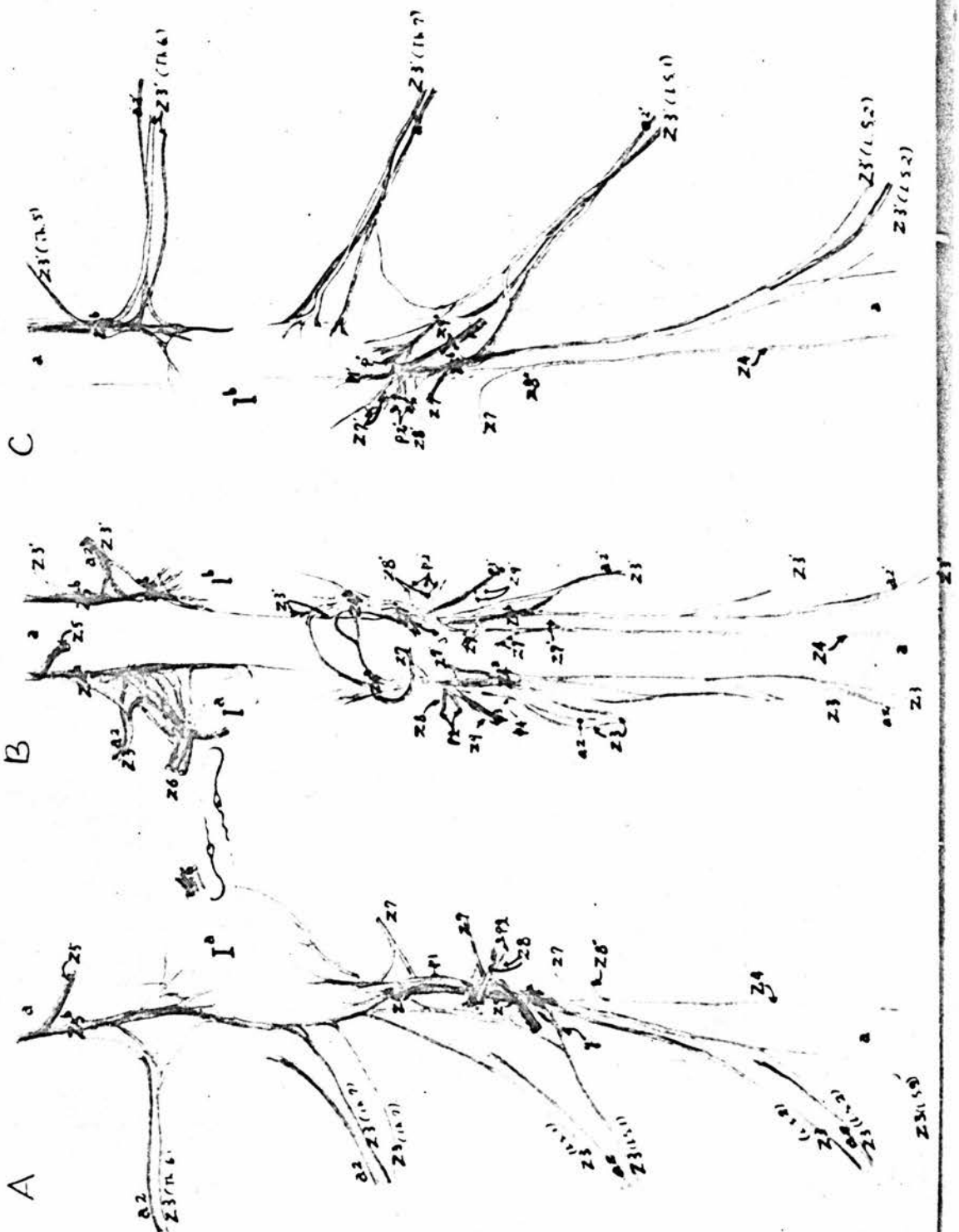


Figure 27.The Intestinal Nerve of Remak and the Anterior MesentericPlexus.

- i. Duodenal branch of right hepatic A.
- l. Anterior mesenteric A.
- m. Jejunal Aa.
- o1. Iliac branch of the ileo-caecal-colic A.

- Z7. Anterior mesenteric plexus.
- Z7b. Branches to the intestinal N.
- Z10. Intestinal nerve of Remak.

- VI. Descending limb of duodenal loop.
- VII. Ascending limb of the duodenal loop.
- VIII. Jejunum.
- IX. Ileum.
- XIV. Pancreas.
- XV. Liver.
- XVI. Lung.
- XVII. Heart.
- XVIII. Ovum.

Figure 28.The Gastric Plexus.

- b. Coeliac A.
 - b'. Right gastro-hepatic A.
 - b''. Gastro-duodenal A.
 - b1. Oesophageal branch.
 - b2. Dorsal proventricular A.
 - c. Left gastro-hepatic A.
 - c1. Ventral proventricular A.
 - c2. Dorsal gastro-epiploic A.
 - c3. Ventral gastro-epiploic A.
 - d. Left hepatic A.
 - e. Left gastric A.
 - f. Superior splenic A.
 - g. Inferior splenic A.
 - h. Right hepatic A.
 - i. Branch to duodenum.
 - j. Right gastric A.
 - k. Pancreatic-duodenal A.
-
- | | |
|-------------------------|----------------------|
| S8. Oesophageal branch. | Z5a. Splenic plexus. |
| S9. Gastric plexus. | Z6. Hepatic N. |
| Z5. Coeliac plexus. | Z6a. Hepatic plexus. |
-
- IV. Spleen.
 - VI. Duodenum.
 - XIX. Glandular stomach.
 - XX. Gizzard.

Figure 29.

The Distribution of the Sympathetic and Vagus Nerves on the Gizzard. The purple points showing the entrances of the sympathetic branches to the substance of the gizzard.

- A. The left surface of the gizzard.
- B. The right surface of the gizzard.

c. Left gastro-hepatic A.

c2. Dorsal gastro-epiploic A.

c3. Ventral gastro-epiploic A.

d. Left hepatic A.

e. Left gastric A.

j. Right gastric A.

S8. Ventral oesophageal trunk.

S9. Gastric plexus.

VI. Duodenum.

XIX. Glandular stomach.

Fig. 29

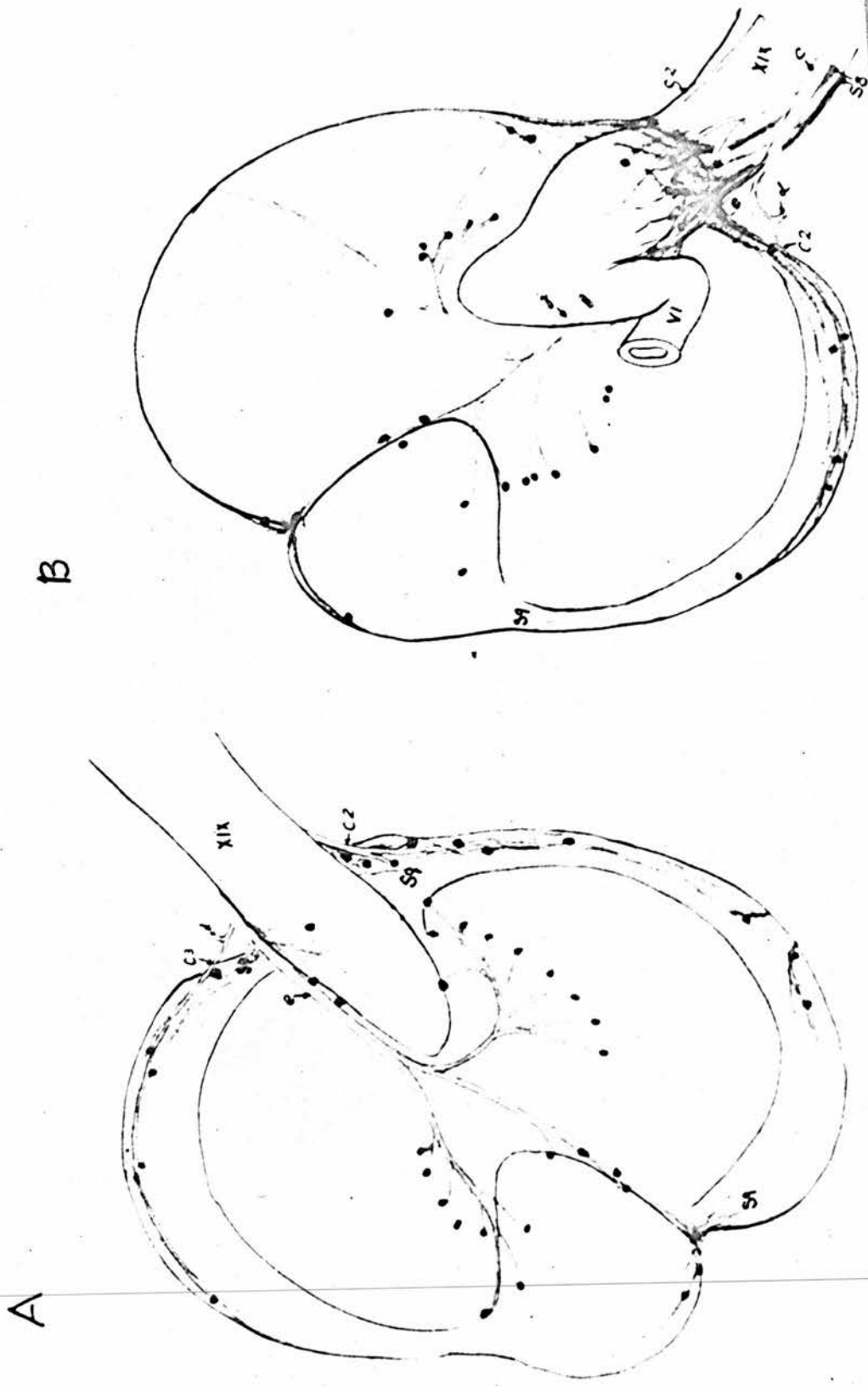


Figure 30.Abdominal Plexuses.

- | | |
|---------------------------------------|------------------------------|
| b. Coeliac A. | b'. Right gastro-hepatic A. |
| b''. Gastro-duodenal A. | b1. Oesophageal branch. |
| b2. Dorsal proventricular A. | c. Left gastro-hepatic A. |
| f. Superior splenic A. | g. Inferior splenic A. |
| h. Right hepatic A. | i. Branch to duodenum. |
| j. Right gastric A. | k. Pancreatico-duodenal A. |
| k1. Caecal branches. | l. Ant mesenteric A. |
| n. Middle colic A. | o. Ileo-caeco-colic A. |
| o1. Iliac branch. | o2. Caecal branches. |
| o3. Colic branch. | t. Posterior mesenteric A. |
| u. Left colic A. | v. Ant rectal A. |
| Z5. Coeliac plexus. | Z5a. Splenic plexus. |
| Z5b. Pancreatico-duodenal plexus. | Z6. Hepatic Nerve. |
| Z10. Intestinal Nerve of Remak. | Z6a. Hepatic plexus. |
| | Z11. Post mesenteric plexus. |
| IV. Spleen. | |
| V. Gall bladder. | |
| Va. Bile ducts. | |
| VI. Descending limb of duodenal loop. | |
| VII. Ascending limb of duodenal loop. | |
| IX. Ilium. | X. Right caecum. |
| XI. Left caecum. | XII. Colon. |
| XIII. Rectum. | XIVa. Pancreatic ducts. |

Fig. 30

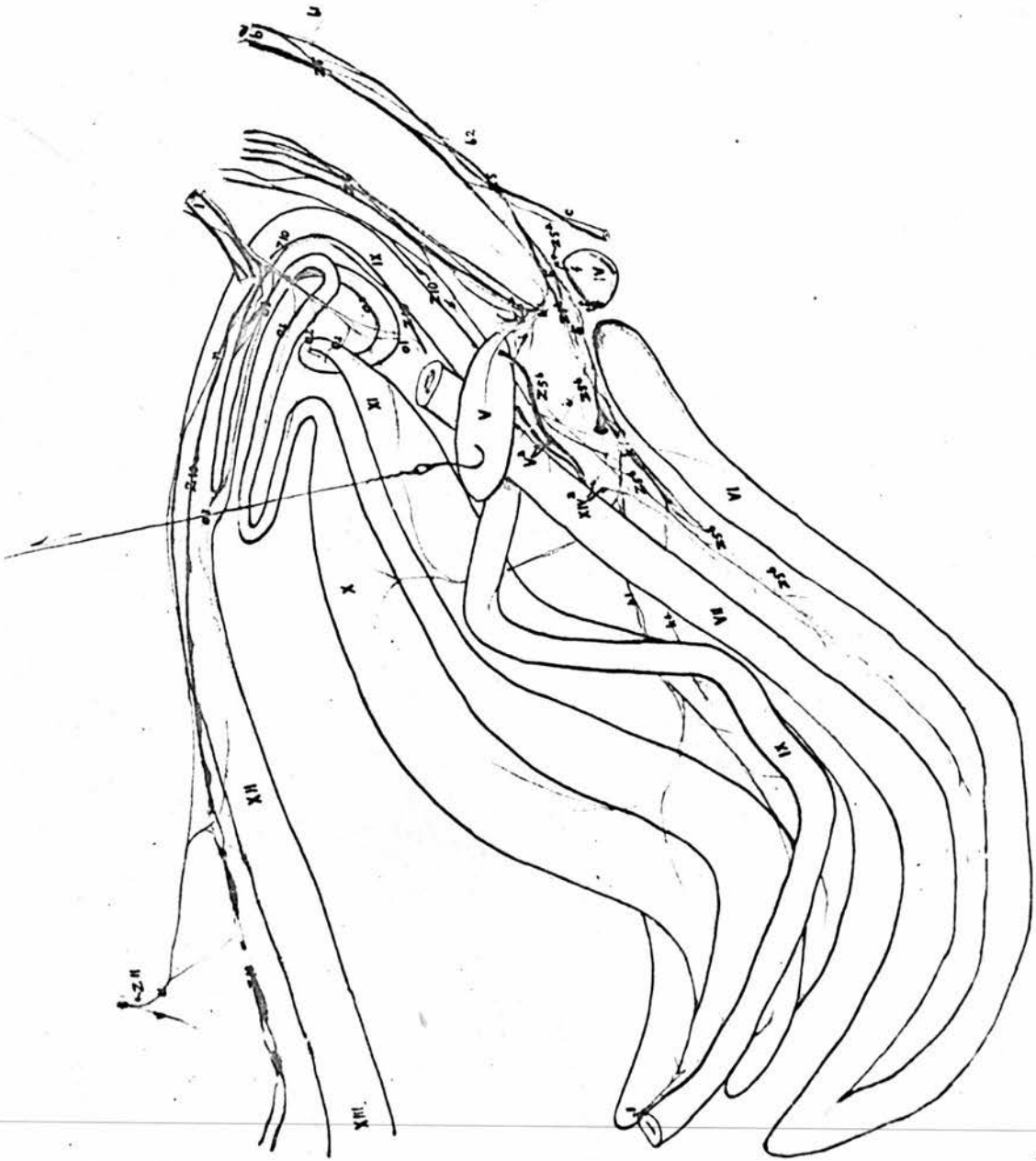


Figure 31.The Posterior Mesenteric, Pelvic and Cloacal Plexuses.

Viewed from the right side. The left pelvic plexus including the left limb of the intestinal nerve of Remak is light purple in colour.

- | | |
|---------------------------------------|--|
| a. Abdominal aorta. | a'. Middle sacral A. |
| a2. Thoracic & lumbo-sacral Aa. | n. Middle colic A. |
| p. Adreno-reno-ovarian A. | p1. Adrenal A. |
| p2. Ovarian Aa. | p3. Ant renal A. |
| q. Accessory ant renal A. | r. Femoral A. |
| s. Sciatic A. | s2. Middle renal A. |
| s3. Post renal A. | t. Post mesenteric A. |
| u. Left colic A. | v. Ant rectal A. |
| w. Hypogastric A. | x. Middle rectal A. |
| x1. Dorsal A. of clitoris. | |
| U4b. Thoracic Nn. | U4c. Common stem of femoral, obturator & ant gluteal Nn. |
| U4d. Sciatic N. | U4g. Pudendal N. |
| U4e. Post gluteal N. | U4h. Perforating cutaneous N. |
| U4i. Ventral coccygeal trunk. | Y. Pelvic splanchnic N. |
| Ya. Ganglia in cloacal plexus. | Y1. Dorsal nerve of clitoris. |
| Z. Sympathetic trunk. | Z1. Sympathetic ganglia. |
| Z2. Communicating branches. | Z3. Splanchnic Nn. |
| Z3'. Splanchnic N. from left side. | Z4. Aortic plexus. |
| Z7. Ant mesenteric plexus. | Z10. Intestinal N. of Remak. |
| Z10a. Right limb of intestinal nerve. | Z10b. Left limb of intestinal nerve. |
| Z11. Post mesenteric plexus. | Z12. Branch to plexus in the ligament of right oviduct. |

Z12'. Branch to plexus in the ligament of the left oviduct.

Z13. Branches to the right pelvic plexus.

Z13'. Branches to the left pelvic plexus.

IX. Ilium.

X. Right caecum.

XI. Left caecum.

XII. Colon.

XIII. Rectum.

XXI. Right ovary.

XXII. Right oviduct.

XXIII. Ureter.

XXIV. Right suspensory muscle of rectum.

XXV. Left suspensory muscle of rectum.

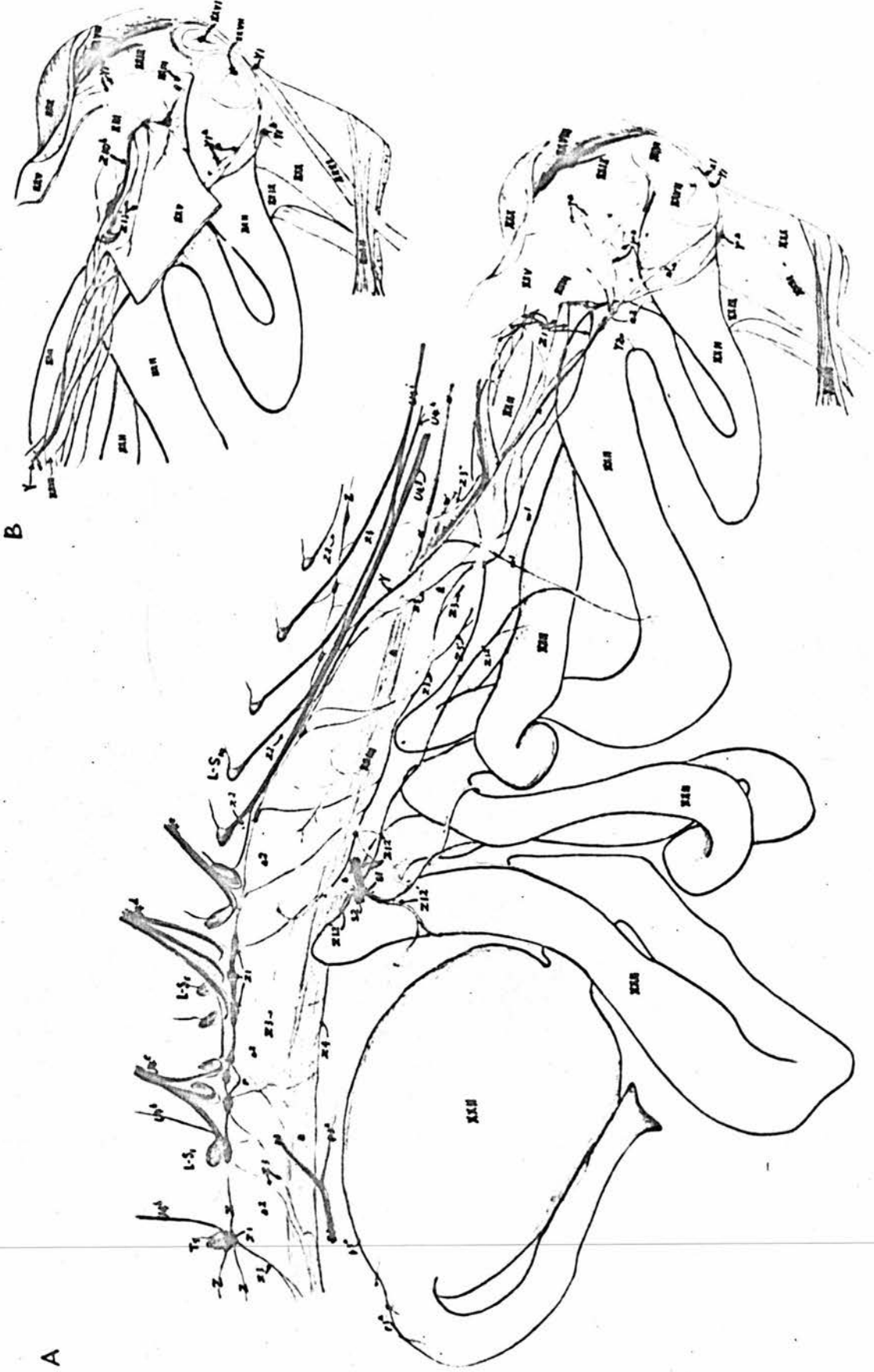
Figure 32.A. Cloacal Plexus and the Plexus in the Ligament of the Oviduct.B. Left Pelvic Plexus.

- | | |
|---|--|
| a. Abdominal aorta. | a'. Middle sacral A. |
| a2. Thoracic & lumbo-sacral Aa. | p3. Ant renal A. |
| p3a. Branches of ant renal A. | r. Femoral A. |
| s. Sciatic A. | s1. Branch to oviduct. |
| s2. Middle renal A. | s3. Post renal A. |
| t. Post mesenteric A. | w. Left hypogastric A. |
| w'. Right hypogastric A. | w1. Branches to oviduct. |
| x. Middle rectal A. | x1. Dorsal A. of clitoris. |
| x2. Branch to oviduct. | |
| U4b. Last thoracic & 1st lumbo-sacral Nn. | |
| U4c. Common stem of femoral, obturator and anterior gluteal Nn. | |
| U4d. Sciatic N. | U4e. Post gluteal N. |
| U4g. Pudendal N. | U4h. Perforating cutaneous N. |
| U4i. Ventral coccygeal trunk. | Y. Pelvic splanchnic N. |
| Ya. Ganglia in cloacal plexus. | Y1. Dorsal N. of clitoris. |
| Y2. Branch to oviduct. | Z. Sympathetic trunk. |
| Z1. Sympathetic ganglia. | Z2. Communicating branches. |
| Z3. Splanchnic Nn. | Z3'. Splanchnic Nn. to post mesenteric plexus. |
| Z3''. Splanchnic N. from right side. | Z4. Aortic plexus. |
| Z10b. Left limb of intestinal nerve of Remak. | |
| Z12'. Branches from the aortic plexus. | |
| Z13'. Branches to the pelvic plexus (left). | |

- XIII. Rectum.
XXII. Active oviduct.
XXIII. Ureter.
XXV. Left suspensory muscle of rectum.
XXVI. Anus.
XXVII. Orifice of the active oviduct.
XXVIII. Wall of the cloaca.
XXIX. Bottom of cloaca.
XXX. Sphincter muscle of cloaca.
XXXI. M. dilatator ani.
XXXII. M. retractor ani.



Fig. 32



Key to Plates I & II.Plate I.Serial Sections to Show the Spinal Root of the Vagus of84 hour Chick Embryo by the Bielschowsky Method.Slide No. 2. (120 sections).

- aa3. 3rd aortic arch.
 aa4. 4th aortic arch.
 aa6. 6th aortic arch.
 aci. Internal carotid artery.
 c1. 1st cervical N.
 c2. 2nd cervical N.
 c3. 3rd cervical N.
 gCou. Ganglion of Couvreur.
 gc2. Ganglionic swelling on spinal root of vagus nerve.
 gc3. Dorsal ganglion of 3rd cervical nerve.
 gc4. Dorsal ganglion of 4th cervical nerve.
 gjug. Jugular ganglion.
 gpr. Petrous ganglion.
 ot. Otocyst.
 rsX. Spinal root of vagus.
 vjug. Jugular V.
 VII & VIII. Premordium of facial and acoustic Nn.
 IX. Glosso-pharyngeal N.
 X. Vagus.
 XII. Hypoglossal N.



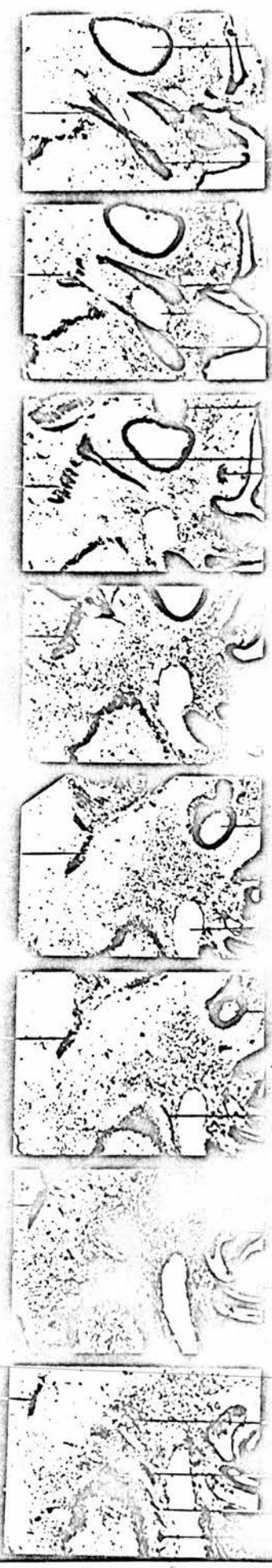


Plate II.

Serial Sections to Show the Neuroblasts in the Spinal Root
of the Vagus of 108 hour Chick Embryo by the Bielschowsky Method.

Slide No. 1. (84 sections).

myel. Myelencephalon.

neur. Neuroblast.

rsX. Spinal root of vagus nerve.

so. Somites.

sp. Spinal Cord.

