

T H. E U R A C H U S.



*Nil.*

THE URACHUS.

AN INVESTIGATION OF ITS DEVELOPMENT,  
ANATOMY AND HISTOLOGY; ITS RELATION TO  
URINARY UMBILICAL FISTULA, WITH A COMPLETE  
ANALYSIS OF THE LITERATURE. ALSO A STUDY  
OF THE HISTORY OF ITS CENTRAL EPITHELIUM  
AND ITS CONNECTION WITH ADENOMATOUS TUMOURS  
OF THE URINARY TRACT AND THE UMBILICUS.



By

ROBERT CAMPBELL BEGG, M.C.,

M.A., M.Sc. (N.Z.);

M.B., Ch.B. (Edin.);

F.R.C.S. (Edin.);

M.R.C.S. (Eng.);

L.R.C.P. (Lond.);

Hon. Surgeon to the Hospital for Sick Children,  
Wellington, New Zealand.

Being a

THESIS FOR THE DEGREE OF M.D. (EDIN.).

---

## I N T R O D U C T I O N .

This Thesis, as originally planned, was to have been confined to the subject of Urinary Fistula and Patent Urachus. An examination of the literature on these topics soon convinced me, however, of the necessity of a personal study of the normal anatomy and histology of the structures concerned, a theme about which the ordinary text-books of anatomy are singularly reticent. I was enabled to carry out, by gross dissection, microscopical dissection and microscopy, a complete examination of twenty-eight specimens of urachus, derived from a consecutive series of post-mortem cases, from dissecting-room bodies and from still-born foetuses. In the course of this examination, much new information was obtained, throwing light on pathological changes in vestigial epithelium, which had hitherto been unexplained. This, to my mind, the most valuable part of the Thesis is embodied in Chapter III. The conclusion was inevitably reached, that the normal conception of the Urachus, as a solid fibro-muscular cord reaching to the umbilicus is incorrect. It is not a solid fibro-muscular cord, nor does it reach to the umbilicus. Such a radical change in anatomical knowledge compelled one to elaborate a new/

new pathology to explain the various types of umbilical fistulae usually ascribed to the presence of a patent urachus. Incidentally, much evidence was found in support of the view that the allantois has nothing to do with the formation of the urachus, which develops, in company with the bladder, from the ventral cloaca.

I have to acknowledge, with sincere thanks, the help given to me in the preparation of this paper by PROFESSOR ASHWORTH of the Zoological Department in the University of Edinburgh, who gave me the facilities of his Department, and allowed me to use his own dissecting microscope which was invaluable in carrying out the fine dissections involved, providing information that neither gross dissection nor microscopical sections could give. Also to PROFESSOR LORRAIN SMITH, who unreservedly placed the resources of his Morbid Anatomy Department at my disposal; and to DR. W. A. ALEXANDER, Lecturer on Morbid Anatomy, Edinburgh University, who took considerable pains and trouble to obtain the required material. PROFESSOR ARTHUR ROBINSON very kindly took an interest in the anatomical part of the research and I am indebted to him for much information, especially on the embryological side. DR. WHITAKER, Lecturer in Anatomy in the School of the Royal/

Royal Colleges, Edinburgh, also helped me considerably and allowed me to use the material of his Department. DR. AGNES MACGREGOR, Pathologist to the Royal Hospital for Sick Children, Edinburgh, provided me with some specimens, while DR. J. W. DAWSON of the Edinburgh Royal College of Physicians' Laboratory and DR. BROWN of the Ante-Natal Clinic, Simpson Memorial Hospital, gave me invaluable assistance in the interpretation of the adenomatous conditions found in the urachus.

To MR A. F. CARROLL I am indebted for the drawings of specimens shown in Plates I to V, while MR — LEWIS took and developed the micro-photographs. MR D. M. GREIG, Curator of the Royal College of Surgeons, Edinburgh, gave me many valuable hints and references to the literature and assisted me in many ways. I have to thank SIR HAROLD STILES and MR ALEXANDER MILES for permission to refer to two hitherto unpublished cases. DR. G. W. NICHOLSON of Guy's Hospital, London, whose work in epithelial glandular structures is well-known, gave me access to his pathological specimens and slides, while PROFESSOR BOYCOTT of University College, London, placed a microscope and projector at my disposal. Thanks to him, I was enabled to complete the examination of the sections and the illustrations of them while still in London.

CHAPTER I.

ANATOMY, HISTOLOGY AND FUNCTION;

WITH A NOTE ON THE DEVELOPMENT

OF THE URACHUS.

---

THE MACROSCOPIC ANATOMY OF THE URACHUS.

It is common to describe the Urachus and Hypogastric Arteries in the adult as three fibrous, or musculo-fibrous cords meeting at the umbilicus; the former bisecting the angle formed by the latter. This description is by no means substantiated on examination, as Lushka pointed out in a review of the subject in 1862<sup>(a)</sup>, and embodied in his well-known anatomy published in 1872<sup>(b)</sup>. As this author's observations have been largely ignored by subsequent anatomical writers, it will be of interest to give a translation of his article in the latter reference<sup>(b)</sup>: -

"Ligamentum Umbilicale Medium.  
(Urachus).

In the adult, this cord-like structure extends upwards from the urinary bladder for a distance of 12 centimetres, gradually narrowing towards the upper extremity; and appears, only in exceptional cases, as a prolongation of the apex (of the bladder). As a general rule, it is a continuation of the upper part of the anterior wall, being overlapped, more or less, posteriorly by the rounded highest part of the bladder. It extends upwards on the outer surface of the peritoneum, along the middle line of the abdominal cavity. IT DOES NOT ALWAYS EXTEND AS FAR AS THE UMBILICUS, but often, before reaching the latter, resolves itself into a number of fibrous threads, which generally connect in a very unsymmetrical manner with the left and right lig. vesicale laterale (obliterated hypogastric arteries), which also intertwine/

(a) VIRCHOW'S ARCHIV - Vol. XXIII. Hefte 1 & 2.

Page 1.

(b) ANATOMIE DES MENSCHEN - Vol. II. Part II.

Page 227.

intertwine with one another, so that a network or plexus is produced rising towards the umbilicus."

In contrast to this may be cited Symington's description in Quain's Anatomy<sup>(a)</sup>, in which it is stated that the Urachus becomes narrower as it ascends and reaches the umbilicus, where it blends with the dense fibrous tissue in this region.

I have made a careful study of the gross anatomy of the urachus in numerous specimens, which confirms Lushka's original observations published in 1862, the most accurate description yet given. His account ten years later, as quoted above, does not tally in many points with my observations and does not follow his own first-published report. A translation of a large part of his article appeared in The British and Foreign Chirurgical Review<sup>(b)</sup>. He there said that the current description in his day - which is, incidentally, still current in our own - was that of a number of the fibres of the detrusor muscle of the bladder passing upward and gradually losing themselves in a paleish yellow tissue consisting chiefly of elastic fibres, serving as a kind of tendon, which gradually gets thinner as it approaches the umbilicus. He then proceeds:-

"Much/

---

(a) QUAIN'S ANATOMY - Vol. IV. Part ii.

(b) BRIT. AND FOREIGN CHIR. REV. LOND. - Vol. II  
(1862). p. 86.

"Much more frequently the urachus does not extend as far as the navel, but about 5 or 6 cm. from the bladder passes into a number of threads."  
(See Plate III).

I am convinced that a correct appreciation of the fact that, except in congenital pathological conditions, the true urachus practically never extends more than 5 or 6 cm. upwards from the apex of the bladder (See Plate II), the distance from the apex to the umbilicus in the adult being 16 to 18 cm., invalidates the common theory of the origin of urachal cysts as dilatations of a urachal canal; and throws grave doubt on the occurrence of acquired vesico-umbilical fistula as being due to a urachus remaining patent. I think it most important, therefore, that the general conception of the anatomy should be corrected and the real nature of the fibrous cord that descends in the middle line from the umbilicus determined. It will be shown<sup>+</sup> that, far from being the remains of the urachus, this cord, where it exists at all, is composed of fibrous tissue derived from the adventitia of the hypogastric arteries.


ANATOMY OF THE HYPOGASTRIC (UMBILICAL)  
ARTERIES AND THE URACHUS IN THE NEWLY-  
BORN.

The umbilical orifice, as observed in a still-born foetus, is an opening left where the rounded medial borders, by which the anterior sheaths of the recti/

<sup>+</sup>See p. 13 &  
Figs. 6 &  
41A.

recti muscles become continuous with the posterior sheath, have failed to fuse with each other across the middle line. It is the contact and fusion of these borders, which forms the linea alba, just as the two sides of a garment are turned over and united with one another to form a seam (Fig. 1.A).

5



At the umbilicus, these two borders fail to unite (Fig. 1.B) and so the customary description of this organ as a deficiency in the linea alba is justified. Lining the internal surface of the posterior sheaths of the recti (and the recti themselves below the semilunar fold of Douglas) is the Transversalis fascia. At the point where the deficiency exists, however, this structure is protruded like the finger of a glove, right through it into the first centimetre of the umbilical cord. The glove finger is here deficient, as it were, at the tip and the protrusion forms a well-marked tunnel through which the umbilical vessels and the fibrous remains of the allantois are conducted through the skin, through the subcutaneous fascia, and through the linea alba into/

10

15

20

into the space between the transversalis fascia and peritoneum in which they lie.

If the whole thickness of the abdominal wall be turned down from above, an instructive view of the urachus and vessels can be obtained <sup>5</sup>. The Urachus <sup>5</sup> See fig. 2. is a tiny structure at this stage, hugging the anterior abdominal wall and being overlapped and almost concealed by the relatively enormous hypogastric arteries which project markedly and have a diameter of 5 to 7 m.m.<sup>+</sup> The length of the urachus varied <sup>10</sup>† Fig.2 A , Hy. in the subjects I examined, between 2 and 2.5 c.m., but, to this must be added half a centimetre for its intramural course to reach the mucus membrane of the bladder. This is in accordance with the estimate of Wutz<sup>(a)</sup>, who studied the anatomy of the urachus <sup>15</sup> in the newly-born in 1883. The latter structure at its base, or bladder end, averaged only 3 m.m. and in the greater part of its course to the umbilicus only 1 m.m. in diameter. The large umbilical vein, <sup>18</sup> Fig. 2 A , U. <sup>20</sup> 1 c.m. in diameter, meets the other structures, all emerging through the tunnel of transversalis fascia already described. A most important change - one which throws light on the subsequent history of the structure - takes place at the upper end of the urachus <sup>25</sup>. At this point it divides into a number of/ <sup>25</sup> - See Fig.2 B.

(a) VIRCHOW'S ARCHIVES - Vol. XCII, p. 387 - 1883.

of fibrous strands - usually three. One of these is attached to, and indeed continuous with, the adventitia of each hypogastric artery; while the third passes through between them into the cord and here breaking up into numerous fine strands is lost at a point about 1 c.m. from the body surface<sup>+</sup>.

+ Fig. 2 B.

These strands represent the remains of the obliterated Allantois and the attachments to the hypogastric arteries are almost invariably present in the adult and serve as useful landmarks to indicate the true upper limits of the urachus.

#### DESCENT OF THE URACHUS.

At birth, the apex of the bladder is four centimetres above the symphysis pubis and as it rapidly descends it brings the urachus with it<sup>g</sup>. The latter, being attached to each hypogastric artery, drags their obliterated ends down with it, so that an anchor-like arrangement is formed (See Plate I) about 3 c.m. above the bladder apex. In one specimen examined, there had apparently been no such attachment and the round occluded ends lay free one on either side of the upper end of the urachus.

<sup>g</sup> Fig. 3.

The connective tissue coats of the arteries, and, indeed, the apex of the urachus itself, become in-

involved in the formation of the extensive fibrous tissue which marks the closure of the fascial tunnel<sup>P</sup> and/

<sup>P</sup> Fig. 2 B, Tn.

and the production of the umbilical scar; and as the arteries and the urachus are dragged down by the bladder descent, this tissue is drawn out into a fibrous cord, as shown in Plate I (F)<sup>#</sup>, a drawing of the parts in a child of three years of age. In other cases, the adventitia of the arteries is teased into a multitude of fibrous strands - the plexus of Lushka<sup>+</sup>. Indeed, the urachus may cling to one artery alone and be bent and pulled over to one side or the other (Plate III). This process of tearing and teasing is further accentuated in the stress of adult life and especially in conditions of abdominal distension, such as ascites or pregnancy. In the bodies of parous women it was not unusual to find a network of fine fibrous strands extending from the urachal apex to the umbilicus, spread over an area no less than three inches in width. As a general rule most of these strands come together again and form a more or less distinct cord below the umbilicus<sup>+</sup>. It is this cord that is frequently found on abdominal section and believed to be the upper end of the urachus.

It is easy to see how in the teasing-out process necessitated by the descent of the urachus, the latter itself, being attached on either side, may be torn asunder and the epithelial cells which always exist/

<sup>#</sup> See also  
Plates II & III.

<sup>+</sup> Plates III  
& II.

<sup>+</sup>Plates I, II  
& III. F.

exist in its core spilled out into the space between the transversalis fascia and the peritoneum. I shall be able to demonstrate later on<sup>+</sup> how cystic adenomatous masses may arise from such cells and cysts be formed in precisely the same manner as inclusion cysts arise when skin epithelium has been carried into the deeper tissues. Not only so, but a continuation of the splitting may actually open the canal of the urachus and allow tiny drops of urine and possibly septic organisms to pass into the transversalis-peritoneal space and give rise to septic effusions. The latter are almost bound to be fairly strictly localized, as the individual fibrous strands gain an attachment to both peritoneum and fascia and thus shut off this space into a large number of compartments.<sup>g</sup>

<sup>+</sup> p. 99 ,  
fig. 39.

<sup>g</sup> p. 78 .

In the examination of a large number of adult specimens, the average length of the urachus was found to be only 5 to 5.5 c.m., so that there is comparatively little increase in its size after birth, viz. - 2 to 2.5 c.m. - the length at birth, as already stated, being about 3 c.m.

The statement of Wutz<sup>(a)</sup> that it grows continuously and rapidly with the development of the individual was therefore founded on a mistaken idea of the anatomy; but I have been able to confirm his other/

(a) Loc. cit.  
See p. 9 .

other observation that far from the epithelial canal tending to be obliterated, it is, in some cases, actually wider and more developed in the adult than in the child.

5 Before passing on to give a detailed description of the anatomy and histology of the urachus as found in the adult, it is as well to state that its actual upper end was determined, not only by the point of junction with the obliterated hypogastric arteries, or some portion of them<sup>+</sup>, but also by cutting and examining sections at various levels. For some distance above the bladder, the patent urachal canal, as observed in sections, is so characteristic a structure<sup>§</sup> that no mistake can be made. Even at higher levels, and right up to the umbilicus in the newly-born, the obliterated core of the canal has a characteristic whorled arrangement<sup>+</sup>; while once the first attachment to the arteries is passed, the sections show merely normal fibrous tissue<sup>§</sup>, clearly proving that at this point the urachus ends.

25 The fibrous strands which carry out the obliteration are longitudinal in direction and appear in cross section as bundles cut transversely. Each of these bundles corresponds to one of the tiny cell columns into which the main block of central epithelium fragments as a prelude to obliteration (Fig. 29, (3) - (12)).

<sup>+</sup> Plates I, II, III. J. and p. 10.

<sup>§</sup> Figs. 4 and 29 (12).

<sup>+</sup> Fig. 4.

<sup>§</sup> Fig. 6 and 41.A.

STRUCTURE AND FUNCTION OF THE  
URACHUS IN THE ADULT.

The limits of the urachus being defined, its general anatomy will now be given, and I shall then consider the variations in the cases I have examined, together with the findings of others who have studied the subject. It extends upwards from the anterior border of the bladder, usually arising about five millimetres to a centimetre below the apex, occasionally from the apex itself and in rare instances from the superior surface close to the apex. Its extreme limits in length are 3 - 10 c.m., but in the vast majority of cases it is 5 to 5½ c.m. It is broad where it leaves the bladder and somewhat flattened from before backwards, having as a rule a breadth of 8 m.m. and it tapers to 2 m.m. at its apex, where it is joined by the obliterated hypogastric arteries. It lies between the peritoneum and transversalis fascia in the space of Retzius, and is surrounded by loose areolar tissue, so that it is freely mobile in its lower part to allow it to move with the expansion of the bladder. At its apex, however, it is more firmly attached and closely applied to both peritoneum and fascia. In no instance that I observed was there any trace of a meson, though Binnie<sup>(a)</sup>/

(a) BINNIE, J.F. Amer. Practice of Surg. Vol. VII. p. 80.

Binnie<sup>(a)</sup> quotes a case where a urachal cyst lay among coils of small intestine and attributed the condition to a persistence of a meson which he alleges always exists in an early stage of development. A good deal of discussion has arisen on this point, but it is mostly based on the erroneous supposition that the urachus reaches the umbilicus and is therefore of little value.

At its upper end, the urachus may become continuous with a cord of fibrous tissue running up to be attached to the lower part of the umbilical circle (Plates I & II F.); it may apparently split into two parts, one attached to each obliterated hypogastric artery; or it may be dragged to one side or even recurved downwards by its attachment to a single artery (Plate III. J).

BLOOD SUPPLY: The blood supply of the urachus is extremely definite<sup>+</sup> and has a bearing on certain pathological features connected with congenital umbilical fistula<sup>§</sup>. It can be well followed in the injected body of a full-time foetus. In the latter, it is to be noticed that no branch arises from the hypogastric arteries between the placenta and the superior vesical arteries. These, minute and hair-like at this stage, take origin from them, one on either side about the level of the symphysis pubis. One of these, usually the left, passes up on the lateral/

+ Figs. 2.A  
& B.

§ See p. 73.

lateral aspect of the bladder (See fig. 2.A, SV) and, reaching the apex, gains a close association with the urachus, lying on its ventral surface. This artery, if the injection has been well carried out, can be traced along the allantoic remains as far as the junction of the umbilical cord with the skin, and in some instances even into the cord itself.<sup>#</sup> It will be shown later<sup>P</sup> how the presence of this artery (which is always a very definite structure in the adult as well as the child, and may be called the urachal artery) causes the increased vascularization of the first part of the cord in cases of congenital fistula. This vascularization prevents the dry gangrene, in virtue of which the cord normally separates; the separation does not take place, and the large red tumour which forms such a remarkable feature of these cases is accounted for<sup>S</sup>.

In addition to the urachal artery itself, the umbilical region receives a blood supply from a branch of the superior vesical artery of the opposite side to that which forms the urachal artery<sup>+</sup>. This branch runs up parallel to the urachus. The deep epigastric arteries, also which gain the external surface of the transversalis fascia, give off branches opposite the apex of the bladder. These run upwards and inwards and once more piercing the transversalis fascia from without inwards anastomose with/

<sup>#</sup> Fig. 2.B.,  
SV.  
<sup>P</sup> p. 73.

<sup>S</sup> p. 70.

<sup>+</sup> Fig. 2.A.,  
st.

with the terminal portions of the urachal and superior vesical arteries (Fig. 2.A, ar.).

STRUCTURE OF THE URACHUS AND ITS  
ATTACHMENT TO THE BLADDER.

5 A systematic study of the structure of the adult urachus was made by Lushka<sup>(a)</sup> in 1862, and again by Wutz<sup>(b)</sup> some twenty years later. The latter made an examination of seventy-four post-mortem bodies and his discoveries as to the proportion of cysts and dilatations will be referred to in a later chapter<sup>†</sup> 10

+ p. 80.

He also examined, as did Lushka, many specimens, and, by attempting to inject the canal and pass bristles into it from the bladder, determined the proportion of instances in which a communication took place.

15 Both these authors by teasing out the elements and treating them with acetic acid, were able, even with the microscopes of that time, to obtain a very just conception of the structures concerned, but the extreme accuracy obtainable by section-cutting and 20 the higher powers of the modern microscope was denied them.

Lushka pointed out that the adult urachus always contained a central epithelial canal, although this was/

(a) VIRCHOW ARCHIV. - Band XXIII, Heft 1 & 2, p. 1 - 1862.  
ANAT. DES MENSCHEN - Vol. II., pt. II. p. 227.

(b) VIRCHOW ARCHIV - Band XCII, p. 387 - 1883.

was interrupted and sacculated at various points, and my own observations enable me to state, dogmatically and with confidence, that the complete obliteration of this canal by fibrous tissue never occurs<sup>+</sup>. It is true that the transitional epithelium lining it frequently fills it with the cells desquamated from its inner layer<sup>§</sup>. No doubt in a viscus such as the bladder, these constant products of desquamation are washed out in the urine, while from the urachus they cannot escape, but, degenerating in the canal, form a kind of cast by which the latter is in places completely filled<sup>(a)</sup>. At other points, what was a canal has later become a solid column of cells<sup>¶</sup>. So far, however, from the epithelial cells being destroyed, they display an activity of reproduction and multiplication, pushing outwards into the connective tissue when they can no longer find room in the canal<sup>#</sup>, that one marvels at the rarity of gross pathological conditions arising in this way. Small adenomatous structures and cysts are the rule rather than the exception<sup>+</sup>.

This matter will be dealt with later<sup>§</sup>, but it is to be hoped that a knowledge of the true histology largely given by Lushka will now receive full recognition in order that those who study the subject may have a good working basis for explaining the somewhat difficult/

<sup>+</sup> Figs. 5-6, 7, 8, 9, 10, & Plate VI.A

<sup>§</sup> Figs. 8 & 9.

<sup>(a)</sup> Plate VI.A.

<sup>¶</sup> Fig. 16. and 38 (2)B. Rarely, however, is there a complete absence of lumen.

<sup>#</sup> See Fig. 9 and Plate VI B.

<sup>+</sup> pp. 81 and 86. Fig. 20, A-D.  
<sup>§</sup> Chap. III.

difficult pathological conundrums that arise. The following, for example, are some of the descriptions given even in the latest editions :-

5 Quain's Anatomy - "The urachus is composed of fibrous tissue mixed at its base with plain muscle fibres". (Vol. II, pt. II). Lushka's description is then given in small type.

10 "This part of the cloaca loses its lumen about the fifth week, and from it is derived the fibrous cord of the urachus. The cavity of the urachus is sometimes not lost so early, and in rare cases has been found persisting in the child or adult as a "pervious channel". (a)

15 "While the epithelium of the urachus completely disappears, the surrounding concentrically arranged connective tissue persists as a cord, which forms the ligamentum vesico-umbilicale medium". (b)

20 "The part of the allantois within the abdomen, stretching from the umbilicus to the apex of the bladder, becomes the urachus, a fibrous cord in which all trace of the allantoic cavity is lost". (c)

From the descriptions of these famous anatomists, it is apparent that the universal persistence of the urachal/

(a) Cunningham's Anatomy, p. 1314 - 1922 ed.

(b) W. Felix - Human Embryol. - "Keibel & Mall", Vol. II, p. 869 - 1912.

(c) Sir Arthur Keith - Human Embry. & Morph., 1921, p. 396.

5  
urachal canal is not generally recognised, though it can easily be verified by the sectioning of any urachus taken at random. Indeed, no better example exists in the body of the extraordinary persistence of epithelium in rudimentary structures, and its renewed activity in adult life.

10  
As far as I can ascertain, the only authors to study the normal anatomy of the urachus (since Lushka and Wutz) have been Binnie and Clendenning<sup>(a)</sup>. The latter examined specimens derived from sixteen adults and six foetuses. His findings differ markedly both from Lushka and my own and may be summarized as follows :-

- 15  
20
1. In seven adults and six foetuses the bladder showed a distinct diverticulum from 1 to 2 c.m. deep where the urachus is attached.
  2. In none of the cases were there found lacunae lined with epithelium.
  3. The average adult urachus was 12 c.m. x 1.5 c.m.

25  
This worker was apparently considering the urachus as reaching the umbilicus, but even so, 12 c.m. was less than that found in any case of my series for this interval. Lacunae lined with epithelium were also found by me in a great percentage of cases and were/

---

(a) J. F. BINNIE - Amer. Prac. of Surg., Vol. VII,  
p. 80.  
Do. - "Development of the Urachus",  
Journal Amer. Med. Assn., Chicago,  
Vol. LVII, p. 109 - (1906).

were, indeed, looked on by Lushka as a normal anatomical feature. While my observations of innumerable adult bladders in the post-mortem and dissecting room, as well as in museums, and by cystoscopy, did not show any communication with the bladder, much less sacculation in so large a proportion as 50 per cent. In the foetus, of five cases examined, there was only a single instance where there was a definite opening of the canal into the bladder<sup>§</sup>. I think this is below the average; but, at the same time, the knowledge gained of the behaviour of the urachal epithelium as studied in sections, rather leads to the conclusion that as the condition is in the new-born child, so will it remain in the adult; or, in other words, no further obliteration of this portion is likely to take place after birth.<sup>(a)</sup>

In its gross anatomy<sup>#</sup>, the urachus presents a constancy of feature that enables one to give a general description of it. On its ventral surface alone, it is lined by peritoneum<sup>+</sup>. This serous coat is deficient where it pursues an intramural course of 1 c.m. in the wall of the bladder<sup>+</sup>. Next to this, from without inwards, is a somewhat loose areolar layer and a fine connective tissue coat<sup>§</sup>. The comparatively/

§ Figs. 14-17.

# See Figs. 7 and 8.

+ Fig. 7.P.

+ Figs. 15 and 16.

§ Fig. 7. An & Adv.

(a) On the other hand, active proliferation leading to cyst occurs more frequently after middle life.

5 comparatively thick adventitial coat of the bladder is not prolonged to cover the urachus. Indeed it is a somewhat striking circumstance that the outer coat of the bladder forms a collar-like deficiency through which the urachus ascends<sup>#</sup>. This should be considered in estimating the relative weakness of the bladder wall caused by the urachal insertion. It will be argued later<sup>†</sup>, that many of the cases of acquired vesico-umbilical fistula that have been 10 attributed to the reopening of a urachus - an impossibility when its real anatomy is considered - are in all probability due to a rupture of the bladder at this point, the urine ultimately passing up in the peritoneo-transversalis space and breaking through at the weak point formed by the umbilical pit. 15 Cases illustrating this will be found - one in the museum of the College of Surgeons in Edinburgh and one in that of the College in London. These cases will be referred to again<sup>#</sup>.

20 The muscle fibres which form the next layer of the urachus<sup>+</sup> arise in quite a definite fashion from the bladder. The musculature of the latter viscus is well described by Schafer<sup>(a)</sup>. Two bands of longitudinal muscle fibres sweep, like broad straps, from the prostate in front to the prostate behind, over the fundus<sup>§</sup>. They pass, on either side, past the/

<sup>#</sup> Fig. 11 (1)

<sup>†</sup> p. 75.

<sup>#</sup> pp. 42 and 44.

<sup>+</sup> Fig. 7.M.  
Fig. 11 (2).

<sup>§</sup> Fig. 11.A  
(3).

(a) QUAIN'S ANATOMY - Vol. II. pt. I.

the urachal canal, contributing no fibres to it. It is easy to see how the contraction of these bands, when the bladder is being emptied, will bring their inner or medial surfaces firmly together, thus forming a strong support, in the moment of danger, for the weak point of the urachal insertion. This is exactly analogous to the support which the contracting recti abdominales give in the moment of their contraction to the weak point in the middle line of the lower abdominal wall.

Superficial to the longitudinal bands of muscle fibre of the bladder are other fasciculi which run more or less obliquely. Many of their fibres pass up along the urachus<sup>+</sup> giving it a complete investment in its lower part, but gradually thinning out as they ascend; and, by their attachment to the upper fibrous part of the structure forming the musculo-tendinous apparatus of Lushka. As the urachus is normally attached to the anterior border of the bladder, it follows that the anterior fasciculi are longer than the posterior ones.

Two points of interest arise in connection with the muscular coat of the urachus :-

- (1.) Its relation to the not uncommon occurrence of sacculation of the canal.
- (2.) Its bearing on the function of the urachus in the adult.

(1)/

+ Fig. 11 (2)

(1) It is a well-known fact that the irregularity of the bladder's muscle fibres causes weak spaces to appear in distension, and through these the mucous membrane is thrust, forming sacculi or diverticula. Such sacculi are not uncommon in the lower part of the urachus; and, while in the section on cysts it will be demonstrated that they have, as a rule, a different etiology, yet, where a communication with the bladder exists, it is possible that similar pressure causes the mucus membrane of the urachus to be thrust between the muscular fibres.

(2) The urachus may be considered from the point of view of its adult function, as a muscle whose tendon gains attachment to the umbilical region through the medium of a fibrous cord derived from the obliterated hypogastric arteries.<sup>#</sup> That its purpose is not that of a mere passive suspender of the bladder apex is suggested by the fact that the intramural part of its canal is tortuous and corkscrew-like in form<sup>+</sup>, suggesting that the whole structure undergoes lengthening and shortening in life.

Its function may be somewhat similar to that of the muscoli papillares of the heart, its purpose being to take in the slack as the bladder empties and so facilitate the process, just as one in emptying a rubber hot water bottle lifts up the bottom end/

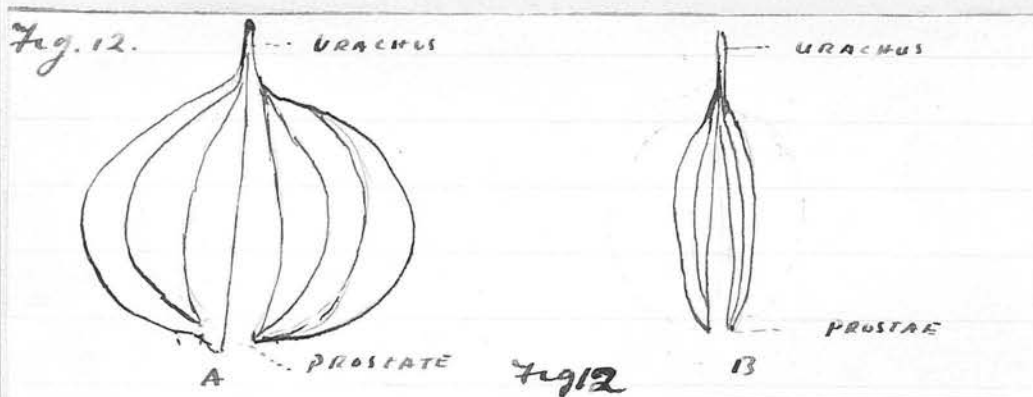
Chap. III.

Plates I & II.

<sup>+</sup> Fig. 11. 4.

end to prevent it flapping over and so hindering the outflow. A cord with a similar purpose is attached by the Arabs to the closed end of their water skin.

It is also helpful to remember that the muscular fasciculi of the urachus spread out in cone-shaped fashion over the bladder, gaining an attachment to the prostate. The urachus may give a "point d'appui" for the contraction of these fasciculi whereby the bladder is compressed uniformly from without in, thus steadying it while the strap-like longitudinal bands of the detrusor urinae are acting. (Fig. 12.A. and B.)



A. Muscle fibres relaxed. B. Muscle fibres contracted.

Deep to the muscle layer, and intimately connected with it, is a dense layer of fibrous tissue<sup>+</sup>, and internal to that, somewhat loosely arranged connective tissue. So loose is this layer that the urachal canal can easily be dissected out with care and appears as a white tubular structure of perfectly uniform bore in/

<sup>+</sup> Fig. 7. c.

in its whole extent. The pyramidal appearance of the urachus as a whole is in no way reflected in it and its general contour suggests a small thoracic duct<sup>5</sup>. Its diameter is one millimetre. It can usually be traced to the upper end of the urachus and always pursues a somewhat tortuous course through the muscular coat of the bladder till it reaches the external surface of the mucous membrane of the latter<sup>#</sup>. #Plate IV. To this point it can, with the aid of the dissecting microscope, be traced with the greatest facility<sup>(a)</sup>; (a) Fig. 42. but its manner of ending is subject to considerable variation<sup>TP</sup>.

In some instances it communicates directly with the bladder\*, its epithelium becoming continuous with the bladder epithelium (Fig. 14, 1). The manner and frequency of this communication is a matter of great interest and will presently be considered at length<sup>+</sup>. + p. 31. In other instances its fibrous coat splits into a number of strands which spread out and lose themselves in the submucosa<sup>5</sup>. Fig. 11, A-H. Plates IV. & V. \* Fig. 44. Fig. 11, A.B. E.F.H.

Plate V. (Fig. 11, G.) shows an instance in which the canal ends blindly in a cystic dilatation<sup>(a)</sup>. (a) but see p. 93. The urachal artery in the adult emerges from the muscular substance of the bladder to become associated with the urachus after it leaves the bladder wall, and does not follow the urachal canal to the submucosa<sup>TP</sup>. TP Fig. 11, 5

MICROSCOPIC STRUCTURE OF THE URACHAL CANAL XX Figs. 5-10  
and 13, A & B

The urachal canal proper is but loosely connected to the outer coats by areolar tissue, and is composed of an external layer of condensed fibrous tissue disposed in a circular manner. This usually shows evidence of proliferation where it abuts on the lining epithelium<sup>†</sup>; the latter being surrounded by one or two layers of young fibroblasts whorled around it. These are in direct contact with the outermost layer of epithelial cells, no basement membrane intervening (Fig. 10.) (Fig. 13. B.).

† Fig. 10. F.  
and 13. A & B.

The epithelium itself is as a rule six or seven layers deep in the child, though there may be no more than two layers<sup>§</sup>. It has rarely the regular structure of the transitional epithelium of the bladder, the deep cells being of the same type as the superficial. In one instance, however, I observed horizontal surface cells with pear-shaped ones fitting into recesses in them as in the vesical epithelium, but two nuclei were seldom present in a single cell. In some instances the nuclei of the outermost layer of cells lie with their long axes at right angles to the diameter of the canal (Fig. 10). In most cases, however, the long axes of the cells and nuclei point towards the centre. The cells of the innermost layer, i.e., those next to the lumen, may usually/

§ Figs. 9 &amp; 10

usually be observed to show a tendency to desquamate<sup>+</sup> and become free; and sometimes aggregations of these degenerated cells almost entirely plug the lumen<sup>S</sup>. It is noteworthy that in those cases where communication with the bladder is established, the lumen remains clear near the opening as the desquamated cells are able to find their way into that viscus and escape with the urine.

+ Fig. 9.

<sup>S</sup> Fig. 5 and  
Plate VI. B.

The nuclei<sup>#</sup> are vesicular and oval and stain lightly. They are about 12 m. in length and 9 m. in breadth. There is a definite nucleolus, sometimes two, and a loosely arranged chromatin network. In view of the active proliferation that was taking place, the absence of clearly defined mitotic figures was remarkable, though division by what appeared to be an amitotic process was frequently observed.

<sup>#</sup> Fig. 13.B.

In most cases the thickness of the epithelial lining was not uniform, the cells being heaped up at one segment into ten or twelve layers while at other points there were only two<sup>P</sup>. The size of the lumen varied from a mere slit to a canal fully half a millimetre in diameter, and appeared to bear no constant ratio to the age of the subject. The general thickness of the epithelial part increased slightly with age, showing that some increase of the elements had taken place; and as the length of the canal is greater/

<sup>P</sup> Plate VI. B.

greater in the adult than in the child, it is apparent that proliferation must have occurred, but not by any means to the extent postulated by Wutz<sup>+</sup>.

+ See p. 12.

Lushka<sup>g</sup> observed that the epithelial tube did not remain central in its fibrous covering throughout its whole course, and a view of a specimen passed between two slides and seen under a low power shows it deviating from side to side in its ascent. The same author noticed that it was beset with numerous "out bulgings"<sup>#</sup>, but a study of sections will show that these owe their origin, as a rule, not to simple dilatations, but to masses of epithelial cells which have become detached from the central epithelium and have given rise to small adenomatous formations, or by central degeneration to tiny cysts<sup>#</sup>. The length of the central canal varies from 3 c.m. to 7 c.m., i.e., it is practically coterminous with the length of the urachus. It is not, however, pervious in its entire extent. Its lumen is obliterated at various points by the accumulation of desquamated cells, by the epithelium of one side meeting that of the other, or by the central core of epithelium splitting up into several smaller cores<sup>+</sup>. It may be patent above and below and impervious in the middle or be shut off into numerous pervious sections like a bamboo-cane.

<sup>g</sup> Loc. cit.  
(See p. 5)

<sup>#</sup> Figs. 43 &  
44.

<sup>#</sup> See p. 80.

<sup>+</sup> Fig. 29,  
(2) - (9)

SECRETION OF THE URACHAL EPITHELIUM.

5 Lushka described the contents of the urachal canal as consisting of pigmentary, fatty and amyloid substances the products of cell degeneration; also of fat molecules and corpora amylacea. Wutz denied the presence of the last-named<sup>(a)</sup>.

10 It is difficult to determine whether the homogeneous pasty mass which may fill some portions of the normal urachal canal and dilatations of it is, in part, a true secretion, or composed entirely of the degenerated remains of desquamated epithelial cells. The point is of importance and has a bearing on the etiology of urachal cysts. I have suggested earlier in this paper<sup>+</sup> that some of these may be of the nature of inclusion cysts arising from cells left in the tissues of the abdominal wall during the descent of the urachus<sup>§</sup>. If these cells produced no secretion, such cysts could hardly arise except by cell proliferation and central degeneration.

20 That the substances found in the lumen are, in part, derived from merely degenerated cells, can be shown by watching in serial sections the whole process of degeneration and by the presence of nuclei in the mass<sup>§</sup>. To settle the point definitely, further investigation is required, but on the whole I am inclined to believe that until there is more evidence/

(a) Nicholson has recently affirmed their presence in adenomatous cysts. I failed to observe them.

+ p. 12.

§ See p. 98. and figs. 39 and 40.

§ Fig. 5.

evidence, we must consider the content of the urachal canal and the adenomatous spaces derived from it, to represent merely epithelial debris. The cysts which undoubtedly arise from detached cells<sup>P</sup> would then in every case be due merely to degeneration taking place in the central parts of the cell masses produced by the multiplication of these cell remains.

<sup>P</sup> Chap. III.

The process of obliteration of the canal proceeds more or less throughout life from above downwards, and in one section taken from a subject over fifty, actual vascular granulation tissue was seen to be invading and replacing the epithelium (Figs. 30 and 31).

This process, however, never reaches very far down and is accompanied in many instances by increased epithelial growth; and the detachment of the cells leads to those curious adenomatous formations so common in the adult urachus<sup>+</sup>.

<sup>+</sup> See Chap. III.

METHOD OF TERMINATION OF THE LOWER  
END OF THE URACHAL CANAL.

From time to time great interest has been taken in ascertaining in what percentage of cases the urachal canal is in communication with the bladder, and the means by which urine is prevented from ascending through the orifice when this is present.

Peyer, at the end of the 17th century, maintained/

maintained, in opposition to Caspar and others, that the urachus was pervious during the foetal period<sup>(a)</sup>. J. G. Walker<sup>(b)</sup> stated in 1775 that the canal was present at all stages of life and capable of admitting a small probe. Meckel and Arnold on the other hand held that it was usually a fibrous cord and only occasionally hollow (a). Wutz<sup>(c)</sup> considered that, in most cases, there was a communication with the bladder and described a small transverse fold of mucous membrane which prevented urine passing. Later writers, notably Doran<sup>(d)</sup>, have discussed the presence or absence of the so-called Wutz valve<sup>#</sup>, in relation to the causation of vesico-umbilical fistula.

# See fig. 14, where valve is absent.

I have approached this subject from two points of view. In the first place, the apical region of the bladder was inspected with a lens of high magnification; and then the urachal canal was dissected out in the same specimen under a dissecting microscope magnifying the image forty times. The exact nature of the termination of the urachus at its bladder end was determined in this way, in a large number of bodies of all ages. Where a communication with the bladder existed, its extent was gauged by passing/

- (a) FREER: "Abnormalities of the Urachus", Anns. Surg. 1887, CVII - 119.  
 (b) J. G. WALKER: Annot. Acad. Berol - 1775.  
 (c) WUTZ: Virchow's Archiv. XCII. p. 357 - 1883.  
 (d) BART.'S HOSPITAL REPORTS: XXXIV, 1898 - 33.

passing a thin bristle and by injecting a methylene blue solution. Finally, serial sections were cut and stained.

In the second place, all the specimens of bladders in both the surgical museums of Edinburgh and most of those in London were examined. As a large number of these specimens were taken from subjects who had suffered from obstruction to the outflow of urine for long periods, it was anticipated that any urachal orifice would be exaggerated and dilated. It was astonishing to find the large proportion of these cases which showed this phenomenon. Twenty-one post-mortem specimens were examined from this point of view and the various methods in which the urachal canal ended are shown in fig. 11 (A - H). In seven, there was a communication between the lumen of the urachus and the bladder. The nature of this communication was as follows :-

1st Method (Fig. 11.E). A sacculus formed of mucous membrane only, was protruded between the fasciculi of the circular muscle of the bladder<sup>+</sup>. This sacculus, present in two cases, would admit the tip of one finger. The membrane lining it was entirely embedded in the muscular wall of the bladder and the mucous membrane of the latter was closed about its vesical orifice in folds, obscuring it and giving much the same appearance as the urethra/

+ See Fig.42.

urethra presents when seen through a urethroscope in process of withdrawal. The urachal canal about .5 m.m. in bore could be injected for about half a centimetre from the apex of the sacculus. Specimen 28 - 50 in the museum of the Royal College of Surgeons, Edinburgh, shows a beautiful saccule of this nature dilated as the result of urinary obstruction.

It may be noted, in passing, that the arrangement of the muscles<sup>+</sup> so strengthens this potential weak point that it is one of the rarest sites for a pathological sacculation; but occasionally a large diverticulum does exist here and may even contain calculi as in a case reported by Capt. Campbell Dykes<sup>(a)</sup> in 1910. In this instance one stone of half an ounce, and one section of another hour-glass one weighing  $1\frac{1}{2}$  ounces were extracted from the dilated lower end of the urachus. In the Royal College of Surgeons' Museum in London, specimens 3728, 3721A, 2232 and 2223, all illustrate a protruding pouch of this nature.

Method 2. This is illustrated in fig. 11.A, and was observed in one case - an adult female. The orifice opens at the apex of a pyramid, resembling the crater at the top of a volcano. Lushka<sup>(a)</sup> observed/

(a) Loc. cit.  
See page 5.

(a) LANCET: 1910, Vol. I, p. 566.

observed a similar condition. A beautiful illustration of it is shown in specimen 3730 in the museum of the Royal College of Surgeons, London, and is described in the catalogue as "a papillary projection of unknown origin".

Method 3. (Fig. 11.B). This occurred in three cases and appears to be the most common form<sup>+</sup>.

+ Fig. 44.

There is no projection or depression: the opening is flush with the mucous surface and appears as a pin-point orifice which does not interrupt the even sweep of the bladder dome as seen from within.

In one of these cases such a valve as described by Wutz guarded the orifice (fig. 11.H). The nozzle of the pipette had to be gently inserted past this valve before the injection fluid would enter the canal. This was the only instance in which such a structure existed; so that my observations confirm those of other writers in believing that Wutz was wrong when he stated that the opening was always so guarded.

Method 4. In the seventh and final case of my series, the urachal canal opened at the bottom of a dimple 3 m.m. in diameter and 3 m.m. deep (fig. 11.F).

A great deal of information could be obtained on this subject if cystoscopists would inspect this part of/

of the bladder more carefully and give their observations as to the frequency and nature of the opening. I have seen a picture of such a sacculus as that shown in Fig. 11.E, as viewed through the cystoscope; and Mr Hartley of Edinburgh referred me to a case he himself had seen in which a septic cyst in the course of the urachus could be seen by cystoscopy discharging into the bladder at the apex.

A longitudinal section showing the continuity of urachal and bladder epithelium, as seen in one of my cases, is shown in fig. 14.

In none of this series did the injection fluid pass in more than 1 c.m., being there blocked by epithelial debris filling the canal. It was also found by subsequent sectioning that the fluid would pass in even when the lumen was not more than .1 m.m. in diameter.

The difficulty of forcing injection fluid further than this even under considerable pressure seems to show the improbability of the formed canal ever reopening in adult life. This discounts the usual explanation of acquired urinary umbilical fistula so frequently given.

Even where there was no communication with the bladder, a slight depression or red spot on the bladder mucous membrane frequently marks the point of insertion of the urachus on its outer surface<sup>(a)</sup>. In all my/ (a) Fig. 11.D.

my cases the fibro-epithelial canal could be traced right down to the submucosa, where it either split into numerous fibres radiating out into the fibrous tissue of this layer (fig. 11.C)<sup>+</sup> or ended in a pear-shaped blind dilatation<sup>(a)</sup>. (Fig. 11.H. Plate V).  
 + Plate IV.

#### DEVELOPMENT OF THE URACHUS.

For a considerable time, it was believed that part of the bladder and the whole of the urachus were derived from the allantois. It is now definitely settled that the latter structure takes no share in the formation of the bladder, which is partially cloacal and partially Wolffian in origin. Entire agreement has apparently not yet been reached in regard to the urachus. Sir Arthur Keith<sup>(b)</sup> still maintains its allantoic origin. On page 390 of his "Human Embryology and Morphology" the following passage occurs :- "The part of the allantois within the abdomen stretching from the umbilicus to the apex of the bladder becomes the urachus".

W. Felix<sup>(c)</sup>, however, writing in Keibel and Mall's "Human Embryology" maintains that the apex of/

(a) It is to be noted, however, that this is not a simple dilatation of the canal but a true adenomatous proliferation of the epithelium (See fig. 25 and 26).

(b) HUM. EMBRYOLOGY & MORPHOL.: 1921, p. 390.

(c) KEIBEL & MALL: Man. of Hum. Embryol. Vol. II, p. 869 - 1912.

of the ventral cloaca is carried in a cephalic direction with the umbilicus and that its upper part is obliterated to form the urachus. He says :-

"In man, a ventro-cloacogenic and mesodermal bladder develops, an allantoic origin such as was formerly supposed to occur does not exist ... A view of the anterior abdominal wall from behind (in embryos of 10-24 m.m.) shows that the two umbilical arteries bound a triangular area, the vesical plate, whose apex is, of course, formed by the umbilicus. Within this area, the bladder lies in such a way that its cranial apex reaches the umbilicus, where it is connected with the remains of the allantoic stalk. This position the bladder retains at birth, except that its apex diminishes more and more and finally becomes the urachus, this structure being accordingly a product of the bladder, i.e., of the cloaca and not of the allantoic stalk."

Professor Arthur Robinson<sup>(a)</sup> also states :-

"The extreme cephalic end of the anterior part of the cloaca tapers gradually and beyond the umbilicus is continuous with the allantois. This part of the cloaca loses its lumen about the fifth week, and from it is derived the fibrous cord of the urachus."

While the essential similarity in origin may still, perhaps, be considered unsettled<sup>(b)</sup>, it is worth noting that in the horse, the apex of the bladder reaches at birth to the umbilicus, so that so-called patent urachus in foals is not a very uncommon condition.

The essential similarity and continuity of the two epithelia, and to a less extent the muscle and fibrous coats of the two organs, is in favour of a common/

(b) See, however, pp. 69 and 83.

(a) CUNNINGHAM'S TEXT-BOOK OF ANAT. 1922, p. 1314.

common origin for the urachus and bladder.

Evidence may also be led from the pathological side. G. W. Nicholson, Lecturer in Morbid Histology at Guy's Hospital, in the course of a somewhat exhaustive study of epithelial rests, makes the follow-

ing generalization<sup>(a)</sup>:- "On summarising these brief abstracts from the literature and on comparing them with the tissue found in the urachus, the following conclusions appear to be justified. All the normal glands of the cloaca as well as those that are formed in pathological conditions, are of one type, namely, prostatic glands. Should parts of the cloaca that disappear during later development, fail to do so, they are able to undergo differentiation into identical glands. This potentiality does not reside exclusively in the endodermal cloaca, but is shared by that part of the mesodermal Wolffian duct that forms the trigone of the bladder and gives off the ureter".

Sections which Dr. Nicholson kindly showed me of glands forming in the bladder wall from down-growth of epithelium, were exactly similar in structure to those I have observed in the urachus; and in one case the same type of gland was seen near the umbilicus, in a child of three years of age<sup>(b)</sup>, where the urachus had descended away from this region altogether. From the pathological side then, the evidence seems to be in favour of the view that the urachus is the modified - not obliterated - upper end of the foetal bladder.

Further evidence will appear in the chapter on fistula, showing that this view of its development is the only one compatible with the actual pathological conditions found in this anomaly (see pp. 69 and 83).

(b) Figs. 39 and 40.

(a) G. W. NICHOLSON: Guy's Hospital Reports -  
January 1922, p. 99.

CHAPTER II.

URINARY FISTULAE DISCHARGING AT THE

UMBILICUS. VARIETIES, PATHOLOGY AND

ETIOLOGY, WITH A SECTION ON THE

ORIGIN OF THE UMBILICAL TUMOURS WHICH

FREQUENTLY ACCOMPANY THEM.

---

VESICO - UMBILICAL FISTULAE.

The condition in which urine escapes from the umbilicus has been known for a very long time and cases are recorded as far back as the middle of the 16th century. Two of the most dramatic incidents in the pathological history occurred when Paget, some eighty years ago, passed his finger down through the umbilicus in a man of 40 and hooked out a ring-shaped calculus from the bladder<sup>(a)</sup>; and when Mickulicz, fifty years later, carried out a cystoscopic examination through the navel in a male child five years of age, where urethra was, of course, too small to admit the instrument<sup>(b)</sup>.

One or two cases, at least, of fistula in the umbilical neighbourhood will probably be remembered by every surgeon of experience; but such a multitude of pathological states may give rise to these discharges that a casual review of the literature is apt to give a false impression of the number of instances in which the discharge was derived from the urinary bladder.

Even in many of those cases reported, where urine escaped from the umbilicus, a careful study will assign other/

(a) MED.-CHIR. TRANS.: 1850, 2 ser. Vol. XV, p. 293.

(b) JAHN. UBER URACHUS FISTELN: Beit. z. Klin. Chir. Zuberg, 1900, Vol. XXVI, p. 323.

other causes than a patent urachus; and, indeed, false conceptions of the anatomy of this structure have led to the far too frequent assumption that it was the vehicle by which the bladder content was conveyed to the fistulous opening. Two museum specimens may be cited in illustration of this. The first is in the museum of the Royal College of Surgeons, Edinburgh, and shows the kidneys, bladder and anterior abdominal wall of a female child, 8 years old. The specimen is described as a patent urachus and the case from which it was derived is reported<sup>(a)</sup> by Caddel. The child suffered for one year from haematuria, followed by a few days of great pain, swelling and hardness of the abdominal wall; and later, by an escape of urine from the umbilicus. The discharge consisted of mixed pus and urine. She died from pyelonephritis. Caddel stated that a No. 6 catheter could be passed into the bladder from the umbilicus.

On re-examination of this specimen, it was noted in the first instance that the kidneys are lobulated and of the foetal type - a common accompaniment of malformations of the urinary tract; in the second place that the bladder is very contracted and chronically/

---

(a) F. CADDEL: Edin. Med. Journal, Vol. XXIV -  
Sept. 1878, p. 221.

chronic ly inflamed; and, in the third - and this is most important - the glass rod passed through the navel along the fistulous track does not pass into the bladder at all, but into the space of Retzius between the transversalis fascia and the peritoneum.

In other words, urine escaped from the bladder into this space and passed up in it till the weak point of the umbilical pit was reached. This was the stage where the child suffered from pain, brawny oedema and hardness of the abdominal wall. This case has been described somewhat fully because I believe that a re-opening of the urachal canal after the descent of the urachus would, on histological grounds, be extremely unlikely, and, if it did occur, would only act as a channel one third of the way to the umbilicus.

A much more feasible explanation of these cases is that the lower end of the urachus - if the canal communicates with the bladder - becomes dilated and weakened by pressure, or sepsis, or both. It gives way and a leakage of urine takes place. This outflow is fairly well confined in a linear channel bounded by transversalis fascia in front, peritoneum behind and the fibrous cords derived from the obliterated hypogastric arteries on either side. The effusion is conducted to the neighbourhood of the umbilicus, and, limited by the intimate adhesions of the peritoneum to the transversalis fascia at this point, finally bursts/

bursts through the comparatively thin partition between itself and the floor of the umbilical depression.

The second museum specimen is No. 3689 in the collection of the Royal College of Surgeons, London. This illustrates the bladder of an adult male the subject of stricture. The organ is dilated and the contents have forced their way through the weak point, just below the urachal attachment. The urine has burst out through the abdominal wall in the mid-line,  $1\frac{1}{2}$  inches below the umbilicus. The fistulous track is quite a well-defined structure; no doubt if the discharge had been at the umbilicus itself, the case would have been diagnosed as the re-opening of a patent urachus. The latter with its normal length of about 5 c.m. can be seen in the specimen lying internal to the fistulous track.

The re-opening of the urachal canal in a normal individual is impossible for more than a short distance (5 c.m.) above the bladder. The epithelial canal, even for the greater part of this distance, is little more than .1 millimetre in diameter and is largely occluded by epithelial debris<sup>+</sup>, while above this level the urine would have to bore its way through the centre of stout fibrous cords - first through the obliterated upper end of the urachus and then through the fibrous bands derived from the hypogastric/

<sup>+</sup> Plate VI.A.

hypogastric arteries<sup>§</sup>. Unless, then, a pathological process existing before birth has so altered the general arrangements that the normal descent and closure of the upper end of the ventral cloaca does not take place<sup>#</sup>, no urachal fistula can occur, though an easy route is provided from the bladder to the umbilicus in the transversalis-peritoneal space; and a weak point for its exit from a dilated bladder exists, in many cases, in a sacculatation of the vesical mucous membrane where the urachus is attached.

A study of recorded cases confirms one's conviction that acquired urinary fistula at the umbilicus is never due to a patent or persisting urachus, always keeping in mind that this structure rapidly recedes downwards from birth and loses its connection with the umbilicus almost at once \* .

#### VARIOUS TYPES OF DISCHARGE AND FISTULAE AT THE UMBILICUS.

Before undertaking the study of congenital patent urachus and its causes, a brief consideration of the pathological tumours and discharges is in order, and indeed essential, to give a clear idea of the differential diagnosis. From time to time, in looking up the literature, one comes across rather extraordinary examples of these conditions.

Professor/

<sup>§</sup> See p. 11  
and fig. 4.

<sup>#</sup> p.66 seq.

The only exception to this is to be found where a congenital fistula that has closed soon after birth re-opens in later life, and even in these cases it is probable that no urachus has formed and the bladder reaches the umbilicus.

\*

Professor T. S. Cullen of the Johns Hopkins University has collected a fund of information on this subject in his book on the Umbilicus<sup>(a)</sup> and I should like, at this point, to acknowledge the help I have received in tracing cases from the excellent Bibliography appended to this work. Among the most important members of the group under consideration are cases of fistula, cysts and tumours arising from the omphalo-mesenteric duct and its remains. Dr. G. W. Nicholson<sup>(b)(c)</sup> has recently made and published some striking observations showing how gastric glands occur in the simple raspberry tumour of the umbilicus, through differentiation of entodermal cells and vitelline duct remains. Dr. Nicholson is publishing further observations on this subject in the next Journal of Pathology and Bacteriology and very kindly showed me some of his slides in advance. So typical is the arrangement here that no confusion could exist between it and that of the structure derived from the urachal epithelium in my sections, which will be further described in the chapter on cysts<sup>+</sup>.

<sup>+</sup> Chap. III,  
p. 98 seq.

In addition to this group, there is, of course, another of inflammatory origin, where granulomatous formations/

- (a) "EMBRYOLOGY, ANATOMY AND DISEASES OF THE UMBILICUS, TOGETHER WITH DISEASES OF THE URACHUS".  
W.B. Saunders - 1916. Phil. & London.
- (b) JOURN. OF PATH. & BACT. Vol. XXV, 1922, p. 201.
- (c) GUY'S HOSP. REPORTS, Jan. 1922, p. 75.

formations, sero-purulent discharges and even calculi occur. An example of the latter occurred in my own practice in a male aged 28, in whom the umbilicus was obscured by a black eschar on the summit of a red induration, surrounded by a circle of blebs - the whole resembling a malignant pustule. From the depths of this umbilicus a shiny oval cholesteatoma fully 2 c.m. in length by one in breadth was removed.

Examples of cases where retroperitoneal and abdominal fluids have escaped from this region, and where the pus from appendix and liver abscesses from peritonitis and even from a suppurating ovarian cyst have discharged here, may all be found. Bile, gallstones and echinococci cysts have been noted and in one remarkable case quoted by Petrequin and Foltz, a uterine sound introduced by an abortionist was lost in the abdominal cavity and ultimately appeared in this region<sup>(a)</sup>.

Another class of case liable to cause confusion is that where a foreign body has been introduced into the navel and caused an abscess, the cause of discharge from which is difficult to diagnose. Fabiege reports a case where a wild-oat straw escaped when an abscess discharging at the umbilicus in a child of one/

(a) LYM. MED.: 1869, III, 509 (rep. Cullen loc.cit.)

one month was opened<sup>(a)</sup>. A hitherto unpublished case occurred in the clinic of Mr Alexander Miles of Edinburgh, by whose kindness I am able to report it. A young single woman aged 23 was admitted on the eleventh of March 1922, complaining that for eleven weeks she had had pain in the umbilical region. She then noticed a ring of redness and the part became tense and painful to the touch. At first there was a watery discharge, then a sero-purulent and finally a purulent one. This was intermittent in character and, on one occasion, was absent for a fortnight. A probe could be passed for some distance into the umbilicus. A provisional diagnosis of abscess connected with urachal or vitelline duct remains was naturally made; but on operation, two pieces of rusty wire one inch and half-an-inch long respectively were removed. Six days later, an X-Ray photograph revealed nothing, but as the wound continued to discharge, a second operation was performed and another piece of wire found. The patient then admitted that she, herself, had inserted all these foreign bodies. A close watch was kept upon her and the wound healed up without further incident.

Many cases of a fistulous track passing down from the umbilicus are reported as of urachal origin and indexed as fistulae of the urachus, just as cases of/

(a) REV. MED. CHIR.: 1848, IV, 353.

of adenomatous proliferation of the urachal epithelium have been published as carcinoma, sarcoma<sup>+</sup>, etc.

<sup>+</sup> p. 83.

The great labour of collecting cases from a scanty and polyglot literature is augmented by the necessity for carefully sifting each one in the original report and rigidly excluding all of doubtful or obviously erroneous pathology. My endeavour has been to read every case in the original; though I have not hesitated to use the careful extracts and translations of reliable authors where this was not possible. Some cases remain where neither the original article or extract from it are available, and these I have simply quoted in a separate category for the sake of others who may be more fortunate. In some the title itself gives a certain amount of information.

The difficulties encountered are well illustrated by Savory's case which may be taken as an example. This case is reported in the Medical Times and Gazette<sup>(a)</sup> of 1852 and is referred to by Caddel<sup>(b)</sup> as one of umbilical fistula in an infant due to growths at the neck of the bladder, causing the urine to be discharged at the umbilicus through a patent urachus. I had already inserted it in the bibliography of congenital fistula when I happened to find reference to it in an address by Doran<sup>(c)</sup>. The latter showed clearly/

(a) MED. TIMES & GAZ., LONDON, Vol. II, p. 106 - 1852.

(b) EDIN. MED. JOURNAL: Vol. XXIV, 1878, p. 221.

(c) DORAN: Bart.'s Hosp. Reports, XXXIV - 1898,  
p. 33.

clearly that the case was Stanley's and that the specimen existed in St. Bartholomew's Museum labelled 2419. Doran was able to give Stanley's original report<sup>(a)</sup> both of the clinical course of the case and of the post-mortem. The child was a male aged 2 and for several months had suffered from obstruction at the neck of the bladder due, as it was proved post-mortem, to multiple papillomata. The abdominal wall just below the umbilicus became intensely inflamed and painful. A puncture was made and some sero-purulént fluid, followed by two ounces of pus, evacuated. Afterwards, all the urine passed by the umbilicus but the child died in a short time. At the autopsy, Stanley found an abscess cavity lying between the recti muscles and the peritoneum and extending right from the fistulous opening to the fundus of the bladder. The urachus was seen projecting from the bladder and its tubular lumen could be traced as far as the bladder wall, but the most careful search did not reveal the finest opening between this lumen and the cavity of the bladder. Stanley, somewhat illogically, still held that the condition had been caused by a urachus dilated from back pressure bursting into the space between the transversalis fascia and the peritoneum and giving rise to the abscess which finally ruptured.

John/

(a) TRANS. OF THE PATH. SOC. OF LONDON: Vol. III,  
p. 127.

John Morgan re-examined the specimen<sup>(a)</sup> in 1898 and then reported that the urachus was merely a small papillae close to the vesical termination of the abscess.

It is inconceivable that all the urine could pass to the umbilicus through a urachus that would not admit the finest bristle even in the fresh condition. This, then, is clearly a case where a rupture had occurred in the bladder at the weak point caused by the urachal insertion. Indeed very many of the reported cases are of this type, as my investigation of the normal urachus would lead one to expect; and while it throws much light on the nature of fistulae, it emphasizes the utmost care required in judging all cases before including them in a given category.

CONGENITAL URINARY FISTULAE AT  
THE UMBILICUS.

Below is a series of 58 cases, where urine flowed from the umbilicus on separation of the cord. In all these, the report has been carefully studied and the nature of the condition verified. In addition to these, three cases (two in detail) were published/

(a) LANCET: March 12, 1898, p. 710.



published of Stadfeld<sup>(a)</sup> but I was able to obtain no particulars except that the subjects were males and suffered from phimosis, In addition, cases reported by Lebebeff, Bonzani, Epstein, Reussen<sup>(a)</sup> were probably of this nature, while those of Cifuentes, Mr Gehee, Reed, Santucci, Bruggeman, Roux, Holscher, Zohrer (2 cases) and MacLennan<sup>(d)</sup> may have been. The rarity of the condition becomes evident when it is considered that all these, totalling 72, represent the complete total of the cases recorded in the whole of the literature. In the last series given, I could obtain access to nothing more than the title and my deductions must be based on the 58 cases. The identification of the fluid as urine in all these is satisfactory, depending on its general colour and odour, acid reaction, presence of urea phosphates, etc.; or the observation of indigo-carmine after intra-muscular, or of starch after intra-vesical injection. In many, also, the condition was verified by demonstrating the communication between the fistula and the bladder, by operation, by sounds introduced through the umbilicus and urethra meeting each other, or by cystoscopy. In only one case - No. 52 (Vaughan) was there the slightest doubt on this point, the fluid/

(a) NORD. MEDIC. ARCHIV., STOCKHOLM: 1871, III, No.23.

(d) See BIBLIOGRAPHY.

fluid being described as clear and limpid; but the case is otherwise so characteristic that it has been included. The exact case reference is given in the bibliography, but for handy reference each case will be referred to by number and the name of the author attached to it. This will give sufficient clue to the location of the full report.

ALPHABETICAL INDEX OF ALL AVAILABLE REPORTED  
CASES OF CONGENITAL UMBILICAL URINARY FISTULAE  
WITH INDEX NUMBER FOR REFERENCE AGAINST NAME  
OF AUTHOR.

1. Alric, Case 1.	25. Jacoby.	49. Tulholske.
2. Alric, Case 2.	26. Jahn.	50. Vander Veer.
3. Annandale.	27. Kennedy.	51. Velpean.
4. Binnie.	28. Lannelongue.	52. Vaughan.
5. Bryant.	29. Lexer.	53. Waller.
6. Cabell.	30. Lugeol.	54. Willard.
7. Cabrol.	31. Marx.	55. Wolff.
8. Charles.	32. Meyer.	56. Yates.
9. Draudt.	33. Meyer-Kempen.	
10. Erdmann.	34. Monod.	57. Smit, Case 2.
11. Florentin.	35. Paget, Case 1.	58. Ashhurst.
12. Freer, Case 1.	36. Paget, Case 2.	
13. Freer, Case 2.	37. Pauchet.	
14. French.	38. Penny.	
15. Garraud.	39. Petit.	
16. Gerster.	40. Pierre.	
17. Graf.	41. Preston.	
18. Gueniot.	42. Rose.	
19. Haran.	43. Smit, Case 1.	
20. Heflin.	44. Smith, T.	
21. Hue.	45. Starr.	
22. Huggins.	46. Stevens.	
23. Imbert.	47. Stierlin.	
24. Jaboulay.	48. Stites.	

The first extensive series of cases studied previously was that of Stadfeld<sup>(a)</sup>. His observations were based on eleven cases from the literature and three of his own, totalling 14, of which 12 were male and 2 female.

Cullen<sup>(b)</sup> tabulates 62 cases without commentary on the pathology. Some of these I am unable to accept as true examples of the condition in question (viz. Smit, Case 1, Delangiere, Draudt, Case 2, Hind, 2 cases, and Goupil). So well has the literature been covered by this author, however, that I am able to add only three cases - Bryant's, Garraud's and Gerster's. He mentions Stadfeld as contributing one, whereas this author had three personal cases. Professor Cullen has maintained his interest in the subject and has contributed a recent note on it<sup>(c)</sup>.

#### SEX INCIDENCE.

Of 58 cases, 32 were males, 15 females and the sex was not stated in 11. In Stadfeld's series, 12 were male and 2 female. This led this author to the conclusion that congenital phimosis was an important causal factor; and it is worthy of note that if 31 cases/

- (a) NORDISKT MEDICINISKT ARKIV., Stockholm, 1871,  
III, No. 23.  
(b) "THE UMBILICUS AND ITS DISEASES": Chap. XXIX,  
pp. 487-514.  
(c) SURG. GYNEC. & OBSTETRICS: Vol. XXXV, p. 282.

cases be artificially separated in my series in which the umbilical flow of urine was very copious, the proportion of males to females is found to be five to one.

Age at which cases were observed.

Birth to one year	...	...	...	...	...	26.
1 year to 6 years	...	...	...	...	...	13.
6 years to 15 years	...	...	...	...	...	8.
15 years to 30 years	...	...	...	...	...	6.
30 years to 45 years	...	...	...	...	...	2.
Over 45 years	...	...	...	...	...	3.
						<u>58.</u>

As the condition appears to have no mortality, these figures indicate that cure, either spontaneous or effected by some simple local procedure, is the rule; and this is borne out by the following table giving the treatment and its result :-

1. Spontaneous cure from 15 days to 3 years	...	3.
2. Cured by cauterizing, ligature of accompanying tumour or simple plastic procedure	22.	
3. Cured by dissection and tying off the fistulous track	...	11.
4. Cure by circumcision or removal of other obstruction to the natural flow of urine	3.	
5. Refused treatment, or untreated	...	17.
6. Failure to cure after cauterizing or sewing up the fistulous opening	...	2.
	<u>Total</u>	<u>58.</u>

In reading through the literature on these cases, one cannot avoid the conclusion that the pathological process is not the same in all. The exact difference is hard to define, but on the whole two separate groups may be distinguished.

In Group 1, as soon as the cord separates, there is/

is a copious flow of urine, sometimes greater at night; sometimes, when the bladder is being emptied. The patient is perfectly well and a cure is easily effected by closing the opening, and, in some cases, by removal of an obstruction in the course of the natural passage. In cases Nos. 49 and 24, which were of this nature, the fistula closed shortly after birth, gave no further trouble, but reopened - in the former, spontaneously, at the age of 48, and in the latter, as the result of an enlarged prostate at 62.

In Group 2, the urine flows only drop by drop or intermittently, there is septic infection, with deep inflammation, and superficial excoriation of the skin around the umbilicus, and the condition is by no means so amenable to treatment.

I shall endeavour to show that these two groups correspond in large measure to two pathological entities<sup>+</sup>. In the first, the bladder reaches to the umbilicus and no urachus has formed; in the second, the urine is discharged through the small central canal of a partially formed urachus, the bladder apex having descended away from the umbilicus. Such a canal is apt to undergo dilatations and the urine contained in it, being denied free egress, becomes septic and gives rise to inflammation and dermatitis.

<sup>+</sup> pp. 66 and 68.

THE ETIOLOGY OF CONGENITAL UMBILICAL  
FISTULAE DISCHARGING URINE.

Two theories of origin suggest themselves :-

- (1). The obstruction theory put forward by Stadfeld;
- (2). The developmental theory.

(1) The Obstruction Theory.

The date in foetal history when the kidneys first secrete urine is difficult to determine; but it is easy to conceive that, if at this period there co-existed some obstruction to the outflow of secretion, the back pressure would keep the allantoic canal open and dilate it, thus giving rise to urinary fistula when the cord separated. That this sequence does not take place apart from developmental anomalies, is sufficiently proved by the large number of recorded cases in which such obstruction did, in fact, exist, causing dilatation of the ureters and hydronephrosis. In practically none of these is there evidence of an abnormal condition at the apex of the bladder. It is, however, undoubtedly true that when the conditions exist which lead to umbilical urinary fistulae, the latter condition is aggravated and perpetuated by them<sup>+</sup>. <sup>+</sup> See p.56.

In the majority of my series no obstruction did, in fact, exist, although it must be remembered that certain occult causes may have been operating which were unknown and overlooked at the time when the records/

records were made. Such, for instance, are the congenital valves of the posterior urethra due to persistence of the urogenital membrane (Barny)<sup>(a)</sup> or <sup>(a)</sup>From Randall See (b). to anomalies of the Wolffian and Mullerian ducts (Lowsley)<sup>(b)</sup>. Young, Fronz and Baldwin collected and recorded thirty-six cases of this kind and Randall<sup>(b)</sup> collected the literature and recorded two further cases of his own in 1921.

Most of the authors of cases of fistula, however, used the very useful criterion of the amount of urine passed and the nature of the flow from the urethra as their guide, and the only definite cases of obstruction were the following :-

Complete Obstruction:<sup>(c)</sup>

- (1) No. 41 - Malformation of Exter. Genital Organs.
- (2) No. 7 - Vesical Orifice closed by membrane.

Almost Complete Obstruction:

- (3) No. 8 - Extreme Phimosis.

Relative Obstruction:

- (4) No. 29 - Phimosis.
- (5) No. 20 - "
- (6) No. 9 - "
- (7) No. 57 - "
- (8) No. 6 - Congenitally Narrow Urethra.
- (9) No. 3 - Congenital Narrowing of Urethra: Only No. 6 (E) catheter would pass in a male aged 39.
- (10) Two cases of Stadfeld, in which phimosis was present.

In/

(b) ANNS. OF SURGERY: 1921, April, p. 477.

(c) A Case of Petit's in which there was a closed urethra should be added to this list possibly - "Traite des Mal. Chirurg!", Chap. XI, 3, 1837. (Limoges).

In every other case either no reference is made to obstruction of the natural outflow, or it is specifically stated that a full stream could be passed by the urethra. In cases Nos. 41 and 7, moreover, it is to be noted that developmental anomalies were present; and in the former these were so gross that the sex of the child could not be determined<sup>(a)</sup>. That the presence of phimosis has an influence in keeping a fistula open is shown by those cases in which the condition was cured by circumcision alone, but even here it must not be forgotten that the majority have a tendency to spontaneous closure.

(2) The Developmental Theory:

The correct explanation of congenital umbilical urinary fistulae should undoubtedly be based on developmental grounds. Before considering the exact nature of the anomaly concerned, it may be useful to tabulate the abnormalities observed in conjunction with the fistula, in the series under review. These are as follows :-

- (1) Patent vitelline duct - Nos. 20 and 29.
- (2) Double undescended testicles - No. 18. Also Lebebeff's<sup>(b)</sup> case.
- (3) Fused labia minora (without urethral obstruction). - No. 54.
- (4) Umbilical and Epigastric Herniae - Nos. 16, 28, 42, 46 and 47.
- (5) The remarkable case of Smith, No. 43, where blood flowed from the fistula at the menstrual period. This may possibly have been due to a horn of the uterus being implicated.

In/

(b) See BIBLIOGRAPHY.

(a) A case of umbilical urinary fistula in an hermaphrodite animal was reported by Kocks in the year 1912.

In regard to (1) it may be noted that, while the condition of combined vitelline and urachal fistula is very rare, a case has been reported by Goupil<sup>(a)</sup> in a boy of 12 who had developed at the age of 9, a combined intestinal and urinary fistula above the symphysis pubis. This probably represented a stage in the production of a true ectopia vesicae, and the penis was represented by a small unperforated tumour. A more fully developed condition, where ectopia vesicae combined with faecal fistula was encountered in a new-born child, came under my own observation.

To these abnormalities, must be added those already given where obstruction co-existed, viz.- Case 41 - malformed genital organs, and No. 7, where the vesical orifice was occluded by a membrane. In the latter remarkable case reported by Cabrol<sup>(b)</sup> as early as 1550, the membrane was punctured with a canula. The patient, a girl of 18, had an elongated tubular projection from whose tip her urine was evacuated. Cabrol also dealt with this and was able to report a complete cure at the end of the twelfth day.

How easily false conclusions may be drawn in regard to causation is illustrated in Nos. 20 and 29.  
In/

---

(a) SUR UN VICE DE CONFORMATION SINGULIERE: Jour. de Med. de Paris, 1756, V., 108.

(b) ALPHABET ANATOMIE, Tournan, 1594, p. 99, XX (Rep. Florentin).

In both instances a phimosis was present and might have been considered a causal factor if obvious mal-development had not been evidenced by the presence of a patent vitelline duct.

The eleven cases of abnormality tabulated above, is not likely to represent the total number. The presence of lobulated kidneys, for example, so common in other congenital defects of the urinary tract that come to autopsy, would obviously not be recorded in this series; though it is in the urinary system that co-existing anomalies would be most likely to manifest themselves.

Consideration must now be given to the exact nature of the conditions present and this involves a further reference to the development of the urachus. This is necessitated by the fact that in a large number of the cases, the fistula was not due to a patent urachus at all, in the more ordinarily understood meaning of that term. That is to say, there was no narrow canal leading up from the apex of the bladder to the umbilicus. On the contrary, the opening at the umbilicus led directly into the cavity of the bladder itself<sup>(a)</sup>, whose apex reaches as far up as the umbilicus. There was no urachus, and this phenomenon can only be understood on the grounds that the latter organ is developed from the ventral cloaca and not from the allantois; or in other words, it is the/

(a) This class corresponds to Group 1 on the clinical side.  
(See p. 56).

the upper part of the bladder that has been narrowed down and whose cavity has been in many instances shut off to form the urachal canal, while, in some, it remains in communication with the parent organ.

Extracts from the authors of the series of cases being considered bring out this point very well. For example:-

No. 3. Annandale Case:

In this male of 39 years, the urine flowed away from the umbilicus spontaneously when he was lying down. The opening would admit the tip of the finger and a number 12 (English) sound passed straight into the bladder through it without effort.

No. 6. Cappel's Case:

This mulatto girl could pass urine either by urethra or by umbilicus at will in full stream.

No. 10. Erdmann's Case:

In this four year old child, a probe passed through the umbilical fistula and waved from side to side like a pendulum, showing that it had entered a large cavity. At operation, the bladder was found to be fusiform in shape and "the urachus which was  $\frac{3}{4}$ " wide and 3" long was apparently continuous with the bladder itself".

No. 16. Gerster's Case:

The patient was a male age 52, and the bladder was/

was examined by cystoscopy through the umbilicus. The fundus appeared to be prolonged directly up to the umbilicus.

No. 17. Graf's Case:

The patient, a man 28 years of age, had an umbilical fistula at birth, which was healed by the use of escharotics. When he was 25, a carcinoma developed and perforated the umbilicus, from which urine was subsequently discharged. Although described as a carcinoma of the mucous membrane of the urachus, this is much more likely to have been a carcinoma of the bladder whose apex had remained open from birth.

No. 21. Hue's Case:

Male, aged 15. The urine flowed out of the umbilical fistula when he was lying down; very little in the daytime.

No. 24. Jaboulay's Case:

Male; 62 years. Urinary umbilical fistula at birth. This closed in fifteen days spontaneously. Prostatic obstruction at the age of 62 and urine again burst forth from the umbilicus. I have already shown that if the urachus had undergone normal descent after birth, no such happening could have taken place.

No. 26. Jahn's Case:

In this boy of five, a cystoscopic examination was carried out through the umbilicus. Afterwards, at/

at operation, Mickulicz found that after a course of 3 c.m., the fistulous canal entered straight into the bladder.

No. 35. Paget's First Case:

Female child, age four months. The skin at the umbilicus was invested and when it was pulled out, urine gushed from the opening.

No. 36. Paget's Second Case:

Male aged 40. The fistula would admit two fingers and the mucous membrane of the posterior wall of the bladder protruded through the orifice. No urine escaped in the act of micturition until this mucous membrane was withdrawn by the emptying of the viscus. So obviously did this opening communicate directly with the bladder that Paget was able to extract a calculus from that viscus through it with his finger.

No. 40. Pierre's Case:

"Behind the fistula was a discoid cavity from which urine escaped".

No. 47. Stierlin's Case:

Female aged 12. Urine flowed freely from the umbilicus when she was lying down, but very little when she was standing. The point of the finger could be passed into the umbilical ring. A No. 9 (English) bougie passed through it at once entered a/  
a/

a cavity. A metallic sound passed through the urethra met this one in the bladder.

No. 48. Tulholske's Case:

Male aged 52. In infancy, urine was passed through the umbilicus but this ceased in the fourth year. At 48, without apparent cause, urine again commenced to flow from the umbilicus. Operation disclosed that there was no urachus and the bladder reached to the umbilicus.

These cases, to my mind, clearly show that in this type of fistula no urachus is formed at all - the whole of the ventral part of the cloaca going to form the bladder. To the apex of the latter the obliterated, or in rare cases possibly the partially open, cord of the allantois is attached and may pass for some distance along the cord as in a case (No. 19) that Haran observed as early as the year 1648. The child was newly born and the ligature had included apparently a patent allantois, for a cystic dilatation appeared between it and the body wall. When this cyst was opened, urine gushed out and continued to flow.

In many infants, no doubt, the same anomaly in the development of the bladder occurs and these escape urinary umbilical fistula because the line of demarcation by which the cord separates just evades the/

the bladder which is thus not opened. Both classes of case are liable to develop a urinary fistula if backward pressure occurs in later life - those who have never had one as children and those whose fistulous opening has closed in the early years of life. A case occurred in the clinic of Sir Harold Stiles<sup>(a)</sup> recently which will serve to illustrate the non-formation of the urachus. A girl aged 15, who had suffered with incontinence all her life, was diagnosed as persistent dilated urachus because the point a sound passed into the bladder could be palpated at the umbilicus. In this case, as proved by examination and subsequent operation, there was no urachus - the bladder itself reached the umbilicus. Accompanying this mal-development, there was a general absence of the musculature of the bladder and urethra, nothing but the thin mucous coat, submucosa and adventitia being present. The right ureter was dilated and the kidneys were lobulated and of the foetal type.

The urachus in the horse<sup>+</sup> is a late development and at birth is not present, the cavity of the bladder extending to the umbilicus. The process of tearing off the cord thus frequently leads to umbilical urinary fistulae in foals. Cullen<sup>(b)</sup> has collected some/

(a) A case not unlike this was reported by Trogneux in 1897 in a male aged 9. There was incontinence. Later on, urine passed by umbilicus. In a great many cases reported as "acquired fistula", the diagnosis was based on the bladder being found right up to the umbilicus. Such were the cases of Timmermann and Marshall (See Bibliography).

+ See also p. 38.

(b) Loc. cit. pp. 523 & 524.

some interesting observations on this subject and I would further refer to the article of Netingang<sup>(a)</sup>. It is thus quite conceivable that many of the subjects of congenital umbilical urinary fistula really show a reversion to an earlier phase in their phylogenic history.

Group 2.  
(See p. 57)

Of course, all cases of the condition are not examples of such an extreme type of lack of urachal development and in many of the 58 cases of the series an actual cord-like urachus was found at operation. These are illustrations of imperfect formation of the urachus and as the patent channel is functioning from birth, its epithelium continues to proliferate and the urachus lengthens to keep pace with the bladder descent in virtue of its being a functioning canal. Such a proliferation does not take place under normal conditions but only where the closure of the upper part of the ventral cloaca is not sufficiently advanced to prevent the urine flowing through it. If the urachus is normally formed, it is impervious, or practically so, no matter what the pressure of the bladder contents. This cannot be better illustrated than by placing two cases side by side for comparison - one, No. 41, seen by Preston in 1876, and one described by Draudt in 1907<sup>(b)</sup>. In the former there was/

(a) AMER. VETER. REVIEW, New York, 1915. XVII. p. 618.

(b) DRAUDT: Beitrag zur Kermtins der Urachus - Anomalie, Deutsh Zeitschr. f. Chir. 1907. LXXXVII. Case 2. p. 487.

was complete obstruction to the passage of urine, all of which passed by the umbilicus, and the child was perfectly well at the age of two. In the latter there was no external orifice to the urethra, but unfortunately for it, the urachus was fully formed, and hence practically impervious. It died on the fourteenth day and sections showed that the urachal canal at the umbilicus was only .1 m.m. in diameter. This case shows (1) that the normal urachal canal - for this diameter is normal - will not become pervious and dilated whatever the back pressure, and, (2) that even total urethral obstruction from the earliest foetal days will not produce an umbilical fistula unless the developmental impulse by which the urachus is formed is also in abeyance<sup>(a)</sup>.

#### CONCLUSIONS:

To sum up, these observations confirm (1) the view that the urachus is entirely developed from the ventral cloaca and not from the allantois<sup>+</sup>; (2) that the bladder is sometimes formed from the whole of the ventral cloaca, there being no urachus at all; (3) that the urachus may be very imperfectly developed, leaving a wide channel between the bladder and the umbilicus/

+ See p. 37  
seq.

(a) It is only fair to consider the possibility of kidney malformation with anuria as a factor here, but the fact that a few drops of urine were squeezed out through the narrow canal is against it.

umbilicus; and (4) that if the formation and descent of the urachus follows the normal lines, it can never at any future period act as a conduit to convey urine from the bladder to the umbilicus.

THE PATHOLOGY OF TUMOURS AT THE UMBILICUS ASSOCIATED WITH URINARY FISTULAE.

A notable feature of this class of congenital fistula is the presence of a tumour at the umbilicus<sup>†</sup>. <sup>†</sup> Fig. 45. This feature occurred in no less than thirty cases in this series. It is described by different authors as resembling a glans penis, a nipple, walnut, pigeon's egg, strawberry, mushroom, etc. In Cabrol's case (No. 7) it was said to be four finger-breadths in length and was like the crest of a turkey-cock. In the remarkable case illustrated and described by Lannelongue (No. 28)<sup>§</sup>, the mother stated that the child <sup>§</sup> Fig. 45. had two penises and that it urinated from both at the same time. In this case, the appearance was partially due to an umbilical hernia pushing the tumour out. Similar protrusions occur more rarely in Group 2; and every obstetrician is familiar with an occasional instance of a tiny granulomatous excrescence persisting in a normal child after the separation of the cord.

I am not aware that the cause of this phenomenon has been explained, but a little consideration will elucidate/

elucidate it. These structures must be clearly distinguished from the protrusions which precede the outburst of urine in acquired urinary fistula, and their origin is due to imperfect separation of the cord. First consideration must be given to the normal mechanism of separation.

PATHOLOGY OF SEPARATION OF THE UMBILICAL  
CORD IN THE NEWLY-BORN (a)

(a) See also  
pp. 15 & 1

It seems to have been taken for granted that the cord will separate from the body after birth, but I am unaware that anyone has answered the question - why should it separate? The fact of tying is no explanation, as the stump of the cord is still in communication with the living tissue of the body and the separation takes place just the same whether it is tied or not. That the process is one of dry gangrene, with removal at the line of demarcation, is, of course, obvious. The question of the cause of this dry gangrene is bound up in the consideration of how Wharton's jelly and the other constituents of the cord obtain their nutriment in utero, and what changes take place after the separation of the placenta and the cessation of foetal circulation.

I can find no allusion to the physiology of Wharton's jelly. Certainly it can live only in a fluid medium, for it dries up when exposed to air, but/

but whether its cells are nourished by permeation from the liquor amnii or from effusion of serum from the umbilical arteries or vein has not, so far as I am aware, been considered. Considering the thick coats of the arteries and vein, I think the former supposition is the more probable. Certain it is that the cord has no direct blood supply from its main arteries or vein for these give off no branches between the placenta itself and the upper superior vesical arteries in the body of the child<sup>+</sup>.

<sup>+</sup> p. 15.

The umbilical arteries being ligatured an inch or two from the body follow the usual rule in such cases, and become obliterated first by coagulum and then by organization of the clot as far as the nearest collateral branch, in this case the superior vesical arteries. The vein is obliterated as far as the liver. Wharton's jelly having lost the nutriment supplied by the liquor amnii and the arterial and venous coats being now deprived of the blood in their lumen, no life remains in the stump of the cord and a line of demarcation forms at the skin which is provided with other arterial supply. This is the normal procedure.

PATHOLOGY OF CORD SEPARATION IN ABNORMAL  
CONDITIONS OF THE URACHUS.

In the section on anatomy<sup>(a)</sup>, it was demonstrated that/

<sup>(a)</sup> See p.  
15 seq.

that the terminal filament of the urachal branch from the superior vesical artery passes along the allantoic remains and in some instances tracks for a short distance into the cord itself<sup>+</sup>. In cases where<sup>+</sup> Fig. 2.B. the urachus has failed to form properly, owing to development defect, while the backward pressure in utero keeps it filled with urine it is quite a thick-walled functioning structure and may bulge into the cord. The allantoic canal itself may, indeed, be filled with urine for some distance<sup>(a)</sup> and consequently its coats greatly hypertrophied. The nett result is that the whole structure requires, and receives, an enhanced blood supply from the very vascular area which sections always reveal in the neighbourhood of the umbilicus. This supply is certainly conveyed in large measure by the urachal artery<sup>(b)</sup> and its connections with the deep epigastrics<sup>(c)</sup>. When the cord is tied and cut, it may be through this very vascular structure, the part of it clothed in amnion and containing Wharton's jelly certainly atrophies, but the central part - the dilated allantois - has no reason for dying, being well supplied with blood from the foetal side.

The raison d'être for separation being now absent, the central structure remains as the well-known projection, while its external surface, being deprived/

(a) Witness  
Haran's case  
No. 19, p.66

(b) Fig. 2.B.  
S.V.

(c) Fig. 2.A.  
ur.

deprived of amniotic coating, presents a red granulating appearance. The whole resembles the glans penis with its central orifice; and where the canal is longer and thinner the turkey-cock's comb of many writers. The tiny raspberry-like projection of granulating tissue in the normal case is due to the slight blood supply which the urachal artery contributes in many subjects to that central core of the cord which lies immediately adjacent to the body surface.

In passing, another source of blood supply that may in very rare cases come into operation must be mentioned. I refer to the omphalo-mesenteric vessels. Interesting observations on the remains of these vessels in the carnivora may be found in the *Journal of Anatomy and Physiology*<sup>(a)</sup>. It is doubtful, however, whether they ever fulfil the function suggested in man, but the remote possibility must be kept in mind.

These remarkable outgrowths have been turned to account in the closure of the fistulae by the surgeon; and in many cases the mere tying of a ligature round the base of them so that the part distal to the ligature sloughs off, has effected a cure.

ACQUIRED/

(a) JOURNAL OF ANAT. & PHYS. Vol. XVII. p. 59, 1883.

ACQUIRED URINARY FISTULAE AT UMBILICUS.

I propose to devote a separate paper to this subject, giving the result of observations of the anatomy of the anterior abdominal wall in the umbilical neighbourhood and an analysis of the vast amount of literature that has been unearthed in the course of this research. To prevent undue length, however, I must, for purposes of this thesis, devote the rest of my space to describing the series of sections of the urachus, in which, for the first time, a reasoned and demonstrated pathology of cysts and tumours of that organ is elaborated. I will, therefore, merely give here in tabulated form the conclusions I have reached and add to that a literature of all ascertained cases before passing on to the next chapter.

These conclusions are :-

1. Acquired fistulae are of two types, neither type being due to a permeable urachus in the usual sense.
2. The rarer type is that in which no urachus is formed<sup>(a)</sup>. As the formation of the urachus seems to be essential to the correct descent of the bladder, the latter does not in these cases descend and the apex remains at the umbilicus. Even under these circumstances, the formation of a fistula is rare unless a congenital one had been present for some time after birth. (a) p. 66 seq.
3. The common type of urinary fistula is due to the bursting forth of a collection of fluid contained in the space between the transversalis fascia and the peritonæum and localized by the lacework of fibrous bands here<sup>(b)</sup>. Dilatation<sup>(b)</sup> of one of the numerous compartments formed by these/ p. 11; & Plate III.

these may give rise to cysts. These cysts, or the true variety formed by degeneration of masses of urachal epithelial cells<sup>(a)</sup>, may communicate both with the bladder and umbilicus.

(a) p. 79.

4. The anatomy of the umbilical depression which is caused by the pull inwards of the leash of fibrous cords referred to above, is such that it forms the easiest exit from the transversalis peritoneal space. Hence urinary fistulae below the umbilicus are less common than at the lower part of its circumference, though they are by no means unknown.
5. The theory that an acquired fistula can be formed by a reopening of a urachus is impossible on developmental anatomical and pathological grounds, and a study of cases, many of which are accompanied by radiograms<sup>(b)</sup> only serves to confirm this.

---

(b) Fig. 18 gives an example of this. The case is quoted by Andre (J. d'urol, med. et chir., Paris, 1912, II, 673). The radiogram is from a male aged 7, who had suffered from cystitis for four years. At the end of this time, urine burst through the umbilicus. The radiogram shows No. (3) type of fistula.

CHAPTER III.

THE PATHOLOGY OF URACHAL CYSTS AND OF

CERTAIN TUMOURS OF THE URACHUS, WITH A

REFERENCE TO GLANDULAR NEOPLASMS AND

EPITHELIAL RESTS OF THE URINARY TRACT.

---

THE PATHOLOGY OF URACHAL CYSTS AND OF  
CERTAIN TUMOURS OF THE URACHUS.

An extensive literature exists on cysts and tumours of the urachus, and it is not my intention to analyse it. I append, however, a bibliography which will enable the student of this subject to study it further. I have, personally, perused a large part of this literature and the result has been to confirm my opinion formed, a priori, by a study of the anatomical points, that the accepted pathology requires complete modifications. Many writers, notably Doran<sup>(a)</sup>, have pointed out that many cases reported as cysts were collections of fluid due to tuberculous peritonitis, etc. The criterion generally laid down as diagnostic is that the encysted fluid is attached to the urachus above and below, that it moves freely from side to side but not in a vertical direction; and, if it communicates with the bladder the diagnosis is considered to be established. On these points I would offer this criticism :-

- (a) That no urachus exists at the site where many of these so-called cysts are observed as it has descended below this level<sup>(b)</sup>.
- (b) That a collection of fluid encysted between two strands of the adventitia of the obliterated hypogastric arteries would give all the signs and symptoms considered diagnostic.

(c)/

(a) MED.-CHIR. TRANS. LOND. LXXVI. 1898, p. 301.  
LANCET, 1909, Vol. I, p. 1304.

(b) Plates I,  
II & III.

- (c) That the common cause of such collections may be irritation set up by a few drops of urine exuding into this space from the lower end of the urachus in the numerous cases where this connects with the bladder. + p. 31 seq.
- and (d) That the sepsis so often associated with these cysts is probably derived from a patent lower end or a saccule of the urachus leaking into the collection of fluid. This patent end is unlikely to extend for more than 1 or 2 centimeters.

A large number of those gross collections of fluid lying outside the peritoneum between the umbilicus and symphysis, that have been reported are, then, not urachal cysts at all; and the explanation given of their formation as being due to simple dilatation of separated parts of a patent urachus is far-fetched both from an anatomical and pathological point of view.

#### TRUE URACHAL CYSTS:

That true cysts of the urachus do exist is, of course, well-known; and by good fortune a systematic study of sections cut from a series of apparently normal specimens has placed in my hands a demonstration of the exact course of their formation. These specimens - presently do be described in detail - have a wider importance. They illustrate the behaviour of shut-off vestigial epithelium and show clearly the origin of many puzzling conditions that have been found at the umbilicus and in the anterior abdominal wall. Not only so, but they throw a flood of/

of light on the etiology of the so-called adenomata of the bladder, a viscus which owns the same origin and is lined by the same epithelium as the urachus. By illustrating the behaviour of vestigial epithelium they also elucidate to some extent the method of origin of bronchial cysts and many allied conditions.

These true cysts of the urachus are small in size and have generally been discovered accidentally during laparotomy or post-mortem; but there is no definite reason why they should not go on to form large tumours of pathological importance. The fact, however, is that the beginning of the process by which they are formed appears to commence in early life, while the finished product in the old man or woman is rarely larger than a rice-grain. It is extremely improbable that many of the reported cases of "urachal cyst" reaching a size of pathological importance are of this nature. They are far more likely to be of the type suggested in the beginning of this chapter<sup>+</sup>.

<sup>+</sup> p. 78 (b)

FREQUENCY OF SMALL CYSTS AND TUMOURS OF  
THE URACHUS.

Lushka<sup>(a)</sup> in 1862 suggested that the diverticula of the urachal canal, which he found in all his specimens/

---

(a) VIRCH. ARCHIV. V. XXIII, hefts 1 & 2, p. 1, 1862.

specimens, might be separated and become cystic. He thought that they might even become of such dimensions as to require surgical interference. In 74 post-mortem subjects observed by Wutz<sup>(a)</sup>, distinct cystic dilatations were found projecting from the urachus in 24.<sup>§</sup> These all occurred within a few centimeters of the bladder. How frequent such dilatations are may be instanced by my own experience. I paid a visit, by kind permission of Professor Robinson, to the dissecting room of the Edinburgh University, and examined the urachus of the six subjects there undergoing dissection. In two of these<sup>(b)</sup> were definite cystic protrusions, two in one case and one in the other. All of them were about the size of barley grains. <sup>(b) 32.5%.</sup> <sup>(b) 33 1/3%</sup>

Still more striking revelations were made when serial sections were examined. The nature of the cystic dilatations and their etiology were readily observed and a large proportion where nothing could be seen macroscopically showed definite early stages of cystic formation. Of 14 cases so examined, no less than eight showed this process at some stage. As these cysts are derived from the degeneration of the central mass after proliferation of the cells, they are really of the nature of cystic adenomata and not/

(a) VIRCH. ARCHIV. V. XCII, p. 387, 1873.

not simply dilatation or retention cysts. They are of the same pathological nature as certain tumours of the urachus that have been reported under various headings, and, before proceeding further, these call for some reference.

TUMOURS IN THE URACHUS RESEMBLING ADENOMA.

1. Dr. Nicholson showed me a specimen of a growth at the lower end of the urachus, found accidentally at post-mortem, in a man who had died from chronic heart disease. The tumour was firm, shaped somewhat like a <sup>PROSTATE</sup> ~~pustule~~ and of about the same size. It was surrounded by a fibrous capsule and was occupied by a number of cysts. A report of this specimen is given in Guy's Hospital Reports, January, 1922, p. 97. Microscopically it consisted of tubules and cystic spaces lined by irregular cubical epithelium. The stroma was dense fibro-muscular tissue and the general appearance was that of prostatic tissue. I showed Dr. Nicholson the specimens depicted in figs. 33 and 34, in which no macroscopic anomaly could be detected; and it was at once evident that the structure was identical and that his specimen showed the ultimate result, due to the progression of the condition observed in mine.

Dr./

Dr. Nicholson, in his article quoted above<sup>+</sup>, gives <sup>+</sup> p. 82. example from the literature where similar structures were observed at the neck of the bladder, (Jores)<sup>(a)</sup>, the fundus of the bladder, (Witzack)<sup>(b)</sup>, the dorsal aspect of the penis, (Lushka)<sup>(c)</sup>, and the trigone of the bladder (Thorel)<sup>(d)</sup>. He concludes that all cloacal glands are of the same type. This generalization will include the urachus which develops from the ventral cloaca; or rather the fact that such structures appear in the urachus in 50% of cases is a further proof of its cloacal origin<sup>s</sup>.

<sup>s</sup> See pp. 38 and 69.

2. At first glance, such tumours have a superficial resemblance to malignant neoplasms. So little was known till recently of their true etiology that they have been reported as carcinomata. A case in point is that of Khaum<sup>(e)</sup>. This also was a post-mortem specimen found in a man 82 years of age. The tumour was a large one, above the symphysis, and adherent to the anterior abdominal wall. It arose from the apex of the bladder and was adherent by its upper pole to the umbilicus. Khaum's drawings of sections show an exactly similar appearance to those of my own and Nicholson's/

- (a) VIRCH. ARCHIV. 1894, CXXXV. 224.  
 (b) CBL. f.d. KRANKH d. HARN u. SEXUAL ORGANE, 1894 V.  
 (c) VIRCH. ARCHIV. 1865, XXXIV. 592.  
 (d) BEITR. z. KLIN. CHIR. 1902. XXXVI, 630.  
 (e) "(PRIMARY CARCINOMA OF THE URACHUS)": Wien Klin-  
 :ische Wuhenshr. 1916, v. XXIX, p. 130-134.

Nicholson's cases. The tumour was undoubtedly a glandular one of the usual type.

3. Klopp's<sup>(a)</sup> case was in all probability a phase of the same condition. A mass of mononuclear cells was observed with a few giant cells in a canal removed from a boy. This canal discharged at the umbilicus. Part of it was lined by squamous epithelium. The growth was doubtless derived from an epithelial rest, as in my case depicted in fig. 39 and not from the urachus itself. While it is always a possibility that such tumours may become malignant, all cases should be carefully scrutinised to make certain that they are not examples of the simple glandular type. The giant-cell formation in a simple cyst was noted by Bondi<sup>(b)</sup> in a published case.
4. The resemblance of the adenomatous structures to normal endometrial tissue is striking, and an example occurring at the umbilicus was considered by Ehrlich<sup>(c)</sup> to represent displaced uterine mucosa. His sections, however, show the typical structure of adenomata of the urachal type.

Sections illustrating the formation of these adenomata/

- (a) ANNALS OF SURGERY. Vol. LXXIII - 1921, p. 643.  
"Sarcoma of the Urachus".
- (b) BONDI, J.: "Zur kassinistik der Nabelcysten  
Monatschi. f. Geb. und Gyn. 1905, v. XXI, p. 729.
- (c) ARCHIV. f. KLIN. CHIR. 1919, LXXXIX, p. 742.

adenomata and adenomatous cysts will be described :-

(a) from epithelial remains left at the umbilicus after the descent of the urachus possibly from cells shed, when the organ in its descent is tearing itself free from the umbilicus; (b) from the middle region of the canal; and (c) from the lower end.

Before the figures illustrating the process are referred to, a short account of what actually takes place may be given :

METHOD OF FORMATION OF ADENOMATA AND ADENOMATOUS CYSTS OF THE URACHUS.

The cells of the epithelium of the urachal canal are constantly proliferating. The effect of this is twofold. Firstly, the cells are heaped up towards the lumen, some being desquamated into its canal<sup>+</sup>; secondly, the periphera. cells proliferate centrifugally and are cut off from the central column by ingrowing fibrous tissue<sup>§</sup>. These separated cells by their multiplication become differentiated into a separate column and by the degeneration of the central cells a new canal is formed. A cross section of such a urachus shows that there is not one canal but several separate ones<sup>+</sup>. By a continuation of the process, masses of cells are formed. These acquire a lumen and by central degeneration or accumulation of secretion and cell debris this lumen becomes lined by only one or two layers of epithelium.

In/

<sup>+</sup> Plate VI.B.

<sup>§</sup> Fig. 20.A-D

<sup>+</sup> figs. 29, 32 and 33.

In some cases one of these vesicles expands and gives rise to the formation of a cyst; in others a more solid tumour of the nature of an adenoma arises. The process will now be illustrated by the figures which represent drawings made from the actual slides, in most cases with the help of a projector apparatus:

SPECIMEN I : TO ILLUSTRATE THE METHOD OF FORMATION OF A SMALL URACHAL CYST.

This specimen<sup>+</sup> was obtained from the dissecting room from the body of an old man. It was 5 c.m. in length and projecting from its lateral surface 1 c.m. from the bladder were two cystic swellings each about 2 m.m. in diameter (fig. 47.B.). Sections cut 4 c.m. above the bladder<sup>+</sup> showed an obliterated canal. One m.m. above the level of the first cyst (Fig. 47.B.a) the canal was patent and the proliferation of epithelium by which this cyst was formed had already begin. The process is illustrated diagrammatically in figs. 46. I-VI, & 47, and by actual drawings in figs. 19-24.

<sup>+</sup> Slides X1, X2 & X3.

<sup>+</sup> Fig. 47.B.d.

I have thought it advisable to give a somewhat detailed account of this case and finally to compare it with a somewhat larger example of a similar specimen obtained in the course of a laporotomy.

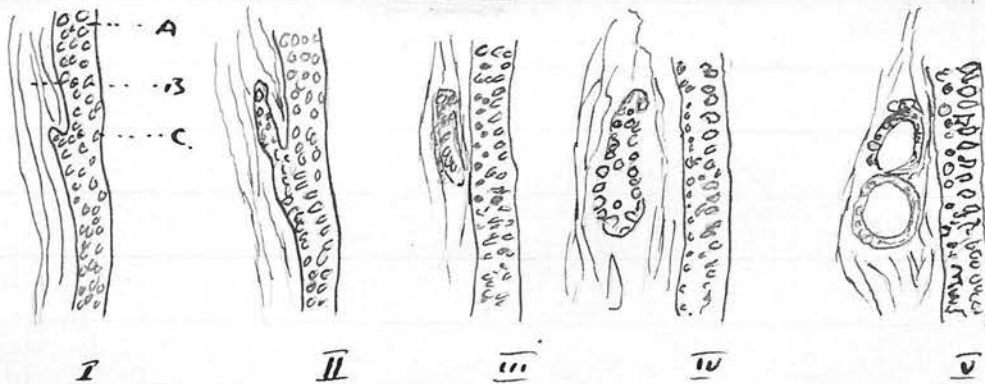
SPECIMEN I.

(Slides Marked X 1-1, 2, 3)

Urachus - 5 c.m. in length and displayed on its lateral/

lateral surface two small cysts of the size of barley grains (2.5 m.m. in diameter). A series of sections, taken from the upper pole of the superior cyst, demonstrates a portion of the epithelial lining being separated by the ingrowth of connective tissue cells as diagrammatically represented in the following series of figures (Fig. 46) :-

Fig. 46.



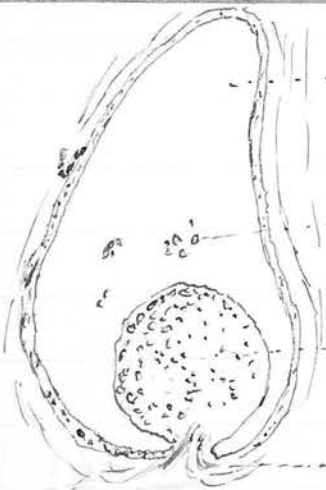
In fig. 46.I, A is the transitional epithelium lining the urachal canal, B is the fibrous tissue surrounding it and C represents a few epithelial cells split off by the invasion of the connective tissue.

Figs. 46. II & III represent a continuation of this process and in the latter the portion of epithelium has become entirely detached.

In Figs. 46. IV & V, the detached epithelium has proliferated and the central cells (Specimen I - Slide X<sub>1</sub>, 3) are breaking down, while in Fig. 46.V the beginning of a cyst lined by several layers of epithelium is definitely seen.

The/

The same slide shows also a heaping up of the normal transitional epithelium into the lumen at another portion of its circumference; while several groups of cells have become detached and lie free in the lumen (Fig. 46. VI).



(Fig. 46 VI)

..... Lumen of Urachus lined by transitional epithelium.  
 ..... Detached cells in lumen.  
 ..... Heaped up, proliferated mass of epithelial cells  
 ..... Connective tissue pushing mass of epithelial cells into the lumen.

Fig. 46. VI. The cone of connective tissue seen here, pushing, as it were, the epithelium before it, appears in other specimens as the core of a definite papillomatous structure projecting into the lumen.

A section made lower down through the centre of the upper cyst is represented in Fig. 47. A :

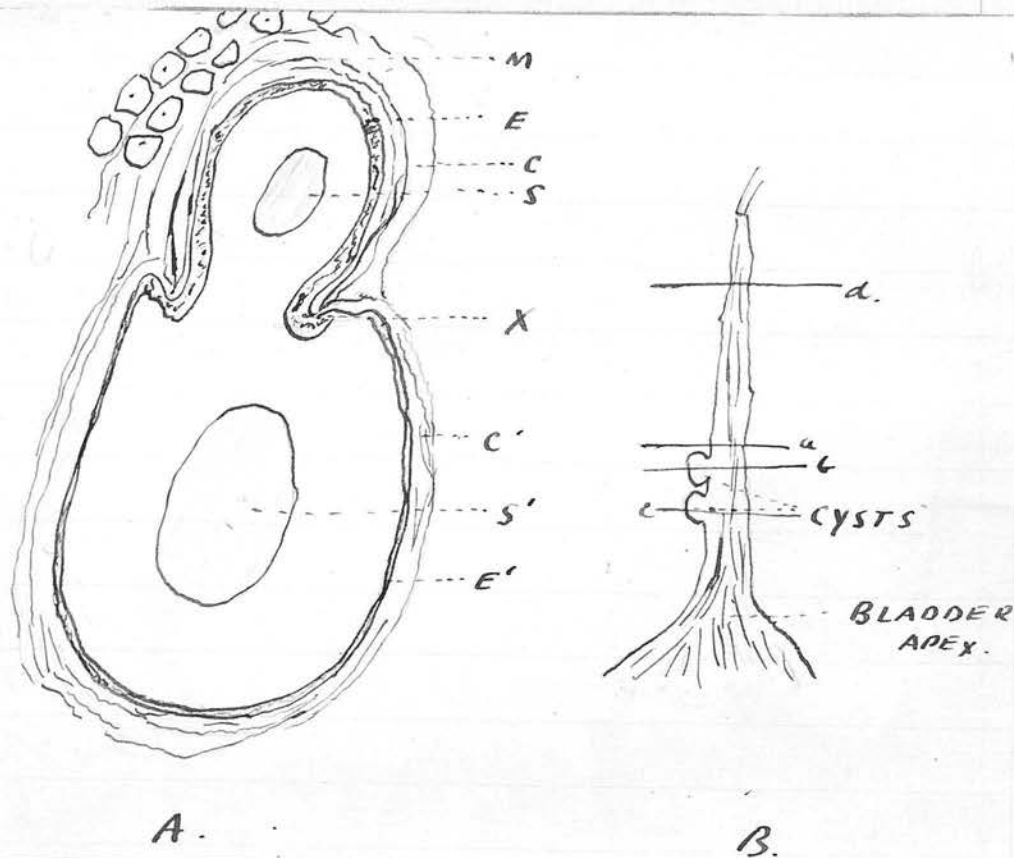


FIG. 47.

Fig. 47. A. is a sketch of a cross section (at the level b. on Fig. 47. B.). It will be seen that at the level X, the epithelium of the urachal canal becomes continuous with that of the cyst; and that here there is a great increase in the thickness of the epithelium. That lining the wall of the urachal canal itself consists in this specimen of only four layers of cells. At the point X there are nine or ten layers; while in the epithelium of the cyst wall there are only one or two layers. In this figure E & E' are the epithelium of the canal and cyst respectively; C & C' the thick layer of connective tissue around the canal, and the thinned out layer round/

round the cyst respectively. S & S' refer to the homogeneous colloid contents and M to the muscle fibres cut transversely.

That the appearances presented are not caused by a diverticulum of the urachal canal will be shown in other specimens where complex adenomatous structures are shown to be formed from similar patches of segregated epithelium.

Fig. 47.B. is a sketch representing the natural size of the specimen and a, b and c show the level at which the sections sketched in Figs. 46, I-VI, Fig. 47.A and Fig. 48 were respectively cut.

Cyst formed by simple dilatation of the  
urachal canal.

A section cut through the lower of the two small cysts presents quite a different appearance (Figs. 48 and 24). In this, there is a uniform spindle-shaped dilatation of the whole lumen of the canal, apparently formed by the mere retention of secretion. This is uniformly surrounded by a thin flattened-out layer of epithelium not more than two cells deep. The whole is filled with the usual homogeneous colloid-like secretion. Probably, however/

however, this cyst has a similar origin to the former, although it appears to be of the nature of a dilatation. (See Figs. 21 and 22)

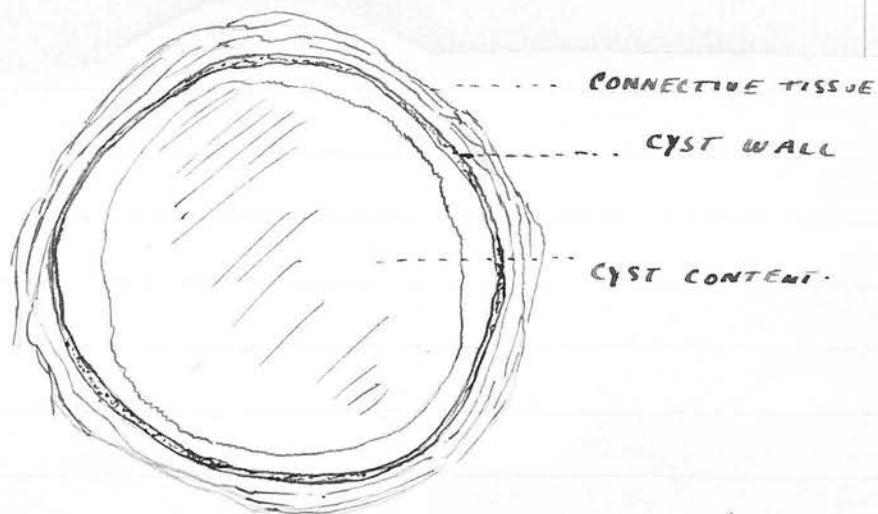


FIG. 48.

(NOTE: The contents have shrunk away from the cyst wall in the preparation of the specimen).

It may here be noted that a similar cyst to that shown in Fig. 48, in a more developed condition, exists in the Museum of University College, London. It was found accidentally in opening the abdomen of an adult woman to deal with a condition of pelvic infection. It is no doubt a type of many similar conditions that have been reported, and which were discovered in analogous circumstances. It is shown in Fig. 49/

Fig. 49 :

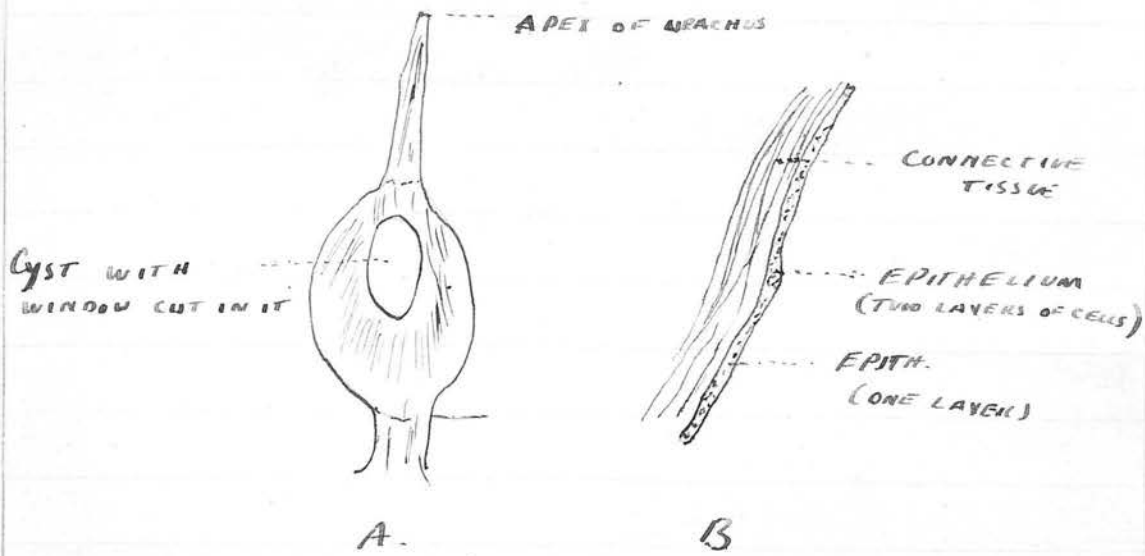


Fig 49

A = MACROSCOPIC VIEW OF CYST

B : LOW POWER SECTION OF PART OF ITS WALL

It is a thin-walled cyst involving the full diameter of the urachus, abruptly defined both at its upper and lower pole. It contained a clear content, is 2.5 x 1 c.m. in area. On section, its wall is seen to consist of connective tissue, lined by a layer of epithelium; in some portions two cells deep, in others consisting of a single layer of cells.

As a study of the normal histology combined with an investigation of reported cases shows clearly that the epithelial canal never exists for more than five to eight centimeters above the bladder apex<sup>(a)</sup> (except <sup>(a)</sup> p. 12. in cases of congenitally patent urachus), it is clear that the so-called urachal cysts encountered just below/

below the umbilicus have a different etiology from those depicted in figures 48 and 24; i.e., they must arise, if they are true cystic adenomata (and this must be rare where the tumour is large) from epithelial rests and not from an existing urachal canal.

The reason that one loculus of an adenoma expands far more than others to form an obvious cyst is to be found in the fact that it has reached the outer margin of the urachus, or is able to push through a weak spot in the muscle coat<sup>(b)</sup>, i.e., it meets with less resistance than its fellows.

(b) See pp.  
23 & 24

SPECIMEN II : TO ILLUSTRATE THAT A CYSTIC DILATATION IS NOT NECESSARILY FORMED FROM THE MAIN URACHAL CANAL.

This specimen<sup>+</sup> is illustrated in Plate V. The urachus ended in a blind cystic dilatation just outside the bladder mucosa. Figs. 25 and 26 are sections through this cyst. It is apparent that the normal urachal canal is present and quite separate from the cyst. The same point is shown in a microphotograph (Plate VII).

+ Slides R.2,  
3 & 4.

Fig. 27 shows a cross section higher up, i.e., further from the bladder. In this, three subsidiary columns of cells have formed all larger than the original urachal canal. Two of these - A and CY - have/

have acquired a lumen; B remains as a solid column. The tubule represented by Cy will dilate, and further down it forms the cyst. All are embedded in the urachal stroma and the urachus at this level appeared to the naked eye to be of normal dimensions. The diagram in Fig. 28 is intended to show the branching off of epithelial columns canal so as to give rise to the appearance shown in the sections.

SPECIMEN III : TO ILLUSTRATE THE OBLITERATION OF THE URACHAL CANAL AT ITS UPPER END, AND HOW EPITHELIAL COLUMNS ARE FORMED IN THE PROCESS.

This specimen<sup>+</sup> was much larger than normal (9 c.m.).<sup>+</sup>Slides<sup>s</sup> 1, 2, 3. Although taken from an adult female, active obliteration was taking place by the ingrowths of capillary loops and the formation of fibroblasts. In the bladder neighbourhood sections presented a normal appearance. Fig. 29 (1) is taken from near the middle and the others in series from below upwards. In (1) the canal is somewhat distorted but single.

- (2) the canal is indented by an ingrowth of fibrous tissue which in
- (3) has separated the upper from the lower part, and two canals appear. The lower canal is becoming constricted.
- (4) Three canals have formed and one of these is being constricted.
- (5) This has divided and four separate canals separated by fibrous tissue appear;
- (6)/

- (6) A further stage;
- (7) Five canals;
- (8) Still five canals, but these are getting smaller and the amount of epithelium is less;
- (9) Now only three small canals. The other two have been replaced by fibroblastic tissue;
- (10) The remaining epithelium is represented by two tiny canals only;
- (11) No epithelium except a tiny nest of central cells;
- (12) Epithelium has completely disappeared, giving place to longitudinal bundles of fibrous tissue which are cut transversely and give the characteristic whorled arrangement of the obliterated urachus.

Note in the central sections of the series how the separated canals give an adenomatous appearance. It is easy to conceive how an adenomatous tumour could form by some of this broken-up epithelium taking on rapid growth and proliferation.

Figs. 30 and 31 show under a high power, the final phase in the obliteration of the urachal canal at its upper end. Fig. 31 represents a section further from the bladder than Fig. 30. Note how the only epithelium remaining is represented by a group of 8 or 9 cells in Fig. 30, the capillary loops and the young fibroblasts, also the round celled infiltration. In Fig. 31, two of the epithelial cells have been separated and are now apparent in the stroma E'. The whole appearance is that of granulation tissue.

In Fig. 32, a more detailed view of two sections from the same case is shown. In A there are two hollow columns, but the solid mass of cells seen at p. is proliferating out into the stroma.

In Fig. 32.B. this column is entirely separated and a small lumen is already apparent.

SPECIMEN IV : SHOWING AN ADENOMA.

This specimen<sup>+</sup> was removed at a post-mortem examination from a woman aged 47 who had died after total hysterectomy. To the naked eye the urachus appeared smooth and regular. It was not enlarged, being spindle-shaped in section and measuring 3 m.m. x 1 m.m.

+ Slides 1 & 2

When a section was cut near the bladder<sup>+</sup>, however, it was found that the whole of the stroma of the urachus, with the exception of a narrow margin, had been replaced by a growth consisting of hollow cystic and tubular spaces or surrounded by cubical epithelium; or of solid columns of cubical epithelium. In fact, the appearance was exactly the same as that observed in the cases of Nicholson and Khaum<sup>(a)</sup>. Stages in the formation of the vesicles from the solid columns and masses of cells are shown in Figs. 34, 35, 36/

+ Fig. 33.

(a) LOC. CIT. See pp. 82 and 83.

36 and 37. These leave no doubt that it is by central degeneration that the vesicles are formed and not by the outgrowth of hollow acini.

An examination of sections higher up in the same specimen showed the exact mode of formation of this adenoma. Fig. 38 is really the most important of the series, for in serial sections it shows the breaking up of one tubular space, the formation of a new column of cells, and the formation of a lumen in the centre of this.

(1) shows the urachal canal surrounded by its capsule of circular fibres. The rest of the layers of the urachus, muscular, adventitial, etc., were all normal; the urachal canal (i.e., fibrous and epithelial coats) was about the usual diameter. It will be noted, however, that in this section it has already two lumina - A and B.

(2) The upper part of the wall of space B has become filled with epithelium (C), that is, the centripetal proliferation of the epithelium has obliterated the canal. The whole has become hour-glass shaped from constriction by the fibrous capsule.

(3) The cells in the centre of C are now breaking down and the process of separation is advanced.

(4) Only a thin cord of epithelial cells now binds B to C.

(5) B is completely separated from C and the latter/

latter has acquired a lumen.

These sections represent the early stages of an adenoma. It is to be noted that the process is exactly the same as that in Specimen III<sup>+</sup> where the canal is becoming obliterated. Thus the remarkable fact is proved that the disturbance caused by the ingrowth of fibrous tissue to obliterate the canal may stimulate the individual cellular elements and lead to the formation of an adenomatous tumour.

<sup>+</sup>Figs. 29-32.

SPECIMEN V : SHOWING AN ADENOMA IN THE NEIGH-  
BOURHOOD OF THE UMBILICUS ARISING FROM  
EPITHELIUM DETACHED FROM THE URACHUS (a).

(a) See p. 12.

This specimen<sup>+</sup> is the same as that figures in Plate III, and was taken from the body of a female child, three years of age, who had died from Tubercular Meningitis.

<sup>+</sup> Slides Q, u, m, 132.

Sections near the bladder showed that the urachus contained its normal central canal (Fig. 41. B. Ur.).

Sections above J in Plate I, of the fibrous cord F. (Plate I) showed no signs of urachus, merely fibrous tissue attached to the transversalis fascia (Fig. 41.A).

A section cut one centimeter below the umbilicus disclosed the appearances shown in Figs. 39 and 40.A and/

and B. A glance at these drawings will show that the structure is identical in nature with that of the adenoma in Specimen IV<sup>(a)</sup> and must undoubtedly have been formed in a similar manner. It is also similar to Ehrlich's Case (See page 84) and strongly resembles the uterine endometrium.

(a) Figs. 33-37.

A striking feature well brought out in Fig. 39 is that the adenomatous growths appear to have been derived from two separate foci, strongly suggesting that two groups or single cells of the urachal epithelium became embedded in the fibrous tissue at the umbilicus when the urachus descended<sup>(b)</sup>. Ad. in Plate I shows the point at which the section was cut. The exact limits downward of the glandular structure could not be determined, but serial sections showed that no epithelium of any kind, or trace of urachal structure, existed for several centimeters above the point J (Plate I).

There can be no doubt that the structure represented had developed into its present condition in the three years between the birth of the child and its death.

#### C O N C L U S I O N /

(b) Just as two colonies will grow separately in a Petri dish if two single cocci are planted.

C O N C L U S I O N .

The five specimens I have selected for detailed description show the essential identity of these adenomatous structures, whether they are found near the bladder, at the umbilicus or in any intervening position. Similar cell proliferation and degeneration no doubt caused the little bulgings and irregularities seen by Lushka in almost every urachal canal he examined; while exactly the same process is at work in the formation of the small cysts that occur in such a large proportion of normal cases<sup>(a)</sup>.

(a) pp. 80 & 81

Further, there seems to be little doubt that the so-called prostatic glandular rests and adenomatous structure found throughout the urinary tract are of the same nature. It becomes a question, indeed, whether the term "glandular" or "adenomatous" can be correctly applied to these conditions, where the so-called acini are formed merely by the breaking down of the central epithelium. The typical structure of these growths is really expressed by describing them as solid columns or masses of epithelial cells surrounded by fibrous stroma; and in this they resemble the carcinomata. In how many instances, if ever, they take on veritable malignant attributes is a problem for future investigation. Another problem that has yet to be solved is whether these small cystic adenomata/

adenomata ever grow to a sufficient size to give the clinical signs of the classical urachal cyst requiring surgical interference.

S U M M A R Y.

S U M M A R Y.Chapter I.

- (1) The current anatomy of the Urachus, as given by standard authorities, requires revision. The structure does not reach the umbilicus, but only one third of the way. It averages 5 c.m. in length; and is attached to the posterior aspect of the navel by fibrous cords derived from the obliterated hypogastric arteries.
- (2) Its epithelial canal is never obliterated by fibrous tissue, but remains patent, although impervious in parts owing to epithelial debris derived from its own cells. The lumen of this canal is in direct continuity with the bladder cavity in about 33% of all subjects.
- (3) The orifice where the canal opens into the bladder is guarded by a valve of mucous membrane in only about 5% of cases. This is the first time this question has been investigated since Wutz, in 1883, asserted that such a valve existed in all cases.
- (4) The lowest centimetre or two of the urachal canal is frequently sacculated in cases where it communicates with the bladder. This sacculus was observed in 30% of museum specimens where the bladder had been dilated from chronic distension.
- (5) This sacculus sometimes ruptures from pressure of urine, and the fluid passes up between the transversalis fascia and the peritoneum. It is circumscribed laterally by the attachments of the hypogastric arteries to both peritoneum and fascia, and vents at the weak point formed by the umbilical pit.
- (6) The normal histology of the urachus is studied and the relation of its component parts to those of the bladder. A suggestion is made that it has an active function in the adult.
- (7) The various methods by which the urachus terminates is considered and it is proved that, in all cases, it has an intramural course through the muscular wall of the bladder, reaching the submucosa. Even where no communication exists with the bladder/

bladder, the urachal canal remains patent to this point.

(8) The development of the Urachus:

It is reasoned that erroneous early views on this subject gave rise to the present false conception of the pathology of congenital urinary umbilical fistulae and urachal cysts. Evidence is given from the clinical and pathological side to support the modern embryological view that the Allantois takes no share in the formation of the Urachus. It is derived from the upper part of the ventral cloaca, the bladder being formed from the lower part. Sometimes no urachus forms, the bladder then reaching to the umbilicus at birth.

Normally, the apex of the urachus reaches the umbilicus at birth, but it is carried down with the descent of the bladder. The lack of closure of the upper end of the bladder, where this occurs, interferes with that organ's descent. In many cases where a urinary fistula existed at the umbilicus the bladder was found to reach that structure. In others, this condition was found at laparotomy for some other reason. Such cases usually appear in the literature described as patent urachus. Further evidence in favour of the cloacal origin of the urachus is given in the fact that epithelial rests and glands were found in it similar in nature to those found in the bladder wall.

## Chapter II.

### Umbilical Urinary Fistula.

- (1) Confusion exists in the literature between true congenital fistulae in which urine is discharged from the umbilicus, and acquired fistula of the same nature. Also between true urinary fistulae and cases where a supposed urachal cyst has ruptured through. The pathology of all three conditions is different.
- (2) Congenital fistulae are of two varieties:
  - (a) Where the urine flows freely or perhaps exclusively from the umbilicus. These cases are due to complete non-development of the urachus - the cavity of the/

the bladder reaching the umbilicus. They are easily closed but tend to reopen if there is backward pressure in later life.

- (b) Where the urine escapes drop by drop. These are due to retarded closure of the ventral cloaca to form the urachus. When once cured, the bladder tends to descend naturally and the urachus forms; so that when once they are cured, there is no tendency for the fistula to reopen.

- (3) A urachus which has once descended and assumed normal proportions can never convey urine from the bladder to the umbilicus.

- (4) It follows that acquired fistulae are of two types:

- (a) Where, through mal-development, there is no urachus, and the bladder apex is at the umbilicus. This condition is shown by reported cases to have been frequently present.
- (b) Urine escapes through the dilated terminal centimetre of the urachal canal, or through the weak point at the junction of the urachus with the bladder. It creeps up in the confined limits of the space in which it finds itself. The peritoneum and transversalis fascia fuse near or at the umbilicus, preventing its further progress and it bursts through the weak point formed by the depression in the lowermost quadrant of the umbilicus.

All the cases existing in the literature are analysed to prove these points.

### Chapter III.

- (1) This deals with cysts and tumours of the umbilicus and a new explanation is given of their pathology. Urachal cysts are of two kinds as they exist in the reports:
- (a) A large variety which are merely collections of fluid outside the peritoneum and may have or not have a connexion with the lower dilated centimetre of the urachal canal.
- (b) A small variety of cyst which is present, in embryonic form at least, in over 50% of all normal subjects past middle age. These occasionally attain sufficient size/

size to attract attention during laparotomy or post-mortem.

- (2) A study of a series of sections shows that these (class (b) ) are of the nature of cystic glandular structures and not merely dilatations of the central canal. The lumina of their loculi are formed by a degeneration of the central cells of the original column, which is derived from the proliferation of the epithelial cells of the central canal. This proliferation is caused by the impetus of the fibrous tissue to close the canal, a goal which it never attains.
- (3) The separated masses of epithelium by proliferation form various columns and masses of cells, so that a solid adenomatous type of growth may be formed instead of a cystic type. Bases of such growths in an advanced state are referred to and they are proved to be identical in structure with the early stage found in my specimens. These growths and the small type of cyst, therefore, own an identical etiology.
- (4) Although the urachus does not ascend more than a third of the way between the bladder and the umbilicus, yet some of its cells may be shed in its descent. By this means typical glandular tumours and cystic structures may be found in this region. An illustration of such a condition is found in one of my slides and illustrated.
- (5) The process of formation of these pathological structures is shown in a series of drawings from actual sections, and no doubt they also illustrate the method by which the puzzling glandular tumours in the bladder wall arise.
- (6) The investigation, therefore, elucidates what is considered a very obscure section of the pathology of the urinary tract.

Finally, a complete Bibliography of all known literature on the Urachus is appended. This includes practically all the cases that have ever been reported.

B I B L I O G R A P H Y .

## C O N T E N T S.

### Page

- I. Literature on the Urachus as a whole.
  - II. Principal Treatises on Urachal Cysts.
  - III. Principal Treatises on Umbilical Urinary Fistula.
  - IV. Literature on the Anatomy of the Urachus.
  - VI. Bibliography of Congenital Fistulae: Key to Cases on p. 54.
  - IX. Additional Cases of Congenital Fistulae reported and not included in the series above.
  - X. Bibliography of Acquired Urinary Fistula at the Umbilicus.
  - XIII. Reported Cases of Patent Urachus - no details available.
  - XIV. Bibliography of Cysts and Tumours of the Urachus.
  - XV. Miscellaneous Articles on Urachus.
  - XVII. Other Articles having some bearing on the subject.
-

LITERATURE OF THE ANATOMY AND PATHOLOGY OF THE  
URACHUS AS A WHOLE.

The only writer who has systematically written on this wide subject is Professor T. S. Cullen of the Johns Hopkins University in monumental book "Embryology, Anatomy and Diseases of the Umbilicus, together with Diseases of the Urachus". Cullen has collected and tabulated all the literature available and given abstracts of the cases. The work is thus invaluable as a compendium of all hitherto known and observed in regard to the Urachus. I was unable to gain access to this book only after my own research was well advanced, but, since that time, I have found it of great assistance in working out the Pathology. Cullen himself was content to summarize the main points of his cases and did not draw any extensive deductions. While in my bibliography of fistula, I have tried to include every case, in my other references I have aimed at making my bibliography supplementary to Cullen's. No doubt in some instances we have overlapped, but the student who has access to both bibliographies will be able to be satisfied that the whole known literature is before him. In a good many cases, I have used Cullen's abstracts either alone or in conjunction with the original article.

II.

PRINCIPAL TREATISES AND ARTICLES ON URACHAL  
CYSTS WHICH CONTAIN REASONED COMMENTARIES ON  
THE CASES.

1. CULLEN	"The Umbilicus", pp. 515-606.
2. CARUSO	"Contributo allo studio anatomo - patologico dei tumori cistici dell' ombelico": Atti della soc. Italiano di Ost. e Ein., 1901, VIII, 293.
3. DORAN	(a) Lancet, 1909, I, 1304. (b) Med. Chir. Trans., London, LXXVI, 1898, p. 301.
4. DELORE and COTTE	"Groskyste de l'ouraoue": Lym med., 1905, CV, 373.
5. HARTMANN	Monograph. Halle, 1911 (mit Kaemmerer)
6. PERE	"G.Kyste de l'ouraoue" (Monograph), Lyon, 1905.
7. SOULIE	(Monograph). Bordeaux, 1919.
8. SCHNELLENBACH	"Uber die Urachusysten": Inaug. disser. Bonn. 1888.
9. WEISER	(Collected 86 cases): Ann. of Surg., XXIV, 529.
10. WOLFF, C.C.	Inaug. dissert. Marburg, 1873.
11. WUTZ, J.B.	Virch. Archiv., 1883, XCII, 387.
12. WYSS	Virch. Archiv., 1870, LI, 143.
13. MEANS	Ann. Surgery, LXIV, 1916.

PRINCIPAL TREATISES AND ARTICLES ON URINARY  
FISTULA AT THE UMBILICUS.

1.	GRUGET	"Les fistules urinaires ombilicales que se produisent par l'ouraque resté ou redevenu perméable": Thèse de Paris, 1872, No. 422.
2.	HOFFMANN	"Zur pathologisch-Anatomischen Veränderung des Harnstrangs": Arch. der Heilkunde, 1870, XI, 373.
3.	MONOD	"Des fistules urinaires ombilicales dues à la persistance de l'ouraque": Thèse de Paris, 1899, No. 62.
4.	SIMON	"Quels sont les phénomènes et le traitement des fistules urinaires ombilicales": Thèse de Paris, 1843, No. 80.
5.	STADFELD	"Bidrag til Læren om den med fødte Vesiko-umbilikal fistel (Urachus-fisteln) og dens Behandling": Nordiskt Mediciniskt Arkiv., Stockholm, 1871, III, No. 23.
6.	VAUGHAN	"Patent Urachus. Review of the Cases reported". A note on tumours and cysts of the Urachus: Trans. Amer. Surg. Assoc., 1905, XXIII, 273.
7.	VEIEL	"Ille metamorphose des Urachus": Diss. Tübingen, 1862.
8.	CULLEN	Loc. cit. pp. 487-525 and 607-619.

LITERATURE ON THE ANATOMY OF THE URACHUS.

- |     |                       |  |
|-----|-----------------------|--|
| 1.  | BINNIE, J.F.          | "Development of the Urachus":<br>Journ. Am. Med. Assoc., 1906, II, 109.  |
| 2.  | CUNNINGHAM            | "Text-book of Anatomy", 1922 ed.,<br>edited by Arthur Robinson, p. 1314.   |
| 3.  | DORAN                 | Bart.'s Hosp. Reports, 1898, XXXIV, 33.  |
| 4.  | DYKES                 | Lancet, 1910, I, 566.  |
| 5.  | FREER, J.A.           | "Abnormalities of the Urachus":<br>Ann. of Surg., 1887, V, 107.  |
| 6.  | HOFFMANN              | "Zur pathologisch-Anatomischen<br>veränderung des Harstrangs":<br>Arch. der Heilkunde, 1870, XI, 373.  |
| 7.  | KEIBELL and<br>MALL   | "Manual of Human Embryology",<br>1912, Vol. ii, p. 869 seq.  |
| 8.  | KEITH                 | "Human Embryology and Morphology",<br>1921 ed., p. 390.  |
| 9.  | LUSHKA                | (1) "Über den bau des menschlichen<br>Harnstranges": Arch. f. Path.<br>Anat. u. Phys. u. f. klin. med.<br>1862, XXIII.<br>(2) "Die Anatomie des Menschen",<br>1873, vol. II, pt. II, p. 227 seq.<br>(3) Virchow's Archiv., 1862, XXIII,<br>hf. 1 & 2, p. 1 (English extract<br>in Brit. & For. Chir. Rev.,<br>London, 1862, II, 86). |
| 10. | MACEWEN, JOHN<br>H.G. | "Surgical Anatomy", Glasgow, p. 185.   |
| 11. | MERIEL                | Gaz. d. hôpit. Paris, 1901, LXIV, 181.<br>("Les dérivés pathologique de<br>l'ouraque").  |
| 12. | MORRIS                | "Anatomy", Reference to Urachal<br>Artery.   |
| 13. | NICHOLSON, G.W.       | Guy's Hosp. Rep., Jan. 1922.<br>("The Heteromorphoses in the<br>Human Body").  |
| 14. | O'BRIEN, J.E.         | "Pervious Urachus; Comparative<br>Anatomy": Obstet. Gaz. Cincinnati,<br>1879-80, V, 365, 1   |

LITERATURE ON THE ANATOMY OF THE URACHUS (Contd.)

- |     |              |   |
|-----|--------------|---|
| 15. | PORTAL       | Hist. Acad. roy. d. sc. 1769, Par. 1772, 287-296:<br>(Trans. in Verh. intgeg. d. de Hooland Maatsch. de. Weetenschr. t. Haarlem, 1770, XII, p. 1, 1-30. ? |
| 16. | QUAIN        | "Anatomy", Vol. II, pts. 1 & 2.   |
| 17. | TAYLOR       | "Applied Anatomy", p. 398.  |
| 18. | VEIEL, E.    | "Die Metamorphose des Urachus":<br>Diss. Tübingen, 1862.  |
| 19. | WALKER, J.G. | Annot. Acad. Berol, 1775.   |
| 20. | WOOLSLEY     | "Applied Surgical Anatomy," p. 290.   |
| 21. | WUTZ         | "Über Urachus and Urachus Cysten":<br>Virch. Arch., 1883, XCII, 387.  |

CONGENITAL FISTULAE, BIBLIOGRAPHY.Key to page 54.

1 & 2. ALRIC (2 cases)	Bull. gen. de ther., 1879, XCVII, 34.
3. ANNANDALE, T.	Ed. Med. Journ., 1875, II, 486.
4. BINNIE	Jour. Am. Med. Assoc. 1906, XLVII, 109.
5. BRYANT	Med. Times and Gaz. Lon., 1862, I, 456.
6. CABELL	Am. Jour. Med. Sci. Phil. 1849, XV, 313. }
7. CABROL	Alph. Anat. Tournon. 1894, p. 99, XX (r. Florentin).
8. CHARLES	Brit. Med. Journ., 1875, II, 486.
9. DRAUDT	Deut. Zeits. f. chir. Leip. 1907, LXXXVII, 487.
10. ERDMANN	Pediat. N.Y., 1908, XX, 356.
11. FLORENTIN	Thèse de Nancy, 1908-9, No. 22.
12 & 13. FREER (2 cases)	Anns. Surg., 1887, V. 107.
14. FRENCH	Lancet. 1882, I, 60.
15. GARRAUD	B.M.J., 1884, II, 1194.
16. GERSTER	Anns. of Surg., 1913, LVIII, 566.
17. GRAF	Deuts. Klinik, 1864, XVI, 166.
18. GUENIOT	Bull gen de ther. LXXXIII (1872) 299.
19. HARAN	La prat. des accouchement, I, p.38 (1648) - (rep. Simon Thèse de Par. 1843, No. 80).
20. HEFLIN	Rep. Cullen: "Umbilicus", 1916, p.492.
21. HUE	Lar Normand, Med. 1905, XX, 311.
22. HUGGINS	Rep. Cullen, loc. cit., p. 503.
23. IMBERT	Rep. Vaughan, Tr. Am. Surg. Ass., 1905, XXIII, 273.
24. JABOULAY	(Rep. Monod). Thèse de Paris, 1889, p. 124.
25/	

## VII.

CONGENITAL FISTULAE, BIBLIOGRAPHY (Contd.):

25.	JACOBY	Ber. Klin. Wenshrf. 1877, XIV, 202.
26.	JAHN	Beitr. z. klin. chir. Tub., 1900, XXVI, 323.
27.	KENNEDY	B.M.J., 1899, I, 1396.
28.	LANNELONGUE	Lec. de clin. chir. Paris, 1905, p. 388.
29.	LEXER	Arch. f. klin. chir. LVII, p. 73.
30.	LUGEOL	Jour. de Med. de Bordeaux, 1879-80, IX, 3.
31.	MARX	Rep. gen. d'anat. et de phys. path. 1827, IV, 120.
32.	MEYER	Caspar's wocken schr. f. d. ges. Heilkunde, 1844, p. 424.
33.	MEYER-KEMPEN	Rep. Ledderhose: Deuts. Chir. 1890, hef. 45.b. p. 109.
34.	MONOD	Thèse de Paris, 1899, No. 62.
35.	PAGET (1)	Med.-Chir. Trans. L. 1861, XLIV, 13.
36.	(2)	Med.-Chir. Trans. L. 1850, 2 s. XV. 293.
37.	PAUCHET	Bull. et Mein de la Soc. de Chir. de Paris 1902, XXVIII, 785.
38.	PENNY	Brist. Med.-Chir. Journ. 1888, VI, 36.
39.	PETIT	Traite des mal. chirurg. Chap. XI, Limoges, 1837, p. 799.
40.	PIERRE	Bull. Soc. de Med. de Rouen, 1888, 2 s., II, p. 32.
41.	PRESTON	Med. Record, N.Y., 1898, LIV, 315.
42.	ROSE	Med. Record. 1877, XII, 516.
43 & 57.	SMIT (2 cases)	Zentralbl. f. Gyn. 1904, 41.
44.	SMITH, T.	Med. Times and Gaz. 1863, I, 320.
45.	STARR	Med. Gaz. 1844, XXXIII, 484.
46/		

CONGENITAL FISTULAE, BIBLIOGRAPHY (Contd.).

- |     |              |  |
|-----|--------------|--|
| 46. | STEVENS      | Lancet, 1904, II, 584.                         |
| 47. | STIERLIN     | Deut. med. wochen. 1897, XXIII, 188.           |
| 48. | STITES       | Amer. Medic. Phil. 1903 - I, 136.              |
| 49. | TULHOLSKE    | St. Louis Med. Rev., Feb.11, 1905.             |
| 50. | VAN DER VEER | Trans. Am. Med. As. Obst.&Gyn. 1889,<br>II, 7. |
| 51. | VELPEAN      | Rep. Gueniot, q.v.                             |
| 52. | VAUGHAN      | Tr. Am. Sur. Ass., Phil., 1905,<br>XXIII, 273. |
| 53. | WALLER       | Med. Bull., Phil., 1885, VII, 371.             |
| 54. | WILLARD      | Med. News, Phil., 1888, LIII, 710.             |
| 55. | WOLFF, C.C.  | Inaug. Dissertation, Marburg, 1873,<br>Case 3. |
| 56. | YATES        | Phil. Med. Journ. 1902, X, 173.                |
| 58. | ASHHURST     | Med. News, Phil., 1882, XLI, 122.              |

ADDITIONAL CASES OF CONGENITAL FISTULA.

No doubt some of the cases imperfectly reported from the old literature as acquired fistula were really of a congenital type. The following are selected as belonging to this category :-

59. PETIT

Case 2. A boy was born with an impervious urethra. At the umbilicus was a tumour the size of a cherry from which all the urine passed.

Traite des mal. chirurg., Chap. XI, 3, Oeuvres complet. 8<sup>e</sup> Limoges 1837 (Cullen, p. 111).

60. HOFFMANN

Archiv. f. Heilk., XI, 1870.

Two cases also are referred to by Freer (loc. cit.) :-

(1) Med. Record, May 18, 1871.

(2) " " Feb., 1879.

BIBLIOGRAPHY OF ACQUIRED FISTULAE DISCHARGING  
URINE AT THE UMBILICUS: CASES REPORTED.

1.	ANDRE	Soc. de Med. de Nancy, July 24, 1912. Also Jour. de Urol. Med. et Chir. Par. 1898, VII, 691.
2.	BEREZKIN	(Complicated by calculus): Vrach. Zapiski, Musk. 1897, IV, 7.
3.	BINNIE, J.F.	Jour. Am. Med. Ass., 1906, II, 109.
4.	BRAMAN	Arch. f. klin. chir. Paris, 1887, XXXVI, 996.
5.	BROWN, J.T.	Weekl. Bull., St. Louis Med. Soc., 1912, VI, 133.
6.	CADDELL	Edin. Med. Journ. 1878, XXIV, 221.
7.	CHAPIN	N. Amer. Jour. Homoep. 1877, 3 s. XII, 286.
8.	CIVIALE	"Traite de l'affection calculeuse", Paris, 1838, p. 261.
9.	COHN	Deut. Med. Wchnshr. Leip. u. Ber. 1915, XLI, 933.
10.	CHOPART	"Malades des roies urinaire" Par. 1792.
11.	DELAGENIERE	Arch. prov. de chir. Paris, 1892, I, 222.
12.	DELORE and MOLIN	Arch. prov. de chir. Paris, 1898, VII, 691.
13.	ELIOT	(With tuberculosis): Med. & Surg. Rep. Presb. Hosp. N.Y., 1900, IV, 30.
14.	FREER	Annals of Surg., 1887, V., 107.
15.	FROHLICH	"Etied. de chir. enfant", Paris (Maloine) 1905, p. 96.
16.	FLORENTIN	Thèse de Nancy, 1908-9, No. 22 (obs. 8) p. 108.
17.	GENNARO	(With calculus), Progr. Med. Napoli, 1890, IV, 161, 200 & 222.
18/		

BIBLIOGRAPHY OF ACQUIRED FISTULAE DISCHARGING  
URINE AT THE UMBILICUS: CASES REPORTED (Contd.).

18.	GIBB	Hosp. Cull. dep. Pub. Chir. N.Y., 1917, 1 ser. No. 4, p. 36-39.
19.	GOUPIL	Journ. de Med. de Paris, 1756, V. 108.
20.	GUISY	(two cases) Ann. de mal. d-org. gen.- urin. Par. 1903, XXI, 986.
21.	HELMUTH	Homoep. Journ. of Obst. 1884, VI, 24 (rep. Freer).
22.	HIND	(two cases) B.M.J. 1902, II, 242.
23.	HOFFMANN	(with carcinoma) Arch. de Heilkunde, 1870, XI, 373.
24.	KUBUNJI	(following pregnancy) Gynaecologia - Budapesth, 1906, p. 117.
25.	LEVEQUE-LA- SOURCE	Journ. de Med. de Paris, 1811, XXI, 124.
26.	LEVIE	Nederl. Tyd. v. Geneesk. Amsterd. 1878, p. 501.
27.	LITTRE	Host de l'Ac. Roy. des Scien. de Paris, Amsterd. 1701, p. 27.
28.	MATTHIAS	Beitr. z. klin. chir. Tübing., 1904, XLVII, 339.
29.	MITCHELL	(With calculus) Rep. Van Hook, Am. Journ. of Surgery, Vol. XXXIII, p. 56.
30.	PEARSE and MILLER	(Tuberculous Urachus) Journ. Am. Med. Ass., Chic., 1912, LVIII, 1684.
31.	PERAIRE	Paris Chirurg. 1912, IV, 316.
32.	ROBINSON, F.B.	Annals of Surg., 1891, XIV, 336.
33.	SCHOV	Neder. Tyd. v. Geneesk, Amsterd. 1918, I, 1668.
34.	SIMON (2)	Thèse de Paris, 1843, No. 80, obs. 7 & 25, p. 133.
35/		

## XII.

BIBLIOGRAPHY OF ACQUIRED FISTULAE DISCHARGING  
URINE AT THE UMBILICUS: CASES REPORTED (Contd.).

35.	STANLEY	Trans. Path. Soc. of London, March 12, 1898, p. 710. (Same case rep. by Savory, Med. Times & Gaz. 1852, II, 106.)
36.	STARCKE	Deusc. Militar arztliche Zeitschr. 1883, XII, 211.
37.	TROGNEUX	Abs. These de Paris, 1897, No. 129.
38.	UNTERBERGER	Monatschr. f. Geb. und Gyn. 1900, XI, 657.
39.	VAUGHAN	Amer. Medic., Phil., 1905, X, 645. Also Trans. Am. Surg. Ass. 1905, XXIII, 233.
40.	WORSTER	Med. Record, 1877, XII, 196.

ADDITIONAL CASES.

41.	D'AUXEROIR	Journ. de Med., Paris, 1766, XXIV, 58.
42.	BARDELEBEN	Lehrbuch der Chir. und Operationslehre, 1882, IV, 223.
43.	JACOBY	"Zur Casuistik der Nabelfisteln", Berl. Klin. Uchischr. 1877, 202.
44.	LEXER	Archiv. f. klin. chir. LVII, p. 73.
45.	RAUSSIN	Mem. de l'Acad. de Chir. Paris, 1752, III, 10.

## XIII.

REPORTED CASES OF "PATENT URACHUS" ;Either not fully reported or article not available.

- |     |                     |   |
|-----|---------------------|---|
| 1.  | BONZANI             | Pensiero Med., Milan, 1911, I, 365.   |
| 2.  | BRUGGEMAN           | Folia Urologica, Jan. 1910, p. 587.   |
| 3.  | CIFUENTES           | Rev. d. Med. e. ch. Trans., Madrid, 1915, CXII, 342.  |
| 4.  | EPSTEIN             | "Ur. fistula in boy of 9 years": Gyogy-<br>:aszat, Budapesth, 1896, XXXVI, 376:<br>also Ungar. Med. Press, B.P. 1896, Vol.<br>1, p. 135.        |
| 5.  | HOLSCHER            | Rep. Gueniot, 9. V.   |
| 6.  | LEBEDEFF            | "Fist. urach. inguinal hernia and cryptor-<br>:chism in one child. Med. b. bozr.<br>Moscow, 1912, LXXVII, 984.                                  |
| 7.  | McGEHEE             | Memphis. Med. Monthly, 1912, XXXII, 321.  |
| 8.  | MacLENNAN           | (Simple reference to case - no details),<br>Glasg. Med. Journ. 1911, LXXV, Sept. 3.   |
| 9.  | ROUX                | "Compte rendu des puric mal. chir."<br>Archiv. gen. de med. 1826, XI, 554.<br>(This is probably same case as that<br>reported by Marx, No. 31). |
| 10. | REUSSEN             | Med. Weekle, Amsterdam, 1897-8, IV, 337.  |
| 11. | REED                | Lancet, Clinic. Cincinnati. 1911, CV, 475.  |
| 12. | SANTUCCA            | La settimana meduca, 1899, Nos. 23 & 24.  |
| 13. | STADFELD            | (German abstr. only, seen): Nord. Med.<br>Arkiv., Stockholm, 1871, III, 23.   |
| 14. | ZOHRER<br>(2 cases) | R. Gueniot, Bull. gen. de ther., 1879,<br>XLVI, 264.  |

BIBLIOGRAPHY OF CYSTS AND TUMOURS OF  
THE URACHUS.

An excellent and exhaustive bibliography of these cases is given in Cullen's Book "Diseases of the Umbilicus", to which the reader is referred. The list below is supplementary to this and brings the literature up to date.

- |              |   |
|--------------|---|
| 1. ALEMAN    | Hygiea. Stockholm, LXXVIII, 1916, tf. 13, p. 952.                             |
| 2. BONI      | Clin. Chir., Milano, 1914, XXII, pp. 195-212, 1 pl.                           |
| 3. DAVIS     | Surg. Clinics. Chicago, 1919, III, 521.                                       |
| 4. EDINGTON  | Lancet, 1922, I, 1791.  |
| 5. GRAMEN    | Hygiea. Stockholm, 1916, LXXVIII, p. 1460.                                    |
| 6. JACOBY    | Urol. and Cutan. Rev., St. Louis, 1916, XX, 383.                              |
| 7. JUDT      | Medycynia i kron. lik Warsaw, 1912, XLVII, 579.                               |
| 8. KOZLOVSKI | Russk. Khirurg. b bozr. Moscow, 1903, I. 144.                                 |
| 9. McLEAN    | Med. Rec. N.Y.. Feb. 8, 1879.   |
| 10. MEENS    | Annals of Surg., 1916, LXIV, 53.  |
| 11. MICHELI  | Boll. d. soc. tosc. di ostet. e genec., Florence, 1903, II, 211-216.          |
| 12. PENDLEY  | (Colloid cancer in cyst wall). Beitr. z. klin. chir., Tübing, 1914, XCI, 681. |
| 13. SOULIE   | (Monograph), Bordeaux, 1919.  |
| 14. THOMAS   | Med. Rec., Jan. 1878.   |
| 15. VAN HOOK | Am. Journ. of Surg. N.Y., 1919, XXXIII, 56-58.                                |
| 16. VEBER    | Khirurg. Arkh. vel. St. Petersburg, 1911, XXVII, 757.                         |
| 17. WARD     | Ann. of Surgery, 1919, LXIX, 329, 1 pl.                                       |

MISCELLANEOUS GROUP OF ARTICLES BEARING ON THE  
URACHUS AND ITS DISEASES, SUPPLEMENTARY TO  
CULLEN'S BIBLIOGRAPHY.

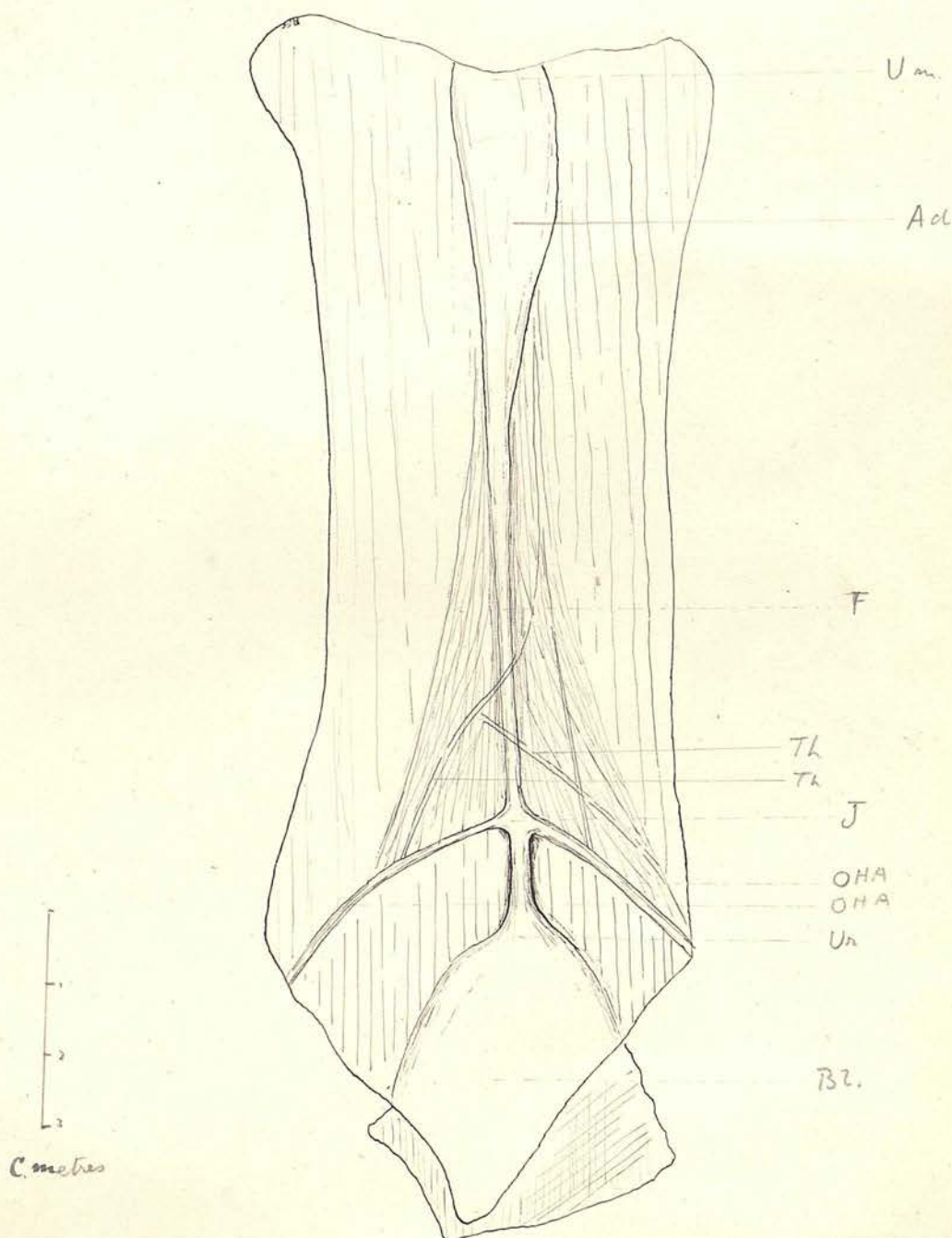
1.	CULLEN	Surg. Gyn. and Obst. 1922, XXXV, 257.
2.	DRAUDT, M.	"Beitrag zur Kenntius der Urachus anomalien": Deutsch. Zeitsch. f. chir. 1907, LXXXVII. 487.
3.	EASTMANN	"Tuberculosis of the Urachus", Am. Journ. of Obst., 1915, LXXII, 640.
4.	FULLE	(Sarcoma). Gazz. internaz. di med. Napoli, 1914, XVIII, 37.
5.	GARRIGAN	(Bladder reached to umbilicus; found at autopsy only). Med. Rec. N.Y. 1899, LVI, 720.
6.	HARTLEY	Personal communication: Abscess as high as umbilicus discharging into the bladder.
7.	HELMUTH	(1) "Contrib. to Gynecol. Surgery", p.16. (2) Homoeop. Journ. of Obstet. 1884, VI, 24.
8.	JOHNSON	Lancet, 1921, II, 1159.
9.	KHAUM	(Glandular tumour erroneously rep. as Carcinoma): Wien klin. wchnschr. 1916. XXIX, 130.
10.	KLOPP	(Fistulous canal at umbilicus, reported as Sarcoma of the Urachus): Anns. of Surg. LXXIII, 1921, p. 643.
11.	LANE Arb.	Guy's Hosp. Reports, XXVIII, 1885.
12.	LOWER	Archiv. Surg. Chicago, 1921, III, 3855.
13.	McNEALY (Nealy)	(Calculus doubtfully reported as connect- ed with the urachus). Inten. Clin., Phil., 1920, 30 s. IV, 45, 2 pl.
14.	MARSHALL	(Bladder reaching to umbilicus). Journ. Obst. and Gyn. Br. Emp. 1907, XI, 259.
15/		

MISCELLANEOUS GROUP OF ARTICLES BEARING ON THE  
URACHUS AND ITS DISEASES, SUPPLEMENTARY TO  
CULLEN'S BIBLIOGRAPHY (Contd.)

- |     |                   |  |
|-----|-------------------|--|
| 15. | MORESTIN          | (Adenomatous Small Cyst). Bull. de la Soc. Anat. Paris, 1900, LXXV, p. 1040.                       |
| 16. | NETTINGANG        | "'Patent Urachus' in foals": Am. Vet. Rev. N.Y., 1915, XLVII, 618.                                 |
| 17. | PRATT and<br>BOND | Lancet, 1890, I, 898.  |
| 18. | SMITH             | Am. Journ. of Surg. 1921, XXXV, 327.   |
| 19. | TAIT, L.          | "Diseases of the Ovaries", 1883, p. 188.<br>(Urachal cysts reported. Probably of other Pathology). |
| 20. | WILSON, B.        | J. Am. M. As. Chic. 1922, LXXVIII, 1981.   |
| 21. | CHILD             | B.M.J. 1906, II, 427.  |

OTHER MISCELLANEOUS REFERENCES TO URACHAL  
CONDITIONS.

1. Bull. et Mem. Soc. de Anat. de Paris, 1922, CXII,  
p. 131.
2. Jour. Am. Med. Assn., Chicago, 1922, LXXVIII.
3. (Rep. by Frer). Canada Lancet, Toronto, XVIII,  
194.
4. Obstet. Gaz. Cincinnati, Vol. II.
5. B.M.Journ. Vol. II, p. 94.
6. Trans. of the Path. Soc. of London, XXXVI.
7. Penniero Med., Milan, 1915, V, 174.



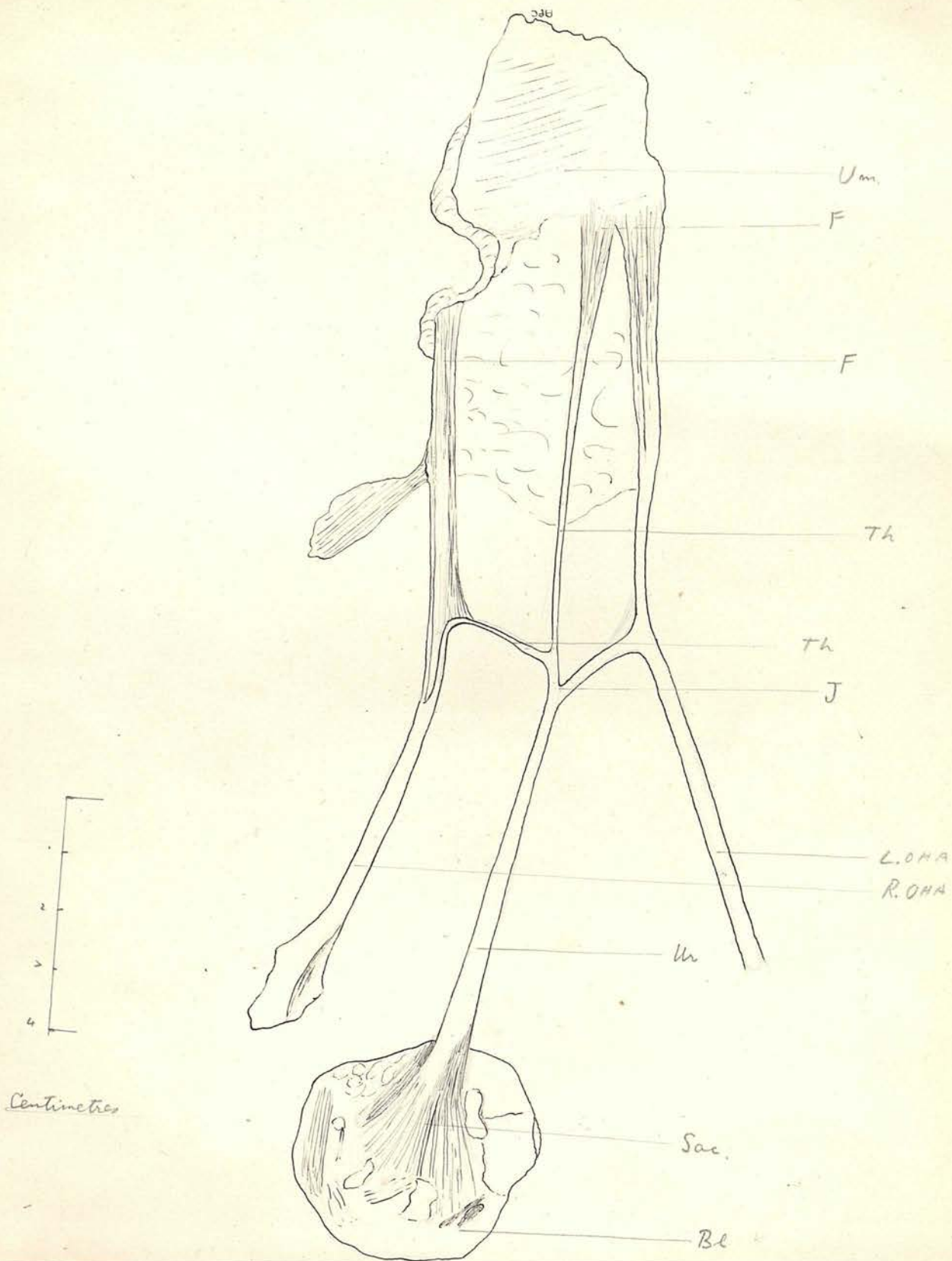
### DESCRIPTION OF PLATE I.

This drawing is made from a female child, three years of age. It represents a view of the anterior abdominal wall from within, and the structures are seen through the peritoneum.

The two obliterated hypogastric arteries (OHA) are seen to approach the urachus (Ur) and join its apex from either side. A fibrous cord (F) formed by the fused adventitia of the two arteries is carried up from the line of junction (J) to the umbilical region (Um). Several loose thread-like bands derived from the same source (Th) are seen to form an interlacement.

The plate represents the natural size of the specimen.  
Bl. = Bladder apex.

# PLATE II



## DESCRIPTION OF PLATE II.

A sketch, natural size, of the urachus and obliterated hypogastric arteries in a man of 56. The Urachus (Ur) ends in a mucous membrane sacculuation of the bladder (Sac) with which its canal communicated. The adventitia of the right obl. hypog. artery (R.OHA) has been pulled off in the form of a fibrous band (Th) by the descent of the urachus.

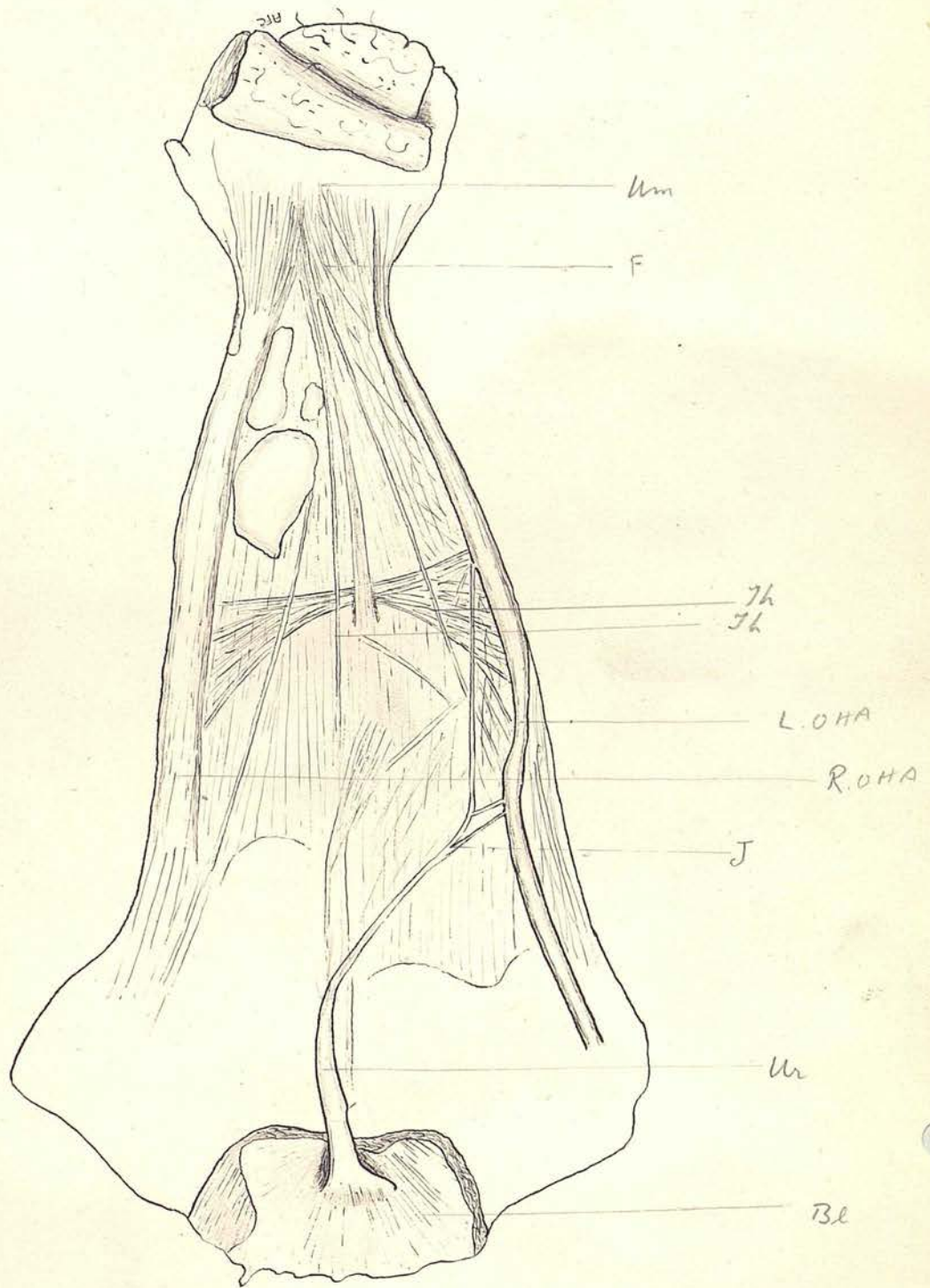
Um = Umbilicus.

F = Fibrous Cords derived from the adventitia of the obl. hypog. arteries.

J = Upper end of the Urachus.

L.OHA = Left obliterated hypogastric artery.

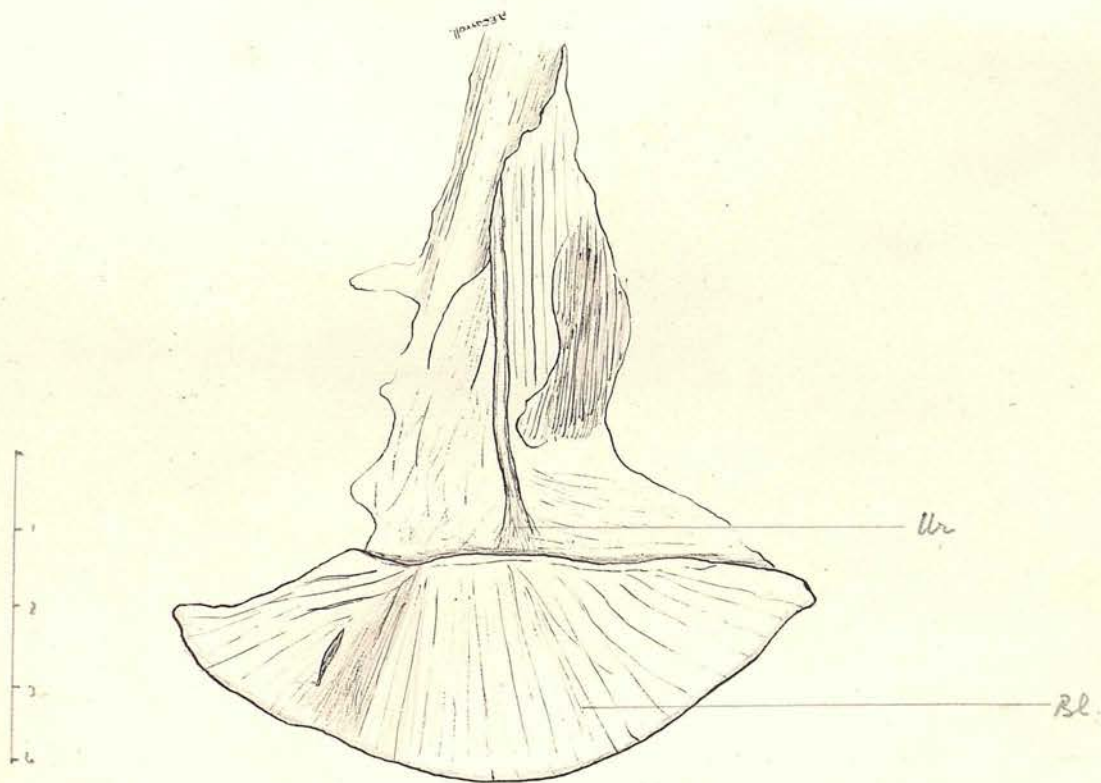
PLATE III



DESCRIPTION OF PLATE III.

Sketch of the same parts as in Plate II, of an adult male. The Urachus (Ur) is attached in more than one place to the left obl. hypog. artery and has been partially curved over and its apex split owing to this attachment. A plexus of fine threads teased from the adventitia of the arteries is shown (Th). Other letters as in Plate II.

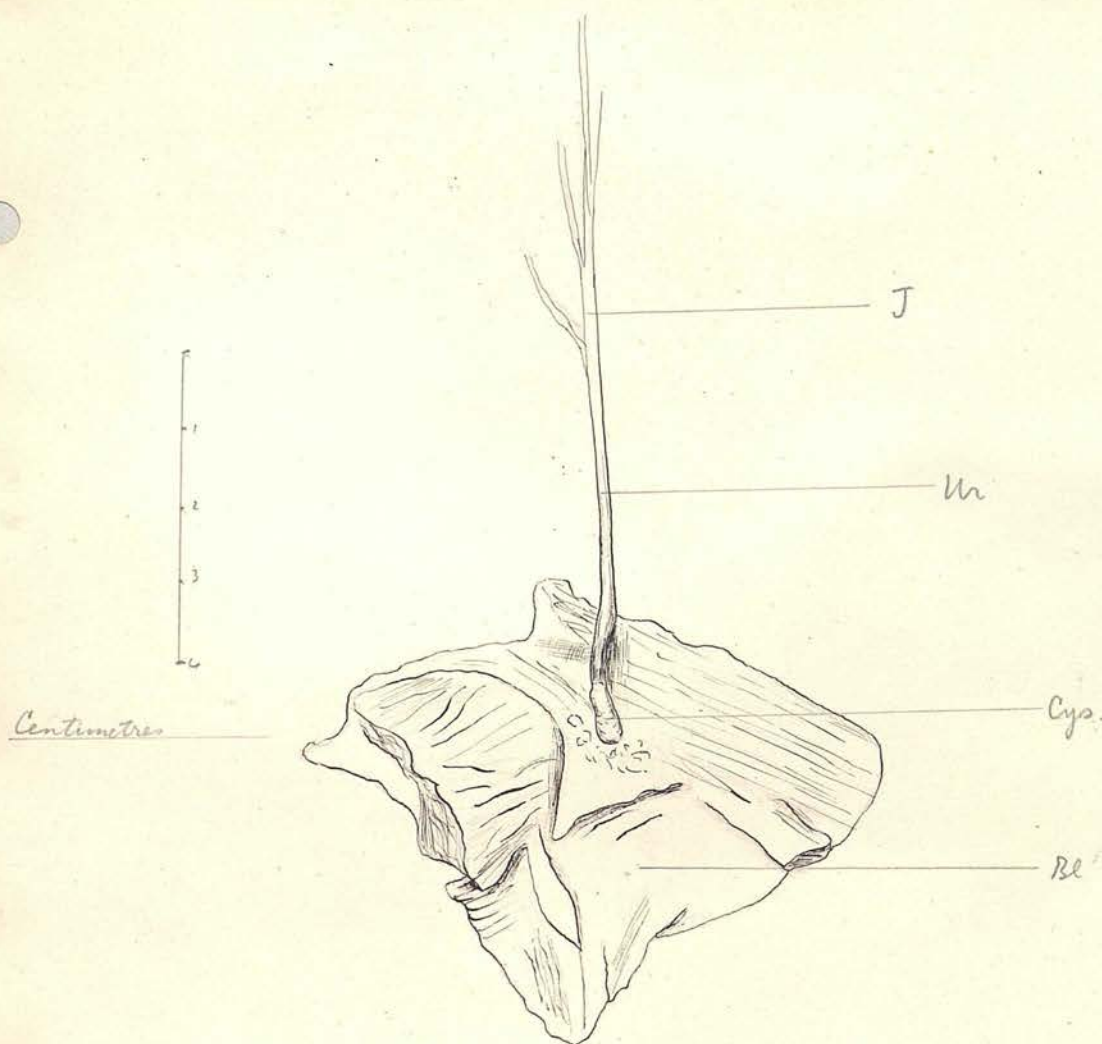
PLATE IV



Centimetres

DESCRIPTION OF PLATE IV.

A natural sized view of the lower end of the Urachus (Ur) in an adult female, showing its termination in a number of fibrous bands radiating out into the vesical submucosa. Bl. = Mucous membrane of the bladder.



DESCRIPTION OF PLATE V.

A view showing the Urachus (Ur) in an adult male terminating in a cystic dilatation (Cys). This was proved by sections to be of an adenomatous nature and not a mere dilatation of the canal. There is no connection between this structure and the cavity of the bladder.

Bl = Mucous membrane of bladder.

J = Upper end of the Urachus being joined by filaments from the Hypogastric arteries.

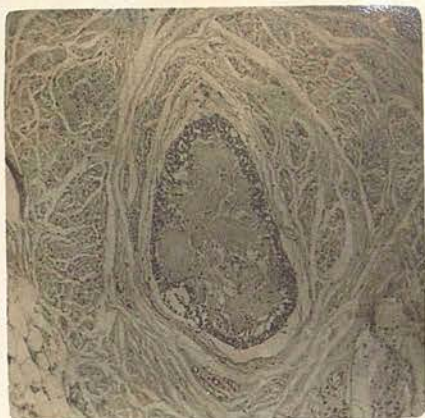

PLATE VI. A.

A section across a normal adult urachus near the bladder end.

- Note (a) The desquamated cells and their debris filling the lumen;  
(b) The circular fibrous coat of the urachal canal; and  
(c) The bundle of muscle fibre cut transversely.

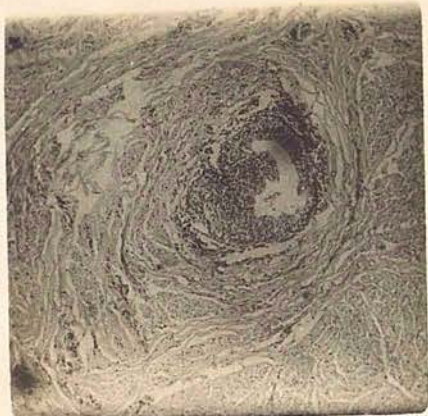


PLATE VI. B.

Another section taken from a different specimen.

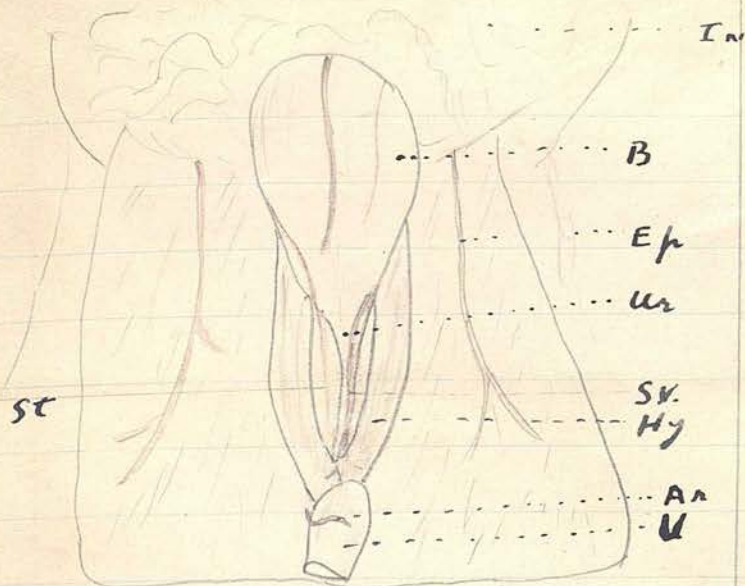
Note how the proliferation of epithelium has taken place more rapidly at one point, where a mass of cells is projecting into the lumen. There are a few desquamated cells loose in the canal.

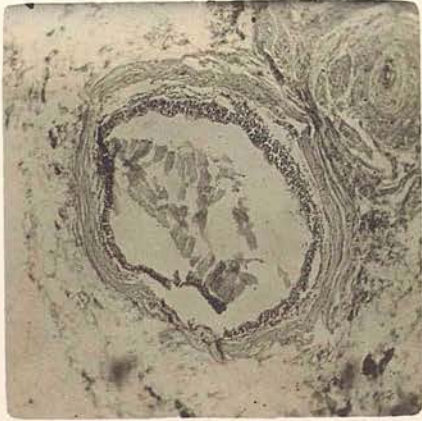

PLATE VII.

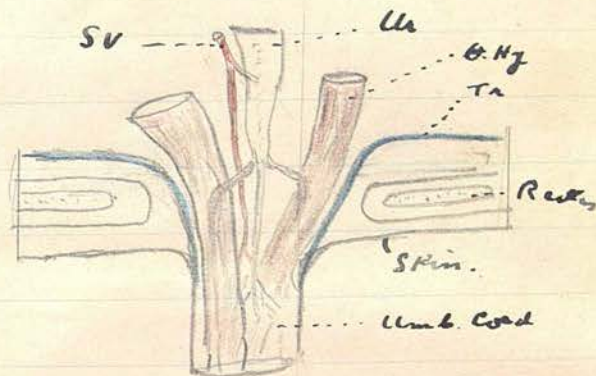
This section demonstrates how the cyst is not a dilatation of the central urachal canal. The cyst is seen in the middle, while the urachal canal, much smaller and more compact, is seen in the top right-hand corner.

Fig 2.



A (2/3 nat size)

Fig. 2. ~~Oh.~~



B




Fig. 2.A. is a view, semi-diagrammatic, of the peritoneal surface of a full-term foetus which shows the general arrangement and arterial supply.

Fig. 2.B. is a diagrammatic representation of the termination of the urachus, showing its division into three parts, one attached to each artery and one passing out into the cord.

A. In = Intestines:

B = Bladder

Hy = Hypogastric artery:

Ur = Urachus with urachal artery from the left superior vesical artery:

Ep = Deep or inferior epigastric artery:

Ar = a branch of the right epigastric artery anastomosing with the urachal artery around the umbilicus:

Sv = Urachal artery:

St = Branch of Rt. Sup. Ves. artery.

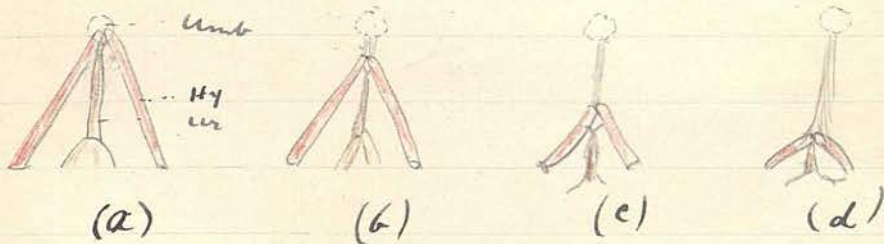
B. Ur = Urachus:

Hy = Hypogastric artery:

Tr = Protrusion of Transversalis fascia:

Sv = Urachal artery showing its termination in the cord.

Fig. 3



A series of four diagrams illustrating how the apex of the urachal-hypogastric tripod is pulled down the abdominal wall in such a way that it lies in the adult only 5 c.m. above the bladder, while all the fibrous cords above this are derived from stretched-out and proliferated connective tissue, in part derived from the adventitia of the arteries, in part from the fibrous tissue produced in the closure of the umbilicus.

(a) Shows condition at birth:

In (b) and (c) the urachus is leaving the umbilicus dragging the arteries with it:

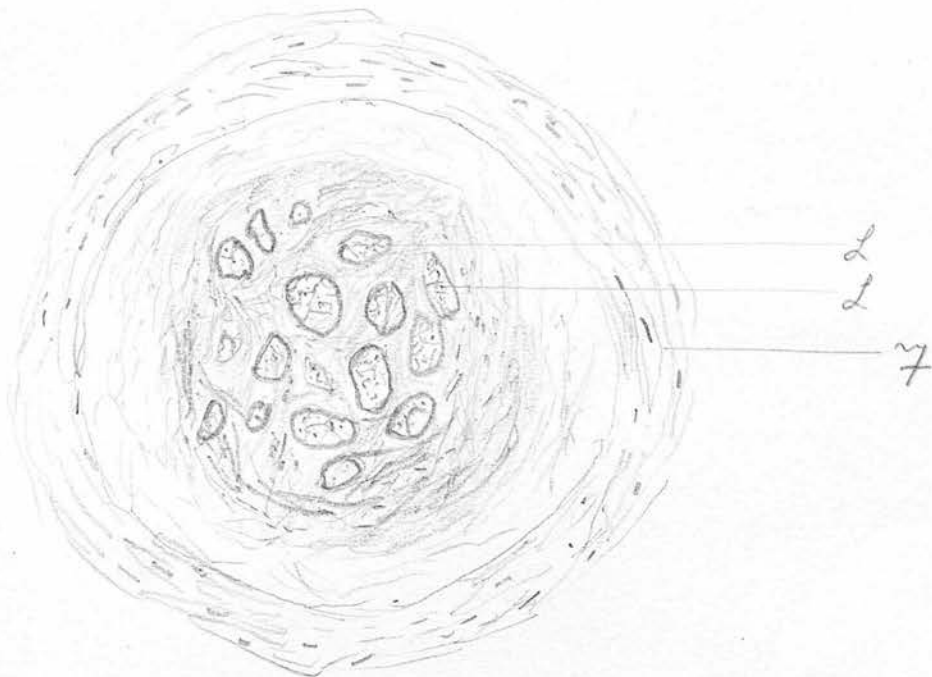
(d) represents the ideal adult condition rarely met with, because instead of the middle single band there are innumerable teased out fibres.

Umb = Umbilicus:


Hy = Hypogastric arteries:

Ur = Urachus.

Fig. 4.



High power view of muscularis b.c.m above bladder to show typical appearance of muscularis whose curl has been obliterated.



SECTION OF URACHUS IN MALE AGE 56 3cm ABOVE Apex of  
BLADDER.

Slide 2.

Fig. 6

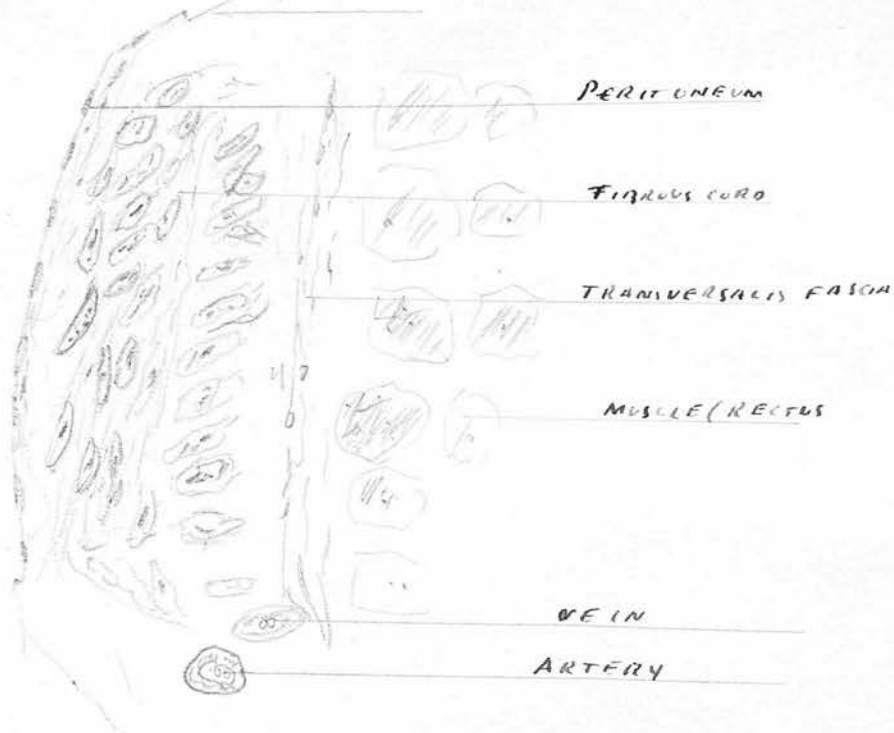

Fig 6

Transverse section of middle fibrous cord and rectus abdominis showing that there is no trace of blood structure. From middle cord with well developed central cord, that would formerly have been described as the nucleus

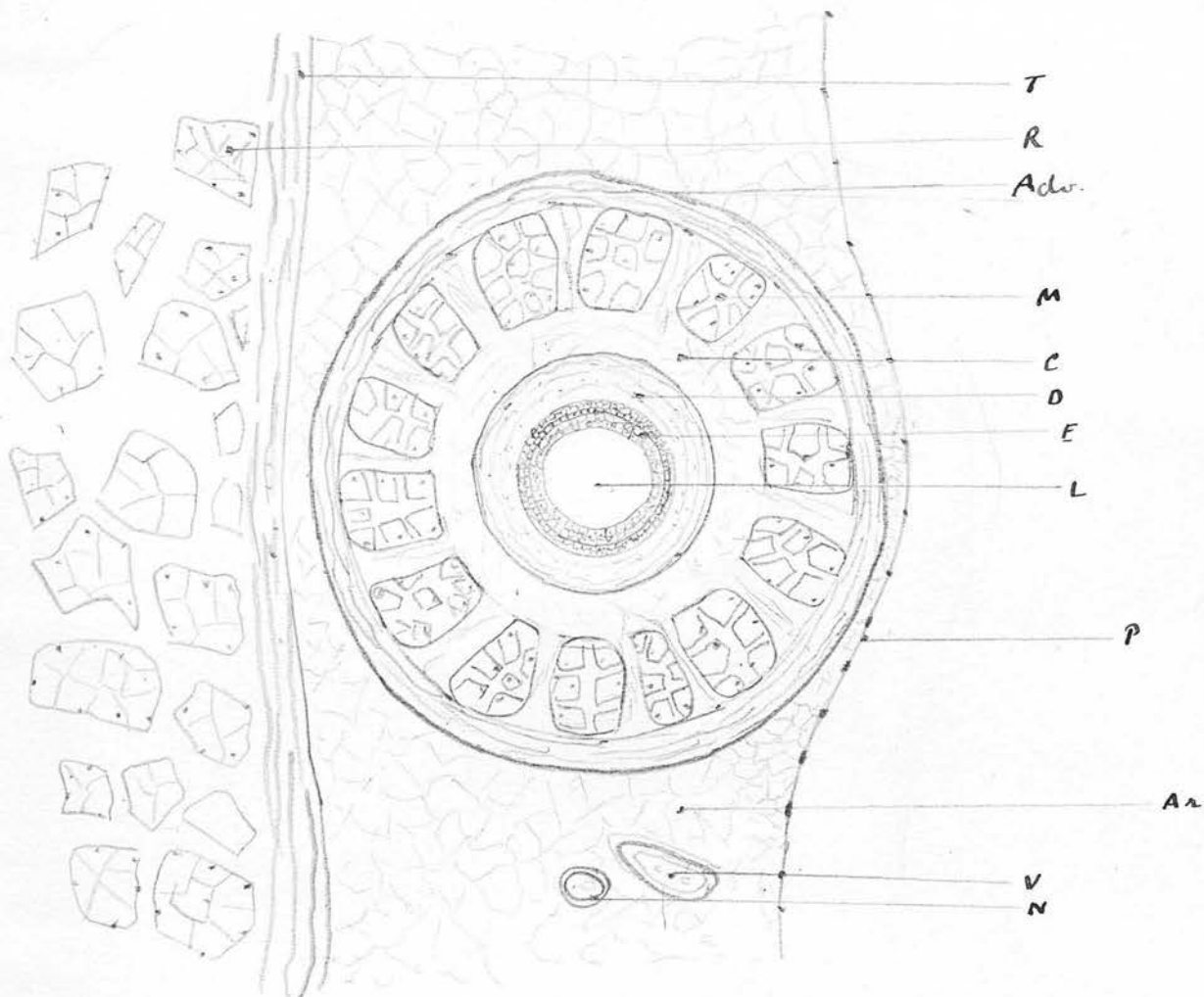


Diagram illustrating structure and relations of urethra as shown by transverse section made in an adult one centimeter above apex of bladder

R - Rectus muscle ; T - Transversalis fascia P - Peritoneum

AR. - loosely arranged areolar connective tissue V - Urethral vein NA - artery

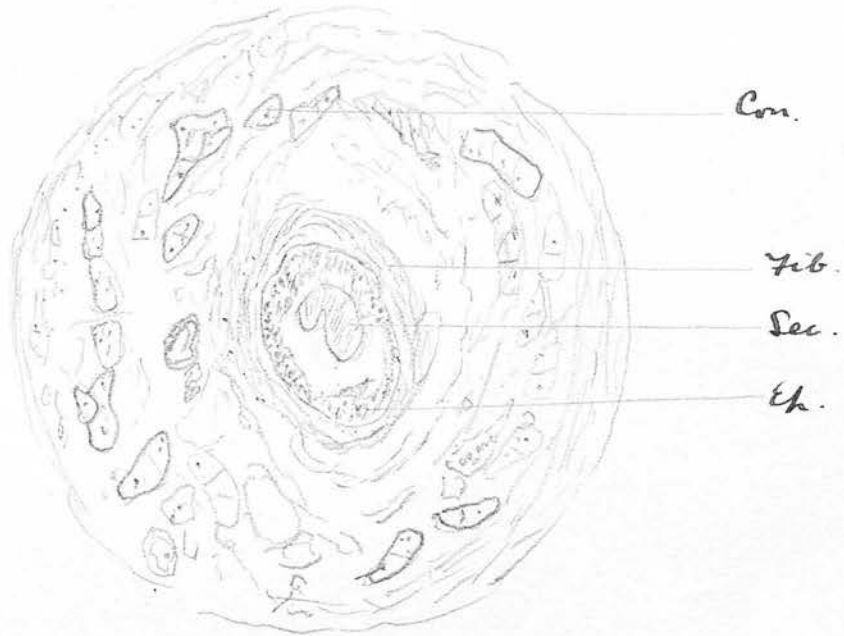
A - outer coat composed of circular bundles of fibrous tissue

M - muscular coat - longitudinal bundles cut transversely, separated by fibrous tissue

Urethral canal proper composed of dense concentrically arranged fibrous tissue D - several layers of lining epithelium E. No basement membrane separates these layers. L - lumen

C - loose connective tissue

Fig 8



x 100

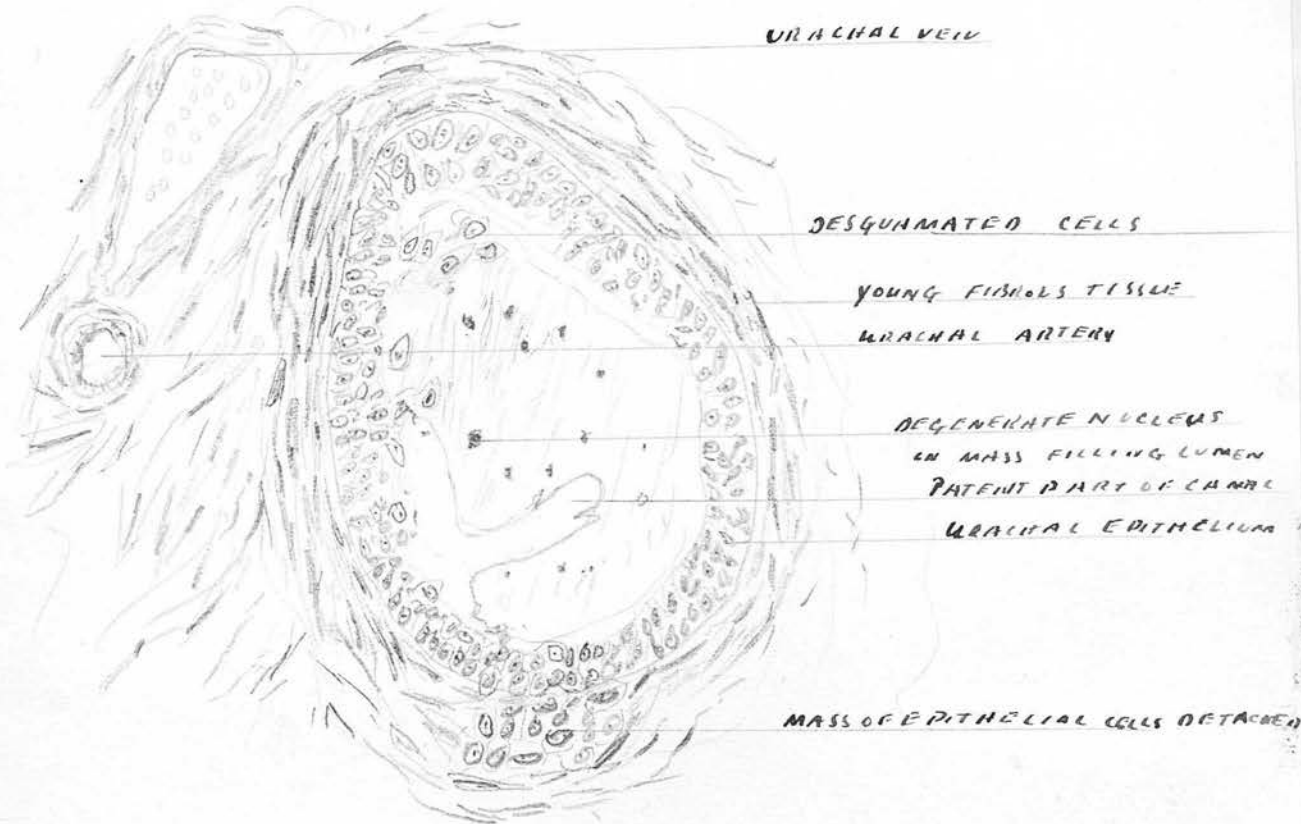
---

Section of adult tracheus - 2 cm. above bladder of 4.

Com. - mixed muscle & connective tissue : Sec. : desquamated cell mass

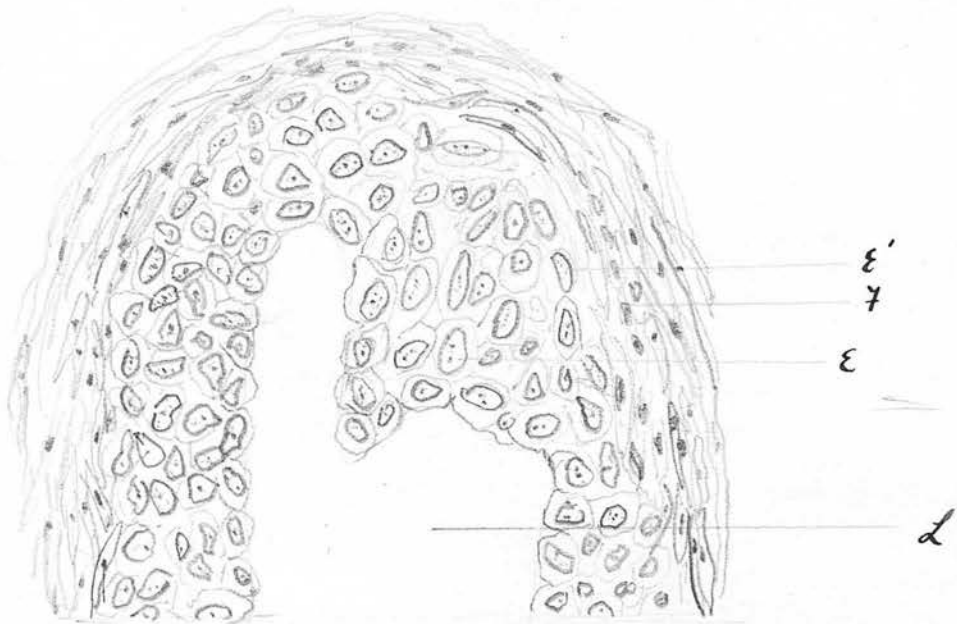
Ep. : - Epithelium : Fib. : Cuticular fibres formed around spiracle canal

---



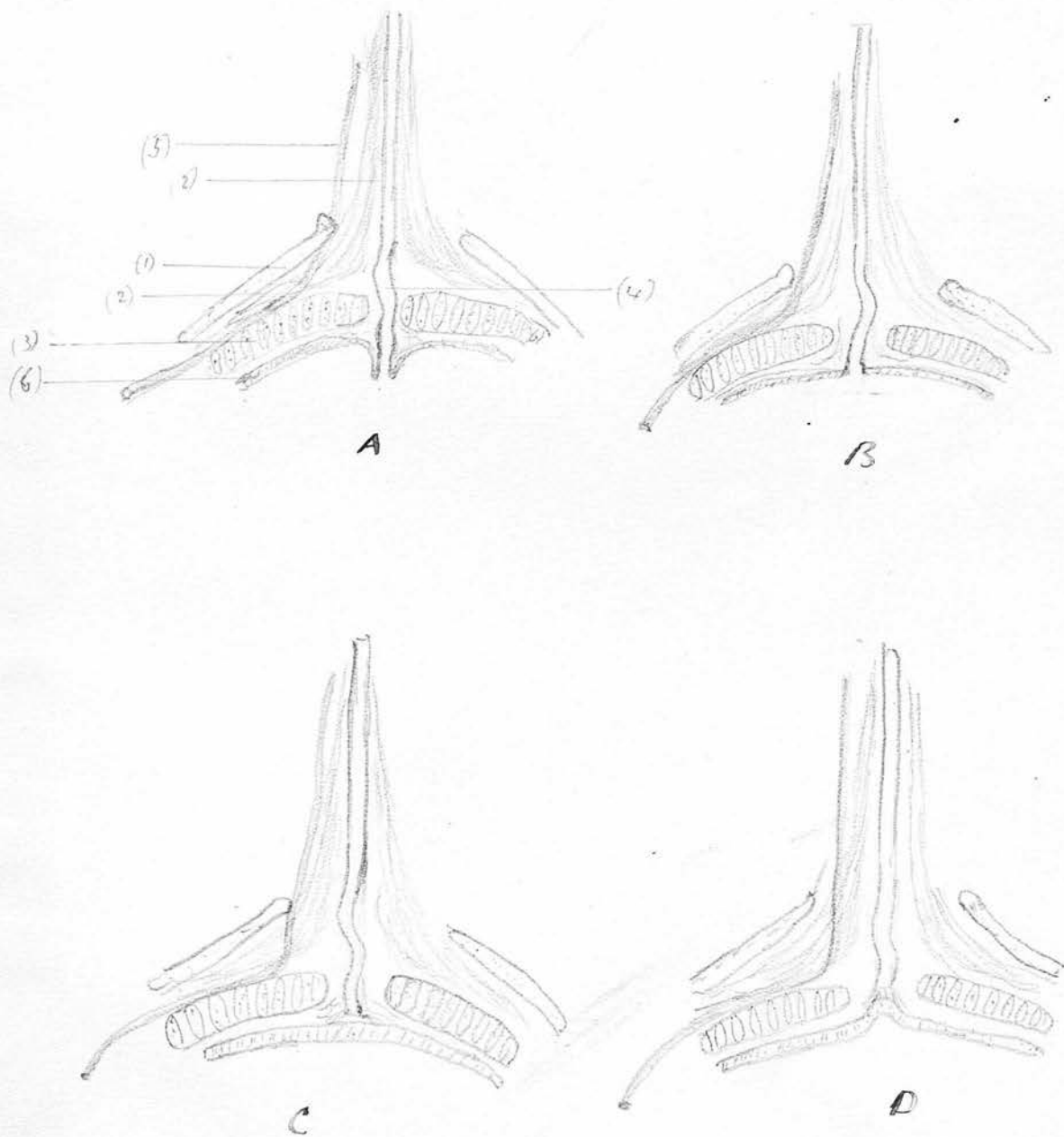
H.P. view of Urachus. Male age 56 showing degenerate cell nuclei embedded in a mass of degenerated cells almost filling canal.

Fig 10



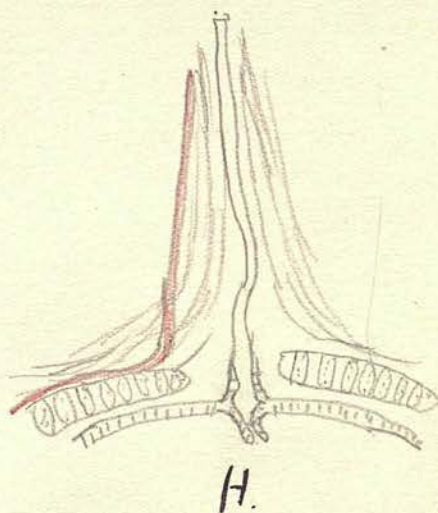
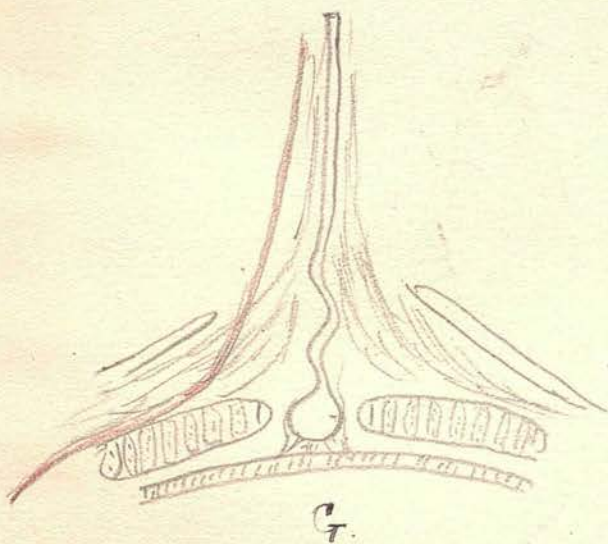
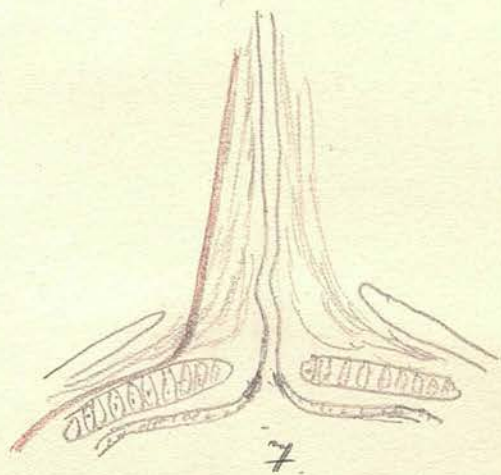
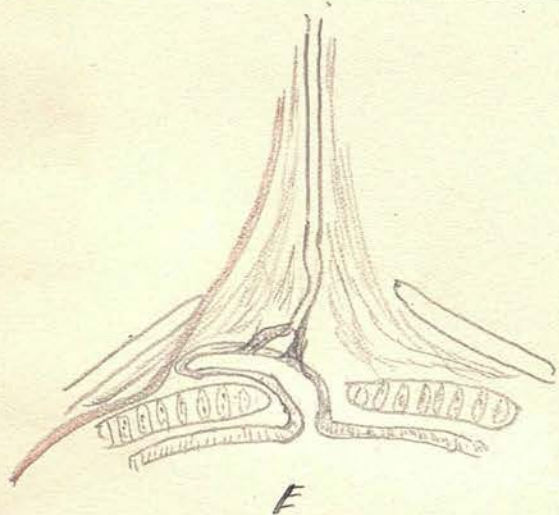
Section to show character of epithelium of ureteral canal seen above the bladder. Note absence of basement membrane.  
E' - outer layer of epithelial nuclei flattened at right angles to lumen  
E - epithelium      F - young fibrous tissue. L - lumen of canal.

Fig. 11.

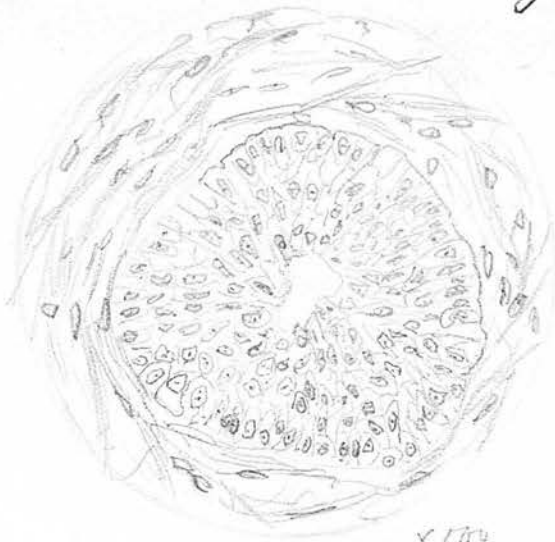

- (1) Bladder adventitia
- (2) Muscle fibres passing to urethrus.
- (3) Middle muscular fasciculi of bladder
- (4) Urachal canal
- (5) Urachal artery
- (6) Bladder muscle

Fig. 11. (cont.)



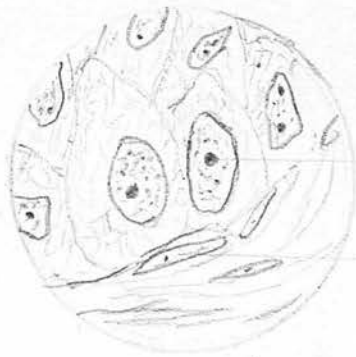A series of diagrams showing the various methods by which the ureter terminates at its bladder end. In A, the explanation of the figures is given, and for further description see text.



A

X 500

B.



Nucl.

f

X 1000

Fig B. Structure of nuclei of External layer in a new born fetus X 1000

Fig. A at H.P. view of central canal in the same cord

Nucl.: Large nucleolus. f: fibroblast

Note absence of basement membrane.

Fig 15

Slide P.B.2



Fig 14

Slide P.B.

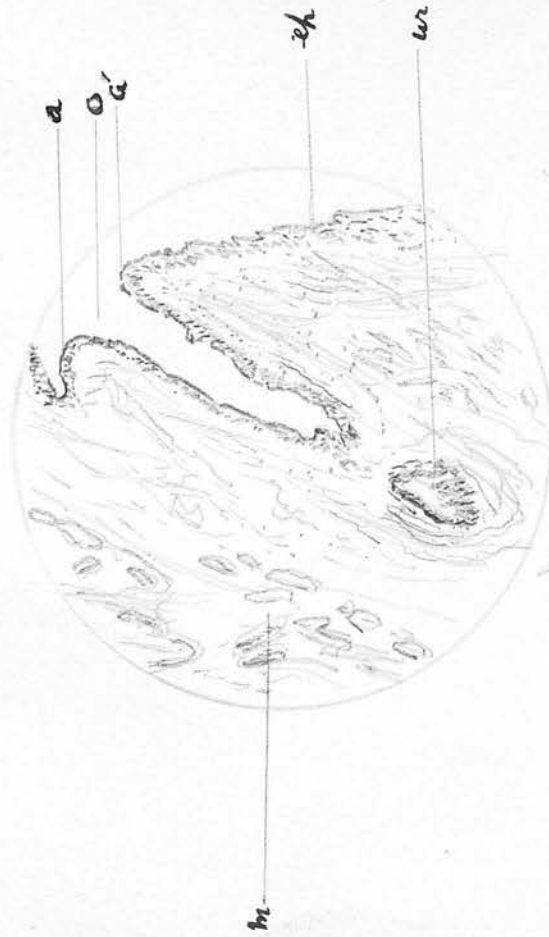


Fig 14 Section (Longitudinal) to show opening of the urethral canal into the bladder. The canal was one of still born male foetus. The section has various portion of the urethras which reappears further up (ur). Fig 15 is section partially longitudinal of the same specimen showing the urethras in its intracanal course. O - opening of urethras into bladder. a, a' - points where the two epithelias become continuous; ch - bladder chamber; m - bladder muscle; m - urethral canal.

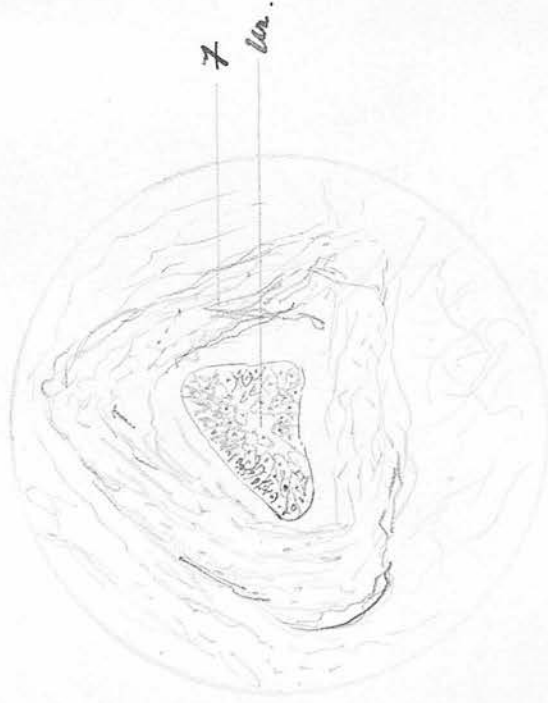
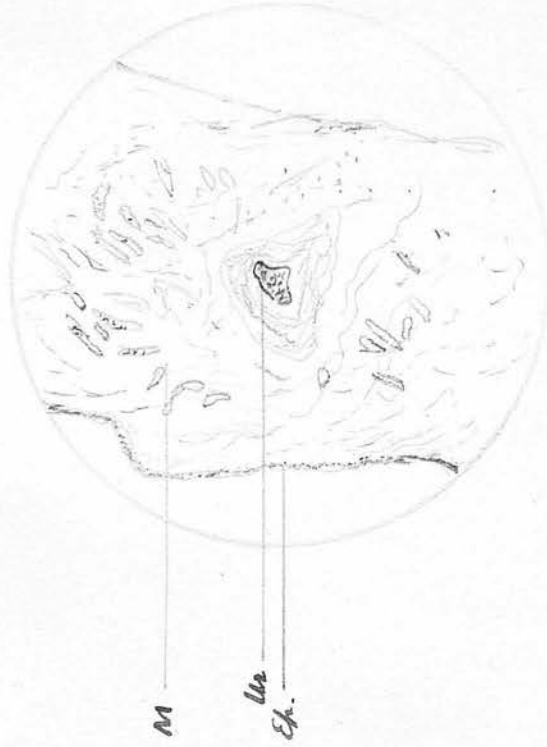



Fig. 16. A section from the same slide as figure 15 but higher up. The urethral canal is still imbedded in the bladder wall. Fig. 17. HP. view of the urethral canal. 7. Fibrous sheath of urethral canal; Ep. bladder epithelium; M, muscularis; Ur. = urethral canal.

X 250

Aug. 18.

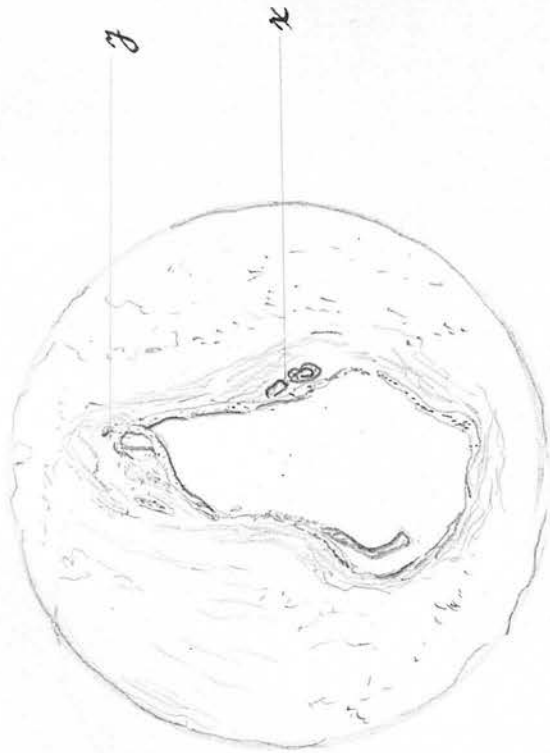


A sketch of a radiogram by Andre, supposed to represent a patent urethrus. The width of the channel between bladder & umbilicus suggests that the ureter was ~~passing~~ filling a large track between the transversal fascia & the peritoneum. Ureth: supposed patent urethrus

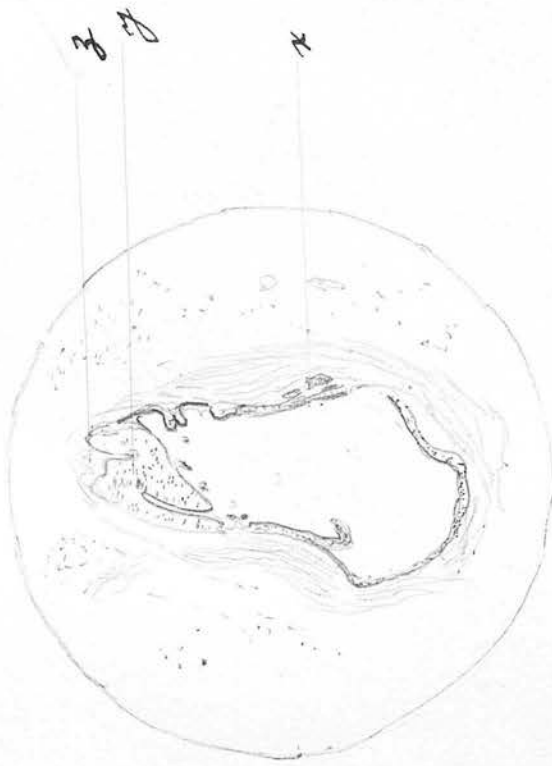
Andre

Fig. 19.

Slide marked X. 1. 3.



A

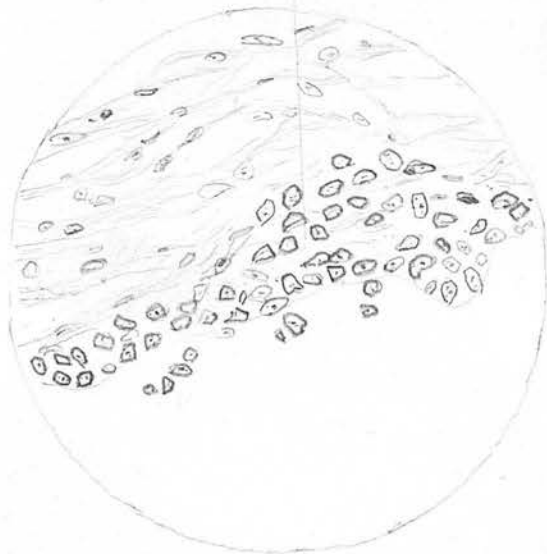


B

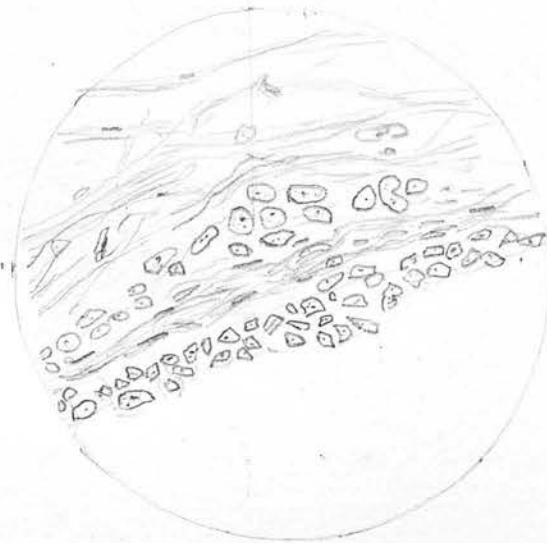
Two low power views of specimen taken above the cyst. B is taken at a slightly higher level than A. At the point of a mass of epithelial cells has formed and is being split by a wedge of fibrous tissue z. At x in B, some cells are being detached from the epithelial canal, and in A there have formed two separate masses and have acquired a lumen. A high power view of the pores is shown in Fig. 20, A to D & in Fig. 16.

Fig. 20

Slide marked X. 13



A

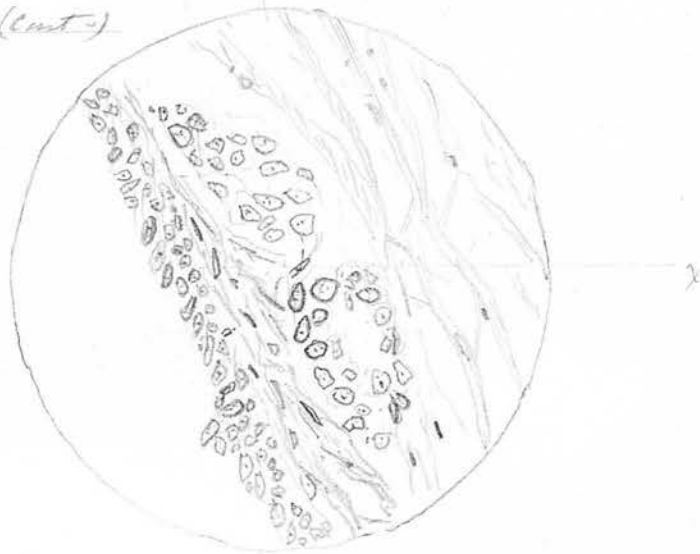


B

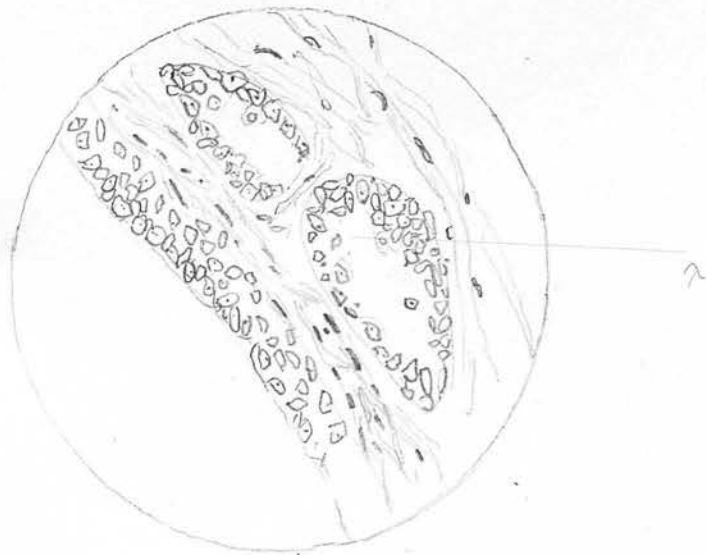
A high power view of Fig 19. X. 1, in four serial sections A-D, showing the steps by which the cells lining the canal pass out into the fibrous tissue and become separate cell columns. In A the cells are passing out into the stroma, in D, they have formed two vesicles lined by cubical epithelium. In this section the central cells are seen to be degenerating to form the lumen.

Fig. 20. (cont.)

713



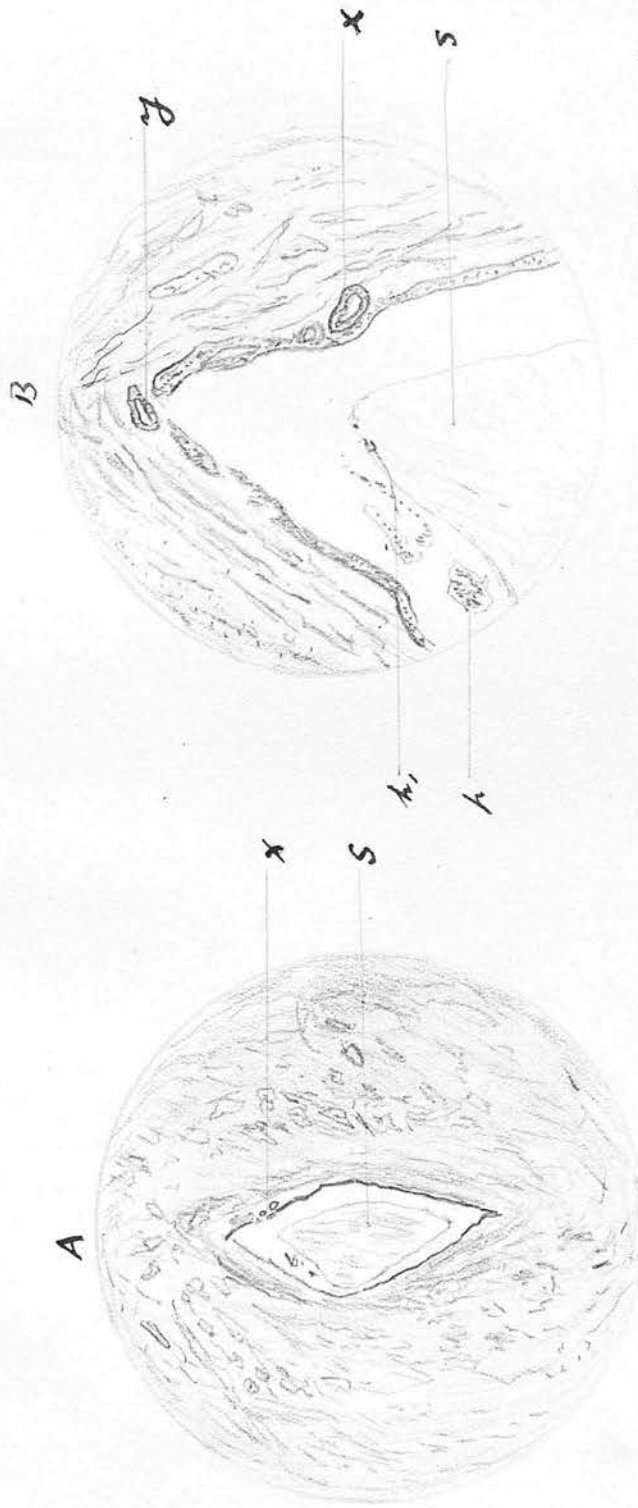
C



D 4

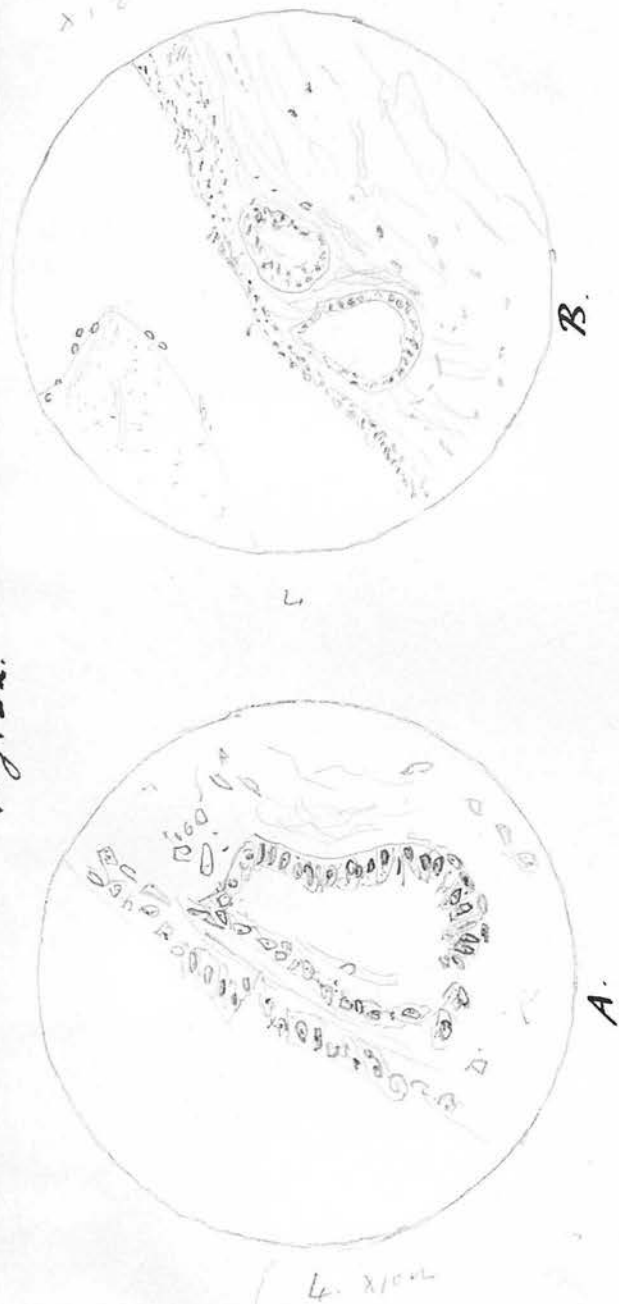Fig 21

Slide X. 1. 2



A section of specimen I, through the upper part of the cyst, nearer the bladder than in Fig 19.  
The point <sup>x</sup> represents the same point as in fig. 19 & 20. This cyst is increasing by proliferation and degeneration of the lining cells, ~~and~~ <sup>which</sup> resembles dilatation. A lamellar formation is seen, however at x & y. S----homogenous cell content, a few degenerate nuclei k, & k

Fig. 22.

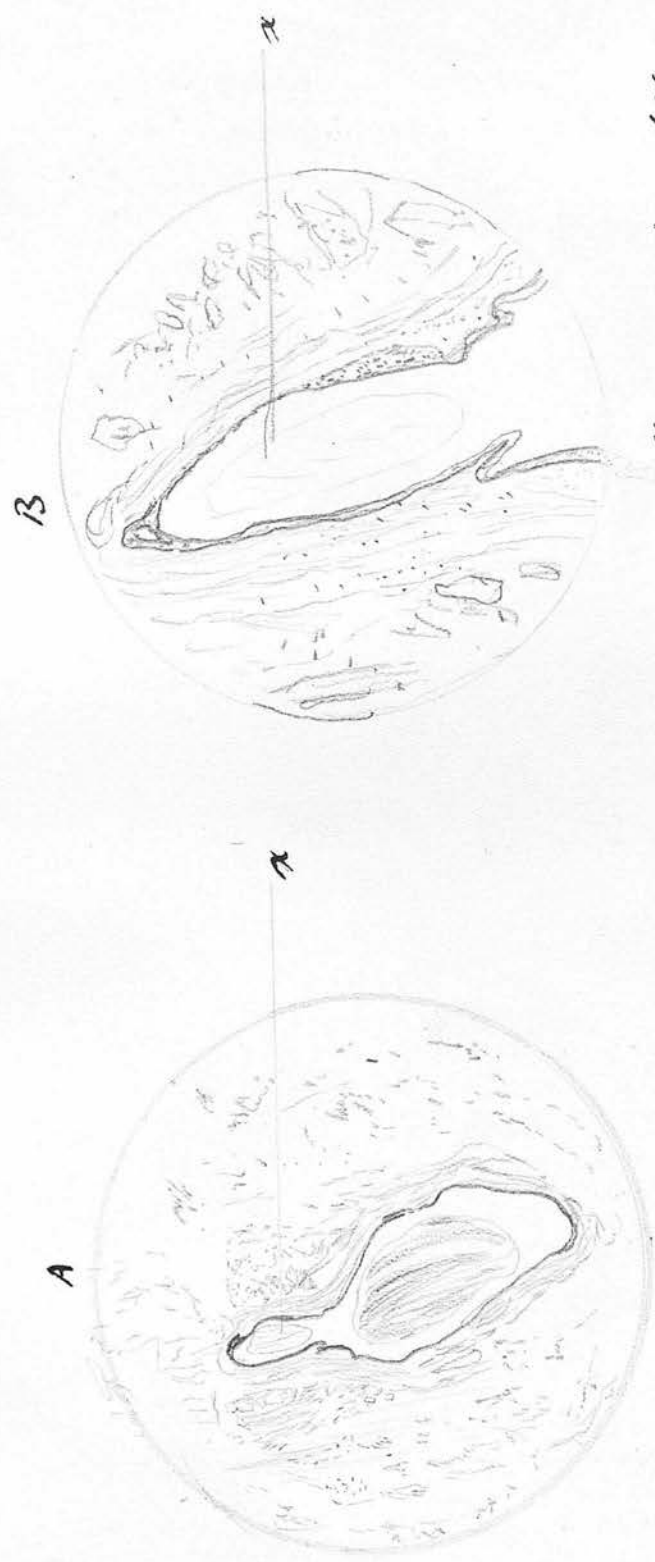


A. (oil immersion) highly magnified view of Fig. 21 x to show  
~~adventitious~~ t-cyctic space

B. High power (x400) view of the same.

Chile X. 1.

Fig 23



Section through centre of upper cyst at a lower level than in Fig 21. The cyst is now bilobular  
and the cystic spaces marked x in figs 19 & 21 have disappeared. They are probably concerned  
in the formation of the upper baculus. (A X25) (B X100)

Slide. X 1.1

Fig. 24



Section through lower cyst (Fig. 17. c)

B. ( $\times 125$ ) shows the circular fibrous coat surrounding the cyst, with the lumen to me around the A. ( $\times 100$ ) shows the upper part of the same cyst. The homogeneous content is well shown.

R<sub>2</sub>  
Slide R<sub>2</sub>

Fig. 25



URACHAL CANAL

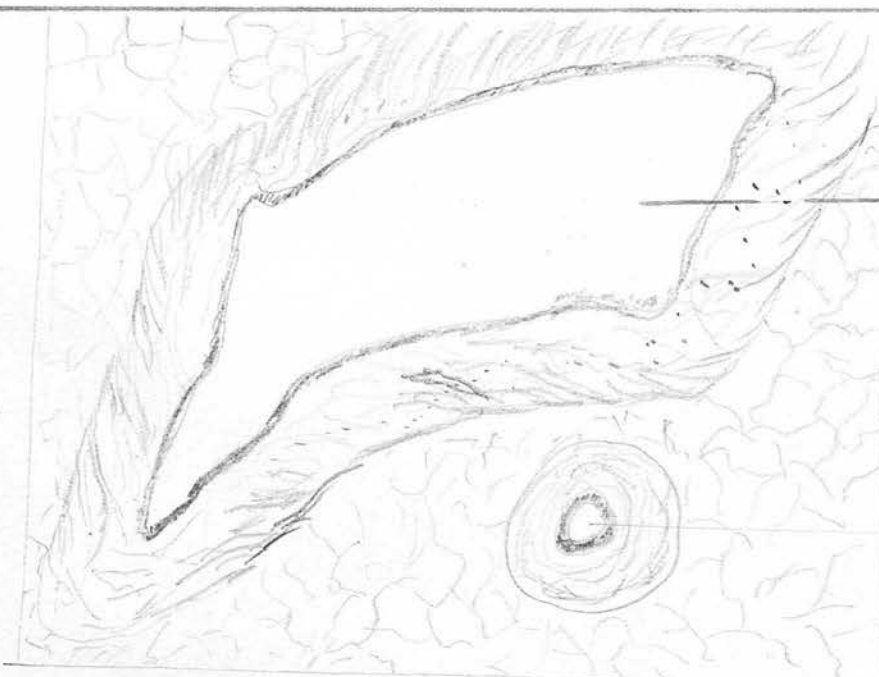
CANAL OF CYSTIC DILATATION  
THE SECTION IS PARTLY LONGITUDINAL




H.P. view of part of cyst wall  
showing epithelium

Fig. 26

R<sub>2</sub>



Slide. R<sub>3</sub>

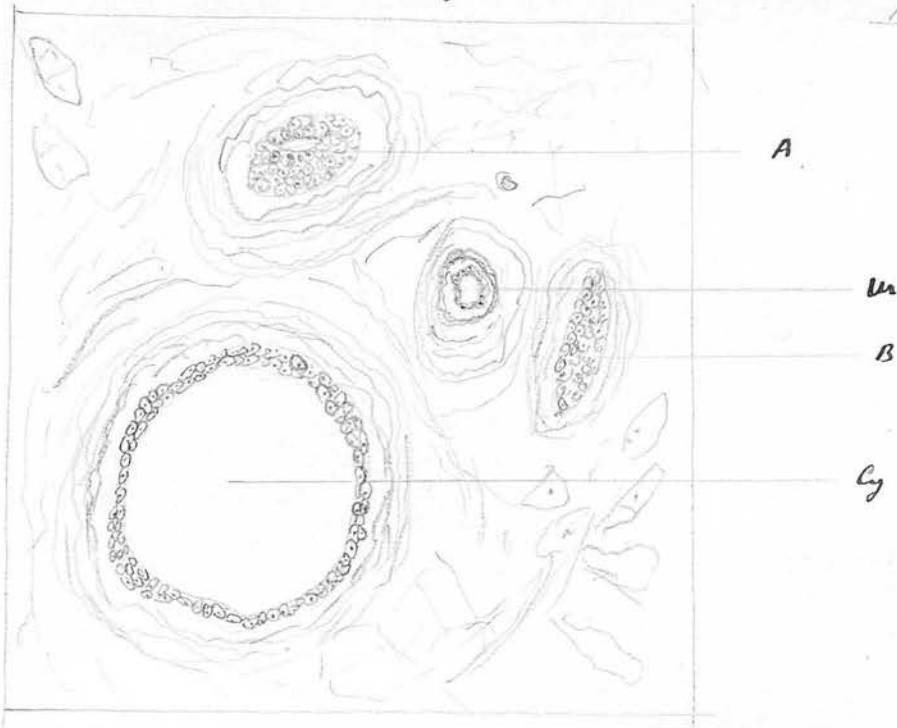


un

H.P. view of part of  
cyst wall

Fig. 26 gives a view of a cross section through the cyst. The normal urachal canal (Ur.) is seen entirely separate from the cyst.  
Fig. 25. is a section of the same further from the bladder.

R 4



A section higher up to show the beginning of crypt. U - wrinkles  
 A + B are solid columns of cells formed from epithelium detached  
 from wrinkles. Cy: a similar column the centre of which has degenerated  
 lower down this will form the crypt in which the wrinkles ends

Fig. 28

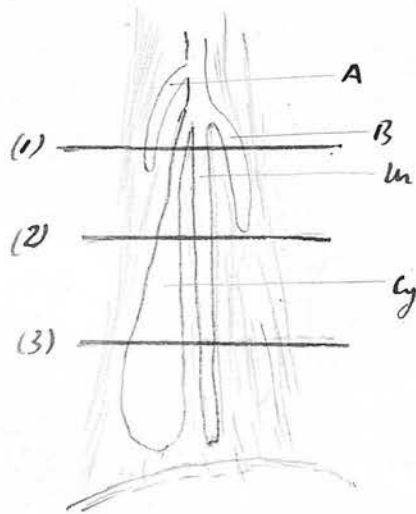
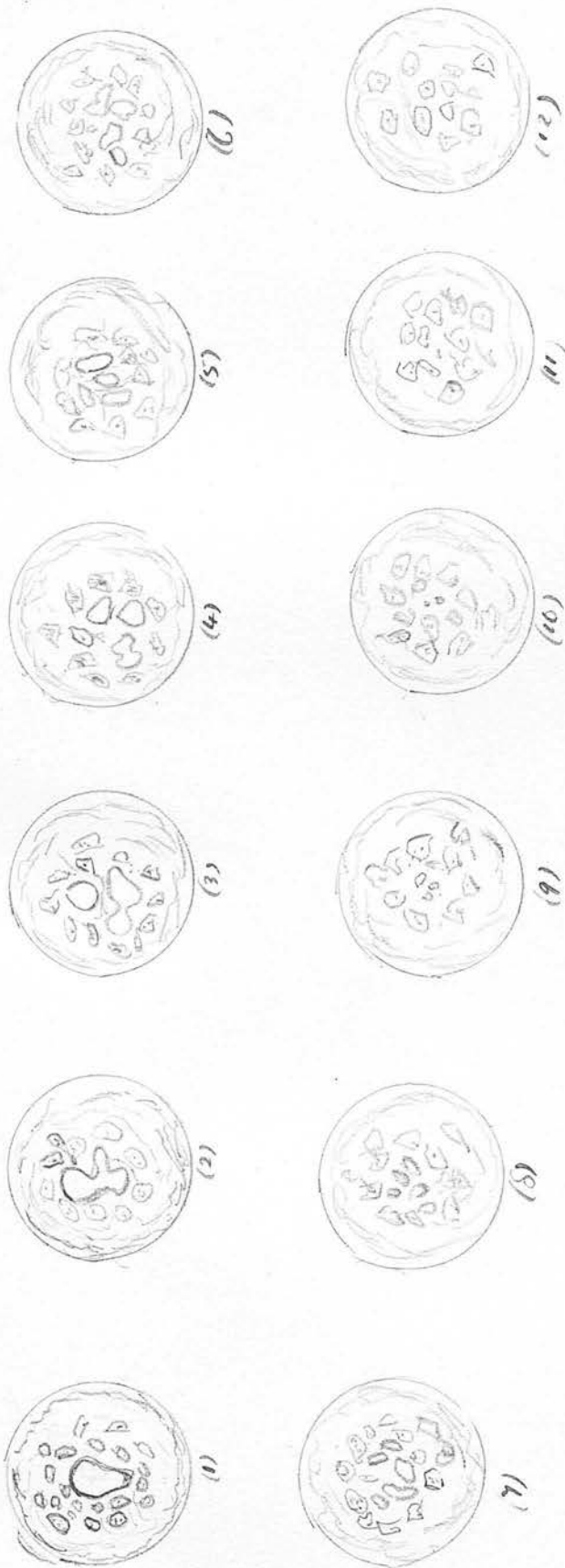


Diagram to illustrate how the crypt branched off from the  
 normal canal. Letters as in Fig 27.

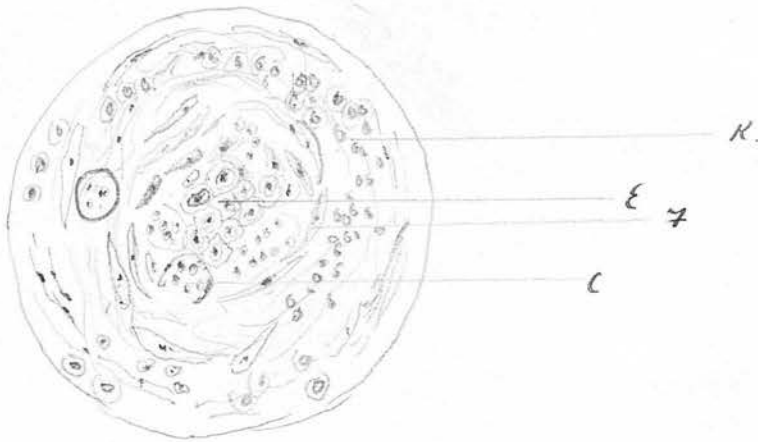
(1) (2) & (3) represent respectively the levels at which Figs 27, 25, &  
 26 were respectively cut.

Fig. 29.



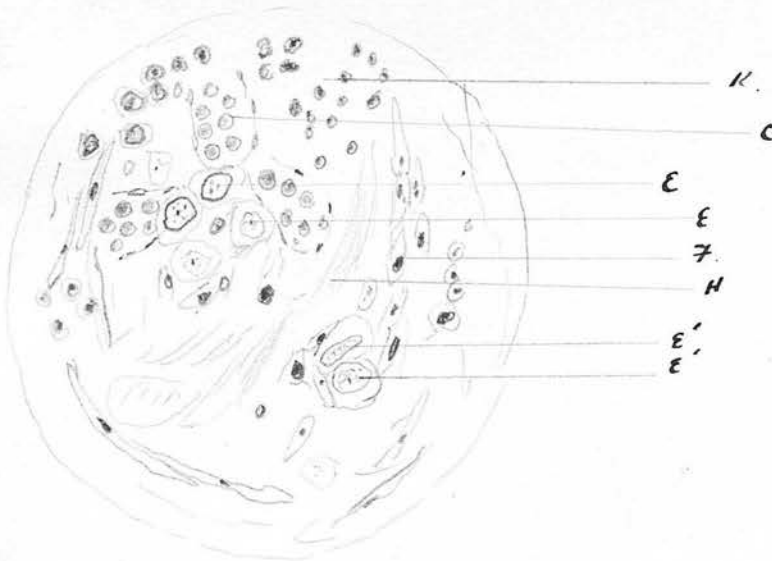
Series of transverse sections from below upwards in an adult male to demonstrate how the single central canal splits into numerous small ones *before*, the latter being ultimately replaced by fibrous tissue whose fibers run longitudinally. The blue rings represent canals lined by epithelium. They are surrounded by longitudinal bundles of fibrous tissue cut transversely.

Fig. 30



Shows the penultimate stage of obliteration of canal. All the lining cells are now in the lumen & the wall is invaded by young capillaries and round cells. For letters as in next figure

Fig 31



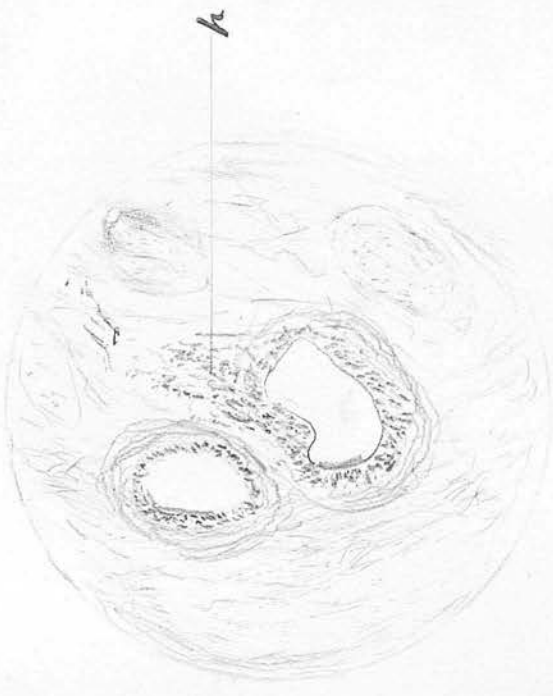
High power view of final stage in obliteration of the urethral canal. 5 cm above bladder. X1000

- E = pale nuclei the last of the epithelial cells to escape absorption
- E' = epithelial cells that have become included in the fibrous tissue
- F = young fibroblast
- C = New capillaries invading the wall
- H = Homogeneous material the remains of the degenerate epithelial keratin
- K. Round celled infiltration around the area of absorption

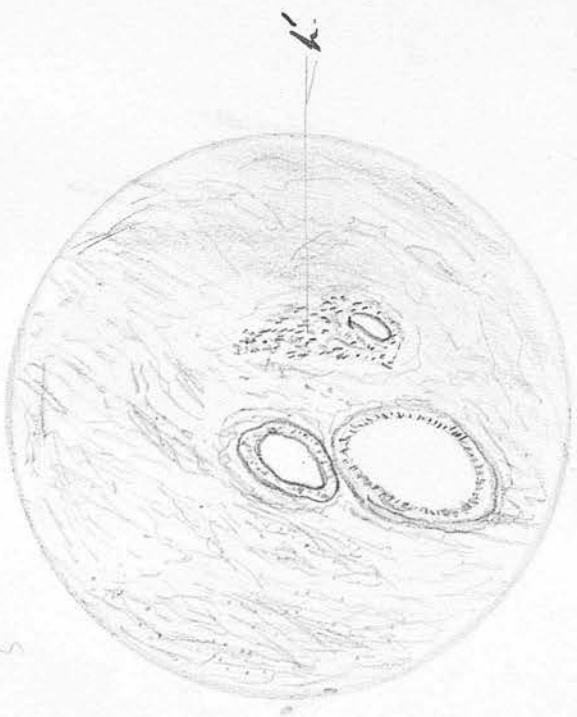Fig 32

White 65-4B

A



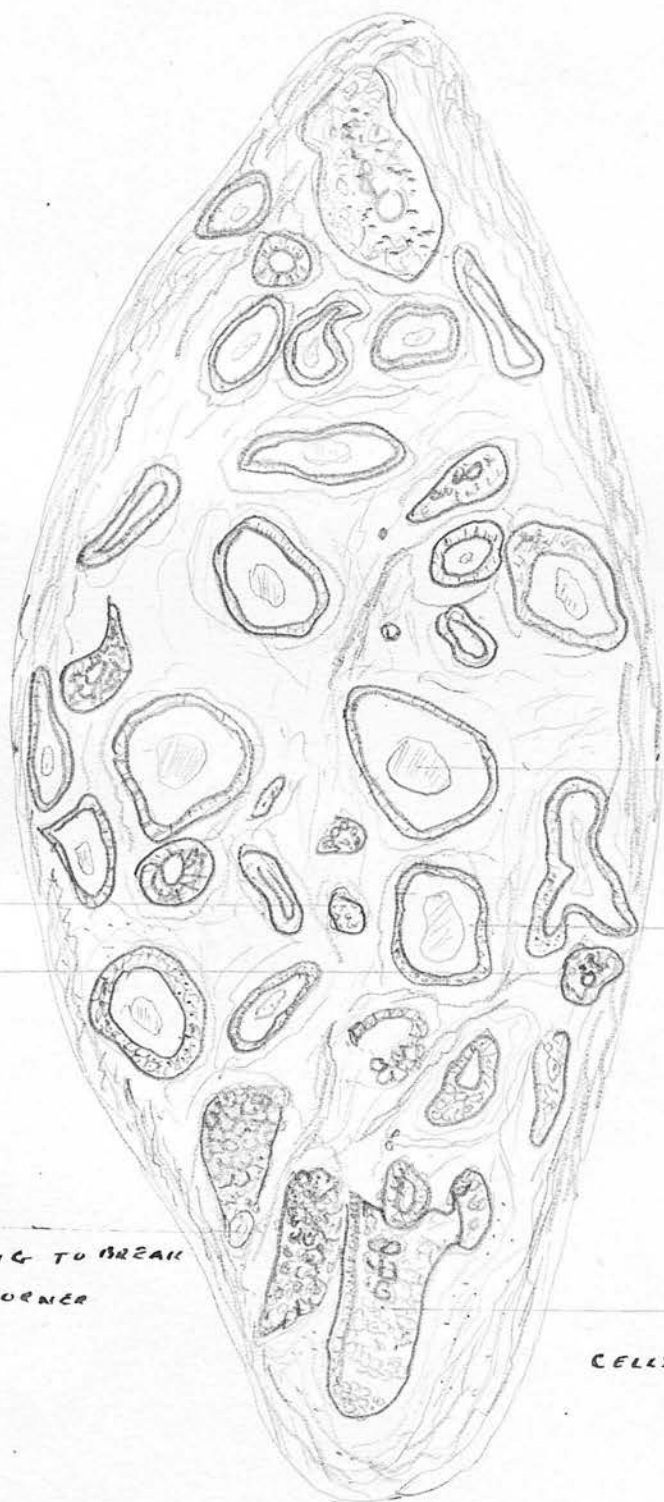
B.



Two sections showing how the epithelium of the urethra may split into two  
A is taken at a higher level than B. The many cells represented at h in A  
have in B to separate a lumen is already formed

# GENERAL. LOW POWER VIEW OF COMPLETE TRANSVERSE SECTION OF URACHUS SHOWING ADENOMATOUS FORMATION

## SECTION OF URACHUS SHOWING ADENOMATOUS FORMATION

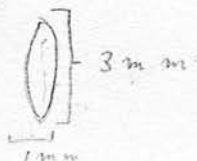


HOMOGENEOUS MATERIAL INTERIOR OF VESICLE

... VESICLE FORMED BY DEGENERATION OF SOLID COLUMN OF CELLS

SOLID COLUMN OF CELLS

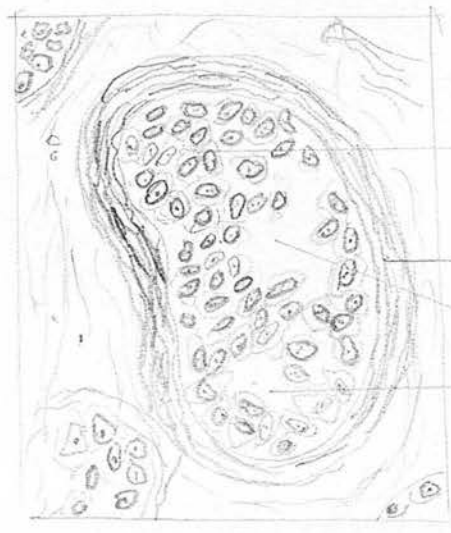
COLUMN OF CELLS BEGINNING TO BREAK DOWN AT ONE CORNER



X = point shown by higher power in Fig. 34  
 Y = .. .. .. .. .. in Fig. 35

Fig. 34.

H.P. view of point X in Fig 33 to show a solid column of epithelial cells breaking down in centre. This is the early stage which will go on to the fully formed vesicle

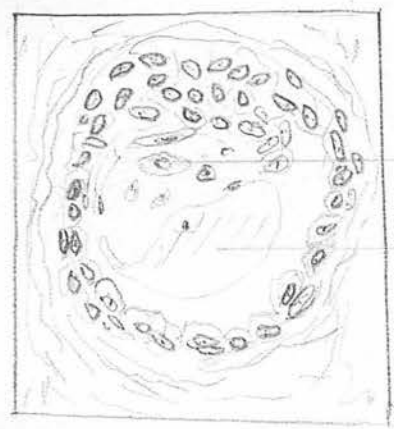

SOLID MASS OF CELLS

CONDENSED CONNECTIVE TISSUE FORMING A FIBROUS CAPSULE

SPACES LEFT BY CELL DEGENERATION

Fig. 35



Degenerating CELLS

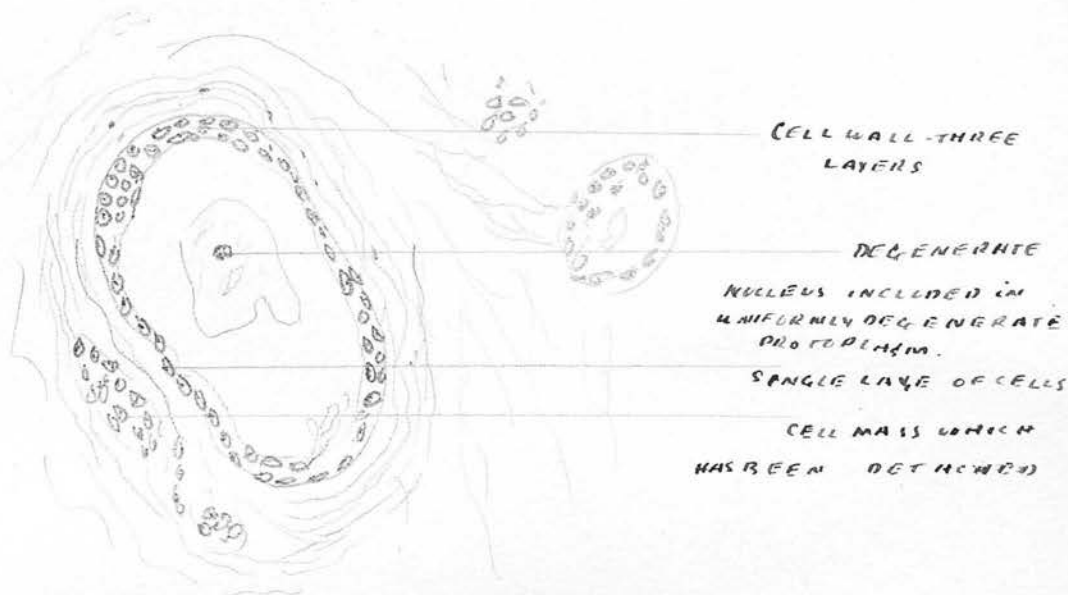
STRUCTURELESS MASS OF DEGENERATED CELLS IN CENTRE OF VESICLE

H.P. view of point marked Y in Fig 35 to show a further stage. The epithelial cells are beginning to take a circular arrangement round the margin, while towards the centre some of the cells have degenerated showing faintly stained protoplasm & nuclei. In the centre is a homogeneous mass representing degenerated cells which has clumped together

Case 1

Same slide as fig 33

Fig 36



Same slide as fig 33

Fig 37

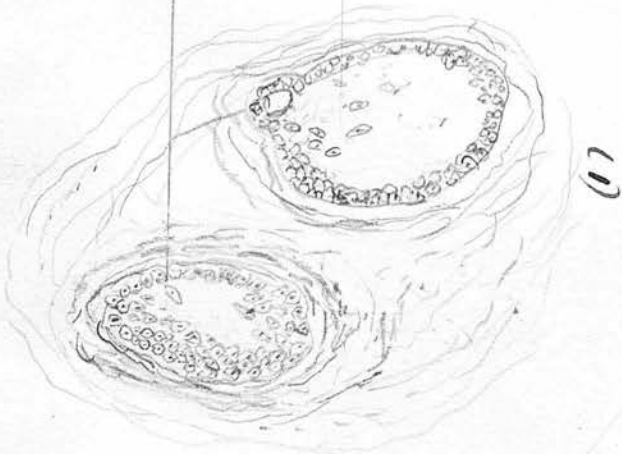


The upper figure shows a further stage, while the lower shows the fully formed vesicle with flattened single lining layer of cells & a structureless mass filling the lumen. The separation of this from the walls of the vesicle is hardly due to the presence of protoplasm.

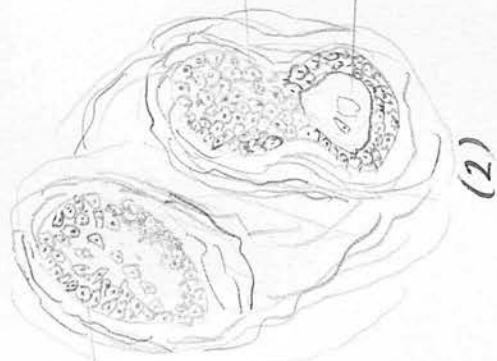
Specimen 62

Level 1

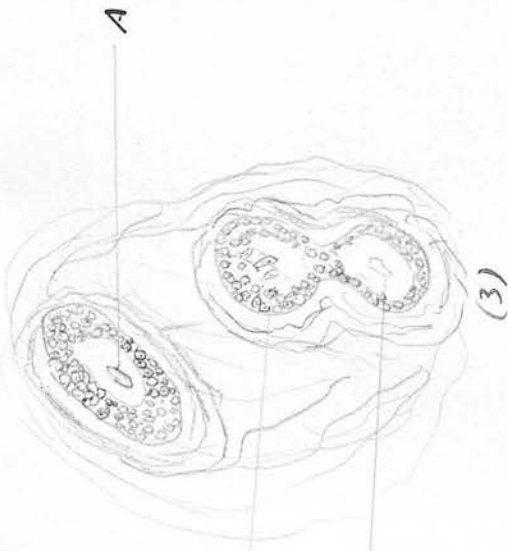
Fig 38



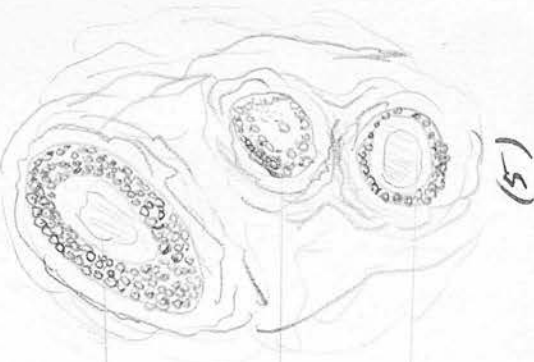(1)



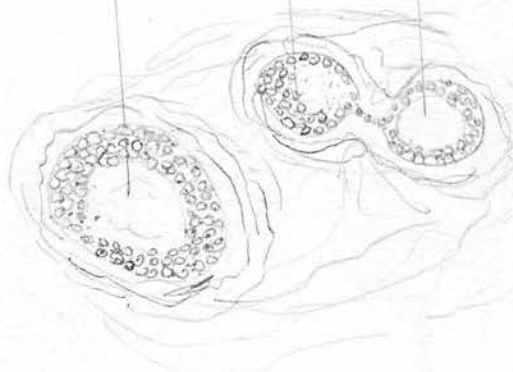
(2)



(3)




(4)



(5)

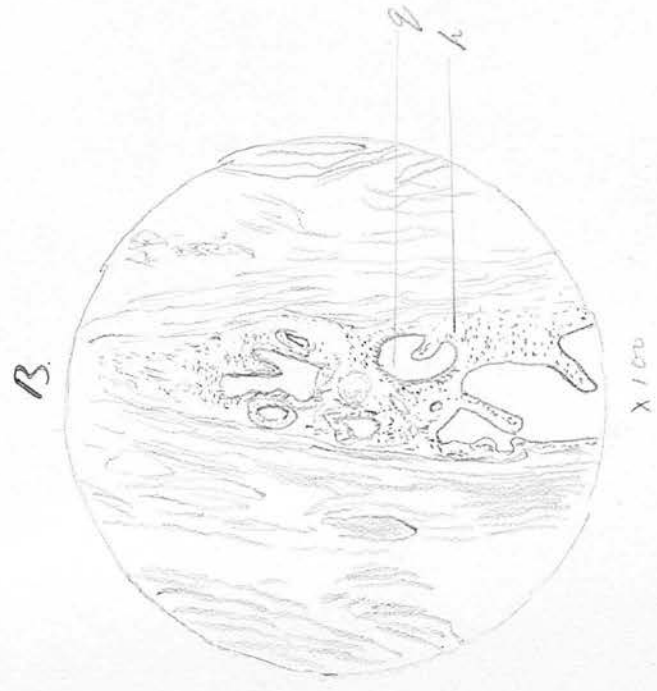
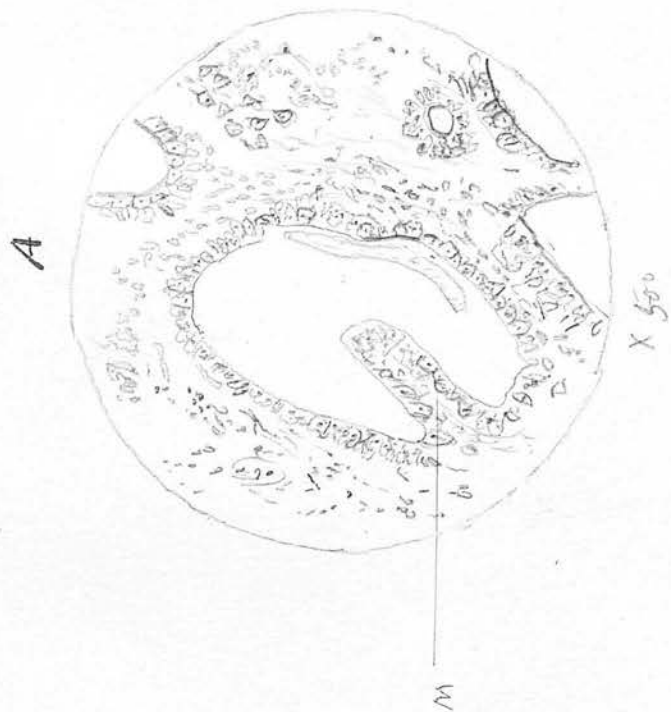
Series from cure ~~to~~ <sup>Case</sup> ~~from same~~ level (from same ~~level~~ <sup>Case</sup> as fig. 33. ~~to show formation of three columns of cells.~~ <sup>show</sup> ~~from~~ <sup>from</sup> ~~three~~ <sup>three</sup> ~~columns~~ <sup>columns</sup> ~~of~~ <sup>of</sup> ~~cells.~~ <sup>cells.</sup> ~~from~~ <sup>from</sup> ~~2~~ <sup>2</sup> ~~cut~~ <sup>cut</sup> ~~chamber~~ <sup>chamber</sup> ~~in~~ <sup>in</sup> ~~other~~ <sup>other</sup> ~~sheet~~ <sup>sheet</sup>)



Low power view (X25) to show total dimensions of an adenoma in a section cut  
 1 cm below the umbilicus in a child of three years. Note the two main cystic  
 dilatations surrounded by other vesicles, all lined by a varying number of layers  
 of cuboidal epithelium. C = circular eroded fibrous tissue surrounding adenoma  
 Z = longitudinal bundles of fibrous tissue cut transversely. X = See Fig 40


From natural slide as Fig 39

Fig 40



B shows a higher power view of point marked X in Fig 39 - g = lumen h = mass of epithelial cells  
 A. a still higher magnification, at M, a papilloma like structure is formed with a fibrous tissue core surrounded by epithelium.

07 brk



A shows a section through the fibrous cord midway between umbilicus and bladder  
 it shows no sign of epithelium. B. section near bladder to show normal  
 uncoiled canal. F = fibrous cord attached to (Ja) hairs vessels (vessels). R = rectus muscle  
 Per. = peritoneum of heart entrance.

U

Fig. 42

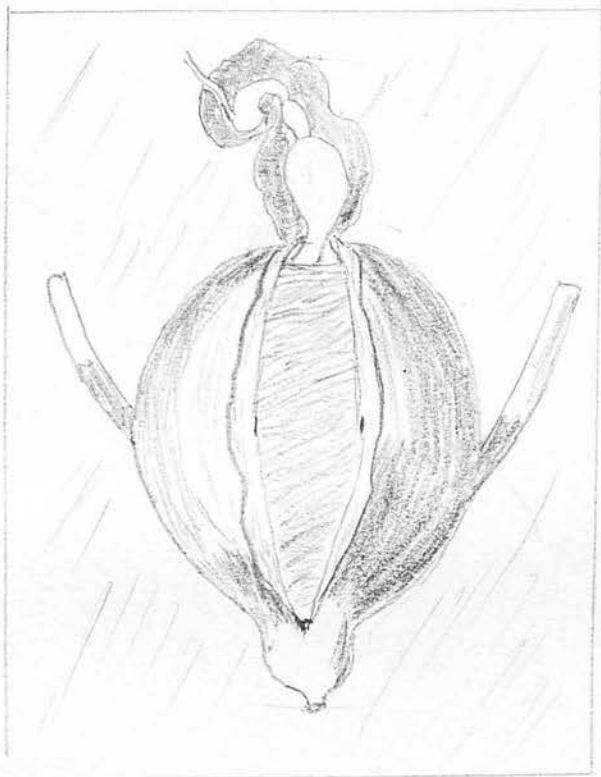


Fig. 42.

Fig. 42. A drawing of a bladder in which the outer muscular fibres have been turned back. It shows the urachus at its lower end, communicating with the bladder. This part of the urachus is sacculated - two cystic swellings are seen higher up. (After Walter.)

Fig 43 and 44




Fig. 43




Fig. 44

Fig. 43 Portion of a ureteral canal  $\times 7$ . It shows numerous cystic protrusions. From a man aged 27. (After Lushka)

Fig 44 This shows the junction of the ureteral canal and its communication with the bladder. A bristle Br has been passed into the canal which shows cystic swellings at its lower end. Natural size

Fig. 45



Fig. 45

Fig. 45. A sketch of Launelougue's case (No. 28) showing an umbilical tumour, resembling a second penis. Urine was voided both through the ordinary channel + through the umbilical tumour. (After Launelougue.)