

CASE No. 1.

JONES (SIR ROBERT) PRIZE FOR ORTHOPAEDIC SURGERY.

MARGARET DONALDSON
Burbidge Lodge,
Leithholm, Goldstraw.

Age, 15 years.

A REPORT AND COMMENTARY ON SIX CASES OF

COMPLAINT: Congenital dislocation of the left hip,
Bilateral clubfeet of the feet.

CONGENITAL DISLOCATION OF THE HIP, ...

HISTORY:

Both conditions have been present since birth. The
hip was treated at the Royal Hospital for Sick Children by
amputation and plaster until the patient was 4 years old,
since when, until the age of seven, she had no special treat-
ment and was well.

TREATED IN THE PRINCESS MARGARET ROSE

There was no history of anterior poliomyelitis; in
particular there was no history of anterior poliomyelitis.
The family history was negative.

HOSPITAL, EDINBURGH.

HISTORY OF PRESENT ILLNESS:

The child was admitted to the Princess Margaret Rose
Hospital, on the 6th June 1933, when she was then aged 7 years.

She was born at home and had a good colour. She was

The child stood with a marked
bowing on the left side;
the right leg lower than the right.
There was a
several triangles;

ARNOLD H. BANTON,
COWAN HOUSE, GEORGE SQUARE,
EDINBURGH.



The left foot was
The left foot was
The right foot was
The great toe. There was

Case No. 1 Continued.

CASE No. 1.

Operative Treatment:

MARGARET DONALDSON,
Bughtrigg Lodge,
Leitholm, Coldstream.

On the left foot - a plaster operation - weakness and
flexor tenotomy.

Age, 15 years.

COMPLAINT: Congenital dislocation of the left hip.
Bilateral deformities of the feet.

HISTORY:

Both conditions have been present since birth. The hip was treated at the Royal Hospital for Sick Children by manipulation and plasters until the patient was 4 years' old, since when, until the age of seven, she had no special treatment and was walking about.

There were no previous illnesses of importance; in particular there was no history of anterior poliomyelitis.

The family history was negative.

HISTORY OF TREATMENT:

The child was admitted to the Princess Margaret Rose Hospital, on the 6th. June, 1933. She was then aged 7 years.

Examination:

The child was healthy and had a good colour. She was quite bright mentally.

Pelvis and lower limbs: The child stood with a marked lumbar lordosis, and the pelvis drooped on the left side; the left natal fold being half-an-inch lower than the right.

Trendelenberg's Test was positive on the left side.

A hollow was present in the left femoral triangle; there was none in the right.

The head of the left femur could be felt above and behind the acetabulum.

There was 1" of shortening of the left leg.

Knees: The left knee showed slight genu recurvatum; the right showed slight genu valgum.

Feet: The left foot showed a talipes equino varus deformity; the right foot a valgus deformity with hallux valgus of the great toe. There was marked weakness of the muscles of the right foot.

Case No. 1 Continued.

When the child was examined lying down, the hip seemed to be in a good position, and the dipping appeared to be due more to muscle misapplication through displacement of the hip, than to any other cause.

Operative Treatment:

On 18th. June, 1933, the following operations were performed by Mr. Cochrane:

On the left foot - a Steinder operation - wrench and flexor tenotomy.

On the right foot - manipulation and plaster.

Open reduction of the left hip:

The operation was performed by Mr. Cochrane on 25/6/33.

The posterior aspect of the left hip was exposed by a short Kocher's incision, and its capsule was incised. The acetabulum was found to be fairly good, though its upper edge was poor. The head of the femur was easily manipulated into position in the socket, and no shelf graft was considered necessary. The capsule, deep tissues and skin were sutured, and a plaster spica was applied to include the left leg and foot.

The plaster spica was renewed on 5th. September, 1933, and finally removed on 6th. October, 1933. The hip was in a good position, and it was fixed in bed with sandbags. Massage and exercise were commenced.

Clinical examination showed a good result, but radiologically it was poor.

The patient was discharged on 27th. January, 1934.

Condition at the time of discharge.

General health was excellent.

Walking: The patient was able to walk with the assistance of one hand; there was still considerable dipping on the left side, but walking was much better than on admission.

Irons kept the feet in good position for walking.

There was some pain in the left foot at the base of the fifth metatarsal. Nothing definite could be made out, and it was probably the result of weight bearing.

Left Hip: The head of the femur was dislocated anteriorly; it was palpable $\frac{1}{2}$ " below and lateral to the anterior superior iliac spine.

Movements: Flexion was slightly limited. Extension was normal. Abduction was slightly diminished. Adduction was rather increased. External rotation was increased. Internal rotation was very limited.

Measurements: Right leg 22 $\frac{1}{2}$ ". Left leg 22".

Case No. 1 Continued.

When the child was examined lying down, the hip seemed remarkably stable, and the dipping appeared to be due more to muscle misapplication through displacement of the hip, than to actual telescoping.

The patient reported back on the 4th. April, 1934. She walked quite well, considering the condition of her hip and feet. The left hip still showed the anterior dislocation, but this was painless. Movements were as on discharge, some telescoping was found to be present.

Re-admission:

The patient was re-admitted for treatment for her feet on 6th. June, 1941.

Examination:

Walking: There was still some dipping on the left side.

Left Hip: Anterior dislocation was still present, and this was associated with flattening of the buttock.

Trendelenberg's Test was positive.

Movements were quite good, except that, as on previous occasions, there was some limitation of abduction and internal rotation.

Measurements: The left leg showed $\frac{1}{2}$ " of shortening.

X ray on 7th. June, 1941. (See figure 1.)

The right hip was quite normal.

On the left side the head of the femur was displaced upwards and outwards, so as to approach the anterior superior iliac spine. The head was somewhat flattened.

The neck of the femur showed a marked shortening.

The greater trochanter was under developed.

The acetabulum appeared as a triangular depression, and it was shallower than normal.

A spina bifida occulta was also observed.

Triple Arthrodesis.

This operation was performed on the right foot on the 27th. June, 1941, and on the left foot on the 11th. July, 1941.

SUMMARY

The case is one of congenital dislocation of the left hip, associated with feet deformities and spina bifida occulta. It was treated by manipulation at the age of four, and open reduction at the age of seven. Dislocation of the hip is still present at the age of fourteen, and shows characteristic features, though these are less marked than before treatment.

CASE NO. 1.

MARGARET DONALDSON
12, Bishop's Street,
Leeds.

Age, 3 years.

COMPLAINT: Bilateral congenital dislocation of the hip.

HISTORY:

The child started to walk when she was 18 months old. Just after she was 2 years old, she fell down and it was noticed after this that she had a waddling gait. The district nurse thought the condition was due to rickets and no treatment was carried out at first. Previous illnesses were mild. There is a sister 2 years younger than she is and has no deformities.

HISTORY OF TREATMENT:

The child was admitted to the Princess Margaret Base Hospital, on the 11th October, 1941. She was then aged 15 years.

The child was normally developed for her age. Her colour and nutrition were good. The hips and lower limbs were well developed. The child stood with a moderate degree of lumbar lordosis. Trendelenburg's Test was positive on the right side. Movements of the right hip showed limitation of abduction; otherwise movements of both hips were normal. Active movements showed nearly the same range as the passive and were painless.

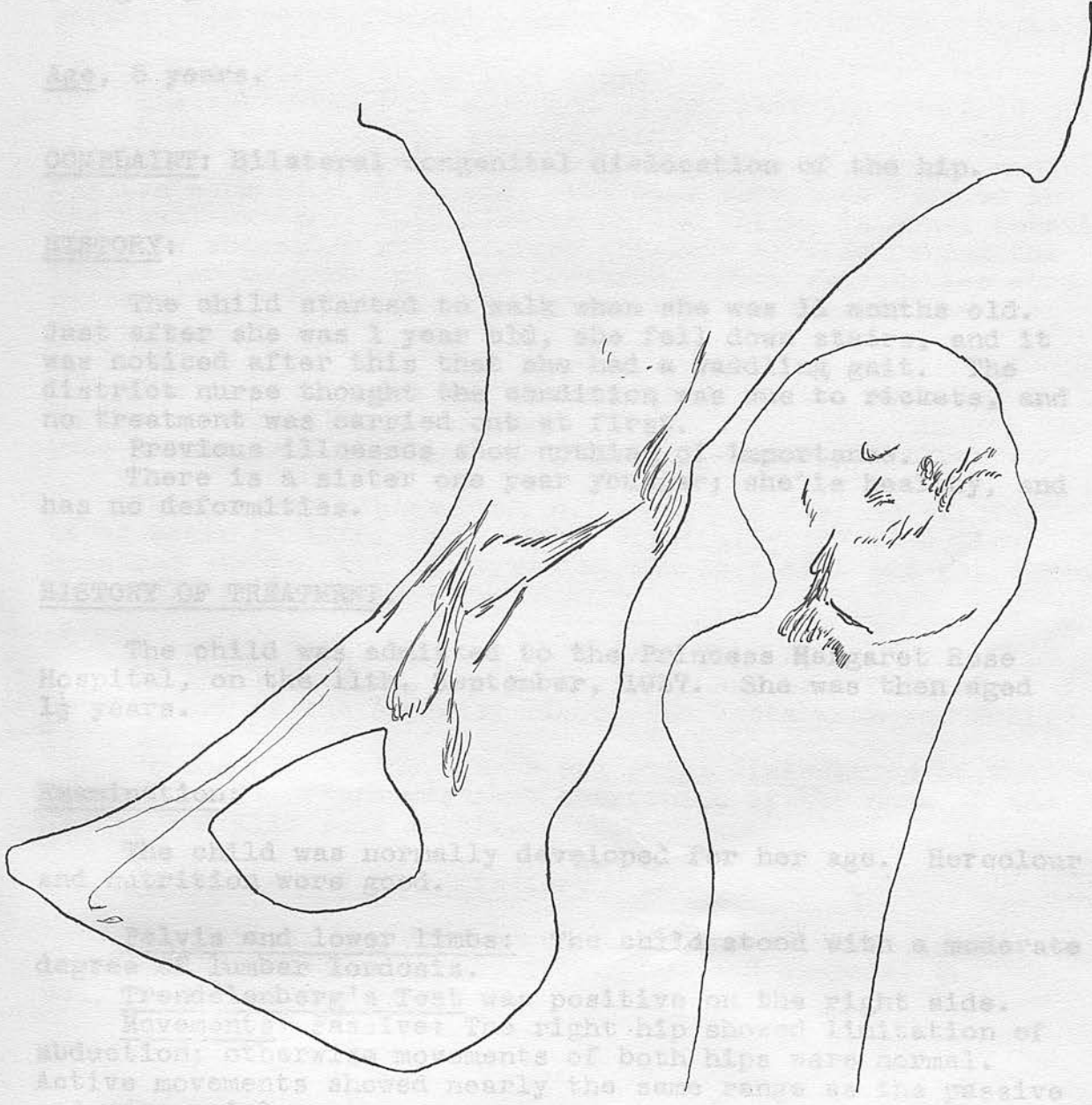


Figure 1.
Margaret Donaldson.
7th. June, 1941.

Right Hip. Left Hip.
11" 11"
8 1/2" 8 1/2"
6 1/2" 6 1/2"

X ray on 10th Oct., 1941 (see fig. 2.)
The upward and outward displacements of the femoral heads characteristic of congenital dislocation were clearly seen on both sides. The acetabula appeared to be fairly well formed.

ELIZABETH WALLACE,
12, Birnie Street,
Lochgelly.

Age, 5 years.

COMPLAINT: Bilateral congenital dislocation of the hip.

HISTORY:

The child started to walk when she was 11 months old. Just after she was 1 year old, she fell down stairs, and it was noticed after this that she had a waddling gait. The district nurse thought the condition was due to rickets, and no treatment was carried out at first.

Previous illnesses show nothing of importance. There is a sister one year younger; she is healthy, and has no deformities.

HISTORY OF TREATMENT.

The child was admitted to the Princess Margaret Rose Hospital, on the 11th. September, 1937. She was then aged 1½ years.

Examination:

The child was normally developed for her age. Her colour and nutrition were good.

Pelvis and lower limbs: The child stood with a moderate degree of lumbar lordosis.

Trendelenberg's Test was positive on the right side.

Movements: Passive: The right hip showed limitation of abduction; otherwise movements of both hips were normal. Active movements showed nearly the same range as the passive and were painless.

Measurements:

	Right	Left.
Ant. Sup. Spine - Med. Mall.	14"	14½"
Girth - Mid thigh. Mall. . . .	9¼"	9½"
Girth - Mid calf	6¾"	6¾"

X ray on 3rd. Oct., 1937 (see fig. 2.)

The upward and outward displacements of the femoral heads characteristic of congenital dislocation were clearly seen on both sides. The acetabula appeared to be fairly well formed.

Operative Treatment:

Prior to operation, weight extension was applied to both lower limbs with the patient on a Pugh's inclined bed, to stretch the pelvi-femoral muscles and thus facilitate reduction.

Closed reduction of both hips:

The operation was performed by Mr. Stirling on 26/10/37.

Under anaesthesia, the adductors of both thighs were stretched and massaged for 15 minutes. The hamstrings and flexors were also stretched. The hips were then reduced in the usual manner - full flexion of the thigh, internal rotation and slow abduction with counter pressure applied behind the trochanter to push the head forwards. Both extremities were enclosed in a bilateral hip spica with the legs in the frog position.

The plaster spica was renewed on 31/12/37, with the child in the same position, and again on 8/3/38. This time the legs were placed in a position of slight extension and abduction.

The plaster was removed and the child started walking about again on 12th. May, 1938. Clinically the reduction appeared stable, but on screening, the left hip did not appear as stable as the right.

X ray on 30th. August, 1938 (see fig. 3)

On the left side, the dislocation had been reduced, and development of the superior rim of the acetabulum was well marked.

On the right side, there was still dislocation of the femoral head. There was some shortening of the neck of the femur, and also some anterversion.

Discharge and re-admission:

The patient was discharged on 5th. Nov., 1938, and re-admitted on 13th. April, 1940. She had exercise and massage during the interval.

Examination:

Lower limbs: Movements: were good on the left side, but abduction and flexion were restricted on the right side.

Measurements:

	Right	Left
Ant. Sup. Spine - Med. Mall.	$16\frac{3}{4}''$	$17\frac{3}{4}''$
Girth - Mid thigh . . .	$9\frac{1}{2}''$	$10\frac{1}{2}''$
- Mid calf . . .	$7''$	$7\frac{1}{2}''$

Operative Treatment:

Radiological evidence, shortening and limitation of movement showed that there was incomplete reduction on the right side. Shortening of the pelvi-femoral muscles had occurred, and traction was applied using the technique described below:

Hoke's Ilio-femoral distraction for right C.D.H.
The operation was performed by Mr. Stirling on 24/4/40. Under anaesthesia, the legs were abducted and fixed on an orthopaedic frame. A small stab incision was made at a point 1" proximal to the right anterior superior iliac spine, and a Steinmann pin was inserted and expressed through the ilium obliquely in a postero-lateral direction, and passing through the skin on the outer side. The Hoke's apparatus was then fitted over the leg and held temporarily out of the way. Another Steinmann pin was drilled through the femur $1\frac{1}{2}$ " above the lower end. The leg, knee and pelvis were covered with sterile dressings. The Hoke's apparatus was held in position and slight manual extension was applied to the right leg. Plaster bandages were then applied, and 2 metal rods attached to the ends of the proximal pin and to the ring of the apparatus, which anchored it against a thick plaster ring round the right leg. The plaster spica was continued and the two metal rods incorporated. The extension pieces were then applied to the dorsal pin and then fixed to the roller at the distal end of the frame, which then took up the strain.

Extension was advanced by one notch on the apparatus per day. The traction apparatus and pins were removed on 29th. May, 1940. Traction was then maintained on the right leg by means of skin traction (8 lb.) This was continued until 16th. August, 1940.

Measurements: Right Left
X ray on 30th. May, 1940 (see fig.4)
The extension treatment had removed the upward displacement of the femoral head, but there was no evidence of it fitting the acetabular fossa, which in fact appeared markedly deficient superiorly. Maldevelopment of the femoral head and gross shortening of the neck was also apparent.

Operative Treatment:

In view of the radiological findings as described above, it was decided that a re-inforcing operation was necessary.

Improvement was not maintained, and examination on 5th. August, 1941, showed that the hip was held in semiflexion and walking was also carried out with the hip in this position. As well as the limitation of movements already mentioned, there was now limitation of flexion, and particularly extension.

Reconstruction of the right hip joint by a shelf graft.

The operation was performed by Mr. Anderson on 31/1/41.

Under anaesthesia the hip joint was exposed through a Smith Peterson incision. The capsule was divided longitudinally, and the hip was manipulated manually so as to bring the head into the acetabulum. The head was largely deformed with marked anteversion of the neck. The acetabulum itself was fairly well formed, but the capsular fold was very strong and large. This was broken down and it was found possible to fix the head by traction. An osteotome was used to turn down the upper border of the acetabulum so as to form a shelf. A plaque of bone was cut from the outer table of the ilium; part of it being used to pack the space made by turning down the shelf, the rest being laid as a plate over the packing. The whole was fixed in position by two bone pegs. The capsule was sutured; the periosteum and muscles stitched to the crest of the ilium and the skin edges were sutured. A double plaster hip spica was applied with the legs in the abducted position, but not in internal rotation.

The patient was sent to the Convalescent Home and the plaster was removed while she was there. She returned to hospital on 6th. June, 1941.

Examination:

Walking: There was now no evidence of a waddling gait. The patient walked with some abduction of the right leg, and she did not stand on it too long - she seemed a little afraid of it yet.

Left hip and lower limb: Movements: were good except for abduction and external rotation, which were very limited. There was no telescoping.

<u>Measurements:</u>		<u>Right</u>	<u>Left.</u>
Ant. Sup. Spine - Med. Mall.		18 $\frac{1}{2}$ "	19"
Girth	- Mid thigh . . .	9 $\frac{1}{2}$ "	10"
	- Mid calf . . .	6 $\frac{3}{4}$ "	7 $\frac{1}{4}$ "

X ray on 9th. June, 1941. (see fig. 5)

The reduction and shelf graft showed a very good result, the graft had taken well and formed a good upper rim for the acetabulum. The femoral head was in a good position.

Further progress:

Improvement was not maintained, and examination on 5th. August, 1941, showed that the hip was held in semiflexion and walking was also carried out with the hip in this position. As well as the limitation of movements already mentioned, there was now limitation of flexion, and particularly extension.

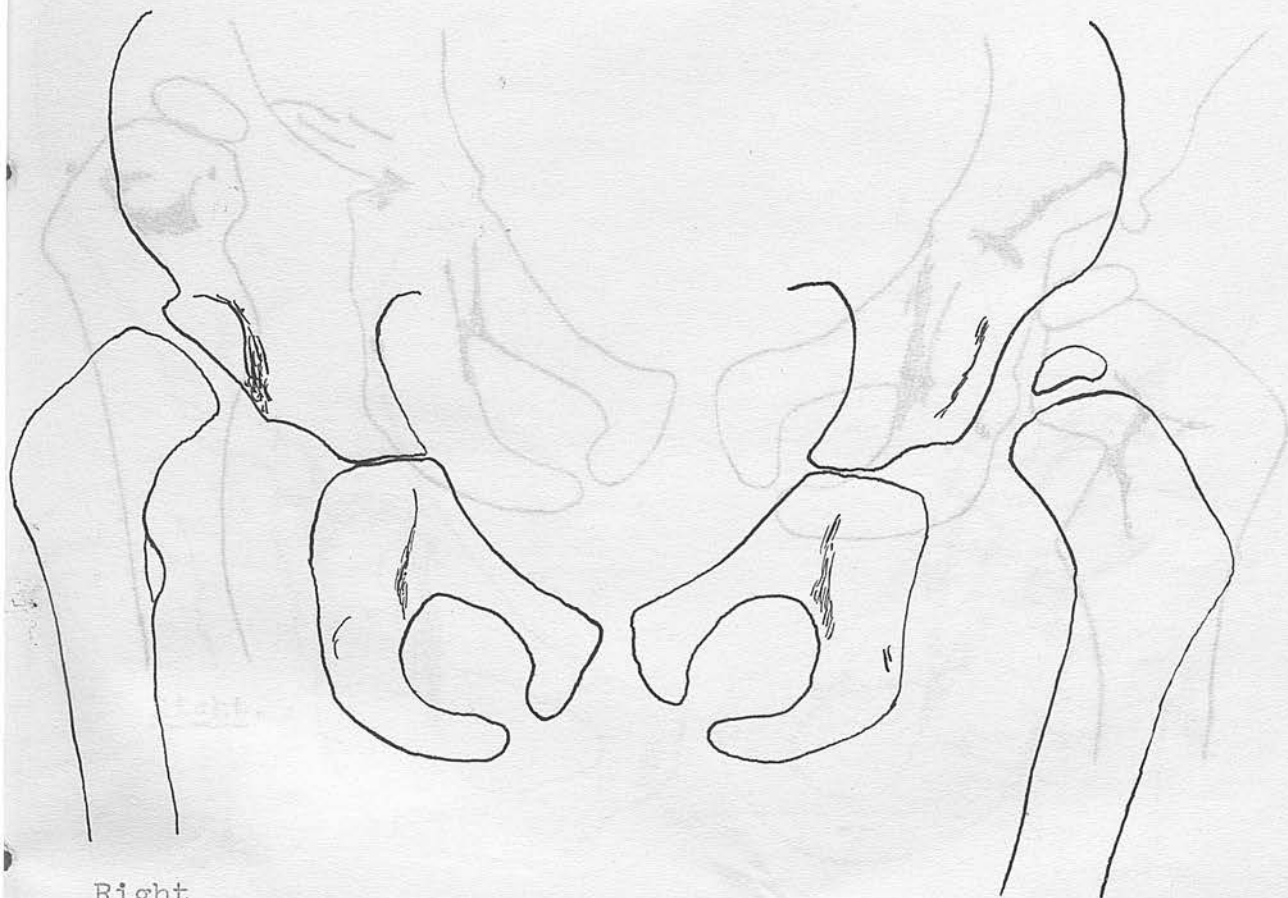
X ray on 28th. July, 1941, (see fig. 6).

The development of the acetabular fossa and the head of the femur showed an improvement on the previous X ray. Shortening and anteversion of the femoral neck were well marked as before. There was some sclerosis of bone on the epiphysis of the femoral head, but otherwise nothing to suggest the cause of the deterioration in the patient's condition.

The cause of this deterioration in the condition of the hip was not clear. It may be that the shelf graft was taking on an exuberant growth and was thus limiting movement, though this was not apparent from the X ray; the sclerosis of the femoral head was a significant finding, and it might be associated with some obscure arthritic change. This problem is considered further in the discussion.

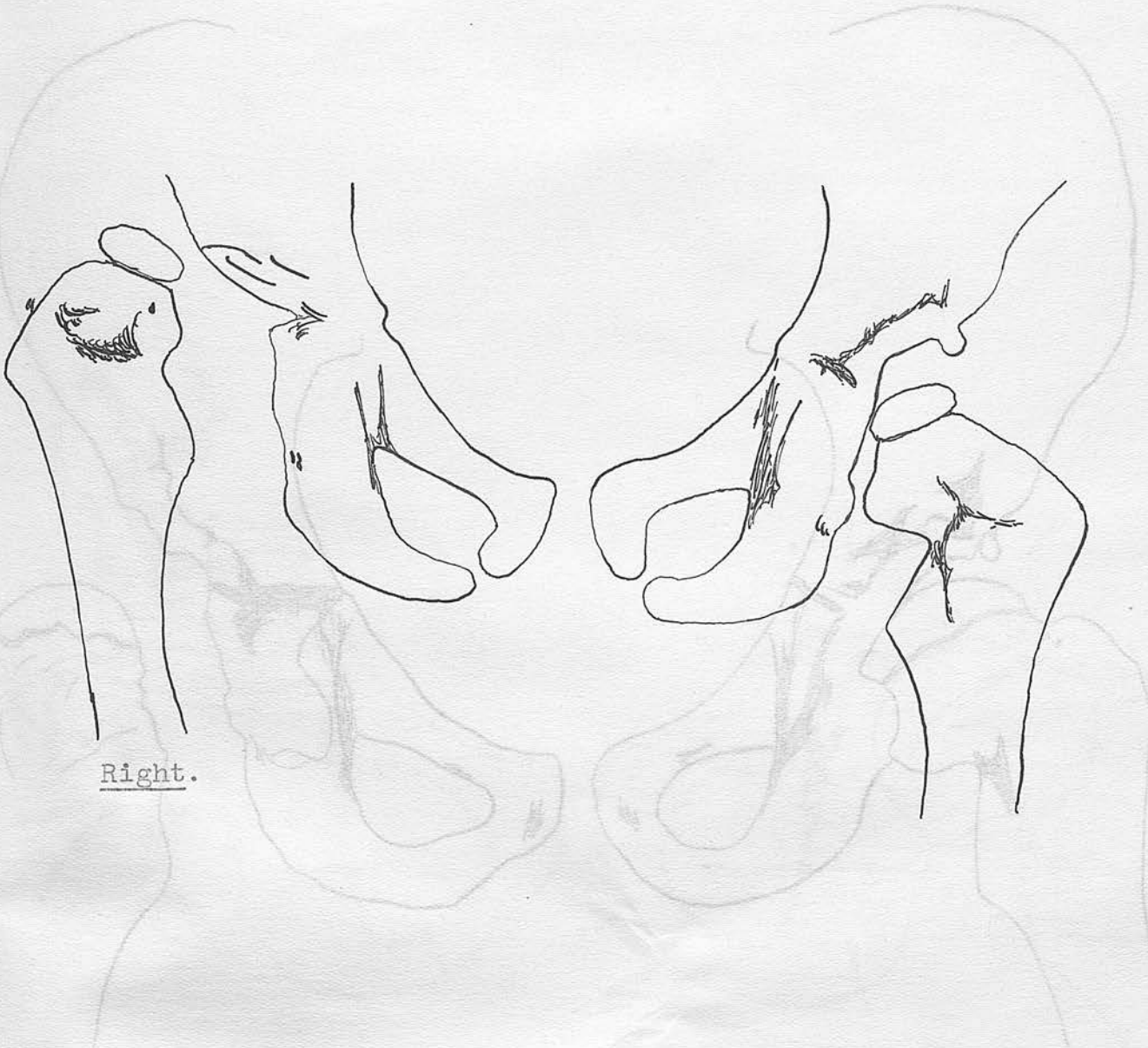
SUMMARY:

The case is one of bilateral congenital dislocation of the hip. It was treated first by manipulation and plaster at the age of $1\frac{1}{2}$ years. This resulted in marked improvement in the condition of the left hip; but further treatment was required for the right hip. Ilio - femoral distraction was employed when the child was aged four, but the condition of the joint was such that a reconstruction operation was necessary. A shelf graft was performed when the child was five. This at first gave marked improvement, but later the condition again degenerated.



Right

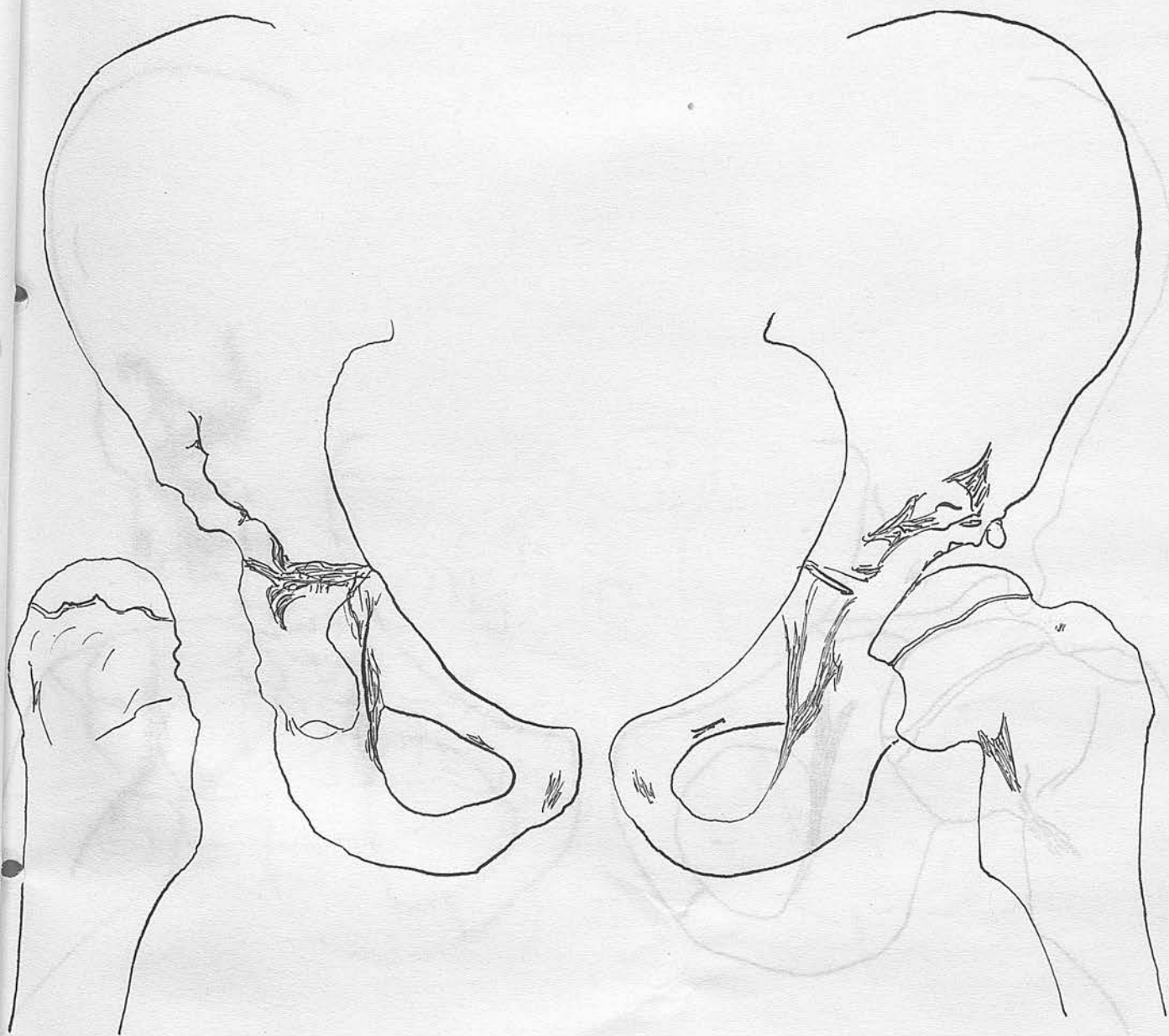Figure 2.
Elizabeth Wallace.
3rd. October, 1937.



Right.


Figure 3.
Elizabeth Wallace.
30th. August, 1938.

Figure 4.
Elizabeth Wallace.
30th. May, 1940.



Right.

Figure 4.
Elizabeth Wallace.
30th. May, 1940.



Right.

Right Hip.

Figure 5.
Elizabeth Wallace.
9th. June, 1941.

10th. July, 1941.

ELIZABETH WALLACE
11, Davis Park Road,
Barnes,

Age, 7 years.

COMPLAINT: Bilateral congenital dislocation of the hip.

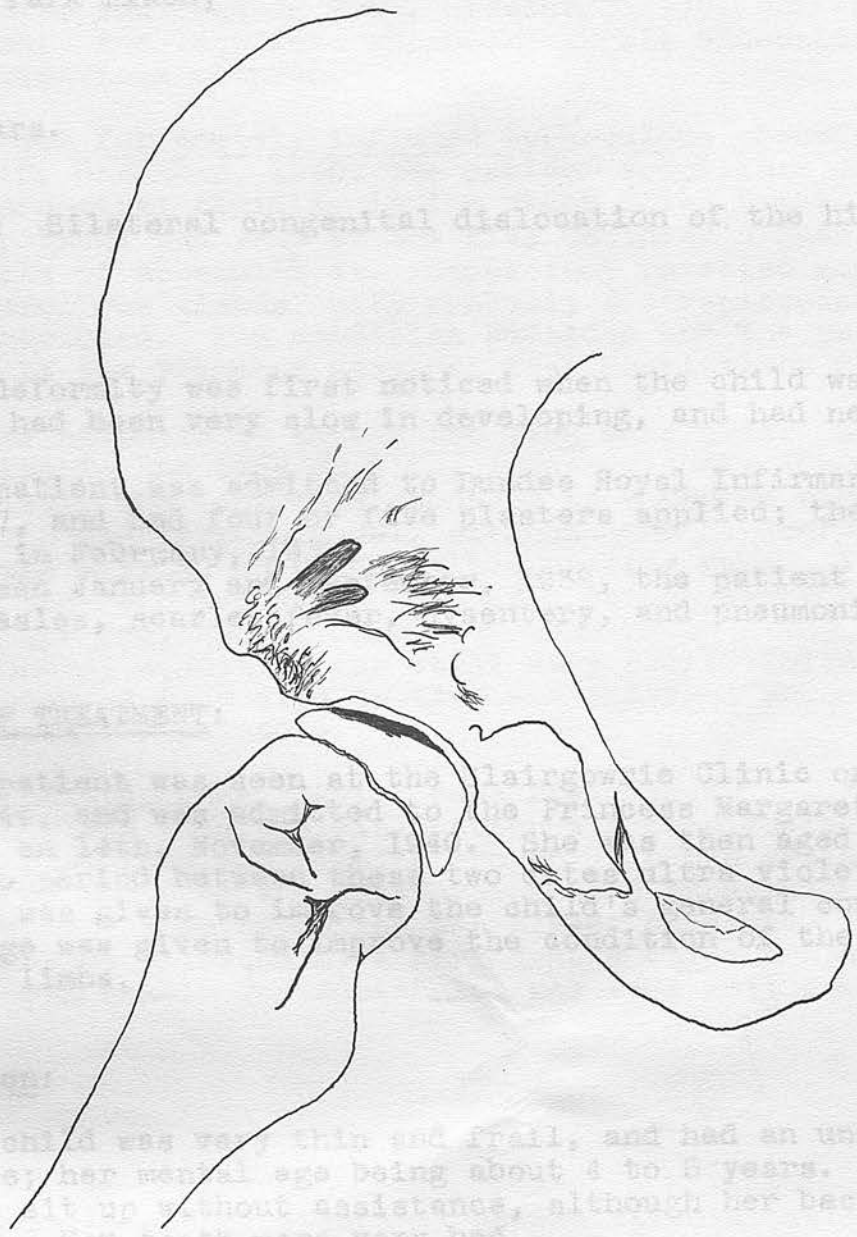
HISTORY:

The deformity was first noticed when the child was 1 1/2 years old. She had been very slow in developing, and had never really walked.

The patient was admitted to St. George's Hospital Infirmary in July, 1937, and had several plaster casts applied; the last one being in February, 1938. In January, 1938, the patient had German measles, and in February, 1938, had pneumonia.

HISTORY OF TREATMENT:

The patient was seen at the Blairgowrie Clinic on 18th. April, 1941, and referred to the Princess Margaret Road Hospital on 24th. April, 1941. She was then aged 8 years. On 24th. April, 1941, two casts were applied under violet light. The casts were given to improve the child's general condition; and were given to improve the condition of the hips and lower limbs.



Examination:

The child was very thin and frail, and had an unintelligent appearance, her mental age being about 4 to 5 years. She was unable to sit up without assistance, although her back was straight. Her teeth were very bad.

Right Hip.

Position of limbs: The legs were abducted, externally rotated, and flexed at the hips. Both femora showed bowing, particularly the left one. Muscular atrophy was very marked. Movements were very limited indeed, the limbs being...

Figure 6.
Elizabeth Wallace.
28th. July, 1941.

...the limitation of extension.
Ankle movement was fairly good, but on flexion of the ankle there was hyperextension of the foot.

Treatment of the Contractures:

CATHERINE MCKERNAN,
15, Davie Park Place,
Rathay.

Age, 7 years.

COMPLAINT: Bilateral congenital dislocation of the hip.

HISTORY:

The deformity was first noticed when the child was $1\frac{1}{2}$ years old. She had been very slow in developing, and had never really walked.

The patient was admitted to Dundee Royal Infirmary in July, 1937, and had four or five plasters applied; the last one being in February, 1939.

Between January and September, 1938, the patient had German measles, scarlet fever, dysentery, and pneumonia.

HISTORY OF TREATMENT:

The patient was seen at the Blairgowrie Clinic on 18th. April, 1940, and was admitted to the Princess Margaret Rose Hospital, on 14th. November, 1940. She was then aged 6 years. During the period between these two dates ultra violet light treatment was given to improve the child's general condition; and massage was given to improve the condition of the hips and lower limbs.

Examination:

The child was very thin and frail, and had an unintelligent appearance; her mental age being about 4 to 5 years. She was unable to sit up without assistance, although her back was straight. Her teeth were very bad.

Pelvis and lower limbs: The legs were abducted, externally rotated, and flexed at the hips. Both femora showed bowing, particularly the left one. Muscular atrophy was very marked.

Movements: were very limited indeed, the limbs being almost fixed in the positions described above.

Knees: There was some limitation of extension.

Ankles: Movement was fairly good, but on flexion of the ankle there was hyperextension of the toes.

Treatment of the Contractures:

This was carried out by means of skin traction. Strapping was applied to the legs on 20th. November, 1940, and weights were applied. The legs were approaching full extension when other complications occurred.

Operation for acutely inflamed tuberculous abdominal glands.

On 10th. December, 1940, the patient complained of vomiting; there was abdominal rigidity in the right iliac fossa. Accordingly the patient was sent to the Sick Children's Hospital with the diagnosis of appendicitis. Laparotomy revealed acutely inflamed tuberculous glands, with probably a streptococcal infection superadded. The condition subsided and the patient was readmitted to the Princess Margaret Rose Hospital on 21/12/40.

Further attempts to extend the legs were made. Strapping was reapplied to the legs on 13th. January, 1941. On the 3rd. February, 1941, the legs were bandaged to a Cramer wire splint. The legs extended extremely well without much discomfort. Extension was applied on a Pugh's bed on 1st. March, 1941, to straighten the left leg still further. Weight bearing was started on the 2nd. April, 1941.

The general condition was still very poor. Colicky abdominal pain occurred from time to time and enlarged abdominal glands were easily palpable.

X ray on 4th. June, 1941, (see fig. 7).

On the right side the dislocation was completely reduced, and the femoral head was fitting properly in the acetabulum. Shortening of the neck and anteversion were apparent.

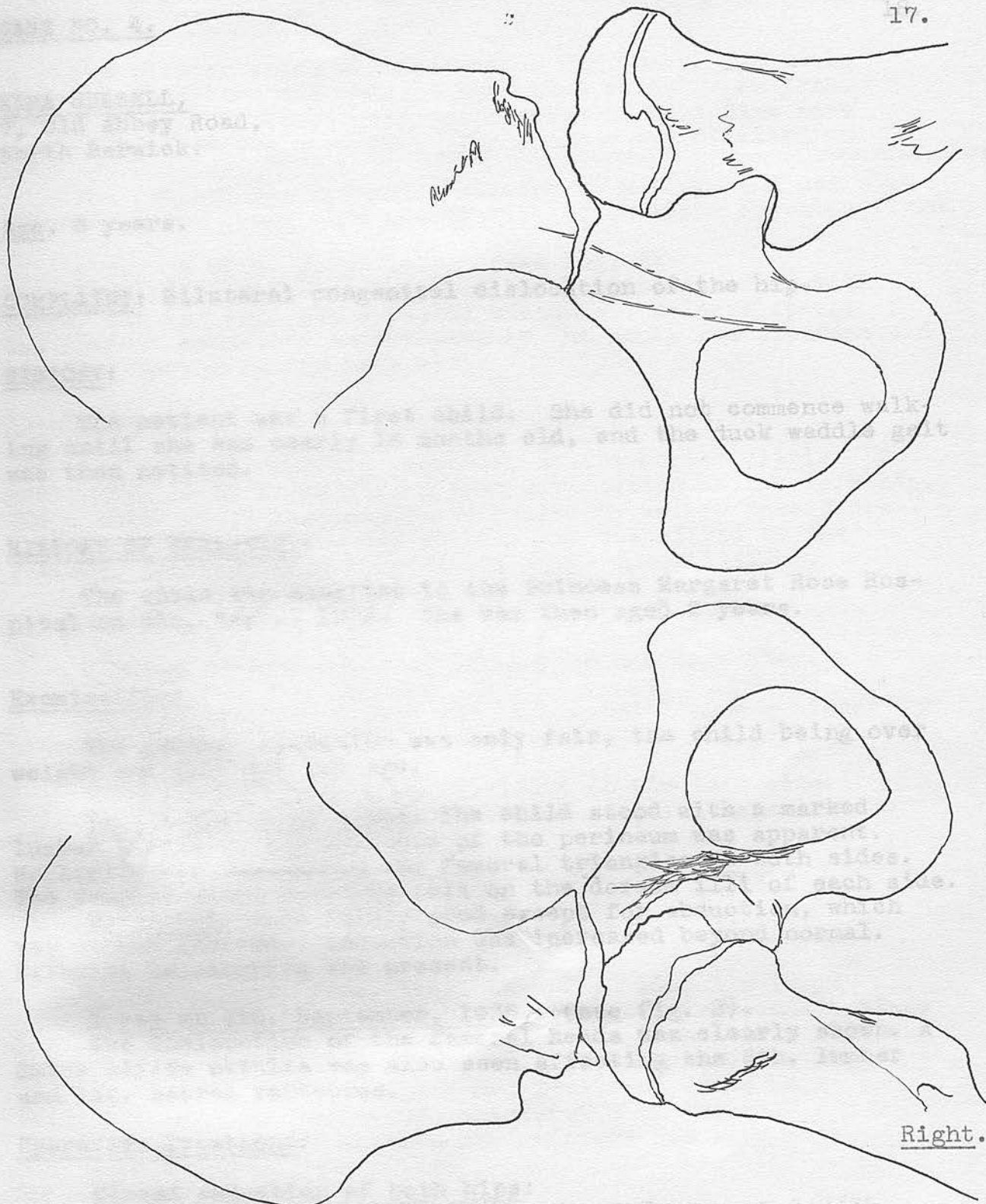
On the left side reduction was almost complete, but the condition was complicated by a marked coxa valga and deformity of the femoral head. The acetabulum was very well developed.

SUMMARY:

The case is one of bilateral congenital dislocation of the hip treated by manipulation at the age of three. Prolonged fixation resulted in contractures forming which were treated by extension. Bowing of the femora was also present. A good result was obtained on the right side, but deformity of the femur prevented complete recovery on the left side.

The condition was complicated by tabes mesenterica.

Figure 7
Catherine McKernan,
4th. June, 1941.



Right.

Figure 7.
Catherine McKernan,
4th. June, 1941.

The plaster spica was renewed on 6th. Dec., 1935, the motion was reduced this time to 45°. On 27th. 7, Old Abbey Road, North Berwick. plaster was again renewed; this time with an angle of 30°. The plaster was bivalved on 25th. June, 1936.

The patient was gradually allowed to sit up, and was then Age, 8 years. feet. She was discharged on 21st. November, 1936.

X ray on 20th. July, 1936. (see fig. 9)

COMPLAINT: Bilateral congenital dislocation of the hip, both hips, but the left hip appeared unstable. Maldevelopment of the femoral heads and anteversion of the necks was apparent and

HISTORY: marked on the left side.

The patient was a first child. She did not commence walking until she was nearly 18 months old, and the duck waddle gait was then noticed. reported regularly at the Dunbar clinic. On

30th. May, 1941, X ray showed some subluxation of the left hip, and a shelf graft was considered necessary before upward dis-

HISTORY OF TREATMENT: She was accordingly readmitted to the Princess Margaret Rose Hospital on 30th. June, 1941.

The child was admitted to the Princess Margaret Rose Hospital on 4th. Sept., 1935. She was then aged 2 years.

Walking: There was some dipping on the left side.

Examination:

Pelvis and lower limbs: The left natal fold was higher than The general condition was only fair, the child being overweight and soft for her age.

Trendelenberg's Test was positive on the left side.

Pelvis and lower limbs: The child stood with a marked lumbar lordosis, and definite of the perineum was apparent. Hollowing was present in the femoral triangles on both sides. The femoral heads could be felt on the dorsum illi of each side.

Movements: were fairly good except for abduction, which was rather limited. Adduction was increased beyond normal. Definite telescoping was present.

X ray on 4th. June 1941. (see fig. 10).

X ray on 4th. September, 1935, (see fig. 8). The dislocation of the femoral heads was clearly shown. A Spina bifida occulta was also seen affecting the 5th. lumbar and 1st. sacral vertebrae. Head had developed quite well, but there was some shortening and anteversion of the neck. Sub-

Operative Treatment: upwards and outwards was apparent.

Oper: Closed reduction of both hips:

The operation was performed by Mr. Anderson on 9/9/35.

The procedure was as described in the case of Elizabeth Wallace - Case No.2. - The right hip reduced fairly easily, and the femoral head seemed stable in the acetabulum. The left hip was dealt with in a similar manner, but there was some doubt about the reduction, and the hip was definitely less stable than on the right side. Clinically, however, the hip appeared to be satisfactorily in place. A plaster spica was then applied with the legs in the full frog position.

The plaster spica was renewed on 6th. Dec., 1935, the angle of abduction was reduced this time to 45°. On 27th. March, 1936, the plaster was again renewed; this time with abduction at an angle of 30°. The plaster was bivalved on 27th. June, 1936.

The patient was gradually allowed to sit up, and was then allowed on her feet. She was discharged on 21st. November, 1936.

X ray on 20th. July, 1936. (see fig. 9)

Reduction of the dislocation had been achieved on both sides, but the left hip appeared unstable. Maldevelopment of the femoral heads and anteversion of the necks was apparent and was more marked on the left side.

Re-admission:

The patient reported regularly at the Dunbar clinic. On 30th. May, 1941, X ray showed some subluxation of the left hip, and a shelf graft was considered necessary before upward displacement occurred. She was accordingly readmitted to the Princess Margaret Rose Hospital on 20th. June, 1941.

Examination:

Walking: There was some dipping on the left side.

Pelvis and lower limbs: The left natal fold was higher than the right, and there was some wasting of the left gluteal region.

Trendelenberg's Test was positive on the left side.

Movements: Abduction and external rotation were limited on the left side.

<u>Measurements</u>		<u>Right</u>	<u>Left</u>
Ant. Sup. Spine - Med. Mall.		28"	27 $\frac{1}{4}$ "
Girth	- Mid thigh	13"	12"
	- Mid calf	10 $\frac{1}{2}$ "	10 $\frac{1}{2}$ "

X ray on 20th. June, 1941, (see fig. 10).

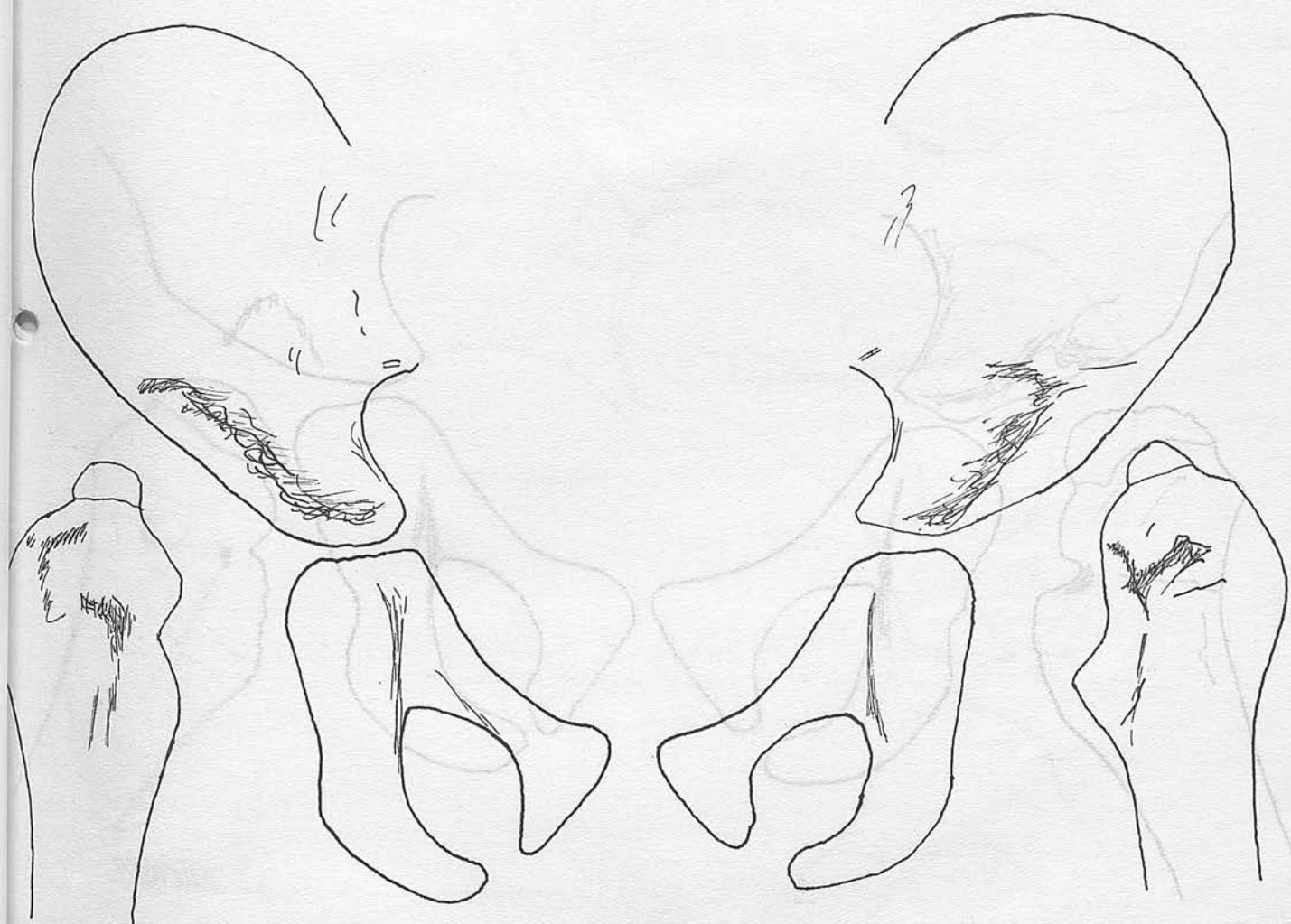
On the right side there had been marked improvement since the last X ray. The head and neck of the femur had developed and the head was fitting fairly well into the acetabulum.

On the left side the head had developed quite well, but there was some shortening and anteversion of the neck. Subluxation of the joint upwards and outwards was apparent.

Operative Treatment:

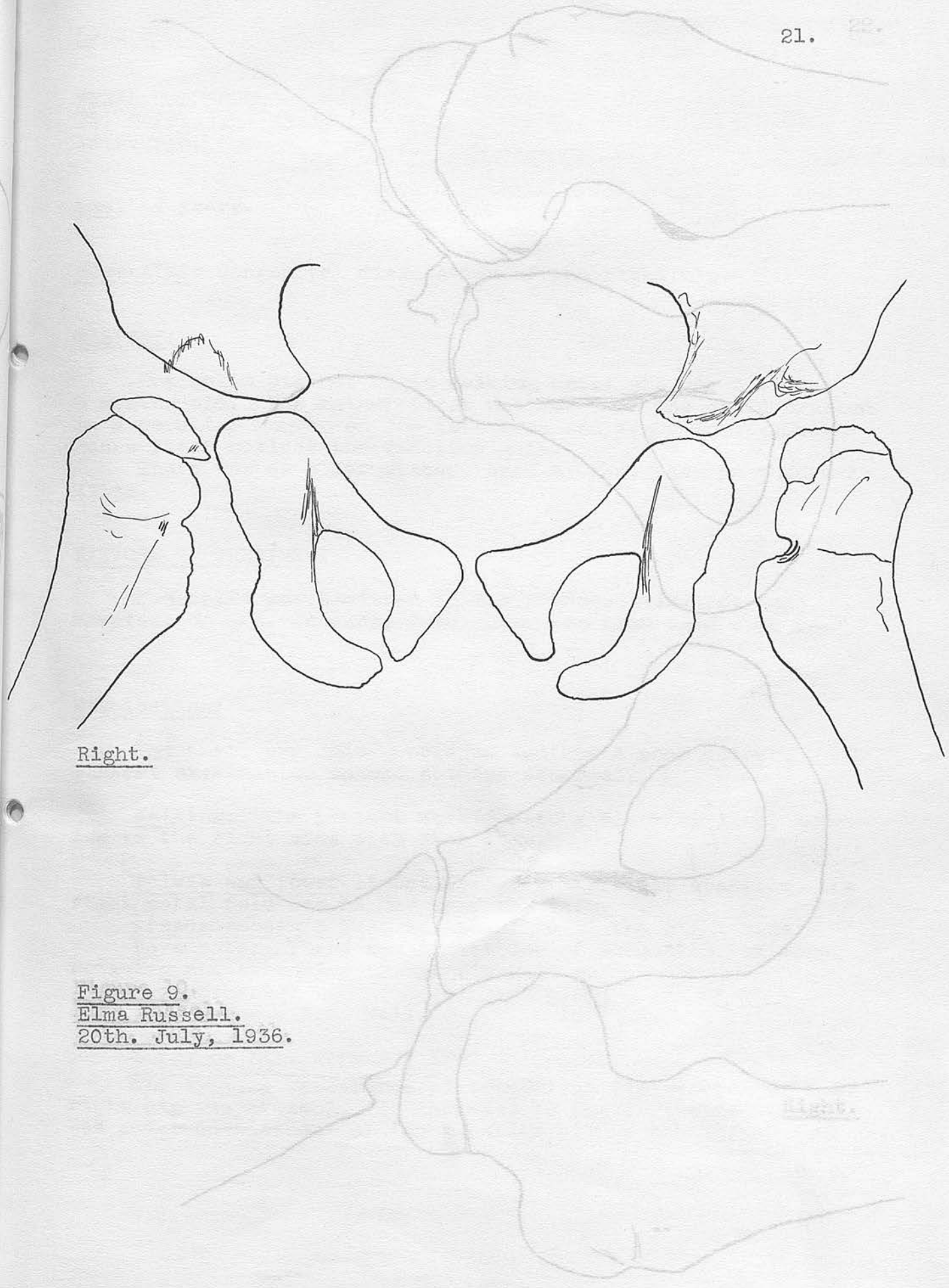
In view of the clinical and radiological findings, it was decided to do a shelf graft on the left side to prevent upward displacement. This operation was later carried out.

SUMMARY: The case is one of bilateral congenital dislocation of the hip. It was treated by closed reduction when the child was aged two. This proved successful on the right side, but some subluxation occurred on the left, and this was treated by a shelf graft, when the child was 8 years old.



Right.

Figure 8.
Elma Russell.
4th. September, 1935.



Right.

Figure 9.
Elma Russell.
20th. July, 1936.

Left.

CASE NO.

PEARL GOLDBERG,
50, Thiristana Road,
Rainburg.

Age, 4 years.

COMPLAINT: Congenital dislocation of the right hip.

HISTORY:

The child did not begin walking until she was 1 year 4 months old. The mother stated that the child crawled in a peculiar manner on the left hip and right foot. Neighbours first noticed the waddling gait. There was an elder sister, aged eleven, with no abnormalities.

HISTORY OF TREATMENT:

The child was admitted to the Princess Margaret Rose Hospital on 3rd. January, 1940. She was then aged 3 years.

Examination:

The child was undernourished and had a poor colour. General examination showed nothing abnormal.

Walking: The patient walked with a distinct limp, lurching to the right side with each step.

Pelvis and lower limbs: When the child was standing, the right natal fold was higher than the left.

Trandelenberg's Test was positive on the right side.

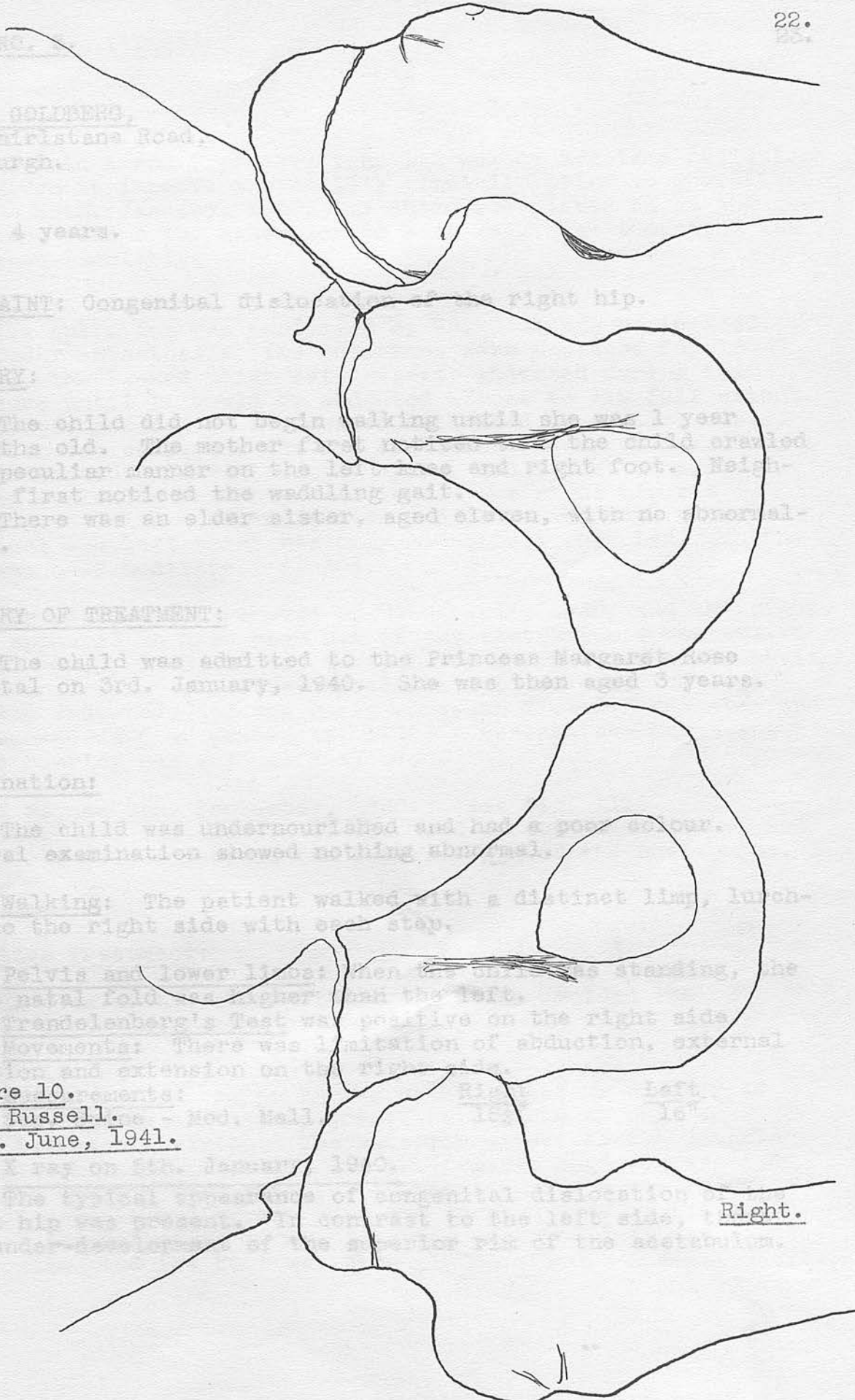
Movements: There was limitation of abduction, external rotation and extension on the right side.

Figure 10.
Elma Russell.
20th. June, 1941.

A ray on 21st. January 1940.

The typical signs of congenital dislocation of the right hip was present. In contrast to the left side, the right hip was under-developed. The superior rim of the acetabulum.

Right.



PEARL GOLDBERG,

30, Thirlstane Road,
Edinburgh.

Age, 4 years. 3 lb. extension to each leg. The abduction was increased regularly.

COMPLAINT: Congenital dislocation of the right hip.

HISTORY:

The child did not begin walking until she was 1 year 9 months old. The mother first noticed that the child crawled in a peculiar manner on the left knee and right foot. Neighbours first noticed the waddling gait. There was an elder sister, aged eleven, with no abnormalities. The left thigh was only moderately abducted, and the knee was only moderately flexed.

HISTORY OF TREATMENT:

The child was admitted to the Princess Margaret Rose Hospital on 3rd. January, 1940. She was then aged 3 years. The plaster was removed on 5th. September, 1940. Massage was begun and weight bearing was gradually allowed.

Examination:

The child was undernourished and had a poor colour. General examination showed nothing abnormal.

Walking: The patient walked with a distinct limp, lurching to the right side with each step.

Pelvis and lower limbs: When the child was standing, the right natal fold was higher than the left.

Trendelenberg's Test was positive on the right side.

Movements: There was limitation of abduction, external rotation and extension on the right side.

Measurements:

	Right	Left
Ant. Sup. Spine - Med. Mall.	$15\frac{1}{2}$ "	16"

X ray on 5th. January, 1940.

The typical appearance of congenital dislocation of the right hip was present. In contrast to the left side, there was under-development of the superior rim of the acetabulum.

Operative Treatment:

Vitamin A and D preparations and carbon arc lamp radiations were given to improve the child's condition prior to operation.

On 26th. January, 1940, the child was placed on an abduction frame with 3 lb. extension to each leg. The abduction was increased regularly.

Closed reduction of the right hip:

The operation was performed by Mr. Cochrane on 26/1/40.

Under anaesthesia, the adductors were massaged for 15 minutes, the flexed thigh being slowly abducted during the procedure until it could be abducted almost to its full extent. The hip was reduced in the manner described in earlier cases. Reduction was easy, but the hip dislocated again when movements were attempted. It was reduced again, and a plaster spica applied enclosing both hips and legs. The right hip was in the frog position - acute flexion and abduction with external rotation; the left thigh was only moderately abducted, and the knee was only moderately flexed.

The plaster was removed on 29th. July, 1940, and the right femur appeared to have come out of the acetabulum somewhat, so on 31st. July, 1940, it was manipulated again under anaesthesia by Mr. Anderson. A plaster spica was applied with the legs slightly abducted, and the knees somewhat flexed. The plaster was removed on 6th. September, 1940. Massage was begun and weight bearing was gradually allowed.

X ray on 6th. September, 1940. (see fig. 11.)

There was sublucation of the head of the right femur, and incomplete development of the superior rim of the acetabulum.

Operative Treatment:

In view of the above findings, it was decided that a reconstructive operation was necessary.

Shelf graft operation on the right hip joint.

The operation was performed by Mr. Cochrane on 6/12/40.

The capsule of the hip joint was exposed through a Smith Peterson incision. The anterior aspect of the joint was incised longitudinally, and the femoral head was exposed. A finger was inserted into the acetabulum, and a contracted band of capsule was broken down and scraped away at the lower part of the socket. The head was now inserted into the shallow acetabulum, and the foot was strongly inverted. A small shelf

of bone was turned down from the upper border of the acetabulum, and a larger plaque was turned down over this from the ilium. The capsule was sutured and an excision pin was inserted up through the neck to control any tendency to twist.

A blood transfusion was given during the operation.

The patient was screened on 3rd. February, 1941. About 90° of anteversion of the neck was apparent. The plaster was bivalved, and the patient was allowed out of the shell during the day, but she remained in it at night with the legs in strong internal rotation. Exercises were started on 31st. May, 1941, following a favourable radiological report.

Examination:

Right hip and lower limbs. The joint appeared to be stable.

Movements: On the right side there was some limitation of flexion, abduction, adduction, and external rotation.

Measurements:

	<u>Right.</u>	<u>Left.</u>
Ant. Sup. Spine - Med. Mall.	$17\frac{3}{4}$ "	$18\frac{1}{2}$ "
Girth - Mid thigh	$8\frac{1}{4}$ "	$8\frac{1}{4}$ "
- Mid calf	6"	$6\frac{1}{2}$ "

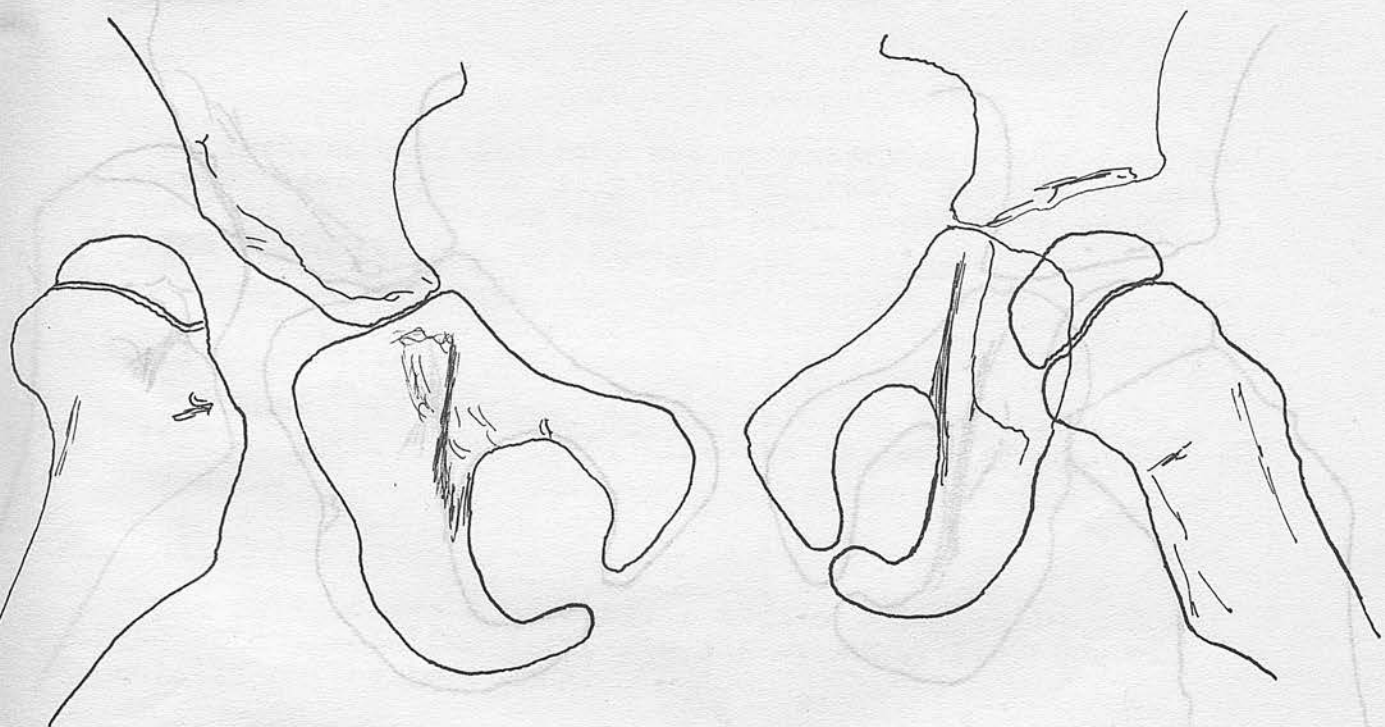
X ray on 12th. July, 1941. (see fig. 12)

The upper rim of the acetabulum was more fully developed than before, but still not so much as it should be. Shortening and anteversion of the neck of the femur were marked. The head was smaller than normal, and rather pyramidal in shape. It was not fitting as well into the acetabulum as one would have liked.

SUMMARY:

The case is one of congenital dislocation of the right hip. Two attempts were made at closed reduction when the child was aged three. The acetabulum failed to develop, however, and the shelf graft operation was performed when the child was four years old, with only moderate success.

Figure 11.
Pearl Goldberg,
5th. September, 1940.



Right.

Figure 11.
Pearl Goldberg,
6th. September, 1940.

Figure 12.
Pearl Goldberg,
12th. July, 1941.

ANITA JACK,
East End,
Callardye,
Anstruther.

Age, 2 years.

COMPLAINT: Bilateral congenital dislocation of the hip.

HISTORY:

Instrumental delivery was necessary at birth, and the child was nursed for only three months. The dislocation was noted at the water when the child started to walk. The child had no illnesses of note.

HISTORY OF TREATMENT:

The child was admitted to the Frimley Hospital on 12th July, 1941. She was two years of age.

Examination:

The patient was healthy, sturdily built child. She walked with a waddling gait, and was somewhat flat-footed especially on the left side.

Right. Hip and lower limb: Both femoral heads appeared to be outside of their sockets. Movements were excessive, and the joints were unstable.

Movements: were all good.

Measurements: The limbs were equal in length.

X ray on 16th July, 1941, (see fig. 13)

Both femoral heads were lying outside of the acetabula, and were somewhat elevated. The acetabula were poorly developed and were shallow.

Operative Treatment:

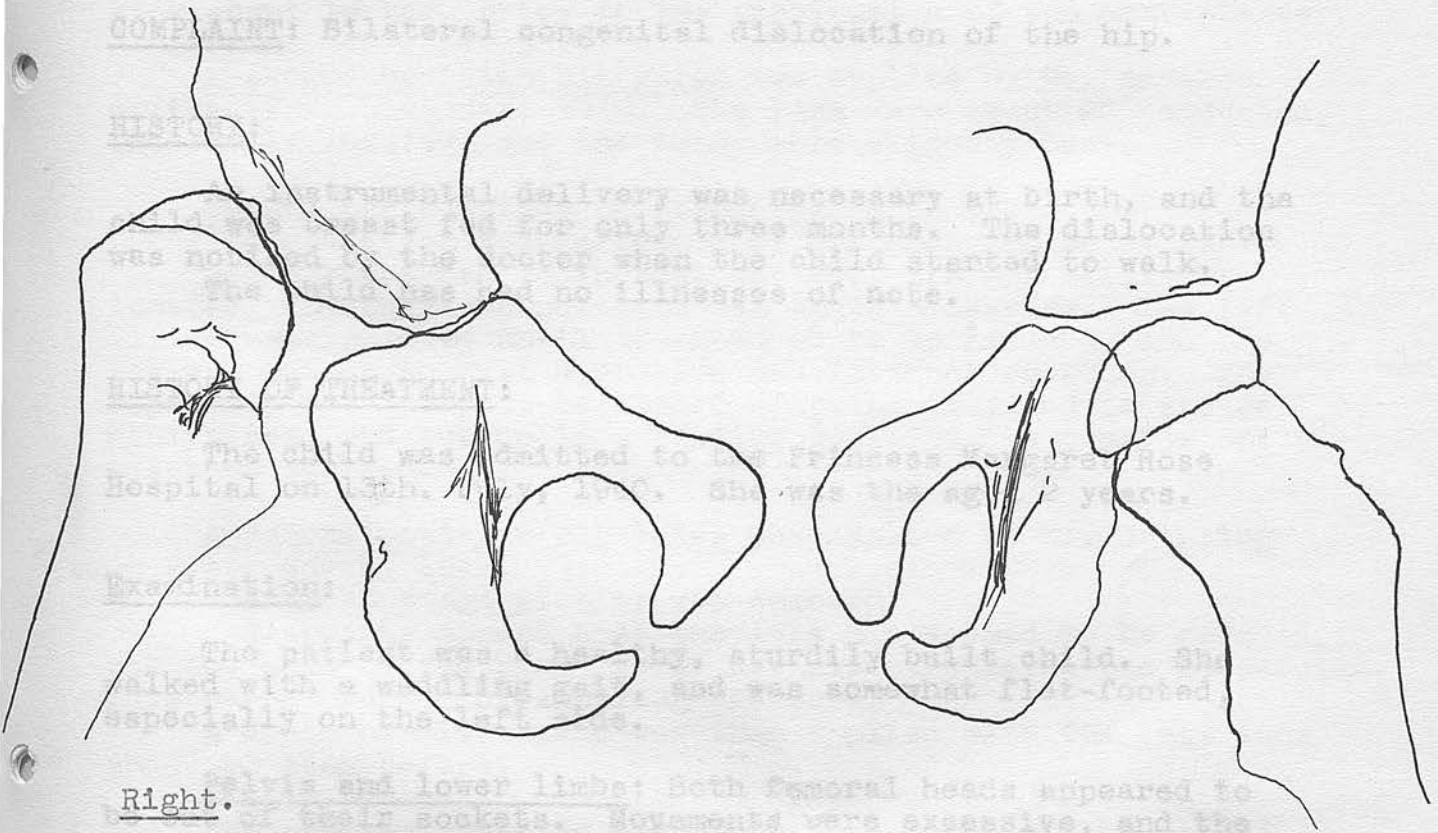
Figure 12.

Pearl Goldberg.

12th. July, 1941.

of both hips:

was performed by Mr. Cochrane on 24/7/41.



Under anaesthesia the adductors of both legs were stretched and massaged until the thighs could be flexed at right angles. heads were then carefully and forcibly manipulated into the acetabula, and a plaster spica was applied with the legs in the frog position.

ANITA JACK,
East End,
Cellardyke,
Anstruther.

The plaster was bi-valved on 4th. November, 1940, and it was found that the hips had become very fixed. The child cried and refused to walk. Massage and gentle movements were employed to mobilise the joints, and the child was allowed to walk about in bed prior to the application of the next plaster.

COMPLAINT: Bilateral congenital dislocation of the hip.

A second position hip spica was applied by Mr. Anderson on the 2nd. November, 1940. The legs were about 20° abducted, 15° rotated, and the knees were slightly bent.

HISTORY:

An instrumental delivery was necessary at birth, and the child was breast fed for only three months. The dislocation was noticed by the doctor when the child started to walk.

The child has had no illnesses of note.

HISTORY OF TREATMENT:

The child was admitted to the Princess Margaret Rose Hospital on 13th. July, 1940. She was the aged 2 years.

Examination:

The patient was a healthy, sturdily built child. She walked with a waddling gait, and was somewhat flat-footed, especially on the left side.

Pelvis and lower limbs: Both femoral heads appeared to be out of their sockets. Movements were excessive, and the joints were unstable.

Movements: were all good.

Measurements: The limbs were equal in length.

X ray on 15th. July, 1940, (see fig. 13)

Both femoral heads were lying outside of the acetabula, and were somewhat elevated. The acetabula were poorly developed and were shallow.

Operative Treatment:

Manipulation of both hips:

The operation was performed by Mr. Cochrane on 26/7/40.

Case No. 6 Continued.

Under anaesthesia the adductors of both legs were stretched and massaged until the thighs could be flexed at right angles. The femoral heads were then carefully and forcibly manipulated into the acetabula, and a plaster spica was applied with the child in the frog position.

The plaster was bi-valved on 4th. November, 1940, and it was found that the hips had become very fixed. The child cried at the slightest movement. Massage and gentle movements were employed to mobilise the joints, and the child was allowed to kick about in bed, prior to the application of the next plaster.

A second position hip spica was applied by Mr. Anderson on the 22nd. November, 1940. The legs were about 20° abducted, internally rotated, and the knees were slightly bent.

Second manipulation of both hips:

The operation was performed by Mr. Anderson on 14/12/40. Radiography had shown that the left hip was still dislocated, and that manipulation was again necessary. The left hip was manipulated until it appeared to be reduced, and the leg was put up in full abduction and internal rotation. The right hip was found to be almost slipping out, and it was re-manipulated and put up in a similar position. A plaster spica was then applied.

A second position hip spica was applied by Mr. Stirling on 21st. March, 1941.

The first stage plaster was removed. Radiography showed that the left hip seemed to be reduced, but the head of the right femur was slightly below the acetabulum. This was corrected by applying pressure.

A fresh plaster spica was then applied with the legs less abducted than before.

The plaster covering the right lower limb was bi-valved on 22nd. April, 1941, and massage and gentle movement were applied. The posterior shell was removed on 2nd. May, 1941, to allow more movements at the right hip.

Manipulation of the right hip joint:

The operation was performed by Mr. Cochrane on 23/5/41.

A radiograph prior to operation showed the right hip joint to be reduced, and in a fairly good position. An anaesthesia was given, however, to test the range of movements and the stability of the joint; and if necessary further reduction could be carried out.

Full range of movements was obtained, and another radiograph showed that the head of the right femur had remained in the acetabulum. No further plaster was applied.

The left plaster spica was not renewed.

The plaster on the left hip was bi-valved on 25/6/41, and the joint was found to be painful as soon as the plaster was removed.

X ray on 25th. June, 1941. (see fig. 14).

The left hip joint was dislocated, and there was also some subluxation of the right hip joint. The upper rims of the acetabula still appeared under-developed on both sides.

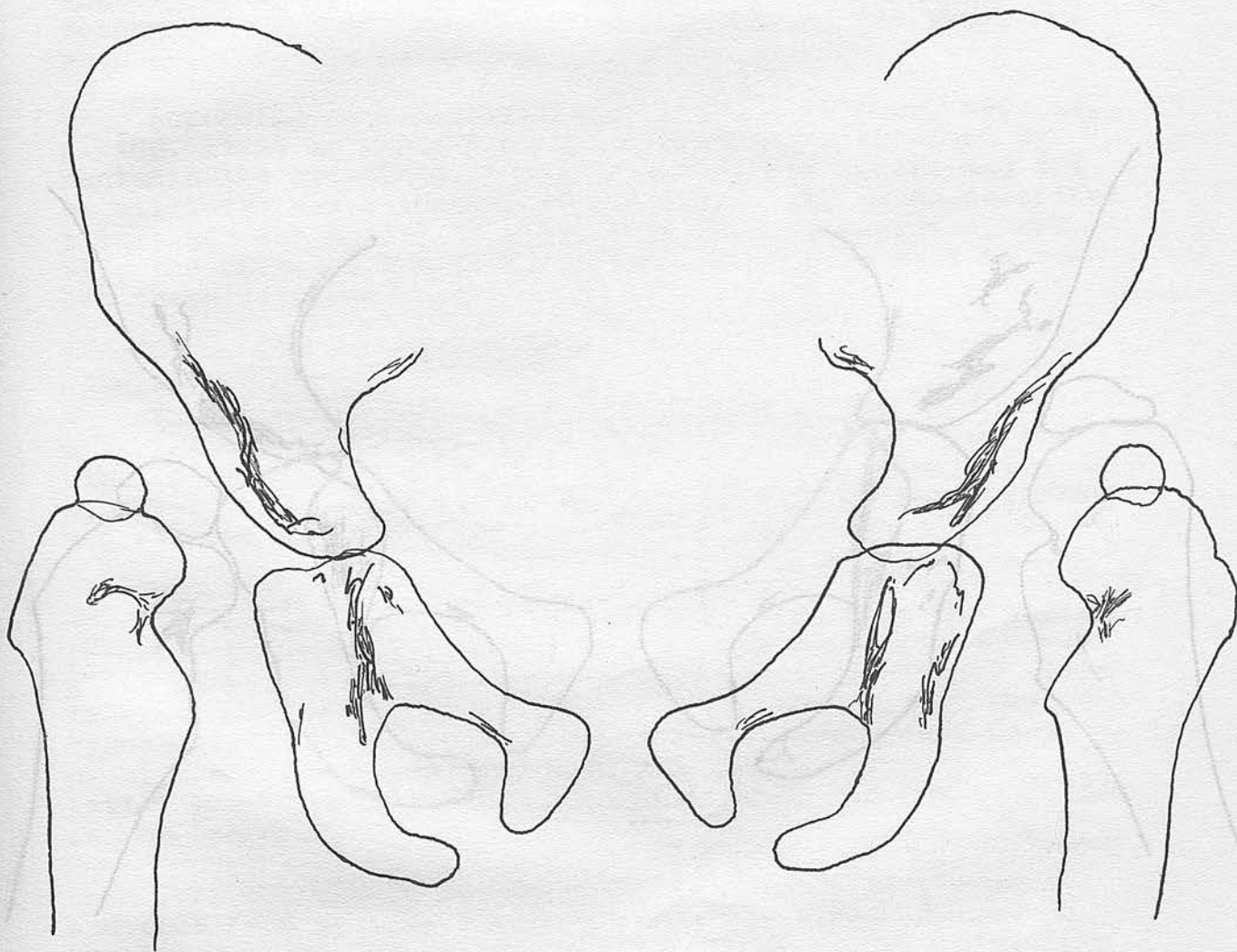
Further reduction of the dislocations will be necessary. It may be necessary eventually to do a shelf graft operation if the upper rims of the acetabula fail to develop, as at the moment, seems likely.

SUMMARY:

The case is one of bilateral congenital dislocation of the hip. It was treated by manipulation on two occasions when the child was 1 year old. Hypoplasia of the upper rims of the acetabula is still apparent, and dislocation of both joints has occurred again.

Right.

Figure 13.
Antise Jack.
15th. July, 1940.



Right.

Figure 13.
Anita Jack.
15th. July, 1940.

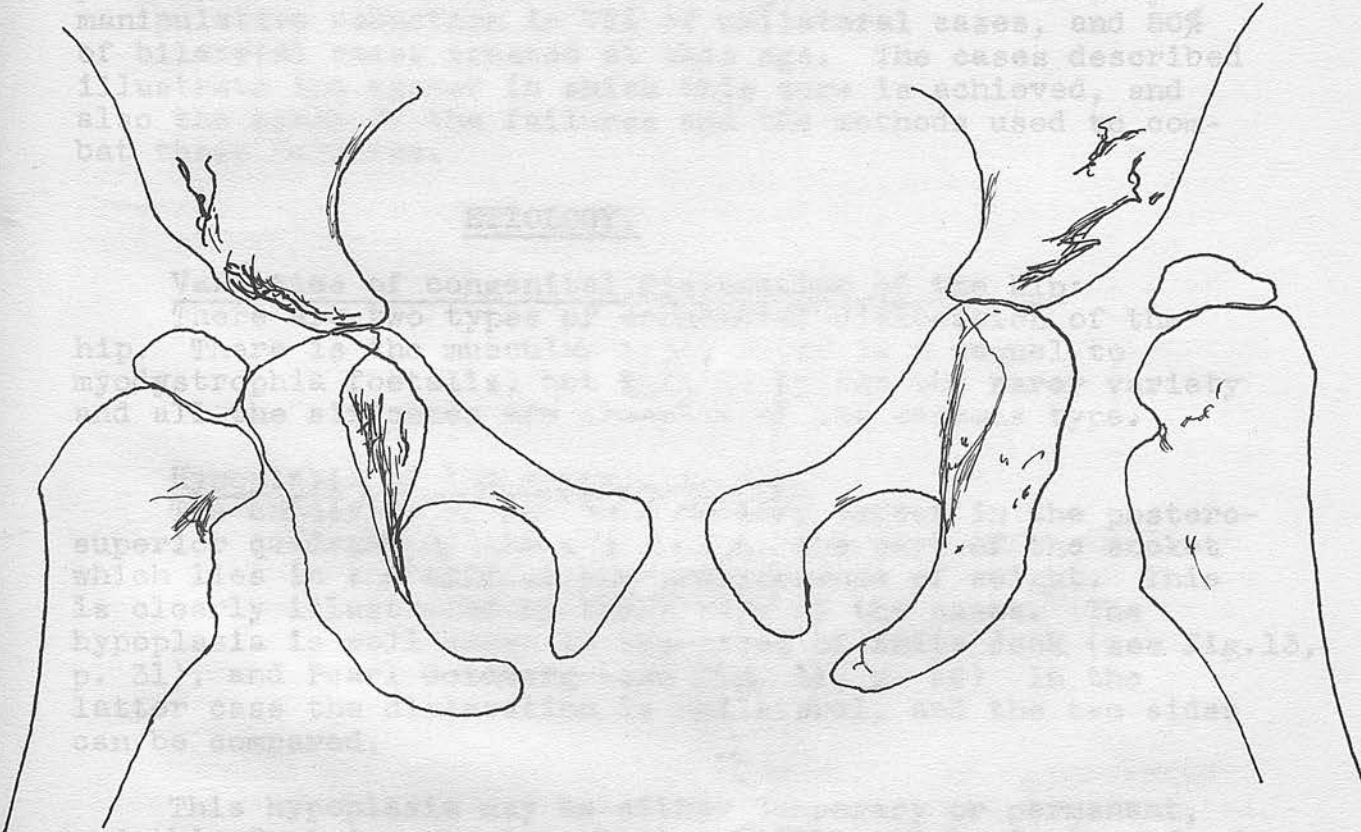
Anita Jack.
26th. June, 1941.

The six cases reported illustrate congenital dislocation of the hip at various stages of treatment. In each case, treatment was begun at an early age - before the age of three - shortly after the child was born. The condition is rarely recognized until after the age of three is the usual age when treatment is begun.

According to the following (Brit. Jour. Surg. vol. 14, p. 103, 1927) the best results to be obtained by manipulative reduction in 75% of unilateral cases, and 50% of bilateral cases, depends on the age. The cases described illustrate the age at which this aim is achieved, and also the methods of reduction and the method used to secure stability.

ILLUSTRATION

Various types of congenital dislocation of the hip have been described. The most common is the type in which the femoral head is displaced laterally and upwards from the acetabulum. In some cases the femoral head is displaced medially and downwards. In other cases the femoral head is displaced upwards and medially. In still other cases the femoral head is displaced downwards and laterally. In the latter case the femoral head is displaced downwards and laterally and the femoral neck is shortened.



Right.

This hypoplasia may be either temporary or permanent, and this fact is very important from the point of view of treatment. The case of Blacklock (Brit. Jour. Surg. vol. 14, p. 103, 1927) is very clearly illustrated in cases 12-14. Development of the superior rim of the acetabulum occurred on the left side but not on the right. Also, in the case of Miss Russell, the acetabulum developed on the right side after reduction but not on the left side.

Why this hypoplasia should remain permanent in some cases is not known. Treves has been suggested as a cause. It is known, however, that as a rule the presence of the femoral head in the acetabulum is necessary for its full development.

Figure 14.
Anita Jack.
25th. June, 1941.

case of Doris Watt - another patient with congenital dislocation of the hip at the Princess Margaret Rose Hospital when The six cases reported illustrate congenital dislocation of the hip at various stages of treatment. In each case, treatment was started at an early age - before the age of three - shortly after the child began to walk. The condition is rarely recognised earlier than this, and so this is the usual age when treatment is commenced.

According to H.A.T. Fairbank (Brit. Jour. Surg. vol. 14, p. 486, 1927) an anatomical cure ought to be obtained by manipulative reduction in 75% of unilateral cases, and 50% of bilateral cases treated at this age. The cases described illustrate the manner in which this cure is achieved, and also the cause of the failures and the methods used to combat these failures.

ETIOLOGY.

Varieties of congenital dislocation of the hip:

There are two types of congenital dislocation of the hip. There is the muscular type, which is a sequel to myodystrophia foetalis, but this is by far the rarer variety and all the six cases are examples of the osseous type.

Hypoplasia of the acetabular rim.

The condition is due to a primary defect in the postero-superior quadrant of the acetabulum, the part of the socket which lies in the axis of the transference of weight. This is clearly illustrated by the X rays of the cases. The hypoplasia is well shown in the cases of Anita Jack (see fig. 13, p. 31), and Pearl Goldberg (see fig. 11, p. 26) In the latter case the dislocation is unilateral, and the two sides can be compared.

This hypoplasia may be either temporary or permanent, and this fact is very important from the point of view of treatment. The case of Elizabeth Wallace demonstrates this point very clearly. (see figs. 2-4, pages 10-12). Development of the superior rim of the acetabulum occurred on the left side but not on the right. Also, in the case of Elma Russell, the acetabulum developed on the right side after manipulation but not on the left side.

Why this hypoplasia should remain permanent in some cases is not known. Trauma has been suggested as a cause. It is known, however, that as a rule the presence of the femoral head in the acetabulum is necessary for its full development. An exception to this rule was shown by the

case of Doris Watt - another patient with congenital dislocation of the hip at the Princess Margaret Rose Hospital when these cases were reported. This patient, aged nine, showed a perfectly developed acetabulum with an unreduced dislocation. Further, if the dislocation has not been reduced by the age of two, the hypoplasia is more liable to remain permanent.

One can draw conclusions, however, in this connection from the two bilateral cases already mentioned; viz. that since in each case hypoplasia persisted on one side and not on the other, it must be due to some local rather than general cause.

Cause of the dislocation:
As far as the actual cause of the dislocation is concerned, very little is known, though many theories have been advanced. In the cases reported there was very little evidence to support any of these theories. Trauma occurred in the case of Elizabeth Wallace, but not until she was 1 year old, and it is very likely that this was the result, and not the cause of the dislocation. There may have been obstetrical trauma in the case of Anita Jack, as an instrumental delivery was necessary at her birth.

Associated deformities:
A combination of deformities often occurs. A spina bifida occulta was present in the case of Margaret Donaldson, and also in the case of Elma Russell. The former also showed feet deformities. The association with spina bifida appears to be common. There was another case in hospital when these cases were reported - Robert John Munro.

Sex incidence:
Females are affected in 86% of cases. The majority of cases in hospital when these cases were reported were females. The six cases were chosen chiefly to illustrate the methods of treatment of the condition, but all bear witness to the female domination in this complaint!

Time of occurrence of the dislocation.
Since the primary condition is a hypoplasia of the acetabular rim, the dislocation is really a secondary effect, which may occur at various ages. Accordingly, John Bruce classifies dislocation as ante-natal, pre-ambulant and post-ambulant. The greater the degree of hypoplasia, the earlier the dislocation occurs.

In actual practice, however, as was shown in all six cases, the dislocation is rarely recognised before the child

starts walking. Diagnosis is possible before this, however, but it is only likely to be made if the doctor or midwife is keenly alert to the possibility of the condition. Radiography is of value in such cases.

PATHOLOGY.

The condition is progressive and the morbid anatomy in an untreated adult case is very different from that in a new born child. This fact is discussed further under 'treatment.'

Bony changes:

The case of Margaret Donaldson illustrates these changes very well, since there was no treatment between the ages of 4 and 7, and open reduction at the age of 7 was not entirely successful. The acetabulum shows the typical shallow triangular appearance, and there is an attempt to form a 'false' acetabulum on the dorsum ilii. There is flattening of the femoral head and shortening and anteversion of the neck.

Shortening of the limb:

This is in part due to the upward displacement of the femoral head, but not entirely. In the case of Elizabeth Wallace (see p. 8) there was still some shortening after the dislocation had been corrected by a shelf graft. The shortening of the limb here is due to the shortening of the neck, and it may be compared to the shortening which occurs in fractures of the neck of the femur.

Muscular changes:

The pelvi-trochanteric muscles are stretched and the pelvi-femoral muscles are shortened. It was for this reason that massage was always applied to the limb to stretch these muscles before manipulative reduction was attempted. The use of Hoke's traction apparatus in two of the cases was also directed to this end.

Capsular changes:

The capsule assumes an hour-glass shape, one cavity containing the head, the other covering the acetabulum. The iliopsoas tendon crosses the constriction. The capsule forms a suspensory ligament for the pelvis. Early changes of this nature were seen at operation in the case of Pearl Goldberg. (see p. 24).

This method was employed in all the six cases reported. In all, 10 hip joints were treated by this method, and a stable, well-developed hip joint resulted in 4 cases from the use of this method alone - Elizabeth Wallace (1), Elma Russell (1), Catherine McKernan (2). In the case of Anita Jack - a bilateral dislocation - this method could be repeated as she was still only 2 years old, and there was yet time for development to occur, though there was no evidence of this occurring to date.

PROGNOSIS.

Results of Treatment.

The treatment of this condition is by no means satisfactory, and the results of Fairbank quoted earlier are probably better than those obtained by most surgeons. The results in the six cases reported may be summarised as follows:

- (a) Bilateral cases 4: - Bilateral recovery, 1;
Unilateral recovery, 2; No recovery (as yet), 1.
- (b) Unilateral cases 2: - Fair recovery, 1;
Unsatisfactory recovery, 1.

Cause of failure in treatment.

Critical analysis of the successes and failures leads one to a unanimous conclusion, viz: Recovery occurs if the hypoplasia of the acetabular rim is only temporary, but where it is permanent the only hope of success lies in a reconstructive operation. It is necessary, however, if the acetabulum is to develop properly that the dislocation should be reduced, and the leg fixed in the position of abduction to remove any strain from the developing upper rim.

TREATMENT.

From the conclusions reached above it will be clear that treatment is directed to giving the acetabular rim every chance to develop from as early an age as possible.

1. Putti's Method.

This is not illustrated by any of the cases, since it is only of value up to the age of 12 months. The aim is to keep the lower limbs abducted for a few months by means of a wedge-shaped mattress.

2. Manipulative Reduction.

This is the method of choice up to the age of 3 years, but after this capsular changes make it extremely difficult to get a proper reduction by this means. Also, after this age, as has already been mentioned, development of the acetabular rim is very unlikely. Owing to the age at which children are first seen, it is the usual initial method of treatment.

This method was employed in all the six cases reported. In all, 10 hip joints were treated by this method, and a stable, well-developed hip joint resulted in 4 cases from the use of this method alone - Elizabeth Wallace (1), Elma Russell (1), Catherine McKernan (2). In the case of Anita Jack - a bilateral dislocation - this method could be repeated as she was still only 2 years old, and there was yet time for development to occur, though there was no evidence of this occurring to date.

The technique of after-treatment of manipulative reduction is well illustrated by the case of Elma Russell. (see pages 18-19). Three plaster spicas are used, each spica being kept on for 3 months. The angle of abduction and flexion is reduced each time the plaster is changed. A point of importance is shown by two of the cases reported, viz: Fixation of the hips in one position must not be continued too long. Some degree of fixation of the hips occurred in the case of Anita Jack after only $3\frac{1}{4}$ months immobilisation. Also, Catherine Mc Kernan had to have extension treatment to overcome the contractures resulting from prolonged fixation. In her case, the constitutional factor may have played some part in causing the contractures. It is interesting to note in her case, that despite the extremely poor general condition of the child, and the bowing of the femora, the acetabular rims developed quite well.

3. Ilio - femoral distraction.

This non-manipulative reduction is of value particularly in cases where there is shortening of the pelvi-femoral muscles. The technique is illustrated by the case of Elizabeth Wallace (see p. 7). In this case it succeeded in overcoming the muscle shortening, and it corrected the upward displacement of the femoral head, but it did not cure the dislocation as the acetabular rim failed to develop.

4. Open reduction of the hip.

Fairbank considers this to be the procedure of choice in children aged three to six years, in which manipulative reduction has proved impossible. The results are not good, presumably because the acetabulum fails to develop in patients of this age group. The operation was employed in the case of Margaret Donaldson, and it was not entirely successful for this very reason.

5. Reconstruction of the acetabulum. Shelf graft operation.

This operation is required when the acetabular rim fails to develop. It was performed in three of the cases reported:

Elma Russell: The operation was performed when she was 8 years old. The result of the operation was not seen, as the hip was still in plaster when the cases were reported.

Anita Jack: The operation was performed when she was 4 years old. The graft helped to replace the deficient acetabular rim to a certain extent, but not so much as one would have liked. Complete reduction of the dislocation was not effected, but the condition of the hip was certainly improved.

Elizabeth Wallace: The operation was performed when she was 5 years old. The graft took extremely well, and radiologically the result seemed excellent. Clinically, however, though the result appeared satisfactory at first, the condition of the hip deteriorated, and no reason could be found for this.

The patient was only aged five when the operation was carried out, and it may be that at this early age there is a tendency to ankylosis following a grafting operation. There was no evidence of this occurring however in the case of Anita Jack, who was operated on at the age of four. The possibility of this being an early Perthes's disease should not be lost sight of.

The optimum age for a shelf graft has not yet been settled, but it is logical to suggest that it should be performed as soon as one can be reasonably sure that the acetabular rim is not going to develop naturally. The cases reported support this view, unless of course the deterioration in the case of Elizabeth Wallace was due to premature operation. If the reconstruction is carried out at an early age, the graft should grow better, and also the child would be at a better age for getting used to the reconstructed hip. Pathological changes would also be less advanced.

6. Lorenz Bifurcation Osteotomy.

This operation is employed in long standing adult cases. It was not illustrated in this series. It is less likely to be used in the future since the tendency is for cases to be diagnosed and treated earlier.

FURTHER POSSIBLE INVESTIGATION

The six cases reported show very clearly that the development of the superior rim of the acetabulum is the crux of the problem of congenital dislocation of the hip. Further investigation in this matter might throw light on the subject, and certain lines for research were suggested by these cases.

Development of the acetabular rim.

Professor Brash has shown experimentally by feeding animals on madder and demonstrating the dye deposited in the bones that the acetabular rim grows in an outward direction from the three bones composing it. Bone is preceded by a cartilaginous outgrowth. Histological investigation of the developing rim has not as yet been attempted.

Biopsy of the acetabular rim.

When open reduction, or a shelf graft operation is performed, it would not add to the difficulties or dangers of the operation if two small pieces of the cartilaginous acetabular rim were excised for a biopsy. One piece would be taken from the postero superior quadrant and one from the normal part of the rim.

It is likely that histological section would show the normal cartilaginous structure with the columnar arrangement of the cells which occurs prior to ossification. Any differences between the two sections, such as absence of this columnar arrangement in one of them, might indicate that the hypoplasia was going to remain permanent. Such a finding would be of prognostic value in cases where open reduction was being performed, since a shelf graft could then be carried out straight away. Trauma, as occurring in forcible manipulation, has already been suggested as a cause of persistent hypoplasia of the acetabular rim. It is quite likely that microscopical appearances would be able to confirm, or refute, this view.

All this is speculative, of course, but it is possible that this investigation might throw some light on the subject. Professor Brash concurs in this view.

SUMMARY.

Six cases of congenital dislocation of the hip are reported illustrating various stages of treatment, and some of the complications liable to occur.

The cases are discussed from the point of view of the etiology, pathology, prognosis, and treatment of the condition.

The development of the superior rim of the acetabulum is the crux of the problem, and biopsy is suggested as a line of investigation, which might throw light on the subject about which there is still much to be learnt.

ACKNOWLEDGEMENTS:

Thanks are due to Mr. W. A. Cochrane, Surgeon to the Princess Margaret Rose Hospital, Edinburgh, for permission to report the six cases which were under his charge; and also to the resident medical staff and nursing staff of the hospital for their ready cooperation which facilitated case taking, and the examination of patients.
