



THE UNIVERSITY *of* EDINBURGH

This thesis has been submitted in fulfilment of the requirements for a postgraduate degree (e.g. PhD, MPhil, DClinPsychol) at the University of Edinburgh. Please note the following terms and conditions of use:

- This work is protected by copyright and other intellectual property rights, which are retained by the thesis author, unless otherwise stated.
- A copy can be downloaded for personal non-commercial research or study, without prior permission or charge.
- This thesis cannot be reproduced or quoted extensively from without first obtaining permission in writing from the author.
- The content must not be changed in any way or sold commercially in any format or medium without the formal permission of the author.
- When referring to this work, full bibliographic details including the author, title, awarding institution and date of the thesis must be given.

THESIS

ON

AN INVESTIGATION INTO THE EHLERS-DANLOS SYNDROME

SUBMITTED FOR THE DEGREE OF

DOCTOR OF MEDICINE

BY

ALEXANDER MORIES, M.B., Ch.B.(Edin.)

APRIL, 1954



CONTENTS

	<u>Page</u>
<u>INTRODUCTION</u>	1
 <u>PART I - REVIEW OF THE LITERATURE</u>	
 <u>Aetiology:</u>	
1. Congenital and Hereditary Origin	4
2. Prematurity	4
3. Congenital, Constitutional and Developmental Mesenchymal Dysplasia	5
4. Disturbance of Calcium Metabolism	6
5. Atavism	6
6. Infection	6
7. Consanguinity of Parents	7
8. Congenital Defect in the Collagen Fibres	7
9. Abnormal Form of von Recklinghausen's Disease	7
10. Developmental Error	8
11. Idiopathic Origin	8
12. Endocrine Origin	8
 <u>Pathology:</u>	
A. Macroscopic	11
(1) Spherules	11
(2) Molluscoid Pseudo-tumours	12
B. Microscopic	12
1. The Changes in the Cells and in Skin Structure	12
(a) Collagen	12
(b) Elastic Tissue	13
(c) Blood Vessels	18
(d) Other Cell Changes	19
2. The Changes Produced in the Skin by Trauma	21
A. The Molluscoid Pseudo-tumours	21
(1) Pathogenesis	21
(2) Microscopy	22
B. The Spherules	23
C. Papyraceous Scars	24
Further Pathological Study	25

Clinical /

Clinical Features:

(1) Hyperelasticity of Skin	26
(2) Fragility of Skin	29
(a) General Effects	29
(b) Papyraceous Scars	30
(c) Haematomata and Molluscoid Pseudo-tumours	31
(d) Spherules	32
(e) Blood Vessel Fragility	34
(3) Hyperlaxity of Joints	36
(4) Muscle Weakness	37
(5) Concomitant Conditions	39
(a) Fractures	39
(b) Facial Characteristics	39
(c) Abnormalities of Teeth	39
(d) Abnormality of Cranial Ossification	40
(e) Mental Retardation	40
(f) Heart Disease	40
(g) Vascular Abnormalities	40
(h) Neurological Abnormalities	41
(i) Tuberculosis	41
(j) Relationship with Other Similar Diseases	41
(k) Breast Size	42
(l) Obstetric Association	42
(i) Toxaemia	42
(ii) Prematurity	42
(m) Diverticula of Alimentary Tract	42
(n) Groenblad Strandberg Syndrome	43
(o) Eye Conditions	43
(p) Psychiatric Effect	43
<u>Radiology</u>	44
<u>Laboratory Investigations</u>	46
(1) Capillary Fragility Test	47
(2) Steroid Excretion in the Urine	47
(3) Circulating Eosinophils	47
(4) Uric Acid/Creatinine Ratio	48
(5) Ascorbic Acid Excretion	48

Differential /

	<u>Page</u>
<u>Differential Diagnosis</u>	48
(a) Blood Diseases	49
(b) Skin Diseases	49
(c) Joint Diseases	50
(d) Muscle Diseases	50
 <u>Genetics</u>	 51
 <u>Prognosis</u>	 54
 <u>Treatment:</u>	
(1) General Management	55
(2) Protection	57
(3) Treatment of the Haematomata	57
(4) Treatment of the Wounds	58
(5) Treatment of the Joint Condition	59
(6) Empirical Treatment	60
 <u>PART II - REPORT OF CASES</u>	 61
 <u>PART III - CONCLUSIONS</u>	 110
 <u>SUMMARY</u>	 115
 <u>REFERENCES</u>	 116

INTRODUCTION

Since the 17th century there has been a certain confusion in diagnosis of what is now called the Ehlers-Danlos syndrome. In 1682 Meekrin described the case of a Spaniard who could make his skin stretch to an enormous extent, and appears to have confused the Ehlers-Danlos syndrome with the condition of cutis laxa. No further significant literature appeared until Unna (1896) described the histology of elastic skin, but the syndrome as such had not then been recognised.

In 1900 Ehlers presented a case at the Danish Society of Dermatology which he described as "Cutis laxa, with a tendency to haemorrhage in the skin and to laxity of the joints", and in the same year Sir Malcolm Morris demonstrated a case at the British Dermatological Society which he called "Loose skin with numerous cutaneous nodules". This was followed in 1906 by a case shown by Hallopeau and Lépinay which they called "Diabetic Xanthorum" but which was probably a case of the Ehlers-Danlos syndrome, as was the case described by Cohn (1907) in Germany. The case of Hallopeau and Lépinay was further reviewed in 1908 by Danlos in France, who described it as "Cutis Laxa with Tumours 'par contusion chronique des coudes et des genoux'". The same case was investigated in the same year by Pautrier who was the first to describe the histology of the condition.

In 1908 Danlos recognised the triad of symptoms which is now regarded as the main basis of the syndrome:-

- (1) Hyperelasticity of skin.
- (2) Fragility of skin.
- (3) Hyperlaxity of joints.

More cases were reported over the years in various parts of the world and among the earlier were those by Joereens (1909) who described a case in association with syringomyelia; Shaw and Hopkins (1913); Poynton and Paterson (1921); and Parkes Weber (1923) who made many contributions to the literature of the subject.

The confusion which has occurred in the terminology of this syndrome may be seen from the many names which have been applied to it:-

- (1) The Ehlers-Danlos syndrome.
- (2) The Ehlers-Cohn-Danlos syndrome.
- (3) The Ehlers-Meekrin-Danlos syndrome.
- (4) Dermatorrhaxis.
- (5) Cutis hyperelastica.
- (6) Cutis laxa.
- (7) Loose skin.
- (8) Chalasoderma or Chalazoderma.
- (9) Cutis pendula.
- (10) Elastic skin.
- (11) India-rubber skin.
- (12) Gummihaut.
- (13) Dermatolysis.

This confusion was partially overcome in 1936 by Ronchese when he reviewed the whole subject and suggested that the condition be known as dermatorrhaxis. However this term has not found general approval because, although skin splitting is the main symptom, it is not the only one, and the triad is still generally known as the Ehlers-Danlos syndrome.

Further cases and small groups of cases were reported in the twenty years to 1949 when Johnson and Falls reviewed the literature /

literature and made a special contribution to the genetics of the subject. A more recent contribution is that of Kanof (1952) who published a report suggesting a possible causal mechanism. Altogether 90-100 cases of the syndrome have been described in the literature.

This thesis deals with 16 patients whom I have personally investigated and one (Case 5) for the details about whom I am indebted to Dr R.G. Macfarlane of the Radcliffe Infirmary, Oxford. The thesis begins with a survey of the literature on the subject, and in this survey there are inserted at appropriate places observations of my own for comparison with those of the authors quoted. The second part of the thesis contains as full a clinical description of these 17 cases as it was possible to arrange for in general practice. In the third part I present the conclusions I have been able to reach as a result of my investigation. The work was started when I found that my eldest child, other members of my family and myself were sufferers from this rare disease (Cases 2, 3, 4 and 1).

In addition to giving me access to the records of Case 5, Dr R.G. Macfarlane kindly allowed me to examine Cases 9-16. I have also to thank Dr G.B. Forbes and Dr S.L. Tompsett for help in the pathological and biochemical investigations respectively, and Dr Q. Evans and Mr F.G. St. Clair Strange who also referred cases to me.

PART I

REVIEW OF THE LITERATURE

Aetiology

A definite cause has not been found for the syndrome but many theories have been postulated. The most important of these are as follows.

1. Congenital and Hereditary Origin

In view of the fact that many of the cases reported have shown a family inheritance, this theory was suggested by both Berggreen (1937) and Klebanov (1937), and more recently by Johnson and Falls (1949). That heredity does play a part in this condition is now established but the exact mechanism by which it does so is not clear. In my series the familial tendency is well demonstrated in Cases 1-4 and 11-16. Other observers have also noted this tendency and further reference to it will be made in the section on Genetics (p. 51).

2. Prematurity

Prematurity has figured largely in the literature connected with the syndrome. Many observers have noted it, included Shaw and Hopkins (1913); Tobias (1934); Ronchese (1936); Rambar (1938); Launay (1940); Skeer and Kaplan (1940); Pittinos (1941); Benjamin and Weiner (1943); and Johnson and Falls (1949). These authors have considered the possibility of whether prematurity is the cause or effect but /

but none could come to a definite conclusion. Five of my cases (Cases 2, 3, 7, 8 and 10) were premature babies but no cause was found for the prematurity. One of them (Case 2) had a sister who was not premature and who was not affected by the condition.

3. Congenital, Constitutional and Developmental Mesenchymal Dysplasia

In view of the lack of evidence of any other cause and the established hereditary nature of the condition, it has been suggested that there is an unknown disturbance of the mesenchyme which produces the changes which take place in the skin and joints. There is no change in the nails or hair which are derived from ectoderm. This theory has been advanced by Hirszfeldowa and Sterling (1924a, b); Weber (1936); Ronchese (1936, 1943); Benjamin and Weiner (1943), and Turner (1949).

It was thought that a disturbance of mesodermal and ectodermal development might produce a lack of the normal tensile strength of the collagen fibres. However, it has recently been shown by Tunbridge et al. (1952), using the electron microscope, that there is no change in the anatomical structure of the collagen; possibly the physiology of collagen is at fault.

Finally, in connection with this theory Sezary et al. (1933) and Sezary and Horowitz (1935) suggested the possibility of a dystrophy.

4. /

4. Disturbance of Calcium Metabolism

The calcium content of the blood is one of the many laboratory investigations which have been made. Barber et al. (1941) found it to be increased, as also did Raybaud and Guidoni (1938), and they suggested that this might be the cause of the syndrome. Other observers, notably Reyn (1933), Dreyfus et al. (1936), Ronchese (1936, 1943) and Rambar (1938) found it to be normal, and Tobias (1939) found it to be lowered. Thus this theory can be discarded on the grounds of insufficient evidence.

5. Atavism

The possibility of a reversion to the ancestral type was considered by both Kopp (1888) and Ronchese (1936, 1943). No definite evidence of this could be produced but it is a very difficult theory to dispute.

6. Infection

It was suggested by Barber et al. (1941) that infection played an important part in the production of the disfiguring scars. In the Report of the Washington School of Medicine (1939) a similar suggestion was made, and Weber and Aitken (1938a, b) also discussed the matter. They excluded syphilis as a cause and thought tuberculosis very unlikely. I think that infection is not the causal agent although it does influence the end results of trauma.

7. /

7. Consanguinity of Parents

This theory has been suggested by a number of authors but there is no real evidence to support it.

8. Congenital Defect in the Collagen Fibres

The suggestion was made by Brown and Stock (1937) that there may be a relative lack of collagen and, as already stated, Tunbridge et al. (1952) have agreed with this, finding the collagen to be deficient in quantity but normal in anatomical structure.

9. Abnormal Form of von Recklinghausen's Disease

Although the aetiology of von Recklinghausen's disease is unknown, the idea that the two might be connected was attractive. Tobias (1939) and Roca and Loiacono (1942) considered this possible, while Bielschowsky (1930) noted some pigmentary deposits in the corium in both conditions. Margarot and his associates (1933a, b) also considered the possibility, while Capurro (1926) noted brown patches and angiomas. Both the latter and Sezary et al. (1933) thought of the possibility of tuberculosis in this connection, but felt a relationship with von Recklinghausen's disease to be more probable.

Weber (1936) believed there was no direct connection with von Recklinghausen's disease, epidermolysis bullosa or idiopathic striae atrophicae. Ronchese (1936, 1943) felt there might be a relationship with idiopathic stria cutis distensia atrophica /

atrophica in adolescents but noted that, in this latter condition, the striae followed the lines of skin cleavage.

10. Developmental Error

Lowe (1939) described a case in which there was a co-existent synostosis of the heads of the radius and ulna, while Debre and Semelaigne (1938) and Debre et al. (1937) noted the delay in cranial ossification in the new-born in connection with the syndrome.

11. Idiopathic Origin

Ronchese (1936, 1943) called the condition "idiopathic dermatorrhesis with or without dermatochalasis and arthrochalasis", and he quoted Nardelli's (1935) paper on the subject.

12. Endocrine Origin

As with many subjects where the cause is unknown, implication of the endocrine glands has been frequently considered. In 1924 Dobrowsorskaya considered the possibility of a multiglandular defect associated with underdevelopment of the primary and secondary sex characteristics. Burrows in 1932 came to no definite conclusion as to endocrinal influence. In 1936 Ronchese tried treatment with a solution of pilocarpine hydrochloride, thyroid extract, parathyroid extract, and a solution of posterior pituitary extract. Success was not achieved with any of these preparations.

In /

In view of the changes in the joints and the acrocyanosis which may be present in the syndrome, Gilbert et al. (1925) and Dreyfus et al. (1936) considered a possible association with the pituitary gland; this association also occurred to Barber et al. (1941), but, like Weber and Aitken (1938a, b), they found it not proven.

Interest has again been aroused in this matter by the publication of an article in 1952 by Kanof which has made a definite contribution to the subject. He found the urinary excretion of 17-ketosteroids increased in his one case. He then tried to correlate this finding with the clinical effects of Cushing's syndrome, those of adrenal cortical hypertrophy, and of an overdosage with cortisone and A.C.T.H. He cited Cope (1950) who showed that cortisone and corticotrophin had a profound effect on collagenous tissue and on delay in granulation. Ragan et al. (1949) found that patients undergoing prolonged treatment with corticotrophin showed a low blood ascorbic acid level and decreased urinary excretion of vitamin C, the same being observed in experimental animals. Goldsmith (1939) found a low blood ascorbic acid level with increased retention after a test dose of ascorbic acid in his patient with the Ehlers-Danlos syndrome.

With this in mind, Kanof (1952) looked for similarities between these conditions, some old cases of the Ehlers-Danlos syndrome and his own case, and tabulated his findings as follows:-

Similarities /

- Similarities:
- (1) Dermatorrhexis.
 - (2) Poor fibroblast response.
 - (3) Fragile blood vessels.
 - (4) Weakness.
 - (5) Osteoporosis.
 - (6) Delayed epiphyseal development.
 - (7) High normal or slightly increased excretion of 17-ketosteroids.
 - (8) Increase in the uric acid/creatinine ratio.
 - (9) Eosinopenia.
 - (10) Delayed healing.

Dissimilarities.- The following occur in hyperadrenalism, Cushing's syndrome and overdosage with cortisone and corticotrophin, but either do not occur or have not been reported in the Ehlers-Danlos syndrome:

- (1) Obesity.
- (2) Hypertension.
- (3) Striae.
- (4) Acne.
- (5) Abnormal dextrose tolerance curve.
- (6) Increase in oxysteroids in the urine.
- (7) Increased ascorbic acid retention (some cases only).
- (8) High blood sodium.
- (9) Low blood potassium.
- (10) Low polymorph count.
- (11) High lymphocyte count.

In this connection, van der Valk (1926) had noted a high sugar tolerance in his case of the syndrome, but this was not supported by Barber et al. (1941) although they did find a slightly raised blood urea. Kurt Wiener (1924) also considered the possibility of a metabolic disorder.

Considerable confusion has occurred owing to the inconsistency of the clinical findings in the adrenal and pituitary /

pituitary syndromes, for example, Read et al. (1950) could not agree with the majority of observers that the eosinophil count is a reliable index of adrenal activity. Bunim (1951) stated that in 18 cases treated with corticotrophin only three developed glycosuria and only two showed signs of potassium depletion. Soffer (1947, 1948) found that less than half of the cases of cortical hyperfunction exhibited some abnormality of the blood electrolytes, and that alteration of glucose metabolism did not occur uniformly. In a later paper, Pascher and Kanof (1953) suggested that the prenatal influence of cortisone might produce the permanent skin effects. The results for hormone excretion in my series of cases are inconclusive, and in this respect I cannot confirm Kanof's work.

Pathology

Relatively little has been written about the gross pathology of this condition, although there is a considerable literature on the histology.

A. Macroscopic

(1) Spherules.- Weber and Aitken (1938a, b) considered that the spherules were not true lipomata but were small nodules produced by trauma in the fragile tissues. These nodules thinned and atrophied, forming free bodies in the subcutaneous tissue owing to lack of blood supply. Fibrosis may /

may take place to form oil-containing cysts where calcification allows their demonstration radiologically as described by Holt (1946).

(2) Molluscoid Pseudotumours.- In 1943 Benjamin and Weiner stated that repeated bruising led to extravasation of blood with the consequent formation of haematomata. These, being only partially absorbed, set up an inflammatory reaction producing infiltration and tumour formation. Such tumours have been called "raisin-like" by various authors.

B. Microscopic

This may be divided into two sections: (1) changes in the cells and in skin structure, and (2) changes in the skin produced by trauma.

No histological changes have so far been described in the joints, but it can be assumed that they are analogous to those in the skin.

1. The Changes in the Cells and in Skin Structure

(a) Collagen.- A decrease of collagen has been noted by Sezary et al. (1933), Bolam (1938), Burrows and Turnbull (1938) Ronchese (1936, 1943) and Johnson and Falls (1949). Ronchese described it as thinned and rarefied and as sometimes showing torsion. Tobias (1934, 1939) noted that it was finely meshed, well separated, and showed a fibrillary structure instead of the loose-woven but thick bundles of the normal. This less dense, cross-striated or beaded formation possessed great expansibility and tensile strength. The Washington School /

School of Medicine report (1939) found the collagen broken and fragmented, and Brown and Stock (1937) suggested that its splitting might be the cause of the disease. Smith (1939) felt that the lack of collagen led to a lack of response by fibroblasts and that this in turn led to the formation of papyraceous scars. Pierard and Palmer (1949) thought that an excess of elastic tissue was the cause of the collagen deficiency, while Ormsby and Tobin (1938) noted that it was in small bundles and that there was a diminution of collagen in the urine.

An increase in collagen was first noted by Williams (1892) but, like Unna (1896), his description was made before the syndrome was fully studied. However, Weber (1913) also noted an increase, especially in the spherules, where the elastic tissue was replaced and an occasional calcium deposit seen. Reyn (1933) likewise noted an increase, while Cohn (1907) and Martin and Maruri (1932) found it hypertrophied and showing torsion. Coe and Silvers (1940) noted a general increase in all the skin elements while Freeman (1950) observed that the collagen extended into the middle part of the cutis.

A normal amount of collagen was found by Pautrier (1908).

(b) Elastic Tissue. - Most authors agree that there is an increase of elastic tissue. Johnson and Falls (1949) noted that it was usually increased but that on several occasions it had been decreased. In their own cases hypertrophy and torsion were seen in association with a wavy arrangement /

arrangement of all the elements of the connective tissue. This hypertrophy with a wavy dense reticulum was also found by the Washington School of Medicine report (1939) and by Tobias (1934, 1939). Tobias, commenting on the paper of Johnson and Falls (1949), considered the possibility of the elastic fibres rupturing more easily than normal and, in the presence of necrotic fat, attracting calcium. Barber et al. (1941) while noting the increase, suspected that the elastic tissue was not regenerated in situ and thus retarded the healing of wounds.

Fragmentation of the fibres together with an increase was commented upon by Benjamin and Weiner (1943) and by Wallach and Burkhart (1950), although Smith (1939) could find no evidence of fragmentation. He did suggest that the same histological changes might be found in the joints, this view being endorsed by Pittinos (1941).

Rambar (1938) agreed with the increase found by other authors and observed a new formation of connective and elastic tissue, while Freeman (1950), agreeing with him, referred to the work of Albright and Reifenstein (1948) in this connection. Stillians and Zakon (1937) noted especially that the elastic tissue was abundant, that it appeared in whorls and clumps, and that there was no cellular reaction around the elastic fibres. They considered the possible association with pseudoxanthoma elasticum but observed that the elastic fibres would stain blue with haematoxylin and eosin /

eosin in this condition. Ormsby and Montgomery (1943) felt that there was a change of some elastic tissue to elastin. Turner (1949) observed that the elastic tissue extended to the mid cutis, replacing the papillary bodies, collagen and subcutaneous fat, and with Weigert's stain for elastic tissue he demonstrated its extension into the epidermis between the basal cells.

Pierard and Palmer (1949) made a very complete study of the elastic fibres, finding the same marked increase and noting that they were arranged in two layers. In a specimen of skin taken from over the deltoid region they found a superficial layer in which the fibres were fine and swept round the sweat glands, while in the deeper layer there was a dense network of thick fibres. In the abdominal skin the same pattern was noted although the authors did not find the degree of abnormality that they had expected. They had the unique opportunity of examining the appendix of their patient, and the only elastic fibres which they could find were those around the blood vessels. They concluded that there was an increase of elastic tissue at the expense of the collagen.

Other authors who have noted an increase are Weber (1913, 1923); Martin and Maruri (1932); Miget (1933); Sezary et al. (1933); Ronchese (1936, 1943); Turnbull (1938); Coe and Silvers (1940); Skeer and Kaplan (1940); Ringrose et al. (1950), and Shapiro (1952). Fig. 1 shows the skin of a patient (whom I did not see) which demonstrates the elastic fibres stretching down to the subcutaneous fat.



Fig. 1.- Photomicrograph of skin of Ehlers-Danlos syndrome, showing elastic fibres stretching down to subcutaneous fat. (Orcein. x 160.)

A decrease of elastic tissue was noted by Cohn (1907) and later by Burrows (1932), who stated that there was a deficiency of all the subcutaneous tissues. His view was that complete deficiency caused lax skin, that incomplete deficiency produced hyperelastic skin and lax joints, and that there was a third group which he classified as a localised form. Again it appears that there was a confusion with cutis laxa, but Burrows did differentiate the syndrome from pseudoxanthoma diabeticum in which the elastic tissue is split longitudinally and fractionated transversely. He compared the syndrome with epidermolysis bullosa in which he felt that the yellow elastic tissue was at fault. It was his opinion that these conditions were due to a lack of internal secretion. Brown and Stock (1937) and Gordon (1942) likewise found a decrease of elastic tissue, the latter quoting a report by Freudenthal, who made a similar observation.

A normal amount of elastic tissue was noted by Williams (1892) and by Pautrier (1908), and more recently by Cockayne (1933) who mentioned the work of Siefert.

As a general reference to elastic tissue the textbook by MacLeod and Muende (1946) may be consulted. The whole subject is admirably discussed by Dick (1947) who described the differences found at different ages, in different sites in the body, in different depths of the skin, in areas exposed to the weather and in certain conditions such as oedema.

The /

The most recent work on the histology of this subject is that carried out by Tunbridge et al. (1952) who have made a great contribution by their electron microscopic studies. They have demonstrated in normal skin that collagen consists of fluffy masses of loose amorphous material with no cross-striations, this making up an estimated 5 per cent. of the total tissue. It also consists of fibrils of uniform thickness (1100 A) following straight paths and frequently grouped in regular parallel arrays. These fibrils are constant in appearance irrespective of age, and these authors attribute the elasticity of the skin to the collagen. The elastic tissue consists of loose ill-defined non-striated fibrils embedded in an apparently amorphous material. These authors quoted Wolpers (1944) who suggested that each collagen fibril is encased in a thin membrane, the whole being surrounded by a ground substance of unknown composition and structure. They also considered the views of Gross (1949) who stated that the elastic fibre is a two-component system formed from bundles of trypsin-resistant threads, of characteristic form and size, embedded in a trypsin-sensitive, heat-resistant matrix.

In the Ehlers-Danlos syndrome Tunbridge et al. (1952) found the general structure of the skin unchanged. The collagen fibrils were few in number but of normal appearance. The main constituents of the skin were loose ill-defined branching elastic fibres of various lengths and thicknesses, showing no cross-striations and very like typical elastic tissue fibrils from the media of the aortic arch. The great extensibility /

extensibility of the skin was due to an increase of elastic tissue and a relative lack of collagen. In the Ehlers-Danlos syndrome they summarised their results as follows:-

<u>Histology</u>	<u>Electron Microscopic Studies</u>
Elastic tissue - excessive	Elastic tissue - excessive
Collagen - scanty	Collagen fibres - trace
	Debris - fairly abundant on a small scale

(c) Blood Vessels.- A number of authors have noted abnormalities in blood vessels, in particular Johnson and Falls (1949) who found that they were irregular in course and winding. Pautrier (1908), Martin and Maruri (1932), Tobias (1934) and Ormsby and Tobin (1938) found thin-walled fragile vessels. Unna (1896) noted thick-walled, unduly coarse vessels; Rambar (1938) agreed with him and noted occasional thrombi. Scolari (1937) found large numbers of blood vessels producing angiomatous growths, while Barber et al. (1941) suggested that the increased blood supply led to angioliomata. Benjamin and Weiner (1943) and Turner (1949) found no abnormality in them. Ringrose et al. (1950) took for their biopsy a piece of tissue which was partly in pigmented skin and partly in normal skin. In the pigmented portion the blood vessels were very numerous but in the normal portion they were small in size. Sezary et al. (1933) found them dilated and showing new formation of capillaries and minute vessels of the deep layers of the dermis. Similar findings were /

were made by Schulmann and Levy-Coblentz (1932). In the case which is reported later (Case 5) and which was seen by Macfarlane (1952), extreme fragility of the blood vessels was noted.

(d) Other Cell Changes. - Myxomatous changes were noted by Bolam (1938), and Barber et al. (1941) found that the pars reticularis was looser than normal. The latter noted giant cells as did Weber and Aitken (1938a), Ronchese (1936, 1943) and Johnson and Falls (1949), clear spaces being present on some occasions in these cells. The last two authors also observed large fusiform and polyhedral mononuclear cells and noted that some of the giant cells were multinucleated and contained acidophilic cytoplasm. They suggested that the clear spaces were due to the presence of fat and that the cyst formation found was due to the splitting of the collagen fibres. This led them to think that similar effects took place in the joint capsules. It was also their opinion that the wrinkling of the epidermis was due to the contraction of the elastic network in the corium. Ronchese (1936, 1943) observed a thinning and flattening of the whole dermis.

It had been suggested by Unna (1896) that the number of muscle fibres was increased, but Smith (1939) and Pittinos (1941) did not verify this.

Skin thickness has been discussed by many authors. Tobias (1939) stated that it was very thin and that his sections had shown only four layers of cells, with a diminution /

diminution of subcutaneous tissues and supporting structures. He found that the corium was half the normal thickness and that the sweat glands and vessels had thin walls, but this has not been confirmed by other observers. He also referred to the work of Pautrier (1908) who had noted loose connective tissue and had concluded that the lesions were due to angiomatous changes in the middle dermis, and to that of Bielschowsky (1930) who had noted pigmentary deposits in the corium and neurones in the cutaneous nerve endings.

Smith (1939) noted that the epidermis was very thin and that the sweat glands were diminished in number. He also found that the cellular content of the malpighian layer was reduced by half and that the connective tissue was less. Bolam (1938) found the malpighian layer thin, the subcutaneous fat almost absent and hyperkeratosis of the skin. He suggested that the myxomatous changes, which he had found throughout his sections, were the cause of the skin weakness. Coe and Silvers (1940) cited Seifert as observing these changes although they found only thinning of the epidermis and an increase of connective tissue. Rambar (1938) also noted the unusual thinness of the skin but with an excess of keratin, and he found foci of lymphocytes and polymorphs in his sections. Stillians and Zakon (1937) noted the absence of papillae and rete pegs. Poynton and Paterson (1921) noted a lack of fibrous trabeculae attaching the skin to the muscles.

Freeman (1950) noted a thin squamous epithelium, while Ringrose et al. (1950) found areas of hyperpigmentation of the skin /

skin with an atrophic epidermis. The connective tissue was loosely arranged and contained an increased number of fibroblasts. Sweat and sebaceous glands were normal throughout. The biopsy scar gaped on the sixth day when the sutures were removed. Turner (1949) found no difference in the skin depth.

Garcia and Fialho (1937) described calcification of Hassell's corpuscles in the thymus gland and also an increase of colloid in the thyroid gland.

2. The Changes Produced in the Skin by Trauma

A. The Molluscoid Pseudotumours

(1) Pathogenesis.- There has been much speculation as to the origin of the molluscoid pseudotumours, the earliest suggestion coming from Cohn (1907) that they were lymphangiectatic tumours. Barber et al. (1941) thought that they were derived from inflamed implantation dermoid cysts which produced a granuloma. They also considered that the absence of elastic tissue, together with the swelling and bulging of the collagen bundles and with giant cell proliferation in the connective tissue, might lead to the bulging which is characteristic of the pseudotumours. Smith (1939) thought that they were produced by folds of skin being subject to repeated haemorrhages. However, Scolari (1937) considered that they were produced by injury which led to new vessels growing into the connective tissue and giving rise to angiofibromatous growth. This growth underwent fatty degeneration with /

with splitting of the collagen fibres and resultant cyst formation, the spaces of which were lined with epithelium and thus enlarged to cavities of considerable size. He also thought that some partially reabsorbed haematomata might produce the pseudotumours.

Danlos (1908), in his early description, suggested that chronic contusion over the bony prominences led to tumour formation with resultant infiltration and inflammation, this being followed by partial resorption and giving the "raisin-like" appearance. He observed that compression of the bruises helped to prevent the formation of these tumours. Shapiro (1952) noted the fact that they were most prominent around bony prominences where the subcutaneous fat was rather lacking. It was his opinion that injured tissue filled with blood and produced the soft consistence and brown colouration of the tumours. The explanation offered by Weber and Aitken (1938a) was that they were analogous to the pseudotumours seen in other dysplastic conditions. Smith (1938) thought that scratching of impetiginous lesions produced both papyraceous scars and pseudotumours. Turner (1949) likened the tumours to angiomata but considered that they were formed, as a result of trauma, by extravasation of blood into lax subcutaneous tissue.

(2) Microscopy. - Because of the marked difficulty in healing of these tissues, few biopsies have been taken for microscopical examination. However, Barber et al. (1941) made some observations. They noted flattening of the epidermis /

epidermis and the presence of large pale bundles of collagen lying in the middle of the pars reticularis, while all the subcutaneous tissue was scanty. The cavity of the tumour contained a soapy substance which was not dissolved by the usual fat solvents. The elastic tissue was coarse and twisted and fibroblasts were prolific around the edges, while there were many foreign body giant cells which, they felt, might have arisen from the sweat glands. In the deeper layers of the dermis below the tumour they found freely movable, redundant fat with scattered collagen bundles and many vascular pedicles. Thus they showed that only the middle layers of the dermis were affected by trauma.

Smith (1938) considered that haemorrhages into the skin led to the formation of blood cysts, with consequent organising granulation tissue of fibrous structure and some lanugo hair follicles in the depths.

I have not examined the microscopical structure of the pseudotumours. There appeared little to be gained by such a study and, from experience of trauma to these lesions, I did not feel that it was justified.

B. The Spherules

As already mentioned under the section on macroscopic pathology (p. 11), the spherules have been investigated in much detail by Weber and Aitken (1938a). These nodules have also been described as lipomata but the general concensus of opinion is that they are not true lipomata. They were shown by /

by Barber et al. (1941) to consist of fat cells containing globules of oil, surrounded by flattened cells. There was no true capsule but a coarse fibrous network attached to a vascular pedicle. Weber and Aitken (1938a) described them as another sign of the Ehlers-Danlos syndrome, but many cases have no such spherules and I consider that they form one of the more variable signs of the condition. They are probably part of the generalised dysplasia. Smith (1939) thought that they resulted from a rupture of fatty tissue, while Launay (1940) particularly noted fat in fibrous capsules. Poynton and Paterson (1921) thought that the nodules were aneurysmal conditions of small arterioles. I have not had the opportunity of sectioning a spherule as none was present in my cases.

C. Papyraceous Scars

These are the direct result of trauma. Cohn (1907) found a lack of subcutaneous tissue under these lesions in which he considered that a collapse developed forming lymphangiectasis. Pautrier (1908) thought that the lesions were angiomatous and he found them in the middle dermis, while Sezary et al. (1933) observed atrophy of the epidermis and subcutaneous fat and the formation of granulomatous material such as is found with a foreign body. Scolari (1937) felt that injury led to the formation of what he called "dystrophic cicatrices" and that prolonged suppuration produced large and irregular scars; also that the poor supporting tissue led to the formation of haematomata. /

haematomata. As already stated, he postulated the same theory for production of the molluscoid pseudotumours. Barber et al. (1941) noted that the collagen in an injured area was pallid and oedematous and in loose bundles. They considered that the excessive elastic tissue and deficient collagen were both probably inferior in quality. Benjamin and Weiner (1943) observed an excess of collagen at the edge of scars, and Turner (1949) thought that the poverty of fibroblasts and collagen bundles caused a contraction of wound edges after injury, the collagen normally increasing the tensile strength and stretch resistance.

Further Pathological Study

In 1949 Tobias (quoted by Johnson and Falls, 1949) suggested the following:-

- (1) The examination of the reticulum or lattice fibres. I have done this and have found no abnormality.
- (2) Special staining of the collagen fibres by picromarmine. I did not carry this out because of the recent success with the electron microscope.
- (3) A study of the superficial involuntary muscle tissue. My biopsies (Case 1) were not deep enough for this.
- (4) The use of dermatoglyphics. As already mentioned (p. 17), the electron microscope has been used with success, but it was not available to me.

It would appear to me that future study will probably entail investigation of the effects of enzymatic digestion on the tissues.

Clinical Features

As already mentioned in the Introduction, the syndrome is rare. Both Sezary et al. (1933) and Gaté (1933a, b) considered it very rare, but I agree with Ronchese (1936, 1943) that the milder degrees are more common than is generally realised. Certainly the extreme cases are rare and I have been fortunate in having been able to add a number of all grades to the literature. In his original description, Ehlers (1901) suggested that recovery from the syndrome took place with the passage of years, but I consider it more likely that with advancing years the victim is less exposed to trauma and consequently there is less new evidence of the syndrome.

A multitude of clinical features have been described but there are only three basic signs and it is this triad which makes the syndrome a clinical entity. As already stated, these signs are: (1) hyperelasticity of skin (dermatochalasis), (2) fragility of skin (dermatorrhesis), (3) hyperlaxity of joints (arthrochalasis). To these may be added as a subsidiary feature: (4) muscle weakness. I believe that the other features which have been described are either a direct result of the triad (with or without trauma) or are concomitant conditions.

(1) Hyperelasticity of Skin

This has been noted by almost all observers but it has often been confused with cutis laxa, in which condition the other two main features of the Ehlers-Danlos syndrome are not present. /

present. An example of this is the case of the Spaniard described by Meekrin in 1682, who showed no evidence of skin fragility.

This hyperelasticity gives the skin a curious, almost diagnostic texture which has been variously described by many authors. Danlos (1908) likened it to the "empty skin of a grape" while Ehlers (1901), whose case showed stretching of the skin of the finger one and a half times round itself, described it as the feel of "peeling a roast apple". Roca and Loiacono (1942) and Sullivan (1942) both thought "indiarubber" was more descriptive, but Schubert (1925) and Smith (1939) favoured "a velvety and putty-like feel". King-Smith et al. (1932) described it as "doughy" while Wallach and Burkhart (1950) likened it to "satin, not in folds but with ecchymotic lesions". Tobias (1934) considered the texture to be like "accordion pleats" and Ronchese (1936, 1943) described it as "the skin you like to touch", while Poynton and Paterson (1921) said it was "like fine chenille and the antithesis of scleroderma".

Johnson and Falls (1949) and Fischer (1931-32) noted that the skin of dogs and cats was remarkably similar to the touch to that of patients with the Ehlers-Danlos syndrome, and I agree with this view. However, the animal skin heals with the greatest ease whereas victims of the syndrome show great difficulty in this respect. I have made sections of the skin of both cats and dogs (Fig. 2), but histological comparison is not easy.

Raspi /

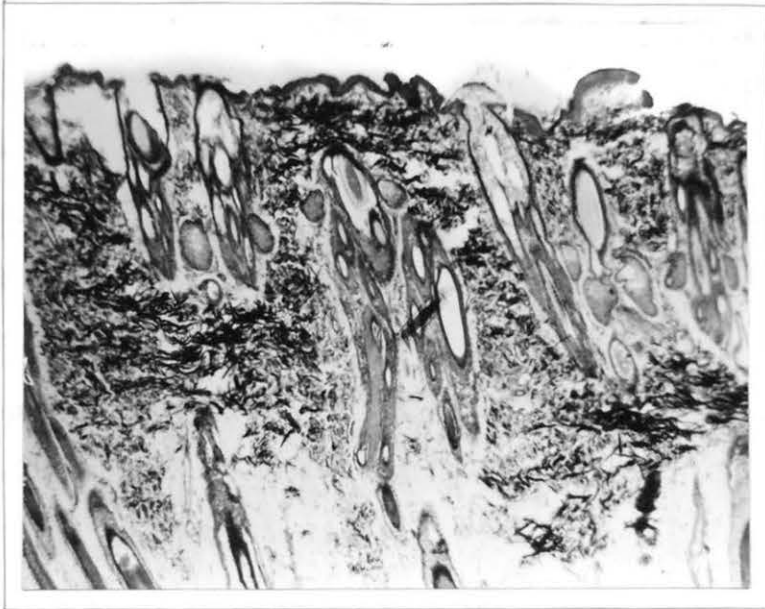


Fig. 2.- Photomicrograph of skin of dog to show
coarse elastic fibres.
(Weigert. x 160.)

Raspi (1927) confused the syndrome with cutis laxa and both Schulmann and Levy-Coblentz (1932) and Taylor (1943) described the "snapping back" of the skin which is not, in my opinion, a feature of the condition. Stuart (1937) found that his patient could pull his skin from the sternum to the mouth which is also a very unusual feature. Sezary et al. (1933) found the elasticity to be two to three times that of the normal.

A number of people have observed that the lax skin was confined to a few areas of the body. Johnson and Falls (1949) found it concentrated in the areas around the bony prominences where the skin is normally fixed and bound. Gordon's (1942) case likewise showed laxity limited to a few areas and Tobias (1939) tabulated the degree of stretch of the affected areas as compared with the normal. Shapiro (1952) noted it to be more pronounced over the metacarpal and phalangeal joints, while the Washington School of Medicine report (1939) noted a marked rugosity of the scalp. In Weber's (1937) case it was most prominent over the elbows and this is the finding in my cases, the skin over the knees also being loose. Weber (1923) described three types of loose skin: (1) hyperelastic, where there is an absolute increase of elastic fibres; (2) loose folds, where there is a lack of elastic fibres; (3) an intermediate type, referred to later by Bielschowsky (1930).

(2) /

(2) Fragility of Skin

(a) General Effects.- All observers who have had true cases of the Ehlers-Danlos syndrome have noted fragility of the skin. This varies from the milder varieties to the extreme degree noted by Macfarlane (1952) in his fatal case. Danlos (1908) considered that scars followed injuries which had been septic especially when the skin was very thin, elastic and vulnerable. Schulmann and Levy-Coblentz (1932) noted fragility of the skin, and in the case of Brown and Stock (1937) 285 stitches had been inserted in the unfortunate victim before his father lost count; comment was also made on this case by Simpson (1937). Bolam (1938) found in his case that a slight twist of the wrist had produced a T-shaped wound which required six stitches for its approximation. In Burrows' (1932) case a small split of the skin had opened the tissue down to the fat, while Kanof (1952) found that venepuncture produced a wound shaped like a star. King-Smith et al. (1932) found that there was no pain with splitting of the skin but this is not the experience of others, although many, including Ronchese (1936, 1943) and Smith (1938), agree with them that sutures easily cut out. Barber (1923) noted, when carrying out a biopsy, friability of the skin without excessive bleeding, and found that the skin specimen had some subcutaneous tissue attached. Poynton and Paterson (1921) described the skin gaping as "in a fish-like manner" and Turner (1949) found that he required adhesive plaster to close the wounds. Barber et al. (1941) considered that the fragility /

fragility decreased with advancing years.

Various observers noted that this skin fragility was associated with an increased sensitivity of the skin. Johnson and Falls (1949) found that rubbing the skin produced pain and van der Valk (1926) noted that all types of skin sensation were increased. Barber (1923) found that a disagreeable sensation was produced by rubbing with a towel and with these observations I am in complete agreement, as will be seen from Cases 1 and 2. It was observed by Weber (1937) that rubbing did not produce blistering or urticaria factitia, but Barber (1923) noted that his case showed an abnormal sensitivity to sunlight and to hot and cold baths. Brain (1936) noted in his case pale brown areas of skin in the lumbar region but decided that they had no direct connection with the Ehlers-Danlos syndrome.

A number of recorded cases should not, I believe, be classified as Ehlers-Danlos syndrome. Among these is one described by Rocher (1932) which, according to Petges (1936), was "the most beautiful", but which Ronchese (1936) asserted was not a true case at all. In this connection Sutton and Sutton (1939) differentiate the syndrome from the condition of dermatolysis.

(b) Papyraceous Scars.— Since everyone is subject at some time to traumata, however minor, these scars can always be found. They have been described as non-adherent, linear, wrinkled, papyraceous, criss-crossed, bulging or ballooning, atrophic /

atrophic or pigmented, not firm like keloids, reducible like herniae, with difficulty of incision and sometimes with fine telangiectases. The Washington School of Medicine report (1939) suggested that the ballooning of the scars should be another criterion for diagnosis. Bolam (1938) and Turner (1949) both noted the atrophic scars, the latter noting that the fat was scanty, while Freeman (1950) found that the subcutaneous tissue was not fully replaced under the scars. Tenderness of scars was also observed by Bolam (1938) while Gilbert et al. (1925) noted bullous lesions without haemorrhage and Meirowsky (1927) showed that scars could be produced by skin bruising without an actual split. Barber et al. (1941) found that the wounds were slow to heal, with which I agree, and they noted the fact that this slowness is not associated with sepsis. I have also observed that the subcutaneous fat "pops out" when the skin is cut and that the wound edges retract and require eversion before suture.

Cohn (1907) found that, on picking up the papyraceous scar tissue, a cord-like feeling was produced and that a similar sensation was noted in the joint capsules. Danlos' (1908) theory was that injury was followed by infiltration and partial or complete resorption resulting in the scars.

(c) Haematomata and Molluscoid Pseudotumours.- These two are really distinct entities but I class them together because on many occasions they have been interconnected. Bolam (1938) suggested the possibility of haematoma formation being /

being the precursor of pseudotumours and both he and Capurro (1926) noted that a rise of temperature accompanied their absorption. Miget's (1933) thesis was well illustrated with pseudotumours. Shapiro (1952) felt that they had a tendency to septic infection, but with this I do not agree. Davies (1938) noted the disappearance with radiotherapy of lesions which he had considered as pseudotumours, but the cure of these must cause doubt to be thrown on the original diagnosis. Cohn (1907) gave an excellent description of these when he said that they sat on the joints like caps, especially over the metacarpal joints. He noted that the skin over them was not distended in the manner of that surrounding them, and that excision was followed by recurrence. Many observers have not been able to demonstrate these lesions at all, and in my cases there are only three examples of molluscoid pseudotumours (Cases 2, 12 and 13).

(d) Spherules. - It is difficult to know under which section these should be included because the exact mechanism of their production is not known. However I have included them in "fragility of skin" because a number of authors have felt that they are the result of injury. The detailed pathogenesis has already been considered under the heading of Pathology and only the clinical manifestations will be mentioned here. Tobias (1934), who described the small lumps as congenital lipomatosis, noted that they were especially common in the buttock region. Their presence had been observed earlier /

earlier by Sir Malcolm Morris (1900), and Shaw and Hopkins (1913) had stated that they were present in the typical case. Langmead's (1923) case of "calcinosis" showed many nodules but there is some doubt as to whether this was a true case of the syndrome or not. He had the chemical composition of the nodules analysed and found that they contained organic material, calcium, magnesium and iodine. Poynton and Paterson (1921) considered them to be another sign of the syndrome, although Ehlers (1901), observing the presence of small nodules in the scapular region and around the elbows which he likened to xanthomata, had not attached any significance to them.

Weber and Aitken (1938b) noted that they were mainly present on the forearm, back of the hands and over the patellar region, while Bolam (1938) observed the presence of calcified nodules. The radiological diagnosis of them, as described by Holt (1946), is detailed later (p.45). Johnson and Falls (1949) suggested that calcium deposits were absent in cases in which the skin lesions were most prominent and considered that their presence in smaller or larger numbers was probably essential to the diagnosis; with this I do not agree. Spherules were not present in any of my cases, all of which were undoubtedly true cases of the syndrome. In Case 1 there had been a small swelling on the right buttock which might have been a spherule but it had disappeared at the time of examination, and X-ray examination of that region did not reveal /

reveal any calcification. In Cases 1 and 2 there were small superficial nodules in the skin.

(e) Blood Vessel Fragility.- This is included in this section on account of the marked interconnection with the skin fragility. Shaw and Hopkins (1913) found that merely holding the arm in their patient produced bruising and Launay (1940) noted that ecchymosis was seen after slight pressure. A black colouration with induration of the dermis after a prick was seen by Danlos (1908), while Tobias (1934), Weber and Aitken (1938b) and Johnson and Falls (1949) all noted ecchymosis, Weber and Aitken finding the Rumpel-Leede test to be positive. Goldsmith (1939) found this test to be negative, although the patient had previously been in hospital on account of purpura. Ringrose et al. (1950) and Turner (1949) likewise found the test to be negative, but Freeman (1950) found it positive at the second attempt. As will be seen from my case reports, I found it positive in one case (Case 2), but this may be explained by an inherited blood vessel fragility from the patient's mother, who was not a case of the syndrome. Two cases (Cases 11 and 16) showed a weak positive result. Excessive bleeding has been noted by Capurro (1926), Sezary et al. (1933), Rambar (1938), Thurmon (1939), Aardenne (1939), Gordon (1942), Pierard and Palmer (1949) and Wallach and Burkhart (1950). All these investigators, as well as Murray and Tyars (1940), found that detailed blood examination including bleeding and clotting times /

times were normal. Brown's (1946) case was most unusual in that the condition was apparently acquired at the age of 53 years and was characterised by this haemorrhagic tendency, hyperelastic skin, a loss of hair and evidence of avitaminosis C. In their case Wallach and Burkhart (1950) found occult blood in the stools as well as a few red blood corpuscles in the urine. They could offer no explanation for this.

Another manifestation of blood vessel instability is to be seen in the number of reports of acrocyanosis. This has been noted by Langmead (1923), Gilbert et al. (1925), Burrows (1932), Martin and Maruri (1932), Cockayne (1933), Dreyfus et al. (1936), Raybaud and Guidoni (1938) and Coe and Silvers (1940). These findings were recorded either with or without the presence of chilblains. In Cockayne's case it was noted that the acrocyanosis was associated with hyperlax joints but with no skin abnormality. Dreyfus' case showed acrocyanosis as well as ecchymosis, the latter being most marked at the time of the menstrual periods.

Thus, with the few exceptions recorded, this clinical evidence of blood vessel fragility was not confirmed by laboratory investigation. In Macfarlane's (1952) case which I have recorded (Case 5), the blood vessels were unable to hold sutures on account of extreme fragility, and this caused the death of the patient. Even in this case there was no gross pathology found in the blood or blood vessels. It can therefore be concluded that this blood vessel fragility is caused /

caused by the same unknown factor which produces the skin fragility.

(3) Hyperlaxity of Joints

This feature is the third of the triad. Although its degree varies, without it no case is complete. Many cases are recorded of lax joints but, unless they are associated with skin fragility and hyperelasticity, they are not cases of the Ehlers-Danlos syndrome.

Many effects of joint laxity have been observed, including recurrent dislocation of the shoulders which was noted by Raybaud and Guidoni (1938). The papers written by both Sullivan (1942) and Benjamin and Weiner (1943) reported shoulder dislocation when a coat was being put on, while Schulmann and Levy-Coblentz (1932) found dislocation of joints and congenital bilateral radio-ulnar synostosis. A voluntary displacement of the radial head was noted by Margarot et al. (1933a) along with extension of the knees which led to a tabetic posture. In their case it was possible to approximate the clavicles to within a few finger-breadths. Burrows' (1932) patient was able to touch the umbilicus with the foot and Lowe's (1939) demonstrated the ability to touch the ear with the back of the opposite arm. The latter also found a congenital bilateral superior radio-ulnar synostosis and noted that there was an effusion into the knee joint after minor injury. Poumeau-Delille and Soulié's (1934) case demonstrated the facility of touching the knees with the face when the legs were /

were in extension.

Both Debre et al. (1937) and Kanof (1952) found congenital dislocation of the hip, while Ehlers (1901) noted dislocation of the patella. The last-named stated that his patient had been late in walking and that there was subluxation of the finger joints back to a right angle, over which there were many haematomata.

Permanent effects in the joints were noted by Pittinos (1941) with a third degree pes planus, and by Brown and Stock (1937) with a tendency to flat feet. Club foot was seen by Hallopeau and Lépinay (1906) and Shapiro (1952) also found a bilateral pes cavus. Rocher (1932) found general hyperlaxity of joints and with this Pierard and Palmer (1949) agreed, noting that there was no impairment of structural efficiency. In the case reported by Martin and Maruri (1932) no articular laxity was noted but this was probably an incomplete case.

Many cases of articular laxity may be missed as cases of the syndrome, by orthopaedic surgeons in particular, and examination of the skin might bring many more cases to light. In my series of cases a remarkably high proportion suffered from pes cavus.

(4) Muscle Weakness

This symptom or sign is not one of the three classical features of the syndrome but it has been noted by so many observers that it must be considered a definite finding.

Ehlers /

Ehlers (1901) observed that his patient was not very strongly built, that his gait was slightly atactic, and that the small muscles of the hypothenar eminences were atrophic. In both cases reported by Schubert (1925) and Smith (1939) the lack of muscle tone had led to a diagnosis of amyotonia congenita being made, and this was also the case in one of my patients (Case 4). Pittinos (1941), who referred to the work of Schwab and Viets (1938) and also to that of Shelton and Taget (1937), investigated this symptom in detail. He found that, in his case, it was associated with a disturbance of creatine metabolism. His findings are reported in full in his paper and of especial note is the fact that muscle biopsy showed no abnormality, and that there was no response to the administration of prostigmine. It seems probable that the creatine metabolic disturbance was in association with, rather than a part of, the syndrome.

Kalz (1935) and Brown and Stock (1937) noted that the muscles were less strong than usual, and Shapiro's (1952) case showed general muscular weakness including such signs as winging of the scapula and deformity of gait. In this case all laboratory investigations were negative and treatment with glycine and ephedrine was useless. I agree with Shapiro that the process which affects the skin and in the same way the joints, sometimes affects the musculature also. Certainly the muscles lack the normal tone and feel flabby to the touch.

(5) Concomitant Conditions

In the investigation of any rare syndrome it is natural that all the features in each case should be noted and suggestions made that these features might be part of the syndrome. This has happened in the case of the Ehlers-Danlos syndrome, and as a result many signs have been accredited to it which in my opinion are purely coincidental but it must be borne in mind that, as stated in Warner's law, congenital abnormalities often occur in multiple. I have therefore tried to distinguish these co-existing features from the main features. Of the following, I could demonstrate only two in my series of cases, namely the obstetric and, to a lesser degree, the psychiatric features.

(a) Fractures.- Johnson and Falls (1949) stated that occasionally osteoporosis occurred with resultant fractures. General instability of joints was also considered to be a cause

(b) Facial Characteristics.- Some authors affirm that there are certain facial characteristics which can help to distinguish the syndrome. Smith (1939) and Turner (1949) both noted widely spaced eyes, a wide bridge of the nose, epicanthic folds and the lack of orbital fat. Shaw and Hopkins (1913) as well as Benjamin and Weiner (1943) noted the epicanthic folds but not the other features.

(c) Abnormalities of Teeth.- Margarot et al. (1933b) found notched incisors and absent upper incisors, while both Hallopeau and Lépinay (1906) and Gilbert et al. (1925) noted supernumerary teeth.

(d) /

(d) Abnormality of Cranial Ossification.- Debre et al. (1937) observed delayed cranial ossification in infants, and Shaw and Hopkins (1913) noted that it took place in their case at the age of five years. Cathala (1937) found microdontia.

(e) Mental Retardation.- Cathala's (1937) case showed this together with microdontia, and Ronchese (1936) commented on poor mental development as did Burrows and Turnbull (1938). Launay (1940) noted intellectual retardation in association with the absence of the lobes of both ears.

(f) Heart Disease.- Cockayne (1933) reported a case in association with mitral stenosis and Freeman (1950) one with an intra-atrial septal defect, a nasal defect and a shortened fifth proximal phalanx, all of which were presumably due to a multiple hereditary defect. Wallach and Burkhart (1950) reported a case associated with the tetralogy of Fallot.

(g) Vascular Abnormalities.- Weber was cited by Lowe (1939) as having seen a case of the syndrome in association with a trigeminal vascular naevus which he considered was also a manifestation of a dysplasia. Ronchese (1943) likewise noted the presence of naevi, and similar features were found by Williams (1892), Martin and Maruri (1932), Tobias (1934), Burrows and Turnbull (1938), Ormsby and Tobin (1938), Smith (1939) and Thurmon (1939). This last author commented on the fact that there was no retinal change, which distinguished it from pseudoxanthoma elasticum.

(h) /

(h) Neurological Abnormalities.- Sullivan (1942) described a case associated with a transient paralysis of the vocal cord, this case also showing a bladder diverticulum. Shapiro (1952), as already reported, showed a case with neurological manifestations but that was essentially, in my opinion, a case of muscle weakness. Joereens (1909) demonstrated a case in which the signs of syringomyelia were present.

(i) Tuberculosis.- In the cases quoted by Sezary et al. (1933) and Capurro (1926) there was the association of pulmonary tuberculosis with the syndrome, but Ronchese (1936) considered that the two were not connected.

(j) Relationship with other Similar Diseases.- Weber (1936) considered the possibility of a relationship with Pick-Herxheimer disease (acrodermatitis) and noted a superficial resemblance to idiopathic striae atrophicae and the so-called striae patellares. In the latter condition, which is intimately connected with idiopathic striae atrophicae, the striae appear without wounding. He also thought that the syndrome was analogous to, but not identical with, a dystrophic type of epidermolysis bullosa because one of his cases showed bullous formation in the skin, lipomatosis and silky hair. Ronchese (1936) similarly noted these features and the malformation of skin appendages. Bielschowsky (1930) mentioned the possible relationship between the syndrome and von Recklinghausen's disease, and Keining (1932) considered the association with other congenital lesions in general.

(k) /

(k) Breast Size.- Johnson and Falls (1949) noted in one of their two cases that the right breast was smaller than the left. Again this is probably an associated congenital lesion.

(l) Obstetric Associations

(i) Toxaemia and Hypertension of Pregnancy.- The subject of pre-eclamptic toxaemia is a vast one and the aetiology is as yet unknown. In the report of my cases it will be seen that the mothers of two of them (Cases 2 and 4) suffered from this condition in the third trimester. It is, of course, evident that this might well have taken place anyway, but the mother of Case 2 did not have the same degree of toxaemia when her second child was expected and this child did not suffer from the syndrome.

(ii) Prematurity.- This aspect has been discussed in the section on Aetiology (p. 4) but it may be considered here also. Again my own experience shows that premature births appear likely to take place in the syndrome. Case 2 was born prematurely at 35 weeks but her younger sister was born at full term and did not show any sign of the disease. In all I have recorded five patients who were born prematurely, and this subject is discussed more fully in the Conclusions (p. 111).

(m) Diverticula of Alimentary Tract.- A case has recently been reported by Brombart et al. (1952) which showed the syndrome in association with hiatus hernia, diverticula of /

of stomach and duodenum, colonic diverticulitis and asideropenic anaemia.

(n) Groenblad-Strandberg Syndrome. - This has recently been described in association with the Ehlers-Danlos syndrome by Pelbois and Rollier (1952).

(o) Eye Conditions. - It has been suggested by Thomas et al. (1952) that the Ehlers-Danlos syndrome may be an aetiological factor in the syndrome of spontaneous dislocation of the crystalline lens. Durham (1953) reported a case with blue sclera, microcornea and glaucoma in association with the syndrome.

(p) Psychiatric Effect. - I consider this to be an indirect effect of the syndrome but not due directly to any of the three classical features. In the report of my cases I attempt to suggest that there are certain psychological effects which occur as a result of a fragile skin, but Pierard and Palmer (1949) reported a case in which a more grave psychological effect was seen. They discussed the case of a patient who was affected by the syndrome and who, on account of the fear which she had of her bleeding tendency, developed a tic on the evening on which she became engaged to be married. She had always known that she was so affected and the prospect of marriage, which she presumed would be followed by pregnancy, suddenly led to a fear of haemorrhage at childbirth. The tic persisted until the merciful intervention /

intervention of acute appendicitis, the operative cure of which relieved her anxiety and convinced her that haemorrhage was not inevitable. This was an unusual effect but shows the possible ramifications of the condition.

Cases of the syndrome with the usual clinical findings have also been recorded by the following authors: Vaglio (1923); Berger (1933); Erbach (1933); Konrad (1933); Balina and Sicardi (1935); Meincke (1936); Comby (1937); Setti (1937); Agostini (1938); Viecelli (1938); Cottini (1940); Fritchley and Greenbaum (1940); Benavides (1952); Delanne (1952); Delanne et al. (1952); Husebye (1952); Laplane et al. (1952); Schaper (1952); Tenconi (1952); Touraine (1952), and Walker and Stewart (1952) (a possible case).

Radiology

A few references have been made to the radiological findings in the syndrome, notably by Tobias (1934) who stated that it did not throw any light on the diagnosis, and by Dreyfus et al. (1936) who noted that the bones of the hand showed small lymph spaces. Bolam (1938) found that some bones showed circular shadows which suggested an increased degree of calcification, and Debre et al. (1937) observed transverse lines on the long bones and delayed ossification in /

in the cranium. In the earlier days, Langmead (1923) had noted calcified nodules. Other authors have noted osteoporosis, delayed epiphyseal development, calcified spherules and abnormal arthritic movements.

The main contribution to the radiology of the syndrome was made by Holt in 1946 who made a particular study of the calcification of the subcutaneous nodules (or spherules as they were first called by Weber). In his cases Holt noted that the main collections of spherules were in the shoulder regions and the lower legs, and found none in the region of the knees and ankles where the skin lesions were worst. A few only were noted in the region of the trochanters, the outer aspect of the thighs and the forearms. Radiologically the spherules showed as a calcified ring with a relatively translucent centre, ovoid, discrete, circular and 1-8 mm. in diameter, and localised to the dermis and subcutaneous tissue.

Holt also noted that the subcutaneous fascial layer was unusually thick and that the muscular shadows showed a reduced translucency. Pes cavus was present in one of his cases and also an osteochondrosarcoma.

The differential diagnosis of spherules is principally from phleboliths, and the diagnostic points are: (a) the clinical differences, and (b) the radiological differences. Phleboliths are deeper, smaller in size, irregular in outline, and have multiple concentric strata of calcium which lead to a crystal-like appearance.

The /

The other condition which may simulate the spherules radiologically is that of calcified parasites, but in this case the clinical condition should differentiate.

Thus the main radiological contribution so far made to the syndrome is the demonstration of calcified spherules. These are not always present, but when they are they are a useful aid if there is any doubt of the clinical diagnosis. In my own cases no radiological abnormality of the bones or soft tissues was noted, but one case (Case 1) demonstrated the large range of joint movement (Fig. 8).

Laboratory Investigations

During the history of the Ehlers-Danlos syndrome almost all possible laboratory investigations have been carried out. With few exceptions these have been entirely negative. Many authors have found negative results in the following investigations:-

- (1) Urine analysis.
- (2) Blood examination which includes the peripheral blood picture.
- (3) Blood clotting. All methods of measuring the bleeding and clotting times have been used, and the prothrombin time, blood fibrinogen and clot retraction times have been estimated.
- (4) Serological tests.
- (5) Blood haemolysis.
- (6) Blood sugar levels.
- (7) Blood cholesterol.
- (8) Blood chlorides.
- (9) Blood urea nitrogen, and urea concentration test.
- (10) /

- (10) Blood sodium.
- (11) Blood potassium.
- (12) Blood inorganic phosphates.
- (13) Serum calcium.
- (14) Serum acid phosphates.
- (15) Van den Bergh reaction.
- (16) Icteric index.
- (17) Total blood proteins.
- (18) Total blood lipids.
- (19) Basal metabolic rate.
- (20) Sternal puncture examination of the bone marrow.
- (21) Renal function tests.
- (22) Electrocardiographic examination.
- (23) Faecal fats.
- (24) Chemical examination of the skin for solids, lipids and cholesterol.
- (25) Sodium and potassium excretion in the 24 hour urine specimen.
- (26) Fractional test meal.

A divergence from normal has been noted in the following tests:-

(1) Capillary Fragility Test (Rumpel-Leede Test). - A positive result in this test was noted by Weber and Aitken (1938a) and three of my cases (Cases 2, 11 and 16) show a similar finding. As will be explained later, it is doubtful if in Case 2 this is due to the Ehlers-Danlos syndrome.

(2) Steroid Excretion in the Urine. - As already discussed in the section on Aetiology (p. 9), Kanof (1952) found that the figure for 17-ketosteroids excretion in the urine was raised, and also noted that the excretion of oxy-steroids was increased. The results in my cases do not confirm Kanof's findings.

(3) Circulating Eosinophils. - Kanof found these to be decreased, showing a figure of 78 per c.mm. The figure for circulating eosinophils in my Case 1 was 75 per c.mm. As this /

this is a somewhat variable factor, little significance can be attached to it.

(4) Uric Acid/Creatinine Ratio.- As already noted in the section on Clinical Features (p. 38), Pittinos (1941) found in his case that this ratio was increased. After excluding all other causes of creatinuria, he considered his finding of 400 mg. in 24 hours was abnormal even for a child, although he quoted Wang as stating that the creatinine excretion varied from day to day. Smith (1939) had found the ratio to be normal.

(5) Ascorbic Acid Excretion.- Kanof (1952) found the excretion of ascorbic acid in the urine to be lowered, as did Barber et al. (1941) in one of their cases. However, this has not been confirmed by others and a dietary deficiency may have been the cause. Pittinos (1941) did not find any evidence of vitamin C deficiency.

Differential Diagnosis

Once a true case of the Ehlers-Danlos syndrome has been seen, future diagnosis of the condition should not present any difficulty because the triad of features is so outstanding. However, it may be difficult to differentiate a mild case from diseases of the blood, skin, joints and muscles.

(a) /

(a) Blood Diseases.- Confusion arises here when bleeding and bruising are prominent symptoms and a few cases have been mistaken for purpura in the first instance. Differentiation is made by the scars left by injuries to the fragile skin in the syndrome. Avitaminosis C, where bleeding from the gums is a common symptom, is another possible cause of diagnostic difficulty. In this case it may be necessary to carry out the investigation of the blood ascorbic acid level, but the dietary history will usually be sufficient for diagnosis. Apart from these aids, nearly all blood conditions can be ruled out by the finding of a normal blood picture in the Ehlers-Danlos syndrome. As reported in one of my cases (Case 2), the platelet count may be low but this is an unusual finding.

(b) Skin Diseases.- The skin scarring has led in the past to many attempts to correlate the condition with other skin conditions which produce the same type of atrophic lesions, such as acrodermatitis, idiopathic striae atrophicae and striae patellares. The difference here is that these diseases do not show the other features of the triad and so the differential diagnosis should be made on clinical grounds alone.

Gordon's (1942) case was first diagnosed as dermatitis artefacta on account of the bizarre nature of the wounds, but the presence of spontaneous splits of the skin settled the diagnosis. The papyraceous scars may be confused with haemangiomas and excision, clearly the wrong treatment, may be /

be advised. Differentiation should be made by the multiplicity of scars in the syndrome.

The spherules, when they are present as the main lesion, may cause some difficulty in diagnosis from other "lumps". Their multiplicity will help to distinguish them, also the fact that they may be calcified and consequently may show on radiological examination, and finally their association with the three main features of the syndrome.

(c) Joint Diseases.- The laxity of joints frequently leads to a diagnosis of simple pes cavus in the case of the feet, or similar diagnoses when other joints are affected. If an underlying cause is sought, the Ehlers-Danlos syndrome may be demonstrable.

(d) Muscle Diseases.- As has been demonstrated in the past and as happened in one of my cases (Case 4), the original diagnosis was that of amyotonia congenita in view of the soft muscles and the lateness in walking. This is a probable diagnosis in a young child, before skin injury due to the Ehlers-Danlos syndrome has taken place. It is important to distinguish the two conditions because the prognosis is poor in amyotonia congenita.

Genetics

A number of observers have noted that this syndrome sometimes appears in members of the same family. Wigley (1938) showed a family history in which a grandfather, father, two brothers and one of three sisters were affected. Brown (1946) listed 19 cases of which he detailed two in four generations, and Ormsby and Tobin (1938) showed three generations to be affected and described one case in full. Stuart (1937) described a mother, son and daughter all of whom were victims of the disease, whereas Coe and Silvers (1940) found only one case in three generations and Brown and Stock (1937) did not find any evidence of a family history.

Murray and Tyars (1940) reported five cases in three generations and observed that there was a family history of at least one feature of the condition. Both Weber and Aitken (1938b) and Ronchese (1936) considered the possibility of consanguinity, and Turner (1949) noted the frequent family history and the equality of sex distribution. Others who noted the hereditary factor were Kopp (1888), Wiener (1924) and Cockayne (1933), and the Standard Classified Nomenclature of Diseases (1935) describes the condition as one "due to prenatal influence".

Gilbert et al. (1925) observed that in members of an affected family there were some who were affected in only a very minor degree - the so-called forme fruste. They together with Stuart (1937) and Goldsmith (1939) suggested from the pedigrees of their cases that there was transmission of /



of the disease by normal persons and that lack of penetration of the gene could occur, leading to a state of incomplete dominance.

Johnson and Falls (1949) discussed the genetics in detail. The pedigree which they demonstrated suggested that transmission of the syndrome takes place by dominant inheritance, but there is a higher ratio of affected individuals than the expected figure of 1:1 of affected to normal siblings. They suggested that a normal parent may produce an affected offspring which shows an incomplete dominance, but the parent may show the condition in a mild form (forme fruste). They considered that the affected person may represent an autosomal recessive form of the gene if there is consanguinity, and they state that diseases inherited are rarely homozygous in humans. They therefore surmised that a person demonstrating the homozygous state may simulate the heterozygous condition. This led them to the possibility that a homozygous state in their two girl patients who were sisters, and whose parents were cousins, may have given rise to the sarcomatous degeneration which took place in one of them. There was a high incidence of miscarriage in this marriage and they felt that this may have been the result of a lethal or semi-lethal dose of the gene as a result of a double dose from the parents. They thought that the condition was more prevalent in men.

Finally they concluded that the method of transmission was by one of the following means:-

(1) /

(1) Person may represent an autosomal recessive form of the disease, that is, he receives an abnormal gene from both parents.

(2) Person may represent the expression of a sex-linked gene transmitted by female carriers. Thus it could be present in many generations of females before appearance in the male.

(3) Affected form may be the expression of a mutation in the germ plasm of one of the two parents and it will be necessary to study this person's offspring before the type of inheritance can be ascertained. It seems that dominance is rarely encountered in the homozygous state.

Johnson and Falls have summarised the genetic findings of other authors in a pedigree table, and their conclusions leave no doubt that the disease is hereditary. In my own cases it is equally obvious that this is true because the first four are members of the same family. The sixth case is apparently an isolated one, but the mother is probably an example of what has already been referred to as the forme fruste. The seventh patient was one who had a son who clearly suffered from the same condition. Another family (Cases 11-15), the genetic details of which I report, shows 17 cases of the syndrome (9 males and 8 females) among 46 people in five generations. The frequency with which this syndrome presents itself in afflicted families makes it quite clear that it must be transmitted by a dominant gene and presumably there is a defect in the germ plasm. To influence the /

the state of the germ plasm is one of the so far impossible tasks in medicine and therefore the possibility of finding a cure seems remote, although this must be the goal of all research into the subject.

Prognosis

Before the diagnosis is established the patient will already be aware of his condition, but may want to know what further complications may arise. This is especially important when the patient is a child. The answer is not always easy to give but there are certain rules which may be given for general guidance. The degree of skin fragility and of joint laxity are the main yardsticks by which the prognosis should be measured, because the hyperelasticity of the skin is of little importance.

Even if the joint laxity is gross it will almost certainly be possible to rehabilitate the patient with physiotherapy and to give him fairly stable joints so that, with care, he will be able to live a reasonably normal life.

More important in estimating the disability of the patient is the degree of skin and blood vessel fragility. The latter is much more difficult to estimate but, roughly speaking, it corresponds to that of the skin. A very fragile skin will probably lead to a number of severe injuries with possible complications of bleeding and sepsis, consequently giving /

giving a poorer prognosis. Advice will have to be given to a child's parents about the advisability of school games and even about the type of school. It is my conviction that reasonable care is compatible with normal life. The fragility of the blood vessels is of more grave import, as Macfarlane's case showed (Case 5).

It will be appreciated that it is not possible to give a standardised prognosis, and that each case will have to be considered on its merits on the above lines.

Treatment

(1) General Management

In the Ehlers-Danlos syndrome the first twenty years of life are the most difficult to manage, and after this the individual concerned can usually lead a normal life. However it must be realised that the condition is, at least in the present state of medical knowledge, life-long, and that the patient's life must be regulated to suit his limitations. According to Ronchese (1936, 1943) the possessor of a fragile skin is a handicapped person, but I consider that in minor cases no special care is needed. In the moderate and more severe cases a definite curtailment of activities should be carried out, and this is especially applicable to a child in its school years. It will be found that team games will usually have to be omitted, particularly the rougher ones such /

such as rugby football. This inability to take part in the usual games, or at best to do so somewhat indifferently, tends to produce a sense of inferiority in the child and it is desirable that some compensation be found, for example in playing games such as golf or tennis or in swimming, in none of which is there any serious chance of bodily injury. It is better to prohibit certain rougher activities absolutely than to leave it to the individual to try to take part and possibly to fail.

Unfortunately the child with a fragile skin quite soon realises that he or she is different from others and this, in my experience, produces the attitude of "I must be careful". The parents also naturally tend to adopt the same attitude and they find it difficult to strike a balance between too much caution and their knowledge that most children must learn by their own experience. I have found it true that even those in daily contact with cases of the Ehlers-Danlos syndrome cannot fully realise the physical and psychological difficulties under which these children labour.

Smith (1938) has suggested that increasing the weight will assist in the management of the condition by reducing the effects of injury, and this may be so, but to increase a child's weight is not easy and in any case not always desirable. In an adult fewer injuries are sustained and therefore the need to increase the weight is less.

It has been recommended by Murray and Tyars (1940) that such /

such people should not be allowed to do national service on account of the serious results which might result from wounds sustained in the course of military duty. In my view, this again depends on the degree of the condition and each case has to be judged accordingly. This syndrome, on account of its rarity, has not to my knowledge been considered by the companies which promote life assurance, but it might be thought to be an increased risk in the more severe cases. This is a matter which would have to be decided by both the life assurance companies and the national authorities, because acceptance by one is not morally compatible with refusal by the other.

(2) Protection

It has been suggested by a number of authors that the only available therapy is that of protection from injury by the use of such means as shin guards, high boots and ankle supports. These have a useful place in severe cases, and in one of mine (Case 8) padded elastic stockings have been fitted. Turner (1949) suggested that artificial hardening of the epidermis with spirituous applications should be undertaken, but this idea has not met with success.

(3) Treatment of the Haematomata

Ormsby and Tobin (1938) advocated that pressure should be applied to these and with this I agree. I have found that the best means of doing so is by a pad of sorbo rubber held /

held under pressure by adhesive plaster; this aids rapid resolution by preventing blood from distending the skin.

(4) Treatment of the Wounds

This constitutes the major difficulty in dealing with the condition. As previously stated, the wounds gape and the edges become inverted making it necessary to evert the edges before suture can be attempted. Many observers have noted that sutures tend to cut out of these wounds, and have consequently drawn the edges together solely with adhesive plaster. However, many of the minor cases will hold sutures and in my experience each wound has to be treated according to its type and one method cannot cover every case. In wounds acquired in situations where the skin is normally abundant, for example the skin around the eyelids, the best result is obtained by simply holding the edges together with plaster, whereas a wound in an area where the skin is more taut is better treated by drawing the edges together with some form of suture and reinforcing them with plaster.

In the cases where sutures will hold, it is my opinion that the choice of suture material is important and I have personally tried most of them. My findings of their relative merits are as follows:-

(a) Silkworm Gut.- The thinner varieties are usually quite effective, but the thicker should be avoided because they tend to leave definite stitch marks which increase the ugliness of the scar.

(b) /

(b) Catgut. - At first sight this would appear to be a most suitable material because it does not require removal. However, if it dissolves too quickly the wound will reopen, while if the process is too slow the wound will again show an ugly appearance. Thus it cannot be recommended for general use, but after some experience it may be of use in certain instances.

(c) Nylon. - Fine nylon is made up in vials for use in eye surgery and this material is, in my opinion, the most satisfactory for the closure of wounds in the Ehlers-Danlos syndrome. It gives adequate approximation of the wound edges and leaves the minimum of scarring.

(d) Horse Hair. - Fine horse hair gives almost the same good results as fine nylon, whereas the coarser variety suffers from the defects of silkworm gut.

(3) Surgical Clips. - In two of my cases (Cases 6 and 8) the best results were obtained by wound closure with surgical clips, but this did not apply to the others and the general opinion is against this form of treatment.

The main aim in the closure of these wounds is to get a good cosmetic result but, whatever method is used, at present no means exist which can prevent the development of thin papyraceous scars and at best one can hope to minimise them.

(5) Treatment of the Joint Conditions

As already stated, changes in the joints, mainly in the foot, are usually present. As a rule these consist of a degree /

degree of pes cavus but pes planus has also been noted. Exercises to develop the weak muscles should be instituted and properly fitting footwear obtained. In extreme cases it may be necessary to resort to orthopaedic surgery, but that should be avoided if possible.

(6) Empirical Treatment

Little can be gained from a discussion of specific treatment until such time as a cause for the condition is elicited, but there are a few cases in which the capillary fragility test shows a positive result. This occurred in three of my cases (Cases 2, 11 and 16), and in one of them (Case 2) use was made of Tablet Rutin (Allen & Hanburys Ltd.) in the daily dosage of 60 mg. This resulted in a reduction of the petechial count from 50 to 12 in three months (see also p. 72). This substance is a derivative of hesperidin and much doubt has been thrown on its efficiency, but clearly it was effective in this case.

It will be seen that therapy in this condition is still unsatisfactory. The ill-effects can be reduced by the careful treatment of wounds, by physiotherapy if required, and by adequate general management of the patient.

PART II

REPORT OF CASES

Case 1

This patient, Dr M., is a man of 32 and the history will be given in considerable detail for reasons already mentioned in the Introduction.

History.- Birth was normal and at full time, the birth weight being $8\frac{1}{2}$ lb. He suffered the usual childhood illnesses of measles, whooping cough and diphtheria and was what is colloquially called a "chesty child", having many attacks of upper respiratory infections and bronchitis. At the age of 6 years the tonsils and adenoids were removed and a year or two later an appendicectomy was carried out. His childhood was punctuated by many accidents, most of which involved breaking of the skin and the insertion of many stitches. The wounds always tended to heal with obvious scarring, especially the appendicectomy wound. At the age of 17 years submucous resection of the nasal septum was performed and this was associated with considerable diffuse haemorrhage in the loose tissues of the face after operation. After a minor injury he dislocated his first right carpo-metacarpal joint.

As a result of the many accidents thin papery scars developed on both knees and over the right medial malleolus, and these gradually became pigmented. It was known that bruising took place very easily and that the skin was soft and /

and velvety to the touch and stretchable to an abnormal degree, especially about the hands and elbows. The feet were difficult to fit with shoes but this was not considered abnormal as it was a "family failing". Bleeding took place easily from the gums (for which dentists had prescribed many remedies without effect) and in his late teens he had what appeared to be spontaneous haemorrhages from the scars on the knees. However, it seems now that these were probably the result of minor traumata of which he was not aware. At one time the knee condition was diagnosed as a haemangioma, and the feet were regarded by an orthopaedic surgeon as a condition of pes cavus.

Examination.- He is now a healthy man, height 6 ft., weight 13 st., and he suffers no real inconvenience from his condition. There is no discoverable abnormality on routine clinical examination of the heart, chest, abdomen, urinary system, or nervous system.

The joints show marked extensibility, especially the small joints of the hands (Fig. 3). There is bilateral pes cavus (Fig. 4) and all the joints show hyperlaxity, but not amounting to the degree seen, for example, in genu recurvatum. The musculature is not of robust character and lacks the normal tone, but is sufficient for normal requirements.

The skin is soft to the touch and hyperelastic, showing a remarkable degree of stretchability, especially over the backs of the hands and the elbows (Fig. 5). In view of the patient's /



Fig. 3.- Case 1. To show the degree of joint hyperlaxity.

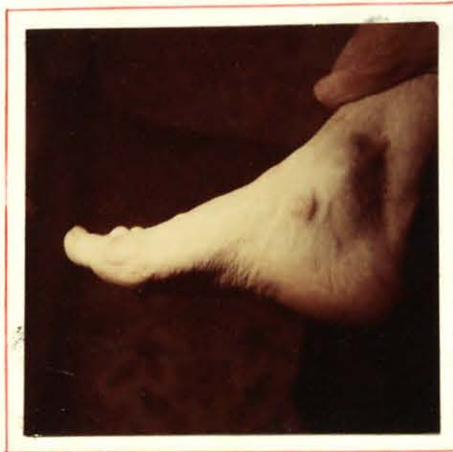

Fig. 4.- Case 1. To show the "pes cavus" type of foot.

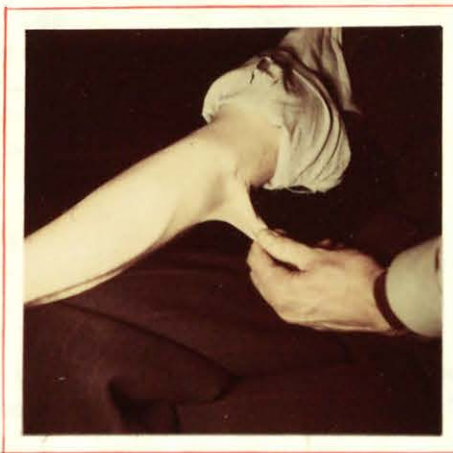

Fig. 5.- Case 1. To show the degree of hyperextensibility of the skin.

patient's age, there is an abnormal amount of wrinkling over the "knuckle" joints of the hands. The knees show thin papyraceous scars in front of each patella, the left one demonstrating the larger scar (Fig. 6). The skin over the right medial malleolus shows similar lesions (Fig. 7), and there are many other scars scattered about the limbs and forehead. These scars are very thin, soft to the touch and break easily. There are innumerable very small nodules over the skin of the trunk and on the head.

As already stated, the patient was aware of most of these signs and thought little of them, until the birth of his elder daughter (Case 2), who showed so many similar signs that a serious attempt at diagnosis was made. It was then that the clinical diagnosis was established and blood examination was carried out with the following results:-

Haemoglobin	- 103%
R.B.C.	- 5.03 M. per c.mm.
C.I.	- 1.02
W.B.C.	- 7,800 per c.mm.
Differential white count:	
Polymorphs	- 50.5%
Lymphocytes	- 47.0%
Monocytes	- 2.0%
Eosinophils	- 0.5%
Eosinophil count	- 75 per c.mm.
Reticulocytes	- less than 1%
Platelets	- 143,000 per c.mm.
Bleeding time (saline)	- 2 min. 11 sec.
Bleeding time (Ivy)	- 3 min. 22 sec.
Clotting time	- 7 min. 30 sec.

Tourniquet test (capillary resistance or Rumpel-Leede test) was negative. (Less than 9 petechiae appeared.)

Radiographs /

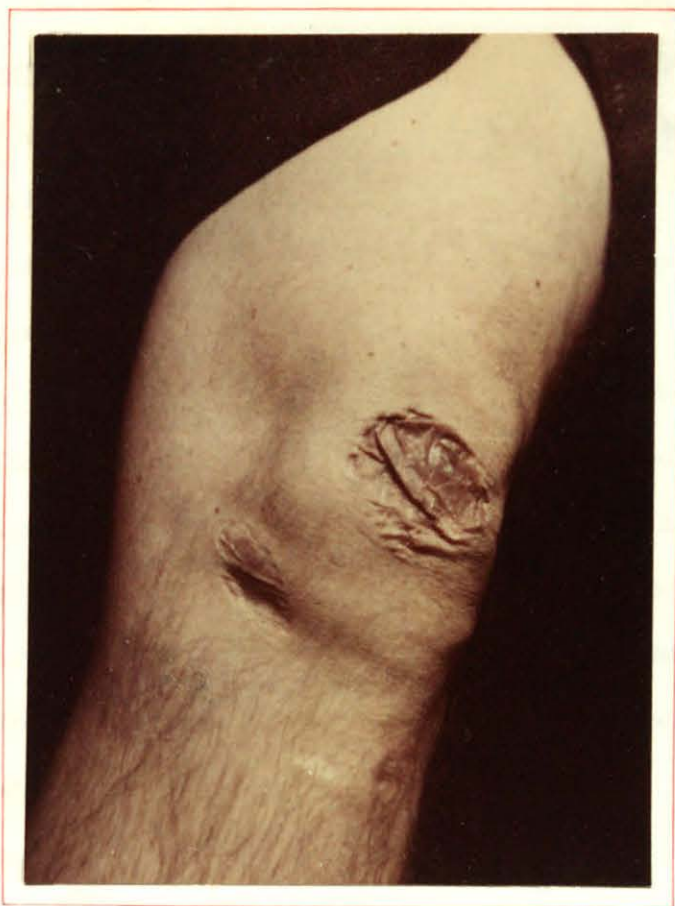

Fig. 6.- Case 1. To show the papyraceous scarring on the knee.

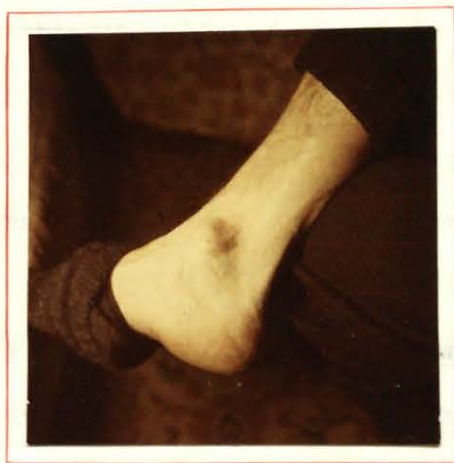

Fig. 7.- Case 1. To show the chronic contusional skin damage on the right medial malleolus.

Radiographs. - These were taken of the shoulder regions, knees, the right buttock (as a small spherule had been felt in this region) and the right hand. No calcified spherules were seen anywhere, but the picture of the right hand showed extreme hyperextension of the joints (Fig. 8).

Biopsy of Skin. - Skin was taken from the palmar aspect of the left forearm, and sections were stained routinely with haematoxylin and eosin, and specifically for elastic (Weigert's iron haematoxylin), for collagen (van Gieson and Masson's trichrome stains) and for reticulum (Gordon and Sweet); Robb-Smith's modification of Foot's method and orcein stains were also used.

A piece of skin from the thigh of a 40-year old subject was used as a control (Fig. 9).

Section Report. - (a) Weigert's elastic stain (Fig. 10): There is an increase in the number and size of the elastic fibres, these fibres forming a rather coarse network of branching and interlacing strands in the dermis, chiefly in the deeper dermis. The fibres are approximately twice the normal thickness, and many show clear-cut square ends suggesting that they had been cut transversely with the scalpel at the biopsy and had then retracted. (b) van Gieson's stain (Fig. 11) and (c) Masson's trichrome stain: There is degeneration and hyalinisation of much of the dermic collagen, which stains red by the Masson method like the collagen of young scars.

Biopsy /

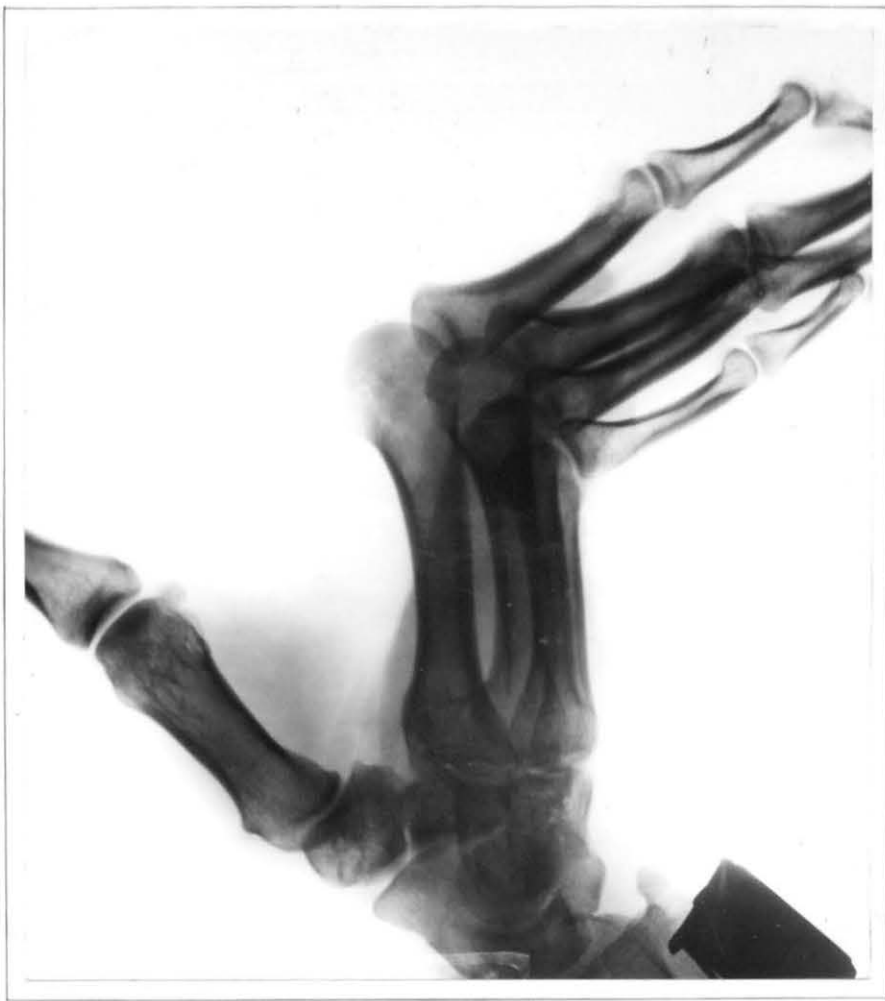

Fig. 8.- Case 1. Radiograph to show the hyperlaxity of the small joints of the hands.

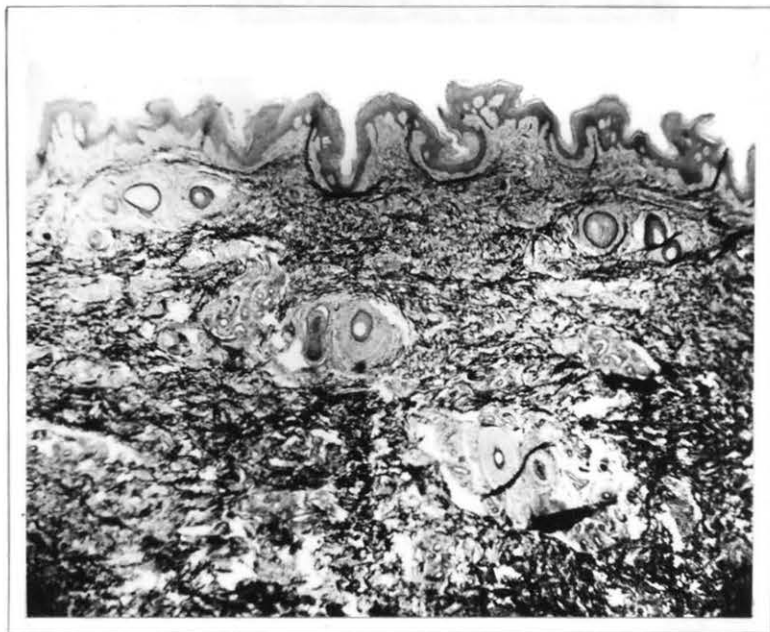


Fig. 9.- Photomicrograph of normal skin to show normal amount of elastic tissue. (Weigert. x 160)

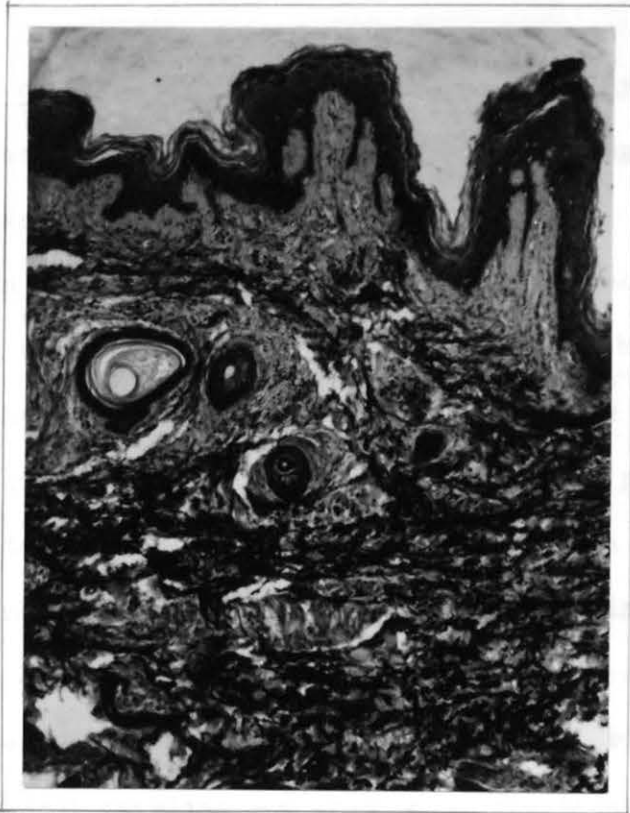


Fig. 10.- Case 1. Photomicrograph of the skin to demonstrate the elastica. (Weigert's elastic stain. x 160.)

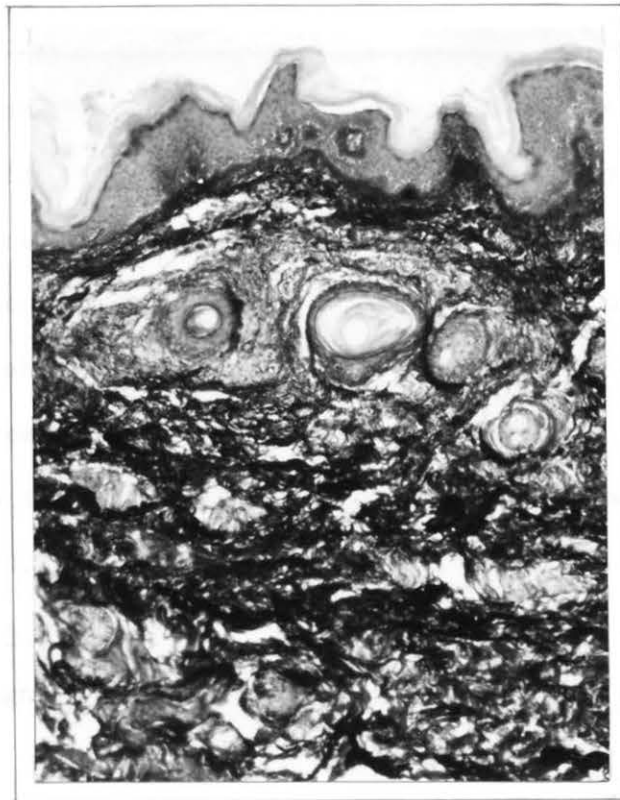


Fig. 11.- Case 1. Photomicrograph of the skin, stained to show the collagen. (van Gieson. x 160)

Biopsy of Scar.- The scar left by the biopsy wound (Fig. 12) was excised and the histological findings (Figs. 13 and 14) are as follows.

Section Report.- There is some doubly refractile material in the section, usually in giant cells, but this is eliminated by micro-incineration and is therefore not siliceous but probably calcareous. The central part of the scar consists of thick bundles of collagen with a surrounding zone of fibrous tissue. There are no elastic fibres in the scar. The overlying epidermis is normal in appearance. The scar presents similar features to a keloid, with coarse collagenous proliferation and absence of elastica (and of elastic staining material which is probably not elastica) from the area of scarring, although it is present in the patient's normal proportions around the margins of the biopsy.

Thus the first biopsy has given rise to a keloid scar, the reason for this being obscure. However, why any scar in a normal person should sometimes give rise to a keloid is equally obscure, and there is apparently no reason why the phenomenon should not occur in the Ehlers-Danlos syndrome. It is interesting to note that in Case 2, one of the scars on the knee is also showing the clinical appearance of a small keloid.

Section of Nodule (Fig. 15).- A nodule was removed from near the right shoulder and found to be a simple squamous papilloma.

Hormonal /

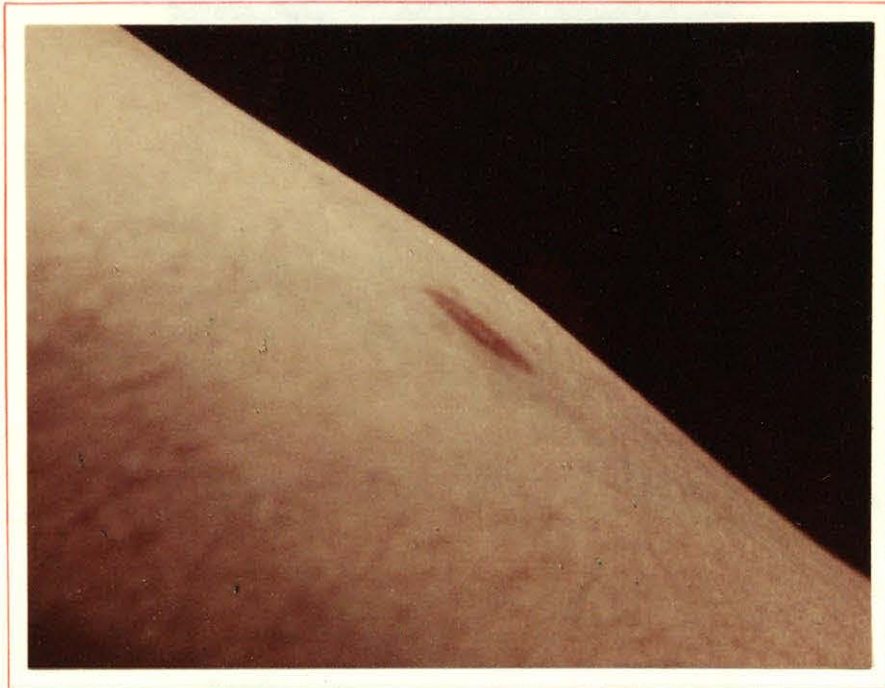

Fig. 12.- Case 1. To show the biopsy scar
after six weeks. This
demonstrates the slow healing
which takes place.



Fig. 13.- Case 1. Photomicrograph of the scar to show the collagen. (van Gieson. x 160.)

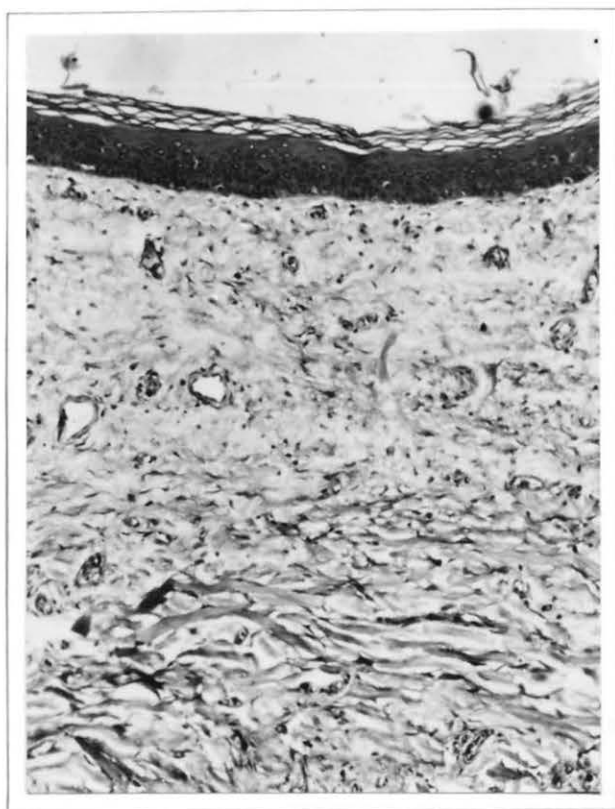


Fig. 14.- Case 1. Photomicrograph of the scar, stained by Weigert's elastic stain for elastica, showing the absence of elastica. (x 160.)

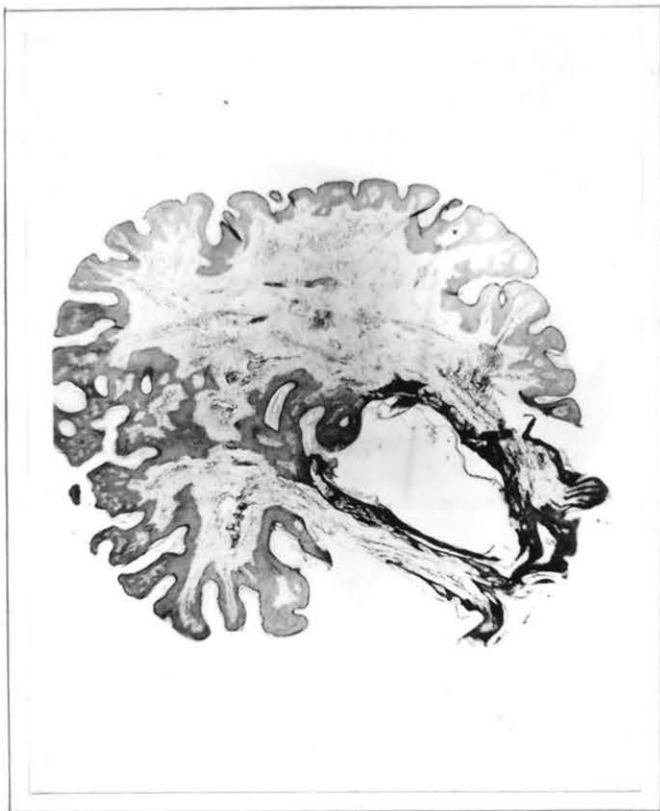


Fig. 15.- Case 1. Photomicrograph of
squamous papilloma excised
from skin of shoulder.
(H. & E. x 160.)

Hormonal Investigations.- Two twenty-four specimens of urine were submitted for examination of the 17-ketosteroid excretion, and in the second the opportunity was taken to carry out the new test for the excretion of the corticosterone-like substances as outlined by Tompsett (1953a). The results were as follows:-

1st specimen

Total volume	- 1,298 ml./day
17-ketosteroids	- 17.0 mg./day (normal)

2nd specimen

Total volume	- 1,410 ml./day
17-ketosteroids	- 10.2 mg./day (normal)
Corticosterone-like substances	- 10.6 mg./day (increased)

Normal Values: In the adult male these have been quoted by Fraser et al. (1941) for 17-ketosteroids as 8.1-22.6 mg./day (average 13.8 mg./day), and by Tompsett (1953a) for the corticosterone-like substances as 4.5-7.5 mg./day.

Psychological and Social Effects.- For obvious reasons it is difficult for me to judge the psychological effects in this case but he appears to be adjusted normally to the world. He has served in H.M. Forces without undue upset and has survived six years as a general practitioner in his normal health. Undoubtedly his earlier life was disturbed by his inability to play rough sports well, the probable reason being that he was subconsciously afraid of what was going to happen to him, although he was not aware of that at the time. There is no interference with his social life now because he restricts himself to such games as golf. He has always given the /

the impression of being accident-prone but this is merely relative because the minor accidents have assumed more major proportions. One interesting sidelight on this is that he has found that, whereas shaving with an ordinary razor produced frequent cuts on the face, the use of an electric shaver has eliminated that source of injury.

Case 2

This patient, F.M., aged 5 years, is the daughter of Case 1.

History.- She was born prematurely at 35 weeks gestation and weighed 4 lb. 15 oz. at birth, the pregnancy which resulted in her birth having been complicated by a mild degree of pre-eclamptic toxæmia in the last week or two. The degree of prematurity caused difficulty in rearing in the first three months of life but she was perfectly healthy. Even at birth it was noticed that the skin was very soft, but the significance of this was not then appreciated. At the age of 12-15 months when active movement started it was noticed that when she fell on a thick pile carpet a large hæmatoma, which was always dark in colour, would form on her forehead. These hæmatomata resolved in time but experience taught the parents that a quicker result could be obtained by pressure on the hæmatomata whenever they were forming, and this /

this was usually done by the application of a pad of sorbo rubber on elastoplast. The first major accident took place at the age of 18 months when she fell out of a car door when the car was moving slowly. She received a large wound on the forehead which gaped to an enormous extent and showed marked retraction and inversion of the wound edges. This wound was sutured with catgut and a remarkably good result obtained.

Many other injuries, both of the bruising and the skin-splitting varieties, followed in the normal course of a child's life and various methods of holding the wound edges were tried. It was found that the best results were not obtained by any one method but varied according to the site of injury and the degree of elasticity of the skin at that point, for example, a wound just above the left eye extending into the orbit healed with the minimum of scarring on the application of elastoplast alone, but when a similar method was used for a wound of the left arm a somewhat puckered scar was produced. In this case it was eventually decided that most wounds of the limbs were best treated by fine nylon suture, but that where the skin was very lax an elastoplast "corset" gave the best result. The normal milestones of a child's life were reached at average times, walking in particular starting at the age of 16 months.

Examination.- This showed a healthy child of good general intelligence and of average height and weight.

Examination /

Examination of the heart, chest, abdomen and nervous system showed no abnormality. The skin demonstrated the effects of injuries some of which have been detailed above; in particular there were many bruises over the tibiae (Fig. 16). Each knee showed a small papyraceous scar, and on the right elbow there was a small but definite "raisin-like pseudo-tumour" (Fig. 17) caused by a series of bruising injuries, there having been no actual break of the skin in this area. The skin was very soft and velvety to the touch, moving easily over the underlying tissues, and was markedly hyper-extensible especially over the elbow and knee regions. It felt rather like the skin of a cat or a dog, as has been described on previous occasions.

The joints showed hyperlaxity, especially the joints of the hands and elbows, but there was no subluxation. The feet showed a degree of pes cavus bilaterally. In the early stages of walking a slight instability was noticed but this disappeared quite quickly.

The muscles were definitely soft to the touch and appeared to lack some tone, but they were normally developed.

Laboratory Investigations.- As the patient was a child and the diagnosis was in no doubt, it was thought best to limit these to the minimum required to rule out any bleeding disease. Thus the following were noted:-

Bleeding /

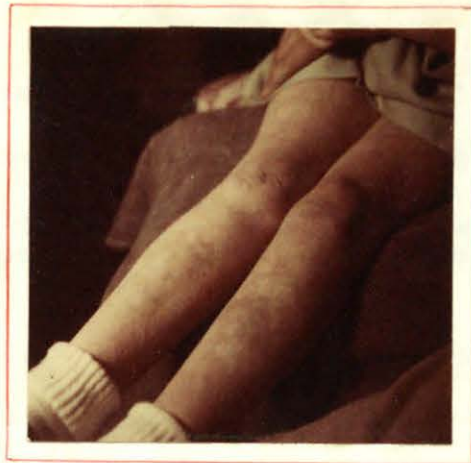

Fig. 16.- Case 2. To show the chronic bruising of the legs and the papyraceous scarring of the knee.

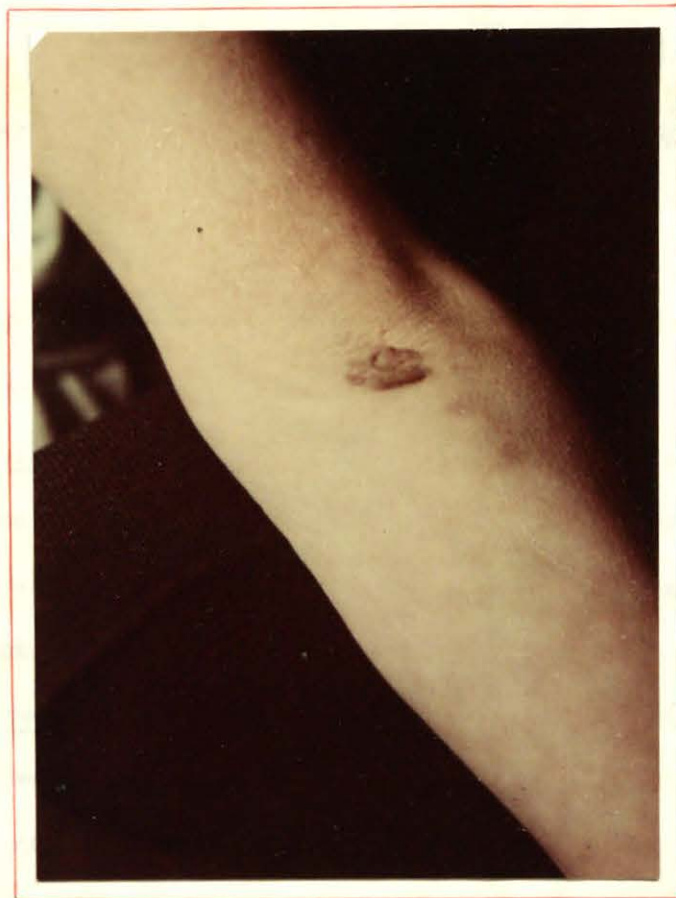

Fig. 17.- Case 2. To show the pseudo-tumour on the left elbow.

Bleeding time (Ivy) - 6 min.
Platelet count - 93,000 per c.mm.
Tourniquet test (capillary resistance or Rumpel-Leede): more than 50 petechiae.

As will be readily appreciated, these findings are unusual in the Ehlers-Danlos syndrome and they may be explained by the fact that the child's mother (who was in no way a case of the syndrome) showed the following findings:-

Bleeding time (Ivy) - 6 min. 30 sec.
Platelet count - 212,000 per c.mm.
Tourniquet test: more than 50 petechiae.

Thus mother and child showed the same degree of capillary fragility and it can be assumed that this was an inherited weakness from the mother. The low platelet count in the child is of no significance as it is a very variable factor at that age.

Radiology.- X-ray photographs of the soft tissues were made of the knees and shoulder regions but no calcified spherules were seen. More penetrating films taken to show bone structure did not demonstrate any change from the normal.

Hormonal Investigations.- As in Case 1, two twenty-four specimens were submitted for steroid investigation with the following results:-

1st /

1st specimen

Total volume - 460 ml./day
17-ketosteroids - 0.9 mg./day (normal)

2nd specimen

Total volume - 320 ml./day
17-ketosteroids - 2.1 mg./day (increased)
Corticosterone-like substances - 3.3 mg./day (increased)

Normal Values: 17-ketosteroids - these have been quoted for a female child aged 2-6 years by Wood and Gray (1949) (who referred to Talbot et al. (1943) and Kenigsberg et al. (1949)) as 0.29-1.2 mg./day. Corticosterone-like substances - Tompsett (1953b) has quoted these for children aged 4-6 years as 2-3 mg./day.

It will be seen that the figures vary but this may be the result of the fact that the child had a fever when the second specimen was taken. Thus the tests in this case are inconclusive.

Psychological and Social Effects.- It will be readily appreciated that a child of this age has not had time to develop many psychological disturbances, but she has a definite fear of injuring herself and a knowledge, even at this age, that she is "different" from other children. She has had so many wounds treated by suture and other methods that she becomes very disturbed at the thought of "stitches" whenever she gets a small cut. This is only a natural reaction and one which it is hoped she will outgrow in time. She has a tendency to avoid the more violent activities of her school life and, although this is not good for her in some respects, it is probably best under the circumstances.

Treatment /

Treatment.- In view of the laboratory findings it was decided to try the effect of Tab. Rutin (Allen & Hanburys Ltd.) on the capillary fragility with a view to reducing the bruising element. It was very difficult to judge the clinical effect as this depended on the number of injuries which the child received, and therefore an attempt was made to assess its value by the tourniquet test. Within three months, with a daily dosage of 60 mg., the number of petechiae was reduced from the original figure of more than 50 in the prescribed area to 12. As this was encouraging it was decided to continue, with the result that this dosage was given for a period of one year. At the end of this time the tourniquet test showed the figure of 20 and it was felt that possibly the effect was wearing off and the treatment was therefore stopped.

As far as the Ehlers-Danlos syndrome itself was concerned, no treatment was possible except that which has been already explained in regard to the wounds.

Case 3

This patient, Mrs C., aged 38 years, is the sister of Case 1.

History.- Birth was two weeks premature and she weighed only 4 lb. 12 oz. She developed quite normally and suffered from the usual childhood illnesses. During her childhood she /

she had many accidents of both a minor and major character and over the years scarring developed on the limbs, especially on the knees. She always had "difficult feet" but, as stated in relation to Case 1, this was considered to be a "family failing"

Family History.- The parents of this patient and her brother (Case 1) were normal and healthy. The father died an accidental death at the age of 35 years, but the mother is alive and well. The mother's nephew, who was killed in the 1914-1918 war, was reputed to have suffered from an "easily broken skin" but there is no way of proving whether or not that was a case of the Ehlers-Danlos syndrome. The other members of both sides of the family are well.

Examination.- This showed a normally developed woman of the aesthetic type. The heart, chest, abdomen and nervous system were normal.

The skin presented the same features as the two previous cases, being soft and velvety to the touch and easily mobile. It was hyperelastic especially over the elbow regions and the feet, and the lower legs showed evidence of chilblains. There was an area of soft tissue thickening on the back of the right heel. The knees showed papyraceous scars in broad bands across the front of the patellae, these having resulted from a severe accident in childhood when she had fallen on ashes. There was evidence of bruising on the skin over the tibiae which was clinical evidence of blood vessel fragility (Fig. 18).

The feet showed bilateral pes cavus and the joints generally /

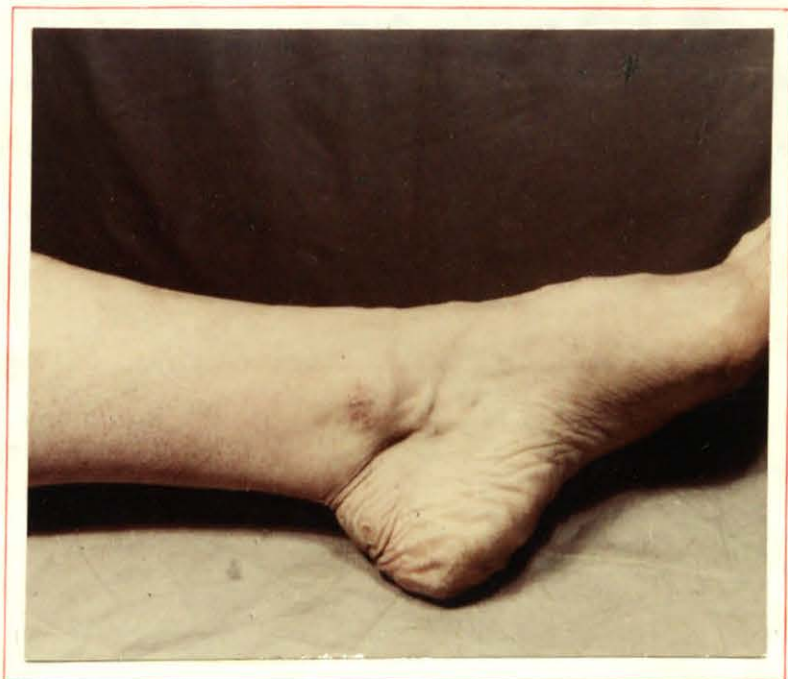

Fig. 18.- Case 3. To show the mild degree of
contusional damage to the medial
malleolus, the "pes cavus" type of
foot, and the effect of a chilblain
on the heel.

generally were hyperextensible, particularly the small joints of the hands and fingers.

The muscles were soft and lacked tone. The patient had not, however, been very active in sport in her younger days.

Laboratory Investigations.- As this patient had no complaints and had simply agreed to be included in this investigation, it was not felt justifiable to submit her to any unpleasant laboratory proceedings. However, she did agree to have a hormonal urine test carried out, with the following results:-

Hormonal Investigations (urine, 24-hour specimen):

Total volume	- 1,200 ml./day
17-ketosteroids	- 3.0 mg./day (low)
Corticosterone-like substances	- 6.0 mg./day (normal)

Obstetrical History.- This patient was the only one of my series in whom the possible effects of pregnancy on the Ehlers-Danlos syndrome could be studied. It was not possible to do this during pregnancy as that did not occur during the course of the investigation. However, the obstetrical history is as follows:-

First pregnancy: This took place when the patient was aged 28 years. The only complication was the development of severe hypertension in the last few weeks. It could not be said that this was a true pre-eclamptic toxæmia but the relationship between that and hypertension of pregnancy is a close one. Eventually delivery was effected normally and a child /

child weighing 6 lb. 6 oz. was born (Case 4). The puerperium was normal and there were no after effects.

Second pregnancy: The patient was 31 years old when this took place. It proceeded normally until six months when the blood pressure again began to rise and despite treatment in bed in a nursing home, this process continued and intra-uterine death of the foetus took place at seven months of pregnancy. Shortly after this the dead foetus was born, in association with an abnormally small placenta. No cause for this was found despite all possible investigations. Unfortunately no post-mortem examination of the foetus was carried out.

To date no further pregnancy has taken place. It may be coincidence that these two pregnancies and that of the mother of Case 2 were complicated by toxæmia or its associated condition of hypertension.

Case 4

This patient, E.C., aged 10 years, is the daughter of Case 3 and the niece of Case 1.

History.- The pregnancy which led to her birth has just been described and it has been stated that her birth weight was 6 lb. 6 oz. She was a healthy child and normal development took place over the first year. However, it became obvious /

obvious that walking was delayed and it was not until the age of 2 years that she actually walked. She had already been seen by a paediatrician on this account and he had considered that the diagnosis was that of amyotonia congenita. After that age the child developed normally but suffered from a number of accidents mostly to the soft tissues, but no major suturing was required. As the result of one accident she suffered a greenstick fracture of the left radius. Her mother noticed that she bruised easily and that her feet were difficult to fit with shoes.

At about the age of 3 years she was troubled with recurrent conjunctivitis and the cause of this was found to be trichiniasis. After many of the offending eyelashes had been pulled out at various times, electrolysis was carried out and repeated at intervals resulting in a complete cure.

Examination.- This revealed a normal healthy girl with no abnormality in the heart, chest, abdomen, nervous system or eyes.

The skin showed the characteristic soft and velvety texture and was hyperelastic especially about the elbow regions, hands and fingers. It showed a few small papyraceous scars around the knees but no pseudo-tumours.

Many of the joints showed hyperextensibility, most marked in the elbows and the small joints of the hands and fingers. Both elbow joints showed recurvature and the knees were also very mobile. Both feet showed a mild degree of pes /

pes cavus and were unusually large for her age.

The muscles were definitely soft to the touch despite the fact that she played the normal amount of games at school.

Laboratory Investigations. - As in the case of her mother, this patient had no complaints and consequently submission to detailed laboratory investigation was not justifiable; in any case, in view of the family history and the clinical findings, it was not necessary in order to establish the diagnosis. However, urine specimens were submitted for hormonal analysis and the results are detailed below:-

Hormonal Investigations (urine, 24-hour specimen):

Total volume	- 1,060 ml./day
17-ketosteroids	- 4.8 mg./day (normal)
Corticosterone-like substances	- 4.0 mg./day (normal)

The average figure for 17-ketosteroid excretion is given by Talbot et al. (1943) as 1.9 mg./day, but the above results may be considered normal for a girl of her age. It is thus clear that this patient shows the syndrome in a mild form, it being fortunately insufficient to interfere with her normal activities. She demonstrated the associated phenomenon of developmental trichiniasis.

Case /

Case 5

This patient, Master G., is the only one of this series whom I did not investigate personally as he had been admitted to hospital and died before I was acquainted with his case. However, because his history is so unique and has not previously been published, I obtained permission from the medical staff of the hospital concerned to include the case in my records.

History.- This boy, the elder of twins, aged 15 years, was admitted as an emergency to hospital with a swelling in the right groin which, his father believed, had been produced by falling from his bicycle. This swelling had been present for two days and was increasing in size. About six months previously he had had a large bruise on the left thigh received when playing with a bicycle; this resulted in his having been kept in bed for five weeks at home. Some years before he had been investigated in hospital for abdominal pain, but no cause had been found.

Examination.- He was an extremely pale and thin boy with a low intelligence quotient. The mucosae were pale and there were multiple abrasions on the right leg. No abnormality was discovered on routine examination of the heart, chest or alimentary system. The blood pressure was 140/80 mm. Hg. The spleen and kidneys were palpable. The locomotory system showed hyperextensibility of the finger joints. The skin showed tissue paper scars over the left patella.

He /

He had a large swelling in the right thigh, which was considered to be a haematoma, and the whole thigh was symmetrically enlarged, with a circumference of $20\frac{1}{2}$ in. measured 12 in. above the patella. The skin was slightly discoloured but the peripheral pulses were palpable. The blood findings were as follows:-

Group A, Rh positive	
Haemoglobin	- 65%
W.B.C.	- 16,000 per c.mm.
Platelets	- 124,000 per c.mm.
Bleeding time	- 15 min. (normal 5 min.)
Coagulation time	- 12 min. (normal 10 min.)

Treatment was carried out with sedation, the limb was raised and put at rest, and use was made of a shock chart. The following day the circumference of the limb at the same point was $\frac{1}{4}$ in. less and he appeared to be settling down. The peripheral pulses were present and the capillary fragility test was negative.

Progress.- The next day the circumference of the swelling was still less but it was extending upwards as far as the midline of the abdomen, with discolouration of the skin of the scrotum, and there was resistance in the right iliac fossa. This process continued and on the following day he was transfused with one pint of blood and two pints of packed cells over a period of 12 hours. His general condition improved under this treatment, but it was clear that the bleeding was continuing because his pulse rate, which had been running at about 100 per minute, increased to 160 per minute. At this time he was seen by Dr Macfarlane who suggested the diagnosis of /

of the Ehlers-Danlos syndrome.

Laboratory investigations were then carried out with the following findings:-

Haemoglobin	- 35%
W.B.C.	- 5,700 per c.mm.
Total polymorphs	- 3,200 per c.mm.
Bleeding time (Ivy)	- 7 min. 28 sec.
Calcium clotting time	- 2 min. 15 sec. (normal)
One-stage prothrombin time	- 18 sec. (normal = 18 sec.)
Two-stage prothrombin time	- 35% of normal.
Antithrombin	- no excess.

Unfortunately no hormonal investigations were carried out.

It was considered that the reduction in prothrombin by the two-stage method was probably secondary to the extensive tissue haemorrhage. No coagulation defect adequate to account for the degree of haemorrhage was found.

Six days after admission to hospital the skin divided over the haematoma on the medial side and this split gradually extended until it was about 6 in. long and 1 in. wide. There was no gross bleeding, the pulse rate again rose to 160 per minute but the blood pressure was maintained at normal.

Operation.- It was then decided to try to ligature the bleeding points in the right groin and operation was undertaken by Professor Trueta and his staff. An incision was made parallel to and lateral to the split, and the haematoma was explored for bleeding vessels. A vessel was, with great difficulty, secured distal to its point of origin from the femoral artery but it immediately tore proximal to the ligature. All the vessels were extremely friable and only after /

after extreme difficulty was a ligature secured on the femoral artery and haemostasis obtained. The wounds were packed with dry gauze and deep tension sutures inserted to keep it in place, it being noted that these sutures cut through the skin with the greatest of ease if any tension was exerted. During the operation one pint of blood was given under pressure and a piece of the artery was taken for biopsy. After the operation the condition of the patient was fair.

Post-operative Progress.- The general condition was satisfactory but the right leg was pulseless. Blood transfusion was continued at the rate of one pint every four hours for the next two days and the pulse rate varied between 130 and 140 per minute. On the day following operation the laboratory investigations showed:-

Haemoglobin	- 36% (5.4 g.)
W.B.C.	- 5,700 per c.mm.
Total polymorphs	- 3,200 per c.mm.
Platelets	- 180,000 per c.mm.
Blood film showed anisocytosis and polychromasia.	
White cells appeared normal in form and distribution.	
Bleeding time (Ivy)	- 7 min. 2 sec.
Clotting time	- 1 min. 55 sec.

After two days the blood transfusions were discontinued and the haemoglobin was then 64%, but the right leg was very cold and cyanotic below the knee. The next day he became extremely talkative and irrational but his general condition was maintained. On the fourth day after operation the wounds were dressed and as the outer dressings were removed and the gauze loosened, bleeding restarted; therefore no further attempt /

attempt was made and the wounds were covered again. He then complained of dysuria and developed a temperature of 101°F. and was treated with sulphatriad, 1 g. 6-hourly. His urinary output was satisfactory and he was well hydrated. On the following day, that is five days after operation, a definite line of demarcation was developing below the right knee. One week after operation he complained of pain in the chest but nothing abnormal was found on examination. The haemoglobin was then 63%. The following day the wounds were redressed and this time the gauze pack was removed without causing bleeding. The wounds were irrigated with hydrogen peroxide and it was noted that the lateral wound was extremely deep and filled with necrotic material and that the skin on the medial side of the medial wound was not very healthy. Although the general condition of the patient was satisfactory it was felt that there was little hope of approximating the wound edges and they were repacked with dry gauze. At this time the haemoglobin was 62% and anisocytosis was again observed.

By nine days after operation the line of demarcation was becoming inflamed and the developing gangrenous area was treated with spirit. During the next few days he complained of various pains especially about the eyes, but no cause was found; his mental state varied although on the whole he was cheerful and rational. At fifteen days the lateral wound was redressed and found to be maggot-ridden and so was again irrigated /

irrigated with hydrogen peroxide. The medial wound was by this time comparatively clean, but he had developed a small pressure sore over the sacrum. Three days later the wounds had greatly improved and it was felt that the medial one would probably be fit for grafting, and it was decided that amputation at the site of election would be done the next week. However, that same night he asked a nurse for a urine bottle and, on her return, she found him to be dead.

Histological Report on Biopsy of Artery.- The specimen was received in two parts: (1) a small piece of blood vessel 0.5 cm. in diameter by 0.6 cm. in length, and (2) a ragged opened piece of tissue measuring 2 x 0.7 x 0.5 cm.

The sections showed both specimens to consist of blood vessels in which intima, media and adventitia were present. A small amount of organising blood clot was present in the lumen. Both longitudinal and circular muscle coats were present and appeared well-formed, and the elastic tissue in the vessel wall appeared normal in amount and distribution.

Autopsy Report.- The cadaver was in a state of early decomposition but all the tissues seemed to be excessively friable. He was an extremely thin wasted boy and the right leg was gangrenous below the mid calf. There were two longitudinal wounds in the right groin, medially 10 x 4 cm., laterally 15 x 6 cm., both wounds extending into the deep tissues and lined with necrotic slough, the overlying and intervening skin being inflamed. The abdomen was distended and /

and there was a green discolouration of the skin over the chest and lower abdomen. There was a small pressure sore over the sacrum, and thin scars over the right patella.

Length: 164 cm.

Weight: 34 kg.

Head: Cranium - natural.

Brain - 1346 g. Meninges over inferior surface of frontal lobes thickened.

Mouth and pharynx - natural.

Thorax: (a) Respiratory system.

Pleural cavities - natural.

Larynx, trachea and bronchi - natural.

Lungs: right 290 g.; left 215 g. Extremely pale and oedematous.

(b) Cardiovascular system.

Heart - 254 g.

Pericardium - natural.

Myocardium - pale and flabby.

Endocardium and valves - natural.

Aorta - good elasticity.

Abdominal aorta - friable.

Pulmonary artery - natural.

Coronary arteries - natural.

Abdomen:

A large blood clot was present in the right iliac fossa which was in continuity, through a rupture of the peritoneum, with a retroperitoneal clot overlying the bladder and filling the pelvis.

The weight of both pieces of clot was 800 g.

The origin of this haemorrhage was not detected.

The right external iliac artery had been ligated proximal to the inguinal ligament, the ligature being in situ.

Gastro-intestinal Tract:

Oesophagus, stomach and duodenum - natural.

Small and large intestines and colon - natural.

Liver - 1415 g., pale, cut surface friable ? post-mortem change.

Pancreas - 61 g. Marked post-mortem change.

Spleen - 180 g. Marked post-mortem change.

Gall-bladder and bile ducts - natural.

Genito-urinary /

Genito-urinary System:

Kidneys - right 150 g., left 150 g. Pale, soft with prominent stellate veins and with the capsule stripping easily.
Urethra, prostate, bladder and ureters - natural.

Endocrines:

Pituitary - natural.
Thyroid - 40 g., natural.
Suprarenals - right 10 g., left 10 g., natural.

Right Groin and Thigh:

Tissues - muscle, fascia and vessels very friable and intravasated with blood. The sutures were intact on the distal ends of the profunda and femoral arteries. No anatomical defect seen.

The most striking feature was the extreme friability of all the tissues. Although all the organs showed fairly extensive post-mortem degeneration the degree of friability appeared to be excessive. The intraperitoneal and extra-peritoneal clot together weighed 800 g. and, in view of the clot retraction which would have taken place, this represented a haemorrhage of the order of two litres. Since the intra-peritoneal clot was not adherent to the peritonæum, it seems that this must have occurred within a few hours of death.

There was no evidence of embolic phenomena and it seems that the immediate cause of death was heart failure due to haemorrhage.

Histology.- The following sections were made:-

1. Skin

(a) Stained by haematoxylin and eosin: no abnormality

(Fig. 19).

(b) /

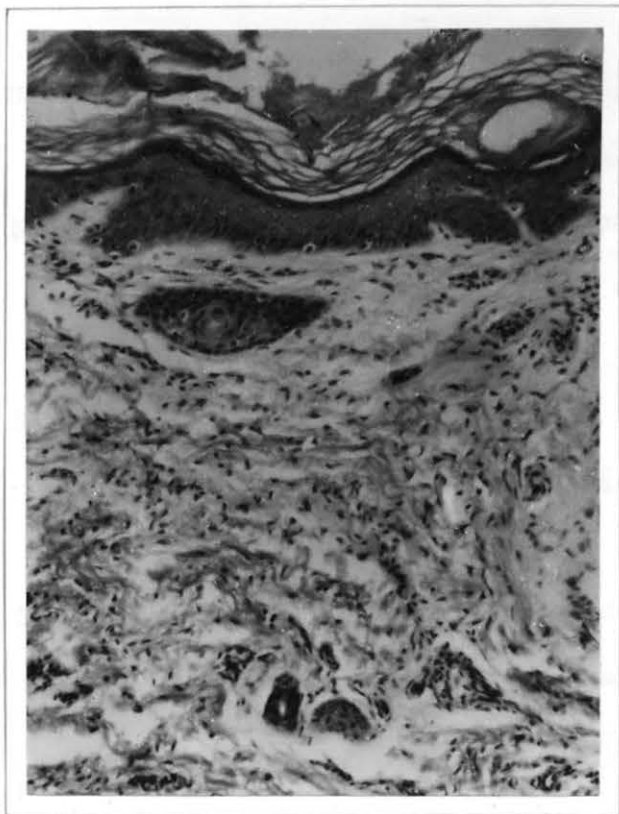


Fig. 19.- Case 5. Photomicrograph of the skin. (H. & E.
x 160.)

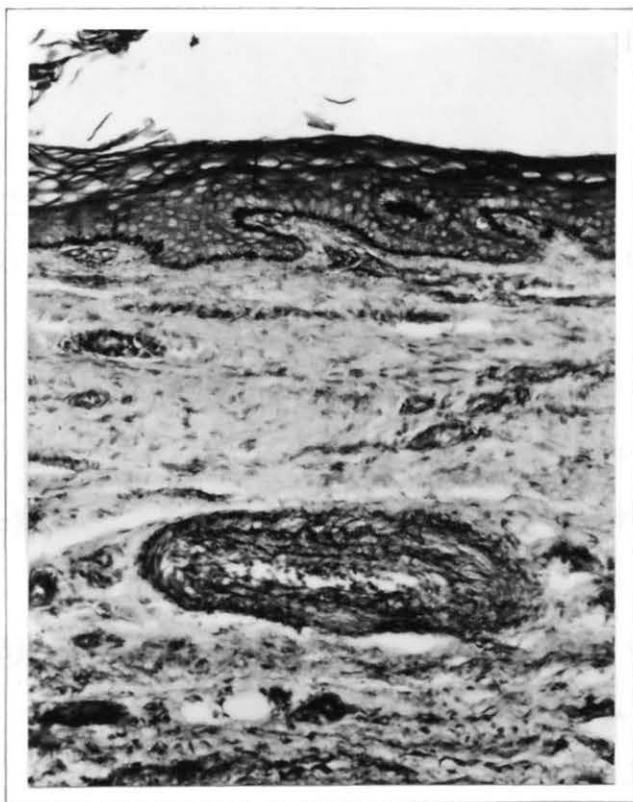

Fig. 20.- Case 5. Photomicrograph of skin stained by
Robb-Smith's modification of Foot's method
for reticulum. (x 160.)

- (b) Stained by van Gieson: increase of elastic tissue and degeneration of collagen.
- (c) Stained for reticulum by the method of Foot with the Robb Smith modification: no abnormality (Fig. 20).
- (d) Stained by Masson's trichrome stain: degeneration and hyalinisation of the dermic collagen (Fig. 21).
- (e) Stained by orcein: there is a considerable increase in orcein-positive material, most of which stains a paler shade and is less sharply defined than typical elastic fibres. This orcein-positive material may be degenerate collagen as this sometimes gives a positive reaction with orcein, but it is difficult to be certain (Fig. 22).

2. Aorta

- (a) Stained by haematoxylin and eosin: no abnormality (Fig. 23).
- (b) Stained by Masson's trichrome method: degeneration and hyalinisation of collagen (Fig. 24).
- (c) Stained by orcein: increase of elastica (Fig. 25).
- (d) Stained by Robb Smith modification of Foot's method: no abnormality (Fig. 26).

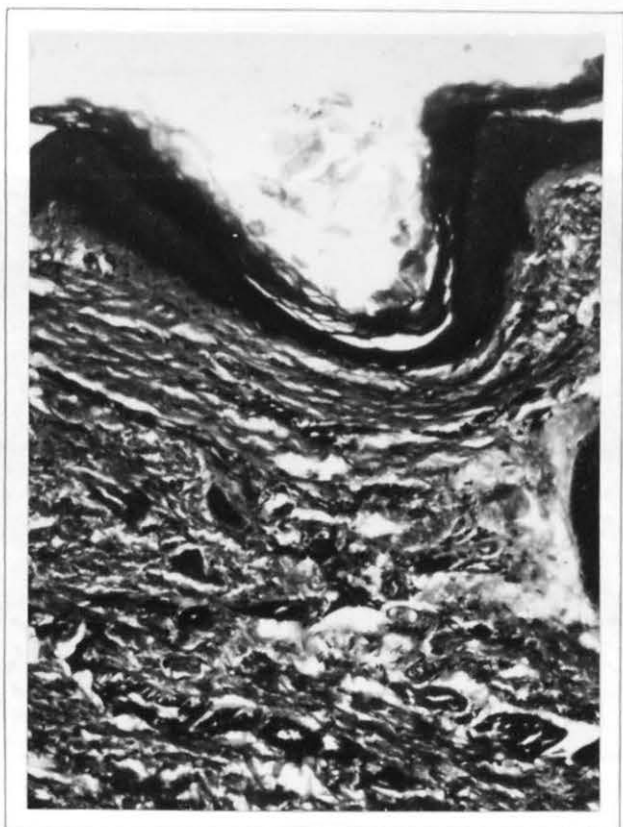


Fig. 21.- Case 5. Photomicrograph of skin to show the degeneration and hyalinisation of the dermic collagen. (Masson's trichrome. x 160.)



Fig. 22.- Case 5. Photomicrograph of skin showing the increase of elastica. (Orcein. x 160.)




Fig. 23.- Case 5. Photomicrograph of aorta. (H. & E.
x 160.)

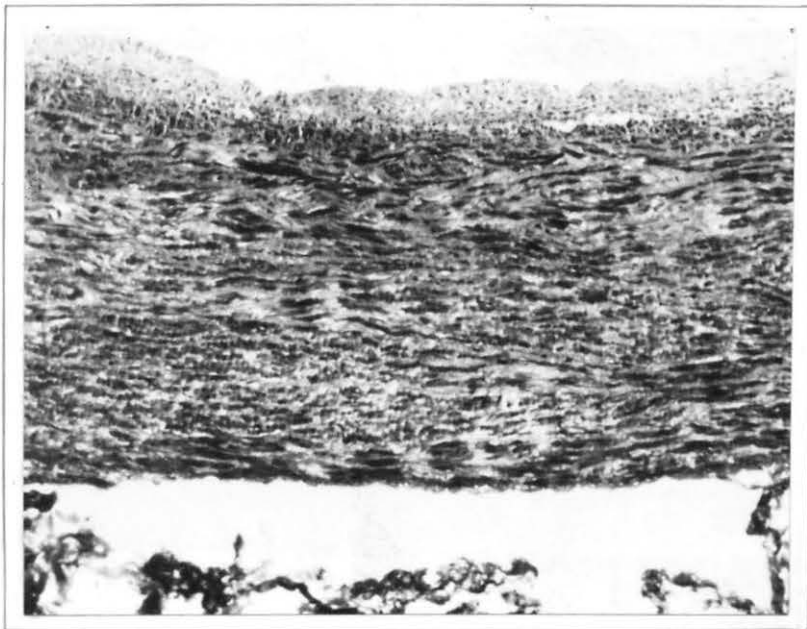


Fig. 24.- Case 5. Photomicrograph of aorta to show
the degeneration and hyalinisation of the
collagen. (Masson's trichrome. x 160.)




Fig. 25.- Case 5. Photomicrograph of aorta showing increase of elastica. (Orcein. x 160.)




Fig. 26.- Case 5. Photomicrograph of aorta stained by Robb-Smith's modification of Foot's method for reticulum. (x 160.)

3. Liver; 4. Kidney; 5. Thyroid Gland; 6. Cardiac Muscle Tissue; 7. Pituitary Gland stained Masson's trichrome: no abnormality.

Briefly, these histological findings show that there is a definite increase in elastic tissue and in tissue which gives a positive staining reaction with elastic stains, associated with a degeneration of collagen.

Case 6

This patient, D.L., is a boy aged 12 years and an only child. He is not related to any of the other patients.

History.- His birth was at full term, a forceps delivery being carried out, and the weight was $6\frac{3}{4}$ lb. The mark made by the forceps on the forehead took a long time to disappear, and even now appears in times of stress. The mother has had no other pregnancy. The boy has had no serious illnesses. From a very early age it was noticed that he bruised very easily and that the skin cut frequently and easily, this being obvious when he started to walk at the age of 15 months. At the age of 2 years he received his first skin wound which required stitching, and since then he has had few periods when surgical attention was not required. His injuries have been in all parts of the body but principally on the legs and face.

Examination /

Examination.- He was a normally developed boy of somewhat frail build. There was no abnormality of the heart, chest, abdomen or nervous system.

Skin: There were many scars on the legs and knees some of which were typically papyraceous in character (Fig. 27). There were no pseudo-tumours, and no subcutaneous spherules could be felt. The skin was lax all over, this being marked in the elbow regions. The forehead showed considerable scarring (Fig. 28).

The joints were hyperextensible, especially the small joints of the hands, but this laxity was not a marked feature of the case.

The muscles were softer than one would expect in a boy of his age and gave the same feeling of lack of tone as in the other cases.

Laboratory Investigations:

Haemoglobin	- 106%
R.B.C.	- 5.11 M. per c.mm.
C.I.	- 1.03
W.B.C.	- 4,400 per c.mm.
Differential Count:	
Polymorphs	- 55%
Lymphocytes	- 43%
Eosinophils	- 1%
Monocytes	- 1%
Platelet count	- 315,000 per c.mm.
Film	- normal.

Unfortunately a specimen of urine was not obtained for hormonal investigations.

Psychological Effects.- It appears that the boy has never been of the masculine type but rather of the more emotional /

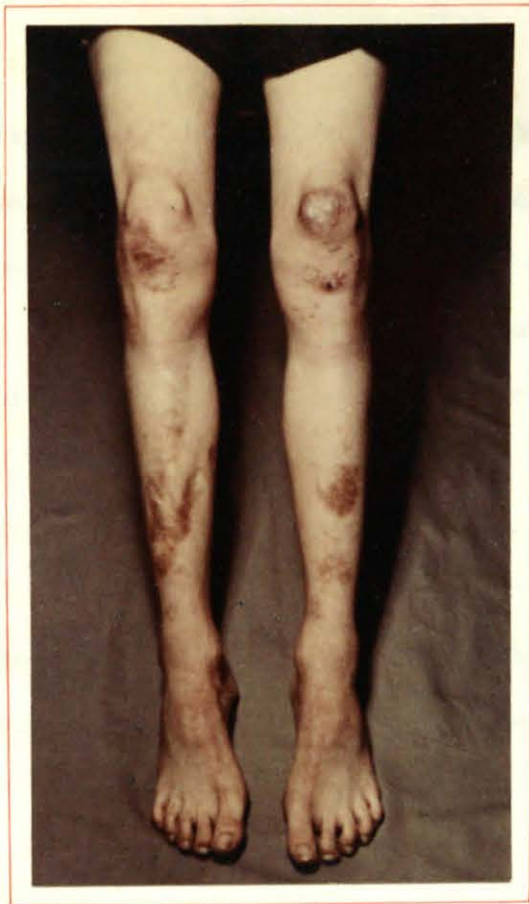

Fig. 27.- Case 6. To show gross degree of scarring of both legs.

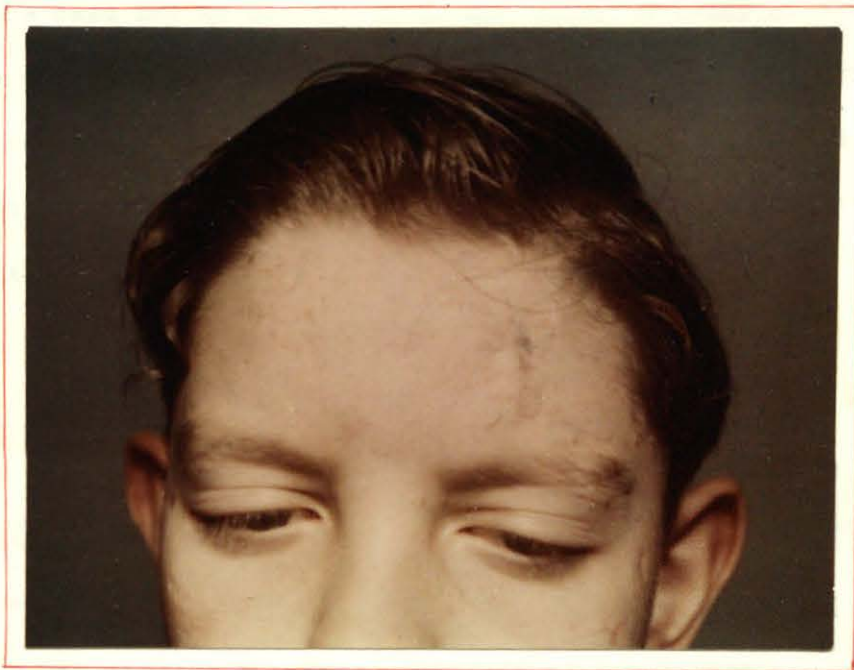

Fig. 28.- Case 6. To show scarring of the forehead.

emotional variety. As a small child he was rather inclined to dissolve into tears and to withdraw into himself when checked. On only one occasion did his father chastise him with force, the force used being very small, but it produced a marked psychological upset as well as a violent reaction in the skin area affected. He has always lacked concentration and quickly tires of any specific occupation. His memory for school subjects is poor but he can remember things which happened many years ago. He has faced the same difficulties as any handicapped boy would in that he has always tried to be the "same as the others" but has suffered in the process. He has played football with the most disastrous results so far as his skin is concerned - in fact he has psychologically overcome his handicap at the expense of physical injury.

Treatment.- No empirical treatment has been attempted in this case but he has had many and varied methods of treatment applied to his injuries. All types of suture material have been tried as well as surgical clips and elastoplast corsetting, and it was found that surgical clips gave the best result.

Case 7

This patient, Mrs B., aged 46 years, is not related in any way to the other cases. She had no complaints and came to my knowledge on the recommendation of a colleague.

History /

History.- She was born prematurely after a pregnancy lasting seven months, and weighed 2 lb. 9 oz. at birth. Early in her life it was noticed that she bruised and that her skin cut more easily than was normal. As a result of this she did not take part in many sports in her youth. She was the only one of her family to be so affected and it was always blamed on her prematurity. It was noticed that stitches tended to tear out and that her wounds were slow to heal although they did not become septic. She married at the age of 26 years and had two children who are now aged 18 and 9 years respectively. Her confinements were normal, the first being so rapid that she was delivered without anyone being present, and the resultant tear of the perineum was stitched successfully. The second birth was attended and no tear resulted.

The only operation of note was the removal of an exostosis of the great toe which took place a few years ago. The skin condition had been diagnosed previously and great care was taken to unit the wound edges with fine sutures and union was thus achieved.

Examination.- The patient was a normally developed woman whose appearance approximated to her age. The face showed the scar of an injury on the right side of her nose which had been caused by a severe scratch from her son when he was a baby. The knees showed papyraceous scars over the front of both patellae and there was evidence of old bruising on /

on the front of both legs. The skin was soft and velvety to the touch and was markedly hyperextensible especially over the elbow regions. There were no spherules to be felt and no pseudo-tumours were present. There was a soft tissue thickening on the back of the right heel similar to that noted in Case 3 and which appeared to be a chronic thickening of the post-calcaneal bursa.

The joints were markedly hyperlax, particularly the terminal joints of the fingers.

Family History. - The elder of the patient's two children apparently showed the same condition in a minor degree but I was unable to see him. No other member of the family was affected.

In this patient it was not possible to carry out detailed investigations, X-ray or clinical photographs.

Hormonal Investigations (urine, 24-hour specimen):

Total volume	- 1,110 ml./day
17-ketosteroids	- 6.9 mg./day (low)
Corticosterone-like substances	- 3.1 mg./day (low)

It is obvious that this patient was a clear-cut but mild example of the syndrome which has not incapacitated her at all in adult life.

Case /

Case 8

This patient, G.D., is a little girl aged 6 years, not related to any of the other patients.

History.- She was born prematurely at seven months, weighing 4 lb. 2 oz. In the neonatal period she bled from the mouth and gums and was not expected to live; she was given one injection of maternal blood in the left buttock region. Thereafter infancy was uneventful except that at the age of about one month a left foot-drop was noted and this was considered to be due to the intramuscular injection given in the region of the sciatic nerve. The fact that she did not walk until nearly the age of 2 years was attributed to this lesion. From this time onwards it was noticed that her skin bruised and cut easily when she fell and that stitches tended to cut out after insertion.

Despite considerable fecundity in the family, no other case could be traced in three generations. On the female side of the family the only noteworthy fact was a high abortion rate.

The patient was referred to an orthopaedic surgeon at the age of 2 years on account of the difference in size of her feet, the left being smaller than the right. The surgeon considered that she was a case of delayed myelination of the spinal cord affecting principally the left leg, and he noted that there were several "angiomatic masses" in the leg and /

and that one of especial size was overlying the left patella. The left foot was then seen to have a moderate degree of pes cavus, but the right was normal. The left foot-drop was treated by various orthopaedic methods including a leg iron support and an inside "T" strap, and much improvement resulted. It was suggested that knock-knees might develop later and this has, in fact, occurred in a mild degree.

At the age of 4 years she went with her family to Africa where she suffered many more injuries but, despite the climate, the wounds appeared to heal more easily than in this country. Many methods of suturing these wounds were tried by various doctors, and in this case it was found that the best results were obtained by the use of plastic clips as the ordinary surgical sutures did not hold.

It is of interest to note that a second child (a boy) was born to the parents three years after the patient and that this pregnancy terminated at full term, the child being in no way affected by the syndrome.

Examination.- The child was of average height and weight for her age and of normal intelligence. Routine physical examination of the heart, chest, abdomen and nervous system showed no abnormality.

The skin demonstrated the typical appearance of chronic skin damage associated with the syndrome. The forehead showed some scarring (Fig. 29), especially on the left side, and /

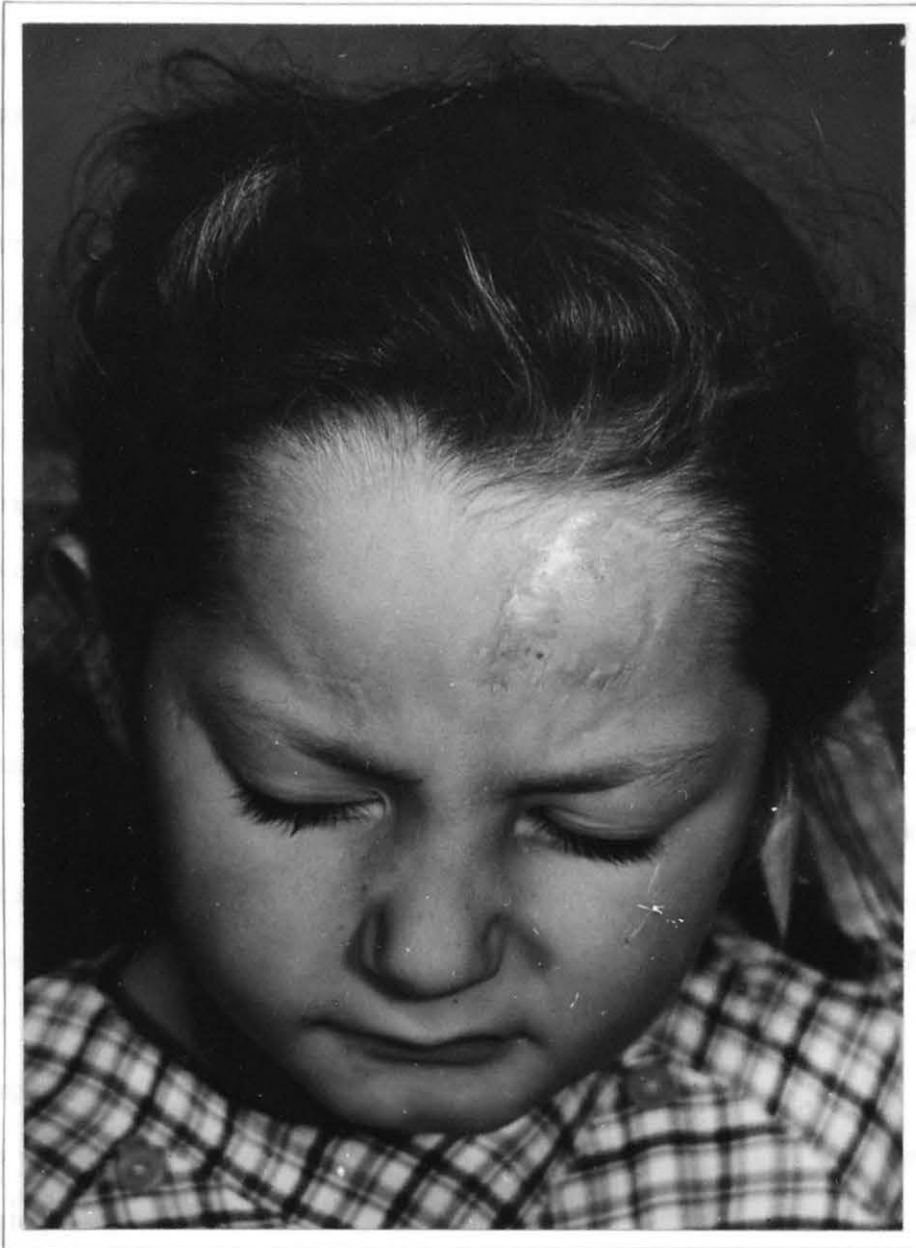

Fig. 29.- Case 8. To show the marked degree of scarring of the forehead.

and there were similar scars on the right leg (Fig. 30), shin, the right arm and the left arm. However, the left leg showed a most extreme degree of scarring involving the whole limb from above the knee down to the ankle, mainly on the front of the leg (Figs. 31 and 32). The scars were all papyraceous and there was scarcely any healthy skin present. The skin over the whole surface of the body appeared thin and was silky to the touch, the elasticity being moderately increased. On the left leg there was a recent wound at which an unsuccessful attempt had been made at stitching (Fig. 33). As a consequence there was a gaping wound about one inch long and half an inch broad which was healing by granulation from the bottom.

There was general hyperlaxity of all the joints, especially the left first carpo-metacarpal joint where completion extension allowed the tip of the thumb to touch the back of the hand. The left foot showed a reduction in size as compared with the right, and was somewhat cavus in nature. The poor dorsiflexion noted in the earlier history had almost disappeared and almost full movement of the foot had been established.

Laboratory Investigations: (Bleeding times noted in this case and all succeeding cases were done by the saline method):

Rumpel-Leede test	-	Negative
Blood	-	Group O, Rh positive
Haemoglobin	-	92%
R.B.C.	-	4,450,000 per c.mm.
C.I.	-	1.03
W.B.C.	-	9,400 per c.mm.
Differential /		

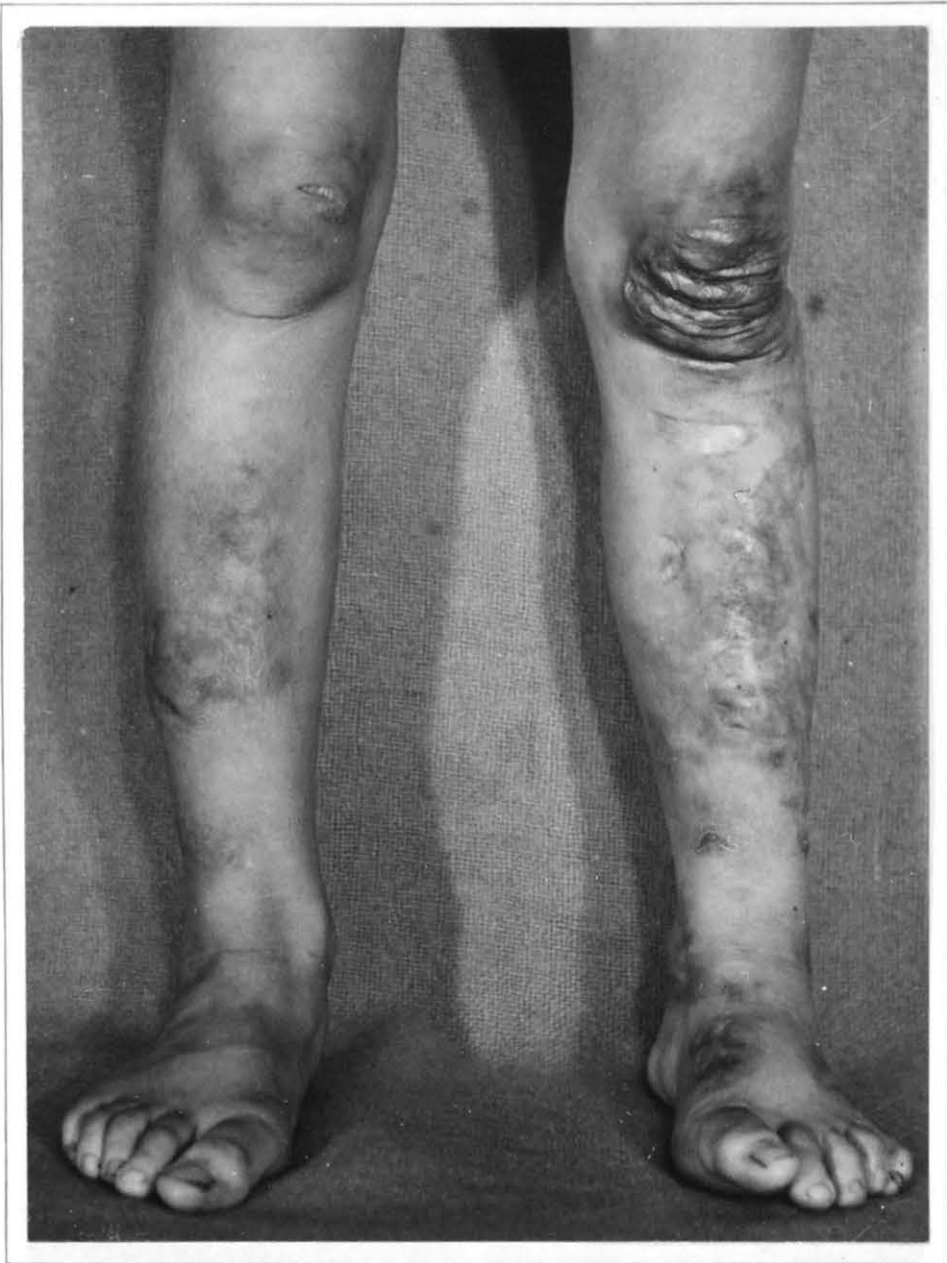

Fig. 30.- Case 8. To show the gross degree of scarring of the legs, especially of the left knee.

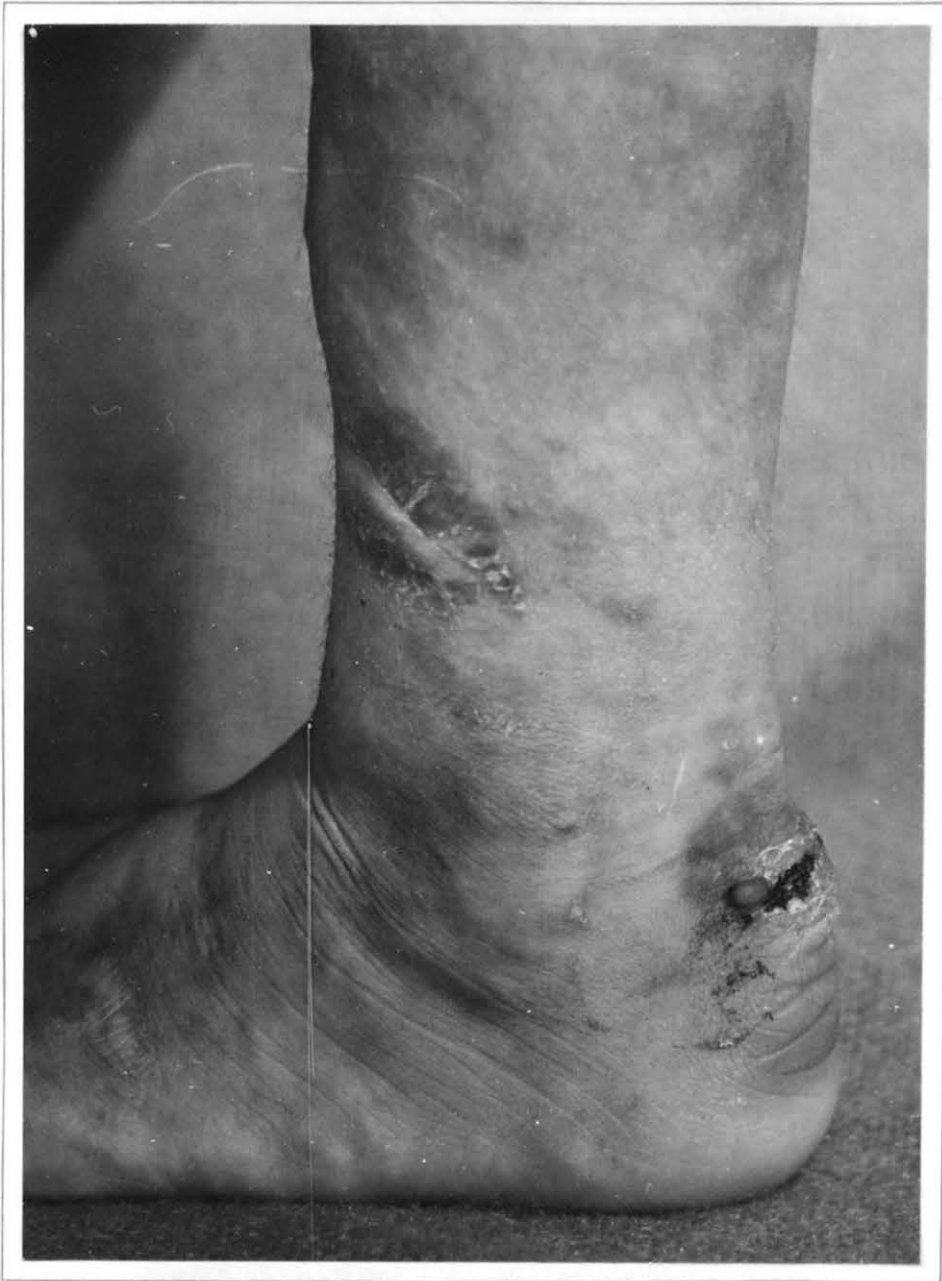

Fig. 31.- Case 8. To show scarring and an open wound of the left lower leg.

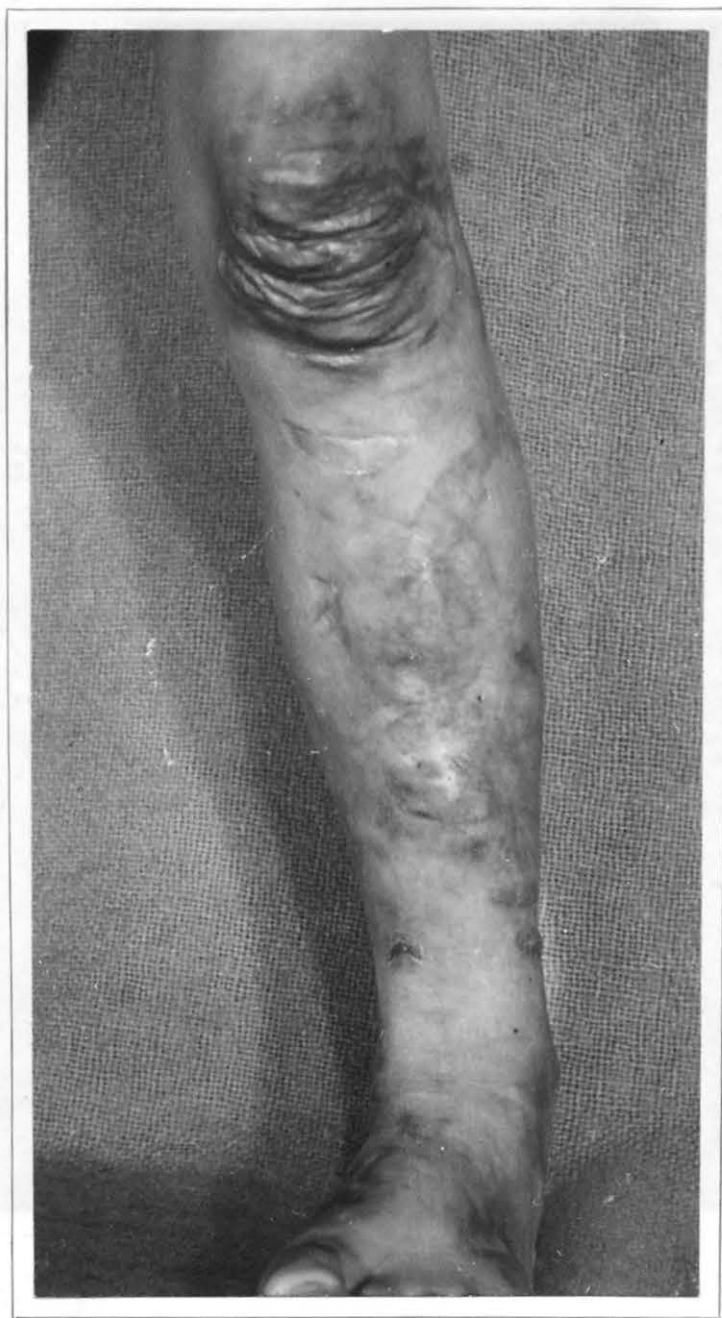

Fig. 32.- Case 8. To show the gross degree of scarring, which was paper-thin over the knee, of the left leg.

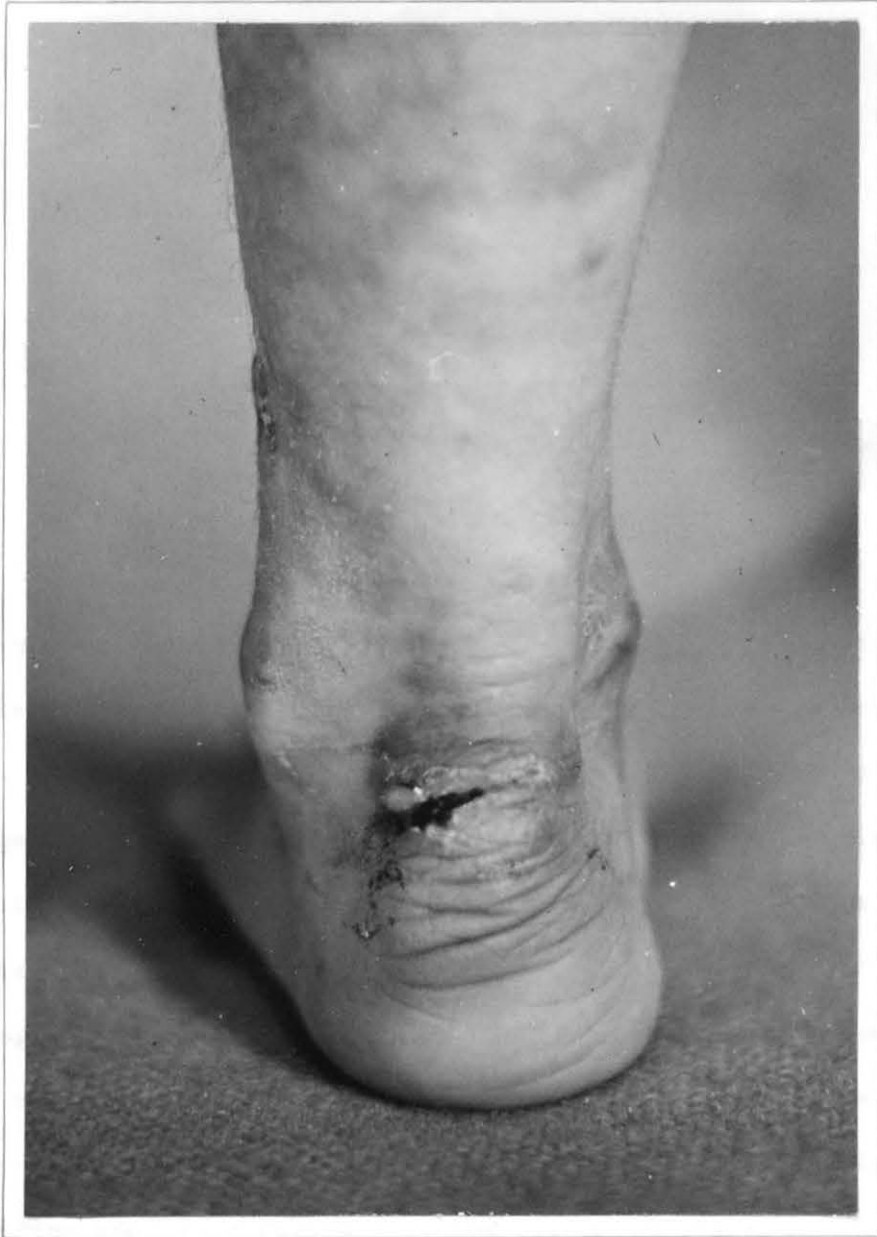


Fig. 33.- Case 8. To show the wound of the left heel.

Differential count:

Polymorphs	-	20%
Lymphocytes	-	60%
Monocytes	-	9%
Eosinophils	-	11%
Eosinophils	-	800 per c.mm.
Bleeding time	-	2 $\frac{1}{2}$ min.
Clotting time	-	4 $\frac{1}{4}$ min.

Hormonal Investigations (urine, 24-hour specimen):

Total volume	-	465 ml./day
17-ketosteroids	-	0.46 mg./day (low)
Corticosterone-like substances	-	1.0 mg./day (low)

Treatment.- It was considered that in view of the extensive skin damage in this case, use should be made of protective clothing, and so the wearing of an elastic stocking with pads over the knees and ankles was advised. It was suggested to the patient's doctor that future skin suturing might be attempted with fine nylon, and that it be supplemented with adhesive plaster to take away the strain from the damaged area. This patient was referred to a plastic surgeon but he did not consider that any treatment should be undertaken when the child was young. However, he felt that the position should be reviewed at the age of 15 years.

This case appears to demonstrate a new mutation because there were no other cases of the syndrome in the family.

Case 9

This patient, Mrs H., aged 64 years, is a housewife. There is no relationship between her and any of the previous patients.

History.- She was a small baby at birth but she did not know her exact birth weight or whether she was premature. She first noticed in her early childhood that her skin bruised and split easily but, fortunately for her, she did not suffer from any major accident. She knew that her skin was very lax and also her joints. Her childhood was punctuated by many minor injuries which left their quota of scars, the result of slow wound healing (or so it appeared to the patient). On one or two occasions suture of the wounds was necessary and the stitches always held. Apart from her disability she had had a healthy life and suffered from no major illnesses.

Obstetrical History.- She married at the age of 28 years and in the course of the next few years she had four pregnancies only one of which came to fruition. She had three abortions at three months' gestation, and only with great difficulty and care carried the next child past this stage. The birth took place at 37 weeks and the baby, a boy, weighed $6\frac{1}{4}$ lb. This child was affected by the syndrome and his case is described next (Case 10). There were no further pregnancies.

Examination.- The patient looked her age of 64 years and was rather markedly wrinkled especially about the face and neck. /

neck. General clinical examination revealed no abnormality in the heart, chest, abdomen or central nervous system. The skin was very hyperelastic and could be stretched about four inches from each cheek. It had the soft velvety feel associated with these cases and showed innumerable small scars on the legs and arms. However there were no major scars, the patient stating that she had always been very careful in her girlhood activities.

The joints were extremely hyperlax, especially the small joints of the hands, giving what is popularly known as "double-jointedness" (Figs. 34 and 35).

Laboratory Investigations:

Bleeding time - 2 min. 50 sec.
Tourniquet test - negative
Blood film - normal

Hormonal Investigations (urine, 24-hour specimen):

Total volume - 1,880 ml./day
17-ketosteroids - 6.3 mg./day (low)
Corticosterone-like substances - 2.7 mg./day (low)

Case 10

This man, Mr H., is the son of the previous patient (Case 9) and is aged 32 years. He is a market gardener.

History.- His story is much the same as that of his mother, except that the condition is not so marked as in her. The pregnancy which had led to his birth has been described, the /

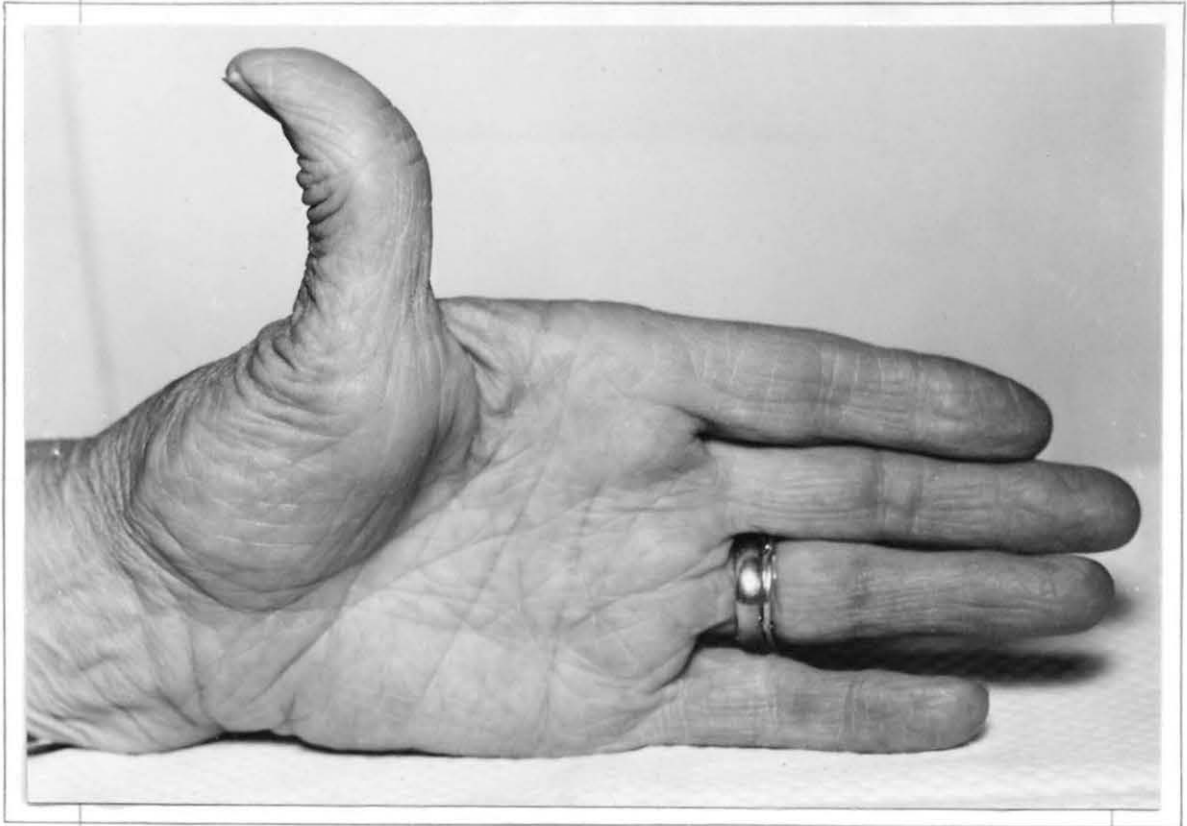

Fig. 34.- Case 9. To show the marked degree of joint mobility of the left hand.

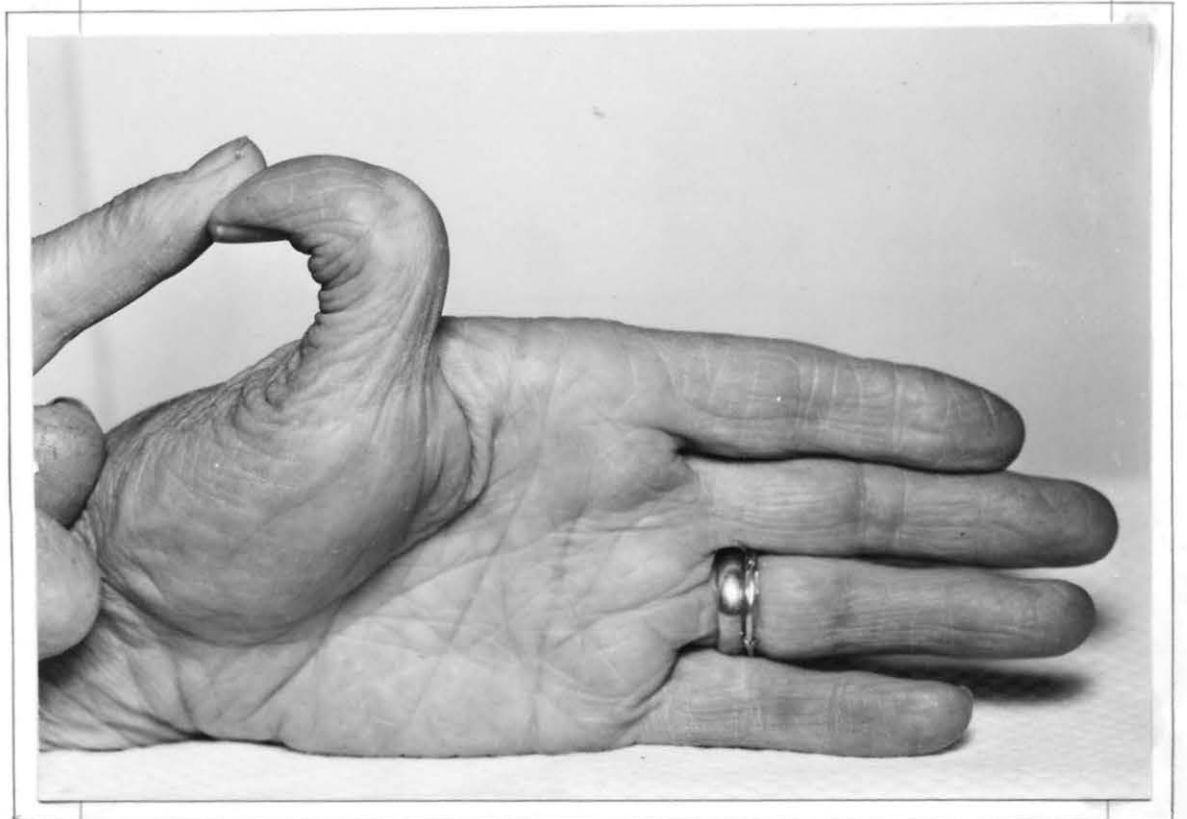


Fig. 35.- Case 9. To show the marked degree of joint mobility of the left hand when put into forcible extension.

the fact of prematurity being noted. He first became aware of his fragile skin when he was at school, realising that it cut and bruised more easily than that of the other boys. He had many small injuries but none of any major significance, and he had arrived at adult life with relatively little scarring. He discovered that the many injuries which he received when shaving were eliminated by the use of an electric shaver.

Examination.- He was a healthy man of 6 feet in height and with no complaints. Routine clinical examination was normal. The skin was definitely elastic and there was evidence of many small cuts on the hands and face. The joints showed very little hyperlaxity but the feet demonstrated the broad forefoot and pes cavus which are associated with the syndrome.

Family History.- This man had one small daughter aged 14 months but she appeared to be normal. She had been born at full time and showed none of the classical features of the syndrome.

Laboratory Investigations:

Bleeding time	- 1 min. 30 sec.
Tourniquet test	- negative
Blood film	- normal

Hormonal Investigations (urine, 24-hour specimen):

Total volume	- 1,970 ml./day
17-ketosteroids	- 10.6 mg./day (normal)
Corticosterone-like substances	- 3.0 mg./day (low)

Case 11

This patient, Mrs W., is one of four sisters who are affected by the condition. Each of them (and their families) is described in turn and their family tree is shown in Fig. 36.

History.- This woman is a housewife aged 41 years. She first realised her condition when she was 6-7 years old but she had been aware of it before in other members of her family. As will be seen from the family tree, her father suffered from it as did her brother and two of her elder sisters. Her birth had been normal and at full term, and her early childhood had not produced any major accident. However, when she went to school and suffered the usual injuries connected with school life, she realised that she was "like the others" in the family. The history was the usual one in these cases in that her life was punctuated by many minor accidents but she did not have any major ones. For some reason her wounds were very seldom stitched, but when sutures were used they held well.

She married at the age of 29 years and has one daughter aged 6 years. This child weighed 5 lb. 15 oz. at birth but was not premature. She also had one abortion before the birth of her child.

She had always noticed that wounds were slow to heal and that "they went septic" easily (this was not noticed by the other members of the family). The wounds bled a great deal /

deal and she had had considerable post-partum haemorrhage with the birth of her child.

Examination.- The patient was a healthy looking woman with no outward appearance of her disability. Clinical examination of the heart, chest, abdomen and central nervous system was normal.

The skin showed the typical hyperelasticity, most marked about the joints. There were many scars particularly around the knees and the right elbow, and the skin in front of the tibiae showed evidence of bruising. The scars were papyraceous but were not large and there were no pseudo-tumours or spherules present.

The joints were markedly hyperlax, especially the joints of the thumbs, and the feet showed pes cavus.

Laboratory Investigations:-

Bleeding time	- 2 min.
Tourniquet test	- weak positive (15 petechiae)
Blood film	- normal

Hormonal Investigations (urine, 24-hour specimen):

Total volume	- 1,440 ml./day
17-ke tosteroids	- 9.0 mg./day (normal)
Corticosterone-like substances	- 3.0 mg./day (low)

Case 12

This patient, Mrs D., is a housewife aged 34 years and one of the sisters of the previous patient (Case 11).

History /

History.- Like her sister she was born at full maturity and had a healthy early childhood. Also like her sister she first noticed the tendency to bruise and cut easily when she went to school. Her life history followed the pattern of her sister's very closely, there being many minor accidents but no major ones. The elbows suffered to the greatest extent, with the result that a state of chronic damage developed producing "pseudo-tumours". Like her sister she has not had wounds stitched except on rare occasions but the sutures did hold.

She married at 22 years of age and has three children - a boy aged 9 years and twins (boy and girl) aged 15 months. The boy of 9 years has only recently shown signs of the syndrome in that he has had an accident at school resulting in a small papyraceous scar of the right knee. The twins so far do not show any sign of the condition although the boy had a "lump" removed from the left shoulder shortly after birth. The cause of this lesion appeared to be a little obscure but the histological picture was that of a simple haematoma.

Examination.- The patient was a normally healthy woman who showed no abnormality on routine clinical examination.

The skin was soft to the touch, unduly elastic and showed many small scars about the knees and legs. There were pseudo-tumours on both elbows (Figs. 37 and 38) but no spherules were present.

All /

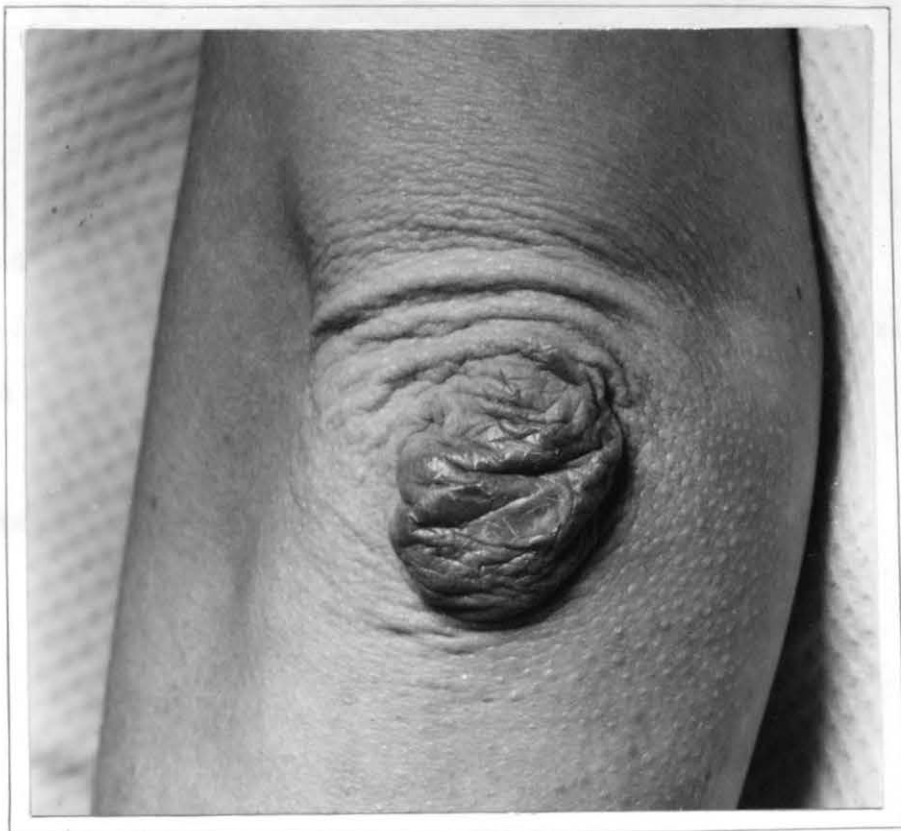

Fig. 37.- Case 12. To show pseudo-tumour on the left elbow.

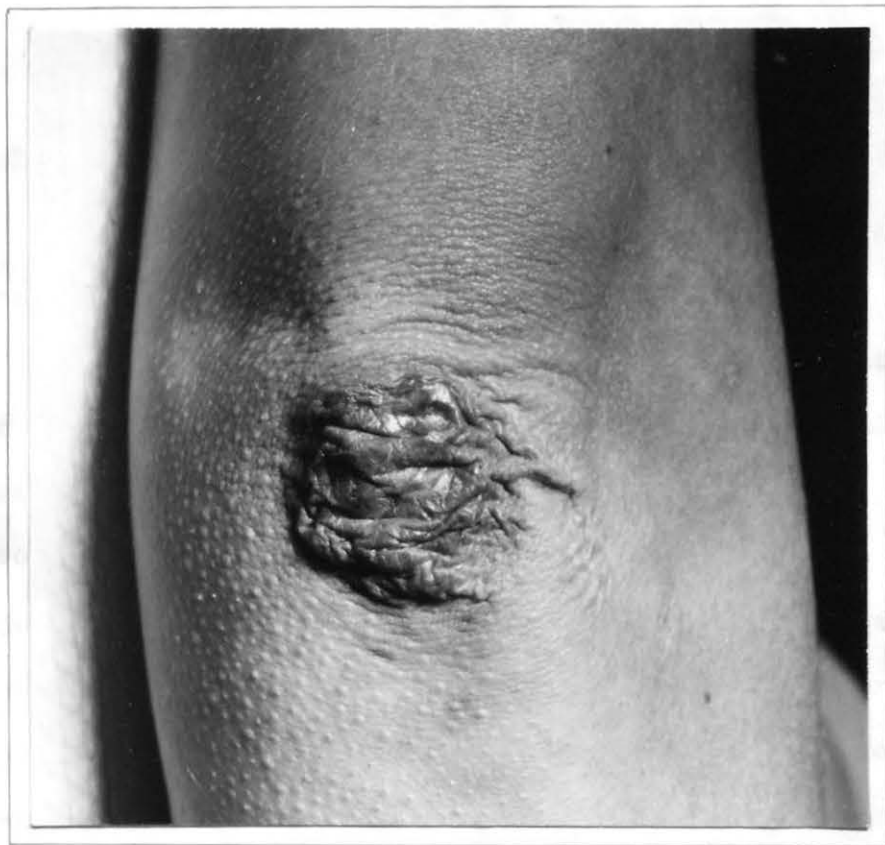

Fig. 38.- Case 12. To show pseudo-tumour on the right elbow. It is less marked than that on the left elbow.

All the joints showed an undue degree of laxity and the hands could form grotesque shapes by manipulation of the small joints (Figs. 39 and 40). The feet showed bilateral pes cavus.

The muscles were rather soft to the touch but not markedly so.

Laboratory Investigations:

Bleeding time - 2 min. 15 sec.
Tourniquet test - negative
Blood film - normal

Hormonal Investigations.- Unfortunately a specimen of urine for hormonal analysis was not obtained.

Case 13

This patient, Mrs MacL., is another of the sisters of Case 11 and is a housewife aged 47 years.

History.- This differs little from that of her sisters, her early childhood and birth being uneventful. She had the usual number of childhood injuries, few of which were sutured. However, about ten years ago she had a severe injury to her left knee and had to be admitted to hospital. On this occasion the wound was sutured with 8 nylon sutures and a very satisfactory result was obtained. About five years ago she developed a breast cyst for which operation was undertaken and satisfactory wound healing resulted.

Obstetrical /

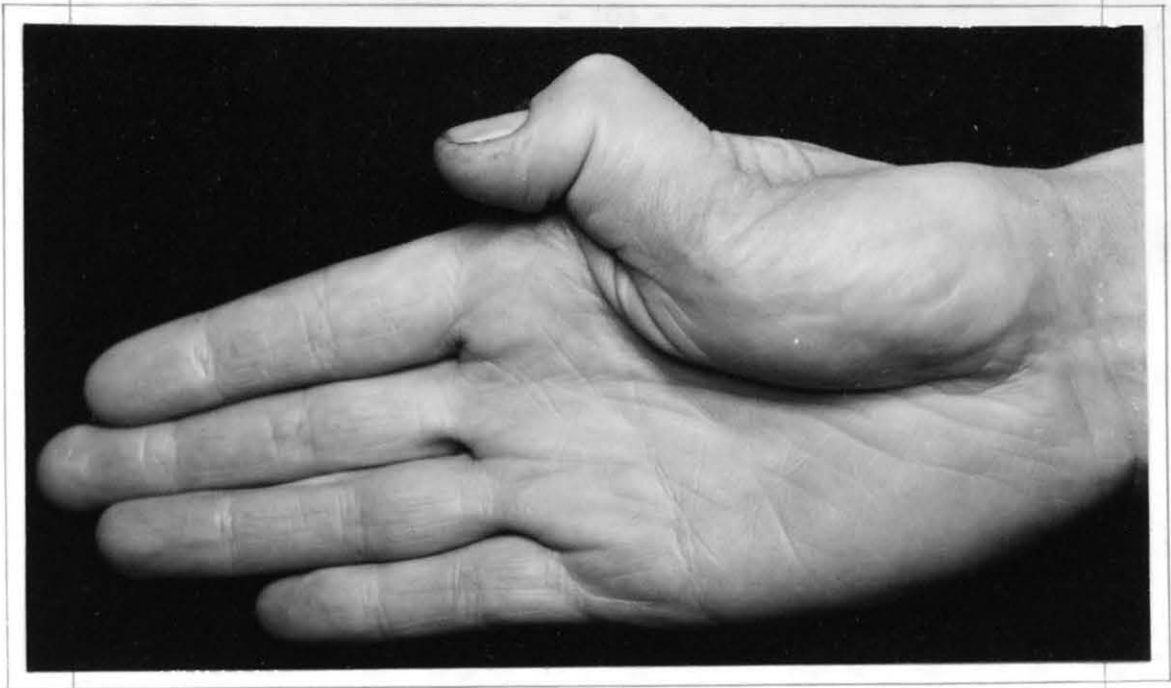

Fig. 39.- Case 12. To show the marked degree of joint mobility of the right hand.

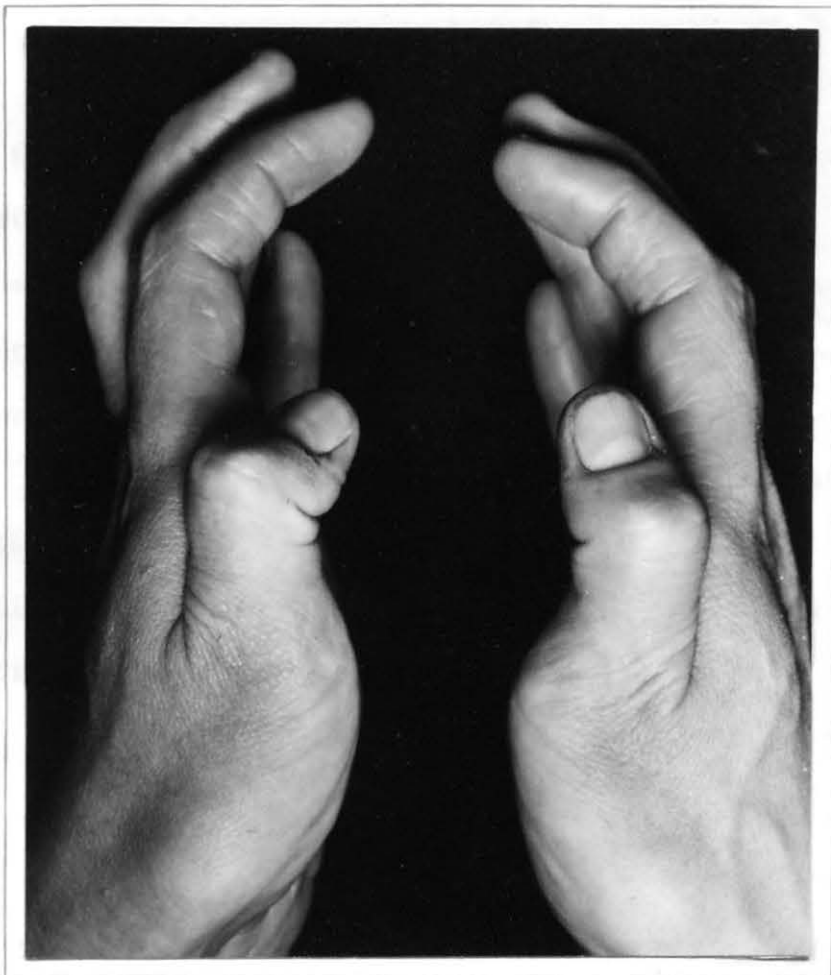


Fig. 40.- Case 12. To show the joint mobility of both hands.

Obstetrical History.- She has two sons neither of whom was premature, their birth weights being $8\frac{1}{4}$ lb. and $8\frac{3}{4}$ lb. She had one abortion and was admitted to hospital on account of bleeding, but no significance can be attached to this as it is a very common condition. Both her sons are affected by the condition (unfortunately they were not available for examination), and one of them has a son who was born prematurely at 36 weeks. This statement is, however, doubtful because the baby was reputed to weigh 7 lb. at birth.

Examination.- She was a healthy looking woman with no complaints and no abnormal physical signs on routine examination.

The skin showed the same features as that of the rest of the family, being soft and velvety to the touch and markedly elastic. There were scars of the papyraceous kind, principally on the knees and elbows, and a pseudo-tumour on the right elbow. At one time this had been excised but recurrence had taken place. There were no spherules.

The joints were hyperlax, especially the small joints of the hand, and the feet showed pes cavus. Like all the family, she had always had great difficulty in getting shoes to fit her.

The muscles appeared to be normal.

Laboratory Investigations:

Bleeding time	- 4 min.
Tourniquet test	- negative
Blood film	- normal

Hormonal /

Hormonal Investigations (urine, 24-hour specimen):

Total volume - 1,205 ml./day
17-ke tosteroids - 4.1 mg./day (low)
Corticosterone-like substances - 4.2 mg./day (normal)

Case 14

This patient, Mrs K., is the last of the four affected sisters (there is a brother also affected but I did not see him). She is aged 38 years and is a housewife.

History.- This is again much the same as that of her sisters, the first recognition of the condition having been at school age. She had had no major wounds but many minor ones, and noticed that when these were left unstitched they took about 6-7 weeks to heal and showed a tendency to sepsis, whereas with suture they healed in a week or ten days.

She has two children - one boy and one girl. She had no abortions. I did not see the boy but apparently he was unaffected, but I did see the girl whose case I will describe next (Case 15).

Examination.- This showed a healthy woman with no clinical abnormality of the internal organs.

The skin demonstrated the usual features of softness and elasticity, and evidence of fragility was shown by the papyraceous scars around the knees and elbows. In her case there /

there was no evidence of pseudo-tumours or spherules.

The joints were lax to a marked degree, particularly, as in the other cases, the small joints of the hands. The usual pes cavus was present.

Laboratory Investigations:

Bleeding time	- 5 min. 45 sec.
Tourniquet test	- negative
Blood film	- normal

Hormonal Investigations (urine, 24-hour specimen):

Total volume	- 1,480 ml./day
17-ketosteroids	- 5.4 mg./day (low)
Corticosterone-like substances	- 3.0 mg./day (low)

Case 15

This patient, Mrs A., aged 22 years, is the daughter of Case 14. She is clearly less affected by the condition than her mother but it is still present to a marked degree. Her history is practically the same as that of her mother, the earliest recognition having been in school life. This patient was not premature. She has not yet had any children.

Examination.- This showed a normal healthy woman with no evidence of disease of the internal organs.

The skin showed the family characteristics already described in the previous four cases.

There /

There was less laxity in her joints than in those of her mother and aunts, but the usual pes cavus was seen.

Laboratory Investigations:

Bleeding time - 2 min. 30 sec.
Tourniquet test - negative
Blood film - normal

Hormonal Investigations (urine, 24-hour specimen):

Total volume - 1,575 ml./day
17-ketosteroids - 9.2 mg./day (normal)
Corticosterone-like substances - 6.3 mg./day (normal)

Case 16

This patient, Mrs D., aged 43 years, is distantly related to the foregoing family.

History.- She had a normal birth and early childhood and first noted her skin peculiarity when she went to school and received injuries which produced skin damage. Her history followed almost exactly the pattern of her distant cousins, there being many minor injuries but no major ones. She married at the age of 19 years and has three children, one son aged 21 years and two daughters aged 18 and 13 years respectively. All were normal births and the son and younger daughter are not affected by the condition, but the middle child has the disability. I was not able to see any of her children.

Examination /

Examination.- Routine clinical examination revealed no abnormality of the internal organs but again the skin showed softness to the touch, hyperelasticity especially around the elbow joints, and many small papyraceous scars, most marked about the elbows and knees (Fig. 41). The joints were not markedly hyperlax but were certainly "looser" than the normal. However, this was not a marked feature of the case. A degree of pes cavus was present.

Laboratory Investigations:

Bleeding time - 3 min. 50 sec.
Tourniquet test - weak positive (14 petechiae)
Blood film - normal

Hormonal Investigations (urine, 24-hour specimen):

Total volume - 1,870 ml./day
17-ketosteroids - 2.8 mg./day (low)
Corticosterone-like substances - 4.2 mg./day (normal)

Case 17

This patient, Mr T., aged 65 years, is a retired office worker and no relation of the other patients.

History.- He stated that his lax skin was not present as a child and that it appeared only after a "nervous breakdown" at the age of 45 years. It had caused him no trouble in the succeeding twenty years.

Examination /

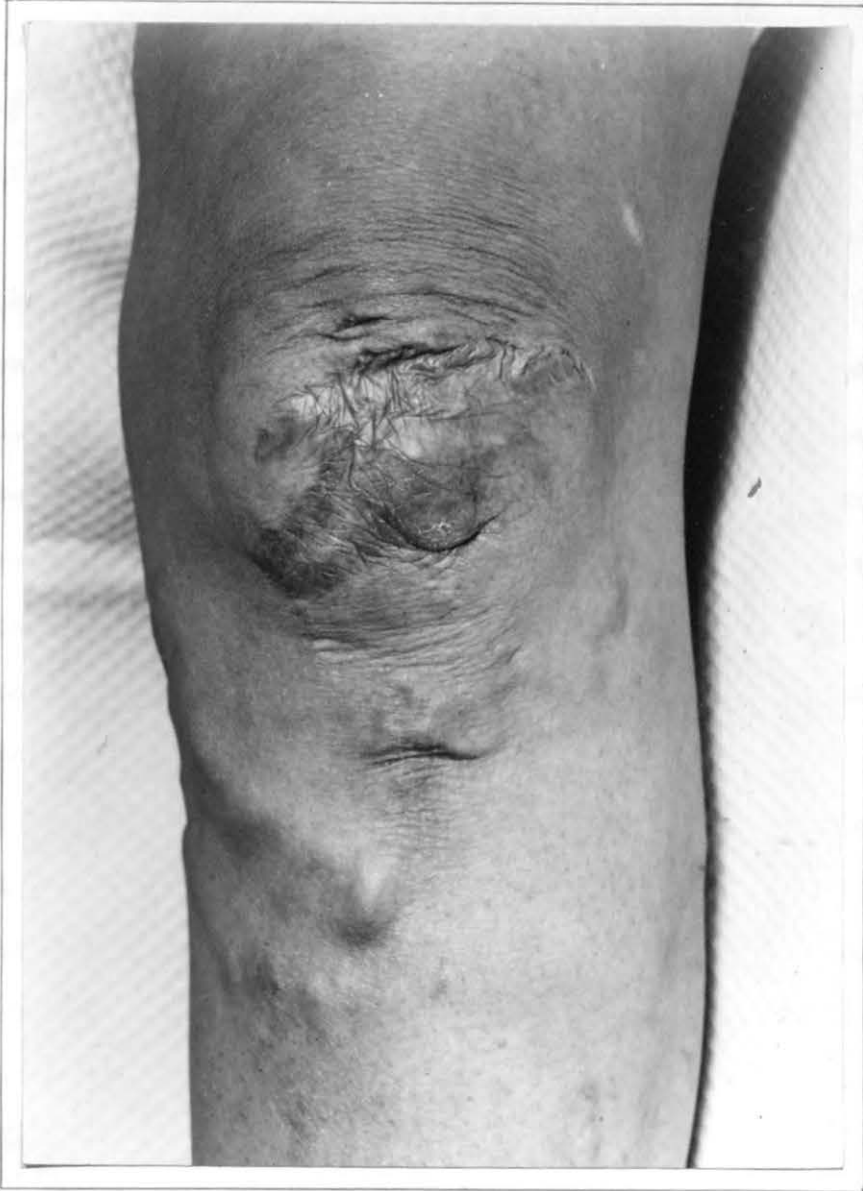

Fig. 41.- Case 16. To show the papyraceous scarring of the left knee.

Examination.- The patient was a man who looked his years, more especially so because his features were very wrinkled. Routine clinical examination did not reveal any abnormality.

The skin was extremely lax, particularly over the elbow and knee joints, and could be stretched to a very great extent. There were a few small scars on the limbs, especially on the front of the left leg, but they could scarcely be said to be of the papyraceous variety. The skin over the knees gave the impression that there was much scarring, but, on pulling the skin, it was seen to be mostly due to wrinkling. The feel of the skin was definitely soft and velvety.

The joints were hyperlax to a marked degree and this was well illustrated by the small joints of the hands. One peculiar feature of this patient was his ability to produce a voluntary dislocation of each patella in a lateral direction. This movement did not cause any pain and could be reproduced by the examiner with the greatest of ease, again without pain to the patient. The feet showed a mild degree of pes cavus.

Family History.- This man was the sixth of a family of nine children and was the only one who had ever shown any peculiarity of the skin or joints. He was married and had two grown-up sons neither of whom had any similar condition and neither of whom had been born prematurely.

Hormonal /

Hormonal Investigations (urine, 24-hour specimen):

Total volume	- 750 ml./day
17-ketosteroids	- 1.3 mg./day (low)
Corticosterone-like substances	- 1.2 mg./day (low)

This case is the most confusing of my series in that the condition reputedly did not appear until the age of 45 years. As already noted, Brown (1946) described the case of a patient in whom the condition was stated to have begun at the age of 53 years. However, in my patient I feel that I have cause to doubt his statement concerning the age at which it became apparent, because I considered that his mental condition was deteriorating with advancing years. It seems probable that his skin condition must have been present all his life, but it could conceivably have started at 45 years as a result of a hormonal disturbance.

PART /

PART III

CONCLUSIONS

The main objective of this investigation was to establish the cause of the Ehlers-Danlos syndrome. Although this has yet to be established with certainty, I feel that a certain amount of progress has been made. The secondary objective was to study the effects of the syndrome on individuals and the degree to which their lives were affected.

Aetiology

I consider that there are two main factors involved in the aetiology of the syndrome: the disturbance of collagen and the hormonal disturbance.

(1) The Disturbance of Collagen.- It has been agreed by the majority of observers that the collagen content of the skin is decreased and I think that this must be accepted as a fact. However, no apparent abnormality of the collagen has been described with the exception of "thinning", "rarefaction" and various other descriptions which cover the diminution in quantity. Investigations with the electron microscope likewise did not discover any abnormality beyond reduction in quantity. It is now generally accepted that the collagen is the material which is responsible for the "stretchability" of the skin and that the elastic tissue plays a supporting role. I consider that this elastic tissue, which is probably degenerate /

degenerate and relatively excessive in quantity, is the result of the collagen deficiency. It is therefore different from cutis laxa where there is a diminution of elastic tissue. This is confirmed by my sections which show a marked increase in "orcein-positive material", a proportion of which may be degenerate collagen. It is unfortunate that keloid formation should have taken place in the scar made by the biopsy in Case 1, because this rather obscures the picture of normal tissue reaction, but it is one of the accepted risks of surgical interference.

Although it cannot be proved histologically, it can reasonably be assumed that the skin changes are reproduced in the joints, muscles and subcutaneous tissues as the clinical findings suggest. Thus I consider that there is a collagen abnormality throughout the whole of the integumentary system, the cause for which is as yet unknown but is clearly hereditary. Consequently there must be an abnormality in the gene which transmits it to the next generation. It is one of the most difficult problems in medicine to find the cause of an inherited disease and even more difficult to find a cure, but I feel that surely it is possible to influence its course. With this in mind, I will now deal more fully with the second factor.

(2) The Hormonal Disturbance.- Throughout the literature the subject of prematurity appears with great frequency and in my first few cases this is particularly evident. However, my /

my Cases 11-16 all come from one family and were either not premature or could not tell the details of their births, although there is a history of possible prematurity in members of the family whom I did not see. Thus in my total of 17 cases there were 5 definite premature babies, 8 full-time deliveries and 4 doubtful, that is, the percentage of prematurity was almost exactly 30 per cent. One interesting fact is that in my series the percentage of premature births varies from family to family, for example Cases 1-4 are of the same family and their prematurity rate is 50 per cent., whereas in Cases 11-16 who are likewise of one family, the percentage is almost nil. In the cases in which there is no other example in their families, the percentage is at least 50 per cent., and in the family of two patients both were probably premature. Unfortunately I was unable to ascertain the birth details of the fatal case. It is clear therefore that one family (exhibiting a mild form of the Ehlers-Danlos syndrome) materially lowered the prematurity rate in my series, but even taking that into consideration, a figure of 30 per cent. is considerably higher than that for the general population which is 7 per cent. (Douglas, 1950).

In a rare syndrome of this kind no one man gets the opportunity of studying a large series of cases and consequently deductions have to be made from a small number, although I realise that this is not altogether desirable. It is my view that prematurity may be caused by a fundamental disturbance in hormonal balance in the foetus which gives rise to the /

the characteristics of the Ehlers-Danlos syndrome, and at the same time influences a normal uterus to expel its contents before full term. Kanof (1952) was also working on these lines when he found in one case that the excretion of 17-ketosteroids was increased. I have carried out this particular hormonal function test and that for the corticosterone-like substances in 14 cases, with the following results:-

<u>17-ketosteroids</u>	<u>Corticosterone-like substances</u>
Increased - 1 case	Increased - 1 case
Decreased - 7 cases	Decreased - 7 cases
Normal - 6 cases	Normal - 6 cases

In my other three cases, these tests were not carried out because specimens of urine were not available.

Because there is a definite tendency for my figures to be lowered, they do not agree with the work of Kanof. For this reason I cannot confirm his suggestion that an increased excretion of 17-ketosteroids is evidence of a possible causal mechanism, but I do agree with him that a hormonal factor is probably involved.

In my series the results for 17-ketosteroids and for the corticosterone-like substances are roughly the same in each case, as a rule being raised or lowered together. So far as I am aware, this is the first occasion on which the estimation of corticosterone-like substances has been undertaken in research /

research into this syndrome. My findings suggest that there is an abnormality of the hormone excretion in about 50 per cent. of cases. Since this investigation was undertaken, a new hormone test, the estimation of hydroxy-steroids, has been evolved, and it is possible that this may further elucidate the problem.

The whole subject of what has come to be called "the collagen diseases" is under investigation at the moment. In the treatment of rheumatoid arthritis and lupus erythematosus, which tend to show an increase of collagen in the tissues, the use of cortisone and its derivatives has led to a great, if temporary, improvement. The Ehlers-Danlos syndrome, on the other hand, usually shows a collagen deficiency, and theoretically should respond to a substance which would neutralise the effects of cortisone.

The Effect on the Individual

As regards the secondary objective, that of estimating the effect of the syndrome on an individual's life, it is necessary to balance physical activities and the psychological effects which result from limitation of these. This is especially applicable when the patient is a child exhibiting a severe degree of the syndrome. As stated in the section on Prognosis (p. 54), the amount of activity allowed should be governed by the degree of fragility of skin and of hyperlaxity of joints. If this is sufficiently severe, the child's recreation /

recreation should be confined to those games in which bodily injury is unlikely to be encountered. Curtailment in this way may predispose to certain psychological conflicts, but these are negligible in comparison with the gross physical injury which may result from rough games. Boys are torn between their natural desire to participate in all the activities of their fellows and their knowledge of what this may mean in terms of injury. Girls, on the other hand, are less affected in this way, but any scars which they do receive may require plastic surgery in adolescence.

Therefore I agree with Ronchese (1936, 1943) that the possessor of a fragile skin is a handicapped person. In severely affected children this is a serious handicap, but in children slightly affected, and in adults, the handicap is a small one.

SUMMARY

A review has been given of the literature on the Ehlers-Danlos syndrome together with the records of 17 personal cases.

The conclusion is reached that the cause of the syndrome lies in a diminution and degeneration of collagen, which is probably due to a hormonal disturbance the exact nature of which is as yet unknown. It is clear that these abnormal factors are transmitted from generation to generation as a Mendelian dominant. This makes the problem of cure a difficult one, but one which it is hoped will be solved in the not too distant future.

REFERENCES

- Agostini, A. (1938). Dermosifilografo, 13, 611.
- Albright, F. and Reifenstein, E.C. (1948). "Parathyroid Glands and Metabolic Bone Disease," p. 165. Baltimore: Williams and Wilkins Co.
- Balina, P.L. and Sicardi, A. (1935). Rev. argent. Dermato-sif., 59, 144.
- Barber, H.W. (1923). Proc. R. Soc. Med., 16, 90.
- Barber, H.S., Fiddes, J. and Benians, T.H.C. (1941). Brit. J. Derm., 53, 97.
- Benavides, L. (1952). Bol. méd. Hosp. infant., Méx., 8, 483.
- Benjamin, B. and Weiner, H. (1943). Amer. J. Dis. Child., 65, 247.
- Berger (1933). Zbl. Haut.-u. GeschlKr., 44, 257. (Abstract)
Quoted by Barber, Fiddes and Benians (1941).
- Berggreen, P. (1937). Derm. Wschr., 104, 374. Quoted by Barber, Fiddes and Benians (1941).
- Bielschowsky, F. (1930). Dtsch. Arch. klin. Med., 166, 96.
Quoted by Barber, Fiddes and Benians (1941).
- Bolam, M. (1938). Brit. J. Derm., 50, 174.
- Brain, R.T. (1936). Proc. R. Soc. Med., 29, 923.
- Brombart, M., Coupatez, G. and Laurent, Y. (1952). Arch. mal. app. digest., Paris, 41, 413.
- Brown, A. (1946). Glasg. med. J., 27, 7.
- Brown, A. and Stock, V.F. (1937). Amer. J. Dis. Child., 54, 956.
- Bunim, J.J. (1951). Bull. N.Y. Acad. Med., 27, 75.
Quoted by Kanof (1952).
- Burrows, A. (1932). Proc. R. Soc. Med., 25, 1319.
- Burrows, A. and Turnbull, H.M. (1938). Brit. J. Derm., 50, 648.
- Capurro, R. (1926). Arch. lat.-amer. Pediat., 20, 713.
Quoted by Ronchese (1936, 1943).
- Cathala, /

- Cathala, J. (1937). Arch. Méd. Enf., 40, 107.
Quoted by Johnson and Falls (1949).
- Cockayne, E.A. (1933). "Inherited Abnormalities of the Skin and its Appendages," p. 117. London: Oxford University Press.
- Coe, M. and Silvers, S.H. (1940). Amer. J. Dis. Child., 59, 129.
- Cohn, P. (1907). Verh. dtsh. dermat. Ges., 9, 415.
- Comby, J. (1937). Arch. Méd. Enf., 40, 107.
Quoted by Barber, Fiddes and Benians (1941).
- Cope, O. (1950). "Adrenal Cortex," p. 121. Trans. 1st Conf. Jos. Macy Jr. Foundation.
- Cottini, G.B. (1940). Gazz. Osp. Clin., 61, 230.
- Darlos, H. (1908). Bull. Soc. franc. Derm. Syph., 19, 70.
- Davies, J.H.T. (1938). Brit. J. Derm., 50, 36.
- Debre, R., Marie, J. and Seringe, P. (1937). Bull. Soc. méd. Hôp. Paris, 53, 1038.
- Debre, R. and Semelaigne, G. (1938). Bull. Soc. méd. Hôp. Paris, 54, 849.
- Delanne, R. (1952). Acta clin. belg., 7, 304.
- Delanne, R., Duwe, G. and van der Meiren, L. (1952). Arch. belges Derm., 8, 106.
- Dick, J.C. (1947). J. Anat., Lond., 81, 201.
- Dobrowskaya, N.W. (1924). Zbl. Haut-u. GeschlKr., 15, 437.
(Abstract.) Quoted by Johnson and Falls (1949).
- Douglas, J.W.B. (1950). J. Obstet. Gynaec., Brit. Emp., 57, 143.
- Dreyfus, G., Weill, J., Martineau, J. and Mathivat, A. (1936). Bull. Soc. méd. Hôp. Paris, 52, 1463. Quoted by Johnson and Falls (1949).
- Durham, D.G. (1953). Arch. Ophthal., N.Y., 49, 220.
- Ehlers, E. (1901). Hospitalstidende, 44, 48.
- Erbach /

- Erbach, O. (1933). Zbl. Haut-u. GeschlKr., 44, 341.
(Abstract.) Quoted by Barber, Fiddes and Benians
(1941).
- Fischer (1931-32). Zbl. Haut-u. GeschlKr., 39, 265.
(Abstract.) Quoted by Barber, Fiddes and Benians
(1941).
- Fraser, R.W., Forbes, A.P., Albright, F., Sulkowitch, H. and
Reifenstein, E.C. jr. (1941). J. clin. Endocrin.,
1, 234. Quoted by Tompsett, S.L. (personal
communication).
- Freeman, J.T. (1950). Amer. J. Dis. Child., 79, 1049.
- Fritchey, J.A. and Greenbaum, S.S. (1940). Arch. Derm. Syph.
N.Y., 42, 742.
- Garcia, M. and Fialho, A. (1937). Arch. Pediat. Rio de J.,
7, 466. Abstracted in Amer. J. Dis. Child. (1937),
54, 175.
- Gaté, J. (1933a). In "Traité de dermatologie clinique et
therapeutique," vol. I, p. 226, by Belot, J. and others.
Paris: Gaston, Dion et Cie. Quoted by Ronchese (1936).
- Gaté, J. (1933b). In "Traité de dermatologie clinique et
therapeutique," vol. II, pt. 2, by Belot, J. and others.
Paris: Gaston, Dion et Cie. Quoted by Ronchese (1936).
- Gilbert, A., Villaret, M. and Bosviel, G. (1925).
Bull. Soc. méd. Hôp. Paris, 49, 303.
- Goldsmith, W.N. (1939). Proc. R. Soc. Med., 32, 1027.
- Gordon, H. (1942). Proc. R. Soc. Med., 35, 263.
- Gross, J. (1949). J. exp. Med., 89, 699.
- Hallopeau, H. and Lépinay, M. (1906). Bull. Soc. franc.
Derm. Syph., 17, 283. Quoted by Tobias (1934).
- Hirszfeldowa, H. and Sterling, W. (1924a). Zbl. Haut-u.
GeschlKr., 16, 803. (Abstract). Quoted by Johnson
and Falls (1949).
- Hirszfeldowa, H. and Sterling, W. (1924b). Pediat. polska,
4, 131. Quoted by Johnson and Falls (1949).
- Holt, J.F. (1946). Amer. J. Roentgenol., 55, 420.

Husebye /

- Husebye, K.O. (1952). Tidsskr. norske Laegeforen., 72, 185.
- Joereens, G. (1909). Med. Klin., 5, 849.
- Johnson, S.A.M. and Falls, H.F. (1949). Arch. Derm. Syph., N.Y., 60, 82.
- Kalz, F. (1935). Arch. Derm. Syph., Wien, 171, 155.
- Kanof, A. (1952). Amer. J. Dis. Child., 83, 197.
- Keining (1932). Zbl. Haut-u. GeschlKr., 40, 27. Quoted by Barber, Fiddes and Denians (1941).
- Kenigsberg, S., Pearson, S. and McGavack, T.H. (1949). J. clin. Endocrin., 9, 426. Quoted by Tompsett, S.L. (personal communication).
- King-Smith, D., Trow, E.J. and Dixon, H.A. (1932). Arch. Derm. Syph., N.Y., 25, 179.
- Klebanov, G.I. (1937). Vest. vener., p. 636. Quoted by Barber, Fiddes and Benians (1941).
- Konrad (1933). Zbl. Haut-u. GeschlKr., 45, 301. Quoted by Barber, Fiddes and Benians (1941).
- Kopp, L.C. (1888). Munch. med. Wschr., 35, 259. Quoted by Johnson and Falls (1949).
- Langmead, F. (1923). Proc. R. Soc. Med., 16, 23.
- Laplane, R., Hartmann, J. and Sebouk, S. (1952). Arch. franc. Pédiat., 9, 617.
- Launay, C. (1941). Bull. Soc. méd. Hop. Paris, 56, 709. Quoted by Johnson and Falls (1949).
- Le Coulant, P. (1934). Gaz. Hebd. Sci. Med., 55, 261. Quoted by Ronchese (1936, 1943).
- Lowe, J. (1939). Proc. R. Soc. Med., 32, 1027.
- Macfarlane, R.G. (1952). Personal communication.
- MacLeod, J.M.H. and Muende, I. (1946). "Practical Handbook of Pathology of Skin," 3rd edn., p. 138. London: H.K. Lewis.
- Margarot, J., Deveze, P. and Coll de Carrera (1933a). Montpellier méd., 3, 133. Quoted by Johnson and Falls (1949).
- Margarot /

- Margarot, J., Deveze, P. and Coll de Carrera (1933b).
Bull. Soc. franc. Derm. Syph., 40, 277. Quoted by
Johnson and Falls (1949).
- Martin, A. Navarro, and Maruri, C. Aguilera (1932).
Act. dermo-sifilogr., Madr., 25, 126. Quoted by
Johnson and Falls (1949).
- Meekren, J. à (1682). "Observationes Medico-chirurgicae,"
chap. 32. Amstelodami. Quoted by Taylor (1943).
- Meincke, H. (1936). Hospitalstidende, 79: Dansk. dermat.
selsk. forh., 49.
- Meirowsky, E. (1927). Zbl. Haut-u. GeschlKr., 24, 577.
(Abstract.) Quoted by Barber, Fiddes and Benians (1941).
- Miget, A. (1933). "Le Syndrome d'Ehlers-Danlos." Thesis.
Paris.
- Morris, Sir Malcolm (1900). Brit. J. Derm., 12, 209.
- Murray, J.E. and Tyars, M.E. (1940). Brit. med. J., 1, 974.
- Nardelli, L. (1935). G. ital. Derm. Sif., 76, 607.
- Ormsby, O.S. and Montgomery, H. (1943). "Diseases of the
Skin." Philadelphia: Lea and Febiger.
- Ormsby, O.S. and Tobin, W.W. (1938). Arch. Derm. Syph., N.Y.,
38, 828.
- Pascher, F. and Kanof, A. (1953). Arch. Derm. Syph., N.Y.,
67, 214.
- Pautrier, L.-M. (1908). Bull. Soc. franc. Derm. Syph., 19, 72.
- Pelbois, F. and Rollier, F. (1952). Bull. Soc. franc.
Derm. Syph., 59, 141.
- Petges, G. (1936). Bull. Soc. franc. Derm. Syph., 43, 66.
- Pierard, B. and Palmer, H. (1949). N.Z. med. J., 48, 377.
- Pittinos, G.E. (1941). J. Pediat., 19, 85.
- Poumeau-Delille, G. and Soulié, P. (1934). Bull. Soc. méd.
Hôp. Paris, 50, 593.
- Poynton, F.J. and Paterson, D. (1921). Proc. R. Soc. Med.,
14, 7.

- Ragan, C., Howes, E.L., Plotz, C.M., Meyer, K. and Blunt, J.W. (1949). Proc. Soc. exp. Biol., N.Y., 72, 718.
- Rambar, A.C. (1938). J. Pediat., 12, 592.
- Raspi, M. (1927). Riv. Clin. pediat., 25, 648. Quoted by Ronchese (1936, 1943).
- Raybaud, A. and Guidoni, P. (1938). Bull. Soc. méd. Hôp. Paris, 54, 738.
- Read, C.H., Venning, E.H. and Ripstein, M.P. (1950). J. clin. Endocrin., 10, 845.
- Reyn, A. (1933). Hospitalstidende, 76, 961. Quoted by Barber, Fiddes and Benians (1941).
- Ringrose, E.J., Nowlan, F.B. and Perry, H. (1950). Arch. Derm. Syph., N.Y., 62, 443.
- Roca, A. and Loiacono, G.J. (1942). Sem. méd., 49, 887.
- Rocher, H.L. (1932). In "Livre jubilaire offert au Professeur H. Hartmann par ses amis et élèves." Paris: Masson et Cie.
- Rocher, H.L., Petges, G. and Le Coulant, P. (1934). Rev. Orthopéd., 21, 673. Quoted by Ronchese (1936, 1943).
- Ronchese, F. (1936). Amer. J. Dis. Child., 51, 1403.
- Ronchese, F. (1943). Uroñ. cutan. Rev., 47, 581.
- Schaper, G. (1952). Z. Kinderheilk., 70, 504.
- Schubert, P. (1925). Zbl. Haut-u. GeschlKr., 16, 162. Quoted by Johnson and Falls (1949).
- Schulmann, E. and Lévy-Coblentz, G. (1932). Bull. Soc. franc. Derm. Syph., 39, 1252.
- Schwab, R.S. and Viets, H.R. (1938). New Engl. J. Med., 219, 226.
- Scolari, E. (1937). G. ital. Derm. Sif., 78, 577. (Abstracted in Brit. J. Derm. (1938), 50, 260.)
- Setti, A. (1937). Lattante, 8, 342.
- Sezary, A., Azerad, E., Miget, A. and Deparis (1933). Bull. Soc. franc. Derm. Syph., 40, 1287. Quoted by Johnson and Falls (1949).

Sezary /

- Sezary, A. and Horowitz, A. (1935). Bull. Soc. franc. Derm. Syph., 42, 1744.
- Shapiro, S.K. (1952). J. nerv. ment. Dis., 115, 64.
- Shaw, H.B. and Hopkins, P. (1913). Proc. R. Soc. Med., 6, 20.
- Shelton, E.K. and Tager, B.N. (1937). Endocrinology, 21, 773.
- Simpson, R.W. (1937). Amer. J. Dis. Child., 54, 957.
- Skeer, J. and Kaplan, A.A. (1940). Arch. Derm. Syph., N.Y., 42, 450.
- Smith, C.H. (1939). J. Pediat., 14, 632.
- Smith, J.F. (1938). Brit. J. Derm., 50, 313.
- Soffer, L.J. (1947). Bull. N.Y. Acad. Med., 23, 479.
Quoted by Kanof (1952).
- Soffer, L.J. (1948). Bull. N.Y. Acad. Med., 24, 32.
Quoted by Kanof (1952).
- Standard Classified Nomenclature of Diseases (1935), p. 126.
New York: The Commonwealth Fund.
- Stillians, A.W. and Zakon, S.J. (1937). Arch. Derm. Syph., N.Y., 35, 342.
- Stuart, A.M. (1937). Proc. R. Soc. Med., 30, 984.
- Sullivan, J.D. (1942). Arch. Neurol. Psychiat., Chicago, 47, 316.
- Sutton, R.L. and Sutton, R.L. Jr. (1939). "Diseases of the Skin," 10th edn. London: Henry Kimpton.
- Talbot, N.B., Butler, A.M., Bermon, R.A., Rodriguez, P.M. and MacLachlan, E.A. (1943). Amer. J. Dis. Child., 65, 364. Quoted by Tompsett, S.L. (personal communication).
- Taylor, F.R. (1943). Urol. cutan. Rev., 47, 378.
- Tenconi, A. (1952). Minerva pediat., Tor., 4, 414.
- Thomas, C., Cordier, J. and Algan, B. (1952). Bull. Soc. belge Ophtal., Feb., p. 375.
- Thurmon, F.M. (1939). Arch. Derm. Syph., N.Y., 40, 120.
- Tobias /

- Tobias, N. (1934). Arch. Derm. Syph., N.Y., 30, 540.
- Tobias, N. (1939). Arch. Derm. Syph., N.Y., 40, 135.
- Tompsett, S.L. (1953a). J. clin. Path., 6, 74.
- Tompsett, S.L. (1953b). Personal communication.
- Touraine, A. (1952). Gaz. méd. portug., 5, 105.
- Tunbridge, R.E., Tattersall, R.N., Hall, D.A., Astbury, W.T. and Reed, R. (1952). Clin. Sci., 11, 315.
- Turner, E.K. (1949). Med. J. Aust., 2, 165.
- Unna, P.G. (1896). "The Histopathology of the Diseases of the Skin." New York: MacMillan & Co.
- Vaglio, R. (1923). Pediatria, Napoli, 31, 321. Quoted by Ronchese (1936).
- van Aardenne, J. (1939). Mandschr. Kindergeneesk., 8, 187. Abstracted in Amer. J. Dis. Child., 59, 440.
- van der Valk, J.W. (1926). Ned. Tijdschr. Geneesk., 70, 2302. Quoted by Johnson and Falls (1949).
- Viecelli, J.D. (1938). Arch. Derm. Syph., N.Y., 38, 498.
- Walker, A.E. and Stewart, J.J. (1952). Arch. Derm. Syph., N.Y., 66, 535.
- Wallach, E.A. and Burkhart, E.F. (1950). Arch. Derm. Syph., N.Y., 61, 750.
- Washington University School of Medicine, Clinics of (1939). Arch. Derm. Syph., N.Y., 40, 137.
- Weber, F.P. (1913). Brit. J. Child. Dis., 10, 97.
- Weber, F.P. (1923). Urol. cutan. Rev., 27, 407.
- Weber, F.P. (1936). Brit. J. Derm., 48, 609.
- Weber, F.P. (1937). Proc. R.Soc. Med., 30, 30.
- Weber, F.P. and Aitken, J.K. (1938a). Lancet, 1, 198.
- Weber, F.P. and Aitken, J.K. (1938b). Proc. R.Soc. Med., 31, 553.
- Weill, J. and Martineau, J. (1937). Bull. Soc. franc. Derm. Syph., 44, 99.

- Wiener, K. (1924). Arch. Derm. Syph., Wien, 148, 599.
- Wigley, J.E.M. (1938). Brit. J. Derm., 50, 93. Also
Proc. R. Soc. Med., 31, 257.
- Williams, A.W. (1892). Mh. prakt. Dermat., 14, 490.
- Wolpers, C. (1944). Klin. Wschr., 23, 169. Quoted by
Tunbridge et al. (1952).
- Wood, M.E. and Gray, C.H. (1949-50). J. Endocrin., 6, 111.
Quoted by Tompsett, S.L. (personal communication).

SUMMARY

OF THESIS ON

AN INVESTIGATION INTO THE EHLERS-DANLOS SYNDROME

By Alexander Mories, M.B., Ch.B. (Edin.)



SUMMARY

OF THESIS ON

AN INVESTIGATION INTO THE EHLERS-DANLOS SYNDROME

By Alexander Mories, M.B., Ch.B.(Edin.)

This thesis consists mainly of a review of the literature on the Ehlers-Danlos syndrome, grouped into sections on aetiology, pathology, clinical features, radiology, laboratory investigations, differential diagnosis, genetics, prognosis and treatment.

The rarity of the condition is indicated by the fact that only 90-100 cases have been reported in the literature, although it is probable that many more of a minor degree have not been recognised. The reports of these cases show that the syndrome may be associated with various other clinical conditions, but the classical triad of clinical signs - hyperelasticity of skin, fragility of skin, hyperlaxity of joints - is accepted as the necessary evidence for conclusive diagnosis. There are varying views on the aetiology of the syndrome, but more general agreement on the pathological findings.

In an attempt to elucidate the condition further, the records of 17 personal cases are given. These patients were investigated as fully as was possible in the course of general /



general practice. The various tests carried out included an estimation of the level of corticosterone-like substances in the urine which, so far as is known, has not previously been applied in this syndrome. The findings in these cases support the general view that the collagen content of the skin is decreased. This is associated with a relative increase of elastic tissue found to stain positive with orcein, and it is suggested that some of this orcein-positive material may be degenerate collagen which is possibly produced by a hormonal disturbance. This series of cases also supports the general finding of an increased rate of prematurity, the cause of which may also be a hormonal imbalance. These abnormalities appear to be transmitted from generation to generation as a Mendelian dominant, and further research will be necessary before it is possible to influence the course of the condition.