

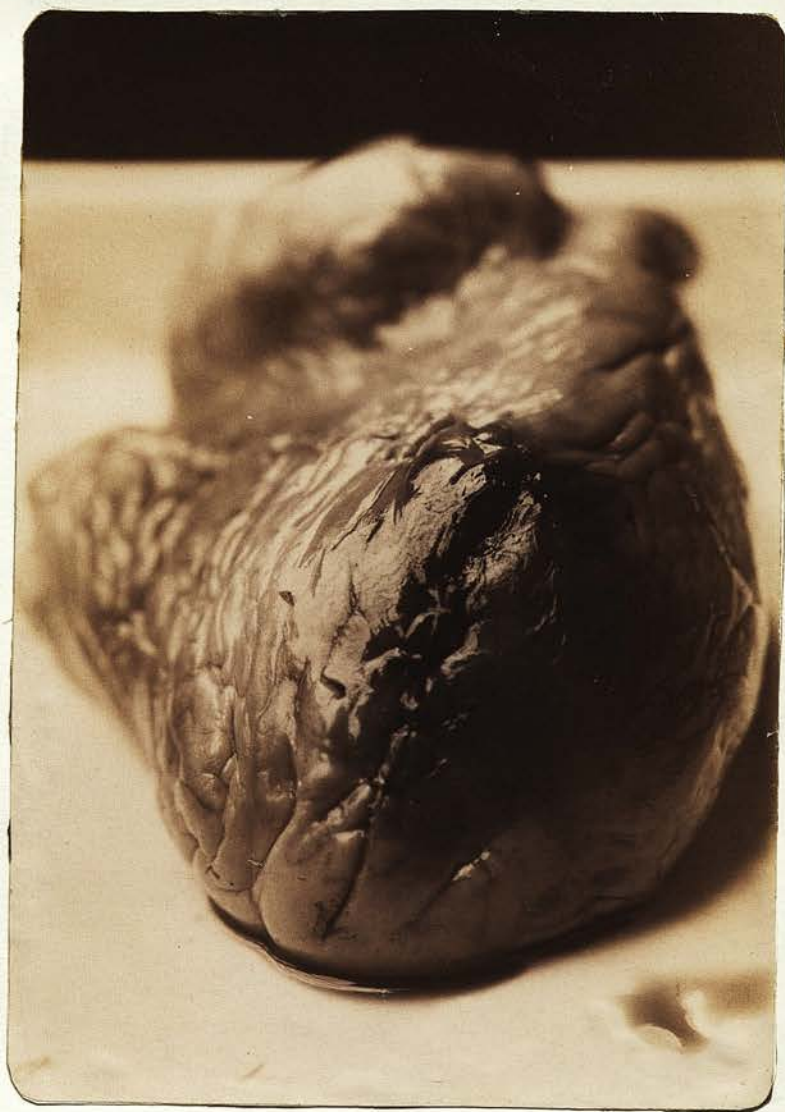(Box of slides)

A Case of Spontaneous Rupture of  
the Heart with its Pathological  
Appearances

by  
*Alex<sup>r</sup> McIntyre*  
A. G. McIntyre. M.B.C.M.

Crichton Royal Institution,  
Dumfries.





Before proceeding to the consideration of the special case to which the microscopic specimens and microphotographs refer, it may be permissible to give a short synopsis of the various opinions held by different authors regarding the cause, site and frequency of this condition.

#### Spontaneous Rupture of the Heart.

Rupture of the Heart may result from external violence or disease of the heart wall. It is the latter class of cases that is denominated spontaneous. Spontaneous rupture of the heart is generally the result of disease. Its chief predisposing cause is chronic softening due to fatty degeneration or fatty infiltration, most frequently the former. It may also result from acute local myocarditis, from thrombosis of the coronary artery or from the bursting of an abscess, very rarely from aneurism of the heart or Aorta. It is said sometimes to occur in the agony of death, thus constituting one of the phenomena rather than the cause of death.

The immediate cause of the lesion is usually some strong mental agitation or physical effort, such as a fit of passion, hurrying for cars, straining at stool etc.; but it sometimes takes place while the subject is at perfect rest.

Males are considerably more liable to rupture of the heart than females, and the occurrence becomes comparatively frequent after the 50th, still more after the 60th year.

In but few cases of heart rupture is the fatal event preceded by symptoms sufficiently marked to attract attention. Sometimes warning, however, is given by phenomena more or less indicative of a diseased condition of the organ, such as breathlessness on exertion, palpitation, irregularity of the pulse and fainting.

On the occurrence of the lesion death is usually instantaneous, although, when the rupture is a small one and oblique in its direction, the patient may survive for several hours or even days.

The special symptoms denoting a fatal termination are - restlessness, severe praecordial pain, dyspnoea, rapid feeble and fluttering pulse, vomiting, cyanosis, pallor, loss of consciousness and convulsions.

The physical signs even when the patient's life is sufficiently prolonged can be seldom accurately observed. They consist of only more or less praecordial dulness, with diminished impulse, muffled distant or imperfectly developed sounds and weak intermittent pulse.

Spontaneous rupture of the heart takes place more frequently in the left ventricle, owing to the greater liability of its walls to suffer degenerative changes and to experience the bad effects of over distension.

The seat of the rupture is given by Quain as most commonly in the left ventricle. (76) and

Rokitansky points out that it so occurs usually through the apex, which is most liable to localised degeneration, then the right ventricle (13), the right auricle (7), septum (4), and left auricle last (2)

The lesion may be complete or incomplete, and the size of the opening varies from a mere slit to an extensive laceration. There is usually one rupture, but as many as five have been observed, sometimes communicating with each other. The rent is ragged, irregular, and occasionally ecchymosed at its edges, and its pericardial and endocardial openings may or may not correspond. In the latter case they are connected by a sort of sinus in the walls of the ventricles.

The fissure runs more frequently parallel to, than across the muscular fasciculi.

These are the appearances in a ruptured heart that is the seat of fatty degeneration. They are different when the rupture is secondary to an abscess, or to haemorrhagic softening, in which case it may assume the form of an ulceration or perforation.

The effect of this accident is the escape of blood into the pericardial sac, which coagulates around the muscular walls, leaving the pericardial sac more or less filled with serum.

From more than one recorded case it would appear that a permanent closure of the fissured opening by a plug of fibrin is among the possibilities.

The following case is one of Spontaneous Rupture of the Heart:-

Mary Lewis, aged 61, single, of no occupation, was admitted 15 years ago to the Crichton Royal Institution suffering from mental weakness, partly congenital and partly the result of alcoholic excess.

On looking into the books as regards her physical condition at that period she is described as a small spare woman in fair bodily health and without any organic lesion of the heart.

Mentally she was as above stated. She afterwards passed gradually into Dementia and remained so till her death, which took place on the 3rd of March 1897.

#### Family History.

Discloses nothing except that the deceased has a sister congenitally of weak mind, who is now in this Institution, and a brother deceased was also insane.

#### History of the Case.

In 1890 patient went to Kinmount, a country house belonging to the Crichton Royal Institution, and remained there till her death.

While there she enjoyed very good health, although never very robust, till November - four months before her death - when she had an attack of pleurisy from which she recovered. On the morning of March the 3rd she complained of not feeling well, and accordingly was at once put to bed. About 1.30 the same afternoon she complained of a pain in her

chest, and when asked to locate it pointed to the precordial region.

She then had an attack of syncope with the usual symptoms, unconsciousness, pallor of the face, lividity of the lips and over the malar regions of both cheeks, profuse perspiration, small thready and irregular pulse, dilated pupils and shallow respiration. On auscultating the heart no distinct murmur could be heard as the sounds were so faint and irregular. The second sound in the aortic area was accentuated. There were no signs of any pulmonary mischief, and her temperature before the syncopal attack was normal.

On restoratives being administered her pulse became a little stronger though still irregular, the lividity of the lips and cheeks was less marked, and she gradually improved and continued to do so until nine o'clock the same evening.

At this time she became restless and thirsty, and was given a little stimulant, but desiring a drink of cold water she suddenly jumped out of bed whilst the nurse's back was turned and on getting it again, fell back and expired.

A post mortem examination was made on 4th March twenty four hours after death, and the following was found.

Thorax.

On reflecting the sternum there was found in the anterior mediastinum a considerable amount of post mortem emphysema, presenting an appearance like

whipped cream and crepitant to touch.

On opening the pericardium it was seen to be filled with about two ounces of dark coloured blood, partly fluid and partly clotted.

On clearing this blood away the heart was exposed, and there was at once seen at the edge of the interventricular septum a complete well marked rupture of the right ventricular wall. This opening was about one inch in length, linear in shape, ecchymosed at its edges, and ran parallel to the septum, the upper end reaching within a few lines of the auriculo-ventricular groove.

The Heart weighed nine ounces; its external appearance was one of well marked fatty degeneration. It was flabby, and on section the walls were seen to be much thinned, of a pale colour, and in texture friable.

On the outer surface there was an extreme degree of fatty deposition, especially over the right auricle and along the anterior interventricular groove.

Both ventricles were contracted and empty, except that a small laminated clot was found in the apex of the right. The walls of both ventricles were thinned, that of the left being fourteen millimetres thick, while that of the right was six, this thinning being most marked at the point of rupture where the wall only measured three millimetres.

#### Microscopic Examination.

Sections were made from the right ventricle away

from, and at the point of rupture.

The left ventricle was also examined, likewise the right and left coronary arteries.

As regards the right coronary artery a piece was taken off at its origin and another piece one inch from its origin. The vessel in both places showed a narrowed lumen and was so hard that both portions had to be decalcified before sections could be obtained.

Preparations were also made from two portions of the left coronary artery. Both pieces showed marked atheromatous change, and the part which came from the posterior interventricular groove presented a nodular thickening, of a blood red colour looking like a thrombus.

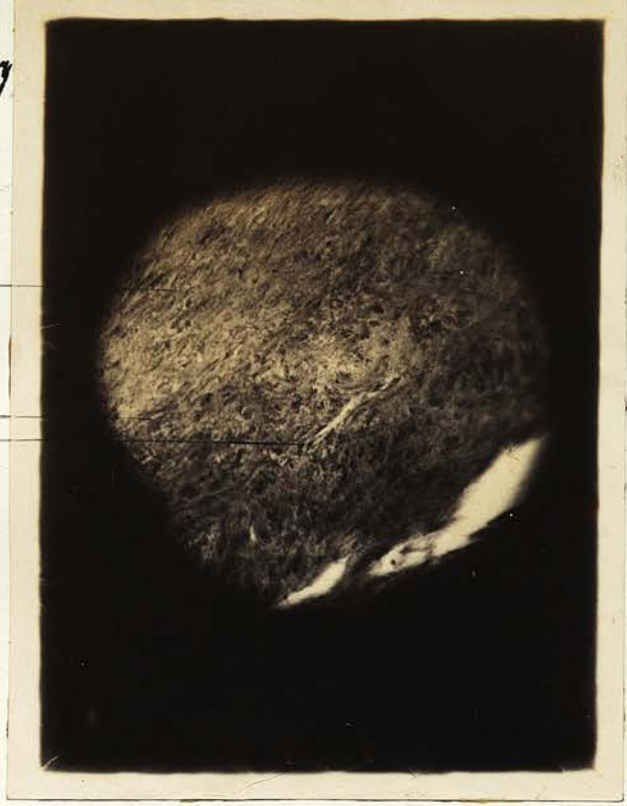The left Coronary Artery stained with Picrocarmine.

With the Low Power (diameter 85), the intima presents a well marked thickening, which, though more marked in parts, may be traced round the whole circumference of the tube. Towards the lumen the subendothelial tissue is of a compact character, and the branched corpuscles are seen on edge between the fibrillated connective tissue.

As the media is approached, this connective tissue becomes more and more open till actual spaces are produced.

The internal elastic lamina shows here and there

Photo. 1. Section 1.  
of Left Coronary Artery  
(X 130).



A. Thickened Intima  
B & C. Elastic Lamellae.

Photo. 2. Section of  
Right Coronary Artery  
(X 26).



A. Thickened Intima.  
B fibrous Tissue.  
C. Tissue of vessel.

the normal wavy character, but in parts it seems to have been stretched and straightened out. In other places again no elastic lamina can be found, and the intima passes over into the media without any distinct boundary.

With the high power (525 diameters) the above conditions are more distinctly seen.

The flattened subendothelial cells in places are so compact as to appear continuous.

As we approach the media the subendothelium becomes more and more irregular and broken up with spaces here and there.

In one place an appearance as of two elastic lamellae may be seen, running parallel with one another. These lamellae were in the main straight, but very much broken up. At one point they could be traced into continuity, and appear to be produced, as Rumpf and Carl V. Rad hold, by the intervention of new formed connective tissue between the normal layers of the lamellae, bursting up and separating them. (Photo 1).

The media at certain places appears looser in texture and in parts seems to be encroached on by the intima.

No vasa vasorum can be seen entering the blood vessel through the media, though they are to be seen in the adventitia and in some cases their walls appear to be thickened.

The same artery stained with Haematoxyline and Eosine.

The low Power shows the thickened intima composed of flattened cells which have formed a reticulum, in the meshes of which are numerous well stained leucocytes.

Under the high power the reticulated net work is more apparent and with the oil immersion lens in the intima a newly formed capillary lined with endothelium can be seen. In this section the elastic lamina cannot be made out, and seems as though it had been broken down by the intima encroaching on the media.

Stained with Osmic Acid.

This section under the low power shows the thickened and irregular intima as in the previous preparations.

The cells here and there in patches show marked dark staining especially towards the lumen of the vessel, due to their having undergone fatty degeneration.

The remainder of the section is unstained and appears white and structureless.

Right Coronary Artery. Section 4.Microphotograph 2.

Stained with Picrocarmine.

The artery in this specimen has a signet ring appearance.

This was seen to be due to the large amount of thickening of the intima especially on one side of the vessel.

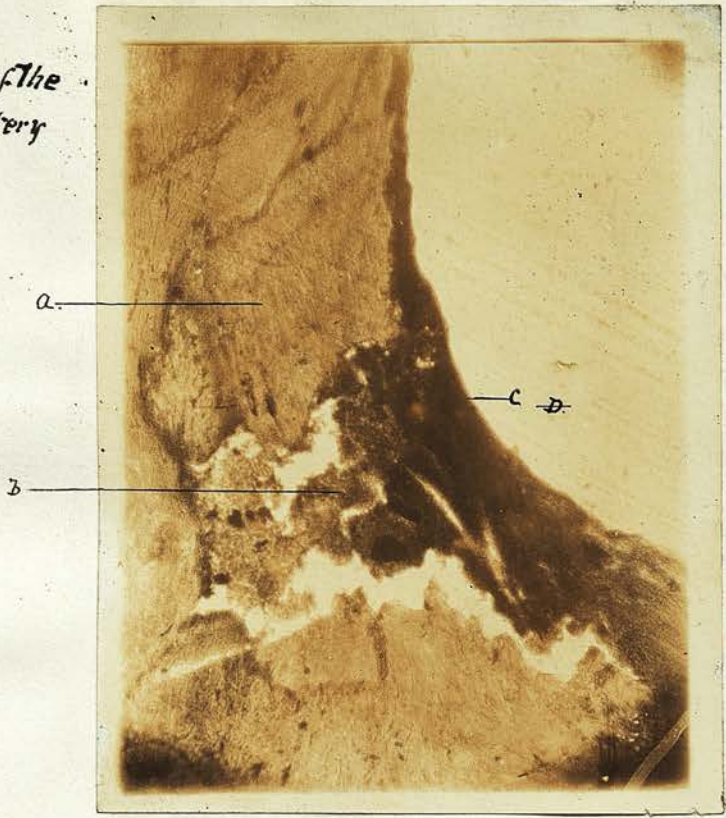
Here the cells seem to have developed into fibrous tissue and to have formed a zone which has surrounded the thickened portion of the arterial wall. This condition has in all probability been brought about by a haemorrhage in the substance of the intima, and the discovery of a quite recent blood clot in the internal layer of another portion of this vessel appears to point to such a conclusion.

A mass of fibrin has in this way been produced, and later on organisation of the clot has led to the development of fibrous tissue. This condition appears to have been of no distant date as is shown by the fact, that in some parts the border of this mass consists of round cells, which have not yet formed fibrous tissue.

Inside this region the tissue has degenerated leaving irregular spaces, which have probably at one time been filled with fat and the products of fatty decomposition.

The cells in the vessel wall opposite the thickened portion near the lumen have become irregular and broken up, whilst others have formed

Photo 3. Section of the  
Right Coronary Artery  
(X36).



- A. Thickened Intima
- B. Blood
- C. Layer of fibrous
- D. Lumen of vessel.

fibrous tissue producing a thickening which has undergone further degeneration into a hyaline like material. The media in part is very much atrophied, and in places broken down.

Right coronary artery stained with Osmic Acid.

Section 5. Microphotograph 3.

This preparation shows, in the intima close to the lumen of the tube, evidence of a very recent haemorrhage. A mass of blood is seen here, while round the periphery and most marked opposite the lumen, this seems to have formed a thin capsule of fibrin. I have already demonstrated the presence of a new formed vessel in the thickened intima, and it seems not at all improbable that this haemorrhage has occurred from the rupture of some such vessel.

Right Ventricle stained with Haematoxyline and Eosine.

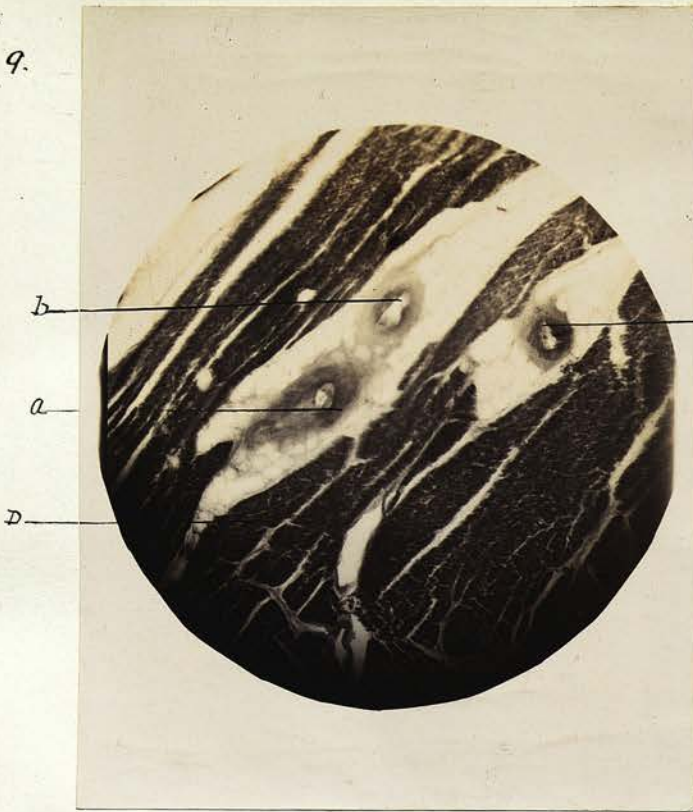
Section 6, also 7, 8, and 9.

Shows the epicardium, composed of fibrous tissue on its outer surface, while towards the muscular substance it is looser in texture and contains apices. These spaces have probably been filled with fatty debris, which has been dissolved out in the preparation of the section, leaving a stroma of delicate areolar tissue.

This fatty infiltration has also invaded the heart muscle, and the bundles can be seen widely separated by the fat cells. Microphotographs 4 and 5.

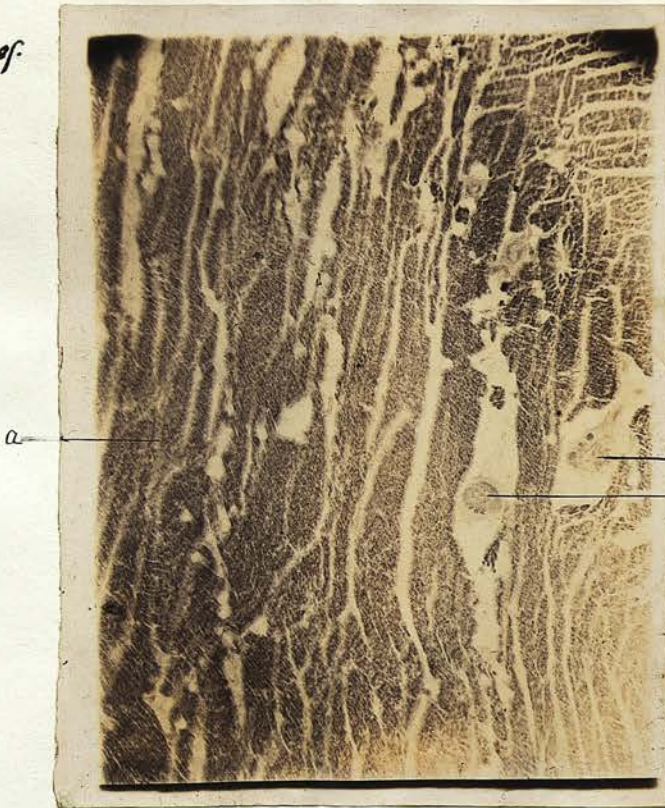
In this preparation an area is seen where the muscular fibres have undergone considerable change.

Photo 4 Section 9.  
Right Ventricle  
(X 36).



a. b. c. Arteries with thickened wall  
D. Muscle

Photo 5 Section 8 of  
Right Ventricle  
(X 26)



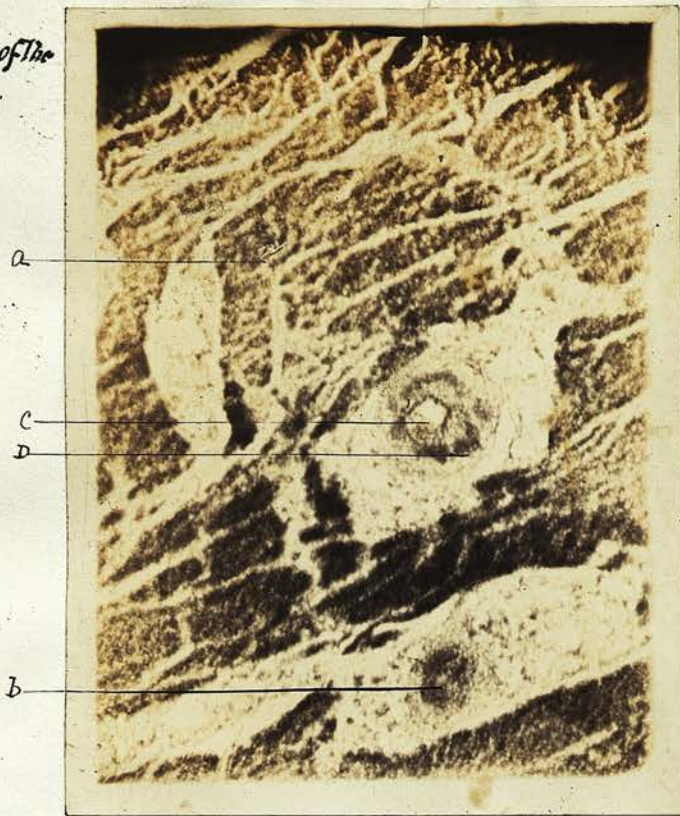a. Muscle  
b. Blood vessel  
c. Blood vessel.

The fibres have broken up into short lengths, the fracture evidently occurring along the line of transverse striation, which is still in many portions fairly marked. A further stage is the breaking up of the fibres into fibrills and many bundles of this description are noted. These small portions of muscle have no fixed relation to one another but are mixed up with a mass of debris, composed of granules with amorphous material and some more highly refractive globules. The affinity for the stain is diminished and ultimately lost as the condition becomes more marked. The whole field suggests that a process of "digestion" is occurring. Round this area there is no evidence of leucocytosis very few or no round cells being visible. Microphotograph 6.

In another part of this section a fibroid change is observed where muscular fibres are being encroached on by fibrous tissue, the striation of the muscle remaining distinct even to where it passes into the fibrous area.

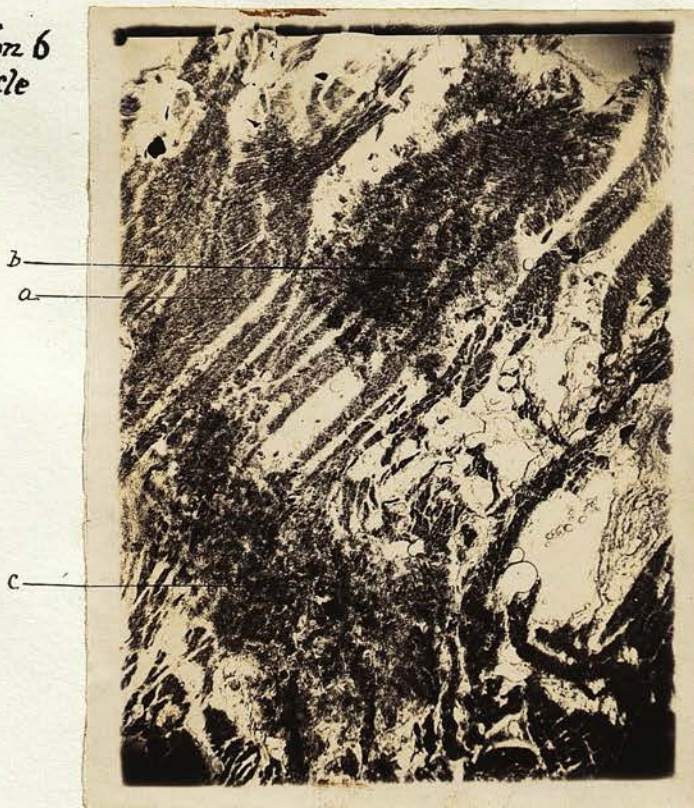An artery with thickened intima and adventitia, which appears hyaline, is seen near the above mentioned necrotic area, and the other vessels in this section are all in much the same state, some even being occluded altogether. The thickening of the intima is composed of dense fibrous tissue with numerous round cells. In parts this round celled infiltration has extended onwards through the media into the adventitia where it has formed distinct

Photo 7. Section 6 of the  
Right Ventricle.  
(x 50).



A. Muscle  
B & C Blood vessels  
D Septum on the blood vessel, C.

Photo 6 Section 6  
Right Ventricle  
(x 25)



A. Muscle  
b + c. Disintegrated Muscular Areas

tufts. Microphotograph 7.

Right Ventricle stained with Osmic Acid. Section 10.

This section shows well marked fatty degeneration and in places also fatty infiltration.

Left Ventricle stained with Haematoxyline and Eosine.

Section 11.

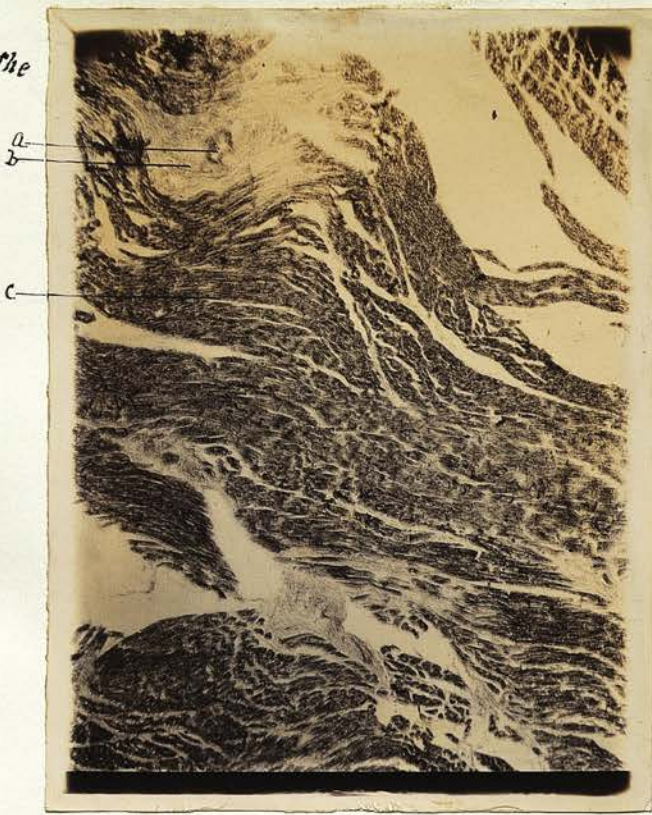In this preparation are seen two processes at work which are frequently associated viz. fatty infiltration and fatty degeneration. The muscular tissue is separated by the connective tissue cells having become distended with fat, which in this section has been dissolved out.

Here again, as in the right ventricle, we have the dense fibrous tissue ramifying between the muscle and in the midst the remains of a blood vessel with degenerated walls and its lumen nearly closed, probably due to its thickened intima and cicatricial contraction of the tissue around. In other parts of this section several vessels can be seen in a similar condition. (Microphotograph 8)

Left Ventricle stained with Osmic Acid. Section 12.

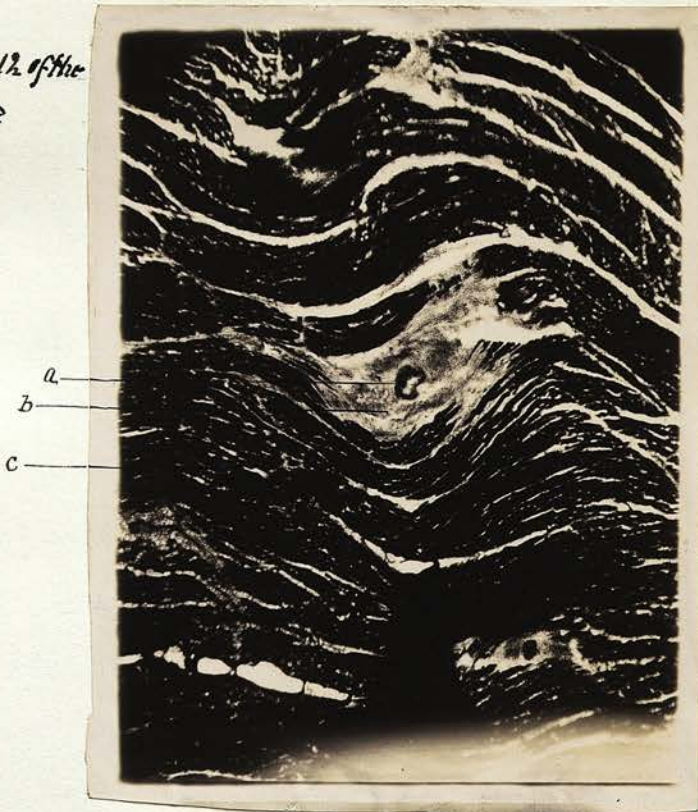
This preparation shows the muscular tissue well stained, and it stands out prominently in marked contrast to the dense fibrous tissue which appears white and glistening. In the midst of these fibroid patches the remains of a blood vessel can generally be seen, whilst the striation of the muscle bordering the area is quite distinct. (Microphotographs 8 & 9)

Photo 8 Section 11. of the  
Left Ventricle  
(X 26)



- A. Blood Vessel.
- B. Fibrous Tissue.
- C. Muscle.

Photo 9 Section 12. of the  
Left Ventricle  
(X 26).



- A. Blood Vessel.
- B. Fibrous Tissue.
- C. Muscle.


Right Ventricle near the point of Rupture stained with  
Haematoxyline and Eosine. Section 13 see also 14.

This preparation shows towards the epicardium numerous fat globules, the connective tissue binding which is much studded with small cells. Surrounded by this fatty tissue is a large branch of the left coronary artery with some smaller twigs and accompanying nerves. Here the coronary artery is markedly atheromatous, and presents a much narrowed lumen. The intima is much thickened this condition extending all round. For about quarter of the circumference the intima almost equals the breadth of the media and adventitia, while over the remainder it is four times that thickness. The thickened intima is composed of numerous round cells and dense fibrous tissue, while abundant spaces are met with especially towards the media. For about quarter of the circumference it is impossible to detect any muscular tissue, this having evidently been encroached on and replaced by the fibrous intima.

The elastic lamina can only be traced for a very short distance running between the still healthy muscular layer, and the comparatively slightly thickened intima.

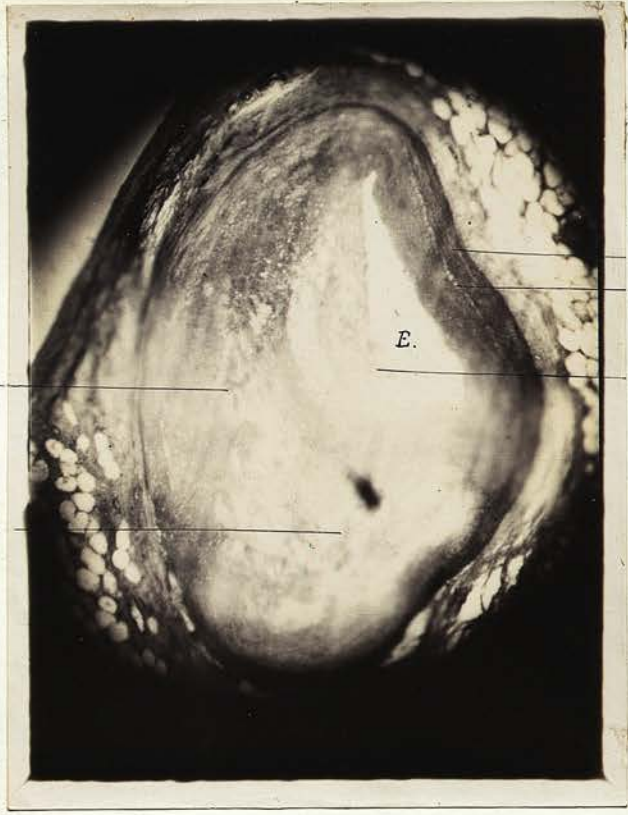All round the adventitia likewise shows a considerable degree of round celled infiltration, but in that particular region where the intima reaches its thickest, and where not a trace of muscular tissue remains, this new formed tissue has spread out for a considerable distance into the surrounding fat.

Photo 10 Section 13 of  
Right Ventricle near point of  
rupture (x26).



- a. Occluded artery.
- b. Cavity in the thickened intima.
- c. Thickened intima.
- d. Lumen of vessel.

Photo 11 Section 13 of  
Right Ventricle near point of  
rupture. (x36)



- a. Thickened Intima
- b. Cavity in thickened intima.
- c. Media.
- d. Internal Elastic lamina.
- e. Lumen of vessel.
- f. Villous like projections into lumen.

There is evidence of a more recent process of endarteritis having taken place round the lumen of the vessel superficial to the older atheromatous lesion. On the inner surface of the intima there is a dense infiltration of round cells, while here and there these are gathered into little clumps or villus-like granulations, which project into the lumen of the tube. Microphotographs 10 and 11.

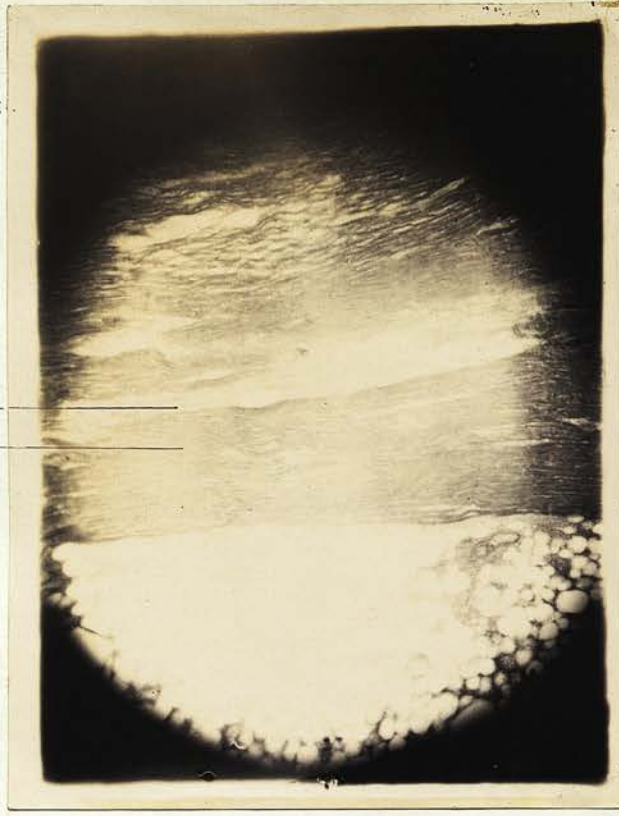Close beside this is a smaller artery the lumen of which is partly occluded by fibrin, which is infiltrated with leucocytes in apparent continuity with those in the vessel wall. Nearer the muscle a smaller twig is to be seen in much the same condition.

In section 15 from which microphotograph 12 was taken, a vessel is found almost occluded by an endarteritic process. Beside this there is noted a vessel of practically the same size with thin walls composed of endothelial cells with a small amount of perivascular tissue. Several smaller vessels are seen in its neighbourhood. These are in all probability new formed and are filled with blood corpuscles, evidently forming a collateral circulation to compensate for the narrowing of the original vessel.

Microphotograph 13 and section 13 show a vessel winding among the muscular tissue. The muscle towards the epicardium is much infiltrated with leucocytes, while near the point of rupture it appears to have undergone a necrotic change and looks pale, its striation almost gone and it stains faintly. At the ruptured spot the tissue is seen broken down, and

Photo 13 Section 13 of the  
right ventricle near point of  
rupture (X36).

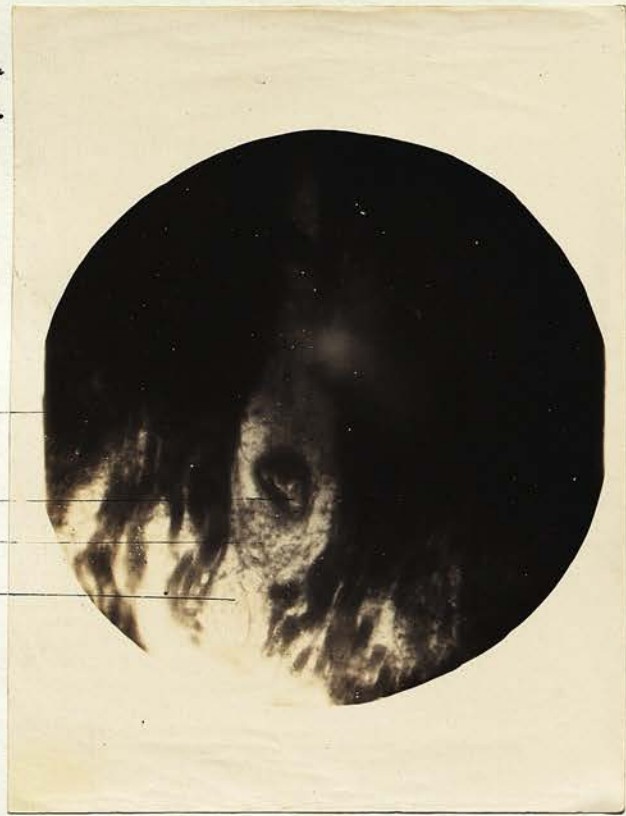
a  
b



a. Blood vessel winding in muscular tissue  
b. Muscle.

Photo 12 Section 15 of the  
right ventricle near point of  
rupture. (X130)

d  
a  
b  
c



a. Nearly occluded blood vessel  
b & c. Newly formed blood vessels.  
d. Muscle.

infiltrated with leucocytes, blood corpuscles and fibrin, while the edge of the rupture is bounded as with a capsule composed of fibrin and leucocytes.

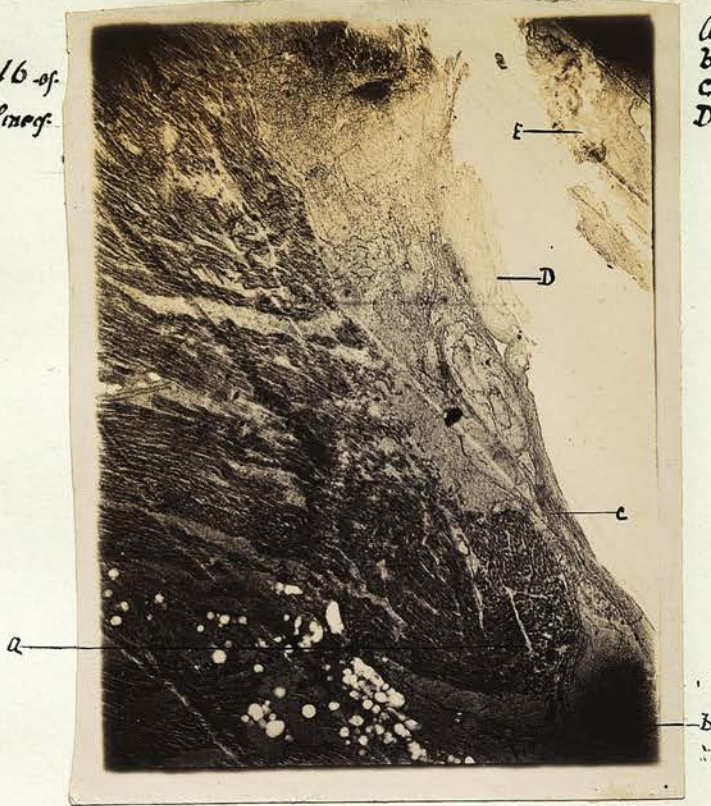External to this capsule a piece of laminated clot can be seen.

Right and left Ventricles through the line of Rupture  
stained with Haematoxyline and Eosine. Sections 16  
and 17.

Examining the right ventricle under the epicardium we have a great deposition of fat which has a regular honeycomb appearance. Towards the heart muscle the process of deposition changes into one of infiltration as is seen by the fatty material insinuating itself between the muscular bundles, not only widening the distance between them but also atrophying them by pressure. That portion of the fatty element which lies near the coronary artery and also the weakest part of the heart wall is infiltrated with small cells as was seen in the last preparation. This infiltration is scarcely at all visible among the fat cells farther away from this place. In the stroma between the fat cells, red blood corpuscles are seen not deforming the cells, as they probably would have done by pressure had the haemorrhage been active, but rather as if they had percolated through the stroma.

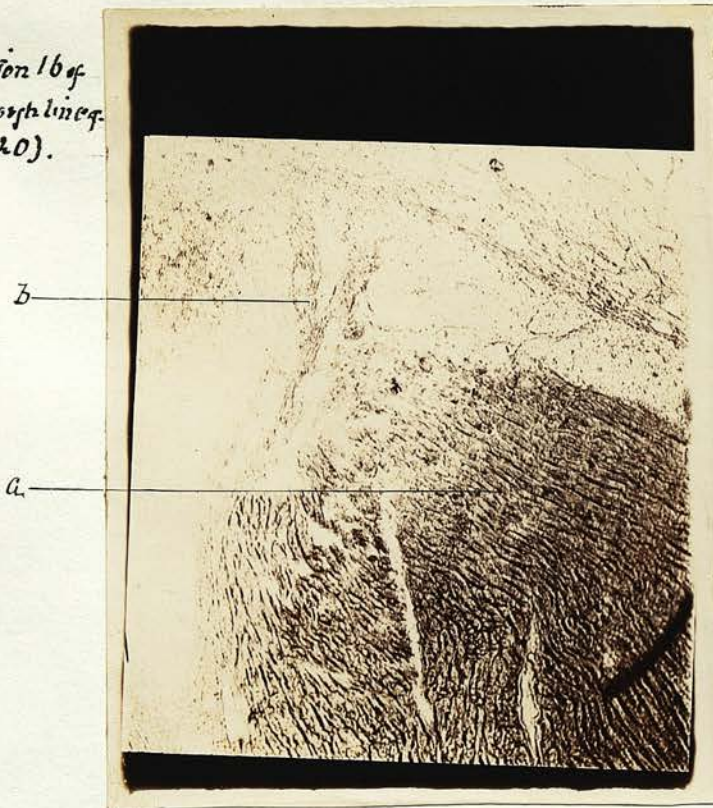
The muscular tissue as we have seen is infiltrated with the fat cells only towards the pericardium to any appreciable extent. The deeper

Photo 14a. Section 16 of  
right ventricle through line of  
rupture. (X 26).



a. Muscle  
b. fibrin and blood  
c. Edge of rupture composed of fibrin etc.  
D & E. Laminated blood clot.

Photo 14b Section 16 of  
right ventricle through line of  
rupture. (X 120).



a. Muscle  
b. Strands of fibrin & blood.

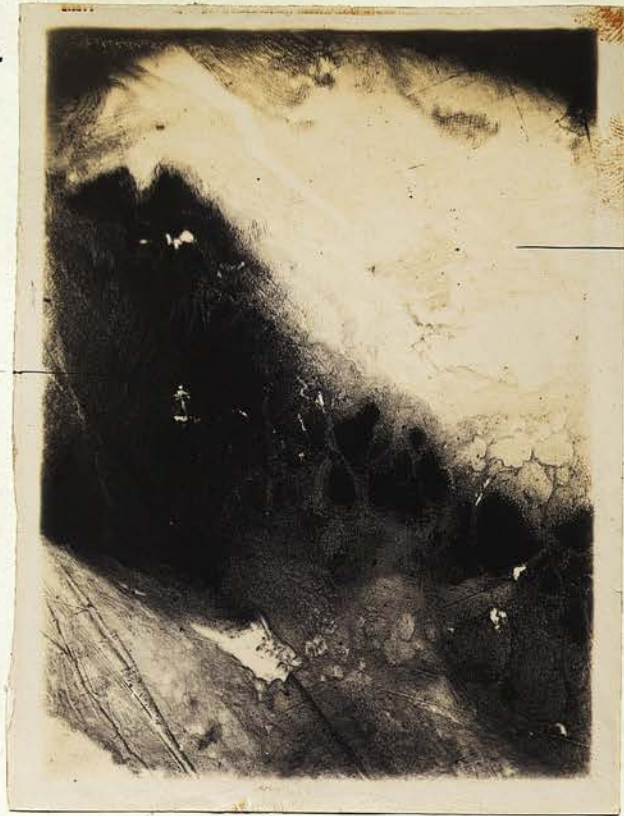portion is crowded with round cells, which is more marked as we approach the rupture. Here the muscle nuclei stain faintly, while in places the striation of the muscle is not very distinct, and becomes less so the nearer we approach the necrotic area. The muscle near the rupture is not so compact being infiltrated with small cells, and has undergone a necrotic change, in many places being structureless with indistinct nuclei. Here and there we come across a piece of muscle showing signs of fatty degeneration.

Moreover there are seen large gaps in the muscle filled with blood corpuscles, the blood having forced a passage through the degenerated and much weakened tissue at the time of rupture.

The margin of the rupture is external to this, and is seen to be formed of strands of fibrin, blood corpuscles and leucocytes, the layers of fibrin along nearly the whole length of the rupture, having the appearance of a laminated capsule. Microphotographs 14a and 14b.

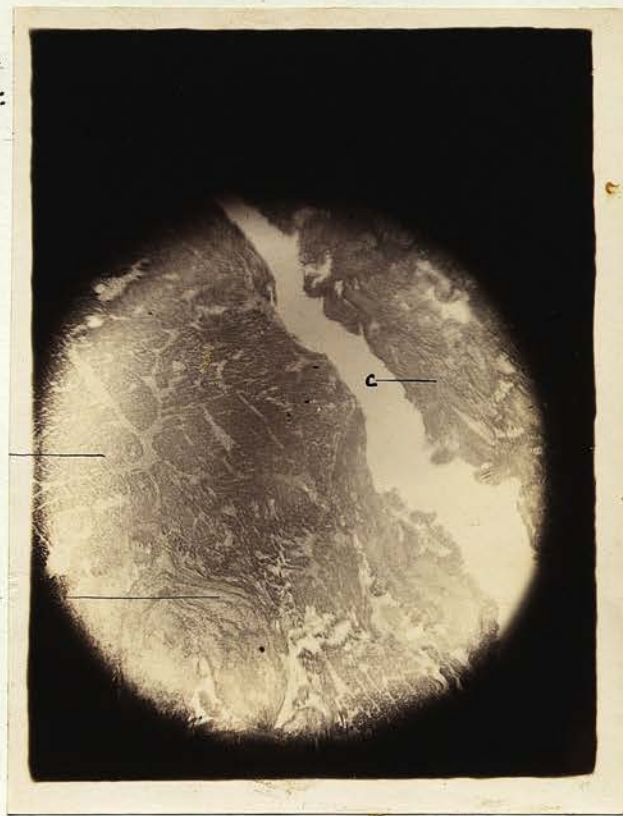The coronary artery with some of its accompanying nerves and branches, is imbedded in the epicardial fat. The intima is at once seen to be greatly thickened and consists of fibrous tissue and small branched connective tissue cells. In fact in part of the circumference of this vessel, to such an extent has the intima grown, that it is impossible to distinguish the media at all. In another part of the vessel wall, a portion of the intima towards the media has broken down and formed a horse shoe shaped cavity containing

Photo 15 Section 16 of the  
Left Ventricle through line of  
rupture. (X 26).



a. Blood clot.  
b. fibrin de.

Photo 16 Section 16 of the  
Left Ventricle through line of  
rupture. (X 130).



a. Muscle.  
b Blood degenerated tissue surrounded  
by fibrin.  
c Laminated clot.

numerous spaces and tissue debris, constituting atheromatous abscess. (Microphotographs 10 and 11)

On the innermost surface of the intima for about quarter of the circumference there is seen an aggregation of small cells deeply stained, which would almost point to a more recent process having been at work.

Owing to the specimen having been preserved in spirit for some time, it was impossible to demonstrate the presence of cholesterol crystals.

Left Ventricle close to the rupture.

A large laminated clot, composed of layers of fibrin, effused blood and leucocytes occupied the space between the right and left ventricles, though it is more closely connected with the latter. The fibrinous strands are well seen towards its pericardial extremity, running through what seems to be more recently effused blood. Between this region and the muscle there is a fibrinous zone, which is infiltrated with small cells and appears as if undergoing the process of organisation. (Microphotographs 15 and 16)

The muscle itself is in the same condition as that of the right ventricle, and infiltrated with small round cells with similar large spaces filled with blood corpuscles, fibrin and leucocytes, between the muscular bundles.

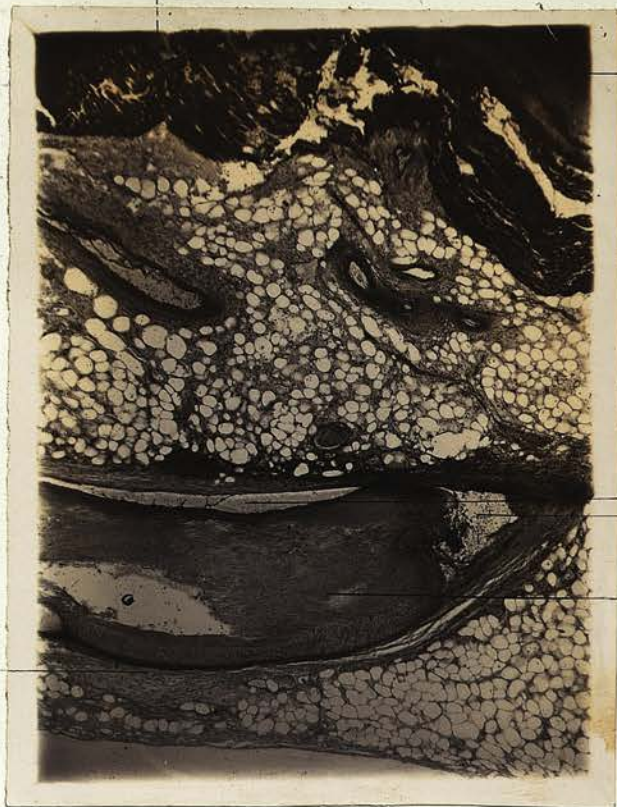Left Ventricle stained with Haematoxyline and Van Giesson's stain. Sections 18 & 19. Microphotograph 17.

This preparation shows some epicardial fat

studded with small round cells especially in the region of the coronary artery. Immediately under this a large gap is present in the muscular substance, which is caused by a large quantity of effused blood, ramifying in which are numerous leucocytes and strands of fibrin which in a manner divide the space into smaller compartments. The muscle itself is densely infiltrated with small round cells and has a disjointed appearance, especially around this haemorrhagic area. The nuclei of the muscle stained fairly well and the striation is still present. The connective tissue corpuscles are exceedingly numerous, not only between the muscular bundles but also between individual fibres. In other parts of the field the tissue is not so compactly laid down as in the normal heart, the intervening spaces being crowded with small cells.

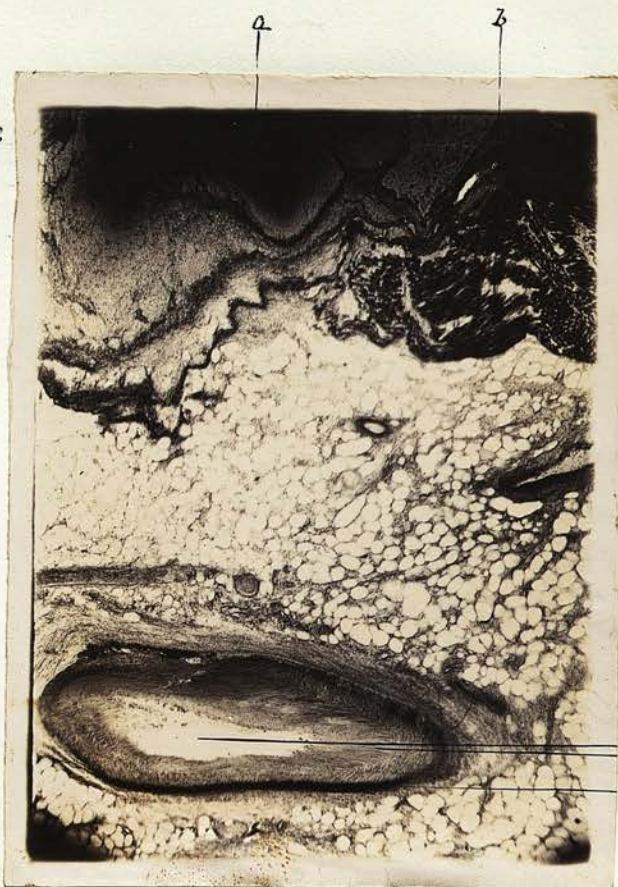A branch of the coronary artery with its accompanying nerves is seen surrounded by the epicardial fat. The lumen of the vessel is much diminished in size and of an irregular elliptical shape. This is due to the intima having grown much more at the opposite sides of the vessel while in the intervening parts of the circumference, the process has not been so active. The intima is composed of fibrous tissue and connective tissue cells, which lose their affinity for stain as we pass from the lumen towards the media. In a portion of the intima small spaces are to be seen filled with small round

Photo 18 Section 20 of the  
Left Ventricle.  
(X26).



- a. Muscle.
- b. Blood & fibrin.
- c. Thickened Intima.
- D. Haemorrhage between media & adventitia.
- E space in intima.
- F Adventitia.
- G. Lumen of vessel.

Photo 17. Section 18 of  
the left Ventricle  
(X26).



- a. Blood and fibrin.
- b. Muscle.
- c. Thickened Intima.
- D Lumen of vessel.
- E Media.

cells and connective tissue corpuscles.

The media in part has become very compact and has a hyaline appearance, while other portions of it are looser in texture and invaded by the intima.

The adventitia likewise is thicker in some parts than in others, and it also has a broken down appearance.

Left Ventricle stained with Van Giesson and Haematoxyline. Section 20. Microphotograph 18.

As in the last section there are many small cells in the epicardial fat, underneath which the effused blood is seen traversed by strands of fibrin, the muscular tissue around this region being much broken up, infiltrated with ~~sm~~ small cells, and in the same condition as in the previous section.

The coronary artery shows even a narrower lumen, probably caused by the section having cut the vessel more obliquely and having got more of the intima.

At one part of the intima bordering the media the tissue seems to have undergone further degeneration leaving a space filled with debris and white blood corpuscles.

As before, the media has a more compact appearance, but in part of the circumference of the vessel it is separated from the adventitia, the space being filled with blood corpuscles, though there are still strands connecting the two portions of the wall.

The adventitia is thick and loose in texture in places, but for the most part it is thin.

21.

Notes on the Pathological Appearances.

A review of the pathological appearances just described leads to the following conclusions. There has been for some time a chronic change of a very extensive character affecting the coronary arteries. This condition has existed long enough to bring about atheromatous abscess, calcification and narrowing of the lumen. In the smaller vessels there has probably been a similar change which has shown itself more as an endarteritis resulting in considerable narrowing of many, and even obliteration of some of them. These conditions are frequently seen together and are believed by some to be correlated.

I consider that in the branch of the left coronary artery the calibre of the tube has diminished to one eighth of its original capacity, see Photo 11. An obliteration to this extent of a vessel of the size of the coronary artery is very rare, and would alone have interfered with the nutrition of the heart, but associated as it was with the narrowing of the smaller vessels, must have produced an intense degree of ischaemia.

In the heart muscle there was found marked fatty degeneration of the muscular fibres with deposit of fat, and connective tissue between the bundles, the connective tissue passing into a fibroid condition. This change has doubtless been produced in great part by the ischaemia, and the alcoholic habit of the patient would tend to further this degeneration.

Fatty degeneration of the muscle has in some cases

been the only condition found, and is in itself sufficient to cause and account for rupture of the heart. But on looking over the sections in this case, appearances are seen which suggest the presence of other factors.

I. In Section 18 and in Photograph 18 it will be noted that small granulation masses project into the lumen of the artery, the detachment of any one of which would cause a blocking of a smaller vessel.

II. In Photograph 3 section 5 there is shown another condition which might cause a similar result. It is quite possible that a portion of the blood clot found here immediately under the endothelium might break loose and form an embolus.

III. The vessels were so narrowed that slight alteration in the blood conditions would readily produce a thrombotic process.

IV. The new formed vessels described in Section 15 Photograph 12 are of interest. They are so thin walled that a rupture and haemorrhage might have occurred from one of them.

The first three conditions would lead to the same result viz. the formation of a haemorrhagic infarction. In the fourth condition however, the resultant haemorrhage would probably not be large, and in any case would be unlikely to produce the nutritive changes, which blocking of an original vessel must entail.

Therefore there is more likelihood of the

condition having been one of haemorrhagic infarction.

For the production of this condition, as Cohnheim has shown, end-arteries are essential. Such are said to exist in the heart by some authors, but this is denied by Langer and Krause; and West has injected the one coronary artery from the other. Admitted that these arteries possess free anastomoses, a condition of haemorrhagic infarction could not be brought about, but these arteries may have been reduced to the condition of end-arteries by the endarteritic narrowing and obstruction of the vessels, which should have formed the collateral circulation.

There is still another mode whereby the normal anastomosing vessels would practically be converted into end-arteries, viz. by numerous emboli simultaneously blocking up many vessels.

The first factor undoubtedly exists in this case, while the second, though not proved, is not improbable.

The appearances round the seat of rupture are such as would have been produced by haemorrhagic infarction. I have shown how this may occur, and I believe that in this case it has occurred. The leucocytosis which was present around the blood effused at the seat of rupture, was undoubtedly a vital process, and must have occurred during the life of the patient. The effusion which attracted these leucocytes must therefore also have occurred during life. What I believe, was that a haemorrhagic

infarction took place, tearing up the muscular tissue, and so weakening the heart wall that any extra strain would cause it to give way. The syncopal attack at 1.30 in the afternoon, was probably coincident with the rupture of the heart through this weakened part. This rupture must have been slight, and from the presence of more recent clot uninvaded by leucocytes, on the top of the older one, I would argue that temporary arrest of the tearing of the heart wall occurred. Such a clot would temporarily repair the damage and evidently did so, so long as the patient kept at rest. The extra exertion entailed by getting out of bed was sufficient to partially dislodge the fresh blood clot, frustrating its cementing action and thus bringing about a further extension of the original laceration.

In this connection it is important to note that the more recent clot was present over a very limited area.

While the presence of a distinct laminated clot, the size of a filbert, in the right ventricle, would signify that a considerable coagulation had occurred on the inner surface of the rupture.

Notes on the Case.

Spontaneous rupture of the Heart is in itself a comparatively rare condition, and the foregoing case is interesting especially as it possesses a few features even more uncommon than is generally found in this affection.

As stated in the pathological conclusions, I believe that a slight rupture took place at 1.30. in the afternoon. This was not preceded by any special exertion on the part of the patient, which probably accounts for the small size of the primary rupture, and is an additional proof of the weakened state of the heart wall, and quite in accordance with my view that the haemorrhagic infarction occurring some time before death, played an important part in this culmination. The physical signs at that time were those of an ordinary syncopal attack, and no signs were present such as a haemorrhage of any extent into the pericardium would have produced. The fact also that the patient lived  $7\frac{1}{2}$  hours after the initial rupture likewise proves that the process must have been at first slight and gradual, and so favoured the formation of a clot which temporarily arrested haemorrhage. But the sudden exertion incurred by the patient jumping out of bed loosed the clot, producing further laceration, haemorrhage and death. Also its occurrence in a female is rather unusual, since males are more liable to all such affections than females.

The site and direction of the rupture are also interesting since the former took place in the right Ventricular Wall, while the latter was oblique and seen parallel with the septum transverse to the direction of muscular fibres.

In contrast to this I may mention the only other case which has occurred in the Crichton Royal Institution during recent years. Here the patient was a male, the rupture was situated in the anterior wall of the left ventricle near the apex, and the direction of the fissure ran parallel with the muscular fibres of the heart. In this case on the other hand, there was organic disease of the heart, and the rupture occurred during an attack of emotional excitement.

"Literature".

1. Byrom Bramwell . . ."Diseases of the Heart" 1884  
P. 652.
2. Carl V. Rad . . . "Uber einen Fall von juveniler  
Paralse auf hereditar leutischer  
Basis mit specifischen Gefassveran-  
dungen" Archiv fur Psychiatrie und  
Nervenkrankheiten 1898.  
Band 30. Heft 1.
3. Coats . . . "Manual of Pathology" 1883.
4. C.H.Fagge . . . "Principles and Practice of Medicine"  
1886. vol.11. P.39.
5. J. M. Fothergill . . . "The Heart and its Diseases".
6. Landois & Stirling . . . "A Text Book of Human  
Physiology" 1888
7. F. F. Roberts . . . "Theory and Practice of Medicine"  
1894 P. 617.
8. Rumpf . . . "Dic syphilit epkrankungen des Nerven  
systems" 1887.
9. . . . "Reference Handbook of Medicine".
10. Schafer . . . "Quain's Anatomy" Vol.11. Part 11.
11. Thoma . . . "Pathology and Pathological Anatomy" 1896.
12. G. B. Wood. "A Treatise on the Practice of  
Medicine" 1855. vol.11. p.191.
13. G.S.Woodhead . . . "Practical Pathology" 1892.
14. Ziegler . . . "A Text Book of Pathological Anatomy  
and Pathogenesis". Translated by  
Macalister 1886".