

INJURIES OF THE KNEE JOINT

BY

I. S. SMILLIE

*O.B.E., M.B., Ch.B. (Edinburgh 1951),
F.R.C.S.(Ed.), F.R.F.P.S.*

THESIS

For the Degree of Ch.M.

February 1946



CONTENTS

CHAPTER	PAGES
I THE IMPORTANCE OF THE QUADRICEPS	1-7
Comparative anatomy 1. Relation of derangement of mechanism to evolution 1. Quadriceps insufficiency 2. Importance of active exercise 2. Vastus medialis 3. Quadriceps exercises 3.	
II TRAUMATIC SYNOVITIS AND HAEMARTHROSIS	8-17
Synovial membrane 8. Origin and function of synovial fluid 10. Reaction of synovial membrane to injury 10. Regeneration of synovial membrane 11. Constituents of a traumatic synovial effusion 11. Rationale and technique of aspiration in traumatic synovitis 12. Clinical features and treatment of traumatic synovitis 13. Reaction of synovial tissues to haemarthrosis 15. Clinical features and treatment of haemarthrosis 16.	
III THE SURGICAL ANATOMY AND PHYSIOLOGY OF THE MENISCI AND MECHANISM OF THEIR INJURIES	19-30
Medial meniscus 19. Relation of menisci to evolution of knee joint 20. Relation of medial meniscus to medial collateral ligament 20. Tibial attachment of medial collateral ligament 21. Relation of the menisci to the femoral and tibial condyles 21. Significant features of joint physiology in flexion and extension 22. Lateral meniscus 23. Relation of lateral meniscus to lateral collateral ligament 23. Mobility of lateral meniscus 24. Function of the menisci 24. Summary of factors which may influence the vulnerability of menisci 24. Mechanism of injury 27.	
IV SURGICAL PATHOLOGY OF THE MENISCI	31-56
Classification of lesions 31. Longitudinal tears 31. Transverse tears 36. Various combinations of longitudinal and transverse tears 38. Cystic degeneration 39. Congenital anomalies 43. Calcification and ossification 46. Healing of torn meniscus 48. Regeneration of menisci following excision 51. Author's statistics 55.	
V CLINICAL FEATURES OF INTERNAL DERANGEMENTS OF THE KNEE JOINT RELATIVE TO THE MENISCI	57-78
History, symptoms, and signs 57. Lateral meniscus 66. Recent injuries 67. Lesions of both menisci 68. Cystic degeneration 70. Congenital discs 74. Retained posterior segment 75. Lesions of regenerated menisci 75. Radiological examination 76. Errors of diagnosis 77.	

CHAPTER	PAGES
VI TREATMENT, AFTER-TREATMENT, AND COMPLICATIONS OF INJURIES OF MENISCI	79-105
Reduction of locked joint 79. Further treatment of torn meniscus 80. Treatment of double injuries 83. Relation of osteo-arthritis to lesions of menisci 84. How much of a torn meniscus should be excised? 85. Pre-operative treatment 86. Instruments 87. Technique of operation 89. Removal of posterior segment through an additional incision 94. Treatment of cystic degeneration 95. Immediate after-treatment and rehabilitation 96. Complications of operation 98. Prognosis 104.	
VII INJURIES OF LIGAMENTS	106-167
Anterior cruciate ligament 106. Classification of injuries 107. Diagnosis and treatment of recent injury 108. Clinical features and treatment of fracture of tibial spine 116. Old ruptures of anterior cruciate ligament 119. Clinical features in old cases of rupture of anterior cruciate ligament 122. Treatment 125. Operation of reconstruction of anterior cruciate ligament using peripheral half of medial meniscus 127. Blair's operation 133. Posterior cruciate ligament 135. Pathological anatomy, diagnosis and treatment in the recent case 136. Old ruptures of posterior cruciate ligament 139. Medial collateral ligament 140. Partial rupture or sprain 141. Post-traumatic para-articular ossification of knee joint (Pelligrini Stieda's disease) 143. Complete rupture 152. Old ruptures 156. Operative procedures 158. Lateral ligament 161. Avulsion of iliotibial tract from lateral condyle of tibia 163. Dislocation of knee joint 164.	
VIII INJURIES OF EXTENSOR APPARATUS	168-206
Classification of injuries 168. Rupture of muscle 168. Avulsion of quadriceps muscle from patella 170. Fractures of patella 172. Rationale of treatment 173. Indications and treatment in fractures of patella 178. Avulsion of ligamentum patellae from patella 186. Fracture of tibial tubercle and separation of epiphysis of tibial tubercle 187. Injuries of patella resulting from direct violence 192. Classification 192. Stellate fracture 192. Marginal fracture 192. Congenital bipartite patella 195. Fracture of articular surface including osteochondritis dissecans 196. Traumatic degenerative fibrillation 197. Dislocation of patella 199. Recurrent dislocation of patella 201.	
IX FRACTURES OF TIBIA AND FEMUR INVOLVING THE KNEE JOINT	207-240
Fracture of tibial table 207. Fracture of lateral tuberosity 207. Fracture by compression 207. Fracture by abduction 215. Fracture of both tuberosities 218. Fracture of medial tuberosity 219. Old fractures of tibial table 219. Arthrodesis of knee joint 220. Genu recurvatum, varum or valgum, due to fractures or old injuries of upper tibial epiphysis 227. Condylar and supracondylar fractures of femur 229. Supracondylar fracture 229. Separation of lower epiphysis of femur 236. Intercondylar fractures of femur 237. Fracture of a single condyle 238.	

CHAPTER	PAGES
X LOOSE BODIES OF TRAUMATIC ORIGIN : FOREIGN BODIES Etiology of osteochondritis dissecans 241. Sequelae of separation of fragment 250. Clinical features of osteochondritis before and after separation of fragment 250. Treatment 252. Operative technique 254. Loose bodies in posterior compartment 257. Foreign bodies in knee joint 260.	241-261
XI WOUNDS OF KNEE JOINT AND SURROUNDING TISSUES Defensive power of articular tissues and synovial fluid 262. Difference between civil and war wounds 264. Controversial issues in treatment of war wounds 264. Articular wounds with fractures 268. The infected joint 269. Classification and treatment of gunshot wounds of knee joint 274. Wounds of surrounding tissues 276.	262-278
XII CERTAIN OTHER INJURIES Traumatic affections of bursae 279. Prepatellar bursitis 279. Bursa between ligamentum patellae and tibia (deep infrapatellar bursa) 281. Popliteal cyst (Baker's cyst, semimembranosus bursa) 281. Injuries of infrapatellar fat pad and synovial fringes 287. Neuritis of a branch of patellar plexus 288.	279-289
XIII THE STIFF KNEE Loss of flexion 290. Prevention 291. In injuries of the joint 291. Factors concerned in loss of range of flexion in knee joint following fracture of the shaft of the femur 291. The violence which produces the fracture also injures the joint 291. Methods of treatment prejudicial to the welfare of the knee joint 292. Errors in the course of treatment 295. Fractures of neck of femur and arthrodesis of hip joint 299. Treatment of temporary stiffness 299. Treatment of persistent stiffness 300. Manipulation 300. Operation 303. Use of cellophane as a mechanical barrier to the formation of further adhesions in the suprapatellar pouch 305. Loss of flexion due to adhesion of quadriceps to femur 306. Thomson's operation 307. Loss of extension 308.	290-311

CHAPTER ONE

IMPORTANCE OF THE QUADRICEPS

THE action of the quadriceps extensor apparatus is the most important factor in maintaining the erect posture in man.

Sir Colin Mackenzie¹ called attention to the fact that the term "quadriceps extensor" has a different value in man able to adopt the erect attitude and in a lower mammal unable to stand erect.

In a study of cases recovering from anterior poliomyelitis he noted that a patient who was unable to stand or raise the heel from the bed with the knee joint in the extended position was able, by lying on the sound side, to extend the fully flexed knee with ease. Such a patient could be regarded as performing the text-book function of the quadriceps, that is, extension of the knee. He concluded that in the recovery from the disease was revealed the functional stages in the evolution of muscle.

The recovery of function, like the loss, follows an ancestral or evolutionary sequence. To maintain knee extension for the erect posture, new muscles have not been evolved—orthograde functions have been superimposed on muscles which in other mammals perform plantigrade motion.

Although similarly placed in the anatomical sense, the action of the quadriceps is vastly different in platybus and in man. The quadriceps in platybus responds to the anatomical test of extension of a flexed knee, but that is a different function from a quadriceps which will support orthograde posture. The quadriceps of the ape has a more complex function than that of the platybus, and so, similarly, has the quadriceps of man in comparison with that of the anthropoid.

Mackenzie pointed out further that the anthropoids dispense with the support of the fore limbs only with reluctance. The ape prefers the knees slightly flexed, with the balance afforded by one or both fore limbs. The assumption of the orthograde posture is undoubtedly an effort.

The bracing of the knee joints by the quadriceps which has enabled man to stand, walk and run, and the ability to dispense with the fore limbs for support, is a late acquisition in man's evolution and is hence unstable. It is little wonder that this delicate mechanism, an acquisition of biologically recent origin, is easily deranged by any injury to the knee joint of a degree of severity sufficient to curtail normal activity and that the loss of volume, tone and control which derangement implies should of itself constitute a disability.

When the knee joint is injured either by accident or operation, reflex inhibition of the quadriceps takes place. This inhibition varies considerably in degree, but cases are frequently encountered which cannot be persuaded to produce even a flicker of contraction and which simulate the appearance

¹ Sir Colin MacKenzie, "The Action of Muscles." H. K. Lewis & Co., Ltd., London, 1940, 180-181.

of flaccid paralysis. Muscle wasting is extremely rapid, and the volume is reduced at a much greater rate than it can ever be regained by even the most conscientious active exercise.

The disability caused by quadriceps wasting has been termed "quadriceps insufficiency." It is a positive clinical entity. Loss of volume, tone and control means that the joint is inadequately protected from the strains and twists of normal weight-bearing. This imperfect protection subjects the ligaments and capsule to repeated stretching and may even permit the synovial membrane to be traumatised. The reaction of these structures to repeated injury is effusion. When effusion occurs, the patient rests the joint which favours resolution of the swelling, but inevitably results in additional wasting of muscle. A further attempt at weight-bearing is invariably followed by another effusion. In this

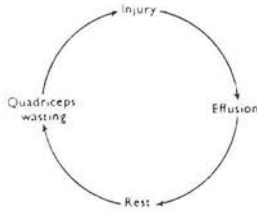


FIG. 1

way a vicious circle is completed (Fig. 1) which can only be broken by non-weight-bearing quadriceps development to a degree sufficient to protect the joint from the normal strains of weight-bearing.

If the truth of these statements be accepted it is obvious that the active treatment of any injury of the knee joint is a matter of urgency, if the period of disability is to be reduced to a minimum and in extreme cases permanent impairment of function avoided.

The treatment consists in overcoming the initial reflex inhibition by active non-weight-bearing exercise of a type which does not produce movement of the joint and cannot therefore produce further aggravation of the injury.

The passive therapeutic measures of massage and faradic stimulation are not a substitute for active exercise. Receptive therapy is of strictly limited application in all orthopaedic cases. It is especially bad in injuries of the knee joint, for it does nothing to encourage the return of voluntary control, nor does it secure the active co-operation of the patient in his own treatment, which is the essential feature of the rapid recovery of function.

Watson-Jones has stated that the instruction "Redevelop the quadriceps. Exercise for five minutes hourly throughout the day"¹ is of the utmost importance in the treatment of every injury of the knee joint. This instruction applies to simple strains with or without traumatic synovitis, injuries of the menisci both as a pre-operative and post-operative measure, sprains and rupture of ligaments, intra-articular fractures and all injuries of the lower limb whose treatment by skeletal traction or plaster fixation produces secondary effects on the knee joint mechanism. There are exceptions to every rule. Open wounds of the joint treated by excision and primary suture with the expectation of healing by first intention, and injuries complicated by haemarthrosis or acute sepsis, require an initial period of

¹ R. Watson-Jones. "Fractures and Other Bone and Joint Injuries." E. & S. Livingstone, Edinburgh, 1940, 524.

complete rest, but this phase of inactivity need seldom be continued for more than three weeks.

VASTUS MEDIALIS

It is important to appreciate that the quadriceps is not a single muscle, but as the name indicates, consists of four parts. For practical purposes however, the extensor apparatus may be regarded as consisting of two components,¹ the rectus femoris, vastus lateralis and vastus intermedius, which extend the knee to within 10–15 degrees of full extension, and the vastus medialis which is selective in action and only comes into force in producing the last 10–15 degrees of extension, although it may be used throughout the whole range in overcoming marked resistance. In spite of the apparent insignificance of an operational range of 10–15 degrees, this muscle is by far the most important component of the extensor apparatus, for not only are these final few degrees of extension the most vital in the whole range, but it is the vastus medialis which is almost entirely responsible for the stabilisation and protection of the joint from injury (Figs. 164 and 165).

If complete extension of the knee joint is an attribute common only to man, then that component of the quadriceps which produces the last few degrees of extension must surely possess the most recently acquired function and should thus show the most marked susceptibility to the effects of injury. This theoretical proposition is supported by the clinical manifestations of disease and injury so that the vastus medialis may well be termed "the key to the knee." It has now been recognised that this component of the quadriceps is so important that it has even been suggested¹ that the term "quadriceps drill" should be abolished, and "vastus medialis drill" substituted.

QUADRICEPS EXERCISES

It has been pointed out¹ that therapeutic measures taking the form of active exercise must be :

(1) **General as well as specific.**—In relation to the recovery of the injured knee joint specific exercises are directed to the redevelopment of the quadriceps, concentrating especially on the vastus medialis, but in addition the rest in bed or restricted activity necessitated by such an injury entails deterioration of all muscles of the locomotor system. The rehabilitation of patients suffering from grave knee joint injuries must therefore include not only exercises directed towards the redevelopment of the all-important quadriceps but general exercises designed to maintain the tone, volume and co-ordination of the musculature of the sound limb, trunk, thorax, neck and upper extremities in addition to the remaining muscles of the injured limb. Only in this way can the injured limb be incorporated into the machine so that it no longer obtrudes as an appendage but becomes an integral part of the whole.

¹ A. E. Nicoll. "Principles of Exercise Therapy." *Brit. Med. Jour.*, 1943, i, 747.

(2) **Regulated with regard to dosage.**—Active exercise will defeat the purpose for which it is prescribed if more demands are made upon the recovering muscle than it is capable of performing. In the early stages of recovery no muscle should be asked to exercise against more than 20 per cent. of the total resistance it is capable of overcoming, although this percentage may be greatly increased as recovery advances. The unsatisfactory results which have been reported¹ from the use of pulley-weight exercises, which are the most useful of the advanced non-weight-bearing exercises, are entirely due to failure to observe the dosage principle.

(3) **Rhythmic in Character.**—Each contraction must be followed by a period of complete relaxation of sufficient duration to permit the tissues to receive an adequate supply of fresh blood and in order that the fatigue-producing waste products of contraction can be carried away. This is of particular importance in muscle atrophy of long standing where inevitable interstitial fibrosis causes impairment of both afferent and efferent circulatory systems.

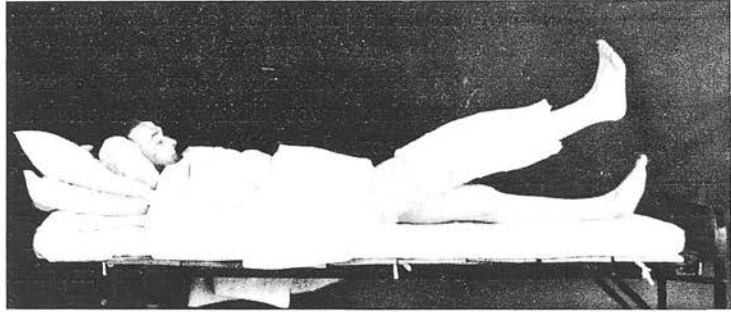


FIG. 2

With the knee in extension the simplest natural quadriceps exercise is straight leg raising.

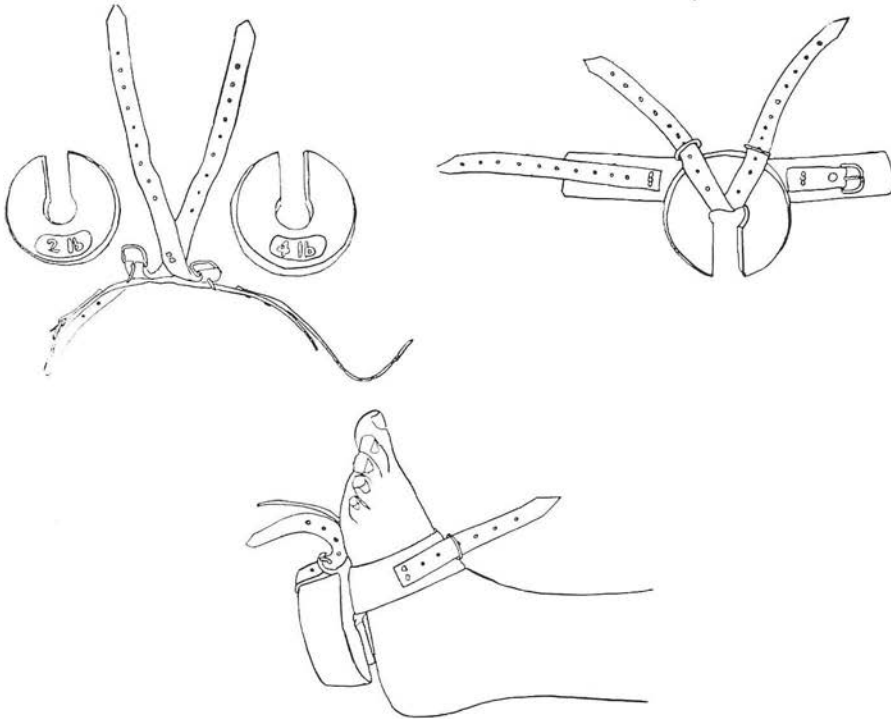
(4) **Progressive.**—Progression is the secret of successful rehabilitation. Faradism may be used to initiate contraction in an inhibited muscle, but must give place to active exercise immediately voluntary control has been regained. Thereafter the muscle must be trained to contract against gradually increasing resistance for gradually increasing periods of time.

(5) **Variable in form.**—A single form of quadriceps drill rapidly becomes monotonous and cannot be performed with enthusiasm over prolonged periods. Several types of specific exercises will be described; for example, pulley-weight exercises may be performed in the prone or the sitting position, and change from the former to the latter constitutes not only a variety in form but satisfies the demand for progression. Furthermore, exercises may frequently be disguised with advantage in the form of suitably chosen games and occupational therapy.

¹ S. A. S. Malkin. "Observations on Injuries to the Semilunar Cartilages in Service Patients." *Brit. Med. Jour.*, 1943, i, 315.

THE EXERCISES

(1) The simplest natural exercise which the quadriceps can perform is **straight leg raising** (Fig. 2). It is an exercise of limited application because the amount of work performed is small and a few degrees of flexion at the knee joint, intentional or unintentional, obviate much of the possible benefit. It has the advantage, however, that the patient is merely required to raise his own leg from the bed, and is not asked to learn anything strange and new at a time when neuro-muscular co-ordination is poor. It has the added advantage, not common to other forms of quadriceps exercise, that it can be assisted.



Figs. 3, 4, and 5

Method of attaching weights to foot for loaded straight leg raising.

At a later stage in the recovery from the injury, operation or the application of a thigh length plaster cast, the muscle may be loaded by the addition of weights, of a series ranging from two to eight pounds, attached to the ankle and used in sequence as the muscle shows evidence of progressive improvement.

Figs. 3, 4, and 5 illustrate the method of use of a strap designed for utilising standard-pattern two and four pound weights.

In the early stages of ambulatory treatment the weight lifting exercises are performed sitting on a chair and raising the loaded and extended leg from the floor to the horizontal position.

(2) The second exercise of wide application is **Rhythmical Quadriceps Drill**, and is of the utmost value. It consists of three phases: (1) *Contraction*, (2) *Contraction sustained*, and (3) *Rest*. The surgeon

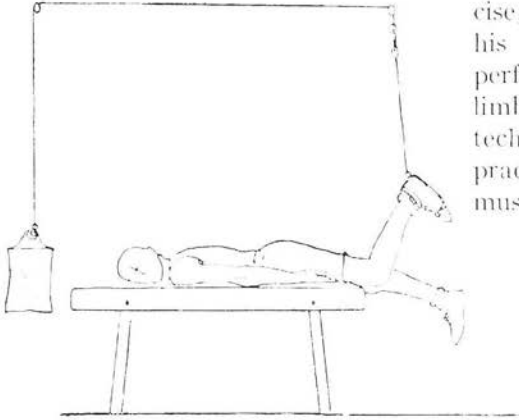


FIG. 6

Pulley-weight exercises in the prone position.

should not merely describe the exercise, he should demonstrate it with his own leg, ask the patient to perform the exercise on the sound limb, and only when the simple technique has been mastered should practice begin with the wasted muscle.

The maximum contraction of the vastus medialis occurs only as a result of the maximum muscular effort. In spite of the fact that on physiological grounds contraction of the muscle should take place slowly and deliberately, practical experience shows that

human frailty is such that the maximum benefit is not obtained unless the exercise is performed with a "punch."

(3) The simplest and most effective system for the production of advanced non-weight-bearing quadriceps exercises is the **Pulley-weight Apparatus**, for it has the advantage not common to other methods of specific redevelopment, in that the resistance can be accurately measured, and thus the dosage readily controlled to produce progression in power, range, and duration of performance.

The apparatus may be used in two forms:

(A) The patient lies in the *prone* position on a gymnasium mat placed on a firm bench. A weight is attached to a light rope which is carried through two overhead pulleys to be fastened to the patient's shoe by means of a foot harness. An adjustable stop must be provided in the circuit to prevent stretching of the muscle during the phase of relaxation and to avoid passive stretching of a stiff joint (Fig. 6).

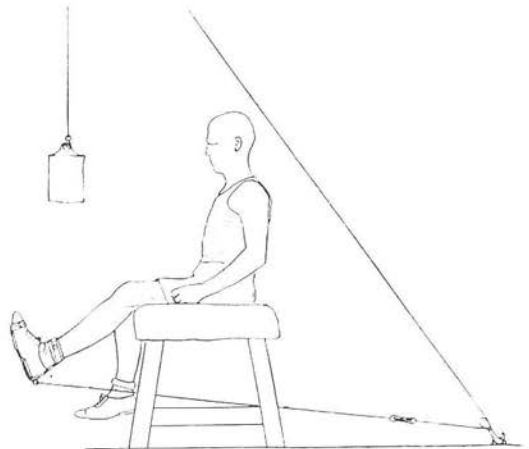


FIG. 7

Pulley-weight exercises in the sitting position.

This is the more elementary and more easily activated of the two

types of circuit, and, being assisted by the weight of the patient's own limb, is thus a suitable method of introducing weight-resisted exercises.

(B) In the circuit which is most commonly used at the present time the exercise is performed in the *sitting* position. Used in sequence with the circuit described above it provides variety of form and advancement in progression in that the limb is raised against gravity (Fig. 7).

C.S.M. Instructor Thomson, A.P.T.C., formerly Senior Physical Training Instructor at Larbert Base Hospital, has ingeniously incorporated this type of circuit in a simple wooden chair, the legs of which are lengthened by the fitting of wooden blocks to enable the patient's feet to clear the ground (Fig. 8). In this form the apparatus is portable, and is thus suitable for use in the ward or in the patient's own home, and has the added advantage that the "knee class" can be held in the open air.

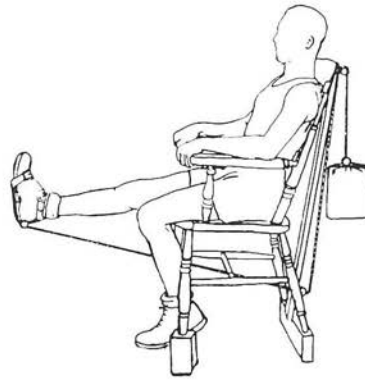


FIG. 8
"Quadriceps chair."

Like all quadriceps exercises, pulley-weight exercises are performed with a slow deliberate rhythm, which provides an adequate period of complete relaxation and ensures that full extension is obtained with each pull.

An example of the practical application of these specific quadriceps exercises, in combination with other knee and general exercises, is given in Chapter Six.

CHAPTER TWO

TRAUMATIC SYNOVITIS AND HAEMARTHROSIS

SYNOVIAL MEMBRANE

A REVIEW of the literature¹ has revealed that from the second part of the nineteenth century the theory that the synovial membrane is a modified connective tissue devoid of specific function has been generally accepted. This theory interpreted the marked differences in structure of the synovial lining in adjacent areas to be due to mechanical factors of stress and pressure. The histological and experimental work of Mayeda,² Timbrell Fisher,³ and Kling⁴ has since demonstrated the presence of special cells in well defined areas, which contain the precursors of mucin. In tissue culture the polymorphism of synovial lining cells and their arrangement, the presence of metachromatic granules, together with the formation of mucin, have been demonstrated by Vaubel.⁵ It follows that external mechanical factors cannot be responsible for the variability in structure. The polymorphism of the synovial lining is a specific property and the formation of mucin is a physiological function of the synovial cell.

Kling has pointed out that in addition to the **infrapatellar** pad of fat, the knee joint, in the majority of cases, shows a fat pad over the periosteum of the anterior surface of the distal end of the femur, which he has named the **posterior suprapatellar** fat pad. A variable accumulation of fat can also be found between the quadriceps tendon above its insertion into the patella and the anterior wall of the suprapatellar pouch. This he has named the **anterior suprapatellar** fat pad. A fourth fat pad is located in the popliteal pouch and may be called the **popliteal** fat pad. He considers that the synovial membrane is a definite entity only in those areas where the synovial secretion is elaborated, namely, over the fat pads, and over the loose connective tissue and its folds and villi, where there is an accumulation of several rows of cells among which are the secretory synovial cells. The lining is definitely distinguishable from the underlying fat or loose connective tissue, but in other areas, especially the lateral aspect of the joint, extensions of the synovial lining lie directly over the fascia of the muscles. Here the synovial lining has taken over the rôle of the capsule. It is evident

¹ Much of the theoretical material in this chapter is based on the scientific and literary investigations of Dr David H. Kling, and incorporated in his admirable monograph, "The Synovial Membrane and the Synovial Fluid," Baillière, Tindall, and Cox, London, 1938, to which reference should be made for further details.

² T. Mayeda. "Experimentelle histologische Studie ueber die Synovialmembran," Mit. a. d. med. Fakult. d. K. Univ. zu Tokyo, 1919 20, 21, 393.

³ A. G. Timbrell Fisher. "Physiological Principles Underlying the Treatment of Injuries and Diseases of the Articulations," *Lancet*, 1923, ii, 54.

⁴ "Chronic Non-tuberculous Arthritis," H. K. Lewis & Co., Ltd., London, 1929.

⁵ David H. Kling. "The Nature and Origin of Synovial Fluid," *Arch. Surg.*, 1931, 23, 543.

⁶ E. Vaubel. "The Form and Function of Synovial Cells in Tissue Cultures," *J. Ex. Med.*, 1933, lxxviii, No. 1, 63.

therefore that neither the synovial membrane nor the capsule by itself is a closed structure. Both together, however, they form a tube which is firmly attached to the margins of the articular surfaces, and, taken in conjunction with these surfaces, comprise a closed sac which is capable of retaining either fluid or gas.

In the development of joints there appears to be a tendency towards an increase of secretory areas and a reduction of simple connective tissue lining. The synovial cavity of the knee joint is the largest of all the joints, contains numerous folds and villi, and has four associated fat pads. It is completely closed against outside structures, in contradistinction to such joints as the shoulder, where the biceps tendon crosses the joint.

The human knee joint has thus attained a much higher developmental level than the knee joint of dogs and rabbits, where the extensor digitorum longus is in free communication with the joint and where only the infrapatellar pad of fat is fully developed. A solution injected into the knee joint of one of these animals spreads down the leg along the tendon. The significance of separation from surrounding structures appears to be that it assures more independent function and forms a barrier against the progress of pathological processes from the neighbouring regions.

Kling considers that the criteria for the classification of the developmental level of joints are :

- (1) The surface area of the synovial lining.
- (2) Separation from other structures (*e.g.*, tendons).
- (3) Number and size of the villi.
- (4) Number of fat pads.
- (5) Extent of secretory areas.

On this basis the human knee joint ranks highest of all joints, thus bringing the joint proper into line with the suggestions which have been made with regard to the quadriceps apparatus in Chapter One.

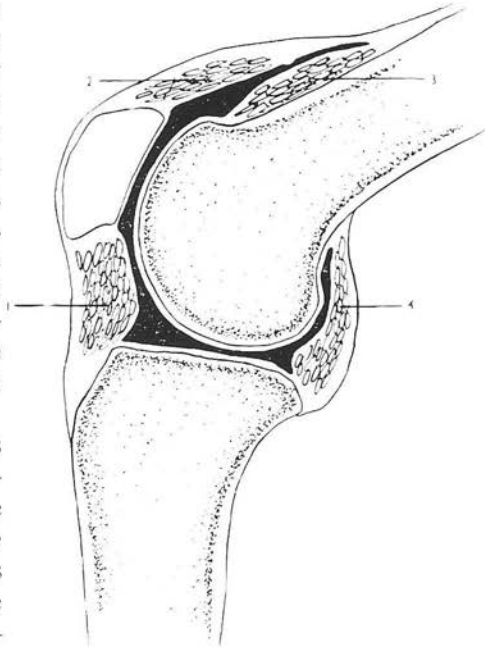


FIG. 9

Diagrammatic representation of the location of the fat pads in the human knee joint. (1) Infrapatellar; (2) Anterior suprapatellar; (3) Posterior suprapatellar; (4) Popliteal. (after Kling).

ORIGIN AND FUNCTION OF SYNOVIAL FLUID

Kling's conclusions regarding the origin and function of the synovial fluid are :

- (1) Normal synovial fluid is elaborated by special cells. It is not a transudate nor is it a product of degeneration.
- (2) Its chief function is the lubrication and protection of the joint surfaces against acid metabolites.
- (3) The physiological stimulus for its production is the normal motion of the joint.
- (4) The chief constituent of normal synovial fluid is mucin, which is responsible for its lubricating and protective properties and for its high alkalinity.
- (5) The liberal blood supply of the synovial membrane assures the prompt dissipation of heat which is destructive to the articular surfaces. In conjunction with the lymphatics it provides for the rapid removal of harmful metabolites and debris which accumulate in the course of traumatic affections.
- (6) Any pathological condition changes the quantity and quality of the fluid. Traumatic effusions are of a dual origin. One component is a transudate (or an exudate) from the circulation and is responsible for the concentration of proteids and crystalloids which is noted in such effusions. The second component is mucin, which is produced as in normal synovial fluid by the special cells of the lining membrane.

REACTION OF SYNOVIAL MEMBRANE TO INJURY

The reaction of the synovial membrane to irritation in the form of trauma is twofold. First, there is a general reaction in the mesenchymal tissues which consists of changes in the circulation, dilatation of blood vessels, extravasation of plasma together with the migration of leucocytes and later of macrophages from the circulation as well as from the tissues. The lymphatics, on the contrary, undergo obliteration, probably due to the increased pressure of the transudate. Increased acidity due to acid metabolites leads to the precipitation of blood colloids, especially of fibrin which forms the basis of granulation tissue. Second, specific reaction in the synovial cells is observed. The irritation provokes increased activity with the production of larger quantities of mucin, and this hyperactivity leads to hypertrophy of the synovial lining cells.

If the injury has been severe, entailing extensive haemorrhage, noxious metabolites are present in the disintegrating haemarthrosis in addition to those present in the irritative exudate. Both contain fibrin and debris which irritate the joint tissues, and explains why cases of traumatic effusion are occasionally followed by chronic synovitis.

REGENERATION OF SYNOVIAL MEMBRANE

Observations on the regeneration of synovial membrane are not conclusive. It has been shown that following the experimental excision of large areas, synovial membrane is reformed by metaplasia of the underlying connective tissue. There is apparently little tendency for surface growth from the edges to cover the denuded areas such as occur in the repair of injuries of epithelial tissues. Kling considers that regeneration of human synovial tissue does not take place to the same extent as in the experimental animal, explaining this phenomenon by the fact that the developmental level of the joints of experimental animals is lower than that of humans. Observations made on joints subjected to a second operation, following such a procedure as arthroplasty, show that the synovial surface consists mainly of smooth, dense fibrous tissue. It is certainly a common finding that after an extensive traumatic pathological process the granulations which have overgrown the synovial lining are not absorbed and result in the formation of dense intra-articular adhesions.

CONSTITUENTS OF A TRAUMATIC SYNOVIAL EFFUSION

The following components are characteristic of traumatic effusions :

(1) RED BLOOD CORPUSCLES

Although it is necessary to differentiate clearly between traumatic synovitis and haemarthrosis, almost all traumatic synovial effusions contain red blood corpuscles. The blood supply of the synovial membrane is so liberal that even trivial injuries may cause some bleeding into the joint. It is for this reason that the presence of blood is no criterion of the severity of an injury.

(2) WHITE BLOOD CORPUSCLES

Both the total and differential white counts vary within wide limits, depending on local conditions. For example, the percentage of polymorphonuclear leucocytes may be high in the presence of reactionary changes associated with the absorption of a haematoma, whereas in effusions of long standing lymphocytes may predominate.

(3) BILIRUBIN

Red blood corpuscles are broken down in the synovial cavity into haemosiderin and bilirubin. The quantity of bilirubin increases with the duration of the traumatic effusion, while the number of red blood corpuscles correspondingly decreases. Kling has found on the average the icteric index of the larger traumatic effusions to be between ten and fifteen units one week after the accident. After a further week it rises to between fifteen and twenty-five units. The same type of result is obtained from the indirect van den Bergh reaction. He has pointed out that except in conditions associated with haemorrhage into joints, such as haemophilia and sarcoma, the bilirubin content of inflammatory effusions is usually under five units and concludes that the bilirubin content is therefore a useful test in

differentiating between traumatic and inflammatory effusions. The reliability of this test has been verified by him in an examination of over four hundred synovial effusions. It is evident that this is a laboratory test of strictly limited application, but which might occasionally prove of value in chronic effusions of "idiopathic" type, and in cases where the attributability to injury is a matter of controversy.

(4) FAT

Although it is possible for minute quantities of fat to escape into the joint in injuries of the capsule and synovial membrane or in rupture of the peripheral attachment of a meniscus, the presence of obvious fat droplets in aspirated fluid may be taken as evidence of the existence of an intra-articular fracture.

(5) MUCIN

The irritant effect of blood in the synovial cavity causes hypersecretion of synovial fluid to take place almost immediately, with consequent increase in the total mucin in the joint. Kling considers that a large haemorrhage may produce prolonged irritation with hypertrophy and hypersecretion of the synovial membrane even after the original extravasation has disappeared. He concludes that this may be a factor in the development of chronic traumatic arthritis.

RATIONALE AND TECHNIQUE OF ASPIRATION IN TRAUMATIC SYNOVITIS

The importance of early aspiration in traumatic effusions is not generally recognised. It is a simple procedure which confers many therapeutic advantages without the possibility of ill effects. The argument that infection may be introduced into the joint has no factual basis. It is impossible if the usual aseptic precautions are observed, and could only occur as a result of gross negligence. The fact that aspiration is followed by recurrence of effusion (usually in lesser degree) does not detract from its value.

The indications for early aspiration of traumatic effusions are based on the consideration of physiological and mechanical factors to which attention has already been directed. Although a small effusion may be of little significance and requires no special treatment, a large accumulation of fluid increases the intra-articular pressure and produces distention of the capsule. It interferes with the circulation, both venous and lymphatic, and, by irritating the nerve endings, produces spasm and contracture of muscles. Movement of the knee is restricted at the limits of flexion and extension, and, the capacity of the capsule being greatest in slight flexion, the joint is maintained in this position, with the result that the vastus medialis cannot be exercised, and with the possibility of other undesirable effects to which reference is made in later chapters. In addition, it is desirable that any blood which may be present in the effusion should be removed, for otherwise its absorption is protracted and it produces reactionary changes in the

synovial membrane. Furthermore, fibrin may be precipitated and organised, forming the basis of adhesions or even of loose bodies.

TECHNIQUE OF ASPIRATION

The skin is washed with soap and water and painted with iodine or other suitable antiseptic. The suprapatellar pouch is the most suitable site for aspiration. A point is selected on the lateral side of the pouch, above the level of the superior pole of the patella, and a weal produced in the skin by means of a hypodermic needle and 2 per cent. novocain. The needle is then entered at right angles to the skin and the deeper tissues infiltrated down to the capsule. Aspiration is performed with the aid of a wide bore needle (Fig. 10) or fine trocar and cannula. At the termination of the procedure the wound is sealed with collodion and a compression bandage applied (page 96).

CLINICAL FEATURES OF TRAUMATIC SYNOVITIS

Effusion is the accompaniment of almost every acute injury of the knee joint. It is evident from the chapters which follow that a very large percentage of the long standing disabilities which are encountered cannot be cured (in the literal sense of the word). The most successful efforts can produce marked improvement of function, but seldom result in a perfectly normal joint. Inability to attain perfection, or the nearest thing to it, is due, in the majority of cases, to failure to establish an exact diagnosis or prescribe the correct treatment in the *acute* injury. Therein lies the danger of the casual diagnosis of "Traumatic Synovitis." It is a label which must be held responsible for much irreparable damage. It is not a diagnosis. It is a sign of injury. If it must be used as a diagnosis the term is only applicable when every possible source of internal derangement has been eliminated.

The clinical features of traumatic synovitis are well known and require no detailed elaboration. It should be a simple matter to distinguish it from acute prepatellar bursitis or acute cellulitis—conditions with which it is known to have been confused. The swelling of effusion outlines the horse-shoe shape of the suprapatellar pouch, and it is clearly evident that it is within the joint from the fact that the patella is floated off the femoral condyles. When this point is not immediately obvious, firm pressure on the suprapatellar pouch will permit the sign of "patella tap" to be elicited.

It is important to differentiate a simple traumatic synovitis from traumatic haemarthrosis, not only because of the slight difference in the treatment to be adopted, but because of the implications which haemorrhage into the joint entails. The points on which the differential diagnosis is based are :

(1) **Interval.**—In acute traumatic synovitis there is usually an interval of at least six hours between the injury and the appearance of the swelling, whereas in acute traumatic haemarthrosis the swelling of the joint occurs within half an hour. It must be remembered, however, that the greater

the percentage of haemorrhage accompanying the synovitis the shorter is the quiescent period.

(2) **Pain.**—The subjective phenomena associated with acute synovitis are distension and discomfort rather than true pain, in contradistinction to haemarthrosis in which the patient frequently suffers acute pain.

(3) **Palpation.**—The contents of the suprapatellar pouch give a considerably greater sensation of resistance in haemarthrosis than in synovitis. This difference is not easy to translate into words, but once the opportunity to make the comparison has occurred, the "feel" of a haemarthrosis is easily recognised in the future.

(4) **Local and Systemic Reaction.**—Simple traumatic synovitis is not usually accompanied by marked local reaction; never by systemic reaction. In haemarthrosis there is a rise in local temperature which may sometimes be accompanied by a general systemic upset.

TREATMENT

Once it has been established by clinical and radiological examination that there is no underlying pathology which is likely to be responsible for a gross internal derangement, active treatment may be initiated. If the effusion is large it is aspirated and a compression bandage applied (page 96); if it is small, a compression bandage alone is sufficient. Weight-bearing is inadvisable in most cases and complete recovery is usually accelerated by rest in bed, but frequently the ideal form of treatment may prove impossible for domestic or economic reasons. Non-weight-bearing quadriceps drill of the type outlined in Chapter One and elaborated in Chapter Six must be commenced immediately. In the absence of exercise, wasting occurs with astonishing rapidity. A month of conscientious exercise may not make good the loss of muscle volume which occurs in a week.

Simple traumatic synovitis is a common condition. It is evident that a large proportion of cases recover, even without treatment. The exceptions are the daily problem of every orthopaedic clinic. The stories bear a curious similarity: "Following an injury which resulted in considerable swelling of the joint, the patient was confined to bed for a matter of two or three weeks. No exercises were practised. At the end of this time the swelling had completely subsided, but on resuming weight-bearing the effusion immediately reappeared. The limb was then encased in plaster for a period of six weeks. No exercises were practised. At the termination of this further period of immobilisation the swelling had again subsided, but reappeared within a short time of resuming weight-bearing. Many weeks have now passed without improvement. Every possible cause of effusion has been suspected and many laboratory investigations have been performed with negative results. The present complaint is that of swelling, weakness, and instability.

Examination reveals effusion, with palpable thickening of the synovial membrane of the suprapatellar pouch, gross wasting of the quadriceps, and 'relaxation' of all the accessory supporting structures of the joint."

This is the picture of a chronic traumatic synovitis which at best will take many months to cure ; at worst it is the initial stage of a traumatic osteoarthritis which will inevitably progress. It was originally nothing more than a simple traumatic synovitis which would have returned to normal in a matter of two weeks if the medical adviser had known a few simple facts about the physiology of the knee joint.

TRAUMATIC HAEMARTHROSIS

REACTION OF SYNOVIAL TISSUES TO HAEMARTHROSIS

The question of whether an extravasation of blood coagulates within the joint has for long been a matter of controversy, and although it is now generally accepted that the synovial membrane and synovial fluid exert an anti-coagulant effect, the answer to this vexed question, in the case of traumatic haemarthrosis, is that it depends entirely on the nature of the causative injury.

In the light of experience of the series of knee joint injuries which form the basis of this monograph, the author considers that in order to understand the subsequent pathology it is necessary to recognise two varieties of haemarthrosis :

- (1) **That in which the blood remains fluid.**
- (2) **That in which coagulation occurs.**

What is the difference between the two ? The first, which is the common variety, follows such injuries as sprain complicated by a tear of the synovial membrane, rupture of the anterior cruciate ligament, and fracture of the tibial spine. In this type, actual tissue damage is small and the anti-coagulation properties of the synovial membrane and fluid are successful in preventing clotting.

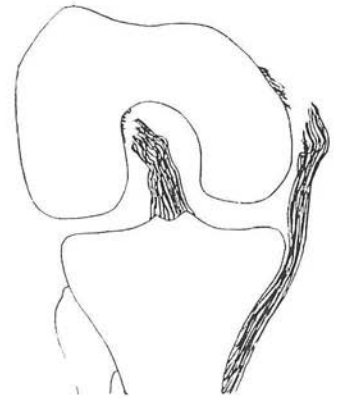
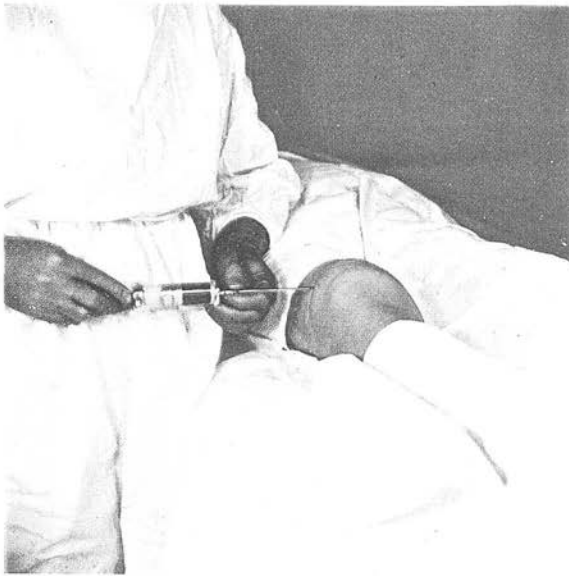
The prognosis in regard to future function, relative to the haemarthrosis alone, is excellent in this type of case whether the joint is aspirated or not.

The second variety is encountered following severe trauma involving extensive soft tissue injuries which communicate with the joint. Such lesions include fracture of the patella by indirect violence, in which the capsular expansions are ruptured on both the medial and lateral sides of the joint, but, most important of all, is that which occurs as a complication of an intra-articular operation such as the excision of a meniscus—a procedure in which an extensive area of sub-synovial tissue is subjected to trauma. In these cases not only does intra-articular coagulation occur as an extension from the peri-articular tissues, but the products of tissue damage completely overwhelm any anti-coagulant property possessed by the synovial membrane and fluid. If the clots are not absorbed organisation takes place and the function of the joint is seriously impaired by adhesion formation.

The irritation produced by the presence of blood provokes reactionary vaso dilatation and hyperactivity in the synovial membrane. The vaso

dilatation aids the absorption of the diffusible components of the haematoma together with the transport of large numbers of leucocytes from the circulation into the joint cavity, while the hypersecretion of the synovial cells results in an increased production of mucin.

In normal conditions lymphatics are the chief channels for the transport of coarse particles, but, as already mentioned, in the presence of effusion and consequent increase of intra-articular pressure, these channels are obliterated and obstructed. In these circumstances the main factor in the absorption of haemorrhagic effusion must be the breaking down of the blood corpuscles into a diffusible solution of bilirubin and the phagocytosis of haemosiderin by histiocytes and macrophages.



FIGS. 10 and 11

Aspiration of haemarthrosis (Fig. 10). This patient *walked* into hospital five days after an injury which he did not consider to be severe. Both the anterior cruciate and the medial collateral ligaments were completely ruptured at the femoral attachment (Fig. 11) and were subjected to operative repair by the methods illustrated in Figs. 113 and 156.

CLINICAL FEATURES OF HAEMARTHROSIS

The clinical recognition of a haemarthrosis is a matter of simplicity to the experienced; to those unfamiliar with the surgery of trauma it may be difficult to distinguish from a simple traumatic effusion (page 13). *There is little doubt that the serious disabilities which follow an undiagnosed rupture of the anterior cruciate ligament would be greatly reduced if every case of traumatic haemarthrosis or even of haemorrhagic effusion was investigated with this possible diagnosis in view* (Figs. 10 and 11).

A haemarthrosis is not a characteristic feature of a torn meniscus because the majority of tears occur in completely non-vascular areas or in areas where vessels are extremely small and scanty. If, for example, in a

meniscus operation, incision of the synovial layer demonstrates the presence of a haemarthrosis, or deeply blood stained synovial fluid, it is possible that the diagnosis is correct and that the meniscus has been torn from its peripheral vascular attachment, but the probability is that an error of diagnosis has occurred and that a rupture of the anterior cruciate ligament has been missed in the examination.

TREATMENT

A large intra-articular haemorrhage is rarely produced by a trivial injury, and although the treatment of the underlying pathology, whether it is a rupture of the anterior cruciate ligament or a fracture of the tibial table, must always include direct treatment of the haematoma, haemarthrosis is undoubtedly a condition in which the treatment is largely that of the cause. On the rare occasions in which it occurs in the absence of a major soft tissue or bony injury it must be aspirated immediately and a compression bandage applied. The joint should be immobilised in the compression bandage for 10 to 14 days until the risk of further haemorrhage is past before quadriceps drill and active knee flexion exercises are prescribed.

The treatment of haemarthrosis occurring as a complication of operation is considered on page 99.

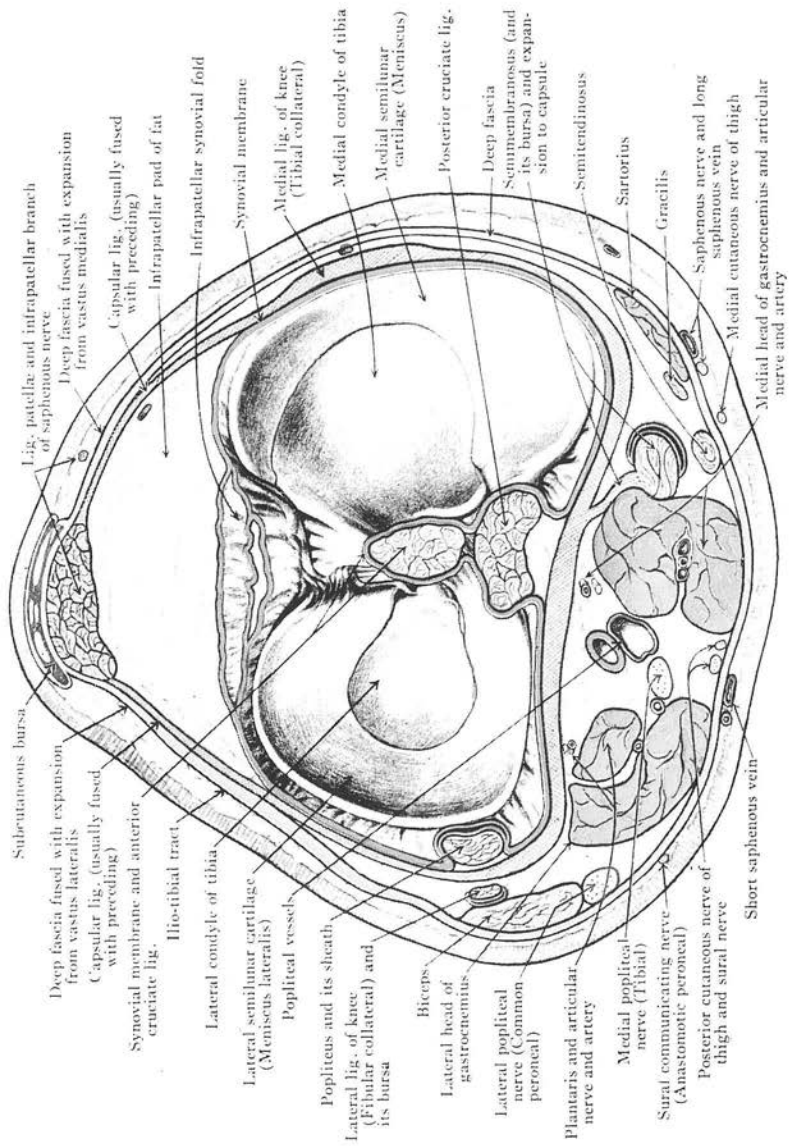


FIG. 12

Relations of the knee joint. (By courtesy of Dr E. B. Jamieson.)

CHAPTER THREE

THE SURGICAL ANATOMY AND PHYSIOLOGY OF THE MENISCI AND MECHANISM OF THEIR INJURIES

MEDIAL MENISCUS

THE medial meniscus or internal semilunar cartilage is, as the name suggests, semilunar in outline, the extremities or anterior and posterior horns being widely separated from one another. The anterior horn is attached to the non-articulating area of the tibia in front of the anterior horn of the lateral meniscus and anterior cruciate ligament in one of several ways :

- (1) Most commonly there is a single attachment of variable strength.
- (2) In addition a band, which also varies in size, and known as the transverse ligament, may pass to the anterior margin of the lateral meniscus.
- (3) A band may pass backwards to the attachment of the anterior cruciate ligament.

The posterior horn is firmly attached to the posterior part of the non-articulating area between the tibial spine and the attachment of the posterior cruciate ligament.

In most cases it will be noted that the width of the meniscus, that is, from the thick convex periphery to the thin concave central margin, differs in the anterior and posterior halves ; the anterior is usually narrow, whereas the posterior is broad (Fig. 13). As might be anticipated in a structure which is discoid in shape in the full-term foetus and which gradually undergoes central absorption, considerable variation in breadth is encountered and in some menisci little difference in width is noted between the anterior and posterior halves. It seems not unreasonable to suppose that the variation of attachment of the anterior horn and especially of the relative breadths of the anterior and posterior segments may well in some measure determine not only the possibility of injury but the site and type of the lesion. Examination of normal medial menisci removed as a result of errors of diagnosis suggests that the narrow meniscus is less

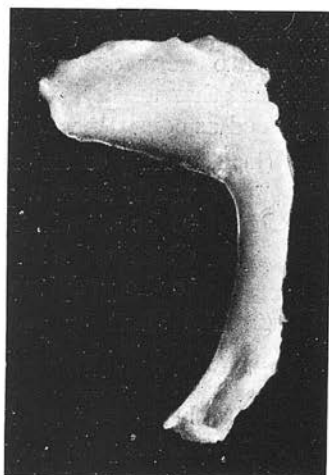


FIG. 13

Normal medial meniscus.
(By courtesy of Brit. Jow. Surg.)

accident prone than the broad. This supposition is justifiable, because being narrow it is subject to less rotatory mechanical purchase by the femoral condyle and is thus not only less likely to be torn but also less likely to have the peripheral capsular attachments stretched. Further proof of this contention is suggested by the rarity of tears of regenerated menisci which are both narrow and firmly attached peripherally (page 75).

RELATION TO EVOLUTION OF KNEE JOINT

The susceptibility of the delicate quadriceps mechanism to injury has been explained on a developmental basis (Chapter One). It will be recalled that man is the only animal able to assume the completely erect posture. The menisci of the human knee joint are relatively larger than those of the lower vertebrates. The menisci which most closely resemble the human type are to be found in the primates,¹ but it is of interest to note that even in the chimpanzee, an animal capable of assuming the semi-erect posture and whose body structure bears a remarkable resemblance to the human being, these structures are of comparatively narrow type. It thus seems probable that the relatively large breadth of the human meniscus is closely associated with the biologically recent acquisition of weight-bearing on the fully extended knee. This association with an attribute, common only to human beings and therefore of recent evolutionary origin, may render the menisci structurally unstable and thus determine their astonishing vulnerability to injury.

RELATIONSHIP OF MEDIAL MENISCUS TO MEDIAL COLLATERAL LIGAMENT

The medial collateral ligament is a strong flat band about 10 cm. long, applied to the medial aspect of the knee joint. The ligament is wider at the joint line than at the proximal and distal attachments, and thus is frequently regarded as consisting of two parts:

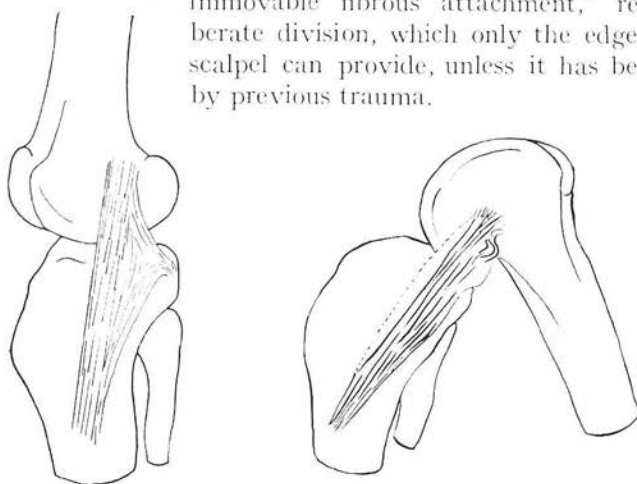
- (1) The long or anterior portion, which inclines downwards and forwards from a point immediately below the adductor tubercle to be attached to the medial surface of the shaft of the tibia distal to the level of the tuberosity. This part is loosely attached to the periphery of the medial meniscus.
- (2) The short or posterior portion, which inclines downwards and slightly backwards to be attached to the postero-medial aspect of the tibia immediately above the groove for the semimembranosus tendon. The deep posterior fibres are closely adherent to the periphery of the medial meniscus (Figs. 14 and 15).

The exact relationship of the posterior deep fibres to the medial meniscus is a subject about which there is considerable divergence of opinion: recently² it has been asserted that although a close approximation exists,

¹ Maurice H. Herzmark. "The Evolution of the Knee Joint." *J. Bone and Joint Surg.*, 1938, xx, 77.

² Otto C. Brantigan and Allen F. Voshell. "The Mechanics of the Ligaments and Menisci of the Knee Joint." *J. Bone and Joint Surg.*, 1941, xxiii, 59.

it is not a fixed immovable fibrous attachment. Experience of a large number of operations on the medial meniscus provides convincing evidence of the firmness of the attachment which, although it may not be a "fixed immovable fibrous attachment," requires deliberate division, which only the edge of a sharp scalpel can provide, unless it has been detached by previous trauma.



FIGS. 14 and 15

The medial collateral ligament in extension and flexion, showing the long anterior and short posterior fibres, and the backward gliding of the ligament in flexion. (Redrawn from Brantigan and Voshell).

TIBIAL ATTACHMENT OF MEDIAL COLLATERAL LIGAMENT

Although the distal extremity of the long anterior fibres of the medial collateral ligament is situated about 7 cm. distal to the articular surface of the medial tibial condyle, the actual point of attachment to the tibia is about 4.5 cm. from the surface of the condyle, that is to say, the ligament is not attached to the bone throughout its whole tibial course (Fig. 15). This point is proved by the presence of the medial articular arteries between the ligament and the bone and the frequent existence of a bursa. The significance of the tibial attachment of the medial collateral ligament becomes evident in a later paragraph.

RELATIONSHIP OF THE MENISCI TO THE FEMORAL AND TIBIAL CONDYLES

The attachments of the menisci suggest that they are accessory to the tibia, but movements of the joint demonstrate that they alter their position with the movements of the femur rather than with those of the tibia.¹ Evidence of the truth of this statement may be obtained from examination of medial menisci removed at operation. The earliest sign of injury in the posterior segment, in the nature of a beginning longitudinal tear, is seen on the inferior aspect and not on the superior surface, which is frequently intact. This confirms the existence of the most intimate contact between

¹T. D. McMurray. "The Semilunar Cartilages." *Brit. Jour. Surg.*, 1942, xxx, 407.

the femoral condyle and the superior surface of the meniscus, the injury taking place as a result of abnormal forces acting between the inferior surface of the meniscus and the tibial head.

SIGNIFICANT FEATURES OF JOINT PHYSIOLOGY IN FLEXION AND EXTENSION

In considering the movements of the joint in relation to the production of meniscus injuries and with special reference to the statements made above it seems of importance that :

(1) In flexion—

- (a) The menisci move backwards. The medial, being relatively fixed, moves through a small range. The lateral, being mobile and accessory to the lateral condyle of the femur, which normally rolls further backwards than the medial condyle, moves through a range which may even exceed 1 cm. in full flexion.
- (b) The posterior halves of the menisci are pressed between the opposing posterior areas of the femoral and tibial condyles.
- (c) The medial collateral ligament glides backwards in relation to the head of the tibia—a movement made possible by the attachment of the ligament distal to the tibial articular surface (Fig. 15).
- (d) A small range of abduction and adduction and varying degrees of internal rotation are possible. These movements are controlled by the capsule, medial collateral and cruciate ligaments. The lateral collateral ligament is relaxed.
- (e) If the joint is retained in internal or external rotation and the movements of flexion and extension superimposed, not only is the free range of antero-posterior movement of the menisci diminished but the close relationship to the femoral condyles is altered. Under these circumstances the menisci remain fixed to the tibial condyles. This observation is of the utmost importance in the mechanism of injury.

(2) In extension—

- (a) The menisci move forward.
- (b) The anterior halves of the menisci are snugly held between the apposing femoral and tibial condyles. Any tendency to hyper-extension subjects the anterior segments to compression.¹
- (c) The final movement of the medial femoral condyle before full extension is reached is medial rotation. This movement, the so-called "screw home" movement, is due to the existence of a larger area of bearing surface on the medial condyle as compared

¹ Otto C. Brantigan and Allen E. Voshell. "The Mechanics of the Ligaments and Menisci of the Knee Joint." *J. Bone and Joint Surg.*, 1941, xxiii, 61

with the lateral. When the whole articular surface of the lateral condyle has been used up the femur rotates round the tibial spine until the extra area of the medial condyle has been used, at which point the joint is "locked" in extension.

- (d) The "screw home" movement having taken place, medial rotation and lateral rotation, abduction and adduction, are impossible. It is therefore not possible for a lesion of a meniscus to occur in extension as an isolated injury. If an injury does occur it must be associated with rupture of a collateral ligament and possibly fracture of the contra lateral tibial condyle.

LATERAL MENISCUS

Many of the statements which have been made regarding the medial meniscus may be applied with equal bearing to the lateral structure. There are, however, noteworthy differences in contour and attachment which are of importance in relation to the mechanism of injury.

The contour of the lateral meniscus is most accurately described as a large segment—almost the entire circumference—of a small circle, whereas, by comparison the medial meniscus is a small segment of a large circle. The periphery is thicker and the width of the meniscus greater and more uniform in the anterior and posterior halves, than the medial structure (Fig. 16). The anterior horn is attached to the tibia immediately in front of the intercondyloid eminence. It may have an additional attachment to the anterior cruciate ligament. The posterior horn is attached between the spines of the eminence. In addition, fibres from the convex posterior border augment the posterior aspect of the posterior cruciate ligament by which these fibres are conducted to be attached to the femur.

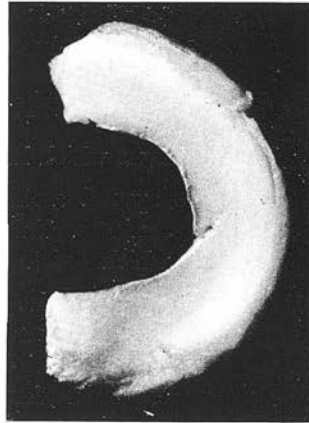


FIG. 16
Normal lateral meniscus.
(By courtesy of Brit. Jour. Surg.)

RELATIONSHIP OF LATERAL MENISCUS TO LATERAL COLLATERAL LIGAMENT

The lateral or fibular collateral ligament is a distinct rounded band attached to the femur immediately proximal to the groove for the tendon of the popliteus. It is attached distally to the lateral aspect of the head of the fibula in close association with the insertion of biceps.

It has already been stated that the fibular collateral ligament is relaxed in flexion and thus can exert no control over abduction, adduction or rotary

movements in flexion. This statement indicates that the intimate relationship between meniscus and ligament which is characteristic of the medial side of the joint does not exist on the lateral aspect and in point of fact the popliteus tendon, surrounded by a synovial sheath, separates the two structures producing a well-defined oblique groove at a point immediately posterior to the mid-point of the periphery.

MOBILITY OF LATERAL MENISCUS

It has been recorded that the lateral is the more mobile of the two menisci and has, in fact, a range of movement which may be as great as 1 cm. The large range of movement is explained by :

- (1) The close proximity of the attachments of the anterior and posterior horns. The horns of the medial meniscus are widely separated, and this feature of itself entails decreased mobility.
- (2) The lack of attachment to the associated collateral ligament which permits movement of the meniscus as a whole. It is thus subject to less stress and strain than the medial structure, which has a point of fixation to the medial collateral ligament.

FUNCTION OF THE MENISCI

The functions which have been ascribed to the menisci are :

- (1) To spread a film of lubricating synovial fluid over the articular surfaces. This function is made possible by the intimate contact which exists between the menisci and the opposing condyles.
- (2) To protect the opposing articular surfaces in that they act as shock absorbers, particularly in hyperflexion and hyperextension. The menisci do not cushion a blow from above or below in full extension, for in this position articular contact is always present, especially on the medial side.¹
- (3) To increase the stability of the knee joint by deepening the articular surfaces of the tibial plateau and filling in the dead space which otherwise would exist at the periphery of the condyles. This function incidentally prevents the intrusion of the capsule and synovial membrane between the adjacent articular surfaces.

SUMMARY OF FACTORS WHICH MAY INFLUENCE THE VULNERABILITY OF MENISCI

(1) EVOLUTION

Man is the only animal to assume the completely erect posture and thus to weight-bear through the completely extended knee joint. Under this heading will be noted :

¹ Otto C. Brantigan and Allen F. Voshell, "The Mechanics of the Ligaments and Menisci of the Knee Joint." *J. Bone and Joint Surg.*, 1941, xxiii, 61.

- (a) **Muscle Function.**—It has been stated (Chapter One) that to maintain knee extension new muscles have not been evolved. Orthograde functions have been superimposed on muscles which, in other animals, perform plantigrade motion. The mechanism of this function is delicate and easily deranged. Loss of quadriceps volume, tone and control, of itself predisposes to injury of the menisci.
- (b) **Skeletal Structure.**—The condyles of the femur and the tibia attain the greatest relative development in the human knee joint.

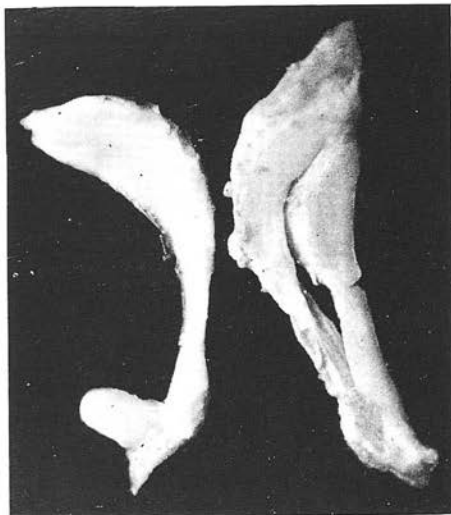


FIG. 17

The medial menisci removed from a case of bilateral genu valgum.

(Left) Pedunculated tag based anteriorly. This was originally a longitudinal tear, the central portion of which eventually lost its posterior attachment.

(Right) Complete longitudinal tear. The sharply defined margins of the anterior extremity of the lesion denotes that the extension of the tear into the anterior half of the meniscus is of recent origin.

- (c) **Structure and Attachment of Ligaments.**—The peculiarities of the medial and lateral collateral ligaments have been noted. The development of the anterior and posterior cruciate ligaments is relatively poor in man as compared with species which adopt flexed knee gait.
- (d) **Menisci.**—The relatively great breadth of the human menisci has been noted and taken as proof of importance of function in weight-bearing on the extended knee. It has been recorded that when flexion or extension is superimposed on internal or external rotation the mobility of the menisci is reduced and they remain fixed to the head of the tibia.

This summary merely restates the view that the human menisci may be biologically weak structures in a joint whose functions are a recent biological acquisition and therefore vulnerable.

(2) VARIATIONS IN HUMAN ANATOMY

- (a) Variations in size and shape of the femoral condyles and especially of the conformation of the tibial condyles is widely recognised.
- (b) In genu valgum, of even minor degree, the medial collateral ligament and capsule become stretched. Furthermore, the alteration of joint mechanics entails some loss of the intrinsic protective qualities of the vastus medialis. In these circumstances a predisposition to injury of the medial meniscus is present (Fig. 17).
- (c) Variations in shape and particularly in the breadth of individual menisci may determine the possibility and even the type of injury, examples of which are seen in the vulnerability of the congenital disc and the location of the incomplete transverse tear to the broad lateral structure.

(3) CONSTITUTIONAL FACTORS

It has been stated¹ that the injury occurs with greater frequency in overweight, poorly muscled, or sedentary men whose pelves are broader than normal in relation to body-weight. This may apply to those cases receiving the injury as a result of a minor domestic accident, and particularly to countries where association football is uncommon and the coal mines have wide seams, but in Britain there is not the least doubt that the large proportion of cases could only be described as healthy young athletes. The suggestion has some bearing however even on healthy young athletes, for the interesting observation has been recorded by McNeill Love² that during the Mesopotamian campaign in the First World War internal derangement of the knee was an epidemic condition especially prevalent in the autumn. The explanation offered was that during the summer months all hostilities ceased and strenuous games were in abeyance. The result of this forced inactivity was that the muscles, ligaments and peri-articular tissues rapidly lost their tone. With the onset of autumn an active life was abruptly resumed, and as a consequence internal derangements relative to the menisci occurred before the muscles guarding the joint regained their tone.

This writer also suggests that a meniscus may be torn for the same reason in the course of a simple effusion when strain is thrown on the joint before the effusion has completely subsided (see page 70).

¹ Edward K. Crayener and Donald G. MacElroy. "Injuries of the Internal Semilunar Cartilage. Possible Predisposition toward; Symptoms and Treatment." *J.A.M.A.*, 1941, cxvii, 1695.

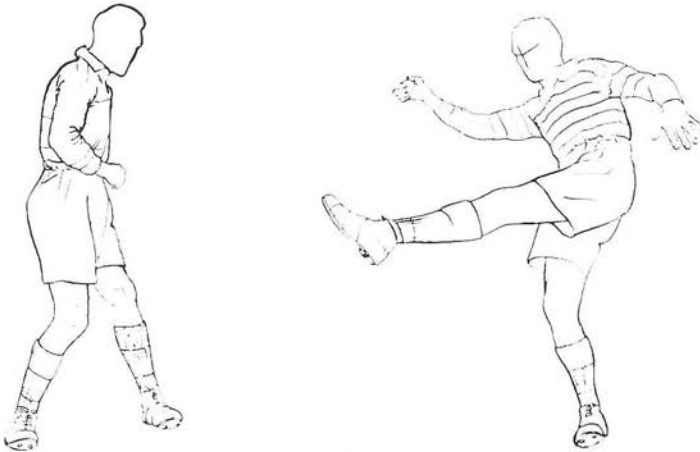
² R. J. McNeill Love. "Prognosis after removal of the Semilunar Cartilages." *Brit. Med. Jour.*, 1923, ii, 324.

(4) **STRESS AND STRAIN OF SPECIFIC TYPE SUCH AS OCCUR IN :**

- (a) **Association Football.**
 (b) **Coal-mining.**

MECHANISM OF INJURY

The observation has already been made that a lesion of a meniscus cannot occur as an isolated lesion in the position of extension. The movement of abduction (or adduction) can only take place in flexion. The production of abduction, although it entails the relaxation of pressure on the meniscus from above and below, does not tend to permit the meniscus affected to slip towards the centre of the joint. The shape of the menisci and the attachment of the anterior and posterior horns must tend to produce the opposite



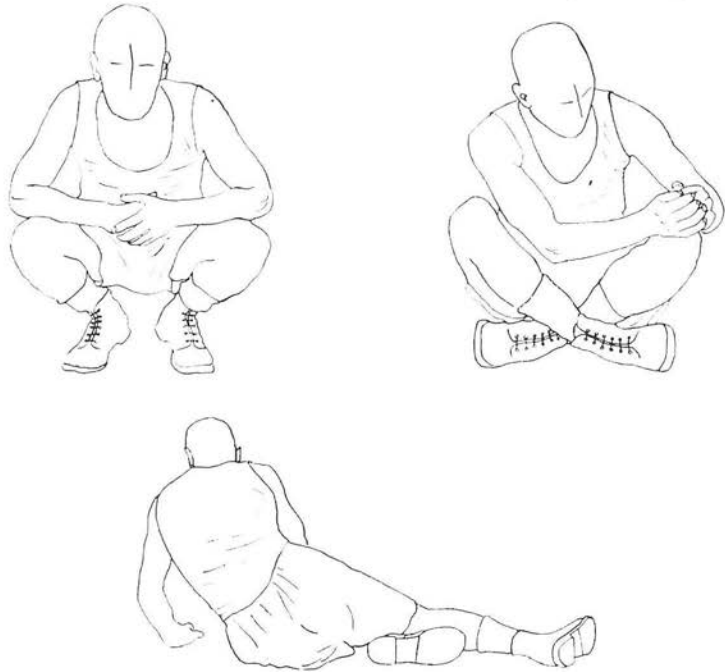
Figs. 18 and 19

In football the menisci are subject to rotary strain because the tibia is fixed to the ground by the studs of the football boot and is unable to follow violent rotation of the femur.

effect. There exists, therefore, an inherent tendency to keep the convex aspect forced towards the periphery, although it is obvious that the markedly separated attachments of the extremities of the medial structure make this inherent force less active on the medial side. Injury to the menisci is therefore only possible when flexion and extension is superimposed upon internal or external rotation or vice versa, for it is only in this combination of movements that the normal accessory motion of the menisci to the femur is restricted and the relationship to the femoral condyles altered. It is only in this combination of movements that the abnormal strains which are liable to terminate in injury are thrown on the menisci.

The clinical conditions which produce these abnormal strains occur on the football field and to a lesser extent in the mining industry. In football the tibia is fixed to the ground by the studs of the football boot and is thus unable to follow violent rotation of the femur (Figs. 18 and 19). In the narrow seams of a coal mine, the crouched position where the tibia is fixed

by the contact of the medial side of the foot with the floor while the knee is abducted and the femur internally rotated, is frequently used. The injury takes place as a result of the rotation of the femur to the mid position, which is an essential movement in order to regain the erect position (Fig. 22).



Figs. 20, 21, and 22

There is no occupation which imposes such constant strain on the knee joints as coal-mining.

Violent internal rotation of the femur on the tibia in flexion causes the medial meniscus to be forced towards the posterior compartment of the joint (Fig. 23), first, by reason of the attachment to the medial collateral ligament which exerts traction in a posterior direction, and second, by the rotary force of the medial femoral condyle which forces it in a postero-central direction.



Fig. 23

Violent internal rotation in flexion forces the posterior segment of the medial meniscus in a postero-central direction where it is trapped on extension.

If the peripheral attachment is stretched or torn (Fig. 24), the relative fixation of the posterior horn does not permit the meniscus to escape directly backwards, and, the major force being postero-central, the line of least resistance is towards the centre of the joint. When the joint is suddenly extended, the meniscus is caught in the abnormal position and trapped against the head of the tibia, resulting in a posterior longitudinal tear. If the longitudinal tear involves the posterior third only, the entire meniscus eventually springs back into the normal position and the joint does not lock. If, however, the tear extends

forward beyond the plane of the ligaments the condyle traps the meniscus against the tibia at the extreme anterior limit of the tear, it cannot regain its normal position, and the joint locks (Fig. 25). The pain suffered by the patient in the former event is probably due not to the actual tearing of the meniscus but to the injury and haemorrhages into the peripheral attachment which displacement towards the centre of the joint must entail (Fig. 24).

Evidence in support of the contention that the mechanism of injury tends to drive the meniscus in a posterior direction may be obtained from examination of the injured structures, when it is seen that the central or anterior portion of the attachment of the posterior horn is frequently damaged, whereas the posterior or peripheral aspect is usually intact.

It is probable that the same mechanism accounts for the less common transverse tear at the junction of the anterior and middle thirds. The same force acting on the posterior half of the meniscus in the posterior half of the joint must put a strain on the junction of the middle and anterior thirds. The strain is thrown on the concave edge, which from its nature is unable to straighten and therefore tears transversely (Fig. 26).

Examination of case histories reveals that the same mechanism is responsible for the common lesions of the posterior segment of the lateral meniscus. Medial rotation causes the lateral condyle to drive the anterior half of the lateral meniscus in an antero-central direction, which tends to tear the posterior half from its peripheral attachment. If, on extension, the posterior half of the meniscus is caught in the abnormal position, it is trapped against the head of the tibia and a longitudinal tear results; if it escapes, the residual lesion is a separation of the posterior segment from its peripheral attachment.

The less common mechanism of external rotation of the femur in flexion and adduction is also responsible for lesions of the lateral meniscus, differing from the effect of medial rotation on the medial meniscus in that the lateral meniscus is more mobile and is not subjected to traction in a posterior direction by the fibular collateral ligament. The frequency with which the incomplete transverse lesion in the form of the "parrot beak" tear (Fig. 42) is encountered suggests that the mechanism described is correct. This injury occurs more often on the lateral side, for the reason that the lateral meniscus is a section of a smaller circle than its medial counterpart and thus any attempt to straighten the concave margin is more likely

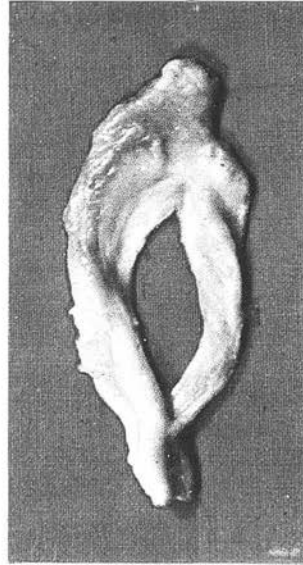


Fig. 24

The inferior surface of a medial meniscus showing a complete longitudinal tear of two weeks duration. Note the recent haemorrhage into the synovial membrane at the periphery of the posterior segment. The posterior peripheral attachment must be stretched or torn before a longitudinal tear can occur.

to result in a transverse tear (Fig. 26). Moreover, the fact that the lateral meniscus is neither attached to nor controlled by the movement of the

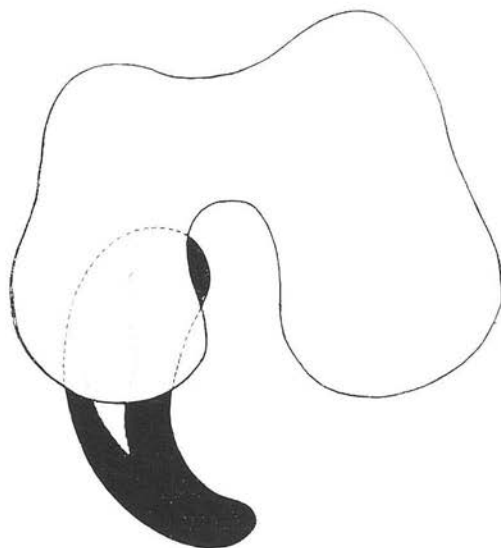


FIG. 25

If the longitudinal tear extends beyond the plane of the ligaments the condyle traps the meniscus against the head of the tibia at the extreme anterior limit of the tear, the central portion cannot regain its normal position, and the joint locks.

fibular collateral ligament means that more strain is thrown on the concave margin.

The method by which the incomplete transverse tear of the lateral meniscus is produced by direct violence is described on pages 41 and 42.




FIG. 26

Any force, whether it is antero-central or postero-central, which attempts to straighten the concave margin of a meniscus will tend to produce a transverse tear. This applies in particular to the lateral meniscus.

CHAPTER FOUR

SURGICAL PATHOLOGY OF THE MENISCI

THE lesions of the menisci may be classified :

(I) **LONGITUDINAL (BUCKET-HANDLE) TEARS**

(A) **Of Posterior Segment.**

(a) Single.

(b) Multiple.

(B) **Complete (involving both Posterior and Anterior Segments).**

(a) Single.

(b) Multiple.

(C) **Of Posterior Peripheral Attachment.**

(In some cases the mechanism of this lesion may differ from that of tears of the substance of the meniscus, but for purposes of simplification of classification it may be regarded as a longitudinal tear occurring outside the peripheral zone.)

(II) **TRANSVERSE TEARS**

(A) **Incomplete or oblique (parrot-beak tear).**

(B) **Complete.**

(III) **VARIOUS COMBINATIONS OF LONGITUDINAL AND TRANSVERSE TEARS**

(IV) **CYSTIC DEGENERATION**

(V) **CONGENITAL ANOMALIES**

(VI) **TEARS OF REGENERATED MENISCI**

(I) **LONGITUDINAL TEARS**

The earliest form of the longitudinal or bucket-handle tear which is encountered is a split or deep longitudinal abrasion of the surface of the posterior segment of the meniscus which does not penetrate the substance of the structure and which is almost always found on the inferior aspect (Fig. 27). It represents the result of momentary trapping of the posterior third between the condyles of the femur and tibia, and in cases where this momentary trapping has taken place on several occasions, two or three or more splits may be found on the under surface parallel to one another (Figs. 28 and 29).

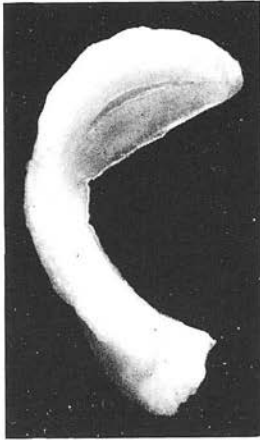
(I) (A) (a) LONGITUDINAL TEAR OF POSTERIOR SEGMENT

FIG. 27

The earliest longitudinal tear of the posterior segment takes the form of a split which does not penetrate through the substance of the meniscus. It is usually located on the inferior surface.

The longitudinal tear of the posterior segment represents the result of a single incident in which the meniscus has been trapped with such force that the split has immediately penetrated the substance, or in a case in which the joint has been the subject of several minor incidents, may represent the end result of superimposed inferior surface lesions which have eventually penetrated the substance of the posterior horn.

Once a longitudinal tear of the posterior segment has occurred the subsequent pathology may take one of several courses :

The lesion may continue as a single longitudinal tear of the posterior horn giving rise to giving-way incidents but not to mechanical locking, or

(I) (A) (b) THE POSTERIOR SEGMENT MAY BECOME SITE OF MULTIPLE LONGITUDINAL TEARS

Once the stretching of the peripheral attachment, which permitted the posterior segment to slip towards the centre of the joint to sustain the original lesion, has taken place, the tendency for recurrence of the same incident remains or is even increased (Fig. 30). The central portion of the

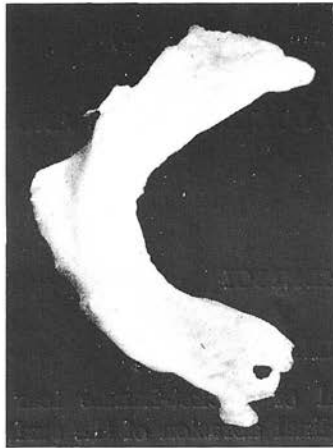


FIG. 28

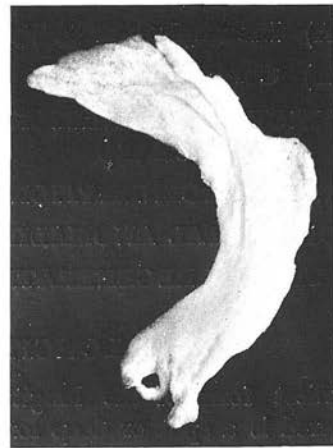

FIG. 29

Lesions of menisci are most marked on the inferior surface and are sometimes limited to the inferior surface.

Lateral meniscus. The superior surface appears to be undamaged (Fig. 28), but the inferior aspect shows multiple longitudinal tears which have failed to penetrate the substance of the structure (Fig. 29).

longitudinal tear frequently hypertrophies and this may increase its liability to be trapped. When several longitudinal tears have occurred, the meniscus

substance between the tears becomes so narrow that each strip can rotate on its long axis and thus further tears can occur, not only in the width, but in the depth of the structure. Furthermore, as the strips become narrower, they become more liable to be divided transversely instead of longitudinally when they are trapped. (See (III).)

One of the most characteristic features of the meniscus, the site of multiple longitudinal tears, is that the injuries are more in evidence on the inferior surface, which is often grossly lacerated, than on the superior surface which may show nothing more than the tears, the surface of the meniscus between the tears being comparatively undamaged. This is further evidence that the meniscus is accessory to the femur and not to the tibia, and that in the mechanism of injury the meniscus is trapped by the femur against the tibia and not vice versa.

As an alternative to the production of multiple tears of the posterior segment, the

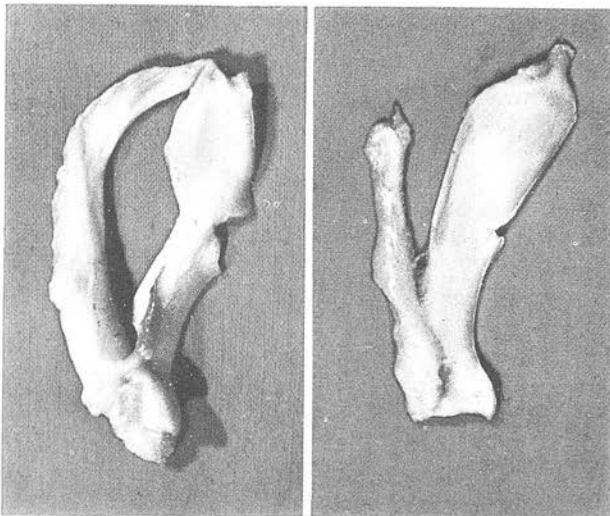
(I) (B) (a) LESION MAY BECOME COMPLETE, *i.e.* EXTEND INTO ANTERIOR SEGMENT

The complete longitudinal tear is the common injury associated with the classical and widely



FIG. 30

Longitudinal tear of the posterior segment of a medial meniscus; the sharply defined edges denote that the lesion is of recent origin. Note the presence of an old standing tear of the posterior peripheral attachment.



FIGS. 31 and 32

Menisci showing recent extensions of previously existing tears.

In both specimens the lesion is confined to the peripheral zone. There is thus evidence of a blood supply in the opposing margins of the fibrocartilage at the anterior extremity of the tear.

recognised symptom of locking. It may occur at the original injury, as evidenced by immediate locking, or may occur as an extension of a previous longitudinal tear of the posterior segment. In the latter event locking is usually preceded by giving-way incidents.

In the recent injury the adjacent margins of the tear have sharply defined edges, and if the tear has extended into the peripheral vascular zone at either the anterior or posterior extremities (Figs. 31 and

LONGITUDINAL TEARS

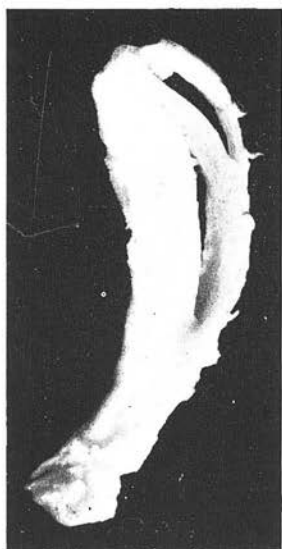


FIG. 33

Original tear of peripheral zone of posterior segment followed by a second tear which extended further forward.

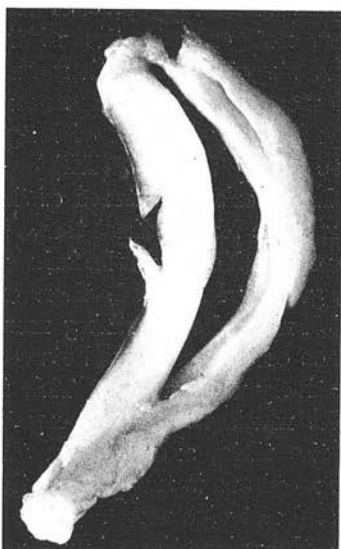


FIG. 34

Original tear of peripheral zone of posterior segment followed by a later tear which extended far forward into the anterior segment. A transverse tear has been superimposed on a recent small longitudinal lesion of the central portion.

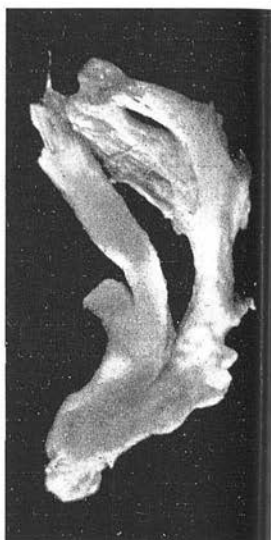

FIG. 35

Original tear of peripheral zone of posterior segment followed by multiple injuries.

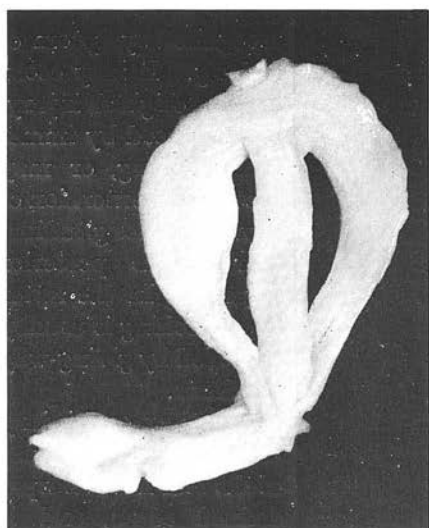


FIG. 36

FIG. 36.—Double longitudinal tear of old standing showing gross hypertrophy of the central strips of fibrocartilage.

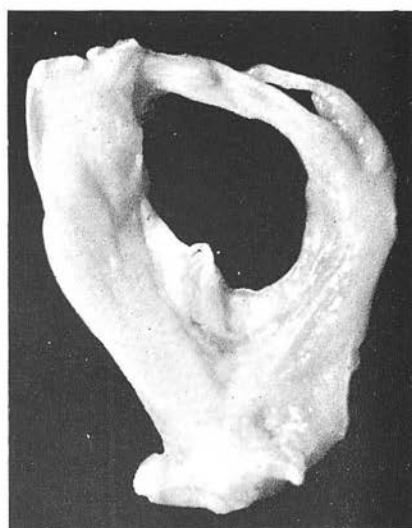

FIG. 37

FIG. 37.—Complete longitudinal tear of the peripheral zone. The central portion has been permanently displaced into the centre of the joint where it has undergone hypertrophy. Note the compression of the fibrocartilage at the anterior extremity and adjacent edges of the tear caused by the pressure of the femoral condyle.

32), some blood clot may be present which may later be transformed into fibrous tissue under favourable conditions of rest, to give the impression of attempted healing; but when the tear has existed for some time, and especially if there have been locking incidents which indicate that the central portion has been frequently displaced into the centre of the joint, the adjacent margins become smooth and rounded.

It has been shown that locking is due to impaction of the femoral condyle against the anterior extremity of the tear, while the central portion is displaced into the centre of the joint (Fig. 25). If the displacement is reduced, only to recur again on some unguarded rotary movement, the central portion is subject to the same subsequent pathology as in longitudinal tears of the posterior segment. If, on the other hand, the tear has been prolonged forward into the anterior horn to an extent which will permit full extension, while the central portion is displaced in the centre of the joint, locking does not occur, and if this condition is maintained for longer than a few days the displacement becomes permanent, giving rise only to vague symptoms and to no classical signs. The displaced portion of meniscus frequently undergoes hypertrophy with the passage of time (Fig. 37). This feature may be so marked that in the excised specimen it is impossible to replace the single or multiple strips of fibrocartilage to reconstitute the normal shape and form of a meniscus.

To complete the picture it is necessary to mention one circumstance in which it is possible for locking to take place in spite of the fact that the original longitudinal tear of the posterior segment did not extend beyond the plane of the collateral ligaments and has not extended as a result of a subsequent injury. It has been recorded above that the strip of fibrocartilage on the concave free margin of a longitudinal tear frequently undergoes hypertrophy. In addition, as a result of constantly recurring minor injuries, the hypertrophied strip may become stretched, so that a time may be reached when a loop is formed, the anterior end of which is capable of passing forward beyond the plane of the ligaments, thus creating a condition in which a mechanical block to extension can occur (Fig. 36).

(I) (B) (b) MENISCUS MAY BECOME SITE OF MULTIPLE COMPLETE LONGITUDINAL TEARS

The etiology and pathology of this type of lesion is similar to that described under (I) (A) (b), with but one important distinction, namely, the additional liability to superimposed transverse tears. (See (III).) This is due not only to the length of the strips of fibrocartilage into which the structure has been divided, but to their extension into the anterior compartment; they slip towards the centre of the joint in flexion and rotation and may be divided transversely on forced extension.

(I) (C) TEARS OF POSTERIOR PERIPHERAL ATTACHMENT

It has been shown that for a longitudinal tear of the posterior horn

to occur, the posterior half of the meniscus must be forced either by traction or rotary strain towards the centre of the joint. This entails stretching of the peripheral capsular attachment in the posterior half (Fig. 24). Any gross exaggeration of this stretching process results in rupture of the peripheral attachment and causes displacement of the entire width of the posterior segment into the centre of the joint, so that the meniscus itself becomes the counterpart of the central portion in the usual longitudinal tear. In these circumstances the longitudinal tear may be described as occurring outside the peripheral zone.

It must be recorded, however, that this lesion is probably less common than a cursory examination of specimens might suggest. Careful scrutiny

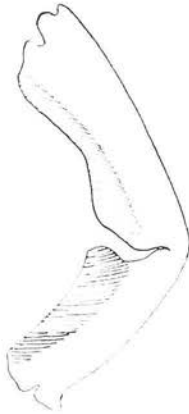

FIG. 38



FIG. 39

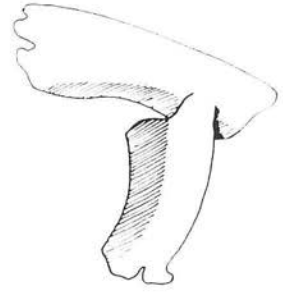


FIG. 40

Diagrammatic representation of the incomplete transverse or "parrot-beak" tear of the lateral meniscus showing the form taken by the horizontal cleavage which permits the convex anterior end of the posterior fragment to pass through the concave posterior end of the anterior fragment.

often reveals that an extremely narrow strip of meniscus remains on the peripheral side of the tear. The strip is so narrow, and so frequently does not even consist of the whole thickness of the structure, that for practical purposes the tear may be recorded as taking place in the peripheral attachment.

The structure and shape of a meniscus embodies the inherent tendency for return to the normal position, and it is thus most unusual for the displacement to be maintained following extension of the joint.

(II) TRANSVERSE TEARS

(II) (A) INCOMPLETE TRANSVERSE OR OBLIQUE TEAR

The incomplete transverse or oblique tear is second in importance and frequency of occurrence only to the longitudinal tear. It is typically a lesion of the lateral meniscus where it occurs at or about the junction of the anterior and middle thirds. The tear begins at the concave edge and extends backwards and laterally in the form of a curve to terminate in relation to

the superior surface of the meniscus, about the junction of the peripheral vascular with the central avascular zone.

This lesion is so commonly associated with cystic degeneration that the theories regarding the mechanism of production of the tear are described under this heading. (See (IV).) Apart from the relationship to cystic degeneration the most interesting feature of the lesion is the horizontal cleavage which occurs in the substance of the meniscus on the anterior margin of the tear, which may be observed in all but the most recent injuries. The mode of production of the horizontal cleavage is clear. The constant motion of the meniscus causes the torn edges to impinge against each other; overlapping is impossible because of the downward pressure of the femoral

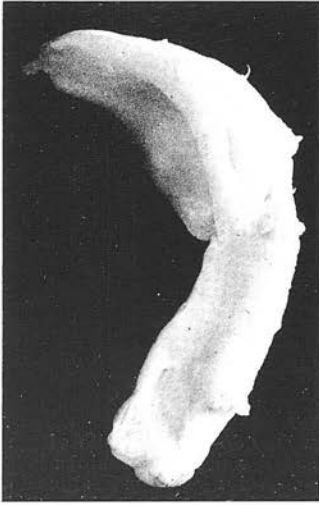


FIG. 41

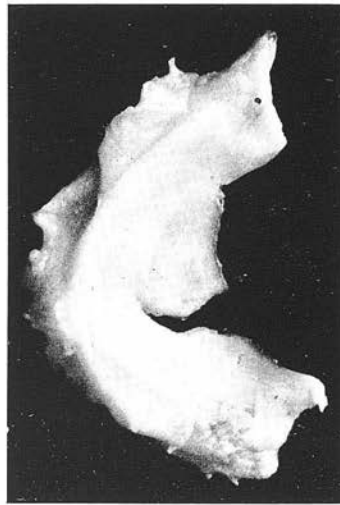


FIG. 42

The parrot-beak tear of the lateral meniscus with complete horizontal cleavage (Fig. 41). In most cases the horizontal cleavage is incomplete and does not penetrate to the periphery (Fig. 42).

condyle and so the convex posterior margin impinges against and insinuates itself into the concave anterior margin, eventually producing a horizontal line of cleavage which may extend across the whole breadth of the meniscus to split even the peripheral border (Figs. 38, 39, 40, and 41). Sometimes the posterior margin may protrude through the line of cleavage to appear as a swelling at the joint line, where it may be mistaken for a cyst of the meniscus (Figs. 83 and 84).

On examination of a specimen of this lesion the resemblance to the beak of a parrot is immediately evident. The small convex posterior margin corresponds to the lower jaw, while the larger concave anterior margin corresponds to the upper jaw. When the margins are opposed the convex lower jaw disappears into the concave upper jaw. The lesion has thus been named "the parrot-beak tear."

(II) (B) COMPLETE TRANSVERSE TEAR

The complete transverse tear is a lesion of extreme rarity (Figs. 43 and 44). It is of academic interest because, communicating directly with the synovial membrane, it was previously known to heal by the ingrowth of fibrous tissue in the experimental animal (page 49).

Only three cases were encountered in this series, one of which was observed to have healed in the manner indicated (Fig. 67).

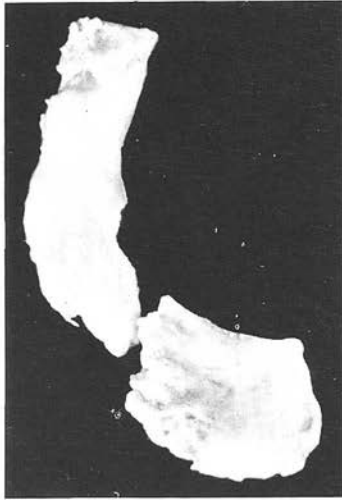


FIG. 43

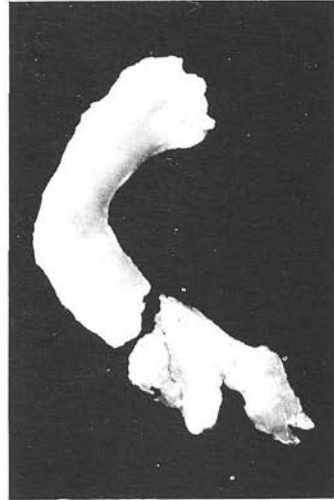

FIG. 44

The complete transverse tear

Complete transverse tears are rare; when they do occur the site of the lesion is usually the junction of the anterior and middle thirds. In both specimens the anterior end of the posterior fragment has become smooth and rounded as a result of movement, whereas the posterior end of the anterior fragment has retained its ragged appearance. (See also Fig. 67.)

(III) VARIOUS COMBINATIONS OF LONGITUDINAL AND TRANSVERSE TEARS

In any attempt to classify the tears of the menisci there exists finally a number of lesions which cannot be described as either longitudinal or transverse. Such lesions include the pedunculated tags of the concave margin which may be based at the anterior or posterior horns or at the middle of the meniscus. In most cases the original lesion was a longitudinal tear, the centrally displaced portion of which has eventually been trapped and divided transversely or torn from its anterior or posterior attachment. By their mode of production or final appearance the innumerable varieties of such lesions may be brought under a single heading as combinations of longitudinal and transverse tears.

When a pedunculated tag or flap is small, locking is impossible, and the symptoms produced are little more than a vague feeling of instability which results from the momentary trapping of the partially detached fragment.

If, however, the flap is large and thick or has undergone the gross hypertrophy which is sometimes encountered, and provided it is based anteriorly or the pedicle sufficiently long to permit invasion of the anterior compartment, a definite block to full extension may occur if it becomes wedged between the condyles at a point anterior to the plane of the lateral ligaments. Occasionally, after a long history of vague symptoms such as may be associated with this injury, the tag becomes detached at its base as a result of a further transverse lesion. The detachment is followed by immediate relief from the symptoms to which the patient has grown accustomed, but subsequently he suffers from recurrent locking of the type associated with a loose body (Fig. 274).

(IV) CYSTS OF THE MENISCI

ETIOLOGY

Since the original description of this interesting condition by Ebner in 1904 many theories as to etiology have been propounded. Broadly speaking these theories fall under three headings: (1) Traumatic, (2) Degenerative, and (3) Congenital.

The evidence obtained from this series, the largest ever recorded, is overwhelmingly in favour of the theory that the cysts are traumatic in origin. This evidence is based on the following observations:

- (1) The condition is almost entirely confined to males of athletic age.
- (2) The condition is most commonly encountered in the middle third of the lateral meniscus.

The periphery of the lateral meniscus is thicker, more exposed and less well protected than the periphery of the medial; it is thus more liable to injury by direct trauma. The maximum peripheral thickness is encountered in the congenital discoid meniscus, a condition in which cystic degeneration is common.

Rotary trauma, the most common injury-producing mechanism, produces lesions between the periphery and the capsule more frequently on the lateral than on the medial side, where, because of the firmer peripheral attachment, lesions take place most commonly within the substance of the meniscus.

- (3) The condition is commonly associated with lesions of the substance of the meniscus.

It is generally accepted at the present time that cysts are not associated with meniscus lesions. Bennett¹ in a recent article goes so far as to say, "it is also a well-established fact that cysts are not associated with tearing of the cartilages." This statement is not borne out by the author's experience. A large proportion of the specimens removed which showed cystic degeneration also showed lesions of the substance of the meniscus. One lesion in

¹G. E. Bennett, "Cysts of Semilunar Cartilages," *Am. Jour. Surg.*, 1939, xliii, 512.

particular is associated with cystic degeneration. It is the incomplete transverse or oblique tear which has been referred to and already described as the parrot-beak tear (Figs. 45 and 46). It is possible that the cyst

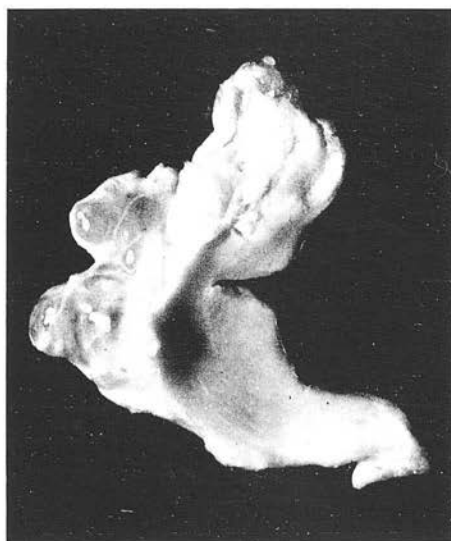


FIG. 45

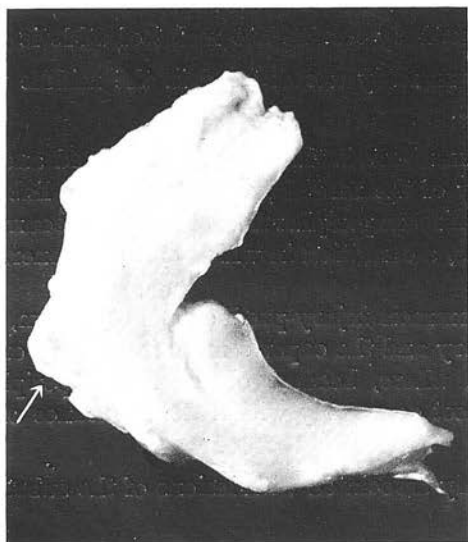


FIG. 46

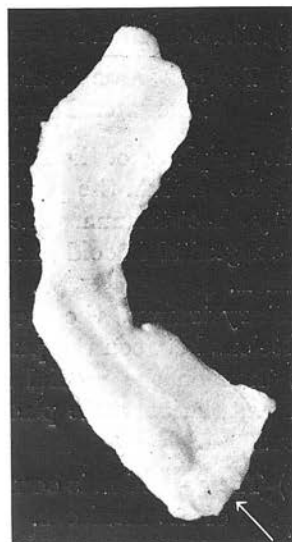

FIG. 47

The lesion of the substance of the lateral meniscus with which cystic degeneration is most commonly associated is the parrot-beak tear (Figs. 45 and 46). When cysts are found in other situations, such as the anterior attachment of the medial meniscus, there is usually evidence of previous trauma (Fig. 47).

occurs first, as a result of direct trauma, and giving rise to surrounding fibrous tissue reaction, produces a point of abnormal fixation of the periphery of the meniscus to the capsule and is thus responsible for the oblique tear.

On the other hand, the oblique tear may take place first and the cystic change occur as a result of traumatic degeneration at the point where the horizontal cleavage, associated with the oblique tear, enters the periphery of the

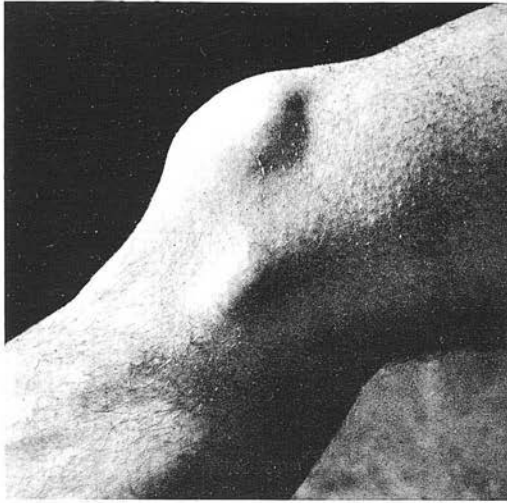


FIG. 48

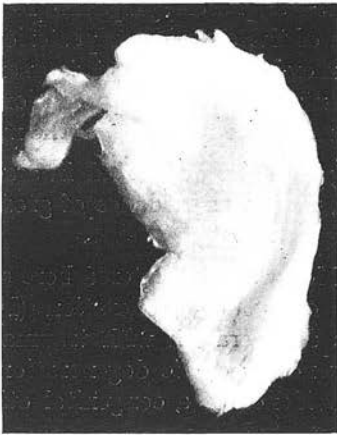

FIG. 49

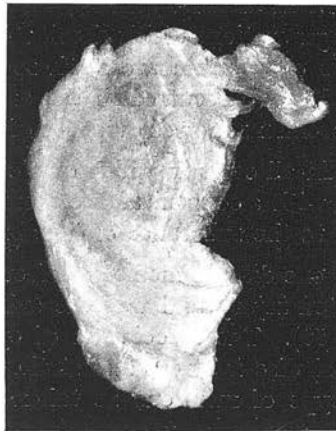

FIG. 50

Cystic degeneration in a congenital discoid medial meniscus which showed no sign of trauma on the superior surface (Fig. 49), but which revealed evidence of repeated injury of the inferior surface (Fig. 50).

meniscus (Figs. 38, 39, and 40). The difficulty here is not that of the theory of origin so much as of the theory of production.

There is, however, another possibility which may explain the combination of cystic degeneration with the parrot-beak tear. A number of these cases give a definite history of a direct kick over the joint line on the lateral side. It is not improbable that this direct kick on the convex periphery forces the meniscus towards the centre of the joint. In ordinary circum-

stances, force directed against a point on the convex periphery of a structure of the shape of a meniscus would cause it either to "buckle" or tear, but the lateral meniscus is tightly gripped between the femur and the tibia and cannot fold or buckle: the concave margin therefore tears transversely.

Although it would appear that the association of this lesion with cystic degeneration has not previously been described, it has been illustrated. Timbrell Fisher¹ observed and illustrated such a meniscus in his monograph "Internal Derangements of the Knee Joint." He stated, "the specimen is of particular interest, as the cystic condition of the meniscus is associated with a definite fracture, of the oblique variety, situated at the junction of the middle and posterior thirds of the semilunar cartilage." He was describing what is now known to be a common pathological entity.

- (4) When cysts occur in areas other than the middle third of the lateral meniscus, they are situated in positions where signs of trauma, as evidenced by old or recent haemorrhages, are frequently encountered in the course of operation, namely, at the peripheral attachment of the anterior and posterior horns (Fig. 47).

Apart from four cases which occurred on the medial side, one of which emerged in front, one behind, and two through the substance of the medial collateral ligament, four lateral menisci were removed on account of symptoms of internal derangement, but without signs or symptoms relative to cystic degeneration, which showed cysts of the anterior or posterior horns. The cysts occurred in areas where haemorrhages are most frequently encountered. Two occurred in the anterior and two in the posterior horns; all the specimens showed evidence of trauma to the substance of the meniscus.

- (5) In all cases in which cystic degeneration was found in association with a congenital disc meniscus there was evidence of gross injury to the substance of the abnormal structure.

The one discoid medial meniscus which was encountered bore evidence of repeated injury and was the subject of cystic degeneration (Figs. 48, 49, and 50). The association of cystic degeneration with trauma in the congenital disc is stressed, lest the presence of cystic degeneration in the discoid type of meniscus be taken as evidence of a congenital etiological factor.

PATHOLOGICAL ANATOMY

The cysts are situated in the peripheral zone of the middle third or junction of the anterior and middle thirds of the lateral meniscus. They are rarely encountered singly but occur in groups, the individual cysts varying considerably in dimensions, from a diameter of one inch to a size which is barely recognisable to the naked eye. The larger cysts are parameniscal in situation, whereas the small cysts, up to a diameter of about two millimetres, may be situated within the substance of the peripheral zone. A group of

¹A. G. T. Fisher. "Internal Derangements of Knee Joint." H. K. Lewis & Co., Ltd., London, 1933. Fig. 40.

small cysts may remain intracapsular, surrounded by a mass of fibrous tissue, but the larger cysts dissect through the capsule of the joint to become almost subcutaneous. Two of the cysts of the medial meniscus, to which reference has been made above, had dissected through the substance of the medial collateral ligament. In many cases however the strong medial capsule as it blends with the medial collateral ligament limits expansion in a peripheral direction, and the growing cyst and surrounding reactionary fibrous tissue thus exert pressure on the medial margin of the articular cartilage so that at operation it is noted that the synovial membrane covering the femoral condyle is deeply injected at its junction with the articular cartilage, which shows localised change of the type associated with osteoarthritis of traumatic origin.

Those cysts which are situated outside the peripheral zone of the meniscus have a well-defined lining membrane which is shining and transparent (Fig. 45): they are distended with clear gelatinous material.

The interpretation of the microscopic appearances of the lining cells has for long been a matter of controversy. The modern view regards the lining of the cavities as consisting of degenerated fibrocartilage or compressed fibrous tissue cells. It is probable that parameniscal cysts in which the lining cells are undoubtedly endothelial in origin do not arise in the meniscus but are synovial pouches, bursae, or popliteal cysts.

CONCLUSION

Cysts of the menisci arise as a result of a degenerative process in an area of the meniscus which has been subjected to a single direct injury or repeated rotary strains causing haemorrhage in the peripheral zone or in the synovial or capsular attachments.

(V) CONGENITAL ANOMALIES

CONGENITAL DISCOID MENISCI

At birth the menisci cover the greater part of the opposing surfaces of the femur and tibia, the larger area of direct contact between articular cartilage being present on the medial side of the joint. The central area gradually increases its size until eventually the areas of direct articular contact reach the normal adult proportions. If the normal process of absorption of the central portion of the meniscus does not take place, the meniscus retains its foetal discoid shape.

Although the occasional persistence of the embryonic discoid shape of the lateral meniscus had been known to anatomists for many years, the first dissecting-room specimen being described by Young¹ of Glasgow in 1889, it was not until 1910 that the association of a discoid lateral meniscus with a snapping knee joint was recorded by Kroinn of Innsbruck. When

¹ R. B. Young. "Cleland, Mackay, and Young's Memoirs and Memoranda in Anatomy." Williams & Norgate, London and Edinburgh, 1889, 179.

Middleton¹ recorded his four cases in 1936, he was only able to trace 49 cases of discoid meniscus causing snapping knee which had been treated by operation since 1910, and 48 of these cases had been published since 1928. Timbrell Fisher² considered that the apparent rarity of the condition is mainly attributable to the fact that it is not sufficiently often recognised. His forecast has been fulfilled by the recording of 20 cases in the series under consideration.

Although the condition is considered to be associated with the classical symptom of "snapping knee," only four of the author's cases exhibited this symptom, and these were the only cases in which the diagnosis was made prior to operation. It appears that the condition is much more frequently accompanied by symptoms of a torn meniscus, or of cystic degeneration, than by a snapping knee joint.

To the present date it has been considered that discoid menisci are only found on the lateral side, but one case of a complete disc of the medial meniscus was encountered by the author which was complicated by inferior surface tears and a large cyst³ (Figs. 48, 49, and 50).

PATHOLOGICAL ANATOMY

The disc varies in form, depending how far the absorption of the central portion has proceeded. The whole meniscus may be considerably thicker than normal (Figs. 53 and 54), tapering only slightly towards the central portion, but in most cases only the peripheral rim is thick, the central portion being thin and transparent (Fig. 51). M'Murray⁴ states that a small hole may be found some distance from the unabsorbed central margin, but the author has not encountered this particular variety of the abnormality, except in the presence of obvious trauma (Figs. 55 and 56). In some cases two notches are seen, one immediately behind the anterior horn, and the other immediately in front of the posterior horn, with a projection of the thin unabsorbed central portion between the two notches (Fig. 51).

The superior surface of the meniscus is smooth at birth, but as the result of weight-bearing a ridge develops, behind and in front of which are concave facets. The condyle of the femur lies in the anterior facet in full extension, and in the posterior facet in full flexion (Figs. 87 and 86). Occasionally there are two ridges, one in front and one behind the facet in which the condyle of the femur rests (Figs. 53 and 54). Although small ridges were present on many specimens, in only four was this abnormality developed to a degree which gave rise to a snapping knee. The remainder, although giving rise to symptoms, either showed no sign of injury, showed multiple longitudinal tears, or were the subject of cystic degeneration. In some cases although there were multiple longitudinal splits in the inferior surface, the

¹ D. S. Middleton. "Congenital Disc-shaped Lateral Meniscus with Snapping Knee." *Brit. Jour. Surg.*, 1936, xxiv, 246.

² A. G. T. Fisher. *Brit. Med. Jour.*, 1936, i, 688.

³ Since this was written a second discoid medial meniscus has been described. It also was torn but was not complicated by cystic degeneration. E. C. Dwyer and C. Taylor. *Brit. Med. Jour.*, 1945, ii., 287.

⁴ T. P. M'Murray. "The Semilunar Cartilages." *Brit. Jour. Surg.*, 1942, xxx, 407.

SOME VARIETIES OF THE CONGENITAL DISCOID LATERAL MENISCUS

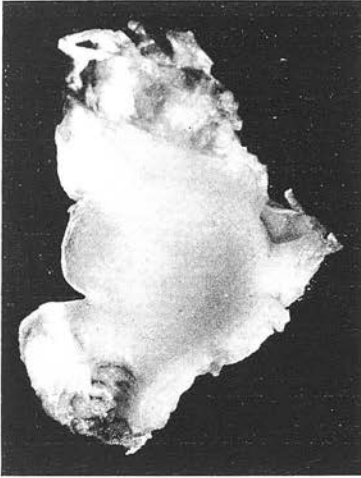


FIG. 51

Showing the notches between which lies the thin unabsorbed central portion.

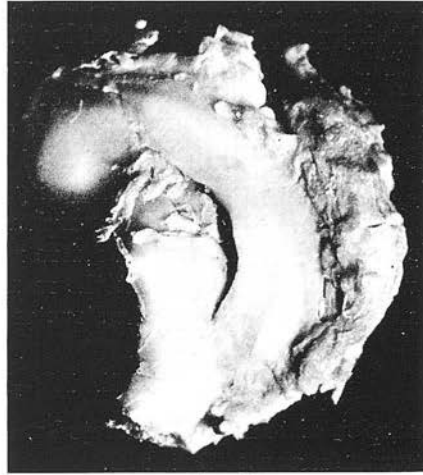

FIG. 52

Cystic degeneration associated with multiple lesions of the inferior surface.

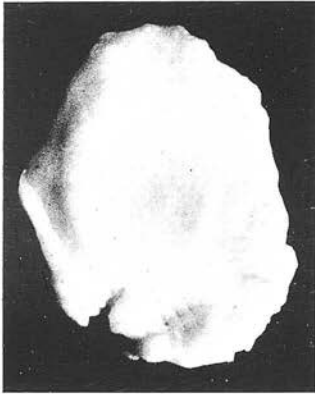


FIG. 53

Figs. 53 and 54
The structure is thick and shows a depression for the femoral condyle on the superior surface which appears undamaged (Fig. 53). Evidence of trauma is limited to the inferior surface (Fig. 54).

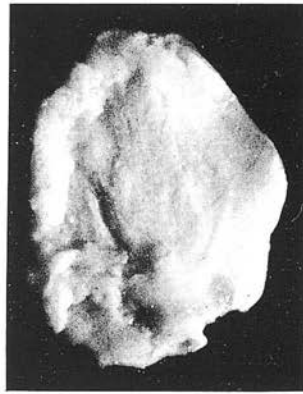

FIG. 54

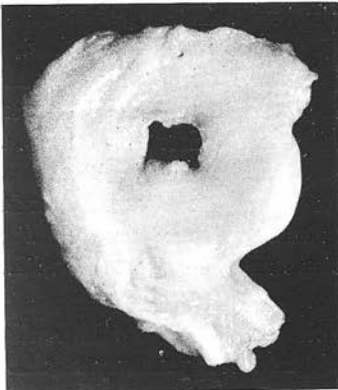


FIG. 55

Figs. 55 and 56

The superior (Fig. 55) and inferior (Fig. 56) surfaces of a congenital disc showing a hole in the centre of the structure.

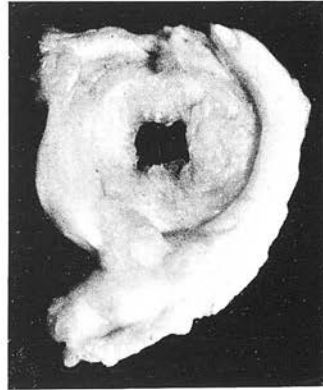


FIG. 56

superior surface was undamaged, which appears to provide additional evidence that the meniscus is accessory to the femur, rather than the tibia, and is injured by being twisted by the femur against the tibial head.

The association with cystic degeneration was found to be common, and in most of the cases a diagnosis of a cystic lateral meniscus was made and it was not known until the joint was opened that a discoid meniscus existed. The presence of cysts in a congenital disc meniscus may be claimed by some to be evidence in favour of the congenital origin of cysts. It is noticeable, however, that not only is the peripheral rim of a congenital discoid meniscus thicker than normal, and therefore more liable to injury, but in every case in which a cyst was present the meniscus was also the subject of multiple tears in the substance of the structure.

(VI) TEARS OF REGENERATED MENISCI

Examples of tears of regenerated menisci which have been encountered are recorded on pages 52 and 53.

CALCIFICATION AND OSSIFICATION OF MENISCI

Calcification of the menisci occurs in two forms¹:

- (1) **Primary or non-Traumatic.**
- (2) **Secondary or Traumatic.**

These two forms are separate and distinct entities which have little in common except the presence of calcium.

(1) **Primary Type** occurs in individuals of 50 years or over who are usually the subject of hypertrophic arthritis both in the knee and in other joints. It is thus considered to be a manifestation of degenerative change, the result of nutritional deficiency due to arthritis and advancing age. There are no special symptoms referable to the calcification. The symptoms, when present, are those of hypertrophic arthritis.

The radiological appearances are characteristic and show calcium laid down in parallel layers in both menisci (Fig. 57).

(2) **Secondary Type** appears in patients of a much younger age group as a result of trauma. There are no special symptoms. The calcification in the meniscus is discovered as a result of the routine radiological examination of a case of internal derangement of the knee joint with symptoms referable to a torn meniscus. The radiograph shows an ill-defined but localised zone of calcification usually at the posterior extremity of the meniscus (Figs. 58 and 59).

The condition is unimportant as a clinical entity and is merely regarded as a manifestation of injury to the meniscus necessitating removal. It is of importance only in that the radiological picture may be confused with a loose body.

Ossification in a meniscus is a condition closely allied to calcification and may be a sequel to calcification. It is considered that primary calcifica-

¹E. F. Cave. "Calcification of the Menisci." *J. Bone and Joint Surg.*, 1943, xxv, 53.

tion rarely if ever progresses to ossification, but that ossification may be found in the secondary type. It is probable that some cases of secondary

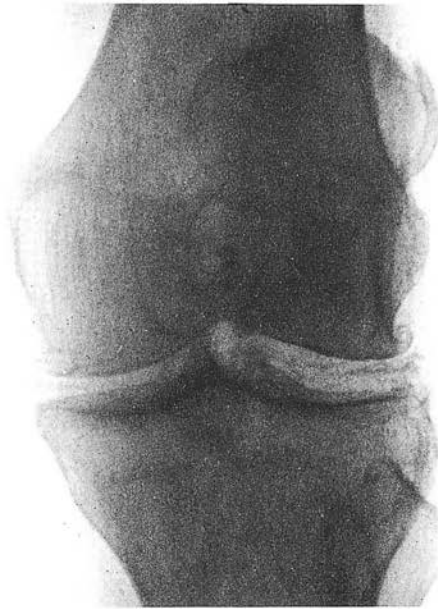

FIG. 57

Primary calcification of both menisci

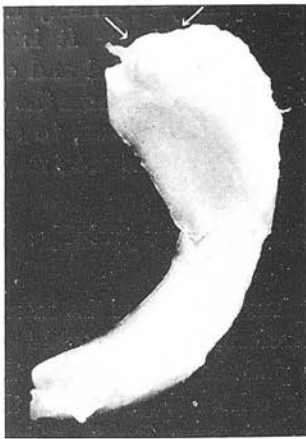


FIG. 58



FIG. 59

Secondary calcification at the posterior attachment of the medial meniscus (Fig. 58) and radiograph (Fig. 59). Evidence of trauma is present in the form of superficial longitudinal tears. (The small transverse tear on the concave margin is an artefact and was produced during the operation.)

ossification are true examples of heterotopic bone formation. One case was encountered in which the ossification had occurred in the peripheral zone of the lateral meniscus (Fig. 60).

HEALING OF TORN MENISCUS

BLOOD SUPPLY

Arterial injection with an opaque medium¹ has shown that the blood supply of the meniscus is limited to the convex border. In this area a network of vessels is seen which enter the meniscus from the capsule and from the delicate layer of synovial membrane which extends inwards for a short distance over the periphery of the structure on both the superior and inferior surfaces. The central and concave zones have no blood supply and it is assumed that they depend for nutrition on the synovial fluid.

It is upon the curious nature of the nutrition that the failure of repair and the poor prognosis of conservative treatment in meniscus injuries depends.



FIG. 60

Radiograph of a lateral meniscus showing ossification associated with abundant evidence of previous trauma.

PRACTICAL APPLICATION OF EXPERIMENTAL AND CLINICAL OBSERVATIONS ON HEALING OF THE TORN MENISCUS

Examination of pathological material obtained from this series of meniscus injuries confirms the observations made by Don King² regarding the healing of experimentally produced tears of the menisci in dogs. It is therefore proposed that each of King's four conclusions be recorded and compared with the evidence available from the human subject, and, from the comparison, in conjunction with relevant theoretical considerations, to draw conclusions of practical value which can be applied to the treatment of the common injuries.

(1) "*Tears which are limited to the semilunar cartilage probably never heal*" (Fig. 61).

It has been stated above that the peripheral border of the meniscus has a blood supply. On theoretical grounds therefore, a longitudinal tear within this peripheral zone should heal. There is pathological evidence that tears extending into this zone do in fact attempt to heal (Fig. 65), but the observation is of no practical importance because tears entirely limited to this area are seldom encountered. The common longitudinal tears of the substance of the meniscus are situated in the avascular zone, or at the junction of the vascular and the avascular zones, and the theory that such lesions cannot heal is amply borne out by both experimental and clinical observations.

¹ E. J. Poth. "A Modification of Hill's Radiopaque Mass for the Injection of Lumina." *J. Lab. and Clin. Med.*, 1934, xix, 1241.

² Don King. "The Healing of Semilunar Cartilages." *J. Bone and Joint Surg.*, 1936, xviii, 333.

(2) "A torn meniscus can be healed by connective tissue if the tear communicates with the synovial membrane laterally" (Fig. 62).

Theoretically such lesions should heal and healing has been observed experimentally. In the human subject, however, transverse or oblique tears, limited to the substance, must be uncommon and were not encountered in this series. This is readily explained by the fact that such lesions can only occur when the meniscus is under tension in its long axis, which, from the shape of the structure, produces the greatest strain on the concave margin. An attempt at healing was, however, quite frequently observed in longitudinal lesions which extended into the periphery of the posterior segment



FIG. 61

Tears which are limited to the substance of the meniscus never heal.



FIG. 62

Longitudinal tears which enter the peripheral or the central attachment tend to heal by the ingrowth of fibrous tissue. (This is of no practical importance.)



FIG. 63

Complete transverse tears will heal by the ingrowth of fibrous tissue from the periphery. (This is of no practical importance.)



FIG. 64

Tears of the peripheral attachments heal without difficulty.

or into the attachment of the posterior horn to the head of the tibia (Fig. 66). Such healing only spreads forward for a short distance into the tear and is thus of no practical importance.

(3) "A complete transverse or oblique tear results in some separation of the fragments, but the intervening space fills in with connective tissues arising from the synovial membrane. This connective tissue is quite firm in three weeks, which suggests the length of time necessary for complete fixation in these cases" (Fig. 63).

A complete transverse tear enters the synovial membrane laterally and will heal by an ingrowth of fibrous tissue from the periphery in favourable circumstances (Fig. 67).

Complete transverse or oblique tears are uncommon by comparison with the incomplete transverse or oblique tear affecting the concave margin, of the type which has been termed the parrot-beak lesion. Only one headed transverse tear was encountered (Fig. 67). The fragments had separated a distance of about one centimetre and the intervening space had filled with fibrous tissue with the same characteristics as the fibrous tissue of the regenerated meniscus. It will be noted that the specimen illustrated shows a recent tear of the posterior horn: this was presumed to have occurred because of the increased length and the loss of normal elasticity which the healing of the separated fragments entailed.

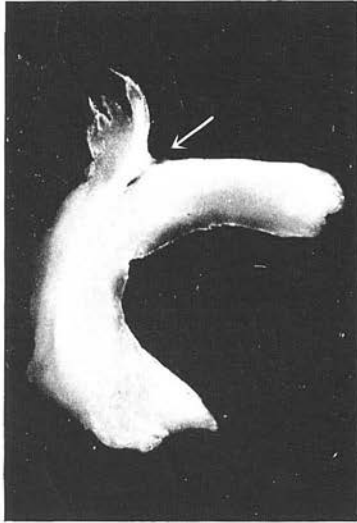


FIG. 65

Attempted fibrous repair of a longitudinal tear in the peripheral zone.

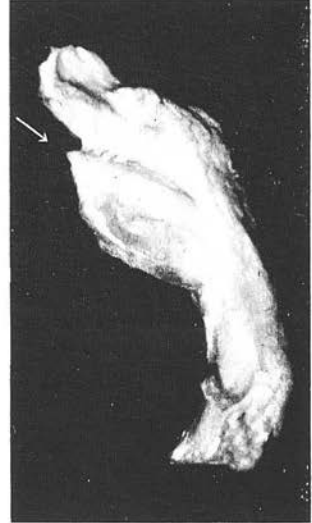

FIG. 66

Fibrous repair of a longitudinal tear which enters the posterior central attachment.

Two cases were encountered in which the complete transverse tear had not healed, and it was presumed that healing had failed to occur because the necessary conditions of rest, which are essential if repair is to take place, had not been provided in the period immediately following the injury.

The fact that the complete transverse lesion does heal in favourable circumstances is of little practical importance, as this particular injury produces no characteristic symptoms and signs, but it does indicate that if conservative treatment is to be adopted in any meniscus lesion, a period of non-weight-bearing immobilisation of at least three weeks is necessary in order to provide even the possibility of success.

(4) "If the meniscus is partially torn from its peripheral attachment, it heals in normal anatomical position without difficulty" (Fig. 64).

This is an observation with important clinical implications. In theory the tearing of the vascular peripheral zone from its vascular synovial attach-

ment should result in healing provided the displaced surfaces are re-opposed, and this has been shown to be true in the experimental animal.

It is obviously difficult to estimate how frequently this lesion occurs in the human subject. It is possibly uncommon in the medial meniscus, but injuries of the peripheral attachment of the posterior segment of the lateral structure are known to be common and may even occur more frequently than longitudinal tears of the substance of the meniscus. It is thus not unreasonable to suggest that in spite of the impossibility of distinguishing a tear of the synovial attachment from a longitudinal tear of the posterior segment, a proportion of lesions of the lateral meniscus will react favourably to a period of non-weight-bearing immobilisation of sufficient duration to ensure re-attachment of the periphery. It is assumed that in those cases in which the posterior segment of the lateral meniscus is found at operation to displace into the intercondylar notch with ease, and in which examination of the meniscus shows loss of the peripheral attachment, as shown by the smooth convex border, have not been immobilised following the original injury. In these circumstances the normal strains of weight-bearing, especially in the presence of effusion, have not permitted re-attachment to occur, or alternatively, have stretched the young fibrous tissue in the healing area before union had consolidated.

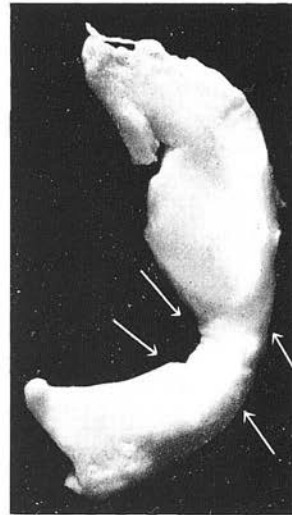


FIG. 67

Repair of a complete transverse tear. In spite of separation of one centimetre, fibrous tissue has grown in from the periphery to fill the gap between the fragments.

REGENERATION OF THE MENISCI FOLLOWING EXCISION

The literature dealing with the surgery of the knee joint contains many conflicting opinions about the possibility of regeneration of the menisci after excision. Until 1944¹ there were only seven recorded cases^{2, 3, 4, 5} of proved regeneration of a meniscus in man to show that the behaviour of the knee joint is similar in every respect to that repeatedly observed after extirpation of a meniscus in animals, when it is invariably found that a new structure grows which resembles the normal meniscus in shape and appearance but is composed entirely of fibrous tissue.

Observations on the earliest stages of regeneration are not possible in man, and it is therefore important to recall the work of Bruce and Walmsley⁶

¹ This section is based on the author's article, "Observations on the Regeneration of the Semilunar Cartilages in Man." *Brit. Jour. Surg.*, 1944, xxxi, 298.

² F. Mandl. *Zbl. Chir.*, 1929, 56, 3256. (3).

³ W. Moeller. *Zbl. Chir.*, 1930, 57, 2790. (1).

⁴ A. G. T. Fisher. *Lancet*, 1936, ccxxx, 1351. (2).

⁵ J. Bruce and R. Walmsley. *Brit. Jour. Surg.*, 1937, xxv, 17. (1).

⁶ J. Bruce and R. Walmsley. *J. Anat.*, 1938, lxxii, 260.



who noted that four days after excision of a meniscus in the rabbit a proliferation of fibroblasts took place beneath the surface of the synovial membrane at the level of the plane of the joint. In the following days this proliferation extended inwards between the bones in two parts, an upper related

LESIONS OF REGENERATED MENISCI




Fig. 68

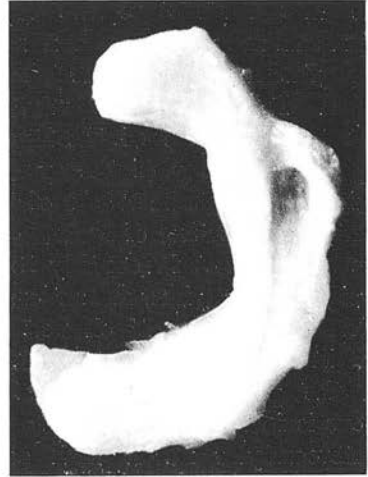


Fig. 69

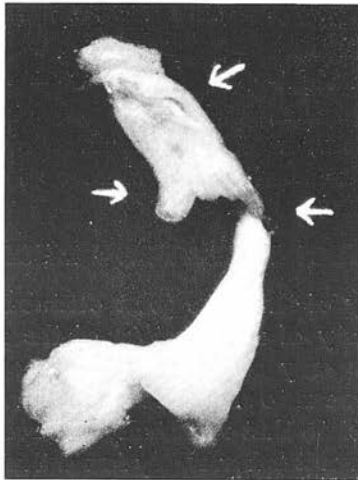


Fig. 70

Fig. 68. — Regenerated medial meniscus. There is a longitudinal tear of the posterior segment which does not penetrate through the substance of the structure. (Compare shape with Fig. 13.)

Fig. 69. — Regenerated lateral meniscus. There is a lesion of the peripheral attachment which has caused the middle portion to be displaced towards the centre of the joint. (Compare shape with Fig. 16.)

Fig. 70. — Regenerated anterior segment and original posterior segment. The arrows, reading from left to right, refer to: (1) tag of original posterior segment protruding towards the centre of the joint; (2) longitudinal tear; and (3) junction of regenerated with original meniscus. The difference in width and colour is clearly seen.

(By courtesy of *Brit. Jour. Surg.*)

to the femur and a lower related to the tibia, the two parts eventually fusing at about the end of the third week to form the new meniscus. They concluded that the early growth of the regenerating meniscus in the form of extensions over the articular surfaces suggests that the primary function of the menisci is the distribution of synovial fluid over the articular surfaces rather than weight-bearing.

One case in this series was subjected to arthrotomy six weeks after the

original operation. He had been admitted complaining of symptoms clearly referable to the posterior segment of the medial meniscus, and as it was known from previous experience that cases from this particular source had only the anterior half of the meniscus excised, a second operation was performed

LESIONS OF REGENERATED MENISCI

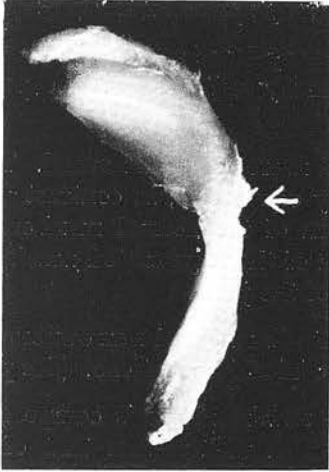


FIG. 71

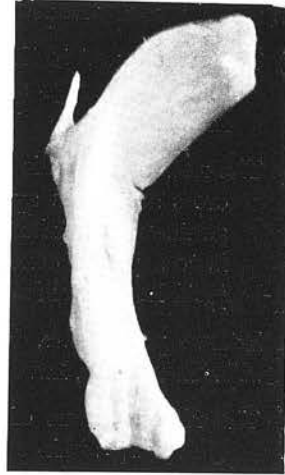

FIG. 72

FIG. 71. Regenerated anterior segment and original posterior segment. The arrow indicates the junction. The difference in colour is clearly seen.

FIG. 72. Regenerated medial meniscus showing loss of attachment of periphery of posterior segment and a small longitudinal tear.

FIG. 73. Regenerated medial meniscus with longitudinal tear of posterior segment.

(By courtesy of *Brit. Jour. Surg.*)

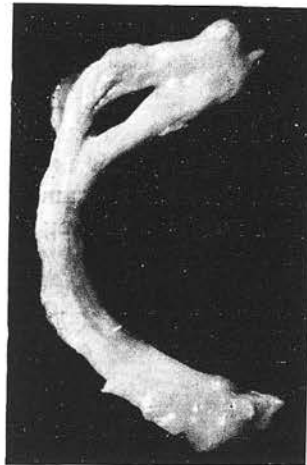

FIG. 73

to remove the retained posterior horn. After this short interval the anterior horn was found to be completely reconstituted (Fig. 70).

1) FEATURES OF REGENERATION WHICH FOLLOWS TOTAL EXCISION OF ORIGINAL MENISCUS

When the entire meniscus is excised a new one grows in from the parietal synovial membrane, and it has much the same form and general appearance

of the normal structure. The characteristic features which distinguish the normal medial from the normal lateral meniscus (Figs. 13 and 16) are reproduced, and Figs. 68 and 69 illustrate the relatively broad posterior horn of the regenerated medial meniscus compared with the more uniform breadth of the regenerated lateral meniscus.

In spite of the evident gross similarity, detailed examination reveals features which permit the recognition of a regenerated meniscus :

- (a) The attachment to the capsule is very dense and there is no obvious line of cleavage such as normally exists between capsule and meniscus.
- (b) The new meniscus is thinner and narrower than normal. Thus the cross section is approximately equilateral, in contrast with the acute-angled triangular section of the normal meniscus ; that is to say, the concave margin of the regenerated meniscus projects less towards the centre of the joint.

Both these points, *i.e.*, density of attachment and narrowness in comparison with the normal, have important clinical implications. (See page 75.)

- (c) The fibrous tissue of which the new meniscus is composed has a glistening surface which is much whiter than that of normal fibrocartilage. The concave edge lacks the sharp definition of the normal meniscus and is thin, wavy, and almost transparent.
- (d) Histological examination reveals fibrous tissue only ; there are no cartilage cells.

The difference in the microscopic features is most marked in comparing a section of regenerated meniscus of recent origin, which is composed of young fibrous tissue, with a section of normal fibrocartilage. The difference is less when the section examined consists of mature fibrous tissue from a regenerated meniscus of long standing, except that there are no cartilage cells.

(2) FEATURES OF REGENERATION WHICH FOLLOWS EXCISION OF ANTERIOR HALF OR TWO THIRDS OF ORIGINAL MENISCUS

In those cases in which the surgeon had failed to remove the posterior third or even half of the meniscus it was found that :

- (a) The excised portion had been replaced by an ingrowth of fibrous tissue with the same characteristics as those noted in reconstitution of the complete meniscus (Figs. 70 and 71).
- (b) The regenerated anterior horn is joined only to the peripheral zone of the original posterior horn, *i.e.*, the zone supplied with blood vessels. The appearance of the junction therefore depends on whether the original meniscus was divided transversely or obliquely. If it had been divided transversely the concave aspect of the stump of the original posterior horn projects

towards the centre of the joint (Fig. 70); if it had been divided obliquely the junction is more uniform (Fig. 71).

- (c) There is no difficulty in distinguishing the type of meniscus found following a previous partial meniscectomy from the normal; the junction of the regenerated anterior horn with the original posterior horn and the difference in colour and width are clearly seen, even in a photograph (Figs. 70 and 71).

These observations afford evidence in favour of total rather than partial meniscectomy, no matter what lesion is encountered, for if it be accepted that the meniscus performs any function, that function can best be performed by the most perfect replica of the original. The most perfect replica possible follows total meniscectomy.

The reaction of the knee joint to meniscectomy may be summarised :

- (1) Total excision of a meniscus is invariably followed by replacement by a structure consisting of fibrous tissue which is almost a replica of the original.
- (2) Partial excision of a meniscus, provided the portion excised includes the peripheral zone, is also followed by replacement.

It has been recorded that joints have been explored in which no vestige of a meniscus could be found. In the author's experience complete absence of these structures is only encountered in joints in the late stages of a degenerative arthritis of either the osteoarthritic or rheumatoid type.

AUTHOR'S MENISCUS STATISTICS

NUMBER OF MENISCI REMOVED 1133.

MEDIAL 727.

LATERAL 406.

BOTH REMOVED FROM SAME KNEE AT ONE OPERATION 73.

BOTH MEDIAL OR BOTH LATERAL REMOVED AT ONE OPERATION 9.

I. LONGITUDINAL TEARS 715.

(A) Of posterior segment 237.

(B) Complete 328.

(C) Of posterior peripheral attachment (including cases with abnormal laxity of attachment with actual evidence of trapping) 150.

II. TRANSVERSE TEARS 51.

(A) Incomplete or oblique (parrot-beak tear) 48.

(B) Complete 3.

- III. VARIOUS COMBINATIONS OF LONGITUDINAL AND TRANSVERSE TEARS 94.
- IV. CYSTIC DEGENERATION 88.
- In combination with various lesions of the substance of the meniscus 27.
- In combination with the parrot-beak tear in particular 44.
- Meniscus otherwise intact 17.
- V. CONGENITAL DISCS 20.
- Lateral 19.
- Medial 1.
- Torn 18.
- Associated with cystic degeneration 8.
- Intact 2.
- VI. REGENERATED MENISCI 30.
- With original posterior segment 19.
- Totally regenerated 11.
- VII. SPECIMENS KNOWN TO BE TORN, BUT UNCLASSIFIED 53.
- VIII. MENISCI REMOVED WITHOUT OBVIOUS PATHOLOGY 82 (7.2 per cent.)

CHAPTER FIVE

CLINICAL FEATURES OF INTERNAL DERANGEMENTS OF THE KNEE JOINT RELATIVE TO THE MENISCI

To be uncertain is to be uncomfortable, but to be certain is to be ridiculous.

—*Chinese Proverb.*

IN the vast field of surgery there are many instances of a well established pathological entity in which the diagnosis may be established with ease, or conversely, only with extreme difficulty following a complete and accurate history and meticulous clinical examination. Internal derangement of the knee joint relative to an injury of the meniscus is an example of this type of case. It may only be necessary to listen to the patient's story for a few moments to realise that he is suffering from a complete longitudinal tear of the medial meniscus, but, on the other hand, a very large proportion of the cases encountered present a complicated problem which can only be solved by balancing every shred of evidence which is available.

HISTORY

It is quite impossible to overstress the importance of the history. The secret of success is thoroughness, and this applies both to the history and physical examination, but to the history in particular because in so many cases of long standing the physical examination reveals no definite sign upon which a diagnosis could be based. In this respect it is hardly an exaggeration of the position to cite a hypothetical situation in which a surgeon is required to establish the diagnosis, either on history or on physical examination but not on both. There is no orthopaedic surgeon of experience who would not agree that in such circumstances he would choose to make his diagnosis from the history.

In arriving at a diagnosis in cases of internal derangement, for comparing the diagnostic conclusion with the operative findings, and for the purpose of keeping records in a simple form, it has been the author's practice to note the details of the patient's history on one side of a 6 by 4 card, entering the results of physical examination and the final diagnosis on the other side. If the case is to be subjected to operation this card is taken to the theatre and the operative findings compared with the diagnostic conclusion. A full scale drawing together with all relevant details of the joint pathology are then recorded on a second card of the same dimensions, the final blank side of which is reserved for progress notes.

If the omission of important details in the history is to be avoided it is necessary to investigate every case according to a definite plan. The notes should be recorded under the following headings :

(1) **Date and exact mechanism of original injury.**

(2) Symptoms at time of original injury.

- (a) Situation of the pain.
- (b) Presence or absence of locking.
- (c) Degree of immediate incapacity, for example: Was he forced to leave the football field?
- (d) Presence or absence of a click, snap or tear.
- (e) Situation of any tenderness noted.
- (f) Presence or absence of subsequent effusion.

(3) Treatment of original injury, and period of incapacity.**(4) History of incidents which have occurred between original injury and present date together with symptoms incurred.****(5) Present complaint, for example: locking? Giving-way?**

Notes on the physical examination are recorded under the following headings:

- (a) **Limitation of flexion or extension**, for example: Is the joint locked?
- (b) **Effusion.**
- (c) **Degree of wasting of quadriceps.**
- (d) **Condition of anterior cruciate and medial collateral ligaments.**
- (e) **Localisation of tenderness.**
- (f) **Localisation of a click.**
- (g) **Result of radiological examination.**

DIAGNOSTIC CONCLUSION**LOCKING**

In this series locking occurred at some period in 50 per cent of cases. It may occur:

- (1) **At original accident.**
- (2) **At recurrent incidents.**
- (3) **At both original accident and recurrent incidents.**

It is not easy to form an accurate estimate of the percentage of cases which lock at the original accident. The pain and excitement of the moment together with the colourful descriptions and varying interpretations of subjective phenomena make the difficulties obvious, but it is quite evident that the number of cases which experience true locking at the original accident is much smaller than is generally supposed. The reason for this is clear. In the young adult male the meniscus is normal at the time of the first injury, that is to say, it has not undergone the degenerative changes

which may be noted in the later age groups. In these circumstances the shape of the meniscus and the properties of the fibrocartilage of which it is composed, and to which reference has already been made on page 27, entail the inherent tendency for it to return to its normal peripheral position in the joint. A large proportion of longitudinal tears are undoubtedly confined to the posterior segment in the initial stages, but even if a tear extends forward beyond this segment, the central fragment will tend to return to the normal anatomical position. Within a short time, however, the effect of the tear on the fibrocartilage is such that the elasticity of the central fragment is lost. When a subsequent incident takes place not only is the liability for the tear to extend into the anterior segment increased but the central portion tends to remain displaced where it constitutes a mechanical block to extension instead of springing back into position within a fraction of a second after the injury as occurred in the first instance.

In the past a history of locking has been regarded by many as the *sine qua non* of the diagnosis of a torn meniscus. This view, for which the medical schools must be held responsible, has been the cause of much misery to the would-be athlete, much industrial disability, and much unnecessary suffering from osteoarthritis.

Locking has been shown to be due to the interposition of a section of the meniscus between the femur and tibia at a point anterior to the coronal plane of the joint (Fig. 25). This only takes place when a longitudinal tear extends into the anterior section of the meniscus, and in a few additional circumstances which are unimportant because of their rarity. The locking which is produced in such circumstances is sudden and definite and the unlocking is equally sudden and even more dramatic.

When true locking has occurred in association with a history otherwise suggestive, it is almost pathognomonic of a torn meniscus and must be regarded as one of the most important of the diagnostic points available, but it is necessary to emphasize that not more than 50 per cent. of cases proved to be torn at operation, exhibit this symptom.

The patient's statement that the knee locked is not enough. He must explain what exactly he means by locking, demonstrate the position in which the knee was fixed and recall any subjective phenomena, such as the feeling of "something slipping back into place," associated with the unlocking. The history that the knee locked and that extension gradually returned in the course of a few hours or days must be accepted with reserve. True locking occurs at a point some fifteen to forty degrees short of full extension but the mere inability to produce extension beyond this point is not of necessity due to a torn meniscus (Fig. 74).

Apart from the locking which follows interposition of a loose body between the articular surfaces—a circumstance which can usually be distinguished from the locking of a torn meniscus both by the previous and subsequent history—loss of extension which may simulate locking is encountered in the presence of a tense effusion or haemarthrosis, hypertrophy or haemorrhage in the retropatellar pad of fat, fracture of the tibial spine, and even a tense popliteal cyst. These conditions should not give rise

to confusion. There are, however, two conditions in the author's experience which are a frequent source of error:

(1) If as a result of a rotation strain, a haemorrhage has occurred between the capsule and the meniscus, either behind or in front of the collateral ligament, not only will there be effusion together with a point of acute tenderness at the injured area, but both flexion and extension will be limited as a result of the muscle spasm induced by the pain which results from the pressure incurred by the haemorrhagic and oedematous area.

(2) If the patient received a knee joint injury several weeks previously, which may or may not have involved a tear of a meniscus but which was followed by a tense effusion which was treated by a rest in bed with the knee flexed over a pillow, the subsequent contraction of the posterior capsule which frequently results may lead to the erroneous conclusion that the joint is still locked.

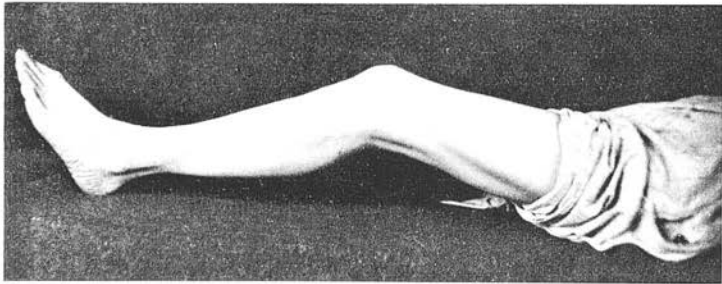


FIG. 74

Locked joint

If the longitudinal tear has only extended to a point immediately anterior to the plane of the ligaments the joint will lock in some 40° of flexion; if it has extended far forward into the anterior segment extension may only be limited by 10°.

Very occasionally the patient relates that at the time when the locking took place a lump appeared at the joint line, and that when this lump disappeared, often as the result of external pressure, joint movement was restored. This uncommon occurrence is explained either by the exclusion of the periphery of the meniscus beyond the margin of the condyles (Fig. 82) or by a long pedicled flap of meniscus, the result of a combination of longitudinal and transverse tears, passing either over or under the main structure to appear as a projection at the joint line (Figs. 77 and 81). In the latter circumstance the flap is protected from the influence of the motion of the femoral condyle by the main body of the meniscus, and cases have been encountered in which the presence of the lump had been a constant feature of the symptoms. Such projections are liable to be confused with cystic degeneration (see page 71).

GIVING-WAY

When the patient complains of the common symptom that the joint "gives-way" or "lets him down" he should be asked, as in the case of "locking,"

to explain what he means by "giving-way." While there are other causes for this symptom, such as an old rupture of the anterior cruciate ligament, quadriceps insufficiency or loss of full extension, by far the most common underlying pathology is a longitudinal tear of the posterior segment of a meniscus, and unless the tear extends forward into the anterior segment, insecurity of the joint may be the only serious symptom present. It is possible, however, to determine from the patient's account of the incidents what is the most likely cause, for whereas in giving-way which is solely due to a rupture of the anterior cruciate ligament, quadriceps insufficiency, or loss of full extension, the patient relates that it occurs on descending stairs or jumping down from a height, but when giving-way is due to a torn meniscus it takes place as a result of such movements as turning round suddenly, walking on uneven ground or stepping on a small stone. In addition, he may relate that the knee appears to give-way inwards or outwards before it collapses under him, and that when the accident does occur he has the sensation of "something slipping about in the joint" or "two bones slipping over one another in the joint." Such points as these suggest the posterior segment of a meniscus as the source of the trouble. None of the standard text-book signs of a torn meniscus may be forthcoming and the diagnosis may be missed in the absence of an accurate history. Once the significance of the details of the history have been appreciated, however, the examiner immediately seeks to elicit the characteristic click which will confirm both the nature and the site of the lesion.

EFFUSION

Effusion is always present following the original accident, whether the knee locked or not. This is due to the stretching or tearing of the peripheral synovial or ligamentous attachments which must have taken place if the meniscus has been trapped and torn between the condyles. It is the direct result of the lesion of the synovial membrane, capsule and ligamentous attachment rather than of the tear of the substance of the meniscus. If the injury was not followed by effusion the examiner's suspicion should be aroused that the meniscus is unaffected and that the site of the lesion is extracapsular, possibly for example, at the femoral attachment of the medial collateral ligament. The presence of effusion alone is, of course, no indication that the meniscus has been injured, as it may follow any minor twist and especially direct contusion, but it is most important to remember that whereas all traumatic effusions are not due to meniscus injuries a meniscus is never torn in the absence of effusion at the original incident. In addition, the recurring incidents of locking or giving-way which follow the original accident are each followed by an effusion, and in this respect it is necessary to repeat that unless the incidents are followed by effusion it is unlikely that the meniscus is responsible for the symptoms. This statement, however, must be qualified. The more frequent the incidents the smaller the consequent effusion, so that a time may come when even locking, which the patient has learnt to reduce himself, may provoke no

reaction whatsoever. Furthermore, in contra-distinction to the effusion intimately associated with medial lesions, synovial effusions in conjunction with lateral lesions are not only of lesser volume but cases are encountered which show symptoms and signs which permit the diagnosis to be established beyond doubt but which will not admit reaction subsequent to any incident other than the original accident.

In this section the words "always" and "never" have been used. While trying not to confuse the issue by apparently conflicting statements it is necessary to record that there is an important exception to the rule. The coal miner who tears his meniscus getting up from the crouched position (Figs. 20, 21, and 22) does not stretch the peripheral attachments by the violent rotary strain which is the usual prelude to trapping of the substance of the structure between the condyles; the stretching has taken place gradually in years of abnormal wear and tear. It is for this reason that cases are sometimes encountered who produced no effusion at the original accident.

QUADRICEPS WASTING

Perfect muscles seldom control imperfect joints. Some degree of quadriceps wasting is the constant accompaniment of an internal derangement of the knee; but because of the rapid loss of volume which may follow even a short period of complete functional inactivity the degree of wasting is not of necessity any indication of the gravity of the underlying lesion.

"The vastus medialis is the key to the knee" (Chapter I.) Thus it is that the earliest manifestations of wasting are seen in this component of the quadriceps apparatus. It is for the same reason that a better estimation of loss of volume and tone may be obtained by inspection and palpation than by the use of an inch-tape. A degree of flattening which cannot be measured can be appreciated by the eye. This is particularly true of a thigh which is clothed with a thick layer of subcutaneous fat.

CONDITION OF ACCESSORY SUPPORTING STRUCTURES

Examination of the state of the ligaments is important, not only because it may reveal the cause of the symptoms in such a lesion as rupture of the anterior cruciate ligament, but in cases of long standing and which have been subject to constantly recurring incidents it is possible from the examination to assess how much damage in the form of residual laxity has been sustained by the supporting structures from the recurrent locking, effusion, and giving-way. This information is of value in attempting to assess the future of the joint, because laxity of the supporting structures is some indication of the condition of the articular cartilage; when it is present a perfect joint should not be promised following excision of the torn meniscus. In such cases convalescence is prolonged, recovery of the volume and tone of the quadriceps delayed, and if the patient's occupation is of an arduous nature he may still be liable not only to giving-way incidents but to slow and inevitable advance of traumatic osteoarthritis.

LOCALISATION OF TENDERNESS

The presence of tenderness over the convex margin of the meniscus is an important clinical sign and suggests the possibility of a lesion of the underlying structure. The tenderness may be present along the whole length of the joint line but as a rule is most acute at one of three points :

(1) **Anterior Peripheral Attachment.** This is the area where the classical point of tenderness in meniscus lesions is said to be situated, but in the author's experience it is neither a common nor a reliable sign when located in this region for it is very frequently present in any acute injury, whether the meniscus is injured or not, and in recurrent cases of old standing could hardly be expected to be present with regularity considering the fact that the particular area of meniscus subjected to pressure is unlikely to be the site of injury or even strain.

The best method of eliciting the sign is to place the thumb in the space to the medial side of the ligamentum patellae while the knee is flexed and then slowly extend the joint. Pain will be experienced towards the limit of extension when the anterior end of the meniscus encounters the pressure of the thumb.

(2) **Posterior Peripheral Attachment.** Tenderness in this area is common for the reason that tearing or stretching of the peripheral attachment of the posterior segment must occur in order to permit the occurrence of a longitudinal tear. In recurrent cases of old standing, with symptoms entirely referable to the posterior segment, tenderness may be limited to this area alone.

(3) **Collateral Ligament** (in reference to the medial meniscus only).

The most constant and reliable region of localised tenderness in injuries of the medial meniscus is the collateral ligament at the level of the joint line. This clinical finding is not well known, in fact its presence is sometimes given as a reason for eliminating the possibility of a meniscus lesion in favour of the diagnosis of a sprain of the ligament. It does in fact indicate a sprain of the ligament, but the sprain affects the deep fibres at their attachment to the medial meniscus and thus points to the meniscus rather than to the ligament as the site of the major lesion. The tenderness which is found in sprains of the medial collateral ligament, existing as an isolated lesion, is localised in the great majority of cases to the upper femoral attachment (page 141).

To summarise the significance of localised tenderness, it is considered that whereas most reliance may be placed on the sign when it is situated in the middle of the medial collateral ligament, even at this point it is only of importance in arriving at a diagnosis when considered in conjunction with all the evidence available. It is clear that tenderness situated either anterior or posterior to this point may refer to injuries of tissues, such as a haemorrhage into the capsule or synovial attachment of the meniscus, other than to the substance of the meniscus proper. Moreover, it must be remembered that the severity of the lesion cannot be gauged by the degree of

tenderness, nor is the absence of tenderness in a case of long standing any indication that the meniscus is intact.

PRESENCE OF A CLICK

The statement that the patient feels a click or snap in the joint must not be accepted as relating to a meniscus till the other possible causes have been eliminated. These are :

(1) Periarticular creaking or grating associated with traumatic osteoarthritis but which is almost a normal feature of joints subjected to considerable wear and tear.

(2) Associated with the patella. Minor clicks as the patella moves on the femoral condyles are not uncommon and are of no significance. Slipping of the patella over the lateral condyle of the femur must be eliminated (see Recurrent Dislocation).

(3) Snapping tendon. The slipping of one of the hamstring tendons round the femoral condyle, the biceps tendon over the head of the fibula, or any muscle or tendon over an exostosis may produce a well marked snap. These conditions may be eliminated by inspection of the joint in motion and by palpation.

ELICITING THE CLICK

It has been indicated that from a detailed history and examination, and in the large proportion of cases from the history alone, it is possible to diagnose a longitudinal tear which extends forward into the anterior half of the meniscus. The tears of the posterior half present a different problem for they never produce true locking but merely the sensation that "something is catching in the joint" accompanied by momentary giving-way or loss of control but by little or no pain. To make the history even more vague the patient can seldom localise the cause of the giving-way, but may recall, on being given a leading question, that incidents used to be followed by a small effusion but that latterly even this symptom has been absent.

This type of case is common. The initiated immediately suspect a lesion of the posterior segment, but to those unfamiliar with such a history the only positive finding is wasting of the quadriceps which leads to the incomplete diagnosis of quadriceps insufficiency. Once the examiner realises that he is listening to the history of a posterior segment lesion it merely requires the click of M'Murray's test to clinch the diagnosis.

TECHNIQUE OF THE TEST

The patient lies in the supine position on a firm couch and the knee is fully flexed until the heel approaches the buttock. While one hand steadies the knee the other hand grasps the heel so that the forearm can be used to produce either internal rotation, which tests the posterior segment of the lateral meniscus, or external rotation (Fig. 75) which tests the posterior half of the medial meniscus. The region of the meniscus brought under

pressure by the rotary movement depends on the degree of flexion of the joint. When the joint is in full flexion the posterior extremity is under review, whereas in right-angled flexion the middle segment is tested. In extension beyond a right angle it is impossible to bring pressure to bear on a meniscus and it is evident that the method is of little value in examination of the anterior half.

When a mobile segment of meniscus is caught between the articular surfaces during rotation, the slipping of the femur over the loose fragment is accompanied by a click or snap which can sometimes be heard but can always be felt. The transmission of this sensation to the examining hand not only enables the site of the lesion to be located but some idea of the size of the detached portion may be judged by the movement transmitted to the tibia and the intensity of the sound produced.

M'Murray's test is undoubtedly one of the most valuable of the accessory methods of examination of the knee joint, but it requires system, patience and practice if the best results are to be obtained.¹ One of the most common faults in its performance would appear to be failure to produce the limit of rotary movement which must sometimes be accomplished with a degree of vigour which produces discomfort almost amounting to pain. The originator suggests that the most simple routine is to bring the leg from the position of acute flexion to a right angle while the foot is retained first in full internal and then in full external rotation. Any abnormality in the meniscus structure in the area under examination will be discovered during the straightening of the joint.

Apart from failure to elicit the click due to inexperience of the method, the only other source of error is misinterpretation of normal for pathological clicks. In children, and in some adults with lax meniscus attachments, clicks can be produced during the manipulation even in the absence of a lesion. M'Murray states that little difficulty should be experienced in differentiating these clicks due to excessive laxity from those caused by fragmented and loose portions of meniscus. When the click occurs with a normal but lax meniscus, the patient experiences no pain or discomfort, but when produced by a torn meniscus, which has already given rise to symptoms, the patient is able to state that the sensation is the same as he experienced when the knee gave-way previously.

A similar method has been devised by the author and used with success on frequent occasions when the click could not be elicited in the usual

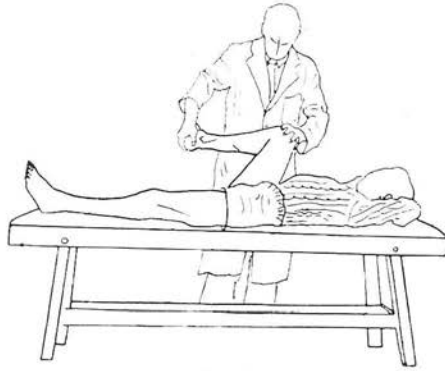


FIG. 75

Eliciting the click. (M'Murray's sign.)

While one hand steadies the knee the other grasps the heel so that the forearm can be used to produce rotation of the tibia.

¹ E. P. M'Murray. "The Semilunar Cartilages." *Brit. Jour. Surg.*, 1942, xxix, 407.

manner. It enables a greater degree of pressure to be exerted on the surface of the anterior end of the middle segment than is possible by any other method. It is, unfortunately, of no service in the examination of the extreme posterior segment.

The patient carries out the examination himself by standing with his full weight on the affected leg, the foot being firmly fixed to the ground, and then rotates his body from side to side so that the rotation is transmitted to the femur but not to the tibia. The rotary movements are carried out to the extreme limit which is possible, first in extension, which brings the anterior end of the middle section of the meniscus under pressure, and then in ever increasing degrees of flexion, until the rotation is being performed with the knee almost at a right angle. The localisation of any click may be effected by placing the palm of the hand lightly against the side of the joint while the movement is in process.

LATERAL MENISCUS

It was formerly supposed that lesions of the lateral meniscus were relatively uncommon by comparison with those of the medial structure, the ratio being considered to be one to seven or eight. Recent statistics suggest that the ratio is one to three or four. In the series under consideration, in which 406 lateral menisci were removed as compared with 727 medial, it is less than one to two. The marked difference in these statistics is explained by the more accurate diagnoses which have followed the recognition that the indefinite symptoms, which formerly did not appear to justify a positive diagnosis warranting operation, are in fact the characteristic feature of lesions of the lateral meniscus.

The symptoms and signs which have been enumerated apply to lesions of either structure but differ in regard to the lateral meniscus in that no single feature is encountered in the same positive form which may be expected from an injury of the medial meniscus. For example :

(1) The original accident is seldom as definite as that which directs attention to the medial side of the joint and may have been of such a trivial nature as to be completely forgotten. An instance of this may be quoted from the parrot-beak lesion in which the original accident may produce nothing more than a minor oblique tear of the concave margin, an injury which produces little effect on the function of the meniscus until antero-posterior movement, which is the accompaniment of normal joint motion, produces extension of the tear in both the vertical and horizontal planes. The extension of the tear may take many months to reach a stage which produces symptoms of instability of a degree which cause the patient to seek advice.

(2) Locking is less common because :

(a) Longitudinal tears tend to remain confined to the posterior segment.

(b) The inherent tendency to replacement following rupture of the peripheral attachment of the posterior segment, or following a longitudinal

tear of the substance of the structure, is more marked in the lateral meniscus - the lateral structure being a larger segment of a circle of smaller diameter.

(3) Incidents may not be followed by effusion. It has been stated previously that the production of effusion following the original accident and subsequent incidents, is, in general, an important feature in the train of symptoms which lead to the diagnosis of a meniscus injury. The exceptions which are encountered refer to the lateral structure where the relatively minor nature of the original and recurrent incidents may not produce synovial reaction. Even when the effusion has been present at the first incident, the tendency for subsequent effusions to appear in ever decreasing volume is even more marked in relation to the lateral than to the medial meniscus.

(4) Finally there exists the curious but most important anomaly that the symptoms of a lateral meniscus injury are often referred to the medial side of the joint, although the converse is rarely true. This feature has been responsible for the removal of many normal medial menisci; it is only when the result proves unsatisfactory that it becomes evident that the lesion is located on the lateral side. It is thus evident that when the symptoms and signs of an internal derangement are not such that the lesion is obviously on the medial side of the joint, and nothing more than a suspicion as to the localisation exists, it is most important to think of the possibility of a tear of the posterior segment of the lateral meniscus. In this respect it is of assistance to remember that although contra lateral subjective symptoms may exist, tenderness to pressure and pain on manipulation coincide with the lesion.

RECENT INJURIES

There are few more difficult problems of diagnosis than determining the exact nature of the lesion in the acute injury with no history of a previous incident. The problem arises in the case seen for the first time at any period varying from a few hours to two or three weeks following the accident and exhibiting little more than effusion accompanied by a vague tenderness localised to the joint line, possibly on both the inner and outer aspects of the knee. If the patient can recall the mechanism of the injury, has felt "something tear" within the joint, and records that the accident was followed by locking which was reduced suddenly by pulling or twisting the joint with the sensation of something slipping back into place, he is giving a straightforward meniscus history and the signs elicited on examination may confirm the nature and site of the lesion. But even with such a history of locking in a knee seen perhaps a week or two after the event, the patient may be unable to recall which side was affected and unless the tenderness is definitely localised to one particular spot the examiner may find no clinical signs which can enable him to determine which of the two menisci is torn.

In regard to this particular problem Sir Robert Jones¹ called attention

¹ Sir Robert Jones. Note 12 of the Appendix to A. G. T. Fisher's "Internal Derangements of the Knee-Joint."

to a method which may prove useful in determining the location of the injury : if the knee is fully extended the site of the pain produced usually coincides with the site of the lesion.

In this common problem, where a complete clinical and radiological investigation reveals no injury other than a potential but unproved internal derangement relative to a meniscus, the attitude to be adopted is one of expectancy. The case should be regarded as a traumatic synovitis and treated as such. No attempt should be made to safeguard the reputation of the examiner by forbidding the return to athletic activities. When the volume and tone of the quadriceps have recovered, the resumption of football should be encouraged rather than discouraged. It is only in this way that the joint can be proved to be sound or otherwise : but the patient must be warned that if he has any trouble—the exact nature of which need not be suggested—he should not merely accept as inevitable the termination of his athletic career but return without delay for further examination which will probably reveal the cause of his disability to be due to a condition which can be completely cured by a minor operative procedure. This is the only means by which many young men can be prevented from having to spend their leisure hours as envious spectators rather than active participants in the game of their choice ; to say nothing of the benefits which early operation on a torn meniscus can bestow in preventing permanent disability and suffering in the form of osteoarthritis which is the inevitable outcome of the wear and tear of every day life on a knee joint which contains a torn meniscus.

LESIONS OF BOTH MENISCI

It is seldom that lesions of both menisci are produced by a single accident. The tearing of the second meniscus in the same joint is usually the sequel to a previous internal derangement either treated or untreated. It may occur in the following circumstances :

(1) An injury of a single meniscus may be associated with an injury of the anterior cruciate or medial collateral ligament as the result of a single accident. If the true nature of the injury goes unrecognised and is merely termed "traumatic synovitis" the patient returns to work on an unsound and unstable knee the site of recurrent effusions, and, as a result of the instability caused by the ruptured cruciate ligament or the torn meniscus, tears the remaining meniscus. Thus it would appear that the wear and tear of every day life in the presence of a torn anterior cruciate for which there is not adequate quadriceps compensation inevitably leads to a condition of the joint in which both menisci are torn (Figs. 76, 77, 78, and 79).

(2) The second meniscus may be torn in a joint in which there is a history of an internal derangement of some years' duration with recurrent lockings, effusion, etc., but in which the anterior cruciate ligament is intact. The tear of the second meniscus in such cases merely results from the relaxation of the capsule and ligaments and the quadriceps insufficiency which is the usual sequel to the recurring incidents which follow an untreated

LESIONS OF BOTH MENISCI

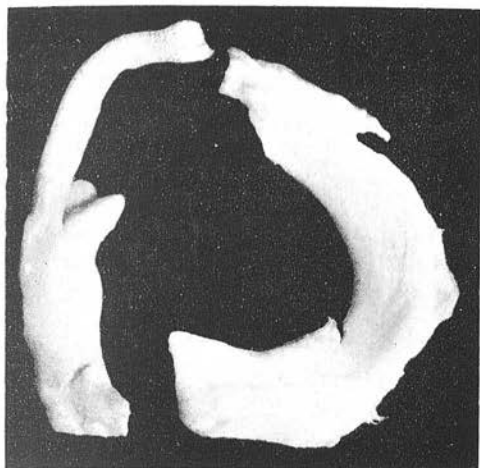


FIG. 76

The medial meniscus shows a longitudinal tear of the posterior segment, the central portion of which has been subjected to a superimposed transverse lesion and has become detached at its posterior extremity.

The lateral meniscus has lost the peripheral attachment of the posterior segment and has been subjected to further longitudinal lesions which have not penetrated through the substance of the structure.

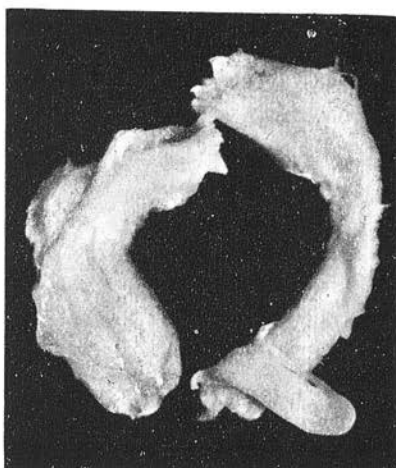


FIG. 77

Inferior surfaces. The medial meniscus shows a complete longitudinal tear, the central portion of which has lost its posterior attachment. The resulting pedunculated tag, based anteriorly, has been displaced underneath the parent structure to present on the joint line.

The lateral meniscus has been subjected to considerable surface trauma.

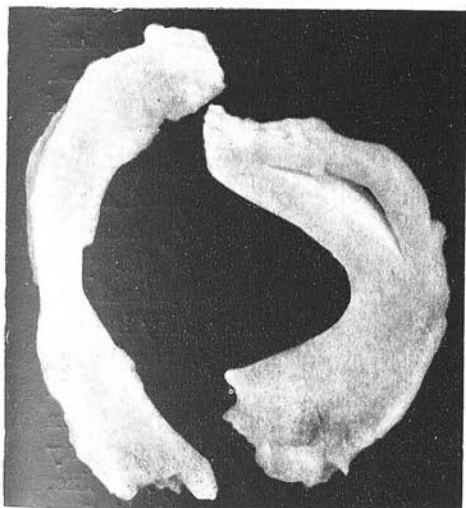


FIG. 78

In this case the patient had been subjected to a previous operation at which the medial meniscus was said to have been removed. It would appear that only the central portion of a longitudinal tear had been excised. Note posterior segment of medial meniscus completely devoid of peripheral attachments. (This is not a complete regenerated meniscus; the only evidence of regeneration is in the anterior segment.) The lateral meniscus shows a recent longitudinal tear of the posterior segment.

This case demonstrates the fallacy of removing the centrally displaced portion of a longitudinal tear.

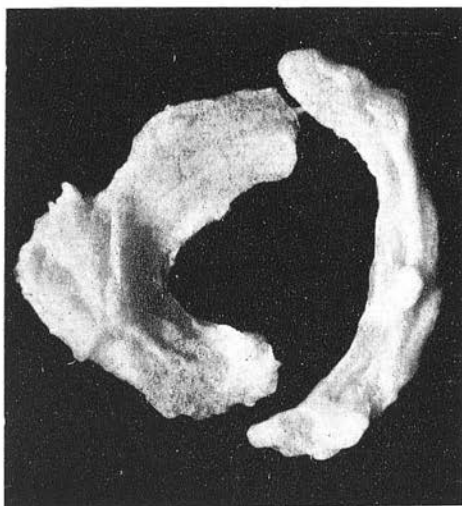


FIG. 79

Inferior surfaces. The medial meniscus shows evidence of numerous trapping incidents.

The lateral meniscus shows similar evidence in the form of longitudinal tears which do not penetrate through the substance of the structure together with cystic degeneration at the usual site (see also Fig. 80).

In each of the above cases there was rupture or attenuation of the anterior cruciate ligament.

longitudinal tear. The same sequel may be encountered in cases which have suffered recurrent incidents following the failure of the operator to remove the posterior horn at the original operation.

(3) The remaining meniscus may be torn in the first few weeks or months of weight-bearing following an apparently successful meniscectomy if arduous work or exercise is permitted in the presence of effusion and wasting of the quadriceps. The inadequate protection afforded to the joint components coupled with the softening of fibrocartilage which is associated with effusion predisposes to the tearing of the remaining structure.

CYSTIC DEGENERATION OF MENISCI

CLINICAL FEATURES

The patient is usually a young adult male in the twenty to thirty age group. In the absence of an associated internal derangement relative to the lateral meniscus the symptoms are characteristic. The patient complains of a dull ache on the lateral side of the joint. The pain, although constantly present, is not incapacitating during periods of normal activity, but is greatly accentuated by any increase of exercise such as a game of football or a round

of golf. If the cyst is large the patient will call the examiner's attention to the presence of a swelling (Fig. 80); if it is small the patient will be unaware of its existence and will frequently give a history of having sought medical advice on previous occasions and received treatment in the form of physiotherapy without alleviation of symptoms.

Examination reveals the presence of a swelling on the lateral side of the joint which may vary in size, position and consistency. The largest cysts may attain the dimensions of a hen's egg and are tense and firm on palpation. They are not of necessity found directly over the joint line, for being entirely parameniscal, they take the line of least resistance and may track forward over the antero-

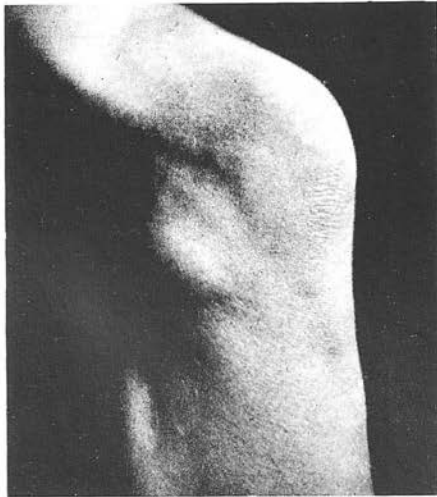

FIG. 80

Cyst of the lateral meniscus. This is the joint from which the menisci illustrated in Fig. 79 were removed.

lateral aspect of the head of the tibia, or dissecting through the capsule, may be situated almost subcutaneously over the lateral aspect of the femoral condyle. The small cysts, which are the most common variety, may be no larger than a pea, and thus may only be recognised with difficulty in the presence of abundant subcutaneous tissue. They are usually situated on the joint line immediately in front of the lateral

collateral ligament and are almost stony hard in consistency. The characteristic feature of the swelling is that it varies in size depending on the position of the knee, reaching the maximum dimensions in extension and decreasing in size on flexion. This feature applies to all cysts except perhaps the largest varieties which have tracked away from the joint line to become fixed to the deep structures overlying the tibia or femur. In addition, the cysts vary in size depending on the time of examination, being largest and most tender on pressure after increased athletic activity, receding after a period of rest in bed. Synovial effusion or marked wasting of the quadriceps is seldom encountered except in those cases in which there is an associated lesion of the substance of the lateral meniscus. Although there are no pathognomonic symptoms or signs in the incomplete oblique or parrot-beak tear—the most common co-existing injury—the association of a cyst with this tear can be distinguished from a cyst occurring as an isolated lesion by the history of instability or giving-way incidents accompanied by effusion.

The symptoms relative to cystic degeneration vary between the lateral and medial sides of the joint. On the medial side the cyst may be extruded under and eventually project behind, in front of, or through the medial collateral ligament and therefore in addition to the usual symptoms associated with cystic degeneration there may be loss of flexion and of the last few degrees of extension due to interference with the function of the medial collateral ligament. When the cyst interferes with the function of this ligament the symptoms produced bear some similarity to those associated with para-articular ossification of the medial collateral ligament.

DIFFERENTIAL DIAGNOSIS

The diagnosis of this condition presents no difficulty as the symptoms are so characteristic that a conclusion can almost be reached without examination of the knee. Some conditions, however, which produce swellings on the joint line may prove misleading :

(I) Lesions of the menisci :

- (a) A pedunculated tag of meniscus, based anteriorly (Fig. 77), or posteriorly (Fig. 81), may be displaced under or over the parent structure to protrude on the joint line. The swelling produced is firm in consistency and reaches maximum dimensions on extension, receding on flexion of the joint.
- (b) The peripheral zone of a meniscus may sometimes be displaced over the superior margin of the tibia to produce a swelling on the joint line which reaches maximum dimensions in extension and decreases in size on flexion (Fig. 82).
- (c) The incomplete oblique or parrot-beak tear which is so commonly associated with cystic degeneration, may, even in the absence of cystic degeneration, produce a swelling on the joint line. The outstanding feature of this lesion is the presence of horizontal cleavage of the substance of the meniscus in the posterior lip of the

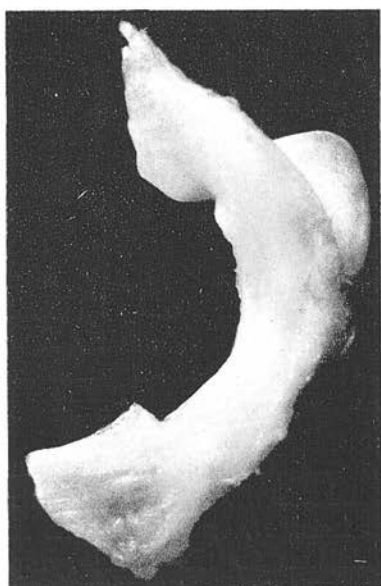
DIFFERENTIAL DIAGNOSIS OF CYSTS OF THE
LATERAL MENISCUS

FIG. 81

The pedunculated tag of meniscus, based posteriorly, has been displaced under the parent structure to present on the joint line.

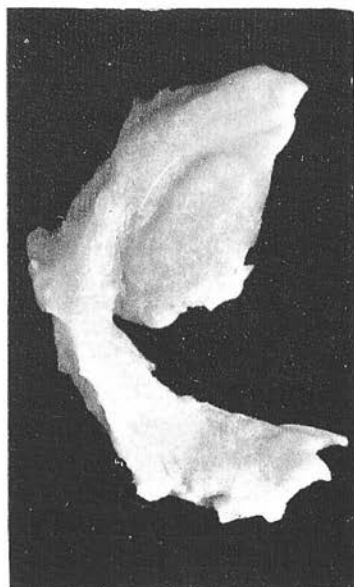


FIG. 82

The peripheral zone of a meniscus may be displaced over the superior margin of the tibia to produce a swelling on the joint line. Note the groove produced by the condyle of the femur on the superior surface of the posterior segment.

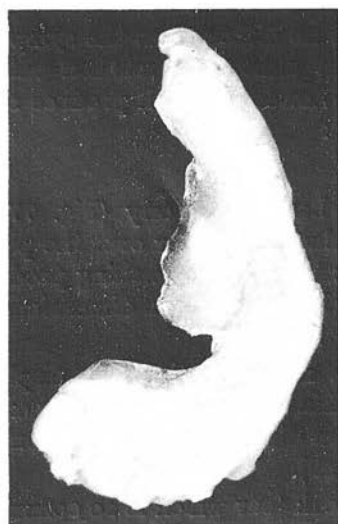


FIG. 83

The parrot-beak tear (Fig. 83) which is so commonly associated with cystic degeneration, may, even in the absence of cystic degeneration, produce a swelling when the anterior end of the posterior segment passes through the horizontal slot to present on the joint line (Fig. 84).

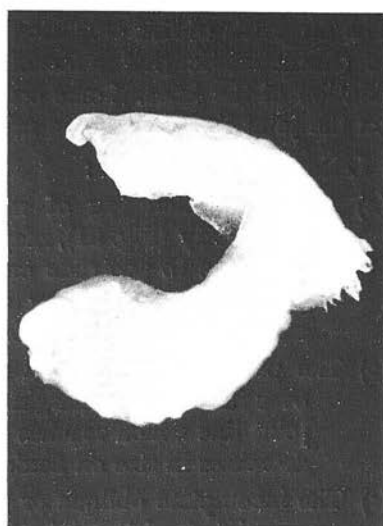


FIG. 84

tear. If the horizontal cleavage extends through the peripheral zone the anterior portion of the posterior segment of the meniscus may pass through the horizontal slot to present on the joint line as a firm swelling which may alter in size on flexion and extension (Figs. 83 and 84).

All of these errors of diagnosis have been made by the author: they are of academic rather than practical importance for their treatment differs in no respect from the treatment of cystic degeneration.

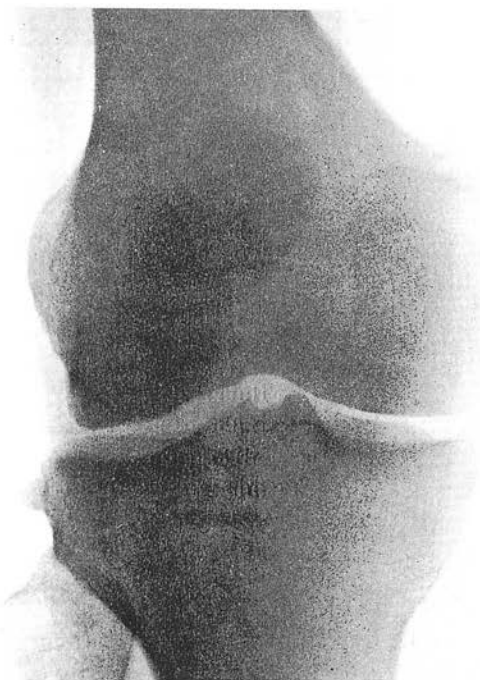

FIG. 85

The soft tissue swelling overlying a traumatic exostosis may be mistaken for a cyst of the lateral meniscus.

(2) A bursa situated deep to the lateral ligament or a true synovial pouch. These conditions may give rise to some difficulty and offer a possible explanation in the occasional case when no cystic degeneration is found at operation and the meniscus is entirely normal. The trauma of operation usually produces fibrosis of the pouch or bursa with complete relief of symptoms.

(3) The presence of a loose body in the lateral compartment which has obtained a synovial attachment. This error is avoidable but occurred on one occasion as a result of careless examination of both the patient and his radiograph.

(4) The presence of an exostosis of traumatic origin. The osteophyte produces irritation of the periphery of the meniscus and of the adjacent synovial membrane which results in a reactionary mass of fibrous tissue. The existence of the osteophyte in the radiograph should suggest the origin of the soft tissue swelling (Fig. 85).

CONGENITAL DISCOID MENISCUS

CLINICAL FEATURES

The diagnosis cannot be made with certainty except in the presence of the classical sign of a snapping knee. The typical snap takes place at the extremes of movement, usually occurring at points about 20 degrees short of full flexion and of full extension. When the snap occurs, a momentary check in the smooth movement of the joint is seen, and the tibia and femur appear to separate slightly on the lateral side of the joint and then come together again. The check in movement and separation of the lateral condyles is momentary and is accompanied by a palpable and plainly audible sound (Figs. 86 and 87).

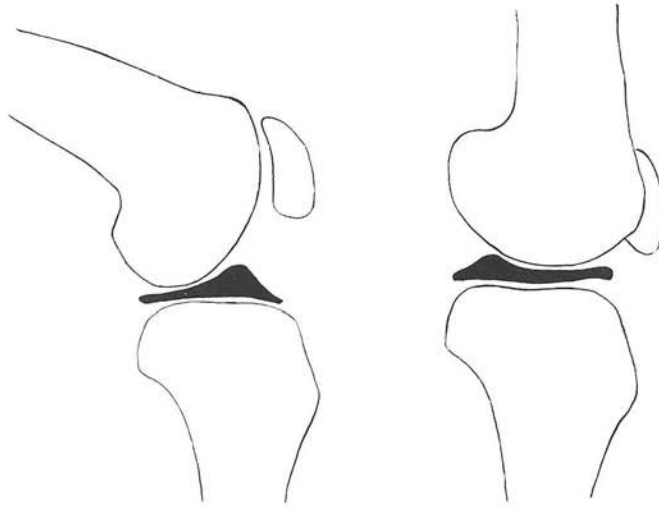


FIG. 86

FIG. 87

Diagrammatic representation of the way in which the ridge on a congenital discoid meniscus causes snapping, and the relationship of the femoral condyle to the ridge in flexion and extension.

(After D. S. Middleton.)

Cases which demonstrate the classical snap may come under observation in early childhood because of the presence of the unusual sound, but as a rule the disability is insignificant and the patient, becoming accustomed to the noise, is not disturbed by it.

Only five cases in this series demonstrated the classical sign, but the author has seen two other cases previously, one of which was a case recorded by Middleton. The cases in this series came to operation as the result of insecurity, momentary locking and recurrent effusions—symptoms usually associated with a longitudinal tear of the posterior horn, and/or with the clinical features of cystic degeneration.

RETAINED POSTERIOR SEGMENT

CLINICAL FEATURES

A patient is occasionally encountered who complains that in spite of a meniscus operation which certainly cured him of his previous symptoms of locking, the knee still lets him down. He will refer to the posterior aspect of the side of the operation as the site of the trouble, stating that the knee gives-way unexpectedly on walking over rough ground, often with the sensation of something slipping about in the joint. Although all the common causes of giving-way such as a torn anterior cruciate ligament, loss of full extension, and quadriceps wasting, are worthy of consideration, with a history of this nature, which obviously refers to the posterior segment of a meniscus, the possibility of a retained posterior horn must be kept in mind. (See also Lesions of Regenerated Menisci) and the confirmatory elick of M'Murray's sign sought. Such cases arise as a result of inability on the part of the surgeon to excise the entire meniscus or failure to appreciate that the etiology and pathology of meniscus injuries is such that excision of the anterior segment only, or of the centrally displaced portion of a longitudinal tear, is likely to terminate in failure to produce complete alleviation of symptoms in a high proportion of cases (Fig. 78).

The obvious difficulties of diagnosis in this condition are frequently increased by the fact that the patient is introduced with the statement "that he still complains of symptoms *in spite of* meniscectomy," and with the added suggestion that the complaints are "functional" in origin or that he is a malingerer.

LESIONS OF REGENERATED MENISCI

The excision of a torn meniscus is a common operation, and it is performed most frequently in young athletic males who are likely to be subjected to further injury which will produce strains; the operation cannot be expected to decrease the susceptibility to injury of the most vulnerable of all joints. In spite of this, lesions of regenerated menisci are apparently rare, even allowing for the fact that a certain number of cases may be missed, especially by those unaware of the possibility of regeneration.

It is evident that the most significant features of a regenerated meniscus are the density of the attachment to the capsule, from which it follows that mobility is reduced; and the small transverse section and decreased projection towards the centre of the joint, which make the liability to injury in an otherwise sound joint extremely unlikely. The phrase "otherwise sound" requires elaboration. In all the cases of lesions of regenerated menisci which were encountered, examples of which are illustrated in Figs. 68, 69, 72, and 73, it was found that either the anterior cruciate ligament was torn or all the accessory supporting structures of the joint were extremely lax. It would thus appear that injury to a regenerated meniscus is possible only in the presence of factors producing gross instability of the joint.

CLINICAL FEATURES

The clinical features are similar to those described under Retained Posterior Segment above, but, whereas the symptoms produced by a retained posterior horn become evident within a short time of the resumption of weight-bearing, in a lesion of a regenerated meniscus there is usually an interval of months or years before the onset of fresh localising symptoms.

RADIOLOGICAL EXAMINATION

Although radiological examination in internal derangements of the knee joint relative to the menisci without the use of contrast media can neither confirm nor refute the clinical diagnosis, it is necessary to obtain antero-posterior and lateral radiographs in every case. The apparent waste of time and material is completely justified by the occasional discovery of some unsuspected condition such as osteochondritis dissecans or the presence of a loose body. It is for this reason that plates which are mere shadows of the femoral and tibial condyles are useless: the radiography must be of a quality which reveals the details of bone trabeculation.

AIR ARTHROGRAPHY

The principle of using contrast radiography in the diagnosis of internal derangements of the knee is well known. The irritant properties of such fluid media as the iodised oils and uroselectan group make their use unjustifiable in the knee joint, quite apart from the obliteration of detail by the

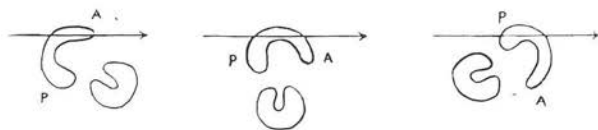


FIG. 88

Projections in air arthrography to reveal lesions of the menisci.

(After Cullen and Chace.)

density of the shadows cast, and in the present stage of development the only safe medium is atmospheric air. The sphere of usefulness of air arthrography is unfortunately limited, for although the major lesions, such as a complete longitudinal tear, which are most easily detected by clinical examination are readily demonstrated, the minor or atypical tears which may be responsible for obscure symptoms and in which some ancillary method of examination would prove of most value, are not demonstrated with a degree of consistency to make the method of practical importance.

Technique.—The skin and capsule are infiltrated with novocain and the suprapatellar pouch punctured half an inch above and lateral to the patella. If an effusion is present it is aspirated and thereafter filtered air is injected with a twenty c.c. syringe attached to the needle by a three-way adaptor. The amount of air used varies from seventy c.c.s. to one hundred and fifty c.c.s. in different cases. Injection is continued until the

patient feels his knee definitely tight and there is sufficient tension to exert backward pressure on the piston of the syringe. The needle is then withdrawn and the puncture sealed.

In order to ensure that the air in the knee joint is under pressure a firm bandage is applied from above downwards to the suprapatellar pouch.¹ Fig. 88 illustrates the projections which are necessary in order to secure the greatest chance of detecting the lesion.

ERRORS OF DIAGNOSIS

The types of meniscus removed at operation fall into three groups:

(1) **Those in which the diagnosis is proved to be correct by the presence of an obvious tear.**

(2) **Those in which the pathology is not immediately evident.** What constitutes a meniscus lesion will remain a matter of controversy, but this group includes those cases in which the peripheral attachment is stretched but not torn and in which the meniscus may sometimes show superficial evidence of having been trapped in the form of erosions or splits on the inferior surface which do not penetrate the substance completely, or in which the structure shows evidence of degeneration as shown by yellow discoloration punctuated by white patches.

This is the group which includes the type of case in which it is necessary to examine the specimen carefully in order to explain the symptoms but which does reveal some pathology which does not overtax the imagination.

(3) **Those cases in which the meniscus is apparently completely normal in every respect.** This last group of cases exists within the experience of every surgeon. The percentage of errors varies with the judgment and diagnostic skill of individuals but depends principally upon the thoroughness with which the history is taken and the care and time expended upon examination. A small number of frank errors in diagnosis is inevitable, in even the most experienced hands, in any condition which is so dependent upon an accurate account of preceeding incidents which must of necessity entail not only the patient's interpretation of subjective phenomena but his prowess as a witness and the veracity of the statements made. The surgeon who states that he has never excised a normal meniscus is either departing from the truth or is missing more diagnoses than he makes.

Internal derangements of the knee relative to a meniscus are so frequent that the common symptoms are well known and thus the history lends itself to those who desire to simulate a disability for personal gain, financial or otherwise. Deliberate attempts to mislead are rare in normal circumstances and they are only encountered in relation to compensation for alleged injury; they are of little importance because operation is not a matter of urgency and the treatment of doubtful cases may be deferred

¹ H. Cullen and G. O. Chance, "Air Arthrography in Lesions of the Semilunar Cartilages," *Brit. Jour. Surg.*, 1943, xxx, 241-245.

until the accuracy or inaccuracy of the statements can be proved by the passage of time. In wartime, however, deliberate attempts to deceive are unfortunately relatively common, and of the normal menisci removed by the author six patients confessed later that they permitted themselves to be subjected to what they considered to be an innocuous operation in the knowledge that the knee joint was normal. A further patient was encountered who persuaded different surgeons to remove all four menisci; all were recorded as normal! (The author was the second of the surgeons deceived.) This man was seen a year later when he had parted with all his menisci, and there was no doubt at that time that he had succeeded in sustaining a permanent disability!

False meniscus histories were found to be favoured by men serving on undesirably isolated islands such as Iceland, Lewis and Tiree; but with the knowledge that deceptions were being perpetrated, the examiners became more wary and the condition came to be known as "Icelandic" or "Hebridean Knee."

CHAPTER SIX

TREATMENT, AFTER-TREATMENT, AND COMPLICATIONS OF INJURIES OF MENISCI

REDUCTION OF LOCKED JOINT

THE optimum time to secure reduction of a locked joint is as soon—within twenty-four hours of the accident—as circumstances will permit. After this period the inherent tendency for the displaced central portion of the longitudinal tear to spring back into its original position is rapidly lost, for the presence of effusion produces softening and swelling of the fibrocartilage with consequent loss of elasticity. Furthermore, weight-bearing on the locked joint, or unsuccessful attempts by the patient to secure full extension, produces compression of the rapidly softening tissue at the anterior extremity of the tear; the tissue becomes thinned and the anatomy distorted, making subsequent replacement impossible (Fig. 37). It is for the same reason that "false reduction," that is to say, the production of extension without the centrally displaced portion of the meniscus returning to its normal position, is of common occurrence if manipulation is deferred for even a few days. Vigorous attempts to secure reduction, instead of causing the displaced central portion to retrace its steps towards the periphery, produces extension of the longitudinal tear in a forward direction through the soft, synovial fluid-soaked tissue at the anterior extremity of the lesion; full extension may be obtained, but the concave portion of the longitudinal tear remains permanently displaced in the centre of the joint.

TECHNIQUE OF MANIPULATION

Without Anaesthesia. (a) The patient sits on a heavy chair, which is preferably fitted with arm rests, or reclines on a low plinth. The surgeon stands facing him and grasps the foot of the affected side firmly between his knees; the upper third of the tibia is held between the hands. While the patient holds on to the chair and attempts to relax the limb the manipulator leans backwards to exert traction on the joint and at the same time rocks the knee from side to side by means of his grip on the head of the tibia, combining this movement with a rotatory action (Fig. 89).

(b) Sir Robert Jones recommended the following method¹: The knee is flexed and the patient told that he will be given the order, "one, two, three—kick!" The patient extends the limb as suddenly as he can and at the same time the surgeon rotates the foot inwards and pulls.

With or without anaesthesia. The patient lies on his back on a firm

¹A. G. Timbrell Fisher. "Internal Derangements of the Knee-Joint." H. K. Lewis & Co., Ltd., London, 1933.

couch. The surgeon stands on the outer side of the affected limb and grasps the foot with one hand while he steadies the knee with the other. The joint is fully flexed to relax the pressure of the femoral condyle on the anterior

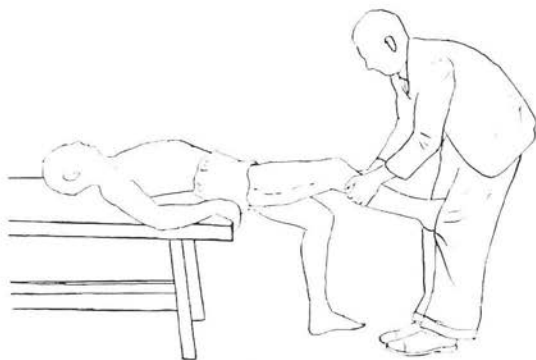


FIG. 89

Reduction of locked joint

The combined hand and knee grip used in the rocking method.

extremity of the longitudinal tear and the tibia gently rotated from side to side. When full medial or lateral rotation has been obtained, depending on whether it is the medial or lateral meniscus which is affected, the joint is suddenly extended (Fig. 90).

If the procedure has been carried out without anaesthesia, the success or failure of the manipulation is seldom in doubt, but under anaesthesia, especially in view of the facts which have

been recorded above, it may sometimes be difficult to be certain that reduction has been accomplished. A false reduction is characterised by an increase of extension beyond the point at which the joint had previously locked, but without achieving complete extension. The check to the last few degrees is accompanied by the sensation of elastic resistance. The further forward the tear extends the more difficult it is to achieve replacement, and thus even if the production of a false reduction is detected the chances of success by further manipulation are greatly reduced. In these circumstances it is in the patient's interests to recommend operation as soon as the skin preparation is complete rather than persevere with conservative treatment or permit a return to weight-bearing on a joint in which extension is incomplete.

FURTHER TREATMENT OF TORN MENISCUS

The question of the further treatment of the torn meniscus following the reduction of the locked joint affords the opportunity of reviewing the whole subject of the treatment of internal derangements relative to the menisci. In the past much confusion of thought and action has existed and it is evident

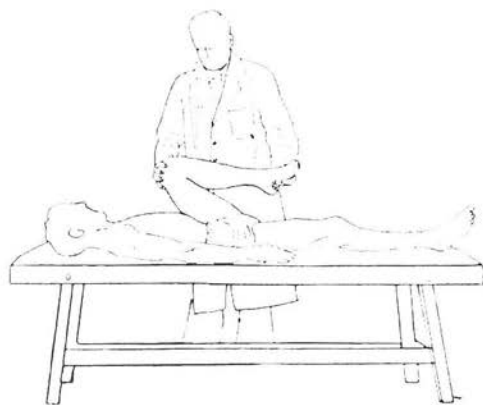

FIG. 90

Reduction of locked joint

When the maximum degree of medial (or lateral) rotation in full flexion has been obtained the joint is suddenly extended.

from the attitude of expectancy which is frequently adopted that the methods in common use bear little relation to the known facts regarding the nature of the lesions or the physiology of repair. It has been shown (Chapter IV.) that the only tears in which there exists the slightest chance of natural cure are those confined to the peripheral synovial attachment or which enter the convex vascular zone, and even these lesions only heal under optimum conditions which include immobilisation for a period of at least three weeks. The tears which fall into these categories are of such comparative rarity that the possibility of healing is of little practical importance in the choice of treatment once there is positive evidence that either meniscus is torn.

Injuries of the menisci are most commonly encountered in one of three forms :

(1) **The joint is locked.** In these circumstances the diagnosis is seldom open to question whether the locking has occurred at the original accident or is the culmination of a previous history suggestive of a meniscus injury. There is unanimity of opinion with regard to the immediate treatment. The locked joint must be reduced. What attitude should be adopted towards the after-treatment of the case? Upon this point depends the rational treatment of meniscus injuries.

In the past it has been the usual practice to apply some form of compression bandage, with or without rigid splinting, following reduction. In some instances rest in bed was prescribed, but frequently the patient was permitted to continue with weight-bearing on the extended knee. When the effusion disappeared and the muscle tone improved as a result of natural processes—for the massage which was commonly employed has little effect on either the synovitis or the quadriceps—the patient returned to his employment in the pit or resumed his athletic activities. The joint never completely recovered, and inevitably, whether it was within a day, week, month or year, the knee locked again. Soon he learned to unlock the knee himself and was thus enabled to continue with his work; but after a few trials he resigned himself to the fact that his football days were over. Finally, as a result of altered circumstances, such as a change of employment or the arduous conditions of military training, he was forced to seek further medical advice; the diagnosis was established and the meniscus removed.

Patients with such a history are the common experience of every orthopaedic surgeon. The tragedy is that these cases never obtain a perfect result. The recurring incidents have produced permanent changes in the joint, the most serious of which is stretching of the accessory supporting structures combined with chronic wasting of the quadriceps which may never completely recover in spite of the most conscientious exercise. These are the cases which are responsible for any evil reputation which the operation of meniscectomy may have obtained. These are the cases which are in part responsible for statistics¹ which suggest that only 50 per cent. of cases obtain a result which will permit retention in a military category of A.1.

¹ Hedley Whyte quoted by Philip H. Mitchener: "Thoughts on Four Years of War Surgery," *Brit. Med. Jour.*, 1944, ii, 37.

It is not the operation which is at fault ; it is the failure of surgeons to appreciate the nature of the pathology at the original accident. The operation is not performed too often, it is performed too little, too late.

The moral of this pitiful tale is clear. Once there is convincing evidence that a meniscus is torn it should be excised. The attitude of expectancy between the original lesion and the time when the patient is driven to desperation should be abandoned. Nothing could be more convincing of the truth of these statements than the examination of a group of cases subjected to meniscectomy six months previously and who have been treated in the same conditions of surgery and rehabilitation. The soundest joints, both subjectively and objectively, are those which received the earliest operation.

The question then arises : if early operation is desirable should it be performed immediately after the original accident in which the meniscus was torn ? It has been accepted by many surgeons that early operation predisposes to persistent post-operative synovial effusion. The author has not found this to be the case in a few cases in which special circumstances demanded that operation should be performed within a day or two of the locking. There are, however, reasons why the procedure should be deferred for one to three weeks. At the original accident more structures are damaged than the meniscus. These tissues should be given an opportunity of returning to normal before being subjected to further trauma. Furthermore, in the presence of an effusion of even a few days' duration the meniscus becomes swollen and soft and thus easily torn by traction in the course of operation.

In these circumstances the mode of action to be adopted following reduction of a locked joint or in the presence of other indisputable evidence of a torn meniscus is :

- (a) The application of a compression bandage, with or without aspiration, depending on the volume of effusion.
- (b) Rest in bed.
- (c) The immediate institution of quadriceps drill.
- (d) Removal of the compression bandage several times daily for knee flexion exercises.
- (e) Operation in one to three weeks, depending on the incidental damage to the joint and the progress of pre-operative treatment.

(2) **It is an acute injury, presenting difficulties of diagnosis which have already been stressed (page 67), and in which a meniscus lesion is suspected but cannot be proved.** In this common situation the only possible course is one of expectancy. The case should be regarded as a traumatic synovitis and treated as such (page 14). The problem involved together with the methods which should be adopted to ensure adequate early treatment if the joint proves to be unsound have already been described (page 68).

(3) **There is a history of recurrent incidents and conclusive evidence on clinical examination of the presence of a torn meniscus**

of long standing. This is the form in which most internal derangements relative to the menisci are encountered. In the absence of any outstanding contra-indication the treatment is excision of the torn structure.

It is extraordinary how many patients are encountered who have endured meniscus symptoms for ten or fifteen years or more and who gave up football, most unwillingly in the large majority of cases, together with all other athletic activities at an age less than twenty as a result of advice received from their family doctor. In answer to the question, "Didn't you ever think of having it operated upon?" they replied, "My doctor advised me against operation as it might leave me with a stiff knee," or, "I have seen a lot of chaps who never played football again after a cartilage operation."

It is difficult to explain the reason for the advice which forms the basis of the first reply. It is certainly unjustifiable in the light of our present knowledge, but a possible explanation is that the older school of practitioners still harbour a fear of complicating sepsis which is distorting to judgment and tends to an irrational degree of conservatism.

The second reply is explained by incomplete excisions of menisci which may have stopped the locking but did not succeed in curing the giving-way, but by far the most common explanation is the failure to recognise the presence of a rupture of the anterior cruciate ligament.

TREATMENT OF DOUBLE INJURIES

What form of treatment should be adopted in the joint with symptoms apparently referable to both menisci? If there is no shadow of doubt that both menisci are torn then both should be removed at a single operative session, but if the diagnosis of a double injury is open to question it is advisable to exercise caution rather than remove one torn and one intact meniscus. Experience has shown that joints in which this error has occurred make slow progress to recovery.

This problem arises, first, because of the vague nature of the symptoms in certain lateral meniscus tears and the fact that symptoms may be referred to the medial side of the joint, and second, the frequency with which joints are encountered in which it is obvious that the internal derangement is referable to a meniscus, but in which there is complete absence of localising signs pointing to one or other structure. The removal of one normal meniscus is not a serious crime and leads to no serious ill effects or delay in recovery provided a normal medial meniscus has not been removed when in reality the lateral meniscus is torn or vice versa. It is hardly necessary to say that the excision of a normal meniscus from a joint, the subject of some more general pathological process, is most undesirable. The best plan to adopt, where a single lesion cannot be localised with precision or in doubtful double lesions, is to weigh the evidence carefully and make a decision as to which meniscus is most likely to be at fault; this meniscus should be removed and if it is found to be torn and there is no sign of a further lesion to be seen in the incomplete inspection of the opposite side which is

possible, the joint should be closed. Recovery is likely to be rapid and time and usage will prove the presence or absence of a lesion of the other meniscus. If, however, the meniscus exposed proves on removal to be normal, there is no alternative but to proceed to the excision of the remaining structure and accept the delay in recovery which usually follows.

RELATIONSHIP OF OSTEOARTHRITIS TO LESIONS OF MENISCI

The relationship between osteoarthritis and trauma is well established. Bilateral osteoarthritis of the knee joint is usually evidence of the arduous nature of an occupation such as coal-mining, where it may accurately be described as "over-use arthritis," but it is clearly evident from the experience gained in the examination of some 4000 cases that it is not generally appreciated that one of the common causes of unilateral osteoarthritis is an undiagnosed or untreated internal derangement of long standing.

It has been suggested as an argument against operation that the excision of a meniscus is followed by arthritis in later life. There is no evidence in support of this contention, but even should it be true there can be no doubt whatever that the advance of arthritic change in a knee joint in which there is a torn meniscus is very much more rapid than any degeneration which might possibly follow the removal of a meniscus. Furthermore, some surgeons hold the view that a meniscus should not be excised in the presence of arthritic change. There can be little doubt that this view is correct in the presence of radiographic changes of extreme degree, but, in mild or moderate degrees of the disease, this attitude is unjustifiable.

The pointed shape of the tibial spine at the inferior attachment of the anterior cruciate ligament and the spike at the inferior pole of the patella are traction lesions which merely indicate hard usage. These minor radiographic abnormalities frequently form the basis of a diagnosis of osteoarthritis and are held to explain apparently obscure symptoms which the taking of a careful history coupled with a meticulous clinical examination might well show to be due to a torn meniscus. In many of these cases where the symptoms are of considerable duration, the meniscus lesion is not only the source of the symptoms but the cause of the radiographic evidence of arthritis.

It is not denied, however, that there may frequently be considerable difficulty in forming an accurate estimate of the relative importance of the many causes which may be responsible for the symptoms. A complaint of sudden giving-way, which may be associated with a meniscus injury, is also encountered in osteoarthritis where it may be due to a variety of reasons, which include alteration in the shape of the weight-bearing surfaces, the presence of osteophytic outgrowths and intra-articular adhesions, in addition to the stretching of ligaments and the nipping of tags of hypertrophic synovial membrane which are the direct result of the loss of protection which follows gross wasting of the quadriceps.

The removal of an unoffending meniscus from an arthritic joint has

more serious consequences than occur in normal circumstances ; it is therefore essential that the greatest care be taken to arrive at an accurate diagnosis.

To summarise the position it may be stated that where the cause of the arthritis is an internal derangement of long standing relative to a torn meniscus, the damaged structure should be excised, provided the process of degeneration has not advanced beyond hope of future improvement. The operation is carried out not because it offers any hope of cure of the arthritis, but because removal of the cause retards the progress of degeneration and permits the redevelopment of the quadriceps, which is the only assurance of improved function. The chronic wasting of muscle which is present in these cases means that convalescence is of necessity protracted and a much longer period of carefully graduated non-weight-bearing exercise is necessary before ambulatory treatment can be resumed.

Where the diagnosis can be established to be due to osteoarthritis, without any underlying internal derangement which is amenable to surgery, or to gross arthritis in which operative interference may be contra-indicated, experience of the rehabilitation of coal miners well past middle life, has shown that the only treatment of value, apart from the palliative effect of radiant heat, is redevelopment of the extensor apparatus until it is capable of providing adequate protection for the damaged joint.

HOW MUCH OF A TORN MENISCUS SHOULD BE EXCISED ?

In the past opinions have differed as to the operative procedure to be adopted in meniscus injuries. Some surgeons consider that only the displaced portion of a longitudinal tear need be removed, leaving the peripheral rim untouched ; some, by choice or necessity, remove only the anterior half ; the majority now hold the view that the meniscus should be removed in its entirety.

When an internal derangement has been localised to one or other meniscus, exploration through the normal small anterior incision cannot confirm or refute the diagnosis. Once the diagnosis has been made the entire structure should be removed. Complete excision is necessary for the following reasons :

- (1) It is not uncommon to find a second or third or even five or more bucket-handle tears in a medial meniscus ; only one handle may be displaced towards the centre of the joint and excision of this portion will not relieve the symptoms (Figs. 33, 34, 35, and 78).
- (2) Excision of the anterior half of a meniscus is quite unjustifiable, for it is only after mobilisation of the posterior segment that the presence of a longitudinal tear can be disclosed (Fig. 30).

If an error of diagnosis has been made and there is no lesion in the posterior horn, as long as the posterior half of the structure has not been

mobilised no serious disability will result from excision of the anterior half only; but even if the meniscus is intact, mobilisation of the posterior half, without excision, will certainly result in serious symptoms at a later date.

- (3) Excision of the centrally displaced portion of a longitudinal tear is not followed by regeneration. The function of the remaining peripheral rim must be imperfect.
- (4) It is only after complete excision that regeneration takes the form of the most perfect replica of the original meniscus.

PRE-OPERATIVE TREATMENT

QUADRICEPS EXERCISES

On admission to hospital the patient is taught the basic quadriceps exercises, straight leg raising and rhythmical quadriceps drill (pages 5 and 6). The relationship between muscular development and rapidity of recovery from operation is explained and the need for conscientious exercise stressed. It is difficult to teach exercises to a patient who has recently suffered an operation on the knee joint. It is therefore essential that the exercises be mastered prior to operation. Quadriceps drill is practised under supervision for five minutes per hour during the forty-eight hour skin preparation.

SKIN PREPARATION

The presence of infection of hair follicles or other skin affection (except psoriasis) in the area of the proposed incision is a contra-indication to operation which should be deferred. The acceptance of risks in knee-joint operations is unjustifiable.

Any rational method of skin preparation may be employed, provided, it is completed with thoroughness and care.

(1) At forty-eight hours

- (a) Wash and shave the leg thoroughly from the inguinal ligament to the toes, using soap and water and a soft nail brush.
- (b) Apply spirit or methylated ether to the whole area.
- (c) Enclose the limb in a sterile square and bandages or a sterile bag.

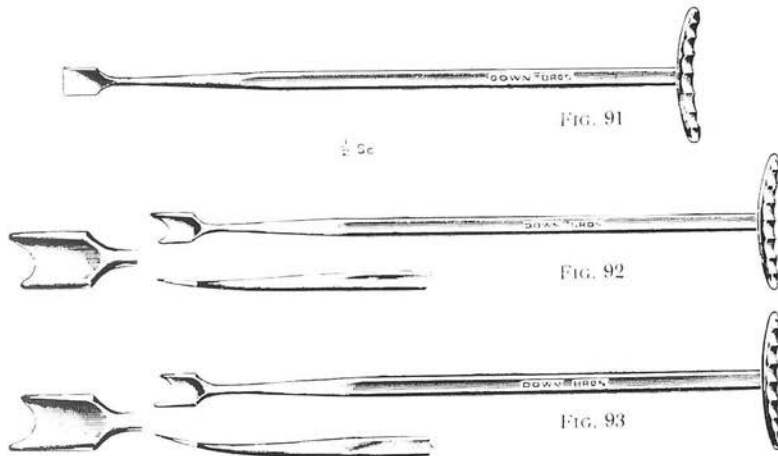
(2) At twenty-four hours

- (a) Wash the limb again.
- (b) Apply spirit or methylated ether followed by weak tincture of iodine.
- (c) Enclose the limb in sterile dressing.

(3) **Immediate.** During the final stages of the induction of the anaesthetic the limb is drained of venous blood by means of a rubber bandage applied from the toes to the point selected for the application of the tourniquet high up on the thigh. The rubber bandage is applied over the surface of the dressing which has been used to protect the prepared skin; the tourniquet is applied over a small sterile towel which encircles

the thigh. When the tourniquet has been secured, the rubber bandage and protective dressings are removed and the skin reprepared from the toes to the tourniquet with spirit followed by iodine.

Several methods of draping the operating table and limb are in common use. The author prefers to drape the table and sand-bag, over which the knee will eventually be flexed, while the limb is held in the extended position by the foot. The leg is then dropped into a sterile square held by the surgeon and his assistant and securely fixed round the foot and upper end of the tibia by means of towel clips. Others prefer the more extravagant method of enclosing the entire limb in stockinette rolled on from the toes.



FIGS. 91, 92, and 93
The meniscus knives of author's design. (Illustration by courtesy of Down Bros.)

The final position of the knee on the operating table should permit flexion to a degree slightly greater than a right angle, so that the plane of the tibial table is horizontal.

INSTRUMENTS

The success of the procedure to be described in securing complete excision of the entire meniscus with minimal difficulty through a single small anterior incision depends entirely on the use of three knives of the author's design (Figs. 91, 92, and 93).

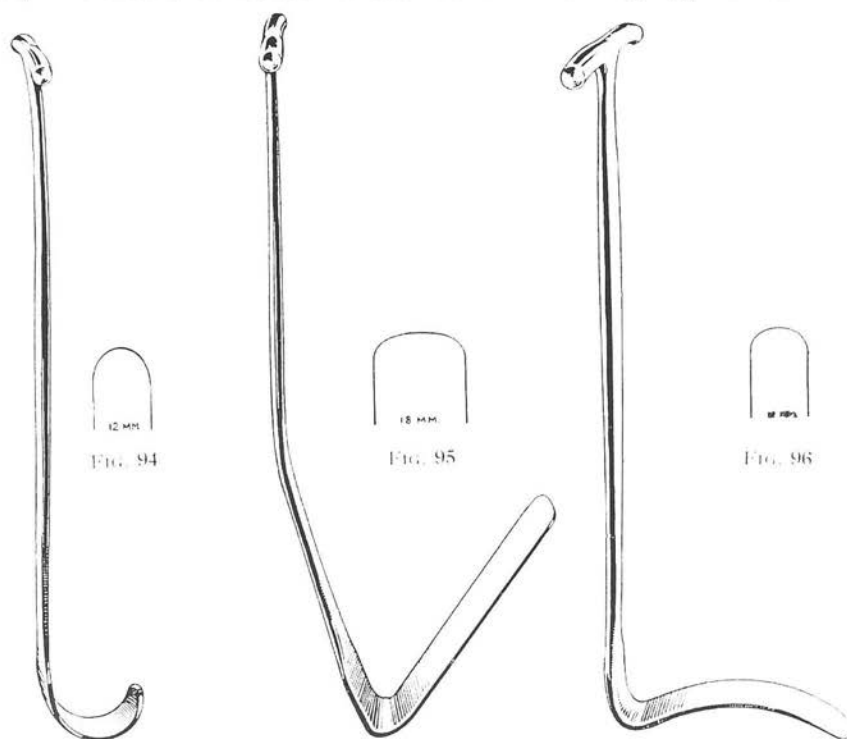
The straight chisel-type knife (Fig. 91) is based on the pattern evolved by Walter Mercer,² but differs from his design in that the type of hand grip used does not obscure the vision. This knife is used to mobilise the middle third of the meniscus (Fig. 98). The curved knives (Figs. 92 and 93) consist of a C-shaped blade bounded by blunt beaks to prevent injury to the articular cartilage of the opposing surfaces of the femur or tibia. The beaks are of different lengths and the curve of the knife is so arranged that the longer beak always rests on the tibial table. Thus the same knife which is used to divide the peripheral attachments of the medial meniscus is also

¹ *Medical Annual*, 1944, 381.

² Walter Mercer, "A New Knife for the Removal of the Meniscus," *Jour. Bone and Joint Surg.*, 1939, xxi, 474.

used to divide the central attachment of the posterior horn of the lateral meniscus, and the knife which is used to divide the peripheral attachments of the posterior horn of the lateral meniscus is also used to divide the central attachment of the posterior horn of the medial meniscus. Figs. 98, 99, and 100 illustrate the method in which these curved knives are employed.

Keeness of edge, the essential feature of efficient service in all cutting instruments, applies in even greater degree to this design of meniscus knife; any difficulties which may be encountered in the course of use can almost always be traced to failure to maintain the cutting edge at maximum



FIGS. 94, 95, and 96
Knee joint retractors.

efficiency. The rounded edge of an Arkansas needle hone is used to sharpen the curved blades; the flat surface for the chisel-type knife. The author makes a point of having the meniscus knives resharpened between each operating session.

The retractors normally employed are simple single-ended instruments of orthodox pattern, designed in an effort to produce the maximum exposure with the minimum of trauma to the capsule and synovial membrane (Fig. 94). In addition, the retractors illustrated in Figs. 95 and 96, and which are based on Burrow's modification of Nystrom's instruments, are occasionally used. That with the broad flat blade (Fig. 95) is used for retracting the ligamentum mucosum when it is particularly bulky and causing obstruction to direct vision of the attachment of the posterior horn

and is particularly useful for inspection of the condyle and meniscus opposite to that directly exposed. The retractor with the narrower curved blade (Fig. 96) is inserted between the collateral ligament and the femoral condyle and is thus useful in the inspection of the periphery of the joint. Both these retractors have a greater sphere of usefulness in the intra-articular manipulations of repair of the anterior cruciate ligament or replacement of the tibial spine than in excision of a meniscus.

TECHNIQUE

It is proposed that the technique of the operation be described in such a manner that the essential points of the procedure are not lost in a mass of detail, and thereafter, under a separate heading, to enumerate the common difficulties which may be encountered.

MEDIAL MENISCUS

The incision, which is made through muslin soaked in spirit, begins close to the infra-medial aspect of the patella and extends downwards and slightly backwards to a point about half an inch below the joint line (Fig. 97). The scalpel used for making the incision is discarded and the skin flaps dissected up for a short distance, using a fresh scalpel. The muslin is now clipped to the skin edges by means of fine Alliss' tissue forceps or Michel clips in such a manner that the skin edges are completely covered. The incision in the capsule is in the line of the skin incision and extends down on to the head of the tibia. Retractors (Fig. 94) are placed in position and the extra synovial fat exposed. The fat is drawn forward towards the operator by means of toothed dissecting forceps and incised, cutting directly backwards towards the medial condyle of the femur and not towards the centre of the joint. This ensures that vision is not obscured at the more difficult phases of the operation by an excess of extra synovial fat.

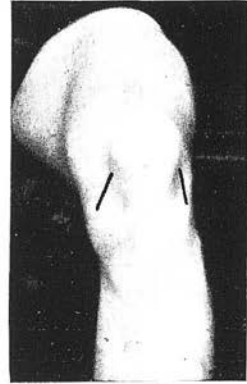


FIG. 97
Incisions for the removal
of the menisci.

The anterior third of the meniscus is mobilised by passing the point of the scalpel between the head of the tibia and the under surface of the structure. The central attachment of the anterior horn is then divided under direct vision and the free end gripped securely with Martin's meniscus forceps.

The anterior half of the meniscus may now be completely freed from synovial attachments by visual scalpel dissection. The portion immediately central to the medial collateral ligament is mobilised, using the straight chisel-type knife (Fig. 98). The attachment of the posterior third to the capsule is divided by means of the curved knife, with the convexity of the curve directed towards the middle of the joint and the longer beak resting on the upper medial edge of the tibial table (Fig. 99). Division

of the attachment is facilitated if the traction on the anterior horn is directed somewhat towards the middle of the joint. This is the most difficult part of the operation and patience spent in mobilising the posterior third is amply rewarded.

It should now be possible to dislocate the entire structure into the centre of the joint. The central attachment of the posterior horn is usually visible and is divided, using the second of the curved knives, the convexity of which faces towards the medial collateral ligament, while the longer beak rests on the articular cartilage of the tibial table. The long beak is thrust beneath the posterior horn and the knife pushed directly backwards under direct vision (Fig. 100). Before the incision is closed any free fragments of fibrocartilage, synovial membrane or articular cartilage should be




FIG. 98




FIG. 99

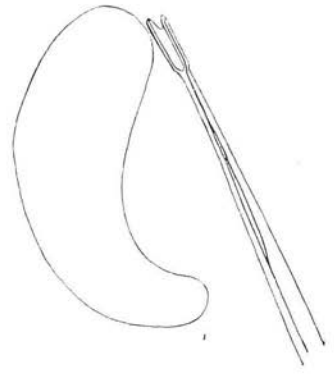


FIG. 100

Diagrammatic representation of the method of use of the author's meniscus knives.

removed and the femoral condyles, cruciate ligaments and opposite meniscus examined for evidence of injury. Suture of the incision is facilitated if the joint is extended by placing the patient's heel on the operator's thigh. It is unnecessary to stitch the synovial membrane and capsule separately. Both layers of tissue are closed with a single line of interrupted sutures inserted in such a manner that the catgut is buried beneath the synovial layer and does not penetrate to appear within the joint cavity. Interrupted silk worm gut sutures are used in the skin.

LATERAL MENISCUS

The incision is made from a point close to the infralateral aspect of the patella and sloped downwards and slightly backwards to cross the head of the tibia and terminate about three-quarters of an inch below the joint line, a little anterior and above the head of the fibula (Fig. 97). The capsule is incised in the line of the skin incision through the weak area which is situated between the patellar tendon and the strong band which forms the medial margin of the termination of the iliotibial tract. It will be found that the depth of extra synovial fat to be traversed is greater on the lateral

than on the medial side and the attachment of the anterior horn situated further posteriorly than that of the medial meniscus. It should only be divided under direct vision.

Once the anterior half has been mobilised the remainder of the operation will be found to prove considerably less difficult than on the medial side because of the absence of attachment to the lateral collateral ligament and the presence of the tendon of popliteus between the meniscus and the capsule. Apart from these points the operation differs little from that described for the excision of the medial structure.

DIFFICULTIES ENCOUNTERED IN REMOVAL OF A MENISCUS

(1) INADEQUATE OR MISPLACED INCISIONS

Many incisions have been described for the excision of the menisci. They may be vertical, oblique, U-shaped, or transverse, and each has advantages and disadvantages. The slightly oblique incision described is anatomical in that it splits the capsule in the line of the fibres and thus does not weaken the structure, provides adequate exposure, and, not being subjected to traction at right angles to its long axis, heals with a narrow scar. The only disadvantage is the possible division of the infrapatellar branch of the saphenous nerve, which may occur if the incision is prolonged down on to the head of the tibia: the importance of this possible fault appears to have been exaggerated (page 103). It is important, however, that the incision should be accurately placed, for only then is the maximum access provided.

It is extraordinary how many patients are encountered, who are alleged to have had a medial meniscus removed but still complain of symptoms, who demonstrate a scar through which it is obvious that the most skilled operator could not excise more than the anterior segment without experiencing the greatest difficulty.

(2) BADLY APPLIED TOURNIQUET

A dry operative field can only be obtained if the limb is drained by means of a rubber bandage applied prior to the application of the tourniquet. If the limb is not drained there is a continuous venous ooze which necessitates swabbing. The forcing of dry swabs into the joint cavity should be unnecessary, and by producing trauma of the delicate synovial layer, causes reactionary synovial effusion. When swabbing is necessitated by the presence of excessive synovial fluid, the gauze swab should be moistened with sterile water or normal saline before it is placed in the joint.

(3) LOSS OF ORIENTATION

Experience obtained in teaching the technique of this operation to junior members of the staff shows that loss of orientation is the major difficulty confronting the inexperienced. This difficulty arises under several circumstances:

(a) **Defining the Anterior Third.**— There is a tendency to divide the retropatellar pad of fat and synovial membrane too close to the centre of the joint. This means that not only must a considerable depth of tissue be traversed before reaching the synovial layer, but when the joint cavity has been entered and the retractors inserted, the operative field is obscured by the mass of synovial and extra synovial tissue on the medial side where the maximum definition is required in the early stages of the procedure. The synovial membrane should be divided vertically over the middle of the condyle where the synovial layer is thin and the bulk of the tissue retracted towards the centre of the joint. The incision should be carried downwards until the edge of the knife encounters the superior aspect of the meniscus, which is then raised from the tibial head by means of toothed dissecting forceps which grip the synovial membrane adhering to the anterior margin of the periphery. In this way the anterior third may be defined and mobilised by the scalpel blade passed horizontally between the meniscus and the tibia with due care not to damage the articular cartilage.

(b) **Defining the Middle Third.**— Considerable difficulty appears to be encountered by the beginner in finding the line of demarcation between the periphery of the middle third and the capsule. The difficulty is accentuated by the fear, which is justifiable in the inexperienced, of cutting the medial collateral ligament, and the caution exercised causes the dissection to proceed in a direction too close to the centre of the joint. This frequently produces laceration of the strong peripheral zone of the meniscus and weakens the structure so that it may rupture with even moderate traction.

The most simple and certain method of defining the line of cleavage is to remove the medial retractor so that the capsule is no longer under tension and the normal anatomy restored, and then to pass the scalpel blade in the direction of the curve of the medial tuberosity of the tibia immediately inside the capsule. If in doubt at any time as to the relation of the knife to the peripheral zone, the operator should look at the *inferior* surface of the meniscus rather than the superior surface which is obscured by synovial membrane. Once this segment has been mobilised the straight chisel-type knife may be passed directly backwards between the medial collateral ligament and the meniscus, leaving only the posterior third to be mobilised.

(4) FAILURE TO MOBILISE POSTERIOR THIRD

In certain cases, especially where an error of diagnosis has occurred and the meniscus found to be normal, mobilisation of the posterior third is difficult as a result of the firm attachment to the posterior capsule. The curved

knife cannot be expected to reach the extreme limit of the attachment to the posterior capsule. This is of no significance in the large majority of cases and does not prevent dislocation into the intercondylar fossa; the problem only arises when the dislocation proves to be impossible. In these circumstances the central bony attachment of the posterior horn should be divided *first*, when it will be found that the meniscus can be pulled forward and the attachment to the posterior capsule brought within easy range of the curved knife. This simple act of reversing the order of the final steps in the excision of a meniscus will be found to be worthy of the attention of the most experienced surgeon.

(5) RUPTURE OF MENISCUS AT MID-POINT

It should be noted that a meniscus is removed by dissection and not by traction. A certain amount of traction is necessary to keep the tissues about to be cut under tension, but this traction should be applied towards the mid-line of the joint and not directly forward towards the operator. It is obvious that strong antero-posterior traction applied to an arc which is particularly weak structurally on its concave margin will tend to produce a transverse tear.

If the meniscus ruptures transversely as a result of excessive traction, or the forceps slip off the anterior horn, the attached portion is liable to recoil suddenly into the back of the joint because of the tension on the posterior horn. This latter accident is most liable to occur in a meniscus which is still firmly fixed at the periphery of the posterior third when it is dislocated into the intercondylar notch by strong traction in order that the central attachment of the posterior horn may be divided. If the greater part of the meniscus is displaced into this inaccessible position it is sometimes possible to draw it forward again by means of a single hook passed between the condyles into the posterior compartment, but if only the posterior segment is involved, it will be impossible to obtain a hold with a hook. It is therefore much better to make a second incision of the same type as that used for removal of the posterior horn rather than subject the joint to unnecessary trauma. When exposure of the posterior compartment has been obtained it will usually be found that the meniscus is lying behind the tibial head, thus explaining the difficulty of drawing it forward by means of an instrument passed backwards between the condyles.

(6) DIVISION OF MEDIAL COLLATERAL, LATERAL COLLATERAL OR CRUCIATE LIGAMENTS

Division of any of these ligaments can hardly be termed an accident; it is due to extreme carelessness or inexperience. The medial collateral ligament is the most vulnerable structure and has been divided on two occasions in the author's experience of teaching the technique of the operation as a direct result of the insertion of a knife horizontally instead of vertically. On both occasions the injury was detected and the opposing surfaces approximated and sutured without difficulty. The joints were thereafter

immobilised for a period of six weeks and neither joint exhibited any undue laxity four months later. The prognosis of open division of the medial collateral ligament is better than in closed accidental division by abduction because the anterior cruciate ligament and other stabilising structures are not injured.

It is only possible to conceive division of the anterior or posterior cruciate ligament by an operator devoid of knowledge of the gross anatomy of the joint and who failed to locate the position of the attachment of the posterior horn of the meniscus by direct vision.

REMOVAL OF POSTERIOR SEGMENT THROUGH AN ADDITIONAL INCISION

INDICATIONS

- (1) Accidental rupture of the meniscus during operation through the anterior incision.
- (2) Failure to mobilise the posterior third through the anterior incision.
- (3) Removal of a posterior segment not excised at a previous operation.
- (4) Removal of a regenerated meniscus.

TECHNIQUE

(1) and (2) **Medial Meniscus.**—If it is found necessary to make a second incision over the posterior segment during the normal medial meniscus operation, the exact point of incision is found by passing a pair of straight mosquito forceps through the joint on the central side of the medial collateral ligament and cutting down on the forceps towards the posterior aspect of the head of the tibia. The skin incision is vertical and need be little more than 1 inch in length (Fig. 101). The saphenous vein is recognised and retracted and a small incision made in the line of the fibres of the capsule, which at this point run downwards and forwards, on to the point of the forceps. The retraction provided by small single hook or double hook retractors provides adequate exposure of the posterior horn.

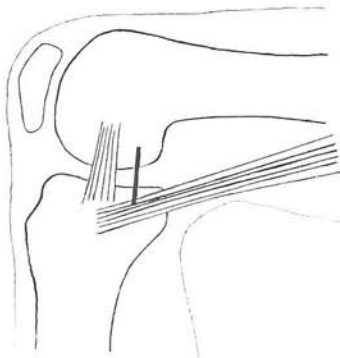


FIG. 101

Exposure of the posterior segment of the medial meniscus through an additional incision. A similar incision is used to remove a loose body from the posterior compartment.

Using one or other of the curved knives the attachment to the posterior capsule may be severed with ease and the remnant of the meniscus mobilised and displaced into the intercondylar notch by traction through the anterior incision. If only the posterior horn remains, its anterior end is pulled out through the posterior incision and the central attachment divided either through the anterior or the posterior incision.

(3) In operating for the removal of a posterior segment which has not been excised at a previous operation it is not sufficient to make a posterior incision only. The anterior segment will have regenerated in the interval between the original operation and the second procedure. This entails the existence of an imperfect junction between the original and the regenerated segment (Figs. 70 and 71). It is thus necessary to make an anterior incision, mobilise the regenerated anterior segment as far as the junction with the original posterior segment, and then make a second incision in order to mobilise the original posterior segment. It is seldom that the junction between the two halves is sufficiently strong to permit dislocation of the complete structure into the intercondylar notch without the danger of rupture.

(4) The same method of attack is necessary in removing a regenerated meniscus which is considered to be torn. A damaged regenerated meniscus is extremely fragile, and even after it has been mobilised as far posteriorly as possible there is always the danger of fracture in attempting dislocation into the intercondylar notch. This complication may be anticipated by mobilising the anterior half of the structure through the normal anterior incision and then mobilising the posterior half through an additional incision. The meniscus may then be displaced into the intercondylar notch with ease and the attachment of the posterior horn divided.

Lateral Meniscus.—The technique used for the removal of the posterior segment of the lateral meniscus differs little from that described above, except that the tendon of popliteus is situated immediately under the capsule and is seen in the upper portion of the incision. It is recognised and guarded from injury before proceeding with mobilisation.

CYSTS OF LATERAL MENISCUS

The treatment of cystic degeneration of the lateral meniscus consists of excision of the entire structure. Physiotherapeutic measures, injection of sclerosing fluid, or local excision of the cyst under the impression that it is a "ganglion of the knee," are followed by recurrence of both the symptoms and the swelling.

The operative technique to be adopted depends on the size of the cyst. If it is small, no modification of the normal technique need be employed, the presence of the cyst is ignored. If it is large, the removal of the meniscus alone may leave a residual swelling, composed principally of fibrous tissue, which, although it may not give rise to symptoms, is undesirable on psychological grounds.

The anterior segment is mobilised as far backwards as the anterior limit of the cystic mass. The skin flap is then retracted and a second incision made in the capsule overlying the swelling; if the swelling is located far back on the joint line, a second skin incision may be necessary. The cystic mass may now be dissected out, taking particular care not to damage the lateral collateral ligament or the tendon of popliteus, and the posterior segment

mobilised. The central attachment is then divided and the meniscus drawn out of the joint through the posterior incision.

AFTER-TREATMENT OF MENISCUS OPERATIONS

IMMEDIATE AFTER-TREATMENT

At the termination of any operation on the knee joint involving the use of a tourniquet a compression bandage must be applied (Fig. 102). This consists of three thick layers of sheet wool, which completely surround the limb, and interposed between each layer is two layers of a wide domette bandage applied with firm even tension,

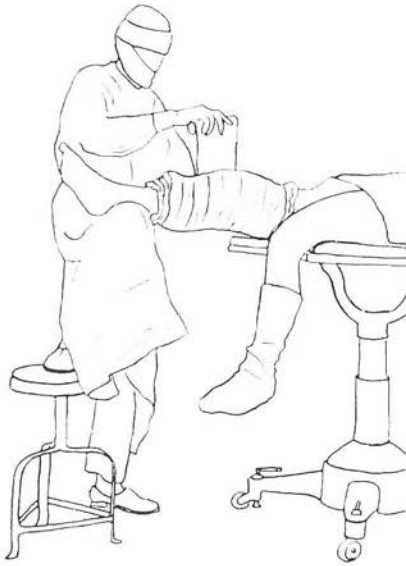

FIG. 102

The surgeon should be responsible for the application of the compression bandage. It is accomplished single-handed in the manner indicated.

leaving a fringe of wool above and below to avoid constriction. No splinting is necessary. The tourniquet is not removed until the compression bandage has been applied. It should be remembered that failure to remove a tourniquet at the termination of a meniscus operation is an accident which is not unknown. It is a possibility which should always be kept in mind; failure to remove the constriction results in loss of the limb. It has been suggested that such a possible tragedy can be obviated if the tourniquet is always tied to the operating table by means of a length of tape.

REHABILITATION

The injuries of the menisci are the most common derangements of the knee joint mechanism which we are called upon to treat. It is therefore proposed that the normal routine of re-education and redevelopment of the quadriceps in relation to such cases be chosen as the example of the practical application of the methods which have been outlined in Chapter I. The routine can be modified and adjusted to suit any knee joint injury, just as it must be modified to suit the individual requirements of each case in which a meniscus has been excised.

On the second or third day following operation the regime of hourly exercise in the form of straight leg raising and rhythmical quadriceps drill is renewed. If progress is satisfactory loaded straight leg raising may be commenced, beginning with a small weight of about two pounds and progressing to four or six pounds, depending on the physique and general muscular development of the patient. It is a mistake to overload the muscle or produce fatigue by prolonged exercise.

It is usually advisable to retain the compression bandage and dressing until the tenth day when the stitches are removed, but knee flexion through a small range may be practised within the confines of the bandage. Full knee flexion returns with such rapidity after the tenth day that there is no reason why any risk of haemarthrosis or contamination of the wound should be run by removing the bandage and dressings before this time in order to practise unnecessary flexion exercises.

At or about the tenth day the stitches are removed and knee flexion exercises added to the progressive loading of straight leg raising and quadriceps drill.

It has been the practice in the past to permit the patient to begin weight-bearing at this time. It seems doubtful if this is in the best interests of the rapid return of normal function, because it is unlikely that the regenerated meniscus is fully developed until at least three weeks have elapsed (page 52) and it is unreasonable to subject the developing structure to the strain of early weight-bearing. The decision to permit weight-bearing should depend on the presence or absence of effusion and the stage of redevelopment of the quadriceps and especially of the vastus medialis. Early weight-bearing on a joint which is unprotected by the extensor apparatus retards rather than accelerates recovery.

In the third week the patient may proceed to the gymnasium wearing a compression bandage. The bandage is removed while he performs non-weight-bearing exercises in the sitting position, such as leg swinging, leg raising, and rhythmical contraction of the quadriceps, together with exercises lying on the mat such as straight leg raising and "cycling."

Within a few days he begins pulley-weight exercises, beginning in the prone position (Fig. 6) and raising a weight of about eight pounds, fifteen times with the unsound limb, fifteen times with the sound limb, and finally a further fifteen times with the unsound limb. It is usually found that the first two days of pulley-weight exercises increase the effusion, but on the third or fourth day the effusion should begin to subside. If the effusion does not subside it is an indication that the work performed is excessive and the weight must be reduced.

Progression is the most important feature of successful rehabilitation; thus the work performed is increased each day by prescribing a greater number of pulls and a gradual increase in the weight pulled. In general, an increase in the number of pulls with a light weight is much to be preferred to a small number of pulls with a heavy weight. The onset or increase of effusion is taken to indicate that the joint is being subjected to excessive strain and necessitates a step backwards in the regime of progression.

The criterion of preparedness for further progression in the form of weight-bearing remedial exercises, physical training and games, is the absence of effusion together with a steady increase in the volume and tone of the quadriceps. The time at which such exercises can be commenced varies considerably in individual cases and depends on many factors, but is usually possible about the fifth or sixth week.

Experience has shown that recovery to a degree of physical fitness

justifying an army category of A.I is rarely possible in less than twelve weeks of organised rehabilitation. This applies in equal degree to those engaged in the manual occupations of heavy industry. Observations on the rate of recovery of coal-miners receiving continuity of treatment in both Hospital and Rehabilitation Centre show that the musculature of the injured joint only reaches a stage of development comparable with the normal in approximately the same period.

COMPLICATIONS OF MENISCUS OPERATIONS

(1) PAIN

Post-operative pain is not a prominent feature of the meniscus operation. It is unusual for patients to suffer more than slight discomfort except when considerable trauma, prolonged compression of retractors and stretching of the capsule have occurred at operation, or the tourniquet has remained in position for an unduly long period. Transient pain localised to the site of operation is to be expected on commencing straight leg raising and quadriceps drill, and results from drag on the incision produced by the contracting muscle. Persistent severe pain is usually due to some local cause and warrants investigation.

Slight reactionary swelling of the limb may follow the ischaemia caused by the tourniquet or from the minor degree of constriction which the use of a firmly applied compression bandage entails. This swelling may be controlled by raising the foot of the bed on blocks. If the swelling does not subside and is accompanied by pain in the knee, it is probable that the bandage is too tight and should be split, over the posterior aspect of the limb, with Böhler scissors and a further domette bandage applied over the split bandage without delay. This would appear to be an extravagant method of loosening a dressing, but it is less dangerous than the unwinding of the bandage and the release of elastic pressure during the two days following operation—a measure which entails a serious risk of haemarthrosis.

(2) HAEMARTHROSIS

This accident occurs :

- (a) As a result of haemorrhage from a large artery divided at operation, but unnoted because of the presence of the tourniquet.

Post-operative haemorrhage resulting from the division of a vessel occurs most frequently after the removal of a lateral meniscus. This is explained by the greater thickness of the peripheral rim of the lateral structure and consequent greater width of attachment to the capsule, and also by the proximity of the inferior lateral geniculate artery, which may be divided in separating the periphery from the capsule (Fig. 103).

- (b) When the dressing has not been applied firmly enough, producing inadequate elastic compression on the joint.
- (c) As a result of too early removal of the bandage and movement of the joint.

In two cases in the series an over-enthusiastic masseuse removed the compression bandage on the second day and began active flexion. The patient on each occasion suffered sudden acute pain in the joint, which immediately filled with blood.

There is no doubt that haemarthrosis which occurs as a complication of operation is a more serious condition than that which results from simple trauma and is more liable to be followed by a protracted convalescence due to adhesions, residual synovial thickening, and persistent effusion. The marked difference in the gravity of the two apparently similar conditions is probably explained by the presence of the large area of raw synovial membrane, from which the meniscus has been dissected, together with the products of recent trauma within the joint cavity. These factors result in rapid coagulation so that the blood is not readily absorbed. Furthermore, the enforced prolongation of the period of rest, which may be the immediate result of the complication, by permitting the organisation of adhesions, contributes further to the delay in the return to normal. (See also Chapter II.)

Diagnosis.—There is wide variation in the reaction of individual patients to the presence of post-operative haemarthrosis. In some cases the condition may pass unnoticed, but in others there is severe pain, swelling, and increase of local temperature. The presence of the local symptoms and signs in association with systemic reaction may make the differential diagnosis from septic arthritis a matter of some difficulty. If any doubt exists as to the cause of the complication investigations must be instituted immediately lest an infective arthritis be missed in the early stages.

Treatment.—When this accident occurs the joint is aspirated and a firm compression bandage applied immediately. If the blood is not evacuated, the convalescence and rehabilitation of the patient is considerably delayed by synovial and capsular thickening and by adhesions which develop in the opposing surfaces of the suprapatellar pouch. When the vessel is considered to be sealed off and the possibility of further haemorrhage passed, recovery may be facilitated by the injection of air into the joint until the synovial cavity is distended. If this treatment produces no undesirable reaction it may be repeated on alternate days with the idea of preventing the formation of adhesions from retarding the return of full flexion.

(3) SEPSIS

This disaster, which is usually the result of faulty aseptic technique, but may be the unfortunate sequel of some untreated focus of infection elsewhere, should be a rare occurrence.

The symptoms are pain and swelling of the joint, accompanied by a swinging temperature and general constitutional upset.

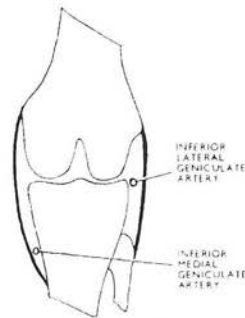


FIG. 103

The location of the inferior geniculate arteries in relation to the menisci.
(After Lee McGregor.)

If sepsis is suspected the joint should be aspirated immediately and an attempt made to classify the organism concerned. Following the initial aspiration a soluble solution of a suitable drug of the Sulpha group is injected into the joint and the patient placed on a full course by mouth. No opportunity to test the efficacy of Penicillin in such a case has arisen, but it is probable that this substance, used both locally and systemically in a similar manner, would prove even more effective.

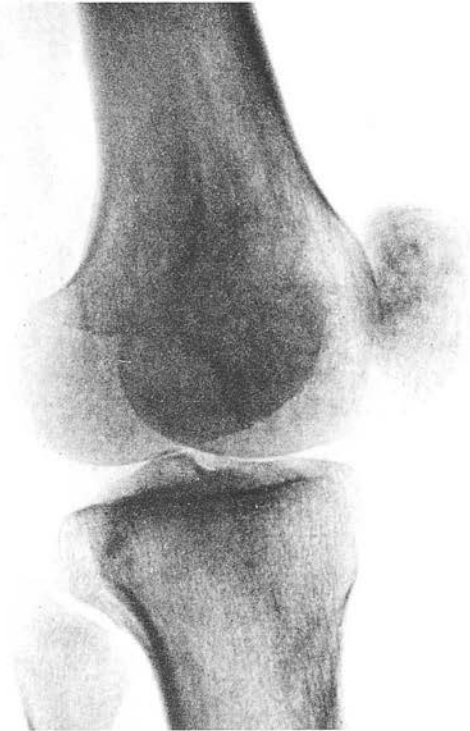

FIG. 104

The patchy decalcification of the patella noted in persistent effusion following meniscectomy.

Skin traction is applied to the limb below the knee with an extension of two to three pounds. The aspiration and injection of the chemo-therapeutic agent is carried out once or twice daily as long as necessary.

This method of treatment should be tried as the first line of attack in every case. No effort should be spared which might avoid the necessity for open drainage.

In this series one case showed obvious signs of sepsis on the second day following operation. He had a large scar over the patella and gave a history of a wound opening into the joint as a result of an accident sustained some four years previously in India. He was treated in the manner described, but the organisms were not isolated as sulphonamide had been administered prior to aspiration of the joint. It was considered at one period that drainage

of the joint would almost certainly be necessary, but perseverance with the method eventually overcame the infection, and after a somewhat prolonged period of convalescence and rehabilitation full function of the joint was restored.

Under this heading is recorded a number of post-operative cases which were referred from a Rehabilitation Centre at about the twelfth week because of failure to make the progress expected. All of these cases gave a history of a wound which had not healed for three or four weeks and of a stormy convalescence. Examination revealed marked synovial thickening and effusion and a scar which could not have resulted from healing by first intention. A radiograph showed relative decalcification of the knee joint, most marked in the subchondral regions and in the patella. Three of the cases examined had been subjected to operation at a source where conditions were known to be unsatisfactory. It is difficult to differentiate the cause of this complication from those described under (4) (*a*) below, but it was considered that the most probable explanation was contamination of the joint at operation in a degree unrecognisable as true sepsis.

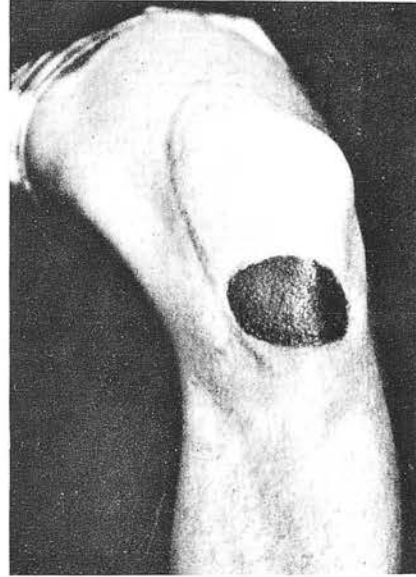

Fig. 105

Area of anaesthesia following division of the infrapatellar branch of the saphenous nerve. This incision was used to excise the medial meniscus!

(4) PERSISTENT EFFUSION

(*a*) **Trauma at Operation.**—There is no doubt that cases in which the operation is performed only with difficulty and in which the medial collateral ligament and capsule are subjected to prolonged stretching by forcible retraction and the synovial membrane exposed to prolonged pressure by retractors and artery forceps, frequently suffer from persistent synovitis in spite of conscientious post-operative exercise. A radiograph taken in the hope of discovering some cause for the intractability of the effusion demonstrates patchy decalcification of the patella (Fig. 104). If quadriceps exercises are continued and weight-bearing activity restricted, the synovitis gradually subsides, but will be found to persist in some degree until the radiographic appearance of the patella has returned to normal.

Evidence of the truth of these statements may be obtained from cases in which an inexperienced assistant is taught the technique of excision of a

meniscus. The operative time is of necessity greatly increased and as a result the soft tissues are subjected to prolonged and forceful retraction. Such cases show a more marked and sustained reaction than is usually encountered.

Persistent synovitis is common following wide exposure of the joint through a long incision. A single incision which permits both menisci to be examined is unjustifiable (Fig. 105). The experienced surgeon can remove the entire meniscus through a single two-inch incision with the minimum of trauma to the soft tissues.

In closing the synovial layer the sutures should be buried so that no portion of the stitch projects into the joint on the inner aspect of the synovial membrane to produce irritation and protracted effusion.

The heading "Trauma at Operation" recalls to memory three post-operative cases from the same source which were referred because of persistent effusion and chronic synovial thickening. No obvious cause could be discovered on clinical examination, but it transpired later that the surgeon who had performed the operations made a practice of washing out knee joints with a "weak" solution of carbolic as a safeguard against possible sepsis and the formation of loose bodies. History relates that the solution used had a strength of 1 in 20!

- (b) **Recent Injuries.**—More effusion is sometimes noted in joints subjected to operation within a short time of the original lesion than in old cases which have locked on many occasions. In recent injuries the joint is "tight" and the difficulties of the operation add to the damage sustained by the soft tissues. In old standing lesions the joint has become "accustomed" to trauma and the operative procedure is simplified by the relaxation of the capsule and the laxity of the ligaments.
- (c) **Over-exercise.**—The importance of quadriceps drill has been stressed, but it is recognised that it is possible to make undue exercise demand on a recovering joint which results in increase rather than diminution of effusion. (See Chapter I.)
- (d) **Quadriceps Insufficiency.**—It is noticeable that cases in whom there is gross quadriceps wasting and who have made little active effort to increase the volume and tone of the muscles often have recurrent effusion with excessive weight-bearing activity. These effusions are the result of quadriceps insufficiency and incomplete control of the joint on walking, with resultant trauma and effusion. Ambulatory activity must be restricted until quadriceps development reaches a degree sufficient to protect the joint from the normal strains of weight-bearing.
- (e) **Abnormal gait.**—It is a mistake to permit a patient to walk with a stiff knee, with the limb externally rotated, or to adopt a "flexed knee gait," following operation. Walking on the toes with the knee fixed in slight flexion produces abnormal strains on the joint and results in irritation and effusion.

- (f) **Traumatic osteoarthritis.**—Patients who have a history of an internal derangement of many years' duration with established traumatic arthritic changes present in the joint frequently suffer from persistent effusion. The synovitis should be regarded as a symptom of chronic quadriceps wasting rather than of arthritis, and, provided the degenerative change is not far advanced, gradual improvement is to be expected with curtailment of weight-bearing until the quadriceps is redeveloped.
- (g) **Malingering.**—Effusion of unexplained origin has been produced by methods such as "patella tapping."
- (h) **Errors of Diagnosis.**

(5) **NEUROMA OF INFRAPATELLAR BRANCH OF SAPHENOUS NERVE : ANAESTHESIA IN DISTRIBUTION OF NERVE**

The saphenous nerve pierces the deep fascia on the medial side of the knee between the tendons of sartorius and gracilis. Before penetrating the deep fascia it gives off the infrapatellar branch which passes forward, about a finger's breadth below the head of the tibia, to form the patellar plexus in association with branches of the lateral, medial, and intermediate cutaneous nerves.

In spite of the very large number of menisci removed and in spite of the continued use of incisions which must of necessity divide the nerve, a neuroma of the infrapatellar branch of the saphenous nerve is a rare sequel of operation.

Naughton Dunn¹ described twelve cases in 1934 and advised a straight oblique incision inclining downwards, forwards, and laterally, to avoid possible division of the nerve ; Timbrell Fisher² advises a similar but curved incision with the same complication in view. Examination of a large selection of post-operative cases from different sources suggests that neither of these incisions are in common use, nor can the formation of a painful neuroma be a common sequel to division of the nerve.

The incisions used in the surgery of other areas frequently divide superficial sensory nerves. Neuromata are encountered, but seldom give rise to severe symptoms. All medial knee joint incisions divide branches of the infrapatellar nerve and many divide the main nerve (Fig. 105). The neuroma which may possibly result causes symptoms in this particular region because the scar to which it is attached is situated in an area of skin which moves with every step and is subject to constant friction from the overlying clothing.

If the diagnosis of a neuroma is established, the scar should be excised, the neuroma isolated and the nerve traced in a proximal direction and divided with a sharp scalpel (Fig. 106). This measure at least ensures that a further neuroma is not adherent to the cutaneous incision.

¹ Naughton Dunn. "Observations on some Injuries of the Knee Joint," *Lancet*, 1934, i, 4268.

² A. G. Timbrell Fisher. "Internal Derangements of the Knee-Joint," H. K. Lewis & Co., Ltd., London, 1933.

A small zone of temporary anaesthesia frequently arises following a medial incision (Fig. 105). The size of the area depends on whether a branch or branches or the main nerve has been divided. The infrapatellar nerve varies greatly in size, and when the nerve is large a correspondingly greater area may be affected. The presence of the patellar plexus implies that sensory overlap is well developed in this region, and it is thus unusual for an area of diminished cutaneous sensation to remain permanently.



FIG. 106
Neuroma of the infrapatellar branch of the saphenous nerve.

While it is not unreasonable to state that a zone of anaesthesia or even a neuroma is not of serious consequence in the average case, demanding little more than explanation and reassurance, either complication may constitute a severe disability in a coal miner whose occupation entails constant kneeling.

PROGNOSIS

The many factors which influence the rapidity of recovery and prognosis of meniscus injuries have been mentioned on so many occasions in this chapter that it seems hardly necessary to refer to the subject again in detail under the specific heading of Prognosis, especially in the absence of a complete follow-up of the 1050 cases which were subjected to operation. It is necessary, however, to attempt to explain some recent statistics which appear to be at wide variance with those which have been generally accepted in the past.

Examples of end results recorded as "good" or "excellent" before the Second World War:

Philip H. Mitchener ¹	74 cases between 1912-1921, 76.7 per cent.
R. J. McNeill Love ²	50 cases, 70 per cent.
Melvin S. Henderson ³	238 cases, 77 per cent.
W. Russell MacAusland ⁴	287 cases, 80 per cent.
A. G. Timbrell Fisher ⁵	61 cases, 96 per cent.
Lorenz Bohler ⁶	1st series, 111 cases, 84 per cent. 2nd series, 51 cases, 92 per cent. 3rd series, 59 cases, 75 per cent.

Examples of end results in Service cases recorded since the beginning of the Second World War:

S. A. S. Malkin ⁷	47 cases, 77 per cent. graded A.I.
------------------------------	-----------	------------------------------------

¹ Philip H. Mitchener, *Brit. Jour. Surg.*, 1922, 23, 8, 221.

² R. J. McNeill Love, *Brit. Med. Jour.*, 1923, ii, 324.

³ Melvin S. Henderson, *Surgery Gynaecology and Obstetrics*, 1930, lxi, 720.

⁴ W. Russell MacAusland, *Annals of Surgery*, 1931, xciii, 649.

⁵ A. G. Timbrell Fisher, "Internal Derangements of the Knee-Joint," H. K. Lewis & Co., Ltd., London, 1933.

⁶ Lorenz Bohler, *Wiener klinische Wochenschrift*, 1938, l, 1166.

⁷ S. Alan S. Malkin, *Brit. Med. Jour.*, 1943, i, 6.

- R. H. Metcalfe¹ 100 cases—
 (A) 71·5 per cent., (B) 20·5 per cent.,
 (C) 7 per cent., (E) 1 per cent.
- W. R. Bristow² 1058 cases operated on in Army and E.M.S.
 hospitals in 1943—
 (A) 51 per cent., (B) 35 per cent.,
 (C) 9 per cent., (E) 5 per cent.
- T. P. McMurray quoted by
 H. A. T. Fairbank³ 206 cases in a convalescent depot receiving
 from a number of hospitals; 56 per cent.
 "good or fairly good," 21·8 per cent.
 "definitely bad."
- J. J. R. Duthie and J. G.
 Macleod⁴ 119 cases discharged from convalescent
 depot A.1; 73 per cent. A.1 six to twelve
 months later.

It is evident from the figures which have been quoted that there is an apparent disparity between war and pre-war results of operation. What is the explanation? Most observers have noted that cases which required down-grading demonstrated laxity of the accessory supporting structures of the joint, as shown by abnormal antero-posterior mobility, or even complete rupture of the anterior cruciate ligament⁵ which had passed unnoticed. The cause of the relaxation of the capsule and ligaments has already been explained; it is due to failure to appreciate the importance of accurate diagnosis and early operation.

This observation is not original. In 186 cases investigated by Duthie and MacLeod,⁶ 60 per cent. attributed the initial injury to football and 50 per cent. admitted a previous period of hospitalisation before meniscectomy was performed. The average duration of symptoms before operation was two years and nine months: their article was concluded with a plea for the earlier recognition of meniscus injuries.

The arduous conditions of modern military training in association with an efficient Medical Service make it evident that diagnosis and treatment is likely to take place at an earlier stage than occurs in normal circumstances. It is thus clear that a post-operative result which may stand up to all the demands of normal civilian life—with the possible exception of serious football—may not withstand the hazards of military training.

¹ R. H. Metcalfe, *Lancet*, 1944, i, 725.

² W. R. Bristow, *Lancet*, 1944, i, 725.

³ H. A. T. Fairbank, *Lancet*, 1944, ii, 131.

⁴ J. J. R. Duthie and J. G. Macleod, *Lancet*, 1944, i, 183.

⁵ T. T. Stamm, *Brit. Med. Jour.*, 1943, i, 483.

⁶ J. J. R. Duthie and J. G. Macleod, *Lancet*, 1943, i, 197.

CHAPTER SEVEN

INJURIES OF LIGAMENTS

THE importance of muscle tone and control in maintaining the integrity of the knee joint has been stressed. Second only in importance to muscular control in protecting the joint from injury are the capsular, anterior cruciate, posterior cruciate, and the medial and lateral collateral ligaments. The infrequency with which the ligaments are injured in comparison, for example, with the menisci is indicative of their inherent structural strength. Complete solution of continuity is only encountered as a result of extreme violence, although minor injuries may occur when strain is thrown upon a ligament when the muscles are caught momentarily "off guard."

ANTERIOR CRUCIATE LIGAMENT

The anterior cruciate ligament is attached to the anterior aspect of the tibial spine and passes upwards, backwards and laterally to the posterior part of the medial surface of the lateral condyle of the femur. It is variously stated in anatomical text-books to be tense in extension or in full flexion, but it seems evident from the fact that the long axis of the anterior cruciate ligament passes through the axis of rotation of the joint that the ligament is tense throughout the range and limits of flexion and extension of the joint. Viewed through the meniscus incision, with the joint in right-angled flexion, it is noted that if an attempt is made to pull the tibia forward on the femur it immediately becomes taut.

The functions of the capsule, medial collateral, lateral collateral and anterior and posterior cruciate ligaments are so closely interrelated in maintaining the integrity and stability of the joint that it is difficult to associate a specific function or functions to any particular ligament.

The observations of Brantigan and Voshell,¹ to which reference has been made previously, suggest that the following functions may be attributed to the anterior cruciate ligament :

- (1) The control of forward gliding of the tibia on the femur. This function is accepted by all authorities and forms the basis of the well-known test for continuity of the ligament. Even in this apparently clear-cut function the interrelationship of the ligamentous components of the knee joint is seen, for it is noted that in rupture of the anterior cruciate ligament forward gliding is most obvious in flexion, when there is some degree of relaxation of the collateral ligaments. In full extension forward gliding should theoretically be possible, but is prevented by the tense medial and lateral collateral ligaments.

¹ Otto C. Brantigan and Allen F. Voshell. "The Mechanics of the Ligaments and Menisci of the Knee Joint." *J. Bone and Joint Surg.*, 1941, xxiii, 44.

- (2) The control of lateral mobility in extension, in association with the capsule, both collateral ligaments, and the posterior cruciate ligament.
- (3) The control of lateral mobility in flexion, in association with the capsule, medial collateral ligament and posterior cruciate ligament. (The lateral collateral ligament is relaxed.)
- (4) The control of rotation in extension, in association with the same structures as in (2).
- (5) The control of rotation in flexion, in association with the same structures as in (3).
- (6) The control of hyperflexion, in association with the posterior cruciate ligament aided by the architecture of the femoral and tibial condyles and the cushioning effect of the menisci, the femoral attachment of the posterior aspect of the capsule and the femoral attachment of both heads of the gastrocnemius.
- (7) The control of hyperextension, in association with the posterior cruciate ligament, both collateral ligaments, the posterior capsule and oblique popliteal ligament and aided by the architecture of the femoral condyles and the cushioning effect of the menisci.

The anterior cruciate ligament may therefore be stretched or ruptured :

- (1) By hyperextension.
- (2) By a force driving the femur backwards when the knee is in flexion with the tibia fixed.
- (3) By violent rotation.
- (4) By abduction, in which case the lesion must be accompanied by rupture of medial collateral ligament and sometimes, in addition, by a depressed fracture of the lateral condyle of the tibia. A similar but less common mechanism is by adduction, in which case the converse associated injuries may be expected.
- (5) By dislocation of the knee.

The enumeration of the functions of the ligament and the complicated interrelationship of joint components together with the mechanisms of injury makes it clearly evident that rupture of the anterior cruciate ligament as a completely isolated lesion must be rare. In practice, all the mechanisms, but especially the common mechanisms such as (3) and (4), may in addition produce lesions of the menisci. The frequent association with a medial collateral ligament injury is widely recognised.

CLASSIFICATION

The injuries of the cruciate ligaments are classified¹:

1. **Total rupture with preserved internal ligamentous structure.**

This is the classical lesion at the inferior insertion, and in the case of the

¹ Palmer's modification of Jirasek's classification.

anterior ligament, takes the form of a fracture of the tibial spine (Fig. 107). See FRACTURES OF THE TIBIAL SPINE.

2. **Total rupture with ligamentous destruction.** This is the characteristic lesion at or near the superior insertion (Fig. 108).

3. **Partial rupture with more or less extensive ligamentous damage.**—In a mechanism in which abduction is the most important element, rupture of the ligament takes place from before backwards and laterally. In these circumstances a remnant may remain which passes from the posterior part of the tibial insertion to the postero-lateral part of the femoral insertion (Fig. 109). In other cases shifting of the antero-medial and postero-lateral fibres in relation to one another may take place (Fig. 110), and, as it is possible for this to happen within the synovial sheath, to external appearances there may be no apparent solution of continuity. These two examples serve to illustrate the early pathology of cases in which the ligament in the healed stage is said to be "overstretched" or "attenuated."

DIAGNOSIS OF RECENT INJURY

Lesions of the anterior cruciate ligament have been considered in the past to occur with relative infrequency. The arduous conditions of modern military training have shown this view to be erroneous. The injury ranks second only in importance to tears of the menisci as a cause of serious disability in the knee joint.

Although the symptoms and signs of an old rupture of the ligament are unmistakable and the diagnosis a matter of simplicity, it is obvious from the number of cases of old standing which are encountered and which give no history of rational treatment, that the diagnosis is seldom established at the time of the original injury. This is not surprising in view of the fact that the violence of the force necessary to produce solution of continuity in a ligament also produces widespread damage to other components of the joint and the resulting reaction tends to mask the underlying and potentially disabling rupture of the anterior cruciate ligament.

Many writers have expressed astonishment at the surprisingly good results obtained from complete dislocation of the knee. This gross but uncommon injury must involve some or all of the ligamentous components of the joint in complete rupture, or at least severe stretching. In apparent contradiction is the accepted fact that rupture of the anterior cruciate ligament and or the medial collateral ligament is a serious injury likely to result in permanent disability. What is the explanation? A dislocation of the knee joint is always recognised, reduced with apprehension, and accorded the respect which the severity of the injury undoubtedly merits. The joint is subjected to prolonged immobilisation in a close fitting plaster case and due attention paid to the development of the quadriceps. In contradistinction, acute injuries of the anterior cruciate ligament are frequently missed, complacently diagnosed as traumatic synovitis and grudgingly conceded three weeks of complete bed-rest to complete the havoc by per-

DIAGRAMMATIC REPRESENTATION OF TYPES OF INJURY OF ANTERIOR CRUCIATE LIGAMENT.

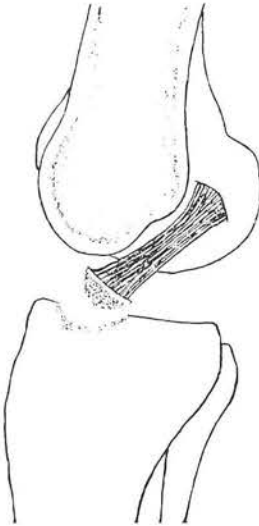


FIG. 107

Rupture of the inferior attachment with avulsion of a fragment of bone. (Fracture of the tibial spine).

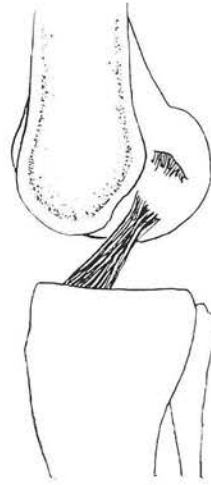


FIG. 108

Complete rupture of the ligament proper near the superior attachment.

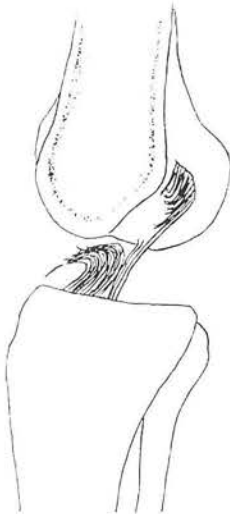


FIG. 109

Rupture at the superior attachment with retained continuity postero-laterally.

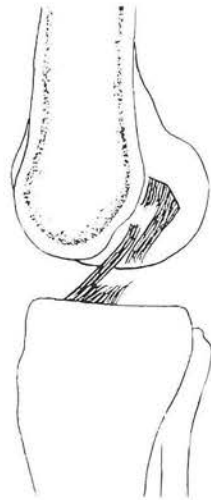


FIG. 110

Partial rupture of both superior and inferior attachments with relative shifting of the fibres concerned in relation to one another.

mitting the quadriceps to waste. It is little wonder that so many old injuries are encountered and that such severe disability results.

The possibility of rupture of the anterior cruciate ligament should be considered from :

(1) **History of Injury.**—The various types of mechanism have been enumerated and the violence of the trauma stressed, but it is noted that although apparently minor accidents which may tear a meniscus are unlikely to rupture the anterior cruciate ligament, a very large percentage of all old cases seen received the injury to which they attribute their symptoms on the football field. Although the possibility of a cruciate ligament injury may be considered following a severe knee injury sustained in a motor cycle accident, there is undoubtedly a tendency to disregard the possibility in the everyday football accident.

(2) **Presence of Haemarthrosis.** Traumatic haemarthrosis occurs :

- (a) In rupture of vessels in the synovial membrane.
- (b) When a meniscus is torn from its vascular peripheral attachment.
- (c) In rupture of the cruciate ligaments.
- (d) In fracture of the tibial spine or tibial table.

All cases of traumatic haemarthrosis should therefore be specifically examined with the possibility of a torn anterior cruciate ligament in view.

(3) **Examination.**—The accurate diagnosis of the acute knee is at all times difficult except perhaps in the presence of a locked meniscus. It is especially difficult in the presence of a rupture of the anterior cruciate ligament because of the associated injury to other structures. The frequent combination with a torn medial meniscus or a sprained or ruptured medial collateral ligament causes the more important lesion to be missed, the examiner being satisfied with the more obvious but often less important half of an incomplete diagnosis. It is considered that the combination of a locked medial meniscus and a ruptured anterior cruciate ligament must be unusual. The abnormal mobility made possible by the ruptured ligament makes spontaneous reduction, or reduction by the patient or his fellow players, more likely than would be the case in an isolated meniscus injury.

The clinical picture in which a torn anterior cruciate ligament should be suspected is a traumatic haemarthrosis in a slightly flexed knee, usually not locked, but with a possible history of momentary locking at the time of the injury. Pain is marked, a traumatic haemarthrosis being characteristically more painful than a traumatic synovitis. The whole joint is tender to touch, the medial and lateral joint lines being especially sensitive. In the recent case the sensitivity of the joint and the presence of the haemarthrosis will rarely permit the joint to be flexed in order that the test for forward gliding of the tibia may be performed (Fig. 111) or the state of the medial collateral ligament established. In the acute phase these tests can only be carried out after aspiration of the joint and the injection of local anaesthetic or the administration of a general anaesthetic.

Aspiration is useful as a therapeutic as well as a diagnostic measure, as it reduces pain, produces indisputable proof of the presence or absence of blood, and reduces the possibility of systemic reaction. The presence of fat globules in the aspirated fluid may be due to injury of the synovial membrane but usually confirms the diagnosis of rupture of the ligament in the form of avulsion of the tibial spine, or suggests a fracture of the tibial table.

A firm compression bandage should be applied immediately the aspiration and forward gliding test have been performed.

The radiograph is negative, except when the injury takes the form of a fracture of the tibial spine.

TREATMENT OF RECENT INJURY

The difficulties of diagnosis in the acute knee joint injury have already been admitted. In practice, accuracy is less easy to accomplish in the recent case

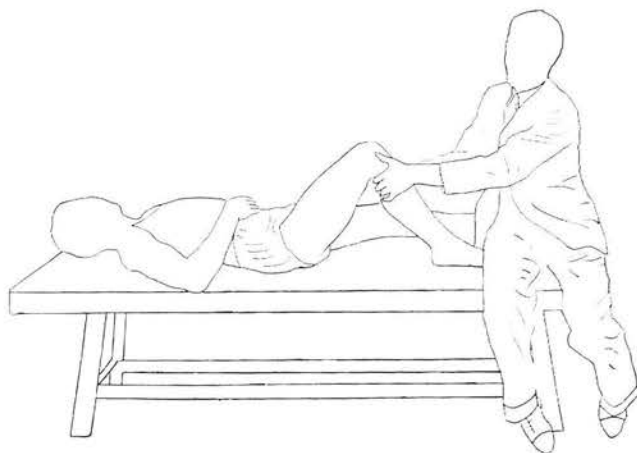


FIG. 111

Method of testing the anterior cruciate ligament: The "drawer sign"—"drawer forwards."

in which a lesion of a meniscus is suspected, than in an injury involving the ligaments. Failure to reach a conclusion is of relative unimportance in the recent meniscus injury (page 68); it is of the first importance in the ligamentous injury.

The diagnosis of an old standing rupture of a ligament is a simple matter: no treatment known can restore perfection of function.

The diagnosis of a recent rupture cannot be made at a glance. It may necessitate the administration of an anaesthetic and certainly demands painstaking patience, but it is seldom that a conclusion cannot be reached. The trouble is worth while; it is only in a recent case that treatment offers hope of recovery of function which will bear comparison with the normal joint.

It is a curious reflexion on modern diagnostic abilities that whereas we are prepared to immobilise or even subject to operation a rupture of the

anterior cruciate ligament at the inferior attachment which takes the form of a fracture of the tibial spine—a lesion we can see in a radiograph—we frequently fail to diagnose, or to treat rationally when we do make the diagnosis, the same injury at the superior attachment—a lesion we cannot see in a radiograph. This paradox reveals the depths of our degradation; we can only hope for rapid advances in the field of contrast arthrography!

It is unfortunate that recent injuries of ligaments, like recent injuries of the menisci, are seldom seen in an orthopaedic hospital in the acute state. The present ignorance of knee joint pathology is such that cases are only referred to hospital months or years later when the possibility of restoration of the normal anatomy has long since passed. In these circumstances, there are but few surgeons with sufficient experience of recent injuries who can speak with authority on the long term results of treatment, either conservative or operative.

It has been the custom in this country, and to a lesser extent on the Continent, to adopt a conservative attitude towards all lesions of the ligaments of the knee joint. It seems evident from a study of the ruptures of the anterior cruciate ligament represented by Figs. 107 to 110 and from those of the medial collateral ligament represented by Figs. 147 to 152 that **all** lesions cannot heal by immobilisation alone. The concentrated clinical experience of five years of war surely confirms this suggestion.

Recently, Ivar Palmer,¹ whose experience of the treatment of injuries of the ligaments of the knee is rivalled by few, has advised operation in all cases in which the clinical picture is clearly one of total rupture. The author cannot yet claim sufficient experience of operative action in recent complete injuries to confirm this recommendation without reserve, but has certainly placed on record more regrets for having adopted a conservative attitude in a known total rupture than in the few cases which have been subjected to operation. It is possible, however, to forecast that with increasing knowledge of the pathology of ligamentous injuries, and of operative technique on the knee joint through non-destructive incisions, the prospects of better results in the future lie in the restoration of normal anatomy by operation in the many cases in which this is undoubtedly possible, than in treatment by immobilisation alone.

Before treatment of a recent rupture of the anterior cruciate ligament is instituted it is necessary to establish whether:

1. *It is an isolated lesion, or,*
2. *Whether it is a combined injury,*
 - (a) with a rupture of the medial collateral ligament and/or
 - (b) a tear of the medial meniscus.

The policy adopted towards these lesions by the author is as follows:

1. If the rupture is an isolated injury the treatment is conservative and consists of immobilisation alone.

¹ Ivar Palmer, "On the Injuries to the Ligaments of the Knee Joint," *Acta Chir. Scandinavica*, 1938, lxxxii, Supplementum liii, Stockholm.

2. If the rupture is associated with complete solution of continuity of the medial collateral ligament the treatment is operative; the exact procedure varies but at least entails repair of the collateral ligament.
3. If the rupture is associated with a tear of the medial meniscus the treatment is operative and consists of excision of the meniscus, retaining the anterior attachment, and repair of the ligament using the meniscus, if necessary, to reinforce the repair.

TECHNIQUE OF TREATMENT

CONSERVATIVE

The joint is aspirated and a compression bandage, with the addition of a padded posterior splint of Cramer wire or an aluminium gutter splint, applied. Quadriceps drill, which forms an essential part of the treatment later, is not advised in the presence of haemarthrosis or until plaster immobilisation has been secured. In about ten days' time, when the swelling of the joint has subsided, a skin tight walking plaster cast of the type used by Bohler,¹ and which permits of ankle and foot movement, is applied (Fig. 112).

It has been the custom in the past to immobilise injuries of the cruciate and collateral ligaments in varying degrees of flexion. If it is accepted that the cruciate ligaments are taut throughout the range of movement of the joint, and that some fibres of the medial collateral ligament are taut even in flexion, this practice would appear to be irrational. It is also undesirable because:

- (a) The patient cannot and should not walk on a flexed knee.
- (b) The return of full extension after a long period of immobilisation in flexion is both prolonged and difficult to attain.
- (c) It does not permit vastus medialis exercises, the most important part of the treatment, to be performed.

The knee joint should therefore be immobilised in extension but **not** in hyperextension.

The type of skin-tight walking plaster cast which permits ankle and foot movement is of the utmost service in many injuries of the knee joint and will therefore be described in detail.

A flexible supporting bandage is applied from the roots of the toes to the tibial tubercle. The most suitable material is zinc gelatine (Unna's paste) which is inexpensive, durable and least liable to the complication of skin irritation provided the ingredients (zinc oxide 3 ozs., gelatine 3 ozs., glycerine 7 ozs., distilled water 7 fluid ozs.) are of high quality. A double layer of an elastic adhesive bandage or a proprietary zinc gelatine bandage may be used as a less satisfactory alternative.

¹ L. 2012 Bohler, "The Treatment of Fractures," John Wright and Sons Ltd., Bristol, 1936, 360.

Application of zinc gelatine paste. The zinc gelatine is melted in a water bath and painted on the limb from the toes to the knee. A short strip of 3-inch open mesh bandage is applied to the tendo-achillis, heel and sole

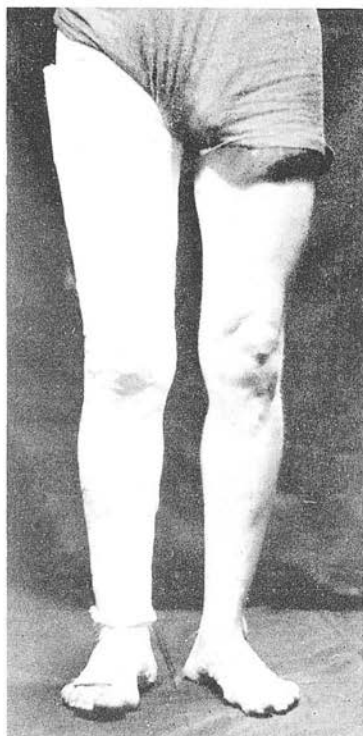


FIG. 112

Plaster cast which immobilises the knee joint but permits weight-bearing through a mobile foot and ankle. The Unna's paste extends from the roots of the toes to the knee; a strip of felt surrounds the leg above the ankle where the plaster overlaps the Unna's paste.

of the foot, from above downwards and in the long axis of the limb and thereafter turns of the same type of bandage are applied to the foot and ankle. A broader bandage of open mesh, 4-6 inches wide, is used for the leg and applied evenly avoiding folds and reverse turns. It is essential that throughout the whole procedure the foot be maintained in maximum dorsiflexion and in the mid position of inversion and eversion, for if the bandage is applied in plantar flexion, walking produces creases over the dorsum and lateral side of the foot which cut into the skin. When three alternating layers of paste and bandage have been applied a final coat of paste completes the support which may then be rendered non-adhesive by gently dabbing the drying surface with a handful of cotton wool.

Application of plaster cast. The unpadded plaster case extends from the ischial tuberosity and base of the greater trochanter to a point two inches above the base of the medial malleolus. The skin overlying the ischial tuberosity and the greater trochanter is protected by a long strip of felt 4 inches wide passed around the thigh so that it lies under the ischial tuberosity, follows the line of the gluteal fold, the two ends meeting over the greater

trochanter. Alternatively, a long narrow roll of wool covered by 2 inch stockinette makes a most satisfactory protective padding. The crest of the tibia at the lower extremity of the plaster is protected by a strip of felt 3 inches wide passed round the leg above the base of the medial malleolus and secured with strapping.

The application of the plaster is delayed until the zinc gelatine is dry. The plaster case, which consists of full length anterior and posterior slabs supplemented by circular bandages, is carefully moulded to the contours of the knee joint and to the padding at the proximal and distal extremities (Fig. 112).

After-treatment. Quadriceps drill is carried out hourly throughout the day, beginning with straight leg raising and progressively loading the

muscle with 2, 4, 6, and 8 or more pounds as tone and volume increase. In the later stages pulley-weight exercises may be used, and, with the knee joint held rigid in a skin-tight plaster, they differ in no essential from the basic exercises, except that performed in the prone and supine positions they help to break the monotony of loaded straight leg raising. Weight-bearing may be resumed after a few days of quadriceps drill.

When the plaster is removed at the end of twelve weeks, active knee flexion exercises are commenced and progressive increase of quadriceps exercise continued for three to six months. There is no injury of the knee joint in which the development of the quadriceps is of more importance, for it is upon the volume and tone of the extensor apparatus that the joint must depend for complete stability in the event of some permanent residual laxity of the ligaments.

OPERATIVE

When the injury is associated with complete solution of continuity of the medial collateral ligament this structure alone may be repaired. (See OPERATIVE TREATMENT OF RECENT INJURIES OF MEDIAL COLLATERAL LIGAMENT.) When the medial meniscus is torn or in other circumstances in which it is decided to attempt restoration of the normal anatomy, the method of attack varies to suit the pathology encountered and the technical difficulties to be overcome. In all cases operation is deferred for a few days to permit the swelling to subside; it should not be unduly delayed lest absorption and shortening of the distal section render approximation impossible.

The technique varies little from that described in detail under OPERATION OF RECONSTRUCTION OF THE ANTERIOR CRUCIATE LIGAMENT USING THE PERIPHERAL HALF OF THE MEDIAL MENISCUS. The medial meniscus is mobilised by the method already described, but leaving the anterior attachment intact. Several procedures are then available depending on the assessment of the state of the ligament made possible by the access which results from mobilisation of the meniscus.

- (a) The torn ligament can be reattached to its superior insertion. This is only possible when the original rupture has taken place at, or very close to, the femur and in the absence of gross fragmentation or loss of tissue. Two strong silk sutures are attached to the proximal end of the distal section of the divided ligament using a small fistula needle and adopting the same method of suture as that described in the replacement of the ligament by the medial meniscus. Two parallel holes are bored from without inwards through the femur, using the drill aligner (Fig. 124), so that the points of exit emerge accurately in the lateral wall of the intercondylar notch at the normal attachment of the ligament. The sutures are threaded through the holes and tied tightly over the intervening bone (Fig. 113).
- (b) If the torn ligament cannot be reattached to its superior insertion, is grossly fragmented or divided in its body at a position which

makes suture impossible, the operation proceeds in exactly the same manner as in replacement using the peripheral half of the meniscus, with the additional feature that the new ligament is reinforced by suturing the distal stump of the original structure to it with fine silk sutures.

After-treatment.—The post operative and ambulant treatment is the same as that described under RECONSTRUCTION OF THE ANTERIOR CRUCIATE LIGAMENT.

FRACTURE OF TIBIAL SPINE

Although a fracture of the tibial spine may take place at any age, it is predominantly the injury of youth which corresponds to rupture of the anterior cruciate ligament in the adult. It may therefore occur as an isolated lesion by any of the mechanisms which produce rupture of the anterior cruciate ligament, the most common of which, in the adolescent patient, is considered to be a direct injury to the anterior aspect of the flexed knee which drives the femur backwards on the fixed tibia. It is for this reason, and also possibly because the injury occurs most frequently in youthful patients whose ligaments are relatively resilient, that it differs from rupture of the cruciate ligament in adults by seldom being accompanied by any gross lesion of the medial collateral ligament.

Like rupture of the anterior cruciate ligament it is an injury which is frequently missed, having been diagnosed as "synovitis" following a football accident. Adult patients are repeatedly encountered with symptoms of an internal derangement relative to a recently torn meniscus who demonstrate the abnormal antero-posterior mobility associated with a ruptured or stretched anterior cruciate ligament, but who, on radiographic examination, demonstrate an old unreduced fracture of the tibial spine sustained in early youth.

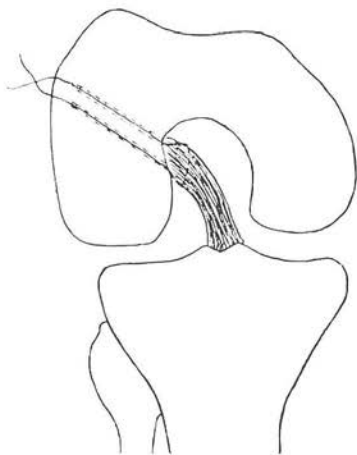


FIG. 113

Diagrammatic representation of the method of re-attaching the superior insertion of the anterior cruciate ligament to bone by means of sutures passed through a double canal in the lateral condyle of the femur. (After Palmer.)

CLINICAL FEATURES

The injury is seldom seen for several hours or days after the accident when it is noted that the joint is swollen as a result of an effusion. The knee is held in slight flexion and an attempt to produce passive extension may encounter a bony block. Palpation of the contents of the suprapatellar pouch and the increase of local temperature suggest the possibility of haemarthrosis and if the contents of the synovial cavity are aspirated before radiographs have been

obtained, the presence of fat globules in the haemorrhagic effusion will have confirmed the possibility of an intra-articular fracture. The generalised pain and tenderness which frequently accompany haemarthrosis will usually preclude the demonstration of abnormal antero-posterior mobility. In some cases there may be a general systemic reaction.

The final diagnosis depends on the radiographs which show that a fragment of bone has been avulsed from the centre of the tibial table (Figs. 114 and 115). The fragment varies in both size and displacement; if it is large and flat it will be seen to be tilted so that the anterior and medial margins are raised to a higher level than the posterior and lateral, that is, the displacement is in the direction of the course of the anterior cruciate ligament.

TREATMENT

The ideal treatment is replacement of the displaced fragment by closed methods followed by immobilisation until union is complete. Unfortunately this ideal cannot always be attained, for, although there is no doubt that sound union can be secured by immobilisation alone, unless the fragment is completely replaced, the anterior cruciate ligament is lengthened with consequent instability of the joint and the tendency to a further internal derangement relative to the menisci. For this reason mere immobilisation in a non-padded plaster must not be accepted as providing adequate treatment in this condition. The short term result may appear satisfactory, but the optimum long term result is only secured following perfect reduction of the displacement. In practice this means that unless closed manipulation results in reduction of the fracture, the question of operative replacement warrants serious consideration.

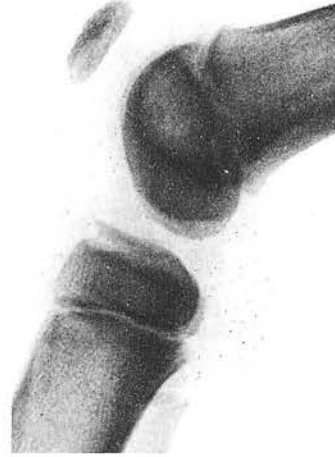

FIG. 114
Avulsion of the tibial spine in a child.

TECHNIQUE OF TREATMENT

CONSERVATIVE

The type of case in which complete replacement is most likely is one in which the area of the superior surface of the fragment is large, that is to say, the case in which the fragment tends to extend under the femoral condyles so that it is subjected to compression when the joint is extended. Small fragments lie between the condyles and are thus not subjected to pressure on extension and are therefore difficult to replace by closed methods.

Under a general anaesthetic the joint is completely evacuated of blood by aspiration. This is necessary in order to obtain full extension and to

prevent the formation of avoidable adhesions. The knee is then hyperextended in order to force the fragment back into the normal position and thereafter a lateral radiograph is taken with the joint in full extension, but not in hyperextension. If reduction has not been obtained at the first attempt further manipulation may secure the desired position. When reduction is considered to be satisfactory a non-padded plaster case, extending from the toes to the base of the greater trochanter, is applied.

After-treatment. In two to four weeks' time when the plaster has become loose, it is changed in favour of a weight-bearing plaster of the type which permits ankle movement: immobilisation is maintained for a total period of eight to ten weeks.

The age of patients suffering from this injury usually lies between ten and twenty and thus no difficulty is encountered in obtaining a rapid return of full flexion.

OPERATIVE

Operation is indicated when the fragment constitutes a bony block to extension which cannot be reduced by manipulation, and also in certain cases where the fragment is small and cannot therefore be replaced by extension or is tilted to a degree likely to result in lengthening of the anterior cruciate ligament.

Replacement of the fragment in the crater in the tibial head can be accomplished without difficulty through a small non-destructive incision, but when the necessity for internal fixation, in addition to replacement, arises, the procedure cannot be carried out with ease except through a large patella-displacing incision which provides complete exposure but entails residual disability which may outweigh the advantages of complete reduction. For this reason the operation of replacement combined with internal fixation should only be performed by an operator who has experience of the intra-articular surgery of the knee joint through limited incisions which do not entail injury to the interrelated structures which maintain the integrity and stability of the joint.

(a) **Replacement.** An incision of the same type as that used for exposure of the medial meniscus is used and enlarged slightly in order to provide better access. The capsule and synovial membrane are incised closer to the midline of the joint than in the meniscus exposure and wide bladed retractors (Figs. 95 and 96) inserted so that the extra synovial fat does not obscure the operative field. In the recent case the lesion can be seen without difficulty and the fragment can be pressed back into the bed from which it was avulsed. In the majority of cases the reduction is stable and no internal fixation is required.

The after-treatment follows the lines suggested under conservative treatment.

(b) **Replacement and Internal Fixation.** In recent cases in which the reduction is unstable, in cases in which an interval of some weeks has elapsed since the injury, or in old injuries in which there is a bony block to

extension, internal fixation is required to supplement reduction. The incision is similar to that described above, but is extended down on to the antero-medial aspect of the tibia for a distance of one to two inches. Access which will permit intra-articular manipulation is gained by dividing the anterior attachments of the medial meniscus close to the centre of the joint or by excising the structure completely. If the injury is of some weeks' duration the fragment may prove difficult to find and may only be defined after cutting its synovial covering. The straight chisel-type meniscus knife will be found to be useful at this stage. If the fracture is three or four weeks old, the depressed crater will still be present to receive the fragment but in older cases it will have filled with callus and must be reconstituted by means of the meniscus knife or a small gouge.

To secure fixation, a point on the antero-medial surface of the tibia is selected at which the suture will eventually be tied. At this point a small bone graft, one inch by a quarter of an inch, is cut in a line horizontal to the long axis of the limb. In the centre of the defect a three sixteenth inch drill is aligned so that the point of exit will coincide with base of the crater. Two small holes are then made in the fragment by means of a straight cutting needle or a fine diamond pointed drill, taking care not to split the bone. The suture is entered from without inwards by means of an eyed probe, passed through the holes in the fragment so that it is buried in the cruciate ligament, and brought to the exterior again to be securely tied over the bone graft (Figs. 115, 116, and 117). If the fragment does not bed down so that the anterior cruciate ligament is taut, the crater may be enlarged in an anterior direction and deepened.

The suture material used by the author up to the present has been braided silk and so far no trouble has been experienced, but it is probable that fine stainless steel wire is not only a safer material to use but would have the added advantage that it could be passed through the small holes in the fragment with greater ease and without the necessity for using a small fully-curved needle which is difficult to manipulate within the joint.

At the termination of the operation a compression bandage of wool and domette is applied, in the outer layers of which a plaster slab or a padded cramer wire splint is incorporated. The use of a tourniquet precludes the application of plaster which does not provide the necessary elastic pressure.

At the end of two weeks a non-padded plaster cast of the type which permits ankle movement is applied and quadriceps drill commenced. Weight-bearing is permitted after a further two weeks. Immobilisation is maintained for a total period of eight weeks.

OLD RUPTURES OF ANTERIOR CRUCIATE LIGAMENT

There are few surgeons who have not noted during the routine examination of the interior of the knee joint at the termination of a meniscus operation that the anterior cruciate ligament is ruptured or entirely absent. They recall no symptoms in the history or obvious signs on examination suggestive

of the presence of the injury, and the convalescence and final result differing little from the normal case, the patient is eventually dismissed as a curiosity.

It would appear therefore that knee joint function within normal limits is possible in the presence of an old rupture of the anterior cruciate ligament. On the other hand it is well recognised that this injury may be

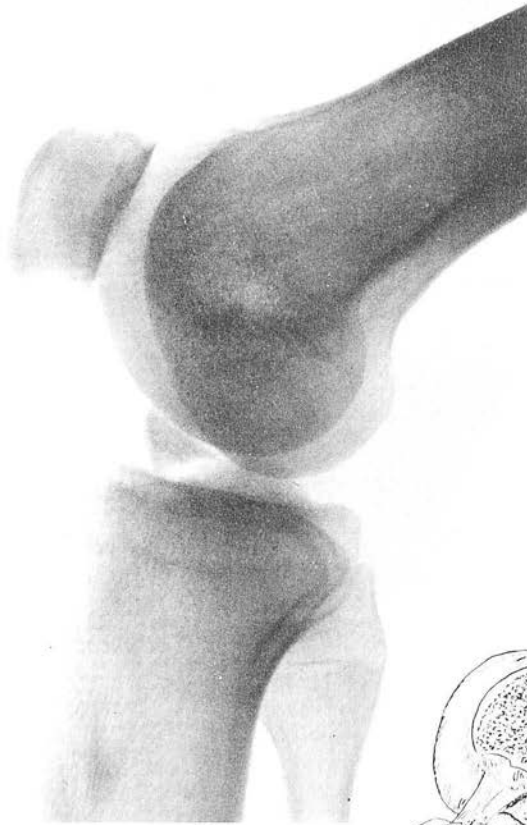

FIG. 115

Fracture of the tibial spine
of eight weeks' duration.

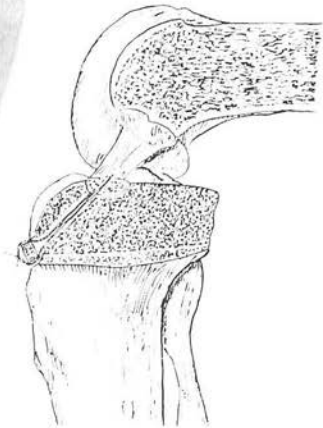

FIG. 116

The method of internal fixation in
fracture of the tibial spine.

so disastrous to knee joint function as to constitute a major problem of orthopaedic surgery. The answer to the question of these apparently contradictory phenomena is to be found in the detail of a careful history of individual cases and in the condition of those structures of the knee joint which have been enumerated as working in close association with the anterior cruciate ligament in maintaining the stability of the knee joint.

The case, noted at the removal of a torn medial meniscus to have an old rupture of the cruciate ligament but without symptoms referable to this injury, will be found to possess quadriceps extensor apparatus of good tone and volume, there is no laxity of the medial collateral ligament nor relaxation of the capsule, and, what is perhaps most important of all, gives no history of recurrent incidents of a serious nature over a considerable number of months or years. He may have suffered symptoms which made

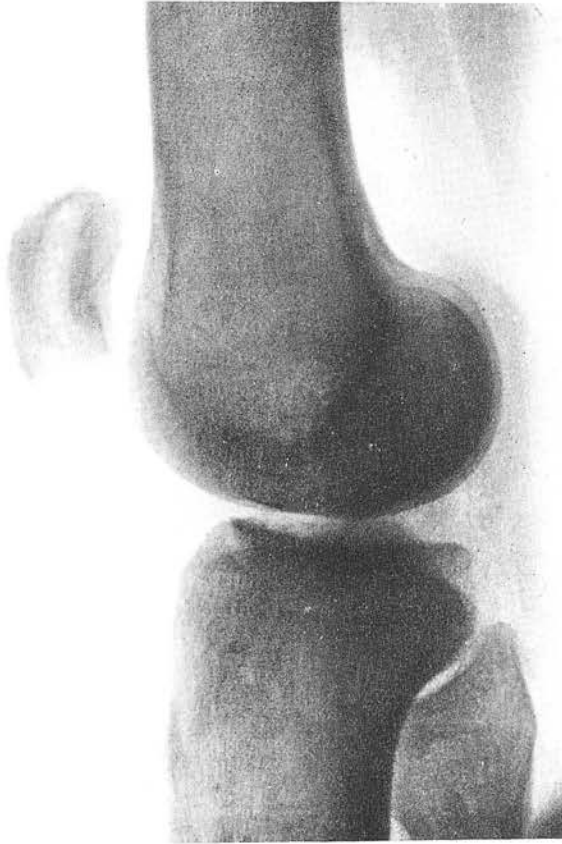

FIG. 117

The reduction achieved by operation and internal fixation in the case illustrated in Fig. 115.

the recognition of a meniscus injury a matter of simplicity, but the nature of his occupation has not made major incidents a matter of common occurrence.

The complete antithesis of this statement is the fact that in every case in which both menisci were diagnosed as torn, and removed at a single operation, the anterior cruciate ligament was ruptured. How is the combination of these three lesions to be explained?

- (1) That both medial and lateral menisci and the anterior cruciate ligament were torn at the original accident.

This explanation is possible but unlikely, especially in the light of the histories, which, following the original accident, point to a lesion of the medial meniscus and months or perhaps years later, following one of the recurrent incidents, points to a lesion of the lateral meniscus.

- (2) That rupture of the cruciate ligament alone or in association with an injury of the medial collateral ligament and in the absence of adequate quadriceps compensation leads eventually, as a result of the deterioration of the other stabilising structures, to tearing of one and eventually of both menisci.

Sufficient evidence exists to make this explanation acceptable.

- (3) That the presence of a torn medial meniscus predisposes to a rupture of the anterior cruciate ligament.

This explanation must also be accepted, for it is obvious that in a joint, which is liable to sudden collapse on rotary movement in flexion, the anterior cruciate may easily be ruptured.

(See also sections on LESIONS OF BOTH MENISCI AND LESIONS OF REGENERATED MENISCI.)

CLINICAL FEATURES IN OLD CASES OF RUPTURE OF ANTERIOR CRUCIATE LIGAMENT

Quadriceps extensor apparatus, of good volume, tone and control in the absence of laxity of the medial collateral ligament and of the other interrelated structures concerned in maintaining the stability of the knee joint, may compensate to such a degree that no serious symptoms may arise which are directly referable to a torn or lax anterior cruciate ligament. In these circumstances the patient is usually able to pursue an arduous manual occupation although the knee joint cannot therefore be assumed to be capable of withstanding the sudden strains demanded by such vigorous athletic activity as association football.

The grave disability associated with this injury is the result of the loss of stability which quadriceps insufficiency entails and the subsequent damage to ligaments, capsule and menisci which results from constantly recurring incidents. It will be deduced from the preceding section, however, that in many cases it is quite impossible to identify cause from effect.

History.—It is usually possible to elicit a history of an original accident, most commonly sustained on the football field, which has been followed by recurring incidents, which may include momentary locking, resulting in effusions which have necessitated periods of bed rest. The intervals of freedom from trouble have become shorter and the instability or insecurity of the joint, which is the principal complaint, has become progressively worse. The knee is constantly giving-way, especially in descending stairs, and there is frequently fear of stepping or jumping down from a height lest the joint collapse. Attempts to resume athletic pursuits were discontinued some time ago and the possibility of playing football is now regarded as hopeless.

Examination shows :

- (a) Wasting of the quadriceps muscle of widely variable degree.
- (b) The characteristic sign of excessive forward mobility of the tibia on the femur is present.

The test is performed with the patient in the supine position and with the knee flexed. A modification of the test, which eliminates the possibility of error due to involuntary contraction of the hamstrings or to a tag of

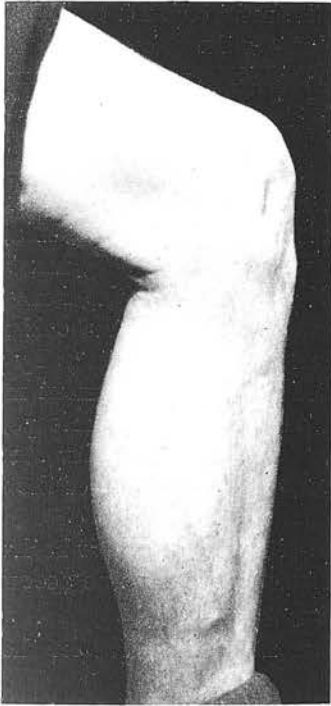


FIG. 118

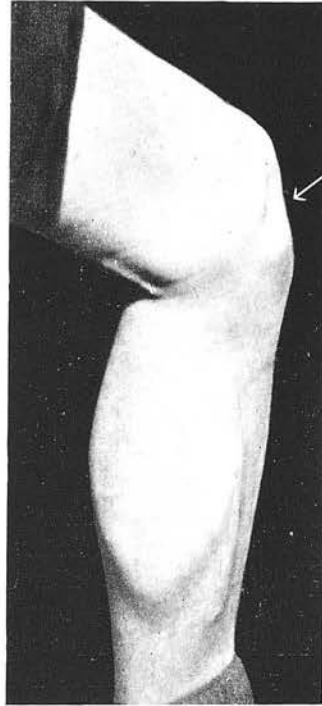


FIG. 119

Rupture of the anterior cruciate ligament. "Trick movement" in which abnormal forward gliding of the tibia on the femur is demonstrated by the patient by contraction of the gastrocnemius. Note old medial meniscus incision.

torn meniscus preventing the tibia from slipping forward on the femur, may be carried out by fixing the patient's foot to the examination couch and then gripping the head of the tibia with both hands, one thumb being placed on each femoral condyle on either side of the patella. With the thumbs pressing the femur backwards and the fingers pulling the tibia forwards the maximum range of movement may be gauged and any sounds emanating from the joint more easily localised (Fig. 111).

It should be appreciated, however, that excessive forward gliding of the tibia on the femur, by comparison with the sound side, does not necessarily mean that there is solution of continuity of the ligament. It has already been recorded that laxity of all the accessory supporting structures

of the joint, including the anterior cruciate ligament, is the common accompaniment of meniscus cases with a long history of incidents prior to

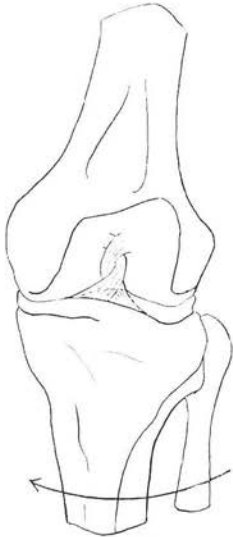

FIG. 120

The cruciate ligaments wind upon each other and thus constitute a check to medial rotation of the tibia on the femur. When the anterior cruciate ligament is ruptured, medial rotation of the tibia on the femur is increased.
(Reprinted from Brantigan and Eschell.)

operation. It is thus necessary to attempt to distinguish such mobility from that associated with complete rupture of the ligament. When forward gliding of the tibia reaches extreme limits, or in the presence of the "trick movement" mentioned below, the diagnosis is no longer open to question but with lesser degrees of mobility some difficulty may arise in even the most experienced hands.

Some cases volunteer the information that they can make the tibia slip forward on the femur. This trick movement, which is demonstrated sitting on a chair with the knee flexed to a right angle and with the foot on the floor, is produced by the contraction of the gastrocnemius, which, in shortening the distance between the femur and the tibia, and in the absence of an intact cruciate ligament causes the tibial head to slip forward on the femoral condyles (Figs. 118 and 119). When the calf muscles are placed at a mechanical disadvantage by passive plantar flexion of the foot this movement may still be produced by contraction of the quadriceps, which, forcing the patella against the inferior surface of the femoral condyles, causes the head of the tibia to slip forwards.

In the presence of lesions of one or both menisci the trick movement described may be accompanied by pain and a clearly audible click.

- (c) There is excessive rotatory movement of the tibia on the femur with the joint in flexion.

The increase of medial rotation is due to the loss of the control of medial rotation normally exerted by the cruciate ligaments which wind upon each other in this movement (Fig. 120). The increase of lateral rotation, which is less marked, is not directly due to the rupture of the anterior cruciate ligament which normally unwinds from the posterior cruciate ligament in this movement, but to laxity of the capsule and collateral ligaments.

- (d) It may be possible to elicit signs indicative of a lesion of the medial or lateral or both menisci.
- (e) There are no characteristic radiological changes except when the original injury has taken the form of a fracture of the tibial spine, but in cases where the instability has existed for many months or years and whose histories are punctuated with recurrent incidents, the changes characteristic of traumatic osteoarthritis may be well marked, and areas of sub-chondral degeneration may be seen in the femoral condyles.

TREATMENT

CONSERVATIVE

If the statements which have been made in the preceding sections be accepted, it follows that the only conservative measure likely to prove of value in improving the stability of the joint is redevelopment of the quadriceps muscle to a degree sufficient to control the instability and inevitable degeneration of other joint components which follows the rupture of the ligament.

The theoretical explanation of muscular control compensating for the rupture of a ligament may exist in the observation that the cruciate ligaments are of relatively small size in man as compared, for example, with tree-climbing animals, and thus are considered to play a less important role in orthograde than in plantigrade motion.

Treatment, which consists of re-education and re-development of the muscle, must be conscientiously and vigorously pursued over a period of at least three months and follows the lines of the progressive quadriceps exercises which have been previously stressed.

Conservative treatment is indicated :

- (1) In cases in which it is certain that the injury is uncomplicated by concurrent injury of the menisci.
- (2) In certain cases in which the existence of an associated meniscus injury is indefinite or alternatively cannot be localised.

Such cases should undergo a period of quadriceps training and a careful subjective and objective examination made at regular intervals, when it may be possible to confirm or reject the possibility of meniscus injury.

- (3) In cases in which the medial meniscus has already been removed and in which the lateral meniscus is considered to be intact.

The use of the knee cage in any of its many forms as a method of controlling an unstable joint is to be condemned except in the aged or the otherwise infirm. A knee cage has yet to be designed which will effectively control an unstable joint to permit any useful freedom of activity and is thus an unjustifiable recommendation in a youthful patient. Its use is the very antithesis of the quadriceps development, which is the only hope of improved function by conservative means, and it does nothing to prevent the trauma of uncontrolled weight-bearing from causing further injury to the ligaments, capsule and menisci which eventually leads to irreparable degenerative arthritis.

OPERATIVE

The physical demands of modern military training call attention to many defects of the locomotor system which are of little importance in civil life. A degree of instability of the knee which makes strenuous athletic pursuits impossible may produce little or no disability even in the occupations of

heavy industry. Fairbank has recorded¹ "In civilians, provided their muscles are in good condition, cruciate damage may cause little if any disability, and in my experience serious instability is quite exceptional."

The crux of the matter lies in the phrase "provided their muscles are in good condition," but, in addition, the complete statement sums up the situation in regard to operation. Patients exhibiting gross instability of the knee joint relative to the cruciate ligaments are unusual; circumstances which demand operation are rare.

At the present time most of the procedures employed for the repair of the anterior cruciate ligament are modifications of the original technique described by Hey Groves,² who first described an operation for the replacement of the cruciate ligaments by strips of fascia lata in 1917. In spite of the frequent incidence of rupture of the ligament these operations are not in common use principally because they are complicated operative procedures, requiring a high degree of technical skill and experience, and which produce end results of widely varying degrees of success and failure. That the results should vary between success and failure is not surprising considering the complex problem which this injury presents and in view of the common association with injury of the medial collateral ligament and menisci, the complication of quadriceps wasting of long standing, and the deterioration of the interrelated structures which maintain the integrity of the joint which inevitably follows.

In the past it would appear that the failure of intra-articular replacement of the anterior cruciate ligament by a strip of fascia lata or a tendon has resulted from:

- (1) Faulty selection of cases.
- (2) The wide operative exposures which most of the procedures necessitate.
- (3) Failure to appreciate that such an operation cannot of itself cure instability of the knee joint but is merely a preliminary incident to the rehabilitation of the quadriceps.

The question of operative treatment is considered in patients in whom youth and occupation demands an opportunity of improved function. In these circumstances operation is indicated in cases:

- (1) Where the medial meniscus or both menisci are torn.
- (2) Which fail to respond to conservative treatment, especially that group to which reference is made under INDICATIONS FOR CONSERVATIVE TREATMENT (2) above, which in spite of redevelopment of the quadriceps still complain of additional symptoms which point to a lesion of the medial meniscus.

These indications are based on three observations:

- (1) The removal of a torn medial meniscus from a joint in which the anterior cruciate ligament is torn results in improvement of function.

¹H. A. T. Fairbank. "Rehabilitation of the Injured in this War and the Last." *Lancet*, 1944, ii, 134.

²E. W. Hey Groves. *Lancet*, 1917, ii, 674-675.

This observation was made before the technique of using the periphery of the torn meniscus to replace the anterior cruciate ligament was evolved in the hope of securing the optimum rather than a mere improvement of function. That improvement of function should follow meniscectomy alone is readily understandable, for by excision of a meniscus the site of a longitudinal tear, the "trigger" which initiates collapse of the joint is removed, and, provided adequate compensatory quadriceps development is secured, improvement of joint stability which will permit a considerable increase of freedom of activity will result.

(2) With but few exceptions all cases of proved lesions of both menisci show a rupture of the anterior cruciate ligament. (See LESIONS OF BOTH MENISCI.)

(3) In all cases which were selected for operation by the author's method the medial meniscus was proved to be the subject of single or multiple longitudinal tears.

Operative treatment is contra indicated :

(1) In cases where treatment has been deferred until the structures associated in maintaining the stability of the joint are grossly lax, wasting of the quadriceps of such long standing that redevelopment to the normal volume and tone is impossible, and in the presence of co-existing arthritis.

(2) As a means to the playing of serious football only.

It will be appreciated that an operation which aims at reconstruction of the anterior cruciate ligament **alone** is doomed to failure if both anterior cruciate and medial collateral ligaments are ruptured (see below).

OPERATION OF RECONSTRUCTION OF ANTERIOR CRUCIATE LIGAMENT USING PERIPHERAL HALF OF MEDIAL MENISCUS

The operation to be described utilises the peripheral half of the medial meniscus to replace a ruptured cruciate ligament. The meniscus is completely detached except at the anterior horn which remains securely attached to the head of the tibia. The concave aspect of the meniscus is excised and the remaining peripheral portion threaded through a drill hole in the lateral condyle of the femur so that the position of the reconstructed ligament corresponds approximately to the normal anatomical position of the anterior cruciate ligament.

The theoretical advantages of the method to be described are :

(1) The trauma inflicted on the knee joint by the operation is little more than is caused by the average meniscus operation. It is an operation which is neither extensive nor destructive and cannot of itself be productive of residual disability. This point is considered to be of importance in relation to all knee joint surgery.

- (2) The material used for the reconstruction has its normal habitat in the knee joint.
- (3) The periphery of a meniscus has a blood supply. This blood supply is in part preserved by retaining the normal anterior attachment, and a further blood supply may be expected to be attained from the lateral femoral condyle where the reconstructed ligament is attached to bone.

The theoretical disadvantages would appear to be :

- (1) The operation should only be attempted by a surgeon who is satisfied that he can remove the entire meniscus without division of the attachment of the anterior horn and without damage to the periphery.
- (2) The material of which the new ligament is to be constructed is not designed for longitudinal strain. It is argued, however, that injury to the medial meniscus usually takes the form of a longitudinal rather than a transverse tear, which suggests that the peripheral fibres may be capable of withstanding strain in the long axis.
- (3) It might be found that frequent incidents have so damaged the medial meniscus that the material which remains does not permit the reconstruction to be performed. It has, however, been possible to obtain an intact peripheral rim in all but one of the cases subjected to operation to the present date. In the event of gross fragmentation of the medial meniscus making reconstruction impossible, the lateral might be used, but it is pointed out that the position of attachment of the anterior horn not only makes the operation more difficult technically but the final result must be less efficient mechanically. It has been stated elsewhere that lesions of both menisci are common accompaniments of rupture of the anterior cruciate ligament. In this event the lateral meniscus would require to be removed.

Technique.—A tourniquet is applied and the knee flexed over the end of the operating table in exactly the same position as used for removal of a meniscus.

The incision begins at the inframedial aspect of the patella and extends downwards and backwards to finish rather less than a finger's breadth below the superior margin of the tibia. The incision is the same as that used for removal of the medial meniscus, but as slightly greater access is advisable it is rather longer.

The capsule is opened and a vertical incision made in the synovial membrane above the meniscus rather closer to the mid-line of the joint than has been described in the simple meniscus operation. Care is taken not to cut into the superior surface of the anterior segment in incising the synovial membrane. The anterior half of the meniscus is now dissected completely free of synovial membrane without dividing the central attachment of the anterior horn.

The operation proceeds as for removal of the meniscus, but is naturally more difficult because the anterior horn has not been detached. Great care must be taken not to cut into the substance of the periphery, which is the portion which will be used for the repair of the ligament. Martin's meniscus forceps must not be used to obtain traction. A single hook, passed over the superior surface and hooked against the concave aspect, is the only method of obtaining gentle traction which is permissible.

In most cases it will be found, especially if the division of the ligament is of long standing, that the meniscus is damaged—a longitudinal tear being the lesion most commonly encountered. As the joint is especially lax in these cases, less difficulty will be found in removing the entire meniscus, including the intact peripheral rim, than might at first be expected.

When the posterior attachment has been divided the meniscus is pulled out of the joint leaving the anterior horn still attached. The central concave zone, usually the centrally displaced portion of a longitudinal tear, is now removed, preserving the largest and broadest attachment of the anterior horn possible.

Two stout silk threads (No. 3 gauge) are then attached to the posterior free end of the preserved peripheral rim. In order that a secure hold may be obtained the needle is passed backwards and forwards through the posterior half inch, so that eventually four long tails of silk suture protrude at the tip of the meniscus (Fig. 121).

Before proceeding to the final stage of the operation the interior of the joint is inspected in order to estimate the possibility of using the tibial stump of the ruptured ligament to reinforce the replaced ligament. It is only on rare occasions that the remaining section is of sufficient length to permit this manoeuvre to be carried out; it should be avoided, as it is a time consuming procedure, if the stump is short and inaccessible.

A vertical incision $1\frac{1}{2}$ ins. to 2 ins. long is made immediately above the lateral condyle of the femur 1 in. in front of the palpable posterior edge of the iliotibial tract. The fascia is divided in the long axis of the limb and the upper aspect of the condyle exposed. A small bone graft 1 in. long by $\frac{1}{4}$ in. wide is cut from the cortex of the femur in the long axis of the limb at the point where the drill is to be passed towards the intercondylar fossa. The point of a $\frac{7}{32}$ to $\frac{9}{32}$ in. drill is then placed in the distal end of the gutter and the drill aligned almost horizontally and driven towards the intercondylar fossa so that its point of exit corresponds as near as possible to the normal attachment of the ligament (Figs. 124, 125). A moist swab is placed between the condyles before the drill is used to catch any fragments or bone dust which otherwise might be left in the joint. A flexible eyed-probe is now passed from without inwards into the joint, the silk sutures threaded through the eye, and pulled back through the hole. By pulling on the silk threads the posterior end of the meniscus is made to enter the drill hole (Fig. 122) and the four silk threads are tied securely over the bone graft which is replaced at right angles to the gutter (Fig. 123). Care must be taken to see that the peripheral rim of the meniscus does actually enter the drill hole and that when the silk threads have been tied the new ligament

is in fact preventing the flexed tibia from slipping forward on the femur. The silk threads are not divided after tying over the bone graft, but additional fixation is obtained by using them in the form of two interrupted sutures to close the longitudinal incision in the iliotibial tract. The skin incisions are then closed.

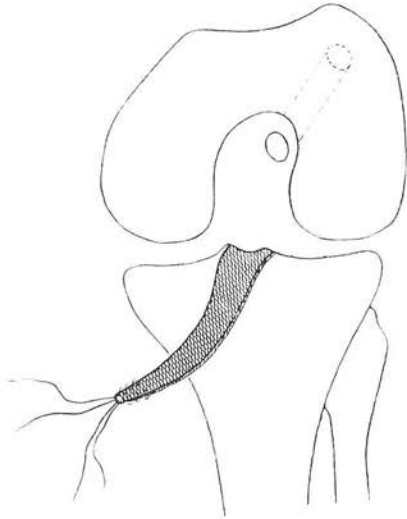


FIG. 121

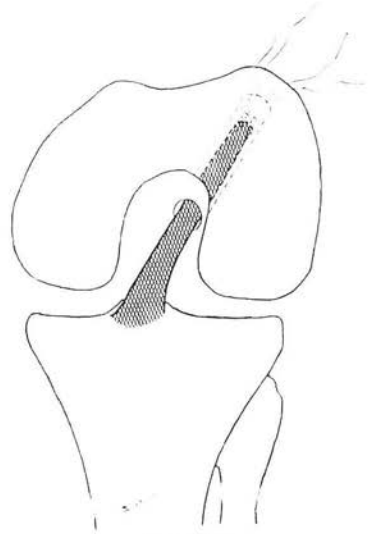


FIG. 122

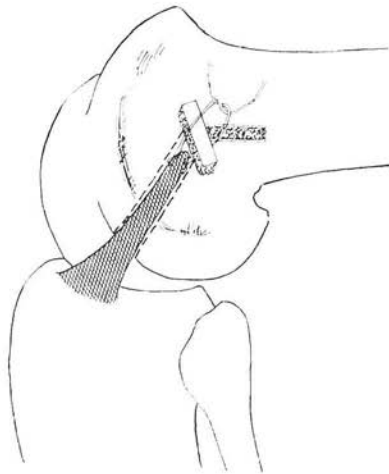


FIG. 123

Figs. 121, 122, and 123. — Reconstruction of the anterior cruciate ligament. The meniscus has been dissected out preserving the anterior bony attachment; the concave zone has been excised. The sutures have been attached and the hole bored through the lateral condyle of the femur (Fig. 121). The new ligament has been threaded through the tunnel in the lateral condyle (Fig. 122). The ligament is secured by tying the sutures over a small bone graft (Fig. 123).

A compression bandage is applied, in the outer layers of which is incorporated a plaster slab or padded aluminium gutter splint to prevent undue flexion of the joint.

It should be remembered that the operative time permissible on a limb constricted by a tourniquet is limited. The operation can be completed in 35 to 50 minutes, depending on experience of the procedure and the minor difficulties encountered.

After-treatment.—The patient practises quadriceps exercises in the form of straight leg raising from the second or third day and on the tenth day the compression bandage is released and the stitches removed. In the presence of a drill hole through cancellous bone, which is not subject



FIG. 124

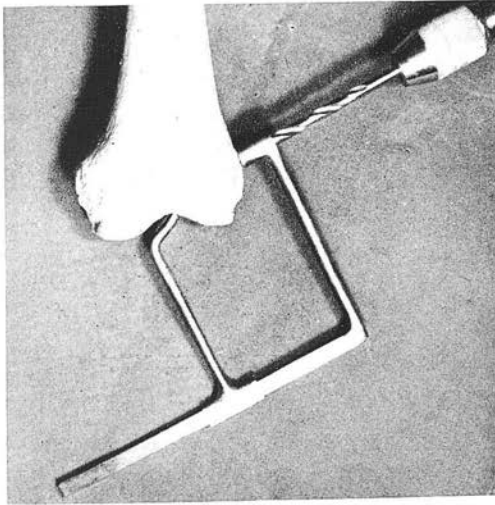


FIG. 125

Adjustable drill aligner based on Palmer's design (Fig. 124), showing the method of use in reconstruction of the anterior cruciate ligament (Fig. 125).

to compression, the possibility of a haemarthrosis is kept in mind and aspiration and reapplication of the compression bandage may be required. Thereafter an Unna's paste bandage is applied from the toes to the knee and an unpadded plaster case, of the type already described, added (Fig. 112).

The patient conscientiously practises quadriceps drill throughout the period of immobilisation, which lasts from six to eight weeks from the date of operation. When the plaster is removed active knee flexing and pulley-weight quadriceps exercises are commenced.

Results of Operation. Although this operation has been described and discussed in considerable detail, it is not intended to convey the impression that the author considers that it provides a solution to this difficult problem. It has been described as a procedure which is worthy of trial in the hands of surgeons with considerable experience of knee joint surgery and who appreciate that such an operation is but an important incident in the re-education and redevelopment of the extensor apparatus.

Many cases have been encountered in the past five years suffering from old standing ruptures of the anterior cruciate ligament whose knee joints, although recognised by the patients to be relatively unsound, did not give rise to severe disability even in manual occupations in civil life, but which broke down completely under the physical stress of military service. In such patients there is no indication for operation, least of all an operation which cannot produce quick results from the Service viewpoint.

Only 17 patients, in whom special circumstances existed, were subjected to operation. In none of these has a follow-up been possible which would justify a claim of successful long term results. Nor is it likely that a fair assessment of the value of a procedure, the criterion of success of which is entirely subjective, could be obtained in a period of national emergency, even if a follow-up were possible. Two cases were considered to be failures; one secured improvement in stability at the expense of loss of flexion, which was limited to a right angle, the other, who suffered from a post-operative haemarthrosis, had only regained sixty degrees of flexion when last examined. Two cases were involved in further accidents; one sustained a complete rupture of the medial collateral ligament before he was considered to be fully rehabilitated; the second ruptured the reconstituted ligament in an accident involving gross violence but he stated that his disability was much reduced during the interval of two years which elapsed between the operation and the accident.

One case returned to hospital of his own accord eighteen months later while on leave in a distant town. He said he had come back to see if the joint could be made perfect! He was satisfied with the result but did not think it was quite as good as the normal knee.

The remaining cases, none of which were seen later than six months after operation, are thought to have benefited. One man, who had been regraded A.1, was returned to hospital as a failure because his knee had given way on one occasion on an assault course! The patient, however, was satisfied that the function of the joint was improved. Another patient wrote to say that he was now able to venture on a dance floor for the first time for five years!

In none of these patients can it be claimed that anteroposterior mobility of the tibia on the femur was eliminated, for although it was frequently considerably reduced by comparison with the original condition,

some laxity persisted. The impression was gained, however, that at the limit of mobility there existed a definite check to further movement.

EXTRA-ARTICULAR STABILISING OPERATION FOR RUPTURE OF ANTERIOR CRUCIATE LIGAMENT

Of the many extra-articular stabilising operations involving the use of fascia lata which have been described, the procedure advocated by Blair¹ appears to offer the greatest prospect of improved function. Blair states that his operation is based on Testut's² observation that the axis of rotation of the knee joint is situated in the posterior portion of the femoral condyles (Fig. 126). He concluded that a strip of fascia which crosses this fixed point should remain theoretically at the same degree of tension at all positions within the range of the joint.

This operation may prove to have a wide field of application:

- (1) When the medial meniscus has already been removed thereby excluding the possibility of reconstruction by the method described.
- (2) As an adjuvant to the intra-articular reconstruction in the presence of marked laxity of the medial collateral ligament. The operation may be limited to the medial side of the joint except in cases of long standing with gross laxity of all the associated stabilising structures.
- (3) As a method of treatment of old injuries of the medial collateral ligament.

Technique.—A strip of fascia lata 12 ins. long by 1 in. broad is removed, divided into four pieces 6 ins. in length by $\frac{1}{2}$ in. wide, and fixed to Gallie needles.

A 6-inch incision is made over the lateral side of the joint and the first strip of fascia secured in the insertion of the biceps to the head of the fibula by suturing it through itself. The free end of the strip is carried obliquely forward to a position near the inferior pole of the patella, passed deep into the lateral expansion and then back on itself to be held securely in position with interrupted catgut sutures.

The second strip is attached to the deep fascia on the anterolateral surface of the tibia and is then carried obliquely backwards to cross the first strip and be attached to the fibres and overlying fascia of the biceps muscle. These two strips cross at the axis of rotation of the joint (Fig. 127).

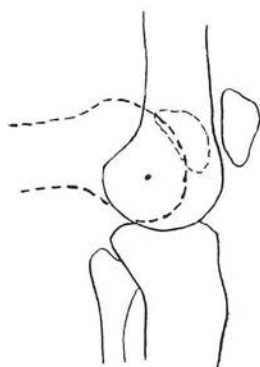


FIG. 126

The axis of rotation of the knee joint is situated in the posterior portion of the femoral condyles. (After Blair).

¹ Harry C. Blair, "A Simple Operation for Stabilization of the Knee Joint." *Surg. Gynec. and Obst.*, 1942, lxxiv, 855-859.

² A. L. Testut, "Traité d'anatomie humaine." Book I. O. Doin and Sons, Paris, 1911.

A similar 6-inch incision is made on the medial aspect of the joint. The third fascial strip is attached to the fibres and over-lying fascia of semimembranosis, semitendinosis and gracilis at the postero-medial border of the tibia at about the level of the head of the fibula. The free end is then carried obliquely forwards and upwards to be securely attached medial to the superior pole of the patella. The fourth and last strip is attached to the anteromedial border of the tibia and then carried obliquely upwards and backwards to cross the third strip and be attached to the substance and overlying fascia of the semimembranosis, semitendinosis and gracilis. These two strips also cross at the axis of rotation in the posterior part of the medial condyle (Fig. 128). No sutures are used other than the interrupted

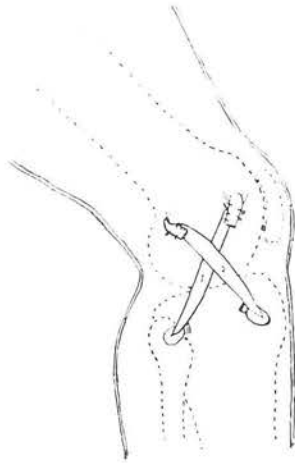


Fig. 127

Blair's operation. Lateral view showing order, position and method of attachment of fascial strips (Fig. 20).

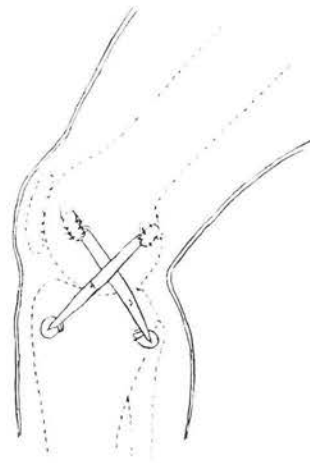


Fig. 128

Medial view showing the position of the third and fourth strips (Fig. 21).

catgut sutures which secure the extremities of the fascial strips. The skin incisions are closed and a compression bandage applied.

After-treatment.—Blair recommends that a skin-tight walking plaster be applied for a period of two weeks after removal of the skin sutures. Thereafter the patient is fitted with a long knee cage with 12-inch leather thigh and leg cuffs. The cage allows 10 degs. of flexion in the initial stages, but the permitted range is gradually increased over a two to three month period. The brace is retained until the volume of the quadriceps muscle has been regained.

Blair has carried out this operation on ten occasions with known satisfactory results in five cases. He states that from evidence obtained from Meekison it would appear that hypertrophy of the fascial strips takes place and concludes that fascial strips applied in the manner described have a normal physiological action.

The author has only used this procedure on five occasions, twice to supplement the intra-articular operation in the presence of marked laxity

of the medial collateral ligament, and three times in relation to the medial collateral ligament alone. Experience of the method is thus limited, but so far the results obtained have been sufficiently encouraging to merit a more extensive trial.

In none of the author's cases was a knee cage employed in the after-treatment; in the cruciate cases the after-treatment detailed on page 131 was used; in the medial collateral ligament cases the period of plaster immobilisation following the removal of the stitches was reduced to four weeks.

POSTERIOR CRUCIATE LIGAMENT

The posterior cruciate ligament is attached distally to the posterior part of the depressed surface behind the tibial spine and close to the popliteal notch. Its fibres pass obliquely upwards, forwards, and medially behind the anterior cruciate ligament, to be inserted into the anterior portion of the lateral surface of the medial condyle of the femur.

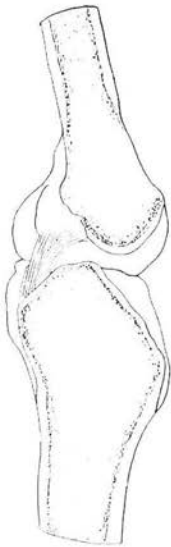


FIG. 129

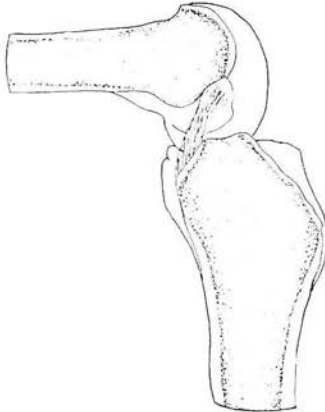


FIG. 130

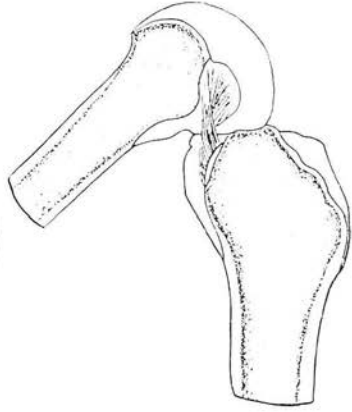


FIG. 131

Fig. 129. In extension the attachment of the posterior cruciate ligament to the femur is horizontal, the greatest stress is on the posterior fibres.

Fig. 130. — In semi-flexion the tension gradually changes to the anterior fibres.

Fig. 131. If full flexion the attachment to the femur is vertical; the greatest stress is on the anterior fibres. (*Redrawn from Brantigan and Voshell.*)

It is said to be taut when the knee is flexed, preventing instability of the tibia on the femur in this position, but as it passes through the axis of rotation of the joint it cannot be accurately described as lax in any position of either flexion or extension. It has been pointed out that this ligament assists in preventing hyperextension and hyperflexion. In extension the attachment to the femur is horizontal, which entails the greatest stress on the posterior fibres (Fig. 129). In semi-flexion the tension gradually changes to the anterior fibres (Fig. 130) until full flexion has been reached when the attachment to the femur is vertical, entailing maximum stress on the anterior fibres (Fig. 131). The assertion that the posterior cruciate is only

taut in flexion, and merely prevents backward gliding of the tibia on the femur, arises because such force is directed in the line of the two attachments of the ligament.

PATHOLOGICAL ANATOMY

Injuries of the knee joint in which the predominant feature is rupture of the posterior cruciate ligament are rare. The lesion is encountered with greatest frequency as part of the general destruction of the ligaments which follows dislocation of the joint.

It follows from the anatomy and function of the ligament that rupture is liable to take place when the head of the tibia is driven backwards on the femur while the knee is in flexion, circumstances which may occur from a kick in a football game (two such cases were encountered) or in automobile accidents from contact with the dashboard.

Total rupture is encountered in one of two forms :

(1) **At Inferior Insertion.** At this site the rupture is of the same type as the corresponding injury of the anterior ligament and produces avulsion of a fragment of bone from the tibial head (Figs. 133 and 134).

(2) **At Superior Insertion.** In this position, as in the corresponding injury of the anterior structure, the rupture takes place at or near the attachment to bone, but, unlike the anterior lesion, produces less extensive damage to the internal structure of the ligament and less fragmentation of the free end.

DIAGNOSIS

The clinical features are similar to those of rupture of the anterior cruciate ligament. The diagnosis is based on the history of the mechanism and the pathognomonic sign of excessive backward mobility of the tibia on the femur — the "drawer sign," in the case of the posterior cruciate ligament, "drawer

backwards" (Fig. 132). If the lesion is at the inferior attachment, the position of the avulsion of the fragment of bone may be partially extra-capsular and this may produce effusion of blood and deep tenderness in the popliteal space. The same circumstances will produce positive radiographic findings.

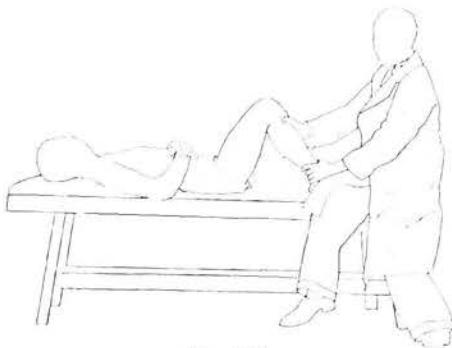


Fig. 132

Method of testing the posterior cruciate ligament : the "drawer sign" — "drawer backwards."

TREATMENT

If the lesion is situated at the inferior insertion, but without displacement of the fragment, a satisfactory result may be anticipated from immobilisation alone. If there is displacement or if there is no radiological lesion, from which it is reasonable to assume that the rupture is located at the superior

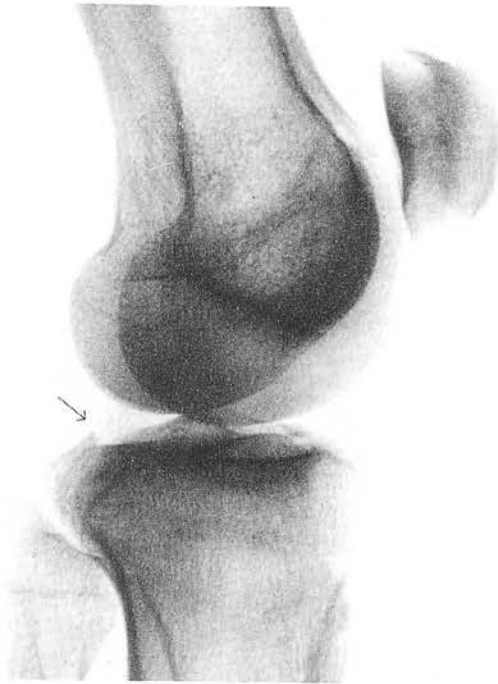

FIG. 133

Avulsion of a large fragment of bone at the inferior attachment of the posterior cruciate ligament.

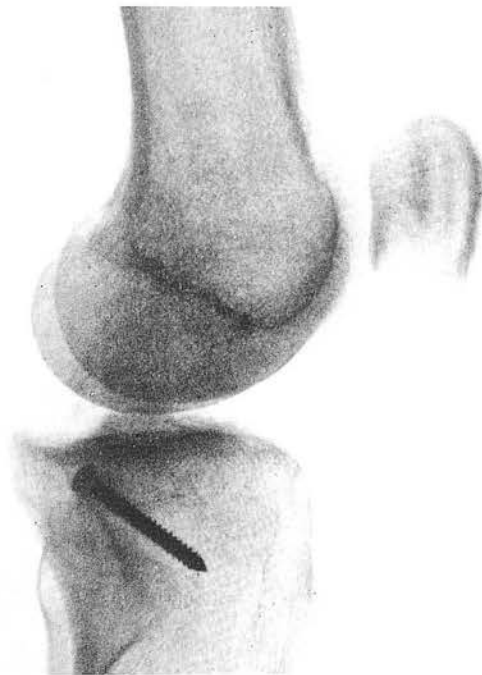


FIG. 134

Rupture of the posterior cruciate ligament at the inferior insertion. The fragment of bone with the ligament attached has been countersunk into the tibia and fixed with a stainless steel screw.

insertion, the only form of treatment which offers prospects of a return to normal function is restoration of the normal anatomy by operation. It is possible to recommend operative action with a greater degree of confidence in recent injuries of the posterior cruciate ligament than in lesions of the anterior structure because the records which are available suggest that the body of the ligament is rarely the subject of gross destruction. In these circumstances no insurmountable technical difficulty will be encountered.

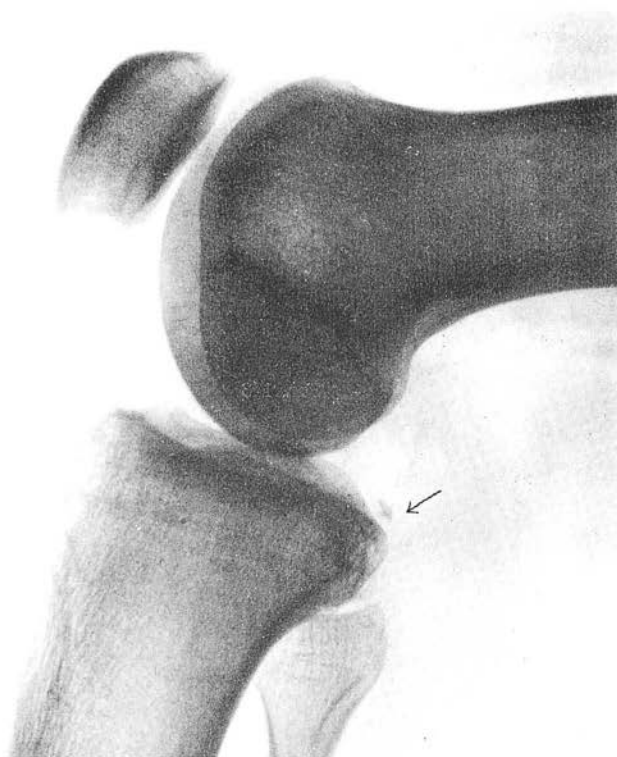


FIG. 135

Avulsion of a small fragment of bone at the inferior attachment of the posterior cruciate ligament. This case, which was seen eight weeks after the injury, had symptoms of instability and showed a marked increase of posterior mobility of the tibia on the femur.

TECHNIQUE OF OPERATION

Inferior Insertion.—The incision and exposure are similar to those used for removal of a loose body from the posterior compartment by the popliteal approach (Chapter X). The crater in the postero-superior margin of the tibia may be visible before opening the joint or a defect may be present in the capsule. If the fragment is large it can be replaced in the crater; reduction is maintained by stitches passed through the capsule¹

¹ Harold G. Lee, "Avulsion of the Tibial Attachments of the Crucial Ligaments," *J. Bone and Joint Surg.*, 1937, xix, 465.

or by means of a stainless steel screw (Fig. 134). If the fragment is small (Fig. 135) or is comminuted it may be necessary to drill a small hole from the normal point of insertion of the ligament to the antero-medial aspect of the tibia and secure fixation by strong silk sutures tied over a small bone graft in a manner similar to that described for fractures of the tibial spine (Fig. 136).

Superior Insertion.—The approach to the superior attachment of the posterior cruciate ligament is the same as that described for either the inferior or superior insertions of the anterior ligament. The procedure, however, presents fewer technical difficulties as a result of better access to the site of injury and the fact that the detached section of the ligament is unlikely to be grossly fragmented; fixation is secured through holes bored in the medial femoral condyle.

OLD RUPTURES OF POSTERIOR CRUCIATE LIGAMENT

The fact that instability of the knee joint, directly referable to an old rupture of the posterior cruciate ligament, is seldom encountered is explained by the exceptional rarity of the injury rather than its failure to give rise to serious symptoms when it does occur. All of the eight cases which were examined, and in which an old rupture of the ligament existed as an isolated lesion, complained of instability described as moderate to severe.

Improvement in function in such cases, as in a large proportion of all cases suffering from instability due to ruptured ligaments, can be obtained from redevelopment of the thigh muscles. It is possible, however, that in selected cases where the injury is located at the inferior insertion and in which a fragment of bone has been avulsed, restoration of the normal anatomy might be accomplished without undue technical difficulty by the method described above.

In this series one patient, in whom the rupture was located at the superior attachment, was subjected to operation by the method described below. The procedure, having been used in one case only, is recorded merely as a matter of technical interest.

REPAIR OF POSTERIOR CRUCIATE LIGAMENT: AUTHOR'S METHOD

The posterior cruciate ligament may be repaired by a method similar to

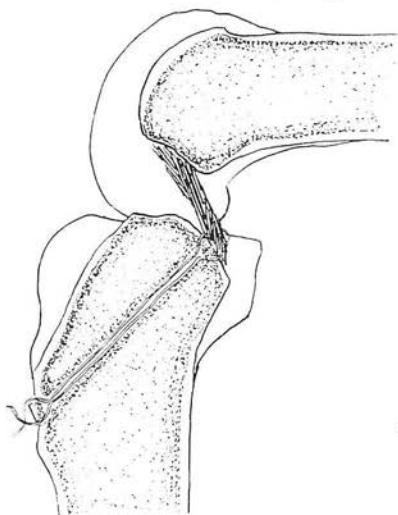


FIG. 136

Operative reduction and internal fixation of the inferior attachment of the posterior cruciate ligament by means of sutures threaded through a tunnel in the tibia and tied over a small bone graft.

that described under repair of the anterior cruciate ligament. The lateral meniscus is mobilised and dislocated into the intercondylar notch, leaving the posterior attachment intact. The anterior half of the meniscus is then threaded through a drill hole in the medial condyle of the femur so that it replaces the torn ligament.

Technique. The lateral meniscus is mobilised as far as the attachment of the posterior horn, through the normal incision enlarged slightly to provide for greater access. The meniscus is dislocated into the intercondylar notch and the central or concave third of the breadth excised.

Two strong silk sutures are attached to the anterior extremity of the strip of fibrocartilage in the manner described under repair of the anterior cruciate ligament.

A 2-in. incision is made in the skin in the line of the long axis of the limb immediately over the medial condyle of the femur on the medial aspect, the distal end of the incision being situated just above the junction of the articular cartilage with bone. The periosteum is erased from the medial condyle and a small bone graft about $1\frac{1}{2}$ in. by $\frac{1}{4}$ in. cut in the short axis of the limb by means of a fine sharp osteotome. When the graft has been removed from its bed a $\frac{1}{4}$ -in. drill is passed through the medial condyle so that its point emerges at the normal attachment of the posterior cruciate ligament. A wire loop is passed through the drill hole towards the intercondylar fossa and the four silk threads attached to the wire loop and thereafter drawn through the drill hole. Traction on the silk threads will cause the anterior end of the meniscus to enter the drill hole. The graft is then replaced in its bed and the four silk threads tied tightly over it so that a new taut posterior cruciate ligament is formed.

After-treatment. The after-treatment is the same as that described under repair of the anterior cruciate ligament.

Although the operation is simple and causes the minimum of trauma to the joint, the anterior position of the posterior end of the reconstructed ligament means that the new ligament is shorter and more vertical than the normal posterior cruciate ligament; it is thus not a perfect mechanical or physiological reproduction of the original. In spite of the theoretical criticism that the procedure may not be based on sound mechanics, the one case treated in this manner resulted in marked improvement of function.

MEDIAL COLLATERAL LIGAMENT

Injuries of the medial collateral ligament are encountered in two forms:

I. PARTIAL RUPTURE OR SPRAIN WHICH MOST COMMONLY AFFECTS THE FEMORAL ATTACHMENT.

II. COMPLETE SOLUTION OF CONTINUITY.

I. Sprain or partial avulsion of the long anterior parallel fibres of the medial collateral ligament at their attachment to the femur is one of the most common injuries of the knee joint. It ranks third in importance, in relationship to frequency of occurrence, to the minor injuries producing traumatic synovitis, the exact etiology of which may be undefined, and internal derangements relative to the menisci. The importance of the injury lies not only in the frequency of occurrence but in the fact that it is so repeatedly misdiagnosed. If the recent injury goes unrecognised, the common complication of the formation of heterotopic bone at the femoral attachment of the ligament which gives rise to the "medial collateral ligament syndrome," commonly miscalled Pelligrini Stieda's disease, is not anticipated and the symptoms which follow are responsible for severe and prolonged disability.

MECHANISM

The mechanism of sprain or partial avulsion of the upper attachment of the ligament most frequently takes the form of a relatively minor rotary strain with the joint in slight flexion. It does not commonly occur as a result of abduction strain in extension, as in this position, especially with the quadriceps braced, the knee is strong and stable. If an abduction strain does take place in this position which cannot be withstood by the muscles and ligaments—an injury which may be sustained in a football game as the outcome of one player falling against the outstretched and extended leg of another—complete rather than partial rupture is the result.

The rotary mechanism is of frequent occurrence in minor ski-ing accidents, which are particularly liable to produce internal or external rotation strains transmitted to the femoral attachment of the ligament.

CLINICAL FEATURES

The patient usually gives a history of a twisting injury, frequently sustained in a football game, and consisting of a mechanism such as external rotation in slight flexion, possibly combined with abduction. The injury caused severe pain on the medial aspect of the joint.

The mechanism and site of pain are thus similar to that of a meniscus injury, but differ in that the joint does not lock and the patient is frequently capable of continuing the game with difficulty, a feat which is seldom possible when the meniscus is torn, only to find himself severely incapacitated some hours later. The mechanism being similar to that which produces a meniscus injury, exceptions to this history exist when both the meniscus and the medial collateral ligament are injured at the same time; such cases give rise to considerable difficulty in diagnosis.

On examination there is a swelling over the medial aspect of the medial femoral condyle and vague tenderness in the line of the collateral ligament with the point of maximum tenderness definitely localised to the femoral attachment of the long anterior fibres.

The injury is distinguished from complete rupture by placing the ligament on the stretch in attempting to abduct the joint in extension;

pain will be produced at the upper femoral attachment, but the stability of the joint is unimpaired.

In the presence of these features and in the absence of synovial effusion no error of diagnosis can arise, but if effusion is present in combination with tenderness of the ligament at the joint line, suggesting the possibility of a meniscus tear, it is obvious that in certain cases an absolute diagnosis may prove impossible. In the absence of these complicating features, however, the point of most importance is the accurate localisation of the point of maximum tenderness combined with the fact that rotation (usually external) produces pain localised to the same spot.

The radiographs show no abnormality.

TREATMENT

It is evident that from the point of view of treatment two types of case are encountered—first, that in which the diagnosis is clear cut with swelling and tenderness localised to the medial femoral condyle (occasionally the medial condyle of the tibia) and the absence of complicating features suggesting an additional internal derangement—and second, that in which there is a marked effusion or other feature rendering absolute diagnosis impossible.

In the first type the treatment of choice is injection of the site of maximum tenderness with a few cubic centimetres of local anaesthetic after the manner of Leriche. Thereafter a 2-inch square of thick sterile orthopaedic felt is placed over the area and a diverging spica of elastic adhesive bandage applied to the joint with the purpose of promoting rapid absorption of the products of injury by elastic pressure. This simple treatment may provide dramatic relief of pain and permit immediate resumption of weight-bearing activity and allow quadriceps exercises to be commenced. If relapse takes place the bandage may be removed and reapplied to permit the infiltration to be repeated every second or third day.

As an alternative to the infiltration technique, the area may be sprayed with ethyl chloride until the skin freezes, permitted to thaw, and the process repeated three times in quick succession prior to the application of the pressure pad and elastic bandage.

In the second type the same injection or freezing treatment may be carried out, but weight-bearing is not permitted, and the effusion treated by the application of a liberal compression bandage of wool and domette and quadriceps exercises instituted without delay.

The attitude to be adopted towards this incompletely diagnosed injury must be expectant. Weight-bearing is permitted when the effusion has subsided, and an increase of activity allowed when the muscles have regained the normal volume and tone by conscientious quadriceps drill. If the meniscus has been injured at the original accident, the presence of the lesion will be revealed sooner or later following the resumption of athletic activity. The patient is therefore instructed to report for re-examination if the joint proves incapable of withstanding the strain imposed by football. It is only in this way that the diagnosis can be finally established and the

patient saved from the consequences of the recurring incidents which follow an untreated internal derangement.

The great majority of simple sprains of the medial collateral ligament, with the exception of the type of case referred to above and in which the complete diagnosis is open to doubt, present no difficulty in treatment and make a rapid and uneventful recovery. In a certain proportion of apparently simple cases, however, the symptoms of pain and restriction of movement, instead of making the rapid progress expected, become more accentuated with the passage of time, and the more strenuous the physiotherapeutic efforts made to accelerate recovery the worse the symptoms become. These patients are usually found to be suffering from ossification of the haematoma at the site of the avulsion of the ligament from the femoral condyle—the condition commonly described as Pelligrini Stieda's disease.

POST-TRAUMATIC PARA-ARTICULAR OSSIFICATION OF KNEE JOINT

Post-traumatic para-articular ossification is not a susceptibility common only to the knee. It is encountered in other regions in association with joints, the ligaments of which are particularly liable to sprains. It is thus seen in the medial collateral ligament of the ankle joint, at both the malleolar and talar attachments, and in the medial collateral ligament of the elbow joint at the humeral attachment. It is less frequently recognised at these sites principally because once it is established that there is no bony injury and the diagnosis of sprain confirmed, the further course of the case is usually uneventful and does not necessitate a further radiograph. In contra distinction, the condition is widely recognised in its grosser forms, when it may involve all the ligaments, as a complication of the major dislocations of the elbow, hip and knee joints.

The importance of the lesion in the isolated form in relation to the medial femoral condyle, by comparison with the elbow or ankle joint, is due to interference with the free action of the medial collateral ligament whose integrity, complex structure and function bear closer relationship to normal flexion and extension than does the medial collateral ligament in relation to either the elbow or ankle joint.

This interference with the function of the ligament occurs not only in the active stages of the condition, when the possibility can be readily appreciated, but is perpetuated into the final and quiescent stage in those cases in which the calcification or ossification is not absorbed and a bony protuberance remains fused to the femoral condyle. The gross limitation of flexion which may be encountered even at this stage is due to adhesions in the medial capsule and in the region of the femoral attachment of the ligament, the nature of which is illustrated by the following case :

The patient, aged 36, gave a history of trouble with his knee during the past fifteen years following a twist sustained playing football which caused the knee to lock. The knee had locked on numerous occasions since, as a result of minor football injuries, but he had always managed to unlock the joint

himself with the sensation of a click on the medial side, until a year ago when, following a further football injury, he found he was unable to unlock the joint and was unsuccessfully manipulated under anaesthesia. A surgeon thereupon removed the medial meniscus, but since then his knee had never flexed more than 40 degrees. Nine months prior to admission, an unsuccessful manipulation was carried out at another hospital in the hope of increasing the range of movement.

On admission he had only 40 degrees of flexion, and a visual and palpable mass of heterotopic bone was noted in the femoral attachment of the medial collateral ligament. The clinical and radiological appearances suggested that the condition was entirely quiescent and a decision was made to excise the bony protuberance and manipulate the joint.

When the patient had been anaesthetised the joint was flexed in order to compare the range of passive movement under anaesthesia with that recorded at the initial examination. The range of movement was found to be exactly the same, and on attempting a little forced flexion an adhesion gave way and it was decided to carry out a full manipulation before proceeding with the operation; the knee flexed to the fullest extent with the breaking of numerous adhesions on the inner aspect of the joint. When the femoral attachment of the ligament was exposed it was found that the protuberance had been fractured by the manipulation and the outer shell of bone detached. Apparently the adhesions to that part of the ligament which should have been capable of moving were stronger than the bone. The fragments attached to the ligament and the remainder of the bony protuberance were excised. Early active movements were instituted and although some new bone reformed in the area the patient made a complete recovery with a full range of flexion.

This experience is of interest not only from the point of view of the pathology of the late case but provides further concrete evidence against the manipulation of such cases in the early stages and explains why additional new bone is laid down if manipulation or passive movement is performed. (See page 147.)

ETIOLOGY

The theories which have been propounded regarding the etiology of this common and interesting condition vary in both complexity and ingenuity, but the clinical course and radiological appearance make it probable that in the large majority of cases the simple explanation of calcification and ossification of a medium of haematoma or oedema, occurring at a particularly opportune site for the development of such a pathological process, is correct.

Although sprain of the upper femoral attachment of the ligament can only be produced indirectly by a rotary strain, or by rotation in combination with abduction, the production of heterotopic bone in the attachment may be produced by any type of trauma which produces a suitable medium for ossification, and thus may follow a localised blow at the attachment of the ligament, in addition to indirect strain.

It has been stated¹ that the clinical symptoms which call attention to the possibility or eventuality of the condition are not pathognomonic but are common to most injuries of the knee joint. This statement is not correct, for although only a small percentage of sprains progress to the production of heterotopic bone, all sprains or direct contusions localised to the femoral attachment are potential forerunners of the condition; it is merely a matter of achieving an accurate diagnosis in the recent injury. Nor is it true that the symptoms and signs of the established lesion are unrecognisable as such; they are clear cut and unmistakable in the large majority of cases, only leading to difficulty in the presence of a concomitant internal derangement.

CLINICAL FEATURES

The clinical features may be summarised as those of a simple sprain of the femoral attachment of the medial collateral ligament, exhibiting all the symptoms and signs which have already been described, but which failed to make the rapid progress to recovery which was expected, and which, after a period of three or four weeks, has become worse rather than better. There is now severe pain, weakness and gross limitation of flexion in the joint.

Examination at this stage shows tenderness to pressure localised to the femoral condyle (Fig. 137) and vague thickening of the deep tissues in the same area. The presence of effusion is not characteristic, but may be noted if the original trauma was

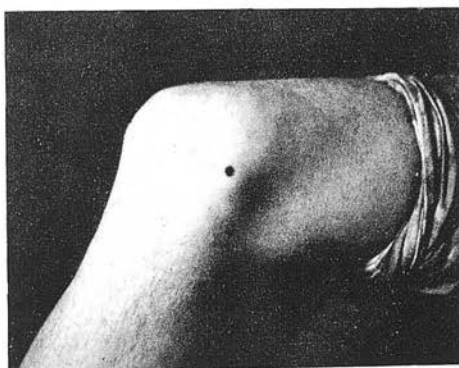


FIG. 137

Post-traumatic para-articular ossification of the knee joint. The location of the point of tenderness on the medial femoral condyle; the marked limitation of flexion.

severe and associated with injury of the peripheral attachment of the meniscus. The most constant and characteristic feature is the loss of flexion (Fig. 137), and it is not uncommon to find that the total range of movement is less than 40 degrees. Any attempt to produce passive movement beyond this point is met by elastic resistance and muscle spasm accompanied by severe pain localised to the upper attachment of the ligament.

At a later date, from three months to a year or eighteen months after the original injury, the symptoms may be similar, although considerably less acute in nature. They consist principally of vague pain in the medial femoral condyle, weakness of the joint and loss of flexion.

On examination a prominence of bony consistency is palpable and

¹J. Kulowski. "Post-traumatic Para-articular Ossification of the Knee Joint." *Amer. Journal of Roentgenology*, 1942, xlvii, No. 3, 392.

frequently visible in the region of the medial condyle. It is usually firmly fixed to bone, but may occasionally be mobile through a small range; it is not adherent to the overlying soft tissues. The quadriceps are wasted and the range of movement limited to about 45 degrees.

RADIOLOGICAL FINDINGS

Although the clinical features enumerated above are almost pathognomonic, the ultimate diagnosis depends on the result of radiological examinations (Figs. 138 to 145). The changes which appear in the third or fourth week following the injury take the form of a thin elongated shadow parallel to the medial aspect of the femoral condyle, or at the point where the shaft merges with the condyle, but characteristically separated from the bone by a clear space (Fig. 138). Thereafter serial radiographs taken at weekly intervals show that the calcification (and later ossification) takes one of two forms¹:

(1) The **Stable** type in which the shadow retains its original thin elongated shape with clear cut margins, becoming increasingly dense up to a time when it may begin to undergo slow absorption (Figs. 139 and 140).

(2) In the **Evolutive** type the shadow becomes large and bulky, giving the appearance of activity by its hazy and ill-defined outline (Fig. 143). This is the form which is frequently seen following direct trauma, gross injuries of the attachment of the ligament such as occur in complete dislocation, and particularly in those cases which have been subjected to constantly repeated well-meaning but ill-advised trauma in the form of massage and passive movement, or early manipulation.

In the later stages either type may undergo partial, and on rare occasions complete, absorption or may become fused to the femur (Fig. 141) or attached by a pedicle often situated at its proximal extremity, so that a pointed or beak-like protuberance may project distally from the condyle. The shape of the bony projection which is frequently encountered may possibly be explained by the mechanism of the injury and the anatomy of the ligament. The torsion strain which separates the fibres of the ligament from the bone is applied from below upwards and therefore causes greatest separation at the lowest level (Fig. 140). In addition, it has been shown that a space exists between the ligament and medial aspect of the femoral condyle below the actual point of attachment. The existence of this space, in combination with the natural motion of the ligament, means that any new bone laid down is likely to be moulded so that it is least wide at its upper limit.

TREATMENT

The most important form of treatment in this condition is prevention, and while it is impossible to be certain whether the complication is entirely avoidable, there is abundant evidence that a very large proportion of the cases which exhibit a crippling disability over a prolonged period can be

¹ J. Kulowski, "Post-traumatic Para-articular Ossification of the Knee Joint." *Amer. Journal of Roentgenology*, 1942, xlvii, No. 3, 392.

eliminated by the immediate diagnosis and rational treatment of the common sprain of the femoral attachment of the medial collateral ligament which is responsible for at least 75 per cent. of the cases encountered.

Treatment may be divided into three phases :

- (1) *Prevention.* Preventative treatment may be summarised as :
 - (a) Accurate diagnosis and recognition of the potentialities of sprain of the femoral attachment of the ligament.
 - (b) Injection of the affected area with local anaesthetic and the application of elastic compression. (The author has not yet encountered a case treated in this manner which has proceeded to the typical syndrome.)
 - (c) Recognition that massage and passive movement in any form are potentially productive of heterotopic bone.
 - (d) Recognition of the symptoms and signs of the complication at the third or fourth week, and thereafter resistance to the temptation to increase the restricted range of flexion by passive movement or manipulation under anaesthesia.

(2) When the diagnosis has been established it should be recognised that the lesion is to a large extent self-limiting, and, provided the popular forms of aggravating the condition are avoided and the policy of masterly inactivity adopted, recovery will slowly but surely take place. The therapy of "masterly inactivity" must be qualified; the patient is permitted to practise rhythmical quadriceps drill and gentle active knee flexing exercises which stop short of the limit imposed by pain. The more vigorous form of quadriceps exercises and all other types of physiotherapy are forbidden. Manipulation under anaesthesia at any time throughout the active phase, which may last from nine months to a year, results in further production of new bone and further decrease of flexion. Surgical interference, in the form of excision of the fragment, performed within the same period, results in recurrence of the bony mass in even more voluminous form than the original and with consequent increase of symptoms.

(3) A small number of cases, an example of which is quoted on page 143, reach a final and completely quiescent state after a period of nine months or a year with a residual disability due to loss of flexion, the result of interference with the free movement of the medial collateral ligament by the bony mass and fibrous adhesions in the associated capsular expansion.

In these cases, and provided there is reasonable assurance that the process is static and the tissues no longer sensitized to the production of new bone, the mass should be exposed through a small vertical incision, separated from the ligament by sharp dissection and detached from the condyle by a fine sharp osteotome. The joint is then fully flexed in order to rupture any additional adhesions, the wound closed and a compression bandage applied. Active knee flexion exercises are commenced on the third or fourth day.

The results of operation are most satisfactory in spite of the fact that recurrence of new bone formation in minor degree can usually be observed.

POST-TRAUMATIC PARA-ARTICULAR
OSSIFICATION OF THE KNEE JOINT

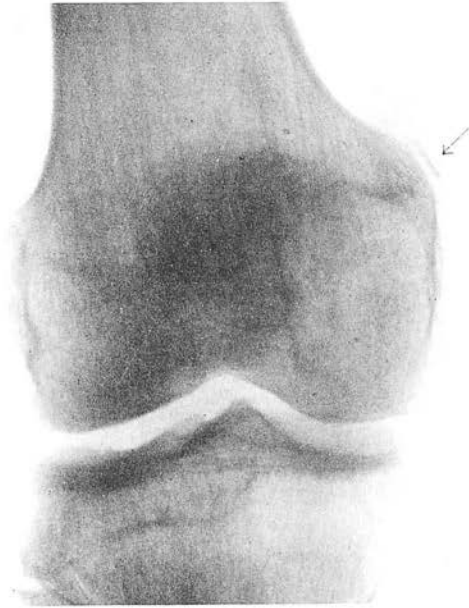

FIG. 138

The changes which appear in the third or fourth week take the form of a thin elongated shadow parallel to the condyle and characteristically separated from the bone by a clear space.

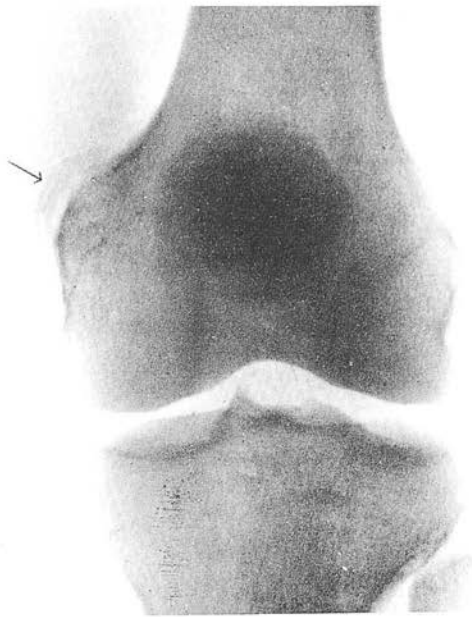

FIG. 139

A later stage of the stable type. A crescent-shaped mass of bone; not fused to the condyle.

POST-TRAUMATIC PARA-ARTICULAR
OSSIFICATION OF THE KNEE JOINT

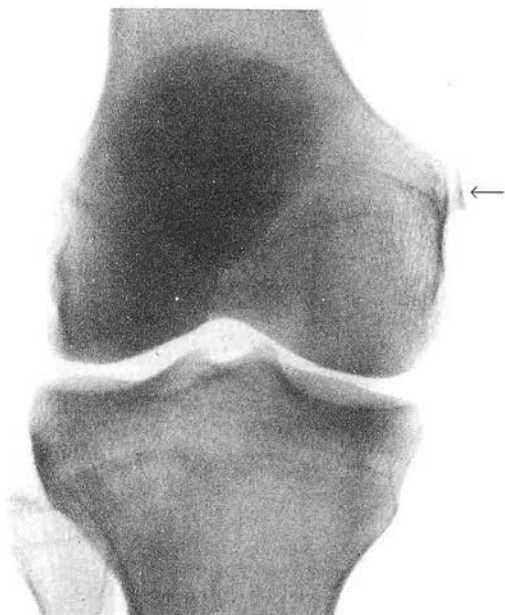


FIG. 140

At this site the anatomy and physiology of the ligament frequently cause the new bone to be moulded so that it is least wide at its upper limit.

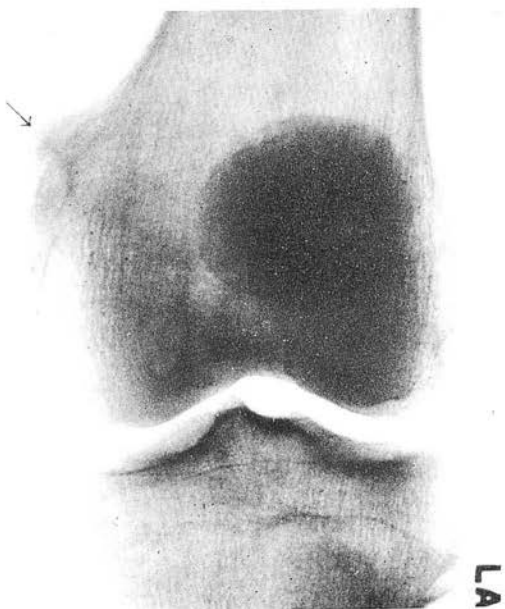

FIG. 141

The mass of bone is fused to the condyle

POST-TRAUMATIC PARA-ARTICULAR
OSSIFICATION OF THE KNEE JOINT

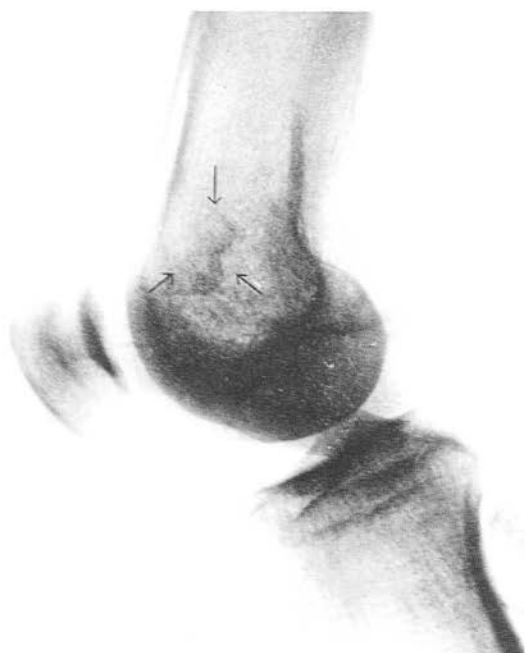

FIG. 142

Lateral view showing the usual location of the heterotopic bone.

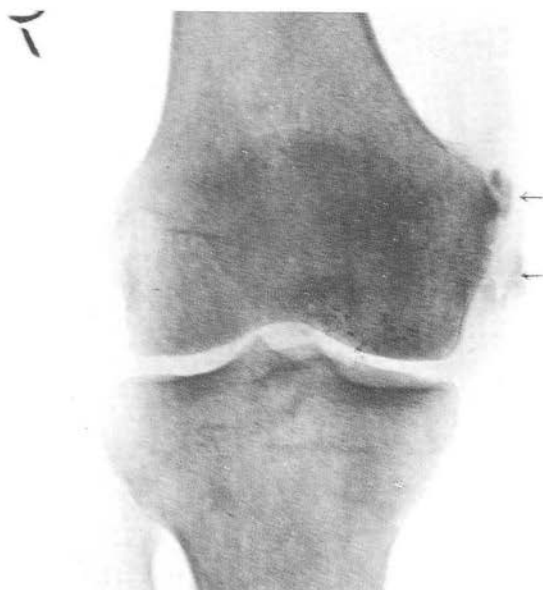

FIG. 143

The evolutionary type which may follow direct trauma or a severe injury such as a dislocation.

POST-TRAUMATIC PARA-ARTICULAR
OSSIFICATION OF THE KNEE JOINT

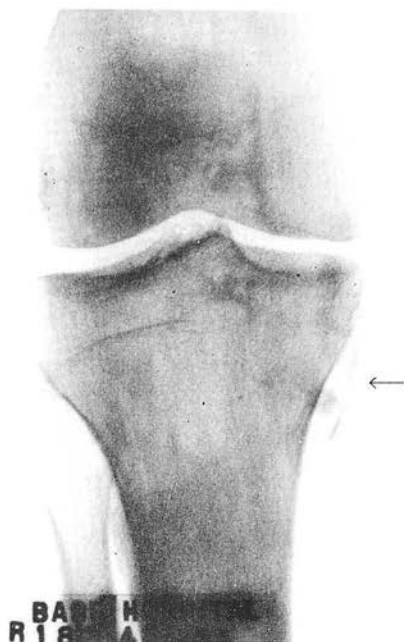

FIG. 144

Post-traumatic para-articular ossification is not necessarily confined to the medial femoral condyle. Heterotopic bone in the tibial attachment of the medial collateral ligament.

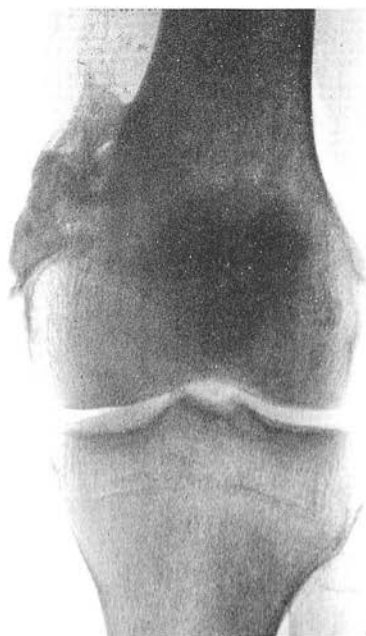

FIG. 145

Massive new bone formation, originally of the evolutive type, but now in the quiescent stage.

COMPLETE RUPTURE OF MEDIAL COLLATERAL LIGAMENT

II. Complete rupture of the medial collateral ligament is a serious, but fortunately relatively infrequent, injury which occurs as a result of a violent abduction strain, such as may be caused by a heavy weight falling against the unprotected lateral aspect of the joint. Like most of the injuries of the stabilising structures it seldom exists as an isolated lesion, but is associated with sprain or rupture of the anterior cruciate ligament, tear or detachment of the medial meniscus, or fracture of the lateral condyle of the tibia. It appears to occur more frequently in association with the last lesion than as an injury involving soft tissues only.

DIAGNOSIS

The diagnosis is made from the history, which is frequently that of a fellow football player falling against the outstretched leg, followed by severe pain and the sensation of "something tearing." The severity of the lesion compels the patient to leave the field and the joint may have swelled to the present dimensions within the course of the next half hour if effusion of blood has taken place.

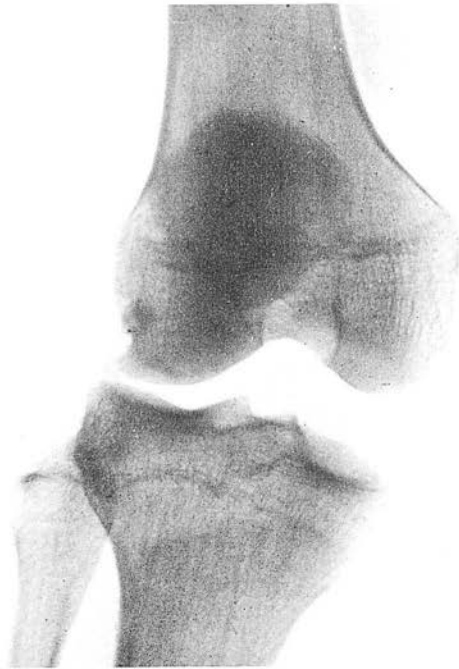

Fig. 146

Complete rupture of the medial collateral ligament. There is no radiological evidence of injury unless the film is taken with the knee joint in abduction.

On examination the joint is swollen, usually as a result of haemarthrosis, and if an interval has elapsed since the accident, ecchymosis is most evident on the medial aspect of the joint. The maximum swelling and tenderness is in the line of the ligament, where it may even be possible to palpate a gap in the capsule (Figs. 148-151).

The final diagnosis must not be assumed until the presence of abduction in extension has been demonstrated (Fig. 146). If pain and muscle spasm prevent the forcible manual abduction which is necessary to demonstrate this cardinal feature, the joint and capsule should be infiltrated

with novocain under morphine and hyoscine narcosis, or a general anaesthetic administered. Advantage should be taken of the opportunity to secure painless aspiration of the contents of the synovial cavity.

In doubtful cases some form of anaesthesia enables the degree of injury to the anterior cruciate ligament to be established, the demonstration of abnormal antero-posterior mobility being rarely possible otherwise.

TREATMENT OF RECENT INJURY

It is accepted that the damage incurred by a ligament, such as the medial collateral ligament, in which the attachments of the anterior fibres are widely separated, is much more extensive and involves more fragmentation and separation of the divided surfaces in a traction lesion, than occurs in an incised lesion in which the cut surfaces can usually be opposed and sutured without undue difficulty. In the traction lesion the gap which exists between the ruptured surfaces heals by fibrous tissue, so that it is inevitable, even with prolonged immobilisation, that the ligament should heal with some degree of lengthening. If this lengthening is not excessive, and provided the tone and volume of the quadriceps is maintained, the final result is satisfactory in the large majority of cases.

On the other hand, in spite of the fact that operative interference in recent ligamentous injuries has but few advocates at the present time, a good case can be made out for operative action in the injuries involving complete solution of continuity of the types illustrated in Figs. 147, 148, 149, and 151. It is clear that immobilisation alone cannot ensure a stable joint in these cases as opposed to those represented in Figs. 150 and 152 in which healing, with or without lengthening, can be confidently anticipated by conservative means. The possible association with an injury of the anterior cruciate ligament is no argument against operation. If operative action results in a normal medial collateral ligament, the future stability of the joint will be much better than will be the case if both ligaments are unduly lax or remain unhealed.

In an attempt to formulate some ruling with regard to indications for treatment it is only possible to say that when examination of the joint, under anaesthesia if necessary, demonstrates beyond shadow of doubt the existence of complete solution of continuity, an attempt should be made to locate the exact site of the lesion, that is, whether it is represented by Figs. 148, 149, 150, 151, or 152. If the possibility arises that the lesion is incomplete, or if the technical difficulties of repair appear insurmountable, there is a strong indication for prolonged immobilisation rather than operation.

TECHNIQUE OF TREATMENT

CONSERVATIVE

Treatment and after-treatment differ in no respect from that described under TREATMENT OF RECENT INJURIES OF ANTERIOR CRUCIATE LIGAMENT.

OPERATIVE

Once the decision has been made to undertake operative repair, the procedure may, with advantage, be deferred for a few days to permit the acute swelling to subside; it should not be unduly delayed lest contraction of the

tissues concerned and difficulties of orientation produce additional technical problems.

Following the application of a tourniquet a straight incision is made in

DIAGRAMMATIC REPRESENTATION OF THE GROSS
LESIONS OF THE MEDIAL COLLATERAL LIGAMENT

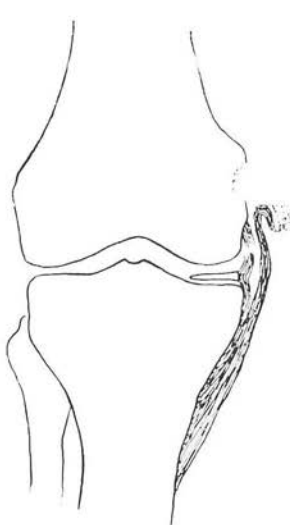


FIG. 147

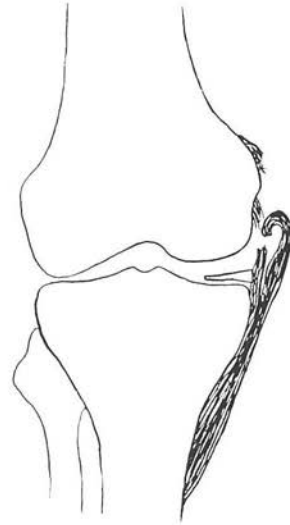


FIG. 148

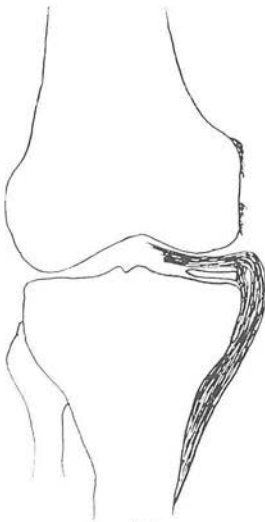


FIG. 149

Fig. 147. Complete rupture of upper femoral attachment with avulsion of fragment of bone.

Fig. 148. Complete rupture of upper femoral attachment which has been torn away from the bone.

Fig. 149. Complete rupture of upper femoral attachment. The free end of the ligament and capsule have been drawn into the joint. (Watson Jones.)

The possibility of injury to the short posterior fibres which are attached to the meniscus has been indicated in each of the drawings.

the line of the ligament; if the lesion can be accurately localised, as in Fig. 147 a short incision (Fig. 154) will provide adequate access, but otherwise the whole length of the structure must be exposed.

If a fragment of bone has been avulsed at the superior attachment (Fig. 147) it is a simple matter to replace it in the crater, maintaining the reduction with a coarse-threaded stainless steel screw (Figs. 153 and 155).

DIAGRAMMATIC REPRESENTATION OF THE GROSS LESIONS OF THE MEDIAL COLLATERAL LIGAMENT

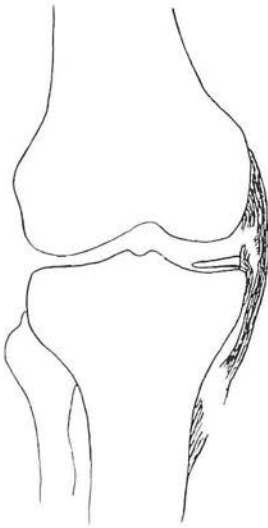


FIG. 150

Fig. 150. Complete rupture close to lower tibial attachment.

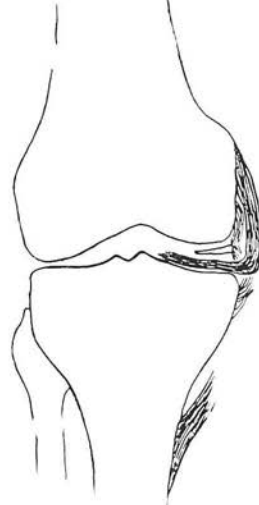


FIG. 151

Fig. 151. Complete rupture close to lower tibial attachment. The free end of the ligament has been drawn into the joint. (Palmer).

Fig. 152. The ligament is "over-stretched." There is no solution of continuity.

The possibility of injury to the short posterior fibres which are attached to the meniscus has been indicated in each of the drawings.

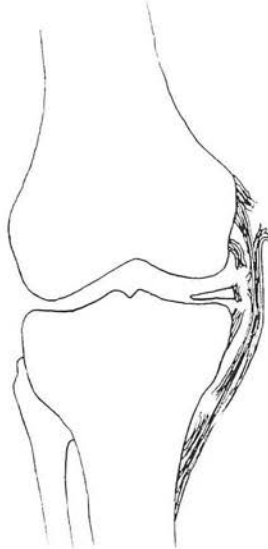


FIG. 152

If either the superior or inferior insertions are detached from bone they are replaced and sutured in position with silk or fine stainless steel wire passed through the periosteum and surrounding soft tissues; if this proves

impossible an $\frac{1}{8}$ to $\frac{3}{16}$ inch hole is bored through the bone to the opposite side and a strong silk suture tied over a small bone graft in the manner illustrated in Fig. 116, or two smaller holes drilled and the suture tied over the intervening bone after the manner of Palmer¹ (Fig. 156). In ruptures at other levels with shifting of the sections in relation to one another (Fig. 150) it is usually possible to approximate the divided ends, reinforcing the suture line if necessary with a strip of fascia lata.

After-treatment. A compression bandage, incorporating a light metal splint or a plaster slab, is applied and retained for ten to fourteen days; thereafter the limb is placed in an unpadded plaster cast (Fig. 112). Weight-bearing is resumed at the end of the fourth week and more vigorous quadriceps drill practised. The immobilisation is discarded about the eighth week.

OLD RUPTURES OF MEDIAL COLLATERAL LIGAMENT

The disability which results from a rupture of the medial collateral ligament of long standing differs in few respects from that associated with an old rupture of the anterior cruciate ligament. The intimate relationship between the two structures has already been stressed. The main difference in the clinical features is that, in the former, the more prominent feature is laxity of the medial collateral ligament, whereas in the latter, antero-posterior mobility of the tibia on the femur overshadows any laxity of the medial collateral ligament which may be present.

Residual disability is due to:

- (1) Failure to establish the diagnosis at the original injury and the permitting of early weight-bearing.
- (2) Treating the recent injury by early massage and passive mobilisation.
- (3) Treating the injury by prolonged immobilisation in plaster without regular quadriceps drill. No traction lesion of an accessory supporting structure of the knee joint which heals by the interposition of fibrous tissue can be expected to withstand the stress and strain of weight-bearing in the absence of the protective rôle of a fully developed quadriceps.

TREATMENT

CONSERVATIVE

The muscles are the first line of defence of the joint; the ligaments are the second.² The treatment of choice in lateral instability is a period of three

¹ Ivar Palmer. "On the Injuries to the Ligaments of the Knee Joint. A Clinical Study." *Acta Chir. Scandinavica*, 1938, lxxxii, Supplementum liii, Stockholm.

² R. Watson-Jones. "Fractures and Joint Injuries." E. and S. Livingstone, Edinburgh, 1943, 703.

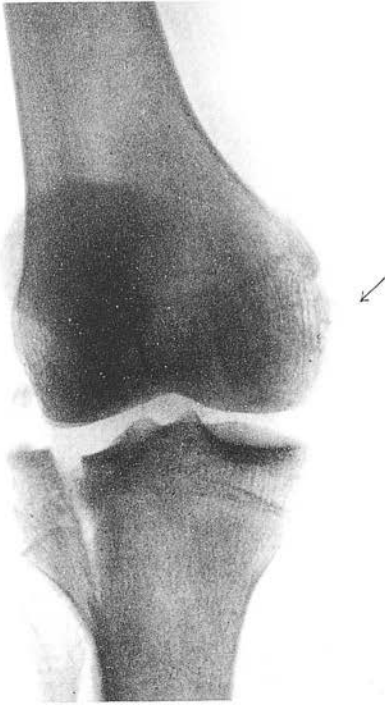

FIG. 153

Fig. 153.—Complete rupture of the upper femoral attachment of the medial collateral ligament with avulsion of a fragment of bone and associated with a fracture of the lateral tuberosity of the tibia.

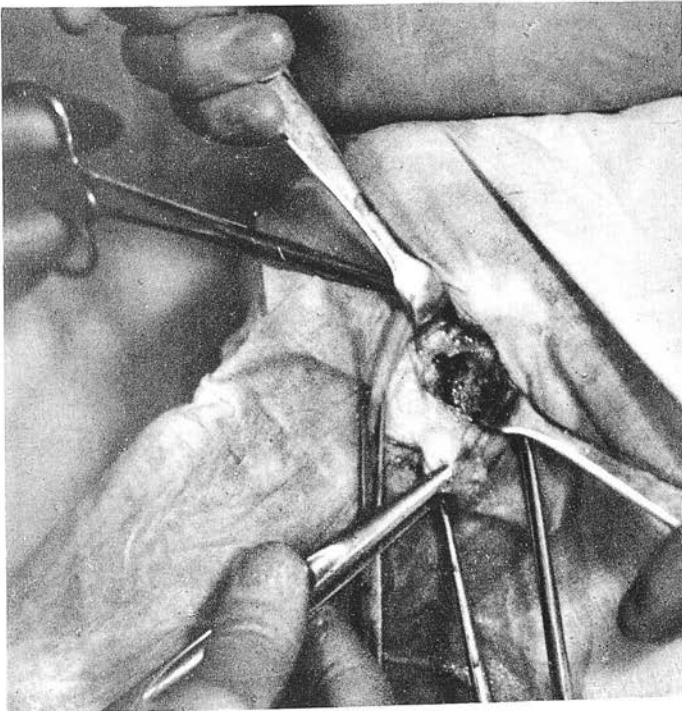


FIG. 154—The detached ligament is held in the dissecting forceps.

months devoted to the redevelopment of the quadriceps, when it will frequently be found that the function of the joint has improved to a degree which renders further measures unnecessary.

Before the maximum benefit can be derived from improvement of the volume and tone of the quadriceps it is necessary to ascertain that no

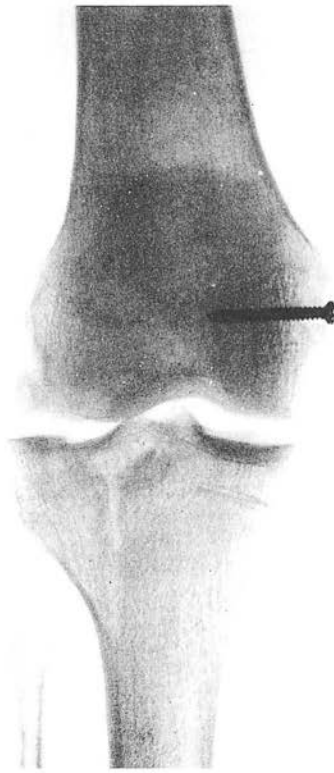

FIG. 155

The case illustrated in Figs. 153 and 154 was treated by operative replacement, fixation of the fragment with a stainless steel screw, and open reduction of the fracture of the tibia through a separate incision.

be expected to prove effective in the absence of normal quadriceps control. No operative measure should be considered until non-weight-bearing exercises have been practised for a period of three months. If incapacity persists, in spite of the certainty that there is no underlying meniscus lesion to account for the instability, there is a reasonable prospect of securing some improvement in function by reconstruction of the ligament, with the proviso that the operator realises that the new ligament is merely an adjunct to the protection provided by the quadriceps.

OPERATIVE PROCEDURES :

(1) Transplantation of the tibial attachment of the medial collateral ligament.

additional internal derangement, relative to the medial meniscus in particular, has taken place in the interval during which the patient has suffered from instability and giving-way incidents consequent to the lax ligaments or the wasted quadriceps. It is not infrequently found that the degeneration of the normal protective apparatus, especially in this particular case where the peripheral attachment of the medial meniscus is affected, results in the production of a longitudinal tear. If the torn meniscus is not excised prior to the prolonged course of muscular development the results will prove disappointing.

The use of a knee cage is unjustifiable. The most accurately fitting apparatus is no substitute for normal quadriceps control. It can support ligamentous control only at the expense of the muscles (see also page 125).

OPERATIVE

No operative reconstruction of the medial collateral ligament can

Mauck¹ contends that in a large proportion of cases the original injury takes the form of avulsion of the ligament from the tibial head, rather than solution of continuity of the structure between the limits of attachment, and points out that instability is due to laxity of the structure rather than actual weakness. He considers that if weakness does exist it is that part of the ligament adjacent to the tibial head, *i.e.*, that portion which has healed by fibrous tissue. Mauck concludes that the rational operative procedure should shorten the relaxed ligament and eliminate the weakened part which is composed of scar tissue.

Technique.—An incision, which extends from the adductor tubercle to a point 4 ins. below the articular surface of the tibia, is made over the medial aspect of the joint (Fig. 157). The skin and fascia are dissected so that the whole inner side of the capsule and of the medial condyle of the tibia are exposed. A triangular flap of bone, 2 ins. long and about $\frac{1}{2}$ inch thick at its base, is removed from the medial aspect of the tibial condyle by means of a broad fine osteotome. The capsule is split vertically to a distance of about 1 inch at the anterior and posterior margins, permitting the bone flap to be reflected upwards on a broad base of capsule and ligament (Fig. 158). The meniscus, a large section of which is now exposed, is excised.

The ligament is shortened by drawing the bone flap strongly downwards and mortising it into the side of the tibia at a lower level in such a manner that it is locked in position (Fig. 159). In this way that part of the ligament which is formed by scar tissue is brought into intimate contact with the denuded bone of the tibial condyle immediately above the base of the flap.

A compression bandage incorporating a padded gutter splint is applied and retained for two weeks; thereafter a walking plaster (Fig. 112) is used and graduated quadriceps exercises commenced. The plaster case may be discarded in a further two to four weeks' time.

(2) Reconstruction of the ligament using the tendon of semi-tendinosus.²

The joint is flexed at an angle of 30 degrees and the medial collateral

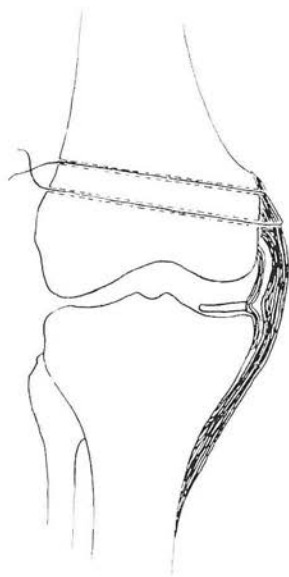


FIG. 156

Diagrammatic representation of method of re-attaching the upper insertion of the medial collateral ligament to bone by means of a suture passed through a double canal in the femur. (After Palmer.)

¹H. P. Mauck. "A New Operative Procedure for Instability of the Knee." *J. Bone and Joint Surg.*, 1936, xviii, 984.

²T. P. M'Murray. "Operative Treatment of Internal Lateral Ligament of Knee." *Brit. Jour. Surg.*, 1918, vi, 377, and 1920, viii, 267.

MAUCK'S OPERATION

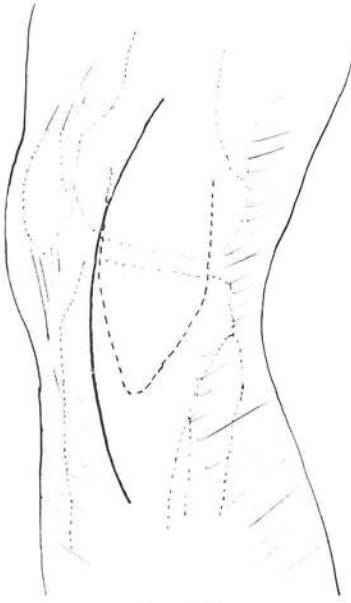


FIG. 157

The skin incision together with the outline of the bone flap and the upward extensions through the capsule.

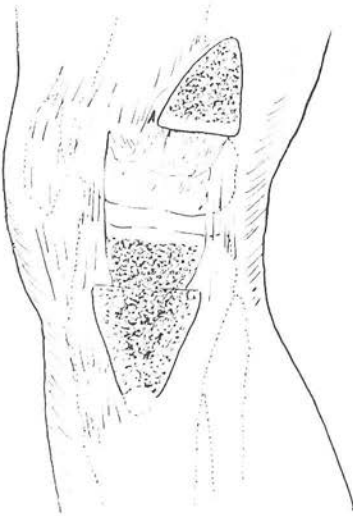


FIG. 158

The bone flap with the ligament and capsule attached; the new bed to receive the bone flap.

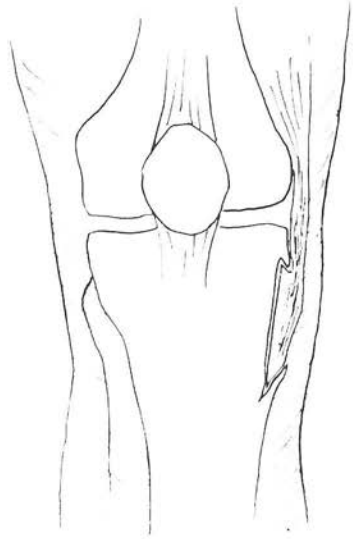


FIG. 159

The transplanted flap in position, showing the locking and the denuded portion of the capsule approximated to the raw bone above the flap.

ligament defined through a vertical incision. The tendon of semitendinosus is mobilised and carried forward so that it lies in the line of the ligament, which is split longitudinally throughout its entire length. Deep grooves are cut in both the femur and the tibia in the line of the ligament at the points of original attachment. The tendon is then stitched into the substance of the split ligament and buried and secured by deep sutures into the bony grooves.

The limb is immobilised in plaster for a period of four weeks, during which non-weight-bearing quadriceps exercises are continued.

(3) Reinforcement of the ligament by strips of fascia.

The author has no personal experience of the procedures outlined above, but has used Blair's operation (page 133), which was designed for the repair of the anterior cruciate ligament, with satisfactory results.

In three cases in which operation was indicated, the anterior cruciate ligament was lax but not torn. This simple operation was chosen because it offered prospects of achieving a double purpose by a single operative procedure. Although a satisfactory improvement of function was obtained, further experience is necessary in order to estimate the prospects of more general application to this particular injury.

LATERAL LIGAMENT

Lesions of the lateral collateral ligament are relatively uncommon. In contrast to the medial collateral ligament it is a rounded band of relative unimportance in stabilising the joint, and, being relaxed in flexion, is not subject to rotation strains. It is reinforced by the presence of the iliotibial band and the biceps tendon and is protected from adduction strains by the opposite limb. It is thus only liable to injury in accidents involving gross violence.

Rupture of the ligament occurs when the joint is exposed to sudden and powerful adduction of the leg on the thigh and in partial or complete dislocations. The injury which results is of importance because complete rupture of the ligament seldom occurs as an isolated injury, but is associated with overstretching or complete solution of continuity of the lateral popliteal nerve (Fig. 160).

The "ligamentous-peroneal nerve" syndrome was first described by

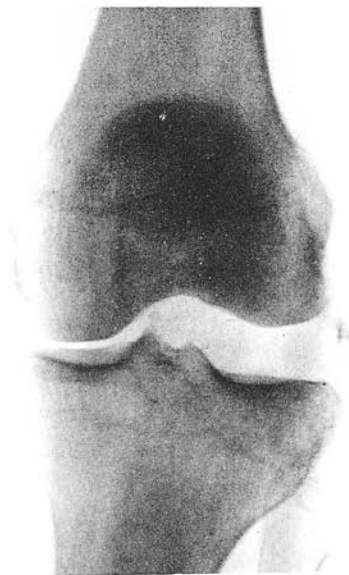

Fig. 160

Old rupture of the lateral collateral ligament; a traction lesion of the lateral popliteal nerve was present.

Platt,¹ who, by 1940, had recorded nine cases, and further information concerning the peripheral nerve injury has been contributed by Highet and Holmes,² who have described eight additional cases.

The features of the lesions are :

KNEE JOINT

- (1) Rupture of the lateral capsule close to the margin of the tibia, producing a large hiatus on the outer side of the joint.
- (2) Avulsion of the styloid process of the fibula, carrying with it the insertion of the lateral collateral ligament.
- (3) Avulsion of the biceps tendon from its fibular attachment.
- (4) The iliotibial tract may be ruptured or avulsed.
- (5) The cruciate ligaments may be damaged.

NERVE

The nerve lesions fall into two groups :

- (1) Overstretching. In these circumstances although macroscopic continuity may appear to be preserved, pathological changes in the nerve extend far above the site of injury in the form of fibre degeneration, intraneural fibrosis, and vascular abnormality.
- (2) Complete rupture.

PROGNOSIS AND TREATMENT

It would appear that the prognosis with regard to joint function is excellent, as might be expected in a lesion of a relatively unimportant stabilising ligament, but the results of both conservative and operative treatment of the peripheral nerve lesion are poor. Traction lesions are characterised by much more extensive damage to the nerve-trunk than is found after injury by incision, laceration, or gun-shot wound. In most of the cases which have been described there has been a delay of several months before exploration and suture could be performed, and although such a delay is not normally of primary importance, if, as has been suggested, the fibrotic and vascular pathological changes which have been mentioned are progressive, it is evident that early exploration and suture offer the greatest chance of recovery. It is interesting to note that in the two cases of complete recovery which have been recorded by Platt, the interval between the accident and operation was sixteen days in one case and six weeks in the other. It would thus appear that the procedure of choice in complete rupture of the lateral collateral ligament, accompanied by a traction lesion of the lateral popliteal nerve, is early exploration, which will not only enable suture of the nerve to be accomplished with the minimum difficulty and with the maximum

¹ Harry Platt, *J. Bone and Joint Surg.*, 1928, x, 403. *Proc. R. Soc. Med.*, 1937, xxx, 863. *Lancet*, 1940, ii, 612.

² W. Bremner Highet and W. Holmes. "Traction Injuries to the Lateral Popliteal Nerve and Traction Injuries to Peripheral Nerves after Suture." *Brit. Jour. Surg.*, 1943, xxx, 212.

chance of recovery, but will afford the opportunity to repair the ligament and the associated capsular lesion at the same time.

AVULSION OF ILIOTIBIAL TRACT FROM LATERAL CONDYLE OF TIBIA

(AVULSION FRACTURE OF LATERAL TIBIAL CONDYLE)

It is evident from the normal operative exposures of the menisci that whereas the capsule on the medial side of the joint is of uniform texture and consistency, the lateral meniscus is approached through a weak area which lies between the ligamentum patella and a strong thickened band of tissue running down to the head of the tibia. This strong band is the iliotibial tract or collateral patellar ligament, which is inserted into the anterior aspect of the region of the lateral condyle, on the posterior aspect of which is situated the articular facet for the head of the fibula. The exact point of insertion is an eminence situated on the upper border of the tuberosity at the junction of its anterior and lateral surfaces.

The experimental work of Segond,¹ referred to by Milch,² has shown that this strong fibrous reinforcement of the capsule, which is the termination of the iliotibial tract, is subject to a marked degree of tension throughout the movement of internal rotation, and he succeeded in producing avulsion of its insertion in seventeen of his thirty-eight experiments.

CLINICAL FEATURES

The injury is produced by forcible internal rotation in flexion and exists either as an isolated lesion or in association with grave injuries of the medial collateral and anterior cruciate ligaments. The lesion fades into insignificance in the latter circumstances, and thus only the features of the isolated injury will be described.

In addition to the essential mechanism of production, the typical features are pain and tenderness accurately localised to the lateral tuberosity of the tibia. If the synovial membrane has been torn, or the bony lesion communicates with the joint, a blood stained synovial effusion or even a haemarthrosis may be present. The most characteristic feature of all is the radiograph which shows the detachment of a flake of bone from the lateral tuberosity of the tibia (Fig. 161).

TREATMENT

Treatment depends on the severity of the symptoms. In some cases the repeated injection of a few cubic centimetres of local anaesthetic is all that is necessary. In others, repeated aspiration, supplemented by the use of a compression bandage, may require to be followed by immobilisation in a skin-tight thigh length plaster case of the type which permits freedom of the

¹ Paul Segond. "Recherches cliniques et expérimentales sur les épanchements sanguins du genou par entorse." *Progrès Méd.*, 1879, vii, 297, 319, 340, 379, 400, 419.

² Henry Milch. "Cortical Avulsion Fracture of the Lateral Tibial Condyle." *J. Bone and Joint Surg.*, 1936, xviii, 159.

ankle and foot. The plaster cast should be retained for a period of three to four weeks.

DISLOCATION OF KNEE JOINT

Complete dislocation of the knee joint is a rare injury. The author has only seen two recent cases, the first of which is illustrated in Fig. 162, but has had the opportunity of examining eight others which were alleged to have sustained such an injury some weeks or months previously.

ETIOLOGY

This injury can only occur as a result of the most extreme direct violence applied to the lower end of the femur when the upper end of the tibia is firmly fixed, or to the upper end of the tibia when the femur is fixed; the direction of the blow determines the type of dislocation produced. On very rare occasions it is known to have taken place by rotary violence.

SURGICAL PATHOLOGY

The dislocations are classified according to the relationship of the upper end of the tibia to the lower end of the femur, and thus (1) anterior, (2) posterior, (3) lateral, (4) medial, and (5) rotary dislocations are possible.

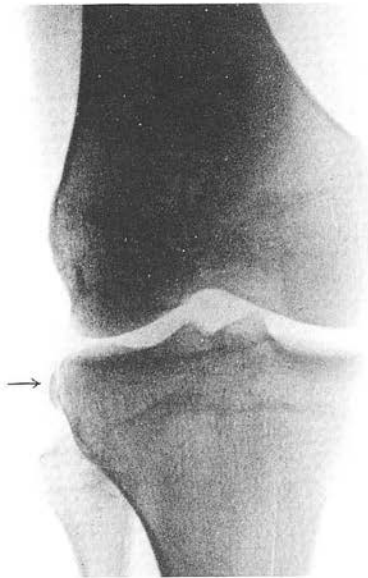


FIG. 161

Avulsion of the iliotibial tract from the lateral condyle of the tibia. The characteristic radiograph.

All types involve partial or complete rupture of the collateral and cruciate ligaments and injury of the popliteus, gastrocnemius and vastus medialis muscles. The posterior dislocation incurs considerable risk of injury to the popliteal artery, and the medial variety is very liable to damage the lateral popliteal nerve. Bohler¹ states that the tendons of semimembranosus, semitendinosus, sartorius and gracilis may slip into the intercondylar notch in the lateral dislocation. The type of force involved and the magnitude of the deformity may produce division or rupture of the skin and underlying soft tissues and thus entail an open wound of the joint.

The following operative findings, which refer to the second case encountered, are recorded to illustrate the extent of the destruction produced by dislocation:

¹ Lorenz Bohler. "The Treatment of Fractures." John Wright and Sons Ltd., Bristol, 1936, 382.

The case—a medial dislocation—was subjected to operation four days after closed reduction for two reasons; first, because clinical examination indicated that the lateral capsule had been drawn into the joint in the manner illustrated in Fig. 149; and second, there was a complete lateral popliteal nerve paralysis.

A straight incision eight inches long was made over the lateral aspect of the joint. It was immediately evident that the capsule was grossly lacerated. The anterior portion had been torn from the lower end of the femur and was displaced

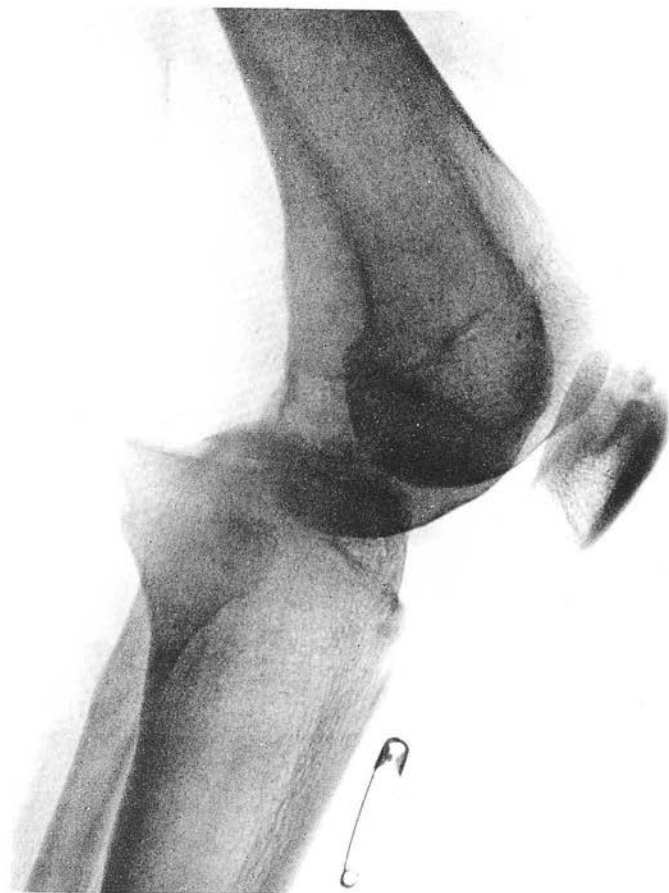


FIG. 162

Dislocation of the knee joint.

into the joint over the superior surface of the meniscus. The posterior portion, including the lateral ligament, had been torn at the inferior attachment and displaced upwards. The iliotibial tract had been avulsed from the tibia and the biceps tendon from the head of the fibula; the head of the fibula was thus exposed and devoid of tissue attachments.

On looking into the joint both the anterior and posterior cruciate ligaments were seen to be torn, the former at its superior attachment and the latter, together with the adjacent capsule, from the tibia. It was possible to pass a finger into the popliteal space and palpate the popliteal artery. The meniscus—a congenital

disc had been torn from its posterior and postero-lateral attachments and was displaced forwards.

The lateral popliteal nerve was lying curled up in the wound, having suffered a traction lesion some eight inches above the level of the joint line. Two nerve fibres which had been avulsed at an even higher level were seen to protrude from the sheath.

No attempt was made to expose the site of rupture of the lateral popliteal nerve, for it was quite obvious that the prospects of recovery, even if repair could have been effected, were hopeless. In these circumstances, all that was done was to excise the meniscus and repair the lateral capsule, attaching the ligament to the head of the fibula with sutures passed through a drill hole. The anterior cruciate ligament was not repaired as the superior attachment lay in the normal anatomical position when the dislocation was reduced.

DIAGNOSIS

A cursory examination of the gross deformity makes the diagnosis evident, but before proceeding with the reduction, which is a matter of urgency, the condition of the circulation should be ascertained and evidence of injury to the lateral popliteal nerve, as shown by loss of sensation and paralysis of the anterior group of tibial muscles, sought. Antero-posterior and lateral radiographs should be secured in order to eliminate the possibility of accompanying fractures.

TREATMENT

Reduction is accomplished at the earliest possible moment, under general anaesthesia, by means of traction and manual pressure on the tibia in the appropriate direction. The so-called irreducible dislocation, in which the ham-string muscles become trapped in the intercondylar notch and to which reference has been made above, is reduced by flexing the joint to a right angle before exerting pressure on the medial aspect of the tibial head.

If the popliteal artery is ruptured or thrombosed, in either the closed or compound dislocation, amputation through the thigh is necessary. Primary suture of a rupture of the lateral popliteal nerve may be carried out in an open dislocation, if conditions are favourable, or deferred, as in the case of a closed dislocation, to a later date.

AFTER-TREATMENT

When reduction has been accomplished a compression bandage, with the addition of a padded Cramer wire backslint, is applied. The circulation of the toes is observed at frequent intervals during the first forty-eight hours, and when the blood supply is no longer in doubt, the effusion of blood should be aspirated and the compression bandage re-applied. At the end of a week an unpadded plaster case of the type which permits free action of the ankle joint (Fig. 112) is applied and quadriceps exercises commenced. After an interval of three to four weeks the original plaster will be no longer skin-tight and must be changed to permit a return to weight-bearing. The second plaster is retained for a further period of eight weeks, during which the quadriceps muscle is conscientiously developed.

If continuity of immobilisation is maintained for three months, and every effort made to redevelop the extensor apparatus, the results of treatment are surprisingly good. The rupture of the ligaments, capsule and muscle, results in the laying down of fibrous tissue and the formation of heterotopic bone which may be seen in relationship to the medial femoral condyle, medial aspect of the head of the tibia and in the region of the tibial spine. In these circumstances a full return of flexion is not to be expected and is undesirable in that it may be associated with a flail joint. The optimum result is a stable joint and the capsular and extracapsular fibrosis assist in the stabilisation, but only at the expense of a varying degree of loss of flexion.

CHAPTER EIGHT

INJURIES OF EXTENSOR APPARATUS

THE injuries of the extensor apparatus may be classified:

- (1) Injuries, usually by indirect violence, which result in partial or complete solution of continuity.
 - (A) Rupture of the muscle.
 - (B) Avulsion of the quadriceps muscle from the patella.
 - (C) Transverse fracture of the patella.
 - (D) Avulsion of the ligamentum patellae from the patella.
 - (E) Fracture of the tibial tubercle or separation of the epiphysis of the tibial tubercle.
- (2) Injuries of the patella by direct violence.
- (3) Dislocation of the patella.

(1) (A) RUPTURE OF MUSCLE

RECTUS FEMORIS

The rupture of a few fibres of the quadriceps, usually of the rectus femoris, is of common occurrence in athletes. It is probable, however, that many so called "pulled muscles" are really nothing more than a small intramuscular haemorrhage from a ruptured vein. The rupture of a group of fibres which can easily be recognised as such may take place from muscular violence alone, when it is usually the result of a miss-kick, or may be produced by some hard object, such as a boot or a head, coming in violent contact with the contracting quadriceps during a game of football. The gross injuries occur when a heavy weight, such as a beam or girder, pins the limb against the ground and divides the muscle against the shaft of the femur.

Clinical Features.—In the minor injuries the patient complains of disabling pain on contracting the muscle, which is a serious handicap to his athletic pursuits: examination reveals a small area of deep tenderness. In the larger ruptures it may be possible to palpate a gap in the fibres which may be associated with discoloration of the skin. Cases are more frequently encountered at a late stage when they exhibit a swelling on the mid-line of the middle third of the thigh, below which is a shallow depression. The swelling, which consists of retracted muscle fibres, becomes larger and firmer on contracting the muscle and the depression more pronounced (Fig. 163). Such local ruptures of the rectus femoris do not affect the strength of the quadriceps and seldom cause any real physical disability. Many patients are anxious about the significance of the lump and complain of the swelling on aesthetic grounds.

Treatment.—In recent cases, complete relief of symptoms which may permit immediate resumption of athletic activities may be obtained by injection of a few c.c.s of local anaesthetic into the area and repeating the treatment at daily intervals if required.

In old cases, operation is only likely to be necessary on cosmetic grounds. Repair of the rupture is technically difficult and likely to prove unsatisfactory for it produces no effect on function, and if there is any recurrence of the swelling the patient will be disappointed. In these circumstances resection of the retracted fibres may produce the most satisfactory solution.

VASTUS MEDIALIS

Small local ruptures which produce no ill effects on function are unknown in this component.

The injuries which are encountered are of a gross nature and occur either as a result of the limb being trapped, in which

case division of muscle fibres takes place (Fig. 164), or in an acute traumatic dislocation of the patella, when the rupture occurs close to the attachment to that bone. It is unfortunate that in neither case is the severity of the lesion nor its effect on the future function of the joint commonly recognised at the time of the accident (Figs. 164 and 165).

Treatment.—In traumatic dislocation of the patella, which is the more common source of disability, the author considers that a large proportion of cases should be subjected to immediate operative repair (see Recurrent Dislocation). When the injury is localised to the muscle fibres alone immediate operative repair is probably inadvisable. It entails the suture of friable muscle, and should thus be deferred for several weeks or even months when the firm scar tissue can be excised and the muscle repaired with strips of fascia lata.

VASTUS INTERMEDIUS

This component is most frequently damaged by haemorrhage which takes place following a kick sustained during a game of football. The patient is seldom disabled at the time of the accident and completes the game. Several hours later he becomes aware that his thigh is enormously swollen, and in extreme cases may be unable to flex the knee because of the tension.

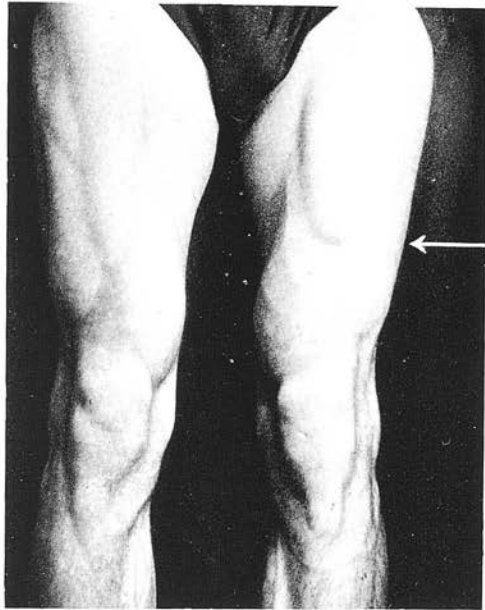


FIG. 163

The common rupture of the rectus femoris. The physical disability is insignificant and the injury rarely warrants operative interference.

Treatment.—This condition is treated with rest in bed, elastic compression to promote absorption, and later, by progressive active flexing exercises. The painful deep massage and passive knee movements which are sometimes employed are contra-indicated and are frequently responsible for the onset of myositis ossificans traumatica (Fig. 166). If this complication does occur, operative interference is absolutely contra-indicated; the bone tends to undergo spontaneous absorption provided passive movements are avoided. If the mass of bone is still responsible for restriction of flexion after an interval of many months, or when a completely quiescent stage has been reached, it should be excised through a lateral incision.

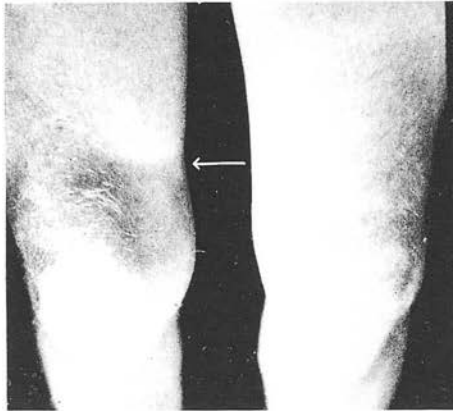

Fig. 164

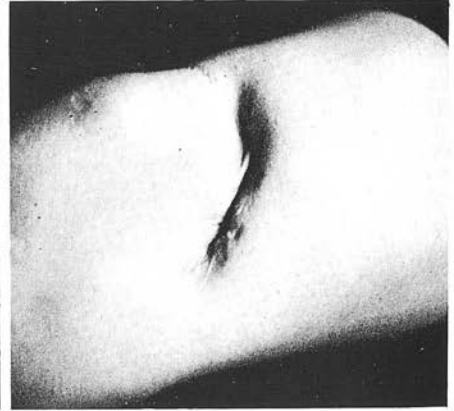


Fig. 165

Two cases of rupture of the vastus medialis caused by trapping of the limb in a road accident. In Fig. 165 an unsuccessful attempt had been made to repair the defect. Both these cases illustrate the importance of the vastus medialis; from each a torn medial meniscus was excised in the absence of a previous history of injury.

VASTUS LATERALIS

This component is seldom the subject of injury and appears to be protected by the powerful iliotibial tract. Muscle herniae, which may follow the removal of strips of fascia from this tract, do not appear to give rise to any disability.

(1) (B) AVULSION OF QUADRICEPS MUSCLE FROM PATELLA

This is an injury of overweight patients, past middle age, who avulse the muscle from the patella in circumstances which, in younger age groups, result in a transverse fracture or avulsion of the ligamentum patellae. The injury is sustained as the result of a stumble, frequently in descending stairs; the whole body-weight is transmitted through the flexing knee, and the patient, in attempting to avert a fall, contracts the quadriceps violently and thereby tears the muscle from its attachment to the superior pole.

Like all subcutaneous ruptures of tendons the diagnosis is frequently

missed. Even when the possibility of a fracture is suspected the absence of radiological confirmation causes the diagnosis to be overlooked. When a second radiograph is taken one month later as a result of the patient's failure to recover, a mass of ossifying haematoma is noted above the superior pole and provides a hint as to the original injury.

CLINICAL FEATURES

The diagnosis is established from the history which consists of a stumble, an attempt to recover, immediately followed by a sharp pain just above the knee which caused the patient to fall. On examination it is found that the patient is unable to produce active extension of the joint and there is tenderness, discoloration, and a palpable gap immediately above the patella.

TREATMENT

If the injury is incomplete, involving the rectus femoris and vastus intermedius, but leaving the principal insertions of the vastus medialis and vastus lateralis to the medial and lateral borders of the patella intact, treatment in the form of splinting will produce a satisfactory result; but if the complete lesion is neglected or treated conservatively, although the mass of new bone which forms in the haematoma eventually fuses with both the muscle and with the patella, the union is unsatisfactory and entails lengthening of the quadriceps apparatus, with consequent loss of power and instability of the joint. The results of operation in recent cases are excellent.

Technique of Operation.—The rupture is exposed through a mid-line or parapatellar incision and the blood clot removed, revealing the posterior wall of the suprapatellar pouch and permitting definition of the nature and extent of the injury. It may be found that attached to the anterior surface of the muscle is a tongue of periosteum torn from the anterior aspect of the patella. In addition, a tag of ligamentous tissue from the posterior surface of the tendon may be attached to the postero-superior surface of the patella; these tags are preserved for use in strengthening the suture line. Two parallel drill holes are made in the long axis of the bone,

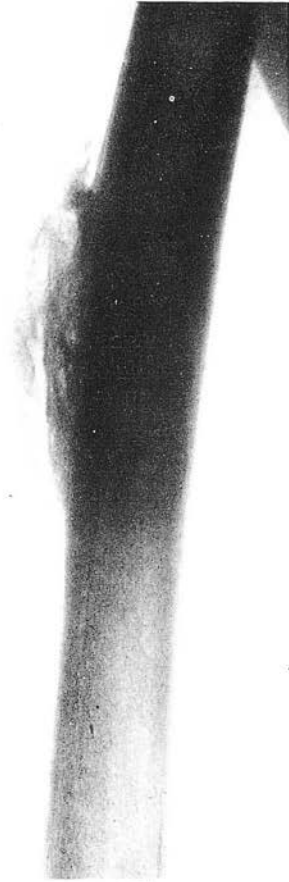

FIG. 166
Myositis Ossificans Traumatica.

beginning on the superior aspect and drilling downwards and forwards so that the exits appear on the anterior surface. A mattress suture of kangaroo tendon, stout chromic catgut or stainless steel wire is passed through the muscle and the ends threaded through the drill holes and tied over the anterior aspect of the patella. If there is a large tag of tissue attached to the bone it is utilised to strengthen the suture line by burying it in a horizontal slot in the muscle substance by means of sutures tied on the medial and lateral sides; this procedure is carried out before the large mattress suture is inserted. The torn expansions of the vastus lateralis and vastus medialis are sutured with interrupted chromic catgut sutures. Finally the tag of periosteum from the anterior surface of the patella is sutured back in position, the wound is closed, and a compression bandage, with the addition of a padded back splint, applied.

After-treatment.—At the end of ten to fourteen days, when the sutures are removed, a plaster back splint or a skin-tight plaster case is applied. Quadriceps drill or straight leg raising in the plaster case is not permitted until the end of fourteen days, when assisted straight leg raising may be commenced. All external splinting is discarded at the end of four to six weeks and more vigorous quadriceps exercises and knee flexing exercises instituted. Weight-bearing with the aid of crutches may begin about the same time.

FRACTURES OF PATELLA

In the classification of the injuries of the extensor apparatus the transverse fracture of the patella, the fracture by indirect violence, has been put under a different heading from comminuted fracture, the fracture by direct violence. The former injury is regarded as a rupture of the extensor apparatus, whereas the latter does not entail complete solution of continuity. For the purposes of treatment, however, both injuries are considered under the same heading.

(1) (C) TRANSVERSE FRACTURE OF PATELLA

In the middle-age group rupture of the quadriceps apparatus usually takes the form of a transverse fracture of the patella. The circumstances and mechanism are similar to those described under Avulsion of the Quadriceps Muscle from the Patella.

CLINICAL FEATURES

The joint is distended by effusion and haemorrhage. The skin is undamaged if the injury occurred as a result of muscular violence alone, but occasionally the subsequent fall causes abrasions of the overlying soft tissues. As the bone is subcutaneous, the fragments together with the intervening gap are palpable; the upper fragment is drawn upwards by contraction of the muscle, whereas the lower fragment is tilted so that the fractured surface looks forward (Fig. 180). The gap between the fragments varies in breadth,

depending on how far laterally the rupture of the expansions extends on either side of the patella. If the medial and lateral expansions are torn, as evidenced by a gap between the fragments, active extension of the joint is impossible, but, curious as it may seem, the joint is less swollen in these circumstances than in the less severe injury consisting of a transverse crack in the bone. This phenomenon is principally due to the escape and dispersal of the haemorrhagic effusion into the superficial soft tissues which takes place through the wide rents in the capsule.

The clinical diagnosis is a matter of simplicity and should rarely be missed. A radiograph is taken as a routine measure to determine the number, shape and size of the fragments.

RATIONALE OF TREATMENT

In view of the multiplicity of the methods and the apparent contradictory nature of the aims of treatment, it is necessary to review the merits and limitations of the various procedures in use at the present time.

These may be classified :

- (1) **Methods which aim at restoration of normal anatomy.**
- (2) **Total excision.**
- (3) **Repair of quadriceps apparatus, retaining one large fragment.**

(1) **Methods which aim at restoration of normal anatomy.**

The methods of treatment which aim at restoration of the normal anatomy of the bone are probably still the commonest in use. They aim at reassembly of the two or more fragments ; with retention of reduction by means of sutures of silk, chromic catgut, kangaroo tendon, stainless steel wire or fascia lata passed through or around the fragments ; with autogenous bone grafts, plates or fixed skeletal traction, to mention but a few of the methods in vogue.

In some cases these procedures, performed with the necessary degree of technical skill, attain the ideal in the restoration of both form and function, but unfortunately in the large majority there are serious objections to the use of any of these methods in both the short and long term restoration of function. These objections are :

(a) *Non-union is common.*

The patella has been shown to be an integral part of the quadriceps muscle, not part of the bony skeleton. It is probable that for this reason its bone reparative properties are low. In addition, the fracture line of this particular transverse fracture is subject to distraction by the quadriceps (Figs. 167 and 168) rather than compression, which is the usual force exerted by muscle tone on a perfectly reduced transverse fracture at other sites. The fact that the vertical fracture produced in the patella-splitting approach used by Robert Jones, and in which the fracture line is subject to compression rather than distraction, always results in bony union may be

further evidence that tension and distraction at the fracture line may be responsible in some degree for the frequent occurrence of fibrous union.

(b) The necessity for a period of immobilisation of eight to twelve weeks in order to secure problematical bony union is a serious disadvantage to the return of the full range of movement in a joint which has been subjected to serious injury, haemarthrosis, and an operation involving the repair of the medial and lateral expansions. Adhesions are inevitable.

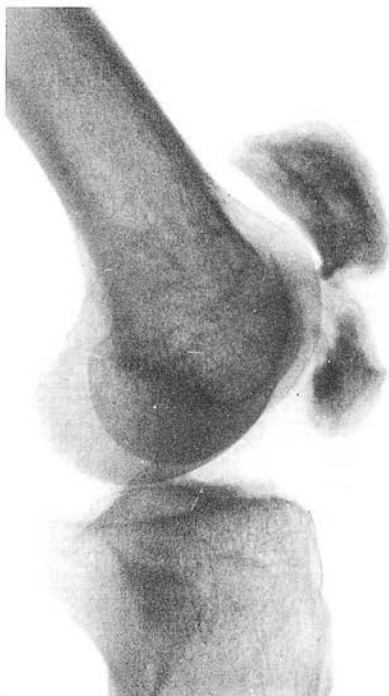

FIG. 167

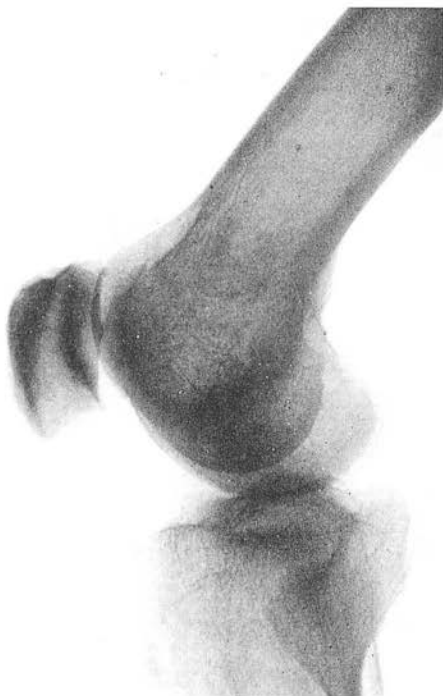

FIG. 168

Non-union is common (Fig. 167). Note the level of the patella by comparison with the normal joint (Fig. 168) (the degree of flexion differs so that the plates are not quite comparable).

(c) No matter how accurate the apposition of the fragments, some degree of roughening of the articular surface, especially in comminuted fractures, is inevitable. Although the immediate result in such a case may be considered to be good, the creation of the ridge or uneven areas on the articular cartilage eventually leads to local osteoarthritis in the patello-femoral compartment and an unsatisfactory long term result (Fig. 169).

(2) **Excision.**—Although it had long been known that excision of the patella was compatible with good knee joint function, it was not until 1937 when Brooke,¹ in advocating excision of the patella in the treatment of fractures, made the astonishing statement, which was supported by no

¹ R. Brooke, "The Treatment of Fractured Patella by Excision. A Study of Morphology and Function," *Brit. Jour. Surg.*, 1937, xxiv, 733.

less an authority than Hey Groves,¹ that not only did excision of the patella result in no loss of function but was even followed by an increase in the power of the joint. Since then excision of the patella has been widely practised for all manner of fractures, to obtain drainage in suppurative arthritis, as an alternative to displacement of the patella in major arthrotomies, and as a method of treatment of recurrent dislocation and osteoarthritis.

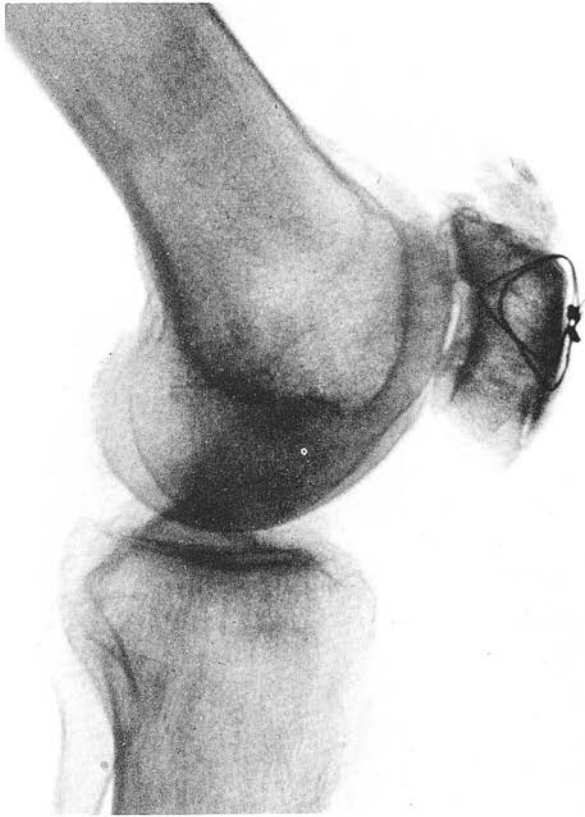


FIG. 169

Old fracture of the patella treated initially by wiring. The range of movement in the joint was almost complete. The patient complained of marked symptoms relative to the patello-femoral compartment. Note the presence of steps on the articular surface of the patella and the local degenerative changes.

The author is of the opinion that total excision of the patella is a radical operation which holds an important and well defined place in the treatment of injuries of the quadriceps apparatus, but cannot support the view that the patella has no functional significance in the mechanics of the knee joint, nor subscribe to the opinion that the power of quadriceps action is actually increased by the operation.

¹ Ernest W. Hey Groves. "A Note on the Extension Apparatus of the Knee-Joint." *Brit. Jour. Surg.*, 1937, xxiv, 747.

In this series many cases of excision of the patella emanating from various sources were examined. Some of the results obtained were considered to be excellent considering the nature of the original injury, but no case was seen in which the function, range of movement and power bore comparison, either subjectively or objectively, with the sound joint.

The case against indiscriminate excision of the patella may be summarised:

(a) There is frequently a residual loss of the final 5 to 15 degrees of extension.

It has been pointed out previously (page 3) that loss of the last 15 degrees of extension constitutes a grave disability and entails loss of the

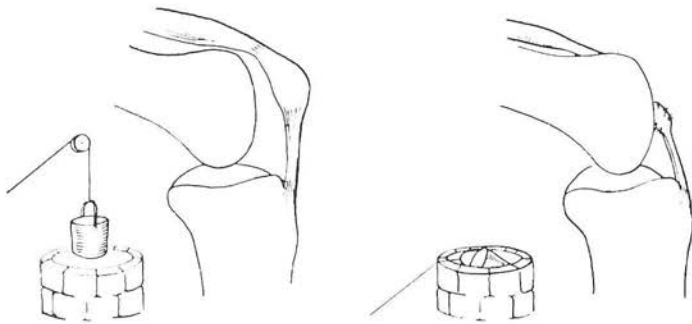


Fig. 170

Fig. 171

The patella carries the tendon away from the femoral condyles and thus increases the leverage action of the quadriceps and lessens the effort required to produce extension. Removal of the patella decreases the leverage action and greater effort is necessary to extend the leg. The principle of patella action is similar to the lessened effort exerted when a bucket of water is drawn up over a pulley rather than dragged over the edge of the well. (*Quoted from Thompson, J. E. M., Surg., Gynaec., and Obstetrics.*)

vital action of the vastus medialis, with consequent loss of power and insecurity of the joint. Loss of volume in the vastus medialis was a salient feature of all the cases examined. Friberg,¹ reporting a series of thirty-two cases of complete removal of the patella, records an average wasting of the thigh muscles of 1.9 centimetres; all his patients had complete extension. Thirteen cases are stated to have excellent results, but it is significant that fourteen, although free from symptoms in ordinary activity, had inadequate strength under exacting conditions, and insecurity in walking on uneven ground.

There are two reasons for loss of power and of full extension:

- (i) This large sesamoid bone has an important function both in flexion and in extension, for it carries the extensor tendon away from the centre of rotation of the knee joint in all positions in the range of movement, and is thus an important factor in increasing the power of the quadriceps (Figs. 170 and 171).

¹ Sten Friberg. "Über Totalextirpationen der Patella." *Acta chir. Scandinav.*, 1941, lxxxv, 361.

- (ii) Extirpation of the patella and suture of the tendon to the quadriceps muscle results in lengthening of the extensor apparatus. This may be avoided by shortening the tendon and overlapping the lateral expansions.

Proof of these two points may be readily obtained during removal of the intact patella through a vertical rather than a horizontal incision in the immediate coverings. When the vertical incision is closed it is quite obvious that the tendon is lax; thus the tendon has been lengthened without solution of continuity, which surely proves that the patella carries the extensor tendon away from the centre of rotation of the joint.

Early in 1938 Tippet¹ observed this phenomenon without realising its significance. "I have found for some reason yet to be explained, those cases in which the incision is made transversely do better than when it is made in a longitudinal direction; though the latter would appear to cause less strain on the sutured aponeurosis, as when the quadriceps contracts, it will tend to pull the edge of the gap together. My best results, however, have all been from the use of the transverse incision."

(b) The patella possesses the important function of protecting the large exposed femoral condyles against future accident and against the trauma of everyday wear and tear. Bruce and Walmsley's² experimental observations on the rabbit suggest that osteoarthritic changes

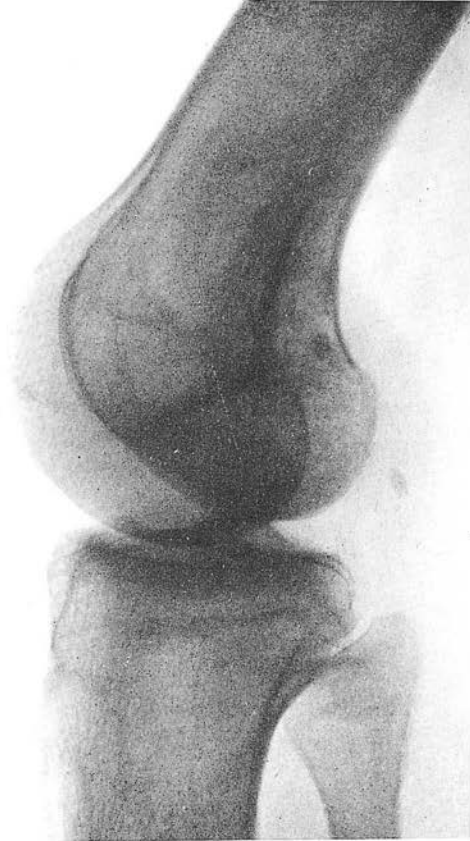

FIG. 172

Complete excision of the patella. The patient, who was seen in 1941, gave a history of excision of the patella eight years previously following a fracture. He was unable to produce full extension; flexion was limited to a right angle. He had no complaints except of difficulty in kneeling due to loss of flexion. Note: (a) the degenerative changes in the femoral condyles, (b) there is no trace of regeneration.

¹G. O. Tippet. "Treatment of Fractured Patella by Excision." *Brit. Med. Jour.*, 1938, i, 383.

²John Bruce and Robert Walmsley. "Excision of the Patella. Some Experimental and Anatomical Observations." *J. Bone and Joint Surg.*, 1942, xxiv, 311.

are to be anticipated following the removal of the bone. They consider that the probable cause of damage to the femoral surface is friction by the quadriceps tendon, although they also think that the patella protects the articular surface from more direct external trauma (Fig. 172).

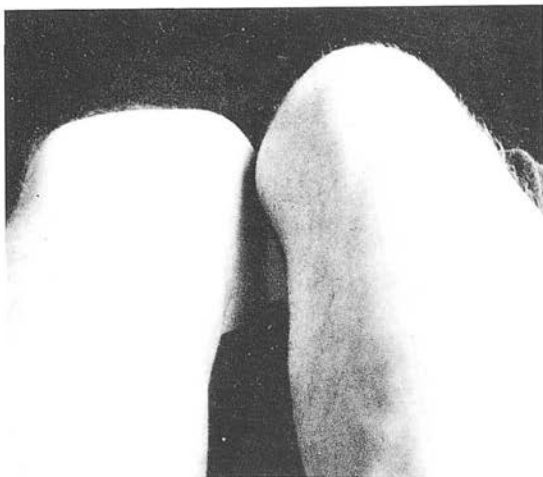


FIG. 173

Contour of the flexed knees following excision of a patella.

(c) There is a residual asymmetry of the knee joint which is not unimportant.

(3) **Repair of quadriceps apparatus retaining one superior or inferior fragment.**—John Thomson,¹ who first advocated this method of treatment in fractures of the patella in 1935, considers that the principle of removing all fragments except one pole and firmly offers the most satisfactory

solution to the problem because :

- (1) It restores the functional integrity of the bone.
- (2) It restores the protective mechanism necessary to the normal knee.
- (3) It does not depend for restoration of continuity on the union of bony fragments with poor osteogenic properties but upon healing in which only soft tissue is involved.
- (4) The symmetry of the knee joints is maintained.
- (5) The period of incapacity is reduced to the minimum.
- (6) The residual disability is minimal.

Thomson has produced convincing evidence of the efficacy of his method in a recent study² of 554 cases treated by 35 surgeons. 433 cases were examined with regard to the residual disability. 350 cases reported no disability whatever, and of the remaining 83 cases with disability 61 had complicating injuries, leaving only 22 patients with fractures of the patella without complication who had any disability.

INDICATIONS AND TREATMENT IN FRACTURES OF THE PATELLA

(1) CONSERVATIVE TREATMENT IS INDICATED IN :

(a) Fractures by indirect violence in which the injury takes the form

¹ J. E. M. Thomson, *J. Bone and Joint Surg.*, 1935, xvii, 431.

² J. E. M. Thomson, "Fracture of the Patella Treated by Removal of the Loose Fragments and Plastic Repair of the Tendon. A Study of 554 cases." *Surg. Gynec. and Obstetrics*, 1942, lxxiv, 860.

of nothing more than a transverse fissure; there is no displacement of the fragments and no injury to the capsular expansions (Figs. 174 and 175).

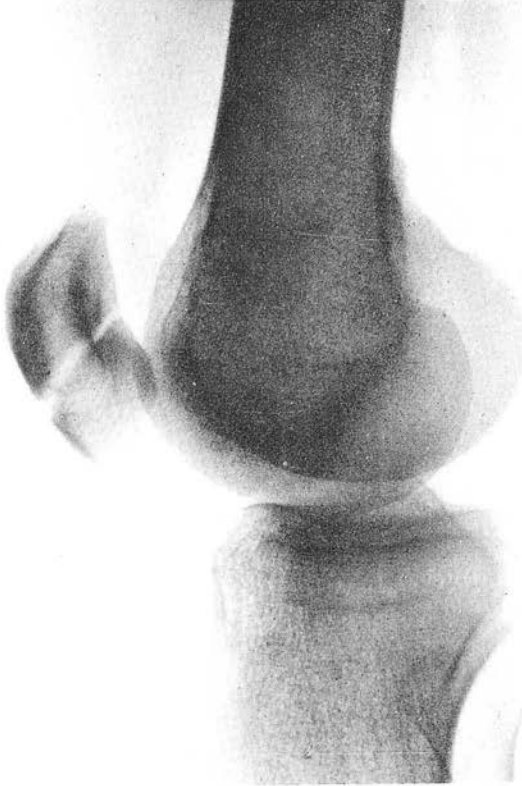


FIG. 174

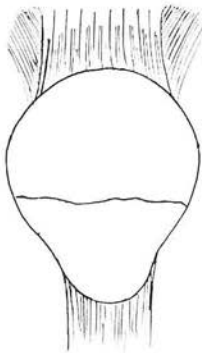


FIG. 175

Figs. 174 and 175.—Transverse fracture without displacement; the lateral expansions are intact; conservative treatment.

(b) Injuries by direct violence in which the fracture takes the form of radiating fissures but without displacement, overriding or step formation (Fig. 178).

(c) Cases in which there are contra-indications to anaesthesia or operation.

Technique of Treatment.—If there is effusion of blood into the joint it is evacuated through a wide bore needle under local anaesthesia. Thereafter a compression bandage is applied, to which is added a padded Cramer wire or aluminium gutter splint.

When the swelling has subsided and the normal contour of the joint restored a walking plaster of the type which does not immobilise the ankle

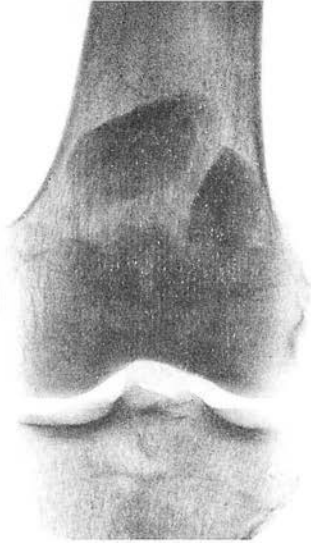

FIG. 176

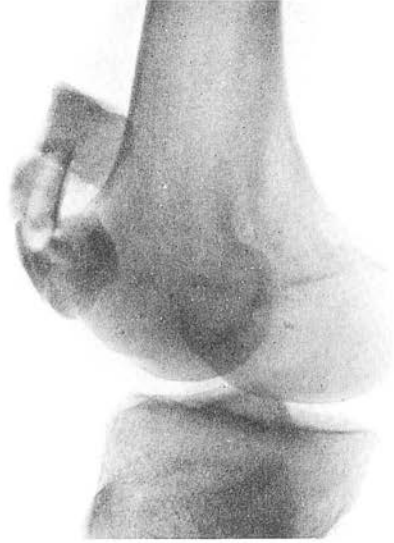

FIG. 177

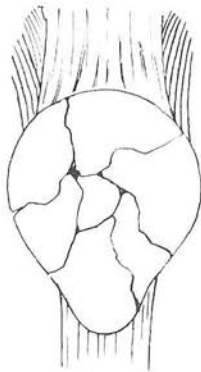


FIG. 178

Figs. 176, 177, and 178. Stellate fracture. If there is no displacement, overriding or step formation, the treatment is conservative. If displacement is present (Figs. 176 and 177), the ideal treatment consists of preservation of a large fragment to which the opposing tendon can be anchored. If this is impossible the entire bone should be excised.

joint is applied (page 113). It is important to secure the maximum immobilisation of the patella by moulding the plaster round the superior and medial and lateral margins. When the plaster is dry the patient may begin active assisted straight leg raising and within a few days may begin weight-bearing. The plaster must be changed if muscle wasting or further subsidence of swelling results in impairment of skin-tight immobilisation.

The plaster case is retained for eight weeks and thereafter more vigorous quadriceps exercises and knee flexing exercises are commenced.

(2) REPAIR OF QUADRICEPS APPARATUS, RETAINING ONE LARGE FRAGMENT

Repair of the torn expansions with excision of all fragments except one pole, either the superior or the inferior whichever is the larger and more

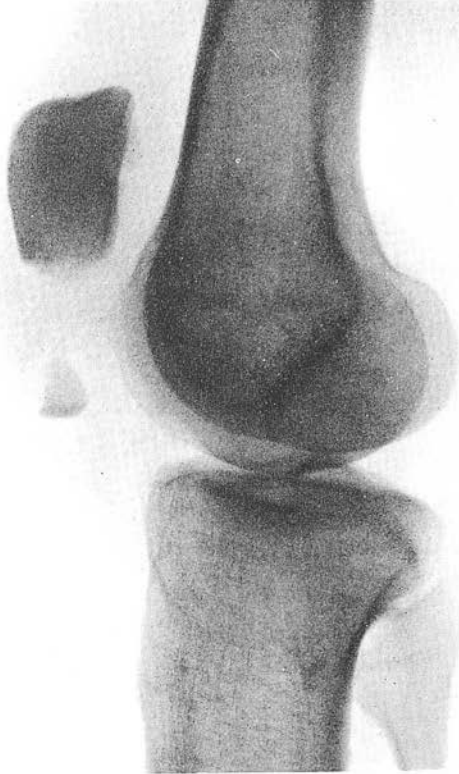


FIG. 179

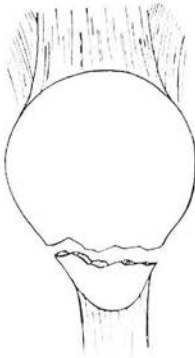


FIG. 180

Figs. 179 and 180. —Fracture of the inferior pole with displacement: the lower fragment should be excised.

suitable, and suture of the selected fragment to the opposing tendon surface is indicated in :

(a) Transverse fractures with displacement (Figs. 179, 181, and 184).

- (b) Stellate fractures in which there is a suitable fragment to which the opposing tendon can be anchored (Figs. 176 and 177).
- (c) Suitable compound fractures (Fig. 186).
- (d) Certain ununited transverse fractures in the absence of gross traumatic osteoarthritic change in the patello-femoral compartment.

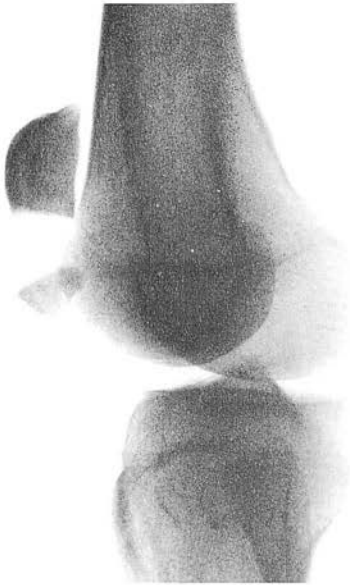


FIG. 181

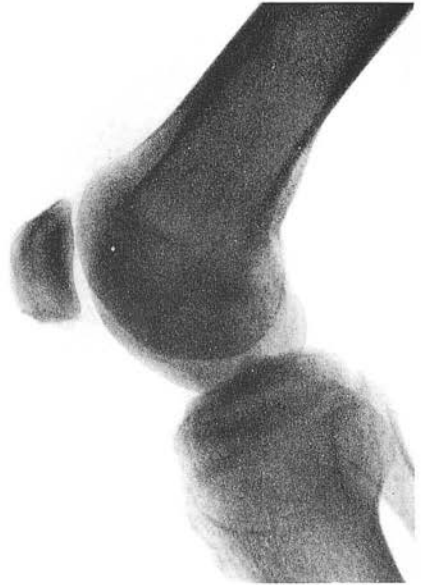

FIG. 182

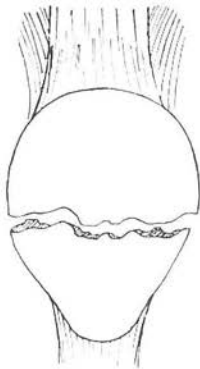


FIG. 183

Figs. 181, 182, and 183. The common transverse fracture with displacement (Fig. 181). The lower fragment should be excised. Fig. 182 shows the final result; note the relationship of the patella to the condyles of the femur.

Technique of Operation.—The patella is exposed through a parapatellar incision and the fragments inspected. As conditions permitting the retention of the superior pole are the more usual, the operation utilising this fragment will be described.

The inferior fragment or fragments are removed from the tendon by means of sharp dissection and the superior surface of the tendon trimmed so

that the largest possible area of soft tissue may be brought in contact with the fractured surface of the superior pole. The edges of the fractured surface of the superior fragment are made smooth and uniform, and thereafter parallel drill holes are made which enter on the fractured surface immediately in front of the articular cartilage, the points of exit appearing on the antero-superior aspect of the bone. A mattress suture of kangaroo tendon, strong chromic catgut or stainless steel wire is used to secure the tendon in accurate contact with the fractured surface (Fig. 187). The final step consists of the careful suture of the capsular expansions on either side of the bone with interrupted chromic catgut sutures (Fig. 188).

The modifications of Thomson's original technique advocated by both Prince and Stern (Figs. 189 and 190) are worthy of attention, for not only do they bring a larger area of tendon in contact with both bone and soft tissue but they have the added advantage of bringing the remaining patellar fragment farther down on to the condyles of the femur, thus preserving the function which is so essential to the strength of quadriceps action.

The fibro-tendinous layer is raised from the anterior surface of the superior pole in the form of a cuff and thereafter holes are bored obliquely from above downwards to appear immediately in front of the articular cartilage. The selected suture material is passed through the patellar tendon

about 1 inch below the upper end, so that when the sutures are tied, bringing the tendon in contact with the fractured surface, there remains a portion of tendon which may be turned over the anterior surface of the superior fragment and packed under the cuff of the fibro-tendinous layer to which it is sutured.



FIG. 184

Fig. 184.—Old fracture of the superior pole of the patella with complete loss of extension. Note the abnormal relationship of the main mass of the bone to the femoral condyles.

This case had been subjected to operative repair but without excision of the superior pole. On resumption of weight-bearing the fragments parted.

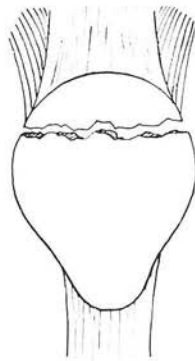


FIG. 185

Fig. 185.—Fracture of the superior pole with displacement: the upper fragment should be excised.

At the termination of the operation a compression bandage is applied to which is added a light padded back splint. The compression bandage and splint or a plaster back shell are retained for three weeks. Quadriceps exercises are commenced at the end of two weeks and graduated weight-

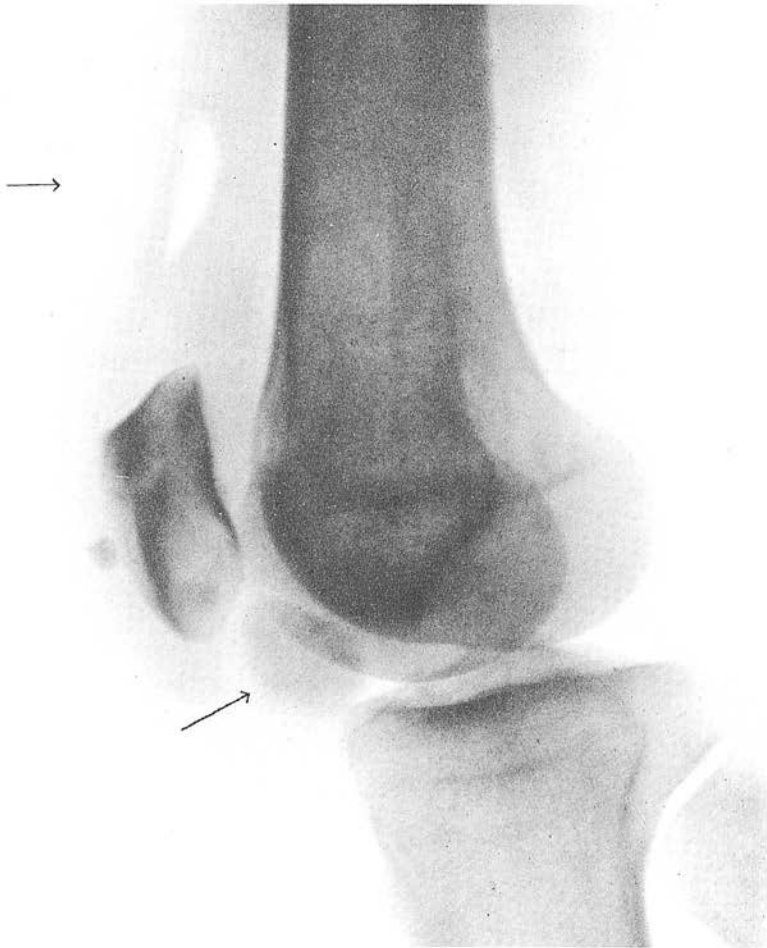

FIG. 186

Compound comminuted fracture of patella with a large fragment displaced into the joint. Note the air in the suprapatellar pouch. The loose fragments were excised and the expansion, to which the large loose fragment had originally been attached, repaired. Full flexion was attained in eight weeks.

bearing with knee flexing exercises instituted between the third and fourth week.

(3) **EXCISION OF PATELLA IS INDICATED IN :**

- (a) Grossly comminuted fractures in which there is no suitable fragment to which the opposing tendon can be anchored.
- (b) Certain compound fractures.

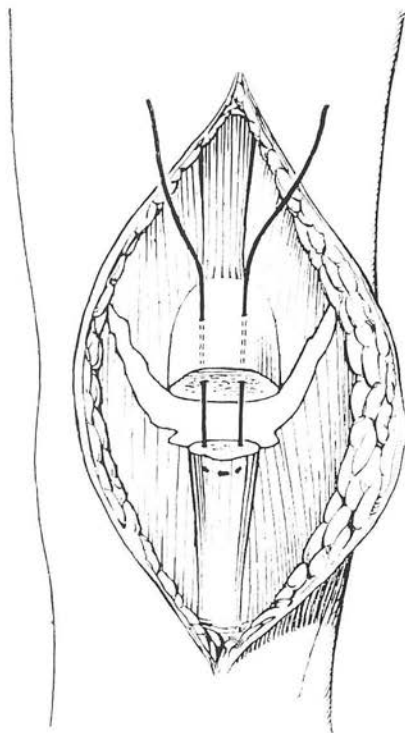


FIG. 187

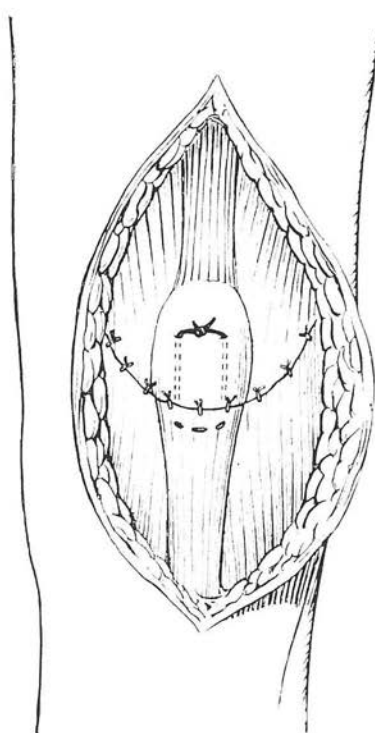


FIG. 188

Thomson's Operation. Fig. 187. —The lower fragment has been excised, holes drilled through the upper fragment, and a mattress suture inserted.

Fig. 188. —The mattress suture has been tied and the torn expansions repaired.

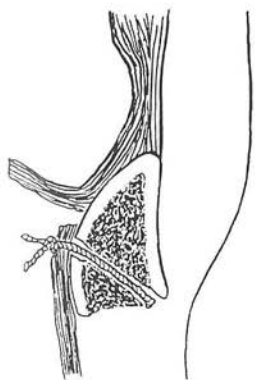


FIG. 189

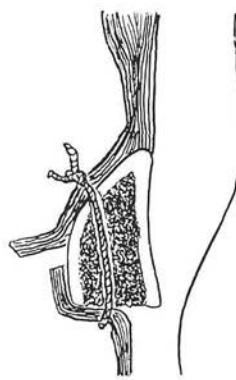


FIG. 190

Modifications of Thomson's original technique advocated by Prince and Stern, which not only secure a larger area of contact between tendon and the bone and soft tissue, but bring the fragment farther down on to the condyles of the femur.

- (c) Old ununited fractures complicated by traumatic osteoarthritis or old malunited fractures complicated by marked loss of flexion and or traumatic osteoarthritis in the patello-femoral compartment.

It might be considered that this indication is a contradiction of the statement that excision of the patella may be followed by arthritis resulting from the loss of the protection of the femoral condyles afforded by the patella. The disability which results from traumatic osteoarthritis complicating an old comminuted fracture of the patella, however, is much greater than the disability produced by the arthritis which may follow excision of the patella.

Technique of Operation. Through a vertical, parapatellar or transverse skin incision, the fracture and tear of the expansions are exposed and the blood clot removed from the joint. The idea, possibly arising from Brooke's original description, that the patella can be shelled out of its aponeurotic covering is erroneous; the fragments can only be excised by scalpel dissection, when it is advisable to keep as close to the bone as possible in order to preserve the maximum volume of soft tissue. Nor is it sufficient to secure end to end apposition of the upper and lower flaps; this results in lengthening of the tendon and some loss of extension, which is, at least in part, avoidable. The opposing tendon ends and the medial and lateral capsular expansions must be overlapped by means of sutures of strong chromic catgut or strips of fascia lata, so that the tendon is as short as possible but without undue tension.

For the same reason the temptation to excise the complete bone through a vertical incision which does not break the continuity of the tendon, in, for example, an old malunited fracture with arthritis or loss of flexion, should be avoided. The bone must be removed through a transverse incision and the tendon ends overlapped.

At the termination of the operation a compression bandage of wool and domette is applied and retained until the stitches are removed. During this time, gentle active flexion and extension exercises are practised within the confines of the bandage and thereafter the scope of the exercises is gradually increased. Weight-bearing may be resumed about the end of the third week and more vigorous exercises instituted. It is especially important to concentrate on the development of the vastus medialis, and for this reason twenty to thirty minutes of faradic stimulation may be a useful adjunct to quadriceps drill during the early stages of recovery.

(1) (D) AVULSION OF LIGAMENTUM PATELLAE FROM PATELLA

Rupture of the ligamentum patellae is an injury of early youth, occurring as a result of sudden contraction of the quadriceps against resistance. The rupture is usually complete and involves not only those fibres which are attached to the inferior pole of the patella but extends into the expansions

on either side. The ligament frequently avulses a small fragment of bone from the lower pole.

CLINICAL FEATURES

Like all subcutaneous ruptures of tendons the diagnosis is frequently missed ; a fracture of the patella is suspected, and the bone being found to be intact, the true nature of the injury remains obscure till the failure of return of function causes a further radiograph to be taken when the mass of new bone which has formed in the haematoma makes the diagnosis clear.

Examination of a recent case shows complete loss of active extension, the patella being displaced upwards as a result of retraction of the quadriceps muscle. It is noted that contraction of the quadriceps does not cause the tendon to become taut and a palpable gap may be felt below the inferior pole. A radiograph may reveal a fragment of cortical bone avulsed from the patella and situated some distance below the inferior pole.

TREATMENT

The rupture is repaired by operative suture as soon as preparation of the skin permits. The injury is exposed through a parapatellar incision and the fragment of bone adhering to the tendon excised. The ligament is sutured back to the inferior pole by means of a mattress suture passed through drill holes in the patella in exactly the same manner as that described under Avulsion of the Quadriceps Muscle from the Patella. The lateral expansions are repaired by interrupted chromic catgut sutures.

When the operation has been completed the joint is splinted by means of a compression bandage, with the addition of a padded metal gutter splint ; this is retained until the stitches are removed when a skin-tight plaster case, well moulded round the superior pole of the patella, is applied. As no difficulty is encountered in securing a rapid return of full flexion of the knee joint in youthful patients, the immobilisation is maintained for a further eight weeks.

(1) (E) FRACTURE OF TIBIAL TUBERCLE AND SEPARATION OF EPIPHYSIS OF TIBIAL TUBERCLE

FRACTURE OF TIBIAL TUBERCLE

The attachment of the ligamentum patellae to the tibial tubercle is merely the central portion of a broad insertion which spreads medially and laterally over the tibial tuberosities. Avulsion or fracture of the tibial tubercle is therefore a rare injury.

The clinical features are similar to those of avulsion of the ligamentum patellae from the patella except that loss of power extension may not be complete. The recognition of the detachment of a large fragment of bone may be possible, especially if the knee joint is flexed.

Treatment.—After a suitable interval for the preparation of the skin, the tubercle is replaced by operation through a short parapatellar incision.

It is usually possible to secure firm fixation by means of chromic catgut sutures through the surrounding soft tissue and periosteum, but if this proves to be impossible, fixation may be secured through drill holes in the crest of the tibia, by autogenous bone pegs (see below), or by a stainless steel screw (Figs. 191 and 192).

At the termination of the operation a compression bandage and back splint are applied which are replaced by a skin-tight plaster case at the end of two to three weeks. Weight-bearing may then be resumed, provided the

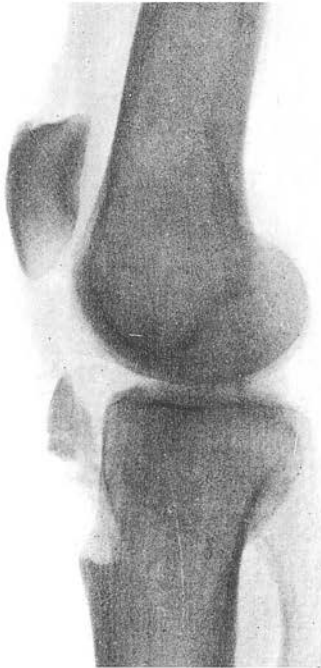


FIG. 191

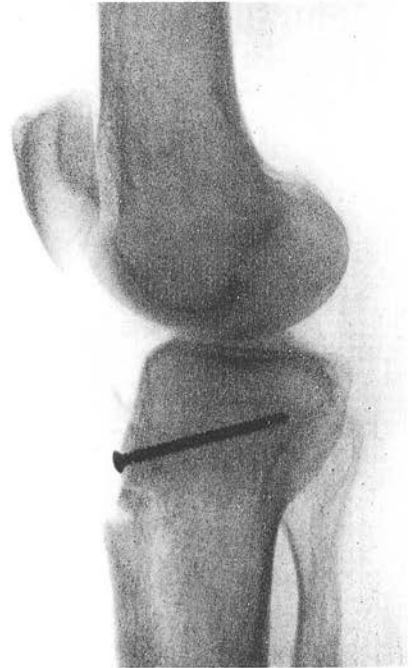

FIG. 192

Complete avulsion of the tibial tubercle (Fig. 191) treated by open reduction and insertion of a long, coarse-threaded stainless steel screw (Fig. 192).

plaster case is very carefully moulded round the superior pole of the patella. Immobilisation is maintained for a total of eight weeks.

SEPARATION OF EPIPHYSIS OF TIBIAL TUBERCLE

Separation of the epiphysis of the tibial tubercle occurs in two forms :

- (1) **Complete avulsion**, which is a relatively uncommon injury.
- (2) **Partial separation**, which is a common and important injury.

(1) COMPLETE AVULSION

The superior half of the tibial tubercle develops in two forms :

- (a) As a tongue shaped protrusion of the upper tibial epiphysis which projects downwards and forwards on to the shaft of the tibia and which fuses with the shaft at the age of 18.

- (b) As a separate centre of ossification which fuses with the epiphysis of the head of the tibia at 16, which in turn fuses with the shaft of the tibia at the age of 18.

Complete avulsion of the epiphysis takes place as a result of violent contraction of the quadriceps against resistance. If the epiphysis takes the form of the more common tongue-shaped protrusion it is either pulled away from the anterior aspect of the tibia (Fig. 193) or may be fractured at its base (Fig. 194). If it has developed as a separate centre, the cartilaginous junction with the upper tibial epiphysis is weak and the epiphysis may be completely avulsed (Fig. 195).

Treatment.—If the tongue-shaped epiphysis has been pulled away from the anterior aspect of the shaft of the tibia, but without fracture, it may be forced back into the normal position under anaesthesia by manual compression or by a blow from a sand-bag. A skin-tight plaster is retained for about eight weeks. If, however, a fracture through the base

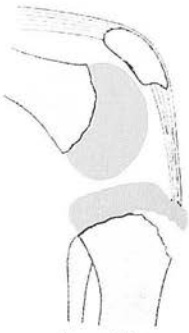


FIG. 193

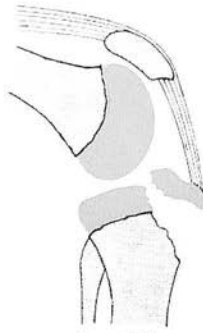


FIG. 194

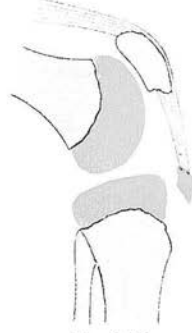


FIG. 195

The three types of avulsion fracture of the upper tibial epiphysis. (Watson-Jones.)

of the upper tibial epiphysis has occurred, or if a separate centre of ossification has been completely avulsed, closed reduction is usually unsatisfactory, and it is necessary to resort to open operation with retention of reduction by means of chromic catgut sutures or small autogenous bone pegs. In either case immobilisation in full extension is maintained for eight weeks.

(2) PARTIAL SEPARATION OF EPIPHYSIS OF TIBIAL TUBERCLE

Until the age of 18 when the superior half of the epiphysis of the tibial tubercle, in either of its two forms, fuses with the shaft of the tibia, the initial strain produced by contraction of the most powerful muscle group in the body is transmitted to the epiphysis of the tibial tubercle. Complete avulsion of the epiphysis is uncommon because of the broad insertions of the medial and lateral expansions into the tibial tuberosities, but the attachment of the tibial epiphysis is nevertheless a weak point in the extensor mechanism at which minor strains are common as a result of the wear and tear of everyday adolescent existence (Fig. 196).

The manifestations of these strains have in the past been called Osgood-Schlatter's disease. No acceptable evidence has ever been produced that the condition is a disease; it is the result of a single injury or repeated minor traumata.

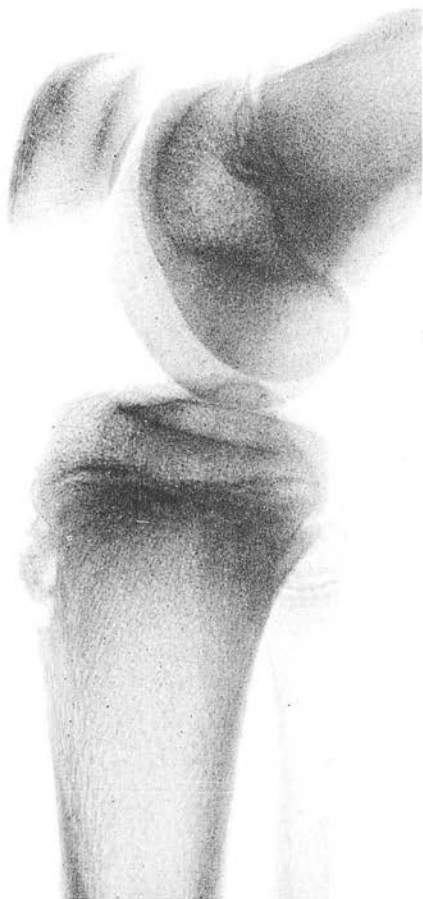

FIG. 196

Partial separation of the epiphysis of the tibial tubercle: epiphyseal sprain.

Clinical Features.—The patient, usually a boy, complains of pain and tenderness localised to the tibial tubercle. Pain is increased by active extension against resistance. Examination of the tibial tubercle usually reveals some enlargement in comparison with the normal side. A limp may be present and slight weakness of extension recorded.

The condition, although primarily an injury of adolescence, does not of necessity undergo spontaneous cure with the passing of the age for closure of the epiphyseal line, but may be perpetuated into adult life. Patients are frequently encountered in the 20 to 40 age group who complain of pain, tenderness and swelling in the region of the tibial tubercle, the pain being particularly marked on attempting to kneel. Inquiry will usually elicit the information that the symptoms have been present prior to the age at which fusion of the epiphysis might be expected, and a radiograph reveals irregular enlargement of the region

of the tibial tubercle and the presence of one or more islands of bone which have failed to fuse with the shaft of the tibia (Figs. 197 and 198).

TREATMENT

(1) Conservative.

In adolescent patients, where the condition is of recent origin, immobilisation of the limb in a thigh-length skin-tight plaster case for a period of three months will effect a cure in a very large proportion of cases.

(2) Operative.

Operative treatment is indicated:

- (a) In adolescent patients, when the condition is of long standing.

- (b) In adolescent cases which are resistant to conservative treatment.
- (c) In all adult patients.

Three procedures are of value :

(1) *Autogenous bone pegging*¹ is indicated in adolescent cases where the epiphysis is tongue-shaped and appears to be "sprung" away from the shaft of the tibia or where failure of healing has taken place and one or more unattached fragments are present in the ligamentum patellae.

The area is exposed through an incision which skirts the ligamentum patellae and is continued down on to the antero-medial aspect of the shaft of the tibia. Two small peg-shaped grafts are cut from the shaft of the tibia

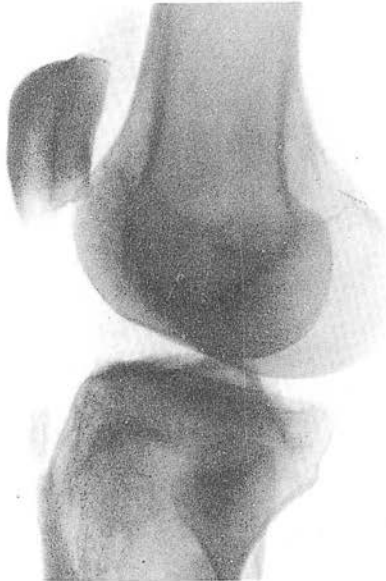

FIG. 197

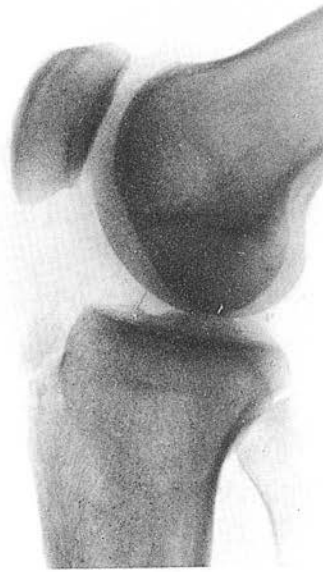

FIG. 198

The symptoms of partial separation of the epiphysis of the tibial tubercle may be perpetuated into adult life. Note the islands of bone which have failed to fuse with the tibia.

and driven through drill holes accurately placed, one above the other, in the tongue-shaped epiphysis or separated fragments. It is important to drive the bone pegs flush with the surface of the bone so that the ends do not protrude, to be responsible for enlargement and deep tenderness in the area at a later date.

Bosworth considers that, as the extensor apparatus has merely been pierced and not divided, prolonged immobilisation is unnecessary. Weight-bearing can be resumed at the end of three weeks.

(2) *Multiple drilling* is indicated in adults or adolescents in which there is enlargement and irregularity of the tubercle, but no separation of the tongue-shaped epiphysis or separate ossicles.

¹ D. M. Bosworth. "Lesions of the Tibial Tubercle and their Treatment," *Am. J. Surg.*, 1939, xliii, 526.

The tubercle is exposed through a short vertical incision placed to one side of the mid-line. With the aid of a motor-driven drill the tubercle and surrounding area of bone is perforated with multiple fine drill holes.

Weight-bearing may be resumed at the end of three weeks.

(3) *Excision of ununited fragments* is indicated in adults where there are one or more separate ossicles which have failed to unite with the shaft of the tibia and are susceptible to strain. The procedure may be considered to be preferable to autogenous bone pegging, which may be difficult unless the fragments are large.

If extensive interference with the attachment of the ligamentum patellae is necessary in order to excise the fragments, the limb should be immobilised in a plaster cast for a period of six weeks before weight-bearing is resumed.

INJURIES OF PATELLA RESULTING FROM DIRECT VIOLENCE ARE:

- (2) (A) STELLATE FRACTURE.
- (D) MARGINAL FRACTURE.
- (C) FRACTURE OF THE ARTICULAR SURFACE, INCLUDING OSTEOCHONDRITIS DISSECANS.
- (D) TRAUMATIC DEGENERATIVE FIBRILLATION.

(2) (A) STELLATE FRACTURE

This is the classical fracture of direct violence and results from crushing of the patella against the femoral condyles. Complete solution of continuity of the quadriceps apparatus does not occur as the injury does not extend into the lateral expansions; active extension of the knee joint is therefore still present.

In addition to effusion of blood into the joint and parietal soft tissues, there is frequently an injury of the overlying skin which varies from a contusion or abrasion to a wound communicating through the fracture with the knee joint (Fig. 186).

TREATMENT

In the classification of injuries of the extensor apparatus, the transverse fracture of the patella has been placed under a different heading from the stellate or comminuted fracture, the former injury being regarded as a rupture of the extensor apparatus, whereas the latter does not entail complete solution of continuity. For the purposes of treatment, however, both injuries are considered under the same heading (see Treatment of Fractures of the Patella, page 178).

(2) (B) MARGINAL FRACTURE

Direct violence, which happens to strike the periphery rather than the centre of the bone, produces a marginal fracture (Fig. 199). The fracture

line is usually vertical and as it runs into the attachment of the capsular expansion and fibro-tendinous covering of the anterior surface, the fragments are securely splinted and there is no appreciable displacement.

In this, as in all other conditions affecting the articular surface of the patella and giving rise to retro-patellar symptoms, an axial X-ray projection (Fig. 200) is essential. In it are revealed many abnormalities which cannot be detected in the usual antero-posterior and lateral views.

The radiological appearances may be confused with the developmental anomaly known as congenital bipartite patella, the characteristics of which are :




FIG. 199

Axial projection showing recent marginal fracture.

- (a) The supernumerary bone is usually situated at the supra-lateral angle (Fig. 201).
- (b) The line of demarcation between the fragments runs downwards and laterally (Fig. 201).
- (c) The opposing margins are smooth and dense (Fig. 201).
- (d) Occasionally there are two supernumerary ossicles (Fig. 202).
- (e) The condition is frequently bilateral.

TREATMENT OF RECENT CASE

It has generally been accepted that this fracture is innocuous, requiring neither operation nor immobilisation. So many cases, however, are encountered months or years later, who complain of severe retro-patellar symptoms that it is evident that this view is erroneous.

Observations on both recent and old cases suggest that in spite of soft tissue attachments, the blood supply of a lateral marginal fragment is unsatisfactory.

It has been stated that the fracture produced in the Jones patella-splitting approach is known to heal (page 173). The conditions of blood supply are not the same at the margins as at the mid-line of the

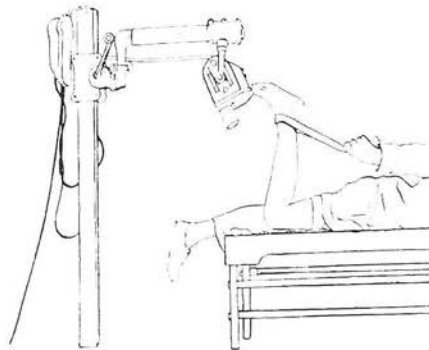


FIG. 200

Method of producing an axial projection of the patella. In it are revealed many abnormalities which cannot be detected in the usual antero-posterior and lateral views.

bone where there are thick tendinous

attachments ; nor, for the same reason, is the fracture line subject to the same degree of lateral compression.

It is not the presence of the ununited fracture which is the source of the late symptoms so much as the cause, namely, loss of blood supply to the

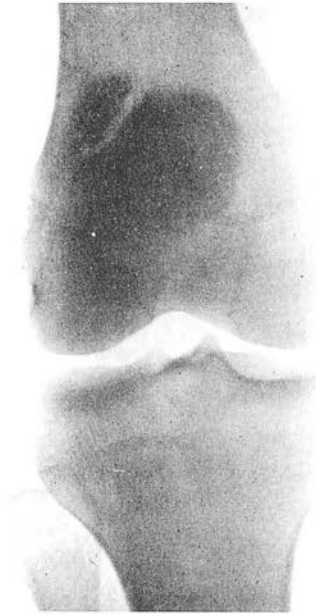

Fig. 201

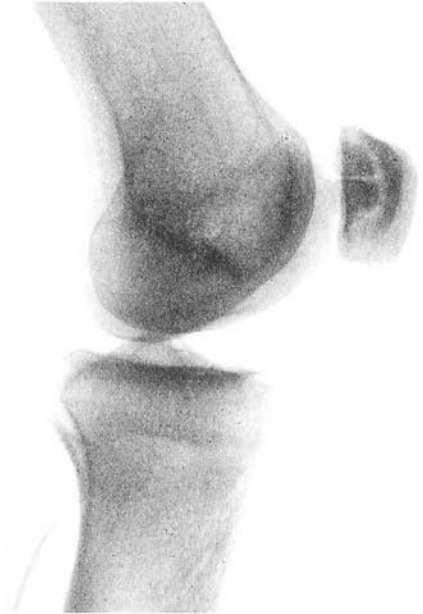

Fig. 202

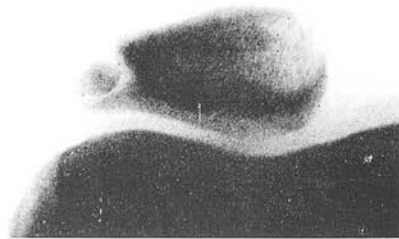

Fig. 203

Figs. 201, 202, and 203 showing congenital bipartite patella.

fragment with consequent degenerative changes in the articular cartilage.

The suggestion that failure of nutrition and consequent non-union may be explained by lack of adequate immobilisation is not borne out by experience. Fig. 204 illustrates a typical case in which an attempt was made to secure union by the usual period of plaster immobilisation. It is for these reasons that the author has abandoned the previously accepted policy towards this fracture in favour of immediate excision of the fragment.

The operation (see below), which is little more than a minor procedure, produces no solution of continuity of the quadriceps apparatus and thus permits a return to weight-bearing within two to three weeks.

CLINICAL FEATURES IN OLD CASES

The complaint is of pain in the retro-patellar region, especially during periods of increased activity; examination reveals the presence of grating accompanied by pain on passive movement of the patella in either the horizontal or vertical plane. The patient indicates that the pain produced by forcing the bone against the condyles of the femur produces the same pain of which he complains. An axial radiograph shows an old marginal fracture with patchy decalcification of the fragment and irregularity of the articular surface (Figs. 205, 206, 207).

TREATMENT

The fragment is excised through a short vertical incision centred over the edge of the patella. The capsule and fibro-tendinous covering of the anterior surface are erased by sharp dissection, the fracture line located, and the fragment removed by means of a fine, sharp osteotome. It is usually found that the fragment is attached to the main mass of the patella by areas of both bony and fibrous union; the articular cartilage shows areas of erosion.

The results of operation are excellent.

SYMPTOMS ARISING FROM SUPERNUMERARY OSSICLE OF A CONGENITAL BIPARTITE PATELLA

The congenital bipartite patella is considered to be completely innocuous, but the author has encountered two cases in which the symptoms described above were found to arise from a supernumerary ossicle which an axial

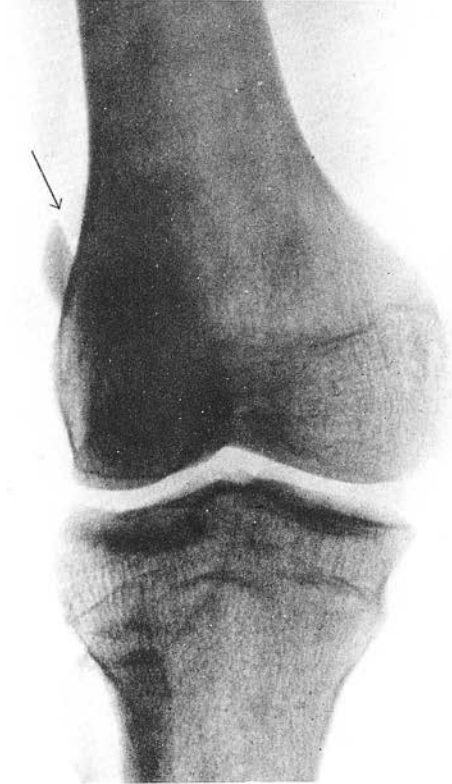


FIG. 204

Recent marginal fracture, following a period of immobilisation. Note the density of the fragment.

radiograph showed to project beyond the plane of the articular surface of the main mass of the bone (Fig. 208).

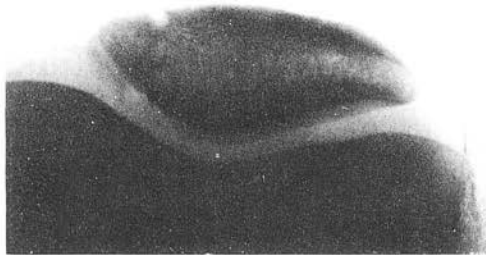


FIG. 205

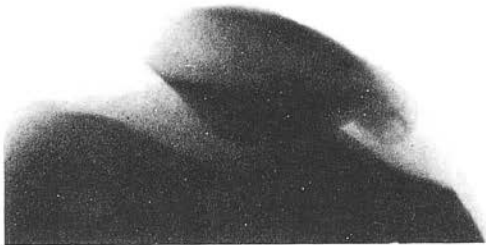

FIG. 206

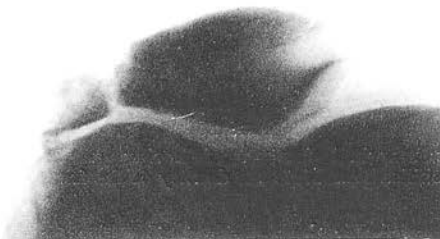

FIG. 207

Old marginal fractures producing retro-patellar symptoms.

the infra-medial aspect of the bone against the lateral femoral condyle.

The author has encountered one case which conformed to Meekison's description, except that the separated fragment was situated in the intercondylar notch. The loose body was discovered during an operation for

plane of the articular surface of the main mass of the bone (Fig. 208). In both cases the anomaly was bilateral, but with symptoms related to one side only. Complete relief followed removal of the ossicle.

(2) (C) FRACTURE OF ARTICULAR SURFACE, INCLUDING OSTEOCHONDRITIS DISSECANS

Direct violence of a lesser degree than that which causes a stellate fracture may result in a localised injury of the articular surface by impingement against the femoral condyles. Unlike the marginal fracture this fracture is not splinted by soft tissue attachments, nor is the blood supply preserved. The fragment is therefore displaced into the joint immediately, or alternatively, undergoing avascular necrosis, is cast into the joint at a later date to be termed "osteochondritis dissecans" (Fig. 209).

Meekison¹ first described this fracture in 1937 when he reported three cases in which fracture occurred at the infra-medial aspect of the articular surface and the separated fragment located in the lateral pouch. He considered that the injury arose as a result of a violent glancing blow on the medial side of the patella, driving

¹ D. M. Meekison. "A Hitherto Undescribed Fracture of the Patella." *Brit. Jour. Surg.*, 1937, xxv, 64.

removal of the medial meniscus and a search for the source of the fragment revealed the defect in the patella. The defect was later demonstrated in an axial radiograph.

CLINICAL FEATURES

The clinical features are not characteristic and may be associated with the original blow sustained by the patella, a concurrent internal derangement, or the presence of the loose body in the lateral pouch. When the condition is suspected the radiographs should be carefully inspected for the presence of a loose body and an axial projection of the patella secured.

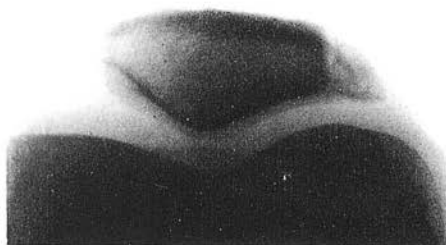


FIG. 208

Congenital bipartite patella. The supernumerary ossicle projects beyond the main mass of the bone. Note sub-chondral degenerative changes.

TREATMENT

Treatment consists of localisation of the fragment and removal through the smallest possible incision.

(2) (D) TRAUMATIC DEGENERATIVE FIBRILLATION OF PATELLA

Traumatic degenerative fibrillation of the patella takes the form of fissuring and erosion of the articular surface with tags of cartilage or fibrous tissue arising from the margins of the fissures. The cartilaginous tags may attain large dimensions, undergoing hypertrophy, such as occurs in pedunculated tags of meniscus, or may be cast into the joint as loose bodies (Figs. 210 and 211).

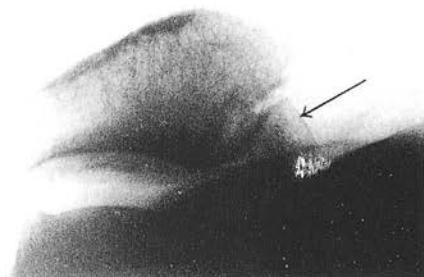

FIG. 209

Fracture of the articular surface at the infra-medial angle due to impingement against the lateral condyle of the femur. The fragment had not separated immediately but would have been cast into the joint at a later date, to be termed osteochondritis dissecans.

The condition may affect a small circumscribed area or may be present throughout the superior two-thirds of the articular surface. The synovial membrane of the posterior wall of the suprapatellar pouch is markedly congested in advanced cases and occasionally an apposing area on the femoral condyles shows changes similar to those seen in the patella. The general appearance of the condition is similar to that commonly observed

on the inferior surfaces of the femoral condyle as a result of injury from a damaged meniscus or as a manifestation of traumatic osteoarthritis.

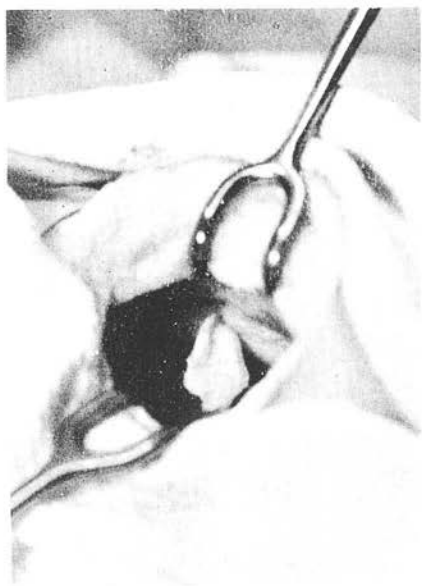


FIG. 210

Traumatic degenerative fibrillation of the patella. Note large pedunculated tag of articular cartilage projecting back into the joint.

- (4) The absence of convincing radiological change even in the axial projection which is taken to eliminate fracture, osteochondritis dissecans, or other abnormality, although occasionally the presence of sub-chondral absorption may be detected in advanced cases.

TREATMENT

If the symptoms are persistent and severe and the diagnosis can be established with a reasonable degree of certainty, the treatment is operative, as neither rest nor physiotherapeutic measures give any measure of permanent relief.

Technique of Operation.—The patella is exposed through a short parapatellar incision and the bone rotated in its long axis until the articular surface can be clearly seen. The area of fibrillation is localised and the cartilage shaved off until only a transparent

CLINICAL FEATURES

The clinical features are :

- (1) A history of injury of the nature of a direct blow on the patella some months or years previously.
- (2) Pain situated directly behind the patella, especially marked during and after a period of increased activity.
- (3) Pain on pressing the patella against the femoral condyle at some point in the range of movement; pain, together with the sensation of grating, on rubbing the patella against the femoral condyles either in a horizontal or vertical direction while at the same time exerting gentle pressure.

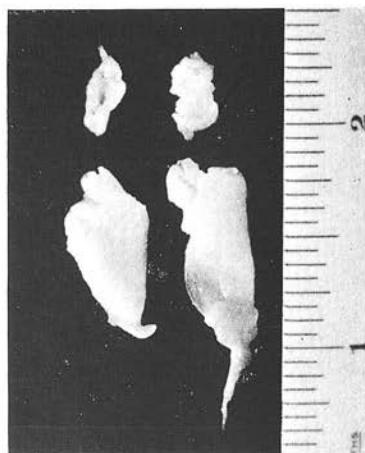


FIG. 211

Two small loose bodies and two large pedunculated tags of articular cartilage from a case of traumatic degenerative fibrillation of the patella.

film covers the bone. A similar procedure is carried out if there is any abnormality of the contiguous area of the femoral condyle. The incision is thereafter closed and a compression bandage applied. Quadriceps drill is commenced within a few days of operation.

The results of operation are satisfactory in all but the most advanced cases, in which there appears to be no satisfactory alternative treatment to excision of the entire bone.

(3) DISLOCATION OF PATELLA

The stability of the patella depends on :

- (1) The integrity of the vastus medialis, from which follows :
- (2) Absence of undue laxity of the capsular expansion on the medial side.
- (3) The height of the lateral femoral condyle, *i.e.*, the depth of the groove between the medial and lateral femoral condyles.

In many knee joints which fall within the limits of normality, an increase of lateral mobility of the patella may exist as a result of minor abnormalities of these stabilising factors. In such joints, relatively slight pressure is sufficient to displace the patella over the margin of the lateral femoral condyle, and a minor direct injury sustained while the quadriceps is relaxed may cause complete dislocation. In the athletic male in whom all stabilising factors are fully developed, traumatic dislocation of the patella is relatively uncommon and occurs only as a result of violence directed against the medial aspect of the patella, such as a kick in a football game or a motor cycle accident.

Complete dislocation of the patella in the normal knee joint invariably entails rupture of the medial capsule and the attachment of the vastus medialis to the patella.

In rare instances the bone may be dislocated medially, or rotated on its long axis so that the lateral border lies between the femoral condyles and has even been known to rotate completely on its long axis so that the anterior surface lies against the femoral condyles.

The dislocation is encountered in two forms :

- (1) **Incomplete**, in which the patella lies on the lateral border of the lateral condyle.
- (2) **Complete**, in which the patella rotates through 90 degrees and the articular surface lies in contact with the lateral side of the lateral femoral condyle.

Either dislocation may reduce spontaneously, or may be reduced by the patient or by the onlookers of the accident, so that the initial examination may reveal nothing more than a traumatic synovitis or haemarthrosis with tenderness along the supra-medial border of the bone. In the complete dislocation, either in the unreduced or reduced state, it may be possible to palpate the tear in the medial capsule and attachment of the vastus medialis.

In the incomplete lesion, occurring in a football match and seen only after the subluxation has been reduced, a cursory history and examination may easily lead to an erroneous diagnosis of the more common meniscus injury. When dislocation is still present at the initial examination, the knee is semi-flexed and the abnormal position of the patella makes the diagnosis unmistakable.

TREATMENT OF ACUTE DISLOCATION

If displacement is still present the dislocation is immediately reduced, frequently without anaesthesia, by extending the joint and forcing the patella by direct pressure over the edge of the lateral condyle of the femur into the normal position. Before undertaking further treatment, and especially in cases where the dislocation has already been reduced prior to the initial examination, it is necessary to establish:

- (1) Whether the dislocation has occurred previously.
- (2) Whether the dislocation was complete or incomplete.
- (3) If the dislocation was complete, what is the nature and extent of the injury to the insertion of the vastus medialis and the medial capsule.

FURTHER TREATMENT

(1) If the dislocation has occurred previously the case is regarded as a recurrent dislocation and investigation of the etiology initiated before further treatment is contemplated. (See Recurrent Dislocation.)

(2) If the dislocation was incomplete it is unlikely that any serious damage to the capsule or attachment of the vastus medialis has occurred.

The reactionary effusion is aspirated under local anaesthesia and a compression bandage of wool and domette applied. Thereafter treatment is directed to the development of the vastus medialis which should receive faradic stimulation for twenty to thirty minutes each day in addition to hourly quadriceps exercises.

(3) In the complete dislocation, injury to the medial capsule and attachment of the vastus medialis, in varying degree, is inevitable, and a vertical rent in the medial capsule may be palpable while the joint is still distended with blood or effusion.

If the injury is considered to be of minor degree, the fluid or blood is evacuated by aspiration and a compression bandage applied. When the joint has reached normal proportions, a skin-tight plaster case, permitting movement of the ankle joint, is applied and retained for six to eight weeks, during which time quadriceps exercises are practised; weight-bearing may be resumed after four weeks. When the plaster is discarded, more vigorous quadriceps drill and knee flexing exercises are commenced, attention being especially directed towards the development of the vastus medialis which, in addition to remedial exercises, may receive twenty to thirty minutes of faradic stimulation each day.

In the past the tendency has been to disregard the rupture of the medial capsule and the injury to the attachment of the vastus medialis, the disloca-

tion being treated on the lines outlined above. The author considers that the failure to recognise the importance of this injury is the most fruitful source of recurrent dislocation. It is surely illogical to recognise that inadequate suture and after-treatment of the medial parapatellar incision frequently leads to recurrent dislocation, and at the same time fail to treat a similar but more extensive lesion produced by accidental trauma. If the presence of a rent is established, the injury should be exposed through a medial parapatellar incision, after a suitable interval for skin preparation, and the tear repaired in layers by interrupted chromic catgut sutures. The after-treatment follows the lines laid down above, plaster immobilisation being maintained for eight weeks from the date of operation.

RECURRENT DISLOCATION OF PATELLA

Watson-Jones¹ has pointed out that the axes of the quadriceps muscle and the ligamentum patellae do not form one straight line, but meet at an angle in the patella. Contraction of the rectus femoris, vastus intermedius, and vastus lateralis would tend to dislocate the patella if it were not for the simultaneous contraction of the powerful vastus medialis (Fig. 212).

It is therefore on the integrity of the medial capsular expansion and attachment of the vastus medialis to the patella together with the volume and tone of the muscle that the normal function of the apparatus depends. Recurrent dislocation may occur in:

- (1) Genu valgum.
- (2) Failure of development of the lateral condyle of the femur.
- (3) External rotation deformity of the tibia beginning above the tibial tubercle.
- (4) Congenital mal-attachment of the iliotibial tract.²
- (5) Trauma alone, in the absence of other abnormality.
- (6) Inadequate suture and after-treatment of the medial parapatellar incision.

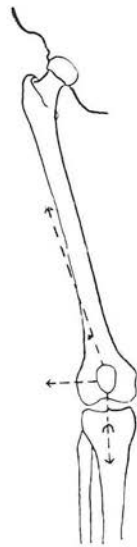

FIG. 212

Fig. 212.—The axes of the quadriceps muscle and the ligamentum patellae do not form a straight line but meet at an angle in the patella.

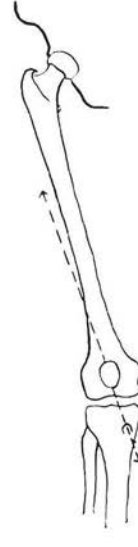

FIG. 213

Fig. 213.—Transplantation of the tibial tubercle corrects the angle between the axes. (After Watson-Jones.)

¹ R. Watson-Jones. "Fractures and Joint Injuries," E. and S. Livingstone, Edinburgh, 1943, 735, 736.

² E. R. Ober. "Recurrent Dislocation of the Patella." *Am. J. Surg.*, 1939, xliii, 497.

Consideration of the major acquired and congenital deformities associated with recurrent dislocation of the patella is beyond the scope of the present work, but a list of etiological factors is necessary in order to make it clear that a minor abnormality of the type already outlined may be encountered in a knee joint where a single injury is considered to be responsible for the onset of the condition.

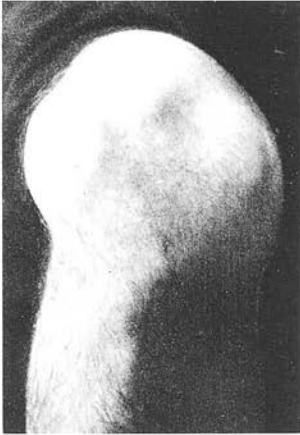

FIG. 214

Recurrent dislocation of the patella. In flexion the patella slips laterally to balance on the lateral femoral condyle.

CLINICAL FEATURES

The symptoms vary with the degree of subluxation. In mild cases, in which the patella slips momentarily over the edge of the lateral condyle, the complaint is that of insecurity or "giving-way" of the joint followed by recurrent attacks of synovitis, and many years may elapse before a complete dislocation occurs. This is the type of case in which the symptoms are difficult to distinguish from those produced by a torn meniscus. Where complete dislocation takes place, the disability is severe and the diagnosis unmistakable; the knee joint collapses without

warning and the patient is thrown to the ground.

On examination, the quadriceps, and especially the vastus medialis, is wasted, and the patellar tendon and the medial capsule lax; mobility of the patella in a lateral direction is increased in comparison with the normal joint. Where the lateral condyle is underdeveloped, flexion of the joint causes the patella to displace laterally (Fig. 214), and in some cases manual pressure on the medial aspect of the bone produces complete dislocation. Congenital or acquired deformities, in a minor degree and of the type indicated above, may be noted.

The trauma of repeated dislocation may produce changes in the articular cartilage and opposing femoral condyles of the type described under Traumatic Fibrillation, and in cases of long standing, traumatic osteoarthritis may be present in the patello-femoral compartment or generalised throughout the joint.

Radiological examination may show the patella to be placed more laterally and at a higher level than the normal bone, and in addition may reveal underlying congenital or acquired abnormalities.

TREATMENT

(1) Prevention.

Primary treatment of both the complete and incomplete forms of acute dislocation on the lines suggested, and careful suture and after-treatment of medial parapatellar incisions will prevent many cases of recurrent dislocation.

(2) **Non-operative.**

Conservative treatment is indicated in cases of minor degree in which the underlying factor is considered to be loss of the protective function of the vastus medialis as a result of wasting and lack of tone. Treatment follows the usual lines of quadriceps redevelopment and consists of hourly quadriceps drill with the addition of faradic stimulation of the vastus medialis for twenty to thirty minutes each day.

(3) **Operative.**

Of the countless procedures which have been described for the relief of recurrent dislocation, the operation of transplantation of the tibial tubercle together with the attached patellar tendon is recommended as simple, physiological, and applicable to the large majority of cases (Figs. 212 and 213). The results are entirely satisfactory.

The major acquired or congenital deformities associated with habitual dislocation, such as genu valgum, may demand osteotomy of the femur or tibia and are considered to be beyond the scope of the present work.

TRANSPLANTATION OF TIBIAL TUBERCLE TO MEDIAL ASPECT OF HEAD OF TIBIA

Technique of Operation.—A curved incision is made on the medial aspect of the knee joint, the lower extremity of which crosses the mid-line a short distance below the tibial tubercle (Fig. 215). When the skin flaps have been dissected, exposing the tibial tubercle and the patella tendon, an incision is made in the periosteum on the head of the tibia immediately medial to the tendon and continued downwards to cross the crest at a point below the tubercle; the periosteum is then raised in the form of a flap based on the medial margin of the head of the tibia. A thick block of bone, $\frac{3}{4}$ inch square, and which includes the attachment of the tendon, is outlined and carefully cut out with a sharp osteotome. When the block of bone has been detached it is necessary to divide the structures on either side of the tendon until the extra-synovial fat is exposed in order to displace the tendon to the medial side without tension. The capsule is divided by means of scissors passed up under the skin on the lateral side of the patella. It will now be found possible to pull the block of bone down to a point lower than its previous insertion, and at this point, a square, slightly smaller than the block and inclined at a few degrees from the horizontal, is outlined on the denuded medial aspect of the bone, so that the tendon is under increased but not undue

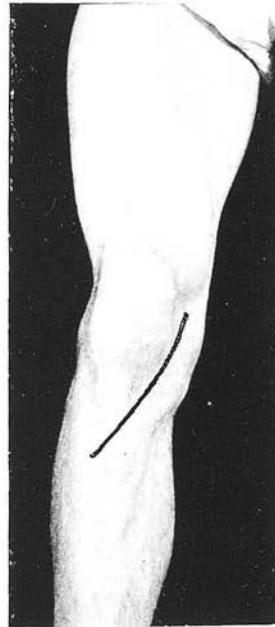


FIG. 215

The incision used by the author for transplantation of the tibial tubercle.

tension (Fig. 216 and 217). Bone is removed by means of a fine bladed osteotome until the defect is of such a size as to permit the block of bone with attached patella tendon to be driven in so that it is held securely. The flap of periosteum is then replaced over the countersunk tibial tubercle and patellar tendon and sutured in position with fine interrupted stitches, while at the same time any undue laxity of the capsule on the medial side is overcome by plication. The skin incision is thereafter closed.

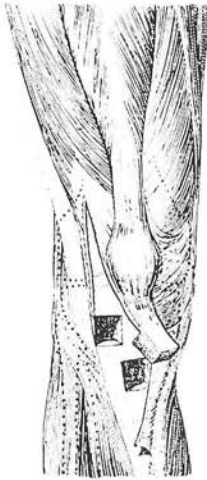


FIG. 216

Transplantation of the tibial tubercle for recurrent dislocation of the patella. The block of bone has been detached, the lateral capsule divided, and the new bed prepared on the medial aspect of the head of the tibia.

If a tourniquet has been used, a compression bandage is applied with the addition of a padded back-splint. If no tourniquet has been used, a thigh length plaster case may be applied at the termination of the operation.

After-treatment.—Provided the security of the displaced tubercle is beyond question, quadriceps exercises may be commenced immediately. At the end of three weeks the stitches are removed and a skin-tight thigh length plaster case is applied and retained for a further four to six weeks. When the plaster case is removed, more advanced quadriceps drill is practised, concentrating especially on the development of the vastus medialis.

AUTHOR'S MODIFICATION TO SECURE MECHANICAL LOCKING OF NEW ATTACHMENT OF TIBIAL TUBERCLE

Although the results of the operation described above are entirely satisfactory the procedure has the disadvantage that the security of the transplanted tubercle depends in the initial stages on a "driving fit" into the cavity in the tibial head, and in the later stages upon the fusion of the bony block with the surrounding tibia. If mechanical locking of the tubercle to its new attachment can be produced, not only is the risk of displacement abolished but weight-bearing and knee flexion can be resumed at an early date.

This modification, which has been used with complete satisfaction in the last 15 cases, is effected in the following manner:

Instead of detaching the patella tendon together with a $\frac{3}{4}$ -inch cube of bone, the tendon is removed attached to a rectangle, $1\frac{1}{4}$ ins. by $\frac{1}{2}$ inch, consisting of cortical bone only, the long axis of the rectangle being in the vertical plane. If it is found necessary to erase the tendon from the superficial aspect of the upper portion of the rectangle for a distance of a quarter of an inch or so (Fig. 219), care is taken to retain sufficient soft tissue attachment lest the tendon pull away from the bone.

A rectangular defect, of the same size as the area of cortical bone removed, is now made on the antero-medial aspect of the head of the tibia.

The position is important; the long axis is inclined at an angle of about 45 degrees to the vertical plane (Fig. 218). Cancellous bone is now excavated 15 mm under the cortical bone at the superior and inferior extremities of the cavity, producing the effect of overhanging margins. The tibial tubercle is now placed in the defect, driven through the cortex into the underlying

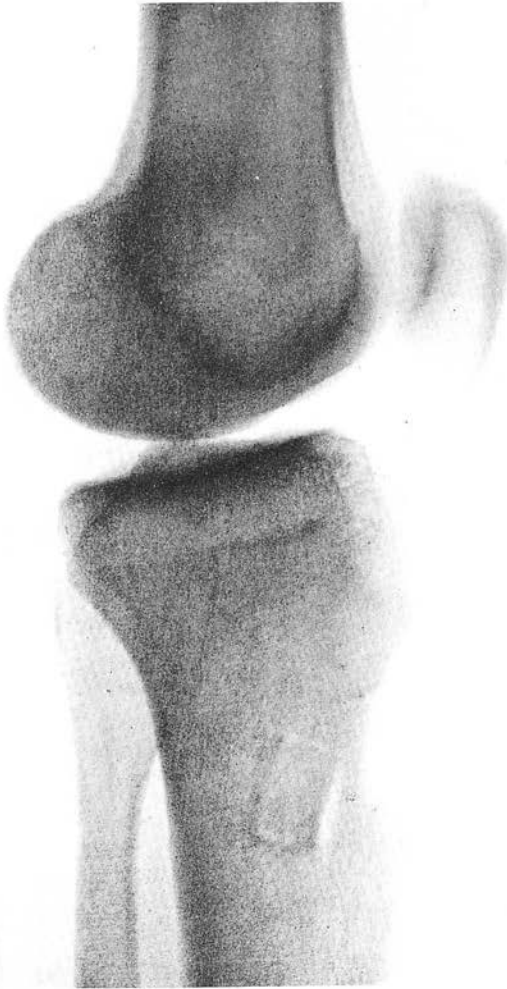

FIG. 217

Transplantation of the tibial tubercle for recurrent dislocation of the patella.

cancellous tissue, and rotated so that its long axis lies in the axis of the quadriceps. This means that the rectangle of cortical bone is locked under the overhanging margins of the defect (Figs. 218 and 219). The vacant supra-medial and infra-lateral corners of the defect (Fig. 218) are then plugged with fragments of bone as an added safeguard against displacement.

After-treatment.—At the termination of the operation, a compression

bandage together with a padded aluminium gutter splint is applied. This is retained for two weeks when a weight bearing skin-tight knee plaster,

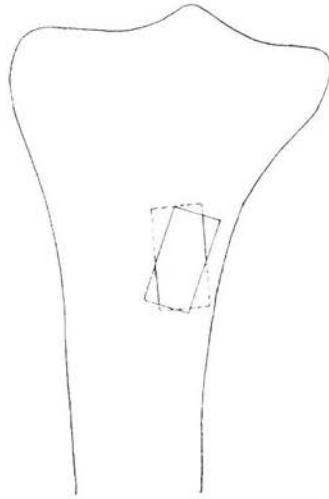


FIG. 218

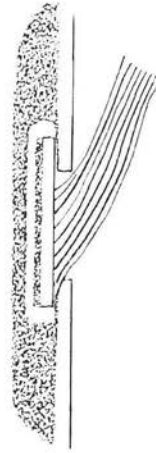

FIG. 219

The author's method of obtaining mechanical locking of the new attachment of the tibial tubercle. The rectangle of bone with the tendon attached is driven through the defect and then rotated so that it is locked under the cortex.

permitting movement at the ankle joint, is applied (page 113) for a further two weeks. All splinting may then be discarded and more advanced quadriceps and knee flexing exercises commenced.

CHAPTER NINE

FRACTURES OF TIBIA AND FEMUR INVOLVING THE KNEE JOINT

FRACTURES OF TIBIAL TABLE

THE tibial table is the most frequent site of intra-articular fractures of the knee joint. The expanded cancellous proximal end of the adult tibia overhangs the shaft on either side and is inadequately supported from below by thin cortical bone. The tibial condyles are thus structurally weak in comparison with the femoral condyles which, although subjected to the same injury-producing mechanisms, are seldom fractured because of their sound architecture and adequate support from above by thick cortical bone.

The principal mechanisms of injury are :

- (1) Force applied to the tibial table from above as in a fall from a height.
- (2) Force applied to the outer or inner side of the limb producing abduction or adduction at the knee joint.

Many injuries are caused by a combination of these two forces. In addition, the fracture may take place as a result of direct violence applied to the upper end of the tibia in combination with an abducting force such as may be produced by a blow from the bumper of an automobile.

FRACTURES OF LATERAL TUBEROSITY

It has been noted previously that injuries of the medial collateral ligament are more common than those of the lateral. This is explained by the fact that the joint is protected from forces tending to produce a varus deformity by the opposite limb. The lateral aspect of the joint is exposed to injury and receives no protection from the opposite limb. The contra lateral injury, which is associated with valgus strains producing rupture of the medial collateral ligament, is fracture of the lateral tuberosity of the tibia and explains the frequency with which this injury is encountered in comparison with fractures of the medial tuberosity.

(1) FRACTURE BY COMPRESSION

It has been stated above that, in general, fractures of the tibial table are produced by force applied from above combined with an abduction strain. In this type of fracture (Figs. 220, 221, and 222) the force applied from above is much the more important element in the total force producing the strain.

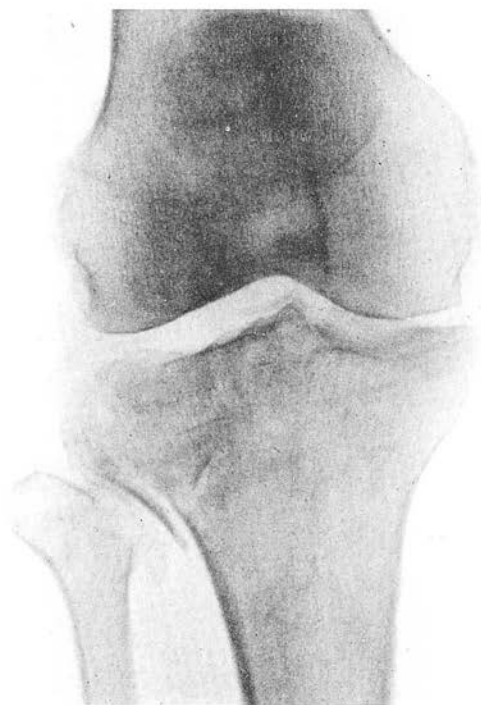


FIG. 220

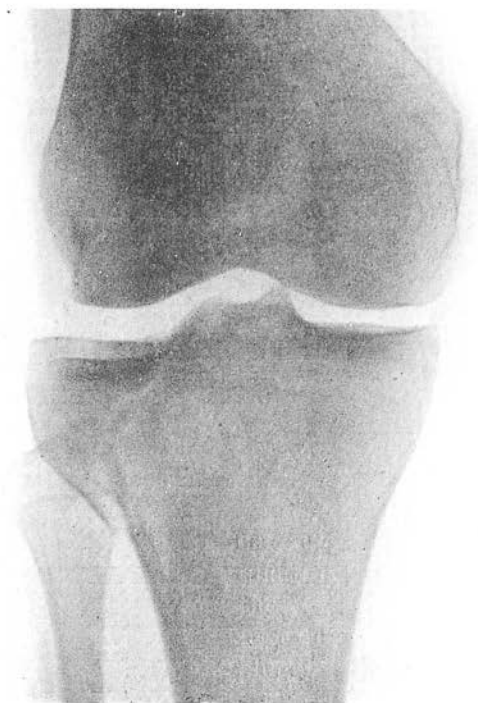


FIG. 221

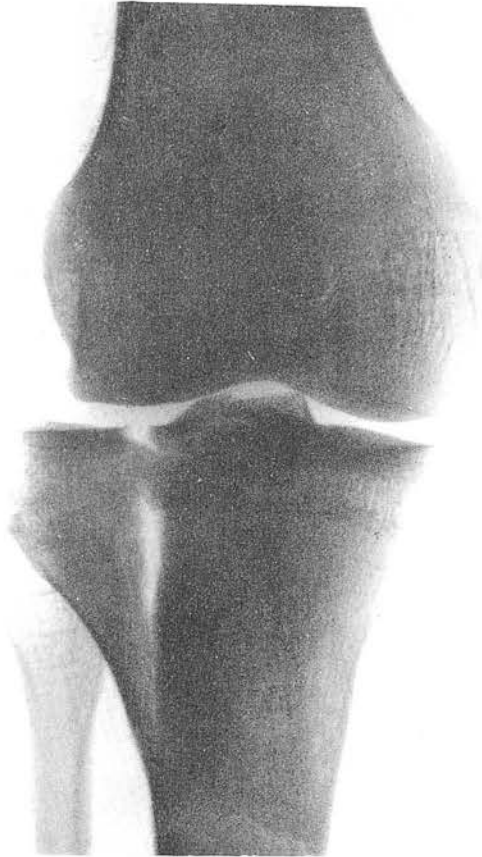


FIG. 222

Figs. 220-222.

Fractures of the lateral tuberosity of the tibia.

In the compression-abduction fracture, in which compression is the major force, the ligaments may escape serious injury and there is no gross comminution of the articular surface; reduction therefore presents no difficulties and the prognosis is good.

The lateral tuberosity is thus subjected to a force evenly distributed over its whole surface and is therefore driven almost directly downwards, or, if the element of abduction is a little greater, may be tilted outwards so that the neck of the fibula is fractured (Fig. 220). Apart from being driven downwards as a whole, or tilted and impacted into the tibial shaft, the articular surface as a rule escapes serious comminution. The medial collateral ligament is strained, or if there is gross tilting of the fragment may possibly be ruptured, but the anterior cruciate and other ligaments escape damage.

(2) FRACTURE BY ABDUCTION

In this type, which is the more serious injury of the two (Fig. 223), abduction is the more important element in the total force involved, or alternatively, acts prior to the downward thrust of the femur. Thus the medial collateral ligament ruptures first and permits the lateral femoral condyle to slip inwards towards the medial side so that when the downward thrust takes place the lateral femoral condyle, instead of driving the tibial condyle downwards as a whole, impinges at a point close to the tibial spine and thus drives only the central portion of the tibial tuberosity downwards. This central portion, forced into the tibial head by the femoral condyle, splits off the lateral portion of the tibial tuberosity and wedges it outwards. The gravity of the lesion lies not only in the difficulty of reduction, which is obstructed by the comminuted central portion of the tibial condyle which has been impacted into the tibial head (Figs. 223, 224, and 225), but by the inevitable damage to the medial collateral and anterior cruciate ligaments (Fig. 223. See also 153, 225, and 229). In addition, the meniscus is torn and possibly displaced into the crater in the tibial head and the articular surface so badly fragmented that anatomical reduction even by operation is practically impossible (Figs. 223 and 224).

CLINICAL FEATURES

The joint is usually grossly swollen both by reason of the effusion of blood and serum into the soft tissues overlying the upper end of the tibia and medial collateral ligament, and as a result of the haemarthrosis; but in cases which have occurred following a relatively trivial injury, such as stepping down suddenly from a high kerb, the clinical signs may not be marked and the true nature of the injury is only revealed following radiographic examination. When the tuberosity is depressed, deformity in the form of genu valgum may be present, but is often masked by the soft tissue swelling.

TREATMENT

(1) FRACTURE BY COMPRESSION

The injury varies between a vertical fissure in the tuberosity without displacement which may not appear radiographically to extend into the peripheral cortical bone, and one which involves the downward displacement or tilting, with or without impaction into the tibial shaft, of the whole lateral tuberosity (Figs. 220, 221, and 222).

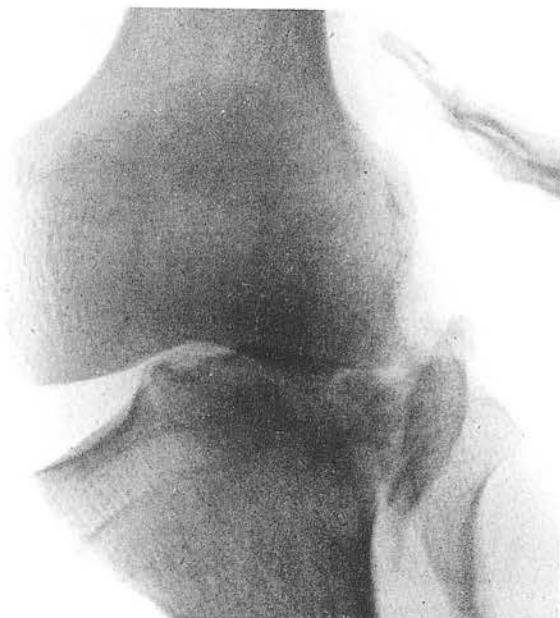

FIG. 223

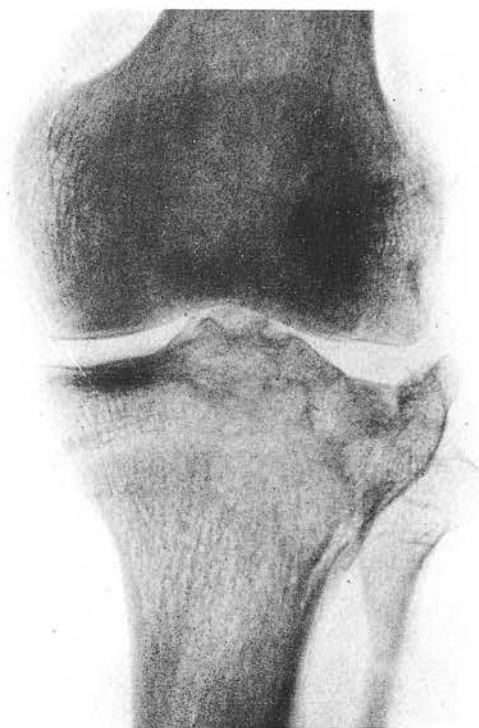

FIG. 224

Fracture of the lateral tuberosity of the tibia.

In the compression-abduction fracture, in which abduction is the major force, both medial collateral and anterior cruciate ligaments may be ruptured (Fig. 223); there is gross comminution of the articular surface. Reduction is therefore difficult and the prognosis less good (Fig. 224).

The treatment varies with the severity of the injury:

(a) In the case of the vertical fissure without displacement, a haemarthrosis may be present, but the ligaments are undamaged and thus immobilisation in a plaster case is both unnecessary and undesirable and merely results in the formation of adhesions. If the joint is distended with blood it is aspirated and a compression bandage applied. After an interval of two to three weeks the bandage may be discarded and active knee flexion exercises and rhythmical quadriceps drill commenced; loaded straight leg raising should be avoided. The patient may then be permitted

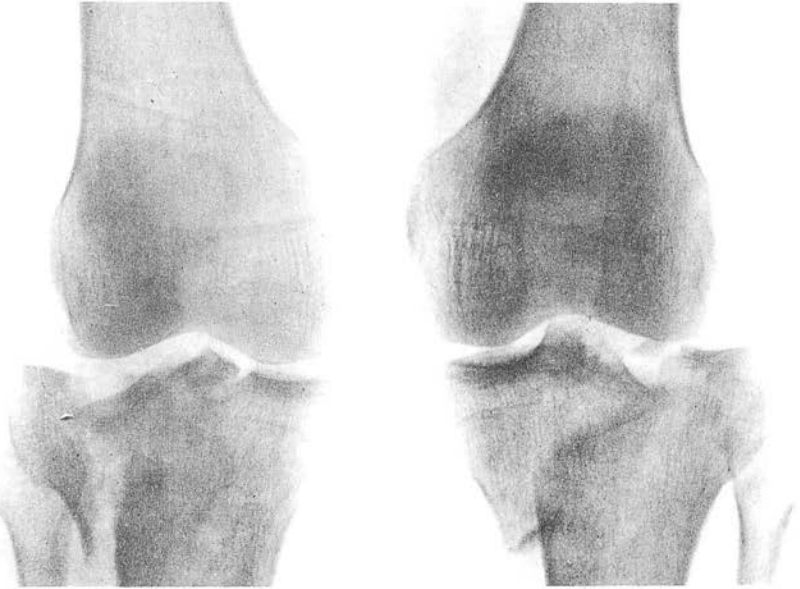

FIG. 225

Bilateral fracture of the tibial table sustained in a crash landing.

to resume ambulation with the aid of crutches and with a patten on the sound leg. No weight-bearing on the injured limb is permitted for a period of ten to twelve weeks, by the end of which time the quadriceps should be developed and full return of knee flexion obtained.

(b) If the fragment has been driven downwards or tilted laterally the optimum result is only obtained following anatomical replacement, provided attainment and maintenance of reduction does not involve factors, such as prolonged immobilisation in extension, likely to prove prejudicial to the return of full flexion.

The methods of treatment in use differ within wide limits. The unsatisfactory results obtained from rigid immobilisation suggested the so-called "functional" treatment which consists of immediate massage and movement, no reduction being attempted. The purpose of this treatment is not fulfilled in the long term result, which consists of a valgus deformity, instability and a rapidly progressive traumatic arthritis.

In contra distinction, the opposite extreme is practised by those who recommend operative replacement with internal fixation by such devices as a bolt passed through the tibial head to the opposite condyle or by wire passed circumferentially round the bone. It is generally accepted, however, that in this particular fracture, as opposed to the injury referred to as the Fracture by Abduction, a satisfactory reduction can usually be obtained by closed methods, the reduction being maintained by means of a close-fitting plaster case. The author concurs with the view that the reduction of this fracture presents no serious difficulties, but does not agree that immobilisation in plaster at or near full extension is a certain method of maintaining reduction or that it is conducive to an early return of full knee flexion. This view is based on the observation that even after a perfect anatomical reduction by traction combined with manual or clamp compression, there is a tendency for the downward pressure of the femoral condyle to redisplace the fragment if the joint is extended and the traction released. This tendency cannot be overcome by the application of a skin-tight plaster closely moulded to the tibial condyles. It is not possible to maintain direct pressure on the condyle of a degree sufficient to maintain reduction in the presence of the intervening soft tissue swelling which is always present and which is likely to be aggravated further by the trauma imposed by the use of a clamp or Thomas wrench. The method used by the author is an attempt to adopt a moderate course which will not only permit the original reduction to be maintained, but overcomes the serious problem of residual stiffness of the joint, which is the usual penalty imposed by plaster immobilisation in this injury.

Technique of Reduction.—A stainless steel Steinmann pin of three or four millimetres diameter is passed through the tibial shaft at a point well below the lowest point affected by the fracture, selecting a site where the skin is undamaged (Fig. 226). A diamond pointed pin should be used and drilled through the tibia or, if only the standard variety of pin is available, a twist drill of similar diameter should be passed through the bone before inserting the pin. It is not possible to drive a pin through the brittle cortical bone of this area in the usual manner without serious risk of local fracture or of a fissure running up into the original fracture. When the pin is in position and the skin punctures sealed, two collars with set-screws are fixed to either side (Fig. 227), so that extension cords may be attached to pull in the line of the tibial shaft without risk of slipping (Figs. 227 and 228). The patient is then returned to the bed in which he is to undergo his further treatment, the limb lying comfortably on the modified Braun splint. Powerful manual traction is now applied by an assistant who grasps the limb above the malleoli, while at the same time the depressed condyle is replaced by manual compression, or if this proves impossible, by means of a screw-clamp. Careful study of the radiographs of individual cases will indicate the method of attack to be adopted, *i.e.*, whether compression only is required or whether the fragment must first be disimpacted. If disimpaction proves impossible, Bohler has recommended¹ that a Steinmann pin be

¹ Lorenz Bohler. "The Treatment of Fractures." John Wright and Sons, Ltd., Bristol, 1936, 396.

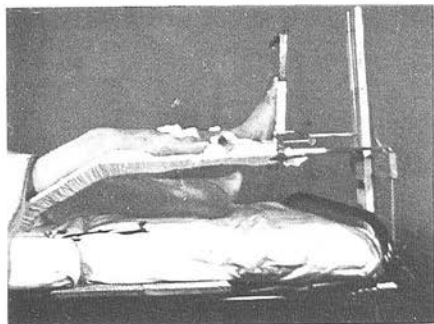


FIG. 226
Fracture of the tibial
tubule treated by the
author's method, on the
modified Braun splint.¹

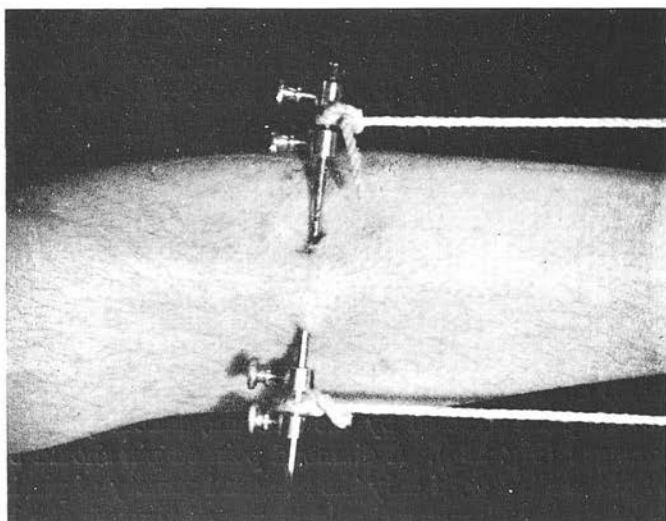
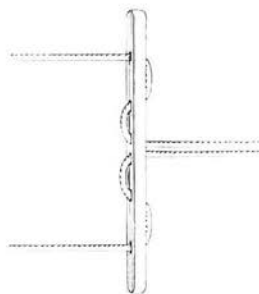


FIG. 227
The method of applying traction in the axis of the tibia.

FIG. 228
The spreader for the traction
cords, which is used for either
skeletal or skin traction.



¹ I. S. Smillie, "Simple System of Splinting for Lower Limb," *Lancet*, 1941, ii, 304.

inserted subcutaneously at right angles to the fracture site and used both to disimpact and elevate the fragment. This mode of reduction is less simple than it might first appear, especially as fragments are often more comminuted than the radiographs suggest, nor is insertion of a pin through a devitalised area of skin and underlying soft tissue a procedure entirely devoid of risk.

When the radiographs indicate that the reduction is satisfactory a firm compression bandage is applied and the manual traction changed to weight extension of from four to ten pounds, the weight selected depending on the force absorbed by the pulleys or other points of resistance. The minimum amount of traction should be used which will separate the joint surfaces and prevent any downward pressure from the femoral condyle.

After-treatment.—At the end of four weeks, when the reaction has completely subsided, gentle active exercises through a small range of flexion and extension are commenced, maintaining the traction throughout the period of activity. After a further two weeks the pin is removed, the traction discontinued, and complete freedom of movement allowed. Weight-bearing is not permitted until twelve weeks have elapsed, but the patient may be allowed to get up using a patten and crutches. A full range of movement combined with good quadriceps development is usually attained by the time weight-bearing is permitted (Figs. 229, 230, 231, 232, and 233).

This method of treatment may seem contradictory to some of the principles laid down in previous sections, particularly in regard to the Fracture by Abduction (see below). For example, continuous traction followed by movement at the end of four weeks contrasts with the twelve weeks of rigid immobilisation advised in complete rupture of the medial collateral ligament, and might appear liable to result in an unstable joint. In practice this has not been found to be the case. The medial collateral ligament heals with some slight lengthening, no matter what form of conservative treatment is instituted, and gentle traction with the knee in flexion has not been found to increase this lengthening. This is probably explained by the fact that on theoretical grounds the long parallel anterior fibres of the ligament should be relaxed in flexion. In addition, gentle traction will only separate the joint surfaces to the distance permitted by the lateral collateral ligament, iliotibial band and capsule, and provided the traction is not sufficiently powerful to stretch these structures, no undue separation of the apposed edges of the torn medial collateral ligament is produced. Furthermore, examination of radiographs of cases in which the injury of the anterior cruciate ligament has taken the form of a fracture of the tibial spine without displacement, in addition to the fracture of the lateral tuberosity, no separation of the fragment attached to the cruciate ligament has resulted from gentle traction in flexion.

(2) FRACTURE BY ABDUCTION

It has been stated in the early part of this section that the fracture by

FIG. 229

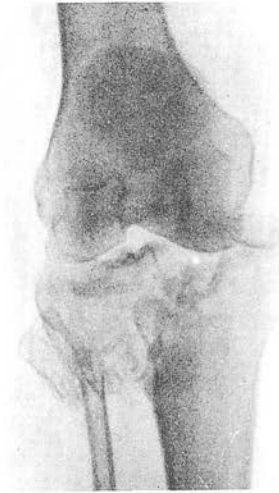

FIG. 230

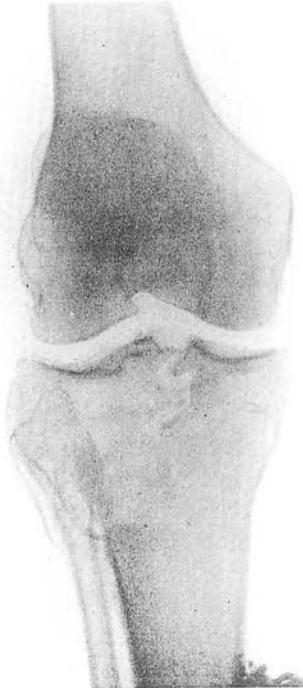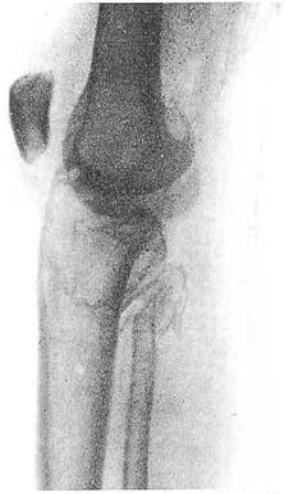


FIG. 231

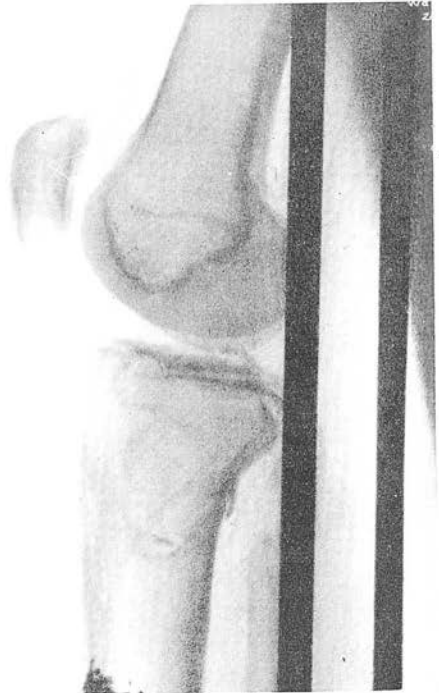

FIG. 232

abduction is a more serious problem than the fracture by compression by reason of the comminution of the articular surface, which may include a large portion from the central zone driven down into the tibial head (Fig. 225) and the almost certain rupture of the medial collateral and possible damage to the anterior cruciate ligament with which the fracture is associated. Examination of the radiograph in this type of fracture will show that elevation of the fragment, or comminuted fragments, which have been driven down into the tibial head is obviously impossible by closed methods, and, in addition, any large fragment which has been wedged between the main mass of bone and the peripheral fragment constitutes a block to reduction. It is for these reasons that operative replacement may be considered to offer the best prospect of a satisfactory result. On the other hand, it must be remem-

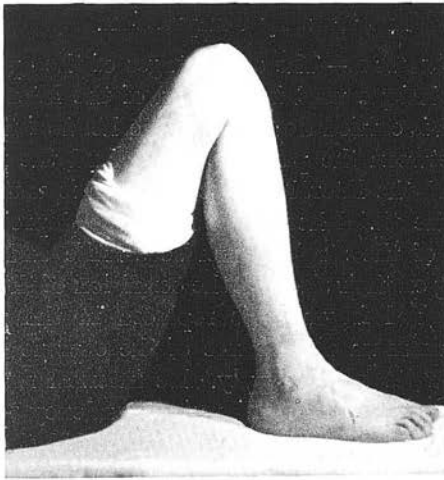

FIG. 233

Figs. 229-233.—Gross fracture of the tibial table treated by the method described showing the reduction and the range of flexion which resulted.

bered that any reconstruction which involves the fitting together of innumerable fragments is no trivial procedure and should not be attempted except by those thoroughly versed in the intricacies of knee joint surgery. Nor does the accurate replacement of the fragments assure the final result because many of the fragments, and the attached articular cartilage, are little more than free grafts after replacement, and may undergo aseptic necrosis (see technique of operation).

The type of closed or conservative treatment used by the author differs in few respects from the treatment adopted in fractures by compression, in spite of the damage to the ligaments which is inevitably present: the results obtained have been most gratifying. The decision must be made before embarking on any treatment, whether closed or operative reduction is to be adopted. It is a mistake to attempt closed reduction, using skeletal traction and powerful compression, decide that the reduction is unsatisfactory, and then resort to open operation. Not only does the presence of the Steinmann

pin increase the risk of sepsis, but the screw-clamp, used to the limit of soft tissue tolerance, causes devitalisation of the skin and underlying tissues in the area of the incision and greatly increases the difficulty and hazards of any future operative procedure.

Manipulative Reduction. The technique of manipulative reduction differs little from that described under Fractures by Compression. The large central fragment which has been driven down into the tibial head cannot be elevated by closed methods or by the subcutaneous introduction of a pin. Reduction must therefore be effected by the powerful compression of a screw-clamp, such as Böhler's redresseur fitted with special jaws designed to fit the tibial tuberosities, which cause the marginal fragment to crush the depressed articular fragment into the soft cancellous tissue of the tibial head. When reduction has been accomplished the after-treatment follows the lines suggested in Fractures by Compression.

Operative Reduction.—The early stages of the operation differ in no respect from the technique used in excision of the lateral meniscus except in the incision which is carried down on to the head of the tibia. The joint cavity is entered between the patellar tendon and the iliotibial band, the blood evacuated, and the lateral meniscus, which is usually torn or driven into the crater in the tibial head, excised. The depressed fragments are elevated by means of the straight meniscus knife and fitted together or discarded, depending on their size and the condition of the attached articular cartilage. The marginal fragment is replaced in the normal anatomical position with the minimum disturbance of the capsule and soft tissues on which it depends for its blood supply. No internal fixation is necessary, but it will usually be noticed that there is a tendency to redisplacement if the joint is extended, which is not present provided the flexed position is maintained. The author therefore prefers to insert a Steinmann pin well below the site of fracture at the termination of operation, apply a compression bandage, and thereafter treat the patient on the same lines as suggested under Fractures by Compression.

The operation is performed with least difficulty by the use of a tourniquet, but care must be taken that no undue delay is incurred lest a tourniquet paralysis or even more serious complication befalls.

FRACTURE OF BOTH TUBEROSITIES

Fracture of both tibial tuberosities, the so-called "Y" shaped fracture, occurs second in frequency to fracture of the lateral tuberosity. The injury usually takes place as a result of a fall from a height and both condyles are driven downwards; but as there is frequently no element of abduction or adduction in the mechanism each condyle may be depressed to an equal degree, the fragments are not impacted into the tibial shaft and there is no gross ligamentous damage. The reduction therefore presents no difficulty and the prognosis is good provided anatomical replacement of the fragments has been accomplished.

TREATMENT

If the joint is distended with blood and there is a gross soft tissue swelling at the upper end of the tibia it is advisable to carry out aspiration, supplemented by compression for a period of seven to ten days, to permit the swelling to subside before undertaking reduction.

The technique of skeletal traction combined with manual compression is the same as that described under the Fracture by Compression, and the after-treatment follows similar lines, although it may be advisable to defer weight-bearing for longer than twelve weeks if it is considered that there is any risk of redisplacement.

FRACTURE OF MEDIAL TUBEROSITY

Fractures of the medial tuberosity are uncommon and the treatment does not differ in any respect from that of the lateral tuberosity. Gross injuries are the result of extreme and unusual types of violence and may entail the rupture of both the lateral collateral ligament and lateral popliteal nerve (see Lateral Collateral Ligament).

OLD FRACTURES OF TIBIAL TABLE

If the presence of a fracture is only established some weeks or months after the injury, the treatment to be adopted depends upon the degree of displacement. If the displacement is minimal, active non-weight-bearing exercises, concentrating especially on the quadriceps, is the treatment of choice, but if there is any marked displacement likely to result in deformity, instability, and arthritis, operation is advisable provided the surgical conditions are suitable and the age of the patient merits the opportunity of a more favourable prognosis.

The operation follows the lines suggested in the Operative Reduction of the Fracture by Abduction. The meniscus is excised not only because it is probably torn, but to increase the visual access and space available for elevation and alignment of the fragment. The increased space between the femoral and tibial condyles simplifies the mobilisation and excision of the meniscus.

The large marginal fragment is mobilised by means of the straight chisel-type meniscus knife, with as little disturbance of the attached soft tissues as possible, and using the greatest care not to split or crush the soft friable bone. When elevation and alignment have been secured stabilisation is obtained by two or three long, thin cortical grafts obtained from the shaft of the tibia, carefully inserted through the fragment at varying angles to each other and driven down into the cancellous bone of the tibial head (Figs. 234 and 235, and 236 to 240).

The use of a tourniquet is of great advantage, but it may have to be removed, or loosened and reapplied, during the course of the operation. Fortunately, a completely bloodless field is only necessary in the early stages of the procedure.

The fixation and stability of the fragment is not such that there is no fear of further displacement in plaster, and therefore the author prefers to insert a Steinmann pin through the lower end of the tibia at the termination of the operation, apply a compression bandage, and thereafter treat the patient on the modified Braun splint with a few pounds of traction and in the same manner as described under Closed Reduction of the Fracture by Compression.

ARTHRODESIS OF KNEE JOINT

Certain cases of gross injury to the tibial table and ligaments, whether

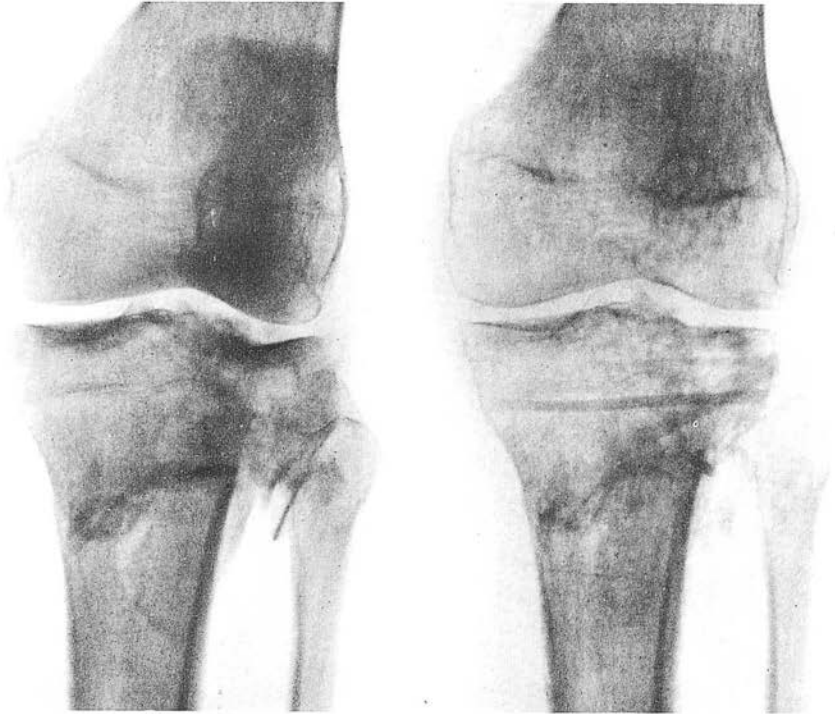


FIG. 234

FIG. 235

Eight weeks old fracture of the lateral tuberosity of the tibia treated by operative reduction and internal fixation with bone grafts.

reduced or unreduced, develop a rapidly progressive degenerative arthritis causing symptoms of the utmost severity. This condition is most likely to develop in the fracture of the lateral tuberosity caused by abduction in which the articular surface is grossly comminuted and in which the joint is unstable, not only by reason of laxity of the medial collateral and anterior cruciate ligaments, but because of wasting of the quadriceps, and especially the vastus medialis, which is unable to protect the arthritic joint from the twists and strains of everyday use. In these cases arthrodesis of the knee will provide a stable painless joint, but as a stiff knee constitutes a severe handicap and is a final step which cannot be undone, it is necessary to analyse the symptoms of each individual patient and attempt to correlate

FIG. 236

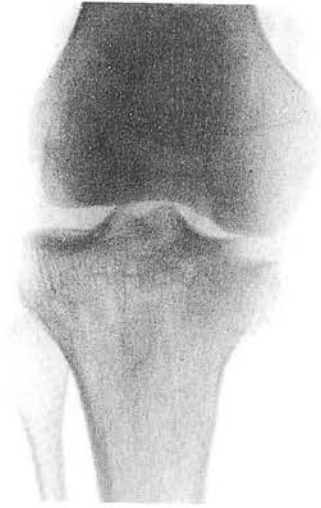

FIG. 237

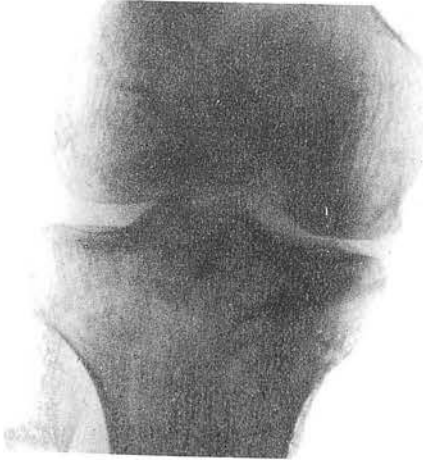
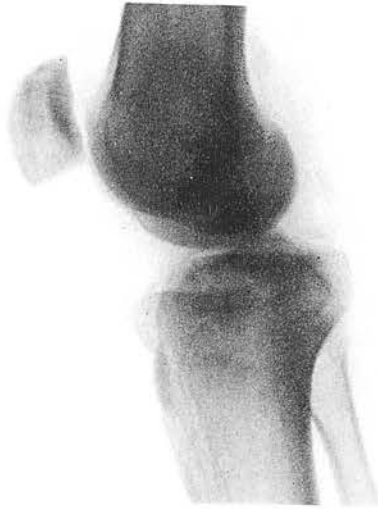
FIG. 238

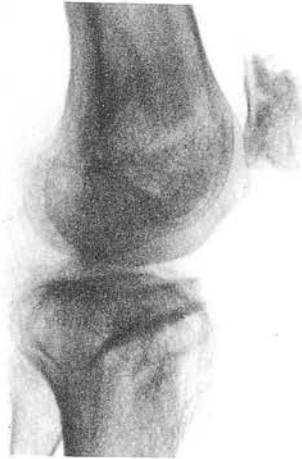

FIG. 239

Figs. 236-240. Six weeks old fracture of the lateral tuberosity of the tibia treated by operative reduction and internal fixation with bone grafts. The patient later wrote to say that he had regained his previous category of AI and had just completed a twelve-mile march without ill effect.



FIG. 240



FIG. 241

Adjustable twin-bladed saw based on a standard back-saw frame and blades.

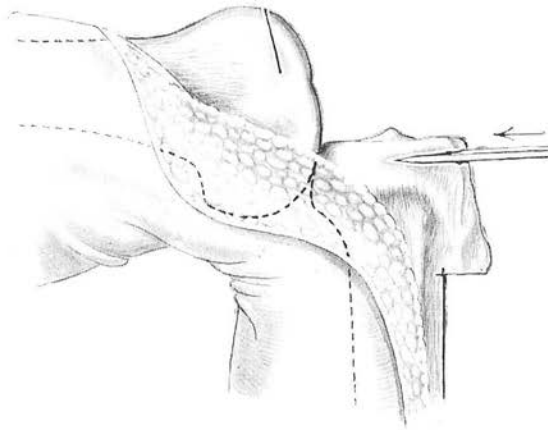


FIG. 242

The saw cuts are completed with an osteotome. (*Brittain.*)

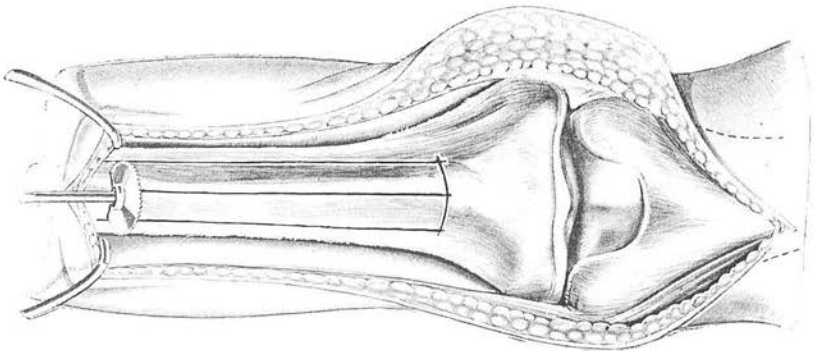


FIG. 243

The grafts are cut from the crest and antero-medial aspect of the tibia. (*Brittain.*)

the symptoms with the findings of clinical and radiological examinations before the case is finally classified as traumatic osteoarthritis and dismissed as incurable except by arthrodesis. For example, the possibility that the symptoms are referable to a torn meniscus should be considered in the light of the knowledge that this structure is frequently injured at the original

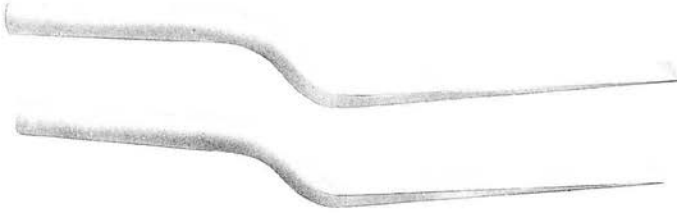


FIG. 244

The cranked osteotomes.

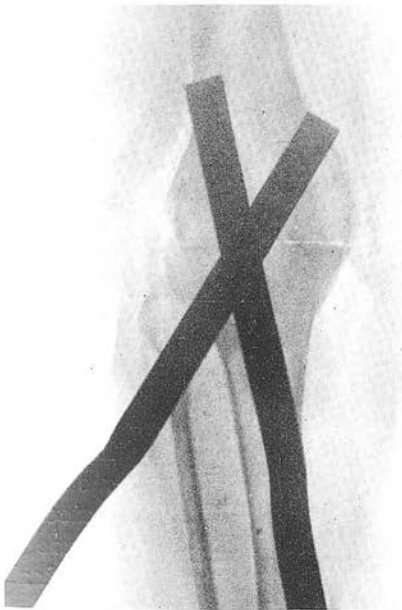


FIG. 245

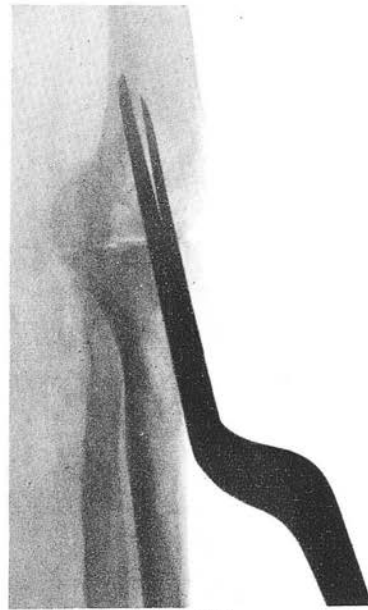


FIG. 246

The osteotomes in position.

accident: the author has encountered three such cases whose symptoms were relieved by a relatively minor operative procedure. If, however, there are only a few degrees of painful movement present the decision to fuse the joint immediately is not unreasonable, but if on the other hand a useful range of movement still remains, redevelopment of the quadriceps to a degree which will afford the joint adequate protection may often render the patient relatively free of symptoms and may defer arthrodesis for many years.

TECHNIQUE OF OPERATION

An anterior mid-line incision is made extending from the upper limits of the suprapatellar pouch to a point about eight inches down the tibial shaft. The quadriceps tendon is split in the same line, beginning at the upper extremity of the pouch and continuing down over the patella to end at the tibial tubercle. The capsule is erased from the medial and lateral tibial tuberosities, the suprapatellar pouch dissected out completely, and the patella excised and discarded. (If it remains attached to the quadriceps it is frequently drawn upwards at a later date and its poor osteogenic qualities makes it of little value in assisting to promote arthrodesis.) The articular surfaces of the femur and tibia are removed by means of a twin-bladed saw, after the manner of Calvé and Galland,¹ permitting two parallel cuts to be made which remove both articular surfaces at the same time, thus ensuring the most perfect apposition of the greatest possible area of raw bone (Fig. 241). The proximity of soft tissues does not permit the whole depth of the bone to be traversed by the saw, which can merely be used to about half the depth, and the remainder of the cut is completed with an osteotome (Fig. 242). The raw bone of the tibia and femur is broken up by driving in a small osteotome at numerous points and partially levering out areas of cancellous tissue in order to increase both the area and the roughness of the opposing surfaces.

Stabilisation is obtained by means of two bone grafts driven up through the tibial table to cross the joint in the form of an X after the manner of Brittain.² The grafts are cut from the crest and antero-medial aspect of the tibia beginning at a point about two inches below the upper limit of the shaft and extending distally for about five inches (Fig. 243). A cranked osteotome, of about half an inch diameter (Fig. 244), is introduced through the upper part of the bed in the tibia from which the bone grafts were taken and left *in situ* so that the second osteotome, which is inserted from the medial aspect of the tibial head, does not encounter it in passing (Figs. 245 and 246). (Osteotomes of this design, by keeping the shaft clear of the bone and soft tissues, are not only easy to insert but can easily be withdrawn by striking the blade side of the crank with a mallet.) One osteotome is then removed and the graft driven into position, and then the second osteotome withdrawn and replaced by the second graft. Care is taken to secure the closest possible contact of the opposing surfaces before the wound is finally closed (Fig. 247).

AFTER-TREATMENT

The employment of a tourniquet precludes the immediate use of a plaster case, which does not provide elastic pressure. It is therefore the author's practice to apply a compression bandage incorporating long, thick, plaster slabs, which reach from the groin to the ankle joint, as a temporary form of

¹and ²H. A. Brittain. "Architectural Principles in Arthrodesis." E. and S. Livingstone, Edinburgh, 1942, 46-52.

splintage. The only satisfactory method of immobilisation for an arthrodesis of the knee is that provided by a plaster spica which includes both hip and ankle joints ; the initial dressing should not be retained for longer than a

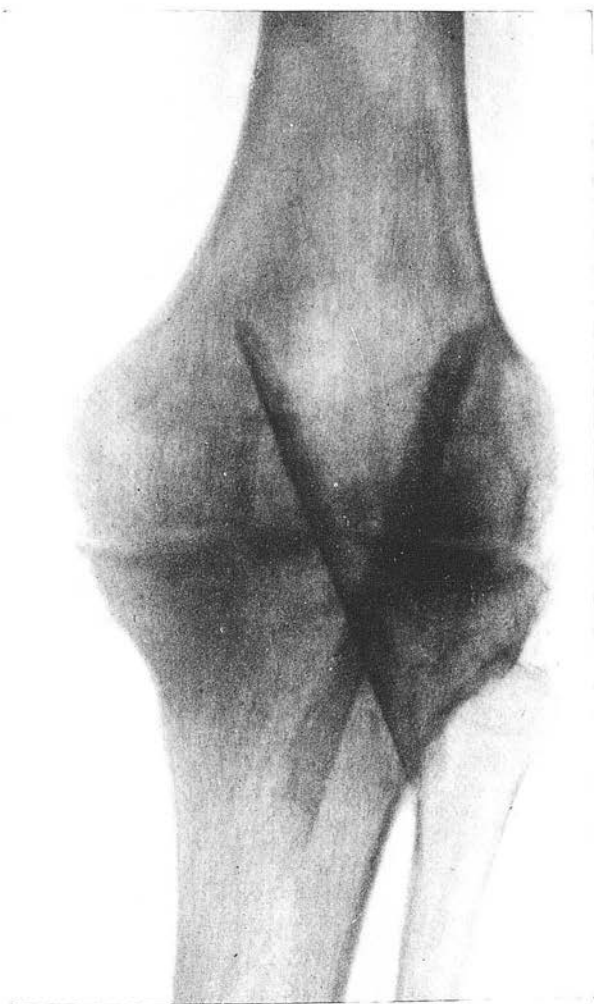


FIG. 247

Arthrodesis of the knee using X grafts after the method of Brittain.

few days, for it rapidly becomes loose and may permit a hyperextension deformity to occur.

In eight to sixteen weeks, depending on the rapidity of fusion, the spica is discarded in favour of a thigh-length walking plaster of the type which permits ankle movement, and this splint is retained until the arthrodesis is completely consolidated.

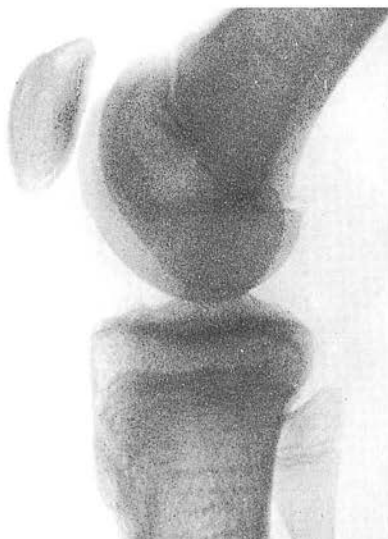PREMATURE FUSION OF THE ANTERIOR PORTION OF THE UPPER TIBIAL
EPIPHYSIS RESULTING IN GENU RECURVATUM

FIG. 248

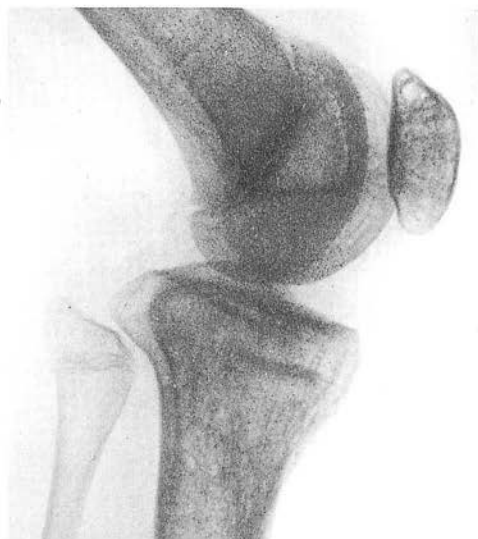


FIG. 249

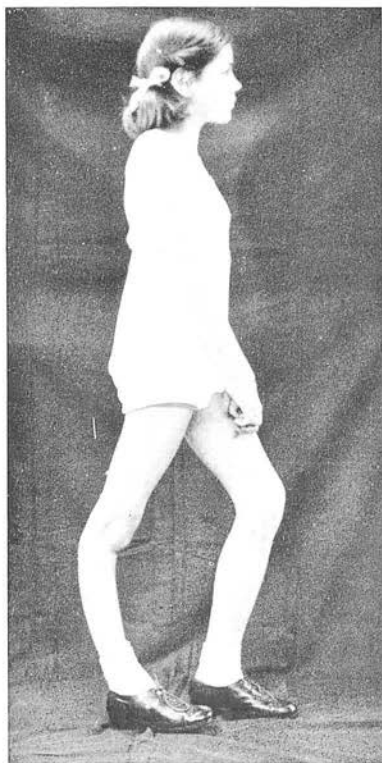

FIG. 250

Fig. 248.—The normal tibia.

Fig. 249. The anterior inclination of the articular surface which resulted from premature fusion of the epiphysis.

Fig. 250.—The deformity.

GENU RECURVATUM, VARUM, OR VALGUM, DUE TO FRACTURES OR OLD INJURIES OF UPPER TIBIAL EPIPHYSIS

The closer a fracture to a weight-bearing joint the more important is accurate anatomical reduction. Fractures within the upper third of the tibia tend to the characteristic displacement of forward angulation of the lower fragment. The small size and location of the upper fragment makes

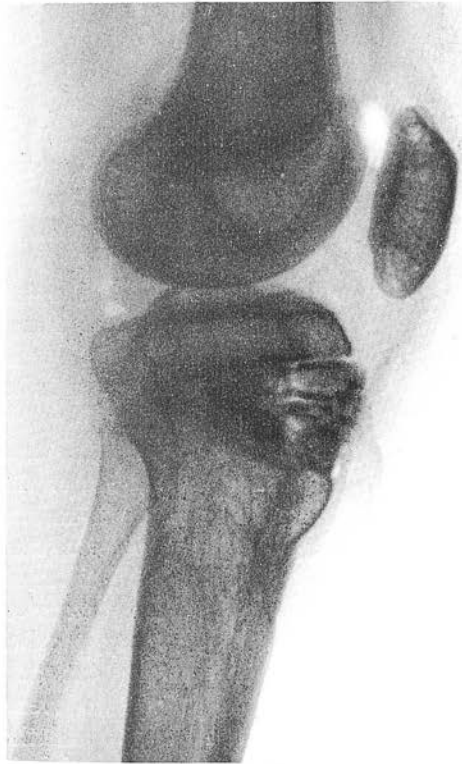

FIG. 251

The anterior inclination has been corrected by linear osteotomy and the insertion of wedge-shaped grafts taken from the ilium.

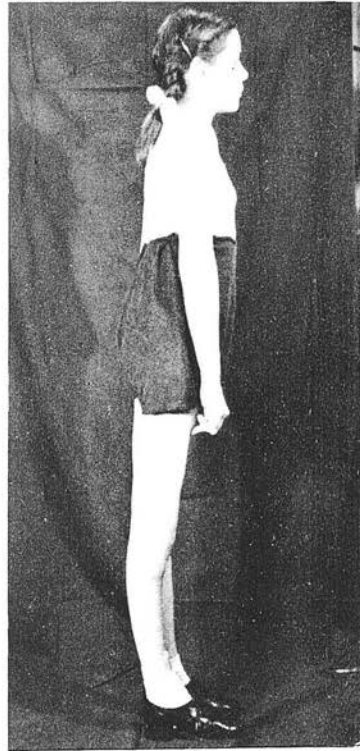


FIG. 252

The final result.

the fracture both difficult to reduce and to control following reduction, so that a residual deformity in the form of genu recurvatum is not uncommon. In early youth, injuries of the tibial epiphysis may result in the same deformity or in genu varum or valgum. In addition, cases are occasionally encountered in which a portion of the epiphysis undergoes premature fusion for reasons which may have no simple explanation. Figs. 248 to 252 illustrate such a case. The patient suffered a compound fracture at the lower end of the tibia in an air raid. There was considerable loss of both soft tissue and bone necessitating a pedicle skin graft and an inlay

bone graft at later dates. When her treatment was almost completed, she sustained a high supracondylar fracture of the femur in a further accident. Anatomical reduction was obtained in both these injuries, but a year later she was noted to have acquired a marked genu recurvatum referable to the upper tibial epiphysis (Fig. 250), the anterior portion of which had apparently undergone premature closure (Fig. 249). It was presumed that the prolonged immobilisation necessitated by the two fractures had produced abnormal stresses which had caused the anterior portion of the epiphysis to fuse.¹

TREATMENT

The deformity is corrected by linear osteotomy above or below the tibial tubercle, depending on the requirements of individual cases. Alignment is maintained with wedge-shaped bone grafts. On first impression an operation carried out below the tubercle would appear to be the less formidable procedure, but in the author's experience this is not the case, for the reason that in this region the cortex is thin and brittle and the sides of the shaft tapered rather than parallel; stability and maintenance of correction is thus difficult to achieve. Above the tibial tubercle the osteotomy is performed through tissue of large section with parallel sides, and, the bone being less brittle, the deformity can be corrected without fracture of the posterior cortex. Moreover, at this site stability is maintained by the collateral ligaments of the joint as division of the bone is affected above the level of their inferior attachments.

Both tibial condyles may be approached through a small transverse curved incision which begins on the lateral side of the patella, crosses the mid-line over the patellar tendon, and is continued down the antero-medial aspect of the tibia for a short distance. There is no necessity to detach the tibial tubercle and patellar tendon. When the skin flaps have been dissected incisions are made on either side of the tendon and both condyles exposed intracapsularly and subperiosteally. A transverse linear osteotomy, parallel and about one centimetre distal to the articular surface, is carried out with a broad fine osteotome, the cortex being left intact posteriorly. Two levers, one on each side of the patellar tendon, are inserted into the gap and the anterior aspect of the upper fragment elevated until the articular surface is at right angles to the tibial shaft. Wedge-shaped grafts are then inserted to maintain the correction. The author does not favour cortical grafts taken from the shaft of the tibia, but prefers to use bone taken from the ilium and cut in such a manner that both tables receive the compression force. The spaces around the wedges are filled with bone chips (Fig. 251).

AFTER-TREATMENT

At the termination of the operation a padded plaster cast is applied from the toes to the groin, maintaining the joint in a few degrees of flexion. The

¹ Premature closure of both lower femoral and upper tibial epiphyses in children subjected to prolonged immobilisation in the course of treatment for tuberculosis of the hip joint has been recorded by Gerald G. Gill (*J. Bone and Joint Surg.*, 1944, xxvi 273-281), who considers that trauma superimposed on extreme decalcification is the probable cause.

stitches are removed in two to three weeks' time, when the plaster is changed in favour of an unpadding cast, which is retained for a further six to eight weeks. Weight-bearing can usually be permitted at the end of twelve weeks.

In the correction of the deformities of the tibial head it should be remembered that any operation which consists of lengthening one side of the tibia produces secondary effects on the tendo achillis, and steps should be taken to prevent or correct the equinus position of the foot which may result.

CONDYLAR AND SUPRACONDYLAR FRACTURES OF FEMUR

SUPRACONDYLAR FRACTURE

The supracondylar region of the femur is structurally strong and fractures occur only as a result of the most extreme direct violence. In spite of the relative infrequency of the injury by comparison with fractures

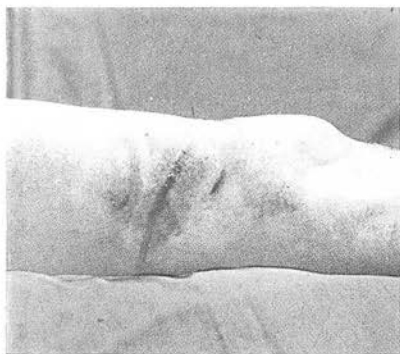

FIG. 253

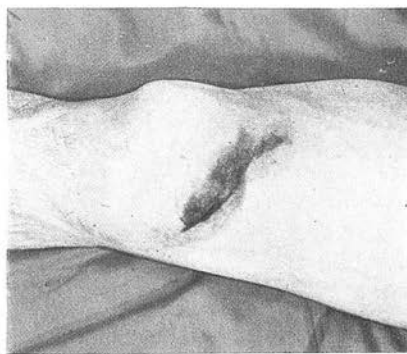

FIG. 254

The supracondylar fracture of the femur

The leg of a coal miner injured by a fall of roof, showing the lateral side (Fig. 253) which was struck by the stone and the medial side (Fig. 254) which was trapped against the ground. The synovial effusion, which later distended the joint, is in process of development.

of the tibial table, it is a common fracture in coal-miners who receive the injury as the result of a fall of roof on the outstretched leg (Fig. 22).

The importance of the injury may be summarised :

- (1) The fracture is not only difficult to reduce but to maintain in reduction. This is due to the fact that the gastrocnemius, which is the only muscle attached to the small distal fragment, causes displacement in the form of flexion so that the upper end of the distal fragment is tilted towards the popliteal space and its small size makes it difficult to control (Fig. 255).
- (2) The fracture may have serious effects on the future function of the knee joint because :
 - (a) The close proximity of the joint to the fracture entails inevitable strain of the supporting structures at the time of the injury.

- (b) The suprapatellar pouch is opened at the fracture site or penetrated by the distal end of the upper fragment (Fig. 255).
- (c) If the quadriceps muscle is traumatised (Fig. 257) treatment in any marked degree of flexion produces loss of active extension due to adhesion of the muscle to the lower end of the femur.¹
- (3) There is the possibility of other serious complications. If the lower end of the upper fragment is displaced backwards it may perforate the popliteal artery (Fig. 256).

TREATMENT

The method of treatment to be described is based on Böhler's original technique in which skeletal traction through the upper end of the tibia was combined with the use of the Braun splint,² the angle of which was placed at the fracture site rather than behind the knee joint. Watson-Jones,³ in whose experience this fracture is rare, denies the efficacy of Böhler's method. The author does not concur with this view. The fracture is not rare in a mining community. In the past five years 32 cases were treated in the manner described below. In no case did the method fail to secure anatomical reduction.

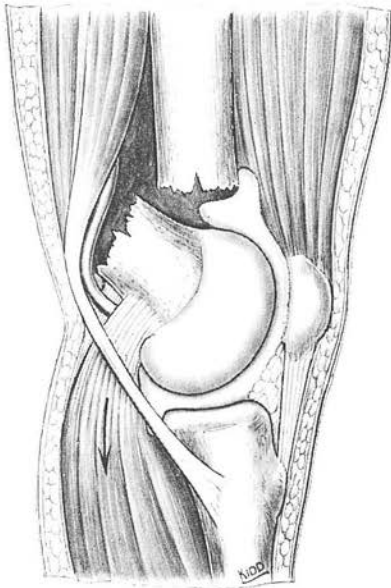


FIG. 255

The upper end of the distal fragment of a supracondylar fracture of the femur is tilted towards the popliteal space by the gastrocnemius (Watson-Jones).

The function of both traction and splint is to maintain a reduction obtained by manual traction, counter traction, and manipulation. If traction on a Braun splint is expected to produce the reduction the method will fail.

TECHNIQUE OF REDUCTION

The patient is anaesthetised and a four millimetre stainless steel Steinmann pin driven through the tibia in the region of the tubercle, and fitted with a rotating stirrup. The patient is then transferred to a bed fitted with fracture boards and a divided mattress, and the limb placed on the author's modification of the Braun splint,⁴ the advantage of which, in this particular instance, is firm fixation to the foot of the bed.

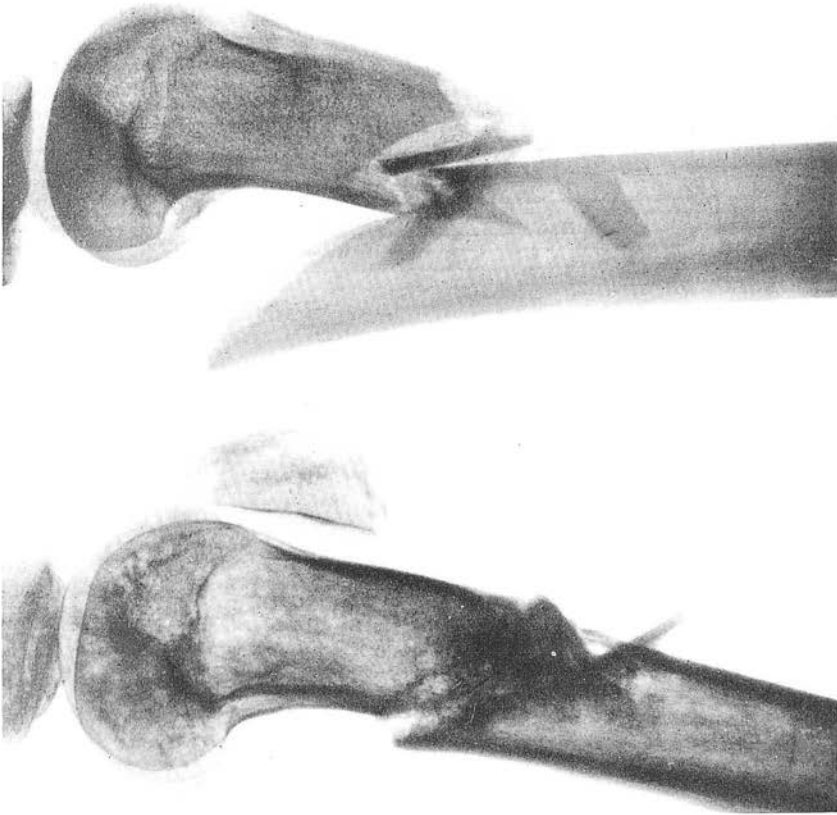
¹ R. Watson-Jones. "Fractures and Joint Injuries." E. and S. Livingstone, Edinburgh, 1943, 694.

² Lorenz Böhler. "The Treatment of Fractures." John Wright and Sons, Ltd., Bristol, 1936, 338.

³ R. Watson-Jones. "Fractures and Joint Injuries." Ed. 3. E. and S. Livingstone, Edinburgh, 1943, 689.

⁴ I. S. Smillie. "Simple System of Splinting for Lower Limb." *Lancet*, 1941, ii 304.

The fracture is reduced by means of strong traction applied manually to the limb by one assistant, while a second assistant presses backwards on the iliac crests to fix the pelvis. When the limb has been pulled out to the full length the manual traction is transferred to the rotating stirrup while the surgeon grips the lower fragment and lifts it forward so that it is brought into line with the upper fragment (Fig. 258). A large roll of soft wool is then



FIGS. 256 and 257

Supracondylar fracture of the femur with gross displacement and comminution. The popliteal artery is endangered by the lower end of the upper fragment (Fig. 256). Although the alignment of the fragments is perfect following reduction by the method described in the text, there is a spike of bone projecting into the quadriceps which will prejudice the return of full flexion (Fig. 257).

placed behind the lower fragment (Fig. 259) and the limb adjusted so that the angle of the splint lies behind the fracture site and not at the knee joint, which is the more usual position. The accuracy of the reduction can be estimated by palpation of the fracture site through the anterior aspect of the quadriceps; it is usually possible to feel the lower end of the upper fragment prior to reduction, and the existence of a palpable depression below this point indicates that the upper end of the lower fragment is still tilted

backwards (Fig. 261) and that further manipulation is necessary. When it is considered that the best possible reduction has been obtained radiographs are taken to determine the exact position of the fragment, and further

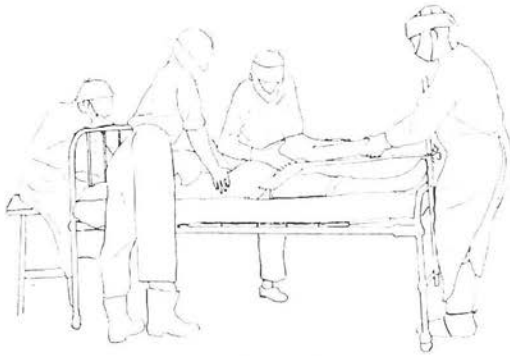


FIG. 258

When the limb has been pulled out to full length by manual traction the surgeon grips the lower fragment and lifts it forward so that it is brought into line with the shaft of the femur.

adjustments and final radiographs taken before the patient is returned to the ward, where the foot of the bed is raised on blocks (Fig. 259).

The success of the method depends on securing accurate stable reduction by traction and manipulation and maintaining the position of the lower fragment by means of the large pad of wool and about ten pounds of traction.

The exact direction of the traction force may be adjusted by raising or lowering the transverse bar to which the pulley

is secured to the splint rest (Fig. 259). The method will fail if the application of traction alone is expected to produce reduction.

Sometimes in a short muscular thigh it is found that it is impossible to exert sufficient manual traction to disengage the fragments and that in spite of all efforts the upper end of the lower fragment remains tilted towards the popliteal space. In these circumstances no pad is placed under the lower fragment, but heavy traction of twenty to twenty-five pounds is applied for twenty-four to forty-eight hours. At the end of this time the femur is of full length, possibly even over distracted. The patient is then given a second

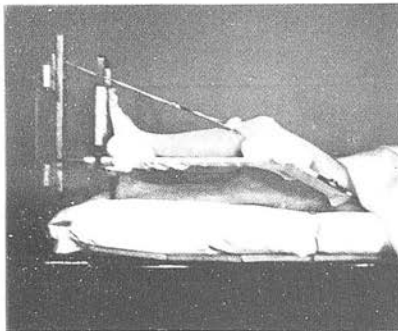


FIG. 259

Supracondylar fracture of the femur treated on the author's modification of the Braun splint.

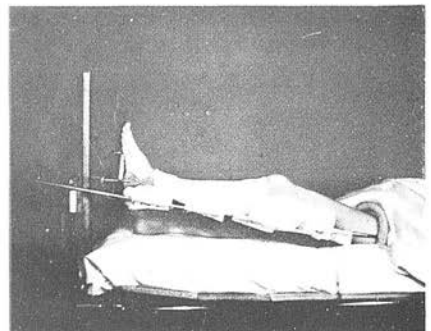


FIG. 260

The same case immediately after transfer to a Thomas splint at the sixth week. The knee flexion is gradually reduced.

anaesthetic, when it will be found that manipulative reduction presents no difficulty. Traction is then reduced to about ten pounds.

Prolonged immobilisation in the flexed knee position is prejudicial to the

rapid return of quadriceps function; the vastus medialis cannot be exercised and wastes rapidly. It is especially important in a fracture which invariably involves injury to the extensor apparatus that the position of flexion should not be continued any longer than is necessary to ensure the maintenance of reduction. The progress of union in fractures occurring in this region of the femur is relatively rapid in spite of the wide variation in the number and form of the fragments. The flexed-knee splint is therefore discarded in favour of a Thomas splint, in which vastus medialis exercises can be practised and guarded knee flexion exercises commenced, as soon as a degree of consolidation has been reached which can overcome the inherent tendency to backward angulation. This stage, which is judged on clinical as well as radiological evidence, is reached between the fourth and eighth weeks; the skeletal traction is discarded and replaced by skin extension and the limb placed in a Thomas splint with the fracture site supported by a padded sling, the joint being maintained in a few degrees of flexion.

With the exception of those cases in which the quadriceps is gravely involved, and provided the rules for the preservation of knee joint function, which apply to all fractures of the femur, have not been transgressed (see Chapter XIII), no difficulty should be encountered in securing a rapid return of flexion (Figs. 262, 263, 264, 265, and 266).

AFTER-TREATMENT

The author has never failed to secure anatomical reduction by the method described nor has any great difficulty been encountered in maintaining reduction. It is admitted, however, that each case requires daily supervision until consolidation has advanced to a degree which will permit the flexed-knee splinting to be discarded.

Attention must be directed to the following points:

(1) There is a constant tendency to backward angulation at the fracture site. This must be overcome by adjusting the splint and pad of wool once daily. Control radiographs should be taken twice weekly

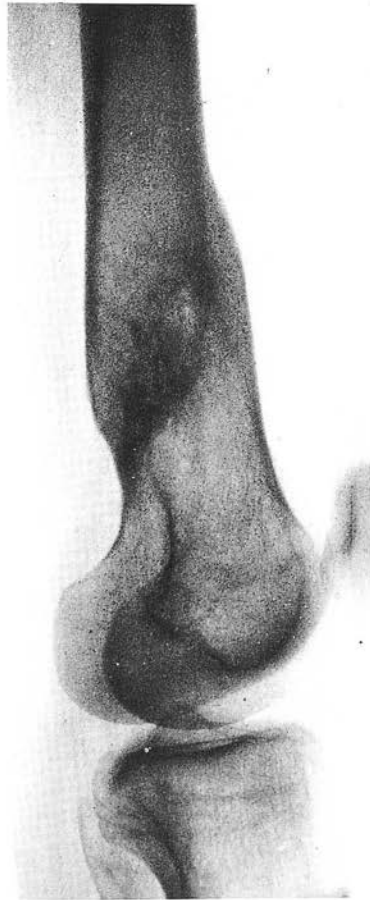

FIG. 261

The closer a fracture to a weight-bearing joint the more important is accurate anatomical reduction. The normal anterior curve of the lower end of the femur has not been reproduced resulting in a moderate degree of genu recurvatum.

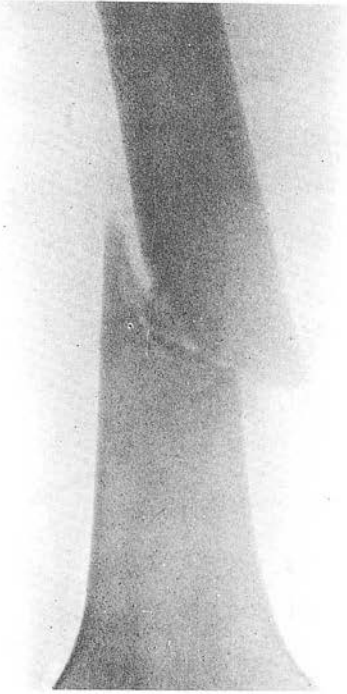


FIG. 262

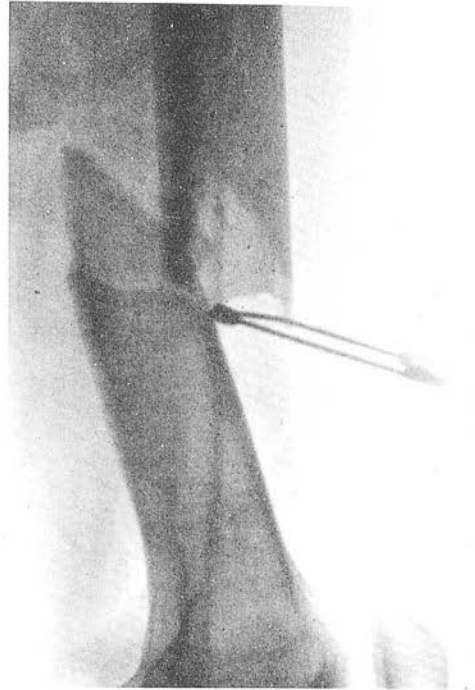


FIG. 263

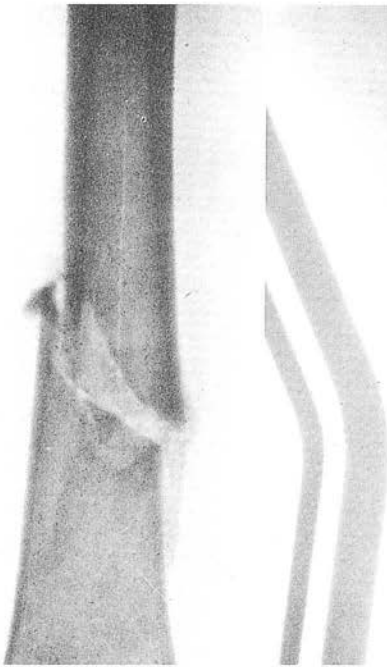


FIG. 264

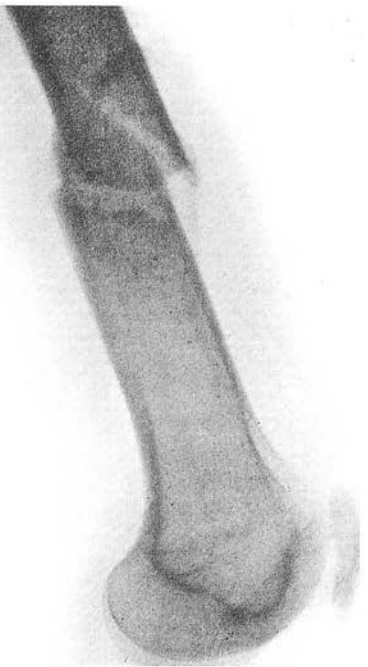


FIG. 265

as long as there is any suspicion that the tendency to displace remains. Malunion with backward angulation causes an unsightly deformity and disability in the form of genu recurvatum (Fig. 261).

(2) The pad of wool must not be permitted to exert pressure of a degree which will cause necrosis of the skin of the popliteal space or paralysis of the lateral popliteal nerve which becomes superficial and thus liable to injury when the knee is in the flexed position. It should thus be changed when it becomes compressed and hard.



FIG. 266

Figs. 262-266

High supracondylar fracture of the femur showing the displacement (Figs. 262 and 263), the reduction and position of the angle of the splint (Figs. 264 and 265), and the final result (Fig. 266).

(3) No difficulty is usually encountered in maintaining reduction in the antero-posterior view, but if angulation does occur it usually takes the form of valgus deformity. This is due to the obliquity of the pelvis which results from traction on the limb and to the pull of the adductors. The angulation can usually be corrected by the use of a screw controlled pressure pad applied against the medial aspect of the distal end of the upper fragment. The longitudinal traction exerted on the distal fragment exerts leverage against the pressure pad and corrects the deformity (Fig. 267).

(4) No dressings are used on the entrance or exit wound of the pin

track, and if the stirrup is rotating freely on the Steinmann pin and is not causing movement of the pin within the bone, suppuration is uncommon. It is usually possible to retain the pin for periods exceeding six weeks,

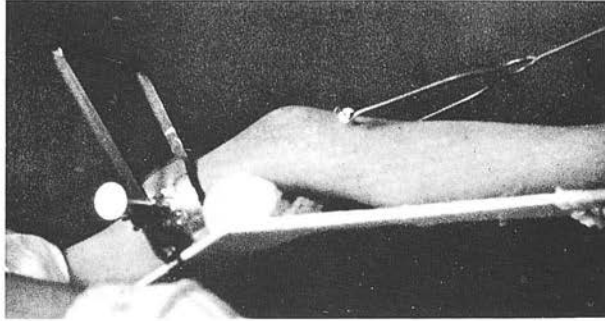


FIG. 267

To reduce a persistent valgus deformity at the fracture site a screw-controlled pressure pad is applied to the medial aspect of the distal end of the upper fragment. The traction exerts leverage against the pressure pad and corrects the angulation.

should this be necessary. If infection supervenes the pin is removed immediately; if extension is still required it should take the form of skin traction applied to both the thigh and the leg (Fig. 268).

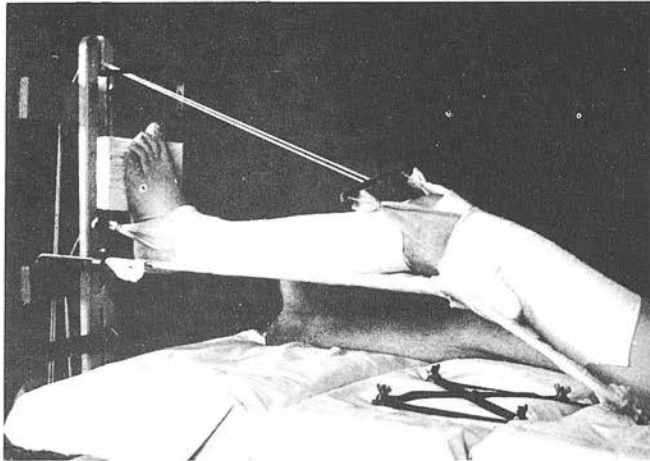


FIG. 268

If there is any suggestion of infection of the pin-track skeletal traction is discarded in favour of skin traction applied to both thigh and leg.

SEPARATION OF LOWER EPIPHYSIS OF FEMUR

Separation of the lower femoral epiphysis differs from the supracondylar fracture in that the mechanism of production is hyperextension or torsion

rather than direct violence. The displacement is similar; the small distal fragment lies in front of the femoral shaft and is tilted by the gastrocnemius (Fig. 269). The posterior edge of the metaphysis projects into the popliteal fossa where the vessels or nerves may be endangered. On the rare occasions when the epiphysis is knocked off by direct violence it may be displaced in any direction.

TREATMENT

Reduction of the displacement is frequently a matter of urgency and should not be deferred; it seldom presents any difficulties. When the concave epiphysis has been replaced on the convex metaphysis the reduction is stable provided the knee is splinted in flexion.

TECHNIQUE OF REDUCTION

When the joint has been aspirated the patient is placed in the supine position and the pelvis fixed to the table by an assistant who exerts backward pressure on the iliac crests. With one hand gripping the ankle and the other behind the upper third of the tibia strong traction is applied to the partially flexed knee. The reduction is completed by flexing the knee to a right angle while direct pressure is exerted over the anterior aspect of the epiphysis by a second assistant. If any difficulty is encountered the patient should be transferred to an orthopaedic table where more powerful traction can be applied by means of a canvas sling passed behind the upper third of the tibia while the knee is maintained in flexion by a manual hold on the ankle.

The joint is immobilised in 90 degrees of flexion by a plaster slab moulded over the front and sides of the limb and secured in position by a domette bandage. Occasionally an even greater degree of flexion is necessary to maintain reduction, but the degree of flexion used must be governed by the swelling which is present and full consideration given to the state of the circulation (Fig. 272). The plaster is changed in three to four weeks' time when the flexion is reduced to about 45 degrees. The second plaster is retained for a further four weeks.

In contra distinction to the supracondylar fracture of adults this injury is not associated with damage to the quadriceps. A rapid return of full movement may thus be anticipated within a few weeks by active exercise alone.

INTERCONDYLAR FRACTURES OF FEMUR

Although the femoral condyles are subjected to the same strain as those of the tibia in the compression-abduction and compression-adduction mechanisms which produce the common fractures of the tibial table, the femoral condyles are rarely injured. In the past five years only three recent "T" or "Y" shaped fracture (gunshot wounds excepted) and only ten fractures of a single condyle were encountered.

TREATMENT

In all intra-articular fractures of weight-bearing joints extreme accuracy

of reduction is of first importance. These injuries are accompanied by a marked haemarthrosis and no attempt is made to secure replacement of the fragments until the joint has been aspirated.

In the "T" or "Y" shaped fracture reduction of the displacement is accomplished by traction assisted by lateral compression of the fragments, produced manually or with the aid of a screw-clamp of the Böhler redresseur type. The technique differs in no essential feature from that described for supracondylar fractures, except that both Braun and Thomas splints should be available at the original reduction; in some cases replacement is most accurate in flexion, whereas in others the position of extension is preferable.

FRACTURE OF A SINGLE CONDYLE

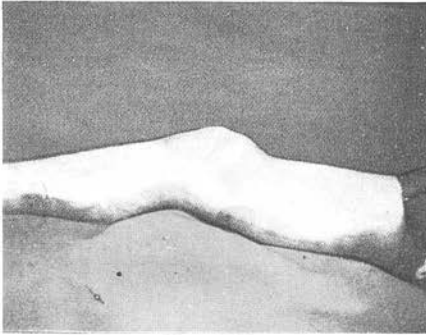


FIG. 269

Fractures of a single condyle of the femur occur in two forms:

- (1) The fracture is roughly vertical and in the sagittal plane; the fragment is displaced upwards.
- (2) The fracture line is vertical and in the coronal plane (Fig. 273), *i.e.*, the prominent posterior portion of the condyle is split off. (In this form the injury may be missed in a cursory examination of the radiographs).

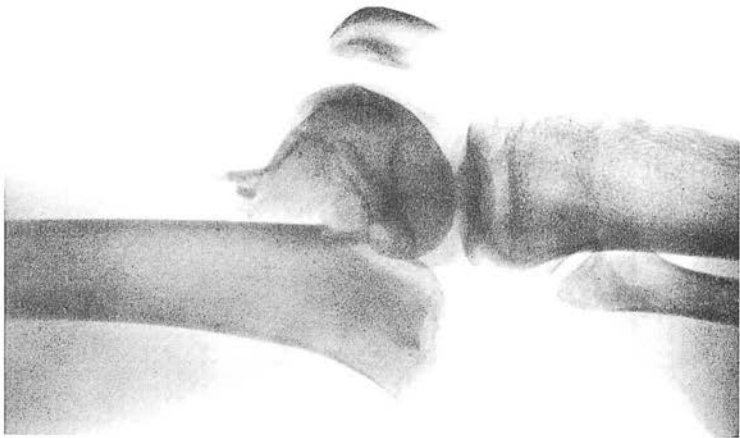

FIG. 270

FIGS. 269 and 270

Backward displacement of lower femoral epiphysis

The deformity is gross and reduction a matter of urgency.

TREATMENT

The fracture is reduced in the same manner as the supracondylar fracture. Skin extension is used in preference to skeletal traction, which is not only

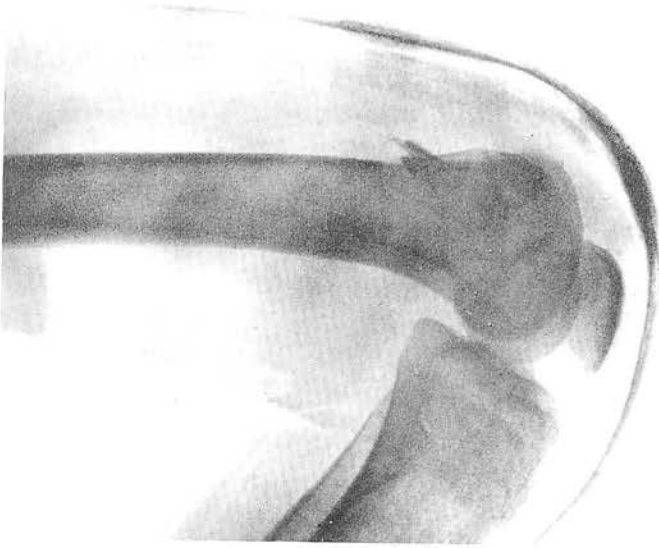

FIG. 271

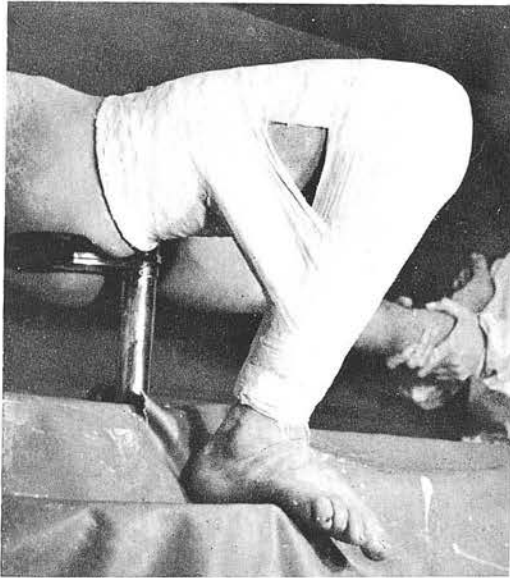

FIG. 272

Backward displacement of lower femoral epiphysis

Figs. 271 and 272.— Reduction is secured by traction and manipulation in flexion and maintained by a plaster cast.

unnecessary but undesirable in that its use may preclude the open operation and internal fixation which is essential if closed methods fail to produce anatomical accuracy. If traction fails to overcome the upward displacement of the condyle due to the valgus or varus position of the lower leg, depending on whether it is the lateral or medial condyle which is fractured, counter pressure applied to the lower third of the femur on the opposite side by

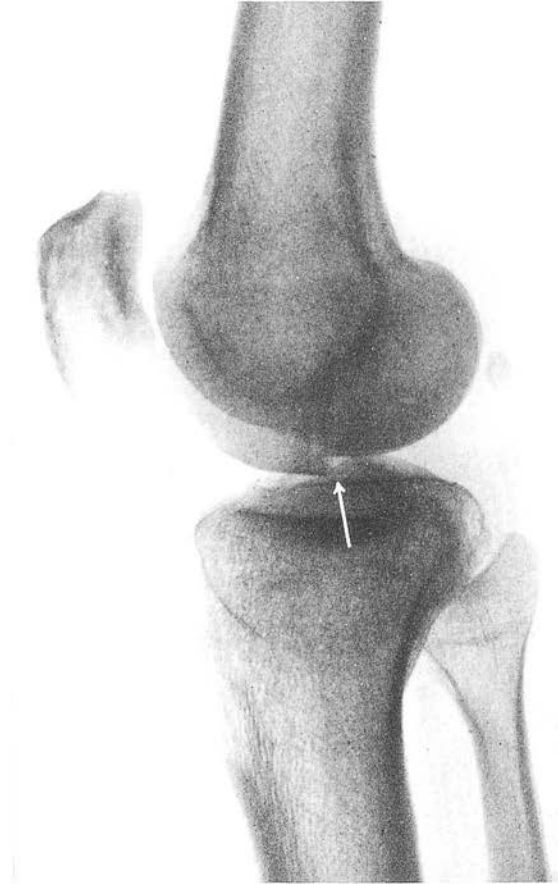


FIG. 273

Fracture of the prominent posterior portion of the medial femoral condyle.

means of a screw controlled pad (Fig. 267) provides a fulcrum which enables the deformity to be corrected.

If the desired accuracy is not obtained by these methods the fragment is exposed through a longitudinal postero-lateral (or postero-medial) incision, replaced, and fixed in position by two or three long, coarse-threaded, stainless steel screws inserted at varying angles to one another. At the termination of the operation, skin extension is reapplied and the patient immobilised on a Thomas or Braun type splint, the traction being reduced to two or three pounds.

CHAPTER TEN

LOOSE BODIES OF TRAUMATIC ORIGIN: FOREIGN BODIES

LOOSE bodies occurring in knee joints which are otherwise apparently normal are derived from either the articular surfaces or the menisci.

A loose body arising from the articular surface is:

(1) Displaced into the joint immediately following a direct injury and usually takes the form of a single fragment of articular cartilage or articular cartilage and bone, or

(2) Displaced into the joint after an interval of months or years from the date of injury. This is the condition known as **osteocondritis dissecans**, and is the most important cause of the presence of a loose body in an otherwise normal joint. The fragment consists of articular cartilage or articular cartilage and bone and is usually single, but two or three fragments emanating from the same defect are not uncommon (Figs. 292 and 293).

Loose bodies derived from the meniscus usually arise from the central portion of a longitudinal tear which is the subject of superimposed transverse lesions so that eventually a hypertrophied tag loses its anterior or posterior attachment and is displaced into the joint (Fig. 274). Numerous small flakes of fibrocartilage are sometimes found when a meniscus has been subjected to repeated injuries over a period of years and is severely lacerated.

The diagnosis and treatment of loose bodies derived from this source will not be discussed here as they differ in no respect from that of the torn meniscus.

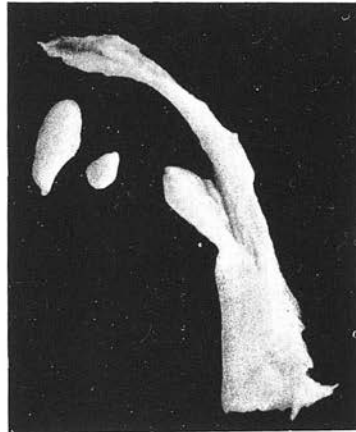


FIG. 274

Longitudinal tear of the medial meniscus, the central portion of which has been subjected to superimposed transverse tears resulting in two loose bodies of fibrocartilage.

ETIOLOGY OF OSTEOCHONDRITIS DISSECANS

Although the etiology of loose bodies consisting of articular cartilage and bone appearing in the joint cavity immediately following a direct injury is clear, the etiology of the condition to which König¹ gave the name "osteocondritis dissecans," in which a fragment of articular cartilage and underlying cancellous tissue slowly separates from the parent bone and is eventually cast into the joint, has long been a matter of controversy.

¹ F. König. "Die Tuberculose der Knochen u. Gelenke," 1884, 54-56.

There are few modern writers who do not accept the traumatic theory, but many seek an additional and elusive factor. König did not deny a traumatic origin in certain cases, but considered that the majority were detached by a spontaneous dissecting osteochondritis, which, without any injury to the joint, led to detachment of areas of articular cartilage. He was unable to determine the nature of the underlying pathology in any of the cases examined microscopically. The additional elusive factor has been considered to be either thrombosis of an end artery or a low grade inflammatory process, but it is most unlikely that either of these two processes could produce such an effect on articular cartilage. Watson-Jones¹ considers the pathology to be that of avascular necrosis, but in quoting a case in which both knee joints and both elbow joints were affected in the same patient, also seeks an additional factor which he considers to be constitutional.

It will be shown that there is an undoubted constitutional factor in those cases in which the condition occurs in the classical situation.

Although the defect may be found in varying situations, the classical site is the inferior aspect of the medial condyle of the femur in the neighbourhood of the attachment of the posterior cruciate ligament (Figs. 275 and 276). The theory that the partial detachment of an area of cartilage and bone arises as a result of impact against the tibial spine is widely held, but there are many who will not accept it on the grounds that such impact is not possible in the normal joint.

Examination of any unselected series of knee joint radiographs demonstrates that with the exception of the lumbo-sacral region there are few areas in the human skeleton which show such widely varying conformations as the head of the tibia. In some cases the table is flat, as the name suggests, with the spine hardly perceptible (Fig. 277), while in others the spine is large and prominent (Fig. 278). If, in addition to a study of a number of normal radiographs, a series from cases suffering from osteochondritis dissecans occurring in the typical situation are inspected, the examiner will be struck by one point of similarity—the prominence of the tibial spines. From this observation, and from other evidence to be put forward, the author is convinced of the traumatic theory, and in regard to the condition situated in the classical position, of a single or repeated impingement of the tibial spine against the medial condyle of the femur as the etiological factor.

While there is little doubt that in the normal joint a single injury of the condyle of a degree of violence which might result in a fracture is most unlikely to pass unnoticed by the patient, such is not the case when the anterior cruciate and medial collateral ligaments are lax; the combination of lax accessory supporting structures with a prominent tibial spine entails an increased risk of a lesion in the classical situation.

The fact that the condition may affect both knee joints has been put forward as evidence that the etiology is other than traumatic. It would seem, however, that the assertion that it may be bilateral is merely added evidence in favour of the traumatic theory, for the high central zone of the

¹ R. Watson-Jones. "Fractures and Joint Injuries." E. and S. Livingstone, Edinburgh, 1943, 107.

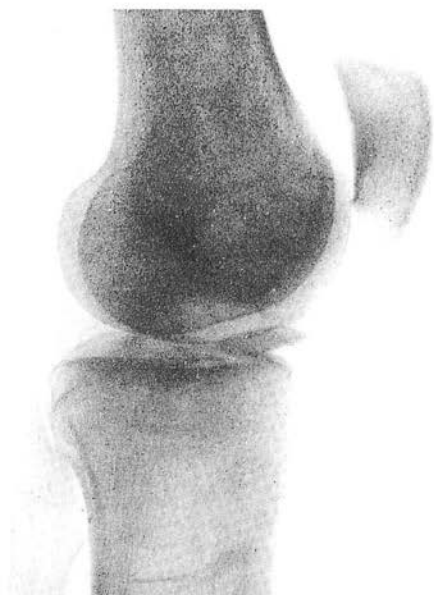

FIG. 275

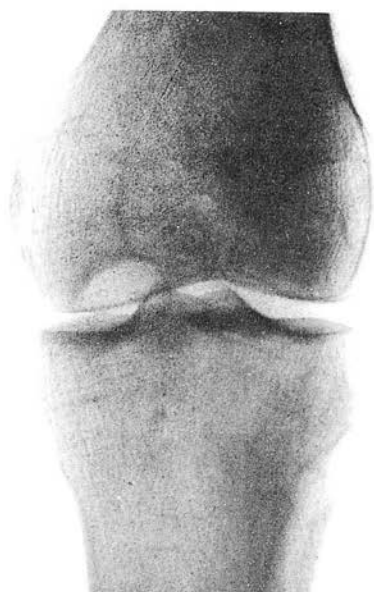

FIG. 276

Osteochondritis dissecans. Lateral view showing the position of the defect and the loose body lying upside down outside the cavity (Fig. 275). The antero-posterior view of the same case showing the relationship of the tibial spine to the defect in the medial condyle; the loose body has been removed (Fig. 276).

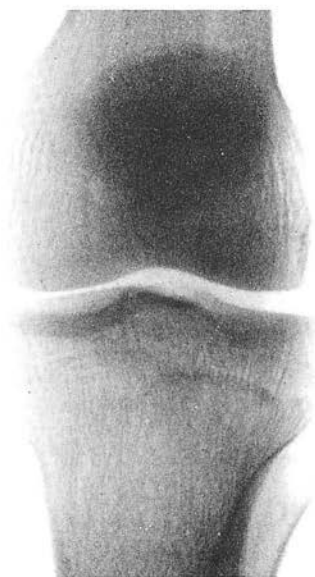

FIG. 277

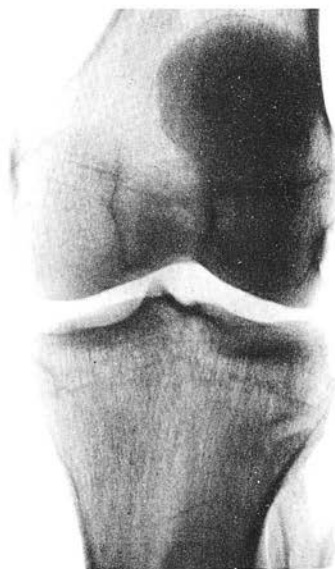

FIG. 278

The conformation of the head of the tibia varies within wide limits. The possibility of impingement of the spine against the medial femoral condyle seems remote in Fig. 277, but might occur in Fig. 278.

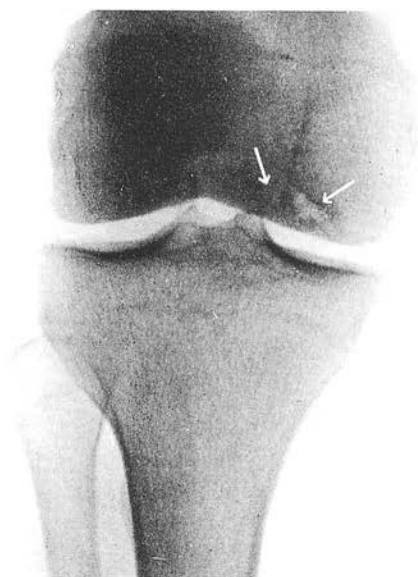


FIG. 279

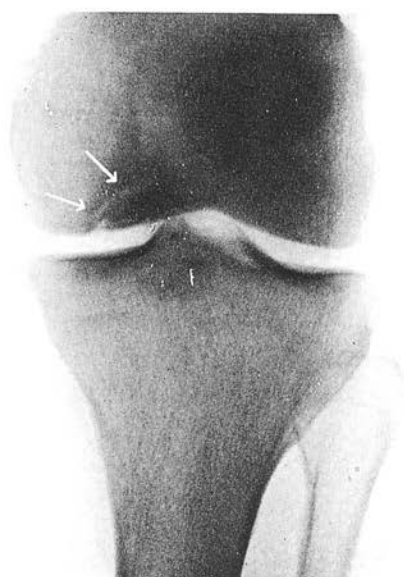


FIG. 280

Bilateral osteochondritis dissecans.

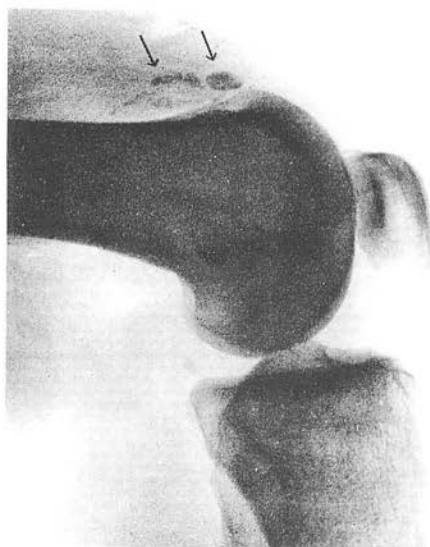


FIG. 281

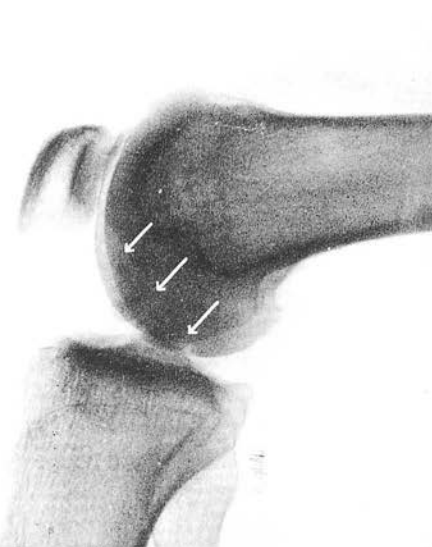


FIG. 282

Bilateral osteochondritis dissecans. The loose body has separated on the left side and is situated in the suprapatellar pouch. The fragment has not yet separated on the right side.

tibial table and prominent spine is also bilateral, and in all the five bilateral cases seen by the author the area of the medial condyle affected has been approximately the same in each case (Figs. 279, 280, 281, and 282). Moreover, the relative constancy of the site in relation to trauma is borne out in both the ankle and elbow joints, where the location of the lesion conforms to the area most likely to be injured by the mechanisms which are so repeatedly described (Fig. 283).

More direct evidence was obtained from a case which had been subjected to a twisting injury in a fall down some steps. A diagnosis of a torn medial meniscus was made and the joint opened after an interval of a week. The diagnosis was found to be wrong, but a fresh fracture, in the usual area affected by osteochondritis dissecans, was noted. There was unmistakable evidence of trauma to the medial side of the tibial spine, and it was clear that impingement of the spine against the femur was responsible for the fracture. The fragment of articular cartilage and bone was not displaced and the fracture was only detected by the presence of a hair-line crack in the articular cartilage. When the straight chisel-type knife was inserted into the crack the fragment was found to have no attachment other than a small hinge of intact cartilage and a few strands of the posterior cruciate ligament. A further haematoma was noted on the lateral side of the fragment where it had been struck by the tibial spine. Re-examination of the original radiographs after the operation, and with the knowledge of the exact site of the fracture, did not reveal any sign of the lesion (see below).

Two further observations concerning the pathology of this condition are of interest, one of which tends to confirm the evidence obtained from the case recorded above. First, it was noted in several cases subjected to operation before the fragment had separated that whereas the articular cartilage overlying the bony fragment was frequently intact and continuous with the surrounding articular cartilage on the medial side—that is, towards the centre of the condyle—it was usually separated from its cartilaginous and bony surroundings on the lateral aspect. This surely suggests that the force which caused the lesion was applied to the lateral side.

The second concerns the attachment of the posterior cruciate ligament, fibres of which must frequently be divided to complete the separation of a fragment. It is probable that although the location of the femoral attach-

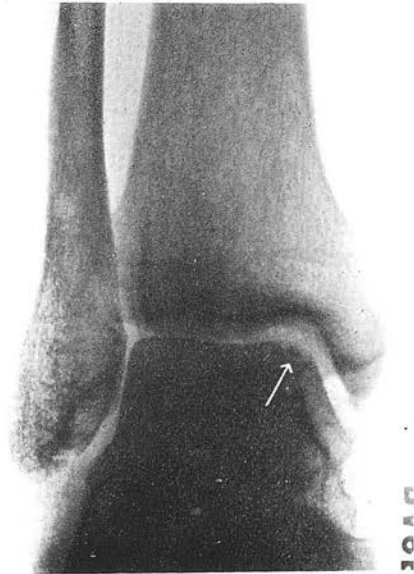


FIG. 283

Osteochondritis dissecans of the talus is due to impingement against the tibia.

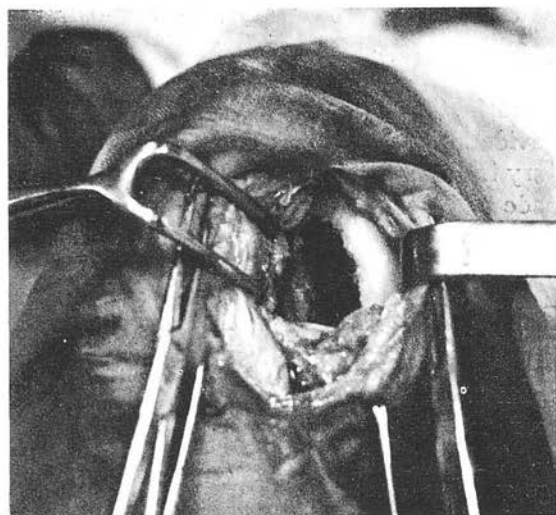


FIG. 284

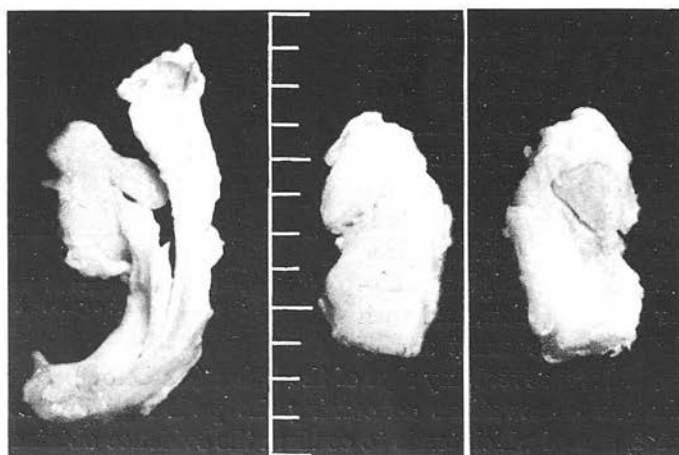


FIG. 285

Osteochondritis dissecans. The largest defect in the lateral aspect of the medial condyle which was encountered (Fig. 284). The loose body and the meniscus from the same case (Fig. 285). The loose body consists of two parts joined by fibrous tissue. Note the fragment of bone on the deep surface of the articular cartilage. The anterior cruciate ligament was ruptured.

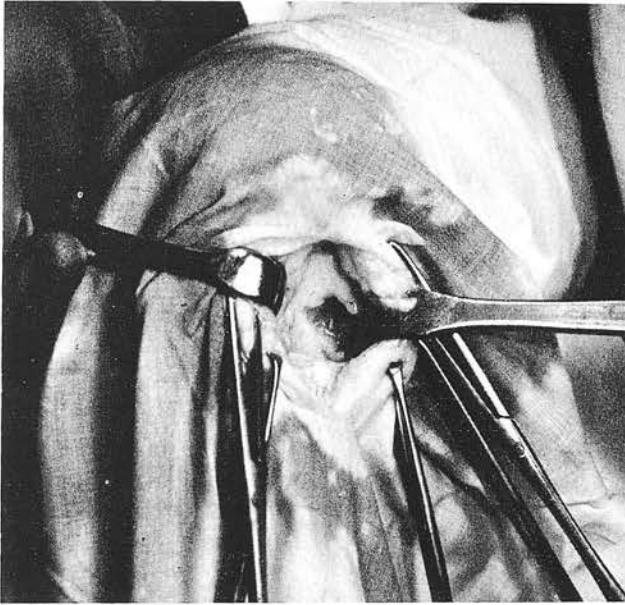


FIG. 286

Osteochondritis dissecans. The lesion is in the middle of the condyle and the position corresponded to the compressed anterior extremity of a longitudinal tear of the meniscus when the joint was extended (Fig. 286; see also Fig. 25).

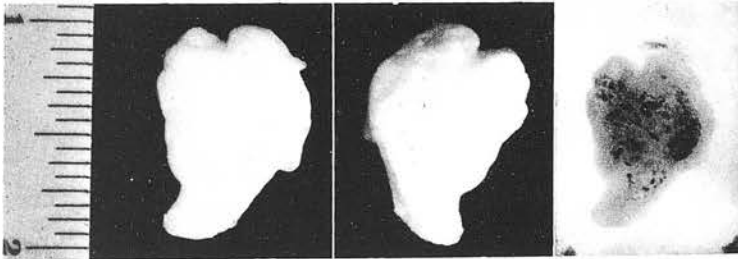


FIG. 287

FIG. 288

FIG. 289

The loose body (Fig. 287), the deep surface of which consisted of minute fragments of bone over which cartilage cells were proliferating (Fig. 288) and the radiograph (Fig. 289).

ment of this ligament, and the blood supply which its presence entails, is responsible for the healing of the lesion which has been observed in young subjects (see below), healing can only take place if the joint is put at complete rest. In the cases where the lesion is situated at the usual site, it is not unlikely that one of the factors which prevents healing is the constant movement to which the fragment must be subjected as a direct result of its position at the attachment of an important ligament concerned in the stabilisation of the joint throughout the entire range of motion.

The origin of the trauma producing a loose body arising from the centre of the articular cartilage of either the lateral or medial femoral condyle cannot be explained by impingement of the tibial spine against the condyle (Fig. 286). In these cases it is almost invariably found that the meniscus is torn, the tear being one of two types:

(a) A longitudinal tear with the central portion displaced towards the centre of the joint.

(b) The combination of a longitudinal with a transverse tear resulting in a hypertrophied tag of meniscus, based anteriorly, and projecting towards the centre of the joint.

On opening the joint where there is a complete longitudinal tear, it is seen that the defect in the condyle lies between the peripheral and central portions of the tear (Fig. 286). The injury in the middle of the articular cartilage of the femoral condyle is thus explained by the impingement of the condyle against the anterior extremity of the longitudinal tear on every attempt to produce full extension of the joint (Fig. 25). The fibrocartilage of the meniscus is seen to be extremely thin and attenuated at the anterior extremity of the longitudinal tear as a result of repeated impact between the condyle of the femur and the head of the tibia.

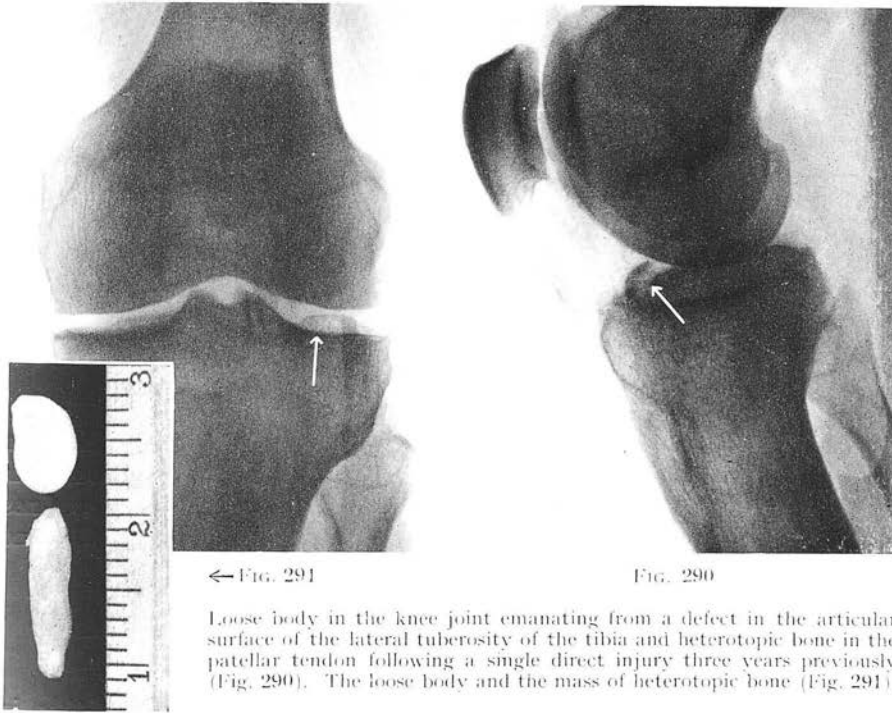
Where the meniscus injury takes the form of a pedunculated tag, based anteriorly, the position of the defect in the femoral condyle is more variable. The hypertrophied tag traumatises the femoral condyle either by being trapped between the condyle and the tibial head or between the condyle and the peripheral portion of the meniscus. Thus the defect may occur at any point in the breadth of the femoral condyle.

The loose body produced by this type of trauma differs from that which results from a single injury in that it consists principally of articular cartilage, with only small flakes of bone at the line of cleavage from the femoral condyle (Fig. 287), as opposed to the large flake of bone which is detached in loose bodies which arise from a single defined incident (Fig. 285).

The location of the lesions produced by direct injury, which usually takes the form of a kick sustained in a game of football, is the same as the fractures which result in immediate separation of a fragment of bone into the joint. The areas affected are those which are least well protected and therefore most vulnerable to direct injury, *i.e.*, the peripheral margins of the femoral condyles, the anterior edge of the tibial table (Fig. 290), and the patella.

Further evidence of the relationship between intra-articular fractures and osteochondritis dissecans, and incidentally to the production of hetero-

topic bone, was obtained from a patient who gave a history of a direct kick on the lateral side of the joint during a game of football three years previously. Eighteen months later he noticed a lump on the lateral side of the joint which reappeared at intervals, but not always in the same place. Occasionally the joint had "jammed" and extension had been limited momentarily. The radiograph showed a single loose body which appeared to have arisen from the tibial table and the presence of heterotopic bone formation in the patellar tendon (Figs. 290 and 291).



← FIG. 291

FIG. 290

Loose body in the knee joint emanating from a defect in the articular surface of the lateral tuberosity of the tibia and heterotopic bone in the patellar tendon following a single direct injury three years previously (Fig. 290). The loose body and the mass of heterotopic bone (Fig. 291).

At operation fibrosis was noted in the extra synovial fat, indicating the site of a previous haematoma. A localised elongated mass of bone was dissected without difficulty from the substance of the postero-lateral aspect of the patellar tendon. A horizontal incision was then made between the lateral condyle of the tibia and the anterior horn of the lateral meniscus, and underneath the meniscus was found a loose body lying in a defect in the articular surface. The loose body had a similar appearance to that observed in osteochondritis dissecans, having a smooth articular surface and a rough cancellous surface over which cartilage cells had grown (Fig. 291). It was evident from the position of the two lesions that the loose body had arisen as a result of a fracture sustained at the same time as the haemorrhage in the posterior aspect of the patellar tendon which gave rise to the heterotopic bone:

SEQUELAE OF SEPARATION OF FRAGMENT

When the fragment is displaced into the joint cavity at the time of the injury or after an interval of months or years, as is osteochondritis dissecans, it may :

(1) **Attain a new attachment to the synovial membrane.**

This advent is more common in the fragment displaced immediately into the joint than after a considerable interval, because in the former circumstance the joint is the subject of haemarthrosis which provides a suitable medium of attachment to the rough cancellous surface and at the same time the joint is usually rested long enough to enable the anchorage to become consolidated.

The position in which adhesion is obtained varies, but for mechanical reasons the most common situations are the lateral compartments. The adhesion takes the form of a pedicle, which frequently becomes elongated as a result of joint motion and thus permits the loose body a limited range of movement, or the fragment is completely encapsulated by synovial membrane, in which case the permitted range of movement is more restricted.

(2) **Remain a freely mobile loose body,** giving rise to the classical symptoms of momentary locking when it becomes trapped between the articular surfaces (Fig. 275).

(3) **Increase in size.** Many single loose bodies, although not adherent to synovial membrane, gradually increase in size as a result of proliferation of cartilage cells and eventually become firmly wedged in the intercondylar notch in front of the point where the cruciate ligaments cross or are confined to the posterior compartment by the posterior capsule (Figs. 297 and 298).

CLINICAL FEATURES OF OSTEOCHONDRITIS DISSECANS BEFORE AND AFTER SEPARATION OF FRAGMENT

The condition, being of traumatic origin, is more common in males than in females and occurs in youth and early adult life. Many, but not all, cases will give a history of a definite injury either of the nature of a twist or a direct blow months or years previously, and state that the joint has never been completely sound since the accident.

The symptomatology is indefinite. There is often a complaint of vague pain, made worse by exercise, and an ache in the joint at rest. There are frequent recurrent effusions brought on by exercise, but which rapidly subside with rest. About half the cases have locking, instability and other symptoms, and signs of a torn meniscus which tend to confuse the issue. The locking may be due to :

(1) **Torn meniscus.** It is known that a large proportion of cases have a torn meniscus possibly sustained at the same time as the injury to the femoral condyle, or possibly the direct cause of the injury to the femoral condyle (Figs. 284 and 285).

(2) **Partial mobility of the fragment while it is still in situ.** At operation the fragment is often noted to be free within the defect except for a hinge of articular cartilage which will permit a limited range of mobility just sufficient to allow it to get caught between the meniscus and femoral condyle (Figs. 292 and 293).

(3) **Presence of a completely free loose body.** Such locking is usually of a momentary nature and patients who suffer from it are frequently aware of the cause.

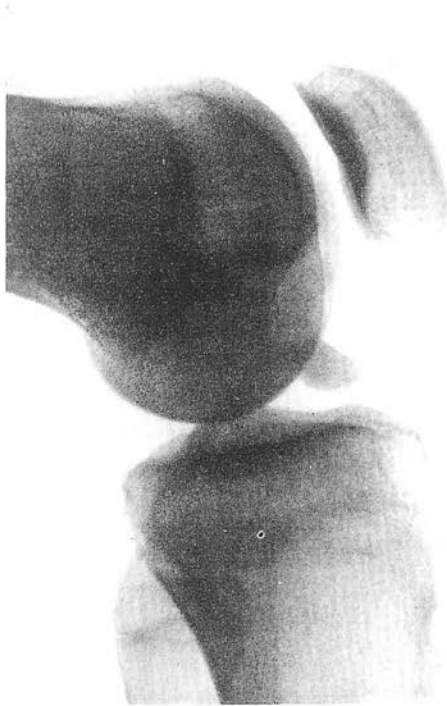

FIG. 292

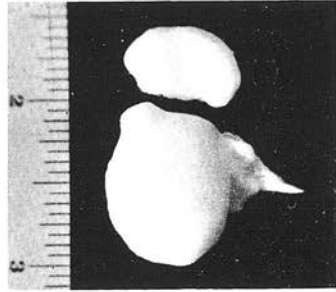


FIG. 293

Figs. 292 and 293.—**Osteochondritis dissecans.** Two fragments of articular cartilage and bone are present, the larger of which was attached by a hinge of fibrous tissue to the defect in the femoral condyle (Fig. 292).

The loose bodies showing the hinge of fibrous tissue (Fig. 293).

Continued locking due to a loose body in the absence of a meniscus tear was noted on three occasions. The loose body had been driven between the anterior segment of the medial meniscus and the tibial table, and by raising the level of the meniscus, constituted a permanent block to extension.

Examination of a case in the early stages may reveal no constant sign except wasting of the quadriceps, which is always present and merely indicates that there is "something wrong with the joint," and it is possibly at this stage that the examiner realises that he is not dealing with a straight-forward meniscus injury and thinks of the possibility of osteochondritis dissecans.

Careful deep palpation of the femoral condyle with the knee in rather more than right-angled flexion, but not full flexion, reveals well marked localised tenderness over the lesion in the articular cartilage, and if the

fragment has already separated into the joint, the defect in the condyle may be readily palpable if it is situated in an accessible area.

The diagnosis usually presents no difficulty if the fragment has separated, for most patients are aware of the existence of a freely mobile loose body and will frequently indicate the site of one which is adherent to synovial membrane. Nor does any difficulty arise when the condition has been present for many months or years, even without separation of the fragment, for in these cases the characteristic features of the radiograph are unmistakable. The problem of diagnosis is, however, extremely difficult in the early case as the presence of apparently normal antero-posterior and lateral radiographs does not rule out the possibility of osteochondritis dissecans because :

(1) **The loose fragment may be composed of articular cartilage alone.**

(2) **The space between the femoral condyle and the separating bone fragment may be so narrow that it does not show in the film.** Langton¹ has pointed out that such circumstances occur and lead to errors of diagnosis in fractures of the carpal scaphoid. Lachmann² has shown experimentally that a space of at least one millimetre between the fragments of a fracture in the knee joint is necessary before the line of separation can be identified radiologically.

(3) **With the exception of gross displacement, even one millimetre of separation will not show unless the rays are tangential to the femoral condyle at the point of the lesion.**

A considerable number of tangential views of the femoral condyle are therefore necessary in a suspected case before the possibility of a radiological abnormality can be eliminated.

The question naturally arises: What interval of time must elapse between the original injury and the presence of recognisable radiological changes? Alternatively: How long does the oedematous fibrous tissue which is found in the base of the defect in the condyle take to attain a thickness of one millimetre? The answer to these questions was not revealed in this series. Langton, however, quotes a case in which the lesion was visible, in the lateral projection only, in six months, but it is quite probable that the interval, in the average case, is considerably greater. It must therefore be admitted that in the present stage of the development of radiographic technique the diagnosis of many suspected cases must depend on clinical and radiological examinations repeated at monthly intervals. Operative exploration of the suspected joint is obviously unjustifiable, although some advance may be possible in the future with the further development of the arthroscope.

TREATMENT

No difference of opinion exists in regard to the treatment of a loose body in

¹ C. D. Langton. "Some Points in the Diagnosis of Osteochondritis of the Knee." *Proc. Roy. Soc. Med.*, 1942, xxxv, 206.

² Lachmann. *Radiology*, 1938, xxxi, 521. (Quoted by Langton.)

the knee joint whether it is displaced into the joint immediately after the injury or after an interval of months or years. The presence of a loose body brings about secondary changes of an osteoarthritic nature, and as a rule the longer the fragment has been in the joint and the more incidents it has caused the greater the advancement of the arthritic change. The loose body or bodies should therefore be removed at operation as soon as the diagnosis is established. Some difference of opinion does exist, however, as to whether the fragment of osteochondritis dissecans should be removed when it is still within the cavity in the femur or whether operation should be deferred until it has been cast into the joint. There is little doubt that the joint structures, including the quadriceps, ligaments, capsule and articular surfaces undergo degeneration throughout the period when the fragment is separating, the rate of degeneration depending on a number of factors such as occupation, degree of wasting of the quadriceps, and the severity of the symptoms. For this reason, and with the exception of certain youthful patients who may be selected for conservative treatment, the author prefers to remove the fragment from its cavity at an early date in the hope that the progress of osteoarthritic degeneration may be interrupted or deferred. There is little doubt, however, that the progress of degenerative change is by no means always interrupted by the removal of a fragment from its cavity or of a free loose body from within the joint, and this is probably why some authorities take such a pessimistic view of the prognosis and only recommend the removal of the loose body after it has separated. From the prognostic viewpoint it seems obvious that a joint such as that illustrated in Fig. 284 can never return to normal, and that for mechanical reasons alone osteoarthritic change is bound to progress.

The long term follow-up of Service patients has not proved possible, and although the short term results in most cases were considered to be satisfactory, years must pass before the final results can be assessed.

One point of interest in the consideration of treatment was noted in cases which had suffered from osteochondritis dissecans some years previously and from whom a loose body had already been removed. Three such cases reported with symptoms arising from a second loose body, which, from the history, had separated recently. It was evident from the shape of the fragment, in comparison with the crater from which it came, that the original area of the condyle had been of the same type as that illustrated in Figs. 292 and 293, and that two loose bodies had been discharged from the defect at different times. This experience suggests that if the loose body removed does not appear to coincide with the radiological appearance of the defect, exposure of the area of the femoral condyle affected may be justifiable in order to make certain that no further fragments are likely to separate.

CONSERVATIVE TREATMENT

The best possible result which could be expected from a case of osteochondritis dissecans would follow the interruption of the process of separation and sound union between the fragment and the parent bone. Spon-

taneous healing has been reported by Axhausen,¹ Kappis,² and Moreau,³ but it is probable that, in the present state of our knowledge, few adult cases are diagnosed before a barrier of fibrous tissue makes healing impossible. In early youth the more liberal blood supply of the growing bone, and of the fragment by way of the posterior cruciate ligament, affords the possibility of attaining the ideal result by conservative means. Such a case is illustrated in Figs. 294 and 295 by the courtesy of Mr James Patrick of Glasgow Royal Infirmary.

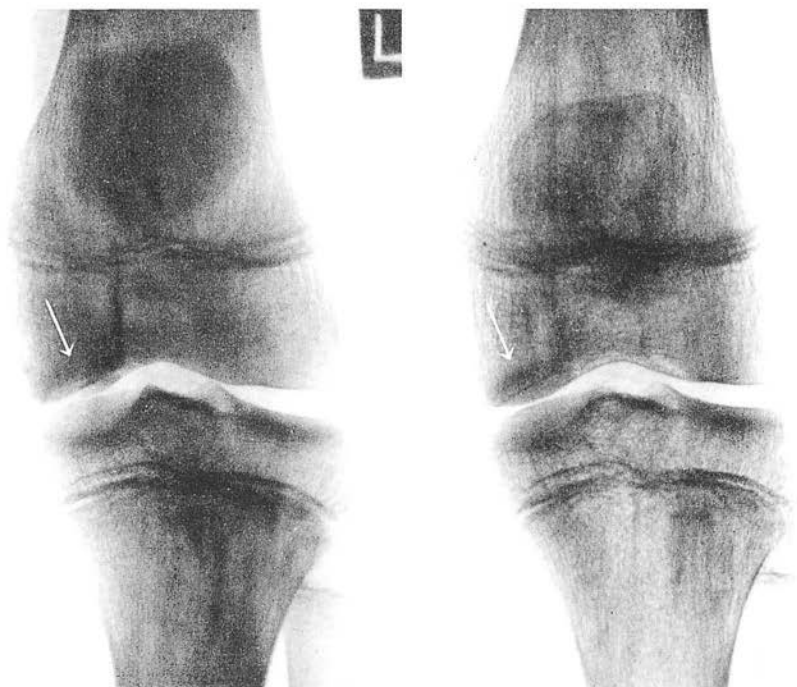


FIG. 294

FIG. 295

Osteochondritis dissecans in a boy aged 12 (Fig. 294). After four months immobilisation in plaster the fragment had united to the condyle (Fig. 295). (Mr James Patrick's case.)

A skin-tight plaster cast is applied from the toes to the groin and weight-bearing prevented by the use of a patten and crutches or bed-rest. Immobilisation is maintained for three months, when the plaster is removed to permit a radiograph to be taken. If any signs of healing are present, the plaster case is reapplied for a further period of three months.

OPERATIVE TECHNIQUE

(1) The fragment is lying in the cavity in the femoral condyle or free in the intercondylar notch anterior to the cruciate ligaments.

In these circumstances an enlarged meniscus incision provides an

¹ Axhausen. *Arch. f. klin. Chir.*, 1914, civ, 581.

² Kappis. *Deutsche Ztschr. f. Chir.*, 1920, clvii, 214.

³ Moreau. *Arch. franco-belges de Chir.*, 1923, xxvi, 131.

adequate exposure which will permit excision of the meniscus and access to the most commonly affected areas of the femoral condyles. If the lesion is in the classical situation the meniscus may not be injured, but if the defect is in the centre of one or other condyle it is not unlikely that a complete longitudinal tear is present. When the meniscus has been excised the fragment is most easily removed from the cavity by means of the straight chisel-type meniscus knife, and thereafter the crater is inspected to make certain that there are no other areas of unhealthy cartilage or bone which are likely to separate at some future date.

No difficulty is encountered in removing a single loose body from the intercondylar notch, provided suitable instruments are used to retract the synovial fat.

(2) The fragment has gained a secondary attachment to the synovial membrane.

The areas affected are either lateral compartment or the suprapatellar pouch. Removal is accomplished with the greatest of ease through a one-inch exposure provided the loose body is localised and held steady with the forefinger and thumb of the left hand while the incision is made.

(3) A single or several loose bodies are freely mobile within the joint cavity.

There is a reason why such loose bodies are termed "joint mice": they are most elusive. This is why some surgeons, rather than exert the necessary patience or run the risk of failure to locate the loose body at a single sitting, explore the joint through a wide parapatellar incision. Complete exposure of the interior of the joint can hardly fail to succeed if removal of the loose body is the sole aim of treatment, but if the object is to secure the maximum functional result in the shortest possible time with the minimum residual disability, it is the wrong incision. Very frequently an opportune moment can be chosen for removal through a small incision by waiting until the patient has located the position of the loose body, or if this procedure is impracticable, localisation can be effected by radiographs, taken with a portable machine, immediately before or even during the operation, should the necessity arise. It is preferable to make two or three small non-destructive incisions or even to defer the removal of the second of two loose bodies to a later date than to explore the joint through a large patella-displacing exposure without adequate reason. The medial parapatellar incision is seldom required in the surgery of the knee joint associated with trauma and should be reserved for cases of multiple loose bodies such as are found in chondromatosis and in which synovectomy is indicated.

Medial Parapatellar Exposure. The incision begins in the mid-line at the upper limit of the suprapatellar pouch and extends distally to a point half an inch above the patella, skirts the patella, and returns towards the mid-line to terminate below and to the medial side of the tibial tubercle. When the fascia has been divided and retracted, the capsule is incised a quarter of an inch from and parallel to the patella and the incision carried

upwards, between the vastus medialis and the quadriceps tendon, avoiding the muscular fibres of the vastus medialis, and downwards to the head of the tibia along the medial border of the ligamentum patellae. The synovial membrane is divided in the same line. When the patella has been retracted towards the lateral side, flexion of the joint will cause dislocation and provide complete exposure of the anterior compartment and the suprapatellar pouch.

The most important step in this radical exposure is the closure of the incision which divides the medial capsular expansion and the vital attach-

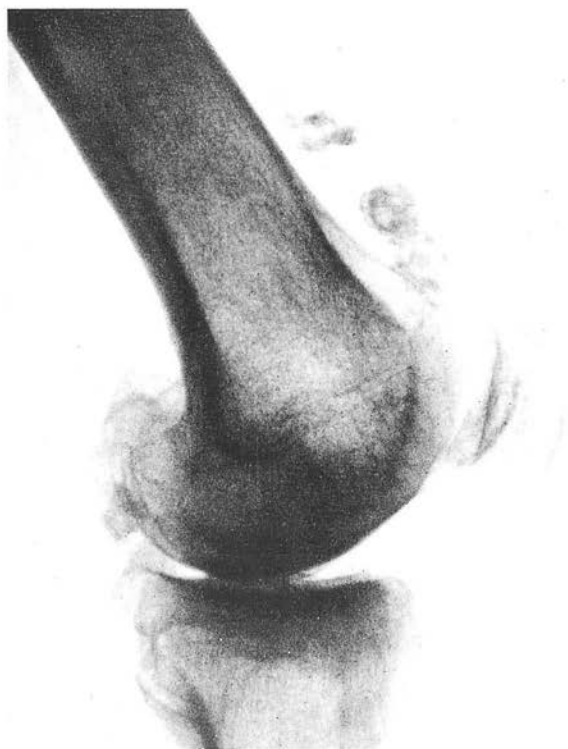

FIG. 296

Multiple loose bodies in the knee joint.

ment of the vastus medialis. Two layers of sutures should be used; the synovial membrane and the deepest layer of the tendinous portion of the vastus medialis expansion are closed with fine interrupted chromic catgut stitches which are inserted so that they do not penetrate into the interior of the joint, and thereafter a second layer of interrupted stitches are used to oppose the intervening and superficial layers.

Failure to secure sound short fibrous union at the suture line in this functionally important area, or neglect to develop the vastus medialis when healing has been obtained, may be a direct cause of recurrent dislocation of the patella.

After-treatment.—The joint should remain at rest, splinted by the compression bandage, for three weeks: neither knee flexion exercises nor quadriceps drill are practised during this period. Both exercises, but especially contraction of the quadriceps, produce strain at right angles to the suture line and are thus unreasonable procedures at this stage of recovery. At the end of three weeks graduated exercises are commenced, concentrating especially on the vastus medialis which may also be treated with twenty minute periods of faradic stimulation once or twice daily in the initial stages. Remedial exercises should be continued for three to four months following this particular incision if some permanent impairment of function is to be avoided.

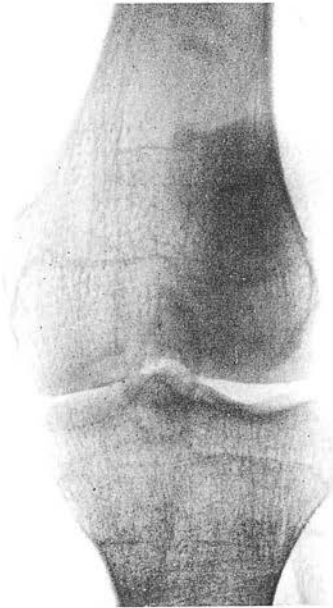


FIG. 297

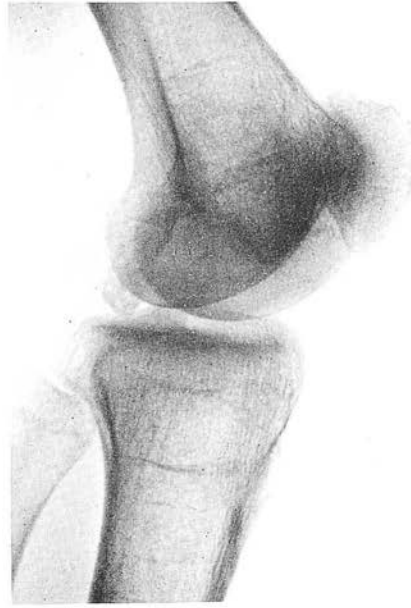

FIG. 298

Loose body in the posterior compartment of the knee joint. Removed through the postero-medial incision.

LOOSE BODIES IN POSTERIOR COMPARTMENT

(Figs. 297 and 298)

Three methods of approach are available for the removal of loose bodies from the posterior compartment of the knee joint:

(1) **The postero-medial**, (2) **The postero-lateral**, and (3) **The posterior mid-line**.

The postero-medial or postero-lateral incision provides a small non-destructive approach which is adequate for the removal of a single large loose body and follows the rule that the less extensive the incision the more rapid and complete the subsequent recovery. The posterior incision pro-

vides more direct access, but entails a more extensive operative procedure which is, unfortunately, frequently followed by a disability as a result of keloid formation in the scar of the skin incision.

(1) POSTERO-MEDIAL APPROACH

This is the exposure favoured by the author.

Following the application of a tourniquet the joint is flexed over the end of the operating table in the same manner as for the removal of a meniscus. The incision is similar to that used for the removal of the posterior horn (Fig. 101), except that it may with advantage be extended to a length of three inches. The saphenous vein is recognised in the postero-inferior region of the wound and retracted posteriorly. A vertical incision is made in the capsule and carried downwards on to the head of the tibia and upwards on to the medial femoral condyle. When retractors have been inserted it is possible to pass a pair of Alliss' tissue forceps along the space, above the attachment of the meniscus to the posterior capsule, towards the posterior compartment of the joint.

(2) POSTERO-LATERAL APPROACH

With the knee in the same position a three-inch vertical incision, similar to that used for removal of the posterior horn of the lateral meniscus, is made, centred over the joint line and placed immediately in front of the head of the fibula. The common peroneal nerve lying under the postero-medial border of the biceps tendon should not be endangered by the approach. A vertical incision is made in the capsule and carried downwards on to the head of the tibia and upwards on to the lateral femoral condyle; the tendon of popliteus is recognised and avoided. When retractors have been inserted, adequate exposure which will permit the localisation and removal of the loose body is provided.

(3) POSTERIOR APPROACH

A six-inch incision, centred over the joint line, is made a little to the inner side of the mid-line of the popliteal space, remembering the general tendency which exists in all posterior mid-line exposures to place the incision at too high a level. The two heads of the gastrocnemius muscle are seen in the upper part of the incision and retracted; the position of the lateral popliteal nerve, which lies parallel with the biceps muscle, should be remembered in retracting the lateral head. All the motor branches of the medial popliteal nerve, except the branch to the medial head of the gastrocnemius, pass to the lateral side, and thus both vessels and nerves should be retracted to that side and the medial branch identified and protected (Fig. 299). The posterior capsule can then be exposed by blunt dissection through the fat of the popliteal space. When the capsule has been cleared the loose body should be localised by palpation before the incision is made. Extension of the joint, by increasing the tension on the capsule, frequently causes the loose body to be extruded spontaneously.

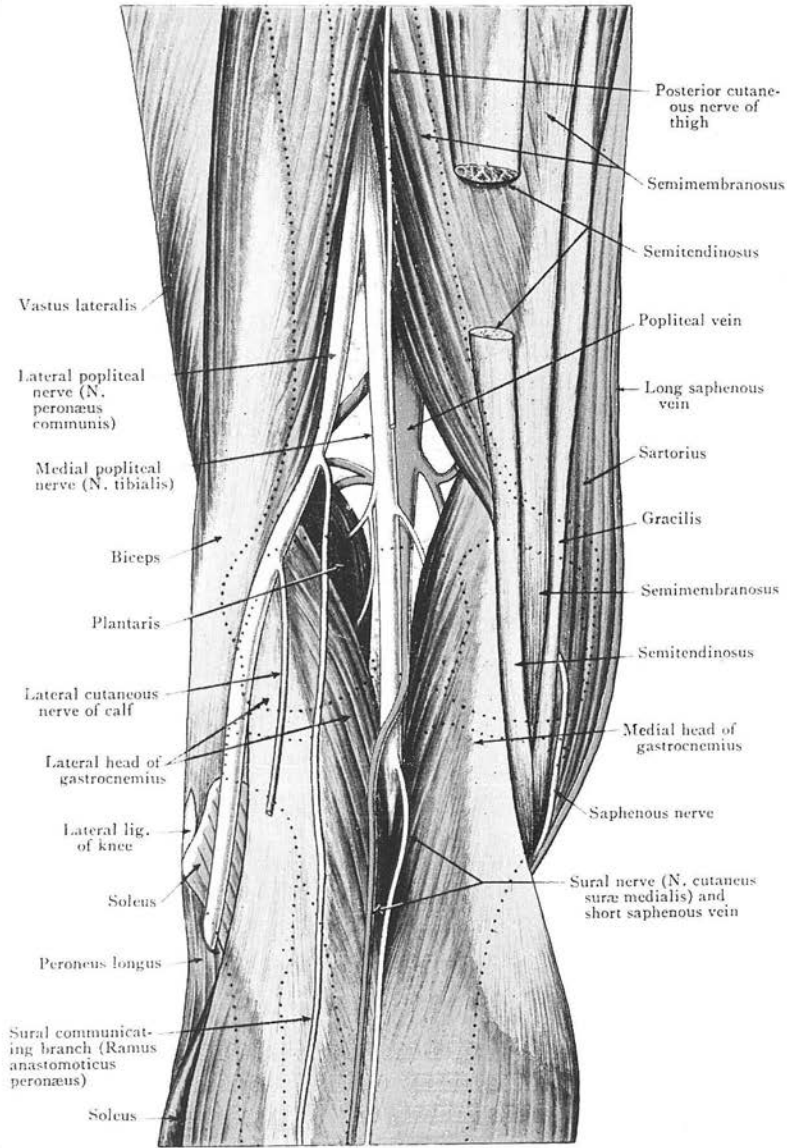


FIG. 299

The anatomy of the popliteal fossa. (The popliteal artery is hidden amidst fat.)
 (By courtesy of Dr. E. B. Jamieson.)

FOREIGN BODIES IN KNEE JOINT

The foreign bodies which are encountered in the knee joint gain entrance in one of two ways :

(1) **Through an accidental puncture wound.**—Foreign bodies introduced in this manner include fragments of metal from missiles or sharp spicules of metal of the type produced when a lathe is in action, sewing needles (Fig. 300), sharp fragments of glass, stone (road accidents), or quartz (South African gold mines).

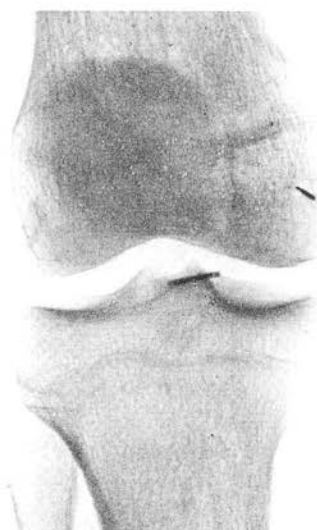


FIG. 300

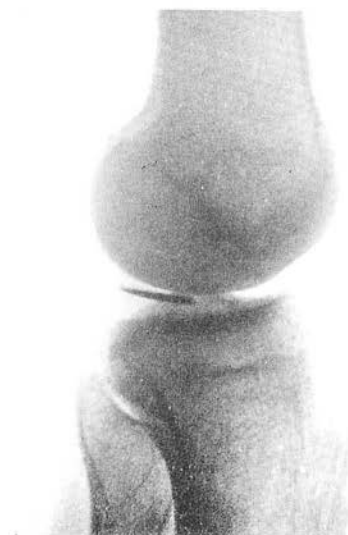

FIG. 301

Fig. 300. —Fragments of a broken needle in the knee joint. The mysterious symptoms produced were only explained by a radiograph; the time and mode of entry were unknown. Although a previous exploratory operation had failed, the fragments were removed without difficulty through two small non-destructive incisions, following accurate radiographic localisation.

Fig. 301. —Distal half of a detachable scalpel blade in the knee joint.

Disregarding the problem of a recent penetrating wound of the joint, which is considered elsewhere, many of these objects may be introduced without the knowledge of the patient, and by producing symptoms in the form of excruciating pain and locking, may give rise to a problem of diagnosis which may only be solved by radiographic examination.

(2) **At operation.**—In the present series four cases were encountered in which the foreign body had been introduced at operation. In no case was the diagnosis made prior to radiographic examination. The foreign bodies consisted of a small fully curved needle, which was assumed to have been left in the joint without the knowledge of the surgeon, the blade of a tenotomy knife, which had apparently been used to divide the attachment

of the posterior horn of the medial meniscus, and the distal half of a detachable scalpel blade on two occasions (Fig. 301).

The existence of the broken knife blades within the joint cavity emphasises the need for caution in the use of knives in the interior of the knee joint in meniscus operations. Neither tenotomy knives nor detachable scalpel blades, which have a weak area where they are attached to the handle, are capable of withstanding the torsion strains to which they are liable to be subjected in a struggle to excise a difficult meniscus. The author recommends the use of the knives illustrated on page 87 as being immune from such accidents.

TREATMENT

The removal of a foreign body, like the removal of a loose body, should not be undertaken light-heartedly and without due consideration as to exact localisation. Wide incisions which permit the whole joint cavity to be explored are both unnecessary and undesirable, for with radiographic control it should be possible to remove almost any foreign body through one or possibly two, small, well-placed incisions. Antero-posterior and lateral radiographs should be taken after the limb has been drained by the rubber bandage and the tourniquet applied, and thereafter the joint maintained in the same position. When the plates have been developed, a few minutes of careful study before the incision is made will be amply repaid. If the object is not found within a reasonable time, and the joint has been subjected to considerable manipulation, further radiographs should be obtained before a more radical incision is contemplated.

CHAPTER ELEVEN

WOUNDS OF KNEE JOINT AND SURROUNDING TISSUES

THE unparalleled experience of the injuries of warfare during the past five years, coupled with the discovery of powerful chemotherapeutic agents affecting the most dangerous invading organisms, has produced a measure of agreement regarding the principles underlying the treatment of wounds hitherto unknown in the history of medicine. The detail of the technique to be adopted in any given wound at any specified interval from the time of injury has no place in the present work ; it will be found in one of the many recent volumes devoted to the subject. This measure of agreement concerning wounds in general can hardly be said to apply with equal force to articular wounds, and especially to those of the knee joint in which there is still very considerable diversity of opinion among surgeons on points which must be considered to be more than mere details of technique. It is proposed, therefore, to refer to the means by which modern methods can be applied to wounds of the knee joint and surrounding tissues and venture to discuss some of the more important subjects about which so much controversy exists.

DEFENSIVE POWER OF ARTICULAR TISSUES AND SYNOVIAL FLUID

It has been the custom to teach that a particularly high standard of aseptic technique is essential in the surgery of the knee joint because of the danger of contaminating tissues lacking powers of resistance to infection. While it is undoubtedly important to insist on the observance of scrupulous asepsis in regard to a joint, the subject of a repetitive standard operation calculated to breed some measure of contempt, and especially where the sequelae of sepsis are so serious—for the danger to life from infection is greater than in any other joint and an ankylosis is a tragedy of the utmost gravity—it is not true to say that the joint is defenceless. On the contrary there is abundant evidence, both experimental and clinical, that the innermost components of joints—the synovial membrane, synovial fluid and articular cartilage—have considerable powers of resistance against invading organisms, and it is not unreasonable to suggest that the knee joint as the largest and most highly developed in the body (Chapter II) has also the greatest relative resistance.

This resistance to infection depends on :—

(1) STRUCTURE OF THE JOINT

It has been pointed out (Chapter II) that the capsule and synovial membrane form a closed sac which excludes infection from the neighbouring

regions (*cf.* shoulder joint). The capsule has no intimate relationship with tendons, as it has in the wrist, ankle and interphalangeal joints, which are frequently involved in the pathological processes affecting tendon sheaths.

(2) ACTIVE BACTERICIDAL PROPERTIES OF SYNOVIAL MEMBRANE AND FLUID

Reference has been made (Chapter II) to the reaction of the synovial membrane to injury. The changes in the mesenchymal tissues consist of dilatation of blood vessels and extravasation of plasma together with migration of leucocytes and later of macrophages from the circulation as well as from the tissues.

It is interesting to note that cultures of synovial fluid are frequently found to be negative in the presence of organisms in the synovial membrane.¹ It has also been shown that cultures from lymph glands may be positive twice as often as cultures from synovial effusions in infective arthritis.² These facts can only be explained by ingestion of bacteria by macrophages and disintegration of the organisms by proteolytic ferments and antibodies.³ In addition, they appear to indicate that certain cells of the synovial membrane have a phagocytic capacity and contribute to the defence against infection.

The outpouring of plasma in trauma and infection, to which reference has been made above, and the capacity of the synovial membrane to transport molecular solutions to the joint cavity, is of particular importance since the introduction of drugs of the Sulpha group; the concentration of Sulphathiazole in the synovial fluid, for example, is roughly the same as that of the blood.⁴ Unfortunately, not every diffusible substance reaches the joint cavity with equal facility. It appears that the synovial membrane is relatively impermeable to penicillin.^{5, 7}

(3) PASSIVE DEFENCE OF ARTICULAR CARTILAGE

Hyaline articular cartilage is completely avascular and its metabolism is very low. Nutritional requirements are minimal and can be supplied from the synovial fluid.

Articular cartilage is highly resistant to infection and many days of persistent and intense infection are required to damage it seriously.⁶

¹ Harry M. Margolis and Anna H. E. Dorsey. "Chronic Arthritis: Bacteriology of Affected Tissues," *Arch. Intern. Med.*, 1930, xlii, 121.

² Claude Ellis Forkner, Alfred R. Shands, and Mary A. Poston. "Synovial Fluid in Chronic Arthritis: Bacteriology and Cytology," *Arch. Intern. Med.*, 1928, xlii, 675.

³ David H. Kling. "The Synovial Membrane and the Synovial Fluid," Baillière, Tindall and Cox, London, 1938, 58.

⁴ J. T. Heyl. *Proc. R. Soc. Med.*, 1941, xxxiv, 782.

⁵ C. H. Rammelkamp and C. S. Keefer. "The Absorption, Excretion and Distribution of Penicillin," *J. Clin. Invest.*, 1943, xxii, 425.

⁶ J. Trueta. "The Principles and Practice of War Surgery," Hamish Hamilton Medical Books, London, 1943, 277.

⁷ Since this was written some evidence has been produced that penicillin administered systemically can reach the synovial cavity at an adequate bacteriostatic level in traumatic synovitis and septic arthritis (I. W. J. McAdam, J. P. Duguid, S. W. Challinor, A. McCall. "Penicillin Treatment of Serous Cavity Infections," *Lancet*, 1945, ii, 848.)

(4) LOWER RATE OF ABSORPTION FROM JOINT CAVITY BY COMPARISON WITH SURROUNDING CELLULAR TISSUE

The whole surface of the synovial membrane is concerned in absorption from the joint cavity, but, like the production of synovial fluid (Chapter II), the process is most active in the areas overlying the fat pads (Fig. 9). Absorption from the knee joint is particularly rapid on account of the large surface of synovial membrane concerned, a fact which accounts for the systemic reaction which sometimes follows a traumatic haemarthrosis.

In spite of the known rapidity of absorption from the knee joint, the process bears no comparison whatever with the rate of absorption which takes place in the cellular tissues which lie between the skin and the synovial membrane. In addition, it is important to record from the point of view of treatment, that just as movement provides the physiological stimulus to the production of synovial fluid (Chapter II), so movement also increases the rapidity of absorption from the joint.¹ This increase, however, is of little moment by comparison with the harmful effect which movement produces in causing spread of infection through the extra-articular cellular spaces.

DIFFERENCE BETWEEN CIVIL AND WAR WOUNDS

The penetrating wounds of the knee joint encountered in civil practice and subjected to operation within a few hours of the accident produced satisfactory results without residual loss of function long before the advent of either sulphonamide or penicillin. The thorough cleansing of the wound and surrounding skin with soap and water followed by excision and suture, aided by the natural defences of the joint, resulted in healing by first intention in a very large majority of cases, provided the principles of rest, elevation and non-interference were observed (Figs. 302 and 303).

There is, however, a vast difference between civil injuries, in which an intra-articular fracture is rarely present (with the exception of compound fractures of the patella), and those of modern warfare, in which there is so frequently a compound fracture entering the joint and with the additional menace of a foreign body lodged in one of the femoral condyles (Figs. 304 and 305). The extreme danger of sepsis in the war wound lies in the compound intra-articular fracture which permits the entry of organisms into the defenceless cancellous tissue of the metaphysis together with the obvious difficulty of controlling haemorrhage into the joint. Even in ideal circumstances when operation is available within a few hours of the injury the removal of the missile and the complete exploration and toilet of the bony fissures is a most formidable undertaking.

CONTROVERSIAL ISSUES IN TREATMENT OF WAR WOUNDS

In civil practice there is little difference of opinion regarding the treatment

¹A. L. Allen. "Penetrating Wounds of the Knee. I. The Production of Experimental Arthritis. II. The Escape of Particulate and Fluid Material from the Knee Joint." *South Afr. J. Med. Sci.*, 1935, 1, 31.

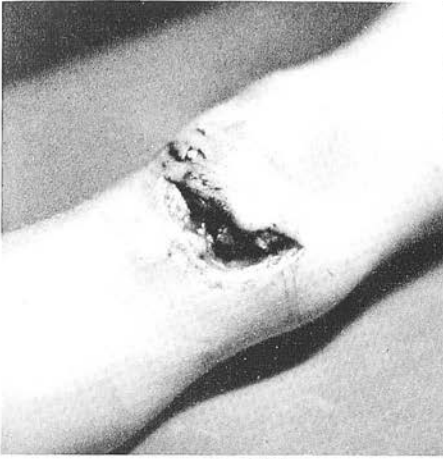

FIG. 302

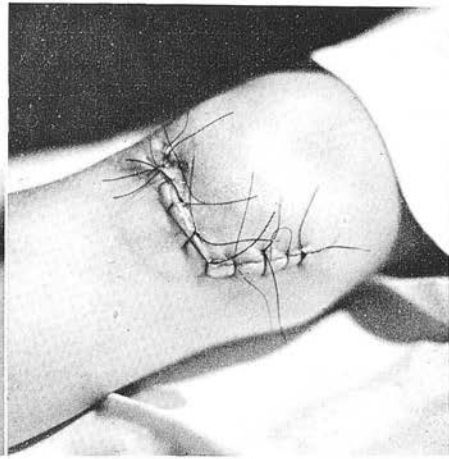


FIG. 303

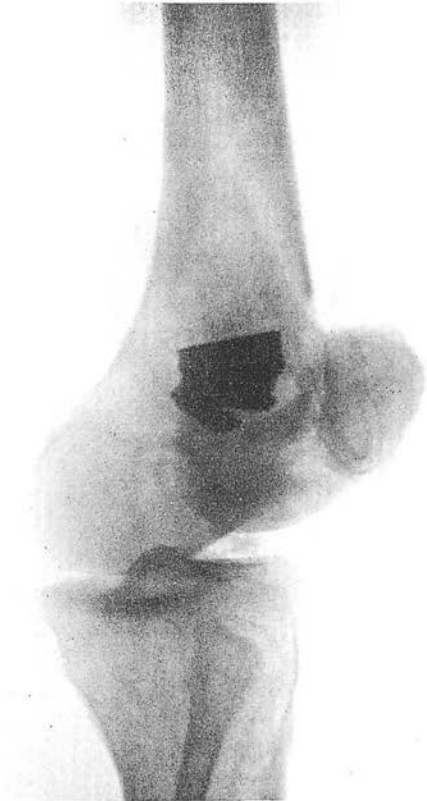


FIG. 304

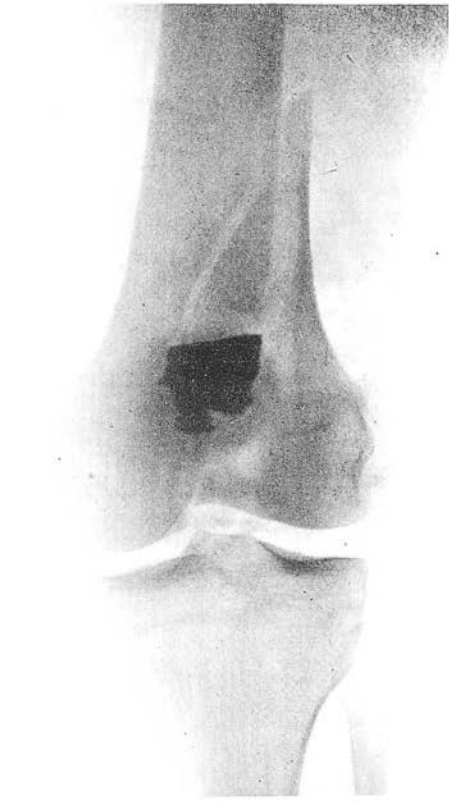


FIG. 305

The penetrating wounds of civil practice are rarely complicated by intra-articular fractures (Fig. 302); both synovial membrane and skin may usually be closed (Fig. 303). Such injuries are not to be compared in potential danger, treatment or prognosis with the grave osteo-articular injuries of warfare (Figs. 304 and 305).

of a penetrating wound which can be subjected to operation within eight hours or so of the accident. Where differences do exist they are upon points of detail which do not appear to be of importance considering the excellent results which have been reported in large series of cases from widely varying sources.^{1 2} It is in the treatment of cases where operation is delayed and in war wounds where conditions are favourable to the onset of sepsis and in which, in field conditions, operation is delayed until long after the infliction of the injury that widely varying opinions are held on points of major importance. Before proceeding to the treatment of the various types of gunshot wound it is proposed to refer briefly to some of the principal points at issue.

SUTURE OF SYNOVIAL MEMBRANE

Böhler³ held the view that in articular wounds only the skin should be sutured. Although this procedure may prove satisfactory in civil practice it has not met with general acceptance and most surgeons prefer to close the synovial membrane provided the use of foreign bodies in the form of absorbable suture material is not excessive. In war wounds the method is to be condemned on the grounds that it frequently entails the burying of extra-articular cellular tissue, with little resistance against infection, the toilet of which may inevitably fall short of perfection. If it is agreed that the skin should not be closed over unsutured synovial membrane then the question immediately arises as to whether it is desirable to close even the synovial membrane. In this matter there are two schools of thought. The first,^{4 5} holds the view that if a satisfactory joint toilet is possible it is advisable to close the synovial layer at all times up to some twenty-four hours from the infliction of the wound, basing the procedure on the known defensive power of both synovial membrane and fluid by comparison with the extracapsular tissues, which should be left open and lightly packed with gauze. The second⁶ holds that even when it is possible, closure of the synovial membrane is often dangerous because the synovial fluid, which distends the joint as a result of trauma and infection, although originally bactericidal, quickly deteriorates and becomes a good medium for the growth of organisms. It is put forward that the bactericidal property of synovial fluid only persists if the old fluid is removed and fresh new fluid allowed to take its place, a measure which can only be achieved by leaving the joint widely open. In reply to the argument that such a joint is liable to secondary infection, it is stated that this is not the case provided conditions of complete immobilisation under a permanent dressing are maintained.

The essential difference between these opposing views would appear to

¹ E. L. Ferguson and L. F. Dangerfield. "Wounds Penetrating the Knee Joint," *Brit. Med. Jour.*, 1940, i, 339. (151 cases treated in four years.)

² Walter Ehalt. (Böhler Clinic) quoted by Kling. (93 cases without infection of the joint.)

³ Lorenz Böhler. "The Treatment of Fractures," John Wright and Sons, Ltd., Bristol, 1936, 386.

⁴ R. Watson-Jones. "Fractures and Joint Injuries," E. and S. Livingstone, Edinburgh, 1943, 221.

⁵ J. Trueta. "The Principles and Practice of War Surgery," Hamish Hamilton Medical Books, London, 1943, 280.

⁶ H. Fruchaud. "Wounds of Joints," *Lancet*, 1944, ii, 235.

be that the former fails to ensure the constant flushing of the articular space with fresh synovial fluid. It is necessary to point out, however, that the exponents of closure of the synovial membrane have usually suggested aspiration of the joint every two days, or daily if necessary. Furthermore, with the universal use of bacteriostatic chemicals it seems unlikely that even stale synovial fluid is any longer a suitable medium for the growth of dangerous organisms.

In an attempt to strike a balance between the opposing views it would seem that with the use of local and systemic penicillin, reinforced by sulphamide drugs which are secreted into the synovial fluid, it is likely that the practice of suture of the synovial layer will tend to increase rather than diminish, especially in view of the fact that even greater developments in chemotherapy are to be expected. On the other hand, in the many cases in which destruction of tissue necessitates leaving the joint widely open, it is reassuring to know that secondary infection is far from inevitable, and that there remains a good chance of regaining a useful range of movement.

IMMOBILISATION

In the last war, and for a considerable period thereafter, it was taught that early mobilisation of the infected, or potentially infected, joint was advantageous in that it ensured the maximum degree of mobility in the final result. This practice has been relegated to the past; movement is accepted to be responsible not only for the rapid dissemination of infection in the extra-articular cellular tissue and throughout the joint cavity, but also for an increase in toxic absorption from the infected tissues. All surgeons now believe in the principles of rest, elevation and non-interference.

No matter what operation is performed, whether it is suture with the prospect of healing by first intention, or radical drainage of a suppurative arthritis, complete immobilisation forms a most important part of the after-treatment. Perfect immobilisation of a joint can be secured only if the joints above and below are also immobilised. In the case of the knee joint this entails the use of a plaster spica which embraces the ankle, knee, hip and pelvis. If primary suture has been carried out, a window is cut in the plaster over the anterior aspect of the joint to prevent intra-articular tension and permit aspiration and the local injection of chemotherapeutic agents to be performed.

The attainment of perfection in immobilisation is not always possible and is occasionally undesirable. In these circumstances skin traction in a Thomas splint, supplemented by a plaster back-shell, form a useful alternative.

If rest is of such importance in the early stages of treatment, when is the right time to begin mobilisation? In the most favourable case, of which the through and through wound produced by a high velocity missile such as a rifle bullet is an example, movements should rarely be commenced under three weeks. Contraction of the quadriceps should, of course, be encouraged in all wounds as soon as the active phase has passed. In other cases, in which more extensive bony damage has been incurred but which

have responded to treatment, active flexion can begin about the sixth week.

It is not an easy matter to decide when weight-bearing should be permitted, but except in the most straightforward case, it is rarely advisable before the twelfth week.

ARTICULAR WOUNDS WITH FRACTURES

In the treatment of the osteo-articular wound opinion is sharply divided. The French school, and more recently the Russians, following the teaching of Ollier of Lyon, practise formal resection of the joint as a primary measure. It is Fruehaud's opinion that if the wound is seen within twenty-four hours of injury a conservative operation should be performed if the bone damage is limited, but a formal resection is advisable if it is extensive. After twenty-four hours formal resection is necessary in every intra-articular fracture except those of a minor nature.

This apparently radical method of treatment is based on the difficulty of executing a satisfactory wound toilet and the risk of infection which is common to all articular wounds with fractures. In addition, it is well known that even if infection is avoided the range of movement which is preserved in gross osteo-articular injuries, especially those involving the femoral condyles, is frequently limited to a few degrees and is thus little better than an ankylosis. In further justification of the procedure Fruehaud suggests that many cases treated conservatively at the start require to be submitted to amputation six, ten or twenty days later because of sepsis. He thinks that it is better to produce ankylosis in good functional position "than to amputate five osteo-articular wounds out of ten, and allow the other five to acquire osteomyelitis."

The British attitude in such matters is traditionally cautious, a view which appears to be justified in Buxton's review of 273 gunshot wounds of the knee joint sustained during the Second and Third Libyan battles:¹

	<i>Second Libyan Battle.</i>	<i>Third Libyan Battle.</i>	<i>Total.</i>
Patients	99	156	255
Knees affected	108	165	273
Non-suppurative arthritis	58	120	178
Suppurative arthritis	50	45	95
Amputations	7	5	12
Deaths	2	3	5

In the series of 273 cases reaching base hospitals, suppurative arthritis developed in 95 (34·8 per cent.). The amputation rate, in relation to suppurative arthritis alone, was 12·6 per cent. It was only 4·4 per cent. for the whole series of 273 knees.

The following case is a typical example of the type of result which can be expected from conservative treatment in an osteo-articular wound with

¹ St J. D. Buxton. "Gunshot Wounds of the Knee Joint," *Lancet*, 1944, i. 682.

a displaced fracture of the medial femoral condyle and a foreign body lodged in the bone (Figs. 304 and 305).

The patient was wounded by a shell splinter in the invasion of Normandy. The entrance wound received a superficial toilet the same day when it was recorded "that there was no perforation of the capsule of the joint." Systemic penicillin and Sulphathiazole were administered.

Three days later, at a base hospital in this country, the wound was "re-excised." The fracture line was explored and loose fragments of bone together with the metallic fragment removed through an incision in the lateral capsule. The joint was irrigated with saline to wash out blood clot and debris; the wound was completely closed. 10,000 units of penicillin were injected into the synovial cavity and the systemic administration of penicillin and sulphathiazole continued. The limb was immobilised in a plaster back-shell only; traction was not applied. Aspiration was performed two days later.

On admission to an orthopaedic hospital ten days later it was evident that the joint was not infected and the wound was practically healed. Quadriceps exercises began at the end of the third week and active flexion in the sixth week. Flexion increased rapidly until a range of 60 degrees had been obtained and thereafter made little progress. Weight-bearing began in the tenth week.

The patient now has a sound, stable, painless knee and when last seen had 70 degrees of flexion. The range of flexion was not expected to increase further, but is certainly preferable to an ankylosed knee.

THE INFECTED JOINT

In an infected joint there are three phases—the hopeful, the doubtful, and the lost.¹ In the conservative attitude towards infection which is generally adopted in this country each of these phases makes different demands. In the **first** or hopeful stage, all that is called for is early and frequent aspiration combined with local and systemic chemotherapy. If immobilisation is complete and if no dead or devitalised tissues remain in the joint following operation, the prospects of a return to perfect function are good. The following is an example of the course and result of such a case:

The patient sustained a gunshot wound of the upper end of the tibia which produced gross comminution of the tibial table and displacement at the exit side on the antero-medial aspect; the fractures communicated with the knee joint (Fig. 306). He was treated the same day by excision of the wounds, aspiration of the haemarthrosis, and injection of 20,000 units of penicillin into the joint. The limb was immobilised in a plaster case extending from the toes to the groin. He was given systemic penicillin, and sulphathiazole by mouth. He was admitted to a base hospital in this country six days later where the systemic administration of penicillin and sulphathiazole was continued and the infected entrance and exit wounds treated with eusol dressings.

He was admitted to an orthopaedic hospital after an interval of ten days, and two days later, under anaesthesia, the wounds were dressed, dusted with sulphathiazole and covered with jelonet. The haemarthrosis was aspirated and replaced with 30 c.c.s. of 10 per cent. soluseptasine. Skin traction was applied to the leg, and the limb placed on a Braun splint. The blood from the knee joint showed, on direct examination, a moderate number of pus cells, occasional gram-positive cocci and gram-negative bacilli. Aerobic culture showed very slight growth of enterococci and *B. coli*. Anaerobic culture was negative.

On the following day the aspiration was repeated and the fluid noted to be more serous in character. A further 10 c.c.s. of soluseptasine was injected.

¹ *Lancet* Editorial, 1944, ii, 247.

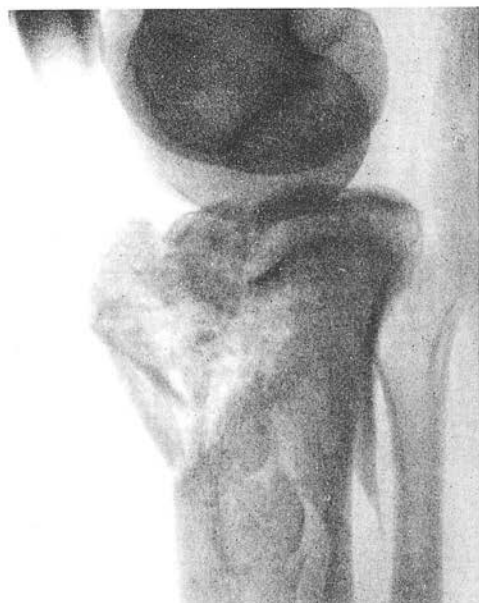

FIG. 306

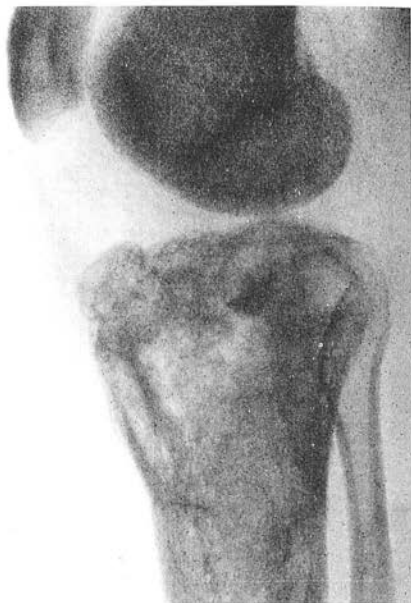

FIG. 307

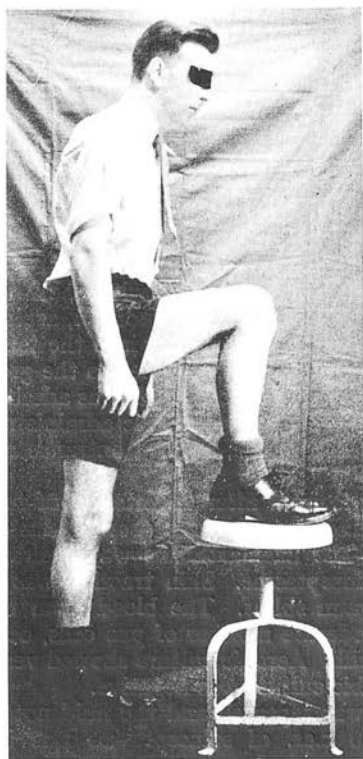

FIG. 308

Figs. 306, 307, and 308. Gun-shot wound of the knee joint producing gross comminution of the tibial condyles (Fig. 306). In spite of infection, reduction was accomplished (Fig. 307) and when he left hospital there was every prospect of a return of full flexion (Fig. 308.)

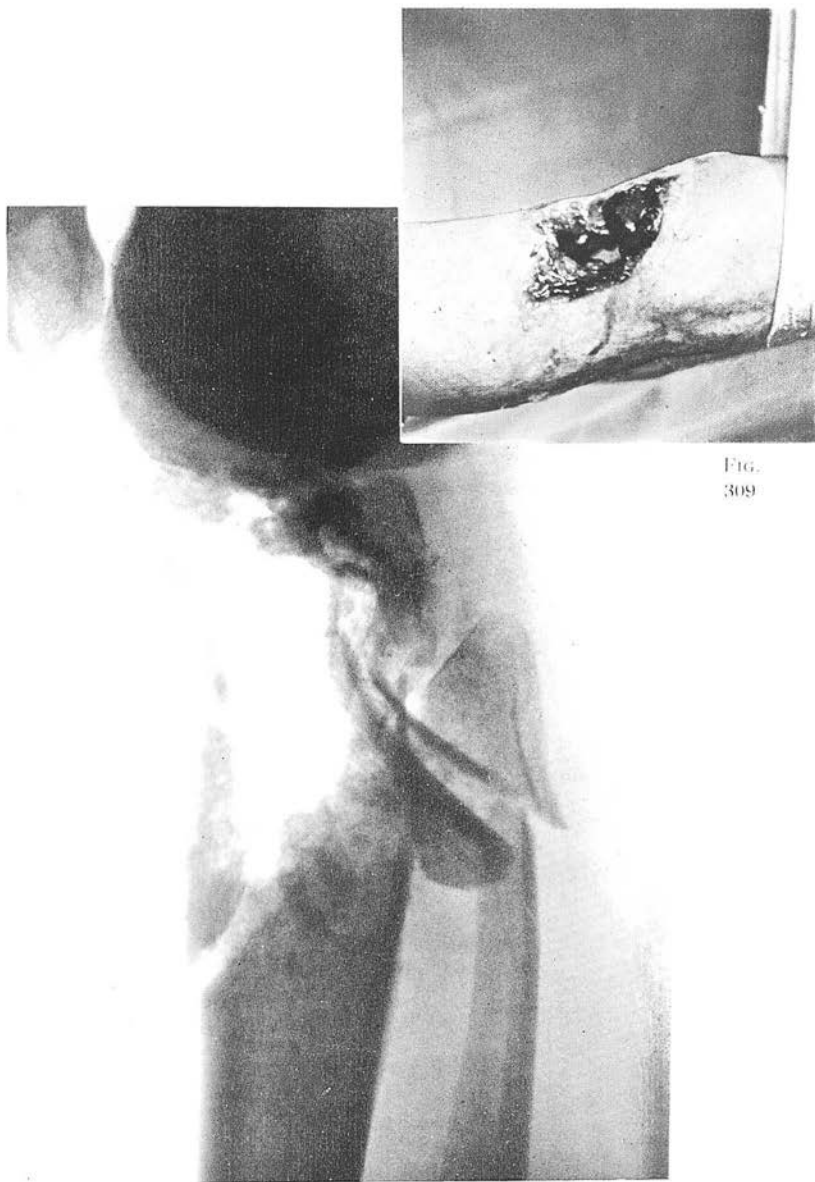
FIG.
309

FIG. 310

Gross destruction of soft tissue and bone by a shell fragment which passed through the joint: the main vessels and nerves were uninjured. A defective ankylosis must be anticipated.

Bacteriological examination of the aspirated fluid showed occasional polymorphs, but no organisms were seen on direct examination. Direct aerobic culture was sterile after twenty-four hours. Aerobic culture and P.A.B. broth culture after forty-eight hours' incubation showed penicillin sensitive staphylococcus aureus in pure culture. Anaerobic culture was negative.

Two days later, as the infection appeared to be subsiding, the grossly displaced fragments of the tibial table were reduced by a blow from a sandbag under general anaesthesia (Fig. 307). Traction was continued.

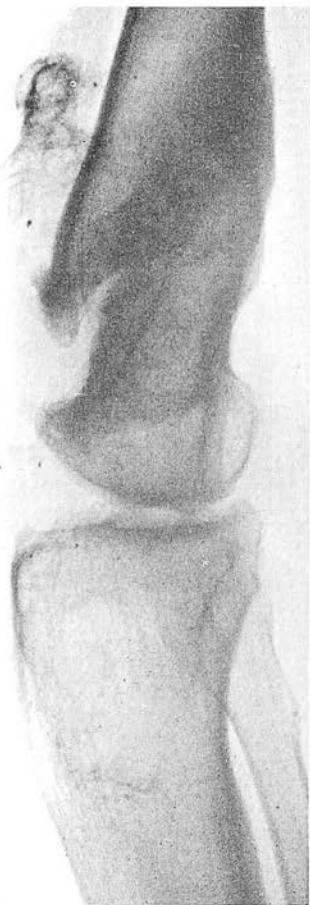

FIG. 311

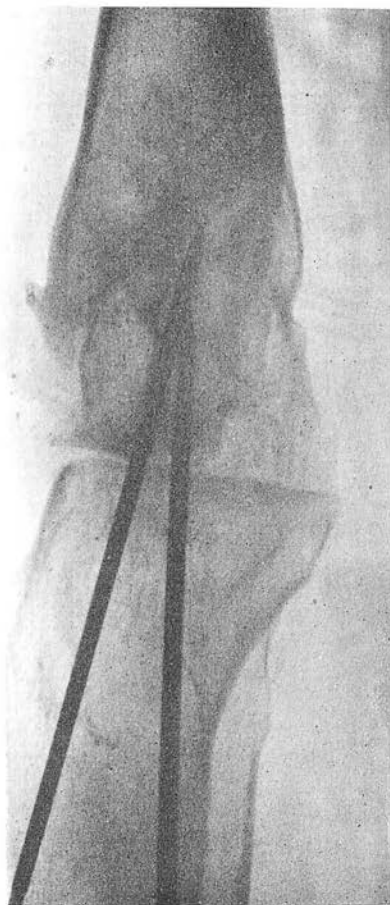


FIG. 312

Osteo-articular wound which involved the complete destruction of the patella and anterior capsule (Fig. 311). When the infection finally subsided the joint was arthrodeseed. Stainless steel pins were used to maintain accurate apposition until the unpadded plaster spica was applied (Fig. 312). The risk of recrudescence of sepsis precludes the use of bone grafts in such a case.

No reaction was produced by the reduction and the patient made rapid progress; three weeks later both entrance and exit wounds were completely healed.

Active knee flexion exercises were commenced eight weeks from the date of injury and at the end of a further four weeks the range of movement was 90 degrees. Weight-bearing was permitted at the end of the twelfth week. The range of movement when he left hospital is seen in Fig. 310, and there was every prospect of further improvement.

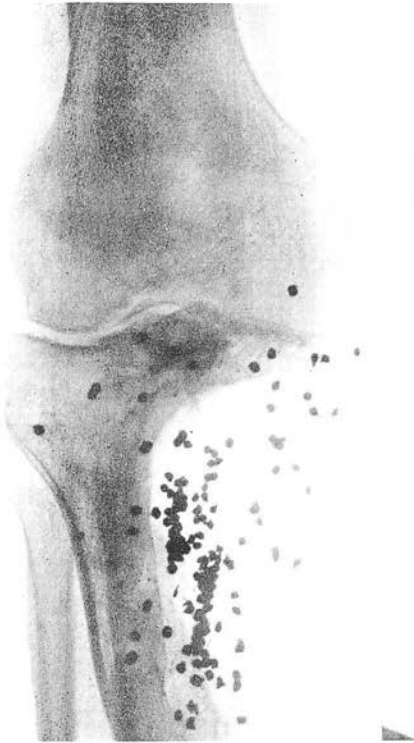

FIG. 313

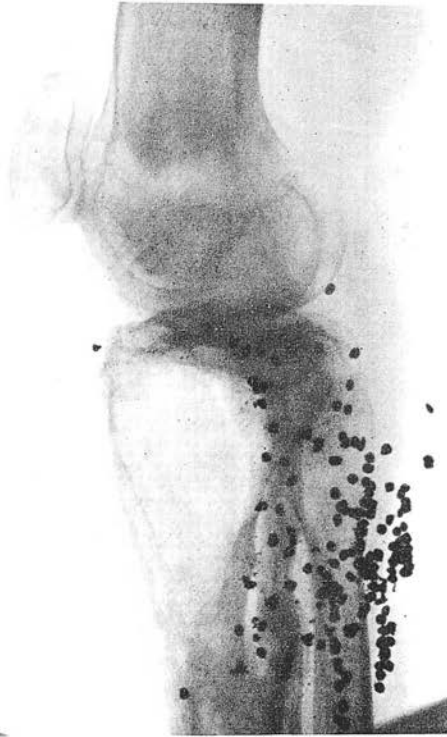

FIG. 314

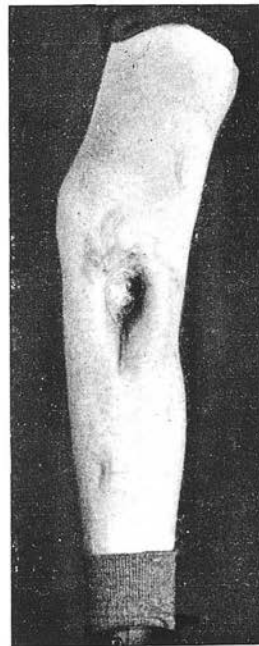


FIG. 315

Figs. 313, 314, and 315.—Infected wound of the knee joint following a shot-gun accident (Figs. 313 and 314) and resulting in ankylosis. Healing of the cavity in the tibial head was obtained by saucerisation and skin grafting (Fig. 315).

In the **second** phase the synovial fluid has become purulent and free drainage is required. This can seldom be accomplished through the original wound, but necessitates long incisions on either side of the patella extending from the upper limits of the suprapatellar pouch above to a position immediately in front of the ligaments below; neither packs nor drains are necessary or desirable. The skin traction and immobilisation are retained and chemotherapy continued.

If the **final** stage is reached all hope of preserving the joint as such has gone and only more radical drainage such as is provided by excision of the patella may prevent the infection from spreading into the intermuscular planes of the thigh. The use of a close-fitting posterior plaster shell may prevent pus tracking into the cellular tissue of the popliteal fossa. Although immobilisation is maintained, the traction must be discarded for the most satisfactory end-result which can be expected is ankylosis.

The French School seeks to avoid the dangers and disasters of sepsis by formal resection of the joint at the earliest opportunity in all infected cases with intra-articular fractures. Fruchaud¹ admits, however, that the operation, carried out in a septic field, is not without risks. He states, "it is sometimes followed by a severe reaction and occasionally by a general septic spread, though sulphonamides taken before and afterwards, orally or intravenously, give some protection. The risk is far less when the secondary resection is performed early—after two, three or four days—rather than later. But whatever the danger resection is better than expectant treatment, which leads inevitably to general infection or severe osteomyelitis; if left most of these limbs will develop a defective ankylosis with suppurating sinuses." Primary resection of the gross osteo-articular wound in the absence of infection bears the hallmark of Gallic logic; resection of the infected joint is heroic surgery. Few British surgeons care to expose large areas of cancellous tissue in the presence of infection. We prefer the patient to acquire osteomyelitis by errors of omission rather than commission.

CLASSIFICATION AND TREATMENT OF GUNSHOT WOUNDS OF KNEE JOINT

In the foregoing sections some of the most outstanding of the controversial issues in treatment have been discussed and the outline of the plan of attack which is most generally accepted has been indicated. Finally, it is proposed to recapitulate, classifying the various types of wound and indicating the line of treatment which should be adopted towards each.

It is possible to identify three types of gunshot wound of the knee joint:²

- (1) **The through and through wound produced by a high velocity missile such as a rifle bullet.**

Treatment.—The edges of the wound are cleansed and if necessary

¹ H. Fruchaud, "Wounds of Joints," *Lancet*, 1944, ii, 236.

² J. Trueta, "The Principles and Practice of War Surgery," Hamish Hamilton Medical Books, London, 1943, 331.

trimmed. The limb is completely immobilised in plaster, or in a Thomas splint with skin extension, and a full course of one of the sulphonamide compounds administered by mouth. Aspiration is carried out if the joint becomes distended, with possible replacement by a soluble solution of sulphonamide or by penicillin.

Under this regime the case usually follows an entirely favourable course and a full return of flexion can be confidently anticipated within three months in a very large proportion of patients (Figs. 316, 317, and 318).

(2) **The wound is produced by a shell or bomb splinter which enters the joint and lodges in the bone.**

Treatment.—This is the potentially dangerous osteo-articular wound which must on no account be treated expectantly but subjected to a thorough exploratory arthrotomy aimed at the elimination of all debris, foreign bodies and devitalised soft tissue. In those cases in which treatment is possible within twenty-four hours

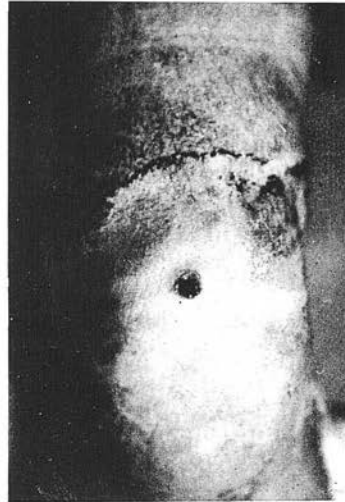


FIG. 316

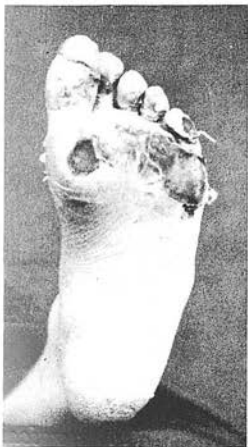

FIG. 317

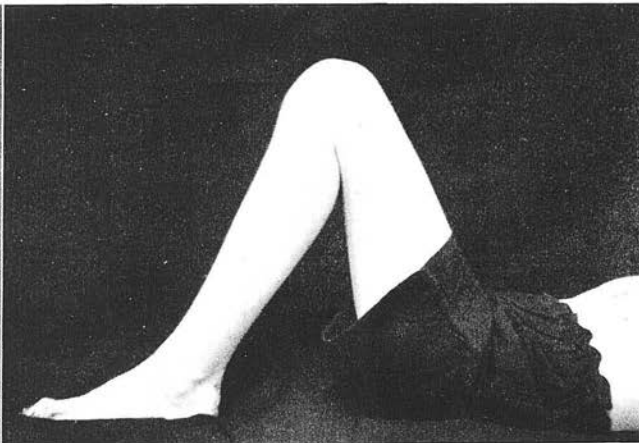

FIG. 318

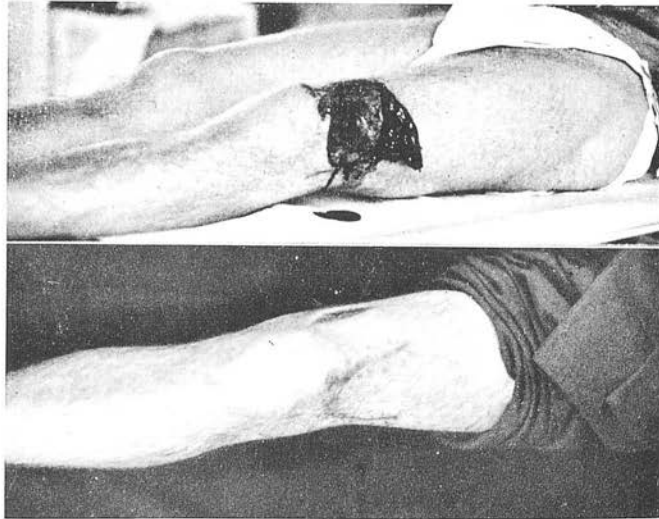
Wound produced by Sten-gun bullet which passed through the patella, scored both femoral and tibial condyles and divided the posterior tibial artery and nerve (Fig. 316). Although amputation at the site of election was eventually necessary (Fig. 317), the full range of movement was retained in the knee joint (Fig. 318).

of the injury, the synovial membrane may be sutured; the skin wound should generally be left open. If infection is already present, or if destruction of soft tissues does not permit suture of the synovial membrane, the joint is left widely open, with or without a loose pack of vaseline gauze. Immobilisation and chemotherapy follow the lines indicated in (1).

If the case follows a favourable course the final range of movement depends on the degree of bone damage. The prognosis in this respect is more favourable in lesions of the tibial table (Figs. 306, 307, and 308) than in fractures of the femoral condyles (Figs. 304 and 305).

The attitude to be adopted if infection progresses to frank suppuration has been indicated on page 274.

- (3) The injury has produced gross destruction of the joint components with extensive loss of skin, muscle and bone, and with possible damage of the vessels (Figs. 309 and 310).



Figs. 319 and 320

Flap wound exposing but not penetrating the suprapatellar pouch (Fig. 319). Although half of the flap had been destroyed a relaxation incision enabled the wound to be closed (Fig. 320).

Treatment.— If there is any hope of obtaining a satisfactory weight-bearing ankylosis, treatment follows the lines suggested in (2). If not, amputation may be required, particularly when there is grave injury of the main vessels.

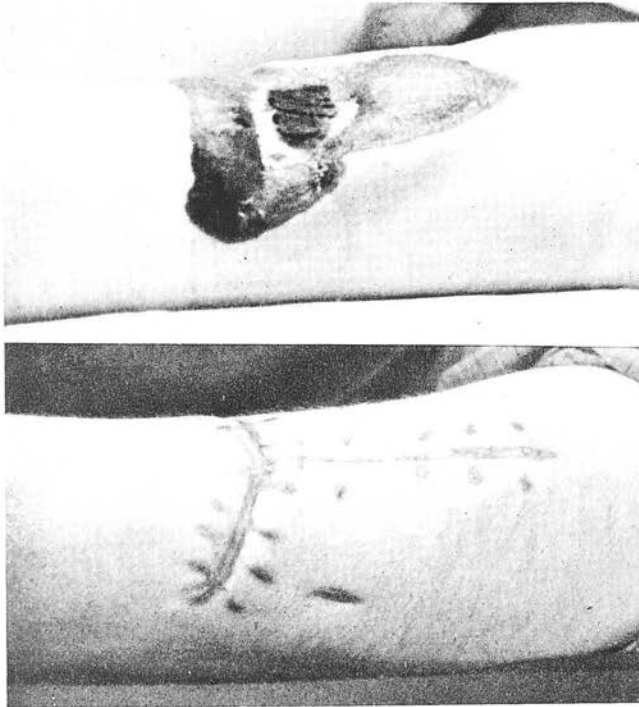
*“ If the surgical treatment is good, the result will be good. If the surgical treatment is bad, neither sulphonamide nor penicillin will atone for the error.”*¹

WOUNDS OF SURROUNDING TISSUES

It has been indicated in the opening paragraphs of the chapter that it is not intended to embark on a detailed consideration of the treatment of the wounds of soft tissues. It is only necessary to recall some of the methods which are in common use in all soft tissue injuries, but which are of particular

¹ J. Trueta, “War Surgery of the Extremities in the Light of Recent Experience,” *Lancet*, 1944, i, 651.

importance in relation to the knee joint, because, unlike the hip or shoulder joints, it is poorly clothed with muscles and the synovial cavity is largely superficial. It is for this reason that wounds overlying the suprapatellar pouch or lateral compartments, even if they do not penetrate the joint, produce deleterious effects on future function if immediate steps are not taken to secure the most rapid healing possible and with the minimum production of scar tissue (Figs. 319 and 320). Reference is made elsewhere to the loss of flexion which follows fibrosis in the region of the femoral



FIGS. 321 and 322

Wound of the quadriceps treated by wide excision of the skin edges in a French C.S. (June 1940). Note large slough of the tendon of rectus femoris (Fig. 321). In spite of the loss of tissue secondary suture was carried out with success following excision of the slough (Fig. 322). The patient left hospital with a full range of movement at the knee joint and negligible disability.

attachment of the medial collateral ligament (Chapter VII) and adhesion of the vastus intermedius to the femur or fibrous replacement of the more superficial components of the quadriceps in the region immediately above the joint (Chapter XIII).

For the purposes of the subject under consideration it is essential to recognise the clear distinction which exists between wounds due to the gaping of incised skin and wounds due to the actual destruction of skin. The immediate treatment of the two types, whether the injury is due to a road accident or a shell splinter, differs, although there is one feature of operative technique

which is common to both. No matter how much devitalised or contaminated subcutaneous tissue and fascia must be excised in the course of the wound toilet, the skin itself must be conserved. The wide excision of skin edges which was practised in the early days of the war (Fig. 321) is now considered to be unnecessary; only in exceptional circumstances need a strip more than two millimetres wide be removed, for skin is a valuable commodity for which epithelised scar tissue is a poor substitute, especially in relation to a superficial joint in which mobility of the parietes is so important.

In civil practice, where there is no tissue loss, the wound can be closed with excellent prospects of healing by first intention, provided the patient is brought to operation within six to eight hours of the injury and provided the wound toilet is adequate. In battle casualties it is generally agreed that primary suture is undesirable and closure must be deferred, to be undertaken at a later date under the titles of delayed primary or secondary suture, procedures which are greatly facilitated by the use of sulphonamide and penicillin.

The second type, in which actual tissue loss has been sustained, is perhaps more common in the knee region than elsewhere because of the exposed and vulnerable position of the joint in road accidents. If the defect is in an important area it can be closed with the aid of a relaxation incision in a less important area (Figs. 319 and 320). If this is impossible the immediate application of an intermediate skin graft is the method of choice. "The best dressing for an excised wound is skin, and if skin has been destroyed the ideal time for its replacement is the time of the primary operation."¹

In battle casualties secondary suture is to be preferred to skin grafting and may be possible in certain areas, provided skin loss is not excessive (Figs. 321 and 322). In other cases, and in situations such as the popliteal fossa, late skin grafting is necessary and should be undertaken at the earliest opportunity.

¹ R. Watson-Jones. "Fractures and Joint Injuries," E. and S. Livingstone, Edinburgh, 1943, 237.

CHAPTER TWELVE

CERTAIN OTHER INJURIES

TRAUMATIC AFFECTIONS OF BURSAE

THE function of bursae is to facilitate movement. They are found where tendons pass over bony surfaces or where the skin and superficial fascia, usually in relationship to a joint, cover a bony prominence. Adventitious bursae occur at sites where the skin and subcutaneous tissue are exposed to abnormal friction or pressure.

PREPATELLAR BURSTITIS

The most important of the various anterior bursae which have been described are :

- (1) Between the skin and the inferior half of the patella and the superior half of the ligamentum patellae—the so-called *prepatellar bursa*.
- (2) Between the skin and the inferior aspect of the tibial tubercle—the *subcutaneous tibial bursa*.

It is unusual to differentiate between these two bursae, and although neither of them is situated in front of the patella, it has been the custom to refer to them collectively as the "prepatellar" bursa.

Prepatellar bursitis occurs in three forms :

(1) ACUTE

Following a period of unaccustomed work involving kneeling or a single injury in the form of a direct blow, an effusion of serous fluid into the bursa may occur which is characterised by local swelling accompanied by acute tenderness which rapidly subsides with rest in bed, the application of heat, and elastic pressure.

(2) CHRONIC

Coal miners and domestic workers whose occupations entail long periods of kneeling frequently suffer from chronic distension of the bursa—usually the bursa situated over the tibial tubercle (Fig. 323). The walls become thickened and irregular adhesions or septa may develop in the interior; occasionally loose bodies of the

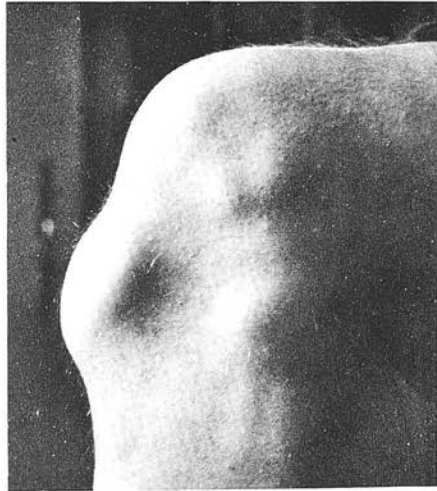


FIG. 323

Chronic distension of the bursa situated over the tibial tubercle.

melon-seed variety may be found. Acute infection may frequently be superimposed.

TREATMENT

The first line of treatment in this condition is prophylaxis. Workers in industries in which the condition is prevalent should wear sponge rubber knee pads to protect the area from constant friction and recurring minor injuries. If the patient has suffered from several acute attacks or if the distension fails to subside the bursa should be excised. The operation is performed in the bloodless field provided by a tourniquet. An incision should be selected, which, if it must cross the mid-line, should do so at a point below the tubercle of the tibia where the scar will not be subject to pressure. The U-shaped incision should be avoided, as the blood supply at

the apex of the flap is poor and it heals with a broad scar. The author uses a curved incision similar to that described in the operation for recurrent dislocation of the patella (Fig. 215), which may with advantage be placed on the lateral side to avoid the infrapatellar branch of the saphenous nerve. The bursa usually strips with ease from the patella and the patellar tendon, but is often densely adherent to the skin from which it must be separated with care by sharp dissection if button-holing is to be avoided.

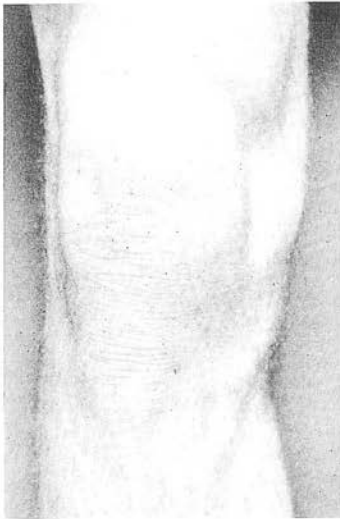

Fig. 324

In the coal miner the skin overlying the patellar tendon and tibial tubercle is thickened and deeply fissured.

(3) INFECTIVE

In the miner who works at the coal face the skin overlying the ligamentum patellae is frequently markedly thickened, and has deep transverse fissures ingrained with coal dust (Fig. 324). As a result of a minor injury, dermatitis, or sometimes, for no apparent reason, the bursa becomes infected from the

fissured skin, resulting in the condition known in the mining industry as "beat knee." It may also follow local wounds, abrasions, or arise as a sequel to sepsis in the foot or toes—an eventuality which may be explained by the structural relationship of superficial bursae to the lymphatic system.

If the infection progresses the walls of the bursa become greatly thickened, the lining membrane is destroyed and the cavity filled with pus. The resulting abscess may burst through the skin, or what is more common, spread into the subcutaneous tissues to produce cellulitis.

TREATMENT

In the early stages rest in bed combined with the time-honoured remedy of a 10 per cent. ichthyol in glycerine soak may produce relief of pain and subsidence of the infection. If suppuration occurs drainage is necessary and is

effected through a medial or lateral incision or by means of a strip of dental-rubber passed between these two incisions. The mid-line incision, which is still encountered, should be avoided even if the abscess tends to point in this area.

The use of sulphonamides and penicillin is of the utmost value in the presence of susceptible organisms.

BURSA BETWEEN LIGAMENTUM PATELLAE AND TIBIA (DEEP INFRAPATELLAR BURSA)

The only other anterior bursa of any significance is that which lies between the ligamentum patellae and the tibia immediately above the attachment of the ligament. This small bursa is rarely affected by disease or injury, but may become the subject of effusion as a result of a direct blow over the ligament, when difficulty may arise in differentiating the condition from haemorrhage into the retropatellar pad of fat. In both cases there is pain and tenderness over the ligament combined with inability to obtain full flexion or extension. The swelling which appears on either side of the ligament is fluctuant in bursitis and is usually situated at a lower level, but aspiration is frequently necessary in order to confirm the diagnosis.

The condition usually subsides rapidly with rest and firm elastic compression.

POPLITEAL CYST (BAKER'S CYST, SEMIMEMBRANOSUS BURSA)

There are six primary bursae associated with the muscles and tendons of the postero-medial aspect of the knee joint. They are situated between:

- (1) The tendons of sartorius, gracilis, semitendinosus and the medial collateral ligament.
- (2) The medial collateral ligament and tendon of the semimembranosus.
- (3) The tendon of semimembranosus and the medial condyle of the tibia.
- (4) The medial head of gastrocnemius and capsule overlying the medial condyle of the femur.
- (5) The superficial surface of the medial head of gastrocnemius and the overlying semimembranosus.
- (6) The semimembranosus and the semitendinosus, occasionally.

The variation in the descriptions of these bursae by different authorities is readily explained by the inconsistency with which some of them are encountered and the frequency with which adjacent bursae communicate with one another or coalesce to form a larger sac. For example, the two bursae surrounding the tendon of semimembranosus (2 and 3) might frequently be described as one when they freely communicate. Furthermore, the two bursae which are considered to be of greatest clinical significance, *i.e.*, that situated deep to the medial head of gastrocnemius (4) and that

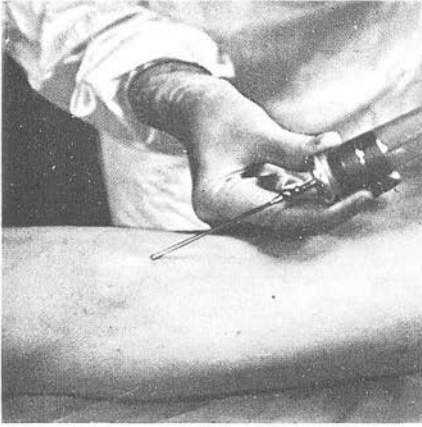


FIG. 325

FIGS. 325 and 326.

Aspiration of acute traumatic haemorrhagic effusion from gastrocnemio-semimembranosus bursa existing as an isolated lesion and unassociated with an effusion into the joint (Fig. 325). Air injected into the bursa shows that there is no connection with the joint (Fig. 326). This type of case does not require operation, but will subside with aspiration and compression.

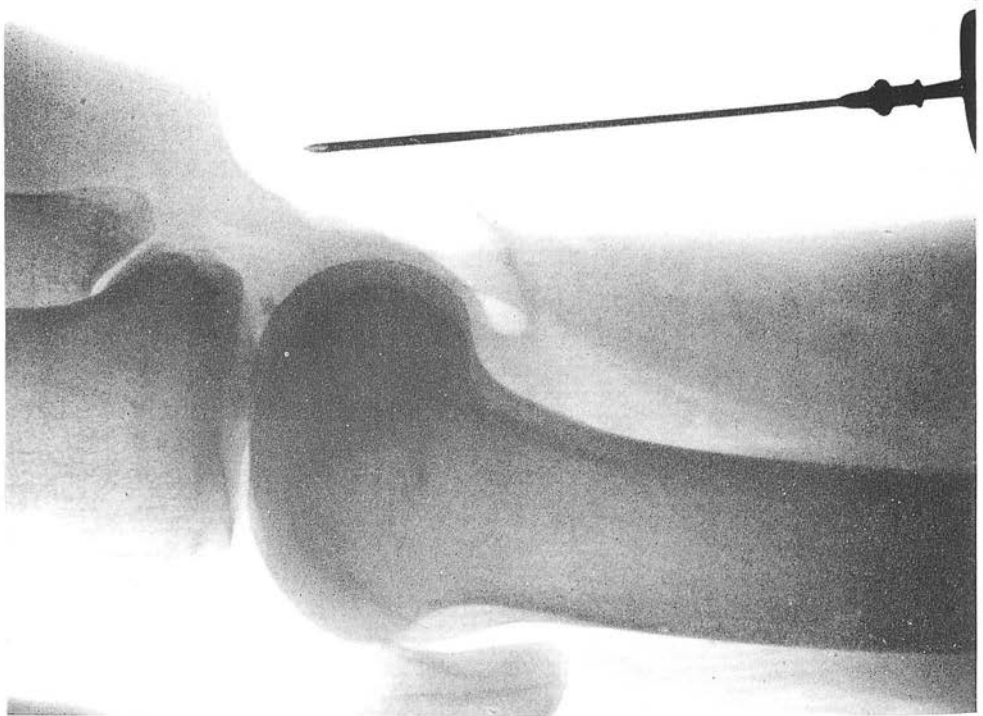


FIG. 326

lying between gastrocnemius and the semimembranosus (5) also frequently fuse to form the largest and most important bursa of the popliteal space, and which communicates with the knee joint in 50 per cent. of cases. It is little wonder, considering the confusion of description which is likely to arise, that there are so many and varying accounts of the etiology and pathology of the cystic swelling of the popliteal fossa known as Baker's Cyst or Semimembranosus Bursa.

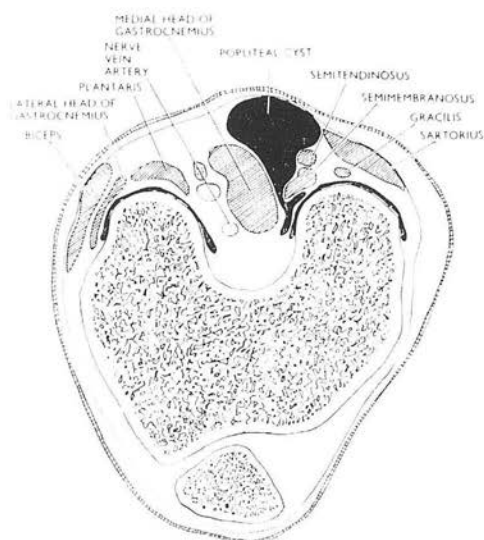


FIG. 327

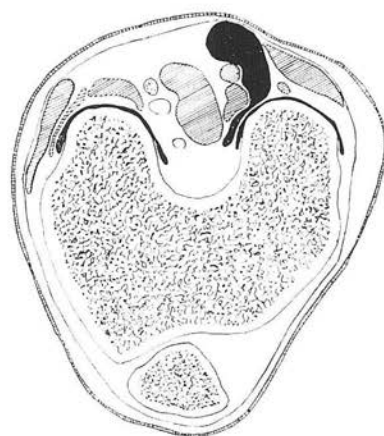


FIG. 328

Two common relationships of the distended gastrocnemio-semimembranosus bursa. Fig. 327 shows the cyst emerging on the lateral side of semimembranosus. (Redrawn from Wilson, Eyre-Brook and Francis). Fig. 328 shows the cyst emerging on the medial side of semimembranosus.

CLINICAL FEATURES

The swelling may appear in childhood, when it is sometimes bilateral and symmetrical, or in adult life, and is frequently unassociated with any other knee joint pathology, although in the elderly patient it may be associated with osteoarthritic change.

The swelling may not be perceptible when the deep fascia is relaxed by slight flexion of the joint, but when the knee is in extension it takes the form of a firm, tense cystic mass situated to the medial side of the mid-line (Fig. 325) or well to the medial side of the fossa, depending on whether it emerges beneath the deep fascia to the lateral or the medial side of the semimembranosus (Figs. 327 and 328).

The symptoms are vague and may consist of nothing more than a complaint of the presence of a swelling, but in some cases there is pain referred to the posterior aspect of the joint, weakness, which may be explained by interference with muscle action, and giving-way, which is sometimes present when the size of the swelling is preventing full extension

of the joint. In elderly patients there may be co-existing symptoms of osteoarthritis.

In one of the author's cases the cyst was so large that the venous circulation was obstructed, causing gross swelling of the leg. In two cases the cyst was filled with loose bodies in the absence of any loose bodies in the joint, and as no communication existed between the cyst and the knee joint at the time of operation the etiology of the condition gave rise to much speculation (Figs. 330 and 331).

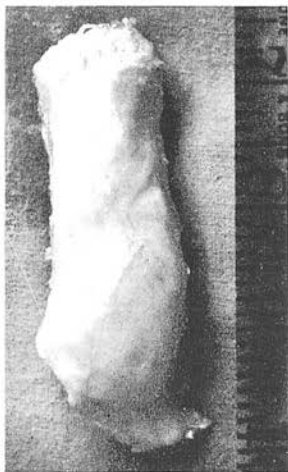

FIG. 329
Distended gastrocnemio-
semimembranosus bursa.

If there is an opening in the posterior capsule, manual pressure may cause the contents to be expressed into the joint, only to return following firm pressure on the anterior aspect of the knee. This phenomenon does not always occur even in the presence of a communication, and it is assumed that this is due to some valve-like action at the point of communication.

It has been stated that the condition is rarely associated with other knee joint pathology, but it has been noted on several occasions by the author in association with an acute synovial effusion caused by a meniscus injury. In no case was the swelling present to the patient's knowledge prior to the internal derangement.

No direct action was taken in regard to the cyst, which disappeared spontaneously following excision of the torn meniscus.

ETIOLOGY AND PATHOLOGY

Observation in the course of operation on popliteal cysts confirms the conclusion of Wilson, Eyre-Brook, and Francis¹ that the so-called Baker's cyst and semimembranosus bursa are one and the same condition, namely, chronic distension of the composite bursa associated with the gastrocnemius and semimembranosus muscles and referred to by them as the gastrocnemio-semimembranosus bursa, although it is possible that hydrops of one of the other bursae enumerated might give rise to a similar condition.

This conclusion is based on:

- (1) The location of the swelling, which is invariably the postero-medial aspect of the popliteal fossa.
- (2) The constant finding of an intimate attachment to the tendinous portion of the gastrocnemius and semimembranosus muscles.
- (3) The constant finding that when the cyst does communicate with the joint, the position of the opening corresponds to the point of communication

¹ P. O. Wilson, A. L. Eyre-Brook, and J. D. Francis. "A Clinical and Anatomical Study of the Semimembranosus Bursa in Relation to Popliteal Cyst." *J. Bone and Joint Surg.*, 1938, xx, 963-984.

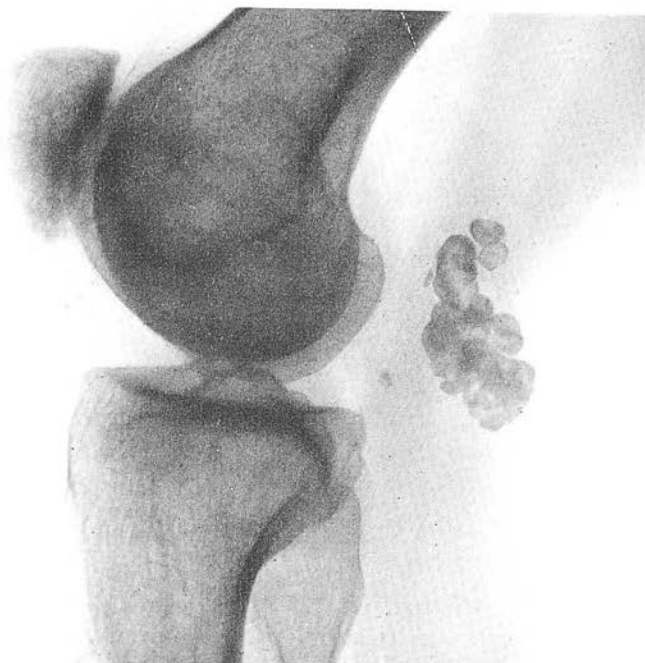

Fig. 330

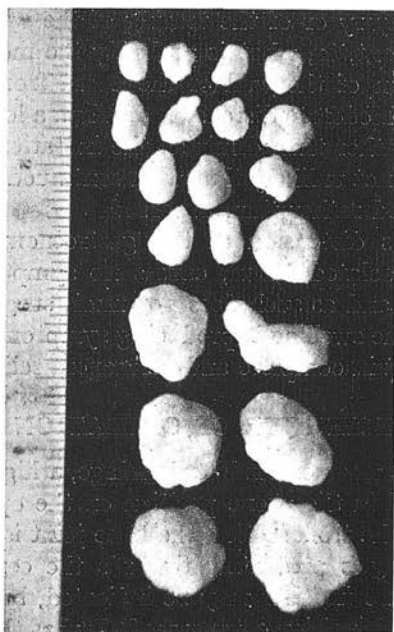


Fig. 331

Loose bodies in a popliteal cyst: there are none in the knee joint (two such cases were encountered).

which is present in about 50 per cent. of normal knee joints between the gastrocnemio-semimembranosus bursa and capsule, *i.e.*, beneath the medial head of the gastrocnemius muscle close to its origin.

These three points make it evident that there is little basis for the theory that the cyst is a hernial protrusion of the synovial membrane of the joint. Such a theory must surely postulate an increase of intra-articular pressure of long standing. The first appearance of a swelling is frequently known to coincide with an acute synovial effusion of traumatic origin, which is hardly likely to be responsible for sudden herniation. The more simple and obvious explanation is the presence of a natural communication between the synovial cavity and a bursa in the popliteal space.

TREATMENT

The etiology of the distension of the bursa must be explained in two circumstances :

- (1) **When the bursa communicates with the joint.**
- (2) **When there is no communication with the joint.**

In the first, the distension is secondary to a pathological condition of the joint causing an effusion, and thus distension of the bursa is most commonly encountered in association with a synovial effusion of traumatic origin and in osteoarthritis. In these circumstances the condition is not a separate pathological entity and the treatment is merely that of the cause.

In the second, it is considered that the etiological factor is trauma in the form of a direct injury or of the tearing of the wall of the bursa by a sudden violent movement, or, what is probably the most frequent explanation, constant irritation of the wall of the bursa from the contraction of the adjacent muscles. Moderate distension of a bursa located in this position will tend to increase rather than diminish the irritation which initiated the effusion, and thus it is not unlikely that with continued activity any effusion tends to be perpetuated rather than absorbed.

In some instances distension of the gastrocnemio-semimembranosus bursa, arising as an isolated lesion, causes no symptoms other than the presence of a swelling, and as such does not merit surgical interference, but in the cases in which the swelling is producing symptoms the only treatment which is likely to result in complete and permanent relief is excision.

TECHNIQUE OF OPERATION

The limb is drained by means of a rubber bandage, a high tourniquet applied, and the patient placed in the prone position on the operating table with a small sand bag under the tibia so that the knee joint is maintained in slight flexion. If the swelling is presenting towards the centre of the popliteal space a vertical mid-line incision may be indicated, but if it is situated on the medial side a curved incision convex medially has the possible advantage that it avoids the slow healing and tendency to keloid formation characteristic of vertical mid-line incisions on the flexor aspect of the knee joint.

The deep fascia is incised longitudinally and immediately reveals the cyst frequently covered with fatty fibrous tissue. No difficulty is encountered tracing the limits of the bursa between the medial head of gastrocnemius and the muscular belly of semimembranosus (Fig. 327), although occasionally the swelling may present between semimembranosus and semitendinosus laterally and sartorius and gracilis medially (Fig. 328).

No line of cleavage will be found between the wall and the semimembranosus and gastrocnemius, and it may therefore be necessary to resect the tendinous superficial layer of these structures together with the cyst if rupture of the wall is to be avoided. If the cyst communicates with the joint it will be found to be adherent to the capsule on the deep surface of the medial head of the gastrocnemius. It is unnecessary to attempt to suture the opening in the posterior capsule through which it communicates with the joint.

The dissection takes place on the medial aspect of the medial head of gastrocnemius and thus the popliteal vessels and nerve are protected throughout the procedure by retraction of the muscle in a lateral direction.

The wound is closed by suture of the deep fascia and skin. A compression bandage is applied and the tourniquet removed.

INJURIES OF INFRAPATELLAR FAT PAD AND SYNOVIAL FRINGES

In the pyramidal space formed behind and above by the condyles of the femur, below by the tibia, and in front by the patellar tendon, is situated the infrapatellar pad of fat. This pad is extrasynovial but intracapsular and changes in shape with every movement of the joint. The synovial layer, which is reflected over the fat pad, sends a triangular fold called the ligamentum mucosum, upwards and backwards to be attached to the intercondylar notch. The free edges of the ligamentum musocum diverge to include the lateral margins of the fat pad and are called the alar ligaments.

When the knee joint is extended the patella is elevated by the contraction of the quadriceps, the fat pad becomes flattened in an antero-posterior direction and the alar ligaments are drawn away from the joint surfaces. If the fat pad is abnormally large, or in the presence of loss of volume, tone and co-ordination in the quadriceps apparatus, the alar ligaments or other synovial fringes may be nipped between the condyles on extension of the joint. Injury to the fat pad or synovial fringes, either by nipping or by direct trauma, results in haemorrhages, hypertrophy and fibrosis. While the conditions of "hypertrophy of the infrapatellar fat pad" and of "nipped synovial fringe" undoubtedly do occur—for example, the latter injury may be seen in the arthritic joint, the subject of peripheral lipping, hypertrophic synovial membrane, and marked wasting of the quadriceps—they are of rare occurrence in the otherwise normal joint. Such labels are similar to the diagnosis of "traumatic synovitis"; they frequently cover the failure to assess the nature of the underlying pathology which closer investigation may reveal to be a lesion of a meniscus.

In the acute form, injury to the fat pad is characterised by retropatellar—or retropatellar tendon—pain, with local pain on forcible extension which exerts pressure on the pad. There is swelling and tenderness to pressure on both sides of the tendon.

In the chronic varieties the symptoms are not characteristic, and may consist of vague retropatellar pain on exertion, occasional sudden stabbing pain which may cause the knee to give way, and even mild effusions; localised tenderness is rarely present. The condition may thus be difficult to distinguish from fibrillation of the patella, and, indeed, in the only two cases of proved nipping of synovial fringes which the author has encountered in healthy young adults, fibrillation of the patella was the erroneous pre-operative diagnosis. In each case the articular surface of the patella was normal, but a hypertrophied tag of synovial membrane, the subject of both recent and old haemorrhages, projected backwards at the inferior pole and had apparently been repeatedly compressed against the femoral condyles. Excision of the tag resulted in complete relief of symptoms.

TREATMENT

It is evident both from the pathology and symptomatology of the traumatic affections of the infrapatellar fat pad and the synovial fringes that these two conditions are closely related and frequently indistinguishable except perhaps in the acute form.

Sir Robert Jones¹ pointed out that as pain only occurs when the joint is fully extended, the addition of half an inch to the heel of the shoe will frequently effect recovery. In using this form of treatment, however, it must be remembered that walking on a partially flexed knee is not only prejudicial to the recovery of an inefficient extensor apparatus which may possibly be responsible for the onset of symptoms, but may result in permanent loss of full extension. It is thus most important that this simple measure be supplemented with regular quadriceps drill.

If conservative methods fail to produce a cure within a reasonable period, the anterior compartment of the joint should be explored through a medial incision extensive enough to permit the articular cartilage of the patella to be examined, any hypertrophied tags of synovial membrane excised, and, if necessary, an excessively large fat pad reduced in size.

NEURITIS OF A BRANCH OF PATELLAR PLEXUS

The condition to which the above name has been attached is characterised by the complaint of an "electric shock" when a small well-defined area of skin overlying the patella, or the immediately adjacent regions, is subjected to the lightest touch, the patient stating that even contact with the material of the trouser leg causes him to pause abruptly in whatever he is doing.

The etiology is obscure. It is merely assumed to be due to a minor direct injury which produces an irritative lesion of a minute sensory nerve.

¹ Sir Robert Jones and Robert W. Lovett, "Orthopaedic Surgery," Oxford University Press.

On examination the "trigger area" can usually be found, adjacent to which is a small area of hyperaesthesia in the region of the patellar plexus. The patient often excuses himself for having complained of such a trivial matter, but has become apprehensive about the unexpected suddenness of the shocks and of the nature of the condition. He may be reassured that although the condition may remain for a few weeks, it is self-limiting and will disappear as suddenly as it came.

CHAPTER THIRTEEN

THE STIFF KNEE¹

LOSS OF FLEXION

LOSS of flexion at the knee joint constitutes one of the most serious problems arising directly as a result of the major injuries of the joint, and indirectly as the result of fractures throughout the entire length of the femur. For this reason the methods which have been described for the treatment of fractures of the tibial plateau, femoral condyles and the supra-condylar region have been selected with the specific purpose of avoiding loss of joint motion. The detailed treatment of the various fractures of the femoral shaft has no place in the present work, but it is necessary to consider the secondary effect on the knee joint of some of the methods in common use in order that the prevention of avoidable residual stiffness may be discussed.

The knee joint is particularly susceptible to the effect of fibrous tissue reaction because of the complex nature of its structure and mechanics. For example, the axis of rotation, although situated in the posterior aspect of the femoral condyles, is not a fixed point, but moves forward in flexion and backwards in extension as a result of the gliding movement which is superimposed upon the hinge action; in flexion, not only must the medial collateral ligament glide freely on the femoral and tibial condyles, but the patella must move through a distance which may be as great as three inches. To permit such free excursion of the interrelated components, the joint is surrounded by the largest and most extensive synovial membrane and capsule in the body. Adhesions in relation to any portion of the synovial cavity or capsule must restrict the free movement of this complex joint.

Adhesions which produce limitation of movement may be situated:

- (1) **Within the joint cavity**; the areas most frequently affected are the suprapatellar pouch and the medial and lateral joint compartments.
- (2) **In the capsular and extracapsular tissues**; the areas most frequently affected are the lateral and medial expansions.
- (3) **In the quadriceps**, as the result of fibrous replacement of tissue loss following an open wound or adhesion of the muscle to the femoral shaft.
- (4) **In the skin and subcutaneous tissue**, as the result of fibrous replacement of tissue loss following an open wound.

¹ Part of this chapter is based on a Honyman Gillespie Lecture "The Problem of the Stiff Knee Joint in Fracture of the Shaft of the Femur" delivered by the author in the Royal Infirmary of Edinburgh, 19th April 1945. (*Edin. Med. Jour.*, 1945, 61, 317-328.)

PREVENTION

I. IN INJURIES OF THE JOINT

The methods of treatment of the individual knee joint injuries which have been described in the preceding chapters have been selected with the purpose of retaining the maximum range of movement in the joint.

II. FRACTURES OF SHAFT OF FEMUR

Of those who seek aid in the months or years following a fracture of the shaft of the femur, the majority suffer from loss of flexion in the knee joint or shortening of the limb of a degree sufficient to cause an unsightly limp and disability with consequent loss of earning power in the labour market. To the working man, and especially the miner, the more important of these disabilities is loss of flexion, and there can be little doubt in the mind of a miner that an inch of shortening is preferable to a stiff knee. Observation of the arduous conditions under which miners work makes it only too evident that a loss of even twenty degrees of flexion constitutes a grave handicap. No surgeon who undertakes the treatment of fractures of the femur has completed his training until he has worked a shift at the coal-face. There are few whose respect for the integrity of the knee joint would not be increased.

FACTORS CONCERNED IN LOSS OF RANGE OF FLEXION IN KNEE JOINT FOLLOWING FRACTURE OF SHAFT OF FEMUR

(1) THE VIOLENCE WHICH PRODUCES THE FRACTURE ALSO INJURES THE JOINT

Fractures of the femur occur most frequently as the result of direct violence. It requires no stretch of the imagination to appreciate that force applied to the lateral aspect of the thigh, of sufficient magnitude to produce a fracture of the shaft of the femur, produces considerable strain on the knee joint prior to the occurrence of the fracture. Critical observation of a series of cases will show that a large proportion of fractures demonstrate the presence of synovial effusion or even haemarthrosis—convincing evidence that the joint has also been subjected to trauma. If the fracture of the femur had not occurred, the condition of the joint would have warranted investigation in order to establish an exact diagnosis and institute the appropriate measures, but the magnitude of the major fracture overshadows the knee joint injury which is disregarded in both the selection and execution of treatment. The treatment adopted, be it skin extension, plaster immobilisation or even traction transmitted by a Steinmann pin to the fracture site via the injured joint, may produce complete reduction and eventually sound union, but ignores the effect which such methods may produce on the function of the all-important knee joint.

(2) METHODS OF TREATMENT

No matter which of the many available methods is chosen, union of a soundness which will permit weight-bearing is seldom established in less than three months. An uninjured joint is little affected by such a period of immobilisation, as shown by the rapid return of full flexion which follows the removal of the thigh length plaster cast used in the fracture of the shaft of the tibia. There must therefore be other factors unfavourable to the rapid return of full flexion in addition to the effect of immobilisation alone. Unfortunately these factors, of which far the most important is powerful traction, are often in force for periods much greater than three months, and it is not uncommon for union to be delayed as long as nine to twelve months in an apparently uncomplicated case.

(3) METHODS OF TREATMENT PREJUDICIAL TO WELFARE OF THE KNEE JOINT

(a) SUPRACONDYLAR SKELETAL TRACTION

A method in common use which affects the knee joint unfavourably is the use of condylar or supracondylar skeletal traction. Infection of the pin track is frequently unavoidable with consequent inflammatory reaction in the nearby suprapatellar pouch. In two cases which came to operation as a result of persistent stiffness, the author encountered walled-off abscesses containing sterile pus in the suprapatellar pouch; in neither case was there any evidence of gross infection of the pin tract. Even in the absence of recognisable infection the prolonged association of a metallic foreign body with this large area of synovial membrane sets up an aseptic inflammatory reaction, the outcome of which is the complete obliteration of the pouch. In this respect it would seem that a Kirschner wire, in spite of its narrow gauge, produces more reaction than a Steinmann pin. The former is drilled through the bone and therefore of less diameter than the hole through which it passes, and, being firmly clamped to the accompanying stirrup, is subject to transmitted rotary movement; the latter is driven through the bone and therefore for some considerable time a perfectly tight fit; it is not subject to transmitted rotary movement from the Böhler type of stirrup. It is not unreasonable to suggest that, if, for mechanical reasons, skeletal traction through the lower end of the femur is considered essential, the method of choice is a Steinmann pin and Böhler stirrup which must be changed in favour of some other method of maintaining reduction within the space of three weeks if the integrity of the suprapatellar pouch is to be respected.

(b) ILL-CONCEIVED OPERATIONS

When the decision is made to resort to open reduction and internal fixation, it is essential to adopt a technique calculated to secure sound union in the minimum time with the maximum regard for the future function of the extensor apparatus and the integrity of the knee joint.

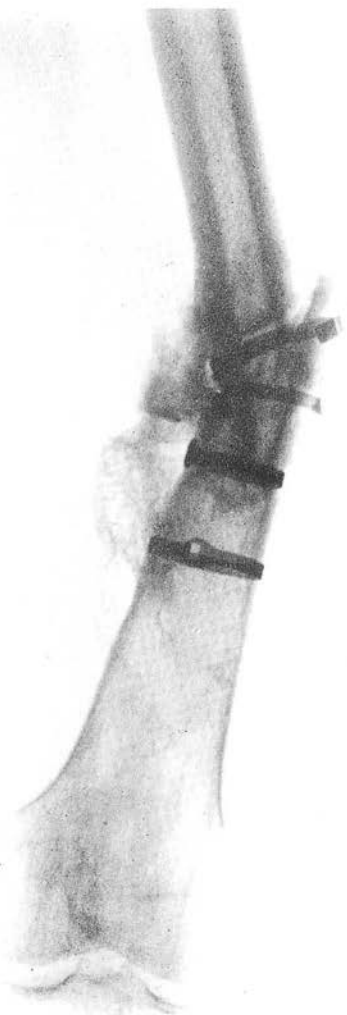


FIG. 332

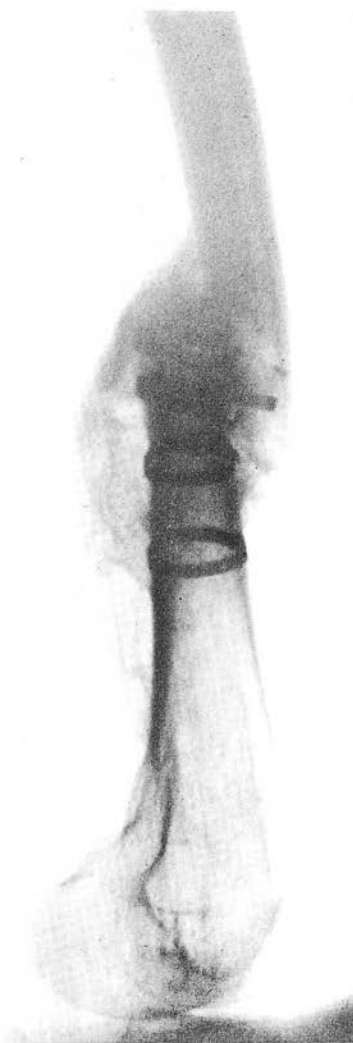

FIG. 333

An ill-conceived operation

The operation had been performed through an anterior mid-line incision which extended down to the superior pole of the patella. There is a zone of rarefaction round each metal band, two of which have broken; angulation has occurred and there is three inches of shortening. The angulation can be corrected by a further operation, but neither manipulation nor operation can cure the permanent fibrous ankylosis of the knee joint.

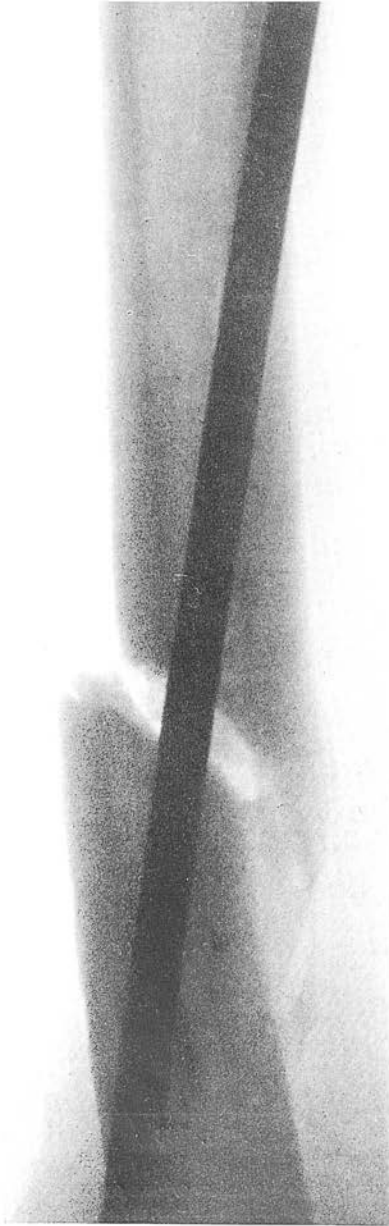


FIG. 334

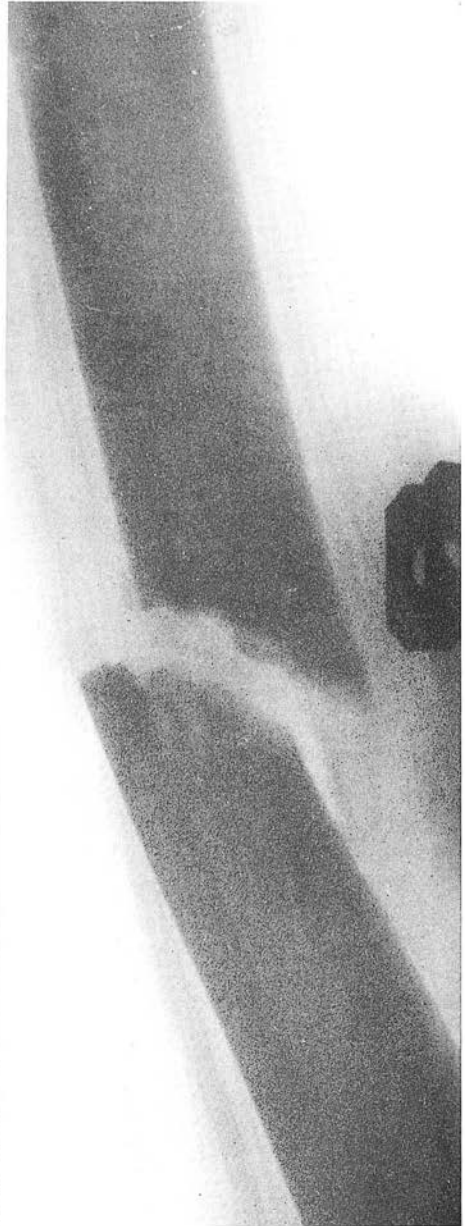


FIG. 335

Fracture of the middle third of the shaft of the femur showing the progress of union at the end of three months. The reason: distraction, uncorrected angulation showing a wide gap at the convex aspect of the angle, and the possible interposition of soft tissue. The decision to resort to operative reduction and internal fixation in such a case should be made within a few days; it should not be delayed for three months.

(i) **Anterior Mid-line Incision.**—The use of an incision which respects neither the anatomy nor the physiology of the quadriceps muscle is indefensible. Patients are still encountered in Physiotherapy Departments and Rehabilitation Centres, struggling to secure a few degrees of flexion against the overwhelming odds produced by adhesion of the rectus femoris and vastus intermedius to the bone and the complete obliteration of the suprapatellar pouch (Figs. 332, 333, 342 and 343).

(ii) **Misuse of Methods of Internal Fixation and Bone Grafting.**—When foreign bodies of the nature of plates and screws are used for the purpose of internal fixation, only non-toxic, non-irritative material such as non-toxic stainless steel or vitallium should be used and the screws must be of the same material as the plate (Figs. 336 and 337). The use of metal plates and screws without these essential qualities, especially in the lower third of the femur, leads to undesirable effects on the knee joint from electrolytic action between plate and screws, fibrosis and even sepsis.

Bone grafting operations are usually undertaken when the knee joint has already been subjected to prolonged traction and immobilisation. The temptation to use the technically simple intramedullary bone peg must be resisted. This method of bone grafting is physiologically unsound and is frequently followed by non-union, or in the most fortunate circumstances, by delayed union. The massive onlay graft, secured by vitallium screws, offers the best prospects of union in the shortest possible time.

(4) ERRORS IN COURSE OF TREATMENT

(a) SELECTION OF METHOD

In selecting the method of treatment suitable to a particular fracture, it is essential to aim at the ideal of securing sound union in the shortest possible time. In order to attain this ideal it is frequently necessary to reconsider the original decision and change the procedure within the first week if the reduction and stabilisation of the fragments is not of a sufficiently high standard.

If, for example, in a fracture in the middle third of the shaft, skin extension in a Thomas splint is the method of treatment adopted, the prospects of rapid union should be assessed when it is considered that the best possible reduction has been obtained. If there is uncorrected angulation still present, with or without distraction at the fracture site, union will at best be delayed (Figs. 334 and 335). It is thus better to make the voluntary decision to carry out accurate operative reduction and the insertion of a vitallium plate than wait for six to twelve months for consolidation to occur, or be forced to insert an onlay graft after a delay of six months in order to secure union. Such prolongation of immobilisation inevitably causes some permanent loss of flexion at the knee joint.

The methods used by the author at the present time with the purpose of preserving knee joint function by the reduction of the period of immobilisation to a minimum are :

(i) **Fractures in Distal Third.**—The method used has been described

in detail under Fractures of the Tibia and Femur involving the Knee Joint. Reduction and maintenance of reduction are simple in this area; the fractures unite rapidly and present no serious problem in the return of knee flexion, except in those cases in which the quadriceps has sustained serious damage at the initial injury and has become adherent to the femur.

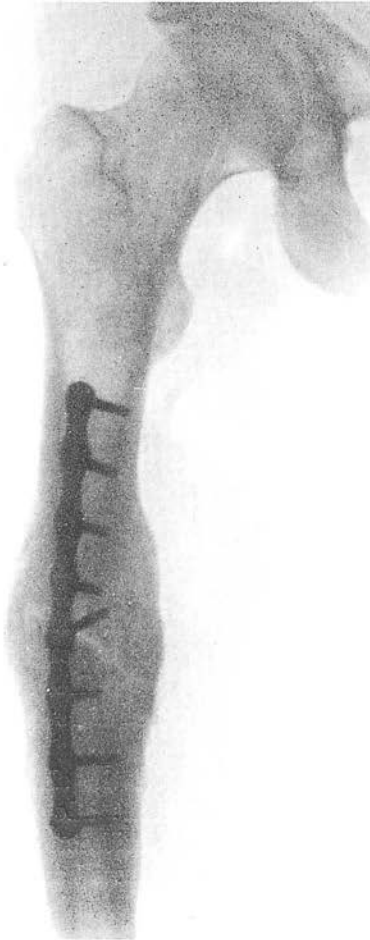

FIG. 336

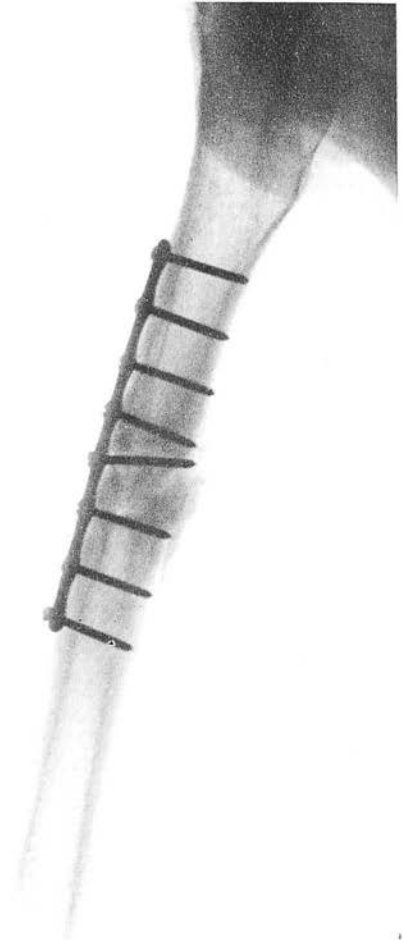


FIG. 337

(ii) **Fractures in Middle Third.** The Thomas splint with skin extension and fixed or weight traction is the method advocated in this region. If reduction is imperfect, especially in the form of uncorrected angulation which leaves a wide gap at the open aspect of the angle, possible interposition of soft tissue, distraction or other factor calculated to produce serious delay in union (Figs. 334 and 335), open operation is performed and a vitallium plate inserted.

(iii) **Fractures in Upper Third of Shaft.**—Open operation with the insertion of a vitallium plate is the method of choice (Figs. 336, 337, 338, and 339).

(b) **PROLONGED POWERFUL TRACTION**

"There has always been a potentially harmful factor inherent in the method of weight-and-pulley traction; but much actual harm has been done since skeletal traction has made it possible to use heavier weights and to leave them at work for longer periods" (*Girdlestone*).¹

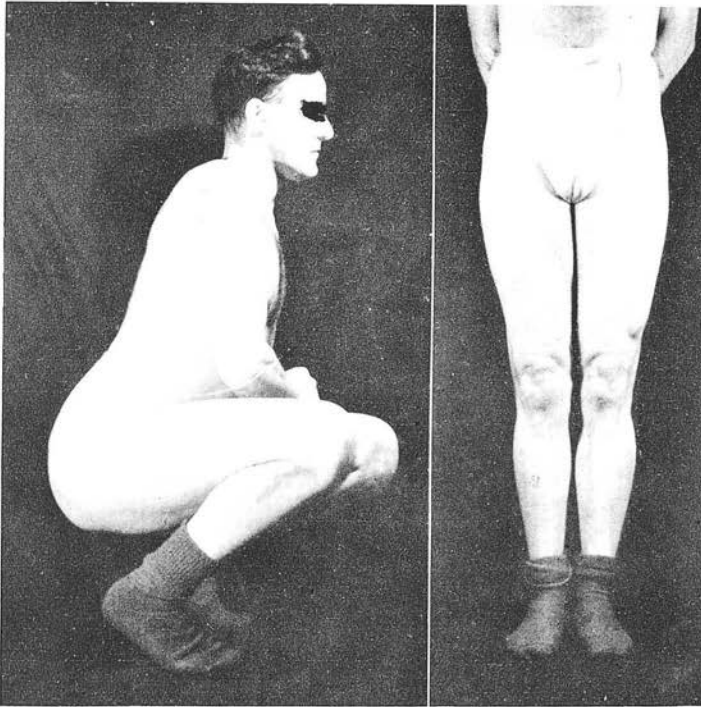


FIG. 338

FIG. 339

Figs. 336-339.—Fracture of the femur at the junction of the upper and middle thirds in a Paratrooper of magnificent stature. Treated by operative reduction and the insertion of a vitallium plate. In four months union is sound, knee flexion full, and the development of both thigh and calf muscles has almost returned to normal.

Prolonged powerful traction is often prolonged merely because it is powerful, and thus in addition to delaying the progress of union produces a most damaging effect on the joint both by reason of its power and the length of time during which it continues to act. The capsular and extra-capsular adhesions which follow are due to direct irritation of the supporting structures, whereas the intra-articular adhesions in the suprapatellar pouch and in the medial and lateral joint compartments may possibly result from

¹G. R. Girdlestone. "Orthopaedic Influence on the Treatment of Fractures." *Lancet*, 1943, ii, 593.

inhibition of the production of synovial fluid. Who has ever seen a stiff knee joint with a synovial effusion ?

In contradistinction, the use of continuous mild traction of five to seven pounds is consistent with rapid return of function. **Traction should not be expected to reduce the fracture, but merely to maintain the accurate reduction secured by the surgeon.**

(c) IMMOBILISATION IN A POSITION OF STRAIN

In addition to the irritation and reactionary fibrosis produced by both the "power" and the "prolongation" of prolonged powerful traction, strain may be produced by immobilisation in hyperextension.

If you fall asleep sitting in a chair with your feet on the mantelpiece, you wake, not because you are rested, but because of pain in the popliteal fossa. The pain is due to stretching of the capsule and posterior ligaments. A knee joint immobilised in a Thomas bed-splint without a pad directly supported by a sling behind the popliteal space soon becomes hyperextended as a result of traction or even of gravity. The same is true of a plaster spica carelessly applied with the knee in full extension ; wasting of muscle and subcutaneous tissue soon permits hyperextension to occur unless the popliteal space is adequately supported. The pain produced in the early stages of hyperextension is the signal that stretching of ligaments is taking place ; the pain soon disappears, but the stretching continues with injurious effects on the future function of the joint.

(d) FAILURE TO BEGIN REHABILITATION DURING PERIOD OF IMMOBILISATION

The intracapsular fracture of the femoral neck, one time "cinderella" of the surgical ward, has, since the introduction of the Smith Peterson nail, been elevated to the status of a highly desirable admission. Fractures of the femoral shaft now hold the unenviable vacated position. The lack of enthusiasm with which these fractures are received is due partly to the lengthy and undramatic nature of the treatment required and partly to the necessity for the large amount of care and attention which is seldom lavished upon them. It is only in an atmosphere of enthusiasm that the wasting of muscle and mind, which has such an evil effect on the final result of this potentially crippling injury, can be avoided.

The rehabilitation of a fracture of the shaft of the femur begins as soon as the reduction is adjudged to be satisfactory and the position of the fragments stabilised. Early direct knee flexion exercises are only possible by the use of such methods as fixed extension in a Thomas splint incorporating a knee flexion piece, or following the insertion of a vitallium plate, but there is no method of immobilisation in common use which will not permit the tone and volume of the extensor apparatus and the anterior and posterior groups of tibial muscles to be maintained. Knee flexion returns most rapidly in the limb in which the maximum muscle volume and tone has been preserved. In addition, the normal mobility of the patella, on which the

return of flexion so largely depends, may be retained not only by quadriceps drill but by passive movement in a superior, inferior, lateral and medial direction, practised by the patient himself at hourly intervals throughout the day.

III. FRACTURES OF NECK OF FEMUR AND ARTHRODESIS OF HIP JOINT

In fractures of the neck of the femur no difficulty arises in those cases which are suitable for the insertion of a Smith Peterson nail, but in the extracapsular fracture which requires traction to maintain reduction, and in those intracapsular fractures in which a M'Murray osteotomy is indicated, the return of flexion presents the same problems as in the fracture of the shaft, with the added difficulty that the patients are elderly and frequently suffer from degenerative or traumatic arthritic change.

The results of arthrodesis of the hip joint are most satisfactory in the large majority of cases and the residual disability surprisingly small—much smaller than in arthrodesis of the knee. Arthrodesis of the hip is, however, notoriously difficult to accomplish and the time involved is frequently protracted. It is most important that the future function of the limb as a whole should be considered during this long period of immobilisation, for although the disability resulting from arthrodesis of the hip may be small, the plight of a patient with the combination of a stiff hip and a stiff knee on the same side is unenviable.

In elderly patients, with fractures of the neck of the femur which require prolonged immobilisation in a plaster spica, and in arthrodesis of the hip joint, the return of knee joint function may be accelerated :

- (1) By maintaining the mobility of the patella by regular quadriceps exercise within the confines of the plaster case.
- (2) By bivalving and making detachable the posterior half of the plaster case from the toes to a point six inches above the knee at about the tenth week. During the remaining period of immobilisation the patient is turned on to his face several times per day and the posterior shell removed for flexion exercises (Fig. 340).

TREATMENT OF TEMPORARY STIFFNESS

Temporary stiffness of a joint follows any period of enforced rest of a duration greater than a few days. Such stiffness follows the trauma and immobilisation imposed by meniscectomy ; it is of no significance, recovering within hours or days of initiating active flexion. In the more serious injuries of the knee joint or femur the period of immobilisation is of necessity prolonged and the temporary stiffness liable to be protracted. It has been indicated in this and the preceding chapters that the most important remedy at our disposal is anticipation of disability by prevention, not only by thinking of treatment in terms of knee joint movement, but by maintaining

neuro-muscular co-ordination and muscle tone throughout the period of enforced rest.

When immobilisation has been completed, recovery of movement is produced by regular active exercise performed conscientiously for five minutes every hour throughout the waking day. The only other physiotherapeutic measure which is permitted is radiant heat for ten to twenty minutes once or twice daily provided it is clearly understood by the patient, and by the supervising physiotherapist also, that radiant heat has no curative value without subsequent exercise.

It is especially important to realise that in the early stages of recovery no treatment is productive of more damage than vigorous passive exercises in the hands of an over-enthusiastic masseuse or early manipulation of the

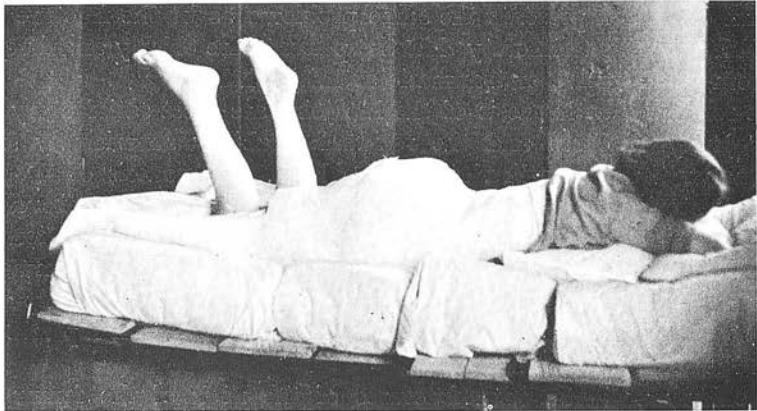


FIG. 340

Bilateral subtrochanteric osteotomy. At about the tenth week the plaster is bivalved in the distal half and the patient turned on to her face several times daily for knee flexion exercises.

joint under anaesthesia. It is better to forbid any "laying on of hands" than risk the permanent disability which may follow "pump handling" of the joint. The knee, like the elbow joint, registers protest to such treatment by progressive increase of stiffness.

Passive stretching may also be employed unwittingly in a pulley-weight system unless the stop is adjusted so that the position of relaxation falls just short of the range of active flexion which has been acquired. Passive movement produced by gravity or momentum in such exercises as "leg swinging" while sitting on a table, or "cycling" lying on the gymnasium floor, is of less importance because the movements are within the patient's control and any excessive ardour which might damage the joint is damped by the production of pain.

TREATMENT OF PERSISTENT STIFFNESS

MANIPULATION

Manipulation under anaesthesia is the most satisfactory method available for the treatment of established loss of range of flexion in the knee joint

due to capsular and extracapsular adhesions resulting directly or indirectly from trauma. The procedure is only indicated when the range of movement in the joint is no longer increasing by the patient's own active exercise.

The success of manipulation depends entirely upon the meticulous care with which the patients are selected. So much harm may follow manipulation of the unsuitable case, or the suitable case at the wrong time, that it is proposed to enumerate the contra-indications rather than the indications.

Manipulation is contra-indicated :

(1) **In the presence of any active pathological process.**

(2) **In the early stages of recovery.** The procedure should not be contemplated until the maximum range of movement has been obtained by regular active exercise, that is to say, until improvement, accurately measured by anglemeter, has been stationary for a period of at least six weeks.

(3) **In a "hot joint."** Swelling and increase of local temperature in the periarticular tissues indicate the presence of a reactionary exudate which will be further increased by the trauma of manipulation.

(4) **In the presence of decalcification of the tibial and femoral condyles or patella.** If manipulation is performed in the presence of osteoporosis, not only is additional risk of injury to the patella incurred, but crush fractures of the tibial condyles may take place as a result of the weakness of the trabeculae supporting the articular cartilage. In the presence of any marked degree of decalcification manipulation should be deferred until weight-bearing and non-weight-bearing activity produces radiographic evidence of increase in the calcium content of the bone.

(5) **In the presence of unsound union in a fracture of the shaft of the femur.**

It is usually possible to assess what success is likely to follow manipulation from the clinical examination of the joint. If the patella is reasonably mobile in all directions and there is no obvious dense fibrosis in the quadriceps or in the suprapatellar pouch and the block at the limit of the range of passive flexion is elastic, the prospects of success are good. If, on the other hand, the patella is tightly bound down by adhesions in the lateral expansions and in the suprapatellar pouch, and palpation of the pouch reveals deep fibrosis, the block at the limit of flexion is usually solid. In these circumstances the prospects of obtaining any increase of flexion without the use of force of a degree likely to cause rupture of the extensor apparatus are poor, and plans should be made for open division of the adhesions before forcible manipulation is attempted.

TECHNIQUE OF MANIPULATION

THE AUTHOR'S METHOD

The patient lies in the supine position on a firm table or plinth. A general anaesthetic is administered until complete muscular relaxation is obtained.

To manipulate the right knee the surgeon grasps the patient's thigh immediately above the patella with his left hand. This action protects the femur and guards the patella against possible fracture. The right arm is passed under the patient's leg so that the back of the wrist rests against the posterior aspect of the upper end of the tibia while he grips his own left wrist with his right hand. The medial aspect of the surgeon's right upper arm is now in contact with the front of the patient's tibia, permitting powerful

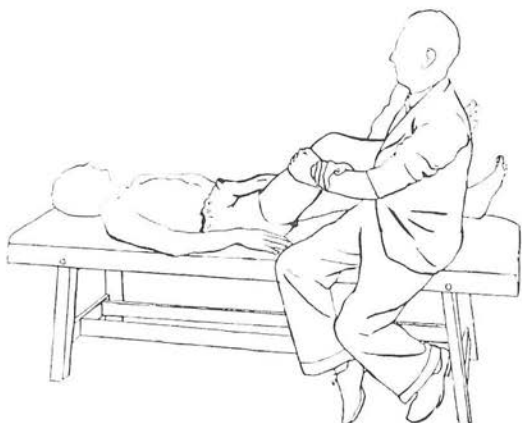

FIG. 341

The author's method of manipulating the knee joint.

but guarded pressure to be exerted by adduction of the shoulder (Fig. 341). The only help which should be sought from an assistant is fixation of the patient's pelvis to the table by backward pressure on the iliac crests. He should not hold the limb or take any active part in the manipulation, as it is impossible for the surgeon to assess what power his assistant is exerting. If the application of pressure at the limit of flexion causes the adhesions in the lateral ex-

pansions to break with an audible snap the operator may proceed carefully to full flexion, but if pressure only produces the gradual tearing of diffuse fibrosis great care should be observed lest the reaction produced aggravates rather than relieves the stiffness. In these circumstances it is preferable to carry out several gentle manipulations at intervals of one to two months than to produce a violent periarticular reaction which precludes the possibility of active exercise and discourages the patient from the full co-operation which is the essential of success.

FRACTURE OF PATELLA DURING MANIPULATION

This accident should not occur with careful selection of cases and the exertion of caution in the execution of the procedure. If it does occur, Watson-Jones has recommended that the manipulation be completed and followed by immediate excision of the patella and repair of the extensor apparatus.¹

Exercise of the joint may be resumed on the following day.

AFTER-TREATMENT

Manipulation is but an incident in the treatment of persistent stiffness and is of little value unless the range of movement obtained is maintained by

¹ R. Watson-Jones: "Fractures and Joint Injuries," E. and S. Livingstone, Edinburgh, 1943, 677.

active exercises instituted at the earliest possible moment. It is for this reason that the selection of cases is important. Manipulation of the knee joint of a patient who is disinterested in his own recovery or who lacks the moral and physical courage to persevere with exercises in spite of discomfort or actual pain is a waste of effort and will only lead to disappointment.

If flexion has been limited by localised fibrous bands which have been snapped by manipulation, no gross reaction need be anticipated and active movement of the joint should begin as soon as the patient has fully recovered from the anaesthetic ; but if the range of movement has only been increased with difficulty and by the tearing of more generalised adhesions, it is sometimes advisable to apply a plaster front-shell with the knee in a position of flexion just short of the maximum range obtained. The joint should then be rested for three or four days to allow the reaction partially to subside, and the initial active movements preceded by ten to twenty minutes of radiant heat. In such cases the total increase in the range of movement at the end of several weeks usually falls short of that obtained at manipulation, so that it is necessary to repeat the process of manipulation followed by further active exercise when the accurate weekly measurements of flexion indicate that improvement is again stationary.

OPERATION

When the patella is bound down to the femoral condyles by fibrous tissue in the lateral expansions and suprapatellar pouch of a density which excludes manipulation, increase in the range of flexion is only possible if the adhesions limiting movement are first divided by open operation.

It is necessary to stress once again that the recovery of a useful range of motion in such circumstances is a long and painful process and treatment should only be considered in patients who are fully aware that the operation is merely the prelude to a regime which requires both patience and determination. The physical contra-indications to operation are similar to those described under " Manipulation."

AUTHOR'S METHOD

A high tourniquet is applied and the limb draped in a manner which will permit manipulation on the operating table without danger to aseptic technique. The knee is then flexed to the limit of passive movement, the strength of the adhesions tested and the presence of fibrous bands sought by palpation. When the gloves have been changed two incisions, about one and a half inches long, are made on either side of the superior pole of the patella. The capsule is divided a quarter of an inch from the bone and the gloved forefinger passed through each incision in turn and the fibrous bands running down to the femur and head of the tibia localised and broken or divided by scissors. Intra-articular palpation is not a recognised orthopaedic custom, but is safe provided the operator realises what he is doing and observes scrupulous asepsis. A further attempt is now made to flex the joint, when it will usually be found that the adhesions in the suprapatellar pouch

are preventing any considerable increase in the range of flexion from being obtained. These adhesions are broken down by inserting the forefinger into the pouch, or, if the fibrous tissue is too dense, by means of scissors. When all the restricting fibrous tissue has been severed it is usually possible to flex the joint through ninety degrees or more, the manipulation



FIG. 342

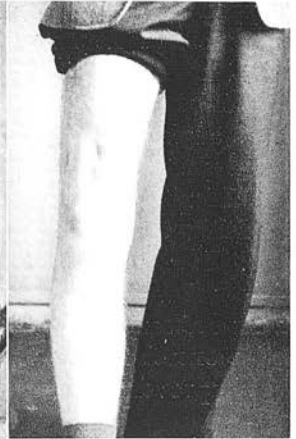


FIG. 343

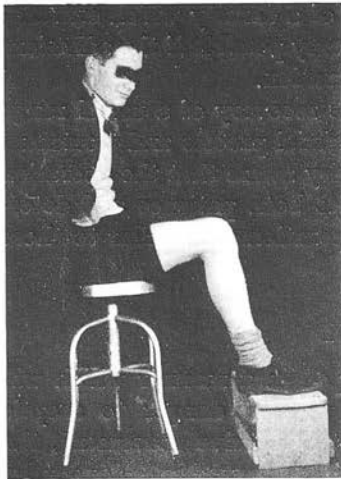

FIG. 344

Figs. 342, 343, and 344. — Range of movement in the knee joint (Fig. 342) following fracture of femur subjected to an initial operation through an anterior mid-line incision (Fig. 343) and subsequently to bone grafting by the lateral approach. Range of movement, following operation on the knee joint by Mr Walter Mercer, using the author's technique (Fig. 344).

being accompanied by the breaking of further minor adhesions in the capsule.

The incisions are then closed and a compression bandage applied with the limb in a position of flexion just short of the maximum range obtained. A thick plaster slab is applied to the flexor surface of the compression bandage to splint the joint in the required position. The tourniquet is then removed.

AFTER-TREATMENT

The after-treatment is conducted on similar lines to those suggested under Manipulation, but in addition it may be advisable to apply a splint, in the form of a skin-tight anterior shell which can be removed for exercises, in order to counteract the tendency to relapse. This splint is constructed when the extra-articular reaction has subsided and the danger of haemarthrosis past, making the use of a compression bandage unnecessary.

The increase in the range of movement obtained by this method varies widely between ten and ninety degrees, depending upon the nature of the local pathology and the fortitude and determination of the patient (Figs. 342, 343, and 344). When progress becomes stationary, after an encouraging improvement in flexion of, say, thirty to forty degrees has been achieved, the whole process may be repeated if necessary with the assurance that a further gain will be effected.

**USE OF CELLOPHANE AS A MECHANICAL BARRIER TO
THE FORMATION OF FURTHER ADHESIONS IN THE
SUPRAPATELLAR POUCH**

It is clear that the painful and protracted process which follows operation could be modified and curtailed by the interposition of some substance between the walls of the suprapatellar pouch and between the lateral expansions and the femoral condyles which would prevent the inevitable formation of further adhesions. The application of this conception is not new. The author had the opportunity of seeing this principle employed when he assisted Mr Walter Mercer, who used cellophane to prevent the formation of adhesions between the pleura and the parietes during the interval between the stages of thoracoplasty. The possibilities in the utilisation of such a substance within a joint appeared most attractive at that time, but the risk of sepsis or other undesirable effect which might be produced by the introduction of a large foreign body into the knee joint seemed to outweigh the obvious advantages. M'Keever¹ has since described the use of cellophane in the suprapatellar pouch to limit adhesions following synovectomy. Stiffness of the knee joint following a fracture of the shaft of the femur is unfortunately more common than pathological conditions of the joint necessitating synovectomy, and thus if the encouraging results can be confirmed by further experience, the use of cellophane as an interposition membrane will prove to have a greater sphere of usefulness in treating established adhesions than in the condition in which it was originally used.

M'Keever has used cellophane, sterilised in an autoclave, and cut in a pattern to fit the suprapatellar pouch and extend medially and laterally on either side of the femoral condyles; he does not consider that any form of fixation is necessary (Figs. 345, 346, 347). The introduction of a piece of cellophane of this shape into the pouch and under the lateral expansions

¹ Duncan C. M'Keever. "The Use of Cellophane as an Interposition Membrane in Synovectomy." *J. Bone and Joint Surg.*, 1943, xxx, 576-580.

can be accomplished without difficulty using the two small non-destructive incisions described above, and, in contradistinction to the single large parapatellar incision, permits immediate muscular activity and early weight-bearing.

M'Keever considers that the function of the membrane in causing modification in the formation of scar tissue is achieved within a few days, and that it might then be removed, but so far he sees no reason why it should not be left *in situ*.

LOSS OF FLEXION DUE TO ADHESION OF QUADRICEPS TO FEMUR

Although it is hardly possible that a normal quadriceps could control extension in the presence of marked changes in the synovial cavity and capsular tissues producing gross limitation of flexion, it has been assumed

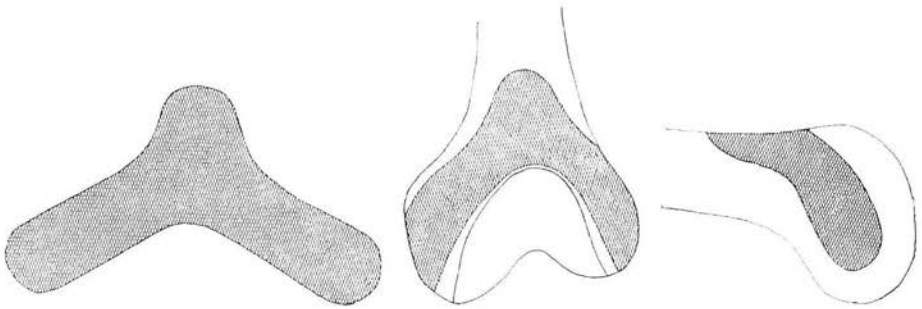


FIG. 345

FIG. 346

FIG. 347

Shape, relative size, and position of the piece of cellophane. (After M'Keever.)

both in the pathology and treatment of the condition already described that no major lesion existed in the quadriceps. In certain simple fractures within the distal third of the femur, in compound fractures, and especially in the grave soft tissue injuries produced by missiles, not only may pathological changes exist within the joint but the quadriceps may be partially destroyed and replaced by fibrous tissue so that subsequently the remaining muscle becomes adherent to the femur by dense scar tissue. The limitation of movement which follows cannot be overcome either by manipulation or intra-articular operations.

The only reparative measure which has undergone an extensive trial and met with any degree of success is that of Bennett¹ who aimed at a return of flexion by lengthening the quadriceps tendon. It is generally accepted, however, that the increase of motion which followed was seldom sufficient to make the operation worth while. Recently T. C. Thompson² has described a procedure, based on Bennett's operation, which preserves

¹ G. E. Bennett. "Lengthening of the Quadriceps Tendon." *J. Bone and Joint Surg.*, 1922, iv, 279.

² T. C. Thompson. "Quadricepsplasty to Improve Knee Function." *J. Bone and Joint Surg.*, 1944, xxvi, 366-379.

intact the rectus femoris component of the extensor apparatus and eliminates the deeper components which are adherent to the femur or replaced by scar tissue. He points out that the rectus differs from the other muscular constituents of the apparatus in its greater length, superficial position, and nerve and blood supply which enter in the upper third of the thigh. He considers that the degree of success to be expected from his method depends entirely upon whether or not the rectus femoris has escaped injury, how well it can be isolated from the scarred non-extensible portions of the quadriceps mechanism, and how well it can be developed by intensive exercises and normal use.

TECHNIQUE OF OPERATION

An anterior incision is made which extends from the junction of the upper and middle thirds of the thigh to the lower border of the patella. The fascia

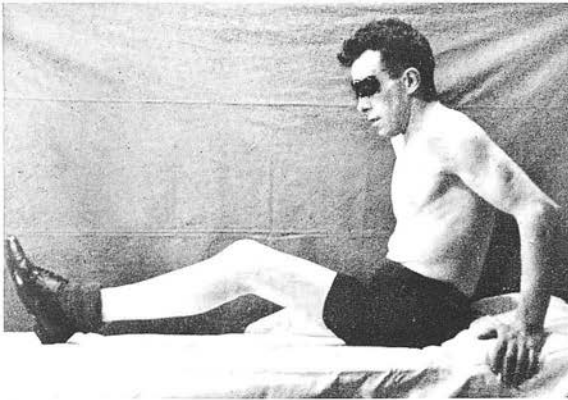

FIG. 348

The range of flexion after twelve months in the fracture illustrated in Figs. 256 and 257 (Fig. 348). The range of flexion eight weeks after Thompson's operation and the interposition of cellophane between the rectus femoris and the lower third of the femur (Fig. 349).

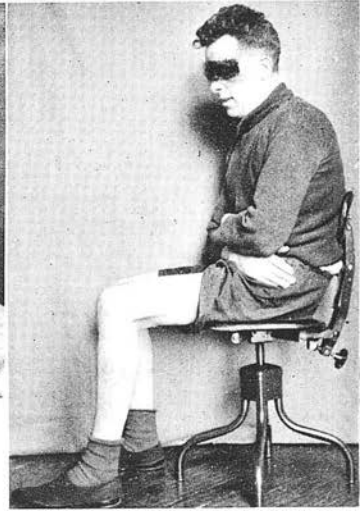

FIG. 349

is divided on each side of the rectus, from the junction of the upper and middle thirds downwards, and the dissection carried deeply on either side so that both the vastus medialis and vastus lateralis are completely freed. Both medial and lateral intermuscular incisions are extended distally into the capsule so that the contracted expansions are divided.

The vastus intermedius will usually be found to be infiltrated with fibrous tissue which is binding both the rectus femoris and patella to the surface of the femur; it is excised completely leaving a fibrous and periosteal covering over the front of the bone.

As the rectus has been entirely freed from scar tissue and is capable of stretching, especially in the upper normal portion, the knee can be manipulated with safety and the remaining adhesions broken down.

To complete the operation the vastus medialis and vastus lateralis are sutured back to the sides of the rectus down to the junction of the lower and

middle thirds of the thigh ; if one or both components are badly scarred, suture is omitted. No attempt is made to close the capsule of the joint.

In cases where the fibrosis has been widespread there is a possibility that the final result may be prejudiced by the formation of further adhesions. This obvious source of failure can be eliminated to a very considerable degree by the interposition of a piece of cellophane between the rectus and the femur, carrying the lateral limits of the membrane round on either side of the rectus femoris so that they lie between that component and the vastus medialis and lateralis (Figs. 348 and 349).

The skin incision is closed and a compression bandage applied.

AFTER-TREATMENT

Active assisted flexion and extension exercises within the confines of the compression bandage are commenced immediately. When the danger of hæmatoma is passed a loose dressing is applied and the limb placed in a Thomas splint with knee-flexion piece or a Braun-type splint ; auto assisted exercises are then instituted in a balanced suspension system. The date of return to weight-bearing depends on progress in both muscle power and range of movement, but should be possible within six weeks.

This operation should result in the recovery of right-angled flexion in a good proportion of cases. It should be appreciated, however, that active extension through the final ten degrees must, in most cases, be sacrificed in the interests of flexion ; its return is hardly to be expected in the absence of the vastus medialis.

LOSS OF EXTENSION

Incomplete extension is a common cause of failure to progress after a meniscectomy or other knee joint injury, or following a fracture of the femur requiring treatment which produces secondary effects on the joint. Loss of full extension entails not only inability to develop the vastus medialis, with consequent loss of security and stability, but an abnormal gait which produces minor traumata and recurring effusions. Conscientious quadriceps drill, in the absence of full extension, develops the rectus femoris, vastus intermedialis and vastus lateralis at the expense of the vastus medialis. If these muscles are unwittingly trained to compensate for the loss of the vastus medialis it may be found that even after full extension has been secured redevelopment of the vastus medialis is impossible and perfect extensor function may prove unattainable.

Incomplete extension in relation to the common injuries may be due to :

(1) **Failure to recognise and reduce a locked joint.** This is the commonest source of a persistent slight flexion deformity. Patients are frequently encountered who have walked about on a slightly flexed knee for many months, either as a result of failure to recognise the cause of the internal derangement, or, in the event of the cause of the locking being

appreciated, to reduce the displaced meniscus before sending the patient home to await admission to hospital for operation. This practice is to be deprecated because the eventual excision of the torn meniscus cannot relax the contracted capsule nor break the habit of walking with a flexed knee gait.

(2) **Injury to the peripheral attachment of the meniscus resulting in a haematoma between capsule and meniscus in either the anterior or the posterior thirds.** This condition causes painful limitation of extension, which may be mistaken for locking due to a longitudinal tear of the medial meniscus.

(3) **Injury to the posterior capsule at operation.**

(4) **Permitting the patient to lie with the knee flexed over a pillow after a meniscus operation and failing to institute straight leg raising and quadriceps drill.**

(5) **Persistent tense effusion.** The capacity of the joint cavity is greatest in slight flexion. An effusion of any magnitude limits the range of both flexion and extension.

(6) **Failure to recognise and treat haemarthrosis.**

Incomplete extension in relation to the treatment of fractures of the femur or tibia is usually due to prolonged immobilisation in splints or plaster in the flexed position. Immobilisation in plaster with the knee at right-angled or more flexion is sometimes used as a method of treatment in displacement of the lower femoral epiphysis and in the supracondylar fracture. If the period of fixation in this position is prolonged in the adult injury, difficulty in securing complete extension is frequently encountered. It is usually unnecessary to maintain this acute flexion for longer than three to four weeks when the plaster should be changed and reapplied in a position of more moderate angulation. When a flexed knee splint such as the Thomas with knee-flexion piece or the Braun is used for supracondylar or lower third fractures of the femur, extension exercises should be instituted as soon as the degree of union will permit.

Some surgeons treat fractures of the shaft of the tibia in plaster with the knee in about forty-five degrees of flexion, maintaining that this is the most certain method of securing absolute immobilisation of the upper tibial fragment. This degree of flexion is both unnecessary and undesirable. Thigh length plasters should fix the knee joint well within the range of the vastus medialis.¹

TREATMENT

It is evident that in the majority of cases the deformity can be anticipated and prevented by accurate diagnosis and careful pre-operative and post-operative treatment. If the condition is already present the method of treatment to be adopted depends upon the nature of the underlying

¹ E. A. Nicoll. "Principles of Exercise Therapy." *Brit. Med. Jour.*, 1943, i, 747.

pathology and on the length of time the flexion deformity has been established :

(1) The most important measure, both for prevention and treatment, is regular quadriceps drill.

(2) If the flexion is noted in the early stages of the post-operative treatment of a meniscectomy it may be corrected by the simple measure of placing a sandbag on the extensor aspect of the joint.

(3) If the deformity is more firmly established it may be necessary to apply some simple form of skin traction to the limb in order to secure reduction.

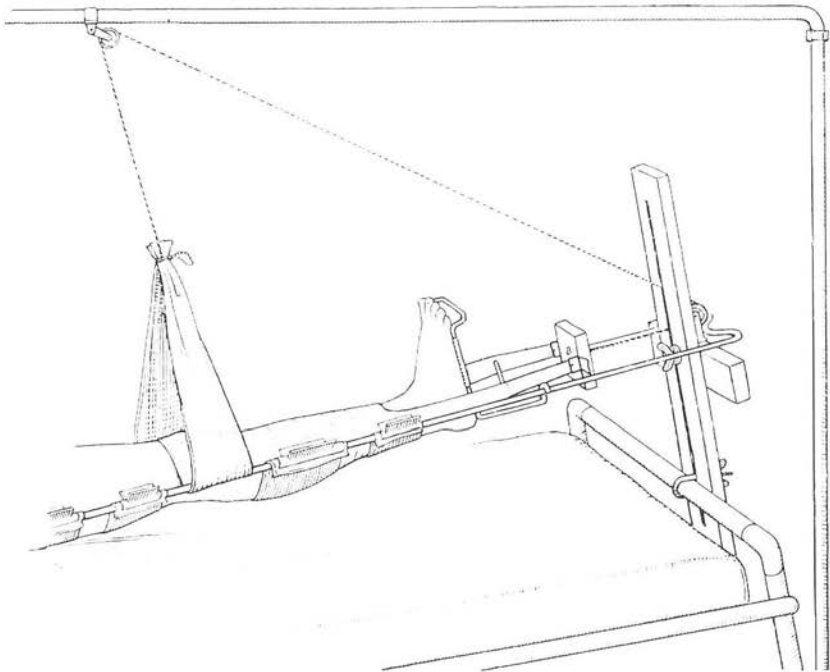


FIG. 350

The author's method of obtaining the last few degrees of extension in resistant cases.

(4) If the condition is of several months' duration and considered to be due to fibrous contracture of the posterior capsule, manipulation of the joint under anaesthesia may produce the desired result provided the contra-indications enumerated on page 304, and which apply to all manipulations, are observed. The tendency to recurrence is overcome by the application of a few pounds of extension in addition to a skin-tight posterior shell which is maintained until the vastus medialis can be re-educated and developed.

(5) If the deformity is resistant to the simpler methods of treatment, or exists in the presence of certain contra-indications to manipulation, the method designed by the author to secure the last fifteen degrees of extension, which are unattainable by the turnbuckle-plaster method of correcting

flexion-contracture of the knee in rheumatoid arthritis, proves equally effective in slight flexion-contracture due to other causes. The method has been concisely if inaccurately termed "auto-reduction" (Fig. 350).

Strapping extension is applied below the knee joint and the limb is placed in a Thomas splint which is fixed to the foot of the bed by means of the Thomas splint rest of the author's design.¹ Extension cord is attached to the strapping and carried by means of a spreader through the under aspect of the pulley on the horizontal support of the splint rest. Two strips of four-inch orthopaedic strapping are stuck together, opposing the adherent surfaces, to form a single strip of double thickness. This strip is passed in front of the patella and under the lateral bars of the Thomas splint so that the two ends finally meet again in front of the knee and are attached to the original extension cord which has been passed through an overhanging pulley attached to a Balkan beam. The bed is then raised on blocks so that the traction of the patient's body weight towards the head of the bed produces traction while counter traction exerts pressure on the flexed joint. The rapidity of reduction, within the limits of the patient's endurance, is controlled by the height to which the foot of the bed is raised. Quadriceps exercises are practised throughout the treatment and the limb released from the apparatus for radiant heat and knee flexing exercises once or twice a day.

(6) In certain cases which fail to respond to any form of conservative treatment, posterior capsulotomy may be indicated.

¹ T. S. Smillie. "Simple System of Splinting for Lower Limb," *Lancet*, 1941, ii, 304.

I N D E X

INDEX

A	
Air arthrography	76
of gastrocnemio-semimembranosus bursa (Fig. 326)	282
Amputation in gunshot wounds	268, 276
Anaesthesia of skin— complication of meniscus operation	104
Anatomy— comparative, ape	1
anthropoid	1
chimpanzee	20
dog	9
platypus	2
primates	20
rabbit	9
surgical, anterior cruciate ligament	106
lateral collateral ligament	23, 161
lateral meniscus	23
medial collateral ligament	21
medial meniscus	19, 23
posterior cruciate ligament	135
Ankylosis— in gunshot wounds	268, 276
Arteries— inferior lateral geniculate	98
popliteal, in separation of lower femoral epiphysis	237
in supracondylar fracture of femur	230
Arthritis— osteo- relation to meniscus injuries	84
suppurative, in gunshot wounds	268, 274, 276
Arthrodesis— after-treatment	224
in old fractures tibial table	220
technique of operation	224
Arthrography, contrast	76
Aspiration— in fractures of tibial table	212
in recent injuries anterior cruciate ligament	111
in traumatic synovitis	12
in wounds of joint	267, 275
technique of	13
Avascular necrosis— in relation to osteochondritis dissecans	242
B	
Baker's cyst, <i>see</i> bursae	
Bandage, compression	96
"Beat knee" infective prepatellar bursa, <i>see</i> bursae	
Bilirubin— in traumatic synovitis	11
Blair's operation	133, 161
Brittain's arthrodesis	224
Bucket-handle tear—longitudinal tear, <i>see</i> meniscus	
Bursae—	
deep infrapatellar	281
gastrocnemio-semimembranosus bursa popliteal cyst—Baker's cyst semimembranosus bursa	281
clinical features	283
etiology	284
pathology	284
technique of operation for	286
treatment	286
prepatellar	279
bursitis, acute	279
chronic	279
treatment	280
infective	280
treatment	280
subcutaneous tibial	279
traumatic affections of	279
C	
Calcification— of menisci	46
Capsulotomy, posterior	311
Cartilage— articular, passive defence of	263
external semilunar, <i>see</i> meniscus, lateral	
internal semilunar, <i>see</i> meniscus, medial	
Cellophane— use in operation for persistent stiffness	305
use in preventing adhesion of quadri- iceps to femur	308
Coal-mining relation to injuries of menisci	27, 28, 62
relation to supracondylar fracture of femur	229, 230
Congenital discoid meniscus clinical features	74
etiology	43
on medial side	44
pathological anatomy	44
relation to cystic degeneration	42, 44
Cysts— of menisci, clinical features	70
differential diagnosis	71
etiology	39
relation to injury	39
of lateral meniscus, operative technique	95
pathology	39
of medial meniscus, pathology	43
D	
Dislocation	107, 164, 167
after-treatment	166
etiology	164
injury to ligaments in	164
prognosis	108, 167
surgical pathology	164
treatment	166

- "Drawer sign"
 in rupture anterior cruciate ligament 110
 in rupture posterior cruciate ligament 136
 Drill aligner 131
- E
- Excision
 patella, *see* fractures
- Exposures, operative
 arthrodesis 224
 both condyles of tibia 228
 lateral meniscus 90
 posterior segment 95
 medial meniscus 89
 posterior segment 94
 medial parapatellar 255
 after-treatment 257
 complications 291
 posterior compartment of knee joint 257
 posterior 258
 postero-lateral 258
 postero-medial 258
 recurrent dislocation of patella 203
- Extension
 loss of 308
 causes, 308
 treatment, 309
- F
- Fascia lata— iliotibial tract
- Fat
 in synovial effusion,
 in fracture tibial spine 111
 in fracture tibial table 111
 in traumatic synovitis 12
- Fat pads
 anterior suprapatellar 8
 infrapatellar 8
 injuries 287
 treatment, 288
 popliteal, 8
 posterior suprapatellar 8
- Fibrillation of patella 197
- Flexion, loss of 290 308
 due to adhesion of quadriceps to femur 306
 treatment,
 after-treatment 308
 technique of operation 307
 prevention 291
 in arthrodesis of hip, 289
 in fracture neck of femur 289
 in fracture shaft of femur 291
 in injuries of joint 291
 treatment 289
 persistent stiffness 300
 manipulation 300
 after-treatment 302
 operation 303
 after-treatment, 305
 author's method 303
 use of cellophane in 305
 temporary stiffness 289
- Football, relation to injuries of menisci 27
- Foreign bodies 260
 treatment 261
- Fractures
 femur,
 condylar and supracondylar 229 240
- Fractures (*contd.*)
 femur (*contd.*)
 intercondylar, 237
 treatment 237
 separation of lower epiphysis 236
 treatment 237
 technique of reduction, 237
 shaft,
 factors concerned in loss of flexion 291
 treatment 295
 distal third 295
 middle third 296
 upper third 297
 single condyle 238
 treatment 238
 supracondylar 229
 after-treatment 233
 treatment 230
- tibula,
 styloid process 162
 patella 172
 articular surface 196
 clinical features 197
 treatment 197
 during manipulation 302
 indications for treatment 178
 marginal 192
 old,
 clinical features, 195
 treatment 195
 recent,
 treatment 193
 rationale of treatment 173
 stellate 192
 treatment 192
 transverse 172
 clinical features 172
 treatment 178
 conservative 180
 indications for excision smaller
 fragment 181
 indications for total excision 184
 technique of excision 186
 Thomson's operation 182
- tibia,
 both tuberosities, 218
 treatment 219
 lateral condyle,
 avulsion fracture 163
 clinical features 163
 treatment 163
 lateral tuberosity 207
 clinical features 210
 fracture by abduction 210
 treatment 215
 manipulative reduction 218
 operative reduction 218
 fracture by compression 207
 after-treatment, 215
 technique of reduction, 213
 treatment 210
 medial tuberosity 219
 spine 107, 116
 after-treatment 118
 clinical features 116
 technique of treatment,
 conservative 117
 operative 118

Fractures (*contd.*)
 tibia (*contd.*),
 table 207, 229
 old fractures 219
 treatment 220
 arthrodesis 220
 tubercle 187
 separation of epiphysis 188
 complete 188
 treatment 189
 partial 189
 clinical features 190
 treatment 190
 treatment 187
 upper epiphysis,
 old injuries 227

G.
 Genu recurvatum 227, 235
 valgum,
 due to fractures or old injuries
 upper tibial epiphysis 227
 recurrent dislocation of patella in 201
 tendency to meniscus injuries in 26
 varum 227
 " Giving-way "
 in meniscus injuries 60
 in osteoarthritis 84
 in rupture anterior cruciate ligament 122

H
 Haemarthrosis, traumatic 15, 98
 aspiration in 17, 99
 cause of incomplete extension 309
 clinical features 16
 coagulation in 15, 99
 complication of meniscus operation 98
 quadriceps exercises in 2
 in rupture of cruciate ligaments 16, 110
 treatment 17, 99
 Haemosiderin, in traumatic synovitis 11
 Healing, of torn meniscus 48
 Heterotopic bone —
 in lateral collateral ligament (Fig. 160) 161
 in ligaments of elbow joint 143
 in ligamentum patellae 248
 in medial collateral ligament 143
 in medial collateral ligament of ankle
 joint 143
 Histocytes, in traumatic haemarthrosis 16
 Hypertrophy, in meniscus lesions 35

I
 Icteric index, in traumatic synovitis 41
 Iliotibial tract—
 avulsion from lateral condyle of tibia 163
 clinical features 163
 treatment 163
 Incisions, *see* exposures, operative.
 Incomplete oblique tear parrot-beak
 tear, *see* meniscus.
 Incomplete transverse tear parrot-beak
 tear, *see* meniscus.
 Instruments, special—
 adjustable twin-bladed saw 224
 cranked osteotomes 224
 drill aligner 131
 meniscus knives 86, 89
 retractors 88

J
 Joints, development of 9
 Jones' Bandage—compression bandage 96

K
 Knee cage 125, 134, 158
 Knives, author's meniscus 86
 mode of use, 89

L
 Leucocytes, polymorphonuclear —
 in traumatic synovitis 11
 Ligaments —

 anterior cruciate,
 attenuation 108
 classification of injuries, 107
 injury in fracture tibial table 210
 mechanism of injury 107
 old injuries 119-135
 clinical features 122
 relation to injuries of menisci 68, 75, 121
 treatment,
 after-treatment,
 author's operation 131
 Blair's operation, 134
 conservative 125
 extra-articular operation 133
 indications for 125, 126
 intra-articular operation,
 author's 127
 operative 125
 results of operation, author's 132
 technique of operations 127, 135
 overstretching 108
 recent injuries,
 after-treatment 114, 116
 clinical features 108
 diagnosis 108
 technique of treatment,
 conservative 113
 operative 115
 treatment 111
 surgical anatomy 106
 test for continuity 110
 injuries of 106, 167
 lateral collateral,
 injuries 161
 ligamentous - peroneal nerve
 syndrome 161
 prognosis 162
 treatment 162
 relation to lateral meniscus 23
 medial collateral,
 in fracture tibial table 210
 in genu valgum 26
 injuries of 140, 161
 in relation to bursa 281
 mechanism of injury 141
 old injuries 156
 treatment 156
 Blair's operation 161
 conservative 156
 knee cage in 159
 Mauck's operation 158
 M'Murray's operation 159
 operative 158
 quadriceps exercises in 158

- Ligaments (*contd.*)
- medial collateral (*contd.*)
 - recent injuries,
 - clinical features 141
 - complete rupture 152
 - diagnosis 152
 - treatment 153
 - conservative 153
 - operative 153
 - after-treatment 156
 - post-traumatic para-articular ossification (Pellegrini Stueda's disease) 143
 - treatment 142
 - relation to medial meniscus 20, 28, 89, 92, 93
 - tibial attachment of, 21
 - patellar,
 - avulsion from patella 186
 - clinical features 187
 - treatment 187
 - posterior cruciate,
 - old injuries 139
 - treatment,
 - author's method of repair, 139
 - after-treatment 140
 - recent injuries,
 - clinical features 136
 - treatment 136
 - operative technique 138
 - relation to osteochondritis dissecans 242, 245
 - surgical anatomy 135
 - surgical pathology 136
 - test for continuity 136
 - Locking
 - in meniscus injuries 58, 81
 - reduction 79
 - in osteochondritis dissecans 251
 - Loose bodies 241, 258
 - derived from articular cartilage and bone 241
 - derived from meniscus, 241
 - in anterior compartment 254
 - in lateral compartments 255
 - in posterior compartment 257
 - in suprapatellar pouch 255
 - Lymphocytes—
 - in traumatic synovitis 41
- M
- Macrophages
 - in traumatic haemarthrosis 16
 - Manipulation
 - in meniscus injuries 79
 - of knee 300
 - author's method, 301
 - contra-indications 301
 - Martin's meniscus forceps 89
 - Mauck's operation 159
 - M'Murray
 - operations,
 - medial collateral ligament 159
 - osteotomy of femur, 299
 - sign 64
 - Mechanism of injuries—
 - anterior cruciate ligament, 107
 - avulsion of patellar ligament 186
 - avulsion of quadriceps, 170
 - fracture tibial spine 116

Mechanism of injuries (*contd.*)

 - fractures tibial table 207
 - longitudinal tears lateral meniscus 29
 - longitudinal tears medial meniscus 28
 - medial collateral ligament, 141
 - posterior cruciate ligament 136
 - rectus femoris 168
 - supracondylar fracture of femur 229
 - transverse tears lateral meniscus 29, 39
 - transverse tears medial meniscus 29
 - vastus intermedius, 169
 - vastus medialis, 169

Meniscus

 - author's statistics 55
 - factors influencing vulnerability 24
 - function 24
 - internal derangements relative to
 - after-treatment 80, 96
 - clinical features 57
 - congenital discs 74
 - cystic degeneration 70
 - errors of diagnosis 77
 - giving-way, 60
 - history, 57
 - lesions of both, 68
 - lesions of regenerated structure 75
 - localisation of tenderness 63
 - locking 58
 - presence of a click 64
 - quadriceps wasting 62
 - radiological examination, 76
 - retained posterior segment 75
 - synovial effusion 61
 - treatment 79, 96
 - author's knives 87
 - author's retractors 88
 - complications of operations, 98, 104
 - cystic degeneration 95
 - difficulties at operation 91
 - double injuries 83
 - incisions 89
 - pre-operative 86
 - prognosis 104
 - reduction of locked joint, 79
 - relation to osteoarthritis 84
 - removal of regenerated meniscus 94
 - removal of retained posterior segment 94
 - skin preparation 86
 - technique of operation 89
 - use of tourniquet 86, 91, 96
 - mechanism of injury 27, 39
 - relation to evolution of knee joint 20
 - relation to femoral and tibial condyles 21
 - surgical pathology 31-56
 - blood supply 48
 - calcification 46
 - combinations of longitudinal and transverse tears 38
 - complete longitudinal tear 33
 - complete transverse tear 38, 49
 - congenital discs 44
 - cystic degeneration 39
 - healing of tears 48
 - incomplete transverse or oblique tear 36, 39
 - longitudinal tear posterior segment 32
 - multiple complete longitudinal tears 35
 - multiple longitudinal tears of posterior segment 32

Meniscus (*contd.*)—
 surgical pathology (*contd.*)
 ossification 46
 regeneration following excision 51
 tears of posterior peripheral attachment 35

Meniscus, lateral
 internal derangements relative to,
 clinical features 66
 mechanism longitudinal tears 29
 mechanism transverse tears 29, 39
 mobility of 24
 relation to lateral collateral ligament 23
 surgical anatomy 23

Meniscus, medial—
 mechanism longitudinal tears 28
 mechanism transverse tears 29
 relation to medial collateral ligament 20
 surgical anatomy 19

Mucin—
 in traumatic synovitis 10, 12
 in traumatic haemarthrosis 16

Muscles—
 adductors of thigh,
 in supracondylar fracture of femur 235
 gastrocnemius,
 injury in dislocation 164
 in relation to bursa 281
 gracilis,
 in relation to bursa 281
 quadriceps,
 adhesion to femur 306
 avulsion from patella 170
 after-treatment 172
 clinical features 171
 treatment 171
 exercises 2, 7, 96, 97
 after meniscus operation 96
 before meniscus operation 86
 dosage 4, 96
 in rupture anterior cruciate ligament 114
 in rupture medial collateral ligament 156, 158
 in traumatic synovitis 14
 non-weight bearing 2, 5, 7
 progression in 4, 7, 97
 pulley-weight apparatus 6, 97
 "quadriceps chair" 7
 rhythmical quadriceps drill 6, 86, 96
 rules governing 3
 straight leg raising 5, 86, 102
 weight-bearing 97
 importance of 1, 7
 insufficiency of 2, 102
 involvement in supracondylar fracture of femur 230, 233
 popliteus,
 injury in dislocation 164
 rectus femoris 3
 rupture 168
 clinical features 168
 treatment 169
 reflex inhibition of 1
 sartorius,
 in relation to bursa 28
 semitendinosus,
 in relation to bursa 28

Muscles (*contd.*)—
 quadriceps (*contd.*)
 vastus intermedius 3
 rupture 169
 myositis ossificans traumatica in treatment 170
 vastus lateralis 3
 injury of 170
 vastus medialis 3
 injury in dislocation 164
 rupture 169
 treatment 169
 wasting in flexed knee splint 233
 wasting of,
 in meniscus injuries 62
 in osteochondritis dissecans 251

Myositis ossificans traumatica 170

N

Nerves—
 infrapatellar branch of saphenous 91, 103
 lateral popliteal,
 in rupture lateral collateral ligament 161
 in supracondylar fracture femur 235
 traction injury 162
 medial popliteal,
 in approach to posterior compartment 258

Neuroma—
 complication of meniscus operation 103

O

Ossification—
 of meniscus 46

Osteochondritis dissecans 241
 clinical features 250
 etiology 241
 sequelae of separation of fragment 250
 treatment 252
 conservative 253
 operative 254
 technique 254

Osteomyelitis 268, 274

P

Parrot-beak tear—
 incomplete oblique or transverse tear, *see* meniscus.

Patella—
 congenital bipartite,
 radiological appearances 193
 symptoms arising from 195
 dislocation 199
 acute 199
 treatment 200
 recurrent 201
 clinical features 202
 treatment 202
 transplantation of tibial tubercle 203
 after-treatment 204
 author's modification 204
 after-treatment 205
 injuries, *see* fractures,
 osteochondritis dissecans 196
 traumatic degenerative fibrillation of clinical features 198
 treatment 198

- Patellar plexus—
 neuritis of branch 288
 " Patellar tap"
 in diagnosis of traumatic synovitis 13
 Pellegrini Stüeda's disease post-
 traumatic para-articular ossification
 Penicillin 100, 269, 275, 276, 281
 Physiology, surgical—
 knee joint 22
 Post-traumatic para-articular ossification 143
 clinical features 145
 etiology 144
 passive movements in 144, 147
 radiological findings 146
 treatment 147
 Prognosis—
 meniscus operations 104
- Q
- Quadriceps, *see* muscles.
- R
- Red blood corpuscles
 in traumatic synovitis 11
 Regeneration of meniscus 51, 86
 excision 94
 tears 52, 75
 clinical features 76
 Rehabilitation—
 fractures shaft of femur 298
 meniscectomy 96
 Resection—
 in primary treatment of wounds 268
 Retractors, author's knee joint 88
- S
- "Screw home" movement 22, 23
 Statistics, author's, of meniscus pathology 55
 Sulpha drugs 100, 263, 275, 276
 Suprapatellar pouch
 adhesions in 290, 292, 295, 297, 305
 penetration of, in supracondylar
 fracture of femur 230
 Synovectomy—
 in chondromatosis 255
 use of cellophane in 305
 Synovial effusion—
 in meniscus injuries 61
 in relation to meniscus operation 70, 97, 101, 103
 Synovial fluid—
 active bactericidal properties 263
 anti-coagulant properties 15
 Synovial fluid (*cont'd.*)
 concentration of sulphathiazole in 263
 defensive power 262
 function 10
 origin 10
 secretion 8
 Synovial fringe, *see* synovial membrane.
 Synovial membrane 8
 active bactericidal properties 263
 anti-coagulant properties 15
 defensive power 262
 nipping 2, 84, 287
 reaction to haemarthrosis 15
 reaction to infection 263
 reaction to injury 10
 regeneration 11
 suture of, in wounds 266
 Synovitis—
 chronic, following traumatic effusion 10
 traumatic,
 aspiration in 12
 clinical features 13
 constituents 11
 differential diagnosis in 13
 quadriceps exercises in 14
 treatment 14
- T
- Tibia—
 spine, *see* fractures.
 tubercle, *see* fractures.
 Thomson's operation (patella) 178, 182
 Tourniquet—
 in meniscus operation 86, 91, 96
 Transverse tear, *see* meniscus.
- V
- Van den Bergh reaction, in traumatic
 synovitis 11
- W
- White blood corpuscles, in traumatic
 synovitis 11
 Wounds 262, 278
 contravertical issues in treatment 264
 gunshot,
 articular with fractures 268
 classification 274
 difference between civil and war 264
 immobilisation in 267
 of tissues surrounding joint 276
 secondary suture in 278
 skin grafting in 278