

A REVIEW OF 54 CASES
OF
ATYPICAL PNEUMONIA.

by

Squadron Leader R.F. Dawson. M.B. M.R.C.P.E. R.A.F.V.R.

with an

Appendix

on PHYSIOTHERAPEUTIC TECHNIQUE

by

Corporal J.H. Smith. R.A.F.



Pulmonary infections constitute a large proportion of all cases admitted to R.A.F. Hospitals. Since the non-tuberculous conditions would appear to differ in some respects from similar conditions in civilian practice, it has been felt that a review of the incidence, clinical features and treatment of a group of fifty four cases of atypical pneumonia might be of value.

It has been found that cases of classical pneumococcal lobar pneumonia are relatively infrequent. In contrast, there have been a comparatively large number of cases of atypical pneumonia which have assumed a greater importance than in civilian practice because of the special circumstances associated with wartime and service conditions. These conditions are, first of all, the paramount necessity of excluding tuberculosis in all cases of pulmonary infections, since this condition has been gradually increasing in incidence during the present war. Secondly, in service medicine, one must reduce to a minimum the periods of illness and convalescence, and the constant aim must be to return a man to full duty in the shortest possible time. In addition, whenever possible, he should have no residual condition which will render him more prone to subsequent ill-health.

Before discussing the actual cases, some of the prevailing local conditions should be explained. Patients are mainly drawn from a number of fairly large hutted camps in which epidemiology is an important factor. It has therefore been the policy that all cases of upper respiratory catarrh, especially with associated pyrexia, and all cases of suspected pulmonary infections are admitted to hospital in their earliest stages, and are not treated as ambulant or semi-ambulant cases until they either recover or until more urgent symptoms supervene. With a few exceptions, two main age groups are involved - young adults of about 18 to 23 years and older men of 33 to 40 years; both these classes have usually less than eight months' service, and within that period have been passed as fit for military service by National Service Medical Boards. Nevertheless, wide variations in physical development and fitness are found.

The term atypical pneumonia as used in this paper is not susceptible of an exact definition. It covers a fairly wide range of conditions, ranging from a benign circumscribed pneumonitis, through types of bronchopneumonia of varying severity to a form with a lobar distribution but running a chronic course. Various names have been suggested, such as pneumonitis (Gill (1938)) (Maxwell (1938)), influenzal pneumonia (Scadding (1937)) low grade pneumonia (Nicholas and Agassig (1938)) and virus pneumonia (Longcope (1942)). None of these terms are altogether satisfactory, since they nearly all describe only one of a number of closely related conditions. The term atypical pneumonia was first proposed by Cole (1928) for all forms of pneumonia which differ clinically from lobar pneumonia. Reimann (1938¹) defines it as an inflammation of the lung, occasionally primary but usually secondary in nature, caused by a single variety of bacteria or by a mixture of them, characterised by a gradual or sudden onset, fever, cough, sputum and termination by lysis. Pathologically the pulmonary lesions are diffuse, multiple and often specific for the ~~causal~~ causal

organisms. The inflammation originates primarily in the walls of the bronchi and bronchioles and spreads to the adjacent lobules and lung parenchyma by way of lymphatics, bronchi or bronchioles, or by continuity.

This definition is wider than the range of cases here described, since it may also include for example post-operative pneumonia, or lipoid pneumonia: but it is the best of the many definitions proposed.

Whether or not atypical pneumonia has increased in frequency is a point which cannot be settled by one observer, but there is no doubt that since the war a much larger number of cases have been observed in this country than before. A number of American reports suggest that the condition has a greater incidence amongst a young adult population leading a communal life, Longcope (1942) Reimann and Havens (1940) Gallagher (1934) and Smiley and Showacre (1939) all describing outbreaks amongst hospital staffs and in colleges and universities in which there was some evidence of infectivity. Accurate comparable figures of the incidence in the ordinary walks of life are impossible to obtain, but this apparent greater incidence in the services is almost certainly partly fallacious, since cases which in civilian life would be confined to bed at home for a few days are now admitted to service hospitals where all cases of lung pathology are fully investigated in view of the wartime increase in pulmonary tuberculosis. As a result, many cases of atypical pneumonia come to light which would otherwise remain undiscovered. It has been our experience that in many of the cases of atypical pneumonia the respiratory mechanics were faulty and it was felt that unless the original lesions were completely cured and the faulty respiratory mechanics remedied as far as possible, then the seeds of further attacks and possible future chronic bronchitis were being sown. This belief was chiefly founded on the tardy resolution which occurred in some of the earlier cases observed. These earlier cases were treated either with sulphapyridine, on the assumption that they were examples of early lobar pneumonia, or in milder cases, by rest in bed and simple expectorant mixtures. In neither case were the results wholly satisfactory, resolution being relatively protracted. Since both sulphapyridine and expectorants had no very obvious effect, recourse was had to physiotherapeutic measures and the results, though difficult to justify statistically, were sufficiently encouraging clinically to suggest their further application.

The use of these physiotherapeutic measures was suggested by Stewart's (1934) results with long-wave diathermy in lobar pneumonia, and McMahon's (1915, 1919) respiratory exercises for cases of wounds of the chest and chronic empyema in the last war. For various reasons, considerable changes in the usual techniques were introduced. Since no long or short wave diathermy was available, it was decided to use in its place infra-red radiations, as these probably had a sufficient degree of penetration (Heald). Postural drainage was also used, the technique being a fairly standard one. Respiratory exercises for various pulmonary disorders are well established in principle though not widely understood in application. Few detailed descriptions can be found apart from McMahon's papers, and a set of exercises were therefore evolved which have proved satisfactory. A detailed description of these techniques is

given in the Appendix, and the indications for their use and the results obtained are discussed later in this paper.

Description of Cases:-

The cases were found to be roughly divisible into three main groups, the criteria being the extent and type of the pulmonary lesion, and the amount of toxæmia present. Group A comprise those cases in which the amount of pulmonary involvement as judged by physical signs and x-ray appearances is mild, and in which there is no toxæmia. Group B is more severe. The lung involvement is not necessarily more extensive, but the lesion is more evidently broncho-pneumonic in character, and there is usually a mild associated toxæmia. Group C comprises cases in which one or more lobes are involved to a marked degree, with high prolonged fever, and marked toxæmia. Two varieties in Group C are recognised, one being mainly lobar in distribution, the other mainly bronchopneumonic. Although the cases have been thus arranged in three groups, the distinction between a case in one group and a case in another need not necessarily be sharp, and many borderline cases occur in which the main features of two groups may be present. But for the purposes of review, it is more convenient ~~to~~ thus ^{to}subdivide them.

Group A. - 26 cases.

A typical case in this group is that of a young adult with no previous history of chest troubles being taken ill with symptoms of upper respiratory catarrh - i.e. dryness of the throat, mild cough, headache, malaise and temperature of 99° - 101°. Persistent cough is very usually present, and is generally a more prominent feature than in ordinary uncomplicated upper respiratory catarrh. After about three days, during which time the symptoms have been becoming gradually more marked, he is found to have a small area of slight dullness at one lung base. The breath sounds in this area are vesicular in character, but much diminished in intensity, and are accompanied by a few fine or medium crepitations. These latter may be accentuated by deep breathing or coughing. The vocal resonance is unaltered or slightly diminished. Sputum is generally scanty and ~~more copious~~ ^{mucopurulent} in the early stages. There is no toxæmia present, and the patient's only complaint is of the local symptoms of cough or headache. An x-ray taken at this time will show a fairly uniform opacity of moderate density. This area is usually situated in the lower lobe, and in P.A. views occupies most frequently the cardiophrenic angle. The outer edge fades off insensibly into surrounding healthy lung. There is nearly always evidence of continuity between the main site of the lesion and the hilum of the lung. The opacity is frequently most marked in the neighbourhood of the main bronchi to the lobe. During the ensuing four to ten days the temperature falls by lysis. By the time the patient is afebrile, the area of impaired percussion has usually practically disappeared, the breath sounds have returned to normal intensity, and the crepitations are coarser, more numerous, and more widespread. Sputum is now looser and more copious, but at no time does it exceed one to two ounces ^a day in amount. The rate of resolution is approximately the same whether it be judged by physical signs or by x-ray appearances, and is usually complete within fourteen to twenty-two days.

The following are some typical cases:-

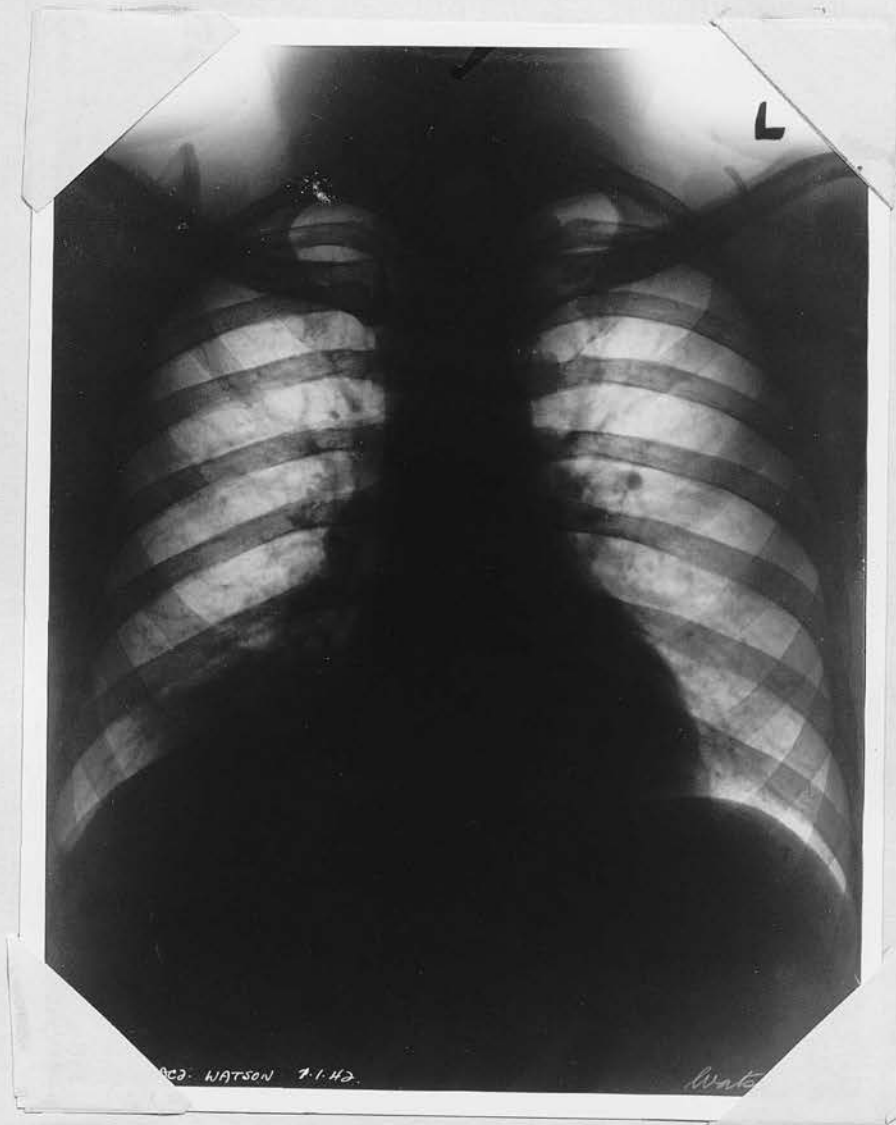
Case 22. An airman aged twenty-nine was taken ill on 28.12.41. with a dry cough, headache and malaise. On admission the following day his temperature was 102.5° , pulse 120/min. respirations 26/min. and cough was persistent. He was found to have a slight degree of impairment of percussion at the right base, with almost absent vesicular breath sounds, occasional medium crpitations, and unchanged vocal resonance. Sputum was scanty, and Micrococci Catarrhalis were isolated from it on culture. X-ray showed a fairly homogeneous opacity at the right base in the cardiophonic angle.

He was treated by infra-red therapy thrice daily, followed by postural drainage and breathing exercises after he became afebrile. On 4.1.42. the breath sounds were almost normal in intensity, with crpitations more numerous and more extensive. From then onwards the crpitations gradually disappeared, and by 14.1.42. there were no abnormal physical signs to be detected. In the same period radiological resolution was also complete.

Case 2. An airman aged thirty-one was admitted on 25.4.42. with a history of shivering, cough and malaise for twenty-four hours previously. On examination, he was found to have a few rhonchi at both bases. The sputum contained H. Influenza on culture at first, and two days later contained Micrococci Catarrhalis. A blood count showed 6,200 leucocytes/c.m.m., of which 67% were Neutrophil Polymorphs. X-ray revealed a mild opacity at the right base extending downwards and outwards from the hilum. He was treated as was the previous case with infra-red radiations until afebrile, and thereafter by postural drainage and breathing exercises. Temperature fell to normal by lysis on the third day, by which time there was slight dullness over the affected area with medium crpitations. The breath sounds were normal in character and intensity. Resolution was complete both clinically and radiologically in eleven days.

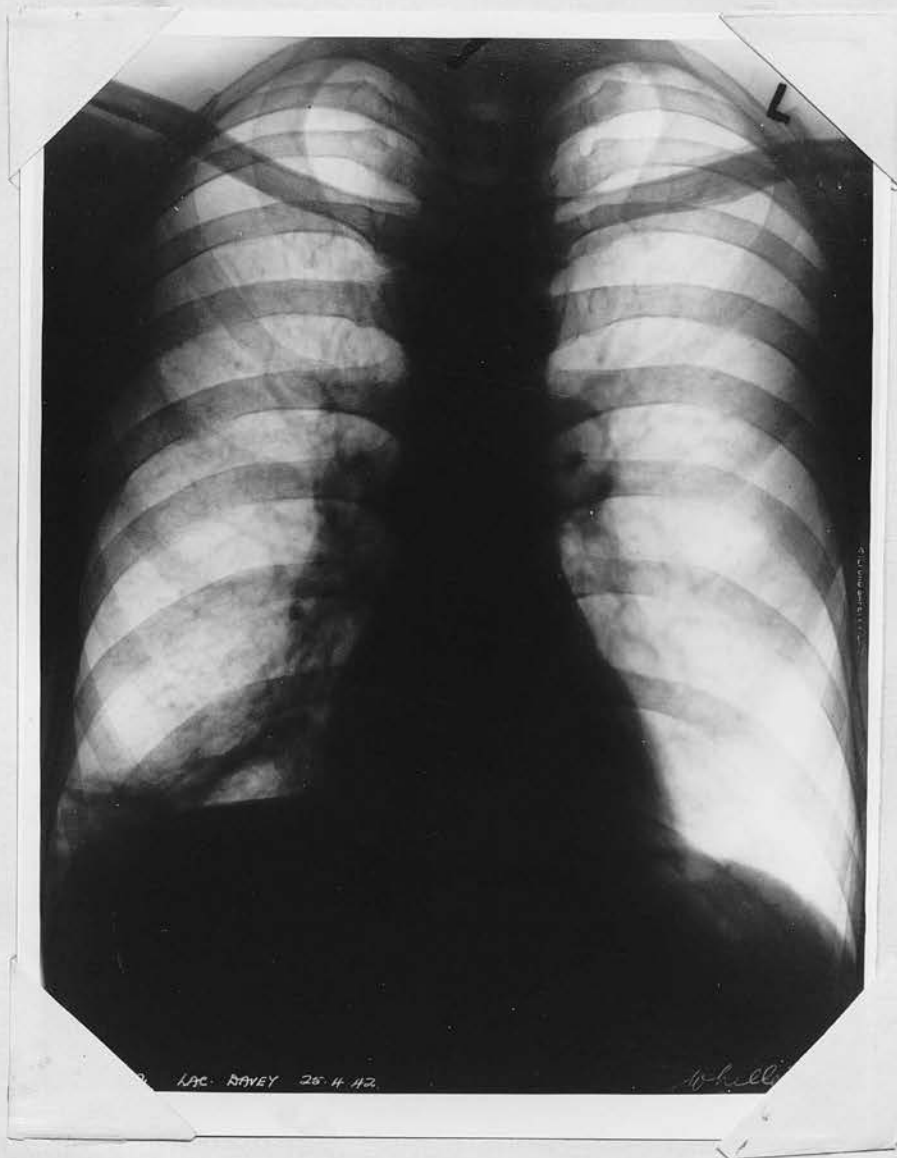
Case 5. An airman aged nineteen was admitted on 13.9.41. with a history of a cold in the head, which had become gradually worse during the preceding four days, and headache, dry cough and malaise for two days. Temperature on admission was 101° , pulse 120/min. respirations 18/min. A profuse growth of Streptococcus Viridans was isolated from the sputum. He was found to have diminished movement and slight dullness on percussion at the right base, with normal breath sounds. On deep inspiration a few high-pitched rhonchi and medium crpitations were heard at both bases. X-ray showed fairly homogeneous areas of opacity in the right lower zone and left midzone. He was treated like the preceding cases by physiotherapy. He was afebrile from the third day onwards, and resolution proceeded satisfactorily, being complete both clinically and radiologically in twelve days.

Case 20. An airman aged thirty-three was admitted on 12.3.42. with a history of cough and cold for the preceding six days, and some dryness of the throat for one day. Temperature on admission was 99.5° , pulse 82/min. and respirations 18/min. He had a small amount of sputum from which pneumococci were isolated. These did not react to either Type I, II or III sera. On examination the only physical signs found in the chest were fairly numerous medium crpitations at both bases. X-ray showed mild bilateral basal opacities of fairly homogeneous texture.



Case 22 - x-ray of chest taken three days after admission, showing opacity of fairly homogeneous texture in right cardio-phrenic area.





Case 2. - X-ray of chest on admission, showing pneumonitic opacity at right base. This is a typical mild case of Group A., and illustrates the tendency towards peribronchial distribution.



He was treated with an expectorant mixture only. The temperature fell by lysis over a period of ten days. Crepitations persisted at both bases for 16 days, by which time there was no further radiological evidence of the condition.

Group B. - 19 cases.

As already stated, the cases in this group do not materially differ from those in Group A except in the degree and type of pulmonary involvement, and in the presence of a certain amount of toxæmia. A typical case might be described as one in which a young adult is admitted to hospital with a history of symptoms of upper respiratory catarrh, usually of rather more than three days' duration. On admission, the temperature is usually between 102° and 104°, with pulse rate about 120/min. and respirations between 20 - 30/min. Local symptoms are mainly headache and cough. On examination, signs of lung involvement are found at one or both bases, or at one base and the midzone on the other side. Physical signs are much as in the previous group - diminished movement and slight dullness over the affected area, with breath sounds which are either vesicular or bronchovesicular in character but diminished in intensity. A few crepitations are usually present, and the vocal resonance is normal or slightly decreased in intensity. These physical signs are most usually found when the lesion is at one or other lung base. When it is in the mid or upper zones, they are generally much more indefinite, and frequently the only abnormality found is a few crepitations. X-ray at this period shows a lesion either unilateral or bilateral, and most commonly, basal. In extent it is greater than is found in Group A: in texture it is much less homogeneous, having a pronounced mottled appearance, the mottled areas being 3 - 10 mm. in diameter, close-set and fading off insensibly into the surrounding congestive appearances are usually fairly extensive. The temperature continues for very varying periods, between three and twenty days, but toxæmia subsides fairly rapidly. Resolution proceeds relatively slowly but appears to become eventually complete in all cases.

The following cases illustrate some of the typical or special features which are found:-

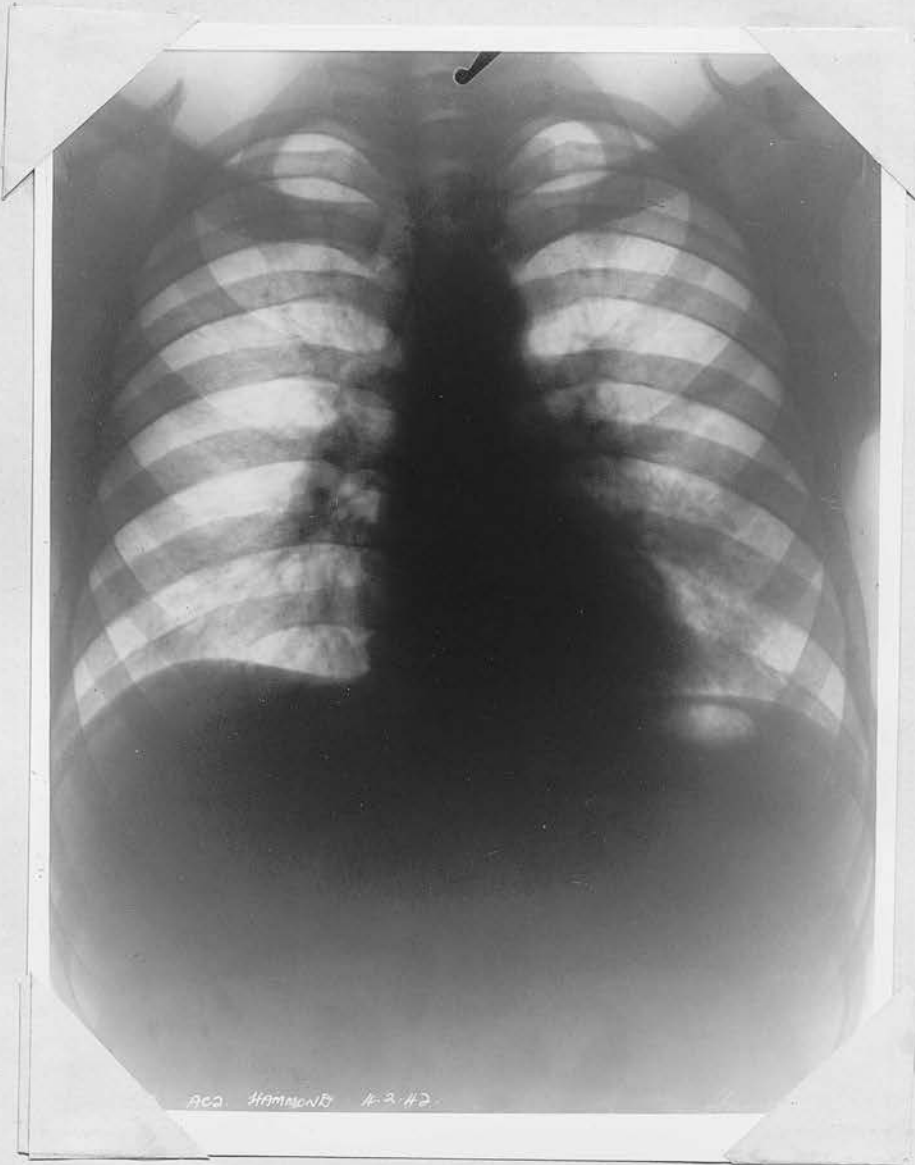Case 31 An airman aged twenty-two with no previous history of chest troubles was admitted on 6.6.42., with a history of malaise and dry cough for the past three days, and dull pain in the left side of the chest for one day. On admission, the temperature was 101.5°, pulse rate 88/min. respirations 20/min. and he was mildly toxæmic. He had scanty mild-purulent sputum in which morphological Pneumococci and Micrococci Catarrhalis were found on culture. The Pneumococci did not react to Type I II or III typing sera. There was a mild leucocytosis of 14,600/c min. On examination of his chest he was found to have slight dullness with vesicular breath sounds of diminished intensity and occasional medium crepitations at the left base. X-ray showed an area of congestion with signs of early ill-defined bronchopneumonic consolidation in the left lower zone and part of the midzone. He was treated with exposure to infra-red radiations thrice daily to the affected area, and the temperature fell to normal by lysis over the five days subsequent to admission. By then, the only physical signs to be found were occasional crepitations in the affected part of the

lung. Radiological resolution lagged considerably behind the physical signs, but was complete by 2.7.42. From the time when he became afebrile, postural drainage and respiratory exercises were instituted.

Case 37. An airman aged nineteen was admitted on 29.1.42. with a history of hoarseness, partial loss of voice and cough for two days. He was slightly toxæmic on admission, with a temperature of 101° , pulse rate of 90/min. and respirations 20/min. The sputum yielded a mixed growth of ordinary respiratory commensals on culture. The only physical signs which could be detected in the chest were a few medium crepitations at both bases. X-ray showed appearances very similar to the preceding case at the left base, but there was in addition some early similar involvement of the right base. Temperature fell by lysis over the five days subsequent to admission, the physical signs became less evident, and x-ray showed that resolution was progressing. In spite of this apparently favourable course, there was a considerable secondary rise in temperature up to 102° for several days from the tenth day onwards. The symptoms of laryngitis were persisting, and on the sixteenth day he was found to have a well marked bilateral antrae infection. Following appropriate treatment for this, there was no further temperature, and resolution was complete after six weeks. Treatment was by infra red irradiation to the affected parts of the lung until afebrile, and then by postural drainage and respiratory exercises.

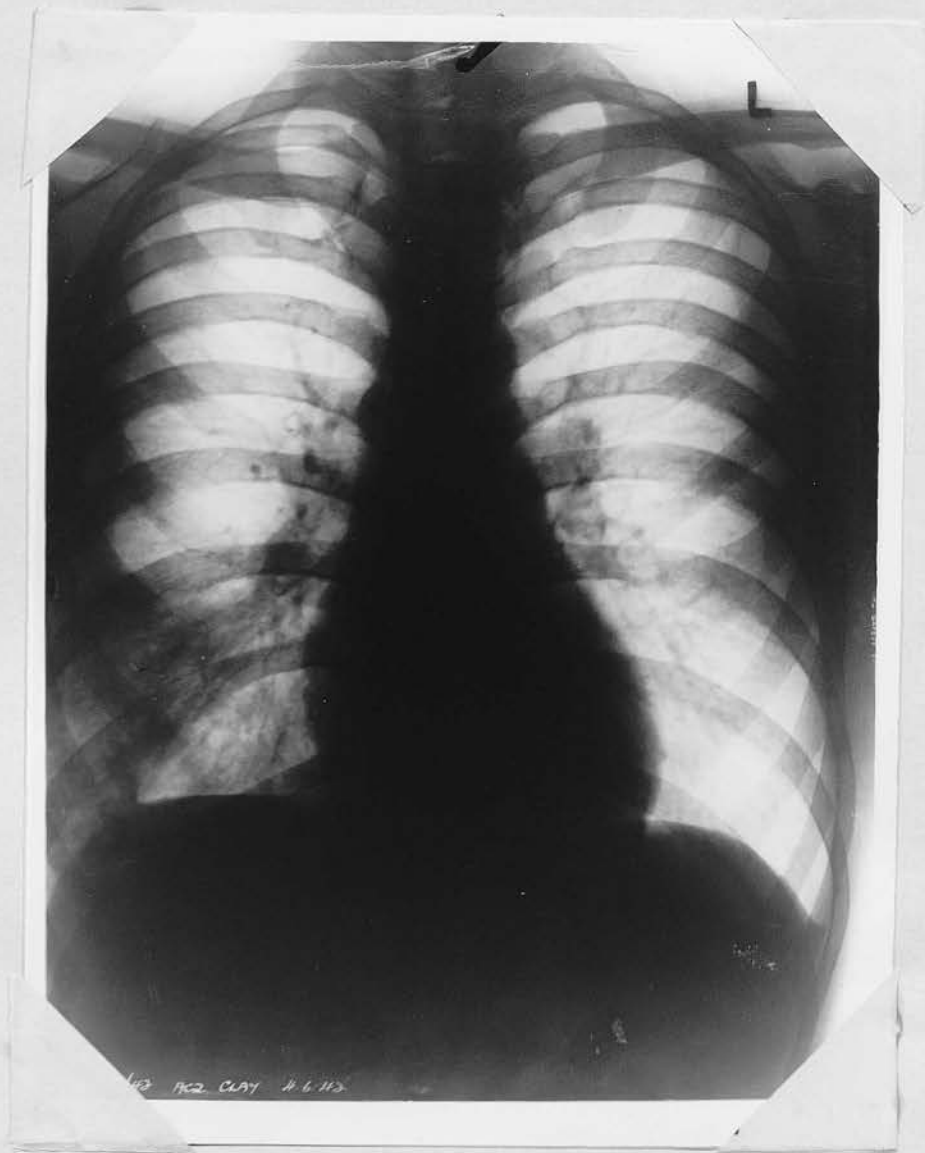Case 39. An airman aged twenty-two was admitted on 7.10.41. with a history of headache, malaise and dry sore throat for one day only. He showed a moderate amount of toxæmia, with a temperature of 102.5° , rising the same evening to 104° . His pulse rate was 130/min. and respirations 30/min. A mixed growth of organisms, predominantly Pneumococci and Streptococci Viridans were obtained from the sputum on culture. On examination of the chest he was found to have a slightly impaired percussion note with vesicular breath sounds of diminished intensity and a few medium crepitations at the right base. X-ray showed the lesion to be bilateral and basal. In both it was bronchopneumonic in appearance with considerable surrounding congestion, but the lesion on the left was very early, whilst that on the right was well marked. The temperature was maintained at fairly high levels for four days, and then fell to normal by lysis. At the same time toxæmia disappeared. He was treated by the same methods as the preceding cases, and resolution proceeded fairly rapidly, being complete in twenty-one days.

Case 33. An airman aged twenty was admitted on 4.6.42., having had gradually increasing headache, malaise and dry sore throat for the previous four days. For one day he had had a dry cough. On admission, his temperature was 100.5° , pulse 104/min., and respirations 20/min. He was moderately toxæmic, and had a leucocytosis of 14,800/c.m.m. The fairly copious mucopurulent sputum contained streptococci on culture. Physical signs in the chest were those of diminished movement and moderate dullness at the right base, with partially suppressed bronchovesicular breath sounds, a few medium crepitations, and slightly increased vocal resonance. X-ray showed an irregular broncho-pneumonic type of consolidation in the right lower zone, of greater density than in the preceding cases. There was no evidence of atelectasis. Treatment was as before with infra red



Case 37 - X-ray of chest 5 days after admission, showing small fine close-set areas of bronchiolo-pneumonia in the left lower zone, with some superadded congestion. The appearances at the right base are not well reproduced.





Case 33 - X-ray of chest on admission, showing well marked but irregular consolidation suggestive of a peribronchial spread.



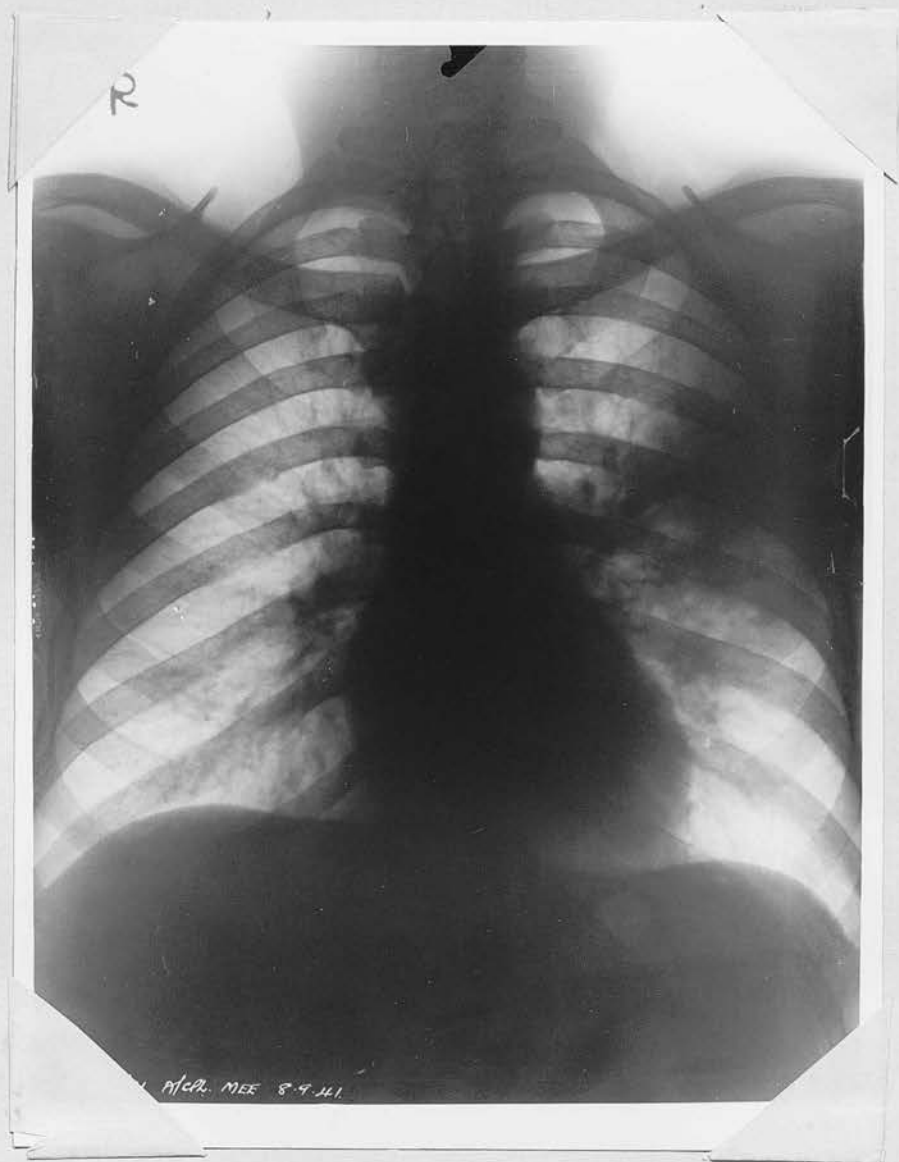irradiations until afebrile, followed after this by postural drainage and respiratory exercises. Toxaemia disappeared rapidly, and he was afebrile from the fourth day onwards. Resolution proceeded at about equal rate as judged by physical signs or x-ray, and was complete in twenty days. Before discharge he was found to have mucopus in the right antrum, for which antral lavage was required.

Group C. - Nine cases.

The cases in this group are characteristic by marked toxaemia, prolonged pyrexia, and a more extensive involvement of the lungs. This latter may be either bronchopneumonic or lobar in distribution, or a mixture of both, and there appears to be a tendency for the lobar type to show delayed resolution. A number of representative cases are described, and their differentiation from acute pneumococcal lobar pneumonia will be discussed later.

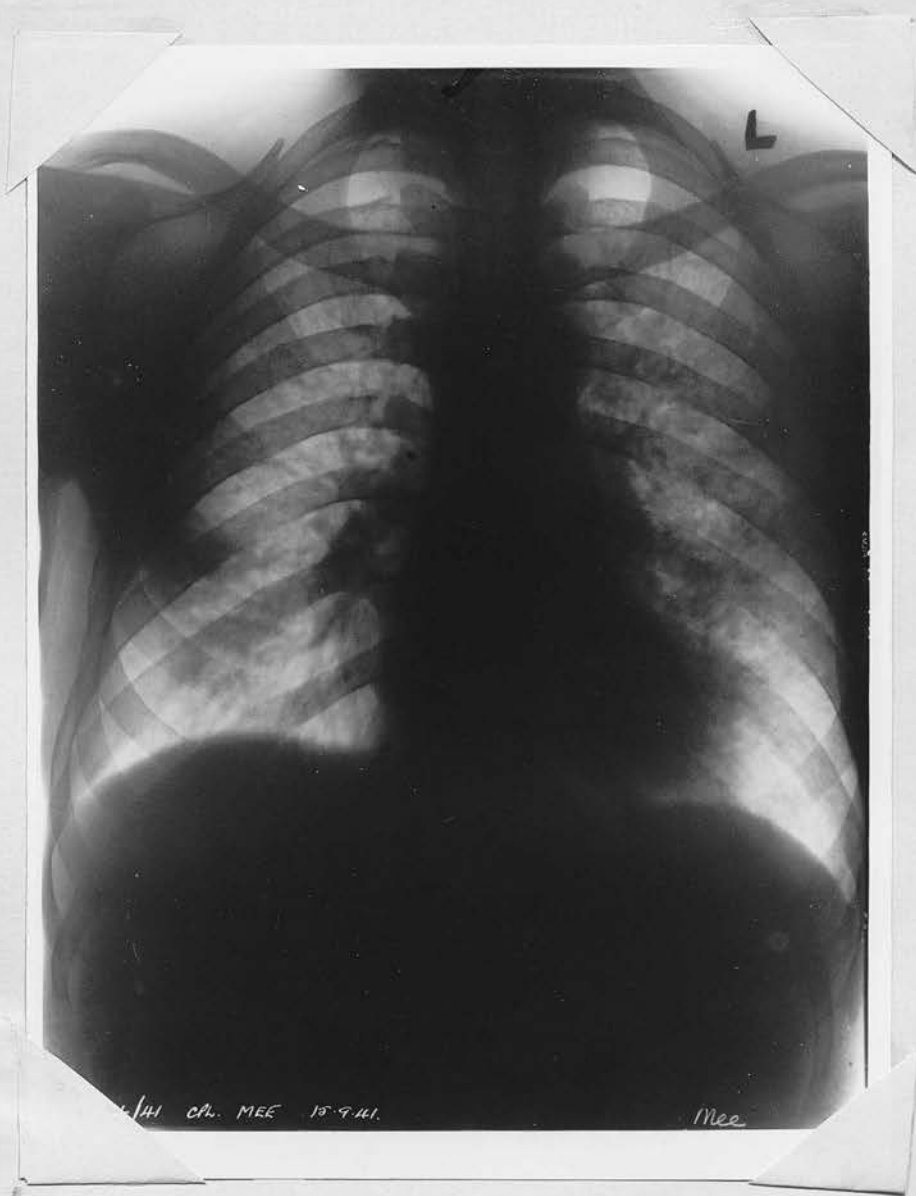Case 52. An airman aged nineteen with no previous history of chest troubles was admitted on 11.3.42. with a history of a gradually worsening cough and cold for the past seven days, and malaise for three days. His temperature was 103°, pulse rate 108/min. respirations 20/min, and he was moderately toxaemic. He had a leucocytosis of 18,200/c.m.m. of which 79% were neutrophil polymorphonucleosis, and a small amount of clear frothy sputum, from which Type I Pneumococci were isolated. The only abnormal physical signs which could be detected in the chest were occasional fine crepitations at the left midzone and right base. X-ray showed a fairly well marked opacity on the left midzone with fine close-set mottling, and a similar but less distinct area at the right base. He was treated with infra red radiations, and although much symptomatic improvement occurred and toxaemia diminished, his temperature continued at fairly high levels for twenty-one days. An x-ray twelve days after admission showed that some resolution was occurring on the left side, but that the appearances on the right side were becoming more marked. Postural drainage was instituted at this phase, followed by respiratory exercises when he became afebrile, and resolution was complete by 7.4.42., having taken twenty-seven days.

Case 51. An N.C.O. aged thirty-two was admitted on 7.9.41. with a history of increasing cough, shivering and malaise for the previous three days, with a small amount of thick purulent sputum. He had no previous history of chest troubles. On admission, his temperature was 101°, pulse rate 102/min. and respirations 28/min., with a marked toxaemia. Culture of sputum mainly yielded a growth of pneumococci, but there were also colonies of Staphylococci and Micrococci Catarrhalis. Fairly marked dullness was present over the left upper and midzones posteriorly, with harsh vesicular breath sounds and many inspiratory crepitations. Vocal resonance was slightly increased. There were also a few crepitations to be heard at the right base. X-ray at this stage showed a large, fairly dense opacity in the left middle zone: the degree of the density was similar to that associated with lobar pneumonia, but in texture it was more irregular and mottled, especially around its margins. There were also signs of early congestion at the right base. Temperature and toxaemia continued, and on



Case 51 - X-ray of chest on admission, showing fairly dense consolidation of irregular texture, especially marginally, in left mid zone; and early changes at the right base.





Case 51 - X-ray of chest taken eight days after admission, showing widespread bronchopneumonia with small close set nodules, and a fresh area of consolidation developing in the outer half of the right mid zone.



the ninth day a patch of pleural friction was found at the left base. X-ray at this time showed that the consolidation in the left mid zone had partially disappeared and there was now a very marked bronchopneumonia with fine close-set mottling involving the whole of the left lung and most of the right lung; in addition, a new area of consolidation had now appeared in the right mid zone. Oral administration of sulphapyridine was begun, nineteen gms. being given over a period of four days. The temperature fell by 1-2° during the administration of the drug, but rose again on its withdrawal. By this time, the only physical signs found were those of a gross bronchitis, but toxæmia was still present, and as a result of the bronchitis, there was intense cyanosis with venous engorgement. X-ray showed that resolution was occurring. A venesection was done at this stage, with marked benefit. Thereafter, progress was steady, if slow, there still being a certain amount of bronchitis present five weeks after admission. Besides those measures already described, he was treated in the usual way with radiant heat until afebrile, followed by postural drainage and respiratory exercises. Complete resolution had occurred after sixty-seven days.

Case 47. An airman aged twenty was admitted on 4.4.42. with a history of slight cough for the past two or three weeks, and shivering, malaise and some pain in the right chest on deep breathing for one day. His temperature was 103.5°, pulse rate 110/min. respirations 32/min. and he showed marked toxæmia. His sputum contained a mixed growth of micrococcus catarrhalis with occasional pneumococci. There was a leucocytosis of 16,000 with 65% polymorphonucleosis. There was marked dullness over the chest at the right base, especially round towards the posterior axillary line. In this area, the breath sounds were bronchial in character, but of diminished intensity. A few ^{re}crpitations were present and the vocal resonance was much increased. X-ray showed a fairly marked consolidation in the right lower zone, with considerable elevation of the right dome of the diaphragm. A lateral view showed that it was the middle lobe which was involved. He was treated by infra red irradiation only at first, with considerable reduction in toxæmia. On the fifth day, administration of Sulphapyridine was begun, and he received twenty-five gms. orally over a period of six days. Following this he became afebrile and there were signs of slow early resolution, but on the twentieth day he had a considerable recrudescence of temperature lasting for a week. No further extension of the process in the lung nor the presence of a pleural effusion or empyema could be demonstrated to account for this. Resolution continued in tardy fashion, and it was not until two months after the onset that the lung fields had returned to normal and the diaphragm had resumed its usual position.

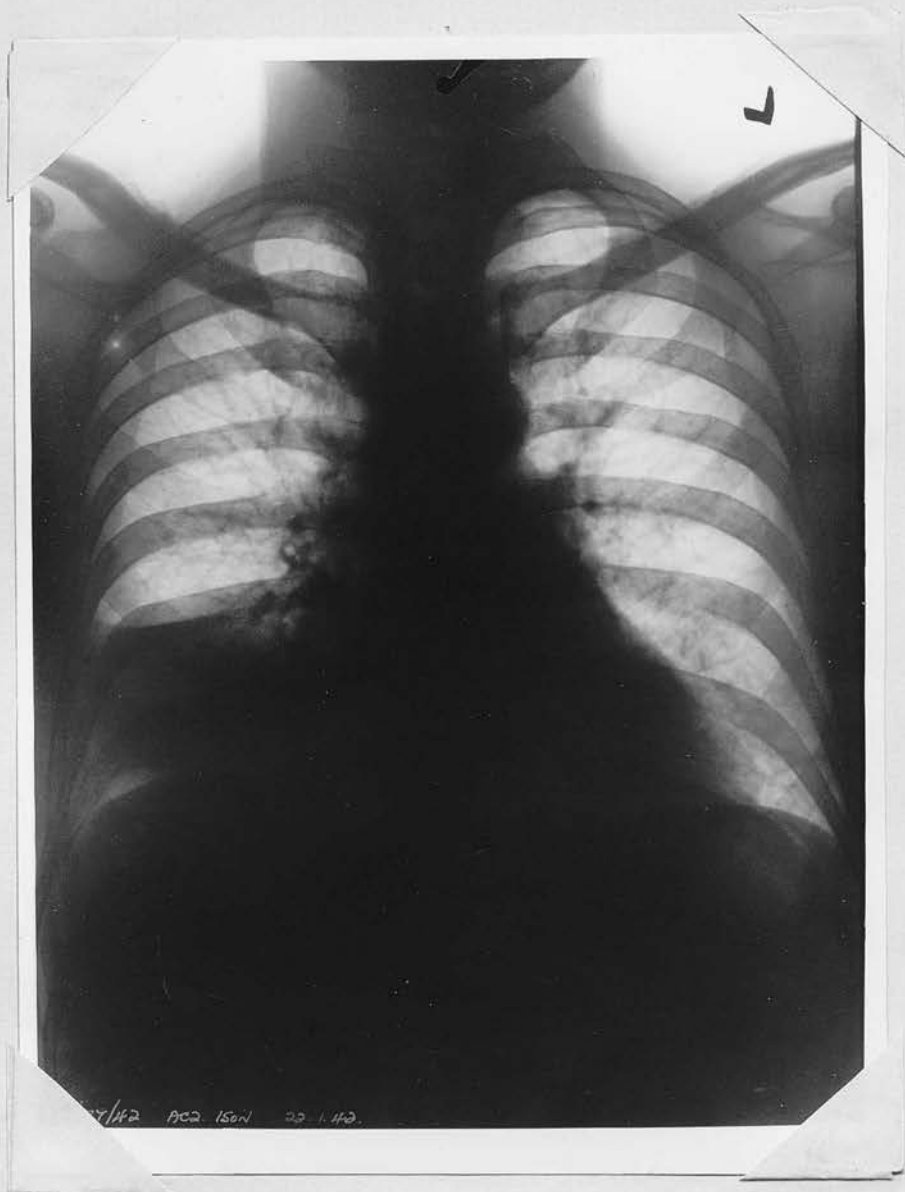Case 50 This airman ^{was} admitted on 21.1.42. with a history that for the preceding twenty-four hours he had experienced considerable malaise, generalised aches and pains, and a dry cough. On admission, the only signs which could be found in his chest were those of a generalised mild bronchitis, but two days later he was found to have marked dullness, with diminished breath sounds and vocal resonance at the right base round into the axilla. X-ray showed this to be due to pneumonia of the

right middle lobe having a sharp line of ~~demarcation~~^{demarcation} at its upper and lower edges. He had a scanty amount of sputum from which Type I pneumococci were isolated and 16,800 leucocytes of which 90% were polymorphonuclears. Radiant heat was commenced immediately with no obvious effect. The temperature continued between 103° and 101° and the amount of toxæmia remained more or less unaltered. On the eighth day of the disease, in the absence of a normal crisis, sulphapyridine was administered and he received a total of twenty-two grams orally over a period of six days. Apart from a transitory fall of temperature for twenty-four hours, the sulphapyridine had no demonstrable effect, and marked pyrexia continued for a period of eighteen days subsequent to its withdrawal. During this period, the physical signs did not alter very greatly except that faint bronchial breath sounds could be heard on the right base in the posterior axillary line, and x-ray showed that the middle lobe, instead of resolving, was getting slightly smaller. It was suspected that an empyema might be present, but no pus or fluid could be found by exploratory puncture. During the succeeding month the breath sounds became slightly stronger and more vesicular in character, and crepitations were present during the greater part of the period, but radiologically there was progressive shrinking of the middle lobe. Energetic regional breathing exercises were carried out during this period, and at the end of three months considerable resolution had occurred. Some fibrosis, however, remained, and on discharge, three and a half months after admission, this was still present. The patients' general health was excellent, and respiratory movements were full and equal and there was no evidence of bronchiectasis. Repeated examinations of the sputum for tubercle bacilli failed to demonstrate them.

Discussion.

Twenty-six cases have been observed which have been placed in Group A, and nineteen cases in Group B. As already stated, the differentiation between cases of each group is not always sharp, and many border-line cases present features of both, since Group A cases merge into those of Group B imperceptibly. The criteria which have been used are that in Group A the cases showed no toxæmia, the x-ray appearances are of a fairly homogeneous texture, and resolution is usually complete within three weeks. In Group B, cases exhibit a certain amount of toxæmia, as evidenced by a mild leucocytosis of twelve to sixteen thousand/c.m.m., the radiological opacities have the woolly and patchy appearances of fine, close set bronchopneumonia, and the condition usually lasts from three to five weeks. In view of their relatively close relationship, it is therefore convenient to review the two groups together as regards their epidemiology, clinical features and treatment.

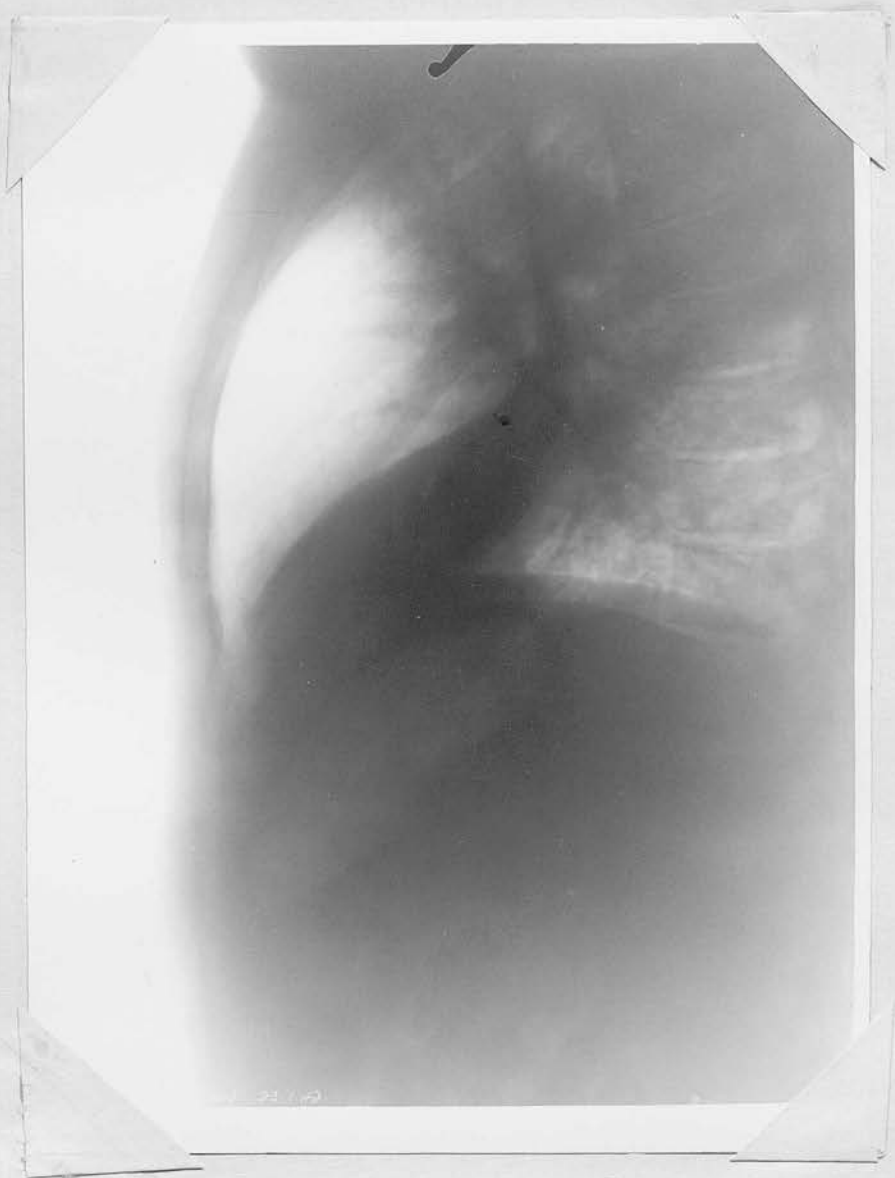Epidemiology. It is a general finding that cases of atypical pneumonia such as have been described under Groups A and B occur most frequently during those periods when acute febrile catarrh and influenza are most common. This finding is confined in the present series. It is also most commonly reported as occurring in institutions, especially in the U.S.A., typical outbreaks being described by Reimann (1938²), Longcope (1940) and Miller and Hayes (1939). From such descriptions, it has been thought that the condition is one which predominantly affects young adults, but it must be borne in mind that young



Case 50.

P.A. view of chest on 22.1.42., showing lobar type of pneumonia in right lower zone. The upper margin is abnormally clear-cut, and the costophrenic angle is not obliterated, suggesting that the middle lobe is affected.

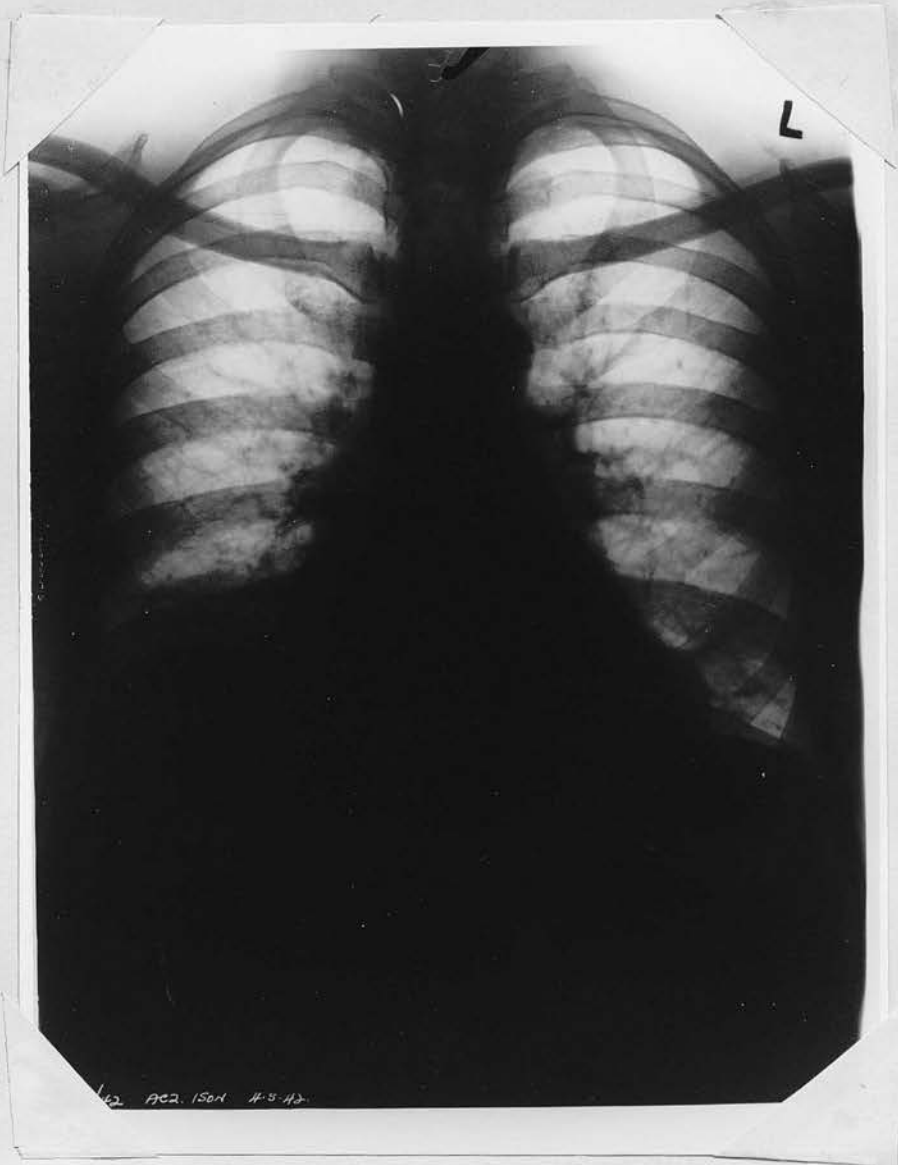




Case 50.

Lateral view, taken 23.1.42., showing complete involvement of the middle lobe.



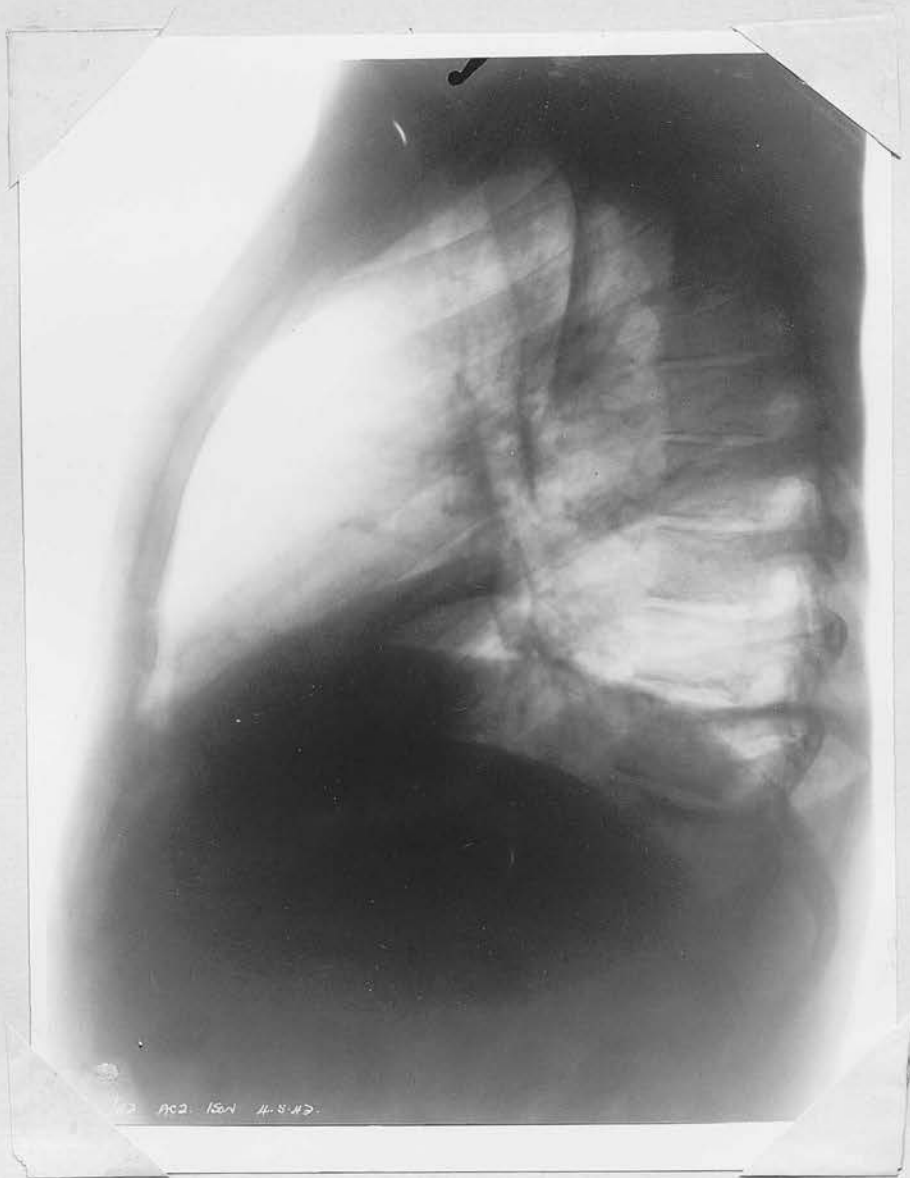


Case 50.

-

P.A. view on 4.5.42. showing residual fibrosis and elevation of the right dome of the diaphragm.





Case 50.

-

Lateral view on 4.5.42. showing residual fibrosis, probably due in part at least to pleural thickening, and the marked elevation of the right dome of the diaphragm.



adults are by far the most numerous inmates of schools, colleges and hospitals. A certain amount of evidence has also been adduced, chiefly by Smiley and Showacre (1939), Hornibrook and Nelson (1936) and Maxfield (1939) that the disease is communicable and that cross infection can occur. Longcope (1940) suggests that the disease is transmittable, with an incubation period of fourteen to twenty-one days. The general incidence as observed in the present series was that, out of a total of 492 cases admitted under fairly constant conditions from one camp with diagnosis of influenza, acute febrile catarrh and nasopharyngitis, but all presenting fairly uniform clinical features of headache, malaise, pyrexia and some upper respiratory catarrh, fifty-seven cases (11.5%) showed clinical and radiological evidence on admission of pulmonary complications, and a further ten cases (2%) developed these complications within two or three days of admission. The period which elapsed between the onset of symptoms and admission to hospital was in the great majority of cases, two to three days. Local circumstances has made it impossible to assess the possibility of the pulmonary complications being infectious: but no examples of cross-infections were noted in the wards of the hospital. These figures can be compared with those quoted by Reimann and Havers (1940) under somewhat similar conditions. In a hospital, 50% of the total nursing staff of 813 were ill: of these, 88% were diagnosed as nasopharyngitis, 6% as tracheobronchitis, and 6% had tracheobronchopneumonia. The clinical description of these latter cases bears a close resemblance to the cases in Group A.

Symptoms and Physical signs.

These fall naturally into two groups, those preceding the appearance of pulmonary involvement, and those during the course of the condition.

Some variation of opinion appears in the various recorded descriptions of the symptoms and signs preceding the appearance of an atypical pneumonia, similar to those which have been described under Groups A. and B. Allen (1936) states that his cases occurred as complications of an outbreak of upper respiratory catarrh. Stansfield (1923) elicited from such cases a history suggestive of a mild influenzal attack approximately a month prior to the onset of the lung changes. In Gallagher's (1934) series all but two out of eighteen cases had symptoms of upper respiratory catarrh. Stewart Harris (1937) differentiates influenza as being typified by sudden onset, marked constitutional upset and few local symptoms. Acute febrile catarrh, on the other hand, begins more insidiously, with less constitutional upset and more marked local symptoms such as hoarseness, sore throat and cough. Following influenza, he notes that the cases were at times followed by physical signs in the chest very similar to those described in this series. He attributes these findings to a bronchiolitis with a patchy atelectasis, and from such cases he isolated the influenza virus on occasions. Scadding (1937) describes fifty-eight cases of influenza, during the course of a mild epidemic. Eighteen of these were uncomplicated, and their clinical features were the typical ones of pyrexia, prostration, headache and shivering. Twenty-two showed signs of pulmonary involvement similar to those described in this series, in some cases the lung signs not appearing until the fourth or fifth day. The remaining nineteen cases showed evidence of actual consolidation

varying from basal bronchopneumonia to cases with incomplete lobar consolidation. French (1920) describes similar conditions occurring as complications during the pandemic outbreak of influenza in 1918 - 1919.

Careful note has been kept of the prodromal symptoms in all the present cases, and it has been found that in 80% of all the cases they corresponded to those which, by Stuart-Harris' classification, would be called acute febrile catarrh, and even in the remaining 20% when the symptoms were more suggestive of influenza, a harsh dry cough was a constant and dominant local symptom. In those cases of acute febrile catarrh which were not complicated by pulmonary changes, it was found that the duration of the symptoms prior to admission was three days, or less in 88% of the cases. In the Group A cases, 69% had had symptoms for three days or less on admission, and 31% for a longer period. In the Group B cases, the percentage of cases with symptoms for three days or less on admission dropped to 52%. In explanation, the day of admission is taken as being relatively constant in the course of the disease, since the patients were all drawn from the same camp, were working under similar conditions, and were, as already explained, admitted as soon as they showed pyrexia. The three types of case, uncomplicated acute febrile catarrh, Group A and Group B atypical pneumonia, would appear therefore to show a progressive slight increase in the duration of the prodromal symptoms. They also show a progressive increase in the duration of the conditions. The average duration in uncomplicated acute febrile catarrh is four to eight days: in Group A atypical pneumonia, nineteen days: and in Group B, twenty-six days. It might be expected from these findings that in each group those cases with the shorter incubation period might have a shorter duration than those with the longer incubation period. In the relatively small number of cases observed, no such difference in duration was noted. The average duration was the same, irrespective of the length of the incubation period.

The symptoms show no particularly characteristic feature. The usual ones present, besides those of headache, malaise and some degree of upper respiratory catarrh, characteristic of the preceding acute febrile catarrh, are cough with a relatively scanty mucopurulent sputum, and pyrexia of 100° - 102° lasting, in the Group A series, an average of six days, and in the Group B series, eleven days. Only in exceptional cases did the patient complain of pain in the chest, and then it was generally of a dull aching type, and was not pleuritic in character. These findings are compared in Table I with those of Allen (1936) and Maxwell (1938).

Examination of the sputum showed that the condition could not be ascribed to any particular one of the ordinary respiratory pathogens and commensals, nor could any particular organism be constantly associated with one or other of the varieties or degrees of pulmonary involvement. In both Groups, it was most commonly found that the sputum yielded a mixed growth of organisms on culture, consisting of two or more members of a group comprising Pneumococci, Streptococci, *Vibrios*, haemolytic and non-haemolytic Streptococci, and *Diphtheroids*. In Group A these comprised 32% of all sputum examined, and 55% in Group B. Next in frequency were Pneumococci in pure culture, 21% in Group A and 25% in Group B.

TABLE I.

	Allen.	Maxwell.	Group A.	Group B.
No. of cases	?	24	26	19
Cough.	86%	91%	84%	100%
Sputum.	-	83%	74%	94%
Pain in chest.	30%	-	11%	10%
Average Temp.	101° - 103°	101° - 102°	101° - 103°	101° - 103°
Duration of Temperature.	95 days.	-	6 days.	11 days.
Fever.	70%	-	100%	100%
Average Duration.	28 days.	14 days.	19 days.	26 days.

Table showing the incidence of some of the symptoms and signs in Groups A and B compared with those of other similar series.

In only one case did these give any reaction with the specific typing sera for Types I, II and III. It was not possible to attempt any differentiation between the various strains of Group IV, nor to attempt the isolation of the influenza virus.

These findings are in general accordance with those of other observers. Gallagher (1934) found the sputum to contain predominantly the usual flora of the upper respiratory tract. Eyre (1910) found that 28% of the sputum contained pneumococci, 16% Streptococci, 7% Staphylococci and 6% *B. Mucosus Capsulatus*. Cole (1926) found 19% due to Pneumococci, 41% to Streptococci, 9% to Staphylococci and 3% to *B. Mucosus Capsulatus*. Nicholas and Agassig (1938) found various types of bacteria, and they too were unable to show any correlation between the type of bacteria present and the type of lesion resulting.

The physical signs most commonly found have already been described, and, briefly, consist of diminished movement and slightly impaired percussion note over the affected area, with vesicular breath sounds of greatly diminished intensity, a few medium crepitations and unaltered or slightly diminished vocal resonance. As recovery occurs, the first alteration to be found

is a return of the breath sounds to their normal intensity. Following upon this, crackles become more numerous, usually coarser, and more widespread, frequently being heard in adjoining areas of the lung which were apparently otherwise unaffected. The crackles then begin to disappear, and as they do so, so also does the dullness, and the normal range of movement is restored. Such are the findings in 70% of cases in both Group A and B, the only difference being that in Group B the rate of resolution is more tardy. In about 20% of cases of both Groups the only physical signs to be found are crackles. It has been noticed that this is most commonly so in cases where the lesion is not at the base but in the midzone. Signs of this consolidation are not found, and only in occasional cases are the breath sounds of greater intensity than normal. In two cases in Group A and three cases in Group B they were of the harsh bronchovesicular type. These are in the main similar to the general descriptions given by other observers such as Gill, Longcope and Scadding. More detailed analyses have been made by Allen and by Maxwell. Allen found crackles in 72% of his cases, dullness to percussion in 6% and no physical signs whatsoever in 20%. Maxwell, in a series of twenty-four cases, records evidence of consolidation in twenty-three, weak breath sounds in eleven, dullness in seventeen, and crackles in thirteen. Neither of these agree altogether with the findings in the present series, which were notable for the relative uniformity of the physical signs. Indeed, with growing experience, it has been found possible, from close examination, to forecast fairly accurately the extent and type of the radiological appearance. These variations in physical signs found by different observers is probably in part due to individual variation in the interpretation of physical signs in the chest.

Maxfield (1939) has suggested that a mild leucopenia is always present in cases such as these. Both Allen and Gallagher agree that the leucocytosis seldom exceeds 14,000/c.m.m., but Allen suggests that this varies directly with the extent of the lesion. It is unfortunate that in this series the leucocytes have only been estimated in a few cases: but in those cases that it has been done, there is no rise above normal limits in Group A, and a mild leucocytosis of 10,000 - 14,000 in Group B.

The radiological appearances constitute one of the most constant differences between the two Groups. In Group A the lesion is most commonly seen at one or other base. It is irregular in distribution, appearing in the P.A. view to spread outwards and downwards from the hilum following the general direction of the main bronchi. The shadow is of moderate density and fairly even texture, and there is but little evidence of surrounding congestion. A typical example is shown in x-ray No. 2. In Group B, the lesion is more extensive. There is a background of congestion in one lobe which fades off imperceptibly into surrounding healthy lung, and in this area of congestion is a fine close mottling, which in later stages coalesces to form more discrete areas of bronchopneumonia. A typical example of this is seen in x-ray no. 3. In both groups the lesion may involve part of one or more lobes, but a lower lobe is the most common site. Bilateral basal lesions are relatively common. The frequency with which the various lobes are involved in this and other similar series is shown in Table II.

TABLE II.

	Number of Cases	Unilateral basal lesions	Bilateral basal lesions	Unilateral lesions in mid or upper zone	Bilateral lesions other than basal.
Group A.	26	69%	23%	-	8%
Group B.	19	58%	26%	5%	11%
Allen.	-	58%	30%	2%	-
Maxwell.	24	62%	4%	33%	-
Hutchison.	12	83%	-	16%	-
Ramsay and Scadding.	21	62%	9%	28%	-

Table showing the anatomical distribution of the lesions in Groups A and B, and in four series of similar cases.

In the present series, it was found that in Group A the site of the lesion made no difference to the duration of disease. In Group B the duration of those cases in which the lesion was confined to one or other lower lobe was slightly shorter than in other cases.

The question of treatment is one which has not received any great measure of attention. This is only to be expected, since the natural course of the condition in both Group A and B is to spontaneous resolution, and no record of death or untoward complications or results has been found in the various descriptions. The most prominent feature about the condition, however, is its relative indolence and the tardy resolution in comparison with the extent of the lesion. Furthermore, it was observed during the treatment of some of the earlier cases in which resolution was protracted that the patients showed a disturbance of their respiratory mechanics and rhythm which appeared to be out of proportion to the extent of the pathological process present. This was interpreted, without any real proof, as being the possible precursor of two late effects. It is comparatively seldom, at least amongst R.A.F. personnel, that one observes a first attack of acute bronchitis. Acute bronchitis is common, but it is almost invariably superadded upon a pre-existing chronic bronchitis of varying severity; and even after a first attack of acute bronchitis, the patient finds that in subsequent attacks of upper respiratory catarrh

there is an increased liability for a certain amount of bronchitis to appear. Now the conditions which have been described under Groups A and B have much in common with bronchitis, many observers being of the opinion that the conditions begin as a bronchitis in one part of the lung and produce the typical lesion by direct extension of the infective process downward into the terminal bronchioles and outwards into the surrounding pulmonary tissue. Breathing exercises are a well established and recognised form of treatment for chronic bronchitis and bronchial asthma and, if they do not reduce the frequency of future attacks, they do at least reduce the amount of respiratory distress which the patient experiences both during and between attacks. With this relationship between acute bronchitis and atypical pneumonias of Groups A and B, it is reasonable to assume that a patient who has suffered from the latter, has, as far as ~~one~~^{one} area of his lung is concerned, an increased susceptibility to further such attacks, or to acute bronchitis. When, as one has already stated, such cases were observed to have poor respiratory excursion in the affected lobe during convalescence and when they were frequently found to have poor respiratory mechanics as a whole, then the introduction of breathing exercises as a necessary part of the treatment during convalescence is justified, on the grounds that the results so obtained represent a more complete cure, and have a possible prophylactic value insofar as an organ which is functioning normally and efficiently is less prone to infection than one which is functioning under some form of disadvantage, whether physiological or mechanical.

The technique of the breathing exercises is described in the Appendix. In their application, they were not instituted until evidence of commencing resolution was clear, since there is no justification for interfering with the state of relative functional quiescence which the organism always imposes upon inflamed tissue. Resolution was presumed to have commenced when the patient had been afebrile for thirty-six to forty-eight hours; when the breath sounds had returned to their normal intensity, or nearly so; and when crepitations had become either more numerous or more extensive, or both.

During the early stages of the condition the cough is usually fairly dry and produces only a small amount of mucopurulent sputum. At or about the time when the patient becomes afebrile, that is, after about six days in the case of Group A and eleven days in the case of Group B, it is usual to find that, coincident with the increase in the number and extent of the moist sounds, there is also a slight increase in the amount of sputum expectorated. But the quantity still remains relatively small, and it has been our practice at this stage to introduce postural drainage, in an effort to facilitate expectoration, and so diminish the amount of damage suffered by the bronchial mucosa as a result of accumulating bronchial secretions lying relatively stagnant in the smaller bronchi.

In an endeavour to increase the rate of resolution in order to obtain both a more complete and a more speedy cure, recourse was had to a variation of the diathermy treatment for lobar pneumonia described by Stewart (1934), Robinson (1930) and Simon (1931) prior to the introduction of sulphapyridine.

This form of treatment had probably its chief vogue in America, and some of the statistics published have shown an improvement in the mortality rate as compared with those of the then generally accepted therapeutic measures. From the experimental work of Binger and Christie (1927. - 1,2,3, - 1938. - 1,2.) it would seem most probable that the therapeutic effect of long wave diathermy is obtained not by the heating effect on the pneumonia tissue, as this seems negligible compared with that produced by the natural pyrexia, but rather by the increased blood supply to the areas treated. Since measures which produce an increased blood supply in and around infected tissues are a well recognised form of treatment, diathermy has a justifiable place in the treatment of atypical and typical pneumonia. Diathermy was not available, however, and for it was substituted infra-red irradiations from a non-luminous source. Two facts supported our use of it. One was that we already had a fairly wide experience of its most beneficial effects in the more superficial inflammations such as boils, whitlows, carbuncles and acute sinusitis, and were therefore fairly conversant with the duration and frequency of exposures required. Secondly, the doubts that were expressed as to its ability to penetrate as far as the lung tissue were allayed by the experiments of Heald (Dr. C.B. Heald. personal communication) who showed that these rays are capable of penetrating at least the whole thickness of the thigh. The technique of the irradiation is described in the Appendix. Two to four exposures a day were given depending upon the severity and extent of the lesion.

The results of these three forms of treatment cannot be clearly demonstrated on such a comparatively small series of cases, but they are at least suggestive, since factors such as the age and physical condition of the patient and his environment were more constant than in an ordinary series of such cases; since the cases were subdivided into the two Groups A and B, in order to make for uniformity in extent and type of lesion; and since the cases so treated were quite unselected. Those cases which were not treated as described usually receive either sulphapyridine, or an expectorant mixture, or both. The results, as shown in Tables III and IV suggest that in both Group A and B the duration of the period of pyrexia was diminished, in Group A from an average of eight days to five days, and in Group B from an average of fourteen days to seven days; and that the total duration of the disease was reduced, in Group A from an average of twenty-four days to eighteen days, and in Group B from an average of thirty days to twenty-two days.

These results, as already stated, cannot be accepted without reservation, owing to the relatively small numbers of cases in the series, but they are as accurate as this small number will allow, and show a probable saving in the number of days spent in hospital. A more important result which cannot be shown statistically, is that we believe that these measures give the man a more complete cure, and that he returns to duty less prone to subsequent pulmonary infections.

Complications in either Group A or B occur but rarely, if ever. One case in Group B developed a Streptococcus tonsillitis during convalescence, and two cases in Group B

26. (a).
Table III.

Group A.

	<u>Treatment.</u> Infra red radiation Postural Drainage. Breathing exercises.	<u>Treatment.</u> Other forms.
Number of cases.	15.	6.
Duration of Pyrexia.	Average, 5 days. Standard Deviation. 1.9.	Average, 8 days. Standard Deviation. 5.7.
Duration of the condition	Average, 18 days. Standard Deviation. 4.4.	Average, 24 days. Standard Deviation. 13.4.

Table showing results of treatment in Group A. Five cases are not included, as there was no radiological proof of their final resolution. Comparing the results, in both cases the difference between the two sets of averages is greater than the standard Error, but less than twice this figure. The results, therefore, are not statistically significant.

--oOo--

Table IV.

Group B.

	<u>Treatment.</u> Infra red radiations. Postural drainage. Breathing exercises.	<u>Treatment.</u> Other forms.
Number of cases.	9.	6.
Duration of Pyrexia.	Average, 7 days. Standard Deviation. 5.2.	Average, 14 days. Standard Deviation. 5.5.
Duration of the condition.	Average, 22 days. Standard Deviation. 7.8.	Average, 30 days. Standard Deviation. 9.5.

Table showing results of treatment in Group B. Four cases are not included, as there was no radiological proof of their final resolution. The difference between the two averages of the duration of the pyrexia is greater than twice the standard Error and is therefore statistically significant. The difference between the average durations is 1.8 times the standard Error.

were discovered to have an antral infection, also during convalescence. In these two latter, the condition was suspected by the persistence of nasal obstruction in one case, and laryngitis in the other, and in both was confirmed by x-ray and antral puncture. In both cases resolution was somewhat longer than the average, but there was no reason to suppose that the presence of the antral infection was anything more than fortuitous.

The cases in Group C do not display the same uniformity as either Group A or B. They vary both in the extent and nature of the lesion, in their response to treatment, and in their end-results. Two main types are recognised, a bronchopneumonic type characterised by migratory lesions and marked toxæmia, and a lobar type which shows delayed resolution. Since only four cases of the former and five of the latter have been observed, only very limited conclusions may be drawn.

The chief distinguishing features of the bronchopneumonic type are marked toxæmia, with extensive bilateral or migratory bronchopneumonic pulmonary lesions. None of the cases gave any history of exposure to chill or to possible infection from another case. Case 53 had a history of pneumonia in childhood, Case 49 had had previous mild attacks of bronchitis, and the other two had had no previous chest troubles. In three of the cases the time elapsing between onset of symptoms and admission to hospital was less than three days. Sputum was generally more profuse than in Groups A and B, especially during the later stages of the disease when it was fairly profuse in amount and of frothy mucoid character. In all the cases pneumococci were found in the sputum, although not necessarily in pure culture. In one case the pneumococci were Type I. The symptoms at onset were cough, malaise, and shivering. Actual rigors were not recorded, and no patient complained of pain in the chest. The temperature when first admitted to hospital was usually of moderate degree, between 99° and 103°. No crisis was observed in any case, and the duration of the pyrexia was from twelve to twenty days. In all but one case the only physical signs found on admission were numerous crepitations over the affected areas of the lung. In the later stages, the breath sounds which at first had been normal, became partially or wholly suppressed although maintaining their vesicular quality: and the percussion note was slightly impaired. In only one case (Case 51), were the breath sounds bronchial in character, and in this instance the lesion was at first of a more lobar character. The X-ray appearances were very similar in texture to those in Group B, that is they were a close set, finely mottled bronchiolopneumonia: but they tended to be more extensive, to be bilateral, and to show a distinct tendency to be migratory. Such lesions can be extremely suggestive of tuberculosis, and in certain cases only their relatively evanescent nature give some hint that they may not be so. In the most severe case (Case 51) the original lesion was of a relatively dense and homogenous nature suggesting a more lobar type of lesion: but this partially resolved in the course of a few days and was replaced by a widespread close set fine bronchiolopneumonia, whose appearance was extremely suggestive of a miliary tuberculosis.

In all four cases complete resolution eventually occurred the duration of treatment being twenty-eight days in the

shortest case and sixty-seven days in the longest. The two milder cases were treated as in Groups A and B with radiant heat, postural drainage, and breathing exercises. The two more severe cases, because of the pyrexia and toxæmia, were given, in addition, a course of sulphapyridine in full therapeutic doses. In one case there was a transitory diminution in the temperature, followed by a return to former levels: in the other case, there was no demonstrable effect on the pyrexia: and in neither case was any effect observed upon the toxæmia or upon the progress and extent of the lesion.

The last variety of atypical pneumonia to be described is characterised by sudden acute onset with marked toxæmia, a partial or complete lobar distribution of pneumonic consolidation with an associated element of atelectasis, atypical physical signs, an absence of any crisis, and delayed resolution. Once again, only five cases have been observed, and therefore no very reliable deductions may be made from them: but there are available a number of cases of typical pneumococcal lobar pneumonia which were admitted from the same sources and treated by the same methods, from which certain comparisons may be made. None of these five cases of atypical pneumonia had any previous history of chest troubles, but two had had an infection of the upper respiratory tract within the month prior to this infection. In all cases the onset was sudden and acute with malaise, shivering and cough. Only one case had the typical tenacious rusty sputum of pneumonia, but two complained of a pleuritic type of pain on the affected side. Sputum in all cases was scanty in amount and mucopurulent in character. On culture, Pneumococci were grown from all, but in four cases there was a considerable co-existing growth of respiratory commensals, and the Pneumococci did not belong to either of Types I, II or III. In only one case (Case 50) were Type I isolated in pure culture. Leucocytosis was not usually well developed, most commonly being between 12,000 and 18,000/c.m.m. In one of the more severe cases it did not at any time exceed 9,000/c.m.m. The temperature in the early stages was in all cases at or about 104°, and fell slowly by lysis, no true crisis occurring in any of the cases. Its duration varied between fifteen days and fifty-four days. In spite of the fact that x-rays showed the process to be one of pneumonic consolidation, affecting the whole or greater part of a lobe, the physical signs were not those generally found in pneumonic consolidation. In all cases the physical signs were most marked in the right lower zone between the mid-axillary and posterior axillary lines. In two cases they were those of grossly diminished movement with marked dullness, which was not stony in character, tubular breath sounds and a few medium crepitations: but within seven days, without any alteration in the degree or character of the dullness, the breath sounds had become almost completely suppressed, and only occasional crepitations could be heard in the affected area. In the other three cases the breath sounds were wholly or grossly suppressed from the outset. A few crepitations could be heard, and dullness was marked but not stony. Vocal resonance was usually accentuated, most markedly in the cases in which the breath sounds were primarily bronchial. Neither the x-ray appearances nor exploratory puncture revealed any collection of fluid or pus within the pleural cavity. In all five cases the x-ray appearances were remarkably constant. In all, the area involved was the right middle lobe, diagnosed by the characteristic

triangular shadow extending forward and downwards from the hilum in the lateral view. The whole lobe was involved in three cases, and the greater part of it in the other two. In all but one case there was marked elevation of the right dome of the diaphragm, but no evidence of any shift of the mediastinum either to the right or to the left. This elevation of the right dome of the diaphragm was usually maximal when the case first came under observation, and became progressively less as resolution proceeded. Elevation of either dome of the diaphragm to a comparable extent was not observed in any of the cases of typical pneumococcal lobar pneumonia which have come under our care from the same sources during the same period of observation. It has, in fact, only been equalled, in cases such as post-operative atelectasis in which the infective element was minimal. In one case (No. 54) an unusual complication occurred. Eleven days after admission, when consolidation of the right middle lobe was marked with a small encysted effusion above it between the middle and upper lobes, x-ray showed the presence of a partial pneumothorax over the right upper lobe, extending down to the level of the effusion. This subsequently re-expanded at a normal speed. Only one similar case has been found in the literature. The x-rays are reproduced by Reimann (1938¹) and appear to be identical in every respect.

In all cases treatment was by infra-red radiations, postural drainage, and breathing exercises. In addition, sulphapyridine was given to four of the cases, owing to the severity of the toxæmia and the prolonged pyrexia. The effects of the infra-red irradiations on these seven cases are obvious to the observer but difficult to justify statistically. No effect on the pyrexia or toxæmia can be truly described in these cases in Group C, but in twenty cases of typical pneumococcal lobar pneumonia, which were treated in a similar manner, four cases became afebrile on the fourth day of the disease, which suggests that these irradiations may have an antipyretic effect, as already indicated by the results obtained in Groups A and B. Apart from this very debatable effect, however, two constant and marked results of such treatment have been noted in both typical and atypical pneumonias. They are not capable of mensuration, but are clinically very apparent. The first is that they induce in the patient a feeling of well-being which lasts for a period up to about two hours after the treatment. This is not entirely due to partial alleviation of pleuritic pain, since it occurs in patients who have neither pleural pain nor pleural friction, but would appear to be a non-specific effect. The second is a corollary of the first, in that this feeling of well being, if produced in the late evening, induces a sound sleep of several hours duration without the necessity of using sedatives. It was a common experience to find that many patients fell asleep during the course of the evening irradiation, and, subsequently slept the night through. Instructions were always left that any case of typical or atypical pneumonia which did not sleep spontaneously was to receive sedatives, but in twenty cases of the former and five of the latter only one case needed a sedative on one occasion. Such periods of natural sleep cannot but have a beneficial effect on the patient's powers of natural resistance. Both these effects have been noted by other observers, using diathermy, and are given especial prominence by Forbett (1937). In these five cases of atypical lobar pneumonia, postural

drainage and breathing exercises were instituted, being begun earlier than in Groups A and B with slight modifications before the patient became afebrile. Two factors suggested this alteration in technique. First, the element of atelectasis present, as indicated by the elevation of the diaphragm on the affected side and the gross suppression of breath sounds with only a relative degree of dullness on percussion, suggested that there was probably some bronchial obstruction present, the most likely cause of this being tenacious bronchial secretions. Postural drainage was therefore introduced when atelectasis was suspected and crepitations were not numerous, and it had the effect of increasing the amount of sputum and the number of crepitations to be heard. It was usually supplemented by fine manual vibrations to the chest wall. Breathing exercises in the form of education in relaxed rhythmical breathing was also instituted at approximately the same period, with the object of alleviating the incipient anoxaemia ^{which} with the rapid shallow breathing produces in such cases. As already stated, sulphapyridine was given to four of the five cases in full therapeutic doses, but in only one case did it have the usual effect (Case 46). In the other three cases there was a transitory drop in temperature of 1 - 2° during the period of administration of the drug, with a subsequent return to previous levels. There was no demonstrable effect upon either the local process within the lung, nor upon the general course of the disease. This phenomenon has also been noted by Longcape (1942), but no very satisfactory reason for its occurrence can be put forward. It may in part be due to the fact that such cases are not due to a pure pneumococcal infection, but this is not a complete explanation, since Type I Pneumococci were isolated from the sputum of case 50, which, as already noted, was resistant to Sulphapyridine. Another possible factor of unknown significance is the relatively low leucocytosis in these cases.

It is as yet too early to assess the final results in these five cases, since all have occurred within the past ten months. In general, resolution has been grossly delayed, and in two cases it has been incomplete. Cases 46 and 48 were completely resolved except for evidence of some residual thickening of the pleura between upper and middle lobes after forty-five and seventy-six days respectively. Case 47 showed only some irregularity of the outline of the right diaphragm after seventy-nine days. Case 50 still showed a small amount of fibrosis in the affected lobe after 103 days. Case 54 showed considerable fibrosis in the affected lobe with commencing traction upon the mediastinum after 134 days. Bronchoscopy was carried out on this case during convalescence, but did not reveal any significant changes. It is unfortunate that Service circumstances made it impossible to follow up these cases for longer periods.

Conclusions:-

The conclusions to be drawn from this series of cases are limited if drawn from them alone, but taken either in conjunction or in comparison with reports of similar cases they have a greater import. The incidence of Groups A and B has already been discussed, and it is probably true to say that the

apparently high incidence amongst service personnel is due to a combination of a true increase coincident with the increase in communal living, and of an increase in the number of cases recognised. This latter is not so much an index of the thoroughness with which cases of upper respiratory catarrh are examined in service hospitals; but rather of the fact that in civil life, such cases would seldom come under observation. No real comment can be made upon the incidence of the rather unusual series of cases described in Group C. The bronchopneumonic type have been regarded as a more virulent and widespread manifestation of the same underlying process as occurs in Group A and B, and they are of relatively rare occurrence. The lobar type have been regarded as intermediate between bronchopneumonia and a typical lobar pneumonia, and are probably relatively rare. Few such cases have been reported, and it would seem most unusual that all the cases here reviewed should have involved only the right middle lobe, and that five such cases should occur over a comparatively short time during which only twenty cases of typical lobar pneumonia occurred. The series is too small and the statistical reviews of pneumonia too beset with pitfalls for any real significance to be attached to this, but in Hutchison's (1942) series, drawn from Army personnel in the present war, the right middle lobe was affected in only one out of forty-one cases of lobar pneumonia.

The aetiology of these cases of atypical pneumonia is probably inconstant, and depends upon the interplay of several factors. The main ones involved are upper respiratory catarrh, irrespective of whether or not this is due to a virus infection, secondary invasion with respiratory commensals or pathogens, and the general and local resistance of the subject. The rôle of upper respiratory catarrh is probably fairly constant. It was found to be present almost without exception in Groups A and B, and as has already been noted, the duration of symptoms prior to admission is longer in the cases in Group B. In the more severe cases of Group C a shortening of the prodromal period occurs, the duration being usually only one day, and the symptoms complained of are those which are common to any acute febrile disease in its invasive stage. But in this connection, it should be noted that many writers postulate that lobar pneumonia is constantly preceded by an upper respiratory infection. In Group C, those cases of the bronchopneumonic type did have some such symptoms, but they were usually lacking in the lobar type. To summarise, acute febrile catarrh would appear, from its constant presence, to play a part in the aetiology of atypical pneumonia of Groups A and B, and the bronchopneumonic type of Group C; and its most likely rôle is that by lowering local resistance, it allows secondary invasion of the lung. As already stated both Stewart-Harris, Scadding and French believe that the precipitating factor is the influenza virus, with subsequent secondary infection with other organisms, the type of lesion resulting being dependant upon the particular organism involved: and the virus has been isolated from a number of such cases. No case of clinical influenza was seen in our series, but there is no reason to doubt that during influenzal epidemics the virus plays the same part as does the causal agent of acute febrile catarrh in ordinary times. From the wide variety of organisms which have been isolated from the sputum, and from the lung itself by lung

puncture or at necropsy, both in this and other series, it would appear that practically all the micro-organisms capable of invading the body may, under suitable circumstances, give rise to any of the possible pulmonary lesions. Both Scadding (1937) and Logan (1921) suggest that pneumococci are more predominant in the more extensive and severe cases, a suggestion which is borne out by our own cases, but it is more probably true in view of the work of Eyre and Cole, that the predominant organism varies from one outbreak to another. The last and unpredictable factor in the aetiology is the group of unknown quantities which are involved in variations in local and general resistance of the patient. Maxwell has suggested that such lesions as have been described in Group A occur when the general and local resistance of the patient is high: that cases such as Group C are the result of low general and high local resistance: and that low local resistance and high general resistance result in lesions such as lung abscess. Such speculation adds nothing to our knowledge of the disease, since we know ^{little} either of the factors controlling these varying resistances and less about their assessment.

The pathology of conditions in which fatal cases are infrequent is largely by inference, but in this case a reasonable guess may be made because of the close similarity between this type of case and those pulmonary complications of acute epidemic influenza. Indeed, the two may very well be regarded as the same condition, since clinically the pulmonary conditions cannot be distinguished, and the only difference lies in the fact that in one the initial illness is an acute febrile catarrh and in the other acute influenza, a difference which is probably one of degree rather than type. There are many descriptions of the early uncomplicated pulmonary lesion found in acute influenza, by French (1920) Malloch and Rhea (1920) and Adams. An invariable finding was a tracheobronchitis involving the region of the bifurcation of the trachea, and spreading upwards towards the larynx and downwards into the main bronchi and their branches. The mucosa was intensely congested and covered with a loose greyish purulent exudate. In the lung, before becoming overlaid by secondary developments, the lesion was a focal interstitial bronchopneumonia, the alveoli involved not being those of the lobule supplied by the affected bronchiole, but rather those alveoli lying immediately adjacent to the bronchiole. The consolidated alveoli were filled with a loose exudate of leucocytes and lymphocytes with a small amount of fibrin, but never to the same extent as in lobar pneumonia. Allen (1936) in a series of cases which did not occur during an epidemic of influenza, describes the process as being an inflammatory and exudative extension from bronchioles into the surrounding alveoli in a localised portion of a lobe or lobes. Bowen (1935) describes it as differing from bronchopneumonia in that it rather resembles the exudative inflammation which surrounds a lung abscess. These descriptions make up a fairly constant picture with which the cases in the present series are quite compatible. The severity of the condition may vary, but the underlying essential process remains constant. The spread outwards from bronchi and bronchiole of the affected lobe or lobes is a characteristic and easily distinguishable feature of the x-rays.

Stewart-Harris believes that there is in addition an element of patchy atelectasis present. In view of the primary seat of the process in the walls of the smaller bronchi and bronchioles and the exudate which forms there, it is quite possible that small areas of partial atelectasis may appear during the course of the disease. Some support is given to this by the way in which the breath sounds return rapidly to normal strength once a productive cough has appeared. In the more severe cases with a lobar distribution, Longcope (1942) has described the post mortem appearances as being a deep red, moist solidification of the affected lobe, with the bronchi filled with pus. Microscopically, the intra-alveolar septa are thickened, and the alveoli contain a loose exudate of erythrocytes, mononucleous and serum. There is considerable oedema of the part, and a marked absence of polymorphs. In even more severe cases this haemorrhagic oedema becomes more profuse, and the appearance of the lungs is very similar to that produced by inhalation of poison gas, as described by Opre (1928). If this pathological state described by Longcope is the one which has been present in the cases in Group C which had a lobar distribution, then the type of this inflammation and the relatively mild leucocytosis which was present are a partial explanation of their protracted course. Two other factors are also present however. These cases would appear to differ from typical lobar pneumonia in their mode of spread. The mode of spread of lobar pneumonia is debatable. On experimental grounds it would seem from work such as that of Blake and Cecil (1920) that the organisms gain entrance near the root of the lung by penetration of the wall of a large bronchus, and thereafter spread along the interstitial tissue outwards from the hilum. Radiologically, however, Reimann (1938¹) Shanks, Kerley and Twining (1938) and Davies, Hodgson and Whitby (1935³) believe that signs of pneumonia are first evident in the more peripheral parts of the lung, and that the so-called central pneumonia is a rarity. Many cases which are apparently central in a P.A. view, showing themselves to start peripherally in a lateral view. In the lobar cases in Group C, the consolidation was not always complete in the early stages, allowing of some appreciation of the lung tissue in the affected lobe, and in these cases it was an invariable finding that the process was most intense around the main bronchi to the lobe and spread radially from there. This suggests that even in these cases with a lobar distribution the process starts within the bronchial walls, and would appear to differ slightly from either the bacteriological or radiological concept of spread in typical lobar pneumonia. The other factor is the suggestion of atelectasis which was present in four of the five cases. Henderson et alia (1930) and Coryllos and Beinbaum (1929) state that the first stage in the development of a lobar pneumonia is the appearance of a catarrh which plugs the airways with a thick sticky secretion, leading to a pneumococcal atelectasis. Davies, Hodgson and Whitby (1935) state that the diaphragm is always raised on the affected side in pneumonia, and suggest that the more rapid the onset of the disease the greater is the likelihood of atelectasis occurring. With this statement it is impossible to agree. In twenty cases of typical lobar pneumonia which have been x-rayed on admission and at frequent intervals during the course of the disease, there has been no evidence of the diaphragm being raised. There would seem to be no doubt, however, that atelectasis can occur in certain cases typical of lobar pneumonia. Telling and Oliver (1938) ascribe it to congestion of the bronchial mucosa,

and Erwin and McGill (1938) describe cases of lobar pneumonia in which breath sounds were absent or grossly suppressed. This they ascribe to coincidental blockage of the bronchi, which in one case was confirmed by bronchoscopy. Nicholas and Agassiz (1938) describe lobar forms of atypical pneumonia usually occurring in the right middle or lower lobes, with an associated element of atelectasis, and often running a chronic course. From a comparison of these descriptions with the cases which have been described in this series, it would seem probable that the pathological process in these lobar forms commences as an acute catarrh in the main bronchi to a lobe, frequently the right middle lobe, coincident with an acute febrile reaction. This local inflammatory process is then augmented by secondary infection and spreads peripherally down the branches of the bronchi, and radially outwards into the adjacent alveoli, producing a loose consolidation in which the predominant cell is the mononuclear. At the same time, the exudate within the bronchi partially occludes their lumen, and leads to varying degrees of atelectasis. Such a process is fundamentally the same as occurs in Groups A and B, the difference being one of degree, and being probably a result of variance in the pathogenicity of the secondary invaders. It also partially explains the relative resistance of such cases to sulphapyridine therapy, and their protracted course. No explanation can be offered for the interesting and unusual predilection of the cases in this Group for the right middle lobe.

Part of the purpose of this investigation has been an attempt to assess the value of physiotherapeutic measures in the treatment of non-tuberculous pneumonic infections. The conclusion drawn is that their value is very real, but has a limited application, chiefly owing to the great calls which they make upon the skill, patience and time of the masseur. The results which have been obtained have already been described, but they may be usefully recapitulated. Infra-red irradiations cannot be proved to have any specific therapeutic effect on a pneumonic process. But it is known that they can penetrate sufficiently far through the body to produce a local effect on the lungs: local heat produced in a pneumonic lung by means of long wave diathermy has been proved experimentally to result in an increase in the local blood supply; and the effect of infra-red irradiations on subcutaneous infections such as whitlows is to produce rapid and satisfactory localisation of the infection with pus formation. By analogy therefore, one may presume some local therapeutic effect, which may be reflected in the probable decrease in the time required for complete cure in cases so treated. Secondly, there is some evidence that the rays have a mild antipyretic action, but this cannot be more than a tentative suggestion, pending further experience. Lastly, their most obvious value lies in the sense of well being and the long periods of natural sleep which they induce. These effects lose some of the value with which they might have been credited prior to the introduction of sulphapyridine. But nevertheless, sulphapyridine is by no means a specific cure for all cases of pneumonia, and ancillary measures are therefore not to be despised. The discussion on the pathology of these cases constitutes the indication for the use of postural drainage as a part of the treatment. In theory, there is a sound physiological basis for the use of postural drainage combined with fine manual

vibrations to the chest wall for facilitating expectoration of sputum. In practice, it is almost invariable to find that patients bring up sputum more copiously and more easily after this treatment has been begun. It is not claimed that this entirely banishes the element of atelectasis present, but it probably hastens the natural re-expansion of the lung, and prevents atelectasis that is already present from becoming worse. It would be most effective if an expectorant mixture were given at the same time. This was never done in this series, as it was desired to observe the effect of postural drainage when used alone. The breathing exercises serve a twofold purpose. During the middle stages of the disease they combat anoxaemia and aid normal drainage of the affected lung; and during convalescence they are, in our opinion, an essential part of rehabilitation. During the febrile stage of any acute pulmonary infection there is always a tendency for anoxaemia to develop, due, as Haldane and Priestley (1935) have shown, to the alteration in respiratory mechanics which occur when a part of the lung is the site of an acute infective process. Such anoxaemia has a deleterious effect upon the patient. It has a none the less real though less marked effect when it is present in slight or subclinical degree. It may be treated either symptomatically, by the administration of oxygen, or fundamentally by giving the patient lessons in relaxed breathing, and teaching him to make efficient use of his functioning lung tissue. The symptomatic relief which the patient enjoys as a result is commensurate with that given by oxygen. According to Boyd (1940) the lung is not a passive agent in respiration, but is a contractive organ permeated with non-striated muscle tissue, and during normal respiration drainage occurs naturally. During pneumonia, however, normal movement in the affected lobe practically ceases, and consequently drainage also diminishes. During the stage of early resolution therefore, breathing exercises are introduced to promote movement in the affected part, and so promote drainage from the part. This is especially valuable when an element of atelectasis is present, and has been applied with success to a number of cases of complete atelectasis of one lobe, occurring especially as a post-operative complication. It might be argued that such measures, by the mechanical effect of disturbing diseased tissues, might light up the inflammation anew and spread it to new foci, or by traction on diseased bronchial walls, lay the seeds of a future bronchiectasis. Against this, it is pointed out that these regional breathing exercises have never been used until after the patient was afebrile, and no indication of reactivation of the lesion or development of fresh lesions was noted as judged either by a return of pyrexia or by untoward physical signs. Also, it is probably more harmful for bronchi to be bathed in infected secretions for a prolonged period than to have these removed relatively promptly by measures which cause movement and traction in the diseased area. Rehabilitation has recently received some much-needed and much-deserved publicity in relation to orthopaedic injuries. Rehabilitation in relation to pneumonia is as important, and does not receive the attention it merits. It is not sufficient after a patient has recovered from pneumonia, to send him to a convalescent hospital for three weeks or so, followed by a return to light duty for a further short period. It is not an unusual experience to see a man who has had pneumonia some months previously reporting sick

complaining of lack of energy, cough and dyspnoea on exertion. On examining such a case, it is usual to find poor movement over the lobe which was affected, with diminished air entry and occasional crepitations. Such cases should be very exceptional with proper rehabilitation. This takes the form of breathing exercises designed to re-educate the patient in the use of the affected part of the chest, and correct any other breathing errors which may be incidentally present. These latter are found frequently. The exercises are given during early convalescence, and the patient continues them at the convalescent hospital. Where there is any doubt about the patient's physical stamina when he is due to return to duty, he is put on light duties and given a course of graduated physical exercises by the Physical Training Officer for two or three weeks. It is our belief that patients who are so treated are subsequently fitter than they otherwise would be. The failure of four cases in Group C to respond to sulphapyridine therapy is a reminder that it is not a panacea for all forms of pneumonia. There is no evidence that its administration in such resistant cases has a deleterious effect, but nevertheless any drug of such potency should not be used indiscriminately but reserved for those cases in which there are clear indications for its use. The results in Groups A and B have been, complete resolution in every case. No record of incomplete cure in such cases has been found, and the prognosis is unfirmly good. In Group C, the bronchopneumonic variety have a fairly good prognosis. The course is longer and more severe than in Group B, but in the four cases observed resolution was ultimately complete, and this appears to be the usual result. In the lobar type, however, there is a much greater risk of incomplete recovery. One of the cases described (Case 50) had some mild residual pulmonary fibrosis when last seen four months after the onset. Another (Case 54) has considerable residual fibrosis with some traction upon the mediastinum at the present time, four and a half months since the onset. There may be some further slight improvement in these two cases, but it would appear that the prognosis in such cases of atypical lobar pneumonia affecting the right middle lobe is worse than that of lobar pneumonia in other sites.

Summary.

- (1) Atypical pneumonia is relatively common in the R.A.F., and a series of fifty-four cases are reviewed.
- (2) The cases can be subdivided according to severity. A number of typical cases from each group are described in detail, and the clinical features are compared with other descriptions.
- (3) The aetiology is probably analagous to that of influenzal pneumonia, in that any upper respiratory infection paves the way for invasion of the lung by pathogenic organisms.
- (4) The pathology is that of an acute tracheobronchitis, with secondary invasion causing a bronchiopneumonia with small areas of lobular partial atelectosis. This fundamental process may be present in all degrees of severity.

- 5) Atypical pneumonia of a more lobar distribution and affecting the right middle lobe, runs a prolonged course, is resistant to sulphapyridine, and has an increased risk of resultant fibrosis.

APPENDIX ON THE
TECHNIQUE OF
PHYSIOTHERAPEUTIC MEASURES.

in the
TREATMENT OF PNEUMONIA.

by

Corporal J.H. Smith. R.A.F.

Observations made during the physical treatment of unresolved and convalescent pneumonias suggested the possibility of extending the use of certain methods to the more acute phase of the disease. It was considered that by so doing, it might be possible to reduce the period required for convalescence: and by exercising more careful control over rehabilitation to secure a higher level of physical efficiency as an ultimate result. Particular interest was centred on the extensive disturbance of respiratory mechanics which accompanies typical and atypical pneumonia and which can constitute a serious embarrassment at a time when the resources of the body are fully mobilised.

The general scheme and sequence of treatment employed in the series of cases reported in the body of this paper is indicated as follows:-

- | | |
|----------------------------|--|
| (1) Early treatment | (a) Long wave infra-red irradiation. |
| | (b) Postural support. |
| | (c) Sedative manual vibrations to chest. |
| (2) Intermediate. | (d) Rhythmic relaxed breathing - change of posture. |
| (3) Commencing resolution. | (e) Postural drainage. |
| | (f) Chest shaking. |
| (4) Advanced resolution. | (g) Chest clapping. |
| | (h) Regional breathing re-education. |
| (5) Convalescence. | (i) Postural re-education & graduated physical training. |

These physiotherapeutic measures were chosen to meet the problems in applied physiology which arise with varying severity throughout the course of the disease. The scheme of treatment outlined above is modified to suit the requirements of each individual case.

1. EARLY TREATMENT.

(a) Infra-Red Irradiation.

The work of Stewart (1922 - 1934) and other observers has established the therapeutic value of long wave diathermy in pneumonia, whilst favourable reports on the more recently introduced ultra short wave therapy have been given by Torbett (1937) Coulter & Osborne (1939). Unfortunately either method requires the use of expensive equipment which is not always at hand. Infra-red radiation however, is provided by relatively inexpensive apparatus which is readily available for use both in hospital and private practice. In our experience, infra-red therapy has, with careful regulation of dosage, proved of value in many types of infective condition and there were reasonable grounds for expecting a favourable response in pneumonia and particularly in the co-existing pleurisy.

Infra-red rays are emanations having a wavelength extending from approximately 8,000 Å.U. to the region of short Hertzian waves. They are generally held to have only limited powers of tissue penetration. This contention is mainly based upon temperature recordings obtained by implanting thermocouples at varying depths and makes the possibility fallacious assumption that a rise in tissue temperature is the sole criterion of therapeutic value. The generally accepted view regarding the penetration of infra-red rays is disproved by an experiment reported by Heald (1938) in which he was able to

demonstrate activation of a photoelectric cell by infra-red radiations after passage through the full thickness of a forearm. Clinical evidence of penetration is furnished by the rapid and favourable response which occurs in acute infections of the maxillary antra and other accessory sinuses. We have found that satisfactory results both in these conditions and in local pyogenic infections were only obtained with short exposures of moderate intensity. In our experience, prolonged exposures to radiation of high intensity have no beneficial effects. The uniformity with which good results are obtained with a standard (minimal dosage) technique, in spite of wide variations in the types of causal organism suggest that the beneficial effects are rather due to the influence of the waves upon the tissues than upon the bacteria.

Experience in the treatment of sinus infections by minimal dosage infra-red irradiation provided the basis of the standardised infra-red technique which we have employed in pneumonia. Fifteen minute exposures are given four hourly throughout the day using non-luminous radiations derived from a Watson "Sunid" infra-red generator. This apparatus employs an open wire-wound element mounted in a large parabolic reflector. Full operational temperature is attained after about five minutes pre-heating and a distance of twenty-four inches from the patient has been found to provide optimum intensity.

Three main fields of irradiation are employed according to the position of the involved areas of lung and distribution of pleuritic pain. The points of focus for these fields are:-

- (1) Infra-clavicular.
- (2) Upper or lower axilla.
- (3) Infra-scapular.

In severe cases this posterior irradiation is not introduced until the patient's general condition justifies the necessary change of position. In addition, irradiation of the anterior chest including the cardiac area is especially used where distress is pronounced and also as a final sedative treatment in the late evening during the period of restlessness and high pyrexia. The marked relief and comfort which is afforded by precordial irradiation may be partly due to stimulation of the coronary circulation, an effect which Stewart (1934) considers to be one of the most important results of diathermy treatment.

(b) POSTURAL SUPPORT.

The possibility of minimising anoxaemia by attention to posture was considered in the light of Haldane & Priestly's conception of respiratory physiology (Haldane & Priestly - 1935). Haldane has drawn attention to the fact that the normal lung movements as described by Keith (1909) are not conducive to the uniform distribution of air within the lung. Experimental evidence is provided which shows that this imperfect alveolar ventilation is greatly accentuated in the recumbent position and that anoxaemia is more readily produced. In view of this, there appeared to be some justification for the maintenance of a more erect position than is generally employed in nursing pneumonic patients. As a further contribution towards improved respiratory mechanics, particular attention was given to supporting the complimentary curves of the spine. The usual arrangement of pillows which raises the head and shoulders without providing adequate support for the lumbar and cervical spine, allows the body to sag and permits postural defects which are unfavourable both to respiration and the subsequent restoration of healthy body

mechanics. The main objects of good postural support are thus enumerated:-

- (1) To secure a more perfect unfolding of the lungs during inspiration with the opening up of fresh alveoli and their associated capillary bed - (relief of anoxaemia)
- (2) To assist diaphragmatic movements which, in their inspiratory phase are considered by Keith to constitute the most important factor in the filling of the right heart. (Augments cardiac output.)
- (3) To enable the abdominal musculature to maintain the positive intra-abdominal pressure which further assists the return of blood to the right heart.
- (4) To avoid serious reduction of antero-posterior diameter of the mediastinum and undesirable compression of the heart and great vessels.
- (5) To maintain the post-vertebral antigravity muscles within their range of maximum postural efficiency.

The clinical significance of these mechanical factors has been stressed by Goldthwait, Brown, Swain and Kuhns in their work on body mechanics. (1937).

(c) Manual Vibrations.

The sedative value of fine manual vibrations is well recognised in Scandinavia. Cyriax, E. (1903, 1924, 1939) & Cyriax, J.H. (1939) have advocated the more extensive use of these manipulations as being of the greatest assistance in the induction of muscle relaxation. An examination of chest movements in acute pneumonia revealed a tendency for inspiratory rib elevation to persist during the expiratory phase. This not only prevents a full tidal expulsion of air but also leads to the sustained alveolar dilatation of an adventitious emphysema. Emphysema is frequently termed "compensatory", a definition we find hard to accept as respiratory compensation can only be established by the active ventilation of fresh alveoli. Emphysema will, through an increase of residual volume and reduction of supplemental air, directly contribute to anoxaemia. Observation suggested that loss of expiratory movement was largely due to the manubrium sterni and upper ribs by over-action of the anterior and lateral cervical muscles. Fine manual vibrations have proved an effective means of reducing this undesirable muscular tension and are applied in conjunction with infra-red treatment. This combined treatment quickly produces relief of pleuritic pain and with the inception of more balanced thoracic and diaphragmatic movements, breathing soon becomes easier and more effectual. Vibrations are applied with the lightest possible touch over the anterior and lateral chest for a period of about five minutes. As Cyriax has pointed out, these manipulations call for skillful application.

2. INTERMEDIATE TREATMENT.

(d) Relaxed Rhythmic Breathing - Change of Posture.

The introduction of relaxed rhythmic breathing marks the transition from the purely passive treatment provided by the methods already described and more vigorous measures in which the patient takes an increasingly active part. Advantage

is taken of the symptomatic relief afforded by earlier treatment and the patient is encouraged to extend the ventilation of the unaffected areas of lung. This does not imply forced or deep breathing. On the contrary, one aims at rhythmic excursions of only moderate depth with full participation of the diaphragm, reducing the use of extrinsic muscles to a minimum. The main object is to obtain relaxation and a normal respiratory rhythm. The value of this relaxed breathing has been shown in the treatment of Da Costa's Syndrome.

"Change of Posture" simply means, short periods in side-lying. It permits infra-red irradiation of the posterior lung fields and reduces the tendency to hypostatic congestion. Twenty minute sessions in side-lying are introduced twice during the day when the stage of initial distress has passed.

3. STAGE OF COMMENCING RESOLUTION.

(e) Postural Drainage - Chest Shaking.

Commencement of resolution is the signal for the introduction of conventional postural drainage. An endeavour has been made to increase the effectiveness of this method by the addition of gentle chest shaking which is given whilst the patient occupies the appropriate drainage position. These manipulations may be regarded as coarse manual vibrations and are applied to the affected side of the chest only during expiration. This ensures that any secretions dislodged from the atrial or bronchiolar walls are carried towards the larger branches of the bronchial tree.

Progress during the more advanced stages of resolution is assisted by gentle chest clapping. This classical Swedish manipulation has long held a place of honour in the treatment of chronic respiratory disease. Its judicious application in the later stages of pneumonic or pneumonitic resolution has proved of definite value and is used in conjunction with relaxed breathing. Sputum is usually increased, gaseous interchange is promoted through agitation of air within the lung and re-expansion and ventilation of alveoli in the involved areas is facilitated. The treatment is stimulating and most patients spontaneously express appreciation of the feeling of general well-being which follows and which does much to arouse an active interest in the final steps leading to full recovery.

4. STAGE OF ADVANCED RESOLUTION

Breathing Exercises.

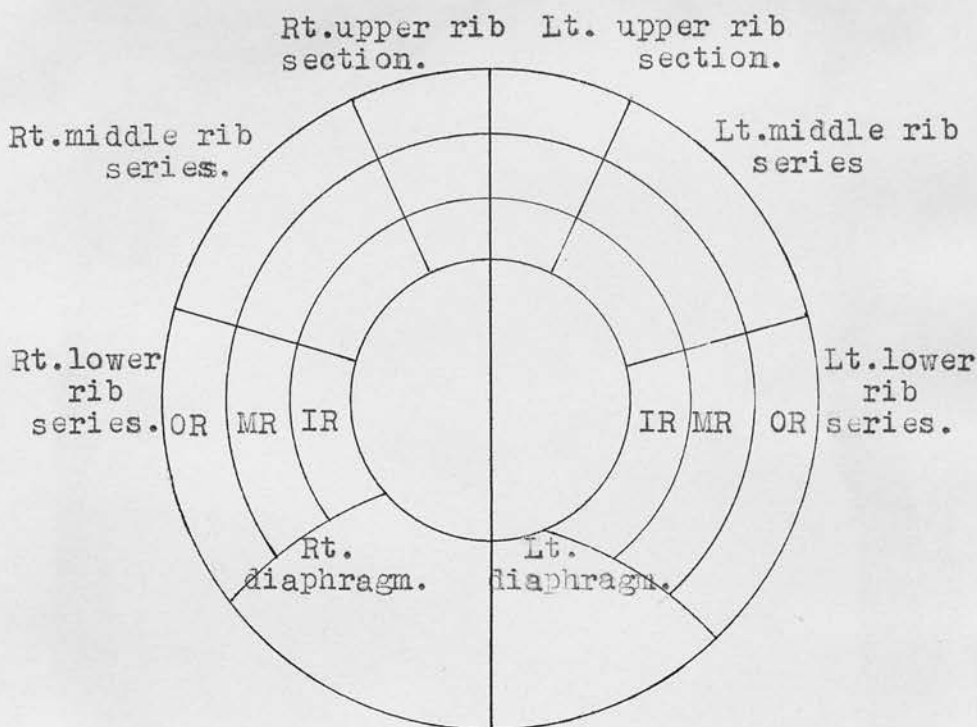
"Ample time should be allowed for convalescence and work should not be resumed for about two months after the crisis. Psychoneurotic symptoms are common in those who return to routine duties too soon. The patient should practice daily for several months, exercises to restore full mobility and expansion in the lung. These exercises are of the greatest importance in children. If carried out as a routine, the incidence of sequelae such as bronchiectasis would be considerably reduced."

.....Lobar Pneumonia....W.D.W. Brooks & Geoffrey Marshall. "Textbook of Medicine - Conybeare".

(h) Regional Breathing Re-education.

As previously indicated, pneumonia is usually associated with alterations in respiratory mechanics which are

not entirely physiological in character. This imbalance tends to persist after resolution of the primary condition thus leading to a continuance of disordered respiration and a lowered functional efficiency. The restoration of sound respiratory mechanics is essentially a process of physiological adjustment based on the accurate interpretation of existing abnormalities. This entails a detailed analysis of thoracic movements and it was felt that the choice of appropriate treatment and the observation of subsequent progress would be facilitated if the results of examination could be recorded in schematic form. A diagrammatic attempt to correlate the essential factors is indicated in the figure shown below.



OR - outer range thoracic movements. MR - middle range thoracic movements.

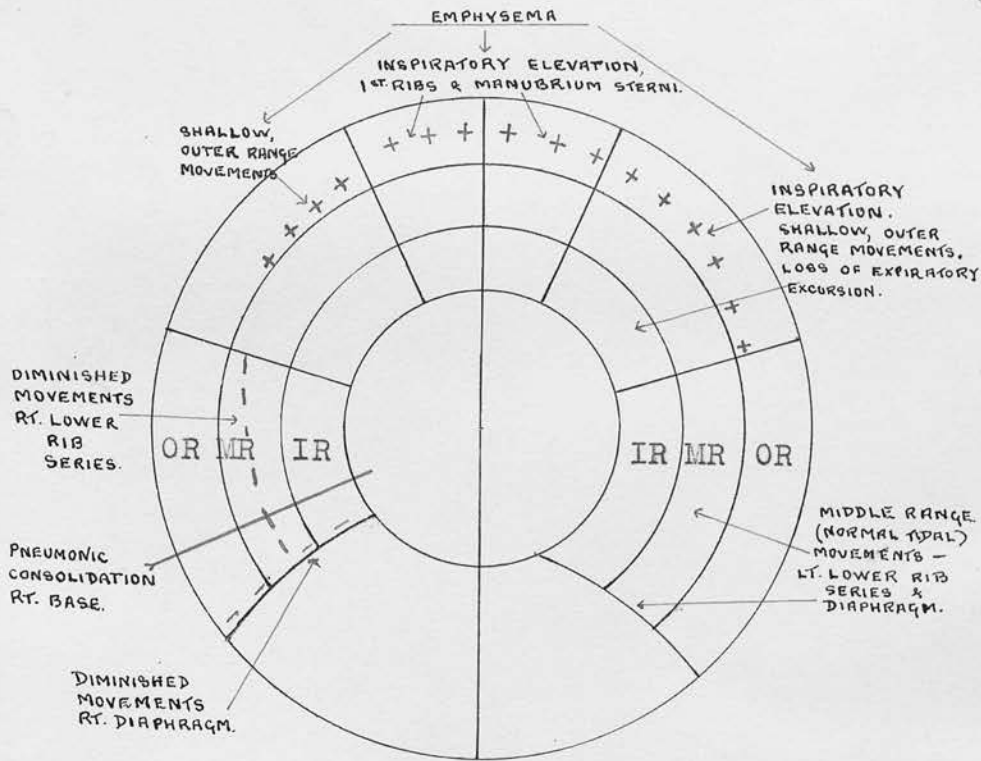
IR - inner range thoracic movements.

Two concentric circles define the arbitrary limits of the total respiratory excursion. The annular space contained by these circles is further divided into three zones corresponding to inner, middle and outer range thoracic movements and designated-IR.MR. and OR., respectively. Either side of the bisecting line which provides for the two halves of the chest, are three sectors which correspond with the segmental division of the thoracic cage as defined by Keith, and comprising:- an upper section consisting of the first rib and manubrium sterni; a middle rib series extending from the second to fifth rib; and a lower rib series embraced by the sixth to tenth ribs. The two leaves of the diaphragm are conventionally depicted in the lower quadrant of the figure.

Analysis of abnormal respiratory mechanics. Loss of ventilation arising from impaired function in any section of the lungs will normally be compensated by increased aeration of the unaffected areas - a physiological response to pathological change. Theoretically, the wide margin between normal tidal volume and maximum supplemental reserve, should permit a large measure of compensation without difficulty. If we consider the normal tidal excursion as the occupying the middle range of thoracic and diaphragmatic movements, physiological increase of ventilation will require an inspiratory extension towards the outer range and a highly important increase of expiratory excursion extending through the inner range. This balanced increase of total movement is essential if a satisfactory ratio between residual and supplemental air is to be maintained. In practice, it is frequently found that demands for compensatory aeration are not met by a balanced adjustment of thoracic and diaphragmatic movement. There is in fact, a marked tendency for certain sections of the chest to over ventilate whilst other sections remain relatively inactive. The work of establishing healthy mechanics will therefore have to recognise the need for inhibiting over-activity in some parts of the thorax whilst stimulating the more active participation of other sections. These points may well be considered in their clinical relationship as it occurs in a typical case of pneumonic consolidation involving the right lower lobe. There may usually be found:-

- (1) Diminished movement of the lower rib series of the affected side.
- (2) Corresponding diminution of diaphragmatic movements on the affected side.
- (3) Bilateral elevation of the upper rib section (1st. rib and manubrium).
- (4) Moderate elevation of the right middle rib series with poor expiratory excursion.
- (5) Marked elevation of the left middle rib series with poor expiratory excursion.
- (6) Middle range movements of the left lower rib series with moderate diaphragmatic movements on this side.

A diagrammatic presentation is seen overleaf.



Disordered Thoracic Mechanics -
Pneumonia Rt. Base.

The above details are described as they may be seen in the acute stage of the disease. Considerable improvement will have resulted from use of the methods already discussed but the initial disturbance of respiratory mechanics remains the guiding factor in final re-education.

The achievement of successful re-education of breathing necessitates the alteration of faulty somatic and visceral reflexes by voluntary regulation and constant repetition of appropriate thoracic and diaphragmatic movements. Such movements are practised under supervision until they are so firmly established that they are executed subconsciously under all circumstances.

TECHNIQUE.General Observations.

Respiratory adjustment is taught with the patient comfortably supported in crook-half-lying (low Fowler's position). At no time are exaggerated "corrective" positions employed. Arm movements are also discarded in this technique. We are primarily concerned with postural activity and extrinsic muscle work must be reduced to a minimum. Good results are largely dependent upon the ability of the operator to engage the interest and co-operation of the patient.

Re-education as applied to the case previously cited as an example. (Pneumonic consolidation - Right Base)

(1) Treatment is initiated by rhythmic breathing and localised movements are not attempted until relaxation is attained. During this preparatory stage, the patient is instructed to allow the thorax to fully collapse during each expiration but forced expulsion of air must be avoided. The operator applies gentle shaking over the lower ribs as the patient exhales.

(2) Bi-lateral increase of lower rib movement with inhibition of the upper rib series.

With only a slight increase of inspiratory depth, the patient is encouraged to spread the lower ribs without expansion of the upper chest. A satisfactory excursion of the lower rib series is to be regarded as an essential prelude to diaphragmatic re-education. If the lower ribs approach their full inspiratory position before contraction of the diaphragm is well established, two favourable factors are introduced:-

- (a) The lower rib elevators are able to enter their inner range of contraction before the powerful diaphragmatic pull becomes manifest.
- (b) The costal origin of the diaphragm is well separated from the central tendon and a maximum inspiratory descent is rendered possible. Good lower rib movements are complementary to diaphragmatic function.

(3) Unilateral localisation of lower rib movement.

This entails selective activation of the right lower rib series with the simultaneous inhibition of movement elsewhere. The patient first exhales and then as he gently inhales, endeavours to expand the right lower chest. It is obvious that only a limited amount of air can be inspired as a result of this localised movement and the patient again exhales before general lung inflation commences. The operator can give some guidance by lightly applying his hands to the chest and indicating by touch, the position and nature of the required movement. Expansion of those areas in which temporary immobility is desired must not be opposed by pressure as external resistance will result in augmented tone and increased re-activity of muscles producing the movement against which resistance is applied.

(4) Symmetrical bi-lateral lower rib movements.

When activation of the affected areas of lung has been achieved by unilateral localisation, movements of the two sides of the chest are co-ordinated to establish uniform basal ventilation. At this stage, the depth of respiration is gradually increased until the lower ribs are freely moving through a full excursion that extends from the inner limits of expiration to the outer limits of inspiration. The voluntary limitation of upper thoracic movement is still continued. In

cases where an element of atelectasis is present, caution is required when increasing the depth of basal breathing, especially the inspiratory phase, in order to minimise the risk of producing bronchial dilatation.

(5) Re-education of diaphragmatic movements.

The diaphragm is generally regarded as the most important component of the respiratory muscle complex and vital capacity is largely determined by its functional efficiency. The longitudinal lung pull which accompanies inspiratory descent of the diaphragm also regarded as being chiefly responsible for apical ventilation - Keith (1909).

Heald (1922) has classified diaphragmatic movement as follows:-

- (a) Normal or physiological.
- (b) Stationary.
- (c) Reversed.

It is necessary to recognise that satisfactory thoracic mechanics can be established and abnormal mechanics of the diaphragm overlooked. This has been frequently recognised on radiological screening when, in spite of satisfactory rib movement, the excursion of the diaphragm may be partly or wholly suppressed or even reversed. When a good lateral excursion of the lower ribs has been achieved, re-education of the diaphragm usually presents no difficulty. The patient exhales and then inhales with expansion of the lower ribs. As these ribs approach their maximum elevation, the patient is instructed to protrude the abdominal wall during the final stage of inspiration. The operator's hands should lightly rest on the lower ribs and abdomen with the thumbs meeting the sub-costal angle and the outspread fingers embracing the costal margins and lateral abdominal wall. By this means it is possible to estimate the sub-costal abdominal movements which reciprocate with those of the diaphragm. The principle of unilateral localisation is applied in a similar manner to that already indicated for rib movements.

GENERAL TREATMENT SCHEME.

Physiotherapy is instituted as soon as pneumonia is diagnosed. Postural support is achieved by the use of a back rest and an ample supply of pillows. These are stacked horizontally to avoid hollows which permit sagging of the lumbar spine. Pillows under the thigh are more comfortable than the conventional knee bolster. The position approximates to Fowler's and, if available, an adjustable bed of the Nesbitt-Evans type is helpful.

Initial treatment consists of a fifteen minute infra-red irradiation of the anterior chest and fine manual vibrations. Subsequent infra-red irradiation is directed towards the affected area of lung with the exception of a treatment in the late evening. This final anterior chest irradiation is given between ten p.m. and midnight.

During the first forty-eight hours, treatment continues on the general lines indicated above. At the end of that time, clinical and radiographic findings are usually sufficiently well defined as to decide the future treatment of the individual case.

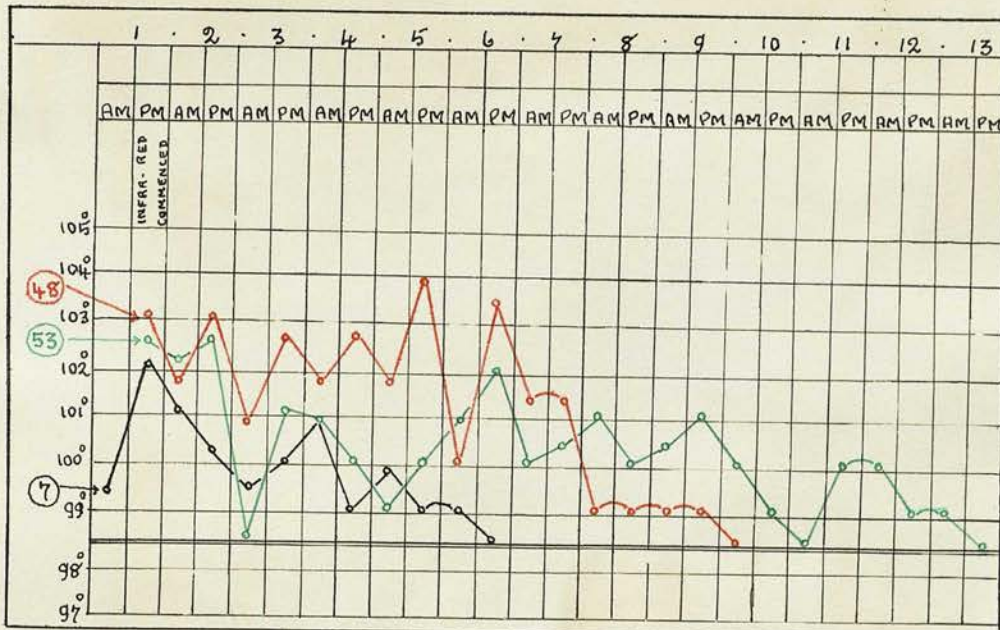
Adaptation of technique to meet clinical variations.

This can be conveniently discussed in connection with actual cases of differing type. Three cases have been chosen, each of which will serve to demonstrate the technique which is broadly applicable to the group it represents.

- (1) Case 7. Pneumonitis - Rt. lower zone.
(Group A).
- (2) Case 53. Broncho-pneumonia - Lt. lower and
mid-zone.
(Group B - extending to C).
- (3) Case 48. Incomplete Lobar Pneumonia with
atelectasis. (Rt. middle lobe.)
(Group C).

The temperature curves of the pyrexial stage of these cases are plotted on the chart shown below:-

Temperature Chart.



Case 7. Pneumonitis - Rt. lower zone.
Group A.

Case 53. Broncho-pneumonia - Lt. lower
Group B. and mid-zone.

Case 48. Incomplete Lobar pneumonia
with atelectasis. Rt. mid-zone.
Group C.

(1) Case 7. Pneumonitis.

X-ray findings:- Loose pneumonic consolidation in right lower zone, most dense towards cardio-phrenic angle. No evidence of atelectasis.

Physical signs:- Slight dullness, diminished air entry, inspiratory crepitations and increased V.R. at right base.

General shape of thorax good - little disturbance of chest mechanics but diminished excursion of Rt. diaphragm.

Treatment.

- 1st. day. Initial treatment scheme-infra-red nocte.
 2nd. day. Infra-red a.m., p.m. and nocte. Rhythmic relaxed breathing started.
 3rd. day. Air entry much improved. A.m. infra-scapular irradiation, gentle expiratory chest shaking, with patient in left side - lying. P.m. Position as above, lower axillary irradiation and expiratory chest shaking. No late treatment.
 4th. day. Rise of temperature previous evening. This reactive temporary pyrexia nearly always occurs when more active treatment is commenced and should return to previous level in twenty-four hours. If increased pyrexia persists, initial treatment scheme should be resumed.
 Treatment as on previous day.
 5th. day. Air entry satisfactory. Occasional medium pitched rhonchi over whole of rt. lung with creps. at base. Infra-~~(sc)~~-scapular and axillary infra-red irradiation continued B.D., postural drainage started and also gentle chest clapping begun.
 6th. day. Treatment as on previous day.
 7th. day. No rhonchi now only coarse creps at base. Infra-red discontinued. Regional breathing ~~(sc)~~ re-education commenced - chest clapping more vigorous. Progressive treatment on these lines was continued throughout the following week. At the end of this time, no physical signs were detected and x-ray showed resolution to be almost complete.

In this particular case, the absence of toxæmia and good general condition of the patient permitted the early institution of fairly active measures. The more severe cases in this group may verge on the broncho-pneumonic type and thus render it necessary to continue conservative treatment for a longer period.

(2) Case 53. Broncho-pneumonia.

- X-ray findings:- Consolidation of broncho-pneumonic type involving left lower and mid zones.
 Physical signs:- Few crepitations heard at left base towards end of inspiration. No dullness and B.S. normal. Slight toxæmia present.

Previous pneumonia in childhood. Aesthetic type - long thorax with narrow sub-costal angle. Movements diminished on affected side.

Treatment.

- 1st. day. Initial treatment scheme - infra-red nocte.
 2nd. day. As above.
 3rd. day. Postural change - infra-red irradiation of infra-scapular and axillary fields - fine sedative vibrations continued but no chest shaking.

- Temperature normal this a.m. but up to 101° in evening. Late infra-red treatment given.
- 4th. day. Treatment as on previous day.
- 5th. day. Feels well. Not much sputum. Slight dullness at left base, with some diminution of B.S., moderate number of medium crepitations and V.R. slightly increased.
Treatment still continues on conservative lines but rhythmic relaxed breathing begun. Infra-red nocte.
- 6th. day. Treatment continued as above.
- 7th. day. X-ray shows inflammatory process to be more marked but has not increased in extent. Now small focus in right infra-clavicular area. Treatment as on previous day - infra-red T.D.S. but late treatment now discontinued.
- 8th. day. Physical signs I.S.Q. - Postural drainage introduced. Still feels well.
- 9th. day. Temperature appears to be settling.
- 10th. day. B.S. at left base more diminished but increasing number of crepitations in mid zone. Some at right base but no diminution of B.S. Present treatment - infra-red bilateral infra-scapular, anterior, and left axillary fields. Rhythmic breathing and postural drainage.
- 11th. day. Temperature down. Gentle expiratory chest shakings added and very light chest clapping. Infra-red B.D. anterior and bilateral infra-scapular.
- 12th. day. Temperature rise last evening, (100°). and perspiring this a.m. - no chest shaking or clapping today.
- 13th. day. X-ray shows left side to be much improved and right side completely resolved.
- 14th. day. Temperature normal again. Basal breathing localisation commenced - chest clapping in prone-lying with chest inclined. Infra-red discontinued.
- 16th. day. Slight dullness at left base only. B.S. normal. Frequent medium crepitations at left base are the only accompaniments. Breathing re-education extended, otherwise treatment as above.
- 21st. day. X-ray shows chest almost clear - chest mechanics greatly improved - good basal localisation and diaphragmatic movements.
- 29th. day. Chest clear - feels very fit - exercise tolerance good.

This case is fairly typical of the broncho-pneumonic condition which requires careful regulation of treatment. Active measures are introduced with caution but the condition must not be allowed to become indolent. If due regard is paid to physical signs, x-ray findings and temperature response, there should be no difficulty in making the appropriate day by day adjustments of technique.

(3) Case 48. Incomplete lobar pneumonia with atelectasis.

X-ray findings:- There is inflammatory opacity of the right lower and middle zones: right diaphragm markedly raised: interlobar septum seen between upper and middle

lobes. Lesion appears to pneumonic process in right middle lobe with associated partial collapse and commencing spread to upper lobe.

Physical signs:-

Marked dullness at right base with tubular B.S. Very occasional crepitations and V.R. aegophonic. Sputum copious, frothy and slightly blood stained.

Grossly diminished movements of right middle and lower rib series and also of right diaphragm. Bilateral elevation of upper ribs section and shallow outer range movements of left middle and lower rib series with moderate movement of left diaphragm.

Treatment.

- 1st. day. Initial treatment scheme - infra-red nocte.
 2nd. day. Treatment continues as above.
 3rd. day. Sputum and physical signs unchanged except that B.S. are diminished although unaltered in character. Infra-red infra-clavicular - a.m. axillary field p.m. Late anterior chest irradiation given. Sedative vibrations continued.
 4th. day. Modified postural drainage begun and infra-scapular infra-red irradiation introduced.
 5th. day. Increased quantity of sputum yesterday following postural change. Much improved: dullness less marked, B.S. diminished intensity, broncho-vesicular in character: numerous medium crepitations throughout middle and lower zones. Gentle expiratory chest shaking begun - infra-red as on previous day. Two twenty minute sessions in left side-lying.
 6th. day. Temperature up to 104° last evening but down to 100° this am. Less sputum yesterday. Rhythmic relaxed breathing begun, remaining treatment as before. Infra-red nocte.
 7th. day. Appears to be re-expanding. B.S. on right side are now normal intensity. Treatment continuing as above.
 10th. day. Physical signs I.S.Q. except frequent coarse crepitations over right middle and lower zones. Gentle chest clapping introduced: infra-red B.D. now, late treatment discontinued.
 14th. day. X-ray shews - resolving at periphery and probably re-expanding. Gentle chest shaking and clapping continued: five minutes relaxed breathing every hour (under patients own control): Full postural drainage, morning and evening.
 16th. day. Only slight dullness: B.S. on right side diminished. No accompaniments - V.R. equal.
 20th. day. X-ray shews - resolution and re-expansion proceeding. Regional breathing commenced. Mainly confined to increased expiratory movements of left side with middle range inspiratory excursion only. (indirect method of gaining expansion of affected side). No infra-red now. Chest clapping still light.
 21st. day. Small patch of broncho-vesicular B.S. above right base with occasional crepitations.

- Elsewhere normal and no accompaniments.
- 25th. day. Diaphragm is now considerably less elevated. Unilateral localisation of basal breathing commenced.
- 30th. day. Good lower rib movements and general thoracic mechanics fairly well balanced. Diaphragm almost completely descended and movement satisfactory.
- 35th. day. Transferred to convalescent home. To practice systematic breathing control according to principles already taught.
- 46th. day. Chest clear - feels fit. X-ray shews complete re-expansion and almost complete resolution. Chest movements symmetrical and ventilation good. Exercise tolerance satisfactory.

Two noteworthy features are presented in this case.

- (1) The presence of copious sputum suggested the early introduction of modified postural drainage. Efficient evacuation of sputum had special importance in view of the atelectasis.
- (2) No deliberate activation of the affected areas by localisation of rib movements on the affected side, was attempted until re-expansion was well established.

We are glad to take this opportunity of
expressing our gratitude to
Wing Commander F.H. Peterson. M.D., M. C.P. & S.,
for his constant help and encouragement.

B I B L I O G R A P H Y.

1. ADAMI. Medical History of the War.
2. ALLEN, W.H. Ann. Intern. Med. 1936.10.441.
3. BINGER, C.A. & CHRISTIE, R.V.
 - (1) J. Exper. Med. 1927. 46. 571.
 - (2) Ibid. 1927. 46. 595.
 - (3) Ibid. 1927. 46. 715.
 - (4) Ibid. 1928. 47. 741.
 - (5) J.A.M.A. 1928. 91. 367.
4. BLAKE & CECIL. J. Exper. Med. 1920. 31. 403.
5. BOWEN, J. Amer. J. Roentgen. 1935. 34. 168.
6. BOYD, W. Pathology of Internal Diseases. 1940.
7. BURRELL, L.S.T. Lancet. 1938. 1. 662.
8. CONYBEARE, J.J. Text-book of Medicine. 1941.
9. CORYLLOS & BIRNBAUM. Arch. Surg. 1929. 18. 190.
10. CULTER, J.S. & OSBORNE, S.L. N.Y. State. J. Med.
 1939. 39. 699.
11. CYRIAX, E.
 - (1) Elements of Kellgren's Manual of Treatment. 1903.
 - (2) Collected Papers on Mechano-Therapeutics. 1924.
 - (3) J. Chart. Sec. Mass. Med. Gym. 1939. 4. 25.
12. CYRIAX, J.H. Brit. J. Phys. Med. 1939. 187. 2.
13. DAVIES, HODGSON & WHITBY.
 - (1) Lancet. 1935. 1. 791.
 - (2) Lancet. 1935. 1. 849.
 - (3) Lancet. 1935. 1. 919.
14. ERWIN, G.S. & MCGILL, R.J, B.M.J. 1938. 1. 891.
15. FRENCH, H. Min. of Health. Report. 1920.
16. GALLAGHER, J.R. Yale. J. Biol. Med. 1934. 7. 23.
17. GOLDTHWAIT, BROWN, SWAIN & KUHNS. Body Mechanics in Health and Disease. Livingstone. 1937.
18. GILL, A.M. B.M.J. 1938. 1. 504.
19. HALDANE, J.S. & PRIESTLEY, J.G. Respiration. Clarendon Press. 1935.
20. HEALD, C.B.
 - (1) Lancet. 2. Aug. 9th. 1922.
 - (2) Proc. Roy. Soc. Med. 31. 1938.
21. HENDERSON, Y. et alia. Arch. Int. Med. 1930. 45. 72.

BIBLIOGRAPHY (Cont'd).

22. HORNIBROOK & NELSON. Pub. Health Report. 1940. 55. 1936.
23. HUTCHISON, J.H. B.M.J. 1942. 1. 487.
24. KEITH, A. Further advances in Physiology. Hill. 1909.
25. LOGAN, W.R. Edin. Med. Journ. 1921. 26. 294.
26. LONG COPE, W.T. (1) Bull. J. Hopk. Hosp. 1940. 67. 268.
(2) Practitioner. 1942. 148. 1.
27. M MAHON, C. (1) Lancet. 1915. 2. 2. 10. 1915.
(2) Ibid. 1919. 1. 697.
28. MALLOCH & RHEA. Quart. J. Med. 1920. 14. 125.
29. MAXFIELD, J.R. Texas. State. J. Med. 1939. 35. 340.
30. MAXWELL, J. Lancet. 1938. 2. 239.
31. MILLER & HAYES. Northwest. Med. 1939. 38. 12.
32. NI GHOLAS, F.G. & AGASSIZ, C.D. Lancet. 1938. 2. 705.
33. OPIE, E.L. Arch. Path. Chicago. 1928. 5. 285.
34. RAMSAY, H. & SCADDING, J.G. Quart. J. Med. 1939. 8. 79.
35. REIMANN, H.A. (1) The Pneumonias. 1938.
(2) J.A.M.A. 1938. 111. 2377.
36. REIMANN, H.A. & HAYERS, W.P. Arch. Int. Med. 1940. 65. 138.
37. ROBINSON, C.A. Proc. Roy. Soc. Med. 1929. 1. 23.
38. SANTE, L.R. J. Missouri. Med. Assoc. St. Louis.
1921. 18. 43.
39. SCADDING, J.G. Quart. J. Med. 1937. 6. ~~434-25~~.
40. SHANKS, S. C., KERLEY, P. & TWINING, E.W. A text-book of
X-ray diagnosis. 1938.
41. SMILEY, D.F., SHOWACRE, E. C. et alia. J.A.M.A. 1939. 112.
1901.
42. STANSFIELD, O.H. Boston. Med. & Surg. J. 1923. 188. 734.
43. STEWART, H.E. (1) Amer. J. Electr. Radiol. Oct. 1922.
(2) Brit. J. Actin & Physiother. Feb. 1930
(3) Brit. J. Phys. Med. 1934. 8. 133.
44. STUART HARRIS. B.M.J. 1937. 2. 516.
45. TILLING, M. & OLIVER, W.A. Lancet. 1938. 1. 1391.
46. TORBETT, J.W. Texas State J. Med. 1937. 33. 432.