

REGIONAL ILEITIS.

A Clinical and Experimental Study.

by

JAMES SNEDDON JEFFREY

M.A., M.B., Ch.B., F.R.C.S.Ed.

---

A thesis presented to the Faculty of Medicine  
of the University of Edinburgh for the degree of  
Doctor of Medicine.

1939.



TABLE OF CONTENTS.

	Page.
INTRODUCTION. . . . .	3
PATHOLOGY OF REGIONAL ILEITIS. . . . .	7
RELATIONSHIP TO OTHER BENIGN INTESTINAL PROCESSES. . . . .	27
CLINICAL FEATURES. . . . .	37
DIAGNOSIS. . . . .	46
TREATMENT. . . . .	57
PERSONALLY OBSERVED CASES. . . . .	66
ANALYSIS OF HOSPITAL RECORDS. . . . .	138
AETIOLOGY; WITH DISCUSSION. . . . .	159
EXPERIMENTAL WORK. . . . .	177
COMMENTARY . . . . .	189
SUMMARY. . . . .	195
ACKNOWLEDGMENTS . . . . .	197
REFERENCES . . . . .	198

-----

## REGIONAL ILEITIS.

### INTRODUCTION.

In 1932, at a meeting of the Section of Medicine at the annual convention of the American Medical Association, Crohn ( 16 ) read a description of what he and his co-workers claimed was a hitherto undescribed entity. He said:- "We propose to describe, in its pathologic and clinical details, a disease of the terminal ileum, affecting mainly young adults, characterized by a subacute or chronic necrotizing and cicatrizing inflammation. The ulceration of the mucosa is accompanied by a disproportionate connective tissue reaction of the remaining walls of the involved intestine, a process which frequently leads to stenosis of the lumen of the intestine, associated with the formation of multiple fistulas."

Crohn's original description and definition of the disease was based on the study of fourteen cases. He went on to say:- "The disease is clinically featured by symptoms that resemble ulcerative colitis, namely fever, diarrhoea and emaciation, leading eventually to an obstruction of the small intestine; the constant occurrence of a mass in the right iliac fossa usually requires surgical intervention (resection). The terminal ileum is alone involved. The process/

process begins abruptly at and involves the ileo-caecal valve in its maximum intensity, tapering off gradually as it ascends the ileum orally for from 8 to 12 inches (20 to 30 c.m.) It frequently leads to fistula formation, usually with segments of the colon, forming small tracts communicating with the lumen of the large intestine; occasionally the abdominal wall, anteriorly, is the site of one or more of these fistulous tracts. The etiology of the process is unknown; it belongs in none of the categories of recognized granulomatous or accepted inflammatory groups. The course is relatively benign, all the patients who survive operation being alive and well."

Whether or not a "new disease" had actually been born, there did seem justification for Crohn and his co-workers segregating from the confused category of intestinal granulomata a distinct clinical entity, and for it they suggested the name "Regional Ileitis".

This contribution immediately aroused great interest, particularly in America, and reports of cases began to be published from various sources (10,28,47,55 ). To date there have been about 300 cases reported in America. In Britain the condition is now well recognised, but there have only been 22 cases published. (2,4,21,30,36,38,44 ) I wish to record 7 original examples of the condition.

In conjunction with the general recognition of regional ileitis it became apparent to observers that exactly/

exactly comparable cases had been reported in the literature during the past hundred years, and I shall make further reference to these cases later in this thesis. (13, 18, 49, 51). Nevertheless very great credit must go to Crohn for his recognition, description and classification of a very interesting condition.

As originally defined by Crohn this was a non-specific inflammation of the lower 25 to 30 c.m. of ileum. It soon became evident that the disease process was not peculiar to the terminal portion of the ileum, for Harris, Bell and Brunn (28) pointed out that jejunal involvement did occur, and Colp (12) demonstrated that the colon may be affected in association with the ileum. Crohn, too, began to encounter identical lesions in the jejunum, and he enlarged his original concept of ileitis to include jejunitis, and to include the ileo-colitis type of the disease. Classically, and in the great majority of cases, however it is the terminal ileum alone that is affected. In the past few years many investigations of the pathology of this condition have been completed, but little of positive value has been added to Crohn's description in 1932 of his original fourteen cases. In 1939 Crohn (15) reviewed his one hundred and ten cases to date, but apart from details of aetiology and pathology had nothing to add to his original conception.

In this thesis I propose to describe and discuss:-

1. The pathology, the clinical features, and the treatment of regional ileitis, as it is commented on in the literature and as I have observed myself;
  2. Seven personally observed cases of regional ileitis;
  3. Certain cases from the past records of the Royal Infirmary, Edinburgh, that might in the light of present knowledge be regarded as examples of the condition;
  4. The aetiology of regional ileitis;
  5. Personally conducted experimental work on the condition.
-

PATHOLOGY OF REGIONAL ILEITIS.

When the condition is discovered at operation it may be seen in one of four stages. In the acute stage the terminal ileum is reddened and oedematous, in the chronic stage it is grey and rigid, and stenosed; and in the intervening stage it has a combination of both acute and chronic features, with an inflammatory appearance and commencing fibrosis. Finally adhesions and fistulae occur.

(1) The Early lesion. (Acute Stage).

Specimens exhibiting the very early phase of the disease are rare, since resection of the affected bowel is seldom done at that time. Most acute specimens are encountered on the operating table, following a short illness and the diagnosis of acute appendicitis. The terminal loop of the ileum is seen to be dark red, or reddish-purple, in colour, with a smooth glistening serous surface. The diameter of the affected portion is rather greater than the healthy bowel above it, and on palpation the wall is felt to be thickened and sodden and oedematous. The feel of this sodden wall has been likened to wet blotting paper, or uncooked meat. The lumen of the bowel can be felt distinctly and is not appreciably altered in diameter.

The length of bowel involved varies from three or four inches to eighteen inches. Typically the swelling/

swelling and redness are most marked at the ileo-caecal valve and immediately proximal to it, the process fading off as the bowel is traced proximally. Sometimes the transition from inflamed to normal ileum is a gradual one, but in most cases there is quite a sudden clear-cut line of demarkation. When at operation this sudden transition between reddened swollen bowel and normal bowel is encountered one always imagines that some constricting band must have been compressing and obstructing the bowel at that point. That this cannot have been so is soon realised when one notes that the inflamed bowel is distal and not proximal to the line of demarkation.

Crohn believes that the inflammatory lesion is not a static one nor is the entire diseased segment affected at one time. The oldest lesions begin at, or just oral, to the ileo-caecal valve, and the most recent ones proximally. In some cases he found isolated lesions separated from the main inflammatory segment by normal mucosa. Harris (28) Jackman (34), and others have commented on these separated lesions, though by far the majority of cases of ileitis that have been reported are confined to the terminal loop of the ileum in a continuous segment. The three cases that I have seen in the acute stage were all of this latter nature.

In the acute stage the caecum is not involved, and it is very striking how this obviously acute process/

process stops short at the ileo-caecal valve as if a barrier had been raised. It resembles the hesitance that a carcinoma of the pyloric antrum of the stomach appears to show about trespassing into the duodenum.

Very characteristically the mesentery of the affected portion of ileum is greatly thickened and oedematous and contains enlarged glands. These glands are soft, and sometimes they may have broken down to abscess formation.

Microscopic: Knowledge of the intra-intestinal changes during the acute stage is very scanty. Crohn describes ulcers in the mucous membrane - scattered, discrete ulcers, oval or round in shape and about 1 c.m. in diameter. They are usually located on the mesenteric border of the small bowel and lying in the long axis, where a sort of groove is formed by the attachment of the mesentery.

Dixon ( 19 ) formed the impression that in its earliest stage regional ileitis consists of enlargement of the mesenteric lymph glands and ulceration of the mucosa. In support of this view he quotes two interesting cases:

(a) A female, aet. 29, came to the Mayo Clinic after intermittent attacks of severe cramping pains in the right iliac fossa for 2 months. Her doctor during that time had noticed tenderness in the right iliac fossa, slight fever, and diarrhoea three or four times a day with no melaena. On examination in hospital/

hospital no palpable abdominal mass or other physical abnormality was detected. X-ray Examination revealed a filling defect in the terminal ileum.

At operation the terminal ileum was carefully examined but looked and felt normal in all respects. Similarly the whole of the small intestine and colon showed no abnormality, and the radiologist's lesion could not be found. The lymph glands adjacent to the terminal ileum however were enlarged slightly. There was no indication to do anything, and the abdomen was closed.

Three months later the patient had again to be operated on because of increase in severity of the symptoms. At the second operation the distal ileum was found markedly thickened, and covered with a thick greyish plastic exudate. A resection was carried out and the patient recovered.

(b) A female, aet. 24, came to the Mayo Clinic with a 6 weeks' history of diarrhoea, fever, and intermittent severe abdominal pain. Nothing abnormal was found on physical examination. The radiologist reported a filling defect in the terminal ileum. At operation however careful examination of the small intestine and caecum revealed no tumour or other abnormality. The patient succumbed to pneumonia 12 days post-operatively. At post-mortem examination the distal ileum was grossly normal, but on opening it an ulceration 5 c.m. in diameter was found.

Whether/

Whether such cases can justifiably be regarded as examples of regional ileitis is questionable, but their clinical features and some of the pathological features are suggestive. Henke and Lubarsch ( 29 ) in their handbook emphasize the frequency of a lesion of the mucosa, e.g. a crack, fissure, or superficial ulcer, as the portal of entry of an infection, slow and of low virulence, leading to the development of an inflammatory mass.

Jackman ( 35 ) describes the microscopic picture in two cases resected in the acute stage. Both were young women with 48 hours' history of abdominal pain and vomiting. Neither had been seriously ill but one had suffered from diarrhoea, previously. The terminal 8 inches of ileum in both cases was deeply congested and oedematous, and the microscopic picture was identical in each. The mucosa throughout the affected area had been almost completely destroyed and replaced by thick fibrino-purulent exudate. In the submucosa, and to a lesser degree in the muscle there was a marked acute inflammatory reaction, and in places the degree of polymorph infiltration approached abscess formation. The subserosa showed a moderate degree of congestion, oedema, and interstitial haemorrhage. There was evidence of previous acute inflammation in the bowel in the form of much dense scar tissue. There was much fibrotic thickening of the submucosa, and extensive areas of the muscle coat had been entirely/

entirely replaced by fibrous tissue. Except for a very occasional small vessel there was no evidence of vascular thrombosis. Bacteria demonstrated in the ulcerated areas were of the intestinal tract group, with streptococci predominating. In the deeper layers no bacteria of any sort could be seen.

While these cases of Jackman's were excised during an acute attack, and the bowel was deep red and congested, it may be questioned whether their microscopic picture represents that of the earliest lesion in view of the suggestive evidence of earlier attacks.

The only other published description of the microscopic appearance is that of Erb and Farmer (22), who reported the cases of four children who were operated on, after a few days illness, with a diagnosis of acute appendicitis. Histological examination was possible in two of the cases. In each there was intense swelling, congestion, and oedema of caecum and terminal 10-20 c.m.s of the ileum. Section through the ileum, ileo-caecal valve, and caecum showed the greater part of the mucosa to be ulcerated and covered with a thick layer of exudate, composed of necrotic cells, fibrin, erythrocytes, and colonies of bacteria which proved to be B. Coli. Here and there a few islands of epithelial cells still remained. The ulceration, in one of the cases, was very marked in the ileum and stopped abruptly at the ileo-caecal valve, although caecum and colon were very oedematous. In both cases the lymphoid tissue had undergone marked necrosis/

necrosis and the Peyer's patches remained as only necrotic shadows of their former structure. An interesting feature was the comparative absence of polymorphs in the presence of such marked necrosis. Such infiltrating cells as there were in the wall were mostly large mononuclears, with oval pale-staining vesicular nuclei. These were interpreted as endothelial leucocytes. In the submucosa the degree of oedema was very striking, and it was oedema rather than cellular infiltration that accounted for the thickness of the bowel wall. The oedema extended up the ascending colon, well beyond the area of ulceration. The muscular wall was little, if at all, affected. The subserosa was slightly oedematous, and the serosa unaffected. Some of the veins, particularly close to necrotic areas, were filled with thrombi, but on the whole the blood vessels were unaffected. The lymphatics were dilated and contained acellular fine granular pink-staining material. The adjacent lymph glands showed varying degrees of congestion and oedema.

It is probable that in the early stages of regional ileitis the lesion is a diffuse one involving mainly the mucosa and submucosa, with widespread destruction of the mucosal epithelium and oedema of the submucosa.

## (2) The Later lesion (Sub-chronic stage).

This is the stage at which mucosal ulceration predominates and there are symptoms of intestinal irritation, with diarrhoea and sometimes blood and mucus in/

in the stool. It is at this stage that the majority of cases are seen at operation. Various stages of acute, subacute and chronic inflammation may be seen, with variation in preponderance of polymorphs, lymphocytes, plasma cells and fibroblastic elements. In the early stages the lesion is a diffuse one mainly in the mucosa and submucosa. The mucous membrane shows areas of destruction, and at times the glandular structure is almost completely gone, leaving an atrophic layer of epithelium. As the process advances the fibrosis in the wall increases.

The process is as a rule limited to the distal 10-14 inches (25-35 c.m.s.) of the terminal ileum, including the ileo-caecal valve and terminating rather abruptly at that point. The most advanced changes are present at the valve, which in some instances is converted into a rigid diaphragm with a small irregular opening. Proximally the process gradually abates, but the shading off to normal mucosa is again rather an abrupt one, over a distance of not more than one or two centimetres. The normal intestinal folds are distorted and broken up by the destructive ulcerative process, and rounded and blunted by oedema, giving a bullous structure and, as Crohn describes it, a cobblestone appearance to the surface of the mucosa. The mucosal ulceration is principally confined to the mesenteric side of the bowel, and the ulcers themselves are circular/

circular, oval, or linear in shape, with deep crypt-like appearance and pouting mouths. Crohn remarks that the linear ulcers may either be original ulcerative lesions, or mechanical erosions due to the formation of a "darmstrasse" by the shortening of the fibrotic mesentery; it is difficult to say which. There is usually a marked capillary dilatation throughout the mucosa, but only slight fibrosis. Fibroblasts may be seen but little or no new connective tissue. Probably the most noticeable feature is the dense infiltration of plasma cells and polymorphonuclear leucocytes.

The submucous, and to a less extent the muscular layers are the seat of marked inflammatory hyperplastic and exudative changes. The inflammatory infiltration is somewhat different from that of the mucous membrane, being mainly of lymphocytes and plasma cells, and sometimes eosinophil cells. The capillaries are widely dilated. There are many fibroblasts and some collagenous fibrosis.

Two other features are sometimes to be seen in the submucosa:

(a) Small abscesses, with walls densely infiltrated with polymorphs. Some of these abscesses are cross sections of deep sinuses leading to a crater-like ulcer.

(b) Occasional small tubercles, consisting of endothelioid cells irregularly arranged, with giant cells both central and peripheral. The giant cells vary considerably in size, with nuclei from one to very/

very many. In some the nuclei are arranged peripherally, in others more irregularly through the cells. Caseation is never seen in any of these tubercles.

These two features of abscesses and tubercles are not referred to by Crohn in his description of the pathology, but have been commented on by one or two writers who have made a careful pathological study of apparently "classical" cases of regional ileitis. Erdmann and Burt ( 23 ) refer to "occasional circumscribed tubercle-like formations composed practically exclusively of atypical giant cells, with numerous minute tentacle-like processes stretching out from the cytoplasm and enclosing small, variously shaped, colorless, glazed particles, representing, apparently, foreign bodies." They were not prepared to say what was the nature of these foreign substances, but suggested that they might have entered through the disintegrated mucosa. Moschowitz and Wilensky ( 53 ), in a comprehensive study of the non-specific intestinal granulomata, found that the described lesions of hyperplastic tuberculosis of the colon were, in the majority of cases, identical with the non-specific granulomata. Further reference to this aspect will be made later in this thesis.

Many writers have commented on the presence of giant cells in the submucous and muscular layers. Special stains show the presence of large pale cells, probably vegetable in nature, in the vicinity of the giant/

giant cells. These, and the giant cells, are not, in Crohn's view, an essential feature of the pathological picture, but accidental findings due to the inclusion of small particles of vegetable matter which have become entrapped in the ulcers, entered the lymphatics, and become encapsulated in the process of healing. The giant cells are regarded as part of the foreign body reaction, but it is their presence that has led some authors to consider this granulomatous condition an unusual form of tuberculosis.

The subserous coat shows congestion and patchy infiltration of small lymphocytes outwards into the fat. The serous coat is congested but there are no polymorphs or exudation to be seen, that is to say no evidence of peritonitis. In the very late stages focal areas of reaction are seen in the serosa, giving the appearance on gross examination of tubercles.

As a general result of the infiltration and fibrosis the wall of the bowel becomes enormously thickened and the lumen is encroached on; and the mesentery becomes chronically thickened and shortened and fibrotic. To the feel the bowel is moderately firm and sodden.

### (3) The Final lesion (Chronic stage).

In this, the oldest phase, the exudative reaction is replaced by a fibrostenotic process. The mucosa is atrophied, the submucous and muscular coats largely/

largely replaced by scar tissue. The serosa loses its gloss and is greyish in colour, and may show tubercle-like structures - islands of fibrous tissue - on its surface. It is at this stage that the cramp-like abdominal pains and vomiting are most marked, and the stenosis of the terminal ileum leads to dilatation of the bowel above and intestinal obstruction. The segment of involved ileum has very characteristically the appearance and feel of a length of hose-pipe, being unpliant and almost rigid.

#### (4) The Fistulae and adhesions.

The fourth stage is really a development and complication of the fully developed intestinal lesion. Crohn early in his study of this condition noted the tendency of the diseased ileum to perforate. The perforation is not freely into the peritoneal cavity but chronically into a neighbouring viscus, parietal peritoneum, or omentum, and is slow enough to permit the formation of dense adhesions. In Cohn's first series of fourteen cases fistulae were formed with the pelvic colon four times, and with ascending colon and caecum once each. Fistulae from the diseased loop to the bladder have been described (15). In one of my seven cases, which I shall later describe, an intractable faecal fistula followed a laparotomy and drainage of a gland abscess at the ileo-caecal angle. Fistulae caused by drainage of such an abscess are/

are not uncommon and are due to the fact that these abscesses are the result of a slow perforation into the mesentery or peritoneum of the diseased ileum, and are in continuity with it. Whether abscesses can occur apart from perforation, i.e. simply by disintegration of an inflamed gland is not quite certain. External fistulae almost always follow some surgical intervention in the neighbourhood of the ileitis, such as the drainage of an abscess or the removal of the appendix. Occasionally they have occurred through an old healed appendectomy scar.

The foregoing are the common pathological features seen in regional ileitis. The division of the process into four stages is an arbitrary one, but a convenient one, for they fit the conditions that are found at operation. There can be little doubt that the disease is a continuous process with the one stage blending into the next, from the very earliest inflammatory lesion, wherever that is, to the final stenotic and fistulous condition.

These are the features of the disease as we commonly see it, and as it was originally described, and the pathology of the combined diseases, when jejunum or colon is involved, is not dissimilar.



this thought in mind they suggested the title "Chronic cicatrising enteritis".

Similarly Brown, Barger and Weber ( 8 ) described chronic inflammatory lesions in various parts of the small intestine other than the terminal ileum, and they considered that as a description the designation "Regional Enteritis" was more accurate than "regional ileitis" or "terminal ileitis".

Crohn agrees with this enlargement of conception of the process. He considers that the main brunt of the disease falls upon the terminal segments of the ileum, beginning abruptly at the ileo-caecal valve and advancing upwards along the intestine for a variable distance. The great majority of cases do not involve more than 12 inches of the terminal ileum, but cases have been observed in which as many as 50 inches have been noted to be continuously affected. The inflammatory process of the ileum is not always continuous, and the pathological unity may be broken up by one or more of what Crohn calls "skip areas". These areas range from 2 to 12 inches. Crohn encountered several cases in which upper ileum and jejunum were involved, but almost invariably the terminal ileum was also involved. Very occasionally the terminal ileum is void of disease and the process involves a limited portion high in the ileum or in jejunum.

(2) Ileo-colitis.

With further experience of this disease it became necessary to recognise still another, though less common, addition to the original concept, namely ileitis with associated colitis. In these cases the terminal ileum is characteristically affected and the colon is involved in a similar process, i.e. ulceration, inflammation and cicatrisation. Usually the caecum and ascending colon are affected in a continuous manner with the terminal ileum, but occasionally "skip areas" are seen in the colon and the disease may be in ascending colon or transverse colon, leaving wide areas of normal mucosa between the affected areas.

Colp (12) was the first to describe the combined lesion, and it has been recognised by Brown (8), and Erb and Farmer (22). I have seen one example of it, and it corresponded with one of the cases of Erb and Farmer, in that the ulceration was marked in the ileum and stopped abruptly at the ileo-caecal valve, although the caecum and adjoining colon was oedematous and fibrous.

Crohn (15) noted this combined lesion in 8 of his 110 cases, and he pointed out that the clinical features, pathological features and treatment are those neither of ileitis or colitis, but that the condition has a course of its own. He believes that it is important to appreciate, what everyone concedes, that/

that in severe ulcerative colitis the ileum may be involved in a retrograde extension of the pathological process, and this is said to occur in 25% of cases of ulcerative colitis. Here however the process in the ileum is destructive and denuding, as it is in the colon, not hyperplastic and granulomatous as it is in primary ileitis. Even when the ulcerative colitis is segmentally limited to caecum and ascending colon the extension into the ileum is not the stenosing, fistulous granulomatous process so characteristic of primary ileitis.

In Crohn's 8 cases of primary ileitis and colitis there was an ulcerative granulomatous inflammation of a severe type involving terminal ileum, and scattered and interrupted segments of the colon, or the contiguous caecum and ascending colon. The whole process may subside spontaneously, or resection of the diseased ileum may allow the colitis to settle down. Resection of the colon is not necessary, which suggests that the ileitis is the dominating factor and as such contributes the main clinical features - cramp-like pains due to stenosis of the ileum, and mild diarrhoea. The diarrhoea is not the severe diarrhoea with passage of bowel-casts as is seen in ulcerative colitis.

Benign granulomatous conditions are not infrequently found in the colon, without any affection of the small intestine at all; such granulomata are not intended/

intended to be embraced in the clinical and pathological concept of regional ileitis, and their aetiology and relationship to ileitis will be considered in a later section. In particular granulomata of the colon are sometimes seen in association with the disease of Lymphogranuloma Inguinale.

#### LYMPHOGRANULOMA INGUINALE AND REGIONAL ILEITIS.

At first sight there does not appear to be much association between these two conditions; the one is a venereal disease characterised by enlarged inguinal lymph glands and the other is a non-specific inflammatory condition of the terminal ileum. Lymphogranuloma inguinale is frequently followed by rectal strictures, with the rectum widely involved in a cicatrising granulomatous condition. Very occasionally it is not the rectum that is involved but the colon higher up. The disease has been proved to be due to a specific virus, and while the rectal strictures could follow a direct spread of the disease from the pudendal region the involvement of colon must be by lymph-borne or blood-borne infection with the virus. A test has been evolved as an aid to diagnosis in lymphogranuloma inguinale, and this test is accurate in almost 100% of cases. It consists of observing the reaction of patient's serum with material obtained from a known case of lymphogranuloma inguinale, and this Frei test may be regarded as specific for the disease/

disease and for the presence of this virus.

Since both regional ileitis and lymphogranuloma inguinale are associated with granulomata in the colon, and since both of them are themselves essentially granulomatous, it is possible that they may have a common aetiological factor, and this will receive further consideration later. I have found it of interest to do the Frei test on the cases of regional ileitis that I am now reporting, and it has always proved negative. Stafford ( 65 ) had the same experience.

Stafford reported ten cases of regional ileitis, the last three of which were tested with the Frei reagent and found negative. The Wassermann reaction was negative in each case. In none of the cases was the colon involved; in five the terminal loop of ileum was involved, and in the other five the ileum involved was 1-3 feet above the ileo-caecal valve. The mesenteric glands were always enlarged. Microscopically various stages of inflammation were seen, with ulceration always. There were several instances of giant cells but no true tubercles.

For comparison Stafford reported three cases that came to the post-mortem room. Each had a granulomatous condition of the large bowel - respectively in pelvic colon, transverse colon, and caecum and terminal ileum. Each had had similar symptoms to regional ileitis, and in each the Frei test had been positive. Microscopically/  
ally/

Microscopically the typical lymphogranulomatous lesion was seen, i.e. tubercle-like structures composed of endothelioid cells with the central portion occupied by polymorphonuclear leucocytes. Similar tubercles were seen in the adjacent glands. Throughout the bowel wall there was a dense infiltration with lymphocytes and there were numerous giant cells. No Tubercle bacilli were found.

Ordinarily in lymphogranuloma inguinale the intestinal changes are found in relation to the lower colon, and Stafford states that there have been no cases of lymphogranuloma inguinale reported which caused ulceration of the small intestine alone. Therefore it may be desirable that cases of "regional ileitis" reported as occurring in small and large intestine should be re-considered from the point of view of lymphogranuloma inguinale.

---

RELATIONSHIP OF REGIONAL ILEITIS TO OTHER BENIGN  
INTESTINAL PROCESSES.

There exists in the medical literature a heterogeneous group of benign intestinal lesions which have now and then been described under the caption of "non-specific, or benign, granuloma". Clinical reports and society discussions abound in reports of surgeons who, at laparotomy, found a tumour which defied classification. It is usually mistaken for malignancy, but is ultimately proved to be of an inflammatory nature.

The loose term "benign granuloma" covers a multiplicity of conditions in which both large and small intestines may be involved; it includes all chronic inflammatory lesions of the intestine whose aetiology is either unknown or attributable to an unusual physical agent. It represents a melting-pot in which are thrown all those benign inflammatory intestinal tumours which are neither neoplastic nor due to specific bacterial agent, and which are recognised as not being carcinoma, lymphosarcoma, tuberculosis, syphilis, Hodgkin's disease, or actinomycosis.

Within this group we find descriptions of foreign body tumours, chronic perforating lesions with gross inflammatory reactions, trauma of the mesentery with intestinal reactions, a late productive reaction to released strangulated hernias of the intestinal wall, and/

and numerous other and similar conditions. The so-called benign granulomas all present a tumour-like inflammatory mass which usually simulates carcinoma, but which eventually unmasks itself as probably an infective process of unknown causation. The multiplicity of the possible sites of gastric, intestinal, or colonic involvement, and the accompanying protean clinical manifestations defeat any effort to include them all in a clear-cut clinical entity.

These non-malignant tumours were most frequently reported as occurring in the colon. In 1907 Moynihan (54) wrote in the Edinburgh Medical Journal on "The Mimicry of Malignant Disease in the Large Intestine." Moynihan remarked that it was not uncommon for tuberculous disease, especially when affecting the caecum or the ascending colon, to be mistaken for carcinoma. The six cases he reported involved the distal colon, and though when he resected the tumours he was under the impression that he was dealing with malignant disease subsequent examinations proved them to be simple inflammatory. Four of these cases were probably due to diverticulitis of the colon, but two of them, one in the rectum and one in the transverse colon, were what we would now describe as granulomata. It is further possible that they were associated with Lymphogranuloma Inguinale, though there is no evidence in the histories on this point. Certainly the rectal stricture/

stricture which Moynihan described as "like thick moss on the rectal wall", is not unlike the condition that may occur with Lymphogranuloma Inguinale.

Mayo-Robson ( 46 ) in 1908 described five similar tumours of the colon which proved to be inflammatory and he believed that the pathology in these cases was "a chronic infiltrating colitis, possibly associated with pouches lodging faecal matter, or simply due to infection spreading through the intestinal walls."

W.J. Mayo ( 45 ) 1901 wrote on "less commonly recognized forms of Surgical Tuberculosis", and brought out several features that we ascribe to the benign granulomata of the colon.

Braun ( 7 ) in 1909 reviewed the subject of granulomata, or non-specific inflammatory tumours, to that date, and his article stimulated other German workers, ( 29,52,67 ) who studied in particular the histological appearances.

Not all these granulomata were described as in the colon however, and as far back as 1813 Combe ( 13 ) reported "a singular case of stricture and thickening of the ileum", and Moore in 1882 reported "Stricture of the intestine at the ileo-caecal valve." It was in 1932 that Crohn and his co-workers made their classification of a separate entity that they described as Regional Ileitis; but, as frequently happens, once attention has been directed to a so-called new disease we find that it existed before any classification was made/

made. Thus the cases of Combe and Moore might be acceptable, and certainly when in 1913 Dalziel ( 18 ) wrote on "Chronic Interstitial Enteritis" he appears to describe a similar lesion.

Dalziel was drawing attention to a condition which he felt had not been fully described, and to which he gave the name Chronic Interstitial Enteritis. In one remarkable case of a doctor with intestinal obstruction "the whole of the intestines, large and small alike, were contracted and rigidly fixed, so that when a loop was lifted from the abdomen it sprang back into its sulcus. That the whole of the intestine was chronically inflamed there was no doubt. ....the glands were enlarged." Whatever may be thought of that case the two other cases that Dalziel described are almost identical with our conception of regional ileitis. In one a portion of jejunum, over two feet in length, was rigid and thickened; in the other a loop in the middle of the ileum was apparently acutely inflamed. Both these specimens were excised, and the one showed the regenerative process in the ascendancy, with young granulation tissue spreading through the coats of the bowel; and the other showed the acute phase with haemorrhages, oedema, and areas of necrosis in the mucous membrane, and infiltration of all coats with polymorphonuclear leucocytes. He noted that the lymphoid aggregations were singularly free from pathological change.

Moschcowitz/

Moschcowitz and Wilensky (53) in 1923 reported four cases of non-specific granuloma of the intestine. One involved the splenic flexure of the colon, two the ascending colon, and the fourth was particularly interesting because it involved successively caecum and ileum, and because from accurate data furnished it may be recognized as regional ileitis as we know it.

The case was that of a young man of 23 who for two years had complained of cramp-like abdominal pains and of diarrhoea, and had lost weight. At operation the caecum was found to be the seat of a firm mass. A local resection was done, and a faecal fistula persisted after operation until it was closed by a second operation a year later. Thereafter he continued to have diarrhoea, until, after several bouts of cramp-like pains, he was admitted to hospital in an attack of acute intestinal obstruction. Again he was operated on, and this time it was found that the terminal foot of the ileum was grossly thickened and stenosed, and its mesentery was oedematous. The affected portion was excised, and the patient got well. The macroscopic and microscopic appearance of the affected caecum and ileum was exactly that which we observe in regional ileitis. Cross-section of the ileum showed an immense thickening of all the coats of the gut so that the lumen was merely a bare slit. The mucosa was intensely inflamed and showed areas of ulceration. The submucous and muscular layers were almost entirely replaced by granulation tissue/

tissue, and throughout all the layers there was a marked infiltration with polymorphonuclear leucocytes and small round cells. Giant cells were abundantly scattered through the wall, many of them containing vague foreign body fragments whose nature was uncertain.

In view of the modern tendency (subscribed to by Crohn (14) ) to widen the scope of regional ileitis, and include associated lesions in the caecum and jejunum, this case corresponds strikingly with our conception of Crohn's disease.

Aetiology of benign, non-specific, granulomata.

In none of the four cases reported by Moschcowitz and Wilensky was there any evidence at all of tuberculosis, carcinoma, syphilis, or Hodgkin's disease. Their cases bore a remarkable resemblance to hyperplastic tuberculosis of the intestine, and from a study of these four cases and of similar ones in the literature they came to the conclusion that many, if not the majority, of the examples of so-called "hyperplastic tuberculosis of the colon" are really simple granulomata.

They cite characteristic quotations from the literature on hyperplastic tuberculosis of the intestine: Lartigau (41) says, "more often the tubercles are mere aggregations of lymphoid cells in which one or more giant cells are seen. Epithelioid cells are/

are usually absent. Many show little tendency to necrotic change; a distinct tendency to fibrous transformation is apparent. The typical histological features of tubercle bacilli are often absent."

Ignard (33) says, "In many cases of hyperplastic tuberculosis of the intestine no tubercles, giant cells or bacilli are found. The lesion is constituted of a mixture of variable proportions of tuberculous and inflammatory elements. In certain cases, the last only exist." Moschcowitz and Wilensky quote similar accounts from the writing of many other early writers on tuberculosis. Doubt seems to have crept into the mind of but one observer, Richter (60). He believed that hyperplastic tuberculosis is really a non-specific inflammation of the caecum, and that the tuberculosis is only an accidental infection and complication, the result of swallowing tubercle bacilli either from a pulmonary focus or in milk.

Moschcowitz and Wilensky themselves could offer no clue as to the aetiology of these granulomatous conditions, though in a few cases foreign bodies or a colitis was the probable cause.

Senn (62) was the first to describe non-specific granulomata in America. He believed that there was a mechanical disturbance in the blood supply causing a necrosis of the tissue supplied by the involved vessels. A low-grade infection ensued, which a separate/

separative process attempted to circumscribe. As a result of this separative process granulation tissue was formed in excess of the destructive forces, and a granulomatous tumour resulted.

Several writers have reported the finding of foreign bodies such as portions of fruit stones, pieces of bone, and silk ligatures within granulomata removed at operation. Tietz ( 67 ) reported a caecal granuloma following appendectomy, in which was found the silk thread used to ligate the appendix. Schreiber ( 61 ) reported a case in which many cherry and plum stone fragments were found in a granuloma in the ileo-caecal region. Morian ( 52 ) and Jaffe ( 37 ) each reported cases in which a piece of bone was found in a granuloma involving the colon.

Not infrequently these granulomata have been found to form at the site of chronic ulcers of the stomach and intestine, usually following a small perforation of an ulcer. And an inflammatory process in the pelvic colon, arising from a diverticula, is a not uncommon finding.

Goto ( 27 ), Monsarrat ( 50 ), Strauss ( 66 ), Felsen ( 24 ) and others have reported dysentery or colitis as preceding the onset of these granulomata.

Mock ( 49 ) reported the formation of a granulomatous mass at the site of a partial intestinal obstruction which had resulted from pericolic adhesions; another mass at the site of a vesico-intestinal fistula/

fistula; one around a silk ligature used in the performance of a gastro-enterostomy; another in which the nucleus was a swab left in the abdomen during a previous cholecystectomy.

Massive ligatures of the omentum have been reported, e.g. Braun ( 7 ), as causing the formation of chronic inflammatory thickening and granulomata.

Erdmann and Burt ( 23 ) summarise the modern views on the formation of these granulomata. They believe that, though the aetiological factor in these cases may not be known, it is probable that there is first an interruption in the continuity of the mucosa as a reaction to the presence of an infectious or toxic agent or an indefinite foreign body, resulting in ulceration of the mucosa. With the destruction of the mucosa active infection follows, and extends into the walls of the intestine, setting up a low grade inflammatory process, which manifests itself in the cellular infiltration and connective tissue formation, which constitute these granulomata.

In the case of the inflammatory and cicatrising and granulomatous condition of the terminal ileum that we are considering, it would seem that the pathological process is similar to that just described by Erdmann and Burt. But whether the aetiology covers a similar wide ground is another matter. The aetiology of regional ileitis itself will be considered in a later section.

Sufficient/

Sufficient will have been gathered from the foregoing description of the non-specific or benign granulomata to appreciate that their very multiplicity defies classification. But it is from this confusion of ideas that Crohn, Ginzburg, and Oppenheimer have separated a group which appears to answer all the requirements of a special clinical entity, with well defined pathology and clinical characteristics, to which they have proposed the name "regional ileitis."

---

## CLINICAL FEATURES OF REGIONAL ILEITIS.

Corresponding to the four pathological phases of the disease there are four types of clinical course under which most cases can be grouped:

- (1) An acute intra-abdominal disease with peritoneal irritation.
- (2) Symptoms of ulcerative enteritis.
- (3) Symptoms of chronic obstruction of the small intestine.
- (4) Persistent and intractable fistulas.

(1) Acute phase. It is impossible to distinguish these cases pre-operatively from acute appendicitis. The symptoms are practically identical in the two diseases, and even if slight differences do exist the chances are still very much stronger that it is an atypical appendicitis, rather than an ileitis, that is the cause of the trouble. The symptoms usually develop rather slower than in appendicitis.

There is generalised abdominal pain, or colicky pains round the umbilicus, settling in the right iliac fossa after 24-48 hours. There may be nausea and vomiting. There is no significant alteration in the bowel movements in the course of this short illness.

The patient may look flushed and ill and anxious, as may any case of appendicitis. Temperature is usually elevated to 101-102°F. There is a moderate leucocytosis/

leucocytosis. And on examination of the abdomen there is marked tenderness and some rigidity in the right iliac fossa. The presence of a mass, even without an abscess, is a fairly constant feature, though it may not become palpable until the patient is under the anaesthetic.

At operation the picture is that of the acute stage, with some clear free fluid in the peritoneal cavity. The future course is unpredictable. A few apparently resolve, but the majority pass to the chronic stage. Those that are drained may develop a fistula.

(2) Ulcerative phase. At this stage diarrhoea is the most constant feature. The bowels may move three to five times a day. The stools are soft and fluid, and the patient may sometimes notice pus, mucus and blood, though there is no gross melaena. The other prominent feature is colicky peri-umbilical pain occurring at odd times of the day.

The patient is usually anaemic, and the haemoglobin may be reduced to 35%. The temperature is slightly elevated. There is loss of weight and strength. This phase passes gradually into the stenotic phase.

(3) Stenotic phase. At this stage there is a small intestine obstruction of varying severity but never complete (as in all stenosing lesions of the small intestine). There are strong cramp-like/

cramp-like abdominal pains, borborygmi and vomiting. The bowels may become more constipated, though an associated colitis with diarrhoea may mask the true obstructing lesion.

The stenotic phase usually follows years of symptoms but may occur as the primary manifestation.

(4) Fistulas. There may be external faecal fistulas in the right lower abdomen, following drainage of an abscess or appendectomy. They remain intractable, and defy attempts at closure, because of the persistence of the underlying inflammation in the bowel, and they give to the skin of the abdominal wound an indurated chronically inflamed appearance. There is not the skin digestion that occurs when the fistula is at a higher level in the intestine.

Internal fistulas may develop with any hollow organ.

In the fistulous stage the patient's other symptoms are those of the disease generally. There is no lessening of the diarrhoea or colic or debility.

In the majority of cases it is only when the disease is becoming chronic that the patient seeks advice about his symptoms. 2 of my 7 cases were seen while the disease was acute, and Crohn (15) in his latest review states that only 11 out of his 110 cases were acute, and most of the others had a history dating/

dating from 1 to 5 years. My 5 chronic cases had histories of from 2 months to 1 year. During this prolonged period of non-recognition various diagnoses are maintained, such as nervous diarrhoea with a psychoneurotic background, non-specific ulcerative colitis, amoebic dysentery, and food allergy.


Fig. 1. indicates the frequency of the signs and symptoms noted in two large series of cases, and in my own 7 cases. The cases reported by Jellen (39) from the Mount Sinai Hospital are Crohn's first 50 cases. Dixon's (20) 30 cases are from the Mayo Clinic.

A study of these tables indicates that the two chief subjective symptoms are cramping pains and diarrhoea. At first there are only occasional bouts of discomfort or diarrhoea, to be followed later by increased frequency of bowel movement, malaise, and pain. The other two prominent features are loss of weight and a palpable mass. Dixon believes that the loss of weight is due more to the patient's fear of eating rather than to the disease itself, and in the clinical histories of his cases the fear of cramp-like pains soon after food was a prominent feature. I cannot say that my Scottish patients revealed this aspect. They lost weight, but they would always take their food.


Diarrhoea is well marked in the cases that have passed the acute stage, though less so than in colitis. There are usually 2-4 semi-solid daily defaecations, sometimes with blood and always with mucus but not pus.  
Blood/

## FREQUENCY OF SIGNS AND SYMPTOMS.

### ILEITIS -- 30 CASES. DIXON.




### ILEITIS -- 50 CASES. MT. SINAI HOSP. (JELLEN.)



FIRST SYMPTOM { Diarrhoea 17 = 34%  
                  { Pain 33 = 66%

### ILEITIS -- 7 CASES. ROYAL INFIRMARY. (AUTHOR.)



FIRST SYMPTOM { Pain 6  
                  { Diarrhoea 1

Fig. 1. Frequency of signs and symptoms in three series of cases.

Blood and mucus were not noted by my patients and by only 6 of Dixon's 30 cases, perhaps because the blood is not bright and obvious.

Anaemia is moderate, but may progress to a severe degree. It, and the diarrhoea and bouts of fever, cause the patient to lose strength. In carcinoma of the caecum, where there is a large ulcerating tumour, the principal features are anaemia and weakness and anorexia, but in regional ileitis these features are less marked.

A slight leucocytosis is a fairly constant feature. No significant blood changes other than anaemia and leucocytosis are seen, unless there is much vomiting in the stenotic phase, when the usual chloride deficiency occurs.

Crohn says that on examination of his patients the most constant findings were:

- (1) Mass in right lower quadrant.
- (2) Evidence of fistula formation.
- (3) Emaciation and anaemia.
- (4) Scar of previous appendectomy.
- (5) Evidence of intestinal obstruction.

The palpable mass is usually the size of a small orange, tender, firm, irregular and only slightly movable. It consists of hyperplastic ileum, stenotic inflamed ileo-caecal valve (which may be four times its normal size), and thickened mesentery. It may indicate/

indicate the matting together of affected loops of bowel, and sometimes it represents a localised low-grade inflammatory process, due to a walled-off slow perforation of the ileum, or abscess formation in a breaking down infected lymph gland. The tumour is palpable per rectum - very high on the examining finger. The palpable and obvious mass is a later manifestation, and was always present in my chronic cases.

Fistulas were found in 20%-30% of the Mount Sinai Hospital and Mayo Clinic cases. Internal fistulas most commonly involve the pelvic colon, which gets adherent to the ileum when the serous surface of ileum becomes inflamed and perforation is threatened. In one of Crohn's cases on sigmoidoscopy a nipple-like projection was seen just above the pelvi-rectal junction. This was subsequently found to be the colonic end of a fistulous tract. In others of Crohn's cases transverse colon, caecum and ascending colon, and even uterus were adherent.

External fistulas follow a fruitless appendectomy, or, as in my only case of fistula formation, drainage of an abscess in the ileo-caecal angle. Such fistulas were thought at one time to be caecal in origin, but in point of fact are communications between diseased ileum and anterior abdominal wall.

The scar of a previous appendectomy operation may indicate that that organ was removed in the early stages of the disease. Of Dixon's 30 cases 22 had been/

been having previous treatment. 13 had had appendectomy performed, and 9 had treatment on the assumption of amoebic dysentery. None of my cases had had any serious treatment. The relationship of appendicitis to regional ileitis will be discussed in considering aetiology in general.

Intestinal obstruction in a subacute form is a feature of the chronic stage, and in one of my cases went on almost to acute obstruction. General distension of the whole abdomen is unusual, but visible loops of bowel are not uncommon in the right lower abdomen. Nausea and occasional vomiting occur, and borborygmi and passage of flatus with obvious relief.

Incidence of the disease. The disease is one of the relatively young, showing a predilection for the third and fourth decades of life. Of Crohn's 110 cases the youngest was 15 years old, the oldest 58 years of age, and more cases were noted between the ages of 20 and 30 years than in all the other decades combined. The average age of his cases, when seen, was 28 years, but many of the older patients had histories of such long duration that the origin of the disease was easily dated in the previous decade of life.

The cases reported in the literature show an even distribution of the sexes, but in Crohn's large series there were 66 males and 44 females, a proportion of 3 males to every 2 females. In my series, which/

which is too small to draw conclusions from, there were 5 females and 2 males.

There is no real evidence that the disease has any racial or colour preference. No cases so far have been reported in negroes. Many of the cases have been Jews, because of the interest of Jewish physicians in the condition. Crohn ~~him~~self attached little importance to the Jewish numbers. He observed that Gentile cases had been reported from Sweden, South Africa, Holland, Canada, England and the United States. All of my seven cases were Gentiles.

---

DIFFERENTIAL DIAGNOSIS.

With increasing interest and recognition of regional ileitis the condition is becoming easier to recognise, at any rate when it has reached the chronic stage. But in the acute stage it cannot be differentiated from acute appendicitis. In both diseases there is the preliminary peri-umbilical pain referred from the obstructed or inflamed organ, with later peritoneal irritation and pain in the right iliac fossa. On the whole appendicitis develops more rapidly and dramatically, but this is not a point that any importance can be attached to, and the diagnosis in all such acute cases must be appendicitis rather than ileitis.

In the chronic cases however the diagnosis should be possible, for the disease runs a typical clinical course, and there are physical and radiological signs that are extremely suggestive. Radiological examination by barium series or barium enema reveal a string-like appearance of the lower end of the ileum that is almost pathognomic. This will be considered in greater detail in a section on X-ray Diagnosis.

The symptom of diarrhoea is such a constant and obvious one that it is usually the first to receive attention. In the absence of the typical X-ray picture all other causes of intestinal irritation must be considered/

considered and ruled out, and in particular ulcerative colitis as a possible cause is considered. A negative sigmoidoscopic examination, and the barium enema which rules out the existence of a right-sided colitis, force one's attention on the small intestine as the probable origin of the diarrhoea. Here diarrhoea due to food allergy, or purely nervous or emotional diarrhoea, require due consideration, and for that purpose a full personal history of the patient must be obtained. Diarrhoea due to gastric achylia, or carcinoma in the stomach or elsewhere in small intestine, can be excluded by gastric analysis and radiology. The stools should be examined for organisms of the typhoid-dysentery group.

From the symptom of diarrhoea alone one could hardly hope to make a proper diagnosis, but at this stage there are usually the other features of a palpable mass, colicky pains, and anaemia. In such cases the diagnosis for all practical purposes rests between ileo-caecal tuberculosis, carcinoma of the caecum, and regional ileitis, and radiological examination is then of very great aid. In carcinoma and tuberculosis the most definite X-ray changes are distal to the ileo-caecal valve, whereas they are proximal in regional ileitis.

Tuberculosis truly of the ileo-caecal valve is actually extremely rare. It is almost always caecal, as Moschowitz and Wilensky ( ) pointed out, and as  
I/

I have found and will indicate in a later section. Carcinoma of the caecum does not usually occur in such young subjects.

A number of less common conditions may be considered in the diagnosis, though as a rule they are not differentiated clinically but only pathologically:-

Primary tuberculosis of the small intestine is extremely rare. Some authorities doubt whether it exists as a primary lesion, and it is certainly true that the great majority are traceable and secondary to a primary focus elsewhere in the body. All cases of suspected regional ileitis should be examined carefully for any primary tuberculous focus in lungs, pleura, glands, joints etc.

Hodgkin's disease and multiple sarcomatosis of the small intestine are very rare in comparison with ileitis. Both of these diseases occupy by predilection higher sites in the small intestine than the terminal ileum, and they both may give rise to profuse haemorrhage and gross melaena, a feature that is unusual in ileitis.

Carcinoma of the ileum causes symptoms of obstruction rather than irritation of the bowel, and is a solitary stricture. The differentiation lies largely in the pathological examination.

Solitary simple ulcer of the ileum, and ulcer of Meckel's diverticulum, frequently cause melaena and anaemia and attacks of abdominal pain. There is no palpable/

palpable tumour and the radiological picture differs from regional ileitis.

Actinomycosis should always be considered when there is fistula formation, although it is uncommon in this region.

Syphilis in the form of a gumma of the ileum is extremely rare. The Wassermann reaction should be tested in all cases as a routine measure.

An appendix abscess in process of resolution and fibrosis gives rise to a similar palpable mass. There is usually a history of an acute fulminating illness. "Typhlitis" is allied to it.

These less common conditions are seldom considered in making a pre-operative diagnosis; and indeed in a young patient between 20 and 40 years of age, with a history of diarrhoea and pain and with a palpable mass in the right iliac fossa, and with an X-ray picture revealing an ileal defect, a fairly confident diagnosis of regional ileitis should be made.

---

X-RAY DIAGNOSIS.

Radiology can be of very great assistance in diagnosing regional ileitis, but it is necessary that the disease should be sought for by focusing attention on the terminal ileum. In the ordinary way, with a patient complaining of indigestion, a Barium Series X-ray Examination is carried out, and in particular the stomach and duodenal cap are observed. Systematic observation of the small intestine is not practicable, for reasons of time, in all cases reported for Barium Series Examination. However in the past year or two increasing interest in the radiographic appearance of the small intestine has been shown by the radiologist and clinician, and any special symptoms or signs arouse his attention, so that the small intestine is now receiving interest comparable to that which the stomach received twenty years ago. In particular in cases of supposed "Colitis" where the Barium Enema Examination has proved negative, is it desirable that the lower ileum should be investigated radiologically.

Barium will begin to fill the terminal ileum about 3 hours after ingestion, and the patient should be "screened" and films taken at 4 hours, 6 hours, and 9 hours. The peak time for showing up the lower ileum is 6 hours after ingestion of the barium. Films are taken with the patient prone, in order to bring up/  
up/

up the loops of bowel from the pelvis. Barium meals are of course contraindicated where there are signs of intestinal obstruction, but in a straight X-ray of the abdomen fluid levels and distended loops of bowel may be seen.

Weber (68), at the Mayo Clinic, prefers to demonstrate the lowermost part of the ileum after it has been filled with barium in the retrograde direction through the ileo-caecal valve. This he does at the end of examination of the colon with barium enema, at which time the coils of ileum are well elevated out of the pelvis, and are well distended, and are readily palpated through the abdominal wall under the X-ray screen. If there is any degree of competence left in the ileo-caecal valve I cannot see that this method will give a uniformly satisfactory delineation of the ileum.

Jellen (39), who X-rayed Crohn's cases in the Mount Sinai Hospital, New York, states that at 6 hours the terminal ileum, caecum and ascending colon should contain barium. Where there is delay, and loss of motility in the terminal ileum, he suspects regional ileitis. In the established case Jellen usually notes these five features:-

(1) Stenosis of the terminal ileum. This demonstration of a cicatrised and stenosed terminal ileum is the essential feature. The normal calibre of the ileum is reduced to  $\frac{1}{2}$  or  $\frac{1}{3}$  normal, and only a thin/



thin stream of barium is seen going to the caecum. This stream usually extends for 5-6 inches, may be 8-10 inches. The narrowing of the bowel is irregular. The margins are usually smooth and there is obliteration of the normal mucosal markings. These changes are constant, so that it is possible to differentiate disease from the spasm that occurs in the ileum normally in some cases.

(2) Constant non-visualisation of the involved segment in some cases. In some instances ulceration of the mucosa may render the ileum so irritable that barium is not retained. It should be noted that sometimes the normal terminal ileum is not satisfactorily demonstrated. Careful examination in the normal ileum will show however that this is not constant.

(3) Dilatation of the intestine proximal to the involved segment. This is not usual until stenosis is marked.

(4) Deformity of the caecum. This usually shows itself as a smooth semi-lunar defect on the medial aspect of the caecum due to pressure of the adjacent mass, but adhesions may sometimes make the caecum constricted and irregular. There is no mucosal ulceration of the caecum - differing from colitis, in which ulceration causes spasm, irritability and hypermotility. Jellen believes that where radiological features of colitis and ileitis are both present, the features are characteristic of Ileo-caecal Tuberculosis.

(5) Displacement of the normal intestine by a mass in the right iliac fossa.

Where the disease has gone on to fistula formation a Barium Series X-ray examination is unsatisfactory, for the barium is inclined to spill out and obscure the picture. A more satisfactory way of defining where the fistulous tract leads to is by injecting lipiodal along the tract under the screen. Jellen states that an internal fistula is difficult to demonstrate by means of Barium meal or enema; but that if such a tract is seen, in a young adult, between ileum and sigmoid colon, one should suspect granuloma of the ileum rather than malignancy of the sigmoid.

There is no doubt that it is the well-marked filling defect of the terminal ileum that is the most constant and characteristic radiological feature. Kantor (40) called it the "string sign", and this term is now accepted generally. The "string sign", according to Kantor, is that "thin slightly irregular linear shadow suggesting a cotton string in appearance, and extending more or less continuously from the region of the last visualised loop of ileum through the entire extent of the filling defect and ending at the ileo-caecal valve. It represents the attenuated barium filling the greatly contracted intestinal lumen." Of the cases of regional ileitis that I am reporting in this thesis all of those that had reached the advanced/

advanced stage of the disease showed this "string sign" at X-ray examination. (Fig. 2 )

It may be said then that radiology is of great value in diagnosis of the established cases. There is no record of an early acute case of regional ileitis ever having a Barium Series examination carried out, since patients with symptoms suggestive of acute appendicitis are not submitted to such examination. The changes seen in the advanced case are characteristic but not pathognomonic, since other stenosing lesions of the terminal ileum give the same picture. These (syphilis, sarcoma, lymphogranuloma) are so rare however that the correct X-ray diagnosis can usually be made with very little reservation. It is when there is much deformity of the caecum that the X-ray appearance may be confounded with that of ileo-caecal tuberculosis. This deformity, in the case of regional ileitis, may be due to pressure from the adjacent mass; or peri-caecal fibrotic and inflammatory changes which result from the proximity of the ileal focus; or very rarely from true involvement of the caecum in the granulomatous mass; or it may be due simply to associated spasm. Kantor has seen such spasm affect the entire caecum and ascending colon in a case affecting the terminal ileum. He states that the spasm is usually most marked at the "sphincter of Busi". This is a sphincter separating the caecal tip from the caecum above it - a caecocolic sphincter in/

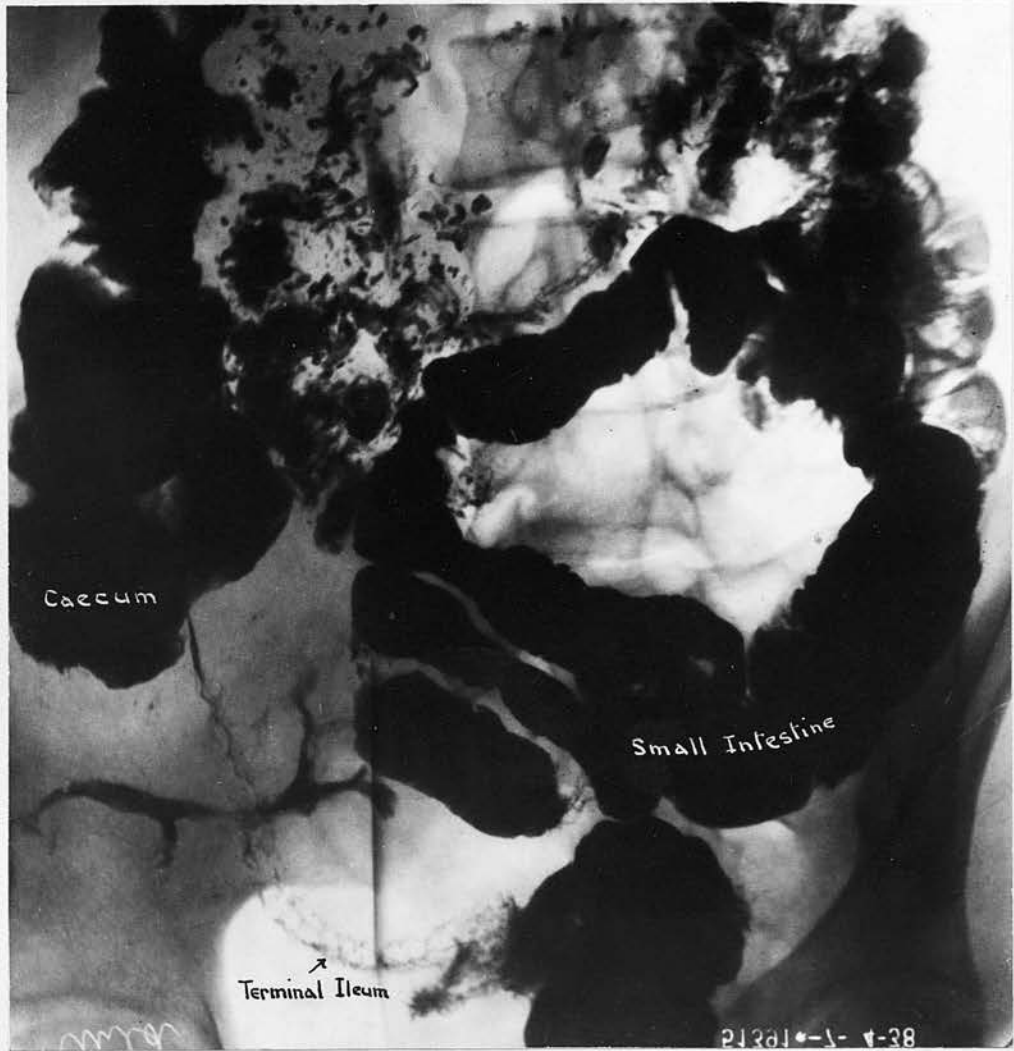


Fig. 2. Stenosis of terminal loop of ileum - the "string sign". Ileum is running up to, and indenting, the caecum. Slight dilatation of ileum proximal to the stenosed segment.

in the strict sense, (Balli. 1. ).

As an aid in the differential diagnosis from tuberculosis all cases should have X-rays of the chest taken. No pulmonary focus of tuberculosis was seen in any of my cases of regional ileitis.

TREATMENT.

All authorities agree that medical treatment is merely palliative in regional ileitis and that treatment should be surgical with resection of the diseased ileum. The lesion cannot be reached by colonic irrigation, and medical treatment for such an ulcerating necrotising stenosing condition can only be futile.

When the disease is encountered in the acute stage the practice is not to resect the affected portion then, and it is conceivable therefore that in the early cases medical measures that are employed in combating any serious infection may be helpful. A generous high caloric, high protein, high vitamin and low residue diet is indicated. Repeated small transfusions of blood and a systematic course of sun baths have been found helpful at the Mayo Clinic ( 3 ).

In the chronic stage, if for some reason operation is not possible treatment is symptomatic and palliative. For the diarrhoea a diet with excess of vitamins and a low residue should be prescribed. For the anaemia liver in large quantities may be necessary. Autogenous vaccines, prepared from prevailing bacteria obtained from the lesions or faeces have been tried at the Mayo Clinic.

The general opinion is against performing resection during the acute stage. This is partly because of/

of the fact that these patients are usually operated on in emergencies, with a diagnosis of appendicitis, and are possibly not in as good general condition as one would like for doing a radical operation; partly because there is risk of disseminating an acute infection by operative handling; and partly because an occasional case does appear to heal spontaneously. Dixon ( 19 ) quotes a case he was informed about by a colleague, the case of a young woman who was operated on for a supposedly acutely diseased appendix. The appendix was not inflamed, but in the terminal ileum, about 10 c.ms. from the ileo-caecal valve, there was a definitely thickened area covered by grey plastic exudate and involving the entire circumference. There were many enlarged glands in the mesentery. The omentum was used to cover the part, and nine months have elapsed and the symptoms have gradually subsided.

Lehman ( 42 ) reported a group of seven cases operated on at the onset of symptoms. They were all treated with nothing more radical than appendectomy, which was performed not with the idea of curing the disease, but because the appendix was readily accessible. Of their seven cases, two have been completely symptom-free for 9 years, one has been symptom-free for 4 years, and one symptom-free for one year. The remaining three cases went on to the chronic stage. In a recent complete clinical and radiological examination of the symptom-free patients there was no evidence/

evidence of disease.

The two cases that I have operated on in the acute stage, and done nothing more than remove the appendix, have no obvious sign of the disease a year after operation, though one still has occasional attacks of pain.

One concludes therefore that the first attack is not the time to perform a radical operation. Some of the cases will undoubtedly resolve spontaneously, and it is safer for the patient to perform no surgery except the removal of glands if available for diagnostic purposes, and possibly the removal of the appendix if it is readily accessible. The question whether the innocuous appendix should be removed is a debatable one. Many surgeons consider that it is unsound to remove an appendix that is not implicated as a causative factor in the disease, in the presence of an acute infection. In addition the risk of establishing an external fistula is considerable, in a disease characterised by its tendency to fistula formation. Mixer (48) quotes examples of patients presenting themselves with faecal fistulas following a previous unnecessary appendectomy. I have had one similar experience, and I believe that the appendix should not be interfered with.

In the chronic stage surgery alone is curative. It is usually, but not always, necessary to remove the diseased portion of the intestine before complete cure results/

results, especially as there is danger of exacerbation and extension of the ileitis. The principle contra-indication to radical excision is where there is a widespread anatomical distribution of the disease, such as is very occasionally seen in diffuse ileo-jejunitis. These cases defy surgical measures, though they may improve considerably with medical treatment. Two such cases of Crohn's gained weight and strength on a low-residue diet, even though X-ray studies continued to show the lesion. Logan and Brown (43) have found that if resection is not carried out hyperchromic macrocytic anaemia of the sprue or pernicious anaemia type may develop, necessitating the giving of large quantities of liver for its relief. Evidently the diseased portion of ileum interferes with absorption, or may even produce a harmful product.

In the operation of radical excision of the diseased terminal ileum, and for excision for any lesion in this region, it is customary to do a right hemicolectomy. For technical reasons it is more satisfactory to perform this extensive resection of terminal ileum, caecum, ascending colon, hepatic flexure and the beginning of the transverse colon, and anastomose ileum to transverse colon, rather than a local resection of the terminal ileum itself. The anastomosis of ileum, proximal to the lesion, with transverse colon may be performed as a first stage, and the resection carried out a few weeks later. And this anastomosis of/

of ileo-transverse colostomy is sometimes the sole operation done, without subsequent resection.

Dixon ( 20 ) gives particulars of treatment and results in the 30 cases from the Mayo Clinic, the clinical features of which we have already noted. Treatment was surgical in all 30 cases, viz:

(1) Single stage resection in 10.

(2) Ileo-transverse colostomy with subsequent resection in 10.

(3) Ileo-transverse colostomy alone in 10.

Dixon states that in those 10 cases in which ileo-transverse colostomy was the only surgical procedure, the patients were advised to return for resection of the diseased segment of bowel, but possibly because of improvement they had not complied at the time of writing. Their present condition is known however, and it is of interest that all but three of these ten patients have the same symptoms as before the short-circuiting operation, but to a lesser degree. I have noted the same feature in one of my cases that was allowed to go for a year between the two stages. Three of Logan and Brown's ( 43 ) cases that refused to have the second stage of the operation done returned with severe macrocytic anaemia. It is probable that the only cases that will be cured by the short-circuiting operation alone are those in which there is very little present ulceration of the ileum, and the symptoms are obstructive due to the cicatricial stenosis/

stenosis of the lumen.

In Dixon's 20 cases in which single or two stage resection was employed, all symptoms completely subsided, except in four cases in which a tendency to diarrhoea remained.

In the series of 30 cases, upon whom 40 operations were performed, there were four deaths: one from pulmonary embolism, one from peritonitis, one from intestinal obstruction, and one from pneumonia. The fact that there was but a single death following the ten primary resections suggests that this procedure should be employed more often, particularly if, as Dixon recommends, a temporary stoma is established in the ileum about 24 to 30 inches proximal to the anastomosis, to prevent post-operative intestinal gaseous distension.

Crohn ( 15 ) advises resection in all but the acute cases of ileitis, as being the procedure which offers the best chance of permanent cure. His 52 resections carried with them a 15% operative mortality, as against a 10% mortality when the short-circuiting operation was performed; and he does not quarrel with the surgeon who prefers the lesser measure, provided he understands that the patient has only an even chance of cure with it. Of his 20 cases who had the short-circuiting operation exactly half were apparently well when examined 2 to 3 years later. The other 10 patients did badly, and had to submit to subsequent/

subsequent resection with a considerably higher operative mortality.

It cannot be denied that a certain percentage of recurrences occur even after what seems to have been a radical and sufficient resection, and in Crohn's series the recurrence figure was 7.7%. These recurrences can only be explained on one basis, namely, the inability of the surgeon to recognise the upper limit of mucosal involvement. Mixer believes that what he calls "the index of resection" is the uppermost limit of enlarged mesenteric lymph glands, but I do not feel that this can be an infallible guide to the extent of the lesion. The uppermost limit of infiltration may be so minimal and so restricted to the mucosa as to create no reddened inflammatory reaction in the serosa, and no enlargement of the glands, thus defying detection either by inspection or palpation. Furthermore failure to note the higher "skip areas", which are occasionally encountered, will mean insufficient resection.

Homans (31) quotes a striking example of recurrence after operation. This was a man with typical ileitis involving the terminal twelve inches of ileum, with many inflamed glands in the mesentery. He resected the area plus twelve inches of ileum above it, plus caecum and half of ascending colon, and made an anastomosis between ileum and ascending colon. Recurrence evidenced itself within a fortnight. He was/

was treated medically for a year with no improvement, and then operated on again. At this second operation so much disease was found in the mesentery and so much ileum was involved that he was considered incurable, and a half-hearted attempt was made to ameliorate the condition by ileo-transverse colostomy, which did no good. The patient then consulted Crohn, at whose instance he was again submitted to resection, since when he has recurred again. In this case it was felt that too much mesentery had become involved, and caused re-infection of the bowel.

As has been said surgical treatment cannot be considered when there is widespread involvement of the ileum and jejunum, but in the combined form of terminal ileitis and colitis resection is the treatment of choice, and its value lies in eradicating the severer lesion, which is in the ileum. Crohn (17) gives an instructive illustration of the treatment of the combined lesion. The case was that of a young man complaining of pains and diarrhoea. Laparotomy revealed a typical sodden oedematous terminal ileum, and a caecum, transverse colon, and pelvic colon that were thickened injected and oedematous, and covered with a shaggy peritoneal exudate. Resection of the whole of this wide-spread area was considered too dangerous, and the abdomen was forthwith closed. This exploratory procedure was followed by a stormy febrile course for several months, and then gradual resolution, cessation of/

of diarrhoea, and gain in weight. Crohn had come to regard this as a striking example of spontaneous remission of the combined disease until two years later when the patient developed intestinal obstruction and came to operation again. A stenosing lesion of the terminal sixteen inches of the ileum was resected, and there was no evidence at all of the previous acute and severe colitis. Apparently the ileitis had lain dormant to appear as a cicatrising stenosing end-stage of the process, and the colitis had resolved spontaneously. Crohn believes that resection of the diseased ileum will usually allow the colitis to cure itself. He gives two further examples where, in the combined form of ileitis involving colitis of the caecum, ascending colon, and transverse colon, resection was done through ulcerated transverse colon yet the patient was cured.

My conclusions as regards the treatment of regional ileitis are that ileo-colostomy and later hemi-colectomy is the ideal to be aimed at; and that resection must be radical and wide of all disease, otherwise the process may spread orally and involve the anastomosis. If resection is adequate there is no reason why all patients should not be permanently cured. The figures of Crohn and of Dixon show that at least 80% are cured after resection, and the failures and recurrences are probably due to inadequate removal of all disease, and are not likely due to setting up of the disease afresh.

PERSONALLY OBSERVED CASES OF REGIONAL ILEITIS.

The following seven cases which I will describe were all observed by me in the Royal Infirmary, Edinburgh. I personally operated on them all in the first instance, and I was privileged to assist Sir David Wilkie and Mr. J.J.M. Shaw in the final resection of three of the cases. It is by the junior surgeon, such as myself, that most cases of ileitis are first seen, because they are frequently admitted to hospital as abdominal emergencies, the treatment of which devolves on the junior surgeon.

During the investigation of these seven cases there were several special features which were of particular interest to me, and to which I would draw attention:-

The symptomatology.

The possibility of X-ray diagnosis.

The pathology of the resected specimen, and in particular the histological distinction between this condition and tuberculosis.

Evidence of bacterial infection of the ileum.  
Any evidence of dysentery.

The Frei test.

The subsequent progress of the patients.

The clinical features and special investigations are from notes made by myself at the time of the patient's stay in hospital. The pathological examination of the resected specimens has been done afresh by me, using the same histological criteria for all the cases.

HENRY WYATT.

Male. Aet. 40. Civil servant.  
Admitted to Ward 13, Royal Infirmary,  
Edinburgh, 29.11.36.

History. Almost exactly a year before admission patient first began to be troubled with colicky pains across the middle of the abdomen, coming on about half an hour after meals and persisting for two or three hours. This was particularly bad after taking greasy foods.

To begin with he had three or four such attacks a week. They were considerably relieved by taking an alkaline medicine prescribed by his doctor. During the Summer of 1936 he was completely free from pains for almost four months. Since then, however, the pains have been coming more frequently and lasting longer. It now bears no very obvious relationship to the taking of food and persists almost all day.

He was able to carry on with his work until 2.11.36 when the griping pain became so severe that he came to hospital, where he was admitted to a Medical ward. While in that ward, for the following four weeks, he was rather constipated but his bowels functioned satisfactorily with the help of liquid paraffin regularly, along with an occasional enema. He had a constant feeling of nausea but no actual vomiting. He was transferred to a Surgical Ward - Ward 13 - where on admission the following was noted:-

He complains of a great deal of flatulence with borborygini and a feeling of distension. His bowels are now rather constipated, but he used to have an occasional attack of diarrhoea. He has never passed any blood in his motions, although occasionally there has been a little slime.

His appetite is poor, and he is afraid to eat on account of the pain which it causes. He has never been stout but has lost a great deal of weight recently, which he can tell by the feel of his clothes on him. He does not become easily breathless on exertion and has had no swelling of the ankles. He has a slight cough.

Previous History. Prior to the onset of the present complaint patient has always been perfectly healthy. He served in France during the Great War, but has never had dysentery.

Family/

Family History. Married. Wife and two children, and patient's father and mother, all alive and well. No family history of tuberculosis.

On Examination. 29.11.36. Temperature 97°F. Pulse 96. Respirations 20.

Patient is extremely wasted looking. He looks tired and ill. Cheeks are hollowed out and the bony features are prominent. Colour is fairly good.

Teeth. Upper artificial. Lower fairly good.

Tongue. Almost beefy in appearance - dark red but somewhat dry.

Abdomen. Long and narrow with a small intercostal angle. No distension. Active visible peristalsis can be stimulated by light palpation. Coils of distended small bowel are seen forming ladder patterns above and below the umbilicus. The movement is accompanied by rumblings clearly audible at the bedside. The skin is lax, dry and inelastic. There has obviously been a great loss of weight. The skin can be picked up readily in redundant folds over the abdominal wall. The muscles are of poor tone, the palpating hand sinking deep into the abdomen all over without eliciting the slightest tenderness. There is a palpable mass, rather firm and elongated but movable, in the Right Iliac Fossa. There is no ascites. The liver and spleen are not enlarged. The lower pole of the right kidney is just palpable.

Per rectum. No palpable tumour. No narrowing. No tenderness.

#### Cardiovascular System.

Pulse. Volume very poor. Pressure not well sustained.

Blood pressure 90/60.

Heart. 2nd left space is resonant and there is no dullness to the right of the sternum. Impalpable cardiac impulse with faint and distant heart sounds.

#### Respiratory System.

Slight repeated unproductive cough. Chest thin and poorly covered, but no undue hollowing or/

or flattening in any area. Expansion is free in all areas. Note resonant. Breath sounds vesicular with no accompaniments. No change in vocal resonance.

X-ray Examination.

Chest - negative.

Abdomen. Straight film - fluid levels present. Hepatic flexure appears to be displaced to the left. (Fig. 3 )

Blood Count.

R.B.C.	4,125,000
Hb.	70%.
C.I.	0.9.
W.B.C.	7,600.

Faeces: Benzidene reaction - negative.

Bacteriology: Many and varied faecal organisms seen. No organisms of the typhoid-dysentery group isolated on culture.

Wassermann Reaction - Negative.

Provisional Diagnosis - Carcinoma of the Caecum.

Operation. 3.12.36. Spinal anaesthesia.

The abdomen was opened through a long subumbilical incision in mid-line. There was a little clear free fluid in the abdomen. The caecum was healthy. The appendix was rather attenuated and contained numerous concretions.

The terminal 5 inches of the ileum showed gross thickening of the walls, the bowel feeling more like a firm solid stalk than a healthy yielding tube. The visceral peritoneum was glistening and apparently unaffected. At one point the thickened portion was acutely bent upon itself, the proximal and distal ends of the loop being firmly adherent to each other. The mesentery was thickened and oedematous, and the glands in it were enlarged and firm.

The coils of small intestine immediately above the/

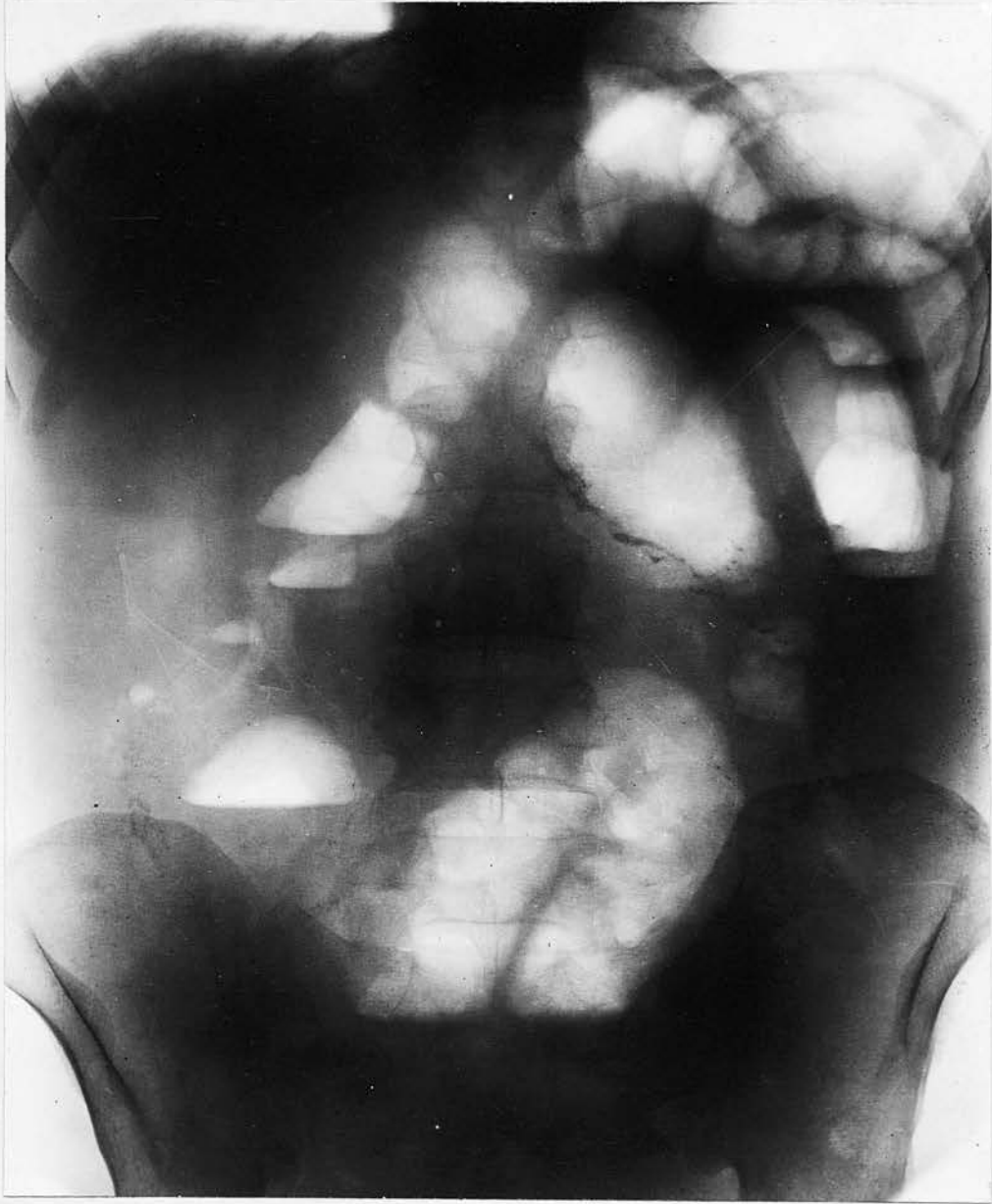

Fig. 3. Henry Wyatt. Straight X-ray of abdomen, showing fluid levels and gas filled coils of bowel, due to intestinal obstruction.

the obstruction were grossly dilated and hypertrophied, looking more like stomach than small intestine. Apart from this there were no stricture or other involvement of the small intestine.

The disease process stopped short distally at the ileo-caecal valve and proximally there was a sudden alteration from the grossly thickened to the dilated bowel. The condition was thought to be that of Regional Ileitis. There were no superficial tubercles to suggest tuberculosis.

The affected portion of ileum and a length of 4 inches above it, the caecum, the ascending colon and half the transverse colon were resected; and a side to side iso-peristaltic anastomosis performed between the lower end of the remaining ileum and the transverse colon. The ileum used in anastomosis was dilated and not very healthy looking.

Summary. Regional Ileitis. Right hemicolectomy. Lateral anastomosis.

After-history.

Patient died three days later after copious vomiting and progressive exhaustion. Post-mortem examination showed a leaking anastomosis with a generalised advanced peritonitis.

It was noted at the post-mortem examination that the wall of the lower end of the remaining ileum was thick and soft and friable, and the stitches of the anastomosis had cut out.

Specimen of terminal ileum, caecum, appendix and ascending colon.

Pathological examination:

Macroscopic (Fig. 4). The terminal 5 inches (13 c.m.s) of the ileum is slightly narrower than normal, and relatively very much narrower than the dilated ileum proximally. The affected portion is reddish-grey in colour, being a deep reddish colour towards the caecum and a dark grey towards the ileum above. The peritoneal surface is smooth and no tubercles are seen. On palpation the affected ileum feels firm and unyielding, and the wall is/

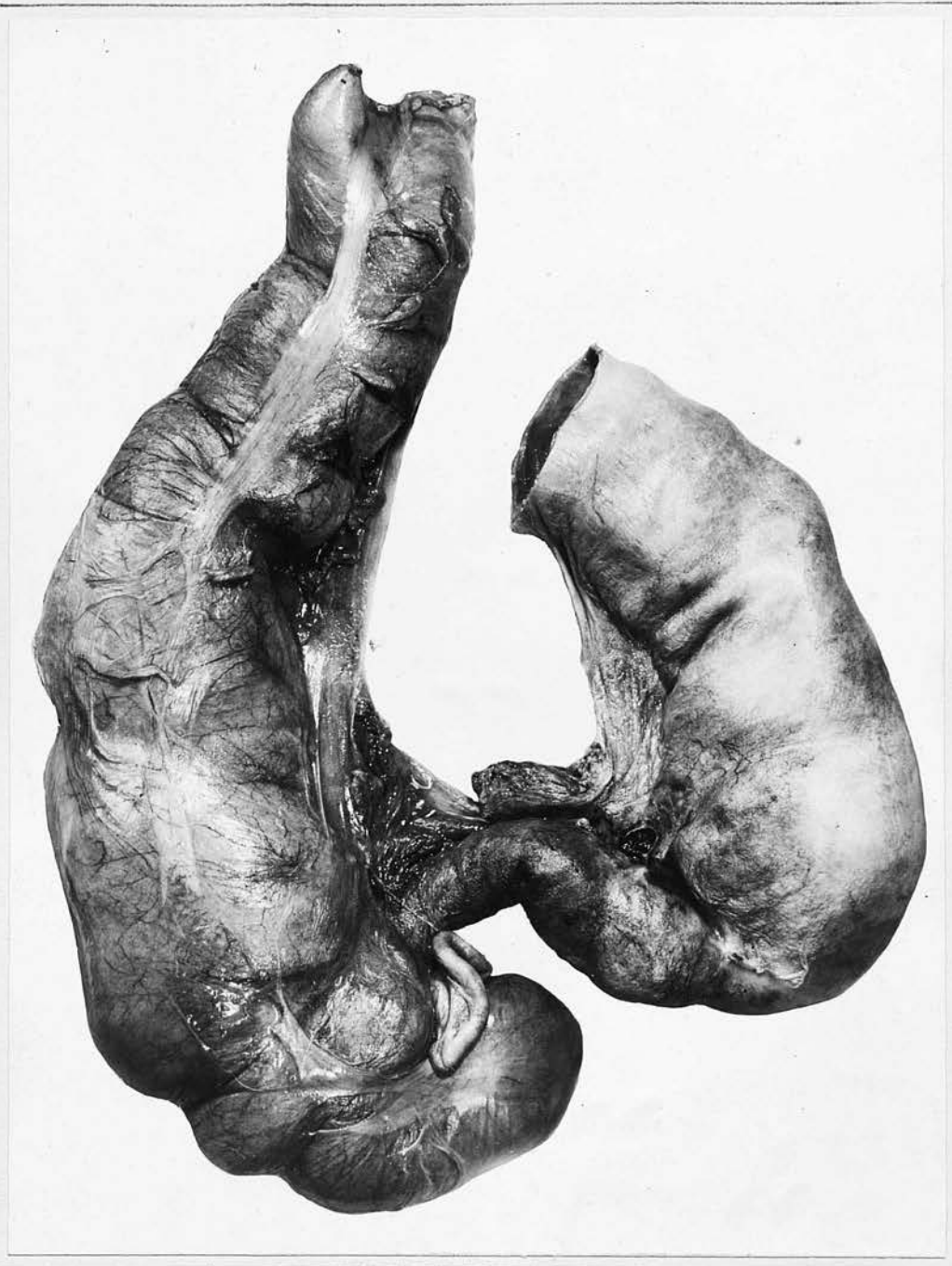


Fig. 4. Henry Wyatt. Stenosis of the terminal segment of ileum. Caecum and appendix unaffected, the disease process stopping abruptly at ileo-caecal valve. Sharp change from affected to healthy ileum proximally.

is thickened so that the lumen is almost obliterated. This affection of the terminal part of the ileum stops short abruptly at the ileo-caecal valve which is also somewhat thickened, and proximally there is an equally abrupt change from stenosed to dilated ileum. The wall of the dilated ileum is thinned out. The caecum and ascending colon are normal in all respects. The appendix lies curled beneath the terminal ileum and appears normal. The mesentery is thickened and oedematous and there are several enlarged soft glands at the ileo-caecal angle.

On opening the bowel along its entire length the mucosa of the stenosed portion of bowel is grossly ulcerated - small semi-circular and oval ulcers, deep and crypt-like, and averaging 2 m.m. in diameter. The ulcers are almost entirely confined to the mesenteric border of the bowel. The mucosa of the ileum proximally is thinned out but not ulcerated. In the caecum the mucosa is normal. The thickening in the wall of the terminal ileum would appear to be principally in the submucous layer. This thickening in the wall has been at the expense of the lumen which is markedly stenosed.

Microscopic (Fig. 5 ) Section from affected ileum.  
Stain - Haematoxylin and Eosin.

The mucous membrane is congested. It shows a marked infiltration with plasma cells, polymorphs, and eosinophils. In places, although with intact surface of epithelial cells, there is a complete disappearance of glands and villi. There is no widespread ulceration, but in places the mucosa is breached by narrow sinus-like ulcers passing deeply into the muscle coat. These are general, and not particularly opposite the mesenteric surface.

The submucosa shows oedema; a moderate degree of diffuse polymorphs and plasma cell infiltration; and a moderate degree of collagenous fibrosis. There are many greatly distended channels, presumably lymphatics, containing homogeneous slightly eosinophil material and some polymorphs. There is an increased number of lymphoid follicles but no tubercles. The sinus-like ulcers are lined by polymorphs and chronic inflammatory granulation tissue.

The muscle layer shows a relatively trifling lymphocyte and plasma cell infiltration.

The subserous layer shows rather more marked infiltration, and many small lymphoid follicles.

The attachment of the mesentery is thickened by oedema and fibrosis.

Throughout/



Fig. 5. Henry Wyatt. Ileum. x 3. Sinus-like ulcers breaching mucosa and passing deeply into muscle. Oedema and fibrosis of submucosa.

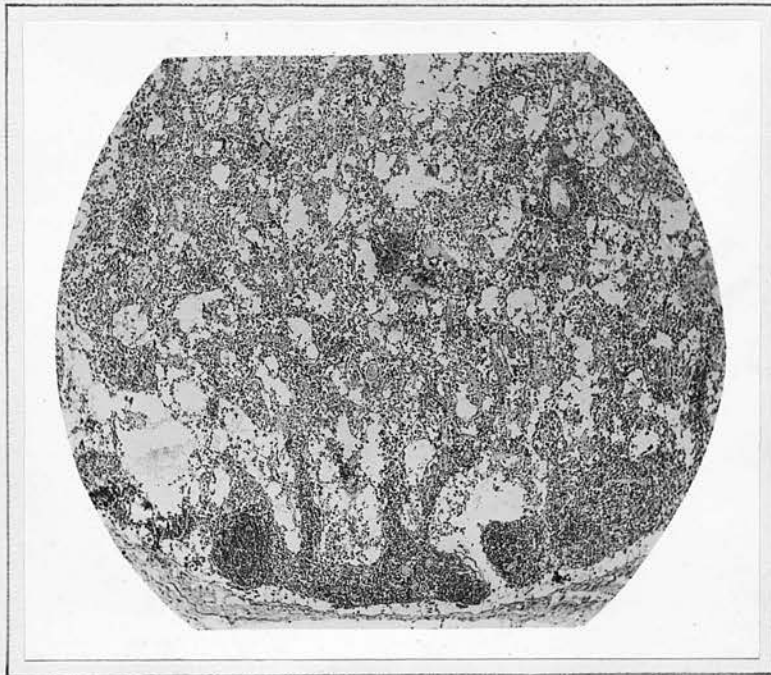


Fig. 6. Henry Wyatt. Gland. x 50. Dilatation of lymph sinuses.

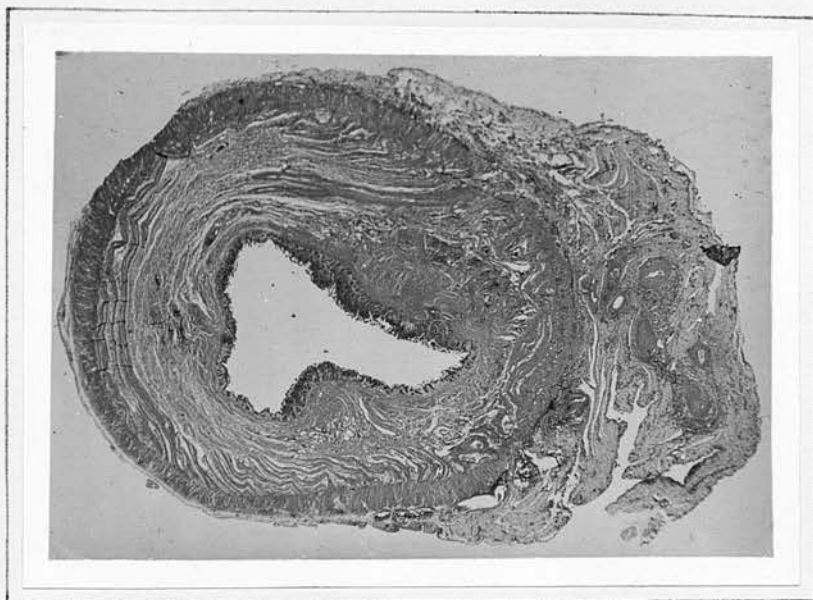


Fig. 7. Henry Wyatt. Ileum above. x 4. Mucosal atrophy and thinning of muscle coat.

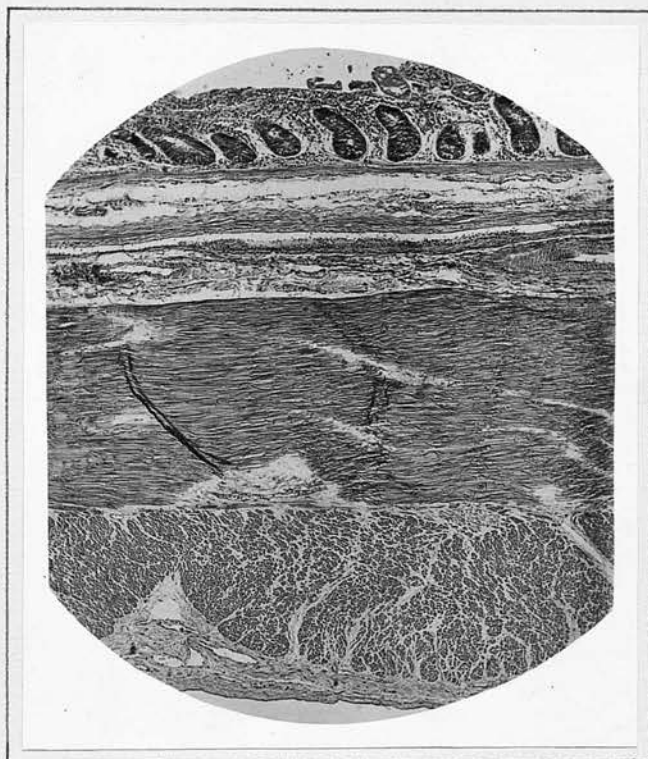


Fig. 8. Henry Wyatt. Ileum above. x 50. Relatively normal appearance of bowel.

Throughout the section no tubercles are seen; no giant cells; and no caseation.

Section from bowel above: There is mucosal atrophy and thinning of the muscle coat. (Fig 7 & 8)

Section from gland. There is enormous dilatation of the lymph sinuses, which contain numerous polymorphs and small numbers of histiocytes. The gland architecture is well preserved. The medullary tissue shows a little polymorph infiltration. The appearance is that of a gland draining an infected area. (Fig. 6)

Section from ileum, stained Ziehl-Neelsen.

No tubercle bacilli seen throughout the section.

Points to note.

- |                                       |  |
|---------------------------------------|--|
| 1. Age 40.                            | 1. Thickened stenosed ileum - strictly confined to terminal 5".                  |
| 2. Colicky pains for 1 year.          | 2. Ulceration of mucosa.   |
| 3. Mild diarrhoea.                    | 3. Oedema and fibrosis, and polymorph and plasma cell infiltration of submucosa. |
| 4. Loss of weight.                    |  |
| 5. Palpable mass.                     |  |
| 6. Eventually intestinal obstruction. |  |

No evidence of tuberculosis, typhoid, or dysentery.

Comment.

An example of Regional Ileitis, strictly confined to the terminal ileum, in the chronic and cicatrising stage, with typical symptoms of diarrhoea in the earlier stages and colicky pains. Microscopically the picture was that of a non-specific granulomatous lesion, with no tubercles seen in the section, and no tubercle bacilli shown by Ziehl-Neelsen's stain. Unfortunately bacteriological cultures of the bowel wall and lumen, and guinea-pig inoculation, were not carried out, so that no definite opinion can be given about organismal infection of the wall of the ileum. In the patient's faeces there were no organisms of the/

the typhoid-dysentery group. And there was no evidence that the condition was tuberculous.

It is possible that the patient might have survived if the resection had been attempted in two stages instead of one.

-----

MRS. ELIZABETH BRASH.

Female. Aet. 39. Housewife.  
 Admitted to Ward 13, Royal Infirmary,  
 Edinburgh, 6.3.37.

History. For about four months patient has been troubled with recurring attacks of upper abdominal pain, griping in character and lasting for two or three minutes. To begin with the attacks usually occurred between meals and not more than two or three times a day. In the past month these attacks have been getting more severe and more frequent, occurring at any time of day, and she is frequently nauseated.

Bowels move daily, and every four weeks she has an attack of diarrhoea. She has never noticed any blood or slime in the motion. The diarrhoea is usually preceded by a great deal of rumbling in the abdomen.

Two days ago the pain became more severe and more continuous. She was however able to go about her work until this evening, when vomiting occurred for the first time. She brought up small amounts of frothy material almost every five minutes.

For three months she has been losing weight. Her appetite is not very good, and she is becoming pale and easily tired. She has been having treatment from her doctor for anaemia. No urinary trouble. Periods regular.

Previous History. No illnesses of note.

On Examination 6.3.37. Temperature 97.8°F. Pulse 120.  
Respirations 24.

Patient is pale and somewhat thin.

Teeth. Upper false. Lower satisfactory.

Tongue Slightly furred but moist.

Abdomen. No fullness or swelling anywhere.

No visible peristalsis. No hyperaesthesia. There is acute tenderness just above the inguinal ligament on both sides with rigidity, both being more marked on the right side. No palpable mass. No tenderness over the gall-bladder which is not palpable. Liver not enlarged.

Per Rectum. There is tenderness high up in the pelvis on both sides.

Per Vaginam. Vagina and cervix healthy. There is acute tenderness in each lateral fornix but no mass can be felt on either side.

Cardiovascular system.

Pulse - regular in time and force.

Heart - not enlarged. Sounds both closed.

B.P. - 134/84.

Respiratory System. Normal lung resonance.

Breath sounds vesicular, with no accompaniments.

Blood Count.

R.B.C.	3,800,000
Hb.	70%.
C.I.	0.9.
W.B.C.	1,200.

Provisional Diagnosis. Intestinal obstruction -  
- ? small intestine adhesions.

Operation. 6.3.37. General anaesthetic - Gas, oxygen and ether.

Low right paramedian incision.

There was a large amount of clear free fluid in the abdomen. The appendix was lying over the pelvic brim, and appeared to be quite healthy. It was removed.

The lowest eight inches of the ileum was found to be the site of a most unusual pathological change. From the ileo-caecal valve to a point about eight inches proximal to it there appeared to be a slight narrowing of the bowel diameter, the point of division between healthy and narrowed ileum being covered with a thin lymph exudate. The peritoneum covering the remainder of this affected segment was very slightly congested but there were no visible tubercles.

It was on palpation however that the greatest change was noted. The bowel wall was felt to be much thickened. The thickening was most marked along the mesenteric border. The walls were very firm but were not hard, giving the bowel the feeling of being almost a pliant, fleshy cord rather than a tube. The mesentery was slightly thickened but there were no palpably enlarged glands.

The/

The caecum appeared to contain a very firm irregular mass, on its medial aspect. There were no enlarged glands found in relation to it, and there were no recognisable tubercles on the peritoneal surface.

There was no evidence of any serious obstruction and no anastomosis was done. It was decided to defer the question of excision of the affected portions until the patient was better prepared for it.

Summary. ? Regional Ileitis. Appendectomy.

After-history. Patient continued to have colicky pains following this operation, and she was given sedatives. Bowels moved regularly and there was no vomiting.

X-ray Examination. 16.3.37. (Fig. 9 )

(1) "Barium examination of the stomach showed it to be normal.

Examination of the small intestine showed that there is no intestinal obstruction but the terminal ileum is dilated proximal to a stenosed 6 c.m. The caput caecum is distorted in outline due to irregular induration.

Conclusion: The appearances are typical of ileo-caecal tuberculosis."

(2) Chest - Negative.

Wassermann reaction - Negative.

In view of persistence of symptoms and the presence of a pathological lesion it was decided that further operation was necessary, and, to prepare the abdomen to react to excision of part of the colon, patient was given injections of anti-streptococcal and anti-B. Coli vaccines.

Operation 18.3.37. Spinal anaesthetic.

Oblique muscle cutting incision. No free fluid in the abdomen. The local condition of the ileum appeared to be improved, there being less congestion. There now appeared to be however numerous tiny tubercles on the peritoneal surface of the lower ileum, and in place of the thickened fleshy feel the terminal/

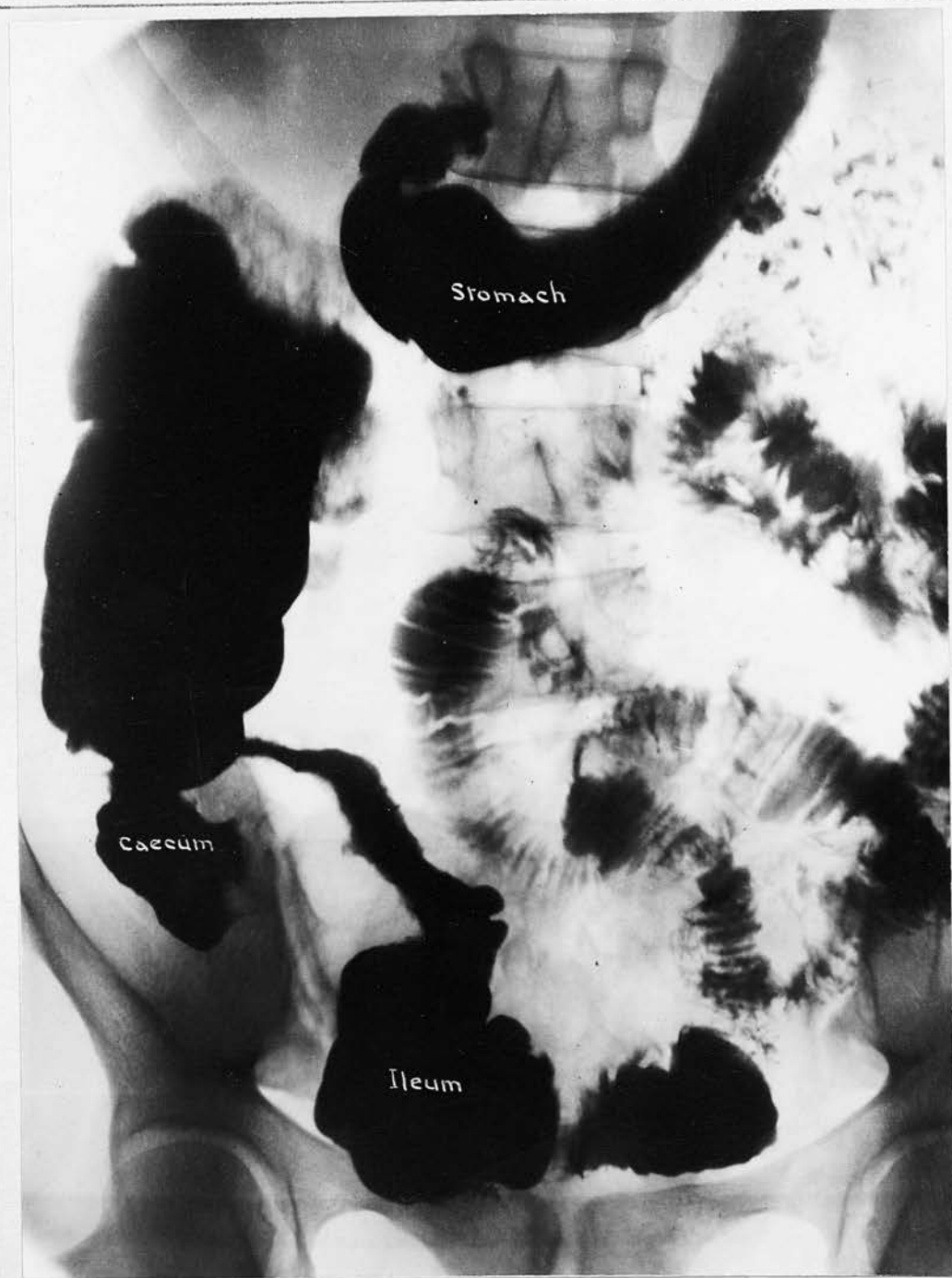


Fig. 9. Mrs Brash. X-ray, barium series. Stenosis of the terminal segment of ileum, with dilatation proximally. Caecum deformed due to induration. Stomach and duodenum, in the upper part of the picture, are normal.

terminal eight inches of ileum now felt firm and impliable. The caecum was still grossly thickened, and it now seemed that the process was one of ileo-caecal tuberculosis.

Resection was carried out, of the lower ileum, caecum, ascending colon, hepatic flexure, and half of transverse colon. A lateral anastomosis was performed between ileum and transverse colon.

Summary. ? Ileo-caecal tuberculosis. Hemi-colectomy.

After-history. For a few weeks following this second operation was troubled with diarrhoea. Thereafter the bowels became more regular and she began to put on weight. During the next twelve months she gained three stones in weight. On examination in February 1939 patient now declares herself free of all symptoms and is still gaining weight.

Specimen of terminal ileum, caecum, and ascending colon.

Bacteriological report.

Cultures from wall of ileum and caecum: No growth was obtained on culture from either specimens.

No tubercle bacilli found in smears.

No organisms of the typhoid-dysentery group were isolated.

Guinea-pig inoculation. Guinea-pigs inoculated with tissue from wall of caecum were killed after 6 weeks, and no evidence of tuberculosis seen.

Pathological examination.

Macroscopic. (Fig.10) The most notable feature is the thickening of the bowel wall, most marked at the ileo-caecal valve, extending into caecum as a broad ring surrounding the caecum opposite the ileo-caecal valve and extending proximally along the ileum to fade away six inches from the valve. The thickening is most marked in the submucosa, and to a lesser extent involves muscle and subserosa. The serous covering everywhere is normal.

Ileum: The lumen of the last six inches of ileum is narrowed to about half-normal. The mucous membrane is thinned out, and there are a few small irregularly placed/

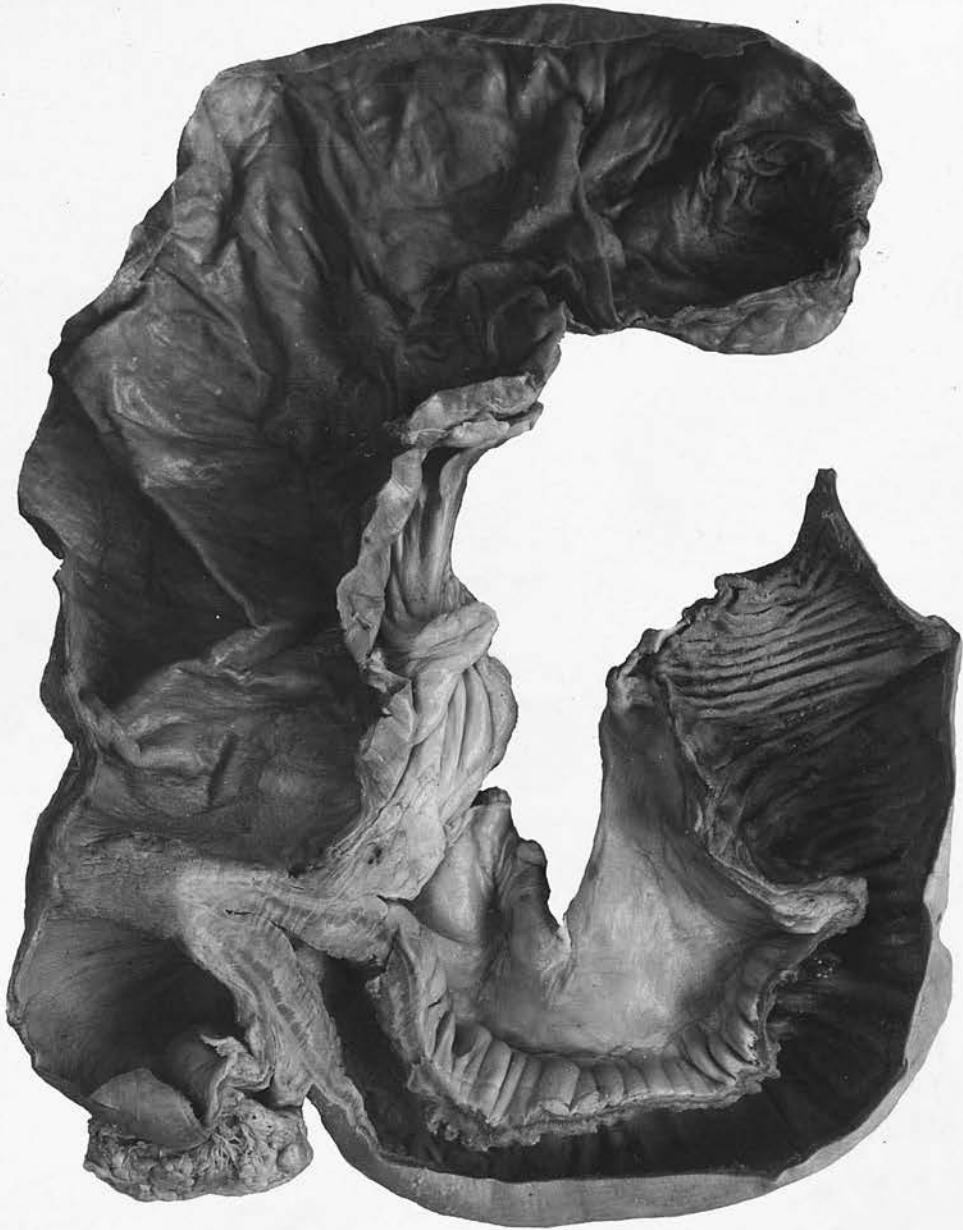

Fig. 10. Mrs Brash. Thickening of wall of ileum, most marked at ileo-caecal valve. Extension into caecum as a firm ring at the caeco-colic valve.

placed ulcers, both linear and circular. The thickening of the wall of the ileum is greatest on the mesenteric border.

The Ileo-caecal valve is represented as a narrow slit between firm unyielding thickened walls.

The Caecum presents a firm bunched up ring of tissue about  $\frac{3}{4}$ " broad opposite and in continuity with the ileo-caecal valve. This ring completely encircles the caecum, but leaves a lumen  $\frac{1}{2}$ " in diameter. The thickening is principally in the submucosa, and nowhere is the mucosa ulcerated. Above and below the encircling ring the caecum is normal. The appendix stump has been invaginated into the lower end of caecum.

The Mesentery of the terminal loop of ileum is thickened.

Microscopic Section from Caecum. (Fig. 11).  
Stain - Haematoxylin and Eosin.

The mucous membrane is not ulcerated. There is considerable chronic inflammatory infiltration with plasma cells and eosinophils.

The submucosa is greatly thickened. Fibrosis is very marked - an old collagenous fibrosis. There are very many lymphoid follicles throughout the submucosa - more than the normal lymphoid tissue. There are several abscesses in the submucosa with walls of chronic granulation tissue. These abscesses are irregular and cruciate-shaped, and measure on an average 5 m.m. by 8 m.m. No tubercles are seen.

The muscle coat also shows marked collagenous fibrosis. There are many lymphoid follicles but no tubercles of histiocytes.

The subserosa unfortunately is not seen in the section. Throughout the section no giant cells are seen, and the whole suggests a non-specific chronic inflammatory condition.

Section from Ileum. Exactly comparable changes are seen in the coats of the ileum - chronic inflammatory infiltration, particularly in the submucosa.  
(Fig. 12)

Section from Caecum - Stain - Ziehl Neelsen.  
No tubercle bacilli seen.

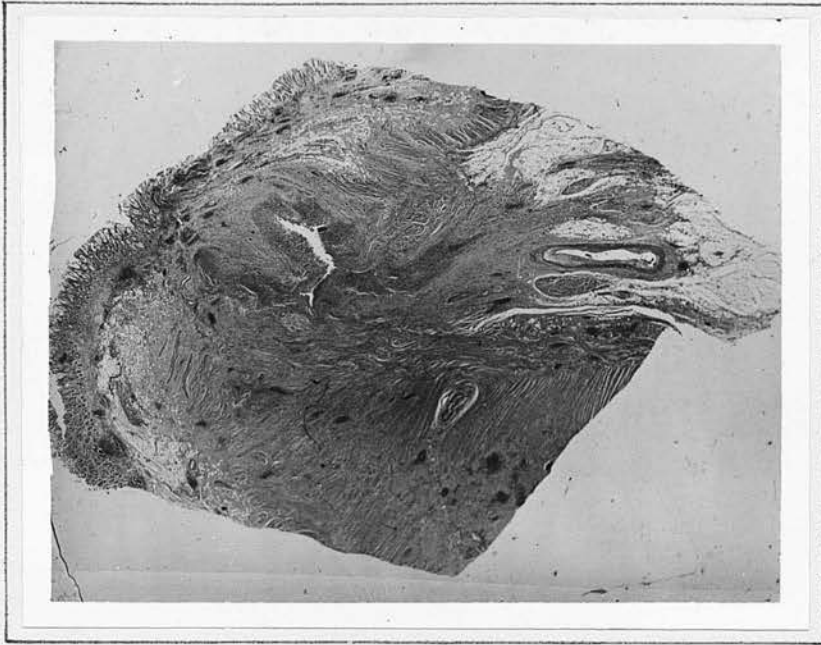

Fig. 11. Mrs Brash. Caecum. x 4. No ulceration of mucosa. Abscess in submucosa. Fibrosis in submucous and muscular layers.

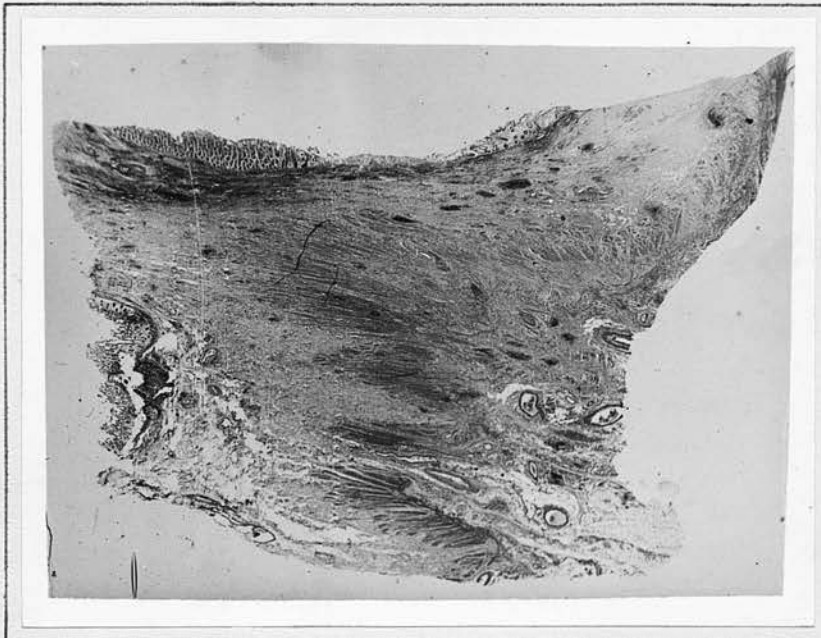

Fig. 12. Mrs Brash. Ileum. x 5. Similar to caecum - chronic inflammatory infiltration, particularly in submucosa.

Points to note.

- |                               |   |
|-------------------------------|---|
| 1. Age 39.                    | 1. Thickened terminal ileum (8") and caecum, with ? tubercles on surface. (clinically). |
| 2. Colicky pains for 4 months | 2. Mucosa not ulcerated in section but infiltrated by plasma cells.                     |
| 3. Diarrhoea.                 | 3. Fibrosis of submucosa.   |
| 4. Loss of weight.            | 4. Abscesses in submucosa.  |
| 5. Intestinal obstruction.    | 5. No tubercles seen.   |
|                               | 6. Cultures from wall - negative.   |

No evidence of dysentery or typhoid. Guinea-pig inoculation negative for tuberculosis.

Comment.

At the second operation the condition found appeared to be characteristic of ileo-caecal tuberculosis, with a mass involving ileum and caecum, and nodules on surface of ileum. Microscopically, however, no tubercles were seen, and the most striking features were the fibrosis in the wall of the ileum and the abscesses in the submucosa. The thickening in the caecum was confined to the caeco-colic valve and was continuous with the ileal fibrosis. The fact that the guinea-pig inoculation was negative for tuberculosis is strong evidence that the condition is not tuberculous, though clinically this is the type of case that would be diagnosed as ileo-caecal tuberculosis.

-----

Points to note.

- |                               |   |
|-------------------------------|---|
| 1. Age 39.                    | 1. Thickened terminal ileum (8") and caecum, with ? tubercles on surface. (clinically). |
| 2. Colicky pains for 4 months | 2. Mucosa not ulcerated in section but infiltrated by plasma cells.                     |
| 3. Diarrhoea.                 | 3. Fibrosis of submucosa.   |
| 4. Loss of weight.            | 4. Abscesses in submucosa.  |
| 5. Intestinal obstruction.    | 5. No tubercles seen.   |
|                               | 6. Cultures from wall - negative.   |

No evidence of dysentery or typhoid. Guinea-pig inoculation negative for tuberculosis.

Comment.

At the second operation the condition found appeared to be characteristic of ileo-caecal tuberculosis, with a mass involving ileum and caecum, and nodules on surface of ileum. Microscopically, however, no tubercles were seen, and the most striking features were the fibrosis in the wall of the ileum and the abscesses in the submucosa. The thickening in the caecum was confined to the caeco-colic valve and was continuous with the ileal fibrosis. The fact that the guinea-pig inoculation was negative for tuberculosis is strong evidence that the condition is not tuberculous, though clinically this is the type of case that would be diagnosed as ileo-caecal tuberculosis.

-----

JANET WIGHTMAN.

Female. Aet. 18. Nurse.  
 Admitted to Ward 8, Royal Infirmary,  
 Edinburgh, 1.6.37.

History. Patient was perfectly well until 36 hours before admission when she was seized with pain in the right side of the abdomen, while at her work as a nurse in a Cottage Hospital. The pain came on not in a moment, but took a few minutes to develop. It was not accompanied by vomiting but was associated with a feeling of nausea. The pain remained localised to the right lower abdomen until admission to hospital. It was constantly present and was not colicky in nature. On the evening of the day of admission she vomited for the first time and the pain increased in intensity, with occasional flitting of the pain across the abdomen. The bowels, which were usually quite regular once a day, had moved twice in the 36 hours, but she did not think it was actual diarrhoea. She had seen no blood or mucus in the motion, which was well formed.

Patient has no urinary symptoms. No cough. Last menstrual period was three weeks ago. Periods are normal and regular. No intermenstrual pain or discharge.

Previous History. A similar attack of right-sided pain occurred three months ago. It too was constant, confined to the right lower abdomen, and was associated with nausea. It lasted 48 hours, and gradually passed. Apart from this patient has had no indigestion, or trouble in her abdomen, and has always been quite healthy. She has never been abroad and never had dysentery. She has never been troubled with diarrhoea.

Family History. Mother and Father alive and well. No history of tuberculosis in the family.

On Examination. 1.6.37. Temperature 99°F. Pulse 118.  
Respirations 22.

Patient is a healthy-looking young woman, who shows no signs of anaemia, cyanosis, or jaundice.

Teeth. All her own and quite good.

Tongue. Slightly dry and furred.

Abdomen. No abnormality on inspection apart/

apart from slightly decreased movement on respiration in the lower half.

There is no hyperaesthesia. On palpation there is a moderate increase in muscular rigidity in the right iliac fossa. There is quite definite tenderness over McBurney's point. Pressure in the left iliac fossa does not cause pain there nor in the opposite side. There is no increase in liver dullness, and no enlargement of the spleen.

Per rectum. No tenderness nor tumour detected.

Circulatory System.

Pulse - regular in time and force.

Heart - not enlarged. Both sounds closed.

B.P. 114/76.

Respiratory System. Lung resonance not impaired. Normal vesicular breathing. No accompaniments.

Blood Count.

R.B.C.	4,500,000.
Hb.	80%.
C.I.	0.9.
W.B.C.	9,600.

Provisional Diagnosis. Acute Appendicitis.

Operation 1.6.37. General anaesthesia (Gas, oxygen and ether).

The abdomen was opened through a grid-iron incision in the right iliac fossa. There was a little clear free fluid in the peritoneal cavity. The appendix was lying in the pelvic position. It was not apparently pathological, and it was removed. The tubes and ovaries on both sides were healthy. On further examination the lowest loop of the ileum was found to be inflamed and oedematous. The colour of the bowel was dark red, but the visceral peritoneum retained its sheen. The wall felt soft and thickened and rather sodden, and it was likened to wet blotting paper. The lumen could be felt quite patent but slightly/

slightly narrowed compared with the normal ileum. The inflammatory process was most marked immediately on the oral side of the ileo-caecal valve - which also felt thickened - and it extended orally for about 8-10 inches. The colour became a lighter red and the swelling decreased gradually as the healthy ileum was approached, and the transference from affected to normal bowel was a gradual one over about  $1\frac{1}{2}$  inches. The mesentery to this last loop of ileum was slightly but quite definitely thickened and oedematous, and there were several enlarged and soft glands in it. The caecum looked perfectly normal, the disease stopping short sharply at the ileo-caecal valve. (Fig 13).

Summary. Regional Ileitis - Appendectomy.

Bacteriological report. (1) From appendix lumen: Enterococci and B. Coli were seen on smears and on culture. No tubercle bacilli seen. No organisms of the typhoid-dysentery group.

(2) Faeces. Enterococci, B. Coli and other faecal organisms seen on smears and cultures. No organisms of the typhoid-dysentery group.

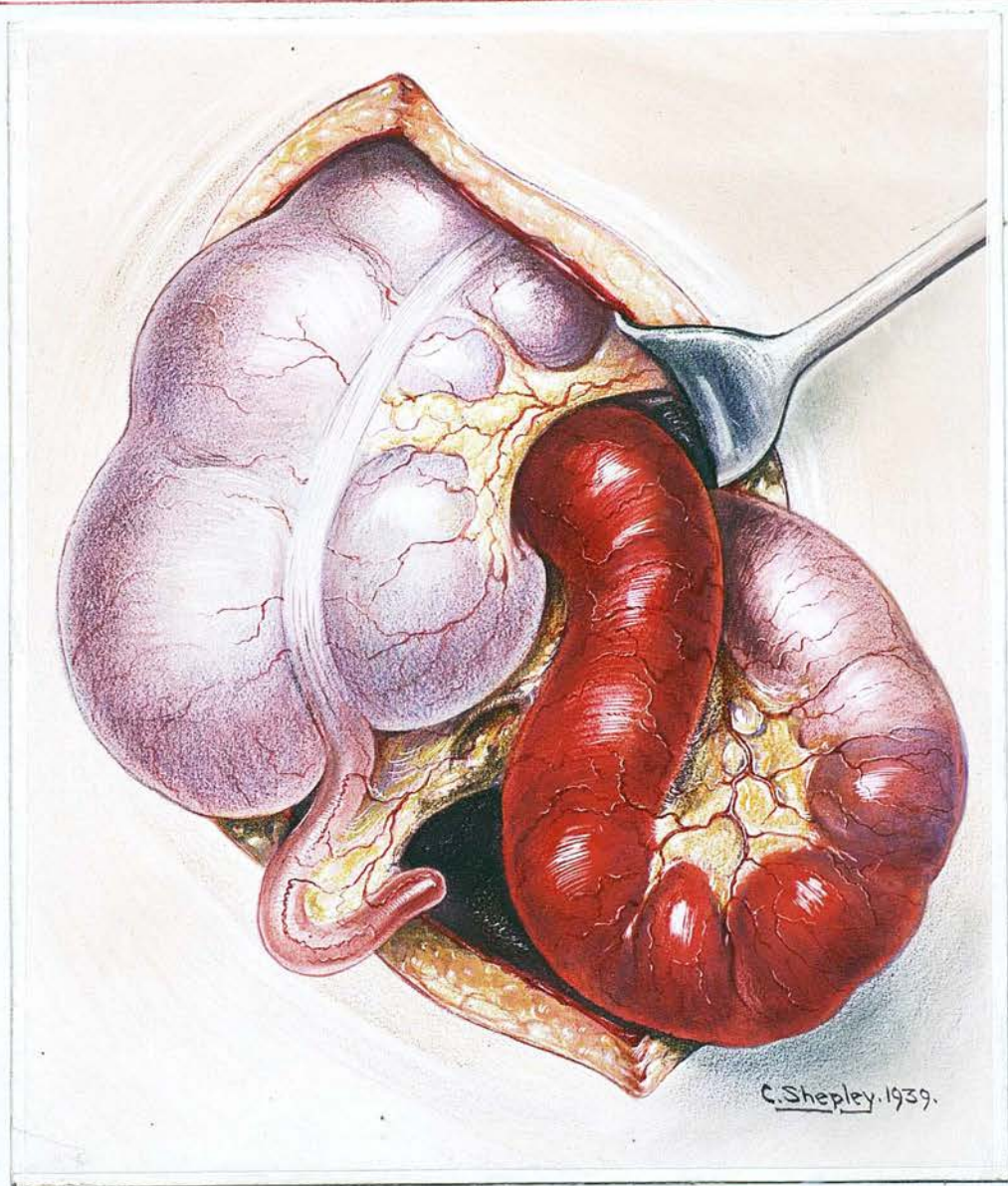
Pathological Report. Appendix. Microscopic: The appendix showed a very slight degree of catarrhal inflammation of the mucous membrane. The submucous and muscle coat showed no change from normal.

Wassermann Reaction - Negative.

After-history. Patient made an uninterrupted recovery from her operation, and since then has continued in good health. By correspondence in February 1939 she informed me that she has had no further attacks of pain in the abdomen. She takes her food well, the bowels move regularly, but with no diarrhoea, and she has not lost any weight.

Points to note.

1. Age 18.
2. Two short attacks of abdominal pain.
3. Sodden and inflamed terminal loop of ileum.
4. None of the typhoid-dysentery group of organisms in appendix or faeces.
5. No evidence of tuberculosis.



**Fig. 13.** Janet Wightman. Acute ileitis, as seen at operation. Caecum unaffected. Thickened and inflamed terminal ileum, with normal bowel clearly demarkated above. Enlarged glands in mesentery.

Comment. An example of Regional Ileitis in its acute form, with no long-standing symptoms. The provisional diagnosis was acute appendicitis.

Unfortunately it has not been possible to have a follow-up X-ray of her intestinal tract done. There is however no reason to suspect other than that the disease has resolved, and that she has made a full recovery from the condition of acute regional ileitis.

---

WILLIAM SMELLIE.

Male. Aet. 30. Ticket Collector.  
Admitted to Ward 13, Royal Infirmary,  
Edinburgh, 6.6.38.

History. At 12 noon on the day of admission patient began to have severe pain in the region of the umbilicus. The pain came in sharp attacks every few minutes, and he likened it to "the colic." He was admitted to Ward 13 six hours later, by which time the pain was tending to settle and remain constant in the right lower abdomen. He had no nausea or vomiting. His bowels had been regular and last moved that morning. He had no dysuria nor increased frequency of micturition. No cough.

His appetite was good and normally he had no indigestion. He never in the ordinary course of events had diarrhoea and he had never noticed any blood or slime in the motion. He had not been losing weight nor strength.

Previous History. A similar attack of abdominal pain had occurred 9 weeks previously. The pain settled in the right lower abdomen and stayed there over night. He felt all right next day.

Apart from this, patient had never previously been ill. He has never been abroad nor suffered from dysentery.

On Examination 6.6.38. Temperature 97.8°F. Pulse 88.  
Respirations 20.

Healthy looking man, well nourished, and not unduly distressed.

Teeth. All his own, and healthy.

Tongue Furred.

Abdomen. Moved freely with respiration. There was no distension or visible peristalsis. On palpation there was moderate tenderness in the right iliac fossa, but no muscular rigidity. The caecum was distended and splashy, but there was no palpable tumour in the abdomen, and no free fluid.

Per Rectum. Tenderness high in the rectum to the right.

Circulatory/

Circulatory System. Pulse - Regular in time and force.

Heart - not enlarged. Both sounds pure.

B.P. 128/70.

Respiratory System. Lung resonant. Breathing vesicular. No accompaniments.

Blood Count 4,700,000.

Hb. 84%.

C.I. 0.9

W.B.C. 12,000

Provisional Diagnosis. Acute Appendicitis.

Operation. 6.6.38. General anaesthetic - Nitrous Oxide and Oxygen, and Ether.

The abdomen was opened through a grid-iron incision in the right iliac fossa. There was a small quantity of clear free fluid present. The appendix was inflamed on its surface but not markedly distended. The tip lay over the brim of the pelvis, and it was tacked down by a few adhesions in the middle.

The terminal loop of the ileum was inflamed. The wall was reddish-purple in colour, though still glistening, and to the feel it was "soggy" and oedematous and quite definitely thickened. The ileum affected was from a point 10 inches from the ileo-caecal valve down to and including the ileo-caecal. At the proximal end the change from healthy uninvolved ileum to thickened red ileum was sudden - a very clear demarcation line. Distally the valve felt as if it were involved in the inflammatory process, but the caecum was perfectly normal. The mesentery of the terminal loop of the ileum was thickened and oedematous, and there were numerous enlarged and soft glands in the mesentery.

The condition was regarded as the acute stage of Regional Ileitis. The appendix was removed, and the abdomen closed without anything else being done.

Summary: Regional Ileitis. Appendectomy.

Bacteriological report: (1) Appendix contents.

Faecal organisms and B. Coli seen in smears and on culture. No tubercle bacilli. No organisms of the typhoid-dysentery group.

(2) Wassermann reaction -  
negative.

Pathological report.

Appendix. The mucous membrane is mildly congested and oedematous. The submucous and muscular coats are normal. The serous coat is congested.

After-history. The patient made an uninterrupted recovery. The wound healed satisfactorily.

In February 1939 - eight months after operation patient was examined again. He stated that since leaving hospital he had had three attacks of colicky abdominal pain, unaccompanied by nausea and vomiting. The attacks lasted about one day. Bowels had been moving once a day regularly. Apart from those three attacks, which he said were similar to his original attack, he had been in good health.

X-ray examination in February 1939 by barium meal showed no stenosis or other abnormality in the terminal ileum. (Fig. 14) X-ray screen examination of the chest showed healthy lung shadows.

Points to note.

1. Age 30.
2. Two short attacks of pain settling in the right iliac fossa.
3. Sudden oedematous congested terminal loop of ileum.
4. None of the typhoid-dysentery group of bacilli in appendix.
5. No evidence of tuberculosis.

Comment. An example of Regional Ileitis in its acute form, with none of the classical symptoms and signs found in the well-established case. The history was identical with that of a case of acute appendicitis.

The persistence of attacks of abdominal pain  
eight/

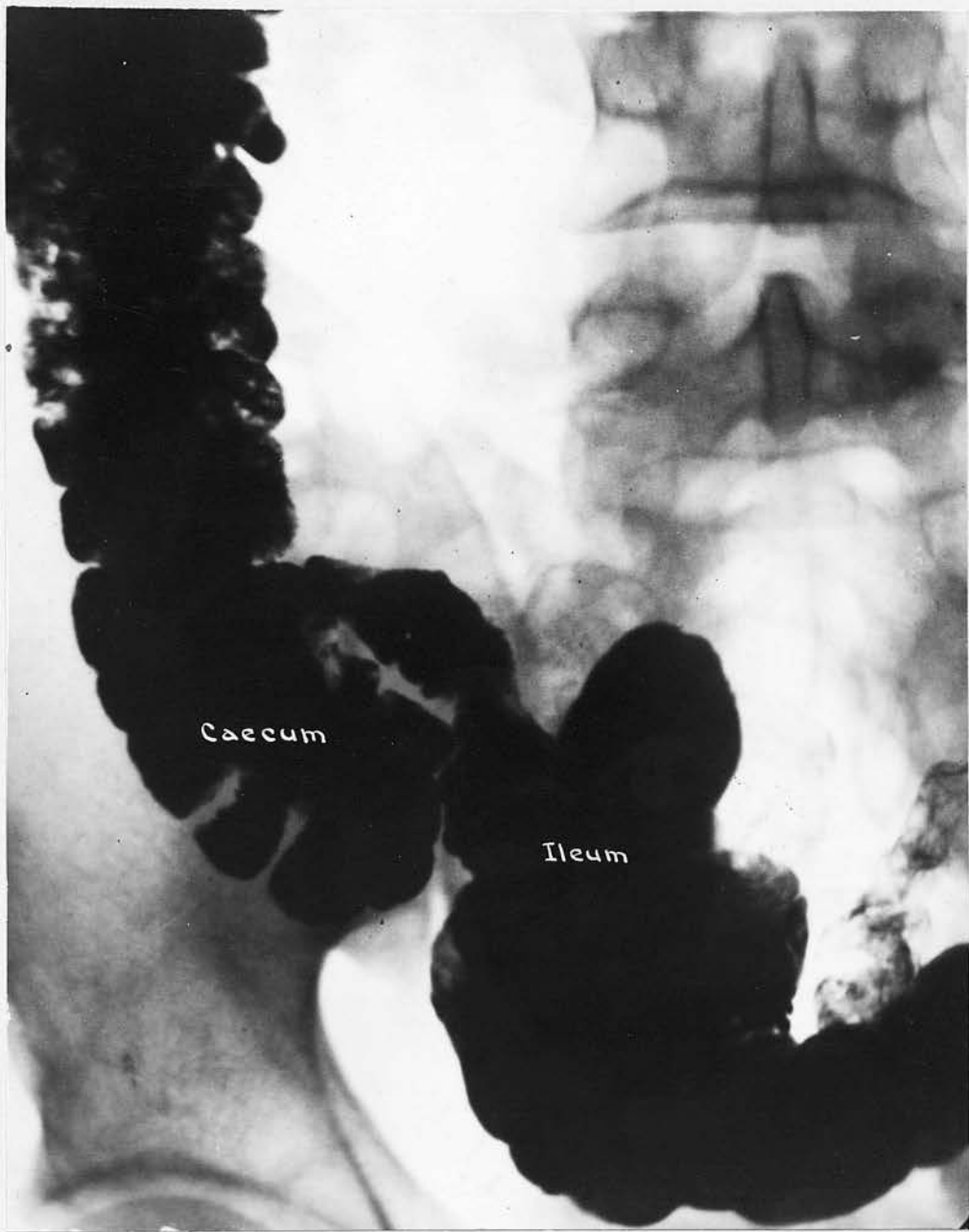


Fig. 14. William Smellie. X-ray, barium series.  
No stenosis or affection of terminal ileum  
seen 8 months after attack of acute ileitis.

eight months after operation suggests that the disease process in the ileum may not have undergone complete resolution. X-ray examination however does not reveal any abnormality. The patient will require to be examined at intervals, and the development of symptoms such as diarrhoea, or loss of weight should at once arouse attention. It may be that resolution will be complete and that he will not go on to the stage of stenosis. But if the chronic stage does develop he should be submitted to further operation as soon as it does manifest itself, rather than wait until intestinal obstruction or fistulas have supervened.

---

MRS. ELIZABETH MARTIN.

Female. Aet 22. Housewife.  
Admitted to Ward 14, Royal  
Infirmary, Edinburgh, 10.6.38.

History. Ten months prior to admission patient became pregnant, and shortly afterwards she began to have lower abdominal pain worse on the right side. It was intermittent and griping in character and became more severe as her pregnancy advanced. Nausea and vomiting occurred frequently during the latter half of the pregnancy.

Her child was born eight weeks before admission, instruments being required. It was her first child. Following the birth of the child the griping pains persisted and she was admitted to a Gynaecological ward of the Royal Infirmary where she was operated on, with a provisional diagnosis of uterine fibroid or parametritis. At operation a large adherent mass was found involving the caecum, and terminal part of the ileum. It was decided to leave this alone and arrange for the transference of the patient to a Surgical ward later. Accordingly after removing the appendix, which was not inflamed, the abdomen was closed.

Following this first operation the pains continued, and she was given codein powders which eased the pain. Four weeks later she was transferred to Ward 13, where the following facts were elicited:

In the past few weeks the griping pains have been getting worse and come on in attacks all day. The attacks are accompanied by nausea and sometimes vomiting. Her appetite is good and she enjoys her food, but she is afraid to eat because she knows it brings on the pain. Throughout her pregnancy the bowels were regular, with a slight tendency to looseness. Latterly they have been moving three or four times a day. The motions are quite well formed, and not offensive; she has never noticed any blood but thinks there has been some slime in the motion occasionally. Her weight was difficult to gauge throughout the pregnancy, but she now is sure that she is at least a stone lighter than before she became pregnant. She has no cough, and no urinary symptoms. She feels tired, has a constant slight headache and a general sense of malaise.

Previous History. Until 11 months ago patient was perfectly fit and has had no previous illness of note. She has never been abroad nor suffered from dysentery.

On Examination 10.6.38. Temperature 97.6°F. Pulse 88.  
Respirations 22.

Patient is rather pale and thin. The eyes are dull and she looks tired. There is no cyanosis or jaundice.

Teeth. Two infected molars. Otherwise all her own and healthy.

Tongue. Moist and clean.

Abdomen. There is slight fullness to be seen in right lower abdomen. The abdomen moves freely on respiration. There is hyperaesthesia in the right iliac fossa. The abdominal wall is lax - no rigidity. There is a palpable mass in the right iliac fossa, hard and very tender to touch. The mass is roughly the size of an orange and is movable slightly in all directions. There is a lesser degree of tenderness in the epigastrium and left iliac fossa. Liver and spleen not enlarged. No apparent free fluid.

Per Rectum. The cervix is palpable anteriorly and rather tender. Tenderness is quite marked in the right fornix, but no swelling can be made out.

Cardiovascular System.

Pulse is regular, with good volume.

Heart not enlarged. Sounds closed and pure.

Blood Pressure 110/70.

Respiratory System. Normal vesicular breathing.

Resonance not impaired. No accompaniments.

Blood Count.

R.B.C.	4,100,000.
Hb.	70%.
C.I.	0.8.
W.B.C.	8,400.

Bacteriological Examination of Faeces. A rich variety of faecal organisms was seen - principally Streptococcus Faecalis and B. Coli.

No organisms of the typhoid-dysentery group were isolated on culture.

Wassermann Reaction - Negative.

Frei Test - Negative.

X-ray Examination. (Fig.15 )

Barium meal: "Oesophagus and stomach normal. Duodenum - there is a duodenal diverticulum, otherwise negative.

3 hours after meal - barium to middle of transverse colon. The terminal ileum is irregularly stenosed for 5 inches proximal to the ileo-caecal valve. This stenosis is associated with a palpable mass in the right iliac fossa.

Chest. - Screen examination negative."

Provisional Diagnosis. Regional Ileitis.

Operation. 21.6.38. Spinal anaesthesia.

Right oblique muscle cutting incision. On opening the abdomen there was a little clear free fluid, and it was found that the terminal loop of the ileum and the caecum were matted together by a large number of adhesions. The ileum was involved evenly from the ileo-caecal valve to about 10 inches orally, where it quite quickly altered to normal healthy undilated ileum. The ileum was sharply kinked upon itself in two places, due to adhesions. The ileum was reddish-grey in colour and its wall felt firm and thickened. There were no tubercles on the surface. The mesentery to the terminal ileum was shortened and thickened, and there were a few enlarged softish glands in it.

A hemi-colectomy was performed, excising the affected portion of ileum and its mesentery, the caecum, ascending colon and the right third of the transverse colon. A side to side anastomosis was performed between the remaining ileum and transverse colon.

During the mobilisation of the caecum and ileum many adhesions had to be divided, and it was necessary to dissect free the right ovary and tube, the ovarian vessels, and the ureter.

Summary. Regional Ileitis. Right hemi-colectomy. Lateral anastomosis.

After-history. Patient made an uninterrupted recovery, and was discharged from hospital after three weeks.

Eight/

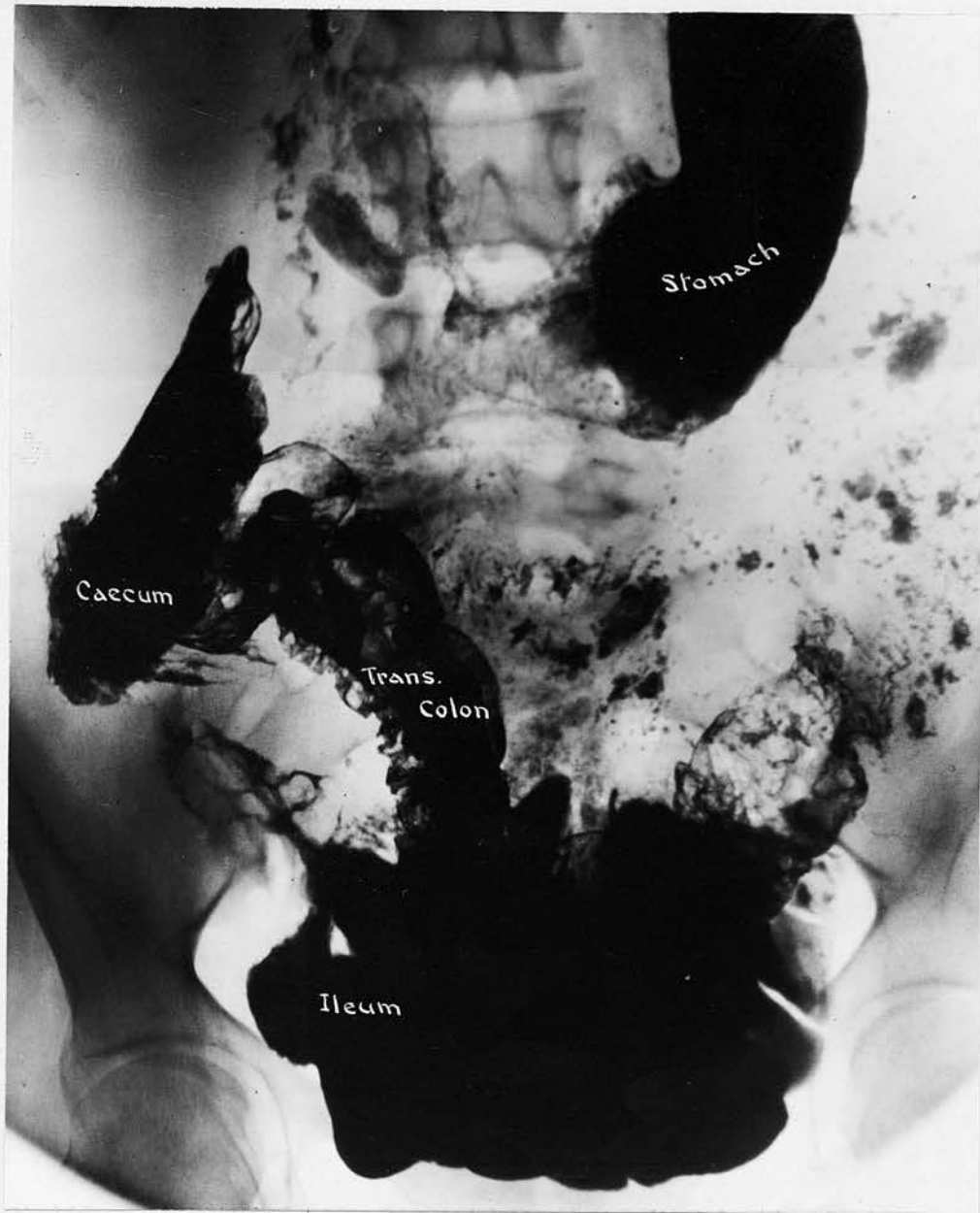


Fig. 15. Mrs Martin. X-ray, barium series. Stenosis of terminal loop of ileum, prior to operation for regional ileitis. Stomach and duodenum, at top of picture, are normal.

Eight months later - in February 1939 - she reported again to hospital, complaining of severe diarrhoea. She stated that this diarrhoea had begun very soon after leaving hospital following the operation, and every day since then the bowels had moved five or six times a day. No blood or mucus was seen in the motion, which was thin and watery. She complained of no general abdominal pain, but an occasional slight stinging pain in the wound. Apart from the diarrhoea she felt fairly well, though easily tired. She had become pregnant again and it was five months since her last menstrual period. The diarrhoea had been occurring before she became pregnant this time.

On examination she was pale but well nourished. Abdomen revealed no tenderness or swelling apart from the pregnant uterus.

X-ray examination was carried out by barium enema in February 1939, and the barium was seen to flow freely to transverse colon, and through the stoma into the ileum. There was no stenosis of the stoma or of the ileum proximal to the stoma, and no evidence of colitis or ileitis. (Fig.16).

It was satisfactory to find that there was no radiological evidence of recrudescence of the disease process. It has been reported ( ) that, if the section through the ileum during the resection operation is not sufficiently clear of the obviously diseased portion, further trouble may ensue in the ileum proximal to the stoma. In this patient's case it was thought that the remaining colon had not yet accustomed itself to storing and absorbing fluid from the ileal contents. She was put on a low residue, high vitamin diet, and if the diarrhoea persists after this pregnancy is completed she will return for further investigation.

Specimen of terminal ileum, caecum, and ascending colon.

Bacteriological report. Cultures from wall of ileum, caecum, and gland from ileo-caecal angle:

A growth was obtained from the three specimens of non-haemolytic streptococci and B. Coli.

No tubercle bacilli seen in smears.

No organisms of the typhoid-dysentery group isolated.

Guinea-pig/

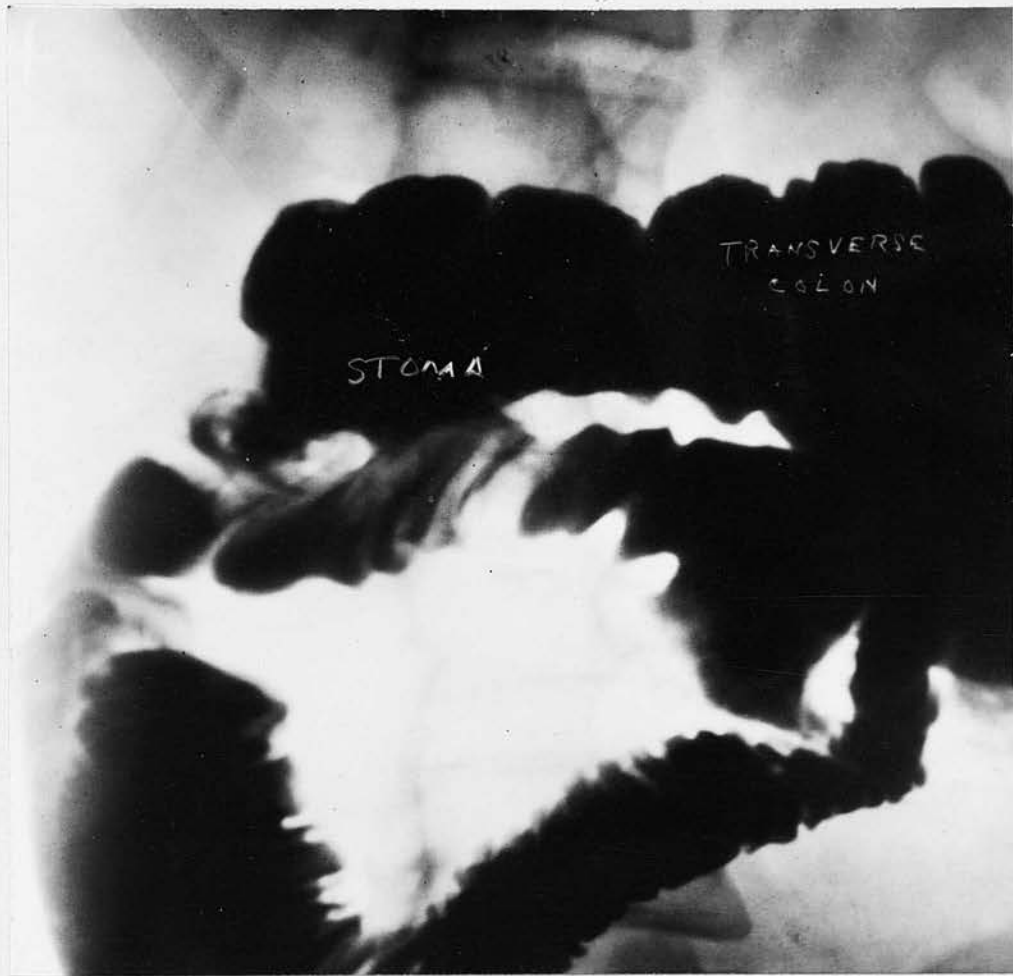


Fig. 16. Mrs Martin. X-ray, barium enema. Eight months after resection for regional ileitis - right hemi-colectomy and ileo-transversecolostomy. Stoma acting satisfactorily. No evidence of colitis or ileitis.

Guinea-pig inoculation.

No evidence of tuberculosis after six weeks in guinea-pigs inoculated with tissue from wall of ileum.

Pathological examination.Macroscopic (Fig.17,18,19,20).

One is at once struck with the stenosis of the ileum immediately proximal to the ileo-caecal valve, and the extreme degree of narrowing of the valve itself which barely admitted a probe. This stenosis is due to thickening in the bowel wall encroaching on the lumen. This thickening of the ileal wall extends proximally from the ileo-caecal valve for seven inches and is almost uniform throughout. The transition from affected ileum to normal ileum is an abrupt one, over a distance of  $\frac{1}{4}$  of an inch. The mucous membrane of the affected ileum is grossly ulcerated, small circular and oval ulcers about  $\frac{1}{8}$  of an inch in diameter, and separated from each other by bridges of roughened mucosa giving a pavement appearance. The ulcers are almost entirely confined to the mesenteric border of the bowel. (Fig. 21).

The ileum is very much twisted upon itself due to adhesions between adjacent parts. At points 1" 6" and 2' 6" proximal to the ileo-caecal valve normal healthy ileum has become adherent to the mass in the ileo-caecal angle. The ileum proximal to the stenosed segment is thin walled and slightly dilated. There is no ulceration in its mucous membrane.

The caecum is relatively unaffected. There is some thickening in the wall and puckering of mucous membrane at its most dependent part where the appendix stump had been invaginated. There is no ulceration in the caecal mucous membrane.

The ascending colon is normal.

The mesentery of the terminal loop of the ileum is grossly thickened, in places  $\frac{1}{2}$  an inch thick. Enlarged glands are prominent, especially at the ileo-caecal angle.

Microscopic Section from ileum - Stain: Haematoxylin and Eosin. (Fig. 22).

There is considerable thickening of the whole wall and marked inflammatory change in all the layers. There is gross ulceration of the mucosa, penetrating into the muscle layer.

The/

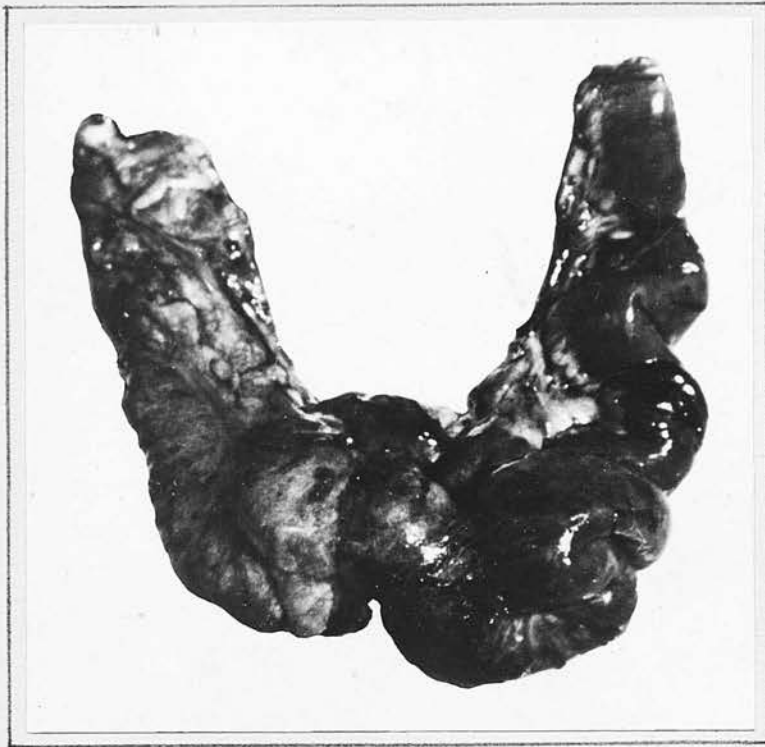


Fig. 17. Mrs Martin. Ileum, caecum, and colon immediately after resection. Terminal loops of ileum are twisted, matted together with adhesions, congested and oedematous. Caecum unaffected.

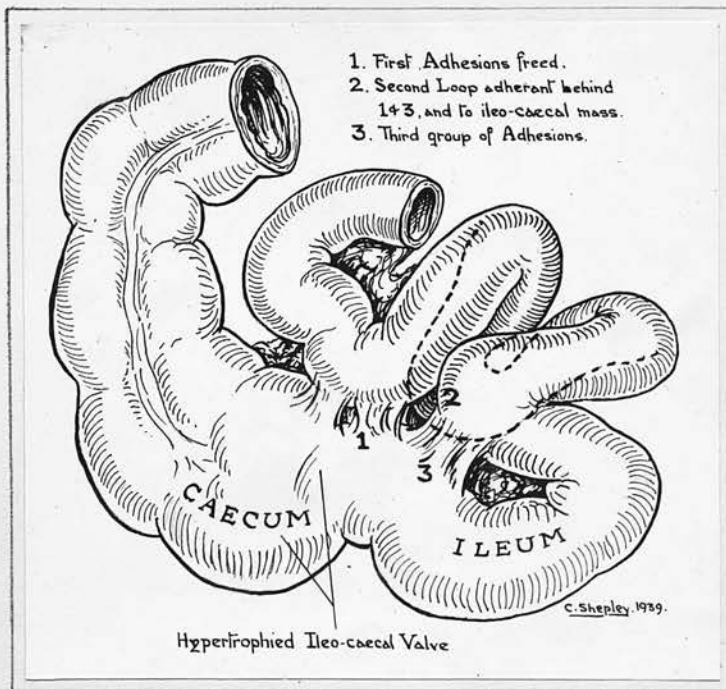


Fig. 18. Mrs Martin. Diagram to illustrate the condition found at operation. Some of the adhesions were freed before the photograph of Fig. 17 was taken.

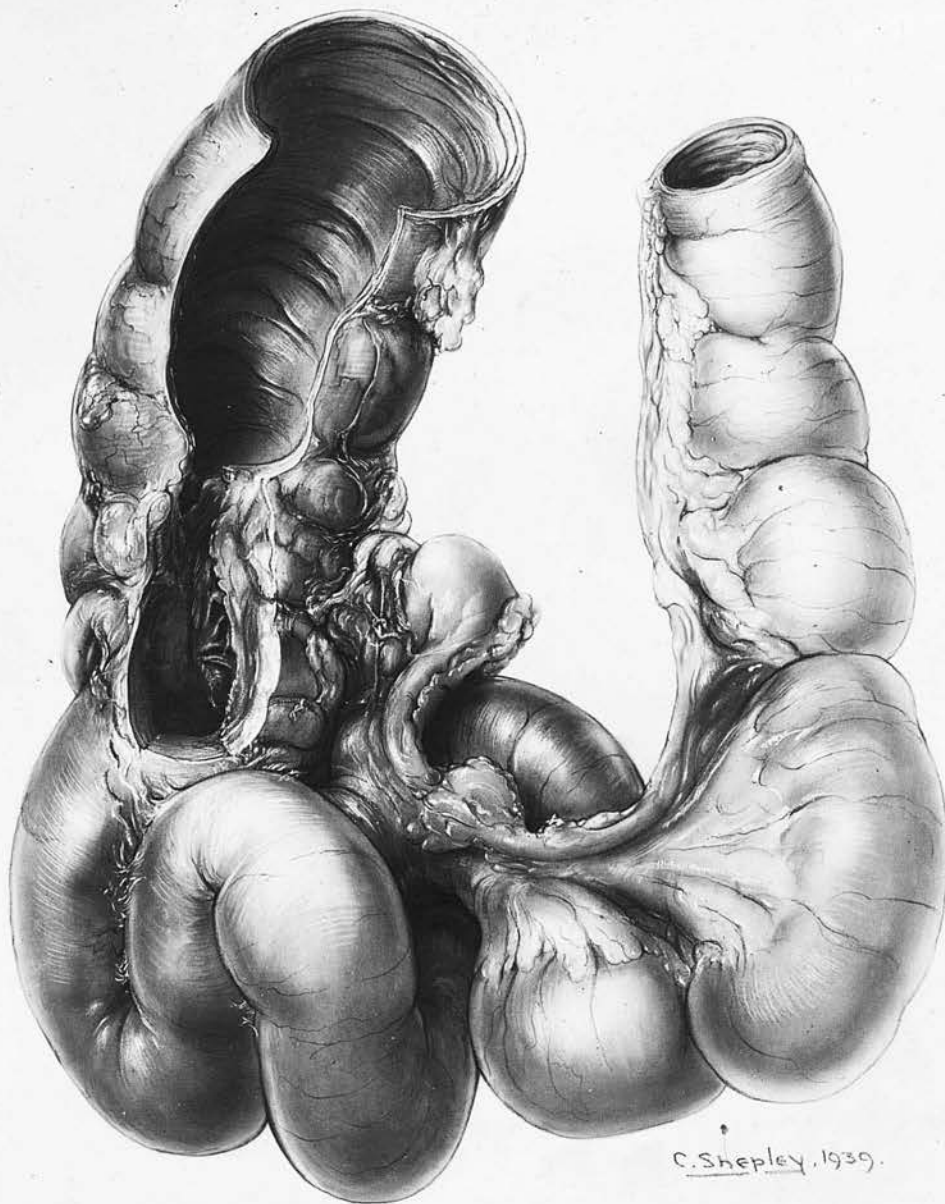


Fig. 19. Mrs Martin. Drawing to illustrate the matting together of lower ileum. Ileum is running up to ileo-caecal valve, which is the site of the maximum thickening of the bowel wall. Beyond the thickened valve is the normal colon.

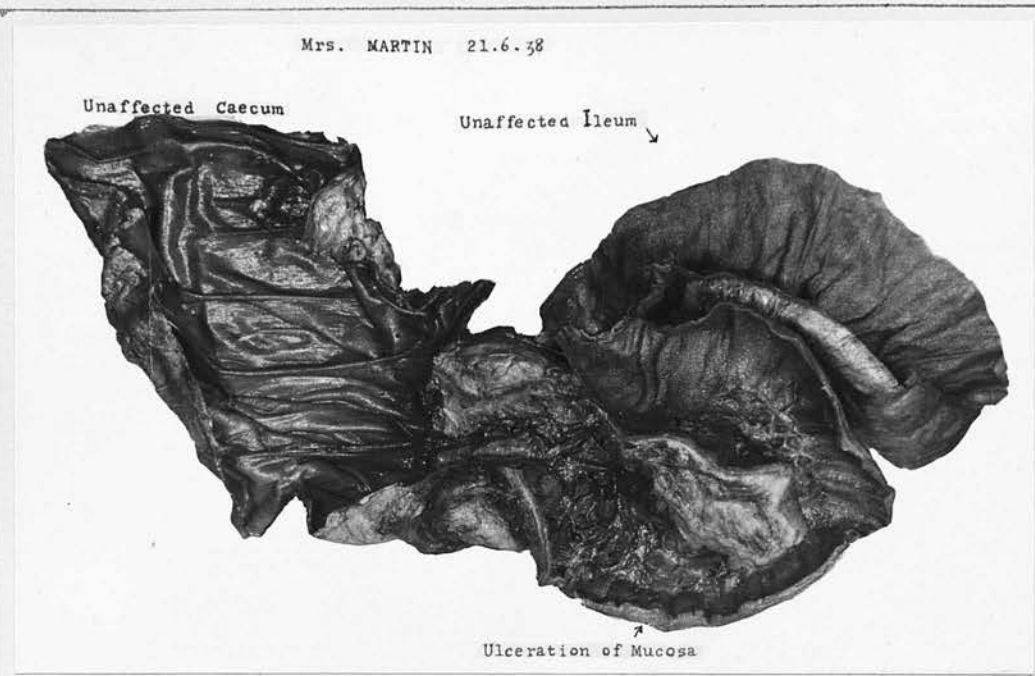


Fig. 20. Mrs Martin. Stenosis of the terminal ileum due to thickening of its wall. Mucosal ulceration on the mesenteric border.

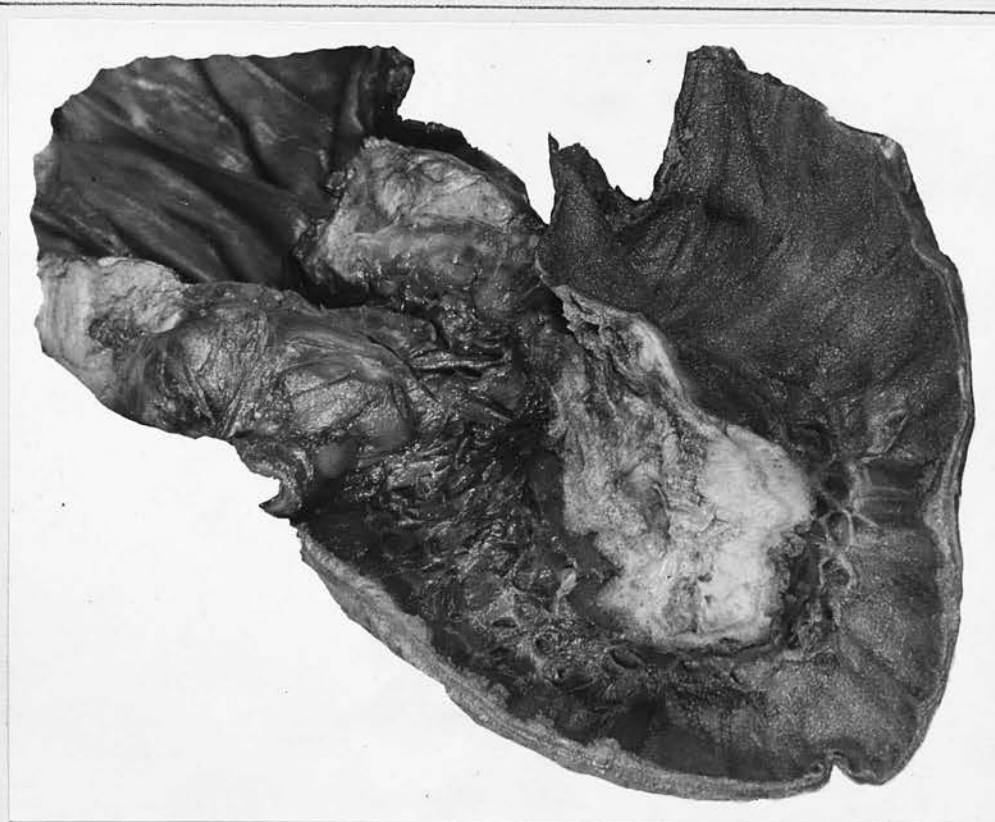

Fig. 21. Mrs Martin. An enlargement of Fig.20, showing the deep crypt-like ulcers on the mesenteric border, and the gross thickening of the ileo-caecal valve. Note the sudden change from healthy ileum above to ulcerated stenosed ileum below.

The mucous membrane shows a dense inflammatory infiltration of mingled plasma cells and polymorphs in about equal proportions. The villi are almost entirely absent but the mucosal glands are relatively well preserved. There is very marked capillary dilatation throughout the mucosa, but only slight fibrosis - fair number of fibroblasts but little or no new connective tissue. There is little or no eosinophil infiltration.

The submucosa shows a somewhat different inflammatory infiltration, i.e. mainly of lymphocytes and plasma cells, of which there is a dense and diffuse infiltration, with very numerous widely dilated capillaries. In addition there are:-

(a) Foci of lymphoid tissue - presumably reactive pre-existing follicles. No germ centres are seen.

(b) Occasional small "tubercles", consisting of endothelioid cells in haphazard arrangement, with giant cells both central and peripheral. The giant cells vary considerably in size, with nuclei from one to very many. In some the nuclei are arranged peripherally, in others more irregularly through the cells. There is no caseation in any of the tubercles. (Fig 23 & 24)

(c) Abscesses. There are many small abscesses in the submucosa, with walls densely infiltrated with polymorphs.

Apart from the tubercles occasional giant cells single or in small clusters are seen through the submucosa. In several of the giant cells a central mass of colourless hyaline material was seen. By polarised light this was not doubly refractile. In some places there is a little collagenous fibrosis, but in no place is it marked.

The muscle layer shows a similar but much slighter diffuse inflammatory infiltration, largely of mononuclear cells. There are occasional lymphoid foci and occasional small "tubercles". No giant cells are seen in the muscle coat, but not dissimilar ganglion cells are seen - large cells with capsular nuclei arranged peripherally.

There is no general fibrosis in the muscle coat, except below the ulcerated area where there is dense fibrosis.

The subserous coat shows congestion and patchy infiltration of small lymphocytes outwards into the fat. No polymorphs are seen in this layer nor evidence of peritonitis. Opposite the area of ulceration there is a moderate collagenous fibrosis of the subserosa.

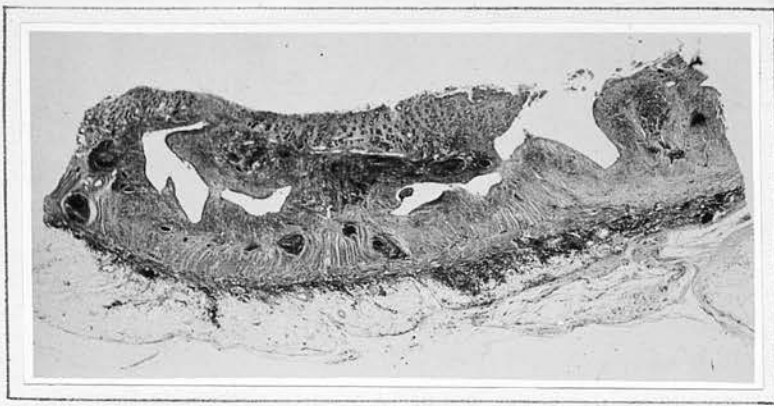


Fig. 22. Mrs Martin. Ileum. x 4. Ulceration of mucosa and abscesses in wall.

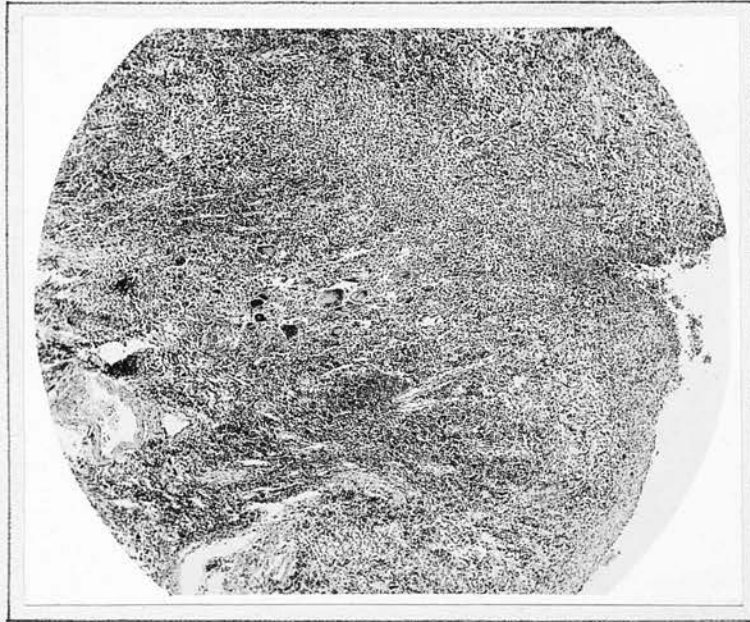


Fig. 23. Mrs Martin. Ileum. x 50. Tubercle in submucosa. Ulceration to right of section.

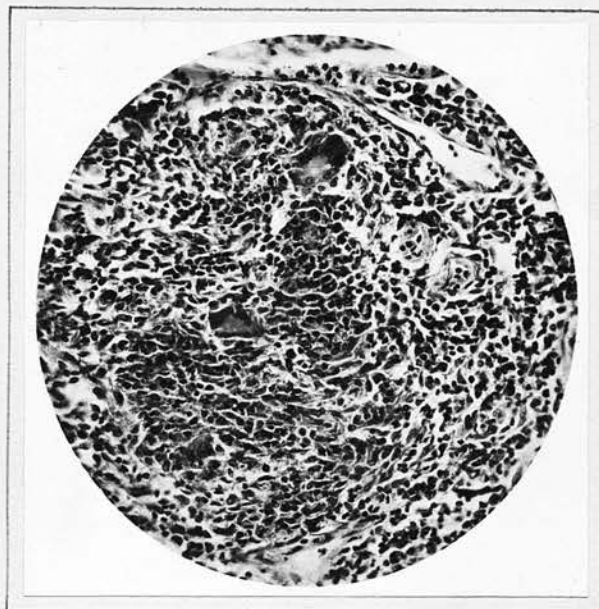


Fig. 24. Mrs Martin. Ileum. x 200. Tubercle. Giant cells with peripheral nuclei. Hyaline in their interior.

Section from Ileum - Stain: Ziehl-Neelsen.  
 No tubercle bacilli seen.

Points to note.

- |  |   |
|--|---|
| <ol style="list-style-type: none"> <li>1. Age 22.</li> <li>2. Colicky pains for 10 months.</li> <li>3. Slight diarrhoea.</li> <li>4. Palpable mass.</li> <li>5. Frei test - negative.</li> </ol> | <ol style="list-style-type: none"> <li>1. Thickened adherent ileum - confined to terminal 7".</li> <li>2. No mucosal ulceration, but diffuse infiltration with polymorphs and plasma cells.</li> <li>3. Dense infiltration of submucosa, lymphocytes and plasma cells.</li> <li>4. Tubercles in submucosa, with no caseation.</li> <li>5. Abscesses in the wall.</li> <li>6. Streptococci and B. Coli in wall.</li> </ol> |
|--|---|

No evidence of dysentery or typhoid. Guinea-pig inoculation negative for tuberculosis.

Comment. Clinically, and from examination of the naked-eye specimen, this case has many of the characteristic features of Regional Ileitis in its chronic form. The presence of tubercles in the microscopic picture casts the first doubts on the diagnosis. The failure to demonstrate tubercle bacilli in the specially stained section, the absence of tuberculous foci elsewhere in the patient, and most important of all the failure of guinea-pigs to develop tuberculosis after inoculation with material from the wall of the affected ileum, are strong points in the evidence against a diagnosis of tuberculosis. The presence of tubercles in the wall is not pathognomonic of the disease due to *Bacillus tuberculosis*.

The negative Frei test indicates that this granulomatous condition is not due to the virus of Lymphogranuloma Inguinale.

-----

JEAN AULD. Female. Aet. 18. Housemaid.  
Admitted to Ward 14, Royal Infirmary,  
Edinburgh 28.2.38.

History. Patient was quite well until a week before admission when she thinks she caught a chill and took to her bed, feeling feverish and out of sorts. Next day she began to have an aching pain in the right lower abdomen, and this constant dull aching pain persisted until she was admitted to hospital. Her doctor saw her throughout this week, and found that she was feverish. He advised fomentations to the abdomen, which relieved the pain slightly. She at no time was nauseated, nor vomited, but merely felt tired and not well. She had no appetite for her food. Her bowels had been moving daily, usually once and occasionally twice.

On the day of admission the pain became sharper and more intermittent, but still confined to the right side. She vomited once.

She had no pain on micturition, nor increased frequency. No cough. Periods regular - the last one a fortnight ago..

Previous history. Patient had always been quite fit until this illness began, and had never had any similar abdominal pain. For the previous year she had had occasional spasms of what she took for "windy" pains in the stomach. Her bowels moved always twice a day, and she thought it was about three years since they began to move twice rather than once a day. She found that the eating of certain foods, for example an orange, always caused the bowels to move easily. She had never noticed any blood or slime in the motion. She had not been losing any weight, nor had she been gaining any. Her appetite normally was good.

Family History. Mother and Father and two brothers all alive and well.

On Examination 28.2.38. Temperature 100.2°F.  
Pulse 120. Respirations 24.  
A thin little girl. She is flushed and looks toxic.

Tongue: Dry and furred.

Teeth: All her own. Good.

Abdomen./

Abdomen. Limited movement on respiration. No hyperaesthesia. Resistance on right side and rigidity in the lower quadrant. Extreme tenderness just medial to McBurney's point where a mass can be felt. The mass is firm and fixed, but not to the skin. No evidence of free fluid in the abdominal cavity. Liver and spleen not enlarged. Kidneys not palpable.

Respiratory System. Lungs resonant. Breath sounds vesicular.

Circulatory System. Heart not enlarged. Sounds closed. B.P. 118/70.

Urine. Contains no abnormal constituents.

Blood Count.

R.B.C.	4,350,000
Hb.	80%.
C.I.	0.9.
W.B.C.	16,000.

Provisional Diagnosis. Appendix abscess.

Operation 28.2.38. General anaesthetic - Ethyl chloride and ether.

Right grid-iron incision. There was a little slightly turbid free fluid in the peritoneal cavity. The appendix was lying retro-caecally. It was not inflamed and was not removed.

Part of the mass was found to be a small gland abscess in the upper ileo-caecal angle anterior to the mesentery. Thick greenish-yellow pus was evacuated.

The terminal fifteen inches of the ileum were greatly thickened and rigid in a uniform manner, with a plum-coloured congestion of the bowel and irregular whitish patches on the surface, but no nodules or strictures. The thickening stopped abruptly at a point fifteen inches above the ileo-caecal valve, and the ileum above this was healthy and not dilated. The caecum appeared normal except for redness and thickening where it was adjacent to the gland abscess.

In the lower mesentery there were numerous small hard calcified glands. Close to the ileo-caecal valve the mesentery was inflamed and oedematous and there were many large and soft glands.

Specimens/

Specimens of pus, calcified, and soft glands were removed for examination.

A rubber dam drain was inserted down the abscess cavity, and the wound closed around the drain.

Summary: ? Regional ileitis with gland abscess.  
Drainage of abscess.

After-history. Patient's recovery was very slow, and it was two months later that she was transferred to the Astley Ainslie Institution.

During the first three weeks after the operation the temperature showed an evening rise to between 99° and 101°F, with return to normal in the mornings. She looked ill, but was never critically so. Pus discharged freely from the wound, and a week after operation faeces was first noticed. This faecal fistula persisted throughout her stay in hospital. Occasionally patient complained of mild colicky abdominal pain, but generally her condition improved. It was hoped that the faecal fistula would close spontaneously at the Astley Ainslie Institution.

#### Investigations.

(1) Bacteriological report: Pus from abscess 29.2.38.

Films showed numerous streptococci and some gram negative bacilli.

There was a growth of gram negative bacilli (B. Coli) only on aerobic culture.

The streptococci failed to grow on aerobic and anaerobic cultures.

(2) Culture from Mesenteric gland from beside abscess 29.2.38. B. Coli were seen in films and on aerobic culture. No tubercle bacilli seen.

(3) Faeces from fistula 7.3.38.  
No organisms of the typhoid - dysentery group were isolated from the stool.

(4) Wassermann reaction - Negative.

Pathological/

Pathological report: (1) Mesenteric gland from beside abscess. 5.3.38.

The specimen consists of fat and connective tissue showing acute congestion, haemorrhage, and gross infiltration with round cells. In certain parts new capillary formation and fibroblastic proliferation are also in evidence.

The features are those of a chronic inflammatory lesion which has undergone a phase of acute exacerbation.

There is no evidence of tuberculosis.

(2) Small calcified gland. 31.3.38.

Sections of gland made after decalcification show only one or two mildly active tuberculous foci outside the calcified area.

7.4.38. X-ray Examination. (Fig. 25)

Films taken at intervals of 2, 4, 6, and 24 hours after giving the barium meal. Oesophagus, stomach and duodenum negative. There is a slight delay in emptying of the small intestine which otherwise functions normally. The 3 and 4 hour films show barium in front of the right ilium which appears to be in an abscess. The source of the barium is not clear but it may be from the caecum which is slightly irregular, suggesting surrounding inflammatory changes.

From April to July 1938 patient was at the Astley Ainslie Institution, with open air convalescent treatment. During the whole of that time the wound discharged thick greenish pus and frequently faecal matter. She developed an ischio-rectal abscess and was transferred back to the Infirmary, where:-

On Examination 4.7.38.

Patient is flushed and feels weak. There is a large ischio-rectal abscess, still hard and tender, on the right side. Abdominal wound is chronically inflamed and indurated and is discharging pus freely. No faeces.

Blood Count.

R.B.C.	4,280,000
Hb.	60%
C.I.	0.7
W.B.C.	14,000.

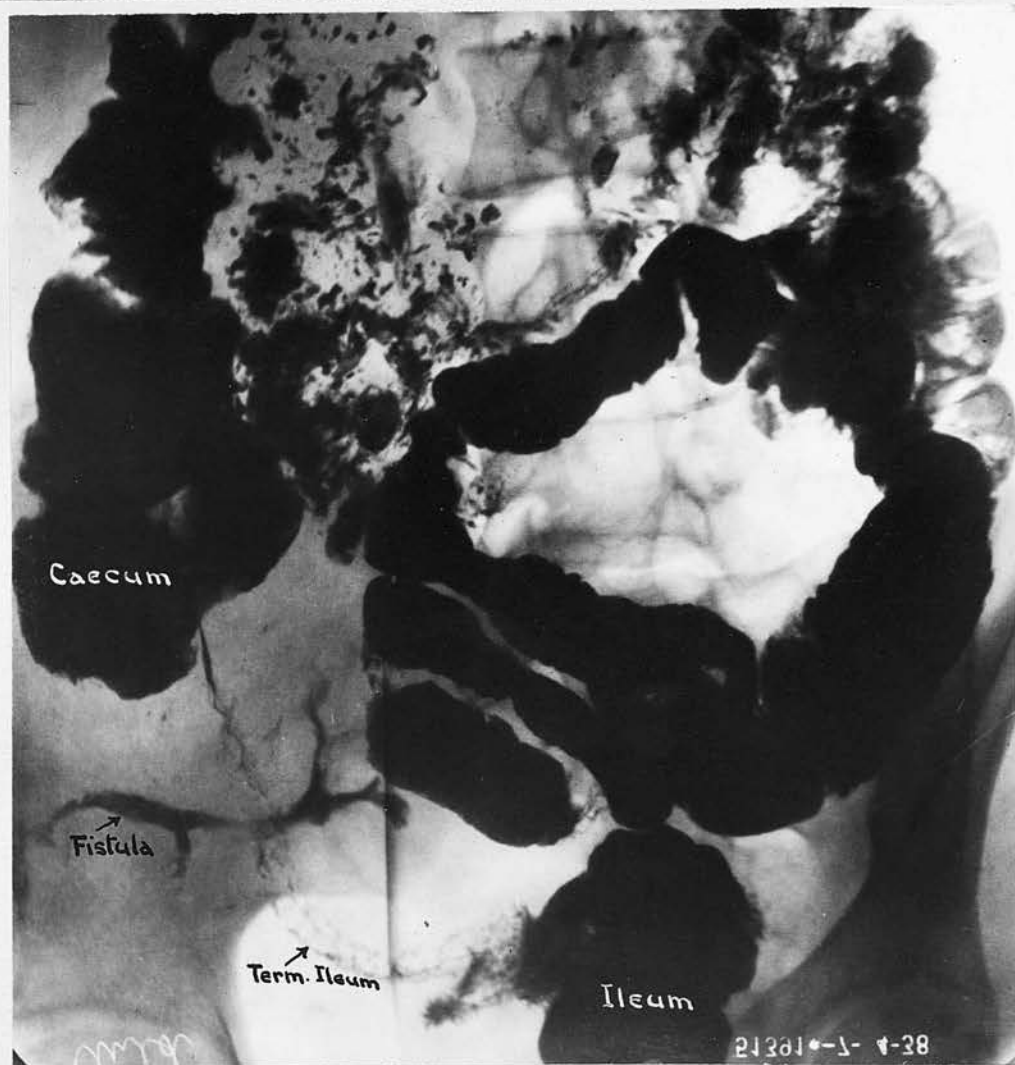


Fig. 25. Jean Auld. X-ray, barium series 7.4.38. String-like effect of the terminal ileum as it runs up to the caecum. Dilatation of ileum proximal to the stenosed segment, and indentation of the caecum distally. The thin transverse streak of barium is in the fistula from the ileum.

Operation. 6.7.38. General anaesthetic.

Ischio-rectal abscess incised. Thick greenish foul-smelling pus evacuated.

Bacteriological report. Pus from ischio-rectal abscess  
7.7.38.

The pus contained faecal organisms. No T.B. were found. It had become apparent that the abdominal abscess and sinus was not going to heal spontaneously, and accordingly further drainage was instituted:-

Operation 26.7.38. General anaesthetic.

Sinus opened and enlarged down to the peritoneum. Pus was found to be welling up extra-peritoneally. The peritoneum was not opened. Rubber dam drain was inserted down to the abscess.

Summary. Discharging sinus. Old ileitis.  
Incision and drainage.

X-ray Examination at this time showed an advance in the stenosis of the terminal ileum:-

29.7.38. X-ray Examination (Fig. 26 ) Barium meal shows that there is an irregular filling defect of the caecum and inflammatory change in the terminal ileum, with some dilatation of the small bowel proximal to this.

Following the operation to improve drainage the wound showed a tendency to heal and a month later it has almost ceased to discharge. However by September 1938 the discharge was as copious as ever. For three months thereafter patient was given short-wave therapy to the part. Short-wave therapy frequently aids an inflammatory process to subside, but in this case the effect was negligible. The faecal fistula was also present.

In December 1938 patient was re-admitted to hospital, with a view to further operation. It had by now become obvious that the discharge of pus and faecal contents would not cease until the diseased bowel, from which they were coming, was excised.

On/

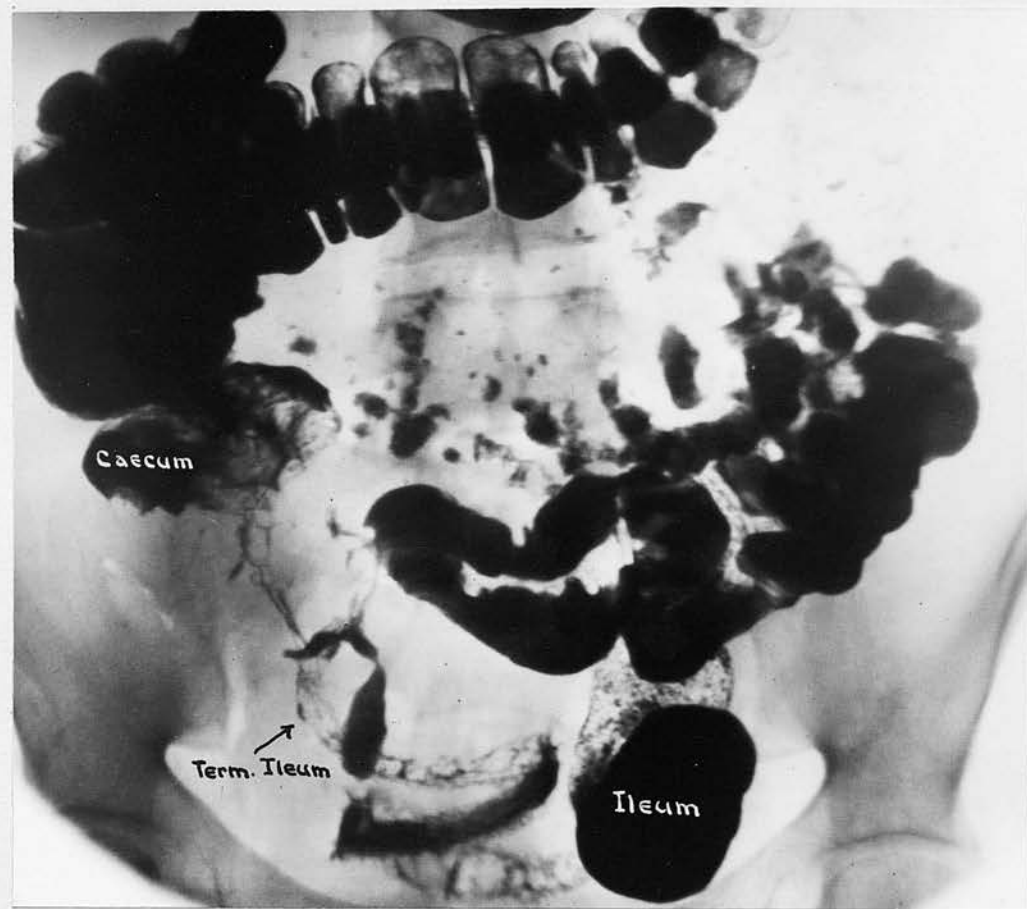


Fig. 26. Jean Auld. X-ray barium series, 29.7.38. Stenosis of lower ileal loops, showing an increase in the extent of the disease compared with the X-ray of 7.4.38 (Fig. 25). Ileum dilated proximally, and caecum deformed.

On Examination 10.12.38. (Fig 27)

Her general condition remained unchanged - still diarrhoea two or three times a day in addition to the discharge of fluid faeces from the fistula; still feeling and looking well on the whole, and not losing nor gaining any weight. She was afebrile. It was decided to perform an anastomosis between ileum and transverse colon as the first stage of a hemicolectomy.

16.12.38. X-ray Examination. Barium enema. Barium flows freely towards the caecum, which showed some irregularity of the caput. The terminal portion of the ileum was filled (suggesting patency of the ileo-caecal valve) but was narrow and irregular showing a persistence of the regional ileitis. The rectum and sigmoid appeared to be displaced to the left. (Fig. 28)

Operation 19.12.38. General anaesthetic. Ethyl Chloride and Ether.

Right paramedian incision. A large number of adhesions were present between the loops of small bowel in the right lower abdomen. These were gently separated, but no attempt was made to explore the ileo-caecal region and the abscess area. Going to that area was a portion of ileum that was thought might be the last loop. Its walls were greyish-red, much thickened, but not rigid.

The ileum about six inches proximal to this thickened area was anastomosed to the transverse colon, by an iso-peristaltic lateral anastomosis.

Summary. Regional ileitis. Faecal fistula. Ileo-transverse colostomy.

Patient was not upset by this operation. The pus and faeces still came away from her wound unabated. Further investigations were carried out during her convalescence:-

Bacteriological report. 6.1.39.

(1) Faeces in stool. There was no cellular exudate, and no organisms of the typhoid-dysentery group were isolated on culture.

(2) Pus from abscess in R.I.F. No Tubercle Bacilli were seen in the direct film.

A good growth of B. Coli was obtained.

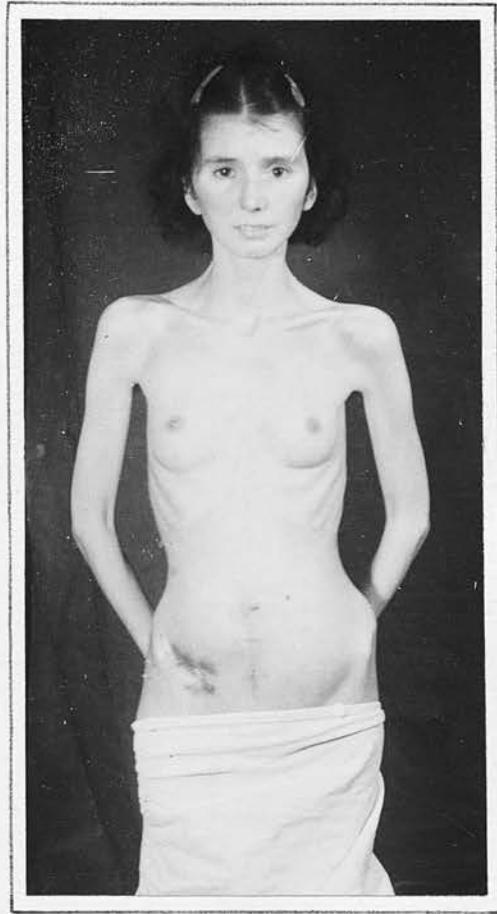

Fig. 27. Jean Auld. 10.12.38. Showing emaciation,  
and the persistent faecal fistula in the  
right iliac fossa.

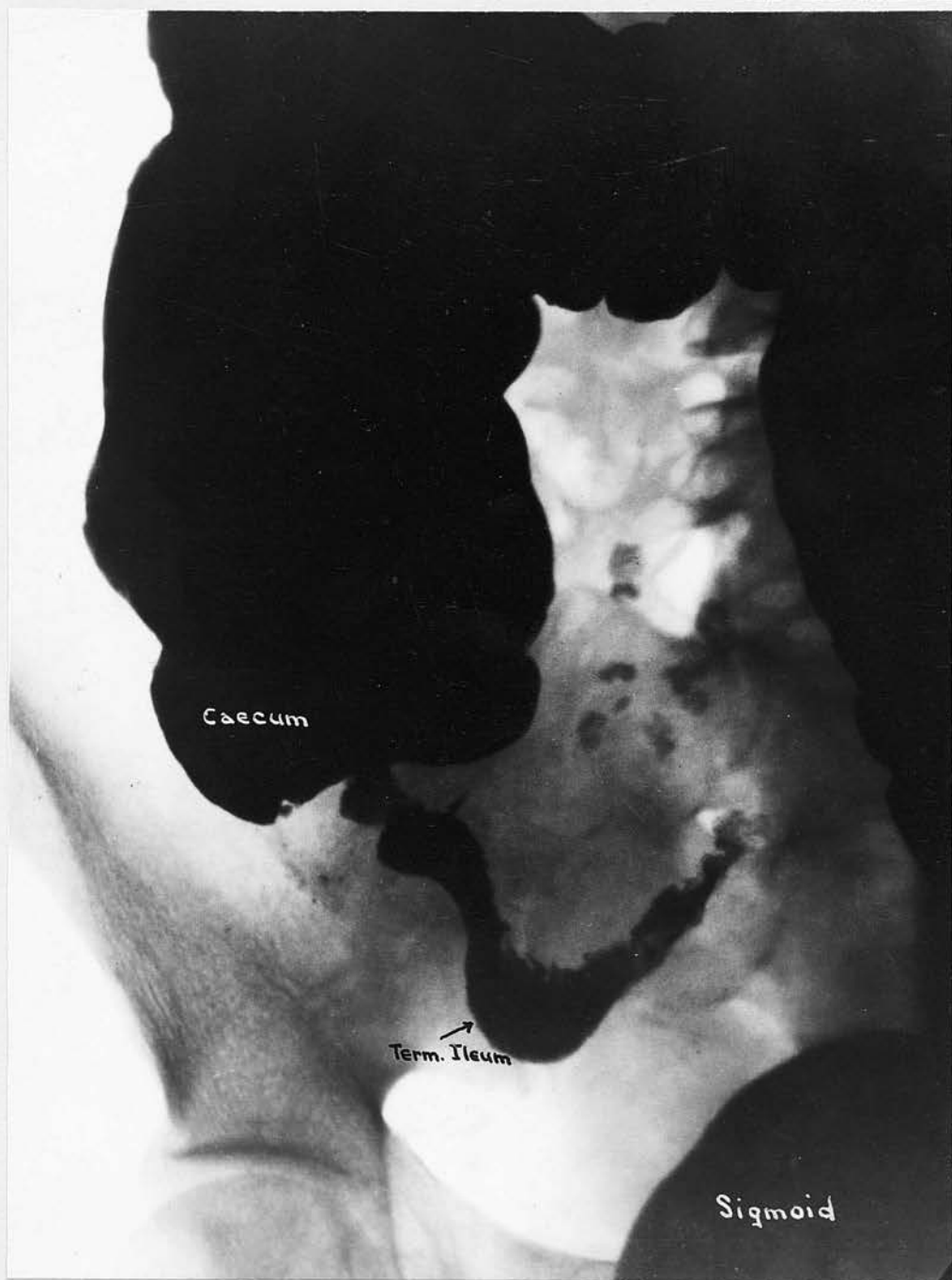

Fig. 28. Jean Auld. X-ray, barium enema. 16.12.38. Barium has flowed freely to caecum, the caput of which is indented by thickened ileum. Terminal ileum is stenosed.

(3) Smear from vagina. No gonococci seen or grown on culture.

(4) Urine. A few epithelial cells and Gram-negative coliform bacilli were seen in the direct films. A scanty growth of B. Coli and staphylococci was obtained on culture. No organisms of the typhoid-paratyphoid group.

(5) Venous blood. The Widal reaction is negative. There was no agglutination of B. Typhosus, B. paratyphosus A, or B. paratyphosus B., in serum dilutions of 1 : 16 upwards.

Frei test 7.1.39. Negative.

In addition to the negative Frei test, patient had no clinical signs of lymphogranuloma Inguinale; nor of any other venereal disease. The venereal diseases expert who examined her stated that the skin around the discharging sinus did not show the characteristic discoloration usual in sinuses due to lymphogranuloma Inguinale.

Two months after the short-circuiting operation patient still had her faecal fistula, and bowels were moving twice a day. Her general condition being stationary it was decided to proceed to resect the diseased ileum.

Operation 23.2.39. Spinal anaesthetic.

Oblique incision in right iliac fossa, encircling the fistulous opening. The peritoneal cavity was opened with difficulty because of adhesions. The fistulous tract was traced down and led to the inferior ileo-caecal angle region. Caecum and ascending colon were mobilised and appeared normal. The ileo-transverse colostomy, previously performed, was identified, and the ileum distal to it traced to caecum. This portion of ileum was found to be thickened throughout its whole length and bent into three short loops by adhesions between adjoining loops. It was greyish-red in colour. It felt firm and unyielding, like a piece of hose-pipe. The thickening extended proximally to about 3 inches from the anastomosis line and then gradually faded away. The ileum at the point of anastomosis was of normal thickness. The mesentery of the terminal ileum was oedematous and grossly thickened.

The/

The ileum from a point 2 inches proximal to the anastomosis, the caecum, and half the ascending colon were excised, and the blind ends invaginated. During this mobilisation and resection several small abscesses were found in the anterior and posterior abdominal wall. The right ovary and fallopian tube were adherent to ileum and appeared chronically thickened.

Summary. Resection of terminal ileum, caecum and ascending colon. (Fig 29)

(Fig 29)

After-history. Patient made an excellent recovery from the operation. The wound healed satisfactorily, and she is now (6 weeks after operation) putting on strength. Bowels are moving once a day.

Specimen of terminal ileum, caecum, appendix, ascending colon and gland.

Bacteriological report: Cultures from wall of ileum, wall of caecum, and gland from ileo-caecal angle:

No tubercle bacilli were found in smears of the specimens. On culture a growth of B. Coli and non-haemolytic streptococci was obtained from the three specimens.

No organisms of the typhoid-dysentery group were isolated.

Guinea-pig inoculation.

Guinea-pigs inoculated with tissue from the wall of ileum showed no evidence of tuberculosis when killed after six weeks.

Pathological examination.

Macroscopic (Fig. 30) The wall of the terminal 15 inches of the ileum is thickened and has caused stenosis of the lumen of the bowel. The thickening and stenosis get progressively greater as the ileum is traced distally, and is most marked at the ileo-caecal valve, which barely admits a probe  $\frac{1}{8}$  inch in diameter. The thickening of the wall is principally/

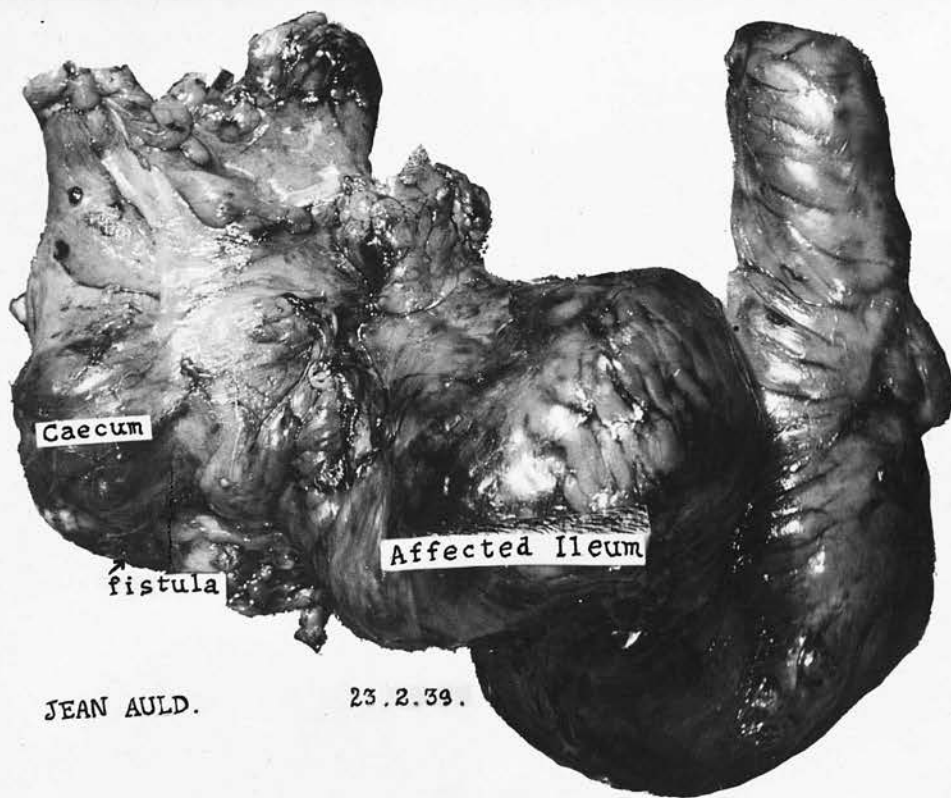


Fig. 29. Jean Auld. The specimen of terminal ileum and caecum immediately after resection. Ileum is thickened and twisted throughout the length resected. The fistula runs behind caecum.

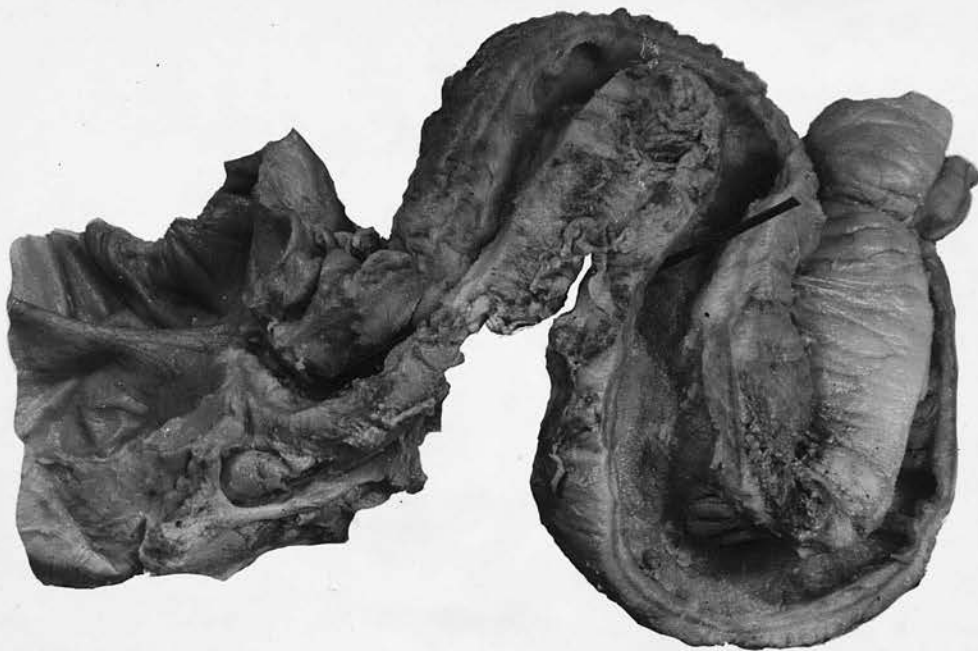

Fig. 30. Jean Auld. Interior of specimen, showing stenosis of ileum due to thickening of the wall. A few ulcers on mesenteric border, and a probe in the internal opening of the fistula. Well marked caeco-colic valve, but caecum unaffected by disease.

principally in the submucosa, though the muscle layer is also affected. The mucosa is shaggy and roughened but actual ulceration is not conspicuous. In the length of this 15 inches of the ileum there are seven ulcers, all on the mesenteric border. They average 2 m.m. in diameter and are deep and crypt-like with pouting mouths. One of them can be traced to a tiny abscess in the submucosa. From the biggest ulcer, situated 6 inches from the ileo-caecal valve, there is a fistulous track to the exterior, running in a groove behind the caecum and appearing at the lower border of caecum. The affected segment of ileum is coiled in three short loops which are bound together by adhesions between the loops.

There is no healthy bowel proximally. At the proximal point of division - the line of section at operation - the ileum is still thickened and stenosed. Omentum is adherent to this portion of bowel.

The caecum and ascending colon are normal, and the cessation of the disease process at the ileo-caecal valve is very striking. The valve between caecum and ascending colon is well marked but not thickened. The appendix is retro-caecal, thin and unaffected.

The mesentery is thickened and shows an increase in fat and several enlarged soft glands. There is a chronic abscess cavity at the postero-inferior aspect of the mesentery, communicating with the fistula from ileum.

#### Microscopic.

##### Section from ileum (Fig 31) (Anti-mesenteric border)

The mucous membrane is not ulcerated, but shows a fairly well marked plasma cell and eosinophil infiltration.

The submucosa shows a moderate degree of oedema and fibrosis and a sparse plasma cell infiltration.

The muscle coat is hypertrophied. It shows little or no inflammatory change, apart from the presence of one tubercle. This is a very proliferative tubercle with many endothelioid cells and in its centre a few polymorphs. There are no giant cells. (Fig 33, 34)

The subserosa shows slight oedema and fibrosis. There is a considerable polymorph and plasma cell infiltration - a greater degree of inflammatory reaction than any of the other coats.

The serous coat is roughened but there is no surface exudate or evidence of active peritonitis.

Section from ileum.(Fig. 32) (whole thickness)

This section was taken from the most proximal and least thickened portion of the specimen. It shows similar features to the other sections of ileum, with the addition of an area of ulceration on the mucosa, and hypertrophy of the muscularis mucosa. This is an irregular thickening from hypertrophy and hyperplasia of the plain muscle cells. There is less inflammatory change in the subserosa, and no tubercles are seen.

Sections from Caecum (Fig.35 ) and Appendix.(Fig 36).

There is a very slight degree of infiltration of the mucosa with plasma cells and eosinophils. The submucosa is slightly fibrotic but not inflamed or infiltrated.

The muscular and subserous and serous coats show no change from normal.

Section from gland (Fig. 37,38).

There is a certain amount of histiocyte reaction in the lymph sinuses. There are also seen one or two ill-defined and small areas of endothelioid cell proliferation, associated with atypical giant cells. Some of the giant cells are quite small, with only two or three nuclei, others are larger with many scattered nuclei. Surrounding the tubercles and interspersed are some eosinophil cells. There is no caseation in any of the tubercles.

Points to note.

- |  |   |
|--|---|
| 1. Age 18.   | 1. Thickened congested terminal ileum (15").  |
| 2. Abdominal pain for one week.  | 2. Ulceration of mucosa on mesenteric border. |
| 3. Slight diarrhoea for three years.                                   | 3. Fibrosis of submucosa.                     |
| 4. Palpable mass.  | 4. A few atypical tubercles.                  |
| 5. Gland abscess and persistent faecal fistula following its drainage. | 5. Streptococci and B. Coli in wall.          |
| 6. Frei test negative.   |   |

No evidence of typhoid or dysentery. Guinea-pig inoculation negative for tuberculosis.

Comment./

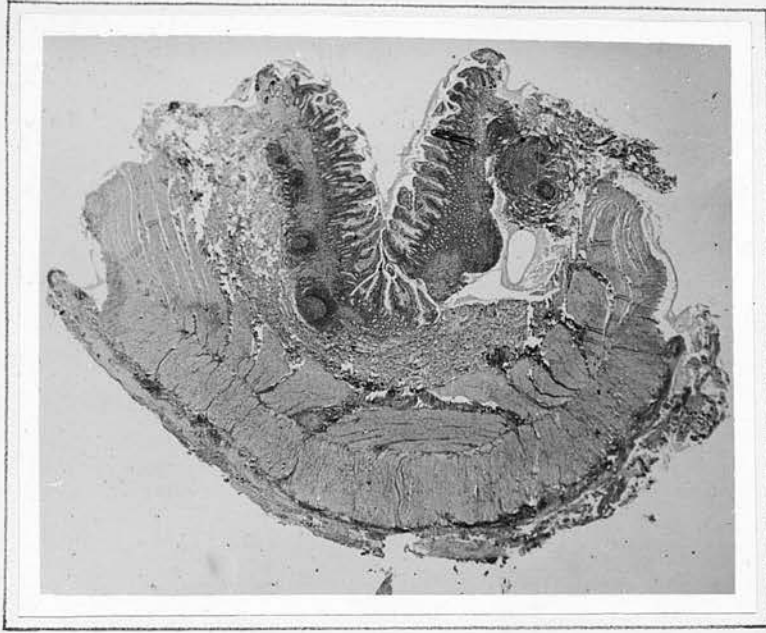


Fig. 31. Jean Auld. Ileum. x 9. No ulceration of mucosa. Moderate fibrosis of submucosa. Hypertrophy of muscle. One tubercle in the muscle layer.



Fig. 32. Jean Auld. Cross section of ileum and mesentery. x 4. Ulceration of mucosa on mesenteric border. Hypertrophy of muscularis mucosa. No tubercles.

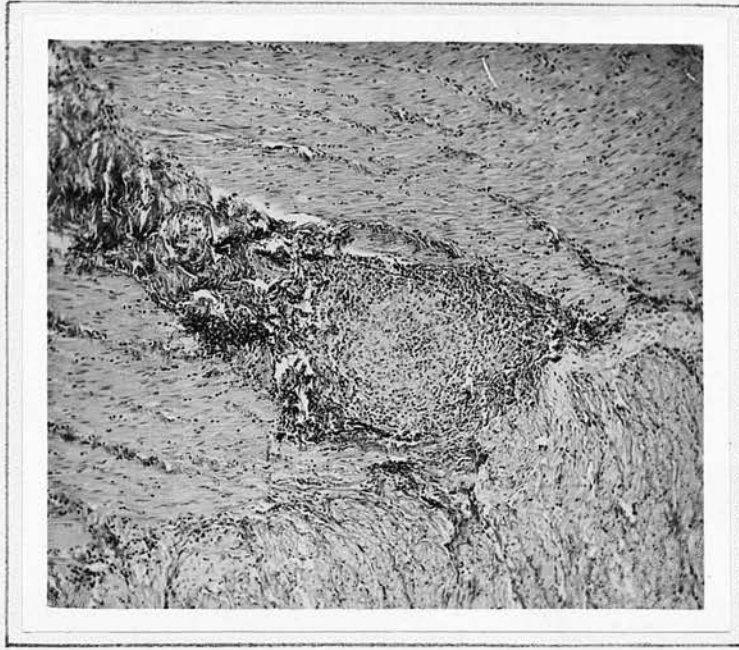


Fig. 33. Jean Auld. Ileum. x 75. Tubercle in muscle.

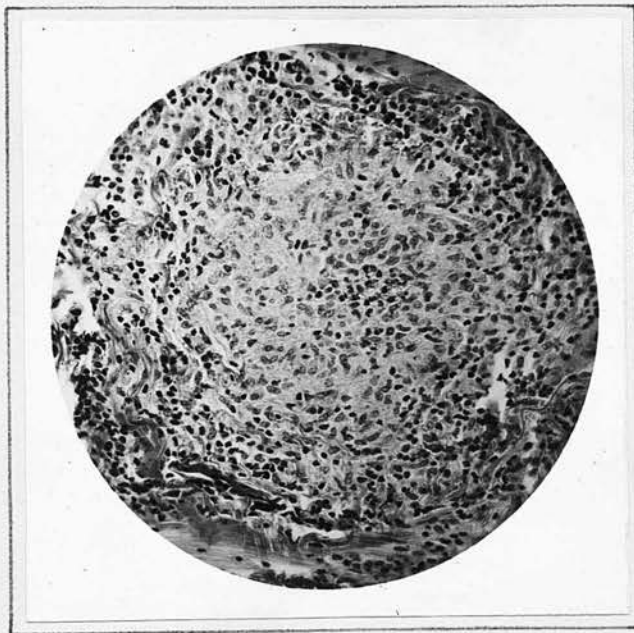


Fig. 34. Jean Auld. Ileum. x 200. Fig. 33 under higher power, showing tubercle in muscle. Endothelioid cells with polymorphonuclear leucocytes in the centre. No giant cells.

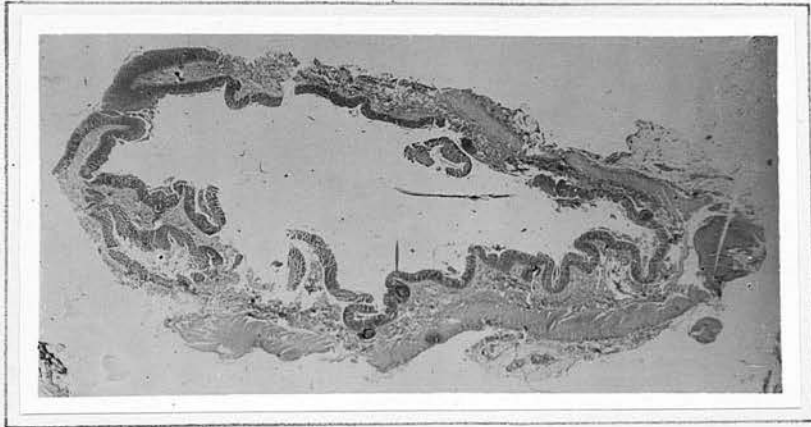

Fig. 35. Jean Auld. Caecum. x 3. Unaffected.

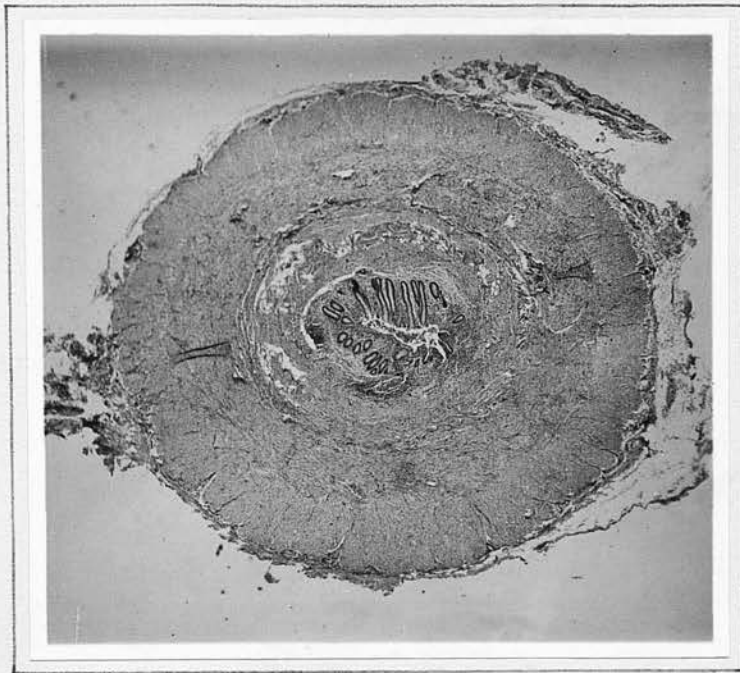


Fig. 36. Jean Auld. Appendix. x 16. Unaffected. Mucosa is intact. The muscle wall appears disproportionately thick compared with the lumen, but is not abnormally so.

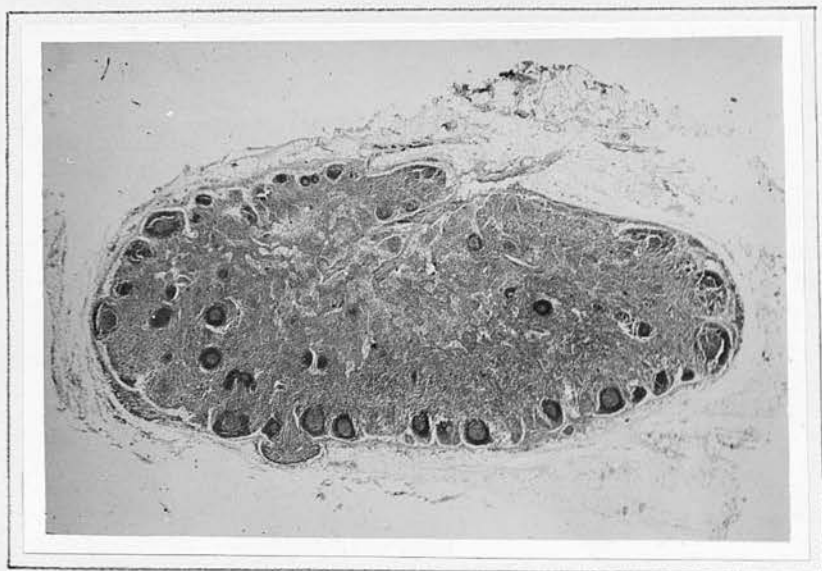


Fig. 37. Jean Auld. Gland. x 12. Histiocyte reaction in the lymph sinuses. One or two ill-defined tubercles, hardly visible under this power.

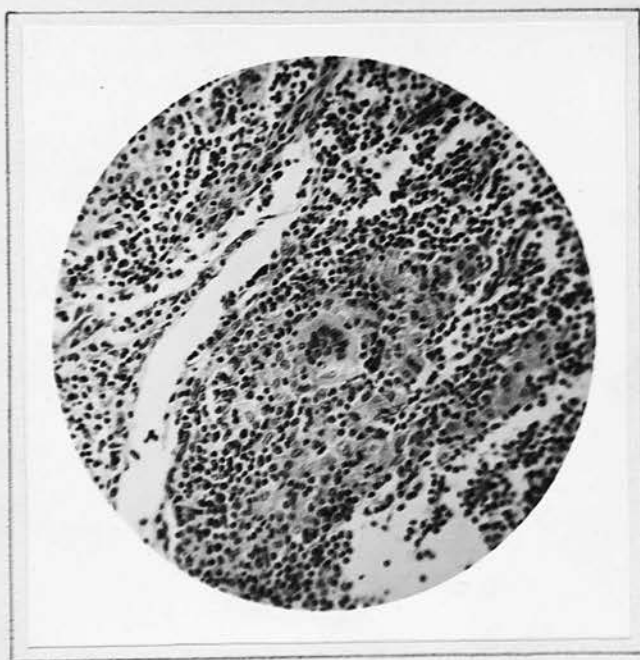


Fig. 38. Jean Auld. Gland. x 200. Ill-defined tubercle. Endothelioid cell proliferation and atypical giant cell.

Comment. This is an example of a characteristic feature of regional ileitis - the tendency to fistula formation. In this case the fistula followed laparotomy and drainage of an abscess close to the diseased segment of ileum. In spite of attempts to lessen and clear up the chronic discharge of faeces and pus, by freer drainage, short wave therapy etc., the sinus remained intractable until the diseased ileum whence it was coming was excised.

When the affected ileum was first observed at operation, after only a week's illness, it had already gone beyond the early acute stage and was firm and thickened. It may be that the disease had begun three years before when the bowel movements first became more frequent. The abscess, then, was in association with a regional ileitis in its chronic, rather than acute, form.

The weight of pathological evidence was against tuberculosis as the cause of the cicatrization in the ileum. Guinea-pig inoculation was negative, and such tubercles as were seen were atypical. An old calcified tuberculous gland from the ileo-caecal area was an un-related finding.

The subsequent progress of this patient will be followed with interest and not a little anxiety. For at the operation for excision of the affected ileum it was seen that the disease came to within a few inches of the anastomosis line (the ileo-transverse colostomy having been done as a preliminary operation), and in the excised segment of ileum there was no part of the bowel proximally that was normal. The patient may have a recurrence of symptoms if the inflammatory process has not been entirely removed.

-----

MRS. ISABELLA CARR. Aet. 49. Housewife. Admitted to Ward 14, Royal Infirmary, Edinburgh 11.1.39.

History. On the evening before admission patient began to have pain in the epigastrium. It came on gradually, increased in intensity during the next ten minutes and then shifted to the right lower abdomen and to the small of the back. After the shift of pain the epigastric pain was absent. The right iliac fossa pain came in spasms lasting three or four minutes, with intermissions lasting about ten minutes during which time pain in that region was wholly absent. The pain in the small of the back came on gradually and persisted constantly except for momentary intermissions. Patient described it as like "cramp", and "like the beginning of labour without the bearing down."

Vomiting occurred about an hour after the commencement of the pain, and thereafter repeatedly whenever the pain was severe. The vomitus was in each case small, and no relief was obtained.

From the time of onset of pain there was diarrhoea, a fluid motion devoid of blood or mucus being passed every hour or two. Whenever the pain was especially severe there was a desire to defaecate and to pass flatus. As vomiting also occurred when the pain was especially severe, the patient repeatedly vomited when she was at stool. There was no nausea between the bouts of vomiting, though there was complete loss of appetite.

Five weeks before admission there was a precisely similar attack of pain and vomiting, coming on in the evening after a hard day's work. The attack lasted for twenty-four hours, and on the day following the attack her doctor told her that the temperature was high. She had no rigors or sweating. The intensity of the pain was not less than it was prior to admission. Diarrhoea was very marked, and she repeatedly vomited. Following this attack she remained in bed for a fortnight and felt very weak. She had no appetite for food, not because of any pain but simply because she "did not feel hungry."

Seven weeks before admission she had her first attack, which was similar but milder to the two following ones, again coming on in the evening after a day's work. Cramp-like abdominal pain, vomiting, and diarrhoea were all present, and the bout lasted twelve hours.

Ever/

Ever since this first attack there has been a discomfort in the right iliac fossa not amounting to pain. The patient described it as "knowing there was something there which shouldn't be there."

The patient was not aware of any recent deterioration of general health, and could do her housework without effort or exhaustion. She thought that she might possibly have lost a little weight - her friends had remarked on her being thinner lately. She certainly was not paler.

Previous History. In 1932 patient had cystitis, since when she has been troubled with slight indigestion. There is a feeling of fullness and cramp-like pain in the pit of the stomach coming on about an hour after meals. Flatulence is troublesome. Waterbrash and heartburn are common. Vomiting is rarer. There are intermissions when the patient can eat anything. Since 1936 either two or three fluid motions have been passed daily, but blood or mucus has never been noticed in the stool.

Patient is para 11. The periods have occurred at intervals of several months for the past two or three years.

On Examination 11.1.39. Temperature 99.4°F.  
Pulse 118. Respirations 20.

Rather stout florid woman, who does not look actually ill.

Teeth. All artificial.

Tongue. Moist and white furred.

Abdomen. Moves moderately on respiration. No hyperaesthesia. Tenderness and guarding are present in the right iliac fossa, but there is no sharply localised point of maximal tenderness. No palpable mass. No increase in liver dullness.

Respiratory System. No cough. Chest resonant, and breathing vesicular.

Cardiovascular System. Pulse regular.  
Heart not enlarged. Sounds pure.  
B.P. - 148/80.

Blood/

Blood Count.

R.B.C.	4,400,000.
Hb.	85%.
C.I.	0.9.
W.B.C.	11,000.

Provisional Diagnosis. Acute Appendicitis.

Operation 11.1.39. General Anaesthetic - Gas, oxygen and ether.

Right grid-iron incision. There was a little clear free fluid in the peritoneal cavity. The appendix was congested on its surface but not distended. It was excised. The last nine inches of the ileum was reddish-blue in colour, but the peritoneal coat was glistening. This portion of ileum appeared thicker than usual, and on palpation the wall had the feel of raw meat. For three or four inches proximal to this terminal six inches the colour, distension, and oedema were progressively less marked, and beyond this the ileum appeared quite normal. The mesentery of the terminal part of the ileum was about half an inch thick with fat and oedema, and there were several enlarged soft glands. There was no evidence of intestinal obstruction so that ileo-transverse colostomy was not performed. A mesenteric gland was excised for biopsy.

Summary. Regional ileitis. Appendectomy.

Post-operative Investigations.

Bacteriological report: (1) Appendix. A growth of enterococci and B. Coli was obtained.

(2) Mesenteric gland. A few colonies of B. Coli on culture.

(3) Wassermann reaction.  
Negative.

Frei test. Negative. Patient showed no clinical evidence of lymphogranuloma Inguinale.

Pathological report.

Microscopic. Section from appendix. The appendix shows a chronic inflammatory scarring of the submucous coat. The mucous membrane is normal in appearance. (Fig 39)

Section from gland. The gland shows follicular atrophy and sinus distension. The sinuses contain amorphous material, presumably coagulated lymph, but not many cells. The cells present are mainly lymphocytes with a few polymorphs. (Fig 40)

X-ray Examination 25.1.39. (Fig.41 ).

Barium Series. Stomach and duodenum normal. The terminal loop of the ileum is stenosed for a length of about nine inches. There is no dilatation of ileum proximal to the stenosed portion. The caecum is not affected. The appearances are those of regional ileitis.

Chest: Normal.

After-history. Patient made a good recovery from the operation and was discharged from hospital a fortnight later. For the first ten days the temperature swung between 98°F. and 99.8°F. Towards the end of her stay the bowels were moving two or three times a day.

In March 1939 patient reported to hospital again. She stated that she was feeling very well, with no abdominal pain. Bowels were moving three times a day, which was her only complaint. On examination the wound was found to be soundly healed. There was definite resistance and slight tenderness in the right lower quadrant of the abdomen, and an indefinite mass could be felt.

X-ray examination by barium series in March 1939 (Fig.42 ) showed a marked and irregular stenosis of the terminal ileum. Compared with the previous X-ray examination the ileitis appeared to have increased in extent. The medial aspect of the caecum was flattened, probably from pressure by adjacent ileum.

Patient was advised to have a further operation, but as she was feeling so well she was unwilling to have this done meantime.

Points/

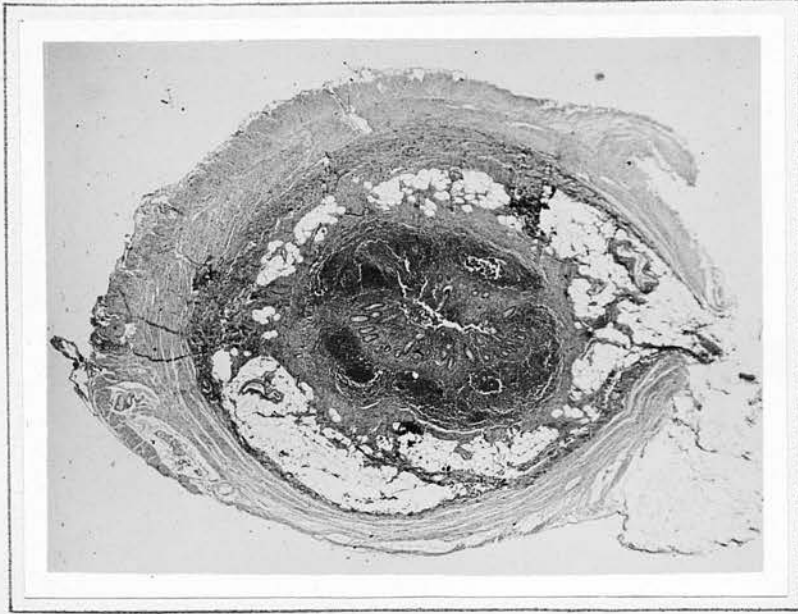


Fig. 39. Mrs Carr. Appendix. x 12. Mucosa unaffected.  
Scarring in submucosa.

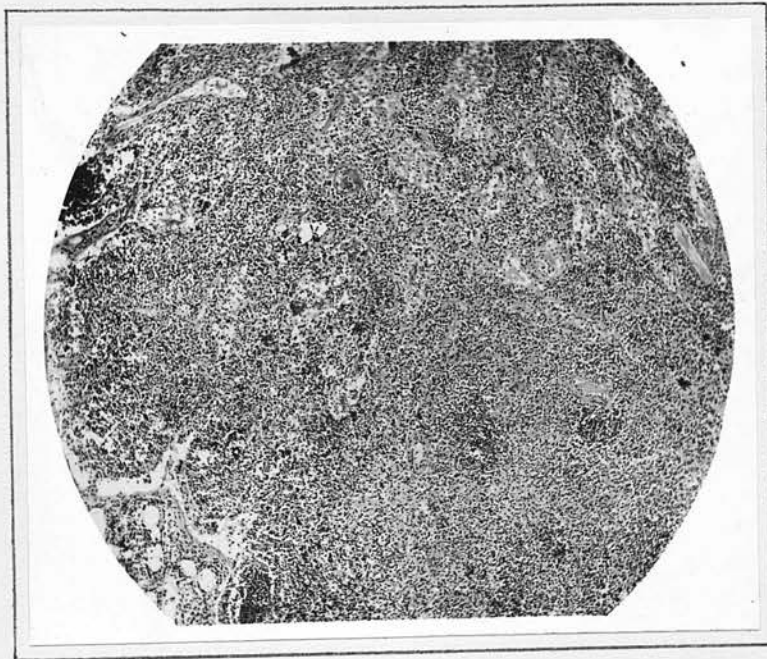


Fig. 40. Mrs Carr. Gland. x 50. Follicular atrophy.  
Sinuses distended with lymph.

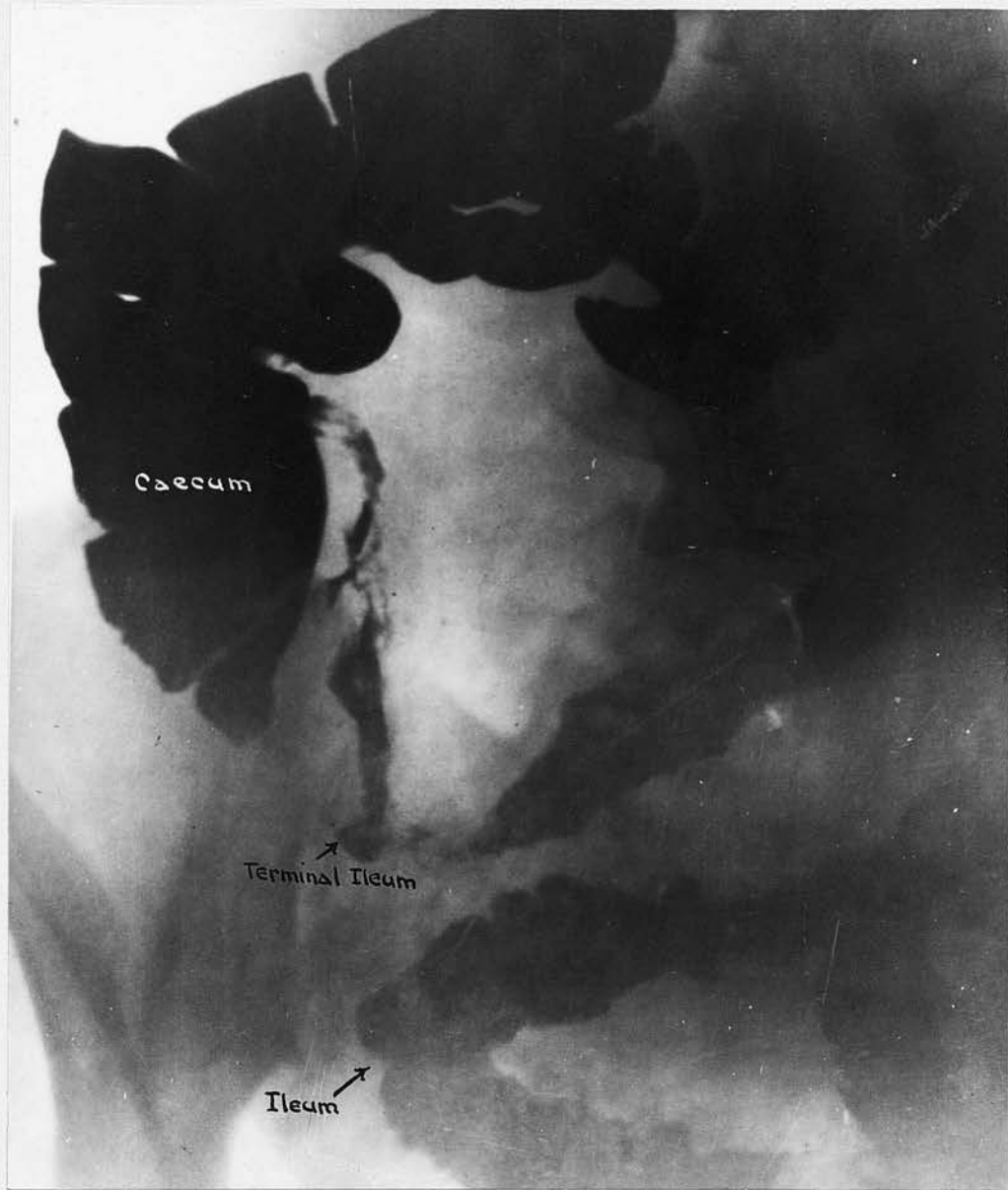


Fig. 41. Mrs Carr. X-ray, barium series; January 1939. Stenosis of the terminal portion of ileum for a length of about nine inches. No dilatation of ileum proximally. Caecum unaffected.

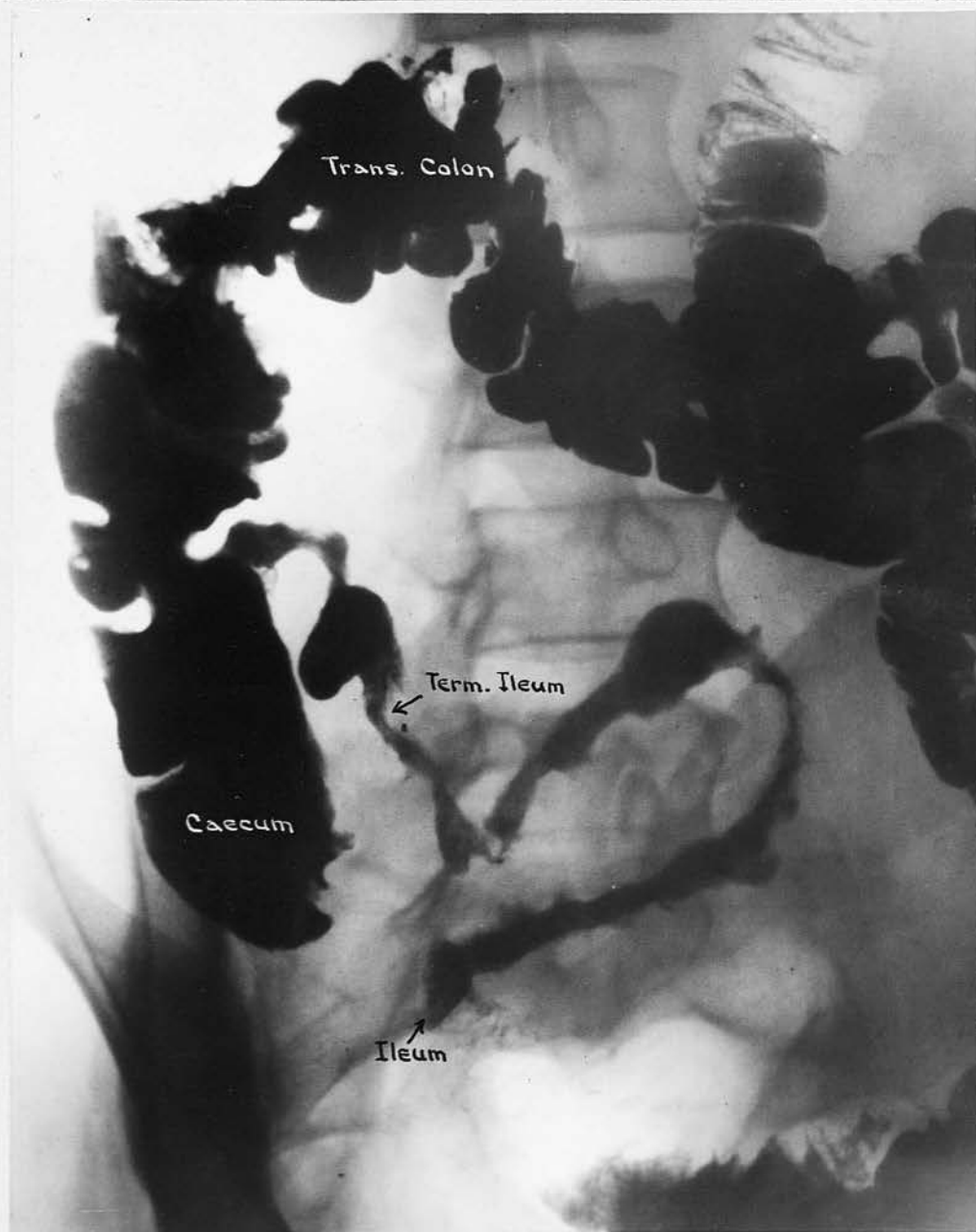

Fig. 42. Mrs Carr. X-ray, barium series; March 1939. Stenosis of terminal loops of ileum. Increase in extent of ileum involved compared with the condition two months previously. (Fig. 41).

Points to note:

1. Three attacks of abdominal pain in seven weeks.
2. Diarrhoea for 3 years.
3. No loss of weight or strength.
4. Reddish-blue thickened terminal ileum.
5. Visible advance in extent of disease in two months.
6. Frei test negative.

Comment. An example of regional ileitis midway between the acute and chronic stages, with evidences of both in the clinical and pathological picture. The patient was operated on in an acute attack and the bowel appeared inflamed. The bowel however felt rather firm, and the X-ray appearance is that of the chronic cicatrising stage. The three short attacks of pain spread over seven weeks, suggested an early lesion, but the diarrhoea for three years may indicate when the disease really commenced.

The somewhat rapid spread, as seen radiologically in the two months since her operation is an indication that further operation and radical excision should be carried out. It would have been better if a preliminary ileo-transversecolostomy had been done as a first stage, but at the time of operation it was thought that the condition was acute and might possibly resolve. Far from resolving the disease has advanced, although the patient still feels quite well apart from her diarrhoea. If excision is not carried out soon it is probable that sub-acute intestinal obstruction will occur, and a fistula may develop between affected ileum and neighbouring viscus or abdominal wall.

-----

ANALYSIS OF HOSPITAL RECORDS.

Of these seven cases of Regional Ileitis that I have described six of them were in the charge of Professor D.P.D. Wilkie in the Royal Infirmary. They had all occurred during the past three or four years, and all since attention to this condition was aroused in 1932. It seemed to me that it would be of interest to examine the histories and findings of all cases that had occurred in Professor Wilkie's charge, and that might, in the light of present knowledge, have been classified under the title of Regional Ileitis. I wanted to know: (a) Is this a condition which, if not new, is at any rate being seen more frequently nowadays?

(b) What label was applied to similar conditions in the past?

(c) Is there evidence that this really is a separate entity from, for example, ileo-caecal tuberculosis?

During his period as a Surgeon to the Royal Infirmary, from 1925 to 1938, Professor Wilkie had charge of 12,000 cases, and while it is true to say that they were of a general surgical nature it is also true to say that there was a considerable proportion of "abdominal" cases, in which branch of surgery Professor Wilkie was particularly interested. From these/

these 12000 cases I have separated 63 which are relevant for discussion as involving ileum, caecum, or both. In this number I have not included cases such as "traumatic perforation of the ileum", "volvulus of the ileum or caecum", "simple adhesions", "tuberculous ileo-caecal glands", and other irrelevant conditions.

The diagnosis attached to these 63 cases was:-

ILEUM (alone).

Tuberculosis	7.
Carcinoma	5.
Regional ileitis	5.
Stricture of ileum	1.
Ileal fistula	1.

The cases of tuberculosis I shall deal with later, in particular those where resection of bowel was performed and the microscopic section of the specimen available for study.

The five cases of carcinoma of the ileum were all undoubtedly malignant, as seen microscopically.

The examples of regional ileitis are those that I have already described. All have occurred since 1936.

The stricture of ileum was thought to be typhoid in origin. It will be dealt with later.

The ileal fistula was in an old man who had had an abdominal faecal fistula ever since an operation 22 years previously. The full record of the previous operation/

operation could not be obtained but it is probable that it was an operation for Meckel's diverticulum. When Professor Wilkie closed the fistula there was nothing abnormal to be seen apart from the communication with a healthy low loop of ileum. While an external fistula is a recognised feature following operations for regional ileitis where diseased bowel is left behind, it could not be suggested that this was an example of such.

CAECUM (alone).

Carcinoma	16
Tuberculosis	5
Typhlitis	4
Simple ulcer	3

The 16 cases of carcinoma of the caecum all had the microscopic criteria of malignancy.

The cases of tuberculosis where resection was performed I shall deal with later.

The 4 cases of typhlitis were all associated with appendicitis. It is certain that a degree of thickening or inflammation of the caecum in association with a true appendicitis must have occurred in more than 4 cases. It had not been thought necessary to classify such as typhlitis. In none of these 4 cases was there any comment on the state of the ileum, which was presumably not the site of obvious disease.

Simple non-specific ulcer of the caecum is a rare but/

but well recognised condition. The ulcer is situated on the anterior wall of the caecum or opposite to the ileo-caecal valve. The aetiology is unknown, and there is a tendency to link them up with ulcers elsewhere in the gastro-intestinal tract ( 9 ). They frequently perforate, but there is no evidence that they ever go on to form a granuloma that might be mistaken for regional ileitis.

INVOLVING CAECUM AND ILEUM TOGETHER.

Ileo-caecal tuberculosis	8.
Carcinoma	7.
Regional ileitis	1.

Certain of the examples of ileo-caecal tuberculosis will be dealt with later.

The 7 cases of carcinoma were all undoubted cases of carcinoma of the caecum with inflammatory adhesions to the lowermost ileum.

The case of regional ileitis I have described.

This seeding-out process left me with:-

Tuberculosis of Ileum	7.
Stricture of Ileum	1.
Tuberculosis of Caecum	5.
Ileo-Caecal tuberculosis	<u>8.</u>
	<u>21</u>

Of these 21 cases many had not had resection performed so that there was no microscopic evidence for/

for or against tuberculosis; and in other cases the section was no longer available. I shall proceed to examine the remaining 6 cases, with the object of deciding whether they may justifiably be considered tuberculous, or whether they might not fit such a diagnosis as "non-specific granuloma". I myself in 1939 have made the fresh pathological examination and report which is attached to the following cases, using the same standards as for examination of the regional ileitis cases. The pathologist's original opinion is indicated in the diagnosis at the head of each case.

-----

DIAGNOSIS: TUBERCULOSIS OF CAECUM.

MRS. MARGARET TAYLOR. Female. Aet 65. Housewife.  
15.2.36.

History. Five months history of soreness and discomfort in the right lower abdomen. No nausea or vomiting. Bowels regular, sometimes constipated. Never any blood in stool. Appetite good. No loss of weight.

On Examination. No tenderness and no palpable mass in the abdomen.

X-ray Barium Series. "Stomach, duodenum and small intestine negative. At five hours the barium meal filled caecum and part of colon, and there was no special evidence of a lesion."

Operation. "A large tuberculous stricture was found in the ascending colon just above the caecum. There were numerous glands in the mesentery but no other sign of involvement of the bowel." A right hemi-colectomy was performed.

After-history. Patient has had no further trouble and is alive and well.

Pathological examination. (Fig 43).

Microscopic. (1) Colon. There is a diffuse inflammatory infiltration of the mucosa with lymphocytes, plasma cells, polymorphs, and eosinophils. There is no general ulceration of the mucosa, but at one area there is either a penetrating ulcer or abscess, containing polymorphs and lined with granulation tissue, extending down into the muscle layer.

There is congestion and oedema of the submucosa, with some fibrosis. There is not much diffuse infiltration of the submucosa, but rather small focal areas of lymphoid tissue and focal accumulations of plasma cells.

Tubercles are seen in both mucosa and submucosa, - typical collections of endothelioid cells and many/

many giant cells, but with no caseation. Some of the giant cells show inclusion of hyaline material. The tubercles are numerous, and they out-weigh the diffuse inflammatory change. (Fig 44)

(2) Gland. The striking feature is the very marked tubercle reaction, and in the centre of one or two of the tubercles early caseation is seen. (Fig 45)

Points to note: Age 65.  
No diarrhoea.  
Stricture in ascending colon, and normal ileum.  
Greater tendency to tubercle formation than diffuse infiltration, especially in submucosa.  
No caseation in bowel wall tubercles.

Comment. The diagnosis of tuberculosis is acceptable, though it would have been more convincing if tubercle bacilli had been seen in a specially stained slide, or the guinea pig inoculation test done.

-----

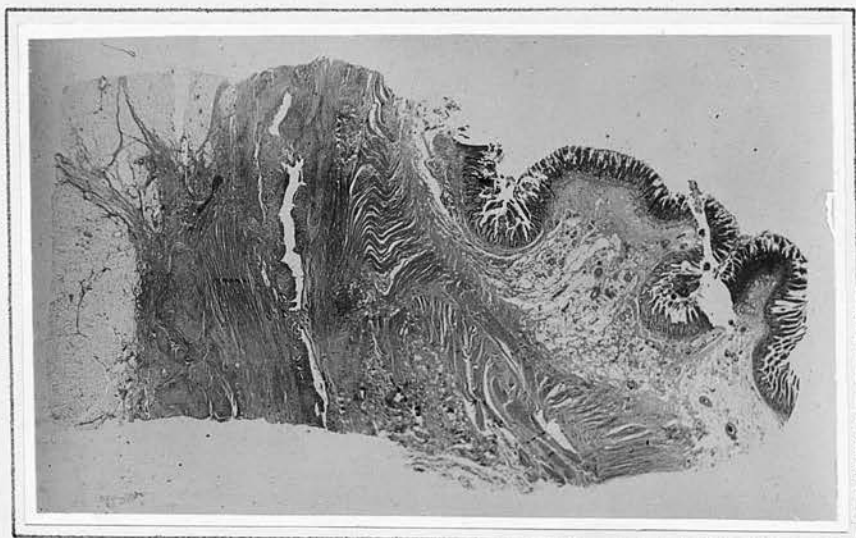


Fig. 43. Mrs Taylor. Colon. x 4. To the right of section - mucosa shows infiltration with mixed cells, but no ulceration. Submucosa shows oedema and some fibrosis. To the left of the section there is a deep ulcer penetrating into the muscle layer. Tubercles in mucosa and submucosa (see Fig. 44).

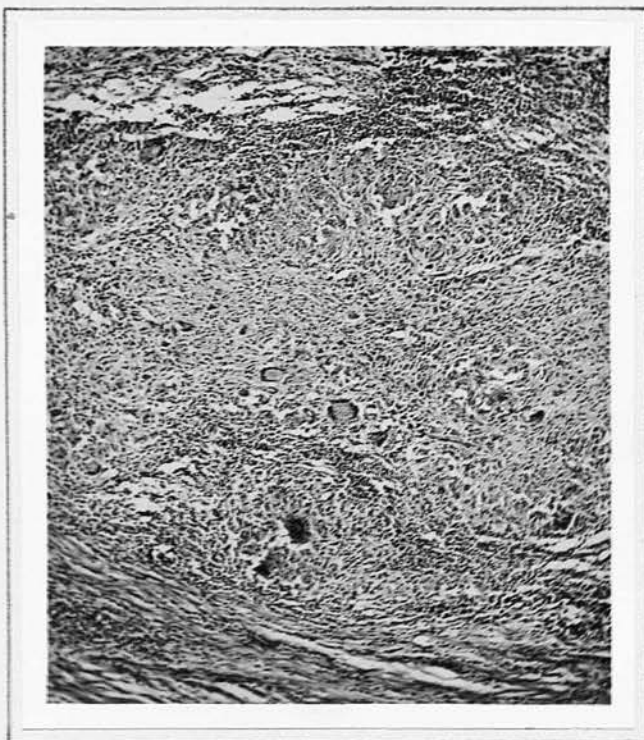


Fig. 44. Mrs Taylor. Colon. x 75. Tubercles in submucosa. Endothelioid cells, and giant cells with peripheral nuclei. Inclusion of hyaline material in some of the giant cells. No caseation.




Fig. 45. Mrs Taylor. Gland. x 75. Tubercules, with early caseation.

DIAGNOSIS: TUBERCULOSIS OF THE CAECUM.

PETER ORMISTON. Male. Aet 57. Roadman.  
Admitted to Ward 13, Royal Infirmary,  
Edinburgh, 17.11.30.

History. Two years history of recurring attacks of lower abdominal pain, the attack being followed and relieved by the passage of a watery motion. Except during these attacks bowels were quite regular with no tendency to diarrhoea. Considerable loss of weight.

On Examination. Pale thin man. No tenderness in abdomen and no palpable mass.

X-ray Barium Series. "Stomach, duodenum and small intestine normal. No delay in emptying."

Operation. "The caecum was found to be somewhat shrunken and of soft consistence, the appearance being that of tuberculosis which had not however caused any appreciable interference with the ileo-caecal valve. There was no evidence of tubercle in the small intestine." A right hemi-colectomy was performed.

After-history. Patient made a good recovery, and when last heard of five years after operation was well, and bowels regular.

Pathological examination. (Fig 46, 47)

Microscopic. Caecum. There is no ulceration and little or no mucosal atrophy. There is a rather patchy lymphocytic infiltration of the submucosa, with a few plasma cells. In addition there are a few scattered tubercles - endothelioid cells, and many giant cells, but no caseation. Some of the giant cells have peripherally situated nuclei, but in many others the nuclei are diffusely scattered. The characteristic feature of this section is the absence of any diffuse inflammatory infiltration, along with the well-formed tubercles.

Points/

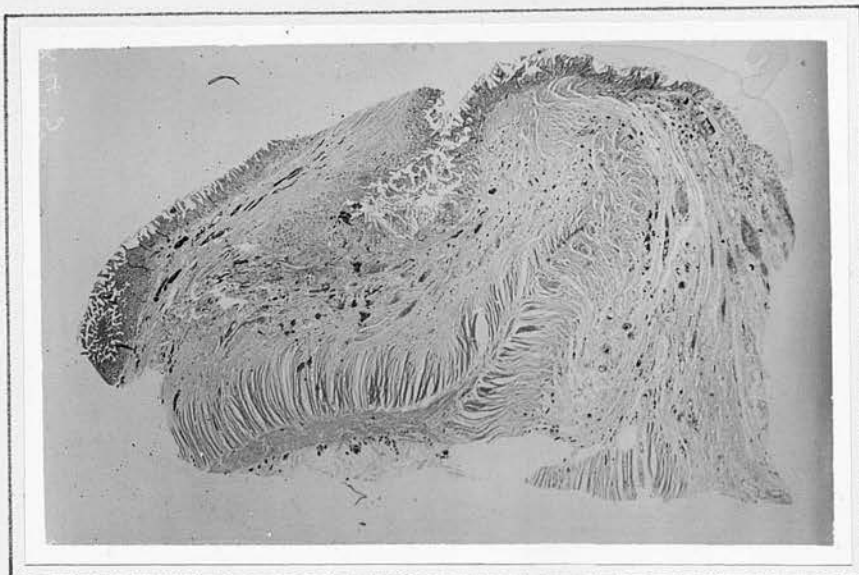

Fig. 46. Peter Ormiston. Caecum. x 4. No mucosal ulceration and very little inflammatory infiltration. A few scattered well-formed tubercles.

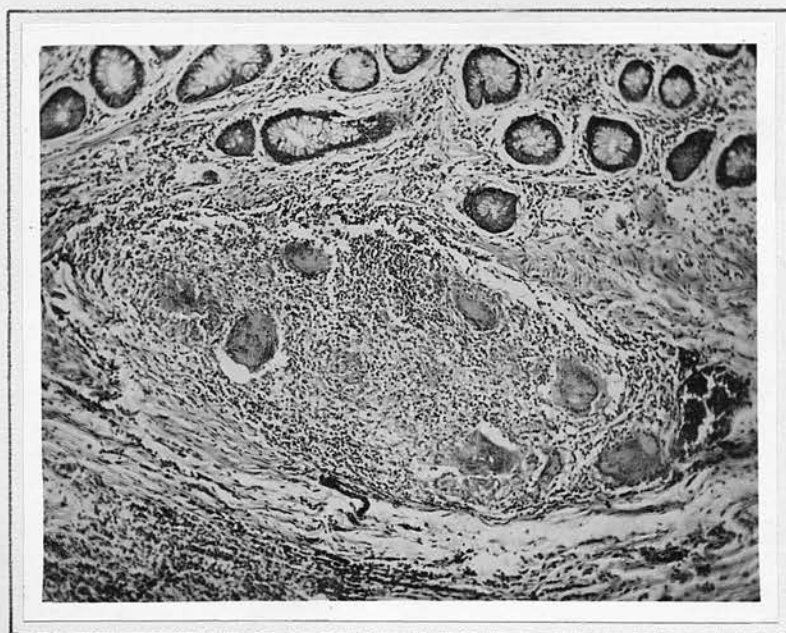

Fig. 47. Peter Ormiston. Caecum. x 75. Tubercle in submucosa. Endothelioid cells and many giant cells. No caseation. Some of the giant cells have peripherally situated nuclei; in others the nuclei are diffusely scattered.

Points to note. Age 57.

No true diarrhoea.

Caecum soft and shrunken. Ileum not involved.

No ulceration of the mucosa.

Tubercle formation rather than diffuse infiltration.

No caseation.

Comment. The diagnosis of tuberculosis is acceptable.

-----

DIAGNOSIS: TUBERCULOSIS OF THE CAECUM.

MRS MARY MORRIS. Female. Aet. 47. Housewife.  
Admitted to Ward 14, Royal Infirmary,  
Edinburgh, 12.1.31.

History. 8 months' history of a cutting pain in the right iliac fossa, shooting across the lower abdomen, and accompanied by vomiting. Constipation, from which she had always suffered, had got very much worse. Never any blood in the stools. Had lost weight during this 8 months.

On Examination. Anaemic looking, thin, tired woman. Abdomen not tender, but in the right iliac fossa there was a mobile swelling, the size of a plum.

Operation. "The caecum was found to be shrivelled and firm, evidently from chronic tubercle. Small intestine not involved. There were several enlarged glands in the ileo-caecal angle." A right hemi-colectomy was performed.

After-history. Patient is alive and well to-day. Bowels tend to be loose rather than constipated.

Pathological examination. Caecum. (Fig 48).

Microscopic. The mucosa shows glandular atrophy. There is a diffuse chronic inflammatory infiltration of the mucosa - with lymphocytes, plasma cells, polymorphs, and eosinophils, but predominantly plasma cell. There is a sinus-like ulcer penetrating into the muscle coat, lined with granulation tissue and containing many polymorphs. In the submucosa there is considerable fibrosis, and a few characteristic tubercles, none of which show caseation.

Points to note. Age 47.  
Constipated.  
Caecum shrivelled. Enlarged glands.  
Ileum healthy.  
Diffuse inflammatory infiltration and fibrosis.  
A few tubercles. No caseation.

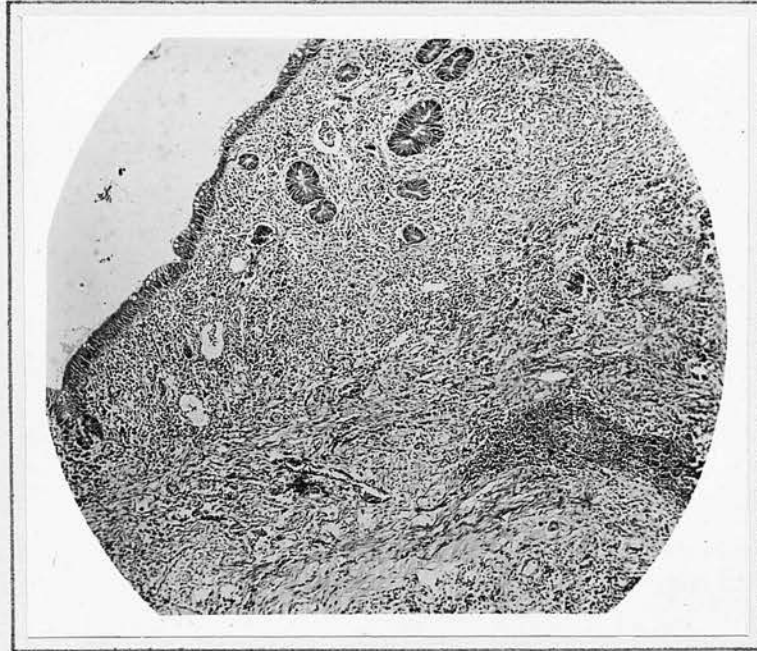

Fig. 48. Mrs Morris. Caecum. x 50. Mucosa shows glandular atrophy, and diffuse chronic inflammatory infiltration with plasma cells predominantly. In lower half of section there is a sinus-like ulcer penetrating into muscle. Submucosa shows fibrosis, and a few scattered tubercles.

Comment.

With the many polymorphs and the sinus-like ulcer this section has certain features seen in regional ileitis, and the microscopic picture would well serve for that diagnosis. The absence of diarrhoea, the non-affection of the ileum, and the fact that the microscopic picture is that of tuberculosis too, make one favour the diagnosis of tuberculosis.

-----

DIAGNOSIS: TUBERCULOUS STRICTURES OF ILEUM.

AGNES MOFFAT. Female. Aet. 23. Laundry-worker.  
16.7.34.

History. Four years' history of colicky peri-umbilical abdominal pains and nausea. Bowels very constipated. Never any blood seen in the motion. Considerable loss of weight and strength.

On Examination. Pale and thin girl. Indefinite tender mass felt in the right iliac fossa.

X-ray. Barium Series. "Appearance after 4 hours suggested slight ileal stasis."

Barium Enema. "The enema flowed rapidly to the ascending colon, which, with the caecum, was much narrowed and slightly irregular but there was no obstruction, the enema entering the small bowel easily."

Operation. "The caecum was found to be small and firm, hyperplastic tuberculosis being marked at the junction of caecum and ascending colon. The ileum was carefully examined and in the last four feet four tuberculous strictures were discovered. No tuberculous lesion was found any higher than four feet above the ileo-caecal valve. There were no glands obviously affected." A right hemi-colectomy was performed.

After-history. Patient had indifferent health for the next year, and had to be operated on again in 1935 for symptoms of intestinal obstruction. At this second operation many fine adhesions between loops of small intestine were divided. There was no sign of any stricture in the ileum.

Since then patient's general condition has improved, but she is now much troubled with diarrhoea. Bowels move every two hours, but never any blood in the stool. Now in 1939 the diarrhoea is showing some improvement, with the patient on a low residue, high vitamin, diet.

Pathological/

Pathological examination. (Fig 49)Microscopic. Ileum.

The striking feature is the very marked fibrosis of the submucous coat, with a mild degree of lymphocytic and plasma cell infiltration of mucous and submucous coats. Considerable number of eosinophils in mucous coat. Patchy glandular atrophy of the mucosa but no ulceration. Occasional tubercles are seen in mucosa and submucosa - endothelioid cells and giant cells, but no caseation.

Points to note. Age 23.

Constipated.

Caecum firm and four strictures in lower ileum.

Ileum showed no ulceration of the mucosa.

Tubercles, but no caseation.

Comment. The lack of diarrhoea, the multiplicity of the ileal strictures, and the absence of ulceration and presence of tubercles, favour the diagnosis of tuberculosis rather than regional ileitis.

I am unable to describe fully any cases where there was tuberculosis of the ileum alone. These cases either had a short-circuiting operation rather than a resection, or their microscopic sections are not available. It is probable that the microscopic picture was similar to that of the last case. The following is what one regards as a typical case of intestinal tuberculosis.

-----

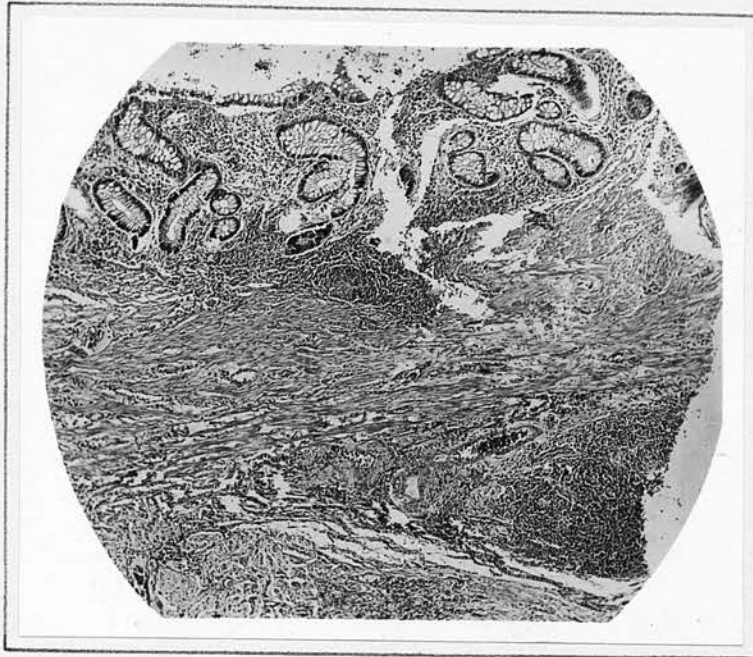


Fig. 49. Agnes Moffat. Ileum. x 50. Mucosa shows no ulceration but infiltration with plasma cells and lymphocytes. Submucosa shows fibrosis. Tubercles in mucosa and submucosa.

DIAGNOSIS:     TUBERCULOSIS OF THE INTESTINE.

WILLIAM ADAMSON. Male. Aet. 31. House painter.  
Admitted to Ward 13, Royal Infirmary,  
Edinburgh 12.1.27.

History. Three years' history of colicky pains round the umbilicus, coming on soon after the taking of food. Much associated nausea and flatulence, and latterly vomiting. Bowels inclined to be constipated. Lost three stones in weight in two years. No cough.

On Examination. Pale, thin and visceroptotic. Obvious loss of flesh. Abdomen revealed splashing in distended stomach or bowel. No tenderness. No palpable mass.

Operation. "Stomach normal. In the small intestine there was a very large number of tuberculous strictures starting  $4\frac{1}{2}$  feet below the duodeno-jejunal flexure. The strictures, which showed numbers of active tuberculous nodules on their peritoneal surfaces, were situated at intervals of about one foot down the small intestine, the lowest being  $2\frac{1}{2}$  feet above the ileo-caecal valve. In the region of the caecum itself, and round the base of the appendix, there was a thickening which was suspicious of further tuberculous disease. The mesenteric glands were slightly enlarged but not markedly so. There was no evidence of tuberculosis in the other organs." An anastomosis was done between loops of small intestine above and below the strictures.

After-history. Patient died in a Sanatorium a year later. There is no record of post-mortem examination.

Points to note. Age 31.  
Constipated.  
Multiple strictures. Tuberculous nodules on bowel wall.

Comment. This differs entirely from the localised granulomatous appearance of regional ileitis.

DIAGNOSIS: STRICTURE OF THE ILEUM. ? TYPHOID.

AGNES MacRAE. Female. Aet. 40. Nurse.  
Admitted to Ward 14, Royal Infirmary,  
Edinburgh, 10.2.32.

History. 18 months' history of attacks of abdominal pain, occurring about once every three weeks. Pain always began as severe colicky pain round the umbilicus, during which time she felt sick and vomited, settling down in the right iliac fossa. Bowels regular and no diarrhoea. Noticed that she became suddenly constipated just before an attack. Stools quite normal. No loss of weight.

On Examination. Healthy looking woman. Tenderness in the abdomen over McBurney's point. No palpable mass.

Operation. "There were some omental adhesions in the ileo-caecal angle. Caecum delivered with some difficulty. Appendix healthy. There was a little, rather brown, apparently blood stained material lying on the caecal wall, the nature of which was not clear. On examining the caecum carefully a number of firm, sclerotic nodules were found on its wall, and there was considerable inflammatory mischief around the ileo-caecal junction.

Tracing the ileum upwards a stricture was encountered about  $1\frac{1}{2}$ " from the ileo-caecal valve, due to a longitudinally placed area of fibrosis. There was no dilatation nor hypertrophy above this. There were no glands in the neighbourhood, and the condition did not resemble tuberculosis. It was not of malignant origin and it was thought that the condition might be due to old leaking typhoid ulcers." The ileum just above the stricture was anastomosed to the lower part of the ascending colon. The appendix was removed.

After-history. Patient made a good recovery from the operation, but it has not proved possible to trace her since.

Points to note. Age 40.  
No diarrhoea.  
Localised area of fibrosis in terminal ileum.  
No enlarged glands.  
Peri-caecal inflammation.

Comment. The diagnosis of this case must always be in doubt. There was apparently nothing in the history to suggest typhoid fever. The clinical features are not those of regional ileitis, though the local condition might fit in with a localised area of that disease. I would favour as a diagnosis the suggested one of an old leaking ulcer.

CONCLUSIONS: FROM THE STUDY OF PAST CASES.

From the available records of Professor Wilkie's 12,000 cases I have been unable to find any evidence that regional ileitis has been going unrecognised or misinterpreted. In one or two cases of "caecal tuberculosis" the diagnosis was open to question, and depended principally on the belief that because tubercles are seen microscopically the condition must be due to the tubercle bacillus. However the diagnosis of tuberculosis put forward in these cases is on the whole acceptable. There were clinical differences, and differences in the distribution of the lesion, from regional ileitis.

It is possible that a search of the records of the 1500 cases of appendicitis that helped to make up the total of 12,000 might have shown that ileitis in its acute form had been noted. This is unlikely, because so gross a lesion as acute ileitis would almost certainly have drawn attention to itself and received attention and classification.

-----

AETIOLOGY; WITH DISCUSSION.

The aetiology of regional ileitis is at present not known, though the ulcerative and inflammatory changes are such marked features that at first sight the condition would appear to be due to infection by some organism. No specific organism has been identified however, and a wide selection of aetiological factors have been put forward to account for the lesion. It has been variously suggested that the disease is due to:

1. Anatomical peculiarities.
2. Accidental causes.
3. Neuro-muscular causes.
4. Primary appendiceal disease.
5. Infection of the ileum by:
  - (a) The common intestinal organisms.
  - (b) Bacillary dysentery.
  - (c) Tuberculosis.
6. Other rare infections and processes.
7. Food allergy.
8. Virus infection.

1. ANATOMICAL PECULIARITIES.

- (a) of the ileum.
- (b) of its mesentery.
- (c) of its blood supply.
- (d) of the caecum, which may be too high; too low; too fixed; too mobile.

2. ACCIDENTAL CAUSES.

- (a) Twisting.
- (b) Angulation.
- (c) Intussusception )
- (d) Volvulus ) partial and intermittent;
- (e) Impaction of a foreign body, such as a fish bone, beneath the mucous membrane.

It is alleged that anomalies of caecal position may lead to stasis which may predispose or actually give rise to the lesion. There is no evidence that the disease is more prone in patients with a high caecum, with a pendulous caecum, or with known caecal stasis.

Ginzburg and Oppenheimer (26) seeking for a reason for the predilection of the disease for the terminal ileum, suggested that there might be some peculiarity of the mesentery or artery, some arrangement which would permit of twisting, angulation, and partial intermittent intussusception or volvulus. They believed that the abrupt termination at the ileo-caecal valve of the inflammatory process could be explained on the basis of a self-reducing intussusception. It is certainly conceivable that twisting of the terminal branch of the ileo-colic artery, in cases where the terminal ileal segment is unduly mobile, might tend to devitalise the part in much the same way as an intussusception, and it is true that there/

there are certain anatomical peculiarities of the terminal ileum that might account for such twisting occasionally. It is a mobile segment of bowel, with its own mesentery, rotating on a relatively fixed point at the caecum, and if the ileal mesentery is unduly long, or the caecum more than usually fixed, then mal-adaptation of the one to the other might possibly occur with a degree of vascular engorgement or strangulation.

On the other hand Bell ( 5 ) reported that he had been unable by interference with the blood supply of the intestinal tract in animals to produce a cicatrising enteritis, ulceration of the mucosa, or any lesion simulating regional ileitis, and he concluded that the pathological process was not one of inadequate blood supply.

Certain experimental work by Reichert and Mathes ( 59 ), to which further allusion will be made later, suggested that blockage of the mesenteric lymphatics might cause absorption from the lacteals, and provoke an infiltration of the wall of ileum by mononuclear cells. Whether such lymphatic blockage is primary or secondary is open to question.

In none of the cases of ileitis that I have seen and described was there anything very apparent in the nature of a primary anatomical or mechanical abnormality that might have initiated the subsequent inflammatory changes. It is of course difficult to assess what/

what was the original state of affairs when one is confronted at operation with an ileum that is rigid and stenosed, a mesentery oedematous and contracted, and a caecum surrounded by adhesions. In the absence of evidence to the contrary it is reasonable to assume that these changes are secondary to the inflammation in the bowel, and are not themselves primary features.

In the acute cases of ileitis that I had an opportunity of observing at operation there were no features, such as undescended caecum, that struck me as being primary defects. The terminal ileum was inflamed and oedematous, and it looked not unlike what one might expect to find in a self-reducing ileo-colic intussusception. Nevertheless one feels instinctively at operation that this is not a reduced intussusception. If an intussusception were the underlying factor in this disease, it is certain that more visual proof of it would have been obtained in at least one of the several hundred cases of ileitis that have been reported to date.

### (3) NEURO-MUSCULAR CAUSES.

It has been suggested that neuro-muscular inco-ordination, such as may obtain in achalasia of the lower end of the oesophagus, congenital hypertrophic pyloric stenosis, and in megacolon, may be a predisposing factor and induce ileal stasis, infection, infiltration and finally obstruction. This/

This can only be a hypothesis, for no evidence has been advanced in support of the theory. In a true achalasia the characteristic features are spasm at some valve of the gastro-intestinal tract, with dilatation and subsequent hypertrophy of the gut proximally. Ulceration and inflammation are not seen, even in a potentially infective region such as the colon.

(4) PRIMARY APPENDICEAL DISEASE.

It is believed by Homans and Hass (32), Erb and Farmer (22), Ravdin and Rhoads (58) and others that there may be a primary appendicitis with secondary involvement of the mesentery. It is of course quite a common occurrence in acute appendicitis for the neighbouring caecum to be involved to a certain extent in the inflammatory process. This involvement of caecum is in the nature of an inflammatory and fibrous reaction of its serous and subserous coats, due to the impingement of the acutely inflamed appendix upon it; and if the appendix is adherent to caecum the two may form a granulomatous mass. There is no spread of infection from lumen of appendix to lumen of caecum.

Those who believe that ileitis follows appendicitis believe that the ileum becomes involved not by surface contact with the inflamed appendix, nor by spread within the lumen of the gut, but by involvement of the mesentery of the terminal loop of the ileum.

Bockus/

Bockus and Lee ( 6 ) conceive the possibility of a lymphangitis and surrounding inflammation in the mesentery which might encroach upon or infect the blood supply, producing a slow devitalisation of the terminal ileum and resulting in terminal ileitis. In this view the involvement of the ileal mesentery is the result of spread of infection, either directly from the surface of the appendix or via the meso-appendix.

Against these views are certain facts about the state of the appendix seen in many cases of regional ileitis. In some of Crohn's cases of ileitis the appendix had been removed many years before the onset of symptoms of ileitis. In about one third of his cases the appendix had been removed at a previous exploratory operation without affecting or inhibiting the course of the ileitis, nor did the appendix show any pathological changes characteristic of the disease. And in half of his cases where resection of the diseased ileum, along with caecum and ascending colon, was carried out it was possible to examine the attached appendix. In none of these cases was the mucosa of the appendix involved, although inflammation of the outer coats was common, due to the presence of adjacent inflammatory disease.

On page 127 can be seen the microscopic picture of the appendix in the case of Jean Auld. Here there was ulceration of the mucosa of the terminal ileum, but the appendix mucous membrane was intact. Macroscopically/

Macroscopically the appendix appeared quite innocuous. It occupied a retro-caecal position and had no contact with the ileum or its mesentery.

The appendix removed from a more acute case of ileitis - Mrs Carr - is represented on page 134, and again the appendix appears relatively normal. The majority of "normal" appendices that are examined microscopically show this appearance of a narrow lumen, intact mucous membrane, and a certain amount of fibrosis in the wall.

Crohn describes how in some of his early cases with fistula formation attempts were made to close the fistula. At operation for closure of the fistula the appendix was frequently found intact. It does not follow of course that, because the appendix mucous membrane is intact, there has never been a true appendicitis. It is quite remarkable how the appendix can return to normal, even in some cases after it has been ruptured and has caused an appendix abscess. So that it is difficult to exclude the possibility that a primary appendicitis might affect the terminal ileum. Nevertheless the almost constant finding of a relatively innocuous appendix, when the ileitis is seen at operation, suggests that it is unlikely that appendicitis is an important aetiological factor.

(5)/

(5) INFECTION OF THE ILEUM.

(a) The common intestinal organisms. The many organisms of the intestinal tract have all been separately suggested as aetiological factors in the disease. These organisms have been found at times in the wall of resected bowel, but there has never been any constancy in the findings, and at present no specific organism is incriminated. In the majority of cases reported in the literature no organisms were detected when cultures were made from the affected parts. In three of my cases of chronic regional ileitis cultures were made from the wall of ileum, wall of caecum, and a gland from the ileo-caecal region. In two a growth of B. Coli and non-haemolytic streptococci was obtained. In the third there was no growth of any organism on culture.

Mixter (48) obtained in two of his less advanced cases an anaerobic streptococcus in pure culture from the free peritoneal fluid and from the cut surface of the mesenteric glands. Jackman (35) reported the finding of streptococci of the intestinal tract group in the floor of the ulcers. Such organisms, e.g. enterococci and streptococcus faecalis, were commonly found in the faeces of my patients, and it is easy to believe that they might be isolated from an ulcer in the terminal ileum. Erb and Farmer (22) isolated B. Coli from the gall-bladder and mesenteric glands of a child in a case that came to post-mortem examination/

examination, but they were not inclined to attach any pathogenic significance to their finding.

Mailer ( 44 ) observed that only bacteriological observations made during the acute phase of the disease would be likely to throw any light on the cause of the condition. It has seldom been possible to obtain culture from the wall of ileum at this stage because resection is rarely carried out. Mailer reported two cases of acute regional ileitis in which streptococcus viridans was isolated on culture, in one case from the blood stream and in the other from the throat. In the case where the organism was found on blood-culture Mailer observed that its presence in the blood might have been due to handling of the bowel at operation, though the finding is no less valid on that account. It is recognised that streptococcus viridans is capable of giving rise to relatively low-grade inflammation similar to that present in regional ileitis, but further confirmation will be required before it can be regarded as an essential aetiological factor in this condition.

Pumphrey ( 56 ) made a very careful bacteriological study of the enlarged glands and segments of diseased bowel in thirteen cases of regional ileitis at the Mayo Clinic. Cultures were taken with various media. No fungi were observed. Many organisms, and mixed groups of organisms, were recovered, but there was none which could be said to be predominant throughout the/

the series. The ones most commonly noted were gram-positive and gram-negative rods, gram-positive diplococci, and gram-positive streptococci in chains. Many of the organisms recovered were cross-agglutinated with the patient's serum, but positive results were not obtained.

(b) Bacillary dysentery. Felsen ( 25 ), who has had the opportunity of studying large epidemics of dysentery, holds strongly the view that chronic non-specific ulcerative colitis and regional ileitis, either alone or as associated lesions, and non-specific ileo-caecal granuloma, are all manifestations of bacillary dysentery. He states that he traced 38 consecutive cases of chronic ulcerative colitis, 11 of chronic regional ileitis, 11 of acute regional ileitis, and 2 of non-specific granuloma to bacillary dysentery, and he believes that the ideal therapy is the prevention of dysentery.

Felsen's evidence is suggestive but not convincing. It depended on follow-up of a large series of cases of dysentery after an epidemic in America. The terminal ileum was found involved along with the colon in 24%, and in one or two cases the ileitis persisted when the other evidences of the disease had cleared up. Crohn, in discussing Felsen's observations, agreed that not infrequently the ileum is involved in a retrograde manner from an ulcerative colitis/

colitis, but observed that involvement of the ileum alone without participation of the colon has never been regarded by any authorities as a manifestation of bacillary dysentery. Felsen's cultures of the dysentery bacillus had always been from the faeces, and neither he nor others had recovered a culture of the organism in resected specimens.

Crohn ( 17 ) was unable to recover a dysentery organism from either the faeces or the resected specimen in any of his operative material. In his hospital (Mount Sinai) they had obtained many positive dysentery cultures in cases of colitis, and were coming to regard ulcerative colitis as dysenteric in origin; but in the case of regional ileitis they had never had a positive culture. Moderately high agglutinations in the patients' serums were observed occasionally; there is however increasing doubt about the value of agglutination reactions as evidence for the existence of bacillary dysentery.

In Stafford's ( 65 ) series, and in my own seven cases of regional ileitis, there was never any history of dysentery, and no organisms of the typhoid-dysentery group were recovered from faeces or specimens. One is unwilling to deny absolutely the bacillary dysentery aetiology of regional ileitis, but the constant failure to isolate the organism is suggestive.

Bockus and Lee ( 6 ) observe that just as amoebic colitis/

colitis and bacillary dysentery may eventually cause the same terminal pathological process as the chronic type of ulcerative colitis of unknown aetiology, possibly due to the inroads of secondary invading organisms, so may chronic regional ileitis result from a number of heterogeneous primary irritating factors.

(c) Tuberculosis. For two reasons tuberculosis may reasonably be regarded as the cause of this condition at the lower end of the ileum. Firstly this has generally been regarded as a common site for tuberculosis of the intestine, in the form of a firm mass mostly in caecum and involving ileum, to which we give the name ileo-caecal tuberculosis. Such a mass resembles regional ileitis when the ileitis has spread to involve caecum; but in ileitis the characteristic firm unyielding length of several inches of terminal ileum is quite dissimilar to ileo-caecal tuberculosis, and to the short strictures of tuberculosis of the ileum. The presence on the serous surface of small tubercles is diagnostic of neither disease, since in advanced cases of ileitis localised patches of fibrosis, or focal collections of lymphocytes, may be seen. Nevertheless surface tubercles are commoner in tuberculosis, and they are not commonly seen in ileitis.

Secondly, in the microscopic section of the resected bowel in some cases of regional ileitis typical/

typical and a-typical "tubercles" are seen. These consist of whorls of mononuclear cells, endothelioid cells and giant cells, and it is not easy in their presence to deny the possibility that the condition really is tuberculous. It should be borne in mind however that tubercles in the wall of the intestine are not pathognomic of the disease caused by the tubercle bacillus; they indicate a reaction to a foreign body or organism. The tubercles that I observed microscopically in two of my cases of ileitis differed slightly from the characteristic tubercles of tuberculosis in that there was never any suggestion of caseation, and the nuclei of the giant cells were usually irregularly placed. The multinucleated giant cells are said very frequently to contain particles of a crystalline or lipoid nature which undoubtedly represent food remnants. Coffey ( 11 ) in a study of these aspects at the Mayo Clinic found that true tubercles, with the endothelioid reaction, central caseation and giant cells, were encountered only in material from patients who had active pulmonary tuberculosis. None of my patients showed any clinical or radiological evidence of tuberculosis.

These distinctions are not vital however, and there is not very much difference between the tubercles in my cases of ileitis and the tubercles seen in Professor Wilkie's accepted cases of tuberculosis. It is in such cases of ileitis, with tubercles seen microscopically,/

microscopically, that the additional tests of specially stained sections and guinea-pig inoculation are of particular value. In none of my cases was the tubercle bacillus seen in sections stained Ziehl-Neelsen, and, most important of all, guinea pig inoculation with material from the wall of the ileum was negative for tuberculosis in the three cases in which the test was tried.

Guinea pig inoculation has not been carried out so extensively as it should, but where it has been done the findings correspond with my own. In five of Crohn's cases guinea pigs, rabbits, and chickens inoculated with tritituated material from mesenteric glands and from intestinal wall showed no evidence of tuberculosis when killed.

Pumphrey (56) carried out guinea pig inoculations in eleven cases. Eight were negative for tuberculosis, two were failures because the animals died the day after inoculation, and one was positive. This last case was a granuloma of the ascending colon in which the pathological picture was that of tuberculosis.

In view of these negative tests for tuberculosis, and in spite of the presence occasionally of giant cells and tubercle-like structures in the granulomatous tissue, it is generally agreed that Koch's bacillus is not an aetiological factor in regional ileitis. Homans and Hass (32) and Snapper (63) drew attention to the similarity between these atypical tubercles and those seen/

seen in Boeck's sarcoid. Both these diseases are now placed, along with similar granulomatous processes, in the class of pseudotuberculosis. Dalziel (18), when in 1913 he wrote on "Chronic interstitial enteritis", compared the condition with Johne's disease - a chronic bacterial enteritis of cattle, which is regarded as pseudotuberculosis, and in which the histological and naked eye appearances are similar to tuberculosis in man. Dalziel quoted the opinion of veterinary surgeons, who stated that the condition in cattle is due to an acid-fast bacillus, similar to, but demonstrably not the tubercle bacillus of Koch, and not giving rise to tuberculosis in guinea pigs.

#### 6. OTHER RARE INFECTIONS AND PROCESSES.

Several rare conditions may be mentioned only to be dismissed.

Syphilis: The Wassermann reaction was negative in all my cases. Spirochaetes have never been demonstrated in regional ileitis by several workers who have searched for them.

Actinomycosis: The persistent sinuses and granulomatosis resemble infection by actinomyces, but the streptothrix has never been demonstrated.

Hodgkin's disease and lymphosarcoma: In its histological picture regional ileitis does not resemble these two conditions.

## 7. FOOD ALLERGY.

It is suggested by some workers that an allergic tendency might account for ileitis. The evidence in favour of this view is slight. Dixon (19 ) quotes a case of Bohn's, in a boy aged 9, who complained of symptoms such as frequently accompany regional ileitis. He was admitted to hospital and given a liquid diet. Each afternoon his temperature rose to 103 - 105°F. By a process of elimination it was found that when milk was not present in the diet the temperature was not above 99 - 100°F, and the cramp-like pains diminished.

Such evidence hardly merits examination. Nevertheless there may be something to be said for an association between regional ileitis as we know it, and the enteritis or mesenteric adenitis of children. I, and indeed probably all surgeons, have had the experience of opening the abdomen of a child or young adult in the expectation of finding an inflamed appendix, but only to find a normal appendix and a number of soft, discrete and enlarged glands in the mesentery at the ileo-caecal angle. These glands are not inflamed glands secondary to an appendicitis, and neither are they tuberculous in origin. If such a gland is excised and examined histologically it shows no evidence of tuberculosis, and little change apart from distension of the sinuses. They are usually regarded as/

as a "non-specific adenitis", and possibly are due to a localised enteritis in the terminal ileum. If such is so then the enlargement of these glands may be an early and slight manifestation of regional ileitis.

#### 8. VIRUS DISEASE.

In the absence of other aetiological factors it is customary in diseases of unknown origin to fall back upon ultra-filterable viruses as a possible cause. There is a certain justification for doing so in regional ileitis, because a not dissimilar granuloma in the colon, secondary to lymphogranuloma inguinale, is quite definitely caused by a virus. Stafford (65) and I, have applied a specific test for lymphogranuloma inguinale, the Frei test, to our cases of ileitis. Always the result has been negative, which has not surprised us because we did not expect that the virus of ileitis (if there is a virus) is the same as the virus of lymphogranuloma inguinale.

Certain experimental work of my own, to which I will refer, has a bearing on this question. At the moment it must be said that there is no evidence that regional ileitis is caused by an ultra-filterable virus.

In concluding a review of the aetiology of regional ileitis one is forced back to the view that Crohn put forward when he first described the condition in 1932: "The aetiology of the process is unknown/

unknown; it belongs in none of the categories of recognized granulomatous or accepted inflammatory groups."

The likelihood is that it is an infection of some sort, the organism gaining access through a breach in the mucous membrane. Bell ( 5 ) postulated that it might be an infection starting in the lymphatics as a lymphangitis, and extending to the wall of the bowel. Most workers believe that, if there is an infection it probably starts in the mucosa and spreads to the intestinal wall, with oedema of the mesentery from inadequate lymphatic drainage.

---

EXPERIMENTAL WORK.

Attempts have been made to reproduce regional ileitis in animals by experimental methods. The attempts have not been successful, but some of the results are interesting.

Following the suggestions that ileitis might be due to a disturbance of the blood supply, as found in self-reducing intussusception and recurrent partial volvulus, Bell ( 5 ) interfered by various means with the blood supply of the intestinal tract in dogs and cats. He was unable thereby to produce anything of the nature of an ulcerating cicatrising enteritis, or any lesion simulating regional ileitis.

Pumphrey ( 56 ) found that organisms obtained on culture from human cases of regional ileitis when injected intravenously in rabbits produced no visible lesion. Rabbits are unsatisfactory for comparative experiments on the intestinal tract because they are herbivorous animals.

A similar but not identical lesion to regional ileitis was produced in dogs by Reichert and Mathes ( 59 ). Without interfering with the blood vascular network they injected the mesenteric lymphatics and subserosal lymphatics of the terminal loop of ileum. They injected, through a fine hypodermic needle, ~~the~~ irritating and sclerosing media, consisting sometimes of rose aniline dye in the form of indelible lead, and at/

at other times of sodium morrhuate added to bismuth oxychloride. The dogs were killed in from 4 weeks to 10 months. The end result of sclerosing and obliterating the lymphatics to a segment of intestine was to produce a bowel thickened from chronic lymph stasis, with the lymphoedema most marked in the submucosal and muscular layers. Microscopically the serosa was thickened and contained dilated thrombosed lymphatics. The muscle coat, both in its inner circular and longitudinal layers, was oedematous, with the muscle fibres swollen and lacking in detail. There was a round cell infiltration just beneath the mucosa, but the mucous membrane itself was intact.

This microscopic picture is not unlike that of ileitis, lacking the mucosal ulceration and the more generalised cellular infiltration. Reichert and Mathes believed that the more extensive stenosis and mucosal ulceration in regional ileitis might be attributed to the persistence of a chronic low grade bacterial infection, and concluded that the two dominant features of "regional cicatrizing enteritis" seemed to be a low-grade chronic infection with a concomitant lymph oedema.

#### AUTHOR'S EXPERIMENTAL WORK.

A series of experiments was devised to test the reaction of the terminal loop of the ileum of cats to infection by various organisms. The organisms were/

were introduced by injecting the end arteries supplying the segment of ileum. Cats were chosen for the experiment because they resemble humans in being carnivorous animals.

It was not expected that it would be possible to reproduce regional ileitis by injection of known organisms, in view of the clinical evidence that no specific organism is responsible for the condition in humans. These experiments were done more in the nature of controls for the more important experiments of injecting emulsions from the glands of human cases of regional ileitis. It was felt that if, as has been suggested, the condition is due primarily to the action of an ultra-filterable virus, the virus should be procurable in an emulsion of a gland from a case of ileitis, and from the wall of the affected ileum. Unfortunately since beginning this series of experiments I have been able to obtain suitable material from only one case of ileitis. It was a case (Mrs. Carr) that was intermediate between the acute and chronic phases of the disease, and had had a recent acute attack. Resection was not performed, but enlarged glands were excised for examination. A growth of B. Coli was obtained on culture from a gland.

Technique. Under general anaesthesia with ether the abdomen of the cat is opened by a mid-line incision. The/

The terminal loop of the ileum and caecum are delivered into the wound. The ileum and caecum in the cat are mobile, the caecum and most of the colon having a full mesentery. The terminal loop of ileum is spread out so as to display the mesentery and the blood vessels running in it. Terminal branches of the arteries are selected, i.e. arteries running from the arterial arcade directly to the portion of wall of ileum they are supplying, and not anastomosing with neighbouring arteries. Through a fine-bored needle injections are made into two or three or four of these arteries. The substances injected were suspensions of organisms in broth culture, with an average of 500 million organisms per cubic centimetre; and saline emulsions of variously infected material, e.g. an inflamed appendix. In a certain number of injections the needle was not fully inside the vessel and there was leakage into the wall of ileum. In these cases the wall of ileum was presumably directly infected, and only 0.2 c.c was injected. If there is no leakage 0.5 c.c. is slowly injected intra-arterially. On injection the fluid can be seen coursing along the vessel, which blanches; and there is a temporary blanching of the segment of ileum. On withdrawing the needle the tendency to bleed from the puncture is checked by temporary digital pressure. Ligature of the vessel is avoided. Two or three or four vessels are injected in this manner, avoiding injecting/

injecting immediate neighbours for fear of compromising the blood supply of the segment of bowel.

In the experiments where a saline emulsion of the cat's own gland is prepared, the gland excised is one from the mesentery in the ileo-caecal angle, where there are normally large masses of glandular tissue. The gland is cut into small pieces and mixed with three or four cubic centimetres of normal saline. The final solution is obtained by squeezing and wringing the gland and saline through a gauze filter.

After an interval of from 10 to 16 weeks the animals are killed and a full examination made, in particular for any evidence of affection of the lower ileum.

Substances injected: The substances injected intra-arterially were:-

1. Normal saline. (Control).
2. Saline emulsion of cat's own mesenteric gland.
3. Saline emulsion of human mesenteric gland.
4. B. Coli in broth culture medium.
5. Haemolytic streptococci in broth culture medium.
6. Staphylococcus albus in broth culture medium.
7. Saline emulsion of human acutely inflamed appendix.

This was an emulsion of acutely inflamed and necrotic tissue, with a mixed infection of B. Coli and Streptococci.

8./

8. Saline emulsion of human inflamed gall bladder.  
This was a case of chronic cholecystitis, in which no organisms were obtained on culture from the wall of the gall bladder.
9. Human peritoneal fluid, from a case of peritonitis following a ruptured appendix. The infection was a mixed one, with B. Welchii and B. Coli.
10. Saline emulsion of human gland from a subacute case of regional ileitis (Mrs. Carr). This gland was excised at operation, placed immediately in 3 c.c. of saline, and injected intra-arterially into cats 3 hours later. It was an enlarged and soft, but not necrotic, gland from the mesentery of the affected terminal loop of ileum.
11. The saline emulsion of gland (10) was injected into cats intravenously, through the femoral vein.
12. Human blood serum from a case of regional ileitis (Mrs. Carr); injected intra-arterially.
13. Human blood serum (12); injected intravenously.

EXPERIMENTS./

EXPERIMENTS.

No.	Substance.	How given.	Amount.	Result.	Post-mortem.
Cat 1.	Normal saline.	Intra-arterial	3 c.c.	Killed 12 weeks.	No change in ileum.
2.	Normal saline.	Intra-arterial	2 c.c.	Killed 16 weeks.	No change, apart from 2 adhesions.
3.	Own gland saline emulsion.	Intra-arterial	4 c.c.	Killed 16 weeks.	No change, apart from 3 adhesions.
4.	Own gland saline emulsion.	Intra-arterial	3 c.c.	<u>Died</u> 12 weeks.	Intestinal obstruction, due to mesenteric band stretched across ileum.
5.	B. Coli (1 c.c. Broth culture = 300 million B. Coli.)	Intra-arterial	2 c.c.	<u>Died</u> 10 weeks.	No change in ileum. Nothing very abnormal elsewhere.
6.	B. Coli (1 c.c. Broth culture = 300 million B. Coli.)	Intra-arterial	2 c.c.	Killed 16 weeks.	No change.

No.	Substance.	How given.	Amount.	Result.	Post-mortem.
Cat 7.	Haemolytic streptococci (1 c.c. Broth culture = 1000 million streptococci).	Intra-arterial	2 c.c.	<u>Died</u> 8 weeks.	No change in ileum. Nothing abnormal detected.
8.	Haemolytic streptococci (1 c.c. Broth culture = 1000 million streptococci)	Intra-arterial	2 c.c.	Killed 16 weeks.	No change.
9.	Staphylococcus albus (1 c.c. Broth culture = 1000 million staphylococci).	Intra-arterial	1 c.c.	Killed 16 weeks.	No change.
10.	Staphylococcus albus (1 c.c. Broth culture = 1000 million staphylococci).	Intra-arterial	1 c.c.	Killed 16 weeks.	No change.
11.	Human ileal gland saline emulsion.	Intra-arterial	2 c.c.	Killed 16 weeks.	No change.
12.	Human ileal gland saline emulsion.	Intra-arterial	2 c.c.	Killed 5 weeks.	Distemper. No change in ileum.
13.	Human inflamed appendix saline emulsion (B. Coli & Strep. mixed).	Intra-arterial	1.5 c.c.	<u>Died</u> 4 days.	No change in ileum. ? Septicaemia.
14.	Human inflamed appendix saline emulsion (B. Coli & Strep. mixed).	Intra-arterial	1.5 c.c.	Killed 16 weeks.	No change.

No.	Substance.	How given.	Amount.	Result.	Post-mortem.
Cat 15.	Human peritonitis fluid after ruptured appendix.	Intra-arterial	1 c.c.	Killed 16 weeks.	No change.
16.	Human peritonitis fluid after ruptured appendix.	Intra-arterial	1 c.c.	<u>Died</u> 4 weeks.	No change in ileum. Very fatty liver.
17.	Human cholecystitis emulsion.	Intra-arterial	2 c.c.	<u>Died</u> 6 days.	No change in ileum. ? Septicaemia.
18.	Human cholecystitis emulsion.	Intra-arterial	1.5 c.c.	<u>Died</u> 7 days.	No change in ileum. ? Septicaemia.
19.	Human Regional Ileitis gland emulsion (Mrs Carr).	Intra-arterial	2 c.c.	Killed 16 weeks.	No change.
20.	Human Regional Ileitis gland emulsion (Mrs Carr).	Intra-arterial	2 c.c.	Killed 16 weeks.	No change.
21.	Human Regional Ileitis gland emulsion (Mrs Carr).	Intravenous	4 c.c.	Killed 16 weeks.	No change.
22.	Human Regional Ileitis gland emulsion (Mrs Carr).	Intravenous	4 c.c.	Killed 16 weeks.	No change.
23.	Human Regional Ileitis blood serum (15 c.c. venous blood: Mrs Carr).	Intra-arterial	2 c.c.	Killed 16 weeks.	No change.

No.	Substance.	How given.	Amount.	Result.	Post-mortem.
Cat 24.	Human Regional Ileitis blood serum (15 c.c. venous blood: Mrs Carr).	Intra-arterial	2 c.c.	Killed 16 weeks.	No change.
25.	Human Regional Ileitis blood serum (15 c.c. venous blood: Mrs Carr).	Intra-arterial	2 c.c.	Killed 16 weeks.	No change.
26.	Human Regional Ileitis blood serum (15 c.c. venous blood: Mrs Carr).	Intravenous	2 c.c.	Killed 16 weeks.	No change.

CONCLUSIONS, FROM EXPERIMENTAL WORK.

The cat is unaffected generally, and its ileum shows no change, when various organisms such as B. Coli and Streptococci, and infective material from humans, are injected into the arteries supplying the terminal ileum, and into the wall of the ileum itself. A saline emulsion of a gland from a human case of regional ileitis when injected intra-arterially, intramurally and intravenously did not affect the cat's ileum. Blood serum from a human case of regional ileitis when injected intra-arterially and intravenously did not apparently affect cats.

These experiments show that nothing in the nature of a regional ileitis can be produced in the cat by injection of the common organisms by the method I have described. Further experiments will have to be done when suitable material presents itself, but as yet I have no evidence that an emulsion of human ileitis gland can yield a virus that can reproduce ileitis. What evidence I have is to the contrary. It is possible that the condition can be produced experimentally by combining intra-arterial injection of organisms and emulsions with Reichert and Mathes's technique for occlusion of the mesenteric lymphatics.

I shall not be satisfied with the virus explanation of aetiology until I can reproduce the local condition by intravenous injection, thereby showing that/

that the virus has a selective action for the terminal loop of the ileum. It is possible that, if a virus is the responsible agent, it will be most readily obtainable from a gland or tissue from the affected bowel during the acute phase of the disease. The later grossly ulcerative and cicatrising effects may be due to secondary infection.

-----

COMMENTARY.

I am satisfied that the seven original cases I have described are all examples of the disease we know as "regional ileitis". They all showed an appearance at the lower end of the ileum that was quite out of the ordinary, and clinically and pathologically had distinctive features not seen in other diseases.

Five of the cases were at varying stages of chronicity, from the subacute inflamed state to the final cicatrising, necrotising and fistulous stage. Clinically they had the characteristic symptoms of diarrhoea, cramp-like pains, and loss of weight. Microscopically the ileum showed typically mucosal ulceration, and a diffuse infiltration of plasma cells, polymorphonuclear leucocytes, and mononuclear cells.

Superficially the diagnosis is easy, when confronted at operation by an inflamed or cicatrised terminal loop of ileum. But it is when one begins the more detailed examination of the resected specimen that doubts begin to arise, and some of my cases bring out these points. In one case (Mrs. Brash) the caecum was involved, and it would be just such a case that heretofore would be described as ileo-caecal tuberculosis. Microscopically no tubercles were seen, and guinea pig inoculation was negative. On the other hand/

hand two cases (Mrs Martin and Jean Auld) showed microscopic tubercles in their specimens; but again guinea pig inoculation was negative.

The significance of these microscopic tubercles is a vexed question, and if, as is doubtless, this condition of regional ileitis was being seen in past years, and not accepted as a separate entity, it is possible that it is the tubercles that have confused the issue. It is not easy to say exactly how they differ from the tubercles of Koch's disease, but there are slight differences. The giant cells are usually atypical, the surrounding whorls of lymphocytes are less apparent, there is never any caseation. It is true that all these differences may be noted in atypical tubercles in tuberculosis, and caseation is not a common feature of hypertrophic ileo-caecal tuberculosis. However, taken all together there is sufficient evidence for one to believe that one is not dealing with true tuberculosis.

Little mention has been made of these tubercles in the literature on regional ileitis, though some workers have commented on the giant cells, which are supposed to be of foreign-body nature. This tubercle reaction is not a common feature of ileitis, but since it does occur it is all the more desirable that subsidiary aids to diagnosis should be made use of in these two conditions of ileo-caecal tuberculosis and regional ileitis. None of my cases showed clinical/  
ical/

clinical or radiological evidence of tuberculosis in the lungs or elsewhere. Tubercle bacilli were not seen in specially stained sections, and guinea pig inoculation was negative.

These last mentioned tests are not generally made use of in regional ileitis. They entail the taking of several sections from the freshly resected bowel, and there is a natural desire to preserve the unusual specimen for demonstration purposes, and to avoid cutting into the bowel until it has been fixed by preservative solutions. Nevertheless for the purposes of diagnosis it is preferable to risk spoiling the pathological specimen.

Another practical point, which accounts for discrepancies in the microscopic picture of ileitis, is that the section for examination is usually taken from the anti-mesenteric portion of the bowel. Unless a "whole section" is taken the mucosal ulceration, which is usually on the mesenteric border, may be missed.

Of my seven cases two were in the acute phase. They had each had a previous attack of pain, so presumably I was not seeing the earliest lesion. It is very uncertain where the very first lesion in this disease is situated, but the reddened oedematous terminal loop of ileum that these two cases showed is an appearance that all observers believe to be early and acute. I would never advise that radical resection of the bowel should be performed at this stage, for/

for apparently many cases of acute ileitis resolve spontaneously. In view of this, and in view of the fact that in patients with chronic ileitis the disease is usually an insidious one without a history of initial acute attacks, one wonders what certainty there can be that it is the same disease being seen in different stages. The case of Mrs Carr should be instructive in this respect. When first seen the ileum had a relatively acute appearance, and the history was a short one. Resection of the affected bowel was not done, and radiology subsequently has shown a continuation and increase in the disease. It will be interesting to observe the final state of the ileum when the patient agrees to resection.

One is sometimes asked by pathologists:-

"How, if this is a new disease, is it that we are not encountering it in the post-mortem room?" The answer may be that, if it be true that the condition is occurring more frequently now, it is a disease principally affecting young people, and either they have not died yet, or they have had their affected bowel resected. In spite of a natural disinclination to accept "new" diseases there can be little doubt that regional ileitis is occurring more frequently than it did, for example, twenty-five years ago when Dalziel described two cases of "chronic interstitial enteritis", or even one hundred and thirty years ago, when/

when Combe described "a singular case of stricture and thickening of the ileum". The increased frequency of the disease is not solely a matter of being able to tabulate a now-recognisable condition, though that aspect does add to the number of cases reported. The late Sir David Wilkie said to me, when on one occasion we discovered a regional ileitis at operation:-

"This is not a condition that we used to see. I have been operating on the abdomen since early this century and I am sure I would have taken note of such a distinctive appearance if it had been occurring. This is something quite different."

Sir David Wilkie agreed that sporadic cases had probably been occurring previously, but they had never come to his notice; whereas in recent years he had seen several examples of the condition. And this can be said to be the experience of many surgeons. Full credit must go to Crohn and his co-workers for so brilliantly separating this condition, with its well-defined clinical and pathological features, from the confused collection of non-specific intestinal granulomata.

When Crohn's disease, as it is sometimes referred to, was first described it was limited to an affection of the terminal loop of the ileum. There has been a tendency to broaden the conception of the extent of bowel that may be involved, so that now it is accepted that jejunum, ileum, and colon may all be affected.

This/

This seems to me to be unfortunate, since it will lead back to the confusion which must occur when different parts of the bowel are affected. No doubt the aetiology and pathology of the process may be the same when the disease affects different portions, but since the great majority of cases are confined to the lower ileum (in my series six out of seven) there is justification for considering the localised disease as, at any rate, a clinical entity, and reserving for it the name "regional ileitis". It must be recognised as a local manifestation of a process which, in the present state of knowledge, we must regard as a non-specific chronic inflammation of the bowel.

---

SUMMARY.

1. "Regional ileitis" is the name given by Crohn in 1932 to a hitherto unclassified affection of the lower ileum.
2. The condition has distinctive pathological features of its own. The chronic phase of the disease has been fully examined, but little is known of the acute phase or the earliest lesion.
3. A broader conception of the disease has resulted from the co-relation with regional ileitis of the combined diseases jejuno-ileitis, and ileo-colitis.
4. The relationship of regional ileitis to other benign non-specific intestinal granulomata has been discussed, and the aetiology of these granulomata considered.
5. The clinical features of the disease have been described. In the acute phase the features are not distinguishable from those of acute appendicitis. In the chronic stage there are certain characteristic symptoms and signs.
6. The differential diagnosis of regional ileitis has been considered, and the clinical and radiological aids to diagnosis indicated.
7. Treatment should be conservative in the acute phase; in the chronic stage radical excision should be performed.
8. Seven original cases of regional ileitis have been described, and the pathological features considered in detail.

9. An investigation has been made of all the cases involving ileum or caecum, or both, from one charge in the Royal Infirmary. There is no evidence that regional ileitis has been going unrecognised in past years.
  10. The aetiology of the condition has been discussed. Tuberculosis, dysentery, and the common intestinal organisms can be excluded as primary aetiological factors. The disease remains one of unknown aetiology.
  11. Certain experimental attempts to reproduce ileitis in animals have not been successful, and as yet there is no experimental evidence that the condition is caused by the common organisms or an ultra-filterable virus. Suggestions for further experiments have been put forward.
  12. The grounds for concluding that regional ileitis may justifiably be considered a separate entity, and to be occurring more commonly than in the past, have been put forward; along with suggestions for diagnostic criteria.
-

ACKNOWLEDGMENTS.

I am grateful to Professor Sir John Fraser, Mr J.J.M. Shaw, and the late Sir David Wilkie for permission to investigate and describe cases that were in their charge in the Royal Infirmary.

I wish to thank Mr F.W. Pettigrew, and his assistants in the Wilkie Surgical Research Laboratory for their assistance in the preparation of the illustrations of this thesis.

The experimental work has been carried out in the Wilkie Surgical Research Laboratory, aided by an expenses grant from the Moray Fund.

-----

REFERENCES.

1. Balli, F.: "The sphincters of the colon".  
Radiology 1929, 12: 484.
2. Barbour, R.F., and Stokes, A.B.: "Regional ileitis". Lancet, 1936, 1: 299.
3. Bargaen, J.A.: "Regional enteritis: Diagnosis, complications and medical suggestions." Proc. Staff. Meet. Mayo Clin. 1938 13: 550.
4. Barrington-Ward, L., and Norrish, R.E.: "Crohn's disease, or regional ileitis". Brit. Jour. Surg. 1938, 25: 513.
5. Bell, H.G.: "Chronic cicatrizing enteritis". California & West. Med., 1934, 41: 239.
6. Bockus, H.L. and Lee, W.E.: "Regional (terminal) ileitis". Ann. Surg., 1935, 102: 412.
7. Braun, H.: Zeits. f. Chir., 1909, 100: 1.
8. Brown, P.W., Bargaen, J.A., and Weber, H.M.: "Chronic inflammatory lesions of the small intestine (regional enteritis)". Am. Jour. Digest. Dis. and Nutrition, 1934, 1: 426.
9. Cameron, J.R.: "Simple non-specific ulcer of the caecum". Brit. Jour. Surg. 1939, 26: 526.
10. Clute, H.M.: "Regional ileitis". Surg. Clin. N. Amer., 1933, 13: 561.
11. Coffey, R.J.: "Pathologic manifestations of regional enteritis". Proc. Staff. Meet. Mayo Clinic, 1938, 13: 541.
12. Colp, R.: "A case of non-specific granuloma of the terminal ileum and caecum". Surg. Clin. N. Amer., 1934, 14: 443.
13. Combe, C.: "A singular case of stricture and thickening of the ileum". Trans. Coll. Phys. Lond. 1813, 4: 16.
14. Crohn, B.B.: "Broadening conception of regional ileitis". Am. Jour. Digest. Dis. and Nutrition, 1934, 1: 97.

15. Crohn, B.B.: "Regional ileitis". Surg. Gynec. and Obst., 1939, 68: 314.
16. Crohn, B.B., Ginzburg, L., and Oppenheimer, G.D.: "Regional ileitis: a pathologic and clinical entity". Jour. Am. Med. Ass. 1932, 99: 323.
17. Crohn, B.B., and Rosenak, B.: "A combined form of ileitis and colitis". Jour. Am. Med. Ass. 1936, 106: 1.
18. Dalziel, T.K.: "Chronic Interstitial enteritis". Brit. Med. Jour. 1913, 2: 1068.
19. Dixon, C.F.: "Regional enteritis". Trans. Am. Surg. Ass. 1938, 56: 369.
20. Dixon, C.F.: "Surgical treatment of Regional enteritis". Proc. Staff. Meet. Mayo Clin. 1938, 13: 552.
21. Edwards, H.C.: "Regional ileitis". Trans. Med. Soc. Lond., 1936, 59: 87.
22. Erb, I.H., and Farmer, A.W.: "Ileo-colitis". Surg. Gynec. and Obst. 1935, 61: 6.
23. Erdmann, J.F., and Burt, C.V.: "Non-specific granulomata of the intestine". Surg. Gynec. and Obst. 1933, 57: 71.
24. Felsen, J.: "Clinical notes concerning distal ileitis as manifestation of bacillary dysentery". Am. Jour. Digest. Dis. and Nutrition, 1935, 1: 782.
25. Felsen, J., and Gorenberg, H.: "Chronic dysentery, distal ileitis and ulcerative colitis". Am. Jour. Med. Sci. 1936, 192: 553.
26. Ginzburg, L., and Oppenheimer, G.D.: Ann. Surg. 1933, 98: 1046.
27. Goto, F.: Arch. f. klin. Chir. 1912, XCVII, 190.
28. Harris, F.I., Bell, G.H., and Brunn, H.: "Chronic cicatrizing enteritis: regional ileitis. (Crohn.) A new surgical entity." Surg. Gynec. and Obst. 1933, 57: 637.
29. Henke, F., and Lubarsch, O.: Handbuch der speziellen pathologischen Anatomie und Histologie. 1929, 295.

30. Hodgson, J.C.: "Regional ileitis: Crohn's disease". *Lancet*, 1937, 1: 926.
31. Homans, J.: (Discussion of Dixon). *Trans. Am. Surg. Ass.* 1938, 56: 377.
32. Homans, J., and Hass, G.M.: "Regional ileitis, a clinical not a pathological entity". *New England Jour. Med.* 1933, 209: 1315.
33. Ignard - quoted by Moschcowitz and Wilensky.(53)
34. Jackman, A.S.: "Regional enteritis". *Surg. Gynec. and Obst.*, 1937, 65: 1.
35. Jackman, W.A.: "Localized hypertrophic enteritis". *Brit. Jour. Surg.* 1934, 22: 27.
36. Jackman, W.A.: "Terminal ileitis". *Proc. Roy. Soc. Med.*, 1937, 30: 691.
37. Jaffe, K.: *Verhandl. d. deutsch. Gesellsch. f. Chir.*, 1908, 37: 218.
38. James, T.G.I.: "Chronic regional colitis". *Brit. Jour. Surg.*, 1938, 25: 511.
39. Jellen, J.: "Regional ileitis: A review of fifty cases". *Am. Jour. Roentgenol.* 1937, 37: 191.
40. Kantor, J.L.: "Regional (terminal) ileitis: its roentgen diagnosis". *Jour. Am. Med. Ass.*, 1934, 103, 2016.
41. Lartigau - quoted by Moschcowitz and Wilensky(53).
42. Lehman, E.P.: (Discussion of Dixon, 19.) *Trans. Am. Surg. Ass.* 1938, 56: 375.
43. Logan, A.H., and Brown, P.W.: "Intestinal infantilism as a result of regional enteritis". *Proc. Staff Meet. Mayo Clin.* 1938, 13: 335.
44. Mailer, R.: "Acute regional ileitis: a report of two cases, with bacteriological findings". *Brit. Jour. Surg.* 1938, 25: 517.
45. Mayo, W.J.: "Less commonly recognized forms of Surgical tuberculosis". *Northwest Lancet*, 1893, 13: 7.

46. Mayo-Robson, A.W.: "Some abdominal tumours simulating malignant disease, and their treatment." Brit. Med. Jour. 1908, 1: 425.
47. Mixter, C.G.: "Regional ileitis". Ann. Surg. 1935, 102: 674.
48. Mixter, C.G.: "Regional enteritis". Surg. Gynec. and Obst. 1939, 68: 322.
49. Mock, H.E.: "Infective granuloma: non-specific chronic tumor-like productive inflammations of the gastro-intestinal tract". Surg. Gynec. and Obst. 1931, 52: 672.
50. Monsarrat, K.W.: "Simulation of malignant diseases by chronic inflammatory affections of the sigmoid flexure". Brit. Med. Jour. 1907, 2: 65.
51. Moore, N.: "Stricture of the intestine at the ileo-caecal valve". Tr. Path. Soc. Lond. 1882, 34: 112.
52. Morian, O.: Deutsche Ztschr. f. Chir. 1912, 114: 267.
53. Moschcowitz, E., and Wilensky, A.O.: "Non-specific granulomata of the intestine". Am. Jour. Med. Sci., 1923, 166: 48.
54. Moynihan, B.G.A.: "The mimicry of malignant disease in the large intestine". Edin. Med. Jour. 1907, 21: 228.
55. Pemberton, J. de J., and Brown, P.W.: "Regional ileitis". Ann. Surg. 1937, 105: 855.
56. Pumphrey, R.E.: "Studies on the etiology of regional ileitis". Proc. Staff Meet. Mayo Clin. 1938, 13: 539.
57. Ralphs, F.G.: "On chronic inflammatory "tumours" of the gastro-intestinal tract". Brit. Jour. Surg., 1938, 25: 524.
58. Ravdin, I. and Rhoads, R.: "Regional ileitis and fibroplastic appendicitis". Ann. Surg. 1937, 106: 394.
59. Reichert, F.L., and Mathes, M.E.: "Experimental lymphoedema of the intestinal tract and its relation to regional cicatrizing enteritis". Ann. Surg. 1936, 104: 601

60. Richter - quoted by Moschcowitz and Wilensky.(53)
  61. Schreiber, J.: Deutsche Arch. f. klin Med., 1902,  
76: 122.
  62. Semm, J.K.: Principles of Surgery 1895.
  63. Snapper, J.: "Pseudotuberculosis in man".  
Amsterdam, 1938.
  64. Snapper, J., Pompen, A.W.M., and Groen, J.:  
"Ileite regionale". Ann. de Med. 1936,  
39: 5.
  65. Stafford, E.S.: "Regional ileitis and ulcerative  
colitis". Bull. Johns Hopkins Hosp.  
1938, 62: 399.
  66. Strauss, K.: Therap. d. Gegenw. 1909, 11: 313.
  67. Tietz, A.: Ergebn d. Chir. u. Orthop. 1920, 12:  
211.
  68. Weber, H.M.: "Regional enteritis: roentgeno-  
logic manifestations". Proc. Staff Meet.  
Mayo Clin. 1938, 13: 545.
  69. Wright, A. Dickson" "Regional ileitis".  
Trans. Med. Soc. Lond. 1935, 58: 94.
-