THESIS

for the degree of

DOCTOR OF MEDICINE

of

THE UNIVERSITY OF EDINBURGH.

The Vomero-Nasal Organ,
the Accessory and Olfactory Bulbs,
and the Anterior Olfactory Nucleus
of the
SPHENODON PUNCTATUM

by Archibald Cotterell McMaster,
M.B., Ch.B., F.R.C.S.E.

THE VOMERO-NASAL APPARATUS
and the Olfactory Bulb
of the
SPHENODON PUNCTATUM

The Vomero-Nasal apparatus has provided a field for research since Jacobson first described it in 1811.

Klein, Beard, Broom and Symington have given us descriptions of the organ of Jacobson and its relationships in many different vertebrates. Broom, (1900) considers that since by reason of its anatomical position this organ and its related cartilages will not be easily influenced by changes in mode of life, we have in it an indicator of relationship and position in phylogeny that is of greater importance to the comparative anatomist then is dentition or placentation. He has drawn up a comparative table (fig. 1.) setting forth the particular features relating to the organ by consideration of which it is possible to classify it. I have introduced into that table the Sphenodon Punctatum whose organ of l.c.

Jacobson bears a very close resemblance to that of the Ornithorhynchus. The organ of Jacobson of the marsupials is described by Broom (1900) as being a modified form of the organ as it is in Monotremes, and that of the lower Eutheria as being a modified form of the organ as it is in marsupials. And he regards the complex development of the nasal floor cartilage as being a thoroughly reliable character by which higher Eutheria can be divided off from lower. So far as I have been able to find, there is no reptilian organ of Jacobson described in literature that approaches so nearly to the arrangement in Monotremes as does that of the Sphenodon Punctatum.

Osawa (1898) was the first to discover that the Sphenodon had an organ of Jacobson. He described its position, but not in sufficient detail to enable us to classify it according to Broom's table, nor did he give its shape or microscopic appearance. Howes and Swinnerton in 1901 confirmed his findings, but added nothing to them.

The Organ of Jacobson.

The material used for this investigation consisted of:

1) Decalcified head of a newly hatched Sphenodon $5\frac{1}{2}$ cm. long, cut in frontal section 250 μ thick and stained and

mounted according to Wilson's method.

2) Decalcified head similar to 1) cut in frontal section 8 μ thick and stained with Heidenhain's iron haematoxylin and eosine.

3) Decalcified head of Sphenodon 10½ cm. long cut in frontal section 6 μ thick and stained with Heidenhain's iron haematoxylin and Van Giessen.

The organ of Jacobson as seen in a recently hatched Sphenodon whose head measured 6.5 mm. in length, is in the form of a tube .5 mm. long. The tube lies rostro-caudally parallel with the nasal septum and close to the rostro-ventral part of it. Its rostral and caudal ends are closed. Proceeding laterally and slightly ventrally from it at about midway between its two ends is a duct which communicates with the naso-palatine duct. (figs.6 to 11).

Projecting laterally from the anterior part of the ventral border of the septum is a shelf of cartilage - the paraseptal cartilage, (figs 6 to 11), the caudal aspect of which is excavated for the reception of the rostral end of the organ of Jacobson. (fig.5+6) A tube of cartilage continues caudally from the paraseptal cartilage and ensheaths the organ, (fig.7). This cartilage is referred to by most writers as

Jacobson's cartilage. It has a gap in it through which the communicating duct passes to the naso-palatine duct. (fig.) Caudal to the level of the communicating duct the gap in Jacobson's cartilage is closed by a process from the vomer. (fig.). Dorsal to Jacobson's cartilage and the paraseptal cartilage is the olfactory cavity. Ventral to it is the vomer, the rostral extremity of which is in the same transverse plane as the rostral extremity of the organ of Jacobson. The septo-maxillary bone is dorso-lateral to the rostral part of Jacobson's cartilage, but is not in relationship with its caudal part.

In transverse section the organ of Jacobson is oval and shows a lumen. The long axis of the transverse section runs laterally and slightly ventrally. The dorsal wall of the organ is more than three times as thick as the ventral wall. (fig.). The organ is separated from the dorsal aspect of its cartilaginous chamber by loose connective tissue in which is a plexus of blood vessels which converts it into erectile tissue, and one relatively large artery which runs caudo-rostrally. (figs.). This erectile tissue, therefore, is in contact with the thick part of the wall of the organ of Jacobson, i.e. with its neuro-epithelium. The thin part of the wall is formed by membrane of a respiratory type. In all other described organs of Jacobson the relative position of the neuro-epithelium and the thin respiratory type of epithelium is reversed, the respiratory membrane being dorsal and the neuro-epithelium ventral(.figs 7.13)The erectile tissue is, however, always dorsal to the organ and, therefore, in other described cases it is in contact with the epithelium of respiratory type. When the venous plexus is turgescent the organ will be emptied, and when the vessels are constricted a negative pressure in the lumen of the organ will cause it to be filled with air or liquid from the naso-palatine duct. The content of the naso-palatine duct may come from either the mouth or the olfactory cavity. Through the loose tissue and among the plexus of blood vessels run nerve filaments from the sensitive epithelium. They run rostro-caudally and emerge at the open caudal end of the cartilaginous chamber when they turn dorsally as the Nerve of Jacobson. (fig.10,11,12). The nerve in leaving the organ passes lateral to the artery of the organ. The cartilage of Jacobson extends just so far caudally as the closed blunt end of the organ of Jacobson. (fig. 11)

The thick neuro-epithelium of the organ is the same in character as that of the olfactory cavity (figs.13,14,15). The cells nearest to the lumen have oval nuclei that are placed deeply in the cells leaving a wide margin of cytoplasm next to the lumen.

From this free surface processes project into the lumen and to it a layer of mucous adheres. Deep to these cells are several layers of cells with larger spherical nuclei. From this membrane the nerve filaments already described are seen to proceed. The ventral wall is lined by cells that are richly ciliated and among them are numerous goblet cells. The nuclei are spherical and are near the free surface. This wall is much thinner than the dorsal wall and is similar to the respiratory membrane of the olfactory cavity.

There are no serous glands in this organ of Jacobson, such as are numerous in the sensitive membrane of the olfactory cavity. In one specimen out of six examined one serous gland was seen. There are no mucous or serous glands round this organ or caudal to it, as is the case in so many mammalia. If, as shown by Broman, (1920), the organ of Jacobson functions only when filled with fluid, the goblet cells of its respiratory epithelium and of the olfactory cavity proper should give an abundant supply for such a purpose. The sections of the 10.5 cm. Sphenodon show great numbers of goblet cells in the neighbourhood of the opening of the naso-palatine duct into the olfactory cavity. (fig.16,17). By closing its lips and then oscillating the floor of its mouth, the Sphenodon can draw the secretion of these cells into the naso-palatine duct and from there by action of the vascular plexus within Jacobson's cartilage as already described, it can be sucked into the organ of Jacobson, with odoriferous particles suspended or dissolved in it.

There is no lymphatic tissue in relation to the organ as is described by Klein, (1882), in the Guinea Pig, Dog and Rabbit. These features are well illustrated in the accompanying photographs. 4

Beard (1889) called attention to the bud-like masses of cells forming the neuro-epithelium. in
This is not seen in the 10½ cm. Sphenodon, but is present in the newly-hatched specimen and may therefore be regarded as an embryonic condition in Sphenodon. (fig. 13,14).

Discussing the organ of Jacobson of the ornithorhyncus, Symington (1892) pointed out that it differed from that of all other mammals in two particulars. Firstly, the paraseptal cartilage is thickened and is excavated on its caudal aspect to receive the rostral end of the organ. Secondly, the organ has a rostral and a caudal part and an opening between the two by which it communicates with the naso-palatine duct. This is exactly what is found in Sphenodon. In snakes and lizards Jacobson's cartilage is never sufficiently developed to form a chamber, and it may be almost absent. In these reptiles the framework dorsal to the organ is formed by the septo-maxillary bone, which in the Sphenodon is dorsal to the rostral part of Jacobson's cartilage. (figs. 6,7). The floor supporting the organ in snakes and lizards is formed by the vomer.

With regard to the anterior vomer, Broom (1896) says, "in almost all mammals possessed of an organ of Jacobson this bone is well developed and developed longitudinally in proportion to the organ. Echidna is the exception. This anterior vomer is on the inner and under side of the cartilage capsule of the organ, sometimes replacing the cartilage largely".

The size of the organ varies greatly in different reptiles. In chelonia it is very large and complicated, so that the accessory bulb is about the same size as the olfactory bulb. (McCotter, 1917). In crocodilia there is a vestige of the organ in the embryo, but no sign of it in the adult, and consequently there is no nerve of Jacobson and no accessory bulb.

An examination of Broom's table (fig. 1.) with the Sphenodon introduced shows that as regards the relation of the septo-maxillary, the absence of a turbinal process, the presence of a venous plexus and provision for the secretion of mucous, the organ of

Jacobson of the Sphenodon conforms to the mammalian type. Its shape and the way in which it is enclosed in cartilage is common to itself and to Ornithorhyncus. The study of this organ, therefore, shows the Sphenodon to be closely related to the Monotremes, the Monotremes to the Marsupialia, and the Marsupials to the lower Eutheria, and shows that the Sphenodon, classified according to this organ, is nearer to the main line of mammalian descent than any other reptile that has been investigated.

Johnston (1915) described the cell masses in the forebrain of the turtle "because of the relationship of the chelonia to the ancestors of mammals", and Nils Holmgren says, "it seems to be certain that turtles are, of now living reptiles, those who are nearest related to the reptilian group." He also states, "Since the discovery of the Sphenodon in New Zealand, this animal has enjoyed a firm reputation as an ancestral form of great importance, and as such Sphenodon has also been introduced by Elliot~~t~~ Smith into the forebrain discussion. Paleontologists, however, seem not to be very inclined to accept the great importance of Sphenodon." He continues, "Professor Johnston's choice of the turtles as object for his investigations upon the reptilian forebrain may be regarded as a very successful one." The present investigation into the organ of Jacobson in the light of Broom's teaching would indicate that the forebrain of the Sphenodon is of even greater importance to the comparative neurologist than is that of the turtle.

There has been much speculation as to the function of this organ, and since in ourselves, if it has escaped destruction by catarrh, it in any case does not function, we cannot go beyond speculation. Broman (1920) has shown experimentally that the organ of Jacobson in mammals is filled with serous fluid when functioning. He shows that it can be used as a mouth-smelling organ or as a hunting organ, and he regards it as corresponding with the olfactory organ of fishes which has become adapted for land life. Nils Holmgren (1925) supports this theory that the nasal sack of bony fishes represents the vomero-nasal organ.

Broman thinks that when the olfactory organ proper is exhausted by long continued use the organ of Jacobson may be called upon to function. Olfactory substances, suspended or dissolved in secretion, will be given time to make their presence felt and minimal amounts will be appreciated. Beard (1889), on the other hand, says it is "a derivative and differentiation of the olfactory sense organ which was there before it." When the organ of Jacobson is well developed the olfactory organ is simple, and when the organ of Jacobson is absent the olfactory organ is more complicated. Holmgren and Beard formed their opinions on embryological grounds.

Jacobson himself considered that there were four possibilities. It might be an organ of taste, of smell, for detection of sex odours, or an organ secreting a lubricant for the nostrils. Mihalkowics (1899) regards it as an organ of sex discrimination. Since it is so well developed in animals intimately associated with earth - lizards, snakes, rabbits, moles, etc., it has been regarded by some investigators as giving information concerning some quality of the earth of which we are ignorant. Others credit it with the power of assisting in the orientation of migrating birds.

When the organ was destroyed experimentally in cats and rabbits no change in their behaviour could be detected.

Herrick (1921) has suggested that impressions received by the sensitive olfactory membrane proper stimulate the somatic system resulting in the acquiring of food, while those transmitted by the vomero-nasal nerve result in the preparation of the digestive system for the reception of the food.

To the comparative neurologist a complete understanding of the reptilian macrosmatic brain is essential, and the first problem in such a study relates to the course followed by olfactory impulses received by the organ of Jacobson and by the olfactory organ proper.

I propose, therefore, to trace the nerve of Jacobson to its "vomero-nasal formation" or accessory bulb, and to describe the olfactory bulb and peduncle, and the relationship between them and the vomero-nasal formation. Since both send relays caudally to the anterior olfactory nucleus that too will be considered.

The Nerve of Jacobson.

The examination of the serial frontal sections of the 5·5 cm. Sphenodon disclosed the course of the nerve of Jacobson clearly. It leaves the organ of Jacobson by escaping from the caudal end of the containing cartilaginous chamber, lateral to the artery of that chamber, and passes at once dorsomedially until it reaches the septum. (fig.10, 11). It then runs dorsally and slightly caudally between the septum and the sensitive membrane of the nasal cavity, in a zig-zag manner, until it reaches the cribriform plate of the ethmoid. (fig. 12). In this part of its course it is joined by nerve filaments from the medial aspect of the olfactory cavity. (fig. 11). Retzius observed similar fibres in the snake which reptile has two vomero-nasal nerves. Two foramina have appeared and transmitted olfactory fibres from the nasal cavity rostral to the foramen for the nerve of Jacobson, so that at the transverse level of this foramen the olfactory bulb has already begun to form. The nerve of Jacobson at once pierces the dura and arachnoid mater and continues to pass dorsally lying lateral to the septum formed by a double layer of arachnoid, until it reaches the dorso-medial segment of the bulb to which it becomes applied. (fig. 12).

which?

In 1896 Elliot~~t~~ Smith described what he called "Jacobson's ganglion" in the ornithorhyncus. He showed that it received fibres from the organ of Jacobson and that it relayed them to the hemisphere.

In 1912 McCotter traced the vomero-nasal nerve of the opossum and other mammals from the organ of Jacobson to the accessory bulb, and demonstrated clearly the anatomical relation of these structures to each other. Sagittal sections, stained by silver methods, show the vomero-nasal nerve of the Sphenodon on the dorso-medial aspect of the bulb, coursing rostro-caudally until it reaches the peduncle and there it terminates in the accessory bulb. (figs. 26, 27).

The Olfactory Bulb.

The olfactory bulb is conical in shape, the base being rostral, and the apex ending caudally in the olfactory peduncle. It is 2 - 4 mm. in length, and its base is 1.5 to 2 mm. in diameter. (figs.2,3,4). Fila olfactoria pierce the cribriform plate, rostral and caudal to the foramen for the nerve of Jacobson, and always in a plane more or less lateral to it. They pierce the dura and arachnoid and proceed caudally to enter the base of the olfactory bulb at all parts of its circumference.(fig 19) Some of the most lateral fila sweep round to the dorsal aspect, and some of the medial ones enter the medial surface ventral to the nerve of Jacobson where it is applied to the bulb.(fig 12,18) Some filaments are seen to leave the nerve of Jacobson and take part in the formation of glomeruli on the dorsal part of the medial surface of the bulb. They are probably those that joined with the nerve as it coursed between the sensitive membrane of the nasal cavity and the septum.

A transverse section of the bulb shows it to be formed of a number of concentric layers surrounding the ventricle of the bulb which is continuous, through the peduncle, with the lateral ventricle of the hemisphere. (fig.19,20,21).

The layers are in the following order from without inwards:-

1. Fila olfactoria.
2. Glomerular layer.
3. Outer granular layer of intra-glomerular cells.
4. Molecular layer.
5. Mitral cell layer.
6. Olfactory tract.
7. Inner granular layer, outer part.
8. Inner granular layer, inner part.
9. Ependyma.

1. The fila olfactoria form a plexus that envelops the bulb. Most of the fila are outside the pia, but those that are about to distribute their fibres to glomeruli are sub-pial. Towards the apex of the bulb the fila on its dorsal aspect diminish in number. (fig.23,27).

2. The glomerular layer is well shown in the photograph. (fig.19,21). In the glomerules the olfactory nerve fibre synapses with dendrites from the intraglomerular cells and from the mitral cells. Crosby (1916-17) describes processes from the cells of the inner granular layer synapsing here also. Unfortunately I have no Golgi preparations and my own material does not show this. Glomerules, like the olfactory nerves, are scanty at the caudal part of the

dorsal aspect of the bulb. (fig. 19).

3. The outer granular layer, or layer of intra-glomerular cells, (figs. 19, 20, 21) is subjacent to the second layer. It is a very definite thin layer two or three cells deep, and from it cells are scattered among the glomeruli, and a few stray into the molecular layer. Three distinct varieties of cell are found in this layer:-

a) Small oval or round cells staining darkly with toluidin blue.

b) Medium sized less darkly stained angular cells.

c) Large faintly stained angular cells.

a) and b) types are present in about equal numbers. Type c) is less numerous.

In all three the nucleus is large and contains a nucleolus. The cytoplasm is occupied by a network of mitochondria, and from the cells dendritic processes are given off in all directions. It seems quite possible that all three cells function in the same way and the different characteristics may be due to the effect of functional activity. They seem to serve as diffusors of stimuli from one glomerulus to others, activating mitral cells in glomeruli that have not received impulses from their own olfactory fibres. If the glomeruli have already been stimulated the effect will be amplified.

4. The molecular layer. (figs. 19, 20, 21). This is a neuropil formed by the above mentioned dendrites, and through it are scattered a few cells of different kinds from the outer granular layer. An occasional mitral cell also wanders into it.

5. The mitral layer. The mitral cells, (figs. 19, 21, 22) are the largest in the bulb. They are scattered through the layer to which they have given their name and are most numerous in the areas where there are most glomeruli. Where there are no glomeruli there are no mitral cells. Among them are a few granule cells of different kinds. They have large nuclei with nucleoli, and thick dendrites are seen extending outwards in opposite directions in both sagittal and transverse sections, so that the cell body appears to be flattened between concentric laminae of fibres. The nuclei cause the cells to bulge, usually towards the ventricle, as in the alligator. (Crosby, 1916-17.) In addition to the thick dendrites there are several fine dendrites. The axons are given off into the olfactory tract, which is the next layer internal to the mitral layer. This is in accordance with Crosby's description of the alligator, but in contrast with Appajee's findings in the hedgehog, where the mitral cells are triangular in shape with the apex towards the ventricle, and the axon that proceeds from the apex passes through the remainder of the wall of

the bulb until it reaches the ependyma, and then proceeds caudally as the olfactory tract. Crosby (1916-17) says a mitral cell usually has two main dendrites and several smaller branches. The larger ones are thick and thorny and go to the glomeruli. The smaller ones have not been seen entering glomeruli. They intermingle with the dendrites of other mitrals and of granule cells, and so make one of the important elements of the plexiform layer, and provide a mechanism for "the increasing and the summating of stimuli." The axons of the mitrals are described as dividing into two branches of equal size. One enters the inner granule layer to come into synaptic relation with its neurones; the other runs caudally, giving off numerous fine collaterals into both the granule and the plexiform layer. The main branch enters the olfactory tract.

6. The Olfactory Tract is made up mainly of the axons of the mitral cells passing caudally to the anterior olfactory nucleus and to the hemisphere. Large goblet shaped cells in the outer part of the inner granular layer send their axons into the tract also. The goblet cell axon on entering the tract divides into two, one part going rostrally and the other caudally. The tract is laminated imperfectly as seen in both sagittal and transverse sections, and in each instance fibres are seen running in the plane of section, but the greater number are rostro-caudal in direction.

The sagittal sections (fig.27) show how the olfactory tract becomes superficial in the peduncle. Where the fila olfactoria end at the apex of the bulb all the layers between the pia and the tract cease, leaving the inner granule layer and the tract to continue towards the hemisphere as the peduncle of the bulb.

7. & 8. <u>The inner granular layer</u>, (figs.19,21,22) lies between the olfactory tract and the ependyma. It is formed of two parts, an outer and an inner. The outer part has a dense matrix in which granule cells are scattered. The inner part consists of an open reticulum of processes radiating like the spokes of a wheel from the ependyma, and connected together by lateral branches that form a network. (fig.21,22). In this network granule cells are supported. They are more numerous than in the outer part. The granule cells are of three varieties as in the intraglomerular layer. The inner part has mostly cells of type b), with a few of type a) scattered through it, especially near the ependyma. An occasional large cell of type c) is also found in this inner part. In the outer part of the inner granular layer cells of types b) and c) occur in about equal numbers. There are also a few cells of type a) and a considerable number of goblet shaped cells. These goblet shaped cells are about the size of the type c) cells and they

stain with toluidin blue to the same degree. The neck of the goblet is directed away from the ventricle and the axon from it enters the olfactory tract and divides there into two branches, one going rostrally and the other caudally as already mentioned. From the body of the goblet cell there are several fine dendrites given off in different directions. Detached strands of olfactory tract, probably the axons of granule cells, are seen passing through the inner granular layer at all levels, (fig. 27) between the ependyma and the olfactory tract layer. The goblet cells are present in the bulb only, but cells of types (a), (b) and (c) are found throughout the peduncle among the fibres of the olfactory tract.

I have not been able to trace dendrites from the inner granule cells to the glomeruli, but it is easy to see them passing from their cells to the trabeculae and travelling with the radiating trabeculae towards the periphery of the bulb.

9. <u>The ependyma of the bulb</u> is two or three cells thick. The cells stain darkly with toluidin blue. They are closely packed in an irregular columnar manner. Their large nuclei are near to the free surface, and are oval or pear shaped with the

stalk of the pear directed away from the ventricle. Processes extend from the ependyma towards the periphery in radial fashion, and can be followed to the mitral layer. (fig. 21,22). Between these processes communicating branches form a network. The spaces adjoining the ependyma are distended with fluid and contain very few granule cells. The ependymal cells are not ciliated.

The ventricle of the bulb is the rostral extremity of the lateral ventricle of the hemisphere with which it communicates through the canal in the peduncle.

The Olfactory Peduncle.

The peduncle is formed by the olfactory tract connecting the bulb with the hemisphere, and in the centre of it is a prolongation from the lateral ventricle.

The fibres of the tract are:

1) the axons of the mitral cells,
2) the axons of the goblet cells,
3) the axons of the second neurones of the accessory bulb,
4) possibly axons of third neurones, i.e. relays from granule cells.

The axons of the mitral and goblet cells originated in the bulb; they have lost their covering layers - mitral, molecular, outer granular and glomerular layers - and are now immediately sub-pial.

The axons from the accessory bulb cannot be distinguished from those of the mitral cells in the Sphenodon. They enter the olfactory tract and are lost. It is probable that they remain on the dorsal aspect of the peduncle, for there is a cell-free mass of fibres there which extends from the accessory bulb caudally. Through the remainder of the peduncle granule cells are scattered. (fig.29,30). If this is so they will either reach the hemisphere by passing dorsal to the anterior olfactory nucleus or they will enter the dorsal part of that nucleus. (fig 31, 32, 33)

A sagittal section through the peduncle shows its structure. Between the fibres there are short single rows of cells, and these rows are more frequent near the ventricle than near the pia. (figs.29, 30). The ventricle is not exactly central, for the dorsal wall of the peduncle is a little thicker than the ventral. The axons from the accessory bulb would account for this. (fig.31,32).

So far as can be ascertained from the material available the fibres do not change their relative position as they proceed caudally in the peduncle.

The cells of the peduncle are continuous with those of the inner granular layer of the bulb. They are of the small darkly stained, and slightly larger lighter stained varieties. Compressed between the lamellae of fibres they become almost oblong in shape. They give off numerous branches, and probably relay for the granule cells of the bulb, thus contributing axons to the tract. In my preparations I have not been able to find evidence of the axons of the olfactory tract relaying through the cells of the peduncle. Moreover their size, staining qualities and dendrites suggest that the cells of the peduncle perform the same function as cells of types (a), (b) and (c) with which they are continuous.

The ependyma of the peduncle is one cell thick. Its cells stain darkly with toluidin blue. The nucleus is large and oval and is near the free surface. When the ventricle is collapsed the ependyma is a columnar epithelium, and when it is distended the cells flatten out and form a pavement epithelium. There are no cilia on the free surface of the cells.

The Accessory Bulb.

The accessory bulb is applied to the dorsomedial aspect of the peduncle at its junction with the olfactory bulb. (figs. 23 - 27). It is not evident to the naked eye, and can be located only by serial sections, which show that it causes a bulge to project into the lumen of the ventricle, and that in shape it is roughly spherical. The glomeruli are heaped together in an irregular mass. They have been described as smaller than the glomeruli of the olfactory bulb in some other species, but in the Sphenodon they are the same size. The cells of the accessory bulb form a wedge-shaped mass, and this is inserted with the apex of the wedge ventral and the base dorsal, between the glomeruli of the accessory bulb medially, and the olfactory tract of the bulb laterally. So that the apex of the wedge of cells is separated from the medial side of the ventricle by olfactory tract fibres only, and the base of the wedge is flush with the dorsal extremity of the glomerular mass medially, and the peripheral lamella of olfactory tract fibres laterally. (fig. 23-25). The wedge of cells is much more pronounced in some sections of the series than in the one photographed. The cells of the accessory bulb may be divided into:

1) Small cells, staining darkly with toluidin blue.

2) Larger cells, staining less darkly than 1), but more darkly than the faintly staining granule cells of types b) and c) of the bulb. These cells vary considerably in size. and are very angular (fig 28)

Both 1) and 2) are conspicuously angular; more so than any cells of the bulb. They differ from the granule cells of the bulb in their structure also. Their cytoplasm is finely granular, stains more uniformly, and does not show the network of mitochondria that is so evident in the granule cells of the bulb.

In silver stained preparations dendritic processes can be seen proceeding from cells of both varieties in all directions. The small darkly stained cells (type 1,) are identical with the intraglomerular cells that are scattered among the glomeruli, but they (intraglomerular cells) are not gathered into a layer between the glomeruli and the remainder of the accessory bulb as in the olfactory bulb.

There is no attempt at lamination in the cell mass. (fig.28,23,24). Silver stained sections show axons from some of the larger cells passing into the olfactory tract lateral to the accessory bulb. Other axons form a thin layer between the base of the cell mass and the pia, and both sets of fibres mingle with the olfactory tract caudal to the accessory bulb and flow with it to the anterior olfactory nucleus and to the hemisphere. In the 5.5 mm. head there is a non-cellular bundle of fibres on the dorsal aspect of the peduncle, and probably the axons from the accessory bulb lie in it.

There are no mitral cells in the accessory bulb of the Sphenodon. Large faintly staining cells scattered through the cell mass act as mitral cells. I have not found any goblet shaped cells in the accessory bulb.

Goldby (1934) described the olfactory bulb of the Lacerta Viridis in terms that show that it conforms in general with the structure of the bulb of the Sphenodon, and he reports that the structure of the accessory bulb resembles that of the olfactory bulb.

Appajee (1934) finds mitral cells in the accessory bulb of the hedgehog, but they do not form a lamina; they are mixed up with the other cells of the accessory bulb.

It would appear that in the archaic reptile - the Sphenodon - the air smelling organ of the land animal developed before the water smelling apparatus had evolved to a great degree of differentiation. When it came to depend upon its land olfactory apparatus further differentiation of its water olfactory apparatus, i.e. its vomero-nasal apparatus, was arrested. The Lacerta Viridis has had a different history. Its vomero-nasal apparatus was well advanced before it fell into relative disuse.

It is evident from the description given that the accessory bulb of the Sphenodon, although doubtless it performs for the vomero-nasal nerve the same function as does the olfactory bulb for the olfactory nerve, has distinct features of its own as shown by cell arrangement and cell structure. This is in keeping with the opinion of Cajal, who in the mouse, rabbit and guinea pig, found the cells of the accessory bulb different in character from those of the bulb.

Nils Holmgren (1925) supports this observation by the results of his embryological investigations on the turtle. He believes that the mitral cells of its accessory bulb are formed from the primordial cortex, and that the mitral cells of its olfactory bulb are sub-pallial in origin. He supports Broman's theory, (1920), that the vomero-nasal apparatus is the more primitive and represents the olfactory apparatus of bony fishes, the olfactory apparatus proper being a more recent development as a necessity of land life.

The Sphenodon did not remain an aquatic animal for a long enough period of time for the force of neuro-bio-taxis to separate the cells of its then olfactory bulb into different layers, and its land life has not provided the stimuli, through the organ of Jacobson, that would bring about this change; thus its accessory bulb remains as we find it. The olfactory bulb receiving from the olfactory organ, upon which the Sphenodon in its land life chiefly depends for its information concerning its environment, has functioned for a long enough period of time to become a highly specialised part of the brain.

We may conclude, therefore, that we have in the accessory bulb an organ which gives to the comparative zoologist information that will assist in the determining of the phylogenitic position of an animal.

The Anterior Olfactory Nucleus.

Figures 2, 3 and 4 show that the peduncle expands as it approaches the hemisphere. The gently expanding part is where the anterior olfactory nucleus is situated. When the hemisphere is reached the increase in the measurement of the circumference increases more rapidly. The nucleus does not terminate caudally where the hemisphere begins, but opens out to embrace its pointed rostral end, which it almost completely envelops, for as will be shown, there is a part of the medial surface that is covered by fibres of the olfactory tract only, and not by any part of the nucleus.

Figure 36 shows the nucleus cut in sagittal section. From this it will be seen that the dorsal part of it extends further rostrally than the ventral part. This section does not show how the nucleus ends caudally, for it opens out on its medial aspect and its caudal part is lateral to the plane of this section.

The nucleus is studied best in serial section, cut transversely, and stained by toluidin s/ blue. Figure 35 is a section that shows the position of the dorsal and ventral parts of the nucleus in the peduncle. There is a cell free area between the pia and each of the parts of the nucleus. fig.34 The dorsal part is bigger than the ventral. The cells of the dorsal part are very large, much larger than those of the ventral part. The cytoplasm is faintly stained and contains very fine rods of mitochondria and very fine granules. The nucleus is large, more darkly stained and contains a coarse network and coarse granules. Flat, contorted, sheet-like processes extend from some of the cells, and end by branching into two or three dendrites. The cells are rather densely packed in small clumps enmeshed in a reticulum of olfactory tract fibres, and they reach to the ependyma.

The ventral part is the smaller, and its cells are smaller. The cells stain more darkly than those of the dorsal part and they are almost filled with large round nuclei which stain uniformly showing no network or granules. These cells resemble the cells of the peduncle. They are not densely packed, but sparsely scattered, or arranged in short rows as in the peduncle, and, like those of the dorsal part, they extend from the ependyma to within a short distance of the pia, leaving a cell free area on the surface. Figure L shows something of these features.

It is evident that the dorsal part of this nucleus is not a collection of peduncular cells and that we have here a new structure.

The ventral part too is a new formation and is not to be regarded as a piece of the peduncle, for when we examine silver stained sections we find that the tract fibres here fall into lamellae that radiate from the ventricle towards the surface. In the dorsal part of the nucleus the fibres tend to lie in concentric lamellae.

The two parts are not joined medially and laterally to form a ring but remain distinct from each other differing in the character of their cells, the arrangement of those cells and the lamella formation of their fibres.

As we examine successively more caudal sections the first change noticed is that a cell-free area develops between the ventricle and each part of the nucleus, and silver stained sections show that this is made up of axons relayed from these cell masses. The olfactory tract superficial to each part of the nucleus also receives reinforcement. Later the dorsal part of the nucleus is noticed to develop a tail that runs from it medially and ventrally, as far as the medial angle of the ventricle, but there still remains a relatively cell free gap between it and the ventral part of the nucleus. This tail is made up of large cells very like those of the dorsal part of the nucleus itself, but definitely smaller. Followed caudally it is found that this is the rostral extremity of the hippocampus. The cell free area between the ventricle and dorsal part of the anterior olfactory nucleus increasing in extent, and the hippocampus growing deeper - ventro-dorsally - cause the displacement of the dorsal part of the nucleus in a dorso-lateral direction. Still further caudally, the medial part of the ventral wall of the ventricle bulges into the ventricle, and in the cell free area adjacent a new formation of cells makes its appearance. (fig.37–42). This new mass displaces most of the ventral part of the nucleus laterally and dorsally. The part not thus displaced moves ventrally and becomes a layer that covers the new mass on its ventral surface. This layer when followed caudally proves to be the tuberculum olfactorium, and the dorso-laterally displaced mass becomes the nucleus of the lateral olfactory tract. Silver stained sections show that the lamellae of fibres in the ventral part of the nucleus, radiating from the ventricle to the surface, sweep laterally just under the cell free layer of the olfactory tract fibres and take part in the formation of the lateral olfactory tract.

While these changes have been taking place ventrally, new developments have occurred in the dorsal part also. The dorsal wall of the ventricle becomes angled, so that the ventricle is now triangular with the hippocampus along its dorso-medial wall. The dorso-lateral wall bulges into the ventricle, and the dorsal part of the anterior olfactory nucleus lies some distance dorso-lateral to it. In the otherwise cell free area between the two there have appeared two cell clusters. The first consists of an elongated mass conforming in shape to the bulge in the ventricular wall. (fig. 41). This is the most rostral part of the hypopallium. The second is first seen further caudally, and appears as a compact clump between the hippocampus and the dorsal part of the anterior olfactory nucleus. This becomes continuous with the hippocampus, and further caudally, with the hypopallium and is in part the rostral end of the dorsal cortex. With the growth in size of the hemisphere the dorsal part of the anterior olfactory nucleus becomes spread out over these new structures and becomes named the pyriform cortex.

The anterior olfactory nucleus in Sphenodon is not, therefore, one uniform structure, but consists of a dorsal part, which is the rostral extremity of the pyriform cortex, and a ventral part, which is the rostral end of the tuberculum olfactorium. Cairney, (1926) recognised these two groups of cells. He remarks also that there is "no sharp line of demarcation between the peduncular gray on the one hand and the pyriform lobe complex or the olfacto striatum on the other."

Goldby (1934) describes the anterior olfactory nucleus of the Lacerta Viridis as being "characteristically a complete ring of cells surrounding the olfactory ventricle. The cells are of medium size and cannot be followed anteriorly into the layer of granule cells. The ring shows no differentiation at first, except that dorso-laterally the cells are rather more numerous and slightly larger, and that a little posterior to this level a similar, but smaller and less definite ventro-medial accumulation, can be seen. Further posteriorly this ring of cells is found to pass gradually into the various regions differentiated in the superficial parts of the hemisphere."

Dart (1920) regards it as part of the pyriform lobe; my investigations show that this is part of the truth. Johnston (1923) considered it as the rostral continuation of the head of the caudate nucleus. The mass of cells that I described as causing a bulge in the ventral wall of the ventricle and as pushing the ventral part of the anterior olfactory nucleus laterally, is seen by following the series of sections caudally, to be the rostral end of the palaeostriatum, so that I cannot accept this as applying to Sphenodon.

Appajee (1934) in describing the nucleus in the Hedgehog says, "The anterior nucleus does maintain its individuality and is easily distinguishable both from the pyriform cortex and the head of the caudate nucleus .... this is entirely different in structure and it disappears as the caudate makes its appearance."

I have endeavoured to show that in Sphenodon Punctatum there is no characteristic ring of cells forming an anterior olfactory nucleus. The rostral part of the structure that receives this name is formed by the pyriform cortex dorsally and the tuberculum olfactorium ventrally.

The so-called ring is completed by the insertion between these of the hypocampal cortex medially, and the development of the nucleus of the lateral olfactory tract laterally.

The pull that olfactory impulses exert on the different parts of the cortex that enter into the formation of the anterior olfactory nucleus seems to have drawn the pyriform cortex and the tuberculum olfactorium into the peduncle well ahead of the rest.

The Sphenodon being a primitive animal has not yet detached these rostral extremities of cortical and other formations and given them an "individuality". They remain in continuity with, and retain the cell characteristics of, the parts to which they belong.

From the foregoing discussion and from the photographs it is evident that the whole of the fibre tracts from the bulb and the accessory bulb do not relay in the so-called anterior olfactory nucleus of the Sphenodon. Some do and others pass on superficial to the cell masses in the peduncle to the hemisphere. These fibres might be described as forming a funnel completely enclosing the cell masses and the rostral extremity of the hemisphere. The tube of the funnel encloses the dorsal and ventral parts of the anterior olfactory nucleus and the cone of the funnel covers parts of the pyriform cortex, the dorsal cortex, the hippocampus, the nucleus septomedialis of Durward (1930), the tuberculum olfactorium and the nucleus of the lateral olfactory tract. These superficial fibres are not divided naturally into different parts; they form a layer of fairly uniform thickness. In the Sphenodon it is impossible to distinguish a medial, lateral and intermediate set of fibres, and it is impossible to differentiate those from the accessory bulb.

On a subsequent occasion I propose to describe the fibre connections of the olfactory tract, but to do so just now would necessitate the consideration of the whole forebrain and would require preparations that are not at my disposal at the moment. Cairney (1926) has already given these connections but since it is now possible to allocate the cells of the peduncle to different cortical areas a revision of the subject is desirable. Elliot Smith (I895) traced the relays from the accessory bulb of the ornithorhynchus to all the cell masses that received olfactory fibres.

Conclusions.

1. The organ of Jacobson of the Sphenodon is well developed. It is mammalian rather than reptilian in type and is very similar to that of the ornithorhyncus. It gives the Sphenodon a place in mammalian phylogeny that is nearer the main line of descent than that of any other reptile hitherto investigated.

2. There is an accessory bulb in the Sphenodon. It receives from the organ of Jacobson. It is primitive in type, showing no lamination. Its cells are different in character from those of the olfactory bulb. This supports the theory that the accessory bulb is an earlier development than the olfactory bulb and that the organ of Jacobson with

which it is related represents the olfactory organ of fishes. The structure of the accessory bulb gives information of phylogenetic value and indicates that the Sphenodon abandoned its aquatic life when very primitive.

3. The olfactory bulb is of the reptilian type and its cells are well differentiated.

4. The axons of the two bulbs - accessory and olfactory - intermingle and probably are distributed to the same centres in the hemisphere.

5. There is in the Sphenodon what corresponds with the reptilian anterior olfactory nucleus. It is formed by the attenuated rostral tip of different parts of the cortex of the hemisphere and is not a detached cell mass.

It was in response to a suggestion from Sir Grafton Elliot Smith that I interested myself in the Sphenodon Punctatum, and it is under the inspiration of his work that this investigation has been pursued.

For my material I have to thank The Hon. Adam Hamilton, the minister for Internal Affairs in New Zealand, who granted me the first permit to collect Sphenodon that had been given for a decade, and also Professor H. B. Kirk of Wellington, New Zealand, through whose kindness I have been able to use some of the young Sphenodon upon which the late Dr. F. G. Maskell had intended to prosecute his researches. For the investigation here made on the organ of Jacobson itself this material exclusively has been used.

I am grateful also to Professor W. P.Gowland of the University of Otago for extending to me the hospitality of his department during my stay in Dunedin when I had at my disposal his very valuable material. Also to Prof. J. P. Hill and to Dr. Una Fielding for their help and advice. Prof. Gowland's technician prepared a transverse and a sagittal series of sections stained by Ranson's method, and Mr. H. E. Barker of the University College prepared the decalcified heads. The photographic work was done by

Mr. F. J. Pittock of the University College. The quality of this work leaves nothing to be desired and earns my deep gratitude.

REFERENCES.

APPAJEE, Y. (1934) The Brain of the Hedgehog. Thesis for M.Sc., London.

BEARD. J. (1889) Morphological Studies. Aus dem Anatomischen Institut zu Freiburg, T/Br. - 4/

BROMEN. I. (1920) Das organ von Jacobsonii ein Wassergeruchsorgan. Anat. Hefte Beiträge, 58. +

BROOM. R. (1900) A Contribution to the Comparative Anatomy of the mammalian Organ of Jacobson. Trans. Royal Soc. Edin. XXXIX. 1897

(1896) The Organ of Jacobson in Monotremata. Journ. Anat. & Phys. Vol.30.

(1915) The Organ of Jacobson in the Insectivora. Proceedings of the Zool~~og~~. Soc. of London.

CAIRNEY. John. (1926) A general survey of the forebrain of Sphenodon. Journ. Comp. Neur. Vol 42.

CAJAL. Ramon Y. (1911) Histologie du Systeme Nerveux. T 2. Paris.

CROSBY. (1917) The forebrain of Alligator Mississippiensis. Journ. Comp. Neur. Vol.27.

DURWARD. A. (1930) The cell masses in the Forebrain of Sphenodon Punctatum. Journ. of Anat. 65.

GOLDBY. Frank, (1934) The cerebral hemispheres of Lacerta Viridis. Journ. of Anat. 68.

HERRICK. C.J. (1924) The nucleus olfactorius anterior of the opossum. Journ. Comp. Neur. 37.

HOLMGREN. N. (1925) Points of View concerning Forebrain Morphology in higher vertebrates. Acta. Zool. Bd.6

HOWES. G.B. and SWINNERTON. H.H. (1901) Trans. Zool. Soc. of London. Vol. XVI. Ptt. No.t Title/

JACOBSON. (1811) Annales de du Museum d'Histoire Naturelle. T. 18.

JOHNSTON. J.B.(1915) The cell masses in the Forebrain of the Turtle Cistudo Carolina. Jour. Comp.Neur. Vol.25.

KLEIN. E. (1882) Quart. Journ. of Mic. N Science. Title

McCOTTER. Rollo E. (1912) The connections of the Vomero-Nasal nerves with the Accessory & olfactory bulb in the Opossum & other mammals. Anat. Record, Vol.6.

MIHALKOWICS.(1899) Anat. Hefte. Bd.II.

NAVRATIL. v. Desider (1926) Zeitschrift für die Gesamte Anatomie. Abt. 1. 81.

OSAWA. G. (1898) Beiträge zur Lehre von den Sinnesorganen der Hatteria punctata. Arch. mikr. Anat. Bd.52.

PARKER. (1922) Monographs in Experimental Biology. Smell, Taste and allied Senses in Vertebrates.

SMITH, Sir Grafton Elliot. (1895-6) Anatom. Anzeiger. II. Jacobson's organ and the olfactory bulb in the ornithorhyncus.

SYMINGTON. Johnson. (1892) Jour. of Anat. & Phys. Vol.26.

TABLE

shewing Relations and Accessories of JACOBSON'S ORGAN.

	Anterior Vomer or Palatine form of Premaxilla			Roof	Turbinal Process.			Accessory to Organ.	
	Inf.	Int.	Sup.	Septo-maxillary.	Int. Cart.	Ext. Cart.	Ext. Cart. and Vomerine Plate.	Mucous Glands.	Vascular Plexus
† Geckonidae	x	-	-	x	-	x	-	-	-
Scincidae	x	x	-	x	x	-	-	-	-
Agamidae	x	x	-	x	-	x	-	-	-
Varanidae	x	x	-	x	-	-	x	-	-
Elapidae	x	x	x	x	-	-	x	-	-
Sphenodon	x	x	-	-	-	-	-	goblet cells	x
Ornithorhyncus	x	x	x	-	-	x	-	x	x
Echidna	-	-	-	-	-	x	-	x	x
Marsupialia	x	x	-	-	-	-	-	x	x
Rodentia	x	-	-	-	-	-	-	x	x
(artiodact.) Ungulata	-	x	-	-	-	-	-	x	-
Carnivora	-	x	-	-	-	-	-	x	-
Chiroptera	-	x	-	-	-	-	-	-	-

A modification of Broom's Table given in Journal of Anatomy & Physiology, Vol. 30. 1896.

Fig. 1.

×5

Fig 2.
Dorsal view

×5

Fig 3.
Lateral view

×5

Fig 4
Ventral view

<u>The Sphenodon brain</u>

f — the olfactory bulb, conical in shape with fila olfactoria entering its base

a — the position of the accessory bulb

a to b — olfactory peduncle

b to c — position of anterior olfactory nucleus

d — pineal eye

e — hypophysis

Fig 5   Transverse section of 6.5 m.m. head   x57

Shows - Septal cartilage (a) and paraseptal cartilage (b)
closed rostral end of olfactory cavity

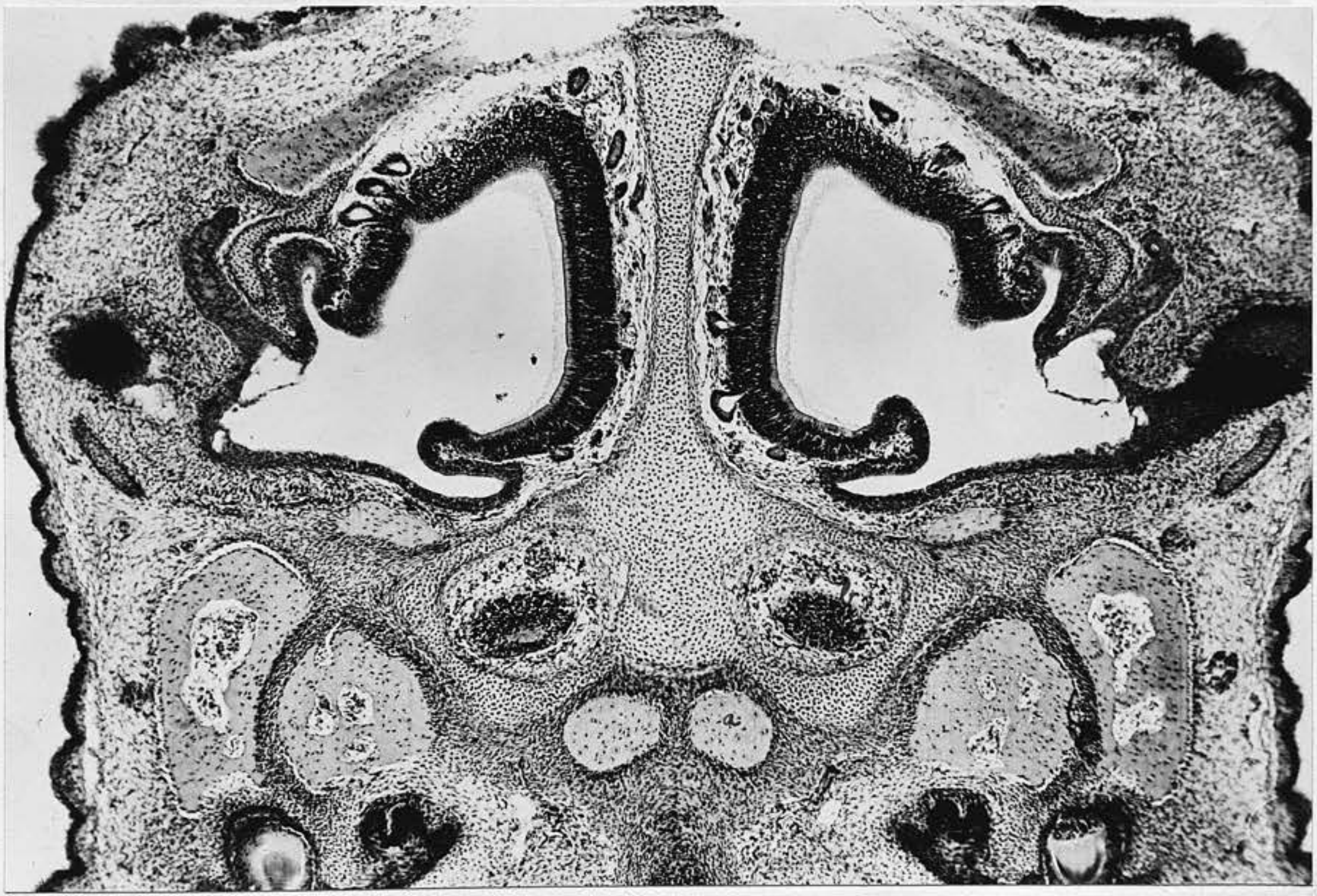

Fig 6   x57

a more caudal section shows the rostral end of Vomer (a)
and rostral end of organ of Jacobson still closed (b)

× 57

Fig. 7

Section caudal to fig. 6.

The Vomer (a) ventral to Jacobson's cartilage (g)

The septo maxillary (f) dorso-lateral to Jacobson's cartilage

The lumen of the organ of Jacobson is seen. The thick dorsal wall is formed of neuroepithelium and the ventral wall of respiratory type epithelium

(d) is the loose tissue with plexus of veins, nerve filaments and the artery of the organ (c)

(e) indicates an olfactory nerve

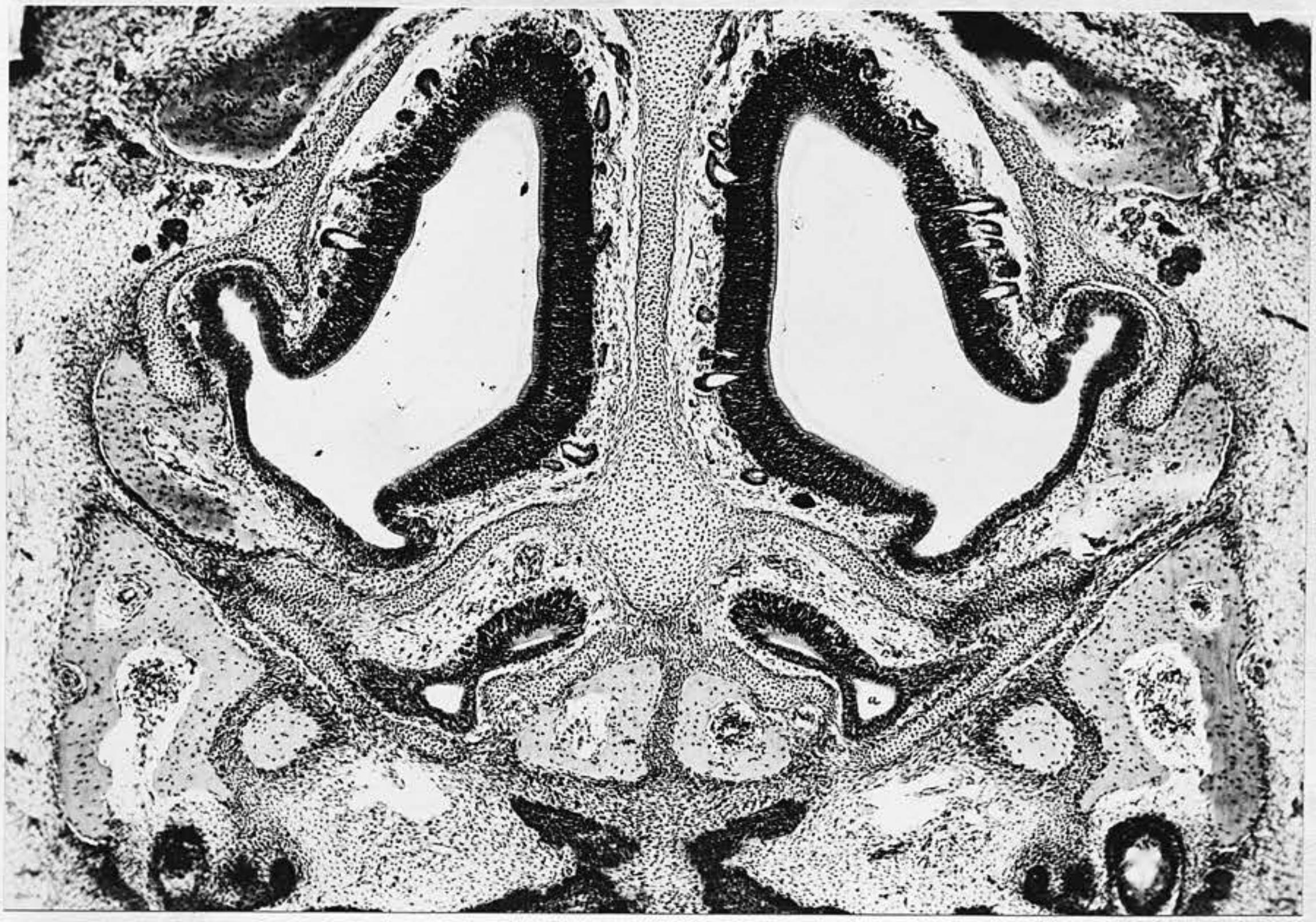

×57

Fig. 8

Section caudal to fig. 7.

The organ of Jacobson is opening into (a) the naso-palatine duct At (b) the Cartilage of Jacobson is giving way

The Vomer is extending laterally

The Septo maxillary is no longer in relation with the organ

X57

Fig 9.

Section caudal to fig. 8. and to the communicating duct

(a) is the naso-palatine duct caudal to the plane in which it received the communicating duct from the organ of J.

(b) and (c) are the openings of the naso-palatine duct into olfactory cavity and oral cavity

(d) is the lateral process from the Vomer that closes the gap in the Jacobson's cartilage caudal to the communicating duct

The transverse section of the organ of Jacobson caudal to the communicating duct is similar to that rostral to the duct.

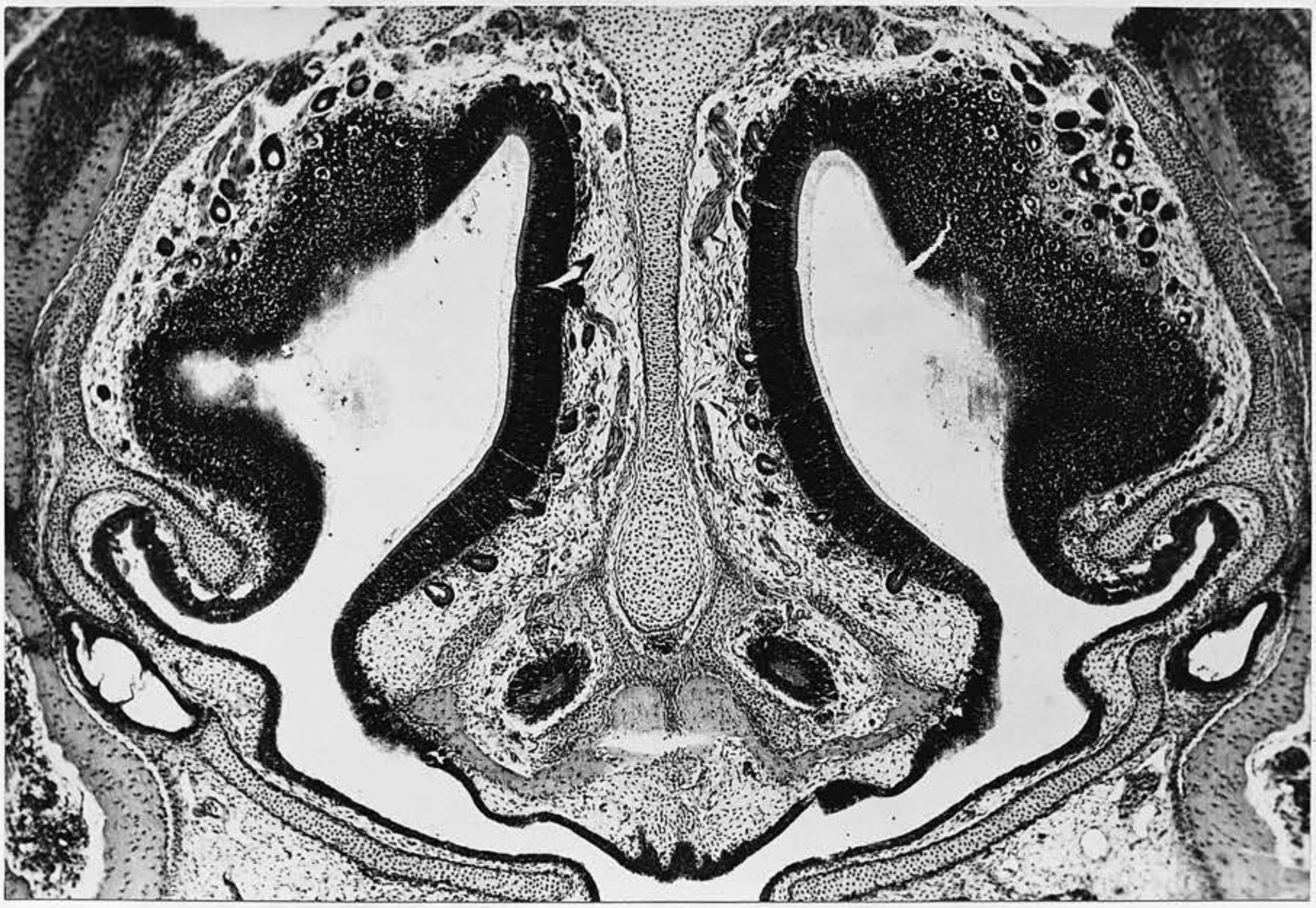

Fig. 10 x 57

(a) The nerve of Jacobson passing lateral to the artery in small bundles then dorsally through a deficiency in the cartilage

Fig 11 (d) Shows caudal fragments of Jacobson's cartilage x 57

(b) The blunt caudal end of the organ of Jacobson

(a) The nerve of Jacobson passing in zig zag manner between septum and neuro-epithelium

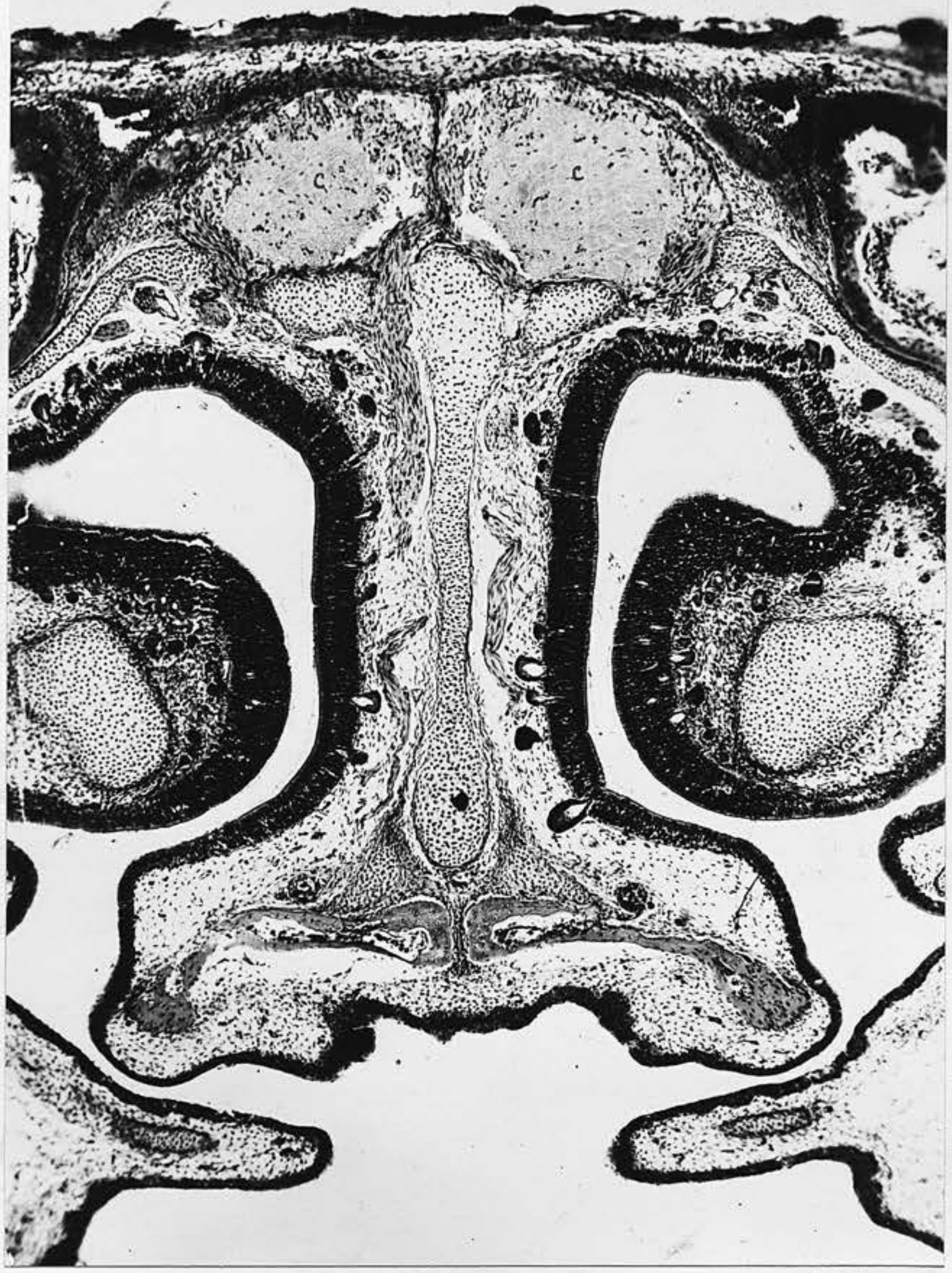

X 57

Fig. 12.

(a) The nerve of Jacobson passing through cribriform plate
(b) The nerve passing dorsally to dorso-medial aspect of bulb.
(c) The olfactory bulb
(d) fila olfactoria

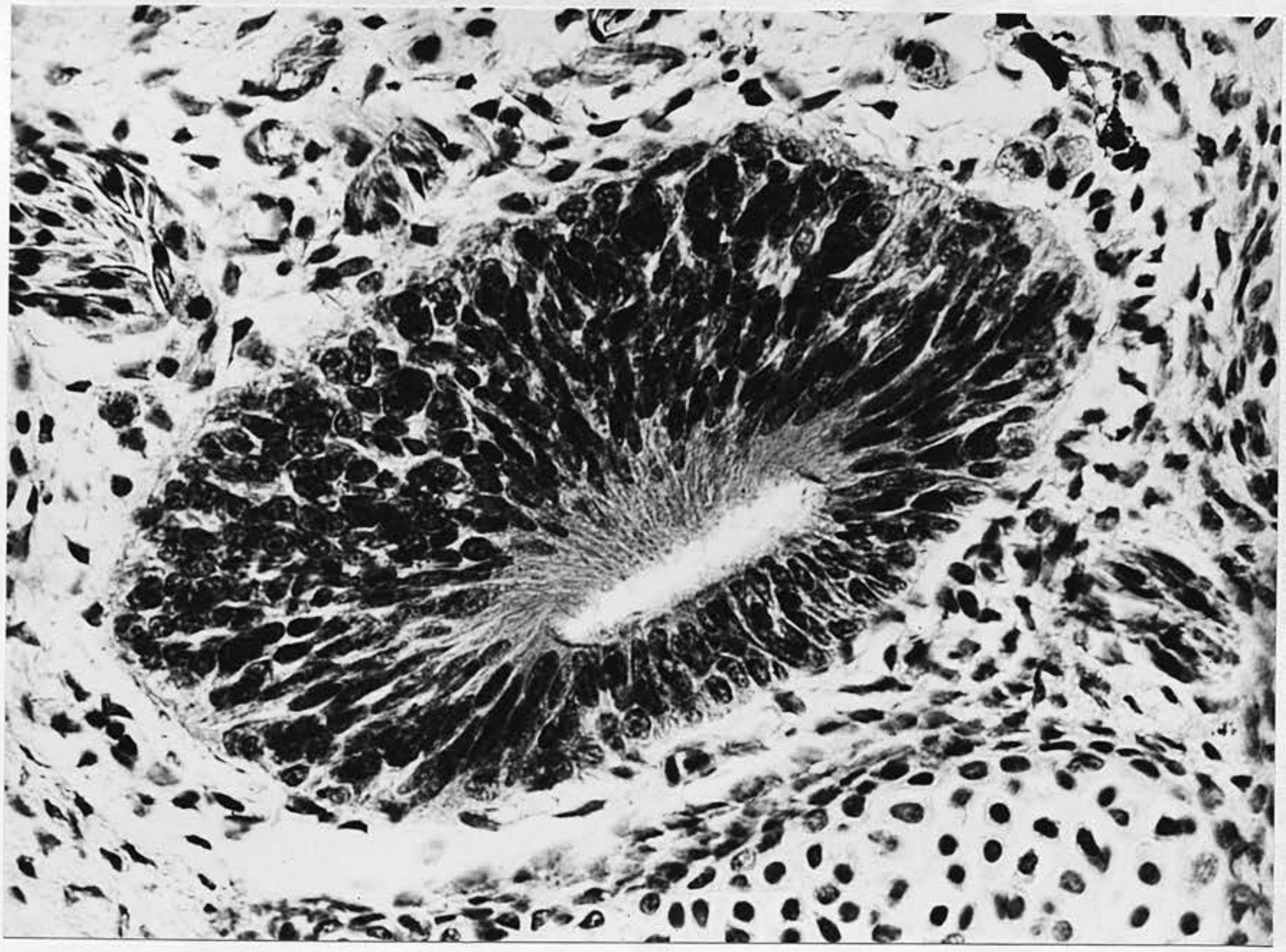

x450

Fig. 13.

The organ of Jacobson. in the 6.5 m.m. head.

The dorsal wall of neuroepithelium is thicker than the ventral wall. The cilia on the ventral wall of respiratory type are shown. The nuclei of the neuro-epithelium are far from the free surface. A tendency towards clumping of the neuro-epithelial cells is noticeable

There is an absence of lymphatic tissue and of serous glands

×300

Fig. 14

The organ of Jacobson from the 10·5 c.m. Sphenodon. This is not a true transverse section. It shows numerous goblet cells in the epithelium of respiratory type.

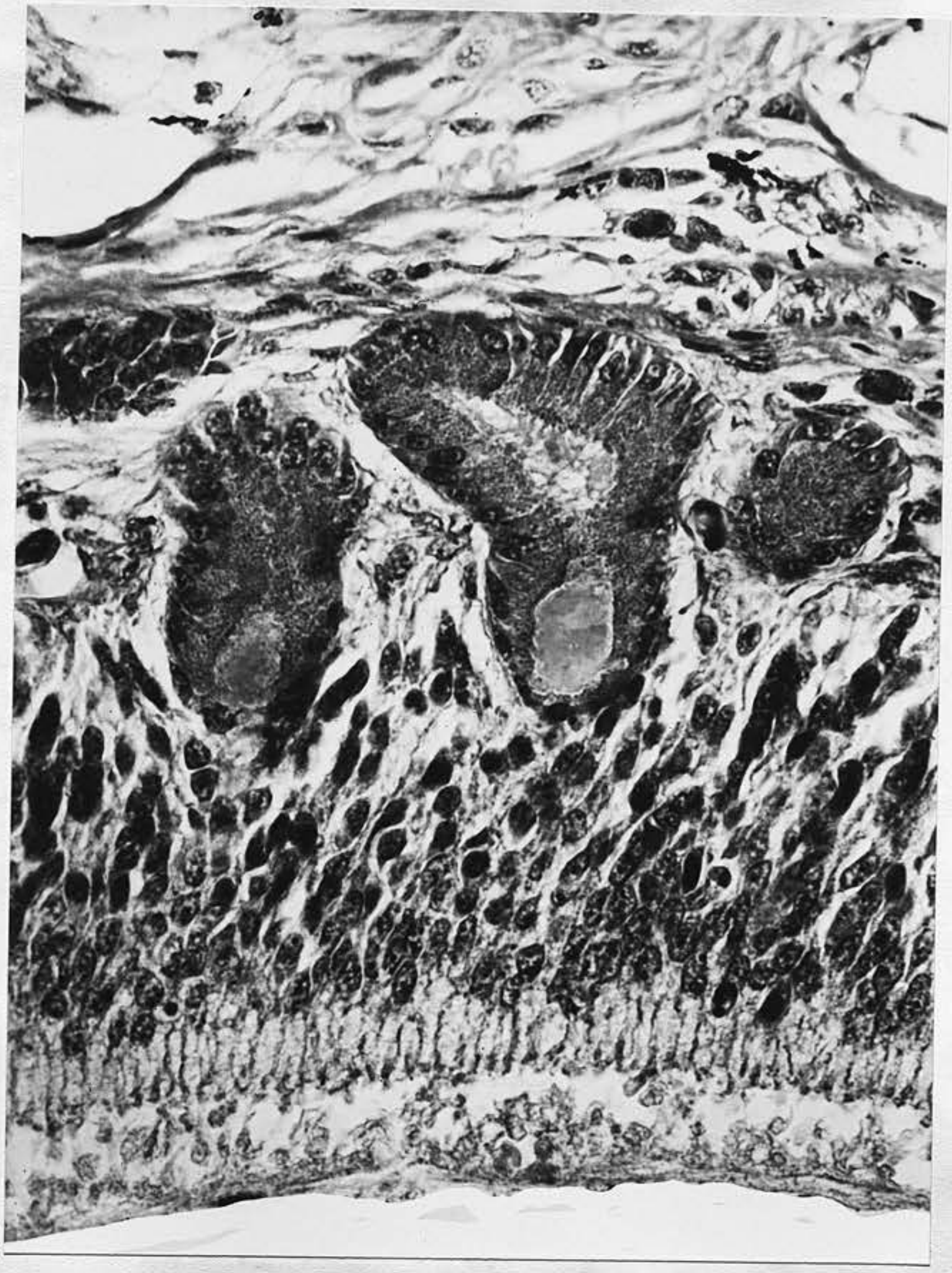

x450

Fig 15

A section through the sensitive epithelium of the olfactory cavity, showing serous glands and the nuclei well back from the free surface

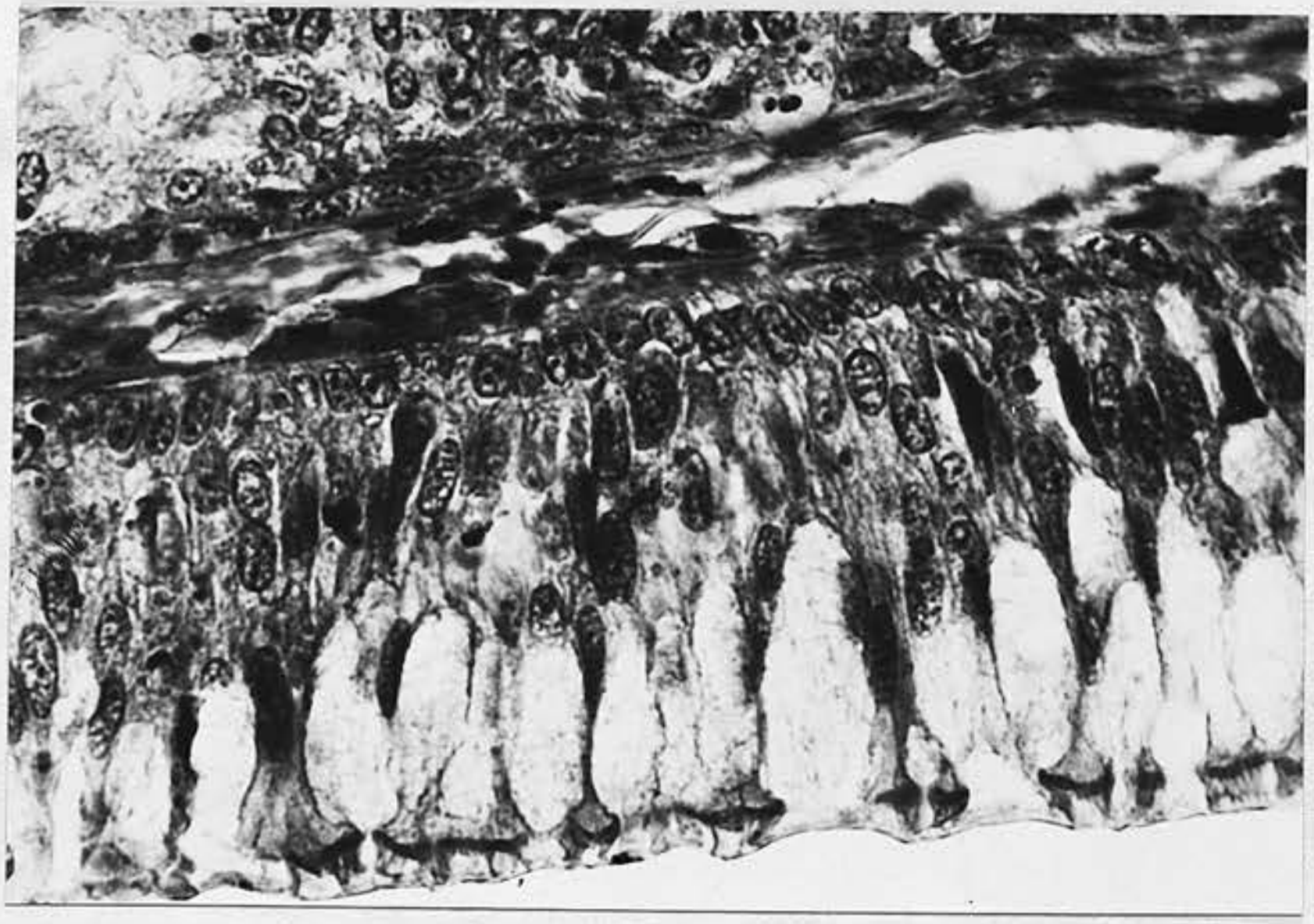

Fig 16 X450

Epithelium of respiratory type in the olfactory cavity of the 10·5 c.m. sphenodon showing numerous goblet cells

Fig 17 × 57

Part of the olfactory cavity of the 10·5 c.m. sphenodon

(a) opening into naso-palatine duct
(b) mucous glands
(c) serous glands
(d) goblet cells
(e) organ of Jacobson
(f) organ of Jacobson opening into naso-palatine duct.

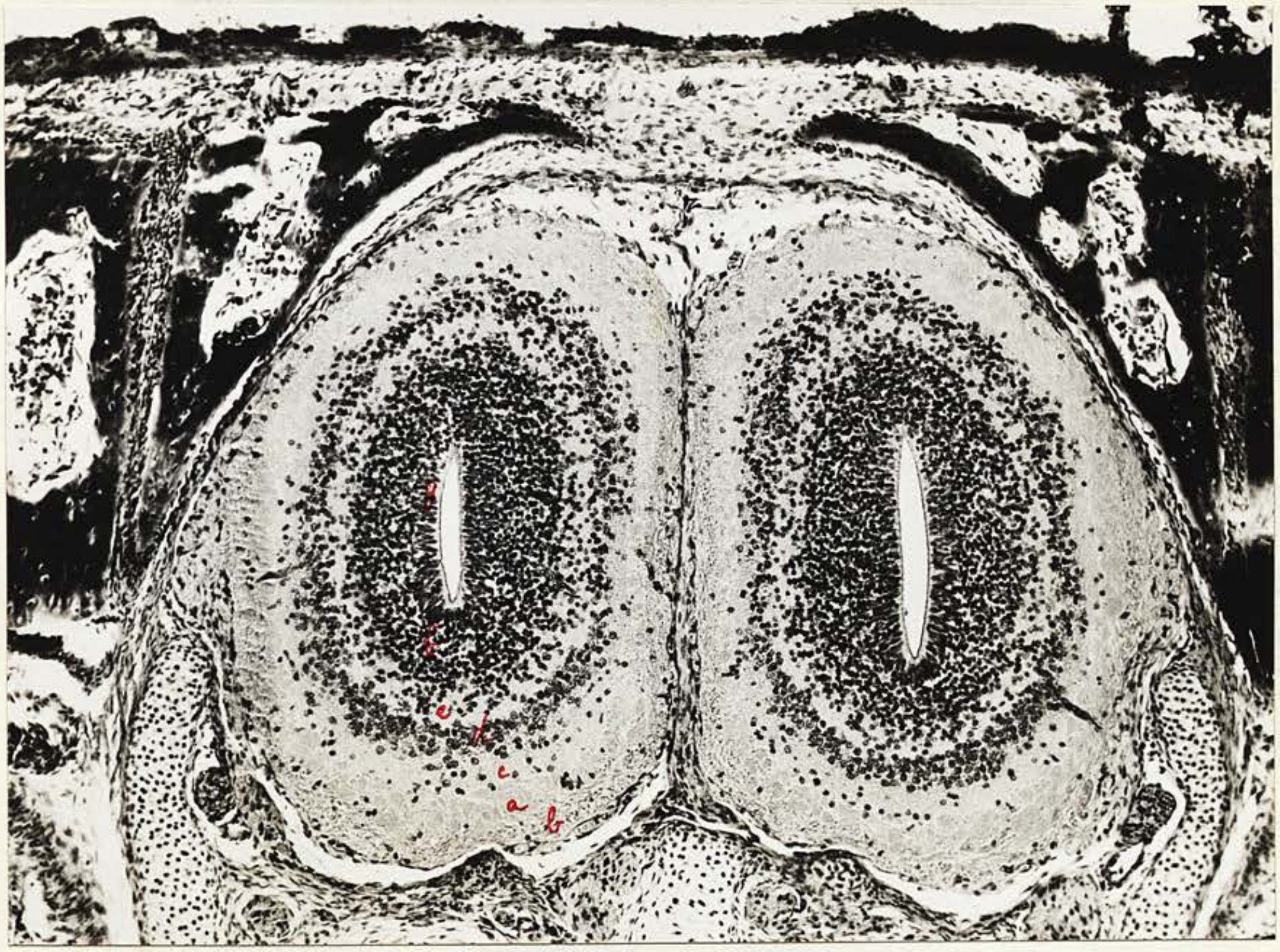

×97

Fig 18

Section cut transversely through olfactory bulbs of 6·5 m.m. head. Stained with H.I.H.&E.

(a) glomerules
(b) fila olfactoria
(c) outer molecular layer
(d) mitral cell layer
(e) olfactory tract
(f) inner granular layer
(g) ependyma

Fig 19 ×75

Transverse section through olfactory bulb stained by Ranson's method. Adult specimen

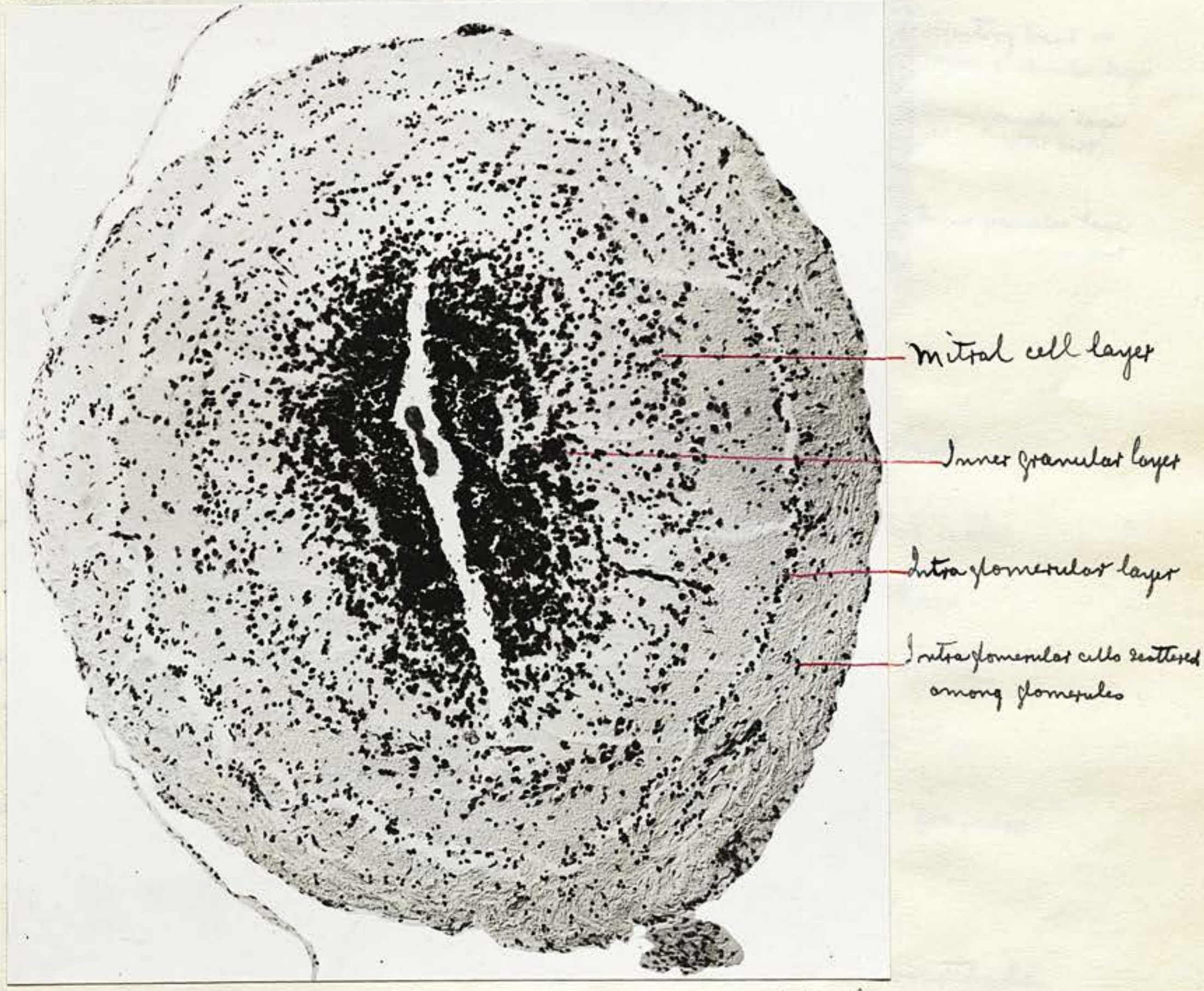

Fig 20 ×46

Transverse section through olfactory bulb of adult Sphenodon stained by Toluidin blue

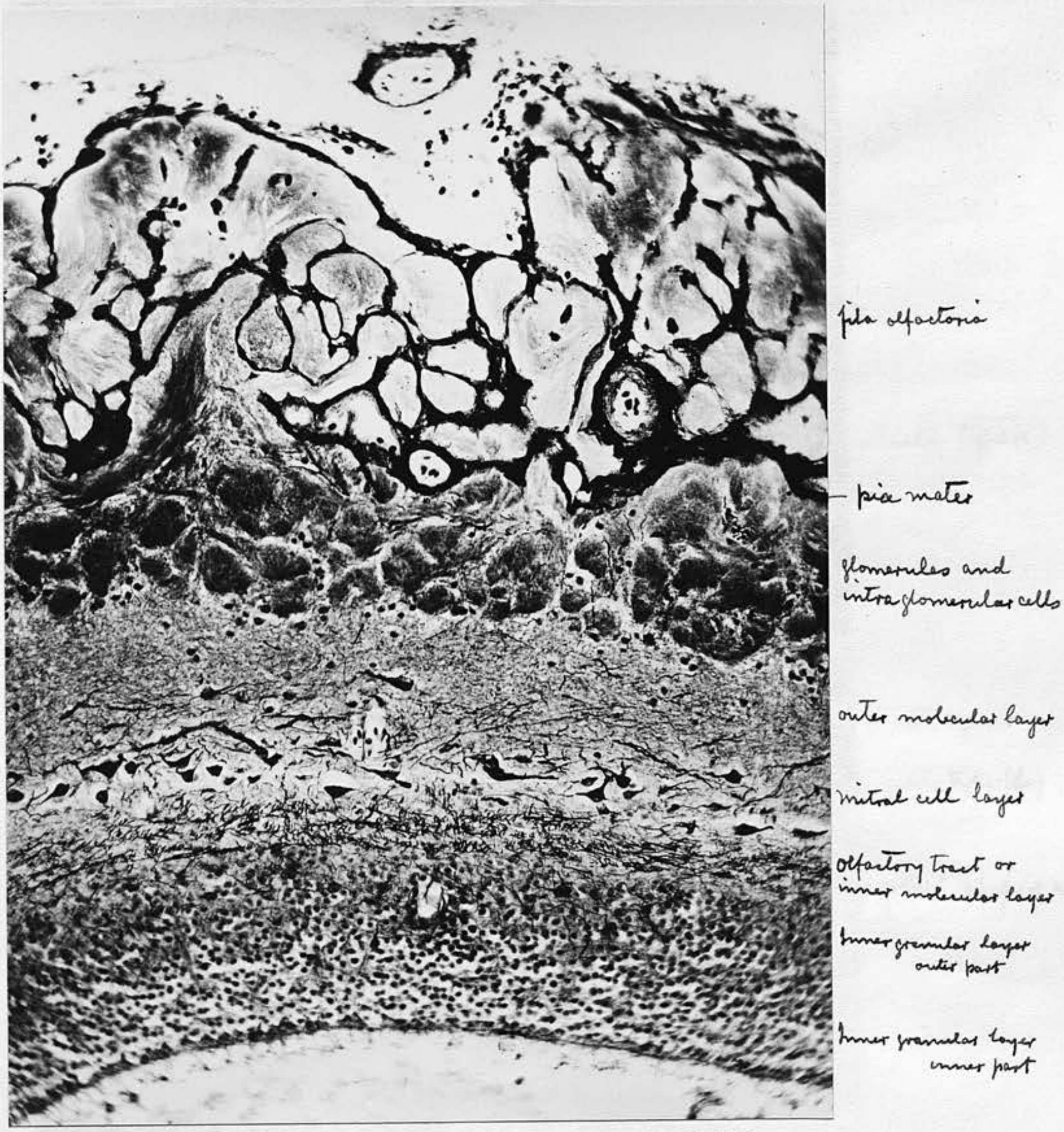

Fig. 21 × 120

Section through adult bulb stained by Ranson's method

In the outer part of the inner granular layer some goblet cells and large cells Type C) can be seen giving off their processes. The reticulum in the inner part of the inner granular layer is well developed in this section and the distinction between the inner and outer part of the inner granular layer can be seen.

The nuclei of mitral cells bulge towards the ventricle

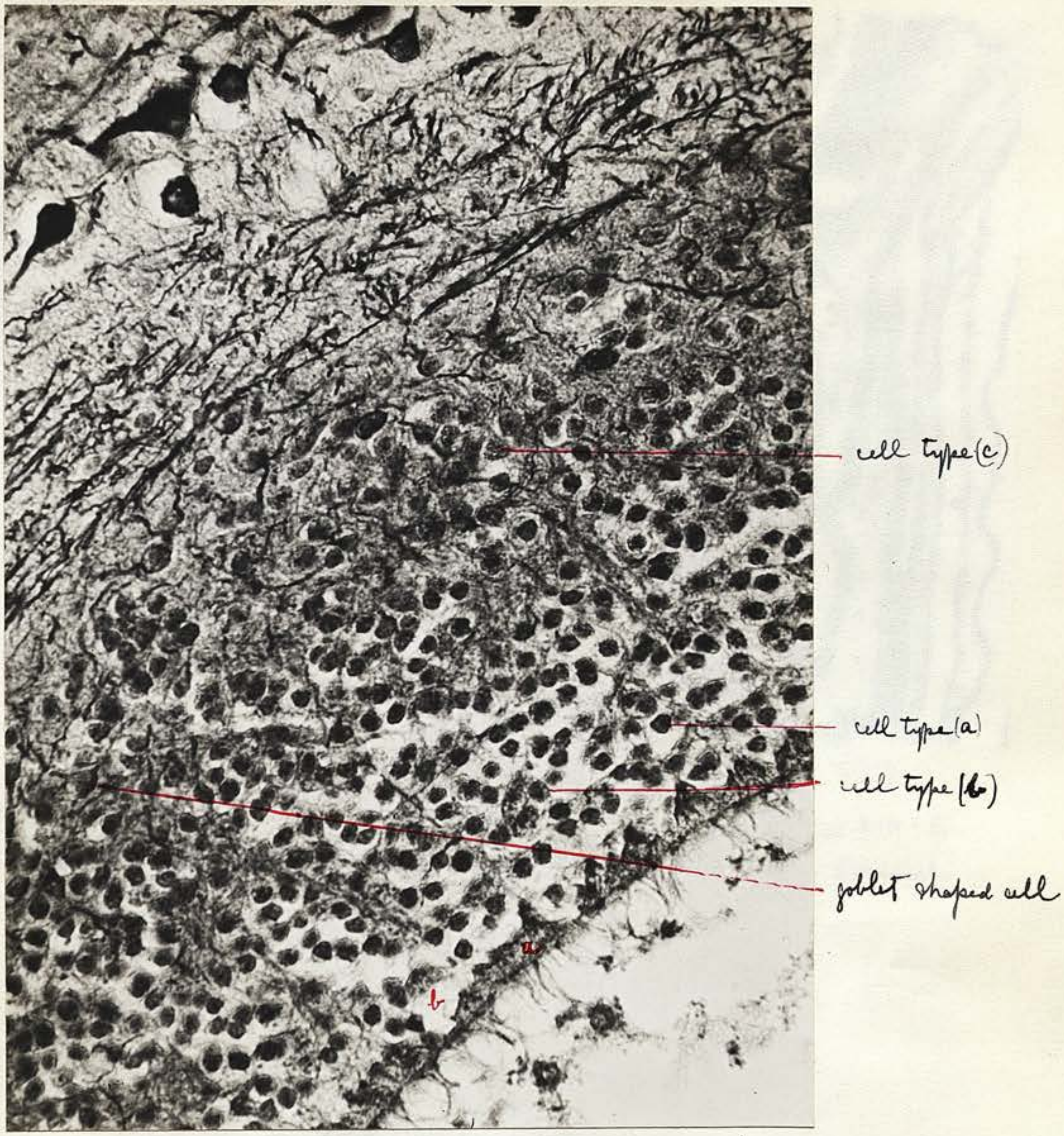

x450

Fig 22

Same as fig 21 but more highly magnified

Processes from many of the granule cells run to the trabeculae that radiate from the ependyma

(a) ependyma

(b) an open space between the ependyma and the granule cells.

The four varieties of cell are indicated

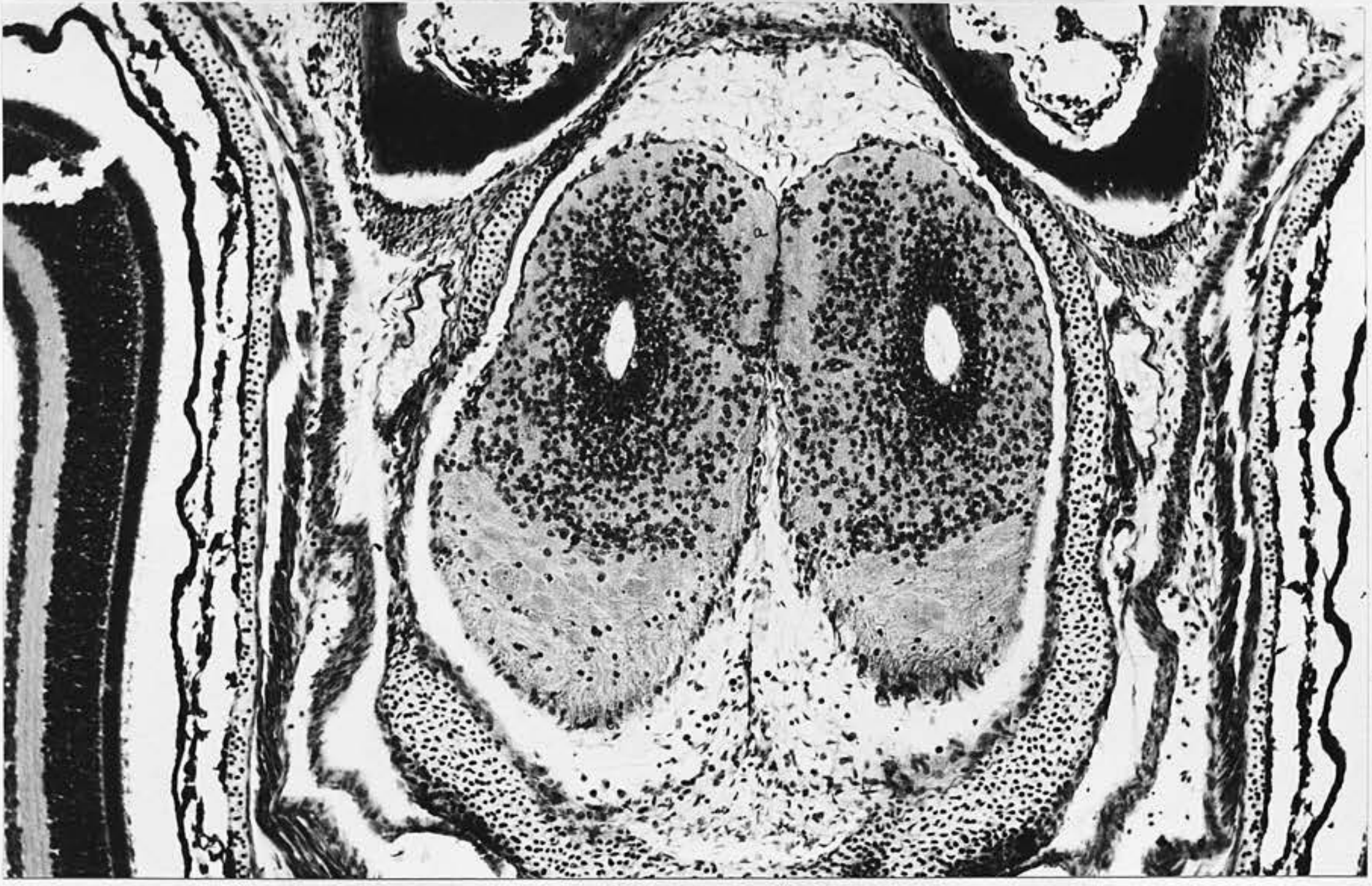

×97

Fig 23

Transverse section through head of the 5·5 c.m. Sphenodon Stained HIH + E There are no glomeruli at this level except ventrally. (a) indicates the glomeruli of the accessory bulb.

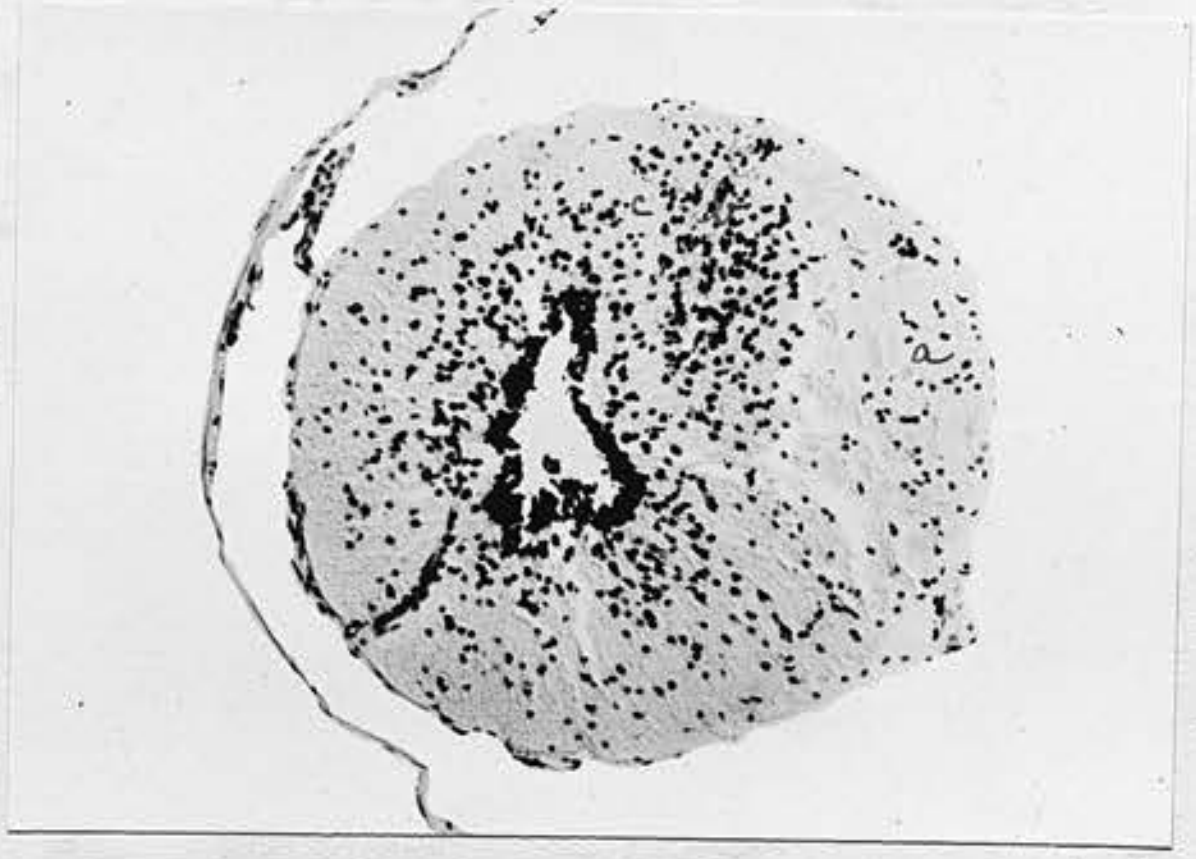

×46

Fig. 24

Transverse section through the peduncle just caudal to the bulb of an adult Sphenodon. (a) glomeruli (as in fig 23) of the accessory bulb. (b) in both figures indicates the cells of the accessory bulb inserted like a wedge between the glomeruli and (c) the olfactory tract of the peduncle

Fig 25 Stained by Ranson's method
a section through adult accessory bulb (a) cells of the accessory bulb
(b) glomeruli and intra glomerular cells (c) olfactory tract from olf. bulb.
which receives axons from accessory bulb also (d) axons from acc. bulb.

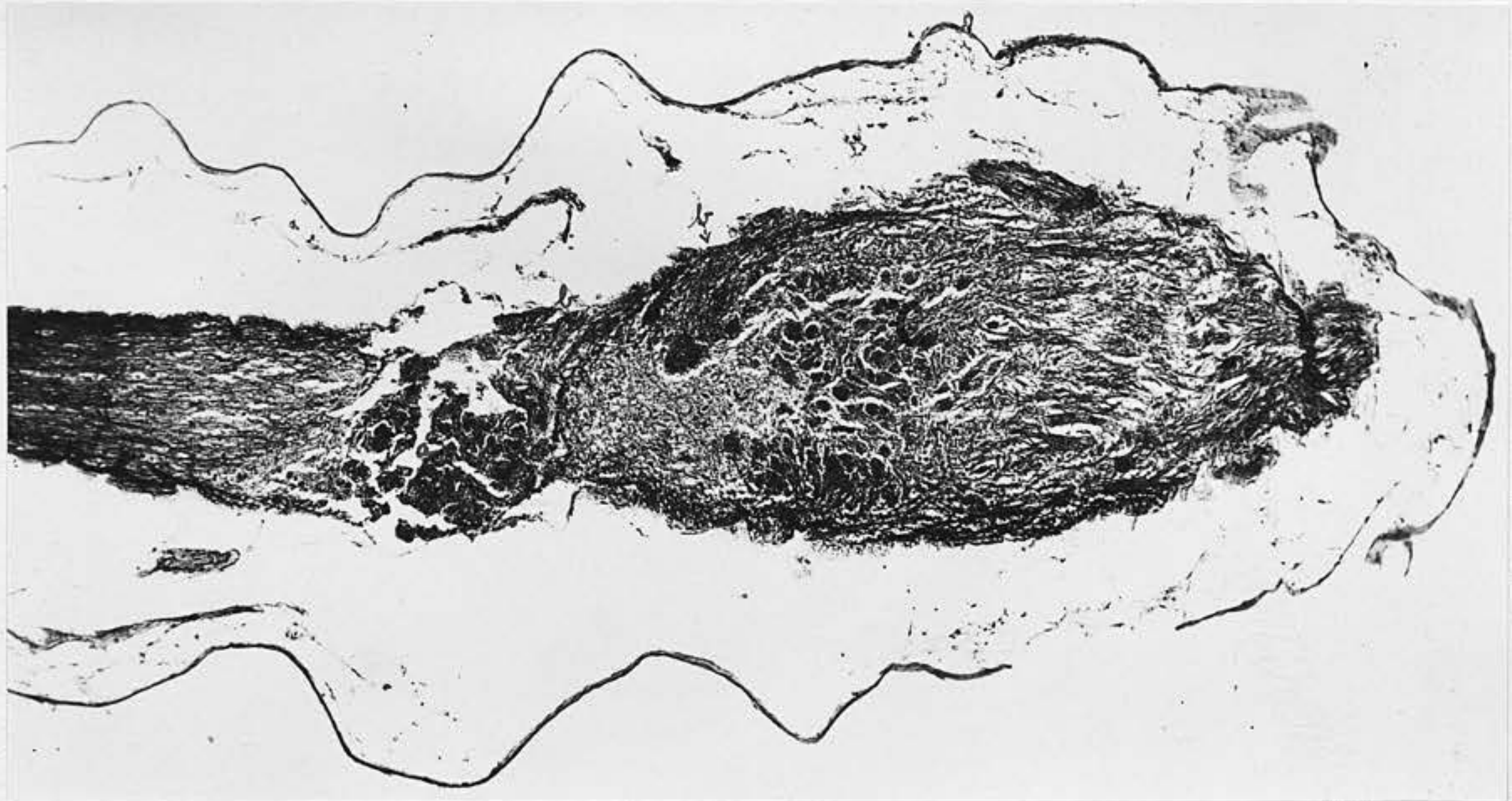

x60

Fig 26 Stained by Ranson's method
A sagittal section near the surface of both (a) acc. bulb and (c) olf. bulb
(b) the nerve of Jacobson on the surface of olf. bulb going to acc bulb (a)

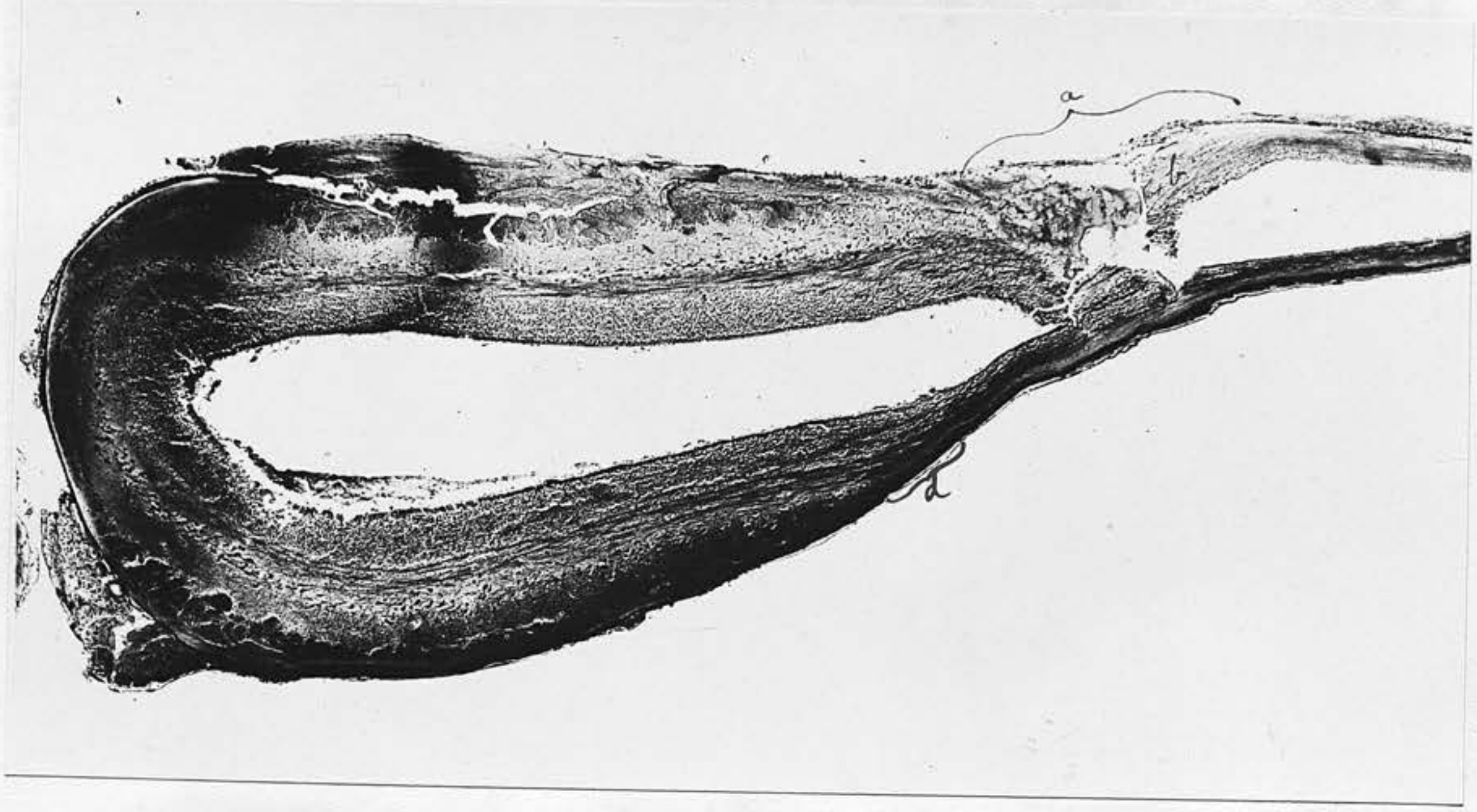

x53

Fig 27. Stained by Ranson's method

Sagittal section through the olfactory and accessory bulbs

(a) access. bulb.; (b) its cells; (c) its glomeruli

This section shows how the olfactory tract and inner granular layer are carried on caudal to the bulb as the peduncle

As the peduncle is approached the granule cells lie between lamellae of the olfactory tract instead of central to them this is seen in the area marked (d)

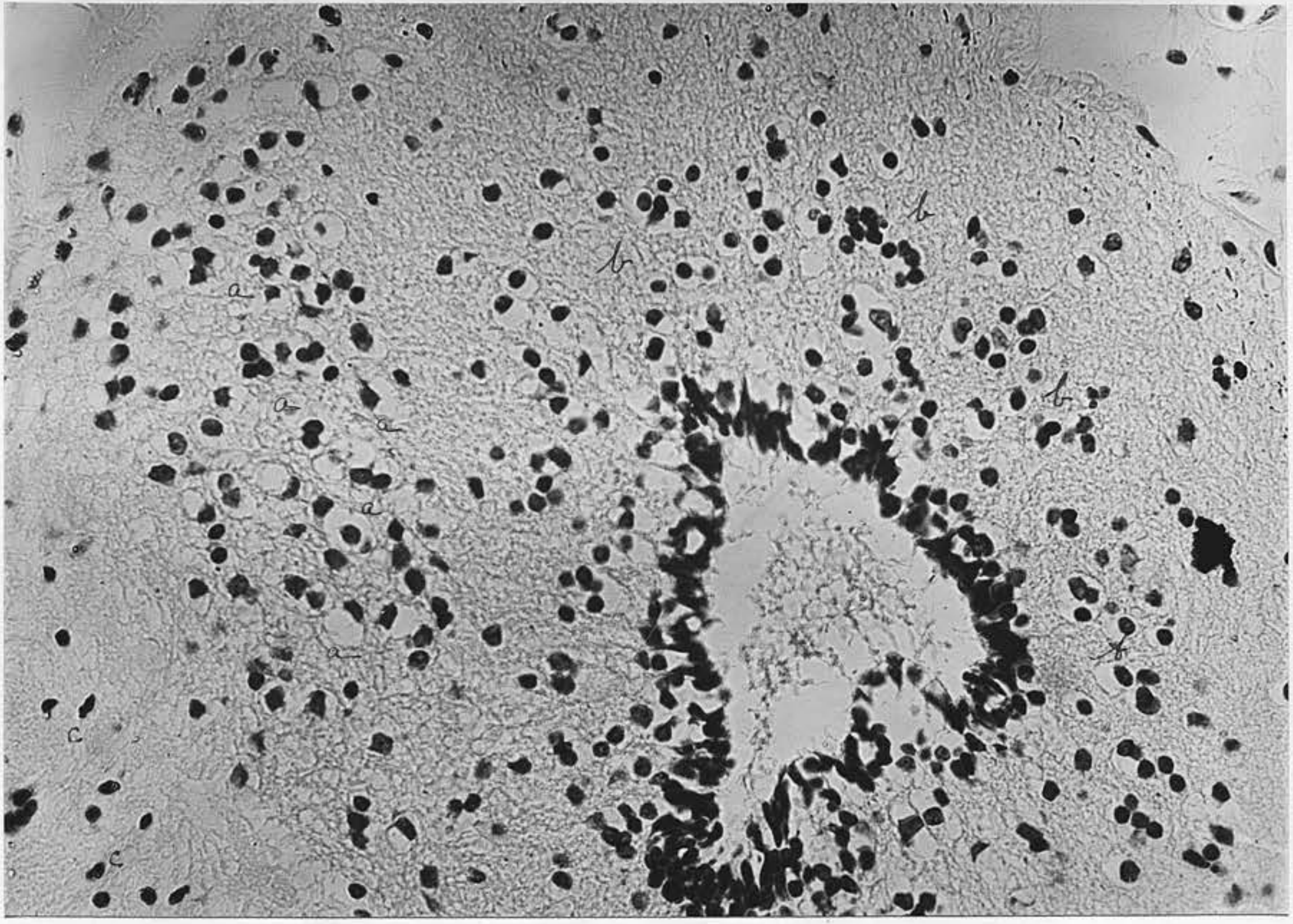

Fig 28 ×300

Transverse section through the peduncle and accessory bulb.
Stained with Toluidin Blue to show cell characters
(a) indicates accessory bulb cells (b) indicates peduncle cells
(a) are larger more angular and more faintly stained than (b)
(c) are the intraglamerular cells of the accessory bulb.

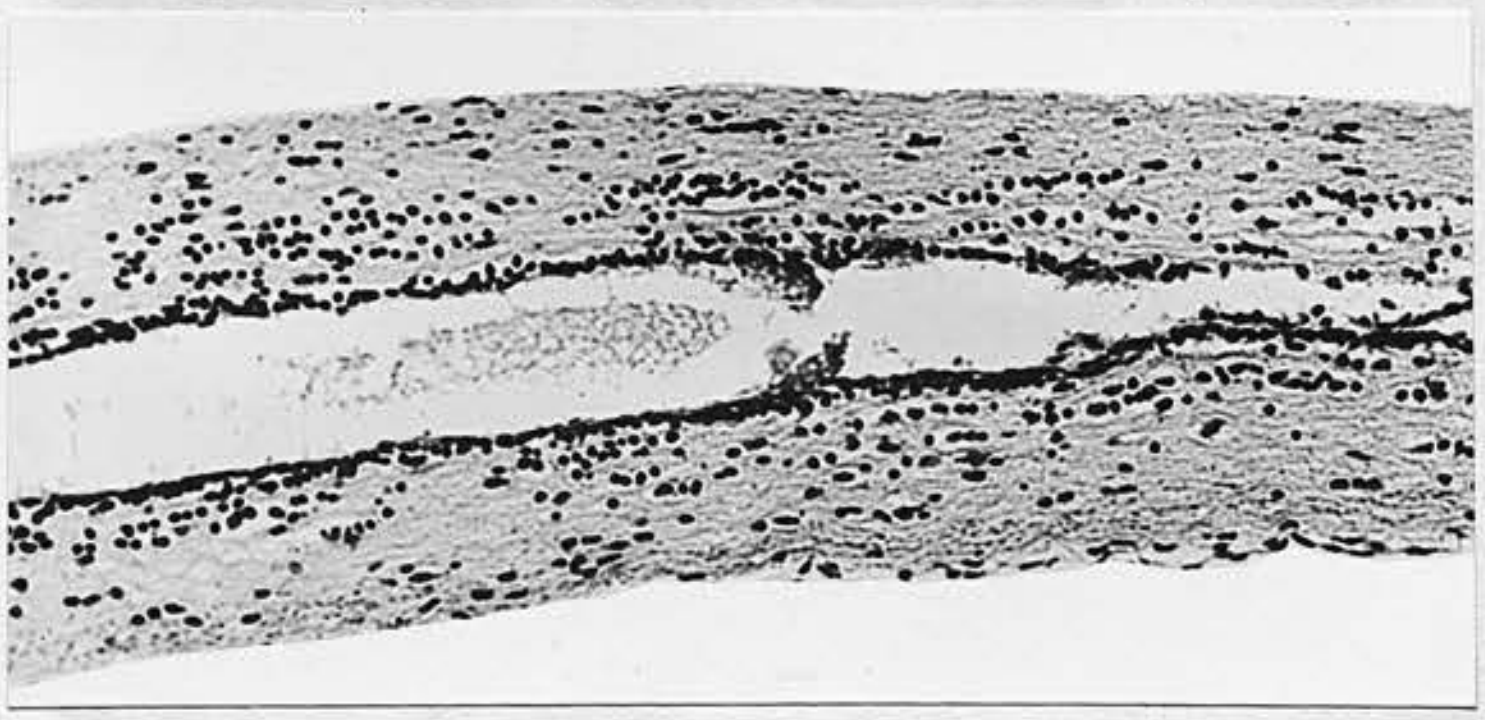

Fig 29 ×66

Sagittal section through peduncle stained with Toluidin Blue. Cells of the peduncle are in short rows between fibres. They are most abundant near the ventricle

Fig 30 ×50

Transverse section of the peduncle stained with Toluidin Blue shows cells scattered near the ventricle

Transverse section of the peduncle 5·5 c.m. sphenodon showing that just caudal to the accessory bulb the most cell-free area is on the dorsal aspect and at the periphery

Fig 31 ×100

Still further caudally the cell free area is more definite.

Fig 32 ×110

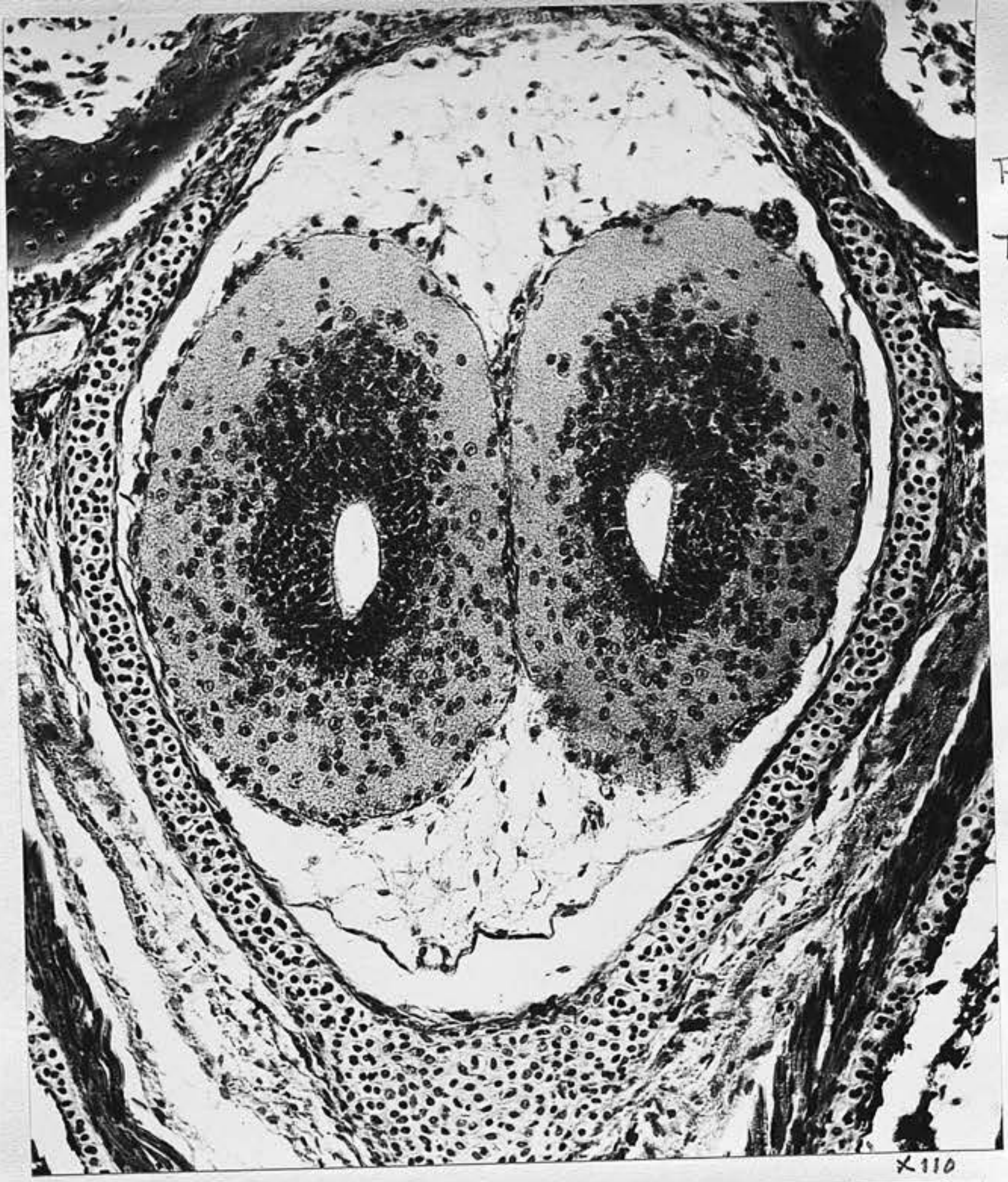

×110

Fig 33

Transverse section through the rostral end of anterior olf. nucleus. The dorsal part of the nucleus is showing, it reaches to the ependyma

There are very few cells superficial to the nucleus

×110

Fig 34

Further caudally than 33

The relay fibres are beginning to collect between the dorsal part of the nucleus and the ependyma at (a)

The ventral part of the nucleus shows in this section (b)

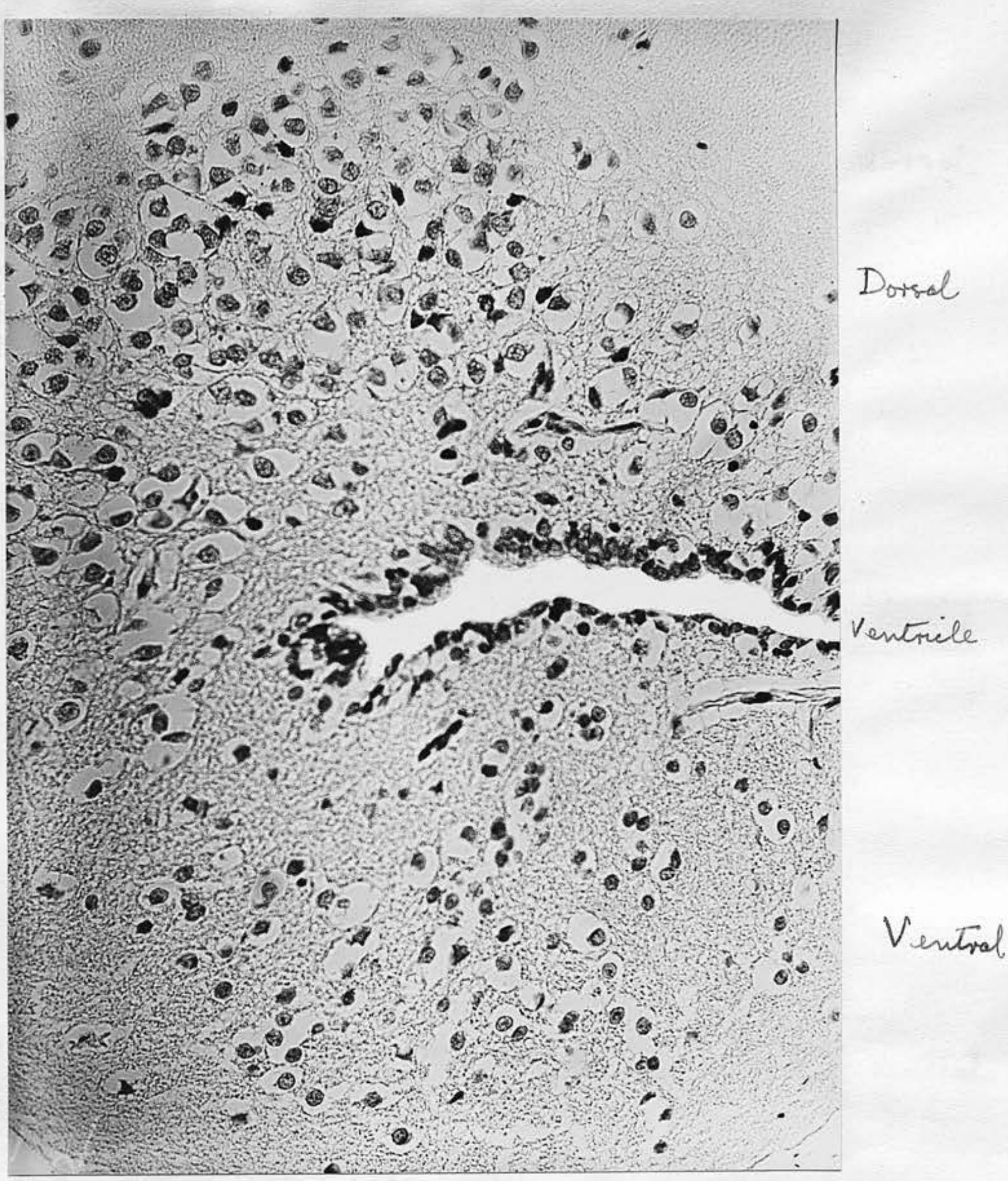

Fig 35

Transverse section through peduncle at level of anterior olf. nucleus. The cells of the peduncle are replaced by the dorsal and ventral parts of the ant. olf. nuc.

The dorsal part is formed of large faintly staining cells with flat sheet like processes that break up into dendrites

The ventral part is smaller cells are more scanty and are smaller and more darkly staining

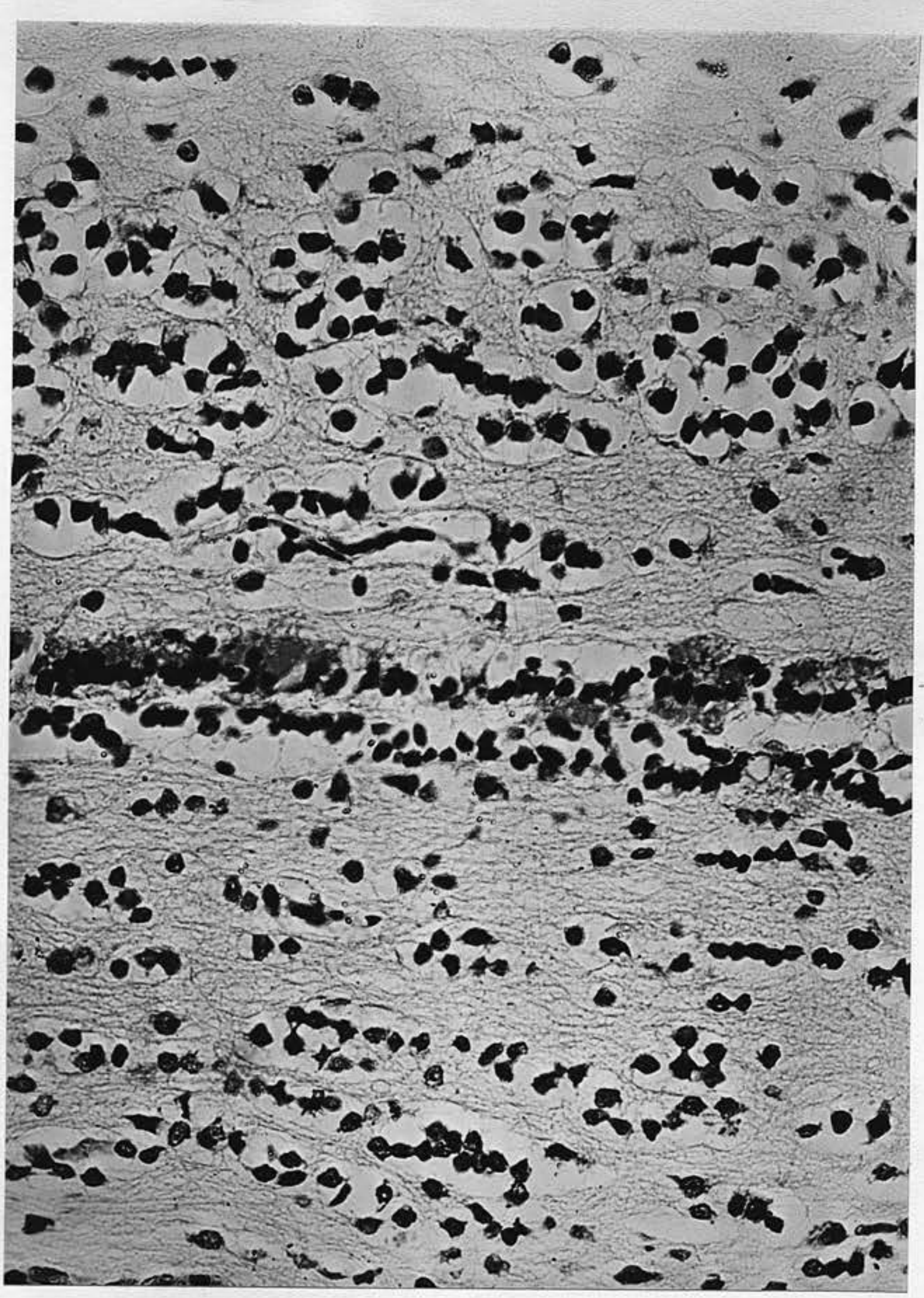

×300

Fig 36

Sagittal section through the ant, olf. nuc. showing the contrast between the dorsal and ventral parts. - compare with fig 35

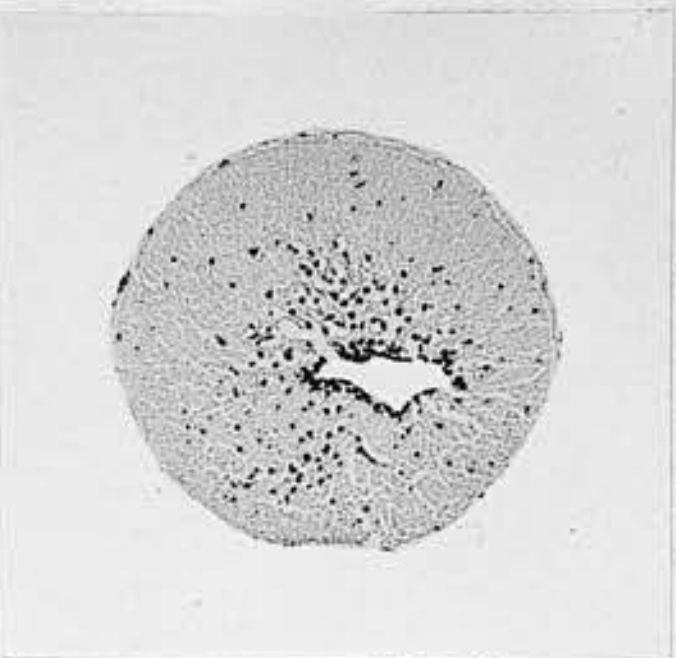

Fig 37

Shows the dorsal part of the ant. olf. nuc. larger than the ventral. Both parts are to the lateral side of the peduncle

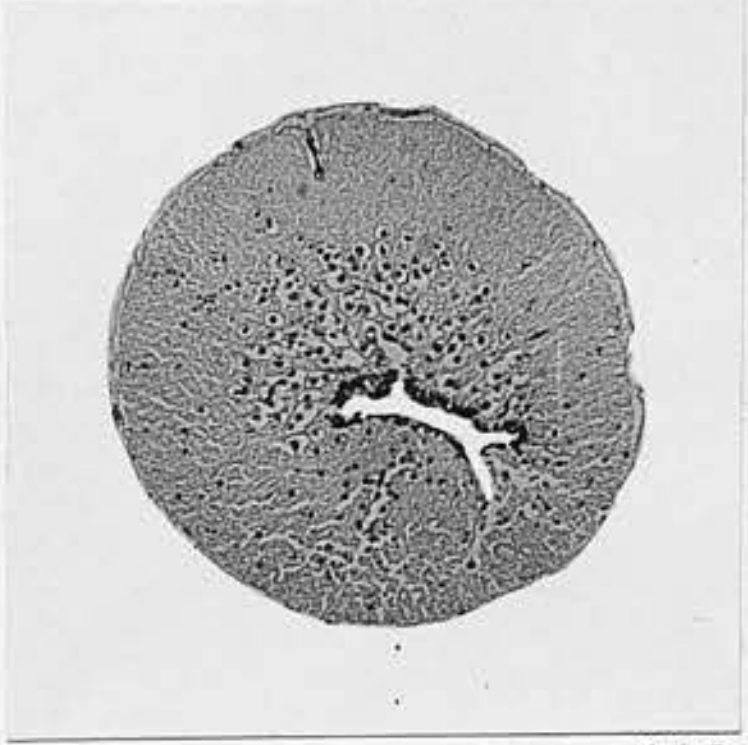

Fig 38

Shows same as 37.
Relatively cell free areas separate the two parts medially and laterally

Fig 39

The dorsal part is being pushed dorso-laterally by fibre tracts that are collecting between it and the ventricle

Fig 40

A tail is established from the medial end of the dorsal part to the medial angle of the ventricle this is made up of cells that can be distinguished and is the rostral end of the hippocampus

Figures 37 to 43 are in series rostro-caudally. The sections are transverse and are stained with Toluidin Blue

Fig 41

x 50

(a) = hippocampus
(b) = hypopallium
(c) = palaeostriatum
(d) = ventral part of ant. olf. nuc.
(e) = dorsal part.

Fig 42

x 50

(a) hippocampus
(b) hypopallium
(c) palaeostriatum
(d) ventral part of ant. olf. nuc.
(e) dorsal part of ant. olf. nuc
(f) dorsal cortex
(g) tuberculum olfactorium
(h) lateral olf. tract - nucleus

X50

Fig 43
The ring of cortex of the hemisphere is now
formed. (a) = hippocampus (b) = hypopallium
(c) = palaeostriatum (d) & (h) = lat. olf tr nucleus.
(e) = pyriform cortex (k) = dorsal cortex

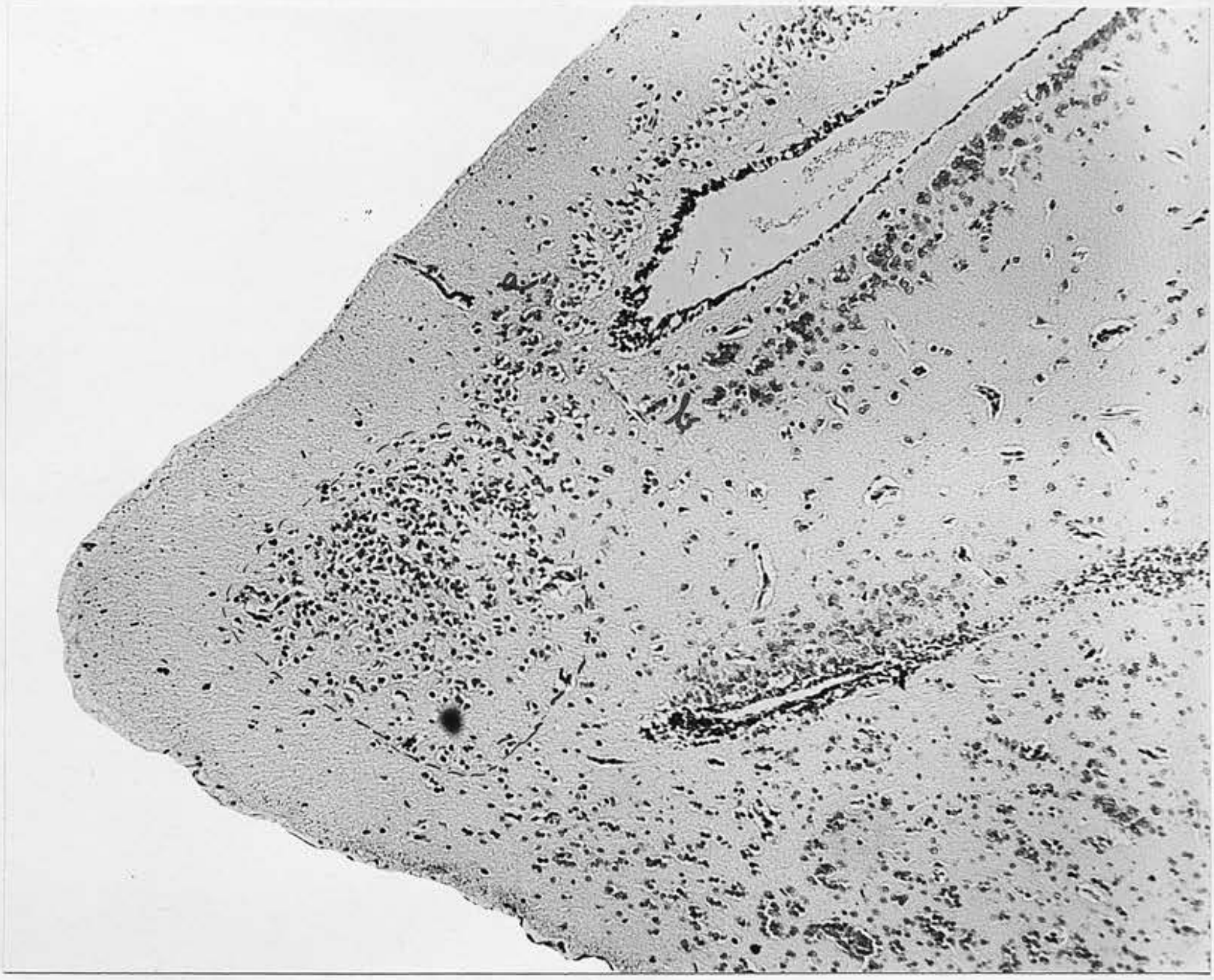

Fig 44

×67.5

A sagittal section of adult brain stained by Toluidin Blue The anterior olf. nuc. is encircled. The dorsal cortex (a) is meeting hyppopallium (b) The formation is distinct from the nucleus

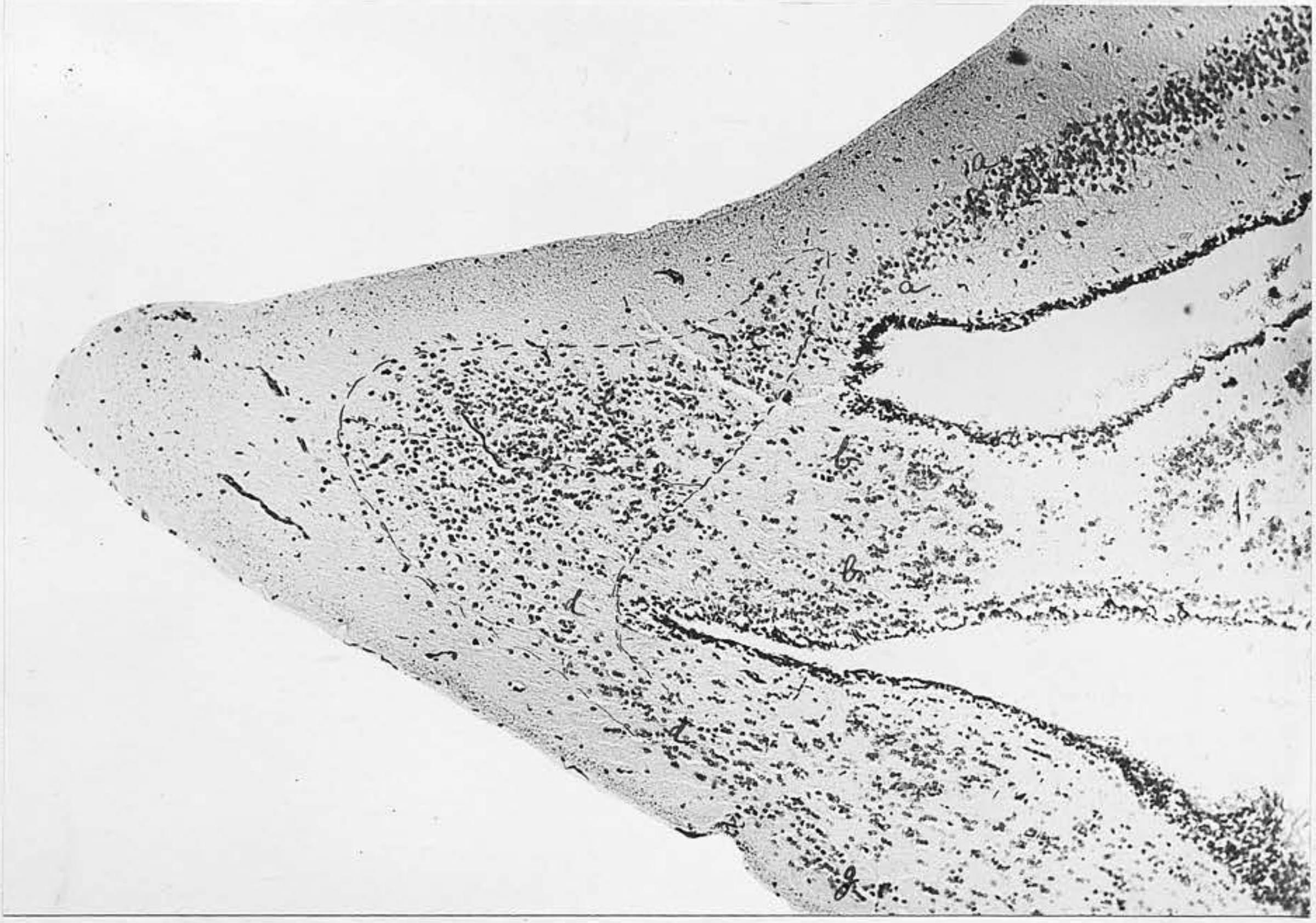

x67·5

Fig 45

Shows the ventral part of the ant. olf. nuc(d) continued into the tuberculum olfactorum (g)

The dorsal part is not continuous with the hyppopallium (b) or with the hippocampus (a) It over laps (a)

The dorsal part can be differentiated from the ventral part

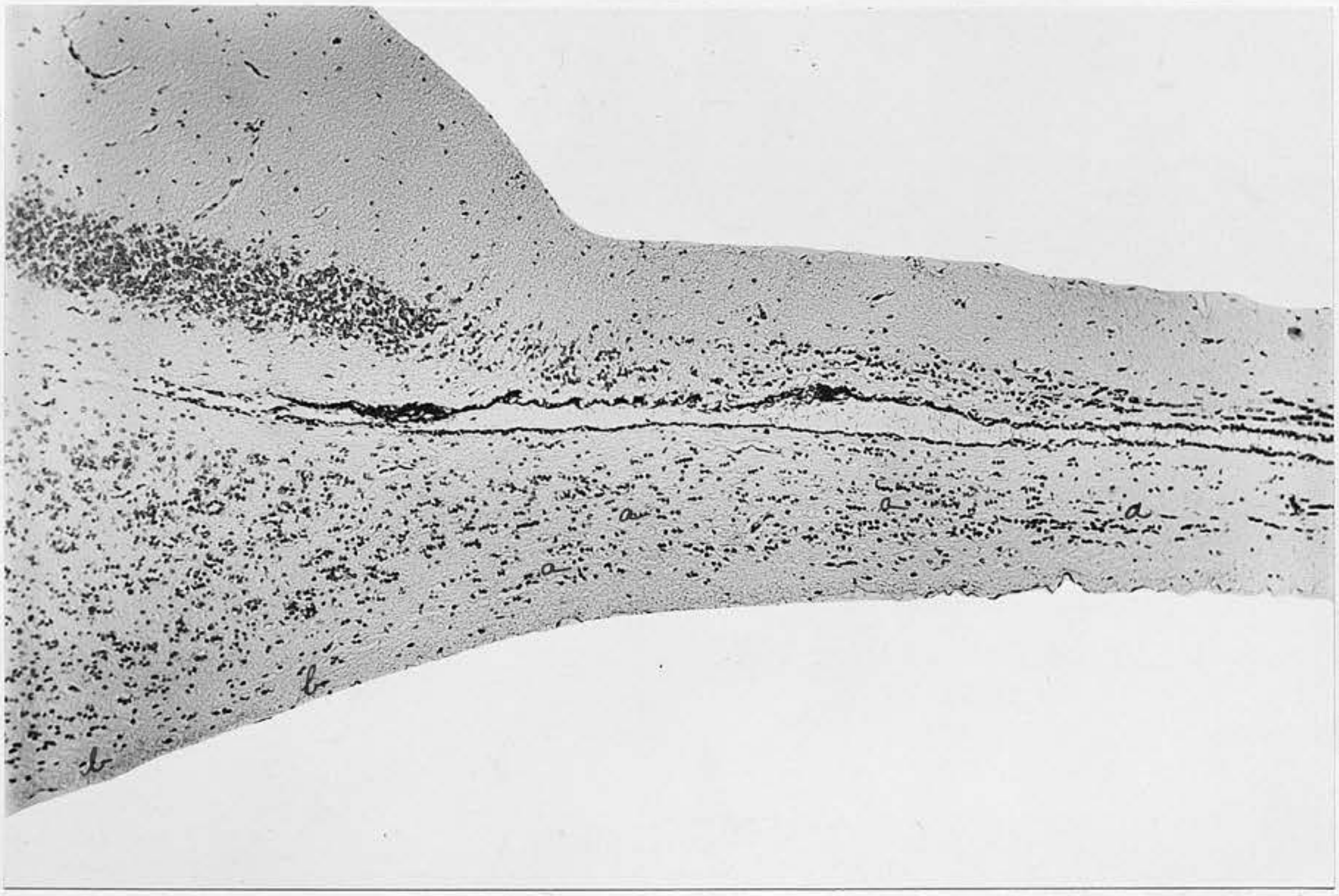

Fig 46 ×67.5

Shows the continuation of the ventral part of the nuc. olf. ant into the tuberculum olfactorium

(a) = ant. olf. nuc, ventral part

(b) = tuberculum olfactorium

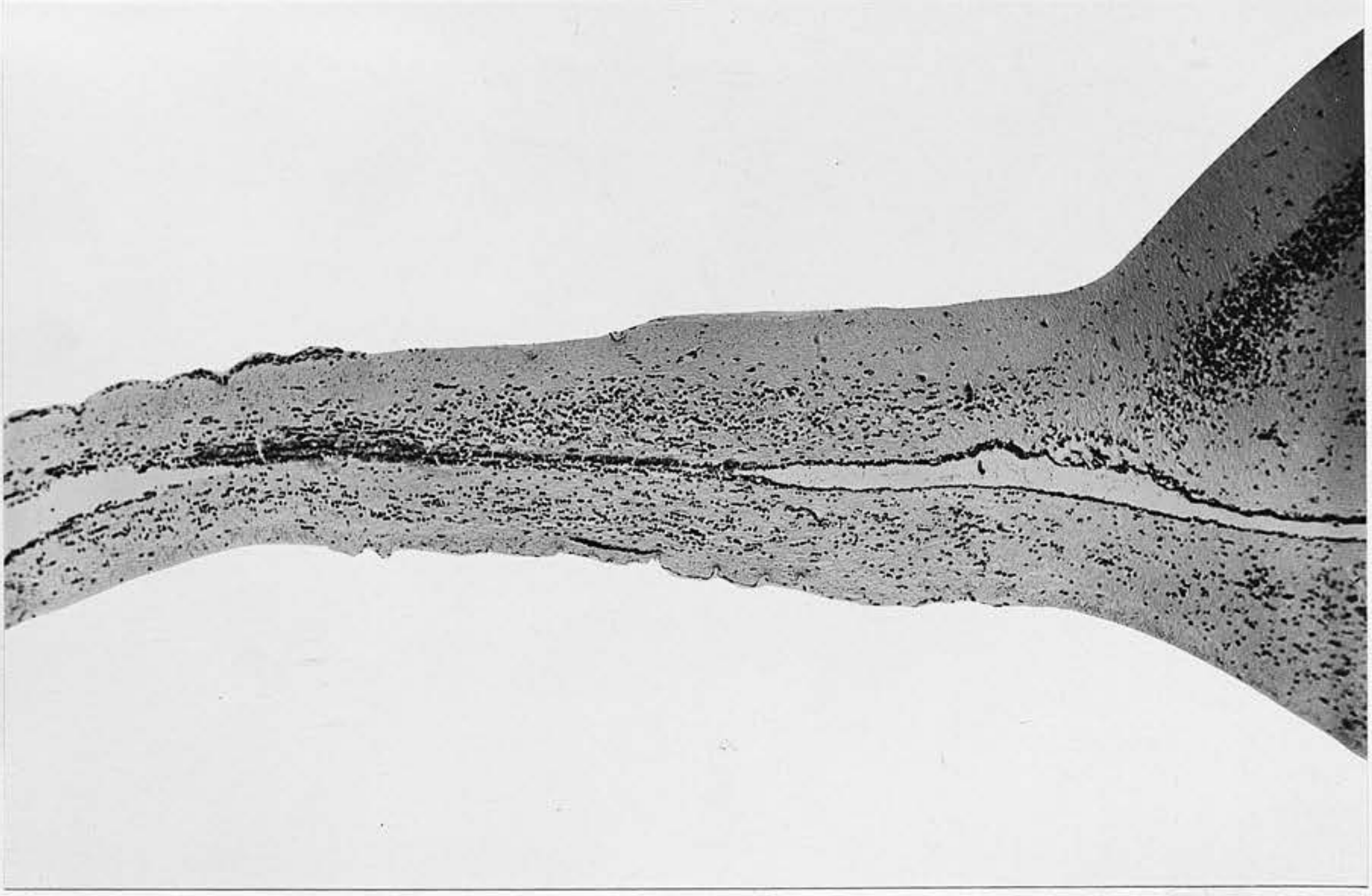

×40

Fig 47
Shows rostro caudal extent of ant. olf. nuc in the peduncle. and shows too that the dorsal part extends further rostrally than the ventral
The cells of the dorsal part are clumped irregularly those of the ventral part are in rows between laminae

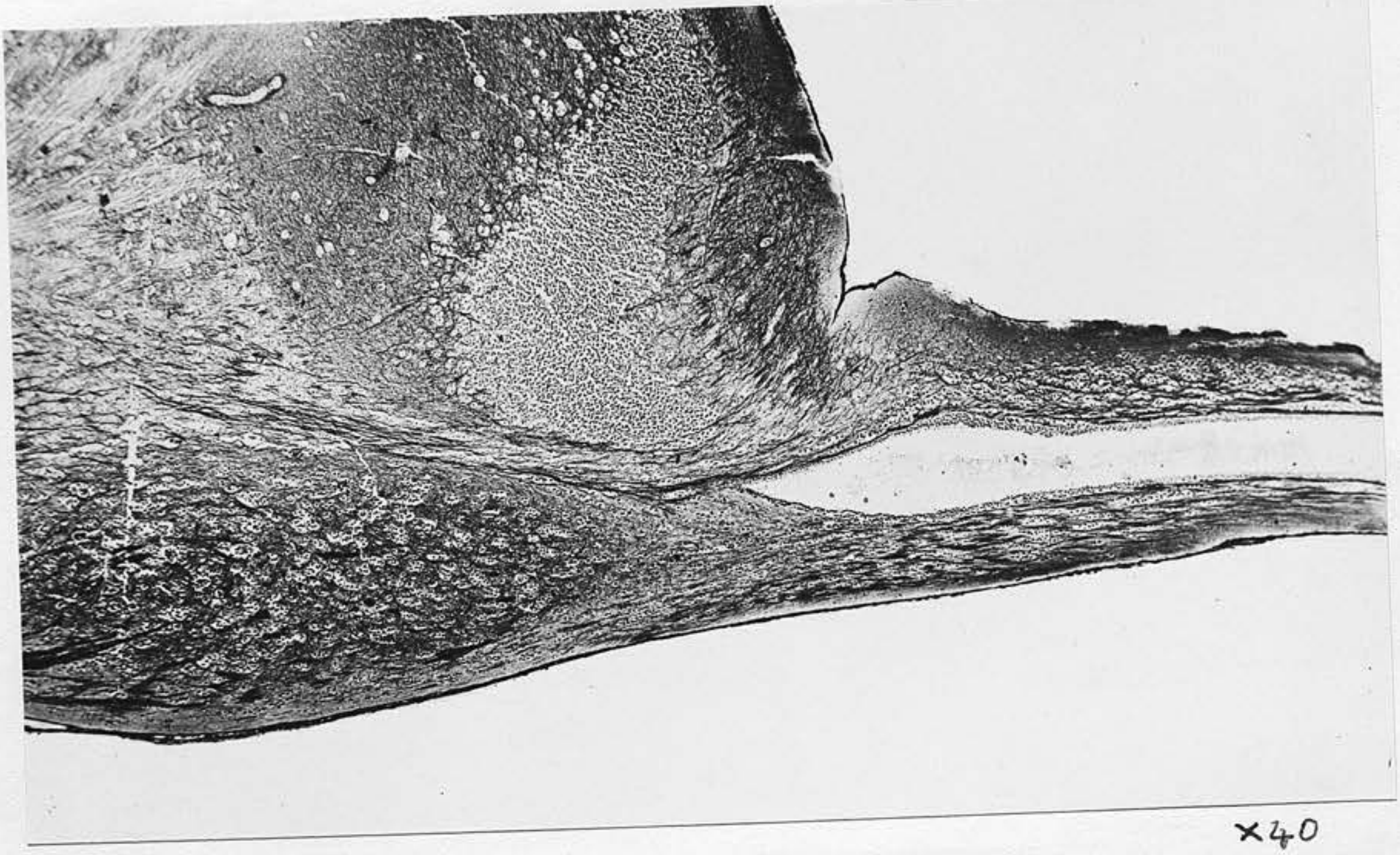

×40

Fig 48 Sagittal section stained by Ranson's method

Shows the laminated character of the ventral part part of the ant. olf. nuc. and shows it continued into the tuberculum olfactorium

The cells of the dorsal part are clumped in small clumps and enmeshed.

×40

Fig 49 Sagittal section stained by Ranson's method

The section is near the medial plane and shows the superficial part of the olfactory tract passing over the ant. olf. nuc to the hemisphere

18. XII. 34