



THE UNIVERSITY *of* EDINBURGH

Title	Molecular analysis and application of tissue microarray technology to the histopathological and immunohistochemical analysis of cervical adenocarcinoma
Author	Tawfik El-Mansi Ali, Magdy M.
Qualification	MD
Year	2006

Thesis scanned from best copy available: may contain faint or blurred text, and/or cropped or missing pages.

Digitisation notes:

- Binding frequently obscures text in guttering.



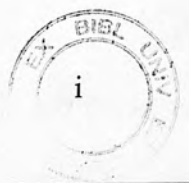**MOLECULAR ANALYSIS AND APPLICATION
OF TISSUE MICROARRAY TECHNOLOGY
TO THE HISTOPATHOLOGICAL AND
IMMUNOHISTOCHEMICAL ANALYSIS OF
CERVICAL ADENOCARCINOMA**

BY

DR. MAGDY M. TAWFIK EL-MANSI ALI
PATHOLOGY DEPARTMENT
UNIVERSITY OF EDINBURGH

**A Thesis Submitted for The Degree of Doctor of Medicine
(MD)**

Medical School, Edinburgh University, 2006



Dedication

I dedicate this thesis to God, Allah, who gave me the power and patience which sustained me during its production.

Thank you Allah.

Magdy

Dr. Magdy Tawfik El-Mahdi

Declaration of originality

I declare that this thesis was composed by me, and that with the exceptions detailed below, the work presented is entirely my own:

1-HPV PCR primers which used for PCR methods were designed and came from publications (Hwang, 1999).

2-The whole paraffin tissue sections and the tissue microarray sections were cut by the technical staff of the Research Pathology Laboratory of the Edinburgh, University Pathology Department

3- Tissue Microarray protocol was designed by Mr. M. Herroit one of the technical staff of the Research Pathology Laboratory of the Edinburgh, University Pathology Department.

Acknowledgements

I wish to thank my advisor, Dr Alistair Williams for his guidance, patience, and critical and helpful criticism during the course of writing my thesis.

The expert teaching of Professor Anthony Busuttil in forensic pathology, Dr. Awatif Al-Nafussi and Dr Kathryn MacLaren in diagnostic histopathology are gratefully acknowledged.

I am deeply grateful to Dr John Bartlett, Department of Surgery, and University of Glasgow, who taught me tissue microarray construction in his laboratory in Glasgow.

I wish to extend my thanks to Mr Robert Morris, Mrs Francis Rae and Mr Michael Herriot for their invaluable technical support.

I wish to express my thanks to Mrs Angela Lamb, Deputy Team Leader, Computing Services, University of Edinburgh, for her expert help with Access database proforma.

Finally, I am grateful to secretaries of pathology department, Edinburgh University, Morag McRae, Marilyn Cole, Angela Mackay and Helena Black for their help and assistance.

Edinburgh, 2006

Dr. Magdy Tawfik El-Mansi

ABSTRACT

Cervical cancer is the second most common cancer among women worldwide. Cervical adenocarcinoma accounts for 15-25% of all cervical cancers and the incidence appears to be increasing. Although some of this increase may be due to better recognition by pathologists, there is evidence that the incidence of both endocervical adenocarcinoma and its preinvasive precursor lesion cervical glandular intraepithelial neoplasia is actually increasing in real terms. In this study, tissue microarray technology was used to study the morphological features of cervical adenocarcinoma archival donor blocks, to evaluate the immunoprofile of a large set of cervical adenocarcinomas with an extended panel of antibodies to compare the profile of AIS with invasive subtypes of cervical adenocarcinomas. The prevalence of HPV 16&18 in cervical adenocarcinoma cases was assessed to evaluate its relation to cervical adenocarcinoma.

Using haematoxylin and eosin staining method 273 samples (blocks) were obtained from 177 biopsies composed of 16 normal cervical biopsies, 139 different patients with endocervical adenocarcinomas, and 22 patients with second biopsies. Pathology reports and cervical smear history reports were reviewed. Morphological and histopathological features of 139 patients with cervical adenocarcinomas revealed that there were 20 patients with adenocarcinoma-in-situ and 119 with invasive adenocarcinoma. Sixteen of 119 patients with invasive adenocarcinoma had early invasive adenocarcinoma which met criteria for FIGO stage IA₁ carcinoma of the cervix.

The tissue microarray technique has been demonstrated to be efficient and applicable to various tumour types, but methodological evaluations are few. A tissue microarray was constructed using paraffin-embedded, formalin-fixed tissues from 273 samples (blocks). Two paired 0.6-mm cores were obtained from selected regions of archival donor blocks and subsequently were arrayed into a recipient paraffin array blocks. More than 2 areas were taken from some tumours. The novel array blocks and some whole sections were used for immunohistochemical analysis and H&E staining. Results revealed that the tissue microarray method yields staining of good quality and

is feasible for histopathological and immunohistochemical studies in cervical adenocarcinoma. In general, the average staining pattern agreed with the whole section in each. Analysis of two TMA cores achieved 100% representation for histopathological type and greater than 97% representation for immunohistochemical studies.

Tissue array sections were immunostained with 8 antibodies, carcinoembryonic antigen (CEA), Cytokeratin7 (CK7), Cytokeratin20 (CK20), estrogen receptor (ER), progesterone receptor (PgR), phosphatase and tensin homolog deleted on chromosome ten (PTEN), MIB-1 proliferation marker, and p53 suppressor gene utilizing the “Power Vision” technique for ER only and “Envision” technique for all other antibodies. Our findings support that all of these 8 antibodies are of potential biomarkers of a panel of antibodies for diagnosis of cervical adenocarcinomas.

HPV DNA was extracted from paraffin-embedded, formalin-fixed tissues of 161 specimens of 139 patients excluding 22 patients with second samples and 16 normal cervical tissues. HPV DNA was detected by PCR test using type specific primers from the *E6* gene and *E7* gene of HPV type 16 and HPV type 18. Out of a total of 257 cervical biopsies from 139 women with various cervical adenocarcinomas lesions, HPV DNA was identified in 87 cases (62.6%) in which, HPV16 was positive for 65 (47%) patients and HPV18 was positive for 41 (29%) patients. Genotyping by RFLP and PCR revealed that HPV type 16 was the most frequent type of infection comprising 46 cases (33%), followed by HPV type 18 in 22 cases (16%), and both HPV type16 and HPV type 18 in 19 cases (14%). HPV typing in all cases of 16 normal cervical biopsies was negative with both HPV type16 and HPV type 18. The findings support that HPV 16, along with HPV 18, may play a possible role in the pathogenesis of adenocarcinoma of the uterine cervix.

ABBREVIATIONS

AIS: adenocarcinoma in situ

AISM: atypical immature squamous metaplasia

AdCx: Adenocarcinoma of the cervix

AISM: atypical immature squamous metaplasia

ACs/ASCs: Adenocarcinomas/ Adenosquamous carcinomas

ACISs/ASCISs; Adenocarcinomas in situ / Adenosquamous carcinomas in situ

CEA: carcinoembryonic antigen

CIS: Carcinoma in situ

CGIN: cervical glandular intraepithelial neoplasia

CK: Cytokeratin,

CK-20: Cytokeratin-20

CIF: Cellular interference factor

CCCs: clear cell carcinomas

CP: Conventional Pap

CT: Computed tomography scanning

CIN: Cervical Intraepithelial Neoplasia

DNA: Deoxyribonucleic acid

DES: Diethylstilbestrol

EGA: Endocervical glandular atypia

EGD: Endocervical glandular dysplasia

EIN: Endometrial Intraepithelial Neoplasia

ER: Oestrogen Receptor

FIGO: International Federation of Gynecology and Obstetrics

FISH: fluorescence in situ hybridization

GA: Glandular atypia

GDs: Glandular dysplasias

GFAP: Glial fibrous acidic Protein

H&E: Haematoxylin & eosin

HIV: Human immunodeficiency virus

hrHPV: high-risk human papillomavirus

HSV-2: Herpes simplex virus type 2

HGSILs: High grade squamous intraepithelial lesions

HCGIN: high grade cervical glandular intraepithelial neoplasia

HPV: human papillomavirus

HRP: Horse Radish Peroxidase

Ifs: Intermediate filaments

K7: keratin7

K20: keratin20

LSIL: low-grade squamous intraepithelial lesions

LCM: Laser Capture Microdissection

LBC: Liquid-based cytology

LCGIN: low grade cervical glandular intraepithelial neoplasia

MIA: Microinvasive Adenocarcinoma

MFL: Microfluorometry

MDA: Minimal deviation endocervical adenocarcinoma

MRI: Magnetic resonance imaging

mRNA: Messenger ribonucleic acid

MGH: Microglandular Hyperplasia

NICE: National Institute of Clinical Excellence

NOS: Not otherwise specified

O.C.T.: Optimal cutting temperature compound

OC's: Oral contraceptive

PgR: progesterone receptor

PTEN; Phosphatase and tensin homolog deleted on chromosome ten

PCR: polymerase chain reaction

PIP-3: phosphatidylinositol 3-triphosphate

PI3-kinase: phosphatidylinositol 3-kinase

PAS: periodic acid Schiff

pRB: Retinoblastoma

RB: Retinoblastoma

RT-PCR: Reverse transcriptase-polymerase chain reaction

RFLP: Restriction fragment length polymorphism

RNA-ISH: RNA in situ hybridization

SCJ: Squamocolumnar junction

STWS: Scott's Tap Water Substitute

SILs: cervical squamous intraepithelial lesions

TGF- β : Transforming growth factor- β

TMA: Tissue microarray

TNM: The tumour, node, metastasis

TNF- α : Tumour necrosis factor- α

TZ: Transformation (transition) zone

TP: ThinPrep

TEM: Tubo-endometrial metaplasia

VLPs: Virus-like particles'

VGC: Villoglandular papillary adenocarcinoma

WHO: World Health Organisation

NO.	TITLE	PAGE NO.
Table 1	Classification of pure cervical adenocarcinoma	5
Table 2	Classification of pure cervical adenocarcinoma	10
Table 3	Classification of adenocarcinoma with a glandular and non-glandular component	11
Table 4	Benign glandular tumours	14
Table 5	Modified FIGO Staging (Sheppard, 1995)	19
Table 6	Specimens of type specific primers used throughout the study	20
Table 7	Restriction enzyme fragment sizes of PCR products	25
Table 8	Comparison between adenocarcinoma in situ and invasive adenocarcinoma with respect to age group	27
Table 9	Association of CIN and/or CCIN in invasive adenocarcinoma	31
Table 10	Cervical histology reports of all cervical adenocarcinoma	32
Table 11	Subtypes of invasive adenocarcinoma and age group	37
Table 12	Subtypes of invasive adenocarcinoma and grade	38
Table 13	Subtypes of invasive adenocarcinoma and stage	39
Table 14	Subtypes of invasive adenocarcinoma with respect to CIN and CCIN association	40
Table 15	Subtypes of invasive adenocarcinoma with respect to follow up status	41
Table 16	Subtypes of invasive adenocarcinoma with respect to the locality of invasion	42
Table 17	Subtypes of invasive adenocarcinoma and AIS with respect to clinical response	43
Table 18	Subtypes of invasive adenocarcinoma with respect to the lymphovascular (LVS)	44

TABLES

NO.	TITLE	PAGE NO.
Table 1.	Benign lesions that mimic adenocarcinoma	6
Table 2.	Classification of pure cervical adenocarcinomas	10
Table 3.	Classification of adenocarcinomas with a gland and non-glandular component	11
Table 4.	Benign glandular tumours	11
Table 5	Modified FIGO Staging (Shepperd, 1995)	19
Table 6	Sequences of type specific primers used throughout these studies	61
Table 7	Restriction enzyme fragment sizes of PCR products	63
Table 8	Comparison between adenocarcinoma in situ and invasive adenocarcinoma with respect to age group	71
Table 9	Association of CIN and/or CGIN in invasive adenocarcinoma	71
Table 10	Cervical smear history reports of all cervical adenocarcinomas.	76
Table 11	Subtypes of invasive adenocarcinoma and age group.	77
Table 12	Subtypes of invasive adenocarcinoma and grade.	78
Table 13	Subtypes of invasive adenocarcinoma and stage.	79
Table 14	Subtypes of invasive adenocarcinoma with respect to CIN and CGIN association.	80
Table 15	Subtypes of invasive adenocarcinoma with respect to pattern of invasion.	81
Table 16	Subtypes of invasive adenocarcinoma with respect to the focality of invasion.	82
Table 17	Subtypes of invasive adenocarcinoma and AIS with respect to stromal response.	83
Table 18	Subtypes of invasive adenocarcinoma with respect to the lymphovascular (LVSI).	84

Table 19 Cervical smear reports history of all early invasive adenocarcinomas.	86
Table 20 immunohistochemical results for 139 patients with cervical adenocarcinomas.	102-103
Table 21 Adenocarcinoma in situ and invasive adenocarcinoma with respect to CK7..	112
Table 22 Adenocarcinoma in situ and invasive adenocarcinoma with respect to CK20.	113
Table 23 Adenocarcinoma in situ and invasive adenocarcinoma with respect to CEA.	113
Table 24 Adenocarcinoma in situ and invasive adenocarcinoma with respect to ER.	113
Table 25 Adenocarcinoma in situ and invasive adenocarcinoma with respect to PgR.	114
Table 26 Adenocarcinoma in situ and invasive adenocarcinoma with respect to MIB1.	114
Table 27 Adenocarcinoma in situ and invasive adenocarcinoma with respect to PTEN.	115
Table 28 Adenocarcinoma in situ and invasive adenocarcinoma with respect to p53.	115
Table 29 Subtypes of invasive adenocarcinoma and AIS with respect to CK7.	116
Table 30 Subtypes of invasive adenocarcinoma and AIS with respect to CK20.	117
Table 31 Subtypes of invasive adenocarcinoma and AIS with respect to CEA.	118
Table 32 Subtypes of invasive adenocarcinoma and AIS with respect to ER.	119
Table 33 Subtypes of invasive adenocarcinoma and AIS with respect to PgR.	120
Table 34 Subtypes of invasive adenocarcinoma and AIS with respect to MIB1.	121
Table 35 Subtypes of invasive adenocarcinoma and AIS with respect to PTEN.	122
Table 36 Subtypes of invasive adenocarcinoma and AIS with respect to p53.	123
Table 37 Adenocarcinoma in situ and invasive adenocarcinoma with respect to HPV16 and HPV18 infection.	168

Table 38 Subtypes of invasive adenocarcinoma and AIS with respect to HPV16 and HPV18	169
--	-----

FIGURES

Table 39 Frequency of HPV16 and/or 18 DNA in cervical adenocarcinoma by hybridization and PCR.	201
--	-----

Fig. 1-1 (a) Invasive adenocarcinoma	17
Fig. 1-1 (b) The organization of circular HPV DNA and its integration into host cell DNA	23
Fig. 1-2 (a) Diagram of TMA organ section. Tissue samples are distributed in TMA sheet using (X,Y) coordinates	55
Fig. 2-1 (a) TMA slide and stain	33

Figures (5-19) ... Results of Chapter 1	87-169
---	--------

I demonstrated different subtypes of cervical adenocarcinoma and its precursors according to the study of the whole H&E sections.

Figures (19-60) ... Results of Chapter 2	170-199
--	---------

Firstly, I demonstrated comparison between the TMA core and the whole section. Secondly, I demonstrated TMA technique as a tool in studying morphological and immunohistochemical features of cervical adenocarcinoma. Finally, I demonstrated TMA technique as a tool in studying immunohistochemical staining of different subtypes of cervical adenocarcinoma.

Secondly, I demonstrated immunohistochemical staining of different subtypes of cervical adenocarcinoma and its precursors.

Figures (21-61) ... Results of Chapter 3	170-199
--	---------

FIGURES

NO.	TITLE	PAGE NO.
(Fig .1)	Endocervical adenocarcinoma	12
(Fig .2)	The organization of circular HPV DNA and its integration into host-cell DNA	23
(Fig.3)	Diagram of TMA organization. Tissue samples are distributed in TMA chart using (X:Y) relationship	55
(Fig 4a & 4b)	TMA block and slide	55
Figures (5-18).....	Results of Chapter 1 I demonstrated different subtypes of cervical adenocarcinoma and its precursors according to the study of the whole H&E sections	87-100
Figures (19-60).....	Results of Chapter 2 Firstly, I demonstrated comparison between the TMA core and the whole section. Secondly, I demonstrated TMA technique as a tool in studying morphological and histopathological features of cervical adenocarcinomas. Finally, I demonstrated TMA technique as a tool in studying immunohistochemical staining of different antigens in cervical adenocarcinomas. Secondly, I demonstrated immunohistochemical staining of different antigens in different subtypes of cervical adenocarcinoma and its precursors	124-165
Figures (61-64).....	Results of Chapter 3	170-173

Contents

PREFACE

Title page.....	i
Dedication.....	ii
Declaration.....	iii
Acknowledgements.....	iv
Abstract.....	v
Abbreviations.....	vii
Tables.....	xi
Figures.....	xiv
Contents.....	xv

PART (I)INTRODUCTION.....1

CHAPTER(1) CERVICAL ADENOCARCINOMA 2

2.1 INTRODUCTION 2

2.2 A ETIOLOGY&RISK FACTORS FOR CERVICAL NEOPLASIA 2

2.2.1 Human papillomavirus (HPV) and other sexually transmitted agents... 2

2.2.2 Oral Contraceptives (OC's)..... 3

2.2.3 Dietary Factors 3

2.2.4 Predisposing Genetic Factors..... 4

2.2.5 Sexual Behaviour..... 4

2.2.6 Reproductive Factors..... 4

2.2.7 Smoking Habits..... 4

1.3 EPIDEMIOLOGY OF CERVICAL ADENOCARCINOMA..... 5

1.4 BENIGN LESIONS THAT MIMIC ADENOCARCINOMA 5

1.5 PREMALIGNANT CERVICAL GLANDULAR LESIONS 7

1.5.1 Morphological features of CGIN 7

1.5.2 Low grade CGIN (LCGIN) or Endocervical glandular dysplasia (EGD). 8

1.5.3 High grade CGIN (HCGIN) or Adenocarcinoma in situ (AIS)..... 8

1.5.4 Glandular dysplasia.....	9
1.5.5 Distinction of invasive from preinvasive adenocarcinoma in the endocervix.....	9
<u>1.6 EARLY INVASIVE ADENOCARCINOMA.....</u>	<u>9</u>
1.6.1 Introduction	9
1.6.2 Identification of early invasive adenocarcinoma.....	10
<u>1.7 MORPHOLOGICAL SUBTYPES OF INVASIVE ADENOCARCINOMA.....</u>	<u>10</u>
1.7.1 Gross Appearance of Cervical Adenocarcinoma).....	11
1.7.2 Adenocarcinoma, Usual endocervical type	12
1.7.3 Variants of Adenocarcinoma, endocervical type.....	12
<u>1.8 DIAGNOSIS OF CERVICAL ADENOCARCINOMAS.....</u>	<u>17</u>
1.8.1 Cervical screening methods	17
1.8.2 Cervical biopsy and radiological imaging techniques.....	18
1.8.3 Cervical cone biopsy in diagnosis and management of glandular lesions	19
2.9.4 Evaluation and Staging.....	19
<u>1.9 PROGNOSIS OF CERVICAL ADENOCARCINOMAS.....</u>	<u>21</u>
<u>1-10 MANAGEMENT OF CERVICAL ADENOCARCINOMAS.....</u>	<u>21</u>

.21

<u>CHAPTER (2) HUMAN PAPILLOMAVIRUSES (HPVS) AND CANCER.....</u>	<u>22</u>
<u>2.1 INTRODUCTION</u>	<u>22</u>
<u>2.2 HPV PATHOGENESIS (LIFE CYCLE).....</u>	<u>22</u>
<u>2.3 THE ORGANIZATION OF CIRCULAR HPV AND ITS INTEGRATION INTO HOST-CELL DNA.....</u>	<u>23</u>
<u>2.4 TYPES OF HPV AND GENITAL TRACT INFECTIONS</u>	<u>24</u>
<u>2.5 HUMAN PAPILLOMA VIRUSES (HPVs) AND CERVICAL PATHOLOGY</u>	<u>24</u>
2.5.1 The integration of HPV-16 and HPV-18 DNA in cervical carcinomas (Fig.8)	24
2.5.2 Prevalence of HPVs in Cervical Adenocarcinoma	25
2.5.3 HPV and p53 Pleomorphism.....	26

2.5.4 HPV Detection and Typing	26
2.5.5 HPV Testing and Cancer Screening	27
2.5.6 Cervical Cancer Prevention	28
<u>CHAPTER (3) TISSUE MICROARRAY (TMA)</u>	29
<u>3.1 INTRODUCTION</u>	29
<u>3.2 TMA CONSTRUCTION</u>	30
<u>3.3 TISSUE MICROARRAYS STAINING AND ANALYSIS</u>	33
<u>3.4APPLICATIONS OF TMAs</u>	34
<u>CHAPTER (4) IMMUNOHISTOCHEMISTRY (ANCILLARY TECHNIQUES)</u>	37
<u>4.1 ANCILLARY STUDIES USEFUL IN DISTINCTION BETWEEN ENDOC- CERVICAL AND ENDOMETRIAL ADENOCARCINOMA</u>	37
<u>4.2 ANCILLARY TECHIQUES USEFUL IN DISTINCTION OF MALIGNANT AND PREMALIGNANT CERVICAL LESIONS FROM BENIGN MIMICS</u>	38
<u>4.3 ANCILLARY STUDIES USEFUL IN DIAGNOSIS OF CERVICAL MESO- NEPHRIC LESIONS</u>	39
<u>4.4 ANCILLARY STUDIES USEFUL IN DIAGNOSIS OF MDA</u>	39
<u>4.5 ANTIBODIES USEFUL IN DIAGNOSIS OF CERVICAL ADENOCARCIN- OMAS</u>	40
4.5.1 Cytokeratins(CK).....	40
4.5.2 Carcinoembryonic antigen (CEA)	44
4.5.3 Estrogen receptor (ER) and progesterone receptor (PgR).....	45
4.5.4 PTEN	46
4.5.5 MIB-1 (Proliferation Marker).....	48
4.5.6 The Suppressor Gene p53.....	48
<u>AIMS OF THE WORK</u>	49

<u>PART(II) MATERIALS AND METHODS</u>	51-66
<u>CHAPTER (1) MORPHOLOGICAL AND HISTOPATHOLOGICAL STUDY</u>	52
<u>CHAPTER (2) TISSUE MICROARRAY (TMA) CONSTRUCTION</u>	54
<u>CHAPTER (3) IMMUNOHISTOCHEMISTRY</u>	58
<u>CHAPTER (4) DETECTION AND TYPING OF HPV DNA</u>	61
<u>4.1 CLINICAL SPECIMENS</u>	61
<u>4.2 DNA EXTRACTION FROM PARAFFIN BLOCKS</u>	61
<u>4.3 POLYMERASE CHAIN REACTION (PCR) METHODS</u>	61
4.3.1 <i>Primer design</i>	61
4.3.2 <i>PCR Protocol</i>	62
4.3.3 <i>PCR Program</i>	62
4.3.4 <i>Agarose gel electrophoresis</i>	62
4.3.5 <i>Gel Visualisation</i>	62
4.3.6 <i>Restriction digestion of genomic DNA</i>	63
4.3.7 <i>Optimisation the HPV PCR analysis</i>	63
<u>4.4 LASER CAPTURE MICRODISSECTION (LCM)</u>	64
<u>STATISTICS</u>	66
<u>PART(III) RESULTS</u>	67
<u>CHAPTER (1) MORPHOLOGICAL AND HISTOPATHOLOGICAL STUDY</u>	68-100
<u>1.1 CLINICOPATHOLOGICAL CHARACTERISTICS</u>	68
<u>1.2 ADENOCARCINOMA IN SITU</u>	69
<u>1.3 INVASIVE ENDOCERVICAL ADENOCARCINOMA</u>	72
<u>1.4 CERVICAL SMEAR HISTORY</u>	76
<u>1.5 EARLY INVASIVE ADENOCARCINOMA(MICROINVASIVE ADENOCARCINOMA)</u>	85

<u>CHAPTER (2) VALIDATION OF TISSUE MICROARRAY TECHNOLOGY</u>	101-165
--	---------

<u>2.1 TISSUE MICROARRAY TECHNOLOGY AS A NEW TOOL FOR CERVICAL</u>	101..
---	-------

<u>2.2 IMMUNOHISTOCHEMICAL RESULTS OF CERVICAL ADENOCARCINOMAS</u>	103
---	-----

<i>2.2.1 GENERAL IMMUNOHISTOCHEMICAL PROFILE</i>	104
--	-----

<i>2.2.2 CYTOKERATIN7 (CK7)</i>	105
---------------------------------------	-----

<i>2.2.3 CYTOKERATIN 20 (CK20)</i>	106
--	-----

<i>2.2.4 CARCINOEMBRYONIC ANTIGEN (CEA)</i>	107
---	-----

<i>2.2.5 ESTROGEN RECEPTORS (ER)</i>	108
--	-----

<i>2.2.6 PROGESTERONE RECEPTORS (PGR)</i>	109
---	-----

<i>2.2.7 MIB1 PROLIFERATION MARKER</i>	110
--	-----

<i>2.2.8 PHOSPHATASE AND TENSIN HOMOLOG DELETED ON CHROMOSOME TEN (PTEN)</i>	111
---	-----

<i>2.2.9 P53 SUPPRESSOR GENE</i>	112
--	-----

<u>CHAPTER (3) HUMAN PAPILOMA VIRUSES 16 AND 18 IN CERVICAL ADENOCARCINOMA</u>	166-169
---	---------

<u>PART(1V) DISCUSSION AND CONCLUSION</u>	174-205
--	---------

<u>CHAPTER (1) MORPHOLOGICAL AND HISTOPATHOLOGICAL STUDY</u>	175
--	-----

<i>1.1 INVASIVE ENDOCERVICAL ADENOCARCINOMA</i>	175
---	-----

<i>1.2 EARLY INVASIVE ADENOCARCINOMA (MICROINVASIVE ADENOCARCINOMA)</i>	177
---	-----

<i>1.3 ADENOCARCINOMA IN SITU (AIS) (HIGH GRADE CGIN H-CGIN)</i>	179
--	-----

<i>1.4 CERVICAL SMEAR</i>	181
---------------------------------	-----

<u>CHAPTER (2) VALIDATION OF TISSUE MICROARRAY TECHNOLOGY</u>	183
--	-----

<u>2.1 TISSUE MICROARRAY TECHNOLOGY AS A NEW TOOL FOR CERVICAL</u>	183
---	-----

<u>2.2 IMMUNOHISTOCHEMICAL RESULTS OF CERVICAL</u>	
<u>ADENOCARCINOMAS</u>	187
<u>2.2.1 CK7 &CK20</u>	188
<u>2.2.2 CEA</u>	189
<u>2.2.3 ER&PGR</u>	191
<u>2.2.4 MIB-1</u>	193
<u>2.2.5 PTEN</u>	194
<u>2.2.6 P53 SUPPRESSOR GENE</u>	197
<u>CHAPTER (4) HUMAN PAPILOMA VIRUSES 16 AND 18 IN CERVICAL</u>	
<u>ADENOCARCINOMA</u>	199-205
<u>COMPOSITION OF SOLUTIONS</u>	206-209
<u>REFERENCE LIST</u>	210-252
<u>APPENDIX</u>	253-260
<u>PUBLISHED PAPERS (THREE ARTICLES)</u>	

CHAPTER I

CERVICAL ADENOCARCINOMA

1.1 INTRODUCTION

Cervical cancer is the second most common type of cancer worldwide. The most common histological type of cervical cancer is squamous cell carcinoma, which comprises approximately 85% of all cervical cancers. Adenocarcinoma, which comprises approximately 15% of all cervical cancers, is a less common malignancy. The incidence of adenocarcinoma has increased significantly in recent years, particularly in women under the age of 30. This increase is thought to be related to the increased use of oral contraceptives and the spread of human papillomavirus (HPV) infection. The pathogenesis of adenocarcinoma is not fully understood, but it is thought to be a result of the increased use of oral contraceptives and the spread of HPV infection.

1.2 AETIOLOGY AND RISK FACTORS FOR CERVICAL ADENOCARCINOMA

1.2.1 Human papillomavirus (HPV) infection

HPV infection is a necessary condition for the development of cervical adenocarcinoma. The most common HPV type associated with cervical adenocarcinoma is HPV 18. Other HPV types associated with cervical adenocarcinoma include HPV 31, 33, 35, 39, 45, 51, 52, 56, 59, 63, 68, 73, 82, and 89. HPV infection is transmitted through sexual contact. The risk of developing cervical adenocarcinoma is higher in women who are sexually active and have multiple partners.

The progression of HPV infection to cervical adenocarcinoma is a multi-step process. The first step is the acquisition of HPV infection. The second step is the development of cervical dysplasia, which is a precancerous condition. The third step is the development of cervical adenocarcinoma. The progression of HPV infection to cervical adenocarcinoma is influenced by several factors, including the type of HPV infection, the duration of HPV infection, and the presence of other risk factors. The risk of developing cervical adenocarcinoma is higher in women who are sexually active and have multiple partners.

CHAPTER 1

CERVICAL ADENOCARCINOMA

1.1 INTRODUCTION

Cervical cancer is the second most common type of cancer in females worldwide. The 2 most common histological types of cervical cancer are squamous cell carcinoma, which comprises approximately 75% of cases, and endocervical adenocarcinoma, which comprises approximately 20% of all cases. Other less common malignancies of the cervix include adenosquamous cell carcinoma, adenoid cystic carcinoma, small cell neuroendocrine tumours, and other rare histological types (Bonds et al., 2002). An absolute increase in prevalence of adenocarcinoma and its precursors has been documented, both in the USA and Europe; therefore interest in cervical adenocarcinoma has grown in recent years. It has been proposed that this may be related to the increased use of brush sampling of the cervix, but may also be a function of increased diagnostic awareness and recognition of glandular pathology in cytological and histological preparations (Mathers et al., 2002).

1.2 AETIOLOGY AND RISK FACTORS FOR CERVICAL NEOPLASIA

1.2.1 Human papillomavirus (HPV) and other sexually transmitted agents

More than 35 types of HPV are associated with anogenital disease, and 30 or more are associated with cancer (Muñoz & Bosch, 1997). Although a strong and consistent association between HPV and cervical neoplasia has been clearly established, the discrepancy between HPV prevalence and the incidence of cervical neoplasia suggests that other cofactors are necessary for the development and progression of the disease. (Brinton, 1992).

The functional status of the immune system is closely associated with the development of cervical dysplasia and cancer in women with HPV infection (Kobayashi et al., 2000). HIV-positive women have been reported to have higher rates of cervical abnormalities, larger lesions, higher grades of lesions, and higher recurrence rates than HIV-negative women do. Mandelblatt et al., (1999) concluded

that HIV is a cofactor in the association between HPV and cervical neoplasia, and this association seems to vary with the level of immune function (Ruche et al., 1999).

Interaction between HSV-2 and HPV 16/18 was detected by several studies however; several recent studies continue to provide conflicting evidence. Serologic studies showed a higher prevalence of HSV-2 antibodies among women with cervical neoplasia than among controls (zur Hausen, 1982).

An association between the presence of antibodies for *Chlamydia trachomatis* and cervical neoplasia persisting after controlling for HPV status and other potential factors has been reported (Boyle & Smith, 1999).

1.2.2 Oral Contraceptives (OC's)

Endocervical glandular lesions have been associated with the use of OC's for quite some time (Dallenbach-Hellweg, 1984; Valente & Hanjani 1986; Ursin et al., 1994; Parazzini et al., 1998; Ljuca et al., 2000). Since the early 1960's, when OC's use began, the incidence of cervical adenocarcinoma has increased, especially in young white women (Schwartz & Weiss, 1986; Zheng et al., 1996). Over the past fifty years, the proportion of cervical carcinoma which is adenocarcinoma is almost 25%. The World Health Organization's Collaborative Study of Neoplasia and Steroid Contraceptives confirmed this increased risk, especially in younger women on OC's for more than 5 years (Thomas & Ray, 1996).

1.2.3 Dietary Factors

Several lines of evidence suggest that some nutrients may have a protective effect against cervical neoplasia, particularly vitamin A, carotenoids, vitamin C, vitamin E, and folic acid (Schneider & Shah, 1989). In addition, a subclinical folate deficiency may act as a cofactor in the integration of the HPV genome into host DNA (Butterworth, 1992). Several studies indicate HPV is more easily contracted when folate levels are low (Li et al., 1995; Durand et al., 1997; Lewis et al., 1998). Reports indicate that high levels of folic acid appear to provide a protective effect against the initiation of HPV-related dysplasias (Butterworth, 1993; Harper et al., 1994; Griot et al., 1993; Liu et al., 1995).

1.2.4 Genetic Factors

Genetic predisposing factors that may influence HPV's behaviour more than environmental factors such as multiple sex partners, smoking have been reported by Magnusson et al., (2000). The common inherited folate gene mutation, MTHFR 677 C-->T, which greatly impairs folate metabolism, has recently been found in association with cervical and endometrial neoplasms (Piyathilake et al., 2000; Thomson et al., 2000).

1.2.5 Sexual Behaviour

In preinvasive cervical disease, the effect of the number of sexual partners is substantially reduced after adjustment for HPV (Becker et al., 1994). However, in invasive lesions, the association with the number of sexual partners remained statistically significant or on the borderline (Herrero et al., 1990; Bosch et al., 1992). Moreover, no association is observed between number of sexual partners and cervical neoplasia among HPV-positive women, whereas a positive association remains among HPV-negative women (Bosch et al., 1992; Koutsky et al., 1992; Schiffman et al., 1993).

1.2.6 Reproductive Factors

An association between parity or number of live births and cervical neoplasia has been reported in six case-control studies after controlling for HPV status (Herrero et al., 1990). However multiparous women found to have approximately 80% higher risk of AIS and invasive cancer compared with nulliparous women (Schiffman et al., 1993; Muñoz et al., 1993; Eluf-Neto et al., 1994). In addition, a strong association between invasive cervical cancer and early age at first birth reported by Bosch et al., (1993), and coupled with the absence of an association with parity.

1.2.7 Smoking Habits

Several epidemiologic studies have provided evidence supporting an association between cigarette smoking and cervical neoplasia. Wilkenstein, (1990a) reported that two-fold increased risk among smokers and a dose-response relationship with duration and intensity of smoking. Although the mechanism of carcinogenesis of smoking in cervical tissue is not fully understood, current biologic, epidemiologic, and clinical studies suggest that cigarette smoking may be a risk factor for cervical neoplasia (Szarewski et al., 1996).

1.3 EPIDEMIOLOGY OF CERVICAL ADENOCARCINOMA

The epidemiology of adenocarcinoma of the cervix has changed substantially over the last two decades. Malignant and premalignant endocervical glandular lesions are relatively rare but their incidence appears to be increasing. Most of this increase is more apparent than real because of the better recognition of premalignant endocervical glandular lesions by histopathologists and the realisation that some poorly differentiated cervical carcinomas are glandular in type. Moreover, there has been a decrease in the incidence of invasive squamous cell carcinoma in many countries because of the success of cervical screening programmes. However, there is evidence that there is also a real increase in the incidence of malignant and premalignant endocervical glandular lesions, which are therefore assuming increasing importance in diagnostic surgical pathology (McCluggage, 2003).

Some believe endocervical glandular atypia (EGA), purportedly composed of cells that are less atypical than cells of adenocarcinoma in situ (AIS), is a preneoplastic precursor of AIS. The precursors of invasive adenocarcinoma of the cervix were recognized in the 1950s (Friedell & McKay, 1953). The best defined precursor, if one exists, is adenocarcinoma in situ, which occurs infrequently in comparison with HGSILs. Adenocarcinoma in situ is associated with HPV DNA, mostly HPV 18, as opposed to HPV 16 in SILs. Adenocarcinoma in situ is less likely to be detected by Pap smear than are SILs (Andersen & Arffmann 1989). In the majority of cases; adenocarcinoma in situ involves the transformation zone and is unifocal (Cullimore et al., 1992). Carcinomas of the cervix, regardless of histology and size of the primary tumour, may contain highly malignant clones of cells that can prove unpredictable and spread extensively (Eifel et al., 1990).

1.4 BENIGN LESIONS THAT MIMIC ADENOCARCINOMA

A wide variety of benign endocervical glandular lesions may be confused with CGIN and even invasive cervical adenocarcinoma, especially the mucinous variant of MDA. These are listed in table 1. Many of these benign mimics are rare and in everyday practice the lesions most likely to be confused with CGIN (Young & Clement, 2002).

Table 1. Benign lesions that mimic adenocarcinoma (Quoted from Young and Clement, 2002).

Endocervical gland hyperplasias
Tunnel clusters
Microglandular hyperplasia
Deep glands and cysts
Lobular endocervical gland hyperplasia, not otherwise specified
Diffuse laminar endocervical gland hyperplasia
Glandular hyperplasia, not otherwise specified
Mesonephric hyperplasia*
Metaplasias and ectopias of endocervical glands
Tubal, tubo-endometrioid and endometrioid metaplasia
Endometriosis
Endosalpingiosis
Endocervicosis
Atypical oxyphilic metaplasia
Intestinal metaplasia
Arias-Stella reaction
Ectopic prostate
Reactive and Inflammatory Lesions
Papillary endocervicitis
Infectious atypias
Radiation atypia
Changes secondary to mucin extravasation
*Not a hyperplasia of endocervical glands but an important benign glandular lesion of the cervix

1.5 PREMALIGNANT CERVICAL GLANDULAR LESIONS

Endocervical glandular dysplasia (EGD) (also known as atypical hyperplasia) and AIS are categorised as premalignant endocervical glandular lesions. A category of glandular atypia is also included. This refers to atypical glandular epithelial changes, such as those associated with inflammation or previous radiotherapy, which are felt to be reactive and less severe than EGD. In the UK, the term cervical glandular intraepithelial neoplasia (CGIN) is in widespread use. CGIN is divided into two grades, low grade CGIN (LCGIN) and high grade CGIN (HCGIN). HCGIN is usually synonymous with AIS and LCGIN with EGD (McCluggage, 2003).

1.5.1 Morphological features of CGIN

In HCGIN, the morphological features of CGIN which are more pronounced than LCGIN are nuclear stratification and loss of polarity, nuclear atypicity and hyperchromasia, macronucleoli, loss of intracytoplasmic mucin, increased mitotic activity, atypical mitoses, apoptotic bodies, goblet cells (also neuroendocrine and Paneth cells) ,and abrupt transition to normal. Not all of these need be present in any individual case. An abrupt transition from normal glands to glands involved by CGIN is often present and this may be seen within individual glands. Both the surface epithelium and the underlying crypts may be involved. Most of the morphological features of CGIN are those expected with any premalignant lesion. The cribriform areas and a microglandular growth pattern may occur in CGIN, their presence (especially when extensive) should prompt consideration of an invasive lesion (Biscotti&Hart, 1998; Moritani, 2002).

A variety of subtypes of CGIN have been described, including endocervical, intestinal, endometrioid and mixed adenosquamous types. The endocervical type retains a basic resemblance to the normal endocervix, with at least focally vacuolated, often granular, pale, basophilic to eosinophilic cytoplasm .The intestinal type displays distention of apical cytoplasm by a large mass of mucin, resembling intestinal goblet cells. The endometrioid type is characterized by cells with densely eosinophilic cytoplasm containing no apparent mucin in routinely stained sections, resembling hyperplastic glands of the endometrium (Zaino, 2000). Moreover, a ciliated variant of CGIN has recently been described (designated endocervical adenocarcinoma in situ of

tubal type). The cases described were associated with typical and atypical tubal metaplasia and with residual tubal morphology, in the form of apical cilia, in the areas of CGIN (McCluggage, 2003).

Park and colleagues (2000) recently described a variant of CGIN, which deserves mention, and has been designated stratified mucinous intraepithelial lesion. This lesion is characterised by a multilayered epithelium resembling CIN. However, numerous cytoplasmic mucin globules are also present throughout the full thickness of the epithelium, creating an appearance reminiscent of atypical immature squamous metaplasia (AISM).

1.5.2 Low grade CGIN (LCGIN) or Endocervical glandular dysplasia (EGD)

Although, diagnosis of LCGIN is difficult, the management should be similar to that of HCGIN. Currently, the natural history of LCGIN is not known and there is some controversy as to whether this is a precursor lesion of HCGIN and invasive adenocarcinoma (Goldstein, 1998; Kurian & Al-Nafussi, 1999). The morphological features of LCGIN are similar to those of HCGIN but are less severe. Some authors have attempted to define precise diagnostic criteria for LCGIN (Brown & Wells, 1996), however it has been proposed that when one gland shows features of AIS a diagnosis of EGD should be made (Jaworski, 1990).

1.5.3 High grade CGIN (HCGIN) or Adenocarcinoma in situ (AIS)

Adenocarcinoma in situ (AIS) of the cervix was first described by Friedell and McKay in 1953. Good evidence supports the existence of AIS as a precursor lesion for invasive adenocarcinoma (Zaino, 2000). Cytologists increasingly encounter atypical endocervical cells, because of the increasing incidence of endocervical adenocarcinoma and the use of improved endocervical sampling devices. These atypical endocervical cells can cause diagnostic problems, especially in recognizing adenocarcinoma in situ (AIS) and distinguishing it from a variety of nonneoplastic changes (Biscotti et al; 1997).

1.5.4 Glandular dysplasia

Brown and Wells in 1986 further distinguished low-grade from high-grade glandular dysplasia on the basis of the paucity of mitoses, absence of vesicular chromatin, and restriction of stratification of nuclei to the basal two thirds of the epithelium in low-grade lesions. In addition, Gloor and Hurlimann in the same year divided dysplasia into three grades on the basis of almost identical criteria. Although it is reasonable to attempt to make the distinction of dysplasia from AIS in the setting of research investigating the pathogenesis of adenocarcinoma, Zaino, (2000) suggested that glandular dysplasia may exist, but no one knows what it is biologically or how to recognize it in a reproducible fashion.

1.5.5 Distinction of invasive from preinvasive adenocarcinoma in the endocervix

The presence of invasion in endocervical adenocarcinoma can be identified by presence of an individual cells or incomplete glands lined by cytologically malignant-appearing cells at a stromal interface and malignant-appearing glands surrounded by a desmoplastic host response. It is critical first to determine that the glands are lined by cytologically malignant-appearing cells, because endocervicitis, microglandular hyperplasia and rupture of mucin-filled glands all may have incomplete glands that at times may be associated with a host response of dense inflammation and, occasionally, oedema or fibrosis. In addition, there are other features which may help to identify invasion in other cases such as architecturally complex, branching, or small glands, which grow confluent or in a labyrinthine pattern, a cribriform growth pattern of malignant-appearing epithelium and the presence of glands below the deep margin of normal glands (Clement & Young, 1989; Zaino, 2000).

1.6 EARLY INVASIVE ADENOCARCINOMA

1.6.1 Introduction

The definition of early invasive adenocarcinoma remained controversial until 1997 when the International Federation of Gynaecology and Obstetrics (FIGO) defined stage IA1 cervical cancer of either squamous or glandular type to be invasive to a depth of less than 3 mm beneath the basement membrane and less than 7 mm of lateral spread (Michael et al., 2001). Clement & Young, 1989 and Yeh et al., 1991

concluded that there is no consensus regarding the criteria for the diagnosis of microinvasive adenocarcinoma (MIA) of the cervix. However, Qizilbash, 1975 and Zaino, 2000 described three patterns of MIA: glandular budding with an associated inflammatory reaction, confluent glands in a complex pattern with little or no intervening stroma, and intraluminal tufting resulting in a papillary pattern. All of the lesions had to be less than 5 mm thick. However, there is no consensus in the acceptable depth of invasion for a diagnosis of early cervical adenocarcinoma (McCluggage, 2003).

1.6.2 Identification of early invasive adenocarcinoma

Identification of the early invasion in HCGIN is more difficult than with squamous lesions. The morphological patterns of early invasive cervical adenocarcinoma are an obvious small adenocarcinoma, a cribriform or solid appearance of glands and the presence of early stromal infiltration from glands involved by HCGIN of small buds of cells, often with a squamoid appearance. In addition, loss of the normal smooth peripheral glandular outlines and a microglandular growth pattern may also be useful features of early invasion. Once early invasive adenocarcinoma is identified, calibrated optics should be used in measurement of this invasion (McCluggage, 2003).

1.7 MORPHOLOGICAL SUBTYPES OF INVASIVE ADENOCARCINOMA

The subtypes of pure endocervical adenocarcinomas are classified in Table 2 in descending order of their frequency; other tumours that have a glandular component but also a nonglandular component are listed in Table 3 and benign glandular tumours in Table 4.

Table 2. Classification of pure cervical adenocarcinomas (Quoted from Young & Clement, 2002).

Typical endocervical type
Variant Well-differentiated villoglandular papillary adenocarcinoma
Mucinous
Variants
(I) Adenoma malignum (minimal deviation adenocarcinoma)
(ii) Intestinal type (including signet-ring cell and colloid adenocarcinoma)

Endometrioid Variant Minimal deviation adenocarcinoma
Clear cell
Serous
Mesonephric

Table 3. Classification of adenocarcinomas with a glandular and non-glandular component (Quoted from Young & Clement, 2002).

Adenosquamous carcinoma
Glassy cell carcinoma*
Adenoid basal carcinoma
'Adenoid cystic' carcinoma
Adenocarcinoma and neuroendocrine tumour
*Although glands are not a feature of pure glassy cell carcinoma these tumours are often admixed with a component of adenocarcinoma.

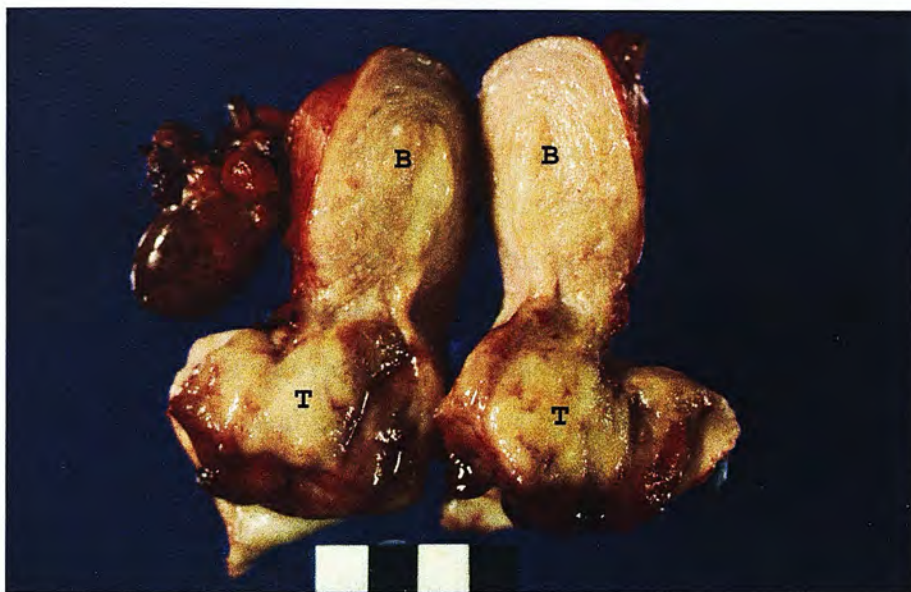
Table 4. Benign glandular tumours (Quoted from Young & Clement, 2002).

Polyps
Adenomyoma I- Endocervical-type II- Endometrioid a. Typical b. Atypical polypoid adenomyoma
Villous and villoglandular adenomas
Mullerian papilloma

1.7. 1 Gross Appearance of Cervical Adenocarcinoma (Fig. 1).

There are no distinctive macroscopic appearances that reliably distinguish adenocarcinoma from squamous or other carcinomas of the cervix. The presence of an obvious mass typical of carcinoma clinically is always something to be borne in mind in pathologic differential diagnosis. Some benign lesions, however, may be striking grossly although they generally differ from carcinoma in usually being at least partly cystic, whereas most cancers are solid. A final comment on gross features is that the

gross appearance of cervical adenocarcinoma is variable. Some early cancers are not appreciable grossly and even deeply invasive tumours maybe somewhat deceptive on gross examination. Grossly evident tumours range from polypoid to ulcerating to those that diffusely thicken the cervical wall (Young & Clement, 2002).



(Fig .1) Endocervical adenocarcinoma (T) occupies the whole endocervix.

B=Body of uterus

1.7.2 Adenocarcinoma, Usual endocervical type

Usual endocervical adenocarcinoma accounts for at least 80% of cervical adenocarcinomas. Most of them are moderately differentiated adenocarcinomas characterized by glands of medium size. Cervical adenocarcinoma is often referred to as mucinous adenocarcinoma but the most common form of endocervical adenocarcinoma is not obviously mucinous, and yet it has a rather characteristic appearance having cells with eosinophilic cytoplasm and brisk mitotic activity with frequent apoptotic bodies (Tambouret et al., 2000; Young & Clement, 2002).

1.7.3 Variants of Adenocarcinoma, endocervical type

1.7.3.i *Well differentiated villoglandular papillary adenocarcinoma (VGC)*

Young and Scully first established villoglandular papillary adenocarcinoma (VGC) as a distinct histological entity and a subtype of well differentiated adenocarcinoma. The superficial parts of the tumours often resemble villous adenomas formed of broad papillae, with fibrovascular cores covered by a mildly atypical columnar epithelium,

whereas deeper portions of the tumour are often formed of branching glands. Nuclear pleomorphism and mitotic activity are mild or moderate, mucin is variable, and a desmoplastic host response is often absent. These tumours may display a conventional cribriform or glandular pattern confined to the deep stromal interface (Zaino, 2000).

1.7.3.ii Mucinous Adenocarcinoma

Three types of mucinous adenocarcinoma occur in the cervix, the most common of which is the endocervical type, which resembles the cells lining the endocervical glands. The neoplastic counterpart is formed of cells arranged in glands that may be simple or branching, tubular or papillary, with basal or stratified nuclei, and pale granular to vacuolated cytoplasm that stains for mucins. The intestinal type mimics colonic epithelium and is characterized by glands that are lined by malignant-appearing cells, some of which have their cytoplasm distended by a single large vacuole of mucin, forming a goblet cell. Signet-ring cell carcinomas may be pure or mixed with either of the other two mucinous types and contain single cells or solid aggregates of polygonal cells with a nucleus displaced eccentrically by mucinous vacuoles (Zaino, 2000).

1.7.3.iii Minimal Deviation Adenocarcinoma (MDA)

Minimal deviation adenocarcinoma (MDA) is a rare form of adenocarcinoma which differentiates well, grows rapidly, spreads early, has poor prognosis and should be treated as intensely as other primary adenocarcinomas of the endocervix (Zhang, 1989). Alternatively called adenoma malignum or extremely well-differentiated adenocarcinoma, the term minimal deviation adenocarcinoma (MDA) reflects a bland histological appearance (Landry et al., 2003). Areas of malignant cytology, vascular invasion, or perineural invasion confirm the diagnosis. Stromal invasion deeper than normal glands is common but not helpful in superficial biopsies. The small number of cases of MDA and generally deep invasion at diagnosis make characterization of behaviour somewhat unreliable, but the majority of women have had nodal spread and ultimately died of tumour (Kaminski & Norris, 1983; Young & Scully, 1993).

1.7.3.iv Intestinal-type adenocarcinoma, not otherwise specified, signet-ring cell adenocarcinoma, and colloid adenocarcinoma

Rare adenocarcinomas of the cervix are lined predominantly by cells with an intestinal appearance, including goblet cells that may be admixed with Paneth and argentaffin cells. Signet-ring cells may be seen within otherwise typical cervical adenocarcinomas and within adenosquamous carcinomas. Pure or almost pure signet-ring cell carcinomas are rare. Microscopic examination shows cells with eccentric nuclei and pale mucin-rich cytoplasm growing singly, in clusters and in nests or columns. Colloid adenocarcinomas are even rarer but listed here for completeness sake (Young & Clement, 2002).

1.7.3.v Endometrioid adenocarcinoma

Endometrioid adenocarcinomas of the cervix are defined as tumours composed of cells that resemble those of typical adenocarcinomas of uterine corpus. The cells of endometrioid adenocarcinomas tend to be stratified and have oval nuclei that are arranged with their long axis perpendicular to the basement membrane of the gland. As most adenocarcinomas of usual endocervical type, the cells of those tumours contain little or no mucin and have less cytoplasm than do the cells of mucinous adenocarcinomas. True endometrioid carcinomas of the cervix are rare. Some workers have found that it accounts for 50% or more of their endocervical adenocarcinomas (Zaino, 2002). Rare endometrioid adenocarcinomas of the cervix have arisen from cervical endometriosis (Chang & Maddox, 1971). These tumours are diagnosable as carcinoma on the basis of a distribution and architecture of glands incompatible with any benign process and at least low-grade malignant cytologic features (Rahilly et al., 1992; Young & Scully, 1993).

1.7.3.vi Clear cell adenocarcinoma

Histological examination of these tumours reveals three basic patterns: tubulocystic, solid, and papillary. In the tubulocystic pattern, tubules and cysts of varying sizes are lined by hobnail, flat, or clear cells. Rarely cells with abundant oxyphilic cytoplasm may be present and occasionally are numerous. The cysts often contain mucin, and intracytoplasmic mucin may be present in occasional cells, and signet-ring cells may

even be present. The solid pattern is characterized by nests and sheets of cells containing abundant, clear, glycogen-rich cytoplasm. The least common of the three patterns, the papillary, is characterized by numerous papillae extending into the tubules or cysts. The papillae vary from small and delicate with inconspicuous fibrovascular cores, to larger papillae with more prominent fibrovascular cores that are often extensively hyalinized. The stroma of nonpapillary tumours is also occasionally prominently hyalinized (Young & Clement, 2002).

1.7.3 vii Serous papillary adenocarcinoma

Serous carcinoma is rare in the cervix and has recently been highlighted as a variant of cervical adenocarcinoma. Its microscopic features is composed of papillae or branching, gaping glands lined by cells with pleomorphic nuclei and often centrally protruding apical cell cytoplasm, resulting in a scalloped configuration (Zaino, 2000). In the largest series in the literature these tumours had a survival that did not differ significantly from that of usual endocervical type adenocarcinoma. The diagnosis of primary serous carcinoma of the cervix should be made only after spread from the ovary, fallopian tube or endometrium has been excluded (Young & Clement, 2002).

1.7.3 viii Mesonephric adenocarcinoma

Mesonephric adenocarcinoma is one of the rarest subtypes of cervical adenocarcinoma (Clement et al., 1995). Microscopic examination reveals a variety of appearances, but a tubuloglandular pattern usually predominates. The tubules and glands, which may be closely apposed, or separated by stroma, are usually small and round but are occasionally larger and resemble endometrioid glands or are cystic. The lumens may contain pink hyaline-like material. Rarely the tubuloglandular pattern merges with solid sheets, slit-like spaces with a 'retiform' appearance, or serous-like papillae. In occasional cases there is a prominent component of spindle cells (Ferry & Scully, 1990).

1.7.3. ix Adenosquamous carcinoma

Adenosquamous carcinomas contain malignant glandular and squamous elements that are recognizable without the use of special stains. The glandular component is usually

of endocervical type but may be mucinous, including signet ring cell, or mixed endocervical and mucinous, endometrioid or clear cell. Occasional tumours contain relatively bland squamous morules (Dougherty & Cotten, 1994; Costa et al., 1994).

1.7.3. x Glassy cell carcinoma

Histological examination reveals sheets of large cells with abundant eosinophilic or amphophilic, ground-glass or finely granular cytoplasm, prominent cell borders, large nuclei with prominent nucleoli, a high mitotic rate, and often a stromal inflammatory infiltrate composed predominantly of eosinophils and plasma cells. Rare foci of squamous or glandular differentiation and intracellular mucin may be present (Cherry and Glucksmann, 1961). Tumours with significant components of glassy cell carcinoma and typical adenocarcinoma should be regarded as mixed carcinomas (Littman et al 1976).

1.7.3.xi Adenoid basal carcinoma

Histological examination reveals widely separated or occasionally closed packed small, round, oval, or lobulated nests of uniform mostly basaloid cells with peripheral palisading and no stromal reaction. The tumour cells usually have bland nuclei and rarely more than an occasional mitotic figure except in some cases with squamous differentiation in which the squamous cells can exhibit severely dysplastic features. (Brainard & Hart, 1998; Young & Clement, 2002).

1.7.3. xii Adenoid cystic carcinoma

Histological examination shows nests of cells often with a focal cribriform pattern resembling that seen in adenoid cystic carcinoma of the salivary glands, as well as sheets, trabeculae, and cords (Ferry & Scully, 1988). The glandular lumens may contain hyaline or mucinous material. There is usually at least focal palisading of cells at the periphery of tumour nests. The neoplastic cells are larger than those of adenoid basal carcinoma and have more pleomorphic nuclei. The mitotic rate is generally high, and necrosis is typically present and may be extensive. An additional difference from adenoid basal carcinoma is the presence of a stromal response, which may be

myxoid, fibroblastic, or hyaline (Albores-Saavedra et al., 1992; Young & Clement, 2002).

1.7.3xiii Adenocarcinoma associated with a neuroendocrine tumour

Most cervical tumours of neuroendocrine type occur in pure form but occasionally they contain a component of adenocarcinoma. The neuroendocrine component is most often small cell carcinoma, but may be a large cell neuroendocrine carcinoma or atypical or typical carcinoid tumour. The only issue is the distinction from pure neuroendocrine tumours, an issue dependent on sampling (Young & Clement, 2002).

1.8 DIAGNOSIS OF CERVICAL ADENOCARCINOMAS

1.8.1 Cervical screening methods

1.8.1.i Introduction

The broadest and most successful application of clinical cytology has been in the diagnosis of invasive carcinoma of the uterine cervix and precursor lesions through the technique popularized by George Papanicolaou at Cornell University and universally known as the Pap test. Today, it is widely used both as a screening test in asymptomatic populations and in the follow-up of patients with cervical carcinomas treated by either conservative surgery or irradiation (Rosai, 1998).

1.8.1.ii Comparative study: conventional cervical and Liquid-based cytology (ThinPrep)[®] Pap tests in a routine clinical setting

Although conventional Pap preparation (CP) has been useful in the detection of precancerous lesions of the cervix, there are limitations associated with this method. A variable false positive and false negative rate is associated with the conventional Pap smear. In addition, the transfer of material from the smear-taking device to the slide can be problematic because cells that remain adherent to the smear-taking device can potentially be lost. Interpretation of the conventional Pap smear is often hampered by the presence of blood or mucus obscuring the diagnostic cells. Another potential problem in interpretation is the presence of air drying, which tends to cause artefactual changes to the cells, thereby rendering accurate evaluation impossible.

Inflammatory exudate is another possible cause of inaccuracy. Consequently, the CP method results in a high unsatisfactory or suboptimal rate.

Due to the above difficulties, great efforts have been made to improve the accuracy of cervical screening with the aim of improving sensitivity and specificity. The ThinPrep (TP) test, a fluid-based method of liquid-based cytology (LBC), is currently being promoted as an alternative methodology to replace the conventional direct PAP smear in cervical cytology. Claims made in favour of LBC include improved sensitivity, improved specificity and reduced numbers of inadequate smears. For this reason, there are several studies to evaluate the Liquid-based cytology method (Grace et al., 2002).

Moseley & Paget (2002) reported the dramatic improvement in specimen adequacy with TP. With such an improvement in specimen adequacy the number of repeat smears is dramatically reduced. This has the potential to reduce costs and also patient anxiety associated with repeat testing. They also noted that, the time taken to screen a TP was half (3-4 min) that of the conventional method. This obviously leads to increased productivity with a reduction in the turnaround time for reporting cervical cytology. The reason for this reduction in screening time is the improved quality of the preparations, the absence of obscuring blood and mucus and the smaller size of the screening area. Another advantage of the TP method of smear preparation is the ability to make extra preparations from the residual material. This can be of value in cases that are difficult to diagnose and also provides invaluable teaching material (Grace et al., 2002).

1.8.2 Cervical biopsy and radiological imaging techniques

The diagnosis of carcinoma is made by pathologic examination of a tissue specimen. A biopsy taken from the periphery of a tumour is more likely to contain morphologically intact neoplastic cells that are best able to represent the tumour pathologically. A biopsy specimen taken from the centre of a tumour mass may include necrotic tumour debris; the result of hypoxia induced by the tumour's outgrowing its blood supply. Therefore, to rely on these dead and distorted cells is to compromise the accuracy of the histological profile (Amano et al., 1998). Lymph node status is not addressed in the FIGO staging system for carcinoma of the cervix, but three

radiologic imaging techniques are available to evaluate lymph node status: CT, MRI, and lymph-angiography. Both CT and MRI have a place in detecting the spread of cervical cancer. Patients with an abnormal Pap smear and no visible lesion require colposcopy and biopsy (Subak et al., 1995; Janus et al; 1989).

1.8.3 Cervical cone biopsy in diagnosis and management of glandular lesions

Although the diagnosis of invasive adenocarcinoma often can be made on small, superficial cervical biopsies, it sometimes cannot be excluded even in cone biopsies, particularly when AIS extends to involve the margin of excision. There is unresolved controversy about the significance of margins in cone biopsies for AIS because the lesion may be multifocal (Goldstein & Mani, 1998). Cervical cone biopsy was recommended for diagnosis of VGC and MDA because VGC may be accompanied by a conventional adenocarcinoma in their deep aspect, but superficial biopsies may not even contain areas of unequivocal tissue invasion and MDA often cannot be diagnosed confidently in superficial biopsies, and a request for additional tissue in difficult cases may yield more obvious areas of stromal invasion or cytologic atypia (Zaino, 2000).

1.8.4 Evaluation and Staging.

Successful therapy planning requires detailed evaluation of the patient's general medical condition and the size and extent of the carcinoma. It is important to apply the FIGO rules (table 5) for clinical staging of cervical adenocarcinoma (Bush, 1986; Hirst, 1986).

Table, 5 showing Modified FIGO Staging (Shepperd, 1995).

Stage	Description
0	Carcinoma in situ, intraepithelial carcinoma. Cases of stage 0 should not be included in any therapeutic statistics for invasive carcinoma.
I	The carcinoma is strictly confined to the cervix (extension to the corpus should be disregarded).
IA	Invasive cancer identified only microscopically. All gross lesions, even with superficial invasion, are stage IB cancers.

	Invasion is limited to measured stromal invasion with a maximum depth of 5 mm and a width no greater than 7 mm.
IA1	Measured invasion of stroma <3 mm in depth and <7 mm in width.
IA2	Measured invasion of stroma >3 mm and <5 mm in depth and <7 mm in width.
IB	Clinical lesions confined to the cervix or preclinical lesions larger than stage IA.
IB1	Clinical lesions <4 cm.
IB2	Clinical lesions >4 cm.
II	The carcinoma extends beyond the cervix but has not extended onto the pelvic wall. It involves the vagina but does not extend as far as the lower third of the vagina.
IIA	No obvious parametrial involvement.
IIB	Obvious parametrial involvement.
III	The carcinoma has extended onto the pelvic wall. On rectal examination, there is no cancer-free space between the tumour and the pelvic wall. The tumour involves the lower third of the vagina. All cases with hydronephrosis or a nonfunctioning kidney should be included unless they are known to result from another cause.
IIIA	No extension onto the pelvic wall but involvement of the lower third of the vagina.
IIIB	Extension onto the pelvic wall or hydronephrosis or non-functioning kidney.
IV	The carcinoma has extended beyond the true pelvis or has clinically involved the mucosa of the bladder or rectum.
IVA	Spread to adjacent organs.
IVB	Spread to distant organs.

1.9 Prognosis in cervical adenocarcinoma

Cervical adenocarcinoma behaves differently from squamous cell carcinoma. The prognosis in cervical adenocarcinoma depends on the clinical stage, amount of tumour (as determined by tumour volume), microscopic grade, and nodal status. In most series, the overall prognosis has been less favourable than for the squamous cell counterpart. There is not much difference among the various histological subtypes, although the endometrioid variety is said to behave slightly better. The presence of nodal metastases is an ominous prognostic sign. Increased serum levels of CA125 and overexpression of c-erbB-2 and nm23-H1 proteins have also been found to represent poor prognostic factors (Rosai, 1998).

1.10 Management of Cervical Adenocarcinoma

In patients with adenocarcinoma in situ, because of the risk of developing invasive adenocarcinoma after fertility sparing surgery, hysterectomy is still the continuing gold standard of the treatment of adenocarcinoma in situ. When margins are compromised and future fertility desired, a second cone should be performed if the subject accepts the risks associated with fertility sparing surgery. In the UK, there is a trend towards more conservative treatment with LETZ for AIS. The fertility sparing surgery such as cervical conization or LETZ may be adequate treatment for selected women with early invasive glandular lesions. (Michael et al., 2001).

With the increasing evidence that the presence of glandular disease is associated with a poorer outcome, extra modalities of treatment to standard care in the management of such patients with established invasive adenocarcinoma have been added. The use of neoadjuvant cytotoxic therapy and/or combined radiation/cytotoxic therapy remains to be established, although such an approach seems attractive in view of the report of an increase in extra pelvic recurrences in women with glandular as opposed to squamous disease (Quinn, 1998).

CHAPTER 2

HUMAN PAPILOMAVIRUSES (HPVs) AND CANCER

2.1 INTRODUCTION

Links between human papillomaviruses (HPVs) and cervical cancer were first suspected almost 30 years ago. DNA of specific HPV types has since been found in almost all cervical cancer biopsies. HPV oncogenes that are expressed in these cells are involved in their transformation and immortalization, and are required for the progression towards malignancy (zur Hausen, 2002).

The expression of specific viral genes (such as E6 and E7) was shown in cervical cancer cell lines and cancer biopsies (Schwarz et al., 1985); a specific opening within the viral ring molecule was shown for integrated genome copies; and the immortalization property of viral DNA and the encoded viral oncogenes supported the initial suspicions. An early epidemiological study pointed to a high rate of infection in younger women and to a decreasing rate of infection with age, although persisting infections still represent a high risk factor for cervical cancer development in older women (Doeberitz et al., 1992; Doeberitz et al., 1994).

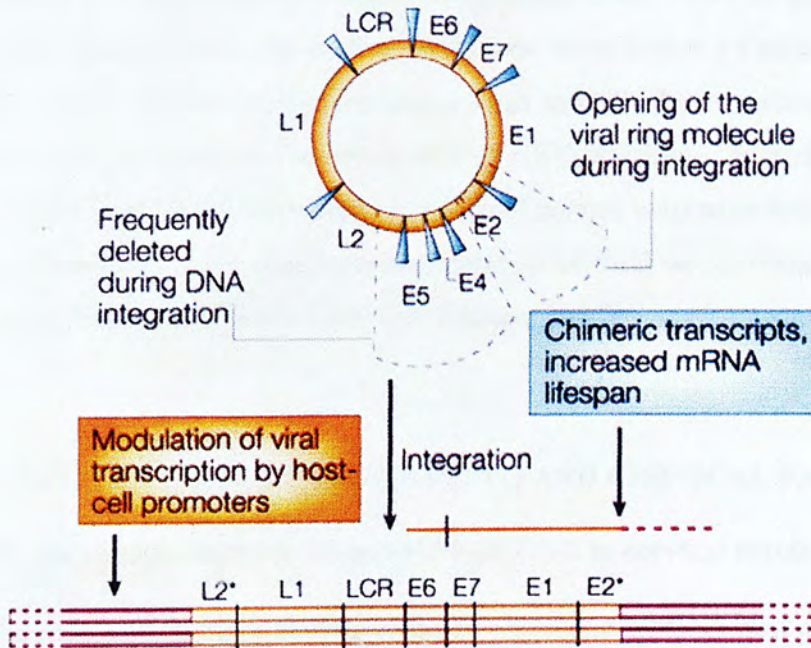
2.2 HPV PATHOGENESIS (LIFE CYCLE)

The papillomavirus life cycle requires the availability of epidermal or mucosal epithelial cells that are still able to proliferate (basal layer cells). Following entry into the suprabasal layers, 'late' viral gene expression is initiated; the circular viral genome is then replicated and structural proteins form. In the upper layers of the epidermis or mucosa, complete viral particles are assembled and released. E5, E6 and E7 are three genes possess proliferation-stimulating activity. As HPV-infected lesions progress to cervical cancer, the episomal viral DNA frequently becomes integrated into host-cell DNA (Figure 6), and a substantial part of the genome, commonly including the E5 coding sequence, is deleted (zur Hausen, 2002). The E6 and E7 genes and their proteins are consistently expressed in malignant tissue, and inhibiting their expression blocks the malignant phenotype of cervical cancer cells. They are able to immortalize various human cell types in tissue culture, but efficiency is increased when they are

expressed together (Münger et al., 1989; McDougall, 1994). Initial observations revealed that E6 interacts with p53, and E7 interacts with RB to block the activity of these tumour suppressors.

2.3 THE ORGANIZATION OF CIRCULAR HPV AND ITS INTEGRATION INTO HOST-CELL DNA (Figure 2).

The human papillomavirus (HPV) genome contains between 6800 and 8000 base pairs and is divided into eight open reading frames E6, E7, E1, E2, E4, E5, and L2 and L1 coding for 'early' (E) or 'late' (L) functions. In the course of cancer development, the viral molecule frequently becomes integrated into host-cell DNA. The ring molecule is most often opened within the E2 open reading frame, disrupting the continuity of that gene. Part of E2 and open reading frames that are adjacent to E2, E4, E5 and part of L2 are regularly deleted after integration (partial genes are represented by an asterisk). Viral transcripts, which uniformly span the E6 and E7 region, and are often linked to flanking cellular sequences, are present and transcription might be modulated (enhanced) by flanking host-cell promoters. LCR, long control region (zur Hausen, 2002).



(Fig.2) The organization of circular HPV DNA and its integration into host-cell DNA (Quoted from zur Hausen, 2002).

2.4 TYPES OF HPV AND GENITAL TRACT INFECTIONS

2.4.1 Types of HPV

There are at least 80 different types, which can be divided into those infecting cutaneous surfaces and those infecting mucosal surfaces. Some types cause benign warts and low-grade premalignant lesions and are not found in malignant tissues which have been classified as “low risk” types. HPV type 6 and 11 (HPV-6, HPV-11) are the most common isolates from these lesions (zur Hausen, 2002). There is another group of viruses that are found in premalignant and malignant tissues which called “high risk” types, and HPV-16 and -18 are commonly associated with these lesions.

2.4.2 HPV and Genital tract infection

HPV infection is the most common sexually transmitted disease, with more than 80% of the population infected at some time in their life. However, there is evidence that HPV can be transmitted from mother to neonate, probably during delivery. Laryngeal warts in young children are thought to arise after such episodes of transmission (Kashima et al., 1985; Fredericks et al., 1993; Austen et al., 1996). In addition, genital infection is also possible after mother to neonate transmission (Cason et al., 1999), but it is unclear whether such transmission leads to clinical disease later in life. The immune system is important in the control of HPV infections. In proliferating cells that are infected by HPV, there are two modes of control exist to protect them against malignant transformation: one involves inhibition of viral oncoprotein function; the other involves transcriptional control (zur Hausen, 2002).

2.5 HUMAN PAPILLOMA VIRUSES (HPVs) AND CERVICAL PATHOLOGY

2.5.1 The integration of HPV-16 and HPV-18 DNA in cervical carcinomas

It is generally accepted that HPV is causally associated with cervical carcinoma and the WHO has declared that HPV-16 and HPV-18 are, indeed, carcinogens. The integration of HPV DNA into host chromosomes plays an important role in the progression to malignancy, but probably not sufficient for progression to invasive cervical cancers. Up to 30% of cervical carcinomas contain episomal forms only of

HPV-16. Das et al., 1993, therefore, suggest that HPV DNA integration may not be necessary for malignant progression. However, one very important finding is that 100% of HPV-18 cervical carcinomas contain integrated forms only of HPV-18 DNA. The physical state of HPV-18 DNA in cervical carcinomas using the combined techniques of Southern hybridisation and PCR analysis studies demonstrated that HPV-18 DNA in cervical carcinomas shows a specific integration pattern with respect to the viral DNA, with a preference to retain a specific region of viral DNA. In general, the regions of HPV-18 that are integrated are similar to HPV-16 with respect to the LCR, E6, and E7 genes only. The total region of integrated viral DNA appears to be much more conserved for HPV-18 than for HPV-16. This is particularly noticeable within the L1 and E1 regions (Corden et al., 1999).

2.5.2 Prevalence of HPVs in Cervical Adenocarcinoma

Prevalence of human papillomavirus (HPV) DNA in adenocarcinoma of the cervix is as high as in squamous cell carcinoma of the cervix. Recent molecular biological studies strongly suggested that HPV acts at least as a cocarcinogen in the female genital organs (Riethdorf et al., 2000). EGD and MGH were lesions coexisting with adenocarcinoma in situ. HPV DNA was not present in cases of microglandular endocervical hyperplasia. Adenocarcinoma in situ may be the earliest event in HPV infection of the endocervical cells to lead to the development of adenocarcinoma of the cervix. None of the GAs was associated with low- or intermediate-risk HPV, and only the GA (which was high grade) unassociated with a SILs contained a high-risk virus type (Anciaux et al., 1997).

Type of HPV might influence the histological subtype of invasive adenocarcinoma, as HPV type 16 predominated in the adenosquamous carcinomas while HPV type 18 was more frequently found in all other subtypes (Duggan et al, 1993). However, Bulk et al, (2006) reported that HPV16, HPV18, and HPV45 display an increased prevalence in cervical cancer compared to cytologically normal smears. HPV16 confers the greatest risk for SCC and HPV18 for adenocarcinoma of the cervix. HPV DNA was identified in >90% of in situ and invasive mucinous adenocarcinomas, which encompass endocervical, intestinal, and endometrioid morphology and account for 97% of all cervical adenocarcinomas. However, cases of MDA were negative for HPV DNA (Ferguson et al., 1998; Skyldberg et al., 1999). Most of serous

adenocarcinomas of the cervix were HPV DNA-positive while nonmucinous adenocarcinomas were negative for HPV DNA, including mesonephric and clear cell carcinomas (CCCs). However, Fujiwara et al., 1995 have reported a highly variable prevalence of HPV DNA in CCCs.

2.5.3 HPV and p53 Pleomorphism

HPV integration in the genome will lead to inactivation of the p53 pathway and the Rb pathway. Recently it was shown that the presence of a common polymorphism within the p53 protein, at position 72, can affect the susceptibility of p53 to E6 mediated degradation. Thus, the p53Arg polymorphic variant is more susceptible to the effects of HPV E6 than the p53Pro (Storey et al., 1998). Interestingly, this pleomorphism lies within the poly-proline region of p53 which has also been recently shown to be involved in the induction of p53 mediated apoptosis. This is particularly important from a therapeutic point of view, since this will determine whether the appropriate signals are already present within these cell lines to activate p53 function (Wentzensen et al., 2002).

2.5.4 HPV Detection and Typing

2.5.4.i Introduction

The absence of an episomal HPV genome in the majority of glandular tumours, as opposed to squamous tumours, may result in a significant underestimation of HPV DNA prevalence in adenocarcinomas (Pirog et al., 2000). Glandular epithelium does not support productive viral infection and HPV DNA in endocervical neoplasms (notably HPV 18), is usually present in the integrated form. Therefore, detection of HPV DNA in adenocarcinomas requires a sensitive detection assay. Further, as the successful amplification of HPV DNA in a PCR assay depends on the presence of intact DNA target sequences, two additional factors may reduce the efficiency of HPV detection: 1) DNA fragmentation as a result of formalin fixation and storage in paraffin; and 2) loss of portions of the viral genome during integration. (Park et al., 1997; Pirog et al., 2000).

2.5.4.ii Techniques of HPV detection

Methods of light microscopy, electron microscopy, immunohistochemistry and molecular biology can be used to detect HPV in cervical biopsies. Molecular biology is now commonly used. Southern blot, Northern blot, Dot (Spot) blot, Filter In Situ, and In Situ hybridization are applied for HPV detection and typing. Recently PCR has been developed to amplify DNA sequences shared by many of the 20 or so different types of genital HPVs. However, no 'gold standard' has yet been established (Jacobs et al., 1995; Gravitt et al., 2000). Currently, an HPV DNA detection system, Hybrid Capture 2 (Digene Corporation, Gaithersburg, Maryland, US) is approved by the Food and Drug Administration for use in patient care. This assay uses signal amplification technology with RNA multiprobe cocktails to distinguish between high-risk and low-risk HPV types, but does not identify the specific HPV DNA type detected.

2.5.4.iii Cytological and Histological detection of HPV

The morphologic hallmark of HPV infection of the cervical squamous epithelium is koilocytosis. The koilocyte is a superficial or intermediate mature squamous cell characterized by a sharply outlined perinuclear vacuolation, dense and irregular staining peripheral cytoplasm, and an enlarged nucleus with an undulating (raisin- or prune-like) nuclear membrane and a rope-like chromatin pattern. Binucleation and multinucleation can occur (Rosai, 1998; Giovagnoli et al., 1996).

2.5.5 HPV Testing and Cancer Screening

Cervical carcinomas are unfortunate complications of longstanding infection with high-risk types of human papillomavirus (hrHPV) (Walboomers et al., 1999). The presence of high-risk HPV (hrHPV) markers needs careful clinical investigation and repeated testing for HPV persistence, which is a significant risk factor for the development of proliferative lesions and their progression. Testing for hrHPV types combined with cervical cytology becomes increasingly attractive as data accumulate that a combined test increases the efficacy of cervical screening programmes and triage policies for women with both equivocal and normal cervical smears (Cuzick et al., 2003; Khan et al., 2005).

2.5.6 Cervical Cancer Prevention

With respect to cancer prevention, in addition to enforcing specific standards of hygiene, cervical screening has reduced the incidence of cervical cancer significantly (Peto et al., 2004) and although a clinical success story, there is evidence to suggest it could be improved by incorporation of adjunctive HPV testing. Although less specific than cytology (especially in young sexually active women), HPV testing is more sensitive for the detection of underlying cervical abnormalities, indeed, HPV testing has been introduced (in combination with cytology) in the US, for women over 30 in primary screening (Sallow et al., 2002). In addition, the UK pilot studies (due to report later this year) were designed to assess the utility of using HPV testing for the triage of women with low grade abnormalities to colposcopy (www.cancer-screening.nhs.uk). There is also good evidence to suggest that HPV testing (in the context of a negative result) could be used as a “test-of cure” of treatment for women with high-grade cervical disease, with the potential to reduce the intensity of post treatment follow-up (Zielinski et al., 2004). Further improvements in the diagnostic accuracy of cytology based screening, such as HPV testing, could be particularly prescient for the reduction of adenocarcinoma as it and its precursor stage are reportedly more likely to be “missed” than squamous cell cytological abnormalities (Brink et al., 2005).

Moreover, two prophylactic HPV vaccines are currently in Phase 3 trials both of which are designed to target HPV 16 and 18 infections. Initial results from these trials would suggest that the vaccines are highly immunogenic, well tolerated and induce seroconversion in more than 99% of vaccinees. They therefore constitute a very exciting prospect for the future of cervical cancer prevention globally (Villa et al., 2005).

CHAPTER 3

TISSUE MICROARRAY (TMA)

3.1 INTRODUCTION

For over a century, tissue has been preserved in formalin and embedded in paraffin for sectioning before microscopic examination. This method has become the standard method of histopathologic analysis (Wright, 1985). In 1998, Kononen and colleagues in the lab of Ollie Kallioniemi invented a mechanism for examining several histological sections at one time by arraying them in paraffin block. These tissue microarrays are assembled by taking core needle "biopsies" of pre-existing paraffin-embedded tissues and re-embedding them in an arrayed "master" block. In this way, tissue from hundreds of specimens can be represented on a single paraffin block that can be analyzed using a variety of techniques, including immunohistochemistry and in situ fluorescence hybridization (FISH) (Kononen et al., 1998; Bubendorf et al., 1999; Moch et al., 1999; Schraml et al., 1999; Mucci et al., 2000; Perrone et al., 2000).

Compared with conventional techniques, tissue microarray (TMA) technology has several advantages. It enables the study of an entire cohort of cases by analyzing just one (or a few) master slide(s) in contrast to traditional techniques, which require the processing and staining of hundreds of slides. In addition, microarray analysis allows that all specimens are processed at one time using identical conditions. Furthermore, it markedly reduces the amount of archival tissue required for a particular study, thus preserving ample remaining tissue for other research or diagnostic needs (Mills et al., 1995; Camp et al., 2000). Moreover, tissue microarray (TMA) technology allows rapid visualization of molecular targets in thousands of tissue specimens at a time, either at the DNA, RNA or protein level. The technique facilitates rapid translation of molecular discoveries to clinical applications. Besides, it paves the way of the standardization of inspection and automation of analysis (Dan et al., 2004). TMAs are ideally suitable for genomics-based diagnostic and drug target discovery by revealing the cellular localization, prevalence and clinical significance of candidate genes. The speed of molecular analyses is increased by more than 100-fold, precious tissues are

not destroyed and a very large number of molecular targets can be analyzed from consecutive TMA sections.(Kallioniemi et al, 2001).

The main problem of tissue microarrays is that they reduce the amount of tissue analyzed from a whole tissue section to a core, 0.6 mm in diameter that may not be representative of the protein expression patterns of the entire tumour because of tissue heterogeneity. Thus, it is important to determine how many tissue disks are required to adequately represent the expression of a particular antigen by a tumour and to determine antigen survival because this new technique has the potential to examine large cohorts of patients with long-term follow-up. Specifically, in determining whether archival tissues retain their antigenicity despite decades of storage as paraffin blocks. There is some evidence to suggest that such tissues remain antigenically intact (Shibata et al., 1988; Ibrahim et al., 1997). On the other hand, although paraffin should protect the tissue from oxidation or other damage, there is evidence that once tissues are sectioned they are subject to rapid loss of antigenicity (Jacobs et al., 1996; Shin et al., 1997). This question is also revisited because maximal sectioning of microarrays requires many array sections to be cut at one time, even if they are not analyzed within the same day or week (Camp et al., 2000).

Finally, tissue microarrays are a population-level screening tool to rapidly analyze frequencies of expression of biomarkers in cell populations, tissues or patients using large sample sets. They are not designed to characterize in detail every “corner” of a particular tumour mass. For this purpose, careful dissection of the tumour and consecutive sectioning throughout the tumour is needed (Nocito et al, 2001).

3.2 TMA CONSTRUCTION

3.2.1 Microarray using paraffin-embedded tissues

Although a device is needed to manufacture TMAs, the preparatory work that involved in making TMAs is traditional pathology work and is very similar to what is needed for traditional studies involving ‘large’ tissue sections. The major difference may lie in the number of tissues involved, which is typically an order of magnitude higher in TMA studies than in traditional projects. First, a list of potentially suited tissues needs to be generated. Then all sections of these specimens are collected from the archive and reviewed by a pathologist in order to select optimal donor blocks. A

morphologically representative area of interest within the donor block is identified under the microscope using an H&E stained section (Fador & De Marzo 2005). Different colours are recommended for marking different areas on one section. Subsequently, the selected blocks are collected from the archive. These blocks and their corresponding marked slides must then be brought together and sorted in the order in which they should appear on the TMA. Meanwhile, the outline of the TMA needs to be defined and a file should be generated that contains the identification numbers of the tissues together with their locations and the coordinates to be selected on the arrayer. A tissue arraying device could be employed after this preparatory work has been done. The only tissue arraying system that is commercially available is identical to the prototype machine used in the early development of TMA technology (Beecher Instruments, Silver Springs, MD, USA). Using this manually operated device, excellent TMAs can be produced in the hands of a talented and experienced person (Bubendorf et al., 2001).

Initial large-core biopsies of over 3 mm in diameter were minimized to 0.6 mm in diameter (Hoos & Cordon-Cardo, 2001). Punched tissue blocks remain fully interpretable for all morphological and molecular analyses if a reasonable number of punches are selected. Since the entire thickness of the donor block tissue is represented in each of the cylindrical tissues of a TMA block, tissue arrays can generate between 100 and 500 sections (Fador & De Marzo 2005).

3.2.2 Tissue heterogeneity (Validation Strategies)

The main concern linked to TMA technology is to what extent tumour heterogeneity would affect the validity of the TMA approach. The 0.6-mm biopsies of tumour specimens on an array may not be representative of the whole tumour specimen because of tissue heterogeneity is the main concern regarding the tissue microarray technique. However, it claimed that, 2-fold redundancy can lead to greater than 97% concordance between the two methods and that the addition of more cores increases concordance to 99.5% with 5 cores per specimen (Camp et al., 2000).

Some immuno-phenotypes can be very complex, and often clinicopathological studies require the application of cut-off values as used for full-section analysis of many markers (Drobnjak et al., 1994; Hoos et al., 2001a). Therefore, it is crucial to evaluate

the number of cores required in conjunction with phenotype complexity. However, tumour heterogeneity can lead to lower concordance rates if more complex phenotypes are analyzed and that some cases may need to be excluded from the analysis if two cores with contradictory readings provide inconclusive data. The addition of a third core can improve concordance rates and prevent the exclusion of such cases because it allows a majority decision ($2 > 1$) (Cote et al., 1998; Hoos et al., 2001b).

It is unavoidable that some alterations are not detected if the analysis of potentially heterogeneous tumours is restricted to samples measuring 0.6 mm in diameter. However, to understand the apparent lack of a major influence of tissue heterogeneity on the results of TMA analyses, it is important to realize that the tissue array approach has been designed to survey tumour populations and not to examine individual tumours. The inability to detect all alterations on a TMA is not only due to true heterogeneity, but also to technical problems often preventing reliable analysis in some areas of a fixed tumour. Therefore, comparison between TMA analysis and conventional analysis need to be carried out with other tissues and other markers (Hoos & Cordon-Cardo, 2001; Hoos et al, 2001b).

3.2.3 Technical considerations for array construction

It is crucial to consider technical problems during construction of a tissue microarray carrying paraffin-embedded tissues so that it can be a source for multiple high-quality sections representing as many arrayed specimens as possible. The main problem is that the arrayed samples have been pre-fixed and embedded in paraffin which could affect the quality of the studies performed on these samples by introducing RNA modifications and damage (Fejzo & Slamon 2001). Tissue loss during sectioning and staining is a common problem of the tissue array technique (Schraml et al., 1999; Mucci et al., 2000; Richter et al., 2000). In addition, staining artefacts at the tissue borders are a well-known phenomenon in immunohistochemistry. Both occur most frequently in the periphery of the tissue microarray.

The orientation of the specimens on the array is crucial because confusion about their localization can threaten the evaluation of the experiment. For keeping the orientation of rows simple, researchers used different normal tissues to allow the identification of every row based on morphology.

The loss rate of assessable cases, resulting from tissue loss during cutting and transfer of array sections and vigorous staining procedures or because of inconclusive data, can be a significant factor of array-based analysis. Previously reported rates of tissue damage range from 10% to more than 30% (Bubendorf et al., 1999; Schraml et al., 1999; Mucci et al., 2000; Richter et al., 2000; Hoos et al., 2001b). Loss of arrayed cases can be minimized without compromising the efficiency of the array technology by using three cores per tumour specimen, as indicated above. In addition, usage of 0.6-mm core diameters and 0.2- to 0.3-mm spacing between the cores.

It is advisable to array uniformly long tissue cores for each specimen to get as many high-quality sections from one multi-tissue block as possible. To avoid problems with micro-movement of cores in the punched holes of the multi-tissue block, cores should be inserted all the way to the bottom of the holes and completed tissue array blocks should be heated at 37° C for 30 minutes to make tissue cores and surrounding paraffin stick together tightly (Hoos & Cordon-Cardo, 2001).

3.3 TISSUE MICROARRAYS STAINING AND ANALYSIS

TMAAs are suited for all analyses that can be done in situ such as immunohistochemistry, fluorescence in situ hybridization (FISH), and RNA in situ hybridization (RNA-ISH). In general, the same protocols can be used as for large sections. The most significant difference compared with traditional large section studies lies in the unprecedented level of standardization that can be achieved within one TMA experiment. All the slides of one TMA study are usually incubated within one jar, ensuring absolutely identical concentrations and temperatures of all reagents (Fador & De Marzo 2005). Moreover, the age of a slide (time between sectioning and use), section thickness, and the exposure times for all steps are also exactly identical in these studies, where all the tissues of one study are located on the same TMA slide. This is a significant difference compared with traditional studies, where a slight variability in some minor experimental parameters (such as slide age or section thickness) is perceived as tolerable. It must be expected that tissues will be heterogeneous in their preservation of proteins and nucleic acids if hundreds of biopsies were all treated individually at the time that they were removed, fixed in buffered formalin, and subsequently paraffin-embedded. This is best illustrated in the outcome of FISH analyses. (Bubendorf et al., 2001).

3.4 APPLICATIONS OF TMAs

TMAs are vital to study tumour biology because it makes it possible to compare different diagnostic or predictive markers or kits with one another on consecutive TMA sections. TMAs are also ideally suited for optimization and quality control purposes. Dozens of different staining or hybridization conditions can be tested (such as pre-treatments or tissues, probe/antibody labeling, detection, etc.) in replicate experiments to achieve optimal performance of the assay. Appropriate positive and negative control tissues can be inserted into each TMA block as internal controls, and it is possible to measure variability of molecular detection schemes and determine which specific step in the detection process causes the most variability. All these issues will be critical to determine each new molecular marker to be introduced for diagnostic purposes (Nocito et al., 2001). Virtually all tissues are suitable to be placed into a TMA. Therefore, the range of TMA application is as broad as the imagination of the users of this technology. Typical TMAs that have been constructed include multi-tumour, progression, and prognostic arrays.

Arrays of multi-tumour are composed of samples from multiple tumour types and utilized to screen different tumour types for molecular alterations of interest (Nocito et al., 2001). Progression TMAs can be used to study molecular alterations in different stages of tumour progression within a given organ. For example, in prostate cancer progression, TMA was constructed containing 371 prostate specimens, consisting of 32 specimens of normal prostate or benign prostatic hyperplasia, 64 incidental carcinomas (stage pT1), 159 organ-confined carcinomas (pT2), 62 distant metastases and 54 recurrent tumours diagnosed after androgen deprivation treatment had failed. Molecular profiling of such tumour progression arrays revealed sets of genetic alterations and gene expression patterns that are characteristic of a specific stage of cancer progression (Nocito et al., 2001). Patient outcome TMAs contain tumour samples from patients for whom clinical follow-up data are available, such as data on tumour recurrence, therapy response and time to metastasis or patient survival. These types of TMAs are most sensitive to the effects of sampling, which needs to be comprehensive enough to capture the clinically meaningful features of tumour

aggressiveness. Analyses of known prognostic parameters (previously discovered and validated using conventional sections) almost invariably can be reproduced in TMA studies (Moch et al., 1999; Mucci et al., 2000).

It will be easy to determine the nature of inter-laboratory discrepancies once such studies are executed on TMAs. Exchanging unstained slides between laboratories that have reported conflicting data would rapidly allow researchers to see whether experimental differences caused the problem. Exchanging stained sections (either in real or as images) would easily clarify whether different modes of interpretation contributed to the confusion. Even differences in tissue processing could be unmasked as a reason for discrepancies if matched series of tumours from different laboratories were placed on one joint TMA (Bubendorf et al., 2001).

TMAs could be useful for educational purposes. While the interpretation of large sections always reflects an attempt to integrate the observations in multiple different regions of a tissue section, the reading of TMAs is much easier and therefore more reproducible. In TMAs, morphological classifications and interpretations of immunostaining are based on the findings within one small, highly defined tissue area. Therefore, the criteria for diagnostic decision-making can easily be applied and learned on TMAs. Examples for analyses that could be trained on TMAs include the histological grading of urinary bladder tumours and the interpretation of HER-2 immunostaining in breast cancers. In both cases, a trainee could read a TMA slide and then be allowed to verify his diagnostic ability by comparing his/her results with those of a recognized expert in the field and generating a survival curve based on his/her own data and comparing it with the survival curve based on the expert's opinion (Bubendorf et al., 2001).

TMAs make it possible to anonymize completely large sets of tissue samples with abundant clinical information, even for internal use. The only requirement to generate such absolutely anonymous tissue collections is to destroy the original biopsy/patient identifiers from the data file attached to a TMA once a TMA block is constructed. As soon as the survival information and pathology information are linked to a TMA coordinate, there is no need to retain information on which patient sample has been

put on which array position. Destruction of this information will make it impossible to trace biological information back to a patient (Bubendorf et al., 2001).

IMMUNOISTEMOLOGY

Specifically there are a large number of articles investigating the use of immunohistochemistry to diagnose gastrointestinal pathology. Although the value of immunohistochemical markers as prognostic indicators in various tumours is very important in surgical pathology, at present there are few established markers of prognostic significance (McCluggage, 2001).

LI CANCER: IMMUNOISTEMOLOGY STUDIES OF THE DISTINCTION BETWEEN ENDOCRYNEAL AND EPITHELIAL ADENOCARCINOMA.

A population distinction between endocrinal and endocervical tumour is supported since primary endocrine tumours may differ. When there is doubt, immunohistochemical studies may assist. Previous studies have separately addressed the value of vimentin, CEA and ER staining (Tahib et al., 1996; Corfield et al., 2001) and a recent study combined these three antibodies (McCluggage et al., 2001). This study concluded that immunostaining with vimentin, CEA and ER was of value in the prognostic distinction between a primary endocrinal and endocervical adenocarcinoma. Endocrinal type endocervical adenocarcinomas are characteristically ER and vimentin positive but negative with CEA (with the exception that endocrinal adenocarcinomas may exhibit low immunoreactivity for CEA). In contrast, primary endocervical adenocarcinomas of endocervical type are characteristically CEA positive with the exception that metastatic endocervical adenocarcinomas often exhibit ER negativity and vimentin and ER negativity. However, this study did not address the immunophenotype of primary endocervical endocervical adenocarcinomas. Immunostaining for human papillomavirus (HPV) is also reported to be of value in the distinction between a primary endocrinal and endocervical adenocarcinoma (McCluggage et al., 2001; McCluggage, 2001; McCluggage, 2002).

Recently it has been reported that the use of anti-vimentin in distinguishing endocrinal and endocervical adenocarcinomas is not as reliable as previously reported (McCluggage, 2002). The use of anti-vimentin in distinguishing endocrinal and endocervical adenocarcinomas is not as reliable as previously reported (McCluggage, 2002).

CHAPTER 4

IMMUNOHISTOCHEMISTRY

Recently there are a large number of articles investigating the use of immunohistochemistry in diagnostic gynaecological pathology. Although the value of immunohistochemical markers as prognostic indicators in various tumours is very important in surgical pathology, at present, there are few established markers of prognostic significance (McCluggage, 2002).

4.1 IMMUNOHISTOCHEMICAL STUDIES USEFUL IN DISTINCTION BETWEEN ENDOCERVICAL AND ENDOMETRIAL ADENOCARCINOMA.

A preoperative distinction between an endometrial and endocervical tumour is important since primary surgical treatment may differ. When there is doubt, immunohistochemical studies may assist. Previous studies have separately addressed the value of vimentin, CEA and ER staining (Dabbs et al., 1996; Castrillon et al., 2002) and a recent study combined these three antibodies (McCluggage et al., 2002). This study concluded that immunostaining with vimentin, CEA and ER was of value in the preoperative distinction between a primary endometrial and endocervical adeno-carcinoma. Endometrioid type endometrial adenocarcinomas are characteristically ER and vimentin-positive but negative with CEA (with the exception that endometrioid adenocarcinomas with squamous differentiation often exhibit strong positivity with CEA). In contrast, primary cervical adenocarcinomas of endocervical type are characteristically CEA-positive (with the exception that mesonephric adenocarcinomas often exhibit CEA-negative) and vimentin and ER-negative. However, this study did not address the immunophenotype of primary cervical endometrioid adenocarcinomas. Immunostaining for human papillomavirus (HPV) has also been found to be of value in the distinction between a primary endometrial and endocervical adenocarcinoma (McCluggage et al., 2001; McCluggage, 2002; McCluggage, 2003).

Recently it has been reported that p16 may also be of some value in distinguishing between an endocervical and an endometrial adenocarcinoma. Strong diffuse positivity involving 100% of cells is the rule in primary endocervical adenocarcinoma,

whereas endometrial adenocarcinoma usually exhibits a lesser degree of staining. However, occasional endometrial adenocarcinomas will exhibit diffuse positivity and there is often strong staining of benign squamous elements for p16. It is necessary to do further studies to refine the diagnostic use of p16 immunostaining in this situation and to ascertain whether those endometrial adenocarcinomas that exhibit diffuse positivity are associated with high risk HPV types (McCluggage, 2003).

4.2 IMMUNOHISTOCHEMICAL TECHNIQUES USEFUL IN DISTINCTION OF MALIGNANT AND PREMALIGNANT CERVICAL LESIONS FROM BENIGN MIMICS.

A wide variety of benign endocervical glandular lesions may be confused with CGIN and even invasive cervical adenocarcinoma, especially the mucinous variant of MDA. Many of these benign mimics are rare and in everyday practice the lesions most likely to be confused with CGIN are tubo-endometrial metaplasia (TEM) and endometriosis.

A close morphological examination usually allows a confident distinction between CGIN and benign mimics. However, in doubtful cases, MIB-1 staining may be useful. Other antibodies may also be of value. Bcl2 is usually positive in cases of TEM but generally negative in CGIN. In addition p16 may be of use in the distinction between CGIN and benign mimics. Cases of CGIN almost invariably show strong diffuse positivity for p16, while most benign mimics are negative or show focal positivity. However, some cases of TEM may be focally positive for p16. A combination of MIB-1, p16 and Bcl2 staining may be of considerable value in the separation of CGIN from TEM and MGH. TEM has been shown to stain positively with vimentin and it has been suggested that this is a useful means of distinguishing TEM from CGIN.

Immunohistochemical staining with monoclonal carcinoembryonic antigen (CEA) may assist in the distinction of neoplastic endocervical glandular lesions from benign mimics (McCluggage, 2002). However, caution should be exercised since adenocarcinomas are occasionally negative or only focally positive for CEA (Speers et al., 1983; Steeper & Wick, 1986). Mesonephric adenocarcinomas are typically CEA-negative. Accordingly, a negative stain for CEA should be cautiously interpreted but intense positive staining throughout the cytoplasm is unlikely in a benign lesion and strongly favours carcinoma. Negative CEA staining is also seen with the other pseudo-neoplastic glandular lesions considered here but experience with CEA staining

of many of them is limited and a diagnosis should not be rendered solely on the basis of immunohistochemical staining results. Normal endocervical glands and those of pseudoneoplastic lesions may exhibit a glycocalyceal pattern of CEA staining that contrasts with the diffuse cytoplasmic staining typically seen in cervical adenocarcinomas (Jones et al., 1991). Moreover, normal endocervical glands may show luminal CEA positivity and MGH may exhibit cytoplasmic positivity, usually confined to areas of immature squamous metaplasia or reserve cell hyperplasia. A combination of CEA, MIB-1 and p53 staining was found to be useful in discriminating benign and malignant endocervical glandular lesions, although p53 expression was found in some cases of MGH. Immunohistochemical expression of CD44 has also been investigated in endocervical glandular lesions. It was concluded that CD44 v5 immunoreactivity may be a useful diagnostic marker of endocervical neoplasia (McCluggage, 2002; McCluggage, 2003).

4.3 IMMUNOHISTOCHEMICAL STUDIES USEFUL IN DIAGNOSIS OF CERVICAL MESONEPHRIC LESIONS

Both cervical mesonephric hyperplasia and adenocarcinoma may cause diagnostic difficulties, the former in the separation from other benign mimics and from adenocarcinoma (especially MDA) and the latter in the recognition of this as a special subtype of cervical adenocarcinoma. CD10 staining in cervical mesonephric remnants and adenocarcinomas has been investigated in a recent immunohistochemical study. In this study, consistent positive staining of cervical mesonephric lesions for CD10 with a characteristic luminal staining pattern was found. In the cervix, CD10 positivity of benign glandular elements appears to be relatively specific for mesonephric derivatives, with little or no staining of normal endocervical glands or of other benign mimics, although some ordinary endocervical adenocarcinomas may be focally positive (McCluggage, 2003).

4.4 IMMUNOHISTOCHEMICAL STUDIES USEFUL IN DIAGNOSIS OF MDA

Recently, it shown that gastric mucins are present in adenoma malignum and that HIK1083, a monoclonal antibody against gastric gland mucous cell mucin, is useful for the diagnosis of this uncommon neoplasm (Utsugi et al., 1999; Ishii et al., 2001). Normal endocervical glands are consistently negative although very small foci of

positivity may be found in ordinary endocervical adenocarcinomas. Less well-differentiated areas in adenoma malignum are usually negative. Thus HIK1083 staining can discriminate between benign endocervical glands and the well-differentiated glands of adenoma malignum. This can be extremely helpful since CEA staining may not always be diagnostic.

The recently described benign endocervical glandular lesion termed 'lobular endocervical glandular hyperplasia', which may mimic adenoma malignum, is now also thought to have a pyloric gland phenotype on the basis of histochemical staining characteristics and immunohistochemistry with antibodies against pyloric gland-type mucins such as M-GG MC-1 (Mikami et al., 2001; McCluggage, 2002).

Histochemical stains may also be useful in the diagnosis of cervical adenoma malignum. A combined Alcian blue–periodic acid Schiff (PAS) stain may be useful because normal endocervical glands, as a result of their high content of acid and neutral mucins, stain a purple/violet colour. In contrast, the glands of cervical adenoma malignum (and conventional adenocarcinomas) stain red using this preparation because of the almost exclusive presence of neutral mucin. In doubtful cases, a combined Alcian blue–PAS stain may be useful in distinguishing normal endocervical glands from the glands of adenoma malignum (Hayashi et al, 2000).

4.5 ANTIBODIES USEFUL IN ASSESSMENT OF CERVICAL ADENOCARCINOMAS

4.5.1 Cytokeratins (CK)

4.5.1.i Introduction

Cytokeratins are constituents of the intermediate filaments of epithelial cells which are expressed in various combinations depending on the epithelial type and the degree of differentiation (Zemer et al., 1998). Studying the CK phenotype of the tumours has a practical importance for differential diagnostic purposes (epithelial vs. nonepithelial tumours, adenocarcinomas vs. squamous and transitional cell tumours), as well as for typing of adenocarcinomas in a search for unknown primary tumours from metastases. Furthermore, studies indicating different CK expressions according to tumour differentiation have been published (Tot, 2000).

4.5.1.ii Keratin expression in human tissues and neoplasms

Keratin filaments constitute type I and type II intermediate filaments (IFs), with at least 20 subtypes named keratin 1-20. Since certain keratin subtypes are only expressed in some normal human tissues but not others, and vice versa, various tissues have been subclassified according to the pattern of keratin staining. Simple epithelia generally express the simple epithelial keratins 7, 18, 19, and 20, while complex epithelia express complex epithelial keratins 5/6, 10, 14, and 15. When an epithelium undergoes malignant transformation, its keratin profile usually remains constant. Therefore, since keratin expression varies so greatly among different epithelia, they have been widely used in the fingerprinting of various carcinomas (Chu & Weiss, 2002).

4.5.1.iii Antibodies to keratins

In the early days of immunohistochemistry, most anti-keratin antibodies used in surgical pathology were not reactive to a specific keratin; rather, they were mixed monoclonal antibodies or polyclonal antibodies that reacted to several keratins. Currently, high-quality anti-keratin monoclonal antibodies to all of the 20 keratins are commercially available from many biomedical reagent vendors. However, one should be aware that some of the anti-keratin antibodies still used by many pathologists today are reactive to several keratins, and many immunohistochemical studies published in literature have used these antibodies (Chu & Weiss, 2002).

4.5.1.iv Keratins in carcinomas

4.5.1.iva General patterns

Virtually all carcinomas, regardless of their tissue origin, are immunoreactive to keratin antibodies. However, keratin expression patterns in carcinomas from stratified epithelia and from simplex epithelia are different. Among anti-keratin antibodies, monoclonal antibodies to K7, K20, K14 and K5/6 have the highest discriminative value among different types of carcinomas. In general, carcinomas of simple epithelial origin are positive for K7 and/or K20 and negative for K14 and K5/6; whereas

carcinomas of stratified epithelial origin are positive for K14 and K5/6, and negative for K7 and/or K20.

4.5.1. *ivb keratin 7 (K7)*

The expression of K7 in epithelial neoplasms is restricted to a subgroup of adenocarcinomas of glandular epithelial origin (Ramaekers et al., 1990; Wang et al., 1995). The vast majority of cases of adenocarcinoma of the lung, ovary, uterus, breast, pancreas, salivary gland and thyroid tumours, cholangiocarcinoma, and transitional cell carcinoma are positive for K7. In contrast, only a small percentage of cases of colorectal adenocarcinoma and gastric adenocarcinoma are K7+. Two-thirds of cases of malignant mesothelioma are positive for K7, and about 20-40% cases of neuroendocrine neoplasms, including small cell carcinoma of the lung, neuroendocrine carcinomas from a variety of organs, and carcinoid tumour, are positive for K7. It is worthwhile to mention that in kidney, papillary, collecting duct and chromophobe renal carcinomas are frequently positive for K7, whereas conventional renal carcinomas are not. Squamous cell carcinomas of the skin are usually negative for K7; however, squamous cell carcinomas arising from non-cornified squamous epithelia, in particular the uterine cervix, are often positive for K7 (Fuchs et al., 1981; Chu et al., 2000).

4.5.1 *ivc keratin 20 (K20)*

K20 expression is restricted to a few organ systems. Over 90% of cases of colon carcinoma, 86% cases of Merkel cell tumour of skin, 68% cases of transitional cell carcinoma, 56% cases of gastric carcinoma, and 52% of cases of pancreatic adenocarcinoma are K20+. The CK20+ staining pattern in Merkel cell carcinoma is cytoplasmic dot-like, which is different from the diffuse cytoplasmic staining seen in cases of CK20+ gastric and colorectal carcinoma.. Since the vast majority of cases of ovarian mucinous tumours actually represent metastases from gastrointestinal tract primaries, they are frequently positive for K20; however, it is believed that the true K20+ rate in primary ovarian mucinous carcinomas is low. In addition, unlike their gastrointestinal counterparts, ovarian mucinous tumours are usually positive for K7 (Chu & Weiss, 2002).

4.5.1.ivd The keratin expression pattern of cervical adenocarcinoma

In cervical adenocarcinoma, the keratin expression pattern is considerably more complex than expected from the results obtained with adenocarcinomas arising in other tissues (Moll et al., 1992). Like other gynaecological adenocarcinomas, cervical adenocarcinoma contains K7, K8, K18 and K19; but it is also frequently positive for K17 and K14 while cervical and vaginal squamous carcinomas are frequently positive for K7, K8 and K18 (Chu et al., 2000). Furthermore, sporadic expression of K4, K5, K10 and K13 may be seen. None of these above keratins is present in the normal columnar cells lining the endocervical canal. Because of this, it has been speculated that cervical adenocarcinoma does not usually arise from columnar cells, but instead derives from reserve cells. Squamous cell carcinoma in situ may thus make the transition to an adenocarcinoma. It may be difficult to distinguish histologically between a primary cervical adenocarcinoma and a metastatic adenocarcinoma arising from the bowel, endometrium, mesothelium, or ovary. This dilemma may be addressed by determining the keratin phenotype of these adenocarcinomas. Colonic adenocarcinomas have a simple keratin expression pattern consisting of K8, K18, K19 and K20, whereas cervical adenocarcinoma contains K7, K17, and frequently K14, and usually lacks K20. Absence of K5/6 in cervical adenocarcinoma can help distinguish this neoplasm from malignant mesothelioma. In discriminating between a primary cervical adenocarcinoma and a metastatic endometrial/ovarian serous or a mucinous carcinoma, the absence of K14 and K17 in the latter may be a useful differential diagnostic tool. Although arising from the same epithelium, cervical dysplasia and invasive carcinoma have different keratin profiles in comparison with normal cervical non-keratinizing epithelia. Normal cervical epithelium expresses K10, but not K7, K8, K17 and K18. In contrast, cervical dysplasia (cervical intraepithelial neoplasia (CIN)) or cervical squamous cell carcinoma tends to express K7, K17 and K18, but not K8 and K10 (Smedts et al., 1993). Using a combination of K10 and K17, it is possible to separate cervical squamous cell carcinoma from benign conditions with a sensitivity of 100% and specificity of 93% (Maddox et al., 1999; Chu & Weiss, 2002).

4.5.2 Carcinoembryonic antigen (CEA)

Cytoplasmic carcinoembryonic antigen (CEA) positivity assists in the distinction of benign and malignant glandular lesions of the cervix, but some cases remain problematic. At the University of Kentucky Medical Centre, van Nagell et al., (1978) found that, levels of carcinoembryonic antigen were elevated (greater than 2.5 ng/ml) in 48% of cervical cancer patients, and varied directly with stage of disease and histological differentiation of the tumour. Plasma CEA levels were more commonly elevated in patients with endocervical adenocarcinoma than in those with squamous cell carcinoma, but were not related to vascular invasion in the specimen or regional lymph nodal morphology. A progressive rise of plasma CEA preceded the clinical diagnosis of recurrence by 1 to 23 months. Patients with progressively rising plasma CEA levels following therapy for cervical cancer should be extensively evaluated to rule out the presence of occult recurrence.

A study by Cina et al (1997) reported that the combination of CEA positivity and a moderate-to-high proliferative index was limited to cases of invasive adenocarcinoma, adenoma malignum, and adeno-carcinoma in situ, as compared with benign glandular lesions ($p=0.005$). A high Ki-67 proliferative index and/or CEA positivity were features of malignant lesions rather than benign mimickers; there were no false positives or false negatives. Similarly, only malignant neoplasms shared a combination of p53 overexpression and CEA positivity ($p=0.043$). Strong staining of more than 10% of the glandular epithelial nuclei was interpreted as positive for p53 protein overexpression. CEA positivity was determined by either diffuse or focal cytoplasmic staining of columnar epithelial cells equalling glycocalyceal staining in intensity. The combination of cytoplasmic CEA positivity in glandular cells and a moderate-to-high MIB-1 (Ki-67) proliferative index is diagnostic of malignancy in endocervical lesions. With the exception of florid microglandular hyperplasia, p53 expression is only seen in neoplastic lesions of the endocervix.

The differential diagnosis of endocervical and endometrial adenocarcinomas can be improved by the demonstration of CEA in tissue by means of immunoperoxidase staining (as already discussed). Also, the extent of the immunoperoxidase localization

of CEA did not seem to correlate with the degree of differentiation in either kind of cancer. Among the positive cases, CEA staining was located over whole cytoplasm in 18 (80%) of 22 positive endocervical adenocarcinomas and on apical surface in 24 (75%) of 32 positive endometrial adenocarcinomas. The pattern of CEA distribution in endocervical adenocarcinoma of endometrioid type was not similar to that observed for primary endometrial adenocarcinoma (Toki et al., 1985).

4.5.3 Oestrogen receptor (ER) and progesterone receptor (PgR)

4.5.3.i Introduction

Biochemical and immunohistochemical studies have identified ER and PgR in the endocervical columnar epithelium and the normal endocervix appears to be the target tissue of steroid hormones because the quantity and quality of endocervical mucus fluctuates in response to hormonal changes during the menstrual cycle (Gaton et al., 1982).

4.5.3.ii ER and PgR Immunocytochemistry

In all cases, normal endocervical cells and fibroblast-like stromal cells of the cervix stained positively for ER and PgR. The staining pattern in the tumour cells was similar to that observed in the normal endocervical cells and was restricted to the nucleus. However, the intensity and distribution of ER and PgR staining in the tumour tissue was more heterogeneous than that observed in the normal tissues. ER and PgR staining in individual tumour cases would often vary from strongly positive to completely negative. In the tumours, staining for both ER and PgR was frequently observed in the nuclei of nonneoplastic stromal cells surrounding the tumour cells.

Mucinous adenocarcinomas of the endocervical type and endometrioid subtypes are the two histologic subtypes most commonly associated with ER and PgR positivity. There is a strong relationship between histologic grade and ER and PgR positivity. ER positivity was somewhat reduced in poorly differentiated (Grade 3) tumours compared with well differentiated and moderately differentiated (Grade 1 and 2) tumours ($p=0.07$). In contrast, no reduction in PgR positivity was observed with increasing tumour grade. However, other study reported no significant difference was observed between tumours that were Stage I and those that were Stage II or higher with respect to ER and PgR positivity. Similarly, no statistically significant

differences in ER and PgR status were observed with age and racial/ethnic group (Fujiwara et al., 1997).

4.5.3.iii ER and PgR Status as a Clinical Prognosticator

In overall survival or disease free survival, no statistically significant differences were observed between PgR positive and PgR negative cases. Similarly, no statistically significant difference was observed between patients with ER positive and ER negative tumours. Although the current data suggested that women with ER positive tumours may have longer disease free survival than women with ER negative tumours ($p=0.06$), this finding must be interpreted with caution because it did not reach statistical significance ($p=0.06$) (Fujiwara et al., 1997).

4.5.4 PTEN

PTEN (phosphatase and tensin homolog deleted on chromosome ten) is a tumour suppressor gene which appears to negatively control the phosphoinositide 3-kinase signaling pathway for regulation of cell survival and cell proliferation by dephosphorylating phosphatidylinositol 3, 4, 5-triphosphate (Myers et al., 1998). The loss of *PTEN* function results in an increased concentration of PIP-3 and this in turn leads to Akt hyperactivation. This suggests that the tumour-suppressor function of *PTEN* is exerted through the negative regulation of the PI3-kinase/Akt cell survival pathway (Furnari et al., 1998; Stambolic et al., 1998). The protein phosphatase activity of *PTEN* is not considered to be as important as its lipid phosphatase activity for tumour suppression. However, *PTEN* function as protein phosphatase has been implicated in the inhibition of cell migration and invasion via dephosphorylation of focal adhesion kinase [FAK], a molecule critical in the regulation of integrin signalling (Tamura et al., 1998; Tamura et al., 1999) and also in the inhibition of cell cycle progression (Hlobilkova et al., 2000).

To date, 110 germline *PTEN* mutations have been reported in patients affected with rare multiple hamartoma syndromes (Eng & Peacocke, 1998). *PTEN* has also been found to be defective in a large number of sporadic human tumours of breast, prostate, brain and endometrium (Li et al., 1997; Steck et al., 1997; Kong et al., 1997). *PTEN* is a good candidate for involvement in the pathogenesis of sporadic colon cancer. However, to date, few somatic *PTEN* mutations or deletions have been identified in

sporadic colon cancers (Frayling et al., 1997; Wang et al., 1998; Taniyama et al., 2001). Somatic *PTEN* mutations are more particularly involved in two types of human cancers: endometrial carcinomas (Kawanishi et al., 1997) and glioblastomas (Rasheed et al., 1997; James et al., 1999). In most cases, these somatic mutations result in protein inactivation and, as with germline mutations, recurrent somatic mutations are found in CpG dinucleotides. A mutagenesis by insertion-deletion in repetitive elements is however specifically observed in endometrial carcinomas (Bonneau & Longy, 2000).

Being one of the initial genetic changes seen in endometrial carcinogenesis, the *PTEN* gene acts as a gatekeeper for this process (Ali, 2000). In normal endometria, isolated *PTEN* negative glands may well be the earliest detectable phases of endometrial tumourigenesis yet seen, but the clinical relevance of such small lesions remains to be determined (Mutter & Lin, 2000; Mutter et al., 2001). It is anticipated that similarly high rates of initiation will be seen in other tissues because comparable biomarkers for neoplastic initiation become available in other tissue sites. Lesions have now fulfilled most of those postulates predicted for clinically relevant precancerous disease. Loss of *PTEN* function occurs quite frequently within the endometrial regenerative pool, at such a high rate that they can be considered part of background“normal” genetic events. These mutant clones remain indistinguishable from non-mutant glands in normal cycling and anovulatory endometrium. Involution or expansion of mutant clones due to non-genetic factors is one possible mechanism whereby the ambient hormonal state may modify the risk of endometrial cancer (Mutter, 2002). Interestingly, the *PTEN* gene appears to be hormonally regulated, with greatest physiological endometrial gland expression in an oestrogen rich environment (Mutter et al., 2000). Thus, the diminished *PTEN* tumour suppressor function effects are probably accentuated under the very circumstances known to increase endometrial cancer risk: protracted oestrogen exposure unopposed by progestins (Curry, 1990; Parazzini et al., 1991). Mutant glands then acquire additional genetic damage and subsequently become recognisable as focal lesions by their crowded architecture and altered cytology (Mutter, 2002).

4.5.5 MIB-1 (Proliferation Marker)

As well as being of use in certain situations in the interpretation of cervical squamous lesions, MIB-1 and other proliferation markers may also be of value in the diagnosis of preinvasive cervical glandular lesions (McCluggage et al., 1997; Ogawa et al., 1999). In the distinction between high-grade CGIN and TEM or MGH, MIB-1 staining is of value. Generally in benign lesions only scattered nuclei are positive, whereas in high-grade CGIN many nuclei are usually positive. One study found that a MIB-1 labelling index of >30% was highly predictive of a malignant or premalignant endocervical glandular lesion (Ogawa et al., 1999). However, in this study cases of low-grade CGIN were not included and it might be expected that there would be some overlap in the MIB-1 labelling indices between low-grade CGIN and TEM. In addition, cases of atypical TEM have been described (sometimes in association with high-grade CGIN of tubal type with cilia) and these might be expected to have a higher proliferation index than typical TEM (McCluggage, 2002). Another recent study found that MIB-1 staining <10% always reflected a benign process whereas a MIB-1 index of >50% was always associated with a neoplastic process. It should be noted that MIB-1 staining is also of value in cervical squamous lesions, especially in the distinction of atrophy or immature squamous metaplasia from CIN III (Young & Clement, 2002). However, there is no significant differences in MIB-1 labelling index existed between the adenocarcinoma and AIS groups (McCluggage et al., 1995).

In addition to these, there were statistically significant differences in HPV 16/18, p53 and MIB-1 expressions between malignant endocervical glandular lesions and EGD, but no significant difference in p53 and MIB-1 expressions in relation to HPV 16/18 expression. In malignant endocervical glandular lesions, HPV 16/18 infection may be a major causative factor, but not be related to p53 and MIB-1 expressions (Yoon et al., 2001).

4.5.6 The Suppressor Gene p53

Alterations of the p53 tumour suppressor gene are correlated with a critical step in the development of many human cancers. The tumour suppressor gene functions include regulation of the cell cycle and the cellular response to DNA damage, initiation of DNA repair and replication, induction of apoptosis and promotion of cell differentiation. Inactivation of p53 may result from a number of events including

mutation of the p53 gene, binding of p53 to cellular or viral proteins and cytoplasm sequestration of the protein. In cervical carcinoma, loss of p53 function can occur through its interaction with the E6 protein of oncogenic HPV types. In addition, DNA of these HPV types is often found integrated into cellular DNA. This integration can result in deletion or mutation of some viral genes. The clinical significance of p53 changes has been evaluated elsewhere for a wide variety of human cancers, including cervical cancer. Although cervical low-grade neoplasia can progress to cervical cancer, few molecular studies have indicated p53 mutation at this stage of the lesion (Oliveira et al., 2002).

It was claimed by McCluggage et al., (1995) that p53 protein expression is frequent in endocervical adenocarcinoma and suggests that mutation of the p53 gene may be important in the evolution of some cases of endocervical adenocarcinoma. Scattered p53-positive cells may be seen in endocervical adenocarcinoma in situ and in non-neoplastic endocervical glandular lesions, the significance of which is uncertain. Bcl-2 protein expression is seen in a proportion of endocervical adenocarcinomas and may play a role in the evolution of these tumours through inhibition of apoptosis. Widespread positivity for bcl-2 protein is seen in most cases of tubo-endometrial metaplasia, suggesting that this type of metaplastic epithelium may represent an unusually stable population of cells.

Skyldberg et al, (1999) reported that the HPV-positive tumours predominantly showed a tetraploid DNA distribution pattern, whereas HPV-negative tumours more frequently showed highly scattered aneuploid DNA profiles. Both HPV-positive and HPV-negative cases displayed high proliferative activity, as indicated by high Ki-67 and cyclin A immunoreactivity. Tumour suppressor gene analysis detected low p53 expression and high p21/WAF1 expression in HPV-positive patients and high p53 expression without simultaneously increased p21/WAF1 (indicative of mutated p53) in HPV-negative cases in the groups of women older than 59 years of age. Moreover, Storey et al, (1998) claimed that, nuclear accumulation of p53 was found to be associated with the presence of HPV. There was no significant difference in parietal infiltration, lymph node involvement and prognosis between HPV+p53+ patients and HPV-p53- patients. Tumour aggressiveness is likely to be enhanced by factors other than HPV infection and p53 overexpression

AIMS OF THE WORK

The objectives of this study were to (1) use tissue microarray technique as a new tool for histopathological studying of archival paraffin-embedded cervical adenocarcinomas cases; (2) use tissue microarray technology to evaluate the immunoprofile of a large set of cervical adenocarcinomas with an extended panel of antibodies, comparing the profile of AIS with invasive subtypes of cervical adenocarcinomas; (3) compare the tissue microarray technique with whole tissue staining in regard to quality of staining, reproducibility, and the impact of tissue heterogeneity, (4) study the morphological and histological structure of cervical adenocarcinomas archival donor blocks; (5) evaluate the diagnostic and prognostic value of different antibodies which are commonly used in immunohistochemistry of cervical lesions; (6) assess the prevalence of HPV 16 and 18 infection in various cervical adenocarcinomas cases using PCR methods and evaluate its relation to other parameters of cervical adenocarcinomas; (7) evaluate the correlation between HPV 16 and 18 and the histological type of preinvasive and invasive cervical adenocarcinoma.

Morphological and Histopathological study

1.1 Thesis title

A retrospective histopathological study was conducted on 100 patients diagnosed with invasive cervical adenocarcinoma at the Royal Infirmary of Edinburgh, Pathology Department from 1992 to 2002. The study was conducted to determine the histopathological features of adenocarcinoma in situ and compare them with a group of non-invasive lesions. Non-invasive adenocarcinomas were classified as endocervical adenocarcinoma in situ and ectocervical adenocarcinoma in situ. The study was conducted on 100 cases of invasive cervical adenocarcinoma. A total of 100 cases were included in the study. From 177 biopsies conducted in the study, 75 were confirmed as adenocarcinoma with endocervical adenocarcinoma and 25 were confirmed as adenocarcinoma with ectocervical adenocarcinoma. The study was conducted on 100 cases of invasive cervical adenocarcinoma. A total of 100 cases were included in the study. From 177 biopsies conducted in the study, 75 were confirmed as adenocarcinoma with endocervical adenocarcinoma and 25 were confirmed as adenocarcinoma with ectocervical adenocarcinoma. The study was conducted on 100 cases of invasive cervical adenocarcinoma. A total of 100 cases were included in the study. From 177 biopsies conducted in the study, 75 were confirmed as adenocarcinoma with endocervical adenocarcinoma and 25 were confirmed as adenocarcinoma with ectocervical adenocarcinoma.

PART (III)

MATERIALS & METHODS

1.1 Histology and immunohistochemistry

From 100 cases, 75 were confirmed as adenocarcinoma with endocervical adenocarcinoma and 25 were confirmed as adenocarcinoma with ectocervical adenocarcinoma. The study was conducted on 100 cases of invasive cervical adenocarcinoma. A total of 100 cases were included in the study. From 177 biopsies conducted in the study, 75 were confirmed as adenocarcinoma with endocervical adenocarcinoma and 25 were confirmed as adenocarcinoma with ectocervical adenocarcinoma. The study was conducted on 100 cases of invasive cervical adenocarcinoma. A total of 100 cases were included in the study. From 177 biopsies conducted in the study, 75 were confirmed as adenocarcinoma with endocervical adenocarcinoma and 25 were confirmed as adenocarcinoma with ectocervical adenocarcinoma.



Chapter 1

Morphological and Histopathological study

1.1 Tissue Samples

A computerized tumour registry search was conducted for all patients diagnosed with invasive cervical adenocarcinoma at the University of Edinburgh, Pathology Department from 1991 to 2001. In addition, twenty cases of adenocarcinoma in situ were used as a sample to compare with invasive cases. Nonprimary cervical adenocarcinomas were excluded. Ethical approval for this study was granted by the local research ethics committee. Surgical cervical specimens were obtained from the archival collections. A total of 273 samples (paraffin-embedded blocks) were obtained from 177 biopsies composed of 16 normal cervical biopsies, 139 different patients with endocervical adenocarcinomas, and 22 patients with second biopsies. Pathology reports and cervical smear history reports were reviewed. Cases with sufficient residual tissue in the archival tissue blocks were selected to ensure an adequate sample for haematoxylin and eosin sections, TMA construction, immunohistochemical analysis and HPV detection. The final set of study cases included samples of glandular tissues including normal endocervical mucosa (16) which were taken from patients suffering from different non-cervical pathologies, adenocarcinoma in situ (20), invasive adeno-carcinoma (119) and 22 cases with second biopsies.

3- μ m serial sections from the routinely processed formalin-fixed, paraffin-embedded tissue blocks were prepared. Before deparaffinizing the sections, they were baked overnight at 60°C and stained with haematoxylin and eosin method to study the morphological and histopathological features of the cervical cases.

1.2 Haematoxylin and eosin method

Fresh 3- μ m sections were cut from each paraffin-embedded block and transferred to glass slides (Dako ChemMate capillary gap microscope slides, 75 mm, Dako A/S, Glostrup, Denmark). Following deparaffinization in xylene (2 times, 5 minutes each time) and rehydration through descending graded ethanol, 100%, 95% and 70% (2

minutes each time), the sections were washed well with tap water for 2 minutes. Staining was performed by placing the sections into haematoxylin (to stain the nuclei of the cells) for 5 minutes and washing in tap water until colour changes from red to blue. The sections were treated with acid alcohol for 5 seconds and placed into tap water until sections again go blue. Then the sections were stained with eosin (to stain the cytoplasm of the cells) for 30 seconds and washed in tap water. After dehydration of the sections through ascending graded ethanol, 70%, 95%, and 100%, (5 seconds each time), the sections were cleared well with xylene. Finally, sections were mounted in DPX by placing one drop of DPX on to a coverslip and placing the slide on top of this covering the section. Then sections were left to dry overnight.

1.3 Reviewing of the Haematoxylin and eosin–stained slides and collection of data

All haematoxylin and eosin–stained slides were reviewed and diagnostic groups were assigned and graded according to standard histological criteria. Histopathologic sections were available for normal endocervical mucosa, all invasive cases, adenocarcinoma in situ cases with smooth peripheral contour and cases of early invasion if there are small buds of malignant glandular cells protruding into the stroma from glands with adenocarcinoma in situ, if the otherwise smooth peripheral contour of adenocarcinoma in situ was absent, or if malignant glands extended below the level of adjacent benign glands or adenocarcinoma in situ. The presence of an associated squamous intraepithelial lesion was recorded. Clinicopathological parameters were obtained from the pathology reports.

Each specimen was associated with a large number of data items. Therefore, database was designed using Microsoft Access to hold the large amount of data that generated from each specimen. Data was verified and entered in the database.

CHAPTER 2

Tissue Microarray (TMA) construction

2.1 Tissue Samples

A fresh 3- μ m section was stained with haematoxylin-eosin from each of 273 samples (blocks) obtained from 177 biopsies composed of 16 normal cervical biopsies, 139 different patients with endocervical adenocarcinomas, and 22 patients with second biopsies. All sections available were reviewed histologically, and areas of morphologically representative, nonnecrotic sites in the tumour were marked with coloured indelible marker on the glass slides of H&E stained sections. In our study, the area of invasive adenocarcinoma was marked by black circle; the area of adenocarcinoma in situ was marked by blue circle while the area of normal endocervical glands within the tumour was marked by red one. From each corresponding paraffin block, two paired tissue cores (0.6 mm in diameter) were sampled from each marked area in the "donor" block and mounted into two "recipient" paraffin blocks, one pair in each paraffin block, by the use of a custom-made instrument (Beecher Instruments, Silver Springs, MD). In the ensuing paraffin array block, the tissue cylinders were aligned, and marked for identification according to a chart (Figure 3).

The final set of tissue samples consisted of 667 tissue cylinders in 6 TMA blocks which included samples of normal endocervical mucosa (32 cores) in one TMA block, normal endocervical glands from the tumours tissue (125), adenocarcinoma in situ (59 cores) in duplicate TMA blocks, and invasive adenocarcinoma (196 cores) in duplicate TMA blocks.

The "recipient" paraffin blocks (TMA blocks) were baked at 56°C for 10 minutes before sectioning and 3- μ m paraffin sections were then made by standard technique. After that, TMAs sections were stained with haematoxylin and eosin method and different antibodies for immunohistochemistry. Finally, H&E –stained TMA sections

were compared with some of whole sections to investigate whether TMAs are representative of the morphology of cervical adenocarcinoma (Figure 4a-14b).




Fig. 3 diagram of TMA organization chart which used in this study. Tissue samples were distributed and located in TMA chart using (X: Y) relationship.

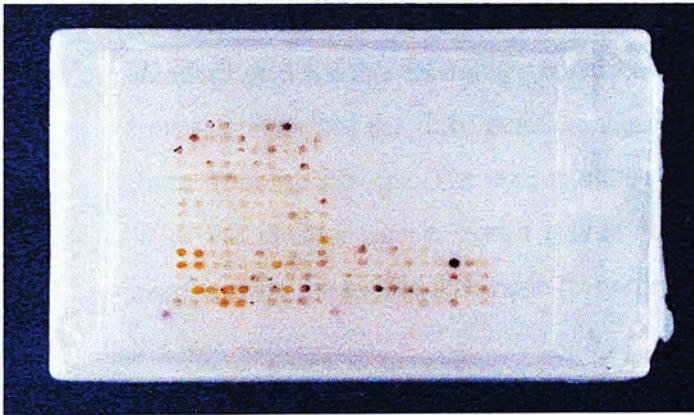


Fig 4a TMA paraffin Block




Fig 4b TMA H&E slide

2.2 Tissue Microarray (TMA) Technique (written by M. Herriot)

1. Prepare blank recipient (array) paraffin blocks. These should be 5-10mm deep. A suitable mould is the large Tissue-Tek 1. Ensure that the wax is free from holes or other irregularities. The array identifier code may be marked at this stage.
2. At least one block of control tissue and two for the tumour samples (adjacent cores to allow for within-tumour variation) should be prepared. The areas for blocking should be circled on the corresponding slides
3. Clamp all recipient blocks into holders, ensuring that they are all in the same position. With the screws facing you, place the block with the number-end on the left, in the rear left corner of the holder and tighten the screws.
4. Place the first block on the Manual Tissue Arrayer (TMA-1) on the magnet and firmly against the back and side rails. Align the (0, 0) position. The standard grid for this laboratory consists of 2 sections of 10 x 15 at 1mm intervals therefore the (0,0) position should be 5mm from the bottom and 9mm from the left side. The micrometers should be zeroed at this position.
5. With the plunger raised, punch a hole at (0,0) using the fine bore (red) needle, twist the needle then raise from the block. Use the plunger to expel the wax core.
6. Move the larger (blue) needle into position and check that it is correctly aligned. Place the donor block bridge on the stage and select a suitable marker tissue (normally liver stained with crystal violet). Punch the block and remove the stage. Bring the needle gently down until it is just touching the array block above the hole. Carefully expel the core into the hole. The core should end up just below the surface of the block.
7. When assembling the tumour arrays, it is convenient to swap blocks after each core is inserted. This ensures that adjacent tumour samples are in the same positions in each array.
8. Move the stage to (1, 1) and punch the next hole using the red needle.

9. Use the blue needle to punch the first test tissue matching the block with the selected area on the slide and expel into the position.
10. Mark the template with the identifying number or score the position off and record the position and identity in a separate book.
11. Move the stage to (2,1) and continue.
12. After (10, 15), move the stage to (11,0) and insert the second marker tissue (usually acid fuchsin stained lung). These markers ensure that however the tissue sections are floated; the array can still be orientated.
13. Move the stage to (12, 1) and continue with the next section.
14. Once the arrays are constructed, remove the blocks from their holders and place in a 56°C incubator for 10 minutes. This softens the paraffin. Gently press down on the surface of the array with a glass slide and allow to cool.
15. The array blocks are now ready to cut. Face-up carefully in order to obtain a cross-section of as many samples as possible - 90% + is acceptable. A common problem is that of samples curling-up. If this happens, repeat the softening of the paraffin at 56°C and press with the glass slide. The array blocks generally cut well.

CHAPTER 3

IMMUNOHISTOCHEMISTRY

3.1 Tissue Samples

A 3- μ m TMA sections (as mentioned previously in chapter 2) and some of the whole sections (as mentioned in chapter 1) were used to study and to compare between them and to evaluate the heterogeneity within the tumours. These sections were stained for the following antigens, carcinoembryonic antigen (CEA), Cytokeratin7 (CK7), Cytokeratin20 (CK20), oestrogen receptors (ER), progesterone receptors (PgR), MIB-1 proliferation marker, and p53 suppressor gene. These antigens were chosen to represent known positive (CK7), expected negative (CK20), steroid receptors (ER and PgR) as examples of potentially heterogeneous expression- to compare staining in whole sections with those in TMA; CEA and p53 to investigate their expression in a large series; and phosphatase and tensin homolog deleted on chromosome ten (*PTEN*) antigen to evaluate it in differential diagnosis between primary endocervical adenocarcinoma and primary endometrial adenocarcinoma. Pathology reports and cervical smear history reports were reviewed.

3.2 Immunohistochemical Staining

Fresh 3- μ m sections were cut from each Microarrays and the original paraffin-embedded block and transferred to glass slides (BDH Superfrost plus microscope slides, 75mm, BDH Laboratory Supplies). Following deparaffinization in xylene (2 times, 5 minutes each time) and rehydration through descending graded ethanol , 100%, 95%, and 70% (2 minutes each time), the sections were washed well with tap water for 2 minutes. Antigen retrieval was performed by immersing tissue sections to be used for CEA, CK20, MIB-1 and p53 antibodies in EDTA (pH 8) and heating them for 15 minutes in a microwave at 750 W, while the sections which will be used for CK7, *PTEN*, and Progesterone receptors, antigen retrieval was performed by immersing in citrate buffer pH 6 with pressure cooking for 6 minutes at 1m bar. The sections were washed well in water then loaded onto Shandon Sequenza staining apparatus. Endogenous peroxidase was then blocked by treatment with 1% hydrogen peroxide for 5 minutes followed by washing in distilled water and then PBS. Using

Dako Envision System, the tissue sections were stained with the following monoclonal primary antibodies for 30 minutes: carcinoembryonic antigen (CEA) (clone 11-7, DakoCytomation, Denmark A/S), incubated at 1:300 dilution; CK20 (clone K_s20.8, DakoCytomation, Denmark A/S), incubated at 1:350 dilution, Ki 67 (clone MIB-1, DakoCytomation, Denmark A/S) incubated at 1:100 dilution; p53 (clone DO-3, DakoCytomation, Denmark A/S) incubated at 1:50 dilution. CK7 (clone OV-TL 12/30, DakoCytomation, Denmark A/S), incubated at 1:10 dilution; *PTEN* (clone 28H6, NovoCastra Laboratories Ltd, UK) incubated at 1:100 dilution and progesterone receptor (clone PgR 636, DakoCytomation, Denmark A/S), incubated at 1:20 dilution.

For each tissue block, negative controls contained samples in which the primary antibody was omitted and positive control tissues of known positivity to these antibodies were performed. The positive tissue control for CK7, PgR and P53 was breast carcinoma, for CK20 and CEA was colonic carcinoma and *PTEN* and MIB-1 was tonsil. The sections were washed well in PBS (2 times, 5 minutes each time). The tissue sections were incubated with Dako EnVision/HRP rabbit/mouse polymer for 30 minutes, and then washed well in PBS (2 times, 5 minutes each time). After that, the sections were incubated at room temperature with 3,3'-diaminobenzidine (DAB) solution for 5 minutes and washed in tap water. Finally, the sections were counterstained with haematoxylin, washed in tap water, then in STWS, dehydrated in ascending graded ethanols, 70%, 95%, and 100%, (5 seconds each time), cleared well with xylene and mounted by DPX.

For oestrogen receptors (ER) staining, PowerVision Poly-HRP Histostaining kit (Biotin-free, anti-mouse/rabbit) was used from ImmunoVision Technologies Co. Negative and positive controls were also performed, the positive tissue control for ER was breast carcinoma. Fresh 3- μ m sections were cut, deparaffinized in xylene, and rehydrated through descending graded ethanol (as mentioned above). The sections were washed well with tap water for 2 minutes. Antigen retrieval was performed by immersing tissue in EDTA/NaOH (pH 8) with pressure cooking for 6 minutes. The sections were washed well in water then loaded onto Shandon Sequenza staining apparatus. Endogenous peroxidase was then blocked by treatment with 1% hydrogen

peroxide for 5 minutes followed by washing in distilled water and then PBS. The tissue sections were incubated in ER (clone 6F11, NovoCastra Laboratories Ltd, UK) diluted 1:150 in Pre-antibody Blocking Solution for 1 hour. A negative control that consisted of omission of the primary antibody and a positive control from tissue for which was known its positivity to ER antibody were performed. The positive tissue control for ER was breast carcinoma. The sections were washed well in PBS (2 times, 5 minutes each time). The tissue sections were incubated with Post-antibody Blocking (Polymer penetration enhancer) for 20 minutes, and then washed well in PBS (2 times, 5 minutes each time). After that, the sections were incubated with Poly-HRP anti-mouse/rabbit IgG for 30 minutes and washed well in PBS (2 times. After that, the sections were incubated with DAB solution for 5 minutes and washed in tap water. Finally, the sections were counterstained with haematoxylin, washed in tap water, and “blue” in STWS, dehydrated in ascending graded ethanols, 70%, 95%, and 100%, (5 seconds each time), cleared well with xylene and mounted by DPX.

3.3 Evaluation of Tissue Staining

To determine how many cores are required to adequately represent a cervical adenocarcinoma histologically, each H&E stained TMA core was analysed separately and in relation to its original whole section. It was decided that in order for an immunohistochemical result to be considered reliable, a minimum of two TMA cores from the tumour should show concordant staining patterns. If divergent staining patterns were obtained, results from third or subsequent cores were assessed, and the case was considered to show positive staining if a minimum of two cores showed specific staining.

In the evaluation of staining, cores were scored if at least 10% of the core area contained tumour and each core was analyzed separately and graded as either positive or negative. Staining was considered positive when the tumour cells showed staining in at least 2 valuable tissue microarrays. Also, the staining reaction was compared between the cores and some of the whole sections. The staining reaction of invasive and preinvasive cases was compared with that of normal tissue with respect with the intensity and distribution of *PTEN* expression. All microscopy was performed with a Zeiss microscope (KPI 10x eyepiece with a high-power field HPF) ($\times 40$).

Chapter 4

DETECTION AND TYPING OF HPV's DNA

4.1 Clinical Specimens

As mentioned in materials and methods in section 1.1

4.2 DNA extraction from paraffin blocks

Three 10- μ m sections of formalin-fixed, paraffin-embedded tissue were collected into tubes after cutting into the block. The microtome blade was changed after each case. Tissue samples were incubated with lysis buffer containing (1 mg/ml) proteinase K (400ul/sample) for 18 hours at 55°C and boiled for 20mins to denature the DNA and destroy the proteinase K. Then 10ul was used from each sample immediately for detection and typing of HPV's DNA 16 and 18 using the PCR methods (Levi et al., 1991).

4.3 Polymerase Chain Reaction (PCR) Methods.

4.3.1 Primer design

The sequences of type specific primers which designed from E6 and E7 ORFs and Used for PCR methods (table 6) came from publications (Hwang, 1999).

Table 6. Type specific primers

Type specific primers	
HPV 16	(F) 5'-TGTCAAAAGCCACTGTGTCC-3' (R) 5'-GAGCTGTCATTTAATTGCTC-3'
HPV 18	(F) 5'-TGCCAGAAACCGTTGAATCC-3' (R) 5'-TCTGAGTCGCTTAATTGCTC-3'

Table 8. Sequences of type specific primers used throughout these studies (Hwang, 1999).

4.3.2 PCR Protocol.

PCR reactions were performed using sterile 0.5 ml RNase / DNase-free tubes and each PCR reaction was made up to a final volume of 50 μ l. A typical 50 μ l PCR reaction contained 100mM-KCL, 20Mm Tris-HCL pH 8.0, 2.0mM MgCl₂, 2.5 mM of dNTP's, 1.5 units of Taq polymerase (Invitrogen, UK), and 25 pmol of each primer. 40 ul from the mastermix was added to each tube and overlaid with 50ul of paraffin oil. 10 ul of sample was added to each tube. To avoid false positives, a negative control tube that consisted of omission of the DNA sample and a positive control tube (HeLa for HPV-18 and SiHa for HPV-16) were performed. Once the PCR was set up, the tubes were carried to run through the PCR program.

4.3.3 PCR Program.

The following program was run on an Omn-E™ thermal cycler with tube temperature control (Hybaid). The mixtures were denatured initially for 90 seconds at 94°C, for 1 cycle, then 40 cycles, at 55°C for 1min, 72°C for 1min, and 94°C for 1min. Finally, they were cycled at 72°C for 10min, for 1 cycle. Once the appropriate number of cycles had been completed or the program had finished, PCR samples were analysed by agarose gel electrophoresis.

4.3.4 Agarose gel electrophoresis

PCR samples were run on 1% agarose (Sigma) gels. Agarose gels were manufactured by mixing 2g of agarose with 100 mls 1x Tris/boric acid/EDTA (TBE) buffer in a glass conical flask and heating in a microwave until all the agarose had dissolved. After heating the agarose solution was allowed to cool at room temperature and 5ul of 5mg/ml ethidium bromide was added and left on the bench until agarose cooled to 60°C. Once the agarose had cooled enough to comfortably hand hold, but was still liquid, it was poured into the a gel tray and the relevant number of wells were created by inserting combs, ensuring no air-bubbles were present. Once solid, the agarose gel (and tray) was transferred into the gel tank which was filled with TBE so that the gel

was completely submerged in the buffer. Firstly, 5 ul Kilobase DNA marker (Invitrogen, UK) loaded onto the gel, then 10ul PCR of each sample was mixed with 3ul loading dye and loaded onto the gel. Gel electrophoresis was run at 75V for 60 minutes depending on how far it was necessary to run the samples. Once the gel had run far enough, the power was disconnected and the gel tray was removed from the gel tank. DNA bands were visualised by UV trans-illumination.

4.3.5 Gel Visualisation

Gels were visualised by UV trans-illumination. Images were saved to floppy disk and were printed using the Enhanced Analysis System (EASY, Scotlab, Coatbridge, Lanarkshire, Scotland). This program allows semi-quantitative analysis of PCR products. It designates the brightest band on the gel a value of 1000 (background = 0) and thus can designate all the other bands a value between 0 and 1000 depending on their intensity. Therefore this program allows the intensity of PCR bands (which is proportional to the amount of PCR product) to be semi-quantitatively assessed following a range of different treatments and conditions.

4.3.6 Restriction digestion of genomic DNA

To test and confirm the subtypes of HPVs DNA-16 and -18, all positive samples were collected and processed through restriction digests which consisted of, 3ul restriction enzyme buffer, 14ul sterile distilled water, 10ul PCR product, and 3ul restriction enzyme Ava II (10 units/ml) (Table 7).The contents of mixture was gently mixed but thoroughly mixed and incubated at 37°C overnight. 10ul of product was run on a 2% agarose gel with 5ul (5mg/ml) of ethidium bromide/100ml gel and visualised by UV trans-illumination (as mentioned previously).

Restriction enzyme	HPV 16	HPV 18
Total length (bp)	238	268
Ava II	157/81	172/96

Table 7. Restriction enzyme fragment sizes of PCR products (Hwang, 1999).

4.3.7 Optimisation the HPV PCR analysis

To optimise the HPV PCR analysis, all HPV-negative adenocarcinomas were subjected to a second HPV test using specific primers from the E6 and E7 genes of HPV 16 and 18 for the PCR reaction. Thereafter, PCR products, indicating infection with HPV 16 or 18, were identified on agarose gels

4.4 Laser Capture Microdissection (LCM)

4.4.1 Tissue Samples

All HPV positive cases which composed of blocks from 87 different patients and detected by previous PCR methods were collected and pathology reports were reviewed. Special LCM processing schedule was followed to avoid contamination. The water bath was cleaned using RNase solutions, rinsed thoroughly with distilled water and was filled with distilled water. All instruments used were cleaned with 100% EtOH (brushes, forceps, and pencil). A new blade was used for each block and 100% EtOH was used to wipe each blade while sectioning. Gloves were worn at all times while sectioning. A 9- μ m section was cut from each paraffin-embedded block and transferred to glass slides (Dako ChemMate capillary gap microscope slides, 75 mm, Dako A/S, Glostrup, Denmark).

4.4.2 Staining of Paraffin Sections

Fresh 9- μ m sections were cut from each paraffin-embedded block and transferred to glass slides (Dako ChemMate capillary gap microscope slides, 75 mm, Dako A/S, Glostrup, Denmark). Following deparaffinization in xylene (2 times, 5 minutes each time) and rehydration through descending graded ethanol, 100%, 95%, and 70% (2 minutes each time), the sections were washed well with tap water for 2 minutes. Staining was performed by placing the sections into haematoxylin (to stain the nuclei of the cells) for 5 minutes and washing in tap water until colour changes from red to blue. The sections were treated with acid alcohol for 5 seconds and placed into tap water until sections again go blue. Then the sections were stained with eosin (to stain

the cytoplasm of the cells) for 30 seconds and washed in tap water. After dehydration of the sections through ascending graded ethanol, 70%, 95%, and 100%, (5 seconds each time), the sections were cleared well with xylene (2 times, 5 minutes each time) which is very important for the efficiency of the LCM. Finally, the tissue sections were left to dry completely (2-4 minutes) and stored in an airtight box containing silica gel.

4.4.3 DNA Extraction Protocol of LCM tissue

After micro dissection (roughly 500-1,000 cells) from the most presentable area of the whole tissue sections of the tumour, the cap was inserted into an Eppendorf tube containing digestion buffer (25 μ l buffer containing 0.1mg/ml Proteinase K, 10 mM Tris-HCL (pH 8.0), 1 mM EDTA, and 1% Tween-20). The tube was placed upside down so that the digestion buffer contacted the tissue on the cap in a shaking oven at 37°C. The incubation was continued overnight at 37°C for 16 hours. Next day the tube was centrifuged for 5 minutes at high speed and the cap was removed. The reaction was heated to 99°C for 10 minutes to inactivate the proteinase K. It can then be used directly as template for PCR (usually small volumes PCR reactions to decrease the amount of DNA used; e.g. total PCR volume - 25 μ l and DNA template-5 μ l). The tissue samples were tested for presence of HPV DNA by Polymerase Chain Reaction (PCR) Methods.

4.4.4 Polymerase Chain Reaction (PCR) Methods.

PCR reactions were performed using sterile 0.5 ml RNase / DNase-free tubes and each PCR reaction was made up to a final volume of 25 μ l. A typical PCR reaction contained 4 μ l sterile DDW, 4 μ l dNTP's (200mM), 2.5 μ l Buffer (100mM-KCL, 20Mm Tris-HCL pH 8.0), 1 μ M of each primer, 1.25 μ l DMSO, 1 μ l MgCl₂ (50 mM), and 0.125 μ l of Taq polymerase. Then, 15 μ l from these mastermix was added to each tube and overlaid with 25 μ l of paraffin oil. 5 μ l of LCM sample was added to each tube. A negative control tube was performed that consisted of omission of the DNA sample and a positive control tube from HELA. Once the PCR was settled up, the tubes were carried to run through the PCR programme. All other steps of PCR method were undertaken same as mentioned previously.

Statistics

The age-group distribution, stromal response, stage of cancer, and grade in the different types of adenocarcinoma groups were compared using the Kruskal-Wallis test. The independence of the type of adenocarcinoma and the immunohistochemistry results, TZ results, CIN/CGIN results, HPV results, pattern of invasion, LVSI, local spread and lymph node spread was examined using the Chi-square test. The age-group distribution and stromal response in the adenocarcinoma-in-situ and invasive adenocarcinoma groups were compared using the Wilcoxon rank-sum test. The independence of type of adenocarcinoma (adenocarcinoma-in-situ or invasive adenocarcinoma) and immunohistochemistry results, and TZ result was examined using Fisher's exact test. The independence of type of adenocarcinoma (adenocarcinoma-in-situ or invasive adenocarcinoma) and CIN/CGIN results, and HPV results was examined using the Chi-square test. All significance tests were exact tests carried out using StatXact-4 package. Professional statistical assistance was provided by the Medical Statistical Unit, University of Edinburgh. Throughout this thesis, p value of < 0.05 was judged to be significant.

Chapter 1

Morphological and Histopathological study

1.1 Clinicopathological Characteristics

The 139 patients with cervical adenocarcinomas ,excluding results from second sample for 22 patients with two samples, used in this study, consisted of 20 patients with adenocarcinoma-in-situ and 119 with invasive adenocarcinoma. Sixteen of 119 patients with invasive adenocarcinoma had early invasive adenocarcinoma which met criteria for FIGO stage IA₁ carcinoma of the cervix. The types of invasive adenocarcinoma are presented in the following table.

Table summaries the subtypes of invasive adenocarcinoma included in this study

Type of Invasive Adenocarcinoma	Number
Adenocarcinoma NOS,	50
Villoglandular papillary adenocarcinoma,	23
Adenosquamous carcinoma,	22
Minimal deviation adenocarcinoma	8
Other types of adenocarcinoma. The other types of adenocarcinoma were;	16
• Microglandular adenocarcinoma,	5
• Endometrioid adenocarcinoma,	4
• Clear cell carcinoma	3
• Intestinal type adenocarcinoma	2
• Signet -ring cell adenocarcinoma	1
• Adenoid basal carcinoma.	1

The specimen types were; 64 LETZ, 34 punch or wedge biopsy, 17 Wertheim's hysterectomy, 8 cone biopsy, 6 cervical polyp, 5 cervical curettings, 4 simple hysterectomy and 1 endometrial biopsy.

Ages of the patients at time of sample ranged from 23 to 89 years old. 58 (42%) patients were \leq 39 years old, 42 (30%) were 40 - 50 years old, and 39 (28%) were \geq 51 years old.

There was one patient with unavailable data. In the other 138 patients CIN was absent in 89 and present (CIN1 or CIN2 or CIN3) in 49 patients, while CGIN was not identified in 45 (33%) and present (low or high grade) in 93 patients. So both CIN & CGIN were absent for 33, CIN only was present for 12, CGIN only was present for 56, and both CIN & CGIN were present for 37 patients.

In the 119 patients with invasive adenocarcinoma, the pattern of invasion was confluent in 22 (18%), diffuse in 1 (1%), infiltrative in 77 (65%), and pushing in 19 (16%). A stromal response was absent in 28 (20%) patients, mild in 47 (34%) patients, moderate in 39 (28%) patients, and intense in 25 (18%) patients. The focality could not be determined for 76 (64%) of the 119 patients with invasive adenocarcinoma. For the 43 patients where the focality was determined 6 had one focus, 4 had two foci, 4 had three foci, and 29 had more than three foci.

Staging of all of the tumours was taken from the pathology reports. The FIGO stage of cancer was Ia1 for 16 (13%), Ia2 for 11 (9%) and Ib or greater for the remaining of the 119 patients with invasive adenocarcinoma.

Of the 119 patients with invasive adenocarcinoma there were 54 (45%) patients with grade 1 (well differentiated) cancer, 36 (30%) with grade 2 (moderately differentiated) cancer, and 29 (24%) with grade 3 (poorly differentiated) cancer.

For the 22 patients with two samples, there was no significant difference between the two samples regarding the morphological and histopathological features.

1.2 Adenocarcinoma in situ

Twenty of 139 patients showed with adenocarcinoma in situ without invasion. These were defined by showing nuclear stratification and loss of polarity, nuclear atypia and hyperchromasia, macronucleoli, loss of intracytoplasmic mucin, atypical mitoses, apoptotic bodies, goblet cells, and abrupt transition to normal. Not all of these findings usually present in every individual case. There was often an abrupt transition from normal glands to glands involved by AIS and this abrupt transition may be seen within individual glands. Both the surface epithelium and the underlying crypts may be

involved. There was common occurrence of apoptotic bodies and mitotic figures in AIS; however their occurrence was not prominent in every case (Fig. 5).

Large masses of densely packed architecturally complex glands with papillary growth process, and cribriform areas were observed in the AIS cases which strongly suggested invasion. There was a gradual thinning of the glandular epithelium until the basement membrane was destroyed and stromal invasion started. This appearance was called “elastic band sign” (Fig. 18)

All subtypes of AIS were seen including endocervical, intestinal, endometrioid, and mixed adenosquamous types. The endocervical type retained a basic resemblance to the normal endocervix, with at least focally vacuolated, often granular, pale, basophilic to eosinophilic cytoplasm. The intestinal type displayed distention of apical cytoplasm by a large mass of mucin, resembling intestinal goblet cells. The endometrioid type was characterized by cells with densely eosinophilic cytoplasm containing no apparent mucin in routinely stained sections, resembling hyperplastic glands of the endometrium. The mixed adenosquamous type was characterized by cells of cervical glands with AIS and squamous epithelium with CIN3 (Fig.6). There were some endocervical glands which showed total replacement by CIN3. The transformation zone (TZ) of the all patients with recorded TZ (13 from 13 patients) had adenocarcinoma *in situ* was involved by the AIS (100%) (Fig.7).

The age group of adenocarcinoma *in situ* is younger than those with invasive adenocarcinoma presented in table 8. Patients with adenocarcinoma *in situ* were younger than those with invasive adenocarcinoma and, there was significant statistical difference between AIS and invasive adenocarcinoma with respect to age group ($p = 0.006$). Fourteen of 20 patients who had adenocarcinoma *in situ* were ≤ 39 years old (70%), four patients were 40-50 years old (20%), and two patients were ≥ 51 years old (10%).

The association of CIN with or CGIN together with invasive adenocarcinoma is presented in table 9 ($p = 0.009$). Most of the patients (42%) with invasive adenocarcinoma associated with CGIN (Fig.6).

Table 8 Age Group in AIS and invasive adenocarcinoma.

Age-group	Adenocarcinoma in situ		Invasive adenocarcinoma	
	N	%	N	%
<= 39 years old	14	70	44	37
40 - 50 years old	4	20	38	32
>= 51 years old	2	10	37	31
Total	20	100	119	100

Table 8 showing comparison between adenocarcinoma in situ and invasive adenocarcinoma with respect to age group using Wilcoxon rank-sum test($p= 0.006$)

Table 9 CIN and CGIN in invasive adenocarcinoma.

CIN and CGIN	Invasive adenocarcinoma	
	N	%
Both absent	33	28
CIN only	9	8
CGIN only	49	42
CIN + CGIN	27	23
Total	118	100

Table 9 showing comparison between adenocarcinoma in situ and invasive adenocarcinoma with respect to CIN and CGIN association using Chi-square test ($p= 0.009$). There was 1 patient with squamoid metaplasia recorded who has not been classified regarding absence/presence of CIN and CGIN (1 invasive adenocarcinoma).

1.3 Invasive endocervical adenocarcinoma

There were 119 patients with invasive cervical adenocarcinomas, excluding results from second sample for 22 patients with two samples, used in this study. They are presented in section 1.1. The clinicopathological characteristics of all subtypes of endocervical adenocarcinomas including the others types of adenocarcinomas in comparison to AIS were presented in tables 11-18.

1.3.1 Adenocarcinoma NOS, usual endocervical type, (Fig. 8).

Fifty of 119 patients with invasive adenocarcinoma had adenocarcinoma NOS, usual endocervical type. Their age group was mainly among ≤ 39 years old (44% of the patients). Most of them, 56% of the patients, had histopathologic grade 1 well differentiated. Most of the patients presented with frankly invasive tumours (58% of the patients). Tumours were characterized by glands of medium size. The arrangement of the glands was highly variable, some being widely spaced, others forming closely packed aggregates with cells often have eosinophilic cytoplasm and atypical nuclei. Occasionally, there were villous papillae presented on the surface. The tumours were associated with CGIN in 52% of the patients. The main pattern of invasion of those tumours was infiltrative (74% of the patients) and their focality could not be determined in 52% of the patients. Stromal response was mild (54% of the patients). Four patients (8%) presented with lymphovascular invasion.

1.3.2 Adenosquamous carcinoma (Fig.9).

Twenty two of 119 patients with invasive adenocarcinoma had adenosquamous carcinoma. Their age group was mainly among ≥ 51 years old (36% of the patients). Most of them, 45 % of the patients, had histopathologic grade 3 poorly differentiated. Most of the patients presented with frankly invasive tumours (82% of the patients). Adenosquamous tumours had malignant glandular and squamous elements that were recognizable without the use of special stains. The glandular component in adenosquamous carcinomas was usually of endocervical type but mucinous, including signet ring cell, or mixed endocervical and mucinous, endometrioid or clear cell were occasionally observed. The tumours were mainly associated with CIN and CGIN (41% of the patients). The main pattern of invasion of those tumours was infiltrative

(86% of the patients) and their focality could not be determined in 95% of the patients. Stromal response of them was moderate (45% of the patients). Two patients (9%) presented with lymphovascular invasion.

1.3.3 Villoglandular papillary adenocarcinoma (VGC) (Fig. 10).

Twenty three of 119 patients with invasive adenocarcinoma had villoglandular papillary adenocarcinoma (VGC). Their age group was mainly among ≤ 39 years old (48% of the patients). Most of them, 52 % of the patients, had histopathologic grade 1 well differentiated. Most of the patients presented with frankly invasive tumours (78 % of the patients). Most of VGC had a major surface papillary component. The papillae were tall and thin and had a fibrovascular stroma, focally infiltrated by lymphocytes and plasma cells. The deep portions of the neoplasms contained elongated and branching glands. The papillae and glands were lined by slightly columnar cells, but there was no cellular tufting or budding. The nuclei were round, oval, or elongated, showed mild to moderate atypia, and contained scanty mitotic figures. The lining epithelium usually was of endometrioid type. However, endocervical mucinous and intestinal-type epithelium were occasionally presented focally. In addition, exophytic tumour was observed in some cases. The tumours were mainly associated with CGIN only (57% of the patients). The main pattern of invasion of those tumours was pushing (65 % of the patients) and their focality could not be determined in 48 % of the patients. The main stromal response of them was mild (52% of the patients). No patients presented with lymphovascular invasion. The spread pattern of those tumours was 100% confined to the cervix, no lymph node spread, and no distant spread.

1.3.4 Minimal deviation adenocarcinoma (Fig.11).

Eight of 119 patients with invasive adenocarcinoma had minimal deviation adenocarcinoma. Their age group was mainly among 40-50 years old (50% of the patients). All of them, 100% of the patients, had histopathologic grade 1 well differentiated. Most of the patients presented with frankly invasive tumours (88% of the patients). They were characterized by glands lined by columnar cells with mucinous apical cytoplasm and basal nuclei of generally bland cytology. These glands were variable in shape and size, often with large size with branching, cystic dilation, or papillary

enfolding of the epithelium. The presence of mitotic figures and a desmoplastic host response was usually rare. Stromal invasion deeper than normal glands was common but cribriform or back-to-back arrangement of neoplastic glands was not seen. There were 2 tumours associated with CGIN only, 2 with CIN only, 1 with CGIN and CIN, and the remaining 3 with CGIN and CIN were absent. The main pattern of invasion of all tumours was infiltrative (100% of the patients) and their focality was determined as >3 foci in 63 % of the patients. The main stromal response of them was absent (88% of the patients). No patients presented with lymphovascular invasion. The spread pattern of those tumours was 88% confined to the cervix, 13% invaded the parametrium, no lymph node spread, and no distant spread.

1.3.5 Other types of adenocarcinoma.

1.3.5.i Microglandular carcinoma (MGC) (Fig.12).

Five of 119 patients with invasive adenocarcinoma had microglandular carcinoma (MGC), three of them had histopathologic grade 2 moderately differentiated and two had histopathologic grade 3 poorly differentiated. The tumours were composed of small glands closely packed to each other with very little or no stroma between them. These glands lined with one layer of malignant cells which had oval atypical nuclei that were arranged with their long axis perpendicular to the basement membrane of the glands and. All of those tumours had areas of microglandular hyperplasia.

1.3.5.ii Endometrioid adenocarcinoma (Fig.13).

Four of 119 patients with invasive adenocarcinoma had endometrioid adenocarcinoma, three of them had histopathologic grade 1 well differentiated and one had histopathologic grade 2 moderately differentiated .The tumours were showed glands lined with malignant cells that resemble those of typical adenocarcinomas of uterine corpus. The cells usually were stratified and had oval atypical nuclei that were arranged with their long axis perpendicular to the basement membrane of the gland. The cells of those tumours had little or no mucin with little amount of cytoplasm.

1.3.5.iii Clear cell carcinoma (CCC) (Fig.14).

Three of 119 patients with invasive adenocarcinoma had clear cell carcinoma (CCC). All of tumours, 100% of the patients, had histopathologic grade 3 poorly differentiated. All tumours revealed tubulocystic pattern. In these tubulocystic patterns, tubules and cysts of varying sizes were lined by hobnail, flat, or clear cells. Rarely cells with abundant oxyphilic cytoplasm were seen and occasionally were numerous. Intracytoplasmic mucin was presented in occasional cells, and a signet-ring cell was also observed.

1.3.5.iv Intestinal-type adenocarcinoma (Fig.15).

Two of 119 patients with invasive adenocarcinoma had intestinal-type adenocarcinoma. The tumours had histopathologic grade 2 moderately differentiated. The tumours composed of glands lined by malignant-appearing cells, some of which had their cytoplasm distended by a single large vacuole of mucin, forming a goblet cell.

1.3.5.v Signet-ring cell adenocarcinoma (Fig.16).

One of 119 patients with invasive adenocarcinoma had signet-ring cell adenocarcinoma. The tumour had histopathologic grade 3 poorly differentiated. The tumour composed of glands lined by malignant-appearing cells with eccentric nuclei and pale mucin-rich cytoplasm growing singly, in clusters, in nests or columns or in solid aggregates of polygonal cells with a nucleus displaced eccentrically by mucinous vacuoles giving appearance of signet-ring.

1.3.5.vi Adenoid basal carcinoma .

One of 119 patients with invasive adenocarcinoma had adenoid basal carcinoma. The tumour had histopathologic grade 3 poorly differentiated. The tumour showed closed packed small, round, oval, or lobulated nests of uniform mostly basaloid cells with peripheral palisading and no stromal reaction. Lumens were formed in the centres of the nests. The tumour cells usually had bland nuclei and increased mitotic figures.

1.3.5.vii Glassy adenocarcinoma (Fig.17).

One of 119 patients with invasive adenocarcinoma had glassy adenocarcinoma. The tumour had histopathologic grade 3 poorly differentiated. The tumour showed sheets of large cells with abundant eosinophilic or amphophilic, ground-glass or finely granular cytoplasm, prominent cell borders, large nuclei with prominent nucleoli, a high mitotic rate, and a stromal inflammatory infiltrate.

1.4 Cervical Smear History

Cervical smear history reports of the all cervical adenocarcinomas (139 patients), excluding results from second sample for 22 patients with two samples, are presented in table 10. 71/119 patients presented with abnormal Papanicolaou smears only. The smear results were mainly adenocarcinoma (37/119). Most of patients 92/119 had colposcopic evaluation before initial treatment.

Table 10 Cervical Smear History

Symptoms	N		Smear result	N
Abnormal smear only	71		Adenocarcinoma	37
Unknown	23		No smear result	28
Abnormal smear +PCT	7		Glandular	20
Abnormal smear +CAC	12		Severe	22
PCBA	12		Negative	16
CAC only	4		?Invasive	7
CAC+Bleeding	4		Moderate	5
Bleeding only	3		Borderline	2
Abnormal smear+bleeding	3		Inadequate	1
Total	139		Total	139

Table 10. Cervical smear history reports of all cervical adenocarcinomas. PCT= previous colposcopic treatment, CAC= clinically abnormal cervix, PCBA= Previous colposcopic biopsy showing adenocarcinoma.

Table 11 Age Group in different subtypes and AIS

Age-group	Adenocarcinoma in situ		Adenocarcinoma NOS		Adenosquamous carcinoma		Villoglandular papillary adenocarcinoma		Minimal deviation adenocarcinoma		Other types of adenocarcinoma	
	N	%	N	%	N	%	N	%	N	%	N	%
<= 39 years old	14	70	22	44	7	32	11	48	1	13	3	19
40 - 50 years old	4	20	17	34	7	32	7	30	4	50	3	19
>= 51 years old	2	10	11	22	8	36	5	22	3	38	10	63
Total	20	100	50	100	22	100	23	100	8	100	16	100

Table 11 showing all subtypes of invasive adenocarcinoma in comparison to AIS with respect to age group using Kruskal-Wallis test(p= 0.003).

Table 12 Grade in different subtypes

Grade	Adenocarcinoma NOS		Adenosquamous carcinoma		Villoglandular papillary adenocarcinoma		Minimal deviation adenocarcinoma		Other types of adenocarcinoma	
	N	%	N	%	N	%	N	%	N	%
1 - well differentiated	28	56	3	14	12	52	8	100	3	19
2 - moderately differentiated	16	32	9	41	5	22	0	0	6	38
3 - poorly differentiated	6	12	10	45	6	26	0	0	7	44
Total	50	100	22	100	23	100	8	100	16	100

Table 12 showing all subtypes of invasive adenocarcinoma with respect to the grade using Kruskal-Wallis test ($p < 0.0001$).

Table 13. Relation between stage and subtypes of invasive adenocarcinoma.

Stage	Adenocarcinoma NOS		Adenosquamous carcinoma		Villoglandular papillary adenocarcinoma		Minimal deviation adenocarcinoma		Other types of adenocarcinoma	
	N	%	N	%	N	%	N	%	N	%
Ia1	14	28	2	9	0	0	0	0	0	0
Ia2	5	10	1	5	5	22	0	0	0	0
Ib	29	58	18	82	18	78	7	88	11	69
II	2	4	1	5	0	0	1	13	5	31
Total	50	100	22	100	23	100	8	100	16	100

Table 13 showing all subtypes of invasive adenocarcinoma with respect to the stage using Kruskal-Wallis test ($p=0.0003$).

Table 14 CIN and CGIN in different subtypes of cervical adenocarcinomas

CIN and CGIN	Adenocarcinoma NOS		Adenosquamous carcinoma		Villoglandular papillary adenocarcinoma		Minimal deviation adenocarcinoma		Other types of adenocarcinoma	
	N	%	N	%	N	%	N	%	N	%
Both absent	9	18	8	36	6	26	3	38	7	47
CIN only present	3	6	4	18	0	0	2	25	0	0
CGIN only present	26	52	1	5	13	57	2	25	7	47
Both present	12	24	9	41	4	17	1	13	1	7
Total	50	100	22	100	23	100	8	100	15	100

Table 14 showing all subtypes of invasive adenocarcinoma with respect to CIN and CGIN association using Chi-square test ($p=0.0004$).

There was 1 patient with squamoid metaplasia recorded that has not been classified regarding absence/presence of CIN and CGIN (1 other type of adenocarcinoma).

Table 15. Pattern of invasion in different subtypes of cervical adenocarcinomas

Pattern of invasion	Adenocarcinoma NOS		Adenosquamous carcinoma		Villoglandular papillary adenocarcinoma		Minimal deviation adenocarcinoma		Other types of adenocarcinoma	
	N	%	N	%	N	%	N	%	N	%
Confluent	9	18	3	14	2	9	0	0	8	50
Diffuse	0	0	0	0	0	0	0	0	1	6
Infiltrative	37	74	19	86	6	26	8	100	7	44
Pushing	4	8	0	0	15	65	0	0	0	0
Total	50	100	22	100	23	100	8	100	16	100

Table 15 showing all subtypes of invasive adenocarcinoma with respect to the using pattern of invasion Chi-square test (P<0.0001).

Table 16 Focality in different subtypes of cervical adenocarcinomas

Focality	Adenocarcinoma NOS		Adenosquamous carcinoma		Villoglandular papillary adenocarcinoma		Minimal deviation adenocarcinoma		Other types of adenocarcinoma	
	N	%	N	%	N	%	N	%	N	%
1 focus	4	8	0	0	2	9	0	0	0	0
2 foci	2	4	0	0	1	4	0	0	1	6
3 foci	4	8	0	0	0	0	0	0	0	0
>3 foci	14	28	1	5	9	39	5	63	0	0
Can not determine	26	52	21	95	11	48	3	38	15	94
Total	50	100	22	100	23	100	8	100	16	100

Table 16 showing all subtypes of invasive adenocarcinoma with respect to the focality of invasion. Focality of invasion can not determined for sufficient proportion of patients.

Table 17 Stromal response in different subtypes of cervical adenocarcinomas

Stromal response	Adenocarcinoma in situ		Adenocarcinoma NOS		Adenosquamous carcinoma		Villoglandular papillary adenocarcinoma		Minimal deviation adenocarcinoma		Other types of adenocarcinoma	
	N	%	N	%	N	%	N	%	N	%	N	%
Absent	19	95	0	0	1	5	1	4	7	88	0	0
Mild	1	5	27	54	4	18	12	52	0	0	3	19
Moderate	0	0	15	30	10	45	7	30	0	0	7	44
Intense	0	0	8	16	7	32	3	13	1	13	6	38
Total	20	100	50	100	22	100	23	100	8	100	16	100

Table 17 showing all subtypes of invasive adenocarcinoma in comparison to AIS with respect to stromal response using Kruskal-Wallis test ($p=0.0001$).

Table 18 Lymphovascular invasion in different subtypes of cervical adenocarcinomas

LVSI	Adenocarcinoma NOS		Adenosquamous carcinoma		Villoglandular papillary adenocarcinoma		Minimal deviation adenocarcinoma		Other types of adenocarcinoma	
	N	%	N	%	N	%	N	%	N	%
Absent	46	92	20	91	23	100	8	100	13	81
Present	4	8	2	9	0	0	0	0	3	19
Total	50	100	22	100	23	100	8	100	16	100

Table 18 showing all subtypes of invasive adenocarcinoma with respect to the lymphovascular (LVSI) using Chi-square test (p=0.23).

1.5 Early invasive adenocarcinoma (Microinvasive adenocarcinoma)

1.5.1 Clinicopathological Characteristics

Sixteen of 119 patients with invasive adenocarcinoma had early invasive adenocarcinoma, excluding results from 22 patients with two samples, and met criteria for FIGO stage IA₁ carcinoma of the cervix. Eight patients (50%) with early invasive adenocarcinoma were \leq 39 years old, 5 (31%) were 40 - 50 years old, and 3 (19%) were \geq 51 years old. The type of carcinoma was adenocarcinoma NOS in 14 patients and adenosquamous carcinoma in 2 patients with early invasive adenocarcinoma. All tumours were histopathologic grade 1 well differentiated. The tumours showed three patterns of early invasive adenocarcinoma: small glandular budding arising from HCGIN, infiltrating the stroma with an associated inflammatory reaction. confluent glands in a complex pattern with little or no intervening stroma, and intraluminal tufting resulting in a papillary pattern. Usually, the early invasive adenocarcinoma was recognized by loss of the normal smooth peripheral glandular outlines, prominent cribriform and/or solid areas, and the architectural complexity of endocervical glands including deep invagination. There was a gradual thinning of the glandular epithelium until the basement membrane destroyed and stromal invasion started, and with respect to its appearance we called "elastic band sign" (Fig.18) which was also noticed in the AIS cases strongly suggest of early invasive adenocarcinoma.

CIN only was present in 8 (50%) patients, and both CIN and CGIN were present in the other 8 (50%) patients. The main pattern of invasion of those tumours was infiltrative in 15 of the patients (94%) and was confluent in one patient (6%). The focality could not be determined for 2 of the 16 patients with early invasive adenocarcinoma. For the other 14 patients where the focality was determined 3 had one focus, 2 had two foci, 2 had three foci, and 7 had more than three foci. A stromal response was mild in 12 (75%), moderate in 3 (19%), and intense in 1 (6%) patient with early invasive carcinoma. No patients were presented with lymphovascular invasion.

1.5.2 Cervical Smear History

Cervical smear history reports of all early invasive adenocarcinomas are presented in table 19. Ten patients presented with abnormal Papanicolaou smears only, two with abnormal Papanicolaou smears and clinically abnormal cervix and two were unknown. 11 patients had colposcopic evaluation before initial treatment.

Table 19 Cervical Smear History

Symptoms	N	Smear result	N
Abnormal smear only	10	Adenocarcinoma	5
		Glandular abnormality	3
Abnormal smear + clinically abnormal cervix	4	Severe dyskaryosis	3
		Moderate dyskaryosis	2
Unknown	2	No smear result	2
		Negative	1
Total	16	Total	16

Table 19. Cervical smear reports history of all early invasive adenocarcinomas.

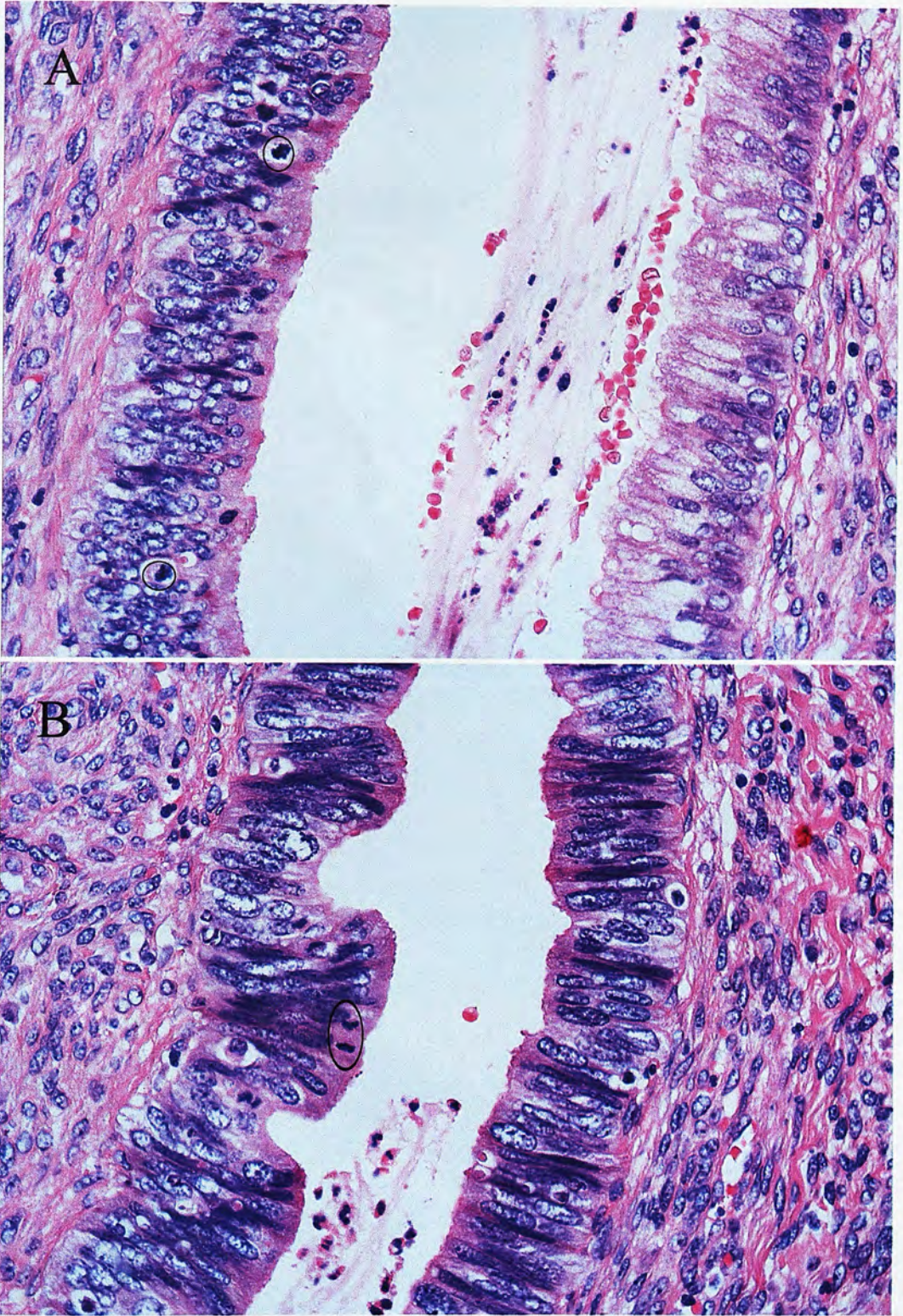


Figure 5 (A) A characteristically sharp comparison between normal endocervical epithelium (right) and adenocarcinoma in situ (AIS) (left) (H&E, x400). **(B)** AIS showing stratified hyperchromatic nuclei, mitotic figures (circle) and easily identifiable apoptotic bodies toward the basement membrane (H&E, x400).

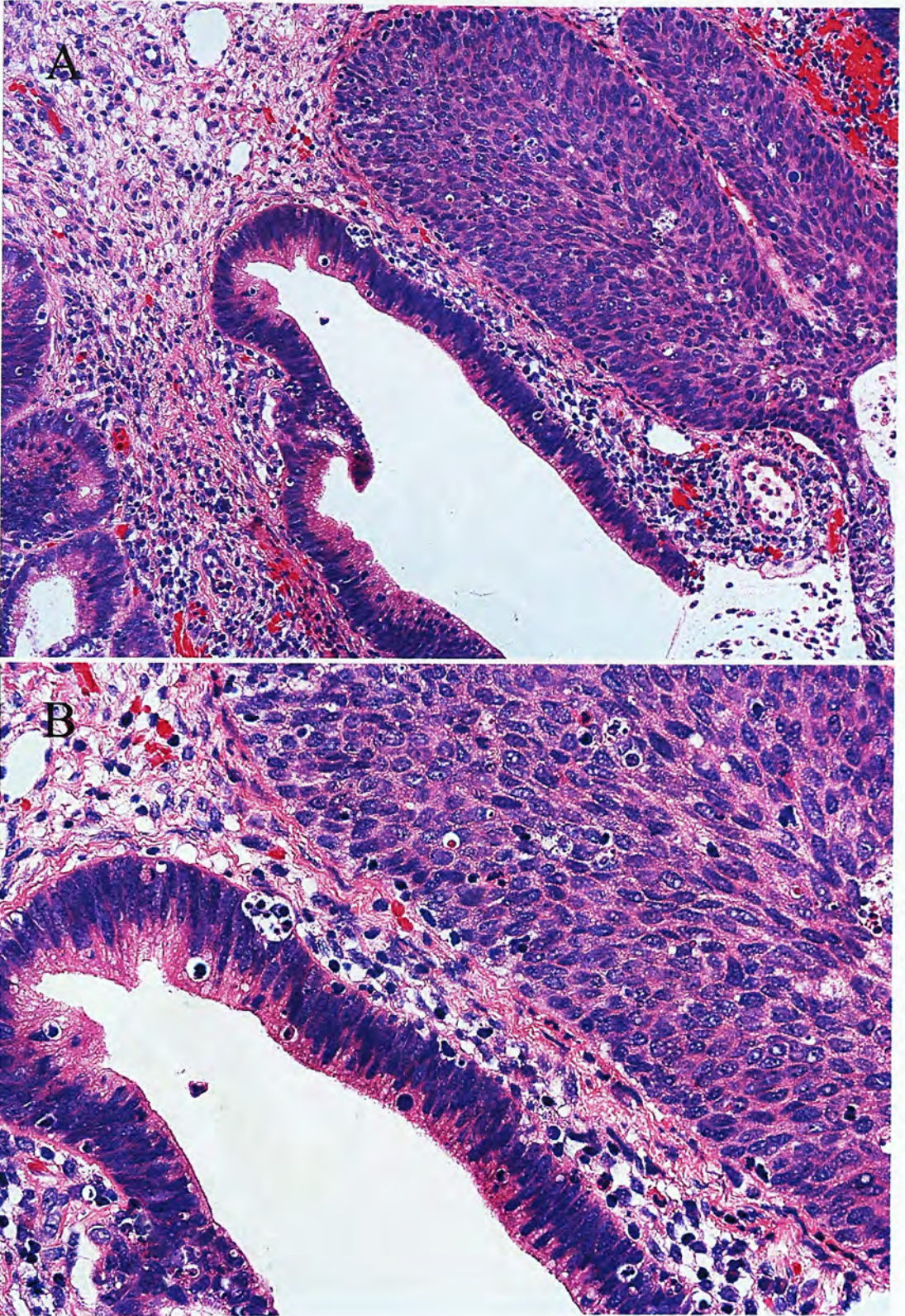


Figure 6 (A) Association of adenocarcinoma in situ (AIS) (left) with squamous carcinoma in situ (CIN3)(right)(H&E,x200). (B) A higher power of the same lesion(H&E,x400).

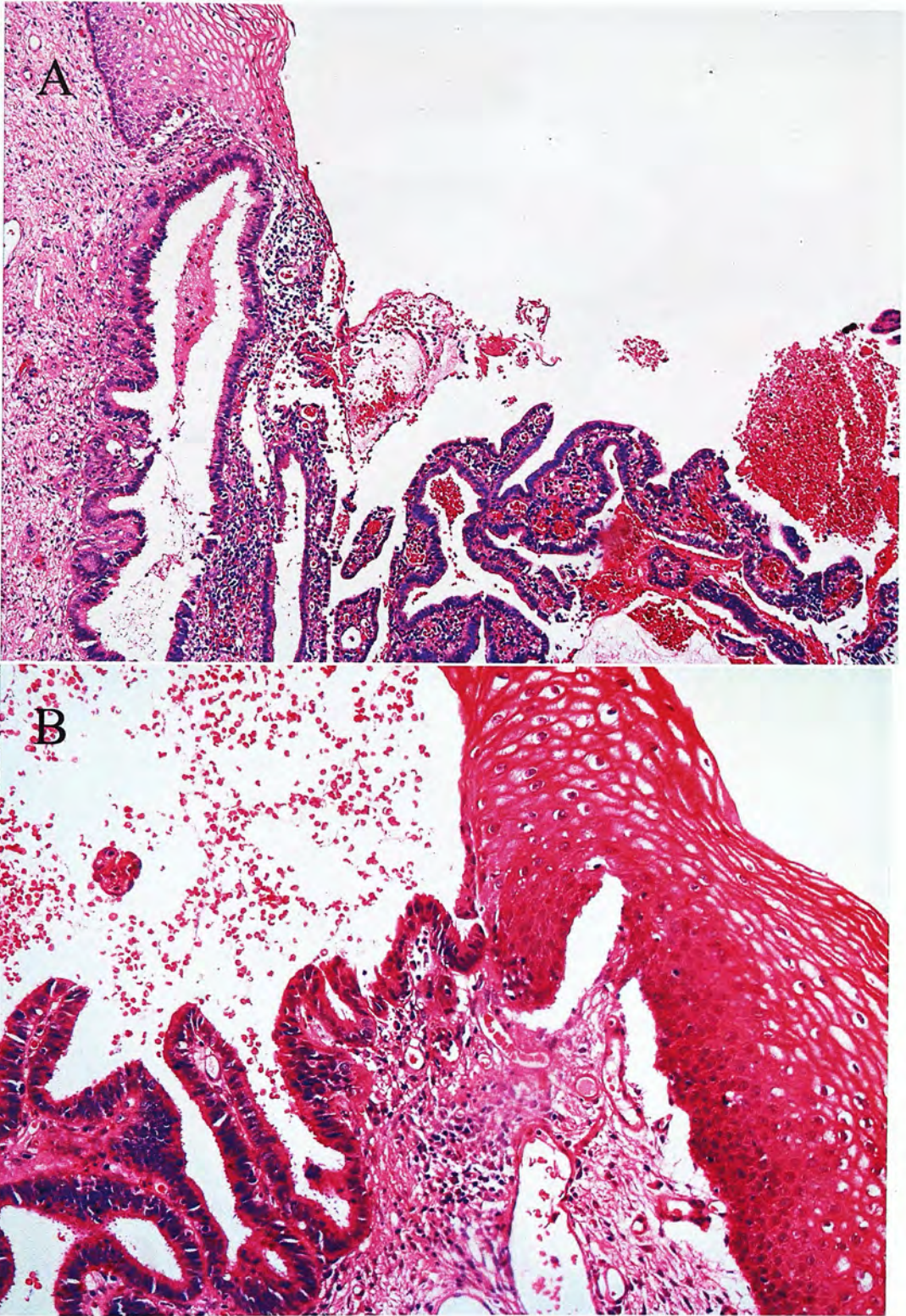


Figure 7 (A) Well-differentiated villoglandular papillary endocervical adenocarcinoma (VGC) at the squamous columnar junction with normal stratified squamous epithelium (H&E, x200). (B) Same findings in other lesion (H&E,x400) .

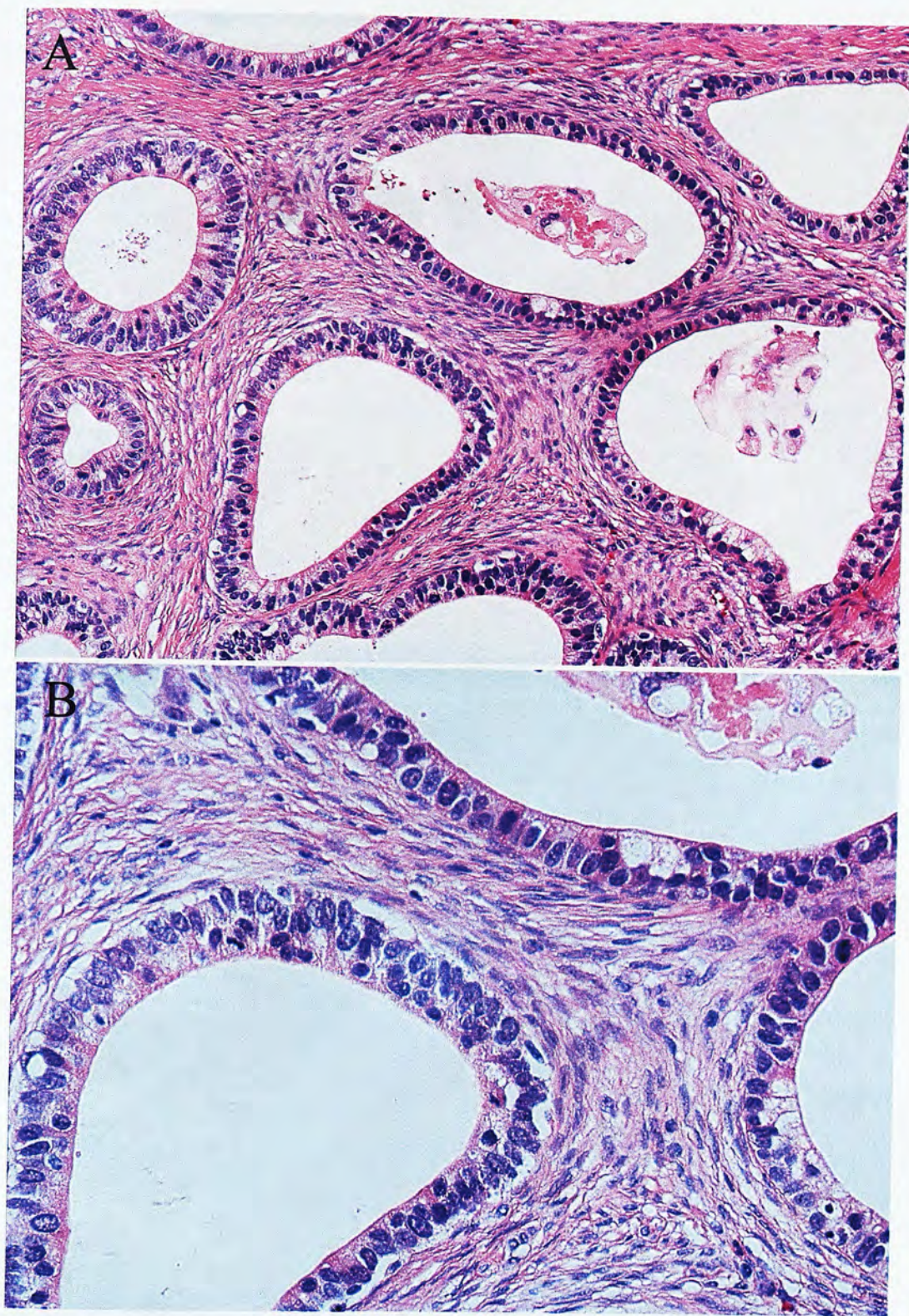


Figure 8 (A) A well differentiated adenocarcinomas of usual endocervical type showing a widely separated glands lined with malignant cells with eosinophilic cytoplasm (H&E,x200). (B) A higher power of the same lesion (H&E ,x400).

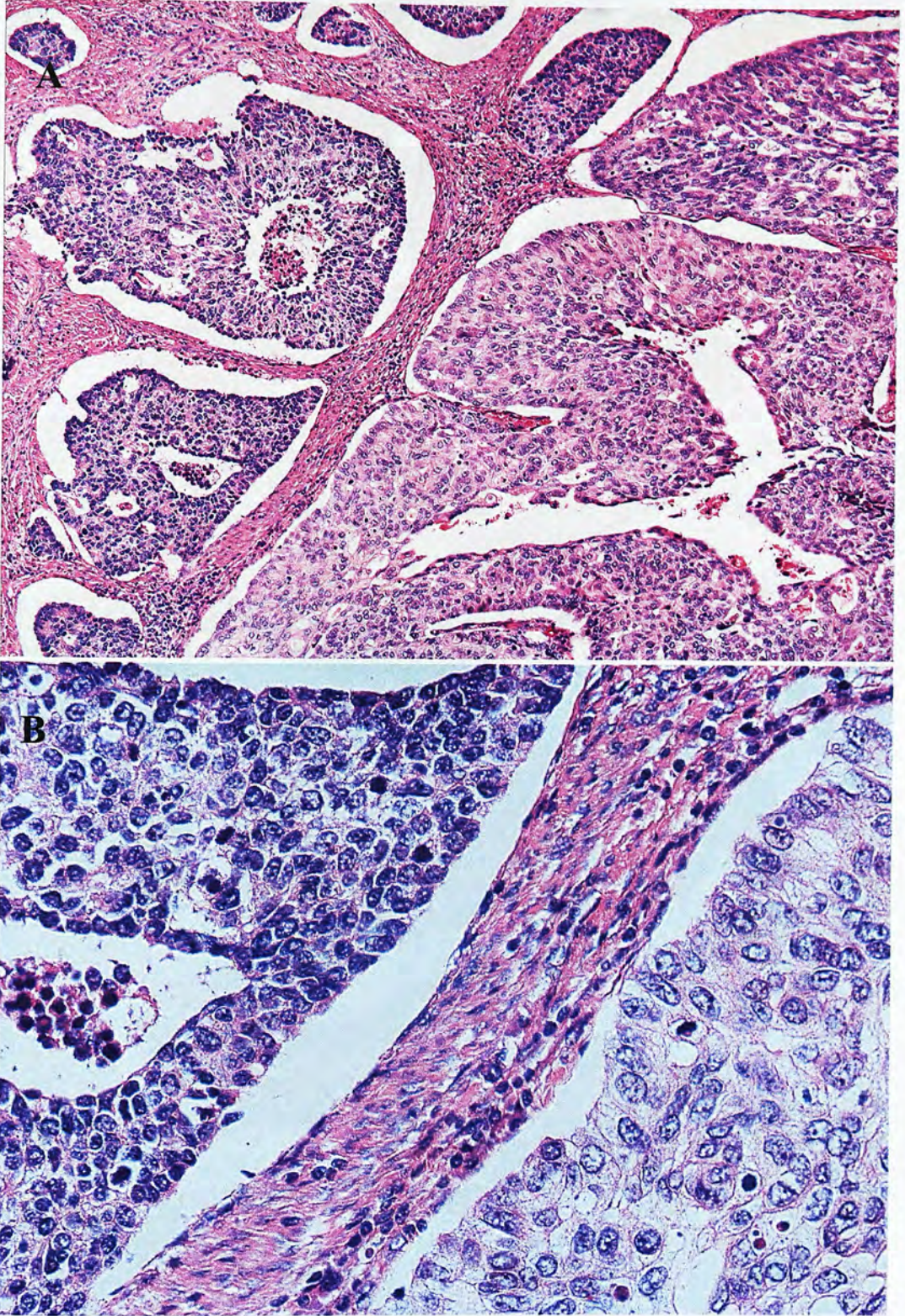


Figure 9 (A) Poorly differentiated adenosquamous carcinoma showing squamous element (right) and glandular element (left). Both the individual cells of squamous and glandular elements have malignant features (H&E, x100). (B) A higher power of the same lesion (H&E, x400).

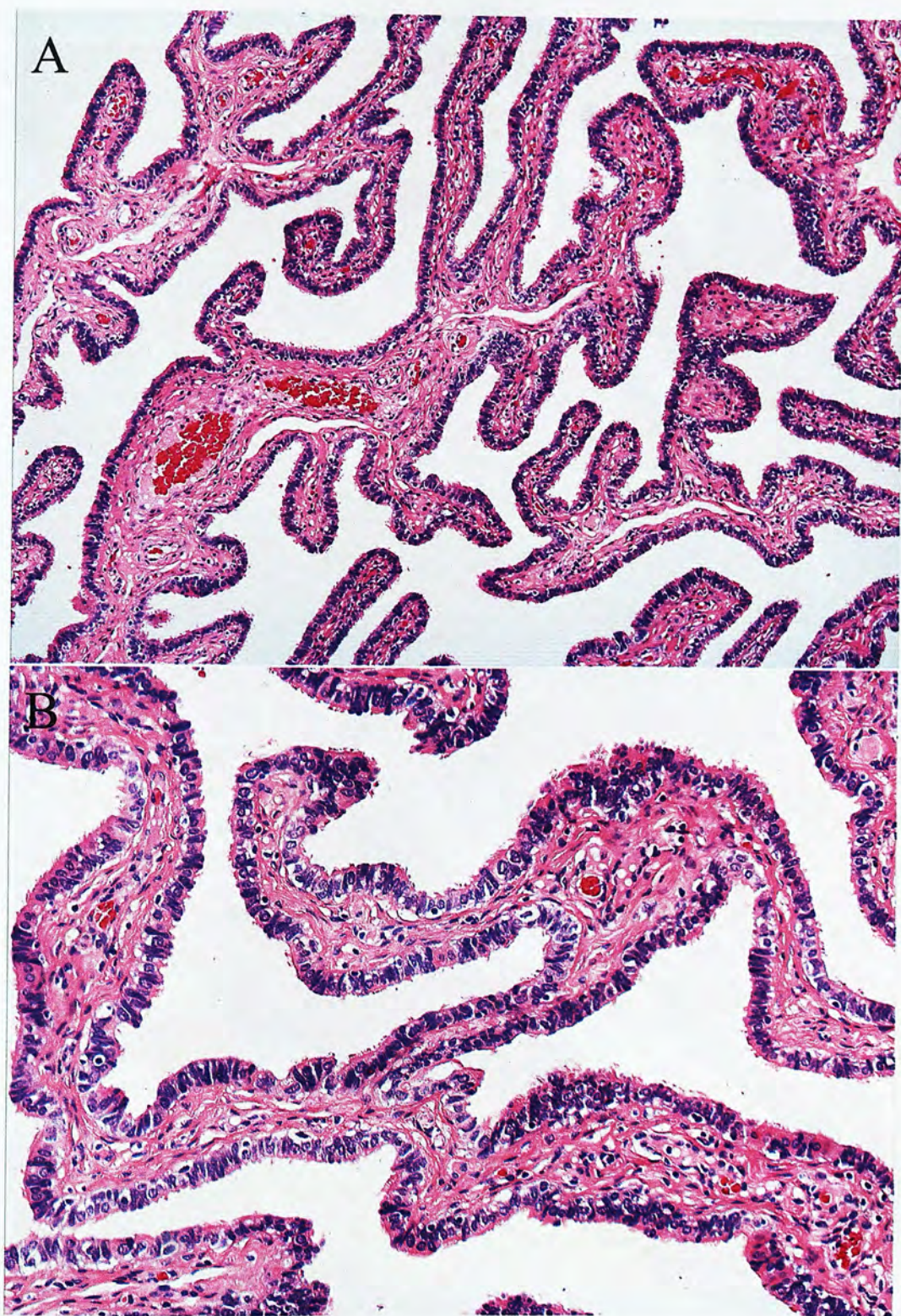


Figure 10(A) Well differentiated Villoglandular papillary adenocarcinoma (VGC) formed of broad, long, branching papillae, with fibrovascular cores covered by a mildly atypical columnar epithelium (H&E x200). (B) A higher power of the same lesion (H&E x400).

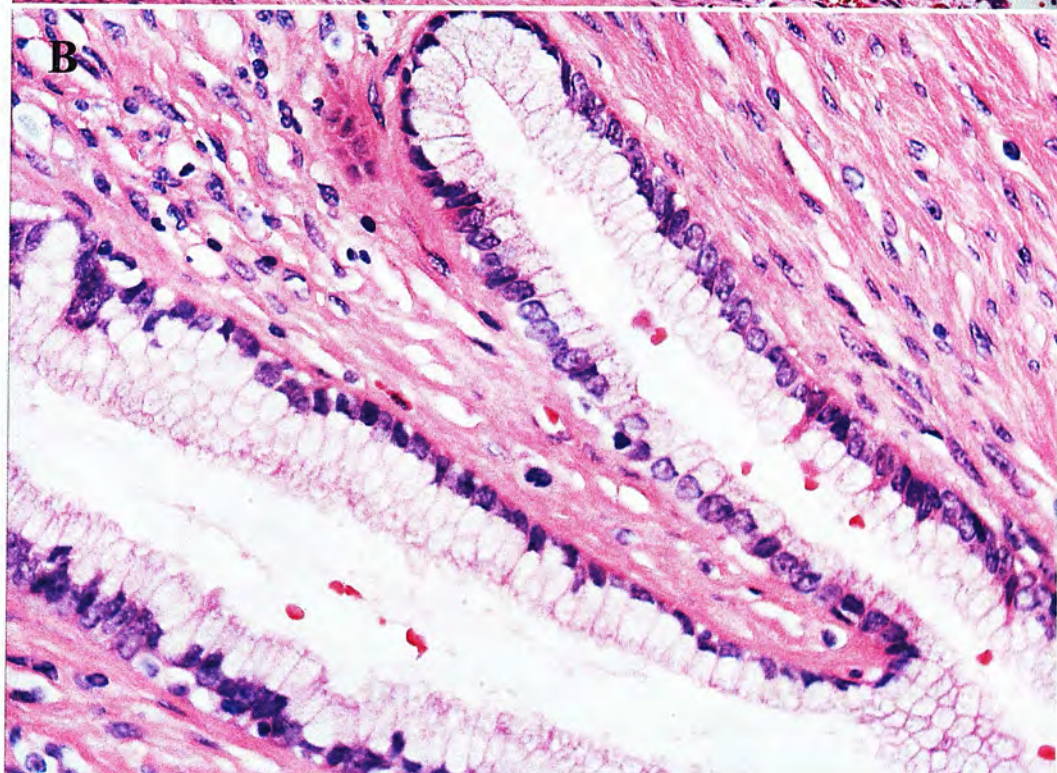
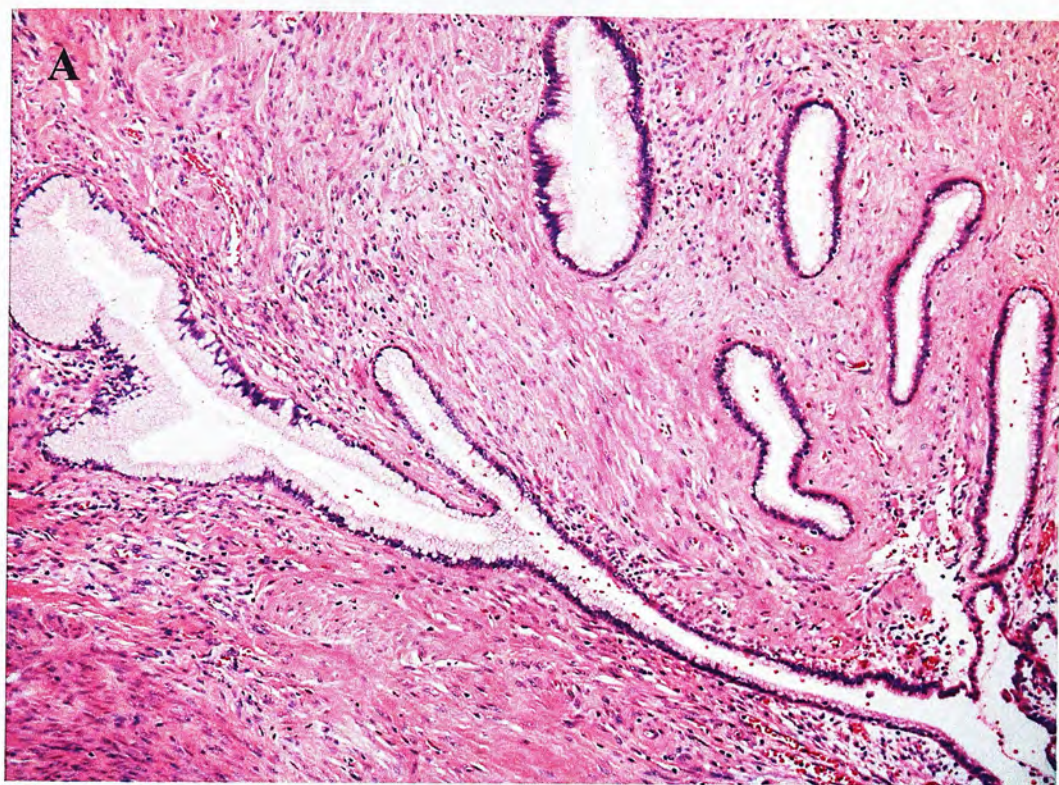

Figure 11(A) Well differentiated minimal deviation endocervical adenocarcinoma showing essentially normal gland structure with minimal deviation of cell structure from normal. Note, elongated glands which extend deep into the cervical stroma with no stromal reaction (H&E,x 100) .(B) A higher power of the same lesion (H&E,x400).

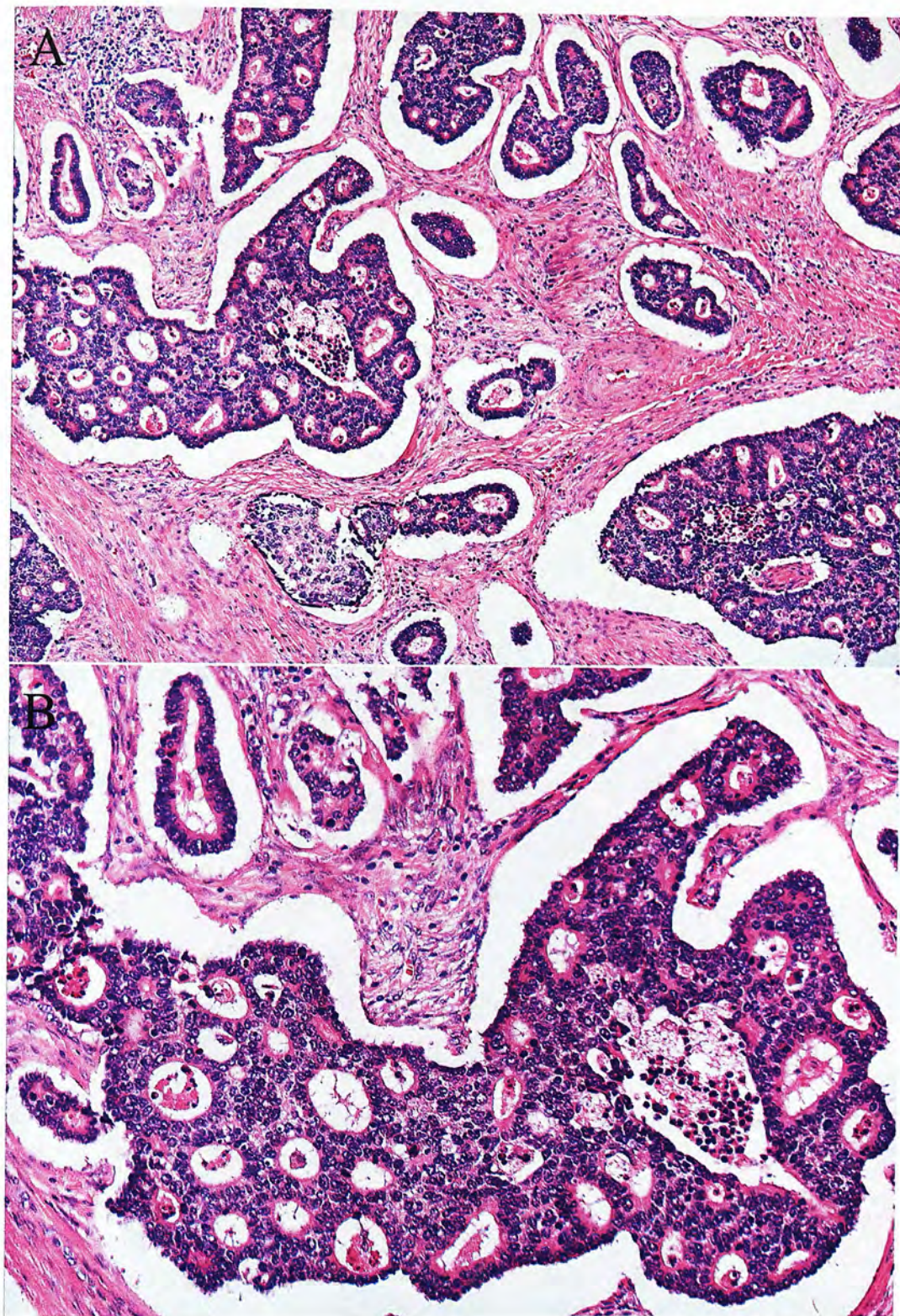


Figure 12 (A) A poorly differentiated endocervical adenocarcinoma, Microglandular carcinoma, showing a confluent glandular invasion pattern with cribriform pattern(H&E,x100). (B) A higher power of the same lesion(H&E,x200).Note, a single layer of atypical oval nuclei surrounding each glandular lumen with very little amount of stroma inbetween.

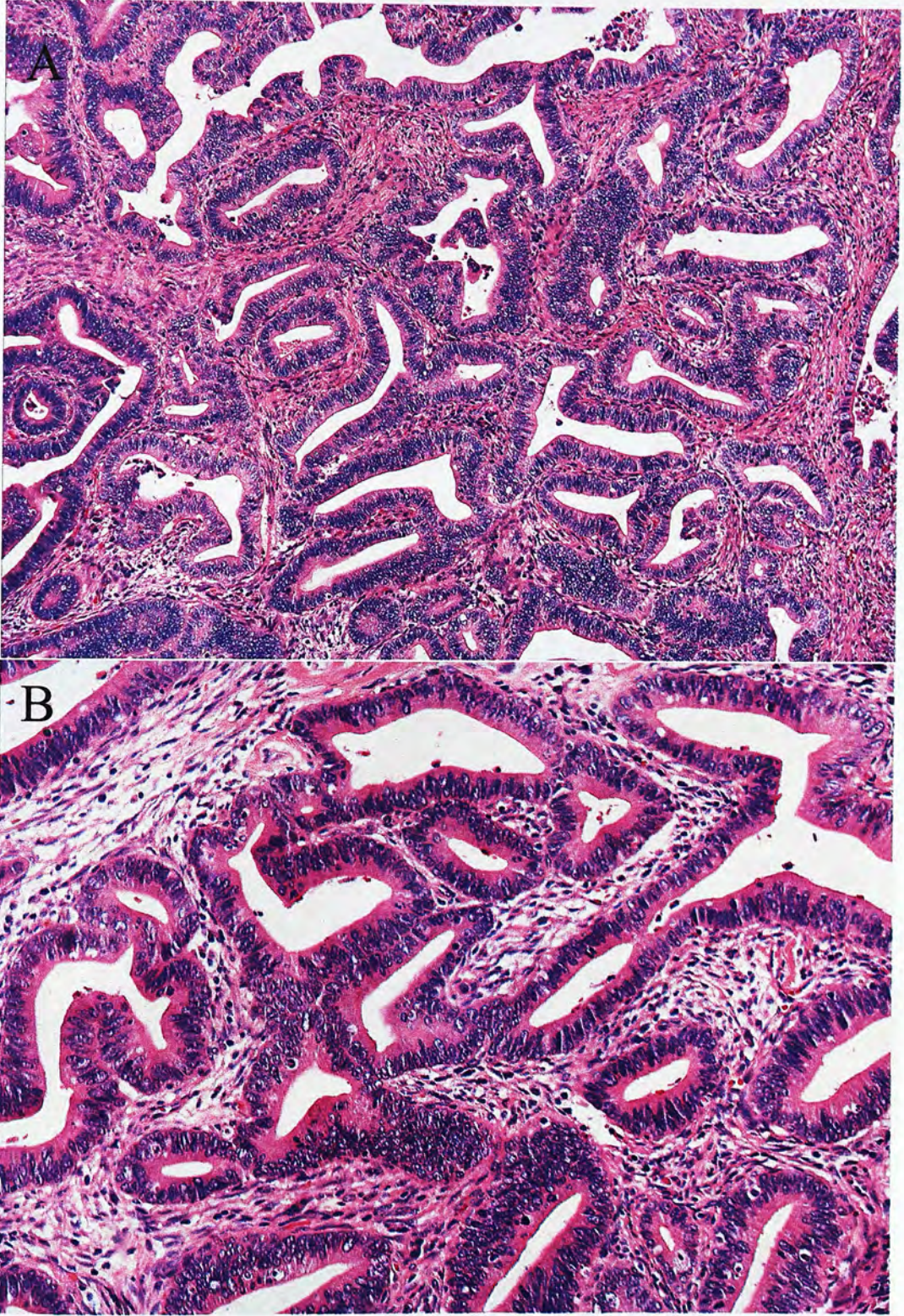


Figure 13 (A) Well-differentiated endometrioid adenocarcinoma showing, typical glandular morphology lined with atypical columnar cells (H&E, x100). (B) High power view of the same lesion (H&E, x200).

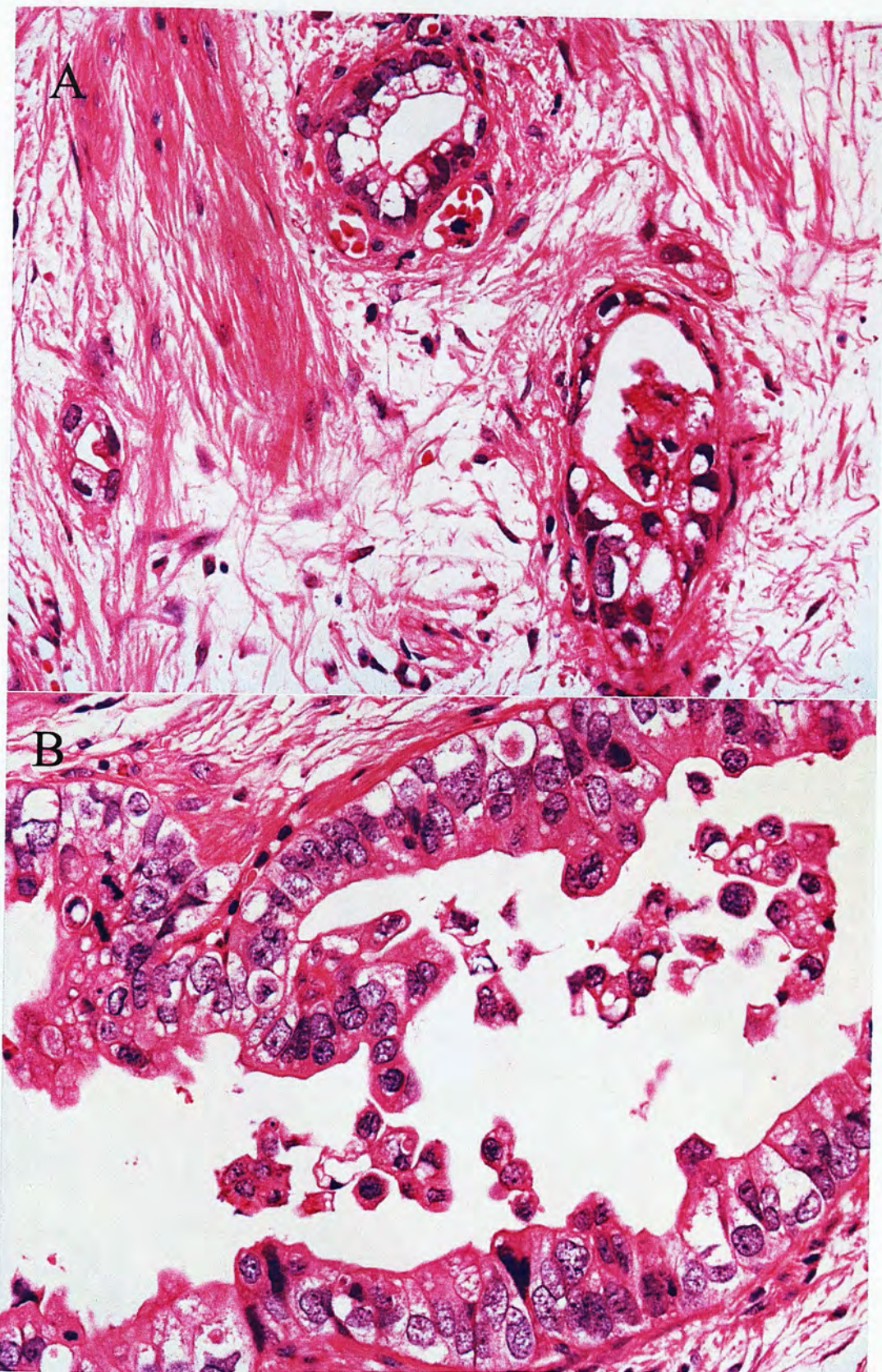


Figure 14(A) A poorly differentiated clear cell adenocarcinoma showing tubules lined by malignant cells with intracytoplasmic mucin and signet-ring cells.(H&E,x400).
(B) A poorly differentiated clear cell adenocarcinoma showing cells with abundant oxyphilic cytoplasm and hobnail, flat, or clear cells(H&E,x400).

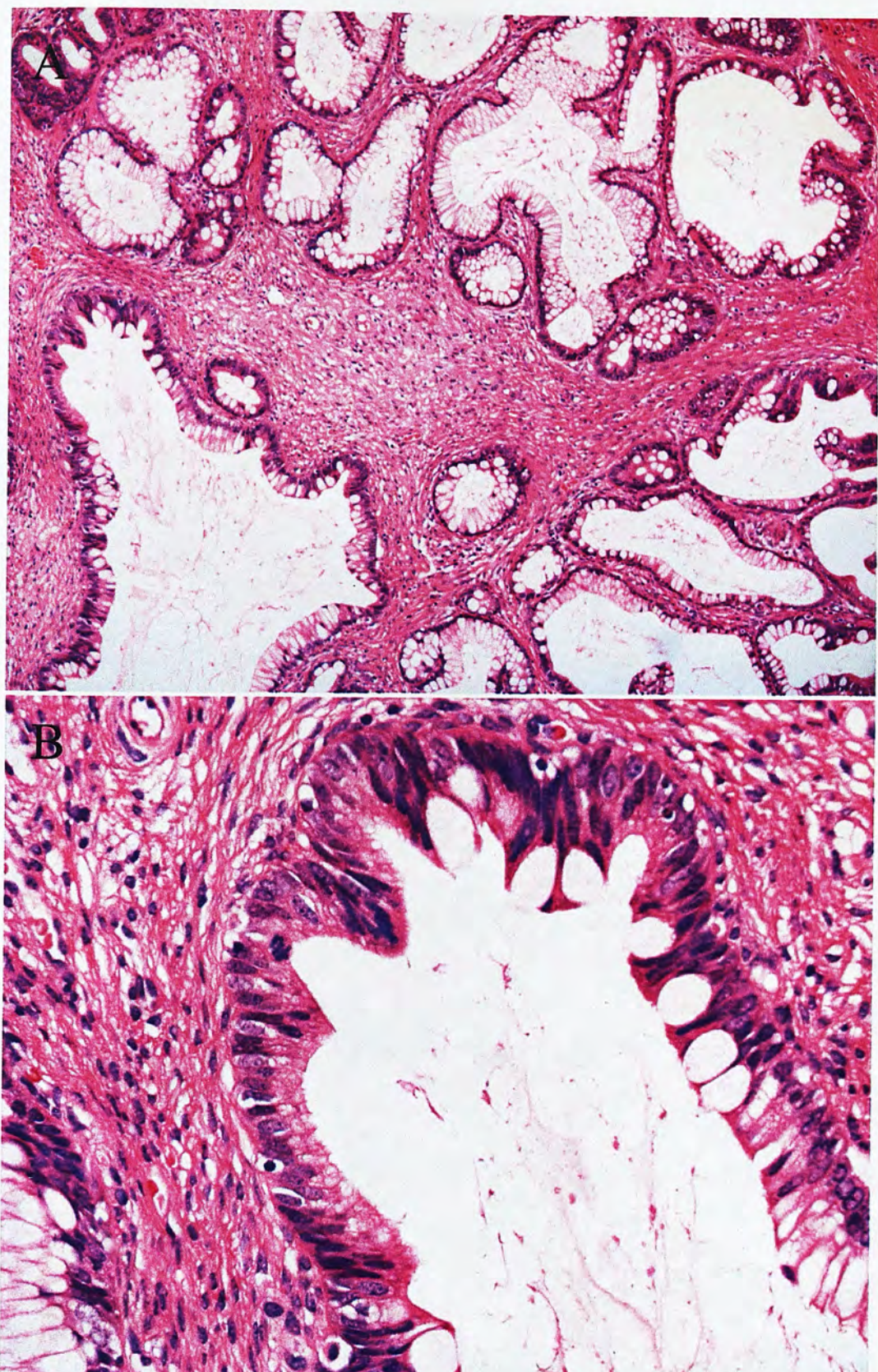


Figure 15(A) Endocervical adenocarcinoma, intestinal type , showing atypical columnar cells with numerous flask shaped goblet cells and intraluminal extracellular mucin (H&E,x200). (B) A higher power of the same lesion(H&E,x400).

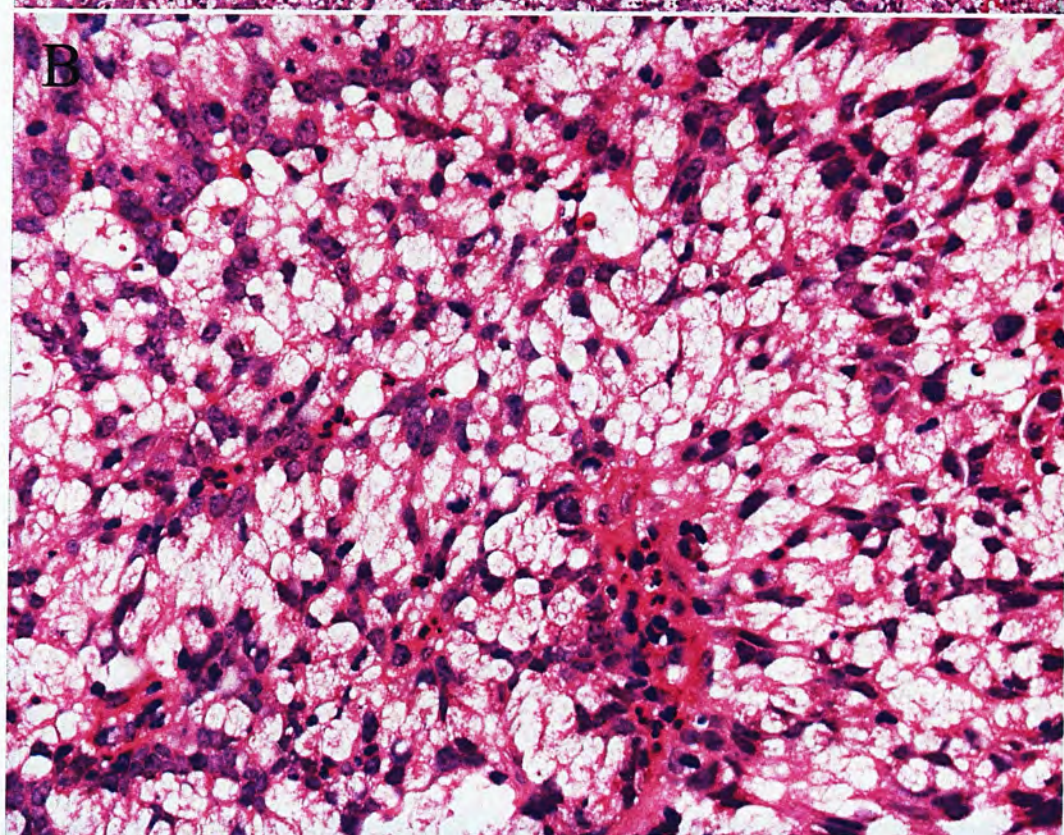
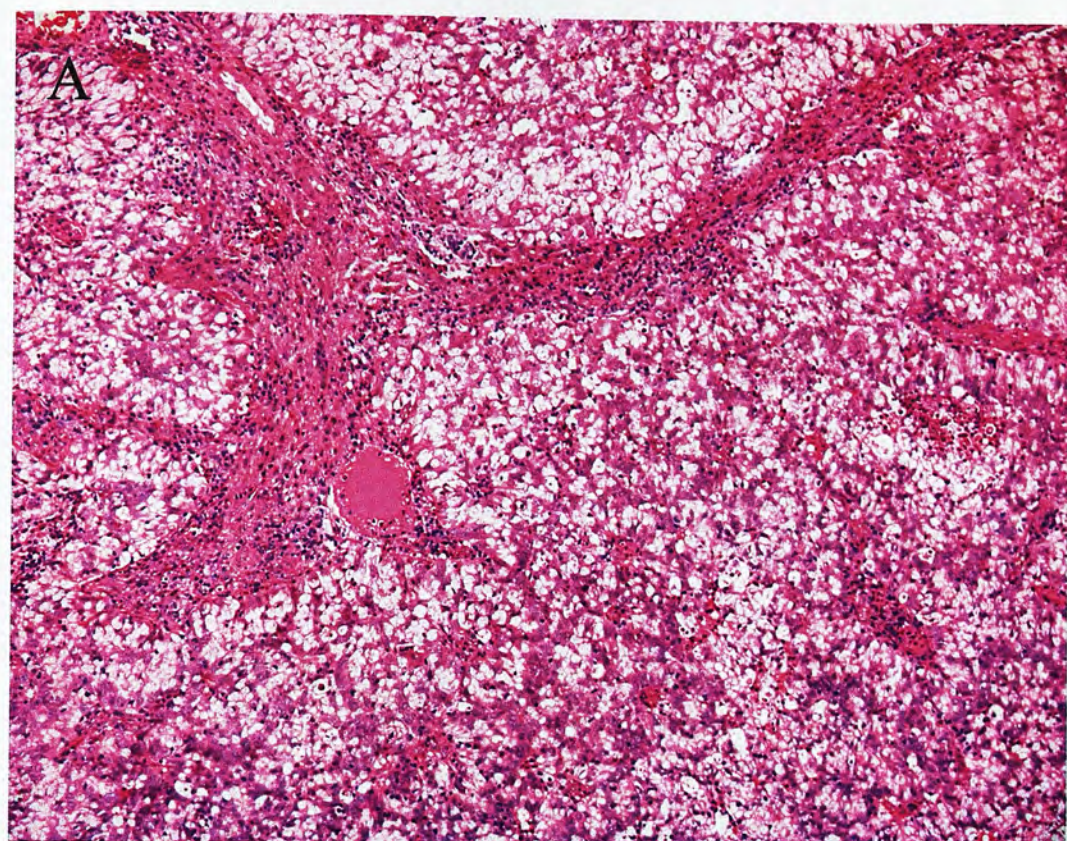


Figure 16 (A) A poorly differentiated endocervical adenocarcinoma , signet-ring cell type, showing a solid area of the tumour formed of signet-ring-like cells with intracellular mucin (H&E,x200). (B) A higher power of the same lesion(H&E,x400).

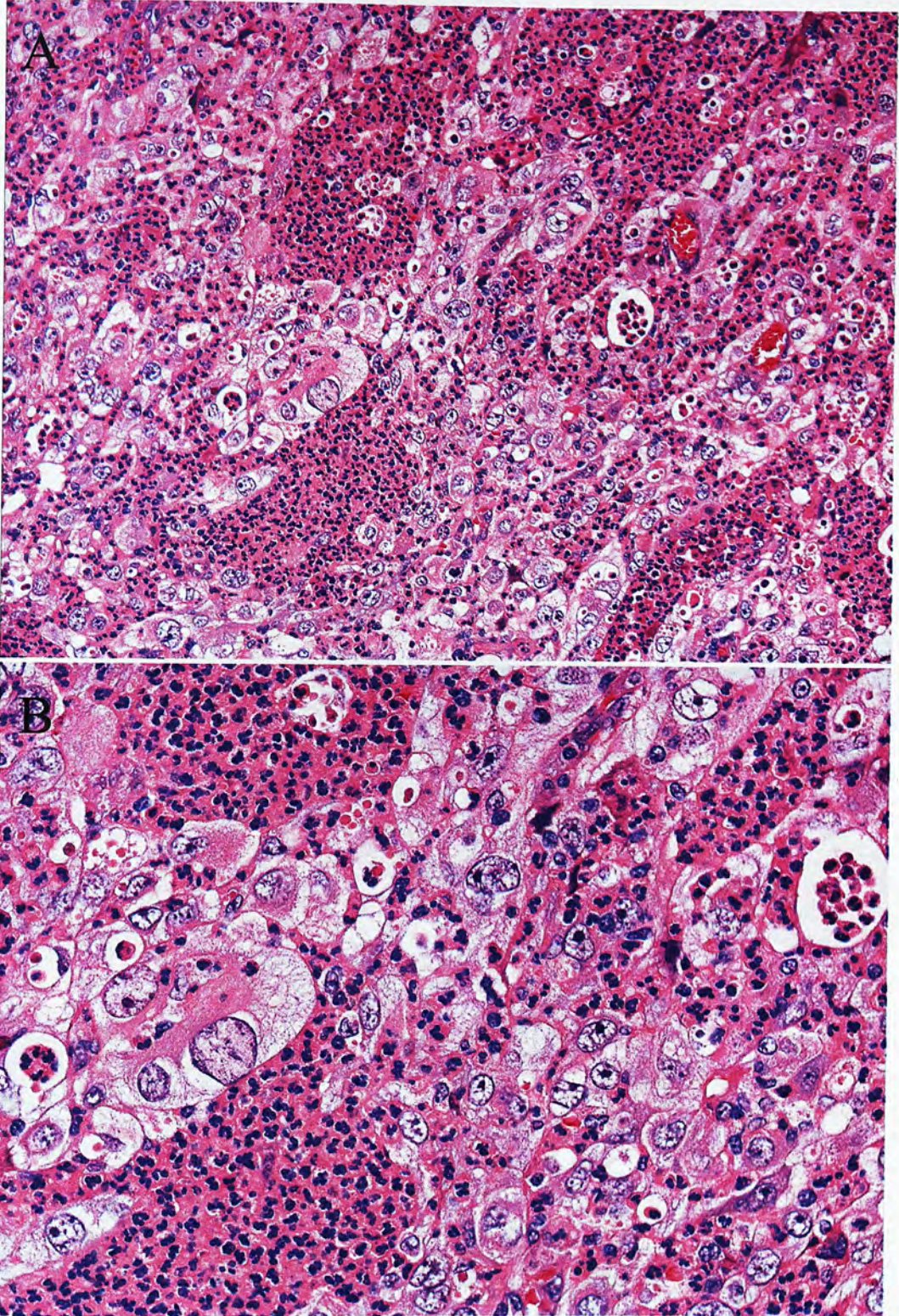


Figure 17 (A) A poorly differentiated glassy cell carcinoma, form of adenosquamous carcinoma, showing sheets of large cells with abundant eosinophilic, ground-glass or finely granular cytoplasm, prominent cell borders, large nuclei with prominent nucleoli, and a stromal inflammatory response (H&E, x200). (B) A higher power of same lesion (H&E, x400).

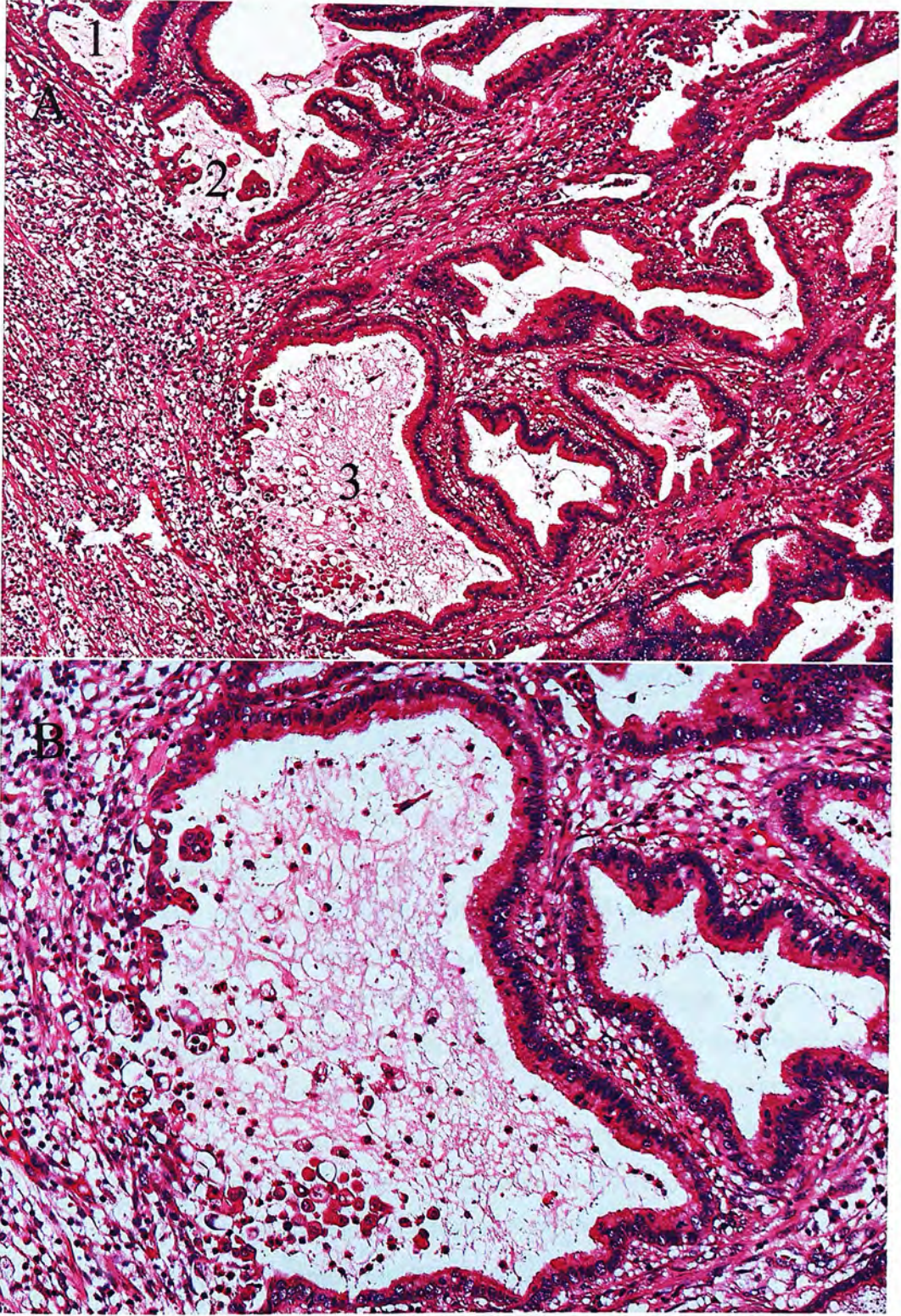


Figure 18(A) Malignant endocervical glands showing gradual thinning of the endocervical columnar epithelium until basement membrane destroyed and stromal invasion started (elastic band).Note, the gradual sequence of the process 1,2,then 3. (H&E,x200). (B) A high-er power of the same lesion(H&E,x400).

Chapter 2

Validation of Tissue Microarray Technology

2.1 Tissue microarray technology as a new tool for cervical adenocarcinoma study

The recent development of tissue microarray technology has potentiated large-scale retrospective cohort studies using archival formalin-fixed, paraffin-embedded tissues. A major obstacle to broad acceptance of microarrays is that they reduce the amount of tissue analyzed from a whole tissue section to a disk, 0.6 mm in diameter (Fig.19-24) that may not be representative. One of the aims of this study was to evaluate whether tissue microarray technology is adequately representative of the histopathology of cervical adenocarcinomas using H&E stain, and of the expression of eight common antigens in cervical adenocarcinomas. The staining of 2 paired TMA cores and the whole tissue sections from which they were derived were examined and compared to each other.

With respect to how many cores are required to adequately represent a cervical adenocarcinoma histologically, each core was analyzed separately and in relation to its original whole section. We found that histological subtype and degree of differentiation were accurately represented in all cases when two duplicate cores were examined, and it was possible to determine histological subtype and degree of differentiation from examination of the TMA core alone, but this always needed to be confirmed by reference to the original section (Fig. 25-32). This is not surprising since the areas are being specifically chosen and this process was performed by a gynaecological pathologist. In cases of adenocarcinoma-in-situ, early invasive adenocarcinoma and well differentiated adenocarcinoma; it was often not possible from the TMA cores to determine whether the lesion was invasive or in situ. This is not surprising, as the histological criteria for diagnosis of invasive disease are often focal. Other important histological features that rely on extensive tissue sampling, such as lymphovascular space invasion, can not be diagnosed reliably in TMA cores.

With respect to antigen expression, we found that two paired TMA cores gave comparable results to analysis of a whole tissue section in more than 97% of cases (Figures 40-60). Microarrays and the original block from which they were derived were stained for carcinoembryonic antigen (CEA), Cytokeratin7 (CK7), Cytokeratin20 (CK20), oestrogen receptor (ER), progesterone receptor (PgR), MIB-1 proliferation marker, and p53 suppressor gene antigens. These antigens were chosen, in part because they are potentially useful in diagnostic specimens of cervical adenocarcinoma. However, phosphatase and tensin homolog deleted on chromosome ten (*PTEN*) was chosen to evaluate it in differential diagnosis between primary endocervical adenocarcinoma and primary endometrial adenocarcinoma. Analysis of those antigens revealed that the average staining of the microarray cores agreed with the whole-section analysis. However, in small number of these cases, one TMA core was discordant with the average staining pattern of the whole section but the other TMA core was concordant. In such cases, analysis of two paired cores was necessary. If positive staining was identified in a minimum of two cores, the case was considered positive. Thus, analysis of two paired TMA cores provided staining results that were consistent with the original whole section in about 97% of cases (Table 20). Therefore, generally, the average staining pattern agreed with the whole section in each.

Table 20 Immunohistochemical results of different antigens

Antigen	Not Available Cases	Available Cases	Positive Cases		Negative Cases	
			N	%	N	%
CK7	3	136	132	97%	4	3%
CK20	5	134	4	3%	130	97%
CEA	3	136	92	68%	44	32%
ER	2	137	64	47%	73	53%
PgR	4	135	50	37%	85	63%

MIB1	5	134	119	89%	15	11%
<i>PTEN</i>	2	137	121	88%	16	12%
P53	4	135	37	27%	98	73%

Table 20 showing immunohistochemical results of eight antigens for 139 patients with cervical adenocarcinomas using TMAs. Number of positive, negative, available and not available cases in each antigen.

For the expression of different antigens in cervical adenocarcinoma, each core was analyzed separately and graded as either positive or negative. The average chance of correctly calling each case was calculated. In the majority of cases, staining was uniform across all the cores and consequently the chance of adequately representing the tumour in each core was 100% to match that of the whole sections from which it came. The results of this analysis demonstrated that, despite the variability of antigen expression between cores, analysis of a single readable core would match the staining pattern of an entire section more than 97% of the time. Analysis of two paired TMA cores achieved greater than 97% representation.

2.2 Immunohistochemical Results of Cervical Adenocarcinomas Using TMA Technology

2.2.1 General Immunohistochemical profile

There were 139 patients with cervical adenocarcinomas, excluding results from second sample for 22 patients with two samples, used in this study. They consisted of 20 patients with adenocarcinoma-in-situ and 119 with invasive adenocarcinoma. The types of invasive adenocarcinoma are presented in chapter 1 (1.1). Excluding results from second sample for 22 patients with two samples, immunohistochemical results for 139 patients with cervical adenocarcinomas using tissue microarray are summarised in table 22.

After reviewing and comparing the immunohistochemical results of the first sample with that of the second sample of the same patient, it was found that, for the 22 patients with two samples, there was no significant difference between the two samples with respect to immunohistochemical staining. These were therefore excluded from the analysis.

After comparing the immunohistochemical staining of normal cervical tissues which were taken from patients suffering from different non-neoplastic cervical pathologies with that of the normal cervical glands samples which were identified and taken from cervical adenocarcinomas cases, it was found that there was no significant difference between the two groups with respect to immunohistochemical staining.

2.2.2 Cytokeratin7 (CK7)

Immunohistochemical staining for CK7 was confined to cytoplasm only. Cytoplasm of the malignant endocervical cells was stained diffusely. Generally, the staining reaction of the endocervical cells was of strong intensity. There were 3 patients where CK7 result was not available. In the other 136 patients the result was negative for 4 (3%) and positive for 132 (97%). In normal endocervical glands, there was diffuse delicate membrane staining, but much of the cytoplasm was unstained. This is in contrast to cells of AIS and invasive adenocarcinoma, where there was diffuse strong cytoplasmic staining. Endocervical stromal cells were negative with CK7 and there was no positivity in all kinds of stromal cells. There was diffuse cytoplasmic staining of positive controls in all cases but no staining of negative controls.

2.2.2i Adenocarcinoma in situ

All cases of adenocarcinoma in situ (eighteen of 139 patients) (100%), excluding 2 patients where CK7 result was not available, were positive with CK7. CK7 results of adenocarcinoma in situ in comparison to those of invasive adenocarcinoma are presented in table 21.

2.2.2ii Invasive adenocarcinoma

Excluding one patient from 119 patients with invasive adenocarcinoma where CK7 result was not available, 114 of 118 patients (97%) with invasive cervical adenocarcinoma were positive with CK7 and the other 4 patients (3%) were negative. CK7

results of all subtypes of invasive adenocarcinoma in comparison to each other and in comparison to adenocarcinoma in situ were presented in table 29.

2.2.2iii Early *invasive adenocarcinoma*.

Sixteen of 119 patients with invasive adenocarcinoma had early invasive adenocarcinoma, excluding results from 22 patients with two samples, met criteria for FIGO stage IA₁ carcinoma of the cervix. There was 1 patient where CK7 result was not available. In the other 15 patients, the result was negative for 1 (7%) and positive for 14 (93%).

2.2.3 Cytokeratin 20 (CK20)

The pattern of immunohistochemical staining for CK20 was cytoplasmic only. The cytoplasm of the malignant endocervical cells was stained diffusely. Generally, the staining reaction of the endocervical cells was of very weak intensity. When present, there were 5 patients where CK20 result was not available. In the other 134 patients the result was negative for 130 (97%) and positive for 4 (3%). Normal endocervical glands were negative with CK20 and there was no positivity in all cells. Endocervical stromal cells were negative with CK20 and there was no positivity in all kinds of stromal cells. There was diffuse cytoplasmic staining of positive controls in all cases but no staining of negative controls.

2.2.3i *Adenocarcinoma in situ*

All cases of pure adenocarcinoma in situ (eighteen of 139 patients) (100%), excluding 2 patients where CK20 result was not available, were negative with CK20. CK20 results of adenocarcinoma in situ in comparison to those of invasive adenocarcinoma were presented in table 22.

2.2.3ii *Invasive adenocarcinoma*

Excluding 3 patients from 119 patients with invasive adenocarcinoma where CK20 result was not available, 112 of 116 patients (97%) with invasive cervical adenocarcinoma were negative with CK20 and the other 4 patients (3%) were positive. CK20 results of all subtypes of invasive adenocarcinoma in comparison to each other and in comparison to adenocarcinoma in situ are presented in table 30.

2.2.3iii *Early invasive adenocarcinoma.*

Sixteen of 119 patients with invasive adenocarcinoma had early invasive adenocarcinoma, excluding results from 22 patients with two samples, met criteria for FIGO stage IA₁ carcinoma of the cervix. There was 1 patient where CK20 result was not available. In the other 15 patients the result was negative for 14 (93%) and positive for 1 (7%).

2.2.4 **Carcinoembryonic antigen (CEA)**

Immunohistochemical staining for CEA was cytoplasmic. The cytoplasm of the malignant endocervical cells was stained diffusely. However, in some cases, there was diffuse delicate luminal staining with CEA but this positivity was considered as negative if there was no cytoplasm staining. Generally, the staining reaction of the endocervical cells was of strong intensity. There were 3 patients where CEA result was not available. In the other 136 patients the result was negative for 44 (32%) and positive for 92 (68%). Normal endocervical glands were negative with CEA and there was no positivity in all cells. Endocervical stromal cells were negative with CEA and there was no positivity in all kinds of stromal cells. There was diffuse cytoplasmic staining of positive controls in all cases but no staining of negative controls.

2.2.4i *Adenocarcinoma in situ*

Excluding 2 patients from 20 patients with adenocarcinoma in situ where CEA result was not available, 13 of 18 patients (72%) with adenocarcinoma in situ were positive with CEA and the other 5 patients (28%) were negative. CEA results of adenocarcinoma in situ in comparison to those of invasive adenocarcinoma are presented in table 23.

2.2.4ii *Invasive adenocarcinoma*

Excluding one patient from 119 patients with invasive adenocarcinoma where CEA CK20 result was not available, 79 of 118 patients (67%) with invasive cervical adenocarcinoma were positive with CEA and the other 39 patients (33%) were negative (table 21). CEA results of all subtypes of invasive adenocarcinoma in comparison to adenocarcinoma in situ are presented in table 31.

2.2.4iii Early invasive adenocarcinoma.

Sixteen of 119 patients with invasive adenocarcinoma had early invasive adenocarcinoma, excluding results from 22 patients with two samples, met criteria for FIGO stage IA₁ carcinoma of the cervix. The CEA result was negative for 5 (31%) and positive for 11 (69%) patients.

2.2.5 Oestrogen receptors (ER)

Immunohistochemical staining for ER was nuclear only. The nuclei of the malignant endocervical cells were stained diffusely either as fine or as coarse granular dots. Generally, the staining reaction of the malignant endocervical cells was of strong intensity. There were 2 patients where ER result was not available. In the other 137 patients the result was negative for 73 (53%) and positive for 64 (47%). In all cases, normal endocervical cells and normal stromal cells of the cervix stained weakly positive for ER. The staining pattern in the tumour cells was stronger than that observed in the normal endocervical cells and was restricted to the nucleus. In addition, the intensity and distribution of ER staining in the tumour tissue were more heterogeneous than that observed in the normal tissues. There was strong nuclear staining of positive controls in all cases but no staining of negative controls.

2.2.5i Adenocarcinoma in situ

Excluding 2 patients from 20 patients with adenocarcinoma in situ where ER result was not available, 13 of 18 patients (72%) with adenocarcinoma in situ were negative with ER and the other 5 patients (28%) were positive. ER results of adenocarcinoma in situ in comparison to those of invasive adenocarcinoma were presented in table 24.

2.2.5 ii Invasive adenocarcinoma

59 of 119 patients (50%) with invasive cervical adenocarcinoma were positive with ER and the other 60 patients (50%) were negative. ER results of all subtypes of invasive adenocarcinoma in comparison to each other and in comparison to adenocarcinoma in situ are presented in table 32.

2.2.5iii Early invasive adenocarcinoma.

Sixteen of 119 patients with invasive adenocarcinoma had early invasive adenocarcinoma, excluding results from 22 patients with two samples, met criteria for FIGO stage IA₁ carcinoma of the cervix. The ER result was negative for 7 (44%) and positive for 9 (56%) patients.

2.2.6 Progesterone receptors (PgR)

Immunohistochemical staining for PgR was nuclear, except for the cytoplasm of goblet cells in intestinal-type adenocarcinoma, signet-ring cells in signet-ring-type adenocarcinoma, and normal endocervical glands from abnormal tissues, which stained diffusely. The nuclei of the malignant endocervical cells were stained diffusely with PgR either as fine or as coarse granular dots. Generally, the staining reaction of the malignant endocervical cells was of strong intensity. There were 4 patients where PgR result was not available. In the other 135 patients the result was negative for 85 (63%) and positive for 50 (37%). In all cases, normal endocervical cells and normal stromal cells of the cervix stained weakly positive for PgR. The staining pattern in the tumour cells was stronger than that observed in the normal endocervical cells and was restricted to the nucleus. In addition, the intensity and distribution of PgR staining in the tumour tissue were more heterogeneous than that observed in the normal tissues. There was strong nuclear staining of positive controls in all cases but no staining of negative controls.

2.2.6i Adenocarcinoma in situ

Excluding 2 patients from 20 patients with adenocarcinoma in situ where PgR result was not available, 11 of 18 patients (61%) with adenocarcinoma in situ were negative with PgR and the other 7 patients (39%) were positive. PgR results of adenocarcinoma in situ in comparison to those of invasive adenocarcinoma were presented in table 25.

2.2.6ii Invasive adenocarcinoma

Excluding 2 patients from 119 patients with invasive adenocarcinoma where PgR result was not available, 74 of 119 patients (63%) with invasive cervical

adenocarcinoma were negative with PgR and the other 43 patients (37%) were positive. PgR results of all subtypes of invasive adenocarcinoma in comparison to each other and in comparison to adenocarcinoma in situ were presented in table 33.

2.2.6iii Early invasive adenocarcinoma.

Sixteen of 119 patients with invasive adenocarcinoma had early invasive adenocarcinoma, excluding results from 22 patients with two samples, met criteria for FIGO stage IA₁ carcinoma of the cervix. The PgR result was negative for 9 (56%) and positive for 7 (44%) patients.

2.2.7 MIB1 proliferation marker

Immunohistochemical staining for MIB1 was nuclear only. The nuclei of the malignant endocervical cells were stained diffusely either as fine or as coarse granular dots. Generally, the staining reaction of the malignant endocervical cells was of strong intensity. There were 5 patients where MIB1 result was not available. In the other 134 patients the result was negative for 15 (11%) and positive for 119 (89%). Normal endocervical glands were negative with MIB1. In all cases, normal endocervical stromal cells were negative with MIB1 and there was no positivity in all kinds of stromal cells. There was marked heterogeneity with respect to the intensity and the distribution of MIB1 staining pattern between and within tumours in the same section. There was strong nuclear staining of positive controls in all cases but no staining of negative controls.

2.2.7i Adenocarcinoma in situ

Excluding 2 patients from 20 patients with adenocarcinoma in situ where MIB1 result was not available, 17 of 18 patients (94%) with adenocarcinoma in situ were positive with MIB1 and only one patient (6%) was negative. MIB1 results of adenocarcinoma in situ in comparison to those of invasive adenocarcinoma were presented in table 26.

2.2.7ii Invasive adenocarcinoma

Excluding 3 patients from 119 patients with invasive adenocarcinoma where MIB1 result was not available, 102 of 119 patients (88%) with invasive cervical adenocarcinoma were positive with MIB1 and the other 14 patients (12%) were

negative MIB1 results of all subtypes of invasive adenocarcinoma in comparison to each other and in comparison to adenocarcinoma in situ were presented in table 34.

2.2.7iii Early invasive adenocarcinoma.

Sixteen of 119 patients with invasive adenocarcinoma had early invasive adenocarcinoma, excluding results from 22 patients with two samples, met criteria for FIGO stage IA₁ carcinoma of the cervix. The MIB1 result was negative for 4 (25%) and positive for 12 (75%) patients

2.2.8 Phosphatase and tensin homolog deleted on chromosome ten (*PTEN*)

Immunohistochemical staining for *PTEN* was nuclear only. The nuclei of the malignant endocervical cells were stained diffusely either as fine or as coarse granular dots. Generally, the staining reaction of the malignant endocervical cells was of strong intensity. There were 2 patients where *PTEN* result was not available. In the other 137 patients the result was negative for 16 (12%) and positive for 121 (88%). In all cases, normal endocervical cells and normal stromal cells of the cervix stained weakly positive for *PTEN*. The staining pattern in the tumour cells was stronger than that observed in the normal endocervical cells and was restricted to the nucleus. In addition, the intensity and distribution of *PTEN* staining in the tumour tissue were more heterogeneous than that observed in the normal tissues. There was marked heterogeneity with respect to the intensity and the distribution of *PTEN* staining pattern between and within tumours in the same section. There was strong nuclear staining of positive controls in all cases but no staining of negative controls.

2.2.8i Adenocarcinoma in situ

Excluding 2 patients from 20 patients with adenocarcinoma in situ where *PTEN* result was not available, 16 of 18 patients (89%) with adenocarcinoma in situ were positive with *PTEN* and the other 2 patients (11%) were negative. *PTEN* results of adenocarcinoma in situ in comparison to those of invasive adenocarcinoma were presented in table 27.

2.2.8ii Invasive adenocarcinoma

105 of 119 patients (88%) with invasive cervical adenocarcinoma were positive with *PTEN* and the other 14 patients (12%) were negative *PTEN* results of all subtypes of invasive adenocarcinoma in comparison to each other and in comparison to adenocarcinoma in situ were presented in table 35.

2.2.8iii Early invasive adenocarcinoma.

Sixteen of 119 patients with invasive adenocarcinoma had early invasive adenocarcinoma, excluding results from 22 patients with two samples, met criteria for FIGO stage IA₁ carcinoma of the cervix. The *PTEN* result was negative for 2 (13%) and positive for 14 (88%) patients

2.2.9 p53 suppressor gene

Immunohistochemical staining for p53 was nuclear only. The nuclei of the malignant endocervical cells were stained diffusely either as fine or as coarse granular dots. Generally, the staining reaction of the malignant endocervical cells was of strong intensity. There were 4 patients where p53 result was not available. In the other 135 patients the result was negative for 98 (73%) and positive for 37 (27%). In all cases, normal endocervical cells and normal stromal cells of the cervix stained negative for p53. There was marked heterogeneity with respect to the intensity and the distribution of p53 staining pattern between and within tumours in the same section. There was strong nuclear staining of positive controls in all cases but no staining of negative controls. P53 overexpression is usually associated with frankly invasive cases. Using the Fisher's Exact test, there was a significant statistical difference of p53 expression between AIS and villoglandular papillary adenocarcinoma ($p=0.014$). However, there were no significant statistical differences of p53 expression between AIS and the other different subtypes of invasive adenocarcinoma (table 36).

2.2.9i Adenocarcinoma in situ

Excluding 2 patients from 20 patients with adenocarcinoma in situ where p53 result was not available, 15 of 18 patients (83%) with adenocarcinoma in situ were negative

with p53 and the other 3 patients (17%) were positive. p53 results of adenocarcinoma in situ in comparison to those of invasive adenocarcinoma were presented in table 28.

2.2.9ii Invasive adenocarcinoma

Excluding 2 patients from 119 patients with invasive adenocarcinoma where p53 result was not available, 83 of 119 patients (71%) with invasive cervical adenocarcinoma were negative with p53 and the other 34 patients (29%) were positive. p53 results of all subtypes of invasive adenocarcinoma in comparison to each other and in comparison to adenocarcinoma in situ were presented in table 36.

2.2.9iii Early invasive adenocarcinoma.

Sixteen of 119 patients with invasive adenocarcinoma had early invasive adenocarcinoma, excluding results from 22 patients with two samples, met criteria for FIGO stage IA₁ carcinoma of the cervix. The p53 result was negative for 13 (81%) and positive for 3 (19%) patients.

Table 21. CK7 expression in AIS and invasive adenocarcinoma

CK7	Adenocarcinoma in situ		Invasive adenocarcinoma	
	N	%	N	%
Negative	0	0	4	3
Positive	18	100	114	97
Total	18	100	118	100

Table 21 showing no difference between adenocarcinoma in situ and invasive adenocarcinoma with respect to CK7 using Fisher’s exact test (p= 1.00). There were 3 patients where CK7 result was not available (2 adenocarcinoma-in-situ, 1 invasive adenocarcinoma).

Table 22. CK20 expression in AIS and invasive adenocarcinoma

CK20	Adenocarcinoma in situ		Invasive adenocarcinoma	
	N	%	N	%
Negative	18	100	112	97
Positive	0	0	4	3
Total	18	100	116	100

Table 22 showing no difference between adenocarcinoma in situ and invasive adenocarcinoma with respect to CK20 using Fisher's exact test ($p=1.00$). There were 5 patients where CK20 result was not available (2 adenocarcinoma-in-situ, 3 invasive adenocarcinoma).

Table 23. CEA expression in AIS and invasive adenocarcinoma

CEA	Adenocarcinoma in situ		Invasive adenocarcinoma	
	N	%	N	%
Negative	5	28	39	33
Positive	13	72	79	67
Total	18	100	118	100

Table 23 showing no significant difference between adenocarcinoma in situ and invasive adenocarcinoma with respect to CEA using Fisher's exact test ($p= 0.79$). There were 3 patients where CEA result was not available (2 adenocarcinoma-in-situ, 1 invasive adenocarcinoma).

Table 24. ER expression in AIS and invasive adenocarcinoma

ER	Adenocarcinoma in situ		Invasive adenocarcinoma	
	N	%	N	%
Negative	13	72	60	50
Positive	5	28	59	50
Total	18	100	119	100

Table 24 showing comparison between adenocarcinoma in situ and invasive adenocarcinoma with respect to ER using Fisher's exact test ($p=0.13$). There were 2 patients where ER result was not available (2 adenocarcinoma-in-situ).

Table 25 PgR expression in AIS and invasive adenocarcinoma

PgR	Adenocarcinoma in situ		Invasive adenocarcinoma	
	N	%	N	%
Negative	11	61	74	63
Positive	7	39	43	37
Total	18	100	117	100

Table 25 showing no difference between adenocarcinoma in situ and invasive adenocarcinoma with respect to PgR using Fisher's exact test ($p=1.00$). There were 4 patients where PgR result was not available (2 adenocarcinoma-in-situ, 2 invasive adenocarcinoma).

Table 26. MIB-1 expression in AIS and invasive adenocarcinoma

MIB1	Adenocarcinoma in situ		Invasive adenocarcinoma	
	N	%	N	%
Negative	1	6	14	12
Positive	17	94	102	88
Total	18	100	116	100

Table 26 showing comparison between adenocarcinoma in situ and invasive adenocarcinoma with respect to MIB1 using Fisher's exact test ($p=0.69$). There were 5 patients where MIB1 result was not available (2 adenocarcinoma-in-situ, 3 invasive adenocarcinoma)

Table 27. *PTEN* expression in AIS and invasive adenocarcinoma

<i>PTEN</i>	Adenocarcinoma in situ		Invasive adenocarcinoma	
	N	%	N	%
Negative	2	11	14	12
Positive	16	89	105	88
Total	18	100	119	100

Table 27 showing no difference between adenocarcinoma in situ and invasive adenocarcinoma with respect to *PTEN* using Fisher's exact test ($p=1.00$). There were 2 patients where *PTEN* result was not available (2 adenocarcinoma-in-situ).

Table 28. p53 expression in AIS and invasive adenocarcinoma

p53	Adenocarcinoma in situ		Invasive adenocarcinoma	
	N	%	N	%
Negative	15	83	83	71
Positive	3	17	34	29
Total	18	100	117	100

Table 28 showing no significant difference between adenocarcinoma in situ and invasive adenocarcinoma with respect to p53 using Fisher's exact test ($p=0.40$). There were 4 patients where p53 result was not available (2 adenocarcinoma-in-situ, 2 invasive adenocarcinoma).

Table 29. CK7 expression in AIS and subtypes of invasive adenocarcinoma.

CK7	Adenocarcinoma in situ		Adenocarcinoma NOS		Adenosquamous carcinoma		Villoglandular papillary adenocarcinoma		Minimal deviation adenocarcinoma		Other types of adenocarcinoma	
	N	%	N	%	N	%	N	%	N	%	N	%
Negative	0	0	2	4	1	5	0	0	0	0	1	6
Positive	18	100	47	96	21	95	23	100	8	100	15	94
Total	18	100	49	100	22	100	23	100	8	100	16	100

Table 29 showing no difference between all subtypes of invasive adenocarcinoma in comparison to AIS with respect to CK7 using Chi-square test ($p=0.061$). There were 3 patients where CK7 result was not available (2 AIS, 1 adenocarcinoma NOS).

Table 30. CK20 expression in AIS and subtypes of invasive adenocarcinoma.

CK20	Adenocarcinoma in situ		Adenocarcinoma NOS		Adenosquamous carcinoma		Villoglandular papillary adenocarcinoma		Minimal deviation adenocarcinoma		Other types of adenocarcinoma	
	N	%	N	%	N	%	N	%	N	%	N	%
Negative	18	100	46	96	21	95	23	100	8	100	14	93
Positive	0	0	2	4	1	5	0	0	0	0	1	7
Total	18	100	48	100	22	100	23	100	8	100	15	100

Table 30 showing no difference between all subtypes of invasive adenocarcinoma in comparison to AIS with respect to CK20 using Chi-square test ($p=0.75$). There were 5 patients where CK20 result was not available (2 AIS, 2 NOS, 1 other type of adenocarcinoma).

Table 31. CEA expression in AIS and subtypes of invasive adenocarcinoma.

CEA	Adenocarcinoma in situ		Adenocarcinoma NOS		Adenosquamous carcinoma		Villoglandular papillary adenocarcinoma		Minimal deviation adenocarcinoma		Other types of adenocarcinoma	
	N	%	N	%	N	%	N	%	N	%	N	%
Negative	5	28	21	42	6	27	4	17	2	25	6	40
Positive	13	72	29	58	16	73	19	83	6	75	9	60
Total	18	100	50	100	22	100	23	100	8	100	15	100

Table 31 showing no difference between all subtypes of invasive adenocarcinoma in comparison to AIS with respect to CEA using Chi-square test ($p=0.36$). There were 3 patients where CEA result was not available (2 adenocarcinoma-in-situ, 1 other type of adenocarcinoma).

Table 32. ER expression in AIS and subtypes of invasive adenocarcinoma.

ER	Adenocarcinoma in situ		Adenocarcinoma NOS		Adenosquamous carcinoma		Villoglandular papillary adenocarcinoma		Minimal deviation adenocarcinoma		Other types of adenocarcinoma	
	N	%	N	%	N	%	N	%	N	%	N	%
Negative	13	72	22	44	14	64	8	35	6	75	10	63
Positive	5	28	28	56	8	36	15	65	2	25	6	38
Total	18	100	50	100	22	100	23	100	8	100	16	100

Table 32 showing all subtypes of invasive adenocarcinoma in comparison to AIS with respect to ER using Chi-square test ($p=0.061$). There were 2 patients where ER result was not available (2 adenocarcinoma-in-situ).

Table 33. Pgr expression in AIS and subtypes of invasive adenocarcinoma.

Pgr	Adenocarcinoma in situ		Adenocarcinoma NOS		Adenosquamous carcinoma		Villoglandular papillary adenocarcinoma		Minimal deviation adenocarcinoma		Other types of adenocarcinoma	
	N	%	N	%	N	%	N	%	N	%	N	%
Negative	11	61	26	54	14	64	15	65	5	63	14	88
Positive	7	39	22	46	8	36	8	35	3	38	2	13
Total	18	100	48	100	22	100	23	100	8	100	16	100

Table 33 showing no difference between all subtypes of invasive adenocarcinoma in comparison to AIS with respect to Pgr using Chi-square test ($p=0.33$). There were 4 patients where Pgr result was not available (2 adenocarcinoma-in-situ, 2 adenocarcinoma NOS).

Table 34. MIB-1 expression in AIS and subtypes of invasive adenocarcinoma.

MIB1	Adenocarcinoma in situ		Adenocarcinoma NOS		Adenosquamous carcinoma		Villoglandular papillary adenocarcinoma		Minimal deviation adenocarcinoma		Other types of adenocarcinoma	
	N	%	N	%	N	%	N	%	N	%	N	%
Negative	1	6	7	14	2	9	1	4	2	25	2	14
Positive	17	94	42	86	20	91	22	96	6	75	12	86
Total	18	100	49	100	22	100	23	100	8	100	14	100

Table 34 showing no difference between all subtypes of invasive adenocarcinoma in comparison to AIS with respect to MIB1 using Chi-square test ($p=0.56$). There were 5 patients where MIB1 result was not available (2 AIS, 1 adenocarcinoma NOS, 2 other types of adenocarcinoma).

Table 35. *PTEN* expression in AIS and subtypes of invasive adenocarcinoma.


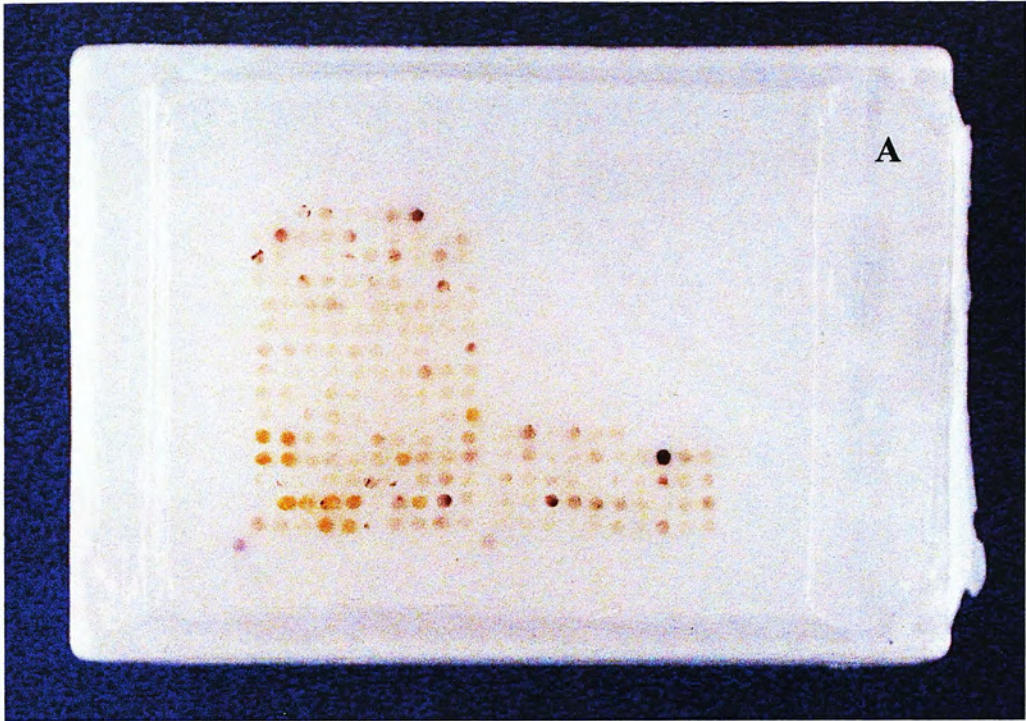
<i>PTEN</i>	Adenocarcinoma in situ		Adenocarcinoma NOS		Adenosquamous carcinoma		Villoglandular papillary adenocarcinoma		Minimal deviation adenocarcinoma		Other types of adenocarcinoma	
	N	%	N	%	N	%	N	%	N	%	N	%
Negative	2	11	8	16	2	9	0	0	0	0	4	25
Positive	16	89	42	84	20	91	23	100	8	100	12	75
Total	18	100	50	100	22	100	23	100	8	100	16	100

Table 35 showing no difference between all subtypes of invasive adenocarcinoma in comparison to AIS with respect to *PTEN* using Chi-square test ($p=0.15$). There were 2 patients where *PTEN* result was not available (2 adenocarcinoma-in-situ).

Table 36. p53 expression in AIS and subtypes of invasive adenocarcinoma.

p53	Adenocarcinoma in situ		Adenocarcinoma NOS		Adenosquamous carcinoma		Villoglandular papillary adenocarcinoma		Minimal deviation adenocarcinoma		Other types of adenocarcinoma	
	N	%	N	%	N	%	N	%	N	%	N	%
Negative	15	83	35	71	20	91	10	45	6	75	12	75
Positive	3	17	14	29	2	9	12	55	2	25	4	25
Total	18	100	49	100	22	100	22	100	8	100	16	100

Table 36 showing all subtypes of invasive adenocarcinoma in comparison to AIS with respect to p53 using Chi-square test (p=0.023). There were 4 patients where p53 result was not available (2 AIS, 1 adenocarcinoma NOS, 1 VGC). Using the Fisher's Exact value, there was significant statistical difference of p53 expression between AIS and villoglandular papillary adenocarcinoma (p = 0.014). However, there were no significant statistical differences of p53 expression between AIS and the other different subtypes of invasive adenocarcinoma.



**Figure 19 showing A- TMA paraffin block
B- TMA slide stained with H&E**

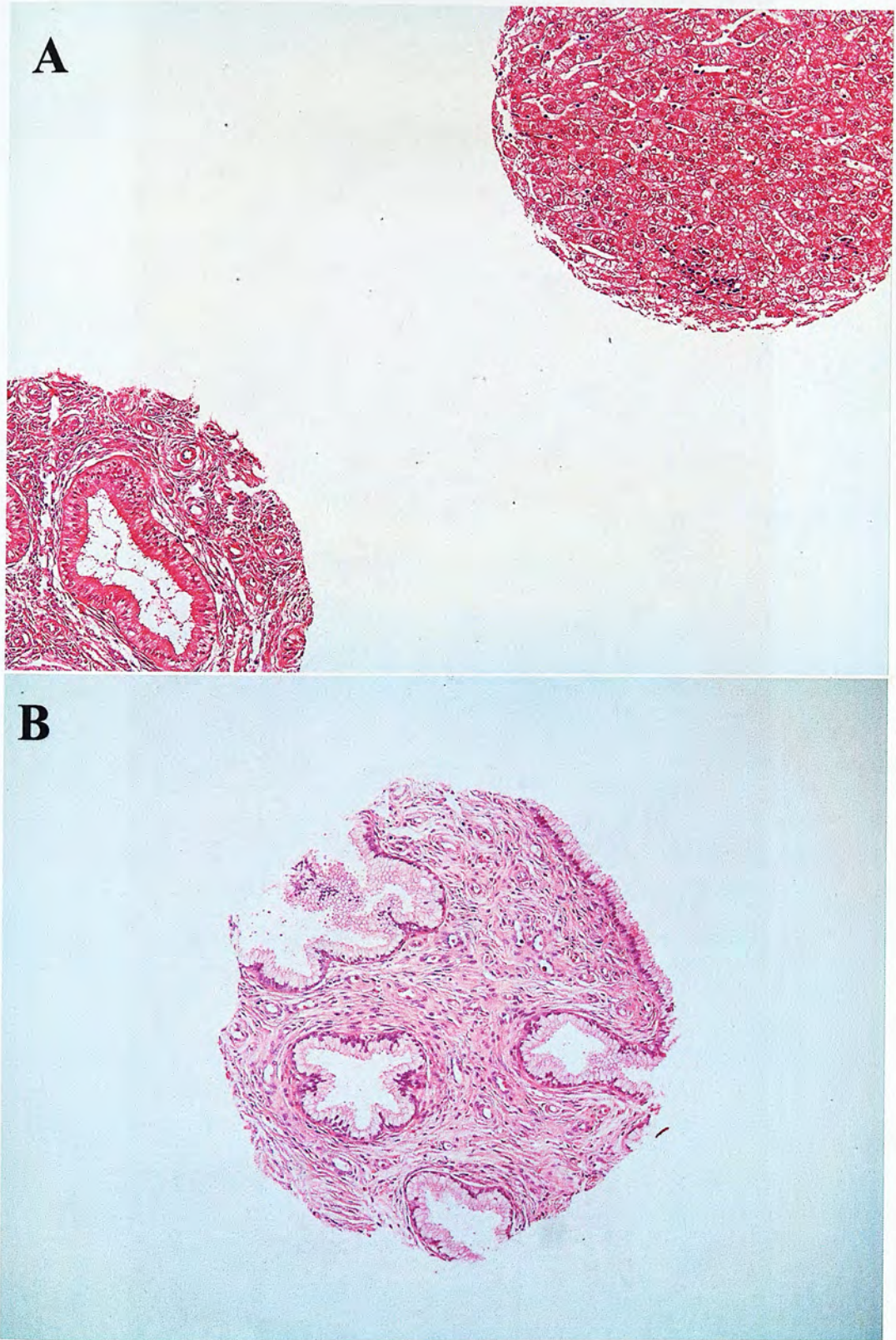


Figure 20 (A) Two H&E-stained tissue-microarray cores biopsies specimens from liver (above) which used as a slide marker and from normal endocervical tissue (below) (H&E, x100). (B) H&E-stained tissue-microarray core biopsy specimen showing normal endocervical glands (H&E, x100).

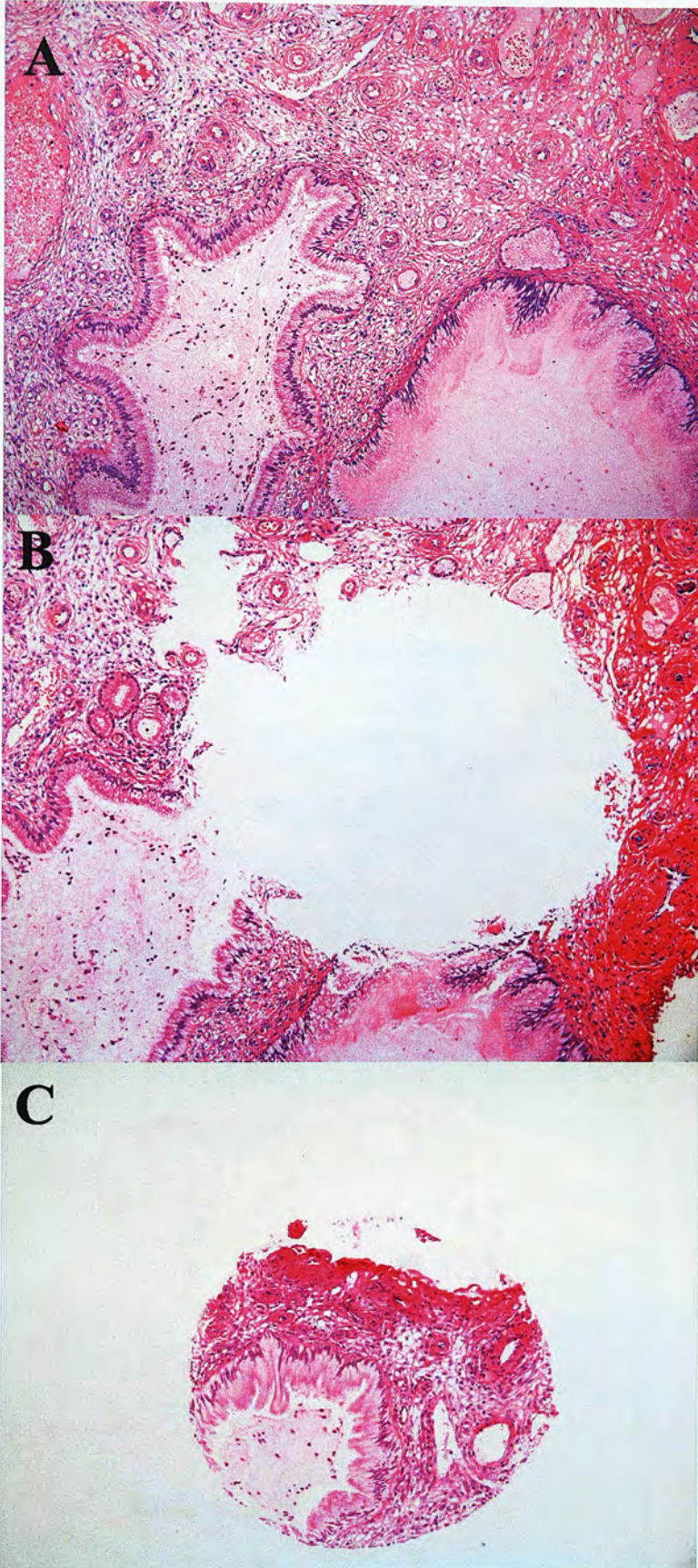


Figure 21 Sequence of H&E-stained tissue-microarray core biopsy sampling from normal endocervical tissue. (A) Before sampling (H&E, x200).(B) After tissue core was removed (H&E, x200).(C) The core (H&E, x100).

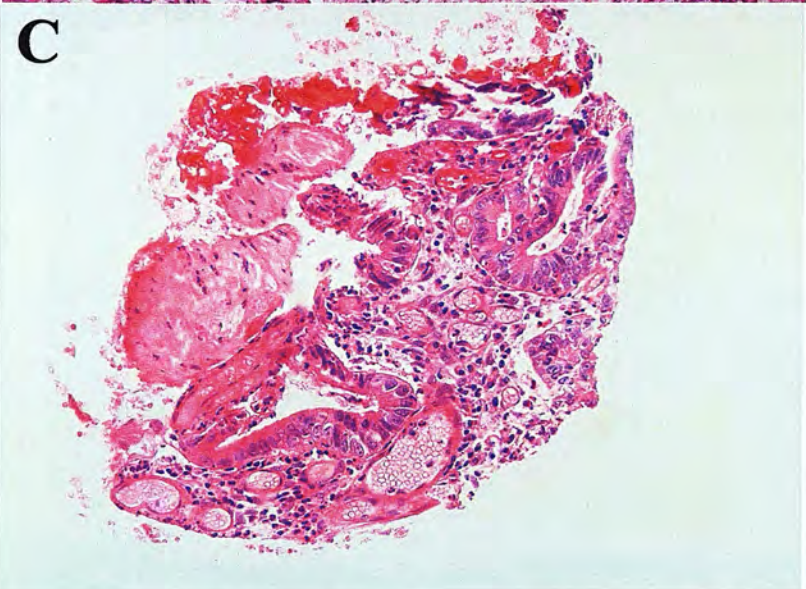
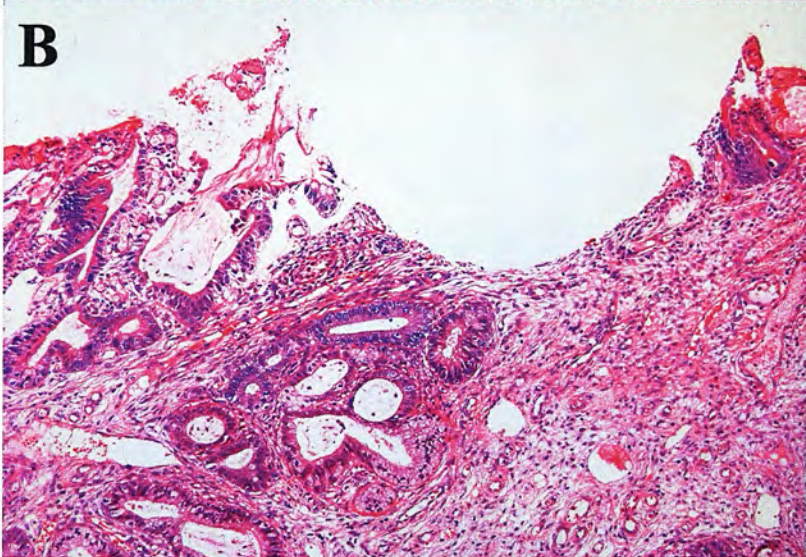
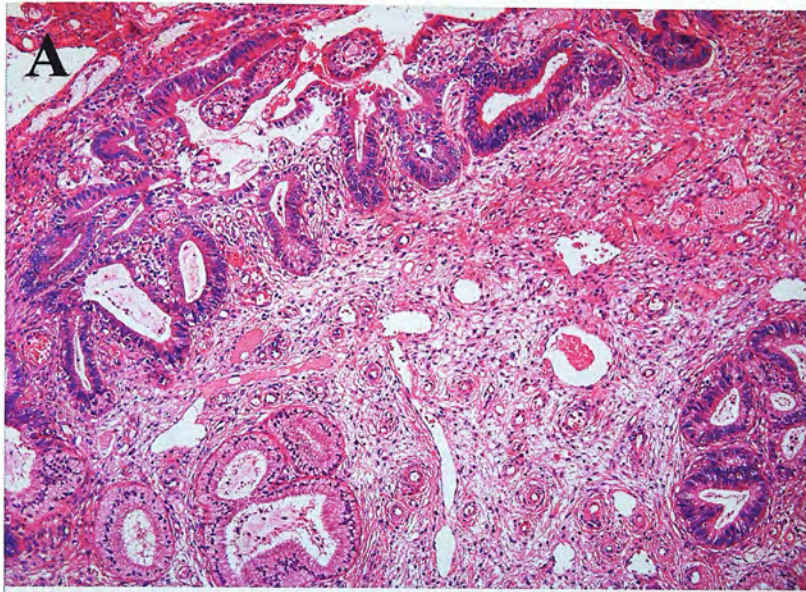


Figure 22 Sequence of H&E-stained tissue-microarray core biopsy sampling from endocervical tissue with adenocarcinoma in situ (AIS). (A) Before sampling (H&E, x200). (B) After tissue core was removed (H&E, x200). (C) The core (H&E, x 200).

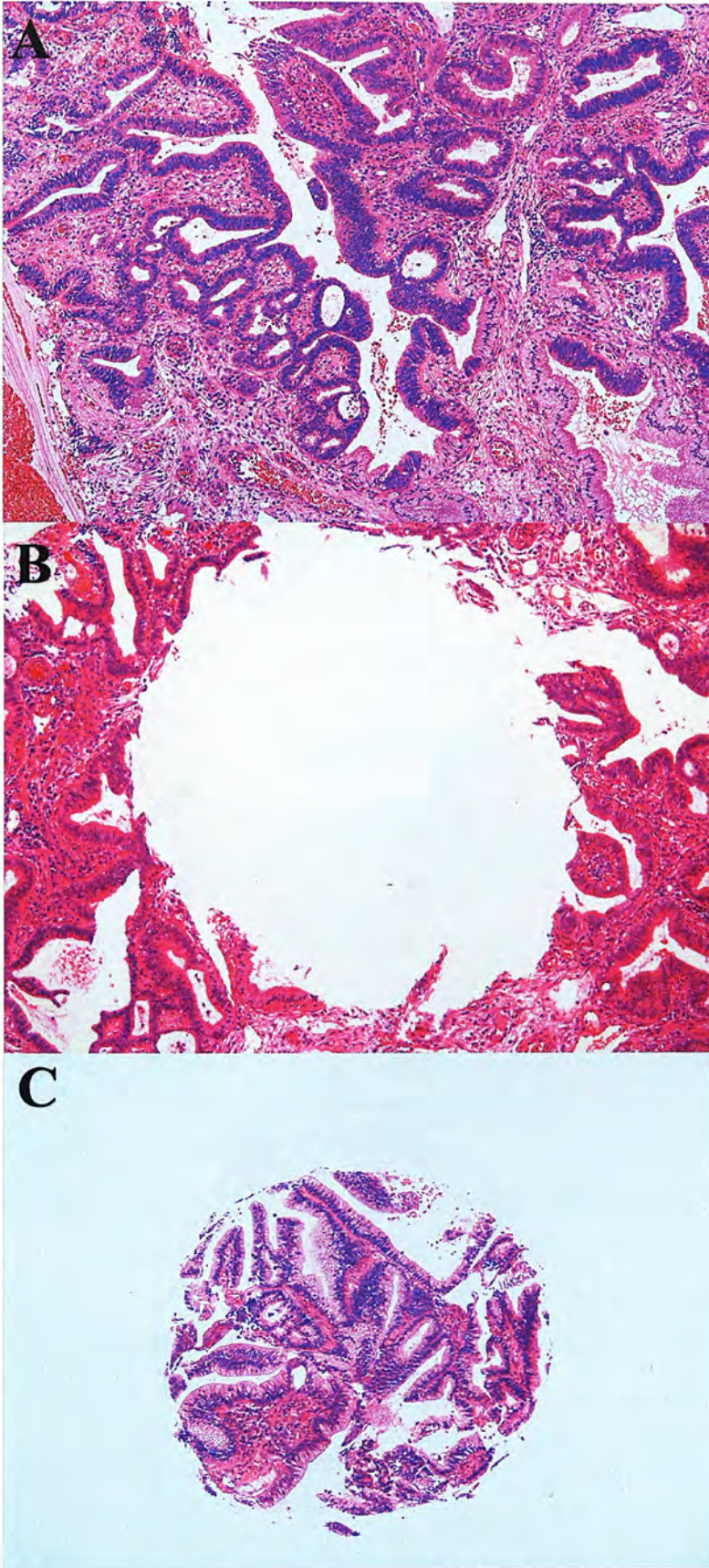
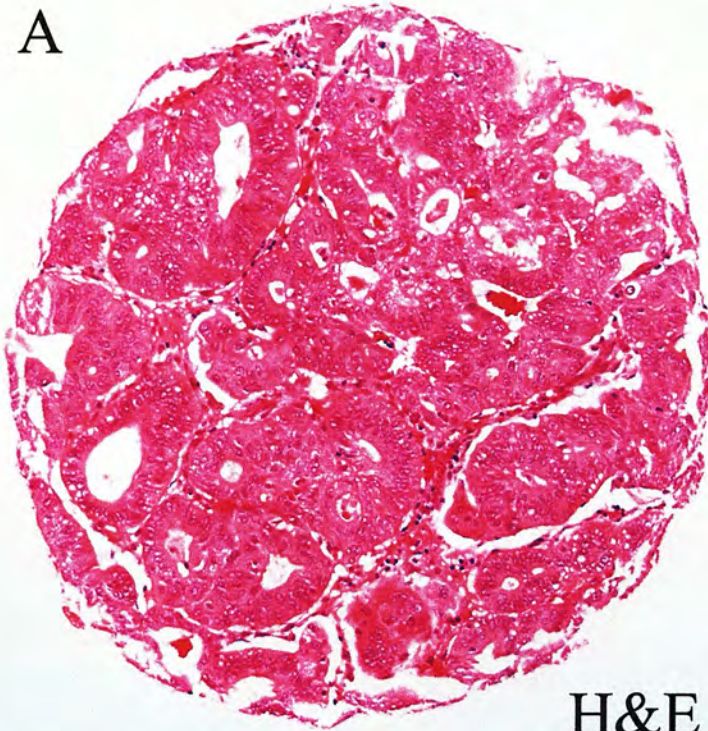

Figure 23 Sequence of H&E-stained tissue-microarray core biopsy sampling from endocervical tissue with invasive adenocarcinoma .(A)Before sampling (H&E, x200). (B) After tissue core was removed (H&E, x200).(C) The core (H&E, x 100).

A



H&E

B

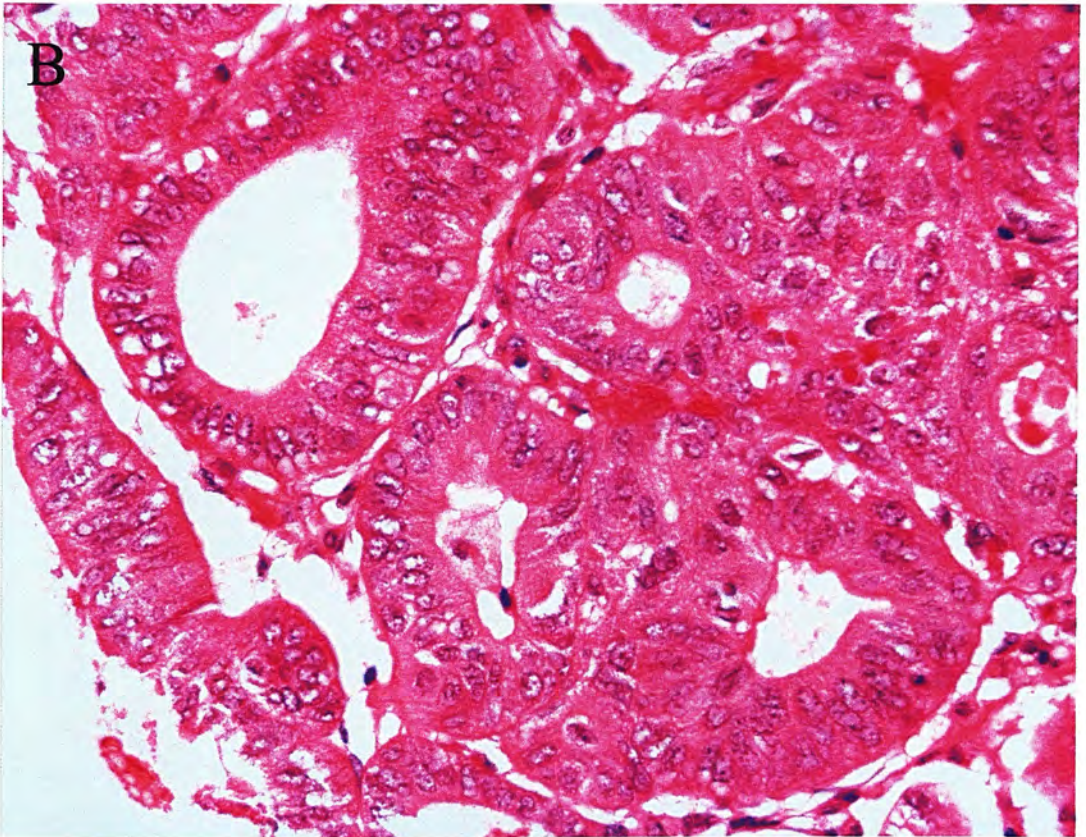


Figure 25 (A) H&E-stained tissue-microarray core biopsy specimen from moderate differentiated endocervical adenocarcinoma, usual type (H&E,x100).(B)A higher power of the the above core showing The glands are lined by cells with atypical nuclei and deeply eosinophilic cytoplasm (H&E, x400).

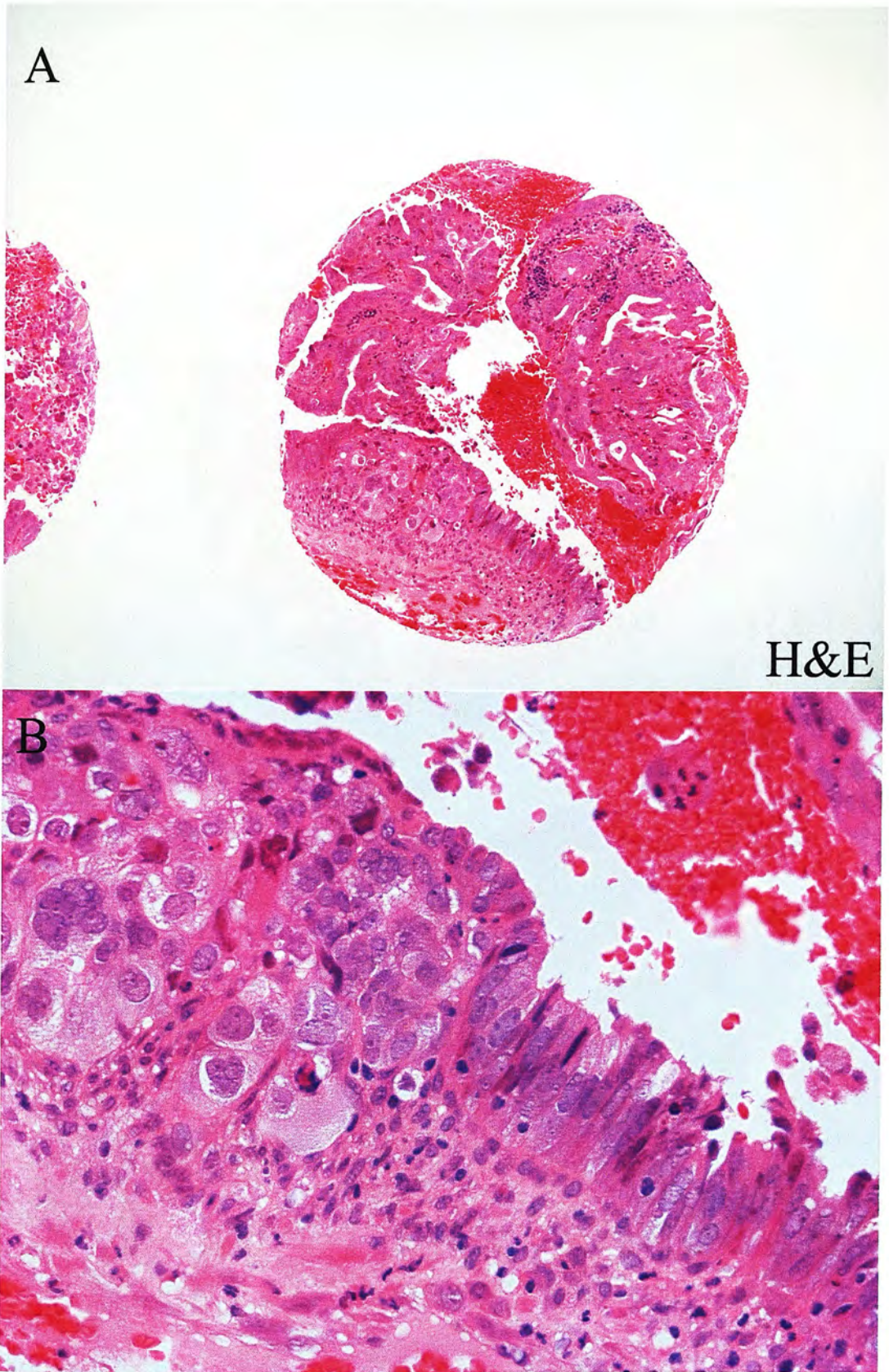


Figure 26 (A) H&E-stained tissue-microarray core biopsy specimen from adenosquamous carcinoma (H&E, x100).(B) A higher power of the the above core showing cohesion between both the individual cells of squamous(left) and glandular elements(right) which have malignant features (H&E, x400).

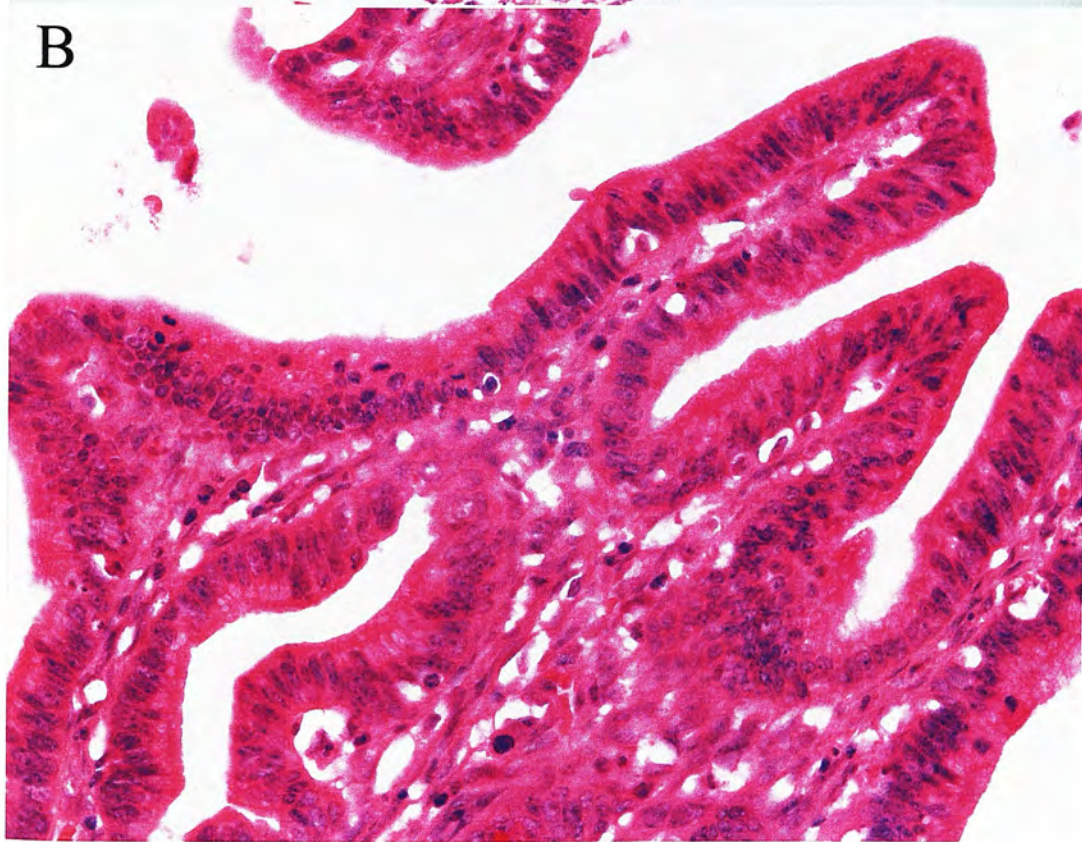
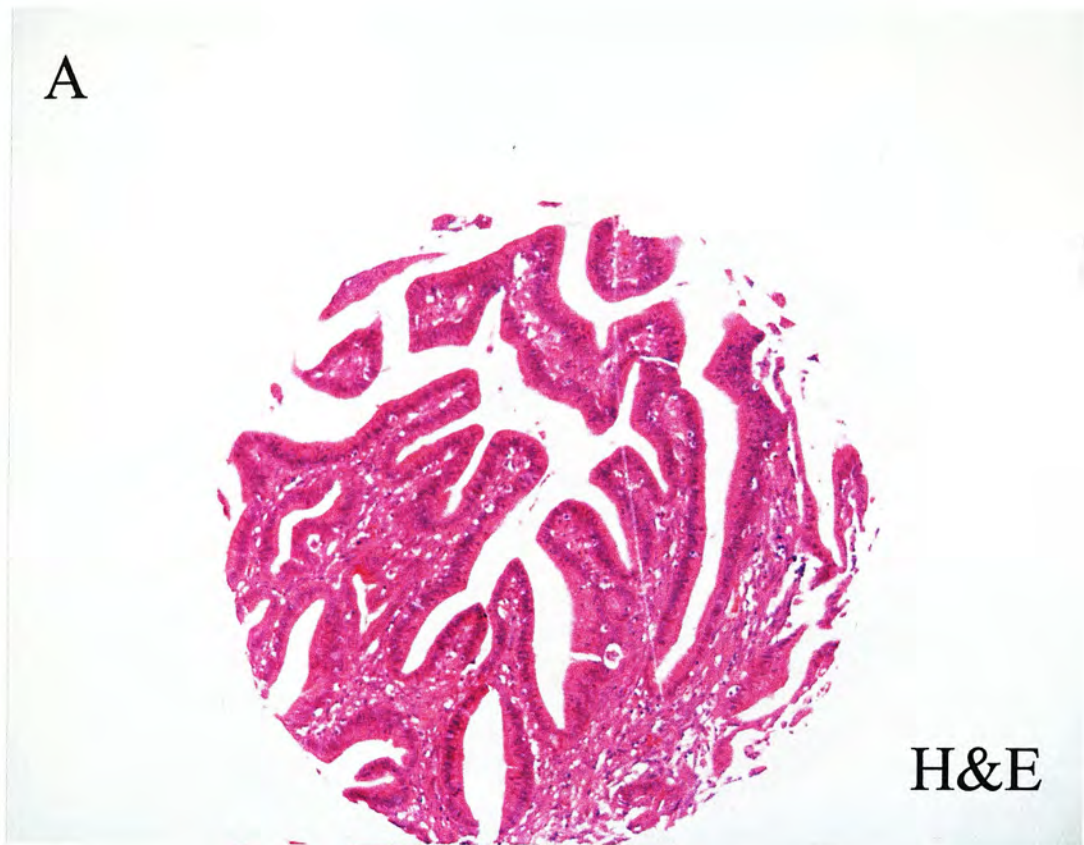

Figure 27 (A) H&E-stained tissue-microarray core biopsy specimen from well differentiated villoglandular papillary adenocarcinoma (VGC) (H&E,x100). (B)A higher power of the the above core showing a broad papillae, with fibrovascular cores covered by a mildly atypical columnar epithelium (H&E, x400).

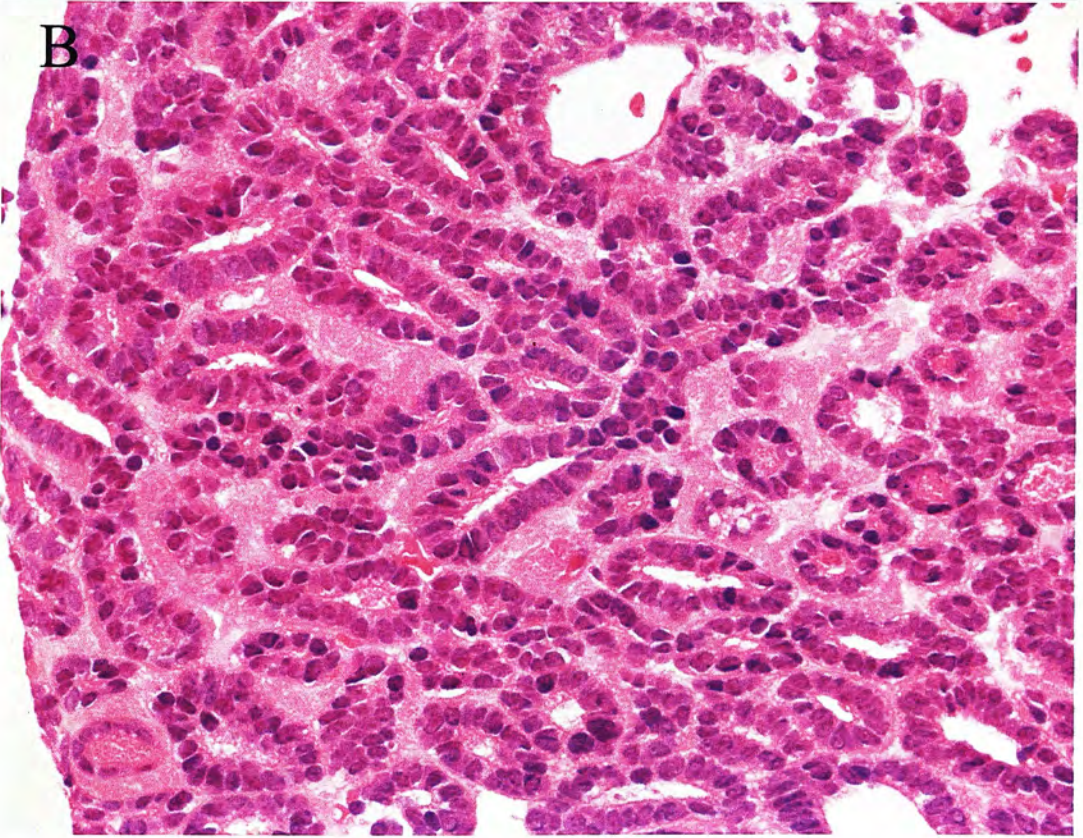
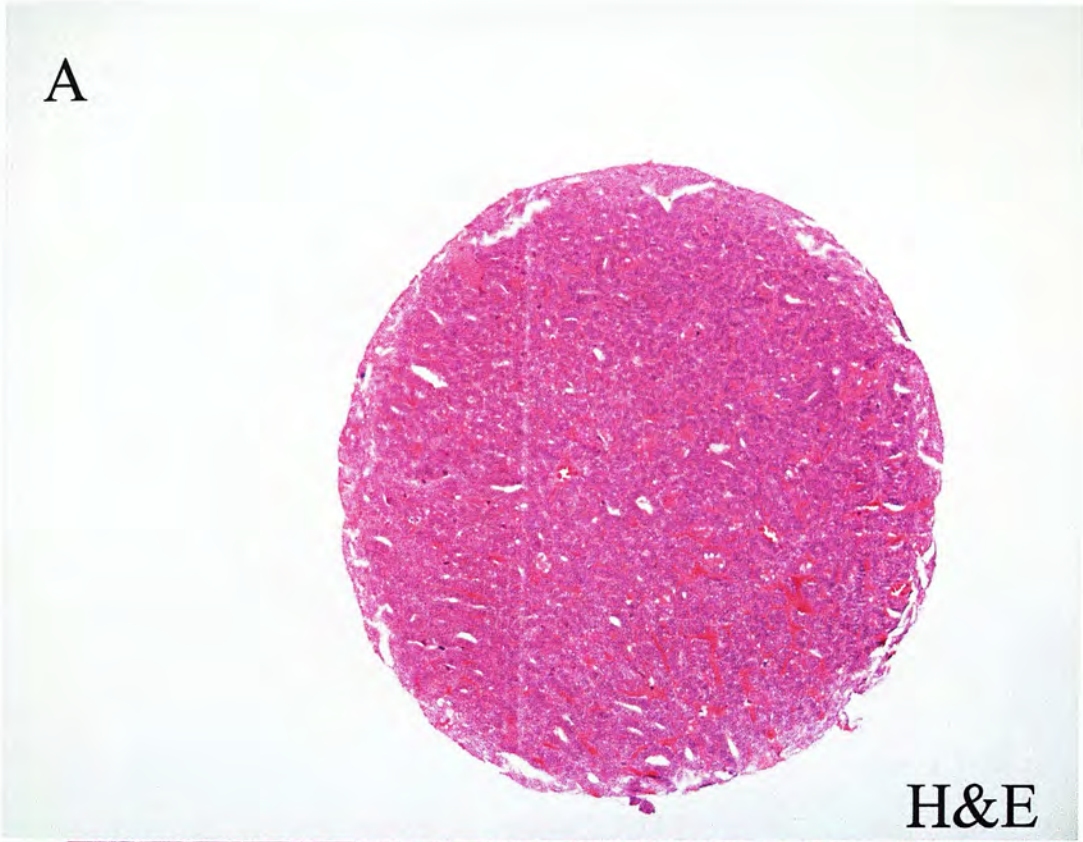


Figure 28 (A) H&E-stained tissue-microarray core biopsy specimen from endocervical adenocarcinoma, Microglandular carcinoma,(H&E,x100). (B) A higher power of the above core showing a single layer of atypical oval nuclei surrounding each glandular lumen with very little amount of stroma inbetween (H&E,x400) . Note,no stratification of lining epithelium of the glands. 133

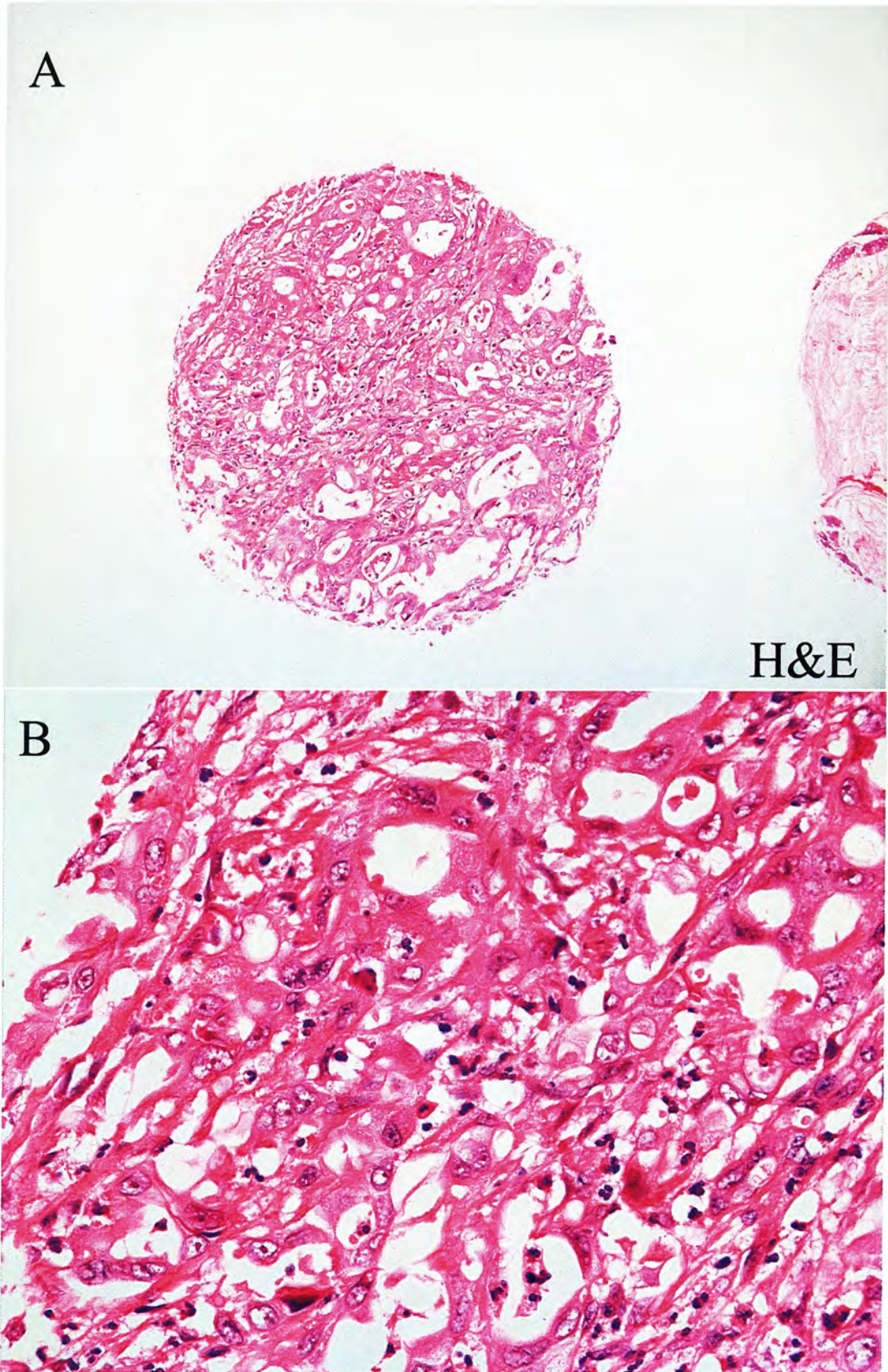
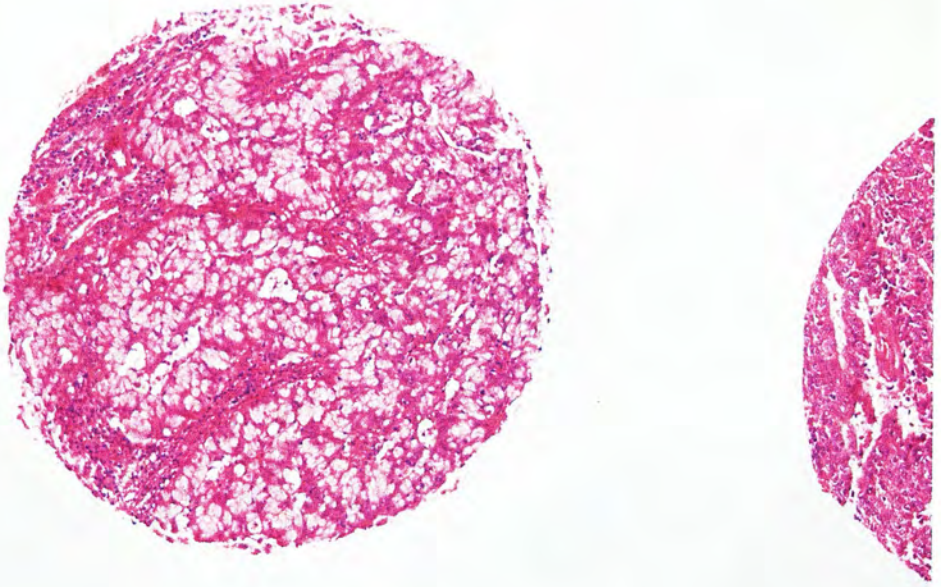


Figure 29 (A) H&E-stained tissue-microarray core biopsy specimen from poorly differentiated clear cell carcinoma (H&E, x100). (B) A higher power of the the above core showing a sheets of large cells with large nuclei with prominent nucleoli, and signet-ring-like cells (H&E, x400).

A



H&E

B

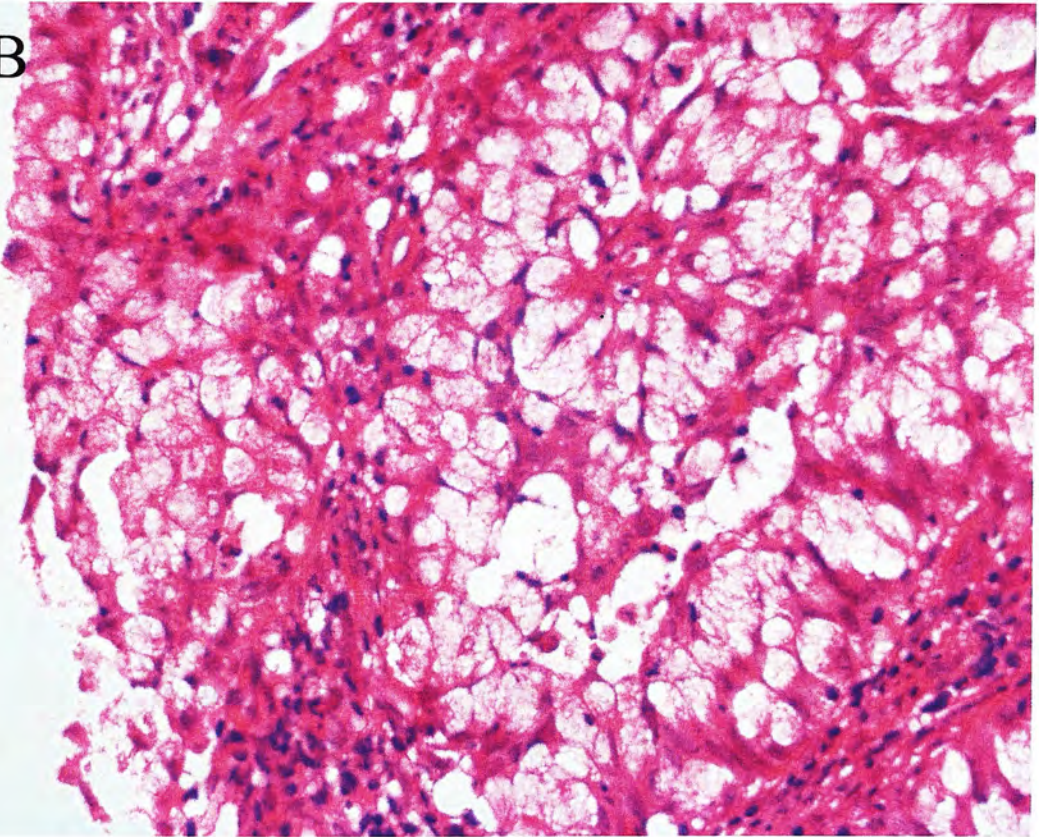


Figure 30 (A) H&E-stained tissue-microarray core biopsy specimen from poorly differentiated endocervical adenocarcinoma, signet-ring cell type, (H&E, x100). (B) A higher power of the the above core showing a solid area of the tumour formed of signet-ring-like cells with intracellular mucin (H&E,x400).

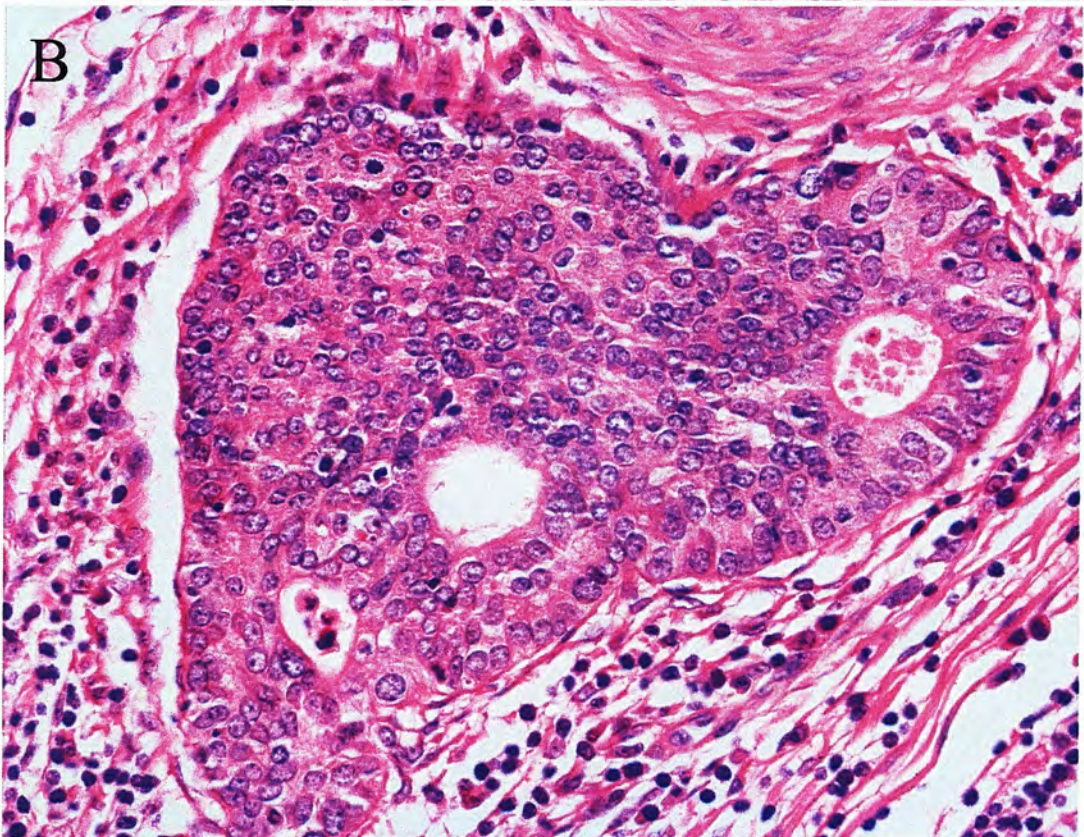
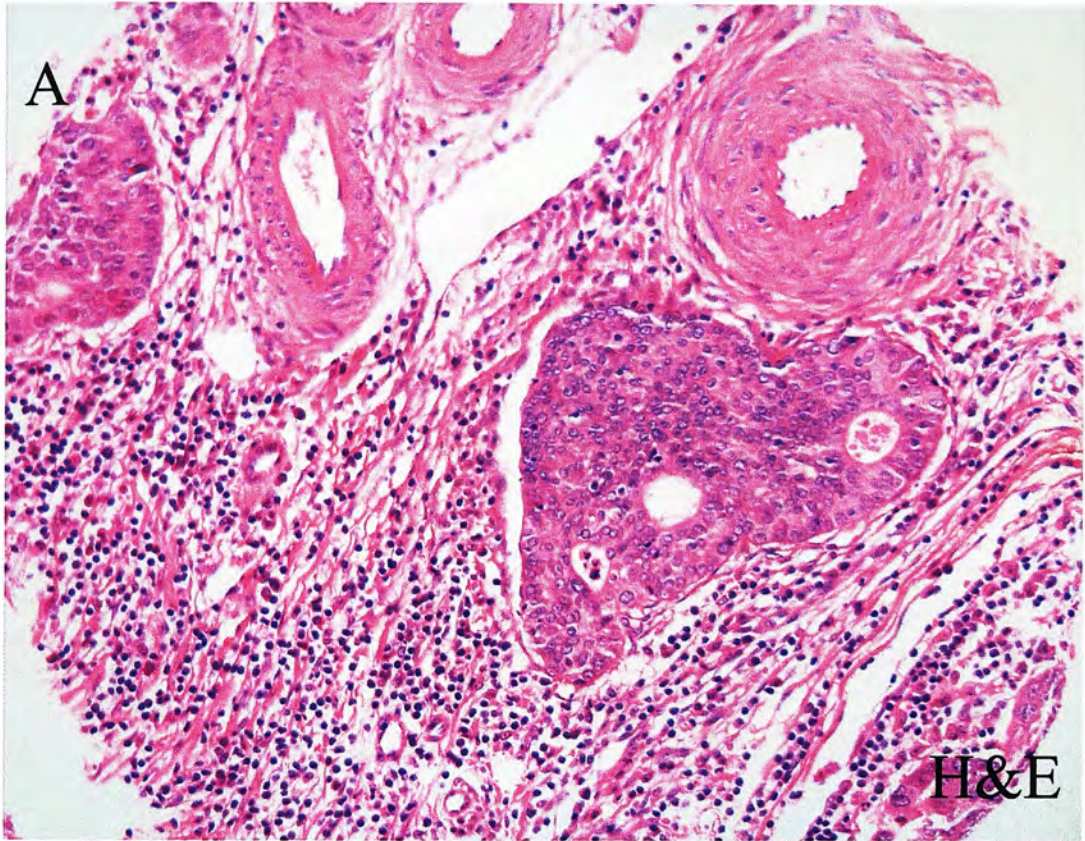


Figure 31 (A) H&E-stained tissue-microarray core biopsy specimen from adenoid basal carcinoma (H&E,x200). (B)A higher power of the the above core showing a nest of uniform mostly basaloid cells with peripheral palisading and no stromal reaction(H&E,x400).

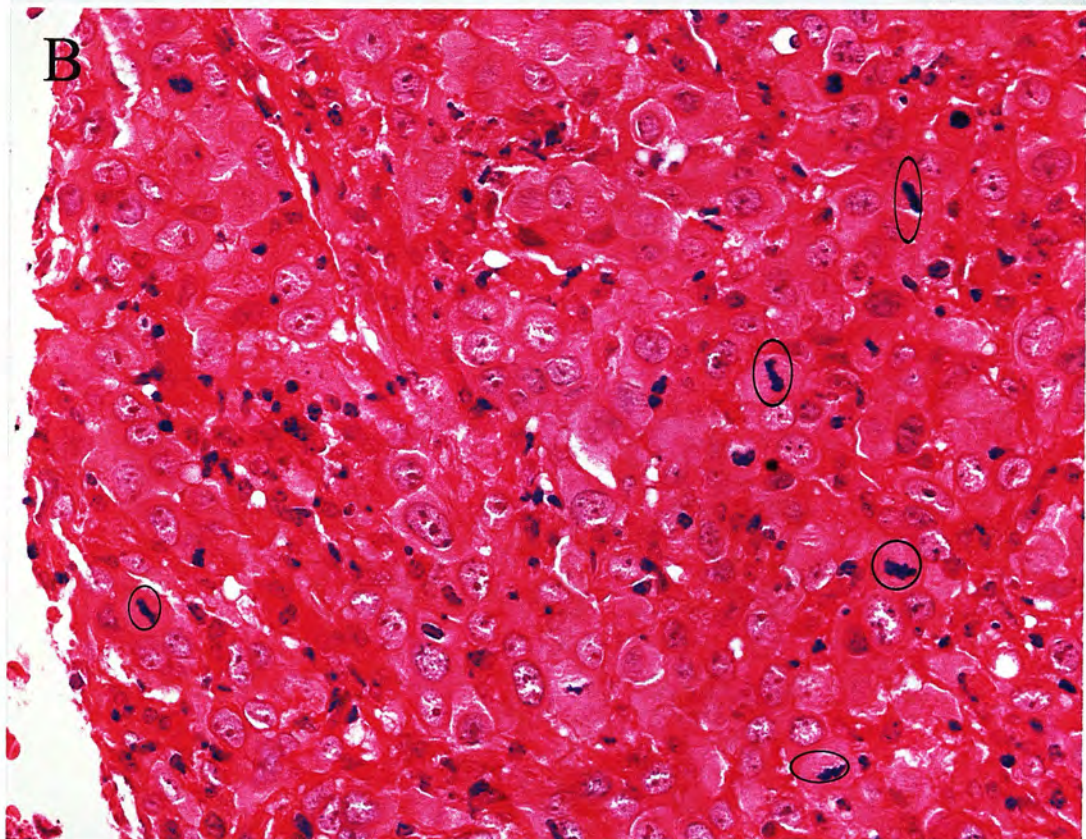
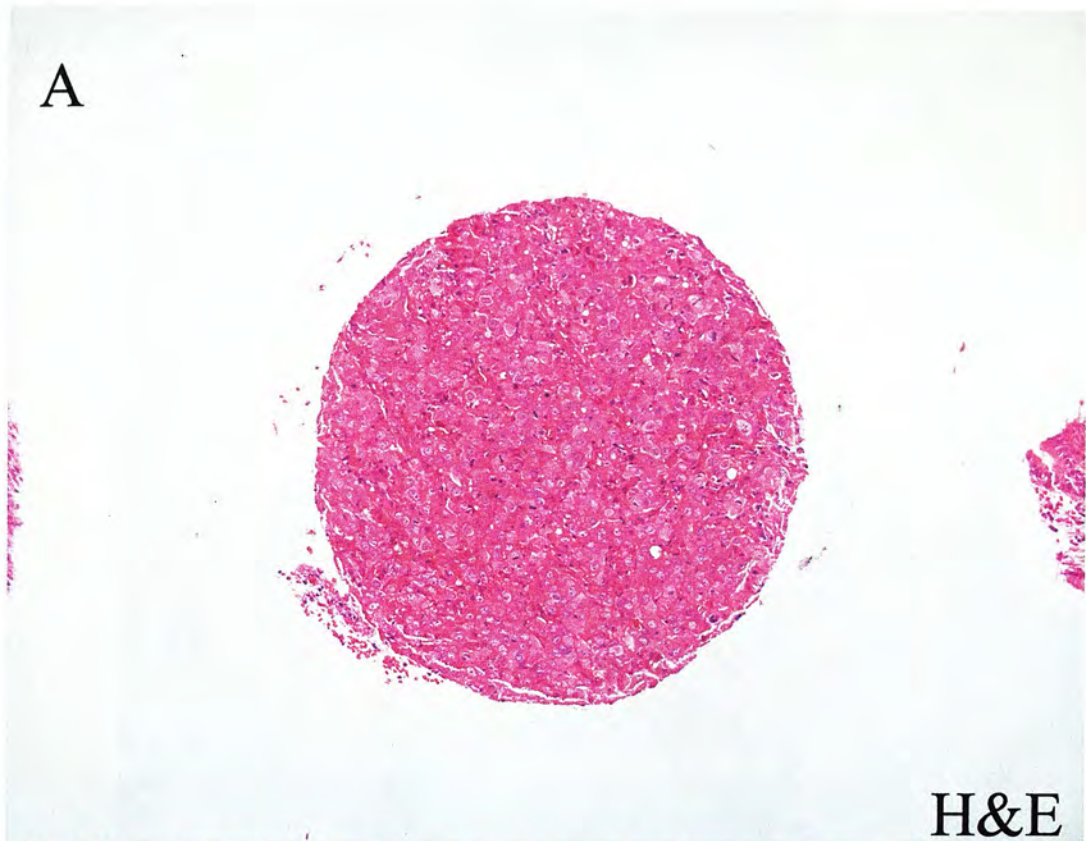

Figure 32 (A) H&E-stained tissue-microarray core biopsy specimen from poorly differentiated glassy cell carcinoma (H&E, x100). (B) A higher power of the above core showing a sheets of large cells with abundant eosinophilic, ground-glass or finely granular cytoplasm, prominent cell borders, large nuclei with prominent nucleoli, with numerous mitotic figures(circles) (H&E, x400).

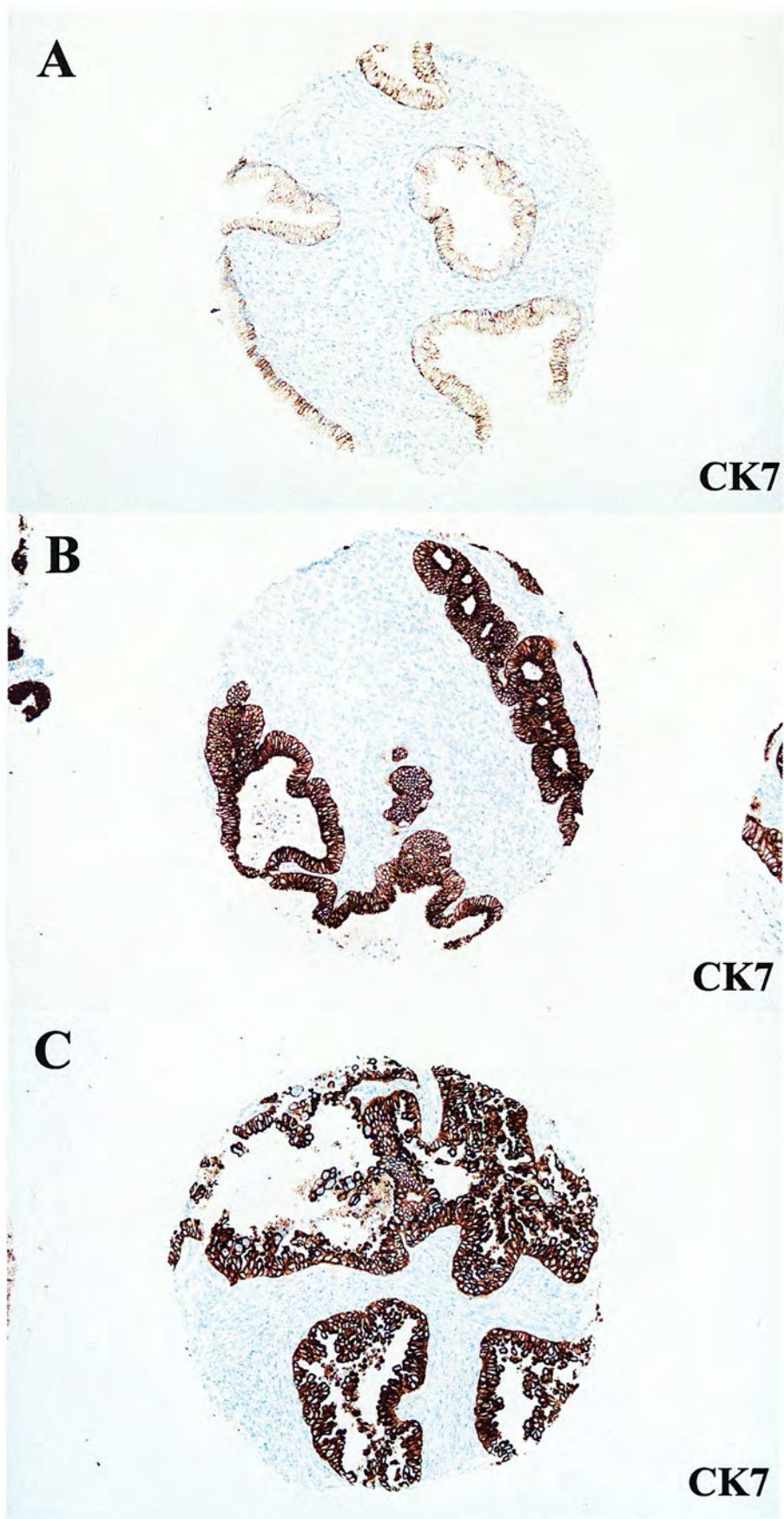


Figure 33 Three CK7-stained tissue-microarray cores biopsies specimens. (A) Normal endocervical glands exhibit no staining (x100).(B) AIS exhibits strong positive cytoplasmic staining (x100).(C) Invasive adenocarcinoma exhibits strong positive cytoplasmic staining (x100).

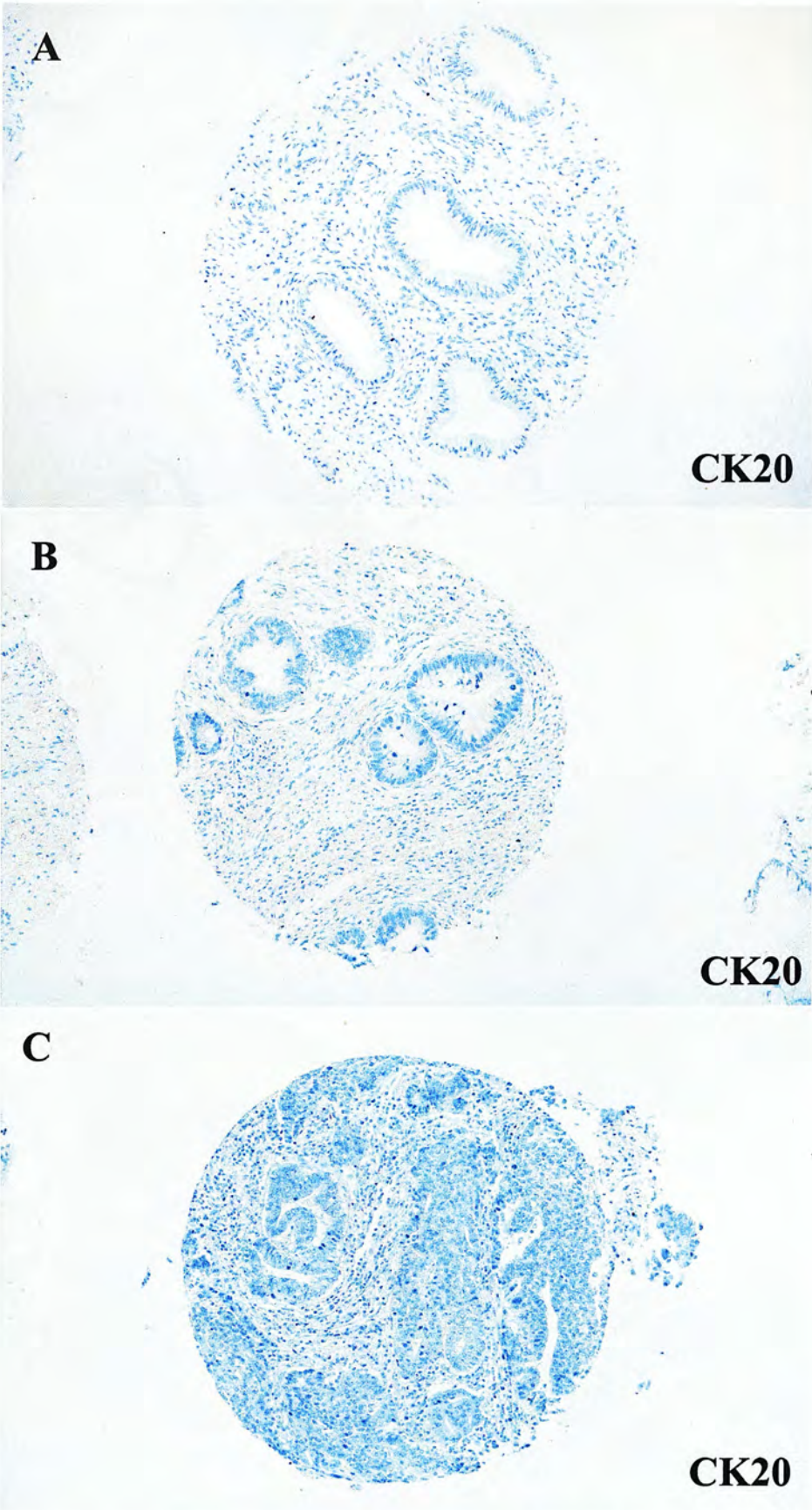


Figure 34 Three tissue-microarray cores biopsies specimens exhibit no staining with CK20. (A) Normal endocervical glands (CK20, x100). (B) AIS (CK20, x100). (C) Invasive adenocarcinoma (CK20, x100).

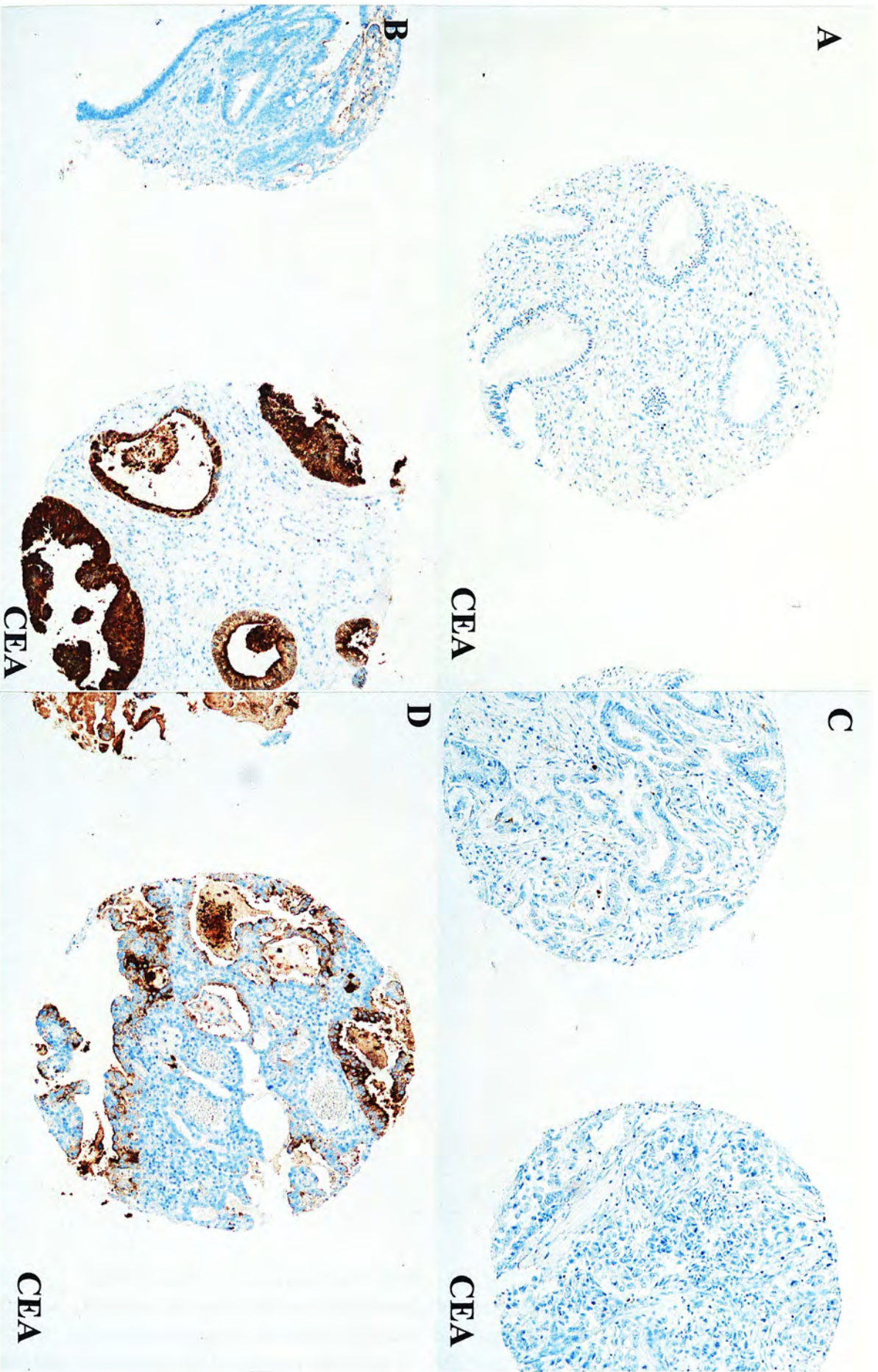


Figure 35 Four CEA-stained tissue-microarray cores biopsies specimens. (A) Normal endocervical glands exhibit no staining (x100). (B) AIS exhibits strong positive cytoplasmic staining (x100). (C) Invasive adenocarcinoma exhibits no staining (x100). (D) Invasive adenocarcinoma exhibits strong positive cytoplasmic staining (x100).

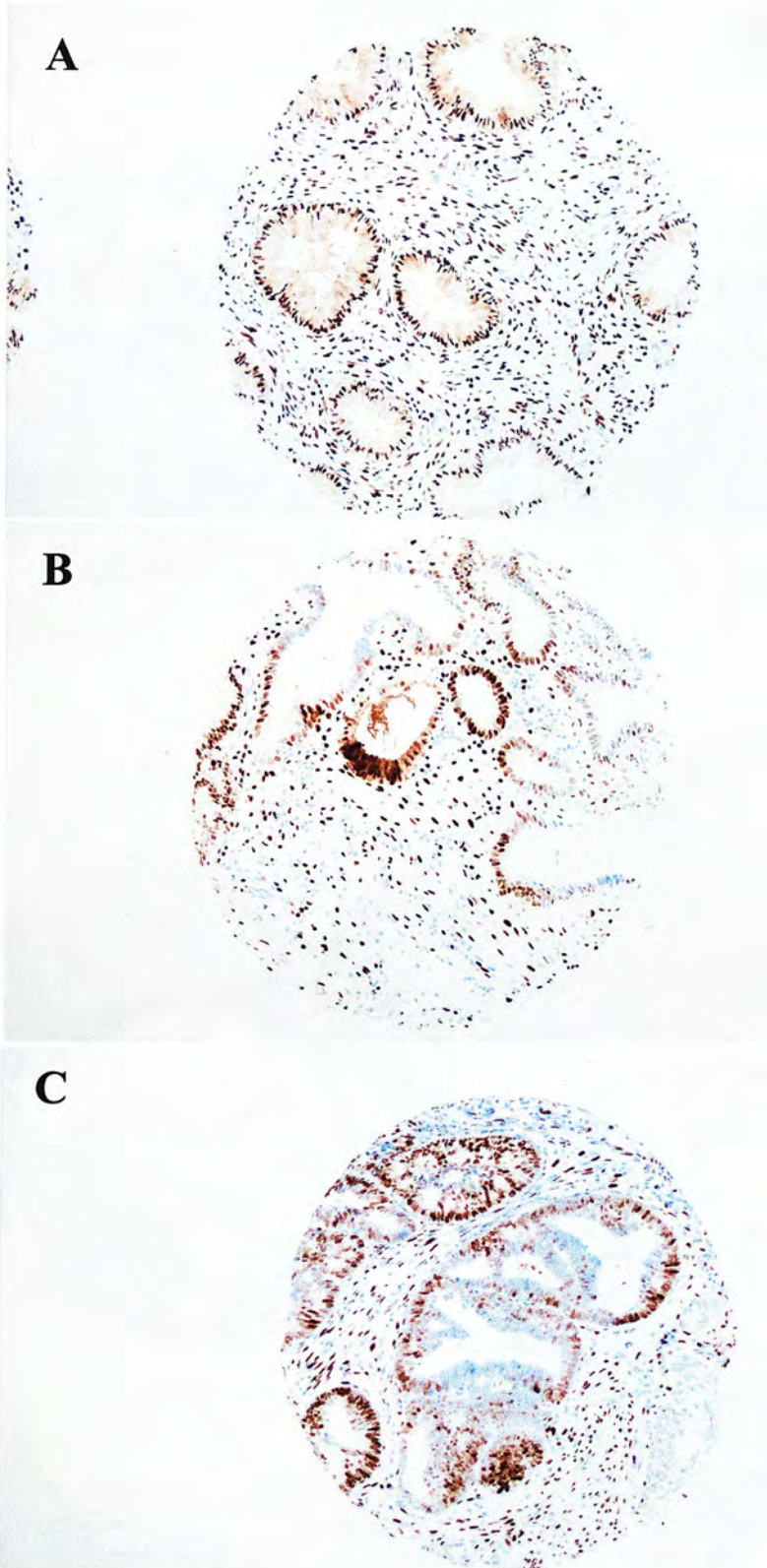


Figure 36 Three progesterone receptors (PgR) -stained tissue-microarray cores biopsies specimens. (A) Normal endocervical glands exhibit normal weak positive nuclear staining (x100).(B) AIS exhibits strong positive nuclear staining (x100).(C) Invasive adenocarcinoma exhibits strong positive nuclear staining (x100).

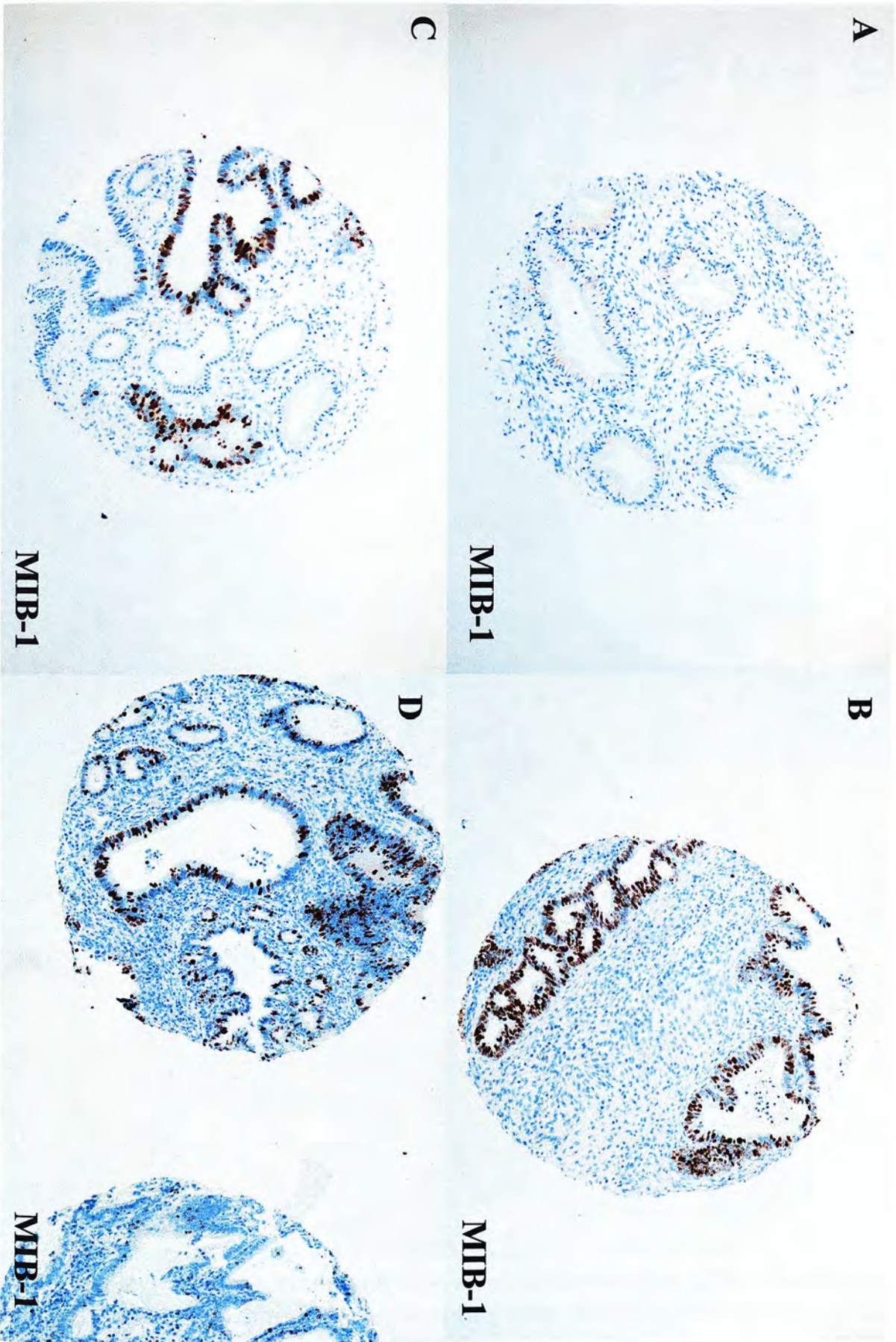


Figure 37 Four MIB-1-stained tissue-microarray cores biopsies specimens. (A) Normal endocervical glands exhibit no staining (x100). (B) AIS exhibits strong positive nuclear staining (x100). (C) LIGGIN exhibits strong positive nuclear staining with normal glands exhibit no staining (x100). (D) Invasive adenocarcinoma exhibits strong positive nuclear staining (x100).

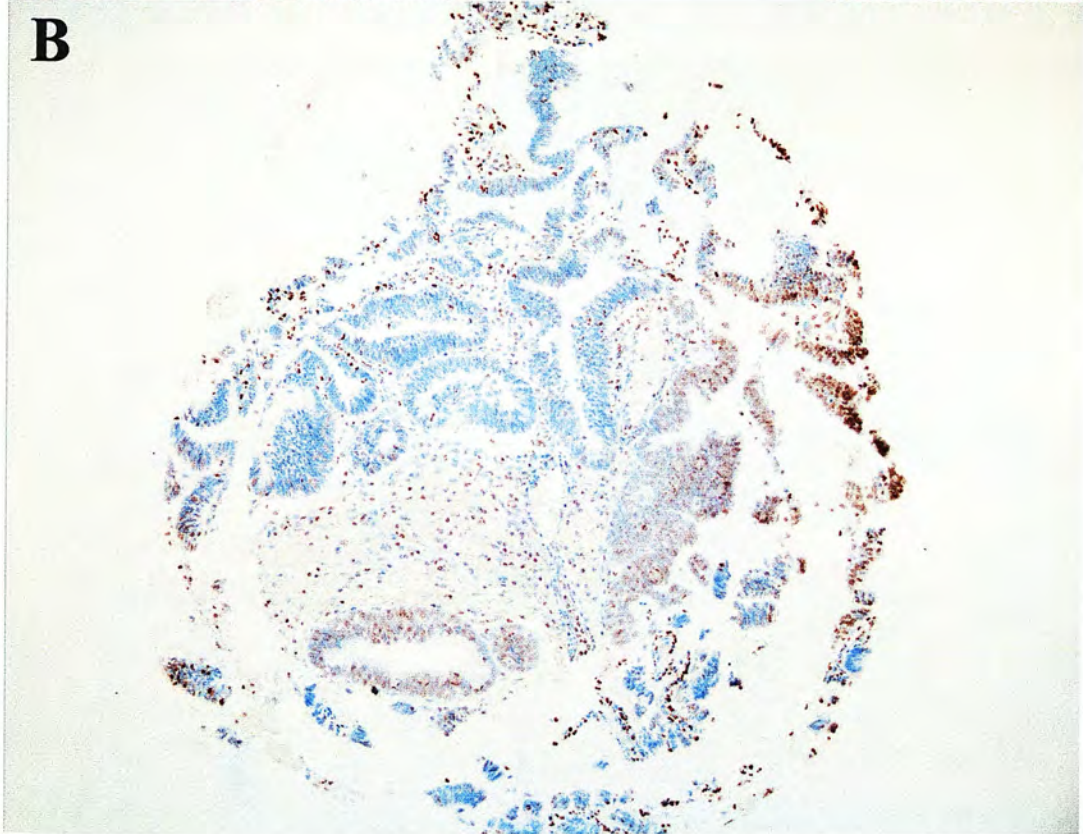
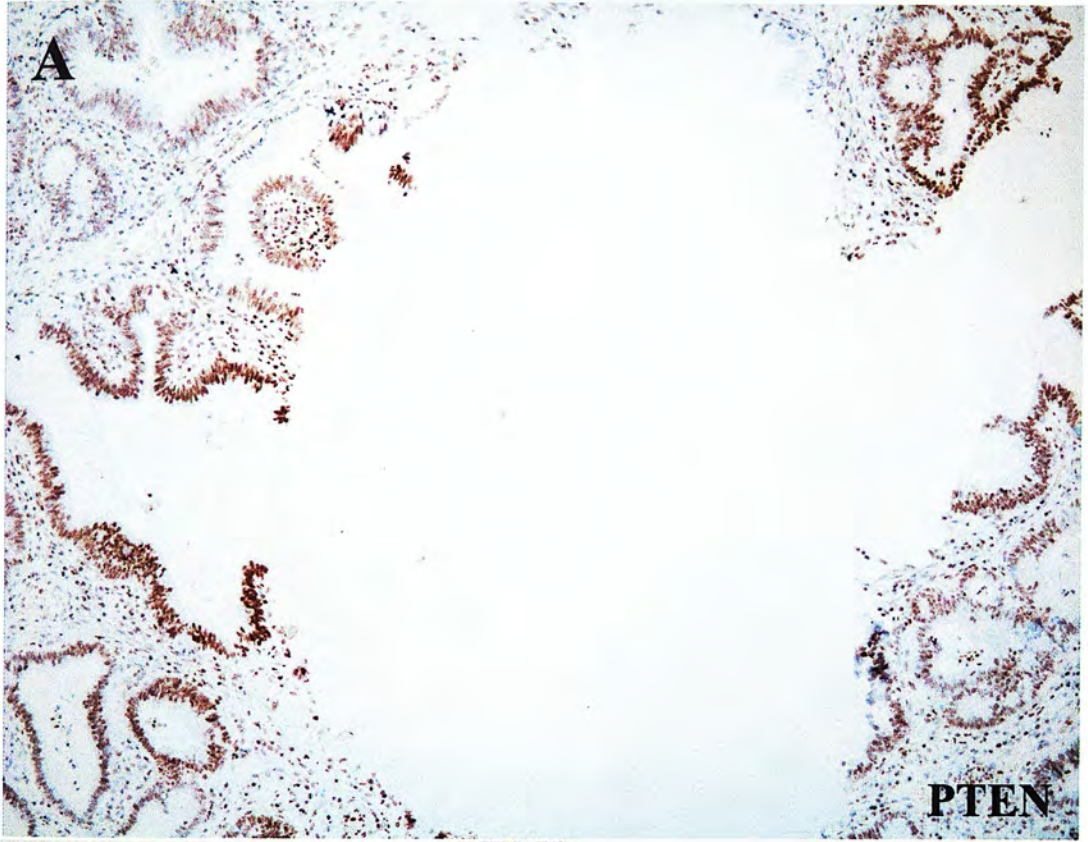


Figure 38 Invasive adenocarcinoma(A)The whole tissue section ,after tissue core was removed , exhibits positive nuclear staining with PTEN (x200).(B)The tissue-microarray core biopsy specimen exhibits the same positive reaction with PTEN as the original whole tissue section with some glands exhibits no staining (x100).

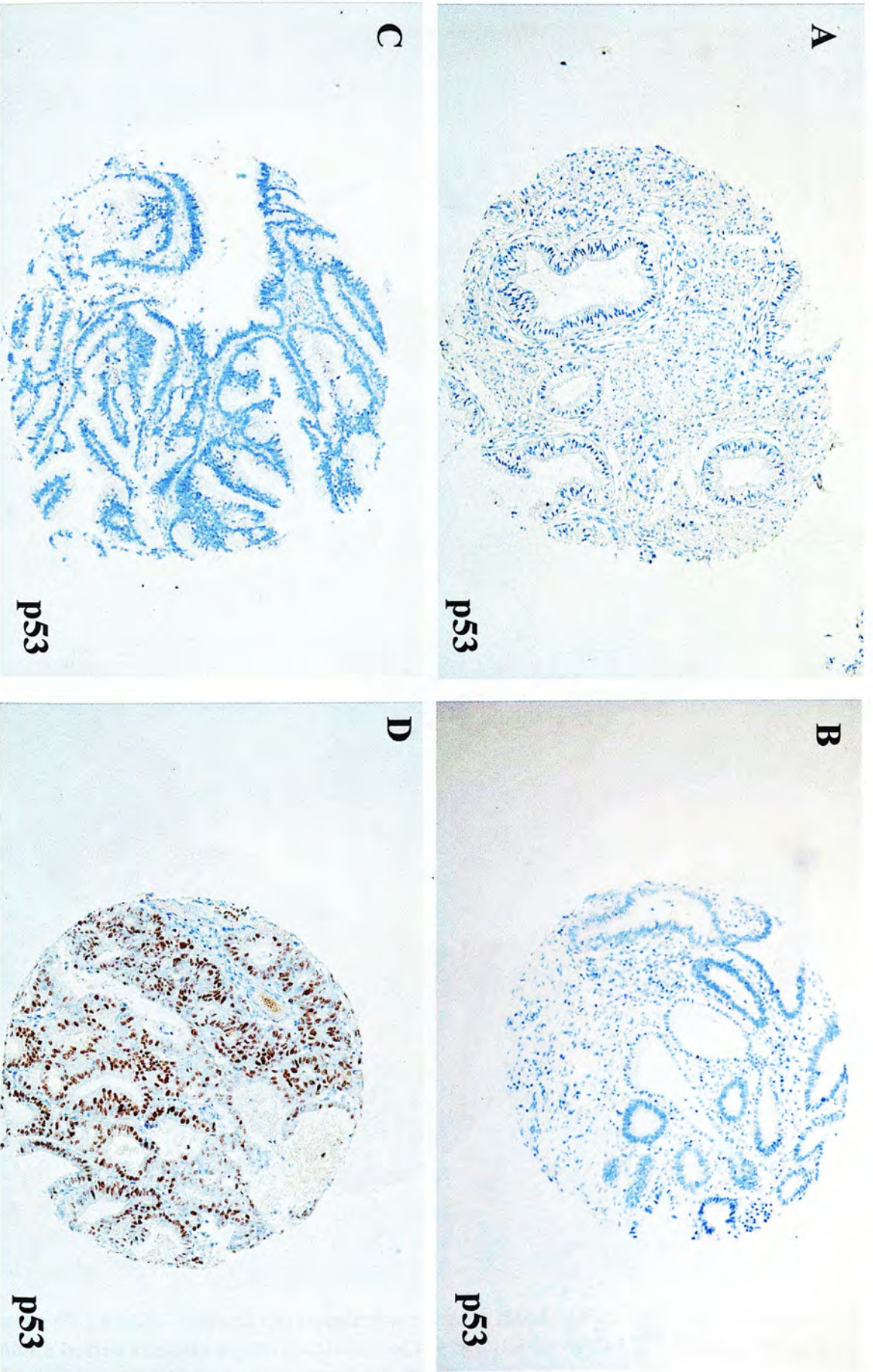


Figure 39 Four p53-stained tissue-microarray cores biopsies specimens. (A) Normal endocervical glands exhibit no staining (x100).(B) AIS exhibits no staining (x100).(C) Invasive adenocarcinoma exhibits no staining (x100).(D) Invasive adenocarcinoma exhibits strong positive nuclear staining (x100).

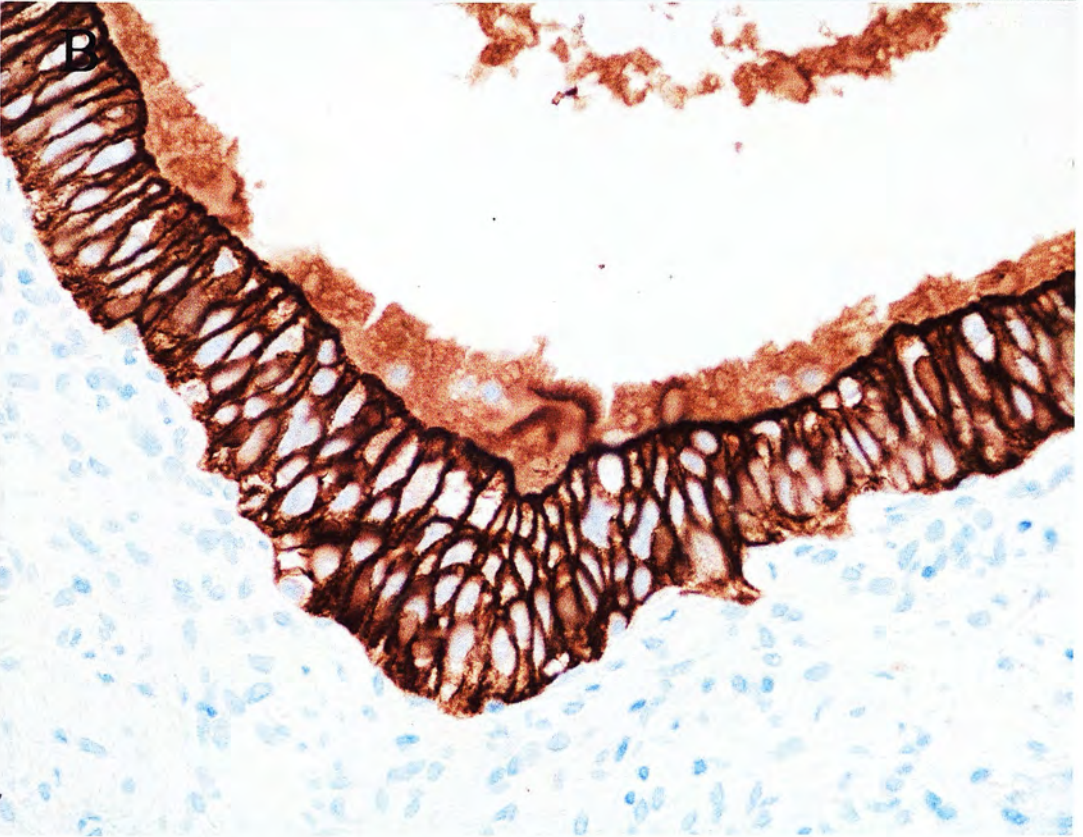


Figure 40 (A) CK7-stained tissue-microarray core biopsy specimen from adenocarcinoma in situ exhibits positive staining of the cytoplasm with CK7 (H&E,x100).(B) A higher power of the above core (H&E, x400).

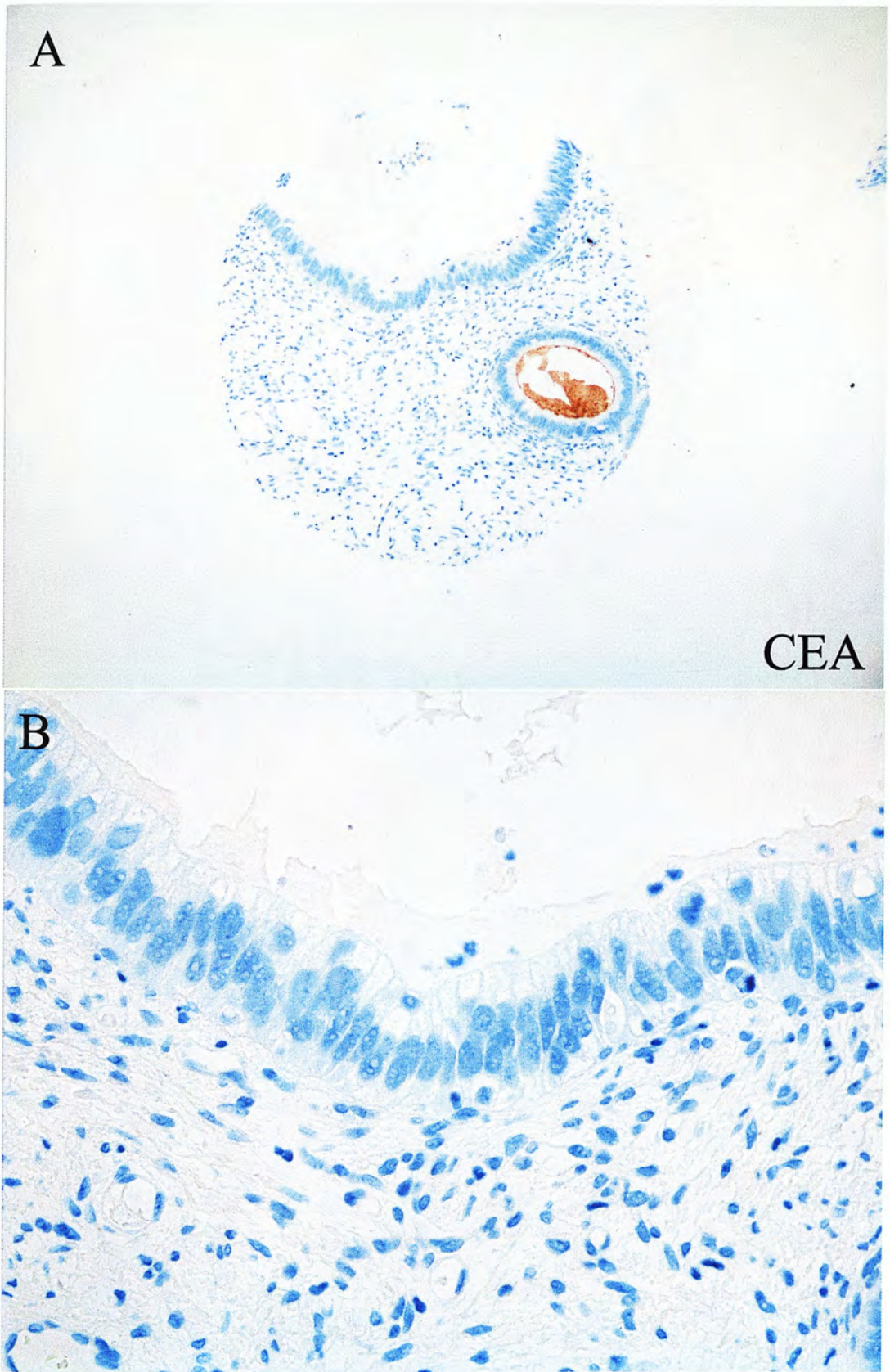


Figure 41 (A) CEA-stained tissue-microarray core biopsy specimen from adenocarcinoma in situ exhibits no cytoplasmic staining with CEA (H&E, x100).(B) A higher power of the above core (H&E, x400).

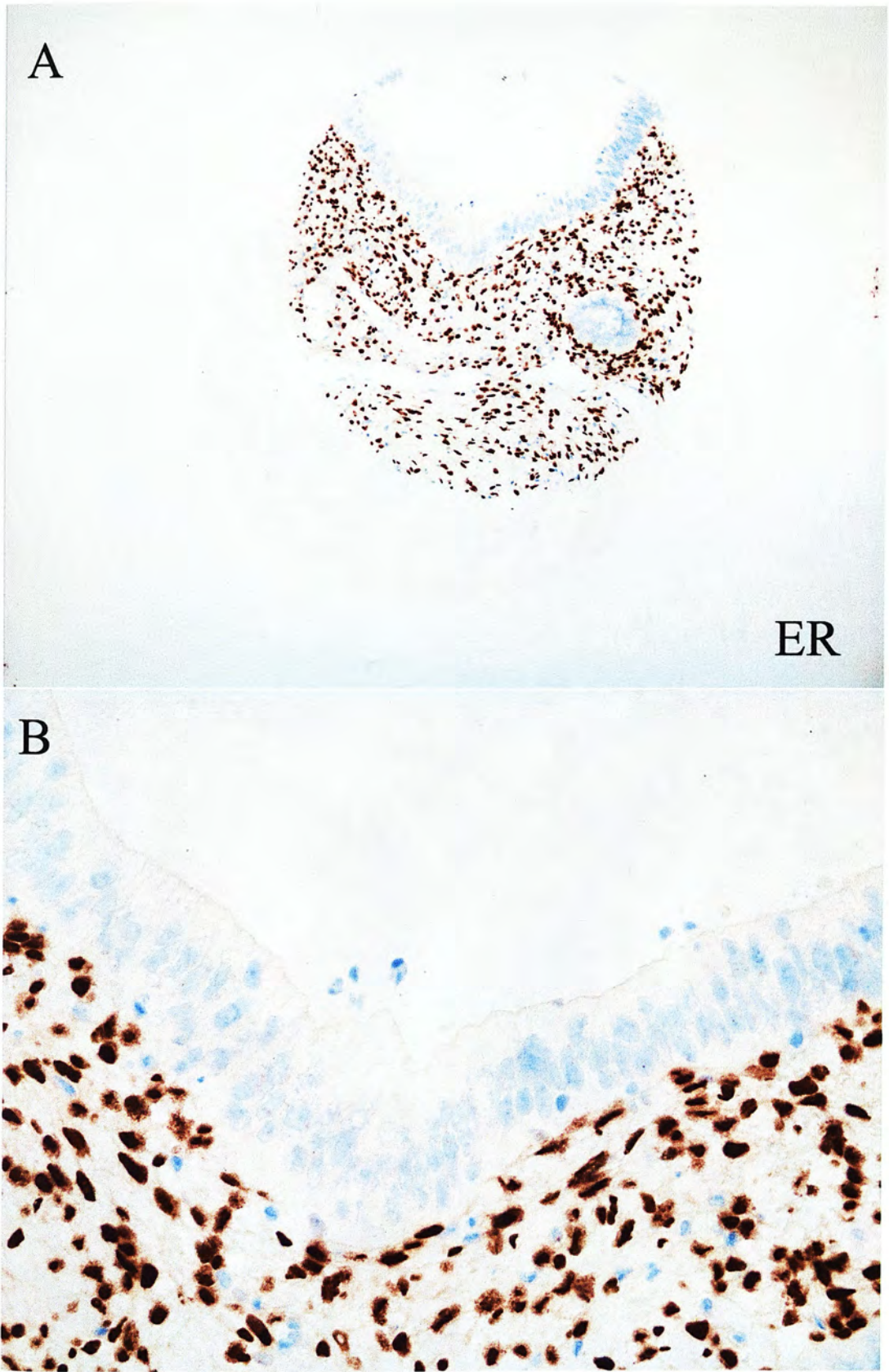


Figure 42 (A) ER-stained tissue-microarray core biopsy specimen from adenocarcinoma in situ exhibits no nuclear staining with ER (H&E, x100).(B) A higher power of the above core (H&E, x400).

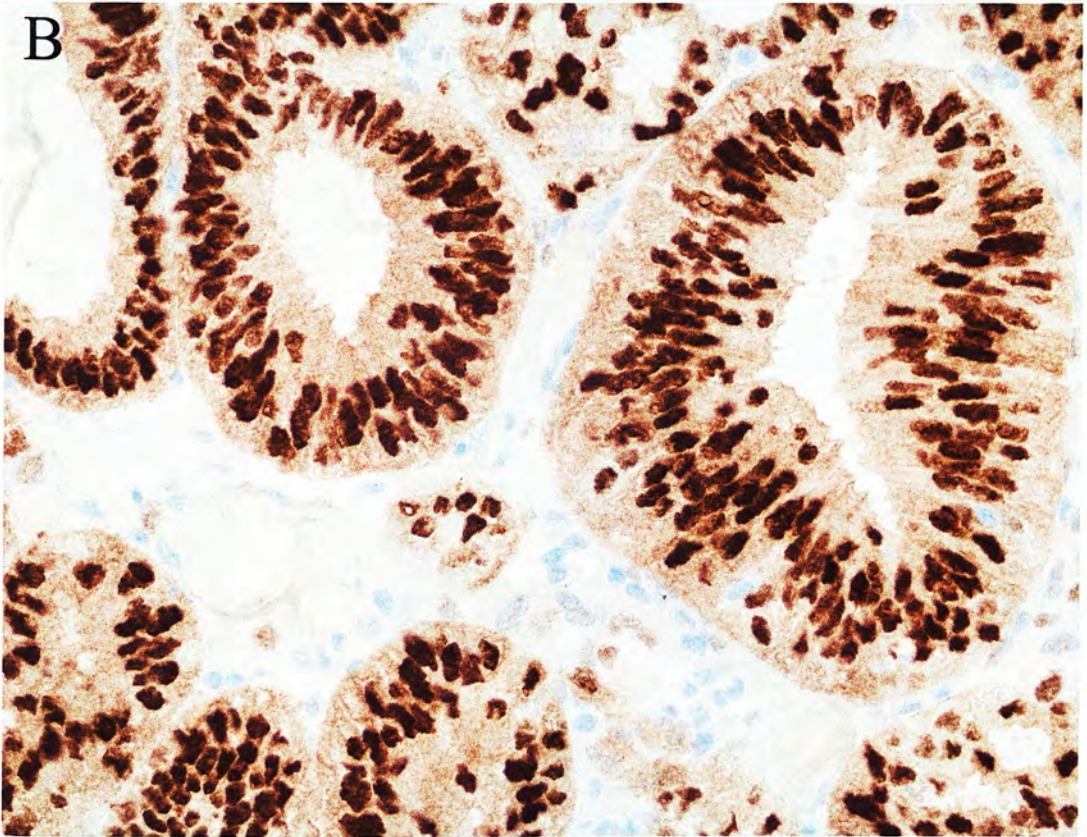
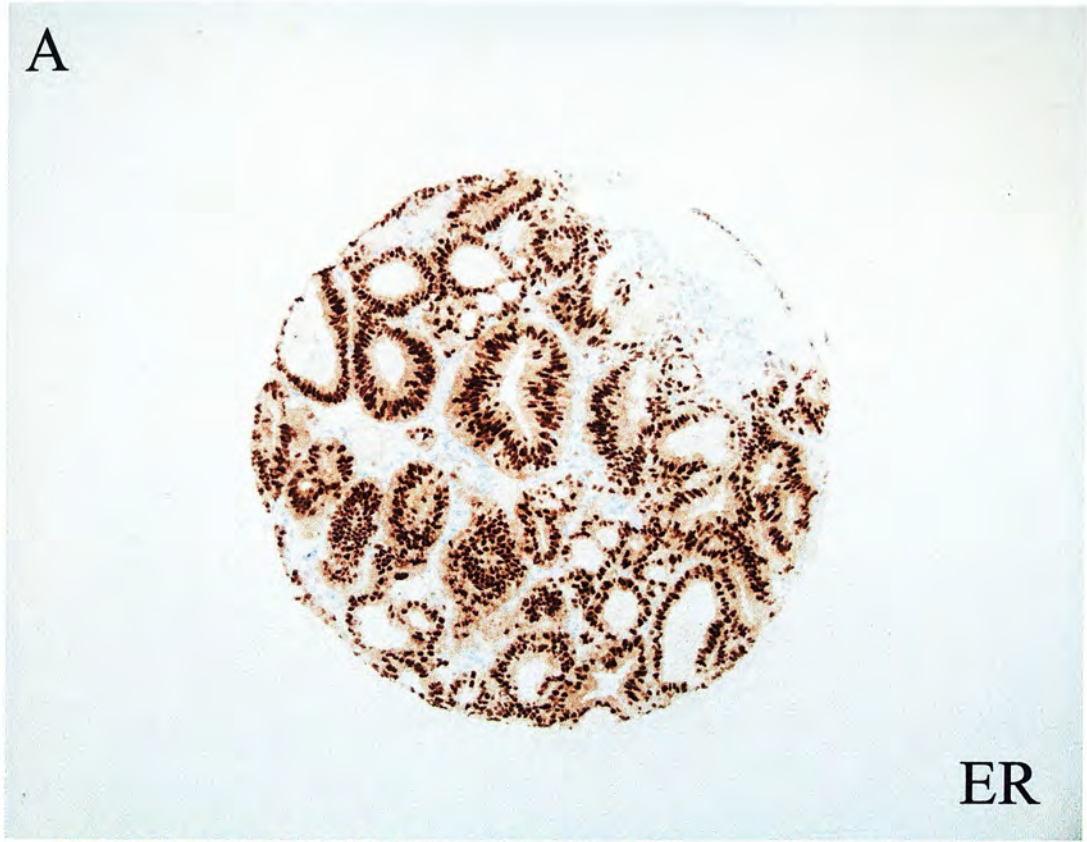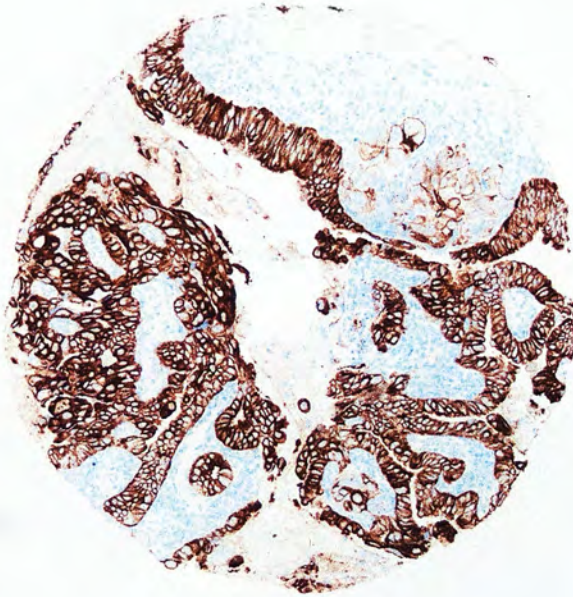


Figure 43 (A) ER-stained tissue-microarray core biopsy specimen from endocervical adenocarcinoma, usual type, exhibits positive nuclear staining with ER (H&E, x100). (B) A higher power of the above core (H&E, x400). Note stromal cells are positive.

A



CK7

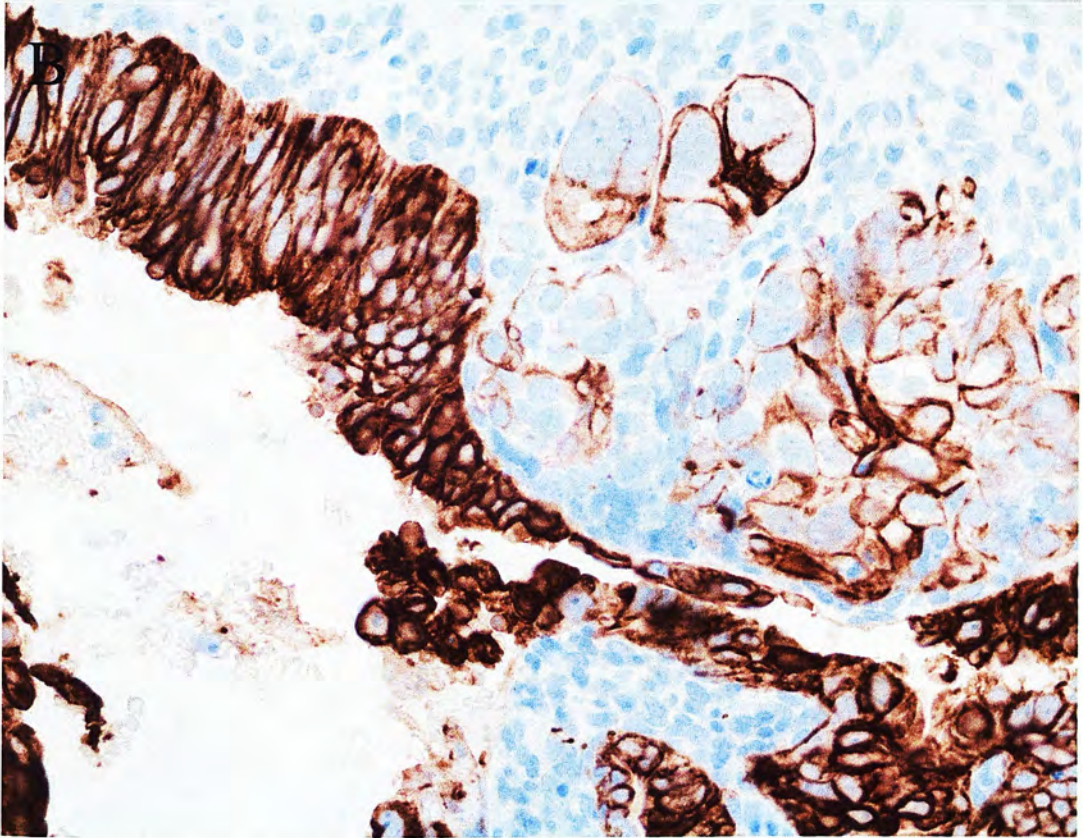


Figure 44 (A) CK7-stained tissue-microarray core biopsy specimen from poorly differentiated adenosquamous carcinoma exhibits positive staining of the cytoplasm with CK7 (H&E, x100).(B) A higher power of the above core (H&E, x400).

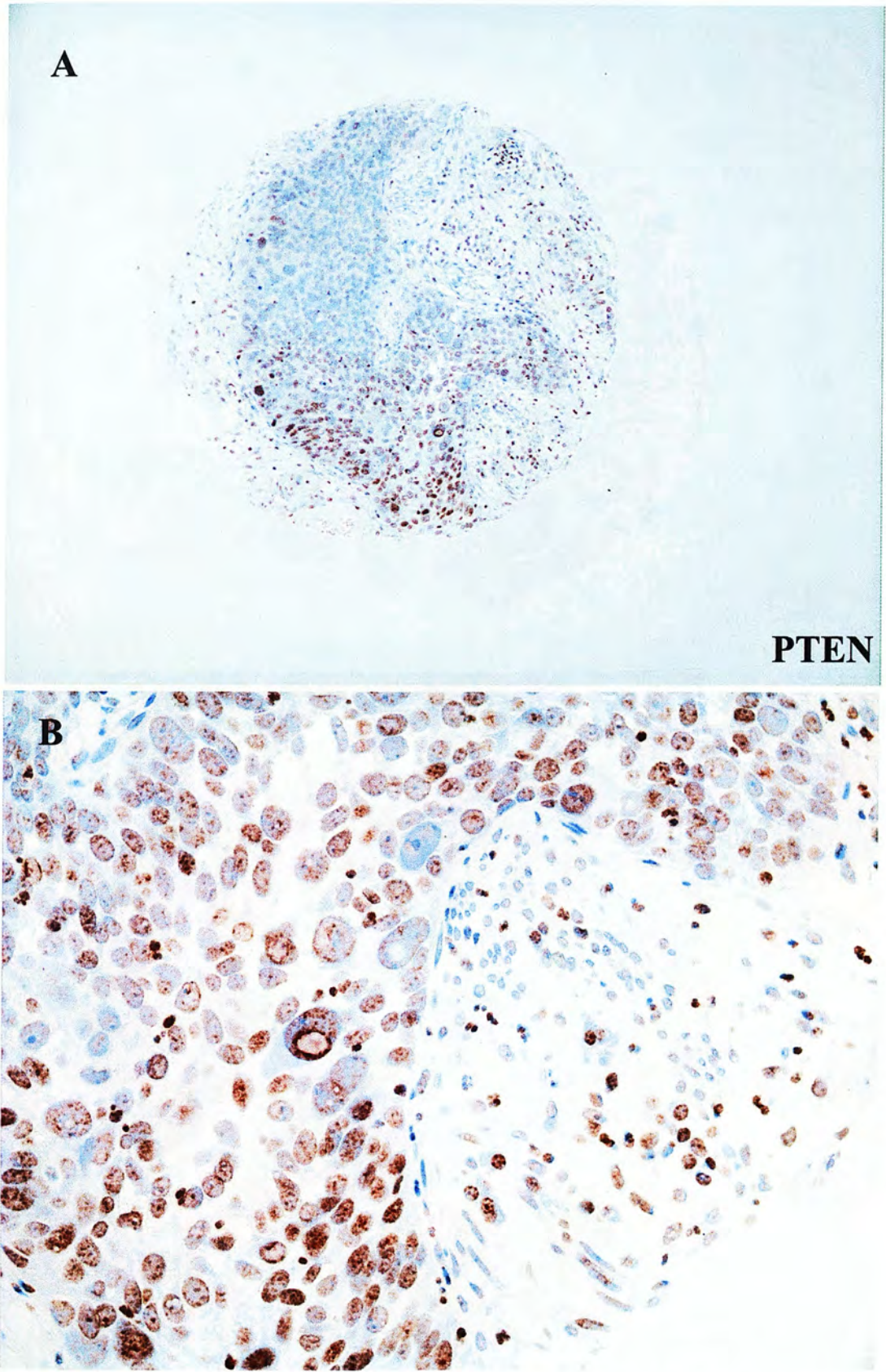
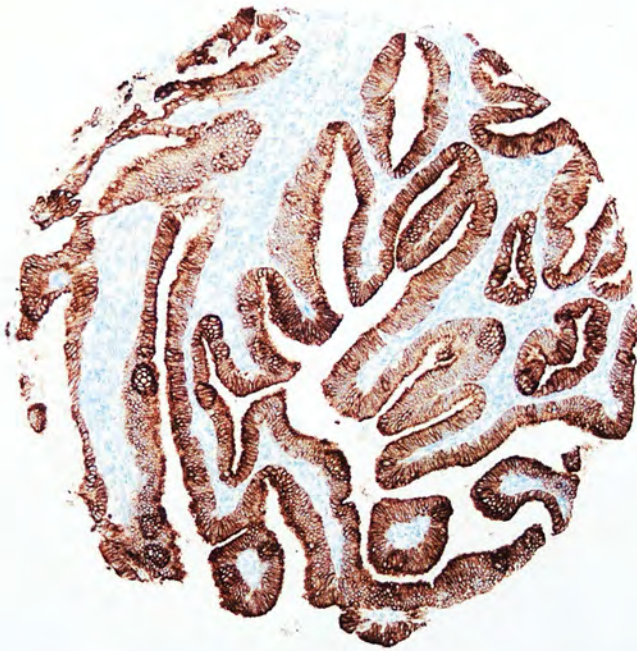


Figure 45 (A) PTEN-stained tissue-microarray core biopsy specimen from poorly differentiated adenosquamous carcinoma exhibits positive nuclear staining with PTEN (H&E, x100).(B) A higher power of the above core (H&E, x400).

A



CK7

B

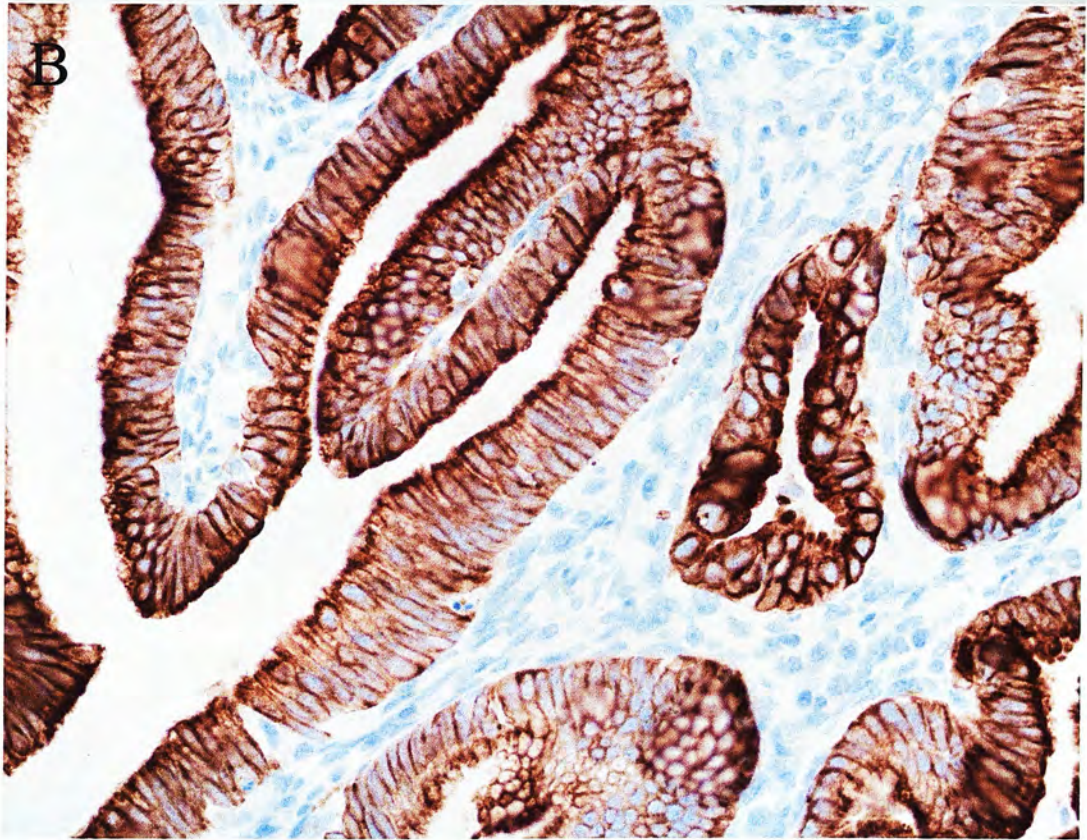


Figure 46 (A) CK7-stained tissue-microarray core biopsy specimen from well differentiated villoglandular papillary adenocarcinoma (VGC) exhibits positive staining of the cytoplasm with CK7 (H&E, x100). (B) A higher power of the above core (H&E, x400).

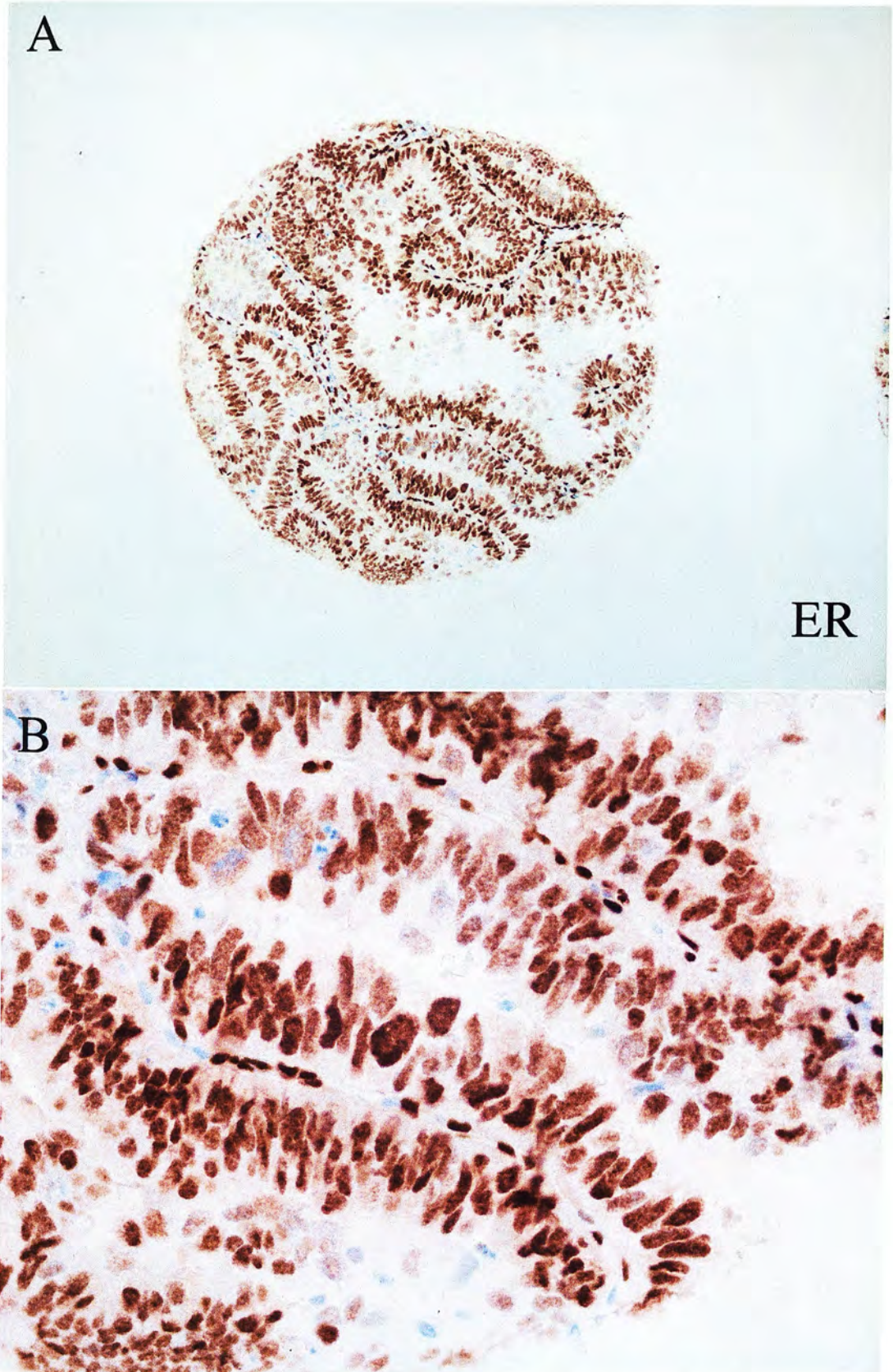


Figure 47 (A) ER-stained tissue-microarray core biopsy specimen from well differentiated villoglandular papillary adenocarcinoma (VGC) exhibits positive nuclear staining with ER (H&E, x100).(B) A higher power of the above core (H&E, x400).

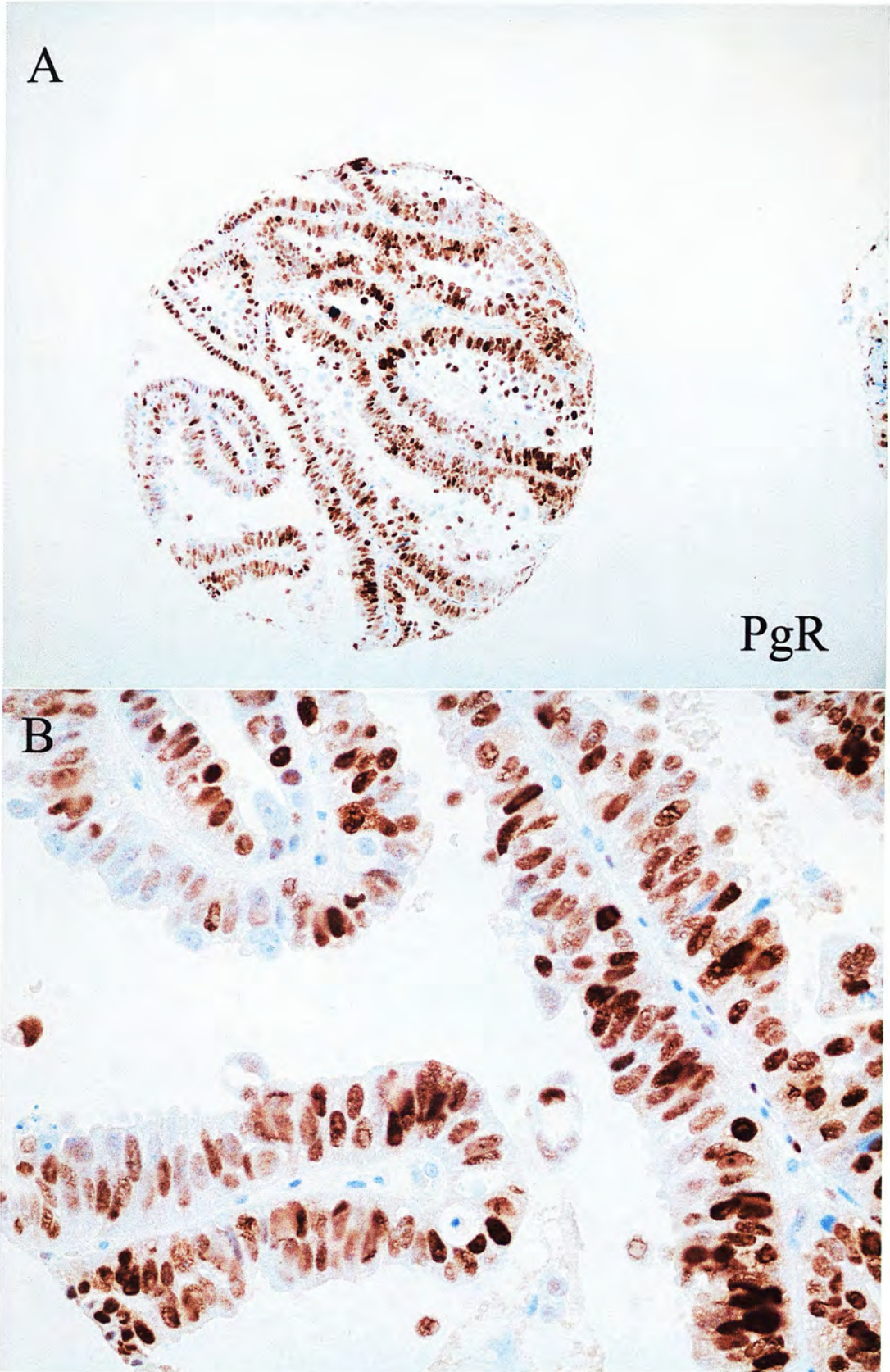


Figure 48 (A) PgR-stained tissue-microarray core biopsy specimen from well differentiated villoglandular papillary adenocarcinoma (VGC) exhibits positive nuclear staining with PgR (H&E, x100).(B) A higher power of the above core (H&E, x400).

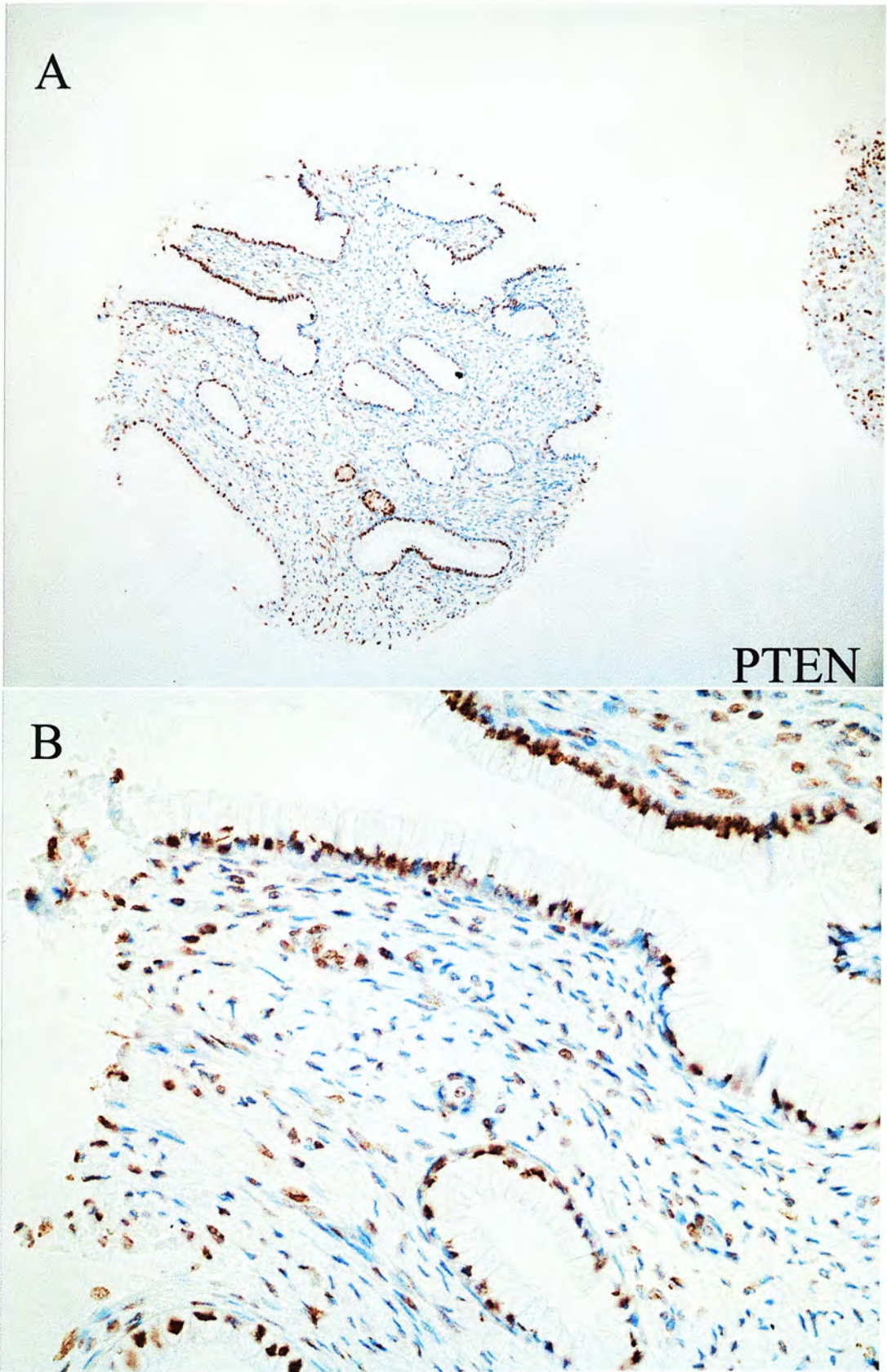


Figure 49 (A) PTEN-stained tissue-microarray core biopsy specimen from well differentiated minimal deviation endocervical adenocarcinoma (MDA) exhibits positive nuclear staining with PTEN (H&E, x100).(B) A higher power of the above core (H&E, x400).

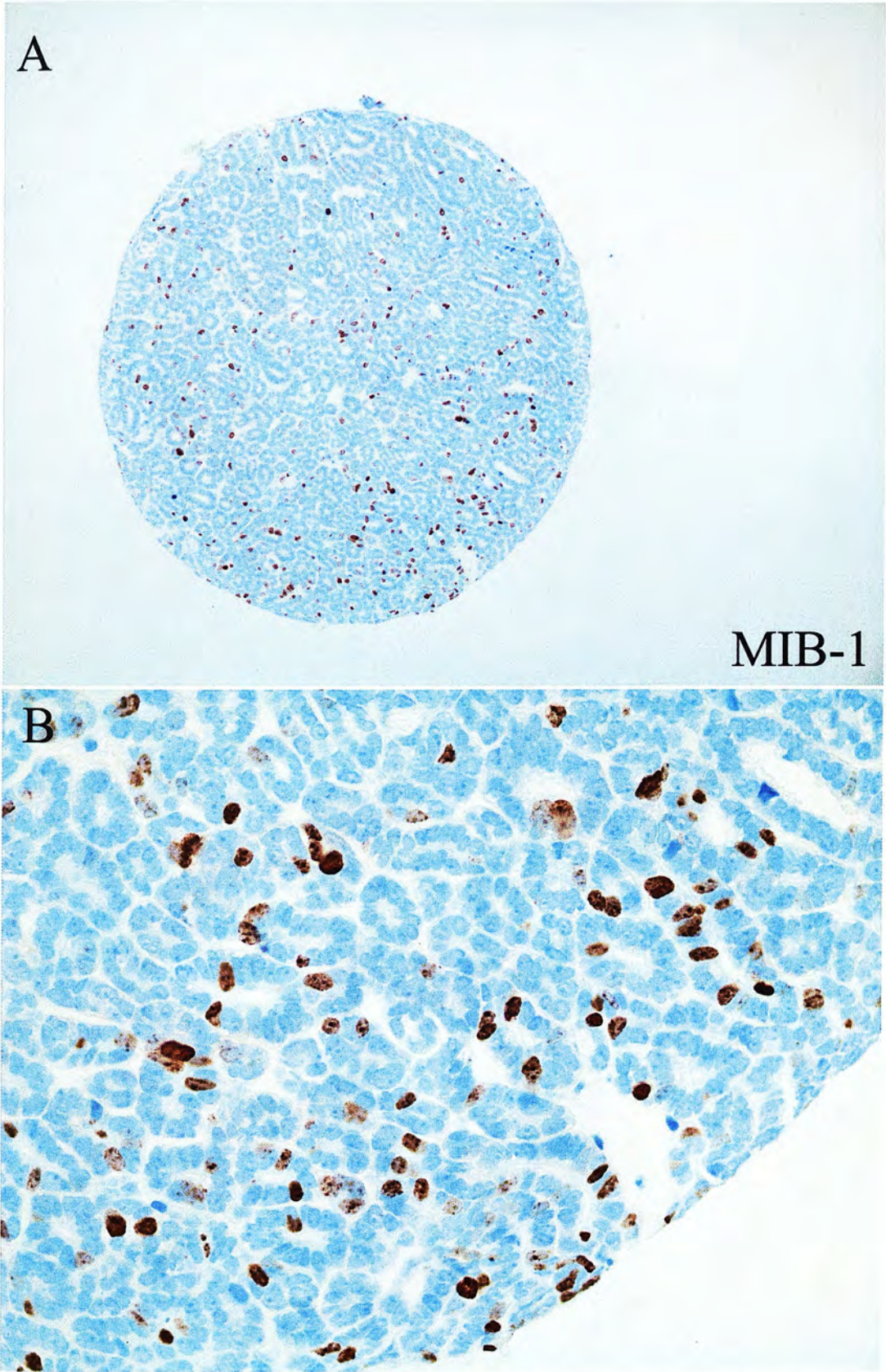


Figure 50 (A) MIB-1-stained tissue-microarray core biopsy specimen from endocervical adenocarcinoma, Microglandular carcinoma, exhibits positive nuclear staining with MIB-1 (H&E, x100).(B) A higher power of the above core (H&E, x400).

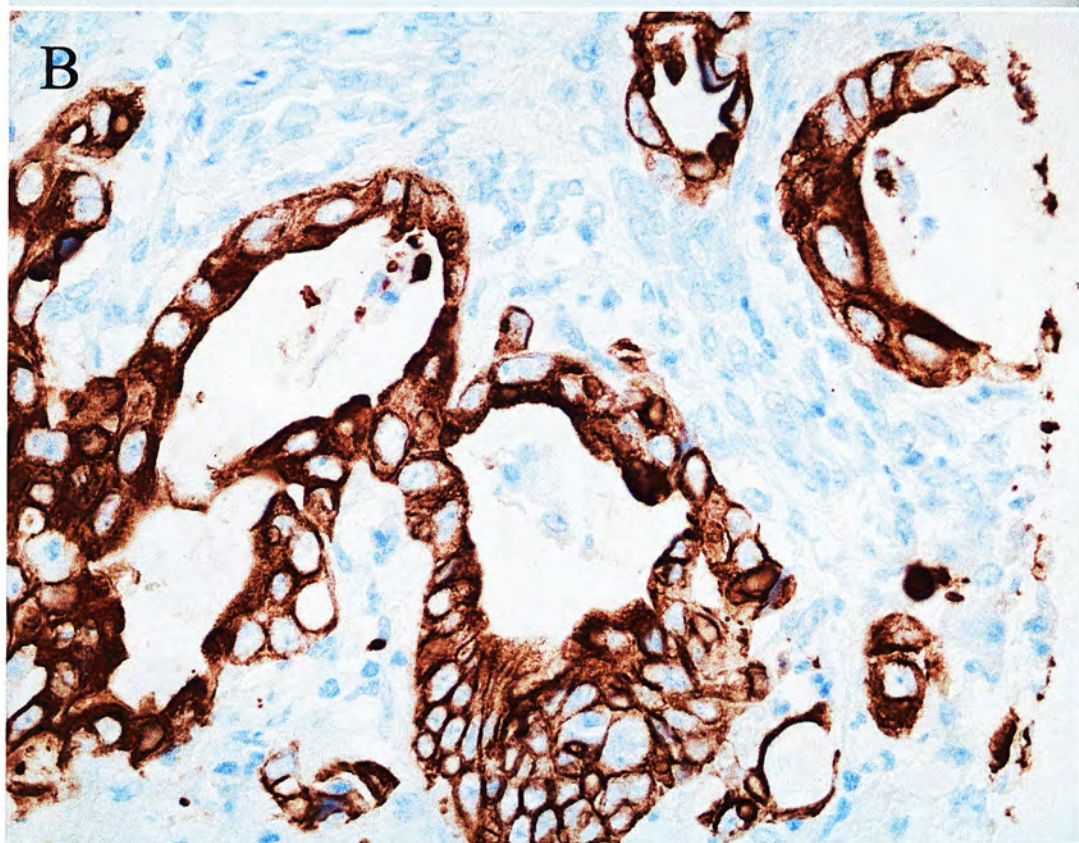
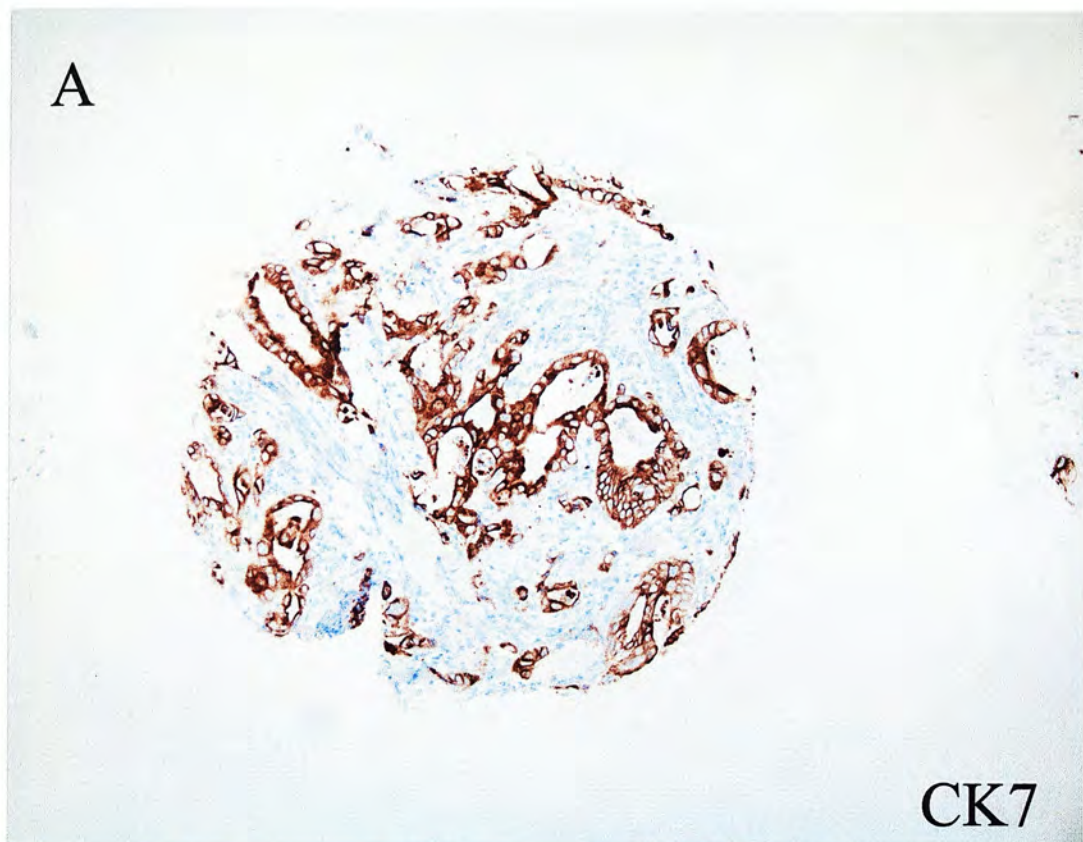


Figure 51 (A) CK7-stained tissue-microarray core biopsy specimen from poorly differentiated clear cell carcinoma exhibits positive staining of the cytoplasm with CK7 (H&E, x100).(B) A higher power of the above core (H&E, x400).

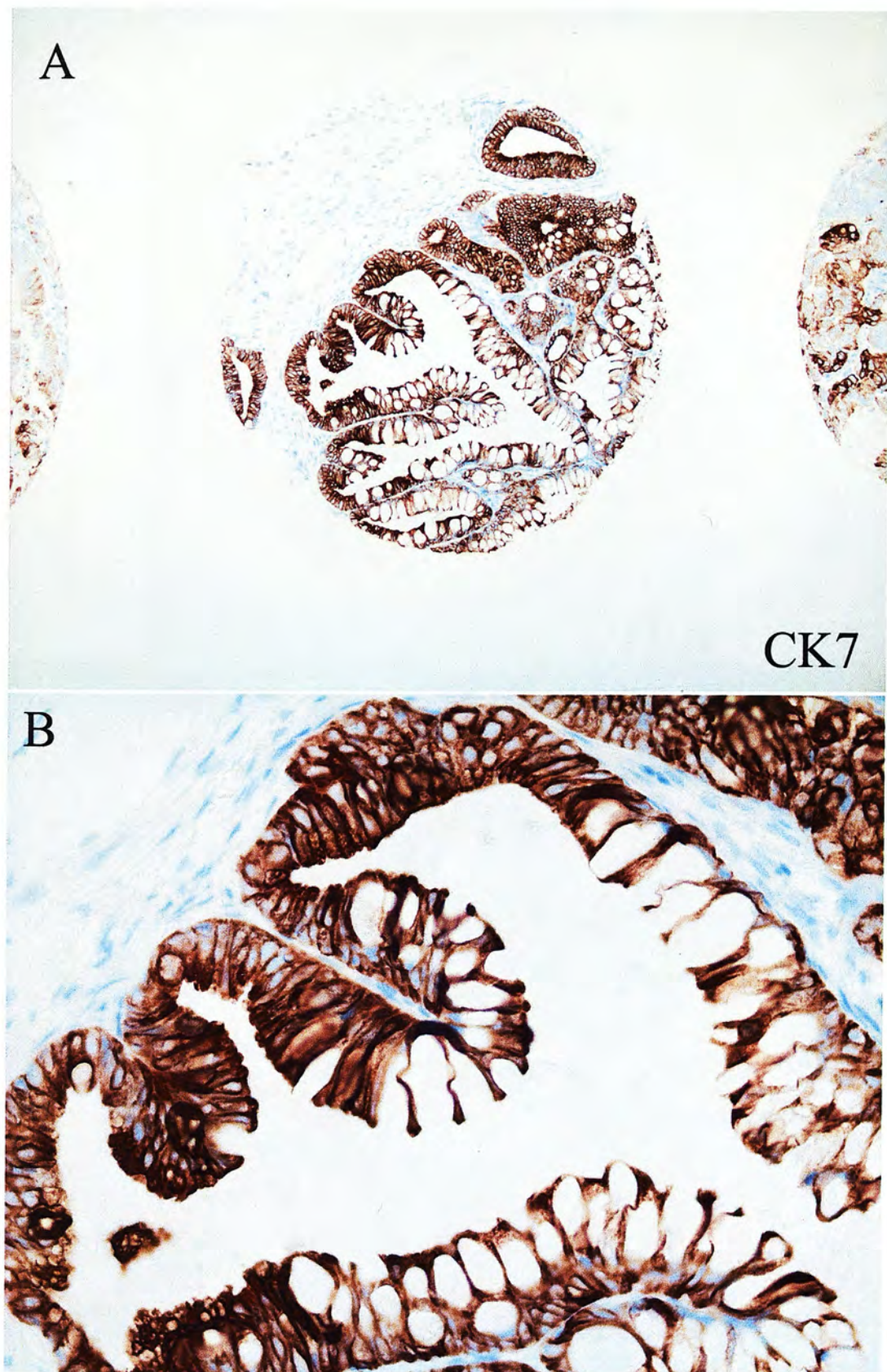


Figure 52 (A) CK7-stained tissue-microarray core biopsy specimen from endocervical adenocarcinoma, intestinal type , exhibits positive staining of the cytoplasm with CK7 (H&E, x100).(B) A higher power of the above core (H&E, x400).

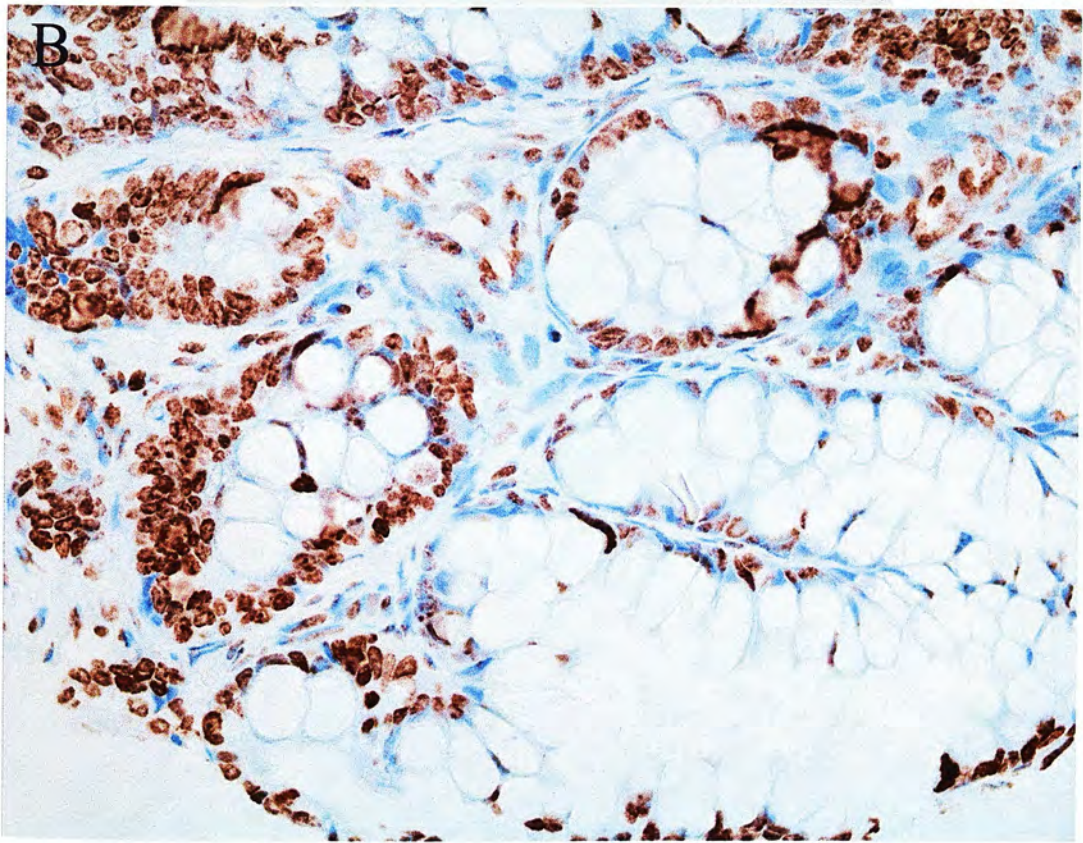
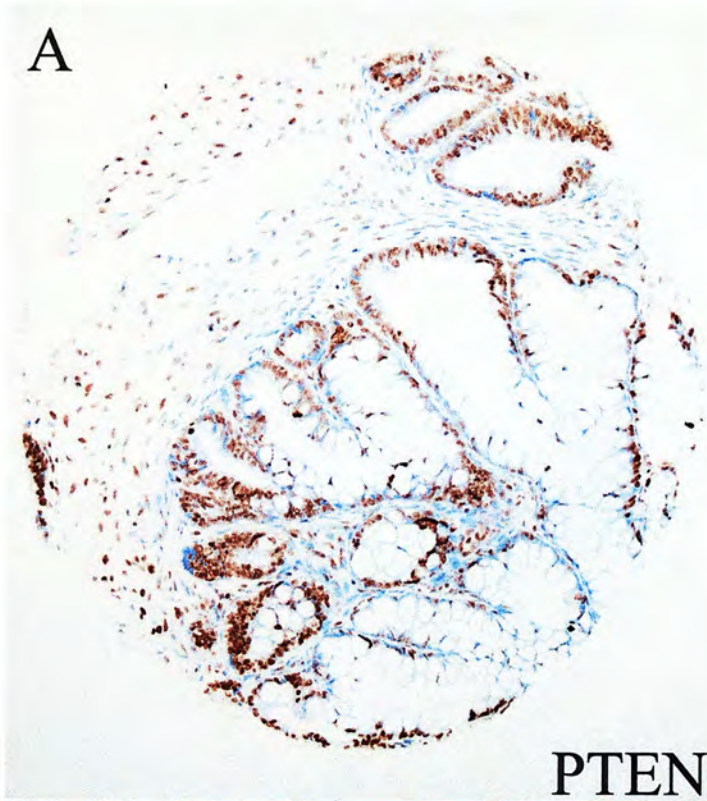


Figure 53 (A) PTEN-stained tissue-microarray core biopsy specimen from endocervical adenocarcinoma , intestinal type , exhibits positive nuclear staining with PTEN (H&E, x100).(B) A higher power of the above core (H&E, x400).

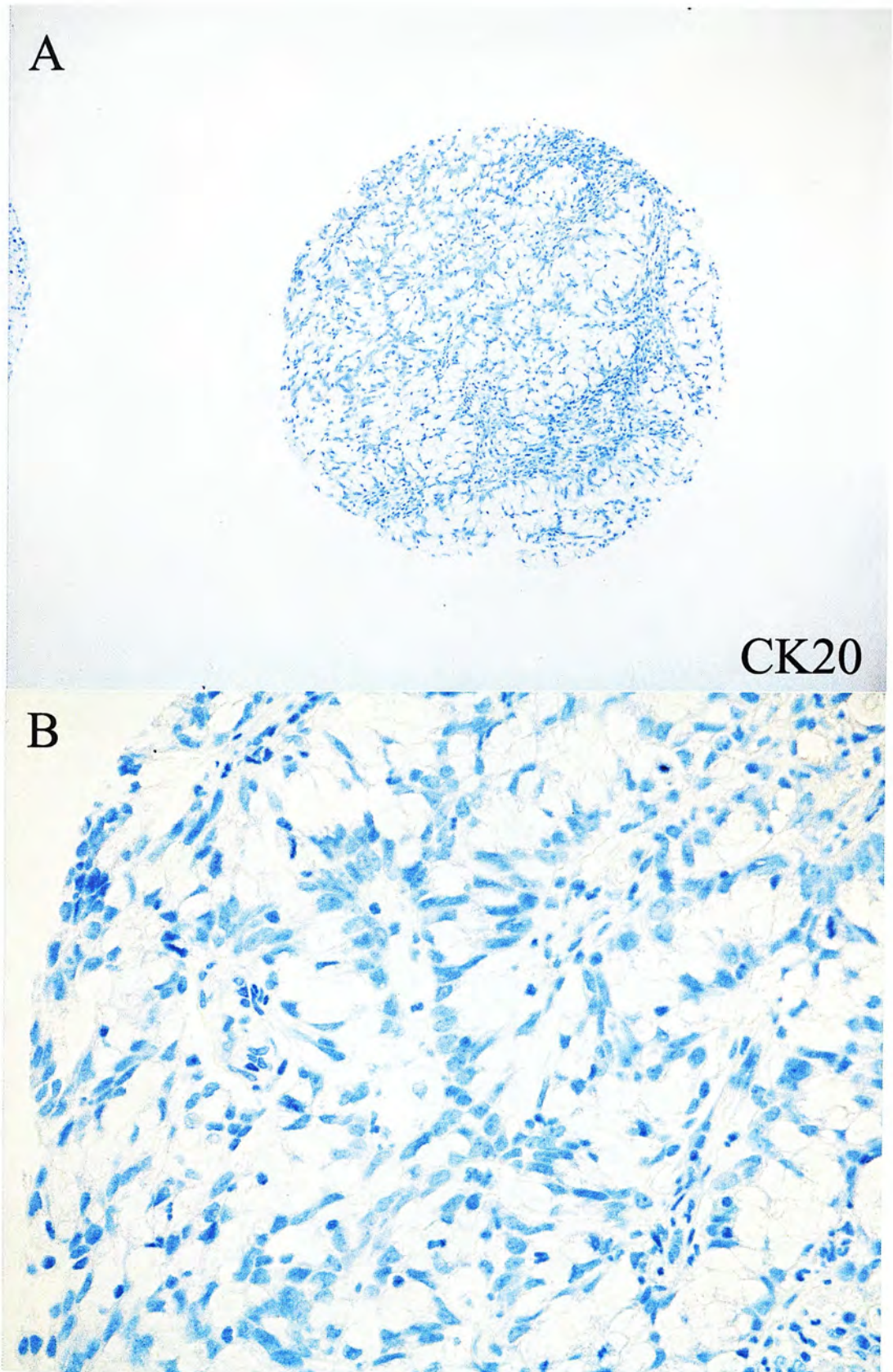


Figure 54 (A) CK20-stained tissue-microarray core biopsy specimen from poorly differentiated endocervical adenocarcinoma, signet-ring cell type, exhibits no cytoplasmic staining with CK20 (H&E, x100). (B) A higher power of the above core (H&E, x400).

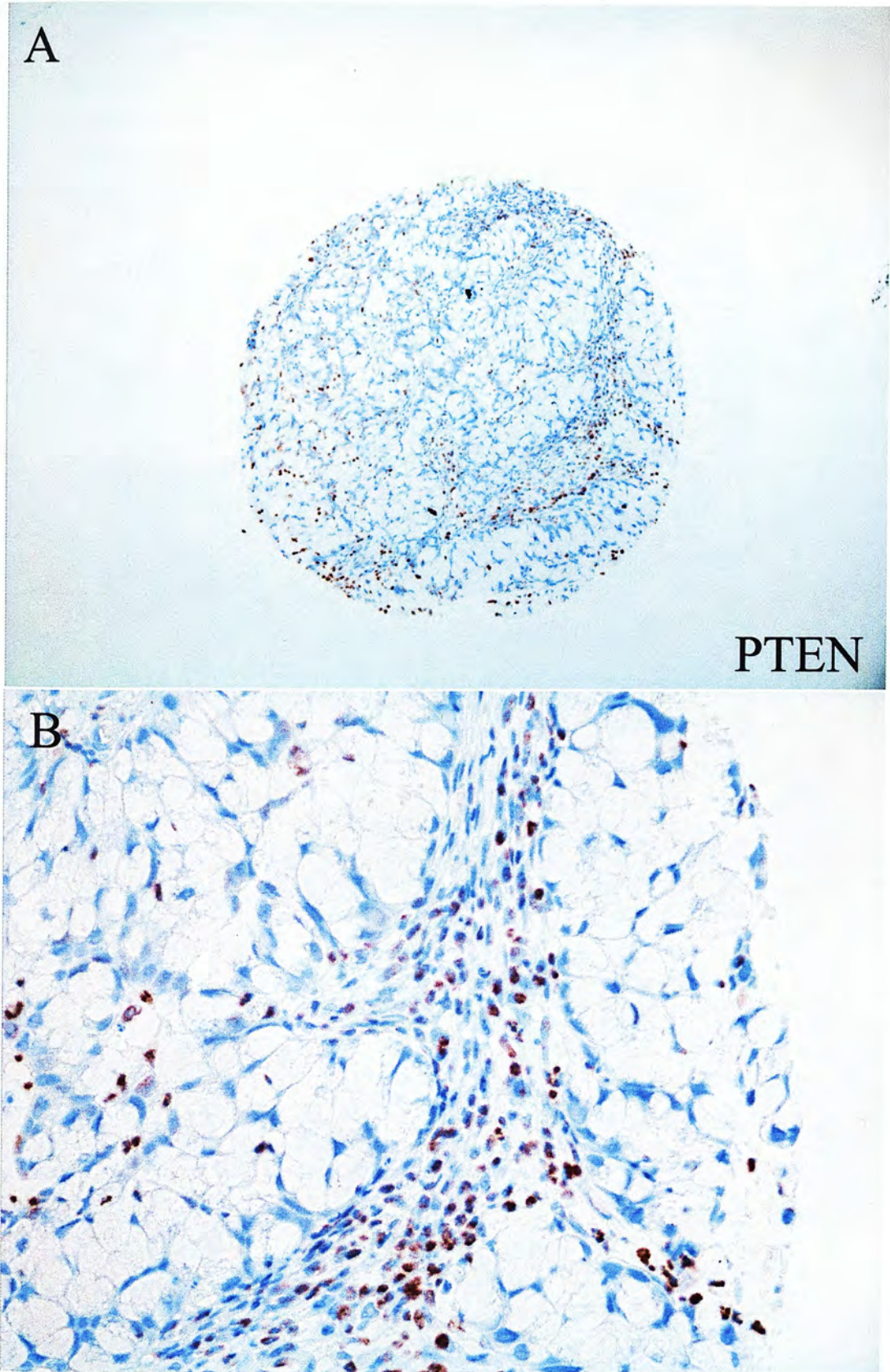


Figure 55 (A)PTEN-stained tissue-microarray core biopsy specimen from poorly differentiated endocervical adenocarcinoma , signet-ring cell type, exhibits no nuclear staining with PTEN (H&E, x100). (B) A higher power of the above core (H&E, x400). Note, stromal cells are positive.

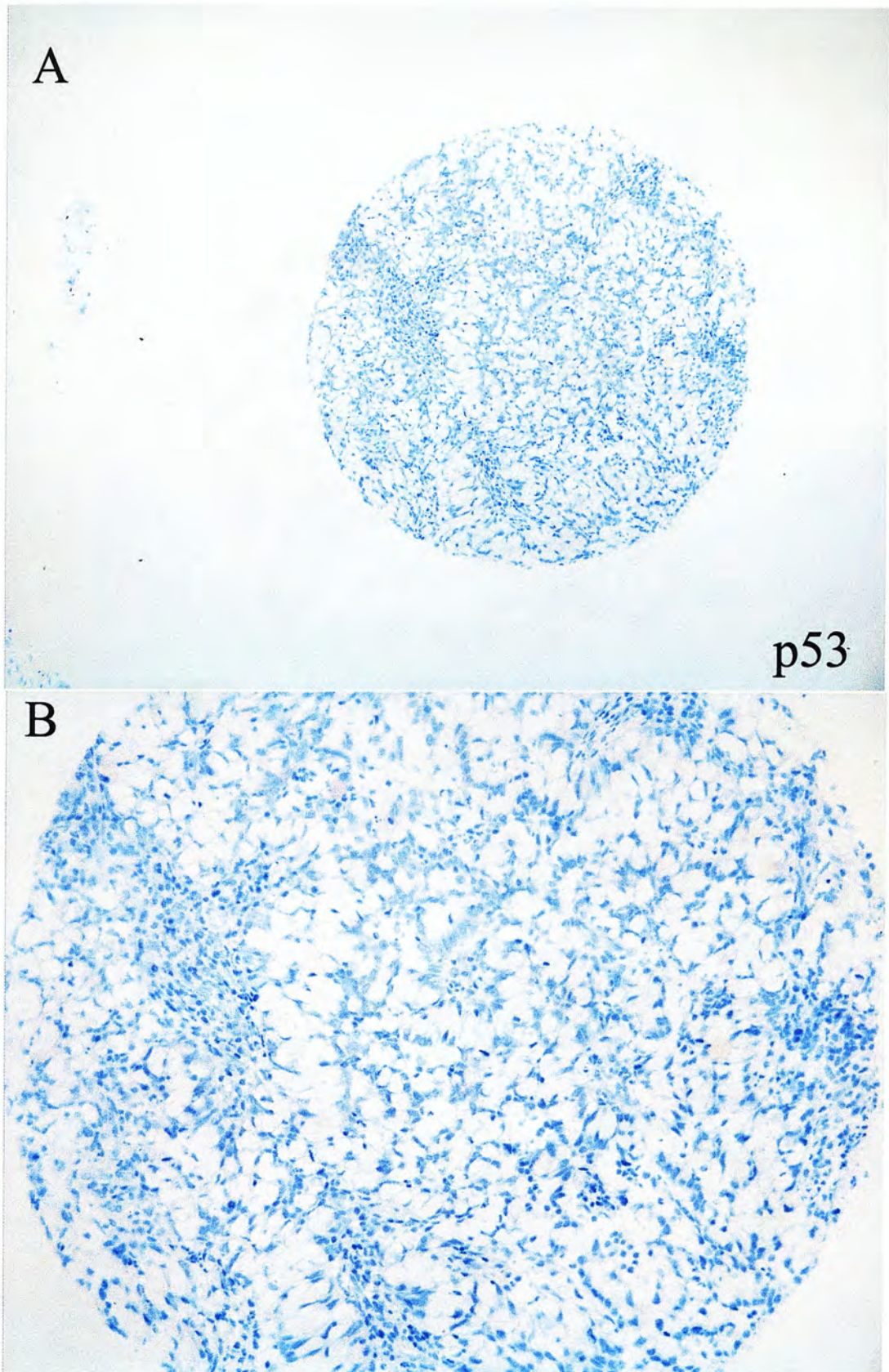
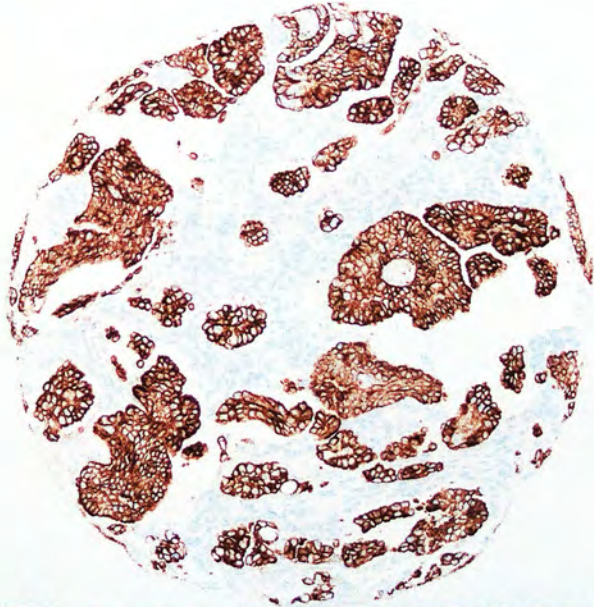


Figure 56 (A) p53-stained tissue-microarray core biopsy specimen from poorly differentiated endocervical adenocarcinoma, signet-ring cell type, exhibits no nuclear staining with p53 (H&E, x100).(B) A higher power of the above core (H&E, x200).

A



CK7

B

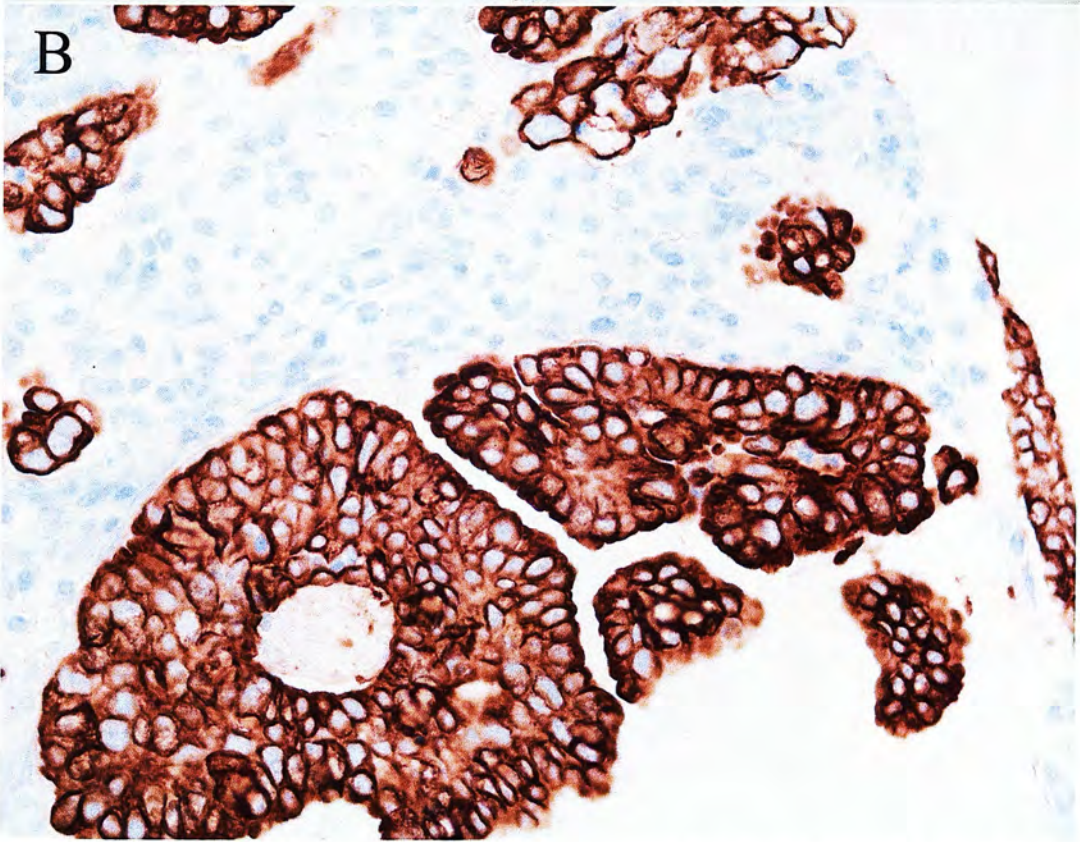


Figure 57 (A) CK7-stained tissue-microarray core biopsy specimen from adenoid basal carcinoma exhibits positive staining of the cytoplasm with CK7 (H&E, x100). (B) A higher power of the above core (H&E, x400).

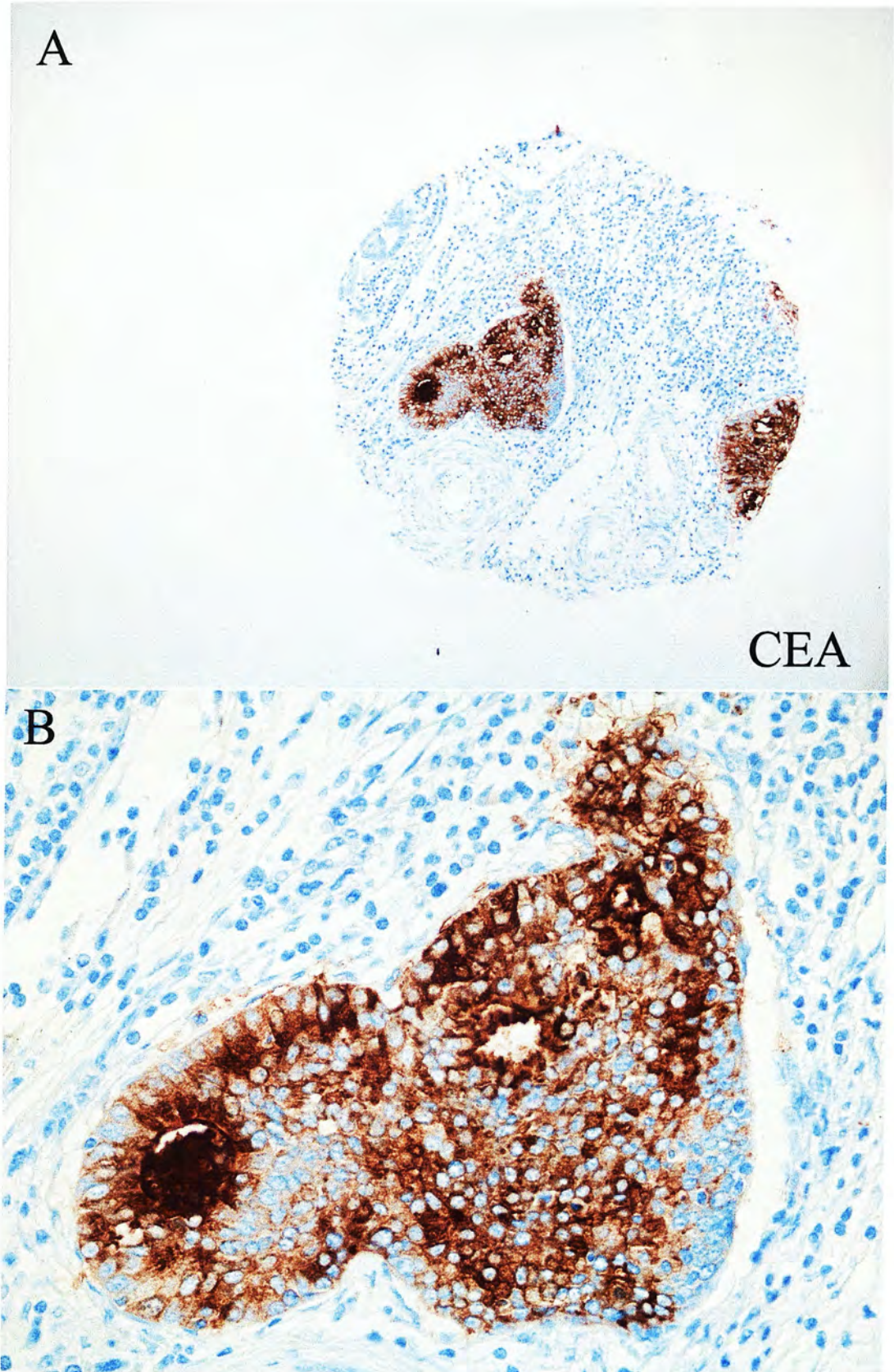


Figure 58 (A) CEA-stained tissue-microarray core biopsy specimen from adenoid basal carcinoma exhibits positive cytoplasmic staining with CEA (H&E, x100).(B) A higher power of the above core (H&E, x400).

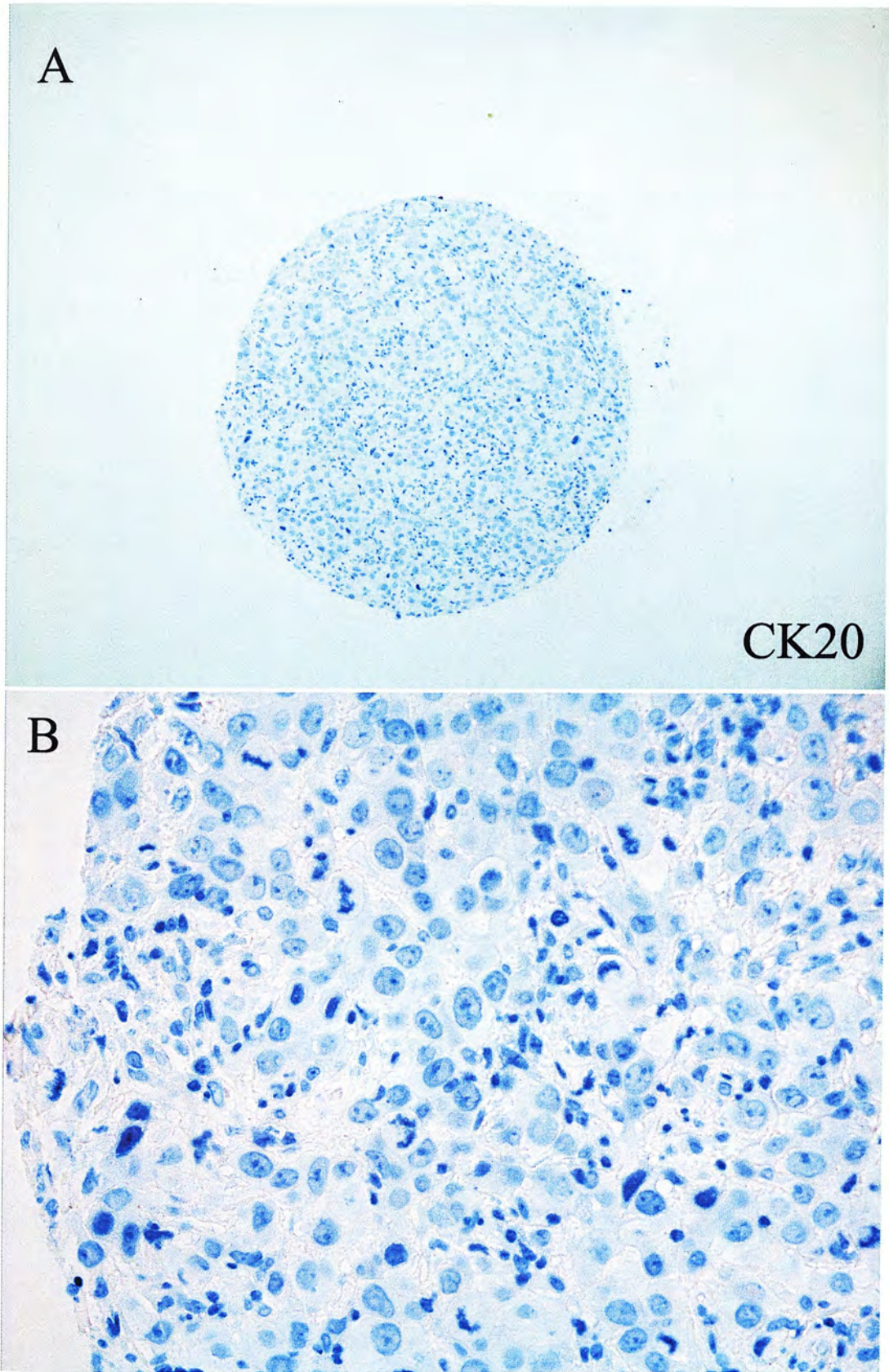


Figure 59 (A)CK20-stained tissue-microarray core biopsy specimen from poorly differentiated glassy cell carcinoma exhibits no cytoplasmic staining with CK20 (H&E, x100).(B) A higher power of the above core (H&E, x400).

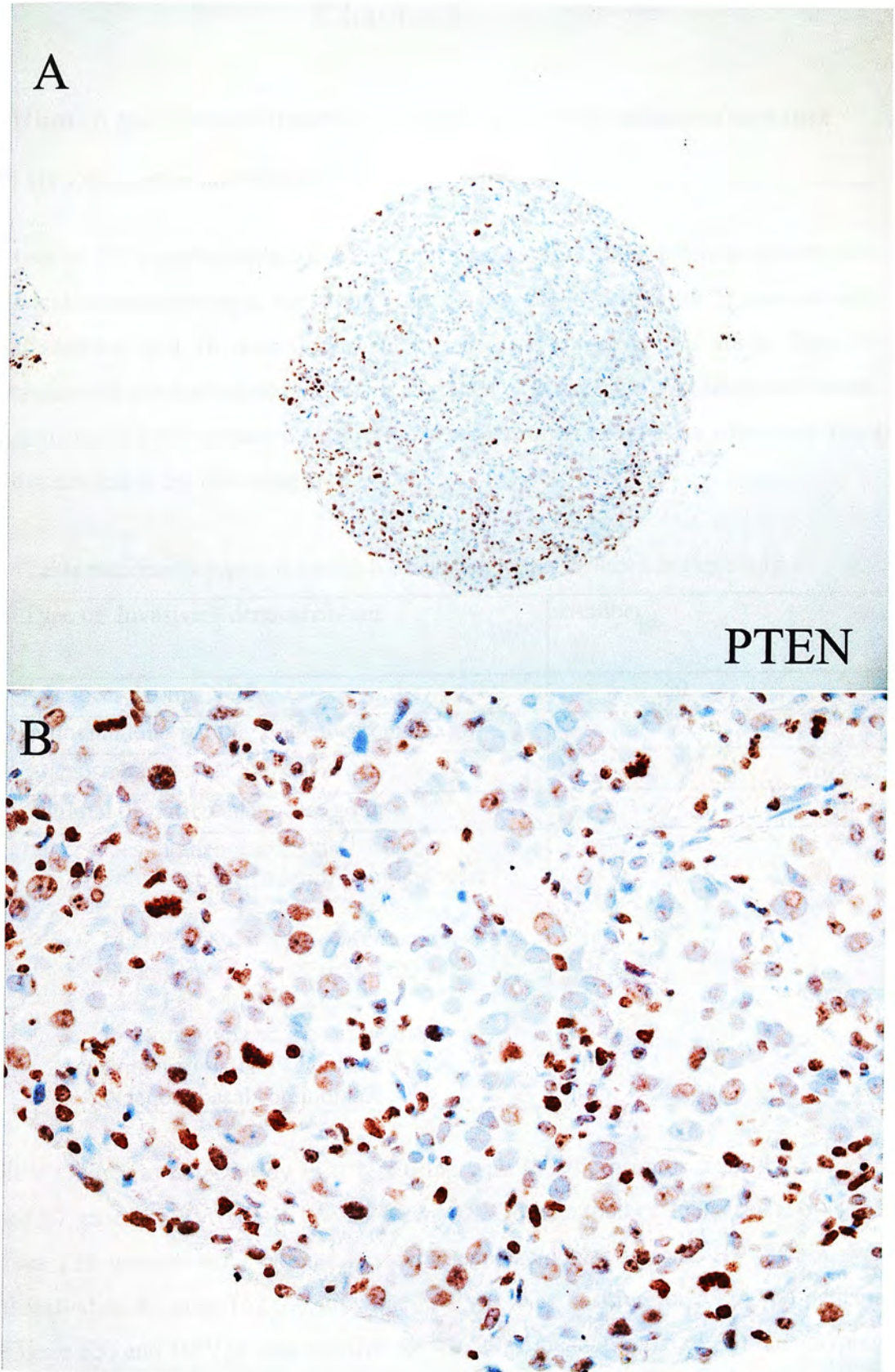


Figure 60 (A) PTEN-stained tissue-microarray core biopsy specimen from poorly differentiated glassy cell carcinoma exhibits positive nuclear staining with PTEN (H&E, x100).(B) A higher power of the above core (H&E, x400).

Chapter 3

Human papilloma viruses 16 and 18 in cervical adenocarcinoma

3.1 HPV Detection and Typing

A total of 257 paraffin-embedded, formalin-fixed tissues of 139 different patients with cervical adenocarcinomas, excluding results from second sample for 22 patients with two samples, and 16 normal cervical biopsies were used in this study. The 139 patients with cervical adenocarcinomas consisted of 20 patients with adenocarcinoma-in-situ and 119 with invasive adenocarcinoma. The types of invasive adenocarcinoma are presented in the following table.

Table summaries types of invasive adenocarcinoma included in this study

Type of Invasive Adenocarcinoma	Number
Adenocarcinoma NOS,	50
Villoglandular papillary adenocarcinoma,	23
Adenosquamous carcinoma,	22
Minimal deviation adenocarcinoma	8
Other types of adenocarcinoma. The other types of adenocarcinoma were;	16
• Microglandular adenocarcinoma,	5
• Endometrioid adenocarcinoma,	4
• Clear cell carcinoma	3
• Intestinal type adenocarcinoma	2
• Signet-ring cell adenocarcinoma	1
• Adenoid basal carcinoma.	1

HPV DNA was detected by PCR test using type specific primers from the *E6* gene and *E7* gene of HPV type 16 and HPV type 18. Out of a total of 257 cervical biopsies from 139 women with various cervical adenocarcinomas lesions, HPV DNA was identified in 87 cases (62.6%) in which, HPV16 was positive for 65 (47%) patients (Figure 63) and HPV18 was positive for 41 (29%) patients (Figure 64). Genotyping by RFLP and PCR revealed that, HPV type 16 was the most frequent type of infection comprising 46 cases (33%), followed by HPV type 18 in 22 cases (16%), and HPV type 16 and HPV type 18 in 19 cases (14%). There were 52 (38%) of 139 of patients

with various cervical adenocarcinomas lesions with HPV type16 and HPV type 18 both negative. HPV typing in all cases of 16 normal cervical biopsies revealed negative with both HPV type16 and HPV type 18.

After reviewing and comparing the HPV infection results of the first sample with that of the second sample of the same patient, we found that, for the 22 patients with two samples, there was no significant difference between the two samples with respect to HPV infection. There were therefore excluded from further analysis.

Regarding results of LCM method from the most presentable area of the whole tissue tumour section, sampling for 87 patients with positive HPV in their paraffin embedded blocks, HPV type 16 was the most frequent type of infection comprising 21 cases, followed by HPV type16 and HPV type 18 in 3 cases. HPV type 18 in 1 case. There were 62 patients from 87 with HPV type16 and HPV type 18 both negative (Fig. 61& 62).

3.2 Adenocarcinoma in situ

In the 20 *in situ* adenocarcinomas patients, there were 7/20 (35%) with HPV 16 only positive, 5/20 (25%) with HPV 18 only positive, 3/20 (15%) with both HPV 16 and HPV 18 positive, and the remaining 5/20 (25%) with both HPV 16 and HPV 18 negative. There was no significant difference between adenocarcinoma in situ and invasive adenocarcinoma with respect to HPV16 and HPV18 infection using Chi-square test ($p=0.53$) was presented in table 37 .

3.3 Invasive Adenocarcinoma

In the 119 invasive adenocarcinomas patients, there were 39/119(33%) with HPV 16 only positive, 17/119 (14%) with HPV 18 only positive, 16/119 (13%) with both HPV 16 and HPV 18 positive, and the remaining 47/119 (39%) with both HPV 16 and HPV 18 negative. The prevalence of HPV varied with different histological subtypes but there was no significant difference between all subtypes of invasive adenocarcinoma in comparison to each other and in comparison to AIS with respect to prevalence of HPV16 and HPV18 infection using Chi-square test ($p= 0.12$) was summarised in table 38.

3.4 Early invasive adenocarcinoma

In the 16 early invasive adenocarcinomas patients, there were 5/16 (31%) with HPV16 only positive, 3 (19%) with HPV18 only positive and 2/16 (13%) with HPV16 and HPV18 both positive, and 6/16 (38%) patients with HPV16 & HPV18 both negative. In general, early invasive adenocarcinomas patients revealed HPV16 was negative for 9 (56%) and positive for 7 (44%) patients, and HPV18 was negative for 11 (69%) and positive for 5 (31%) patients.

Table 37. HPV 16 and 18 infection in AIS and subtypes of invasive adenocarcinoma.

HPV16 and HPV18	Adenocarcinoma in situ		Invasive adenocarcinoma	
	N	%	N	%
HPV16 -ve and HPV18 -ve	5	25	47	39
HPV16 +ve and HPV18 -ve	7	35	39	33
HPV16 -ve and HPV18 +ve	5	25	17	14
HPV16 +ve and HPV18 +ve	3	15	16	13
Total	20	100	119	100

Table 37 showing no significant difference between adenocarcinoma in situ and invasive adenocarcinoma with respect to HPV16 and HPV18 infection using Chi-square test ($p=0.53$).

Table 38. HPV 16 and 18 infection in AIS and subtypes of invasive adenocarcinoma.

HPV16 and HPV18	Adenocarcinoma in situ		Adenocarcinoma NOS		Adenosquamous carcinoma		Villoglandular papillary adenocarcinoma		Minimal deviation adenocarcinoma		Other types of adenocarcinoma	
	N	%	N	%	N	%	N	%	N	%	N	%
HPV16 -ve and HPV18 -ve	5	25	20	40	6	27	6	26	4	50	11	69
HPV16 +ve and HPV18 -ve	7	35	16	32	10	45	7	30	1	13	5	31
HPV16 -ve and HPV18 +ve	5	25	9	18	3	14	5	22	0	0	0	0
HPV16 +ve and HPV18 +ve	3	15	5	10	3	14	5	22	3	38	0	0
Total	20	100	50	100	22	100	23	100	8	100	16	100

Table 38 showing no significant difference between all subtypes of invasive adenocarcinoma in comparison to AIS with respect to HPV16 and HPV18 using Chi-square test ($p=0.12$).

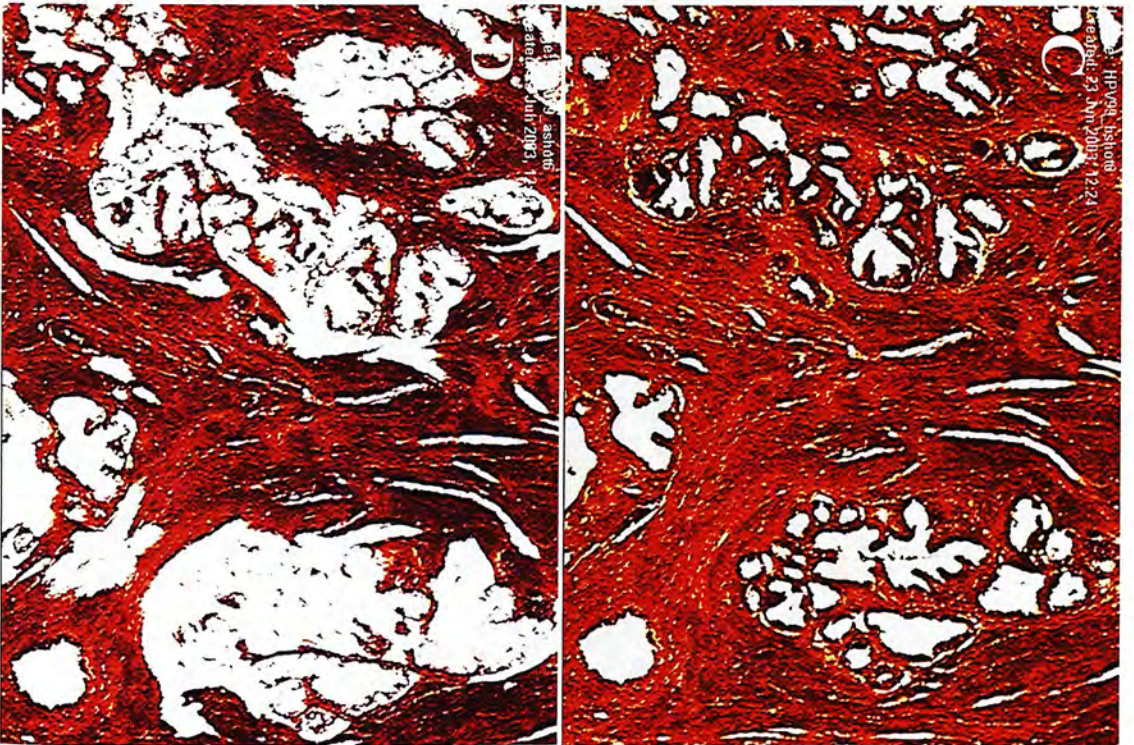
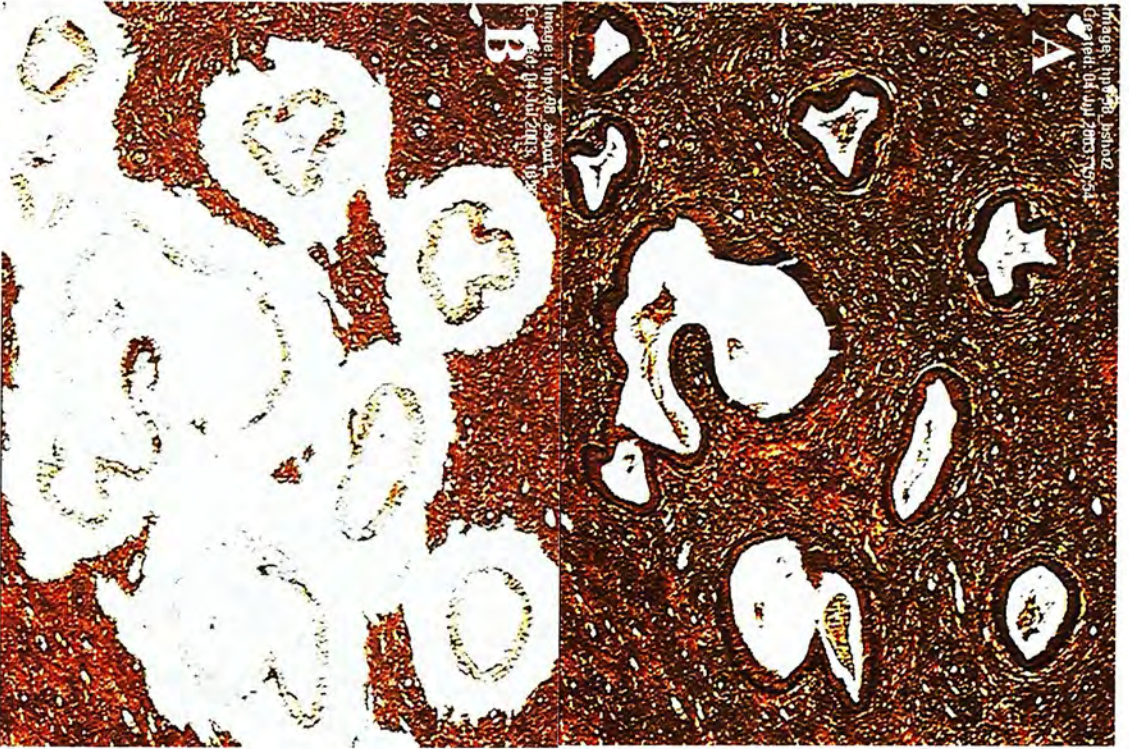


Figure 61 Lazer capture microdissection (LCM) process for cervical adenocarcinomas tissue stained with H&E. (A) Adenocarcinoma in situ before dissection. (B) Adenocarcinoma in situ after dissection. (C) Invasive adenocarcinoma before dissection. (D) Invasive adenocarcinoma after dissection.

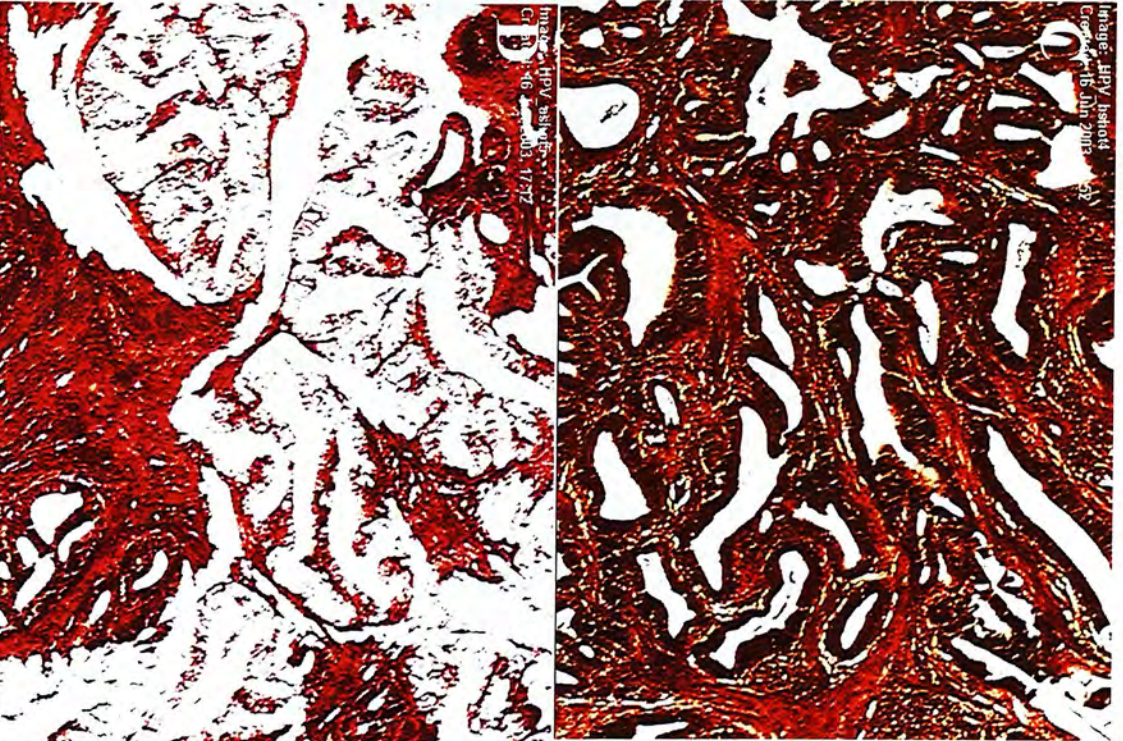
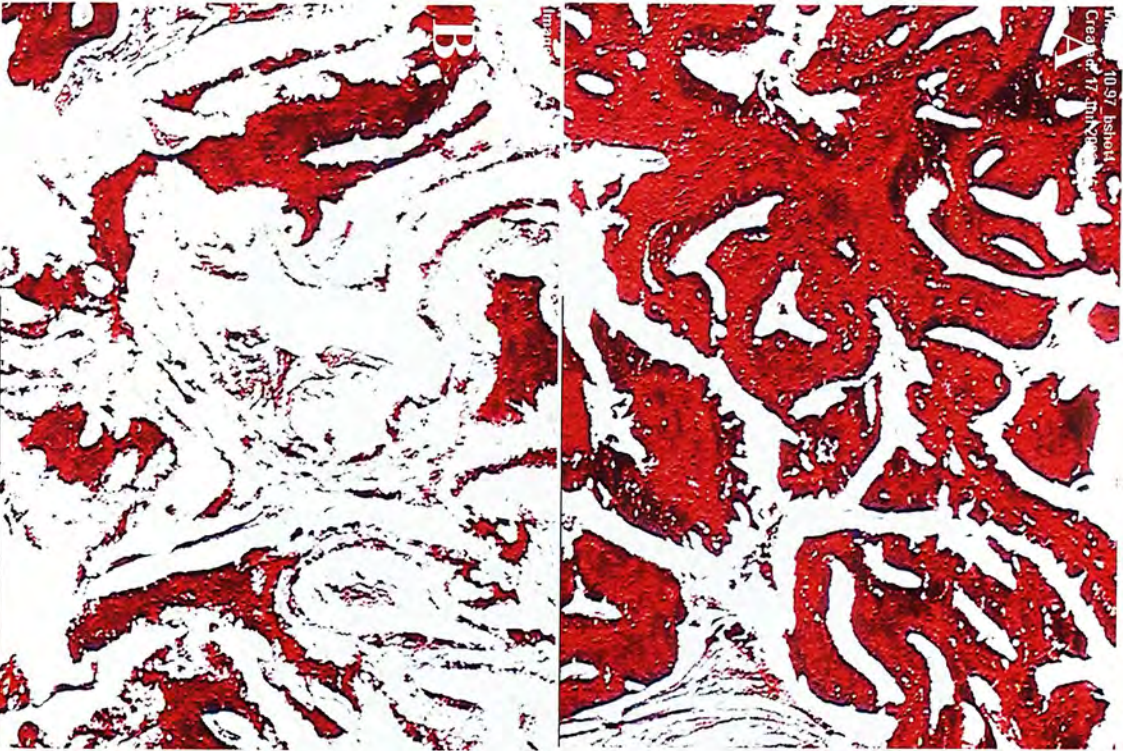


Figure 62 Laser capture microdissection (LCM) process for cervical adenocarcinomas stained with H&E. (A) Invasive adenocarcinoma before dissection. (B) Invasive adenocarcinoma after dissection. (C) Invasive adenocarcinoma before dissection. (D) Invasive adenocarcinoma after dissection.

Figure 63. HPV type 16 in Cervical Adenocarcinoma

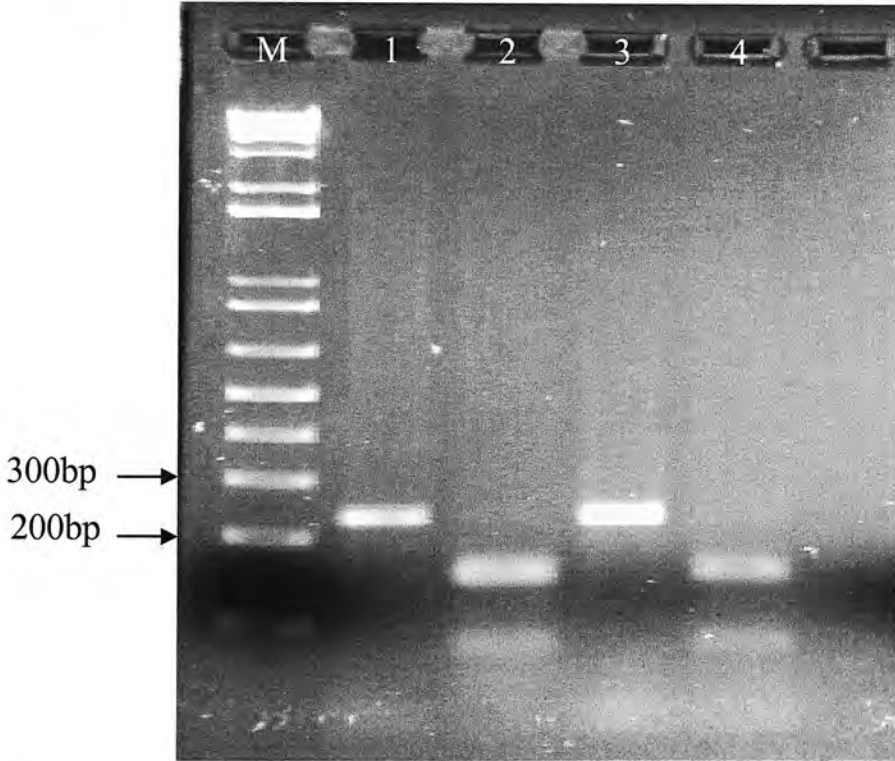


Figure 63 showing determination and confirmation of HPV type 16 by RFLP pattern and PCR using specific primers. Sample was taken from the whole tissue section of cervical adenocarcinoma. Using this method, an HPV- 16 specific pattern is evident as 157 nt and 81 nt fragment and its total length is 238bp on a 2% agarose gel.

Lane M: Kilobase DNA Marker

Lane 1 : PCR products of HPV 16 extracted from paraffin section (Uncut)

Lane 2 : *AVa* II fragments of lane 1 (Cut)

Lane 3 : Positive control SiHa (Uncut)

Lane 4 : *AVa* II fragments of lane 3 (Cut)

Figure 64. HPV type 18 in Cervical Adenocarcinoma

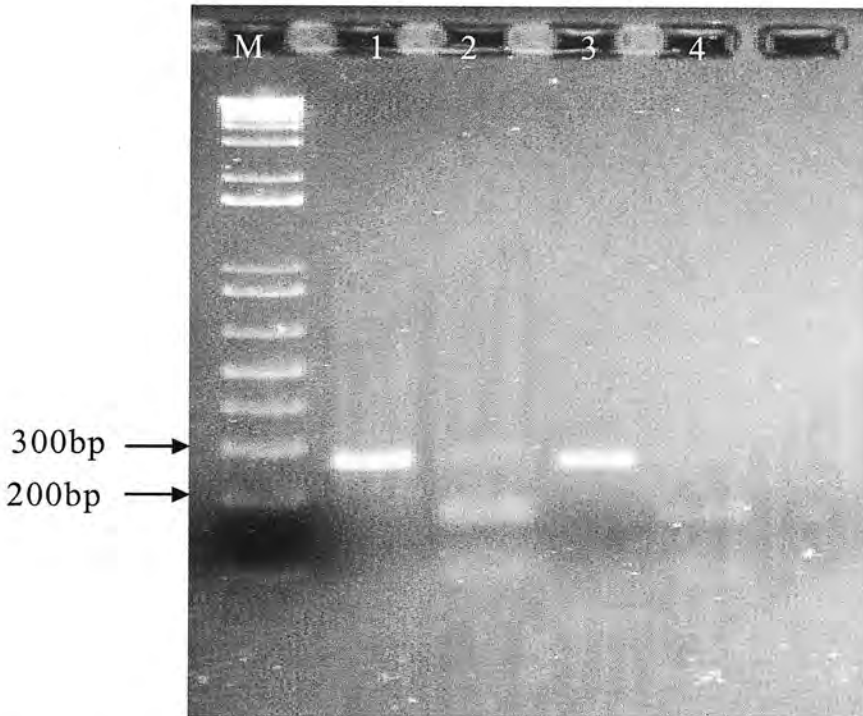


Figure 64 showing determination and confirmation of HPV type 18 by RFLP pattern and PCR using specific primers. Sample was taken from the whole tissue section of cervical adenocarcinoma. Using this method, An HPV-18 specific pattern is evident as 172 nt and 96nt fragments and its total length is 268bp on a 2% agarose gel.

Lane M : Kilobase DNA Marker

Lane 1 : Positive control HeLa (Uncut)

Lane 2 : *AVa* II fragments of lane 1 (Cut)

Lane 3 : PCR products of HPV 18 extracted from paraffin section (Uncut)

Lane 4 : *AVa* II fragments of lane 3 (Cut)

PART (IV)

DISCUSSION AND CONCLUSION

Chapter I

Morphological and Histopathological study

1.1 Invasive endocervical adenocarcinoma

There is evidence that there is a real increase in the incidence of malignant and premalignant endocervical glandular lesions of the cervix which are therefore assuming increasing importance in diagnostic surgical pathology (McCluggage, 2003). There is also a relative increase mainly due to efficient cervical cytological screening for preinvasive squamous cell carcinoma. Figures for the proportion of invasive adenocarcinomas of cervix range from 6% in the 1950s to 26% in the 1990s in different studies (Nieminen et al, 1995; Rutledge et al 1975; Kjorstad 1977; Shingleton et al 1995). This increased incidence may be only apparent and attributable to better diagnosis with mass screening programmes (Leminen et al 1990; Hopkins et al 1988), or real, particularly in women under age of 35 (Horowitz et al 1988; Angel et al 1992). HPV infection, particularly HPV 18, is the most widely recognised aetiological factor (Brand et al 1988). Focus has also been put on other factors affecting the incidence of cervical adenocarcinoma including oral contraceptives, diabetes, obesity and pauciparity (Schwartz et al 1986; Brinton et al 1993), although these factors can not fully explain the observed incidence pattern for invasive adenocarcinoma (Zheng et al 1996), and the pathogenic mechanism remains unclear.

In this series 139 patients with cervical adenocarcinomas were studied, consisted of 20 patients with adenocarcinoma-in-situ and 119 with invasive adenocarcinoma. Sixteen of 119 patients with invasive adenocarcinoma had early invasive adenocarcinoma which met criteria for FIGO stage IA₁ carcinoma of the cervix. This mix of cases was a result of a computerized tumour registry search which conducted for all patients diagnosed with invasive cervical adenocarcinoma at the University of Edinburgh, Pathology Department from 1991 to 2001. In addition, twenty cases of adenocarcinoma in situ were used as a sample to compare with invasive cases. Unlike squamous cell carcinoma, frequently diagnosed after an abnormal cervical smear, adenocarcinoma presents in a variety of different ways. The identification of early invasion in cervical glandular lesions may not always be possible and in 10–15%

of cases the pathologist may be uncertain. CGIN and even invasive cervical adenocarcinoma can be confused with a wide variety of benign endocervical glandular lesions particularly the mucinous variant of minimal deviation adenocarcinoma (McCluggage et al, 2003).

The annual growth rate of cervical adenocarcinoma in young women aged 25-49 years in both England and Scotland was about 10% for cohorts born between 1935 and 1955 (Vizcaino et al 1998). In the present study, ages of the patients at time of sample ranged from 23 to 89 years old. 58 (42%) patients were \leq 39 years old, 42 (30%) were 40 - 50 years old, and 39 (28%) were \geq 51 years old. While the outcome of our patients was not studied, the effect of age as a prognostic factor is widely debated. For some authors, age influences overall survival (Kilgore et al 1988), but in other series (Angel et al 1992; Hopkins et al 1991) no effect has been found.

Clinical stage usually determines the prognosis of cervical adenocarcinoma. However it is equally well known that the clinical course of patients within the same stage of disease may differ considerably (Graflund et al, 2002). In our series, based on pathology reports, It was found the FIGO stage of cancer was Ia1 for 16 (13%), Ia2 for 11 (9%) and Ib or greater for the remaining of the 119 patients with invasive adenocarcinoma. However Graflund et al, 2002 found stage I lesions in 63.8% of cases, stage II in 13.4% and stage III-IV in 12.8%. Mixed forms with an epidermoid component occur in 13% (Tamimi et al 1982) to 40% (Fu et al 1982) and many authors have been unable to demonstrate poorer prognosis (Leminen et al 1990; Korhonen 1984; Harrison et al 1993).

In the current series, with respect to histological grading of the tumours, it was found of the 119 patients with invasive adenocarcinoma there were 54 (45%) patients with grade 1 (well differentiated) cancer, 36 (30%) with grade 2 (moderately differentiated) cancer, and 29 (24%) with grade 3 (poorly differentiated) cancer. Many investigators have reported that poorly differentiated adenocarcinoma showed a poor prognosis (Eifel et al 1990; Berek et al 1985), whereas others have found histological differentiation to be of little prognostic value (Leminen et al, 1990; Milsom et al 1983). However Kilgore and Helm,(1990) include it among prognosis factors to define risk groups. Other factors influencing survival have been explored, such as

lymph-vascular invasion (Siago et al, 1986; Matthews et al, 1993).and stromal invasion of the cervix (Hopkins et al, 1991; McLellan et al 1994; Berek et al 1985; Kilgore and Helm, 1990). In our study a stromal response was absent in 28 (20%) patients, mild in 47 (34%) patients, moderate in 39 (28%) patients, and intense in 25 (18%) patients. The focality could not be determined for 76 (64%) of the 119 patients with invasive adenocarcinoma. For the 43 patients where the focality was determined 6 had one focus, 4 had two foci, 4 had three foci, and 29 had more than three foci. Moreover lymph-vascular invasion were reported in 9 cases of 119 of invasive adenocarcinomas.

Conclusion

In view of the increasing incidence of adenocarcinoma of the cervix in young women, separate monitoring of incidence and mortality for adenocarcinoma of the cervix remains necessary. Further studies on the causes of cervical adenocarcinomas are required to elucidate the reasons behind this increase.

1.2 Early Invasive Adenocarcinoma (Microinvasive Adenocarcinoma)

Patients with microinvasive adenocarcinoma who meet criteria for FIGO stage IA₁ cervical carcinoma have disease limited to the cervix, and excellent prognoses. Many investigators reported clinical outcomes of patients with microinvasive cervical adenocarcinoma, but none have rigorously defined lesions that might be managed conservatively (Kaku et al 1997; Ostor et al 1997; Kaspar et al 1993). In this study, it was found that 16 of 119 patients with invasive adenocarcinoma had early invasive adenocarcinoma and met criteria for FIGO stage IA₁ carcinoma of the cervix. Kaku et al (1997) reviewed 30 cases of microinvasive cervical adenocarcinoma and among 21 with less than 3 mm invasion in their study, none had evidence of disease beyond the cervix, and none developed recurrent disease. In a clinicopathologic study of 77 women with microinvasive cervical adenocarcinoma, Ostor et al (1997) found disease confined to the cervix and no recurrences among 43 patients with up to 3 mm invasion. Kaspar et al (1993) reported two recurrences among 36 patients with less than 3 mm invasion, yet both were considered stage IB₁ because of tumour width exceeding 7 mm.

In this study, based on the pathology reports, it was found that all FIGO stage Ia tumours were histopathologic grade 1 well differentiated. The tumours showed three patterns of early invasive adenocarcinoma: small glandular budding arising from HCGIN, infiltrating the stroma with an associated inflammatory reaction, confluent glands in a complex pattern with little or no intervening stroma, and intraluminal tufting resulting in a papillary pattern. Usually, the early invasive adenocarcinoma was recognized by loss of the normal smooth peripheral glandular outlines, prominent cribriform and/or solid areas, and the architectural complexity of endocervical glands including deep invagination. Similar results were reported by Mulvany & Ostor, (1997), Ostor et al (1997), and Rollason et al, (1989). Moreover, it was noticed that there was a gradual thinning of the glandular epithelium until the basement membrane destroyed and stromal invasion started, and an appearance which was called "elastic band sign" which was also noticed in the H-CGIN cases strongly suggestive of impending early invasive adenocarcinoma. However, there is very little information on the incidence of microinvasive adenocarcinoma and its relation to H-CGIN (Kurian & Al-Nafussi 1999).

Lymph-vascular space invasion and grade 3 carcinomas have been reported in less than 10% of patients with microinvasive adenocarcinoma, yet both are independent risk factors for recurrence in squamous cell cervical carcinoma (Kaku et al 1997; Ostor et al 1997; Delgado 1990). None of the patients in our study had these histopathologic findings. However, we found that the main pattern of invasion of those tumours was infiltrative in 15 of the patients (94%) and was confluent in one patient (6%). For the 14 patients patients with early invasive adenocarcinoma where the focality was determined 3 had one focus, 2 had two foci, 2 had three foci, and 7 had more than three foci. A stromal response was mild in 12 (75%), moderate in 3 (19%), and intense in 1 (6%) patient with early invasive carcinoma. However, Schorge et al, 1999 were not able to stratify the data to evaluate specifically the importance of multifocal disease or invasion beyond 2 mm, as a result of the small number of patients in this preliminary study.

Eight patients (50%) with early invasive adenocarcinoma in our study were \leq 39 years old, tumours in 10 of patients were located at the transformation zone and CGIN

was present in 8 (50%) patients. Similar results were reported by Schorge et al, 1999 who found that invasive lesions arose predominantly from the endocervical surface, at or within 5 mm of the squamocolumnar junction, regardless of whether lesions were unifocal or multifocal. Topographic studies suggest that the vast majority of microinvasive and adenocarcinoma in situ lesions are located at the transformation zone, with contiguous involvement of the endocervical canal for a variable distance (Bertrand et al 1987; Nicklin et al; 1991).

Conclusion

The results of this study suggest that, the vast majority of microinvasive and adenocarcinoma in situ lesions are located at the transformation zone. Stromal response and an appearance we called "elastic band sign" which was noticed in the H-CGIN cases are strongly suggestive of early invasive adenocarcinoma.

1.3 ADENOCARCINOMA IN SITU (AIS) (High grade CGIN)

Many studies supported the view that H-CGIN is a precursor of invasive adenocarcinoma (Boon et al, 1981; Gloor & Ruzicka 1982; Kurian and Al-Nafussi, 1999). The proportion of adenocarcinomas of the cervix in the United States has increased from approximately 11% to 23% over a 23-year period, probably reflecting both a decrease in squamous carcinomas and an increase in adenocarcinomas (Plaxe et al 1999). Cervical cancer screening programs have been effective in decreasing both the incidence and mortality from squamous carcinoma, but although adenocarcinoma mortality rates have declined, incidence rates have not (Nieminen et al 1995). This may reflect the difficulty in detecting adenocarcinoma in situ, but also suggests that invasive adenocarcinoma is being detected at an earlier stage. The diagnosis of AIS is often problematic. Endocervical abnormalities such as dysplasia, tubal metaplasia, cervical endometriosis, and pathological or histological changes due to previous biopsy, cervicitis, and use of OCs have been misdiagnosed as AIS (Valente & Hanjani 1986; Yeh et al; 1991; Pacey et al 1988; Lee, 1988), and others have reported on the difficulty of distinguishing AIS from microinvasive lesions (Kudo et al 1991) and even invasive disease (Fu et al 1987). In our study, twenty of 139 patients showed adenocarcinoma in situ without invasion. These were defined by

showing nuclear stratification and loss of polarity, nuclear atypia and hyperchromasia, macronucleoli, loss of intracytoplasmic mucin, atypical mitoses, apoptotic bodies, goblet cells, and abrupt transition to normal but without invasion of stroma. Not all of these findings usually present in every individual case. There was often an abrupt transition from normal glands to glands involved by AIS and this abrupt transition may be seen within individual glands. Both the surface epithelium and the underlying crypts may be involved. In all patients with adenocarcinoma in situ (13 from 13 patients), the transformation zone (TZ) was involved by the AIS (100%). Similar results were reported by Lee et al, (2000); Teshima et al, (1985); Oster et al, (1984) and Noda et al, (1983) who observed that most cases of invasive adenocarcinoma evolve from an adenocarcinoma in situ precursor located within or just proximal to the transformation zone.

In this series, large masses of densely packed architecturally complex glands with papillary growth process and cribriform areas were observed in the AIS cases which strongly suggested invasion. There was a gradual thinning of the glandular epithelium until the basement membrane was destroyed and stromal invasion started. There is a window of approximately 5 years between clinically detectable adenocarcinoma in situ and early invasive adenocarcinoma, indicative of an opportunity for screening and detection before invasion (Lee et al, 2000; Boon et al 1981). However, the detection of adenocarcinoma in situ has been challenging for a number of reasons. Papanicolaou smears may be less sensitive than they are for squamous precursors because adenocarcinoma in situ may mimic endometrial cells or reactive endocervical cells (Lee et al, 1997). Also, benign conditions such as tubal metaplasia (Novtny et al 1992; Wells et al 1986) and cervical endometriosis (Pacey et al 1988) may cytologically mimic adenocarcinoma in situ. Colposcopic evaluation and sampling are said to be more difficult because of the location of adenocarcinoma in situ within the endocervical canal (Christopherson et al 1979).

In this study, we found the age group of AIS is younger than those with invasive adenocarcinoma. Patients with adenocarcinoma in situ were younger than those with invasive adenocarcinoma ($p=0.006$). Fourteen of 20 patients who had adenocarcinoma in situ were ≤ 39 years old (70%), four patients were 40-50 years old (20%), and two patients were ≥ 51 years old (10%). Kurian and Al-Nafussi, (1999) reported the

mean age of women progressively increased from 39 years for L-CGIN, to 43 years for both H-CGIN and microinvasive adenocarcinoma, and 48 years for adenocarcinoma, a span of approximately 10 years. The difference in mean age, however, between H-CGIN and frankly invasive disease was only five years. This concurs with previous studies showing CGIN preceding invasive adenocarcinoma by an interval ranging from two to eight years (Boon et al 1981; Boddington et al, 1976; Kashimura et al, 1990). Other studies have shown that women with H-CGIN are 10 to 20 years younger than those with invasive adenocarcinoma (Brown & Wells 1986; Boon et al 1981; Gloor & Ruzicka 1982).

Conclusion

The results of this study support the view that AIS is usually located at TZ and recorded in patients younger than those with invasive adenocarcinoma.

1.4 Cervical Smear

The cytological features of glandular neoplasia have been refined (Anderson, 1995; Biscotti et al 1997; Bousfield et al, 1980). Incidence rates and registrations of adenocarcinoma and squamous cell carcinoma in the population served by a single NHS Health Authority are reported during a 12-year period, which covers the introduction of comprehensive cervical screening (Herbert et al, 2001). Although there was a significant fall in the incidence of squamous cell carcinoma, from 14.0 to 7.2 per 100,000 women years, there was no consistent rise or fall in that of adenocarcinoma. The relative proportion of adenocarcinoma increased from 17% to 30%. It is well recognized that screening as currently performed is less effective in preventing adenocarcinoma than squamous cell carcinoma (Mitchell et al 1995; Herbert et al 2001). In this study, according to cervical smear history reports of the 139 patients with cervical adenocarcinomas, it was found that 71/119 patients had abnormal Papanicolaou smears. The largest category of smear results was mainly adenocarcinoma (37/119) and the remaining are presented in table 13. Most patients 92/119 had colposcopic evaluation before initial treatment. Clinical symptoms such as bleeding were reported in a few cases. However, Luesley et al 1987 reported that 71% of their cases had at least one cervical smear suggesting glandular abnormality in the

preceding 12 months. Widrich et al (1996) reported that 19 of 45 cases of adenocarcinoma in situ (42%) had glandular abnormality on smear test, while Casper et al 1997 reported that only 23% of low grade CGIN was screen detected. Our findings support the importance of cervical screening programme to detect tumours early, and confirm the importance of colposcopy in management in most cases.

Chapter 2

Validation of Tissue Microarray Technology

2.1 Tissue microarray technology as a new tool for cervical adenocarcinoma study

Archival formalin-fixed, paraffin-embedded tissues of cervical adenocarcinoma are the most widely used tumour material in the search for novel prognostic markers to analyze using tissue microarray technology. In this study we investigated whether the tissue microarray technique could be used to preserve valuable tumour material. We have therefore evaluated the tissue microarray technique for immunohistochemical staining in cervical adenocarcinoma using the following antigens, carcinoembryonic antigen (CEA), Cytokeratin7 (CK7), Cyto-keratin20 (CK20), oestrogen receptor (ER), progesterone receptor (PgR), phosphatase and tensin homolog deleted on chromosome ten (*PTEN*), MIB-1 proliferation marker, and p53 suppressor gene. These antigens were chosen to represent known positive (CK7), expected negative (CK20), steroid receptors (ER and PgR) as examples of potentially heterogeneous expression- to compare staining in whole sections with those in TMA; CEA and p53 to investigate their expression in a large series; and *PTEN* to evaluate it in differential diagnosis between primary endocervical adenocarcinoma and primary endometrial adenocarcinoma. All tumours showed a concordant presence or absence of staining in all tumours investigated. Thus, good correlation was obtained between the results from the whole tissue sections and the tissue microarray studies indicating that tissue microarrays may be reliable tools for high-throughput clinicopathological and immunohistochemical analyses of cancer specimens. Similar results have been reported in previous evaluations of the tissue microarray technique in different cancer specimens and cell lines (Hoos & Cordon-Cardo, 2001; Hoos et al, 2001b).

However, in this series, analysis of TMA cores was comparable to a whole tissue section in all of cases for morphological study of cervical adenocarcinomas and in more than 97% of cases for immunohistochemical staining. In 5% of cases, the core biopsy sections were nonevaluable because of loss of material during sectioning and staining. This loss of data, due to tissue loss or inconclusive data, has been reported in previous evaluations of the tissue microarray technique in soft tissue tumours

(Engellau et al., 2001; Hoos et al., 2001) and in rectal cancer (Fernebro et al, 2002) where 17% of the core biopsy sections were nonevaluable.

The main problem to broad acceptance of tissue microarrays is that they reduce the amount of tissue analyzed from a whole tissue section to a core, 0.6 mm in diameter that may not be representative of the protein expression patterns of the entire tumour because of tissue heterogeneity. In this study, we constructed microarray blocks using 0.6 mm core biopsy which was representative in 100% for morphological study of cervical adenocarcinoma and in 97% for immunohistochemical staining of different antigens. The process of selecting representative viable tumour regions from which to obtain the core biopsy specimens is crucial and should be performed by an experienced pathologist. Therefore TMAs are constructed by careful selection of these regions especially in a morphologically heterogeneous tumour to provide more representative results.

Although the development of TMA technology started using 3 mm needles, it is felt, that increasing the needle size will be of limited value in the assessment of heterogeneous tumour markers since tumour heterogeneity is likely to a minor degree within a still very small tissue fragment measuring 3 mm in diameter. However, it would be more advantageous to array two or more samples from different areas of each tumour if a better representation of an individual tumour is required. Similar results were reported by Bubendorf et al (2001). Large diameter punches (typically 2-4 mm) have been used by some investigators in an effort to provide more representative samples for TMA analysis. Although this approach multiplies the amount of tissue analyzed, there is little practical evidence that such a sampling strategy is more representative than 0.6-mm punches. Therefore, the acquisition of multiple small "tissue cores" from distinct, perhaps histologically different, regions of the tumour is dramatically more effective than increasing the size of a single punch to improve the sampling efficiency. Based on these considerations, the 0.6-mm sample size is preferable. In addition, the substantial disadvantage of using larger (2-4-mm samples) is it greatly reduces the number of samples that can be arrayed on a single slide and the number of punches that can be taken from 1 original tumour block. These results and suggestions were supported in previous evaluations of the tissue microarray technique in different cancer specimens and cell lines (Hoos & Cordon-

Cardo, 2001; Hoos et al, 2001b). Moreover, Camp et al., (2000) concluded that the tissue microarray technique, with 2-fold redundancy, in breast cancer is a valuable and accurate method for analysis of protein expression in large archival cohorts.

To determine the number of tissue cores required to obtain a result equivalent to a conventional tissue section, we constructed an array with 2 pairs of cores from each of 119 cases of invasive cervical adenocarcinoma, 20 adenocarcinoma in situ and 16 normal endocervical tissues. Cores were scored if at least 10% of the core area contained tumour. Then we analyzed each core separately and graded it as either positive or negative. Most cases had two scorable cores for each antibody tested. However, most cases had more than 3 cores with sufficient tumour for evaluation. In the majority of cases, staining was uniform across all the cores and consequently the chance of adequately representing the tumour in one punch was 100%. Moreover, the results of this analysis demonstrate that, despite the variability of antigen expression between cores, analysis of two disks achieve greater than 97% representation. Therefore we suggest that a minimum of 2 usable cores was required to be included in the analysis. For practical purposes, therefore, it is desirable to identify the minimal number of core biopsy specimens needed to achieve good accuracy. With a loss of 5% of the core biopsy specimens and since using 4 core biopsy specimens only marginally affected the accuracy level, we suggest that 4 tissue biopsy specimens should be taken from each tumour. This conclusion is in concordance with the results obtained from validation of the tissue microarray technique for immunohistochemical staining in soft tissue tumours (Engellau et al, 2001; Hoos et al, 2001), in rectal cancer (Fernebro et al, 2002) and in breast cancer (Camp et al,2000). These studies have suggested that analysis of triplicate core biopsy specimens per tumour increases the number of concordant readings, lowers the number of lost cases, and provides a reliable immunohistochemical expression profile.

According to this data and our experience, we have developed a standard procedure in which 2 pairs of cores are punched in various regions of the tumour mass, including both the leading edge and the tumour centre. This process ensures that at least two, and in most cases three, punches are available for evaluation, resulting in adequate representation of the whole-section staining pattern in more than 97% of cases. Although expression of some antigens such as oestrogen receptor, and progesterone

receptor, in cervical adenocarcinoma is regarded as particularly heterogeneous, it is possible that other antigens in other tumour types may exhibit even greater heterogeneity. Consequently, similar analyses may be required to validate the use of tissue microarrays in other tumour types. A similar suggestion is reported in tissue microarray evaluation in breast cancer by Camp et al, (2000).

The question of how many core punches it takes to reliably achieve two readable cores in each case was affected by several factors. Foremost among these was the ability to identify areas of tumour distinct from desmoplastic stroma, normal epithelium, and/or in situ adenocarcinoma. Although some histological detail was retained in microarray cores, it could be difficult to distinguish certain types of in situ from invasive carcinoma. In invasive adenocarcinoma there was in situ adenocarcinoma component admixed with the invasive component, increasing the chances of spurious readings. To reduce this confounding effect, areas of invasive carcinoma were outlined distinctly from the in situ component on the slide by indelible marker. This process was performed by a gynaecological pathologist. Other factors include the technical expertise of the individual constructing the array blocks and slides. In our laboratory, one person performed these tasks. Presently our rate of usable cores exceeds 97%. Finally, the thickness (depth) of the original embedded tissue sections can affect the number of usable slides able to be cut from the master array block. Therefore, efforts were made to select blocks that had sufficient residual tissue in the archival tissue blocks to ensure an adequate sample for TMA construction.

Conclusions

We conclude that the tissue microarray technique is a rapid and tissue-saving method, yields staining of good quality and is feasible for immuno-histochemical studies in cervical adenocarcinoma. Four cores are sufficient to produce representative sampling of the morphology of tumours even if occasional cores are lost on slides. TMAs will substantially accelerate studies associating novel molecular discoveries in the field of genomics and proteomics with specific pathologic, demographic, clinical and follow-up information of cancers and cancer patients. TMAs containing well-characterized tissues enable researchers to perform studies involving thousands of patient specimens

with substantial increases in speed, quality of data, information content and savings of cost and time. Since the diagnostic tumour biopsy specimens are often small, the use of the tissue microarray contributes to tissue preservation, but because of the risk for tumour loss, multiple (4) biopsy specimens should be taken. Furthermore, the tumour areas from which the tissue core biopsy specimens are obtained must be carefully selected to reduce the number of nonevaluable core biopsy sections containing nonrepresentative tissue.

2.2 Immunohistochemical Results of Cervical Adenocarcinomas Using TMA Technology

Over the last several decades the relative proportion of both endocervical adenocarcinoma and its precursor lesion cervical glandular intraepithelial neoplasia to invasive squamous cell carcinomas of the cervix has been increasing and several studies have reported an increase in the absolute number of cervical adenocarcinomas (Shingleton et al, 1981; Vesterinen et al, 1989). These increases have heightened interest in the diagnosis, pathogenesis, and management of women with invasive adenocarcinoma of the cervix (Chilvers et al, 1991; Prempreet et al, 1985). As well as recognizing cervical glandular intraepithelial neoplasia per se, it is also necessary to distinguish this from non-neoplastic endocervical glandular lesions such as tubo-endometrial metaplasia, endometriosis and microglandular hyperplasia. Therefore, if a panel of antibodies was of value in the distinction of invasive adenocarcinoma of the cervix, cervical glandular intraepithelial neoplasia from non-neoplastic endocervical glandular lesions, this would be extremely useful (Cameron et al, 2002).

Excluding results from second sample for 22 patients with two samples, immunohistochemical results for 139 patients with cervical adenocarcinomas are summarised in the following table.

Table 20 showing the immunohistochemical results of different antigens

Antigen	Not Available Cases	Available Cases	Positive Cases		Negative Cases	
			N	%	N	%
CK7	3	136	132	97%	4	3%
CK20	5	134	4	3%	130	97%
CEA	3	136	92	68%	44	32%
ER	2	137	64	47%	73	53%
PgR	4	135	50	37%	85	63%
MIB1	5	134	119	89%	15	11%
<i>PTEN</i>	2	137	121	88%	16	12%
P53	4	135	37	27%	98	73%

Table 20 showing immunohistochemical results of eight antigens for 139 patients with cervical adenocarcinomas using TMAs. Number of positive, negative, available and not available cases in each antigen.

2.2.1 CK7 & CK20

Cytokeratins are constituents of the intermediate filaments of epithelial cells which are expressed in various combinations depending on the epithelial type and the degree of differentiation. Simple epithelia generally express the simple epithelial keratins 7, 18, 19, and 20, while complex epithelia express complex epithelial keratins 5/6, 10, 14 and 15. When an epithelium undergoes malignant transformation, its keratin profile usually remains constant. The constitution and expression patterns of keratin filaments in human epithelial neoplasms are complex and often distinctive (Chu & Weiss 2002). The keratin expression pattern of cervical adenocarcinoma is considerably more complex than expected from the results obtained with adenocarcinomas arising in other tissues (Moll et al, 1992).

In the present study, the expression of CK7 was positive in almost all cases of cervical adenocarcinoma, 100% of AIS cases, and 97% of invasive cases. In contrast, the expression of CK20 was negative in 100% of AIS cases, and 97% of invasive cases. Similar results were reported by Chu & Weiss (2002) who reported that cervical adenocarcinoma contains K7, K8, K18 and K19, like other gynaecological adenocarcinomas, but it is also frequently positive for K17 and K14. None of these above keratins is present in the normal columnar cells lining the endocervical canal. Because of this, it has been speculated that cervical adenocarcinoma does not usually arise from columnar cells, but instead derives from reserve cells. Squamous cell carcinoma in situ may thus make the transition to an adenocarcinoma (Smedts et al, 1993). It may be difficult to distinguish histologically between a primary cervical adenocarcinoma and a metastatic adenocarcinoma arising from the bowel, endometrium, mesothelium, or ovary. This dilemma may be addressed by determining the keratin phenotype of these adenocarcinomas. Colonic adenocarcinomas have a simple keratin expression pattern consisting of K8, K18, K19 and K20, whereas cervical adenocarcinoma contains K7, K17, and frequently K14, and usually lacks K20. Although arising from the same epithelium, cervical dysplasia and invasive carcinoma have different keratin profiles in comparison with normal cervical non-keratinizing epithelia. Normal cervical epithelium expresses K10, but not K7, K8, K17 and K18. In contrast, cervical dysplasia (cervical intraepithelial neoplasia (CIN)) or cervical squamous cell carcinoma tends to express K7, K17 and K18, but not K8 and K10 (Smedts et al, 1993; Smedts et al, 1992, Chu et al, 2000).

Conclusion

Our findings show that expression of CK7 was positive and CK-20 was negative in most of cases of cervical adenocarcinoma.

2.2.2 CEA

Previous studies have investigated the value of other markers in the distinction of cervical glandular intraepithelial neoplasia from histological mimics. Antibodies employed have included carcinoembryonic antigen (CEA), which is usually positive in neoplastic, but not benign lesions (Gilks et al, 1989; Micheal et al, 1984). Negative immunohistochemical staining for CEA supports a diagnosis of MGH (Speers et al.,

1983; Steeper & Wick, 1986). In the present study, the expression rate of CEA was positive in 68% of all cervical adenocarcinoma cases, AIS and invasive, 72 % of AIS cases, and 67% of invasive cases. Similar results were reported by van Nagell et al., (1978) who found that, plasma CEA levels were more commonly elevated in patients with endocervical adenocarcinoma than in those with squamous cell carcinoma. Moreover, we found that there was no statistically significant difference in the expression of CEA in different subtypes of invasive cervical adenocarcinoma (table 39). However, caution should be exercised since adenocarcinomas are occasionally negative or only focally positive for CEA. Mesonephric adenocarcinomas are typically CEA-negative. Accordingly, a negative stain for CEA should be cautiously interpreted but intense positive staining throughout the cytoplasm is unlikely in a benign lesion and strongly favours carcinoma. Negative CEA staining is also seen with the other pseudoneoplastic glandular lesions considered here but experience with CEA staining of many of them is limited and a diagnosis should not be rendered solely on the basis of immunohistochemical staining results. In our study, we considered CEA is positive when the cytoplasm of the malignant endocervical cells stained diffusely. This is because CEA is a type of intracytoplasmic protein. However, in some cases, there was diffuse delicate luminal staining with CEA but this positivity considered as negative if there is no cytoplasmic staining because CEA is not one of intramembranous components. Normal endocervical glands and those of pseudoneoplastic lesions may exhibit a glycocalyceal pattern of CEA staining that contrasts with the diffuse cytoplasmic staining typically seen in cervical adenocarcinomas (Jones et al., 1991). The pattern of CEA distribution in endocervical adenocarcinoma of endometrioid type was not similar to that observed for primary endometrial adenocarcinoma (Toki et al., 1985).

Cina et al., (1997) confirmed that the combination of cytoplasmic CEA positivity in glandular cells and a moderate-to-high MIB-1 (Ki-67) proliferative index is diagnostic of malignancy in endocervical lesions. With the exception of florid microglandular hyperplasia, p53 expression is only seen in neoplastic lesions of the endocervix. Therefore, a combination of CEA, MIB-1 and p53 staining was found to be useful in discriminating benign and malignant endocervical glandular lesions (McCluggage, 2002; McCluggage, 2003).

Conclusion

Our findings confirm that expression of CEA is a potential biomarker for diagnosis of cervical adenocarcinoma.

2.2.3 ER&PgR

Most studies have reported that risk factors and prognostic indicators for women with adenocarcinomas are similar to those for women with squamous cell carcinomas of the cervix (Kjaer et al, 1993; Parazzini & La Vecchia, 1990). The major prognostic indicators for both histological types include FIGO clinical stage, histological grade, size of the lesion, lymph-vascular space involvement, and lymph node metastases (Attanoos et al, 1995; Ireland et al, 1985). One possible prognostic indicator that might be expected to be more important for cervical adenocarcinomas than for squamous cell carcinomas is steroid hormone receptor status (Fujiwara et al, 1997).

Several studies have measured ER and PgR in cervical carcinomas. In the present study, using immunohistochemical assays, ER has been detected positive for 64 (47%) of cervical carcinomas and PgR in 50 (37%). However, the prognostic significance of hormone receptor status remains unclear. Some studies have found that ER or PgR status has no significant impact on either disease free survival or length of overall survival in women with primary invasive cervical carcinoma, whereas other studies have found hormone receptor status to be a significant prognostic indicator (Hunter et al, 1987, Martin et al 1986). Potish et al, (1986) reported that both ER and PgR positivity were independently associated with enhanced overall survival in premenopausal, but not postmenopausal, women with invasive cervical carcinoma, whereas Hunter et al, (1987) found a weak association between survival and PgR positivity, but not with ER positivity. However, these studies were of women with all histological types of cervical carcinoma, and relatively few cases of primary invasive adenocarcinoma of the cervix were included. Only two previously published studies have specifically analyzed the clinical significance of ER and PgR status in primary invasive adenocarcinomas of the cervix. Masood et al, (1993) assessed ER and PgR status in a series of 54 women with primary cervical adenocarcinoma and found that patients with either ER or PgR

positive tumours had significantly improved overall survival compared with patients with ER and PgR negative tumours. However, another study of ER and PgR status in 47 women with primary cervical adenocarcinoma found an increase in disease free survival among women with ER positive tumours but not with PgR positive tumours (Ghandour et al, 1994).

The current series assessed hormone receptor status in 119 women with primary invasive cervical adenocarcinoma and 20 women with AIS. In the current series 47% of the cases were classified as ER positive whereas 30% of the cases in the series of Masood et al, (1993) and 26% of the cases in the series of Ghandour et al, (1994) were classified as ER positive. In the current series ER positivity was more frequent in invasive (50%) and early invasive (56%) cervical adenocarcinomas than in AIS (28%) which suggest that high ER levels are possibly associated with more advanced disease. However, this finding contradicted the study of Geisinger et al, (1986) who reported that high ER and PgR levels are more frequent in well-differentiated adenocarcinomas and is possibly associated with a better prognosis. Moreover, we found that high ER and PgR levels are more frequent with MDA and adenosquamous adenocarcinomas (tables 34, 35) which support that ER and PgR are a useful prognostic factor and are more likely to be more frequent in the tumours of worse prognosis. In the series of Masood et al,(1993) ER positivity was inversely associated with histological grade, whereas no association between histological grade and ER positivity was observed by Ghandour et al,(1994). However, Masood et al, (1993); Ghandour et al, (1994) reported the associations between specific histological subtypes of invasive cervical adenocarcinoma and hormone receptor positivity. Mucinous adenocarcinomas of the endocervical type and endometrioid carcinomas have the highest rate of ER and PgR positivity. Mucinous adenocarcinomas of the intestinal type, clear cell carcinomas, and glassy cell carcinomas have been found to be uniformly ER and PgR negative.

Conclusion

High ER and PgR levels were more frequent with MDA and adenosquamous adenocarcinomas than in other histological subtypes therefore further studies in larger

case series are needed. There is, however, evidence of altered distribution and intensity of ER and PgR expression in cervical adenocarcinoma cells compared with normal endocervical cells. Also, there was marked heterogeneity of the intensity and the distribution between and within tumours in the same section. There is no significant difference in distribution or intensity of ER and PgR expression between adenocarcinoma in situ and invasive adenocarcinoma. Also, different histological subtypes of cervical adenocarcinoma showed no significant differences in ER and PgR expression. In addition, larger studies will also allow a more detailed analysis of the role of hormone receptor status in less frequent histological subtypes that showed interesting patterns of steroid hormone receptor status.

2.2.4 MIB-1

The proliferative nuclear antigen Ki-67 is found in proliferative cells and is expressed in cells in the G1, S, G2 and M phases of the cell cycle. The MIB-1 murine monoclonal antibody, which reacts with the Ki-67 antigen, is a marker for proliferating cells (Graflund et al, 2002). Several studies have investigated the value of MIB1 in distinguishing between cervical glandular intraepithelial neoplasia and benign histological mimics(Pirog et al, 2002; Hockenberry et al, 1990). It should be noted that in such cases, the endocervical glands may exhibit a high MIB1 proliferation index as a result of regenerative activity (Pirgo et al 2002). Determination of MIB-1 (proliferation factor) is a good prognostic marker in many malignant tumours, particularly in breast (Wintzer et al, 1991) and ovarian cancer (Kerns at el, 1994). High proliferative activity, measured using MIB-1, reflects a greater malignancy of these carcinomas, resulting in a high frequency of recurrences and metastases. In cervical cancer, the association between this marker and prognosis is still controversial (Nakano et al, 1997). Nakano and Oka (1993) showed significantly greater histology responses to radiation with high Ki-67 than with a lower index. Avall-Lundqvist and Silfversward (1997) found no predictive value of MIB-1 for long-term survival in SCCs. ter Hamsel and Mudén (1998) examined 159 stage I-II cervical cancers, and the study revealed no association between MIB-1 activity, the prognosis of the patient, stage of disease, or lymph node status. These results were also confirmed by Graflund et al, (2002).

In the present study, MIB-1 expression rates of AIS and invasive adenocarcinoma were 94% and 88%, respectively. The expression rates of AIS and invasive adenocarcinoma were 47.5% and 60.0%, respectively (McCluggage et al, 1997), and 30 to 80% of positive rate in adenocarcinoma was reported (van Hoesven et al 1997). Cina et al, 1997 reported no MIB-1 reactivity in EGD. However, Leteutre et al 1998, endocervical glandular atypia showed focal expression with 40% of labelling index, but endocervical glandular dysplasia displayed diffuse expression with more than 50% of labelling index. Our results were consistent with all these previous reports which support that high MIB-1 could be a suggestive finding for malignancy.

Conclusion

Level of MIB-1 expression was high in cervical adenocarcinomas therefore, quantification would be necessary to get the proliferation fraction in the cervical samples but time and resources did not permit this to be performed in this study.

2.2.5 PTEN

PTEN, a recently discovered tumour suppressor gene, appears to cooperate in tumour suppression and stimulate tumour cell proliferation, with decreased survival being related to allelic loss (Di Cristofano et al, 2001). Somatic *PTEN* mutations are involved in a variety of tumours, including endometrial carcinomas, where *PTEN* expression is diminished (Mutter et al, 2000). There are likely to be multiple but distinct tissue-related pathways involved in tumour genesis and tumour progression. In prostate and breast cancers, it appears that loss of *PTEN* function may be compounded by loss of protein expression by transcriptional or translational mechanisms. In prostate tissues, genetic aberrations and expression losses have been reported (Taniyama et al, 2001) and in a recent immunohistochemical study of sporadic breast carcinomas, 15% of cases had complete loss of *PTEN* protein, a phenomenon that appeared to correlate with monoallelic deletion of the gene (Perren et al, 1999). Although loss of heterozygosity (LOH) of *PTEN* can be found in sporadic colon cancer (Frayling et al, 1997), studies have not found *PTEN* mutations to be as frequent as is found in tumours of the brain and the prostate. Guanti et al, (2000) studied 32 cases of sporadic colon cancer, but observed only one case with a biallelic genomic alteration that caused loss of function of the gene and Wang et al,

(1998) found only one somatic mutation of the *PTEN* gene in 72 colon cancer cases. Taniyama et al, (2001) reported the analysis of *PTEN* RNA transcripts during colorectal tumour progression confirming that both *PTEN* transcriptional and translational mechanisms are operative in colorectal cancer. However, it remains possible that *PTEN* protein function is compromised via peptide structure or by inefficient interaction with co-factors, but such studies will require the development of a reliable enzyme activity assay. In accordance with mutational and LOH analyses performed on sporadic colon cancer specimens, these findings suggest that *PTEN* expression is maintained in sporadic colon cancers.

In this study we examined expression of *PTEN* in a series of cervical adenocarcinomas and precursors. In 137 patients with invasive or preinvasive adenocarcinoma, *PTEN* expression was negative in 16 (12%) and positive in 121 (88%). Moreover, there was no difference in distribution or intensity of *PTEN* expression between adenocarcinoma in situ and invasive adenocarcinoma. Also, different histological subtypes of cervical adenocarcinoma showed no significant differences in *PTEN* expression. Moreover, in all cases, normal endocervical cells and normal stromal cells of the cervix stained weakly positive for *PTEN*. The staining pattern in the tumour cells was stronger than that observed in the normal endocervical cells and was restricted to the nucleus. In addition, the intensity and distribution of *PTEN* staining in the tumour tissue were more heterogeneous than that observed in the normal tissues. There was marked heterogeneity with respect to the intensity and the distribution of *PTEN* staining pattern between and within tumours in the same section. However, Halvorsen et al, (2003) reported on their studies on prostate cancer that lack of *PTEN* protein expression was found in 27% of the cases, comparable with 20% negative cases in a study of McMenamin et al, (1999). *PTEN* expression was found to be associated with increasing tumour diameter and advanced primary tumour stage, as indicated by carcinomatous infiltration of the seminal vesicles, and was also related to time to local recurrence, supporting the importance of *PTEN* for prostate cancer growth and local invasion, possibly reflecting changes in cell cycle regulation, migration, or loss of cell cohesion influenced by *PTEN* (Tamura et al, 1999). These data strongly suggest an important role of *PTEN* for the progressive growth and local invasion of prostate cancer in series of patients treated with radical prostatectomy for localized and presumed organ-confined tumours (Halvorsen et al, 2003).

In surgical pathology practice, immunohistochemistry may be required to distinguish primary endocervical adenocarcinomas from primary endometrial tumours. A panel of antibodies is commonly used which includes oestrogen receptor (ER) and vimentin (both usually positive in endometrial carcinomas and negative in endocervical) and CEA (usually negative in endometrial and positive in cervical). However, immunophenotypes vary, and occasional cases remain problematic. For example, our own (unpublished) results with ER staining in this series of cervical adenocarcinomas indicate that around 50% of cervical adenocarcinomas show positive ER staining. Published results from other studies report CEA staining to be found in a majority (62%) of endocervical adenocarcinomas (Casrillon et al., 2001), but a significant proportion are negative. we therefore suggest that *PTEN* may be a useful addition to the panel of antibodies used to make this distinction. The results of this study have shown that 88% of cervical adenocarcinomas show positive *PTEN* staining, contrasting with published results for *PTEN* expression in endometrial adenocarcinomas, in which diminution of expression has been found in 97%, with complete absence in 61% of endometrial adenocarcinomas (Mutter, 2000).

Conclusion

In conclusion, our findings show that unlike the case in most endometrial carcinomas, *PTEN* expression is retained during the process of carcinogenesis in the glandular cervix. *PTEN* expression was positive in 105 of 119 patients (88%) with invasive cervical adenocarcinoma and 16 of 18 patients (89%) with adenocarcinoma in situ. Therefore, *PTEN* expression could be a potential biomarker for diagnosis of cervical adenocarcinoma and for distinguishing between primary cervical adenocarcinoma and primary endometrial adenocarcinoma. There is, however, evidence of altered distribution and intensity of *PTEN* expression in cervical adenocarcinoma cells compared with normal endocervical cells. Also, there was marked heterogeneity of the intensity and the distribution between and within tumours in the same section. There is no significant difference in distribution or intensity of *PTEN* expression between adenocarcinoma in situ and invasive adenocarcinoma. Also, different histological subtypes of cervical adenocarcinoma showed no significant differences in *PTEN* expression.

2.2.6 p53 suppressor gene

The role of p53 change in cervical neoplasia has been extensively studied. p53 inactivation has been found to be important in the development of cervical cancer (Miwa et al 1995; Manek & Wells 1996; Thomas et al 1999) although p53 is frequently wild type in cervical cancers. A significantly higher frequency of p53 mutation was found among cervical carcinomas with no or low HPV load (Helland et al, 1998; Skyldberg et al, 1999). P53 immunoreactivity has been demonstrated to be different between normal cervical epithelium, CIN or invasive cancer independent of HPV infection (Jeffers et al 1994, Hunt et al 1996; Troncone et al 1998; Lie et al 1999; Ngan et al 1999a). The finding of increased p53 expression in adenocarcinoma compared to squamous cell carcinoma confirms the biologic difference between the two subtypes (Quinn 1997). The expression of p53 in cervical adenocarcinoma in the literature was less frequent than its squamous counterpart (Abd El All et al, 1999).

In the present study, we found that P53 expression rate is higher in invasive adenocarcinoma (29%) than in AIS (17%). Similar findings were reported by (Yoon et al, (2001). Moreover, McCluggage et al, 1997 reported that the expression of p53 protein was 70% in invasive adenocarcinoma and 20% in AIS but negative in benign glandular lesions, and these findings suggested that p53 gene mutation might be the late event in the endocervical carcinogenesis. However, Cina et al, (1997) reported that p53 protein expression was negative in AIS but positive in cases showing florid microglandular hyperplasia, and p53 protein expression did not mean malignant nature. In our study, there was significant statistical difference of p53 expression between AIS and villoglandular papillary adenocarcinoma ($p = 0.014$). However, there were no significant statistical differences of p53 expression between AIS and the other different subtypes of invasive adenocarcinoma (table 38)

There is controversy regarding the prognostic value of P53 in cervical carcinoma. In our study we found p53 expression to be higher in invasive cervical cases than non invasive cases. Similar finding was reported (Uchiyama et al 1997, Crawford et al 1998). However, some studies found no association between p53 overexpression or

the presence of mutant p53 protein and clinical outcome (Hunt et al 1996, Pillai et al 1999). Other studies failed to demonstrate staining in 13 adenocarcinoma examined (Mittal et al, 1995).

Conclusion

We have documented p53 immunoreactivity was associated more with invasive adenocarcinoma than AIS. This supports that p53 overexpression is usually associated with frankly invasive cases. There was significant statistical difference of p53 expression between AIS and villoglandular papillary adenocarcinoma ($p=0.014$). However, there were no significant statistical differences of p53 expression between AIS and the other different subtypes of invasive adenocarcinoma.

Chapter 3

Human papilloma viruses 16 and 18 in cervical adenocarcinoma

Cervical cancer is the second most common type of cancer in females worldwide, with over 500,000 new cases diagnosed each year. It has been shown that HPV is associated with a continuum of genital tract disease from dysplasia to invasive squamous cell carcinoma. A high prevalence of HPV DNA, predominantly types 16,18,31,33 and 35, has been detected in several previous studies in women with cervical carcinoma (Chen et al, 1994; Wu CH et al, 1994; Liaw et al, 1995).

Tenti et al (1996) reported a higher prevalence of HPV DNA in cervical adenocarcinomas when compared to most previous reports and similar to that reported for cervical squamous cell carcinoma (Bosch et al, 1993). The relative difficulty in detecting HPV DNA in adenocarcinomas, in contrast to squamous cell carcinomas, may be attributed to a lower viral load in glandular lesions as compared to squamous lesions. Premalignant and malignant squamous lesions, in particular those associated with HPV 16, contain a large number of episomal viral particles, in addition to integrated HPV sequences (Stoler et al, 1992). Glandular epithelium does not support productive viral infection and HPV DNA in endocervical neoplasms (notably HPV 18), is usually present in the integrated form (Park et al, 1997). As a result, detection of HPV DNA in adenocarcinomas requires a sensitive detection assay. Further, as the successful amplification of HPV DNA in a PCR assay depends on the presence of intact DNA target sequences, two additional factors may reduce the efficiency of HPV detection: 1) DNA fragmentation as a result of formalin fixation and storage in paraffin; and 2) loss of portions of the viral genome during integration. Integration of HPV DNA may result in deletion of the viral genome containing the sequences targeted in the PCR reaction. In such cases, the detection of HPV DNA in the assay will depend on the presence of intact episomal HPV copies. The absence of an episomal HPV genome in the majority of glandular tumours, as opposed to squamous tumours (Park et al, 1997) may result in a significant underestimation of HPV DNA prevalence in adenocarcinomas (Pirog et al, 2000).

In this study, sensitive detection of HPV has been achieved by the utilization of PCR. In PCR for HPV-DNA, consensus primers targeting E6 and E7 regions are most widely used for comprehensive detection. In general, L1 region primers provide higher sensitivities with wider coverage of HPV types than E6 and E7 region primers. However, it is well known that frequent deletion of the L1 region occurs when HPV is integrated. This was elucidated in recent study (Yamaguchi et al, 2002), where it noted that a number of cases, which could not be detected using L1 primers (Yashikawa et al, 1991), were clearly identified as HPV types 16, 18 and 31 using E6 and E7 primers (Fujinaga et al, 1991). Therefore we used consensus primers targeting E6 and E7 regions not L1 region for HPV-DNA detection.

Our findings show that HPV infection was absent in all cases of normal cervical biopsies, contrasting some previous studies in other countries, which also employed the PCR technique and showed quite high prevalence rates for HPV infection in normal cervical tissues (Meanwell et al, 1987; Tidy et al, 1989). Such differences may be partly due to some geographical and/or racial factors. One must also be cautious about PCR results, since the technique is notorious for false-positivity due to laboratory contamination. Furthermore, PCR techniques with higher detection sensitivities, such as two-step PCR, might increase the rate of HPV detection. Indeed, some of the papers were later retracted (Tidy et al, 1989).

We found HPV 16 or 18 infections in 87 cases (62.6%) out of a total of 257 cervical biopsies from 139 women with various cervical adenocarcinomas lesions. This result was somewhat lower than other reports showing 68 to 84% positivity (Chen et al, 1993; Williamson et al, 1994; Van den Brule et al, 1989; Kristiansen et al, 1994). HPV DNA was identified in 87 cases (62.6%) in which, HPV16 positive for 65 (47%) patients and HPV18 positive for 41 (29%) patients. Genotyping by RFLP and PCR revealed that, HPV type 16 was the most frequent type of infection comprising 46 cases (33%), followed by HPV type 18 in 22 cases (16%), and both HPV type 16 and HPV type 18 in 19 cases (14%). There were 52 (38%) of 139 of patients with various cervical adenocarcinomas lesions with HPV type 16 and HPV type 18 both negative.

The association of HPV with cervical adenocarcinoma has been reported (Maier and Norris, 1980; Tenti et al, 1998). A comparison of the prevalence of HPV 16 and/or 18

infection in cervical adenocarcinoma in different countries using different techniques is summarized in (Lee et al, 1993) (Table 39). In the present studies, the detection rate of HPV 16 (33%) in cervical adenocarcinoma was higher than that reported in parts of Europe and the USA, and we found HPV 16 to be the predominant type in cervical adenocarcinoma. Only a few studies concluded that the rates of HPV 16 DNAs were higher than HPV 18, 80% (4/5) (Griffin et al, 1991), 71.4% (5/7) (Das et al, 1993), 66.7 % (2/3) (Lee et al 1993) and 55% (6/11) (Uchiyama et al, 1997) in cervical adenocarcinoma. However, many studies reported that HPV 18 is the predominant type (Leminen et al, 1991; Duggan et al, 1993; Johnson et al, 1992; Chen et al, 1994; Yamakawa et al 1994; Heller et al, 1991). It might be attributed in part to geographical and or/ racial differences.

Table 39 Frequency of HPV16 and 18 in different countries.

Author	Country	Pat ient no	Techniques	HPV (%)	HPV 16 (%)	HP V 18 (%)	HP V 16/ 18 %
Leminen	Finland	106	ISH (16,18)	18	2	14	2
Duggan	Canada	77	DBH (16,18)	44	18	23	nm
Das	India	12	ISH (16,18)	58.3	41.6	16	0
Griffin	England	16	PCR (16,18&S)	31.3	25	6.3	0
Bjersing	Sweden	26	PCR (E6/E7&S)	42.0	15	27	0
Johnson	US,Michigan	22	PCR (E6/E7&S)	82	23	59	0
Hording	Denmark	50	PCR (16,18&DBH)	70	18	52	0
Lee	US,Vermont	20	PCR (16,18&S)	15	10	5	0
Chen	Taiwan	42	PCR(L1,E6/E7,MY09,MY11)	67	19	48	0
Yamakawa	Japan	43	PCR (16,18&S)	56	21	33	2
Tenti	Italy	138	PCR (16,18&S)	85	28	30	27
Iwasawa	Finland	108	PCR (16,18& MY09,MY11)	75	17	56	3
Parker	US,Washington	32	PCR (16,18)	50	22	28	0
Uchiyama	Japan	32	PCR (L1,16,18&MseI&RsaI)	34	19	12	3
Ferguson	Us,Michigan	27	PCR (L1&MseI&RsaI)	59	26	26	nm
Tenti	Italy	74	PCR (16,18&S)	76	20	33	23
Lee	Taiwan	69	PCR(MY09,MY11&S&RsaI)	32	16	14	1.5
M.Tawfik El-Mansi (Current study)	Scotland	139	PCR (16,18)	62.6	33	16	14

Table 39 Showing frequency of HPV16 and /o r 18 DNA in cervical adenocarcinoma by in situ hybridization and PCR. ISH: in situ hybridization, S: Southern, DBH: dot blot hybridization (Modified from Lee et al, 1993).

In the present study, the difference between prevalence of HPV infection caused by HPV 16 only, HPV 18 only or/and both in adenocarcinoma *in situ* and the invasive cervical adenocarcinoma was not statistically significant (Table 39). It was reported that expression rate of AIS was 70% and endocervical glandular dysplasia adjacent to AIS also showed the presence of HPV, therefore HPV might be the causative agent in the development of endocervical glandular dysplasia and AIS (Leary et al, 1991). Higgins et al, (1992) reported that HPV expression rate in CGIN was 95.2% and HPV might be involved in the early stage of carcinogenesis because higher grade lesions showed stronger expression. In another report (Farnsworth et al, 1989), HPV was expressed in AIS lesion, but negative in endocervical glandular atypia and normal endocervix. Tase et al, (1989) regarded endocervical glandular dysplasia as a reactive lesion because HPV expression rate of endocervical glandular dysplasia was only 6% in contrast to 64% of coexisting AIS, microinvasive adenocarcinoma and CIN lesion.

AIS lesion was not infrequently associated with CIN and both lesions expressed HPV 16/18, which suggested that HPV plays a role in the development of both squamous and glandular lesions (Alejo et al, 1993). Duggan et al, (1994) studied HPV16/18 in AIS associated with CIN, and HPV expression rate was 66% and concluded that HPV 18 might be more important in the development of AIS. According to Anciaux et al, (1997) adenocarcinoma showed similar HPV expression rate regardless of coexistent squamous neoplasia; however, HPV expression rate of endocervical glandular dysplasia associated with squamous neoplasia was 64.2% and that of endocervical glandular dysplasia without squamous neoplasia was 16.7%. Their results indicated that squamous and glandular neoplasia of cervix might have different pathways in carcinogenesis. In our study using PCR, high expression rate of HPV16/18 in malignant endocervical glandular lesions indicates that HPV may be involved in the development of endocervical adenocarcinoma.

In this study, HPV 16/18 prevalence in all subtypes of invasive adenocarcinoma has shown that there are no significant differences between different subtypes. The comparison of all histological subtypes of invasive adenocarcinoma concerning HPV 16/18 infection is presented in table 38.

However, several previous studies have found a high HPV prevalence in cervical mucinous tumours, especially in those with endocervical morphology (Ferguson et al, 1998; Duggan et al, 1993; Tenti et al, 1996). Other investigators have reported a highly variable prevalence of HPV DNA in clear cell carcinoma (Duggan et al, 1993; Tenti et al, 1996). Of note, CCC of the cervix has to be differentiated from clear-cell squamous carcinoma and clear-cell adenosquamous carcinoma, as both of the latter tumours are associated with HPV (Fujiwara et al, 1995). The histological subtypes of adenosquamous (not otherwise specified), adenoid basal, adenoid cystic, glassy cell, and clear-cell adenosquamous carcinoma have been found to be associated with HPV in a high percentage of cases (Yamakawa et al, 1994; Kenny et al, 1992). Another group of cervical tumours which display focal glandular and squamous differentiation are neuroendocrine carcinomas. These tumours also have a high prevalence of HPV DNA, ranging from 53 to 85%, and are associated with both HPV 16 and 18; however, HPV 18 seems to be the most predominant in the small-cell carcinoma histological subtype (Ambros et al 1991).

Results of LCM were unsatisfactory, this might be due to different factors such as, little amount of DNA, degradation of DNA particles and an absence of episomal HPV genome in the majority of the glandular tumours as opposed to squamous tumours, may results in a significant underestimation of HPV DNA prevalence in adenocarcinoma (Park et al 1997 and Pirog et al 2000).

It remains the fact however that there are few studies that have assessed type-specific HPV prevalence and diversity in invasive adenocarcinoma and its precursors (An et al., 2005). Due to the comparative rarity of adenocarcinoma, related HPV prevalence data are often lumped together with SCC cases, without being teased out or are not included at all (due to their absence) in studies of smaller cohorts. Thus the potential of HPV testing and vaccination on the reduction of adenocarcinoma per se is less clearly defined by this “swamping” effect. The remits of this study were therefore to assess the prevalence of HPV “vaccine type” (16 and 18) in a large set of cervical adenocarcinoma using PCR methods. Another dimension was to evaluate any potential HPV type specific association with histological type of preinvasive (High grade CGIN/ Adenocarcinoma in situ) and invasive cervical adenocarcinoma.

In terms of the potential usefulness of a prophylactic vaccine in the prevention of adenocarcinoma, the results that we present are extremely positive. We have shown that both HPV 18 (as detected by other investigators) and perhaps more interestingly, HPV 16 are indeed prevalent in pre-invasive and invasive adenocarcinomas. Phase 3 trials of two commercial vaccines, which are designed to be protective for HPV 16 and 18 infection are ongoing. If the findings are positive (as the results of the phase 2 trials would indicate (Villa et al., 2005), we can speculate from that the vaccines have the potential of reducing the incidence of adenocarcinoma significantly.

In terms of using adjunctive HPV testing in cytology screening, our results again would suggest that adenocarcinoma, undetected by cytology, could potentially be detected/exposed by the use of a commercially available HPV test. For example, the Hybrid Capture® 2 (HC II) Test (Digene), which is currently the only HPV test that has FDA approval and is used in the US for screening and triage, includes both types 18 and 16 within its detection remit. Although we exclusively looked at AIS or worse, Derchain et al, (2004) also found a high prevalence of HR-HPV in atypical glandular cells (AGC), which some argue, are the precursors of AIS. Again, the authors postulate the beneficial role that HR-HPV screening could have on the improved detection of glandular abnormalities at an early stage.

Our results combined with data from epidemiological, clinicopathological, and molecular studies indicate that squamous cell carcinomas and adenocarcinomas of the cervix share a common pathogenesis that involves infection with oncogenic HPV types. Although little is known about the molecular genetic events involved in the pathogenesis of cervical adenocarcinoma after HPV infection, it is well-established that expression of the high-risk HPV E6 and E7 oncoproteins in keratinocytes (squamous cells) disrupts the function of the cell cycle-regulating proteins p53 and pRB, respectively (Werness et al, 1990; Dyson et al, 1989). The same mechanism of HPV-related carcinogenesis may occur in cervical glandular epithelium.

Conclusions

Typing of HPV is likely to be helpful in predicting the consequence of endocervical atypia, since HPV 16 and 18 have both been shown to be more related to cancer presence than the other HPV types. HPV typing by PCR has typically been performed

by restriction enzyme analysis. However, such a technique may not be suitable for routine use due to the additional necessary procedures and relatively expensive running cost. Consequently, we chose type-specific PCR and tried to establish an optimized condition for the two major types of HPV. Laser capture microdissection is not a good method for extraction and detection of HPV DNA in cervical adenocarcinoma samples. Thus, the combined type-specific PCR, followed by agarose electrophoresis, can be effectively applied for detection of HPV DNA.

Of 87 HPV -positive specimens (62.6%), HPV type 16 was the most frequent type of infection comprising 46 cases (33%), followed by HPV type 18 in 22 cases (16%), and both HPV type 16 and HPV type 18 in 19 cases (14%). Moreover, the difference between prevalence of HPV infection caused by HPV 16 only, HPV 18 only or/and both in adenocarcinoma in situ and the invasive cervical adenocarcinoma was not statistically significant. However, 16/18 prevalence in all subtypes of invasive adenocarcinoma has showed that there are no big differences between each other. Nevertheless, HPV 16 and HPV 18 DNAs were detected with significant frequency in the tissue sections obtained from cervical adenocarcinoma patients. Taken together, our findings support that HPV 16, along with HPV 18, may play a possible role in the pathogenesis of adenocarcinoma of the uterine cervix. More than 22 HPV types have been found in the genital tract and the possibility of tumour specimens containing HPV types other than those screened for here can not be excluded. Therefore, it is important to identify the presence of HPV types other than HPV 16 and HPV 18.

COMPOSITION OF SOLUTIONS

Composition of solutions

Haematoxylin and Eosin Stain

1% acid alcohol

1ml hydrochloric acid

100mls 74 O.P.

(CARE: this is extremely corrosive).

70% alcohol

70mls 70 O.P

30mls tap water.

90% ethanol / 10 % formalin

90mls absolute ethanol

10mls 37% formaldehyde

DNA Analysis

Lysis buffer

10mM Tris pH 8.3

50mM KCL

0.45% Tween 20

2.5mM Mg Cl₂

dNTP's :

100mM stock - dilute 6.25ul of each nucleotide in 475ul DDW

Store at -20°C

Agarose gel (TBE) Buffer

(x10 conc. usually prepared and diluted immediately before use).

10.8g Tris

5.5g boric acid

3.72g EDTA

Add DDW to 800ml and pH to 8.0, make up to a final volume of 1L with DDW.

Blue gel loading buffer:

30% glycerol

0.25% bromophenol blue

in agarose gel buffer

Microwave Antigen Retrieval

Citrate Buffer

1.05g Citric acid

500ml Distilled water

Dissolve citric acid in water and adjust to pH6.0 with 2N NaOH.

2N NaOH

8g NaOH

100ml Distilled water

1mM EDTA

0.073g EDTA

100ml DEPC Water

Adjust to pH8.0 with 1M NaOH.

Envision System

DAB solution

Depending on number of slides, transfer 1 ml of buffer from bottle 3a into test tube .

For each ml of buffer, add one drop (20ul) from bottle 3b. Mix immediately and solution is ready for use. This solution is stable for 5 days at 4° C.

STWS (Scott's Tap Water Substitute)

2g Potassium bicarbonate

20g Magnesium sulphate

1 liter Distilled water

Reference List

- (1) Abd el All, Rey A, Duvillard P. Expression of heat shock protein 70 and c-myc in cervical carcinoma. *Anticancer Res* 1998; 18(3A):1533-1536.
- (2) Abd el All, Rye A, Duvillard P. p53 immunohistochemical expression of Egyptian cervical carcinoma. *Pathol Oncol Res* 1999; 5(4):280-284.
- (3) Albores-Saavedra J, Manivel C, Mora A, Vuitch F, Milchgrub S, Gould E. The solid variant of adenoid cystic carcinoma of the cervix. *Int J Gynecol Pathol* 1992; 11:2-10.
- (4) Alejo M, Macedo I, Matias-Guiu X, Prat J. Adenocarcinoma in situ of the uterine cervix: clinicopathological study of nine cases with detection of human papillomavirus DNA by in situ hybridization and polymerase chain reaction. *Int J Gynecol Pathol* 1993; 12(3):219-223.
- (5) Alfsen GC, Thoresen SO, Kristensen GB, Skovlund E, Abeler VM. Histopathologic subtyping of cervical adenocarcinoma reveals increasing incidence rates of endometrioid tumours in all age groups: A population based study with review of all nonsquamous cervical carcinomas in Norway from 1966 to 1970, 1976 to 1980, and *JO - Cancer*. 2000; 89:1291-1299.
- (6) Ali IU. Gatekeeper for endometrium: the *PTEN* tumour suppressor gene. *J Natl Cancer Inst* 92[11]: 861-863. 2000.
- (7) Alkushi A, Irving J, Hsu F, Dupuis B, Liu CL, Van De RM et al. Immunoprofile of cervical and endometrial adenocarcinomas using a tissue microarray. *Virchows Arch* 2003; 442(3):271-277.
- (8) Amano M, Kato T, Amano Y, Kumazaki T. Using MR imaging to predict and evaluate the response of invasive cervical carcinoma to systemic chemotherapy. *AJR Am J Roentgenol* 1998; 171:1335-1339.

- (9) Ambros RA, Park JS, Shah KV, Kurman RJ. Evaluation of histologic, morphometric, and immunohistochemical criteria in the differential diagnosis of small cell carcinomas of the cervix with particular reference to human papillomavirus types 16 and 18. : Erratum in: *Mod Pathol* 1992; 5(1):40.586-593.
- (10) An HJ, Kim KR, Kim IS, Kim DW, Park MH, Park IA, Suh KS, Suh KS, Seo EJ, Sung SH, Sohn JH, Yoon HK, Chang ED, Cho HI, Han JY, Hong SR, Ahn GH. Prevalence of human papillomavirus DNA in various histological subtypes of cervical adenocarcinoma: a population-based study. *Mod Pathol*. 2005; 18(4): 528-534.
- (11) Anciaux D, Lawrence WD, Gregoire L. Glandular lesions of the uterine cervix: prognostic implications of human papillomavirus status. *Int J Gynecol Pathol* 1997; 16(2):103-110.
- (12) Andersen ES, Arffmann E. Adenocarcinoma in situ of the uterine cervix: a clinicopathologic study of 36 cases. *Gynecol Oncol* 1989; 35:1-7.
- (13) Anderson MC. Glandular lesions of the cervix: diagnostic and therapeutic dilemmas. *Baillieres Clin Obstet Gynaecol* 1995; 9(1):105-119.
- (14) Andersson S, Rylander E, Larsson B, Strand A, Silfversvard C, Wilander E. The role of human papillomavirus in cervical adenocarcinoma carcinogenesis. *Eur J Cancer* 2001; 37(2):246-250.
- (15) Angel C, DuBeshter B, Lin JY. Clinical presentation and management of stage I cervical adenocarcinoma: a 25 year experience. *Gynecol Oncol* 1992; 44(1):71-78.
- (16) Arraiz GA, Wigle DT, Mao Y. Is cervical cancer increasing among young women in Canada? *Can J Public Health* 1990; 81(5):396-397.
- (17) Attanoos R, Nahar K, Bigrigg A, Roberts S, Newcombe RG, Ismail SM. Primary adenocarcinoma of the cervix. A clinicopathologic study of prognostic variables in 55 cases. *Int J Gynecol Cancer* 1995; 5(3):179-186.

- (18) Austen DF, Reynolds P, Schottenfeld D, Fraumeni JF. *J Laryngeal Cancer*. New York: Oxford University Press Inc, 1996.
- (19) Avall-Lundqvist EH, Silfversward C, Aspenblad U, Nilsson BR, Auer GU. The impact of tumour angiogenesis, p53 overexpression and proliferative activity (MIB-1) on survival in squamous cervical carcinoma. *Eur J Cancer* 1997; 33(11):1799-1804.
- (20) Barlund M, Monni O, Kononen J, Cornelison R, Torhorst J, Sauter G et al. Multiple genes at 17q23 undergo amplification and overexpression in breast cancer. *Cancer Res* 2000; 60(19):5340-5344.
- (21) Barlund M, Forozan F, Kononen J, Bubendorf L, Chen Y, Bittner ML et al. Detecting activation of ribosomal protein S6 kinase by complementary DNA and tissue microarray analysis. *J Natl Cancer Inst* 2000; 92(15):1252-1259.
- (22) Barnes W, Delgado G, Kurman RJ, Petrilli ES, Smith DM, Ahmed S et al. Possible prognostic significance of human papillomavirus type in cervical cancer. *Gynecol Oncol* 1988; 29(3):267-273.
- (23) Battifora H. The multitumour (sausage) tissue block: novel method for immunohistochemical antibody testing. *Lab Invest* 1986; 55(2):244-248.
- (24) Bayo S, Bosch FX, de Sanjose S, Munoz N, Combita AL, Coursaget P et al. Risk factors of invasive cervical cancer in Mali. *Int J Epidemiol* 2002; 31(1):202-209.
- (25) Beaudry GA, Bertelsen AH, Sherman MI. Therapeutic targeting of the p53 tumour suppressor gene. *Curr Opin Biotechnol* 1996; 7:592-600.
- (26) Becker TM, Wheeler CM, McGough NS, Parmenter CA, Stidley CA, Jamison SF et al. Cigarette smoking and other risk factors for cervical dysplasia in Southwestern Hispanic and non-Hispanic white women. *Cancer Epidemiol Biomarkers Prev* 1994; 3:113-1119.

- (27) Beral V, Hermon C, Munoz N, Devesa SS. Cervical cancer. In: Doll R, Fraumeni Jr JF, Muir CS, editors. Trends in Cancer Incidence and Mortality. Woods Hole, MA: Cold Spring Harbor Laboratory Press, 1994: 265-285.
- (28) Berek JS, Hacker NF, Fu YS, Sokale JR, Leuchter RC, Lagasse LD. Adenocarcinoma of the uterine cervix: histologic variables associated with lymph node metastasis and survival. *Obstet Gynecol* 1985; 65(1):46-52.
- (29) Berezowski K, Stastny JF, Kornstein MJ. Cytokeratins 7 and 20 and carcino-embryonic antigen in ovarian and colonic carcinoma. *Mod Pathol* 1995; 9:426-429.
- (30) Bertrand M, Lickrish GM, Colgan TJ. The anatomic distribution of cervical adenocarcinoma in situ: implications for treatment. *Am J Obstet Gynecol* 1987; 157(1):21-25.
- (31) Biscotti CV, Gero MA, Toddy SM, Fischler DF, Easley KA. Endocervical adenocarcinoma in situ: an analysis of cellular features. *Diagn Cytopathol* 1997; 17(5):326-332.
- (32) Biscotti CV, Hart WR. Apoptotic bodies: a consistent morphologic feature of endocervical adenocarcinoma in situ. *Am J Surg Pathol* 1998; 22(4):434-439.
- (33) Bjersing L, Rogo K, Evander M, Gerdes U, Stendahl U, Wadell G. HPV 18 and cervical adenocarcinomas. *Anticancer Res* 1991; 11(1):123-127.
- (34) Boddington MM, Spriggs AI, Cowdell RH. Adenocarcinoma of the uterine cervix: cytological evidence of a long preclinical evolution. *Br J Obstet Gynaecol* 1976; 83(11):900-903.
- (35) Bonds L, Baker P, and Gup C, Shroyer KR. Immunohistochemical localization of cdc6 in squamous and glandular neoplasia of the uterine cervix. *Arch Pathol Lab Med* 2002; 126(10):1164-1168.

- (36) Bonneau D, Longy M. Mutations of the human PTEN gene. *Hum Mutat* 2000; 16(2):109-122.
- (37) Boon ME, Baak JP, Kurver PJ, Overdiep SH, Verdonk GW. Adenocarcinoma in situ of the cervix: an underdiagnosed lesion. *Cancer* 1981; 48(3):768-773.
- (38) Bosch FX, Munoz N, Sanjos, S, Izarzugaza I, Gili M, Viladiu P et al. Risk factors for cervical cancer in Colombia and Spain. *Int J Cancer* 1992; 52:750-758.
- (39) Bosch FX, Munoz N, de Sanjos, S. Human papillomavirus and cervical intraepithelial neoplasia grade III/carcinoma in situ: a case-control study in Spain and Colombia. *Cancer Epidemiol Biomarkers Prev* 1993; 2:415-422.
- (40) Bose S, Kannan V, Kline TS. Abnormal endocervical cells. Really abnormal? Really endocervical? *Am J Clin Pathol* 1994; 101(6):708-713.
- (41) Bousfield L, Pacey F, Young Q, Krumins I, Osborn R. Expanded cytologic criteria for the diagnosis of adenocarcinoma in situ of the cervix and related lesions. *Acta Cytol* 1980; 24(4):283-296.
- (42) Boyle DC, Smith J. Infection and cervical intraepithelial neoplasia. *Int J Gynecol Cancer* 1999; 9:177-186.
- (43) Brennan MJ, Donegan WL, Appleby DE. The variability of estrogen receptors in metastatic breast cancer. *Am J Surg* 1979; 137(2):260-262.
- (44) Brink AA, Zielinki GD, Steenbergen RD, Snijders PJ, Meijer CJ. Clinical relevance of human papillomavirus testing in cytopathology. *Cytopathology* 2005; 16(1): 7-12.
- (45) Brinton LA. Epidemiology of cervical cancer-overview. In: Munoz N, Bosch F, Shah KV, Meheus A, editors. *The Epidemiology of Human Papillomavirus and Cervical Cancer*. Lyon: IARC, 1992: 3-23.

- (46) Brinton LA, Herrero R, Reeves WC, de Britton RC, Gaitan E, Tenorio F. Risk factors for cervical cancer by histology. *Gynecol Oncol* 1993; 51(3):301-306.
- (47) Brinton LF, Reeves WC FAU, Brenes MM FAU, Herrero RF, de Britton RC FAU - Gaitan, Gaitan E FAU - Tenorio et al. Oral contraceptive use and risk of invasive cervical cancer.(0300-5771).
- (48) Broker TR FAU, Jin GF, Croom-Rivers AF, Bragg SM FAU, Richardson MF, and Chow LT FAU et al. Viral latency--the papillomavirus model. (1424-6074).
- (49) Brooks SA, Leathem AJ. Expression of the CD15 antigen (Lewis x) in breast cancer. *Histochem J* 1995; 27(9):689-693.
- (50) Brown LJ, Wells M. Cervical glandular atypia associated with squamous intraepithelial neoplasia: a premalignant lesion? *J Clin Pathol* 1986; 39(1):22-28.
- (51) Bubendorf L, Kolmer M, Kononen J, Koivisto P, Mousses S, Chen Y et al. Hormone therapy failure in human prostate cancer: Analysis by complementary DNA and tissue microarrays. *J Natl Cancer Inst* 1999; 91:1758-1764.
- (52) Bubendorf L, Kononen J, Koivisto P, Schraml P, Moch H, Gasser TC et al. Survey of gene amplifications during prostate cancer progression by high-throughout fluorescence in situ hybridization on tissue microarrays. *Cancer Res* 1999; 59(4):803-806.
- (53) Bubendorf L, Nocito A, Moch H, Sauter G. Tissue microarray (TMA) technology: miniaturized pathology archives for high-throughput in situ studies. *J Pathol* 2001; 195(1):72-79.
- (54) Burghardt E, Holzer E. Diagnosis and treatment of microinvasive carcinoma of the cervix uteri. *Obstet Gynecol* 1977; 49:641-653.
- (55) Bush RS. The significance of anemia in clinical radiation therapy. *Int J Radiat Oncol Biol Phys* 1986; 12:2047-2050.

- (56) Butterworth CE. Effect of folate on cervical cancer. *Ann N Y Acad Sci* 1992; 669:293-299.
- (57) Camp RL, Charette LA, Rimm DL. Validation of tissue microarray technology in breast carcinoma. *Lab Invest* 2000; 80(12):1943-1949.
- (58) Cardillo MR, Yap E, Castagna G. Molecular genetic analysis of TGF beta1 in breast cancer. *J Exp Clin Cancer Res* 1997; 16(1):57-63.
- (59) Cason J, Best JM, Raju KS. Vertical transmission of human papillomaviruses [letter: comment]. *American Journal of Obstetrics & Gynecology* 1999; 180:774775.
- (60) Casper GR, Ostor AG, Quinn MA. A clinicopathologic study of glandular dysplasia of the cervix. *Gynecol Oncol* 1997; 64(1):166-170.
- (61) Chan JK, Wong CS, Ku WT, Kwan MY. Reflections on the use of controls in immunohistochemistry and proposal for application of a multitissue spring-roll control block. *Ann Diagn Pathol* 2000; 4(5):329-336.
- (62) Chang SH, Maddox WA. Adenocarcinoma arising within cervical endometriosis and invading the adjacent vagina. *Am J Obstet Gynecol* 1971; 110:1015-1017.
- (63) Chang WC, Maticic J, Zhou C, Thomson T, Clement PB, Hayes MMM. Cytologic features of villoglandular adenocarcinoma of the uterine cervix Comparison with typical endocervical adenocarcinoma with a villoglandular component and papillary serous carcinoma. *Cancer Cytopathology* 1999; 87(1):5-11.
- (64) Chen SL, Han CP, Tsao YP, Lee JW, Yin CS. Identification and typing of human papillomavirus in cervical cancers in Taiwan. *Cancer* 1993; 72(6):1939-1945.
- (65) Chen TM, Chen CA, Wu CC, Huang SC, Chang CF, Hsieh CY. The genotypes and prognostic significance of human papillomaviruses in cervical cancer. *Int J Cancer* 1994; 57(2):181-184.

- (66) Cherry CP, Glucksmann A. Histology of carcinomas of the uterine cervix and survival rates in pregnant and non-pregnant patients. *Surg Gynecol Obstet* 1961; 111:763-776.
- (67) Chilvers C, Mant D, Pike MC. Cervical adenocarcinoma and oral contraceptives. *Br Med J (Clin Res Ed)* 1987; 295(6611):1446-1447.
- (68) Christopherson WM, Nealon N, Gray LA, Sr. Noninvasive precursor lesions of adenocarcinoma and mixed adenosquamous carcinoma of the cervix uteri. *Cancer* 1979; 44(3):975-983.
- (69) Chu P, Wu E, Weiss LM. Cytokeratin 7 and cytokeratin 20 expression in epithelial neoplasms: a survey of 435 cases. *Mod Pathol* 2000; 13(9):962-972.
- (70) Chu P, Weiss L. Keratin expression in human tissues and neoplasms. *Histopathology* 2002; 40(5):403.
- (71) Cina SJ, Richardson MS, Austin RM, Kurman RJ. Immunohistochemical staining for Ki-67 antigen, carcinoembryonic antigen, and p53 in the differential diagnosis of glandular lesions of the cervix. *Mod Pathol* 1997; 10(3):176-180.
- (72) Clement PB, Young RH. Deep Nabothian cysts of the uterine cervix. *Int J Gynecol Pathol* 1989; 8:340-348.
- (73) Clement PB, Young RH, Keh P, Ostor AG, Scully RE. Malignant mesonephric neoplasms of the uterine cervix: A report of eight cases, including four with a malignant spindle cell component. *Am J Surg Pathol* 1995; 19:1158-1171.
- (74) Cooper K. Human papillomavirus and endocervical adenocarcinoma. *Hum Pathol* 1994; 25(2):216-217.
- (75) Cooper P, Russell G, Wilson B. Adenocarcinoma of the endocervix--a histochemical study. *Histopathology* 1987; 11(12):1321-1330.

- (76) Corden SA, Sant-Cassia LJ, Easton AJ, Morris AG. The integration of HPV-18 DNA in cervical carcinoma. *Mol Pathol* 1999; 52(5):275-282.
- (77) Cordon-Cardo C. Mutation of cell cycle regulators: Biological and clinical implications for human neoplasia. *Am J Pathol* 1997; 147:545-560.
- (78) Costa MJ, Kenny MB, Judd R. Adenocarcinoma and adenosquamous carcinoma of the uterine cervix: Histologic and immunohistochemical features with clinical correlation. *Int J Surg Pathol* 1994; 1:181-190.
- (79) Cote RJ, Dunn MD, Chatterjee SJ, Stein JP, Shi SR, Tran QC et al. Elevated and absent pRB expression is associated with bladder cancer progression and has cooperative effects with p53. *Cancer Res* 1998; 58:1090-1094.
- (80) Creasman WR. Prognostic significance of hormone receptors in endometrial cancer. *Cancer* 1993; 71:1467-1470.
- (81) Cullimore JE, Luesley DM, Rollason TP, Byrne P, Buckley CH, Anderson M et al. A prospective study of conization of the cervix in the management of cervical intraepithelial glandular neoplasia (CIGN): a preliminary report. *Br J Obstet Gynecol* 1992; 99:314-318.
- (82) Curry SKS. Cancer of the female genital tract: overview. In: Osteen R, ed *Cancer manual* Boston: American Cancer Society, 1990; 253-257.
- (83) Cuzick J, Szarewski A, Cubie H, Hulman G, Kitchener H, Luesley D, McGoogan E, Menon U, Terry G, Edwards R, Brooks C, Desai M, Gie C Ho L, Jacobs I, Pickles C, Sasieni P. Management of women who test positive for high-risk types of human papillomavirus: the HART study. *Lancet* 2003; 362: 1871-1876.
- (84) Cuzick J, de Stavola BL, Russell MJ, Thomas BS. Vitamin A, vitamin E and the risk of cervical intraepithelial neoplasia. *Br J Cancer* 1990; 62:651-652.
- (85) Dabbs DJ, Sturz K, Zaino RJ. The immunohistochemical discrimination of endometrioid adenocarcinomas. *Hum Pathol* 1996; 27:172-177.

- (86) Das BC, Gopalkrishna V, Das DK, Sharma JK, Singh V, Luthra UK. Human papillomavirus DNA sequences in adenocarcinoma of the uterine cervix in Indian women. *Cancer* 1993; 72(1):147-153.
- (87) Delgado G, Bundy B, Zaino R, Sevin BU, Creasman WT, Major F. Prospective surgical-pathological study of disease-free interval in patients with stage IB squamous cell carcinoma of the cervix: a Gynecologic Oncology Group study. *Gynecol Oncol* 1990; 38(3):352-357.
- (88) Derchain SF, Rabelo-Santos SH, Sarian LO, Zeferino LC, Oliveira Zambeli ER, Do Amaral Westin MC et al. Human papillomavirus DNA detection and histological findings in women referred for atypical glandular cells or adenocarcinoma in situ in their Pap smears. *Gynecol Oncol* 2004; 95(3): 618-623.
- (89) Di Cristofano A, de Acetis M, Koff A, Cordon-Cardo C, Pandolfi PP. Pten and p27KIP1 cooperate in prostate cancer tumour suppression in the mouse. *Nat Genet* 2001; 27(2):222-224.
- (90) do Horto dos Santos Oliveira L, de Paula FA, Brunno LSX, de Vasconcelos E, Machado R, Silvia MBC. Analysis of the p53 gene and papillomavirus detection in smears from cervical lesions. *Sao Paulo Med J/Rev Paul Med* 2002; 120(1):20-22.
- (91) Dougherty CM, Cotten N. Mixed squamous cell and adenocarcinoma of the cervix. *Cancer* 1964; 17:1132-1143.
- (92) Drobnjak M, Latres E, Pollack D, Karpeh M, Dudas M, Woodruff JM et al. Prognostic implications of p53 nuclear overexpression and high proliferation index of Ki-67 in adult soft tissue sarcomas. *J Natl Cancer Inst* 1994; 86:549-554.
- (93) Duggan MA, Benoit JL, McGregor SE, Nation JG, Inoue M, Stuart GC. The human papillomavirus status of 114 endocervical adenocarcinoma cases by dot blot hybridization. *Hum Pathol* 1993; 24(2):121-125.

- (94) Duggan MA, Benoit JL, McGregor SE, Inoue M, Nation JG, Stuart GC. Adenocarcinoma in situ of the endocervix: human papillomavirus determination by dot blot hybridization and polymerase chain reaction amplification. *Int J Gynecol Pathol* 1994; 13(2):143-149.
- (95) Dyson N, Howley PM, Munger K, Harlow E. The human papilloma virus-16 E7 oncoprotein is able to bind to the retinoblastoma gene product. *Science* 1989; 243(4893):934-937.
- (96) Eide TJ. Cancer of the uterine cervix in Norway by histologic type, 1970-84. *J Natl Cancer Inst* 1987; 79(2):199-205.
- (97) Eifel PJ, Morris M, Oswald MJ, Wharton JT, Delclos L. Adenocarcinoma of the uterine cervix. Prognosis and patterns of failure in 367 cases. *Cancer* 1990; 65(11):2507-2514.
- (98) Eluf-Neto J, Booth M, Munoz N. Human papillomavirus and invasive cervical cancer. *Br J Cancer* 1994; 69:114-119.
- (99) Eng C, Peacocke M. *PTEN* and inherited hamartoma-cancer syndromes. *Nat Genet* 1998; 19[3]: 223.
- (100) Engellau J, Akerman M, Anderson H, Domanski HA, Rambech E, Alvegard TA et al. Tissue microarray technique in soft tissue sarcoma: immunohistochemical Ki-67 expression in malignant fibrous histiocytoma. *Appl Immunohistochem Mol Morphol* 2001; 9(4):358-363.
- (101) Farnsworth A, Laverty C, Stoler MH. Human papillomavirus messenger RNA expression in adenocarcinoma in situ of the uterine cervix. *Int J Gynecol Pathol* 1989; 8(4):321-330.
- (102) Fedor HL, De Marzo AM. Practical methods for tissue microarray construction. *Methods Mol Med* 2005; 103: 89-101.

- (103) Ferguson AW, Svoboda-Newman SM, Frank TS. Analysis of human papillomavirus infection and molecular alterations in adenocarcinoma of the cervix. *Mod Pathol* 1998; 11(1):11-18.
- (104) Fernebro E, Dictor M, Bendahl PO, Ferno M, Nilbert M. Evaluation of the tissue microarray technique for immunohistochemical analysis in rectal cancer. *Arch Pathol Lab Med* 2002; 126(6):702-705.
- (105) Ferry JA, Scully RE. 'Adenoid cystic' carcinoma and adenoid basal carcinoma of the uterine cervix: A study of 28 cases. *Am J Surg Pathol* 1988; 12:134-144.
- (106) Ferry JA, Scully RE. Mesonephric remnants, hyperplasia and neoplasia in the uterine cervix: A study of 49 cases. *Am J Surg Pathol* 1990; 14:1100-1111.
- (107) Finzer P, Aguilar-Lemarroy A, Rosl F. The role of human papillomavirus oncoproteins E6 and E7 in apoptosis. *Cancer Lett* 2002; 188(1-2):15-24.
- (108) Fisher B, Redmond C, Fisher ER, Caplan R. Relative worth of estrogen or progesterone receptor and pathologic characteristics of differentiation as indicators of prognosis in node denegative breast cancer patients: findings from National Surtected gical Adjuvant Breast and Bowel Project Prot JO - *J Clin Oncol*. 1988; 6:1076-1087.
- (109) Frayling IM, Bodmer WF, Tomlinson IP. Allele loss in colorectal cancer at the Cowden disease/juvenile polyposis locus on 10q. *Cancer Genet Cytogenet* 1997; 97(1):64-69.
- (110) Fredericks BD, Balkin A, Daniel HW, Schonrock J, Ward B, Frazer IH. Transmission of human papillomavirus from mother to child. *Aust NZ J Obstetrics Gynaecol* 1993; 33:3032.
- (111) Friedell GH, McKay DG. Adenocarcinoma in situ of endocervix. *Cancer* 1953; 6:887.

- (112) Fu YS, Reagan JW, Fu AS, Janiga KE. Adenocarcinoma and mixed carcinoma of the uterine cervix. II. Prognostic value of nuclear DNA analysis. *Cancer* 1982; 49(12):2571-2577.
- (113) Fu YS, Berek JS, Hilborne LH. Diagnostic problems of in situ and invasive adenocarcinomas of the uterine cervix. *Appl Pathol* 1987; 5(1):47-56.
- (114) Fuchs EV, Coppock SM, Green H, Cleveland DW. Two distinct classes of keratin genes and their evolutionary significance. *Cell* 1981; 27:75-84.
- (115) Fujinaga Y, Shimada M, Okazawa K, Fukushima M, Kato I, Fujinaga K. Simultaneous detection and typing of genital human papillomavirus DNA using the polymerase chain reaction. *J Gen Virol* 1991; 72(Pt 5):1039-1044.
- (116) Fujiwara H, Mitchell MF, Arseneau J, Hale RJ, Wright TJ. Clear cell adenosquamous carcinoma of the cervix: An aggressive tumour associated with human papillomavirus-18. *Cancer* 1995; 76:1591-1600.
- (117) Furnari FB, Huang HJ, Cavenee WK. The phosphoinositol phosphatase activity of *PTEN* mediates a serum-sensitive G1 growth arrest in glioma cells. *Cancer Res* 1998; 58[22]: 5002-5008.
- (118) Gaton E, Zejdel L, Bernstein D, Glezerman M, Czernobilsky B, Insler V. The effect of estrogen and gestagen on the mucus production of human endocervical cells: a histochemical study. *Fertil Steril* 1982; 38:580-585.
- (119) Geisinger KR, Marshall RB, Kute TE, Homesley HD. Correlation of female sex steroid hormone receptors with histologic and ultrastructural differentiation in adenocarcinoma of the endometrium. *Cancer* 1986; 58(7):1506-1517.
- (120) Ghandour FA, Attanoos R, Nahar K, Gee JW, Bigrigg A, Ismail SM. Immunocytochemical localization of oestrogen and progesterone receptors in primary adenocarcinoma of the cervix. *Histopathology* 1994; 24(1):49-55.

- (121) Gilks CB, Young RH, Aguirre P, DeLellis RA, Scully RE. Adenoma malignum (minimal deviation adenocarcinoma) of the uterine cervix. A clinicopathological and immunohistochemical analysis of 26 cases. *Am J Surg Pathol* 1989; 13(9):717-729.
- (122) Gilks CB, Young RH, Clement PB, Hart WR, Scully RE. Adenomyomas of the uterine cervix of endocervical type: A report of ten cases of a benign cervical tumour that may be confused with adenoma malignum. *Mod Pathol* 1996; 9:220-224.
- (123) Giovagnoli MR, Mancini R, Carraro C, Mazzei E, Carico E, Vecchione A. [Quantitative evaluation of endocervical cells in women with human papillomavirus infection]. *Minerva Ginecol* 1996; 48(3):65-71.
- (124) Gloor E, Ruzicka J. Morphology of adenocarcinoma in situ of the uterine cervix: a study of 14 cases. *Cancer* 1982; 49(2):294-302.
- (125) Glucksmann A, Cherry CP. Incidence, histology and response to radiation of mixed carcinomas (adenoacanthomas) of the uterine cervix. *Cancer* 1956; 9:971-979.
- (126) Goldstein NS, Ahmad E, Hussain M. Endocervical glandular atypia: Does a preneoplastic lesion of adenocarcinoma in situ exist. *Am J Clin Pathol* 1998; 110:200-209.
- (127) Goldstein NS, Mani A. The status and distance of cone biopsy margins as a predictor of excision adequacy for endocervical adenocarcinoma in situ. *Am J Clin Pathol* 1998; 109(6):727-732.
- (128) Gompel C, Silverberg SG. Pathology in gynecology and obstetrics. Philadelphia: Lippincott, 1994.
- (129) Grace P, Mcbrearty S, Troost M, Thornhill E, Kay AY, Leader M. Comparative study: conventional cervical and ThinPrep_ Pap tests in a routine clinical setting. *Cytopathology* 2002; 13:200-205.

- (129) Gravitt PE, Peyton CI, Alessi TQ. Improved amplification of genital human papillomaviruses. *J Clin Microbiol* 2000; 38: 357-361.
- (130) Gray IC, Stewart LM, Phillips SM. Mutation and expression analysis of the putative prostate tumour-suppressor gene PTEN. *Br J Cancer* 1998; 78:1296-1300.
- (131) Griffin NR, Dockey D, Lewis FA, Wells M. Demonstration of low frequency of human papillomavirus DNA in cervical adenocarcinoma and adenocarcinoma in situ by the polymerase chain reaction and in situ hybridization. *Int J Gynecol Pathol* 1991; 10(1):36-43.
- (132) Guanti G, Resta N, Simone C, Cariola F, Demma I, Fiorente P et al. Involvement of PTEN mutations in the genetic pathways of colorectal cancerogenesis. *Hum Mol Genet* 2000; 9(2):283-287.
- (133) Guerrieri C, Franlund B, Malmstron H, Boeyrd B. Ovarian endometrioid carcinomas simulating sex cord stromal tumours: a study using inhibin and cytokeratin 7. *Int J Gynecol Pathol* 1998; 17:266-271.
- (134) Halvorsen O, Haukaas SA, Akslen LA. Combined Loss of PTEN and p27 Expression Is Associated with Tumour Cell Proliferation by Ki-67 and Increased Risk of Recurrent Disease in Localized Prostate Cancer. *Clinical Cancer Research* 2003; 9:1474-1479.
- (135) Han- Lei Dan, Ya-Li Zhang, Yan Zhang, Ya-Dong Wang, Zuo-Sheng Lai, Yu- Jie Yang, Hai-Hong Cui, Yan-Tang Jian, Jian Geng, Yan-Qing, Chun-Hai Guo, Dian-Yuan Zhou. A novel method for preparation of tissue microarray. *World J Gastroenterol* 2004; 10 (4): 579-582.
- (136) Harrison TA, Sevin BU, Koechli O, Nguyen HN, Averette HE, Penalver M et al. Adenosquamous carcinoma of the cervix: prognosis in early stage disease treated by radical hysterectomy. *Gynecol Oncol* 1993; 50(3):310-315.

- (137) Hayashi I, Tsuda H, Shimoda T. Reappraisal of orthodox histochemistry for the diagnosis of minimal deviation adenocarcinoma of the cervix. *Am J Surg Pathol* 2000; 24:559-562.
- (138) Heller MJ, Burgart LJ, TenEyck CJ, Anderson ME, Greiner TC, Robinson RA. An efficient method for the extraction of DNA from formalin-fixed, paraffin-embedded tissue by sonication. *Biotechniques* 1991; 11(3):372-374.
- (139) Herrero R, Brinton LA, Reeves WC, Brenes MM, Tenorio F, de Britton RC et al. Risk factors for invasive carcinoma of the uterine cervix in Latin America. *Bull PAHO* 1990; 24:263-283.
- (140) Higgins GD, Phillips GE, Smith LA, Uzelin DM, Burrell CJ. High prevalence of human papillomavirus transcripts in all grades of cervical intraepithelial glandular neoplasia. *Cancer* 1992; 70(1):136-146.
- (141) Hirst DG. Anemia: a problem or an opportunity in radiotherapy. *Int J Radiat Oncol Biol Phys* 1986; 192(12):2009-2017.
- (142) Hlobilkova A, Guldborg P, Thullberg M, Zeuthen J, Lukas J, Bartek J. Cell cycle arrest by the PTEN tumour suppressor is target cell specific and may require protein phosphatase activity. *Exp Cell Res* 2000; 256:571-577.
- (143) Hockenbery D, Nunez G, Milliman C, Schreiber RD, Korsmeyer SJ. Bcl-2 is an inner mitochondrial membrane protein that blocks programmed cell death. *Nature* 1990; 348(6299):334-336.
- (144) Hoos A, Lewis JJ, Antonescu CR, Dudas ME, Leon L, Woodruff JM et al. Characterization of molecular abnormalities in human fibroblastic neoplasms -a model for genotype-phenotype association in soft tissue tumours. *Cancer Res* 2001; 61:3171-3175.
- (145) Hoos A, Cordon-Cardo C. Tissue microarray profiling of cancer specimens and cell lines: opportunities and limitations. *Lab Invest* 2001; 81(10):1331-1338.

- (146) Hoos A, Urist MJ, Stojadinovic A, Mastorides S, Dudas ME, Leung DH et al. Validation of tissue microarrays for immunohistochemical profiling of cancer specimens using the example of human fibroblastic tumours. *Am J Pathol* 2001; 158(4):1245-1251.
- (147) Hopkins MP, Sutton P, Roberts JA. Prognostic features and treatment of endocervical adenocarcinoma of the cervix. *Gynecol Oncol* 1987; 27(1):69-75.
- (148) Hopkins MP, Schmidt RW, Roberts JA, Morley GW. The prognosis and treatment of stage I adenocarcinoma of the cervix. *Obstet Gynecol* 1988; 72(6):915-921.
- (149) Hopkins MP, Morley GW. A comparison of adenocarcinoma and squamous cell carcinoma of the cervix. *Obstet Gynecol* 1991; 77(6):912-917.
- (150) Hording U, Daugaard S, Visfeldt J. Adenocarcinoma of the cervix and adenocarcinoma of the endometrium: distinction with PCR-mediated detection of HPV DNA. *APMIS* 1997; 105(4):313-316.
- (151) Horowitz IR, Jacobson LP, Zucker PK, Currie JL, Rosenshein NB. Epidemiology of adenocarcinoma of the cervix. *Gynecol Oncol* 1988; 31(1):25-31.
- (152) Howayda AE-A, Annie R, Pierre D. p53 Immunohistochemical Expression of Egyptian Cervical Carcinoma. *Pathology oncology research* 1999; 5(4).
- (153) Hunter RE, Longcope C, Keough P. Steroid hormone receptors in carcinoma of the cervix. *Cancer* 1987; 60(3):392-396.
- (154) Hwang T. Detection and Typing of human papillomavirus DNA by PCR using consensus primers in various cervical lesions of Korean women. *J Korean Med Sci* 14, 593-599. 1999.

- (155) Ibrahim SO, Johannessen AC, Vasstrand EN, Lillehaug J, Nilsen R. Immunohistochemical detection of p53 in archival formalin-fixed tissues of lip and intraoral squamous cell carcinomas from Norway. *APMIS* 1997; 105:757-764.
- (156) Ireland D, Hardiman P, Monaghan JM. Adenocarcinoma of the uterine cervix: a study of 73 cases. *Obstet Gynecol* 1985; 65(1):82-85.
- (157) Ishii K, Kumagai T, Tozuka M, Ota H, Katsuyama T, Kurihara M. A new diagnostic method for adenoma malignum and related lesions: latex agglutination test with a new monoclonal antibody,HIK 1083. *Clinica Chimica Acta* 2001; 312:231-233.
- (158) Jacobs MV, Husman AM, van den Brule AJ, Snijders PJ, Meijer CJ, Walboomers JM. Group-specific differentiation between high- and low-risk human papillomavirus genotypes by general primer-mediated PCR and two cocktails of oligonucleotide probes. *J Clin Microbiol* 1995; 33: 901-905.
- (159) Jacobs TW, Prioleau JE, Stillman IE, Schnitt SJ. Loss of tumour marker-immunostaining intensity on stored paraffin slides of breast cancer. *J Natl Cancer Inst* 1996; 88:1054-1059.
- (160) James CD, Galanis E, Frederick L, Kimmel DW, Cunningham JM, Atherton-Skaff PJ et al. Tumour suppressor gene alterations in malignant gliomas: histopathological associations and prognostic evaluation. *Int J Oncol* 1999. 15[3]: 547-553.
- (161) Janice Matthews-Greer, Hugo Dominguez-Malagon, Guillermo A. Herrera, James Unger, Jose Chanona-Vilchis, Gloria Caldito, Elba A. Turbat-Herrera. Human Papillomavirus Typing of Rare Cervical Carcinomas *Archives of Pathology and Laboratory Medicine*. 128 (5)., 553-556. 2004.

- (162) Janus CL, Mendelson DS, Moore S, Gendal ES, Dottino P, Brodman M. Staging of cervical carcinoma: accuracy of magnetic resonance imaging and computed tomography. *Clin Imaging* 1989; 13:114-116.
- (163) Jaworski R. Endocervical glandular dysplasia, adenocarcinoma in situ and early invasive (microinvasive) adenocarcinoma of the uterine cervix. *Semin Diagn Pathol* 1990; 7:190-205.
- (164) Johnson TL, Kim W, Plieth DA, Sarkar FH. Detection of HPV 16/18 DNA in cervical adenocarcinoma using polymerase chain reaction (PCR) methodology. *Mod Pathol* 1992; 5(1):35-40.
- (165) Jones MA, Young RH, Scully RE. Diffuse laminar endocervical glandular hyperplasia: A report of seven cases. *Am J Surg Pathol* 1991; 15:1123-1129.
- (166) Jones MW, Silverberg SG. Cervical adenocarcinoma in young women: possible relationship to microglandular hyperplasia and use of oral contraceptives. *Obstet Gynecol* 1989; 73(6):984-989.
- (167) Kaku T, Kamura T, Sakai K, Amada S, Kobayashi H, Shigematsu T et al. Early adenocarcinoma of the uterine cervix. *Gynecol Oncol* 1997; 65(2):281-285.
- (168) Kallioniemi OP, Wagner U, Kononen J, Sauter G. Tissue microarray technology for high-throughput molecular profiling of cancer. *Hum Mol Genet* 2001; 10(7):657-662.
- (169) Kaminski P, Norris H. Minimal deviation carcinoma (adenoma malignum) of the cervix. *Int J Gynecol Pathol* 1983; 2:141-152.
- (170) Kashima H, Levanthal B, Mounts P. Scoring System to Assess Severity and Course in Recurrent Respiratory Papillomatosis. Alan R Liss. New York: 1985.
- (171) Kashimura M, Shinohara M, Oikawa K, Hamasaki K, Sato H. An adenocarcinoma in situ of the uterine cervix that developed into invasive adenocarcinoma after 5 years. *Gynecol Oncol* 1990; 36(1):128-133.

- (172) Kaspar HG, Dinh TV, Doherty MG, Hannigan EV, Kumar D. Clinical implications of tumour volume measurement in stage I adenocarcinoma of the cervix. *Obstet Gynecol* 1993; 81(2):296-300.
- (173) Kawanishi M, Kohno T, Otsuka T, Adachi J, Sone S, Noguchi M et al. Allelotype and replication error phenotype of small cell lung carcinoma. *Carcinogenesis* 1997; 18[11]: 2057-2062.
- (174) Kenny MB, Unger ER, Chenggis ML, Costa MJ. In situ hybridization for human papillomavirus DNA in uterine adenosquamous carcinoma with glassy cell features ("glassy cell carcinoma"). *Am J Clin Pathol* 1992; 98(2):180-187.
- (175) Kerns BJ, Jordan PA, Faerman LL, Berchuck A, Bast RC, Jr., Layfield LJ. Determination of proliferation index with MIB-1 in advanced ovarian cancer using quantitative image analysis. *Am J Clin Pathol* 1994; 101(2):192-197.
- (176) Khan MJ, Castle PE, Lorincz AT, Wacholder S, Sherman M, Scott DR, Rush BB, Glass AG, Schiffman M. The elevated 10-year risk of cervical precancer and cancer in women with human papillomavirus (HPV) type 16 or 18 and the possible utility of type-specific HPV testing in clinical practice. *J Natl Cancer Inst* 2005; 97: 1072-1079.
- (177) Kilgore LC, Soong SJ, Gore H, Shingleton HM, Hatch KD, Partridge EE. Analysis of prognostic features in adenocarcinoma of the cervix. *Gynecol Oncol* 1988; 31(1):137-153.
- (178) Kjaer SK, Brinton LA. Adenocarcinomas of the uterine cervix: the epidemiology of an increasing problem. *Epidemiol Rev* 1993; 15(2):486-498.
- (179) Kjerstad KE. Adenocarcinoma of the uterine cervix. *Gynecol Oncol* 1977; 5(3):219-223.
- (180) Kobayashi AF, Miaskowski CF, Wallhagen MF, Smith-McCune K. Recent developments in understanding the immune response to human papilloma virus infection and cervical neoplasia.(0190-535X).

- (181) Kong D, Suzuki A, Zou TT. PTEN1 is frequently mutated in primary endometrial carcinomas. *Nat Genet* 1997; 17:143-144.
- (182) Kononen J, Bubendorf L, Kallioniemi A, Barlund M, Schraml P, Leighton S et al. Tissue microarrays for high-throughput molecular profiling of tumour specimens. *Nat Med* 1998; 4(7):844-847.
- (183) Korhonen MO. Adenocarcinoma of the uterine cervix. Prognosis and prognostic significance of histology. *Cancer* 1984; 53(8):1760-1763.
- (184) Koutsky LA, Holmes KK, Critchlow CW, Stevens CE, Paavonen J, Beckman AM et al. A cohort study of the risk for cervical intraepithelial neoplasia grade 2 or 3 in relation to papillomavirus infection. *N Engl J Med* 1992; 327:1272-1278.
- (185) Kristiansen E, Jenkins A, Kristensen G, Ask E, Kaern J, Abeler V et al. Human papillomavirus infection in Norwegian women with cervical cancer. *APMIS* 1994; 102(2):122-128.
- (186) Kubbutat MH, Vousden KH. Keeping an old friend under control: regulation of p53 stability. *Mol Med Today* 1998; 4:250-256.
- (187) Kudo R, Sagae S, Hayakawa O, Ito E, Horimoto E, Hashimoto M. Morphology of adenocarcinoma in situ and microinvasive adenocarcinoma of the uterine cervix. A cytologic and ultrastructural study. *Acta Cytol* 1991; 35(1):109-116.
- (188) Kurian K, Al Nafussi A. Relation of cervical glandular intraepithelial neoplasia to microinvasive and invasive adenocarcinoma of the uterine cervix: A study of 121 cases. *J Clin Pathol* 1999; 52:112-117.
- (189) Kurman RJ, Schiffman MH, Lancaster WD, Reid R, Jenson AB, Temple GF et al. Analysis of individual human papillomavirus types in cervical neoplasia: a possible role for type 18 in rapid progression. *Am J Obstet Gynecol* 1988; 159(2):293-296.

- (190) Landry D, Mai KT, Senterman MK, Perkins DG, Yazdi HM, Veinot JP et al. Endometrioid adenocarcinoma of the uterus with a minimal deviation invasive pattern. *Histopathology* 2003; 42(1):77.
- (191) Layfield LJ, Saria E, Mooney EE, Liu K, Dodge RR. Tissue heterogeneity of immunohistochemically detected estrogen receptor. Implications for image analysis quantification. *Am J Clin Pathol* 1998; 110(6):758-764.
- (192) Leary J, Jaworski R, Houghton R. In-situ hybridization using biotinylated DNA probes to human papillomavirus in adenocarcinoma-in-situ and endocervical glandular dysplasia of the uterine cervix. *Pathology* 1991; 23(2):85-89.
- (193) Lee KR. False-positive diagnosis of adenocarcinoma in situ of the cervix. *Acta Cytol* 1988; 32(2):276-277.
- (194) Lee KR, Howard P, Heintz NH, Collins CC. Low prevalence of human papillomavirus types 16 and 18 in cervical adenocarcinoma in situ, invasive adenocarcinoma, and glandular dysplasia by polymerase chain reaction. *Mod Pathol* 1993; 6(4):433-437.
- (195) Lee KR, Minter LJ, Granter SR. Papanicolaou smear sensitivity for adenocarcinoma in situ of the cervix. A study of 34 cases. *Am J Clin Pathol* 1997; 107(1):30-35.
- (196) Lee KR, Flynn CE. Early invasive adenocarcinoma of the cervix. *Cancer* 2000; 89(5):1048-1055.
- (197) Leminen A, Paavonen J, Forss M, Wahlstrom T, Vesterinen E. Adenocarcinoma of the uterine cervix. *Cancer* 1990; 65(1):53-59.
- (198) Leteurtre E, Boman F, Farine MO, Leroy JL, Gosselin B. [Importance of the study of the expression of MIB-1 (Ki-67) for the diagnosis of endocervical glandular lesions]. *Ann Pathol* 1998; 18(3):172-177.

- (199) Levi S, Urbano-Ispizua A, Gill R, Thomas DM, Gilbertson J, Foster C et al. Multiple K-ras Codon 12 mutations in cholangiocarcinoma demonstrated with a sensitive polymerase chain reaction technique. *Cancer Res.* 51[13], 3497-3502. 1991.
- (200) Liaw KL, Hsing AW, Chen CJ, Schiffman MH, Zhang TY, Hsieh CY et al. Human papillomavirus and cervical neoplasia: a case-control study in Taiwan. *Int J Cancer* 1995; 62(5):565-571.
- (201) Littman P, Clement PB, Henriksen B. Glassy cell carcinoma of the cervix. *Cancer* 1976; 37:2238-2246.
- (202) Luesley DM, Jordan JA, Woodman CB, Watson N, Williams DR, Waddell C. A retrospective review of adenocarcinoma-in-situ and glandular atypia of the uterine cervix. *Br J Obstet Gynaecol* 1987; 94(7):699-703.
- (203) Maddox P, Sasieni P, Szarewski A, Anderson M, Hanby A. Differential expression of keratins 10,17 and 19 in normal cervical epithelium, cervical intraepithelial neoplasia, and cervical carcinoma. *J Clin Pathol* 1999; 52:41-46.
- (204) Madeleine MM, Daling JR, Schwartz SM, Shera K, McKnight B, Carter JJ et al. Human papillomavirus and long-term oral contraceptive use increase the risk of adenocarcinoma in situ of the cervix. *Cancer Epidemiol Biomarkers Prev* 2001; 10(3):171-177.
- (205) Maier RC, Norris HJ. Coexistence of cervical intraepithelial neoplasia with primary adenocarcinoma of the endocervix. *Obstet Gynecol* 1980; 56(3):361-364.
- (206) Mandelblatt JS, Kanetsky P, Eggert L, Gold K. Is HIV infection a cofactor for cervical squamous cell neoplasia. *Cancer Epidemiol Biomarkers Prev* 1999; 8:97-106.
- (207) Marlina Schoenberg Fejzo and Dennis J. Slamon. Frozen Tumour Tissue Microarray Technology for Analysis of Tumour RNA, DNA, and Proteins. *American Journal of Pathology.* 2001; 159: 1645-1650.

- (208) Martin JD, Hahnel R, McCartney AJ, De Klerk N. The influence of estrogen and progesterone receptors on survival in patients with carcinoma of the uterine cervix. *Gynecol Oncol* 1986; 23(3):329-335.
- (209) Masood S, Rhatigan RM, Wilkinson EW, Barwick KW, Wilson WJ. An immunocytochemical study: Expression and prognostic significance of estrogen and progesterone receptors in adenocarcinoma of the uterine cervix. *Cancer* 1993; 72:511.
- (210) Masood S, Rhatigan RM, Wilkinson EW, Barwick KW, Wilson WJ. Expression and prognostic significance of estrogen and progesterone receptors in adenocarcinoma of the uterine cervix. An immunocytochemical study. *Cancer* 1993; 72(2):511-518.
- (211) Mathers ME, Johnson SJ, Wadehra V. How predictive is a cervical smear suggesting glandular neoplasia? *Cytopathology* 2002; 13(2):83-91.
- (212) Matthews CM, Burke TW, Tornos C, Eifel PJ, Atkinson EN, Stringer CA et al. Stage I cervical adenocarcinoma: prognostic evaluation of surgically treated patients. *Gynecol Oncol* 1993; 49(1):19-23.
- (213) McCance DJ, Champion MJ, Clarkson PK. Prevalence of human papillomavirus type 16 DNA sequences in cervical intraepithelial neoplasia and invasive carcinoma of the cervix. *British Journal of Obstetrics & Gynaecology* 1985; 92:1101-1105.
- (214) McCluggage G, McBride H, Maxwell P, Bharucha H. Immunohistochemical detection of p53 and bcl-2 proteins in neoplastic and non-neoplastic endocervical glandular lesions. *Int J Gynecol Pathol* 1997; 16(1):22-27.
- (215) McCluggage WG, Maxwell P, McBride HA, Hamilton PW, Bharucha H. Monoclonal antibodies Ki-67 and MIB1 in the distinction of tuboendometrial metaplasia from endocervical adenocarcinoma and adenocarcinoma in situ in formalin-fixed material. *Int J Gynecol Pathol* 1995; 14(3):209-216.

- (216) McCluggage WG, Maxwell P, Sloan JM. Immunohistochemical staining of ovarian granulosa cell tumours with monoclonal antibody against inhibin. *Hum Pathol* 1997; 28:1034-1038.
- (217) McCluggage WG, Sumathi VP, McBride HA, Patterson A. A panel of immunohistochemical stains, including carcinoembryonic antigen, vimentin and estrogen receptor, aids the distinction between primary endometrial and endocervical adenocarcinomas. *Int J Gynecol Pathol* 2002; 21:11-15.
- (218) McCluggage WG. Recent advances in immunohistochemistry in gynaecological pathology. *Histopathology* 2002; 40(4):309-326.
- (219) McCluggage WG. Endocervical glandular lesions: controversial aspects and ancillary techniques. *J Clin Pathol* 2003; 56(3):164-173.
- (220) McDougall JK. immortalization and transformation of human cells by human papillomavirus. *Curr Top Microbiol Immunol* 1994; 186:101-119.
- (221) McLellan R, Dillon MB, Woodruff JD, Heatley GJ, Fields AL, Rosenshein NB. Long-term follow-up of stage I cervical adenocarcinoma treated by radical surgery. *Gynecol Oncol* 1994; 52(2):253-259.
- (222) McMenamin ME, Soung P, Perera S, Kaplan I, Loda M, Sellers WR. Loss of PTEN expression in paraffin-embedded primary prostate cancer correlates with high Gleason score and advanced stage. *Cancer Res* 1999; 59(17):4291-4296.
- (223) Meanwell CA, Cox MF, Blackledge G, Maitland NJ. HPV 16 DNA in normal and malignant cervical epithelium: implications for the aetiology and behaviour of cervical neoplasia. *Lancet* 1987; 1(8535):703-707.
- (224) Michael H, Grawe L, Kraus FT. Minimal deviation endocervical adenocarcinoma: clinical and histologic features, immunohistochemical staining for carcinoembryonic antigen, and differentiation from confusing benign lesions. *Int J Gynecol Pathol* 1984; 3(3):261-276.

- (225) Michael T, McHale TDL, Robert A, Burger M, Gu Joanne L, Rutgers et al. Fertility sparing treatment for in situ and early invasive adenocarcinoma of the cervix. *Obstetrics & Gynecology* 2001; 98(5):726-731.
- (226) Mikami Y, Hata S, Melamed J, Fujiwara K, Manabe T. Lobular endocervical glandular hyperplasia is a metaplastic process with a pyloric gland phenotype. *Histopathology* 2001; 39:364-372.
- (227) Milde-Langosch K, Schreiber C, Becker G, Loning T, Stegner HE. Human papillomavirus detection in cervical adenocarcinoma by polymerase chain reaction. *Hum Pathol* 1993; 24(6):590-594.
- (228) Miller BE, Flax SD, Arheart K, Photopoulos G. The presentation of adenocarcinoma of the uterine cervix. *Cancer* 1993; 72(4):1281-1285.
- (229) Mills SE, Fechner RE, Frierson HF, Kempson RL, Wick MR, Dehner LP et al. Guardians of the wax and the patient. *Am J Clin Pathol* 1995; 104:365-367.
- (230) Milsom I, Friberg LG. Primary adenocarcinoma of the uterine cervix. A clinical study. *Cancer* 1983; 52(5):942-947.
- (231) Mitchell H, Medley G, Gordon I, Giles G. Cervical cytology reported as negative and risk of adenocarcinoma of the cervix: no strong evidence of benefit. *Br J Cancer* 1995; 71(4):894-897.
- (232) Mittal KR, Lin O, Chan W, Goswami S, Demopoulos RI. Cervical squamous dysplasias and carcinomas with immunodetectable p53 frequently contain HPV. *Gynecol Oncol* 1995; 58(3):289-294.
- (233) Moch H, Schraml P, Bubendorf L, Mirlacher M, Kononen J, Gasser T et al. High-throughput tissue microarray analysis to evaluate genes uncovered by cDNA microarray screening in renal cell carcinoma. *Am J Pathol* 1999; 154(4):981-986.

- (234) Moll R, Levy R, Czernobilsky B, Hohweg-Majert P, Dallenbach-Hellweg G, Franke WW. Cytokeratins of normal epithelia and some neoplasms of the female genital tract. *Lab Invest* 1983; 49:599-610.
- (235) Moll R, Lowe A, Laufer J, Franke WW. Cytokeratin 20 in human carcinomas: A new histodiagnostic marker detected by monoclonal antibodies. *Am J Pathol* 1992; 140:427-447.
- (236) Moritani S, Ioffe OB, Sagae S. Mitotic activity and apoptosis in endocervical glandular lesions. *Int J Gynecol Pathol* 2002; 21:125-133.
- (237) Morrison EA, Ho GY, Vermund SH, Goldberg GI, Kadish AS, Kelley KF et al. Human papillomavirus infection and other risk factors for cervical neoplasia: case-control study. *Int J Cancer* 1991; 49:6-13.
- (238) Moseley RP, Paget S. Liquid-based cytology: is this the way forward for cervical screening-. *Cytopathology* 2002; 13:71-82.
- (239) Mucci NR, Akdas G, Manely S, Rubin MA. Neuroendocrine expression in metastatic prostate cancer: Evaluation of high throughput tissue microarrays to detect heterogeneous protein expression. *Hum Pathol* 2000; 31:406-414.
- (240) Mulvany N, Ostor A. Microinvasive adenocarcinoma of the cervix: a cytohistopathologic study of 40 cases. *Diagn Cytopathol* 1997; 16(5):430-436.
- (241) Munger K, Phelps WC, Bubb V, Howley PM, Schlegel R. The E6 and E7 genes of human papillomavirus type 16 are necessary and sufficient for transformation of primary human keratinocytes. *J Virol* 1989; 63:4417-4423.
- (242) Munoz N. The causal link between human papillomavirus and invasive cervical cancer: a populationbased case-control study in Columbia and Spain. *Int J Cancer* 1992; 52:743-749.

- (243) Mutter GL, Ince TA, Baak JP, Kust GA, Zhou XP, Eng C. Molecular identification of latent precancers in histologically normal endometrium. *Cancer Res* 61[11], 4311-4314. 2001.
- (244) Mutter GL, Lin MC, Fitzgerald JT, Kum JB, Eng C. Changes in endometrial *PTEN* expression throughout the human menstrual cycle. *J Clin Endocrinol Metab* 2000; 85[6]: 2334-2338.
- (245) Mutter G. Diagnosis of premalignant endometrial disease. *J Clin Pathol* 2002; 55:326-331.
- (246) Mutter GL, Lin MC, Fitzgerald JT, Kum JB, Baak JP, Lees JA et al. Altered *PTEN* expression as a diagnostic marker for the earliest endometrial precancers. *J Natl Cancer Inst* 2000; 92(11):924-930.
- (247) Myers MP, Pass I, Batty IH. The lipid phosphatase activity of *PTEN* is critical for its tumour suppressor function. *Proc Natl Acad Sci U S A* 1998; 95:13513-13518.
- (248) Nakano T, Oka K. Differential values of Ki-67 index and mitotic index of proliferating cell population. An assessment of cell cycle and prognosis in radiation therapy for cervical cancer. *Cancer* 1993; 72(8):2401-2408.
- (249) Nakano T, Oka K, Ishikawa A, Morita S. Correlation of cervical carcinoma c-erb B-2 oncogene with cell proliferation parameters in patients treated with radiation therapy for cervical carcinoma. *Cancer* 1997; 79(3):513-520.
- (250) Nicklin JL, Wright RG, Bell JR, Samarasingha H, Cox NC, Ward BG. A clinicopathological study of adenocarcinoma in situ of the cervix. The influence of cervical HPV infection and other factors, and the role of conservative surgery. *Aust N Z J Obstet Gynaecol* 1991; 31(2):179-183.
- (251) Nicklin JL, Perrin LC, Crandon AJ. Microinvasive adenocarcinoma of the cervix. *Aust N Z J Obstet Gynaecol* 1999; 39:411-413.

- (252) Nieminen P, Kallio M, Hakama M. The effect of mass screening on incidence and mortality of squamous and adenocarcinoma of cervix uteri. *Obstet Gynecol* 1995; 85(6):1017-1021.
- (253) Nocito A, Kononen J, Kallioniemi OP, Sauter G. Tissue microarrays (TMAs) for high-throughput molecular pathology research. *Int J Cancer* 2001; 94(1):1-5.
- (254) Noda K, Kimura K, Ikeda M, Teshima K. Studies on the histogenesis of cervical adenocarcinoma. *Int J Gynecol Pathol* 1983; 1(4):336-346.
- (255) Novotny DB, Maygarden SJ, Johnson DE, Frable WJ. Tubal metaplasia. A frequent potential pitfall in the cytologic diagnosis of endocervical glandular dysplasia on cervical smears. *Acta Cytol* 1992; 36(1):1-10.
- (256) Nucci MR, Ferry JA, Young RH. Ectopic prostate tissue in the uterine cervix: a report of four cases and review of ectopic prostatic tissue. *Am J Surg Pathol* 2000; 24:1224-1230.
- (266) Ogawa K, Johansson SL, Cohen SM. Immunohistochemical analysis of uroplakins, urothelial specific proteins, in ovarian Brenner tumours, normal tissues, and benign and neoplastic lesions of the female genital tract. *Am J Pathol* 1999; 155:1047-1050.
- (267) Oka K, Nakano T, Arai T. Adenocarcinoma of the cervix treated with radiation alone: prognostic significance of S-100 protein and vimentin immunostaining. *Obstet Gynecol* 1992; 79(3):347-350.
- (268) Ostor A, Rome R, Quinn M. Microinvasive adenocarcinoma of the cervix: a clinicopathologic study of 77 women. *Obstet Gynecol* 1997; 89(1):88-93.
- (269) Ostor AG, Pagano R, Davoren RA, Fortune DW, Chanen W, Rome R. Adenocarcinoma in situ of the cervix. *Int J Gynecol Pathol* 1984; 3(2):179-190.

- (270) Pacey F, Ayer B, Greenberg M. The cytologic diagnosis of adenocarcinoma in situ of the cervix uteri and related lesions. III. Pitfalls in diagnosis. *Acta Cytol* 1988; 32(3):325-330.
- (271) Packeisen J, Buerger H, Krech R, Boecker W. Tissue microarrays: a new approach for quality control in immunohistochemistry. *J Clin Pathol* 2002; 55(8):613-615.
- (272) Parazzini F, La Vecchia C. Epidemiology of adenocarcinoma of the cervix. *Gynecol Oncol* 1990; 39(1):40-46.
- (273) Park JJ, Sun D, Quade BJ. Stratified mucin-producing intraepithelial lesions of the cervix: Adenosquamous or columnar cell neoplasia. *Am J Surg Pathol* 2000; 24:1414-1419.
- (274) Park JS, Hwang ES, Park SN, Ahn HK, Um SJ, Kim CJ et al. Physical status and expression of HPV genes in cervical cancers. *Gynecol Oncol* 1997; 65(1):121-129.
- (275) Perou CM, Jeffrey SS, Rijn v. Distinctive gene expression patterns in human mammary epithelial cells and breast cancers. *Proc Natl Acad Sci U S A* 1999; 96:9212-9217.
- (276) Perren A, Weng LP, Boag AH, Ziebold U, Thakore K, Dahia PL et al. Immunohistochemical evidence of loss of PTEN expression in primary ductal adenocarcinomas of the breast. *Am J Pathol* 1999; 155(4):1253-1260.
- (277) Perrone EE, Theoharis C, Mucci NR, Hayasaka S, Taylor JM, Cooney KA et al. Tissue microarray assessment of prostate cancer tumour proliferation in African-American and white men. *J Natl Cancer Inst* 2000; 92(11):937-939.
- (278) Peto J, Gilham C, Fletcher O, Matthews FE. The cervical cancer epidemic that screening has prevented in the UK. *Lancet* 2004. 364 (9430), 249-256.

- (279) Phillips AN, Davey S. Cigarette smoking as potential cause of cervical cancer: has confounding been controlled. *Int J Epidemiol* 1994; 23:42-49.
- (280) Pirog EC, Kleter B, Olgac S, Bobkiewicz P, Lindeman J, Quint WG et al. Prevalence of human papillomavirus DNA in different histological subtypes of cervical adenocarcinoma. *Am J Pathol* 2000; 157(4):1055-1062.
- (281) Pirog EC, Isacson C, Szabolcs MJ, Kleter B, Quint W, Richart RM. Proliferative activity of benign and neoplastic endocervical epithelium and correlation with HPV DNA detection. *Int J Gynecol Pathol* 2002; 21(1):22-26.
- (282) Plaxe SC, Saltzstein SL. Estimation of the duration of the preclinical phase of cervical adenocarcinoma suggests that there is ample opportunity for screening. *Gynecol Oncol* 1999; 75(1):55-61.
- (283) Potish RA, Twiggs LB, Adcock LL, Prem KA, Savage JE, Leung BS. Prognostic importance of progesterone and estrogen receptors in cancer of the uterine cervix. *Cancer* 1986; 58(8):1709-1713.
- (284) Prempre T, Amornmarn R, Wizenberg MJ. A therapeutic approach to primary adenocarcinoma of the cervix. *Cancer* 1985; 56(6):1264-1268.
- (285) Qizilbash A. In-situ and microinvasive adenocarcinoma of the uterine cervix. *Am J Clin Pathol* 1975; 64:155-170.
- (286) Quinn M. Adenocarcinoma of the Cervix. *Ann Acad Med Singapore* 1998; 27:662-665.
- (287) Quinn MA. Adenocarcinoma of the cervix--are there arguments for a different treatment policy? *Curr Opin Obstet Gynecol* 1997; 9(1):21-24.
- (288) Rahilly MA, Williams ARW, Al Nafussi A. Minimal deviation endometrioid adenocarcinoma of cervix: a clinicopathological and immunohistochemical study of two cases. *Histopathology* 1992; 20:351-354.

- (289) Ramaekers FC, van Niekerk CC, Poels L. Use of monoclonal antibodies to keratin 7 in the differential diagnosis of adenocarcinomas. *Am J Pathol* 1990; 136:641-655.
- (290) Rasheed BK, Stenzel TT, McLendon RE, Parsons R, Friedman AH, Friedman HS et al. *PTEN* gene mutations are seen in high-grade but not in low-grade gliomas. *Cancer Res* 1997; 57[19]: 4187-4190.
- (291) Richter J, Wagner U, Kononen J, Fijan A, Bruderer J, Schmid U et al. High-throughput tissue microarray analysis of cyclin E gene amplification and overexpression in urinary bladder cancer. *Am J Pathol* 2000; 157(3):787-794.
- (292) Riethdorf S, Riethdorf L, Milde-Langosch K, Park TW, Loning T. Differences in HPV 16- and HPV 18 E6/E7 oncogene expression between in situ and invasive adenocarcinomas of the cervix uteri. *Virchows Arch* 2000; 437(5):491-500.
- (293) Rollason TP, Cullimore J, Bradgate MG. A suggested columnar cell morphological equivalent of squamous carcinoma in situ with early stromal invasion. *Int J Gynecol Pathol* 1989; 8:230-236.
- (294) Rosai, J. Female reproductive system,chapter 19C.In: *Ackerman's Surgical Pathology*. Mosby,Inc., 1998.
- (295) Rosen PP, Menendez-Botet CJ, Urban JA, Fracchia A, Schwartz MK. Estrogen receptor protein (ERP) in multiple tumour specimens from individual patients with breast cancer. *Cancer* 1977; 39(5):2194-2200.
- (296) Ruche GL, You B, Leroy V, Welffens-Ekra C, Dabis F. Is HIV infection a cofactor for cervical squamous cell neoplasia: [letter]. *Cancer Epidemiol Biomarkers Prev* 1999; 8:729-730.
- (297) Ruth Z, Amiram F, Bernheim J, Zimlichman S, Markowicz O, Altaras M et al. Expression of Cytokeratin-20 in Endometrial Carcinoma. *Gynecologic Oncology* 1998; 70(3):410-413.

- (298) Rutledge FN, Galakatos AE, Wharton JT, Smith JP. Adenocarcinoma of the uterine cervix. *Am J Obstet Gynecol* 1975; 122(2):236-245.
- (299) S Bulk, J Berkhof, N W J Bulkman, C D Zielinski, L Rozendaal, F J van Kemenade, P J F Snijders and C J L M Meijer,. Preferential risk of HPV16 for squamous cell carcinoma and of HPV18 for adenocarcinoma of the cervix compared to women with normal cytology in The Netherlands . *British Journal of Cancer* 2006; 94: 171-175.
- (300) Saigo PE, Cain JM, Kim WS, Gaynor JJ, Johnson K, Lewis JL, Jr. Prognostic factors in adenocarcinoma of the uterine cervix. *Cancer* 1986; 57(8):1584-1593.
- (301) Saslow D, Runowicz CD, Solomon D, Moscicki AB, Smith RA, Eyre HJ et al. American Cancer Society guideline for the early detection of cervical neoplasia and cancer. *CA Cancer J Clin* 2002;. 52(6): 342-362.
- (302) Schiffman MH, Bauer HM, Hoover RN, Glass AG, Cadell DM, Rush BB et al. Epidemiology evidence showing that human papillomavirus infection causes most cervical intraepithelial neoplasia. *J Natl Cancer Inst* 1993; 85:958-964.
- (303) Schneider A, Shah K. The role of vitamins in the etiology of cervical neoplasia: an epidemiological review. *Arch Gynecol Obstet* 1989; 246:1-13.
- (304) Schorge JO, Lee KR, Flynn CE, Goodman A, Sheets EE. Stage IA1 cervical adenocarcinoma: definition and treatment. *Obstet Gynecol* 1999; 93(2):219-222.
- (305) Schraml P, Kononen J, Bubendorf L, Moch H, Bissig H, Nocito A et al. Tissue microarrays for gene amplification surveys in many different tumour types. *Clin Cancer Res* 1999; 5(8):1966-1975.
- (306) Schwarz E. Structure and transcription of human papillomavirus type 18 and 16 sequences in cervical carcinoma cells. *Nature* 1985; 314:111-114.

- (307) Segal GH, Hart WR. Cystic endocervical tunnel clusters. A clinicopathologic study of 29 cases of so-called adenomatous hyperplasia. *Am J Surg Pathol* 1990; 14(10):895-903.
- (308) Shepperd JH. Staging announcement: FIGO staging of gynecologic cancers: cervical and vulva. *Int J Gynecol Cancer* 1995; 5:319.
- (309) Shibata D, Martin WJ, Arnheim N. Analysis of DNA sequences in forty-year-old paraffin-embedded thin-tissue sections: A bridge between molecular biology and classical histology. *Cancer Res* 1988; 48:4564-4566.
- (310) Shiliang L, Robert S, Yang M. Research letter: Cervical cancer: the increasing incidence of adenocarcinoma and adenosquamous carcinoma in younger women. *CMAJ* 2001; 17:164.
- (311) Shin HJ, Kalapurakal SK, Lee JJ, Ro JY, Hong WK, Lee JS. Comparison of p53 immunoreactivity in fresh-cut versus stored slides with and without microwave heating. *Mod Pathol* 1997; 10:224-230.
- (312) Shingleton HM, Gore H, Bradley DH, Soong SJ. Adenocarcinoma of the cervix. I. Clinical evaluation and pathologic features. *Am J Obstet Gynecol* 1981; 139(7):799-814.
- (313) Shingleton HM, Bell MC, Fremgen A, Chmiel JS, Russell AH, Jones WB et al. Is there really a difference in survival of women with squamous cell carcinoma, adenocarcinoma, and adenosquamous cell carcinoma of the cervix? *Cancer* 1995; 76(10:Suppl):Suppl-55.
- (314) Silva EG, Kott MM, Ordonez NG. Endocrine carcinoma intermediate cell type of the uterine cervix. *Cancer* 1984; 54:1705-1713.
- (315) Skyldberg BM, Murray E, Lambkin H, Kelehan P, Auer GU. Adenocarcinoma of the uterine cervix in Ireland and Sweden: human papillomavirus infection and biologic alterations. *Mod Pathol* 1999; 12(7):675-682.

- (316) Smedts F, Ramaekers F, Troyanovsky S, Pruszczynski M, Robben H, Lane B et al. Basal-cell keratins in cervical reserve cells and a comparison to their expression in cervical intraepithelial neoplasia. *Am J Pathol* 1992; 140(3):601-612.
- (317) Smedts F, Ramaekers FC, Vooijs PG. The dynamics of keratin expression in malignant transformation of cervical epithelium: a review. *Obstet Gynecol* 1993; 82(3):465.
- (318) Snijders AM, Meijer GA, Brakenhoff RH, van den Brule AJC, van Diest PJ. Microarray techniques in pathology: tool or toy. *J Clin Pathol Mol Pathol* 2000; 53:289-294.
- (319) Speers WC, Picaso LG, Silverberg SG. Immunohistochemical localization of carcinoembryonic antigen in microglandular hyperplasia and adenocarcinoma of the endocervix. *Am J Clin Pathol* 1983; 79:105-107.
- (320) Stambolic V, Suzuki A, de la Pompa JL, Brothers GM, Mirtsos C, Sasaki T et al. Negative regulation of PKB/Akt-dependent cell survival by the tumour suppressor *PTEN*. *Cell* 1998;95[1]; 29-39.
- (321) Steck PA, Pershouse MA, Jasser SA, Yung WK, Lin H, Ligon AH et al. Identification of a candidate tumour suppressor gene, *MMAC1*, at chromosome 10q23.3 that is mutated in multiple advanced cancers. *Nat Genet* 1997;15[4]: 356-362.
- (322) Steeper TA, Wick MR. Minimal deviation adenocarcinoma of the uterine cervix ("adenoma malignum"). An immunohistochemical comparison with microglandular endocervical hyperplasia and conventional endocervical adenocarcinoma. *Cancer* 1986; 58(5):1131-1138.
- (323) Storey A, Thomas M, Kalita A, Harwood C, Gardiol D, Mantovani F et al. Role of a p53 polymorphism in the development of human papillomavirus-associated cancer. *Nature* 1998; 393(6682):229-234.

- (324) Subak LL, Hricak H, Powell CB, Azizi L, Stern JL. Cervical carcinoma: computed tomography and magnetic resonance imaging for preoperative staging. *Obstet Gynecol* 1995; 86:43-50.
- (325) Szarewski A, Jarvis MJ, Sasieni P, Anderson M, Edwards R, Steele SJ et al. Effect of smoking cessation on cervical lesion size. *Lancet* 1996; 347:941-943.
- (326) Tamimi HK, Figge DC. Adenocarcinoma of the uterine cervix. *Gynecol Oncol* 1982; 13(3):335-344.
- (327) Tamura M GJMKASPRYKM. Inhibition of cell migration, spreading, and focal adhesions by tumour suppressor *PTEN*. *Science* 280[5369], 1614-1617. 1998.
Ref Type: Generic
- (328) Tamura M, Gu J, Danen EH, Takino T, Miyamoto S, Yamada KM. PTEN interactions with focal adhesion kinase and suppression of the extracellular matrix-dependent phosphatidylinositol3-kinase/Akt cell survival pathway. *J Biol Chem* 1999; 274:20693-20703.
- (329) Tamura M, Gu J, Tran H, Yamada KM. PTEN gene and integrin signaling in cancer. *J Natl Cancer Inst* 1999; 91(21):1820-1828.
- (330) Taniyama K, Goodison S, Ito R, Bookstein R, Miyoshi N, Tahara E et al. PTEN expression is maintained in sporadic colorectal tumours. *J Pathol* 2001; 194:341-348.
- (331) Tase T, Okagaki T, Clark BA, Twiggs LB, Ostrow RS, Faras AJ. Human papillomavirus DNA in glandular dysplasia and microglandular hyperplasia: presumed precursors of adenocarcinoma of the uterine cervix. *Obstet Gynecol* 1989; 73(6):1005-1008.
- (332) Tenti P, Romagnoli S, Silini E, Zappatore R, Spinillo A, Giunta P et al. Human papillomavirus types 16 and 18 infection in infiltrating adenocarcinoma of the cervix: PCR analysis of 138 cases and correlation with histologic type and grade. *Am J Clin Pathol* 1996; 106(1):52-56.

- (333) Tenti P, Pavanello S, Padovan L, Spinillo A, Vesentini N, Zappatore R et al. Analysis and clinical implications of p53 gene mutations and human papillomavirus type 16 and 18 infection in primary adenocarcinoma of the uterine cervix. *Am J Pathol* 1998; 152(4):1057-1063.
- (334) Teshima S, Shimosato Y, Kishi K, Kasamatsu T, Ohmi K, Uei Y. Early stage adenocarcinoma of the uterine cervix. Histopathologic analysis with consideration of histogenesis. *Cancer* 1985; 56(1):167-172.
- (335) Tidy JA, Parry GC, Ward P, Coleman DV, Peto J, Malcolm AD et al. High rate of human papillomavirus type 16 infection in cytologically normal cervixes. *Lancet* 1989; 1(8635):434.
- (336) Toki T, Oikawa N, Tase T, Wada Y, Yajima A, Suzuki M. Immunohistochemical localization of carcinoembryonic antigen in adenocarcinoma of the endocervix and the endometrium. *Tohoku J Exp Med* 1985; 146(1):27-32.
- (337) Tortolero-Luna G, Mitchell MF, Swan DC, Tucker RA, Wideroff L, Icenogle JP. A case-control study of human papillomavirus and cervical squamous intraepithelial lesions (SIL) in Harris County, Texas: differences among racial/ethnic groups. *Cadernos de Saude Publica* 1998; 14(Suppl3):149-159.
- (338) Tot T. The cytokeratin profile of medullary carcinoma of the breast. *Histopathology* 2000; 37(2):175.
- (339) Uchiyama M, Iwasaka T, Matsuo N, Hachisuga T, Mori M, Sugimori H. Correlation between human papillomavirus positivity and p53 gene overexpression in adenocarcinoma of the uterine cervix. *Gynecol Oncol* 1997; 65(1):23-29.
- (340) Ueda G, Sawada M, Ogawa H, Tanizawa O, Tsujimoto M. Immunohistochemical study of cytokeratin 7 for the differential diagnosis of adenocarcinomas in the ovary. *Gynecol Oncol* 1993; 51:219-223.

- (341) Ulbright TM, Gersell DJ. Glassy cell carcinoma of the uterine cervix. A light and electron microscopic study of five cases. *Cancer* 1983; 51(12):2255-2263.
- (342) Utsugi K, Hirai Y, Takeshima N, Akiyama F, Sakurai S, Hasumi K. Utility of the monoclonal antibody HIK1083 in the diagnosis of adenoma malignum of the uterine cervix. *Gynecol Oncol* 1999; 75:345-348.
- (343) Valente PT, Hanjani P. Endocervical neoplasia in long-term users of oral contraceptives: clinical and pathologic observations. *Obstet Gynecol* 1986; 67(5):695-704.
- (344) van den Brule AJ, Claas EC, du MM, Melchers WJ, Helmerhorst T, Quint WG et al. Use of anticontamination primers in the polymerase chain reaction for the detection of human papilloma virus genotypes in cervical scrapes and biopsies. *J Med Virol* 1989; 29(1):20-27.
- (345) van Hoesen KH, Ramondetta L, Kovatich AJ, Bibbo M, Dunton CJ. Quantitative image analysis of MIB-1 reactivity in inflammatory, hyperplastic, and neoplastic endocervical lesions. *Int J Gynecol Pathol* 1997; 16(1):15-21.
- (346) van Netten JP, Algard FT, Coy P, Carlyle SJ, Brigden ML, Thornton KR et al. Heterogeneous estrogen receptor levels detected via multiple microsamples from individual breast cancers. *Cancer* 1985; 56(8):2019-2024.
- (347) van NJ, Jr., Donaldson ES, Gay EC, Rayburn P, Powell DF, Goldenberg DM. Carcinoembryonic antigen in carcinoma of the uterine cervix. 1. The prognostic value of serial plasma determinations. *Cancer* 1978; 42(5):2428-2434.
- (348) Vesterinen E, Forss M, Nieminen U. Increase of cervical adenocarcinoma: a report of 520 cases of cervical carcinoma including 112 tumours with glandular elements. *Gynecol Oncol* 1989; 33(1):49-53.
- (349) Villa LL, Costa RL, Petta CA, Andrade RP, Ault KA, Giuliano AR et al. Prophylactic quadrivalent human papillomavirus (types 6, 11, 16, and 18) L1

- virus-like particle vaccine in young women: a randomised double-blind placebo-controlled multicentre phase II efficacy trial. *Lancet Oncol* 2005; 6(5): 271-278.
- (350) Vizcaino AP, Moreno V, Bosch FX, Munoz N, Barros-Dios XM, Parkin DM. International trends in the incidence of cervical cancer: I. Adenocarcinoma and adenosquamous cell carcinomas. *Int J Cancer* 1998; 75(4):536-545.
- (351) von Knebel Doeberitz M, Rittmuller C, zur Hausen H, Durst M. Inhibition of tumourigenicity of cervical cancer cells in nude mice by HPV E6-E7 antisense RNA. *Int J Cancer* 1992; 51:831-834.
- (352) von Knebel Doeberitz M, Rittmuller C, Aengeneyndt F, Jansen-Durr P, Spitkovsky D. Reversible repression of papillomavirus oncogene expression in cervical carcinoma cells: consequences for the phenotype and E6-p53 and E7-pRB interactions. *J Virol* 1994; 68:2811-2821.
- (353) W.A.A.Tjalma, T.R. Van Waes, Van den Eeden, j.j.p.m. Bogers. Role of human papillomavirus in the carcinogenesis of squamous cell carcinoma and adenocarcinoma of the cervix. *Best Practice & Research Clinical Obstetrics & Gynaecology* 2005; 19(4): 469-483.
- (354) Wahlstrom T, Lindgren J, Korhonen M, Seppala M. Distinction between endocervical and endometrial adenocarcinoma with immunoperoxidase staining of carcinoembryonic antigen in routine histological tissue specimens. *Lancet* 1979; 2(8153):1159-1160.
- (355) Walboomers JM, Jacobs MV, Manos MM, Bosch fx, Kummer JA, Shah KV, Snijders PJ, Peto J, Meijer CJ, Munoz N. Human papillomavirus is a necessary cause of invasive cervical cancer worldwide. *J Pathol* 1999; 189, 12-19.
- (356) Walker J, Bloss JD, Liao SY, Berman M, Bergen S, Wilczynski SP. Human papillomavirus genotype as a prognostic indicator in carcinoma of the uterine cervix. *Obstet Gynecol* 1989; 74(5):781-785.

- (357) Wang ZJ, Taylor F, Churchman M, Norbury G, Tomlinson I. Genetic pathways of colorectal carcinogenesis rarely involve the PTEN and LKB1 genes outside the inherited hamartoma syndromes. *Am J Pathol* 1998; 153(2):363-366.
- (358) Wells M, Brown LJ. Glandular lesions of the uterine cervix: the present state of our knowledge. *Histopathology* 1986; 10(8):777-792.
- (359) Wentzensen N, Ridder R, Klaes R, Vinokurova S, Schaefer U, Doeberitz MK. Characterization of viral-cellular fusion transcripts in a large series of HPV16 and 18 positive anogenital lesions. *Oncogene* 2002; 21(3):419-426.
- (360) Werness BA, Levine AJ, Howley PM. Association of human papillomavirus types 16 and 18 E6 proteins with p53. *Science* 1990; 248(4951):76-79.
- (361) Widrich T, Kennedy AW, Myers TM, Hart WR, Wirth S. Adenocarcinoma in situ of the uterine cervix: management and outcome. *Gynecol Oncol* 1996; 61(3):304-308.
- (362) Wilkenstein W. Smoking and cervical cancer-current status: a review. *Am J Epidemiol* 1990; 131:945-957.
- (363) Williamson AL, Brink NS, Dehaeck CM, Ovens S, Soeters R, Rybicki EP. Typing of human papillomaviruses in cervical carcinoma biopsies from Cape Town. *J Med Virol* 1994; 43(3):231-237.
- (364) Winer RL, Lee SK, Hughes JP, Adam DE, Kiviat NB, Koutsky LA. Genital human papillomavirus infection: incidence and risk factors in a cohort of female university students. *Am J Epidemiol* 2003; 157(3):218-226.
- (365) Wintzer HO, Zipfel I, Schulte-Monting J, Hellerich U, von Kleist S. Ki-67 immunostaining in human breast tumours and its relationship to prognosis. *Cancer* 1991; 67(2):421-428.

- (366) Wright JJ. The development of the frozen section technique, the evolution of surgical biopsy, and the origins of surgical pathology. *Bull Hist Med* 1985; 59:295-326.
- (367) Wright TC, Kurman RJ, Ferenczy A. Precancerous lesions of the cervix. In: Kurman RJ, editor. *Blaustein's Pathology of the Female Genital Tract*. New York: Springer Verlag, 1994: 229-277.
- (368) Wu CH, Lee MF, Chang MC, Ho SC. Detection of human papillomavirus types in cervical lesions of patients from Taiwan by the polymerase chain reaction. *Sex Transm Dis* 1994; 21(6):309-314.
- (369) Yamaguchi A, Hashimoto N, Tsutae W, Seino K, Ebina Y, Tokino T et al. Detection of human papillomavirus DNA by PCR/ microfluorometry for screening of cervical cancer. *Clinica Chimica Acta* 2002; 318:41-49.
- (370) Yamakawa Y, Forslund O, Teshima H, Hasumi K, Kitagawa T, Hansson BG. Human papillomavirus DNA in adenocarcinoma and adenosquamous carcinoma of the uterine cervix detected by polymerase chain reaction (PCR). *Gynecol Oncol* 1994; 53(2):190-195.
- (371) Yeh IT, Li VA, Noumoff JS. Endocervical carcinoma. *Pathol Res Pract* 1991; 187(2-3):129-144.
- (372) Yoon HK, Kim YJ, Kang MS. Human papillomavirus 16/18 expression of endocervical glandular lesions: relationship with p53 and MIB-1 Expressions. *J Korean Med Sci* 2001; 16(2):169-174.
- (373) Yoshikawa H, Kawana T, Kitagawa K, Mizuno M, Yoshikura H, Iwamoto A. Detection and typing of multiple genital human papillomaviruses by DNA amplification with consensus primers. *Jpn J Cancer Res* 1991; 82(5):524-531.
- (374) Young RH, Scully RE. Minimal-deviation endometrioid adenocarcinoma of the uterine cervix: a report of five cases of a distinctive neoplasm that may be misinterpreted as benign. *Am J Surg Pathol* 1993; 17(7):660-665.

- (375) Young RH, Clement PB. Endocervicosis involving the uterine cervix: A report of four cases of a benign process that may be confused with deeply invasive endocervical adenocarcinoma. *Int J Gynecol Pathol* 2000; 19:322-328.
- (376) Young RH, Clement PB. Endocervical adenocarcinoma and its variants: their morphology and differential diagnosis. *Histopathology* 2002; 41(3):185-207.
- (377) Zaino RJ. Glandular lesions of the uterine cervix. *Mod Pathol* 2000; 13(3):261-274.
- (378) Zaino RJ. Adenocarcinoma in situ, glandular dysplasia and early invasive adenocarcinoma of the uterine cervix. *Int J Gynecol Pathol* 2002; 21:314-326.
- (379) Zaino RJ. The fruits of our labors: Distinguishing endometrial from endocervical adenocarcinoma. *Int J Gynecol Pathol* 2002; 21:1-3.
- (380) Zemer RF, Fishman AF, Bernheim JF, Zimlichman S, FAU - Markowicz, Markowicz OF, Altaras MF et al. Expression of cytokeratin-20 in endometrial carcinoma.(0090-8258).
- (381) Zhang JM. [Minimal deviation endocervical adenocarcinoma--clinical, histologic and immunohistochemical study]. *Zhonghua Zhong Liu Za Zhi* 1989; 11(4):275-277.
- (382) Zheng T, Holford TR, Ma Z, Chen Y, Liu W, Ward BA et al. The continuing increase in adenocarcinoma of the uterine cervix: a birth cohort phenomenon. *Int J Epidemiol* 1996; 25(2):252-258.
- (383) Zielinski GD, Bais AG, Helmerhorst TJ, Verheijen RH, de Schipper FA, Snijders PJ et al. HPV testing and monitoring of women after treatment of CIN 3: review of the literature and meta-analysis. *Obstet Gynecol Surv* 2004; 59(7): 543-553.
- (384) zur Hausen H. Human genital cancer: synergism between two virus infection or synergism between a virus infection and initiating events. *Lancet* 1982; 2:1370-1372.

- (385) zur Hausen H. Papillomaviruses in anogenital cancer: a model to understand the role of viruses in human cancers. *Cancer Res* 1989; 49:4677-4681.
- (386) zur Hausen H. Viruses in human cancers. *European J Cancer* 1999; 35:1878-1885.
- (387) zur Hausen H. Papillomaviruses in human cancers. *Proc Assoc Am Physicians* 1999; 111(6):581-587.
- (388) zur Hausen H. Papillomaviruses and cancer: from basic studies to clinical application. *Nat Rev Cancer* 2002; 2(5):342-350.

APPENDIX

PRESENTATIONS:

1. Manchester International Conference of British Association Cancer Research
Poster presentation: Detection of human papillomavirus DNA types 16 and 18 in cervical adenocarcinoma and its precursors by PCR, **Magdy Tawfik El-Mansi**, ARW Williams, RG Morris, 27-30 June 2004
2. Annual Meeting of the Pathological Society of Great Britain and Ireland: Amsterdam
Oral presentation: Validation of Tissue Microarray Technology using Cervical Adenocarcinoma and its Precursors as a Model System, **Magdy Tawfik El-Mansi**, ARW Williams, 6-9 July 2004.
3. ASCP 2004, American society of clinical pathology (Annual Meeting in San Antonio, TX,US)
Poster presentation: Evaluation of *PTEN* expression in cervical adenocarcinoma by tissue microarray, **Magdy Tawfik El-Mansi**, ARW Williams, 7-10 October 2004.
4. Annual Meeting of the British Society of Colposcopy and Cervical Pathology (BSCCP), Edinburgh,.
Poster presentation: Evaluation of *PTEN* expression in cervical Adenocarcinoma by tissue microarray, **Magdy Tawfik El-Mansi**, ARW Williams, 28-30 April 2005
5. Annual Meeting of the Pathological Society of Great Britain and Ireland: Newcastle,
Poster presentation: Immunohistochemical Expression of Oestrogen Receptors (ER) and Progesterone Receptors (PgR) in Cervical Adenocarcinoma and its Precursors using tissue microarray technology, **Magdy Tawfik El-Mansi**, ARW Williams, 5-8 July 2005.

6. Birmingham International Conference of NCRI (National Cancer Research Institute)

Poster presentation: Evaluation of CK7, CK20 and CEA expression patterns in cervical adenocarcinoma and its precursors using tissue microarray, **Magdy Tawfik El-Mansi**, ARW Williams, 2-5 Oct. 2005.

ABSTRACTS (Published)

1- DETECTION OF HUMAN PAPILLOMAVIRUS DNA TYPES 16 AND 18 IN CERVICAL ADENOCARCINOMA AND ITS PRECURSORS BY PCR

Magdy Tawfik El-Mansi, ARW Williams, RG Morris

Department of pathology, Royal Infirmary of Edinburgh and University of Edinburgh, 51 Little France Crescent, Edinburgh, EH16 4SA, Scotland, UK

ABSTRACT published in British Journal of Cancer, Vol 91, supplement 1, July 2004

Objective: To determine the prevalence of human papillomavirus (HPV) types 16 and 18 in cervical adenocarcinoma and its precursors of Scottish patients. **Methods:** HPV DNA was extracted from paraffin-embedded, formalin-fixed tissues of 161 specimens of 139 patients, including x cases of invasive adenocarcinoma and x of pre-invasive precursors (high grade CGIN). HPV DNA was detected by PCR test using type specific primers from the E6 gene and E7 gene of HPV type 16 and HPV type 18 followed by restriction enzyme digestion. **Results:** Out of a total of 139 women with various cervical adenocarcinomas lesions, HPV DNA was identified in 87 cases (62.6%) in which, HPV16 was negative for 74 (53%) and positive for 65 (47%) patients and HPV18 was negative for 98 (71%) and positive for 41 (29%) patients. Genotyping by RFLP and PCR revealed that HPV type 16 was the most frequent type of HPV detected, comprising 46 cases (33%), followed by HPV type 18 in 22 cases (16%), and HPV type 16 and HPV type 18 in 19 cases (14%). There were 52 (38%) of 139 of patients with various cervical adenocarcinoma lesions with HPV type 16 and HPV type 18 both negative. HPV typing in all cases of 16 normal cervical biopsies was negative with both HPV type 16 and HPV type 18. **Conclusions:** Our findings support that HPV16 (mainly), along with HPV18, may play a role in pathogenesis of cervical adenocarcinoma and its precursors.

2-Validation of Tissue Microarray Technology using Cervical Adenocarcinoma and its Precursors as a Model System

Magdy Tawfik El-Mansi, ARW Williams,

Department of pathology, Royal Infirmary of Edinburgh and University of Edinburgh,
51 Little France Crescent, Edinburgh, EH16 4SA, Scotland, UK

ABSTRACT published in *The Journal of Pathology*, July 2004

The recent development of tissue microarray (TMA) technology has potentiated large-scale retrospective cohort studies using archival formalin-fixed, paraffin-embedded tissues. One obstacle to broad acceptance of TMAs is that they reduce the amount of tissue analyzed from a whole tissue section to a disk of 0.6mm diameter. In this study, we used a large series of cervical adenocarcinomas to investigate TMA technology in assessment of immunohistochemical staining. A TMA was constructed using 273 archival paraffin blocks from a series of 139 patients with 119 invasive and 20 preinvasive cervical adenocarcinomas, and 16 normal controls. Two paired of tissue cores were obtained from specific regions of donor blocks selected at histological review, and subsequently were arrayed into a recipient block. The novel array blocks and some whole donor blocks were sectioned and used for immunohistochemical analysis for CEA, CK7 and CK20. We compared staining in the microarray disks with the whole tissue sections. The TMA was found to yield good immunohistochemical staining which was concordant with that of the whole section from which it originated. Two paired of TMA cores achieved representation of the whole section in immunohistochemical studies in over 97% of cases. Our results suggest that TMAs can be successfully used for immunohistochemical studies of cervical adenocarcinomas. The TMA technique is a rapid, cost effective, and tissue-saving method for high-throughput immunohistochemical studies. The areas sampled from donor blocks must be selected by careful review of sections from the original blocks, and we have shown the cores to accurately represent the morphology of the tumour in all cases. Two paired of TMA cores will provide representative immunohistochemical results in over 97% of cases.

3-Evaluation of *PTEN* Expression in Cervical Adenocarcinoma By Tissue Microarray

Magdy Tawfik El-Mansi, ARW Williams,

Department of pathology, Royal Infirmary of Edinburgh and University of Edinburgh,
51 Little France Crescent, Edinburgh, EH16 4SA, Scotland, UK

ABSTRACT published in American Journal of clinical pathology (AJCP) October issue, 2004

PTEN, a recently discovered tumour suppressor gene, appears to negatively control the phosphoinositide 3-kinase signalling pathway for regulation of cell proliferation and cell survival. Somatic *PTEN* mutations are involved in a variety of tumours, including endometrial carcinomas, where *PTEN* expression is diminished. In this study we examined expression of *PTEN* in a series of cervical adenocarcinomas and precursors, using tissue microarray (TMA) technology. TMA blocks were constructed using paraffin-embedded, formalin-fixed tissues from 273 samples derived from 16 normal cervical biopsies, 119 cases of invasive adenocarcinoma and 20 high grade CGIN. Fresh 3- μ m sections were cut and immunostained with *PTEN* antibody and expression was correlated with clinicopathological variables, including histological subtypes of adenocarcinoma. In 137 patients with invasive or preinvasive adenocarcinoma, *PTEN* expression was negative in 16 (12%) and positive in 121 (88%). In all cases, normal endocervical cells and normal stromal cells of the cervix stained weakly positive for *PTEN*. The intensity and distribution of *PTEN* staining in the tumour tissue were more heterogeneous than that observed in the normal tissues. There was no difference in distribution or intensity of *PTEN* expression between adenocarcinoma in situ and invasive adenocarcinoma. Also, different histological subtypes of cervical adenocarcinoma showed no significant differences in *PTEN* expression. Our findings show that unlike the case in most endometrial carcinomas, *PTEN* expression is retained during the process of carcinogenesis in the glandular cervix. There is, however, evidence of altered distribution and intensity of *PTEN* expression in cervical adenocarcinoma cells.

4- Immunohistochemical Expression of Oestrogen Receptor (ER) and Progesterone Receptor (PgR) in Cervical Adenocarcinoma and its precursors Using Tissue Microarray (TMA) Technology

Magdy Tawfik El-Mansi, ARW Williams,

Department of pathology, Royal Infirmary of Edinburgh and University of Edinburgh,
51 Little France Crescent, Edinburgh, EH16 4SA, Scotland, UK

ABSTRACT published in The Journal of Pathology, July 2005

Few studies have investigated the expression and clinical significance of (ER) and (PgR) in adenocarcinoma of the cervix. In this study, we examined expression of ER and PgR in a series of cervical adenocarcinomas and precursors, using TMA technology. TMA blocks were constructed using paraffin-embedded, formalin-fixed tissues from 273 samples derived from 16 normal cervical biopsies, 119 cases of invasive adenocarcinoma and 20 high grade CGIN. Fresh 3- μ m sections were cut and immunostained with ER and PgR antibodies, and expression was correlated with clinicopathological variables, including histological subtypes of adenocarcinoma. In 139 patients with invasive or preinvasive adenocarcinoma, ER expression was positive in 64 (47%) with 2 cases not available and PgR was positive in 50 (37%) with 4 cases not available. In all cases, normal endocervical cells and normal stromal cells of the cervix stained weakly for ER and PgR. The intensity and distribution of ER and PgR staining in the tumour tissue were more heterogeneous than that observed in the normal tissues. ER positivity was more frequent in invasive (50%) and early invasive (56%) cervical adenocarcinomas than in AIS (28%) which suggest that high ER levels are possibly associated with more advanced lesions. Moreover, high ER and PgR levels were more frequent in minimal deviation adenocarcinoma and adenosquamous carcinomas, consistent with the suggestion that ER and PgR expression are more frequent in tumours of worse prognosis. Our findings suggest that ER and PgR status may be useful markers in women with cervical adenocarcinoma. Further assessment of the impact of ER and PgR status on the clinical outcome of patients with primary invasive adenocarcinoma of the cervix in larger case series is needed.

PUBLICATIONS (ARTICLES)

A- FULL PUBLICATION (ARTICLES)

1-Evaluation of *PTEN* expression in Cervical Adenocarcinoma by Tissue Microarray

Magdy Tawfik El-Mansi, ARW Williams,

Department of pathology, Royal Infirmary of Edinburgh and University of Edinburgh,
51 Little France Crescent, Edinburgh, EH16 4SA, Scotland, UK

published in International Journal of Gynaecological Cancer-- issue 3/16 (May / June)
2006

2-Validation of Tissue Microarray Technology using Cervical Adenocarcinoma and its Precursors.

Magdy Tawfik El-Mansi, ARW Williams,

Department of pathology, Royal Infirmary of Edinburgh and University of Edinburgh,
51 Little France Crescent, Edinburgh, EH16 4SA, Scotland, UK

published in International Journal of Gynaecological Cancer-- issue 3/16 (May / June)
2006

3- Prevalence of Human Papillomavirus types 16 and 18 in Cervical Adenocarcinoma and its Precursors in Scottish Patients.

Magdy Tawfik El-Mansi, KS Cuschieri, RG Morris, ARW Williams,

Department of pathology, Royal Infirmary of Edinburgh and University of Edinburgh,
51 Little France Crescent, Edinburgh, EH16 4SA, Scotland, UK.

published in International Journal of Gynaecological Cancer-- issue 3/16 (May /
June) 2006

B-IN PREPARATION

1-Cervical Adenocarcinoma and its Precursors, A review article.

2-Immunohistochemical Expression of Estrogen Receptor (ER) and Progesterone Receptor (PgR) in Cervical Adenocarcinoma and its Precursors using tissue microarray technology.

3-Expression of p53 in cervical adenocarcinoma and its precursors using tissue microarray technology and its relation to HPV 16 and 18 infection.

Validation of tissue microarray technology using cervical adenocarcinoma and its precursors as a model system

M. TAWFIK EL-MANSI & A.R.W. WILLIAMS

Department of Pathology, Royal Infirmary of Edinburgh and University of Edinburgh, Edinburgh, Scotland, United Kingdom

Abstract. Tawfik El-Mansi M, Williams ARW. Validation of tissue microarray technology using cervical adenocarcinoma and its precursors as a model system. *Int J Gynecol Cancer* 2006;16:1225–1233.

The tissue microarray (TMA) technology has potentiated large-scale retrospective cohort studies using archival formalin-fixed, paraffin-embedded tissues. We used a large series of cervical adenocarcinomas to investigate TMA technology in assessment of immunohistochemical staining. A TMA was constructed using 273 archival paraffin blocks from 139 patients with 119 invasive and 20 adenocarcinoma *in situ* and 16 normal controls. Two paired cores were obtained from specific regions of donor blocks selected at histologic review and were arrayed into a recipient blocks. The novel array blocks and some whole donor blocks were sectioned and used for immunohistochemical analysis for carcinoembryonic antigen, cytokeratin 7, and cytokeratin 20 antibodies as potential diagnostic markers. We compared staining in the microarray disks with the whole tissue sections. Two paired TM cores were found to yield good immunohistochemical staining that was concordant with that of the whole section from which it originated in about 97% of cases, and the cores accurately represented the morphology of the tumor with respect to tumor typing and differentiation in all cases. Our results suggest that TMAs can be successfully used for immunohistochemical studies of cervical adenocarcinomas. The areas sampled from donor blocks must be selected by careful review of sections from the original blocks.

KEYWORDS: CEA, cervical adenocarcinoma, CK7, CK20, tissue microarray (TMA) technology, immunohistochemistry.

Cervical cancer is the second commonest type of cancer in females worldwide, with an estimated annual incidence of up to 500,000 new cases. Although its incidence is declining in developed countries owing to established cytologic screening programs, it is still responsible for significant morbidity in industrialized nations⁽¹⁾. The two most common histologic types of cervical cancer are squamous cell carcinoma, which comprises approximately 75% of cases, and endocervical adenocarcinoma, which comprises approximately 20% of cases⁽²⁾. To date, there has been less emphasis on glandular lesions of the cervix, and less information is available regarding the natural history, pathology, and clinical aspects of cervical adeno-

carcinoma. An absolute increase in prevalence of adenocarcinoma and its precursors has been documented, both in the United States and in the Europe⁽³⁾. In addition, because immunohistochemistry is commonly used for identification of molecular markers that predict patient survival^(4,5), newer markers may become increasingly useful clinically in early diagnosis and treatment of cervical adenocarcinoma⁽⁶⁾.

The standard method of histopathologic analysis is microscopic examination of sections of formalin-fixed, paraffin-embedded tissue⁽⁷⁾. The tissue microarray (TMA) technique was described in 1998 by Kononen *et al.*⁽⁸⁾ and allows immunohistochemical analysis of 500–1000 samples simultaneously. TMA uses 0.6-mm-diameter tissue core biopsy specimens that are retrieved from selected regions of archival donor blocks and subsequently arrayed into a recipient paraffin array block. On average, the novel array block can yield 100 sections and can be used for techniques

Address correspondence and reprint requests to: Dr Magdy Tawfik El-Mansi, MBChB, MSc, Histopathology Department, Clinical Science Building, Wythenshawe Hospital, Southmoor Road, Manchester, M23 9 LT, UK. Email: magdy.elmansi@smuht.nwest.nhs.uk

such as immunohistochemical analysis and fluorescent *in situ* hybridization^(8–13).

TMA have a number of advantages compared with conventional techniques that require the processing and staining of hundreds of slides. Microarray technology enables the study of an entire cohort of cases by analyzing just one (or a few) master slide(s), and all specimens are processed at one time using identical conditions. Moreover, it markedly reduces the amount of archival tissue required for a particular study, thus preserving ample remaining tissue for other research or diagnostic needs^(14,15). Furthermore, the technique has been demonstrated to be efficient and applicable to various tumor types; therefore, most of the applications of the TMA technology have come in the field of cancer research but methodologic evaluations are few^(16–18).

Although conferring technical advantages, the reduction of the amount of tumor analyzed is also the greatest potential disadvantage of this new technology. Thus, it is important to determine how many tissue disks are required to adequately represent the expression of a particular antigen by a tumor and to determine antigen survival. Specifically, it is important to determine whether archival tissues retain their antigenicity in this technique, despite decades of storage as paraffin blocks and very small volume tissue samples. There is evidence to suggest that such tissues remain antigenically intact^(19,20). The results of two studies showed that twofold redundancy can lead to greater than 95% concordance between the two methods and that the addition of more cores increases concordance to 99.5% with five cores per specimen⁽¹⁵⁾. Moreover, the impact of data discrepancies between array and full section has been evaluated, and it has been reported that this comparison has not shown any significant change in clinicopathologic correlations between the two methods, indicating that TMAs may be reliable tools for clinicopathologic analyses of cancer specimens^(21,17).

Previous immunohistochemical studies of cervical adenocarcinoma have used whole tissue sections, and very few studies have used TMA technology in evaluation of immunoprofile of cervical adenocarcinoma⁽²²⁾. In this study, we chose to examine immunohistochemical expression of three antigens—carcinoembryonic antigen (CEA), cytokeratin 7 (CK7), and cytokeratin 20 (CK20) in a large set of cervical adenocarcinomas. Those markers have been shown to have differing patterns of expression in cervical adenocarcinomas and allowed comparison between TMA and whole-section staining. CK7, a low molecular weight cytokeratin, is homogeneously expressed in the great majority of cervical adenocarcinomas, while CK20 is negative⁽²³⁾.

CEA is positive in the majority but not in all cervical adenocarcinomas, and there may be heterogeneity of expression within different areas of a tumor⁽²⁴⁾. By examining these markers, we aimed to investigate sampling requirements for demonstration of these antigens in cervical adenocarcinoma using TMAs and to compare the TMA technique with whole-tissue staining in regard to quality of staining, reproducibility, and the impact of tissue heterogeneity. Moreover, we evaluated expression patterns of these antigens as potential diagnostic markers in cervical adenocarcinomas and its precursors, comparing the profile of adenocarcinoma *in situ* (AIS) with invasive subtypes of cervical adenocarcinomas.

Materials and methods

Tissue samples

A computerized search was conducted for all patients diagnosed with cervical adenocarcinoma at the University of Edinburgh, Pathology Department, from 1991 to 2001. Ethical approval for this study was granted by the local research ethics committee. Surgical cervical specimens were obtained from the archival collections. A total of 273 samples (paraffin-embedded blocks) were obtained from 177 biopsies composed of 16 normal cervical samples taken from patients suffering from different noncervical pathologies and specimens from 139 different patients with endocervical adenocarcinomas. Pathology reports and cervical smear history reports were reviewed. Only primary cervical adenocarcinomas were included. The final set of study cases consisted of samples of glandular tissues including normal endocervical mucosa (16), high-grade cervical glandular intra-epithelial neoplasia (CGIN)/AIS (20), and invasive adenocarcinoma (119) of which 16 were early invasive, meeting FIGO criteria for stage IA1. Three-micrometer serial sections from the routinely processed formalin-fixed, paraffin-embedded tissue blocks were prepared.

TMA construction and hematoxylin and eosin

All sections available were reviewed histologically, and areas of morphologically representative, nonnecrotic sites in the tumor were marked with colored indelible marker on the glass slides of sections stained with hematoxylin and eosin (H&E). From each corresponding paraffin block, two paired tissue cores (0.6 mm in diameter) were sampled from each marked area in the "donor" block and mounted into a "recipient" paraffin block by the use of a custom-made

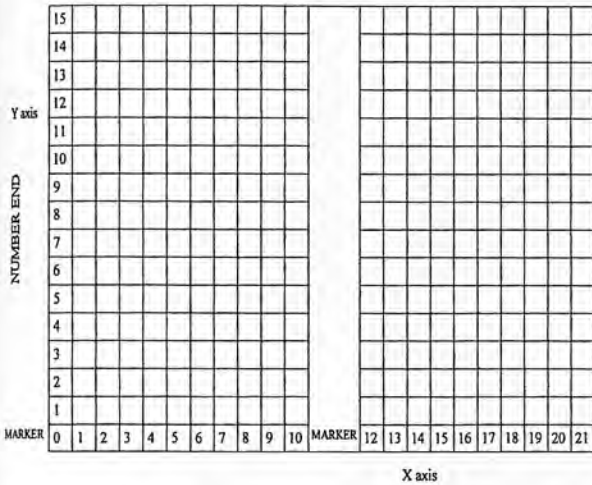


Figure 1. Diagram of TMA organization chart that used in this study. Tissue samples were distributed and located in TMA chart using (x:y) relationship.

instrument (Beecher Instruments, Silver Springs, MD). In the ensuing paraffin array block, the tissue cylinders were aligned and marked for identification according to a chart (Fig. 1). The final set of tissue samples consisted of 542 tissue cylinders in five TMA blocks that included samples of normal endocervical mucosa (32 cores) in one TMA block, AIS (59 cores) in duplicate TMA blocks, and invasive adenocarcinoma (196 cores) in duplicate TMA blocks. The recipient paraffin blocks (TMA blocks) were baked at 56°C for 10 min before sectioning, and 3- μ m paraffin sections were then made by standard technique (Fig. 2). Finally, TMA sections stained with H&E were compared with whole sections to investigate whether TMAs are representative of the morphology of cervical adenocarcinoma.

Immunohistochemistry

Fresh 3- μ m sections were cut from each microarray and the original paraffin-embedded block and transferred to glass slides. Following deparaffinization in xylene and rehydration through descending graded ethanol, the sections were washed well with tap water for 2 min. Antigen retrieval for CEA and CK20 antibodies was performed by immersing tissue sections in ethylenediaminetetraacetic acid (pH 8) and heating them for 15 min in a microwave oven at 750 W, while for the sections to be stained for CK7, antigen retrieval was performed by immersing tissue sections in citrate buffer (pH 6) with pressure-cooking for 6 min at 1 m bar. The sections were washed well in water and then loaded onto Shandon Sequenza staining apparatus. Endogenous peroxidase was then blocked by treatment

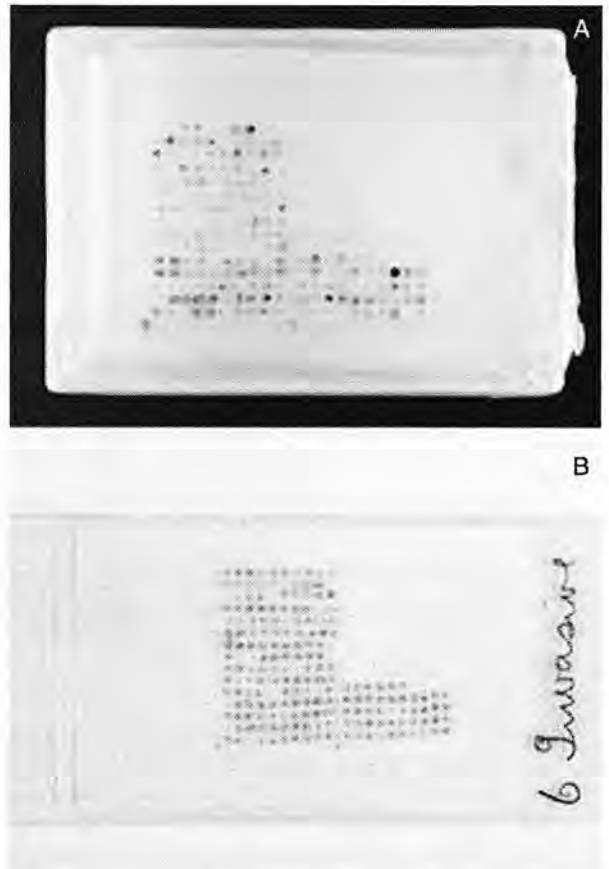


Figure 2. A) TMA paraffin block and B) TMA slide stained with H&E.

with 1% hydrogen peroxide. Using Dako EnVision System, the tissue sections were stained with the following monoclonal primary antibodies for 30 min: CEA (clone 11-7, DakoCytomation, Denmark A/S, Denmark; 1:300 dilution), CK20 (clone K₅20.8, DakoCytomation, Denmark A/S; 1:350 dilution), and CK7 (clone OV-TL 12/30, DakoCytomation, Denmark A/S; 1:10 dilution). Negative controls contained samples in which the primary antibody was omitted and washed in phosphate-buffered saline solution and positive control tissues of known positivity to CEA, CK7, and CK20 were performed. The positive tissue control for CK7 was breast carcinoma and for CK20 and CEA was colonic carcinoma. The sections were washed well, incubated with Dako EnVision/horseradish peroxidase (HRP) rabbit/mouse polymer for 30 min, and then washed well again. Sections were then incubated at room temperature with 3,3'-diaminobenzidine solution for 5 min and washed in tap water. Finally, the sections were counterstained with hematoxylin, washed, dehydrated, cleared well with xylene, and mounted by DPX.

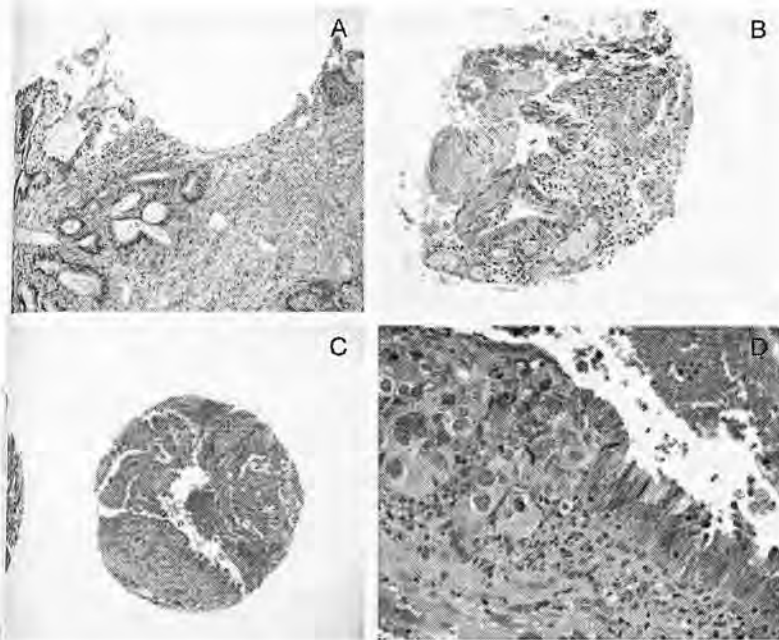


Figure 3. TMA cores are representative morphologically of different cervical lesions. A) Whole tissue section of AIS after removal of tissue core ($\times 100$). B) TMA-core biopsy specimen representative of the whole section in A ($\times 200$). C) TMA-core biopsy specimen of adenosquamous carcinoma ($\times 100$). D) A higher power of C ($\times 400$).

Evaluation of tissue staining

To determine how many cores are required to adequately represent a cervical adenocarcinoma histologically, each TMA core stained with H&E was analyzed separately and in relation to its original whole section. We decided that in order for an immunohistochemical result to be considered reliable, a minimum of two TMA cores from the tumor should show concordant staining patterns. If divergent staining patterns were obtained, results from third or subsequent cores were assessed, and the case was considered to show positive staining if a minimum of two cores showed specific staining.

In the evaluation of staining, cores were scored if at least 10% of the core area contained tumor, and each core analyzed separately and graded as either positive or negative. However, staining for CEA, CK7, and CK20 was considered positive when the tumor cell cytoplasm showed diffuse staining in at least two valuable cores to confirm the similar expression patterns in both. Also, the staining reaction was compared between the cores and some of the whole sections. All microscopy was performed with a Zeiss microscope (KPI 10 \times eyepiece with a high-power field) ($\times 40$).

Results

With respect to how many cores are required to adequately represent a cervical adenocarcinoma histologically, we found that histologic subtype and degree of

differentiation were accurately represented in all cases when two duplicate cores were examined, and it was always possible to determine histologic subtype and degree of differentiation from examination of the TMA core alone, but this always needed to be confirmed by reference to the original section (Fig. 3A–D). In cases of AIS, early invasive adenocarcinoma, and well-differentiated adenocarcinoma, it was often not possible from the TMA cores to determine whether the lesion was invasive or *in situ*. This is not surprising as the histologic criteria for diagnosis of invasive disease are often focal. Other important histologic features that rely on extensive tissue sampling, such as lymphovascular space invasion, cannot be diagnosed reliably in TMA cores.

Microarrays and the original block from which they were derived were stained for CEA, CK7, and CK20. Comparison of immunohistochemical staining for CK7, CK20, and CEA of TMA cores and parent sections showed that for all three antigens, in about 97% of cases, two paired TMA cores showed staining that was concordant (Fig. 4). In three cases, one TMA core was discordant with the average staining pattern of the whole section but the other TMA core was concordant. In such cases, analysis of two paired cores was necessary. If positive staining was identified in a minimum of two cores, the case was considered positive. Thus, analysis of two paired TMA cores provided staining results that were consistent with the original whole section in about 97% of cases (Table 1).

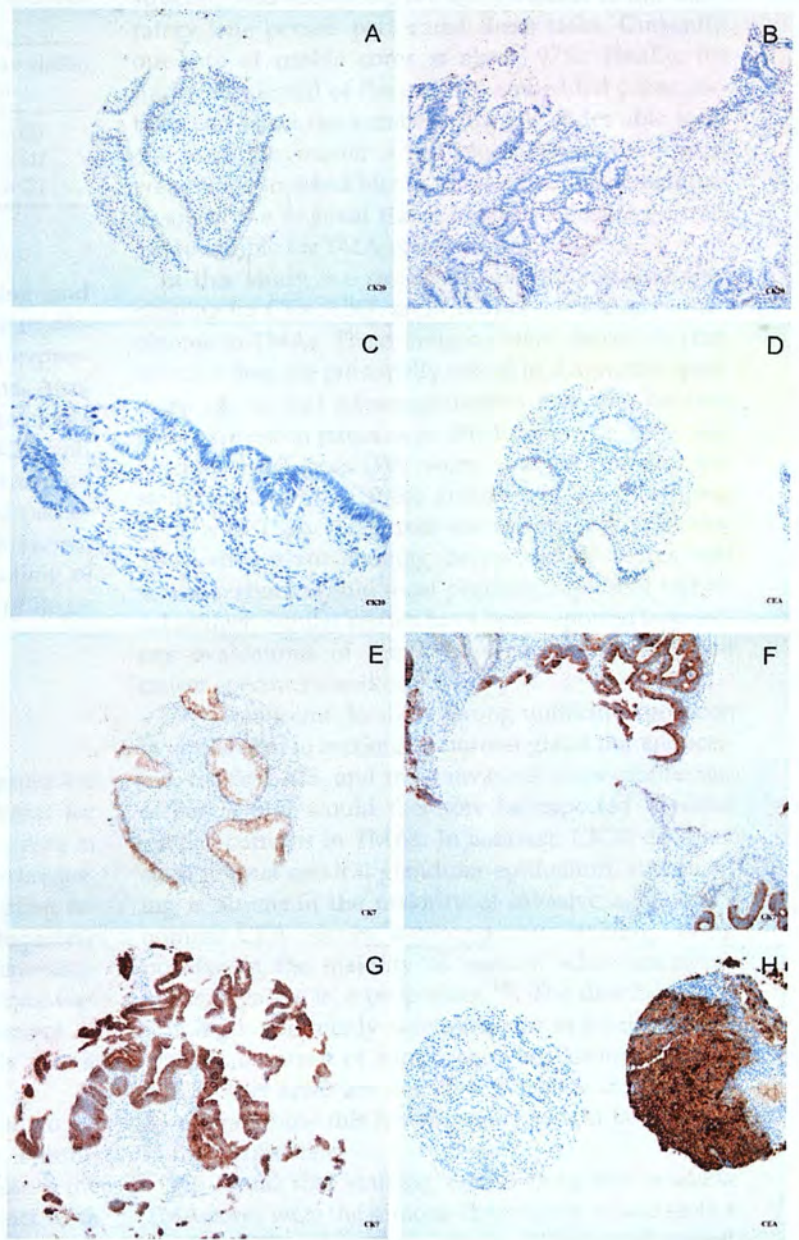


Figure 4. Immunohistochemical demonstration of CK7, CK20, and CEA in cervical tissues. Three CK20-stained cervical tissues show no staining: A) normal cervical tissue ($\times 100$), B) whole tissue section of AIS after removal of tissue core ($\times 100$), C) TMA-core biopsy specimen shows the same staining reaction as the whole section in B ($\times 200$), D) TMA-core biopsy specimen of normal cervical tissue shows no staining with CEA. Three CK7-stained cervical tissues: E) normal cervical tissue shows diffuse delicate membrane staining, but much of the cytoplasm is unstained ($\times 100$), F) whole tissue section of invasive adenocarcinoma after removal of tissue core shows strong positive cytoplasmic staining ($\times 100$), G) TMA-core biopsy specimen shows the same staining reaction as the whole section in F ($\times 100$), H) two CEA-stained TMA cores of different invasive adenocarcinomas, one shows no staining and the other is positive.

In 139 patients with invasive adenocarcinoma or preinvasive disease (high-grade CGIN/AIS), immunohistochemical staining patterns for CK7, CK20, and CEA were cytoplasmic only and were positive in 132 patients (97%) for CK7, 4 (3%) for CK20, and 92 (68%) for CEA. Generally, the cytoplasm of the malignant endocervical cells was stained diffusely for CK7, CK20, and CEA (Fig. 4F–H). However, in normal endocervical glands, there was diffuse delicate membrane

staining with CK7, but much of the cytoplasm was unstained (Fig. 4E). This is in contrast to cells of high-grade CGIN/AIS and invasive adenocarcinoma, where there was diffuse strong cytoplasmic staining. Normal endocervical glands were negative, and there was no positivity in all cells. Endocervical stromal cells were negative, and there was no positivity in all kinds of stromal cells (Fig. 4A–H). In up to 4% of cases overall, the core biopsy sections were nonevaluable

Table 1. Details on number of positive, negative, and not available cases for each antigen

Antigen	Total number of cases	Positive, N (%)	Negative, N (%)	Not available, N (%)
CK7	139	132 (97)	4 (3)	3 (2)
CK20	139	4 (3)	130 (97)	5 (4)
CEA	139	92 (68)	44 (32)	3 (2)

because of loss of material during sectioning and staining. There were no significant differences in distribution or intensity of CK7, CK20, and CEA expression between AIS and invasive adenocarcinoma. Also, different histologic subtypes of cervical adenocarcinoma showed no significant differences in CK7, CK20, and CEA expression patterns (Table 2). Correlation between CK7, CK20, and CEA expression and pathologic variables of cervical adenocarcinomas is shown in Table 2. There was diffuse cytoplasmic staining of positive controls in all cases, but no staining of negative controls.

Discussion

Archival formalin-fixed, paraffin-embedded tissues are the most widely used source of tumor material for TMAs, but there has been little consideration given in the literature to the sampling issues of the technique. We performed this study to investigate sampling requirements in order for TMA cores to be adequately representative of whole tumors in cervical adenocarcinoma and to determine whether TMA technique was appropriate for immunohistochemical assessment of antigens with differing distributions in this tumor type.

The question of how many cylinders need to be taken in order to obtain two readable cores is influenced by several factors. Foremost among these is the ability to identify areas of tumor tissue distinct from stroma, normal epithelium, and/or AIS. Although good histologic detail is usually retained in microarray cores, it is often difficult or impossible to distinguish AIS from better differentiated variants of invasive adenocarcinoma. Moreover, other important histologic features such as lymphovascular space invasion, which are essential for staging of cervical adenocarcinoma, cannot be diagnosed reliably in TMA cores. We found that it is crucial to perform careful assessment of the original sections, and to mark the slide with indelible marker prior to core sampling of the corresponding paraffin block. Other important factors include the technical expertise of the individual con-

structing and sectioning the array blocks. In our laboratory, one person performed these tasks. Currently, our rate of usable cores is about 97%. Finally, the thickness (depth) of the original embedded tissue sections can affect the number of usable slides able to be cut from the master array block. Therefore, efforts were made to select blocks that had sufficient residual tissue in the archival tissue blocks to ensure an adequate sample for TMA construction.

In this study, we evaluated immunohistochemical staining for CEA, CK7, and CK20 of cervical adenocarcinoma in TMAs. These antigens were chosen, in part, because they are potentially useful in diagnostic specimens of cervical adenocarcinomas and also because their expression patterns in this tumor type show significant differences. We were able to compare the staining patterns of these antigens in the whole sections with TMA cores from the corresponding blocks. Thus, discordant staining between TMA cores and whole sections would most probably represent technical artifact. Similar results have been reported in previous evaluations of the TMA technique in different cancer specimens and cell lines^(21,17).

CK7 was found to show strong uniform expression in epithelium in sections of normal glandular endocervix, cervical AIS, and most invasive adenocarcinomas of cervix and would therefore be expected to show similar patterns in TMAs. In contrast, CK20 does not stain normal cervical glandular epithelium, and staining is absent in the majority of invasive adenocarcinomas. CEA shows heterogeneous staining, being positive in the majority of cervical adenocarcinoma but is negative in a proportion⁽²⁴⁾. The distribution of staining is commonly heterogeneous in positive cases, with some areas of tumor showing strong staining, while other areas are negative. We were interested to investigate how this heterogeneity would be reflected in the TMA cores.

We found that staining results from two readable TMA cores were the same as those of the whole section in about 97% of cases. In up to 4% of cases overall, the core biopsy sections were nonevaluable because of loss of material during sectioning and staining. This loss of data, due to tissue loss or inconclusive data, has been reported in previous evaluations of the TMA technique in soft tissue tumors^(16,5) and in rectal cancer⁽⁶⁾ where 17% of the core biopsy sections were nonevaluable.

The main problem of TMAs is that they reduce the amount of tissue analyzed from a whole tissue section to a core, 0.6 mm in diameter, that may not be representative of the protein expression patterns of the entire tumor because of tissue heterogeneity⁽²¹⁾. In this

Table 2. Showing immunohistochemical results of CK7, CK20, and CEA in AIS and subtypes of invasive adenocarcinoma.

	AIS, N (%)	A-NOS, N (%)	ADSQ, N (%)	VGC, N (%)	MDA, N (%)	Others, N (%)
CK7						
Negative	0 (0)	2 (4)	1 (5)	0 (0)	0 (0)	1 (6)
Positive	18 (100)	47 (96)	21 (95)	23 (100)	8 (100)	15 (94)
Total	18 (100)	49 (100)	22 (100)	23 (100)	8 (100)	16 (100)
CK20						
Negative	18 (100)	46 (96)	21 (95)	23 (100)	8 (100)	14 (93)
Positive	0 (0)	2 (4)	1 (5)	0 (0)	0 (0)	1 (7)
Total	18 (100)	48 (100)	22 (100)	23 (100)	8 (100)	15 (100)
CEA						
Negative	5 (28)	21 (42)	6 (27)	4 (17)	2 (25)	6 (40)
Positive	13 (72)	29 (58)	16 (73)	19 (83)	6 (75)	9 (60)
Total	18 (100)	50 (100)	22 (100)	23 (100)	8 (100)	15 (100)

ADSQ, adenosquamous carcinoma; MDA, minimal deviation adenocarcinoma; NOS, not otherwise specified; A-NOS, adenocarcinoma NOS; VGC, villoglandular papillary adenocarcinoma; others, other types of adenocarcinoma.

study, 0.6-mm cores accurately represented tumor morphology in all cases of cervical adenocarcinoma. TMAs should not be constructed from randomly or blindly selected regions of each tumor. Careful selection of the regions of interest in a morphologically heterogeneous tumor provides more representative results. This process of selecting representative, viable tumor regions from which to obtain the core biopsy specimens is crucial and should be performed by an experienced pathologist.

A frequent question is whether a larger diameter of the needle used for TMA construction (eg, 3 mm instead of 0.6 mm) could help minimize sampling errors caused by heterogeneity. Although the development of TMA technology started using 3-mm needles, it is considered that increasing the needle size is of limited value in the assessment of heterogeneous tumor markers since tumor heterogeneity is likely to a minor degree within a still very small tissue fragment measuring 3 mm in diameter. If a better representation of an individual tumor is required, it would be more advantageous to array two or more samples from different areas of each tumor. Similar results were reported by Bubendorf *et al.*⁽²⁵⁾. Some investigators have been tempted to use larger diameter punches (typically 2–4 mm) in an effort to provide more representative samples for TMA analysis. Although this approach multiplies the amount of tissue analyzed by a factor of 10–45, there is little mathematical or practical evidence that such a sampling strategy is more representative than 0.6-mm punches. Typical primary tumors often measure 2–15 cm in diameter. Even if the concept holds that small subpopulations are critical for tumor behavior, the likelihood of detecting the decisive clone in a 3-mm sample is not much larger than detecting it in a 0.6-mm

area. To improve the sampling efficiency, the acquisition of multiple small tissue cores from distinct, perhaps histologically different, regions of the tumor is more effective than increasing the size of a single punch. Based on these considerations, the 0.6-mm sample size is preferable. Using larger (2- to 4-mm) samples also has the substantial disadvantage that it greatly reduce the number of samples that can be arrayed on a single slide (only about fifty 4-mm biopsies fit on a single TMA slide) and the number of punches that can be taken from one original tumor block. These results and suggestions were supported in previous evaluations of the TMA technique in different cancer specimens and cell lines^(21,17). Moreover, Camp *et al.*⁽¹⁵⁾ concluded that the TMA technique, with twofold redundancy, in breast cancer is a valuable and accurate method for analysis of protein expression in large archival cohorts.

To determine the number of tissue cores required to obtain an immunohistochemical result equivalent to a conventional tissue section, we constructed an array with two pairs of cores from each of 119 cases of invasive cervical adenocarcinoma, 20 AIS, and 16 normal endocervical tissues. We analyzed each core separately and graded it as either positive or negative. About 97% of cases had at least two scorable cores for each antibody tested. However, most cases had more than three cores with sufficient tumor for evaluation. In the majority of cases, staining was uniform across all the cores, and consequently, the chance of adequately representing the tumor in one punch was 100%. Moreover, the results of this analysis demonstrate that microscopic analysis of two disks achieves about 97% representation. Therefore, we suggest that staining results from a minimum of two cores should be included in immunohistochemical

assessment of TMA technique in cervical adenocarcinoma. For practical purposes, therefore, it is desirable to identify the minimal number of core biopsy specimens needed to achieve two readable cores for immunohistochemistry. With a loss of up to 4% of the core biopsy specimens, we suggest that four tissue cores should be taken from each tumor. This conclusion is in concordance with the results obtained from validation of the TMA technique for immunohistochemical staining in soft tissue tumors^(16,5) in rectal cancer⁽⁶⁾ and in breast cancer⁽¹⁵⁾. These studies have suggested that analysis of triplicate core biopsy specimens per tumor increases the number of concordant readings, lowers the number of lost cases, and provides a reliable immunohistochemical expression profile.

According to all of these data and our experience, we have developed a standard procedure in which two pairs of cores are punched in various regions of the tumor mass, including both the leading edge and the tumor center. This process ensures that at least two, and in most cases three, punches are available for evaluation, resulting in adequate representation of the whole-section staining pattern in about 97% of cases. Although expression of some antigens, such as estrogen receptor and progesterone receptor, in cervical adenocarcinoma is regarded as particularly heterogeneous, it is possible that other antigens in other tumor types may exhibit even greater heterogeneity. Consequently, similar analyses may be required to validate the use of TMAs in other tumor types. A similar suggestion is reported in TMA evaluation in breast cancer by Camp *et al.*⁽¹⁵⁾.

In conclusion, the TMA technique is a rapid, cost-effective, and tissue-saving method, yields staining of good quality, and is feasible for immunohistochemical studies in cervical adenocarcinoma. Four cores are sufficient to produce representative sampling of the morphology of tumors even if occasional cores are lost on slides. TMAs will substantially accelerate studies associating novel molecular discoveries in the field of genomics and proteomics with specific pathologic, demographic, clinical, and follow-up information of cancers and cancer patients. TMAs containing well-characterized tissues enable researchers to perform studies involving thousands of patient specimens, with substantial increases in speed, quality of data, information content, and savings of cost and time. Since the diagnostic tumor biopsy specimens are often small, the use of the TMA contributes to tissue preservation. Furthermore, the tumor areas from which the tissue core biopsy specimens are obtained must be carefully selected to reduce the number of non-

evaluable core biopsy sections containing nonrepresentative tissue.

Acknowledgments

We are grateful to Dr. Awatif Al-Nafussi and Dr. Sezgin Ismail for their critical assessment of the manuscript.

References

- Andersson S, Rylander E, Larsson B, Strand A, Silfversvard C, Wilander E. The role of human papillomavirus in cervical adenocarcinoma carcinogenesis. *Eur J Cancer* 2001;37:246-50.
- Bonds L, Baker P, Gup C, Shroyer KR. Immunohistochemical localization of cdc6 in squamous and glandular neoplasia of the uterine cervix. *Arch Pathol Lab Med* 2002;126:1164-8.
- Mathers ME, Johnson SJ, Wadehra V. How predictive is a cervical smear suggesting glandular neoplasia? *Cytopathology* 2002;13: 83-91.
- Cordon-Cardo C. Mutation of cell cycle regulators: biological and clinical implications for human neoplasia. *Am J Pathol* 1997;147: 545-60.
- Hoos A, Urist MJ, Stojadinovic A *et al.* Validation of tissue microarrays for immunohistochemical profiling of cancer specimens using the example of human fibroblastic tumours. *Am J Pathol* 2001; 158:1245-51.
- Fernebro E, Dictor M, Bendahl PO, Ferno M, Nilbert M. Evaluation of the tissue microarray technique for immunohistochemical analysis in rectal cancer. *Arch Pathol Lab Med* 2002;126:702-5.
- Wright JJ. The development of the frozen section technique, the evolution of surgical biopsy, and the origins of surgical pathology. *Bull Hist Med* 1985;59:295-326.
- Kononen J, Bubendorf L, Kallioniemi A *et al.* Tissue microarrays for high-throughput molecular profiling of tumour specimens. *Nat Med* 1998;4:844-7.
- Bubendorf L, Kononen J, Koivisto P *et al.* Survey of gene amplifications during prostate cancer progression by high-throughout fluorescence in situ hybridization on tissue microarrays. *Cancer Res* 1999; 59:803-6.
- Moch H, Schraml P, Bubendorf L *et al.* High-throughput tissue microarray analysis to evaluate genes uncovered by cDNA microarray screening in renal cell carcinoma. *Am J Pathol* 1999; 154:981-6.
- Schraml P, Kononen J, Bubendorf L *et al.* Tissue microarrays for gene amplification surveys in many different tumour types. *Clin Cancer Res* 1999;5:1966-75.
- Mucci NR, Akdas G, Manely S, Rubin MA. Neuroendocrine expression in metastatic prostate cancer: evaluation of high throughput tissue microarrays to detect heterogeneous protein expression. *Hum Pathol* 2000;31:406-14.
- Perrone EE, Theoharis C, Mucci NR *et al.* Tissue microarray assessment of prostate cancer tumour proliferation in African-American and white men. *J Natl Cancer Inst* 2000;92:937-9.
- Mills SE, Fechner RE, Frierson HF *et al.* Guardians of the wax and the patient. *Am J Clin Pathol* 1995;104:365-7.
- Camp RL, Charette LA, Rimm DL. Validation of tissue microarray technology in breast carcinoma. *Lab Invest* 2000;80:1943-9.
- Engellau J, Akerman M, Anderson H *et al.* Tissue microarray technique in soft tissue sarcoma: immunohistochemical Ki-67 expression in malignant fibrous histiocytoma. *Appl Immunohistochem Mol Morphol* 2001;9:358-63.
- Hoos A, Lewis JJ, Antonescu CR *et al.* Characterization of molecular abnormalities in human fibroblastic neoplasms: a model for genotype-phenotype association in soft tissue tumours. *Cancer Res* 2001; 61:3171-5.
- Kallioniemi OP, Wagner U, Kononen J, Sauter G. Tissue microarray technology for high-throughput molecular profiling of cancer. *Hum Mol Genet* 2001;10:657-62.
- Shibata D, Martin WJ, Arnheim N. Analysis of DNA sequences in forty-year-old paraffin-embedded thin-tissue sections: a bridge

between molecular biology and classical histology. *Cancer Res* 1988;48:4564-6.

20 Ibrahim SO, Johannessen AC, Vasstrand EN, Lillehaug J, Nilsen R. Immunohistochemical detection of p53 in archival formalin-fixed tissues of lip and intraoral squamous cell carcinomas from Norway. *APMIS* 1997;105:757-64.

21 Hoos A, Cordon-Cardo C. Tissue microarray profiling of cancer specimens and cell lines: opportunities and limitations. *Lab Invest* 2001;81:1331-8.

22 Alkushi A, Irving J, Hsu F *et al*. Immunoprofile of cervical and endometrial adenocarcinomas using a tissue microarray. *Virchows Arch* 2003;442:271-7.

23 Chu P, Weiss L. Keratin expression in human tissues and neoplasms. *Histopathology* 2002;40:403.

24 Cina SJ, Richardson MS, Austin RM, Kurman RJ. Immunohistochemical staining for Ki-67 antigen, carcinoembryonic antigen, and p53 in the differential diagnosis of glandular lesions of the cervix. *Mod Pathol* 1997;10:176-80.

25 Bubendorf L, Nocito A, Moch H, Sauter G. Tissue microarray (TMA) technology: miniaturized pathology archives for high-throughput in situ studies. *J Pathol* 2001;195:72-9.

Accepted for publication September 15, 2005

Evaluation of *PTEN* expression in cervical adenocarcinoma by tissue microarray

M.TAWFIK EL-MANSI & A.R.W. WILLIAMS

Department of Pathology, University of Edinburgh, Edinburgh, Scotland, United Kingdom

Abstract. Tawfik El-Mansi M, Williams ARW. Evaluation of *PTEN* expression in cervical adenocarcinoma by tissue microarray. *Int J Gynecol Cancer* 2006;16:1254–1260.

PTEN, a tumor suppressor gene, appears to negatively control the phosphoinositide 3-kinase signaling pathway for regulation of cell proliferation and cell survival. Somatic *PTEN* mutations are involved in a variety of tumors, including endometrial carcinomas, where *PTEN* expression is diminished. We examined expression of *PTEN* in a series of cervical adenocarcinomas and precursors, using tissue microarray (TMA) technology. TMA blocks were constructed using paraffin-embedded, formalin-fixed tissues from 273 samples derived from 16 normal cervical biopsies, 119 cases of invasive adenocarcinoma, and 20 high-grade cervical glandular intraepithelial neoplasia (CGIN). Fresh 3- μ m sections were cut and immunostained with *PTEN*, and expression was correlated with clinicopathologic variables, including histologic subtypes of adenocarcinoma. In 137 patients, *PTEN* expression was positive in 121 (88%). The intensity and distribution of *PTEN* staining in the tumor tissue were more heterogeneous than those observed in the normal tissues. There were no significant differences in distribution or intensity of *PTEN* expression between adenocarcinoma *in situ* and subtypes of invasive adenocarcinoma. Our findings show that unlike the case in most endometrial carcinomas, *PTEN* expression is retained during the process of carcinogenesis in the glandular cervix. There is, however, evidence of altered distribution and intensity of *PTEN* expression in cervical adenocarcinoma cells.

KEYWORDS: cervical adenocarcinoma, immunohistochemistry, *PTEN*, tissue microarray (TMA).

PTEN (phosphatase and tensin homolog deleted on chromosome 10) is a tumor suppressor gene that appears to negatively control the phosphoinositide 3-kinase signaling pathway for regulation of cell survival and cell proliferation by dephosphorylating phosphatidylinositol 3,4,5-triphosphate (PIP-3)⁽¹⁾. The loss of *PTEN* function results in an increased concentration of PIP-3, and this in turn leads to Akt hyperactivation. This suggests that the tumor suppressor function of *PTEN* is exerted through the negative regulation of the phosphatidylinositol-3(PI3)-kinase/Akt cell survival pathway^(2,3). The protein phosphatase activity of *PTEN* is not considered to be as important as its lipid phosphatase activity for tumor suppression. However, *PTEN* function as protein phosphatase has been implicated in the inhibition of cell migration and invasion via dephosphorylation of focal adhesion kinase, a molecule critical in the regula-

tion of integrin signaling^(4,5) and also in the inhibition of cell cycle progression⁽⁶⁾.

To date, 110 germ line *PTEN* mutations have been reported in patients affected with rare multiple hamartoma syndromes^(7,8). *PTEN* has also been found to be defective in a large number of sporadic human tumors of breast, prostate, brain, and endometrium^(7,9,10). *PTEN* is a good candidate for involvement in the pathogenesis of sporadic colon cancer. However, to date, few somatic *PTEN* mutations or deletions have been identified in sporadic colon cancers^(10–13). Somatic *PTEN* mutations are more particularly involved in two types of human cancers: endometrial carcinomas⁽¹⁴⁾ and glioblastomas^(15,16). In most cases, these somatic mutations result in protein inactivation, and as with germ line mutations, recurrent somatic mutations are found in CpG dinucleotides. A mutagenesis by insertion–deletion in repetitive elements is, however, specifically observed in endometrial carcinomas⁽¹⁷⁾.

Being one of the initial genetic changes seen in endometrial carcinogenesis, the *PTEN* gene acts as a gatekeeper for this process⁽¹⁸⁾. In normal endometria, isolated

Address correspondence and reprint requests to: Dr Magdy Tawfik El-Mansi, MBChB, MSc, Histopathology Department, Wythenshawe Hospital, Southmoor Road, Manchester M23 9 LT, UK. Email: magdy.elmansi@smuht.nwest.nhs.uk

PTEN-negative glands may well be the earliest detectable phases of endometrial tumorigenesis yet seen, but the clinical relevance of such small lesions remains to be determined^(19,20). It is anticipated that similar high rates of initiation will be seen in other tissues because comparable biomarkers for neoplastic initiation become available in other tissue sites. Lesions have now fulfilled most of those postulates predicted for clinically relevant precancerous disease. Loss of *PTEN* function occurs quite frequently within the endometrial regenerative pool, at such a high rate that they can be considered part of background "normal" genetic events. These mutant clones remain indistinguishable from nonmutant glands in normal cycling and anovulatory endometrium. Involution or expansion of mutant clones due to nongenetic factors is one possible mechanism whereby the ambient hormonal state may modify the risk of endometrial cancer⁽²¹⁾. Interestingly, the *PTEN* gene appears to be hormonally regulated, with greatest physiologic endometrial gland expression in an estrogen-rich environment⁽¹⁹⁾. Thus, the diminished *PTEN* tumor suppressor function effects are probably accentuated under the very circumstances known to increase endometrial cancer risk: protracted estrogen exposure unopposed by progestins^(22,23). Mutant glands then acquire additional genetic damage and subsequently become recognizable as focal lesions by their crowded architecture and altered cytology⁽²¹⁾.

The role of *PTEN* in cervical carcinogenesis is unclear and has not been investigated before. Therefore, in this study, we examined *PTEN* expression immunohistochemically in a large set of cervical adenocarcinomas, comparing the profile of adenocarcinoma *in situ* (AIS) with invasive subtypes of cervical adenocarcinomas using tissue microarray (TMA) technology to assess its expression in this common human cancer type and its potential as a prognostic factor.

Materials and methods

Tissue samples

A computerized tumor registry search was conducted for all patients diagnosed with cervical adenocarcinoma at the University of Edinburgh, Pathology Department, from 1991 to 2001. Ethical approval for this study was granted by the local research ethics committee. Surgical cervical specimens were obtained from the archival collections. A total of 273 samples (paraffin-embedded blocks) were obtained from 177 biopsies composed of 16 normal cervical samples and specimens from 139 different patients with endocervical adenocarcinomas. Pathology reports and cervical smear history reports were

reviewed. Nonprimary cervical adenocarcinomas were excluded. The final set of study cases included samples of glandular tissues including normal endocervical mucosa (16), high-grade cervical glandular intraepithelial neoplasia (CGIN)/AIS (20), and invasive adenocarcinoma (119) of which 16 were early invasive, meeting FIGO criteria for stage IA1. Three-micrometer serial sections from the routinely processed formalin-fixed, paraffin-embedded tissue blocks were prepared. Before deparaffinizing the sections, they were baked overnight at 60°C and stained using hematoxylin and eosin method to choose the morphologically representative areas.

Tissue arrays and immunohistochemistry

Areas of morphologically representative, nonnecrotic sites in the tumor were marked with colored indelible marker on the glass slides. From each corresponding paraffin block, two paired tissue cores (0.6 mm in diameter) were sampled from each marked area in the "donor" block and mounted into a "recipient" paraffin block by the use of a custom-made instrument (Beecher Instruments, Silver Springs, MD). In the ensuing paraffin array block, the tissue cylinders were aligned and marked for identification according to a chart. The "recipient" paraffin blocks (TMA blocks) were baked at 56°C for 10 min before sectioning, and 3- μ m paraffin sections were then made by standard technique. After that, TMAs sections were stained with phosphatase and tensin homolog deleted on chromosome 10 (*PTEN*) antibody. In addition, some slides from the whole tissue blocks were stained.

Fresh 3- μ m sections were cut from each microarray and the original paraffin-embedded block and transferred to glass slides (BDH Superfrost plus microscope slides, 75 mm, BDH Laboratory Supplies). Following deparaffinization in xylene (two times, 5 min each time) and rehydration through descending graded ethanol, 100%, 95%, and 70% (2 min each time), the sections were washed well with tap water for 2 min. Antigen retrieval was performed by immersing tissue sections in citrate buffer pH 6, with pressure-cooking for 6 min at 1m bar. The sections were washed well in water and then loaded onto Shandon Sequenza staining apparatus. Endogenous peroxidase was then blocked by treatment with 1% hydrogen peroxide for 5 min, followed by washing in distilled water and then phosphate-buffered saline (PBS). Using Dako Envision System, the tissue sections were stained with *PTEN* (clone 28H6, NovoCastr Laboratories Ltd., UK) for 30 min and incubated at 1:100 dilution. Negative control (omission of the primary antibody) and positive control tissues of known positivity to *PTEN* were

ed. The positive tissue control for *PTEN* was tonsil. The sections were washed well in PBS (two times, 5 min each time). The tissue sections were incubated with Dako EnVision/HRP rabbit/mouse polymer for 30 min and then washed well in PBS (two times, 5 min each time). After that, the sections were incubated at room temperature with 3,3'-diaminobenzidine solution for 10 min and washed in tap water. Finally, the sections were counterstained with hematoxylin, washed in tap water, "blued" in Scott's Tap Water Substitute (STWS), dehydrated in ascending graded ethanol, 70%, 95%, and 100% (5 seconds each time), and cleared well with xylene and mounted by DPX.

Evaluation of tissue staining

We decided that in order for an immunohistochemical result to be considered reliable, a minimum of two TMA cores from the tumor should show concordant staining patterns. If divergent staining patterns were obtained, results from third or subsequent cores were assessed, and the case was considered to show positive staining if a minimum of two cores showed specific staining.

In the evaluation of staining, cores were scored if at least 10% of the core area contained tumor, and each core analyzed separately and graded it as either positive or negative. However, *PTEN* staining was considered positive when the tumor cell nuclei showed staining in at least two valuable TMAs. Also, the staining reaction was compared between the cores and some of the whole sections. Moreover, we compared the staining reaction of invasive and preinvasive cases with that of normal tissue with respect to the intensity and distribution of *PTEN* expression. All microscopy was performed with a Zeiss microscope (KPI 10× eyepiece with a high-power field) (×40).

Statistical analysis

Associations between pathologic variables and expression of *PTEN* were analyzed using StatXact-4 package. Fisher's exact test was used in comparison between AIS and invasive adenocarcinoma, while Chi-square test was used in comparison between different subtypes of invasive adenocarcinoma. *P* value of <0.05 was judged to be significant.

Results

PTEN expression in the cervix

There were two patients where *PTEN* result was not available. In the other 137 patients, the result was neg-

ative for 16 (12%) and positive for 121 (88%). Immunohistochemical staining for *PTEN* was nuclear only. In all cases, normal endocervical cells and normal stromal cells of the cervix stained weakly positive for *PTEN* (Fig. 1A). The nuclei of malignant endocervical cells were stained diffusely either as fine or as coarse granular dots. Generally, the staining reaction of malignant endocervical cells was stronger than that observed in the normal endocervical cells and was also restricted to the nucleus. In addition, the intensity and distribution of *PTEN* staining in the tumor tissue were more heterogeneous than those observed in the normal tissues. Also, there was marked heterogeneity of the intensity and the distribution between and within tumors in the same section (Fig. 1D-H). There was strong nuclear staining of positive controls in all cases, but no staining of negative controls.

Correlation between *PTEN* expression and pathologic variables of cervical adenocarcinomas

High-grade CGIN/AIS

Excluding 2 patients from 20 patients with AIS where *PTEN* result was not available, 16 of 18 patients (89%) with AIS were positive with *PTEN*, and the other 2 patients (11%) were negative. There was no significant difference in distribution or intensity of *PTEN* expression between AIS and invasive adenocarcinoma (Fig. 1B, D). *PTEN* results of AIS in comparison to those of invasive subtypes of adenocarcinoma are shown in Table 1.

Invasive adenocarcinoma

A total of 105 of 119 patients (88%) with invasive cervical adenocarcinoma were positive with *PTEN*. In addition, different histologic subtypes of cervical adenocarcinoma showed no significant differences in *PTEN* expression (Fig. 1D-H). *PTEN* results of all subtypes of invasive adenocarcinoma in comparison to each other and in comparison to AIS are shown in Table 1.

Early invasive adenocarcinoma

Sixteen of 119 patients with invasive adenocarcinoma had early invasive adenocarcinoma that meet criteria for FIGO stage IA1 carcinoma of the cervix. The *PTEN* result was negative for 2 (13%) and positive for 14 (88%) patients.

Discussion

A recently discovered tumor suppressor gene, *PTEN*, encodes a dual activity phosphatase and has been

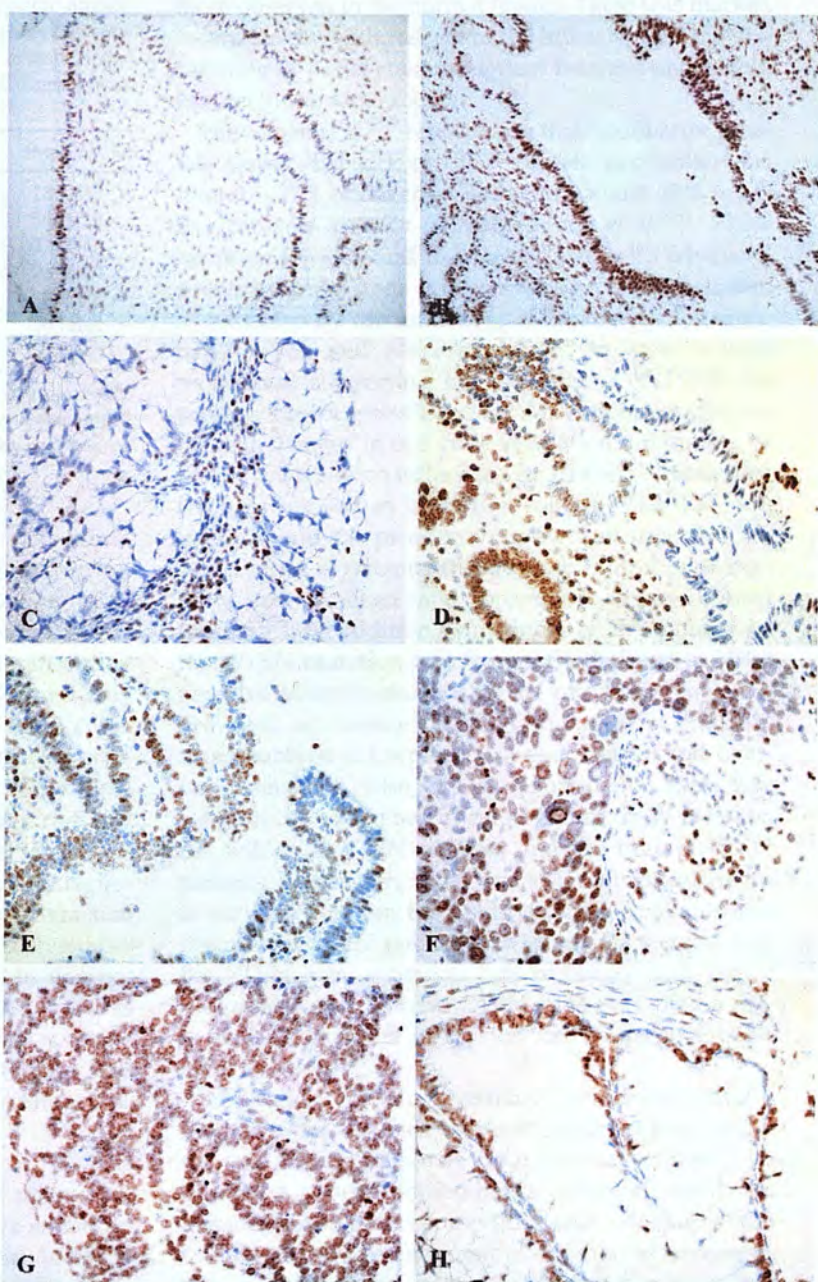


Figure 1. Immunohistochemical demonstration of *PTEN* in cervical tissues. A) In normal cervical tissue, there is weak positive staining of stromal cells and nuclei of cervical glandular cells ($\times 200$). B) In AIS, there is strong positive nuclear staining ($\times 200$). C) In endocervical adenocarcinoma, signet ring cell type, there is no nuclear staining with positive stromal cells ($\times 400$). D) In AIS, there is strong positive nuclear staining ($\times 400$). In endocervical adenocarcinoma of all other subtypes, there is strong positive nuclear staining: E) villoglandular papillary adenocarcinoma ($\times 400$), F) adenosquamous carcinoma ($\times 400$), G) microglandular carcinoma ($\times 400$), and H) intestinal-type adenocarcinoma ($\times 400$). Note: The intensity and distribution of *PTEN* staining in the tumor tissue are stronger and more heterogeneous than those observed in the normal tissues.

involved in cell cycle regulation and cell adhesion properties including migration⁽²⁴⁾. Loss of *PTEN* function leads to increased Akt activity and, subsequently, cell survival⁽³⁾. Somatic mutations of *PTEN* are involved in a variety of tumors such as endometrial carcinomas where *PTEN* expression is diminished⁽²⁵⁾. There are likely to be multiple but distinct tissue-related pathways involved in tumorigenesis and tumor progression. Loss of *PTEN* function in prostate

and breast cancers may be compounded by loss of protein expression by transcriptional or translational mechanisms. In prostate tissues, genetic aberrations and expression losses have been reported⁽¹¹⁾, and in breast carcinomas, a recent immunohistochemical study showed that 15% of cases had complete loss of *PTEN* protein, a phenomenon that appeared to correlate with monoallelic deletion of the gene⁽²⁶⁾. Although loss of heterozygosity of *PTEN* can be found in

Table 1. *PTEN* expression of all subtypes of invasive adenocarcinoma and AIS. There are no significant differences between adenocarcinoma subtypes and between AIS and invasive adenocarcinoma. There were two patients where *PTEN* result was not available (two AIS)

<i>PTEN</i>	Negative, N (%)	Positive, N (%)	Total, N (%)
AIS	2 (11)	16 (89)	18 (100)
A-NOS	8 (16)	42 (84)	50 (100)
ADSQ	2 (9)	20 (91)	22 (100)
VGC	0 (0)	23 (100)	23 (100)
MDA	0 (0)	8 (100)	8 (100)
Others	4 (25)	12 (75)	16 (100)
Total	16 (12)	121 (88)	137 (100)

A-NOS, not otherwise specified; A-NOS, adenocarcinoma NOS; ADSQ, adenosquamous carcinoma; VGC, villoglandular papillary adenocarcinoma; MDA, minimal deviation adenocarcinoma; others, other types of adenocarcinoma.

sporadic colon cancer⁽¹²⁾, studies have not found *PTEN* mutations to be as frequent as is found in tumors of the brain and the prostate. Guanti *et al.*⁽²⁷⁾ studied 32 cases of sporadic colon cancer but observed only one case with a biallelic genomic alteration that caused loss of function of the gene and⁽¹³⁾ found only one somatic mutation of the *PTEN* gene in 72 colon cancer cases. Taniyama *et al.*⁽¹¹⁾ reported, during colorectal tumor progression, the analysis of *PTEN* RNA transcripts confirming that both *PTEN* transcriptional and translational mechanisms are operative in colorectal cancer. However, it remains possible that *PTEN* protein function is compromised via inefficient interaction with cofactors or by peptide structure, but such studies will require the development of a reliable enzyme activity assay. Subsequently, with mutational and loss of heterozygosity analyses performed on sporadic colon cancer specimens, these findings suggest that *PTEN* expression is maintained in sporadic colon cancers.

In this study, we examined expression of *PTEN* in a series of cervical adenocarcinomas and precursors. In 137 patients with invasive or preinvasive adenocarcinoma, *PTEN* expression was negative in 16 (12%) and positive in 121 (88%). Moreover, there was no significant difference in distribution or intensity of *PTEN* expression between AIS and invasive adenocarcinoma. Also, different histologic subtypes of cervical adenocarcinoma showed no significant differences in *PTEN* expression. In all cases, normal endocervical cells and normal stromal cells of the cervix stained weakly positive for *PTEN*. The staining pattern in the tumor cells was stronger than that observed in the normal endocervical cells but was still restricted to the nucleus. In addition, the intensity and distribution of *PTEN* staining in the tumor tissue were more heterogeneous than

those observed in the normal tissues. There was marked heterogeneity with respect to the intensity and the distribution of *PTEN* staining pattern between and within tumors in the same section.

Halvorsen *et al.*⁽²⁸⁾ reported on their studies on prostate cancer that lack of *PTEN* protein expression was found in 27% of the cases comparable with 20% negative cases in a study of McMenamin *et al.*⁽²⁹⁾. *PTEN* expression was found to be associated with advanced primary tumor stage and increasing tumor diameter, as indicated by carcinomatous infiltration of the seminal vesicles, and was also related to time to local recurrence, supporting the importance of *PTEN* for prostate cancer growth and local invasion, possibly reflecting changes in cell cycle regulation, migration, or loss of cell cohesion influenced by *PTEN*⁽³⁰⁾. These data strongly suggest an important role of *PTEN* for local invasion and the progressive growth of prostate cancer in series of patients treated with radical prostatectomy for localized and presumed organ-confined tumors⁽²⁹⁾. In addition, Minaguchi *et al.*⁽³¹⁾ observed that *PTEN* mutation was frequently detected in HPV-negative adenocarcinomas of the cervix and the most prevalent occurrence of *PTEN* mutation in endometrioid subtype is keeping with endometrial and ovarian carcinomas. Also, it was reported that there was a significant difference in stage III versus IV between the wild-type *PTEN* patients and the mutant *PTEN* patients. In addition, there was a significant difference in survival between the wild-type *PTEN* patients and the mutant *PTEN* patients. These results suggest that the *PTEN* gene mutation rate increases with tumor progression and that the *PTEN* gene may play a role in both progression of cervical carcinoma and treatment outcome⁽³²⁾.

In surgical pathology practice, immunohistochemistry may be required to distinguish primary endocervical adenocarcinomas from primary endometrial tumors. A panel of antibodies is commonly used that includes estrogen receptor (ER) and vimentin (both usually positive in endometrial carcinomas and negative in endocervical carcinomas) and carcinoembryonic antigen (CEA) (usually negative in endometrial and positive in cervical carcinomas). However, immunophenotypes vary, and occasional cases remain problematic. For example, our own (unpublished data) results with ER staining in this series of cervical adenocarcinomas (Tawfik El-Mansi & Williams, April 2005) indicate that around 50% of cervical adenocarcinomas show positive ER staining. Published results from other studies report CEA staining to be found in a majority (62%) of endocervical adenocarcinomas⁽³³⁾, but a significant proportion are negative. A recent study showed

that p16 may also be of some value in distinguishing between an endocervical and an endometrial adenocarcinoma. Strong diffuse positivity involving 100% of cells is the rule in primary endocervical adenocarcinoma, whereas endometrial adenocarcinoma usually exhibits a lesser degree of staining⁽³⁴⁾. Many of benign mimics such as tuboendometrial metaplasia and endometriosis are most likely to be confused with CGIN. It is stressed that p16 may be of use in the distinction between CGIN and benign mimics. Cases of CGIN almost invariably show strong diffuse positivity for p16, while most benign mimics are negative or show focal positivity⁽³⁵⁾. Immunohistochemical expression of CD44 has also been investigated in endocervical glandular lesions. It was concluded that CD44 immunoreactivity may be a useful diagnostic marker of endocervical neoplasia^(34,35). We therefore suggest that PTEN may be a useful addition to the panel of antibodies used to make this distinction. The results of this study have shown that 88% of cervical adenocarcinomas show positive PTEN staining, contrasting with published results for PTEN expression in endometrial adenocarcinomas in which diminution of expression has been found in 97%, with complete absence in 61% of endometrial adenocarcinomas⁽²⁵⁾.

In conclusion, our findings show that unlike the case in most endometrial carcinomas, PTEN expression is retained during the process of carcinogenesis in the glandular cervix. PTEN expression was positive in 105 of 119 patients (88%) with invasive cervical adenocarcinoma and 16 of 18 patients (89%) with AIS. Therefore, PTEN expression could be a potential biomarker for diagnosis of cervical adenocarcinoma and for distinguishing between primary cervical adenocarcinoma and primary endometrial adenocarcinoma. There is, however, evidence of altered distribution and intensity of PTEN expression in cervical adenocarcinoma cells compared with normal endocervical cells. Also, there was marked heterogeneity of the intensity and the distribution between and within tumors in the same section. There is no significant difference in distribution or intensity of PTEN expression between AIS and invasive adenocarcinoma. Also, different histologic subtypes of cervical adenocarcinoma showed no significant differences in PTEN expression.

Acknowledgments

We are grateful to Dr. Awatif Al-Nafussi and Dr. Sezgin Ismail for their critical assessment of the manuscript.

References

- Myers MP, Pass I, Batty IH *et al*. The lipid phosphatase activity of PTEN is critical for its tumour suppressor function. *Proc Natl Acad Sci U S A* 1998;95:13513-8.
- Furnari FB, Huang HJ, Cavenee WK. The phosphoinositid phosphatase activity of PTEN mediates a serum-sensitive G1 growth arrest in glioma cells. *Cancer Res* 1998;58:5002-8.
- Stambolic V, Suzuki A, de la Pompa JL *et al*. Negative regulation of PKB/Akt-dependent cell survival by the tumour suppressor PTEN. *Cell* 1998;95:29-39.
- Tamura M, Gu J, Matsumoto K, Aota S, Parsons R, Yamada KM. Inhibition of cell migration, spreading, and focal adhesions by tumour suppressor PTEN. *Science* 1998;280:1614-7.
- Tamura M, Gu J, Danen EH, Takino T, Miyamoto S, Yamada KM. PTEN interactions with focal adhesion kinase and suppression of the extracellular matrix-dependent phosphatidylinositol3-kinase/Akt cell survival pathway. *J Biol Chem* 1999;274:20693-703.
- Hlobilkova A, Guldborg P, Thullberg M, Zeuthen J, Lukas J, Bartek J. Cell cycle arrest by the PTEN tumour suppressor is target cell specific and may require protein phosphatase activity. *Exp Cell Res* 2000;256:571-7.
- Li J, Yen C, Liaw D *et al*. PTEN, a putative protein tyrosine phosphatase gene mutated in human brain, breast, and prostate cancer. *Science* 1997;275:1943-7.
- Eng C, Peacocke M. PTEN and inherited hamartoma-cancer syndromes. *Nat Genet* 1998;19:223.
- Steck PA, Pershouse MA, Jasser SA *et al*. Identification of a candidate tumour suppressor gene, MMAC1, at chromosome 10q23.3 that is mutated in multiple advanced cancers. *Nat Genet* 1997;15:356-62.
- Kong D, Suzuki A, Zou TT *et al*. PTEN1 is frequently mutated in primary endometrial carcinomas. *Nat Genet* 1997;17:143-4.
- Taniyama K, Goodison S, Ito R *et al*. PTEN expression is maintained in sporadic colorectal tumours. *J Pathol* 2001;194:341-8.
- Frayling IM, Bodmer WF, Tomlinson IP. Allele loss in colorectal cancer at the Cowden disease/juvenile polyposis locus on 10q. *Cancer Genet Cytogenet* 1997;97:64-9.
- Wang ZJ, Taylor F, Churchman M, Norbury G, Tomlinson I. Genetic pathways of colorectal carcinogenesis rarely involve the PTEN and LKB1 genes outside the inherited hamartoma syndromes. *Am J Pathol* 1998;153:363-6.
- Kawanishi M, Kohno T, Otsuka T *et al*. Allelotype and replication error phenotype of small cell lung carcinoma. *Carcinogenesis* 1997;18:2057-62.
- Rasheed BK, Stenzel TT, McLendon RE *et al*. PTEN gene mutations are seen in high-grade but not in low-grade gliomas. *Cancer Res* 1997;57:4187-90.
- James CD, Galanis E, Frederick L *et al*. Tumour suppressor gene alterations in malignant gliomas: histopathological associations and prognostic evaluation. *Int J Oncol* 1999;15:547-53.
- Bonneau D, Longy M. Mutations of the human PTEN gene. *Hum Mutat* 2000;16:109-22.
- Ali IU. Gatekeeper for endometrium: the PTEN tumour suppressor gene. *J Natl Cancer Inst* 2000;92:861-3.
- Mutter GL, Lin MC, Fitzgerald JT, Kum JB, Eng C. Changes in endometrial PTEN expression throughout the human menstrual cycle. *J Clin Endocrinol Metab* 2000;85:2334-8.
- Mutter GL, Ince TA, Baak JP, Kust GA, Zhou XP, Eng C. Molecular identification of latent precancers in histologically normal endometrium. *Cancer Res* 2001;61:4311-4.
- Mutter GL. Diagnosis of premalignant endometrial disease. *J Clin Pathol* 2002;55:326-31.
- Curry SKS. Cancer of the female genital tract: overview. In: Osteen R, ed. *Cancer manual*. Boston, MA: American Cancer Society, 1990:253-7.
- Parazzini F, La Vecchia C, Boccione L, Franceschi S. The epidemiology of endometrial cancer. *Gynecol Oncol* 1991;41:1-16.
- Di Cristofano A, de Acetis M, Koff A, Cordon-Cardo C, Pandolfi PP. PTEN and p27KIP1 cooperate in prostate cancer tumour suppression in the mouse. *Nat Genet* 2001;27:222-4.
- Mutter GL, Lin MC, Fitzgerald JT *et al*. Altered PTEN expression as a diagnostic marker for the earliest endometrial precancers. *J Natl Cancer Inst* 2000;92:924-30.
- Perren A, Weng LP, Boag AH *et al*. Immunohistochemical evidence of loss of PTEN expression in primary ductal adenocarcinomas of the breast. *Am J Pathol* 1999;155:1253-60.
- Guanti G, Resta N, Simone C *et al*. Involvement of PTEN mutations in the genetic pathways of colorectal cancerogenesis. *Hum Mol Genet* 2000;9:283-7.

- Halvorsen O, Haukaas SA, Akslen LA. Combined loss of *PTEN* and *p27* expression is associated with tumour cell proliferation by Ki-67 and increased risk of recurrent disease in localized prostate cancer. *Clin Cancer Res* 2003;9:1474-9.
- McMenamin ME, Soung P, Perera S, Kaplan I, Loda M, Sellers WR. Loss of *PTEN* expression in paraffin-embedded primary prostate cancer correlates with high Gleason score and advanced stage. *Cancer Res* 1999;59:4291-6.
- Tamura M, Gu J, Tran H, Yamada KM. *PTEN* gene and integrin signaling in cancer. *J Natl Cancer Inst* 1999;91:1820-8.
- Minaguchi T, Yoshikawa S, Yasugi T *et al.* Association of *PTEN* mutation with HPV-negative adenocarcinoma of the uterine cervix. *Cancer Lett* 2004;210:57-62.
- 32 Harima Y, Sawada S, Nagata K, Sougawa M, Ostapenko V, Ohnishi T. Mutation of the *PTEN* gene in advanced cervical cancer correlated with tumor progression and poor outcome after radiotherapy. *Int J Oncol* 2001;18:493-7.
- 33 Casrillon DH, Lee KR, Nucci MR. Distinction between endometrial and endocervical adenocarcinomas: an immunohistochemical study. *Int J Gynecol Pathol* 2001;21:4-15.
- 34 McCluggage WG. Endocervical glandular lesions: controversial aspects and ancillary techniques. *J Clin Pathol* 2003;56:164-73.
- 35 McCluggage WG. Recent advances in immunohistochemistry in gynaecological pathology. *Histopathology* 2002;40:309-26.

Accepted for publication October 8, 2005

Prevalence of human papillomavirus types 16 and 18 in cervical adenocarcinoma and its precursors in Scottish patients

M. TAWFIK EL-MANSI, K.S. CUSCHIERI, R.G. MORRIS & A.R.W. WILLIAMS

Department of Pathology, University of Edinburgh, Edinburgh, Scotland, United Kingdom

Abstract. Tawfik El-Mansi M, Cuschieri KS, Morris RG, Williams ARW. Prevalence of human papillomavirus types 16 and 18 in cervical adenocarcinoma and its precursors in Scottish patients. *Int J Gynecol Cancer* 2006; 16:1025-1031.

Our aim was to determine the prevalence of human papillomavirus (HPV) types 16 and 18 in cervical adenocarcinoma (and its precursors) in Scottish patients. Nucleic acid was extracted from paraffin-embedded, formalin-fixed tissues. We examined 119 cases of invasive adenocarcinoma, 20 cases of adenocarcinoma *in situ*, and 16 cases of normal glandular epithelium. HPV DNA was detected by polymerase chain reaction using type-specific primers for the E6 and E7 genes of HPV-16 and HPV-18 with confirmation of HPV genotype by subsequent restriction fragment length polymorphism. HPV DNA was identified in 87 (62.6%) cases, with HPV-16 being detectable in 65 (47%) cases and HPV-18 in 41 (29%) cases. All the cases of normal tissue tested negative for HPV-16 and/or HPV-18. No significant relation between infecting HPV type (16 or 18) and subtypes of disease (within the invasive category and between the preinvasive and the invasive categories) was noted. Our findings support that HPV-16, along with HPV-18, are likely to play a significant role in the pathogenesis of cervical adenocarcinomas and that cervical cancer screening strategies that incorporate oncogenic HPV testing, and prophylactic vaccines that target these types, will be beneficial for the reduction of adenocarcinoma and associated glandular precursors.

KEYWORDS: cervical adenocarcinoma, human papillomavirus (HPV), polymerase chain reaction (PCR), screening.

Cervical cancer is the second commonest type of cancer in females worldwide, with an estimated annual incidence of up to 500,000 new cases¹. The two most common histologic types of cervical cancer are squamous cell carcinoma, which comprises approximately 75% of cases, and endocervical adenocarcinoma, which comprises approximately 20%². Although this latter type is rare, it is considered a more aggressive neoplasm with a worse associated prognosis. Moreover, an absolute increase in prevalence of adenocarcinoma and its precursors has been documented, both in the United States and in the Europe³.

It is widely accepted that squamous cell carcinoma and adenocarcinoma of the cervix share a common pathogenesis that involves persistent genital infection with an oncogenic human papillomavirus (HPV) type

or types⁴. There are over 30 HPV types that can infect the genital tract; the types that cause benign genital warts are classified as "low-risk" (LR) types, the most common of which are HPV types 6 and 11. The types that are found in premalignant and malignant tissue are termed as high-risk (HR) types. HPV-16 and HPV-18 are the most frequently detected HR types, although a large number of less common HR-HPV types (including HPV-31 HPV-33, and HPV-45) are thought to have a similar pathogenesis⁵. Although HPV-16 and HPV-18 are regarded as essentially similar, it should be noted that these two viruses only share 50% homology at the nucleotide level⁶.

Type of HPV might influence the histologic subtype of invasive adenocarcinoma, as HPV type 16 has been found to predominate in adenosquamous carcinomas, with HPV type 18 more frequently found in all other subtypes⁷. HPV oncogene expression was not dependent on histologic subtype of *in situ* or invasive adenocarcinomas. Normal glandular epithelia and glandular dysplasias were always negative concerning

Address correspondence and reprint request to: Dr Magdy Tawfik El-Mansi, MBChB, MSc, Department of Histopathology, Wythenshawe Hospital, Southmoor Road, Manchester M23 9 LT, England, UK. Email: magdy.elmansi@smuht.nwest.nhs.uk

HPV oncogene expression. Interestingly, Riethdorf *et al.*⁸ suggested that HPV E6/E7 expression of the same HPV type in both *in situ* or invasive adenocarcinomas and associated cervical intraepithelial neoplasia II/III indicates that these lesions might be histogenetically related. A recently reported study showed that HPV DNA was identified in more than 90% of *in situ* and invasive mucinous adenocarcinomas that encompass endocervical, intestinal, and endometrioid morphology and account for 95% of all cervical adenocarcinomas. Cases of minimal deviation adenocarcinoma were negative for HPV DNA.⁹

With respect to cancer prevention, organized, cytology-based cervical screening has reduced the incidence of cervical cancer significantly¹⁰ and although a clinical success story, there is evidence to suggest it could be improved by incorporation of adjunctive HPV testing. Although less specific than cytology (especially in young sexually active women), HPV testing is more sensitive for the detection of underlying cervical abnormalities; indeed, HPV testing has been introduced (in combination with cytology) in the United States, for women over 30 years of age, in primary screening¹¹. In addition, the UK pilot studies (due to report later this year) were designed to assess the utility of using HPV testing for the triage of women with low-grade abnormalities to colposcopy (www.cancer-screening.nhs.uk). There is also good evidence to suggest that HPV testing (in the context of a negative result) could be used as a "test-of cure" of treatment for women with high-grade cervical disease, with the potential to reduce the intensity of posttreatment follow-up¹². Further improvements in the diagnostic accuracy of cytology-based screening, such as HPV testing, could be particularly prescient for the reduction of adenocarcinoma as it and its precursor stage are reportedly more likely to be "missed" than squamous cell cytological abnormalities¹³.

Moreover, two prophylactic HPV vaccines are currently in phase 3 trials, both of which are designed to target HPV-16 and HPV-18 infection. Initial results from these trials would suggest that the vaccines are highly immunogenic, well tolerated, and induce seroconversion in more than 99% of vaccinees. They therefore constitute a very exciting prospect for the future of cervical cancer prevention globally¹⁴.

However, it remains the fact that there are few studies that have assessed type-specific HPV prevalence and diversity in invasive adenocarcinoma and its precursors¹⁵. Due to the comparative rarity of adenocarcinoma, related HPV prevalence data are often lumped together with squamous cell carcinoma (SCC) cases, without being teased out, or are not included at

all (due to their absence) in studies of smaller cohorts. Thus, the potential of HPV testing and vaccination on the reduction of adenocarcinoma *per se* is less clearly defined by this "swamping" effect. The merits of this study were therefore to assess the prevalence of HPV "vaccine type" (HPV-16 and HPV-18) in a large set of cervical adenocarcinoma using polymerase chain reaction (PCR) methods. Another dimension was to evaluate any potential HPV type-specific association with histologic type of preinvasive (high-grade cervical glandular intraepithelial neoplasia (CGIN)/adenocarcinoma *in situ* (AIS)) and invasive cervical adenocarcinoma.

Materials and methods

Clinical specimens

A computerized search was conducted for all patients diagnosed with cervical adenocarcinoma at the University of Edinburgh, Pathology Department, from 1991 to 2001. Consequently, surgical cervical specimens in the form of paraffin-embedded, formalin-fixed blocks were obtained from the archival collections. Pathology reports and cervical smear history reports were reviewed, and nonprimary cervical adenocarcinomas were excluded. Ethical approval for this study was granted by the local research ethics committee. The final study set of cases constituted 119 cases of invasive carcinoma (of which 16 were early invasive, meeting FIGO criteria for stage IA1), 20 cases of AIS, and 16 cases of normal endocervical tissue.

DNA extraction from paraffin blocks

Three 10- μ m sections of formalin-fixed, paraffin-embedded tissue were collected into tubes after cutting deep into the block. The microtome blade was changed after each case. Paraffin removal and rehydration of sections were achieved by 2- \times 10-min incubations in xylene prior to 3- \times 10-min incubations in absolute ethanol, followed by 2- \times 10-min incubations in distilled water. Tissue samples were incubated with lysis buffer containing (1 mg/mL) proteinase K (400 μ L/sample) for 18 h at 55°C and boiled for 20 min to denature the DNA and to inactivate the proteinase K. A volume of 10 μ L was used from each sample for subsequent detection of HPVs using the PCR methods¹⁶.

HPV PCR methods

Amplification of E6 and E7 HPV DNA of HPV-16 and HPV-18 was performed according to the method of

Hwang¹⁷. Primer sequences used were (F) 5'-TGTC A AAAGCCACTGTGTCC-3' and (R) 5'-GAGCTGTCA TTTAATTGCTC-3' for HPV-16 and (F) 5'-TGCCA GAAACCG TTGAATCC-3' and (R) 5'-TCTGAGTC GCTTAATTGCTC-3' for HPV-18.

PCR reactions were performed using sterile 0.5-mL RNase-/DNase-free tubes, and each PCR reaction was made up to a final volume of 50 μ L. A typical 50 μ L of PCR reaction contained 100 mM KCL, 20 mM Tris-HCL pH 8.0, 2.0 mM MgCl₂, 2.5 mM of dNTPs, 1.5 units of Taq polymerase (Invitrogen, Paisley, UK), 25 pmol of each primer, and 10 μ L of sample. To avoid false positives, a negative control tube that contained no DNA sample and a positive control tube that contained DNA from HPV immortalized cell lines (HeLa for HPV-18 and SiHa for HPV-16) were used. After thermal cycling (initially for 90 sec at 94°C for 1 cycle; then 40 cycles at 55°C for 1 min, 72°C for 1 min, and 94°C for 1 min; and finally 1 cycle at 72°C for 10 min), 10 μ L of the PCR reaction(s) were analyzed by agarose gel electrophoresis for identification of a 250 nt amplicon. All HPV-negative adenocarcinomas were retested for HPV-16 and HPV-18 using the methods described previously to ensure that a positive result had not been "missed" initially.

Restriction digestion of genomic DNA

For confirmation of type-specific identification of HPV-16 and HPV-18 DNA, all HPV-positive samples were collected and subjected to restriction fragment length polymorphism (RFLP). Reactions consisted of 3 μ L of restriction enzyme buffer, 14 μ L of sterile distilled water, 10 μ L of PCR product, and 3 μ L (10 units/mL) of restriction enzyme *Ava*II, according to the method described by Hwang¹⁷. Using this technique, an HPV-16-specific pattern is evident as 157 nt and 81 nt fragment, and its total length is 238 bp. An HPV-18-specific pattern is evident as 172 nt and 96 nt fragments, and its total length is 268 bp¹⁷ on a 2% agarose gel.

Statistical analysis

The association of HPV types 16 and 18 with pathologic variables of cervical adenocarcinoma was analyzed using StatXact-4 package. The Chi-square test was used to assess if HPV type distribution differed between preinvasive and invasive disease and within the different subtypes of invasive adenocarcinoma. A *P* value of <0.05 was judged to be significant.

Results

HPV detection and typing

Out of the 139 women with various cervical adenocarcinoma lesions (119 with invasive disease and 20 with AIS), HPV DNA was identified in 87 cases (62.6%), with HPV-16 being detected in 65 (47%) cases (Fig. 1) and HPV-18 in 41 (29%) cases (Fig. 2). Coinfection of HPV-16 and HPV-18 was evident in 19 cases (14%). A total of 52/139 patients (38%) with various cervical adenocarcinoma lesions tested HPV negative for both HPV-16 and HPV-18. All normal cervical biopsies tested negative for HPV-16 and/or HPV-18.

Correlation between HPV-16 and HPV-18 infection and pathologic variables of cervical adenocarcinomas

High-grade CGIN/AIS

In the 20 AIS patients, there were 7 (35%) patients with HPV-16 only positive, 5 (25%) with HPV-18 only positive, 3 (15%) with both HPV-16 and HPV-18 positive, and the remaining 5 (25%) with both HPV-16 and HPV-18 negative. There was no significant difference between AIS and invasive adenocarcinoma with respect to HPV-16 and HPV-18 infection (Fig. 3)

Invasive adenocarcinoma

In the 119 invasive adenocarcinomas patients, there were 39 (33%) patients with HPV-16 only positive, 17

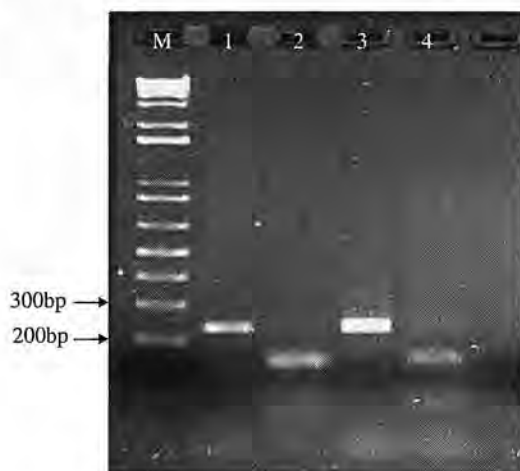


Figure 1. Showing determination and confirmation of HPV type 16 by RFLP pattern and PCR using specific primers. Lane M, kilobase DNA marker; lane 1, PCR products of HPV-16 extracted from paraffin section (uncut); lane 2, *Ava*II fragments of lane 1 (cut); lane 3, positive control SiHa (uncut); lane 4, *Ava*II fragments of lane 3 (cut).

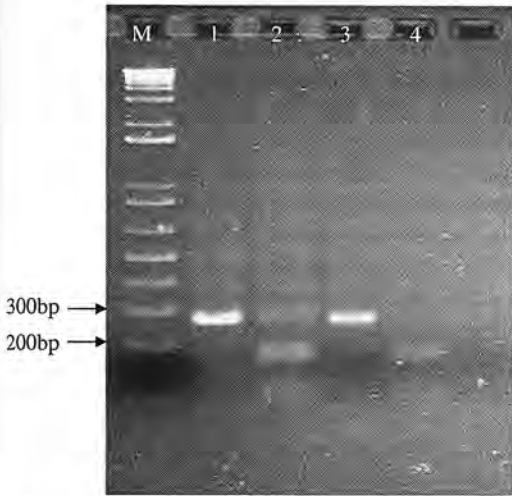


Figure 2. Showing determination and confirmation of HPV type 18 by RFLP pattern and PCR using specific primers. Lane M: kilobase DNA marker; lane 1, positive control HeLa (uncut); lane 2, *AVaII* fragments of lane 1 (cut); lane 3, PCR products of HPV-18 extracted from paraffin section (uncut); lane 4, *AVaII* fragments of lane 3 (cut).

14%) with HPV-18 only positive, 16 (13%) with both HPV-16 and HPV-18 positive, and the remaining 47 (39%) with both HPV-16 and HPV-18 negative. The prevalence of HPV varied with different histologic subtypes. However, there was no significant difference between all subtypes of invasive adenocarcinoma in comparison to each other and in comparison to AIS with respect to prevalence of HPV-16 and HPV-18 infection (Table 1).

Early invasive adenocarcinoma

In the 16 early invasive adenocarcinomas patients, there were 5 (31%) patients with HPV-16 only positive,

Comparison between AIS & invasive cervical adenocarcinoma regarding to HPV's infection

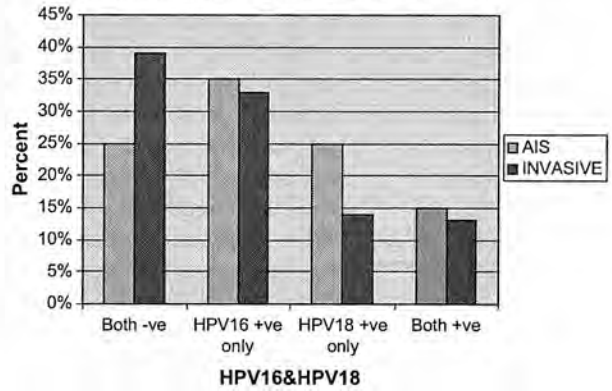


Figure 3. Showing no significant differences between AIS and invasive adenocarcinoma with respect to HPV-16 and HPV-18 infection using Chi-square test ($P = 0.53$). Invasive, invasive adenocarcinoma.

3 (19%) with HPV-18 only positive, 2/16 (13%) with HPV-16 and HPV-18 both positive, and 6/16 (38%) patients with HPV-16 and HPV-18 both negative. In general, in early invasive adenocarcinomas patients, HPV-16 was negative for 9 (56%) and positive for 7 (44%) patients and HPV-18 was negative for 11 (69%) and positive for 5 (31%) patients.

Discussion

We found HPV-16 and/or HPV-18 infections in 87/139 women with various cervical adenocarcinoma lesions (62.6%). PCR and RFLP showed that HPV-16 was the most abundant type in this neoplasm, being detected (in the absence of HPV-18) in 46 cases (33%). Comparatively, HPV type 18 was detected (in the absence of HPV-16) in 22 cases (16%), with coinfections

Table 1. Showing no significant differences between all subtypes of invasive adenocarcinoma in comparison to each other and in comparison to AIS with respect to HPV-16 and HPV-18 using Chi-square test ($P = 0.12$)

HPV-16 and HPV-18	AIS, N (%)	Adenocarcinoma NOS, N (%)	Adenosquamous carcinoma, N (%)	Villoglandular papillary adenocarcinoma, N (%)	Minimal deviation adenocarcinoma, N (%)	Other types of adenocarcinoma, N (%)
HPV-16 negative and HPV-18 -ve	5 (25)	20 (40)	6 (27)	6 (26)	4 (50)	11 (69)
HPV-16 positive and HPV-18 negative	7 (35)	16 (32)	10 (45)	7 (30)	1 (13)	5 (31)
HPV-16 negative and HPV-18 positive	5 (25)	9 (18)	3 (14)	5 (22)	0 (0)	0 (0)
HPV-16 positive and HPV-18 positive	3 (15)	5 (10)	3 (14)	5 (22)	3 (38)	0 (0)
Total	20 (100)	50 (100)	22 (100)	23 (100)	8 (100)	16 (100)

NOS, not otherwise specified.

of HPV-16 and HPV-18 being detected in 19 cases (14%). A total of 52 of 139 (38%) of patients with various cervical adenocarcinoma lesions tested negative for both HPV-16 and HPV-18. Our HPV prevalence rates are somewhat lower than prevalence rates of other reports that have shown from 68% to 84% positivity¹⁸⁻²¹. In our series, we did not perform PCR of a housekeeping, cellular gene that controls for cellular adequacy such as beta-globin. It could be the case that some of the nucleic acid was excessively degraded for successful amplification (DNA fragmentation as a result of formalin fixation and storage in paraffin), which was reflected, in our comparatively lower prevalence rate. Moreover, our remit was to assess the prevalence of HPV-16 and HPV-18 exclusively, and it could be that other HR-HPV types were present in the biopsies that could not be detected by the (HPV-16 and HPV-18 type specific) PCR used in this study.

The relative difficulty in detecting HPV DNA in adenocarcinomas, in contrast to squamous cell carcinomas, may also be attributed to a lower viral load in glandular lesions as compared to squamous lesions. Premalignant and malignant squamous lesions, in particular those associated with HPV-16, contain a large number of episomal viral particles, in addition to integrated HPV sequences²². Glandular epithelium that

does not support productive viral infection and HPV DNA in endocervical neoplasms (notably HPV-18) is usually present in the integrated form²³. As a result, detection of HPV DNA in adenocarcinomas requires a sensitive detection assay. Potentially, the application of a PCR strategy designed to amplify an even smaller HPV target sequence than the 250-nt region targeted by the PCR described here could have increased our HPV detection rate. The GP5 + 6 + primers, for example, amplify a sequence of approximately 150 nt²⁴.

Our findings show that HPV infection was absent in all cases of normal cervical biopsies, and this finding contradicts some previous studies (undertaken out-with the UK) that also employed PCR techniques and showed quite high prevalence rates for HPV infection in normal cervical tissues^{25,26}. However, this disparity could be explained by virtue of the fact that the number of normal biopsies that were tested in our series was small ($n = 16$).

There is evidence of geographical variation in prevalence of associated HR-HPV subtypes¹⁷. A comparison of the prevalence of HPV-16 and/or HPV-18 infection in cervical adenocarcinomas in different countries (using different techniques) is shown in Table 2²⁷. In this study, the detection rate of HPV-16 in cervical adenocarcinoma was higher than that reported in

Table 2. Showing frequency of HPV-16 and/or HPV-18 DNA in cervical adenocarcinoma in different countries by *in situ* hybridization and PCR (Lee *et al.*²⁷)

Author	Country	Patient number	Techniques	HPV (%)	HPV-16 (%)	HPV-18 (%)	HPV-16/18 (%)
Leminen <i>et al.</i> ³⁰	Finland	106	ISH (16, 18)	18	2	14	2
Duggan <i>et al.</i> ⁷	Canada	77	DBH (16, 18)	44	18	23	Nm
Das <i>et al.</i> ²⁸	India	12	ISH (16, 18)	58.3	41.6	16	0
Griffin	England	16	PCR (16, 18 and S)	31.3	25	6.3	0
Bjersing	Sweden	26	PCR (E6/E7 and S)	42.0	15	27	0
Johnson <i>et al.</i> ³¹	United States, Michigan	22	PCR (E6/E7 and S)	82	23	59	0
Hording	Denmark	50	PCR (16, 18 and DBH)	70	18	52	0
Lee <i>et al.</i> ²⁷	United States, Vermont	20	PCR (16, 18 and S)	15	10	5	0
Chen	Taiwan	42	PCR (L1, E6/E7, MY09, MY11)	67	19	48	0
Yamakawa <i>et al.</i> ³³	Japan	43	PCR (16, 18 and S) PCR (16, 18)	56	21	33	2
Tenti	Italy	138	PCR (16, 18 and S)	85	28	30	27
Iwasawa	Finland	108	PCR (16, 18 and MY09, MY11)	75	17	56	3
Parker	United States, Washington	32	PCR (16,18 and S)	50	22	28	0
Uchiyama <i>et al.</i> ²⁹	Japan	32	PCR (L1, 16, 18 and <i>MsiI</i> and <i>RsaI</i>)	34	19	12	3
Ferguson <i>et al.</i> ⁹	United States, Michigan	27	PCR (L1 and <i>MsiI</i> and <i>RsaI</i>)	59	26	26	Nm
Tenti	Italy	74	PCR (16, 18, and S)	76	20	33	23
Lee <i>et al.</i> ²⁷	Taiwan	69	PCR (MY09, MY11 and S and <i>RsaI</i>)	32	16	14	1.5
M. Tawfik El-Mansi	Scotland	139	PCR (16, 18)	62.6	33	16	14
Current study							

ISH, *in situ* hybridization; S, Southern; DBH, dot blot hybridization.

parts of Europe and the United States; indeed, we found HPV-16 to be the predominant type in cervical adenocarcinoma. Only a few other studies have shown HPV-16 to be the most frequently detected type in cervical adenocarcinoma^{28,29}, with many studies reporting that HPV-18 predominates^{7,30-34}. This phenomenon could be attributed in part to geographical and/or racial differences between settings; different genetic and environmental factors may contribute differently to the pathology of cervical adenocarcinoma induction by HR-HPV types.

In our study, HPV-16 and HPV-18 were prevalent in all subtypes of invasive adenocarcinoma, and no significant relation between type of HPV and subtype of disease was noted. Accumulated evidence would suggest that HPV type is not predictive of tumor grade, volume, depth of invasion, lymphovascular space involvement, age at presentation, or year of diagnosis⁷, and on the basis of our data, we would include histologic subtype of adenocarcinoma to this list.

In terms of the potential usefulness of a prophylactic vaccine in the prevention of adenocarcinoma, the results that we present are extremely positive. We have shown that both HPV-18 (as detected by other investigators), and perhaps more interestingly, HPV-16 are indeed prevalent in preinvasive and invasive adenocarcinomas. Phase 3 trials of two commercial vaccines that are designed to be protective for HPV-16 and HPV-18 infection are ongoing. If the findings are positive (as the results of the phase 2 trials would indicate¹⁴), we can speculate from that the vaccines have the potential of reducing the incidence of adenocarcinoma significantly.

In terms of using adjunctive HPV testing in cytology screening, our results again would suggest that adenocarcinoma, undetected by cytology, could potentially be detected/exposed by the use of a commercially available HPV test. For example, the Hybrid Capture² (HC II) Test (Digene, Gaithersburg, MD), which is currently the only HPV test that has Food and Drug Administration (FDA) approval and is used in the US for screening and triage, includes both types HPV-18 and HPV-16 within its detection remit. Although we exclusively looked at AIS or worse, Derchain *et al.*³⁵ also found a high prevalence of HR-HPV in atypical glandular cells, which some argue, are the precursors of AIS. Again, the authors postulate the beneficial role that HR-HPV screening could have on the improved detection of glandular abnormalities at an early stage.

In summary, our findings support that HPV-16, along with HPV-18, may play a possible role in the pathogenesis of adenocarcinoma of the uterine cervix

and the concept that proposed HPV screening and vaccination strategies are likely to have a positive impact on the reduction of adenocarcinoma. For future studies, it will be of importance to investigate HPV type-specific diversity in preinvasive and invasive adenocarcinoma beyond types HPV-16 and HPV-18 in order to evaluate their importance in pathogenesis of this disease.

References

- Andersson S, Rylander E, Larsson B, Strand A, Silfversvard C, Wilander E. The role of human papillomavirus in cervical adenocarcinoma carcinogenesis. *Eur J Cancer* 2001;37:246-50.
- Bonds L, Baker P, Gup C, Shroyer KR. Immunohistochemical localization of cdc6 in squamous and glandular neoplasia of the uterine cervix. *Arch Pathol Lab Med* 2002;126:1164-8.
- Mathers ME, Johnson SJ, Wadehra V. How predictive is a cervical smear suggesting glandular neoplasia? *Cytopathology* 2002;13: 83-91.
- Anciaux D, Lawrence WD, Gregoire L. Glandular lesions of the uterine cervix: prognostic implications of human papillomavirus status. *Int J Gynecol Pathol* 1997;16:103-10.
- zur Hausen H. Papillomaviruses and cancer: from basic studies to clinical application. *Nat Rev Cancer* 2002;2:342-50.
- Corden SA, Sant-Cassia LJ, Easton AJ, Morris AG. The integration of HPV-18 DNA in cervical carcinoma. *Mol Pathol* 1999;52: 275-82.
- Duggan MA, Benoit JL, McGregor SE, Nation JG, Inoue M, Stuart GC. The human papillomavirus status of 114 endocervical adenocarcinoma cases by dot blot hybridization. *Hum Pathol* 1993; 24:121-5.
- Riethdorf S, Riethdorf L, Milde-Langosch K, Park TW, Loning T. Differences in HPV 16- and HPV 18 E6/E7 oncogene expression between in situ and invasive adenocarcinomas of the cervix uteri. *Virchows Arch* 2000;437:491-500.
- Ferguson AW, Svoboda-Newman SM, Frank TS. Analysis of human papillomavirus infection and molecular alterations in adenocarcinoma of the cervix. *Mod Pathol* 1998;11:11-8.
- Peto J, Gilham C, Fletcher O, Matthews FE. The cervical cancer epidemic that screening has prevented in the UK. *Lancet* 2004; 364:249-56.
- Saslow D, Runowicz CD, Solomon D *et al.* American Cancer Society guideline for the early detection of cervical neoplasia and cancer. *CA Cancer J Clin* 2002;52:342-62.
- Zielinski GD, Bais AG, Helmerhorst TJ *et al.* HPV testing and monitoring of women after treatment of CIN 3: review of the literature and meta-analysis. *Obstet Gynecol Surv* 2004;59:543-53.
- Brink AA, Zielinski GD, Steenbergen RD, Sniijders PJ, Meijer CJ. Clinical relevance of human papillomavirus testing in cytopathology. *Cytopathology* 2005;16:7-12.
- Villa LL, Costa RL, Petta CA *et al.* Prophylactic quadrivalent human papillomavirus (types 6, 11, 16, and 18) L1 virus-like particle vaccine in young women: a randomised double-blind placebo-controlled multicentre phase II efficacy trial. *Lancet Oncol* 2005; 6:271-8.
- An HJ, Kim KR, Kim IS *et al.* Prevalence of human papillomavirus DNA in various histological subtypes of cervical adenocarcinoma: a population-based study. *Mod Pathol* 2005;18:528-34.
- Levi S, Urbano-Ispizua A, Gill R *et al.* Multiple K-ras codon 12 mutations in cholangiocarcinoma demonstrated with a sensitive polymerase chain reaction technique. *Cancer Res* 1991;51:3497-502.
- Hwang T. Detection and typing of human papillomavirus DNA by PCR using consensus primers in various cervical lesions of Korean women. *J Korean Med Sci* 1999;14:593-9.
- Chen SL, Han CP, Tsao YP, Lee JW, Yin CS. Identification and typing of human papillomavirus in cervical cancers in Taiwan. *Cancer* 1993;72:1939-45.
- Williamson AL, Brink NS, Dehaeck CM, Ovens S, Soeters R, Rybicki EP. Typing of human papillomaviruses in cervical carcinoma biopsies from Cape Town. *J Med Virol* 1994;43:231-7.

- 20 van den Brule AJ, Claas EC, du MM *et al.* Use of anticontamination primers in the polymerase chain reaction for the detection of human papilloma virus genotypes in cervical scrapes and biopsies. *J Med Virol* 1989;29:20-7.
- 21 Kristiansen E, Jenkins A, Kristensen G *et al.* Human papillomavirus infection in Norwegian women with cervical cancer. *APMIS* 1994;102:122-8.
- 22 Stoler MH, Rhodes CR, Whitbeck A, Wolinsky SM, Chow LT, Broker TR. Human papillomavirus type 16 and 18 gene expression in cervical neoplasias. *Hum Pathol* 1992;23:117-28.
- 23 Park JS, Hwang ES, Park SN *et al.* Physical status and expression of HPV genes in cervical cancers. *Gynecol Oncol* 1997;65:121-9.
- 24 de Roda Husman AM, Walboomers JM, van den Brule AJ, Meijer CJ, Snijders PJ. The use of general primers GP5 and GP6 elongated at their 3' ends with adjacent highly conserved sequences improves human papillomavirus detection by PCR. *J Gen Virol* 1995;76 (Pt 4):1057-62.
- 25 Meanwell CA, Cox MF, Blackledge G, Maitland NJ. HPV 16 DNA in normal and malignant cervical epithelium: implications for the aetiology and behaviour of cervical neoplasia. *Lancet* 1987;1:703-7.
- 26 Tidy JA, Parry GC, Ward P *et al.* High rate of human papillomavirus type 16 infection in cytologically normal cervixes. *Lancet* 1989;1:434.
- 27 Lee KR, Howard P, Heintz NH, Collins CC. Low prevalence of human papillomavirus types 16 and 18 in cervical adenocarcinoma in situ, invasive adenocarcinoma, and glandular dysplasia by polymerase chain reaction. *Mod Pathol* 1993;6:433-7.
- 28 Das BC, Gopalkrishna V, Das DK, Sharma JK, Singh V, Luthra UK. Human papillomavirus DNA sequences in adenocarcinoma of the uterine cervix in Indian women. *Cancer* 1993;72:147-53.
- 29 Uchiyama M, Iwasaka T, Matsuo N, Hachisuga T, Mori M, Sugimori H. Correlation between human papillomavirus positivity and p53 gene overexpression in adenocarcinoma of the uterine cervix. *Gynecol Oncol* 1997;65:23-9.
- 30 Leminen A, Paavonen J, Forss M, Wahlstrom T, Vesterinen E. Adenocarcinoma of the uterine cervix. *Cancer* 1990;65:53-9.
- 31 Johnson TL, Kim W, Plieth DA, Sarkar FH. Detection of HPV 16/18 DNA in cervical adenocarcinoma using polymerase chain reaction (PCR) methodology. *Mod Pathol* 1992;5:35-40.
- 32 Chen TM, Chen CA, Wu CC, Huang SC, Chang CF, Hsieh CY. The genotypes and prognostic significance of human papillomaviruses in cervical cancer. *Int J Cancer* 1994;57:181-4.
- 33 Yamakawa Y, Forslund O, Teshima H, Hasumi K, Kitagawa T, Hansson BG. Human papillomavirus DNA in adenocarcinoma and adenosquamous carcinoma of the uterine cervix detected by polymerase chain reaction (PCR). *Gynecol Oncol* 1994;53:190-5.
- 34 Heller MJ, Burgart LJ, TenEyck CJ, Anderson ME, Greiner TC, Robinson RA. An efficient method for the extraction of DNA from formalin-fixed, paraffin-embedded tissue by sonication. *Biotechniques* 1991;11:372-4.
- 35 Derchain SF, Rabelo-Santos SH, Sarian LO *et al.* Human papillomavirus DNA detection and histological findings in women referred for atypical glandular cells or adenocarcinoma in situ in their Pap smears. *Gynecol Oncol* 2004;95:618-23.

Accepted for publication October 13, 2005