

- Case No.1.Supracondylar and Intercondylar fracture of Femur in a boy of 20.  
Case No.2.Supracondylar and Intercondylar fracture of Humerus in a man of 28.  
Case No.3.Supracondylar fracture of Femur in a child of 3.  
Case No.4.Abduction impacted fracture of the neck of the Femur and avascular necrosis of the femoral head in a woman of 53.  
Case No.5.Perthes disease in a boy of 9.  
Case No.6.Scheurermann's disease in a boy of 17.
- 

Reports and commentaries written by I.A.Ruthven-Stuart.

---



Name: Baldry, John.  
Age: 20 years.  
Address: [REDACTED]  
Occupation: Apprentice Electrical Engineer.  
Doctor: Dr. Watt, Inverleith Row, Edinburgh.  
Admitted: To Ward 7. 12.2.50.  
Diagnosis: Traumatic Supracondylar and intercondylar - fracture  
Right Femur.

History: (About Noon).

On the 12th of February, which was a Sunday morning, this lad was practising ice hockey on the Haymarket ice rink. The puck had been knocked into a corner, and he went after it at full speed, the manoeuvre was one he frequently carried out, but for some reason he over estimated his stopping ability, and hit the wooden barrier travelling at some 20 m.p.h. This rink is not suitable for the game, because of a projecting shelf some 3 ft. from the ground, which hit him just above his slightly flexed right knee; because of this flexion his thigh at the point of impact was only protected by felt, and not by the wooden slats incorporated in the knee length trousers. His momentum threw him forward and he hit his face just below his right eye on the barrier. He can not recollect hearing the bone snap; he fell backwards and on to his left side on the ice, with his right leg buckled under him and lying over, or on top of his left leg. He knew without doubt that it was broken and did not try to get up: the stretcher bearers attempted to straighten his leg, which gave him great pain, which had been quite bearable up to that point. There was a little blood coming from a wound above his knee from which he thought bone was protruding. His knee started to swell at once. He was quite unable to move his foot and toes, but describes no sensation of numbness or cold in the foot. He was nauseated, but did not vomit; this soon passed off. He asserts that he was fully conscious the whole while and remembers the incident clearly. (This differs slightly from the account he gave to the House-Surgeon to whom he said he lost consciousness.)  
He has had no previous bone injury or disease to his knowledge.

Previous History. Fevers of Childhood.

A sweat-rash has been the only cause for him to consult a doctor in the last 10 years.

No previous operations.

Family History.

Both his parents are alive and well. He has a brother of 17 and two sisters of 16 and 14 respectively. He is the oldest and is unmarried.

Social History.

He is an apprentice electrical engineer working a 6 day week from 8 a.m. until 4.30 p.m. In addition, he attends evening classes 3 days a week. He does not smoke, and drinks on festive occasions only. He was evacuated to Canada during the war and so was attracted to ice hockey, which he has now played for some 12 years. He is extremely keen and plays as an amateur for Kirkcaldy Juniors, but he has set his heart on playing for Edinburgh, next year.

Examination. On admission. A young healthy looking lad, in discomfort, but not obviously shocked.

A. Local. The Right leg lay in external rotation and the knee was flexed. The thigh was swollen, and 1-2" above the patella margin, there was

a small wound about  $\frac{1}{2}$  inch in length, from which there was slight bleeding.

No bone fragments were visible.

No active movement could be carried out at all at the knee, ankle or toes.

There was considerable tenderness on palpation above the knee. Compared with the left thigh, there was about 2" of shortening, as measured from anterior superior iliac spine to the lower border of the patella.

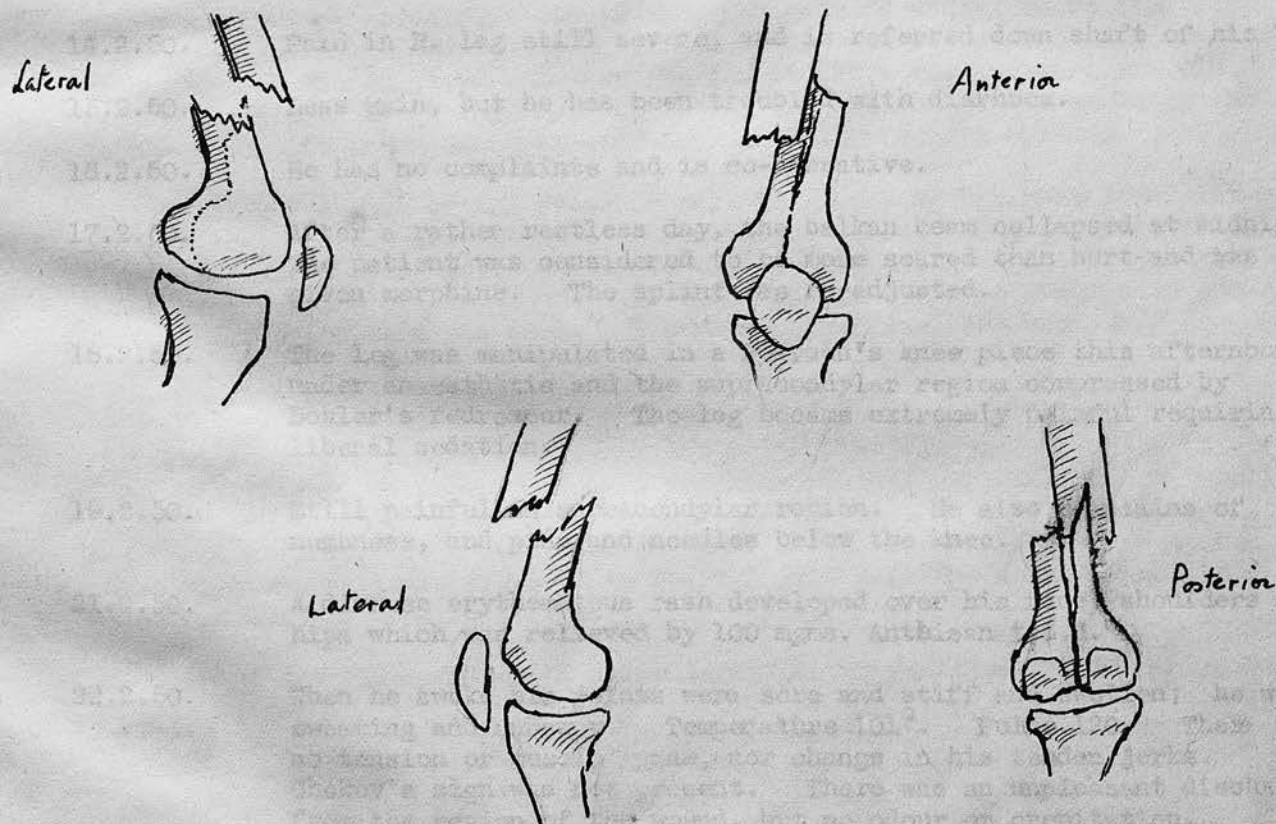
Both the posterior tibial and dorsalis pedis pulses could be felt, and the skin temperature was identical on both sides. Cutaneous sensation over the dorsum, and sole, appeared to be absent.

B. General. Alimentary System. No subjective symptoms except nausea. Tongue moist and clean. Teeth excellent.

Cardiovascular System. Pulse 90/min. Regular in time and force. Vessel wall barely palpable. Apex beat in 5" interspace about  $2\frac{1}{2}$ " from the mid-line. Heart sounds normal; no murmurs. B.P. 160/100.

Respiratory System. Good symmetrical chest expansion. No deviation of trachea. Breath sounds clear, vesicular, no accompaniments.

X-ray. revealed a supracondylar and intercondylar T. fracture of the femur with backward displacement and rotation of lower fragments.



The patient was prepared therefore for operation and received 1/100 gr. atropine and 1/6 Omnopeon, and was taken into the theatre about 9 p.m., penicillin having been started at 2 p.m., 250,000 units, and having received 3,000 units A.T.S. and 10,000 units mixed A.G.G.S.

Operation. Surgeon. Mr. Macpherson. Assistant Dr. Smith. Anaesthetist Dr. Griffiths. Anaesthetic. Pentothal; Spinal; Gas and Oxygen.

Procedure.

A Steinmann pin was inserted through the tibial tubercle, and temporary traction was made through it onto the end of a Thomas splint. The skin wound was incised and enlarged, and revealed a rent in the quadriceps attachment. Using Lane's bone slides the quadriceps was levered out from between the bone ends and was sutured with No. 2 interrupted chromic catgut.

The position of the fragments were such that the lower end of the proximal fragment had torn through the rectus femoris and vastus intermedius above their insertion into the patella.

The distal fragment lay posteriorly, and was slightly flexed. The Thomas splint was bent at the knee to an angle of about 25° and a KRAMER wire splint well padded was placed behind the thigh, to reach as low as the popliteal fossa, and traction was made by means of a 30lb. weight from the pin over a BALKAN beam. A large Haemarthrosis of the knee joint had to be evacuated. The skin was sewn with interrupted silk stitches after penicillin and sulphonamide powder had been insufflated. At the close of the operation, the condition of the foot was good, the posterior tibial artery pulse being easily felt.

It was not felt however that all the muscles had been levered out from between the bone surface.

Summary:

Compound fracture of the lower end of the femur involving the joint and tearing the quadriceps insertion. Excision of wound and suture of quadriceps. A Steinmann pin through the tibial tubercle, and traction on a Thomas splint.

Progress:

He recovered well, but is not particularly comfortable.

13.2.50. Quite a lot of pain requiring sedation. Foot warm but anaesthetic.

14.2.50. Pain in R. leg still severe, and is referred down shaft of his leg.

15.2.50. Less pain, but he has been troubled with diarrhoea.

16.2.50. He has no complaints and is co-operative.

17.2.50. After a rather restless day, the balkan beam collapsed at midnight. The patient was considered to be more scared than hurt and was given morphine. The splint was re-adjusted.

18.2.50. The leg was manipulated in a Pearson's knee piece this afternoon under anaesthetic and the supracondylar region compressed by Bohler's redresser. The leg became extremely painful requiring liberal sedation.

19.2.50. Still painful in supracondylar region. He also complains of numbness, and pins and needles below the knee.

21.2.50. A diffuse erythematous rash developed over his face, shoulders and hips which was relieved by 100 mgms. Anthisan t.i.d.

22.2.50. When he awoke his joints were sore and stiff and swollen; he was sweating and unhappy. Temperature 101°. Pulse 120. There was no tension or muscle spasm, nor change in his tendon jerks. Chekoy's sign was not present. There was an unpleasant discharge from the region of the wound, but no odour or crepitation, inflammation or discolouration. He was therefore sponged down and given anti-pyretics, and anthisan continued, since it was considered that this was a serum sensitivity reaction. W.B.C. 7,200.

23.2.50.)  
24.2.50.)

Improving, joint and muscles less painful.

27.2.50. A pressure sore has developed behind the knee, possibly caused by the pressure against the bar of the the splint by traction from the weights. The foot and ankle show pitting oedema, and there is a loss of touch and pain below the knee. The foot and leg are quite warm and circulation is brisk. He received a further 3,000 A.T.S.

and 25,000 A.G.G.S.

- 27.2.50. Because there has been a little odourless discharge from the wound above the knee, the wound was explored with sinus forceps after he had been anaesthetised. Brownish material escaped. The wound was left open and powdered with penicillin. The knee was straightened, and the Thomas splint well padded. He slept after this, but by midnight his lips were becoming swollen and 200 mgm of anthisan was given.
- 28.2.50. He is sure the right leg is much more comfortable in the new position, his lips are still oedematous and he has an urticarial rash presumably from the serum.
- 2.3.50. He still has no sensation or movement below the knee, but he feels very severe pain radiating up from his heel and calf. His wound is still odourless but is discharging the reddish-brown material which the bacteriologist report is staphylococcus albus, highly sensitive to penicillin and streptomycin. His knee is swollen still and ankle oedema persists.

---

### Commenatary.

#### Treatment.

A supracondylar fracture is an uncommon fracture even in war, and combined with the intercondylar or T fracture is both a rarity and a serious orthopaedic problem.

This cannot be regarded as a simple supracondylar fracture, to be treated by a Bohler-Braun frame and traction, or the dubious method of applying traction with the knee flexed at  $90^{\circ}$ , or even by longitudinal and vertical traction from pins in the distal fragment and tibial tubercle which is probably the method of choice in an uncomplicated supracondylar fracture.

An open fracture of the femur is said to be one of the most important of all surgical emergencies, because of the massive surrounding muscles, which if devitalised, provide ideal culture media for organisms especially *B. Welchii*, *B. oedematis*, and *Cl. septique*. No open fracture is more frequently complicated by infection than one such. The special difficulties here then are:-

- (1) Compound fracture of femur.
- (2) Intercondylar fracture of femur involving the joint space making it very difficult to employ orthodox supracondylar reduction-fixation technique.

Any fracture treatment should seek to reduce, fix and restore to function; here these exacting criteria are hard to fulfil; the last two depend upon the first, which has not yet been fulfilled.

The alternative methods of immobilisation and fixation in this case seem to have been:

- (1) Manipulative reduction and continuous traction.
- (2) Mechanical reduction and skeletal transfixion.
- (3) Operative reduction and internal fixation.

(1) It was thought some years ago that skin traction and Thomas splint was sufficient, as release of muscle spasm was followed by tilting automatically of the lower fragment, but this is not the case. The popliteal artery may be perforated by the persistently displaced fragment.

(2) Theoretically if the calf muscles are relaxed by flexing the knee to  $45^{\circ}$  it was argued that reduction was possible by skeletal traction from the tibial tubercle. This also is incorrect, because flexion greater than  $45^{\circ}$  would be necessary which would be very dangerous to the popliteal artery, cause quadriceps fixation and loss of extension and in fact is unsuccessful in practice.

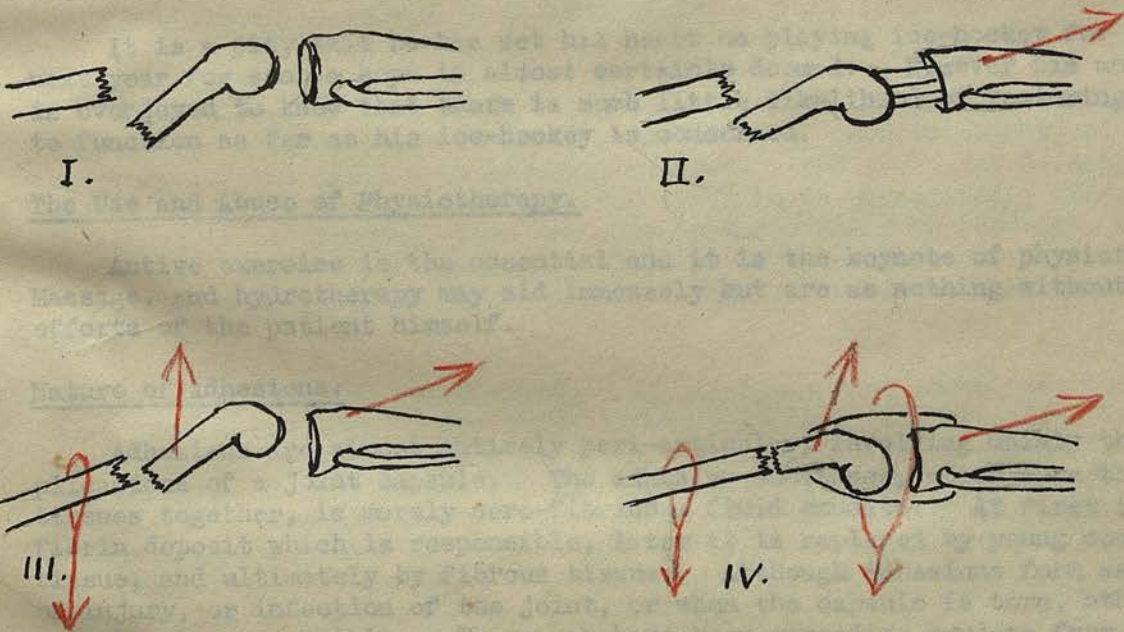
Bohler's modification of a Braun splint, even with the angle behind the fracture

and not the knee, may actually make the tilting worse.

(3) Operative reduction alone, results inevitably in redisplacement; combined with internal fixation there is the bogey of joint stiffness looming large ahead.

In this complex case the cart may well be put before the horse, that is to say consideration of the unlikelihood of a return to complete function, and the admittance of the fact that a stiff knee is inevitable whatever treatment was adopted; the choice of a method which will give him least disability, least pain, and maximum function, is imperative. The only method which will really secure adequate fixation, in good position, is the Watson-Jones vertical and horizontal traction method, with pins through the distal fragment and in the tibial tubercle, remembering always that the case is complicated by an intercondylar fracture which under the circumstances demands operative reduction, by opening the joint through an antero-lateral or postero-lateral incision, and placing vitallium screws from one fragment to the other; unless this is done there is loss of apposition of fragments, because of the interposition of muscle between the bone ends, and despite the fact that full length can be regained by skeletal traction, it may prove utterly impossible to make contact between the fractured surfaces however viscious the lateral pressure. Then by placing a pin through the upper part of the distal fragment a vertical traction may be made, after all possibility of wound infection has subsided.

Watson-Jones Reduction Method.



If such a decision is made, the pins should be incorporated in a plaster spica to minimise the very real danger of infection of the track, which would jeopardise the knee joint and fracture and for this reason simple vertical traction in a Thomas splint cannot be justified, which will allow movement and rotation of the pins. The pins could be removed some three weeks later, the plaster continued for a further 8 - 10 weeks and skin traction continued on a Braun's frame for a further month.

Additional complications arose at the outset here for this was a compound fracture and therefore potentially infected. Organisms may be met by chemotherapy; but extensive surgical procedure involving bone and joints cannot be carried out under its cover, in the fond hope that the absence of scrupulous aseptic technique is justified. Under all these vicarious vicissitudes it seems that the correct treatment was carried out initially,

and it is fair to wait for complete healing of the wound, thereby enabling rigid 48 hr. skin preparation to be carried out, so that there can be no remote question of introducing infection, when further operative measures, as indicated, are carried out.

Flexion at the knee carries its full quota of complications. The ruptured quadriceps tendon carrying with it a fragment of patella will be retracted still further and the gap fills with scar tissue or becomes adherent to the supra-condylar region, with permanent limitation of active extension in both cases; operative suture is indicated as soon as the condition of the skin and wound will permit. The knee joint should be extended almost fully after the fracture is reduced, and before plaster is applied, and this is only possible if a supra-condylar pin is incorporated, to avoid displacement of the distal fragment by such extension.

#### Peripheral Nerve Complication.

His foot is completely anaesthetic to light touch and pain stimuli and he is unable to move his foot and toes in any way whatsoever.

His leg is warm but his foot tends to get cold; the posterior tibial and dorsalis pedis can easily be felt pulsating. These phenomena are certainly due to involvement of the lateral and medial popliteal nerves, presumably contusion and pressure from the oedema rather than neurotmesis or axonotmesis.

Prognosis. Unfortunately, though this injury may be purely a "physiological" block its effects may be permanent as the lateral popliteal is a nerve which withstands such compression very badly indeed. This aspect further complicates a gloomy outlook.

It is a pity that he has set his heart on playing ice-hockey for Edinburgh next year for such a hope is almost certainly doomed. However his mother is overjoyed to know that there is such little likelihood of restoring his leg to function as far as his ice-hockey is concerned.

#### The Use and Abuse of Physiotherapy.

Active exercise is the essential and it is the keynote of physiotherapy. Massage, and hydrotherapy may aid immensely but are as nothing without the efforts of the patient himself.

#### Nature of Adhesions.

Adhesions are almost entirely peri-articular, involving mainly the plications of a joint capsule. The adhesive substance, which gums the adjacent tissues together, is merely sero-fibrinous fluid exudate. At first it is the fibrin deposit which is responsible, later it is replaced by young connective tissue, and ultimately by fibrous tissue. Although adhesions form as a result of injury, or infection of the joint, or when the capsule is torn, other factors may also be responsible. There may have been spreading exudate from a distant injury, or recurrent oedema of adjacent tissue, or more simply venous stasis and congestion, due to muscular inactivity and disuse. Adhesions form when the sero-fibrinous exudation recurs and persists. If the joint tissues are continually soaked, adhesions will form whether immobility is complete or not, or whether the joint is injured or not. Even a severe fracture, where there is no repetition of injury, will cause less adhesions than the trivial but continued injury of passive stretching by an enthusiastic masseuse.

#### Immobility.

This is not in itself a major factor in the development of adhesions. Even if the joint has been immobile for months a normal range can be expected. When immobility of the joint is associated with other factors, then the outlook is changed, and the adhesions become dense.

#### Immobility and Injury.

The injury forms an obvious source of exudate and haemorrhage, from the

synovia, from the fractured bone and from the torn capsule and periosteum; but this initial exudate will rapidly absorb, and if it does not recur by reason of infection, through early movement or passive stretching, adhesions need not be too seriously feared, and there should be complete recovery by the patient's own exertions within a few weeks.

Electrical stimulation of the muscles may help as this is a form of active exercise and is excellent from the psychological aspect.

#### Disuse.

The additional factor of functional disuse besides immobility is important in promoting adhesions, whether the joint is injured or not. This is due to venous stasis. Immobility of the muscles leads to engorgement of the tissues with blood. The bone becomes decalcified and considerable adhesions occur. Herein lies the difference between the excellence and virtue of active exercise, and the crime of passive stretching, for active efforts involve the use of muscles with consequent acceleration of the circulation, in contrast with passive movement, which tears one adhesion in order to form two new ones.

#### Recurrent Oedema.

The greater the swelling after a fracture, the greater is the necessity for early movement. A tendency to oedema will disappear when the dilated tissue spaces are obliterated, and the muscle tone regained by active exercise; in the leg this is guarded against by the initial wearing of a supportive bandage until the leg is able to look after itself.

No joint should ever be manipulated while still subject to recurrent oedema.

The role of the surgeon then is to prevent swelling by firm strapping, and prevent immobility by the painless active exercises of the patient themselves without a masseuse to do it for him.

#### Passive Stretching.

When adhesions form round a joint, and are violently stretched there is reactionary oedema, which lead to fresh oedema. Such treatment can only delay recovery and the joint gets steadily stiffer. The treatment defeats its own object and increases the stiffness for which it is prescribed. If such treatment is not stopped, then not only is there delay in recovery, but a permanent limitation of movement. Some physiotherapists are quite unable to resist the temptation to "hurry a joint along". Movement must recover at its own rate.

Manipulation is a two edged sword. It may break down adhesions, but it will also produce new ones. The cases in which it is useful are those in which there is discomfort and weakness rather than limitation of movement. If a manipulation is carried out the rule must be, little and often. The response depends upon when the adhesions are localised, or diffuse, and whether the manipulation is gentle or brutal, and upon whether after treatment is active on the part of the patient, or passive on the part of a masseuse, who must none the less be enthusiastic and encouraging.

#### Infection and Foreign Bodies.

Infection causes a spreading sero-fibrinous, exudation with oedema, and consequent immobility. Foreign bodies are usually inseparable from a low grade infection, especially where the body penetrates the skin, so that there is a low grade infection of the track. The infection may be quite minimal, and show no outward manifestation, but it can and does account for continuous exudation in neighbouring tissue, and may well increase the disability from stiffness.

#### Stiffness.

In the supracondylar region a pin will cause dense adhesions, and movement beyond the right angle may never recover. Stiffness from the tibial tubercle traction can be entirely remedied when the tone of the thigh muscles is regained so long as traction has not been excessive. In addition to these factors there was traumatic haemarthrosis, and patella fracture, and tearing of the quadriceps, necessitating operative reduction, all of which, alone, may cause a stiff knee. Stiffness due to quadriceps fixation to bone usually remains

permanently. To minimise the stiffness in this case, the following steps should be adhered to where possible.

- (1) Immobilisation in good position at the earliest date compatible with strict asepsis.
- (2) If supracondylar traction is eventually used, avoidance of ice-tong callipers which cause rotation of the pin.
- (3) Quadriceps exercises from about the 5th week.
- (4) Firm knee bandaging when weight bearing is resumed to avoid recurrent oedema.
- (5) Regaining knee movement by active exercise, and not by passive stretching.
- (6) Elevation of the limb in the splint to lessen oedema.

The important causes of joint adhesions to be seen in this case are:-

- A. Functional inactivity and disuse, resulting in lymphatic stasis and waterlogging.
- B. Joint Injury. The torn capsule exuding sero-fibrinous fluid, which effectively glues structures together.
- C. Reactionary traumatic oedema in the early stages, which may be minimised by elevation and immobilisation.

Proposed measures however will further increase a tendency for the formation of joint adhesions:-

- D. Supracondylar pin which causes a reactionary and low grade inflammatory serous effusion.
- E. Operative fixation of the condyles, which like a supracondylar pin, causes a foreign body reaction.

#### Summary.

A Compound supracondylar and intercondylar traumatic fracture of the right femur in a lad of 20 is described, treated by a Steinmann pin through the tibial tubercle with traction on a Thomas splint, (after repair of the torn quadriceps), and suspension from a Balkan Beam, with medial and lateral popliteal nerve involvement.

The available methods of treatment, whereby function may be restored in whole or part and the role of physiotherapy for stiff knee are discussed. In this case the prognosis as regards ultimate function is very poor indeed.

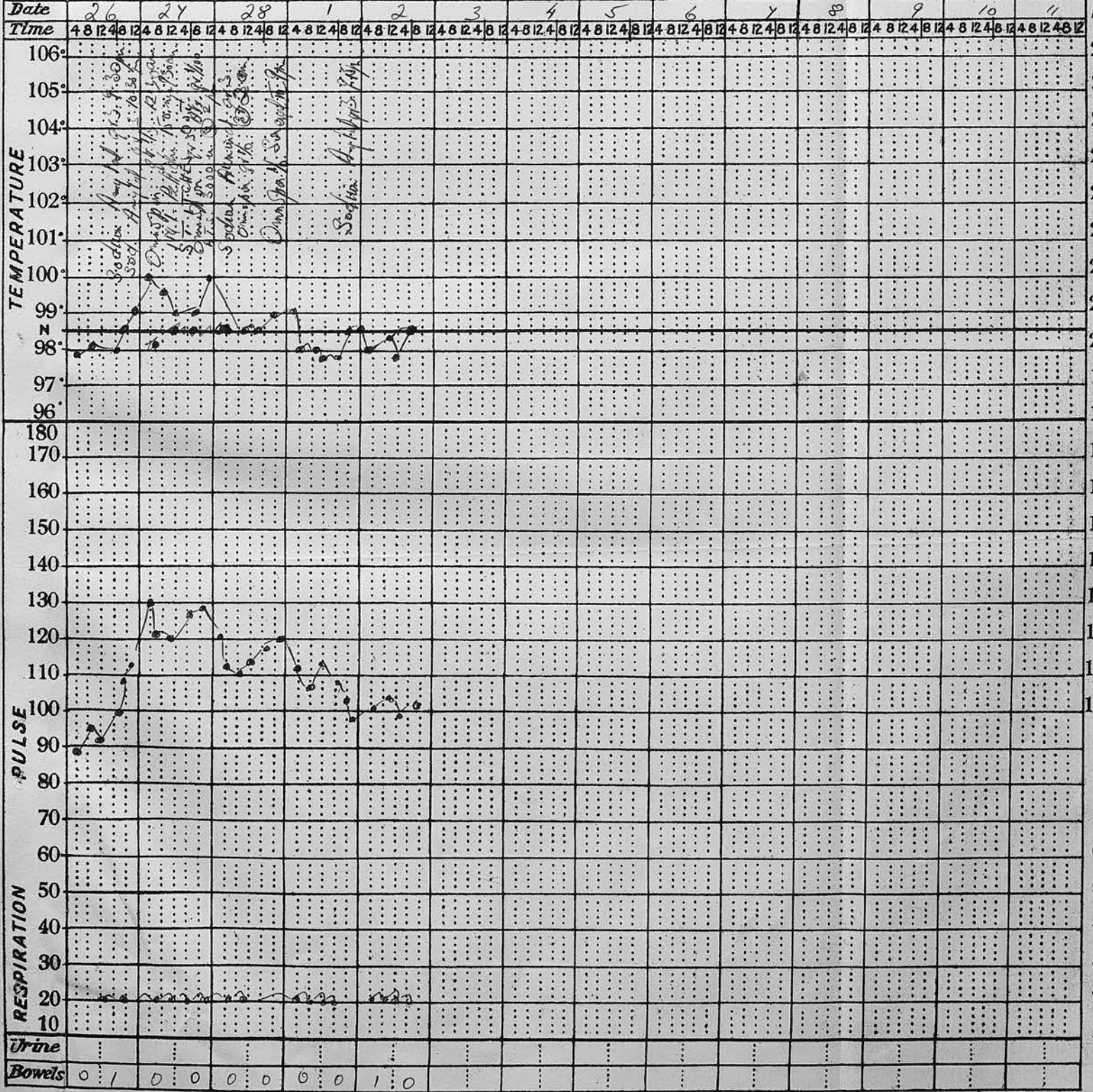
By permission of Professor Sir James Learmonth.

#### References.

- |                      |  |
|----------------------|--|
| COTTON AND PETERSON. | Journal Bone and Joint Surgery. 16, 658. 1934. |
| COLE.                | Lancet. 1, 163. 1943.                          |
| HOULDING.            | B.M.J. 2, 429. 1941.                           |
| NICOLL.              | B.M.J. 1, 501. 1941.                           |
| WATSON-JONES.        | Textbook of Fractures and Joint Injuries.      |
| WATSON-JONES.        | B.M.J. 1, 403. 1942.                           |
| WATSON-JONES.        | Lancet. 1, 172. 1943.                          |



WARD Y.	Date of Admission	Name, and Age of Patient	Doctor Clinical Clerk		
	12. 2. 50.	JOHN BALDREY 20 YRS.	W. P. T. INVERLEITH. EDIN.		
Date	DIET AND MEDICINES	Date	DIET AND MEDICINES	Date	LABORATORY EXAMINATIONS
27.2.50.	191. Anti Tetanus Serum 3000. Anti Gas. Prophylaxis Serum. 25,000 units.	27. 2. 50.	191. Penicillin 250,000 @ 6pm. 100,000 @ 10pm.		
		28. 2. 50.	" " @ 2am. " " @ 6am. " " @ 10am. " " @ 2pm. " " @ 6pm. " " @ 10pm.		
		1-3. 50.	" " @ 2am. " " @ 6am. " " @ 10am. " " @ 2pm. " " @ 6pm. " " @ 10pm.		
		2.3. 50.	" " @ 2am. " " @ 6am. " " @ 10am.		
MARCH. 1950.					



Name. Joske, Edmund.  
Age: 28 years.  
Occupation. Miner.  
Admitted. Ward 13, R.I.E. at 5.45 a.m. on 15.2.50.  
Discharged.  
Diagnosis. Supracondylar T-fracture of the Right Humerus.

History. At approximately 3.a.m. on Wednesday morning this Pole was on the night-shift working a pneumatic drill in an open cast coal mine at the coal-face.

The drill sprang back at him when he was slightly off guard and it smashed into him, hitting him severely on his right arm a few inches above his elbow which he thinks was only slightly flexed at the time. The drill fell from his hands to land on his right foot.

The pain was indescribable, and he fell to the ground in agony. First aid men fixed crude splints on and he was carried off on a stretcher and sent to hospital without further delay. He says that the arm was bleeding fairly freely; he was unaware of nearly everything else that went on because of his preoccupation with the intense and unrelenting pain, and therefore cannot describe any other sensations.

Examination. On admission he was in extreme distress but not shocked. The house surgeon's report states, that in the surgical outpatient department this man was suffering dreadful pain. He lay screaming and quivering, and no examination of the injured arm was attempted. He was sent at once for X-ray of the Right humerus and Right foot and then to the Ward. In S.O.P.D. his right hand was very cold compared to the left one, and no radial pulse could be palpated at the wrist. The left radial pulse was strong and was running at 100/min.  $\frac{1}{4}$ gr. of intravenous morphine had little immediate effect.

X-Ray. (See below), of Right Humerus showed a transverse comminuted fracture of the lower end of the shaft of the humerus with gross backward angulation of fragments. There was a completely separated fragment of bone lying in the angle between the main upper and lower fragments. There was a T-shaped supracondylar fracture of the humerus involving the elbow joint.

Further Examination. Local (1). He lay with his right arm slightly flexed. There was gross swelling and bruising extending from the middle of the forearm up to the middle of the arm, where there was a small transverse wound about 1-1 $\frac{1}{2}$ " in length. On the flexor surface of the forearm there was an irregular lacerated wound just below the elbow on the ulnar side. Both of these wounds were filled with clot, and had ceased bleeding. His arm and hand was covered in coal-dust, and thus the colour of the hand was more than difficult to assess. Neither radial nor ulna pulses could be palpated, and capillary circulation in the nail beds was very sluggish. The temperature difference between forearm and hand was very striking, the former being warm down to the level of the wrist-joint. Movement of elbow and wrist and fingers was absent except for slight twitching. Sensation of the whole hand up to the level of the ulnar styloid had vanished.

(2) There was marked deformity and bruising of the Right great toe.

The proximal phalanx was angulated downwards and there was shortening of the toe, over which there was an abrasion of skin. There was no other bony injury.

General Cardiovascular System.

Pulse regular in time and force. Rate 100/min. Apex beat in 5th space, 3" from midline. Heart sounds normal; no murmurs.

Respiratory System.

Breath sounds loud and clear on both sides. No accompaniments. Respiration rate 22/min.

Alimentary System.

Nauseated. Teeth poor. Mucosa well coloured. Premediation. Morphia gr.  $\frac{1}{4}$ , atropine gr.  $\frac{1}{100}$ .

Operation.

Surgeon. Mr. McCormack.

The wounds already present were enlarged and the Right arm and forearm explored. A large amount of blood clot was expressed and the deep fascia incised. The detached portion of the humerus lying close to the brachial artery was removed, and the contused brachial artery exposed. Above the point where the fragment of bone had lain, the vessel was visibly pulsating, but it narrowed to a segment the size of an average knitting needle looking like nothing so much as a piece of string. Below this stricture the vessel was of normal calibre, but its colour was not quite normal. Warm saline packs were applied and a periarterial injection of novocaine was made which seemed to relieve the spasm to some extent, but the distal part of the vessel could not be felt pulsating and the surgeon feared that it was thrombosed. The wounds were sutured. The upper limb was immobilised in a plaster back slab and the hand put in the position of function over a roll of wadding, with the elbow in about  $140^{\circ}$  of extension. The reduction of the fracture of the proximal phalanx of the right great toe was carried out by flexing the distal fragment, and immobilising in plaster.

Progress.  
15.2.50.

Two hours after the operation the hand was seen to be both warm and pink with active capillary circulation. Neither the radial nor ulnar pulse could be felt however. He was in considerable pain. Heparin was given. 10,000 units.

16.2.50.

In order to reduce the fracture and increase comfort, a brachio-thoracic plaster was applied, with the elbow in  $90^{\circ}$  flexion. Neither pulse could be felt. The hand was warm & More comfortable in this plaster.

17.2.50.

Hand cold and loss of feeling. Patient very unhappy.

18.2.50.

The hand was cold and discoloured; capillary circulation absent. He was quite unable to move or feel the hand.

19.2.50.

The hand was beginning to swell. He was therefore taken to the theatre and the brachio-thoracic plaster removed under an anaesthetic. A posterior plaster slab with the limb in extension was applied and the hand elevated. Heparin was given. Toward evening the patient was very distressed, in considerable pain and his temperature was  $103.8^{\circ}$ , and the hand blotchy and cold. No pulses. Capillary circulation was virtually absent.

20.5.50.

He felt better but he was still in great distress; the hand was still swollen, blue and cold.

21.2.50.

He is requiring a lot of sedation, although he seems almost apathetic at times, and finds it difficult to express his feelings either in English or German. His hand is almost corpse like; there is no movement whatsoever; no pulses felt, and the fingers are flexed both at the interphalangeal joints and the metacarpal-phalangeal joints.

- 23.2.50. The hand is rather less swollen, but otherwise as before.
- 24.2.50. He is quite listless; he spent a bad night. The hand is blue black in colour and there is a clear line of demarcation extending around the ulnar styloid, in front of the wrist over the proximal carpal bones and proximal to the thenar eminence and over the back of the wrist.
- 25.2.50.) He had not very much pain but is inclined to shiver. His hand  
26.2.50.) has become quite black and gangrenous.
- 28.2.50. An upper arm amputation was carried out. The pathological report showed that all the peripheral vessels were thrombosed.

Commentary.

(1) Vascular Trauma.

Vascular surgery up until 1939 was based upon Makins' monograph (1919) of "Gunshot wounds in the blood vessels", and he believed that successful therapy in arterial injury depended upon the elimination of wound sepsis, secondary haemorrhage, or thrombosis, following repair and ischaemia, after primary ligation, and that even if after suture, a vessel closed up, the advantage of slow closure had been gained. In the 1939-45 war brachial artery injuries formed the largest percentage of all arterial injuries (24%) (De Bakey 1946). It was hoped therefore that by elimination of sepsis by chemo-therapy and antibiotics, of secondary haemorrhage by improved technique, and absence of infection, of thrombosis by anticoagulants, that results in this war would be spectacular. Such has not been the case, and it is concluded that amputation should not be regarded as a failure of surgery, but as the inevitable result of initial injury; Ischaemia of sudden onset will continue to take a high toll in amputations. Briefly, results of an injury such as this man has sustained could have resulted in (1) Spasm. No histological abnormality is demonstratable.

(2) Contusion. There is bruising on the outer surface of the vessel and tearing of the intima which may lead to thrombosis and distal embolism. Healing leaves a weakened area and in presence of sepsis could result in secondary haemorrhage, or give way later and form a delayed traumatic aneurysm. Alternatively it could cause a reflex contraction of the potential collateral vessels and so imperil vitality.

(3) The artery is wounded directly by bone and is either completely or partially severed. If complete the intima curls up and there is little haemorrhage; if incomplete the muscle coat serves to make the wound gape so that haemorrhage is severe. Bleeding will also depend upon soft tissue damage, which may allow free external bleeding.

Effects of Injury on Peripheral Circulation.

Injury will result in interference with blood flow, varying from complete to slight reduction. The peripheral circulation is maintained by blood flow through the injured vessel, through collaterals or through both. The arterial injury may cause spasmodic contraction of the potential collaterals so preventing collateral development upon which survival will depend.

Effects of Ischaemia.

In 1881 Von Volkmann was the first to attribute contractures of sudden onset following trauma to arterial injury. Griffiths in 1940 showed that exactly as in the case of bone infarction, so in muscle infarction does the tissue die though the contour is preserved. Fibrosis proceeds from without in and replaces the dead muscle. He also showed that contracture followed embolism of the peripheral arteries as well as in fracture at the elbow. Mere ligation of the vessel did not produce the condition unless the collaterals were also ligated. Trueta and Barnes (1942) conclude that while the effect on the damaged artery may be myogenic in origin; the reflex closing of the collaterals is brought about by stimulation of the sympathetic. Loss of peripheral pulses is not a true indication of peripheral blood flow, because the collaterals may be adequate for nutrition.

However periods of complete ischaemia, from 15/30 mins. will result in organic damage to nerves causing paralysis and anaesthesia, from 6 - 8 hours will result in muscle destruction, from 10 - 24 hours the skin will be destroyed; if the collateral circulation is entirely inadequate no tissue can survive, and gangrene results.

Treatment of fracture with arterial injury.

In any case in which there is both a fracture and arterial damage, the treatment of the last must take precedence except in so far as displaced bone is causing ischaemia directly. Gentle reduction is always advocated, but rarely if ever does it result in a spontaneous return of blood flow. Manipulation itself may cause a degree of vascular spasm.

In this case a fragment of bone was seen lying, in the X-ray, in a position which suggested its proximity to the brachial artery, and which was very suggestive of its being the agent which had caused vessel interference.

Diagnosis:

The cold pulseless hand of doubtful vitality merits exploration at once to establish an exact diagnosis, but before any incision is made, the surgeon should have a clear idea of what he may find, and so will not be surprised if he is met with an almost uncontrollable gush of blood. Spasm is not the commonest cause of suppression of the pulse, often the vessel is divided, sometimes thrombosed or stretched over a long bony spike, or is caught between the bone ends. The vessel may even be compressed by an enlarging haematoma. It is tempting to wait and see, for spasm alone may often spontaneously vanish, unfortunately one cannot be sure of this, and therefore where any doubt exists, exposure must be performed, for, if the limb is to survive operation should not be delayed more than six hours at the very most.

The following table gives a guide under the circumstances:

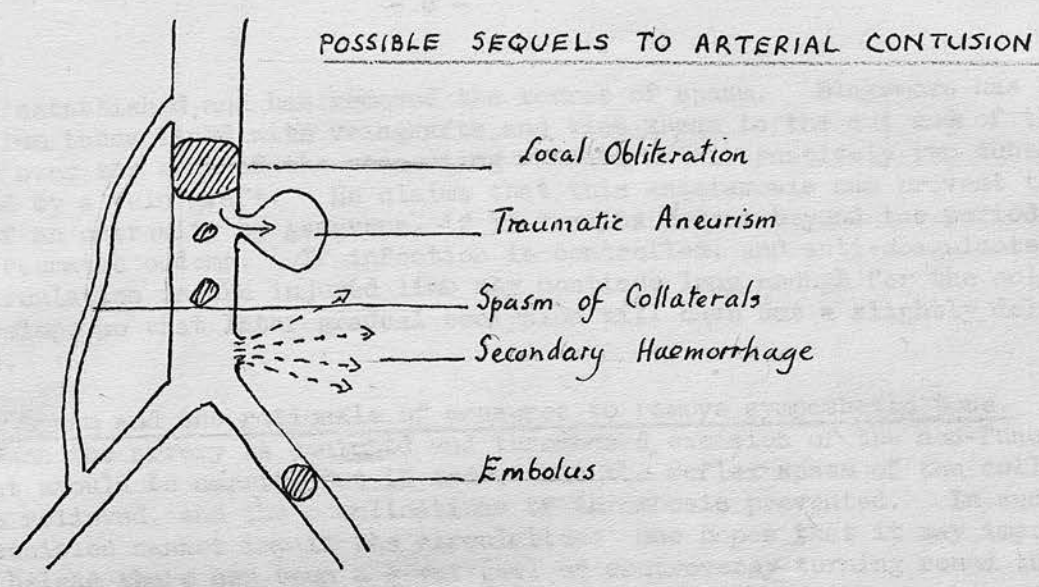
<u>Lesion.</u>	<u>Swelling</u>	<u>Murmur</u>	<u>Peripheral Pulse.</u>
Arterial Spasm.	} No	No	Absent or diminished
Transection			
Contusion or thrombosis	} "	"	" "
Early Haematoma	Yes	No	" "
Late Haemorrhage or Aneurysm	Yes	Soft Systolic Murmur	Diminished
Aneurysmal Varix	No	Continuous Machinery Murmur	Diminished.

The differential diagnosis would therefore appear to lie between (1) Arterial Spasm. (2) Contusion and thrombosis. (3) Early Haematoma. (4) Transection.

Complete transection was unlikely from a blow of this nature, though it is possible; it would be more probable that a piece of bone had caused a tear, which bleeds more than a complete transection, for the lumen remains gaping and cannot contract. The swelling was not pulsatile, so it seemed most probable that arterial spasm with or without contusion existed. Operative exposure revealed that the vessel was in spasm, and that the detached bone fragment was indeed lying next to the artery, and that there was possible thrombosis of the artery distal to the obstruction.

When an artery is contused, it may appear almost normal, yet the intima is contused and fissured. More severe violence may also break the elastic fibres, and even the muscle coat may be divided. Contusion is a serious threat therefore because (1) Thrombosis occurs at the site of damage which may either occlude the vessel, or provide emboli, which plug the vessel distally and make massive gangrene certain. (2) In the presence of infection from a compound fracture the wall may give way and produce violent haemorrhage.

- (3) The weak part of the wall may form a traumatic aneurysm.
- (4) The damage apparently sustains constriction in all the limb vessels.



Method of Treatment.

Under such circumstances various procedures have been advised.

- (1) Washing with warm saline. This can be effective where the contusion is negligible.
- (2) Periarterial stripping or local injection of anaesthetic. Neither of these measures have the slightest effect on spasm, therefore Leriche has advised;
- (3) Excision of the affected segment. This would seem to be somewhat radical unless thrombosis is obviously present, but it may be justified in certain circumstances.
- (4) Paravertebral sympathetic block. It must be frequently repeated and there is no real proof it has been successfully infiltrated if there is no obvious vascular response, unless a Horner's syndrome develops. (Local anaesthetic of prolonged action followed by alcohol can partly overcome this.) It is probably most successful in cardiac embolic cases where trauma and damage is minimal, and the collaterals less likely to be spastic.
- (5) Preganglionic sympathectomy. This may give good results but Seddon believes that it is not necessarily efficient in relieving spasm, and he cites a case of supracondylar fracture of the humerus in which sympathectomy failed to bring any relief. Operation confirmed the diagnosis of spasm; the segment was excised with immediate relief to the collaterals and restoration of the circulation.
- (6) Reflex vasodilatation in such cases is hardly a treatment per se, but rather an adjunct to whatever other method is instituted.
- (7) If arterectomy is performed, some workers have ligated the concomitant vein, but statistics and experience show that this furnishes no protection whatsoever against the development of gangrene after acute arterial occlusion.

The decision is difficult; if there is thrombosis in the distal segment, the outlook is somewhat altered.

The aim of treatment.

The aims and principles involved must be kept clearly before the surgeon. The aim is to restore full function to the limb in no way crippled by ischaemia by:-

- (1) Preserving the blood flow to the periphery, preferably by repair of the main vessel, or if this is not possible, to avoid any damage to collaterals.
- (2) Developing collaterals, by maintaining blood flow through normal channels for as long as possible, to give the collateral circulation time to adapt itself to the new conditions, and by removing any constrictor influences.
- (3) Keeping the limb under optimum conditions for survival when ischaemic changes are in the balance.

Repair of Main Vessel.

If at first the indications for amputation are to be based primarily upon the integrity of the main vessels, a simple, quick method of joining them together should have much to commend it. The method at the moment is neither quick nor is it simple, except in the hands of the masters; but if such a method succeeds one has gained valuable time in which the collaterals may

become established, and has removed the source of spasm. Blakemore has used vitallium tubes lined with vein grafts, and ties these to the cut ends of the artery over the ends of the connecting cannula, or alternatively two tubes bridged by a vein graft. He claims that this anastomosis can prevent the loss of an extremity by gangrene, if it remains patent beyond the period of post-traumatic oedema. If infection is controlled, and anti-coagulants used, the circulation in the injured limb may continue long enough for the collaterals to develop, so that later gradual occlusion will have but a slightly deleterious effect.

#### Reflex Spasm and the rationale of measures to remove sympathetic tone.

When the artery is contused and thrombosed, excision of the non-functioning segment should be carried out in order that the reflex spasm of the collaterals may be relieved, and the complications of thrombosis prevented. In such a case excision cannot impair the circulation; one hopes that it may improve it. Nevertheless there has been a great deal of controversy turning round the rationale of sympathectomy and arterectomy in vascular spasm.

Cohen believed that the sympathetic system was not concerned in the local spasm of the artery, but acted by keeping the cutaneous circulation closed, and prevented the blood pooling in the skin at the expense of the muscle, which is the tissue most in need of sustenance. He regards a cold and clammy skin not as nature's mistake, but as a direct result of nature's endeavour to preserve the most vulnerable cells. Skin temperature estimations, he argues, are useless in estimation of flow in muscle, as a cold skin may be associated with dilatation of the deep vessels.

Leriche for a long time has said that the damaged vessel maintains in spasm the collaterals, by means of a "reflex" mechanism, and recommends excision of the affected segment on these grounds, but Cohen has questioned any such reflex action. He argues that arterectomy has a value purely for mechanical reasons, such as removal of clot from a contused segment; the local contusion does not by itself act as an irritant focus and maintain spasm, rather it is the initial blow, which caused stretching of the smooth muscle of the artery wall. This reacts like stretched smooth muscle elsewhere, and contracts. In its new length the muscle fibres need but little oxygen to survive while the tissues around may be dead and dying. If this is a purely reflex mechanism, it is very odd that the spasm should continue after the limb is ischaemic, and presumably all nerve conduction has ceased. If it were a local reflex or one via ascending afferents, novocaine should release the spasm, but it does not. This spasm may still persist during a spinal anaesthetic, after the limb has been completely denervated, and even in the amputated limb, and therefore, he concludes, that the continuance of spasm is not apparently dependent on afferent impulses traversing the network in the adventitia. Cohen goes so far as to say that sympathectomy for traumatic arterial spasm can lead to Volkmann's Ischaemic contracture, because of the diversion of blood from muscle to skin, and therefore he deprecates any such treatment; however he advocates its use to control vasospasm following a crushing injury, on the grounds that this spasm is a reflex autonomic phenomenon.

There appear to be three fallacies in this argument. Firstly, he assumes that spasm can be initiated reflexly by one type of trauma and not by another, secondly he assumes that block can both at once be injurious and beneficial, for vasospasm initiated by different types of trauma. Thirdly, the contention that release of the sympathetic tone would benefit the blood flow to the skin at the muscle's expense is not admissible, in view of the work of Barcroft (1946), who has established that there are sympathetic vaso-constrictor fibres to the vessels of the limb muscles in man; despite this it is odd that Volkmann's contracture is more common in a limb where there is a nerve lesion as well as an arterial lesion, than with an arterial lesion alone. Learmonth points out that periarterial stripping and block are useless for two reasons:-

- (1) A thrombosed segment may impose spasm on its collateral vascular bed when the limb is denervated.
- (2) The effects of injection will not restore the circulation after any interval shorter than those that have characterised cases, in which apparent spontaneous recovery has occurred.

A sudden interruption of the flow of blood, through such an artery as the brachial, is usually attended by marked spasm out of all proportion to the local injury to the main artery; it is significant that it is on the contrary extremely rare for gangrene to follow simple ligation of a main vessel unaccompanied by any form of trauma. In Makin's (1918) series of 200 brachial

artery injuries, only eight developed gangrene, and in Sencert's series, (1918) ligature of 70 main vessels resulted in only two cases of gangrene, so that obviously obliteration of the brachial artery alone does not cause gangrene.

Learmonth quotes the case of a boy of 14 with a supracondylar humeral fracture who had a cold and pulseless hand, both before and after adequate reduction; on exposure the brachial artery was bruised and in intense spasm, so it was resected. The boy recovered completely and within 26 hours reflex vasodilatation which did not differ materially from the normal, could be demonstrated in the injured hand, illustrating that the collaterals are more than ample to provide nourishment of the extremity, the vascular reserve being scarcely diminished.

It may be that the trauma which injures the main vessel also injures the collaterals directly, and thus may decide the ultimate fate of the limb; it is rare that either adequate reduction of the fracture or local injection alter the prevailing state of affairs.

Careful analysis of the use of sympathectomy and sympathetic block in arterial injuries in the battle casualties in the whole of the U.S. Army in World War II reveals that there is no substantial evidence in favour of sympathectomy, or that it was of any value. The incidence of amputation in the group in which a block had been performed is only slightly lower than the incidence in the group as a whole, while the incidence of gangrene in those in which sympathectomy was done is actually greater than that for the entire series; however the groups are not strictly comparable, for sympathectomy seems to have been reserved for those cases in which it was considered that the limb was already moribund. In spite of lack of statistical evidence, and Cohen's forebodings, there is conclusive evidence of the excellence of the clinical results in some cases, despite the curious fact that the blood flow in the freshly sympathectomised hand lasts no longer than 48 hours, and by the end of the first week it has declined to about one quarter of its post operative rate and after two weeks it has decreased to about one eighth. The reason for the intrinsic recovery of tone is not yet explained.

If the disturbance is due to a vasomotor reflex, as seems likely, in the traumatised tissue, and since constrictive impulses presumably are transmitted by way of the sympathetic, interruption of these seems rational. The primary object of developing the collateral circulation is to lead blood past the affected segment, and return it to the main trunk below the obstruction, and therefore one must try and ensure patency of the lumen distally, by ligating above and below a thrombosed segment, with excision of the latter, so minimising the risk of secondary haemorrhage and embolism, which is incalculable from external inspection of the vessel alone, and removing the strong stimulus to vasoconstriction of the collateral circulation.

The stagnation of the blood brought about by vasoconstriction favours progressive arterial thrombosis. If the clotting of the blood is progressive, it may quickly overcome the efficiency of the collaterals, by actual extension into the collateral arteries. The immediate use of heparin may effectively control the progression of the intravascular clot, but it can not affect the thrombosis which has already taken place. The effects of excision are often very striking, yet no change has been made in the permeability of the vessel; only the collaterals can have been altered.

#### Expectant Treatment.

The justification for the adoption of expectant treatment in such cases of contusion depend upon:-

- (1) The character of associated wounds.
- (2) Exact clinical diagnosis.
- (3) A thorough assessment of the peripheral circulation.
- (4) Facilities for keeping the patient under constant and skilled observation.
- (5) A knowledge of possible complications of the injury and indications for immediate operation.

Many arterial injuries are necessarily associated with nerve injuries, and therefore to determine and recognise a progressive ischaemia, a careful initial

record of the area of sensory loss is essential to such treatment. The danger of complications such as pressure on the collaterals from the rapid enlargement of a haematoma, or thrombus, might contra-indicate conservatism, but operation may be carried out at any time that the ischaemia increases. Primary surgery resulting in ligation, and therefore an abrupt cessation of flow, is not a procedure of choice in many cases, though it may well be one of necessity. Conservative measures may result in an increase in ischaemia, but if there is no collateral spasm, valuable time has been gained should spasm later develop, but its adoption must depend on the ability to recognise at once when it has failed. The selection of cases for conservative management requires therefore expert surgical judgement as well as more than average courage. Generally speaking therefore, it is best to explore even trivial wounds, with the idea of performing remedial surgery if there is evidence of interruption of the circulation.

#### General care of the Ischaemic Limb.

In order that the blood supply may be conserved to the periphery, and diminish the metabolism while the blood supply is reduced, these criteria must be followed:-

- (1) Environment. The limb must be kept cool at room temperature without bed clothes. Allen has gone so far as to suggest that the limb should be frozen by ice, because it slows the metabolism. This advantage is counter weighed however by reduced oxygen dissociation at these temperatures, healing progresses less satisfactorily, wound infection tends to progress more rapidly and be more serious, and the nerves in the cooled area are liable to damage. No evidence in fact exists that this method has saved limbs after arterial damage; Learmonth has pointed out that there is a minimal temperature below which vasomotor responses virtually cease; Watson Jones advises a middle course, the policy being to maintain the threatened limb at about 34°C
- (2) Position. In general if there is no oedema, slight dependency is a good thing by raising the head of the bed, but should the limb be swollen it should be elevated; this might be expected to accentuate the ischaemia by forcing the blood flow to overcome gravity pull, but Cohen disagrees. He advocates elevation because it does not empty the arterial tree or cause capillary anoxia, and it diminishes venous pressure, and increases lymph flow so preventing oedema.
- (3) Skin Care. This should be quite scrupulous, especially between the fingers as any break in continuity can lead to infection.
- (4) Infection. If infection supervenes, the metabolism increases with a call for more blood, and therefore chemotherapy and antibiotics should be given.
- (5) Pressure. Any form of encircling bandage, or plaster, or any manoeuvre of the limb, which causes possible kinking or pressure on vessels, should be avoided at all costs.
- (6) Anticoagulants. Heparin is often given in cases where there is obvious thrombosis, but generally, unless it is given extremely early, the distal portion would have been deprived of blood far too long a period for the pathological changes, which quickly appear in the absence of the circulation, to be reversible. In fact no significant advantage is to be observed from their use in a survey of all arterial injuries in the war in the U.S. Army casualties.
- (7) Anaemia. Any blood lost should be restored, else the oxygen carrying capacity is reduced. Oxygen inhalation might be desirable, with a view to increase the available oxygen in the tissues, but under normal respiratory conditions an increase in the partial pressure of oxygen, in the inspired air, has little effect upon the oxygen content of the blood, which is already nearly fully saturated. Theoretically a slight increase in the gradient between capillary oxygen and tissue oxygen might be gained. It seems much more important to correct the oligoemia and anaemia.
- (8) Smoking. Tobacco is a vasoconstrictor and should be avoided. Even in a normal subject the bloodflow is reduced in a limb by smoking cigarettes.

- (9) Rest. Exercise increases all demands for blood and so rest should be complete.
- (10) Tension. Swelling and mechanical obstruction to the vessels must be removed. In any arterial lesion more particularly a supracondylar fracture, one must first relieve any accessory or extrinsic obstruction to flow, particularly flexion at the elbow, which has for long been recognised as a dangerous position, for acute flexion can, in the normal individual, obliterate the radial pulse. Any bandage, splint, or plaster, can only increase the circulatory embarrassment, by pressure on the collaterals over bony points. Fasciotomy is performed on the grounds that release of tension must bring relief. The damaged capillaries exude fluid into the muscles and enveloping fascia, the pressure within rises to impair the circulation further, and a vicious circle is set up. But the incisions may destroy the collaterals, and increase the need for blood, by the introduction of infection. The results have sometimes been reasonable.

#### Management of this Case.

It is easy to be wise after the event, but it seems a little unfortunate that a day after the injury a brachio-thoracic plaster was applied, which necessitated flexion at the elbow, when the peripheral pulses could not be felt. This could only result in stasis, favouring complete thrombosis. The reason for applying such a plaster is that it is extremely comfortable, since the arm and thorax move as one, and painful movements are minimised. This type of plaster was used frequently during the war, principally however as initial treatment, so that the patient could be more easily transported without pain. It does not seem justified when there is arterial injury.

If disaster is to be avoided the diagnosis must be made within a few hours by the coldness, the pallor, the swelling, the pain, the insensitivity and the immobility. Since thrombosis was suspected at operation it might have been wise to do an arterectomy to avoid spreading thrombosis, and to remove the cause (?) of spasm, and not to rely on the effects of local injection and heparin both of which are of very doubtful value. To make such a decision at the time of operation must always be difficult. Wherever thrombosis is manifest then a high incidence of failures and poor results would be expected whatever the treatment, since this type of lesion is likely to cause widespread interference with the blood flow through the collateral vascular bed.

The treatment of this extensive fracture itself is of course difficult, but when vascular complications ensue there can be but one consideration, and that is to secure the optimum conditions for survival; there is absolutely no drawback in waiting some time before the fracture is properly treated, and unless one does do so, any treatment is rendered null and void by the necessity for amputation, or by the onset of Volkmann's ischaemic contracture, which is an extremely rare condition in fracture clinics, though when it does occur supracondylar fracture of the humerus accounts for some 25% of the cases.

Summary. A supracondylar and intercondylar fracture of the right humerus in a man of 28 with contusion, and thrombosis of his brachial artery with ensuing spreading thrombosis, Gangrene of the hand necessitating amputation through the humerus is described. The reason for the poor results following arterial injury are discussed in the light of the effects of injury and ischaemia in the limb. The rationale of the available methods of treatment are described, and the retrospective management of this case examined in that light.

By Permission of Mr. D.M. Douglas, F.R.C.S.

#### References.

- ALLEN. Am. J. Surg. 52, 225, 1941  
ALLEN. J. Inter Coll. Surg. 7, 423. 1944.  
ALLEN. Am. J. Surg. 68, 170. 1945.  
BARNES. Brit. J. Surg. 30, 74. 1942.  
BARCROFT J. Physiol. 100, 21. 1943.  
BARCROFT Lancet. 2, 513. 1946.  
BARCROFT Lancet. 1, 441. 1948.  
BARCROFT Lancet. 1, 1035. 1949.

BLAKEMORE Annals Surg. 117, 481. 1943.  
BLAKEMORE Annals Surg. 121, 435. 1945.  
BROOKS. Annals Surg. 114, 1069. 1941.  
COHEN. Guys Hosp. Rep. 90, 201, 1940.  
COHEN. Lancet. 1, 1 1-6, 1944.  
COHEN. Brit. Med. Bull. 2, 144. 1944.  
CLARK. B.M.J. 2, 167. 1943.  
DEKAKATS. J. Am. Med. Ass. 110, 1075. 1938.  
DEBAKEY. Annals Surg. 123, 534. 1946.  
GAGE. Surgery. 71, 983. 1942.  
GRIFFITHS. Brit. J. Surg. 28, 239. 1940.  
HENRY. Am. J. Surg. 56, 49. 1942.  
HERMANN. Am. J. Surg. 74, 560. 1947.  
HERMANN. Surgery. 26, 59. 1949.  
HOMANS. Am. J. Med. Sc. 205, 313. 1943.  
HURLEY. Aust. & N.Z. J. Surg. 15, 235. 1946.  
KINMONTH. Quoted by Barcroft. 1949.  
LARGE. Annals. Surg. 120, 727. 1944.  
LEARMONTH. Ed. Med. J. 47, 225. 1940.  
LEARMONTH. Ed. Med. J. 50, 140. 1943.  
LE RICHE. "The Surgery of Pain", London. 1939.  
LE RICHE. Lancet. 2, 296. 1940.  
LEWIS. Vasc. Disorders of the Limbs. Macmillan. 1936.  
LORD. S. Clin. N. America. 28, 373, 1948.  
MAYBURY. Brit. Med. Bull. 2, 142. 1944.  
MASON-BROWN P. Roc. R. Soc. Med. 39, 483. 1946.  
MAKINS. Gunshot Inj. to the Blood Vessels. Wright. Bristol 1919.  
MACFARLANE. Journal Bone and Joint Surgery. 24, 739. 1942.  
MONTGOMERY Journal Am. Med. Ass. 105, 1741. 1935.  
PRIDIE. Lancet. 1, 267. 1943.  
SIDDONS. Lancet. 2, 77. 1945.  
TAYLOR. U.S. Navy Bull. 42, 911. 1944.  
WATSON JONES. Fractures and Joint Injuries. 1943.  
WHITE. Surgery. 23, 834. 1948.

---

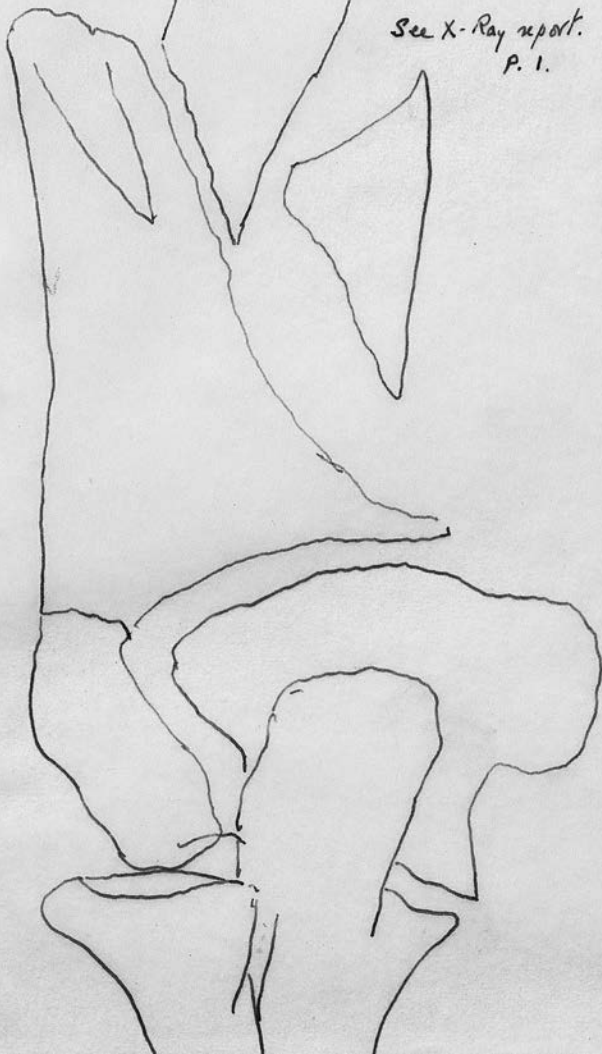
EDMUND JOSKE,

18. 2. 50.

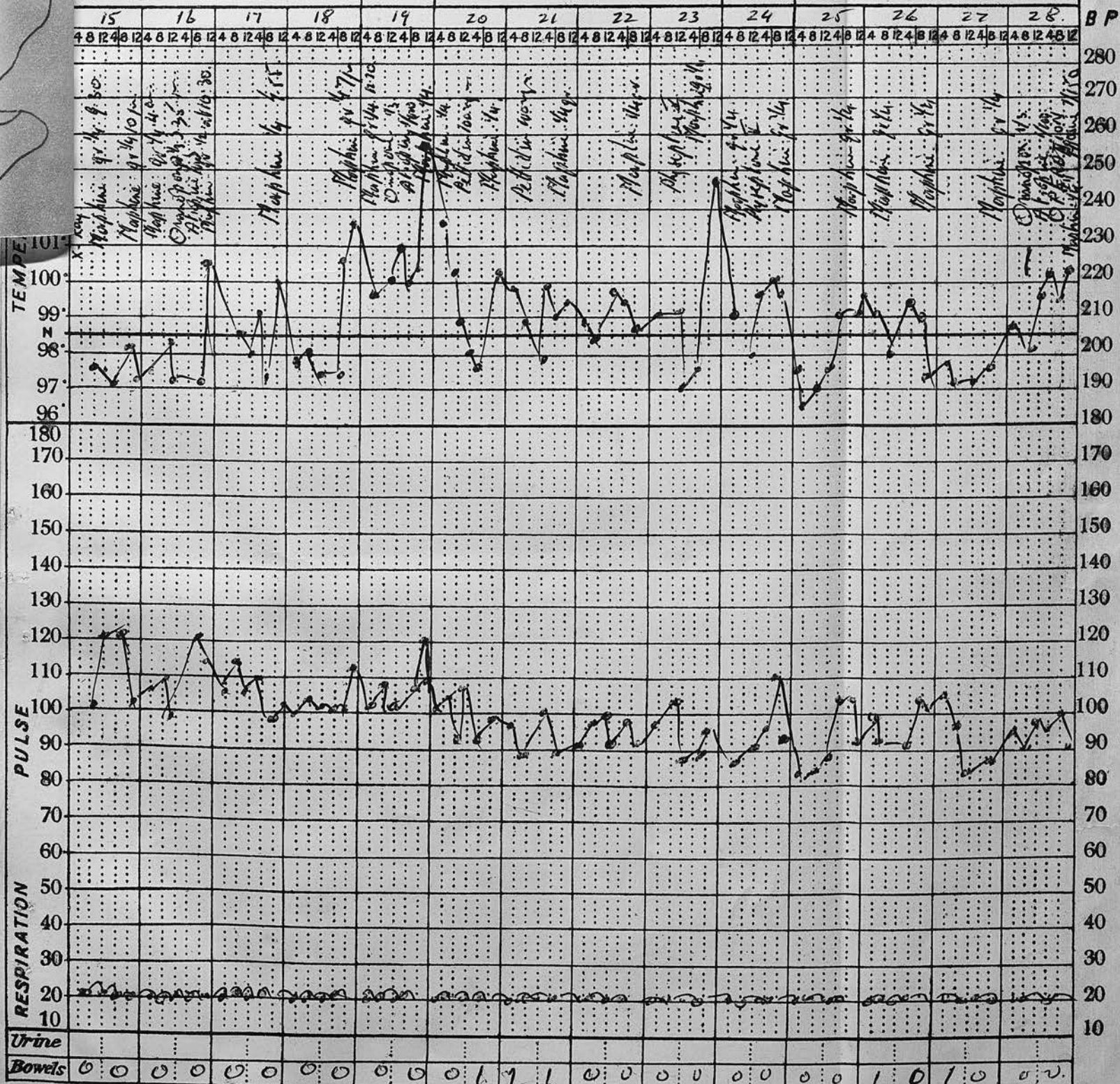
---

See X-Ray report.

P. 1.



Date of Admission 15.2.50		Name, and Age of Patient EDWARD JOSKE. 28 YRS.		Doctor Clinical Clerk	
DIET AND MEDICINES		Date	DIET AND MEDICINES	Date	LABORATORY EXAMINATIONS
		15.2.50.	1Ml. Penicillin. 250,000 4hrly.		
		21.2.50.	1Ml. Penicillin 500,00 8hrly.		
		21.2.50.	Veganin. Tabs ii tid. 8sp. Veganin.		



WARD 13.	Date of Admission 15. 2. 50.	Name, and Age of Patient EDWARD JOSKE. 28.		Doctor Clinical Clerk	
Date	DIET AND MEDICINES	Date	DIET AND MEDICINES	Date	LABORATORY EXAMINATIONS

Date	1	2	3	4	5	6	7	8	9	10	11	12	13	14.	B P
Time	4 8 12 4 8 12	4 8 12 4 8 12	4 8 12 4 8 12	4 8 12 4 8 12	4 8 12 4 8 12	4 8 12 4 8 12	4 8 12 4 8 12	4 8 12 4 8 12	4 8 12 4 8 12	4 8 12 4 8 12	4 8 12 4 8 12	4 8 12 4 8 12	4 8 12 4 8 12	4 8 12 4 8 12	
TEMPERATURE															
PULSE															
RESPIRATION															
Urine															
Bowels	0	0	0	1	0	0									

Name: Simpson, Ella.

Age: 2 (26.3.46).

Address: Wildcatgate, Jedburgh.

Sponsor: Roxburghshire.

Doctor: Dr. Grieve, Jedburgh.

Admitted: 27.8.48.

Discharged:

Complaint: Walking with a limp.

Diagnosis: Left C.D.H. followed by Supracondylar fracture of left femur.

History: Normal birth. No instruments were used. In February it was noticed that the child walked with a dip to one side.  
20.4.48. Seen by Mr. Stirling. X-rays taken 4.3.48. were examined and were found to show a dislocation of the left hip; the head having subluxated outwards. Treated by plaster fixation.

Previous illnesses: None. (Immunised but vaccination did not take.)

Examination: General. Normal.

Orthopaedic: There is an apparent shortening of the left hip. Telescoping of this hip is present and there is a definite limitation of abduction, rotation and extension.

28.10.49. DISCHARGED.

Summary: This child was admitted on 27.8.48. with a left congenital dislocated hip. She was treated by manipulation and plaster and is now walking fairly satisfactorily, although she has a dip to the affected side. "She should attend the local clinic for exercises and be seen there in not longer than a month's time."

22.11.49. This youngster was walking about very well until a fortnight ago when she had a tumble and complained of her left femur just above the knee where there appears to be a very definite thickening in the bone, probably an old fracture. The leg, as a whole, is 1" short which is probably due to damage of the femur. It is thought she should be sent to Fairmilehead for an X-ray and check-up on Monday, and kept off her feet.

Readmitted.

28.11.49. This child was seen as an Out-patient to-day, complaining of pain and tenderness above the left knee. X-ray showed a supra-condylar fracture of the left femur with slight forward angulation. The fragments were impacted and a fair degree of callus was present.

Operative Manipulation.

28.11.49.

Pre-operative seconal. Gas, oxygen, ether and trilene.  
(Dr. Goldsmith). Surgeon: Mr. Sutherland.

Under anaesthesia an attempt was made to correct the forward angulation. Owing to the amount of callus present this was found to be impossible and a plaster was applied from groin to foot.

Summary: Attempted manipulation and plaster of leg.

To be seen on Monday regarding the possibility of a corrective osteotomy.

7.12.49.

Pre-operative, seconal and atropine. Gas, oxygen and cyclopropane.

(Dr. Goldsmith). Surgeon: Mr. Pollock.

A short incision was made on the outer side of the lower thigh, and this was deepened to expose the lower end of the femur and the site of the fracture. There was a considerable amount of callus present on the posterior side of the bone. A 'V' shaped osteotomy was performed just above and through the site of fracture, and the alignment of the bone corrected. A lateral X-ray taken in the theatre showed that correction was not quite adequate so further manipulation was performed. This had to be again repeated and a third X-ray showed that the fragments were now in a more satisfactory alignment. The wound was closed and the limb immobilised in a plaster spica.

Summary: Osteotomy, lower end of left femur.

30.1.50.

Plaster bivalved and new X-ray taken. Clinical and radiological union is now complete, and she should be allowed to get up.

17.2.50.

This little girl has now got most of her knee movements back again and she is fit for discharge.

24.2.50.

DISCHARGED.

Summary.

This little girl was re-admitted on 28.11.49. having sustained a supra-condylar fracture of her left femur while at home. Owing to the amount of callus present on admission, manipulation attempted to correct the angulation was found to be impossible and so an osteotomy was performed. She is now up and about and her leg movements are good. She should attend the local clinic for exercises for the knee and be seen there in a month's time.

---

SIMPSON, Ella. (Cont.)

Commentary.

The interest, in this child, lies in the fact of the rarity of a supracondylar fracture of the femur in a child of 3, which went almost unrecognised.

The fact that she was suffering from congenital dislocation of the same hip, is probably not significant per se, but it seems not unlikely that continued immobilisation in this child has led to osteoporosis, and therefore predisposed to a pathological fracture, when the child put some strain on it, by stumbling. It is not without the bounds of possibility that the physiotherapist, or her exercises, may have produced the fracture which had attention drawn to it by the fall.

Influence of Age on the Rate of Repair.

Capacity for the growth of new tissue is greater in the child than in the adolescent, and still greater than in the adult. So it is striking, but not surprising, that but 4 - 5 weeks after the injury, enough callus had formed for it to be impossible to move the fragments under anaesthesia in order to improve the position; this illustrates the overwhelming rapidity of healing in childhood, as compared to the weeks of immobilisation necessary in an adult, with the same fracture. Radiological evidence of union of the fracture was obtained some 7 weeks after the osteotomy, and with exercises she had practically no limitation of knee movement; a very satisfactory result. The moral to be drawn is that, after disuse osteoporosis, resumption of activity should not be too sudden and care must be taken to avoid undue strains, before recalcification is complete. Such osteoporotic fractures in the aged are of course typically seen in the neck of the femur.

Type of Fracture and rate of Repair.

The larger the area of exposed marrow cavity, the larger the vascular area to promote tissue growth; the vascularity of the fragments determines whether union is to be fast or slow in any given case, because the growth of the granulation tissue which starts the healing process, depends upon an active hyperaemia. At the end of long bones, like the femur, there are many vascular foramina, through which blood flows to the bone, and in children this metaphyseal area is more richly endowed with blood than any other part of the body. If the fracture is impacted, there is no gap for the callus to bridge, and natural fixation is doubly quick.

Angulation of Fracture.

It was important to correct the angulation here, because:-

- (1) The weight bearing line is otherwise altered, and would tend perhaps in this case to redislocate the hip. (The superior acetabular buttress still being poorly formed, despite the long immobilisation in the frog position.
- (2) If the displacement is not corrected, the fracture unites with forward angulation, and the disability is serious, resulting in limitation of extension and osteo-arthritis of the knee joint in years to come.

Summary.

A case of supracondylar fracture of the femur in a child of 3 is described following upon long recumbency and immobilisation for a congenital dislocation of the hip in the frog position. The very swift repair and factors influencing this in the child are briefly discussed.

By Permission of Professor Mercer & Mr. Sutherland, F.R.C.S.

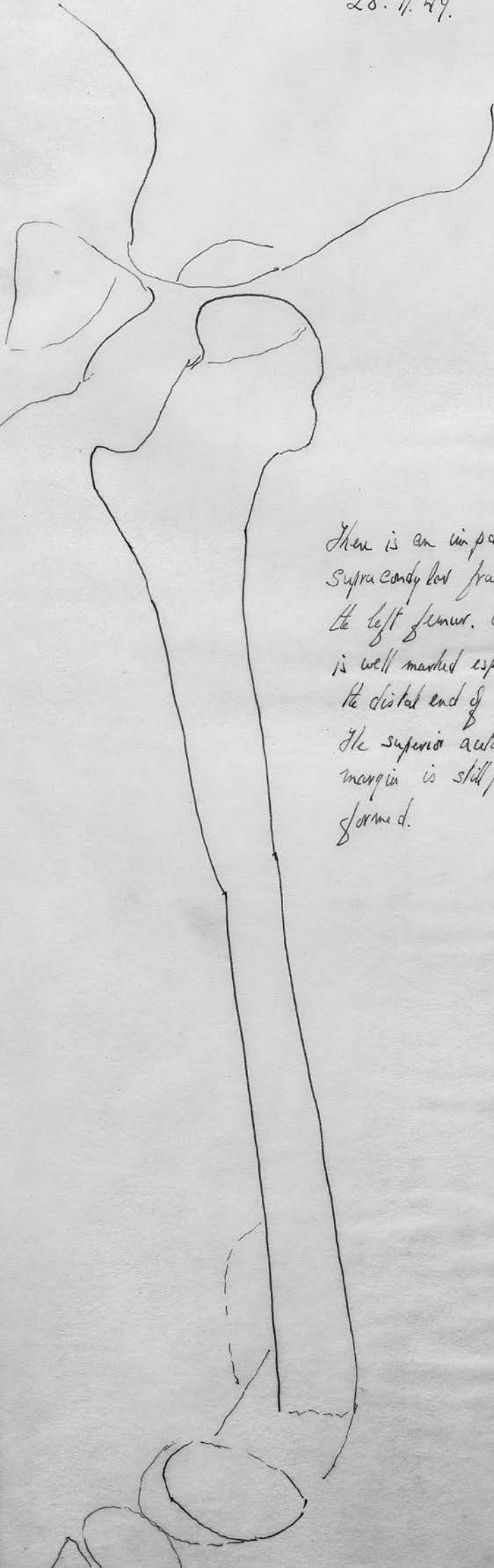
References:

- |               |                               |       |
|---------------|-------------------------------|-------|
| WATSON-JONES. | Fractures and Joint Injuries. | 1943. |
| MERCER.       | Textbook Orthopaedics.        | 1943. |
| McMURRAY.     | Practice of Orthopaedics.     | 1947. |

ELLA SIMPSON.

28. 11. 49.

L.



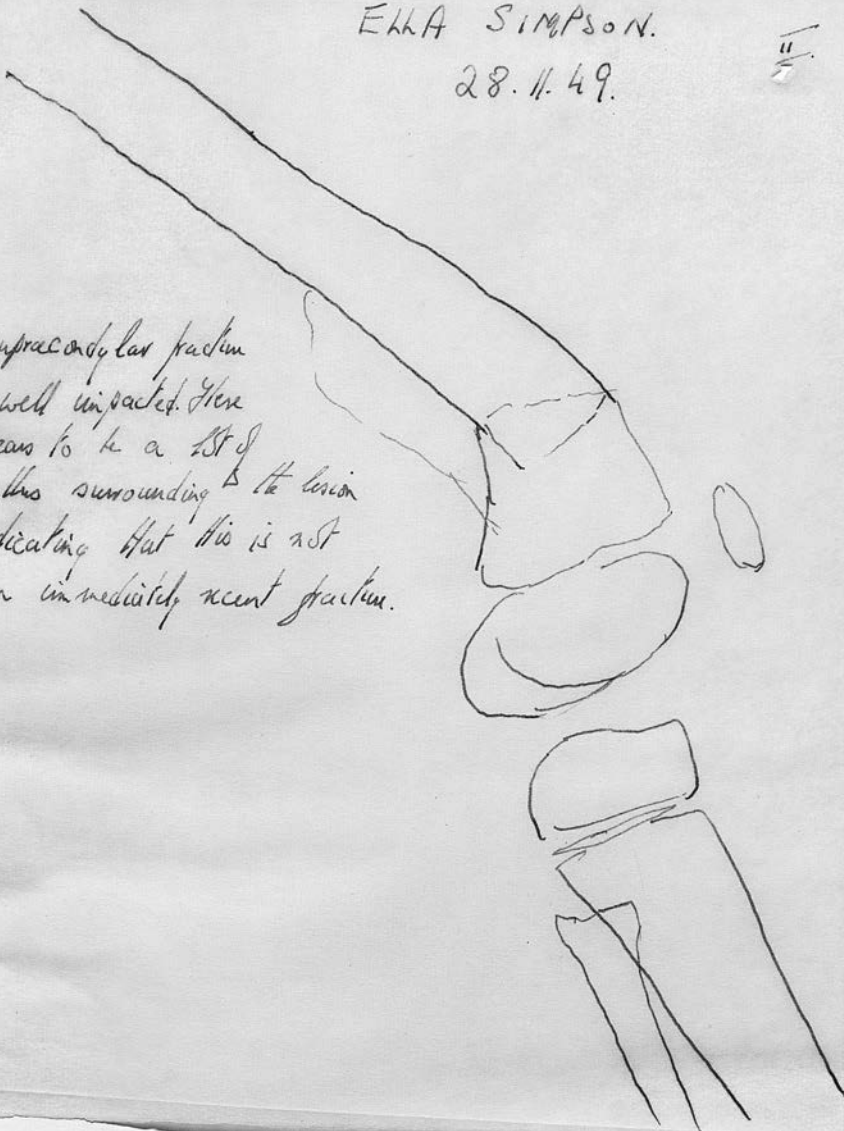
There is an impacted supracondylar fracture of the left femur. Osteoporosis is well marked especially at the distal end of the femur. The superior acetabular margin is still poorly formed.

ELLA SIMPSON.

28. 11. 49.

11  
5

supracondylar fracture  
well impacted. There  
appears to be a lot of  
callus surrounding the lesion  
indicating that this is not  
an immediately recent fracture.

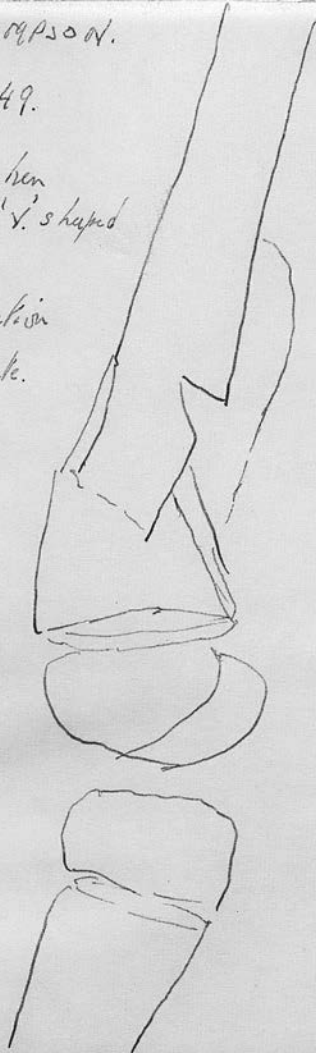


ELLA SIMPSON.

11

7.12.49.

X-ray was taken  
several. A 'V' shaped  
fracture has been  
seen; the connection  
is not adequate.

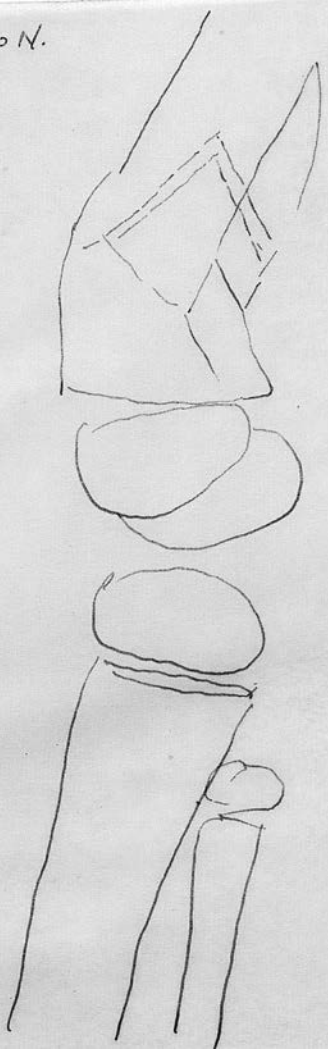


ELLA SIMPSON.

7.12.49.

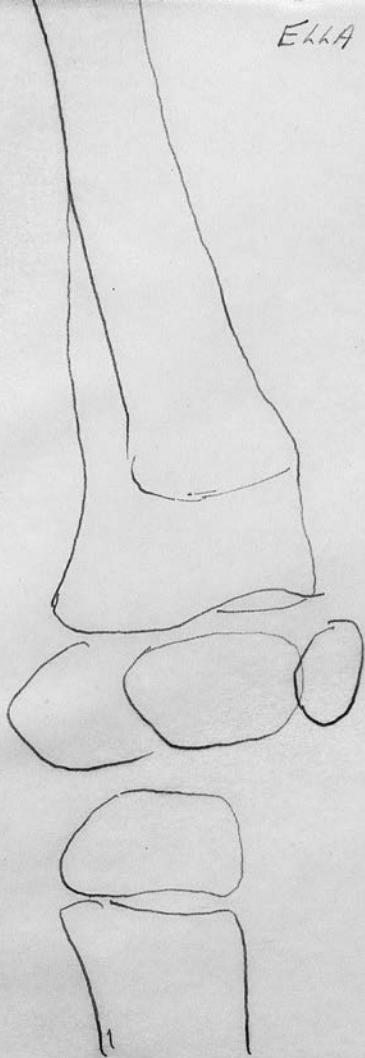
IV

Taken during  
operation. The  
osteotomy can be  
seen.  
The alignment is  
adequate.



ELLA SIMPSON. V.

25.1.50.



ELLA SIMPSON. VI

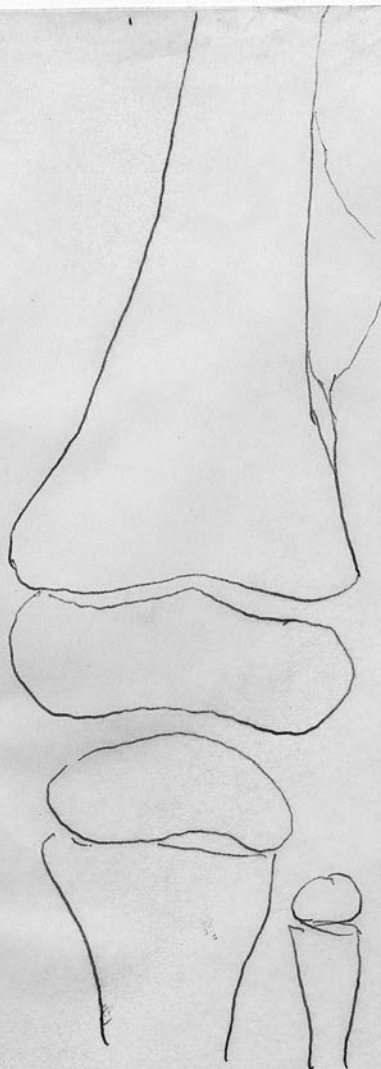
25. 1.50.

The union is excellent.

Alignment is good.

The result is very satisfactory.

Callus may still be seen.



## General Considerations of Cases I, II and III.

Fractures in the region of joints are always of a serious nature as far as ultimate function of the joint is concerned, but fractures in the region of the knee and elbow carry in addition the risk of nerve and vessel damage; this is a veritable sword of Damocles for it may drop at any moment if it has not already done so by the time it reaches the surgeon. In war, associated tissue damage, often of very considerable nature, lends it weight to an unstable and precarious position, so that the surgeon may be surprised and gratified if the result is good. In civil practice, destruction is rarely so extensive, but still good results are elusive.

It is significant that in the child, impaction of the fragments resulted in no very great deformity, apart from slight forward angulation, and it presumably would have gone on to complete union with that deformity limiting full extension and great disability later on in life. This rapid healing stands in marked contrast to the other case of supracondylar fracture of the femur, which though immobilised, will take much longer for union to occur and when it does do so, function will almost certainly be unavoidably terrible, even if physiological nerve continuity takes place.\* Case II serves to illustrate the disastrous effects of arterial injury complicating fractures round the joints and the extreme care and consideration necessary for a successful conclusion.


### Summary.

Three cases of supracondylar traumatic fractures are described, two of these involved the femur and one the humerus. The humeral injury involved the brachial artery, with gangrene of the hand, necessitating amputation. One of the injuries to the femur was caused by very severe trauma and resulted in an intercondylar T fracture, and possible damage to the popliteal nerves, a very poor prognosis being given; the other femoral injury occurred in a child of 2 years, following prolonged immobilisation for congenital dislocation of the hip, after apparent trivial injury; the end result was perfect.

\*This boy is now in imminent danger of losing his leg because of permanent nerve damage, and because the traction pin unfortunately cut out, presumably because of too great traction.

---

Patient's Name: Geddes, Chrissie



Age: 53 yrs.

Occupation Housekeeper.

Doctor's Name Dr. Clark  
Comely Bank,  
Edinburgh.

Recommended by: Dr. Clark.

Date of Admission: 1.11.48.

Date of Discharge: 6.11.48.

Final Diagnosis: Abduction Fracture of neck of femur and avascular  
necrosis of head of femur.

Complaint: Injury to left leg.

History: At 9.p.m. tonight the patient caught her foot in a hole in the pavement and fell down. She could not walk afterwards but did not regard the injury very seriously. She was brought into hospital.

Past History Several operations; appendicectomy 1934;  
Gastro jejunostomy; operations for fibroids; and transplant  
of tendons in left foot for drop foot.

Examination: General appearance; Well nourished, healthy looking, middle aged woman. Not shocked or in obvious pain.

Lower limbs: There is no obvious deformity of the legs.  
The patient is lying with the left heel on top of the right foot which is supporting it, as she says that this position is the most comfortable.

Left Leg: No external rotation or shortening. The patient can move the left hip through a considerable range of movement, the movements only being limited by pain.  
There are no other signs of injury.

Cardiovascular System: Pulse 80/min. regular in time and force  
Vessel wall not palpable. Apex beat 5th space, inside  
midclavicular line. Heart sounds closed in all areas.

Tongue: Clean and moist. Teeth: false.

Abdomen: Upper right paramedian gridiron, and lower central  
scar. Otherwise nothing abnormal.

Respiratory System; Both sides of chest move well and equally  
Breath sounds vesicular. No accompaniments.

Central Nervous System: N.A.D.

X-Ray: Left femur: Impacted abduction sub-capital fracture  
of the neck of the femur.

GEDDES, Chrissie, (cont.).

Progress:

- 1.11.48. Admitted.  
Treated with rest in bed. Allowed to move limb as she wishes
- 3.11.48. Condition satisfactory. Still considerable discomfort from her leg
- 5.11.48. Moving leg well. Very little pain.
- 6.11.48. Discharged home.
- 4.12.48. Movements free except some limitation of extreme flexion and lateral rotation.  
Painfree, except after movement on and off trolley this morning.  
To begin weight bearing.
- 8.1.49. Walking well. Movement free, satisfactory. Some pain on passive external rotation. X-ray: position satisfactory, union progressing. To report in two months time.
- 22.2.49. Complaining of pain in the left hip on external rotation, and pain shooting down front of the thigh to knee and then to front of leg when lying on the left side. Hip appears to lock after sitting for a time.  
Hip: full flexion, extension with external rotation limited by 10 degrees by pain. X-ray of hip.
- X-ray Report: fracture has probably united with slight varus deformity, and slight lipping of articular surface of the margin of the head of femur.
- 9.4.49. Pain in front of hip joint, radiating to the inside of the knee. Movements normal. Refer physiotherapy: exercises and short wave diathermy.
- 18.6.49. Pain as before. Movements normal. Discontinue physiotherapy.
- 13.7.49. Adduction, abduction, rotation limited. Flexion is free to about 90 degrees. X-Ray indicates aseptic necrosis of the head of the femur with some osteoarthritis. Rest advised.
- 31.8.49. Flexion 90 degrees. Rotation 30 degrees. Total abduction 30 deg. Adduction 20 degrees.
- 9.9.49. Mr. Jack considered, that, in view of the fact that a progressive arthritis seemed certain, a fusion of the hip would ultimately be the best line of treatment, and in the meantime fitted her with a weight bearing caliper.
- 11.11.49. Much less pain with caliper.
- 4.2.50. She is still comfortable in her caliper.  
X-ray shows definite crushing is occurring in the head of femur.

SUMMARY.

Miss Geddes, 54, fractured her left neck of femur in November 1948. Since the fracture was an impacted abduction type, she was allowed up in five weeks and she felt well. She began getting pain radiating to knee and ankle from the hip about Feb. 1949. Retrospectively, the X-rays begin to show signs of avascular necrosis in January and February 1949.

COMMENTARY.

Importance of Avascular Necrosis of the head of the Femur.

All fractures are liable to the complication of avascular necrosis with extension of disability from months to years, permanent disability replacing recovery. Complete loss of blood supply of one fragment is no barrier to sound union, if immobility is sustained, and repair allowed its own time to effect its purpose.

But if the fragment should carry with it, articular cartilage, the

outlook is changed. Repair can now be nothing but hopelessly imperfect, because articular cartilage suffers permanent damage and is replaced by fibrous tissue, and fibro-cartilage; the joint space narrows, movement is restricted, and even in the absence of weight bearing, degenerative arthritis takes place. The joint contours become irregular, because the newly formed bone is soft and easily distorted and therefore collapse easily occurs.

#### Blood Supply of the Femoral Head.

The upper end of the femur derives its blood supply from three sources, the nutrient artery of the shaft, the retinacular vessels of the capsule, and the vessels of the ligamentum teres, the foveolar artery.

The nutrient artery enters the mid shaft of the femur and runs up in the medullary cavity, anastomosing with cervical branches of the retinacular arteries. These vessels do not appear to cross the epiphyseal plate in children, though they may well do in adults.

The retinacular vessels arise from the medial and lateral circumflex. There is an extra-capsular anastomosis in the region of the trochanteric fossa, to which the inferior gluteal, profunda, obturator and circumflex contribute. The retinacular vessels consist of three groups, the posterior superior, the posterior inferior, and anterior groups. These vessels are the chief supply to the epiphysis and femoral head at all ages. The posterior superior and inferior groups are branches of the medial circumflex, and run along the upper and lower border of the neck. If the head is looked at from its medial aspect, the superior group are found between 11 and 2 o'clock, and the inferior group between 5 and 7 o'clock. The posterior group may be the sole supply to the epiphysis.

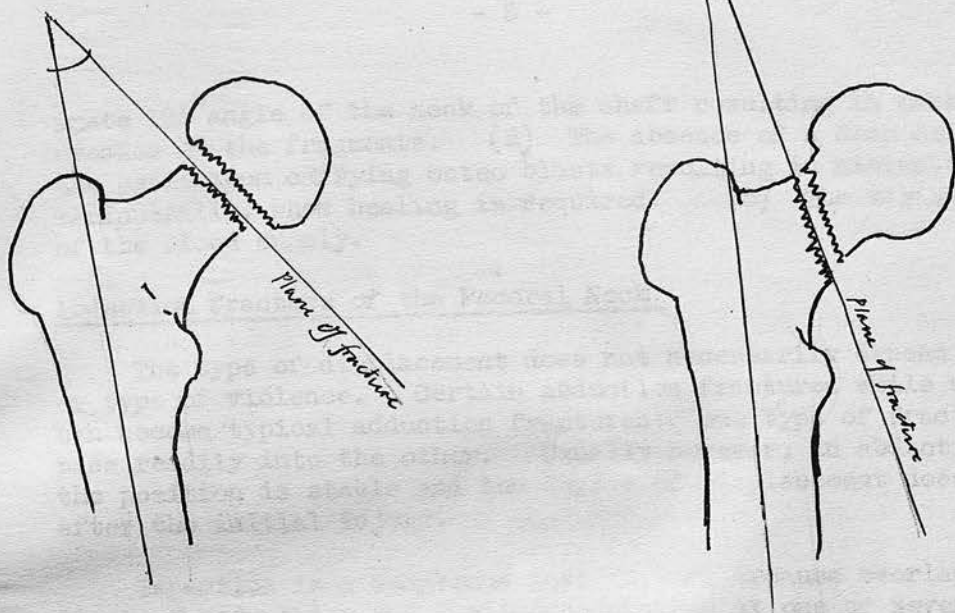
The anterior group are variable and do not contribute a large supply. These vessels lie loosely concealed under the synovial membrane, sometimes in "mesenteric like folds" of synovial membrane.

Despite their attachments, the branches in the mid-cervical parts of the retinacular vessels are quite mobile, in contrast to the fixity, which may be noticed as they approach the articular cartilage. The superior group do not pierce the epiphyseal cartilage, but cross the plate at its periphery, and turn towards the centre of the head, anastomosing with the other retinacular branches and with the nutrient and foveal vessels.

The foveal artery arises from the obturator, or the medial circumflex femoral or from both. It passes into the acetabulum under the transverse ligament and runs along the ligament to the head. The size of this vessel seems to vary enormously. In children, the foveal supply appears to concern itself only with the fibrous tissue and cartilage, and not with the head. In the adult they pierce and penetrate the head and they are of greater calibre.

#### Fracture of the Neck of the Femur and consequent blood supply to the head.

In the adult the united epiphysis generally receives additional nourishment since the foveolar vessels increase in size and capability. When the neck of the femur is fractured, the fate of the head must depend upon the residual vascularity, which is decided at the moment of maximum displacement, which is not necessarily at the time of injury. The vessels running within the bone are divided, and therefore the head relies on the retinacular and foveolar arteries. Displacement is to some extent dependent upon the angle of the fracture; Pridie suggests that when the "fracture-shaft" angle is greater than  $37^{\circ}$ - $40^{\circ}$  displacement is insufficient to cause disruption of the retinacular vessels, but when it is less than this, then rupture may lead to necrosis of the head because there is a variable foveolar supply to the head in some 70% of cases.



### Pindie's Fracture-shaft angle

#### Pathological and X-Ray Changes.

The entire head, including the cortex, trabeculae and marrow generally becomes necrotic with the exception of the articular cartilage which may rarely survive. Since the necrotic head without blood supply cannot participate in the disease decalcification of adjacent bone, it will retain its original density, and cast a shadow of greater intensity in the X-ray than the surrounding living bone.

Three to four months are required for sufficient atrophy to take place before this contrast is distinguishable radiographically. If, however, there is early walking, there is insufficient time for density differences to develop, and the complication temporarily goes unrecognised. The patient resumes full activity, and bears weight on the devitalised head, until late changes, due to collapse, or degenerative arthritis, cause the return of pain. This is usually the first clinical indication that epiphyseal necrosis has followed. X-rays will now show late evidence of necrosis, in the form of progressive replacement of avascular dense bone by less dense irregular living bone, and alterations in the shape of the head following collapse and possibly signs of arthritis. Creeping replacement of the dead portion of bone by living bone may gradually progress, and in from 1 - 3 years it may be complete. If the new bone does not reach the under surface of the articular cartilage within several months, it becomes necrotic, and is subsequently invaded, and replaced by fibrous tissue, fibro cartilage or even bone. The invasion of the head by this highly vascularised connective tissue, is followed by absorption of dead bone and marrow, with replacement by living bone through the process of "creeping substitution."

In the area of transformed bone the trabeculae are irregularly arranged, and less dense than the adjacent unreplaced dead bone. All osseous elements may however be replaced by fibrous tissue, producing cyst like zones of reduced density in the X-ray. When the transformation approaches the peripheral portions of the epiphysis, the bony articular cortex becomes absorbed, along with subcortical bone. Articular cartilage obtains part of its nutrition from synovial fluid, and its chances of survival are therefore enhanced, if there is a rapid revascularisation of the underlying bone. If cartilage necrosis occurs, there is over growth by fibrous tissue, and fibro-cartilage, and osteo-arthritis becomes apparent by villous synovitis, acetabular sclerosis, marginal osteophytes and even loose bodies in the joint. Necrotic heads that have been completely replaced by new bone may be extremely porous with irregular articular surfaces, and are usually bound to the acetabulum by extensive adhesions. They may be recognised in X-rays by this porous nature and blurred uneven shadows of the articular cortex. The peculiarities of structure of the neck which make for frequency of avascular necrosis are (1) The approx-

imate 125° angle of the neck of the shaft resulting in marked shearing and erosion of the fragments. (2) The absence of a deep cellular layer to the periosteum carrying osteo blasts, resulting in minimal callus formation peripherally, when healing is required. (3) The variable arrangement of the blood supply.

#### Abduction fracture of the Femoral Neck.

The type of displacement does not necessarily depend on the direction or type of violence. Certain abduction fractures while under observation can become typical adduction fractures; one type of fracture can probably pass readily into the other. Usually however, in abduction fractures, the position is stable and the degree of displacement does not increase after the initial injury.

Impaction is a dangerous word to use, because overlapping of shadows, in the X-ray plate, may indicate impaction at one or several places. In general such an appearance indicates no more than close contact between the fragments, with limited breaking of bone tissue in one region. There is much to be said in favour of the assumption, that impaction, in the sense of interlocking of the fragments, does not exist, for after all an "impacted" fracture, may easily be displaced by the simple process of inserting a three flanged nail which is presumably of less consequence than continued weight bearing with its shearing force. It is too often believed that because a patient may actively move his or her leg without pain or even walk on it, that there is impaction, but the explanation may well be that displacement is not yet sufficient to cause a loss of stability. The assumption of impaction depends usually on close contact between the fragments, a moderate compression of bone and a reasonable stability, but these do depend essentially on the fact that the degree of displacement was limited by the resistance of bone, in relation to the degree of injury. It is a dangerous thing to assume that an impacted fracture differs from all others for it is sustained like any other fracture, the only apparent difference being that there is some degree of initial stability. Such an impacted fracture may be, after all, no more than the first stage in a movement, which, if continued, will give rise to greater displacement and injury. The criterion of impaction is often based on a belief that because the head moves with the shaft, contact indeed must be close. But limitation of displacement near the end of a long bone, such as the femur, is often due to the mobility of the adjacent joint, coupled with the fact that there is no long lever proximally, and within limits, the articular fragment can follow movements of the longer fragment.

Speed holds that if the impacted fracture is at an angle less than the normal angle of the neck, it may be expected that the impaction will be broken up by attempted use or manipulations and the usual displacements will result. Weight bearing and movement existing at the head from the moment of reduction, or continuous on the active process of attempted bone healing, is the one factor which seems understandable as leading to delayed union, or aseptic necrosis of the head.

MacAusland thinks that the impacted fracture is either one of the incomplete variety, or a complete fracture, in which, because of the good preservation of the capsule and periosteum, only slight deformity is present, and power of movement retained.

The successful treatment of "impacted abduction" fractures, by free movement from the start, is successful probably because the fracture is incomplete. In an impacted subcapital high cervical fracture, the head may have as its only blood supply the foveal artery, until the injured vessels at the site of impaction have become re-established. This would seem to make the impacted subcapital fracture prone to non-union and necrosis, but in any statistics produced, this does not seem to be wholly the case, and the reason may be that under this term are included incomplete fractures which appear to be impacted, and therefore to treat every such fracture with early weight bearing does not seem justified.

Consideration of this case. (See over).

### Consideration of this Case.

Despite the anatomical and other factors already described, which might contribute to avascular necrosis, it is rare to see it develop in the complete absence of any manipulation or surgical intervention. Children are more likely to develop such a complication because of the peculiarity of the foveal supply, and possibly because of the greater physiological need for blood in the growing bone.

One may safely infer that in this case the foveal vessels have been damaged, as the necrosis seems to centre around the area which its vessels supply.

The X-rays indicate the progressive nature of this lesion. Although the head may spontaneously revascularise, instead of collapsing further, the time has now long passed when any hope could be held out for the articular cartilage, which will be irreversibly changed, with osteoarthritis and inevitable pain as its sequelae, and therefore fixation is obviously indicated.

### Treatment.

It might seem reasonable to save the head, if bony union could be obtained. The only way in which the surgeon may help to restore the circulation is by an operation which results in bony union; the untransformed head may then be invaded by blood vessels or by fibrous tissue which crosses the fracture, and transformation may then proceed. If replacement should come about with little or no collapse, the functional result might be reasonable if arthritis is not too severe. It has been claimed that a bone graft across the fracture line serves to conduct blood vessels from the distal fragment into the dead head, but since the graft is compact bone, the number of vessels reaching the head by growth through it, must be infinitesimal, as compared with those growing directly across the fracture bone. Its use must lie in its fixation of the fragments and as a bridge for new bone. But where the head is really avascular, no type of grafting or nailing can be justified.

If a hip joint is soundly fixed in the position of function a very minor disability is brought about, and to compete with it any form of arthroplasty must indeed be perfect functionally. No form of activity need be barred to those with well ankylosed hips. The optimum position is one of neutral rotation with no abduction, adduction or flexion deformity. To attain this a three flanged Smith-Peterson nail is used, in order to obtain bony union between the pelvis or femur, by driving the nail through the femur into the pelvis and securing the nail by a cross pin. Denuding the articular cartilage alone without nail fixation is probably of not much use, because it will be at least a year to two years, before the new blood supply can reach the regenerated head, and consolidate the arthrodesis by new bone formation.

### Summary.

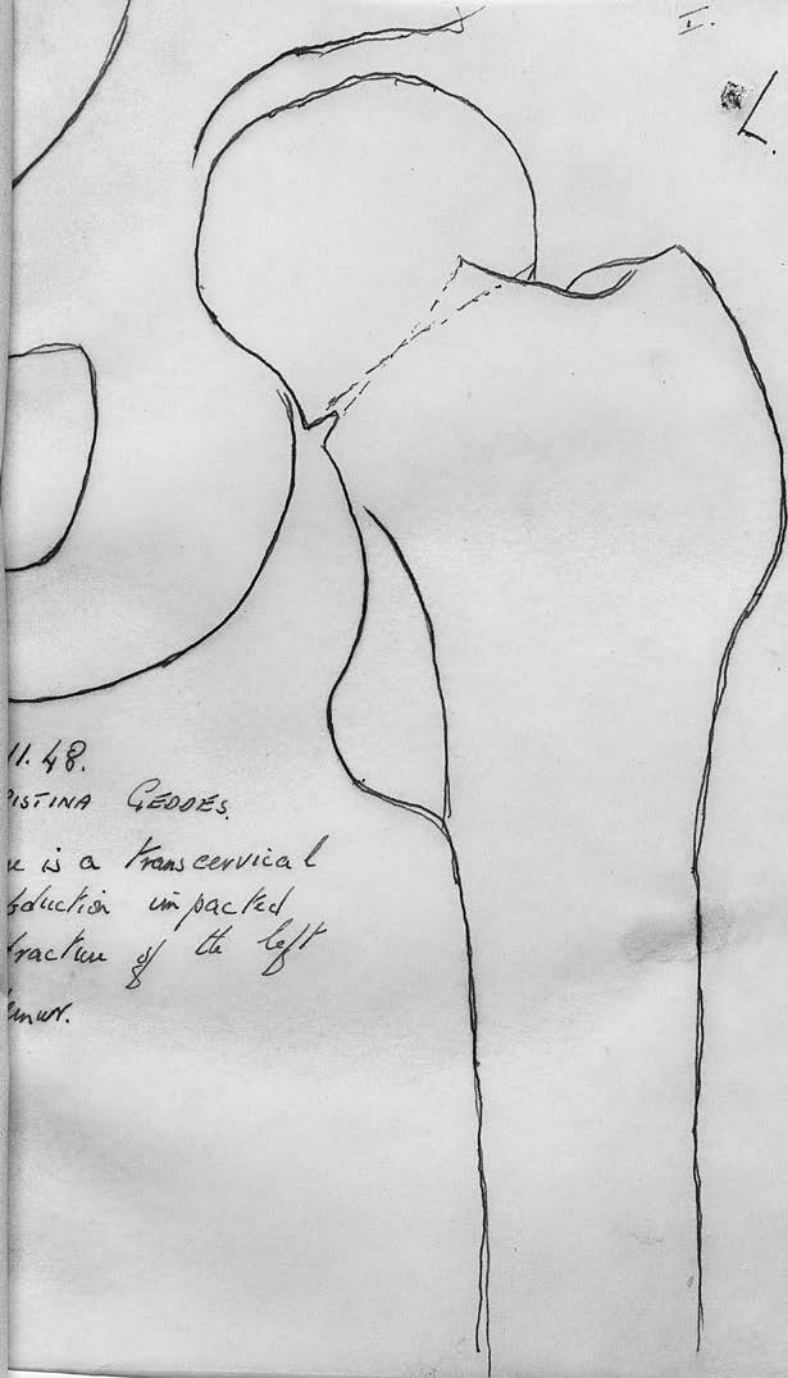
An unusual case of avascular necrosis of the head of the femur following an abduction impacted cervical fracture is described; it is unusual, because it followed no manipulation, or interference, which might have injured the blood supply.

The importance of the condition, the pathological and X-ray appearance, and the blood supply of the head, are outlined, and a query made as to the advisability of treating abducted impacted fractures in the classical manner with early weight bearing and movement.

By Permission of Mr. Jack, F.R.C.S.

### References.

- BANKS. Journal Bone and Joint Surgery. 23, 753. 1941.  
BAILEY. Lancet. 1, 980. 1939.



11. 48.

JUSTINA CEDDES.


is a trans cervical  
fracture impacted  
fracture of the left  
humerus.

BRILLSFORD.	Journal Bone and Joint Surgery.	25, 249.	1938.
BRACKETT.	" " " " "	20, 93.	1938.
CHRISTOPHER.	" " " " "	22, 161.	1940.
COLONNA.	" " " " "	17, 110.	1935.
EVANS.	" " " " "	190, 31B.	1949.
LORENZ.	N.Y. Med. J.	27, 130.	1923.
LINTON.	Journal Bone and Joint Surgery	31B, 184.	1949.
McMURAY.	" " " " "	18, 319.	1936.
MACAUSLAND.	Surg. Gyn. Obst.	58, 679.	1934.
PHEMLSTER.	Journal Bone and Joint Surgery	12, 769.	1930.
PHEMLSTER	Arch. Surg.	41, 1455.	1940.
PHEMLSTER.	Journal Bone and Joint Surgery	21, 681.	1937.
PRIDIE	Brit. Journ. Surg.	29, 115.	1941.
SANTOS.	Arch. Surg.	21, 470.	1930.
SEDDON.	Royal Soc. Med.	30, 210.	1936.
SPEED.	Annals of Surgery.	89, 270.	1924.
TUCKER.	Journal Bone and Joint Surgery	82,	1949.
WATSON-JONES.	Journal Am. Med. Ass.	110, 278.	1938.

U.

R

L.



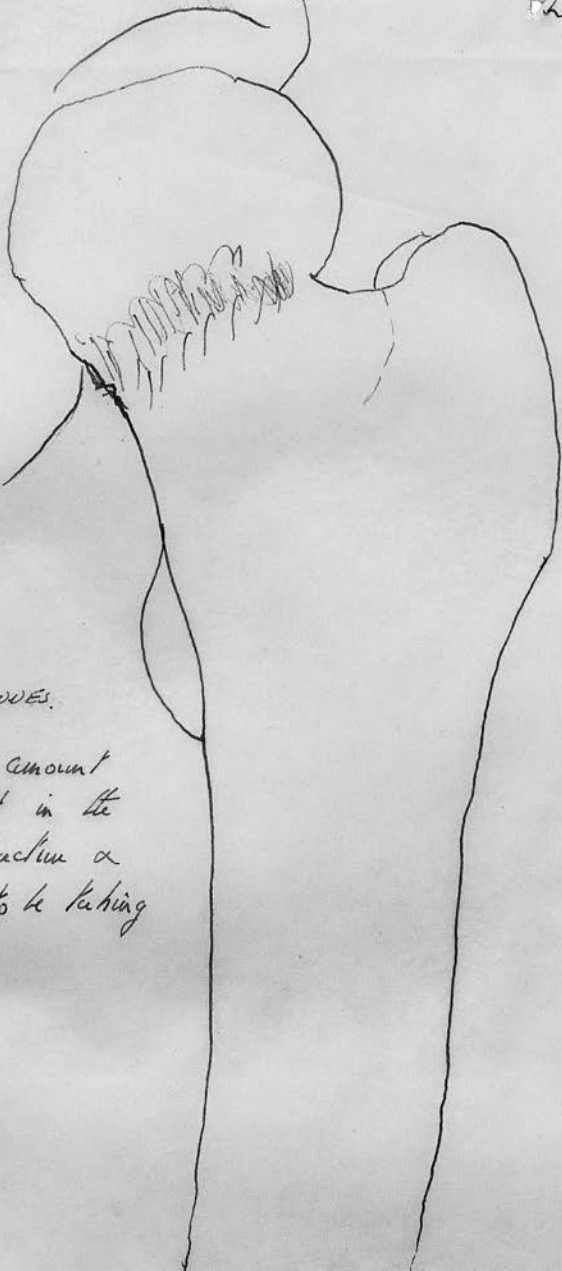RISTINA GEDDES.

FRUIT. ~~Fig. 4~~ 4.12.48.

which appears to be  
a young plant.

ut.

ch.



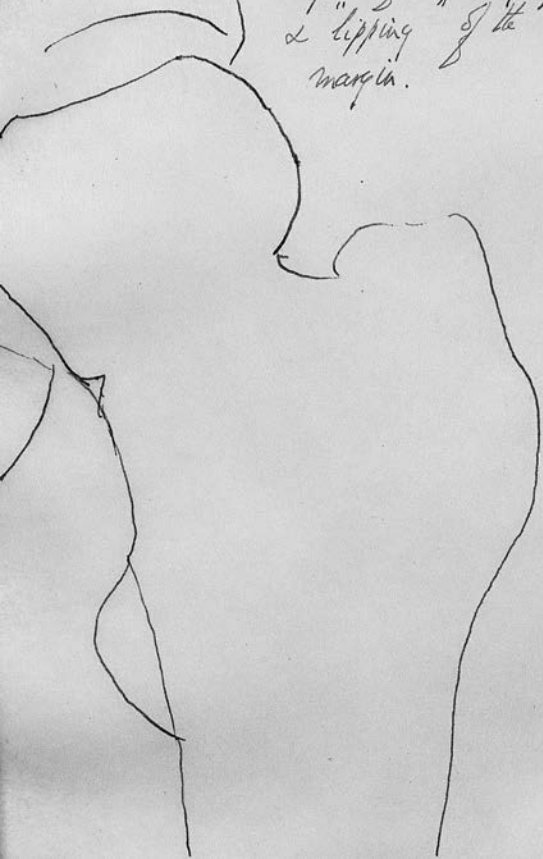INA. GEWES.

is a fair amount  
present in the  
of the fracture &  
seems to be taking

CHRISTINA GEDDES.

26.2.49.

The fracture has united with some  
varus deformity. There is  
slight flattening of the head  
& "beaking" of the articular  
margin.



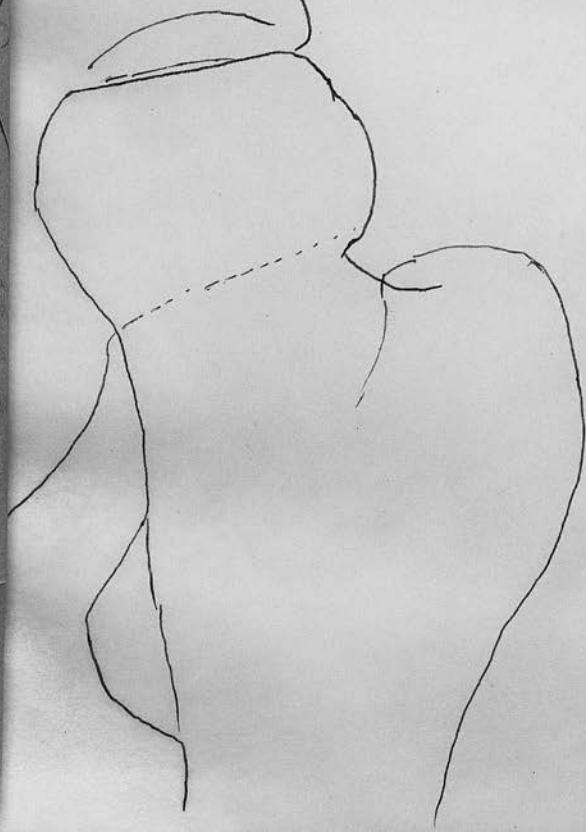
I.

CHRISTINA GEDDES

16.5.49.

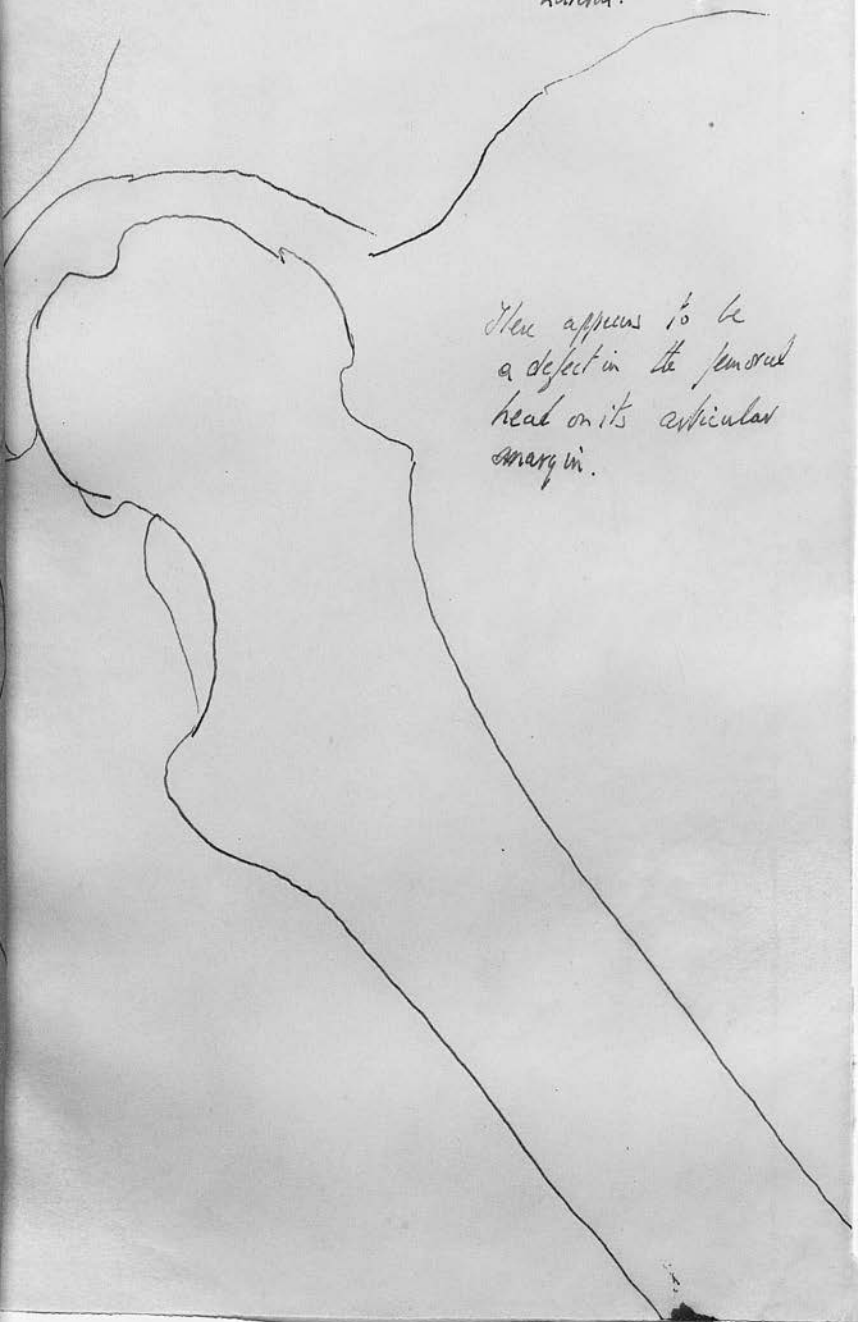
The fracture line is still  
just visible.

The flattening of the head  
is more marked. The  
head is relatively more radio-  
opaque than the right femur




CHRISTINA GEDDES.

VI.  
13. Y. 49.  
lateral.



There appears to be  
a defect in the femoral  
head on its articular  
margin.



articular line is no longer seen.  
 is deformity of the femoral head  
 slight flattening; the trabeculae are  
 present, but there appears to be an  
 amount of relative sclerosis in the femoral  
 head.

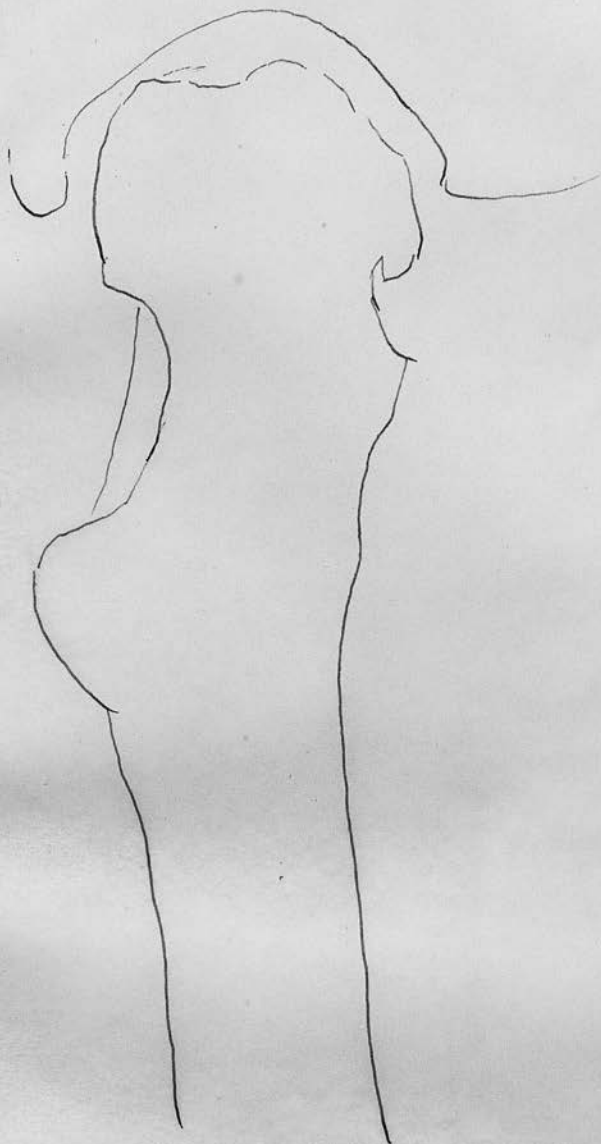
CHRISTINA GEODES.

31.8.49.

VIII.

LATERAL.

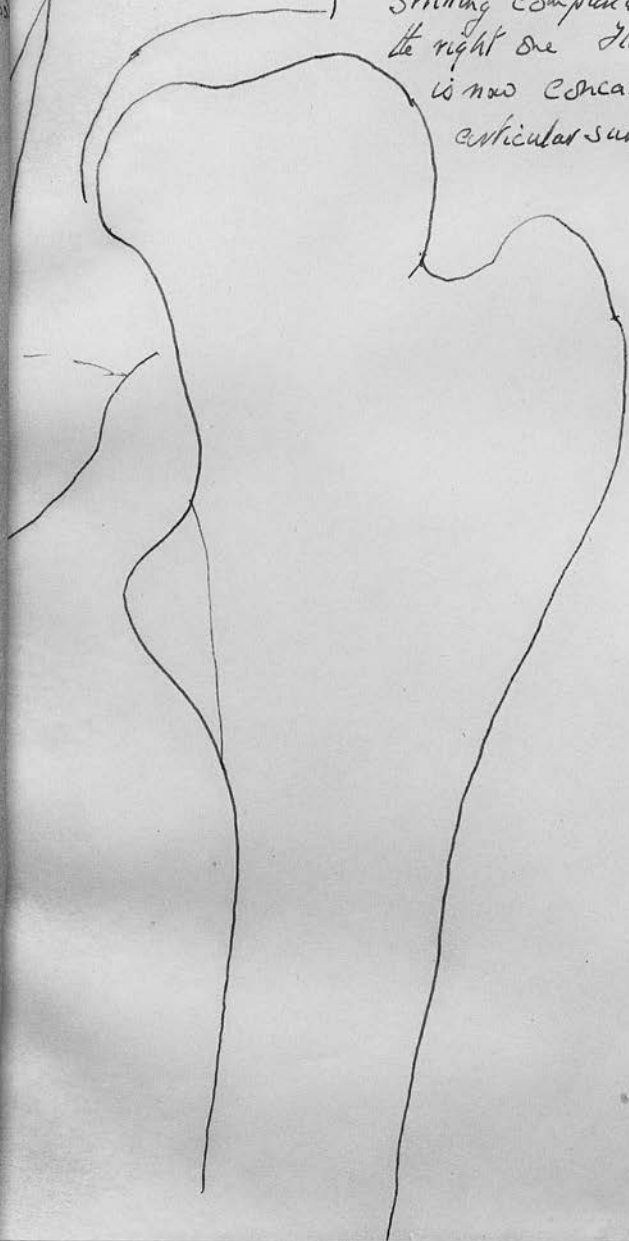
is destruction of the articular surface  
clear trabecula markings subcondally.



CHRISTINA GEDDES.

31.8.49. 14.

The haziness in the left  
femoral head is very  
striking compared with  
the right one. The head  
is now concave on its  
articular surface.




CHRISTINA GEDDES. X.

8.2.50.

LATERAL.

There is deformity of  
the head of the femur  
& the sclerosis is very  
marked in the hatched  
area.




CHRISTINA GEWES.

XI.

4.2.50.

There is flattening deformity of  
the head of the femur &  
patchy sclerosis in the hatched  
area particularly.



SURGICAL CASE REPORT.P.M.R.

Name: Hamilton, David.

Age: Born 24.3.38.

Address: [REDACTED]

Doctor: Dr. McCutcheon, Midcaldor.

Sponsor: West Lothian.

Admitted: 14.11.47.

Discharged:

Diagnosis: Perthes' Disease, right hip.

Previous Illnesses: Measles, Whooping-cough, chicken-pox, (Has been inoculated against: diphtheria and vaccinated.)

History: In May of this year, this boy's parents noticed that he was slightly lame on the right side. He was seen by Mr. Stirling at the Royal Infirmary on 12.5.47, when Perthes' Disease was diagnosed and the parents were recommended to keep him at rest as much as possible. It was impossible to keep the boy resting at home, however, so he was allowed back to school, but his name was placed on the waiting list for P.M.R. Owing to the difficulty of keeping him immobilised, he was brought up here a week ago and encased in a plaster-shell.

General health. The father states that the child's health has been good on the whole, but at the age of 5 he was admitted to R.H.S.C. with what was thought to be meningitis, but turned out to be a severe chill. Since that time, whenever the boy "takes a chill" he becomes highly feverish and delirious!

Family History: One brother aged 14 is healthy.

14.11.47. Plaster bivalved, and X-rays taken out of plaster.

17.11.47. "This boy can now go up on leg traction, and have a new hip-spica fitted this week. "

22.12.47. This boy is continuing his immobilisation in plaster-spica and extension and his condition is satisfactory. Mr. Stirling states that he expects a good result as the head of the femur has not been grossly malformed.

2.2.48. Recently this boy's skin has shown signs of breaking down under the skin traction. It appears, however, to be an allergy to the skin adhesive. This was removed, and the skin treated but, on re-application of plaster, his skin broke down again. Webbing traction was then instituted and his skin has progressed satisfactorily since then. He was seen by Mr. Stirling, who was satisfied with the X-rays but wishes to see his routine X-rays in a fortnight's time.

9.2.48. Fresh X-rays of the right hip seen by Mr. Stirling. He is quite satisfied with the progress there, and wishes treatment to continue as at present.

26.2.48. Progress report sent to doctor.

1.3.48. Patch test carried out on this boy's skin this last week showed an idiosyncrasy to all types of adhesive plaster.

He was seen by Mr. Stirling, who discussed the question of this traction, which is at present being maintained by means of webbing.

- 8.3.48. This boy's traction is still being maintained by means of webbing extensions. He was seen to-day by Mr. Stirling, who considers that he should be maintained as he is, until that time.
- 29.3.48. Skin remains fairly healthy beneath Mastosol extensions.
- 19.4.48. X-rays of hips show that the disease is still active and that there is considerable flattening of the head due to the osteoid tissue in its centre.
- 24.5.48. This patient has developed a sore due to the pressure on the lower end of the circular bandages retaining the extension apparatus on his leg. Extensions to be re-applied, however, above this and dressings to be carried out.
- 31.5.48. Extensions to be re-applied, and the sore which was reported last week has now almost healed.
- 26.7.48. Seen to-day, when X-ray appearances showed that the disease was still active, and it was recommended that he should have a complete blood examination. There is an increase of the joint-space as compared with the last film, and it is thought that he should have a Collodion splint applied in order that the traction may remain fixed.
- 3.8.48. On examining recent X-rays it was seen that there was some sub-metaphyseal absorption and it was decided to try and fix the extensions with Hussner's glue.
- 23.8.48. This boy's leg was examined to-day and it was seen that previous forms of applying traction had proved unsuccessful and the skin was badly marked. It has now been decided to try a Sinclair's skate on an abduction frame.
- 15.11.48. Progress satisfactory. To continue as at present.
- 3.1.49. Condition fairly satisfactory. Traction is at present being maintained by means of a clubfoot shoe as it was found impossible to keep the Sinclair Skate in position. It was suggested that his blood calcium level should be ascertained as any abnormality in it might have some bearing on his skin sensitivity.
- 8.1.49. Seen by Dr. Peterkin who instituted treatment with Ung. Hydrarg. Amon. for his skin condition.
- 14.1.49. Skin shows signs of some improvement.
- 14.2.49. Blood examination. Calcium - 10.2 mg%
- 18.3.49. To continue with skin extension and weights.
- 24.3.49. Jones abduction frame fitted. Continuing with weights. X-rays show improvement in the condition of the hip.
- 24.4.49. Continuing.
- 2.5.49. X-rays show some improvement. To continue.
- 6.6.49. X-rays show considerable improvement.

- 10.7.49. The extension strapping on this boy's legs are causing skin irritation, so they have been removed. He will have to lie on his frame without extension until the skin improves.
- 18.7.49. X-rays show continued improvement of the head of the right femur, which has retained a very good shape. He is to continue lying on his frame.
- 28.8.49. Patient is comfortable in his frame.
- 22.8.49. This boy is comfortable on his frame. Extension has not been re-applied because every time it is put on he gets a skin irritation which takes some weeks to clear up.
- 9.9.49. No change to report. Patient remains comfortable.
- 10.10.49. Patient comfortable.
- 21.11.49. This boy has been put up again in traction on a frame.
- 9.1.50. X-rays seen by Mr. Stirling, who recommended that he be left for a further period of 3 months, as the radiological appearance is not yet quite normal.
- 30.1.50. Remains comfortable.
- 18.2.50. Comfortable.

#### Commentary.

Perthes Disease. (Osteochondritis Deformans Coxae Juvenalis; Coxa Plana; Pseudo-Coxalgia; Legg-Calve-Perthes Disease.)

This deforming condition of the femoral head, resulting from a disturbance of growth at the epiphyseal cartilage, was first described by Legg of Baltimore. The aetiology has not yet been determined. It occurs essentially in boys between 5 and 10 years, and may be bilateral in about 10% of cases.

#### Clinical Features.

1. Stage of onset. The child may begin limping, and complain of pain along the course of the obturator nerve, which is worse with activity, and there may actually be disinclination to take active exercise, or join in any forms of sport. Muscular spasm, and slight thickening of the soft tissues can be detected at this stage.
2. Active stage. This may be said to last from 3 - 18 months. Platt thinks that this stage lasts from the time of first symptoms, to the time when recovery appears clinically to have taken place. The spasm disappears slowly, but a little limitation of abduction, medial rotation and flexion remain; at first because of the spasm of the adductors and later, after its disappearance, from true shortening of these muscles. There is a little disuse atrophy to be seen, but no shortening of the limb.
3. Recovery. After any period from 1½ - 4 years, function becomes nearly normal, but trochanteric thickening, and limitation of abduction persists throughout life.

Waldenstrom considers that most cases heal with a deformity, which is only slightly troublesome, and Gill states that the end results are practically perfect hips.

#### Comparison of Perthes Disease of the hip joint and Avascular Necrosis.

There is a very close resemblance of Perthes disease of the femoral head to the epiphyseal changes seen in avascular necrosis following fracture of the neck of the femur, or dislocation of the hip, and some authorities have assumed that

Perthes disease is a simple avascular necrosis due to concealed injury, and thrombosis of the vessels of the ligamentum teres or capsule. Watson Jones believes that rupture of the capsular vessels is the pathology of degenerative arthritis after traumatic dislocation, after fracture, after epiphyseal displacement and of Legg-Perthes disease, and probably of many cases of mono-articular degenerative arthritis of the hip joint. He further claims that Perthes disease is not a hypothetical osteochondritis, but an avascular necrosis of the upper femoral epiphysis, due to fracture of the femoral neck in children, traumatic dislocation, operative reduction of congenital dislocation, any capsular injury, thrombosis or embolism. He concludes that osteo-arthritis of the hip joint is the adult form of Legg-Perthes disease, and each is an avascular necrosis, due to obvious sources of impaired blood supply.

Brailsford maintains that the sequelae of Perthes disease, traumatic reduction of congenital hips, fractures of the neck, and displacement of the diaphysis from the capital epiphysis are not identical. They vary from complete restoration to complete destruction of the joint though avascular necrosis may arise in any of these conditions.

It has been said by Watson-Jones that if the avascular fragment carries with it the articular cartilage of the joint, then the whole outlook is changed; replacement of this hyaline cartilage with fibrous tissue, or with imperfect fibro-cartilage is almost inevitable, and the survival of the joint relatively rare. This is certainly not the clinical or X-ray finding in Perthes disease. The characteristic feature of the carefully treated case, is the absence of change in the articular surface, and a return to normal function. In Perthes disease the appearance of fragmentation is seen in the destructive phase whereas in the case of surgical trauma it occurs in the regenerative phase; thus in the one the deformity occurs during disintegration, in the other during re-organisation. Trauma shows rapid changes usually, and may be associated with real damage to the growth cartilage, a feature which is absent from Perthes disease. It cannot be said that Perthes disease is the juvenile form of avascular necrosis, because avascular necrosis frequently follows a fracture of the femoral neck in children and the picture is dis-similar.

Banks holds that, in traumatic dislocations of the hip in children, with death of the femoral head, the X-ray appearances are somewhat similar to those in Perthes disease, and the immediate end results equally satisfactory. When the femoral head in older children becomes necrotic the pathological alterations are similar to those seen in adults, and the results are equally poor. This appears to be true whether the primary condition is a traumatic dislocation, a fracture of the neck, or a slipping of the upper femoral epiphysis.

#### The Role of trauma and other hip conditions in Perthes disease.

Trauma has always been invoked as an aetiological agent in cases of Perthes disease. Cases have been described following congenital, and traumatic dislocated hips, coxa vara of a rickety, infantile or epiphyseal type, and in arthritic conditions of the hip such as tuberculosis. The uncertainty of such a factor as trauma in the aetiology is shown by the fact that it is variously estimated of being of importance in from 14 - 50% of cases, perhaps because the time interval between obvious injury and onset of symptoms varies greatly. It seems clear however that about 75% of cases are boys, and this might lend support to the traumatic theory. There must be few boys however, if closely enough questioned, cannot give some account of a trivial injury to the hips within the last 12 months. Some cases reported as Perthes disease following definite severe injury have been reported; but the fact that they may have been co-incidental cannot be over looked. Sundt in 1920 reported two cases of traumatic subluxation followed by typical Perthes disease some 3 and 9 months later. In 1919 Elmslie reported an identical case and so have Rehbein and Nicolaysen.

Goldenberg holds that the number of instances in which clinical and X-ray evidence of Perthes disease becomes manifest in hips following upon severe trauma indicates a more than casual relationship between the trauma and subsequent development of Perthes disease. If injury is the cause of Perthes disease, vulnerability of the epiphysis to infarction will be greatest when the blood supply is derived largely from the posterior-superior group of vessels

(as described in connection with Case IV), because this group is more susceptible to injury from pressure by the acetabular lip at its labrum in the position of forced abduction and external rotation of the hip, and it will be these children, with this pattern of supply, who will be most prone to Perthes disease. The epiphysis in the child is much more dependent upon retinacular vessels than is the corresponding area of bone in the adult, and this together with peculiarity of distribution may account for frequency of avascular necrosis and Perthes disease in the child.

#### Radiological Appearances.

In aseptic necrosis the changes consist of an increase in density, relative or real of the trabeculae; the bone texture is perfectly preserved, although the picture may become confused, by reason of secondary collapse following upon weight bearing. It is only later that the trabecular structure is lost in places by reason of the advancing areas of rarefaction, which mark the inroad of osteo-clastic and granulation tissue.

In Perthes disease on the other hand there is complete destruction of the bone texture at an early stage in the disease, and in addition there is lysis of trabeculae, apart from mere cell death, and Jackson Burrows claims that this destruction precedes the invasion of young phagocytes and reparative tissue. Taking the changes chronologically as seen by X-ray the sequence is first a slight globular swelling of the capsule which results in an enlarged joint space medially because of subluxation laterally. There is no change in the shape of the articular cartilage but the ossified portion of the epiphysis flattens. The epiphyseal line appears wider and is irregularly decalcified at its junction with the neck, and this change stands out well if the X-ray is slightly over-exposed.

The capital epiphysis appears irregularly dense, and enlarges so that it seems to "creep out" of the acetabulum in the direction of the greater trochanter. The head becomes wider, flatter, and thinner, and the neck thicker and shorter. Gradually over time the soft tissue swelling gradually subsides, but scarring and inelasticity develop; the epiphysis gradually recalcifies, and the bony islands coalesce, while the proximal part of the neck becomes convex and grows into the head. More gradually the decalcified areas are recalcified. Eventually normal trabeculae may be seen, but the head stays slightly mushroom shaped and does not fit the acetabular well, and so the deformity remains throughout life. The acetabulum is rarely affected; if it is, areas of condensation and zones of irregular absorption may be seen.

#### Pathological Changes.

The bony picture of Perthes disease consists of the presence of areas of gross destruction in which the trabeculae have disappeared and only debris remains. The bone is not only dead, it is decayed. The changes are most commonly seen subchondrally. Eventually young connective tissue invades the necrosed areas, and tends to lay down osteoid tissue and cartilage. These changes may be summarised as:

- (1) Necrosis of a special kind with trabecular lysis.
- (2) Invasion by young connective tissue resulting in (a) phagocytosis.  
(b) regeneration.

Besides the bone changes and usually before them, is soft tissue involvement, of the synovial membrane, the capsule and the periosteum. The tissues become swollen, oedematous and hyperaemic. There is microscopic oedema, hypervascularity and synovial thickening. Perivascular lymphocytic and plasma cell infiltration is usual. The increase vascularity causes decalcification and softening of the distal side of the disc. Dense areas appear in the head due to condensation, or increased calcification, which is later invaded, as described, by granulations, which tend to absorb them.

#### Osteochondritis.

This term is now held to include all manner of diseases which are also described as epiphysitis, but the term osteochondritis juvenalis. refers specifically to coxapiana, or Perthes disease and should therefore be reserved for similar conditions elsewhere, ONLY if there is reasonable evidence for relationship both histiologically and radiologically.

These diseases include, Freiberg's disease of the metatarsal, Kohlers

disease of the navicular, Keinboch's disease of the scaphoid, Panner's disease of the capitulum of humerus, Osgood-Schlatter's disease of the tibial tubercle, Sever's disease of the calcaneus, Larsen-Jansen's disease of the patella, and Scheuermann's disease of the vertebral epiphyses.

Nearly all of these "diseases" can occur following a clear history of trauma; the lesions always occur in those parts of the joints, knee, elbow or ankle which are in fact most susceptible to injury or where true fractures of the joint are often seen, and it is therefore tempting to decide that these are all after all, cases of avascular necrosis, but where multiple lesions of this nature are found, it is hard to believe that there is not a general factor, and it is to be remembered that Perthes disease itself occurs in both hips in 10% of cases which is significant in this respect. Many of the so called osteochondritic conditions fundamentally may be in reality, avascular necrosis following upon a vascular disturbance due to any one of several causes.

Possible Causes of difference between osteochondritis and aseptic necrosis.

(1) Anatomical differences of epiphysis in the child and the bony centre in the adult. This does not account for the fact that when true aseptic necrosis does occur in the child it is pathologically and radiographically dis-similar to Perthes disease, and similar to the same condition in the adult, except that there is a better end result explainable by the greater healing powers of the child.

(2) A gradual diminution in the blood supply to the epiphysis, as contrasted with a swift cutting off in avascular necrosis, whereby the epiphyseal cartilage would become more susceptible to any possible trauma. This does not seem likely, for one would have to postulate a reason for gradual diminution; the pathological picture does not fit in either, for the tissue is not struggling to live; it has decayed. Experiments on animals suggest that arterial anaemia is not responsible, the results of occlusion in young rabbits being merely aseptic necrosis.

(3) Haematoma within the nucleus following upon trauma. This does not explain why epiphysitis should occur rather than aseptic necrosis.

(4) It is proposed therefore that a venous obstruction may be the primary cause resulting from haemorrhage into a closed space, or from some other obstructing factor as in Scheuermann's disease which is discussed in relation to Case VI. The result is very similar to the production of a haemorrhagic infarct; there is intense venous engorgement of the venules and capillaries, many of which may rupture and produce haemorrhage. If a transient arthritis is postulated, which produces an effusion leading to venous obstruction then the similarity of changes, seen following tuberculous arthritis, and dislocations, when the changes differ from those seen in avascular necrosis, to Perthes disease may be explained. Recently it has been observed that muscle infarcts can, and do occur, not only after the artery has become blocked, as in peripheral vascular disease, and heart disease when emboli are thrown off, but also following obstruction to the venous outflow of certain muscles. If this is accepted, then one might expect to see a similar picture to Perthes disease in the adult resulting from venous obstruction, people in whom venous changes are common all over the body; this might then account for some of the cases of osteo-arthritis.

Watson Jones believes that a vulnerable blood supply to the head of the femur can explain the incidence of Perthes disease in children, and osteo-arthritis of the hip in adults when it occurs more commonly than in any other joint. There is the same mottling, irregular density and cyst-like formation with narrowing of the joint space and flattening of the head radiographically, and he decides that the most usual cause of osteo-arthritis is avascular necrosis and that the source of deprivation of blood supply can be obvious as in fractures and dislocations, or can be concealed and due to twists and strains injuring the ligamentum teres and causing thrombosis of the vessels. Although it is accepted that this may be the cause in some cases, it is proposed that venous stasis is the initiating factor in Perthes disease, and could explain the destructive elements of the disease, by reason of the increased venous pressure; the walls of the veins are injured, and fluid escapes into the surrounding tissues, causing further pressure and oedema and a vicious circle is set up resulting in arterial damage. The bone cells become degenerated and atrophic, as a result of inability to exchange their metabolites, and the phagocytes so typically seen in venous congestion elsewhere, may serve to lyse the remaining cells.

The head appears relatively radio-opaque because of the reactive hyperaemia

in the adjacent bone, and also because the venous circulation is unable to remove the calcium. The cause for the excellent result of treatment in the adolescent is their capacity for forming a collateral venous circulation in the course of time, which if collapse of the bone has been prevented will result in a reformed relatively normal head. The reason for the poor results in adults with similar conditions could perhaps be explained on the basis of their inability to reform adequate collaterals and the changes in cartilage which have been subjected already to years of trauma.

#### Treatment.

As recently as 1931 the editors of "Progress in Orthopaedic Surgery" made the following comment in relation to Perthes disease. "We question whether it is often necessary to employ immobilisation, even in the acute stages of this condition. It is often symptomless, and we do not believe there is any evidence to show that its course can be modified by treatment."

Platt concurred in this statement, when a short while after he said "There are no definite reasons for the adoption of a prolonged period of immobilisation."

There is now abundant evidence to refute these beliefs. It is known that the deformities are due to the mechanical forces of weight bearing, and muscle tension, and if these can be effectively removed, at an early stage, complete preservation of the contour of the head, with but little deformity, can be attained.

More recently drilling of the head has been carried out. It is impossible to determine the results of such treatment, unless the phase of the cycle is accurately known when the drilling is done. If the operation is done near the end of the degenerative period, it will be credited with the improvement which would have occurred in any case.

#### Summary.

A case of Legg-Perthes disease is described, and its aetiology and relationship to avascular necrosis, and other diseases described under the generic term of osteochondritis, discussed.

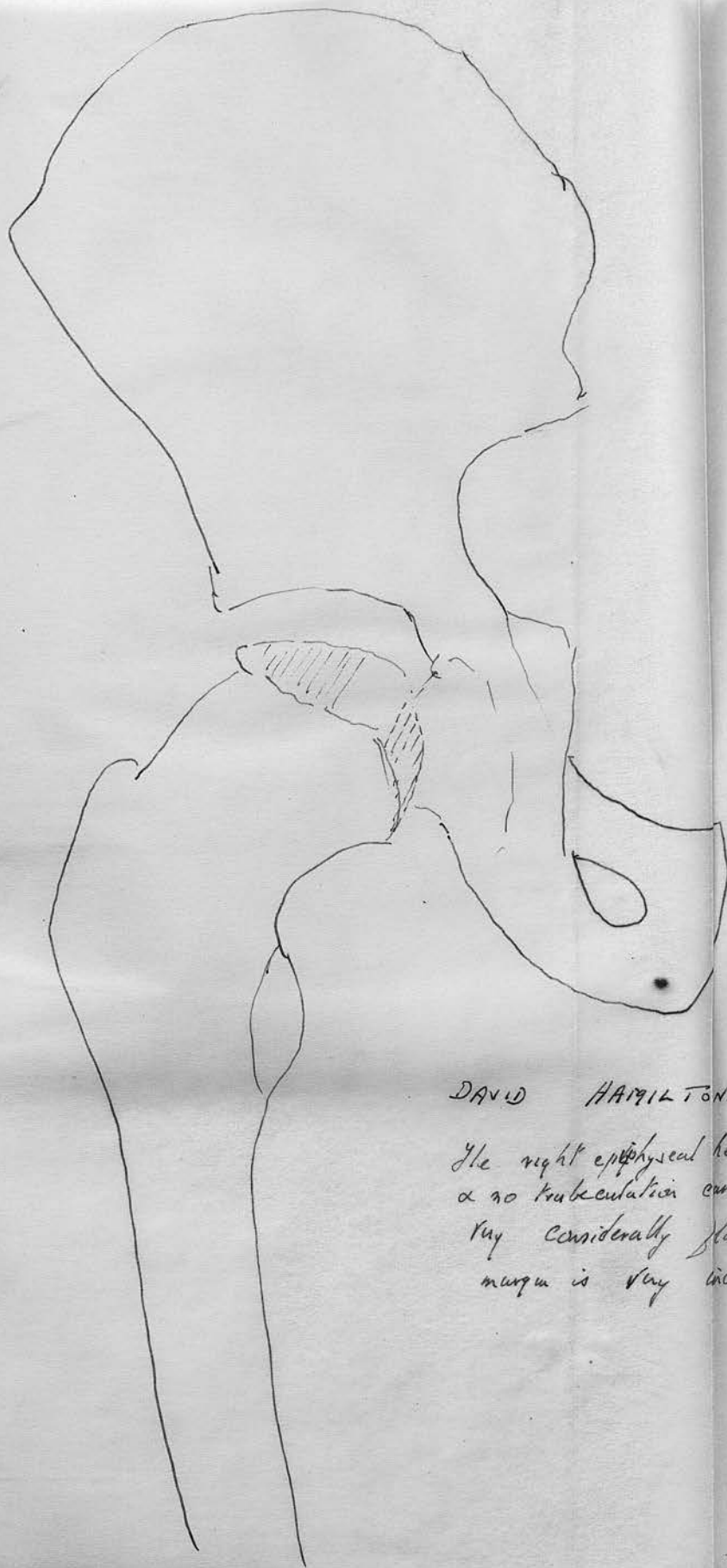
It is concluded that venous stasis could account for the initial changes seen in Perthes disease and in similar changes of the femoral head in later life, and that the aetiology and pathology of Perthes disease and avascular necrosis are not alike.

By Permission of Professor Mercer and Mr. Sutherland. F.R.C.S.

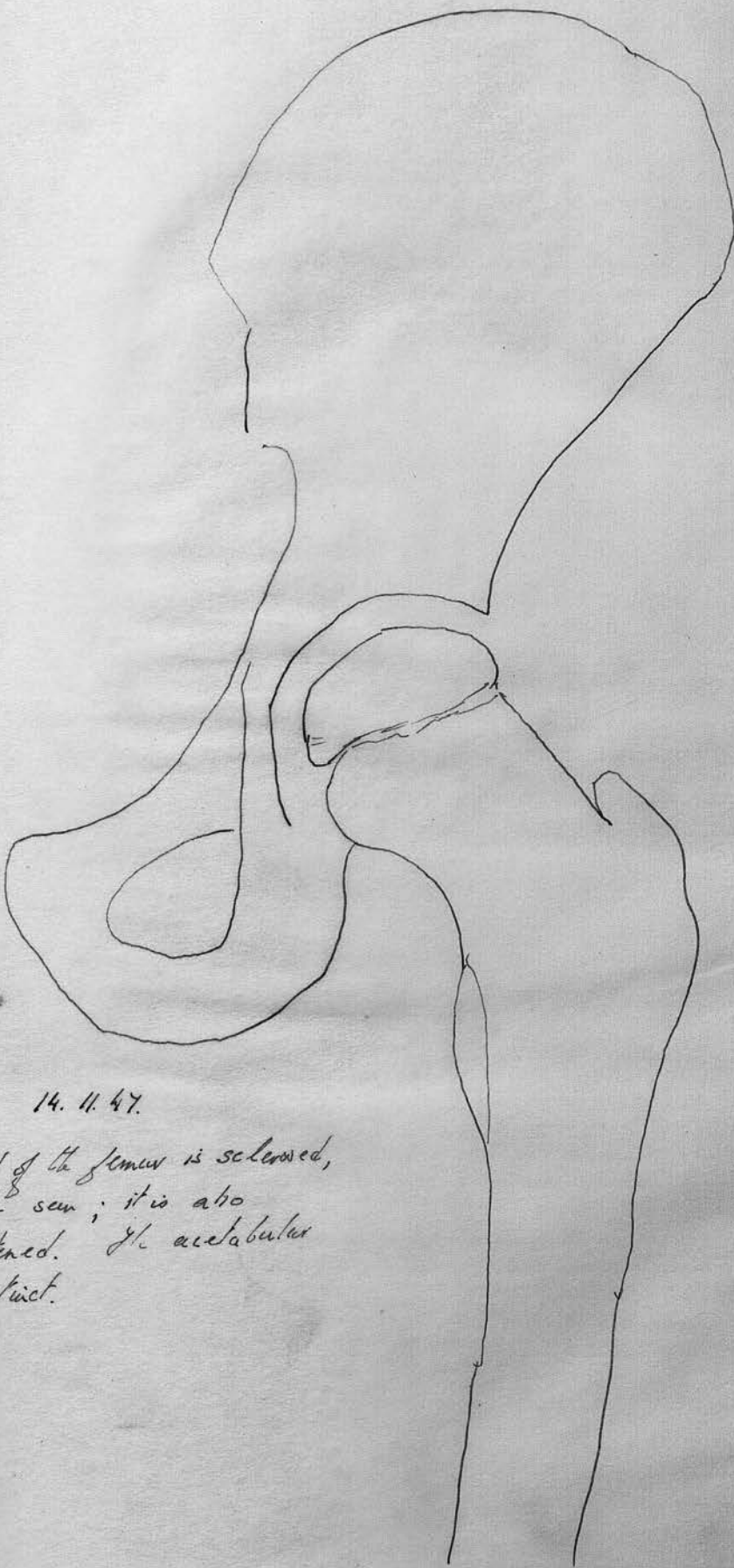
#### References.

- |                 |  |
|-----------------|--|
| BANKS.          | Journal Bone and Joint Surgery. 23, 753. 1941. |
| BRAILS福德.       | B.M.J. 504. 1942.                              |
| BUCHMAN.        | Surg. Gyn. Obst. 49, 447. 1929.                |
| DANFORTH.       | Journal Bone and Joint Surgery. 16, 516. 1934. |
| ELMSLIE         | J. Orthop. Surg. 1, 109. 1919.                 |
| GILL            | J. Bone and Joint Surgery. 22, 1013. 1940.     |
| GOLDENBERG      | " " " " " 770. 1938.                           |
| HOWORTH         | " " " " " 601. 1948.                           |
| JACKSON BURROWS | Brit. J. Surgery. 29, 23. 1941.                |
| MERCER          | Textbook of Orthopaedics. 1943.                |
| McMURRAY        | Practice of Orthopaedics. 1946.                |
| NICOLAYSEN.     | Quoted by Goldenberg.                          |
| REHBEIN.        | Deutsche Zei. Chir. 24, 416. 1922.             |
| ROBERTS         | Brit. J. Surg. 21, 461. 1934.                  |
| SUNDT.          | Zentralb. f. Chir. 47, 538. 1920.              |
| WALDENSTROM.    | Journal Bone and Joint Surg. 20, 559. 1938.    |
| WATSON-JONES.   | Brit. Med. J. 504, 1942.                       |

R.



H.  
L.



DAVID HAMILTON. 14. 11. 47.

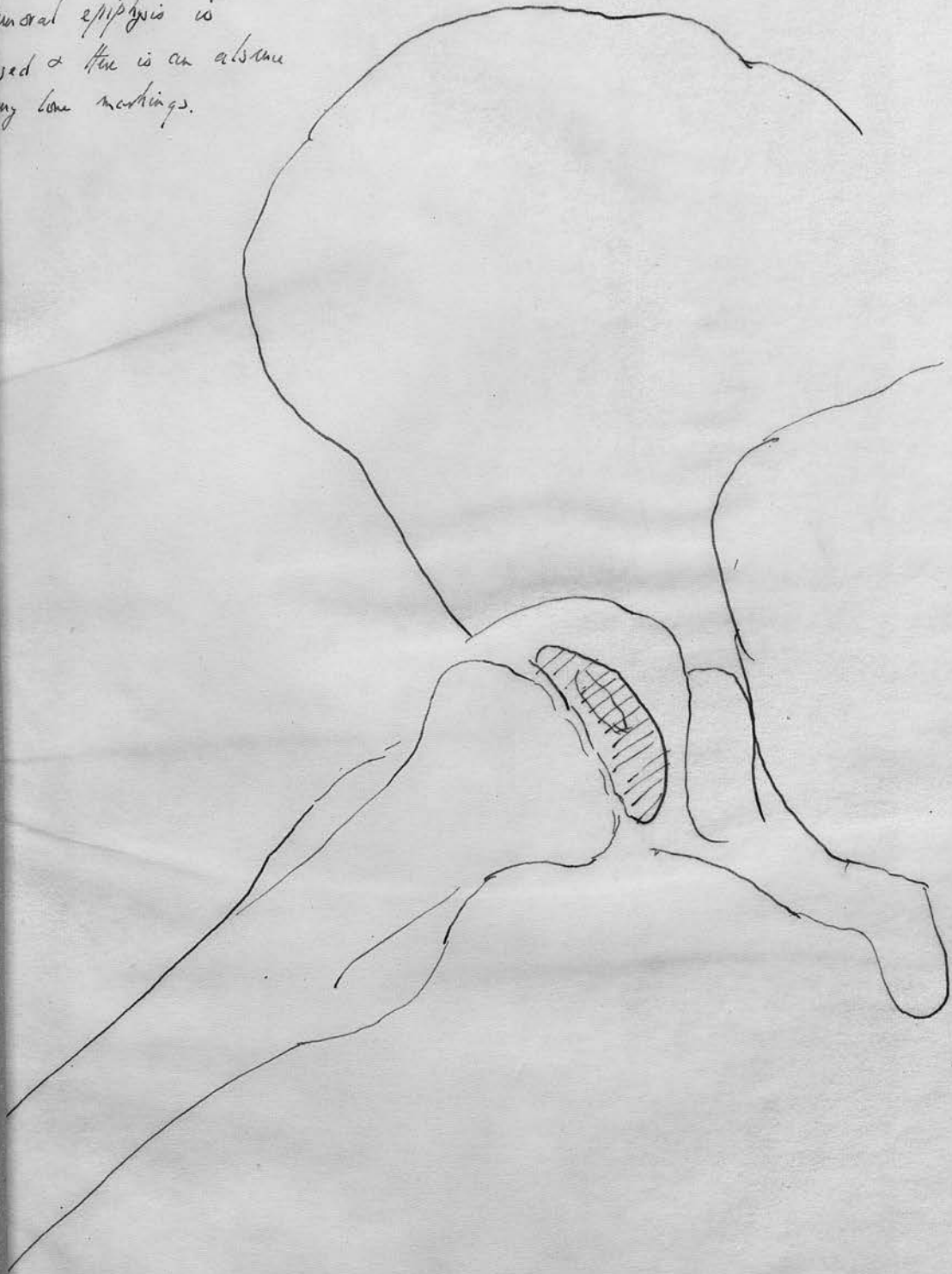The right epiphyseal head of the femur is sclerosed,  
& no trabeculation can be seen; it is also  
very considerably flattened. The acetabular  
margin is very indistinct.

DAVID HAMILTON.

6.

4.2.48.

Coracal epiphysis is  
used & there is an absence  
of any bone markings.

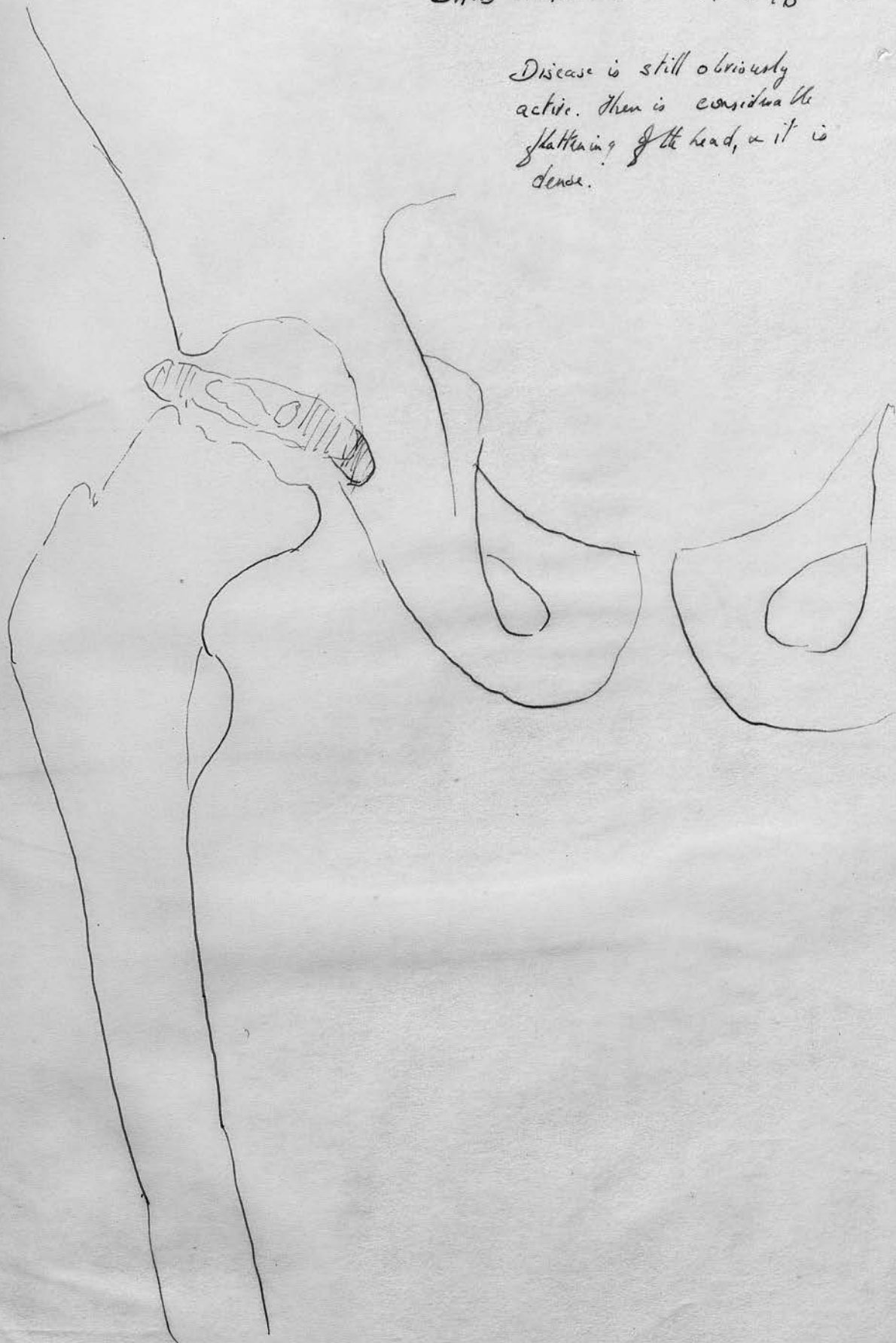


DAVID HAMILTON.


14. 4. 48

III.

Disease is still obviously  
active. There is considerable  
flattening of the head, & it is  
dense.



The disease is still active. There is  
an increase of the joint space  
& the epiphysis shows greater destruction.

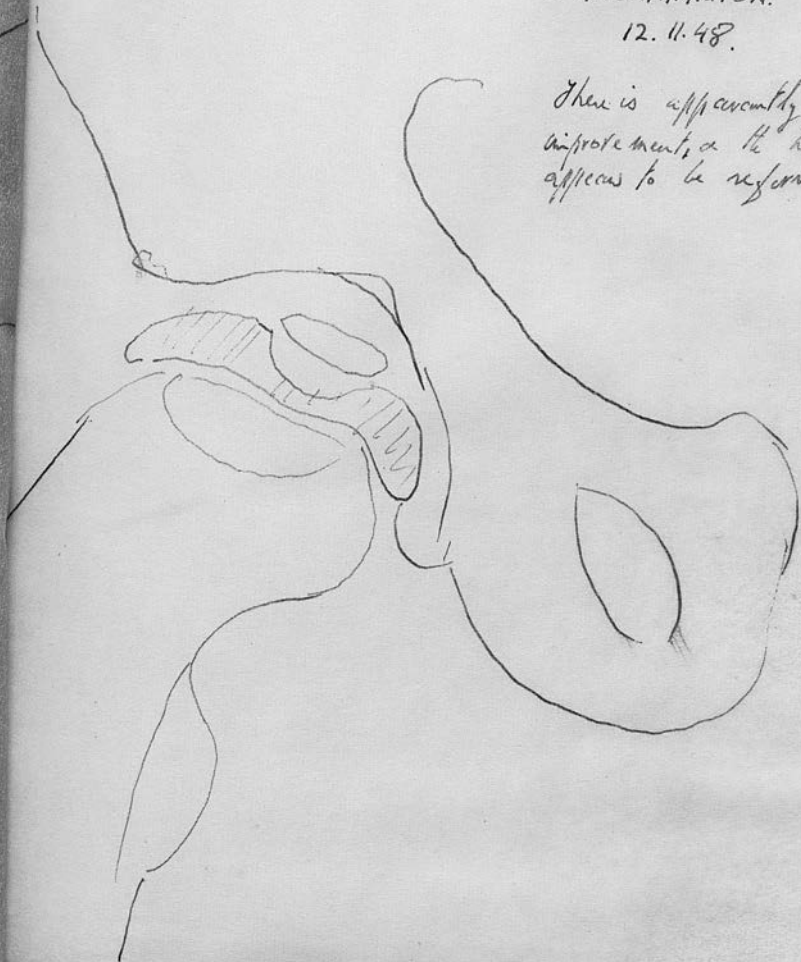


D AYID HAMILTON.

12. 11. 48.

V.

There is apparently some  
improvement, as the head  
appears to be reforming.

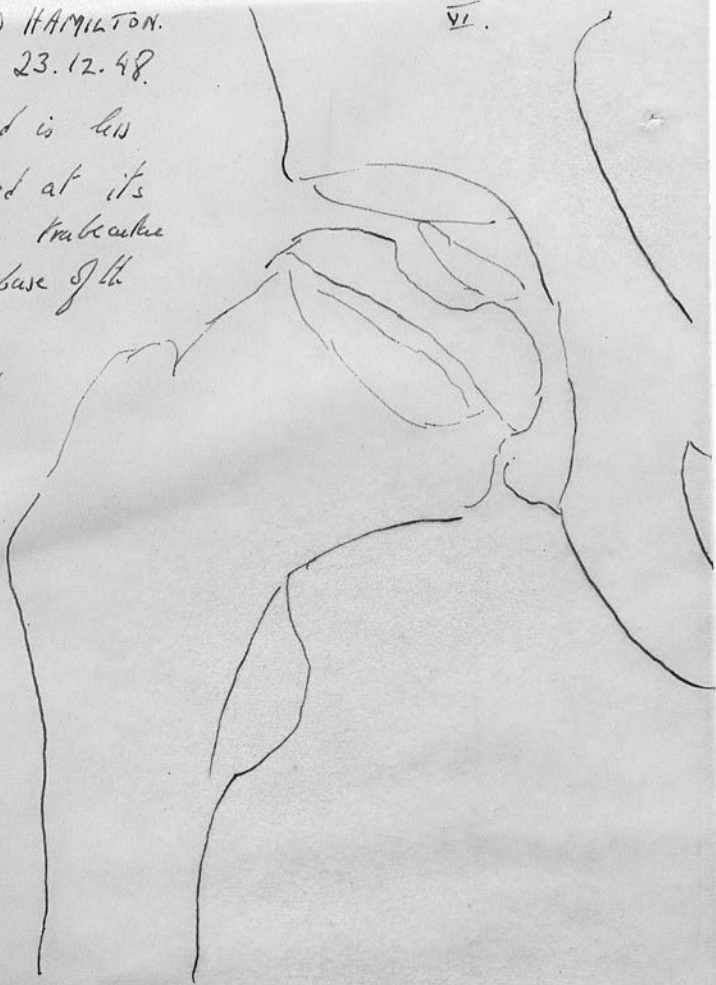


DAVID HAMILTON.

23. 12. 48.

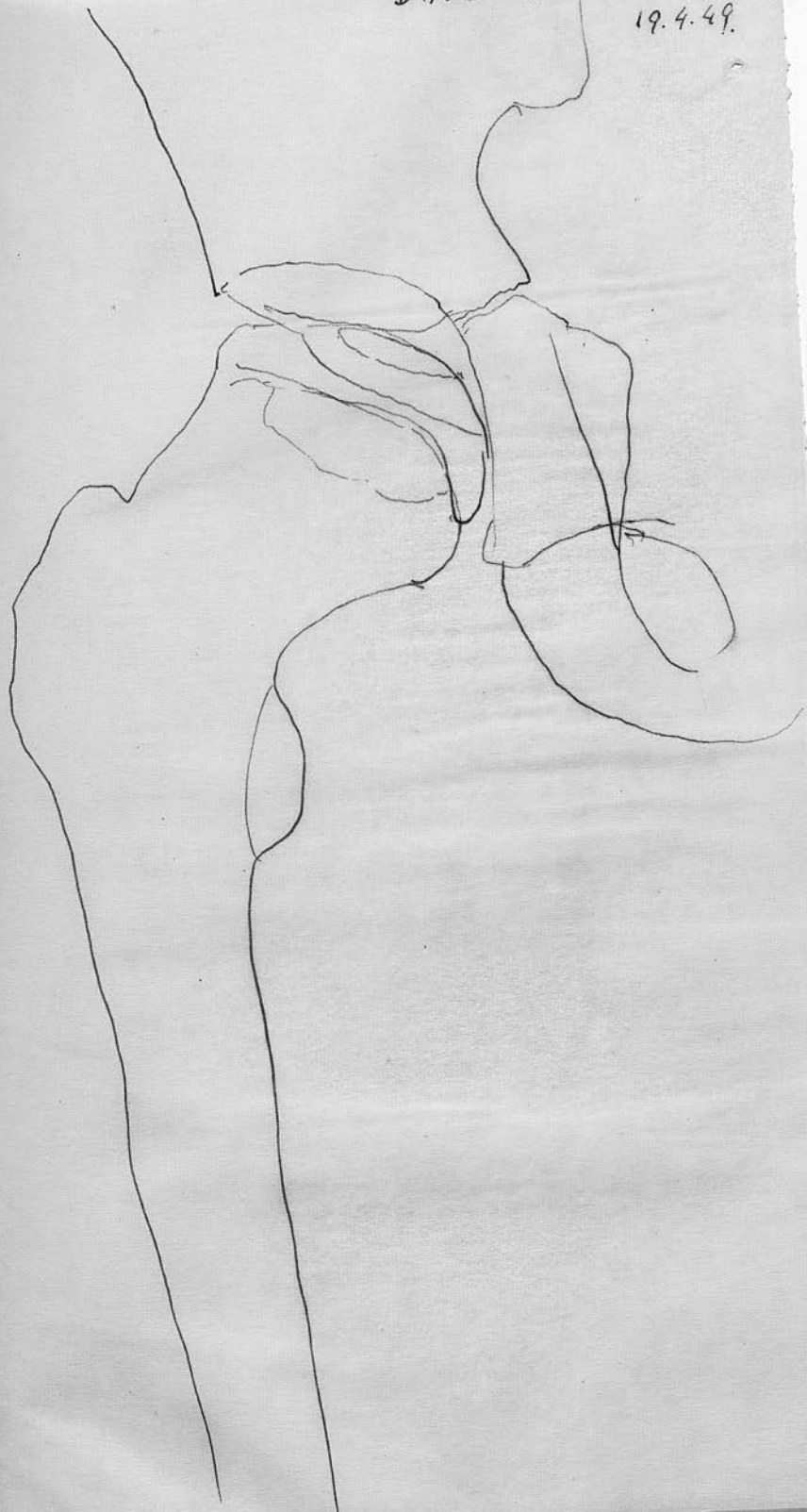
VI.

epiphyseal head is less  
only sclerosed at its  
alar margin & trabeculae  
to seen. The base of the  
tysis is still  
richly sclerosed.



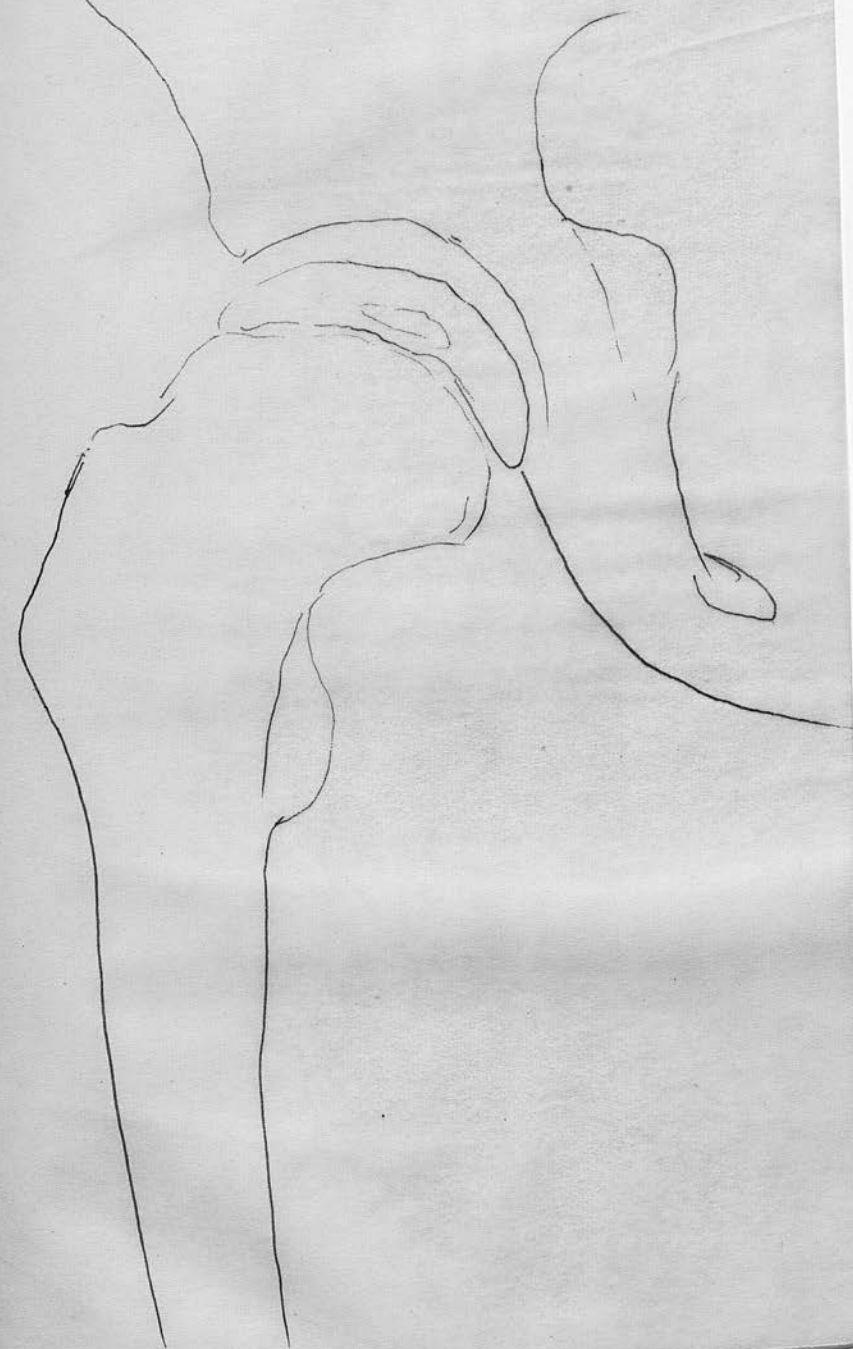
DAVID HAMILTON. VII.

19.4.49.



DAVID HAMILTON. 3.6.49. VIII

The epiphysis shows less obvious  
relative sclerosis; this seems  
to be important.

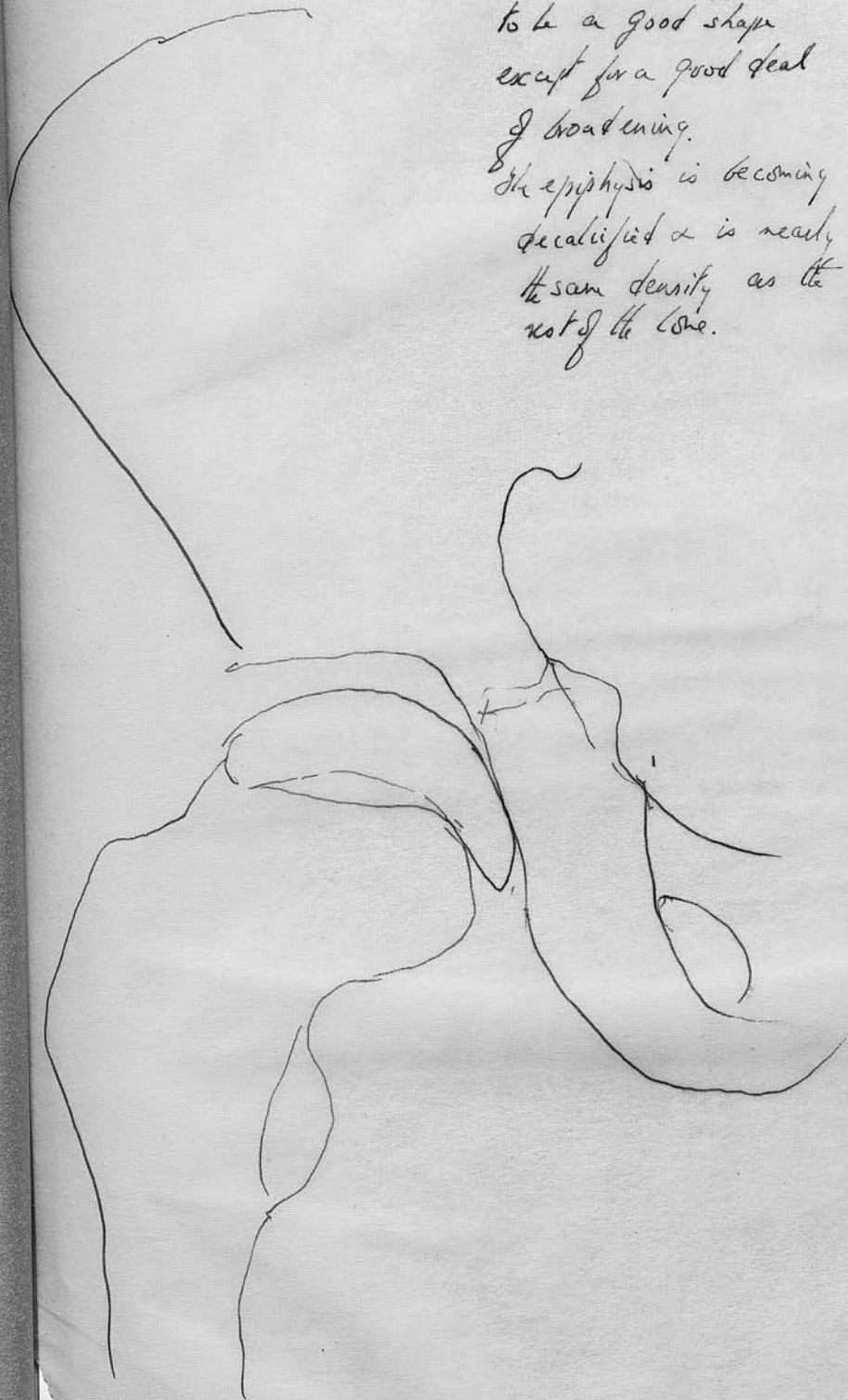


DAVID HAMILTON. 13.7.49. IX

R.

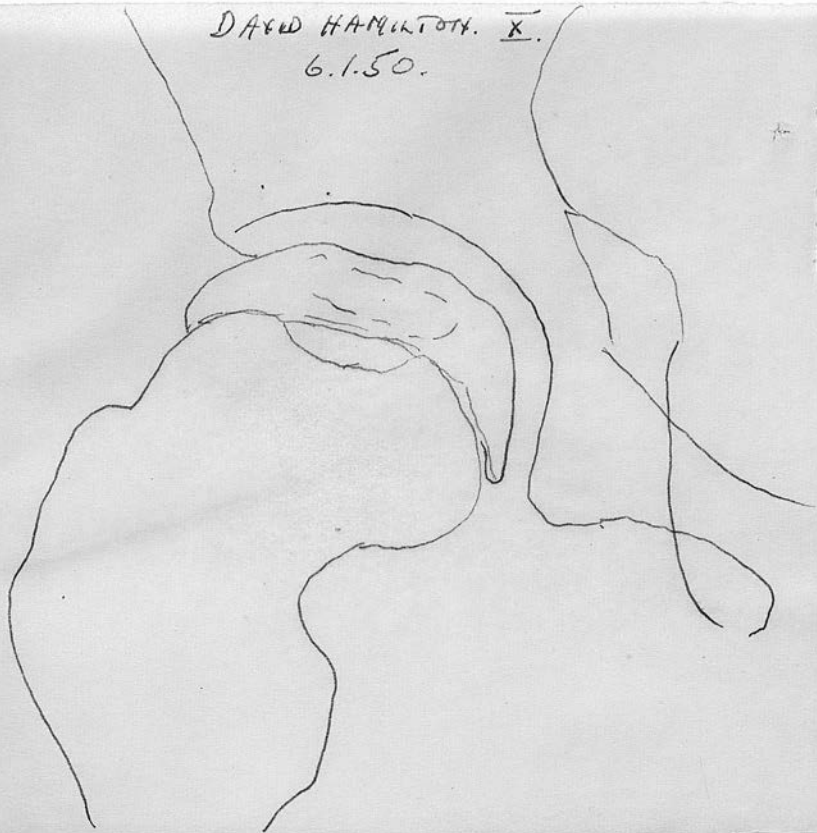The head now appears  
to be a good shape  
except for a good deal  
of broadening.

The epiphysis is becoming  
decalcified & is nearly  
the same density as the  
rest of the bone.



DAVID HAMILTON. X.


6.1.50.



AXID HAYK TON. 6.1.50.

XI

Head is now a relatively good shape,  
though somewhat blocky still;  
density is much the same as that on the  
other side & adjacent bone.



Name: Dryburgh, Alec.

Age: 17. (Born 29.12.32)

Address: [REDACTED]

Doctor: Dr. Jones, Kirkcaldy.

Sponsor: Kirkcaldy Burgh.

Admitted: 27.1.50.

Discharged:

Diagnosis: Vertebral epiphysitis. (Scheuermann's disease.)

History: This boy suffers from asthma, and has always been fairly round-shouldered. He has been almost free of his asthma for the last 2 years. The boy has never had any pain or trouble with his back at all, but he is rather self-conscious about it. On this account he went to his doctor in the summer of 1949, and he referred him to see Mr. Paterson at Kirkcaldy Hospital. He attended there for exercises, and was given a night shell. He was later put on the waiting list.

Seen by Mr. Paterson at Kirkcaldy, 18.10.49.  
"This is a case of chronic asthma, with a very severe epiphysitis, affecting particularly D8 to L2. I fear that the condition is now almost stationary and that the deformity may be permanent. I would like, however, to try the effect of corrective plaster and hard intensive exercises."

Family history: None.

Previous illnesses: Measles and scarlet fever.

Examination: General Examination. Heart, abdomen and C.N.S. reveal no abnormalities. Examination of the chest reveals a barrel-shaped chest with poor expansion, and the signs of asthma present.

Orthopaedic examination. When standing, this boy has a very poor posture, and there is a kyphosis present in the dorsal region. Movements are very restricted, but there is no pain present.

X-ray reveals a very marked epiphysitis affecting mainly the 8th-12th thoracic vertebrae, which are in an advanced state of wedging

30.1.50. To have plaster shell made.

15.2.50. To have the plaster shell wedged.

6.3.50. This boy has had his plaster shell wedged about 6" from its upper end. The process seems quite futile, and the only effect is to damage the plaster shell.

Nomenclature.

Scheuermann's disease is generally referred to as vertebral epiphysitis, without any real evidence to indicate the underlying pathology. This is partly due to Scheuermann himself whose contention it was that the disease was due to malformation of the epiphyses, and as a result it has been called vertebral epiphysitis without anything to show that the epiphyses are truly primarily, or predominantly involved. Many theories have been put forward, but few substantiated. Some

regard the disease as a sequel to disproportion between the capacity of the spine and the load it has to bear, others favour an endocrine basis, and trauma is not forgotten. Before considering the aetiology and examining these theories further, the actual chronological sequence of events, pathologically and radiographically may be recorded, together with the clinical aspects of the disease.

#### Clinical Features. (1) Orthodox.

Typically the patient is an adolescent boy between 12 and 17 years, who comes because his parents or friends have noticed a rounding of his back; he does not usually complain of pain, and he may not have noticed the condition at all. The boy is usually healthy and muscular, with no obvious constitutional disturbances. Clinically he is unable to straighten out the kyphos, which may be of any degree of severity, but it is always rounded rather than angular, and may be associated with a slight scoliosis, and the ribs may be flared out. This normal antero-posterior curve of the lower dorsal spine is greatly exaggerated, and it does not disappear on recumbency, or suspension, and as a result there is a compensatory lordosis of the lumbar spine. The boy may be employed at heavy work, or he may be still at school. Rarely is there any direct evidence of injury of any kind. This patient shows no unusual characteristics.

#### (2) Heterodox.

(a) In 1937 Cloward and Bucy produced some dozen cases, in which kyphosis dorsalis juvenalis was associated with proven cases of spinal extradural cysts of a non parasitic nature, in some of whom, besides the kyphosis, were definite neurological signs of cord compression, which gave rise to the presenting symptoms of spastic paraplegia, with increased knee and ankle jerks, Babinski signs and ankle clonus. The superficial sensation was rarely impaired, but deep sensation, position sense, and vibration sense were involved or absent. A block was demonstrated by lumbar puncture, and Queckenstedt's test, in some cases, and the causative cyst demonstrated at operation. The sex and age incidence appeared to be identical with Scheuermann's disease; this will be further discussed.

(b) Lambrinudi (1934) wrote, that many children he had examined in London who presented with a kyphos of an adolescent type, had either uni-lateral or bi-lateral tight hamstrings, which in the stooping or sitting position, he argued, produced excessive strain on the vertebrae.

(c) Kemp (1948) has sought to show that juvenile osteochondritis of the vertebrae is associated with, or partly related to, malnutrition, and has described typical kyphotic cases occurring in children simultaneously with dental fluorosis, which can only take place in children, who are both badly fed, and in whom there is a high natural intake of fluorine, generally in the water. Therefore in addition to the classical features described, neurological signs, tight hamstrings, and malnutrition, perhaps with dental fluorosis, may also accompany the kyphosis.

#### Pathological and X-ray Findings.

Edelstein describes three stages to the disease. (a) A deforming or florid stage, in which there is a rounding off of the antero-superior and antero-inferior borders, which continues until small step like defects appear at these points. There is mottling of the upper and lower ring epiphyses, and the upper and lower surfaces of the vertebral body appear fuzzy and uneven, the intervertebral space is diminished and the wedged bodies may come into contact.

(b) A destructive stage in which there is fragmentation and disappearance of the epiphyses, and upper and lower corners of the body which appear most atrophied at the apex of the kyphos. Prolapses of the intervertebral discs into the softened and decalcified vertebral bodies take place.

(c) Reparative stage in which the epiphyses may once again become definable, by reason of increased density, commencing at the anterior aspect of the body. The rounded kyphosis remains permanently, with wedging of the vertebrae, and at the anterior corners there may often be a spur like shape, causing buttressing and bridging of the spondylitis deformans type. Because the form and nature of certain of the structures are important in consideration of the aetiology, the anatomy of the relevant points are briefly reviewed.

#### The Epiphyses.

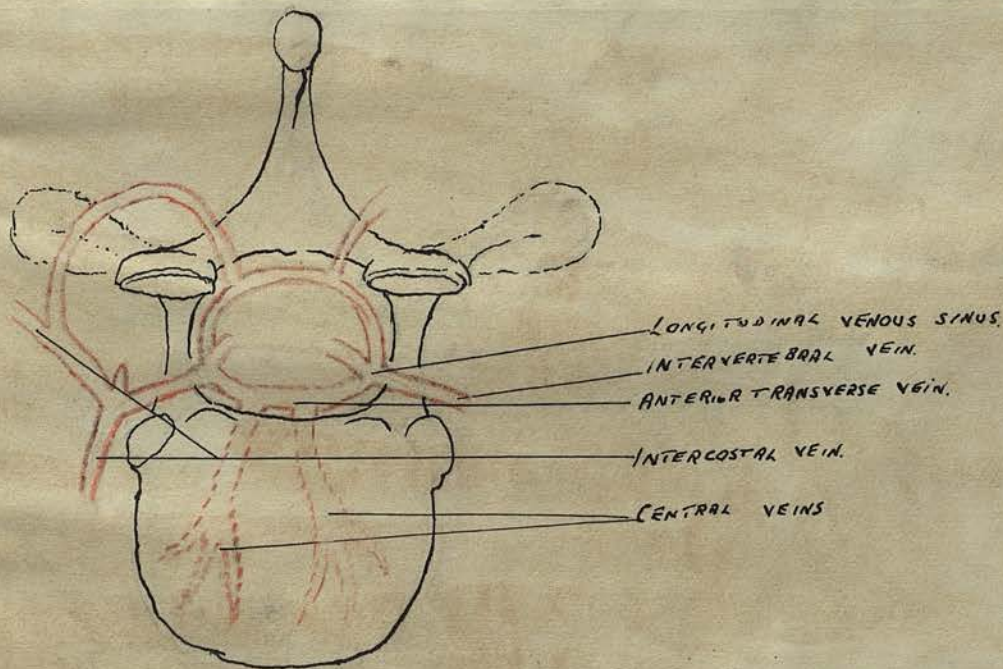
It is only in the lateral X-ray that the epiphyses are clearly seen; they

appear about puberty, above and below each vertebral body as small tri-angular shadows, in close proximity to their antero-inferior and antero superior corners; from these triangles, thin linear shadows extend backwards to become slightly broadened. The plates are biconcave, and between them and the body are the transparent epiphyseal cartilages. These epiphyses unite with the bodies at 22 - 24 years.

### The Intervertebral Disc.

This disc is a complex structure, consisting of the nucleus pulposus, the cartilage plate and the annulus lamellosus. The nucleus is a remnant of the notochord, semi-fluid and under pressure. Its function is as a water cushion, and a pivot upon which the movement of the vertebrae take place. Because of its fluid nature it distributes pressure evenly over the whole surface, and so prevents and guards any one part of the bone taking more weight than another. If it did not exist in the dorsal region where there is already a kyphosis, the anterior parts of the body would bear increase weight and become wedge shaped.

The cartilage plate consists of hyaline cartilage, which on its bony aspect plays the part of the epiphysis, and on its intervertebral aspect prevents pressure atrophy of adjacent bone. The annulus serves to attach the two cartilage plates one to another, and encloses the nucleus. It is very strong and elastic, and its fibres arise from the matrix of the cartilage plate above and below, and from the anterior longitudinal ligament, and the front of the bodies.



ANATOMY OF VENOUS DRAINAGE.

### The Venous drainage of the Vertebrae.

Each body is drained by a large central vein which leaves the body at the centre of its posterior surface and enters the spinal canal. There are also a few small veins leaving anteriorly and laterally. This posterior central vein on entering the spinal canal connects with the anterior transverse veins and anterior longitudinal sinuses of the spinal canal, which in turn are drained through the intervertebral veins, these pass out through the intervertebral foramina, to join the intercostal veins, and empty into the azygos system.

### The Theories of Aetiology.

Ever since 1921 when Scheuermann of Copenhagen drew attention to the significance of the epiphyses above and below the vertebrae, the condition, which he described associated with the epiphyses, has been shrouded in obscurity. Special types of kyphotic deformity such as Pott's disease, rachitic kyphosis, senile kyphosis, and kyphosis of ankylosing spondylitis have been well recognised and explained.

Inadequate recognition has been given to this curvature of the spine, taking place in adolescence, and which has such a definite clinical and pathological entity. Is this deformity, the consequence of interference with the normal development of those structures which are responsible for proper growth, height and shape of the vertebra, or is it the effect on those structures, a kyphosis from other causes? Buckman points out that changes of structure can be seen to precede those of form, but it is best to consider the possibilities in turn.

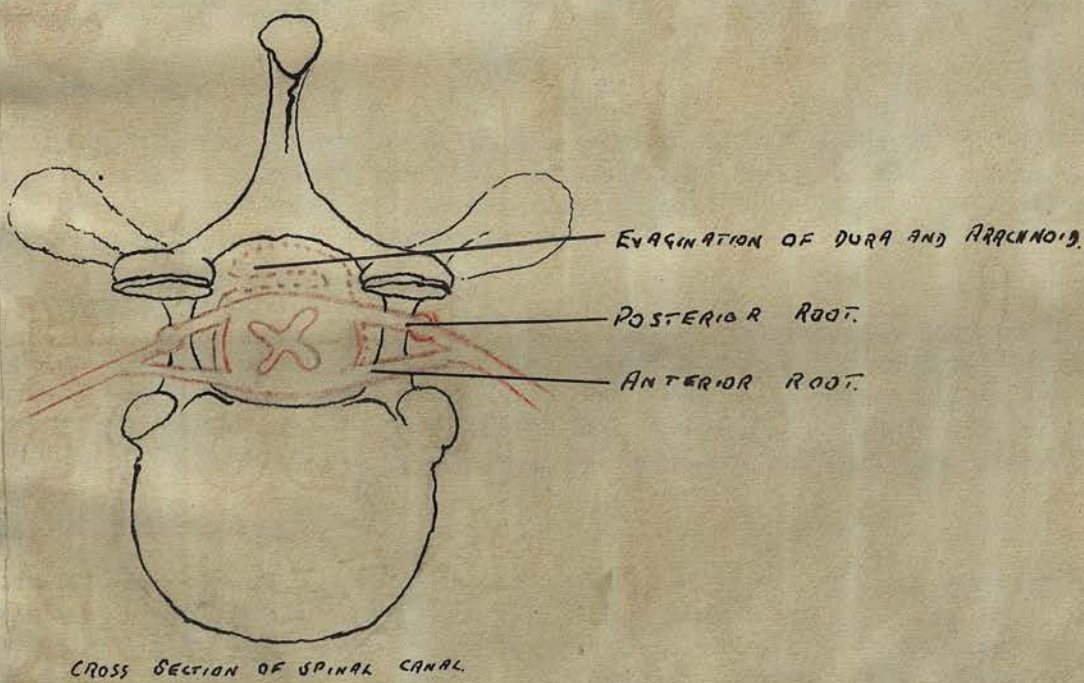
Factors diminishing the functional capacity of the vertebrae.

1. Circulatory disturbance.

(a) Diminution of arterial supply to the epiphyses.

This disease has been compared with Legg-Perthes disease, because it has been said both are due to avascular necrosis, but not only is the condition quite different in Legg-Perthes disease, but it is also quite different in Scheuermann's disease. True arterial deprivation does not present this picture, and even were there some similarity, it would be difficult to postulate arterial occlusion affecting a whole range of vertebral epiphyses. Circulatory disturbances at the line of growth from functional trauma leading to vaso spasm, ischaemia, and aseptic necrosis, fail to explain why some children are so much more vulnerable than others. It is difficult to see how emboli could simultaneously reach a limited number of vertebrae over a certain area at a certain age.

(b) Venous stasis, or diminution of Venous return from the vertebrae.  
Association of Extradural Cysts with Adolescent kyphosis.



Non parasitic extradural spinal cysts are so rarely encountered, that up to 1934, only a handful of cases had been published. Cloward and Bucy collected some dozen of such cases. These cysts appear to arise in the lower mid-thoracic region (6, 7, 8, 9) of adolescent boys, associated with spastic paraplegia, and kyphosis, and alterations in the vertebrae, indistinguishable from kyphosis dorsalis juvenalis. The sex and age incidence of these cases appear to be identical with that described by Scheuermann. In true cases of cysts, X-ray may demonstrate an increase in size of the vertebral canal on A.P. view; the pedicles are reduced in thickness, and the interpeduncular distance at the spinal level is increased. The concavity of the dorsal surface of the vertebral body may also be seen. Some of these changes are seen in various other types of expanding intraspinal lesions. Lumbar puncture in these cases may or may not reveal a block by Queckenstedt's test. The bony changes may be explained by the fact of abnormal pressure; the normal pressure within the epidural space approximates to that of the atmosphere; with a cyst it is increased from the atmospheric to the intraspinal pressure and bony absorption occurs. The discs do not show a similar absorption, so that the dura is slung between the discs, like so many hammocks, thus the margins of the dorsal surface are protected from pressure, while the whole of the increased pressure is directed maximally at the centre of the body.

The cyst is an evagination of the dura mater and arachnoid, fused, to form the wall of the cyst. The pedicle of the cyst may or may not communicate with the arachnoid space at the point of emergence of a spinal root from the dura. (See diagram). Now every case of spinal extra dural cyst described has been associated with kyphosis which is more than mere co-incidence. The cyst may be found with only the very earliest signs of kyphosis, so that it cannot be that the kyphosis is responsible for the cyst.

In the normal subject, the C.S.F. pressure surrounding the cord within the meninges at the mid-thoracic level when standing, is about 300 m.m. of water. This pressure is restrained within the meninges, and not transmitted extradurally. Now within the epidural space, lies tissue containing thin walled veins, which drain the vertebral bodies. If a cyst transmits the increased pressure, these vessels will be occluded and give rise to capillary and venous stasis, consequent vasodilatation and hyperaemia of the vessels behind the obstruction.

It would appear that not only is a venous congestion and stasis responsible for this destruction of the vertebrae, but this vascular abnormality must occur in growing vertebrae at a time when they are subjected to a considerable force. The lesions occur in those bodies subjected to most pressure because of the shape of the spine; any compressing force acting from above down in the thoracic region will to increase the thoracic concavity, forcing the bodies closer together, and thus the anterior margins will be most subject to increased pressure, and this force will also compress the intervertebral disc, causing herniation into the body, if it is sufficiently soft.

So it would appear that kyphosis dorsalis juvenalis may be the result of venous congestion and stasis in the intervertebral bodies whatever the cause of the obstruction may actually be.

## (2) Infection.

There can be few if any bones in the body which if infected do not give rise to pain, except possibly the jaw; in addition, there is the extreme unlikelihood that several particular epiphyseal rings should fall victims to bacteria simultaneously, and at a particular age.

## (3) Endocrine.

(dystrophia adiposo genitalis.)

This theory has arisen because of the cases associated with Frohlich's Syndrome. Careful examination reveals that it is only those epiphyses which have to bear a shearing strain, which are affected and therefore one is fairly safe to attribute the changes solely to abnormal weight, typically seen in such cases.

## (4) Metabolic and Chemical.

Buckman has been unable to show any chemical changes in this disease, and the calcium and phosphorus levels fall within normal levels, but we must remember that there are many aspects of bony metabolism of which we know nothing. Rickets has at one time been held responsible for this and all other causes of epiphysitis, but it is difficult to see how it could account for it in normal times, when the recognised stigmata of rickets is virtually absent in the children of to-day.

Kemp and others have put forward the theory that, juvenile osteochondritis is in part related to malnutrition, and have commented on the beneficial effects obtained by improvements in the diet. These workers showed that dental fluorosis is seen in children in whom there has been malnourishment and a high intake of fluorine; a high intake of fluorine alone does not produce the picture. They were struck by the prevalence of juvenile osteochondritis associated with dental fluorosis, and therefore by inference with malnourishment. They compared two groups. One from a public school, and the second from poor quarters in Oxford. Some of the first group (and presumably better nourished), had fluorosis, but none in the second in whom the fluorosis intake is negligible. Since the boys from the public school came from all over the country, their fluorine intake was obviously not measurable. These two groups were compared with a third, where both dental fluorosis and poverty prevailed. In this group spinal changes were three times more common as in the other two groups. They conclude that whatever the intimate pathology of Scheuermann's disease may be, the practical implications are quite simple. They think that even the most severe cases could be prevented, if proper measures were taken to assist the promotion of health and welfare in

children, by means of good dietary during adolescence, particularly in rural areas. If this is so it is obviously not the whole answer, for cases continue to occur in children in whom there can be no suspicion of poor diet; it may well be a contributory factor.

(5) Congenital Disc prolapse.

Beadle points out that phylogenetically the erect posture is a recent development, and as a result, certain parts of the human frame are more prone to degeneration than others. Minute rents and tears may occur in the cartilage plate, by wear and tear, and the nucleus pulposus insinuates itself, and prolapses into bone.

Professor Schmorl has carried out extensive examinations on some 4000 spines removed post mortem. He reports that no less than 38% have evidence of these herniae. His theory is that the vertebral bodies are approximated as a result of this herniation of the nucleus into the body, setting up a hyperaemia which results in decalcification. This enucleation occurs, according to him, because the plate like epiphyses on the upper and lower surfaces of the vertebral bodies act as buffers against the protusion, and spread of the nucleus pulposus of the intervertebral disc, and if this disc is in any way deficient, the nucleus protrudes into the epiphyseal substance, diminishing and destroying the blood supply to the anterior part of the plate, thus producing fragmentation and consequent interference with growth. But according to his own evidence the vertebral epiphyses are found as rings which lie only along the superior and inferior surfaces of the body, and are thicker anteriorly than posteriorly. They do not contribute to the growth of the main mass of the body, but give rise to a thin flat ring of compact bone about the edges of the superior and inferior surfaces, and it is therefore difficult to conceive how ANY interference with this development could result in a condition of the vertebrae, which entailed defects and craters in the body, and in its final collapse. The main objections to this theory is that the primary change is not a herniation but an erosion of the anterior corner of the body and in addition such herniae are NOT present in all cases and may also be found without any other changes whatsoever.

Schmorl seeks to make all these protusions congenital; some indeed may be so; but it seems more reasonable, to think of the changes as secondary to softening and decalcification of the bodies, and as the result of compressing forces, to which the vertebrae are normally subjected; and to regard the disc lesion as secondary, and as the inevitable complication of any process, by which the plate and underlying bone are weakened. That nuclear prolapse occurs is NOT denied, but that it has ANY bearing on the aetiology of adolescent kyphosis is NOT proven. If one discards Schmorl's theory, one is forced to the conclusion that a developmental disturbance arises de novo during puberty.

(6) Robery puts forward the theory that the factor most prominent in juvenile kyphosis, is an over-acceleration of the endochondral ossification during the period of most active body growth causing ossification in the metaphysis of the vertebrae to lag behind a predominantly proliferation of cartilage. He bases this conclusion on a study of patients in whom kyphosis developed subsequent to tetanic convulsions. Although there is a greater tendency for fracture to occur in adults, the majority of such cases of post tetanic kyphosis occur in adolescents, and in an age group corresponding to juvenile kyphosis. He claims that the similarity is complete except for the level of the lesion, which is explained by the dynamic level of stress in tetanus in contrast to the static level in juvenile kyphosis.

However a critical survey of his findings would not appear to support his contentions, for the radiological findings are by no means identical being much more like wedge fractures occurring in subjects in whom there is a definite physiological weakness common to all adolescents at this growth period.

II. Factors causing Increased Load of the Vertebra.

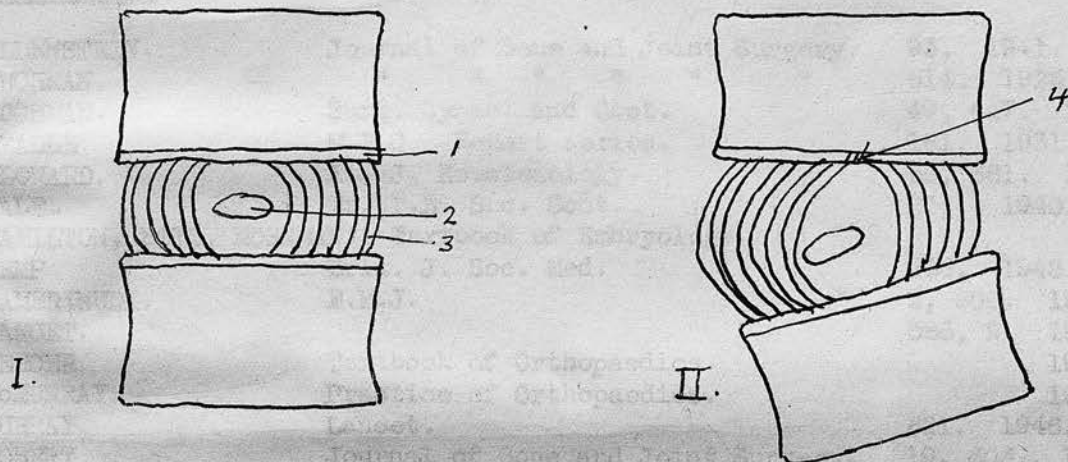
(i) Increase in body weight. All normal children increase in body weight so that it does not explain why some are afflicted and others are spared. Shantz thought the deformity due to excessive strain in underdeveloped subjects, but Scheuermann pointed out that these patients are nearly all well developed. If it is a factor at all it would seem to be covered by "trauma".

(ii) Multiple minor trauma. Scheuermann's opinion is that "the ossifying process

is affected, either by an isolated severe trauma, or by a series of occasional traumatic lesions. There is then a temporary overloading, which produces in the anterior part of the vertebrae, where the effect of the lesion is greatest, a temporary arrest of ossification. He has suggested the analogy of the condition with Perthes disease and suggests that fragmentation of the epiphyses is the result of abnormal pressure on the growing epiphyseal plates. This strain factor is quite unconvincing. It could only be an aggravating factor, if a factor at all. Trauma is too often considered the cause of any disease of unknown aetiology.

(iii) Shortening of the Hamstrings.

Lambrinudi explains the weakening of the cartilage plate, and underlying bone, by stress and strain, caused by short hamstrings, when the body weight is obviously normal and there is no history of trauma. He thinks that if the hamstrings are tight, then, in the stooping position and when sitting the back is fully flexed and the pelvis is fixed. There is then no spring left in the hamstrings, therefore any hyperflexion, from games or from gymnastic exercises, will throw weight on the anterior part of the body of the vertebra. If the force is sufficiently powerful, and frequent, small crush fractures or subchondral haemorrhages occur, and even fissures in the cartilage plate. There are no nerve endings in the discs and so there is no pain, consequently no opportunity for repair is obtained.



I. Normally resting.  
 2. Forcible flexion. " The nucleus pulposus is pinched like a cherry stone between finger and thumb causing strong traction on the cartilage plate and so ruptures it."

- (1). Cartilage plate.
- (2). Nucleus pulposus.
- (3). Annulus lamellosus.
- (4). Rent in plate.

Summary and Conclusions.

Physiologically between the ages of 3 and 6, and again between 12 and 17 there are periods of active growth; there is a relative weakness of the bones because of the vulnerability of the rapidly growing cell, and it is postulated that at this time venous stasis may arise from thrombosis, or some other obstruction, and cause the condition known as Scheuermann's disease, which is predisposed to, or aggravated by malnutrition, and by the effect of tight hamstrings. Although the epiphyses are affected in this disease it is not primary and therefore the term epiphysitis is hardly appropriate. The obscurity covering these diseases (osteochondritis) is partly due to the search for the same underlying pathology in each, no matter when it may occur, although the fact that these may be such common underlying pathology, which is modified according to the position and its peculiar stresses or strains, is not excluded. It is probably better to approach such a condition in an unbiased attitude, without preformed conceptions, based on apparently similar disease elsewhere.

Treatment of the established condition can only really, at the present state of ignorance, attempt to limit the deformity by eliminating weight bearing by bed rest.

By Permission of Professor Mercer and Mr. Sutherland,  
F.R.C.S.

References.

ALDENSTEIN.	Journal of Bone and Joint Surgery.	93, 1941.
BUCHMAN.	" " " " " "	814. 1925.
BUCHMAN.	Surg. Gynae. and Obst.	49, 447. 1929.
BRADLE.	M.R.C. Report series.	161. 1931.
CLOWARD.	Am. J. Roentology.	58, 681. 1937.
DALE.	Tr. T.B. Soc. Scot.	25, 1940.
HAMILTON, BOYD, MOSSMAN.	Textbook of Embryology.	
KEMP	Brit. J. Soc. Med.	266. 1948.
LAMBRENUDI.	B.M.J.	2, 800. 1934.
LANCET.		386, 2. 1948.
MERCER.	Textbook of Orthopaedics.	1943.
McMURRAY.	Practice of Orthopaedics.	1947.
MURRAY.	Lancet.	821. 1946.
ROBERT	Journal of Bone and Joint Surgery.	19, 603. 1937.
SCHEUERMANN.	Zeitung. of Orthop. Chir.	41, 305. 1921.
WILKIE.	Brit. J. Radiol.	13, 213. 1940.

---

ALCO DRYBURGH. 27.1.50. LATERAL X. RAY OF DORSAL SPINE.

There is a very marked thoracic kyphosis affecting D. 8-12 particularly.

These vertebrae are in an advanced stage of wedging. The A.P. view shows a slight scoliosis convex to the right.

There is a very great osteoporosis in these vertebrae, & the change from D. 12 to L. 1 is very striking.

